

THE

PATHOLOGY OF THE TEETH.

THE
PATHOLOGY OF THE TEETH

WITH SPECIAL REFERENCE TO THEIR

ANATOMY AND PHYSIOLOGY.

BY

CARL WEDL, M.D.,

PROFESSOR OF HISTOLOGY IN THE UNIVERSITY OF VIENNA, ETC.

TRANSLATED FROM THE GERMAN

BY

W. E. BOARDMAN, M.D.

WITH NOTES

BY

T. B. HITCHCOCK, M.D., D.M.D.,

PROFESSOR OF DENTAL PATHOLOGY AND THERAPEUTICS IN HARVARD UNIVERSITY, ETC.

WITH ONE HUNDRED AND FIVE ILLUSTRATIONS,

PHILADELPHIA:
LINDSAY & BLAKISTON.

1872.

Entered according to Act of Congress, in the year 1872,
By LINDSAY & BLAKISTON,
In the Office of the Librarian of Congress, at Washington, D.C.

SHERMAN & CO., PRINTERS.

TRANSLATOR'S PREFACE.

PROF. WEDL is widely known as a very expert and thorough investigator and a distinguished scholar. His "Rudiments of Pathological Histology," published by the Sydenham Society in 1855, will justify the assumption that anything from his pen will prove valuable.

A definite idea of the object and scope of the present work may be obtained from the author's preface and table of contents. From these it will be seen that the work covers the whole ground of the Anatomy, Physiology, and Pathology of the teeth and their adnexa. As far as was practicable, the researches of others were made use of, and, in addition, there will be found much that is entirely original. Indeed, the work forms the most complete treatise of its kind that has appeared in any language. When we consider the vast amount of labor required in the original investigations of the author, in the collection of material and the reviewal of the very extensive and exceedingly scattered literature of the subjects of which he treats, it must be acknowledged that he is deserving of great credit. It is believed that the work will prove a valuable one for the dental profession in this country, since the recent advances which have been made here in the requirements of the students of dental science necessitate a complete work for the purpose of a guide in future original investigations as well as of studying the results of the researches which have already been made. General practitioners, also, of medicine and surgery, and students of histology will find in it much of interest and value.

I have endeavored to make the translation as literal as possible and, at the same time, to avoid German idioms; this has been a difficult task on account of the peculiarities in the author's style of writing as well as of the difficult nature of the subjects of which he treats. I have

been unable to obtain, for the purpose of comparison, several works and journals to which he refers and from which he quotes. I have thought it best to retain everything and to add but little. It was suggested that explanatory notes should be introduced in reference to many points with which students of dental science alone might be unacquainted, but it was found that too much space would be required in order to make these complete. Many of the works to which reference is made in the text are readily accessible, and from them the reader can obtain more satisfactory information and at greater length, than could be included within the limits of ordinary notes.

I am well aware that the critical reader will find many blemishes in the translation and inelegant diction, which I trust will be pardoned. Perhaps I have not correctly appreciated the author's meaning in some instances; errors of this description I hope the critic will clearly prove.

Prof. Hitchcock has carefully reviewed the translation, and the fewness of the notes which he has found necessary to add will indicate the clearness and completeness of the author's treatment of the subjects. I am greatly indebted to Prof. Hitchcock for the assistance which I have derived from conversations with him and from his library and pathological collection.

Before the appearance of the present work, Prof. Wedl published an "Atlas to the Pathology of the Teeth," which contains one hundred and forty-five beautiful engravings in illustration of malformations and diseases of the teeth, together with explanations of the same, both in German and English. Although this Atlas is not absolutely essential to the understanding of the present work, still, as I have found, the full appreciation of the latter will be facilitated by the perusal of the former, especially of those portions to which reference is made in the text.

The illustrations, with which the book is enriched, are from electrotypes, the same as used in the original German edition. The author's index has been enlarged considerably; though still incomplete, it will, I believe, commend itself to the readers as a valuable addition.

Prof. Wedl, reserving the right of translation, sent a copy of the original edition to his friend and former pupil, Dr. Francis H. Brown of this city, with the request that he would translate and publish the same. He concluded, however, that his numerous duties would necessitate too great a delay, and so he honored me with the request to as-

sume the duty. I must here express my sincere thanks to him for his undiminished interest in the progress and success of the work, and for much valuable assistance. To many others, also, whom it is my privilege to consider my friends, I take this opportunity of renewing my thanks for their uniform kindness, their willing and valuable aid in many ways.

In closing, I will express the hope that the present work will contribute to the advancement of the study of dental science in this country, and that its readers will derive at least as much information and pleasure from its perusal as I have received in the more laborious work of its translation.

W. E. BOARDMAN, M.D.

BOSTON, MASS., September, 1872.

AUTHOR'S PREFACE.

THE collection of the vast amount of material requisite for a work upon a special branch of pathology is attended with manifold difficulties. Our efforts are the sport of capricious fortune and must be continued unremittingly during many years before a foundation can be laid. Carabelli made collections during about twenty, and Heider during twenty-three years, and they succeeded in obtaining valuable series of specimens illustrating the anomalies of teeth. The latter collection, however, was by far too limited for the requirements of a special study; indeed, this furnished only thirty-four illustrations for the "Atlas to the Pathology of the Teeth," not one-fourth of the entire number. Heider and I, therefore, were compelled to devise some method for obtaining, in the first place, the necessary material for our work. At our request, we were very kindly furnished with thousands of extracted teeth from the Hospital of the Charity Friars in Vienna. The teeth alone, however, are insufficient for our purpose, as is self-evident; it is necessary to observe them *in situ*, in the cadaver and the skeleton, in order to study the connection of the phenomena in succession. In common with those of experience, I can recommend such a collection of diseased teeth as a fertile source of instruction to the practical dentist.

By the kindness of my esteemed friend, Dr. Ph. Steinberger, Vice-President of the Austrian Dental Society, I have had the opportunity, not only of examining Heider's collection together with the children's skulls which were collected by the dentist Terzer, and of making use of a number of plaster casts, but I have also had at my disposal the dental library and journals. I am indebted to numerous colleagues, whose names are introduced in connection with the proper illustrations, for very important additions to the materials at my disposal.

After the death of Heider, his wife, Marie Heider, allowed me to peruse his manuscripts upon subjects connected with dentistry. These comprised outlines of lectures upon dentistry, which I availed myself of, a minute description of the exterior of the teeth, which I have followed, almost word for word, and a synopsis of abnormal sets and anomalies of teeth, which I have rearranged under different heads with additions, illustrations and special explanations. Finally, before his death, Heider furnished me with written communications concerning his clinical observations with reference to caries and inflammation of the root-membrane, which I have introduced under his name.

The papers published by Heider and myself in common and, likewise, by myself alone, in the "Deutsche Vierteljahresschrift für Zahnheilkunde," I have introduced in the text either unchanged or with additions, or rewritten.

Special reference has been made to the ancient and modern literature, so far as space and the means at my disposal would allow, and in this connection I have derived much assistance from the analects of A. zur Nedden, in the "Deutsche Viertelj. f. Zahnh." Unfortunately, I was unable to avail myself of several valuable monographs which were not to be obtained through the booksellers.

After much reflection upon the subject, I decided to divide the morbid processes into seven groups or families, and to consider the diseases of the different organs in connection with each group. In this way, I think, the subjects have been treated in a more connected manner. The anatomico-physiological basis has been adhered to strictly throughout the book and, when it has appeared advantageous, comparative pathologico-anatomical data have been introduced in order to elucidate the processes. Whenever the needs of the dentist seemed to require it, clinical observations have been combined with the pathologico-anatomical and, in this way, more life has been infused into the latter.

In such a recent doctrine as the pathology of the teeth, it is absolutely necessary to dwell upon isolated observations which cannot be confirmed until a later period.

The pathological is preceded by an anatomico-physiological part which, I think, contains several new points, the results of my own observations.

For the more minute literature of this portion of the subject, of

which, perhaps, there is an excess at present, I refer to the familiar text-books. In this part, also, it was my endeavor invariably to keep in view the requirements of the dentist, and, with this idea, therefore, I have also paid especial attention to the growth of the jaws which is connected so intimately with the anomalies in the position of the teeth.

I have endeavored to give a definite idea of the connection between the various anomalies of formation, which are so important to the dentist, and an exposition of the phenomena of development. Many gaps in our knowledge of the latter processes are yet to be filled up, a fact which is only too apparent; but it may safely be said that many of the pathological processes, which occur in the later years of life, owe their origin to an abnormal process in the development of the teeth.

The inflammations which came within the province of the present work have been considered connectedly; the atrophies, particularly the changes incident to old age, have received especial study. I have taken into consideration those new-formations which have their seat in the jaws and stand in a certain relation to the teeth, in addition to those which belong properly to the teeth. An interstitial growth of bone and dentine has been demonstrated, especially in connection with the new-formations in the teeth, but with reference to other new-formations also. I may have exposed myself to criticism by classing caries of the teeth with anomalies of the secretions. I think, however, my exposition of the subject will justify my course. I have endeavored, as far as our present knowledge will allow, to place the neuroses upon a scientific basis.

Although the book forms a complete work by itself, I have, nevertheless, continually made reference to the "Atlas to the Pathology of the Teeth," without, however, encroaching upon the text. The Atlas and the Pathology herewith presented, together form a complete whole, and the understanding of the latter will be promoted essentially by the former. All the illustrations in the present work are original and were drawn upon wood by Dr. Heitzmann, of Vienna, with the rare skill peculiar to him, and were engraved with great accuracy by Mr. Flegel, of Leipsic. I am persuaded that they will render valuable aid in the appreciation of the text. The explanation of each figure is given in detail and thereby interruptions in the text are avoided.

In closing, I hope that this book, which, I may truly say, has required a considerable expense of time and labor, may meet with such a

favorable reception as was accorded to the Atlas, and that it may aid in directing more attention to the doctrine which hitherto has been neglected somewhat as a whole, although portions of it, to be sure, have been elaborated.

CARL WEDL.

VIENNA, November 4th, 1870.

CONTENTS.

	PAGE
TRANSLATOR'S PREFACE,	5
AUTHOR'S PREFACE,	9
INTRODUCTION,	17

PART I.

ANATOMY AND PHYSIOLOGY.

General Characters of the Teeth,	28
Classification of the Teeth,	30
Description of the Temporary and Permanent Teeth,	31
Temporary Teeth,	38
The Hard Tissues of the Teeth,	43
Cement,	51
The Pulp,	54
The Gum,	57
The Root-Membrane, Periosteum of the Root,	58
Development of the Teeth,	60
First Dentition,	73
Second Dentition,	76
Third Dentition,	87
Growth of the Jaws,	88

PART II.

PATHOLOGY.

I. IRREGULARITIES IN THE FORMATION OF TEETH,	98
1. Irregularities of Size,	98
2. Irregularities of Number,	99
Deficiency of Teeth,	104

	PAGE
3. Irregularities of Arrangement,	108
A. Irregularities in the Arrangement of the entire Dental Arches,	108
B. Irregularities in the Position of the separate Permanent Teeth,	112
Central Incisors,	113
Lateral Incisors,	114
Canine Teeth,	116
Bicuspids and Molars,	118
Irregularities in the Position of the Milk Teeth,	121
C. Irregularities in the Position of separate Permanent Teeth which are Imbedded within the Jaw,	122
D. Retention of Teeth without Displacement,	127
4. Irregularities of Structure,	130
<i>a.</i> Flexions and Torsions of the Crowns and Roots,	130
<i>b.</i> Excessive Growth upon the Crowns and Roots,	134
<i>c.</i> Defective formation of the Crowns and Roots,	139
<i>d.</i> Blending or Fusion and Coalition or Concrescence of adja- cent Teeth,	147
<i>e.</i> Malformations,	154
 II. INFLAMMATIONS,	 176
Pulp,	176
Gum,	192
Diseases occasioned by the First Dentition,	199
Diseases occasioned by the Second Dentition,	201
Root-Membrane,	204
Alveolar Abscess,	216
Nasal Cavity and Antrum,	228
 III. ATROPHIES,	 232
Pulp,	232
Senile Dentine,	242
Cement,	244
Resorption of Senile Dentine and Cement,	245
Enamel,	246
Surfaces produced upon the Crowns by Attrition,	247
Gum,	254
Root-Membrane and Alveolus,	255
Maxillary Periosteum and Maxillary Bones,	257
 IV. HYPERTROPHIES,	 271
Cement,	271
Root-Membrane,	277
Gum,	279

	PAGE
V NEW-FORMATIONS,	284
Pulp,	285
New-Formations of the Hard Dental Tissues,	286
Musket-balls in the Teeth of Elephants,	301
New-Formations of Osseous Substance in connection with Abscesses in the Ivory of the Tusks of Elephants,	304
Fractured Teeth,	307
Cement, Osteomata, Exostoses,	312
Root-Membrane,	316
Gum,	319
Mucous Membrane of the Mouth,	321
Alveolar Processes,	322
Cysts of the Jaws,	331
Osteophytes upon the Jaws,	335
Enostoses in the Jaws,	337
Chondromata of the Jaws,	339
Fibromata of the Jaws,	340
Sarcomata of the Jaws,	343
Gelatinous Tumors, Myxomata,	348
Carcinomata,	349
Antrum,	351
VI. ANOMALIES OF THE SECRETIONS,	354
Saliva,	354
Coating upon the Teeth,	357
Tartar, Odontolithus,	361
Caries of the Teeth,	367
Appearances presented by the Enamel in Caries,	376
Appearances presented by the Dentine in Caries,	384
Appearances presented by the Cement in Caries,	391
Extension of Caries to the Roots,	392
Caries of the different kinds of Teeth,	393
Frequency of Caries,	397
Effects of Carious Teeth upon the rest of the Body,	403
Caries of Reinserted Human Teeth,	404
Caries of Teeth made of Ivory from the Hippopotamus,	406
Experiments upon the Teeth with Various Substances,	407
Caries of the Teeth of Animals,	410
Theories of Caries,	411
VII. NEUROSES,	426
ALPHABETICAL INDEX,	445

INTRODUCTION.

IF it be asked, with reference to the history of dental science, why the doctrines of the latter have matured at a comparatively late period, the answer is obvious, namely, because its study was not pursued systematically as that of a natural science. Until about the middle of the last century, dentistry was almost exclusively in the hands of the laity, not of physicians, and was, and is at the present time, neglected by the latter as a sort of stepchild of surgery. The so-called dentists of former times had no knowledge of the discoveries of the great anatomists of the fifteenth and sixteenth centuries; indeed, it was not possible for them, since they did not have access to any scientific models, and consequently knew nothing about them. They took no pains to determine the simplest matters of fact; disputed as to the number of teeth possessed by men and women, respectively. The belief was prevalent for a long time that the milk teeth have no roots. The renowned French dentist, P. Fauchard (1728), (Carabelli, *Geschichte der Zahnheilkunde* and Linderer's *Zahnheilkunde*), and later, Bourdet (1757), endeavored, upon anatomical grounds, to disabuse men of this erroneous idea; nevertheless, forty years afterwards, I am sorry to say, we read in German writings that the milk teeth have no roots, but are capable of giving off roots, if they are not detached at the proper time. The great J. Hunter, Fox and his pupils, were the first to follow a system of natural science and to initiate unprejudiced and trustworthy methods of observation, while Germany, during the preceding and in the first decade of the present century, took scarcely any share in the progress of dental science.

If we call to mind the history of the forceps, we now wonder,

and with reason, that people ever ventured to extract teeth without having informed themselves beforehand with regard to the construction and arrangement of the crowns and roots in the jaw, &c. Indeed it is the fact, that they ventured only with great reluctance to extract a tooth for more than a thousand years after Celsus. Notwithstanding the manifold improvements, during the preceding and commencement of this century, in the art of extracting teeth, it was not until our own time, principally through the exertions of J. Tomes, Richardson and others, that the mechanism of the forceps was accurately adapted to the separate teeth, in the upper and lower jaw, on the right and left side, and to their arrangement in the jaw, so that now there is danger of fracturing the tooth, its socket, or the jaw, in exceptional cases only.

It is conceivable that, in consequence of the danger attending the extraction of teeth, a great variety of expedients were employed for the benefit of the unfortunate patients, and that attempts were made to ascertain the causes of the pain. In the absence of all anatomical and physiological knowledge, the gnawing and piercing pains seem to have given rise to the idea of the presence of parasites. The fringes of the thickened periosteum of the root, or the root pulps, which remain attached to teeth after their extraction, may have given weight to the hypothesis that worms are developed within the tooth and give rise to the pain. Indeed, it was said, worms might originate at any part *per generationem æquivocam*. This hypothesis held possession of men's minds during the seventeenth century, and still prevails among the common people whose character for implicit belief in traditions is by no means eradicated. The belief in the existence of the worms was so general that, in 1757, J. Ch. Schäffer, of Regensburg, published a monograph, entitled "The Imaginary Worms of the Teeth," wherein he proved that the existence of these worms is a chimera, and that the so-called tooth-worms, which fall from the teeth after fumigation with winter-cherry and wax, are nothing but the volatilized germs of the winter-cherry seed-corns. Thus dentistry prolonged a wretched existence, depending for its support upon popular tradition.

The instructors in the old universities trod, for the most part, in a beaten track of doctrine which was based upon faith in authority, but when, in the study of the natural sciences in general, inquiries were instituted with reference to the connection of cause and effect between separate phenomena, and the latter were subjected to the most searching analysis and referred to fundamental laws of general application, then the natural sciences made such comparatively rapid strides that they soon invaded every branch of human knowledge. As the mass of material to be digested accumulated, the necessity of a further and further division of labor in the field of natural sciences became apparent, and from this principle of division has resulted, among others, the branch of dental science; this was elevated to the rank of a special study, and demanded, therefore, special instruction, which, in England and the United States of America particularly, has attained a high degree of excellence. During the last ten years, thanks to the exertions of individuals, dentistry has entered upon a scientific career in Germany, and there is reason to expect that it will soon be rescued from the realms of mere empiricism.

While we recognize fully the endeavors of those of former times to aid their suffering fellow-beings with the means at their command, it must, however, be conceded that it was not until modern times that the reach of thought was broad enough to enable men to establish a truly scientific basis for a rational system of therapeutics. Anatomy and physiology, the guiding stars of pathology, have by degrees shed their salutary light upon dentistry, and afforded an insight into the life of the tooth, though, to be sure, it is only partially satisfactory. Bearing this in mind, I have deemed it advisable to preface the Pathology with a section upon Anatomy and Physiology.

THE
PATHOLOGY OF THE TEETH.

PART I.
ANATOMY AND PHYSIOLOGY.

THE dentist is occupied specially with the cavity of the mouth, a thorough knowledge of which is indispensable to him, and by the consideration of which, from his standpoint, much is elucidated which the anatomist cannot touch upon without interfering with his more general plan. It does not come within the scope of the present work to enter into full anatomical descriptions, but the object in view necessitates rather references to details which receive only slight, if any, notice from the anatomist, but which acquire importance in dentistry.

With regard to the physiological portion of our subject, which is connected so intimately with the anatomical portion that the two cannot conveniently be considered apart, our knowledge has not made very marked progress since, in the investigations into the individual life of the tooth, many difficulties are to be contended with, and extensive, subtile researches are requisite. Many of the latter have already been made, but, at present, their results are widely scattered and do not yet admit of incorporation into a profitable whole. The advances made in our knowledge of the laws of embryonic development have indeed cleared up many obscure points, yet the theory of the complex animal-cell-life still rests upon widely diverging hypotheses and mostly arbitrary interpretations.

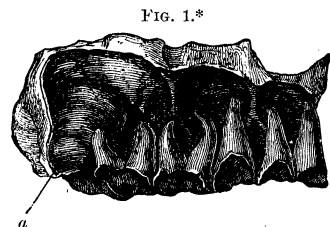
The bony framework of the cavity of the mouth is formed,

laterally, by the alveolar portions of both jaws, and, above, by the palatal plates of the upper jaw and palate bone.

The alveolar process of the superior maxillary bone forms a projection from the inferior portion of the body of the jaw, in the form of a comb, and, upon the inside, is in relation with the palatal plates of the upper jaw and palate bone. It incloses a row of cells which are arranged in the form of an elliptic arch and serve for the reception of the roots of the teeth.

Each *tooth-cell* (*alveolus*) is composed of a finely porous, compact plate of bone which, when it is perfectly formed, is sunk into the spongy tissue of the jaw, in the form of a cul-de-sac or funnel, and, towards the open extremity, comes into intimate relation with the cortical substance of the bone. At the closed extremity of the cell, there are a few quite large foramina which lead to the alveolar canals, and serve for the passage of the dental nerves and vessels. These relations may be demonstrated most clearly in the jaws of children by the careful removal of the facial wall, together with the spongy tissue, so that the cells and their delicate attachments to the cortical substance of the bone at their open extremities are exposed to view. The cells then are presented in the form of clearly defined, conical

prolongations of compact bony tissue (Fig. 1). Again, if longitudinal sections be made through the teeth and jaw of an adult before he has attained to old age, it will be seen that the root lies within a quite firm bony capsule with thin walls, which dips down from the



alveolar border, and is surrounded by a very lax, spongy, bony tissue.

* Fig. 1 shows the alveoli of milk teeth of the right segment of the upper jaw, from which the investing spongy bony tissue has been removed, and also the rounded alveolus (*a*) of the first permanent molar. The facial wall of the alveoli does not extend so far downward as the lingual wall, and presents an excavated, crescentic margin; the third or lingual roots of the two milk molars do not appear in the section. The posterior external root of the second milk molar rests upon the convex surface of the alveolus which incloses the crown of the first permanent molar. Natural size.

The number of sockets corresponds with that of the roots of the teeth. Teeth with one root have a single socket, while those with more than one root have sockets composed of two or three cells, according to the number of roots. As the cells are casts, as it were, of the roots, they correspond with the latter in form and direction, and the ridge-like elevations of the cells fit into the furrows in the roots.

The alveoli are separated from each other by bony *septa*, which increase in thickness towards the apices of the former, and upon the alveolar border present a few foramina, which are most conspicuous in the jaws of young persons, for the passage of the interalveolar vessels and nerves. The cells of the compound alveoli, moreover, are separated from each other by additional *septa* for each root. Hence, in the cells for the upper teeth with three roots we find, in addition to the anterior and posterior primary *septa*, two secondary *septa*, one of which has an antero-posterior direction and the other extends from the outside towards the inside. The anterior or facial festooned border at the free extremities of the sockets is excavated more deeply than the posterior or lingual border.

The border of the alveolar arch of the upper jaw from a young adult, when viewed from the facial side, presents a double curve, namely, one with a downward inclination, from behind forwards, with the convexity directed downwards, and one extending upwards towards the anterior segment of the arch, and with its concavity directed downwards. Upon the lower jaw the relations of the serpentine curve are the reverse of the preceding, *i. e.*, the convexity of the upper corresponds to the concavity of the lower arch. This undulatory curve is scarcely perceptible on the alveolar arches of old people or young children.

The external or facial wall of the alveolar portion of the upper jaw is thinner and more yielding than the internal or lingual wall, and from the former project oblong folds which are produced by the subjacent roots of the teeth. These may be felt distinctly even during life, and afford some evidence with regard to the size and direction of the roots. They are the so-called *juga alveolaria*. Not unfrequently a portion of the alveolar wall is wanting, together with the corresponding portion of

the dental socket, and the root of the tooth is exposed in the oblong opening.

The body of the upper jaw incloses a cavity of great importance to the dentist on account of the diseases which have their seat within it. This is called the *Maxillary Sinus* or *Antrum of Highmore*; its floor is situated above the sockets of the molars and second bicuspid, and its roof is formed by the inferior portion of the wall of the orbit. The anterior and posterior walls are formed by the corresponding surfaces of the jaw. The internal wall towards the nasal cavity presents an aperture which communicates with the middle meatus of the nose and is contracted considerably by the inferior turbinated bone and by portions of the ethmoid and palate bones. The floor of the antrum frequently presents conical processes, which are occasioned by the projection of the apices of the roots of the above-mentioned subjacent teeth, and also one or two more or less prominent laminae by which the bottom of the cavity is divided into compartments. The root of the second bicuspid tooth is situated beneath the anterior smaller division of the cavity. The antrum belongs to the system of communicating cavities which are lined by the nasal mucous membrane, and, in common with which, it is frequently the seat of disease; it forms a portion of the respiratory apparatus.

The *inferior maxillary bone*, the *lower jaw*, is curved in the form of a parabola, and consists of a body and two extremities; the latter ascend in vertical planes and are called the rami or branches. Both the body and the rami present for examination an external or facial and an internal or lingual surface, directed towards the cavity of the mouth. On the external surface of the body, equidistant from the median line on either side, is a roundish, occasionally transversely divided foramen which communicates with the inferior dental canal, and is called the anterior or external orifice of the latter (*foramen mentale*). It is situated six to ten millimetres below the alveolar border, usually in a perpendicular line drawn between the first and second bicuspids, and not infrequently a little more anteriorly or posteriorly, beneath the first or second bicuspid.

Extending obliquely upwards from the vicinity of the first

molar is a well-marked ridge, the *external oblique line*, which is continuous with the anterior border of the ramus, and near the posterior segment of the alveolar process is bounded by a shallow groove. The corresponding portion of the external wall of the lower jaw is rendered thicker and less yielding by this prominent ridge, a condition of practical importance to the dentist.

The internal surface presents, opposite the median line, a rough eminence, the internal mental process (*prominentia mentalis int.*). Upon either side of this process commences a ridge, the *internal oblique line*, which extends obliquely upwards towards the molar teeth, and serves to give strength to the alveolar process upon the lingual side of the jaw, and for the attachment of muscles.

The inferior border of the lower jaw is rounded, and above it rises the alveolar process, which in adults contains sixteen alveoli for the reception of the teeth. The last three alveoli on either side are compound, each being divided into two secondary cells by an additional septum. The alveolar process of the lower jaw describes a parabolic curve, and its posterior extremities are separated by a wider interval than are those of the upper jaw. This inequality, which would not permit the mutual adaptation of the teeth, is compensated for by the fact that the superior alveolar process has an outward inclination throughout its whole extent, while the lateral portions of the inferior process are inclined inwards, and hence the teeth preserve a corresponding inclination. As has already been stated, the facial wall of the superior alveolar process is thinner and more elastic than the lingual, but this is true of the facial wall in the lower jaw only as far as the region of the first molar, beyond which point the lingual wall is thinner than the facial. The concavities of the festooned alveolar border of the lower jaw are directed upwards, and the septa between the alveoli project beyond the level of the latter.

The rami of the inferior maxillary arch, forming obtuse angles with the body, extend obliquely upwards and a little outwards, and each terminates in two processes separated by a crescentic notch; the anterior or coronoid process rises behind the last alveolus, frequently encroaches upon the latter to a consider-

able degree, so that its lingual surface even not infrequently renders the upper wisdom tooth difficult of access; the posterior or condyloid process is of much greater importance; it terminates in a small, cylindrical, convex, articular condyle, the long axis of which is transverse. The long axes of the two condyles are not horizontal, but are inclined somewhat obliquely upwards and backwards, so that if prolonged they would meet at an angle of about 150° . Articular condyles, however, are met with whose long axes are nearly horizontal.

The lingual surface of the ascending ramus presents the posterior or internal orifice of the inferior dental canal, partially covered in front by a small bony plate, the spinous process of the lower jaw. The inferior dental canal commences at this opening, and, decreasing in size, extends through the body of the jaw beneath the alveoli, terminating at the mental foramen, and is lined by a thin lamella of bone, finely porous upon its inner surface.

The *articulation of the lower jaw*, by means of which the approximation of the two jaws is effected, has recently been made the subject of special investigation by C. Langer.* The articular or glenoid fossa of the temporal bone is formed partly by the squamous portion and partly by the vaginal process or tympanic lamina of the latter, and is smooth only upon its anterior portion. In front of the fossa is the *eminentia articularis*, the whole of which is concerned in the formation of the joint, and usually is obliquely disposed. The interarticular cartilage (*meniscus interarticularis*) is a biconcave plate which is inserted between the articular eminence above and the condyle below, and is connected with both bones. The edges of its smooth surfaces are attached upon either side to the articular capsule, so that the joint is divided into two cavities. The only proper ligament of the joint is situated externally, the *ligamentum laterale*, which is attached above to the root of the zygoma and below to the neck of the lower jaw.

The mobility of the lower jaw is limited. The movements of the two joints are simultaneous and take place in three direc-

* Sitzungsberichte der Wiener Akademie, 1860, and Lehrbuch der menschlichen Anatomie, 1865.

tions, namely, forwards or backwards (sagittal), from side to side (horizontal), and downwards (frontal). In the latter, the articular condyle glides upon the articular eminence and the chin is moved downwards in the arc of a circle.

The *movements in mastication* are accomplished by four pairs of powerful muscles, two of which are attached to the external, and two to the internal surface of each ramus of the lower jaw. They are the masseter, temporal, external, and internal pterygoid muscles. C. Langer* investigated their actions, which he describes as follows: "The masseter, temporal, and internal pterygoid muscles elevate the jaw and press the lower dental arch against the upper. Their only antagonists are the hyoid muscles and the platysma. The external pterygoid exerts no action in a vertical direction, but draws the jaw and the meniscus forwards in a horizontal plane and assists, therefore, in the forcible opening of the mouth; hence, in the latter respect, it is an antagonist of the first mentioned muscles and cannot act in unison with them except in moving the jaw forward when it is closed. On the other hand, the three elevators are required to move the jaw backwards, since their action has a tendency in a direction from in front backwards and in a horizontal plane. Symmetrical contractions give rise to the sagittal movements; asymmetrical movements, to either side, require the contraction of the muscles upon one side alone, and, as it appears, the action of the external pterygoid is the principal element in the production of this movement."

The three principal movements of the lower jaw admit of an endless variety of modifications in which the different kinds of teeth variously participate. As a general rule, the movements of the front teeth are more extensive than those of the back teeth. In the lateral movement, the teeth of one half of the lower jaw are displaced to the outside of the corresponding teeth of the upper jaw, while the teeth of the other segment are removed to an equal distance towards the median line. The extent of the lateral movements of the teeth bears a definite relation to the construction of the articulation of the lower jaw, and is diminished with the more horizontal position of the

* Anatomie S. 238.

articular condyle. In the latter cases, approximation of the jaws is effected with the teeth more nearly in a perpendicular plane. The difference in the extent of the movements of the front and back teeth, respectively, is most noticeable in the frontal movement, while in the sagittal it is scarcely perceptible.

The three different movements employed in mastication pass into each other, but these transitions are impossible while any one movement is exercised to its maximum degree. In biting, the frontal movement is employed; in cutting, the sagittal, and in triturating the food, all three movements occur in rapid succession.

The entire mechanism of the act of mastication acquires a still more complicated character when the undulatory curves and the inclinations of both the upper and lower rows of teeth are taken into consideration. In consequence of these, the movements of the separate teeth are variously modified. The mechanism, also, is advantageous for the purpose of fixing the morsels which are to be triturated.

GENERAL CHARACTERS OF THE TEETH.—All the teeth may be considered as wedges. These assume the most varied forms in the animal kingdom, and occur in the form of chisels, sharp-pointed or blunt, narrow or broad, long or short, rounded or laterally compressed cones and plates; their forms are either simple or compound; the long conical teeth, in some cases, serve as weapons of offence and defence. By the interlocking of the wedges of the lower jaw with those of the upper, and the powerful action of the muscles of mastication, solid articles of food are crushed. Portions which escape uncrushed are replaced again between the wedges by means of the action of the tongue and the muscles inserted into the sides of the mouth. By these means, assisted by the mucous and salivary secretions which are abundant during the process of mastication, the solid food is converted to a pulp suitable for deglutition.

The *specific gravity* or *density* of the teeth varies considerably. At my request, Dr. B. Kopezky examined sections of fourteen teeth, four deciduous and ten permanent teeth, with reference to this point. In the former, the density varied from 1.09 to 2.17; in the permanent teeth he found a variation between 1.98

and 2.53, amounting, therefore, to 0.55. The lowest sp. gr. was afforded by a much worn upper molar with horny translucent roots and containing a dentinal new-formation which completely filled the pulp-cavity; the greatest density was found in a much worn bicuspid. The permanent teeth showed an average density of 2.25. These summary statements, based upon the examination of a small number of teeth, cannot be regarded as conclusive, and are merely intended as an incentive to more extended investigations with reference to varieties in individuals and at different ages.

The *hardness* of the dentine of human teeth is placed by Kopecky between 5 and 6 in Moh's scale,* *i. e.*, between apatite and felspar; the enamel, which emits a spark with steel, ranks with 7 in the order of hardness.

The property of *cleavage* may be demonstrated in the crowns and roots of teeth by means of the vice, and in teeth which have been dried and treated for a considerable time with dilute hydrochloric acid; they split in certain directions which are determined by the fact of their possessing single or multiple papillary elevations. Incisors, especially the hard and brittle ones of old people, are well adapted to show this property; it is not an uncommon occurrence for these to break into median and lateral halves, merely from compression exercised with slowly increased force upon the prominent portions of the facial and lingual surfaces. A similar division of round, straight roots may be effected, but this is impossible with curved roots, as will be evident, except in those in which the curve is very slight. Crowns which are flattened upon either side split in a direction corresponding with the greatest transverse diameter. A case came under my observation in which the cleavage of all the teeth in the lower jaw of a large dog was shown in a very marked manner. The lower jaw was dried and placed in dilute hydrochloric acid; decalcification ensued slowly and, finally, the previously scarcely perceptible cracks in the enamel became gaping

* Moh's scale of hardness is the following: 1, talc; 2, gypsum or rock salt; 3, calc spar (or any cleavable variety); 4, fluor spar; 5, apatite (crystallized); 6, felspar (any cleavable variety); 7, limpid quartz; 8, topaz; 9, sapphire or corundum; 10, diamond.—Trs.

fissures, extending to the bottom of the crowns. The crowns of the incisors were separated into symmetrical median and lateral halves, those of the canines, into facial and lingual halves, and the coronal denticles of each molar were divided into equal segments from their apices to their bases.

The cracks or fissures, which are observed frequently in the enamel during life and are considered at length in the subsequent pages, sometimes occur in the above-mentioned planes. The reason for the splitting upon the median line is to be found in the symmetrical development of the two halves of the tooth.

The teeth, together with the bony tissue partially investing them, have a high degree of *elasticity*, in consequence of which they may be subjected to marked compression and still return to their previous condition upon the removal of the source of the latter; these physical properties appertain to the dentine in particular, which, in addition to a solid structure, presents a delicacy of texture that admits of a high degree of tension.

CLASSIFICATION OF THE TEETH.—The teeth present an enamelled and a non-enamelled portion; the former is visible in the cavity of the mouth, and is called the *crown*; the latter is wedged in the alveolus and is called the *root*; the portion between these two is described commonly as the *neck*. The discrimination of the neck of the tooth, however, is more practical than it is theoretically correct, since the neck cannot be determined except while the tooth is implanted in the jaw; it is really that portion of the root, just above the edge of the socket, which is invested by the gum. Upon a detached tooth, then, that portion may be designated as the neck which is in immediate proximity to the terminal border of the enamel. The distinction of this portion is of practical importance to the dentist, since he applies his instrument to this part in the extraction of teeth.

The classification of the teeth is based upon their locality, duration, and external form. In reference to their locality, the teeth are divided into those of the upper and those of the lower jaw; the former being called the *upper*, and the latter the *lower* teeth.

The human race is supplied with two sets of teeth; those which first make their appearance exercise their functions during

a few years only, while the second set is intended for service during the remainder of life; hence, in reference to their duration, they are divided into *milk*, *temporary* or *deciduous*, and *permanent* teeth. The milk teeth are twenty, and the permanent teeth thirty-two in number; twenty of the latter occupy the places of the previous milk teeth, and are termed *permanent renewed* or *substituted teeth*, in contradistinction to the twelve which have no predecessors, and therefore are described as *permanent unrenewed* teeth.

It is customary with dentists to divide the permanent teeth into four kinds, according to their form, namely: *incisors*, *canines*, *bicuspids*, and *molars*. In anatomical manuals, frequently only three kinds are distinguished, incisors, canines, and grinders or molars; the latter being divided into small and large molars. Hunter, however, divided those previously called grinders into two kinds, bicuspids and multicuspid, upon anatomical and physiological grounds, and since that time this more rational nomenclature has been adopted by dentists. The milk teeth are divided into incisors, canines, and molars, but it is to be borne in mind that the latter differ in respect of their construction from their permanent successors, and are to be classed rather with the permanent unrenewed molars and, therefore, they are described sometimes by English dentists as temporary multicuspid or molars.

The following surfaces are distinguished usually upon the teeth: facial (labial or buccal), anterior or external, and lingual, posterior, or internal. The contiguous surfaces of adjacent crowns receive different names from authors: inner and outer, anterior and posterior, medial and lateral, or mesial and distal.*

DESCRIPTION OF THE TEMPORARY AND PERMANENT TEETH.—It is convenient to commence with the description of the *permanent teeth*, since, in this way, that of the milk teeth will be shortened considerably. †

* Comp. Tomes's System of Dental Surgery, 1859, p. 38.

† Carabelli (Anatomie des Mandes, 1841) was the first to make extended investigations into the structure of the teeth, with reference to the needs of the dentists. E. Mühlreiter has recently published a minute description of the human teeth with special reference to the requirements of mechanical dentistry. (Leipsic, 1870.)

The *incisors*, considered collectively, present common peculiarities; they have, namely, a wedge, or shovel-shaped crown and two inclined surfaces which form, by their junction, a cutting edge; the anterior or labial surface is slightly convex, the lingual or posterior presents a corresponding concavity; the lateral surfaces are thin and triangular in shape; the enamel cap extends to a greater distance towards the root upon the labial and lingual than it does upon the lateral surfaces. The cutting edge of the crown in recently cut incisors always presents three, more or less prominent eminences, the middle one projecting the most. These are short and blunted, and disappear as soon as the teeth are brought into use. They have single roots.

Upper incisors.—These are larger, more convex upon their labial, and more concave on their lingual surfaces, and, in general, have a more rounded form than the lower incisors. Their labial surfaces increase in breadth towards the cutting edge, and are convex in each direction. The transverse convexities of the teeth upon the right and left side respectively face in opposite directions, so that the surfaces of the teeth upon the right side are directed to the right; those upon the left side, to the left, and in this way the anterior convexity of the dental arch is produced. The lingual surfaces present a corresponding arrangement of the arches. A pit in the enamel is met with frequently in the upper portions of the lingual surfaces, particularly of the lateral incisors; this communicates with a groove, and frequently is the seat of the commencement of caries, though in this connection it is very likely to be overlooked.

The crowns of the right and left upper incisors, in addition to the above-mentioned arrangement of their arches, are distinguished by their angles. The two angles formed by the junction of the gradually narrowing lateral surfaces with the cutting edge, are not uniform. Upon the right incisors, the distal lateral surfaces join the corresponding incisive edges by means of a gentle curve, while the mesial lateral surfaces and the edges form sharp right angles. Upon the left incisors the relations of the angles are exactly the reverse of the latter; hence, from these data alone, it is possible to distinguish a right or left

incisor. Well-formed incisors have single roots, which are conical, straight, and afford circular transverse sections. Now and then their terminal portions are bent, in which cases the apex is directed posteriorly towards the adjacent tooth, *i. e.*, the apex of the right central towards the right lateral, that of the left central towards the left lateral, &c. This observation is applicable not only to the upper incisors, but to all the permanent teeth.

The lateral upper incisors present, in general, all the characteristics of the centrals, but differ from them, however, in the relation of the length to the breadth; while they differ but little in length, the breadth of the laterals is a third less than that of the centrals, so that the former present a more slender appearance than the latter; their edges, moreover, are not so sharp, and they are, generally, more rounded than the latter.

The connection of the upper incisors with the alveolar process may be shown by means of vertical sections through the middle of the tooth and jaw (Fig. 2). The anterior or facial wall of the compact process is found to be much thinner than the lingual, and the latter becomes thicker from below upwards.

Lower Incisors.—These are smaller than the upper, the convexities and concavities of their surfaces are less decided; they do not present the gentle curve at the outer or lateral angle of the incisive edge, and consequently lack this element of distinction between the teeth of the right and left sides. The laterals, moreover, are broader than the centrals, differing in this respect from the upper teeth. The side to which a lower incisor belongs can only be determined by the curvature of its surfaces, which, as observed above, is not very decided, and the distinction therefore requires considerable practice. It is more difficult to distinguish the centrals than the laterals. The roots are single, flattened upon the medial and lateral surfaces, and grooved longitudinally.

FIG. 2.*



* FIG. 2.—Vertical section through the middle of a right upper central incisor, showing the connection of the latter with the alveolar process; behind the latter appears the incisive canal in an oblique position. Natural size.

Canines (dentes cuspidati).—These have a strong club-shaped crown, terminating in a point. The labial surface is convex and divisible into two equal portions, a medial, more convex, directed towards the lateral incisor, and a lateral, more flattened, directed towards the first bicuspid. The lingual surface is slightly concave, and inclined towards the labial. The lateral surfaces of the crown also are convex; the medial, towards the lateral incisor, is moderately arched, the lateral, towards the first bicuspid, is still more convex, the latter forming a blunt protuberance. The canines have a single root which is distinguishable from the roots of the rest of the teeth in the set by its greater length; the roots of the upper canines are somewhat longer than those of the corresponding lower teeth; the axes of the roots describe a slight curve with the convexity directed towards the lips. The apices of the roots are inclined more or less towards the posterior adjacent tooth. The roots are flattened somewhat upon either side and grooved; the lateral grooves upon those of the lower teeth are deeper than those upon the upper teeth. The root canals of the upper canines are oval in shape, those of the lower are more compressed from either side and present a more or less marked incurvation.

The right and left canine teeth are distinguished by the greater arch of the medial halves of the labial coronal surfaces, which look toward the lateral incisors, and especially also by the curvature of the labial surfaces, which is in opposite directions upon the teeth of either side.

Bicuspids (dentes bicuspidati).—These have crowns essentially different from those of the teeth which have already been described. The masticating surface is uneven, and is divided by a groove which extends from the front to the back, into two pointed tubercles or cusps, of which the outer is the larger. The masticating surface of the crown is bounded by four surfaces, which run into one another without forming edges. The outer or buccal and inner or lingual surfaces are rounded. The lateral surfaces, which comprise the anterior (medial or mesial) and posterior (lateral or distal), are somewhat flattened. The crowns of all bicuspids are slightly inclined from before backwards. The buccal or external surface of the crown of

each upper bicuspid is indicated by the greater convexity of its anterior or medial segment, while its posterior is more flattened and inclined, and by the fact that the posterior coronal surface is somewhat more convex than the anterior. Their roots are more or less flattened, often single, smooth, and frequently are traversed in their length by a groove, and sometimes are divided more or less deeply at their extremities, this division occurring more frequently in the first than in the second bicuspid.

The crown of the first lower bicuspid resembles that of the adjacent canine tooth, inasmuch as the outer or buccal cusp projects more than the inner, and hence the masticating surface has a more oblique direction toward the median line. The second lower bicuspid has a larger, more spherical crown, and both cusps are of nearly equal size, so that the first and second lower bicuspids may easily be distinguished. The inner cusp is sometimes furrowed, giving the appearance of two inner cusps with corresponding depressions. Transverse sections of the lower bicuspids are oval in shape.

The masticating surfaces of the upper bicuspids are divided by a deep groove extending from before backwards; the outer cusp is somewhat larger and more prominent than the inner, which is rounded on the lingual surface.

Not infrequently the first and second upper bicuspids cannot be distinguished when separated from the jaw, but those of the right or left side may be recognized by the more decided curve of the anterior segment of the facial surface of the crown, by the more flattened and larger posterior segment of the same surface, and by the larger buccal cusp of the crown.

The *molars* have a quadrilateral crown, surmounted by several tubercles or cusps, and two or three roots. The *upper* molars have irregularly four-sided rhomboidal crowns. The outer and inner coronal surfaces are convex, the latter, indeed, to a considerable degree; the surfaces looking toward the adjacent crowns are flattened. The upper surface is surmounted generally by four tubercles or cusps, separated from each other by three grooves. One extends from the anterior to the posterior margin of the crown, and forms a continuation of the groove upon the upper surfaces of the bicuspid teeth. The other two extend

from the middle of the outer and inner margins of the crown respectively without coming in contact; the outer furrow is directed obliquely forward and the inner obliquely backward, forming a flattened bow. In this way four tubercles are formed, of which the front pair is the larger. The rhomboidal grinding surface presents two acute angles, one directed forwards and outwards, and the second backwards and inwards; and two obtuse angles, one directed forwards and inwards, and the other backwards and outwards. The side to which each upper molar belongs may easily be determined by observing these angles, together with the convexity of the outer surface, and also by the fact that the anterior inner cusp is the largest. Sometimes only three cusps are observed, at others there are five, and, in the latter cases, the larger number is found in the outer row.

The upper molars have three roots. One springs from the inside of the crown and is rounded, while the two proceeding from the outside are flattened. The anterior external (facial) is broader and longer than the posterior external root. The three diverge, and the inner or lingual root is inclined towards the palate, while the other two, situated one behind the other, are turned towards the outer wall of the jaw. Hence, by the arrangement of the roots a right or left upper molar may easily be recognized, even without examining the crown.

An additional cusp sometimes is met with upon the inner wall of the crown, which, during the eruption of the tooth, frequently pierces the gum toward the palate, and gives the appearance of the emergence of a second tooth. The first molar is the largest, the third, or wisdom tooth, the smallest. The cusps of the latter frequently are stunted, and the three roots seldom perfect, their development being interfered with from want of space. The roots appear, therefore, as if compressed together, or are indicated merely by grooves. The roots incline backwards.

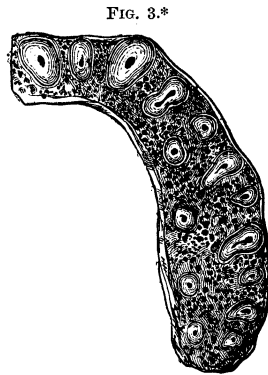
The *lower* molars have a rectangular quadrangular crown and only two roots. The upper and lower molars may therefore be distinguished either by their crowns or roots. On the upper surface of the first molar are found five cusps, three of them in an outer row, two in an inner; of the three outer, the

anterior is the largest, the posterior the smallest, and, therefore, by this arrangement of the cusps the crown of a right or left first molar can be recognized. On the upper surface of the second lower molar there are only four cusps, separated from each other by a crucial depression. The wisdom tooth frequently presents upon the surface of its crown the crucial depression with the four cusps, but quite often they are less distinct, and at times merely indicated by the existence of small rounded eminences. The outer or buccal are more convex than the inner or lingual surfaces of the crowns.

The two roots of each molar are flattened, grooved, and are placed in front and behind respectively. The anterior root is broader and longer than the posterior, and in connection with the easily recognized external surface of the crown, serves to distinguish the right and left teeth. The crowns and roots of the wisdom teeth are frequently stunted; the roots are commonly connate, curve backwards in the form of a hook, and not infrequently project into the coronoid process of the lower jaw.

Transverse sections of the jaw, at the distance of twelve to fourteen millimetres from the grinding surfaces of the teeth, afford an instructive view of the size, form, and position of the separate roots in relation to each other. With the exception of the lingual roots of the upper molars and the frequently cloven roots of the first upper bicuspid, they have an irregular oblong form, are broader on the facial and narrower on the lingual side.


In the upper jaw (Fig. 3), excepting the lingual roots of the molars and of the first or second bicuspid, all the roots are located quite near to the facial wall of the jaw, upon which surface they are broader.



* FIG. 3.—Transverse section of the right half of the superior maxillary arch, with the corresponding roots and root canals. This case is exceptional, since the root of the second bicuspid presents in this section two apices. Natural size.

The lingual roots of the molars and bicuspid are imbedded in the cancellated substance of the bone; sections of the central incisor and the canine have a rounded triangular shape; those of the lateral incisor an oval, and those of the first and second bicuspid, before their final occasional division into two apices, a biscuit [dumb-bell] shape. If the bicuspid have two deeply-notched roots, the buccal root is flattened and presents three

FIG. 4.*



rounded angles. The buccal roots of the molars are convex on the facial side, and considerably narrower on the lingual side; the lingual roots are nearly circular. In the under jaw (Fig. 4) the roots are arranged in a row, one behind the other, and are somewhat thicker on the facial than on the lingual side, the biscuit shape predominating. The roots of the incisors, canines, and bicuspid, and also the larger anterior root of the first molar, are pressed against the facial wall of the jaw; the smaller posterior root of the first molar and the roots of the second and third molars are placed in the middle of the jaw, equidistant from the

facial and lingual wall. The compact cortical substance is considerably thicker, the cancellated substance thinner than in the upper jaw.

The thickness of the roots corresponds exactly with that of the crown; that is, if the crowns are thicker upon one side, then the roots upon the corresponding side are also thicker. The larger projecting coronal cusps have thicker roots corresponding with them, as was observed in the case of the anterior buccal roots of the upper molars. The outlines of transverse sections of the root canals correspond with those of the roots.

TEMPORARY TEETH.—These, generally speaking, closely resemble the permanent teeth. A description of the crowns of the milk *incisors* and *canines* is unnecessary, as the preceding ob-

* FIG. 4.—Transverse section of the left half of the inferior maxillary arch and the corresponding roots and root canals. The posterior root of the wisdom tooth is abnormally formed. It should have a biscuit shape. Natural size.

servations in reference to the crowns of the permanent incisors and canines are equally applicable to those of the former. The milk teeth with single roots can only be distinguished from the corresponding permanent teeth by the generally roundish roots of the former and by their inclination in a direction opposite to those of the permanent teeth.

The deciduous molars alone deserve particular consideration. With children these teeth take the place of the permanent or true molars, and have the same general form. The first deciduous molar resembles the permanent bicuspid in form, while the second is an exact counterpart of a permanent molar. It is hardly necessary, therefore, to mention that the first molar is smaller than the second.

The *first upper milk molar* has a broad crown, is flat upon the anterior (medial) and posterior (lateral) surface, while the external and internal surfaces are convex. Projecting forward from the anterior half of the outer surface, near the neck of each tooth, a prominence is found, by means of which also they may always be recognized. The grinding surface presents two cusps, separated by a longitudinal groove, one of which is on the outside, the other on the inside.

The crown of the *second upper molar* has, on a smaller scale, exactly the form of the first permanent molar. All the upper molars have three roots, the position and shape of which correspond exactly with those of the upper permanent molars, except that the former are more divergent than the latter.

The *lower deciduous molars* have more elongated crowns, that of the first resembling somewhat that of a permanent bicuspid, while that of the second is very similar to the crown of the first permanent molar. The first are characterized further by a protuberance found on the outer surface of the crown, and by two small depressions on the grinding surface, of which the first is the smaller, both being surrounded by elevations of enamel. Upon the grinding surface of the second, the cusps are more distinct, and frequently five in number, three on the outside, and two on the inside, the anterior external one being the largest. The lower teeth, like the lower permanent molars, have two flat-

tened widely separated grooved roots, each of which is formed, as it were, by the blending together of two contiguous roots.

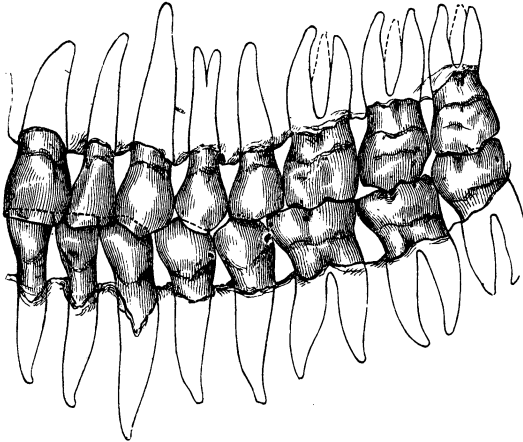
The *distinctions between the milk and permanent teeth* are found principally in their *color, form, and size*. The milk teeth present, even externally, the indications of a more delicate texture. They have a much whiter, even milk-white, color, and as the period for their detachment approaches, a bluish-white color. On the other hand, permanent teeth, particularly when they first appear, are of a yellowish shade, which passes into a decided yellow near the gum. This difference is much more noticeable if a milk tooth happens to be next to a lately cut permanent tooth. Milk teeth, as before stated, are also smaller in all their dimensions as they are placed in the still undeveloped jaws of childhood. Permanent teeth, when first cut, have quite as broad a crown as in later life, and therefore the difference in size between them and the milk teeth is much more striking. The cutting edges of the permanent incisors, as before stated, are divided into three blunted denticles by two notches; two shallow grooves also traverse the labial surfaces of these teeth, disappearing gradually toward the necks; these denticles and grooves can be seen only in young incisors, for they disappear from attrition in the course of a few years. These are also present in young milk teeth, but as they immediately wear away, their absence affords a quite positive basis of distinction between milk and young permanent teeth. One of the most notable points of distinction between the teeth of the two sets is afforded by the fact that the milk teeth, at the period of shedding the teeth, are considerably worn away, while the new teeth have very sharp edges and eminences. The roots of the deciduous molars diverge considerably, because they include the crowns of the permanent bicuspid between them, like a pair of tongs.

Arrangement of the Permanent Teeth.—In their normal condition, the two rows of teeth form two arches, lying one above the other, with their convexities directed forwards and their concavities backwards. When the mouth is closed the bicuspid and molars of the two rows are situated in the same perpendicular planes; the upper incisors and canines, on the contrary, are directed somewhat obliquely forwards, in a direction oppo-

site to that of the corresponding lower teeth, and project slightly beyond the latter. The intervals between the upper and the lower central incisors, and the two *frena labiorum* are in the median line.

The upper row of teeth forms a quite uniform, nearly semi-elliptical arch, with its posterior extremities drawn towards each other, while the lower teeth form a parabolic curve, narrower in front, the arms of which diverge posteriorly. The upper incisors, as a whole, are broader than the lower, and the upper canines also include a larger space than the lower, consequently the right anterior upper teeth do not stand directly over the corresponding lower ones, but the central upper incisor covers

FIG. 5.*



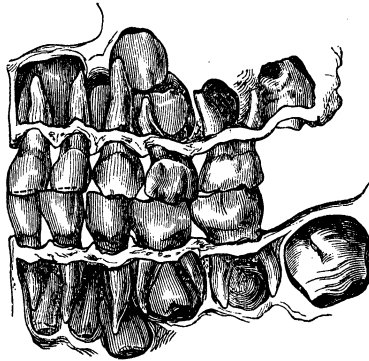
the whole of the edge of the opposite central and the medial half of the lateral lower incisor. The upper lateral incisor covers the distal half of the lower lateral incisor and the medial

* FIG. 5.—A well-developed set of permanent teeth, projected upon a plane in order to show the mutual relations of the upper and under teeth and the curve described by the upper and under rows of teeth. Facial view. The first five teeth in this case project over the under ones in a decreasing proportion, that is, the first upper incisor projects the most, and the second upper bicuspid the least; each of these five teeth also overlaps the tooth adjacent to its immediate opponent. The size of the crown of the first lower molar is such that the crowns terminate on the same line. Natural size.

half of the canine. The upper canine tooth is inserted between the lower canine and first bicuspid; the first upper bicuspid between the first and second lower bicuspid. But as the second upper bicuspid has a narrower crown than the first, while the reverse is true of the lower bicuspid, it is found usually that the first upper molar stands directly over the lower, and is in relation with only a slight portion of the edge of the second lower molar. Finally, as the upper wisdom tooth is generally smaller than the lower, it results that the complete dental arches are equal in length. Variations are of frequent occurrence.

The incisive edges and masticating surfaces of the two rows of teeth form *serpentine curves* which correspond with the previously mentioned wavy outlines of the margins of the alveolar

FIG. 6.*



processes, and are conformable to the variations in the lengths of the crowns. In the upper jaw this curve presents convexities downwards in the middle of the two lateral portions, corresponding to concavities directed upwards in the lower jaw, while

* FIG. 6.—A well-developed set of deciduous teeth, together with the crowns of the permanent teeth inclosed in their capsules, projected upon a plane. The three anterior upper milk teeth project over the lower ones. The upper canine overlaps the lower one somewhat posteriorly. As the crowns of the upper are smaller than those of the lower molars, the second molars terminate posteriorly upon the same line. The curves described by the upper and lower rows are evident, but are less marked than in the permanent set. Natural size.

the converse is true of the relations presented by the arches of the anterior portions of the jaws.

In the further description of the dental arches it may be mentioned that a single sharp edge extends along the summits of the three front teeth, while upon the bicuspids and beyond it is double and is formed by the two rows of cusps. Between these two rows a shallow groove extends backwards.

Generally the crowns diminish in length from before backwards, so that the incisors project the most, the wisdom teeth the least, from their sockets.

The arrangement of the milk teeth differs from that of the permanent, inasmuch as the second molars terminate the rows of the former posteriorly, and the deciduous molars generally have larger crowns than the permanent bicuspids. The three upper front teeth project over the lower to a comparatively less degree (Fig. 6).

THE HARD TISSUES OF THE TEETH.—Human teeth are composed of three separate tissues; the dentine (tooth-bone) constitutes the principal mass, while the remainder is composed of the enamel, which forms a covering for the crown, and the cement, which covers the root.

The *dentine*, *ivory* or *tooth-bone*, forms the principal part of the tooth, and gives to it its form, so that the different kinds of teeth may easily be recognized, even after the separation of the enamel and cement. Comparative histology also illustrates this fact, for in tracing back teeth of the animal kingdom to a rudimentary form in the order of their development, the dentine is found to occur earlier than the enamel and cement.

The dentine presents for consideration a peripheral or outer surface, which is in relation with the enamel and cement, and an inner surface which incloses the pulp-cavity or root canal, and has an organic connection with the pulp.

The elements which characterize the dentine are the dental canals or tubes imbedded in the basis-substance, which ramify in various directions from the inner surface toward the periphery. These canals gradually become more narrow as they approach the periphery and everywhere pursue a wavy course. In its course the principal canal divides dichotomously, at an

acute angle, into branches which also subdivide at regular intervals. At uniformly short distances from the periphery of the dentine the canals are divided into numerous minute branches; but throughout the entire course of the main tubes and their branches there occur also at short intervals quite numerous twig-like branches which ramify in various directions, in some cases forming transverse and oblique anastomoses with the neighboring canals, in others, connecting with each other by means of sharply curved loops. According to Welcker* the dental canals pursue a spiral course.

In order to obtain a definite idea of the great multitude of secondary branches, a thin section should be placed in pure Canada balsam, or slightly macerated in very dilute hydrochloric acid, when the delicate tubules, divided transversely and obliquely, will be brought clearly into view. Under very high magnifying powers the macerated portions present a foveated or honeycombed appearance. The question whether the fine tubules also terminate in free extremities within the basis-substance is difficult to determine. It is quite probable, however, that they form an inclosed system, from the fact that clearly defined anastomoses are so numerous.

Formerly the canals were considered to be mere cavities, through which circulated a fluid containing calcareous salts in solution, and an analogy was drawn between them and the canals of bone. Since, however, J. Tomes† has shown that each dental tubule is tenanted by a soft fibre, this earlier impression must be abandoned.‡

* Zeitschr. für rationelle Med. N. F. Bd. viii.

† Phil. Trans., v. 146.

‡ E. Neumann (Beitrage zur Kenntniss des normalen Zahn- und Knochengewebes) maintains the existence of special calcareous sheaths of the dental fibres. These he calls *dental sheaths*, and he asserts that they may be isolated, while he bases his opinion upon the ground that maceration or incineration destroys the fibres, and that the felted mass of filaments, which remains after the destruction of the basis-substance by means of hydrochloric acid, must be regarded as the persisting sheaths of the fibres. The correctness of this theory of the destruction of the fibres by maceration or by incineration I am inclined to doubt, until a distinction is established between the fibres presented in a non-macerated specimen of dentine and those which are isolated in one which has been subjected to the process of

The *intertubular* or *basis-tissue* of the dentine is so generally traversed by the dental canals that it is difficult to make a proper morphological analysis of it. It has the appearance of a homogeneous substance, with a double refractive power, which, after the extraction of the calcareous salts by means of hydrochloric acid, furnishes an organic residue resembling ossein, the so-called *dental cartilage*, which also possesses the property of double refraction. Whether the calcareous salts are present in the dentine in a crystalline form is a question upon which hardly anything is determined as yet. If a section of a tooth, that of a horse for example, be very slightly and carefully treated with acids, fine markings, perpendicular to the canals, are brought into view which may possibly imply such a condition.

The *globular masses* or *dentinal globules* are composed of an agglomeration of transparent, resisting, spherical bodies of various sizes, which, particularly with very young persons, occur upon the inner wall of the dentine; as a rule, also, upon its periphery, and almost always, to a greater or less degree, between the dentinal laminæ, and, therefore, may be designated as inner, outer, and intercalary globular masses. Where several dentinal globules are contiguous, they inclose a jagged space, *Ozermack's interglobular space*, which is filled with a substance, visible to the naked eye and called interglobular substance. The latter, with its jagged periphery, might be mistaken for a bone-corpuscle; on more careful examination, however, it will always be seen that the delicate ramifications of the bone canaliculi are wanting.

The dentinal canals are not everywhere uniformly arranged, but are separated more or less into larger or smaller groups by a homogeneous basis-substance, or by globular masses. The

maceration. The view which seems to me most plausible is that the dentinal fibres consist of a cortical, more dense, and a central vitreous substance, which latter dries up as soon as it is exposed to the air, so that the dentinal tubules become filled with air. The familiar luminous ring which, in transverse sections, is seen to surround the dentinal canals, and upon the theory of the existence of an isolable sheath, is interpreted as a calcareous dentinal sheath, in my opinion, is to be regarded as a homogeneous basis-substance, which invests the dentinal tubes like a sheath.

directions of the canals are often very plainly perceived in cross sections of the neck, and correspond with the laminated structure of the dentine. The globular masses inserted between the laminæ are often found in great abundance in otherwise perfectly normal human or animal teeth, and are then to be considered as evidences of interruptions in the regular process of development. Under the head of Pathology will be found a further consideration of the question, whether the globular substance represents a primary stage in the development of the dentinal tissue (globular formation), or an osseous tissue.

Comparative history furnishes two other dentinal formations which may be alluded to in this connection, though their consideration is included under the head of Pathology. They are the so-called *vaso-dentine* and *osteo-dentine* of R. Owen, described in his "Odontography." The first is characterized by a system of cylindrical vascular canals which, like the Haversian canals of bone, traverse the dentine and are connected with the bloodvessels of the pulp. The osteo-dentine is observed, generally, upon the surface of the pulp-cavity and seems to be a combination of irregular dentine with more or less accurately defined osseous tissue.

The *enamel* forms a hood-like investment of the coronal portion of the dentine, and is composed of a very hard, brittle substance, which is thickest upon the edges of the incisor teeth, and upon the cusps of the others, is less thick where it forms a lining to the coronal depressions, and becomes gradually thinner towards the commencement of the root, where it terminates abruptly, and is slightly overlapped by a rudimentary layer of cement.

The outer exposed surface of the enamel is everywhere smooth normally, but the inner surface, on the contrary, which unites with the dentine, presents everywhere slight irregularities. Upon the external surface, particularly in the teeth of young persons, and most plainly upon the labial surfaces of the front teeth, delicate ridges may be seen with a lens, running transversely, and separated from each other by tolerably equal intervals.

In the teeth of older people, or in those where the enamel is not regularly developed, these lines or ridges are less distinctly

or only partially visible, and sometimes are entirely imperceptible; the lingual surfaces of the enamel have, usually, the more polished appearance. In order to examine the dentinal surface, it is best, as recommended by Giebel, to corrode the dentine by a boiling fifty per cent. solution of sulphuric acid, by which means the enamel cap may be detached. If now the inner surface of the dried cap be examined under a sufficiently high magnifying power and with reflected light, a series of diminutive rounded elevations will be perceived.

The thickness of the enamel varies in the different kinds of teeth. On the front ones, it is somewhat thicker on the labial than on the lingual surface, measuring on the incisors nearly one millimetre, and on the canines somewhat more; on the bicuspids and molars the enamel is thicker than on the front teeth, and is thickest on the first molars. It attains its greatest thickness at the summits of the cusps, where it measures two, sometimes even three millimetres. The thinning of the enamel towards the roots is quite gradual on the front teeth, while on the back ones it terminates somewhat more abruptly, and presents a proportionately rapid increase in thickness.

The elementary organs of the enamel are calcified, cylindrical cells, blended together in their long diameters, so as to present the appearance of striated fibres—the so-called *enamel fibres*; in transverse sections, they present a polygonal appearance, on account of their being packed closely together, but occasionally are more or less rounded. These longitudinal chains of calcified cells are united into bundles which pursue a wavy course and decussate one with another. Therefore, in longitudinal and transverse sections of the enamel cap, longitudinal, transverse, and oblique sections of the enamel cylinders (enamel prisms) are met with.

Isolation of the enamel fibres may easily be effected by means of dilute hydrochloric acid. The fibres becoming swollen and varicous, present on the depressed portions an apparent transverse striation, and between the opposing contiguous portions, narrow fissure-like intervals remain which have given rise to the view entertained by some investigators that canals are found in the enamel. The appearances presented by a section in which

the fibres pursue a longitudinal course are particularly deceptive ; but with careful examination these intervals cannot be confounded with canals, for it will be seen that they have no branches and cannot be isolated. The intervening substance between the enamel fibres is transparent normally, but, in frequent anomalous conditions it presents, in many places, a foraminated, indistinctly granular appearance.

The calcareous salts are deposited in the enamel fibres in a crystalline form. If a very thin section of enamel be treated with largely diluted hydrochloric acid, the edge will be seen to become uniformly indented, and, as the action of the acid continues, a precipitation of acicular crystals ensues, which immediately redissolve. If cross sections of the enamel fibres are carefully examined after a slight action of the acid, they will appear to be filled with angular grains, which also are the needle crystals of phosphate of lime in transverse sections.

It is difficult to generalize the *direction* and *grouping* of the *enamel fibres*. They vary in different kinds of teeth and differ in the same tooth in accordance with the varieties in its formation. The fibres are of unequal length and thickness, and are collected together into bundles which decussate with each other so as to present in many places a felted mass. If sections in the longitudinal axes of the crowns of the incisors are examined, it will be seen that entire bundles which have fallen within the section are separated from each other by uniform intervals, while the latter are occupied by those which are cut across transversely and obliquely. A similar relation, in respect of arrangement, prevails throughout the entire enamel, and is more distinctly displayed in sections corresponding with the longitudinal axes of the coronal cusps of the bicuspid and molars. The fibres of the latter, however, in those portions where the enamel becomes thinner, not infrequently assume a parallel direction. The decussation of the bundles also affords an explanation of an optical phenomenon which is presented when such a longitudinal section of enamel is examined under the lens by means of very oblique reflected light, and with a dark background. Under such circumstances the transversely divided bundles are presented in the form of luminous striæ, while those

which are seen in their long diameters have an opaque appearance. The converse view is obtained with transmitted light. If we examine an entire set of teeth, it will be found that decussations of the bundles are most marked in portions corresponding to the papillary projections, a fact readily understood when it is considered that the directions taken by the formative enamel cells in their growth vary the most in localities where the greatest curvatures occur.

Transverse sections of enamel present a series of striations which follow concentrically the contour of the dentine. They are curved like a bow, are sharply defined, nearly equidistant from each other, and may be regarded as probably only an expression of the laminated mode of formation of the enamel.

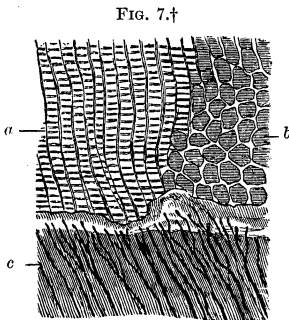
The enamel of the teeth of young persons is transparent in thin layers, and of a yellowish color. The color, however, presents numerous varieties which bear a certain relation to the durability and hardness. As a rule, it may be said that yellowish enamel is the most durable; its fibres also are more uniformly disposed. In this connection it would be well to ascertain whether the organic matters are not more abundant in the latter enamel than in other forms. A very durable enamel, has a uniformly dense, resisting texture, a smooth surface, offers considerable resistance to the action of a file, and has a certain degree of transparency. The enamel of whiter teeth generally is of more moderate strength, breaks more easily, and contains perhaps less organic substance. In teeth of chalky whiteness, it is often thicker and crumbles easily. In such cases the enamel contains an opaque granular mass which renders the recognition of its fibres impossible. Bluish-white teeth are the most delicate, and have a thin layer of enamel. Less durable enamel is of an irregular, less compact texture, which offers less resistance to the file, and with transmitted light thin sections of it are often clouded by dark spots, which appear white with reflected light.

Enamel frequently contains light or dark brown deposits of pigment. In the teeth of animals, this brown discoloration is observed sometimes towards the periphery of the enamel, at other times internally, near the dentine, and even the fibres are

impregnated with the coloring matter. The enamel of human teeth, also, contains light and dark brown pigment without the least trace of cohesion of the particles. The dark pigment is found also in the limiting or cortical substance of each enamel fibre, in consequence of which a transverse section of the latter presents the appearance of a circle of pigment. This cortical pigmentary deposit in the enamel fibres not infrequently reaches only to a certain depth in the layer of each fibre, and to this circumstance is to be ascribed the fact that the concentric striæ are more distinct in enamel containing pigment.

Enamel, as is well known, has a property of *double refraction*, which has recently been investigated by Hoppe-Seyler.* When fully developed, it exhibits negative double refraction, and positive while its development is in progress. By heating to 800°, the negative refraction becomes positive. Cross-sections of the prisms present no double refractive power.

The *junction of the enamel with the dentine* is effected by



a transparent, irregularly wavy, boundary layer which, in some parts, is encroached upon by separate dentinal canals (Fig. 7), and in others by elongated cleft-like cavities, of irregular shapes and different dimensions. Into these cavities, which are mostly filled with opaque, amorphous calcareous masses, one or another of the dentinal canals frequently enters.

Sometimes, though quite rarely, a terminal loop is seen in the hyaline boundary layer. These cavities penetrate more or less deeply into the enamel, and are found most commonly in parts corresponding to the incisive and masticating portions of the

* Virchow's Archiv, Bd. 24.

† FIG. 7 shows the line of junction between the dentine and enamel in a longitudinal section of an incisor. The enamel fibres are divided, partly in their longitudinal axes (*a*), and partly in a transverse direction (*b*). The boundary layer is irregularly wavy. The dentinal canals (*c*) present very delicate branches, which ramify toward the bordering layer. Magnified 500 diameters.

crown. Usually they run obliquely to the direction of the enamel fibres. They seem to occur more frequently in the teeth of elderly people, in which the crowns have been worn away partially by attrition.

If we take into consideration these circumstances, viz., the encroachment of the dentinal canals upon these bounding layers, the occurrence of oblong cavities inclosing dentinal canals, the penetration of these cavities only to a certain depth into the enamel, and their more frequent occurrence in old age, I think there is ground for considering this bounding layer, which becomes more evident in the teeth of larger mammals, as belonging to the dentine, and therefore for regarding the cavities as results of resorption of the dentine rather than of defects in the development of the enamel. If the crown of a tooth be subjected to the action of very dilute hydrochloric acid for about twenty-four hours, the delicate membrane, first observed by Nasmyth (*Nasmyth's membrane*), will be detached. It may, however, even without the employment of acid, be demonstrated by suitable sections of the enamel, as a transparent layer with a sharply defined exterior. The detached membrane is smooth upon its exposed surface; upon the internal surface, it is connected with the enamel fibres, between the rows of which it sends processes, and hence it presents, in many places, an impression as it were of the contiguous portions of the rows of enamel prisms. In the disposition of the pigment in the periphery of the enamel, these impressions become still more distinct. Kölliker, who designated the membrane the "cuticle of the enamel," found that it remained unchanged in boiling water and mineral acids. Waldeyer states that, when boiled with caustic potash or soda, it becomes softened; and when burned, it yields an odor resembling that of burnt horn. He was unable to detect any lime in it.

Cement.—This forms an osseous covering, shaped like a sugar-loaf, of the root portion of the dentine. It is thickest at the apex and gradually becomes thinner towards the so-called neck of the tooth. At the apex of each root it is reflected toward the internal surface of the canal of the root, upon the outermost portion of which it is disposed.

The external surface of the cement, in many young teeth which perhaps are quite normal, presents delicate transverse striations, which, to the naked eye, resemble the striations which may be seen upon the surface of the enamel. In other normal teeth, this surface is more polished or marked by very slight elevations and depressions which become more decided near the extremities of the roots.

Sections of normal cement, in which the outer surface is preserved intact, show that a mass of minute nodules, which may be termed the external calcareous-granular layer, forms the outermost stratum, directly beneath which appear the bone-corpuscles. This layer has an organic connection with the periosteum of the root or root membrane, and, as the development of the cement proceeds from the latter, this layer is to be regarded as representing the primary stage in the formation of the cement, analogous to the layer of dentinal globules on the inner surface of young dentine.

In the thicker portions of the cement the bone-corpuscles are disposed in numerous layers, one over another, which subsequently pass into a single row, and finally disappear altogether. They differ from true bone-corpuscles, inasmuch as they are generally somewhat larger, present a greater number of radiations, and a greater diversity of form and arrangement. The very numerous canaliculi given off from them immediately divide into branches at very acute angles, the two together presenting a tuft-like appearance. Sometimes the canaliculi radiate from the bone-corpuscles in parallel rows, and extend a considerable distance without forming a network. The form of these bone-corpuscles varies, being spindle-shaped, rounded, triangular or polygonal, pyriform, &c. Their arrangement also varies, the long axes of the elongated ones being parallel with sometimes, and at others perpendicular to that of the root of the tooth. Some are met with closely packed, one upon another, as it were blended together, and others which are far apart, and between the latter a considerable amount of inter-corpuscular substance is inserted, which sometimes occupies the entire field of view. This latter, particularly in the cement of old teeth, presents a finely lamellated structure, which may be

demonstrated by means of very dilute hydrochloric acid, or, still better, lactic acid. The thickness of the lamellæ, in portions adapted for observing them, is so slight as to be immeasurable, when viewed by ordinary methods, and they resemble the regular lamellation presented by the agate. In other parts the basis-substance is generally diffused, molecular or vitreous, homogeneous.

At the periphery of the teeth of old people, in which the cement everywhere, but especially near the apices of the roots, is thicker than in those of younger persons, bone-corpuscles are met with not infrequently, one, two, or more of which are invested by a clear, highly refractive layer. The radiation of the canaliculi takes place within this bounding layer, which presents a lobulated appearance when it incloses several corpuscles. This condition of the osseous substance evidently corresponds with a developmental stage, an interstitial growth, in which the resorption of the envelope of the bone-corpuscles has not yet taken place. Vascular canals frequently occur in the cement of old teeth, and at the extremities of the roots of younger teeth, also, one or another may be found extending from the surface of the cement through the dentine to the root canal.

If the cement be traced upwards towards the crown of the tooth, its transition into a mere rudimentary osseous substance may be observed. The separate rows of bone-corpuscles disappear and are succeeded by minute irregular cavities. The most striated portion of the basis-substance of the osseous tissue continues its course alone, and, decreasing in thickness toward the attenuated border of the enamel, it projects over the latter for a short distance. At this part, therefore, the hard tissues of the teeth, cement, enamel, and dentine, are joined together.

The dentine and cement are connected together by means of a layer composed of an agglomeration of transparent globules, and of varying degrees of thickness. The spaces intervening between the latter (interglobular spaces) are irregularly notched and frequently in very close proximity to one another; they are filled with an opaque, granular, calcareous substance, and very often are in direct connection, on one side with dental canals, and on the other side with the bone-corpuscles of the


cement. Sometimes this intermediate layer is very finely granular, and the spaces between the grains are exceedingly small. The cement proper commences outside of this layer, and its canaliculi rarely come into direct connection with the dentinal canals.

THE DENTAL PULP occupies the cavity of the crown and the canal of the roots of each tooth, and is the persisting germinal bed of the dentine, its organ of nourishment and sensation. Its exterior corresponds with that of the tooth, so that if it be isolated completely, its appearance alone will indicate to which kind of tooth it belongs.

The pulp is divided into the crown and radical portion. The former is provided with one, two, or more conical processes, which correspond with the tubercles upon the summit of the crown, and divides into as many radical portions as there are roots. The lengths of the conical processes of the pulp bear a direct relation to the height of the coronal cusps, and hence in the pulps of the incisors they are barely discernible as three, pointed elevations. The thickness of the pulp also corresponds with the exterior of the tooth, that is, the relatively thickest coronal portions are found in the canine and molar teeth; the radical portions are flattened within the compressed roots. With young persons the pulps are thicker than with the aged, and they decrease in thickness as age advances. The pulp is smooth upon its surface, of a yellowish, reddish-yellow, or even deep blood-red color, corresponding with the blood which it contains; its transparency is such that the course of the vessels is distinctly perceptible at the margins; its consistency is almost like that of young, succulent connective tissue; its connection with the dentine, particularly in young teeth, is formed by a delicate, lax tissue. The outer surface of the pulp is covered with conical cells, the *dentinal cells* (*odontoblasts*), from the broad faces of which, directed outwards, comparatively thick processes extend. Boll* observed several processes extending from a single cell towards the dentine, and also short lateral ones which connected adjacent cells.

* Archiv für mikr. Anat., iv.

The dentinal processes enter the contiguous dentinal canals, and, like the latter, divide into branches and numerous ramifications. The protoplasm of the cells is finely granular, and the nuclei are oval. A more slender process, which occasionally divides, extends internally from these cells and disappears in the connective tissue, or is united with a spindle-shaped nucleated cell, which latter indeed is to be regarded as a formative cell, cell of repair (*Ersatzzelle*) (Fig. 8).



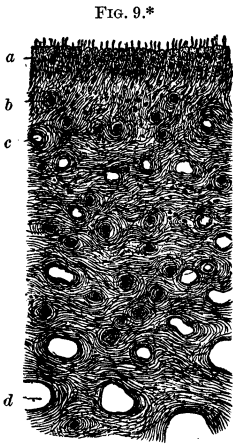
The basis-tissue of the pulp consists of a loose connective tissue containing scattered connective-tissue cells of various forms, among which the spindle shape predominates. Bundles of wavy connective tissue serve to give it firmness, while it is totally destitute of the elastic element. In aged persons the pulp is more dense and tenacious, and contains, also, a larger quantity of fibrillated connective tissue.

The bloodvessels are very abundant; several main trunks enter and leave the pulp, and in the root portion, partly also in the crown, pursue a straight course for the most part. Transverse sections of the pulp give a good idea of the multitude of the vessels and their respective distances from each other (Fig. 9). The wider vessels are found internally, where their ramifications present a bushy appearance. The sharply-curved terminal loops of the capillaries are found everywhere beneath the layer of dentinal cells, and are grouped in a manner similar to that presented by the ramifications of the vessels in the

* FIG. 8.—Transverse section of the marginal portion of the pulp from the tooth of a colt. The dentinal cells, arranged side by side, present, at their peripheral extremities, free, elongated, thick processes, which have been isolated from the dentine; the former contain within their finely granular protoplasm one or two oval nuclei, in close proximity or at a distance from each other, present a sort of annular constriction and, internally at their pointed extremities, are in relation with the connective-tissue corpuscles of the parenchyma. The cavities of numerous bloodvessels, divided transversely and obliquely, appear in the section. Magnified 400 diameters.

papillæ of the tongue. Lymphatic vessels have never been demonstrated in the pulp.

The nerves of the pulp are extremely numerous, and are united into several bundles, the latter forming a network of ramifications in the body of the pulp. They extend in the neighborhood of blood-vessels, and the manner of their disposition may be demonstrated by cross-sections of the body of the pulp (Fig. 9). The primitive nerve-tubes are quite small in diameter. We are enabled through the researches of Czermak and H. Müller to recognize portions of the latter; but the delineation of the exact mode of their termination is attended with extreme difficulty. Boll† observed the transition of medullated (markhaltig) into numerous non-medullated (marklos) nerve-tubes, which latter also gave off very delicate branches between the dentinal cells. Whether these actually enter the dentinal canals remains undecided.‡



* FIG. 9 — Transverse section of the pulp of a canine tooth; (a) row of dentinal cells with their isolated, elongated processes; (b) numerous bundles of nerve-tubes and (c) capillaries divided transversely. The cavities of the vessels increase in diameter towards the central portion of the pulp (d). A network of connective-tissue bundles forms the stroma. Magnified 400 diameters.

† Loc. cit.

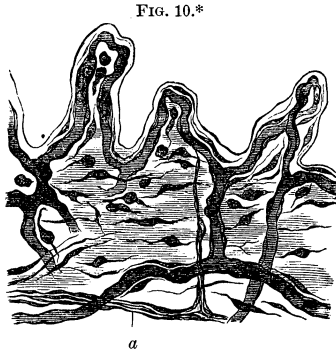
‡ We know, from the clinical observations of J. Tomes, that the outer surface of the dentine is remarkably sensitive to the action of mechanical and chemical agents, and that the same is true of the inner portions, though to a less degree. As soon as the pulp is destroyed, the sensibility of the dentine ceases. J. Tomes concludes from this fact that the sensitiveness of the dentine depends upon its connection with the pulp, and that its proper hard tissue possesses no inherent sensitive properties. He is of the opinion that the sensitive properties of the dentine are due to the solid dentinal fibres which formerly were thought to be tubes, and it seems to him by no means necessary to assume that these fibres are actual nerves. He has succeeded no better than others in proving a connection between dentinal and nerve-fibres. The anatomical reasons for the sensitiveness of the dentine remains, therefore, a postulate.

The GUM is that portion of the mucous membrane of the mouth which surrounds the alveolar margins of the jaw. It is closely adherent to the necks of the teeth and is distinguished by several peculiarities. It is divided into a labial (external) and lingual (internal) portion, and the curved laminæ which arch transversely in the intervals between the teeth. It is of a pale flesh color, attenuated, has a glittering appearance and a compact structure. Two layers of the gum require particular consideration, viz., the papillary portion with the epithelium, and the submucous connective tissue. The latter is intimately connected on the one hand with the periosteum of the bone, and on the other with the root membrane (periosteum of the root). The *papillæ*, situated upon its surface, are finger-shaped prolongations of the corium of the mucous membrane, which are arranged in rows. In different portions, and in different individuals presenting apparently normal gums, many variations occur in respect of the size and manner of grouping of the papillæ. For example, in somewhat swollen gums particularly, groups of several papillæ may be seen arising from a common base, or a main stem may divide into secondary ones from which corresponding papillary groups arise. The structure of these papillæ can be demonstrated properly only after the removal of the epithelium. The outer homogeneous layer of connective tissue (lining [basement] membrane), under very high magnifying powers, presents minute indentations, which serve for the reception of the analogues of the aculeated or furrowed cells of the Malpighian layer. In the body of the papilla lie fusiform, sometimes rounded, connective-tissue corpuscles situated at regular intervals, the long axes of the spindle-shaped ones corresponding with the curve of the papilla, while in the lower part of a papilla the direction of their long axes becomes more horizontal. In the very firm submucous connective tissue of the gum, delicate elastic fibrils also are found, while they are wanting, as a rule, in the papillary portion.

The bloodvessels are very numerous, and the relatively large arterial and venous trunks pursue a more or less horizontal course at the base of the papillary portion, where the afferent and efferent branches are given off towards the papillæ. The

final division of the branches takes place, generally, at the angle of junction of two papillæ (Fig. 10). Each papilla contains but one anastomotic loop

which pursues an undulatory course. In elongated, pointed papillæ, the direction of the ascending canals is more nearly in a straight line.



The nerve-fibres are thick, and form a horizontally disposed network of ramifications; from these, separate nerve-tubes extend nearly at right angles toward the base of the papillæ

and, gradually diminishing to delicate filaments (axis-cylinders), finally disappear altogether from view (Fig. 10).

The thick epithelium is composed of several layers of flat cells, with oval nuclei. Those of the deeper or mucous layer present upon their borders delicate dotted markings, an appearance produced by a row of aculeated projections from the lateral margins of the cells; these unite with similar ones of neighboring cells, forming a sort of suture (Atlas, Fig. 135).

There are no glands belonging properly to the gums, though sometimes acinose glands are found upon the lingual portion close to its margin. With children the gums frequently inclose rosette-shaped aggregations of epithelial cells, appearing, at times, to the naked eye like small nodules, which probably are merely the remains of the lateral convolutions of the enamel germ.

The **ROOT-MEMBRANE** or **PERIOSTEUM OF THE ROOT** is a delicate connective-tissue membrane containing an abundance of vessels and nerves; it is intimately connected with the sub-

* FIG. 10 shows three papillæ from the gum of a rabbit, with the epithelium removed, treated with chloride of gold and acetic acid. Each papilla contains a vascular loop. Rounded and spindle-shaped connective-tissue cells are scattered throughout the tissue. From the nerve-tube (*a*) an axis-cylinder, which gradually becomes smaller, is given off at a right angle, and extends up to the base of a papilla. Magnified 400 diameters.

mucous layer of the gum and with the periosteum of the alveolar process, and covers the root of the corresponding tooth. It is of unequal thickness, being somewhat thicker near the gum and at the apex of the root than in the intermediate portions. Individuals, too, present varieties in regard to its thickness; for instance, well-preserved grooved teeth have a comparatively thicker root-membrane.

Generally it is of moderate density; the bundles of connective tissue forming it contain no elastic fibres, and inclose fusiform connective-tissue corpuscles; in addition to these, roundish elementary organs are met with. According to E. Magitot,* the root-membrane consists of two portions: an inner, which does not admit of being teased into fibrils; and an outer, lying near the alveolar wall, which has the appearance of a fibrous structure. The same writer also mentions the occurrence of "cellules myéloplaxes," similar to those found in the periosteum of bone, and cytoblastions (nuclei invested with a layer of protoplasm), which occur still more rarely.

The bloodvessels of the root-membrane originate from, and have their exit into, three different localities, viz.: 1, numerous tufts of vessels having a longitudinal direction are given off from the vessels of the submucous connective tissue of the gums; 2, similar tufts arise from the dental vessels which supply the pulp; 3, vessels enter from and empty into the osseous vessels of the porous alveolar wall. These relations, which have been mentioned, are much more clearly perceptible in the incisors and canines than in the bicuspid and molar teeth, since the root-membranes of the latter, in human teeth, but more particularly those of the molars of larger mammals, have a less smooth appearance, and, where the roots diverge, are thickened. The network of capillary vessels presents a very uniform arrangement; the separate meshes have an elongated form generally; are directed towards the surface of the root, and are narrower in the vicinity of the neck and apex of the root.

The *interalveolar vessels*, inclosed in a porous, osseous canal, pursue a vertical course between two adjacent dental sockets,

* Mémoires sur les Tumeurs du Périoste Dentaire, 1860.

and are accompanied by the corresponding narrow bundles of nerves and loose connective tissue. The distinctness of the interalveolar canals varies. For example, the foramina leading to the interalveolar canals, which may be seen between the necks of the teeth upon the lingual wall of the alveolar process, are quite wide in the jaws of young persons, and become obliterated with increasing age. The interalveolar vessels divide into branches at their exit upon the margins of the alveolar process, and supply the lingual side of the gum.*

The periosteum of the root is supplied with a rich network of nerves. The nerve-tubes are of various diameters, very thick and thin ones being united together into bundles. They are branches of the dental and gingival nerves, as can easily be demonstrated, and in part also are composed of filaments which come through the foramina in the alveolar walls, and from the interalveolar canals.

DEVELOPMENT OF THE TEETH.—In order to render this subject more clear, I have divided the phenomena, in the order of their occurrence, into the following groups. Human embryos, at so early a period as the second month of pregnancy, are rarely available for histogenetic investigations, as they are generally injured by maceration after the death of the ovum

* The injection of the inferior alveolar arteries is most easily made by forcibly enlarging the posterior portion of the canal of the inferior maxillary bone to the depth of a few lines, when the artery may be sought for and attached to a fine tube corresponding to it in diameter. The mental branch, as it emerges from the mental foramen, should either be tied or compressed, particularly in larger animals, while the injection is being made. On account of the anastomoses existing between the periosteal vessels and those of the gum, the papillæ of the latter also will be filled. The under jaws of the calf, roe, dog, or sheep, are well adapted for injection. The delineation of the periosteal vessels of the roots of the upper teeth is more minute, inasmuch as the alveolar artery of the superior maxillary bone supplies only the bicuspid and molar teeth, the incisors and canine teeth, on the other hand, being supplied by a branch of the infraorbital artery. Injections of the superior alveolar artery will extend to the vessels of the posterior portion of the mucous membrane of the antrum of Highmore and the nasal cavity.

The capillary vessels of the periosteum of the root possess, according to the assertions of Ch. Robin, an epithelial covering. I, too, have observed an appearance somewhat like this upon many of the capillaries, but could not convince myself of its constancy.

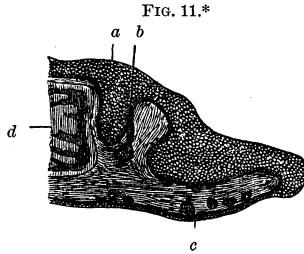
within the uterus. It is, therefore, generally necessary to employ the embryos of calves, pigs, sheep, &c.

1. The first indication of the commencement of the development of the germ is afforded by a proliferation of the epithelial structure of the mucous membrane covering the edges of the maxillary arches, in the form of a fold, called the *dental ridge* (Marcusen), which is composed of several layers of large, flattened, nucleated cells.

Corresponding with a superficial, shallow groove, which appears upon the ridge, the mucous layer becomes depressed from without inwards, in the form of a short [on transverse section] cul-de-sac, which is tenanted by the cells of the latter layer. This tubular depression gradually expands in the form of a pouch, as its development progresses interiorly, while, externally, toward the outer surface of the mucous layer, it presents a narrowing or constriction. This follicle of mucous cells was demonstrated by Kölliker to be the *enamel germ*. These relations are most plainly visible in the incisors (Fig. 11).

Coincident with the depression of the epithelium of the mucous layer appears, as has been observed, a shallow groove upon the dental ridge, called the *dental groove*, which is bounded by two elevated borders or lips, that upon the facial side being the more prominent of the two.

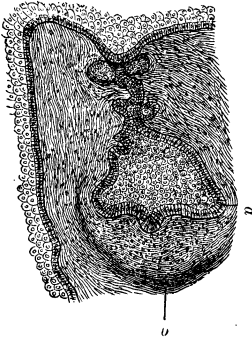
2. From the floor of the pouch-like expansion of the enamel germ, which, upon its periphery, is covered by the cells of the mucous layer, and in its central portions is occupied by extremely delicate nucleated elementary organs, rises a papilliform process of connective substance; this is the primary stage of the



* FIG. 11.—Primary stage in the development of an incisor of the lower jaw; from the embryo of a calf. Section made perpendicular to the arch of the jaw. (a) Dental ridge, consisting of large epithelial cells; from the mucous surface of the epithelium, a follicular process (b), which already presents a constricted neck and is lined throughout with epithelium, extends from without inwards, and is the rudiment of the enamel germ; (c) epithelium of the margin of the under lip, with rudimentary hair-follicles; (d) osseous trabeculae covered with periosteum. Magnified 15 diameters.

dentinal germ, and appears as a single papilla when it represents an incisor or canine tooth, and as an elevation with several cusp-like processes when it represents the deciduous molars. As the neck of the enamel germ becomes more elongated, its walls become broken up into folds, which are lined throughout with the cells from the mucous layer and give to the neck an appearance

FIG. 12.*



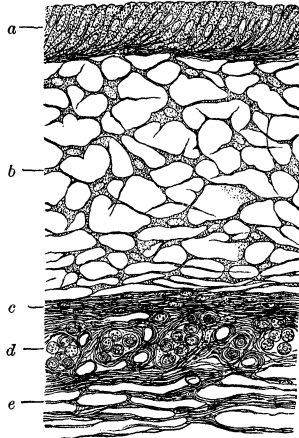
like that of a follicular gland with lateral offshoots. At a definite distance from the surface of the dentinal germ a shaded lunate outline becomes visible, which is the primary stage of the *dental sac* (Fig. 12).

3. The development of the enamel germ, which becomes directed towards the face and undergoes a flexion in its constricted portion, now goes on to completion. As the enamel germ increases in volume, and the dentinal germ is developed from below upwards, more and more into the follicle, the former comes to invest the dentinal germ like a cap. A differentiation of the tissue of the enamel germ ensues, which gives rise to a structure consisting of several layers, the so-called *enamel organ*. In consequence of the above-mentioned upward development of the conical dentinal germ, and the gradually increased invagination of the follicle, the peripheral epithelial layer of the latter becomes separated into an external and an internal lamina, the external epithelium (Thiersch) and the internal. The latter is disposed upon the dentinal germ, the former upon the roof of the dental sac. Between the two epithelial laminæ lies an intermediate layer.

* FIG. 12 shows the development of an enamel germ, with numerous folds, of a lower bicuspid from the embryo of a calf. Transverse section. The mucous layer of epithelium sinks into the mucous membrane, forming several secondary sinuations, and expands in the form of a sac, having numerous folds, being surrounded everywhere by connective tissue. The cells lining the walls of the follicle have a cylindrical form (*a*). The cells of the interior are small and flattened. The rudiment of the dental sac is indicated by a shaded outline (*b*). Between *a* and *b* the rudiment of the dentine is elevated into papilliform processes. Magnified 80 diameters.

The *enamel organ* acquires a gelatinous appearance, contains no vessels, and becomes thinner as it approaches the base of the cap, at the summit of which also it is generally somewhat thinner than it is below. The thinnest portion is met with at the base of the cap, at the place of reflection, where the external and internal epithelium are in close proximity. It is composed of three principal laminæ: (*a*) the internal epithelial layer, also called the *layer of enamel cells*, which is composed of elongated conical cells, with their broad extremities directed toward the developing enamel, while, on the other hand, the narrow extremities unite with spindle-shaped formative or reparative cells (*Ersatzzellen*), or are inserted between them. The enamel cells, as well as their obliquely arranged formative cells, inclose a granular protoplasm and an oval nucleus. The formative cells are connected by means of a filamentous layer with the second principal lamina (*b*), the spongy tissue. This forms the principal mass of the enamel organ, and its transparent basis-substance is occupied by cells with stelliform radiating processes. The bodies of the cells inclose an oval nucleus; the processes unite to form a network, the meshes of which become more narrow from within outwards, and are in relation with an inter-


FIG. 13.*



* FIG. 13.—Transverse section of the enamel organ of an incisor from a human fœtus, the section taken from the vicinity of the reflection of the cap, where the organ has already become quite thin. (*a*) Enamel cells (external [?] epithelium), with the gradually more obliquely disposed formative cells (*Ersatzzellen*), which ultimately assume a horizontal direction, and become spindle-shaped; (*b*) multiradiating flattened cells, which form a network by means of their connecting processes, and belong to the spongy layer; (*c*) layer of spindle-shaped cells, with oblong nuclei, analogous to those adjoining the layer of enamel cells; (*d*) groups of cells belonging to the external epithelium, and lying in sac-like cavities; between the groups are the openings of capillary bloodvessels. The papillæ of the dental sac, on account of their oblique position, are represented obliquely within the sections; (*e*) lax connective tissue of the dental sac. Magnified 400 diameters.

mediate layer composed of horizontally disposed spindle-shaped cells. Outside of the latter appears (*c*) a group of cells, called the external epithelium, which invest the papillæ projecting into the enamel organ from the wall of the dental sac (Fig. 13).†

FIG. 14.*



The *dental sac*, from the floor of which proceeds the dentinal germ, is developed opposite the surface of the latter, and invests it and the enamel germ, forming a connective tissue envelope around the two, the continuity of which is broken only at that part which has been described as the constricted portion or neck of the enamel germ, and is connected with the mucous layer of the epithelium. It


* FIG. 14.—Injected bloodvessels from the dental sac of a new-born child. The larger ones lying outside form a network, with elongated meshes. Interiorly, delicate capillaries are given off and form anastomotic loops, here and there, directed toward the enamel organ. Magnified 30 diameters.

† The spongy tissue was formerly considered to be a gelatinous connective tissue, until Huxley and Kölliker demonstrated that it is to be classed with the epithelial structures. Opinions are still divided as to the manner in which the enamel is developed out of the enamel cells. One theory, which I also uphold, maintains that it is by the direct calcification of the enamel cells, and Waldeyer (S. Stricker's *Handbuch der Gewebelehre*) adduces, as strong evidence in support of this view, the occurrence of enamel cells and fragments of enamel prisms in intimate connection, the latter remaining adherent to the former in the form of processes. According to his view petrification (*petrifizieren*) of the enamel cells commences in the investing zone, while the axial portion of the protoplasm retains its softness for a time, and in isolated cells forms a kind of process (Tomes' Processes of the Enamel Cells). The other view, which Kölliker formerly held, is based upon the idea, that the enamel is a cuticular structure. Guillot, Robin, and Magitot, as the result of their investigations with reference to this subject, assert that the teeth and their appendages are developed in the submucous tissue, entirely free and independent of all other tissues. Max Reichert, also, was inclined to this erroneous view (Dubois-Reichert's *Archiv*, 1869), according to whom, the enamel organ originates from the corium, and not from the epithelium of the mucous membrane of the mouth. The gelatinous tissue, together with the stellate cells of the enamel organ, he regards as connective tissue. Kollmann has recently published a work, agreeing essentially with Kölliker's theories (*Entwicklung der Milch- und Ersatzzähne*, *Zeitschr. f. wiss. Zoologie*, Bd. 20).

is closed, at a quite early period, in the manner already described, before there is the least trace of the tooth cap. It becomes richly supplied with bloodvessels and nerves. That portion of the sac, particularly, which invests the enamel organ, becomes elevated into rows of papillary excrescences which are covered by the cells of the external epithelium of the developing enamel organ. The wall of the sac is divided into a compact peripheral or outer, and an inner lamina of a more lax tissue. It is traversed by numerous interlacing bundles of nerves, and the bloodvessels also are very abundant; the larger of these are distributed in the outer, and the smaller in the inner lamina. As they pursue a generally straight course, they give rise to oblong meshes (Fig. 14). In that lamina of the dental sac which is in relation with the enamel organ, capillaries extend into the corresponding papillæ, where they form anastomotic loops. These vascularized papillæ are so intimately united with the enamel organ, that, together with the anastomotic loops, they remain adherent to the enamel organ after the dental sac has been detached (Fig. 15).

The *dentinal germ* receives bloodvessels and nerves from that portion of the dental sac with which it is in contact, and becomes developed into one or several papillæ or prominences, according to the number of tubercles which the crown is to present. Consequently the rudiments of canine teeth present one, and those of molar and bicuspid teeth several papillæ. Well-developed dentinal cells with their processes, such as have been described in connection with the pulp, are observed at a comparatively early period. Large vascular twigs extend up and down from the base of the germ, and ramify in various directions towards its surface, where


FIG. 15.*



* FIG. 15.—Injected capillaries which remained adherent to the enamel organ of a bicuspid tooth, from a calf, the dental sac having been detached. The anastomotic loops have been torn from their connection with the vessels of the dental sac, and reach almost to the layer of enamel cells. Magnified 80 diameters.

they terminate in loops. The latter pursue a straight course in young germs (Fig. 16). The connective tissue of the germ is

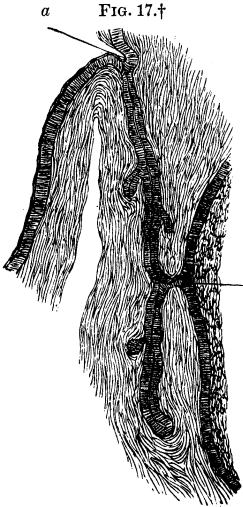
FIG. 16.*



very soft, contains numerous cells, and becomes exceedingly cloudy on the addition of acetic acid. The dentinal cap, which primarily is exceedingly thin, is blended with the enamel cap, while, from the beginning, the enamel and dentine are developed in opposite directions. The dentine is formed by the deposition of new layers from without inwards, while the enamel, as above demonstrated, is developed in a similar manner from within outwards.

The enamel germ of a permanent tooth, which has a single root, is developed, at an early period, upon the lingual side of the milk teeth, in the form of a cul-de-sac. It commences

FIG. 17.†



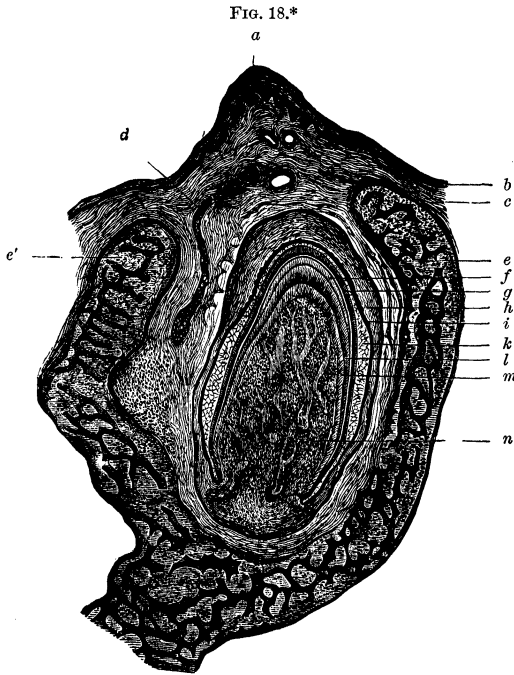
in the form of a direct depression of the mucous layer of the epithelium from the dental groove, between the facial and lingual lips of the dental ridge, and has a common origin with the enamel germ of the milk tooth (Fig. 17). The follicle presents lateral folds, which not unfrequently occur in large numbers. The closed terminal portion of the follicle was recognized by Kölliker as the enamel germ of the permanent tooth. The connecting branch of the follicle, which extends outwardly towards the face, is in direct communication with the external epithelium of

the enamel organ of the deciduous tooth.

* FIG. 16.—Injected terminal loops from the pulp of a permanent incisor of a new-born child. The vessels pursue a straight course. The loops are partly single and partly complex. Magnified 30 diameters.

† FIG. 17 shows a follicle of mucous cells extending from the dental ridge to the enamel germs of the milk and permanent teeth; from a human embryo of three months' growth. The cells of the mucous layer of epithelium dip

The connection of the outer with the inner epithelium, as well as a general view of the developing crown, the tooth cap, and the dental sac, together with the parts in the immediate vicinity, may be observed in sections of the jaws of embryos of a suitable age, which have been decalcified by means of diluted hydrochloric and chromic acids. The inner epithelium commences at the base of the dentinal germ (Fig. 18), and extends along the



down into the substance from the dental groove (*a*) of an incisor of the lower jaw, and resemble, somewhat, a tubular gland with lateral offshoots. At about the middle of the follicle, which is lined throughout with cylindrical cells, it is connected by a transverse process (*b*) with the external epithelium of the enamel organ, the spongy layer of which is represented (*c*). The inferior closed portion of the follicle is the enamel germ of the permanent incisor tooth. Magnified 80 diameters.

* FIG. 18.—Sagittal section of a lower jaw from the embryo of a dog, showing an incisor within its dental sac. (*a*) Facial lip of the dental ridge; (*b*) epithelium; (*c*) corium, with papillæ in the dental ridge, and cavities of transversely divided vessels; (*d*) enamel germ of the permanent incisor containing an aggregation of epithelial cells; its connection with the enamel

entire outer surface of the dental cap. The thickness of the pulp bears a direct relation to that of the cap; that is to say, the thicker the former, the thinner the latter; and the pulp rests upon the floor of the dental sac. The latter has a rounded form, corresponding with the developing dental crown, lies beneath the facial lip of the dental ridge, within the maxillary groove, and is intimately connected with the exceedingly vascular and nervous submucous connective tissue of the gum, and with the layer of connective tissue which lines the maxillary groove.*

organ of the deciduous tooth does not appear in the section; (*e*) anterior, (*e'*) posterior, osseous lamella of the jaw with rounded summits; (*f*) completed enamel of the dental cap; in the section it is separated, somewhat, from the (*g*) layer of enamel cells; (*h*) retiform connective tissue of the dental sac; (*i*) outer epithelium of the enamel organ completely investing the papillæ of the dental sac; (*k*) spongy layer of the enamel organ; (*l*) completed dentine of the cap; (*m*) layer of dentinal cells; (*n*) dental pulp with wide vessels in its interior. Magnified 20 diameters.

* The mode of development of the dentine is so far determined that we know positively that the dentine is developed from the dentinal cells. We may also readily demonstrate that, as soon as the connection of the dentinal with their formative cells occurs, the calcification of the contents of the dentinal cells begins; that their principal and accessory processes remain attached and are transformed into dentinal fibres, and that a constant deposition of calcareous salts into the cells takes place from the blood.

By the continuous transformation of formative cells into dentinal cells, the process goes on, and new layers of dentine are deposited constantly by progressive calcification. Kölliker (op. cit.) maintains another view, a modification of the last, namely, that the calcified substance, which is found between the dentinal fibrils (basis-substance, or matrix, of the dentine), is to be considered an excretion from the dentinal cells, and consequently is not a product of the immediate calcification of the latter.

Another question arises, viz., how do the globular masses originate, and what relation do they bear to the normal development of the dentine? The globular masses found on the inner surface of the dentine of the teeth of children are permeated by dentinal canals, and in accordance with the first theory may be considered to be the result of a coalescence of separate groups of calcified dentinal cells. There are two possibilities, in regard to the globular masses which are intercalated between the systems of dentinal canals, without being pierced by them, namely: that in these localities the processes within the groups of calcified cells were prematurely destroyed, or that, in consequence of an arrest of development, the process of calcification of the dentinal cells progressed merely to the formation of globules of calcareous salts.

4. The *dental cap*, considered as the aggregate of calcified dentinal and enamel cells, maintains during its development the shape given to it by the arrangement of the cells; it increases in thickness, and eventually becomes the crown of the tooth; contemporaneous with the growth of the latter the enamel organ gradually becomes thinner, and finally shrivels up completely. When the development of the crown is accomplished, that is, when no new layers of enamel are formed, the growth of the radical portion of the tooth, from the edge of the crown, commences; the dentinal cells adopt a more horizontal position, and consequently the dentinal canals also assume a more horizontal direction. At the margin of the crown the dental sac contracts, and upon its inner surface the formation of the cement is effected, increasing gradually as the formation of the root advances; the lower segment of the dental sac becomes, therefore, the root-membrane of the tooth.

Contemporaneous with the latter processes occurs the formation of *Nasmyth's enamel membrane*, which is interpreted in various ways. This membrane, called by Kölliker the cuticle of the enamel, is considered by him to originate in this manner, viz.: that an additional coherent layer (cuticle) is secreted by the enamel cells, after the completion of the formation of the enamel, to serve as a protection for the whole. Waldeyer regards it as the product of the cornification (*Verhornung*) of cells. J. Tomes holds the opinion, that the membrane belongs to the cement, because it is continuous from the crown upon the cement, as may be demonstrated on teeth which have been treated with dilute hydrochloric acid; moreover, the membrane is thickened in the depressions upon the crowns of the molars, and in these localities distinct bone-corpuscles likewise occur. These arguments, together with data furnished by comparative and pathological anatomy, uphold the latter view, in my opinion. In the development of teeth with irregularities in the enamel, the adaptations of the dental sac and the enamel organ to depressions in the crowns may easily be demonstrated, and there remains, finally, an outer covering of cement upon the masticating surfaces of the crowns. The case illustrated in the Atlas, Fig. 9, where the radical cement passes without interruption into a

well-marked coronal cement, which covers the entire masticating surface and insinuates itself between the folds of enamel, is explained by the latter theory.

5. The growth of the pulp root and the contiguous zones of the dentine keeps pace with the formation of the cement which takes place externally to the latter. While the growth of the dentine in thickness gradually diminishes, that of the cement increases. As the peripheral portions of the dentine are always formed first, it will readily be understood why an incomplete root presents at its extremity a sharp margin and a dome-shaped cavity, called by the dentists an unclosed root. The formation of the root is completed when its canal no longer presents a funnel-shaped expansion at its extremity.

6. The development of the osseous walls of the teeth is first indicated by an osseous dental groove, which is more distinctly marked upon the lower jaw, and is inclosed by a facial and lingual lip. It is shallow and flattened posteriorly (Fig. 19). As this groove becomes deeper and wider, lamellar projections appear upon its interior

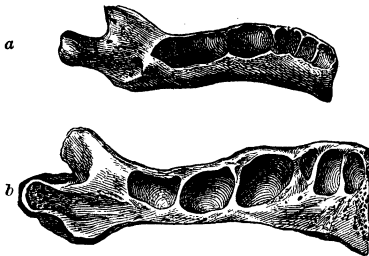


FIG. 19.*

wall, the first making its appearance between the two dental sacs of the incisors. At about the same time, flattened spinous processes also appear toward the upper margins of both the labial and lingual walls (Fig 20 a). These processes grow towards one another and gradually complete the continuity of

the wall. In this way an osseous case, of a fine spongy texture, is formed around the dental sac, which gradually contracts, but remains permanently open externally. It may be demonstrated separately, and is called the *bony socket*, or *alveolus of the dental crown*. The size, position, and re-

FIG. 20. a, b.†



* FIG. 19.—Lower jaw of a human fœtus, at the commencement of the third month of pregnancy, seen from above, in order to give a view of the groove in the bone, which becomes flattened from before backwards. The coronoid processes and condyles are already indicated. Natural size.

† FIG. 20, a.—Macerated left half of the inferior maxillary arch, from a

spective distances of the sockets from each other can be demonstrated to the best advantage in sections of decalcified jaws, corresponding with their curves. All the cells are equidistant from the edge of the gum, while their distance from the inferior margin of the lower jaw decreases from before backwards, that is, the socket of the middle incisor is most distant, and that of the second molar is nearest, which relation corresponds with the growth of the bone in depth from before backwards (Fig. 20 *b*). When the growth of the root commences, and the corresponding segment of the dental sac becomes the root-membrane from which the cement originates, a partial process of resorption takes place in the osseous coronal sockets. This is but a temporary process, and continues only so long as the crown is in an embryonic condition. As far as I know, Tomes was the first to call attention to the important circumstance, to be considered later, namely, the fact that resorption of a portion of the walls of the alveoli ensues in order to prepare the way for the passage of the teeth through the gum.

7. The formation of the twenty osseous alveoli of the crowns is nearly completed in the eighth month of pregnancy, only the facial walls of the alveoli of the canine teeth, and the posterior wall of the second deciduous molar, particularly in the upper jaw, remaining, for the most part, membranous. Consequently the osseous septum between the second deciduous and first permanent molar is wanting. Since the posterior are considerably wider than the anterior alveoli, it will be seen that the facial lamina of the alveolar process of the upper jaw describes a wide

fœtus, at the seventh month of pregnancy. View from the lingual side. The partitions or septa for the incisors are partially formed; the facial wall of the canine tooth still presents a gap. The septa for the milk molars are indicated by slight ridges; that for the first permanent molar is already perceptible towards the coronoid process. Natural size.

FIG. 20, *b*.—Left half of the inferior maxillary arch, from a new-born child; decalcified by means of dilute hydrochloric acid, and bisected by an incision corresponding with its curve. The incised surface of the outer half is exposed to view; the dental sac and contents are removed. The separate walls for the dental sacs of the milk teeth are completely developed; the septum for the first permanent molar is seen to be partially developed within the coronoid process. Natural size.

and semicircular curve, internal to which lies the narrower semi-elliptical bow of the lingual lamina. In the lower jaw the laminae of the alveolar process extend nearly parallel to each other, from before backwards; the anterior segments extend from the median line outwards; behind the alveoli of the canine teeth they bend abruptly backwards, and thus describe curves similar to the letter S; the posterior extremities of the two rami of the lower jaw consequently present a greater divergence than those of the upper.

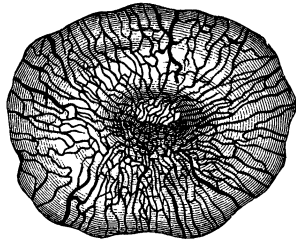
If the inferior maxillary arch be examined from below at this same period of development (the eighth month), in its relation to the superior arch, both jaws being left in their natural position so that the suture of the palatal processes and the symphysis of the lower jaw lie in the same perpendicular plane, the greater divergence of the posterior segments of the inferior arch will be perceptible. A profile view presents a notable projection of the upper beyond the lower jaw, an appearance occasioned in part by the fact that the mental process is not yet developed.

The *alveoli for the crowns* of the incisors are broader on the facial than on the lingual side. While they expand, with the growth of the crown, their orifices upon the alveolar ridge become contracted, because the facial and lingual walls, as they are developed from below upward, incline toward each other. The alveoli of the canine teeth are characterized externally by a prominent ridge, the canine eminence, and generally bulge more than the other sockets. Their facial walls in the upper jaw are almost entirely ossified at the commencement of the second month after birth. The openings leading to the oblong alveoli of the milk molars, particularly that of the second molar, are wide at first, but later contract gradually. In the first months after birth, the facial and lingual walls, together with the septa between the alveoli, are developed from below upward, and incline toward each other. The margins of each of the sockets, in the course of their development, present a concavity, at first usually slight, but still perceptible, which is the result of commencing resorption. These taken together give rise to the festooned appearance of the edges of the alveolar borders. The

latter conformation is exhibited first of all and most distinctly by the alveoli of the incisors.

FIRST DENTITION.—The growth of the root in length keeps pace with the process of resorption at the alveolar borders. The crown presses against its membranous covering, and becomes perceptible to the touch externally, as the so-called tooth prominence (Zahnpille). In consequence of the continuous pressure of the crown upon the vessels and nerves of the summit of the dental sac, the latter undergoes complete atrophy; the interlacing bundles of connective tissue acquire a dried and tense appearance and a yellowish color. That part of the gum which is in immediate relation with the dental sac undergoes a similar process, its numerous vessels being subjected to extreme tension (Fig. 21). The membranous coverings gradually become thinner, and at last trans-

FIG. 21.*



parent, when the edge of an incisor, or the tubercles or cusps of the canine and molar teeth, are exposed to view. On account of the constant onward pressure of the crown, which is commensurate with the advancing growth of the root, the gum necessarily recedes and, after the eruption of the crown is completed, attaches itself to the neck of the tooth, by which means its submucous layer maintains its connection with the dental sac, which latter becomes the root-membrane.

The preparation for the *eruption of the central incisors* is manifested by the above-mentioned process of resorption, which gradually becomes more evident, upon the lingual and facial walls of their alveoli, by an increase in the concavity of their margins. Recently cut incisive edges of the central and lateral deciduous incisors present two shallow indentations. The resorption upon the alveolar margins of the lower incisors is much

* FIG. 21.—Injected gingival bloodvessels of the prominence (Zahnpille) over the molar of a new-born sheep. View from above. The vessels converge toward the summit, where a capillary network is presented. Magnified 5 diameters.

more evident at first than it is on those of the upper. The resorption of the latter, however, soon follows, and commonly is more conspicuous on the facial than on the lingual walls of milk teeth.

The central incisors advance perpendicularly, while the *lateral incisors* present a lateral inclination of the facial coronal surfaces, which is more decided when still inclosed within their bony capsules than is the case after their eruption; they must, therefore, during the latter process, be twisted considerably toward the median line of the jaw.

The *first milk molars* generally are cut in the first months of the second year, and not unfrequently earlier in the upper than in the lower jaw. When the masticating surfaces of these teeth have already advanced to their proper level in the dental range, their roots are barely half formed, and the extremities of the latter present a wide cavity and a sharp edge. While the *canine teeth* are still deeply imbedded in the jaw, within their alveoli, they present the most notable inclination of all the teeth, their crowns being inclined toward the median line of the jaw, and their necks laterally. As they approach the summit of the alveolar ridge, they experience a slight lateral inclination in order that they may advance in the space between the lateral incisors and first molars. Another peculiarity of the canines is afforded by the fact that they lie farthest from the alveolar ridge and consequently are obliged to traverse the greatest distance in order to reach it. There is, however, another circumstance which is very much in their favor, namely, that the resorption upon their alveolar margins extends higher in the upper, and deeper in the under jaws than is the case with the remaining teeth. When their eruption has progressed so far that the coronal extremities have reached the level of those of the adjacent teeth, the roots have barely attained half their final length.

The *second upper molars* not unfrequently make their appearance before the corresponding lower teeth. With these, the first set of teeth, the milk or deciduous set is completed, generally by the end of the second, or occasionally not until the end of the third year.

When the crowns of all the milk teeth have attained their full growth and proper relations, the growth of the roots is still more or less incomplete, in proportion to the early or late eruption of their respective crowns. Even the extremities of the roots of the central incisors are scarcely closed at this period.

The periods at which the eruption of the milk teeth commences and terminates vary considerably. While, in rare cases, children enter the world with their lower central incisors already cut, sometimes the latter do not make their appearance until the end of the first year after birth. As has been observed before, the eruption is completed generally at the end of the second year after birth, though, frequently, it is prolonged many months beyond this period.*

It would be an interesting point to determine the normal intervals between the eruption of the different kinds of teeth, since, from the longer or shorter intervals, an approximate conclusion might be deduced concerning the growth of the jaw in its different dimensions; variations, however, in this respect are presented in the same individual. In general, it may be said that the interval between the completed eruption of the central and the lateral incisors, and between that of the latter and the first molars, is about ten or twelve weeks for each kind mentioned, while that between the eruption of the first molars and canine teeth is prolonged to twenty or twenty-four weeks; the second molars succeed the canine teeth after a similar period. The intervals before the appearance of the canine teeth and second molars, therefore, are about twice as long as those between the first mentioned kinds of teeth.

In regard to the eruption of the teeth in the upper and lower jaw respectively, it is the rule that the lower incisors appear

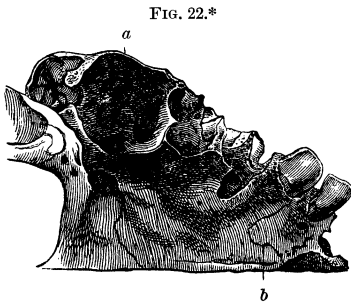
* The eruption of the deciduous teeth usually takes place at about the following ages:

Central incisors,	7th month.
Lateral incisors,	9th "
First molars,	12th "
Canines,	18th "
Second molars,	24th "

first, and generally the upper ones succeed them in a very short time. The reverse is the case, frequently, with the molars.

SECOND DENTITION.—The eruption of the *first molars* ushers in the shedding of the teeth. They appear in the seventh year and generally in the upper jaw earlier than in the lower. Toward the end of the second year, the crowns of those in the upper jaw are situated high up in the maxillary tuberosity, and those in the lower jaw, in the coronoid process, and as the development of the jaws progresses, they descend towards the dental range. The alveoli of the crowns undergo a process of gradual resorption in the vicinity of the summits of the latter, and contemporaneously with this process, the growth of the

radical portion commences. For some time before the emergence of the first molars, the margins of their alveoli have undergone a considerable amount of resorption, but are still separated from the alveoli of the second molars by partially membranous septa (Fig. 22). Concurrent with the emergence of the teeth, the alveoli for the roots



in the upper jaw form three broad, cup-like depressions, separated from one another by projecting partition-walls or septa. In the lower jaw are found two similar shallow, flattened depressions. Generally, at this period of their development, the roots present remarkably sharp edges and broad cavities.

* FIG. 22.—Right half of the upper jaw of a child between five and six years of age. View of the palatal surface. The process of resorption is seen to have made considerable progress upon the margins of the coronal alveolus of the first permanent molar (near *a*), and the latter communicates with the coronal alveolus of the second permanent molar. The three depressions at the bottom of the cavity correspond with the three incompletely formed roots belonging to the detached tooth; (*b*) incisive fissure which is met with, sometimes, in adults. Upon the lingual wall of the alveolar process, and corresponding to the localities of the lateral incisor and first molar of the milk set, openings are visible for the corresponding permanent teeth, produced by the process of resorption. Natural size.

When the coronal cusps of the first molars have reached the level of those of the deciduous molars, their roots are scarcely more than a few millimetres in length. The subsequent growth of the roots in length and of the jaws in depth is a comparatively rapid process.

The *shedding of the teeth* involves all the milk teeth, and commences as soon as the crowns of the permanent teeth, through reason of the development of their roots, draw near to the alveoli of the milk teeth. A series of phenomena then ensues in the alveoli, and in the milk teeth themselves, which have been embraced under the general term *resorption*. This process manifests itself by a loss of substance which commences in the alveoli of the milk teeth, then usually attacks the apices of their roots, and finally the entire roots and, in many cases, involves a large portion of the crowns. Generally this process attacks the milk tooth upon the side towards the advancing crown of the permanent tooth, though frequently it commences at many points simultaneously, and gives rise to pitted or funnel-shaped depressions, grooves, or irregular facets, looking like the effects of corrosion, all of which are characterized by their rough, exposed surfaces and sharp edges. We are indebted to Tomes for the first thorough histological investigation and correct interpretation of the various phenomena presented by this process of resorption.

If we examine closely a portion of the cement of the root of a deciduous tooth which has been affected by this process, we find what at first appears to be a simple depression; under the microscope, however, this is found to be made up of a number of smaller, cup-shaped excavations, which, seen from above, are bounded by sharp, elevated laminæ and, upon still closer examination, display, in suitable places, a network of projections in each microscopic cavity. The bone-corpuscles, together with the intermediate substance, undergo a decomposition: first of all, a molecular cloudiness occurs in their immediate vicinity, and also in the intercorpuscular substance; the radiating bone-canalliculi become indistinct, disappear, and the bone-corpuscles, deprived of their radiating canalliculi, are isolated within the cavities which become more clear by the solution of the substance con-

tained in them, and in which the network of delicate projecting laminæ gradually disappears; the walls of contiguous cavities become thinner, and finally are entirely absorbed (Atlas, Fig. 112). As the same process is repeated, and gives rise to larger and smaller groups of such indentations (Resorptionsalveolen), the cement substance in the affected localities is entirely destroyed, so that, finally, cross-sections present an excavation with an irregularly notched boundary.

The same process also takes place in the dentine when similar indentations are produced by resorption and occasion a roughness of the surface. Not merely those portions adjacent to the cement are attacked by this process, but the inner portions also, which inclose the root canal (Atlas, Fig. 111).

Resorption of the milk tooth is frequently accompanied by a new formation of osseous substance, a phenomenon of frequent occurrence with new formations, that is to say, involution by the side of evolution.

The new formation and resorption can readily be studied in that portion of the cement where no rows, or, still better, where a single row of bone-corpuscles occurs. In addition to the indentations produced by resorption already described, which quite frequently are coated with the remains of the organic basis-substance, cross-sections also present clear, hemispherical, sharply defined masses imbedded in the cement; these are either separate or grouped together, and gradually extend beyond the boundary of the cement even into the dentine, and not unfrequently assume a radiating arrangement.


The central portion of these masses contains irregular cavities, which denote the points where the process of resorption commenced. The osseous substance, which encroaches considerably upon the dentine, is always sharply defined; the corpuscles, likewise, either singly or in groups, are inclosed by a bright capsular layer (Atlas, Fig. 110). Such corpuscles resemble young, immature bone-corpuscles, the canaliculi of which have not yet formed their mutual connections. Not unfrequently the corpuscles are irregularly formed, elongated; present several long offshoots, or are large, without any definite form, as if resulting from a blending together of separate ones. As they increase in

volume, and lose their proper characteristics, they assume an appearance like that of gaps, resulting from *interstitial* resorption, and filled with amorphous calcareous salts, and all the more so from the fact that very decided evidences of resorption are found in their vicinity.

The newly-formed osseous substance is immediately subjected to a *peripheral* resorption, while the capsule of the corpuscles thickens, and the latter, finally, are destroyed. The cloudy, granular, discolored substance contains a greater or less amount of fat, which is the remains of the disintegrated tissue.

When the resorption of the milk teeth has progressed so far that a small portion only of the crown remains, the enamel, likewise, becomes eroded and resorption indentations make their appearance in it also (Fig. 23). Tomes has also observed the development of osseous substance upon the outside of the enamel.

If a milk tooth, in which resorption has made some progress, be separated from the jaw, a loose, spongy substance remains adherent to it, which a long time ago, was claimed by Laforgue and Bourdet to be the absorbent organs. It was supposed that the latter secreted a fluid capable of dissolving the substances of the tooth. Tomes made a microscopic examination of this papillary organ, and states that its surface is made up of peculiar multiform cells, each one being composed of several smaller cells, the number varying from two or three to as many as fourteen or fifteen. Some few deviating forms bear a strong resemblance to the cells, described by Kölliker as myeloid cells.



* FIG. 23.—Resorption indentations which penetrate from the surface of the enamel toward the deeper layers, resembling, in the manner in which they are grouped together, glandular lobes, and filled with a cloudy, granular mass. The contiguous portion of the enamel is in its normal condition. Magnified 250 diameters.

Each hemispherical depression of the absorbent surface of the tooth is occupied by such a cell as has been described. Beneath the surface of the papillæ, there are commonly found nucleated cells and free nuclei, and, in the deepest layers, a fibrous tissue in the process of development.

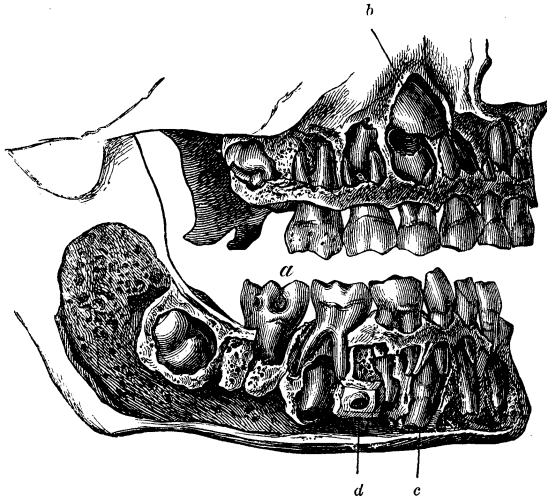
According to my experience upon this point, which indeed is limited, these compound cells (Tomes) are not of constant occurrence; I have not been able to discover them in some cases, but have perceived merely aggregations of single cells of connective tissue. Hohl has succeeded only in one case in discovering a few gigantic cells, and he is of the opinion that the large cells described by Tomes are nothing but nests of cells with connective-tissue capsules. How the destruction of the hard substances of the tooth is accomplished by these cells, we have no clear conception; to me it seems more probable that a fluid is secreted by the cells, which dissolves the hard substance, than the theory, held by some, that these cells are of a parasitic nature, that is to say, that the dental substances are eaten up, as it were, since the cells absorb the latter. Possibly amœboid movements may be the occasion of the wasting of the tissues.

The so-called absorbent organ, however, induces also an osseous formation, already described, since the cement, notwithstanding its partial resorption, evinces, on the other hand, a productive activity which results in the development of osseous substance within the dentine and upon the exterior of the enamel. When the cells of the milk teeth are absorbed, those of the permanent teeth are completed.*

* The organ of resorption probably is developed from the connective tissue of the root-membrane of the milk tooth, and from the medullary matter of the adjacent osseous tissue, and is, essentially, a granulation tissue, similar to that which we find in many inflammatory affections of the bone, or in tumors which are developed in the osseous substance. We also find, on the one hand, upon the periphery of sarcoma, cancer, &c., a resorption of the contiguous bone, and on the other hand, frequently a growth of trabecular osseous tissue. Therefore, during the shedding of the teeth, an hyperæmic condition occurs in the root-membrane and the medullary matter of the bone adjacent to it; the activity of the cells becomes augmented, in consequence of which the whole process of nutrition is carried on more rapidly than under ordinary conditions; the young, more vigorous cells supplant the older, enfeebled ones. In the organism of youth, also, we find that in the

When the resorption of the milk tooth is completed with the exception of a certain portion, variable according to local circumstances, its alveolus has, for the most part, disappeared, and that of the permanent tooth occupies its place. This, however, is not always the case, particularly when the milk teeth are shed prematurely, or the permanent teeth occupy anomalous positions, and in such cases there remains upon the summit of the alveolar process an oval or circular channel, in the centre of which is found a conical osseous papilla, which is to be considered as the remains of the bony substance which, in its growth, occupied the pulp-cavity (Atlas, Fig. 3).

FIG. 24.*



growth of bone, there occurs upon one side resorption, and upon the other production, as for example, in the flat bones of the skull, resorption occurs on the inner surface, growth on the outer surface which is in relation with the galea aponeurotica. Again, in the tibia, resorption takes place in the central medullary canal, and growth upon the periosteum and epiphyses. These processes, too, explain the increase in size of the cranial cavity and central medullary canal of the tibia.

* FIG. 24.—Set of milk teeth with the corresponding permanent teeth still imbedded within the jaw. The first permanent molars (*a*) have already emerged from the jaw both above and below, so that the second dentition has commenced. Profile view from the right side. The somewhat inclined crowns of both permanent incisors are visible behind the extremities of the roots of the milk incisors. The crown of the upper canine tooth (*b*) presents

Before passing to the consideration of the *separate teeth*, it is to be premised that the permanent teeth in the upper jaw are arranged somewhat differently from those in the under jaw, in their relations to the milk teeth, and also that the different kinds of teeth present variations in this respect (Fig. 24).

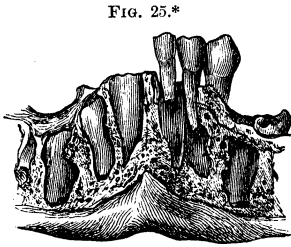


FIG. 25.*

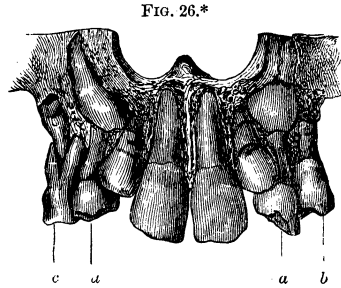
Commonly, toward the end of the fourth year, small, barely perceptible apertures appear in the *under jaw*, behind the central milk incisors, and adjacent to the lingual alveolar margin; these gradually enlarge so as to admit the incisive edges of the permanent central incisors between their smooth borders. In the meantime, similar apertures become visible behind the lateral incisors. When the edges of the permanent central incisors have reached the level of the lingual alveolar margin, the edges of the lateral incisors are still some millimetres deeper, and are inclined somewhat toward the median line and backwards (Fig. 25). Since the total breadth of the crowns of the two permanent incisors is greater than that of the corresponding milk

a marked inclination, and is situated high up in its alveolus; the lower permanent canine (*c*) likewise occupies a deep position. The crowns of the permanent bicuspid are grasped by the diverging roots of the milk molars. The mental foramen (*d*) is seen between the first and second milk teeth. The crowns of the second permanent molars, inclosed within their alveoli, are imbedded in the maxillary tuberosity and coronoid process. Natural size.

* FIG. 25.—Front view of the lower jaw at the commencement of the process of shedding the teeth, showing the relative positions of the anterior milk and permanent teeth. On the left side, the two milk incisors and canine were left in their natural positions, with reference to the permanent teeth lying posteriorly and inferiorly. The process of resorption is farther advanced in the extremity of the root of the central incisor, than it is in that of the lateral. On the right side, the milk teeth have been removed; the permanent teeth lie within their alveoli in an inclined plane. The notched edges of the permanent central incisors have reached the alveolar margin, those of the laterals being situated about two millimetres lower down; the latter teeth, also, are inclined somewhat toward the median line, although to a less degree than the conical crowns which are deeply situated and inclosed within their alveoli. Natural size.

teeth, the eruption of the former, side by side, would be impossible, so long indeed as the milk canine teeth remained *in situ*, if provision were not made to secure sufficient space, as will be shown farther on in connection with the subject of the growth of the jaw.

Similar phenomena attend the cutting of the permanent incisors of the *upper jaw*, with the exception that, in consequence of the greater difference in size between the milk and permanent incisors, the upper permanent lateral, before it is cut, has a still greater inclination than the under one toward the median line and posteriorly. Hence still more space must be provided in the upper jaw than in the lower, for the eruption of the permanent incisors (Fig. 26).



The first *bicuspid*s generally are the next to take their places in the dental range; it is not an infrequent occurrence, however, for their eruption to precede that of the lateral incisors; the second bicuspid usually succeed the canine teeth. The alveoli of the permanent bicuspid of the lower jaw are situated between the anterior and posterior root of each milk molar. As the inclosed crowns of the permanent bicuspid, taken together, occupy less space than those of the milk molars with their diverging

* FIG. 26.—Front view of the upper jaw, of a child seven years of age, presenting an abnormal dentition. The central incisors have descended to the level of the dental range; the edges of the lateral incisors are situated seven millimetres higher up; the latter also are still inclined somewhat toward the median line and backward, and consequently have not yet completed their slight rotation. The crowns and the already completed roots of the permanent canine teeth are situated high up in the anterior segment of the septum between the nasal and maxillary cavities, and are inclined toward the median line. The extremities of the roots of the milk canines (*a, a*), the crowns of which are affected with caries, are already absorbed. The first permanent bicuspid on the left side (*b*) has descended nearly to the level of the dental range, while the first milk molar on the right side (*c*) is not yet shed, and retains, between its roots, the first permanent bicuspid, the radical portion of which is developed to a slight degree. Natural size.

roots, space is reserved anteriorly, after the eruption of the first permanent bicuspid, for the permanent canine teeth. As the second lower milk molar is considerably larger than the first, while the second lower permanent bicuspid is of nearly equal size with the first, the roots of the first lower milk molar undergo a more notable resorption. In consequence of the fact that the permanent bicuspid are embraced by the roots of the milk molars, as if by forceps, it is necessary to exercise especial care in connection with the extraction of the latter, for if it becomes necessary to extract the milk molar on account of its unsoundness before resorption of its roots has commenced, the crown of the permanent molar will necessarily be extracted at the same time, because it is so tightly embraced by the roots of the milk tooth (Atlas, Fig. 15).

The permanent *canine teeth* remain within their temporary alveoli very deeply imbedded in the under jaw, with their long diameters inclined towards the median line, until the eruption of the perfectly developed permanent incisors is completed, and the first permanent molars with their roots are entirely formed; the milk molars, however, have not yet been shed. When, in consequence of continued resorption of the root, the milk canine tooth becomes so loose that it falls out, the permanent canine tooth necessarily is slightly tilted laterally on its long axis, becomes more upright, and enters directly into the space left vacant by the lower milk canine. Since, however, the latter space is too small, the space reserved after the succession of the first bicuspid now comes into play. The position of the upper canine teeth in their temporary alveoli, is analogous, that is to say, their long diameters are inclined somewhat toward the median line, and the developing roots, together with the large rounded crowns, are implanted in the osseous wedge (Knochenzwickel) between the facial wall of the upper jaw, and the septum of the nasal cavity and antrum of Highmore. The canines, when inclosed in their bony capsules, occupy the highest position of all the teeth in the upper jaw, and their crowns experience, in their descent, a slight lateral tilting, by means of which their crowns acquire a more perpendicular direction.

When the first molars have emerged completely, the prepara-

tions for the eruption of the *second molars* are completed. The jaws have increased in length in their posterior segments, and oval apertures are perceptible upon the summit of the alveolar process behind the first molars. In the lower jaw, these apertures are at the base of the coronoid processes and, in the upper jaw, in the upper part and to the outside of the tuberosities. From the posterior margins of these apertures extends a more or less distinct, shallow, short, narrow, bony groove, which is known as the *posterior dental groove*. About the end of the eighth year the apertures enlarge, and the coronal cusps of the second molars may be seen at the bottom of them. If the facial wall of the jaw and the corresponding segment of the rounded alveolus be removed, the lateral portion of the incomplete crown will be exposed. The subsequent phenomena attending the growth of these teeth are similar to those attending the development of the first molars. The process, however, is slower, their eruption not being completed until the twelfth or thirteenth year, making an interval of five to six years between the eruption of the first and second molars.

The above-mentioned posterior dental groove, ascending from the base of the coronoid process, and bending upwards like a bow over the tuberosity, bears a striking resemblance to the dental groove in the jaw of a three months' foetus. It is covered with a delicate mucous membrane. At a later period there appears in the posterior segment a small crypt (Alveole) about the size of a millet-seed, which is intended for the *third molar*, or *wisdom tooth*. A spicula of bone, the unabsorbed remains of the outer extremity of the alveolus, frequently is found, at this period, attached to the outer edge of the aperture produced by resorption, and continues to obstruct the entrance to the alveolus of the second lower molar. Concurrent with the expansion of the crypt-like depression for the wisdom tooth, an osseous lamina is developed behind the alveolus of the second molar, the alveolar septum, which gradually becomes more prominent. About the twelfth year the alveolus of the wisdom tooth, shaped like a shallow dish, attains the size of a small lentil, but still is situated high up in the tuberosity of the upper, and in the base of the ascending coronoid process of the lower jaw. As the growth of the posterior segments of the jaws is

advanced considerably, which process takes place much more slowly than in the earlier years, the alveoli of the wisdom teeth begin to advance, and finally reach the level of the dental range. In the meantime the alveoli of their crowns have become deeper and wider, and the coronal cusps become perceptible in the apertures upon the alveolar processes and gradually become larger by resorption. Their eruption occurs, as is well known, a few years before or after the twentieth year of life.

The opinion is entertained by some that the germ of the wisdom tooth is derived from a process of that of the second molar. But the facts which have been mentioned that, as the growth of the posterior segment of the jaw advances, the mucous membrane becomes extended over the posterior dental groove, and that the development of the alveolus of the wisdom tooth occurs within the latter, are much more in favor of the view that the germ of the wisdom tooth, like those of the other teeth, is the product of the formation of a sac and papillæ directly from the epithelium and corium of the mucous membrane. I have been unable to obtain histological evidence in proof of the latter theory, yet I consider it, nevertheless, as probable. According to the recent statements of Kollmann,* the enamel germs of the second and third molars are not developed directly from the epithelium of the oval cavity, but from the enamel germ of the first molar.†

* Op. cit.

† The second dentition sometimes does not commence until the second or third decade. D. Fricke, of Lüneburg (*Deutsche Vierteljahressch. f. Z.*, 1869), saw two girls, one eighteen and the other sixteen years old, both of whom still retained all the twenty milk teeth which were worn away very much.

[The permanent teeth usually appear at about the following ages, and in the following order :

First molars,	6th to 7th year.
Central incisors,	7th to 8th "
Lateral incisors,	8th to 9th "
First bicuspid,	9th to 10th "
Second bicuspid,	10th to 11th "
Canine,	11th to 12th "
Second molars,	12th to 14th "
Third molars,	17th to 21st "

T. B. H.]

THIRD DENTITION.—The possibility of the occurrence of a third dentition is doubted, and even openly denied by many. Its opponents assert that cases of presumed third dentition are merely instances in which the teeth have not emerged, but have remained imbedded within the jaw until the occurrence of senile resorption of the alveolar processes. Deceptions may easily occur in regard to them, particularly among the ignorant, as will be evident from reference to the section upon the retention of teeth. On the other hand, however, we ought not to persist in the denial of the occurrence of a third dentition, on the ground that it is contrary to the current physiological doctrines.

The writers of former times,* Aristotle, Eustachius, and Albinus, mention a repeated renewal of the teeth. In recent times, Fauchard, Bourdet, J. Hunter (the latter observed a third set of teeth in both jaws), Van Swieten, Haller, collected several such cases from different writers. Hufeland describes a case which came to his knowledge. In the one hundred and sixteenth year of life, new teeth were said to have made their appearance; six months after the loss of these, new molars appeared in each jaw. Serres observed two cases in the Hôpital de la Pitié; one of a man thirty-five years old, whose two lower central incisors fell out, and were replaced after a few months; the other of a man seventy-six years old, who, during convalescence from a bilious fever, experienced pain and swelling in the gum of the under jaw, which disappeared on the eruption of a tooth with several eminences in the place of the second molar on the left side. The margins of the alveoli had not yet disappeared in this old man.

C. A. Harris† has no doubt that a third dentition does occur in extremely rare cases, and instances a number of examples where individuals, who for a long time had been toothless, acquired several teeth, or even an entire set, in extreme old age. According to the authority of Dr. Bisset, of Knayton, twelve molars made their appearance in a woman ninety-eight years old. Harris himself observed two cases, the second of which is,

* Carabelli's and Linderer's *Geschichte der Zahnheilkunde*.

† *Principles and Practice of Dental Surgery*. Phil., 1850.

worthy of note, where four central incisors made their appearance, one after the other, on one side of the upper jaw. Such teeth, he remarks, seldom lie in alveoli, and have either no roots or stunted ones. He thinks it not improbable that duplicatures of the mucous membrane occur during the healing process which ensues after the extraction of one or more teeth. M. Carre relates the case of a woman eighty-five years old, who cut a left upper canine, and a few months later, a left lateral incisor and first bicuspid on the right side in each jaw.* Heider reported a case of multiple formation of a dwarfish canine tooth in a woman not very old.†

If we admit the occurrence of a third dentition in very rare cases, it is by no means necessary to assume, as Harris thinks, the origin of a new dental germ after the permanent teeth have been detached, since it cannot really be denied that germs may lie dormant for many years in the animal organism, until they are subjected to favorable conditions which enable them to develop. The possibility that during a long series of years a germ may remain dormant in the lateral folds of the enamel gum, cannot be rejected on theoretical grounds. Kollmann even asserts that the germs for such a late dentition have their origin in the earliest years of childhood. The fact that the crowns only are formed while the roots are stunted is clearly due to the small depth of the jaws in old age.

GROWTH OF THE JAWS.—Ossification of the *upper jaw* commences at a very early period. Sappey‡ describes five centres of ossification. As the ossification advances, sutures make their appearance, which directly disappear again. The most conspicuous suture, easily distinguished both in the fœtus and in the first years after birth, and even later, is the *sutura incisiva*, which extends from the foramen incisivum across to the septum, between the alveoli of the lateral incisor and canine. In rare cases it is also continued upon the facial wall of the upper jaw, between the above teeth, and can be traced into the nasal process as far as the inner portion of the inferior margin of the

* Med. and Surg. Reporter, 1860.

† *Vide* Anomalies of Formation.

‡ Anatomie Descriptive, 2d ed.

orbit. The alveolar portion of the upper jaw is divided by it into a smaller anterior segment, which includes the sockets of both incisors, and a larger posterior segment, which contains the remaining sockets. In such cases its analogy with the *os incisivum* of mammals is evident. The deformity known as *wolf's jaw* denotes a persisting fissure between the intermaxillary bone and the rest of the alveolar process. In *hare-lip* these bones are united, but the fissure of the upper lip persists, corresponding in its position to that of the junction of the bones. If the two upper jaws are not united at the palatal suture, the deformity known as *cleft palate* results. These malformations are considered to be the results of arrest of development, the cause of which is unknown.

The *lower jaw* is formed very soon after the collar-bone. According to Sappey (op. cit.), it has two centres of ossification, which make their appearance about the thirty-fifth day. In the fœtus, the lower jaw is divided into two halves, which are not wholly united until some time in the course of the first year after birth. With a deformity of a median fissure of the lower lip, a persistence of the median separation of the lower jaw is observed only in a slight degree or not at all.

The *direction of the growth of the under jaw* may be ascertained in part from the direction of the rays of bone. The latter may be seen in an embryo, extending along the facial wall from the head of the articulating process, which, as yet, projects scarcely above the level of the alveolar border, and in front of the margin of the ascending ramus, in horizontal and somewhat oblique directions towards the anterior segment of the maxillary arch; the latter are joined by those descending from the coronoid process which, as yet, is but slightly developed. The first-mentioned rays become closely compacted, especially in the vicinity of the lower border of the jaw, which thereby increases in thickness. The inferior dental canal primarily is open above like a groove. The growth of the lower jaw is most conspicuous upon its facial wall and inferior border. The radiation of the bone is not distinctly marked on its lingual surface, where are formed instead imbricated lamellæ or delicate networks of trabeculæ. Another centre of ossific radiation

during embryonic life, which easily escapes observation, is beneath the mental foramen. Here the osseous trabeculæ are arranged in a crescentic form around the inferior margin of the foramen. A similar radiation, with the convexity of the crescent turned downwards, may be seen about the infraorbital foramen in the upper jaw.

Towards the end of the third, and the beginning of the fourth month after birth, the articular process of the under jaw increases considerably in length, and the formation of the neck portion takes place. By a corresponding growth of the coronoid process, the saddle-like concavity of the sigmoid notch becomes more distinctly marked. At about this period, a third system of osseous rays is met with, which at a later period becomes more apparent, and extends downwards from the head of the condyle to the obtuse angle of the under jaw.

At birth, the lower jaw generally is still separated into its two halves. The facial surface of the future symphysis presents a triangular, fibro-cartilaginous portion, in which several ossific centres appear during the first months after birth. Coincident with the latter occurs the union of the two halves, together with the formation of the mental process; the former takes place from below upwards and is completed at the period of the eruption of the central incisors.

At birth, the angle of the lower jaw presents only a slight bend. Upon the convexity of this curve the osseous substance is deposited subsequently in such a manner that the vertex of the angle gradually becomes more pointed (during a year or year and a half). The angle formed by the junction of the horizontal and ascending rami changes but little during this time, but in the subsequent years it gradually becomes smaller by the deposition of bone in increasing proportion from the head of the condyle towards the vertex of the angle, while the ascending branch, at the same time, gradually increases in length.

Previous to the eruption of the second milk molar, the growth of the posterior segment in length makes considerable progress. When the growth necessary for the milk teeth is completed, a delicate, porous, osteophyte-like osseous layer is observed upon the posterior segment of the inferior maxillary arch, and also

upon the tuberosity of the upper jaw. The growth in thickness takes place principally upon the inferior border of the lower jaw, that in height is displayed in the fan-shaped ossific radiation in the alveoli, and likewise in their ascending septa. The spongy substance of the bone between the alveoli and the maxillary wall is not developed at first, and the latter lie in juxtaposition until the growth of the bone in thickness is considerably advanced, when the spongy substance makes its appearance. In the first and second years after birth, the external and internal oblique lines, together with the *spina ment. int.*, &c., are rendered more prominent by means of increased muscular action.

Changes in the Jaws during the Second Dentition.—Hunter* was the first to assert that in the portions of the jaws in which the milk teeth are placed growth ceases after the completion of the first dentition. Fox† agreed with him substantially. They reached this conclusion by measurements of macerated lower jaws. Delabarre,‡ on the other hand, endeavored by means of clinical observations to establish the fact of the growth of the bone in length after the first dentition. He asserts that, at the age of five to six years, the milk teeth separate from each other, and says, that those people with whom this does not occur are liable to have an irregular second dentition. Fox had recognized this occurrence before Delabarre, but did not give to it the same significance, for he states, “the anterior portion of the jaw undergoes scarcely more than an alteration in form; it adapts itself to the permanent teeth there situated, and scarcely receives any increase in size.” Th. Bell§ asserts emphatically that no reliance can be placed upon the comparison between jaws of different individuals. The only way to get at the truth of the matter is to examine the same jaw at different ages, and then compare the various results. “This,” says Bell, “I have repeatedly tried, and do not hesitate to say that the ten front permanent teeth occupy a somewhat wider arch than the milk teeth which preceded them.” C. A. Harris|| coincides with

* Natural History of Teeth. † Natural History of Human Teeth.

‡ *Seconde Dentition*, 1819.

§ *Anatomy, Physiology, and Diseases of the Teeth*, 1835, 2d ed.

|| *Op. cit.*

Bell's opinion, and states that the transverse and perpendicular dimensions of the anterior portions of the bone continue to augment until the completion of the second dentition, and even during youth. J. Tomes inclines to Hunter's opinion, and opposes the idea of an interstitial growth of the bone.

According to Hüter,* the growth of the inferior maxillary arch in its perpendicular dimensions is chiefly periosteal, while horizontally it is the result of the expansive osseous growth. In his opinion no notable growth takes place after birth in the whole of that part of the lower jaw between the third grinders (first permanent molars). Welcker's measurements, also, confirm this statement. Hüter opposed the idea of an interstitial growth of bone, while Rich. Volkmann, long since, and again recently,† advocated its occurrence. C. Ruge‡ and Julius Wolff,§ also, are in favor of the same view. I, myself, agree with the latter, for the reasons already given.

There can be no doubt that, as already stated, an enlargement of the maxillary arch is produced chiefly by the deposition of osseous substance upon the facial surface, and also by resorption which takes place upon the lingual surface. In this way the front teeth are pushed forward, and the back teeth outwards. This change of the location of the teeth, however, is conceivable only in case resorption also takes place in the interior of the bone, since, otherwise, the teeth, covered as they are by new layers upon the facial surface, must finally be pressed nearer the lingual surface, which evidently is not the case. An *interstitial resorption* must, therefore, take place. Fox advocates, to be sure, a change of form in the maxillary arch during its growth, but this is true only of the upper jaw. If we compare, he says, the jaw of a child with that of an adult, a marked difference will be observed; that of the child has nearly the form of a semicircle, while that of the adult presents a semi-ellipse. These changes in the maxillary arches will be considered at greater length farther on.||

In order to ascertain *the relative growth in the under jaw*, we

* Virchow's Archiv, 9 Bd.

† Centralblatt für med., Wiss., 1870.

‡ Virchow's Archiv, Bd. 49.

§ Centralblatt für med., Wiss., 1869.

|| Vide p. 95, et seq.

must first endeavor, if possible, to select points that are not liable to change, from which to make our measurements. It is self-evident that absolute accuracy is impossible, and that approximate results only can be obtained. The unavoidable errors of observation acquire greater importance the smaller the distances which are to be measured. The longitudinal dimensions are much less difficult to ascertain than the transverse and perpendicular.

I instituted a series of measurements of forty-five children's skulls, with reference to the growth in length of the inferior maxillary arch, partly also with the view of ascertaining the individual differences, making use of a thin slip of paper slightly moistened and accurately adapted to the peripheral surfaces. Measurements taken by means of a pair of compasses give a sector, when applied to a curved object, which may be the same with different curves. The mental foramen is taken as a fixed point for measurements upon the anterior segment of the lower jaw; it must, however, be remembered that the locality of this aperture is not constant. In the under jaws of adults its anterior margin falls sometimes in a line between the two bicuspids, at times directly under the first, or under the second bicuspid, and at others on a line with the posterior coronal surface of the second bicuspid. These variations, even in a small series of under jaws, give an error of from three to four millimetres. Disregarding the latter, and employing the measurements of the peripheral distance from the line of junction of the two halves of the under jaw (which may easily be marked with a pencil) to the anterior margin of the mental foramen, we found that, in a five months' foetus, the distance measured 10 mm.; in new-born children, 12 to 13 mm.; in children from 4 to 11 months old, 15 to 18 mm.; in others from 1 to 7 years old, it remained about the same, 18 to 19 mm.; in four cases, one a child 1 year 5 months 27 days old, who had cut the central incisors, it reached a length of 20 mm.; in one 1 year 10 months 10 days old, with a first molar cut, 21 mm.; in a child 5 years old, with its complete set of milk teeth, 21 mm.; in one 6 years 1 month old, with a large set of teeth, 23 mm.; from 7 to 12 years, inclusive, it varies from 22 to 24 mm., and in comparative

measurements of adults' under jaws, between 23 and 29 mm. If we disregard extreme cases, we find the most notable growth of this part of the under jaw during the first months of life, and an interval of rest after the eruption of the milk teeth, and again an increase during the shedding of the teeth, amounting to at least 3 mm. In order to meet the objection, that no account was taken of the thickness of the facial wall, separate measurements were made after the removal of the facial wall; they showed, however, as indeed was anticipated, no material difference.

Further measurements were made, in the same manner by means of a slip of paper, of the whole length of the facial surface of the under jaw from the junction of the halves, which was marked, to the most prominent point of the condyle, which may be done as long as the latter does not project very far above the level of the alveolar margin. This peripheral boundary measures, in a fœtus of five months, 40 mm.; in one of 7 months, 43 mm.; in a new-born child, 45 to 52 mm.; it increases until the fourth month to 58 mm.; till the seventh month to 62 mm.; till the first year to 67 mm.; till the end of the second year, after the eruption of the first molar, to 77 mm.; in the fourth, fifth, and sixth years, with the entire set of milk teeth, from 78 to 85 mm.; in a child seven years old, with the first permanent molar, to 100 mm. After this age such measurements cannot be made with precision. If we subtract from the latter the measurements of the anterior segments of the two halves of the lower jaw, made from the median line as far as the anterior margin of the mental foramen, we obtain a series of measurements for the posterior segments, from the last-named margin to the prominent point of the condyle. This latter series gives an increase of from 30 to 77 mm., while we found that the anterior segments increased from 10 to 23 only. The total increase represented by the quotients of the latter, 2.56 and 2.3 respectively, presents a difference which is due to the greater degree of growth of the posterior segment of the jaw. J. Tomes employed also the tubercles on the lingual surface of the lower jaw, which serve for the attachment of the *genio-hyo-glossus* and *genio-hyoideus* muscles, as a point from which to take measurements. According to my experience, however, these tuber-

cles are, often, so indistinct in the foetus, and likewise in the new-born child, and vary so much in form, size, and height in children, and particularly in adults, that the value of such measurements appears doubtful, and all the more so in the case in hand, from the fact that the calculation involves such small quantities.

Measurements of sets of teeth, taken on the facial margin of the alveolar border, from the line of junction of the jaws across the necks of the teeth to the posterior portion of the neck of the second bicuspid, gave for half the set of lower milk teeth, 32 to 34 mm.; the peripheral extent of the permanent teeth, measured in the same manner, varied from 32 to 37 mm. In many cases, therefore, the size of the under set of milk teeth conforms exactly to the corresponding segment of the permanent set; in some cases the former may even be larger, but generally the reverse is the case.

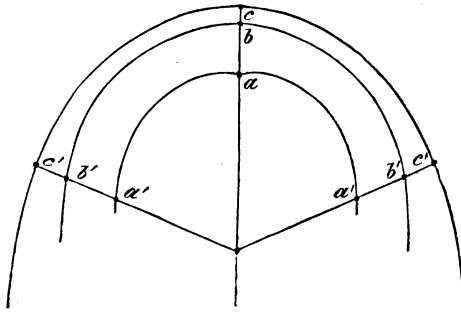
Just as the new layers of bone are deposited upon the facial wall of the growing maxillary arch, and resorption takes place upon its lingual surface, so in the development of the posterior segment of the jaw, deposition of new osseous layers takes place upon the posterior surface of the articular and osseous process, while anteriorly upon the coronoid process and condyle resorption of the osseous substance ensues. G. M. Humphrey* has proved this fact experimentally. He introduced wire ligatures through the middle of the ascending ramus of the lower jaw of a young pig, near the anterior and posterior margins of the ramus, and ascertained that, after the expiration of a certain interval, the front loop was loose and projecting, while the back one lay deeply imbedded within the posterior portion of the ramus. He states that a somewhat analogous process occurs in the upper jaw, and, on the whole, agrees with the views of J. Tomes.

In order to illustrate the *changes which take place in the arch* of the milk teeth, in comparison with that of the permanent teeth, the arches formed by a permanent and milk set and that of the outer alveolar plate of a seven months' foetus, placed one

* Transactions of the Cambridge Philosophical Society, vol. xi, part 1.

inside the other, were employed as a basis for measurements. The commencing and terminal points of the measurements were as follows: The centre of the space between the edges of the two central incisors, and the points of the intersection of the posterior coronal with the masticating surfaces of the crowns of the second permanent bicuspids and milk molars, and, in the seven months' foetus, the point of junction of the two halves of the jaw, upon the facial alveolar margin, and the outer extremity of the alveolus for the second milk molar. As they were made upon a well-developed set of milk teeth and a large set of a man twenty-two years old, they are not the mean measurements and have no claim to a very general application.

FIG. 27.*



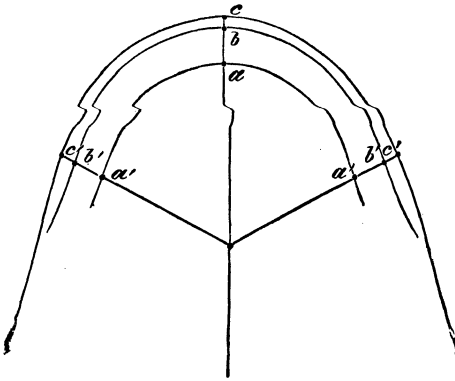
In the upper jaw (Fig. 27), it will be seen that the curve *a, a'*, obtained by the above measurements in a seven months' foetus, is very nearly the segment of a circle; in the milk set, *b, b'*, it describes a concentric arc of a circle; in the permanent set, on the other hand, it has changed into the segment of an

* FIG. 27.—Diagram illustrating the changes in the dental arch during the growth of the upper jaw. (*a*), lowest point in the junction of the anterior portions of the two segments of the upper jaw, from a foetus in the seventh month; (*b*), central point of the space between the edges of the two central incisors of a set of milk teeth; (*c*), the same of a permanent set; (*a'*), posterior and external termination of the alveolus for the second milk molar; (*b'*), point of intersection of the posterior coronal with the masticating surface of the second milk molar; (*c'*), point of intersection of the posterior coronal with the masticating surface of the second permanent bicuspid. Natural size.

ellipse, c, c' . We find, further, that the point a has advanced to b and finally to c , anteriorly, while posteriorly the displacement of a' to b' measures the same as that of a to b , but that the point c' is displaced comparatively farther outwards; in other words, $a, b = a', b'$, but $b, c < b', c'$. The permanent second bicuspid occupies a more outward position towards the face than the permanent central incisor.

A similar method was applied to the lower jaw (Fig. 28), and it was found that, in corresponding segments, the increase in growth is less than in the upper jaw, and that the curves con-

FIG. 28.*



tinue nearly parallel, that is to say $ab = a'b'$, and $bc = b'c'$ nearly; the second permanent bicuspid is placed only a little farther externally than the second milk molar, and does not, as is the case in the upper jaw, undergo a notably greater facial displacement than the central permanent incisor. If a moderately well-developed set of permanent teeth be chosen and compared with a large, well-developed set of milk teeth, the curves b, b' and c, c' coincide, and the latter curve may be met with even smaller than the first.

* FIG. 28.—Diagram illustrating the change in the dental arch, during the growth of the lower jaw; a , the highest point in the line of junction of the anterior surfaces of the two segments of the lower jaw in a foetus of seven months. The rest of the letters indicate corresponding points with those in the last figure. Natural size.

PART II.

PATHOLOGY.

I. IRREGULARITIES IN THE FORMATION OF TEETH.

THE teeth are subject to manifold anomalies which are deserving of careful consideration, since, in addition to the mere theoretical interest which they possess, many require a special operative treatment. They present for particular consideration abnormal conditions in respect of size, number, arrangement, position, and structure. The permanent teeth will be considered first, since their irregularities are the more important and of more frequent occurrence.

1. IRREGULARITIES OF SIZE.

Excessive size, so great as to constitute a disfigurement, is seldom presented by the entire rows of permanent teeth, more frequently by the front ones alone. With this condition, the crowns of the upper central incisors are particularly conspicuous, in consequence of their very great extent of surface, while their roots remain comparatively short and stunted. Sometimes the excessive size of the upper central incisors is compensated for by the lesser, retarded growth of the laterals. Occasionally the excessive growth involves both the crowns and the roots of the canine teeth, which then resemble the fangs of animals. Disproportions in size between the jaw and teeth are accompanied by corresponding changes in the arrangement of the latter which will be considered at length in subsequent pages.

Excessive growth is limited to one or another tooth, and must not be confounded with the excessive size occasioned by the coalescence of two teeth, the incisors, for example, a mistake very easily made, since the longitudinal groove which is

produced by the coalescence of the teeth is perceptible on the roots only, and not upon the blended crowns.

On the other hand, teeth may not attain the average size, and still there may be no interruption in the contiguity of the dental range. If, however, the maxillary arch is too wide, in proportion to the dental arch, intervals occur now and then between the teeth, especially between the front ones. These intervals will be so much the more conspicuous, if either of the front teeth is unusually small in comparison with the others. They occur most frequently between the two upper central, and lateral incisors, and more rarely between the lower centrals. The interval between the two upper centrals is often so wide, and occasions such a disfigurement that Heider was required frequently to fill up the abnormal space by the insertion of a tooth. In many cases, these large intervals are occasioned by the prolonged retention of a large milk incisor, which prevents the normal advance and approximation of the two permanent incisors. Generally, however, they are due to the great resistance of the alveolar septum, or the suture which unites the two segments of the upper jaw. Wisdom teeth, particularly, are liable to be stunted in their growth.

In many children, milk teeth are found so uncommonly large and strong, that they may easily be mistaken for permanent teeth, and on the contrary, in others, they are remarkably small, and at times, the milk incisors, for example, do not afford surface enough for the application of an ordinary pair of children's forceps, without danger of grasping the contiguous tooth at the same time. When the milk teeth are too large, the incisors, in particular, frequently overlap one another on account of the deficiency of space. Milk canine teeth, both in the upper and lower jaw, sometimes are unusually long and pointed.

2. IRREGULARITIES OF NUMBER.

Deviations from the normal number occur more frequently with the permanent than with the milk teeth, and a number of teeth less than normal is observed more often, perhaps, than the opposite condition. J. Tomes, on the contrary, asserts that an excess of the normal number is perhaps more common.

The excess of the normal number of teeth is either *absolute*, that is to say, there are more than the thirty-two normal teeth present; or it is *relative* if there is an excess of one or another kind, while the total number does not exceed, and, indeed, may even be less than the normal number. If it is desired to enumerate accurately the number of teeth in a set, it is not sufficient to give merely the total number of teeth existing, but the different kinds of teeth should be enumerated separately, and then all the teeth together. An adult may have the requisite number of thirty-two teeth, and still present both a deficiency and an excess of one or more teeth. It may happen that the upper jaw contains two supernumerary lateral incisors, while the wisdom teeth are wanting. Hence the total number is not altered but remains thirty-two, and yet there is an excess and a deficiency of two teeth to be specified.

Supernumerary teeth may be divided into two groups, those which can be ranked with one or another of the members of the dental series, and those which differ in form from the latter, called the conical teeth (Dutton-oder Zapfenzähne).

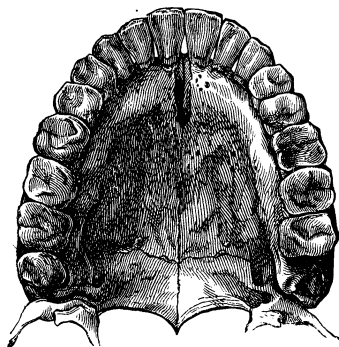
Those belonging to the first group are, most frequently, incisors and bicuspid. Sometimes five, and in very rare cases, six incisors instead of four are met with in one jaw. The supernumerary tooth usually is a lateral incisor, and generally is so well arranged in the series that this anomaly easily escapes observation, especially in the under jaw.

An extra canine tooth has been observed, but it is a very uncommon occurrence. The cases in which a milk tooth is retained in later life in close proximity to a permanent one, evidently do not belong to this class, but are liable to be misinterpreted by an inexperienced observer. Heider observed a remarkable case, that of a woman who had several canine teeth in succession, which, to be sure, were stunted in their growth. Three months after he extracted the well-developed canine, which had become diseased, a hard body, resembling the latter, made its appearance in the upper part of the socket, upon the external surface of the gum. It was of the size of a rice-kernel, and its extremity was covered with enamel. About the same interval having elapsed after the extraction of the

latter, a second, and finally a third appeared, so that in the course of a year three such canines, each provided with its root, were extracted from this woman's jaw. When three, instead of two, bicuspidis are met with, the supernumerary one generally stands inside the dental range, towards the tongue, crowded into the space between the two normal bicuspidis, so that together they form an equilateral triangle. In rare cases, three bicuspidis are met with on each side, but scarcely ever three in the upper and under jaw at the same time.

Wisdom teeth are sometimes duplicated, one standing within, and the other without the dental range. The latter is always the supernumerary tooth, occurs upon the outer side of the one in the range, and generally has a much smaller crown and a stunted, roundish root. Supernumerary molars are extremely rare, and still more rare is their arrangement in the normal dental row, as in the case of a set, belonging to a negro, which, besides four molars in each maxillary segment, contained a supernumerary bicuspid, making altogether five teeth more than in the normal condition (Figs. 29 and 30). This case suggests further inquiry, whether supernumerary molars occur more frequently, and anomalies of position more rarely, and also whether the anterior segment formed by the inferior dental arch is more circular, and the jaws longer, in the negro than in the Caucasian race? †

FIG. 29.*

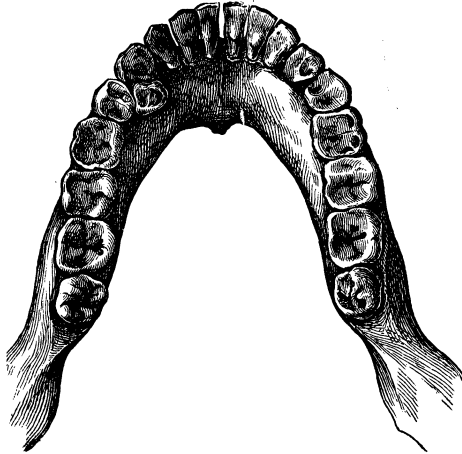


* FIG. 29.—Shows supernumerary molars in the upper jaw, from the skull of a negro (for the use of which the author is indebted to Prof. Langer). The set of teeth is remarkably well developed and regular. Behind the three large, well-developed molars, upon the right side, the wisdom tooth is placed in the dental range; on the left side it has not yet protruded, but is imbedded in the tuberosity, and may be seen in the opening made in the part. Two-thirds natural size.

† J. Mummery (Transactions of the Odontological Society of Great Britain, New Series, vol. ii) ascertained that with the Ashantees, the

An excess of normally-shaped *milk teeth* is occasioned, usually, by one or another supernumerary incisor.

FIG. 30.*



The second group of supernumerary teeth includes the so-called *conical teeth*, which can be ranked with neither of the four kinds of teeth. They resemble most the canine teeth in form, though there is no danger of confounding the two. In most cases the crown, as well as the invariably single root, is conical, and the three dental tissues are well developed; the

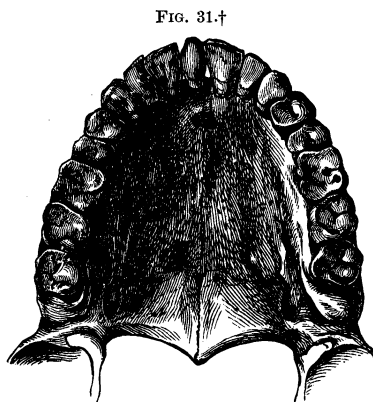
inhabitants of Dahomy and a few neighboring tribes on the west coast of Africa, the dental arches are very wide, and adduced the frequent occurrence of supernumerary teeth among them as a noteworthy fact. He observed six cases, in each of which there was a fourth extra molar in the upper jaw, in five of the cases on both sides, and in the other on one side; three cases of an extra third upper bicuspid on one side; an extra upper canine tooth in a regular position on each side, and an extra well-developed right upper central incisor. In the under jaw he did not meet with a single example of a supernumerary tooth, but the third molars were frequently larger than the second.

* FIG. 30 shows three supernumerary teeth in the lower jaw, from the same negro's skull. The arrangement of the dental row is regular. On the left side, and lingual surface, between the two bicuspids, lies a supernumerary bicuspid, which is twisted so that its lingual coronal surface is turned towards the median line of the jaw. The wisdom teeth on both sides are located behind the three large molars. Two-thirds natural size.

exposed upper surface is encircled, sometimes, by transverse grooves; the pulp-cavity is elongated into a single dental canal. In rare cases the crown is three-sided, resembling a pyramid, in which cases the root, also, presents similar surfaces, but the planes of the coronal surfaces correspond to the edges of the roots (Atlas, Fig. 1).* Sometimes these teeth are disproportionately short and thick, but ordinarily they are slender, and present many variations in respect of size.

Their locality is variable; they are placed either among the permanent teeth in the dental range, or, as is generally the case, stand upon one side of the latter. They are found implanted between the central upper incisors (Fig. 31), or between the upper centrals and laterals, frequently behind the centrals or laterals, or in pairs on the palatal portion of the upper jaw, and also at the side of the bicuspids or molars in both the upper and lower jaws. They seem never to occur in the vicinity of the lower incisors.

Their eruption takes place during the first or second dentition, or in the interval between the two. J. Tomes reports two cases, which occurred in his practice, of supernumerary conical teeth



* Fox, Nat. Hist. of the Human Teeth, p. 69, with instructive illustrations.

† FIG. 31 shows a supernumerary tooth situated at the right side of the median line and between the central incisors of the upper jaw. It has a conical crown, is well covered with enamel, and somewhat worn away transversely at the extremity. The incisors upon the right side slightly overlap, while those upon the left side stand within the dental range. The right segment of the dental arch extends about three millimetres more posteriorly than the left, on account of the insertion of the supernumerary tooth. The latter probably emerged sooner than the right incisors, and produced only a slight variation in the dental arrangement, on account of the breadth of the maxillary arch. Two-thirds natural size. (The author is indebted to Prof. Langer for the use of this specimen.)

in children five years of age. In most cases, however, they belong to the second dentition, and are permanent. The question as to whether they are secondary developments from the germs of milk or permanent teeth may be answered negatively, inasmuch as they differ in shape from normal teeth. Reasoning from the latter point of view, it is more probable that they are independent dental germs, products of the superficial mucous membrane, and do not originate, like the permanent teeth, from secondary germs.

As their eruption is coincident, generally, with that of the permanent teeth, they are more likely to interfere with the regular arrangement of the latter when the maxillary arch is too narrow or too short, and are the origin of a variety of anomalies in the position of teeth. As they occasion a disfigurement, and interfere with articulation when they are situated in the palate, in which case also the tongue is especially liable to injury, further, as they favor the occurrence of caries when they are placed by the side of bicuspid or molars, and, finally, as they are of no particular service, if allowed to remain, it is customary to extract them. A thorough acquaintance with them, therefore, is indispensable to the practitioner. In cases where the supernumerary teeth are well arranged in the dental row between the central incisors, or occupy the position of lateral incisors, it is the common practice to allow them to remain, since in the former case a disfiguring oblique position of the permanent teeth is to be anticipated under any circumstances, and in the latter it cannot be expected that the sockets of the supernumerary teeth will be filled up by a lateral displacement of the remaining teeth. The treatment is to be determined only by a careful consideration of the circumstances in each case.

The extraction of such teeth from their alveoli is attended with no difficulty, on account of the favorable form of their roots, but the adaptation of the forceps is sometimes interfered with in certain localities.

Deficiency of Teeth.—Cases of the absence of all the permanent teeth certainly are very rare. Linderer* reported the case

* Zahnheilkunde, p. 137.

of a woman fifty years of age, who never had any teeth. The examination of her mouth gave no grounds for doubting the truth of her assertion. J. Tomes* relates one or two similar cases, though in his practice he has never met with a person who did not present some indication of second teeth. Carabelli,† also, never observed such a case; and he asserts that the entire absence is an improbable, though not an impossible occurrence. Heider, in the course of twenty-three years, never met with an instance of total deficiency.

Sometimes, though rarely, *very many of the permanent teeth are wanting*, the whole set containing but a few teeth. Such cases now and then come under the observation of extensive practitioners and are referred to in nearly all the larger works on dentistry. Fox saw a young woman about twenty years of age, who retained the central milk incisors of the under jaw and, in the upper jaw, all the milk incisors except one lateral, which had fallen out. He also relates a case in which there were only four teeth in each jaw, and still another, in which there was but one incisor in the upper jaw. J. Tomes relates an instance where there was one molar on each side of the upper and lower jaw. These four molars, together with four incisors, two in each jaw, composed all the permanent teeth. It is a curious fact that the milk teeth presented no peculiarities in regard to their number, or the time at which they were shed, according to the statements of the patient and his friends.

The *absence of single permanent teeth* is not of rare occurrence. The utmost caution is requisite in judging in a given case, whether a tooth is wanting naturally or has been detached, since the statements of patients are exceedingly untrustworthy; sometimes they cannot remember which teeth, if any, have been extracted. A thorough examination of the teeth, which remain, of the sockets and jaws, is necessary before coming to a decision. Especial attention should also be given to the fact whether such defects are hereditary or not, for it often happens that the same tooth is deficient with several members of the same family.

Individuals are met with, now and then, who have only one

* Op. cit., p. 206.

† Anatomie des Mundes, p. 127.

large incisor in the upper jaw, which mars considerably the symmetry of the dental range. When this is seen, it may be assumed, almost with certainty, that the second incisor, now missing, formerly stood in its place, and was lost by a blow, fall, &c., soon after it was cut. Heider mentions a case which occurred in his practice, where a surgeon, after extracting an upper central milk incisor, the root of which was entirely absorbed, mistook the projecting extremity of the permanent incisor for the broken root, seized it, and consequently extracted the entire immature, secondary tooth. Afterwards the parents brought the latter secondary tooth to him, to be replaced in the child's jaw, but this, of course, was impracticable, with the root only half developed.

Many similar mistakes are liable to be made with the rest of the milk teeth, and the fact that these pass unnoticed in so many cases, accounts for the frequent deficiency in the number of the secondary teeth, particularly when it is considered that the gaps which remain after the extraction of teeth at such an early age are entirely effaced by the approximation of the succeeding teeth, so that the dental range presents a complete appearance, and, in such cases, many are entirely ignorant of the fact of the loss of a tooth, thinking nature failed to produce a secondary tooth.

In many cases the lateral incisors are wanting upon one side only, but a deficiency upon both sides is of more common occurrence. Of the canines, sometimes one is absent in the upper or under jaw, or both are wanting and, almost always, are concealed within the jaw, as in the case, Atlas, Fig. 4. Sometimes only one bicuspid is present upon one or both sides, and generally that is the first; the second bicuspid is often absent, but usually it is concealed in the jaw, its eruption being prevented by want of space, since it is obliged to emerge between the first bicuspid and first molar. As is well known, sometimes the upper, and, at others, the under wisdom tooth is out of sight entirely, perhaps on account of the non-formation of the germs, or, it may be that they lie imbedded in the jaw and are prevented from emerging in consequence of want of space, which latter is fre-

quently the case with the lower wisdom teeth, on account of the marked projection of the coronoid process in front.

The inspection of the relations of the locality and thorough examination of the neighboring sockets and portions of the jaw will indicate whether disproportion of space hinders the development of the tooth, or whether the latter is actually wanting. By a careful examination of the jaw with the finger, the bulging corresponding with the location of the concealed tooth may frequently be felt distinctly, and often furnishes presumptive evidence in regard to the position of the latter. Operative interference should very seldom be decided upon at once; an attempt should not be made to provide room by the removal of permanent or milk teeth which stand in the way, until, after repeated examinations, there remains no doubt about the existence of a concealed tooth, the position and development of which may be assumed to be normal, with a considerable degree of probability, upon the ground of the prominent bulging of the jaw which has been mentioned.

The absence of all the *milk teeth* is allowed to be an occurrence of extreme rarity. J. Tomes* has never had the opportunity of examining such a case, either in a living subject or in a prepared specimen. He was informed, recently, by a gentleman, that a member of his family, a female about fifteen years of age, had been from the time of her birth, and was then, entirely edentulous, and that the lower part of her face preserved the appearance usually presented by a child before the eruption of the teeth.

A diminution in the ordinary number of milk teeth is not so rare; generally in such cases the lateral incisors are absent. In regard to this anomaly, however, it is to be borne in mind that the deficiency of one or another tooth may only be apparent, since, in consequence of the contracted space their eruption may be utterly impossible, or else they can emerge only partially. Suppuration of a dental sac or alveolus, which occurs in scrofulous children particularly, involves, of course, the destruction of the corresponding tooth, and deserves mention in connection with the subject of the deficiency of teeth.

* Op. cit., p. 39.

3. IRREGULARITIES OF ARRANGEMENT.

A. Irregularities in the Arrangement of the Entire Dental Arches.—In the deviations of the set from the normal position, which occur in the Caucasian races, either the upper or the lower jaw, or both together, are more or less elongated anteriorly; their alveolar processes describe an unusually broad or narrow, oval or circular arch; the undulatory curves of the dental arches are more shallow or deeper than is the case ordinarily; the six anterior sockets of one or both jaws are more everted or inverted; the teeth, implanted in these sockets, have very long or short, broad or narrow crowns, and the latter are well or badly arranged; the dental arch presents an abnormal internal or external curvature, together with a frequent want of symmetry between the two halves of the jaw; the molars present an excessive mesial or lateral inclination, and the ascending ramus of the lower jaw is too short or too long. These examples of the principal irregularities which occur in the position of sets of teeth, give rise also to various deviations from the normal conformation of the mouth.

a. Sometimes all the incisors and canine teeth, particularly those in the under jaw, instead of being arranged side by side, in the form of an arch, are placed in a straight line so that the canine teeth meet the bicuspid nearly at right angles. The lower half of the face thus loses its oval curve, becomes broader, and gives rise to the *flat mouth*. A less degree of this irregularity is produced very frequently by a slight overlapping of the crowns of the lower incisors.

b. If the middle portions of the two alveolar arches project forwards considerably, and, at the same time, are everted, then the canine teeth and incisors, implanted in these portions, will also project obliquely forwards, and this gives rise to the so-called negro mouth (*os æthiopum*). As, with this irregularity, the front teeth in closing come together obliquely, or not at all, the pressure and counterpressure necessary for their fixation cannot take place, and consequently such teeth emerge gradually from their cells, appear to grow longer, and finally fall out much earlier than others.

c. The alveolar process of the upper jaw is often unusually deep and very prominent; the teeth implanted in it being very long and generally broad, the incisors and canines are pushed outward so far, that between them and the under teeth there is left a vacant space, in some cases five or six lines in width; frequently the palatal arch forms a sharp curve and is narrow, and the upper bicuspid and molars are everted, although to a less degree than the front teeth, so that merely their internal coronal cusps and the outer coronal edges of the corresponding under teeth come in contact; in these cases, the labial fissure is wide and the upper lip usually very short; the inferior maxillary arch presents a contracted appearance; when the mouth is closed, the lower lip lies behind the upper front teeth, and the lower incisors impinge upon the posterior gingival portions of the upper teeth. As with such an arrangement of the dental arches, and such a misshaped mouth, a person exposes nearly all the upper teeth, together with the anterior portion of the upper gum, especially in speaking and laughing, this deformity is usually called the *grinning mouth* (Fletschenmund). J. Tomes* calls attention to the fact that, in most of these cases, the molars are unusually short, and finds that there is a short alveolar process, and a short rectangular ascending ramus of the lower jaw. This conformation he regards as probably the primary cause of this deformity. G. Prochaska,† in a skull presenting an irregularity in the position of the teeth, in which the lower incisors stood three lines behind the upper ones, when the jaws were approximated, observed that the convexity of the superior alveolar arch, in comparison with that of the under jaw, was unusually great.

d. Sometimes the lower incisors and canine teeth are half an inch in advance of the corresponding teeth of the upper jaw, and, in such cases, the crowns of the lower front teeth frequently are so deep as entirely to conceal the upper incisors, when the jaws are closed. The prominent under lip overlaps the contracted upper one, and the chin is thrown forwards.

* Op. cit., p. 124.

† Observ. Anat. de Decremento Dentium, 1800.

This deformity is produced by a want of relationship between the superior maxillary arch, which is shorter, and the inferior, which is longer, than in the normal condition, and by an excessive development of the alveolar portion of the lower jaw. According to Gynnel, a natural, partial luxation, which takes place at the articulation of the lower jaw, is also to be taken into account, as contributing to its production. The deformity of the mouth which it occasions is called "*underhung*" (das Hundemaul) (la ganache of the French).

e. When the six upper front teeth are placed directly over the lower ones, so that their respective incisive margins meet edge to edge, there results the so-called *upright set*, one of the most frequent irregularities, and accompanied, usually, by the flat mouth. This position of the teeth is very favorable for mastication, for, in biting, the teeth act in a perpendicular line and become firmly pressed into their sockets, and the masticating surfaces operate to the best advantage, while the teeth are not so likely to be loosened as is the case when the front teeth are everted; on the other hand, they are subjected to more wear from attrition, so that the incisive edges and points become transformed into small masticating surfaces.

f. Another irregularity of the dental arches occurs when the incisive margins of the front teeth meet edge to edge, but both the upper and under incisors are inverted, producing a sort of channel, opening outwards, where the dental arches are in contact. In these cases, the chin projects very much, and the lips are considerably retracted. The mouth shaped by this irregularity is called, from its resemblance to that of an old person, the *senile mouth* (os senile).

g. Cases in which the mouth remains open continually, in which the sets of *teeth stand apart*, form a very disagreeable and troublesome deformity. Many people cannot bring together the anterior portions of the two rows of teeth, so that between the upper and under incisors there remains a space from two to ten millimetres in width. This space, between the two rows of teeth, gradually becomes smaller from before backwards, as far as the second molars, the masticating surfaces of the latter being partly, while those of the wisdom teeth are wholly in contact

with those of the opposite teeth. This repulsive arrangement of the two dental arches is due, generally, to a short articular process of the lower jaw, as a result of which the anterior segment of the inferior maxillary arch and the chin assume an unusually depressed position. Less frequently, the reason may be found in an irregular conformation of the alveolar process, the posterior alveoli of which are much higher, instead of lower, than the anterior ones. Still more rarely is it due to a curve or an oblique direction of the lower jaw from behind forwards and downwards. It might be attempted also to refer this deformity to the crowns of the last molars, but as the latter are always found unusually low, it is evident that the evil will not be remedied by filing or by extracting them.

h. C. Langer* mentions a form of want of relationship between the dental rows which occur in giants; the jaws are developed in height nearly in proportion to the rest of the body, and the size and shape of the lower jaw, especially, assume really monstrous proportions, the latter exceeding in its development that of the upper jaw to such an extent that its dental row frequently forms a wide arch which envelops that of the latter. The smaller the cranium so much the more marked is this monstrosity of the under jaw.

i. In cases of asymmetrical development of the two halves of the same jaw, the set of teeth presents a distorted appearance, and projects more or less, either obliquely upwards or downwards upon one side or the other.

To recapitulate, the irregular (abnormal) sets comprise, *a*, those which are flattened in front; *b*, those in which both the upper and lower ranges project; *c*, those in which the upper row is most prominent; *d*, those in which the lower is most prominent; *e*, the upright sets; *f*, those in which both rows are inverted; *g*, those in which the two rows are separated in front; *h*, those in which the lower row is too broad; *i*, the distorted sets. These include the principal forms, between which innumerable varieties may occur. The latter are the more frequent, since complex cases occur so often, which combine irregularities in the position of the entire set with those of separate teeth.

* Sitzungsber. der Wiener Akad. d. Wiss. vom, 1 Juli, 1869.

B. Irregularities in the Position of the separate Permanent Teeth.—The irregularities in the position of separate teeth may arise from several causes: 1. From the growth of the jaws being absolutely insufficient in proportion to the space required in the maxillary segments for the corresponding teeth. It has been shown in connection with the growth of the jaws, that the anterior portions of the maxillary arches grow comparatively less than the branches upon either side, subsequent to the eruption of the milk teeth, and, therefore, it is easy to understand that irregularities in the position of the anterior permanent teeth are of more frequent occurrence; 2. From a disproportion between the very wide maxillary segment and the small crowns of the teeth; 3. From an interruption in the process of shedding the teeth; when a milk tooth is retained, the corresponding permanent tooth is forced to take another position; 4. From an irregularity in the process of shedding the teeth, that is, when one or another tooth is shed and replaced prematurely, the adjacent secondary tooth is compelled to adopt another position; 5. From the early removal of a permanent tooth, in which case the socket cicatrizes and, consequently, the adjacent permanent tooth, which has not yet emerged, is compelled to assume another position; 6. From the existence of an unabsorbed alveolar cicatrix, resulting from the premature shedding or extraction of a milk tooth, which forces the secondary tooth to take another position; 7. From an anomalous position of the milk tooth, which necessitates an irregular position of the permanent tooth; 8. From the partial or complete occupation of the place of a permanent by a supernumerary tooth; 9. From an exostosis upon the alveolar process, especially upon its posterior segment; 10. From abscesses of the alveoli of the milk teeth; 11. From the presence of tumors within the jaws, collections of pus, &c.

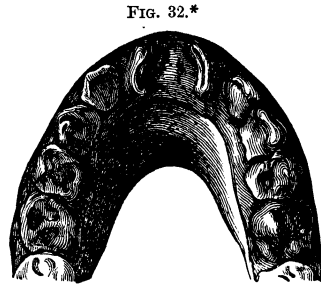
Commonly the following irregularities are presented: The long diameter of the tooth is inclined too much externally or internally towards the median line of the jaw or laterally, and frequently, if there is sufficient space to allow it, the tooth assumes a nearly horizontal position. The tooth may undergo a quarter or half revolution upon its long axis. The intervals between certain teeth and the adjacent ones may either be too

wide or too narrow, and in the latter case the teeth sometimes partially overlap their neighbors either upon the facial or lingual surfaces.

Central Incisors.—A slight degree of irregularity in position is presented by an unusually wide separation of the adjacent teeth, which occurs less frequently with the lower incisors. These large intervals, which frequently amount to a deformity, in many cases are occasioned by the protracted retention of a large milk incisor, which prevents the normal emergence and approximation of the two permanent incisors. Generally, however, they are due to the firmness of the suture which unites the two segments of the upper jaw.

Twisting of the central incisors upon their axes is by no means of rare occurrence. This may take place in the direction of the median line or laterally, to various degrees, 45° , 90° , and, in rare cases, even 180° . According to the manner and extent of the revolution, the labial surface becomes turned towards the adjacent central or lateral incisor, and, in rare cases, it is changed so as to look towards the tongue. The torsion is generally limited to one central incisor, but instances are recorded in which each has experienced a twisting upon its axis (Fig. 32).

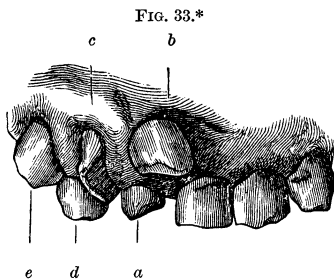
By a lateral inclination of the central incisors the crowns frequently overlap. Sometimes the central incisors are inserted more or less towards the hard palate, or the lips. In many cases one of them stands outside the range anteriorly, and the other



* FIG. 32 shows a twisting of both central upper incisors, occasioned, probably, by a hyperostosis in the palatal suture. The labial surfaces of both permanent central incisors are turned laterally, the lingual towards the median line; the lateral milk incisors are twisted laterally at an angle of nearly 45° ; the milk molars are in their normal positions; the first permanent tooth has emerged. The maxillary arch is narrow. Natural size. (From a plaster cast, for the use of which the author is indebted to Prof. Strasky.)

posteriorly, so that the lower incisors are inserted between the two when the jaws are closed. The upper incisors are frequently inclined posteriorly.

The causes of these mal-positions are numerous. The retention of the central milk incisor or its root, the premature appearance of the lateral permanent incisor, which offers an impediment to the growing tooth, or perhaps an arrest of development in the corresponding portion of the jaw, or a supernumerary tooth (Fig. 33), may be cited as predisposing causes.



As the tooth during its growth must adapt itself to the space provided for it, so does its eruption ensue regularly, or a mal-position occur in accordance with the dimensions of the space it is to occupy.

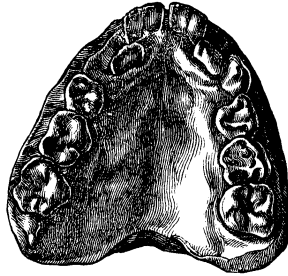
Lateral Incisors.—The axial torsions of these teeth occur almost always in such a manner that their labial surfaces are turned, to a slight degree only, towards the median line of the jaw, or laterally, and consequently are overlapped by, or themselves overlap, the lateral borders of the central incisors.

The torsion may amount to 90° , and in rare cases it reaches 180° . The lower laterals are more frequently the subjects of slight rotations than the upper ones. When the latter are involved, their axes are directed towards the canine teeth or the central incisors. It frequently happens that they are implanted

* FIG. 33 shows a displacement of the upper front teeth on the right side, produced by a supernumerary tooth. The front teeth upon the left side of the broad upper jaw were quite normally arranged, while upon the right side a conical supernumerary tooth (*a*) occurred within the dental range, adjacent to the left central incisor; this pressed the right central incisor (*b*) forwards and upwards. The lateral incisor (*c*) is twisted upon its axis, so that its labial surface is turned laterally. The milk canine tooth (*d*) is retained, and the permanent one (*e*) is implanted without the dental range, toward the face. Natural size. (From a plaster cast, for the use of which the author is indebted to Prof. Strasky.)

at the side of the dental range, either upon the facial or lingual side, the latter mal-position being most marked in narrow wedge-shaped upper jaws. In the latter, which commonly are asymmetrical, the lingual surfaces of the central incisors face each other, and the lateral incisors are implanted behind the dental range at a greater or less distance from the palatal suture (Fig. 34).

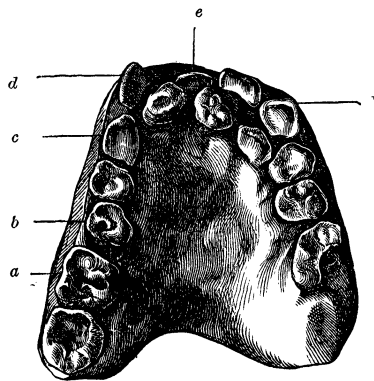
FIG. 34.*



Marked mal-positions of the front teeth are produced very often by the presence of supernumerary teeth in the anterior portion of the upper jaw, since the latter are the first to make their appearance and interfere with the eruption of the normal teeth (Fig. 35).

In the under jaw it is not uncommon to find the lateral incisors implanted upon the lingual side of the dental range; sometimes they stand directly behind the central incisors (Atlas, Fig. 138), and

FIG. 35.†

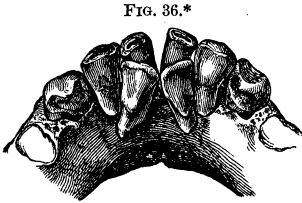


* FIG. 34.—A wedge-shaped narrow upper jaw of a young person, in which both lateral incisors have emerged upon the lingual side of the dental range, in consequence, perhaps, of some interruption in the development of the jaw, or, it may be, from the protracted retention of the lateral milk incisors. The right milk canine tooth has fallen out. (From a plaster cast.) Two-thirds natural size.

† FIG. 35 shows an asymmetrical conformation of the upper jaw in which two supernumerary teeth are implanted behind the displaced incisors. The right maxillary wall bulges forwards in front, and, between the first molar (*a*) and the second bicuspid (*b*), presents a flexion towards the median line. A deviation of the dental arch, therefore, occurs at this point, and the front teeth on this side, the canine (*c*) and the laterally twisted lateral incisor, stand in a straight line. The central incisor, upon the right side (*e*), which has not emerged completely, is located upon the median line. The

at other times they present a combination of axial torsion and mesial or lateral inclination (Fig. 36).

Probably the most frequent predisposing causes of these irregularities of position are to be found in the development of the osseous tissue in the anterior segment of the jaw, which may be too slow to correspond with the growth of the permanent teeth, or may be arrested, or abnormal in its dimensions. The developing crowns will



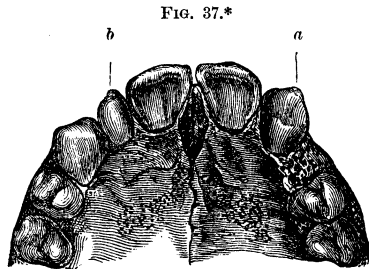
be found, even within the dental sacs, in abnormal positions. A protracted retention of the lateral milk incisors or canine teeth, or the premature cutting of the permanent canines, may occasion irregularities, and the latter may crowd the lateral incisors, before they are properly and firmly fixed, towards the median line of the jaw, or towards the tongue, and sometimes may even occasion resorption of the extremities of the roots of the latter teeth. If the canine tooth emerges upon the lingual side of the dental range, it may press the lateral incisor towards the lips.

Canine Teeth.—Irregularity in the position of these, especially of the upper ones, occurs frequently; they are situated more or less without the dental range and overlap the lateral incisor or first bicuspid, either upon the facial, or, more rarely,

left central incisor is implanted upon the left side, and the left lateral incisor upon the lingual side of the left canine tooth (*f*). (From a plaster cast.) Two-thirds natural size.

* FIG. 36.—Anterior segment of the lower jaw. View from the lingual side. The two lateral incisors are implanted behind the centrals, are twisted and inclined towards the median line of the jaw, and, together with the centrals which are inclined laterally and considerably worn away upon their coronal edges, inclose a quadrilateral space. As the lateral incisors are implanted behind the dental range, and their edges are below the level of the masticating teeth, they have not been employed in mastication and, indeed, do not in the least present any indications of abrasion. These irregularities of position were produced by an interrupted development of the jaw and, perhaps, a premature eruption of the canine teeth, which are very much worn away upon their coronal extremities. Natural size.

upon the lingual surface. In the latter case, after the complete emergence of the crown of the canine tooth, there occurs an outward displacement of the lateral incisor or first bicuspid. The inclination of the axes of the canines usually is towards the median line of the jaw. They are frequently twisted upon their axes to a slight degree and, in rare cases, present quarter and half revolutions. A quarter revolution of the crown, before it has cut through the gum or before the formation of the root is completed, may prevent the eruption of the tooth, since the facio-lingual diameter of the crown in this position is relatively too great to enter between the lateral incisor and first bicuspid. The canine tooth, therefore, remains concealed within the jaw, on account of its abnormal torsion. Sometimes the canine tooth abandons its proper place entirely, and is found by the side of the central incisor (Fig. 37), in which case the lateral incisor is located either upon the lin-



gual or lateral side of the displaced canine tooth. Much more rarely, the canine tooth is inserted between the two bicuspids.†

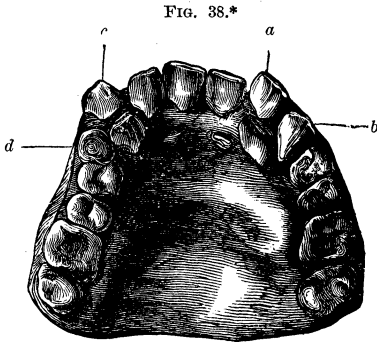
The frequent irregularities in the position of canine teeth may readily be explained when we consider that their normal eruption is provided for by the vacant spaces which remain

* FIG. 37 shows a displacement of the upper left canine (*a*) to the side of the central incisor. Posterior to the former is an alveolar cicatrix, probably the remains of the socket of the lateral incisor which emerged subsequently to the canine. Upon the right side, the canine occupies its normal position; the lateral incisor (*b*) is stunted; the bicuspids upon either side retain their normal positions. Natural size. (For the use of this specimen the author is indebted to Dr. Friedlowski.)

† The museum of the Harvard Dental School contains a cast taken from the mouth of a young woman, in which the left inferior lateral incisor and canine are transposed, the canine being turned so that its labial surface is presented towards the central incisor and the median line, while its lingual surface is presented towards the lateral incisor and backwards.

Another cast of the lower jaw of a person about sixteen years of age presents the canines between the second bicuspids and first molars.—T. B. H.

between the first bicuspids and lateral incisors, after the latter have already assumed their positions, and that these spaces are



too narrow when the growth of the jaw in length is suspended. A premature or delayed eruption of the permanent canines, a protracted retention of the milk canines, sometimes even to the third decade of life, or the insertion of a supernumerary tooth in the dental range, may also give rise to these displacements (Fig. 38).

Bicuspids and Molars.—The first bicuspids seldom, the second more frequently, are met with without the dental range and generally in the so-called small or anterior oval cavity. A premature loss of the second milk molar promotes the advance of the first permanent molar, in consequence of which the second permanent bicuspid is forced to emerge either upon the facial or lingual side of the dental range. In many cases, one or both bicuspids are twisted in such a manner that their cusps become located anteriorly and posteriorly, instead of externally and internally (Fig. 39). Insufficient space is, almost always, the predisposing cause.

* FIG. 38 shows displacement of both canines produced by the retention of the milk canines, and by the presence of a supernumerary tooth. The upper jaw is broad and has an irregular conformation. The central incisors are slightly inclined to the left side, where the milk canine (*a*), worn away by attrition, is seen, adjacent to the central incisor, while the lateral is located upon the lingual surface behind the milk canine; the permanent canine (*b*) is in the dental range, in front of the first bicuspid. Upon the right side, the lateral incisor is in the dental range; the permanent canine (*c*) is inserted without the dental range, towards the face; the milk canine, the crown of which is considerably worn away, is crowded towards the tongue. Between the canine and the first bicuspid, on either side, is a supernumerary tooth (*d*), the crown of which is very much worn away. Behind the central incisors are seen lunated folds of mucous membrane. Two-thirds natural size. (From a plaster cast, for the use of which the author is indebted to Prof. Strasky.)

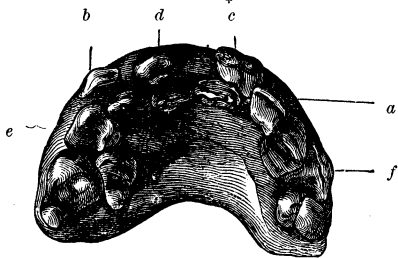
An axial revolution of 180° is extremely rare. Werner* states that in those cases, in which the milk molars are retained with the permanent bicuspid, the latter assume an oblique position. J. Tomes observed a displacement of the bicuspid, resulting from caries of the milk molars, which was followed by an alveolar abscess, and also axial rotations of the second bicuspid, occasioned by the retention of the palatal root of the second milk molar. The lower bicuspid sometimes stand so far apart, in consequence of the great abundance of room, that a person unacquainted with the true condition will be convinced either that teeth existed previously, or are to appear, in this interspace.

FIG. 39.†



The notable derangement which supernumerary teeth occasion in the position of the normal teeth, when they occur in the anterior segments of the jaws, may also extend so far as to involve the bicuspid, particularly the second, which generally in such cases are implanted towards the tongue (Fig. 40).

FIG. 40.‡



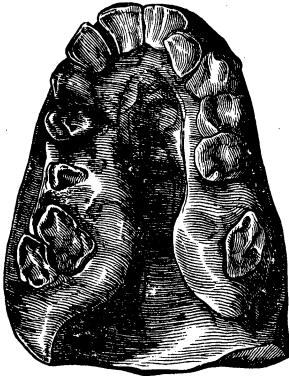
* Anomalien der Zahnstellung. Inauguraldissertation, Giessen, 1868.

† FIG. 39 shows a segment of the right half of the upper jaw. The two bicuspid are placed close to one another with their facial surfaces twisted posteriorly about 90° ; the first is crowded somewhat externally, and is in contact with the second, which is pressed slightly towards the tongue. Natural size.

‡ FIG. 40 shows marked displacement of the upper incisors, canines, and bicuspid, occasioned by two large supernumerary teeth. The two central incisors are implanted upon the lingual side of the dental range, the left slightly overlapping the right in front; the left lateral incisor (*a*) is located outside the dental range towards the face; behind the right lateral (*b*) is located the first bicuspid. Two conical supernumerary teeth (*c*) and (*d*), which are worn away upon the crowns, have emerged on the side towards the lips. The first bicuspid on the right side (*e*) is twisted several degrees towards the median line of the jaw, the second is inserted upon the lingual

An arrest of development in the posterior segments of the

FIG. 41.*



jaws sometimes occasions a displacement of the three molars, by which they are inserted so as to form a triangle. Wisdom teeth, especially those in the under jaw, when their roots are imbedded in the coronoid process, not infrequently are inclined anteriorly to a considerable degree towards the second molars, with the posterior coronal surfaces of which their masticating surfaces come in contact. Frequently their crowns present a lingual, and, more rarely, a facial inclination.

In the upper jaw, the wisdom teeth are inserted sometimes high up towards the tuberosity, and the masticating surfaces may even face posteriorly. Slight displacements of these teeth without the dental range, generally to the lingual side, are of frequent occurrence.

Marked irregularities in the position of the molars, accompanied, at times, by deformity of the upper jaw, are produced by a hyperostosis upon the alveolar process (Fig. 41).†

side of the dental range. Upon the left side, the bicuspid are separated somewhat from each other by an angular interval which opens externally, and in which projects the coronal portion (*f*) of the canine tooth. Two-thirds natural size. (From a plaster cast, for the use of which the author is indebted to Prof. Strasky.)

* FIG. 41 shows a narrow upper jaw, as if compressed from side to side. Plaster cast. The six front teeth, with the exception of the left lateral incisor which is implanted upon the lingual side of the dental range, are ranged in contiguity so as to form a very narrow arch, the arms of which are nearly parallel to each other. Three molars present a curved arrangement forwards and outwards. The extremity only of the crown of the first right molar (?) has emerged. Distinct folds of the mucous membrane are perceptible, and also hyperostoses on the lingual aspect of the posterior segments of the alveolar process, which diminish the breadth of the channel-like cavity formed by the high arch of the hard palate. Two-thirds natural size.

† In the Dental Review (1859), a curious instance is mentioned of the malposition of a wisdom tooth between the upper incisors. A. zur Nedden (Deutsche Viertelj. f. Z., 1868), obtained a plaster cast of an upper jaw in

Irregularities in the Position of Milk Teeth.—The milk teeth are very rarely met with without the dental range, and only in those cases in which all the milk teeth are very large, when, in consequence of a deficiency of space, the incisors overlap. In many cases the sharp edges of the upper incisors are inclined very much towards the tongue, and the canines, uncommonly long and pointed, are crowded towards the face.

In extremely rachitic individuals, abnormal positions of milk teeth are frequently met with, since in these cases the growth of the jaws in length is retarded by a hyperplasia of the connective tissue in the bone (Atlas, Figs. 144 and 145). In the latter case, moreover, it is to be observed that, although the process of decalcification has made such progress in the bony structure that the latter has become flexible and may be cut with a knife, it has not in the least affected the crowns and the growing roots of the teeth. The development of the tooth, therefore, continues, notwithstanding the notable interruption to the growth of the bone. If the rachitis does not become very decided until after the milk teeth are cut, then the permanent teeth, still inclosed in the dental sacs, may be displaced from their normal positions.

Abscesses of the periosteum of the root, which occur particularly in scrofulous children and sometimes after cutaneous eruptions, may produce considerable destruction of the bone, dis-

which a molar occupied the place of a central incisor, neither of the normal incisors being present.

All teeth which are inserted upon one side of the dental range, or overlap the anterior or posterior contiguous teeth either upon the facial or lingual surface, are very liable to be affected with caries, because, even with the utmost cleanliness, the particles of food cannot be removed entirely from the intervals between the teeth. Moreover, it is a very difficult matter to apply to them the ordinary methods of treatment, for a tooth, which is inserted externally, cannot be reached upon the inside, and one situated internally cannot be reached upon the outside, on account of the close proximity of the adjacent tooth. Therefore they require peculiar and extremely difficult methods of treatment. When a bicuspid is twisted to the amount of 90°, the operative treatment is attended with still greater difficulties, because the surfaces of its roots are directed outwards and inwards, and consequently offer greater resistance by reason of their more numerous points of contact with the walls of the alveolar process.

placements and partial destruction of the milk or permanent teeth, which are still inclosed in the dental sac.

C. Irregularities in the Position of Separate Permanent Teeth which are Imbedded within the Jaw.—It sometimes happens that a tooth, during its development, acquires a more or less inclined or horizontal position, and consequently, when its development is completed, projects but little, if any, beyond the alveolar wall. The causes of these extremely curious deviations of position can be ascertained only by a special anatomical examination of each individual case. As a general rule, it may be assumed that the change of position must occur prior to the development of the root. The growth of the latter, modified by the local relations, takes place in an opposite direction to that of the incisive margin or masticating surface of the tooth whose position is changed, *i. e.*, if the masticating surface is inclined forwards, the root grows from before backwards. These irregularities include a great variety, and all the predisposing causes which have been mentioned previously are equally applicable to them. J. Tomes* illustrates a case in which the crown, as well as the root of the right *central incisor*, is imbedded in an oblique position within the bone, beneath the floor of the nasal cavity, its normal position being occupied by a supernumerary tooth, which, it is obvious, prevented the emergence of the incisor.

Figs. 2 and 3 of the Atlas illustrate a case in which a well-formed *lateral incisor* occupies a horizontal position in the angle formed by the floor of the antrum and the nasal process of the upper jaw, its incisive edge projecting through an oval opening with smooth edges, at the side of the *apertura pyriformis*. The cause of this displacement is obvious in the presence of an irregularly formed tooth which is inclosed in a smooth-walled osseous capsule, and projects near the edge of the alveolar process, and, perhaps, is the rudimentary lateral milk incisor, since its position is directly over that which a milk incisor should occupy; or it may be the shapeless mass of a supernumerary tooth.

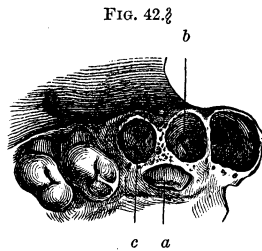
The *canine teeth*, more frequently than any others, are the subjects of total displacement, a fact quite easily understood; the upper canines are more frequently displaced than the lower,

* System of Dental Surgery, p. 183.

as the front teeth of the upper jaw require more space. Albinus* describes a case with a canine situated between the nasal cavity and the orbit on either side, whose crowns were directed upwards. J. Hunter† reports a similar case. Wait observed a case where the radical extremity of a canine pierced the gums externally. J. Tomes‡ gives a series of illustrations in which the permanent canine is displaced behind the dental range, the root being curved very much, or placed across the dental arch, with its apex directed towards the median line of the palate, its crown towards the cheek and projecting slightly, or in a horizontal position, with the coronal apex in front and the root extending posteriorly or into the floor of the nasal cavity.

The succeeding series of figures will serve to illustrate the causes of partial or complete permanent embedment of the canine teeth within the jaw. In the case, Fig. 42, the retention of an upper milk canine occasioned a twisting of the crown of the permanent tooth, and forced it to assume an oblique position, pointing towards the median line, so that its eruption progressed to a slight degree only behind the dental range.

In the under jaw similar conditions are met with. In Fig. 43 the retained milk canine tooth produced an axial revolution of the developing crown of the permanent canine, as in the preceding case, and has inclined it towards the horizontal line, so



* Adnot. Acad., i.

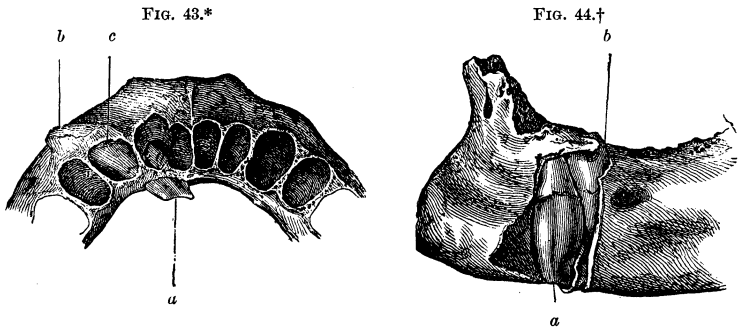
† Nat. Hist. of Teeth.

‡ Op. cit.

§ FIG. 42 shows the incomplete eruption, upon the palatal surface of the alveolar process, of the crown of the right upper canine which has an oblique direction towards the median line. (The specimen is from a young subject, and for the use of it the author is indebted to Dr. Friedlowsky.) The permanent incisors and the temporary canine have been detached by maceration. The slightly projecting crown of the permanent canine tooth (a) has given rise to a sharp-edged opening, the result of absorption, upon the alveolar process, and, in the same manner, the corresponding portion of the alveolus of the lateral incisor (b), and also that of the milk canine (c), has been absorbed. The first bicuspid was slightly twisted by the curved root of the permanent canine which is imbedded within the jaw. Natural size.

that its extremity only has emerged beneath the alveolar margin.

A forward inclination and quarter revolution on the part of the first bicuspid may also produce an axial revolution of the growing canine, and entirely prevent its eruption (Fig. 44).



Goethe observed‡ in an osteological preparation in the possession of Rapp, in Stuttgart, 1797, a total displacement of a *bicuspid* which was located in the nasal cavity beneath the margin of the orbit, its roots firmly attached to a small, round, plaited osseous mass; it extended obliquely downwards and

* FIG. 43 shows the anterior segment of the lower jaw in which the left canine tooth is placed horizontally beneath the alveolar margin. The coronal extremity has emerged upon the lingual wall of the lower jaw (*a*). The labial surface of the crown is upwards. The root is turned obliquely outwards, projects beyond the labial wall of the jaw, and has given rise to resorption in the corresponding portion of the wall (*b*). A portion of the posterior wall of the alveolus of the left lateral incisor has been removed by resorption; the superior circumference of the alveolus of the milk canine (*c*) is still well preserved. Natural size.

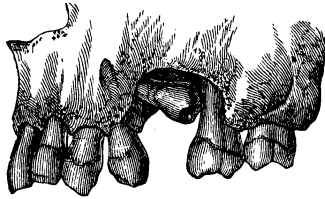
† FIG. 44 shows a segment of the lower jaw from which a portion of the facial wall was removed in order to display the left canine and first bicuspid, which are not yet cut. The canine remains in a perpendicular position, and its radical extremity (*a*) reaches to the inferior border of the lower jaw; its labial surface is directed forwards and inwards, and its coronal and radical portions are in contact with the first bicuspid (*b*) which, also, is imbedded within the jaw, its internal coronal cusps alone being slightly exposed, and is inclined anteriorly and twisted on its axis to the extent of a quarter of a turn. Natural size.

‡ Schweizerreise.

backwards, and emerged from the palatal portion of the upper jaw behind the incisive canal, where its crown was but slightly exposed upon the surface of the palate. J. F. Meckel* met with an upper second bicuspid, the crown of which pointed directly upwards. The first bicuspid was detached at an early period, and there was a large gap between the canine and first molar. An abscess of the root-

membrane of the first milk molar may have given rise to the rotation of 180°. A nearly horizontal position of the second left bicuspid in the upper jaw, as shown in Fig. 45, in all probability was occasioned by an inflammation of the periosteum of

FIG. 45.†



the root of the first molar, which was followed by a destruction of the corresponding portion of the alveolus and, without doubt, occurred at an early period while the process of shedding the milk molars and eruption of the bicuspid was in progress. The cicatrization, which encroached upon the territory of the second permanent bicuspid, may have been the cause of the deviation of its coronal portion, in consequence of which the masticating surface became directed backwards and slightly downwards. The tooth emerged in the gap in the dental row, while the growth of the radical portion took place in a direction forwards and a little upwards. By the removal of the alveolar wall it was ascertained, further, that the roots of the first and second bicuspid were not blended together, since their extremities had been kept apart by a thin osseous lamina.

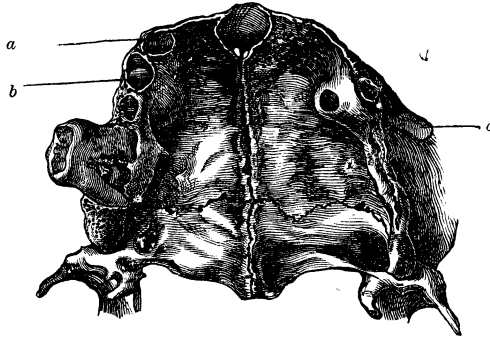
Abnormally short jaws sometimes contain several permanent teeth imbedded within them in irregular positions, which do not

* *Tabulæ Anat. Path. Fasc., iii.*

† FIG. 45.—Facial view of the left upper jaw. The second bicuspid has a nearly horizontal position, its masticating surface being directed towards the anterior facial roots of the second molar; the crown and neck lie in the upper part of the alveolar process, within an excavation which probably resulted from an alveolar abscess of the first molar. Two-thirds natural size. (For the use of this specimen the author is indebted to Prof. Langer.)

make their appearance until the occurrence of senile atrophy of the alveolar process, and then only partially emerge (Fig. 46).

FIG. 46.*



The *wisdom teeth* are more frequently the subjects of a total displacement. The reason for this is quite obvious, from the fact that they are the last to take their places in the dental series and therefore have reserved for them that space only which remains vacant at the posterior extremity of the jaw. In the upper jaw an axial displacement, by which the masticating surface becomes directed posteriorly, is the most frequent. If the coronal portion is bent from its normal position, so as to

* FIG. 46 shows a bicuspid upon the right and left side imbedded within the short, distorted upper jaw of an old person. On the right side, behind the alveolus of the canine tooth (*a*), the alveolar process becomes prominent and presents two cavities, at the bottom of which are seen the two coronal cusps of a bicuspid (*b*), with the longitudinal groove between them extending from side to side. Finally, this segment of the jaw also presents the wisdom tooth imbedded within the maxillary tuberosity in a horizontal position, with its crown directed posteriorly and its roots inserted between those of the second molar, as may be seen upon the buccal surface of the maxillary wall. Upon the left side cicatrization has taken place in all the alveoli. The crown of the bicuspid, however, which is imbedded within the jaw in an oblique position, may be seen through the openings resulting from resorption in the bulging portion of the alveolar process, while its radical portion (*c*) forms an oblique projection upon the buccal surface of the jaw. The lower jaw corresponds to that of extreme old age and is edentulous, with the exception of one bicuspid. Natural size. (For the use of this specimen the author is indebted to Dr. Friedlowski.)

describe an arc of 90° , the growth of the roots takes place from behind forwards, in a more or less horizontal direction, and the latter come in contact with those of the second molar, sometimes even blend with them, so that the second and third molars, by the coalescence of their roots, form an inseparable whole (Atlas, Figs. 18 and 19). If now the growth of the roots of the wisdom tooth continues from behind forwards, the crown necessarily emerges posteriorly and, consequently, induces a partial resorption, varying in extent, of the maxillary tuberosity of the upper jaw. The crown of the wisdom tooth may also be inclined externally or internally, and the roots be placed across the jaw in a more or less horizontal position. The rotation sometimes amounts to 180° , so that the masticating surface is directed upwards and the roots downwards.

In the lower jaw, an inclination of the crowns of the wisdom teeth from behind forwards, is most common, in which cases the growth of the roots takes place in the ascending ramus. Werner* also mentions cases which came under his observation where the lower wisdom tooth assumed a nearly horizontal position, the roots being inclined obliquely downwards and backwards, and the crown forwards, so that only the posterior and upper portion of the crown was visible. Sometimes the germ of the coronal portion of this tooth is displaced so far posteriorly, that the crown of the tooth becomes imbedded within the ascending ramus of the lower jaw, reaching nearly to the level of the sigmoid notch. Finally, the crown of the wisdom tooth may be the subject of a rotation on its transverse axis to the extent of 180° , in which case the inverted crown is grasped by the roots of the second molar.†

D. Retention of Teeth without Displacement.—Cases are frequently met with, where completely developed permanent teeth remain during life, partially or entirely inclosed within the jaw, in the places where their development took place. The position of such teeth is not really anomalous, and becomes irregular

* Op. cit.

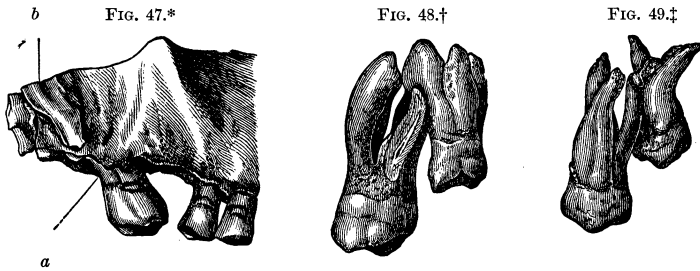
† Compare the instructive illustrations given by J. Tomes, op. cit., p. 192 et seq.

only because it persists during the later periods of life. Those teeth are most frequently the subjects of this irregularity, which, as their growth continues, should occupy the spaces left vacant by the already developed adjacent teeth, namely, the canines and second bicuspid. The canine tooth, as we know, is obliged to insert itself between the permanent lateral incisor and first bicuspid, after the latter have taken their positions in the dental series, and the second bicuspid enters the interval left vacant between the first molar and the first permanent bicuspid which have already emerged. If, therefore, from any cause a disproportion exists between the above-mentioned intervals and the circumference of the crowns of the teeth which are to occupy them, the complete eruption of the canine or second bicuspid will be prevented partially or entirely.

An instructive case is illustrated in the Atlas, Fig. 4, where both canine teeth are imbedded within the lower jaw and are slightly twisted upon their axes, the right towards the lateral incisor and median line of the jaw, the left laterally towards the first bicuspid. The development of the radical extremities of both canines, in the direction of their long diameters, was possible only to a certain extent, and they are bent at nearly right angles, each in a different direction. The case, therefore, is quite complicated, as it illustrates not only a retention of both canines within the under jaw, but also an axial revolution and a deviation in the direction of growth of the radical extremities. The extent to which the incisors are worn away indicates that the specimen belonged to a person of advanced age, and so it may be assumed that, had all the adjacent teeth become detached and an atrophy of the alveolar process ensued, the coronal extremities of both the imbedded canines would have made their appearance. Possibly the prolonged retention of the milk canines occasioned the axial revolution of the permanent teeth and, consecutively, prevented the eruption of the latter, but this point cannot be determined.

Wisdom teeth, especially those of the under jaw, are most frequently subject to retention. The space necessary for their eruption in the maxillary arches, which so frequently do not grow to a sufficient length, is preoccupied by the teeth which

have made their appearance, and, therefore, there is no room left for the wisdom teeth. Sometimes the upper second molar is crowded so far backwards towards the tuberosity, that the further descent of the third becomes impossible. In the same way, the space in the lower jaw becomes diminished when the second molar is crowded close up to the ascending ramus. In addition to the disproportion between the lengths of the maxillary and dental arches, special causes, which are not readily distinguishable, also occasion the retention of the wisdom teeth. Sometimes, during the process of cicatrization which ensues after the detachment of the first upper molar, the second molar acquires a forward inclination which prevents the emergence of the wisdom tooth, since the posterior external root of the former impinges upon and opposes the advance of the crown of the latter (Fig. 47).



* FIG. 47 shows an obstacle to the descent of the right upper wisdom tooth, in a facial view of the posterior segment of the upper jaw. The first molar was detached some time previously; the second is inclined anteriorly, and the extremity of the posterior facial root (*a*) has a corresponding deviation posteriorly, and presses against the descending masticating surface of the wisdom tooth, the facial surface of which (*b*) has been exposed by the removal of the alveolar wall. Two-thirds natural size.

† FIG. 48 shows the union of the roots of the upper second molar on the left side, with those of the wisdom tooth, as seen from the facial side. The posterior facial root of the second molar, which has been filed away to show the root canal, impinges upon the anterior facial root of the wisdom tooth, and is united to it by means of cement; in the same manner, the lingual root of the second molar is united with the anterior facial root of the wisdom tooth by means of a quite thick layer of cement. These teeth were extracted on account of chronic inflammation of the root-membrane and suppuration of the gum. Natural size. (For the use of this specimen the author is indebted to Dr. Jurié Gustav.)

‡ FIG. 49 shows a union of the posterior facial root of the upper second

Sometimes a union of the roots of the second upper molar with those of the wisdom tooth, also, prevents the descent of the latter. In such cases the wisdom teeth are found in a normal position, but are situated one centimetre higher than usual (Figs. 48 and 49).

Teeth which are retained within the jaw frequently make their appearance unchanged in the later periods of life, when their emergence is promoted by the loss of the other teeth and by the changes which take place in the jaws in old age. People who are ignorant of this fact interpret the occurrence falsely as an evidence of remarkable vigor, when, in reality, it is only an indication of old age. These teeth always emerge very slowly, and are rarely of much value to the possessor.

4. IRREGULARITIES OF STRUCTURE.

These involve either all the teeth in common, or a part of them, most frequently, however, separate teeth or only their coronal or radical portions. In general terms, they comprise growth in an abnormal direction; excessive, stunted, or arrested development of the dental tissues; the coalescence of two dental germs and the blending of roots; monstrous malformations of the crowns and roots, and double malformations of the teeth.

a. Flexions and Torsions of the Crowns and Roots.—In rare cases, teeth which have single roots are bent at right or more obtuse angles in the coronal portions or in their immediate vicinity, while the roots, in these cases frequently stunted, retain their normal positions. With the crowns of incisors, rectangular flexions are most frequently observed, their incisive edges being directed forwards or backwards, or inclined to either side. When the crown of an upper incisor is bent towards the lips, the palatal surface of the tooth is directed downwards, and upwards when the flexion is towards the tongue. The reverse is the case with the incisors of the lower jaw.

molar on the left side with the blended facial roots of the wisdom tooth. View from the facial side. Natural size. (For the use of this specimen the author is indebted to Dr. Friedlowski.)

The development of a crown which is the subject of this distortion may go on to completion; examination of the enamel, however, in the vicinity of its terminal portions, will show a variation from the normal arrangement of the layers, inasmuch as the enamel is thicker at the vertex of the angle of flexion, while the margin of the enamel is furrowed in some cases, and raised into a fold in others (Figs. 50 and 51). Sometimes cleft-like gaps, lined with very thin layers of enamel, are met with, which likewise indicate irregularity and interruption in the development of the enamel. These circumstances justify the assumption that the flexion takes place prior to the completion of the formation of the enamel cap of the crown. The growth of the roots may continue in the normal direction after the occurrence of flexion of the coronal portions.

These flexions should be studied carefully by practitioners to whom such teeth are presented for the purpose of being straightened, because the distortion can neither be removed nor improved, and there is nothing to be done except to extract the tooth affected. Care should be taken not to confound cases presenting this deformity with those in which normally formed teeth assume an oblique or a nearly horizontal position, and which, under favorable circumstances, may be treated with success. A careful examination of the teeth and jaws, and particularly the existence of slight irregularities upon the crown of the tooth in question, for example, notable bulging upon either

FIG. 50.*

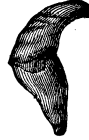

FIG. 51.†



* FIG. 50.—Lateral view of an upper central incisor. The crown is completely developed; the extremity of the short, thick root is turned towards the lips. On the edge of the enamel, on the lingual surface, rises a sharp ridge, corresponding to which, upon the labial surface, is a constriction. Natural size.

† FIG. 51.—Lateral view of a lower central incisor. The crown is bent at a right angle, so that the incisive edge, with its three denticles, is directed towards the lips. The lingual surface is turned obliquely upwards. In the vicinity of the neck of the tooth, at the part corresponding to the vertex of the angle of the flexion, a distinct layer of enamel is presented, which resembles a flattened nodule and, when examined with a lens, seems to be separated from the enamel of the crown by a narrow zone of dentine. Natural size.

surface of the horizontally placed crowns, a very narrow neck, and a marked mobility of the tooth under slight pressure, will indicate, with a considerable degree of probability, the existence of a flexion of the crown at an angle with the root.

Flexions of the *roots* are met with near the necks, in the middle portions, or at the extremities, and are of various degrees. Those of a moderate degree are limited to a slight S-shaped curvature; those of a higher degree present a step-like deviation (Atlas, Fig. 7), or a sharply defined bend of the axis of the tooth (Fig. 52). Flexions at the extremities are the most common, and are single, double, or zigzag (Fig. 53).

FIG. 52.*



FIG. 53.†



The pulp-cavity is inclined in correspondence with the flexion of the crown, and the root-canal, in conformity to the flexion of the roots, presents one or two deviations from the straight course. The continuity of the dentine is uninterrupted, as its canals adapt themselves to the direction of the deviating portion.

Axial torsions of the crowns present an appearance such as would be produced by twisting the coronal portion about its axis, so that the corresponding surfaces of the crown and root do not lie in the same planes. Such irregularities of formation are met with only in teeth with single roots, particularly in canine teeth, but also in bicuspid. They are twisted from 90° to 180° , so that the facial surface of the crown is turned towards the tongue, which, however, does not prevent the root from retaining its normal position. Deficiency of space, at the time when the crown is just formed, may, with reason, be assumed to be the cause of this phenomenon, while, during the subsequent expansion of the contracted space, the root would be enabled to develop in its normal position. Similar circumstances, namely, the adaptation of the growth of the root to the varying space

* FIG. 52.—Lateral view of a central upper incisor, which presents a sharply-defined flexion in the upper half of the root. Natural size.

† FIG. 53.—Lateral view of an upper central incisor, which presents a double flexion towards the extremity of the root. Natural size.

provided for the latter, may also be the cause of the spiral twisting of roots which is met with.

From the appearances which are found upon the bent crowns and roots, there can be no doubt that the direction of growth of the tooth may be altered by external influences, and in the following manner: either the crown undergoes a more or less distinct deviation in the direction of its growth, prior to the completion of its development, or a deviation takes place subsequently, in which case it occurs at the neck, or in the vicinity of the middle or the extremity of the root. The process may be conceived of as occurring in the following manner. The development of the formative cells of the enamel, upon the surface of the enamel organ, is arrested in some parts by external influences, while, in others, a proliferation of the cells ensues. Similar influences induce a variation in the arrangement of the dental cells which become inclined in one or another direction.

J. Tomes* first directed attention to that remarkable irregularity of formation, which he describes as "dilaceration of partially-developed teeth from the formative pulp," and considers it to be the result of a forcible displacement of the cap of developed dentine from the pulp, the development of the dentine being continued in this abnormal position. That the incisors and bicuspid are the subjects of dilaceration, he explains by the fact that they are more exposed to accidental influences.

In many cases, external mechanical influences apparently do give rise to flexion of a tooth during its formation; in such instances, however, sufficient evidence must be adduced to show that the blow or kick, and the like, really occurred during the process of formation of the tooth. Generally, however, patients are unable to recall any such occurrences, which may have been mechanical causes; indeed such a cause often is not in the least to be thought of in cases in which the bent crown has emerged only partially or not any. Evidently, also, dilaceration, resulting from a kick, blow, or fall, could not have been intended in the sense that portions of the soft dental tissues are ruptured; in that case a circumscribed cicatricial tissue could be demonstrated,

* Lectures upon Dental Phys. and Surgery, and System of Dental Surgery.

which, however, is not the fact, for only a displacement of the dental tissues is met with. With this view of the subject the term "dilaceration" was not well chosen.

In particular cases it is quite possible that continued pressure of a tooth already cut upon one whose development is interrupted, or whose eruption is retarded, may give rise to a flexion or displacement of the coronal portion. The singular fact, that up to the present time these coronal flexions have been observed only in teeth with single roots, cannot be satisfactorily explained.

Flexions, at the commencement, in the middle or at the extremity of roots, evidently cannot be caused by any accidental external influences, but always are induced by the contracted proportions of the space provided for them, of which mention has been made. In many cases a want of proportion between the depth of the jaw and the length of the root gives rise to a flexion, as also may the retarded eruption of a tooth, which compels the root, as its growth continues, to turn off at an angle. The facial or lingual wall, especially of the under jaw, may also exert an influence, if the roots, growing in an irregular direction, strike against the wall.

Flexions of the crown or neck have a deceptive resemblance to a united fracture of a tooth, and have been regarded as such, as in the case described by H. Hertz;* but the principal evidence in proof of the occurrence of a fracture, the formation of a callus, is wanting in these cases.†

b. Excessive Growth upon the Crowns and Roots.—The lesser irregularities coming under this head comprise chiefly the so-called *enamel nodules*, which are of small size and, also, occur in particular localities. Most of them are hemispherical superficial growths, varying in size between diminutive nodules barely visible to the naked eye and those two to four millimetres in diameter. They are located upon the necks of teeth with multiple roots, at a slight distance from the boundary of the enamel, or even upon or between the roots (Atlas, Figs. 23, 25, and 26). They have a white, polished, pearly, clear, rounded appearance,

* Virchow's Archiv, Bd. 38.

† C. Wedl, über Knickungen und Drehungen an den Kronen und Wurzeln der Zähne, Deutsche Viertelj. f. Z., 1867.

always are attached by the flat surface of the spherical segment, and, not infrequently, are united with the zone of the enamel by a narrow, spinous, sharp lamina. Heider and I, up to the present time, have observed well-formed enamel nodules only upon the molars of the upper jaw; and have never met with them upon teeth with single roots, but J. Tomes* gives an illustration of a case in which a large nodule of enamel is attached to the neck of a tooth with a single root.

Occasionally *ridges of enamel* are met with on the molars of the lower jaw, which, commencing at the boundary of the enamel on the neck of the tooth, are prolonged directly between the anterior and posterior roots, but without forming nodular enlargements.

Although these enamel nodules are of rare occurrence, still they are more common than is supposed, since, on account of their unusually small size, they are liable to escape observation on teeth which have just been extracted and are covered with blood. It is obvious, that the nodules or ridges which are met with upon the molars are the results of localized continuations of the development of the enamel between the already developed basal portions of the roots, and are produced by the strip of the enamel organ which has persisted longer than the rest.

If a section be made through an enamel nodule, it will be found that the enamel forms a thick layer upon a truncated cone of dentine (Atlas, Fig. 24). In many nodules, cross-sections of the enamel have a light color and indicate a normal formation, while others present an abundant deposit of pigment and an irregular arrangement of the prisms. The dentinal cone is a direct prolongation from the dentine of the neck or root, and contains dentinal canals which assume a regular arrangement and a radiating course. Occasionally one or more empty spaces or cavities are met with which are filled with minute granules of calcareous salts.

With reference to their structure, the enamel nodules are to be regarded as lateral offshoots from the teeth, and are to be classed with the small dentiform excrescences which are met

* System of Dental Surgery, Fig. 102.

with, sometimes, upon the facial or lingual surfaces of the molars, especially those of the lower jaw. In many cases, particularly upon the upper milk molars, a cusp, covered with enamel, is met with upon the lingual aspect of the neck, the apex of which projects through the gum as if it were isolated, and may lead to the false supposition that it is a new tooth which is just emerging.

An excess in the number of *roots* is not uncommon. Supernumerary roots sometimes are stunted in their growth, at others, they are completely developed, and occur either in the form of lateral offshoots, or are produced by a division of the flattened roots, as is the case, particularly, with the lower incisors and canines (Fig. 54), the upper bicuspid, and upper and lower molars.

It is very uncommon to find two completely separate roots upon the upper incisors and canines, or upon the lower bicuspid, that is to say, upon the teeth which properly have, single, conical roots (Fig. 55). A partial division at the radical extremity of a lower bicuspid is extremely rare. Supplemental roots, consisting of lateral offshoots which are located in the region of the neck of the tooth and attain scarcely one-third the length of the normal root, are met with, though rarely (Figs. 56 and 57).

Roots which arise from a division are always conical, in other words, cross-sections of them are circular.

Carabelli* observed an extremely rare case, in which all the bicuspid of a skull had three roots. The upper ones were seen to possess three entirely distinct roots, and the existence of the same number upon those of the lower jaw was indicated by deep depressions corresponding to them. Bicuspid, first ones especially, with three roots, are frequently met with, in which cases the arrangement of the roots is similar to that of the roots of the molars, but they stand close to one another, so that the teeth are more easily extracted (Fig. 58). Sometimes the upper bicuspid have two separate, divergent roots (Atlas, Fig. 6); the divergence, in some cases, being so great, that ex-

* Anatomie des Mundes.

traction of the teeth is accomplished very seldom without fracture of one of the roots.

The occurrence of upper molars with five, and lower ones

FIG. 54.*



FIG. 55.†



FIG. 56.‡



FIG. 57.§



FIG. 58.||



with four roots is accounted for by a division of all the flattened roots belonging to them. When the upper molars have four regularly formed roots, the two flattened ones, as is the case normally, are placed upon the outside, and the rounded ones, opposite the first, upon the inside. Consequently the second internal root is to be regarded rather as a supplemental one, that is to say, not the result of a division.

Sometimes all the lower molars have a third root which is roundish and located internally, towards the cavity of the mouth. It gives to the lower molar a form similar to that of an upper and might, therefore, lead to a confounding of the two; but they may be distinguished by the fact that, in the lower molar, this third root always arises from the inner surface of

* FIG. 54 shows a longitudinal section of a canine, with two root-canals in the divided root. Canines are also met with, in which a single root presents two root-canals. Natural size.

† FIG. 55 shows a lower bicuspid with two broad roots; the latter are of equal length, separate, flattened, and marked by a shallow groove. Natural size.

‡ FIG. 56 shows an upper central incisor with a short, conical supplemental root, arising from the neck of the tooth. View of the labial surface. Natural size.

§ FIG. 57 shows a much worn lower incisor, the lingual surface of which is bevelled, and upon its neck is located a short, conical, supplemental root. Natural size.

|| FIG. 58 shows the anterior surface of an upper bicuspid, with three distinct, slightly divergent roots, and a normally formed crown. Natural size.

the base of the posterior root, and never from the middle portion of the neck of the tooth, as is the case with the rounded root of the upper molar. Five entirely separate, completely formed roots also are met with (Atlas, Fig. 11), in which cases, the fifth, which is located upon the lingual side, is not the result of a division into three roots, but is a supplemental formation. Both upper and lower molars with more than five roots have also been observed, but such cases, it is evident, are the result of the union of two molars.

Under the head of excessive formations are also to be considered the *unusually long or thick roots*, as well as, in most cases at least, the *unusually divergent, or curved roots*, and finally the *condyloid or nodular enlargements*, which are met with at the extremities of roots and are not to be confounded with hypertrophy of the cement.

The length of the roots may be excessive either absolutely or relatively, *i. e.*, in proportion to the depth and thickness of the jaw. In some cases, the second bicuspids, or the first and second molars, are inserted to an unusual depth into the floor of the antrum of Highmore, where they form hump-like prominences, and their extraction is likely to occasion quite serious injuries.

The three roots of the upper molars frequently present an excessive thickness and divergence. Sometimes the roots of the lower molars are very broad, and separated by unusually wide intervals. The extraction of the latter teeth is the more difficult when the two adjacent teeth are still present in the jaw. It is not uncommon, in teeth with several roots, to find that the development of the latter, in respect of size, is in an inverse proportion, *i. e.*, if the internal ones are well developed, the two outer ones are found to be stunted, and *vice versa*.

Curves of all or of separate roots, which are absolutely or relatively too long, occur in every conceivable form, and a knowledge of them is of special interest to the practitioner, since very slight deviations may be important obstacles in the way of extraction. For a long time, therefore, practitioners have devoted their attention to these curves of the roots, and the student will find in every manual of dentistry descriptions and illustrations of such irregularities.

In rare cases, an incisor or canine root is curved posteriorly like a hook, or the radical extremities of upper and lower teeth with multiple roots converge in the shape of a bow which, sometimes, forms a hook-like curve with a very decided bend (Atlas, Fig. 5). It is not uncommon for the extremities of each of the roots of wisdom teeth to present a strong curve, or for one of them or all of them blended together, to be bent like a hook (Atlas, Fig. 10). A quite uncommon irregularity is that in which one root is inserted between two others of the same tooth, as the thumb may be inserted between the index and middle fingers (Atlas, Fig. 14).

The condyloid enlargements upon the extremities of the roots, when they are due to irregularities of formation, are to be ascribed to a hyperplastic process which takes place subsequent to the completion of the root extremities. Of such a character are the larger or smaller pisiform nodules which occupy the extremities of the roots of the lower molars, and offer serious obstacles to the extraction of these teeth. Pisiform, condyloid enlargements are also met with, though very rarely, upon the extremities of the radical portions of the upper molars.

Among the excessive formations in the dentine of the root, may be included the concentric dentinal formations (comp. dentinal new formations), when they are located in the root-canal, near the apex, in very young teeth.

c. Defective Formation of the Crowns and Roots.—Stunted crowns are indicated by a diminished superficial area, and by the fact that the incisive edges, eminences, and cusps are less marked than is usually the case. The enamel layer frequently is unusually thin, or forms an incomplete investment. The enamel cap is not everywhere smooth upon its outer surface, the polished appearance peculiar to it and its transparency are, in a measure, lost.

The four upper incisors, and, more frequently, the two laterals, sometimes present, upon their lingual surfaces, deep longitudinal grooves, which commence upon the roots and extend to the ends of the crowns. Upon the same surfaces of these teeth, it is not uncommon to find deep funnel-shaped depressions, or pits, surrounded by a fold-like elevation of the dental tissues.

To the practitioner, these grooves and pits have an important signification, from the fact that they almost always are the seat of the commencement of caries, though the latter very frequently continues unrecognized until, finally, a bluish spot becomes perceptible through the facial surface of the incisor. The crowns of the upper lateral incisors, also, often possess narrow, stunted incisive edges, in comparison with the well-developed ones of the centrals.

The crowns of the wisdom teeth, especially of the upper ones, are most frequently stunted in their growth. When the upper wisdom teeth are duplicated, the normal, well-developed tooth is located in the dental range, while the supernumerary one is located without the latter, upon the buccal side, and attains scarcely two-thirds the size of the other.

A *diminution in the number of roots* is produced by a partial or complete blending together of the separate roots of a molar. In this manner, molars with two, and single roots are formed, upon which, however, the outlines of the roots, which should have occurred normally, are more or less distinctly indicated.

When the three roots of the upper first molars are united they acquire a pyramidal form (Atlas, Fig. 12). In many cases, however, merely the extremities of the two external roots are united, leaving a cleft-like interval, occupied by the septum which necessarily must be removed with the teeth when they are extracted. When the two external roots are united in their entire length, a deep longitudinal groove extends along the external surface. Less frequently the extremity of the internal rounded root is united with the two external ones. When the extremities of the three roots are united together, the latter form an annular inclosure around the septum which is inserted into the space intervening between them. It is evident, that such teeth cannot be extracted without fracture of the septa between the roots (Atlas, Fig. 63).

The roots of the first lower molars, in many cases, are united throughout into single, wedge-shaped roots, the lines of junction upon the outer and inner surfaces being indicated by grooves.

Coalescence of all the roots is met with most frequently on

the molars, since there is, usually, insufficient space for their normal development. Generally the roots are grooved throughout, indicating the parts where union has occurred. When the roots are completely united, which is more likely to occur with the upper wisdom teeth, the single root assumes a generally rounded appearance without any grooved markings, but the extremities may diverge and be inserted in the jaw in the form of a trident, a condition which renders the extraction of such a tooth impossible without fracture of the socket (Fig. 59).

FIG. 59.*



In most cases the coalescence of the roots of a molar tooth is due partly to an unusually short or narrow maxillary arch. The union is formed by cement, which partially or entirely prevents the development of the partition walls of the socket between the roots. In certain instances, where the roots are separated by normal intervals and are united by osseous substance, we may assume the occurrence of a hyperplastic growth of cement from the dental sac.

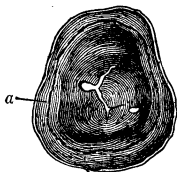
Frequently the *distribution of the enamel* over the surface of the coronal dentine is *not uniform*; here and there, it is defective, while the dentine, corresponding with the very distinct depressions and grooves upon the crowns, either is entirely unprotected or covered merely by a thin layer of enamel; on the other hand, the enamel is disproportionately thick in some localities; for example, upon the dental cusps and eminences where the enamel occurs in the form of pediculated nodules. These appearances are presented generally by the greater number of the teeth in a set and, not uncommonly, are hereditary.

The permanent teeth are more frequently, and the milk teeth more rarely, the subjects of these conditions; they are most conspicuous upon the incisors, canines, and upper first molars, and are met with less frequently upon the lower first molars

* FIG. 59 shows a stunted upper wisdom tooth from the right side. The masticating surface of the crown presents four blunt cusps. The roots are united into one cylindrical root, the extremity of which expands into three short prongs, so that the tooth could not be separated entirely without breaking away a portion of the alveolar process. Natural size. (For the use of this specimen the author is indebted to Dr. Friedlowski.)

and bicuspid. The appearances presented by the malformed enamel in these cases are very characteristic. The surface of the enamel otherwise smooth, frequently is studded like a thimble, with numerous minute pits, some of which extend as far as the dentine; sometimes it is traversed by transverse grooves which are bounded by ridges. In such instances, however, it is to be borne in mind that, although the external enamel layers

FIG. 60.*



present numerous pits, the internal layers towards the dentine are invariably found to be smooth (Fig. 60). The thickened deposits of enamel occur upon the crenated incisive edges of the incisors where fenestrated openings are met with which dip down as far as the dentine. Such teeth present a transversely grooved appearance.

The cribriform, foraminated enamel upon the crowns of teeth with multiple roots is commonly limited to the masticating surfaces, where, also, are located the papilliform thickened deposits of enamel. Not infrequently half the crown is destitute of enamel, only the portion adjacent to the neck of the tooth being covered.

These defects in the formation of the enamel are generally included under the head of Atrophy in the manuals of dentistry, but this latter term is incorrectly applied, since defective formation and atrophy are not identical.†

* FIG. 60.—View of the interior of the enamel cap of a fully formed molar, from the jaw of a young person; its outer surface was studded with numerous depressions; the cap was isolated by means of a fifty per cent. solution of sulphuric acid. The central portion of the grinding surface presents a bifurcating fissure, to the right of which is a cavity the result of a suspension of the process of enamel formation at this point. Within the parietal wall is a groove (*a*), having the character of a sort of suture, where, likewise, the development of the enamel was interrupted for a certain period. Magnified two diameters.

† These malformations are considered, without reason, by many practitioners, to be caused by hot drinks, sweet and sour articles of food, the use of acid preparations for the teeth, or other medicaments. They are referred, also, to a scrofulous diathesis by some who, however, adduce no plausible reasons for such an opinion. The truth is, that the only explanation which can be relied upon is to be attained upon anatomical grounds, and this way

It is the general opinion that teeth of this kind, with so many depressions upon their coronal surfaces giving to them a disagreeable appearance, are very liable to be affected with caries at an early period, but they may, however, be preserved with proper care and cleanliness.

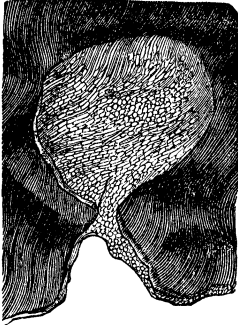
Recently-cut molars are met with occasionally in which, whether they are the subjects of the enamel defects just described or not, the continuity of the enamel at the bottom of the grooves is interrupted, so that a fine probe may be inserted into the fissures which remain, as far as the dentine. In these cases, evidently, the development of the enamel has been defective, since the enamel caps, which should cover the prominences of the teeth and form continuous layers in the grooves between them, present interruptions in their continuity.

Defectively developed enamel is characterized histologically by the granular cloudiness of separate portions in which the structure is more or less altered and irregularly jagged borders are directed towards the normally developed enamel. With this condition, the enamel is capable of less resistance and easily crumbles. Very frequently, abundant deposits of dark-brown or blackish-brown pigment are observed, which render the structure of the enamel quite unrecognizable in places.

was suggested long ago by Bourdet (*De l'art du Dentiste*, 1757, p. 79), who treated of such deformities under the name of *Erosion*, and considered them to be due to rachitis, scorbutus, low forms of fever, measles, variola, and, in general, to all those diseases in which the quality of the fluids is at fault. If, he says, the appearance of the disease is coincident with the commencement of ossification in the formation of the tooth, that portion which has not yet attained its proper consistence becomes principally affected and deficient in enamel; as soon as the disease comes to an end and the fluids acquire a favorable condition, then the development of the remainder of the tooth is resumed in a regular manner, so that the enamel is white and smooth in the vicinity of the root, and abnormally formed towards the extremity of the coronal portion. The surgeon, Tenon, exhibited to Bourdet a series of jaws, by which it could be demonstrated that the erosion took place while the tooth was still within its capsule, and that the tooth, when it was ready for eruption, was less liable to erosion; those teeth, whose formation was most advanced, exhibited the least traces of the erosion towards the upper coronal surface, and the most notable evidences towards the neck of the tooth; finally, those teeth whose crowns had emerged nearly to a level with the alveolar margins, and whose roots were still short, were barely affected.

The depressions in the enamel present, externally, a wide opening, or, less frequently, are constricted, so as to form a sort of neck. The entire internal surface of the depression is covered with enamel, which may be of a normal character, with the exception of a variation in the arrangement of the prisms (Fig. 61).

FIG. 61.*

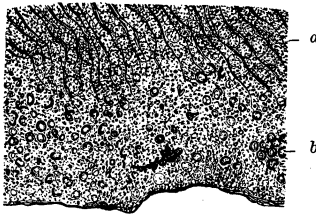


Where portions of the enamel, especially its peripheral layers, are extremely cloudy in appearance, its imperfect formation has resulted in a granular calcareous mass (Fig. 62).

The furrows upon transversely-grooved crowns give a terraced appearance to the enamel, when seen in profile, though upon the surface towards the dentine the enamel is smooth, and, therefore, the portions corresponding to the depressions are thinner than others (Atlas, Fig. 16).

The laminae of grooved enamel conform, in their disposition, to the terrace-like outline of the exterior, that is to say, they extend, from one terrace (Absatz) to another, in a series of planes parallel to the outer surface; when viewed in a longitudinal section of the crown, they describe a system of concentric arches, and beneath each transverse depression, the system of laminae, which is more remote from the incisive

FIG. 62.†



* FIG. 61 shows a spherical excavation in the enamel. A funnel-shaped depression dips down from the surface to a considerable depth into the enamel, where it is connected with the spherical cavity by means of a sort of neck. The wall, which appears intact in the transverse section, is covered with normally-formed enamel prisms which, for the most part, are divided transversely and obliquely. Magnified 250 diameters.

† FIG. 62.—Imperfectly-developed enamel with extreme granular cloudiness and numerous pits in its peripheral portions. In the brownish-clouded mass of the deeper layers, enamel prisms, divided transversely and obliquely, (a) may still be recognized. Towards the masticating surface, however, the

edge or coronal apex, and is situated posteriorly in the horizontal plane, joins the adjacent system in front of it. The depressed portions commonly are the seat of extensive deposits of pigment.

The continuity of the dentinal tissue of grooved teeth is always interrupted, here and there, by the interposition of large globular masses. The latter extend from the white zones, which are perceptible upon the exterior of the roots, in an oblique direction towards the crown, where they are crowded together. The substance of the globular masses is transparent, while, on the contrary, the interglobular masses frequently have a brownish-yellow color, varying from this to a dark brown. The internal surface of the dentine not infrequently presents disordered systems of dentinal canals and, in the vicinity of the extremity of the root, concentric dentinal formations.

The cement of grooved teeth, likewise, presents some anomalies of development. The exterior is not everywhere even, and in some localities is so thin that the globular masses which are disposed in the superficial dentinal layer are visible through it, at certain intervals, in the form of the white zones mentioned above. Towards the apex of the root flattened, tuberculated elevations of the cement are frequently met with. In the latter locality, also, irregular cavities are often found, which extend into the dentine.

Teeth of such a character as have been described are due to disturbing causes which occur at intervals during the process of their formation, and prevent their uninterrupted development. In proof of the periodical occurrence of a disturbing cause may be cited the following: *a*, in reference to the enamel, that its laminae do not fall away uniformly from the incisive edge or coronal apex towards the neck and diminish in number, but breaks (*Absätze*) are formed, each of which includes a system of layers; *b*, the fact, that imperfectly-developed dentine, in the form of globular masses, is intercalated, and conforms in its disposition to that

latter do not preserve their arrangement in rows, but lie scattered in a granular basis-substance, are grouped together here and there (*b*), present a shrivelled appearance, are indicated by a dark-bordered outline and, now and then, are transformed into a brownish-black mass of pigment. Magnified 400 diameters.

of the layers forming the coronal and radical portions; hence may be inferred the occurrence of an interruption to the complete formation of the dentine; moreover, the irregular disposition of the layers upon the internal surface of the dentine favors the view of an interruption to its symmetrical development; *c*, in regard to the cement, the fact that its development progresses merely to the formation of a thin layer, and that the evidences of resorption in the cement as well as in the dentine occur at the radical extremity; consequently, the growth of the extremity of the root was not uniform. Another circumstance in favor of the above view is, that these anomalies of formation are never found except in teeth whose development takes place at about the same period and, also, under nearly similar conditions, while teeth formed at a later period commonly are quite free from these irregularities.*

* Hutchinson asserts that certain deviations in the forms of teeth are valuable as diagnostic marks of the existence of congenital constitutional syphilis, and he classes them with syphilitic interstitial keratitis. Albrecht (*Deutsche Viertelj. f. Zahnheilk.*, 1862), in an extended criticism of these statements, observes that he cannot conceive, in the first place, why the permanent canines and incisors only are affected, and why the milk teeth were not also included by Hutchinson in his observations. From the descriptions given of the deviations in form, that, namely, the upper central incisors, after their eruption, are generally short, compressed laterally in the direction of the cutting edges, and are very thin; that, after some time, a crescent-shaped piece becomes detached from the cutting edges, leaving a shallow groove; that the two teeth frequently converge towards one another, and at times are wide apart; that they have a peculiar color, and a narrow quadrangular shape: all these are insufficient to afford positive grounds; the pre-existence of syphilis, moreover, is not proved in many cases. Adequate proofs therefore are still wanting of the occurrence of an hereditary syphilitic deformity of the teeth.

[This is contrary to the opinion of many prominent medical men in this country and Europe.

Mr. Jonathan Hutchinson, in summing up a large number of cases of interstitial keratitis in reference to the deformity of the teeth, says (*Ophthalmic Hospital Reports*, 1859, vol. ii, page 96): "In those who had cut their permanent set, the condition of the incisor teeth was very peculiar, both in form, color, and size. As diagnostic of hereditary syphilis, various peculiarities are often presented by the others, especially the canines; but the upper central incisors are the test teeth. When first cut, these teeth are short, narrow from side to side at their edges, and very thin. After awhile,

d. Blending or Fusion, and Coalition or Concrecence of Adjacent Teeth.—Fusion (Verschmelzung) of two adjacent

a crescentic portion from their edge breaks away, leaving a broad, shallow, vertical notch, which is permanent for some years, but between twenty and thirty usually becomes obliterated by the premature wearing down of the tooth. The two teeth often converge, and sometimes they stand widely apart. In certain instances in which the notching is either wholly absent or but slightly marked, there is still a peculiar color, and a narrow squareness of form, which are easily recognized by the practiced eye. . . . Since I have made it a rule always to look into the mouth, however, I have not met with a single example of well-characterized interstitial keratitis in which the teeth were of normal size and shape. Indeed there can be no doubt whatever as to the truth of the assertion that malformed upper incisors (permanent set) are all but invariably coincident with this disease. A few months' observation at any large ophthalmic institution will satisfy any one of this clinical fact."

Dr. B. W. Richardson, in "The Medical History and Treatment of Diseases of the Teeth and the Adjacent Structures," London, 1860, page 15, says: "In reference to the effects of the syphilitic poison on the development of both the temporary and permanent teeth, the influence is undeniable, and I think it possible that there is scarcely any chronic disorder of the dental structure which is not influenced more or less by the effects of the syphilitic diathesis when present. But there seems also to be a special affection of the teeth due to the hereditary syphilitic disease." He then refers to Mr. Hutchinson's investigations as supporting his statement.

Dr. Langdon Down, in a paper read before the "Odontological Society of Great Britain," "On the Relation of the Teeth and Mouth to Mental Development" (Transactions, 1871, vol. 4), in speaking of this peculiar deformity as occurring in the feeble-minded who have come under his observation, says (page 17): "Very few have had syphilitic teeth; but when I did discover them, I always had confirmatory evidence of the syphilitic history of the case, and the condition of the teeth was always associated with the chronic inflammation of the cornea to which Mr. Hutchinson has called attention."

Dr. E. Magitot (in "Traité de la Carie Dentaire," 1867, page 67) says: "Syphilis, especially, produces disastrous effects upon the teeth, and we see that children affected with hereditary syphilis present small teeth, deformed, showing deep channellings; and the enamel and dentine, imperfectly calcified, are covered with opaque spots, and remain permanently weak and friable."

Henry W. Williams, M.D., Professor of Ophthalmology in Harvard University, a very eminent authority in this country, in "Recent Advances in Ophthalmic Science," 1871, also confirms Mr. Hutchinson's observations. He says (page 56): "The central incisors of the second dentition have a peculiar crescentic notch at their lower margins, and the lateral incisors and canines, as well as the molars, are often small, peg-shaped, and with tuber-

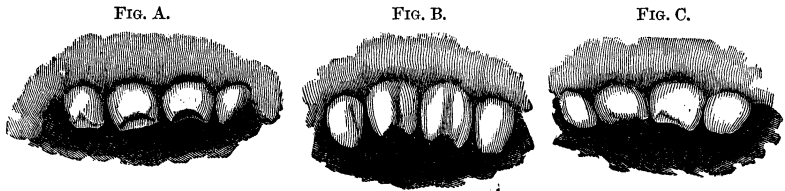
teeth signifies an organic union between them, which takes place during their development. Coalition (*Verwachsung*) denotes

culated prominences upon their surface. They are perhaps also irregularly set in the jaw, and of bad color, or prematurely decayed."

These conditions have for some years been recognized by many dental practitioners. They must not be confounded with those which occur as the result of interrupted development, illustrated by the longitudinal grooving, with depressions or pits, in the enamel, caused by a perversion of nutrition induced by some of the non-specific infantile diseases.

The appearance of syphilitic teeth is well shown by the accompanying plates, which were kindly furnished through the courtesy of Dr. Williams. "Figures A and B show the condition of the teeth in a boy and girl aged about twelve and fourteen. In Figure C, from a girl of seventeen, the notched appearance has already become lessened by wear of the teeth."

T. B. H.



Albrecht considers it strange that only the permanent incisors and canines are affected, but Dr. Williams has shown that the molars also are subject to a peculiar deformity. A close examination of Mr. Hutchinson's paper shows, that in a number of cases he does include the temporary teeth, giving several instances of their early destruction or loss. This is also verified by the observations of Dr. Williams, as well as by a cast in the Museum of the Dental Department of Harvard University.

The reason that this condition of the temporary teeth has not been recognized more often is, probably, because the subjects of interstitial keratitis generally do not come under the observation of the oculist until from ten to eighteen years of age, when most of the temporary teeth are lost, and their places have been supplied by those of the permanent set.—T. B. H.]

Hohl (*Deutsche Viertelj. f. Z.*, 1869) found a very abundant secretion of an acid saliva in a child, seven years of age, affected with congenital hydrocephalus. All the teeth were of a grayish-yellow color, and smaller than milk teeth; the enamel was wanting almost entirely, without any evidences of caries. In the cement and dentine there were to be seen numerous canals, and also gaps resulting from resorption, and in the latter was an evident disposition to laminated arrangement, with numerous interglobular spaces. Hohl considers that, in this case, there was an arrest of the development of the teeth, and a decalcification of the same upon their outer surfaces. Owing to the absence of *Leptothrix buccalis*, he says, caries could not have occurred.

an organic union by means of cement, which ensues after the completion of their development. The former arises from the coalescence of two adjacent germs, and must not be confounded with a twin-malformation, by which is understood a malformation by duplication instead of a unification of normally existing parts. In fusion, the tissues of the teeth which in other cases are separated by an interval pass from one to another without interruption, and the line of demarcation between the teeth is indicated by a more or less deep groove, similar to a raphé.

Fusion is of two kinds, *complete*, when both the coronal and radical portions are united, and *partial*, when the union is limited to the crowns or the roots. The teeth may be united in their normal positions or at angles with each other, so that one tooth may preserve its normal position, while the other is twisted 180°, with its lingual surface facing outwards.

Blended crowns contain common pulp-cavities, blended roots, common or divided canals. Adhesions of adjacent teeth are confined to the roots, each of which contains a separate canal.

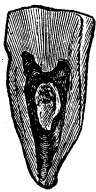Fusions belong to the category of rare occurrences, and affect both the milk and permanent teeth. They are particularly liable to be overlooked in the milk teeth, because, corresponding with the line of junction of the borders, there is a deep groove generally, which is likely to be mistaken for a complete division between the two teeth. Heider mentions nineteen examples of blended teeth, in his collection, eight of which belong to the milk, and eleven to the permanent teeth. The latter include three cases of fusion of the upper left central with the lateral incisor, and one of the lower right central with the lateral incisor; two cases, upon the right and left sides respectively, in which the upper second molar is blended with the wisdom tooth, and one instance similar to the latter, where the lower second molar and wisdom tooth are united; in one case, a lower right wisdom tooth is blended with a supernumerary wisdom tooth; and finally, one presents a fusion between a lower wisdom and a so-called conical supernumerary tooth. (Two cases are not specified.)

The blended milk teeth are limited chiefly to those of the

upper jaw; in three of the cases, the central is united with the lateral incisor; in four of them, the laterals are blended with canines, and, finally, in one case a lower milk canine is united with the first milk molar.

A more precise anatomical examination of blended teeth with single roots, verifies the opinion which might be inferred beforehand, merely from a superficial inspection: a common pulp-

FIG. 63.*



cavity prolonged into each of the two crowns and a root-canal common to the two in some cases and, in others, divided (Fig. 63). Under the microscope, cross-sections show an immediate transition of the dentine of one tooth into that of the other, a more circuitous course of the dentinal canals, as if they were bent, being perceptible only at the points corresponding with the external groove. The enamel surrounds the coronal portion of the dentine in a very uniform manner and dips down to the bottom of the grooves, in order to cover them throughout in the same way as upon multicuspoid teeth (Atlas, Fig. 22). Hence it follows that it is impracticable to think of separating blended teeth at the groove by means of a file, since by such a procedure, the pulp-cavity would evidently be opened, the pulp injured, and the existence of both teeth jeopardized.

A complete fusion is not conceivable except it occurs in a dental sac, common to the two teeth, and since we know from the history of its development, that the formation of the dental sac belongs to an early period, therefore the fusion must necessarily be of early origin. We are able, however, to go still farther and say, that the fusion ensues contemporaneously with the first development of the enamel organ and dentinal germ, since we find that the dentine of one passes directly, without interruption, into that of the other tooth, and a continuous enamel cap covers the united coronal portions of the dentine. As the cement of a single root is formed from a single sacciform

* FIG. 63.—Perpendicular section through two teeth (the central and lateral milk incisors) which were blended together. View of the posterior half, showing the communication between the two pulp-cavities and the union of the two root-canals at the extremity of the root. Natural size.

elongation of the dental sac, and a double root presupposes a double elongation of the dental sac, we may explain the occurrence of the separation of the respective roots of crowns, which themselves are blended together, by the supposition of a division of the dentinal germ which forms the root. The raphé corresponds to the line of junction and fusion of the two germs.

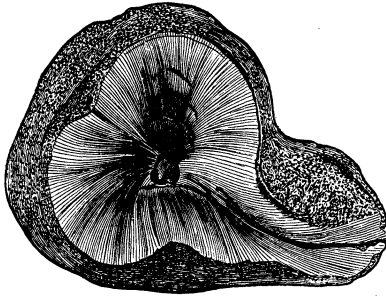
The possibility, that two separate crowns might be blended together by a resorption of the proximal surfaces, or that two perfectly formed and separate roots, each with its canal, might be united into one root with a common canal, is quite inconceivable.

The *fusion of the roots* of adjacent teeth implies a union of the root-pulp of one tooth with that of the adjacent one, in such a manner that ultimately by the junction of the root-canals of both teeth, usually at an acute angle, a single canal is produced, terminating in the single root extremity. Such a union cannot take place except during the development of the roots of adjacent teeth, and it is impossible for it to be induced by a pathological process occurring after the complete formation of the roots of the two teeth.

An example may serve to explain the preceding observations. A right upper jaw presents a fusion of the posterior external root of the first molar with the anterior external root of the second molar. The cavity of an abscess surrounds the two roots mentioned and the anterior external root of the first molar. The extremities of the roots involved lie exposed, while the facial wall of the jaw and the alveoli have been destroyed by suppuration. The crown and internal root of the first molar have been destroyed by caries. The proximal surfaces of the two first-named roots are completely united in their upper halves. Both teeth are movable together. The fusion of the two roots has occurred in such a manner that there is one root-canal common to both which corresponds more nearly to the direction of the anterior root of the second molar. The dentinal canals radiate from this canal in such a manner that there is no separation between the dentine of the two roots; the canal mentioned forms therefore the common centre of the two roots. The cement forms an uninterrupted investment to the latter,

except at a point upon the posterior root of the first molar,

FIG. 64.*



where can be seen with the naked eye a fissured defect in the substance. Upon cross-section the fissure may be traced in the form of a raphé, into the common central canal (Fig. 64).

As the blending of the roots in the way described cannot be the result of an abscess of the root-membrane, it must rather be ad-

mitted, although, as is well known, an interval of about six years occurs between the eruption of the crowns of the first and second molars, that, nevertheless, a fusion of these roots and the formation of a common root-canal took place during the process of their development.

An anatomical examination alone can determine whether a case in hand is one of fusion. Therefore it admits of doubt whether the cases cited as fusions (Atlas, Fig. 18 and 21) are really such, in the strictly correct sense of the word.

Coalition or concrescence of the roots of adjacent teeth takes place subsequent to the complete formation of the roots and, evidently, cannot occur without the previous resorption of the alveolar segments between the two roots which are united. In these cases, the question at once arises, why the cement layer of the root does not become adherent to the alveolus? I have frequently sought for such adhesions, but have never observed anything but mere contact with a very small portion of the alveolus; remove this fragment, which may easily be done, and the root lying beneath it, presents a very smooth appearance, nor does a cross-section of the part in question indicate any adhesion. The explanation of this fact is to be sought for in the periosteum of the root, which, as before observed, is a product

* FIG. 64 shows a fusion of the posterior external root of the upper first molar with the anterior external root of the second molar. Magnified ten diameters.

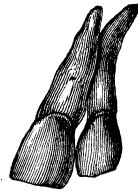
of the submucous layer of the gum. The capillary, vascular system of the root-membrane lies upon the surface towards the cement; in that direction, therefore, the plastic elements for the new osseous layers are excreted, and it is impossible for them to be deposited in the opposite direction.

When now resorption of the contiguous alveoli and the osseous septa between the roots has occurred, which probably is promoted by the vessels of the septum, the periosteum of the two roots comes into contact and, from the continued deposition of new layers of cement, there results, finally, a coalition of the two roots.

These adhesions of the roots of adjacent teeth are found, in most cases, towards the extremities, but they also occur in the middle portions. If the union takes place before one or the other tooth has advanced to its proper level in the dental range, then will its complete eruption be prevented (compare Retention). This form of union seems to occur most frequently between the upper second molars and wisdom teeth. The probable reason for this may be found in the fact that the roots of the upper molars, in consequence of their great divergence, are very liable to come into close relation with one or another root of the adjacent teeth, and, further, that the eruption of the wisdom teeth occurs comparatively slowly and, not infrequently, is attended with important obstructions, among which may be mentioned an hypertrophy of the cement. Probably an irritation, applied to a larger or smaller portion of the root-membrane, is the predisposing cause, the result of which, a notable thickening of the cement, is illustrated in Figs. 48 and 49.

In rare cases, the roots of the front teeth may be united in their middle portions in consequence of their very marked convergence (Fig. 65).

FIG. 65.*



* FIG. 65 shows an organic adhesion, about five millimetres in extent, between a permanent upper left central and the lateral incisor, at the middle portion of the contiguous surfaces of the roots. The two crowns, necks and radical extremities are entirely separated. The central incisor is inclined laterally. The descent of the lateral to the level of the dental range was prevented in consequence of the adhesion. Natural size.

Many persons suppose they have seen cases in which all the teeth, even upon the crowns, were adherent to one another, but such an occurrence is not conceivable, when it is considered that the teeth make their appearance singly, at different periods, and after intervals of years in some cases. Sömmering and Blumenthal, indeed, have shown that these supposed organic adhesions are produced by the tartar of the teeth which cements them together; nevertheless this fable of travellers still has its believers.

These organic unions by fusion and by coalition, which have been mentioned, are of interest to the practitioner from the fact that, without making proper examination, he may commit the error of extracting not only the tooth he desires to remove, but also its neighbor at the same time. Of course, the latter evil cannot be avoided, when the extraction of the tooth at fault has become an imperative necessity. Still it is always an unpleasant occurrence for the practitioner not to have recognized, beforehand, the actual conditions, though, to be sure, this is a very difficult thing to do, in many cases, and sometimes is impossible. Organic fusions of the crowns, however, may be recognized in all cases, by the fact that it is impossible to separate them by the ordinary mechanical means (caoutchouc, wedges of wood, &c.). When the union either by fusion or coalition involves the roots, it cannot be recognized except by an attempt at extraction, when it will be seen that the adjacent tooth is moved at the same time with the one which is being extracted, a circumstance that does not escape the observation of a careful operator, who is enabled thereby to suspend the operation at an opportune moment, in cases in which there may be important reasons for the retention of the adjacent tooth, and the circumstances admit of a delay in the operation or allow it to be abandoned altogether.

e. Malformations.—These comprise irregularities of structure which involve the whole tooth or its greater portion, whereby its proper form is more or less lost and, sometimes, it is changed into a shapeless mass. Collections of such teeth form a series of most remarkable deformities which are not merely of histogenetic interest, but which it is necessary for a practitioner to

be able to recognize, since, in very rare cases, it devolves upon him to decide whether certain formations are dental structures. In some respects, under this head should also be classed supernumerary teeth which have been considered in connection with excess in the number of teeth, in accordance with common practice; these are distinguished not so much by an irregularity of structure, or of the relations of the arrangement of the dental tissues, but rather by deviation in their external conformation, so that they cannot properly be classified with any of the different kinds of teeth.

The malformations of teeth have their analogies in other organs; in extremely rare cases they involve the *whole set of teeth*; but generally are limited to separate ones. Heider observed, in one instance, a very remarkable malformed set of teeth. In the place of the upper and lower incisors, canines, and bicuspid, there were throughout roundish, large, pisiform, hard formations covered with fine white enamel, which were flattened a little only at the points of contact between the upper and under rows.

The malformations may also occur primarily in the soft parts of the developing tooth, whereby the development of the hard tissues becomes arrested.*

Their *development* is still a matter of uncertainty in many respects, and we are able merely to infer it from the malformation already produced; the opportunity of tracing it anatomically, in its different stages, has been afforded only in extremely rare cases.

* All deformities of this description have been distinguished of late years as *odontomata*, and Virchow (*Krankhafte Geschwülste*, Bd. ii) divides them into two classes, namely, those which are a product of the developmental period of the teeth, and the so-called *odontomata interna*, which make their appearance after the period of development. Broca (*Gaz. Hebd. de Med. et Chir.*, 1868) assumes four periods of their formation, and divides them into *odontomata embryoplastica*, *odontoplastica*, *coronaria*, and *radicularia*. The cases under 3 (p. 158) would be classed with his *odontomes odontoplastiques*, and Broca states, that the latter are to be considered merely as deformities resulting from a disease of the pulp. The absence of histological investigations in his account and, especially, his disregard of the history of the development of the teeth, afford an explanation of such a misunderstanding.

The malformations are confined, in most cases, to the coronal portions. Upon these, then, there is found an arrest of development at a stage prior to that of their complete formation; pathological processes, however, always enter into both the enamel and dentinal formation, concerning the predisposing causes of which we know nothing. The more frequent occurrence of malformations of the second and third molars may possibly indicate that interruptions in the growth of the bone in length, a dislocated wisdom tooth, or a deficiency of space in general, exercise an influence upon the coronal formation, which is productive of disease. The enamel organ, excited to too great productive activity, or impeded in its normal productivity or in the direction of its growth, acquires manifold irregular sinuosities, the calcification of the enamel cells, which probably have never attained to maturity, is interrupted, and the formation of enamel prisms does not occur everywhere; homogeneous resisting masses of a yellowish color and sometimes of a granular structure occur, which are all the more to be regarded as rudimentary enamel, since, here and there, they present indications of enamel prisms. The enamel cap, which not infrequently has a cribriform appearance, loses its proper form more or less. Sometimes, also, an unusually protracted persistence of the enamel organ, especially when associated with abnormal development of the dentine, may have a share in producing the irregular enamel formation.

Contemporaneous with that of the enamel occurs a deviation from the normal development of the dentine. The dentinal germ acquires multifarious papillary excrescences containing bloodvessels. The latter become obliterated as the formation of dentine continues; the connective tissue, in which they lie, becomes calcified; there remains, consequently, a system of irregular calcified tubes and cavities surrounded by dentine. The development of the dentine, in many parts, is arrested at the stage of the formation of globules with interglobular spaces. Frequently the globules are met with in the form of long streaks in the midst of well-developed dentine, and also extending between the enamel layers. When there are multiple contiguous dentinal formations within the pulp of the malformed tooth, the

cavity of the latter becomes reduced, ultimately, to a cleft-like gap containing, usually, the calcified remains of the pulp. The canals, with their distinct, smooth walls, within the dentine, give to the latter the appearance of vaso-dentine, and not infrequently also of osteo-dentine.

The development of the roots is impossible when sufficient space is not reserved for them in the jaw, or their growth is interfered with by a developing crown which lies behind them. Under the latter circumstances it is evident that the development of the cement is arrested at an early stage, or, if it reaches a more advanced stage, the cement terminates the malformed tooth in the form of a stunted root.

Our knowledge in regard to the malformations of the teeth is still too limited to allow of a systematic division of them. The following classification, based upon general appearances, requires, therefore, still further additions in order to make it complete.

1. *Dwarfish Malformation of the Crowns and Roots.*—Dwarfish growth affects the wisdom teeth most frequently, and occurs by itself, unaccompanied by any other deformity (*vide* Fig. 59). In a dwarfish growth both the stunted crown and the roots are malformed (Atlas, Figs. 30, 31, 32); in place of the pulp-cavities are found fissure-like spaces; the dentine presents evidences of various interruptions in its development, which are indicated by numerous aggregations of globular masses towards the enamel boundary and, indeed, extending even into the enamel in wide, sharply-defined canals. It is probable, therefore, that, at the time of the primary formation of the enamel cap, interruptions in its continuity were produced corresponding with the imperfectly-developed portions of the dentinal germ, and the structureless lining membrane of the canals in the enamel (Atlas, Fig. 32) may be regarded as possibly the remains of the stunted dentinal germ. Osteo-dentine also is met with, interposed in the dentine, and may extend even as far as the enamel boundary and, here and there, is invested by a narrow border of enamel. In such cases the radical portion of the pulp is not developed. J. Tomes* observed a rare case which

* *Op. cit.*, p. 229.

belongs to this class, of an upper central incisor, irregular in shape, and only one-fourth the size of the corresponding tooth.

2. *General monstrous development of the Crown, with well-developed Roots*, is illustrated in the Atlas, Fig. 9. The exterior of the crown presented such colossal proportions, in this case, that Heider and I were led to question as to its being a human tooth. The structure of the root portion, however, corresponds so exactly with that of a human upper molar, that we were decided in pronouncing it such. The roots, indeed, are large; but it is a frequent occurrence to meet with roots as large as these in association with normal crowns. The most prominent points to be observed in the crown are, the uniform longitudinal folds of enamel, and the thick layer of osseous tissue which everywhere invests the enamel folds and is in immediate connection with the cement of the root. It is quite remarkable that a crown three centimetres in length and two and a half centimetres in breadth should, on the whole, present such slight evidences of interrupted development, and, besides, that the structure of the roots should remain normal. The dental sac must have required for itself an extremely large space, and it is evident that the thick osseous layer still continued its development even after the coronal eminences emerged. Special conditions also must have existed to prevent suppuration and necrosis subsequent to the complete formation of the crown.

3. *General Malformation of the Crown of a Molar with undeveloped Roots, in association with the deeply imbedded Crown of a Wisdom Tooth*.—Few cases of this description have been recorded up to the present time, since formerly no attention was given to the anatomical examination of them. They correspond with one another, in so far that the surface of the crowns, which is occupied by numerous warty excrescences, has a convex outline, while the portion turned towards the crown of the wisdom tooth presents an impression as it were of the latter which not infrequently is bounded by a rim of enamel; they are composed, principally, of vaso-dentine cavities containing, mostly, calcareous salts, and an irregular, sometimes notably interrupted, formation of enamel folds. The pulp-cavity is apparent, but in a rudimentary condition of narrow cleft-like channels. The

very great clinical interest which attaches to these cases leads me to enter more into particulars concerning them.

A case in point occurred in the practice of Dr. Jarisch, Sr.* A female silk-weaver, twenty-five years of age, of a weakly habit of body, reported the appearance during the night of a tumor upon the side of the angle of the right lower jaw. Later, severe pains were felt, and a swelling was perceived in the region of the right wisdom tooth, which led to the opinion that the eruption of the tooth was in progress. This condition continued two to three months, and then, with symptoms of trismus, a collection of pus was formed, which escaped upon the side of the neck through three fistulous openings. Fifteen months after the first appearance of the tumor, the patient came under the observation of Dr. Jarisch. At this time there was a very extensive inflammation of the lower jaw and its vicinity, with profuse suppuration; the bone was notably enlarged. Emollients were ordered. After a few days, the swelling had diminished, and upon the right side, in the region of the wisdom tooth, there was found a body, the size of the end of the little finger; it was pale, covered with pus, and when tapped upon, gave a sound like enamel. After the inflammation had subsided still more, this body was removed by the forceps, with very little difficulty. The parts having been cleansed, the wisdom tooth was brought into view at the bottom of the cavity; the probe could be passed entirely around it, and its crown exactly fitted into the base of the solid formation which was extracted.†

The malformed tooth, described in the Atlas, Figs. 34-38, inclusive, for the report of which we are indebted to Prof. Strasky of Lemberg, was removed from the jaw of a strong man, twenty odd years of age, who presented a tumor of the cheek on the right side, which lasted for several weeks and was accompanied by difficult deglutition, trismus, and pain. Strasky made an examination of the mouth with great difficulty, as the jaws could not be separated more than an inch, and found that the gum upon the affected side, from the first bicuspid poste-

* Reported by C. Wedl in the *Zeitschr. der Gesellschaft der Wiener Aerzte*, 1851.

† For the anatomical description of this solid body, *vide* Atlas, Fig. 39.

riorly, was considerably swollen, reddened, sensitive, and, on pressure in direction of the angle of the jaw, it yielded some pus. All the wisdom teeth were wanting. Examination with the probe showed that the right second molar, merely the rough masticating surface of which had emerged, was loosened. The diagnosis was made of an impeded eruption of the wisdom tooth, and the loosened malformed tooth removed, a difficult operation, with so slight a separation of the jaws, and the only thing to be done was to turn the tooth over to the outside. A considerable amount of pus mixed with blood escaped after the extraction of the tooth. The tumor diminished rapidly within eight days, and after a few months the eruption of the normally-formed wisdom tooth occurred.

The latter case, in its clinical history, is analogous to the former; the type of the deformity also, in the two cases, is similar; in structure, the latter tooth is distinguished by the fact that the enamel in its numerous folds is of a much higher grade of development, and that the osseous substance between the enamel and dentine and in isolated spots, is perfectly developed; consequently, the three hard dental tissues are more perfectly developed in this case than in the former.

A very instructive case occurred in the practice of Dr. Steinberger,* where it was difficult and particularly important, to form a correct diagnosis, because upon this depended the decision of the question, whether to remove a portion of the jaw or to separate the morbid formation from the cavity in which it was imbedded. The patient, a girl, eighteen years of age, presented quite a large tumor upon the right lower jaw, extending from the coronoid process as far as the second bicuspid tooth, and two inches in depth. The protrusion of the maxillary wall was much greater upon the outside than upon the inside. The whole tumor was covered by considerably thickened mucous membrane. Separation of the jaws was impeded and painful. These inflammatory symptoms continued eight days, and resembled closely those attending the eruption of a wisdom tooth. Steinberger

* Jahresber. des Vereines öster. Zahnärzte, in the deutschen Vierteljahresschr. f. Zahnh., 1869.

was confident of the existence of the latter, but was not a little surprised to find, on examination of the jaw, that all the molars on this side were absent. According to the statement of the patient, the first molar had been extracted several years previous to that time, while the two others had never made their appearance. As the molar upon the right side of the upper jaw caused pain by pressure upon the swollen gum which was spread over the tumor, the molars and bicuspid on the left side of the lower jaw were capped with hard rubber, which was to be worn day and night.

After a few days, the pain had quite subsided, and the inflammatory symptoms almost disappeared, subsequent to the formation and evacuation of an abscess, but the lower jaw continued to be considerably thickened. After three weeks had elapsed, by removing the gum which covered the tumor, a yellowish-white, solid body, with a rough surface, imbedded within the jaw, was detected by means of a probe. After this Steinberger was assured that the case was not one of a cyst in the bone, but of a malformation of a tooth. In order, however, to render the diagnosis still more positive, he trephined the body, and gave me a fragment, about two millimetres in diameter, for examination, and this showed the essential elements of irregularly-developed dentine.* All doubts being thus removed, Dr. Weinlechner decided to undertake the removal of the malformed monstrous tooth from the mouth. As only a small portion of the malformation was exposed to view, the greater part of it being overlapped by the alveolar plates of the jaw, a simple operation for the extraction was out of the question; it was evident, that a portion of the jaw must be removed with the chisel. Weinlechner, in the first place, detached the gum from the alveolar margins with a scalpel, and endeavored to separate the tumor from the alveolar borders by means of an elevator. Then, with a wide-expanding forceps, he tried to seize the mass, but without success, because the solid formation was overlapped upon the outside by the edge of the bone. Thereupon he inserted a Serres' screw into the hole previously made by the trephine, by which means he was enabled to move the solid body, after he had cut

* Deutsche Vierteljahrssch. f. Zhlk., 1869.

away a portion of the external alveolar wall. Having enlarged the entrance to the cavity in the vicinity of the coronoid process, by means of chisel and hammer, he introduced the chisel between the external bony wall and the solid body, and by using the former as a lever, loosened the tumor and displaced it internally. At the bottom of the cavity the crown of the growing wisdom tooth was seen, so that the diagnosis was confirmed by the operation, and the patient's jaw preserved, though in all probability it would have been sacrificed had she applied to a surgeon instead of a dentist. Such is the account given by Steinberger.

The deformed tooth is about the size and shape of a chestnut. The long diameter, from before backwards, measures 29, the height 19, the breadth, from the outside to the inside, 18 millimetres. Its weight, when moist, is 12.37 grammes, the color a clear, pale yellow, the consistence apparently firm; when tapped with a knife-blade, it yields a clear tone, of a high pitch, like that given by a tooth. The upper surface is convex, and occupied by numerous masses of tuberculated, small, resisting, yellowish, globular excrescences. The lateral surfaces are curved and traversed by grooves. The inferior surface presents a cavity with a quadrangular border; this is situated somewhat to the outside, and obliquely; is three to four millimetres in depth, and, in size and shape, corresponds with that of the crown of a lower molar (Fig. 66). That portion of the surface of the cavity which faces outwards has a smooth appearance, while that portion which is directed inwards is



studded with several quite large and many small excrescences similar to enamel nodules.

Delicate, firmly-adherent fringes are attached to the entire periphery of the malformation, excepting to the cavity in its under surface. In several places, short strips of a thin membrane, which is intimately united with the superficial layer of

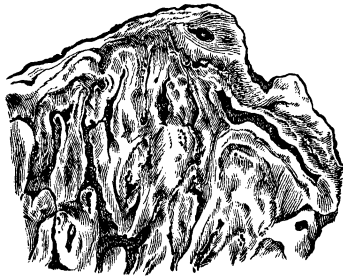
* FIG. 66.—Malformed crown of the second lower molar on the right side. The cavity was produced by the crown of the wisdom tooth which was located beneath it. Natural size. (For the use of this specimen the author is indebted to Dr. Steinberger.)

the solid body, spread over the peripheral warty excrescences. Interlacing bundles of wavy connective tissue form the principal constituent of the fringed membranous investment, which contains within its tissue collapsed capillary bloodvessels with oblong nuclei longitudinally disposed, the larger presenting also nuclei running in transverse directions. Besides these, sharply-defined, bifurcating, here and there closed tubes, lined with a layer of cells like epithelium, are also met with. In a few places, flattened papilliform excrescences are to be seen, which present upon their external surfaces rows of cells terminating in pointed extremities, and suggestive of dentinal cells. Finally, in many localities, tolerably large flattened cells, with large nuclei, occur, in regard to which, also, it is still undetermined, whether they belong to the rudimentary gelatinous layer of the enamel organ (*Organ adamantinæ*).

Polished sections of the tooth, made by sawing through it in its longitudinal axis, show no pulp-cavity, but merely a number of hard formations which inclose a central mass, visible even to the naked eye, but more clearly appreciated by means of a lens; these hard formations penetrate from the surface into the substance of the tooth, are well defined, and terminate like a shut sac; in cross-section, they present a variety of shapes between circular and oval, and are mutually adapted, one to another.

Thin, ground sections afford a more definite idea of the textural relations (Fig. 67). The three dental tissues are apparent, though their distribution is quite abnormal. The principal mass is composed of dentine, the canals of which, in varying numbers, radiate from cavities (the central masses of the above-mentioned mutually adapted hard formations), and, after

FIG. 67.*



* FIG. 67.—Segment of a transverse section from the same malformed crown. The dark streaks extending in different directions are the remains of the pulp around which the systems of dentinal canals are grouped. Magnified 10 diameters.

traversing a longer or shorter distance, become lost to view in the peripheral, abundant, globular masses which invest the system of canals, or more often in the interglobular spaces, after numerous dichotomous divisions. Here and there, the neighboring systems of dentinal canals unite and decussate with each other. The arrangement and course of these canals are quite normal, in some localities, while, in others, they are fewer in number, assume tortuous courses in great variety, and do not present the bushy appearance peculiar to them. The abundant globular masses not infrequently penetrate to a considerable distance between the dentinal layers.

The above-mentioned irregular cavities of various dimensions contain opaque, amorphous, calcareous salts, and are the more to be regarded as the remains of the pulp-cavity, since blood-stained portions also are met with. Besides these cavities, the dentine also contains canals, filled with hyaline, calcareous grains which, here and there, have the appearance of being still imbued with fresh blood; therefore a formation of vasodentine likewise occurred, to which, here and there, there was a continued supply of blood.

In the vicinity of the inferior excavated surface, the enamel presents very distinct nodular projections, while, laterally also, it is elevated into an irregular narrow ridge. Irregular conical processes of enamel are prolonged, in many places, into the dentinal layers. Generally speaking, completely developed enamel, with longitudinally, obliquely and transversely divided prisms, is not of frequent occurrence; but it is, for the most part, rudimentary in character, composed merely of diffused, yellowish and dark-brown, resisting masses containing traces of prisms.

The cement is more or less distinct upon the upper convex surface of the malformation, of unequal thickness, and is marked, here and there, with indentations, the results of the process of resorption. True bone-corpuscles, with multiradiating canaliculi, and a striated intercorpuscular substance, are to be seen in many localities, while in others the cement is retarded in its development. Finally, there remains to be noticed, the occurrence of one or more groups of well-marked bone-corpuscles

which are interpolated in the neighborhood of the globular substances in the deeper layers of the malformation, care being requisite in order to avoid confounding interglobular spaces filled with calcareous salts, with bone-corpuscles.

The origin of this monstrous tooth can only be conjectured. This much, however, may with reason be admitted; that the interlacing of the systems of dentinal canals is explained by the existence of numerous new formations of dentine (odontomes), extending in various directions into the pulp; for the same reason, also, the pulp-cavity is represented merely by cleft-like gaps. From the abundant and very irregular folding of the enamel organ, the conical prolongations, extending inwards, resulted. As before observed, I agree with J. Tomes, in considering *Nasmyth's membrane* to be a continuation of the cement layer and, also, a rudimentary osseous tissue, so that to my mind, the occurrence of an osseous substance, in an advanced stage of development, is readily explained.

There can scarcely, indeed, be any doubt but that, in this case which, clinically, was carefully studied, a dislocation of the germ of the wisdom tooth occurred during the growth of the second molar, in consequence of a deficiency of space, whereby the former, instead of assuming a position behind, became located beneath the second molar; the subsequent formation of its crown prevented the development of the radical portion of the molar tooth and, in all probability, was the general exciting cause of the whole mischief. In the imperfectly formed crown of the second molar, both the dentine and enamel, as well as the cement, became developed in abnormal directions, and the growth of the separate tissues in some parts was excessive and in others defective. The fact, that the growth of the malformed tooth continued beyond the ordinary period until its eruption, is confirmed by the demonstrable, well-preserved bloodvessels contained in the connective tissue fringes of the exterior, and that the deformed mass was penetrated by the wisdom tooth lying beneath it, is indicated by the cavity presented by the under surface of the deformed tooth, which is a cast of the crown of the wisdom tooth.

In view of the great interest of his case, Dr. Steinberger, at intervals of several months, prepared three plaster casts of the surface of the lower jaw, and kindly loaned me the models. The illustrations given in Figs. 68 and 69 correspond with the

FIG. 68.*

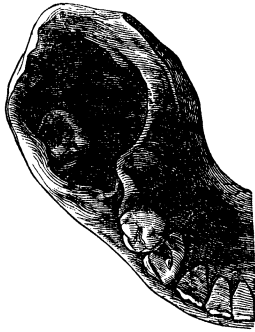
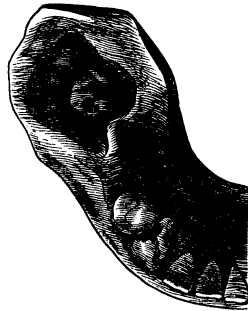
FIG. 69.†



first two periods and show the variation in the cavity, which was occupied by the malformed tooth, and the change in the position of the wisdom tooth.

If a horizontal plane be projected posteriorly from the masticating surface of the second bicuspid tooth, and the distance from the posterior coronal border of the latter to the anterior border of the wisdom tooth, in the visual plane, in other words, if their distance from each other upon the longitudinal plane, at the first period, be measured and compared with the distance at the second period, it will be found, that the longitudinal dis-

* FIG. 68.—Plaster cast of a right half of a lower jaw, showing, posterior to the alveolar cicatrix of the first molar, a cavity from which the malformed second molar was removed by operative means. At the bottom of the cavity may be seen the wisdom tooth displaced to one side. The cast was taken soon after the operation. Two-thirds natural size.

† FIG. 69.—Plaster cast of the same segment of the right lower jaw, taken several months after the removal of the malformed tooth. The dimensions of the cavity have diminished, and the crown of the wisdom tooth has reached a higher level and moved towards the median line. Two-thirds natural size. (For the use of both casts the author is indebted to Dr. Steinberger.)

tance between the two teeth = sixteen millimetres has remained unchanged, but that on the other hand, the masticating surface of the wisdom tooth has been raised about nine millimetres and lies only three millimetres below the level of the second bicuspid. The wisdom tooth, however, has also been displaced from the outside inwards, so that it is but a few millimetres to the outside of its normal position. The dimensions of the cavity present a considerable diminution in the later period; the longitudinal diameter being about twelve millimetres, the transverse about six millimetres; the approximation of the facial to the lingual maxillary wall has been brought about by the process of cicatrization, the contraction of the cavity being analogous to that of the alveoli subsequent to the extraction of teeth.

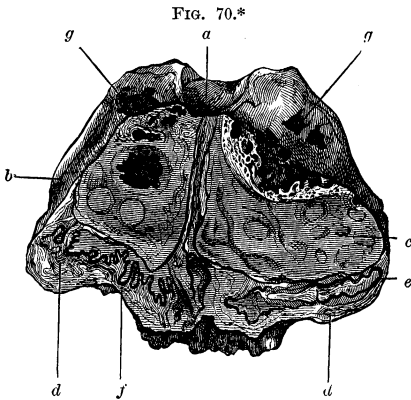
J. Tomes* reports a very similar case. The deformed molar of the lower jaw, likewise located over the wisdom tooth, was several times larger than the latter, the development of which was retarded. The nature of the case was not rightly understood, consequently a portion of the jaw was removed.

Analogous malformations are met with in animals, and have been observed in the horse by Etienne Geoffroy St. Hilaire, and Rousseau. I am indebted to Prof. Bruckmüller, of the Vienna Veterinary Institute, for an extremely rare example of a malformed left molar from a horse. The colossal tooth attained about the size of an orange and, evidently, was located within the dental range, for upon the anterior and posterior surfaces are to be seen, in directions oblique to each other, the abraded surfaces produced by friction with the contiguous surfaces of the adjacent molars. The monstrous formation presents one surface, convex, rough, studded with numerous dentations, and another, excavated, and polished in appearance, corresponding to the masticating surface. The latter presents a substance composed of enamel and dentine, which is transversely disposed from the outside to the inside, one to five millimetres in width, sharply defined, and divides the excavation into two unequal portions.

The remainder of the tooth is composed of finely porous osse-

* Op. cit., p. 224.

ous substance and dentine. The enamel extends from the masticating surface (Fig. 70),



into the substance of the tooth, where it forms narrow zigzag folds, which are accompanied by the dentine. Towards the lower portion, the peripheral cement penetrates to various depths. The pulp-cavity is wanting, its upper portion being filled with osteo-dentinal masses, which distend the walls of the cavity.

4. J. Tomes† also mentions *partial deformities of the crown in the form of excrescences*. An outgrowth of this kind came under his observation, upon the anterior surface of an upper central incisor, and consisted of imperfectly developed and irregularly arranged dental tissues. He also states, that a case described by Salter in the “Pathological Transactions,” under the title of a “Warty Tooth,” comes under this head.

5. *Fissures*.—During the development of the tooth, it hap-

* FIG. 70 shows a carious, malformed left molar from a horse. (For this specimen the author is indebted to Prof. Bruckmüller.) Sagittal section. The smooth, masticating surface (a) has a polished appearance, is deeply excavated and divided into two unequal portions by a substance composed of enamel and dentine, which extends from below upwards. One of the two abraded surfaces, produced by friction with the anterior and posterior adjacent teeth, is visible, (b). The osseous substance is, comparatively, more abundant than the other tissues, and forms the mass lying upon either side, like a kernel in a shell, in which mass are imbedded striated markings of dentine, (c). At the outer part of the substance forming the shell, osseous tissue (d, d) is met with, which is united with irregular folds of enamel (e), and internally to the latter, with dentine. Confused masses of dentinal tissue (f), however, which are traversed by canals, are met with, also, in immediate connection with the cement. The occurrence of caries upon the superficial portion of the grooved masticating surface has left jagged, discolored cavities. Two-thirds natural size.

† Op. cit., p. 227.

pens, sometimes, that the continuity of the enamel cap becomes interrupted, and the dentine appears to penetrate into the cleft-like gaps of the enamel. The dentine, also, is developed beyond its normal limits in many places, and hence another source of cleft-formations. The fissures in the enamel are sharply cut and filled with dentinal globules (Atlas, Fig. 32). In most cases, the growth of the dentine does not extend into the fissures, and we find merely cleft-like gaps in the substance of the enamel cap.

The dentine may, however, attain a higher grade of development in the fissures, as is illustrated by Fig. 33 in the Atlas, where the crown and root of a wisdom tooth present an appearance as if they had been divided by a longitudinal section, and a flattened plate of dentine had been introduced into the fissure, where it had continued to grow and become firmly adherent. Fissures in the roots are due to defective union of the two radical halves. A fissure in the neck extending into the root-canal, and surrounded by a layer of enamel which extends perhaps to the bottom of the cleft (Atlas, Fig. 27), sometimes occurs, though it is extremely rare.

6. *Monstrous outgrowth of Dentine and Cement (osteodontoma) upon the Root.*—Rare tumors of this description are developed, during the formation of the roots, from a circumscribed portion of the radical pulp. The hard tissues of the tumor comprise bone and dentine, but, as the crown is not involved, enamel is not found (Atlas, Figs. 28 and 29). The cortical tissue of the tumor is composed of cement, beneath which is found a comparatively thin, but normally formed layer of dentine; immediately internal to the latter expands the abundantly vascularized osseous mass which forms the principal component of the tumor and, from the fact that it is encompassed by dentine, must have originated from the pulp of the root. Heider,* who previously described this malformation, was inclined to regard it as an instance of the fusion of a normally formed wisdom tooth with a malformed supernumerary dental germ. In my opinion, the supposition of a supernumerary dental germ

* Mittheilungen des Centralv. deutsch. Zahnärzte, 1860.

cannot be entertained, from the fact of the entire absence of all traces of enamel in the tumor. Heider was unable to obtain any history of the case.

Th. Billroth reported a case which may be classed under this head, from Langenbeck's Clinic in Berlin.* A girl, sixteen years of age, complained for several months of a swollen and painful cheek on the right side. During the same period, the second right (large?) molar of the upper jaw acquired an oblique position and a slight displacement inwards, and at the same time, a hard mass made its appearance upon the outside, which the patient supposed to be another tooth. She was utterly ignorant as to the length of time during which the latter irregularity had existed. On examination, the external wall of the antrum was found to be distended, where an indistinctly defined, hard tumor, the size of a walnut, could be felt. Neither the tooth nor tumor were movable. With a stout English forceps, both were seized and extracted together. The mass was of a bony hardness, the size of a walnut; its upper surface was very uneven, warty, and entirely destitute of soft parts, the whole tumor presenting an appearance as if it had been wedged into a sort of large alveolus. The tooth was firmly attached to the tumor, its roots apparently being entirely imbedded in the new formation. No second crown could be discovered anywhere. The surface of a section resembled very much the polished surface of an agate. Microscopical examination showed it to be made up principally of dentine, with cavities and canals, and bone-corpuscles, which were of extremely irregular forms. No enamel was to be found.

7. *Double or Twin-formations.*—The essential characteristic of these is, that instead of a single, there is formed a double dental germ, which remains inclosed in a single dental sac, and as a result of this, a partial or complete fusion of the twin-formations ensues. There are, consequently, two crowns and two radical portions belonging to the same kind of tooth. Herein lies the distinction between twin-formation and the fusion of two teeth. Sometimes the development of one of the

* Virchow's Archiv., Bd. viii.

pair is considerably retarded, and, ultimately, it may present such a deformity, that the form of the crown, or root, which should denote the kind of teeth to which it belongs, is unrecognizable, and, therefore, the basis is lost for determining whether or not the case is one of twin-formation.

The only cases of twin-formation in man, as far as I know, which have been observed up to the present time, are those of wisdom teeth, and such a one is described in the Atlas, Fig. 20. Whether they occur with other kinds of teeth is a question to be decided by more extended investigations. Animals, also, occasionally present deformities of this kind, and A. Friedlowsky reported* an instance of twin-formation of the left tusk of an elephant, the one on the right side being stunted in its growth; the former is composed of two of unequal size, the larger of which is wound around the smaller in the form of a long spiral; the anterior segments of both roots and the greater portion of the bodies are fused together, but the apices of the tusks are separate.

8. The parenchyma of the embryonic dental pulp degenerates in various ways which are imperfectly understood. The unique case observed by Robin† may, as Virchow‡ states, be regarded as one of fibrous degeneration; in this case, there was found upon the lower jaw of a child, two and a half years of age, apparently a fibrous tumor, in which papillæ with quite distinct dentine and enamel could be recognized.

Virchow designates Leisering's case, observed upon the lower jaw of a calf, as a myxomatous proliferation of the dental germ. This was developed in the vicinity of the sixth molar, forced the dental wall asunder, and made its appearance as a free polypoid tumor, three inches in length and seven and a half inches in breadth. It presented upon its surface papillæ, which here and there were covered with quite firm enamel and dentine and, besides, was composed of connective tissue, blood-vessels, dentinal cells, &c.

9. A very remarkable series of phenomena is presented by

* Sitzungsber. der Wien. Akad. d. Wiss., 1869.

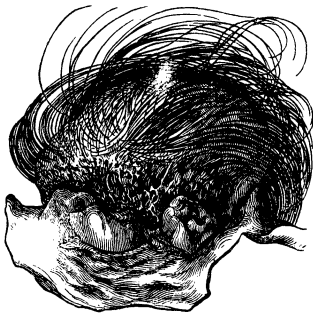
† Mem. de la Soc. de Biologie, 1863.

‡ Krankhafte Geschwülste, Bd. ii, p. 57.

dentigerous cysts, where several germs, belonging to the same kind of teeth, (?) are contained within a capsule of connective tissue. Nelaton found eight bodies in a dental cyst, and pronounced the case one of multiple dental formations within a single alveolus. Broca modified the latter view, and asserted that the eight bodies were not dental follicles, but dental germs which arose from an eight-fold division of the original dental germ.

Imperfectly Developed Teeth in a Multilocular Ovarian Cyst.—In concluding the subject of anomalies of formation, I will add some observations with reference to teeth, which, though they do not come within the province of the dentist, still deserve an interest on his part; but I must express my regret that I have been unable to obtain more than the following single case of teeth in ovarian cysts. Dr. Weinlechner extirpated, with a successful result, a multilocular ovarian cyst, about the size of the fist. The largest cyst, oval in shape, measured 7.5 centimetres, in its long diameter, and

FIG. 71.*



inclosed a disk of bone twenty-seven millimetres in diameter, attached to a cushion of dermal tissue which was the seat of a growth of hair. Into this disk are inserted three teeth which are surrounded by a fold of mucous membrane. The contiguous external skin may be divided into two portions, one covered with woolly hair and flattened, conical,

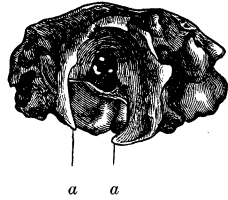
* FIG. 71 shows three upper teeth implanted in a slightly convex disk of bone and, behind these, a pad of skin with long hairs. Taken from a multilocular ovarian cyst. The middle tooth is the largest; its crown corresponds with that of a permanent molar; its roots, resembling those of wisdom teeth, are bent in the shape of a bow. The long diameter of the oblong crown measures eleven, and the short diameter eight millimetres. The adjacent milk molar to the left has an inclined position; that to the right also corresponds with a milk molar. The three teeth are surrounded by a smooth mucous membrane, which extends to the pad of dermal tissue and becomes continuous with the external skin which is furnished with hair. Natural size.

comparatively large papillæ, and the other furnished with tufts of glossy, dark pigmented hair. This dermal tissue presents a thickness of four millimetres in its thickest portion, and is continued in the form of a thin layer over the cyst-wall, the latter being about one millimetre or less thick. Numberless hairs also are implanted everywhere in the thin layer of skin.

By the removal of the periosteal layer of the bone together with the hairy cushion of skin, a very singularly-formed osseous framework was brought into view beneath, forming a continuation of the osseous plate into which the three upper teeth are inserted (Fig. 72). This plate, which is to be considered as the rudimentary upper jaw, presents an outer, *i. e.*, turned towards the cyst-wall, convex and smooth, and an inner, concave, uneven surface. Upon the latter project the roots of the teeth. Upon the continuation of the osseous framework behind the rudimentary upper jaw rise two perpendicular, tolerably thick, compact, slightly curved, osseous laminae, which terminate in blunt-pointed processes that incline towards each other. The basal portions of the laminae are united in the direction of the dental plate and partially, also, upon the opposite side; and hence an incomplete excavation is formed, which is filled with an unctuous, fatty mass (cerebral?), and lined with a separable fibrous membrane; adherent to the anterior portion of the excavation are two black pigmental masses of lax connective tissue, the size of millet-seeds, containing several groups of epithelium cells with black pigment together with cords containing pigment (belonging to the choroidea?). Several apertures also found here probably serve for the passage of bloodvessels and nerves.

In two other cysts rudimentary fragments of the jaw were found in the form of osseous plates in which teeth were implanted.

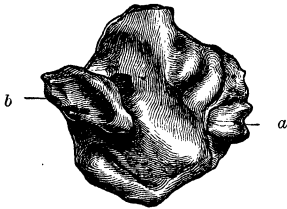
FIG. 72.*



* FIG. 72 shows an osseous framework presented by the previous specimen. Posterior view. *a, a*, blunted, convergent, terminal extremities of the two elevated osseous laminae. At the bottom of the cavity are three apertures for the transmission of bloodvessels and nerves. Natural size.

The larger plate has a discoid form, a diameter of nearly two centimetres, and is from 0.5 to 4 millimetres thick. The exterior surface, *i. e.*, the surface turned towards the cyst-wall, is smooth and slightly convex, while the interior is occupied by several irregular osseous protuberances.

FIG. 73.*



From one sharp edge of the plate projects the crown of a milk molar (Fig. 73), which, on close inspection, presents a defect in the enamel; the outer segment of the crown and roots, also, is wanting, and gives to it, when viewed from the external wall of the plate, the appearance as if it had been split longitudinally. Upon the other side of the

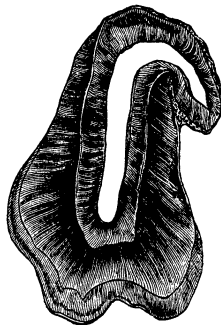
plate rises a perpendicular process of bone which has a cylindrical shape, is excavated at the upper part and, upon one side of its base, presents a shallow cavity which is traversed by several osseous trabeculae. Upon either side of the process is a minute foramen and a groove for the afferent bloodvessels and nerves. The greater portion of the osseous plate, in this case, as in the one previously described, was covered with a cushion of skin and a growth of hair.

Again, in a third cyst, with a small, flattened fragment of the upper jaw, two teeth, in this case still concealed within the gum, were found, next to a tegumentary cushion, having conical papillae flattened upon two sides and covered with hair. The membrane stretching over the crown presents an appearance exactly like that which is found at the time of the eruption of a normal tooth, that is to say, clouded interlacing bundles of fibrous tissue, without perceptible vessels, and nuclei, form the principal portion. One of the teeth, a bicuspid (Fig. 74), presents a hook-like bend at the extremity of the root, and a notable peculiarity. If, namely, the general course of the thin

* FIG. 73 shows an osseous plate taken from a second cyst of the same ovary. View of the internal surface directed towards the cyst-cavity. At (a) is inserted an imperfectly-developed lower milk molar; (b), perpendicular process of bone (rudimentary ascending ramus of the lower jaw). Natural size.

cement be traced, it will be seen, that it invaginates the dentine near the extremity of the root, where it is continued as a sharply-defined luminous zone (globular masses with interglobular spaces) between the outer and inner dentinal segments. The dentinal canals, commencing at the pulp-cavity, terminate at the luminous zone in anastomotic loops, or in its interglobular spaces. The pulp-cavity and canal are of nearly equal breadth, and inclose a pulp, presenting the condition of net-like atrophy. The enamel is well developed. In my opinion, the condition presented by the dentine, in this case, is an indication of the occurrence of an interruption to the dentinal development; in the interval, the process terminated with the formation of globular masses, and subsequently the growth of dentine ensued in a regular manner. The second milk molar of the same cyst presents upon its neck a distinct defect, with sharp edges, in appearance as if a file had been used upon the crown. A sclerosed, clouded mass of connective tissue was adherent at this point. Without doubt, more extended investigations, with reference to the teeth contained in ovarian cysts, will prove a fertile field for the study of anomalies of teeth. The imperfectly-developed bicuspid mentioned by Richard Owen† also presents an anomalous formation similar to that of the upper bicuspid in the figure.

FIG. 74.*



* FIG. 74 shows a section of an upper bicuspid from a third cyst of the same ovary. The crown, neck, and commencing portion of the root are well developed. The apex of the root presents a strong flexion. In general the tooth has an appearance as if a fresh cylindrical piece of dentine had been inserted into the tooth prior to the closure of its root. Magnified 4 diameters.

† *Odontography*, Plate 124.

II. INFLAMMATIONS.

DENTAL PULP.—When we consider the great amount of ill usage to which the teeth are subjected, we may well wonder that primary or idiopathic inflammations of the pulp are not of more frequent occurrence. (J. Tomes goes so far even as to say that, in ninety-nine out of a hundred cases, the diseased action is consequent upon perforation of the pulp-cavity by caries.) Heider,* also, expresses a similar opinion.

The difficulties attending the recognition of an idiopathic inflammation are rendered still greater from the fact that, in making the diagnosis, caries is to be excluded, and this is a difficult matter to determine in not a few cases. Again, an inflammation of the periosteum of the root may be misinterpreted as one of the pulp. A third element of difficulty lies in distinguishing between a commencing inflammation and the hyperæsthesia of the pulp which is occasioned by a congestive condition. When the objective symptoms are wanting and it becomes necessary to depend upon the subjective ones exclusively, then the course which the disease takes can only decide the point. If the affection presents decided intermissions, and hyperæsthesia of other organs, also, occurs, there will be good grounds for excluding inflammation.

If we trace the history of an inflammation of the pulp, occasioned by so-called perforating caries, and, first of all, the pain, it will be found that the latter is localized primarily, and subsequently extends to the neighboring teeth, and even over the whole side of the face. The partially exposed pulp is sensitive to external influences; a current of air, cold water, acid substances, when brought into contact with it, give rise to painful sensations, while pressure upon the tooth is well borne, provided the exposed pulp is not pressed upon. The intensity of the pain varies according to the irritability and age of the individual; frequently it is more severe during pregnancy or at the

* Zeitschrift der k. k. Gesellsch. der Wiener Aerzte, 1846. Abhandl. über Zahnschmerz.

menstrual period. In most cases, the inflammation becomes *suppurative, i. e.*, the circumscribed portion of the surface of the pulp presents a purulent coating, while the latter often has an oedematous appearance or is covered with a limpid adhesive fluid. If there is no obstruction to the escape of the pus, when it is formed, there will be notable remissions in the piercing, dragging, throbbing pains; frequently, indeed, a complete intermission, and the patient is only reminded of the affected pulp by pain induced by special exciting causes. The acute form then passes into the chronic.

In cases where the pulp-cavity is not yet exposed by the carious process, and the pulp is shut in by a thin layer of dentine merely, external influences may still produce their effects, even when indirectly applied. In such cases, that condition is presented, which dentists term *odontalgia nervosa ex carie*. "Inflammation," says Heider, "does not appear to be present, for the accessions of intense pain occur without any warning, and even with great intensity, but frequently, however, intervals occur, during which there is entire freedom from pain. Cold applications, which diminish the pains induced by inflammation, increase them in these cases.

"A considerable period having elapsed," he continues, "after the appearance of a dark spot and the subsequent destruction of the crown of the tooth at the part corresponding to the discoloration, the tooth becomes sensitive to changes of temperature; heat and cold occasion slight and transient pains, and hence the patient is careful to avoid cold and hot food and drinks, and that side of the jaw, upon which the carious tooth lies, is no longer employed in mastication, because the pressure, even of the particles of food which are force a into the carious cavities in masticating, now causes quite severe pain. After this state of things has continued a longer or shorter period, a pain suddenly occurs in the pulp, usually after biting something, of such severity as not infrequently to bring tears into the eyes, and if it continues very long it becomes intolerable. In a few minutes, its severity diminishes to a more tolerable degree, but it is still quite severe and continues, perhaps, for an hour, with exacerbations and intermissions, and finally ceases by degrees,

when an interval, usually brief, of freedom from pain ensues, but soon it is reproduced, for now the pulp-cavity is exposed, and all external agencies act directly upon the nerves. The patient, however, is not always free from severe pains until the opening of the pulp-cavity; frequently, after the occurrence of transient slight pains, a mild attack is succeeded by a more acute and lasting toothache, with intermissions of hours, or half a day."

Inflammation of pulps which have been denuded by penetrating caries, may be *circumscribed* or *general*. The former is found in those cases especially where the perforation of the hard tissues by the carious process is confined within narrow limits; only a portion of the body of the pulp is implicated, perhaps the extremity of a papilla of a bicuspid or molar.

The most prominent indication is the redness, which is due either to a hyperæmic condition of the bloodvessels, or to the imbibition, by the pulp-tissue, of the coloring matter of the blood, which is deposited from the red blood-corpuscles. Intermediate between the congestive and diffusive, stands the hemorrhagic redness which occurs in the form of reddish points or spots. The borders of the extravasation generally fade away imperceptibly in the parenchyma of the pulp. In cases of circumscribed inflammation, the redness is limited to a portion of the body of the pulp, and diminishes from the periphery towards the centre; it involves one or another root, or perhaps only the broader portion. The intensity of the redness varies between a light rose red and a deep blood red, frequently mixed with gray, which preponderates more or less. When the inflamed pulp is accompanied by an œdematous enlargement, it acquires a yellowish-red appearance, and, attended by a superficial supuration, is of a pale greenish-yellow color.

The *increase in the volume* of the pulp, when swollen from the effects of inflammation, is restricted to certain limits by the resisting dentinal capsule, within which it lies, and the view has often been expressed, that the resistance of the capsule is the cause of the intense throbbing and lancinating pains. Though it cannot be doubted that the inflammatory toothache is modified by local relations, still, on the other hand, we think it should

be remembered in this connection that intensive neuralgias occur under the most varied anatomical relations. The swelling of the pulp, in cases of circumscribed inflammation, is limited to one or another portion, but a circumscribed swelling can hardly be determined in many cases, and is best recognized in those cases where the inflammation occurs in an atrophic pulp.

With reference to their duration, inflammations are divided commonly into *acute* and *chronic*, both of which present various degrees of intensity. The more acute the case, so much the more rapidly is the parenchyma destroyed, and the more chronic the case, the more moderate are the symptoms and the longer are the intervals between them. In the former case, the organ also undergoes a relative decrease in its consistence, and may even become transformed into a soft, pultaceous mass.

The *suppurative process* is developed, almost always, as a sequence of caries, and is limited to the superficial layer of the body of the pulp or of the root portion corresponding to the carious locality; the suppuration manifests itself in the form of a greenish-gray or greenish-yellow, semi-fluid, thready covering, containing pus-corpuscles as its characteristic morphological elements. The latter, for the most part, have undergone fatty degeneration, so that on treating them with acetic acid, the numerous nuclei are obscured by the presence of the fat-granules; indeed, it is not an uncommon occurrence for the corpuscles to be so shrivelled and degenerated that they are no longer recognizable. The fluid basis of the purulent mass is rendered turbid by the fat-globules suspended in it, which latter, also, are presented in agglomerated granular masses. By adding acetic acid, the mucus is precipitated in the form of a cloudy, stringy mass.

Cases are met with frequently, where not a single pus-corpuscle, but mere agglomerations of shrivelled, turbid nuclei imbedded in a mass resembling coagulated albumen, are to be found, in the superficial, apparently purulent, substance.

If the examination is extended from the purulent, infiltrated portion of the pulp to the deeper layers, it will readily be seen, in acute cases, that a proliferation of the cells of the parenchyma has taken place and may be traced into the internal por-

tions even far down into the root-pulp. In order to show this, it is well to place sections of such pulps in paraffine, glue, or some other suitable substance. The connective-tissue cells of the pulp, especially in young individuals, sometimes present a marked proliferation. For instance, binucleated, roundish, and spindle-shaped cells, are frequently observed, as the principal forms, and these, together with many others derived from them and variously shaped, occur in such large numbers that they are closely compacted, especially in the vicinity of the focus of inflammation. Finally, still more closely packed, agglutinated, elementary organs are found, consisting, usually, of a round nucleiform body surrounded by a layer of protoplasm which becomes exceedingly small.

If we examine the *bloodvessels*, structural changes may be discovered at the points where they pass into the focus of inflammation, as follows: A swollen and lax condition of the fibrous sheaths of the small arteries and veins; a cloudiness of the sheaths, occasioned by scattered or aggregated fat-granules, or by larger or smaller nuclei, often in clusters, which not infrequently surround the entire vessel, whereby the characteristic elements of the bloodvessel are lost, and it can only be recognized by its continuity. Albrecht* called attention to the notable increase in the volume of the vessels and to their directions, which, instead of being in straight lines, are exceedingly tortuous.†

* *Krankheiten der Zahnpulpe*, 1858.

† This condition is observed especially in connection with chronic inflammation. The prolonged and frequently repeated, augmented pressure of the blood occasions a diminution of the elasticity and contractility of the vascular walls; coincident with the proliferation of the connective-tissue elementary organs, the vessel loses a certain amount of its basis-tissue which has become succulent; after expansion, it cannot recover its former length or transverse diameter, but becomes longer and wider, acquires lateral flexions, and frequently varicose expansions which, when they lie superficially, easily rupture and give rise to the above-mentioned extravasations of blood; the latter subsequently occasion pigmental degeneration and cloudiness.

When the vessels are permanently expanded, disturbances of the circulation are more liable to occur. The interchange of materials in proper

The *bundles of nerve-tubes* in the vicinity of the focus of inflammation, also, present evidences of *structural changes*. The most notable indication is afforded by the cloudiness produced by deposits of fat-granules which, partly disseminated and partly aggregated, are deposited between the nerve-tubes and also in their interior (neuritis). The fat-granular metamorphosis does not uniformly involve the medullary matter even of one bundle of nerves, that is to say, the nerve-medulla of individual nerve-tubes is unaffected by fatty degeneration. Sometimes, groups of oval or round nuclei, analogous to those in the bloodvessels, are met with in the fibrous sheaths of the nerves, and indicate a proliferation of the connective-tissue elementary organs (Atlas, Fig. 80).

Hence it may be concluded that the occurrence of inflammation in the nerve-bundles of the pulp, whether it results in a fatty degeneration of the nerve-medulla or in a cell proliferation of the interstitial connective tissue of the bundles, necessitates a disturbance of the conductivity of the axis-cylinder, which is manifested by a sensation of pain.

The protoplasm of the dentinal cells, in the vicinity of the focus of inflammation, is rendered cloudy by fat-granules; their cohesion becomes lax, and gradually they undergo complete disintegration.

In cases which run an acute course, the fatty metamorphosis is more intensive and extensive than in chronic cases, and, coincident with this, occurs the production of a lax condition of the pulp-tissue, and subsequently dissolution ensues, so that, finally, there remains merely a discolored membrane adherent to the still intact wall of the pulp-cavity and prolonged into the root-pulps and containing the shrivelled remains of the pulp.

From a general view of the phenomena attending an inflammation of the pulp, it appears that the anomaly in the inter-

amounts, can no longer continue, so that excretory elements are retained, which in turn occasion still further impairment of function.

In consequence of the stagnation of the blood, both the red and white corpuscles become necrotic; the former yield their coloring matter to the fluid in which they are immersed, and the pulp becomes impregnated with the coloring matter of the blood.

change of material is manifested by an augmented supply and diminished withdrawal of the blood, an increased transudation, and an accumulation of excretory materials: further, by a proliferation of cells which form the stroma of the pulp and the connective-tissue investments of the bloodvessels and nerves, and by an abundant development of pus-corpuscles or unusually large, rapidly shrivelling nuclei, which proliferations, together, induce a partial or complete disorganization of the parenchyma of the pulp.

Acute inflammation of the pulp frequently results in a *gangrenous destruction*; usually this is a sequence of caries of the milk and permanent teeth, but it also occurs after inflammation of the root-periosteum and, more rarely, is developed independently. As is the case with other organs, two principal forms of gangrene of the pulp are distinguished, the so-called *moist* and *dry*. The former is characterized by a dirty deep red, brownish-red, reddish-gray or greenish-gray discoloration; a diminution of the consistence to that of a thick, pultaceous mass, which has a decided penetrating, fetid, characteristic gangrenous odor. Sometimes, also, the pulp becomes transformed into a pulpy, unctuous, caseous, disintegrated mass, with a nauseating odor.

The inflammatory character of the changes in the tissues may be recognized, unless the gangrene has made too great progress, and, for this purpose, it is well to commence the investigation in the root proper and to continue it in the direction of the coronal pulp. The sheaths of both the nerves and bloodvessels exhibit the above-mentioned proliferations, which increase proportionately as the gangrenous focus is approached, and finally cover the whole field of view. The evidences of fatty degeneration, also, are apparent in rapidly increasing progression. Here and there, the contents of the nerve-tubes are disintegrated. The walls of the bloodvessels have a fat-granular appearance and disintegrate as if they had been macerated; the oblong nuclei of their organic muscular fibre layers are scattered in confusion. Where the gangrenous destruction is complete, a dirty yellow, brownish-yellow molecular detritus is found, containing, generally, numerous interposed, long, bow-

shaped, fatty acid crystals, similar to those found in the sputa in gangrene of the lungs.

In the so-called *dry gangrene*, nothing is left of the pulp but a blackish-brown, brownish-red, tinder-like, shreddy or membranous, slightly moist mass, which only partially fills the pulp-cavity, the remaining space being occupied by a gaseous fluid. The principal histological elements comprise red or dark-brown, cylindrical masses (necrotic blood) inclosed within still recognizable sheaths (bloodvessels), dirty yellowish or brownish agglomerations of nuclei, diminutive pigment grains, crystals of hæmatoidin.

In most cases there is no perforation of the pulp-cavity, though caries has preceded the gangrenous condition of the pulp. In certain cases filling the tooth may be the predisposing cause. The primary gangrene appears to occur particularly in teeth which have been worn away by attrition. Besides these causes there are general, obscure, injurious external agencies which also promote the occurrence of gangrene in the inflamed pulp.

When the red coloring matter of the blood-corpuscles transudes through the intact vascular walls, or escapes from the corpuscles after the rupture of the latter, it penetrates the *dentine* and imparts a *reddish color* to the teeth,* which generally is first noticed upon the neck of the tooth, where the enamel about the dentine terminates. In many cases the redness, which is a pale rose color, is limited to a short streak upon the neck in the vicinity of the root, and fades away towards the latter. In other cases the redness is more intense, and spreads towards the extremities of the roots, being more marked, generally, upon one side than upon the others. The coloring may, however, be most decided even upon a portion of the root.

If sections are made to show the amount of the redness presented by the different dentinal layers, now and then instances are met with where the inner dentinal zones, towards the pulp-cavity or canal, exhibit very slight or no redness; next to this is a broader or narrower middle zone of a brighter tinge, which

* M. Heider und C. Wedl über geröthete Zähne: Deutsche Viertelj. f. Zahnheilk. 1863.

passes into the weaker color of the outer zone. Sometimes the inner dentinal zone is the most highly colored.

Thin sections furnish a clear idea of the relative amounts of the coloring substance in the different dentinal zones. The dentinal canals are filled with the red coloring matter, from their origins even to their most delicate ramifications, while the basis-substance, apparently, is not colored in the least. The coloring matter presents the red hue of the blood and has the appearance of a homogeneous, not granular, substance filling the canals. It is evident that these appearances are not due to the phenomena of interference, from the fact that sections of normal teeth do not present such discolorations. As is well known, similar colorings may be produced artificially, *e. g.*, by means of carmine, madder, Prussian blue, blood-red, &c. It may quite readily be shown by experiment, that the cement takes up none of the coloring matter. If the latter is allowed to act from the pulp-cavity, the dentine becomes colored, while this does not ensue if the root of the tooth is surrounded by the coloring matter, a fact which is self-evident if the root-canal is closed.*

The varying degrees of redness presented by the different dentinal layers may be referred to various causative conditions.

* We immersed dried human teeth, the crowns of which were broken off, in the fresh blood of a rabbit diluted with about one-fourth the amount of water, upon which a layer of oil was poured in order to prevent evaporation. About forty-eight hours afterwards, the dentinal surfaces were exposed and found to be colored more or less, in some places a deep red, in others a pale rose-red. Sections were made, which showed the red coloring matter deposited within the dentinal canals.

In order to solve the question, whether the red color is imparted to the dentine in a direction from the root-canal or from the cement layer, *i. e.*, from the inside or from the outside, the following experiment was made. A glass tube, six inches in length and of a suitable diameter, was fitted to an opening into the pulp-cavity of a lower molar. Rabbit's blood was then introduced into the tube until a column stood above the pulp-cavity. Further, some teeth, which were quite intact, were placed in fresh rabbit's blood, the openings of the canals at the extremities of the roots having previously been closed with sealing-wax. The result of the two experiments was conclusive. In the first case the dentine acquired a very deep red color, while in the latter not even a trace of discoloration was perceptible in several sections of the teeth.

It is to be remembered that the middle dentinal zone is traversed by more numerous ramifications of canals than the inner one. Our perception of the red color of the dentine must be the effect of the totality of the reddened canals which are visible to a certain depth through the basis-substance. If the latter presents various degrees of transparency, then the red coloring will also exhibit corresponding modifications. The reddish-yellow, rose-red or gray-red, or reddish-gray color of the different teeth, and the various shades in the several dentinal zones, are not due to casual variations in the coloring matter of the blood, nor to the diminished imbibition of the latter (one can satisfy himself, even by inspection, of the uniform coloring of the tubules), but within certain limits are dependent upon the degree of transparency of the dentinal basis-tissue. With caries of the teeth, with atrophy of the dental pulp, the dentine, as is well known, presents a dirty white, sometimes yellowish-gray color, particularly towards the pulp-cavity and dental canal, in localities, in fact, which the caries has not attacked. Accompanying this condition there is diminished transparency of the basis-substance in the inner dentinal zone, which obstructs the perception of the coloring matter within the canals. The degree of redness depends, also, upon the disposition of the reddened canals. If the dentine is arranged in such a manner that only small portions of the canals are presented to view, as it were in cross-section, then the sensation of redness produced will be less marked than if they are arranged with their long dimensions exposed to view, so that a larger quantity of the coloring matter is presented to the retina.

Since the dentinal canals inclose the ramifications of the processes of the dentinal cells, it appears much more reasonable to assume a process of imbibition by the latter, rather than capillary attraction.

The occurrence of reddened teeth is confined principally to such as are carious, whose pulps present a deep-red color or extravasations of blood, which latter correspond in location to the reddened portions of the dentine. It is, also, a well-known fact, that when incisors are treated with arsenic or caustic paste previous to the operation of filling, their crowns acquire a rose-red

color in the course of a few weeks or a month after the operation of filling. This discoloration often occurs without any symptoms; frequently, however, it is attended by symptoms of a congestion, and this is the case always with teeth whose pulps were not removed after the application of caustic paste.* Moreover, red-colored teeth are observed also as a post-mortem appearance, after cholera, typhus, and death by suffocation. Rose-red teeth, with a variation in the shading upon the different sides, occur also as a variety of formation.†

Chronic Inflammation of the Pulp.—The anatomical appearances which characterize this affection comprise a more limited extension of the usually pale redness; diminished succulence and greater consistence of the tissues; limited, usually not very pronounced, proliferation of the connective-tissue elementary organs in the portions denuded by the carious process; sometimes superficial suppuration; in many cases, an atrophic condition of the pulp, particularly net-like atrophy in which extravasations of blood are commonly found; a secretion of a serous fluid with an offensive odor like that of macerating bone, which however does not properly belong to the fluid, but is generated by the putrefaction of the organic constituents of the dentine. The paroxysms of pain are less severe and less prolonged as a rule. Indeed there may be no pain, if there is no obstruction to the escape of the usually thin serous or purulent fluid upon the surface of the exposed portion of the pulp. Heat, cold, chemical or mechanical injuries of the exposed portion, always produce an uneasy sensation which may be increased to severe pain.

Chronic Abscesses in the Pulp, independent of Caries, are very rare. The case illustrated in the Atlas, Fig. 51, of calci-

* [The pulp often dies as the result of the use of arsenic to obtrude sensitive dentine, even when it is left in the cavity of decay but a short time. In these cases the tooth almost always becomes reddened. For this reason, in this country, the use of arsenic, except to devitalize the pulp, has been almost if not entirely given up. Even when it is used for destroying the pulp, unless a free opening is made through the walls of the pulp-cavity that the fluids may find exit, infiltration of the dentine and discoloration follow.—T. B. H.]

† Heider aus der Praxis: Deutsche Viertelj. f. Z., 1862.

fication of the root-pulps of a grooved molar of the upper jaw may, perhaps, be regarded as a case in point, where the coronal pulp contains, besides calcareous deposits, a cyst-like, spherical, quite large cavity, with smooth walls, which is separated by a transverse membranous expansion from an analogous cleft-like cavity extending to the bottom of the pulp-cavity. There is, to be sure, no actual proof that the cavity in question is that of an abscess; but the only other probability is that it is the cavity of a serous cyst. Still more rare is the occurrence, in man, of an excavation of the coronal portion, extending *into the dentine*, as the result of an abscess. Th. Bell* reported a single case which came under his observation. A physician suffered, for a long time, from severe pain in the right side of the upper jaw, apparently referable to the second molar tooth which, however, presented no external evidences of disease. After some time had elapsed, an inflammation of the root-membrane ensued, and the tooth became loosened a little. It now was obvious that this tooth was the source of the pain, which finally became intense, and so it was extracted; as its exterior presented no indications of disease, Bell divided it with a saw, at the upper part of the crown, and found a completely circumscribed cavity in the dentine; the surface was white and apparently sound and unbroken. The rest of the tooth did not present the least evidence of disease, excepting that the root-membrane, which had been inflamed for a long time, had also begun to suppurate. It seems, remarks Bell, that the inflammation arose primarily in the dentine, from some local cause; that the bloodvessels of the dentine (of the pulp, rather) developed suppuration, and absorption ensued in consequence of pressure, and, in this way, a cavity was produced for the reception of the pus. We shall frequently have occasion to refer, in the following pages, to the fact, that pus produces a "usure," a wearing away (usurire) of the dentine.

In the teeth of large mammals, *abscess cavities* will be found quite frequently *in the dentine*, if one only takes pains to search for them.

* Op. cit., p. 173.

The *tusks of elephants*, on account of their large size and great projection, are exposed to manifold mechanical injuries, and it is, also, a well-known fact, that it is not an uncommon occurrence, in working ivory, to find bullets imbedded in the tooth, which then presents pathological changes, that render it unsuitable for the purposes of the ivory turner. The attention of Goethe* was attracted long since to the changes in ivory which are produced by bullets imbedded within it; he speaks of cavities in the diseased limits, which are partially lined by a delicate membrane.

We are indebted to J. Tomes† for the very thorough description of cavities of this nature in two tusks. The dentinal substance in each of the two tusks presented a newly-formed cavity, having no connection with the pulp-cavity, nor indeed any outlet. One of them was quite empty, dry, and contained a small quantity of a desiccated membranous mass, or a fluid, which was apparent in the most dependent portion of the cavity, where it had become inspissated. In the other case, the cavity was broader, also without any outlet, encompassed by dentinal substance and lined with a dried membrane; here and there, small spinous processes of dentinal substance projected from the walls of the cavity. The dentine encompassing the cavity had a veined appearance like marble, occasioned by the different directions assumed by the dentinal tubules, and also was traversed by numerous canals of the character of bloodvessels and visible to the naked eye. The lining membrane of the cavity was detached and macerated in water, and proved to be a fibro-cellular tissue. According to these statements, Tomes appears to have taken no notice of the new formation of osseous substance around the abscess-cavity.‡

Albrecht holds the view, for which there are grounds, that the vessels in the dentine of the second case can have been formed only by the prolongation of the vessels of the pulp. He assumes, then, that vaso-dentine does not occur in the tusk of the elephant. According to R. Owen,§ small bloodvessels ex-

* Osteologische Mittheilungen, 1798.

† Albrecht, Krankh. d. Zahnpulpe, p. 23.

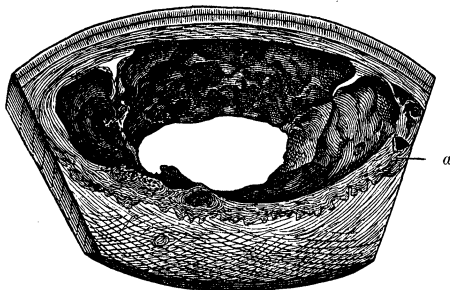
‡ Compare New-formations.

§ Odontography.

tend forward in the axis of the tusk as far as its apex, and the bloodvessels may, also, penetrate, even to the dentine, from those of the root-membrane, if the abscess-cavity be located near the outer surface.

By the kindness of Prof. von Schroff, I had the opportunity of examining segments of elephants' tusks which were labelled ulcers. They contain extensive abscess-cavities in the dentine, apparently entirely shut in, of the size of a pigeon's, a hen's, even of a goose's egg and, here and there, present irregular parietal sinuations. The cavities are lined by a desiccated, dirty-yellow, brownish-yellow, dark-brown and black mass. The portions adjacent to the cavities have a mottled look, and consist, principally, of vascularized osseous tissue, which forms a layer of varying thickness encompassing the abscess-cavities, dips more or less deeply into the dentine, and presents in sections various sinuations and islands (Fig. 75). If we trace the

FIG. 75.*



process of resorption of the ivory from the side of the encroaching osseous tissue, it will be observed that both the main

* FIG. 75 shows a section from the tusk of an elephant, containing a large abscess-cavity which upon one side approaches to within six millimetres of the periphery. It presents various cup-like excavations and is lined with an adherent, dried, dirty brownish-yellow mass. That portion of the wall which incloses the inferior segment of the cavity, is transformed into an ununiform tissue (*a*) (osseous tissue) to a depth of five to ten millimetres, the line of demarcation between it and the normal dentine being sharply defined. This tissue has a wavy outline, a spotted and striped appearance, and its consistence is less than that of normal dentine. Two-thirds natural size.

trunks and the lateral branches of the dentinal canals present numerous varicous expansions, while portions of them are transformed into jagged, elongated cavities, or give place to a globular, transparent substance. In other portions, large, multi-radiating bone-corpuscles have encroached upon the dentine, or vascular canals have become surrounded by concentric layers of osseous substance. From the wall of another abscess-cavity, conical processes, one-half to one millimetre broad at the base and two to four millimetres in length, project into it, and are composed partly of a minutely lobulated (*kleindrüsig*), globular mass, together with bone-corpuscles, and partly of dentinal canals, anastomosing without irregularity in various directions and, here and there, forming tufts which extend in the direction of the axis of the conical process.

A condition, also, is presented which essentially bears a close analogy to that observed by Tomes. The new hard formations upon the wall of the abscess (*abscedirenden Wand*) form a reparative tissue which tends to replace the substance lost by the suppurative process, and probably their development would have gone on still farther, so that they would have diminished the area of the cavity, had they been supplied with fresh formative material by the bloodvessels. As I had only sections at my disposal, I was unable to make special investigations with reference to the origin of the bloodvessels, which are the necessary antecedents to the production of both the new dental and osseous tissues and, also, of the suppurative process. In all probability, the newly-formed bloodvessels were outgrowths from those of the pulp. The elucidation of this question remains for future special investigation.

The chronic inflammation of the periphery of the abscess (*Abscesshaut*), in these cases, led to the production of solid tissues (osseous and dentinal), both of which must have been developed from cells. But even if we are willing to admit that the bloodvessels of the new-formed substances are derived from other pre-existing ones, still the appearance of the new osseous and dentinal substance in the wall of the abscess-cavity continues to be an extraordinary phenomenon, and the assumption in relation to their appearance, that the cell-life of the con-

nective-tissue parietes of the abscess is exalted to a differentiation, as in embryonic life, is open for discussion, since, indeed, we cannot by any means presuppose that the germs of the formative cells are transported to the part with the blood.

As a general rule, as has been shown above at considerable length, *inflammation of the pulp imparts a reddish color to the dentine*. Albrecht* observed dark-colored portions of dentine in localities corresponding to small defects which were visible in the lining of the wall of the pulp-cavity and extended as far as the enamel layer. It was observable, however, that the dark color was confined principally to the dentinal canals, and was much less perceptible in the intervening substance. The affected tooth, he says, undergoes a change of color, under these circumstances, the dentinal substance becomes gray-black and assumes the condition of a gray, pulverous, structureless mass, which is perceptible through the enamel layer, the latter remaining intact for a much longer period. Apparently, he observed no circumscribed defect in the dentine upon the inside, and, indeed, this is found only very rarely in conjunction with a discoloration of the tooth. Dr. Steinberger informed me, that he could call to mind only a single instance which occurred in Heider's practice, where the dentine had become softened by the extension of gangrene from the pulp-cavity. In this case, Heider exposed and filled the cavity, and succeeded in preserving the tooth. Cases of this kind may possibly have given rise to the supposition of the occurrence of *caries interna* (compare Anomalies of the Secretions).

Chronic inflammations in the pulp lead to various forms of atrophy, among which, chronic fatty degenerations and calcifications are to be mentioned especially. The new-formations, which are consequent upon an irritation of the elementary organs of the pulp, include those of dentine, osseous substance and connective-tissue cells (sarcomatous proliferations).† The return to an entirely normal condition is very exceptional, and whenever there seems to be a probability of such an occurrence, frequent relapses will undeceive one. In fact the pathological

* Op. cit., p. 21.

† Vide New-formations.

germs of the cells persist, and the latter are called into renewed activity under the influence of trifling causes. Chronically inflamed pulps may, also, become gangrenous and transformed, partially or entirely, into a fetid, pultaceous mass.

An important affection, which frequently occurs as a *sequel* of inflammation of the pulp, is that of the periosteum of the root, a fact easily explained, when the relations of the bloodvessels and nerves are taken into consideration. This membrane becomes swollen, abscesses are formed, generally at the extremities of the roots, and the pus finds an exit into the substance of the gum or into other regions, to be mentioned farther on.

GUMS.—According to the locality and symptoms, there is distinguished a superficial inflammation of the gums, which is confined to the outer mucous-membrane layer, and a general parenchymatous inflammation which is not limited to the outer, but attacks, as well, the deeper layers. The character of these inflammations is controlled by the genetic conditions which are the foundation of the processes, and its determination presents manifold difficulties. The mere form, independent of all other clinical evidence, affords insufficient grounds for an opinion as to its character. Individual peculiarities modify the general effect of the disease, and the combinations of different processes produce a variability in the phenomena. In many cases it is possible merely to make distinctions with reference to the course of the disease, that it is acute or chronic. Every inflammation of the gums may give rise to a superficial or deep destruction of the substance of the gum and, likewise, may cause a destruction of neighboring tissues.

In *catarrhal inflammation* of the gum, the latter assumes a rose-red color which is most apparent upon the free edges; subsequently, white spots appear and disappear, which are produced by the exfoliation of the epithelium. The gum feels uniformly, though not notably, swollen, smooth, and hot. The patient complains of annoying sensations of itching, tickling, and burning, which are diminished temporarily by grinding the teeth. A livid gray, mucilaginous, frequently puriform secretion collects in the pockets formed by the gum, and oozes out, when the finger is pressed along its border.

This inflammation occurs most frequently upon the labial surface of the incisors and canines of the lower jaw, and more rarely upon the same surface of the corresponding upper teeth. In the latter case, the covering of the hard palate of the affected side becomes involved. Still more rarely are the gums of the bicuspid, and almost never are those of the molars attacked. The affection either is limited to the gums of a few teeth merely, or invades those of all the incisors and canines of one jaw, less frequently of both jaws, and never those of all the teeth of either jaw.

The inflammation may continue months and even years, particularly upon the lower jaw where the secreted fluid accumulates within the pockets formed by the gums. In cases of unusually long duration, it spreads to the periosteum of the root, gives rise to resorption of the margin of the alveolus and loosening of the tooth in its socket.

The more acute forms, in most cases, are due apparently to the same causes which generally give rise to catarrhal conditions, to excessive variations in temperature, damp and cold weather, &c. Another very frequent cause, particularly of inflammation of the gums of the incisors and canines, is the prolonged, continually-repeated mechanical injury, to which these teeth are subjected in closing the jaws, when several molars and bicuspid are wanting. With the latter condition the incisors and canines are pressed together more firmly in chewing and experience slight movements in their sockets, whereby the gums and root-membrane become irritated and swollen. As the mechanical injury continues, a process of resorption of the margins of the alveoli, also, is induced, the tooth becomes loose and finally falls out.

An accumulation of tartar with its rough outer surface, also, produces a mechanical irritation of the margins of the gums and gives rise to a chronic catarrh, while the secretion of the latter, on the other hand, occasions an increased formation of tartar. Each process, consequently, promotes the development of the other.

In cases where caries has destroyed the greater part or the whole of the coronal portion of the tooth, the sharp edges of the

cup-shaped carious cavity become a source of irritation of the margins of the gums; the putrid products of decomposition, which result from the carious process, also have a similar effect. If the neck of the tooth, also, or a portion of the root is destroyed by caries, the gum loses its support, becomes detached, inverted, and acts as an additional constant source of irritation.

With tobacco chewers and those who smoke filthy pipes and strong cigars, especially if they do not pay proper regard to cleanliness, the tobacco juice becomes an important source of irritation.

Catarrhal inflammation is observed, also, as an accompaniment of catarrh of the intestinal tract.

The character of the catarrhal secretion is essentially modified by the constitutional peculiarity of the individual. In tuberculous people, generally a very abundant, frequently puriform, secretion is observed, and the affection is usually very obstinate, while with individuals who are healthy in other respects, it disappears directly on the removal of the irritating cause. Superficial ulceration of the gums is a not uncommon sequel of a neglected or obstinate catarrhal inflammation; such ulcers are flattened and covered, at the base, with a firmly-adherent gray mass; they heal finally without leaving a perceptible breach of substance.

If the old epithelium, even in the minor catarrhal affections, is not removed, but, remaining adherent, becomes mixed with the débris of food, and if, in addition, there is also a gastric catarrh, the cells become disintegrated, their contents thickened, and between the layers are found the familiar fermentation fungi (*mucor*), which are very abundant in mucus, under the favorable conditions afforded especially by individuals presenting evidences of impaired nutrition, *e. g.*, in the marasmus of infants or the emaciating diseases engendered by unhealthy surroundings (thrush). The mucous membrane which has now acquired a deep red color is beset with soft, white nodules, or is covered with membraniform layers which may be stripped off; the latter spread to the adjacent portion of the oral mucous membrane, but rarely are attended with an ulceration. In cases of this description the catarrhal affection is not to be referred to

the fungi (*Oidium albicans*) as a cause, although, to be sure, there is no doubt but that the latter, in consequence of their enormous productivity, become a source of irritation in the inflamed mucous membrane and, consequently, tend to continue and add to the catarrhal process already developed. Bacteria are found associated with copious mucous or puriform, fetid secretion of the gums; these will receive special consideration in connection with the subject of Anomalies of Secretion.

In the vesicular, *herpetic* (?) inflammation of the gum, vesicles are formed which give rise to itching and burning sensations. The vesicles collapse or rupture and there remains a superficial erosion which heals without cicatrization. Usually it extends to regions adjacent to the gum.

Inflammatory affections of the gum are developed in the course of the acute exanthemata, such as variola, scarlet fever, measles, and are accompanied by indications peculiar to these diseases. With persons affected with syphilis, who have not been under the influence of mercury for a long time, a very marked softening of the gum is said to occur, according to G. Delestre.*

In mercurial salivation, according to the statements of Corfe which J. Tomes confirms, the action is indicated primarily by the gums, indeed several hours prior to the occurrence of the flow of saliva; according to J. Tomes the indications are as follows:† “The mucous membrane of the gums, where it is firmly adherent to the tissues beneath, assumes an opaque, white color, contrasting strongly with the non-adherent portion, which preserves its natural hue or becomes more red. The free edge of the gum is movable, but that portion which lies upon the alveolar margin is firmly attached to the periosteum, and as the margins of the alveoli have a festooned outline, so the whitened mucous membrane presents corresponding undulations. Again, the mucous membrane preserves its natural color, where it is reflected from the gum to the cheek. The diminished tenacity of the epithelial cells contributes to the production of the whiteness of the gum. When the epithelium exfoliates, the reddened

* Du ramollissement des gencives. Paris, 1861.

† Dental Phys. and Surg., p. 299.

capillary portion becomes exposed, and the gum acquires a mottled appearance."

Lead may give rise to a partial bluish coloring of the gums. Dr. Brinton* observed this condition, in a case of lead colic, upon the edge of the gum corresponding to the incisors of an entirely sound set of teeth. He regarded the blue edge as due to a sulphuret of lead, produced by a deoxidation of a salt of lead. Probably the saliva contained lead, and the deoxidation was occasioned by the sulphureous matter contained in the atmosphere.

Croupous inflammation of the gum is an affection of considerable importance, both on account of its sudden occurrence and, also, because it is liable to assume a diphtheritic character.

Steinberger† describes the occurrence of the malady as follows: "In the first stage, the edge of the gum is covered with a whitish, gray, structureless, membraniform exudation, scarcely half a line in thickness, which may be detached in flakes. The mucous membrane, deprived of its epithelium, is slightly swollen, tender to the touch, and bleeds easily. Generally the exudation first appears upon the outer side, that is upon the margin of the gum of the lower jaw which faces towards the lips and cheeks, and frequently within the limits of the lower incisors, whence it spreads gradually over the whole anterior, and also the posterior margin which faces the tongue. It is a rare occurrence for it to attack the edges of the gums of the upper and lower jaw at the same time.

"The exudation takes place very rapidly, often in a few hours, not infrequently during the night, and is accompanied by a very painful sensation which the patient describes as a dragging pain, and this is increased if the patient remains in warm localities, or in bed. There is only slight febrile movement; frequently it is scarcely perceptible. The cervical glands of the affected side are swollen.

"The exudation degenerates very rapidly into an offensive, sanious mass, so that the affection becomes manifest from the

* Quar. Jour. of Dental Science, 1857.

† Croupöse Entzündung des Zahnfleischrandes und ihre Folgen: deutsche Vierteljahresschr. f. Zahnheilk., 1861.

patient's breath, even at a distance of several paces. The decomposed matter dips down, especially in the lower jaw, between the gums and the tooth, towards the root-membrane, which becomes inflamed and finally is destroyed by the corroding sanious matter. The teeth are loosened and fall out, or may readily be removed. Subsequently the bone, from the imbibition of the sanious matter, becomes necrosed, without, however, at least in most cases, the occurrence of any swelling, showing that the necrosis originates from the alveolar cells and not from the periosteum of the jaw.

“In the upper jaw, as a rule, the destructive process is not so extensive, in consequence of the ready escape of the purulent fluid.

“If the inflammatory process leads to the death of the gum and the facial wall of the alveolar process (in other words, if a diphtheritic slough is formed), the necrosed portions of the bone exfoliate, and in children the dental germs are exposed.

“Children are more frequently the subjects of the latter affection than adults, and those children particularly who have been reduced by scarlet fever, measles, and typhus. Still it also attacks healthy, robust persons.

“The predisposing cause, in most cases, is exposure in a cold, damp dwelling, or to a cold, damp draught of air or excessive exposure to moisture and cold in travelling and hunting. The disease acquires a contagious character in hospitals for children.

“The duration of the disease depends upon its intensity and extent, the general health of the patient, and external circumstances. The more mild cases terminate in eight to fourteen days, and the more severe ones often last several months.”

Since the croupous inflammation, which has been described, often spreads to a considerable distance in the mucous membrane of the oral cavity, consequently attacks portions beyond its original seat, the gums, it is called by the general term stomatitis, and from the fact that it is associated with ulceration, Taupin* called it stomatitis ulcero-membranacea, and maintains that it is entirely distinct from diphtheritis. Distinguished writers, on the other hand, admit a transition from croup into diphtheritis.

* Barthez and Rilliet. Diseases of Children.

Phlegmonous inflammation of the gums involves both the corium and the submucous connective tissue, and is attended by considerable swelling and redness.

Under this head may be classed the series of cases which Pye Smith* collected, and to which he gave the name stomatitis hæmorrhagica. The accession is sudden and without any febrile movement; the oral mucous membrane, especially that of the gums, becomes swollen without any participation on the part of the neighboring mucous membrane, the fauces, nasal mucous membrane, and larynx. Ulceration occurs in small, shallow, yellowish spots, or is in the form of a large, phagedenic ulcer. Actual necrosis of the osseous substance may ensue. The intervening mucous membrane is always tumid, spongy, very sensitive, and easily bleeds. Recovery is very slow. The disease was observed in well-nourished, otherwise healthy persons, who presented no indications of scorbutus or syphilis.

Suppurative (abscedirend) inflammation generally issues in a circumscribed formation of pus, an abscess (*parulis*), which latter usually opens externally, but sometimes undergoes resorption. Its course depends upon the causes to which it owes its origin. If it is produced by a mechanical cause, such as compression, contusion or laceration, it heals directly, with the occurrence of suppuration. If the suppuration results from an inflammation of the root-membrane, in connection with caries, it disappears immediately with the removal of the inflammation of the root-membrane, and if the latter assumes a chronic character, the inflammatory irritation becomes extended to the gums and a fistulous track is formed, which opens externally upon the surface of the gum, where it presents indurated edges, while the other extremity communicates with the suppurating root-membrane, or maxillary periosteum, or with an abscess within the bone (Atlas, Fig. 118). The fistula evidently cannot be expected to heal until after the removal of the causes which give rise to the irritation.

Acute or inflammatory œdema of the gums is accompanied by a considerable, pale tumefaction and great tension, and fre-

* Virchow's Archiv., 1870; zur Gingivitis.

quently is developed very rapidly by the action of mechanical or chemical irritants.

Gangrene of the mouth (noma) also attacks the gums, which become decomposed into a gangrenous slough or sanies in which float the necrotic fringes. As is well known, if the gangrene attacks the deeper parts, the maxillary periosteum and the root-membrane are destroyed, and the patients (who usually are weak, badly-nourished children, living in dark, low, cold, and moist rooms), lose the incisors, canines, or bicuspid; portions of the bones become denuded and necrosed and, sometimes, the greater portion of the upper or lower jaw is lost.*

DISEASES OCCASIONED BY THE FIRST DENTITION.—It is well known that, with children born of healthy parents and whose external surroundings in life are not detrimental, teething is unattended by morbid phenomena which latter, however, make their appearance in children of unhealthy parents, or in those who are subject to the influences of obnoxious external agencies. While abnormal dentition may, perhaps, have been over-estimated by the physicians of former days, it is, on the other hand, sometimes too little regarded, indeed, even disregarded entirely by those of recent times, as a cause of affections of the nervous system, intestinal tract, respiratory organs, &c. Up to the present time, as far as I know, no one has yet made the endeavor, which it is hoped will be made, to establish first of all an anatomical basis for abnormal dentition, by its pathologico-anatomical study. Physicians, as a general rule, are not familiar enough with the process of dentition, and dentists are not disposed, nor do they have the opportunity of prosecuting that study to any great extent.

Fox, and with him a large number of English dentists, having in mind the morbid processes consequent upon difficult dentition, attached great importance to lancing the gums. “If the nurse,” he says, “be attentive, she will notice that the child does not take the nipple with the same degree of force as usual, or holds it but a short time, and soon lets it go; the gums feel hot and are redder than usual; the cheeks appear flushed, the

* Barthez and Rilliet, vol. ii.

eyes look heavy, and the child is uneasy. When these symptoms appear, the mouth should be examined and if there be any fulness of the gums, or they have the appearance of inflammation, they should be lanced at that part. The order in which the teeth appear should always be kept in mind, and then there will be little probability of mistake, as to the spot where the cause of irritation is seated. To delicate children there is often danger attending the cutting of the canines and first molars, since these teeth advance in growth almost at the same time, so that there are eight teeth making pressure upon the gums at the same time."

According to Trousseau,* the swelling of the gums is not an arching produced by the tooth beneath, but is due rather to the inflammation, and he adduces in support of his assertion, the fact that this turgescence occurs and disappears again, without the emergence of the tooth through the gum; direct experiment also confirms this view, for if a needle be inserted into the swollen gum, it is found to be three to four millimetres in thickness, from the surface down to the tooth. He found that the inflammation of the gum was always much more marked around the upper incisors, than around the lower ones. Trousseau does not coincide with the older physicians, in the opinion that teething is the cause of most of the diseases of infancy, and states that the local condition plays merely an accessory part. The painful swelling of the gum and the toothache give rise to various symptoms, particularly to flushing of the cheeks, salivation, fever, agitation, and likewise to a few nervous symptoms. He doubts, however, that the diarrhoea is the secondary result of the pain, and remarks that diseases which occur during the process of dentition, such as broncho-pneumonia, pneumonia, and enteritis, are always more severe and dangerous, and further that among all the methods of local treatment, lancing the gum is by far most in favor, but it surely merits no recommendation.

Inflammatory swellings of the gums, attending the eruption of the milk teeth, may assume a very alarming character. "In

* Barthez and Rilliet, vol. i.

some, fortunately rare cases," says O. Weber,* "the inflammation may lead to a periostitis of the jaw, particularly of the upper jaw, which, if it be not treated very carefully, may give rise to gangrenous destruction similar to noma. In such cases, the cheek becomes swollen, then œdematous, and later acquires a phlegmonous condition. The eyelids assume a puffy appearance, the whole face becomes swollen and tense, and a careless physician might regard the case as one of erysipelas. If the condition of the teeth is not recognized, and exit is not given to the pus already formed beneath the periosteum, by free incisions, the cheek may become gangrenous and the jaw necrosed and destroyed. It is unnecessary to state that this condition is attended with high fever. In one case of this kind in which gangrene was imminent, I preserved the life and the face of a child only by general incisions at various parts, since the suppuration had advanced already to the region beneath the orbits and beyond the zygoma." This all goes to show that inflammations of the gums during the eruption of the milk teeth are to be watched with the greatest care, and we must not assent to the nihilistic doctrine (Nihilismus), in respect of the influence of difficult teething upon the infantile organism (compare Neuroses).

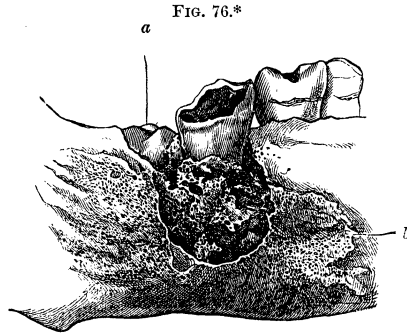
DISEASES OCCASIONED BY THE SECOND DENTITION.—The eruption of the wisdom teeth not infrequently gives rise to morbid phenomena which, as Hunter has observed, are more localized, while in the first dentition they are apt to be more general than local. The diseases† comprise, 1, neuralgic affections of the facial and temporal nerves, occasionally of an intermittent type; 2, a very obstinate cough like hooping-cough; the paroxysms are shorter and the prolonged inspiration is wanting; 3, very obstinate attacks of dysenteric diarrhœa, which continue five, six, even seven months, while the general condition and appetite are not disturbed.

The difficult eruption of the wisdom teeth is due, in most cases, to their faulty position, together with insufficient length

* Handbuch der allg. und spec. Chirurgie redig. v. Pitha und Billroth, Bd. iii, p. 234.

† Barthez and Riiliet, vol. i.

of the jaws, and especially of the lower jaw, or to some affection of the adjacent tooth. For example, Fig. 76 represents an ex



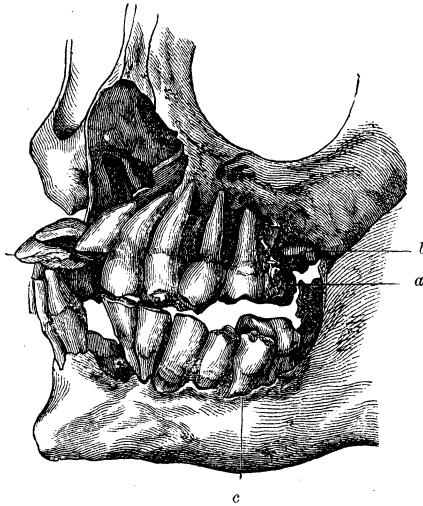
tensively carious, lower second molar, on the left side, the alveolus of which, together with the surrounding portion of the jaw, was infiltrated with sanious matter. The pathological process commenced with an inflammation of the periosteum of the root which was followed by periostitis and the formation of a minutely porous osteophyte, and necrosis of the contiguous portions of the jaw. The eruption of the wisdom tooth, which was inclined somewhat anteriorly, had commenced, and the anterior segment of the alveolus was involved in the sanious ulceration. If, in this case, the second carious molar had been extracted at the proper time, the consecutive inflammatory processes would not have been so extensive.

A notable disturbance is presented at the time of the eruption of the wisdom teeth, if ulceration of the alveolar processes and

* FIG. 76 shows a circumscribed necrosis upon the lingual wall of the left lower maxillary arch, corresponding to the carious second molar, and also a finely porous osteophyte-formation upon the adjacent portion of the maxillary wall. The wisdom tooth (*a*) has just made its appearance. The discolored, necrosed portion is sharply defined, and adjacent to it is deposited a thin finely-porous osteophyte, which spreads anteriorly upon the lingual surface as far as (*b*), and posteriorly nearly to the articular condyle. A fistulous opening was formed upon the facial wall of the jaw beneath the posterior root of the second molar. The porous osteophyte extends anteriorly upon this surface as far as the mental foramen and posteriorly to the condyloid process. Natural size.

subsequent dislocation of the teeth have ensued (Fig. 77). In this case, it is very probable that a retarded eruption of the

FIG. 77.*



* FIG. 77 shows the teeth, on the left side of the upper and lower jaws, bent forwards, in consequence of a partial destruction of the alveolar processes, probably the result of a diphtheritic periostitis, which was caused by the eruption of the deeply-imbedded wisdom teeth on the left side. (For the specimen from the Anatom. Museum, the author is indebted to Dr. Friedlowski.) The two central incisors and the left lateral of the upper jaw are bent upwards into a nearly horizontal position; the left upper canine and the two bicuspid are inclined to a less degree; the first molar, on the left side, occupies its normal position; the second is displaced towards the tongue and is covered with a deposit of tartar (*a*); the emergent wisdom tooth (*b*) has a marked forward inclination and is located to the outside of and behind the second molar. In the lower jaw, the coronal borders of the central incisors are separated by an interval of eighteen millimetres from each other, the result of an ulcerative inflammation of the alveolar process; notwithstanding this notable gap, no tooth has fallen out; the incisors, canine, and two bicuspid of the left lower jaw, are inclined towards the lips, and the second bicuspid (*c*) is displaced to the front of the buccal surface of the first molar; the second molar is bent towards the tongue; the wisdom tooth has a horizontal position with its masticating surface directed obliquely towards the tongue. The bone around the latter tooth, like that upon the maxillary tuberosity of the upper jaw, is destroyed, and to such an extent, that the roots are exposed for the most part. The wisdom teeth, upon the right side, occupy normal positions within the dental ranges; the

wisdom teeth, on the left side, gave rise to an inflammation of the gums, which extended upon the facial surface of the latter, along the upper and under dental arches, involved the periosteum of the facial walls of the alveolar processes and destroyed these walls and, also, the anterior walls of the dental sockets. The osseous substance surrounding the wisdom teeth was necrosed, a result of the periostitis. The lingual walls of the alveolar processes were not, but, as may be seen, the margin of the incisive fossa on the frontal process of the upper jaw, and the anterior borders of the ascending coronoid process of the lower jaw, were involved in the ulcerative process. The teeth, deprived of the support afforded by the facial walls of the alveolar processes and jaws, became very much inclined. This case shows what may be the results of neglect and ignorance. If the wisdom teeth are deeply imbedded in an oblique position, they may, during their eruption, give rise to fistulous abscesses.* A case came under the observation of Heider, in which resorption of the single root with exposure of the pulp-cavity of the second molar occurred in connection with a very marked forward inclination of an erupted wisdom tooth. He also saw another case, which presented resorption of the root of a lateral, permanent incisor, in connection with the retarded eruption of an abnormally located canine.† Wisdom teeth of the lower jaw, which lie in a horizontal or oblique position, may also be the foundation of the occurrence of tumors in the osseous substance.‡

ROOT-MEMBRANE.—Inflammation of the periosteum of the root is of especial importance, not merely on account of its frequent occurrence, but also from its tendency to invade the neighboring tissues; its importance, however, was not fully estimated until within the last decades of this century. John Hunter considered it to be an inflammation of the socket of the

teeth of this side, in part, are notably affected by caries. There remains, finally, to be mentioned, an accumulation of tartar upon the lingual surfaces of the dental crowns on the left side. Two-thirds natural size.

* Durand. Ill effects produced by the eruption of a wisdom tooth, in *Part Dentaire*, Paris, 1860.

† *Deutsche Viertelj. f. Z.*, 1862.

‡ *Dental Register*, 1869. *Affections of the Jaw.* Waterman.

tooth, and described it as "gum boil," which is still its popular name. Lefoulon (1841) distinguished it as periodontitis; Linderer (1842), as an inflammation of the external dental membrane. We are indebted to Albrecht* for a monograph upon the subject.

With reference to the extent, there is distinguished a *localized*, limited to one tooth or perhaps to one root of a tooth with multiple roots, and *general* inflammation which spreads over a whole row of teeth of the upper or lower jaw, as with phosphornecrosis, for instance, or hydrargyriasis, and diphtheritic inflammation of the gums. It is further separable into a *primary* and *secondary*, an *acute* and *chronic* form.

Bearing in mind the anatomical relations of the root-membrane, its connection with the vessels and nerves which enter the pulp, with the alveolus and gums, and with the periosteum and bony substance of the jaw, the phenomena that accompany the inflammation are readily accounted for. Although these make their appearance in regular succession, it is customary, for the sake of greater clearness, to divide them into stages as follows:

1. Inflammatory thickening, with hyperæmia and commencing proliferation of the elementary organs of the connective tissue, which takes place both in the parenchyma of the root-membrane and also in the fibrous sheaths of the bloodvessels and nerves. Groups of nuclei, presenting the familiar forms which result from their division and inclosed within a protoplasm, become apparent and occasion faint, cloudy spots.

2. In the second stage, the cloudiness increases and pervades the entire thickened root-membrane which acquires a gray-red-dish appearance. The groups of proliferating elements assume larger proportions; the nuclei and also the investing protoplasm acquire a molecular cloudiness; here and there, they present a shrivelled appearance, vessels and nerves become unrecognizable, the basis-substance, the intercellular tissue is displaced, for the most part, by the products of the proliferation, and supplanted by fat-granules. In many cases, the inflammatory process terminates with this proliferation.

* Die Krankheiten der Wurzelhaut der Zähne, 1860.

3. In the third stage suppuration takes place, and the same series of pathological phenomena ensue, as have been described above in connection with the suppurating pulp (Atlas, Fig. 80).

In very acute cases the proliferation of the elementary organs takes place very rapidly, and their degeneration ensues immediately.

The *clinical history* of the first stage, in the acute form, as given by Heider, is as follows: Sensitiveness of the root involved, which at first is not continuous and is characterized as a dull, undefined sensation of oppression in the tooth. After this has continued some time (for days or hours), uninterrupted pains occur in the tooth, which are notably increased by contact with anything, especially by attempts to chew, by simply closing the mouth, or by percussing the tooth, particularly in the direction of the root. The pains are also intensified by the local application of warmth and by general heating of the body, by active movements, the horizontal position, and spirituous drinks. There is now developed a distinct sensation, as if the tooth was increasing in length and becoming loose. The former is subjective merely, the latter, evidently, is objective also, since the affected tooth can be moved with the application of but slight force. These same symptoms are also presented, to a less degree, by the two teeth adjacent to the one originally affected.

Then occur the phenomena presented by the gums, which, at the corresponding portions, become more red, more hot to the touch, swollen and sensitive to pressure with the finger, particularly in the vicinity of the apex of the root.

The secretion of saliva is augmented, and increased heat and redness is observed upon the affected side. With irritable persons, there is general indisposition, a coated tongue, loss of appetite, and sometimes febrile movement.

These symptoms oftentimes continue only a few hours, and again may last for days, and then all at once become more marked. The pains become more intense, almost intolerable; the patient can no longer endure contact of anything with the tooth, not even of the tongue; the mouth cannot be closed; the tooth apparently increases in length, since it is raised perceptibly above the level of the dental range, especially when

the tooth has several roots; there is a corresponding increase in its mobility; the contact of anything hot cannot be borne, and the patient is unable to take solid, cooked food, or even tepid liquids; cold local applications produce a temporary relief, but the pain returns in a more severe form. At the same time the swelling of the gums increases considerably and also extends to the mucous membrane of the cheek, and to the integument of the face, which becomes œdematous as the disease progresses. When the front teeth are affected, the lips become swollen and produce a marked disfigurement; their mucous membrane becomes elevated into bullæ, and the ala of the nose on the corresponding side is swollen. When the bicuspid and molars of the upper jaw are attacked, the lower eyelid becomes œdematous, and this condition may increase so as to produce a complete closure of the eye. With the affection of the teeth of the lower jaw, the œdema spreads downwards upon the neck, principally, and may, especially when the wisdom teeth are involved, extend to the mucous membrane of the soft palate, and, if not checked, œdema of the glottis may ensue. The neighboring glands, parotid and sublingual, likewise, are swollen, as might be expected. Accompanying these symptoms, the oral cavity becomes quite hot, the tongue thickly coated; an extremely offensive, purulent odor is emitted from the mouth, and the mucous secretion becomes very adhesive. At this stage, there is an accession of general symptoms, including more or less notable febrile movement, general indisposition, headache, thirst, and even delirium with very irritable, plethoric individuals.

With the latter symptoms, suppuration occurs, while the pain loses its acute character and assumes a more dull and beating form. The portion of the gum adjacent to the tooth, which was primarily affected, swells considerably and projects in the form of a fold. The tumor, which now has attained its greatest dimensions, becomes soft and fluctuating and in time presents a yellowish spot, where the pus becomes perceptible and makes its exit, if the tumor is left to itself. As soon as the pus is evacuated, there is a very rapid diminution in the intensity of all the symptoms; the œdema disappears in a few hours, and after the lapse of about twenty-four hours, the swelling is re-

stricted to the locality of the tooth originally affected. If the suppuration diminishes considerably during the succeeding days, then the tooth resumes its original position and firmness, and becomes serviceable again; on the other hand, circumstances may give rise to additional suppuration, the looseness of the tooth and the discoloration increase, and finally its death ensues and it is lost. The average duration of the acute process, such as has been described, is seven to eight days.

The suppuration is reduced, in the course of time, to a minimum, where it is kept up for a considerable period, until the small opening in the membrane becomes closed, the location of which is then denoted by a small nodule. Relapses are occasioned by slight causes, among which may be mentioned exposure of the feet to cold, in particular, overheating, stimulating drinks, &c. A small vesicle is formed at the original seat of disease which becomes filled with pus, and is ruptured by the movements in mastication and evacuated. Usually the opening closes after this, and in a few days again a small pustule is formed at the same place which runs the same course as the first. Sometimes the latter process is repeated for months, without troubling the patient, and is due to a chronic inflammation of the root-membrane.

The clinical history of chronic inflammation comprises the following most prominent symptoms: An uneasy, sometimes painful sensation, referred to the root, which is increased by pressure upon the tooth and by chewing. The gum of the affected tooth is reddened, and pressure in the vicinity of the apex of the root gives rise to pain. The tooth sometimes appears to be longer than usual and loose, which, however, is merely an imaginary sensation on the part of the patient. At first, these symptoms are altogether of such an ill-defined nature, that they easily escape the notice of less observant patients, who are not made aware of the affection until, in the course of time, either severe pains are felt at the apex of the root, or the edge of the gum becomes tumid, and a yellowish mucus oozes out between the latter and the neck of the tooth. In consequence of detrimental agencies, the latter process progresses, and intermittent, inflammatory pains are developed, especially

when the inflammation is located at the apex of the root. The redness of the gum increases, its margins become swollen, the outer wall of the alveolus is very sensitive to pressure, the tooth cannot be employed in chewing, becomes loose and, apparently, increased in length. Frequent remissions occur, but the same process is repeated after longer or shorter intervals, and ends with the loss of the tooth. The process continues, throughout, a local one and the general system is not disturbed. This condition of things is observed most frequently in well-nourished, vigorous, middle-aged persons.

While, in the acute form, the proliferation of the cellular elements of the connective tissue is arrested in the embryonic stage of the latter and a partial degeneration is induced by the luxuriance of the cell-production, in the chronic inflammation a higher grade of organization is attained, but under favorable conditions, the chronic may be changed into the acute form.

The periosteum of the root presents a gradual increase in thickness towards the apex of the root, its tissue is compact, its outer surface not infrequently like felt and, sometimes, highly vascular (Atlas, Fig. 122). Besides the roundish or ovoid connective-tissue cells, rows of spindle-shaped, elongated cells, also, are met with; later in the progress of the affection, wavy, curled bundles of connective tissue appear in the basis-substance, between which rows of roundish cells are imbedded. In such localities the nerves and vessels undergo a perceptible wasting away, while the larger bloodvessels are expanded. The proliferating connective tissue undergoes a partial involution [retrograde metamorphosis] which is manifested by the appearance of fat-granules, partly within the protoplasm of the cells themselves, and partly in the intermediate substance; but, nevertheless, germs of proliferation may persist, which will be excited to renewed activity with the occurrence of an irritation. If the degenerative process goes on to the transformation of the tissue into a minutely molecular mass (detritus), which frequently occurs without any perceptible suppuration, it always displays itself first on the outer zone of the root-membrane (Atlas, Fig. 123). It is self-evident, that the connection of the root-membrane with the alveolus, at the latter locality, becomes

destroyed, and the tooth is loosened in its socket by this process.

Inflammation of the closed extremity of the periosteum of the root, with suppuration in the inner layers of tissue, sometimes occurs, giving rise to the formation of a *spherical sac of pus*, which may attain the size of a small pea. As is well known, it is not an uncommon occurrence, when the affected tooth is extracted, to find the sac unbroken and attached like a berry to the apex of the root. According to Hulme, sacs of this kind very rarely result from an acute, but almost invariably from a chronic inflammation.

The fibrous envelope of the pus sac (in subacute cases?) forms a thin, transparent wall, which is traversed by a network of bloodvessels and incloses a distinctly fluctuating, purulent mass, mixed with more or less blood. In chronic cases, the envelope is thick, less smooth upon its outer surface, and fluctuation is less distinct. In the latter cases, it is composed of three separate layers; *a*, an external, thicker, more resistant layer in which cells of an oblong shape, imbedded in a fibrous stroma, predominate; *b*, a middle, less firm, more succulent layer, containing, principally, rounded, nucleated cells which are inserted into a felted mass of filaments, in parallel rows or in irregular clusters; *c*, an internal layer, a sort of granulation tissue, with the pus adherent to it. The thicker the wall of the sac, the less recognizable is the central focus of suppuration, and in that case, cross-sections present a network of branching trabeculæ of connective tissue, inclosing groups of stellate connective-tissue cells. In old purulent deposits, a disintegrated mass containing fat-granules and cholesterin, is accumulated at the centre of the sac.

Chronic inflammation also gives rise to hypertrophy and tumors of the root-membrane and, sometimes, leads to hypertrophy or exostosis of the cement.

That portion of the root-membrane, which is in relation with the submucous connective tissue of the gums, appears to be attacked secondarily, in most cases, in consequence of the extension of the disease either from the inflamed closed extremity of the root-membrane or from the inflamed gums. In these cases,

the gum becomes detached from the neck of the tooth, and pressure upon the alveolus forces out a puriform fluid. This condition, which has been described as *pyorrhœa alveolaris*, particularly by French writers,* results, without notable pain, in the loss of the affected tooth. It also attacks whole sets of teeth in one or another jaw, and is met with, more frequently, in persons of middle age, and may last several months, even years. At last all the teeth in the jaw become loose and are lost. While the latter effect is being produced, the inflammatory symptoms in the gums often disappear apparently; but if pressure be made with the finger along the root, towards the neck of the tooth, a tenacious gelatinous fluid oozes out, indicating the existence of the inflammatory affection. The latter secretion invariably appears, first of all, upon the facial segment of the gums, but later is found also upon the lingual. Albrecht is of the opinion, that the pressure of the tongue and its constant sucking action upon the lingual surfaces of the alveolar processes, prevent the accumulation of the purulent matter, and that pressure by the finger upon the latter surfaces does not give vent to a puriform fluid, unless the affection is very far advanced. In these cases, then, we have to do, first of all, with a catarrhal inflammation of the gum, which afterwards extends to the root-membrane.

In very acute cases the inflamed root-membrane degenerates into an unctuous, fetid, ichorous, pulpy covering of the surface of the root, *i. e.*, it undergoes *gangrenous metamorphosis*. In such cases we find a clouded, dirty-yellow or brownish-yellow, granular mass (detritus), containing, usually, shrivelled nuclei which are barely recognizable, and numberless rod-shaped, slender, occasionally undulating bodies (Bacteria) which were regarded by Pasteur as a putrefactive ferment.

If we bear in mind the intimate connection of the root-membrane with the vessels and nerves of the pulp, which has been referred to repeatedly, also with bloodvessels which enter from, and return through the alveolar walls, and with nerves coming from the foramen in the alveolus and the intra-alveolar canal, it is easy to understand that an inflammatory condition of the

* Toirac, and subsequently Desirabode.

root-membrane cannot persist without implicating the adjacent structures.

The *changes in the hard tissues of the root*, which occur chiefly with chronic suppurating inflammation of the periosteum of the root, consist in necrosis and resorption, according to the nature of the tissue. If the superficial cement be not discolored, dull, whitish, indistinct spots may be observed, sometimes, incorporated in it. If these are cut out in thin plates and examined with transmitted light, they present a clouded dirty yellow, brownish-yellow, and from this to a black-brown color. The bone-corpuscles become less discernible in the mass as the transparency diminishes; the intercorpuscular substance is transformed chiefly into a minutely granular mass, and frequently has a foraminated appearance.

In consequence of resorption following suppuration, the outer surface of the root becomes rough, sometimes, as it were, corroded, covered with irregular excavations; its extremity is hollowed out like a funnel at the part corresponding with the entrance to the canal, or sharpened to a point, like a needle. The histological appearances produced by the process of resorption are displayed in a manner similar to those which were observed in the resorption of the roots of the milk teeth, *i. e.*, there are circumscribed depressions upon the outer surface of the cement, which are made up of groups of closely approximated, shallow, cup-shaped indentations. In the ridge-like elevations which bound the excavations, well-preserved bone-corpuscles are to be found, while they become gradually less discernible in the deeper portions. Necrosis of the cement not infrequently is associated with resorption, in which cases sections made in directions perpendicular to the surface of the root present spots of a dark color and with obscurely defined margins between the excavations produced by resorption.

If the cement is entirely destroyed (usurirt), here and there, by the suppuration, the dentine becomes similarly affected and acquires a roughened or corroded appearance. If the affected portions are examined carefully, they will be found to be irregularly notched with numerous cup-shaped excavations with sharp outlines, which sink into the dentinal substance, are crowded

together, frequently into groups, and contain the corroding pus. The adjacent portions of the dentine, with the tubules running from them, retain their normal transparency. The indentations themselves are lined with a molecular mass which, frequently, is impregnated with a yellow, or brownish-yellow coloring matter; their projecting margins are delicately notched; their exposed surfaces are occupied by transversely and obliquely-divided dentinal tubules (Atlas, Fig. 115). There are, consequently, no indications of a vital action on the part of the dentine. The theories advanced to explain the manner in which the excavations are produced by resorption are mere suppositions; they may be regarded as induced either by the activity of the pus-corpuscles, or by a fermentation process; with regard to the former, it is conceivable, that the amœboid movements of the corpuscles might wear away the dental substances; in the latter case, the generation of an organic acid might be assumed. In chronic cases, the eroded portions are covered by a thin membrane of connective tissue or by a layer of granulation tissue.

Sometimes, on the other hand, the inflammation spreads from the root-membrane to the socket of the tooth; when this occurs, the canals of the latter in the vicinity of the focus of suppuration become expanded; excavations, in the form of pits and grooves, are formed in it, and, finally, there ensues a partial resorption of the alveolus, which process is induced by the proliferation of the elementary organs of the connective tissue.

Etiology of Inflammation of the Root-Membrane.—The most common origin is a pre-existing *inflammation of the pulp* which itself is produced by penetrating caries, in most cases. Hence the affection becomes a complicated one. The cause of the subsequent inflammation of the root-membrane is to be found, as has been observed before, in the direct transmission of the irritation from the inflamed nerves and vessels of the pulp to those of the periosteum of the root. If the pulp be irritated by a too early filling of a carious cavity, or if the escape of the pus from an inflamed and exposed pulp be prevented by filling, symptoms of the inflammation of the root-membrane are very likely to occur, since the decomposing pus rises or sinks within the canal

of the root, and acts as a strong irritant upon the portion of the membrane at the extremity of the root.

Persons who work in match-factories, where they are exposed to the *fumes of phosphorus*, are liable to be attacked with inflammation of the root-periosteum, if they have carious teeth. The affection always originates, asserts Albrecht, at a part where the fumes of phosphorus have access to the membranes covering the bone, and, in the mouth, the best opportunity for this end is afforded by the diseased teeth in which the pulp-cavities have become exposed. The noxious element is carried to the part chiefly by the saliva which becomes saturated with the fumes, as is manifested even by the characteristic penetrating odor that escapes from the mouth, by means of which alone a worker in phosphorus may be recognized; further, by the inspired air which, on expiration, frequently becomes luminous in the dark. The pus of phosphornecrosis is said to contain a large amount of phosphorus, the truth of which assertion, however, Hoppe-Seyler considers very doubtful. The fumes themselves appear to exercise no destructive effects upon the hard dental tissues; I have noticed merely a blue-gray tinge. Albrecht observed a faceted appearance upon the extremities of the roots, if the teeth are retained for a considerable period. An hypertrophy of the cement appears not to take place, nor does a destruction of the cement layer occur, probably because the process runs its course, producing a complete destruction of the root-membrane, too quickly; the roots appear to him to be somewhat more transparent at their extremities, and of a horny character.

The extension of the inflammation of the periosteum of the root of one tooth to that of the adjacent one is effected by means of the periosteum of the jaw, which becomes swollen contemporaneously with the former and, like it, is destroyed, "absceded" (abscedirt). In cases, where the jaw contains no carious tooth, and still inflammation of the root-periosteum occurs, as an effect of the fumes of phosphorus, the saliva, impregnated with the latter, affects the gums primarily, and then the root-membrane.

The inflammatory affections of the gums hereby induced spread also to the root-membrane; this occurs more frequently with the teeth of the lower jaw, because pus or sanious matter accumulates

more readily in the pouches formed by the gums of these teeth, and produces an irritation upon the root-membrane which is in immediate contact with the submucous connective tissue of the gums. Consequently the original cause of this inflammation of the root-membrane is the same with that of the inflammatory affection of the gums.

Mercury, likewise, acts upon the root-membrane through the gums, and may even affect the whole set of teeth; but the teeth of the under jaw, which are bathed with the saliva, are the soonest involved. The teeth are lifted out of their alveoli, without any special sensations of pain, in consequence of the swelling of the root-membrane, and, as the process advances, they become loosened so much that they are easily separated from the alveoli. The root-membrane is then found to be covered with a tenacious unctuous, viscid mass.*

Mechanical causes, e. g., a kick or blow, dental operations which are not conducted with proper care, especially with persons who are very susceptible to injuries of any kind, a ligature around the neck of the tooth, foreign bodies which become forced into the pouches formed by the gums or into the root-canals of carious teeth, e. g., bits of toothpicks, stumps of teeth which have become fastened to the root, concussion of the jaw from a fall, &c., may give rise to an inflammation of the root-membrane and are more likely to do so, if the latter is in an irritated condition previously. Pressure in chewing, exerted in an abnormal direction upon one or another surface of the roots of an obliquely-located tooth by its antagonist, may irritate the root-membrane and lead to an inflammation. In a wisdom tooth, with its crown inclined anteriorly and impinging upon the second molar, the root-membrane is exposed to injury in consequence of the concussion occasioned during the act of mastication. Albrecht mentions a case, which came under his observation, of an inflammation of the root-membrane of the milk molars, which was

* Albrecht states, that several other substances may produce similar effects, but that it is not such a common occurrence with them as it is with mercury. Affections of the root-membrane have been observed following the use of preparations of gold, copper, arsenic, antimony, iodine, and the employment of digitalis and opium, castor and croton oil, and cantharides.

induced in consequence of the advance of the permanent bicuspids prior to the complete resorption of the roots of the milk teeth.

In *replantation* of children's teeth which have been forced from their alveoli in surgical operations or separated from their alveoli, without any fracture of the same, by a kick, fall, or blow, it is well known, that they will become fixed under favorable circumstances, more readily, to be sure, when the interval of time is short and the teeth remain attached to the gums. *Transplantation* of the teeth of different individuals, immediately after their extraction, as Hunter proposed, does not, on the whole, furnish favorable results, since the roots of corresponding teeth, in different individuals, vary so much in thickness, length, and curvation; consequently, the alveolus is either injured or incompletely filled, and the subsequent inflammatory processes prevent the desired fixation. Mitscherlich* relates instances of partially successful results from the implantation of dead teeth, in which cases the inserted tooth becomes fastened by osseous tissue which grows into the dentine from the maxillary surface.

The root-membrane is subject, also, to a *rheumatic affection* which may be either primary or secondary: in the former case, it remains localized or spreads to the periosteum of the jaw; it is accompanied by other rheumatic symptoms. In the second case it extends from the periosteum of the jaw to that of the root, and involves the whole set of teeth. The pains have no special character, so that it is impossible to speak of a typical, rheumatic toothache. Almost always there are one or more unsound teeth, whose diseased periosteal membranes excite a consecutive swelling of the maxillary periosteum with the symptoms of rheumatism.

ALVEOLAR ABSCESS.—When an abscess of the periosteum at the extremity of the root is left to itself, and there is no exit for the pus, either through the root-canal and exposed pulp-cavity or along the surface of the tooth to the margin of the gums, one side of the alveolus, particularly in debilitated per-

* Langenbeck's Archiv. für Chirurgie, 1862.

sons, undergoes a complete resorption from the proliferation of the connective-tissue cells in the wall of the abscess or from the eroding pus; that portion of the maxillary wall which incloses the alveolus, together with its periosteum, becomes involved within the limits of the abscess. A suppurating ("absceding") periostitis is produced, the subsequent progress of which is modified by the special local relations.

It is not an infrequent occurrence for a purulent infiltration into the spongy, osseous tissue surrounding the alveoli to take place, and the more abundant this tissue is, the greater is the liability to the occurrence of infiltration. When the necrotic pus has perforated the maxillary periosteum, it flows downwards from its own weight, in the loose connective tissue, unless its course is obstructed, when it seeks an exit in another direction, which is governed by the local anatomical relations. The fistulous track not infrequently attains a remarkable length and terminates in a fistulous ulcer upon the external integument, in the mucous membrane of the cavity of the mouth, or in some other cavity. The arrest of this affection, which lasts sometimes for years, not infrequently endangers life and often is not fully recognized by physicians, can only be effected by operative interference, which is to be determined by a thorough examination of all the parts involved in the region of the oral cavity.

An abscess, originating at the closed extremities of the root-membranes of the *incisors of the upper jaw*, generally perforates the anterior alveolar wall at a point corresponding to the apex of the root. The periosteal portion of the gums becomes conjointly involved, and a fistulous track is formed which opens in the outer cavity of the mouth upon the facial surface of the gum, and more or less below the level of the focus of suppuration. The pain ceases as soon as an exit for the pus is afforded. The cavity of the abscess attains, on an average, half the size of a split pea, and is lined with a membraniform layer of connective tissue. In the skeleton, the former cavity of an abscess presents a sharp outline; its rounded internal surface, tolerably smooth, presents indentations which result from the eroded cancelli (Atlas, Fig. 124). When the central incisors are affected,

the incisive canal on the corresponding side, also, becomes involved, subsequent to the destruction of the inner alveolar wall. The cavity of the abscess sometimes, also, takes an upward course upon the incisors, and perforates the floor of the nasal cavity. The opening in the anterior segment of the osseous floor acquires the size of a lentil or pea. Not infrequently the pus-sac extends downwards and backwards in the direction of the inner cavity of the mouth, and occasions resorption of the thick osseous layer in the most anterior portion of the hard palate, in consequence of which, a round hole, sometimes, of considerable size, is formed. Within the pus-cavity, projects the root of one or those of both, incisors (Atlas, Fig. 125). The margins of the hole, in the palatal process, are smooth, rounded or sharp at the edges, as if cut with a knife. Sometimes, it also happens, that the same abscess spreads in all the three above-mentioned directions, towards the labial, nasal, and palatal surfaces, and perforates the cortical, osseous layers. As a result of this, the outer (vestibulum oris) and inner cavities of the mouth, and the nasal cavity upon the affected side communicate with each other by means of fistulous tracks (Atlas, Fig. 126).*

Several cases of aneurism of the superior palatine artery have been observed, which admonish us to be on our guard against making a too hasty diagnosis and opening an imaginary abscess.

The *upper canine teeth* are less frequently the subjects of a suppurative inflammation of the root-membrane. When they are attacked, the disease is, generally, an extension from the lateral incisor, or from the first bicuspid, and there are pathological specimens of these spreading abscesses in which whole rows of roots are exposed, by the melting away (Schmelzung) of the anterior or posterior maxillary wall.

Sewill† reports a case of a fistulous opening at the inner canthus of the right eye of a child, ten years of age. There had been a constant purulent discharge from the opening for some months, and, to all appearances, it resembled a lachrymal

* Teirlink, Castle, Herapath.

† Odontological Society of Great Britain, 1868.

fistula. The sound was passed into the opening, and it extended as far as the canine tooth, which was discolored. This tooth was extracted and recovery speedily ensued.

Alveolar abscesses upon the *upper bicuspids* and *molars* commonly open upon the facial wall of the jaw, and it is not uncommon to find the extremities of several roots projecting into the cavity of the same abscess. Sometimes, the cortical layer of the external maxillary wall is raised in the form of a projecting wall, with a sharp edge, towards the cavity of the abscess (Atlas, Fig. 127). Occasionally, the lingual portion of the alveolar process presents a breach in the osseous substance which is bounded by sharp edges and corresponds with the partially denuded, carious roots of the molars.

After the pus has undermined or perforated the periosteum of the jaw, it forces its way along the connective-tissue sheaths of the muscles and, not infrequently, escapes externally through the integument (buccal fistula), or penetrates the parotid gland and produces a salivary fistula. If the extremities of the roots project far into the antrum, the pus may perforate the mucous membrane and escape into the cavity or, if the teeth or roots are extracted, give rise to a fistula of the antrum, which is displayed in the skeleton as a funnel-shaped depression with a corresponding opening in the floor of the cavity. The maxillary tuberosity frequently becomes infiltrated with the pus from the abscesses of the roots of the upper wisdom teeth (Atlas, Fig. 139). J. A. Salter* relates the following grossly neglected case of inflammation of the root-membrane of an upper molar. A female, twenty-four years of age, was attacked with a severe toothache, referred to the first upper molar on the right side, the pain being accompanied by an extensive swelling of the same side of the face and attended with intense suffering. The eyeball became protruded, and she soon noticed, that she was unable to see with that eye. In a short time after this, the abscess pointed in the vicinity of the inner, and later near the outer canthus, and a large quantity of pus escaped. The openings then closed again and the general symptoms remained the

* Medical Times, 1862.

same. The latter condition continued three weeks. On admittance to the hospital, the patient presented a repulsive disfigurement of the face, œdema of the lids, livid skin. The first upper molar on the right side, together with other carious teeth, were removed, and the antrum could be reached through the partially absorbed alveolus of the first tooth. There was considerable necrosed bone, including a large portion of the inner and outer walls of the orbit, which was separated. The mobility of the iris was restored, but not vision. The author relates an analogous case from the practice of Pollock, where there was an intense inflammation of the whole maxillary region, occasioned by a carious tooth; it involved also the organs in the orbit. The inflammation yielded after the extraction of the tooth, but the power of sight was lost.

C. Williams* reports a case of an alveolar abscess, which occurred subsequent to the extraction of an upper molar and opened upon the inferior margin of the orbit, just beneath the outer commissure of the eyelids. The pus made its way beneath the zygomatic process along the temporal muscle, its escape in the temporal region being prevented by the latter and the strong fascia investing it; it made its way through the sphenomaxillary fissure into the outer and lower portion of the orbits, and escaped by means of a fistulous opening. There was marked exophthalmia of the left eye, combined with serous chemosis. After the pus was evacuated by means of incisions in the temporal region, improvement soon followed.

Abscesses of the periosteum of the roots of the *under teeth*, perforate the facial, more frequently than the lingual wall of the jaw. The molars, however, form an exception to this rule. Destructive processes in the bone are less intensive and extensive than in the upper jaw. Still it is not uncommon for the entire facial wall, both of the alveoli and the jaw to be destroyed; the lingual wall, also, of the lower jaw is frequently perforated, especially opposite the apices of the roots of the incisors. The margins of the bone, which bounds the parts where destruction has taken place, always terminate in thin edges and, generally, have an oblique direction from below upwards.

* Dental Cosmos, 1867.

With abscesses of the periosteum of the roots of the under teeth, there is, always, great danger of the formation of fistulous tracks along the fasciæ and, whether the fistulæ open upon the cheek (salivary fistulæ), upon the margin of the lower jaw, in front of or behind the ear, in the cervical region, upon the nape of the neck or the thorax, their true character, frequently, is not recognized by physicians, and they are improperly treated.

In proof of this fact, may be cited the following communication, which was made to me by Prof. Strasky: "Several years ago, I was consulted by an elderly lady in regard to a set of artificial teeth. Presently, to my surprise, she began to arrange the dressing of a purulent ulcer, upon the left side of the chest, opposite the armpit, in the region of the fourth or fifth rib. To my question, as to what ailed her, she replied, that for three years, she had been under the care of the most noted physicians in the city, who had treated this ulcer with all sorts of salves and plasters, but to no purpose, for the ulcer which commenced as a small abscess, gradually increased in size, and became more painful. When I examined the mouth for the purpose of fitting the set of teeth, I found the left lower wisdom tooth deeply imbedded within the gums; the crown was quite destroyed by caries, the gums around it were detached, sensitive, and, upon pressure, pus oozed out from them. As I had previously conjectured that the ulcer upon the thorax was dependent upon an affection of the tooth, I applied pressure from the angle of the jaw along the surface of the neck to the region of the ulcer, and became satisfied that pus escaped from two points of the ulcerated surface. The carious tooth was extracted, and the ulcer healed in the course of a few weeks."

Pagello* had under treatment a fistula which opened in the dimple of the chin and resisted every kind of treatment. The teeth, apparently, were sound. An infusion of madder was injected into the fistulous track, and, in a few days, the incisor, situated above the track, acquired a red color. The tooth was extracted, and the fistula speedily and entirely healed.

Finally, it may be remarked, that inflammations of the peri-

* L'abeille Medicale, 1856.

osteum of the root, resulting in abscesses and erosions of the jaw or tooth, occur also in animals. I have had the opportunity of observing instances of this kind in the horse and dog. In these cases, caries does not furnish the starting-point, as is, usually, the case in man.

Inflammatory affections of the periosteum of the jaw are of frequent occurrence, as a sequence of an inflammation of the pulp or root-membrane.

The cases that, for the most part, come under the notice of dentists, are those of periostitis occurring upon the alveolar process as a sequence of caries of the teeth and which is confined within narrow limits, though to be sure, now and then, it is quite extensive. This inflammation is manifested primarily by the appearance of a tumor upon the bone, which is occasioned by an œdematous swelling in the perimysium and subcutaneous connective tissue, in consequence of a hindrance to the circulation. If purulent infiltration into the alveolus has taken place, the maxillary periosteum readily becomes similarly affected. Hence is developed a circumscribed periostitis, which ends in suppuration and destroys the contiguous portions of the bone (Atlas, Figs. 124-127 inclusive).

Inflammations of the maxillary periosteum of this description are of frequent occurrence and are very much neglected, after the subsequent suppuration, especially by patients of the poorer classes, since, if the pus has a free exit, the sensitiveness of the bone persists, to be sure, but the pain is not of such a severe character as to compel the patient to apply for relief. When the pus has a free exit, the face even is not perceptibly disfigured. The inflammation may assume an acute character and give rise to an abundant purulent mass, which undermines the neighboring periosteum, cuts off the vascular supply to the corresponding segment of the jaw, and hence occasions a necrosis of the latter.

When the suppurating periostitis, especially in neglected or badly treated cases, has occasioned the death of the subjacent bone, the dead portion acts as a foreign body and induces a consecutive suppuration in its vicinity. A fistula is formed, leading to the necrosed portion of the alveolar process. The

detachment of the sequestrum is a slow process and, often, does not occur for months, recurrences of the inflammation being very frequent. A repair of the destroyed portion of the bone takes place in most cases.

It is a familiar fact, that the alveolar process is fractured, not infrequently, by carelessness in the extraction of teeth, especially of the lower molars. Unfavorable circumstances, for instance, deep position of the teeth, hooked roots, notable divergence or length of the same, marked fragility of the bone in persons of advanced age, render a fracture of the process possible, even with the utmost care in extraction. When a fracture occurs, it depends upon its extent and complexity, whether or not several teeth, together with their alveoli, will become necrosed. As a general rule, a slight splintered fracture readily heals, after the exfoliation of the fragments. Stumps of teeth and the attached root-membranes, which remain after ineffectual attempts at extraction, not infrequently give rise to a localized periostitis, which is recovered from as soon as the necrosed stumps are extracted or expelled.*

Periosteal inflammations occurring during the period of dentition are of especial importance, since, with children, inflammatory affections generally run a more rapid course than with older people, particularly in an organ in which development takes place within small limits with comparative rapidity. The more extensive the infiltration of the maxillary periosteum, the greater is the danger that a larger portion of the jaw will become necrosed. Children of a scrofulous or tuberculous habit are the more liable to the occurrence of partial necrosis of the jaws, from the fact that in them the infiltration undergoes a speedy degeneration on account of the rapid proliferation of

* Leynseele (Bullet. de la Soc. de Gand, 1855) describes a case of meningo-encephalitis which resulted from an ineffectual attempt to extract a tooth. The lower jaw was splintered at the part where the extraction was attempted. Pus worked its way along the bone, which became denuded, and ascended upon the inner surface of the ramus of the jaw to the base of the cranium; it then entered the cranial cavity through the foramen ovale, spinosum and rotundum, where it spread out upon the base of the brain and became the origin of a meningo-encephalitis.

the elementary organs. C. O. Weber* relates two cases which came under his observation (in children two and six years of age, respectively), where the periostitis acquired alarming proportions.

Children, who are attacked with the eruptive diseases during the primary shedding of the teeth, especially when their surroundings are unfavorable or they are the subjects of the above-mentioned diatheses, are liable to be affected with a periostitis and necrosis of the jaw which Salter† has described as exanthematous. Two cases of this kind came under his observation after variola, five after measles, fifteen or sixteen after scarlet fever and most of these cases occurred in children, five years of age.

Periostitis with necrosis, occurring as a sequence of retarded eruption of the wisdom teeth, has already been described (*vide* p. 202).

Rheumatic periostitis, which generally is associated with carious teeth, is due to exposure to cold and damp. Its symptoms do not differ from those of common periostitis. Traumatic periostitis from fracture or contusion of the jaw, specific, from the effects of phosphorus or mercury, dyscrasic, which accompanies scorbutus and cachexias, generally, do not usually come under the treatment of the dentist, although, the frequent existence of carious teeth and the consecutive inflammation of their periosteal membranes form an essential predisposing cause, or aggravating element, and require special treatment.

The *symptoms* of periostitis of *the upper jaw*, induced by inflammation of the periosteum of the root, vary according to its original seat. Albrecht‡ gives an excellent description of them, in the following words: "When the periosteum of the roots of the front teeth is involved, the alveoli become distended, the interalveolar depressions disappear, and the inflammation spreads to the nasal cavity; the secretion of the mucous membrane of the latter is arrested, and its cartilaginous portions become sensitive. If the affection extends from the alveoli of the small incisors to those of the canines and bicuspid, the irregularities

* Handbuch der allg. u. speciell. Chirurgie, redig. v. Pitha und Billroth.

† Surgical diseases connected with the teeth in Holmes' System of Surgery, vol. iv.

‡ Op. cit., p. 45.

on the facial surface disappear, the canine fossa is obliterated and bulges out if the intensity of the periostitis of the alveolar process increases sufficiently, and the periostitis extends, usually, even to the nasal process of the upper jaw, which becomes somewhat swollen and sensitive to pressure. If the inflammation starts from the molars and bicuspid, instead of a depression, a firm swelling becomes perceptible beneath the zygoma, produced by the swollen, upper jaw. If the two sides of the face are compared with each other, provided the periostitis is not bilateral, an extremely rare occurrence, the filling up of the zygomatic fossa becomes quite evident to the touch, even if it is inconsiderable. On the other hand, the swelling may attain such magnitude, that the surface of the jaw projects beyond that of the zygoma. The inflammation, sometimes, extends far beyond the affected tooth. The periosteum of the root may return to its normal condition, while the inflammatory process, or its sequelæ, still persist in the periosteum of the jaw and give rise, in the latter locality, to important diseased processes. When this occurs, it becomes a difficult matter to ascertain which tooth was the starting-point of the affection, as it is often requisite to remove this tooth in order to afford an escape for the pus which is pent up within the bone.

“Periostitis, resulting from an extension of inflammation, occurs more frequently in the *lower jaw* than in the upper. After the alveolus of the tooth originally affected has become notably distended and painful, the ridge, which runs along above the basilar portion of the under jaw (*basis manibulæ*), disappears in the portions corresponding with the molars and becomes continuous with the basis. The latter then increases in thickness, becoming, in some cases, even five and six times as thick as it is in the normal condition; the margin of the jaw now presents a thick shapeless bunch, which has the hardness of bone and spreads both to the outside and to the inside towards the cavity of the mouth. As long as the swelling is moderate in amount, it may be known that the process is still confined to the periosteum of the jaw; but when it attains such large dimensions as mentioned above, either the inflammation has extended to the spongy portion of the bone, or purulent

infiltration has taken place into the bony tissue from the alveoli."

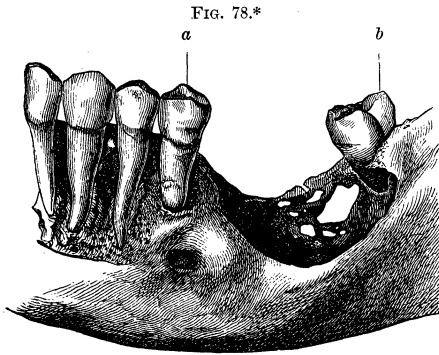
If we make an anatomical study of jaws within which are carious teeth and abscesses of the root-periosteum, and observe the frequency and marked degree of purulent infiltration which takes place into the periosteum and bones, the suspicion arises, that there is far from sufficient attention given to this affection by physicians, and that, perhaps, many diseases, which terminate fatally, originate from a consecutive suppurative periostitis or otitis of the jaws. Fortunately, most cases of purulent infiltration result, finally, in perforation of the maxillary walls, and the pus obtains a free escape through the fistula which is formed in the gums.

The infiltration of pus takes place chiefly in the spongy portion of the osseous tissue, and hence it is found, in the upper jaw, upon the lingual side of the incisors and canines and, also, of the bicuspids and molars, especially between the roots of the latter, and in the tuberosity. In the lower jaw, the liability of infiltration is greater, since the spongy tissue, particularly near the molars, extends to a considerable depth in the jaw and along the coronoid processes and condyles. Moreover the cortical layer of the bone is more compact, generally, so that perforation by the pus takes place with greater difficulty.

In the lower jaw, the enlargement of the bone, in consequence of purulent infiltration, is most apparent on the facial wall, in the vicinity of the external oblique line, the latter becoming more or less effaced; in the upper jaw, on the facial wall in the vicinity of the front teeth and towards the tuberosity. The cancelli of the bones are distended in appearance, of a bright blood-red color or reddish-gray, or discolored. The evidences of resorption, in consequence of the purulent infiltration, are displayed in the form of sharp-edged holes, excavations, and grooves, upon the surfaces of the alveolar processes, and the resorption starts from the Haversian canals and cancelli, as may easily be demonstrated by the graduated form presented in the development of the breaches in the osseous substance.

When a portion of the alveolar process is destroyed by supuration or by necrosis, a cicatrization of the remaining portion

ensues, similar to that which takes place after the extraction of teeth, except that the distortion is greater, varying with the amount of the previous loss of substance, that is, the cicatrix forms a deeper fossa-like depression upon the alveolar arch (Fig. 78). The adjacent surfaces of the alveoli of the contiguous



teeth are frequently defective, in consequence of which the roots and their periosteal layers are exposed in the cicatrix.

The pre-existence of a chronic periostitis may be clearly inferred, even in macerated jaws after the separation of the periosteum, if there is a deposit of a minutely-porous osteophyte (comp. New-formations). The very delicate and thin osteophyte formation, which may easily escape notice, is of frequent occurrence and, generally, is limited to a quite small circuit in the vicinity of an alveolar abscess; upon the lower jaw, however, it occurs, at intervals, over the greater portion of the facial wall, even along the coronoid and articular processes. Now and then,

* FIG. 78 shows a segment of the left lower maxillary arch, in which is the cicatrix of a circumscribed necrosis of the alveolar process, corresponding to the first and second molars. The mental foramen, somewhat more posteriorly than usual, is situated underneath the apex of the root of the second bicuspid (*a*). The facial wall of the three front teeth is removed. The wisdom tooth (*b*) has a forward inclination, and most of the anterior wall of its alveolus is wanting. Between the latter tooth and the second bicuspid, a considerable loss of osseous substance is to be seen, in the form of a bowl-like fossa, with sharp outlines. In the persisting portion of the lingual wall of the jaw are several holes of various sizes. The fossa was lined with a thin, easily separable, connective-tissue membrane. Natural size.

in connection with caries of a single tooth, an osteophyte is met with which extends along the entire lower jaw upon both maxillary walls.

Chronic periostitis, in the vicinity of the alveolar borders, frequently gives rise to proliferations of the compact osseous substance, which are described in connection with increase in volume, as *hypertrophy of the alveolar processes*, or as exostoses or osteomata (comp. New-formations).

NASAL CAVITY AND ANTRUM.—When there is insufficient or no escape for the pus of abscesses of the root-periosteum of the upper incisors or canines, and the abscess spreads upwards, the bony floor of the nasal cavity becomes involved, as has already been observed; its periosteal covering and the corresponding portion of the mucous membrane become inflamed and perforation, sometimes, ensues, by means of which the pus escapes into the anterior nasal region. The skeleton, in such cases, presents, usually, an oval aperture, with sharp edges, the long diameter of which, transversely disposed, sometimes measures nearly one centimetre, so that it communicates with the incisive fossa on the same side (Atlas, Fig. 126). In two specimens, I find that the abscess of the root-membrane, which penetrated the floor as above, originated from the lateral incisor. My collection also contains a specimen, in which the perforation is in the middle segment of the floor, adjoining the ascending lateral wall, of the nasal cavity, and the disease originated from a periosteal abscess of the lingual root of the first molar. With extensive carious affection of the molar roots, accompanied by chronic inflammation of the root-membrane and periosteum of the jaw, the purulent infiltration also spreads within the osseous tissue beyond the floor of the nasal cavities. Inflammatory affections of the nasal mucous membrane, attended with catarrh or fistulous ulcers, appear then to be a more frequent sequence of chronic inflammatory diseases of the teeth than was formerly supposed.

We sometimes meet with jaws, in which the lingual root, particularly of the first molar, covered with a thin osseous layer, projects about three to four millimetres beyond the floor of the antrum, or where the respective roots of the first two molars or that of the second bicuspid, covered with their periosteum, form

free projections within the cavity. Less frequently, humped protuberances are found which are produced by the roots of the wisdom teeth or first bicuspid. When such a condition of things occurs, it is easy to understand, that, as a sequence of an inflammation of the root-membrane which ended in an abscess, the purulent accumulation has given rise to an inflammatory affection of the periosteal covering and, finally, of the mucous membrane of the antrum. *Inflammatory, catarrhal swelling of the antrum*, occurring either with or without periosteal inflammation of the contiguous teeth, occasions a sensation of dull pain; the bone becomes sensitive, at times even under the slightest pressure; the cheeks become somewhat swollen and oedematous, and, sometimes, the skin presents red spots. The affection is now termed empyema, and is accompanied by continual pain with more or less intense exacerbations. T. Bell mentions the occurrence of caries (?) and exfoliation of the bones, in unfavorable cases, especially in scrofulous persons, and, according to his observations, if communication with the nasal cavity becomes closed, in consequence of the swelling of the mucous membrane, the symptoms become more serious from the accumulation of puriform mucus; the molars and bicuspid, on the same side, become loosened and tilted from their normal position, and the gums swollen and spongy. In cases, he says, where it cannot be expected that the teeth will become firm again, they should be extracted. Bell never saw a case of closure of the opening into the nasal cavity by granulations, but mentions an instructive case of a cyst filled with puriform mucus. One case of a purulent cyst of the antrum, in connection with extensively carious roots of the bicuspid and molars, came under my observation. When the fluid, accumulated within the antrum, had a more serous character, the affection used to be called *hydrops*. In these cases, the mucus also acquires a gelatinous appearance occasionally.

As the cavity of the antrum increases in extent, the facial wall bulges considerably and becomes quite thin and transparent. The distension may also be perceptible in the direction of the palate or orbit and, sometimes, occasions a deviation of the eye from its normal position. As the former attains increased

proportions, the facial wall of the bone undergoes partial re-sorption, so that nothing is left but a membranous wall here and there, and the contained fluid may be determined by its fluctuation.

The diagnosis is attended with difficulties, in some cases, and the case may easily be confounded with an entirely different tumor. Henry Smith* relates a case, where there was a purulent collection in the antrum, forming a notable tumor which it was decided to extirpate; but it began to improve, and the operation was abandoned. In doubtful cases, therefore, it is best, always, to make a puncture into the antrum through the alveolus of the second molar, after extracting the tooth, or through the canine fossa. The manner in which an exploratory puncture shall be made depends, however, upon the special circumstances of the case.

In favorable cases, the puriform mucus escapes through the nasal cavity or downwards in the alveolar arch, if the carious root has fallen out or has been extracted. Sometimes a fistulous track persists, which, frequently, is as fine as a hair and easily becomes occluded. The discharge may also occur in the direction of the orbit or the cheek, and give rise to an abscess and necrosis (comp. Salter's case, above).

Chronic irritation of the mucous membrane of the antrum, with or without a fistulous track leading from it, leads to thickening, recurrent, inflammatory swellings, papilliform, exuberant growths of connective tissue, or other kinds of new-formations.

Inflammation of this mucous membrane may also be induced by the penetration of foreign bodies into the antrum, *e. g.*, tooth picks, stumps of teeth which have been forced into it in efforts to extract them, fragments of bone from fractures or gunshot wounds, &c. Prof. Strasky, of Lemberg, gave me a brief account of a case of this kind. A boy nine years old came to him on account of pain in a left milk molar, and an ulcer of the cheek on the same side. The father stated that a year before, the boy fell into a water conduit, one and a half fathoms in depth and framed with oaken posts and planks. After the hemorrhage

* British Journal of Dental Science, 1867.

from the cheek was checked, suppuration occurred in the cheek, and an ulcer was formed, which would not heal, in spite of very careful treatment. Strasky found a well-marked parulis, and extracted the painful, loose tooth which had pushed forward in its socket; a probe was then introduced through the socket from which pus mixed with blood escaped; it easily passed into the antrum, and by means of it a foreign body could be felt, which could, also, be reached by introducing the probe through the ulcer on the cheek. He succeeded, by means of a pointed pair of forceps, in extracting the foreign body which proved to be a conical piece of oak wood, fifteen millimetres in length and five millimetres thick. The part was carefully cleansed by syringing, and a sponge-tent was introduced, in order to avoid a premature closure, and kept in place until the healing of the bone and skin took place. In about three or four weeks, both the wounds, that upon the alveolus and the other upon the cheek, were cicatrized.

F. Steiner* reported a case of dropsy of the antrum, which occurred in the private practice of Prof. Billroth. The affection appeared as a sequence of a very irregular, extremely defective dentition, in a scrofulous girl, sixteen years of age. The only teeth that had made their appearance in the the upper jaw were three temporary and, subsequently, the three corresponding permanent ones. The tumor had been forming for a year in the left upper jaw, and had attained the dimensions of an apple of medium size. The anterior wall of the cavity was partially removed, and, on examination at that part, no abnormally located tooth was found, but on excision of the posterior wall of the gum, the imbedded crown of a bicuspid was discovered.

* Wiener med. Wochenschr., 1870.

III. ATROPHIES.

ATROPHY of an organ arises from a partial or an entire permanent withdrawal of its nutrition, and is either *primary, senile*, induced by the gradual decline in the interchange of materials incident to advancing age, or *secondary, consecutive*, occasioned as a sequence of inflammations, anomalies of the secretions, hypertrophies or new-formations in the organ itself or outside in the immediate vicinity, or in distant organs having a definite relation with the atrophic organ.

It is scarcely possible to determine in every case, whether it is one of senile, or consecutive atrophy, and a careful observation of the clinical history of the case can alone furnish a basis for reasoning, especially when it is required to determine the predisposing causes of the consecutive atrophy.

The senescence of the organs of mastication needs to be minutely studied in order that the natural involution of an organ, which occurs in old age, may not be confounded with a pathological process. The period at which the natural decay takes place is not fixed; one organ may be subjected to such unfavorable conditions of nutrition that either the whole or parts decay prematurely, while the other organs or the remaining portions of the same organ undergo comparatively no alteration within the same period. Premature decay is induced by hereditary disposition, excessive irritation, and untimely abrasion. In all cases the diminished assimilative power of the elementary organs gives rise, finally, to degenerated products within the protoplasm and surrounding substance, which products are repeated in the various organs except that they occur under different forms (Modalitäten).

DENTAL PULP.—Diminished vital activity in the pulp is displayed in manifold ways.* *Fatty degeneration* is of frequent occurrence and is manifested, in a general way, by its dimin-

* *Vide* deutsche Viertelj. f. Zahnheilkunde 5. Jahrg. über Atrophien der Zahnpulpe von M. Heider und C. Wedl.

ished volume and succulency, its recession and pale reddish-gray discoloration, with a trace of yellow. These indications, of course, are presented both by the coronal and radical pulp.

Pulps of this description are covered by a cloudy layer, separable in the form of a membrane and composed of degenerated dentinal cells. The outlines of the latter are preserved, more or less, and they contain numerous luminous granules of various sizes, which produce the optical effect of fat-globules, but, also, lie loose between the cells and, evidently, are the occasion of the diminished transparency. The parenchyma of the pulp, also, shows a similar fatty degeneration, though to a less degree. In some parts, the fat-globules form chain-like or fusiform aggregations and follow the course of the vessels and nerves; in others, the minute fat-molecules are scattered in the interstitial connective tissue which may be cleared up by the addition of acetic acid or carbonate of soda. In consequence of the abundance and ready accessibility of the nerves in the pulps and their roots, it is quite easy to demonstrate the granular, fatty metamorphosis of the nerve-tubes which are uniformly thickened without any varicous enlargements (Atlas, Fig. 47^a). It cannot be asserted, however, notwithstanding the existence of the latter evidences of necrobiosis, that the sensibility of such nerves is entirely destroyed, because the axis-cylinder may still be preserved, though the nerve medulla has undergone a molecular degeneration, and still may be capable of performing its functions, though its conductivity be reduced to quite a low degree. On the other hand, it is impossible to assert absolutely that the medulla of each and every nerve-tube has undergone the fatty metamorphosis.

The pulps of milk teeth, also, while the latter are undergoing resorption during the period of dedentition and, really, are senescent teeth, sometimes become the subjects of the above fatty degenerations which occur in the same manner and form as with the subsequent teeth.

When *calcifications* occur, the coronal pulp, except in its peripheral portions, is rendered less transparent by the deposition of roundish calcareous grains within its parenchyma which conveys a gritty sensation when touched with a needle, and becomes

more opaque in the mass as the calcification progresses. In the pulps of the roots, the appearances are still more striking; the calcareous particles, generally, are more completely arranged in them, so that, in some cases, they become as stiff as a wire. In order to examine calcifications with the eye alone, or with the aid of a lens, it is best to remove the pulp and allow it to dry, or to make longitudinal or cross-sections through the teeth containing calcified pulps. The chalky-white calcareous portions are rendered much more distinct in the dried condition (Atlas, Figs. 51 and 53).

The calcifications or cretefactions form, in rare cases, a quite large coherent mass, as is the case, for example, upon the pleura or in atheromatous arteries; generally, however, they are presented in a reticular or nodular form. The cohesion is less than might be expected, even in those cases where calcification of the pulp is very extensive, since even these admit of separation in the direction of the organic envelopes which inclose the calcified portions.

Upon minute examination the calcareous concretions in the coronal pulp appear in the form of nodules, of various sizes, imbedded in a mass of fine connective tissue (Atlas, Fig. 46), the outer surfaces of which, especially if they have attained considerable size, present a very delicate network or arborescence and, sometimes, cup-shaped depressions when high magnifying powers are employed (Atlas, Fig. 52). If the calcareous salts are removed by means of hydrochloric acid, there remains an ill-defined filamentous network, composed of numerous concentric layers, which bears a resemblance to coagulated fibrin, but cannot be regarded as such in a decalcified condition since there are no reasonable grounds for such a view.

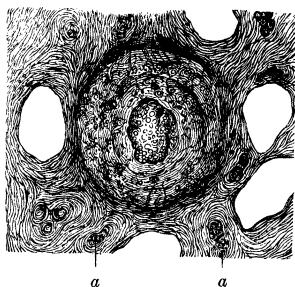
The small, nodular, calcareous concretions in the parenchyma, in all probability, are produced in one of two ways: either by a calcification of cells, or in a manner analogous to that in which they are produced in the urine of herbivorous animals, directly from the semi-fluid, organic mass impregnated with calcareous salts, without the intervention of cells. As soon as a nucleus of crystallization is established in the form of a firm transparent grain or an aggregation of minute granules, the growth proceeds,

as may readily be demonstrated, by the deposition of new concentric layers around the grain; frequently, similar grains attach themselves to the periphery of the primary grain and give rise to the familiar mulberry forms; contiguous grains, in some cases, coalesce and finally produce the larger nodular concretions which are visible to the naked eye in the form of spheroids or spherical segments, arranged in clusters of a few or aggregated into a large mass. Now and then occur calcareous grains of a round, oval, or dumb-bell shape, around which are deposited very sharply defined, uniform, cortical layers, scarcely 0.001 of a millimetre apart from each other, which persist after the removal of the calcareous salts. (Fig. 79.)

The calcareous nodules present the following properties: a strong refractive power; the property of producing double refraction; if treated with dilute hydrochloric acid, decomposition ensues, with the liberation of bubbles of gas and a residue of an organic basis-structure; if treated with dilute sulphuric acid, numerous crystals of sulphate of lime are deposited.

In the root-pulps, sometimes, also, in those of the crown, the concretions assume an oblong, cylindrical, spicated, or spindle form with two pointed extremities and their long diameters corresponding with that of the radical pulp. They are located in the firm, interstitial bundles of connective tissue, the sheaths of the bloodvessels and nerves. In the *tunica adventitia*, especially, of

FIG. 79.*



* FIG. 79 shows a calcareous deposit in the central portion of a transversely divided pulp of the incisor of a horse. The deposit is seen in the centre and, like analogous ones which occurred in other places, presents a highly refractive power, a granular condition, a nucleus-like structure composed of minute spherical concretions, and a rounded outline. As these agglomerations were located near the central portion of the pulp, cavities of wide bloodvessels, transversely divided bundles of nerves (*a, a*), and capillaries, interspersed here and there, occur in the section. Upon the periphery, connective-tissue fibres extending from the margin are to be seen, and roundish connective-tissue cells, also, are visible. Magnified 250 diameters.

arteries, concretions of this description are frequently interspersed in elongated patches (Atlas, Fig. 48). The narrow cylindrical forms occasionally send out ramifications in the manner of fungus-threads, and these forms, probably, are produced by obliterated thin bloodvessels which have undergone calcification. The trunks of the nerves not infrequently are so concealed within the calcareous shells that a careful dissection is necessary in order to bring them into view, and the nerve-medulla of the tubes frequently degenerates into a rigid highly refractive mass which does not completely fill the cavity of the tubes (Atlas, Fig. 47^b); the interstitial connective tissue of the trunks is reduced to membraniform, more or less friable lamellæ. The bloodvessels are obliterated and, except here and there where they are filled with necrotic blood, are generally empty and collapsed. Nothing is left of the dentinal cells but a scanty residue when the calcification is very extensive.

Cases occur less frequently where the walls of the bloodvessels, especially in the bodies of the pulps, undergo quite extensive calcification, so that the vessels of medium calibre, together with their branches or anastomotic loops, are inclosed in calcareous envelopes (Atlas, Fig. 49), which give to the vessels a rigid appearance, a brittle character and a rough exterior. Here and there, the inner coats of the vessels are seen to project from out the calcareous cavity, which fact serves to indicate that the *tunica adventitia* of the vessels is the true seat of the latter calcareous incrustation. Occasionally flattened, quite large, reticulated concretions are met with, the marginal portions of which may present evidences of resorption (Atlas, Fig. 52). A combination of net-like calcareous plates with a rarefied dentinal new-formation also occurs.

The frequent occurrence of calcifications of the pulp is not confined merely to old age and to the period of the resorption of the roots of the milk teeth, but it occurs quite early in many teeth, independent of caries. The larger calcareous grains must not be confounded with the smaller dentinal new-formations. The latter, generally, consist of a compact, yellowish, transparent mass, with a more or less nodulated surface and located beneath the superficial layer of the pulp or united with the dentine, and

containing dentinal canals, which, however, are rarefied. It is a fact of considerable interest, in a clinical point of view, that sensations of pain are not necessarily engendered, notwithstanding the very abundant calcareous deposits in the interstitial connective tissue of the nerves. Under certain special conditions, however, which we cannot explain and are difficult to determine, the calcareous agglomerations probably do excite a painful irritation.

Colloid deposits are entirely absent in many cases of atrophic pulps, while in others they are present in abundance. They present the familiar globular formations which refract the light like opaque glass, and are unaffected by dilute acids; they lie among the fibres of connective tissue; frequently are attached to the tunica adventitia of the bloodvessels, or are adherent, within the cavities of the latter, to the inner coats and, also, are imbedded within the nerve-tubes. When the colloid masses are abundant and of small dimensions, with the exception of their glassy aspect, they correspond somewhat with connective-tissue cells or their nuclei, at least with respect to their size, shape, and arrangement, and, probably, are the products of a colloid metamorphosis of these elements. The smooth, firm, transparent bodies which occur singly, in clusters, or are fused together into a glue-like mass, and fill, more or less, the cavity of the bloodvessel (Atlas, Fig. 50), are identical with the minute, shining grains observed in the necrotic blood, which are colloid masses formed by a transformation of the globulin of the blood-corpuscles in the interior of the vessel. The different steps in this process of the transition of the red blood-corpuscles into colloid masses may, indeed, be traced in suitable cases.

The *net-like atrophy* or perversion of the pulp is a very interesting form, in a histological point of view. Pulps of this description are recognizable with the naked eye, by their flattened, shrivelled appearance and finely indented outer surfaces which, otherwise, are smooth. Their color is darker, gray-yellow or reddish-brown, according as they contain a smaller or larger amount of necrotic blood which produces, also, indistinct, generally rust-brown spots. Further, they have a dry appearance, are brittle, and of about the consistence of parchment. The action of acetic acid, by means of which the connective-tis-

sue substances swell up and become clear, is reduced to a minimum. The pulp may become so diminished in thickness that it is as thin and translucent as tissue-paper.

The diagnosis of net-like atrophy cannot, however, be made with the unaided eye in cases where it is not so pronounced as in the above description, or is confined to narrow limits. A magnifying power of ten to twenty diameters is sufficient to give quite a definite idea, where it is desired to observe, principally, the network upon the outer surface and papilliform processes which are located at uniform intervals from each other upon the marginal portions (Atlas, Figs. 40 and 46). The different colors produced by the blood, and the dilatations of the vessels, may, also, be seen very well with the same magnifying power.

If now one investigates more closely pulps of this description, beginning with the dentinal cells, the different phases of the net-like degeneration must be taken into consideration. In the less advanced cases, tolerably well-preserved dentinal cells, groups of them at least, are met with; as the process continues, they fade away and become unrecognizable, so that nothing is left of them, in quite large tracts, but a scanty residue, consisting of short filaments extending from a diaphanous, membraniform substance and penetrating the dentinal tubules. The bodies of the dentinal cells, consequently, have disappeared entirely. If such a wasted group of dentinal cells be examined from the surface, it presents the appearance of a diaphanous membrane perforated like a sieve, and is suggestive of a cross-section of dentinal tubules (Atlas, Figs. 42 and 44).

The anatomy of the pulp, which has been considered in a preceding section, is to be taken into account in connection with the development of net-like atrophy; there occurs, namely, a withering of the reticulated connective-tissue cells and, also, of the peripheral bloodvessels and nerves. The process may be traced out in a series of cases. The network, which remains as a final product and maintains throughout essentially the same character, is made up either of small meshes and disposed in numerous layers, or of larger meshes, and, sometimes, in a single layer. Occasionally, very brilliant nuclei may still be

recognized at the points of junction of the trabeculæ; in more advanced cases, however, or elsewhere in the same pulp, they have disappeared. The resisting, rigid trabeculæ have a yellowish color, with transmitted light, a high refractive power, and give off processes which penetrate the delicate membraniform, intermediate substance that fills up the meshes. The marginal portions of the network upon the periphery of the pulp display to the best advantage the membraniform nature of the intermediate substance.

The anomalies which are produced in the bloodvessels, in connection with net-like atrophy, are very characteristic. In the pulp of teeth with single roots, the vessels of wider calibre not infrequently attain a transverse diameter of 0.2 of a millimetre, and even are larger; usually they are entirely empty, pursue an undulatory course (Atlas, Fig. 40) and their walls no longer present their proper arterial or venous character, those of the veins consisting merely of a delicate membrane containing barely discernible, shrivelled nuclei. In the smaller vessels, varicosities, lateral pouch-like dilatations, or bud-like offshoots are frequently met with (Atlas, Fig. 45). Very often, also, contractions of the larger vessels and strictures of the smaller ones are produced by the connective-tissue trabeculæ, which give rise to various, more or less, sinuous forms. In other places, coils of the vessels prevail. They contain only small clots of blood at intervals. It is worthy of remark, in reference to these orange-colored, rigid columns that form a homogeneous mass, that they present at one end a concavity in the form of a meniscus, a condition which may be explained by the adhesion of the glutinous blood to the wall of the vessel at the period of stasis (Atlas, Figs. 43 and 44). Usually these are combined with products of metamorphosed blood in the form of molecular precipitates, fatty-acid crystals, plates of cholesterin, &c.; not infrequently the reticulated tissue has become tinged with blood from previous extravasations. Here and there the red corpuscles may still be recognized, deprived of their coloring matter, necrotic, and angular in consequence of their mutual pressure one against the other.

The nerve-tubes present, very distinctly, the atrophic charac-

ter which has been described above, and in transparent portions it may be traced without any previous preparation, by their notably flattened, as it were, mummified condition.

Net-like atrophy occurs as an independent involution of the tissues, which, apparently, is unattended with pain, runs a chronic course and affects, chiefly, the much worn teeth of old persons, but, also, the milk teeth at the period of shedding the teeth and, more particularly, those which have but a single root.

It arises from nutritive disturbances which are induced, primarily, by varicous expansions and spiral curvations of the vessels which are succeeded by stasis and effusion of the blood: The capillary system becomes entirely obliterated, and the connective tissue, which serves as a stay or support for the nerves and bloodvessels, likewise shrivels up. Nutrition and sensibility are completely arrested. The explanation of the more frequent occurrence of general atrophy in the pulps than in other organs may, perhaps, be found in their diminutiveness, in the comparatively powerful pressure to which the worn away crowns are subjected in mastication, and in the diminished elasticity of the dentine in old age.

Sclerosis belongs to the rare affections of the pulps. Tense, cord-like bundles of connective tissue interlace in the very tenacious, resisting bodies of the pulps, forming sharp angles with each other, and between them minute fat-granules, also, occur. As the metamorphosis advances, the bundles of nerves waste away.

The different processes which have been described as occurring in the retrograde metamorphosis of the dental pulp, sometimes are combined, so that fatty degeneration occurs with calcification, colloid deposits with sclerosis, net-like atrophy with calcification and colloid deposits. Fatty degeneration and net-like metamorphosis very rarely are combined.* Atrophic pulps may even become the subject of an inflammatory affection, in case the atrophy has not advanced too far. For instance, now and then a marked net-like atrophy is complicated with a purulent infiltration into the superficial portion of the pulp, from

* Hohl: Deutsche Viertelj. f. Zahnheilkunde, 1866.

caries of the crown; partial gangrene, even, may ensue in an atrophic pulp. New-formations of dentine are frequently the forerunners of the atrophic process.

Adhesions of the pulp to the internal surface of the dentine occur. The two structures become intimately united, so that, instead of admitting of ready and complete separation, as was the case originally, they become united by a delicate, transparent membrane which, even with the most extreme care, is easily torn and remains adherent, in patches, to the dentine. Such adhesions occur more often in the pulp-cavity than in the canal; are limited usually to a quite small portion and are, most frequently, the concomitants of the net-like atrophy and chronic wasting of the pulp, in conjunction with caries. It may be observed in this connection, that when such agglutinations take place between the pulp and the dentine, the surface of the latter not infrequently has a rough appearance, being marked with numerous elevations and depressions. In a case of sclerosis of the pulp of a canine, the apex of the pulp was attached to the internal surface of the dentine by means of a cord-like band which stretched between the dentine and apex of the root.

The pigment deposits in atrophic pulps, varying according to their mode of origin, form dirty-yellow, reddish-yellow, brown-red, or dark-brown spots. Care must be taken, in particular cases, not to regard the deposits of pigment as a direct element of the atrophic process, since they belong much more to an accessory pathological process. Thus, circumscribed or diffused extravasations of blood occur in conjunction with different forms of atrophy and various transformations of color ensue, accompanied by the precipitation of numerous crystals of hæmatoidin, just as in other organs, a subject which was considered in the section upon inflammatory affections of the pulp.

The highest grade of atrophy is displayed in the *degeneration of the pulp into a soft, greasy mass*, unaccompanied by the odor of decomposition; it is never a primary affection, but is the result of a previous inflammatory process. The mass is composed merely of a dirty brownish-yellow detritus, or traces of a fibrous structure, together with clusters of stellate fatty-acid crystals, may also be identified. A tooth, which has been

the subject of a total decay of this description, is no longer firmly attached within its alveolus.

A notable diminution in the size of the pulp-cavity and dental-canal occurs in advanced age. The size diminishes in various ways, but is effected, always, by the continued deposition of new dentinal layers. The pulp-cavities of the lower molars, especially, are reduced, not infrequently, to a transverse fissure with narrow, short prolongations extending towards the masticating surface. In teeth with a single root, the pulp-cavity is not diminished so much in length, as it is contracted from side to side. The internal dentinal surface is marked, frequently, with tiny, resisting, rounded excrescences. In old age, also, the growth of the dentine is disproportionately active within a limited area, and is abnormal in character, in other words, new-formations of dentine occur.* The root-canals become more narrow, and the apertures at the extremities of the roots not infrequently become indiscernible.

SENILE DENTINE has, generally, a yellowish *color*, with, sometimes, a sprinkling of brownish or dirty gray. Its *fragility* and brittleness may become so great that if such teeth are compressed sufficiently in a vice, they may easily be cracked in definite directions, and teeth with a single root may be divided into two symmetrical portions. Another physical peculiarity is presented in the increased translucency of certain portions, the so-called *horny character*.

As is well known, the latter is met with most frequently at the extremities of the roots, but may be continued, in old, much worn teeth, as far as the necks, indeed, in places, even into the crowns. It is distinguished, also, by a yellowish hue which, upon the surface of cross-sections, is interrupted by the chalky-white tracings of the dentinal tubules filled with air, and, not infrequently, presents an infundibuliform prolongation towards the enamel layer. In the peripheral zone of such diaphanous dentine, where the numerous, delicate ramifications of the dentinal canals occur, a faint tinge of gray becomes perceptible.

By means of thin sections, it may readily be demonstrated

* *Vide* the section upon Dentinal New-formations.

that the increased translucency of the dentine is dependent upon the absence of air in the dentinal tubules, and that the more opaque portions, which usually correspond exactly with the course of the tubules and are white with reflected light, owe these peculiarities to the air contained in the tubules.

The question at once arises: Do the dentinal tubules, or more strictly speaking, do the processes of the dentinal cells, generally, still persist in the diaphanous portions of the dentine? In order to determine this point, thin cross-sections were prepared from translucent portions of the extremities of roots, and by means of heated, dilute, hydrochloric acid, the processes in question were brought into view. In these experiments, no essential difference could be discovered between the translucent and less diaphanous portions of the dentine.

In order to show whether processes of the dentinal cells of such horny roots still retain the property of imbibition, thin cross-sections of the latter in a dried condition were heated slightly and placed in a strong, ammoniacal, carmine solution, and afterwards treated with dilute acetic acid. The tinged sections were then allowed to dry, or were treated with absolute alcohol, and placed in Canada balsam, when it was found that the coloring matter had penetrated even to the finest ramifications of the processes of the dentinal cells.

Since, then, it is proved beyond a doubt, that the processes of the dentinal cells do exist in the translucent portions of senile dentine, and that they still retain the property of imbibition, it may be assumed, with a certain degree of plausibility, at least, that these processes, as well as other tissues, in the decay of advanced age have lost, more or less, their distensibility; that their central vitreous substance has disappeared,* and that, together with the investing walls of the dentinal tubules, they have become closed in such a manner that the entrance of atmospheric air is no longer possible.

Still another point may be taken into consideration, as to whether or not a change is induced in the aggregation of the basis-substance, which may contribute to the production of the

* Compare p. 44.

translucency. Premising that the so-called dental cartilage gradually loses its succulency, then the inorganic particles, the calcareous salts, which are organically combined with the cartilage, become more closely approximated, and their relative positions with respect to each other become altered. By this process, the general dimensions of the tooth will be lessened, and its physical properties will suffer a perceptible alteration. The subject of the resorption of senile dentine will be considered farther on in connection with that of the cement.

CEMENT.—The *thickening of the cement incident to old age* is analogous to the continued formation of dentinal cells upon the internal surface of the dentine. As is well known, thickened cement is a very frequent occurrence; upon teeth with a single root, it is confined to the extremity and increases rapidly towards the apex, while upon teeth with multiple roots, it extends not infrequently towards the neck of the tooth as far as the junction of the roots and forms, therefore, a uniform covering over a considerable portion; contemporaneous with this thickening process occurs a resorption of the dental socket, and, in this respect, an analogy with bone is presented, in which, also, resorption and the continued development of osseous tissue may be concurrent processes. For instance, upon the surfaces of the flat bones of the skull, an expansion of the openings of the Haversian canals and distinct excavations from resorption are met with, and, at the same time, a progressive synostosis in the vicinity of the sutures. Ossification of the synchondroses, along with the resorption of other portions of the bone, is a familiar occurrence in advanced age.

The new layers of cement are not always deposited in a concentric manner about the older ones, but frequently form more or less acute and even right angles with the latter. The symmetrical development of the bone-corpuscles does not obtain everywhere, since the striated, frequently turbid, intercorpuscular substance acquires such a preponderance in some localities that the bone-corpuscles become dispersed at wide intervals from each other. In other places, the bone-corpuscles are closely approximated, sometimes fused together, as it were, so as to form a jagged, quite large cavity which is filled with calcareous salts.

The necrobiotic portions are of interest and may be traced for a considerable distance in layers of the thickened cement by the very turbid, dirty-yellow or yellowish-brown discolorations. Apparently, the intercorpuscular substance degenerates into granular, amorphous calcareous salts, amongst which the bone-corpuscles may still be recognized here and there. The cement of the teeth of old, larger mammals, is particularly instructive upon this point.

The thickened senile cement is traversed, usually, by vascular canals which communicate with the vessels of the root-membrane, enter the cement, as a rule, in directions perpendicular to the surface of contact with the latter membrane, branch dichotomously and anastomose with each other by means of their branches. They are prolonged in their course as far as the dentine, indeed, under certain circumstances, even into the latter; their cavities are comparatively wide and, frequently, obliterated by amorphous, calcareous salts (comp. p. 53.)

RESORPTION OF SENILE DENTINE AND CEMENT.—If we compare the periphery of the dentine of a series of teeth from old persons, even with the naked eye a zone will be perceived, corresponding to the globular layer between the dentine and cement and appearing quite opaque with transmitted light and very white with reflected light. The interglobular spaces, replete with amorphous calcareous salts, have increased in extent and appear as cavities with irregularly indented outlines and fissure-like channels filled with calcareous salts. These cavities and channels not unfrequently penetrate into the substance of the dentine, where their dentiform prolongations are in direct connection with the dentinal tubules. Varicous, spindle-shaped dilatations in the course of the dentinal tubules are met with, or opaque cavities with three, four or more dentations which are clustered in varying numbers between the dentinal tubules, and must not be confounded with bone-corpuscles. In very rare cases, the dentine is studded, quite generally or almost entirely, with uniformly distributed cavities filled with amorphous calcareous salts, which give to it a mottled appearance. This condition may be explained by the occurrence of resorption of the dentinal substance along the dentinal tubules as a result of

which these cavities are produced which become filled with amorphous calcareous salts.

It has been mentioned above, that vascular canals occasionally penetrate from the cement into the peripheral portions of the dentine, where they may be traced for some distance, but they become obliterated directly by the deposition of calcareous grains and, occasionally, are surrounded by an osteoid substance.

Excavations from resorption do not make their appearance upon the periphery of the dentine until the contiguous portions of the cement have undergone complete resorption.

Cement which has undergone partial resorption frequently presents an appearance that is observed in connection with resorption of the roots of the milk teeth. While the familiar indentations produced by resorption are making their appearance upon the periphery of the cement, sharply defined, lobulated formations of osseous substance are observed in the zone adjacent to the dentine, which not infrequently reach some distance into the latter. (Atlas, Fig. 113.)

The peripheral zone of the dentine, consequently, undergoes resorption in various ways, namely, by an increase in the number and size of the interglobular spaces; by an extension of the resorption process from the cement and by the encroachment of young osseous tissue.

ENAMEL.—The enamel of the teeth of elderly persons acquires the brittleness of glass, is cracked quite easily when subjected to pressure, and presents a smooth or splintered and, also, a conchoidal fractured surface. Senile enamel is distinguished by a yellowish or brownish-yellow color which is interspersed, sometimes, with dark-brown spots. The latter are of limited areas and pass imperceptibly into the lighter layers; they are by no means to be considered as indicative of commencing caries, and may exist for years, as is very well known, without any further deterioration of the teeth. The dark discoloration may be present at intervals throughout the entire thickness of the enamel, and yet the continuity of the latter may remain unimpaired; this condition has its analogy in the occurrence of deposits of pigment in other organs during advanced age. A molecular degeneration, however, also occurs in the enamel,

which is displayed, even to the naked eye, in the form of white zones or spots; it is associated with an interruption in the continuity of the prisms and is morphologically identical with the imperfect formation of enamel.

The *enamel-membrane* of senile teeth, as much of it as still persists, in comparison with that of younger, normal teeth, is thicker frequently, often contains deposits of dark-yellow, gray-brown or deep-brown, and from this to a black-brown pigment, or presents a molecular cloudiness, and is occupied by a mass of drops which have the shining appearance of fat and may be removed with ether. Sometimes this membrane presents tear-like, firm, colloid-like bodies with broad bases, the convex surfaces of which project at the points where the membrane is reflected upon itself; they are distinguished by a faint lustre, a rounded exterior, and are irregularly disposed, being isolated in some parts and grouped together in others. (Atlas, Fig. 82.)

SURFACES PRODUCED UPON THE CROWNS BY ATTRITION.—These are found upon the masticating surfaces and at the parts where adjacent crowns come into contact with each other. In the former case, they are produced by the trituration of food. Hence the nature of the latter, the manner in which it is prepared, its uniformity or variety, will have an important influence in the production of these surfaces. This, to be sure, is a difficult matter to determine in the case of man, but with animals which receive special care and attention, with stud horses, for example, it is a matter of recognized importance. The more dry, and tougher the fodder, the longer and more forcible will be the process of mastication, and the sooner will corresponding abrasion of the teeth ensue.*

* John K. Mummery (Trans. of the Odont. Soc. of Great Britain, new series, vol. ii) instituted very extended investigations to show that there is a notable difference with respect to the form in which, and the means by which, the teeth become worn away. Nations, like the Egyptians, and the Indians of the northwest coast of America, take but little pains in the preparation of their food which, consequently, often contains sand, so that, usually, their teeth are worn away evenly. If the food consists of hard seeds, roots, or tough meat, then the surfaces of the first molars are found to be most worn away, upon the lingual side in the upper jaw and upon the labial side in the lower jaw. With those who subsist upon an abundance of highly

Generally speaking, the surfaces become worn away upon the tubercles and edges at the points of contact between the upper and lower teeth, where they glide upon each other in certain directions during the act of chewing. Projecting crowns are worn down very soon; if their axes are nearly perpendicular, they are worn away in a more or less horizontal direction; those obliquely situated are worn in an oblique direction, and those having no crowns opposite them are not subjected to friction. Since the crowns, and particularly the incisive edges and tubercles of the teeth of the upper and lower jaw, respectively, are inclined towards one another, and the act of chewing is performed in definite curves, the facets, produced by attrition, are observed, also, to assume an oblique disposition, those of the lower teeth being located upon the facial side, and those of the upper teeth upon the lingual side. The approximation of the planes of the facets to the horizontal direction depends upon the angles of inclination of the opposing coronal axes.

When the entire thickness of the enamel has been worn away, the summit of the dentine, at the corresponding point, becomes similarly involved, so that the surface of attrition presents an island of dentine surrounded by enamel. If the crown is worn down nearly to the neck of the tooth, a greater portion of the dentine becomes exposed and presents a polished surface like that of a mirror, not infrequently becomes excavated as the process progresses, has a yellowish or brownish-yellow color and, at last, forms merely a thin covering over the dental pulp. The enamel persists only upon the remaining lateral portions. If the abrasion of the thin dentinal covering is continued, the atrophic dental pulp, which generally has been rendered firm by a dentinal new-formation or has undergone partial calcification, becomes exposed and is perceptible in the centre of the masticating surface as a defined body surrounded by dentine. If a shrinking of the alveolar process has already commenced, then

nitrogenous food, the pulps of the teeth gradually become solidified with secondary dentine and the tooth frequently is worn away as far as the neck without the occurrence of an alveolar abscess; on the contrary, in cases where there is a defective nourishment, inflammations, abscesses, and extensive resorption of the alveoli are constantly observed.

the entire neck of the tooth will become worn away, and even the contiguous projecting portions of the roots may be involved in the process.

As the crowns become more and more worn away, the serpentine curve, which is described by all the coronal margins in common, gradually disappears, and finally the dental arches of the upper and lower jaws come into contact by means of broad surfaces, and the lower half of the face is shortened.

From the degree to which the teeth are worn away, a probable conclusion may be drawn in regard to the age of an individual. After considerable practice, it is possible to determine the age within at least five years, from the latter and accessory data, as, for instance, from the variations in the color of the teeth and from the changes presented by the alveolar borders, &c. In drawing conclusions of this kind, however, individual peculiarities must also be taken into account. The time required for a certain amount of wear depends upon the hardness or density which varies in different teeth. This may be determined, most satisfactorily, in regard to milk teeth which, in consequence of their slight density, present evidences of attrition in a comparatively short period. Frequently, also, sets of teeth are found in young persons which are comparatively stronger than usual, and such teeth are but little worn when the individuals become advanced in age.

With animals that are fed upon a uniform kind of food, the teeth become worn away in a quite constant manner. The two Güchters, father and son, of Hanover,* investigated this point and ascertained that the amount lost by attrition upon the permanent incisors of the anterior and posterior jaws observed a tolerably constant measurement, namely, a line annually. The shape of the surfaces produced by attrition of the incisors corresponds with transverse sections of the latter, and are roundish, triangular, oblong, &c. Hence, from these data it is possible to determine the age of a horse with tolerable accuracy beyond the period of dentition, even to the thirtieth year. As the horse grows old, and the uniform abrasion of the incisors is continued,

* Beurtheilungslehre des Pferdes.

the arches formed by the respective sets of teeth disappear, and the teeth gradually acquire a position in a straight line.

In entirely normal sets of human teeth, facets from attrition first make their appearance upon the incisors, the prominent blunt points upon the incisive edges of which disappear; they then become perceptible upon the outer portions of the crowns of the first and second molars of the lower jaw, and later upon the internal coronal borders of the corresponding teeth of the upper jaw. The explanation of these familiar appearances is to be found in the position of the teeth, in accordance with which the facial coronal borders of the lower molars impinge upon the lingual borders of the upper molars, and the two become subjected to friction, in the vibratory movements of mastication. In this way, facets are produced opposite each other upon the prominent points of the above-mentioned coronal borders; these, at first, are barely a millimetre square, but as the process continues, they increase in size, and the prominence of their edges gradually becomes lost; still later, quite large inclined facets are produced which involve the entire outer and inner sides of the crowns respectively. The previously sharp borders of the molars frequently are rounded, with scarcely any faceted appearance. The wisdom teeth, on account of their late and often incomplete advance to the level of the masticating surfaces, become worn away at a later period and to a less degree than the other teeth.

The facial, coronal tubercles of the bicuspid of the lower jaw are worn away obliquely outwards; the lingual tubercles, small and situated at a much lower level, are not involved until the former are almost entirely worn away and the dentine, even, has become exposed in the form of a yellow band. Upon both tubercles of the upper bicuspid, facets are produced which are inclined in opposite directions. That upon the facial tubercle appears first, and is larger than the other.

The lower canines present two obliquely-situated facets upon their facial surfaces, one of which is directed anteriorly, and the other posteriorly. As the process continues, the two small facets disappear and give place to a larger one directed towards the face, in the centre of which the polished dentine becomes

perceptible as a transverse band. The upper canines, likewise, present two facets which meet at an angle; these, however, are located upon the lingual side of the coronal apex; in the more advanced stages, a larger facet, inclined towards the tongue, is met with.

Upon the lower incisors, the facets are obliquely situated, being directed from the coronal edge towards the face, while those upon the upper teeth are directed towards the tongue. In advanced stages of the process, the dentine is exposed and presents the appearance of a transverse yellow band; a quite opaque, firm portion is frequently observed in the centre of the latter, which Hunter, long ago, and Prochaska, described as a commencing hard new-formation which is to serve for the closure of the pulp-cavity (comp. Dentinal New-formations).

As the character of the attrition depends upon the position of the two opposing teeth in the upper and lower jaw respectively, and anomalies of position occur very frequently and in infinite variety, it follows that the surfaces which are produced by attrition present an endless variety. With very prominent jaws, these facets assume an oblique direction which approximates the perpendicular. With an upright set of teeth, in which the axes of the dental crowns have a nearly perpendicular direction from above downward, the facets necessarily assume a horizontal direction.

With asymmetrical jaws, where the masticating surfaces of the two sets do not correspond with each other, chewing is confined to one side, and the teeth of that side become much worn, and in a very oblique direction. The teeth, as a whole, then acquire a distorted arrangement, and give rise to a corresponding distortion of the mouth.

When all the teeth of one or another kind are wanting, for example, all the upper molars on the right side, mastication is performed only upon the left side posteriorly, and the molars upon the latter side become worn down obliquely and much earlier. If the upper molars of both jaws are wanting, mastication is transferred to the front teeth which acquire large, more or less obliquely or horizontally-disposed facets.

When a tooth is lost, the opposite one, deprived of its antago-

nist in biting, ceases to exercise its function and experiences no more wear from attrition. The tooth which loses the support of its neighbor upon one side, as will be noticed later in connection with the subject of cicatrization of the dental sockets, becomes inclined towards its newly-acquired neighbor, and, as a result of this, the correspondence between the crown of the dislocated tooth with that of its non-dislocated opposite is destroyed. If, for example, a second lower molar acquires an inclination from behind forwards, subsequent to the loss of the first molar, then the facet from attrition upon the former will be directed obliquely backwards, and that upon the second upper molar obliquely forwards. We may, also, determine the position of its opposite from the direction and size of the facet upon a tooth.

The dental crowns, also, are subjected to attrition at the points where they come into contact with the crowns of adjacent teeth, a familiar fact to every dentist. The *frictional surfaces on the crowns*, produced in this way, are described by A. Zsigmondi* as "*interstitial.*" They are produced by the movements of the teeth in their sockets during mastication and, therefore, can occur only when adjacent teeth come into contact with each other. Of course, the wisdom teeth present none upon their posterior coronal surfaces. The nature of the contact varies with different teeth and, therefore, we find a variety in the shapes presented by the frictional surfaces; indeed the latter necessarily change, if the position of a tooth in its relation to that of its neighbor is altered in any way. With reference to the latter point, Zsigmondi makes the following special observations: "The frictional surfaces resulting from the contact of the incisors with each other, and with the canines (corresponding with the thin lateral margins of the former), are narrow, longitudinally disposed, and more or less oval in shape; where the rounded posterior surfaces of the canines come into contact with the first bicuspids, they are roundish; those resulting from friction between the first and second bicuspids are somewhat larger, transversely disposed, and more or less oval or polygonal in shape; finally, those from friction between the second bicus-

* Vierteljahrschr. f. Zahnh., 1865.

pids and first molars and, also, from contact of the molars with each other (corresponding to the broad surfaces of contact of the latter), are considerably larger and broader, and, like the preceding ones, are disposed from side to side and of an oval or polygonal shape."

Wedge-shaped defects upon the facial surfaces of the necks of teeth.—Sometimes, though rarely, a curious breach of substance (Usur) is observed upon the facial aspect of the neck, particularly of the incisors and molars. These defects are bounded by sharp edges, as if artificially made with a file (Atlas, Fig. 99), and present two surfaces, one horizontal and the other inclined at an angle of 45° . The wedge-shaped depressions are one to two millimetres in depth, their edges are very sharp, their surfaces have a polished appearance. Persons, upon whose teeth they occur, know nothing respecting their origin, nor have dentists, as it appears, made any extended investigations with reference to this point. Fox* speaks of a removal of the enamel which is not produced by caries. This affection, he says, occurs upon the labial surfaces of the incisors particularly, which appear as if they had been gnawed. After the enamel is destroyed, a portion of the dentine becomes involved, and the rest acquires a brownish color, is highly polished in appearance, and will often remain in this condition for a number of years. In other cases, he observed teeth which presented an appearance as if a small round file had been applied to their labial surfaces, in close proximity to the gums. In these cases, the molars participate in the disease. He states that, possibly the saliva may have some influence, and that the friction of the lips, also, may contribute to the removal of the enamel.

The view, that these cases are instances of healed caries of the gum, cannot be entertained, as the defect is too sharply defined; nor is it possible to detect any traces of previous caries of the gum. The fact, that such defects, so far as our present knowledge extends, are never found upon the lingual surfaces of the neck, indicates that their cause is to be sought for upon the facial side. Sometimes, the mucous membrane of the cheeks

* Op. cit., p. 49.

and lips is raised into a fold opposite the dental arches. In many cases, a tendinous expansion is observed upon the facial surface of the gums of the lower jaw, which gradually becomes narrower and terminates with a ridge of connective tissue which is attached to the neck of a bicuspid or molar tooth. It may be well to consider in future cases, whether any relation exists between the defects upon the neck of the tooth and these folds or ridges.*

GUMS.—The clinical appearances presented by *senile atrophy* of the gums comprise, chiefly, loss of their red color and uniform turgescence. The color is changed to a gray-reddish, gray-yellowish and, sometimes, blue-reddish when the venous character is in excess, in which latter cases circumscribed swellings occur here and there. The dimensions of the gums are diminished, since the margins recede from the necks of the teeth. Not infrequently, superficial erosions occur which are covered with a thin discolored layer. Generally, the gingival margins of the lower incisors are the first to be affected with senile atrophy; those of the upper incisors are less frequently involved than the preceding, and those of the lower molars and bicuspids, also, are more often affected than those of the corresponding upper teeth.

In senile atrophy there ensues an attenuation of the papillary portion, corium, and submucous connective tissue, together with a wasting of the contiguous periosteum of the alveolar processes. The epithelial layers become quite dry and hard, and exfoliate, leaving the jaws covered with a layer of cells undergoing a fatty degeneration. The attachment of the gums to the necks of the teeth is loosened. The papillæ of the gums are flattened, their parenchyma is clouded by a molecular fat-granular mass, the capillaries are obliterated. The nerve-trunks of the submucous connective tissue acquire a molecular cloudiness, and their more delicate branches are no longer recognizable, in consequence of the cloudiness of the contents of the nerve-tubes, and of the connective-tissue investments. The connective-tissue cells and their nuclei present, in places, a shrivelled appearance. The connective tissue is sclerosed.

* Comp. the remarks, p. 175.

Various causes may give rise to a premature atrophy, among which may be enumerated abrasion of the contiguous dental crowns in an oblique direction, neglect of cleanliness, accumulation of tartar upon the necks of the teeth and the adjacent coronal portions.

Atony of the Gums.—From the fact that the first indications of that affection of the blood called scorbutus are presented by the gums, which acquire a deep red color, become spongy and bleed spontaneously, it has been customary to apply the term *scorbutic* to all those affections of the gums which present one or more of the above appearances, although they may have nothing in common with scorbutus, except, perhaps, a few symptoms. The condition of sponginess and laxity of the tissue, and even those changes, also, which are induced by tartar, are described as an atonic condition.

Lax gums present a dark-red color, a swollen, spongy, and inelastic texture; the margins, which should form a firm investment around the necks of the teeth, are swollen and uneven, recede from the necks, or, as is the case frequently, cover over half the crown. The points of junction of the gingival arches upon two adjacent teeth are transformed into shapeless masses. Under even very slight contact, an effusion of dark-red blood ensues. In some cases, this condition involves the entire gums, in others, it is limited to a portion of them. As it is impossible, with such a condition, to keep the teeth clean, tartar accumulates beneath the lax and swollen gums and, in this case, is the result and not the cause of the affection. Passive congestions, induced by the atony of the organic muscular fibres of the bloodvessels, give rise to hemorrhages which, in rare cases, are so severe as to be checked with difficulty.

ROOT-MEMBRANE AND ALVEOLUS.—In old age, the root-membrane becomes thicker, more compact, less succulent, firmer, more cloudy, and is more adherent to the root and to the interior of the socket by means of fibrous tissue which is insinuated between it and the above surfaces; hence it acquires a felted appearance and, sometimes, the lustre of tendon. The histological changes in it are analogous to those presented by the atrophic gum.

Calcifications are not infrequent occurrences in the root-membrane of old age. Sometimes, they are found in the form of small granular concretions; at others, they present larger globular bodies which have a strong refractive power; in some instances, they are without any recognizable structure, in others, they present a radiated or concentric lamination; they produce the phenomena of double refraction, and when treated with dilute hydrochloric acid, a decomposition ensues with the liberation of bubbles of gas, and a deposit of an organic basis-substance. (Atlas, Fig. 121.)

It is a notable fact that ossification of the root-membrane has never been observed, at least in man, notwithstanding the frequent occurrence of calcifications.

The effects of its atrophy may be traced partly in the cement of the tooth and partly in the socket. The cement, which, usually, has become thicker with advancing age, undergoes resorption (*vide supra*), and the socket likewise is similarly affected. The extent of the resorption upon the socket bears a direct relation to the deposit of osseous layers upon the cement, and is most apparent at the closed extremity of the former from the fact that the cement layers are more numerously disposed near the apex of the root. The wasting of the socket occurs upon the free margin, is still more apparent in the vicinity of the latter, especially upon the facial side, and is distinguished by an increased porosity. The foramina in the alveolar wall, for the transmission of bloodvessels and nerves, become broader, their osseous margins are sharpened to a thin edge. Excavations produced by resorption, such as have been referred to frequently, may be found in suitable thin sections, and dense connective-tissue substances are met with, associated with the obliteration of the bloodvessels and nerves. Sometimes, adjacent foramina, by the resorption of their borders, are united so as to form a quite large aperture with a festooned margin.

As the resorption of the osseous substance of the socket advances round about the alveolar border, the walls of the socket, the facial especially, become shorter, the gums recede at the same time, and the neck and contiguous portions of the roots, sometimes, even as far as the apices, are exposed. In conse-

quence of this process, the attachment of the teeth becomes loosened, and all the more so when there is a contemporaneous resorption of the cement.

Wasting of the sockets generally occurs, primarily, upon those teeth whose gums present evidences of atrophy.

MAXILLARY PERIOSTEUM AND MAXILLARY BONES.—Atrophy of the former presents the same morphological changes as the periosteum of the root.

Senile wasting of the bone is accompanied, in many cases, by a marked fatty metamorphosis of the soft parts contained in the medullary spaces and canals, whereby a yellowish fat pervades the osseous substance, which imparts a greasy sensation to the touch. As fatty degeneration of the medullary matter becomes extensive, the osseous lamellæ, which have become attenuated, are hidden from view by the general fatty appearance imparted by the former. The medullary spaces become expanded and the cortical substance is reduced, finally, to a thin plate. If the senile wasting is unaccompanied by fatty degeneration, these appearances are all the more evident.

The upper jaw, with its thin cortical substance, displays the senile rarefaction of the bone much more distinctly than the lower jaw, with its thicker cortex and more compact structure generally. The palatine process of the upper jaw, the facial wall of the antrum and, also, the horizontal portions of the palate bones, become as thin as the *lamina papyracea* of the ethmoid bone. The branching Haversian canals upon the superficial portions of these bones present the appearance of very delicate vascular ramifications, which appear luminous with reflected light and opaque with transmitted light. If very thin transparent sections, which may readily be made with the scissors, are examined, localities will be found which do not contain any, or only a few bone-corpuscles, and present, principally, excavations produced by resorption. In such places, a peripheral has succeeded the above-mentioned central resorption in the cancelli of the bone. The extreme degree of brittleness of the bone incident to old age approaches the condition which Lob-

stein* described as *osteopsathyrosis (fragilitis vitrea)*, and Rokitsky† as *excentric atrophy*.

The marked brittleness of senile jaws is to be borne in mind by the practical dentist, when he is called upon to extract teeth still firmly implanted, on account of caries, or to adapt an artificial set, since, even with all possible care in the operation of extraction, particularly with the posterior molars of the upper jaw, a fracture of the contiguous portion of the jaw is very easily produced, which is all the more troublesome, from the fact that the parts unite very slowly.

The processes which ensue in the alveoli, whether the teeth fall out spontaneously or are extracted artificially, are essentially the same, and their description is introduced here because, without a thorough knowledge of the *process of cicatrization*, the changes which ensue in atrophy of the jaws cannot be appreciated, and, moreover, the process is accompanied by *atrophy of the socket*. Heider and Wedl published a series of investigations with reference to this subject.‡

When a tooth is extracted, the bloodvessels and nerves of the periosteum of the root with the connective tissue accompanying them, and the afferent and efferent vessels of the pulp, together with the nerves in relation with them, are torn away, and the socket, deprived of the tooth, is filled with coagulated blood which serves as a natural plug in checking further hemorrhage. If the socket and gums receive no more injury than is incident to the mere separation of the tooth, then the gums maintain their normal color and, after a few days, their free margins are found to be approximated towards each other; between them, a pale grayish substance, decolorized fibrin of the blood, is frequently observed, which, sometimes, deceives the patients, so that they not infrequently return to the dentist with the idea that they have discovered suppuration in the wound. In cases where the gums are not lacerated or bruised and the socket is not fractured, the cicatrization always ensues without any suppuration; indeed, the whole process is unattended with pain, and

* Path. Anat. übers. von Neurohr., Bd. ii, p. 179.

† Manual of Path. Anat., trans. by C. H. Moore, vol. iii, p. 113.

‡ Viertelj. f. Zahnheilk., 1865.

in a few weeks the patients are able to chew upon the side from which the tooth was extracted. But when teeth are removed during the existence of an inflammation of the root-membrane, painful sensations persist for several days within the socket, and, in very rare cases, an acute very intense pain, without any definite inflammatory symptoms, succeeds the extraction of a tooth.

The root-membrane, especially with teeth extracted from jaws of young persons, remains attached in the form of a closely adherent investment, extending from the neck to the apex of the roots, and the vascular ramifications, injected with the blood, may be distinctly traced. In most cases, however, the contiguous portion of the membrane is torn, so that a part of it remains adherent to the alveolus, while the remainder is attached to the extracted tooth. That portion, on the other hand, which is in immediate relation with the submucous layer of the gums and is distinguished by its more compact structure and its numerous nerves and vascular plexuses, is always separated from its attachment to the neck of the tooth. Since then, in most cases, the root-membrane is partially, sometimes, even entirely, separated by the extraction of a tooth, and frequently, indeed, is destroyed by a previous morbid process, without effecting any variation in the phenomena of the cicatrization, it cannot be claimed that the root-membrane has any share in the latter process. The alveolus undergoes entire resorption, since no trace of it can be discovered in the completed cicatrix.

If an entire series of macerated alveolar cicatrices are examined in the first stages of the process, by means of horizontal and longitudinal sections, it will be seen that, first of all, osseous trabeculæ with free, pointed, or clavate extremities, are developed into the cavity previously occupied by the root, where they unite with others. Similar trabeculæ penetrate from the alveolar border and join with those which extend from the former wall of the socket; these together form a spongy, slender, framework of osseous substance which fills up the cavity, near the superficial portion of which a fossa-like depression is still perceptible, and this disappears more and more, as the cicatrization progresses (Atlas, Fig. 132); the delicate, porous, osseous

layer of the socket and its free margin, likewise, gradually disappear. Vascularized, connective-tissue granulations form the centre of ossification of the cicatrix; these grow out from the gaps of the alveolus, and become ossified; they also appear to give rise to the resorption of the latter.

The laceration of the gum, produced by its separation from the neck of the tooth, is healed contemporaneously with the granulation in the socket. At the commencement of the cicatrization of the membrane, very soft, deep-red papillæ of connective tissue, which bleed easily (granulations—Fleischwärtchen), are observed growing out from the margins of the wound, and these soon cover the socket. The papillæ become flattened, coalesce, and then there is presented a swollen, succulent, vascularized cicatrix of the mucous membrane, which is smooth upon its outer surface and covered with epithelial scales.

The second stage, that of consolidation, now succeeds to the first. The swelling, redness, and succulency diminish, the pallid, cicatricial tissue becomes more compact; it presents for a considerable period, a shallow groove, with slightly swollen margins in close proximity to each other, which follows the direction of the alveolar border and, eventually, acquires nearly the consistence of tendon. Perpendicular sections of such a dense cicatrix of the gum display a gradual disappearance of the papillary portion, in the vicinity of the cicatrix (Atlas, Fig. 117), leaving only a flattened corium which presents a few, slight elevations and depressions and is covered with a thick layer of laminated epithelium. The bloodvessels and nerves, which, in the gum, were uniformly disposed, since branches extended perpendicularly towards the papillæ from the horizontally disposed vessels and nerves, assume in the cicatricial tissue a more oblique arrangement and irregular distribution. The bloodvessels are obliterated as the condensation and thickening of the cicatrix increases, and the latter undergoes a corresponding contraction. Finally, a tense, sharp ridge is formed, not infrequently, along the cicatrized alveoli.

Coincident with the consolidation of the cicatrix of the mucous membrane occurs that of the bony callus. That portion of the maxillary periosteum which invests the outer surface of

the cicatrix, becomes very dense, and consists of tendon-like, tough bundles of fibres which are intimately united with the superficial bony substance. The osseous lamellæ within the socket are more closely compacted, especially near the masticating surface, this condition being more distinctly marked in the under than in the upper jaw.

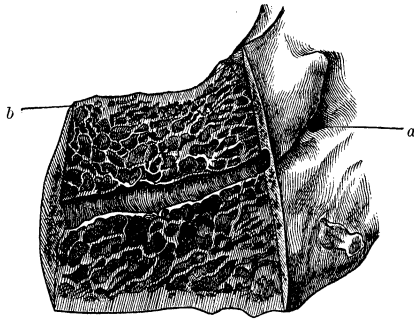
When only one tooth is removed, the teeth adjacent to the socket become approximated so closely, that the cicatrix disappears, apparently, more properly speaking, becomes partially concealed. Hunter called special attention to this process and illustrated, in a very instructive manner, the changes of position. On examination, namely, it will be found that a crescent-shaped depression remains upon the cicatrized alveolar border, extending, upon either side, to the borders of the adjacent teeth which are still retained. In the upper jaw, this depression is directed downwards, and upwards in the lower jaw, its greatest depth, corresponding with the longitudinal axis of the pre-existing alveolus, measures about one-fourth that of the axis mentioned.

When the cicatrization involves two or more contiguous sockets, the perpendicular septa between them undergo a partial resorption, and from both the facial and lingual walls a bevelled, sharp-edged callus is developed, composed of a compact cortical substance (Fig. 80). Sometimes the cicatrix is more flattened and the projecting lamellæ upon its surface lock into one another, presenting, not infrequently, an appearance similar to that of a bony suture. Small, irregular, pitted depressions filled with sclerotic connective tissue are often met with upon the site of the cicatrix, or a shallow groove inclosed by walls with notched, tuberculated edges. (Atlas, Fig. 131.)

The process of cicatrization experiences interruptions in consequence of diseases of the gum, socket or maxillary periosteum. Abscesses, especially, which have their origin in the root-membrane of a tooth, may be adduced with reference to this point; these frequently spread over the alveolar process, give rise to a destruction of the bony substance and involve the gums and periosteum. Under such circumstances, the callus, particularly in the vicinity of the upper molar and wisdom teeth, becomes

distorted, spreads over a greater surface and is studded with irregular, flattened tubercles and corresponding depressions. The process of ossification may even be arrested here and there, as is manifested by the abundant deposits of calcareous salts without evidences of further organization. Sometimes the ex-

FIG. 80.*



tremity of one or another of the roots remains inclosed. The submucous connective tissue of the gum degenerates into a callous, cartilaginous, tuberculated tissue, and is intimately united with the felted, tendinous portions of the maxillary periosteum.

Further, the process of cicatrization may be interrupted by recurrent abscesses of the gum, or arrested by a protracted suppuration in the bone; the pus, in some instances, does not make its escape, but the cavity of the abscess, shut in by the callous connective tissue, becomes obliterated, and the pus is found transformed into an unctuous, caseous mass. The region of the tuberosity of the upper jaw, mentioned above, is, likewise, the more frequent seat of such an arrest. (Atlas, Fig. 139.)

* FIG. 80 shows a median section through the posterior segment of a lower jaw, together with the cicatrized sockets of the molar teeth. The inferior dental foramen is seen at (*a*); the inferior dental canal is bisected in its length; above and below the latter extends the spongy osseous substance. The cicatrization is entirely completed; the alveoli have disappeared and, towards the outer surface, a compact bony substance (*b*), corresponding with the firm sharp-edged callus, has been formed. Natural size.

A fracture of the alveolus, if limited to the site of the extracted tooth, does not interfere with the healing process unless, perhaps, an irritation of the contiguous gum is produced by the sharp edges or points, or loose spicula remain within the socket, which cause pain and give rise to suppuration that continues until the necrosed spicula are expelled, or removed by operative interference. At the part corresponding with the fracture, the cicatrix presents a more contracted appearance, and its surface is upon a deeper level. When, however, the fracture extends across the alveolus of an adjacent tooth with a permanent loss of the fragment, the socket is not reproduced and, as a result of this, the gum recedes and, consequently, the tooth becomes loose.

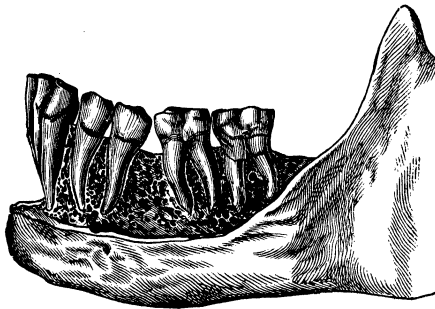With adults and those whose teeth are still firmly implanted, cicatrization occupies a period of three to six months, generally, but it is by no means at an end when the cicatrix of the gum is completed, since the formation of the bony callus together with the resorption of the osseous substance in the neighborhood require months longer than the above mentioned period. The reverse is the case with teeth which have been quite loose, from the fact that, in proportion to their looseness, the bottom of their sockets have already become more or less filled with new osseous substance and the alveolar margins have already undergone resorption, so that cicatrization in these cases may be completed in a comparatively short period, sometimes in four to six weeks. Practitioners are well aware that the cicatrices are subject to variations in form for a long time subsequent to the extraction of teeth, since it is a frequent occurrence, that plates which have been adapted six months after the extraction of the teeth, become displaced in a few months and no longer occupy the site from which the teeth were removed originally. Casts of the jaw, taken at this latter period and compared with those of the earlier periods, also indicate, conclusively, the occurrence of changes of form.

The subsequent variations in the position of the adjacent teeth during the process of cicatrization form a subject of considerable importance. In order to obtain a thorough insight into this process, it is of advantage to remove either the facial or

lingual wall from a series of macerated jaws in which the teeth are defective, in order that we may be able to obtain an accurate idea of the location of the respective roots.

The deviation from the normal position may be expressed in general terms as consisting in an inclination towards the cicatrix of the crowns of the teeth adjacent to the latter, which deviation is most distinctly marked with the largest teeth, as the molars. It is exceedingly instructive to observe the difference in the deviation presented in those cases where the teeth are defective upon one side only. If the coronal portion of one of the above-named teeth is tilted forwards in consequence of the absence of the adjacent tooth in front, the anterior segment of the crown becomes depressed below, and the posterior is raised above its previous level, to a degree varying with the amount of the inclination. The root portion necessarily experiences a corresponding backward displacement and is elevated slightly (Fig. 81). In addition to the above approximation of the axis of the tooth towards the horizontal line, an inclination of a few de-

FIG. 81.*



grees towards the median line of the jaw, also, occurs, sometimes, indeed, the lingual wall of the crown of a wisdom or molar tooth experiences a slight rotation towards the median line and pos-

* FIG. 81.—Right half of a lower jaw from which the facial wall has been removed in order to show the approximation of the second bicuspid and second molar teeth towards each other within the sockets, subsequent to the loss of the first molar. The crowns are almost in contact near the masticating surfaces, while their roots diverge from each other. Two-thirds natural size.

teriorly. If the alveolar cicatrix occupies the place of three or four teeth, *e. g.*, the two bicuspid and first molar or all the molars, that portion of the alveolar process which remains opposite the angle of the lower jaw, together with whatever teeth are still retained, sink down, so that they occupy a lower level than the corresponding teeth upon the other side where such a defect does not exist.

Inclinations of the wisdom and molar teeth of the upper jaw, in connection with the loss of teeth, are less marked, as a rule, and in certain respects, present relations the reverse of those presented by the same teeth of the lower jaw; the anterior segment of the crown becomes raised, somewhat, the posterior, depressed to an equal degree, producing a greater or less dislocation of the posterior portion of the neck of the tooth from out the socket. Axial rotations are less liable to occur, from the fact that the corresponding teeth of the upper jaw are supplied with three divergent roots. The forward inclination of the second upper molar, subsequent to the loss of the first, may retard the eruption of the wisdom tooth in certain cases (*comp. p. 129*).

Dislocations of the bicuspid are not so notable, in most cases, since they are held in their positions by the canine teeth which, as is well known, are the last to fall out in old age and are least liable to be affected with caries. When cicatrization of the socket of the first bicuspid takes place, the second bicuspid presses towards the canine tooth and experiences a slight axial rotation anteriorly and an inclination towards the median line of the jaw.

Subsequent to the completion of the cicatrization of the socket of the lateral incisor, the central becomes inclined towards the canine, now and then with a slight rotation of its anterior coronal surface towards the latter tooth. If the incisors on both the right and left sides are removed, then the crowns of the retained canines become inclined towards each other. If a canine tooth is wanting, the lateral incisor is inclined in the direction of the cicatrix to a degree commensurate with the smaller bulk of its root in comparison with that of the canine.

The changes of position, produced by alveolar cicatrices, necessarily have an influence upon the act of mastication which

becomes variously modified; the age of an individual, also, is an element of importance in this connection, for, with young persons whose jaws are not completely developed, the bony cicatrix frequently is so slight that scarcely any deviation of the contiguous teeth ensues, and their crowns frequently come into relation with each other in a normal position.

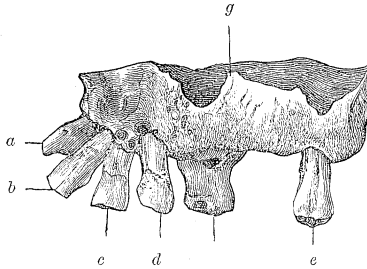
Finally, the question arises, what influence does the extraction of the milk teeth exercise upon the development of the permanent teeth? The effect of cicatrization in these cases varies according to the age of the child and the kind of tooth. The older the child, the nearer is the period for the eruption of the corresponding permanent tooth, and so the latter process will be expedited by the extraction; on the other hand, when the milk teeth are extracted too early, a callus is formed which retards the eruption of the permanent teeth and may deflect them from their normal course. The eruption of the permanent bicuspid is retarded, merely, by the thickening of the superficial portion of the capsule occasioned by the callus, but the incisors and canines, according to their location with reference to the pre-existing milk teeth, may also be deflected from their normal course by the thickened alveolar wall in front or behind them.

When, in old age, a marked wasting of the alveolar process and sockets ensues, associated, frequently, with a chronic inflammation of the periosteal membranes of the roots, the teeth which still remain gradually become deprived of their support, since the greater portion of the roots become denuded and merely their extremities remain fixed in the jaw. The teeth, consequently, acquire abnormal positions and become displaced towards the face or tongue, under the influence of mastication (Fig. 82).

With edentulous jaws of advanced age, the reverse relations obtain with reference to the prominence of the jaws. When all the teeth are present and properly located, the upper set projects somewhat beyond the lower; but the toothless upper jaw of old age recedes to such an extent that the toothless lower jaw projects considerably in advance of it (Fig. 83). This appearance is to be explained in the following manner. The alveoli are deeper and occupy a greater extent of space in the

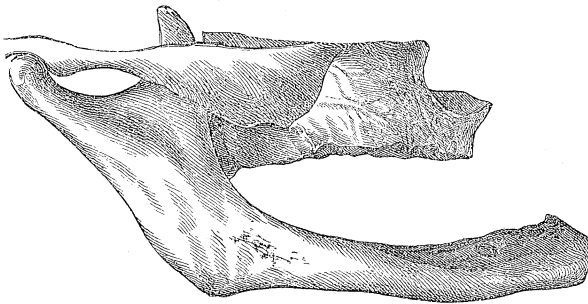
abundant spongy tissue of the upper jaw, and therefore their cicatrices contract more and acquire deeper depressions, especi-

FIG. 82.*



ally those corresponding to the large cavities occupied by the molars with three roots, than is the case with the lower jaw,

FIG. 83.†



* FIG. 82 shows marked displacement of the teeth of the upper jaw, the results of senile wasting of the alveolar process. Lateral view. The roots of the six remaining teeth are almost entirely denuded, being attached, within the remains of the alveoli, at their extremities only. The right central incisor (*a*), which is worn away upon its incisive edge, has a nearly horizontal position. The crowns of the left central incisor (*b*), the axis of which is elevated at an angle of about 45°, of the lateral incisor (*c*), and the canine (*d*), diverge from one another. The left wisdom tooth (*e*), and first right molar (*f*), present the least deviation from the normal position. The facial wall of the antrum (*g*) has become reduced to a transparent bony plate, as thin as tissue-paper; the posterior segments of the palatal plates, also, are remarkably thin and transparent. The rest of the hard, bony portions present a yellowish color, induced by fatty degeneration. Two-thirds natural size.

† FIG. 83 shows a view in profile of a toothless upper and lower jaw, from an aged person, in their natural position with respect to each other. The

which is more compactly formed, for the attachment of its powerful muscles. The lower half of the face obviously diminishes in length to a degree commensurate with the height to which the crowns projected from their sockets, added to the entire depth of the alveolar processes in the two jaws. The latter, seen in profile, form a re-entering angle in front, which occasions a retraction of the lips and the characteristic mouth of old age.

The ridge, formed along the alveolar cicatrices after the detachment or extraction of the teeth, gradually loses its sharpness, becomes rounded and, finally, flat, with increasing age, especially upon the posterior segments of the lower jaw, where the cicatrices acquire the form of a continuous, finely-dentated, bony suture. The palatal processes of the upper jaw become flattened and form a horizontal bony roof to the mouth, between which and the facial wall the alveolar cicatrices are elevated in the form of a blunt ridge. Transverse sections establish the fact that flattened cicatrices undergo a progressive resorption. Their flattened portions towards the masticating surface are composed of compact osseous substance, several millimetres in thickness, the outer surface of which presents an irregularly notched appearance, occasioned by indentations produced by resorption.

The cicatrices of the gums of senile, toothless jaws, are char-

resorption of the alveolar processes is complete, the process having progressed to a greater extent in the upper than in the lower jaw; the former, also, is retracted to a considerable distance towards the latter. The cicatrized alveolar edge of the upper jaw forms a curve, with its concavity directed downwards, while that of the lower jaw has its concavity directed upwards. The suture of the flattened palatal plates of the upper jaw projects in the form of a ridge, wasting of the bone having ensued everywhere, in consequence of which the fatty Haversian canals are apparent upon the facial wall of the jaw. The facial wall of the inferior maxillary arch, in consequence of the wasting of the bone, has undergone a displacement posteriorly, and the widened mental foramen has acquired a nearly horizontal position. The coronoid process is very thin, the neck of the articular condyle is quite narrow, and the articular tubercle of the temporal bone is flattened. The facial length is diminished nearly three and a half centimetres, in consequence of the loss of all the teeth and the wasting of the alveolar processes. Two-thirds natural size.

acterized by a very dry, callous condition; frequently, also, they present ridges of a cartilaginous consistence, composed of degenerated connective tissue, and often contain one or more roots which may be the source of irritation and subsequent abscesses. Bundles of tense fibrous tissue extend from the periosteal layer of the gums between the serrated bony margins of the cicatricial substance, and are intimately united to them. Whenever an irregular groove remains in consequence of a want of junction between the bony substance on either side, it is also found to be filled with firm fibrous tissue.

In old age, the angle of the lower jaw becomes more obtuse, resembling, therefore, that of the infantile jaw. This change, as Hunter has shown, is occasioned by resorption of the bone at the angle, as is indicated to the touch by the rough surface, and this process takes place in a manner essentially similar to that already described in connection with senile cement. The indentations produced by resorption upon the surface of the latter are, generally, small, and, on cross-section, present irregular, festooned borders; on close inspection, however, deeper, dome-shaped concavities may also be found, and even proliferated, young, osseous substance, as is the case upon the cement of the milk teeth at the period of dedentition or upon senile teeth. Bone-corpuscles, inclosed within a capsular investment, also, occur; hence, development and resorption of osseous tissue are presented side by side. This *peripheral* is succeeded by a *pericellular* resorption upon the interior of the cancelli or medullary spaces of the bone which, in cross-section, instead of the finely-indented margins produced by the openings of the bone canaliculi, present the segments of indentations of resorption in which the usure of the bone-corpuscles is apparent. The periosteum and endosteum [medullary membrane] are transformed into a tense, firm, fibrous mass.

The masseter and internal pterygoid muscles which are attached to the angles of the lower jaw participate in the senile wasting of the tissues, as is indicated by a diminution in the quantity of the muscular substance, its pale color and great friability, by the fatty metamorphosis of the muscular fibrillæ and, sometimes, by an abundant multiplication of fat-cells between

the primitive muscular fasciculi. The movements of mastication are performed with diminished energy.

The wasting of the coronoid process and condyle of the lower jaw is quite marked; the circumference of the articular head of the condyle is diminished, and its surface presents numerous, small bony excrescences, as the cartilaginous investment is destroyed.

The flattening of the articular eminence of the temporal bone exercises an influence upon the act of mastication to which Thomas Bell* alludes as follows: "In children the area of the articular cavity for the lower jaw is scarcely greater than that of the condyle; the articular eminence is not yet formed. The movements consist simply in raising and depressing without the least approach to the rotation of the jaw. In fact, the condyle is the centre of movement. With old people, too, who have lost all their teeth, the lower jaw is simply moved up and down. As the teeth are absent, it is only necessary to open the mouth slightly for the reception of food."

* Op. cit., p. 51.

IV. HYPERTROPHIES.

THE augmented nutrition of any organ requires an increased supply of nutritive material from the bloodvessels which either enter the organ directly or, without entering it, effect the interchange of materials by their close proximity to it. An increased supply is rendered possible by increased contractility of the bloodvessels, and subsequent thickening and dilatation of their cavities. A continued irritation of the nerves involved accompanies this process. In hypertrophy, the elementary organs assume an unwonted activity; they increase in volume and proliferate more largely than usual. While they manifest augmented productivity, their development is frequently arrested at an embryonic stage.

If, now, a greater amount of formative material is excreted from the blood than can be appropriated, the accumulated material must necessarily undergo a retrograde metamorphosis, or the reverse may occur, the multitude of elements which are produced may be insufficiently nourished by the formative material with which they are supplied, and, therefore, a portion of them are destroyed.

In true hypertrophy, the elementary organs are identical in quality with those originally belonging to the part; their deviation from the normal condition has reference, for the most part, merely to the stage to which their development attains, and to their disposition, because the ordinary relations of constructive and destructive metamorphosis are altered. We have to consider hypertrophy of the cement, periosteum of the root, and gum, true hypertrophies of tissues belonging to the category of connective substances.

CEMENT.—Hypertrophy of this tissue occurs along with hypertrophy of the periosteum of the root, since it is induced by a chronic irritation of the latter membrane. Various modifications are distinguished which present transitions from one into

another, several of which sometimes occur together; they are based upon the disposition and form of the bone-corpuscles, the basis-substance, the occasional vascular canals, the interstitial development of new osseous tissue, and the retrograde metamorphosis.

With reference to the external form, a cap-shaped variety is distinguished, in which the hypertrophic cement extends over the greater portion of the root, or invests it completely as far as the neck of the tooth, becoming gradually attenuated towards the non-hypertrophied portion. Nodulated, tuberculated, warty forms are designated, commonly, as exostoses, and will be considered in connection with the subject of new-formations.

When viewed with the lens, the outer surface of hypertrophic cement is seen to be marked with shallow pits and grooves, to which are attached, generally, the remnants of the periosteum of the root. Its color is rather light, frequently inclining to white, and is quite conspicuous, particularly on the yellowish teeth of elderly persons. The apertures at the apices of the roots, which serve for the transmission of the dental nerves and bloodvessels, are often diminished in size, or are occupied by a growth from one side. Sometimes, several, very small apertures are found, and in such cases, it is easy to understand that the dental nerves are bent from their course, lacerated, or pressed upon by the bony substance which is developed around the extremity of the canal; the branches, likewise, which are distributed to the periosteum of the root from the dental nerves, previous to the entrance of the latter into the dental canal, are displaced by the abnormal local relations, and the occasionally severe neuralgias consequent upon these conditions may be explained by the unusual tension to which the nerves are subjected.

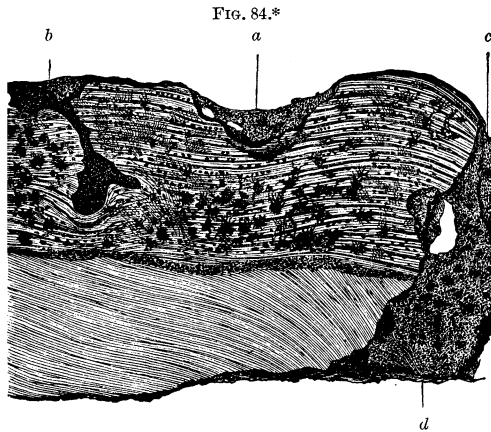
As a general rule, it may be said that the occurrence is quite rare upon the front teeth; occasionally, however, these, especially the upper ones, present a notable hypertrophy. The cap-shaped variety is observed more frequently upon the upper bicuspids (Atlas, Fig. 100), and next in frequency it occurs upon the wisdom teeth with blended roots (Atlas, Fig. 101). Frequently, also, it is found upon the anterior facial roots of the

upper molars. Sometimes, both facial roots are united by cement, and, in quite rare cases, the apices of the three roots are united by a hypertrophic growth (Atlas, Fig. 102). Now and then, the hypertrophy is confined to the contiguous surfaces of these roots (Atlas, Fig. 103). Upon the extremities of the roots of the lower molars, it forms a rounded knob.

Upon close examination, it will be seen that in some places tolerably uniform intervals are preserved between the bone-corpuscles, the long diameters of which are disposed horizontally, *i. e.*, are perpendicular to the axis of the tooth or have a direction parallel or at an oblique angle with the latter, and in other places they are crowded together or are situated far apart. The former relations are observed more particularly in concentric hypertrophies (Atlas, Fig. 106), in which numerous layers of cement encircle the dentine in a manner similar to the annual rings in wood. Generally, however, this lamination is limited to certain localities, while in others an excessive proliferation occasions clusters of numerous bone-corpuscles and, occasionally, cross-sections, especially, present elongated, isolated layers of densely packed bone-corpuscles, the canaliculi of which must have suffered an arrest of development. Frequently, the bone-corpuscles attain quite large dimensions, are abundantly supplied with canaliculi, which are of considerable length and furnished with anastomotic loops; smaller bone-corpuscles are sometimes attached to the sides of the larger ones, or are blended with them; large and small ones also occur separately. When they are separated by very wide intervals, the intervening canaliculi are nearly parallel with one another, resembling in this respect, the dentinal canals, or, in some instances, are wanting, and the intervals are occupied merely by a finely-granular basis-substance.

Sometimes, *peripheral resorption* takes place in hypertrophic cement which, then, has a rough exterior and presents a serrated appearance in cross-sections (Atlas, Fig. 116). The appearances produced by this process are not uniform in character, for, at one part, the cement layers may be affected but slightly, and at others the resorption may induce a total destruction of them and even involve the dentine, and, in many places, it oc-

casions a circumscribed or localized breach of substance (Atlas, Figs. 98 and 106). Again, especially upon the roots of carious teeth, it attacks the peripheral layers of the cement at many points and involves the entire thickness of the latter tissue and even of the dentine, as far as the cavity of the root, its course being marked by rough channels. It is induced by a proliferation of the connective-tissue elementary organs of the periosteum of the root, or suppuration, and is called *perforating resorption* (Fig. 84).



Interstitial resorption of hypertrophic cement is displayed in the form of cavities of which several types are distinguished. Some of them present radiating canaliculi, and hence they are the results, apparently, of the resorption of adjacent bone-corpuscles, while, in others, these canaliculi are absent; notched vacuities, also, are met with of various dimensions and shapes;

* FIG. 84 shows the results of resorption which extended from without inwards, in places even as far as the pulp-canal, upon the roots of a carious molar with hypertrophic cement. The resorption has given rise to cup-shaped excavations (*a*), and occasionally bifurcating, flask-shaped cavities (*b*). A very wide flask-shaped cavity, only half of which is represented in the figure (*c*), extends through the entire thickness of the cement and dentine, as far as the wall of the dental canal which, likewise, is eroded (usurirt) to a certain extent. Minute examination shows the cavities to be made up of indentations which are lined with a cloudy mass. Magnified 80 diameters.

some present annular constrictions, while others occur in the form of flask-shaped expansions which terminate, frequently, in narrow necks, present lateral cavities and are filled with amorphous calcareous salts, fat-granules, dirty yellow pigment, or a fluid. As a rule, they are met with most frequently in the older layers of cement adjoining the peripheral globular layer of the dentine, where they form, sometimes, irregular, elongated cavities from which processes extend far into the dentine. They may arise in various ways. Where several adjacent bone-corpuscles undergo resorption, the canaliculi which radiate from the cavity that is formed are destroyed as the latter expands. The penetration of bloodvessels into the cement frequently occasions a resorption of the corresponding portion of the latter, and the former may be obliterated and become transformed into vacuities or channels containing calcareous salts and the products of fatty metamorphosis. Another form of interstitial wasting consists in a granular disintegration of the intercorpuscular substance which acquires a color varying between dirty-yellow and brown. Portions thus affected pass imperceptibly into the neighboring tissue, and in them the outlines of the bone-corpuscles are still recognizable, except at those parts where the degeneration is very extensive. These instances of resorption which have been described are met with most frequently upon carious roots.

The vascular canals, which are of frequent occurrence in hypertrophic cement, penetrate from the outer surface, give off lateral branches or, perhaps, form a network of ramifications and extend as far as, and even into the dentine and, generally, they form an oblique angle with the latter and are tolerably uniform in size. It is a peculiarity belonging to them that their sheaths undergo an extensive calcification which, ultimately, occasions an obliteration of their cavities. Hence, elongated channels, filled with calcareous granules, are met with (Atlas, Fig. 105), the hollow nature of which is indicated by cross-sections and, also, by sections in which the channels are presented in their length, by the presence of air in portions which have become emptied of their contents. The vessels do not completely fill the channels, have thin walls, comparatively wide cavities, generally termi-

nate with closed extremities and, only exceptionally, contain blood.

The vascular canals sometimes are surrounded by a substance which forms an investment of variable thickness and is separated from the basis-substance by a brighter boundary layer; it presents a notched, sharply defined border, a radiated, granular structure, and is to be regarded as an external limiting layer of rudimentary osseous substance (Atlas, Fig. 105); for, when traced in its further progress, groups of young bone-corpuscles have been found imbedded within it. Hence, there is presented a development of new osseous substance around the vascular canals, and it may be traced even as far as the border of the dentine.

Finally, bone-corpuscles are met with beneath the outer surface of hypertrophic cement, in the intermediate portions or even in the vicinity of the dentine, which, either in pairs or in groups of three or more, are encapsulated by an indented highly refractive layer and present an appearance as if they were inserted within the proper layers of cement. The young corpuscles, sometimes, inclose a distinct cellular body together with a nucleus, and multiply by a progressive segmentation; generally, but few canaliculi radiate from them, and these unite with the adjacent canaliculi in the same group, while they do not join with those of the concentric laminæ of the cement, being cut off by the capsular layer.

A twofold hypertrophic growth of cement must, therefore, be distinguished, namely, a *peripheral concentric*, which conforms to the disposition of the pre-existing layers, and an *interstitial*, intercalated hypertrophy. The latter, probably, is brought about by the penetration of the branches of the periosteal blood-vessels into the cement. I have generally found such a growth upon cement in which numerous vascular canals have been developed and, also, in the hypertrophic cement upon the teeth of the hippopotamus, horse, cattle, lama, and stag. It cannot, however, be said that a vascular canal occurs in all cases where groups of young bone-corpuscles are developed; it is much more reasonable to assume that the formative material which induces the resorption of the old and out of which the new osseous sub-

stance is developed, may permeate to a certain depth. The circulation within the canals of the hypertrophic cement is quite imperfect and represents an embryonic stage, since canals, with closed extremities, are met with very often, and only exceptionally do we find a plexus; indeed, the reason for the premature calcification of the canals is to be sought for in this defective development.

The osseous growth not infrequently extends beyond its proper limits and encroaches upon the dentine. Cases occur in which single bone-corpuscles or groups of them have displaced the dentine, being separated from the latter by a hyaline, notched, limiting layer. A similar occurrence has been referred to before (Atlas, Fig. 110),* in connection with the resorption of the roots of the milk teeth during dedentition, and we can explain it only as an instance of interstitial growth of bone. The vascular proliferations, which frequently penetrate deeply into the dentine, sometimes are invested with a layer of rudimentary osseous substance containing bone-corpuscles which are stunted in their development, as may be demonstrated in the interior of the dentine by means of cross-sections. Deep funnel-shaped prolongations of the cement-substance into the dentine (Atlas, Fig. 109) are met with in a few cases. It is quite common to find hypertrophy of the cement in combination with a new growth of osseous substance upon the surface of the canal of the root, which becomes lined by it, in some cases, for a considerable distance from the extremity.

ROOT-MEMBRANE.—In addition to the senile form, an hypertrophy occurs as a sequel of chronic affections of the root-membrane, consisting, essentially, in a thickening and a more or less advanced callous formation. In order to investigate this subject, detached preparations are employed and also cross-sections which, perhaps, it is unnecessary to add, should only be made upon decalcified portions of the jaw containing the corresponding roots, and all the more from the fact that there is a question respecting the connection of the periosteum of the root, on one side, with the root, and, on the other, with the alveolus. The

* Comp. p. 78.

generally straight bundles of fibrous tissue often pursue a radiating course for the most part, *i. e.*, they extend from the outer surface of the cement, towards the alveolar wall, forming a series of closely-packed arches, and are inserted, by a fan-shaped expansion, into the osseous trabeculæ. During their passage, the bundles inclose spaces which, likewise, are traversed by thin bundles. These are the depositories for the aggregations of ovoid cells which, here and there, form radiated prolongations to the cavities, their number bearing an inverse proportion to the density of the thickened periosteum. Besides these latter cells, and more nearly in the course of the bundles, spindle-shaped cells occur which have oblong, frequently fibre-like, elongated nuclei.

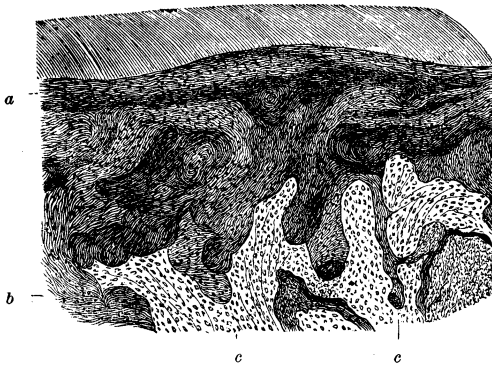
The bundles of connective tissue, especially in cases of very irregular hypertrophy, interlace with one another in various directions, forming a sort of felted work of bundles which penetrate the enlarged foramina in the alveolar wall. Cross-sections of periosteum of this description present, therefore, numerous protuberances and conical prolongations (Fig. 85). In consequence of the increase of the fibrillated tissue of the periosteum, its consistence becomes augmented and it may even acquire a tendinous character, so that its tenacity and consequent power of resistance in extraction are increased.

The fringes presented by the membrane when extracted along with the root are, manifestly, pulled out from the vascular foramina of the socket and consist of cloudy tough bundles of connective tissue, containing numerous, usually shrivelled nuclei and inclosing bloodvessels with their external coats very much thickened. They form an intimate, quite firm union between the root-membrane and the socket, in consequence of which fragments of the alveolar wall, particularly those portions which correspond with the neck of the tooth, are very liable to be removed along with the tooth, in the extraction of the latter.

Elastic fibres do not occur in the sclerotic periosteal membrane. The nerve-branches are so concealed from view by the fibrous connective tissue that they cannot be identified until they are cleared up by treatment with the proper reagents. The nerve-tubes are filled with a mass of diminutive fat-granules,

and present an appearance similar to that found in senile atrophy of this membrane. Here and there, the bloodvessels are isolable in short segments and, in places, are obliterated. The veins are considerably dilated in some cases, and form a network with large meshes (Atlas, Fig. 122).

FIG. 85.*



Deposits of pigment occur in the callous root-membranes and may be seen with the naked eye in the form of diffused specks of a dark-brown or reddish-brown color, or of various shades between the latter and a grayish-black. It may be assumed, with good reason, that these originate from previous extravasations of blood, from the fact that blood-corpuscles, deprived of their coloring matter, are frequently met with in connection with the interposed pigment molecules.

GUMS.—Hypertrophy of the gums occurs frequently among the sequelæ of a chronic inflammatory condition of the root-

* FIG. 85.—Proliferation of the straight connective tissue in the periosteum of the root of a carious upper bicuspid. Cross-section. The fibrillated bundles of connective tissue encircle the root of the tooth in more or less parallel layers (*a*) and, also, form small concentric lamellæ which evidently correspond to the proliferations of the fibrous sheaths of the bloodvessels and penetrate more or less deeply into, and fill, the medullary spaces of the upper jaw (*b*). At this part the alveolar wall has disappeared under resorption and the lamellæ of the spongy tissue of the bone (*c, c*) have been displaced by the proliferating connective substance. With higher magnifying powers, the familiar erosions resulting from resorption may be seen upon the margins of the bone. Magnified 80 diameters.

membrane following caries of the teeth, and is induced, also, by the irritation of the gums produced by the products of the degeneration of the hard tissues of the teeth. The sharp edges of stumps, too, which remain after the destruction of the coronal portions and necks of the teeth, become the sources of irritation.

The hypertrophy occurs both in the papillary portion and, beneath the latter, in the corium of the mucous membrane. When it occurs in the former, it is most conspicuous upon the facial surface of the gums and is confined to the region of one tooth or a few teeth, or acquires more extended limits in cases of caries involving the crowns or roots of several teeth.

While the papillæ occur in clusters in the normal state, in the hypertrophied condition, the manner in which they are grouped together becomes much more evident. They present smooth, pale or reddish, clavate, conical projections, several millimetres in length and attached to a common stalk; they are confined to the region of the gum, *i. e.*, they extend as far as the alveolar process and, consequently, present an arched outline when viewed together (Atlas, Fig. 118). Frequently, the hypertrophic condition becomes less marked from the gingival border towards the commencement of the alveolar process, while, in the opposite direction, it is prolonged into the intervals between the teeth and becomes visible upon the lingual surface of the gum in the form of tumid protuberances covered with thick epithelial layers. Papillary proliferations, in the earlier developmental stages, give to the gums a velvety appearance.

Each of the above-mentioned conical projections is composed of a group of hypertrophied papillæ which are covered by numerous layers of flattened epithelium common to them all, and are not distinctly visible until after the removal of the latter. The groups are separated from one another by intervals of varying depth, and include a larger (ten to fifteen) or smaller number of finger-shaped papillæ which, usually, are several times larger than in the normal condition (Atlas, Fig. 119). Some of the hypertrophied papillæ present a distended appearance, with an irregular outline, others lateral or terminal excrescences or buds, which indicate a continued growth; they contain in their interior a continuous vascular loop; the bloodvessels in

them frequently pursue an irregular, distinctly wavy or spiral course, divide dichotomously and form a network; they are considerably dilated, the recurrent capillaries more particularly, and frequently are filled with a homogeneous, colloid mass. Fine elastic fibres occur in considerable abundance. If marked cellular infiltrations into the corium of the gums occur, they also extend into the papillæ and along the capillaries. The parenchyma of the papillæ, in consequence of nutritive disturbances, sometimes acquires a clouded appearance, has a dirty-brownish color, or is interspersed with numerous fat-globules.

The epithelium, also, participates in the hypertrophy which affects the papillary portion; the nuclei swell up, the nucleoli become more prominent; occasionally a double nucleus is met with. The groups of papillæ are covered by the cells of the horny layer, disposed in several layers common to them all and having a slightly wavy outline. The cells of the mucous layer, likewise, are increased in number; their protoplasm frequently presents a molecular cloudiness; they invest the individual papillæ, between the groups of which they form conical prolongations, extending, in many cases, to a considerable depth into the corium.

It is found, also, that the papillæ increase in length and thickness and, also, by the development of lateral processes; in place of a simple hypertrophy, therefore, there succeeds a new-formation of papillæ, a papilloma, which, in its general form, resembles the acuminate condyloma. Contemporaneously with the growth of the papillæ, the bloodvessels, also, increase in length, become wider in parts, and give off branches by means of which a plexus of capillaries is formed. The nerves do not appear to participate in the process. As the dimensions of the papillary portion increase, the separate laminæ of epithelium, also, become augmented, the proliferation of the cells of the mucous layer being especially notable. The development of the latter and that of the papillæ take place in opposite directions, namely, that of the papillæ towards the free outer surface, and that of the cells of the mucous layer towards the corium.

The hypertrophic corium of the gum is infiltrated with cells which frequently are disposed in rows and in part accompany

the bloodvessels and nerves so that they form a meshed work, in the bright vacuities of which connective-tissue corpuscles, united together so as to form a network, are visible (Atlas, Fig. 119). Moreover, a proliferation of ovoid and radiated elementary organs of the connective tissue, at a distance from the bloodvessels and nerves, is also observed. These cellular infiltrates sometimes are so extensive as nearly to fill the corium layer in places, and to occasion a notable tumefaction and succulency. These products of proliferation, as well as the former, of a higher order of development, frequently undergo retrograde metamorphoses, become the subject of fatty degeneration, pigmentary deposits, shrinking, colloid degeneration, the latter being presented in the form of minute, cloddy masses. In the deepest layers of the mucous membrane, in the submucous connective tissue, quite extensive zones of ovoid cells are often met with, or even groups of fat-cells, though I have never observed any very marked proliferation of the latter; here also are found, occasionally colloid or jelly-like formations and, sometimes, pigmentary, brownish-yellow masses.

That portion of the hypertrophied gum which extends between the teeth sometimes presents a lamellar development, with superposed, enlarged, papillary elevations, while the mucous layer of epithelium dips down to a considerable depth between the lamellæ.

The secretion of mucus usually is increased in connection with papillary hypertrophy, and partial exfoliations of the epithelium occur, leaving superficial erosions. Bleeding readily occurs from the painless swellings, even from slight mechanical irritations.

Sometimes the papillary portion is not involved and the proliferation is confined to the corium, occasioning a swelling of the gum, which has a smooth exterior. In these cases, which are more protracted, the cellular infiltrations give rise to a tendinous connective tissue; in other words, the hypertrophic gum becomes sclerosed, and, consequently, it presents an increased power of resistance and a diminished succulency. The gradually obliterated papillary portion is covered by a common, thick, superficially smooth layer of epithelium. Notwithstanding the increased consistence of the corium, cellular infiltrates are met

with in the form of long chain-like rows or clusters of ovoid cells, which are inclosed within a capsule of fibrous tissue. Since the periosteum, also, beneath the indurated gum is thickened, it is by no means strange that cross-sections of the latter sometimes present slender trabeculæ in the process of growth, together with young bone-corpuscles. In very marked callosities, such as are presented so frequently in alveolar cicatrices, the tense fibrous tissue contains between its bundles cells which, for the most part, are shrivelled and present a granular cloudiness; the obliterated portions are indicated, principally, by a speckled, cloudy appearance, the nerves being shrivelled up and the bloodvessels obliterated. But, even in cases of marked induration, groups of well-formed, apparently vigorous cells, which still retain their germinal properties, are met with.

V. NEW - FORMATIONS.

It is not possible, in all cases, to draw a line between new-formations and hypertrophies, so that many of the former can only be described as localized hypertrophies. In a new-formation, the proliferation originates in one textural portion of an organ and spreads within certain limits, displacing more or less in its progress the normal elements. The proliferating tissue is not of a parasitic nature, that is to say, it does not appropriate already formed tissues, as nutritive material, but, rather, induces reabsorption of them. The more vigorous, younger, displaces the older, enervated cell, whether it is a homologous or heterologous elementary formation. The young cells, endowed with increased productivity, supplant the old ones. A new-formation premises an increased vitality on the part of the blood-vessels, together with proliferation of those vessels which are destined to convey nutriment to the proliferating organ. The augmented supply of blood which is thereby afforded necessitates in turn an increased cell-formation in the part to which it is distributed. The vascular system takes a prominent part in the production of a new-formation, whether the connective tissue, which forms the framework of an organ, alone participates, or the elementary organs, which govern the function of an organ, also share in the process. The tissue of the organ becomes the subject of an excessive growth within the affected limits and, also, of a corresponding alienation. The nervous system is implicated only secondarily and, in exceptional cases, only, appears to take a prominent part in the process.

New-formations occur in the hard and soft tissues of the teeth and are only few in number, while the contiguous parts, particularly the jaws, present a very great variety, a knowledge of which comes within the province of dentistry and is necessary to the practical dentist, since the opportunity is frequently

afforded to him, first of all, to diagnosticate them and to give timely advice with regard to operative interference.

PULP.—New-formations of the pulp have their origin either in the germs of the connective tissue or of the dentine. The parenchyma of the pulp can only be the seat of an increased productivity when there is sufficient space to allow the necessary increase in volume; such a condition is impossible so long as the pulp-cavity remains entirely encompassed by dentine, and can only occur when space is provided by the destruction of a portion of the wall of the cavity.

When the new-formation has its origin in the dentinal germs, the circumstances are different; either the already-formed dentine or the pulp-tissue becomes displaced, and is replaced by a newly formed hard structure.

If caries has destroyed a portion of the wall of the pulp-cavity and the corresponding segment of the pulp is denuded; if the individual is young in age; if the irritation of the pulp is moderate in character and there is no purulent destruction; if, besides, the local relations of the carious tooth and the locality of the caries in the tooth itself are such that the proliferating substance is protected against mechanical injuries, there arises upon the pulp, and projecting more or less beyond the perforated carious portion, a soft secondary formation with a rounded outer surface which is covered, frequently, with a layer of muco-purulent matter. Such a formation, usually, is described as a polypus of the pulp.

The new structure may acquire about the size of a small pea, sometimes has a bluish-red color, at others is flesh-colored; it is of a spongy or fleshy consistence, not sensitive to the touch, nor when slightly pricked, and is organically united with the coronal and radical portions of the pulp. It contains an abundance of roundish and spindle-shaped cells, the bodies of the cells varying slightly in extent, which, together with a small amount of fibrous intercellular substance, compose the principal portion of the tumor (Atlas, Fig. 79). The groups of cells are in long rows and have a radiated arrangement. The cells, which are provided with processes, unite here and there to form a network; rows of spindle-shaped cells, also, are met with. The

bloodvessels pursue a tortuous course from the interior towards the periphery, are numerous, comparatively large, and invested with thick, fibrous sheaths. The type presented by the capillary ramifications is different from that found in the pulp. Nerves or remains of the parenchyma of the pulp are not to be seen. I have never observed an epithelial covering upon the outer surface. Occasionally, a purulent infiltration occurs in the vicinity of the latter and the bloodvessels extend quite near to it, so that hemorrhage is easily produced.

The parenchymatous connective tissue is the seat of the proliferation described as *sarcoma of the pulp*, in which the parenchyma gradually is destroyed, as is indicated by the absence of nerves and the altered character of the bloodvessels. As the sarcoma is located upon the outside of the remains of the pulp, it serves in a measure to protect the latter.*

NEW-FORMATIONS OF THE HARD TISSUES OF THE TEETH.—These were first recognized by the anatomists of the previous century, and have occupied the attention of dentists and pathological anatomists of recent times. Of late years, manifold controversial opinions have arisen respecting their clinical significance and importance.†

* Salter (*Des pulpo-dentaires*, Archives Generales, 1857) distinguishes two classes: 1. Hypertrophy of the pulp in which there is no change in the texture, which retains its normal sensibility and, occasionally, is the seat of pain. This he never found in carious teeth and only in connection with fractures. This class obviously does not belong to the sarcomata (polypi), but rather to the cicatricial formations. 2. In this class the tumor is not sensitive and occurs in connection with caries in the teeth of young persons, generally in the molars of young, weakly females. In two cases the tumor acquired quite large dimensions and corresponded histologically with the gum; superficially there was a thick layer of polygonal epithelial cells, beneath which were small, irregular papillæ. Indeed, both of these cases might easily have been confounded with a tumor of the gum.

† J. Hunter (*Nat. History of the Teeth*) devotes a special paragraph to these, in which it is shown that, in teeth which are worn away by attrition, that portion of the pulp-cavity, adjacent to the abraded surface, becomes filled with a new substance which occupies the centre of the abraded surface and, generally, is softer than the rest of the tissue of the tooth. Prochaska (*Adnotat. academ. Prag. 1780*) treated of the same subject in his *observat. anatom. de decremento dentium corp. humani*. Oudet (*Dictionnaire de médecine*, article dent., 1835), gives a good description of these new-

A new-formation of the hard tissues of the tooth cannot be produced except from their formative elements, and since those of the enamel wholly disappear when the formation of the crown of the tooth is completed, it follows that the new-formations are limited to those of dentine and of bony substance. In these new-formations, the dentinal cells play the principal part, as in the formation of ordinary dentine, while an accessory or independent new-formation of bony substance alone is produced from the connective tissue of the parenchyma of the pulp through the medium of its bloodvessels.

The new-formations which are to be taken into consideration, are located upon that surface of the body or root portion of the pulp which is directed towards the already-formed dentine, in the parenchyma of the pulp, or are imbedded in the substance of the dentine. Hence, many varieties may be distinguished. According to their situation they are parietal, ad-

formations, which he divides into two classes, the adherent and unattached. He paid no attention to their histological structure; their connection with the pain in many of the cases cited may be doubted. Other writers (*vide* R. Hohl's *Monographie über Neubildungen der Zahnpulpe*, 1868), as Rousseau, Nasmyth, Bertin, Raschkow, and Ryding, met with these hard formations both in human teeth and in those of animals. R. Owen (*Odontography*) illustrates numerous new-formations of osteo-dentine, but does not go very deeply into the subject. Salter (*Guy's Hospital Reports*, ix) treats of osteo-dentinal formations in addition to simple calcifications of the pulp, calcareous granular deposits. He regards them as the result of a pathological process. We are indebted to J. Tomes (*A Course of Lectures on Dental Phys. and Surgery*, 1848) for their first minute anatomical description, and to F. Ulrich (*Zeitschrift der K. K. Gesellschaft der Aezte. zu Wien*, 1851), who distinguishes in them two kinds of tissues, a dentinoid, an osteoid, and a combination of the two. Wedl (*Grundzüge der pathol. Histologie*, 1854), Heider and Wedl (*Deutsche Vierteljahrsschr. f. Zahnheilk.*, 1864), give further anatomical details, and the latter endeavor to determine the mode of development of these new-formations. R. Hohl, in the work cited above, furnishes a critical treatise (1868), based upon independent investigations, and applies to these formations, the terms odontoma, osteoma, and osteo-odontoma. Many writers have described the dentinal new-formations as odontomata, but since this term has been selected to designate certain dental malformations, it is inadmissible to apply it to a new-formation of dentine, and, therefore, a distinction must be made between the odontomata occurring before and after the completion of the development of the tooth, namely, odontoma congenitum and acquisitum.

herent to the wall of the pulp-cavity, or external; free or internal; and interstitial or imbedded in the dentine; according to their number they are single or multiple; in form they are flattened, round, wedge-shaped, conical, berry-like, warty, attached by means of a pedicle to the wall of the pulp-cavity; with respect to their position, they are located upon the wall of the pulp-cavity towards the masticating surface, upon its radical or lateral wall, and fill, more or less, the pulp-cavity or root-canal; with reference to the period at which they are developed, they may be premature or senile; in respect of their origin, they are consecutive, engendered by external causes or spontaneous, and in size, they are very small, or may fill nearly the entire pulp-cavity or root-canal.

A fine specimen of new-formation of dentine in the pulp-cavity or root-canal presents to the naked eye a yellowish, amber color, a certain degree of transparency, and a hardness nearly equal to that of dentine. The exterior, invested by the pulp-tissue, always has a rounded outline and, generally, is nodulated.

Their structure varies according to the circumstances under which they are developed. If, from a new-formation of dentine which has arisen subsequently to the abrasion of the crown and is perceptible upon the abraded surface as a central spot surrounded by polished dentine, sections through the middle portion, perpendicular to the abraded surface, be examined, it will be found that the new hard substance is more transparent than the original dentine, that the new canals extend in a radiated manner towards the old and preserve, essentially, the same directions as if they were central prolongations of the latter. In most places, there is observed proportionately rapid diminution in their transverse diameters, and an insertion of their twig-like continuations between the old, wide canals; in many places, therefore, there is no communication between the respective canals, while in others an immediate transition of the new into the old canals may be identified. From these facts it is evident that, in these cases, there occurs a continued development of dentine within certain limits determined by an irritation, and that the new layers are deposited in immediate contiguity with the old and, in parts, are intimately and organically united with

the latter. Dentine of this description, which serves as a protective covering of the pulp, is called *dentine of repair*, *secondary dentine* (Ersatzdentin), as is that dentine, also, which is formed in cases of chronic caries upon that portion of the wall of the pulp-cavity corresponding to the carious locality and projects into the carious cavity in the form of a spherical segment. In the latter cases, also, we find that the new dentinal canals are continuous with the old; there is, usually, an abundant basis-substance, and the canals are separated by quite wide intervals. Frequently there is a want of uniformity in development; for instance, the continuity of the dentinal substance is interrupted by small and quite large, elongated, jagged cavities which are filled with amorphous calcareous salts. Some of these are the results of resorption, similar to those observed frequently in senile dentine, and others are interglobular spaces (Atlas, Fig. 72). The less compact structure of the new dentine is due to these.

A different structure is presented by the *concentrically laminated* forms, two varieties of which are distinguished, the *simple* and *complex*. These correspond, in some respects, with the nodular calcifications described by Salter. These new-formations of dentine, especially if they are quite small, are liable to be confounded with simple calcifications. The latter, however, occur as discrete, roundish bodies in the parenchyma of the pulp, and never as confluent, very large grains, and, also, are met with, especially in the pulp of the root, in the form of needle-shaped, resistant bodies. A detailed description of them has been given, already, in connection with atrophies.

Thin cross-sections of these new-formations present a central basis-substance, composed, in many cases at least, of transparent, discoid, homogeneous, structureless, nucleus-like masses, either single, in pairs, or in large numbers (Atlas, Fig. 58), around which concentric layers are disposed in a manner similar to those around the Haversian canals in bone. The central substance not infrequently contains globular masses and small interglobular spaces. If the basis-substance is unusually abundant, a very delicate, retiform, structure may sometimes be distinguished with a high magnifying power and suitable light. By

means of very careful and slight corrosion, the concentric and concentrically-disposed radiated layers are brought distinctly into view. Here and there, cloudy spots, together with molecular degeneration of the substance, presenting a gray or dirty-yellowish color, are observed.

The canals of the concentric dentinal new-formations have a centripetal course, *i. e.*, they converge from the periphery towards the centre (Atlas, Fig. 65). As a rule, they are shorter than in normal dentine, and, therefore, their diameters diminish more rapidly; they deviate, frequently, from a direct course, branch without uniformity and often terminate in a tuft of twig-like branches. On account of the irregularity in which they run, the intervals between them are variable; when there are globular masses present, they terminate at the centre in the interglobular spaces. Anastomotic loops are met with, frequently, particularly in the complex forms.

From the facts which have been stated above, it is apparent, since the existence of dentinal canals implies the pre-existence of dentinal cells, that the latter must have acquired a circular arrangement at the time of the formation of the new growth, and that, as their proliferation progressed, they became separated from each other by larger intervals and, also, suffered deviations in the direction of their development.

Not infrequently the canals are filled with grains, arranged like a string of pearls, or imbued with the coloring matter of the blood, probably in consequence of extravasations of blood or of inflammatory processes in the surrounding soft tissues. Erosions from resorption are observed, occasionally, upon the periphery of the new-formation which is surrounded by the atrophic pulp, and indicate a reaction on the part of the still vital pulp. There can be no doubt, therefore, that these new-formations are closely connected with morbid processes in the persisting, though to be sure, in many cases, scanty remains of the pulp.

Such a probability is strengthened by the anatomical examination of these remains. Even though one portion of the pulp, which becomes reduced, frequently, to a thin membrane, has acquired a tendinous character or undergone a net-like atrophy,

another portion may still be traversed by well-preserved vessels containing fresh blood, and even bundles of nerve-fibres of normal appearance occur, which are still capable of transmitting sensations of pain. In many cases, it is true, these remains are totally obliterated.

When the parietal, nodulated new-formations *are organically united to the old dentine*, a dividing layer is present, commonly, which usually has a light color and is perceptible to the naked eye, since the bounding layer of the old dentine is distinguished by the uniform appearance presented by the canals extending from it, while the canals of the new-formation meet those of the old dentine generally at an acute angle and, here and there, at nearly right angles; the latter rectangular diversion of the canals is most marked in many of the larger adherent new-formations (Atlas, Figs. 61 and 62). Globular masses with opaque interglobular spaces are observed, here and there, in these transitional zones. In general, it may be stated that in secondary dentine following caries or abrasion of the teeth, the direction of the dentinal canals will be found to correspond with that of the canals of the old dentine, while in the parietal, concentrically laminated, nodulated new-formations, there is no correspondence in the direction of the respective canals.

The periphery of the concentric new-formations usually presents deep channels containing a varying number of bloodvessels (Atlas, Fig. 57), which, however, do not completely fill the cavities. Sometimes the coloring-matter of the blood is still perceptible and well preserved, and a corresponding reddish color of the dentinal canals, also, is observed; generally, however, the coloring-matter is changed to a dirty yellow, yellowish-brown, or to the different shades between this and a dark-brown. The wider channels are filled, more or less, with atrophic retiform connective tissue in which the cavities of one or more bloodvessels with their sanguineous contents are perceptible. They vary in diameter, occasionally branch and, particularly in the complex forms, several even unite and form a sort of network. They frequently undergo calcification, in which cases the calcareous particles in mutual contact compose the peripheral portion of their contents. Frequently they are surrounded by

an accessory layer of varying thickness and with an indented surface towards the new-formation, in the folds of which a cellular body may, perhaps, be found, here and there, and I have even met with well-formed, multiradiated, bone-corpuscles in them, so that it can be said that an osteoid mass is developed around the bloodvessels.

It may be assumed with reason, that the above-mentioned bloodvessels are derived from those of the pulp, contemporaneously with a connective tissue which has a tendency to ossification (Atlas, Fig. 59).

These channels, which often are replete with calcareous salts and frequently contain bloodvessels, must not be confounded with the usually smaller, but occasionally more extensive, irregular cavities which, as shown above, occur in the central portions of the new-formations, and in which the canals frequently terminate. I have met with a few cases only of *true new-formations of osseous substance* within the parenchyma of the pulp. They occurred in the pulps of milk teeth which were undergoing resorption, and one of these cases is reported in the above-cited communications by Heider and Wedl. Upon the posterior surface of a milk incisor which was extracted, there was a deeply-grooved breach of substance, about six millimetres in length, extending from the neck of the tooth towards the root, and the corresponding portion of the coronal and radical pulp was denuded. The contents of the nerve-tubes of the latter had undergone a molecular degeneration, and the nerve-tubes themselves presented in places a shrivelled appearance. Within the pulp, which was tinged with blood, a firm lamella was found united with the tissue of the pulp, about two millimetres in length and one millimetre in breadth. Upon very close examination of the structure, it was found that the central, more compact portion was ossified, while the marginal portion was composed of aggregations of minute calcareous grains. The lamella contained, as is the case, generally, with young, osseous plates, several oval, sharply-cut foramina for the transmission of bloodvessels; very distinct bone-corpuscles, which were in clusters, were furnished with short processes and, on the whole, bore a strong resemblance to those of a young for-

mation. The new-formation of osseous substance, in this case, was due to the irritated condition of the pulp, engendered by its exposure.

The greater portion of the very common *osteo-dentinal formations* is composed of dentine; the bony substance occurs in very small quantity, and may consist merely of a group of a few bone-corpuscles. The osseous substance not infrequently attains only a rudimentary development and resembles that which occurs upon the cement towards the neck of the tooth. It has been stated that bone-corpuscles sometimes make their appearance in the peripheral layer of the bloodvessels which have penetrated the new-formation; they are also met with, however, either towards the periphery of the new-formation, where they occur in groups (Atlas, Fig. 69) and are separated from the new dentine by globular masses, or they occur in the central portion of the new-formation. Cases in which the central portion of the new-formation is occupied by an extensive mass of osseous substance are quite rare and, apparently, occur only when the formation acquires unusually large dimensions and presents a regularity in its development. In such cases, too, vascular canals are present in the bony tissue. A very fine illustration of a case of this kind is given in "Wedl's Pathological Histology," Fig. 141 B, where the formation is attached to the wall of the dental canal of a bicuspid and is oval in shape, its long diameter measuring five millimetres; it presents a peripheral dentinal tissue, nearly a millimetre in thickness, which forms an annular investment to the central osteoid tissue.

In these new-formations, both the bony and the dentinal tissues experience frequent interruptions in their development, as is indicated by the frequent occurrence of irregular, jagged cavities in the new dentine, and by the variable or dwarfish forms and the irregular disposition of the bone-corpuscles.

Many of the parietal new-formations of dentine or osteo-dentine, which are firmly adherent to the wall of the pulp-cavity or root-canal, displace more or less of the original dentine at the points of attachment, so that shallow depressions are perceptible upon the walls after the removal of the new-formations; a partial resorption, therefore, must have taken place at these points.

Not infrequently, also, new-formations are intercalated in the original dentine and are then distinguished as *interstitial*. They are, commonly, multiple and, according to my experience, almost always occur in the roots of the molars. Fig. 66 in the Atlas illustrates such a formation, and Figs. 63 and 64, also, afford a very good general view of them. They are met with, sometimes, in close proximity to the cement. Their structure always presents the same type, viz., their canals have a centripetal course and open in central, larger or smaller, cavities resembling bone-corpuscles, and in interglobular spaces when there are globular masses present. Not infrequently, ramifying, vascular canals traverse the multiple formation and unite to form a network. Each of the formations has its own system of dentinal canals which are invested by, and decussate freely with, the canals of the original dentine without, however, entering into direct communication with the latter. Just as in the preceding pages, in connection with hypertrophy of the cement, we assumed an interstitial growth of bone, so, in the present case, we have to assume the occurrence of an *interstitial dentinal development*.

The conditions of the occurrence of the latter remain undetermined with our still defective knowledge concerning the life of the teeth in general, and of the dentinal cells in particular; this much, however, is established, that resorption of the original dentine is brought about by the interposition of the new, and it is very probable, that the bloodvessels which, by their growth from the root-pulp, penetrate the dentine (Atlas, Figs. 59, 97, and 98), have a definite connection with, and are the medium through which, on the one hand, the resorption, and on the other, the new-formation is accomplished. We see, first of all, a canal containing a bloodvessel which may be traced to its origin in the root portion of the pulp. Accompanying these are spheroidal, transparent, sharply-defined masses, presenting a lobulated appearance from their mutual apposition, and containing a minutely granular matter which presents, in more extensive masses, a structure of radiated concentric laminae; these are to be regarded as the rudiments of an osteoid substance, and all the more so from the fact that the vascular canals, now and then, are surrounded in places by globular masses merely,

and at other times are found to be invested by an accessory, well-developed bony tissue with an indented, sharply defined margin directed towards the dentine. There occurs, then, an excentric development of the pulp-vessels and dentinal cells; the new, more vigorous tissue displaces the old; the proliferating, fresh dentinal cells occupy the place of the dentine as the latter gradually undergoes resorption.

On the other hand, isolated, either single or multiple, dentinal and osteo-dentinal formations are met with in the substance of the pulp, having a diameter of from one to several millimetres, and a rounded, frequently lobulated form (Atlas, Figs. 57 and 68). With regard to the development of these isolated, encysted new-formations, Heider and I, in the communications cited above, have maintained the view of the occurrence of an *inversion of the layer of dentinal cells*, and upon the following grounds: 1. The dentinal canals pursue a centripetal course; therefore, the dentinal cells, which enter into the formation of the latter and the development of which proceeds from the periphery of the inverted portion (Einbuchtung) towards the centre, must have assumed an adequate arrangement; 2. With multiple, encysted new-formations, we observed stelliform groups of dentinal cells which we interpreted as the primary stage of the inverting process (Insinuation); 3. An inversion of a group of dentinal cells and their detachment corresponds, also, to physiological processes, *e. g.*, to the formation of the vesicles of the thyroid gland or ovarian follicles. Obviously, the inversion includes, at first, a very minute space which becomes filled with new dentine; as the proliferation of the radiated groups of dentinal cells progresses, new layers of dentine continue to be formed in the mass until the final separation occurs. The dentinal cells upon the periphery of the new-formations do not admit of direct identification, when the growth of the latter has ceased and they are invested by an atrophic tissue.*

* R. Hohl (über Neubildungen der Zahnpulpe und Deutsche Viertelj. f. Zahnheilkunde, 1868) does not accept this simple interpretation, and says, if this be the correct view, then we ought to find a sort of pedicle in every case, but he has never seen anything of the kind. New-formations are met with, however, indeed, they are by no means of rare occurrence, which are

A new-formation of enamel cannot occur after the development of the enamel-cap is completed. Hence, in the combination illustrated in the Atlas, Fig. 69, it is not to be considered that the osteo-dentine and conical process of enamel, together, compose a new-formation; the pear-shaped, sharply defined cone of enamel, which encroaches upon one side of a truncated conical prolongation of the new-formation and is invested by an annular layer of radiating dentinal canals, is the result of an anomaly in the development of an upper wisdom tooth, and an organic union has taken place between the new-formation of osteo-dentine and the dentinal layer which invests the cone of enamel.

The *combination with calcifications*, especially in the smaller varieties of new-formations, is met with, sometimes, where the dentinal canals are very few in number, while the remaining portion presents concentrically disposed radiated laminæ, or a minutely reticulated, calcified mass and, consequently, the concretion or, in other words, the calcification of the organic basis-substance of the new dentine apparently predominates. The calcareous grains, as is the case in atrophic pulps (Atlas, Fig. 46), are true concretions and occur, also, as accessory products in connection with hard new-formations, but never enter into organic union with the original dentine; they are located within the parenchyma of the pulp and are calcifications in the connective tissue. In general, it may be stated that all those processes which ensue in connection with atrophy, such as pigmental degeneration, obliterations, scleroses, accumulations of colloid masses within and outside of the vascular system, &c., occur also in pulps containing hard new-formations.

attached to the original dentine by means of a pedicle (Atlas, Fig. 54), and in cases where there is no connection by a pedicle, detachment has ensued. With regard to the character of the tissue within the fold, we have expressed a decided opinion, namely, that it is new dentine. Hohl finds it necessary to have recourse to a new formation of dentinal cells in the midst of the pulp-tissue and, with this idea, conceives that the pulp-cells give off processes towards the centre, which participate in the new-formation. The occurrence of such a transformation of a pulp into a dentinal cell, however, does not harmonize with the views entertained at the present day, with regard to the development of the dentine. The dentinal cells, according to Hohl, acquire a roundish form, with the increasing age of the individual, an assertion, however, which I am unable to confirm.

Ulrich and J. Tomes called attention to the fact, which has been confirmed by many, that hard new-formations are of frequent occurrence in the much worn teeth of elderly persons, and that no distinction can be made as to their more frequent occurrence in the incisors, canines, bicuspid, or molars. With many individuals there exists a predisposition (Diathesis) to the development of these new-formations, since they are found in several teeth in very great abundance. Finally, even the sound teeth of children are not exempt. The milk teeth, which enter upon a stage of senescence towards the period of dentition, not infrequently contain hard formations in their pulps at the latter period of involution.

These formations may be studied to great advantage in the teeth of mammals. The first histological investigations, under the head of osteo-dentine, are contained in the "Odontography" of R. Owen. In the teeth of these animals, also, aside from other causative influences, the frequent occurrence of this formation is a phenomenon connected with the senescence of the tooth. Corresponding to the centre of the transversely abraded surface of a much worn lower incisor of a dog, I found a deposit of transparent secondary dentine, measuring one-half a millimetre in depth, and with its canals extending in conformity to those of the original dentine. In several worn front teeth of the lower jaw of a common hedge-hog (*Erinaceus Europ.*), I have met with multiple osteo-dentinal formations attached to the wall of the root-canal. These were of an ellipsoidal or cylindrical shape, their long diameters measuring, in some cases, one millimetre; elongated vascular canals traversed a few of the larger ones; their central substance was occupied by bone-corpuscles, and their peripheral portions were traversed by an abundance of centripetal dentinal canals. In a molar from a horse, the coronal surface of which was much worn away and hollowed out in the form of a channel, and the root of which was notably contracted upon either side, had become atrophied, several concentrically laminated new-formations, which were united to the dentine, were found in the single, considerably narrowed canal. In the atrophic roots, near their junction towards the neck of

a molar from an ox, I met with very finely developed, vascularized, multiple, interstitial, dentinal new-formations.

It is not an uncommon occurrence to find, in the ivory from the hippopotamus, spherical or cylindrical deposits (interstitial new-formations), which are removed by the dental artificers as unserviceable; they are composed of remarkably fine concentric layers of dentine, in which the canals of the different laminae pursue a centripetal, undulatory course, at uniform intervals from each other. The new-formations are connected with the ivory by means of a transparent, intermediate layer which does not possess the structure of dentine, but presents a structureless, minutely granular basis-substance, with sharply defined, lobulated borders towards the dentinal layers. Sometimes, quite distinct bone-corpuscles may be recognized in this connective zone, and, therefore, there can be no doubt but that we have presented in it an osteoid substance, in which extend numerous vascular canals with occasional sac-like dilatations.

The stalactitic forms, which occur upon the wall of the pulp-cavity of elephants' tusks, were recognized by A. Haller. R. Owen states that they are, obviously, the result of circumscribed inflammation or malformation of the pulp. In the root-portion of tusks, I have observed very numerous hard new-formations projecting into the pulp-cavity and presenting a great variety of forms, as conical, dentiform, nodular, lamellar, &c. The very thin lamellar forms are composed, principally, of bony tissue, while the dentiform or superficially smooth, nodular, thicker forms consist of bone, together with dentine in its various transitional stages, or principally of the latter.

It is not uncommon to meet with very imperfect ivory in the root-portion of the tusk; for instance, osseous tissue may be imbedded in it in a very irregular manner and to a considerable extent, or the dentine is traversed by numerous vascular canals, at tolerably uniform intervals, or spherical, encapsulated, new-formations of dentinal substance are interposed; in consequence of the presence of these, the surface of a cross-section presents confluent or discrete yellowish grains, interspersed with lighter masses; the grains vary in size from that of the head of a pin to that of a pea, and may even be larger. These faulty formations

sometimes extend into the projecting coronal portion and are well known to the ivory turners, since the ivory containing them is unsuitable for very delicate work on account of its diminished hardness and elasticity, nor is it capable of receiving so fine a polish. In a technical point of view, therefore, they are of importance.

In regard to the question whether these hard formations in the pulp have a *physiological or a pathological signification*, it must, first of all, be borne in mind how difficult a matter it is, as a rule, to distinguish between a physiological and a pathological phenomenon, and this is all the more the case in the present instance where we have to do with senile changes in an organ, in the majority of cases. Hence, it must be admitted that the answer cannot be given with absolute precision. Where do the senile phenomena end and the pathological begin? The fact that the hard new-formations occur in quite old teeth, presenting abraded coronal surfaces without any further evidences of disease, and that they are of frequent occurrence in the older teeth of animals, indicate, to a certain degree, that we are not to lay very much stress upon the pathological element; on the other hand, special conditions appear to be necessary for their development, from the fact that they are not found in all senile teeth. They are to be considered as the results of an independent process, which is based upon a hyperplastic, localized development of dentine, which process is unaccompanied by pain; it is to be observed, however, that pulps containing dentinal new-formations do not lose their susceptibility to painful impressions, since the nerves in the vicinity of the new-formations may be well preserved and capable of conduction; it is quite possible, also, that, under special conditions, in teeth on which the dentinal covering has been very much worn away they may occasion a painful sensation in consequence of a mechanical injury and that, as their growth continues, they may give rise to derangements in the circulation and even to inflammatory processes in the remaining portions of the pulp, and to consecutive periosteal inflammation.

E. Mühlreiter* considers the new-formations of dentine and

* Deutsche Viertelj. f. Zahnheilkunde, 1868.

the calcifications to be independent processes, which of themselves give no indications of their occurrence and are unaccompanied by painful sensations. When these processes are associated with other pathological changes, especially with those of an inflammatory nature in the pulp-tissue which is not implicated in the development of the new-formation, then they acquire a clinical interest from their influence upon the course of the morbid process. According to McQuillen,* new-formations of dentine in the pulps of teeth, not affected with caries, sometimes give rise to the most intense neuralgias which, not infrequently, are referred to other teeth and considered to be the result of sympathetic irritation. A continuous, boring, pain which is felt invariably at one and the same spot, he remarks, is a quite positive indication of the presence of a new-formation. If this be the case, consecutive periodontitis ensues. In a case reported by Tanzer,† there was unremitting pain referred to the last tooth in the lower jaw; this was removed and the pain returned in the next tooth in front; in consequence of the repeated migration of the pain to the adjacent tooth, one tooth after another was extracted, as far as the lateral incisor, during a period of eight to nine years. Each of the teeth extracted presented well-marked examples of unattached and parietal new-formations, and, in the opinion of Tanzer, this man, who was then thirty-four years of age, probably will not obtain release from his suffering until all the teeth have been removed.

The new-formations also derive importance in connection with the operation of filling, and Hulme‡ expresses his ideas upon this point in the following manner: "There can be no question, if it is possible to preserve the pulp of a tooth and then stop it, that such a tooth is in a far more healthy condition than where the interior of the crown and the fang is filled with gold or any foreign material. I am fully convinced that many of the teeth which of late years have been treated by destroying the pulp might, under another mode of treatment, have been preserved without sacrificing this essential portion of the organ. So long

* Dental Cosmos, 1868.

† Deutsche Viertelj. f. Zahnh., 1869.

‡ Dental Review, 1861.

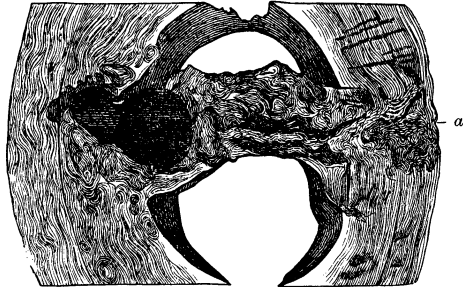
as there is a layer of dentine existing over the pulp, as a general rule, it should never be removed, even if the dentine is softened nearly to the surface of the pulp."

MUSKET-BALLS IN THE TEETH OF ELEPHANTS.—Elephant-hunters very frequently employ firearms and take aim at the eye, ear, and mouth, so that it will readily be seen that the balls, instead of penetrating through the skull into the base of the brain, may enter one or another tooth and give rise to processes in the dentine and the wall of the pulp-cavities, which acquire a great pathological interest. Goethe, long ago (1798), investigated the subject of diseased ivory from the elephant's tusk resulting from the impaction of iron or leaden balls; the process appeared to him to be a sort of coagulation (*Gerinnung*); he also mentions the occurrence of exostosis upon the wall of the pulp-cavity in cases where a ball entered the posterior, weak, and hollow portion of the tooth. Cuvier, also, recognized the irregularity in the dental mass around the balls. R. Owen was the first to call attention to the change produced in the histological structure, and says that musket-balls and other foreign bodies which become imbedded in ivory become surrounded by osteo-dentine, in greater or less amount. If the ball penetrates the root portion and enters the pulp, the track made in the passage of the former becomes filled by a thick deposit of cement from without and of osteo-dentine from within.

By the kindness of Prof. von Schroff, I had the opportunity of examining five specimens from elephants' tusks in which iron balls were imbedded, from the pharmacological collection. The malformed dentine, which is recognizable by the naked eye, is shown very distinctly in cross-sections; it has, generally, a dirty-yellow color, is tolerably well defined towards the sound dentine, its general outline, as well as its extent, being variable. The tissue is wanting in uniformity and presents an abundance of interlacing wavy striated markings. This faulty formation, however, is not confined to the immediate vicinity of the impacted ball, but is found, also, at various distances from it in the form of isolated, concentrically-striated patches. The reaction which is induced by the presence of the foreign body sometimes leads to the formation of an abscess in the dentine (comp. p. 188).

The faulty formation may be traced along the track made by the ball (Fig. 86). A depression, corresponding in size with that

FIG. 86.*



of the ball, together with several smooth excrescences as large as the head of a pin (new-formations), may be seen upon the exterior of the tooth, especially in cases where the ball has penetrated in a direction transverse to the long axis of the tooth.

If the ball traverses the pulp-cavity in a transverse direction, crushing the pulp in its passage, there ensues a formation of osteo-dentine which, in the case illustrated, has a smooth appearance upon the surface presented in the pulp-cavity and consists of pyramidal tubercles and nodules having a yellowish color. Thin transverse sections of the latter present abundant globular substance and entangled, confused masses of dentinal canals and, in other places, multiradiated bone-corpuscles. In these new-formations especial interest is afforded by a few oblong,

* FIG. 86 shows a section taken from an elephant's tusk, and upon the left side the segments of two iron bullets which have pressed through the dental pulp and become fixed, partly to the wall of the pulp-cavity and partly to the contiguous dentinal tissue. The point at which the bullets entered is seen at (a); in a transverse direction from the latter may be traced the track traversed by them, which is indicated by an irregular, zigzag course of the striæ. The dentine, both in the vicinity of the latter and, also, of the transversely-divided bullets, is transformed into osteo-dentine which is quite sharply defined, displays wavy striæ and, for the most part, a dirty-yellowish color. The hard formation, which forms a transverse bridge across the pulp-cavity, presents in cross-section an irregular, multiple, concentrically-laminated osteo-dentine. In the vicinity of the larger bullet a circumscribed supuration occurred. Two-thirds natural size.

defined, interposed dentinal portions, from one to several millimetres in thickness, which have a rectilinear, angular configuration, present the texture of the normal dentine and are encapsulated by a thin layer of osseous tissue. Evidently, they are spicula of ivory which became impacted in the pulp and gave rise to a proliferation of bone-corpuscles by means of which they became invested by osseous tissue in the form of a sheath. The osteo-dentinal formation, then, succeeded the latter.

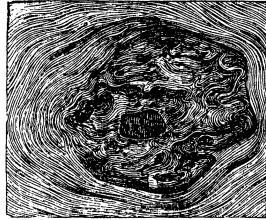
In cases where the ball penetrates to the wall of the pulp-cavity and the corresponding portion of the wall becomes implicated in the faulty formation of the dentine (Fig. 87) a proportionately large osteo-dentinal mass, with jagged and warty excrescences, is found projecting into the pulp-cavity.

The pulp-wall may, however, be protruded, merely, by the ball and remain smooth (Fig. 88). Osteo-dentinal formations, which first make their appearance at some distance from the locality of the ball, may owe their origin to displaced dentinal fragments, or a local concussion, merely, may be sufficient to occasion their development.

As ivory admits of a certain amount of expansion, in consequence of its elasticity, and, moreover, since the shattered portions become filled with a reparative tissue, the point of entrance of the ball upon the exterior of the tooth may easily escape observation, and the ivory turner is first made aware of the presence of a ball when he attempts to saw through the tusk.

The molars from elephants are employed less frequently in

FIG. 87.*



* FIG. 87 shows a segment from the tusk of an elephant, containing small fragments of an iron ball in the wall of the pulp-cavity. From the appearance of the surface of the section presented in the figure, it is seen that an abnormal tissue, with a sharply defined outline towards the normal dentine, is disposed upon the periphery of the ball, forming a capsule for a certain portion of the latter, and represents the basal portion of a new-formation which, upon the opposite surface of the preparation, projects into the pulp-cavity in the form of notched and warty, superficially smooth osteo-dentine. Natural size.

the arts and, therefore, there is rarely an opportunity to obtain sections of them; the teeth, moreover, being inclosed within the mouth, are less liable to be penetrated by balls. A case in point, however, is illustrated in Fig. 89, where, in a molar, an osteo-dentinal mass, inclosing a flattened, leaden ball, is interposed between the folds of the enamel, on the other side in the substance of the dentine and is in relation with the cement.

FIG. 88.*

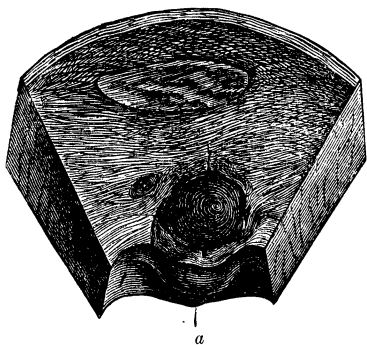
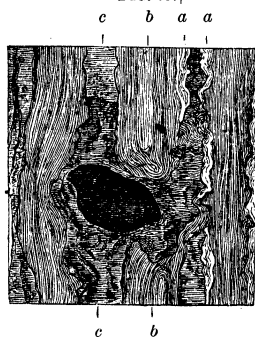

FIG. 89.†



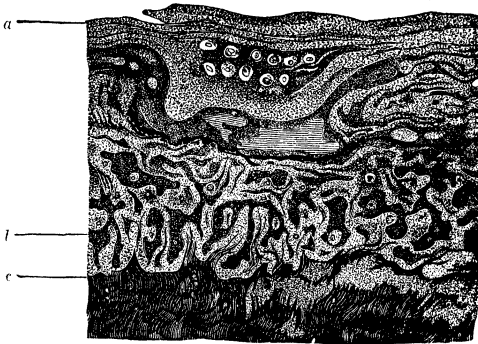
NEW-FORMATION OF OSSEOUS SUBSTANCE IN CONNECTION WITH ABSCESSSES IN THE IVORY OF THE TUSKS OF ELEPHANTS.—The reparative tissue which is formed upon the wall of an

* FIG. 88.—Segment from the tusk of an elephant, containing an iron ball which has penetrated as far as the pulp-cavity and has formed a bulging protuberance upon its wall which has given rise to several, superficially smooth, warty new-formations with broad bases, partially visible at (a) in the oblique view of the preparation. In the immediate vicinity of the ball, the cavities of small abscesses and, also, osteo-dentine, are perceptible. Two-thirds natural size.

† FIG. 89 shows a portion of a transverse section of the molar from an *Elephas Indicus* from Ceylon, containing the flattened segment of a leaden ball. (For the use of this specimen the author is indebted to Prof. D. L. Schmarda.) If the three dental substances be traced out, it will be seen that the enamel (a, a), at a certain distance from the fragment of the ball, and also the dentine (b, b), have been displaced by a substance (c, c), which forms an investment of varying thickness around the fragment of the ball and, when traced farther, is found to enter into immediate connection with the cement. Hence the new-formation was developed by a proliferation into the enamel and dentine. Natural size.

abscess in ivory, is osseous substance, as has been shown before (compare Inflammations, p. 188). The very marked proliferation of the osseous tissue encroaches upon and induces a resorption of the ivory at the corresponding parts; the contour of the interstitial new-formation, therefore, is not clearly defined. The zone of proliferating osseous tissue varies in its extent between several square millimetres and, perhaps, a square centimetre, and presents a marbled appearance. (Fig. 90.) The

FIG. 90.*



brighter, more transparent portions correspond to the osseous substance, the less transparent, insulated portions, hemmed in

* FIG. 90 shows an osseous new-formation from the wall of the cavity of an abscess in the tusk of an elephant. (The specimen was taken from the portion of the segment indicated by *a*, in Fig. 75.) From the internal surface (*a*) of the cavity of the abscess as far as (*c*), where the normal dentine commences, the dentine is displaced by an abundantly vascularized osseous layer. The bloodvessels are transversely divided, for the most part, and are surrounded by a luminous ring. The opaque, dotted portions (*b*) correspond with the localities where granular cloudiness is visible, and, here and there, the remains of the ivory may still be recognized. The brighter spots contain, for the most part, bone-corpuscles which appear in the figure in the form of puncta; in many places, *e. g.*, near the middle portion (indicated by transverse lines), the bone-corpuscles are wanting, and in place of them is seen merely a diffused, granular mass. At the zone of transition into normal dentine (*c*), quite bright spots are perceptible upon the right side, which are suggestive of clustered globular masses; upon the left are the openings of transversely and obliquely divided bloodvessels, which are surrounded by a luminous ring and are imbedded within the dentinal substance. Magnified five diameters.

by the latter, correspond to the dentine which has undergone resorption.

The osseous substance in the vicinity of the cavity of the abscess presents all the characteristics of a young bony tissue; the osteoblasts inclose a nucleus together with prominent nucleoli, and present a variety of forms resulting from division; their canaliculi are met with, chiefly, in the form of short, den- tated prolongations from the body of the cell; several osteo- blasts, also, are inclosed within a common cavity with an indented outline. In the deeper layers of the new-formation which sur- rounds the cavity of the abscess, young, osseous substance occurs, particularly in the neighborhood of the vascular canals, which latter are invested, as with a sheath, by a light substance composed, in part, of minute globules and, in part, of con- centric layers with radiated markings. It is hardly necessary to add that the latter corresponds to an osteoid formation. Numerous vascular canals are prolonged into the ivory, ad- vanced guards, as it were, which serve as the medium through which the resorption of the ivory and the formation of bony sub- stance are effected; I have been unable to ascertain their origin, as only segments of tusks were at my disposal.

I endeavored to identify, in the dried mass which lines the cavity of an abscess, a vascularized connective tissue from which the bloodvessels, that are prolonged towards the ivory, may pos- sibly have originated, but was unable to come to any satisfactory conclusion, in consequence of the marked degeneration of the mass.

The resorption of the ivory is presented in various stages, as has been referred to before (compare Inflammations, p. 189). The first indications are afforded by the appearance of numerous minute cavities, with indented margins, which resemble inter- globular spaces and gradually render the dentinal canals less recognizable, so that, finally, there remains only a substance re- sembling minute globular masses, the limits of which are gradu- ally contracted by the encroachment of the osseous substance. We find, then, that in the vicinity of these chronic abscesses, also, a more vigorous reparative tissue is developed in the place of the less vigorous; in other words, *an interstitial growth of*

osseous substance ensues in the vicinity of the cavity of the abscess.

FRACTURED TEETH.—Since fractures of the teeth, produced by blows, thrusts, falls and awkward attempts at extraction, cannot be regarded as uncommon occurrences, it might be expected that among a very large number of teeth an instance of a reunited fracture would be met with now and then. But we may examine thousands of teeth which have been extracted during life or removed after death without meeting with a single case of a reunited fracture. Formerly, therefore, the occurrence of the latter was doubted, but the accurate observations of modern times have settled the matter beyond cavil. Hohl recently* collected all the known cases of reunited fractures, fourteen in number, including two cases observed by himself. Three cases occurred in the teeth of the hippopotamus, two in those of the horse, one in the tooth of an antelope, seven in human incisors, and one in an upper bicuspid. If we add the case of Rogers, mentioned by Tomes,† in which an upper molar was broken off transversely at the neck, there will be fifteen cases in all.

When we consider the great frequency of conflicts among animals, it will readily be understood that the canines of the larger mammals, which are employed as weapons for giving blows, present a large, unprotected surface and are exposed to manifold external influences, are quite liable to meet with severe mechanical injuries, and it is probable that more careful observations will show that with these animals, fractures of the teeth are not such rare occurrences as has been supposed.

Reunited, comminuted fractures afford evidence of the remarkable increase in the vital activity which may be manifested in a tooth. J. Tomes‡ mentions an instance of a severely comminuted fracture of the tusk of a hippopotamus, within the socket and with considerable displacement and quite wide separation of the fractured portions. In this case, union took place, and was effected by the development of cement. In a case of reunited fracture of the lower canine of a hippopotamus, de-

* Deutsche Viertelj. f. Zahnheilk., 1870.

† System of Dental Surgery.

‡ System of Dental Surgery.

scribed by Owen,* the reparative tissue was composed of osteodentine, and this may, possibly, be the case in all instances where the pulp participates in the reparative process.

Two cases of united fracture, one of a human upper bicuspid and the other of a lower incisor of an antelope, which were reported by myself,† and are illustrated in the Atlas, Figs. 73-78, inclusive, afford a very clear idea of the character of the reparative tissue.

In both cases, which are distinct from each other, there is presented a completed reparative process which originated in the root-pulp in the first case, where the fracture was through the root of the tooth, and in the coronal pulp in the second case, where the fracture occurred in the crown. In both, a firm reparative tissue was developed, consisting essentially of three different substances, namely, dentine, globular masses, and bone. In the first case, it formed a firm cement by means of which the union of the two fractured ends was effected, and in the other, a protective covering for the body of the pulp. In the latter case, then, it was more like a cicatrization of the pulp.

In the first case, the regeneration of hard tissues was effected, principally, from the root-pulp, and only to a limited degree from the periosteum of the root. The systems of dentinal canals, which are interposed in the substance of the callus, must have originated from a proliferation of the dentinal cells between the fractured ends. The new-formed osseous substance, which is disposed upon the fractured portions of the dentine, is, likewise, a product of the root-pulp, the production of osseous substance from the latter being possible, as we know; the cement-layers corresponding with the fracture, are not thickened and, therefore, the periosteum of the root, the medium through which the nourishment and growth of the cement is effected, has furnished merely a cementing substance upon the periphery of the fracture. The proliferation of the osseous substance between the fractured surfaces of the dentine is prolonged for some distance into the substance of the latter, so that the fractured portions are intimately united.

* Odontography.

† Deutsche Viertelj. f. Zahnheilk., 1867.

In the second case, in which the outer segment of the crown was broken off, an osteo-dentinal mass was developed from the body of the pulp outwards, and presented the following appearances. The proliferated, abundantly vascularized, dentinal substance was covered over with bone which, likewise, was traversed by numerous vascular canals, an arrangement similar to that presented in the first case. It is very common, indeed, to observe that a new-formation of dentine is accompanied by that of bloodvessels, which latter, however, gradually become obliterated and undergo calcification. In consequence of a defect in the wall of the pulp-cavity, it was possible for the proliferating hard tissue to project beyond the edge of the fracture, and the surface beyond the new dentine became the seat of an ossification process.

A concurrence of favorable circumstances is requisite in order to insure the complete union of a *transverse or oblique fracture of the root of a tooth*. First of all, it is necessary that the fracture should be simple, as nearly as possible, and without any aggravating complication. If the pulp is subjected to great traction, is crushed or lacerated, its suppuration or gangrene will be all the more likely to occur and to interfere with the reparative process and occasion the death of both the fractured portions. If, on the other hand, a large portion of the periosteum of the root is injured, a consecutive inflammation will furnish an insurmountable obstacle to the process of repair. The connection of the tooth with its socket must not be so far broken that the fixation of the former in the latter is impossible. A repair also requires a healthy, vigorous condition of the individual, and a proper care of the fractured parts after they have been approximated. Absence of these favorable conditions and neglect of proper precautions are to be regarded as the probable causes of the comparative infrequency of reunited fractures of the roots of teeth, which the dentist is called upon to extract in consequence of the intense pain which the patient experiences from them.

In a case observed by Saunders,* the fracture extended ob-

* J. Tomes' Lectures on Dental Physiology and Surgery.

liquely through the middle of the root of a human incisor; perfect union took place with slight displacement. In a case which occurred in the practice of J. Tomes,* a front tooth of a patient under twenty years of age, was fractured transversely by a severe fall. After the lapse of some time the patient determined to submit to no further inconvenience, and the tooth was extracted. The tooth had been broken transversely, some distance within the socket, and the fractured surface had been coated over subsequently with cementum. Had the tooth, continues Tomes, been kept for a time by any mechanical means in a state of rest, it is probable that a union of the fractured surfaces would have been effected.† A case of reunited fracture of an incisor is contained in the Breslau Anatomical Museum.‡ The root of a student's incisor was broken across with a fencing foil, in the gymnasium. The fragment was found to be still attached to the gum, and was pressed back into the socket by the surgeon in attendance. It regained its original firmness, but there ensued such intense pain that it afterwards became necessary to remove the tooth, which presented a slight lateral displacement of its consolidated fragments; the nerves were found to be bent from their course at the corresponding part, and this condition, together with the compression to which they were subjected by the encircling callus, gave rise to the odontalgia. In a case of a perfectly united fracture of an upper bicuspid, in Heider's collection, there is scarcely any displacement of the fractured surfaces which are separated by an interval of only 0.7 of a millimetre, the latter being occupied by newly-formed compact tissue, which unites the two surfaces. Hohl§ refers to the following case: "A boy, thirteen years of age, fell from the roof of a house and fractured the right upper central incisor in such a way that its crown could be moved backwards and forwards, and it

* System of Dental Surgery.

† The author has neglected to insert an important portion of Tomes' description of this case, in which "a front tooth was broken across and a molar tooth loosened by the fall. The latter tooth was allowed to remain, on the chance of its regaining its original firmness of implantation. After the lapse, &c."—Trs.

‡ Hyrtl, Topograph. Anatomie, Bd. I.

§ Op. cit.

was feared that the tooth would drop out. However, it became firmer from day to day, and in a few weeks it regained its normal firmness. I saw the boy about a year after the occurrence of the fracture. The tooth differed from the rest of the teeth present in the mouth, neither in respect to color or degree of firmness. The crown presented two small defects in the enamel. Upon the labial surface of the alveolus of the tooth in question, a slight bulging could be felt quite distinctly, about fifteen millimetres from the edge, and this, evidently, was the locality of the fracture."

Longitudinal fractures of the crown and root, also, may become perfectly united, and even the enamel in the fractured portion may become united by cement tissue. Hohl reported the following case: "Prof. V., as he was about entering a railway car, on his way to take charge of a hospital in Bohemia, in the year 1866, fell, striking his mouth upon the sharp edge of an iron step in such a way that the upper large incisor on the right side was broken lengthwise. The fracture separated the tooth in the middle of the crown so completely, that the two fragments diverged from each other and could be moved back and forth. After the lapse of fourteen days, during which time intense pain entirely prevented the use of the fractured tooth, a more comfortable condition ensued, and in a few weeks more the tooth completely resumed its normal functions. At the present time, the two halves of the tooth are firmly adherent to one another, and the direction of the fracture is indicated merely by a fine line, with a slightly brownish tinge. As the line is perpendicular to the transverse axis of the tooth, it is to be presumed that the fracture also involved the root." To this category, also, probably belong the united fractures of two molars of a horse, contained in the Museum of Berne, with regard to which Valentin* states that the fissures of both the enamel and true dentine, which were produced by the original injury, are closed by true bony tissue.

Transverse and oblique fractures of the crown, in which the pulp is wholly or partially exposed, lead in rare cases to a re-

* Wagner's Handwörterbuch der Physiologie, Bd. I.

markable cicatrizing process on the part of the pulp. J. Tomes* reports a case in point from Arnold Rogers. A patient applied to have the roots of a first molar removed, the crown of which had been broken off, previously, when attempts were made to extract it for the relief of intense pain consequent upon caries. After the lapse of several months, the remains of the broken tooth occasioned annoyance and, therefore, were removed. It was found that secondary dentine had been formed, which not only projected from the cavity but, also, overlapped and concealed the sharp edges produced by the fracture. We have met with a case quite similar to the latter, in an oblique fracture of the crown of a tooth of an antelope.

The diagnosis of a fracture of the root, now and then, may be attended with difficulty, and Hohl refers particularly to the danger of confounding such a case with a luxation. Extracted teeth which present irregularities of formation in the form of bent or twisted crowns or bent roots (comp. p. 134), may be misinterpreted as cases of fracture, if sufficient care be not exercised in ascertaining the true condition.

CEMENT—OSTEOMATA—EXOSTOSES.—Although these are, essentially, localized hypertrophies, it is justifiable, however, from a clinical point of view, to consider them separately, since they are, sometimes, the cause of very severe pain and even of neuroses in remote parts, which is not the case, usually, with ordinary hypertrophies.

Osteomata are distinguished as single and multiple, discrete and confluent. The solitary osteomata generally have the form of tuberous excrescences (Knötchen), with broad basal portions, and, usually, occur in the vicinity of the apex of the root; generally they have a diameter of a few millimetres, and a rounded convex outer surface which, in most cases, is marked with minute elevations and depressions. They rarely attain such dimensions as were presented in the case of a canine tooth illustrated by J. F. Meckel,† where the osteoma originated at the neck and invested the entire root; the thickest portion was upon the facial side; the surface was smooth in some places,

* System of Dental Surgery.

† Tabulæ anat. pathol., Fasc. III.

while in others, it was marked with several pits. According to the illustration, the thickest portion of the tumor measured 2.7 centimetres. The knotty, discrete osteomata occur in groups of two or three, at slight intervals from each other, or are massed together so as to present a warty appearance (Atlas, Fig. 108). Numbers of delicate spinous and lamellar excrescences, which are to be distinguished from appearances resulting from resorption and, sometimes, spread over the entire periphery of the root, impart a rough character to the outer surface of the cement. The bicuspid and molars, more frequently than other teeth, present this condition, and sometimes, merely one surface of the root is the seat of a large osteoma, while the remaining roots or surfaces of a root are entirely free.

Histologically, they consist of circumscribed superpositions of new layers of osseous substance, which are developed, one over another, in the form of a dome, with the base resting upon the original cement (Atlas, Fig. 107); they form irregular undulations beyond the level of the cement, and compose the sole elements of the pyramidal excrescence, the outer surface of which, generally, is covered with tuberculated prominences. Their substance is rendered cloudy, always, by the presence of less transparent and even opaque layers, and to this condition is to be referred the fact that, when viewed with the naked eye, the osteomata appear brighter and whiter in comparison with the normal cement.

In respect of size, form, disposition, and number, the bone-corpuscles present a great variety. The remarkably uniform laminæ, which are readily brought into view after the extraction of the calcareous salts by means of dilute hydrochloric acid, are disposed in a concentric manner, present radiated markings and are most conspicuous where the basis-substance occurs in greatest abundance and the bone-corpuscles, consequently, are separated by the widest intervals. The radiating, striated markings cannot possibly be occasioned by the bone-canalculi; indeed, even with the use of very high magnifying powers, there are places which do not contain a single canaliculus; but reasoning from the analogy between them and the appearances presented by the

concentric radiations of concretions, *e. g.*, of carbonate of lime in the urine of herbivorous animals, especially of the horse, and in renal cysts, or of uric acid in vesical calculi, it seems to me in the highest degree probable that they are produced rather by a *radial disposition of needle crystals of calcareous salts in the layers of the basis-substance*. In another view, this arrangement also occasions a minutely-granular marking, which, sometimes, assumes a yellowish or yellow-brownish color from the deposit of pigment.

Young, interstitial bone-corpuseles, clustered together and surrounded by a capsule, are met with, sometimes, in the peripheral zones, and are crowded, as it were, into the older layers. The latter undergo a necrobiosis in places, and the still transparent bone-corpuseles lie in the dirty yellow, yellow-brownish, brownish-black basis-substance which has undergone a granular metamorphosis. Those bone-canalliculi, which are elongated, extend in parallel rows and, in this respect, are suggestive of dentine, become the seat of accumulations of an opaque, granular mass, in consequence of which they frequently present a more voluminous appearance. The necrobiosis commonly occurs in circumscribed spots, and is associated with the frequently-obliterated vascular canals which for the most part are of small calibre and quite few in number as a general rule. I have not met with any case in which ramifications of the latter were to be seen.

If a decalcified section be boiled in very dilute hydrochloric acid until it acquires a pultaceous consistence, or nearly liquefies, the sharply-defined osteoblasts with their short processes will be brought into view, either isolated, in consequence of the liquefaction of the basis-substance, or still imbedded in the latter which becomes remarkably clear. The more delicate ramifications of the bone-canalliculi succumb immediately to the liquefying action of the acid, while the elongated, thicker ones, which extend towards the periphery, resist the action much longer and may be traced to a considerable distance; in the vicinity of the peripheral portions of the new-formation, isolated osteoblasts with thick, frequently varicous processes are met with, which, prob-

ably, belong to the derivative forms. The younger the osteoblasts, the more readily may they be isolated.

The cement osteomata are developed slowly, give rise, frequently, to intense, piercing, gnawing, lancinating pains, and may even occasion *prosopalgia* (comp. Neuroses). A case came under the observation of J. L. Levison,* where death ensued from an exostosis of the root, which gave rise to an affection of the membranes of the brain. The marked painfulness is due to the increased tension of the nerves of the periosteum of the root, and to the secondary affection of the branches of the nerves of the pulp. The location of the exostoses, at the apex of the root, renders the latter all the more liable to occur. Whether or not the existence of gout favors their development is still undetermined.

Quite extensive bony excrescences upon the cement also occur as anomalies of development, and the two following are to be regarded as cases in point. Forget, in his anomalies of the teeth, cites a case, communicated to himself by Maisonneuve, where a carious lower molar presented a tumor as large as a pigeon's egg, which was attached to the root, rather upon the lateral surface, by means of a pedicle, and was composed entirely of osseous substance. A longitudinal section displayed a line of demarcation between the tumor and the root. The connection of the two was so intimate that in the preliminary extraction of the tooth for the purpose of facilitating the examination and separation of the encysted mass, the latter, also, was removed. Letenneur† met with a tumor in the lower jaw of a woman, thirty-four years of age. When extirpated, it presented an irregular form and was three and a half centimetres in length and two and a half in breadth; the adjacent bicuspid was completely developed, of a white color, and attached by its apex to one side of the tumor. The latter presented a gray color, the hardness of ivory, and resulted from an hyperplasia of the cement, which process commenced during the second dentition (at the age of seven or eight years) and twenty-six years later

* Quarterly Journal of Dental Science, 1857.

† Gazette des Hôpitaux, 1868.

was succeeded by a necrosis which was ushered in by the appearance of an abscess. The tumor attached to the radical portion of a wisdom tooth, illustrated in the Atlas, Figs. 28 and 29, is an osteo-odontoma which was developed in connection with the formation of the dentine of the roots, and differs essentially in structure from the two cases which have been cited.

The cement, even when it is hypertrophic, as has already been observed, in consequence of resorption following inflammation or hypertrophy of the periosteum of the root acquires a rough outer surface which is not to be confounded with the roughness presented by osteophyte-like outgrowths on the cement. In consequence of the resorption accompanying inflammation of the root-membrane, a thorn-like process sometimes is formed at the radical extremity, which is merely the remnant of the apex and upon which the indications of resorption may be identified; such a process, if not carefully examined, may be mistaken for a thorn-like exostosis.

ROOT-MEMBRANE.—New-formations of this membrane occur either primarily or secondarily in the form of localized thickenings or tumors which are to be classed with the fibrous, sarcomatous, or cancerous. E. Magitot collected eighteen cases in a monograph upon this subject.* In his opinion, the tumors, under certain conditions, originate in the intervals between the roots or involve the greater portion or the whole of the root-membrane; they vary in size between that of a pea and a hazelnut; they are very variable in form, occur only upon the bicuspid and molars, at any time of life, and generally are single, but in quite rare cases, several tumors, independent of each other, are met with. From examinations conducted by Robin, Magitot concluded that a substance, which is a modification, more or less, of the root-membrane, always forms the stroma and the fundamental tissue of the alteration, and he divides the tumors of the dental periosteum into five groups, as follows: 1, fibrous, in which there is an hypertrophy of the normal elements with a predominance of fibrous tissue; 2, fibroplastic, with a predominance of nuclei, or spindle-shaped cells; 3, epithelial (epithelioma,

* *Mémoire sur les Tumeurs du Périoste Dentaire*, 1860.

cancer of authors), with flattened, sometimes multi-nucleated cells in the condition of fatty degeneration; 4, tumors with myéloplaxes, the principal constituents of which are multi-nucleated cells; 5, tumors with cytoblastions, in which free nuclei with granular contents and with no nucleolus are the prevailing elements.

I have, likewise, observed the first three of the above-quoted developmental forms; the fourth, where the myéloplaxes (multi-nucleated, gigantic cells) are the principal elements, apparently are of quite rare occurrence, since Magitot cites only one observation of the kind. The fifth group I class with the sarcomata and the nuclei are not free, but are surrounded by a layer of protoplasm. Between the fibrous, more consistent tumors which consist, principally, of spindle-shaped cells with a well-marked, fibrillated intercellular substance, and the sarcomatous which contain, principally, small cells, with scanty, ill-defined fibrillated intermediate substance, there are mixed forms in which the tumor presents a predominance of the fibrous element in some places, and in others, of the sarcomatous. A purulent infiltration sometimes takes place in the peripheral portions of the new-formation, when it becomes implicated in an inflammatory affection.

Cancerous tumors of the root-membrane I have observed only in association with cancerous infiltrations of the surrounding parts, in which cases the root-membrane was thickened, more or less, or marked with pale, smooth, conical protuberances (with epithelial cancer). Cross-sections present a wide-meshed network of thin connective-tissue bundles, the meshes of which are filled with agglomerations of flattened, polymorphous cells, containing one or two large nuclei and a generally minutely granular, cloudy protoplasm. Numerous layers of these cells are found upon the surface of the cones. In connection with cancer of the bone of the upper jaw, I have also observed cancerous infiltration of the periosteal membranes of the front teeth.

Magitot divides the symptoms induced by tumors of the root-membrane into those which are local, confined to the affected part, those which have their seat in the adjacent part, those arising from affections of the terminal branches of the fifth pair

of nerves, and those which are general and are occasioned, commonly, by the intensity of the local disturbance. The local symptoms, which sometimes are the only ones, indicate, as a rule, the commencement of the disease; the affections of the nerves usually succeed and, apparently, are dependent upon the former; sometimes, however, these are the first to appear, and continue to be the only symptoms. The general symptoms are the last to make their appearance, and are developed, also, during certain periods of the disease.

The local symptoms simulate those of chronic inflammation of the root-membrane, and the existence of a tumor of the root-membrane can only be determined as probable when the carious or non-carious tooth has become loosened and dislocated, since chronic, circumscribed suppurations (*Eiterungsherde*) produce these results; even the occasional consecutive appearances presented by the gums, as swelling and suppuration, occur alike with chronic inflammation and with tumors of the root-membrane. An acute inflammation of the periosteal membrane may quite readily be discriminated from the latter.

The progress of the tumor is quite slow, being prolonged during many months; there are exacerbations in the inflammatory symptoms, sometimes severe pain and very acute sensitiveness which is manifested in chewing or by contact with anything. Magitot observed, also, a certain degree of disturbance of vision in cases complicated with orbital neuralgia, or tinnitus aurium and partial deafness in connection with neuralgia in the ear.

Magitot, in an appendix to his monograph, gives a description of polypi of the dental periosteum, accompanying caries, which are attached by means of a pedicle to the neck of the tooth and are composed of the same tissue as the normal periosteum but in an hypertrophic condition; he did not meet with epithelium or myéloplaxes in these.

These polypous outgrowths upon the necks of teeth, which occur in connection with caries, indeed tumors upon the carious roots, also, are especially liable to be confounded with proliferations of the gums, when the latter, in consequence of partial resorption of the alveolus, extend to the neighborhood of the

radical apices, become inserted between the roots or are attached to the necks of the teeth. The well-marked papillary structure of the proliferating gum, together with its epithelial covering, afford quite positive grounds for its distinction from the former affection.

GUM.—*Papillomata* of the gum are, essentially, localized hypertrophies of the papillary portion; generally they are associated with caries and are located upon the facial surface of the gum; their diminutive conical elevations form dome-shaped enlargements and present an analogy with acuminate condylomata. The remarks which have already been made in connection with hypertrophy of the gum are applicable to the structure of papillomata.

Sometimes proliferation of the submucous connective tissue of the gum coexists with that of the papillary portion, in which cases the tumors acquire larger dimensions and firmer consistence.*

Fibromata of the gum occur in the submucous connective tissue in the form of projecting, superficially smooth, compact

* Salter (Guy's Hospital Reports, series iii) reported the following interesting case from the practice of W. S. Granger. In a man fifty-seven years of age, the upper first bicuspid being loose was removed; to all appearances the tooth was sound, as, also, was the surrounding gum. Four months later, a slight unevenness and swelling was noticed upon the same side of the palate, extending from the inner alveolar margin of the gum, at the point where the bicuspid was located, in the direction of the arch of the palate and covering a space about as large as a finger nail. While smoking, this place became sensitive but at other times it was not painful. After cauterization, distinct papillæ were developed. Eleven months after the extraction of the bicuspid, the tumor had attained half the size of a walnut and spread from the alveolar margin upon the hard palate towards the median line. Its color, a creamy-white (probably from the exfoliation of the epithelium), contrasted with the dark-purple of the investing mucous membrane and between the two was a sharply defined boundary. In extirpating the tumor, Cock found it so firmly united with the periosteum of the hard palate that it was necessary to remove the sound portion of the latter which was beneath the tumor. Three months later the wound was closed by a healthy cicatrix; there was not the least trace of glandular swelling and no recurrence of the tumor. Two small pieces of bone exfoliated, probably in consequence of the separation of the periosteum and the free cauterization. The tumor was composed of fibrous tissue, and its outer surface presented, everywhere, large, closely packed papillæ.

tubercles, which slope away towards the surrounding tissues; they are by no means of rare occurrence, especially those of smaller dimensions, and are composed of firm bundles of connective tissue with numerous interacements, and imbedded cells. Linhart* extirpated a fibroma of the submucous connective tissue, nearly as large as a hen's egg.

The *sarcomata*, likewise, have their seat in the submucous connective tissue of the gum; they project in the form of tolerably firm tumors, as large as a pea or bean, and inclose, in their outermost layers, roundish, in the deeper, spindle-shaped cells, together with a scanty, fibrillated basis-substance.

Angiomata (vascular tumors) are of rare occurrence and sometimes give rise to hemorrhage which endangers life. Salter† reported a new-formation of this kind, which was composed of numerous convoluted bloodvessels and connective tissue. The surface of the tumor, which was lobulated, located upon the neck of a tooth and as large as the berry of the common winter cherry, was covered with papillæ like those of the gum and with epithelium. The latter condition serves to indicate that the new-formation was seated in the submucous connective tissue of the gum and not, as alleged, in the dental periosteum.

Epithelial cancer sometimes occurs primarily in the gum and generally is met with in the vicinity of the molars. First of all, minute knotty elevations are developed, which increase in number and extent and spread to the submucous connective tissue, dental periosteum, alveolus, and alveolar process. The epithelium undergoes notable proliferation and imparts a brighter color to the knots; it also dips down to a considerable depth into the substance, where the familiar rosette-shaped, nest-like groups of flattened, often distinctly ribbed cells are met with. Sometimes the papillæ of the gum, also, grow considerably in length and breadth, and the cancer acquires the appearance of a succulent wart which finally ulcerates. Schuh‡ observed the origin of the epithelial cancer upon the internal buccal surface,

* Würzburger med. Zeitschr., Bd. II.

† Trans. of the Path. Soc., 1854.

‡ Pathologie und Therapie der Pseudoplasmen.

usually in the vicinity of the last molars. Here, also, he says, it maintains, for a time, the character of the broad (flach) cancer, that is, of a form of cancer which increases only in its extent of surface, not in depth, remains superficial, therefore, resembling a granulating surface, and slowly destroys the organic parts.*

Medullary cancer sometimes spreads to the gum from the adjacent parts, but it can hardly be said to affect the former primarily.

MUCOUS MEMBRANE OF THE MOUTH.—Notably projecting proliferations of this membrane are met with, now and then, in connection with caries, *adjacent to the lingual surface of the gum*, particularly in the vicinity of the upper molars; they contain a layer (one-half centimetre and upwards in depth) of acinose glands beneath a turgid corium, and are to be regarded as *adenomata*. The importance of these glandular enlargements, in connection with the carious process, will be considered further on.

A. Förster† not infrequently observed a swelling of the glands of the oral mucous membrane, together with a transformation

* Under this head is to be classed the remarkable case of a papillary tumor upon the alveolar margin of the right lower jaw, in a man eighty years old, which came under the observation of W. Fergusson, and was reported by J. A. Salter (Guy's Hospital Reports, series iii). The tumor, having the appearance of long-macerated flesh which had acquired a bad color, was removed, and fourteen days later it returned presenting the same character, so that it became necessary to repeat the operation. The patient died from old age, as it was alleged, soon after this operation. It was stated that there was no swelling of the lymphatic glands in the neighborhood, and the tumor was unconnected with the bone. Salter found an aggregation of papillæ, pointed at their free extremities and united together at their bases, many of which were nearly an inch long and resembled the papillæ filiformes of the tongue, while others were similar to the papillæ fungiformes. The mass consisted almost entirely of pavement-epithelium, and the cells were also arranged in the form of birds' nests, as in epithelial cancer. The elongated filiform papillæ were striped longitudinally and were readily separable into smaller hairy processes; their edges were composed of very compact cells which by themselves presented no evidence of an epithelial character, while, on the contrary, the more superficial cells were decidedly epithelial. He was unable to distinguish any limiting layer of the papillæ, nor any vascular loops in them. The basis of the new-formation was composed of fibrous tissue.

† Handbuch der pathol. Anat., 2 Aufl., Bd. II.

of the glandular secretion into a mucilaginous or colloid mass. When the acini are confluent, cysts are developed, containing a mucilaginous mass in which, in certain cases, larger or smaller calcareous concretions may also be found at a later period. He met with the latter tumors also adjacent to the gum. I have, also, repeatedly observed them in the latter location, and have found the mucous glands degenerated in the manner described; occasionally, the development progressed to the formation of young, gelatinous connective tissue.

The white excrescences upon the mucous membrane of the cheeks, lips, and palate, described by Schuh,* belong to this category, in the opinion of Förster. The former described them as white, curved folds, which project from one to four lines, are two to three lines broad, and may acquire a length of over an inch. They terminate occasionally in discrete knots the size of millet-seeds. Sometimes several folds of this description are found in close proximity. Their outer surface is tolerably smooth or minutely granular, and their consistence like that of the broad condylomata. They are never painful. Their complete development occurs within a few weeks. In two cases, they disappeared spontaneously in a few months; in a third, during the external and internal use of iodine; in a fourth, the affection had lasted several years, and increased slowly always in a uniform manner. The affection returned after extirpation. Schuh did not investigate them very closely, and, therefore, their pathological classification is, as yet, undecided.

ALVEOLAR PROCESSES.—It has been customary of late to class *epulis* with the diseases of bone, and to understand thereby tumors growing from the maxillary periosteum, particularly from that of the alveolar processes, and from the bony substance of the latter. Virchow† considers it best to employ the term *epulis* only in a topographical sense, to signify a tumor of the alveolar process. This restriction of the term, he states, is convenient in that it enables us to speak of *epulis sarcomatosa*, *myxomata*, &c.

Epulis, in the restricted sense of an affection of the bone,

* Pseudoplasmen, 1854.

† Die krankhaften Geschwülste, Bd. II.

originates in an irritated condition of the periosteum and bone. Traumatic causes, *e. g.*, crushing and splintering produced in extraction, particularly of the milk and permanent bicuspids and molars, in all probability give origin to it in some cases. Positive proof of a trauma is difficult to obtain, however, in many cases. A congenital or acquired obliquity of one or another tooth may also be regarded as an occasional cause. Carious roots are said to be a frequent predisposing cause.

Schuh regarded epulis as a local affection which may occur at any period from the second year after birth, even to old age, and in either sex or with any habit of body. It occurs, however, more frequently in young persons. Many writers assert that it is of more frequent occurrence with females than with males, and is met with more often on the lower than on the upper jaw.

The tumor is distinguished, *in situ*, as a firm, immovable, convex, knotty protuberance of variable size, covered with reddened mucous membrane; it spreads over one or more teeth, dislocates them from their normal positions, and loosens them so that eventually they fall out. As a rule, it does not occasion any pain in the teeth, nor do the latter present any perceptible anomaly after extraction. Generally its site is in the vicinity of the teeth which have multiple roots.

When the epulis, in the course of time which may be prolonged for several years, has attained considerable size, so that it produces a notable bulging upon the facial surface, a distortion of the nostril, a deviation of the angle of the mouth and of the external angle of the eye, and spreads upon the lingual side as well, hemorrhages easily occur, in consequence of the hyperæmic condition of the veins of the tense superjacent gum, and erosions are produced, which result in ulcers that are, sometimes, disgusting in appearance and emit a foul odor. If the disease be neglected, even perforation of the external skin may ensue, a portion of the tumor may suppurate and then life itself may become endangered. In consequence of the irritation produced by the disease, the lymphatic glands in the superior cervical region sometimes become swollen.

Epulis fibromatosa generally has a firm, compact, tough,

fibrous, slightly succulent texture, and towards its broad basal portion presents either scattered agglomerations of calcareous grains, or a trabecular new-formation of osseous substance. The fibrous basis-substance is abundant, and there are bundles of elongated fibres which interlace extensively. The long diameters of the spindle-shaped connective-tissue cells correspond with the direction of the fibres. Where the cells have several processes, the latter unite to form a network. Chain-like groups of granular ovoid cells are imbedded in the parenchyma, where they form numerous layers. The agglomerations of calcareous grains are surrounded by tough fibrous tissue; the calcareous salts may be extracted by means of the proper acids when there remains the organic basis of the grains. In such cases, therefore, the process of bone formation progresses merely to the stage of excretion of calcareous salts, but in comparatively few places isolated groups of bone-corpuscles are met with.

When the osseous substance of the base of the tumor is an outgrowth from the periosteum, retiform, osseous trabeculæ are met with, imbedded in the bundles of connective tissue, which become less conspicuous towards the periphery of the tumor (Atlas, Fig. 136). Isolated groups of delicate trabeculæ, also, are found. In order to display the newly-formed osseous framework of the *osteoid* tumor, it should be macerated.

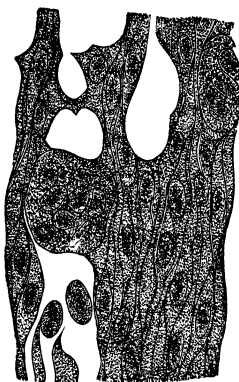
When tumors of this description have attained considerable size, it is also found that separate portions acquire a gelatinous (myxomatous) character, and in these portions numerous groups of cells are discernible within a delicate, trabecular stroma.

The submucous connective tissue of the gum is in immediate relation with the epulis, and the gum is subjected to considerable tension as the tumor continues to grow. The papillary portion, notwithstanding its remarkable mirror-like smoothness, may still readily be identified (Atlas, Fig. 135).

As the development of the tumor progresses, the gum is stretched to such a degree that it becomes necrosed. In consequence of the unavoidable irritation and foulness, occasioned by food, liquids, &c., purulent infiltration of the tumor ensues in connection with the above-mentioned offensive ulceration, a condition of things which may lead to an erroneous interpretation of the tumor as one of a cancerous nature.

In cases of epulis in which there is a predominance of the *sarcomatous*, to the exclusion of the fibrous element, an abundant cellular structure is presented to view, which sometimes attains such a preponderance as to displace, almost completely, the fibrillated substance, and we find only aggregations of large spindle-shaped cells, together with encapsulated groups of roundish cells, generally with a single nucleus, and a scanty fibrillated substance. There is a notably frequent occurrence, even in the fibrous epulis, of flattened, large cells which present variously shaped processes, a minutely granular protoplasm, and inclose two, twenty, and even many more, oval nuclei, and have been described by Robin as *myéoplaxes* (medullary plates), and not as cells; he found these in normal marrow, particularly in that of young, growing bone. This view, however, has not met with very general acceptance. Paget called these formations, multi-nucleated cells, and Virchow designates them as multi-nucleated, gigantic cells. Since the gradual multiplication of the nuclei in a series of these elementary organs may easily be traced, and a progressive division of the nuclei, together with a corresponding increase of the protoplasm, may be identified with very high magnifying powers, and since there is nothing to indicate the occurrence of casual fusion of cells, I consider it to be settled that they originate from uni-nucleated cells. These flattened, gigantic cells are disposed between the fusiform cells and, frequently, fall out from sections of the tumor, leaving corresponding empty spaces (Fig. 91). Virchow regards them as heteroplasic formations which arise from the proliferating elements of the periosteum. This heteroplasia, according to him, does not involve the idea of malignancy, even in the narrowest clinical sense; at all events, he is not aware of a case where

FIG. 91.*



* FIG. 91 shows a section from an epulis sarcomatosa, which includes in its basal portion numerous bony spicules, and contains in its fleshy portion interdigitating fusiform cells with prominent nuclei, which, also, surround

the process extended by metastasis from an original epulis to internal organs, or where it spread even to the nearest lymphatic glands.

Several varieties of epulis sarcomatosa are distinguished. According to their seat, E. Nélaton* has divided such tumors into two forms, which he describes as *péri-osseuse ou sous-péri-ostique*, and as *intra-osseuse*, both of which, in his opinion, arise from an hypergenesis of the medulla of the bone. These two varieties, in the opinion of Virchow, evidently correspond with the two forms of sarcoma, the periosteal and myeloid. He opposes, with reason, the view of Nélaton, that they are produced, invariably, by an hypergenesis of the medulla of the bone, since, he says, it is not uncommon for the tumor to have an osseous basal portion which forms a considerable elevation beyond the surface of the original bone, and the softer portion of the tumor, which contains the myéloplaxes, becomes separated from the surface of the old bone by this bony basis. I, also, have had the opportunity of observing such an osteoid sarcoma, but am of the opinion that our present knowledge in regard to the occurrence, propagation, and signification of the multi-nucleated, gigantic cells is still too defective to enable us to form a definite idea in respect to their origin.

If we examine, before and after maceration, a sarcoma which grows in the medulla of the bone, together with the tooth which is inserted into the tumor, we find that the cancelli of the remaining bony framework are dilated and filled with a tolerably consistent new-formation. The latter contains numerous ovoid and fusiform cells, besides bloodvessels with thick walls, whose external coats swarm with proliferating cells. The osseous trabeculæ which are still retained in the new-formation undergo a gradual resorption which, also, visibly involves the alveolus of

multi-nucleated, gigantic cells, so-called myéloplaxes. The latter are flattened, present short, blunted or pointed processes, vary in size, and inclose, within a protoplasm of minute granules, numerous oval and multifariously indented nuclei. The transition from uni-nucleated ovoid to the large cells may be followed out. The section shows several vacuities, the sites of gigantic cells which have fallen out. Magnified four hundred diameters.

* Virchow, op. cit., p. 313.

the tooth. If the new-formation comes into contact with the periosteum of the root, after the complete resorption of a portion of the alveolus, the tooth, of course, becomes loosened in its socket.

When the epulis is confined to a small portion of the alveolar process, the operation proposed by Salter, to extract the corresponding teeth, with the view of preventing a recurrence of the superficially-extirpated tumor by means of the resorption of the dental alveolus which ensues after the extraction, may sometimes be of service. In many cases, however, the removal of the teeth will have no effect in inducing the involution of the tumor, if the latter be a myeloid and deeply rooted, and the germs are allowed to remain and to continue their development after cicatrization of the alveolus is completed. Schuh states explicitly that teeth which have become loosened by the disease not infrequently are extracted before the patient has any suspicion of the existence of the affection. If the tooth is only a little loose, we may be assured that the bony alveolus is involved, and the tooth should be extracted; the degenerated portions should be excised with a strong knife and the cut surfaces thoroughly scraped or carefully singed with the actual cautery. He lays stress, therefore, upon a radical extirpation.

Osteomata or exostoses of the alveolar process usually are considered under the head of hypertrophies in the manuals of dentistry. They are not by any means of very rare occurrence, and are met with frequently in the cadaver, in more or less advanced stages of development.

They present manifold variations in size, from that of minute knots to that of excrescences as large as millet-seeds, peas, or beans; the latter sometimes coalesce and form a ridge or crest. The diminutive forms often disappear during life, or are mistaken for callosities of the gum and are not recognized except upon the skeleton. They are less likely to attract the attention since they occasion no annoyance. Upon the alveolar border of the labial side of the lower jaw, particularly in association with the firm structure of the jaws and teeth in elderly people, or with closely-approximated or overlapping teeth, I have frequently found tuberiform excrescences, two to three millimetres in diam-

eter and one millimetre thick, which were traversed in a perpendicular direction by shallow vascular grooves, were very compact and only in very rare cases presented larger measurements than those mentioned. Coalescence of adjacent nodosities is not uncommon, in which cases they form rounded ridges with hump-like elevations corresponding in locality with that of the different dental roots.


Upon the lingual side of the lower jaw, the excrescences attain larger dimensions. The case illustrated in the Atlas, Fig. 138, shows compact protuberances of bony substance which present depressions and grooves upon their smooth, rounded outer surfaces, are attached by a broad base to the alveolar process, just beneath its margin, and are located opposite the bicuspid and first molars. The anterior segment of the maxillary arch presents no exostosis, and upon the posterior segments, opposite the second molars and wisdom teeth, there is merely a ridge of bone. In this case, the exostoses attained a diameter of hardly more than five millimetres, but, in another case, which we observed, they were considerably larger. In the latter case, there are two flattened protuberances upon the lingual surface of the anterior segment of the maxillary arch, and situated behind the lateral incisor and canine on either side; there are, also, two large osteomata, one behind the bicuspid and first molar on either side. The surface of the osteoma upon the right side, which measures sixteen millimetres in its antero-posterior diameter, is smooth, that of the one on the left side, with a diameter of nineteen millimetres, is traversed by perpendicular grooves and has a diameter of seven millimetres from above downwards. A bony ridge extends upon either side along the lingual surface of the alveolar process, from the large exostoses to the vicinity of the second and third molars.

I have met with osteomata, appearing as if they had been dropped upon the alveolar process of the upper jaw, only upon the facial surface and corresponding to the localities of the canines, bicuspid, and molars. They occur either in the form of an exuded, as it were, quite consistent and, therefore, quite white osseous mass which covers the alveolar process near its margin, or, especially in the region of the molars, in the form

of pad-like elevations, the size of a lentil or even larger, which have a broad base, sometimes project beyond the alveolar margin, are polished upon their outer surface and, now and then, are traversed by several vascular grooves. In other cases, we find merely a projecting bony ridge which unites the alveolar borders.

Microscopic examination of sections of these growths shows that they are composed of the compact osseous tissue of the cortical substance. The lamellæ are disposed in the form of arches and are very uniform; the vascular canals form a series of flattened arcs, with oblique anastomoses, and, generally, are of small diameter (Fig. 92). Hence arises the notable compactness

FIG. 92.*



and white appearance of the osteoma. The alveoli are not involved in the process and, therefore, the teeth retain their normal position.

Close examination of the osteoma establishes beyond doubt the fact of an *interstitial development of bone* in many places. We find, namely, interposed bone-corpuscles, isolated in some cases and grouped together in others, which are separated from the original systems by a hyaline, indented or festooned, dividing

* FIG. 92 shows an osteoma from the lingual wall of the anterior segment of a lower jaw. The tumor forms an elevation upon the wall, seven millimetres in height, rises abruptly upon one side and upon the other presents a more gradual slope. Its surface is smooth, the osseous tissue throughout is compact like that of the cortical substance of the bone. The narrow Haversian canals are disposed at tolerably uniform distances from each other, and their direction corresponds with the arched formation of the tumor. The commencement of the spongy tissue is shown at the broad base of the tumor. Magnified three diameters.

layer. The extent of these new interstitial systems is variable; they are wanting in uniformity and are disposed around the vascular canals, or penetrate, are wedged in, as it were, between the rows of the old systems which, frequently, present a granular cloudiness and correspond with parts in which resorption has begun.

The peripheral, very compact zones of the superficially smooth osteomata not infrequently contain elongated bone-canalliculi which extend, in nearly parallel rows, from the interior towards the periphery, in a direction oblique to that of the tangential planes. They are wider than the ordinary bone-canalliculi, pursue a straight course, bifurcate at acute angles, at one extremity are in immediate connection with the bone-corpuscles and terminate in free extremities at the periphery. I am undecided whether or not they have any connection with Sharpey's fibres. We have become acquainted with quite isomorphous (isomorphe) canalliculi in hypertrophic cement, and in both instances they give to the corresponding portion of the bone an obliquely-striped appearance, recognizable even with quite low magnifying powers.

The origin of these localized proliferations of osseous substance, which are ushered in by an hyperplastic condition of the periosteum of the alveolar process, is still undetermined. The fact already mentioned, that they are found in connection with powerful jaws and strong sets of teeth, or with closely-set or overlapping teeth, suggests the supposition that the primary irritation is induced by the act of mastication which, in these cases, is conducted with such force as to produce an undue facial displacement of the teeth in the upper jaw, especially of the bicuspid and molars, and an abnormal lingual displacement of those in the lower jaw. With this view, the classification of the osteomata would become evident. Syphilis, abundant deposits of tartar, or caries take no part in their production.

They require treatment in exceptional cases only on account of their excessive size. They do not give rise to pain. With very large tumors upon the lingual surface of the lower jaw, the movements of the tongue are interfered with. The pectinated

proliferations afford a lodgement for particles of food, or they produce a disfigurement. They may also form a hindrance to the adaptation of sets of artificial teeth.*

The spongy tissue of the alveolar process may, likewise, acquire an hyperplastic condition, whence an *enostosis* becomes developed, which occasions resorption of the alveolus, dislocates the tooth from its normal position and, eventually, loosens it so much that it falls out. The enostosis forces the lingual and facial walls of the alveolar process farther apart, or produces a wider separation of adjacent teeth and, therefore, exerts an ill effect upon the entire set of teeth.

CYSTS OF THE JAWS.—Under this head are comprised those hollow-formations which have their seat, principally, in the spongy tissue of the alveolar process, embracing upon one side the facial or lingual surface of one or more roots, while, upon the other, as they increase in extent, they protrude and occasion a partial resorption of the cortical substance of the bone.

Carabelli observed cysts in both the upper and lower jaw, without, however, recognizing them as such; he described them in his lectures as *Hydrops Antri Highmori* and *cellulæ dentis*

* Bourdet (*L'art du Dentiste*, 1757) observed five or six cases of exostoses, of different sizes up to that of a pea, upon the facial wall of the alveolar process of both the upper and lower jaw, and corresponding in locality to that of the incisors and canines. They occasioned no pain, but produced a disfigurement. They returned after removal by means of the bone-forceps, but disappeared under the application of the actual cautery. Tomes remarks that in one case only has he seen hypertrophy of the alveolar process attended with inconvenience. In this case "the whole of the alveolar bone was greatly enlarged; it projected upwards in the lower, and downwards in the upper jaw, carrying before it a red and thickened gum and concealing within the groove formed by the lingual and labial portions of the alveolar ridge the corresponding surfaces of the whole of the teeth. The thickening in the front part of the mouth was so great that the lips could not be closed. At the back part of the alveolar arch, the thickened and elevated gums of the respective jaws, although mutually flattened, were not sufficiently depressed by the action of the jaws to allow the molar teeth to come in contact. The patient was a half-witted strumous child, whose age did not exceed thirteen years, and whose general appearance justified the assumption that the disease was but a local manifestation of the presence of a strumous diathesis." No treatment was undertaken.

and from them he drew a conclusion respecting the structure of the dental periosteum which he held to be a serous membrane. Albrecht,* in nine thousand three hundred and fifty patients treated by himself, met with only seven cases of cystic formation beneath the oral mucous membrane upon the upper and lower jaws, and in every case the tumor was situated behind the bicuspid.

Cysts are met with more frequently in the upper than in the lower jaw, and are more frequent in front of than behind the bicuspid.†

Since, in the earlier stages of their development, their growth is inconsiderable and their increase is not accompanied by any painful sensations, they escape observation for a long time, until, in consequence of a more rapid increase in their volume, a distention and bulging of the maxillary wall ensues, when, for the first time, they are perceived by the patients. They, therefore, date their origin from the time when they first observe them and, usually, consider them to be tumors of the teeth, but, experiencing no pain from them, they do not apply for professional advice in regard to them, until it is found that, notwithstanding the employment of emollients, the supposed dental tumors increase in size and show no disposition to disappear. A month, sometimes six months and more, are allowed to pass from the time when they are first noticed, and, usually, the swelling becomes perceptible even externally without, however, being accompanied by redness or heat of the skin. The patients are unable to assign any reasons for their occurrence. On examination, a bulging, from the size of a hazel-nut to that of a half walnut, is found, usually, upon the facial wall of the jaw; it is sharply defined, not movable, imparts the sensation of fluctuation, and the portion of the maxillary wall which is protruded by the tumor feels like parchment and crepitates; the tooth corresponding to the most prominent part, usually, is loosened, and if this is extracted, the contents of the tumor may be evacuated immediately by means of firm pressure upon it with the

* Klinik der Mundkrankheiten.

† Heider und Wedl in the Deutsche Viertelj. f. Zahnheilk., 1865.

finger or after puncture of the wall of the cyst within the socket with a sharp instrument. The fluid which escapes, usually, is albuminous, viscid, ropy, yellowish, and clear.

It depends upon the situation of the cyst, whether the outer or inner wall of the jaw is distended the most; in the upper jaw the facial wall, usually, is the one involved. When the cysts of the upper jaw are developed in the region of the bicuspid and molars, they project even into the antrum. The cystic growths in the mucous membrane of the latter will be considered farther on.

Retarded eruption, especially of the wisdom teeth in consequence of their oblique position may be the predisposing cause of a cyst-formation, and in such cases the question arises whether the dental sac degenerates into a cyst which incloses the retarded tooth or whether the growth of the tooth in an abnormal direction exercises an irritation upon the surrounding osseous substance by reason of which the latter becomes abnormally developed in the form of a cyst. Fackeldey* mentions two instructive cases, from Volkmann's clinic, of very extensive cysts of the lower jaw; in one of them, the right wisdom tooth was located upon the posterior wall of the cyst; its roots were imbedded in a peculiar manner and, obviously, in consequence of a deficiency of space. In the other case, the crown of a molar (large?) was found projecting into the cyst from the lingual side of its anterior portion. Its roots were small and bent to one side, evidently in consequence of a want of space. The tooth, finally, was displaced so far in consequence of the gradual distention of the jaw to the colossal cyst, that it was located at least an inch and a half below the level of the rest of the teeth of the lower jaw.

The mode of development of cysts of the jaw has not yet been determined, and further anatomical investigations are necessary in order to elucidate this subject. We communicated, in the paper cited above (*vide*, also, Atlas, Figs. 133 and 134), the results of an anatomical examination of a cyst in the alveolar process of the upper jaw, behind the root of the right central incisor. The development of the cyst was not sufficiently ad-

* Inaugural dissertation, 1869. Deutsche Viertelj. f. Zahnheilk., 1870.

vanced to occasion a protuberance upon the lingual surface of the mucous membrane of the mouth, and, consequently, it had escaped clinical observation. A portion of the cortical layer of the lingual wall, five millimetres in extent, was wanting, and the corresponding portion of the cyst wall, consequently, came into immediate relation with the subcutaneous connective tissue of the gum; before long, therefore, a protuberance would have become perceptible. Moreover, the growth of the cyst towards the osseous tissue was indicated by the fact that a new, minute cyst was located laterally upon the fibrous layer of the larger. Fackeldey,* with special reference to this case, thinks there are grounds for considering the question whether the cysts of the alveolar process, which are lined with a membrane, are not due to an anomaly of development, a degeneration of the dental sac or a lateral budding of the enamel germ. Without denying the possibility of the connection of cysts of the jaw with retention or follicular cysts, it may be observed, however, in objection to this view that both simple and compound cysts with a fibrous lining are met with in other bones, and the cysts in the upper jaw, especially, are developed commonly upon its facial side, a locality with which the occurrence of follicular or retention cysts is scarcely compatible.

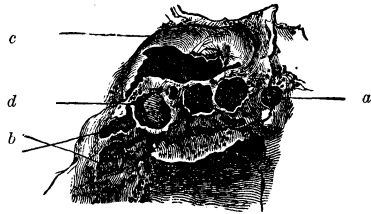
In several cases, I have found the lining membrane of the cyst tough, compact, and coated upon its internal surface with a layer of epithelium, consisting of several laminæ of flattened, nucleated cells which, frequently, interlocked with one another by means of blunt processes. These cells are the organs of production of the serous, viscid or gelatinous fluid, while the continuous proliferation of the fibrous membrane, which is furnished with wide bloodvessels with thin walls, occasions the gradual resorption of the bone. Sometimes, also, the cysts become the seat of an inflammatory process and, in such cases, contain a puriform fluid.

When the cyst attains such magnitude as to invest several teeth, extend beyond the limits of the alveolar process and occasion a resorption of its spongy tissue, the alveoli of the corre-

* Op. cit.

sponding teeth become involved simultaneously, the latter are loosened, dislocated, and their connection with the alveolar borders is broken. The resorption of the bone occasioned by the extension of the cyst,

FIG. 93.*



takes place upon both the facial and lingual surface, and effects a not inconsiderable breach in the substance of the bone (Fig. 93). The margins of the parts where resorption (usure) has taken place, are serrated, the distended facial wall is transparent, thin as tissue-paper, is perforated by numerous, minute foramina for the passage of vessels and, upon its internal surface towards the cavity of the cyst, presents extensive erosions, the resorption excavations which have frequently been mentioned in the preceding pages.

Cysts can only be confounded with other affections which occasion swellings in the jaws, as enchondromata, sarcomata, myxomata, abscesses. and with collections of fluids in the antrum. An abscess, however, may be distinguished by its acute course, and by the fact that the tumor formed by it is never so sharply defined as is the case with cysts; with dropsy of the antrum, the distention of the facial wall of the jaw is more uniform always than it is with cysts. In some cases, the diagnosis cannot be determined accurately until after an operation.

OSTEOPHYTES UPON THE JAWS.—Sometimes, in consequence of diseases of the teeth and, particularly, of chronic inflammation of the root-membrane, an irritation is induced in the maxil-

* FIG. 93 shows a cyst of the right upper jaw, embracing in its extent both incisors and the canine. View from the cavity of the mouth. It has an oval form and a long diameter of two centimetres; internally it is limited by the incisive foramen (*a*), and externally by the cicatrized alveoli of the bicuspid (*b*). The labial wall is distended like a bladder (*c*). Considerable destruction of tissue, which is defined by a sharply cut outline, has occurred upon the hard palate. A portion of the alveolar process, corresponding with the two incisors and canine (*d*), still remains unaffected by the process of resorption. The internal surface of the cavity of the cyst is smooth and perforated like a sieve. Natural size. (For the use of this specimen the author is indebted to Dr. Friedlowski.)

lary periosteum, which is attended by its tumefaction and sensitiveness, occasions consecutive œdema and, not infrequently, gives rise to the formation of an osteophyte of a fine spongy texture.

If a series of macerated jaws, which have contained carious teeth, be examined, several of these growths will usually be found, in the form of cribriform, unyielding lamellæ, generally adherent to the facial wall, more commonly to that of the lower jaw, and distinguished by a quite bright color. When peeled off and examined in thin sections they prove to be young osseous substance. They are located, almost always, upon the posterior segment of the jaw, are of very variable extent and present very irregular outlines; their thickness varies from one-quarter to one millimetre. They occur in isolated patches and, occasionally, spread over the entire surface of the maxillary wall.

The period of puberty, together with the retarded eruption of the wisdom teeth, appear to be especially favorable for the development of osteophytes, and, when associated with an incomplete growth of the jaws, they are to be connected with unusual succulence of the periosteum.

The case, illustrated on page 202, of partial necrosis of the lower jaw, which occurred in connection with the eruption of the wisdom tooth, was accompanied by an extensive osteophyte-growth that spread over the lingual wall of the jaw. Very delicate, branching, separate, osseous trabeculæ, first of all,

FIG. 94.*



a

make their appearance; these increase in size and unite with one another. The lamellæ formed in this way are always perforated with sharp-edged foramina which lead to the vascular canals upon the surface of the jaw. As the layers increase in thickness, they are disposed one over the other like the tiles on a roof, and are marked with manifold tortuous grooves and indentations, which give to the whole the appearance of a remarkably fine filagree work (Fig. 94).

* FIG. 94 shows a section from an osteophyte, with a delicate spongy texture, which forms an excrescence upon the smooth facial wall of the lower

Extensive, thick osteophytes, developed in association with the symptoms of chronic periostitis, are met with in connection with phosphornecrosis of the jaws. Primarily (Lorinser, Geist), they have a fine spongy texture, and gradually they become compact; finally a new bony shell is formed, while the original, encapsulated bone becomes necrosed. With exacerbating symptoms, suppuration and sanious ulceration (Verjauchung) occur upon the surface towards the necrotic bone, and cloacæ are formed in the osteophyte, by which its continuity is interrupted. A well-marked case of a newly formed bony shell, which is separated from the necrotic lower jaw, is illustrated in the Atlas, Fig. 137. The shell presents fenestrated openings, the result of ulceration; notwithstanding the latter process, the processes, grooves, tubercles and spines, and even the mental foramen, are seen to have been formed anew. The specimen was taken from a woman, twenty-two years of age, who had worked for twelve years in a match factory and who came under the treatment of Dr. Lorinser, on the 30th of March, 1847. The disease had already existed for six months. She died from tuberculosis on the 27th of August, 1847.

ENOSTOSES IN THE JAWS.—Virchow* proposes to limit the term enostosis to certain osseous growths which are developed from the medulla in the interior of bones; he met with only one case, a porous enostosis in the spongy extremity of the tibia of a child. He also includes under this head the *corps osseux encystés* of Cruveilhier which are distinguished by their great compactness. As the latter new-formations are of extremely rare occurrence and frequently escape observation on account of their diminitiveness, our knowledge with reference to their origin and development is still defective.

Schuh has described, under the head of rare new-formations, a bony tumor of the left upper jaw in a girl fourteen years of

jaw, where a fistulous opening from a tooth (α) is perceptible. The new-formation displays extremely delicate, shallow, channel-like, vascular grooves which run in various directions, interlace in a retiform manner and inclose minute lamellæ of osseous tissue. Magnified fifteen diameters. (Viewed with oblique light.)

* Krankh. Geschwülste, II.

age, which is to be considered as a spongy enostosis.* The immovable new-formation, the size of a hen's egg and of bony hardness, originated in the diploetic structure and not from the external surface of the bone, pressed the anterior surface of the jaw outwards and, by its continued development inwards, encroached upon the cavity of the antrum, a small portion of which, the superior and posterior, alone remained. It spread from the incisors on the left side as far as the maxillary tuberosity and from the teeth to the lower margin of the orbit; it was not painful even when subjected to firm pressure. The teeth of the affected side were normally arranged and firmly implanted within the distended alveolar process. A fragment of the bone was removed and presented throughout the texture and consistence of delicate spongy bone and was composed essentially of a retiform trabecular stroma and a very richly vascularized connective tissue which filled the vacuities formed by the stroma. These vacuities presented no marked variations in respect of size, hence the newly formed bony mass preserved quite a uniform compactness. The bone-corpuscles varied considerably, here and there, were more closely approximated than in normal bone, and the intermediate substance presented, in places, a dirty-yellowish color. The bloodvessels were of comparatively large diameters. The girl received a blow in the face five years previously, and this was assigned as the primary cause of the tumor. The latter was extirpated, the wound cicatrized rapidly without any disfigurement, and there was no recurrence.

Forget† found, in the socket of a normal canine from the upper jaw of a horse, an encysted bony tumor entirely unconnected with the tooth, the latter being displaced towards the median line. The tumor was as large as an egg, irregular, and composed of bony substance merely; the cyst was undergoing suppuration.

I have had the opportunity of examining an analogous bony tumor from the jaw of the horse, for which I am indebted to

* Oesterr. Zeitschrift für prakt. Heilk. und Gesammelte Abh., 1862.

† Des Anomalies Dentaires, 1859.

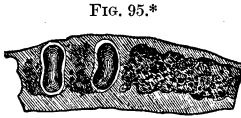Prof. Bruckmüller. It was encysted, as large as a small hen's-egg, of the density of ivory; its outer surface was tuberculated, indeed, altogether, one would be inclined to consider the case as one of an encysted, malformed tooth. On section, however, it displayed throughout a very compact bony tissue traversed by numerous, comparatively thin, vascular canals.

As neither of these two encysted, compact, bony tumors presented any dentinal texture, there are no positive grounds for considering them to be dental malformations, and, therefore, I have introduced them here provisionally.

CHONDROMATA OF THE JAWS.—Cartilaginous tumors are developed from the surface of the bone or from its spongy tissue. Their growth, as a rule, takes place very slowly, and particularly is this true of the earlier stages. Pressure upon them occasions no painful sensation. They are consistent, acquire tolerably large dimensions, are intermixed with a considerable amount of fibrous dense tissue so that merely isolated portions display interspersions of fibro-cartilage and, therefore, are to be designated as *fibro-chondromata*. If a partial ossification has taken place, they are called *osteoid-chondromata* in which, sometimes, calcification occurs only in circumscribed spots. If the oral mucous membrane becomes necrotic in consequence of the very marked extension of these tumors, and ulceration ensues, the discolored ulcer may be the occasion of confounding them with cancer. The more defined outline of the tumors and the absence of swelling of the lymphatic glands serve to distinguish them from cancer. Recurrence after extirpation is very common.

The chondromata (enchondromata) which take root in the deeper layers of the bone, especially of the lower jaw, acquire a malignant nature in so far as they grow quite rapidly and give rise to notable, supple, even fluctuating swellings from liquefaction (*Colliquescenz*). The proliferating, cartilaginous tissue undergoes a marked fatty metamorphosis and solution and, in the liquefied localities, becomes bathed in a yellowish, viscid fluid. The cartilage is partly hyaline (Atlas, Fig. 140), but it is also met with in the form of a delicate network. As the cartilaginous

tissue encroaches upon the spongy substance of the bone, it induces a wasting of the osseous lamellæ and even of the alveolus; the corresponding tooth becomes detached, and in the place of the socket is found the cartilaginous adventitious substance (Aftersubstanz). (Fig. 95.) The pulps of the teeth are not perceptibly affected by the proliferation.



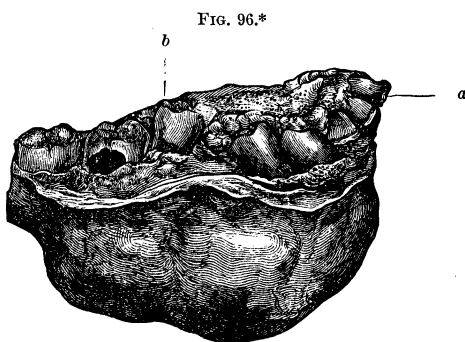
FIBROMATA OF THE JAWS.—These are firm, circumscribed, painless, fibrous tumors, of slow growth, which are prone to ossify. Sometimes they acquire considerable dimensions and are composed of conglomerate knobs, or lobules of a uniform texture. According to Paget, they are of periosteal or enosteal origin. Virchow lays stress upon the heteroplastic nature of these tumors and, especially, of the enosteal fibroma—heteroplastic not in the sense of malignant, but signifying a developmental process which gives rise to a tissue of a different type from that of the parent tissue.

Their primary seat and mode of development are unknown. When superficially located, they displace the cortical, and when located more deeply, the spongy tissue; partial displacement of the alveolar process, also, ensues, and the teeth are dislocated from their normal positions. As the fibroma continues to grow, the cortical tissue undergoes resorption, leaving a portion of the former covered merely by the mucous membrane, while the teeth are loosened and detached, from the extension of the tumor beneath them.

In a circumscribed, firm fibroma of the lower jaw (Fig. 96), fibrous tissue alone was found towards the facial and lingual walls of the bone, while the central portions of the tumor were occupied by particles which crackled when cut with the knife,

* FIG. 95 shows a segment of the ramus of a lower jaw divided horizontally, with chondromatous proliferation in the spongy substance. The two roots of the first molar are divided transversely; those of the second and third molars, together with their alveoli, are wanting; a succulent, adventitious substance occupies their places, and spreads to the cortical layers of the bone. In this, numerous oval cartilage-cells are interposed in a delicately-fibrous, succulent basis-substance. Natural size.

and conveyed the sensation of roughness. The teeth were notably displaced in consequence of the resorption of the corresponding alveoli, their roots were inserted directly into the newly-formed mass, the fibrous bundles of which were in immediate connection with the periosteal membranes of the roots of the corresponding teeth. Further, as the fibroma continued to grow, it encroached upon the limits of the alveolar process which became flexible.

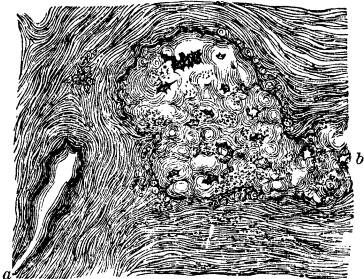


The firm substance of the tumor is composed essentially of a confused mass of interlacing bundles of connective tissue, between which narrow, fusiform cells, following the course of the fibres, are interposed at tolerably uniform intervals. The cen-

* FIG. 96.—View from above of a fibroma of the lower jaw, from a patient fourteen years of age. The jaw was resected in a line extending from the left central incisor (*a*) along the right horizontal ramus as far as the wisdom tooth. Marked displacement of the teeth was occasioned by the presence of a rounded, encapsulated, firm tumor, 6.4 centimetres in length, 4.5 centimetres in height and 4.8 centimetres in breadth. The incisors are inclined obliquely and laterally. The canine and first bicuspid are inclined still more, so that their summits are directed posteriorly and towards the median line of the jaw. The second bicuspid (*b*) is separated from the first by a considerable interval, in consequence of the proliferation of the growth between them, and the masticating surface of the former is directed anteriorly and towards the median line, so that the axes of the two bicuspids cross each other at nearly a right angle. The first molar, which is carious, presents a slight inclination; the second molar occupies its normal position. Two-thirds natural size. (For the use of this specimen the author is indebted to Dr. Weinlechner.)

tral, rough spots are occupied, in places, by calcified bodies,

FIG. 97.*



merely, having a homogeneous, polished appearance and a roundish, often spherical, or an elongated form, and are invested by straight fibrous tissue. In other places, development has progressed to the formation of minute osseous trabeculæ of various forms, containing jagged bone-corpuscles and presenting, upon

their peripheral portions, superposed roundish formations (Fig. 97).

The opinion formerly entertained that the tumor merely distends the bone, forces the external layer outwards, is disputed by Virchow on the ground that these tumors sometimes attain such magnitude, that, if there is merely a distention, it would be impossible for the bony shell to continue unbroken. It is much more probable that a new-formation of osseous substance takes place upon the outer surface from the periosteum, in the same manner in which the apposition of fresh layers ensues in growing bone. In the case cited, a complete destruction of a portion of the maxillary wall ensued from resorption.

In the upper jaw, also, the fibromata attain quite large dimensions. Several of the tumors which I have had the opportunity of examining contained so many calcareous deposits that the surfaces of sections through them communicated a gravelly feel-

* FIG. 97.—Section from the central portion of the same fibroma. Straight bundles of fibrous tissue include fusiform cells containing oblong nuclei, and interlace with one another. Nests of ovoid cells are imbedded here and there. The highly-refractive calcified portions have a homogeneous appearance and a roundish or elongated form (*a*). The isolated trabeculæ have the character of young, imperfectly-developed, osseous substance, and are surrounded by roundish, nucleated formative cells (*b*). The basis-substance, in many places, has a coarse granular appearance; the jagged bone-corpuscles are more or less minute, and notched cavities filled with amorphous calcareous salts are brought into view here and there. Magnified 400 diameters.

ing. Dr. Friedlowski showed me a skull, from the anatomical collection, which presented a breach involving the facial wall of the antrum of the left side, a portion of the horizontal plate of the superior maxillary bone, and of the inferior turbinated bone. The second molar on the left side was inclined anteriorly, and the alveolus of its anterior facial root was entirely destroyed. The alveolar process was wanting, from the canine as far as the second molar. The breach in the bones extended upwards to the vicinity of the zygomatic arch and was bounded everywhere by sharp edges. The tumor which occupied the smooth-walled cavity corresponded in character to those above described, according to the statements of Dr. Friedlowski.

Since these tumors may be enucleated, resection may be avoided in suitable cases.

SARCOMATA OF THE JAWS.—Without taking into consideration those which are developed from the alveolar process and have been treated of in the preceding pages, sarcomata are of frequent occurrence, especially in the lower jaw, in the form of simple, cysto-, and osteo-sarcomata.

The cysto-sarcoma is developed in the spongy tissue of the bone, which is very abundant in the lower jaw. A portion of this tissue undergoes complete resorption, and in its place occur sarcomatous masses and cyst-like cavities of various dimensions, some being very small while others are tolerably large (Atlas, Fig. 143). The larger cavities are lined with a separable, connective-tissue membrane, the internal surface of which is covered with a coating of small cells. Reddish, succulent proliferations of a roundish, tuberculated, nodulated, mulberry-like form, project into these spaces which are filled with a thin, yellowish, yellow-brownish, or a thick, viscid, stringy, ropy fluid.

In the case illustrated in the Atlas, Figs. 142 and 143, the sarcomatous mass has a quite remarkable structure. There is a fibrillated stroma of connective tissue; in this are imbedded vesicular and tubular cavities which, here and there, subdivide and everywhere are lined with cylindrical epithelium, the whole presenting the appearance of a utricular gland with many terminal vesicles as if detached by constriction. These adenoid masses inclose multifariously-sinuated cavities which attain con-

siderable size in consequence of the secretion of a fluid on the part of the columnar epithelial cells and their proliferation. The adenoid structure is apparent wherever a sarcomatous mass is to be seen, and is wanting wherever a dense, firm, fibrous, connective substance occurs, as in the cicatricial gum corresponding to the detached teeth. This case, therefore, may be termed, more appropriately, cysto-sarcoma adenoides.

The origin of the heterologous, adenoid substance is quite obscure. It is barely possible that it is to be referred to manifold budding outgrowths from an enamel germ. I am unacquainted with the record of a similar case.

According to the report of the case by Podraski,* the affection commenced in a vigorous man, thirty-three years of age, about seven years previously, at which time a carious lower molar on the left side was extracted on account of severe pain. For eighteen months afterwards, there was an absence of symptoms. After this period had elapsed, a tumor made its appearance in the gap left by the extracted tooth; this increased, however, quite slowly, and at the expiration of several months had attained scarcely the size of a hazelnut; it then imparted a distinct sensation of fluctuation and, according to the report of the surgeon who was consulted at that time, presented the appearance of a cyst, which was opened by an incision and a puriform, thin fluid was evacuated. Seven months later the cyst was filled again with a dense mass of a pale-red color; it gave rise to no pain, but interfered with mastication. The tumor was partially cut away, burnt and cauterized, but to no purpose. It continued to grow without occasioning any disturbance of the general system and, finally, attained to a considerable volume. Resection was performed and cicatrization ensued speedily without the least disfiguration.

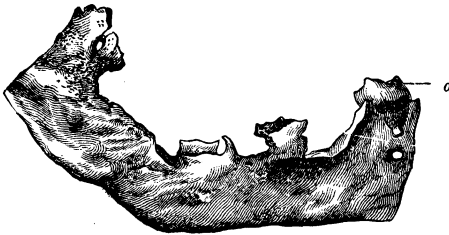
The proliferations of sarcomatous masses take place in all directions and give rise to resorption of the corresponding portions of the alveolar processes, the alveoli and even the dental roots; the surface of the root becomes roughened and studded with delicate needle-like points; the teeth become displaced,

* Wittelshöfer's mediz. Wochenschrift, Spitalszeitung, 1864.

loosened and, finally, detached. When the proliferations assume a direction towards the face and the tongue, portions of the compact bony walls undergo complete resorption, leaving the tumor covered merely by the distended maxillary periosteum.

In order to obtain a definite idea respecting the extent and the details of the resorption, and the condition of the teeth, it

FIG. 98.*



is best to examine the resected jaw, after it has been stripped of the soft parts. Fig. 98 illustrates a segment of the jaw, prepared in this way, in which the cysto-sarcoma acquired about the size of an orange. The oral mucous membrane was very tense, swollen, and upon the lingual surface presented an opening from which oozed a stringy fluid. In the substance of the jaw lay a larger cyst, filled with fetid, decomposed pus, and a smaller one filled with a serous fluid which was tinged with blood. The greater portion of the alveolar process, the lingual and facial walls were wanting, the result of the destruction of the bone by the sarcomatous new-formation.

Upon resected, macerated jaws where the newly-formed mass has not effected a marked destruction of the bone, the compact bony walls, which are involved in the resorption, present a dis-

* FIG. 98 shows a resected, inferior maxillary arch from the left side, from which the soft parts have been removed. (From the clinic of Prof. Pitha.) View from the facial side. As the cysto-sarcoma did not involve the inferior, compact portion of the maxillary arch, the bone at this part was sawn horizontally, and obliquely upwards. The wisdom tooth (*a*), still inclosed within the dental sac and inclined towards the median line of the jaw and somewhat anteriorly, was the only tooth remaining. Natural size.

tended appearance and, upon their internal surfaces corresponding with the cavity, are beset with delicate, projecting laminæ of bone which assume a fan-shaped arrangement where the teeth are still present.

The cysto-sarcomata are developed slowly and, frequently, exist for many years without giving rise to any painful sensations; at last resection is demanded by the patients on account of the marked disfigurement of the face and the interference with the act of mastication which they occasion. They occur chiefly with young persons.

There is a special occurrence to be observed in these cases which has never been duly appreciated and is deserving of thorough investigation, namely, a retarded eruption of the wisdom tooth in consequence of its oblique position (forward or internal inclination), or a permanent retention of a tooth within the jaw, on account of its obliquity. It is conceivable that, under special circumstances, the growing roots may occasion a continued irritation of the inferior maxillary nerves and vessels, which gives rise to the pathological new-formation.

Sarcomatous proliferations may manifest themselves even while the development of the tooth within the dental sac is in progress. E. Neumann* reports a case of a tumor of the lower jaw which occurred in connection with a degeneration of the connective tissue of a tooth-sac. A spherical mass, as large as an apple, occupied the interior of the maxillary bone. This mass contained, besides a cyst and numerous concretions, a soft, red, spongy tissue, principally, and was invested by a capsule of connective tissue; it consisted of papillary, dendritic excrescences supplied with wide capillary loops which Neumann considered to be derived from the normal papillæ that project from the walls of the dental sac into the gelatinous tissue of the enamel organ. The two, somewhat stunted, roots of a molar tooth were firmly mortised into the capsule, while the crown, having four cusps and imperfectly covered with enamel, projected into the cyst. The tooth was located upon the lower portion of the bony wall facing the oral cavity, directly beneath

* Langenbeck's Archiv. für Chirurgie, Bd. IX.

the anterior bicuspid. Its roots, directed downwards, rested upon the floor of the bony shell, its crown was directed upwards. In this case, then, we find, in connection with a retention-cyst of a molar, a spongy new-growth which, possibly, had its origin in the commencement of the growth of the roots of a very deeply located tooth, whereby the vascular and nervous trunks were subjected to an irritation.

The simple *periosteal sarcomata* are located upon the surface of the jaw, but spread into the substance of the bone, especially if they are of long duration. They are composed of multifariously interlacing bundles of elongated, fusiform cells. *Myeloid sarcomata*, also, are recognized, which grow out from the medullary portion of the jaw and inclose, together with others, the multi-nucleated, gigantic cells which have been mentioned before (comp. p. 325).

The *osteo-sarcomata*, regarded by Virchow as that variety of sarcoma which is more nearly allied to the osteomata, have their representatives in the ossifying *epulides* and, likewise, occur upon the jaw without the alveolar process. Schuh* introduces, under the head of secondary osteoids, a variety as having originated from cellular-tissue tumors, which require notice in this connection. According to his observations, soft, painless tumors, uniform to the touch and of remarkably slow growth, exist for several years, prior to the occurrence of ossification, in healthy individuals (in one case in a man with tuberculosis), at the middle period of life; after ossification of the greater portion has ensued, proliferations of new, roundish lobules of connective tissue sometimes take place in connection with an increased formative action. They arise, generally, upon the outer surface of the lower jaw; sometimes they acquire such enormous dimensions that the tooth becomes displaced, loosened and detached, and the mass, rendered indistinctly lobulated and botryoidal by the ossified portions, extends from the chin to the articulation of the lower jaw, or from the nose to the mastoid process, and from the zygoma beyond the inferior margin of the body of the maxillary bone.

* Pseudoplasmen.

GELATINOUS TUMORS (Rokitansky), MYXOMATA (Virchow).— These are developed within the jaws, may acquire notable dimensions and are characterized, chiefly, by a predominance of young connective-tissue cells in an areolar stroma. The mixed varieties, myxoma fibrosum, enchondromatosum and cystoides have been observed. The following history of a remarkable example of the last variety is given in detail in consequence of its infrequent occurrence and its malignant character.

An extensive tumor was developed with great rapidity in the lower jaw, upon the left side, and was accompanied by very severe pain. Resection was performed by Dr. Lewinsky, and the wound healed *per primam intentionem*.

The neoplasm, consisting of several protuberances united together, commencing just beneath the condyloid process on the left side, extended as far as the canine tooth on the same side, having a long diameter of nearly one decimetre. Only a very small portion of the compact cortical substance of the bone remained, from the condyloid process downwards and upon the left of the canine tooth. The thickened periosteum of the corresponding portions passed immediately into the dense, membranous investment of the tumor. At the angle of the jaw, several protuberances, as large as a chestnut, projected downwards and inwards and, having a very much softened bony covering, afforded an indistinct sense of fluctuation. The horizontal and ascending rami of the jaw were movable towards each other. The coronoid process was entirely concealed by the tumor which ascended from the knobbed inferior margin of the jaw to a height of seven to eight centimetres. Two of the protuberances, about the size of a walnut, had ruptured internally and presented in their interior, a gelatinous, viscid fluid which was tinged with blood. These cavities were lined with a framework of minute, intercommunicating cysts and numerous, smooth, reddish, soft excrescences.

The oral mucous membrane was considerably swollen. The crown of an upward-displaced molar tooth projected between the swollen gums.

The muscles attached to the ramus of the jaw appeared as if they had been permeated by a gelatinous (sulzig), reddish sub-

stance; the mylo-hyoid nerve presented a fusiform swelling in its course, from an infiltration of a similar substance.

A section through the entire tumor, from the middle of the condyloid process as far as the sawed surface, showed the bone to have been displaced by a gray-reddish mass, in the process of degeneration here and there, and inclosing cavities the size of a lentil or pea. The osseous substance, with the exception of very slight portions, had disappeared. The histological appearances are illustrated in the Atlas, Fig. 141.

It may be remarked, further, that the muscular fasciculi inserted into the ramus of the jaw, their tendinous expansions, the gum and the dental periosteum, but not the pulp of the molar tooth, were affected in a similar manner by the proliferation, with the exception that the small cysts (resembling those of the thyroid gland), together with their hyaline contents, appeared to be less abundant and in their stead merely agglomerations of nuclei were formed, for the most part. So the primitive fasciculi of the masseter muscle, where they were inserted into the tendinous expansion, presented, here and there, proliferations of oval nuclei, surrounded by layers of protoplasm, upon the interior of the sarcolemma whence the swollen bundles no longer displayed any transverse striation. At other points, the proliferation occurred between tendinous bundles, nerves and blood-vessels.

The malignant character of this new-formation (cysto-myxoma) is indicated by the multifarious prolongations into the neighboring organs, the painfulness and the rapid growth. The results of its histological examination, however, exclude the idea of a cancerous nature.

CARCINOMATA.—*Epithelial* cancer in the oral cavity, for the most part, takes its origin in the gums of the upper molar teeth, or in the mucous membrane of the palate. The infiltration spreads to the dental periosteum of the corresponding tooth, as has been mentioned before, but does not extend to the pulp. The cancer finally spreads anteriorly in the body of the upper jaw, and the lymphatic glands, usually, are attacked at a very early period.

Epithelial cancer of the borders of the maxillary bones is dis-

tinguished from other varieties, according to C. O. Weber,* by its decided non-malignant character, and is curable by the removal of all the diseased portion.

Medullary cancer has its seat more frequently in the upper jaw. According to the observations of Schuh, it originates with elderly people most frequently in the anterior wall of the upper jaw, in the region of the canine fossa and the infraorbital foramen. It forms, at first, an immovable, painless, firm tumor and, sometimes, takes on a rapid growth and spreads to the neighboring bony tissue in two to three months. If it extends downwards, towards the alveolar process, the teeth become loosened and fall out, in which cases I have, likewise, found an infiltration of the dental periosteum, but could never detect a similar condition of the pulps.

Schuh† met with other cases of medullary cancer where the affection first made its appearance upon the alveolar process opposite the molar teeth, and, in one case, upon both sides simultaneously. The teeth became detached while the tumor was yet of small size and the covering of mucous membrane was quite unaffected. It was distinguished from parulis and necrosis by the absence of pain and by the non-occurrence of exfoliation of the hard, bony portion, and, moreover, the offensive odor emitted from the sockets of the teeth, the simultaneous affection of both sides in one case and the marked cachectic appearance, indicated a malignant formation. The occurrence of the latter symptoms was succeeded by death, in consequence of the concurrent affection of the internal organs, while the tumor of the jaw had not acquired notable dimensions.

Medullary cancer may be confounded with epulis, and the surest means of discrimination is afforded by a microscopical examination of an excised portion.

Grohe‡ describes a *melanotic cancer* of the intermaxillary bone, which originated in the dental sacs of the incisors of a boy five years of age. All the incisor teeth were wanting, with the exception of the left lateral, and the eruption of that was only imperfectly effected. Grohe regards the dental sacs of the

* Op. cit.

† Pseudoplasmen.

‡ Virchow's Archiv, Bd. 29.

permanent incisors as the starting-point of the tumor and states, as his opinion, that the development of the former began at a very early period and was arrested prior to the formation of the dental capsules. The dental sac of the lateral permanent incisor on the left side was found, but it contained no trace of the dental tissues; it was located directly behind the milk tooth. In the place of the lateral permanent incisor on the right side, a bean-sized, melanotic mass was found, which was united anteriorly to the milk teeth, posteriorly and upon either side, to the compact bony tissue; no remains of the permanent tooth were discovered. Finally, the localities of the two central permanent incisors, no trace of which was found, were occupied by the very large new-formed mass. C. O. Weber* recorded four cases of melanotic cancer in this locality, and states that the affection often spreads from the gums of the incisors to the alveolar border and to the body of the jaw.

Fibrous cancer, extending from the gums, was not met with by Schuh; in the upper jaw it originated either at a point corresponding to the anterior wall of the antrum, or in the middle portion at the line of junction of the alveolar processes. On the lower jaw it usually has its origin in the interior of the bony tissue; at first it is tolerably circumscribed and is likely to be confounded with fibroma or epulis. Frequently, the pain attending it is very slight, indeed may be wanting entirely, even under pressure, whereby its resemblance to epulis is all the more marked; but the glands become swollen from infiltration at a very early period, and the patient always has a cachectic appearance. The combination of the fibrous and medullary forms is not an uncommon occurrence.

Gelatinous cancer, especially in the form of cystoid-gelatinous tumors of the upper jaw, observed by Rokitansky, and *osteocarcinomata*, with a new-formation of a radiating or alveolated bony tissue or of a compact bony shell inclosing the soft, cancerous mass, are of very rare occurrence.

ANTRUM.—*Cysts* of the antrum are met with, frequently, and are of special interest to the dentist in a clinical point of view,

* Op. cit.

when they are developed upon the floor of the cavity, in the mucous membrane which, together with the subjacent periosteal layer, is in immediate relation with the roots of one or another molar or of the second bicuspid. They are liable to give rise to a fistula of the antrum when they are accompanied by an inflammation of the dental periosteum of the corresponding teeth, which necessitates a removal of the latter.

Luschka* made a special study of these cysts and found that, in some cases, they occur singly, and in others, a number are developed, some of which present broad, basal attachments, and others project into the cavity, pushing the mucous membrane before them, and appear to be pediculated. The smaller cysts, usually, contain a quite consistent mass resembling boiled sago; these masses, varying in size up to that of a hazelnut, inclose a yellowish, caseous matter, besides a light-colored fluid. Frequently, also, he found the contents resembling inspissated mucus, in which cases the cysts presented a generally clouded appearance.

From his observations, Luschka is inclined to the opinion that by far the greater number of the cysts of the antrum have their origin in a glandular degeneration, since in very many of the branching utricular mucous glands in adults, he met with cyst-like expansions, here and there, both of the principal tubes and ultimate follicles.

In about sixty examinations, post mortem, Luschka met with the so-called *polypi of the mucous membrane* in the antrum in five cases at least. According to him, these polypi are clavate or pyriform, and attached by means of their narrow extremities. In other cases, they have a flattened, lobulated form, and are attached by their broad extremities. Usually, the outer surfaces are smooth and seldom, at least to the naked eye, present an indented or foraminated appearance. Those observed by him varied from one-half to two centimetres in length.

The favorite seat of the polypi of the antrum is upon its internal wall, where they may completely block up the apertures of communication with the middle meatus, and hence give rise

* Virchow's Archiv, Bd. 8.

to accumulations of mucus. In most cases, only a single polypus was found. In one case, he found six, which, together with a number of cysts and an abundance of tough mucus, entirely filled the cavity. The parenchyma of the polypi appeared to him to be a lax, vascularized, connective tissue, containing an abundance of cell-nuclei. He has, as yet, been unable to detect glands of any sort in them.

These polypi occasion no inconvenience so long as their size does not exceed certain limits;* if they continue to increase, they distend the walls of the cavity and occasion attenuation and resorption of the latter. In still more advanced stages, they give rise to a feeling of distention and weight on the cheek of the corresponding side; hemorrhages occur from the nose, and a discharge of a thin, mucilaginous, later sanious and foul-smelling fluid. After the cavity is filled by the polypi, the tumor increases in size and the pain becomes more severe in consequence of the distention. Most frequently, the nasal wall of the antrum is perforated between the second and third turbinated bones, or the polypus enters the nasal cavity and is developed therein, always, however, towards the posterior nares. Sometimes perforation takes place in the hard palate; a third location for the same process is the anterior wall of the upper jaw, and a fourth, the orbit, into which the polypus presses, either through its inferior wall or through the spheno-maxillary fissure or the nasal fossa along the pterygo-palatine canal, or through the spheno-palatine foramen. The vision becomes affected in consequence of pressure upon the bulbs and the optic nerves. Finally, the polypus extends through the nasal cavity into the posterior nares and the pharynx.

Passing over other tumors in regard to which it is doubtful whether or not they are growths which originate in the antrum rather than in other parts, it remains to be noticed that entozoa are said to have been found in these cavities;† these may possibly have been the larvæ of flies.

* Adelman, *Krankhafte Zustände der Oberkieferhöhle*, Dorpat, 1844.

† Benj. Bell, 1787, and Ludw. Frank, 1815.

VI. ANOMALIES OF THE SECRETIONS.

The teeth are bathed constantly with a fluid which is furnished by the salivary and mucous glands that empty into the oral cavity. The secretion of the three pairs of salivary glands, the parotid, submaxillary, and sublingual, amounts to about fifteen hundred grammes in twenty-four hours, according to the measurements of Bidder and C. Schmidt, of Dorpat.

The *saliva* varies in character in the different salivary glands. Hoppe-Seyler* describes the secretion of the parotid in man and animals as a fluid which is always clear, limpid, and watery, without the slightest viscosity, has an alkaline reaction and, when boiled or exposed to the air at the ordinary temperature, is rendered turbid by the precipitation of carbonate of lime. The inorganic matter, according to the results of most analyses, amounts to scarcely 0.5 per cent. The fluid secreted by the submaxillary glands is colorless, gelatinous, viscid, and thready, and has a faint alkaline reaction; it throws down no deposit when exposed to heat or allowed to stand in the air, but effervesces slightly on the addition of acids. The saliva of the sublingual is still more tenacious and viscid than that of the submaxillary glands, and also has an alkaline reaction. The name *ptyaline* has been given to the mucous or albuminoid matter which has not yet been sufficiently investigated. From these results obtained by Hoppe-Seyler, it appears that the secretion of the submaxillary, but more particularly that of the sublingual gland, contains mucin and in this respect, then, resembles the secretion of the mucous glands.

The *mucous glands* of the oral cavity, which claim notice in this connection, are the marginal glands of the tongue, namely, those of constant occurrence upon either side of the apex and at the root, and those occasionally met with at the middle; further, the large labial glands, the less numerous buccal glands, and those of the hard and soft palate.

The mucus is a viscid, sometimes clear and colorless, and at

* Handbuch der physiol. und path. chemischen Analyse, 3. Aufl., 1870.

others, somewhat turbid secretion, and generally has an alkaline reaction.

Moreover, there exudes from every portion of the mucous membrane where there are no glands, and even from the gums, a fluid containing the effete, flattened, epithelial cells, which are replaced by younger cells. There is a *continual process of decay and repair* in the oral cavity.

The *mixed saliva* of the mouth is a compound of saliva and mucus. According to Hoppe-Seyler, the saliva which escapes from the mouth, when it is kept open and no attempt is made to swallow, usually, and always after eating, has an alkaline reaction; after prolonged fasting, however, and particularly after continued talking, it may become acid.

Sulphocyanide of potassium is found in the mixed saliva and is peculiar to the latter, having never been detected in any other part of the organism. Hoppe-Seyler states that in man the mixed saliva very frequently contains *sulphocyanic acid*, while it cannot be found in either of the secretions which compose the saliva, and adds, this acid, therefore, undoubtedly is a product of decomposition, and is formed primarily within the oral cavity, since it is not usually present after eating and, with some individuals, is never found, especially with those who have sound teeth, though even with such persons it is frequently formed in the saliva, when the latter is exposed to the air at the temperature of the blood. According to these statements, this acid has a pathological importance with reference to the teeth. Schönbein detected usually, but not always, a nitrous acid salt.

Wright, in his familiar monograph,* laid the foundation of a pathology of the saliva. The conclusions drawn by him, obviously with reference to the mixed saliva and requiring revision, certainly, in many respects and more extended investigations, have a considerable degree of interest in connection with our present subject. He says, the acidity of the saliva in different diseases is due to the presence of divers acids. Lactic acid is found in gout, rheumatism, intermittent fever, diabetes,

* On the Physiology and Pathology of the Saliva, 1842-44.

gastro-enteritis; acetic acid with aphthæ, scrofula, scorbutus, variola, indigestion, and after the use of acid wines; hydrochloric acid in connection with simple gastric disturbances; uric acid in gout, and oxalic acid with digestive derangements. Alkalinity of the saliva occurs: *a*, in consequence of the presence of an excess of soda. It is considered to imply, pathologically, general or local disturbances of the nerves. The local affections of the nerves comprise chiefly facial neuralgia and odontalgia, dependent upon denudation of the pulp without inflammation of the periosteum of the root and the adjacent tissues. The alkalinity, frequently, is an important aid in diagnosis, inasmuch as the purely nervous facial pain is accompanied almost always, by an alkaline, and the rheumatic pain by an acid saliva; *b*, alkaline saliva, in consequence of the presence of ammonia, is of quite rare occurrence, and is met with in severe catarrhal affections, putrid fever, scorbutus, and purpura hemorrhagica. A calciferous saliva, containing carbonate of lime, gives rise to the formation of tartar, salivary calculi, and ranula. The latter condition, by no means of rare occurrence, is accompanied by dyspeptic symptoms.

According to the statements of Kühne,* urea is the only abnormal substance that has been identified with certainty in the (pure) saliva; this is found in Bright's disease and, also, in the secretion from the submaxillary glands of animals, after the ligature of the ureters. The sugar found in the oral cavity of persons affected with diabetes, he says, is never a product of true saliva, but, probably, of the bronchial mucus, since it cannot be detected except in cases where the oral cavity is not properly cleansed or after hard coughing. Further investigations, he adds, are necessary in order to determine whether the characteristic, often very noticeable odor, emitted from the mouths of diabetic persons, is dependent upon an ingredient of the saliva.

In febrile affections, as is well known, the salivary secretion is diminished, the mouth is dry, and the epithelium accumulates, since it is not removed by the saliva.

* *Physiolog. Chemie*, 1868.

In catarrhal inflammation of the oral mucous membrane and, especially, in mercurial salivation, as much as one per cent. of inorganic salts has been found in the saliva of the oral cavity.

The normally thin, slightly turbid, pellucid, odorless *coating upon the teeth*, is a secretion of the gums mixed with the oral saliva, and accumulates particularly in the intervals between the teeth. In the recent condition, this coating is neutral and, exceptionally, it is slightly acid. In man, at least, it is the frequent seat of living organisms, concerning the nature of which there has been much discussion.*

When the coating forms a pultaceous, unctuous, cloudy mass having, occasionally, a feculent odor, it consists, principally, of a uniformly fine-granular mass which formerly was considered to be organic detritus, but at present is regarded as so-called matrix of leptothrix and sometimes is distinguished as micrococcus. The grains are disposed upon the outer surface of the exfoliated epithelial cells, but, in consequence of their minuteness and rapid multiplication, their cell-nature and division are scarcely recognizable with the optical appliances in use at the present day. The epithelial cell becomes masked by the in-

* Leeuwenhoek, who discovered these (1695), describes them as lines of varying length and uniform thickness, bent in some places, straight in others, and irregularly disposed. He conjectured that these bodies were animals, from the fact that he had met with them alive in water; he could, however, detect no movement in those of the coating of the teeth. Bühlmann (1840) demonstrated their property of withstanding the action of concentrated sulphuric and nitric acids and caustic alkalies. For some time, in consequence of the uncertainty regarding their nature, they were termed Bühlmann's fibres. Henle was the first to suggest the vegetable nature of these filaments, while, on the other hand, Ficinus (1846) advocated their animal nature, and designated the animated organisms as *denticolæ*, and connected them with caries of the teeth. Robin (1847) placed them in the family *Leptotrichæ* of Kützing, and applied to them the name *Leptothrix buccalis* which has generally been accepted. Robin, consequently, ranked leptothrix with the algæ, while, in modern mycology, they are classed with the fungi. Hallier (1860) is inclined to have leptothrix, as a generic term, banished from mycology, considering this fungus to be merely a vegetation form of different lower fungi which he denominates leptothrix series. Hallier goes still further and states that leptothrix buccalis is merely a form of development of the ordinary mould fungus, *penicillium glaucum*.

crease of the granular formations, and to the latter, attach themselves, in the course of time, bundles of tolerably long, usually interlacing, uniformly thick filaments; these frequently are short, rod-shaped, and commonly are designated by the term Bacteria. These vary in length and thickness, usually are isolated, less frequently occur in chain-like rows, and manifest periodical oscillatory movements. Leber and Rottenstein* obtained a violet color from the leptothrix grains and filaments, by treatment with iodine and acids, a reaction which ensues much more readily, as I have also convinced myself, if dilute hydrochloric acid be employed, after the fungus has been treated with an aqueous or alcoholic solution of iodine; a mixture of glycerine and tincture of iodine, I have also found to be advantageous. The reaction, as Leber and Rottenstein have shown, displays the transverse markings of the filaments in a beautiful manner. The interior portions are colored, and the septa of the filaments remain without being colored. The same reaction ensues, as is self-evident, with the matrix and threads of leptothrix in the coating of the tongue.

The extremely delicate, coiled filaments (Spirillum), which occur in fewer numbers in the coating upon the teeth and were included by Ficinus in his *Denticolæ*, are regarded by several mycologists as swarm-spores of leptothrix. The abundant, animated grains, according to the opinion of Hallier, are likewise swarm-spores which arrange themselves in the form of continuous chains. Now and then a mycelium is met with identical (isomorph) with that found in the fungus of *aphthæ* [*Oidium albicans*].

Leptothrix is found very frequently in the oral mucous membrane. Robin† cites H. I. Bowditch, who found that out of forty-nine individuals taken from all classes of the community, not one of whom exhibited a diseased mouth, forty-seven presented vegetable or animal parasites in the intervals between the teeth or in the localities corresponding with the junction of the latter with the gums. Bowditch considered them to be merely the result of a want of cleanliness.

* Ueber Caries der Zähne, 1867.

† Histoire Naturelle des Végétaux Parasites, 1853, p 354.

Individuals with swollen gums, pregnant women, or those who are afflicted frequently with dyspepsia, with inflammation of the tonsils and mucous membrane of the fauces, or with mercurialismus, scrofulosis, scorbutus, or who live in a confined atmosphere and are especially exposed to agencies which produce an irritation of the gums, are very liable to be affected with leptothrix, notwithstanding an abundant secretion, and even with the utmost cleanliness.

The colored, firmly-adherent deposit on the teeth assumes a decided green, gray-green, gray-brownish, gray-yellowish, or brown color. The green deposit occurs, not merely in advanced age, but also upon the teeth of young persons, both upon normally-formed and abnormal teeth, whether they present accumulations of tartar or not, and whether they are affected with, or do not show the least evidence of caries.

It is most conspicuous upon the labial surfaces of the front teeth of the upper jaw, in the form of a superficial discoloration of the enamel, which follows the lunated margin of the gum and acquires its greatest intensity at a certain distance from the gingival margin and towards the incisive edges, coronal eminences and cusps of the teeth. The discolored portions present spots where the tinge is more or less intensified. The latter, usually, are more evident in the depressions produced by erosion of the teeth.

The thin deposit, which is distributed without uniformity, cannot be washed off with water nor wiped off, but must be scraped away with a sharp knife, when the enamel will be found bright and intact.

Examined with reflected light, the deposit is found to be a granular mass. It is more advantageous to make use of the green deposit, after it has been scraped away, for investigation, or still better, the membrane of the enamel [Nasmyth's] which may be detached by means of dilute hydrochloric acid; by these means, it may readily be demonstrated that the deposit is a green, green-yellowish, uniformly minutely granular mass which is morphologically identical with the matrix of leptothrix.

If the membrane of the enamel is preserved in glycerine, the

green not unfrequently disappears in a few days, leaving a dirty yellow, yellow-brownish color.

I have never observed a penetration of the green, granular mass into the peripheral enamel layer, though I have met with systems of enamel prisms, containing deposits of pigment, which have acquired a greenish color in their cortical layers, a condition which may be explained by the penetration of the green coloring matter.

The dark-brown deposit, as it occurs with habitual smokers, is observed upon the lingual surfaces of the teeth, especially of the upper molars; almost always it is very thin, may be scratched off, accumulates, particularly, in the depressions of the enamel and, ultimately, forms a sooty covering over the entire lingual surfaces, from the masticating surfaces to the borders of the gums which, usually, are considerably retracted, especially opposite the lingual roots of the upper molars.

If we examine the surfaces of transverse sections through the necks of teeth presenting the sooty coating from the use of tobacco, the dentinal layer nearest the deposit presents a grayish discoloration, giving an appearance as if the adjoining dentine had become involved in the staining process, so that it might be supposed that the coloring matter had penetrated to the dentine. This, however, is not the fact. If a portion of the sooty coating be scraped off, the dark discoloration of the corresponding portion of the dentine disappears, showing that it was due to the transparency of the dentine. This appearance becomes more conspicuous in a cross-section of a senile tooth with a sooty coating and horny translucent dentine.

If the scrapings of the sooty coating are treated with dilute hydrochloric acid, a few bubbles of gas will be set free and there is left a dark-brown, laminated mass, consisting of amorphous, brittle plates with an angular fracture, and containing neither matrix nor filaments of leptothrix.

A peculiar *deposit with a metallic lustre* is met with especially upon the teeth of cattle. If scrapings of this are treated with hydrochloric acid, the morphological elements present very thin lamellæ of cornified epithelium which has acquired a yellow color. The metallic lustre, therefore, is a phenomenon of inter-

ference occasioned by the superposition of the uncommonly thin, cemented lamellæ.

The *formation* of the adherent deposit upon the teeth may readily be explained. Since the gums are attached to the dental necks and the extremities of the papillæ upon the gingival borders project slightly, accumulations of the secretion of the gums are the more likely to take place in these localities. This secretion flows downwards upon the upper teeth and accumulates especially in the depressions and grooves of the enamel surface. In consequence of the frequent occurrence of leptothrix in the oral cavity of man, this epiphyte finds a lodgment in the viscid coating containing effete epithelium. The latter, in conjunction with the proliferating leptothrix, becomes saturated with the constantly secreted saliva, the calcareous salts of which are precipitated in the minutely-porous substratum. In this way, there is formed a cemented mass which cannot be removed from the surface of the enamel except with the aid of sharp instruments. With regard to the deposit upon the teeth of cattle, and to the brown deposit produced by tobacco-smoking, it is obvious that leptothrix is not required in their formation.

Several varieties of *odontolithus*, *tartar* are distinguished, the most common of which are the white porous, the gray-brownish, dark-brown with black superficial layers, now and then like ebony, and the dirty green.

The *white* tartar, which occasionally has a tinge of gray or yellow upon its outer surface and in cross-section presents a chalky whiteness, occurs upon the facial aspect of the dental necks and in greatest abundance upon the bicuspid and molars, particularly upon those of the upper jaw; its exposed, rounded, outer surface is polished more or less by friction with the mucous membrane. Its formation begins at the border of the gum and, sometimes, it acquires dimensions sufficient to envelop completely the crowns and their masticating surfaces. If the roots of the teeth are deprived of their protective coverings in consequence of a continued accumulation of tartar and chronic suppuration of the gums, periosteum of the roots and alveoli, the tartar then extends to the apices of the roots and may spread even beyond them. As it is disposed about the separate teeth, and the latter

admit of a certain degree of movement during mastication, it is obvious that adjacent masses of tartar become smooth from friction with each other. The lingual surfaces of tartar are rendered smooth by the movements of the tongue. Fig. 128 in the Atlas illustrates a colossal mass of tartar inclosing four teeth, which was reported by Heider.* Strasky, of Lemberg, removed this deposit from the mouth of a Polish Jewess who went to Lemberg for the purpose of being operated upon for the removal of a supposed tumor of the bone, for which she had been treated at home, without success, with iodine and mercurial preparations.

The explanation of the fact that tartar is formed in greater abundance upon the facial surfaces of the upper bicuspids, and molars, is to be sought in the local relations, in the fact that Stenon's duct empties directly opposite the second upper bicuspids. The saliva washes over the above-named teeth in great abundance and is rapidly removed from their lingual surfaces by the movements of the tongue, while upon their facial surfaces, in consequence of the contact of the cheeks with the teeth, comparatively less is removed.

Large accumulations of tartar are formed upon those teeth which are deprived of their antagonists, or upon painful teeth which compel the patient to abstain from using the corresponding side in chewing and biting, and to neglect proper cleanliness. In either case, abrasion of the forming tartar is prevented.

The lingual and facial surfaces of the necks of the lower incisors, likewise, are frequently the seat of the yellowish-white, porous tartar. The saliva from the submaxillary and sublingual glands collects upon the floor of the oral cavity and gives rise to an increased deposit which sometimes spreads nearly to the apices of the dental roots.

Castle asserts that the tartar sometimes is deposited even in the foramen which serves for the transmission of the dental nerves, and occasions severe neuralgias in the branches of the fifth pair; that it is deposited, also, upon artificial teeth, upon

* Mittheilungen des Centralvereines deutscher Zahnärzte, 1860.

the gold and silver or gutta-percha in which the artificial teeth are set, but never within or upon the alveolar processes.

Polished surfaces of sections of the larger deposits of tartar display concentric laminæ corresponding in their direction with the curvature of the outer surfaces. Thin slices are not instructive since they present merely amorphous, opaque masses which, for the most part, afford a considerable amount of organic residue when treated with acids. I have succeeded better in delineating the details of the laminations, by making sections of fragments of the tartar by means of a sharp knife and treating them with heated acetic acid. When the calcareous salts have been removed, coherent systems of mortised, delicate, sharply-defined layers, separated from one another by intervals measuring scarcely 0.001 millimetre, are brought into view. Roundish disks of various diameters form the foci; around the whole or portions of these, the layers are disposed as in the agate, presenting a resemblance to those displayed in very thin sections of urinary calculi of uric acid. Here and there, laminated or separate, effete epithelial cells, and the granular matrix or numerous filaments of leptothrix, are met with. If a number of thin slices of tartar are treated with very dilute hydrochloric acid for the purpose of studying the organic residuum, in addition to occasional vegetable remains, thallus-threads of oidium are found, occasionally, in not inconsiderable numbers (Atlas, Fig. 129), forming free projections upon the corroded portions.

The *gray-brown or dark-brown* tartar is considerably harder than the preceding, accumulates in smaller masses and more slowly and attaches itself chiefly to the lingual surfaces of the necks of the lower incisors; it occurs often upon the upper incisors, canines, and bicuspid, less frequently upon the lingual surfaces of the molars and still more rarely upon their buccal surfaces.

Surfaces of sections of this form of tartar display irregularly wavy laminæ, presenting various shades of dirty-brown, gray and yellow. The laminæ vary in thickness, for the most part, present imperceptible transitions from one into another and, here and there, form a distinctly stratified system. Since, in many places, the dark and bright layers are arranged in close

proximity, an appearance is presented, bearing a strong resemblance to the white porous tartar (Atlas, Fig. 130).

Thin sections or slices, from which the calcareous salts have been removed by means of dilute hydrochloric or heated acetic acid, do not present any lamellæ of effete incrustated epithelium, but contain an abundant homogeneous mass of minutely granular leptothrix. Quite numerous leptothrix filaments, likewise, occur in tufts here and there; numbers of isolated, so-called bacteria, also, may readily be demonstrated by means of trituration. The brown color, in many layers, arises partly from dark and light brown, free granules, and in part, also, it is due to the general brownish tinge of the molecular mass. Sometimes, a color shading into greenish is met with.

The *gray-green* tartar is very hard and forms a ring around the neck of the tooth, generally several millimetres broad; quite often it is covered by the gums and has a more or less nodulated outer surface; it is thickest in the portion adjacent to the gingival border, and becomes attenuated both in the direction of the root and towards the crown.

Hydrochloric acid slowly extracts its calcareous salts, leaving a comparatively large amount of greenish leptothrix matrix, together with numerous filaments. Brown, granular agglomerations are imbedded here and there.

Tartar is very common on the teeth of *old animals*. In the horse, white tartar is distinguished by its containing an unusually large amount of carbonate of lime, which is indicated by the very active effervescence produced on the addition of acids. In the dog, the green tartar exhibits a comparatively large amount of organic matter. The tartar with a metallic lustre, which is found on the teeth of cattle, is of especial interest, from the fact that in this the mass of leptothrix and the necrotic epithelial layers are sharply distinguished from each other. Even with the naked eye, a number of fine pores may be seen upon the surface of this form of tartar; with the aid of a lens, thin, decalcified slices display a network of canals which prove to be cavities filled with a mass of leptothrix. Between these cavities lie the multifarious, brittle, yellow lamellæ of cornified epithelium.

Mandl* has advanced the view that tartar is composed of a cluster of vibriones which are encased in a coating of lime. Though it is true that parasitic organisms participate in the formation of tartar, nevertheless the view of Mandl is untenable, according to the ideas of the present day, since the supposed vibrios are constituent portions of leptothrix and possess no calcareous coats.

The amount of calcareous salts, the relative proportion of carbonate and phosphate of lime, the quantity of organic matter, the quantity of leptothrix buccalis distributed in the calcified portions and the occasionally included particles of food present many variations in the different kinds of tartar. Generally speaking, it is observed that tartar contains the same constituents as salivary calculi with the exception that it has a greater amount of phosphate of lime than the latter. Berzelius, as is well known, also demonstrated the existence of an albuminoid substance in tartar, called *ptyaline*, a fact of importance inasmuch as the participation of the saliva in the formation of tartar is vindicated even upon chemical grounds.

Two elements are to be discriminated in connection with the formation of tartar, in the first place, the organic cement and in the second place, the inorganic salts. The former is furnished by the mucus and epithelium from the gums, by the mucin-holding substance of the mixed saliva, and by the leptothrix buccalis which proliferates in the degenerating substances. It cannot be asserted that the latter is an essential ingredient of tartar; it gives firmness, however, to the organic cement and increases the consistence of the green and brown tartar.

The calcareous salts are deposited chiefly from the saliva. If the latter contains an unusually large amount of such salts and, especially, if the salivary secretion is augmented, the tartar is deposited with comparatively greater rapidity. Hoppe-Seyler asserts that, in cases of iodine and mercurial salivation, the saliva contains an abundant admixture of the secretion produced by the catarrhal inflammation of the mouth and throat and, hence, on being boiled with the addition of a little acid, it

* Comptes rendus de l'Acad. des Sciences de Paris, t. 17.

usually affords an abundant coagulum, particularly in cases of mercurial salivation; moreover, as has already been observed, it contains nearly one per cent. of inorganic salts, while normal saliva contains a much smaller amount.

The concrement becomes foraminated by the constant action of the saliva upon the surface of the tartar; indentations and fissures are formed (Atlas, Fig. 128), which afford a favorable nidus for the proliferation of *leptothrix buccalis*. These circumstances explain the occurrence of sharply defined channels filled with a mass of *leptothrix*, which are so conspicuous in the tartar of the teeth of cattle.

Fox* stated explicitly that, with the exception of caries, nothing is so pernicious to the healthy condition of the mouth and the durability of the teeth as the accumulation of tartar. Hunter, and previous to him, the French dentists Fauchard and Bourdet, were quite well aware of the injurious effects of tartar. These comprise the production of a catarrhal inflammation of the gums, the loosening of the adhesion of the latter to the necks of the teeth; the tenacious mucus collects in the pockets formed by the gums and forms an incrustation upon the necks of the teeth and a superficial ulceration takes place upon the borders of the gums. Not infrequently the irritated gums become swollen and superficial hemorrhages ensue. If the gum is involved where it becomes continuous with the root-membrane, a sensitiveness of the tooth is produced. The accumulated purulent mucus undergoes decomposition and emits a fetid odor from the mouth; it undermines the contiguous alveolar wall in which it induces a resorption; then the tartar is deposited directly upon the cement of the root, without affecting the dental substances in the least, and it is not an uncommon occurrence for the corresponding root to be incrustated as far as its apex in consequence of which, the tooth, especially if it has but a single root, becomes loosened and detached. Frequently, however, the sensitiveness becomes so marked in consequence of the affection of the periosteum of the root, that patients decide upon extraction even before the tooth has become loose.

* Nat. Hist. of Human Teeth, p. 95.

The tartar, therefore, does not injure the teeth directly, but merely in an indirect manner through the irritation produced by its more or less rough, tuberculated surface upon the gum, chiefly within the pockets formed by the latter. If it has sharp edges projecting over the gum, as is wont to be the case, particularly upon the lingual surfaces of the lower incisors, or if one or another portion of the tartar break away, still further injurious effects are produced. Large masses of tartar do not occasion more serious effects, since their outer surfaces become smooth.

It is impossible as yet to explain, in every case, the deposit of tartar upon the teeth of many persons, in spite of the utmost cleanliness.

Calciferous saliva and catarrh (comp. inflammations of the gums) favor the formation of tartar, as also does advanced age, principally because at this period the secretions are diminished in quantity and the regeneration of the epithelium of the gums takes place more slowly.

CARIES OF THE TEETH.—It was quite natural to transfer to the teeth the signification implied in the expression “caries (Beinfrass) of bone,” indeed the fundamental phenomena, namely, the destruction of the hard tissues, offered a striking analogy. In their development, however, the two processes by no means present such an identity. Caries of the bone, as is well known, is an inflammatory process (ostitis) which originates in the soft parts of the bone and erodes its hard tissues. This is not the case with the carious process in the teeth, which commences in the hard tissues and spreads to the vascularized and nervous dental pulp. Upon close investigation, the latter process is found to be so entirely distinct from the former that the attempt has repeatedly been made to expunge altogether from the nomenclature of diseases of the teeth, the expression caries of the teeth, and Klenke has proposed to substitute the general term “decay (Verderbniss) of the teeth.” This proposition, however, did not meet with very general acceptance, and it must be acknowledged that, on the one hand, nothing is gained by the introduction of so vague an expression, and on the other hand, it would be almost an impossibility to give up a

term which has become naturalized in dentistry and, indeed, even with the general public.

There is by no means a unanimity of opinion in regard to the category of diseases under which caries of the teeth is to be classed. The ground which we have taken is indicated by the fact that caries is introduced under the head of anomalies of the secretions, or, in other words, it is considered to be the result of abnormal secretion. The reasons for this view will appear in the following pages.

The importance of the process in this very frequent affection, the treatment of which forms the largest part of the practice of the dentist, leads me to enter minutely into the *history of caries*. The latter, moreover, is instructive, inasmuch as it indicates the marked proneness of the human mind, from its natural tendency to investigate the causal connection of phenomena, to wander in the mazes of hypotheses, when, in the absence of sufficient preliminary knowledge, it is prevented from penetrating the realms of truth. Notwithstanding the fact that our knowledge is advancing, unquestionably, with the continual additions to the auxiliary means at our command for carrying on the work, it must, however, be acknowledged that a theory with regard to caries, with a thoroughly scientific basis in all its details, is still wanting.

Hippocrates and his pupils, as is well known, were humoral pathologists, and hence they referred caries to the bad condition of the humors, a view which was maintained by most physicians for more than a thousand years and, even at the present day, is upheld by the traditions of the common people. Imperfect observation and, perhaps, intentional deception, gave birth to the worm-hypothesis which furnished a decidedly more concrete idea of the genesis of caries. Various means were employed to destroy the intruders. Fauchard (1728) took a great deal of pains in order to discover the worms supposed to be the most common cause of toothaches, both in carious teeth and in tartar; he never succeeded in finding any.

Fauchard distinguished several forms of caries: a scorbutic, variolous, scrofulous, a moist or putrid and a dry, a superficial, of little consequence, and a deep form which gave rise to severe

pain. He assumed an internal and an external cause for caries, as he did for all diseases of the teeth. The former, he states, acts upon the roots, both upon their outer and inner surfaces, meaning by the latter, the root-canal, and also upon the internal surface of the dental cavity; caries, which is induced by internal causes, he continues, is recognized with considerable difficulty, especially when the roots or the necks of the teeth, merely, are attacked, since it is concealed from view by the gums and the dental sockets; caries, depending upon external causes, attacks the outer portion of the tooth, *i. e.*, the enamel, sometimes the neck, and at others the roots; the internal causes are referable, generally, to the quantity or quality of faulty, acrid or corrosive lymph.

Bourdet* maintained similar views with Fauchard, and states that, when the fluids contained in dental vessels are too thick, they coagulate, putrefy, since they are confined, and act directly upon the tooth. He explains why it is that, when a tooth decays, the corresponding tooth on the opposite side almost always is similarly and symmetrically affected shortly afterwards. Since corresponding teeth, he says, commonly ossify simultaneously, and pursue the same order of development, so the common morbid process manifests itself in the corresponding teeth; the large molars, therefore, succumb earlier to caries, if they are attacked during their ossification. He evidently alludes here to the erosion of the teeth (comp. p. 143).

Hunter started with false physiological views; he regarded the teeth as foreign substances, in a certain degree, since they receive nourishment only while sound and fit for service and, when they are diseased, they do not receive the common benefits received by other parts which they resemble and with which they stand in a certain connection. He was inclined to regard caries as a sort of cold gangrene or mortification, but he states, further, that during life there is some operation going on in the tooth which produces a change in the diseased part. If a portion of the tooth is dead, he says, the remaining living portion has not the power of throwing it off and forming an external

* De l'art du Dentiste, t. i, 1757.

surface capable of supporting itself like the rest of the body. The caries, sometimes, though rarely, begins on the inside of the tooth, and in this case, the latter acquires a shining blackness from the dark color being seen through the remaining external shell of the tooth, and no opening is found leading to the pulp-cavity.

Fox* considered the proximate cause of dental caries to be "an inflammation in the bone of the crown of the tooth, which, on account of its peculiar structure, terminates in mortification."

The dental pulp, he says, becomes the subject of inflammation, and induces caries; he draws a parallel between pulp-membrane and periosteum of bone and, evidently, confounds necrosis with caries.

Thomas Bell† lays stress upon the erroneous application of the term caries in connection with the teeth, which, he says, is not in the least analogous to true caries of bone, and proposes the term gangrene (Brand) for the teeth; this he defines as mortification of some portion of the tooth, which occasions a progressive destruction of the dental substance. He corrects the erroneous ideas entertained by Fox, but agrees with him in believing that inflammation is the cause of caries, that the hard dental tissues give way to the inflammatory process in the manner of bone, that the symptoms in either case are identical and that, now and then, the tooth presents spots which are injected with the red constituents of the blood. Bell probably means by this the portions of dentine which are imbued with the coloring matter of the blood, the reddened teeth. With reference to the occurrence of caries which proceeds from without internally, he considers that those portions most removed from the nutrient vessels and nerves are least capable of resisting decay, as we know is the case in other parts of the organism. He denies that the destruction which occurs in artificial teeth is analogous to caries, and maintains the falsity of the view that caries is due to external causes which act upon the enamel. In him, therefore, we find an advocate of the pure vital theory of dental caries.

* Op. cit., p. 12.

† Anat. Phys. and Path. of the Teeth, 1835, p. 120.

Desirabode* states that the different views in regard to the nature of caries arose from the fact that all the various pathological changes upon the crowns of teeth have been included under this name; that the degenerations to which the term caries is applied are occasioned in part by local agencies, and consist in a chemical destruction of the dental tissues, which process takes place in a direction from without inwards; in other cases, they arise from some injury to the pulp or from a congenital defect in the dentine, and are developed spontaneously from within outwards. The term caries, he adds, is more applicable to the latter variety than to the former.

Regnard† upholds the pure chemical theory with reference to dental caries, considering it to be merely a destruction by acids which are formed within the mouth. He adds, silk ligatures wound around the teeth occasion the destruction of the enamel; caps applied over the teeth, whether of wax or of some metallic substance, promote their destruction; human teeth, artificial sets and separate teeth, made of the ivory from the tusk of the hippopotamus, undergo destruction.

Linderer‡ gives a correct description of the carious process in enamel and dentine, and directs attention to the light dentinal tissue surrounding the carious portion. Inflammation in dentine, he says, is not conceivable, since it contains no bloodvessels. According to his view, caries is a chemical destruction of the teeth, induced by the oral fluids. He distinguishes three stages; in the first, the enamel is destroyed and the lime of the dentine is set free; in the second, the discoloration of the previously affected tissue becomes manifest, and in the third, the diseased mass liquefies, and a cavity is formed in the tooth. He denies the occurrence of the so-called internal caries, and admits that of an inherited caries only in the sense that the disposition is inherited.

Ficinus§ thinks he has discovered the soil in which caries

* *Éléments de l'art du Dentiste* (1846), t. i, p. 220.

† *Gazette des Hôpitaux*, 1838.

‡ *Zahnheilkunde*.

§ *Journal für Chirurgie und Augenheilkunde von Walther und Ammon*, 1846.

germinates in the "cuticle of the enamel;" the brownish, sometimes black deposit upon the teeth, he says, is occasioned by the superficial decomposition of the membrane which covers the enamel; this decomposition either is consequent upon, or has, as its sequel, a putrefactive process which, in part, is caused by the presence of myriads of infusoria in the teeth (his *Denticolæ*, which, he admits, become Bühlmann's fibres by conjugation), and in part is developed from the first in the ordinary manner and occasions a gradual exfoliation of the membrane. The putrefaction thus induced, he continues, spreads to the enamel-cells, where its progress is slow, extracts their inorganic portions, ruptures their mutual connections and, finally, reaches the tubular dentinal tissue, into which it extends in a similar manner, but with greater rapidity, and terminates only with the destruction of the entire tooth. He opposes the view of Erdl who, from the external similarity of the deposit on the teeth to *Protococcus*, assumes the presence of a parasitic cryptogam which, however, cannot germinate except upon a dental surface that has undergone a pathological change.

Klenke* opposes the assertion that caries, in every instance, is due to destructive oral fluids, and advocates the occurrence of a central or inflammatory dental caries. There is a second form, he says, in which the dental tissues are destroyed by a phyto-parasite which he calls *Protococcus dentalis*. A third form, the putrid, consists in a true putrefactive process, whereby, with the co-operation of infusoria, the dental tissues are decomposed. In this he agrees with the views elaborated by Ficinus. In a fourth form, which he distinguishes as *dissolutio chemica s. chronica*, a disintegration of the dental tissues is occasioned by purely chemical means on the part of the oral fluids, and by a disposition inherent in the chemical combination of the dental tissues.

Tomes† has extended our knowledge with regard to the pathological changes presented by the cartilaginous softened carious dentine; he asserts that, in cross-sections, the tubules of the

* Die Verderbniss der Zähne, 1850.

† System of Dental Surgery.

latter are surrounded by a very thick sheath, the outline of the formative cells has been restored, in fact, by the diseased condition, the tissue is broken up, to a certain extent, into its histological elements. This appearance is not found except in dentine which has acquired a cartilaginous consistence, in consequence of caries; he knows of no artificial means whereby the appearances, such as have been described, can be brought about. He also discusses the vital phenomena which, according to his view, are coincident with structural changes in carious dentine; under this head he includes an increased sensibility and even painful sensations, chiefly in the peripheral portion of the dentine; after the destruction of vitality in this part of the tooth has been completed, the sensation of discomfort, for the most part, passes away. The transparent zone in the vicinity of the carious portion, he considers to be due to the consolidation of the dentinal fibrils within the tubes; a reaction on the part of the dentine is manifested by the calcification of its fibrils, which necessarily exercises a considerable influence in arresting the progress of disease. He refers the extraction of the calcareous salts to the acid condition of the mucus, especially to that of the gums. In many cases, he says, an acid saliva appears to cause a rapid destruction of the teeth. He also demonstrates the formation of new dentine on the wall of the pulp-cavity corresponding to the carious locality.

Oudet* considers caries to be a disease which primarily attacks the dentine exclusively, and secondarily involves the contiguous portion of the enamel.

E. Neumann† endeavored to prove the vital reactionary power of the dentine against the carious process; he considered the thickening and consolidation of the tubes and fibres, mentioned by Tomes, to be a thickening of the dentinal sheaths, at the expense of the basis-substance, together with a final obliteration of the canals. By means of the imbibition of carmine, he demonstrated, in the thickened dentinal fibres, uncolored and brightly colored segments, alternating with each other with considera-

* Recherches anatomiques, phys. et microsp. sur les dents, 1862.

† Archiv für klinische Chirurgie, Bd. vi.

ble uniformity, and is inclined to regard the colored portions as nucleiform bodies. Upon an eroded ivory peg which had been driven into a bone in the treatment of a pseudarthrosis, he was unable to detect such a condition as is presented by carious dentine; this fact he regards as a confirmation of his view, and considers that there is a marked correspondence between the changes in dental caries and the phenomena presented in caries of bone. Between caries of the teeth and of bone, he says, the distinction is purely formal, depending upon the difference between the forms of the cellular elements contained in each of the tissues respectively, the roundish bone-cells on one side and the elongated dentinal fibres on the other, which latter become thickened and detached. He observed a calcification of the dentinal fibres only in one instance, and remarks that the latter is referable to an excessive disposition to the deposit of calcareous salts at the expiration of an inflammatory process, a phenomenon which is observed in bone.

Magitot* holds the opinion that caries is a purely chemical action upon the enamel and dentine, and denies the existence of a *caries interna*. The reaction on the part of the dentine, he says, is manifested usually by the appearance of a cone or white zone, which is occasioned by obliterated dentinal canals; secondary dentine sometimes is formed at a later period in the pulp; the saliva, he observes, is the cause of the caries when it becomes the seat of acetous fermentation, or the vehicle of foreign substances which act directly upon the enamel and dentine. Upon the authority of numerous experiments, he asserts that caries may be induced artificially by imitation of those conditions which occur in the oral cavity, and that this artificial caries presents the same characters as the natural form, with the exception of the reactionary phenomena.

Hertz† undertook the examination of caries induced by artificial fluids, according to Magitot's method, and also of a number of artificial teeth which became carious within the mouth. He found merely a brownish-yellow color of the dentine, together with disintegrated and decomposing, larger or smaller

* *Carie dentaire*, 1867.

† *Virchow's Archiv*, Bd. xli.

portions of basis-substance. He found nothing abnormal in the dentinal fibres, and hence he coincides with the view that the changes in the dentine in natural caries correspond to a vital process. As pathological appearances of the dentinal fibres, he mentions that they appear swollen, cloudy, homogeneous in character, replete with fat-granules, and take up calcareous salts, and these he considers to be primary affections.

Th. Leber and J. Rottenstein* assert that there are no recorded observations which authorize the assumption of an active reaction, a kind of odontitis, on the part of the dentine in caries of the teeth, and that caries does not depend upon the changes referred to by Tomes, Neumann and others, although the occurrence of very slight histological changes in the dentine at the commencement of the process cannot be denied with absolute certainty. They came to the conclusion by proving that artificially inserted human teeth, which have become carious within the mouth, and also carious teeth, manufactured out of ivory from the hippopotamus, displayed the microscopic changes in the dentine which were regarded as proof of a vital process in the dentine. They treated leptothrix in the dentine with iodine and acids and obtained a violet color of the widened dentinal canals which were filled with a minutely granular mass, and consider it to be indisputable that the elements of the fungus proliferate within and extend the canals, sometimes to a considerable degree. The fungus, they add, apparently is incapable of penetrating enamel of normal hardness; even normally hard dentine offers considerable resistance to its entrance, if, indeed, it permits it in the least. When, however, in consequence of the action of the acids within the mouth, the enamel and dentine have lost, somewhat, their power of resistance, or a breach of substance, however small, has been produced upon the surface of the dentine, then it becomes possible for the fungus elements to penetrate into the interior of the dental substances, and by their proliferation, particularly in the dentine, to occasion a more rapid progress of the softening and destructive process than would have been the case under the action of the acids

* Caries der Zähne, 1867.

alone. A very marked destruction of the teeth within the mouth, they say, requires a participation of the fungus; in the earliest stage, only while the surface of the tooth is still smooth and intact, is the fungus undemonstrable, and hence it is apparent that in this stage, that of dry caries properly speaking, the changes are to be ascribed exclusively to the action of acids.

From this cursory survey of the various theories with regard to caries, of the vital, chemical, and parasitic, with their combinations, the advance in our knowledge becomes apparent, although the interpretations of phenomena, in many cases, present wide differences. A critical consideration of the views which have been adduced will be found in the following pages, in connection with the theory of caries.

APPEARANCES PRESENTED BY THE ENAMEL IN CARIES.—Before entering upon the consideration of these, we must allude to the *cracks or fissures in the enamel*, which have an importance in connection with the development and extension of caries. During life, these interruptions of continuity are observed very frequently upon the otherwise healthy, sound teeth of young persons and especially upon those of persons in advanced age, and they follow, as a general rule, the planes of cleavage in the enamel (comp. p. 30).

Upon close inspection, by means of a lens, they are found to be much more numerous than one would suspect at first. Not infrequently, besides the principal crack, we find a number of smaller, secondary ones which unite, in some cases, so as to form a web, and in others, diverge in the manner of rays. Their edges gape only in exceptional cases and, consequently, there is presented an appearance of narrow fissures.

The cracks vary in character in the different kinds of teeth. The enamel of the incisors not infrequently presents upon its labial surface one or even several straight fissures, reaching from the neck to the incisive edge; usually they are not so deep as to form a gap, but are limited to the superficial layers. Oblique cracks, also, occur upon the lateral portions of the crowns of these teeth and extend also from the incisive edges, from which particles of the enamel have been broken away. Irregular, zigzag fissures sometimes extend from the edges towards the

neck. Sometimes, when the edges are worn down, the fissures extend transversely or obliquely, subdividing here and there, across the abraded surfaces and, consequently, encroach upon the abraded dentine.

Upon the canines, they generally extend from the coronal apex towards the neck. Upon the bicuspid and molars, longitudinal fissures extend from the coronal cusps. They are met with, also, in the grooves of the latter teeth. When the cusps are worn away, dichotomous fissures are frequently found upon the abraded surfaces.

Towards the neck of the tooth, where the enamel becomes thinner, closely approximated fissures, which often intersect each other, are of very frequent occurrence upon all the teeth. The stellate form is not very common and usually originates in a minute defect in the enamel. Longitudinal fissures in the interstitial frictional surfaces of the dental crowns are quite common. Teeth with numerous depressions in, and excrescences upon, the enamel often contain a large number of extremely irregular fissures.

Fissures which communicate in the interior of the substance are frequently met with in the dirty-grayish or brownish-discolored portions from commencing caries, and in these cases the conditions presented by the membrane of the enamel are of especial interest. If the latter be removed in the ordinary way, by means of dilute hydrochloric acid, manifold perforations are brought into view, partly in the transparent, colorless, partly in the thickened portions of the membrane which is covered with the matrix of leptothrix and contains deposits of pigment; these are distinguished as simple, resembling cleft-like gaps, and compound. The latter form a system of ramifications which gradually become more narrow, presenting an appearance not unlike that of the veins on the leaf of a plant, and are more likely to be found in that part corresponding to the thinner portion of the enamel layer towards the neck of the tooth. The membrane in the latter localities usually is covered with a uniformly disposed, firmly adherent leptothrix mass (Atlas, Fig. 83).

A minute *interruption of continuity*, which is confined to narrow limits, manifests itself in the *commencement of caries*, espe-

cially in that developmental stage in which a quite light, more or less white spot makes its appearance. As the continuity of the enamel prisms becomes interrupted, the corresponding portion of the enamel loses its transparency, and, with the more extensive rupture of their cohesion, the enamel crumbles away, leaving a breach of varying depth. The surface of the enamel, corroded as it were, is uneven, rough and full of holes. White spots occur here and there, independently of caries, and indicate an imperfect development of the enamel or a localized (for some time at all events), permanent lax condition of the enamel prisms.

The *pigment deposits* in the enamel, in connection with caries, form a very conspicuous feature. With reflected light they present various shades of color, from brownish-red to blackish-brown, a dark-gray, yellow, or yellow-gray; with transmitted light, they are tinged with a vivid brownish-red, light reddish-yellow or deep-yellow color. The pigment is limited to a small portion at first and gradually traverses the entire thickness of the enamel; the darker shades, therefore, are found near the surface, and the lighter, in the deeper enamel layers; a dark zone is commonly found in the deepest layers adjoining the unaffected portions of the enamel (Atlas, Figs. 87 and 88).

The outlines of the portions containing deposits of pigment present variations which depend principally upon their locality; where the enamel dips down into the grooves or becomes attenuated towards the neck of the tooth, the pigmented portions usually occur in streaks with irregularly wavy outlines. The discolorations, particularly in the thicker portions of the enamel, frequently occur in the form of a cup or cone, the base of which is directed outwards, sometimes, but more frequently inwards towards the dentine.

Occasionally in chronic caries, streaks or spots are very conspicuous where the transparency of the enamel is increased; these occur within circumscribed limits in the vicinity of a portion discolored by the presence of brown pigment, and are brought very clearly into view by means of the lens and with reflected light. The structure of the transparent enamel has a

more homogeneous appearance since the transverse markings of the prisms are less distinctly perceptible than in other localities.

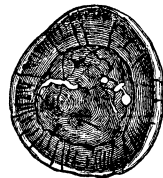If we examine thin sections of carious enamel containing deposits of pigment, and trace out its various shades of color, we find that the structure of the enamel is wholly unrecognizable where the coloring matter is most abundant or the brown presents a tinge of gray, while in the portions containing less pigment, the transverse markings of the enamel are very conspicuous and the transverse striations of the elementary parts are even broader in appearance.

The diminution in the consistence (compactness) of the portions which become the seat of deposits of pigment in connection with caries is an important element in the process. Scrapings from the surface of a section of the enamel present a mortar-like disintegration, powdered fragments of enamel. The prisms lose their proper transparency and the homogeneity of their contents, which acquire a finely-porous appearance, is destroyed.

In order to obtain a definite idea of the *appearance of the enamel-cap when it presents fissures or carious spots*, it is advisable to detach the cap by means of a fifty per cent. solution of sulphuric acid, as recommended by H. Beigel. For this purpose, teeth should be selected in which the caries is not very far advanced, because, in the later stages, the caps easily crumble. In this way, a clear and definite view of the fissures may be obtained. In the molars, deep cracks are quite common, extending from the carious portion across the masticatory, and along the lateral wall of the enamel-cap, and also radiating from the affected portion (Fig. 99).

At the same time we are enabled to compare

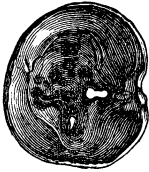FIG. 99.*



* FIG. 99 shows numerous fissures with several holes and clefts in the enamel-cap of a molar, in a view of the internal or dentinal surface. Most of the fissures are deep; some of them extend from the carious portions of the masticatory wall upon the annular or lateral wall of the enamel-cap, here and there presenting ramifications. In this case, several holes and clefts with sharp edges and no deposit of pigment in the adjoining portions

the appearances presented by the carious locality upon the external and internal surfaces of the enamel-cap. It may readily be shown that, when the pigment deposit consequent upon caries is limited to a scarcely perceptible dark-brown, minute dot upon the masticating surface, it is more extensive upon the internal or dentinal surface where it has a roundish or jagged outline. When caries in the groove of a molar tooth is displayed in the form of a very narrow streak containing pigment, the affected portion upon the internal surface of the cap measures a fourth of a millimetre and upwards. When a cleft-like loss of substance is occasioned by caries, the portions around the margins of the gap contain deposits of pigment and frequently are thickened somewhat (Fig. 100). The pigment deposits, consequent upon caries, which occur in the contiguous coronal surfaces and usually have a light or grayish-brown color, penetrate the entire thickness of the enamel at first only in the thinnest portion near the neck of the tooth.

FIG. 100.*



It happens, sometimes, that a portion of the summit of the still hard dentine, with a brownish-yellow pigment deposit corresponding with the carious locality, remains unaffected, while the rest of the dentine is destroyed by the boiling dilute sulphuric acid. It has not yet been determined whether or not a casual, unusually great power of resistance on the part of the dentine is to be assigned as the reason for this occurrence.

If we select a series of teeth which are affected with caries in its earlier stages and belong to the different periods of life, and treat them with very dilute hydrochloric acid, it may readily be

of the enamel are to be observed; these are not the results of abrasion or caries, but are to be regarded as defects in the formation of the enamel. Magnified 2 diameters.

* FIG. 100 —Interior view of the enamel-cap from a molar affected with chronic caries. The latter occurred in the crucial groove. The wall corresponding to the masticating surface presents a few gaps and several dark spots; the enamel tissue in the vicinity of the former and in the latter had a dirty-grayish and reddish-brown color, and is fissured and full of excavations; the carious affection is more extensive upon the inner than upon the outer surface. Magnified 2 diameters.

demonstrated that the portion of the detached *enamel membrane* corresponding to the carious locality has undergone a *perceptible thickening*. The transparent membrane, moreover, where the transition into the carious portion is apparent, is clouded, brittle and variously stained. The colors vary between gray, grayish-brown, brownish-yellow, syrupy-brown, reddish-brown, and reddish-yellow. With regard to the carious localities, it is to be borne in mind that one has to do not only with the membrane of the enamel, but also with the organic remains of the enamel.

The frequent *gray cloudiness* presented by the detached membrane is found to be due to a uniformly-diffused mass of granules of nearly equal size and arranged side by side and over one another at uniform distances. The molecular mass is the so-called matrix of *leptothrix buccalis* which is united so intimately with the enamel membrane and the organic remains of the enamel that together they form an inseparable whole. The thickness of the matrix varies, and the thickening of the membrane is due, in a great measure, to the latter; the brittleness and friability of this membrane, also, is occasioned by the superposition of the matrix. As proof that the latter appertains to the *leptothrix* may be adduced the fact that it is not uncommon to find tufts of *leptothrix* threads hanging from the edges of the granular mass.

The *brown portions* present light or dark-brown, transparent, homogeneous masses which are fissured in such a manner as to display a lamina composed of irregular polygons. The perforation of the enamel-membrane, mentioned above as resembling the nerves of a leaf, presents a strong resemblance in its configuration to the brown mass in question; the latter, however, is thicker and proceeds from the enamel which is deprived of its calcareous salts, transformed into a homogeneous mass and foraminated.

The familiar mosaic appearance produced by the transverse division of some of the prisms is beautifully shown, in some cases, after the extraction of the calcareous salts from carious enamel. Some of the prisms contain a homogeneous, highly refracting, light or dark brown, and others a granular, mass of

a similar color (Atlas, Fig. 84). The persistence of the contours of the enamel prisms in places after treatment with acids is unexplained, at present. Possibly it may be due to the proliferation of a leptothrix mass into the decalcified enamel.

The carious enamel sometimes, also, is transformed into a coarse-granular, brown mass; now and then the granules are blended together and are to be regarded as the organic remains of the shrivelled enamel-prisms. The mass is intimately united with the enamel-membrane, upon the outside of which, in many places, is located the matrix together with the attached threads of leptothrix.

When the deposits of pigment impart a blackish-brown color to the carious enamel, the prisms are no longer distinguishable. After the extraction of the calcareous salts from the enamel, there is left, sometimes, a brittle, friable, blackish-brown mass which presents sharp and angular edges when broken. In the later stages, the enamel-membrane acquires a syrupy-brown discoloration.

When the carious enamel presents superficial greenish spots, this color is participated in by the externally-attached matrix of leptothrix, the enamel-membrane and even the organic remains of the enamel-prisms, to a varying degree.

If so-called eroded, cribriform, foraminated [honeycombed], and, consequently, irregularly-developed enamel, which is affected with commencing caries, be decalcified, the enamel-membrane will display an alveolate appearance, *i. e.*, it presents round, sharp-edged pits of various sizes, within which the membrane is thinner and perhaps wanting entirely, here and there, and a leptothrix-mass has taken up its abode. Between the light-colored alveoli lies a yellow, syrupy-brown substance.

In many cases, the remaining organic matter of the enamel from the teeth of old persons, which are affected with commencing caries, presents the appearance of a diffuent, coagulated, transparent, structureless, effused substance, in the interstices of which is lodged a molecular, dirty-gray leptothrix mass.

Usually in the course of the process, an *undermining caries of the enamel* is met with, *i. e.*, the caries is more extensive in the deeper layers of enamel than is apparent externally upon

the surface, just as if the process commenced in a groove, depression, or fissure. The particles of enamel crumble away and are detached, leaving a gap or a pit which increases in extent in the deeper layers. The undermined portion may easily be broken away, when the enamel upon the excavated surface may be scraped off, displays a chalky or mortar like disintegration, often presents a dirty-brown color and contains the fragments of enamel-prisms. As might be anticipated, the dentine is exposed to greater danger by this undermining process; it is denuded to a greater extent and subjected to the action of injurious external agents. When the deposit of pigment in the carious enamel takes place in the form of a cone with its base directed externally, the affection of the dentine is confined to more narrow limits.

Heider informed me that caries of the enamel frequently escapes *clinical observation* at its commencement, and that this is the more likely to be the case since at this stage the disease gives the patient no uneasiness and, usually, occurs at points which cannot be seen except with difficulty. By a careful examination with a very fine probe and mouth-mirror, a slight roughness is detected in the enamel which may readily be removed with a sharp instrument. By means of the mirror the color is brought into view; this varies according to circumstances, and is particularly distinct with those teeth which it is possible to examine in the mirror with the light transmitted through them, as, for instance, with the posterior surface of the incisors when they are examined in the mirror with the light falling directly upon them. A diffused cloudiness with a quite dark central portion characterizes the primary appearance of caries, before a pit-like breach of substance is produced by the disintegration of the enamel. Observed in the above manner, the color of the spot varies from a chalky-white to a bluish-white, and is gray, brown, and black.

These different colors, however, do not correspond to different stages of the process, but characterize the various modifications of the same. The lighter the spot, the deeper extends the destruction and the more rapid is the progress of the disease. The darker the color, the more limited and circumscribed is the dis-

colored portion of the enamel, and the slower is the course of the affection.

Let the discoloration be what it may, the subsequent pathological changes in the enamel present a tolerable degree of uniformity. The connection existing between its constituent elements becomes broken. Oftentimes, also, a fissure may be detected, which bisects the discolored portion. If, however, this is not the case, the enamel is always found to be perforated with holes, is friable, breaks up and crumbles away, and in this way the already more or less softened dentine becomes denuded.

In the primary stage, that of discoloration, the process which has been described is entirely painless. When perforation commences, patients who are attentive to their teeth experience, at first, especially during the mastication of a very firm substance, an unpleasant sensation which is induced by partaking of acids, fruit, syrup and, sometimes, even by sudden changes of temperature. Generally, however, this sensation escapes observation and the patient is first made aware of the destruction which has taken place, by the occurrence of occasionally severe, but transitory pains, occasioned by the impaction of particles of food within the deep cavities where the surface of the dentine has been extensively denuded.

APPEARANCES PRESENTED BY THE DENTINE IN CARIES.—That portion of the dentine which lies beneath the enamel-cap becomes involved before the deposit of pigment in the carious enamel has reached the dentinal boundary (Atlas, Figs. 87 and 88). The affection of the dentine is manifested by a *diminished translucency* and a *discoloration* of the corresponding portion of the dentinal crown. The portion adjacent to the enamel boundary has a very intense, reddish-brown color; this passes into a reddish-yellow which, finally, becomes a straw color towards the central portion. The opaque condition forms a greater or less contrast with that of the adjacent dentine. In most cases, the affected portion of the periphery of the dentine assumes the form of a cone, the base of which, directed outwards towards the enamel, is broad in comparison with the discolored portion of the enamel. The apex of the cone is directed towards the central portion, and it is evident that the configuration of the

cone is occasioned by the radiation of the dentinal canals. This disposition, however, does not always obtain in respect of the opacity and discoloration; it is far more common to find lateral prolongations from the carious dentinal cone. The yellowish pigment not infrequently is distributed with great irregularity, extends to a considerable depth in the carious dentine, and gives rise to the appearance of insulated patches of yellowish, discolored dentine, in transverse and longitudinal sections.

The still compact, affected portions of the dentine present a clouded appearance, due in part to the presence of grains which have a linear arrangement, are spherical, for the most part, sometimes, also, elongated, and fill the cavities of the dentinal canals. This granular condition is very perceptible, also, in the yellowish discolored portions and even in the interglobular masses. The cloudiness in the canals not infrequently is due to a molecular condition, and in this connection I will merely remark that it is morphologically identical with that met with, both in the vicinity of the abraded surfaces and of the cement, in the canals of senile teeth which have been worn down to the dentine but do not contain the least trace of caries.

It is a difficult matter to determine the nature of these grains, but I have no doubt that they belong, for the most part, to liquid fat. If thin sections of the dentine in question be subjected to the action of dilute hydrochloric acid, a number of drops, exactly resembling fat-globules, always make their appearance, both upon the surfaces and edges of the sections; indeed, they are often found in the interior of a canal. If a section of dentine of this description be decalcified completely, by means of dilute hydrochloric acid, and then carefully boiled with the same acid, in order to effect the familiar isolation of the processes of the dentinal cells, we obtain, in some places, grains arranged in the form of a chaplet and diminishing in size to that of minute molecules, and in others, varicous processes, the contents of which present the glitter of fat. Many of the processes remain entirely free from this metamorphosis; from many others the fat obviously has been pressed out and the globules have united to form drops. The appearance is exactly similar to that obtained from senile, much worn dentine (Atlas, Fig. 95).

If, on the other hand, the question be asked if the fine granules do not belong to leptothrix, in my opinion, a negative reply should be given. I have been unable, in this primary stage of the carious affection of dentine, to obtain a reaction from the treatment of leptothrix with iodine and acids, according to the method suggested by Leber and Rottenstein.

The discoloration of the carious dentine extends to the canals and intertubular tissue and is intense even in very thin, transverse sections. The interglobular masses, also, contain deposits of pigment. Coincident with the development of the opacity and the pigmental degeneration, in the commencement of the carious affection of the dentine, an *increased translucency* is observed, frequently, in the portions adjacent to the boundary of the carious portion. With reflected light, these portions have a horny appearance, similar to that found in senile roots, and, with transmitted light, they present hyaline bands and spots. The focus (Herd) of the caries is surrounded by a diaphanous halo. The opaque, carious dentinal cone, therefore, is invested by a translucent zone, extending from the periphery towards the centre; around a more spherical, carious portion of the dentine, a crescentic diaphanous halo is met with sometimes. The light portions, finally, vary exceedingly in respect of their outlines, according to the form in which the carious limits are extended, being radiated, kidney-shaped, &c. (Atlas, Fig. 91).

No diminution in the compactness of such dentine can be detected, and it is an easy matter to prove the impossibility of the admission of air into the desiccated dentinal canals. I have been unable, in thin sections, to discover a further anomaly in the tissue. J. Tomes* speaks of a consolidation of the dentinal fibrils as being the cause of the translucency, and regards the fibrils as calcified, since, in thin sections, made with a sharp knife from a well-selected tooth in the direction taken by the dentinal tubes from the discolored portion, he saw the fibrils within the tubes broken into short fragments. These statements may be correct, but Tomes has yet to prove the calcification of the fibrils, since he neglected to try the reaction with acids;

* Op. cit., p. 313.

moreover, the evidence obtained from preparations made in such a manner are not to be depended upon.

If the carious, discolored, but still compact dentine remains denuded for some time, exposed to the action of external agents, and any acid be allowed to act upon its surface, a decalcifying process will ensue and that condition will be induced which is termed *cartilaginous softening*. In many cases, this is a very slow process and even appears to be arrested for a time, while it takes place rapidly in some cases. The latter form is designated commonly as *acute, moist caries*, in contradistinction to the former which, more properly, is termed *chronic*.

When the dentine has become deprived of its calcareous salts to an extent sufficient to admit the insertion of a needle, a superficial disintegration ensues. Leber and Rottenstein, therefore, with reason, divided the carious affection of the dentine into two stages which, however, cannot always be nicely discriminated, a preparatory stage of decalcification and softening and a stage of direct disintegration.

Upon the examination of dentine which has undergone the cartilaginous softening and may be cut with a knife, no marked change can be detected, except a yellowish, reddish-yellow, reddish-brown discoloration; the dentine presents an appearance as if it had been decalcified by means of hydrochloric acid and subsequently dyed. Localities, however, are observed, chiefly in cases where the softening has been very extensive, in which the dentine has undergone such a remarkable alteration that it can scarcely be recognized as human dentine, a metamorphosis which was discovered by J. Tomes and has been confirmed by numerous writers.

In sections made in a direction transverse to the axes of the radiating dentinal canals, a greater or less number of canals are met with, whose limiting walls (the so-called dentinal sheaths) describe unusually large circles, and whose cavities are replete with a mass which has, in some places, a homogeneous, in others, a molecular appearance and forms convex projections beyond the surface of the section (Atlas, Fig. 92). The transverse diameters of the widened and filled canals vary, some being at least three times as large as others. The intertubular tissue

presents a molecular cloudiness and is beset with grains having the appearance of fat. In sections made parallel to the long axes of the canals, they are quite clearly seen to be unequally filled by the foreign mass, since they present manifold varicosities and constrictions which, also, explain the variations in the diameters of the widened canals.

If a section made in the direction of the varicous canals is boiled for some time in water or in very dilute hydrochloric acid, until it begins to break up into delicate, fimbriated tufts, in other words, if the dentinal fibres or processes of the dentinal cells are isolated, a still more definite idea of the various degrees of thickenings and knotty swellings of the same may be obtained. A molecular mass covers these fibres nearly everywhere; sometimes, also, they present transverse fissures which give to them a peculiar, as it were, scarified appearance. Minute grains, also, like the head of a pin, rest upon the fibres at tolerably uniform intervals from one another and are highly suggestive of *Micrococcus*.* Lateral branches are given off from the fibres at fixed angles (Atlas, Fig. 95). In consequence of the blending of the intertubular tissue, a considerable number of fat-globules are produced, which, in many places, impart a notable cloudiness to the cartilaginous softened dentine.

The question naturally arises, what is the nature of the mass which fills the canals? Leber and Rottenstein, by a fortunate application of an iodine solution and acid, succeeded in demonstrating the proliferation of *leptothrix buccalis* in the softened dentine. One may readily convince himself, both in longitudinal and transverse sections, of the violet color which is imparted to the contents of the canals. Hence, by their proliferation, the grains of *leptothrix* occasion the manifold swellings and varicous enlargements of the fibres, and are so closely cemented together, that their connection cannot be broken even after the action of heated hydrochloric acid.

Upon a very close examination of the disintegrating portions of the superficial softened dentine, the matrix of *leptothrix* may be found everywhere in the perforations; irregular chan-

* Comp. Karsten, *Chemismus der Pflanzenzelle*, 1869, p. 25.

nels, spherical cavities, which are found, here and there, still connected with a thickened fibre, are replete with the matrix.

In consequence of the superficial disintegration of the dentine, there arises, at first, a shallow indentation which, however, shortly acquires larger dimensions when the caries *undermines* the dentine, as is the case nearly always in the acute form. A cavity with a narrow outlet is formed which contains the so-called carious matter. Particles of food, forced into this during mastication, easily become impacted, and give rise to a process of fermentation; sometimes, innumerable monads are found moving in the fluid vehicle, and upon the wall of the cavity are attached large masses of leptothrix and linked chains of oidium. Fragments of dentine, which have not been decalcified, sometimes exfoliate during the undermining process and are of frequent occurrence within the cavity. In the dried condition, the wall of the cavity has a gray, grayish-brown, dirty yellowish-brown color, or it is not uncommon for it to be colorless, like asbestos, and the loosened dentinal layers may be detached in fragments or thin lamellæ, by means of a needle.

If the carious cavity has extended so far that nothing but a thin layer of dentine separates it from the pulp-cavity, or it has reached the pulp, then occur those constant pains which are induced by inflammation of the pulp (compare p. 176).

Exceptional cases occur where the destruction of a large portion of the crown of the tooth may be accompanied by very slight, if any, pain. This fact may be ascribed, in part, to a generally diminished sensibility on the part of the individual, but, for the most part, it is due to an atrophy, a calcification, or a dentinal new-formation corresponding to the carious locality.

Cases of *caries of the dentine which runs a chronic course* differ from the foregoing in that the decalcification and disintegration progress slowly. While, in acute cases, months only, in chronic cases as many years are required for the destruction of the crown of a tooth. Between these two extremes, a large number of cases occur which have a longer or shorter duration. In the moist, acute caries, the discoloration of the affected dentine is of a light shade, the lighter the shorter the duration of the disease, and the cartilaginous softening acquires a notable

extent, while, on the other hand, in the chronic form, the discoloration is of a darker hue, and the consistence of the nearly black dentine is slightly diminished. The reaction of the contents of the carious cavity with litmus-paper, also, furnishes a familiar element of distinction between the two forms, namely, a more strongly marked acid reaction is given in cases where the destruction is most rapid. The cartilaginous softened layer of the dentine has a marked acid reaction, while in connection with chronic destruction the latter is not decided.

The dark shaded, consistent, carious dentine occasionally displays a very narrow zone of cartilaginous softening, but in well-marked chronic cases, this cannot be identified. In the latter, therefore, we have to do with very dry caries. A dark powder containing the fragments of dentine may be scraped off by means of a sharp knife, and besides the dark-brown discoloration, no other anomaly is presented by the dentine. I have been unable to satisfy myself of the calcification of the fibrils in these cases.

In the course of chronic caries, the dentinal layers exfoliate, the surface of the affected portion is rough, as if it had been scratched with a sharp instrument; as the dentine disappears, there is left, at first, a minute, gradually enlarging, carious indentation with a sharp margin and a blackish-brown discolored wall.

When the coronal dentine is affected primarily, as sometimes happens when the masticating surfaces have been worn away very much, bands and spots make their appearance, having a color varying between dark-brown and black and invested by a quite broad, light-brown uniform zone. Both discolorations extend nearly to the wall of the pulp-cavity. In such cases, frequently, it is a matter of doubt whether we have to do with dental caries or with senile necrobiosis. One must be careful not to pronounce every brownish discoloration of the dentine to be caries (compare remarks upon the senile changes in dentine, p. 242).

Thin sections of dentine affected with well-marked chronic caries display a dark pigmental degeneration, but no other structural change; it is especially noticeable that, even after a

preliminary décalcification, they present no expansions of the dentinal canals containing proliferating leptothrix and, moreover, that grains and threads of leptothrix are rarely met with upon the surface of the carious dentine.

APPEARANCES PRESENTED BY THE CEMENT IN CARIES.—Caries makes its appearance upon the *neck of the tooth*, usually in the vicinity of the border of the enamel, and commences in the form of a discoloration (barely perceptible at first, and of a brownish tinge) of the cement layer which, in this locality, is very thin. In a short time, the latter is destroyed, the dentine becomes affected, the enamel attached to the neck becomes undermined by the formation of a carious excavation and projects in the form of a lamella with sharp edges. The excavation, shallow at first, becomes more extensive as the carious process spreads from the border into the adjoining portions of the neck. A cavity of considerable size is developed by the carious process, which usually occurs in the more acute form, and the danger to the tooth is measured by the extension of the caries around the neck.

If a portion of the root of the tooth is deprived of its bony and membranous covering, in consequence of the wasting of the alveolus, the carious process may attack the *cement of the root primarily* and produce one or several breaches of substance, up to the size of a pin's head, which extend through the entire thickness of the dentine and occasion a denudation of the corresponding portion of the root-pulp, as the disease advances. These carious excavations usually have sharp edges, are patelliform and, occasionally, occur without an affection of any other portion of the tooth.

Caries of the cement presents, at first, a more or less circumscribed, yellow or brown discoloration, without any other change of the bony substance. Perforations immediately begin to make their appearance, which extend from without internally and give rise to a disintegration and breach of the superficial layers of the cement. The surface of the discolored cement also acquires an eroded appearance and is beset with shallow pits with serrated edges. When the caries extends from the

cement to the dentine, the latter becomes perforated, usually in the direction of the dentinal canals.

EXTENSION OF CARIES TO THE ROOTS OF THE TEETH.—If the coronal portion be undermined by caries, extending from the masticating surface, the surfaces adjacent to the contiguous teeth, or from the neck, so that a large cavity with a fragile, shell-like wall is formed, the latter gradually crumbles away leaving merely the corresponding roots. Although the carious process may have run a well-marked acute course in the coronal portion, it is much more protracted in the roots, and as Hunter asserted long ago, it is a rare occurrence to meet with a root which has been excavated as far as its apex. The process appears to be suspended, sometimes, or at all events, to advance very slowly. The carious excavation usually is shallow, the elevated edges frequently are attenuated and jagged. In one instance, only, I have met with a flask-shaped cavity with a narrow outlet. The extremities of the root become blunted, rounded and discolored, this condition being more conspicuous, the smaller the portion of the root which is retained.

After the destruction of the coronal pulp, the inflammation assumes a decided chronic character in the radical pulp, and we find nothing but the scanty remains of the latter in the carious roots, though the chronic inflammatory process may have been terminated for a long time. Atrophic, shrivelled, connective tissue with a tinge of dirty-yellow and brown, here and there, presenting barely traces of net-like atrophy, accumulations of crystals of hæmatoidin and calcareous grains compose the principal constituents.

A chronic inflammatory condition of the root-pulp, in quite rare cases, leads to a new-formation of bony substance or osteodentine upon the interior surface of the root-canal and may even give rise to the development of anastomosing, rapidly obliterated vascular canals which are prolonged from the vessels of the root-pulp into the dentine and, in places, are invested by a layer of globular masses and even by an accessory, well-developed bony substance with a sharply-defined, indented border directed towards the dentine; this substance occasionally follows

the course of the root-canal, forming a complete investment about it (Atlas, Fig. 98).

The periosteum of the root usually is notably thickened and sclerosed, and consequent upon this occur hypertrophies and interstitial proliferations of the cement into the dentine. On the other hand, a marked resorption may occur, involving either the entire cement or portions of it and causing numerous breaches of substance in the hypertrophic cement, in consequence of which the surface of the carious root sometimes presents deep excavations and is rough to the touch (comp. p. 273).

The carious discoloration of the dentine usually does not extend to a great depth and the cartilaginous softening, likewise, is moderate in amount. A discoloration of the cement is met with only in exceptional cases when, in consequence of resorption, it remains projecting from the margin of the carious cavity. The dentinal substance within the carious locality sometimes presents a gray cloudiness from the accumulation of finely-divided fat, which may be demonstrated by the application of hydrochloric acid. Grains of leptothrix occasionally proliferate in large numbers within the perforated dentine.

CARIES OF THE DIFFERENT KINDS OF TEETH.—As a general rule, caries originates in the external depressions of the teeth, which afford localities for the accumulation of foreign matter, the removal of which is difficult or utterly impossible. The localities primarily affected comprise chiefly the longitudinal and transverse grooves upon the masticating surfaces of the bicuspid and molars, the contiguous surfaces of crowded teeth, all the deep and manifold indentations and grooves which occur upon surfaces that are smooth normally and are occasioned by malformations of the enamel, and, finally, all surfaces which are repeatedly or constantly brought into contact with the labial or buccal mucous membrane or the secretion of the gums, as the facial surfaces of the necks of the teeth. The surfaces directed towards the cavity of the mouth nearly always remain unaffected by caries, since foreign matters adhere to them only with difficulty, being readily removed by the movements of the tongue, except in those cases where there are depressions from defects in the enamel. Caries seldom originates upon the contiguous

surfaces of teeth which are separated by slight intervals from each other, or stand alone in consequence of the detachment or extraction of the adjacent teeth.

Permanent Teeth.—The labial surfaces of transversely-grooved *upper central incisors* are liable to be attacked. A uniformly dirty-yellow spot, corresponding to the locality of the transverse groove, is observed at first. If a breach of substance has occurred, there is found a transverse oval depression. If the facial surfaces, especially in the lower segments, present a number of depressions, these, particularly the larger ones, are very liable to become the seat of caries. The medial, contiguous surfaces of both teeth, when the crowns are closely approximated or overlap, are attacked in the vicinity of the incisive edges. The lateral (distal) surfaces are more frequently the subjects of the disease, particularly if the lateral incisor has an oblique position and the contact of the surfaces of the lateral and central incisors respectively is more extensive and closer than is the case ordinarily. The crowns of these teeth, at the carious localities, present hemispherical excavations which, facing each other, form a roundish cavity. The facial surfaces of the necks of the upper central incisors not infrequently are the seat of extensive caries. The lingual surfaces are affected only when an infundibuliform depression between two folds of enamel (comp. p. 33) or transversely-disposed indentations are present.

The not infrequently displaced and distorted *upper lateral incisors* are very likely to become affected with caries, the liability being increased by the multiplication of the points of contact with the adjacent teeth. The surfaces which come into contact with the contiguous teeth or the facial surfaces of the necks are most frequently the seat of the origin of caries. We have also seen cases where the disease arose in connection with transverse grooves upon the facial surface, and with indentations or an infundibuliform depression upon the lingual surface.

The upper canines are affected primarily upon the facial surface of the necks and less frequently upon the surfaces in relation with the adjacent teeth, which usually are previously affected with caries; the facial surfaces of the crowns are at-

tacked only when they present depressions and grooves in the enamel.*

The *upper bicuspid*s are invaded in the depressions upon the masticating surface, more frequently upon the surfaces which come into contact with the adjacent teeth, and upon the buccal surfaces of the necks.

In the *first upper molars*, the disease very frequently makes its appearance in the depressions formed by the branching grooves and very commonly at several points simultaneously, if the abnormally developed enamel contains numerous depressions and grooves. The masticating surfaces of the *second* and *third molars* are less frequently the seat of primary caries than those of the first molars. The buccal surfaces of the wisdom teeth, in consequence of their close contact with the mucous membrane of the cheeks, are quite liable to become affected. Frequently the molars are attacked upon their surfaces of contact, and upon their necks when the teeth are worn down upon their masticating surfaces, while there may be no perceptible affection of any other portion of the crown.

The *lower incisors* are attacked upon their surfaces of contact, upon the surfaces of the necks and those of the crowns presenting depressions in the enamel, and upon the surfaces of slightly overlapping and displaced teeth, which come into immediate contact.

The disease makes its appearance in the *lower canines*, generally in consequence of contact with carious portions of adjacent teeth, upon the surfaces of contact and upon the facial portions of the necks.

The primary affection of the *lower bicuspid*s occurs in the depressions upon their summits, frequently upon the surfaces of contact, especially when there is a displacement, and upon the facial surfaces of the necks.

The *lower molars* become affected at the points of intersection

* In this country, caries of the upper canines occurs most frequently upon their proximate surfaces, the facial surfaces of their necks seldom being diseased. In the tables of Mr. Tomes, in fifty-eight extractions of canines from the upper jaw, nine were carious upon their proximate surfaces and but one on the facial surface.—T. B. H.

of the grooves, at the points of divergence of the lateral grooves, frequently upon the surfaces of contact and, sometimes, upon the facial surfaces of the necks. The wisdom teeth, particularly, and the first molars, in consequence of the frequent occurrence of anomalies in the development of the enamel, are attacked in more than one place.

Carious Roots of Permanent Teeth.—One would be astonished at the large number of carious roots which may be found by examinations, post mortem, a fact to be accounted for by the gross neglect of the teeth, particularly among the lower classes of people. The roots of the molars rank first; these are excavated, present sharp edges and points and, sometimes, the remains of enamel. In consequence of the frequent occurrence of alveolar abscesses, the carious roots become deprived in part of their support, particularly upon the facial wall of the upper jaw, and it is not uncommon for them to become twisted slightly and inclined to a considerable degree towards the face; in some cases, the alveoli are destroyed almost entirely by suppuration, and the roots occupy a nearly horizontal position, attached to the closed terminal portions of the alveoli by means of the thickened root-membrane. In consequence of suppuration of the alveoli, the carious roots of the lower molars acquire a marked inclination anteriorly.

Carious roots of teeth which have but one root generally retain their normal positions, but sometimes acquire a facial or lingual inclination, particularly if they are employed in chewing during the progress of chronic caries, which fact will be indicated by the surfaces, grooves, and step-like breaks produced by chewing. It is self-evident that abraded surfaces of this description can only be produced when several of the neighboring teeth are wanting, or merely their roots remain.

Milk Teeth.—In consequence of their less compact character (Thomson, of Glasgow, found less than thirty-seven per cent. of organic matter in the milk teeth), the thinness of their enamel layers and the profuse secretion from the gums and glands of the oral cavity, caries has a more acute course in the temporary teeth. The molars are attacked most frequently; their crowns are destroyed to a considerable extent, the carious cavities are

comparatively large; the dentine frequently is studded with several light-brown spots; a considerable portion of the thin enamel, of the incisors especially, becomes detached quite easily, leaving the light-brownish discolored, and superficially softened dentine exposed. If the caries has a very acute course, it involves the entire circumference of the crown which, finally, is destroyed. The disease attacks, primarily, the depressions and grooves upon the masticating surfaces of the molars, the facial surfaces of the necks and the surfaces of contact with adjacent teeth. The extension of the disease from a carious tooth to its sound neighbor (infection) takes place quite rapidly; it is not uncommon to find most of the teeth in a jaw affected.

FREQUENCY OF CARIES.—Magitot* tabulated a series of cases, ten thousand in number, showing the relative frequency of caries in the different kinds of permanent teeth. Taking all the cases into consideration, it appears, he says, that the relative frequency of caries in the upper and lower teeth respectively, is in the proportion of 3 : 2. This proportion, however, is not applicable to the molars, since the first and second lower molars are affected more frequently than the corresponding teeth of the upper jaw. From his tables, however, this result may be stated more in detail, as follows: The quotients, expressing the ratio of frequency, presented by the several kinds of teeth in the upper and lower jaw respectively, are in round numbers, 20 for the central and 24 for the lateral incisors, 6 for the canines, 2.5 for the first, and 1.6 for the second bicuspid, 0.8 for the first, 0.6 for the second, and 1.5 for the third molars; that is to say, the upper central incisors are affected twenty times as often as the corresponding teeth of the lower jaw, and so on. No important difference is observed between the teeth on the right and left side respectively. According to Magitot's tables, the different kinds of teeth present the following order, in respect of the frequency of their affection with caries, beginning with those most frequently affected: lower first molar, upper first molar, lower second molar, upper first bicuspid, upper second bicuspid, upper lateral incisor, upper second molar, upper cen-

* *Op. cit.*, p. 48.

tral incisor, lower second bicuspid, upper canine, lower first bicuspid, upper wisdom tooth, lower wisdom tooth, the two lower incisors. The scale drawn up by Hasler Harris* corresponds very nearly with this. †

* Quart. Jour. of Dental Science, 1857.

† The following is the table by Dr. E. Magitot, referred to in the text :

Central Incisors,	642	{ Superior,	612	{ Right,	304
		{ Inferior,	30	{ Left,	308
				{ Right,	20
				{ Left,	10
Lateral Incisors,	777	{ Superior,	747	{ Right,	369
		{ Inferior,	30	{ Left,	378
				{ Right,	20
				{ Left,	10
Canines,	515	{ Superior,	445	{ Right,	198
		{ Inferior,	70	{ Left,	247
				{ Right,	20
				{ Left,	50
1st Bicuspids,	1,310	{ Superior,	940	{ Right,	345
		{ Inferior,	370	{ Left,	595
				{ Right,	170
				{ Left,	200
2d Bicuspids,	1,310	{ Superior,	810	{ Right,	400
		{ Inferior,	500	{ Left,	410
				{ Right,	270
				{ Left,	230
1st Molars,	3,350	{ Superior,	1,540	{ Right,	728
		{ Inferior,	1,810	{ Left,	812
				{ Right,	910
				{ Left,	900
2d Molars,	1,736	{ Superior,	690	{ Right,	380
		{ Inferior,	1,046	{ Left,	310
				{ Right,	497
				{ Left,	549
3d Molars,	360	{ Superior,	220	{ Right,	100
		{ Inferior,	140	{ Left,	120
				{ Right,	60
				{ Left,	80
Total,	10,000		10,000		10,000
Superior,	6004	{ Right side face,	4791		
Inferior,	3996	{ Left, " "	5209		

This table differs in several respects from one prepared by me, from records of filling and extractions of permanent teeth in twenty thousand cases. Though this includes extractions from all causes, yet the percentage removed for other diseases than caries is so small, that the tables are worthy of comparison.

T. B. H.

With regard to the *sex*, according to Magitot's enumeration, the ratio of 3 : 2 expresses the relative frequency of caries of the teeth in females as compared with the same in males. Harris asserts that with females caries occurs nearly three times as often as it does with males. The period of pregnancy, as is well known, is especially favorable to the development of caries.

With regard to the *age*, caries is most frequent between the tenth and twentieth year of life. Later in life (about the fiftieth year), it is not uncommon for another period to occur in which teeth, previously sound, are destroyed by caries within a short time. Magitot drew up some instructive tables in detail, showing the age at which the several corresponding teeth in both jaws were affected. With regard to the milk teeth, he ascer-

Central Incisors,	2,189	{ Superior, 2,101	{ Right, 1,058
		{ Inferior, 88	{ Left, 1,043
			{ Right, 37
			{ Left, 51
Lateral Incisors,	1,954	{ Superior, 1,827	{ Right, 939
		{ Inferior, 127	{ Left, 888
			{ Right, 68
			{ Left, 59
Canines,	1,261	{ Superior, 1,058	{ Right, 504
		{ Inferior, 203	{ Left, 554
			{ Right, 101
			{ Left, 102
1st Bicuspids,	2,073	{ Superior, 1,588	{ Right, 767
		{ Inferior, 485	{ Left, 821
			{ Right, 264
			{ Left, 221
2d Biscuspids,	2,585	{ Superior, 1,715	{ Right, 906
		{ Inferior, 870	{ Left, 809
			{ Right, 467
			{ Left, 403
1st Molars,	4,499	{ Superior, 2,273	{ Right, 1,189
		{ Inferior, 2,126	{ Left, 1,084
			{ Right, 1,092
			{ Left, 1,034
2d Molars,	3,615	{ Superior, 1,675	{ Right, 838
		{ Inferior, 1,940	{ Left, 837
			{ Right, 938
			{ Left, 1,002
3d Molars,	1,924	{ Superior, 899	{ Right, 470
		{ Inferior, 1,025	{ Left, 429
			{ Right, 513
			{ Left, 512
Total,	20,000		20,000
Superior,	13,136	{ Right side face,	10,151
Inferior,	6,864	{ Left " "	9,849

tained that caries may be observed as early as the third and fourth year, and that its frequency increases in regular progression from this period up to the twelfth year, the period at which, on the average, the last milk tooth becomes detached.

In respect of *race*, notable differences are observed. Broca, and more particularly Mummery, carefully examined large collections of skulls, for the purpose of ascertaining the frequency of dental caries. The latter found a percentage of 41.66 as expressing the frequency of caries among those of the ancient Egyptians, 2.94 among those of the ancient Britons with elongated skulls, 21.87 among those with round skulls, 28.67 among those of the Romano-Britons, 15.78 among those of the Anglo-Saxons. Among the modern races, he obtained the lowest percentage from those of the Esquimaux, natives of the northern coasts of America, New Zealanders, and inhabitants of the northern parts of the East Indies. In Europe, the results show a percentage in favor of the Slavonic race.

In connection with the peculiarities in the structure of the teeth according to race may be considered those which are manifested according to *family*. It is a familiar fact to all dentists, that children's teeth very frequently resemble those of the father or mother and, therefore, that many defects and malformations of the teeth are hereditary in a family, *e. g.*, the absence of the upper lateral incisor, the oblique position of a certain tooth, the shape of the teeth, spots upon them, &c. In the same way, also, is the familiar and curious fact to be explained, that with children of the same family the corresponding teeth become carious in the same order, at similar points and at a certain age.

Many are inclined to ascribe the differences in respect of the frequency of caries, to locality and the articles of diet. Climatic and geological peculiarities, or the water, are assigned as the causes, though authoritative grounds cannot be adduced in support of these views. Mummery endeavored to establish a parallel between the ordinary food of the different races and the percentage illustrating the frequency of caries, but definite results cannot be drawn from these data. As a matter of course, adequate nutritive material is just as requisite for the formation and maintenance of the teeth as it is for the rest of the body,

whether it be of an animal or vegetable nature. If it be true that geological and climatic conditions, and the means of subsistence which are connected with the same, have such a preponderating influence in respect of the frequency of caries, then it is impossible to explain the fact that foreigners belonging to different races, who are exposed to the same conditions with the native inhabitants, still retain the typical structure of their teeth as well as that of their bodies, and continue to furnish the proportion of dental caries peculiar to their race. This is found to be the case with the isolated Slavonic races of Austria and the descendants of the Celtic race in France.*

Popular customs promote or retard and may even give rise to caries. Steinberger† remarks, in this connection, that the crowns of the upper milk incisors, especially in children of the lower classes, are mostly or entirely destroyed by caries even in the second or third year of life, while the lower incisors are scarcely ever so extensively affected and the molars, usually, are still entirely sound. It is found in such cases that the children have been accustomed for months and even years to use a sucking-bag containing cracker or white bread which is first soaked in milk and then in a weak solution of sugar. In this way, he says, all the conditions necessary for the rapid formation of vinegar are afforded; the sugar acts during the process of its fermentation, and the action of acid *in statu nascenti* is much more intense.

Tobacco-smoke or juice is considered by many to be a preservative, or a means of preventing caries, though it is not stated whether the secretion of the gums acquires an alkaline condition or the proliferation of leptothrix is diminished. On the other hand, it is quite common to find teeth with a sooty covering,

* As geological, climatic, and social conditions exercise a predominant influence upon the growth and development of the various races mentally as well as physically, it is evident that the development of the dental organs cannot fail to be controlled by the same causes. In this country, which is annually receiving large numbers of foreigners by emigration, the typical traces of race are usually effaced after the lapse of a generation or two, the descendants possessing all the peculiarities, and their teeth apparently being as liable to caries as the teeth of Americans generally.—T. B. H.

† Deutsche Viertelj. f. Zahnh., 1862.

from tobacco-smoke, upon the lingual surface and, at the same time, an extensive carious affection of the facial surface of the neck.

An enumeration has been made of the articles of diet which are said to tend to increase the frequency of caries, such as fruit, food which has become sour, curdled milk; but sugar is regarded as the most injurious. Larrey* asserted that teeth are acted upon by a solution of sugar, the enamel acquiring an opaque appearance, the tooth readily crumbling and becoming almost gelatinous. In this connection, stress is laid upon the affinity of the sugar for the lime with which it enters into combination. Marchand denied the accuracy of these experiments, and asserted that no perceptible changes can be detected in teeth which have lain for weeks in a solution of sugar. It has also been stated by English writers that the natives of the East Indies eat a large amount of sugar and with a mere vegetable diet have very good teeth; to be sure, they keep their teeth very clean. Magitot recently experimented with sugar and obtained a result corresponding with that of A. Westcott (1843), namely, that sugar exercises no direct, *i. e.*, in the condition of sugar, injurious effect upon the teeth, since solutions of sugar occasioned extensive destruction of the tooth only after some time (two years) had elapsed, when the solutions were left alone or materials were added to them which acted the part of ferments. The fermentative process gives rise to the development of lactic acid and, subsequently, butyric acid and a few of its derivatives, as propionic and valeric acids, &c. Mantegazza, of Pavia, experimented in another way; he placed teeth, which had previously been dried and weighed, in solutions of sugar of various degrees of concentration, in distilled water and in saliva which was removed directly from the mouth, and, after a few days, noticed an acid reaction of the fluid which contained traces of lime; the teeth had lost in weight. His conclusions coincide pretty nearly with those of Magitot.

Various *occupations* are directly or indirectly injurious. It is a well-known fact that the teeth of confectioners and cooks

* Gaz. Med. di Milano, 1844.

are very apt to be affected, and it is supposed that the dust from the sugar enters into combination with the mucus of the gums and the deposits on the teeth, and occasions an acid fermentation. Richardson calls attention, in his lectures, to the fact that dental caries is exceedingly common among the fur-dyers, since the teeth are acted upon by the fumes of the nitric acid which is employed for cleansing and imparting a yellow color to the furs. The fumes produce a dryness and irritated condition of the oral mucous membrane of the tongue and fauces; as a rule there is constipation, pain in the occipital region and a sensation of constriction of the chest. The drying-room, in which are placed the damp skins impregnated with the nitric acid, is filled with the fumes of this acid. The teeth lose their enamel and, occasionally, are entirely destroyed. The fumes of ammonia, also, and the dust occasioned by beating the dried skins, exercise an injurious action.

Many *diseases of the general system* promote the development of caries, especially those during the existence of which the mixed saliva generally acquires an acid reaction, including many forms of dyspepsia, cancer of the stomach, diabetes, scrofula, rachitis, phthisis, and aphthæ.

EFFECTS OF CARIOUS TEETH UPON THE REST OF THE BODY.—

Although, in many cases, it is hardly possible to decide absolutely whether the caries is the result or the cause of a certain affection, still approximate results may be obtained from the observation of cases in which a healthy condition is restored after the removal of carious teeth. Every dentist has opportunities enough for observing cases of this kind.

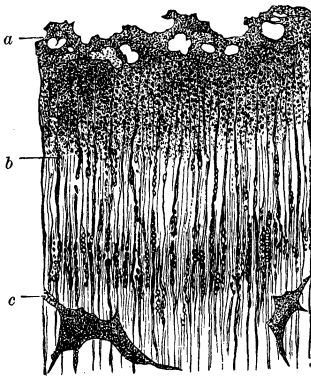
The effects are manifested in adjacent or more distant organs with which the mixed saliva comes into contact. The sharp edges of carious teeth sometimes give rise to ulcerations having a cancerous appearance upon the oral mucous membrane, the tongue, or lips, a fact readily explained since the wounded parts are constantly exposed to the foul products of decomposition, resulting from the carious disease. Liston ascribed a number of local and general affections to the presence of carious teeth or decomposed fragments of teeth. The consecutive inflammations of the pulp, root-membrane, gums and periosteum, the ab-

scesses in the alveoli and jaws, have been considered in the preceding pages. Liston also considers caries of the teeth to be a frequent cause of swelling of the tonsils, intense and long-continued headache, various digestive derangements and gastralgias, which affections disappear as soon as the offending carious teeth are removed.

CARIES OF REINSERTED HUMAN TEETH.—As a rule, the necks of these, and especially of the front teeth of the upper jaw, become the seat of the disease which generally affects their entire circumference. This fact is easily explained when we consider that the gum does not become attached to the neck, and hence accumulations of the secretions occur more readily. The dentine in the above locality acquires a dirty-yellow, brownish-yellow, dirty-brown discoloration and undergoes a superficial cartilaginous softening which spreads beneath the enamel-layer adjacent to the neck, and the enamel acquires an eroded appearance.

The deposits of pigment, consequent upon the carious process, may be traced to a depth of 1 to 2 millimetres into the dentine; adjacent to the pigmented portion occurs a dark zone which adjoins another, in many cases, very light zone. Upon close examination of the dark zone and its transition into the pigmental and light portions, respectively, the same changes are found as in ordinary caries of the teeth. The canals are filled with rows of minute grains which generally have a roundish, in some

FIG. 101.*



* FIG. 101 illustrates a carious affection of the dentine of a reinserted human incisor. The portion of dentine examined still retained sufficient consistence to allow a thin and polished section to be prepared. At the upper surface (*a*) are sharply defined cavities; these were filled with masses of lepto-*trix* which have fallen out. Next in order is a granular, cloudy portion where the canals, which are more clearly visible beyond (*b*), are filled with grains arranged in rows like strings of pearls. The interglobular spaces (*c*) are clouded by accumulations of dirty-brownish molecules. Magnified 500 diameters.

cases, an elongated, rod-like shape, are very clearly distinguishable from the intermediate substance and, when they are of larger size, form chains like strings of pearls (Fig. 101). If the calcareous salts be removed from dentine of this description, by means of hydrochloric acid, and heat be applied until the processes of the dentinal cells are set free, knotty swellings make their appearance upon them, in precisely the same manner as in ordinary carious dentine. The processes, here and there, are beset with grains of leptothrix; quite a large portion of the granular mass in the canals and clouded intertubular tissue, however, is composed of fat, as is shown by the fact that it forms a large number of drops on the addition of hydrochloric acid. The interglobular masses are light in some places; in others they present a molecular cloudiness and, sometimes, a dirty-brownish discoloration.

The outer surface of the softened, cartilaginous dentine presents very distinct perforations which extend to a considerable depth into its substance. These form the chief abode of the masses of leptothrix which occupy the manifold excavations and may be traced in the irregular pouches which dip down deeply along the course of the dentinal canals (Fig. 102). The dentinal fibres, beset with an abundance of grains of leptothrix, form free projections beyond the borders of the section, when there is a marked degree of cartilaginous softening, and in cross-sections display, here and there, a notable thickening. A violet color may readily be imparted to the leptothrix mass by means of iodine and hydrochloric acid.

Fig. 102.*



* FIG. 102 shows softened, cartilaginous, carious dentine, from a reinserted human tooth. Proliferations of leptothrix-matrix have taken place from irregular, pouch-like excavations into the dentine, along the course of the canals. Magnified 500 diameters.

In addition to the above, mycelium tubes, similar to those of *oidium albicans*, are met with, sometimes, upon the surface of the decomposed dentine.

Caries, as is well known, frequently makes rapid progress in the dentine of reinserted teeth. I observed a case where, in fourteen days after the insertion of a pivoted tooth, the dentine in the vicinity of the pivot was found to have acquired a deep black color, to the depth of about one-third of a millimetre. Brown and light spots pervaded the dentine.

The eroded border of the enamel presents cup-shaped excavations and numerous cracks which extend in short segments along the undulatory courses of the enamel fibres, or form a network. In the vicinity of the affected portions, the enamel has a mottled, clouded appearance, the prisms have a dark or black-brown color, with a reddish tinge, now and then, and are in the process of disintegration.

CARIES OF TEETH MADE OF IVORY FROM THE HIPPOPOTAMUS.—Thomson calculated the specific gravity of this ivory to be 1.866, and the amount of its organic substance to be 33.41 per cent. The caries, which frequently is very extensive, does not confine itself to the artificial teeth, but spreads beyond the groove which serves for the reception of the alveolar arch. The discolorations are very marked, being sometimes light-colored, at other times, dark-brown; the cartilaginous softening is so extensive that sections may readily be made. The loss of substance may be quite considerable, both upon the necks and lateral portions of the crowns, and hemispherical defects, sometimes, are formed upon adjacent teeth, in the same manner as in natural teeth; it is obvious, therefore, that the carious process spreads from one artificial tooth to its neighbor. Caries generally commences upon the facial and lingual surfaces, and upon the molars; it originates in the grooves where it forms irregular excavations and, also, in the vicinity of cracks in the dentine and about those portions where pivots have been inserted, or plates have been adapted.

The yellow, light, or dark-brown pigmental degeneration commences upon the carious surface and extends into the dentine to a depth of a few millimetres. Next to this portion are dark

and light zones and, beyond the latter, the contents of the dentinal canals present transverse breaks, in many places. Sometimes the dentinal fibres or processes of the dentinal cells display such uniform transverse fissures that one might imagine them to be thallus-threads, composed of minute articulations; in other places, however, the irregularity of the clefts does not admit of such an interpretation. The manner in which the metamorphosis in the dentinal canals within the dark and pigmental zone takes place is quite evident. Minute, sometimes glittering grains, arranged closely together in rows and following the direction of the canals, and, towards the outer surface, rod-like bodies, isomorphous with Bacteria, are inclosed in the canals. Sections, which have been decalcified and heated until the isolation of the dentinal fibres has been effected, establish the fact beyond any doubt that a fatty degeneration has ensued in the affected dentine and that a proliferation of leptothrix has taken place within the canals. The dentinal fibres, frequently thickened to five and ten times their normal size and presenting varicous swellings, are beset with grains of leptothrix. A violet color is produced by the latter in the dentinal canals, on the addition of iodine and acid to thin sections.

Sections of the softened, cartilaginous dentine, made in a direction perpendicular to that of the canals, present appearances exactly similar to those found in carious reinserted human teeth or in ordinary caries of normal teeth, *i. e.*, we find, besides the normal canals which are considerably thickened, have a glittering appearance and are surrounded by a light halo, groups of others, inclosing, sometimes, a finely-granular mass, the contents of which assume a more or less distinct violet color on the addition of a solution of iodine and acids.

In artificial teeth in which the dentinal canals have a direction parallel to that of the carious surface, caries extends into the substance, independent of the course of the dentinal canals.

EXPERIMENTS UPON THE TEETH WITH VARIOUS SUBSTANCES.
—A. Westcott (1843) and Allport (1858) made special investigations in order to determine the effects of acids and other substances upon the teeth. Their results coincided in showing that mineral and vegetable acids affect the enamel in such a way that

it may easily be scraped off. The former, also, ascertained that salts, whose acids have a stronger affinity for lime than for their own bases, likewise act upon the teeth; that vegetable substances only act when they undergo acetous fermentation, as sugar, for example, and that the action of animal substances is very slow, if, indeed, they exert any action, even in association with very advanced decomposition.*

Magitot submitted teeth to the action of acids, salts and albumen, during certain, quite long intervals (up to two years), and asserts that he produced conditions analogous to caries. He obtained positive results with *lactic acid* in the proportion of 1:100 parts of water. The teeth were allowed to remain in this fluid for two years, when it was found that their roots had become flexible, gelatinous, as it were, and shorter; the enamel was chalky, friable, separated from the coronal surface in places and readily reducible to a white powder by trituration. The whole dental mass presented a general brownish color. Teeth which were covered with resin, with the exception of one portion, became affected with penetrating caries, in some cases to a depth of 3 to 4 millimetres. A solution composed of a gramme of lactic acid to a litre of water made no perceptible effect upon teeth which were kept immersed in it for two years.

According to his experiments, *butyric acid* produces very nearly the same effects as lactic acid; the color produced by the caries, also, is analogous. It is a fixed acid not susceptible of fermentation.

With *citric acid*, also, there was no indication of fermentation, and he found its deleterious action to be quite intense, so that, at the expiration of two months, it was quite marked even with a solution of 1:1000 parts of water. He states that this acid is more injurious than any others which act upon the teeth. It occasions no discoloration, which leads to the conclusion that it naturally induces a white caries.

From experiments with *malic acid* and *cider*, he found that the former, in the proportion of 1:100 parts of water, acts with more energy than the latter.

* Leber und Rottenstein über Caries, p. 68.

Magitot repeated the experiments of Berzelius and Dumas, of decalcifying teeth by subjecting them to the action of *carbonic acid*, as it occurs in Seltzer water which, usually, contains one volume of water to five volumes of gas. The enamel became friable, the dentine became softened. When equal volumes of water and gas were employed, he was unable to detect any change in the teeth which were immersed in the solution during eight days. For reasons which may readily be understood, he is of the opinion that acidulated waters do not act upon the teeth.

Teeth which were allowed to remain in fluid containing *fermenting albuminoid* substances acquired a general and uniformly softened condition in the course of two years; the roots became transparent and soft, the enamel friable and opaque. Teeth which were protected entirely, excepting at one point, presented the characters of true caries at the exposed part. During the putrefaction, fatty acids formed, of the acetic and benzoic series; the putrid odor suggested butyric and valerianic acids.

A solution of *alum* (1:100 parts of water), which at the end of two years had an acid reaction, had not affected the roots in the least during this period, while the enamel lost its glazed appearance, became opaque and had the appearance and brittleness of a layer of chalk; the dentine and the cement were not in the least affected.

The action of a solution of *binoxalate of potash* (1:100 parts of water) was very similar to that of the solution of alum, that is, it was limited to the enamel.

Acetic acid (1:100 parts of water) induced a very peculiar change in teeth which were allowed to remain in it for two years. The roots became softened throughout, flexible, yellowish and considerably thinner, while the coronal portions remained unaffected. The enamel retained its polished appearance and firmness.

Tartrate and bitartrate of potash (1:100 parts of water), also, left the enamel intact and attacked the cement and dentine, but their action penetrated to a less depth than that of acetic acid.

A solution of *chloride of sodium* (1:100 parts of water), con-

taining a few drops of creasote, manifested no action upon the teeth.

Tannin (1:100 parts of water) acted upon the cement and dentine, but not in the least upon the enamel.

Magitot divided the substances, according to his experiments, into four groups: 1. Those which attack all the dental substances; 2. Those which occasion a disorganization of the enamel exclusively; 3. Those which act exclusively upon the dentine and cement; 4. Those which induce no change in either of the three dental tissues.

Unfortunately, Magitot neglected to make histological examinations of the teeth in which caries was induced artificially, as this would be necessary in order to establish the identity between natural and artificial caries.

Leber and Rottenstein repeated a number of Magitot's experiments, with these modifications, however, that they diminished the duration of the action and, as it appears, allowed the substances to act only upon the entire surfaces of the teeth and not upon separate portions. They took exception to the experiments of Magitot and showed that the results are not due to the acids alone, but, also, to the decomposition of the organic substance of the tooth, to putrefaction and fermentation, and that the effects produced by the low vegetable and animal organisms which are developed in the latter processes, also, are to be taken into account. They were unable to satisfy themselves that the mere action of acids produces changes exactly similar to those observed in caries. Their experiments with tartaric and acetic acids, oxalic acid and alum gave results different from those reported by Magitot in regard to the non-affection of the enamel and cement respectively.

CARIES OF THE TEETH OF ANIMALS.—I have had an opportunity of examining only a few carious teeth from the horse, which were furnished to me by Prof. F. Müller. As is well known, caries of the teeth is a very rare occurrence with animals. They were cases of so-called dry, chronic caries, with no evident, separable, cartilage-like, softened layers in the dentine or cement.

In one premolar, the carious affection was presented in its

early stage, in the form of a blackish-brown, circumscribed spot, the size of a lentil, upon the much worn, excavated, grinding surface, and made its first appearance on the prominent fold of enamel. The carious pigmental degeneration extended, in many places, through the entire thickness of the enamel, as far as the line of junction with the dentine, and, in well-marked localities, was indicated by an intense sap-brown color, the line of demarcation being well defined. The enamel prisms appeared to be filled with a molecular mass which I did not consider to be leptothrix, since the surface of the enamel was found to be smooth, and without any deposit upon it.

Where the caries was more extensive, in the tray-shaped abraded, grinding surface, and involved, also, the bony and dentinal tissues, the encroachment of the affection upon the dentine was so slight that cross-sections presented merely a narrow streak of carious, blackish-brown discoloration. No finely granular contents were visible in the dentinal canals adjacent to the affected portions, and no leptothrix-mass was attached to the latter.

The strong bony tissue of the premolar became undermined by the carious process in such a manner, that carious cavities were met with at a considerable depth below the grinding surface. Here, also, the light-brown discoloration involved only a few rows of bone-corpuscles which, together with the interglobular substance, were uniformly pervaded.

The exterior of the carious bony tissue of the tooth was free from leptothrix; the peripheral layers of the latter tissue, as well as of the carious dentine, had a more homogeneous, transparent appearance; it is still undecided if it be allowable to regard this as a slow process of decalcification.

THEORIES OF CARIES.—From the historical account which has been given, it is evident that the theory of caries has been sought for chiefly in three directions; some have given prominence to the vital, others to the purely chemical and to the parasitic processes, and still others have advocated divers views, based upon various combinations of the latter processes.

Formerly, the knowledge of the structure of the tooth was so defective that there was no anatomical basis for the study of

the carious process, and, until the fourth decade of the present century, when the histology of the tooth became determined by degrees, it was impossible for an accurate investigation of the structural changes in the carious tooth to be made. In order to complete our knowledge of the subject, however, a gap remained to be filled up, until within the last ten years, namely, the establishment of the history of the development upon a sound basis. As soon as these preliminary results were obtained, it became possible, with the aid of the improvements in optical instruments, to trace the process in its different phases.

The writers of the earlier times, for the most part, were vitalists, since they professed to recognize a life in the tooth and appear to have referred the destructions attending dental caries, resembling, in the general appearances, the gangrene of other organs, to a vital process.

As soon, however, as organic chemistry furnished the analyses of the tooth and secretions of the mouth, although these are still unsatisfactory, and explained the process of fermentation with its manifold products, it became necessary, in connection with the decalcification process in dental caries, to take into account the action of acids developed in the secretions or in fermentation. Hence arose the chemical theories.

During the past ten years, our knowledge with reference to the marked diffusion of parasites and their injurious effects upon the animal economy has gradually increased; search was made for such animated beings in the carious tooth; they were found, or were supposed to have been found, and hence the parasitic theory was constructed.

Then came the fusionists, some of whom attempted to combine the vital and the chemical theories of dental caries and considered the latter to be a reaction, of the nature of an inflammatory process, on the part of the hard dental tissue which is chiefly affected, the dentine, and, at the same time, retained the views with regard to the agencies in the process of decalcification. Another class combined the effects of chemical agents with those of parasites. Still another class endeavored to unite all these theories and, therefore, assumed the occurrence of several kinds of caries. It was admitted that the caries is de-

pendent, in most cases, upon external agencies and extends from the outside towards the interior, but, on the other hand, it was asserted that the same process may also take place in the opposite direction and hence caries which is developed from the pulp towards the exterior was described as *caries interna*.

Since we know that an interchange of material takes place in the dentine and cement during life, as is proved by the occurrence of atrophies, hypertrophies and new-formations, and that the dentine possesses a degree of sensibility, we cannot reject absolutely the idea of a reaction on the part of both hard tissues against the effects of external agents. Some authors seem to have had an intimation of this idea, since they were inclined to consider the textural changes in carious dentine as vital processes.

There can be no doubt that the sensibility, sometimes increasing to actual pain, of the dentine, when deprived of its protective covering, is a vital action, and that this becomes diminished when the most sensitive, the peripheral portion, is destroyed by an external agent. These facts, however, are by no means sufficient to enable us to draw a conclusion in favor of the reactionary power of dentine in parts which are attacked by caries.

The thickening and varicous swellings of the dentinal fibrils were ascribed to a vital process by J. Tomes, E. Neumann and H. Hertz. The former asserts that the outlines of the formative cells are restored by the diseased condition; E. Neumann goes still farther and observes a proliferation of cellular elements of the dentine in sections which have been colored with carmine, and hence establishes an analogy between dental caries and inflammatory and ulcerative processes in the soft parts. Leber and Rottenstein merely state that, in cross-sections especially, the contents of the widened canals are seen to be broken up into rod-like segments which, sometimes, are separated by slight intervals. They did not find, nor have I succeeded in observing the prominent nucleiform bodies in the thickened dentinal fibrils, after coloring the specimen with carmine, as they were described and illustrated by Neumann.

The increased transparency of the dentine around the focus of caries and the still problematical calcification of the dentinal

fibrils are regarded by J. Tomes as attempts on the part of nature to arrest the progress of caries. The carious dentinal cone is interpreted by Magitot as an evidence of a reaction on the part of the pulp against the agent which acts from the outside. This condition of irritation, he says, is manifested, on one side, by the production of secondary dentine and, on the other, by a molecular deposit in the dentinal canals which become obliterated. He, therefore, regards the latter appearance, also, as a vital process.

Although it cannot be denied that the living pulp does react against external agencies, still the interpretations of the above-named writers, according to which an inflammatory process of the pulp manifests itself in carious dentine in the different ways already mentioned, are incorrect, as Leber and Rottenstein have shown. Carious dentine of reinserted human teeth and of artificial teeth made from the ivory of the hippopotamus presents the same appearances as are found in ordinary caries, in respect of the pigmented, dark and light zones, the granular condition of the dentinal fibrils, the thickening and varicous enlargement of the latter. The phenomena ascribed to odontitis, therefore, do not really belong to it.

Dentinal new-formations, which are developed upon the wall of the pulp-cavity at a point corresponding to the carious locality in the dentine, can be induced only by an irritation in the contiguous portion of the pulp; they are an expression of the efforts of nature, a reparative tissue, to compensate for the peripheral destruction. They are particularly frequent in connection with caries with a tendency to a chronic character. Numerous cases present no trace of such repair, although the dentine presents all the appearances which have been mentioned. Inflammatory affections of the pulp generally do not make their appearance until the dentine has suffered a considerable loss of substance, or, as is the case frequently, until the pulp is covered by a thin layer of dentine, merely, or a perforation into the pulp-cavity has occurred. There are no grounds, then, for ascribing the changes in the dentinal fibrils to an inflammatory irritation of the pulp.

It is a familiar fact, that dead animal tissues undergo a

marked fatty degeneration under certain circumstances. In pathological cases, a fatty metamorphosis of organs is frequently met with, and this fact has been adduced, in some cases, to prove that fat is formed by the transformation of protein substances. It is not singular, therefore, that fat may also be deposited, under favorable circumstances, in dead dentine; indeed it is found interposed in the dentinal canals in the form of drops.

On the other hand, there is abundant proof that fungi penetrate living, dying, and dead animal tissues, and there is a fungus, probably belonging to *Mucor*, whose spores sometimes are found in drinking-water, and which, by proliferation in the dead bone and dentine, produces a considerable loss of substance.* This fungus has no connection with caries of the tooth and occurs casually in carious teeth which are kept in water. Quite as little is the part taken by the *Protococcus dentalis*, described by Klenke as occurring in association with a special form of caries, which he termed vegetative decay of the teeth (*Zahnverderbniss*). I have met with this in a single instance; its relation to dental caries has not been confirmed by any writer; it is an accidental occurrence, like the *Puccinia graminis* in the favus crust.

Leptothrix buccalis, on the contrary, occurs so frequently in connection with dental caries and so clearly lodges, here and there, in the cartilage-like, softened, decalcifying dentine, that Leber and Rottenstein went so far as to state that the variations in the course of caries must depend upon the part taken by the fungus proliferation in the carious process. The proliferations of the elements of the fungus without doubt penetrate and expand the dentinal canals, but, according to my observations, this cannot occur until the decalcification of the dentine is complete, or, at all events, until the first stage of this process. I have never detected a proliferation of fungus in the deeper layers of the still hard, carious dentine, and, in my opinion, the death of a certain amount of dentine, in consequence of the action of the acid, is necessary before it is possible for the proliferation of

* C. Wedl: Ueber einen im Knochen und Zahnbein keimenden Pilz. Sitzungsber. der kais. Akad. d. Wiss. zu Wien, 1864.

the fungus to occur. The extension of caries, in the dentine, therefore, according to my view, is effected by the acid and not by the fungus. If the acid be neutralized by the saliva, *e. g.*, on the lower incisors, caries does not occur, notwithstanding the presence of thick layers of leptothrix, such as are met with in tartar. Leptothrix has no direct connection with the origin of caries; previous to the formation of a carious pit on the neck of the tooth, I have been unable to find any deposit of leptothrix upon the exterior, or any rows of leptothrix-grains in the interior, of the dentine. The grains which occur in the dentinal canals in chronic caries are minutely-divided fat.

The action of an acid, therefore, I consider a fundamental condition of the occurrence of caries in all cases where there is evidence of a decalcification, however slight. In other cases, where no evidence of the latter has been furnished (in a manner, indeed, not to be relied upon, as in the *caries carbonacea*, as it is termed by dentists), the chemical process is still in darkness.

Although the action of acids is admitted, still our knowledge is not yet sufficient to enable us to answer the questions, whether one or several acids, what form of the same, how and where they are formed?

The constituents of the mixed saliva vary, not merely in different persons but, also, in the same individual. Its well-known property of converting insoluble starch into dextrine and grape-sugar, which latter may enter upon an acetous fermentation in the presence of a ferment, was turned to account by Leber and Rottenstein, who concluded that the acid reaction in the oral cavity is due principally to the acetous fermentation of particles of food. If it is proper to give such prominence to the latter, then it will be impossible to understand why caries of the teeth is such a very rare occurrence with animals, which are unable like men to remove the particles of food that remain between the teeth. Many races of men, who certainly are not very careful in observing cleanliness of the mouth, *e. g.*, the Esquimaux and New Zealanders, furnish a very small percentage. In well-marked chronic caries, the remains of food manifest no perceptible action; in so-called central caries, also, a cartilaginous softening of the dentine ensues without the co-operation of the

remains of food. With many derangements of the intestinal tract an acid or saline taste is observed, entirely independent of the food. Acid sputa, increased acidity of the vaginal or vesical mucous membrane attest that mucous membranes of themselves may furnish an abnormal acid secretion.

Magitot considers the saliva to be the active agent in the production of caries, when the former becomes the vehicle of acid substances. Leber and Rottenstein state that, if it is true that fungi play any part in the acetous fermentation within the oral cavity, a point, however, which remains to be proved, they are inclined to ascribe the action to leptothrix, and assert in common with Oehl, that in all probability lactic acid is formed in the acetous fermentation. Spence Bate* holds the view, that in consequence of a decomposition of the dentinal fibrils within the tubes, carbonic acid is set free; the latter *in statu nascenti*, is brought into contact with the calcareous salts of the tissue, which then become decomposed with the development of acid. The acid which is set free, he says, is phosphoric and not lactic acid.

In my opinion, especial consideration is claimed by the secretion of the gums, which comes into immediate contact with, and forms a partial viscid covering of the teeth. It is found, oftentimes, to be acid without the presence of the débris of food. When the secretion is unusually abundant, as, for instance, with children, young persons and, especially, with women during pregnancy, caries assumes a more or less acute character. It is not uncommon, remarks Tomes, with persons who have many carious teeth, to find the gums swollen, very vascular, and covered with a coating of thick, adhesive mucus which may be drawn from the gums in long strings. He mentions a case where the teeth were rapidly destroyed by caries and, coincident with this process, the salivary secretion was scanty in amount; at a later period, the whole of the remaining teeth were almost simultaneously attacked near the edge of the gum, producing around each tooth an annular belt of softened tissue. He states that when there is an abundant flow of saliva and a free secre-

* Odontological Society of Great Britain Reports, 1865.

tion of mucus, the latter is found clinging to the teeth, instead of becoming dissolved in the saliva, and that the mucus must be regarded as furnishing the agent by which the dental tissues are decomposed. Tomes' conclusion, that the gum when irritated may furnish an acid secretion, which he regards as justified by the fact that caries already existing is promoted by the insertion of cotton between the teeth, is invalid, as Leber and Rottenstein have shown, since these results may be due to the fact that the cotton, being a porous substance, necessarily favors the processes of decomposition and fermentation which are in progress in the vicinity. I have frequently met with tumefaction of the gum and papillary hypertrophy in association with dental caries in the cadaver; these, to be sure, may, in part, be consecutive affections, still the frequent coincident occurrence of an affection of the gum is deserving of notice.

When there is a diminished secretion of oral fluids and from the gum, as is the case in old age, caries assumes a well-marked chronic course. In those localities, where only a slight action of the secretion of the gum is possible or the latter is removed readily by the movements of the tongue, caries is a rare occurrence. When the caries is acute and the crown is destroyed, its progress in the roots is a slow process, in consequence of the fact that the action of the secretion of the gum becomes less direct. While the greatest prominence is given to the action of the abnormal secretion of the gums, it must not be assumed that the influence of the anomalies in the secretions of the salivary and mucous glands and of the mucous membrane of the oral cavity is underrated, as, indeed, is sufficiently apparent from the preceding observations. Injurious effects, however, as a general rule, are to be ascribed to the débris of food only in cases where the structure of the tooth is defective or there is a carious breach of substance.

It must be acknowledged that our knowledge with regard to the quality of the secretions of the oral cavity is imperfect and, at all events, it is a question whether the injurious effects are due to them alone or rather to the products of their decomposition. It is not known whether a larger or smaller amount of an acid (perhaps lactic, and with regard to which organic chemistry

teaches us that it occurs frequently in partially-decomposed animal fluids) shortens or prolongs the process, or if different acids modify, in various ways, the course of caries. The presence of lactic acid, particularly, is assumed since C. Schmidt, of Dorpat, has succeeded in demonstrating the frequent occurrence of this acid in the usually acid juice (Saft) obtained from long bones affected with osteomalacia. It also remains to be decided whether butyric, valeric, or formic acids, which H. Fischer obtained from strongly-alkaline or acid pus, do not occur as products of the decomposition of the puriform secretion of the gums.

If the continuity of the enamel membrane is interrupted by fissures in the enamel, or has become brittle and friable in consequence of the presence of leptothrix masses, and acids have access to the enamel, then the calcareous salts within the prisms are reached quite readily since the organic investments of the latter are capable of offering only slight resistance; indeed, we learn by chemical analysis that the organic substances of the enamel amount to scarcely more than three per cent. Primarily, the action of the acid is confined to narrow limits, and it may be assumed upon good grounds that a simple solution of the calcareous salts does not take place, but that the acid enters into combination with the latter and the newly-formed salts, destitute of an organic cement, readily become disintegrated. If we consider that the acid spreads in the course of the groups of enamel fibres, it will readily be understood that, on the one side, the action is confined to definite limits and, on the other, an undermining of the adjacent portions of the enamel ensues. If the continuity of the enamel prisms is broken, the normal transparency of the enamel, at the corresponding part, is destroyed and a white spot makes its appearance. If the action of the acid is slow, we find a more abundant deposit of pigment. Possibly, decalcification and putrefaction occur in common in this case.

When a circumscribed breach of substance has been effected in the enamel, materials entering from the outside, tenacious mucus, leptothrix and particles of food, are more likely to become impacted in the jagged excavation which then affords a more favorable locality for the action of acid; with this condi-

tion, the acid continues its deleterious action undisturbed by the neutralizing property of the salivary fluid, and its effects are manifested by a yellowish discoloration of the adjacent portions of the dentine, even while the latter is still covered by a thin layer of enamel.

As will be evident, the larger the carious cavity in the enamel and the smaller the aperture leading to it, so much the greater will be the danger that the dentine will be extensively involved. As the dentine contains 28 per cent. of organic matter, the process of decalcification in it takes place quite rapidly leaving behind the organic residue, the so-called dental cartilage. In consequence of the action of the acid, death of the affected dentine ensues, and its decomposition, in which, as above observed, *leptothrix buccalis* is the active agent, takes place from the exterior towards the central portions. A carious cavity is formed in the dentine, usually larger than that in the enamel; this affords a receptacle for particles of food, which frequently cannot be reached except with difficulty, and hence readily becomes the seat of acetous fermentation.

The shape of the carious cavities in the enamel and dentine depends partly upon the location in the tooth and partly upon the quality of the enamel and dentine. Near the neck of the tooth, the carious excavations are flattened, while those upon the masticating surfaces of the molars are always very large in comparison with the orifices leading to them. The thicker and more compact the enamel, the greater resistance does it offer and the more extensive is the destruction of the dentine beneath the enamel; in these cases, therefore, the cavity is always very deep, while flattened cavities occur where the enamel is thin and has a more lax structure. The greater the extent of the exposed dentinal surface, the more extensive will be the portions affected.

The cause of the very marked carious pigment deposits in the enamel and dentine remains undetermined; it cannot lie in the organic, changed matter alone, since the discoloration is manifested with equal intensity in both tissues, and between the latter there is a marked difference in respect of the percentage of organic matter which they contain. When the action of the acid

upon the enamel and dentine takes place slowly, the intense, carious pigmental degeneration does not extend to a great depth, the cartilaginous softening is limited to a narrow zone, and the disintegration ensues so gradually that the proliferating leptothrix buccalis could not possibly penetrate except to a very short distance.

The distinction between caries of bone and of dentine is illustrated by caries of the cement which is characterized, also, by its progress from the exterior towards the central portion of the tooth and by a progressive deposit of pigment, together with a peripheral softening. In the premolar of the horse, where the vascularized osseous substance forms such thick layers, the process is the same as in the cement of human teeth, with the exception that in the former it assumes a well-marked chronic character. The death of the osseous substance spreads, gradually, from the exterior without any manifestation of an inflammatory reaction.

Since, then, caries gives evidence of its dependence upon external causes in all three dental tissues, the question arises, what processes occur in connection with the very rare softening and melting down of the dentine in the direction from the pulp-cavity towards the periphery? A case has been related (compare p. 191) where a central softening of the dentine occurred without any trace of ordinary caries. Leber and Rottenstein,* also, report a case of so-called central caries, where a bluish discoloration appeared upon three incisors without any trace of caries. By means of holes made in two of them, the entire internal portions, as far as the enamel, were found to be completely softened, decomposed and of a brownish hue; even the roots were deeply excavated. The third tooth was not touched. The patient recollected that she had a fall, in her childhood, striking upon the teeth, and that this was followed by a swelling of the face. Leber and Rottenstein express no opinion as to the cause of the destruction of the dentine in this case and state that such cases ought not to be confounded with ordinary dental caries. A. Scheller, of Warsaw,† reported two cases of

* Op. cit., p. 11.

† Deutsche Viertelj. f. Zahnk., 1870.

this description, the second one of which is of especial interest and is similar to that of Leber and Rottenstein. He expresses an opinion that the central caries of the teeth is to be regarded as a process of decomposition which is engendered by the disorganization (*Verjauchung*) of the pulp.

The condition found in gangrene of the pulp (compare p. 183) points to the presence of a fatty-acid as a product of decomposition; it may be possible, then, that a fatty-acid is formed in the necrotic pulp, capable of destroying the dentine. Magitot ascertained (compare p. 408 *et seq.*) that butyric and lactic acids are very similar, in respect of the mode and degree of their action upon the teeth. At all events, the so-called central caries cannot be regarded as a variety of ordinary caries, but, obviously, must be classed with the inflammatory affections of the pulp.

“In proof of the occurrence of an internal caries, which has been classed with caries of bone,” says Heider, “the foul, sometimes exceedingly nauseating odor occasioned by carious teeth has been taken into account and referred to a secretion from carious dentine. But,” he continues, “the peculiar, purulent odor never occurs except with a patent pulp-cavity and arises from the gangrenous pulp; while the foul odor of carious teeth, when the pulp-cavity is closed, is occasioned by the putrefying débris of food, which accumulates in such cavities, and disappears if the latter are kept clean. The preceding must not be confounded with the foul odor occasioned by the accumulation of the secretion of the gum between the teeth and, perhaps, by coagulated blood, or is communicated by plugs of cotton in the cavities.”

The carious process may be checked, but it cannot be cured. An acute form may become chronic, and an arrest may ensue; this is a particularly common occurrence, as has been observed before, on the carious roots, upon which, however, it is possible, always, to discover a carious superficial layer containing deposits of pigment.

Duval* and various other authors have applied the term caries,

* Magitot, *op cit.*, p. 30.

which resembles a “*usure*” (Usur), to a partial defect which occurs upon the neck of the tooth, and has been described as wedge-shaped (comp. p. 253). Although Magitot admits that these defects present all the appearances of a true usure, still he has pronounced them to be instances of healed caries of the neck of the tooth or dry caries, without, however, adducing any reasons in support of this opinion. The healing process is said to be induced partly by the resistance of the pulp and partly by the removal of the injurious exciting cause.

The action of the acid requires a certain length of time, whether the secretions of the gums, the lips, the buccal mucous membrane or the débris of food, act as its vehicle, and this period is shorter or longer, as the local relations are more or less favorable for the reception of the acid vehicle. Hence caries makes its first appearance in the pits and grooves or on the contiguous and facial surfaces of the teeth.

The effects of equivalent acid vehicles vary in the different kinds of teeth in the same individual and, also, in those of different persons. The frequency of caries is diminished under the following circumstances: *a*, if the effect of the acid is neutralized, as is the case upon the lower incisors which are bathed in saliva almost constantly, and upon which deposits of tartar are very common. The deposition of the latter, probably, prevents the occurrence of the carious process in the contiguous locality, but still chronic caries may be in progress upon one surface, while the deposit of tartar takes place upon another; *b*, if the position of the teeth is corrected so that their contiguous surfaces correspond with the normal arrangement; *c*, if the teeth receive proper care and they are protected against the action of injurious agents; *d*, if the tooth is constructed in a solid manner and its surface presents a normal smoothness; *e*, if all the teeth and the oral mucous membrane, together with the glands, are regularly constructed with reference to the modifications engendered by race and hereditary tendencies.

The last-mentioned factor is the most important element in the determination of the frequency of caries in general and is intimately connected with the structure of the entire organism.

The quality of the nutritive material has only a secondary importance.

The structure of the individual tooth has an essential influence upon the course of caries, and the teeth may be divided into groups with reference to their power of resisting the disease. Our present methods of investigation are not yet perfect enough to enable us to determine with exactness, the individual differences in the degrees of hardness of the enamel and dentine, the knowledge of which is of importance in determining the treatment and prognosis. A. Alphons, of Cracow,* divided the teeth into six classes, with reference to the treatment of caries by filing and filling.

Heider communicated to me his views upon this point as follows: With regard to the predisposing conditions in the structure of teeth which are attacked by caries, it is found that bluish or grayish-white teeth, with a slight polish, very frequently are attacked simultaneously by acute caries, while, on the other hand, yellowish-white teeth, with smooth, polished enamel, usually are affected by chronic caries only, and in isolated cases. The first-named kind of teeth is furnished with less solid enamel and less compact dentine, as is indicated most decidedly by the use of the file and excavator. Some teeth can be operated upon with great ease, even with inferior files, and leave upon the file a large quantity of dentine, reduced to a white, unctuous mass, while, on the other hand, the second named kind of teeth offers great resistance to the action of the file and is affected only to a slight degree, comparatively speaking, even by the best files, upon which they leave only a scanty, white, powdered mass of dentine. The enamel and dentine, therefore, present two varieties in quality, the gradations of which determine the varying susceptibility of the teeth to caries.

If it is true, as Gladstone cites from Lasseigne, in his lectures, † that the molar teeth contain a greater amount of mineral substance than the incisors, and that, with increasing age, the teeth present, especially, a large decrease in the amount of carbonate,

* Deutsche Viertelj. f. Zahnheilk., 1867.

† Quarterly Journal of Dental Science, 1857.

as compared with that of phosphate of lime, then we should have several datas as to the course of the carious process according to the kind of tooth affected and to the age.

From the foregoing observations, it appears that caries of the teeth is a process which has its origin, chiefly, in the abnormal secretions of the gums and, likewise, in those of the rest of the oral mucous membrane and of the salivary glands, and, commencing at suitable points upon the exterior of the tooth, spreads in the direction of the pulp-cavity. In consequence of the decomposition of the secretions, acids are formed which extract the calcareous salts from the hard tissues and give rise to a disintegration of the affected portions of the latter, in which no inflammatory reaction occurs. The destructive process is promoted, essentially, by the accumulations of secretions and particles of food, and opportunity is afforded for the proliferation of *leptothrix buccalis*, in the dead and softened dentine. The exclusion of an acid in the development of well-marked chronic caries (*caries sicca*, *carbonacea* of writers) is not established upon scientific grounds.

VII. NEUROSES.

UNDER this head we have to consider the disorders of sensibility within the territory of the trifacial nerve which, as we know, is a mixed nerve, being composed, for the most part, of sensitive, but, also, containing motor and secretory fibres. The portion of its territory of particular interest to us includes the branches of the second and third divisions, which supply the teeth and gums on the corresponding side, but, at the same time, it is necessary to keep in view the territory of the other ramifications, the points of their origin, together with the numerous anastomoses and ganglionic communications throughout the entire course of the nerves, in order to appreciate fully the complicated morbid phenomena of nerve-life.

In consequence of the obscure nature of the subject and our present imperfect means of observation, only a few *anatomical changes in the nerves and ganglions* in neuralgias are recognized. I had the opportunity of examining a series of nerves which were resected by Schuh for the relief of facial neuralgia, and satisfied myself that, in the majority of cases, it is possible to demonstrate disordered conditions both in the neurilemma and in the nerve-tubes. In the former, an hyperæmic swelling occurs, and the interstitial connective tissue of the nerve-tubes acquires a finely granular cloudiness; in the latter, a finely granular metamorphosis of the medulla is observed. The latter abnormal, refractive, protruding contents, however, are found only in separate tubes or in a small group of tubes, while the remaining tubes contain a perfectly normal medulla. In old chronic cases, pigmented granular spots are found in the neurilemma, and a crumbling disintegration of the greater portion of the medulla is observed. The grains which fill and protrude from the nerve-tube, sometimes, are quite large, glittering, and roundish, at others, minute molecules; the axis-cylinders, when removed, present similar grains which are adherent and collected to-

gether in clusters. In one instance, I found quite large, highly refractive, roundish bodies, symmetrically arranged in longitudinal chains and resting upon separate nerve-tubes. These were entirely soluble in hydrochloric acid and, therefore, were calcareous grains. They were also found interspersed in the interstitial connective tissue.

These appearances which have been described clearly indicate that, in most cases, a *neuritic process* [neuritis] ensues, which pursues a more or less active course and, in protracted cases, induces an obliteration of the nerve-medulla.

Rosenthal* also mentions knotty swellings of resected branches of the trifacial nerve (consisting of connective tissue and interposed nerve-fibres), like the knots which are met with in the divided nerves after amputations.

We know nothing in regard to the affections of the ganglions in the course of the trigeminus, in connection with neuralgias; in one instance, in a case of *prosopalgia*, I found an evident pathological change in the Gasserian ganglion.† The ganglions on both sides presented numerous calcareous grains of various forms. The ganglionic cells contained abundant deposits of pigment. The ganglion of the affected side presented a quite noticeable swelling, and the bloodvessels of the connective tissue, which invested it and surrounded the nerve-bundles of the nodular enlargement, were very full of blood, so that there could be no doubt of a previous exudative process in this ganglion. An inflammatory affection at the point of origin of the trifacial nerve was observed by Bensow, and Beveridge described a new-formation upon the trunk of the fifth nerve.

These inflammatory processes in the continuity of the trifacial nerve are consecutive in most cases, and may have their *focus of irritation* (Reizungsherde) at the periphery of the branches of the second and third divisions, the consideration of which is involved in our present subject. The following are the *exciting causes* of neuralgias within the precincts under consideration; *a*, chronic inflammation of the pulp, since this and its products

* Handbuch der Kinderkrankheiten, p. 490.

† Schuh Ueber Gesichtsneuralgien, p. 19.

maintain a constant irritation of the pulp-nerves; *b*, new-formations of hard dental tissues within the pulp, inasmuch as they irritate the remaining nerves of the pulp, under certain circumstances; *c*, proliferations of cement at the extremities of the roots, whereby the nerves which enter the teeth are bent more or less from their proper course or the same nerves at a distance from the apices of the roots, together with the nerves of periosteum of the root, are irritated; *d*, chronic inflammation of the root-membrane, with its sequelæ, particularly in the vicinity of the apex of the root; *e*, new-formations of the root-membrane when they encroach upon the precincts of the nerve-branches; *f*, periostitis, especially in the grooves or the foramina which serve for the transit of the dental nerves; *g*, osteophytes, which occasion an irritation of the periosteal nerves; *h*, tumefaction of the mucous membrane and periosteum of the antrum of Highmore give rise to pain and even a neuralgia of the posterior, superior dental nerves (Schuh) in otherwise sound teeth, which circumstance Luschka explains by the fact that the dental nerves pass through complete bony canals in some places, but in others lie in very shallow grooves in the bone, so that they are in immediate contact with the tissue of the periosteum, and, if the latter be removed, they become exposed; *i*, anomalies of position, whereby resorption of one or another root or of the crown of the adjacent tooth, is occasioned by the growth of the roots of the displaced tooth, and the contiguous portion of the root of the former is subjected to a continual irritation; *k*, teeth which remain imbedded within the jaw sometimes irritate the dental nerves of other teeth by the growth of their roots; *l*, inflammatory irritation of the gingival nerves which cover the coronal portions of teeth during the first dentition; *m*, inflammatory irritation of the gingival nerves in connection with the difficult eruption of teeth during the second dentition, especially of the wisdom teeth; *n*, tumors of the jaws, inasmuch as they sometimes occasion an irritation of the dental nerves; *o*, foreign bodies which have penetrated into the pulp; *p*, lesions produced by unsuccessful extractions of teeth.

When such peripheral foci of irritation exist, as the resected nerves in facial neuralgia show, the trunks, from which the

dental nerves are given off, become inflamed, their sheaths are found in an hyperæmic condition, and hence the possibility is afforded for communicating nerves, which are contained in a common fibrous envelope, to become involved. Moreover, it is readily explicable that hyperæsthesia is induced by inflammatory swellings in localities where the radiation of the divisions of the trifacial nerve is confined to a contracted space. Hyrtl* calls attention to the fact, that the branches of this sensitive cranial nerve traverse tightly-inclosed, long canals in the bones, as the infraorbital, alveolar, zygomatic branches, &c., and, therefore, on the occurrence of nutritive disturbances of their sheaths from rheumatism or congestion, with thickening and tumefaction, they are subjected, necessarily, to pressure which is manifested by sensations of pain.

Rosenthal† states that periostitis, involving portions of the bones through which the passage of the trifacial nerve takes place, is a frequent exciting cause, and says neuralgia of this nerve is due, most frequently, to exposure to cold. Without detracting from the influence of the latter, I am convinced, nevertheless, that in most cases there is a primary neuritic condition [neuritis] of a peripheral branch of the trifacial nerve, and that the exposure to cold simply furnishes a cause for the farther extension of the previous inflammatory condition in the course of the branches of the nerve.

Peripheral irritations of the trifacial nerve, as we know, frequently arise at the point of exit of the nerve from the cranial cavity, in consequence of inflammatory affections or tumors at the base of the brain, and a thorough examination is required in order to determine whether the focus of irritation is centric or peripheric. In this case, it is supposed, of course, that the patient refers the pain to the periphery and not to the irritated portion of the nerve.

Another and frequent source of error, in the determination of the focus of irritation, arises from the *irradiation* of the pains, by which is meant that they extend far beyond the limits of the

* Topograph. Anatomie, 5 Aufl., I, p. 345.

† Op. cit., p. 193.

seat of irritation and, sometimes, are more severe than the pain felt at the original focus of irritation. In these facts, we have an explanation of the inexact and varying statements of patients with regard to the locality of the pain, whereby the surgeon is not a little perplexed in deciding upon the resection of one or another nerve.

Further proof of the difficulty attending the localization of the focus of irritation is furnished by the fact that resection of painful branches of the trifacial nerve, in most cases, affords only temporary relief from pain, which rarely continues longer than a year. Resection of a sensitive nerve really effects nothing but an interruption of its conductivity and, as soon as the latter is restored by the regeneration of the nerve, the pain is renewed and becomes as violent as it was previous to the operation; hence it is proved that the focus of irritation was not detected and that it must have been located somewhere else than in the resected portion; the irritation persisted after the resection, but consciousness of it was lost since its connection with the brain was cut off.

Another important question arises: Is there any point to which the pain is referred constantly? Schuh,* after very extensive observations, came to the conclusion that the fixed pain is wanting very frequently, although Valleix maintains the opposite view. It is described by the patients, he says, as dull, heavy, gnawing, dragging and somewhat burning, and is not perceived throughout the entire course of the nerve or branch, but is limited to a circumscribed locality. Usually, it is not very severe and, sometimes, it continues, with varying intensity, for hours or days together. I am disposed to agree with Schuh, since it is a physiological fact that the sensibility of nerve-fibres may become blunted, at least for some time, if they are subjected to severe or continued irritation. If, however, we find no continually painful locality, it becomes a more difficult matter to ascertain the locality of the focus of irritation.

If the *clinical phenomena* indicate such a fixed point, they may be divided into those which are confined to the focus of

* Ueber Gesichtsnuralgien, 1858, p. 3.

irritation, *local* or *primary*, and into *periodical* or *secondary*. The most prominent symptom is the disorder of sensibility, which we term pain. Besides the sensitive fibres of the trifacial nerve, its motor and secretory fibres and even those of other nerves are attacked by reflex action through the small reflex centres, the ganglions, or through the central nervous system. Fibres of the sympathetic, also, become involved in the irritation.

With regard to the localities from which the pain radiates in the paroxysms, Schuh observes, they originate either at the points where the sensitive branches of the fifth pair emerge from the canals or grooves of the bone and enter the soft parts of the face, in the peripheral, terminal ramifications in the skin, mucous membrane, or teeth, or, finally, where the terminations of the two divisions of the nerve join or communicate with one another. Among the painful points determined by Schuh and Valleix, the following may be mentioned, in the present connection: *a*, the point of exit of the infraorbital nerve from the infraorbital canal; *b*, the gum of the upper jaw in which the anterior, middle or posterior dental nerves are the seat of the affection; *c*, the condyle of the jaw, when the pain appears to be located in the inferior dental nerve, in most cases, and particularly at the point of its entrance into the dental canal; *d*, the point of exit of the mental nerve on the chin.

The *reflex phenomena* have reference both to the motory and secretory fibres. The motor symptoms are manifested, chiefly, in the facial muscles, by clonic or tonic contractions. According to the statements of Schuh, with intensely painful neuralgias, especially when the cause is seated within the cranial cavity, it also happens that, not only the muscles of the face and eyes, but nearly all the muscles of the body are thrown into a state of tonic contraction, so that the patients appear rigid and immovable, like a statue, and retain, perfectly, the position in which they were at the moment of the attack. The rigidity of the muscles continues until the paroxysm of pain ceases. Very rare cases have been observed where the sensibility of certain points was so acute that the sudden and unexpected contact of anything would even cause the patient to fall, with loss of consciousness and convulsions.

The affection of the secretory apparatus is manifested upon the surface of the skin, by perspiration in the region of the face, and an increased secretion, subsequent to the paroxysm, from the mucous membrane and corresponding glands, as the mucous, salivary, and lachrymal glands.

Irritation of the fibres of the sympathetic is effected through the ganglions within the territory of the trifacial nerve, namely, in the eye through the ciliary ganglion, in the ear through the sphenopalatine and otic ganglions, in the secretory apparatus on the floor of the oral cavity, through the submaxillary ganglion.*

It is necessary to refer in this connection to a *special exciting cause of facial neuralgia*, which, in my opinion, is of great importance, namely, *the extraction of teeth*. Schuh observes that it is particularly noticeable, that very many patients date the origin of their suffering from the time of the extraction of one or several decayed teeth. Although he suggests caution in accepting this statement, he is convinced, nevertheless, from extensive observations upon the subject, that the extraction of unsound teeth, especially if the operation is performed with violence or is repeated at one sitting, sometimes is the cause of neuralgias, in consequence of the stretching and laceration of the delicate nervous filaments. Many well-informed persons, who were accustomed to observe, carefully, their sensations and conditions of body and have stated confidently and positively that they were able to distinguish a difference between the toothache which they felt before, from the slight and soon increasing

* Through irritation of the sympathetic nerve the uterus is brought into close relation with the teeth. It is a well-known fact that pains of the teeth often occur during pregnancy as well as during certain inflammatory affections of the uterus, and cases have been recorded of recovery from pains and symptoms of disease in the uterus upon the extraction of one or more teeth. In a large number of cases of diseases of the uterus, the teeth are seriously affected by caries. Out of more than twenty-five patients suffering from uterine disease, in a hospital for diseases of women in this city, examination of their mouths showed extensive caries of the teeth in all but one. This is a subject which needs thorough investigation. At the present time, our knowledge is so limited that we cannot say with much assurance how much the teeth and the uterus affect each other in the reciprocal action of conditions of disease.—T. B. H.

neuralgia which occurred a few hours after the extraction of the tooth, would admit no other exciting cause than the one in question.

If we consider the fact that, in connection with caries of the teeth, the pulp becomes inflamed and entire bundles of nerves manifest evidences of degeneration, while, in the neuritic process, which occurs in neuralgia, single nerve-tubes only are affected in the manner already described, there are grounds, in my opinion, for the assertion that the two processes present anatomical differences, and that the darting pains in facial neuralgia are due to the affection of the separate nerve-tubes.

If we consider, also, that, after amputation of the limbs, sensitive nerve-tubes sometimes grow in large numbers from the surfaces of the transversely-divided nerves, as I proved* in the year 1855, it is probable, that an analogous process occurs in nerves which have been lacerated in the extraction of teeth; indeed we have an intimation of such an occurrence in the pains in the sockets from which teeth have been extracted. If, now, a predisposition (Diathese) to the development of new-formations of nerves of this description exists in an individual, or if, in consequence of unskilful extraction, the nervous branches which supply the teeth are not separated from their attachments to the main stems, but are badly bruised and crushed, and the main stem itself is injured more or less, the condition of irritation which is produced in the nerves may, sometimes, induce a proliferation of the sensitive fibres. Actual proof of this supposition remains to be established in the future. With regard to the diathesis, we may call to mind that such a condition has been established for the new-formations of dentine, cement, periosteum of the root and gum, and we may, upon good grounds, speak of a progressive new-formation, *i. e.*, of one which extends to the adjacent tooth. It is quite reasonable, therefore, to assume a diathesis for the proliferation of nerves after their laceration. Premising this, it is quite easy to understand that the extraction of teeth for the relief of facial neuralgias only aggravates the evil.

* Zeitschr. d. Gesellsch. d. Aerzte zu Wien.

From this point of view, I regard the suggestion of Döbbelin* as a fortunate one, namely, to substitute another operative treatment in place of the resection, which necessitates deep incisions and, indeed, affords relief for a few months only, when the focus of irritation is located in the nerves of single teeth. He cites a series of cases which occurred in his practice, where he produced a complete cure of facial neuralgia, particularly of the infra-orbital nerve, by exposing the pulp-cavity with a trephine and killing the nerves of the root in all non-carious bicuspid and molars, and by killing the nerves of the coronal and radical pulp in cases in which perforating caries had occurred. One case is particularly instructive, where the infraorbital nerve together with a portion of the upper jaw around the infraorbital foramen had been removed, but without a successful result; he trephined all the bicuspid and molars which remained in the jaw, and effected a cure.

With the multiplicity of the above-mentioned foci of irritation of the dental nerves (comp. p. 427) and the indefiniteness of the painful sensations, it frequently happens that nothing is left in the way of treatment, but to destroy, experimentally, the supposed focus of irritation in an affected tooth or in a root. The result, then, will confirm or disprove the correctness of the supposition. It is self-evident that, in an isolated case in which the experiment is attended with a successful result, we must be on our guard and avoid the false conclusion, *post hoc, ergo propter hoc*. If, however, in a series of observations we find that the same favorable effect ensued in equivalent cases, or a complete and permanent cessation of the symptoms followed the removal of the centre of irritation in individual cases, or a notable abatement was observable, then in one case the supposition is raised to a certainty, and in the other it is reduced to a mere probability, or the latter, even, may be questionable.

When the nerves of the gum are subjected to a severe irritation by the advancing crowns during the first dentition, pain of a radiating character is developed in the sensitive organism of the child, reflex phenomena occur in the form of convulsions or

* Deutsche Viertelj. f. Z., 1868.

epileptiform paroxysms; in a series of well observed cases, these symptoms disappeared immediately after the division of the irritated nerves of the gum with the lancet. Hence, in these cases, the centre of irritation without doubt was located within the gum. Upon pure theoretical grounds, also, the above-mentioned consecutive irritations of the central nervous system must have their origin in the irritated nerves of the gum.

The recorded observations of many observers, also, show that anomalies in the second dentition, in children of a nervous temperament, sometimes occasion neuralgias, convulsions and epileptiform paroxysms, and, therefore, it is evident that, in such cases, the physician should not neglect to examine the condition of the teeth. An unusually difficult eruption of the wisdom teeth may be the cause of similar symptoms and even of mental aberration.

The following series of cases, which I have endeavored to make quite extensive in consequence of the great importance of the subject, will serve to illustrate the preceding observations with reference to the focus of irritation, when it is situated in the dental nerves.

Breithaupt* reported a case of prosopalgia caused by an impacted canine in the upper jaw. The affection was removed by the extraction of the tooth. Forget† observed a case of neuralgia which was occasioned by a wisdom tooth in the axis of the jaw. Hesse‡ met with a case of neuralgic pains in the lower jaw, induced by a wisdom tooth which was imbedded within the jaw in an oblique position, with its crown directed towards the molar in front of it. The molar was removed, the pain ceased and the patient soon recovered. F. H. Thomson§ observed a case of facial neuralgia resulting from the concrescence of the roots of the wisdom and second molar tooth, which prevented the descent of the former. Esquirol reports the case of a woman who recovered from insanity after a crucial incision was made in the gum in order to promote the eruption of the wisdom tooth. Ashburner relates the case of a young man, seventeen

* Deutsche Viertelj. f. Zahnk., 1861. † Des Anomalies dentaires, 1859.

‡ Gazette des Hôpitaux, 1856.

§ Dental Review, 1860.

years of age, who was afflicted with delirium, destructive mania and delusions. Incisions were made in the gum covering the wisdom teeth, and recovery ensued in a week. Forget cites a case of severe dental neuralgia, caused by a wisdom tooth, the crown of which was inclined anteriorly and exerted a strong pressure upon the second molar. The affection led the patient to commit suicide. He jumped from the upper story of a house, tetanus succeeded and, finally, death. Hancock observed a recovery from trismus and pain under the right ear, after the extraction of the first molar. Döbbelin cites a case where tetanus occurred simultaneously with the extraction of a tooth. Benson* had under his treatment a young man suffering from very severe neuralgia in the upper first molar which, evidently, was free from any disease. Extraction proved to be useless, and the patient died on the fourth day after the operation. Examination after death showed nothing worthy of observation in the mouth; the brain was healthy; at the origin of the fifth nerve, a collection of pus, the size of a mustard-seed, was found. I am inclined to question whether this was not the result of the unavoidable injury to the nerves of this tooth in extraction, which were in a condition of hyperæsthesia.†

* British Journal of Dental Science, 1867.

† J. Tomes (System of Dental Surgery) states that two cases came under his notice in which epilepsy was consequent upon diseased teeth, the most prominent feature being exostosis of the roots. "A lad, a farm laborer, from Windsor, was admitted into the hospital for epilepsy. The usual remedies were tried for six weeks without effect. His mouth was then examined, and the molar teeth of the lower jaw were found to be much decayed, and of some of these the fangs only remained. He did not complain of pain in the diseased teeth or in the jaw. The decayed teeth were, however, removed, and the fangs of each were found to be enlarged and bulbous from exostosis. During the eighteen months that succeeded the removal of the diseased teeth, he had not suffered from a single fit, though for many weeks previous to the operation he had two or three per day. This is a case of singular interest, inasmuch as there was no complication of maladies, and hence there could be no doubt as to the cause of the disease, seeing that it immediately subsided when the teeth were removed; and it is further useful in showing that a sufficient source of local irritation to induce functional derangement may exist without pain being felt in the part where the irritation is applied."

"A similar but less marked case occurred shortly afterwards, in the person

Fox* relates the following case: "The patient was a young lady, twenty years of age; for more than a year she had suffered from deepseated pain in the face, and in the teeth and gums. The pain gradually extended to all the teeth, and one by one all those of the lower jaw, with the exception of the four incisors, were removed. During this time every kind of medical treatment had been resorted to, but without affording her any alleviation to her sufferings. At the time the patient consulted Mr. Fox, she was only able to take fluid nutriment, for the teeth of the upper jaw were so tender that the slightest touch caused extreme pain. There was a constant flow of saliva from the mouth, and the palpebræ of one eye had been closed for nearly two months [and when opened the sight of the eye was affected]. The most painful tooth was extracted. This was the first molar of the upper jaw, situated under the eye, the palpebræ of which had become closed. The fangs of the tooth were much enlarged; its removal was attended with great benefit, and two days after, the affected eye could be opened. This only afforded partial relief, and eventually all the teeth were removed, when the patient was at length relieved from her sufferings." This case, probably, was one of a progressive proliferation of cement, where the process advances from one tooth to another, and, in my opinion, it would have been a suitable case for the method of treatment recommended by Döbbelin (comp. p. 434). Thomson† describes a case of prosopalgia resulting from exostoses of the roots of the wisdom teeth.

of a policeman. He had fits, which were greatly relieved by the removal of an inferior wisdom tooth, the subject of caries and of exostosis."

With reference to the first case, an essential point in the argument for the stated source of local irritation is wanting, in my opinion, namely, that it was possible to bring on the fits by irritation of the decayed teeth. It is, also, to be borne in mind that, as Rosenthal observes (l. c., p. 311), particular caution is enjoined, both in respect of the prognosis and the estimation of the results of treatment, by the frequency of recurrences, even after a remission of the paroxysms for several years. Again, no little importance is to be attached to the fact that the regulation of the diet, which obtains in the hospital, exercised a beneficial influence in diminishing the frequency of the fits with the two epileptics.

* *Vide* Hulme's Lectures, Dental Review, 1862.

† Glasgow Med. Journal, 1867.

Hilton* reports the case of a man whose hair, upon the left temporal region, became gray, as a result of a carious affection of a lower molar. He suffered from neuralgia in the left side of the face, for the relief of which he was treated in various ways without success. He wore a wig, as the rest of his hair was black. The carious, lower second molar was extracted and the neuralgia disappeared almost entirely. It is not stated whether the hair upon the temple became black again, since the patient was not seen again.

Von Stellwag† regards it as probable that irritations in remote portions of the trigeminus nerve may be transmitted through the ciliary system to the nervous apparatus which serves for the reception of luminous impressions, occasion an increased excitation in this and, by producing hyperæmia and inflammation, give rise to amaurosis (amaurosis trifacialis of Beer). "It is a well-known fact," he says, "that it is, by no means, an uncommon occurrence for intense irritations of one or another division of the trifacial nerve to lead to *hyperæsthesia*, and later to *hyperæmia and inflammation in the territory of the ciliary nerves*." "Hyperæsthesia of the ciliary nerves‡ may also be induced by exfoliation of an alveolar process, abscesses in the roots of a tooth, and the impaction of foreign bodies in an alveolus." He cites the following cases in his notes. Galenzowski cured a complete amaurosis which occurred in conjunction with a most violent, intermittent neuralgia in the temporal region, face and, especially, in the eye, by the extraction of a carious bicuspid upon the root of which there was a splinter of wood that had produced an irritation of the dental nerves. (I once found a splinter of wood which entirely filled the root-canal of a carious tooth and, evidently, was a fragment of a tooth-pick.) Teirlink relates a case where an impacted fragment of a tooth in the upper jaw of a woman occasioned frequent attacks of odontalgia, which were accompanied, at different times, by intense pain in the eyes, intolerance of light, a profuse secretion

* Lancet, 1861.

† Ophthalmologie vom naturwiss. Standpunkt, ii, p. 657.

‡ Ibid., p. 321.

of tears, dimness of vision, contraction and immobility of the pupil. All treatment was unsuccessful until the fragment was removed, when the pain ceased immediately. Hay observed a case where a man, who had overworked himself at a fire, suffered from an excessive intolerance of light which continued even in a dark room. The uncomfortable sensation seemed to start from one of the upper incisors. Tapping upon this tooth with a key produced most violent, twinging pains. Upon the extraction of this tooth, an abscess was found in the root. Recovery ensued after the removal of the tooth, and six years afterwards there had been no recurrence of the affection.*

Hutchinson† observes that far too little attention is given to the condition of the teeth as the possible cause of functional or nutritive derangements in the globe of the eye or in the cerebral centres of vision, and remarks especially upon the importance of taking advantage of every opportunity to clear up the subject of the possibility of the evil effects of stumps of teeth which are left in the jaws.

In confirmation of this opinion, I will cite the following cases. Dr. Emmeuch‡ suffered for fourteen years from notable congestions in the region of one eye, profuse secretion of tears and intolerance of light. These symptoms were increased by slight errors of diet. He found a carious tooth upon the side corresponding with the affected eye. Almost immediately after the extraction of this tooth, the symptoms referable to the eye began to abate and, in a short time, they disappeared entirely. Teirlink mentions two cases. A first upper bicuspid was extracted from the jaw of a young man, for the relief of very severe toothache; the patient stated that he suffered from quite severe pains in the eye upon the same side, and, on another day, he came with a complaint that his sight was affected. The pupil was very much dilated. Extract of opium and opium ointment were inserted in the alveolus and effected a contraction of the pupil and restoration of sight. A woman complained of

* Comp. also von Stellwag's *Lehrbuch der Augenheilkunde*, 4 Aufl., p. 854.

† *Ophthalmic Review*, 1866.

‡ *Dublin Medical Free Press*.

defective vision and excessive secretion of tears. After the extraction of a carious root, the sight was restored gradually and the excessive lachrymal secretion ceased. Hancock* reported three cases. A lad, eleven years of age, on waking from sleep one month previously, found that he was entirely blind. Previously he had nothing the matter with his eyes, and when he went to bed on the preceding night he could see distinctly. Treatment had availed nothing. The pupils were dilated, the iris was motionless and did not respond to the excitation of light. He was unable to distinguish light from darkness. Upon examination of the teeth, Hancock found them tightly wedged and crowded together. Two permanent bicuspid and four milk molars were extracted; the same evening, the boy could distinguish light from darkness, and in the following morning he was able to make out objects. From this time the boy's sight improved, and eleven days after the operation, he was discharged well. A man came to the Westminster Ophthalmic Hospital on account of amaurosis of the right eye, which had existed for eight months and came on suddenly. He could distinguish between light and darkness; the pupil was dilated and fixed. Medical treatment did no good. The second upper molar on the right side was found to be diseased, and it was extracted. Two days afterwards, he was able to distinguish objects, although imperfectly. A few days later, he returned home, cured. A patient, twenty-two years of age, had been affected with strabismus for three years. A ptosis had existed about a fortnight. The left eye was closed. The affection came on suddenly, without pain, either in the head or eye. After treatment had been employed without success for nine days, two carious teeth were found in the left side of the upper jaw, which were not painful. The affection had assumed an intermittent character. In the morning, the eye was open; towards noon, the lid dropped down and, at evening, it resumed its original position. In four days after the administration of quinine, the ptosis was cured, the strabismus was improved, so that, in fact, no operation was done. Kempton† observed a

* *Lancet*, 1859.

† *Dental Review*, 1861.

case, where a woman had suffered for a fortnight from severe pains in the right temporal region, which extended over the nape of the neck, sometimes affected the side of the face, and were accompanied by shooting pains in the globe of the eye. Cold applications within the mouth and externally alleviated her suffering. There was no toothache. The lower right wisdom tooth was extensively carious, and the gum was swollen. During the extraction, she experienced a severe pain across the right side of the head, which lasted a few seconds, but no pain in the locality from which the tooth was removed. The neuralgia disappeared.

De Witt,* in a man who stated that he had been nearly blind in the right eye for twelve years, so that he could merely distinguish light from darkness, found a cavity filled with white metal in the first bicuspid, and a fistulous opening in its alveolus. Upon the removal of the filling, a foul-smelling, sanious matter escaped from the cavity of the tooth. Three weeks later, when the right eye had recovered so that it performed its functions nearly as well as the other, the sensitiveness of the gum returned and, at the same time, the vision again became affected. The tooth was then extracted, and the amaurosis disappeared immediately(?). Six days afterwards, the patient was able to see with the right eye as well as with the left, except that small objects were not clearly recognizable. De Witt remarks that the amaurosis had its origin in an irritation of the fifth nerve.

Cases, also, are recorded which indicate the effect of diseased teeth upon the *hearing*. Certain sounds, such as a creaking noise, produce sensations in the teeth. Carious teeth sometimes occasion paroxysmal pains in the ear. The following case came under the observation of Harvey. A man, twenty-two years of age, suffered for three years from attacks of neuralgia in the ear, which, occasionally, were accompanied by a foul-smelling discharge from the external meatus and lasted several hours. The most intense pain was felt in the direction of a carious wisdom tooth. This was extracted and the neuralgia was cured. Vautier† reported a case of facial neuralgia and deaf-

* American Journal of Medical Sciences, 1868.

† Gazette des Hôpitaux, 1860.

ness, which was cured by the extraction of an upper wisdom tooth.

James Salter, in his instructive article upon nervous affections induced by diseases of the permanent teeth,* expresses the opinion that, next to the branches of the trigeminus, the cervical and brachial plexuses are most frequently affected by an irritation of the teeth. He cites a series of instructive cases.

Thomas Bell† reported two cases in point. In one, the patient had suffered for a year from irregular paroxysms of pain which was felt, at first, in the ear and, afterwards, extended across the neck and shoulder and along the arm, producing impairment of motion in the hand and fingers. Bell ascertained that, two years previous to that time, the lower second molar had been broken off, in an attempt to extract it, and the roots were still in the jaw; the anterior one had emerged, partially, from the socket and lay upon the gum, in an oblique position; the posterior root was still firmly imbedded and, evidently, occasioned considerable irritation in the surrounding parts; pressure upon this root increased the pain which, in a measure, assumed the character of the paroxysmal pains from which the patient had suffered so long. The stumps were removed and the paroxysms did not return. In a second case, there was slight impairment of motion in the right arm, with occasional pain and the peculiar sensation of formication which is felt when pressure is exerted upon a nerve. Finally, the patient noticed that a paroxysm was accompanied by an acute pain in the lower second molar upon the same side. This fact led to a careful observation of the succeeding attack. Bell became satisfied that the contact of a sharp instrument with this tooth occasioned a return of the sensation in the arm. The tooth was extracted and a complete cure ensued, although not immediately.

F. H. Thomson‡ mentions three cases of facial neuralgia, consequent upon caries of the wall of the antrum.

These cases are sufficient to show that facial neuralgias and

* Guy's Hospital Reports, xiii, 1868.

† Anat. Phys. and Path. of the Teeth, 2d ed.

‡ Dental Review, 1860.

various affections of the eye, ear, the cervical and brachial plexuses not infrequently have their origin in an irritation in the teeth, and that dentists, and surgeons, especially, should not neglect to make a careful examination of the teeth in connection with these affections; the experience and knowledge of an educated dentist, of course, is requisite for this purpose; the mere extraction of a tooth at random is of no avail.

Anæsthesia of separate teeth occurs in connection with atrophy of the dental nerves, consequent upon previous inflammations, new-formations, within the pulp or outside of the same, following chronic inflammation of the root-membrane, abscesses at the extremities of roots, &c. Anæsthesia of one or another side of a set of teeth has its origin in the trunks of the dental nerves or in more central localities. The possibility of the existence of new-formations ought to be taken into account as a cause of this affection. When apoplexy, tabes, hysteria, tumors of the pons Varolii and the posterior lobes of the cerebrum, which encroach upon the territory of the trigeminus (second and third divisions), give rise to anæsthesia of parts corresponding to the anatomical distribution of the nerves, as shown by Ch. Voigt, then the teeth and the gums,* also, become deprived of their sensibility. Rosenthal† cites a case, which came under his observation, where, in connection with anæsthesia of the second division of the trigeminus on the right side, the upper teeth and gums were entirely insensible, while the lower teeth and the floor of the oral cavity manifested the normal sensibility. At the autopsy, a new-formation, as large as a nut, was found in the left half of the pons Varolii.

* Rosenthal, op. cit., p. 500.

† Ibid., p. 77.

ALPHABETICAL INDEX.

	PAGE
Abscesses in the alveoli,	216
coronal dentine of human teeth,	187
dentine of animals' teeth,	187
gums,	198
jaws,	225
maxillary periosteum,	222
pulp,	177, 179, 186
root-membrane,	210
root, the cause of affections of the ciliary nerves,	438
tusks of elephants, new-formation of osseous substance	
with,	304
Absorbent organ,	79
Adenomata,	321
Adhesion of all the teeth impossible,	154
the pulp to the dentine,	241
Alveolar abscess,	216
arteries, injection of the,	60
process, affection of the ciliary nerves caused by exfoliations	
of the,	438
arch of the,	23
enostosis of the,	331
epulis of the,	322, 347
exostosis of the,	228, 327
hypertrophy of the,	228
interstitial development of bone in exostoses of the,	329
necrosis of the,	222, 226
new-formations of the,	322
of the lower jaw,	25
of the upper jaw,	22
osteomata of the,	228, 327
purulent infiltration into the,	217
results of fractures of the,	223
senile resorption of the,	266
Alveoli, abscesses in the,	216
cicatrizatization of the,	258
description of the,	22, 25

	PAGE
Alveoli, fracture of the,	223, 263
growth of the coronal,	70
partial resorption of the, previous to the eruption of the teeth,	71
resorption of the, in connection with inflammation of the root-	
membrane,	213
resorption of the, after extraction of teeth,	259
senile,	255
septa of the,	23
Amaurosis consequent upon dental caries,	439, 441
the impaction of foreign bodies in the teeth	
and jaws,	438
the malposition of teeth,	440
trifacialis,	438
Anæsthesia of the teeth,	443
Anatomical changes in the nerves and ganglions in neuralgias,	426
Aneurism of the superior palatine artery, to be distinguished from an	
abscess,	218
Angiomata of the gums,	319
Angle of the lower jaw, peripheral and pericellular resorption of the,	269
senile changes in the,	269
Anomalies of the secretions,	354
Antimony, effects upon the root-membrane, from the use of,	215
Antrum of Highmore,	24
catarrhal inflammation of the,	229
cysts of the,	351
dropsy of the,	229, 231
empyema of the,	229
entozoa in the,	353
facial neuralgia, caused by caries of the wall of the,	442
fistula of the,	219, 352
foreign bodies in the,	230
inflammation of the membranes of the, a sequel of that of the	
root-membrane,	229
polypi of the mucous membrane of the,	352
Appearances presented by carious cement,	391
dentine,	384
enamel,	376
Arsenic, effects of, upon the root-membrane,	215
Articular eminence of the temporal bone, senile flattening of the,	270
Articulation of the lower jaw,	26
Artificial caries,	374, 375, 407
teeth, caries of,	374, 376, 406, 414
Atony of the gums,	255
Atrophies,	232
Atrophy, eccentric, of Rokitansky,	258
net-like, of the pulp,	238
of the maxillæ,	257
maxillary periosteum,	257

	PAGE
Atrophy of the pulp,	232
resulting from inflammation,	191
root-membrane,	255
socket,	258
primary or senile,	232
secondary or consecutive,	232
senile, of the gums,	254
Axial torsions of the crowns,	132
Bacteria,	195, 211, 358, 407
Bicuspids, description of the,	34
Blending of adjacent teeth,	147
distinguished from twin-formation,	149
milk teeth,	149
Bloodvessels of the pulp in inflammation, changes in the,	180
Bone, caries of, distinguished from that of teeth,	367, 370, 374, 421
interstitial development of,	78, 92, 276, 306, 329
growth of, in the jaws,	92
resorption of, in the jaws,	92
Brachial plexus of nerves, affections of the, consequent upon irritations of the dental nerves,	442
Buccal fistula,	219
Bühlmann's fibres,	357, 372
Calcifications, combination of, with new-formations of dentine,	296
of the pulp,	191, 233
consequent upon inflammation,	191
senile root-membrane,	25
Cancer, cystoid-gelatinous, of the upper jaw,	351
epithelial, of the gums,	320
jaws,	349
fibrous, of the gums,	351
jaws,	351
gelatinous, of the jaws,	351
medullary, of the gums,	321
jaws,	350
melanotic, of the dental sac,	350
intermaxillary bone,	350
of the root-membrane,	317
Canine teeth, description of the,	34
Cantharides, effects of, upon the root-membrane,	215
Carcinoma, <i>see</i> Cancer.	
Caries of the teeth,	367
acute or moist,	387 <i>et passim</i>
appearances presented by the cement in,	391
dentine in,	384
enamel in,	376

	PAGE
Caries, artificial,	374, 375, 407
carbonacea,	416, 425
cartilaginous softening of dentine in,	387 <i>et passim</i>
change in the color of the hair consequent upon,	438
chronic,	387 <i>et passim</i>
of the dentine,	389 <i>et passim</i>
consolidation of the dentinal fibrils in,	323, 386, 413
deposits of pigment in the enamel in,	378
diminished consistence of the enamel in,	379
translucency of the dentine in,	384
discoloration of the dentine in,	384
extension of, to the root,	392
frequency of, <i>see</i> Frequency of Caries,	397
historical sketch of,	368
increased translucency of the surrounding dentine in,	386
increased transparency of the enamel in,	378
interna, 191, 369, 371, 372, 374, 413, 421, 422	393
localities of,	393
neuralgic affections consequent upon,	438 <i>et passim</i>
of artificial teeth,	374, 376, 406, 414
pivoted teeth,	406
reinserted human teeth,	404, 406, 414
teeth made from hippopotamus-ivory,	406
signification of,	367
distinguished from that of bone,	367, 370, 374, 421
the different kinds of teeth,	393
permanent teeth,	394
milk teeth,	396
roots of permanent teeth,	396
teeth of animals,	410
wall of the antrum, the cause of facial neuralgias,	442
sicca,	390, 423, 425
symmetrical affection of corresponding teeth with,	369
theories of,	411
undermining, of the dentine,	389
enamel,	382
white,	408
Carious teeth, amaurosis consequent upon,	439, 441
deafness consequent upon,	441
effects of, upon the rest of the body,	403 <i>et passim</i>
neuralgic affections of the ear consequent upon,	441
ptosis consequent upon,	437, 440
Cartilaginous softening of carious dentine,	387 <i>et passim</i>
Cases illustrating neuroses depending upon affections of the teeth,	435
Castor oil, effects of, upon the root-membrane,	215
Catarrhal inflammation of the antrum,	229
gums,	192

	PAGE
Cavity of the mouth, bony framework of the,	21
Cement,	51
caries of the,	391, 421
changes in the, in connection with the process of shedding the teeth,	77
development of the,	69
hypertrophy of the,	271
in grooved teeth,	149
interstitial hypertrophy of the,	276
resorption of hypertrophic,	274
junction of the, with the dentine,	53
neuralgias consequent upon hypertrophy of the,	272
new-formations of,	272, 312
perforating resorption of the,	274
peripheral-concentric hypertrophy of the,	276
resorption of hypertrophic,	278
progressive proliferation of the,	437
resorption of senile,	247
senile thickening of the,	244
Cervical plexus of nerves, affections of the, consequent upon irritations of the dental nerves,	442
Changes in the jaws during the second dentition,	91
form of teeth, indicative of syphilis,	146
temporary and permanent dental arches compared,	95
Chondromata of the jaws,	339
Cicatrization of the socket,	258
variation in the position of adjacent teeth during,	263
Ciliary nerves, affections of the, consequent upon abscesses of the root,	438
affections of the, consequent upon exfoliations of the alveolar process,	438
affections of the, consequent upon irritation of the tri- facial nerve,	438
affections of the, consequent upon the impaction of foreign bodies in the teeth and jaws,	438
Classification of malformations of the teeth,	157
the teeth,	30
Cleavage of the teeth,	29, 376
Cleft-palate,	89
Coalition of the roots,	147, 152
Coating upon the teeth,	357
living organisms in the,	357
Colloid deposits in the pulp,	237
Concrescence of roots,	147, 152
facial neuralgia consequent upon the,	435
Condyle of the lower jaw, senile wasting of the,	270
Condyloid or nodular enlargements upon the extremities of roots,	138, 139
Conical teeth,	100, 102

	PAGE
Consecutive atrophy,	232
Consolidation of the dentinal fibrils in caries,	373, 386, 413
Convulsions during the first dentition,	434
in connection with anomalies in the second dentition,	435
Copper, effects of, upon the root-membrane,	215
Coronoid process of the lower jaw, senile wasting of the,	270
Cracks in the enamel,	30, 168, 376
Cretefactions in the pulp,	234
Croton oil, effects of, upon the root-membrane,	215
Croupous inflammation of the gums,	196
Crowns, axial torsions of the,	132
flexions of the,	130
surfaces produced by friction upon the,	247
and roots, dwarffish,	157
Cuticle of the enamel,	51, 69
Cystoid-gelatinous cancer of the upper jaw,	351
Cysto-myxoma of the jaws,	349
Cysto-sarcoma adenoides,	344
of the jaws,	343
Cysts, dentigerous,	172
of the antrum,	351
jaws,	331
ovarian, containing rudimentary teeth,	172
Cytoblastions in the root-membrane,	59, 317
Deafness consequent upon caries,	441
Deciduous teeth, <i>see</i> Temporary Teeth.	
Defective formation of the crowns and roots,	139
Defectively developed enamel, histology of,	143
Defects in the enamel, causes of,	142 and Note
wedge-shaped, upon the facial surface of the neck,	253
Deficiency of milk teeth,	107
permanent teeth,	104
Degeneration of the parenchyma of the embryonic pulp,	170
pulp into a soft, greasy mass,	241
Density of the teeth,	28
Dental arches, comparison of the changes in the temporary and per-	
manent,	95
canal in old age,	242
cap,	69
cartilage,	45, 244, 420
groove,	61
posterior,	85
membrane, inflammation of the external,	205
pulp, <i>see</i> Pulp.	
ridge,	61
sac, development of the,	64

	PAGE
Dental sac, melanotic cancer of the,	350
primary stage of the,	62
sarcomatous proliferation of the,	346
Denticolæ,	357, 358
Dentinal canals or tubes,	43
cells,	54
inversion of the layer of,	295
fibres,	44
consolidation of the, in caries,	373, 386, 413
germ, development of the,	65
primary stage of the,	61
globules,	45
sheaths, of E. Neumann,	44
Dentigerous cysts,	172
Dentine,	43
abscesses in the,	187
adhesion of the pulp to the,	241
appearances presented by carious,	384
cartilaginous softening of the carious,	387 <i>et passim</i>
chronic caries of the,	389 <i>et passim</i>
combination of calcifications with new-formations of,	296
concentrically laminated new-formations of,	289
diminished translucency of carious,	384
direction of the development of the,	66
discoloration of carious,	384
duration of the development of the,	66
growth of the radical portion of the,	70
hardness of the,	29
increased translucency of the contiguous portions of carious,	386
in grooved teeth,	145
interglobular spaces of the,	45
interstitial development of,	294
intertubular tissue of,	45
junction of the cement with the,	53
enamel with the,	50
pulp with the,	54
new-formations of,	286 <i>et passim</i>
of repair,	289
of animals' teeth, abscesses in the,	187
of the tusks of elephants, new-formation of osseous substance with abscesses in the,	188, 304
red color of the, with inflammation of the pulp,	183, 370
secondary,	289
senile,	242
sensitiveness of the,	56
theories concerning the mode of development of the,	68
undermining caries of the,	389

	PAGE
Dentition, <i>see</i> First, Second, and Third Dentition.	
Development of the cement,	69
dentine,	68
enamel,	64
germs of the first and second permanent	
molars,	86
interstitial, of bone,	78, 92, 276, 306, 329
dentine,	294
of malformations, mode of the,	155
the teeth,	60
wisdom teeth,	86
Digitalis, effects of, upon the root-membrane,	215
Dilaceration,	133
Diminution in the size of the pulp-cavity and dental canal in old age,	242
Diphtheritic inflammation of the gums,	205
Diphtheritis,	197
Displacement, retention of teeth without,	127
Distinctions between the milk and permanent teeth,	40
Double or twin-malformations,	170
Dropsy of the antrum,	229, 231
Durability of the enamel,	49
Dwarfish malformations of the crowns and roots,	157
Dyscrasic periostitis of the jaws,	224
Ear, neuralgic affections of the, consequent upon caries,	441
Edentulous jaws,	226
Effects of carious teeth upon the rest of the body,	403
various substances upon the,	215
Elasticity of the teeth,	30
Elephants' teeth, musket-balls in,	301
Empyema of the antrum,	229
Enamel,	46
appearances presented by carious,	376
cap, appearances presented by the carious,	379
detachment of the,	47
causes of defects in the,	142 and Note
cells,	47, 63
cracks or fissures in the,	30, 168, 370
deposits of pigment in carious,	378
direction of the development of the,	66
durability of the,	49
fibres,	47
germ,	61
germs of permanent teeth with a single root,	66
the first and second permanent molars,	86
wisdom teeth,	86
hardness of the,	29

	PAGE
Enamel, histological appearances of defectively developed,	143
irregular distribution of the,	141
junction of the, with the dentine,	50
membrane (Nasmyth's),	51, 69, 165
appearance of the carious,	381
in old age,	247
new-formations of,	296
nodules,	134
of grooved teeth,	144
organ,	62
prisms,	47
property of double refraction of the,	50
senile,	246
striae of the,	48
theories concerning the mode of development of the,	64
thickness of the,	47
undermining caries of the,	382
Enchondromata of the jaws,	339
Enostoses of the alveolar process,	331
jaws,	337
Entozoa in the antrum,	353
Epilepsy consequent upon exostosis of the roots,	436
Epileptiform paroxysms in association with anomalies in the second dentition,	435
Epileptiform paroxysms during the first dentition,	434
Epithelial cancer of the gums,	320
jaws,	349
Epulis,	322, 347
fibromatosa,	323
sarcomatosa,	325
varieties of,	325
Erosion (<i>Note</i>),	143
Eruption of the milk teeth,	73
intervals between the,	75
first permanent molars,	76
permanent teeth,	82
second permanent molars,	85
wisdom teeth,	86
Exanthemata, inflammation of the gums in the,	195
Exanthematous periostitis of the jaws,	224
Excentric atrophy of Rokitansky,	258
Exostoses of the cement,	272, 312
cement, prosopalgia consequent upon,	315
alveolar process,	228, 327
interstitial development of bone in,	329
roots, epilepsy consequent upon,	436
Experiments with different substances upon the teeth,	407

	PAGE
Extension of caries to the roots,	392
Extraction of teeth, a special cause of facial neuralgias,	432
Facial neuralgia consequent upon caries of the wall of the antrum,	442
imbedded teeth,	435
exostoses,	315
the concrecence of roots,	435
Fatty degeneration of the pulp,	232
resulting from inflammation,	191
of milk teeth,	233
Fibro-chondroma of the jaws,	339
Fibromata of the gums,	319
jaws,	340
Fibrous cancer of the gums,	351
jaws,	351
Filling, importance of new-formations in connection with the operation of,	300
First dentition,	73
convulsions during the,	434
diseases occasioned by the,	199
epileptiform paroxysms during the,	435
reflex symptoms during the,	434
Fissures or cracks in the enamel,	30, 168, 376
Fistula, buccal,	219
in the gum,	198
of the antrum,	219, 352
salivary,	219, 221
Flexions and torsions of the crowns and roots,	130
of the roots,	132
Foreign bodies in the antrum,	230
teeth, the cause of affections of the ciliary nerves,	438
Formation, defective, of the crowns and roots,	139
of the teeth, irregularities in the,	98
Fractured teeth,	307
cases of,	307
conditions necessary for the union of,	309
union of, longitudinally,	311
Fracture of the alveolus,	223, 253
Fragilitas vitrea,	258
Frequency of caries,	397
influence of age upon the,	399
diseases of the general system upon the,	413
family upon the,	400
food upon the,	400, 402
locality upon the,	400
occupations upon the,	402

	PAGE
Frequency of caries, influence of popular customs upon the,	401
race upon the,	400
sex upon the,	399
the use of tobacco upon the,	401
in the different kinds of teeth,	393
Fusion of teeth, <i>see</i> Blending.	
Ganglions and nerves, anatomical changes in the, in neuralgias,	426
Gangrene of the mouth (Noma),	199, 201
pulp, moist and dry,	182
Gangrenous degeneration of the root-membrane,	211
Gelatinous cancer of the jaws,	351
tumors of the jaws,	348
Glands, mucous,	354
salivary,	354
secretion of the salivary,	354
Globular masses of the dentine,	45
Globules, dentinal,	45
Gold, effects of, upon the root-membrane,	215
Groove, dental,	61
posterior dental,	85
Grooved teeth, peculiarities of the tissues in,	145
Growth of the jaws,	88
direction of the,	89
lower jaw, measurements of the,	93
"Gumboil,"	205
Gums,	57
abscesses in the,	198
action of lead upon the,	196
acute or inflammatory œdema of the,	198
angiomata of the,	320
atony of the,	255
atrophy, senile, of the,	254
bloodvessels of the,	57
cancer of the,	320
epithelial cancer of the,	320
epithelium of the,	58
fibromata of the,	319
fibrous cancer of the,	351
fistulæ in the,	198
glands of the,	58
hypertrophy of the,	279
inflammations of the, <i>see</i> Inflammation.	
in mercurial salivation,	195
lancing the,	199
medullary cancer of the,	321
nerves of the,	58

	PAGE
Gums, new-formations of the,	319
papillæ of the,	57
papilloma of the,	281, 319
sarcoma of the,	320
scorbutic,	255
secretion of the,	355
senile atrophy of the,	254
vascular tumors of the,	319
Hair, change in the color of the, resulting from caries,	438
Hardness, Moh's scale of,	29
of the dentine,	29
enamel,	29
Hard tissues of the teeth,	43
Harelip,	89
Hearing affected by diseased teeth,	441
Herpetic (?) inflammation of the gums,	195
History of caries,	368
Horny character of senile dentine,	242
Hydrargyriasis,	205
Hydrocephalus, teeth in a case of congenital,	148
Hydrops antri,	229, 281, 331
Hypertrophies,	271
Hypertrophic cement, interstitial resorption of,	274
perforating resorption of,	274
peripheral resorption of,	273
root-membrane, pigment deposits in the,	279
Hypertrophy of the alveolar process,	228
cement,	271
neuralgias caused by,	272
interstitial,	276
peripheral concentric,	276
gums,	279
root-membrane,	277
Incisors, description of the,	32
Inflammations,	176
Inflammation of the gums,	192
during the first dentition,	200
during the second dentition,	204
catarrhal,	192
causes of,	193
croupous,	196
diphtheritic,	205
herpetic (?),	195
in syphilis,	195
in the exanthemata,	195

	PAGE
Inflammation of the gums, modified by individual peculiarities, . . .	194
phlegmonous,	198
rare sequels of,	201
suppurative,	198
the origin of ulceration,	194
mucous membrane and periosteum of the antrum,	
consequent upon that of the root-membrane,	229
nasal mucous membrane and periosteum, conse- quent upon that of the root-membrane,	228
pulp,	176
acute,	176, 179
changes in the bloodvessels in,	180
nerves in,	181
chronic,	176, 179, 186
circumscribed,	178
terminating in acute or moist gangrene,	182
general,	178
leading to that of the root-membrane,	192
leads to atrophy,	191
calcifications,	191
fatty degenerations,	191
redness in,	178
suppurative,	177, 179, 186
the cause of the reddish color of dentine,	183
increased volume in,	178
root-membrane,	204
changes in the hard tissues of the root in,	212
acute,	205, 206
chronic,	205, 208
consequent upon that of the pulp,	192
etiology of,	213
in animals,	222
resorption of the alveolus in,	213
resulting in gangrene,	211
stages of,	205
Inflammatory or acute oedema of the gums,	198
Injection of the alveolar arteries,	60
Insanity, resulting from the difficult eruption of a wisdom tooth,	435
Interalveolar bloodvessels,	59
nerves,	60
Interglobular spaces of the dentine,	45
Intermaxillary bone, melanotic cancer of the,	350
Interstitial development of bone,	78, 92, 276, 306, 329
dentine,	294
facets from the friction of contiguous crowns,	252
growth of bone in the jaws,	92

	PAGE
Interstitial hypertrophy of cement,	276
resorption of bone in the jaws,	92
hypertrophic cement,	274
Intertubular tissue of the dentine,	45
Intervals between the eruption of the milk teeth,	75
Inversion of the layer of dentinal cells,	295
Iodine, effects of, upon the root-membrane,	215
Irregularities in the arrangement of entire sets of teeth,	108
distribution of the enamel,	141
formation of teeth,	98
number of permanent teeth,	99
position of the milk teeth,	121
permanent teeth,	112
separate permanent teeth imbedded within	
the jaw,	122
size of the milk teeth,	99
permanent teeth,	98
structure of the teeth,	130
Jaw, <i>see</i> Upper and Lower Jaw, and Maxilla.	
Jaws, abscesses in the,	226
atrophy of the,	257
cancer of the,	349
changes in the, during the second dentition,	91
arch of the,	95
chondromata of the,	339
cystoid-gelatinous cancer of the upper,	351
cysto-myxoma of the,	349
sarcoma of the,	343
cysts of the,	331
direction of the growth of the,	89
edentulous,	266
enchondromata of the,	339
enostoses in the,	337
epithelial cancer of the,	349
fibro-chondromata of the,	339
fibroma of the,	340
fibrous cancer of the,	351
gelatinous cancer of the,	351
tumors of the,	348
growth of the,	88
interstitial growth of bone in the,	92
medullary cancer of the,	350
melanotic cancer of the,	350
myeloid sarcoma of the,	347
myxomata of the,	348
necrosis of the, during dentition,	223

	PAGE
Jaws, osteoid-chondroma of the,	339
osteophytes upon the,	335
osteo-carcinoma of the,	351
sarcoma of the,	347
periosteal sarcoma of the,	347
periostitis of the, <i>see</i> Periostitis.	
purulent infiltration of the,	225
relative growth of the,	92
sarcomata of the,	343
senile wasting of the,	257
wolf's,	89
Juga alveolaria,	23
Lancing the gums,	199
Leptothrix buccalis,	357 <i>et passim</i>
reaction of, with iodine and acids,	358
Longitudinal fracture through the crown and root, union of a,	311
Lower jaw, <i>see</i> Jaw.	
articulation of the,	26
description of the,	24
direction of the growth of the,	89
measurements, showing the relative growth of the,	92
movements of the,	26
ossification of the,	89
periostitis of the, <i>see</i> Periostitis.	
senile changes in the,	269
Malformations of the teeth,	154
classification of the,	157
dwarfish, of the crowns and roots,	157
general, of the crown of a molar, with undeveloped roots, in connection with the deeply imbedded crown of a wisdom tooth,	158
mode of the development of the,	155
monstrous, of the coronal with a well-formed radical portion,	158
of the teeth of animals,	167
Malposition of the teeth, amaurosis consequent upon,	440
neuralgias consequent upon,	435, 436
Masseter muscles, senile wasting of the,	269
Mastication, actions of the muscles in,	27, 270
movements in,	27, 270
muscles of,	27
Maxillæ, <i>see</i> Jaws.	
Maxillary periosteum, abscesses in the,	222
atrophy of the,	257

	PAGE
Maxillary periosteum, inflammatory affections of the, from those of the pulp or root-membrane,	222
sinus,	24
Measurements showing the relative growth of the jaws,	93
Medullary cancer of the gums,	321
jaws,	350
Melanotic cancer of the dental sac,	350
intermaxillary bone,	350
Membrane, Nasmyth's enamel,	51, 69, 165
of the root, <i>see</i> Root-Membrane.	
Meningo-encephalitis, consequent upon the extraction of a tooth,	223
Mental aberration, consequent upon the second dentition,	435
foramen,	24
Mercurial salivation, gums in,	195
Mercury, effects of, upon the root-membrane,	215
Micrococcus,	357
Milk teeth, <i>see</i> Temporary Teeth.	
Mixed saliva, <i>see</i> Saliva,	355
Moh's scale of hardness,	29
Molars, description of the,	35
development of the enamel germs of the first and second per- manent,	86
eruption of the first permanent,	76
second permanent,	85
Monstrous malformation of the crown with well-formed roots,	158
outgrowth of dentine and cement upon the root,	169
Mouth, bony framework of the cavity of the,	21
gangrene of the (Noma),	199, 201
the flat,	108
grinning (Fletschenmund),	109
negro (os Æthiopum),	108
senile (os senile),	110
Movements of the lower jaw,	26
Mucin,	354
Mucor,	194, 415
Mucous glands,	354
membrane of the antrum, inflammation of the, consequent upon that of the root-membrane,	229
membrane of the antrum, polypi of the,	352
mouth, new-formations of the,	321
nasal cavity, inflammation of the, consequent upon that of the root-membrane,	228
secretion of the,	355
Mucus,	354
Multilocular ovarian cysts containing imperfectly developed teeth,	172
Musket-balls in the teeth of elephants,	301
Myeloid sarcomata of the jaws,	347

	PAGE
Myélopaxes,	59, 317
Myxomata of the jaws,	348
Nasal cavity, inflammation of the mucous membrane and periosteum of the, consequent upon that of the root-membrane,	228
Nasmyth's membrane,	51, 69, 165
Necrosis of the alveolar process,	222, 226
cement, consequent upon inflammation of the root- membrane,	212
jaw, during dentition,	223
Nerves and ganglions in neuralgias, anatomical changes in the,	426
of the pulp in inflammation, changes in the,	181
resection of, for the relief of neuroses,	430
Net-like atrophy of the pulp,	238
Neuralgia in a molar, resulting in death,	436
Neuralgias, anatomical changes in the nerves and ganglions in,	426
clinical phenomena of,	430
consequent upon caries,	438 <i>et passim</i>
Döbbelin's operation for the relief of,	434
exciting causes of,	427
extraction of teeth, a special cause of,	432
foci of irritation in,	427
irradiation of the pain in,	429
occasioned by anomalies in the second dentition,	435
impacted teeth,	435
painful points in,	431
reflex phenomena in,	431
resection of nerves in,	430
Neuritic process [Neuritis],	427, 429
Neuroses, <i>see</i> Neuralgias,	426
consequent upon affections of the teeth, abstract of cases of,	435
New-formations,	284
importance of, in connection with the operation of fill- ing,	300
in the teeth of animals,	297
literature of,	286
of cement,	312
dentine,	286
combination of, with calcifications,	296
concentrically laminated,	289
enamel,	296
osseous substance with abscess in elephants' ivory,	188, 304
the alveolar process,	289
gums,	319
hard dental tissues,	286
oral mucous membrane,	321
pulp,	191, 285

	PAGE
New-formations of the root-membrane,	316
osteodentinal,	293 <i>et passim</i>
physiological or pathological signification of,	299
progressive,	434
dentinal,	300
Nitrous acid salt in the saliva,	355
Nodules of enamel,	134
Nodular or condyloid enlargements at the extremities of roots,	138, 139
Noma,	199, 201
Oblique fractures of the crown, exposure of the pulp in,	311
roots,	309
Odontalgia nervosa ex carie,	177
Odontoblasts,	54
Odontolithus,	361
Odontomata (<i>Note</i>),	155
Œdema of the gums, acute or inflammatory,	198
Oidium albicans,	195, 358, 406
Opium, effects of, upon the root-membrane,	215
Organ adamantinæ,	163
Os Æthiopum,	108
senile,	110
Ossification of the lower jaw,	89
upper jaw,	88
senile root-membrane,	255
Osteoid chondromata of the jaws,	339
Osteo-carcinoma of the jaws,	351
dentine,	46, 293 <i>et passim</i>
in the teeth of animals,	297
odontomata,	169, 316
sarcomata of the jaws,	169, 343
Osteomata of the cement,	312
prosopalgia consequent upon,	315
alveolar process,	228, 327
interstitial development of bone in,	329
Osteophytes upon the jaws,	202, 228, 335
Osteospathyrosis of Lobstein,	258
Ostitis,	367
Ovarian cysts, teeth in,	172
Papillæ of the gums,	57
Papilloma of the gums,	281, 319
Parulis,	198
Penicillium glaucum,	357
Perforating caries,	176 <i>et passim</i>
resorption of hypertrophic cement,	274
Pericellular resorption of the angle of the lower jaw,	269

	PAGE
Periodontitis,	205
Periosteal sarcoma of the jaws,	347
Periosteum of the root, <i>see</i> Root-Membrane.	
Periostitis of the alveolar process, consequent upon caries,	222
jaw, during the first dentition,	223
second dentition,	202
dyscrasic,	224
exanthematous,	224
rheumatic,	224
specific,	224
traumatic,	224
lower jaw, symptoms of,	224
upper jaw, symptoms of,	225
Peripheral-concentric hypertrophy of the cement,	276
resorption of hypertrophic cement,	273
the angle of the lower jaw,	269
Permanent and temporary dental arches, comparison of the changes in the,	95
teeth, arrangement of the,	40
caries of the different,	394
cariou roots of the,	396
deficiency of the,	104
description of the,	32
eruption of the,	82
imbedded within the jaw, irregular position of,	122
irregularities in the arrangement of entire sets of,	108
irregularities in the number of,	99
position of separate,	112
size of,	98
Phlegmonous inflammation of the gums,	198
Phosphornecrosis,	205, 214
Phosphorus, effects of the fumes of, upon the teeth and adjacent struc- tures,	214
Pigment deposits in atrophic pulps,	241
cariou enamel,	378
the hypertrophic root-membrane,	279
Pivoted teeth, caries of,	406
Polypi of the mucous membrane of the antrum,	352
pulp,	285
root-membrane,	318
Posterior dental groove,	85
Primary atrophy,	232
Progressive dentinal new-formation,	300
new-formations,	434
proliferation of cement,	437
Proliferation, sarcomatous, in the pulp,	191
of the dental sac,	346

	PAGE
Prosopalgia, <i>see</i> Facial Neuralgia.	
Protococcus dentalis,	372, 415
Pterygoid muscles, senile wasting of the,	269
Ptosis consequent upon dental caries,	437, 440
Ptyaline,	354, 365
Puccinia graminis,	415
Pulp, dental,	54
abscesses in the,	177, 179, 186
adhesion of the, to the dentine,	241
atrophy of the,	232
resulting from inflammation,	191
basis tissue of the,	55
bloodvessels of the,	55
calcifications of the,	233
resulting from inflammation,	191
colloid deposits in the,	237
combination of different atrophic processes in the,	240
cretefaction of the,	234
degeneration of the, into a soft, greasy mass,	241
parenchyma of the embryonic,	171
fatty degeneration of the,	232
resulting from inflammation,	191
gangrene, moist and dry, of the,	182
inflammation of the, <i>see</i> Inflammations.	
in transverse and oblique fractures, exposure of the,	311
junction of the, with the dentine,	54
nerves of the,	56
net-like atrophy of the,	238
new-formations of the,	191, 285
of the milk teeth, fatty degeneration of the,	233
pigment deposits in atrophic,	241
polypus of the,	285
sarcoma of the,	286
sarcomatous proliferation of the,	191
sclerosis of the,	240
cavity and dental canal, diminution in the size of, in old age,	242
Purulent infiltration of the alveolar process,	217
jaws,	225
Pyorrhœa alveolaris,	211
Redness of the pulp in inflammation,	178
Reddish color of the dentine with inflammation of the pulp,	183, 370
teeth, occurs as an anomaly of formation,	186
Reflex phenomena in connection with neuralgias,	431
the first dentition,	434
the second dentition,	435
Reinserted human teeth, caries of,	404, 406, 414

	PAGE
Replantation of teeth,	216
Resection of nerves for the relief of neuroses,	480
Resorption of bone in the jaws, interstitial,	92
hypertrophic cement, interstitial,	274
perforating,	274
peripheral,	278
senile dentine and cement,	245
the angle of the lower jaw, peripheral and pericellular,	269
the alveolar process, senile,	266
the alveoli, after extraction of the teeth,	259
consequent upon inflammation of the root-	
membrane,	213
previous to the eruption of the teeth, partial,	71
the hard tissues of the root, consequent upon inflamma-	
tion of the root-membrane,	212
process in shedding the teeth,	77
Retention of teeth without displacement,	127
Rheumatic affection of the root-membrane,	216
periostitis of the jaws,	224
Ridge, the dental,	61
Root-membrane,	58
abscesses of the,	210
affections of the, consequent upon the replantation	
and transplantation of teeth,	215
affections of the, consequent upon the use of various	
substances,	214, 215
atrophy of the,	255
bloodvessels of the,	59
calcification of the,	255
cancer of the,	317
cytoblastions in the,	59, 317
gangrene of the,	211
hypertrophy of the,	277
inflammation of the, <i>see</i> Inflammation.	
myéloplaxes in the,	59, 317
nervés of the,	60
new-formations of the,	316
symptoms of the,	317
ossification of the,	256
pigment deposits in the hypertrophic,	279
polypi of the,	318
rheumatic affection of the,	216
senile,	255
tumors of the,	316
Root, periosteum of the, <i>see</i> Root-Membrane.	
Roots, abscesses of the, causing affections of the ciliary nerves,	438

	PAGE
Roots and crowns, dwarfish,	157
flexions and torsions of the,	130
condyloid or nodular enlargements at the extremities of the, 138, 139	
diminished number of,	140
extension of caries to the,	392
facial neuralgia, consequent upon the concrescence of,	435
flexions of the,	132
formation of the, when completed,	70
general monstrous malformation of the crown with well-formed, 158	
general malformation of the crown of a molar with undeveloped, 158	
growth of the,	70
of permanent teeth, caries of the,	396
supernumerary,	136
union of the,	140, 147, 152
unusually long or thick, divergent and curved,	138
Saliva, acidity of the,	355
alkalinity of the,	356
appearance and properties of the,	354
the mixed,	355
nitrous acid salt in,	355
sugar in,	356
sulphocyanic acid in,	355
urea in,	356
Salivary calculus,	365
fistula,	219, 221
glands,	354
secretion of the,	354
Sarcomata of the gums,	320
jaws,	343
pulp,	286
Sarcomatous proliferations in the pulp,	191
of the dental sac,	346
Sclerosis of the pulp,	240
Scorbutic gums,	255
Scrofulous teeth (<i>Note</i>),	142
Second dentition,	76
changes in the jaws during the,	91
convulsions caused by anomalies in the,	435
diseases caused by the,	201
epilepsy caused by anomalies in the,	435
mental aberration caused by anomalies in the,	435
neuralgias caused by anomalies in the,	435
Secondary atrophy,	232
dentine,	289
osteoids,	347

	PAGE
Secretion of the gums,	355
mucous glands,	354
membrane,	355
salivary glands,	354
Senile alveolus,	255
atrophy,	232
of the gums,	254
cement,	244
calcification of the root-membrane,	256
changes in the angle of the lower jaw,	269
dentine,	242
enamel,	246
membrane,	247
flattening of the articular eminence of the temporal bone,	270
ossification of the root-membrane,	256
resorption of the alveolar process,	266
cement,	245
dentine,	245
root-membrane,	255
wasting of the coronoid processes and condyles of the lower jaw,	270
masseter and pterygoid muscles,	269
maxillæ,	257
Sensations produced in the teeth by certain sounds,	441
Sensitiveness of the dentine,	56
Shedding the teeth, process of,	77
Socket, atrophy of the,	258
cicatrizization of the,	258
Specific gravity of the teeth,	28
periostitis of the jaws,	224
Spirillum,	358
Stomatitis,	197
hemorrhagica,	198
ulcero-membranacea,	197
Structure of the teeth, irregularities in the,	130
Supernumerary roots,	136
teeth,	100, 155
Surfaces upon the crown, produced by friction,	247
Sutura incisiva,	88
Syphilis, changes in the form of teeth indicative of,	46
inflammation of the gums in,	195
Tartar,	361
Teeth, <i>see</i> Temporary and Permanent Teeth.	
anæsthesia of the,	443
artificial caries of the,	374, 375, 407
blending or fusion of adjacent,	147

	PAGE
Teeth, caries of artificial,	374, 376, 406, 414
reinserted human teeth,	404, 406, 414
the,	357
different kinds of,	393
changes in the form of, indicative of syphilis,	146
classification of the,	30
cleavage of the,	29, 376
coalescence or concrescence of adjacent,	147
coating upon the,	357
formation of the,	361
living organisms in the,	357
conical,	100, 102
deficiency of,	104, 107
density of,	28
development of the,	60
distinctions between temporary and permanent,	40
effects upon the hearing caused by diseased,	441
elasticity of the,	30
extraction of, a special cause of neuralgias,	432
fractured,	307
cases of,	307
conditions necessary for the union of,	309
general characters of the,	28
hard tissues of the,	43
in a case of congenital hydrocephalus,	148
in ovarian cysts,	172
irregularities in the, <i>see</i> Irregularities.	
Magitot's experiments with various substances upon the,	407
malformations of the, <i>see</i> Malformations.	
neuralgias consequent upon impacted,	435
neuroses consequent upon affections of the, abstract of cases of,	435
new-formations of the, <i>see</i> New-formations.	
of animals, caries of the,	410
malformations of the,	167
new-formations of the,	297
wear of the,	253
of elephants, musket-balls in the,	301
peculiarities of the tissues in grooved,	44
relation between affections of the uterus and those of the (<i>Note</i>),	432
pivoted, caries of,	406
reinserted human, caries of,	374, 376, 406, 414
replantation of,	216
retention of, without displacement,	127
shedding the,	77
resorption in connection with,	77
specific gravity of,	28

	PAGE
Teeth, supernumerary,	100, 135
transplantation of,	216
trephining the, Döbbelin's operation for the relief of facial neuralgia,	434
Teething, <i>see</i> Dentition.	
inflammation of the gums attending,	199
rare sequelæ of inflammation of the gums attending,	201
Temporary and permanent dental arches, comparison of the changes in the,	95
Temporary teeth, arrangement of the,	43
blending of the,	149
caries of the,	396
deficiency of the,	107
description of the,	38
distinction between permanent and,	40
eruption of the,	73
excessive number of the,	102
fatty degeneration of the pulps of,	233
intervals between the eruption of the,	75
irregularities in the position of the,	121
size of the,	99
Tetanus following the extraction of a tooth,	436
Theories of caries,	411
Third dentition,	87
Thrush,	194
Tomes' processes of the dentinal cells,	64, 68
Torsions and flexions of the crowns and roots,	130
axial, of the crowns,	132
Transplantation of the teeth,	216
Transverse fractures of the crowns, exposure of the pulp in, root,	311 309
Traumatic periostitis of the jaws,	224
Trephining the teeth for the relief of neuralgias,	434
Trifacial nerve, affections of the ciliary nerves and apparatus of vision from irritation of the,	438 436
Trismus cured by the extraction of a first molar,	316
Tumors of the root-membrane,	317
symptoms of the,	188, 304
Tusks of elephants, abscess in the,	140, 170
Twin-malformations,	149
distinguished from blended teeth,	149
Ulceration of the gums consequent upon catarrhal inflammation,	194
Undermining caries of the dentine,	389
enamel,	382
Underhung,	110

	PAGE
Union of roots,	140, 147, 152
Upper jaw, <i>see</i> Jaw.	
cystoid-gelatinous cancer of the,	351
description of the,	22
ossification of the,	88
periostitis of the, <i>see</i> Periostitis.	
Uterus, relation between affections of the teeth and those of the (<i>Note</i>),	432
Upright teeth,	110
Vascular tumors of the gums,	320
Vaso-dentine,	46, 188
Vestibulum oris,	218
Volume of the pulp, increased in inflammation,	178
Wearing away of the teeth by attrition, forms in which and means by which it is effected (<i>Note</i>),	247
Wedge-shaped defects upon the facial surface of the dental neck,	253
White caries,	408
Wisdom teeth, development of the,	86
duplication of the,	140
eruption of the,	86
Wolf's jaw,	89

THE END.


June 1, 1880.

CATALOGUE
OF
MEDICAL, DENTAL,
AND
SCIENTIFIC BOOKS,

PUBLISHED BY

LINDSAY & BLAKISTON.

All of which are for sale by Booksellers generally, any of which will be sent by mail, postage paid, on the receipt of the retail price, or by Express, C. O. D.

 Special Attention given to Filling all Orders.

LINDSAY & BLAKISTON,

MEDICAL PUBLISHERS,

25 South Sixth Street, Philadelphia.

HANDY BOOKS

Moderate in size and price, by gentlemen of established reputation, adapted to the wants of all classes of the Medical Profession.

- The Student's Guide to the Practice of Midwifery.*** By D. LLOYD ROBERTS, M.D., Vice-President of the Obstetrical Society of London, Physician to St. Mary's Hospital, Manchester. With 95 Engravings. Price, \$2.00
- The Student's Guide to the Diseases of Women.*** With numerous Illustrations. By ALFRED LEWIS GALABIN, M.D., Assistant Obstetric Physician and Joint Lecturer on Midwifery, Guy's Hospital. 12mo. Cloth. \$2.00
- The Student's Guide to Dental Anatomy and Surgery.*** By HENRY E. SEWILL, M.R.C.S. Eng., L.D.S., Dental Surgeon to the West London Hospital. With 77 Engravings. \$1.50
- The Complete Hand-Book of Obstetric Surgery;*** or, Short Rules of Practice in Every Emergency, from the Simplest to the most Formidable Operations in the Practice of Surgery. By CHARLES CLAY, M.D., Fellow of the London Obstetrical Society, etc. With 101 Illustrations. \$2.00
- Surgical Emergencies.*** A Manual containing Concise Descriptions of Various Accidents and Emergencies, with Directions for their Immediate Treatment. By W. P. SWAIN, M.D., Surgeon to the Royal Albert Hospital, etc. With 82 Wood Engravings. \$2.00
- A Manual of Minor Surgery and Bandaging,*** for the Use of House Surgeons, Dressers, and Junior Practitioners. By CHRISTOPHER HEATH, F.R.C.S., Surgeon to University College Hospital, etc. With a Formulæ and 86 Illustrations. \$2.00
- A Hand-Book of the Diseases and Injuries of the Ear.*** By W. B. DALBY, F.R.C.S., Aural Surgeon to St. George's Hospital. With 21 Illustrations. \$1.50
- The Student's Hand-Book of the Practice of Medicine.*** With Microscopic and other Illustrations. By Prof. CHARTERIS, of Glasgow University. \$2.00
- Practical Gynæcology.*** A Hand-Book for Students and Practitioners. With Illustrations. By HEYWOOD SMITH, M.D., Physician to the Hospital for Women, etc. \$1.50
- A Guide to Surgical Diagnosis.*** By CHRISTOPHER HEATH, F.R.C.S., Surgeon to University College Hospital, etc. 12mo. Cloth. \$1.50
- Practical Surgery.*** Including SURGICAL DRESSINGS, BANDAGING LIGATIONS, and AMPUTATIONS. By J. EWING MEARS, M.D., Demonstrator of Surgery in the Jefferson Medical College, etc. 227 Illustrations. \$2.00
- Athill's Clinical Lectures on Diseases Peculiar to Women.*** Fifth Edition. Revised and Enlarged. With numerous Illustrations. \$2.25
- Fenwick's Outlines of the Practice of Medicine.*** With special reference to the Prognosis and Treatment of Disease. With Formulæ and Illustrations. Large 12mo. \$2.00

CATALOGUE
OF THE
MEDICAL AND DENTAL PUBLICATIONS
OF
LINDSAY & BLAKISTON,

No. 25 SOUTH SIXTH STREET. PHILADELPHIA.

ACTON (WILLIAM), M.R.C.S., etc.

The Functions and Disorders of the Reproductive Organs.
Their Physiological, Social, and Moral Relations. Fourth Edition. Price 2.50

AGNEW (D. HAYES), M.D.

The Lacerations of the Female Perineum, and Vesico-vaginal Fistula. Their History and Treatment, with numerous Illustrations. Price 1.50

AITKEN (WILLIAM), M.D.

The Science and Practice of Medicine. Third American, from the Sixth London Edition. Containing a Colored Map, a Lithographic Plate, and nearly 200 other Illustrations. Two volumes, royal octavo.
Bound in cloth, price 12.00; in leather, 14.00

ANSTIE (FRANCIS E.), M.D.

Stimulants and Narcotics. With Special Researches on the Action of Alcohol, Ether, and Chloroform on the Vital Organism. Octavo. Price, 3.00

ATTHILL (LOMBE), M.D.

Clinical Lectures on Diseases Peculiar to Women. Fifth Edition, Revised and Enlarged, with numerous Illustrations. Price 2.25

BARTH AND ROGERS.

Manual of Auscultation and Percussion. Price 1.00

BIDDLE (JOHN B.), M.D.

Materia Medica, for the use of Students. With Illustrations. Eighth Edition, Revised and Enlarged. Price 4.00

BLACK (D. CAMPBELL), M.D., L.R.C.S., Edinburgh.

The Functional Diseases of the Renal, Urinary, and Reproductive Organs. With a General View of Urinary Pathology. Price 2.00

BLOXAM (C. L.).

Laboratory Teaching; or, Progressive Exercises in Practical Chemistry. Fourth Edition. Eighty-nine Engravings. Price 1.75

BYFORD (W. H.), A.M., M.D.

Practice of Medicine and Surgery. Applied to the Diseases and Accidents Incident to Women.

BYFORD (W. H.), A.M., M.D.

On the Chronic Inflammation and Displacement of the Unimpregnated Uterus. A New; Enlarged Edition, with numerous Illustrations. Price 2.50

CARSON (JOSEPH), M.D.

History of the Medical Department of the University of Pennsylvania, from its Foundation in 1763. With Sketches of Deceased Professors, etc. Price 2.00

CAZEAUX (P.), M.D.

A Theoretical and Practical Treatise on Midwifery. Including the Diseases of Pregnancy and Parturition. From the Seventh French Edition, Revised and Greatly Enlarged, with numerous Lithographic and other Illustrations. Price, in cloth, 6.00; in leather, 7.00

CHARTERIS (MATTHEW), M.D.

Students' Hand-Book of the Practice of Medicine. With Microscopic and other Illustrations. Price 2.00

CHAVASSE (P. HENRY), F.R.C.S.

The Mental Culture and Training of Children, and other Subjects Relating to their Health and Happiness.

Price 1.00

CLAY (CHARLES), M.D.

A Complete Hand-Book of Obstetric Surgery. With Rules of Practice in Every Emergency, and numerous Illustrations. Price 2.00

CLEAVELAND (C. H.), M.D.

A Pronouncing Medical Lexicon. Containing the Correct Pronunciation and Definition of Terms used in Medicine and the Collateral Sciences. Improved Edition. Price, cloth, 75 cents; tucks, 1.00

COHEN (J. SOLIS), M.D.

Inhalation. Its Therapeutics and Practice. Including a Description of the Apparatus employed, etc. With Cases and Illustrations. A New Enlarged Edition. Price 2.50

COHEN (J. SOLIS), M.D.

Croup. In its Relations to Tracheotomy. Price 1.00

CORR (L. H.), M.D.

Obstetric Catechism; or, Obstetrics Reduced to Questions and Answers. With Illustrations. Price 2.00

DALBY (W. B.), F.R.C.S.

On the Diseases and Injuries of the Ear. With Illustrations.

Price 1.50

DAY (WILLIAM HENRY), M.D.

Headaches: Their Nature, Causes, and Treatment. Third Edition, Revised and Enlarged.

Price, 2.00

DILLNBERGER (DR. EMIL).

A Handy Book of the Treatment of Women and Children's Diseases.

Price 1.50

DIXON (JAMES), F.R.C.S.

The Practical Study of Diseases of the Eye. Third Edition.

Price 2.00

DUNGLISON (RICHARD J.), M.D.

The Practitioner's Reference Book. Containing Therapeutic and Practical Hints, Dietetic Rules, and General Information. Second Edition.

Price 3.50

DURKEE (SILAS), M.D.

Gonorrhœa and Syphilis. The Sixth Edition, Revised and Enlarged, with Portraits and Eight Colored Illustrations. Octavo.

Price 3.50

FENNER (C. S.), M.D., etc.

Vision: Its Optical Defects. The Adaptation of Spectacles, Defects of Accommodation, Optical Defects of the Eye, etc. Test Types and 74 Illustrations. Octavo.

Price 3.50

FLINT (AUSTIN), M.D.

Clinical Reports on Continued Fever. The Identity of Typhus and Typhoid Fever; Diagnosis, etc. Octavo.

Price 2.00

FOTHERGILL (J. MILNER), M.D.

The Heart: Its Diseases and Their Treatment, including the Gouty Heart. Second Edition, Entirely Rewritten and Enlarged, with Lithographic Plates and Forty other Illustrations. Octavo.

Price 3.50

FULTON (J.), M.D.

A Text-Book of Physiology. Second Edition, Revised and Enlarged, with numerous Illustrations. Octavo.

Price 4.00

GALLABIN (ALFRED LEWIS), M.D.

The Student's Guide to the Diseases of Women. With numerous Illustrations.

Price 2.00

GROSS (SAMUEL D.), M.D.

American Medical Biography of the Nineteenth Century. With Portrait of Benjamin Rush, M.D. Octavo.

Price 3.50

HABERSHON (S. O.), M.D., F.R.C.P.

On Diseases of the Stomach. The Varieties of Dyspepsia, their Diagnosis and Treatment. Third Edition. Octavo.

Price 1.75

HANDY (WASHINGTON R.), M.D.

Handy's Text-Book of Anatomy and Guide to Dissections.
For the use of Students. 312 Illustrations. Octavo. Price 3.00

HARRIS (CHAPIN A.), M.D., D.D.S.

The Principles and Practice of Dentistry. Tenth Revised Edition. In great part Rewritten, Rearranged, and with many new and important Illustrations. Edited by P. H. Austen, M.D., Professor of Dental Science and Mechanism in the Baltimore College of Dental Surgery. With nearly 400 Illustrations. Royal octavo. Price, in cloth, 6.50; in leather, 7.50

HARRIS (CHAPIN A.), M.D., D.D.S.

A Dictionary of Medical Terminology, Dental Surgery, and the Collateral Sciences. Fourth Edition, Carefully Revised and Enlarged. By Ferdinand J. S. Gorgas, M.D., D.D.S., Professor of Dental Surgery in the Baltimore College, etc. Royal octavo. Price, in cloth, 6.50; in leather, 7.50

HAY (THOMAS), M.D.

History of a Case of Recurring Sarcomatous Tumor of the Orbit in a Child. With Illustrations. Price 50 cts.

HEADLAND (F. W.), M.D.

On the Action of Medicines in the System. Sixth American Edition, Revised and Enlarged. Price 3.00

HEATH (CHRISTOPHER), F.R.C.S.

Manual of Minor Surgery and Bandaging. For the use of House Surgeons, Dressers, and Junior Practitioners. With Formulæ and numerous Illustrations. Price 2.00

HEATH (CHRISTOPHER), F.R.C.S.

A Guide to Surgical Diagnosis. For Practitioners and Students. 12mo. Cloth. Price 1.50

HEWITT (GRAILY), M.D.

The Diagnosis, Pathology, and Treatment of Diseases of Women, Including the Diagnosis of Pregnancy. Third Edition, Revised and Enlarged, with new Illustrations. Octavo. Price, in cloth, 4.00; in leather, 5.00

HEWSON (ADDINELL), M.D.

Earth as a Topical Application in Surgery. Being a full Exposition of its use in Cases requiring Topical Applications. With Illustrations. Price 2.50

HIGGINS (CHARLES), F.R.C.S.

Hints on Ophthalmic Out-Patient Practice. Second Edition. 16mo. Cloth. Price .60

HILLIER (THOMAS), M.D.

A Clinical Treatise on the Diseases of Children. Octavo. Price 2.00

HODGE (HUGH L.), M.D.

On Fœticide, or Criminal Abortion.

In paper, 30 cents; in cloth, .50

HODGE (H. LENNOX).

Note Book for Cases of Ovarian Tumors. With Diagrams, etc.
Price .50

HOFF (O.), M.D.

On Hæmaturia as a Symptom of Diseases of the Genito-
Urinary Organs. Illustrated. Cloth. Price .75

HOLDEN (EDGAR), A.M., M.D.

The Sphygmograph. Its Physiological and Pathological Indications.
Illustrated by Three Hundred Engravings on wood. Price 2.00

HUFELAND (C. W.), M.D.

The Art of Prolonging Life. Edited by Erasmus Wilson, M.D.
Price 1.00

JAMES (PROSSER), M.D., M.R.C.P.

Sore Throat: Its Nature, Varieties and Treatment, Including its Connection
with other Diseases. Fourth Edition, Revised and Enlarged, with Colored
Plates. Price 2.25

KIDD (JOSEPH), M.D., M.R.C.S.

The Laws of Therapeutics, or the Science and Art of Medicine. 12mo.
Cloth. Price 1.25

KOLLMAYER (A. H.), A.M., M.D.

Chemia Coartata; or, The Key to Modern Chemistry. With Numerous
Tables, Tests, etc., etc. Price 2.25

LAWSON (GEORGE) F.R.C.S.

Diseases and Injuries of the Eye, their Medical and Surgical
Treatment. Containing a Formulary, Test Types, and Numerous
Illustrations. Fourth Edition. Preparing.

LEBER AND ROTTENSTEIN (Drs.)

Dental Caries and Its Causes. An Investigation into the Influence of
Fungi in the destruction of the Teeth. With Illustrations. Price 1.25

LEWIN (Dr. GEORGE).

The Treatment of Syphilis by Subcutaneous Sublimate Injections. With
a Lithographic Plate, etc. Price 1.50

LIZARS (JOHN), M.D.

The Use and Abuse of Tobacco. Price .50

LONGLEY (ELIAS).

Student's Pocket Medical Lexicon. Giving the Correct Pronunci-
ation and Definition of all Words and Terms in general use in Medicine and
the Collateral Sciences. Cloth, 1.00; leather, with tucks and pocket, 1.25

MAXSON (EDWIN R.), M.D.

The Practice of Medicine. Price 3.00

MAYS (THOMAS J.), M.D.

On the Therapeutic Forces; or, The Action of Medicine in the Light
of the Doctrine of Conservation of Force. Price 1.25

MEADOWS (ARFRED), M.D.

A Text-Book of Midwifery. Including the Signs and Symptoms of Pregnancy, Obstetric Operations, Diseases of the Puerperal State, etc. Second Edition, Revised and Enlarged. 145 Illustrations. Price 3.00

MEARS (J. EWING), M.D.

Practical Surgery. Including Surgical Dressings, Bandaging, Amputation, etc., etc., with 227 Illustrations. Price 2.00

MEIGS AND PEPPER.

A Practical Treatise on the Diseases of Children. By J. FORSYTH MEIGS, M.D., Fellow of the College of Physicians of Philadelphia, etc., etc., and WILLIAM PEPPER, M.D., Physician to the Philadelphia Hospital, etc. Sixth Edition, thoroughly Revised and Enlarged. A Royal Octavo Volume of over 1000 pages. Price, bound in cloth, 6.00; leather, 7.00

MEIGS (J. FORSYTH), M.D.

On the Internal Use of Water for the Sick, and on Thirst. 12mo. Paper. Price .25

MENDENHALL (GEORGE), M.D.

Medical Student's Vade-mecum. A Compendium of Anatomy, Physiology, Chemistry, the Practice of Medicine, Surgery, Obstetrics, etc., etc. Eleventh Edition. 224 Illustrations. In cloth. Price 2.00

MILLER (JAMES), F.R.C.S.

Alcohol, Its Place and Power. Cloth. Price .50

MILLER & LIZARS.

Alcohol: Its Place and Power; and The Use and Abuse of Tobacco. The Two Essays in One Volume. Cloth. Price 1.00

NORRIS (GEORGE W.), M.D.

Contributions to Practical Surgery, including numerous Clinical Histories, etc. Price 4.00

OTT (ISAAC), M.D.

The Actions of Medicines. With Twenty-two Illustrations. Price 2.00

PENNSYLVANIA HOSPITAL REPORTS.

Edited by a Committee of the Hospital Staff. J. M. DA COSTA, M.D., and WILLIAM HUNT, M.D. Vols. 1 and 2, containing Original Articles, by former and present Members of the Staff, with Lithographic and other Illustrations. Price per volume 2.00

PEREIRA (JONATHAN), M.D., F.R.S., etc.

Physician's Prescription Book. Containing Lists of Terms, Phrases, Contractions and Abbreviations used in Prescriptions, Explanatory Notes. Grammatical Construction of Prescriptions, Rules for the Pronunciation of Pharmaceutical Terms, etc., etc. Sixteenth Edition.

Price, in cloth, 1.00; in leather, with tucks and pocket, 1.25

PHYSICIAN'S VISITING LIST, PUBLISHED ANNUALLY.

SIZES AND PRICES.

For 25 Patients weekly.	Tucks, pockets, and pencil,	1.00
50 " "	" " "	1.25
75 " "	" " "	1.50
100 " "	" " "	2.00
50 " " 2 vols.	{ Jan. to June }	"	2.50
	{ July to Dec. }		
100 " " 2 vols.	{ Jan. to June }	"	3.00
	{ July to Dec. }		

INTERLEAVED EDITION.

For 25 Patients weekly, interleaved, tucks, pockets, etc.,	1.25
50 " " " " " "	1.50
50 " " 2 vols.	{ Jan. to June }	"
	{ July to Dec. }	

This Visiting List, now in its twenty-ninth year, contains the Metric or French Decimal System of Weights and Measures, a Posological Table with the Doses in both the Apothecaries' and Decimal Metric System of Weights and Measures, a new Table of Poisons, etc.

PIGOTT (A. SNOWDEN), M.D.

Copper Mining and Copper Ore. With a full Description of the Principal Copper Mines of the United States, the Art of Mining, etc. Price 1.00

POWER, HOLMES, ANSTIE, AND BARNES.

Reports on the Progress of Medicine, Surgery, Physiology, Midwifery, Diseases of Women and Children. Price 2.00

PRINCE (DAVID), M.D.

Plastic and Orthopedic Surgery. Containing a Report on the Condition of, and Advance made in, Plastic and Orthopedic Surgery, etc., etc., and numerous Illustrations. Price 4.50

RADCLIFFE (CHARLES BLAND), M.D.

On Epilepsy, Pain, Paralysis, and other Disorders of the Nervous System. With Illustrations. Price 1.50

REESE (JOHN J.), M.D.

Analysis of Physiology. A Condensed View of the most important Facts and Doctrines for Students. Second Edition, Enlarged. Price 1.50

REESE (JOHN J.), M.D.

The American Medical Formulary. Price 1.50

REESE (JOHN J.), M.D.

A Syllabus of Medical Chemistry. Price 1.00

REYNOLDS (J. RUSSELL), M.D., F.R.S.

Lectures on the Clinical Uses of Electricity. Second Edition. Price 1.00

RICHARDSON (JOSEPH), D.D.S.

A Practical Treatise on Mechanical Dentistry. Third Edition, much Enlarged. With over 150 Illustrations. Octavo. Preparing.

RIGBY AND MEADOWS.

Obstetric Memoranda. Fourth Edition, Revised and Enlarged, by
ALFRED MEADOWS, M.D. Price .50

RINDFLEISCH (DR. EDWARD).

Text-Book of Pathological History. Translated from the German,
by WM. C. KOLMAN, M.D., assisted by F. T. MILES, M.D. 208 Microscopical
Illustrations. Octavo. Price, bound in cloth, 5.00; in leather, 6.00

ROBERTS (FREDERICK T.), M.D., B.Sc.

The Theory and Practice of Medicine. Third American, from
Fourth London Edition. Revised and Enlarged. With Illustrations.
Price, cloth, 5.00; leather, 6.00

ROBERTS (D. LLOYD), M.D.

The Student's Guide to the Practice of Midwifery. With 95
Illustrations. Price 2.00

RYAN (MICHAEL), M.D.

Philosophy of Marriage, in its Social, Moral, and Physical Relations;
the Diseases of the Genito-Urinary Organs, etc. Price 1.00

SANDERSON, KLEIN, FOSTER, AND BRUNTON.

A Hand-Book for the Physiological Laboratory. Being
Practical Exercises for Students in Physiology and Histology. With over
350 Illustrations, appropriate letter-press explanations and references to the
text. 2 vols., cloth, \$7.00. Price, in one vol., cloth, 6.00; in leather, 7.00.

SANSOM (ARTHUR ERNEST), M.B.

Chloroform. Its Action and Administration. Price 1.50

SEWILL (H. E.), M.R.C.S., Eng., L.D.S.

The Student's Guide to Dental Anatomy and Surgery.
With 77 Illustrations. Price 1.50

SMITH (HEYWOOD), M.D.

Practical Gynæcology. A Hand-Book for Students and Practitioners.
With Illustrations. Price 1.50

STILLE (ALFRED), M.D.

Epidemic Meningitis; or, Cerebro-spinal Meningitis. Price 2.00

STOKES (WILLIAM).

The Diseases of the Heart and the Aorta. Octavo. Price 3.00

SWAIN (WILLIAM PAUL), F.R.C.S.

Surgical Emergencies: Containing Concise Descriptions of Various
Accidents and Emergencies, with Directions for their Immediate Treatment.
With Illustrations. Price 2.00

SWERINGEN (HIRAM V.), M.D.

A Pharmaceutical Lexicon; or, Dictionary of Pharmaceutical Science.
Containing explanations of the various subjects and terms of Pharmacy, with
appropriate selections from the collateral sciences. Formulæ for officinal, em-
pirical, and dietetic preparations, etc., etc. Price, in cloth, 3.00; in leather, 4.00

TAFT (JONATHAN), D.D.S.

A Practical Treatise on Operative Dentistry. Third Edition, thoroughly Revised, with Additions. Over 100 Illustrations. Octavo.
Price, in cloth, 4.25; in leather, 5.00

TANNER (THOMAS HAWKES), M.D., F.R.C.P., etc.

The Practice of Medicine. Sixth American Edition. Revised and Enlarged. With extensive Formulæ for Medicines, Baths, etc., etc. Royal Octavo; over 1100 pages.
Price, in cloth, 6.00; leather, 7.00

TANNER (THOMAS HAWKES), M.D., F.R.C.P., etc.

Index of Diseases and their Treatment. Second Edition. Carefully Revised. With many Additions and Improvements. By W. H. BROADBENT, M.D., F.R.C.P. Octavo. Cloth.
Price 3.00

TANNER (THOMAS HAWKES), M.D., F.R.C.P., etc.

A Practical Treatise on the Diseases of Infancy and Childhood. Third Edition, Revised and Enlarged. By ALFRED MEADOWS, M.D.
Price 3.00

TANNER (THOMAS HAWKES), M.D., F.R.C.P., etc.

A Memoranda of Poisons. Fourth Edition, much Enlarged. Price .75

TIBBETS (HERBERT), M.D.

A Hand-Book of Medical Electricity. Sixty-four Illustrations.
Price 1.50

TOLAND (H. H.), M.D.

Lectures on Practical Surgery. Second Edition. With Additions and numerous Illustrations.
Price, in cloth, 4.50; in leather, 5.00

TRANSACTIONS OF THE COLLEGE OF PHYSICIANS OF PHILADELPHIA.

New Series, Vols. I, II, III, and IV. Price, per volume, 2.50

TROUSSEAU (A).

Lectures on Clinical Medicine. Delivered at the Hôtel Dieu, Paris. Translated from the Third Revised and Enlarged Edition by P. VICTOR BAZIRE, M.D., and JOHN ROSE CORMACK, M.D. With Index, Table of Contents, etc. Complete in Two Volumes, royal octavo.
Price, bound in cloth, 8.00; in leather, 10.00

TROUSSEAU (A).

Sydenham Society's Edition, 5 Volumes.
Volumes I, II, and III, 4.00 each; Volumes IV and V, 3.00 each.

TYSON (JAMES), M.D.

The Cell Doctrine. Its History and Present State, with a Copious Bibliography of the Subject. With Colored Plate, and numerous other Illustrations. Second Edition.
Price 2.00

TYSON (JAMES), M.D.

A Practical Guide to the Examination of Urine. For the Use of Physicians and Students. With a Colored Plate and numerous other Illustrations. Third Edition.
Price 1.50

TURNBULL (LAURENCE), M.D.

The Advantages and Accidents of Artificial Anæsthesia.
A Manual of Anæsthetic Agents, Modes of Administration, etc. Second
Edition, Enlarged. 25 Illustrations. Cloth. Price 1.50

WALKER (ALEXANDER), M.D.

Intermarriage; or, the Mode in which, and the Causes why, Beauty, Health
and Intellect result from certain Unions; and Deformity, Disease and Insanity
from others. With Illustrations. 12 mo. Price 1.00

WARING (EDWARD JOHN), F.R.C.S., etc.

Practical Therapeutics. Considered chiefly with reference to Articles
of the Materia Medica. Third American, from the last London Edition.
Price, in cloth, 4.00; leather, 5.00

WEDL (CARL), M.D.

Dental Pathology. With Special Reference to the Anatomy and Physi-
ology of the teeth, and notes by THOS. B. HITCHCOCK, M.D., Prof. of Dental
Pathology, Harvard University. 105 Illustrations.
Price, cloth, 3.50; leather, 4.50

WHEELER (C. GILBERT), M.D.

Medical Chemistry: Including the Outlines of Organic and Physiological
Chemistry, Second Edition. Cloth. Price 3.00

WILSON (JOSEPH), M.D.

Naval Hygiene; or, Human Health and means of Preventing Disease,
With Illustrative Incidents derived from Naval Experience. Illustrations,
etc. Second Edition. Price 3.00

WOODMAN AND TIDY.

A Text-Book of Forensic Medicine and Toxicology. By
W. BATHURST WOODMAN, M.D., Assistant Physician and Lecturer on Physi-
ology, London Hospital; and C. MEYMOTT TIDY, M.A., M.B., Lecturer on
Chemistry, and Professor of Medical Jurisprudence, London Hospital. Nu-
merous Illustrations. Price, cloth, 7.50; leather, 8.50

WYTHE (JOSEPH H.), A.M., M.D.

The Physician's Pocket Dose and Symptom Book. Contain-
ing the Doses and Uses of all the Principal Articles of the Materia Medica, and
Original Preparations. Eleventh Revised Edition.
Price, in cloth, 1.00; in leather, tucks, with pockets, 1.25

WYTHE (JOSEPH H.), A.M., M.D.

The Microscopist: A Manual of Microscopy and Compendium of the
Microscopic Sciences, Micro-Mineralogy, Micro-Chemistry, Biology, Histology,
and Practical Medicine. Fourth Edition, 252 Illustrations. Nearly ready.

OVERMAN (FREDERICK), M.E.

Practical Minerology, Assaying, Mining. Tenth Edition.
Cloth, 1.00

MATTHIAS (BENJAMIN), A.M.

A Manual for conducting Business in Town and Ward
Meetings. Sixteenth Edition. Cloth, price, 50

MEDICAL TEXT-BOOKS

PUBLISHED BY

LINDSAY & BLAKISTON, PHILADELPHIA.

- Robert's Hand-Book of the Practice of Medicine.** Octavo. Price, bound in cloth, \$5.00; leather, \$6.00.
- Trousseau's Clinical Medicine.** Complete in two volumes. Octavo. Price, in cloth, \$8.00; leather, \$10.00.
- Aitken's Science and Practice of Medicine.** Third American, from the Sixth London Edition. Two volumes, royal octavo. Price, in cloth, \$12.00; leather, \$14.00.
- Sanderson's Hand-Book for the Physiological Laboratory.** Exercises for Students in Physiology and Histology. 353 Illustrations. Price, in one volume, cloth, \$6.00; leather, \$7.00.
- Cazeaux's Text-Book of Obstetrics.** From the Seventh French Edition, Revised and greatly Enlarged. With Illustrations. Cloth, \$6.00; leather, \$7.00.
- Waring's Practical Therapeutics.** From the Third London Edition. Cloth, \$4.00; leather, \$5.00.
- Rindfleisch's Pathological Histology.** Containing 208 elaborately executed Microscopical Illustrations. Cloth, \$5.00; leather, \$6.00.
- Meigs and Pepper's Practical Treatise on the Diseases of Children.** Sixth Edition. Cloth, \$6.00; leather, \$7.00.
- Tanner's Practice of Medicine.** The Sixth American Edition, Revised and Enlarged. Cloth, \$6.00; leather, \$7.00.
- Tanner & Meadow's Diseases of Infancy and Childhood.** Third Edition. Cloth, \$3.00.
- Biddle's Materia Medica for Students.** The Eighth Revised and Enlarged Edition. With Illustrations. Price, \$4.00.
- Harris's Principles and Practice of Dentistry.** The Tenth Revised and Enlarged Edition. Cloth, \$6.50; leather, \$7.50.
- Woodman and Tidy's Forensic Medicine and Toxicology.** Illustrated. 8vo. Cloth, \$7.50; sheep, \$8.50.
- Byford on the Uterus.** A New, Enlarged, and thoroughly Revised Edition. Numerous Illustrations. Price, \$2.50.
- Hewitt's Diagnosis and Treatment of the Diseases of Women.** Third Edition. Cloth, \$4.00; leather, \$5.00.
- Headland on the Action of Medicines.** Sixth American Edition. Price, \$3.00.
- Athill's Diseases of Women.** Fifth Edition. Numerous Illustrations. Price, \$2.25.
- Meadow's Manual of Midwifery.** Illustrated. Third Enlarged Edition, including the Signs and Symptoms of Pregnancy, etc. Price, \$3.00.
- Fothergill's Complete Manual of the Diseases of the Heart, and their Treatment.** Second Edition. Price, \$3.50.
- Bioxam's Laboratory Teaching.** Fourth Edition. 89 Illustrations. Price, \$1.75.
- Taft's Operative Dentistry.** Third Edition. 100 Illustrations. Cloth. Price, \$4.25.
- Sweringen's Dictionary of Pharmaceutical Science.** Octavo. Price, \$3.00.
- Tanner's Index of Diseases, and their Treatment.** A New Edition. Price, \$3.00.
- Charteris' Hand-Book of Practice.** Illustrated. Price, \$2.00.
- Fenwick's Outlines of the Practice of Medicine.** With special reference to the Prognosis and Treatment of Disease. With Formula and Illustrations. Large 12mo. Price, \$2.00.

ROBERTS' TEXTBOOK of the THEORY and PRACTICE of MEDICINE.

THIRD AMERICAN, FROM THE FOURTH LONDON EDITION.

ONE VOLUME, OCTAVO.

Price, bound in Cloth, \$5.00. In Leather, \$6.00.

The unexceptional large and rapid sale of this book, and the universal commendation it has received from the profession, seems to be a sufficient guarantee of its merit as a Textbook. The publishers are in receipt of numerous letters from Professors in the medical schools, speaking favorably of it, and below they give extracts from the medical press, American and English, attesting its superiority and value to both student and practitioner. The present edition has been thoroughly revised and much of it re-written.

"The best Textbook for Students in the English language. We know of no work in the English language, or in any other, which competes with this one."—*Edinburgh Medical Journal*.

"It is a remarkable evidence of industry, experience, and research."—*Practitioner*.

"Dr. Roberts' book is admirably fitted to supply the want of a good handbook, so much felt by every medical student."—*Student's Journal and Hospital Gazette*.

"It contains a vast deal of capital instruction for the student."—*Medical Times and Gazette*.

"There are great excellencies in this book, which will make it a favorite with the student."—*Richmond and Louisville Journal*.

"To the student it will be a gift of priceless value."—*Detroit Review of Medicine*.

"We heartily recommend it to students, teachers, and practitioners."—*Boston Medical and Surgical Journal*.

"It is of a much higher order than the usual compilations and abstracts placed in the hands of students."—*Medical and Surgical Reporter*.

"It is unsurpassed by any work that has fallen into our hands as a compendium for students."—*The Clinic*.

"We particularly commend it to students about to enter upon the practice of their profession."—*St. Louis Medical and Surgical Journal*.

SECOND EDITION, ENTIRELY RE-WRITTEN.

THE HEART AND ITS DISEASES,

WITH THEIR TREATMENT; INCLUDING THE GOUTY HEART.

By J. MILNER FOTHERGILL, M.D.,

Author of "The Practitioner's Handbook of Treatment," "The Antagonism of Therapeutic Agents," etc.

OCTAVO. PRICE, \$3.50.

"It is the best, as well as the most recent work on the subject in the English language."—*Medical Press and Circular*.

"To many an earnest student it will prove a light in darkness; to many a practitioner cast down with a sense of his powerlessness to cope with the rout and demoralization of Nature's forces, a present help in time of trouble."—*Philadelphia Medical Times*.

"The work throughout is a masterpiece of graphic, lucid writing, full of good sound teaching, which will be appreciated alike by the practitioner and the student."—*Student's Journal*.

"Dr. Fothergill's intention has rather been to present the natural history of heart disease as a series of vivid pictures before the imagination of the reader, and to carry the doctor as a living actor into the scene. For this purpose he has properly chosen to use academic detail, not exhaustively, but as a means to this end, and he has brilliantly succeeded."—*Westminster Review*.

"The most interesting chapter is undoubtedly that on the gouty heart, a subject which Dr. Fothergill has specially studied, and on which he entertains views such as are likely, we think, to be generally accepted by clinical physicians, although they have not before been stated, so far as we are aware, with the same breadth of view and extended illustration."—*British Med. Journal*.

"Dr. Fothergill's remarks on rest, on proper blood nutrition in heart disease, on the treatment of the sequelæ of it, and on the actions of special medicine, all indicate that, in studying the pathology of heart disease, he has earnestly kept in view the best means of mitigating suffering and of prolonging life."—*The Lancet*.

LINDSAY & BLAKISTON, Publishers,

PHILADELPHIA.

AMERICAN HEALTH PRIMERS.

Edited by **W. W. KEEN, M. D.,**

Fellow of the College of Physicians of Philadelphia; Surgeon to St. Mary's Hospital, etc.

This series of American Health Primers is prepared to diffuse as widely and cheaply as possible, among all classes, a knowledge of the elementary facts of Preventive Medicine, and the bearings and applications of the latest and best researches in every branch of Medical and Hygienic Science. They are not intended (save incidentally) to assist in curing disease, but to teach people how to take care of themselves, their children, pupils, employees, etc.

They are written from an American standpoint, with especial reference to our Climate, Sanitary Legislation, and Modes of Life; and in these respects we differ materially from other nations.

The subjects selected are of vital and practical importance in every-day life, and are treated in as popular a style as is consistent with their nature. Each volume, when the subject calls for it, is fully illustrated, so that the text may be clearly and readily understood by any one heretofore entirely ignorant of the structure and functions of the body. The object being to furnish the general or unscientific reader, in a compact form and at a low price, reliable guides for the prevention of disease and the preservation of both body and mind in a healthy state.

The authors have been selected with great care, and on account of special fitness, each for his subject, by reason of its previous careful study, either privately or as public teachers.

Dr. Keen has supervised the Series, as Editor; but is not responsible for the statements or opinions of the individual authors.

I. *Hearing, and How to Keep It.* With Illustrations. By CHAS. H. BURNETT, M. D., of Philadelphia, Consulting Aurist to the Pennsylvania Institution for the Deaf and Dumb, Aurist to the Presbyterian Hospital, etc.

II. *Long Life, and How to Reach It.* By J. G. RICHARDSON, M. D., of Philadelphia, Professor of Hygiene in the University of Pennsylvania, etc.

III. *The Summer and its Diseases.* By JAMES C. WILSON, M. D., of Philadelphia, Lecturer on Physical Diagnosis in Jefferson Medical College, etc.

IV. *Eyesight, and How to Care for It.* With Illustrations. By GEORGE C. HARLAN, M. D., of Philadelphia, Surgeon to the Wills (Eye) Hospital.

V. *The Throat and the Voice.* With Illustrations. By J. SOLIS COHEN, M. D., of Philadelphia, Lecturer on Diseases of the Throat in Jefferson Medical College.

VI. *The Winter and its Dangers.* By HAMILTON OSGOOD, M. D., of Boston, Editorial Staff *Boston Medical and Surgical Journal*.

VII. *The Mouth and the Teeth.* With Illustrations. By J. W. WHITE, M. D., D. D. S., of Philadelphia, Editor of the *Dental Cosmos*.

VIII. *Brain Work and Overwork.* By H. C. WOOD, JR., M. D., of Philadelphia, Clinical Professor of Nervous Diseases in the University of Pennsylvania, etc.

IX. *Our Homes.* With Illustrations. By HENRY HARTSHORNE, M. D., of Philadelphia, formerly Professor of Hygiene in the University of Pennsylvania.

X. *The Skin in Health and Disease.* By L. D. BULKLEY, M. D., of New York, Physician to the Skin Department of the Demilt Dispensary and of the New York Hospital.

XI. *Sea Air and Sea Bathing.* By JOHN H. PACKARD, M. D., of Philadelphia, Surgeon to the Episcopal Hospital.

XII. *School and Industrial Hygiene.* By D. F. LINCOLN, M. D., of Boston, Mass., Chairman Department of Health, American Social Science Association.

The volumes are sold separately. Price 50 cents each, neatly bound in cloth, or the set complete, put up in boxes, price \$6.00; with a specially liberal discount to the Trade when ordered by the dozen volumes *assorted*, or in larger quantities.

PRESLEY BLAKISTON, Publisher,
1012 Walnut Street, Philadelphia.

LINDSAY & BLAKISTON'S

PHYSICIANS' VISITING LIST,

PUBLISHED ANNUALLY.

For twenty-nine years this Visiting List has steadily increased in popularity, and the publishers have constantly modified or re-arranged it as the wants of the profession have become known, and reduced the prices as the sale has become greater.

NEW FEATURES FOR 1880.

- A New Table of Poisons and their Antidotes.
- The Metric or French Decimal System of Weights and Measures.
- Posological Tables, showing the relation of our present system of Apothecaries' Weights and Measures to that of the Metric System, giving the Doses in both.

This is a most valuable addition and will materially aid the Physician. So many writers now use the metric system, especially in foreign books and journals, that one not familiar with it is constantly confused, and in many cases unable to understand the measurements or doses.

SIZES AND PRICES.

For 25 Patients weekly.	Tucks, pockets, and pencil,	\$1 00
50 " " "	" " "	1 25
75 " " "	" " "	1 50
100 " " "	" " "	2 00
50 " " " 2 vols.	{ Jan. to June } "	2 50
	{ July to Dec. }	
100 " " " 2 vols.	{ Jan. to June } "	3 00
	{ July to Dec. }	

INTERLEAVED EDITION.

For 25 Patients weekly, interleaved, tucks, pockets, &c.,	1 25
50 " " " " " " "	1 50
50 " " " 2 vols.	{ Jan. to June } " "	3 00
	{ July to Dec. }	

NOTICES OF THE PRESS.

"It is certainly the most popular Visiting List extant."—*N. Y. Medical Journal*.
 "Its compact size, convenience of arrangement, durability, and neatness of manufacture have everywhere obtained for it a preference."—*Canada Lancet*.
 "The book is convenient in form, not too bulky, and in every respect the very best Visiting List published."—*Canada Medical and Surgical Journal*.
 "This standard Visiting List makes its usual annual visit. For completeness, compactness, and simplicity of arrangement it is excelled by none in the market."—*New York Medical Record*.

☛ Sent by mail post paid to any address upon receipt of the price, or can be had through any Bookseller in the United States or Canada.

LINDSAY & BLAKISTON, Publishers,
 25 S. SIXTH ST., PHILADELPHIA.

