

12**AUTOPSY REPORT****ADULT FORM PROTOCOL**No.
2013-01364
LAM, ELISA

I performed an autopsy on the body of →

at the DEPARTMENT OF CORONER

Los Angeles, California

on 2/21/2013

0935

(Date)

(Time)

From the anatomic findings and pertinent history I ascribe the death to:

(A) DROWNING

DUE TO OR AS A CONSEQUENCE OF

(B)

DUE TO OR AS A CONSEQUENCE OF

(C)

DUE TO OR AS A CONSEQUENCE OF

(D)

OTHER CONDITIONS CONTRIBUTING BUT NOT RELATED TO THE IMMEDIATE CAUSE OF DEATH

BIPOLAR DISORDER

Anatomic Summary: As listed below

21 year old Asian woman found in a water storage tank on the roof of her hotel

- I. Moderate decomposition
- II. No trauma
- III. History of bipolar disorder
- IV. See separate toxicology report
- V. See separate microscopic report

12**AUTOPSY REPORT**No.
2013-01364
LAM, ELISAPage 2

CIRCUMSTANCES:

See Investigator Report form #3

EXTERNAL EXAMINATION:

The body is identified by toe tags and is that of an unembalmed refrigerated, adult female Asian who is in moderate decomposition. She appears the given age of 21 years. The body weighs 121 pounds, measures 66 inches, and is thin. The skin shows a 1 inch scar on the right knee and a 1/4 round abrasion on the left knee. Wrist scars are absent. Tattoos are not present. Rigor has been abolished. Livor mortis is not appreciated.

The head is normocephalic and covered by brown hair. There is no balding and the hair can be described as straight. Examination of the eyes reveals irides that appear to be brown in color and sclerae that are white. There are no petechial hemorrhages of the conjunctivae of the lids and/or sclera. The oronasal passages are unobstructed. Upper and lower teeth are present. Dentures are absent. The neck is unremarkable. There is no chest deformity. There is no increased anterior-posterior diameter. The abdomen is flat. The genitalia are those of an adult female. The anus is edematous and shows pooling of blood in the subcutaneous tissues surrounding the orifice. The extremities show no edema, joint deformity, abnormal mobility, non-therapeutic punctures or needle tracks.

The body is in a state of moderate decomposition with greening of the body sparing the lower legs and feet. There is marbling seen on the upper thighs. The scalp skin and hair easily sloughs with slight pulling. The head and face is bloated with bulging eyes. The face shows skin slippage on the forehead and right cheek that is dry and brown in color. Skin slippage is present on the chest, back, arms and left lower leg. The skin shows marked wrinkling of the palms, fingers, soles of feet and toes. The internal soft tissues and organs show emphysematous change and autolysis.

AUTOPSY REPORT**12**

No.

2013-01364

LAM, ELISA

Page 3

EVIDENCE OF THERAPEUTIC INTERVENTION:

There is no evidence of any previous recent hospitalization. There has not been postmortem intervention for organ procurement.

EVIDENCE OF EXTERNAL TRAUMATIC INJURY:

None.

CLOTHING:

The body was not clothed and I inspected the clothing. The clothing consisted of: 1 pair of black shorts size men's medium with a logo on the left front leg; 1 green shirt labeled JJM size large with a logo on the back neck labeled Alexander Keiths India Pale Ale and a logo on the left front chest of a deer with antlers and the words turn over the tartan; 1 pair of black underwear with lace trim labeled Calvin Klein size S/P; 1 pair of black polka dot sandals labeled Birki's with following numbers and letters written on the heels 39 55 250 L8M6; 1 red sweat shirt zipper front with hood labeled American Apparel size XS that is wet.

All of the items had sand like particulate attached to the fabric and loosely present in the fold of the clothes and on the drying mats.

INITIAL INCISION:

The body cavities are entered through the standard coronal incision and the standard Y-shaped incision. No foreign material is present in the mouth, upper airway and trachea.

EVIDENCE OF INTERNAL INJURIES:

None.

AUTOPSY REPORT**12**No.
2013-01364
LAM, ELISAPage 4

NECK:

The neck organs are layer wise dissected and removed en bloc with the tongue. There is a focus of erythema in posterior left tongue deep in the tissue. There is no trauma seen. No lesions are present nor is trauma of the gingiva, lips or oral mucosa demonstrated. There is no edema of the larynx. Both hyoid bone and larynx are intact. There is no evidence of gross hemorrhage in the areas. The tissue is further fixed for dissection. The soft tissues are removed from the larynx and show no areas of hemorrhage. The thyroid cartilage is removed from the larynx and shows no evidence of trauma or fractures. The larynx and proximal trachea are cut transversely along its length and does not show any trauma of the mucosa, submucosal or cartilage. The hyoid bone does not show trauma. No hemorrhage is present in the adjacent throat organs, investing fascia, strap muscles, visceral fascia. Both lobes of the thyroid show focal erythema on the anterior surface. There are no prevertebral fascial hemorrhages. The tongue when sectioned shows no trauma.

CHEST/ABDOMINAL CAVITY:

Both pleural cavities contain dark brown fluid; 300 cc on the right and 200 cc on the left. The lungs are voluminous. Soft tissues of the thoracic and abdominal walls have late postmortem softening, discoloration and crepitation. The subcutaneous fat of the abdominal wall measures 1/2 inch. Breasts are examined and sectioned in usual manner and show no abnormalities. The organs of the abdominal cavity have a normal arrangement and none are absent. There is no fluid collection. The peritoneal cavity is without evidence of peritonitis. There are no adhesions.

SYSTEMIC AND ORGAN REVIEW

The following observations are limited to findings other than injuries, if described above.

AUTOPSY REPORT**12**No.
2013-01364
LAM, ELISA

Page 5

MUSCULOSKELETAL SYSTEM:

No abnormalities of the bony framework or muscles are present.

CARDIOVASCULAR SYSTEM:

The aorta is elastic and of even caliber throughout with vessels distributed normally from it. There is no tortuosity or widening of the thoracic segment. The abdominal aorta has no atherosclerosis. There is no dilation of the lower abdominal segment. No aneurysm is present. The major branches of the aorta show no abnormality.

Within the pericardial sac, there is a minimal amount of serous fluid. The heart weighs 175 grams. It has a normal configuration. The right ventricle is 0.3 cm thick, the left ventricle is 1.0 cm thick, and the septum is 1.3 cm thick. The chambers are normally developed and are without mural thrombosis. The valves are thin, leafy and competent. The circumference of the valve rings are: Tricuspid valve 11.0 cm, pulmonic valve 6.0 cm, aortic valve 5.0 cm, and mitral valve 10.0 cm. There is marked postmortem softening of the myocardium. There are no defects of the septum. The great vessels enter and leave in a normal fashion. The ductus arteriosus is obliterated. The coronary ostia are widely patent. The right coronary artery is the dominant vessel. There is no coronary atherosclerosis of the major coronary arteries. The blood within the heart and large blood vessels is liquid but only a scant amount is present.

RESPIRATORY SYSTEM:

Scant secretions are found in the upper respiratory passages. The mucosa has brown postmortem discoloration. The lungs are crepitant and there is postmortem softening. The left lung weighs 250 grams. The right lung weighs 350 grams. The visceral pleura are smooth and intact. The parenchyma has postmortem gaseous distention and edema. The pulmonary vasculature is without thromboembolism.

AUTOPSY REPORT**12**No.
2013-01364
LAM, ELISAPage 6

GASTROINTESTINAL SYSTEM:

The esophagus is intact throughout. The stomach is not distended. It contains scant red fluid. The mucosa shows postmortem change. Portions of tablets and capsules cannot be discerned in the stomach. The external and in-situ appearance of the small intestine and colon are unremarkable. The small intestine and colon are opened along the anti-mesenteric border and show postmortem discoloration. The appendix is present. The pancreas occupies a normal position. There is early autolysis. The parenchyma is lobular and firm. The pancreatic ducts are not ectatic and there is no parenchymal calcification.

HEPATOBIILIARY SYSTEM:

The liver weighs 1025 grams, is of average size and is red-brown. The capsule is intact and the consistency of the parenchyma is soft. The cut surface is smooth. There is postmortem discoloration. The gallbladder is present. The wall is thin and pliable. It contains 10 cc of bile and no calculi. There is no obstruction or dilation of the extrahepatic ducts. The periportal lymph nodes are not enlarged.

URINARY SYSTEM:

The left kidney weighs 125 grams. The right kidney weighs 125 grams. The kidneys are normally situated and the capsules strip easily revealing a surface that is smooth. The corticomedullary demarcation is obscured by congestion. The pyramids are not remarkable. The peri-pelvic fat is not increased. The ureters are without dilation or obstruction and pursue their normal course. The urinary bladder is unremarkable. It contains no urine.

GENITAL SYSTEM:

The uterus is symmetrical and the uterine cavity is not enlarged. The fallopian tubes are unremarkable. The endometrium shows postmortem discoloration.

AUTOPSY REPORT**12**No.
2013-01364
LAM, ELISAPage 7

The cervix and vagina have a normal appearance for the age and show marked postmortem discoloration. The cervix and superior vaginal walls are saved for further dissection. Subsequent dissection of the superior vaginal wall does not show evidence of trauma. The ectocervix and endocervical canal are unremarkable. Vertical cuts are made circumferentially around the cervix and show no trauma to the underlying tissues. The ovaries are normal for the age.

HEMOLYMPHATIC SYSTEM:

The spleen weighs 75 grams and is of average size. The capsule is intact. The parenchyma is mushy. There is no increased follicular pattern. Lymph nodes throughout the body are small and inconspicuous. The bone is unremarkable. The bone marrow of the rib is unremarkable.

ENDOCRINE SYSTEM:

The thyroid is unremarkable. The parathyroid glands are not identified. The adrenals are unremarkable. The thymus is not identified. The pituitary gland is not identified due cerebral necrosis.

SPECIAL SENSES:

The eyes are not dissected. The middle and inner ear are not dissected.

HEAD AND CENTRAL NERVOUS SYSTEM:

There is no subcutaneous or subgaleal hemorrhage of the scalp. The external periosteum and dura mater are stripped showing no fracture of the calvarium or base of the skull. There are no tears of the dura mater. There is no epidural, subdural or subarachnoid hemorrhage.

12**AUTOPSY REPORT**

No.

2013-01364

LAM, ELISA

Page 8

The brain weighs 1100 grams. The brain is dusky gray in color and soft. The leptomeninges are thin and transparent. A normal convolutionary pattern is observed. Coronal sectioning is limited due to the softness of the parenchyma but demonstrates a uniformity of cortical gray thickness areas observable. The cerebral hemispheres are symmetrical. There is no hemorrhage of the white matter on observable areas. The basal ganglia are not identifiable. Cerebral contusions are not present. The ventricular system is not identifiable. The pons, medulla and cerebellum are unremarkable and uninterpretable after removal of the brain due to maceration. The cranial nerves and vasculature are not recognizable.

SPINAL CORD:

The entire cord is not dissected.

HISTOLOGIC SECTIONS:

Representative sections from various organs are preserved in two storage jars in 10% formalin. Sections of vital organs are submitted for slides. The slide key is described on the microscopic report.

TOXICOLOGY:

Bile, heart blood, liver tissue, stomach contents, spleen, and brain have been submitted to the lab. A comprehensive screen was requested.

PHOTOGRAPHY:

At scene photos are available. Photographs have been taken prior to and during the course of the autopsy.

AUTOPSY REPORT**12**

No.

2013-01364

LAM, ELISA

Page 9

RADIOLOGY:

The body is fluoroscoped and x-rays are taken of the head, chest, abdomen, pelvis and shoulders (7).

WITNESSES:

Detectives Wallace Tennelle (#22628) and Stearns (#31611), of LAPD witnessed the autopsy.

DIAGRAMS USED:

Diagram Forms #16, 20, 20G, 38 and 43 were used during the performance of the autopsy. The diagrams are not intended to be facsimiles.

12**AUTOPSY REPORT**

No.

2013-01364


LAM, ELISA

Page 10


OPINION:

The decedent died as a result of drowning. A complete autopsy examination showed no evidence of trauma and toxicology studies did not show acute drug or alcohol intoxication. Decedent had a history of bipolar disorder for which she was prescribed medication. Toxicology studies were performed for the presence of these drugs. However, quantitation in the blood was not performed due to limited sample availability. Therefore, interpretation is limited. Police investigation did not show evidence of foul play. A full review of the circumstances of the case and appropriate consultation do not support intent to harm oneself. The manner of death is classified as accident.

The case was discussed with the Chief Coroner/Medical Examiner/Interim Director, who concurred with this opinion and death certification.


 Jason P. Tovar, M.D.
 ASSOCIATE DEPUTY MEDICAL EXAMINER

6/19/13
 DATE


 Yuhai Wang, M.D.
 SENIOR DEPUTY MEDICAL EXAMINER

6/19/13
 DATE

6

WAS ORIGINAL SCENE DISTURBED BY OTHERS? Y [] N [X]
IF YES, NOTE CHANGES IN NARRATIVE FORM #3.

2013-01364
Lam, Elisa
Und.

DATE 2/19/13
AMBIENT #1 NT °F TIME _____
AMBIENT #2 _____ °F TIME _____
WATER _____ °F TIME _____

THERMOMETER # _____

LIVER TEMPERATURE #1 NT °F TIME _____

LIVER TEMPERATURE #2 _____ °F TIME _____

DATE & TIME FOUND 2/19/13 LAST KNOWN ALIVE 2/1/13

APPROX. AGE 21 SEX F EST. HEIGHT 66 EST. WEIGHT 121 CLOTHED? YES NO IF YES, DESCRIBE:

DESCRIPTION AS TO WHERE REMAINS FOUND AND CONTACT MATERIAL TO BODY:

see narrative - water tank on rooftop

SCENE TEMPERATURE REGULATED? YES NO IF YES, THERMOSTAT SET AT _____ DEGREES F.

LIVOR MORTIS: TIME OBSERVED 1730

RIGOR MORTIS: TIME OBSERVED 1730

NECK FLEXION: Resolved

Fixed

ANTERIOR _____

POSTERIOR _____

RT. LATERAL _____

LT. LATERAL _____

JAW _____ HIP _____

SHOULDER _____ KNEE _____

ELBOW _____ ANKLE _____

WRIST _____

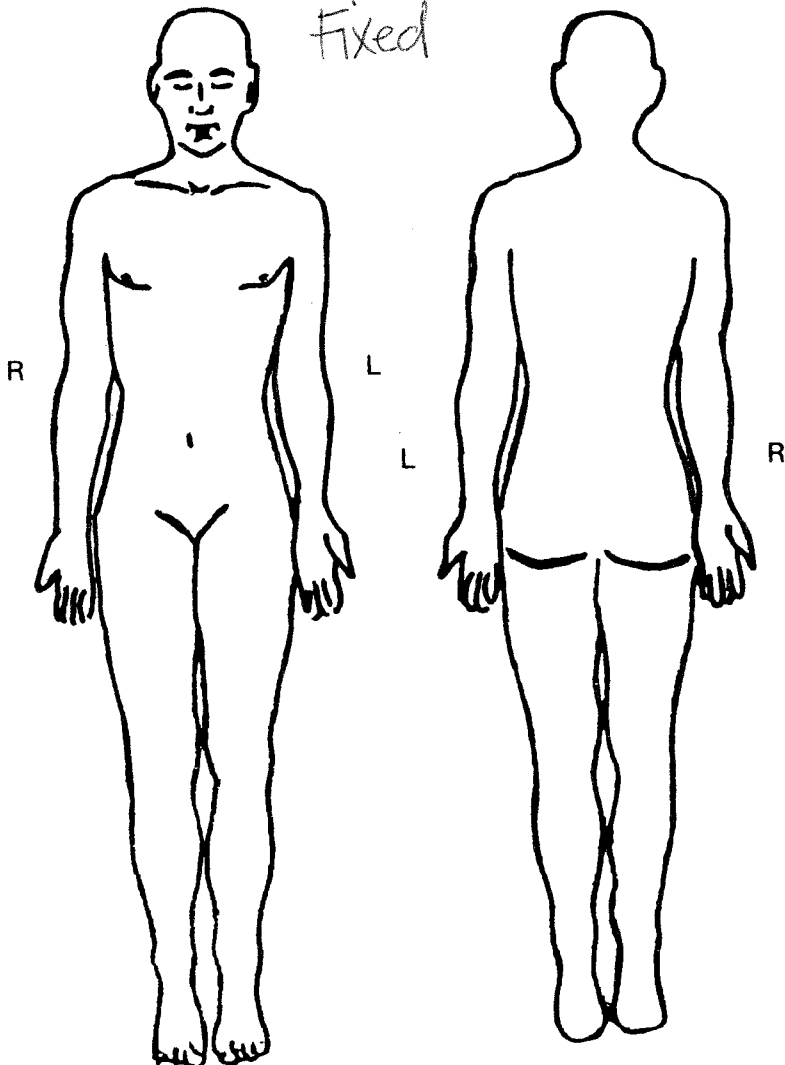
SCALE

- 0 = ABSENT/NEGATIVE
- 1 +
- 2 +
- 3 +
- 4 = EXTREME DEGREE

USE SCALE TO DESCRIBE INTENSITY OF RIGOR MORTIS.

SHADE DIAGRAMS TO ILLUSTRATE THE LOCATION OF LIVOR MORTIS.

DESCRIBE INTENSITY OF COLORATION AND WHETHER LIVOR MORTIS IS PERMANENT OR BLANCHES UNDER PRESSURE.



[Signature]
CORONER'S INVESTIGATOR

REVIEWED BY [Signature]

132013-01364
Lam, Elisa
(Decedent)**Los Angeles County Department of Coroner
Criminalist Report**Investigating Agency: **Los Angeles Police Department
Robbery-Homicide Division**

Agency Investigator: Stearns; Tennelle

Agency File No.: **130106275**

Page 1 of 2

Also see Coroner Investigator Report for additional information, including scene description, case circumstances, condition of body, possible additional evidence.

On 19 February 2013 at 1636 hours I was notified by Coroner Supervising Investigator F. Corral that a criminalist was needed for evidence collection once the case arrived at the Forensic Science Center.

At 1721 hours, I observed the decedent, an adult female, lying supine on a service table. She was nude, had dark or black, wavy head hair; clothing items accompanied her on the table. The decedent was in an advanced state of decomposition, having bloating to the face and abdomen, marbling at the abdomen, and pronounced green discoloration of the abdomen and upper legs; the rectal tissue was prolapsed. The hands and feet were waterlogged and all of the clothing was sopping wet. The body had reportedly been recovered along with the clothing and a wrist watch after being submerged in a hotel water supply tank for many days. Sand and small, flat, whitish and fragile flecks of unknown material were on or throughout all the clothing, and several dark hairs or fibers at least several inches in length were noted on a couple of the garments. The fibers and debris were left in place with the clothing items.

I collected Hair, Fingernail, Pubic Hair, and Sexual Assault Evidence Kits. Coroner Investigator K. Yagerlener released the watch and a hotel card key to Los Angeles Police Department detectives.

Evidence collection was completed at 1850 hours.

EVIDENCE – see following page

13

Page 2 of 2

2013-01364

EVIDENCE

The following items were collected by me and placed into evidence.

EVIDENCE COLLECTED AT FORENSIC SCIENCE CENTER**Physical Evidence**

1. Sexual Assault Evidence Kit
 - A) Oral Swab set and slide set.
 - B) External Swab set and slide set.
 - C) Vaginal Swab set and slide set.
 - D) Cervical Swab set and slide set.
 - E) Rectal Swab set and slide set.
2. Fingernail Kit.

Clothing (each item individually packaged in its own brown paper bag)

3. Red hooded sweatshirt; front zipping; 'American Apparel' brand; size Sx.
4. Green shirt; a T-shirt, light green, short-sleeved, with crew neck; 'jjm' brand, size L/G.
5. Black shorts; 'Saxon' brand 'authentic gamewear, Men's,' size M/M.
6. Black panties; black lace trim; 'Calvin Klein' brand, size s/p.
7. Pair sandals; Birkenstocks or 'Birki's' brand, with three black fabric straps having small white dot pattern overall and two buckles; labeled with numerals that may indicate code for European sizing: 39 55
250
L8 M6

Reference Specimens

8. Hair Kit.
9. Pubic Hair Kit.

02-27-13
Date report written

3-22-13
Date report signed

Mark S. Schuchardt
Mark S. Schuchardt
Senior Criminalist

cc: Medical File
Laboratory Case File

MMS,
Reviewed 3/25/13
3-28-13

14

I performed a microscopic examination on →

2013-01364
LAM, ELISA

at THE DEPARTMENT OF CORONER

Los Angeles, California

Microscopic description


Lung, kidney, live, heart, thyroid are autolyzed.

Slide Key:

- 1. Lung
- 2. Liver, Kidney
- 3. Heart, Thyroid

Diagnosis:


- I. All tissue sections are autolyzed.



 Jason P. Tovar, M.D.
 Associate Deputy Medical Examiner

3/12/13

 Date



 Yulai Wang, M.D.
 Senior Deputy Medical Examiner

6/19/13

 Date

15

AUTOPSY CLASS: A B C Examination Only D

FAMILY OBJECTION TO AUTOPSY

Date: 2/21/13 Time: 0935 Dr. Tovar/Wang
(Print)

FINAL ON: 6/18/13 By: Tovar/Wang
(Print)

APPROXIMATE INTERVAL BETWEEN ONSET AND DEATH

DEATH WAS CAUSED BY: (Enter only one cause per line for A, B, C, and D)

IMMEDIATE CAUSE:

(A) Drowning

Rapid

DUE TO, OR AS A CONSEQUENCE OF:

(B)

DUE TO, OR AS A CONSEQUENCE OF:

(C)

DUE TO, OR AS A CONSEQUENCE OF:

(D)

OTHER CONDITIONS CONTRIBUTING BUT NOT RELATED TO THE IMMEDIATE CAUSE OF DEATH:

Bipolar Disorder

NATURAL SUICIDE HOMICIDE
 ACCIDENT ~~COULD NOT BE DETERMINED~~

If other than natural causes, HOW DID INJURY OCCUR?

In Water Tank

WAS OPERATION PERFORMED FOR ANY CONDITION STATED ABOVE: YES NO

TYPE OF SURGERY: _____ DATE: _____

ORGAN PROCUREMENT TECHNICIAN: L. Bivens
 PREGNANCY IN LAST YEAR YES NO UNK NOT APPLICABLE
 WITNESS TO AUTOPSY EVIDENCE RECOVERED AT AUTOPSY
Item Description: _____

Age: 21 Gender: Male / Female

PRIOR EXAMINATION REVIEW BY DME

BODY TAG CLOTHING
 X-RAY (No. 7) FLUORO
 SPECIAL PROCESSING TAG MED. RECORDS
 AT SCENE PHOTOS (No. 23)

CASE CIRCUMSTANCES

EMBALMED
 DECOMPOSED
 >24 HRS IN HOSPITAL
 OTHER: _____ (Reason)

TYPING SPECIMEN

TYPING SPECIMEN TAKEN BY: _____

SOURCE: _____

TOXICOLOGY SPECIMEN

COLLECTED BY: Tovar
 HEART BLOOD STOMACH CONTENTS
 FEMORAL BLOOD VITREOUS

TECHNIQUE:

BLOOD SPLEEN
 BLOOD KIDNEY
 BILE Brain
 LIVER
 URINE

URINE GLUCOSE DIPSTICK RESULT: 4+ 3+ 2+ 1+ 0

TOX SPECIMEN RECONCILIATION BY: AS

HISTOLOGY


Regular (No. 3) Oversize (No. _____)
Histopath Cut: Autopsy Lab


TOXICOLOGY REQUESTS

FORM 3A: YES NO
 NO TOXICOLOGY REQUESTED
SCREEN C H T S D
 ALCOHOL ONLY
 CARBON MONOXIDE
 OTHER (Specify drug and tissue)
Limited Blood.

REQUESTED MATERIAL ON PENDING CASES

POLICE REPORT MED HISTORY
 TOX FOR COD HISTOLOGY
 TOX FOR R/O INVESTIGATIONS
 MICROBIOLOGY EYE PATH. CONS.
 RADIOLOGY CONS.
 CONSULT ON: _____
 BRAIN SUBMITTED
 NEURO CONSULT DME TO CUT
 CRIMINALISTICS
 GSR SEXUAL ASSAULT OTHER

RESIDENT 

DME 

16

Decomposed

2013-01364

LAB. LIST

38

EXTERNAL EXAM

Sex Female
Race Asian
Age 21
Height 66 inch
Weight 121 lbs
Hair
Eyes
Sclera
Teeth
Mouth
Tongue
Nose
Chest
Breasts
Abdomen
Scar
Genital
Edema
Skin
Decub
HEART Wt 175
Pericard
Hypert
Dilat
Muscle
Valves
Coronar

ectomorph

T 11 86
M 10 85
RV 0.3
LV 1.0
Septum 1.3

AORTA
VESSELS
LUNGS Wt
R 350
L 250

For normal gas

Adhes
Fluid - 200 left 300 R side
Atelectasis
Oedema
Congest
Consol
Bronchi
Nodes

PHARYNX
TRACHEA
THYROID
THYMUS
LARYNX
HYOID
ABDOMINAL WALL FAT 1/2 inch

large vessel neck dissection
Ant. Hemorrhoidal embolism

PERITONEUM

Fluid 3 mm
Adhes 3

LIVER Wt 1025

Caps
Lobul
Fibros
G B
Calc
Bile ducts

SPLEEN Wt 75

Color
Consist
Caps
Malpig

PANCREAS

ADRENALS

KIDNEYS Wt

R 125
L 125

Caps
Cortex
Vessels
Pelvis
Ureter

BLADDER

GENITALIA

Prest
Testes
Uterus
Tubes
Ovar

OESOPHAGUS

STOMACH

Contents

DUOD & SM INT

APPENDIX

LARGE INT

ABDOM NODES

SKELETON

Spine
Marrow
Rib Cage
Long bones
Pelvis

SCALP

CALVARIUM

BRAIN Wt

Dura
Fluid
Ventric
Vessels
Middle ears
Other

PITUITARY

not ID

SPINAL CORD

not examined

TOXICOLOGY SPECIMENS

Heart blood, Bile, Liver,
Stomach contents, Saliva,
Brain

SECTIONS FOR HISTOPATHOLOGY

Lung

MICROBIOLOGY

none

DIAGRAMS

X-RAYS

(5)

OTHER PROCEDURES

neck dissection, thyroid
& larynx for criminalist

GROSS IMPRESSIONS

see protocol

Date

2/21/13

Time

1:00

Deputy Medical Examiner

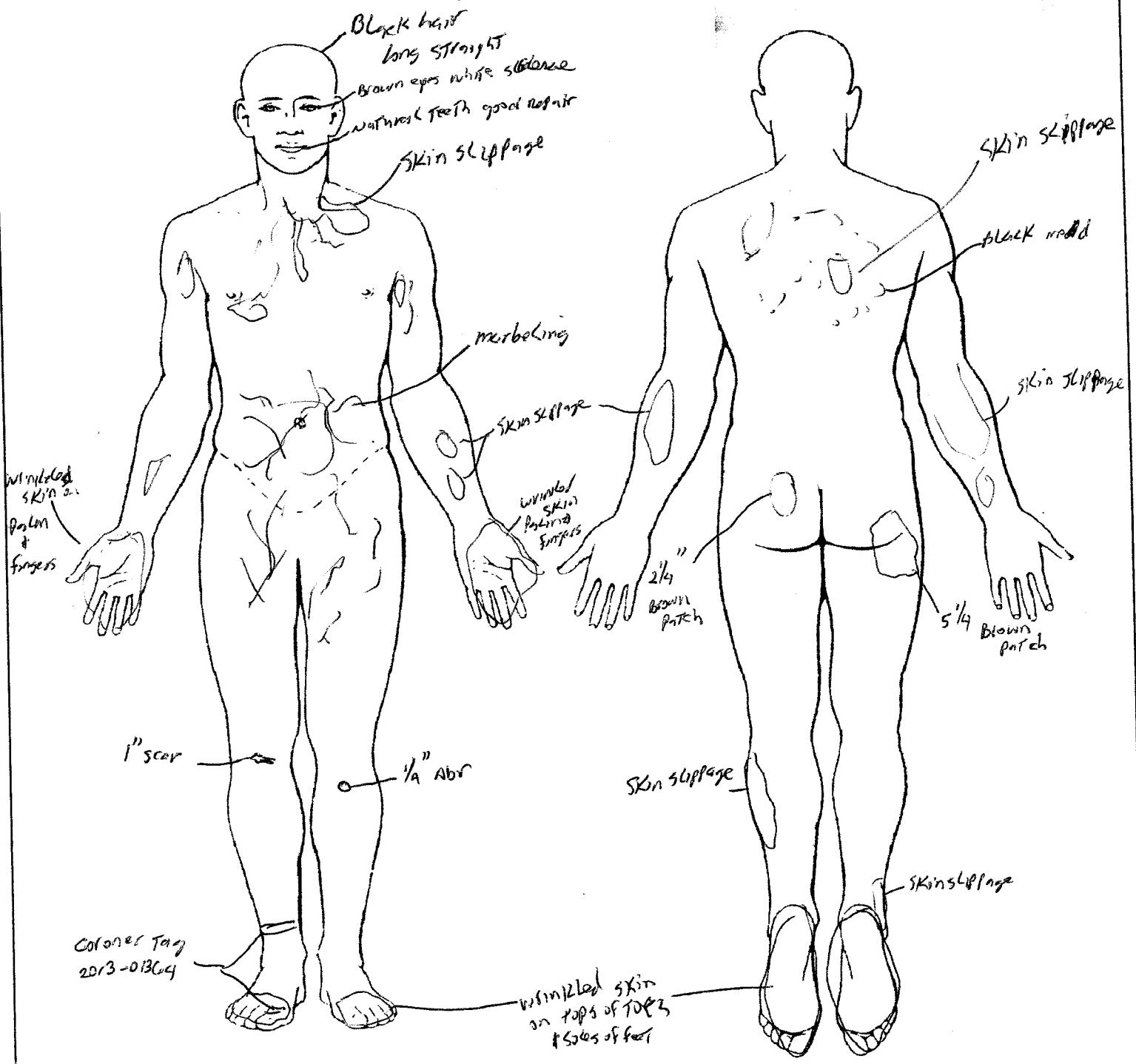
[Signature]

20

early decomposition
post mortem phenomena loss the lower legs

2013-01364
LAW. ELISA

38




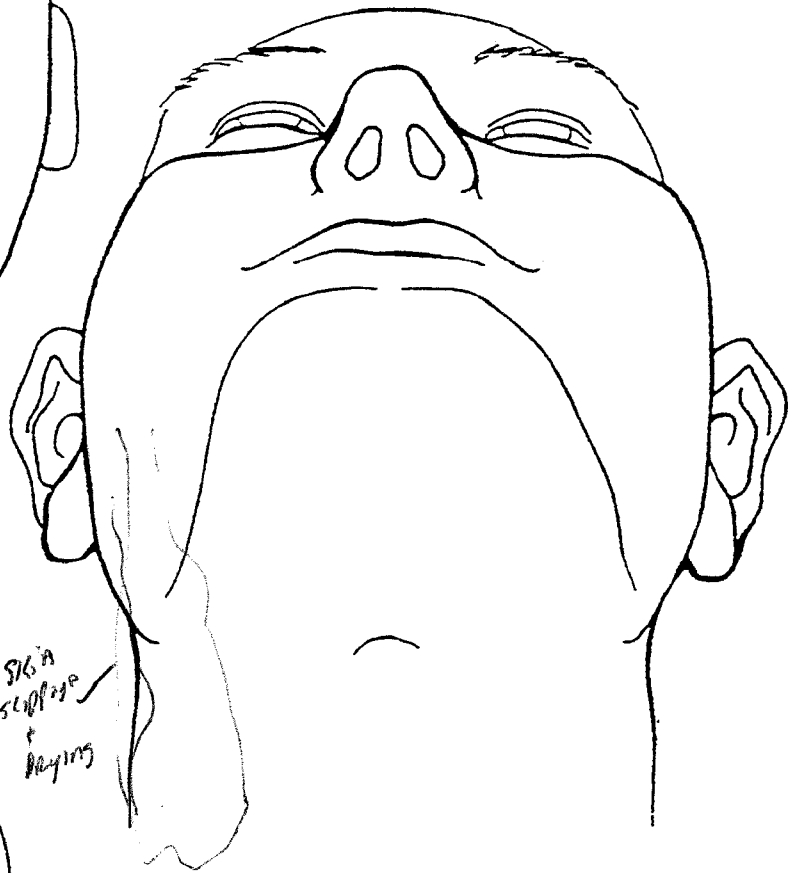
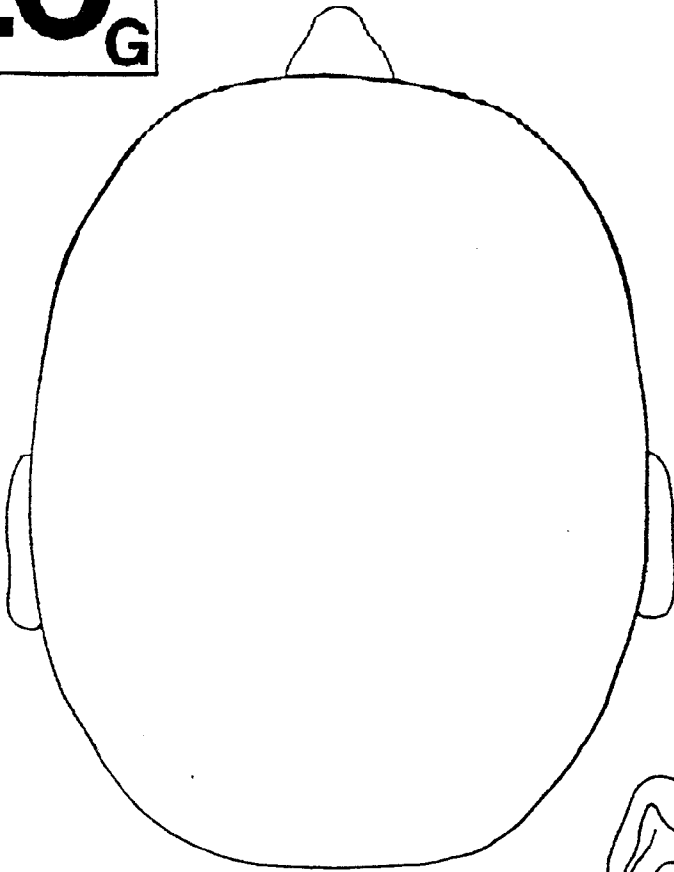
Date 2/2/13

[Signature] M.D.
 Deputy Medical Examiner

20
G

2013-01364
LAN, ELISA

38



skin
suffuse
&
bruising

Date 2/21/13

[Signature]

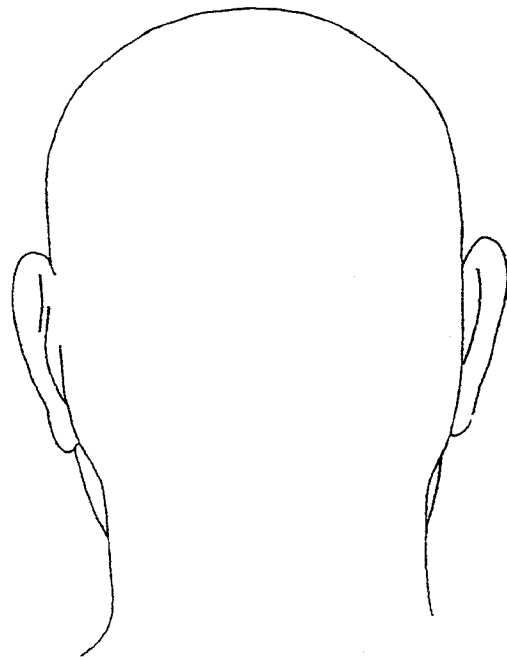
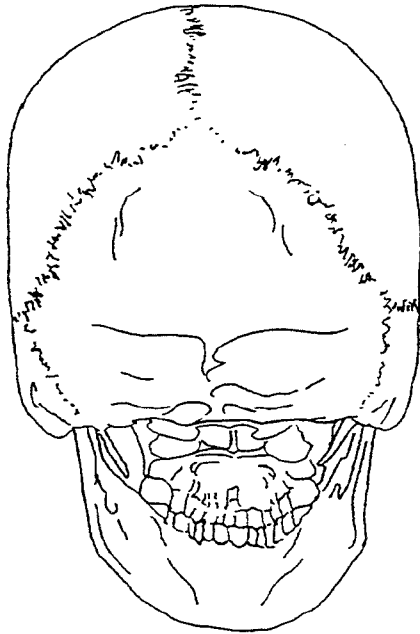
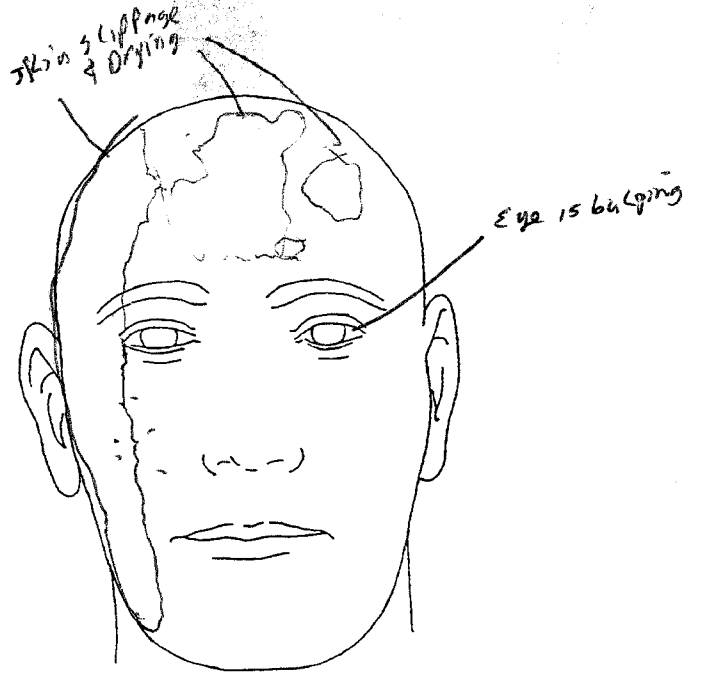
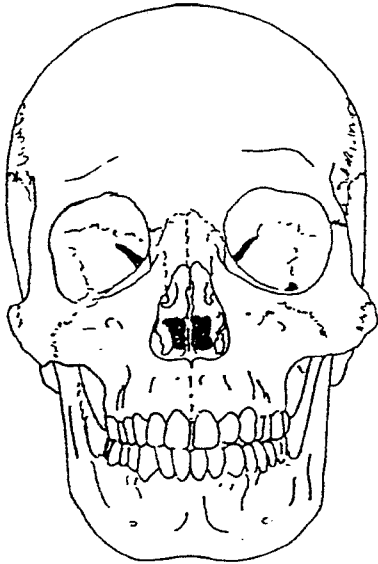
M.D.

Deputy Medical Examiner.


38

2013-01364
LAN, ELISA

38



Date 2/20/13

 M.D.
Deputy Medical Examiner



County of Los Angeles, Department of Coroner
Investigator's Narrative



Case Number: 2013-01364

Decedent: LAM, ELISA

Information Sources:

Detective Tennelle, Los Angeles Police Department Robbery Homicide division, 213-486-6850

On scene investigation

Investigation:

On 02/19/2013 at 1249 hours, Officer Sanchez reported this death to our office.

Lt. Cheryl MacWillie assigned the call to me at 1310 hours.

I arrived to the scene at 1348 hours and cleared from the call at 1700 hours.

According to a missing person report filed on 02/04/2013, the decedent was last seen on 01/31/2013 at the Cecil Hotel in downtown Los Angeles. She was traveling alone from Vancouver, Canada and arrived in Los Angeles on 01/26/2013. Her final destination was Santa Cruz, CA. She used public transportation including Amtrak and buses.

Video of a surveillance camera in the hotel showed the decedent in an elevator at the Cecil Hotel exhibiting strange behavior. There are no other people seen in the video and it does not appear that she is being chased or in distress. She is wearing the same clothing found in the water tank with the decedent. The video is reported to be from 02/01/2013.

The decedent was transported from the scene to the Forensic Science Center by Forensic Attendant M. Aparicio.

Criminalist Mark Schuchardt notified and present at the Forensic Science Center for evidence collection.

Location:

Place of Possible Injury: Cecil Hotel, 640 S. Main Street, Los Angeles, CA 90014

Place Found: water tank on rooftop of Cecil Hotel, 640 S. Main Street, Los Angeles, CA 90014

Informant/Witness Statements:

Detective Tennelle gave me the following limited information. On 02/19/2013 at 1000 hours, the decedent was found in a rooftop water tank by a maintenance worker for the hotel. The maintenance worker was sent to check on the water tanks after complaints of poor water pressure. 911 was called and Los Angeles Fire Department #9 responded to determine death at 1022 hours. She was last known alive on 02/01/2013.

Sara Lam, sister, gave me the following information. She said her sister had a history of depression and bipolar disorder. She was taking 4 medications, Wellbutrin, Lamotrigine, Quetiapine and another that she could not recall. She had no suicidal ideations or known prior attempts.

Scene Description:

It was the rooftop of the Cecil Hotel, a 15 story hotel built in the 1920's. The rooftop has four 1000 gallon water tanks reportedly used to supply the hotel with water. The decedent was found floating face up in the tank to the northeast. It appeared to be approximately 1/2 - 3/4 full when I looked into the tank. There was an unsecured metal removable hatch on the top of the tank. Clothing and shoes were also found in the tank.

A hotel key card and watch were found amongst the clothing and released to Detective Stearns as evidence.

Kms



County of Los Angeles, Department of Coroner
Investigator's Narrative



Case Number: 2013-01364

Decedent: LAM, ELISA

Evidence:

See evidence log.

Body Examination:

The decedent was a female Asian adult. She was nude. She was in a state of decomposition noted with marbling, green discoloration, bloating, foul smell and skin separation. The decedent appeared to have mold spots on her legs and buttocks. A possible scar was noted to her right knee. A mole was seen on her right chest. There was no obvious evidence of trauma seen. Rigor mortis was resolved. Livor mortis was fixed. The ambient, algor and water temperatures were not taken.

Identification:

The decedent was identified by her Canadian passport as Elisa Lam, DOB 04/30/1991.

Next of Kin Notification:

The decedent's parents, _____, were notified of the death by detectives on 02/19/2013. I verified notification with _____ and she told me her sister was not married and had no children.

Tissue Donation:

Not addressed due to time lapse since death.

Autopsy Notification:

See case notes.

KELLY YAGERLENER

SUPERVISOR

02/20/2013

Date of Report

3A

CASE # 2013-01364
 DECEDENT'S NAME:
 LAM, ELISA
 DOD: 2/19/2013
 INCOMING MODE:

Drug Name	Rx Number	Date of Issue	Number Issued	Number Remaining	Form	Dosage	Rx Directions	Physician	Pharmacy Name/ Comments
ADVL	LOOSE			11	CAPSULE	200 MG			LOOSE PILLS
DEXEDRINE SPANSULE	LOOSE			2	CAPSULE	10 MG		DR. SARAH E. SCARFE	LOOSE PILLS- LIQUITABS
LAMOTRIGINE	7153988	1/11/2013	60	70	TABLET	100 MG	1 TAB QD	DR. SARAH E. SCARFE	LONDON DRUGS #56 604-570-0252 PRESCRIBED TO DECEDENT, CANADIAN PHARMACY
QUETIAPINE	7153992	1/11/2013	30	20	TABLET	25 MG	2 TABS QHS PRN	DR. SARAH E. SCARFE	LONDON DRUGS #56 604-570-0252 PRESCRIBED TO DECEDENT, CANADIAN PHARMACY
SINUTAB	LOOSE			2	TABLET			DR. SARAH E. SCARFE	LOOSE PILLS- BLISTER PACK LOT 16112
VENLAFAXINE XR	7153990	1/11/2013	60	64	CAPSULE	150 MG	1 CAP QD (+ 75 MG)	DR. SARAH E. SCARFE	LONDON DRUGS #56 604-570-0252 PRESCRIBED TO DECEDENT, CANADIAN PHARMACY

Paraphernalia Description

1- PILL CUTTER, TWO PILL CASES, ONE DIVIDED PILL CASE. 5 PRESCRIPTION RECEIPTS AND PERSONAL MEDICATION HISTORY WERE PLACED IN CASE FILE.

Investigator: *D. Bestone*
 KELLY YAGERTNER (489129)

Date: 2/22/2013

3A

CASE # 2013-01364
 DECEDENT'S NAME:
 LAM, ELISA
 DOD: 2/19/2013
 INCOMING MODE:

Drug Name	Rx Number	Date of Issue	Number Issued	Number Remaining	Form	Dosage	Rx Directions	Physician	Pharmacy Phone/ Comments
VENLAFAXINE XR 75 MG	7153989	1/11/2013	60	60	CAPSULE	75 MG	1 CAP QD (+ 150 MG)	DR. SARAH E. SCARFE	LONDON DRUGS #56 604-570-0252 PRESCRIBED TO DECEDENT, CANADIAN PHARMACY
WELLBUTRIN XL	7153987	1/11/2013	60	57	TABLET	300 MG	1 TAB QAM	DR. SARAH E. SCARFE	LONDON DRUGS #56 604-570-0252 PRESCRIBED TO DECEDENT, CANADIAN PHARMACY
<p>Paraphernalia Description 1- PILL CUTTER, TWO PILL CASES, ONE DIVIDED PILL CASE. 5 PRESCRIPTION RECEIPTS AND PERSONAL MEDICATION HISTORY WERE PLACED IN CASE FILE.</p>									
									<p>Investigator: <i>D. Beaton</i> KELLY YAGERLENER (489129)</p> <p>Date: 2/22/2013</p>

3A

CASE # 2013-01364
 DECEDENT'S NAME: LAM, ELISA
 DOD: 2/19/2013
 INCOMING MODE:

Drug Name	Rx Number	Date of Issue	Number Issued	Number Remaining	Form	Dosage	Rx Directions	Physician	Pharmacy Phone/ Comments
ADVIL	LOOSE			11	CAPSULE	200 MG			LOOSE PILLS
DEXEDRINE SPANSULE	LOOSE			2	CAPSULE	10 MG			LOOSE PILLS
LAMOTRIGINE	7153988	1/11/2013	60	70	TABLET	100 MG	1 TAB QD	DR. SARAH E. SCARFE	LONDON DRUGS #56 604-570-0252 PRESCRIBED TO DECEDENT, CANADIAN PHARMACY
QUETIAPINE	7153992	1/11/2013	30	20	TABLET	25 MG	2 TABS QHS PRN	DR. SARAH E. SCARFE	LONDON DRUGS #56 604-570-0252 PRESCRIBED TO DECEDENT, CANADIAN PHARMACY
SINUTAB	LOOSE			2	TABLET				LOOSE PILLS- BLISTER PACK LOT 16112
VENLAFAXINE XR	7153990	1/11/2013	60	64	CAPSULE	150 MG	1 CAP QD (+ 75 MG)	DR. SARAH E. SCARFE	LONDON DRUGS #56 604-570-0252 PRESCRIBED TO DECEDENT, CANADIAN PHARMACY

Paraphernalia Description
 1- PILL CUTTER, TWO PILL CASES, ONE DIVIDED PILL CASE. 5 PRESCRIPTION RECEIPTS AND PERSONAL MEDICATION HISTORY WERE PLACED IN CASE FILE.

Investigator: *DBailey*
 KELLY YAGERLENER (489129)

Date: 2/22/2013

3A

CASE # 2013-01364
 DECEDENT'S NAME:
 LAM, ELISA
 DOD: 2/19/2013
 INCOMING MODE:

Drug Name	Rx Number	Date of Issue	Number Issued	Number Remaining	Form	Dosage	Rx Directions	Physician	Pharmacy Name/ Comments
VENLAFAXINE XR 75 MG	7153989	1/11/2013	60	60	CAPSULE	75 MG	1 CAP QD (+ 150 MG)	DR. SARAH E. SCARFE	LONDON DRUGS #56 604-570-0252 PRESCRIBED TO DECEDENT, CANADIAN PHARMACY
WELLBUTRIN XL	7153987	1/11/2013	60	57	TABLET	300 MG	1 TAB Q AM	DR. SARAH E. SCARFE	LONDON DRUGS #56 604-570-0252 PRESCRIBED TO DECEDENT, CANADIAN PHARMACY

Paraphernalia Description
 1- PILL CUTTER, TWO PILL CASES, ONE DIVIDED PILL CASE. 5 PRESCRIPTION RECEIPTS AND PERSONAL MEDICATION HISTORY WERE PLACED IN CASE FILE.

Investigator: **D Bertone**
 KELLY XAGERRENER (769129)
 Date: 2/22/2013



Department of Coroner, County of Los Angeles
FORENSIC SCIENCE LABORATORIES

1104 North Mission Road Los Angeles, CA 90033



Laboratory Analysis Summary Report

Wang, Yulai M.D.

Deputy Medical Examiner
 1104 North Mission Road
 Los Angeles, CA 90033

PendingTox

The following results have been technically and administratively reviewed and are the opinions and conclusions of the Analyst:

Coroner Case Number: 2013-01364 **Decedent:** LAM, ELISA

<u>SPECIMEN</u>	<u>SERVICE</u>	<u>DRUG</u>	<u>RESULT</u>	<u>ANALYST</u>
Bile	Alcohol-GC/FID-HS	Ethanol	0.02 g%	M. Schuchardt
Blood, Heart	Alcohol-GC/FID-HS	Ethanol	Negative	M. Schuchardt
	Bases-GC/NPD &/or MS	Bupropion	ND	E. Fu
	Bases-GC/NPD &/or MS	Bupropion Metabolites	* Present	E. Fu
	Bases-GC/NPD &/or MS	Quetiapine	ND	E. Fu
	Bases-GC/NPD &/or MS	Quetiapine Metabolite	ND	E. Fu
	Bases-GC/NPD &/or MS	Venlafaxine	* Present	E. Fu
	ELISA-Immunoassay	Barbiturates	ND	B. Ciullo
	ELISA-Immunoassay	Cocaine and Metabolites	ND	B. Ciullo
	ELISA-Immunoassay	Fentanyl	ND	B. Ciullo
	ELISA-Immunoassay	Marijuana: Carboxy-THC	ND	B. Ciullo
	ELISA-Immunoassay	Methamphetamine & MDMA	ND	B. Ciullo
	ELISA-Immunoassay	Opiates: Codeine & Morphine	ND	B. Ciullo
	ELISA-Immunoassay	Opiates: Hydrocodone & Hydromorphone	ND	B. Ciullo
	ELISA-Immunoassay	Phencyclidine	ND	B. Ciullo
	GC/MS	Amphetamine	ND	C. DalChele
	GC/MS	Methylenedioxyamphetamine	ND	C. DalChele
	Neutrals-GC/MS	Ibuprofen	QNS	S. Pearring
	Neutrals-GC/MS	Lamotrigine	QNS	S. Pearring
Liver	Bases-GC/NPD &/or MS	Bupropion Metabolites	Present	E. Fu
	Bases-GC/NPD &/or MS	Venlafaxine	5.2 ug/g	E. Fu
	Neutrals-GC/MS	Ibuprofen	ND	S. Pearring
	Neutrals-GC/MS	Lamotrigine	14 ug/g	S. Pearring


SPECIMEN SERVICE DRUG RESULT ANALYST

NOTE: *Volume not sufficient for quantitation.

Legend:		mg/dL	Milligram per Deciliter	QNS	Quantity Not Sufficient
g	Grams	mg/L	Milligram per Liter	TNP	Test Not Performed
g%	Gram Percent	ND	Not Detected	ug	Micrograms
Inc.	Inconclusive	ng/g	Nanograms per Gram	ug/g	Micrograms per Gram
mg	Milligrams	ng/mL	Nanograms per Milliliter	ug/mL	Microgram per Milliliter

In accordance with the Department's Evidence Retention Policy, the blood specimen(s) will be retained for one-year and all other specimens for six-months from Autopsy.

Administratively reviewed by:



Daniel T. Anderson, M.S., FTS-ABFT, D-ABC
Supervising Criminalist II
TOXICOLOGY

(323) 343-0660 Danderson@coroner.lacounty.gov

Handwritten initials and date: 4/1/13
Handwritten initials: SW