


UC-NRLF



B 4 601 030

Commoner Diseases of the Eye *

WOOD and WOODRUFF.



THE COMMONER DISEASES OF THE EYE

How to Detect and How to Treat Them.

FOR STUDENTS OF MEDICINE

With 250 Illustrations, many of them original, of which
seven are colored plates.

— BY —

CASEY A. WOOD, C. M., M. D., D. C. L.

Professor of Clinical Ophthalmology in the University of Illinois; Professor of Ophthalmology in the Post Graduate School, Chicago; Ophthalmic Surgeon to St. Luke's Hospital, Chicago; Consulting Ophthalmologist to the Emergency and St. Anthony's Hospital, Chicago; Ex-Chairman of the Ophthalmic Section, American Medical Association; Fellow of the American Academy of Medicine; *Mitglied der Ophthalmologischen Gesellschaft*, etc.

AND

THOMAS A. WOODRUFF, M. D., C. M., L. R. C. P., London.

Professor of Ophthalmology in the Post Graduate Medical School, Chicago; Ophthalmic Surgeon to St. Luke's Hospital and Dispensary and St. Anthony de Padua Hospital, Chicago; Fellow of the American Academy of Medicine; Editorial Secretary of the *Ophthalmic Record*; *Mitglied der Ophthalmologischen Gesellschaft*, etc.



CHICAGO:
G. P. ENGELHARD & COMPANY,
1904.

Copyright 1904,
BY G. P. ENGELHARD & CO.

PREFACE.

Some years ago one of us ventured to write a short treatise entitled Lessons in the Diagnosis and Treatment of Eye Diseases. In the present volume it is intended to amplify this work so that *it shall consider ophthalmology from the standpoint of the physician in general practice*. It is proposed, mainly by describing only the commoner diseases of the eye (never using a technical term when a simpler word is available), by numerous illustrations, synopsis-headings, and a complete reference-index, to popularize a study that is too often considered difficult and unprofitable.

We are well aware that the conduct of the busy practitioner toward such ocular affections as occur in his practice usually differs from his treatment of most other diseases. The acquirement of even a moderate degree of knowledge respecting diseases of the eye—especially those requiring the use of the ophthalmoscope—necessitates considerable study and frequent chances for observation. The every-day routine of practice affords neither opportunities for the one nor time for the other, and it is not, therefore, surprising that such cases are usually referred to a confrère who makes a special study of them.

While one must admit the advantages that, on the whole, accrue to both patient and medical man

from such a disposition of this class of maladies, it is not without its drawbacks.

There is a fairly well-defined and important group of diseases, affecting various parts of the visual apparatus, whose signs and symptoms are especially prone to be overlooked or misinterpreted by the general practitioner simply because he has abandoned the inspection of the eye. In this group are some that call for recognition in tones so loud that they ought to be detected at once by any man who will use his ordinary powers of observation, while others require stricter attention upon the part of the observer. Many of them, too, are by no means simple matters. When not recognized and promptly treated by the surgeon, they go on, in the ordinary course of events, either to a more or less rapid destruction of the organ itself, or to considerable impairment of its function. The claims which the study of this particular set of diseases makes upon the profession become all the more urgent when one reflects that in every instance an early diagnosis may be correctly made by the exercise of the same quality and amount of care and intelligence which are commonly brought to the investigation, let us say, of affections of the lungs and uterus.

It is not claiming too much, we are sure, of the *student of medicine* that he should have at least a fairly intimate knowledge of the eye signs and symptoms of disease in general. Chapters

on this important subject have been carefully prepared and profusely illustrated, especial stress being laid upon those evidences of systemic involvement that the ocular structures so commonly exhibit.

For the additional assistance of the student a table of contents, giving the headings of each chapter, as well as a cross (reference) index, have been provided so that any subject treated in this handbook may be readily consulted.

Many of the illustrations are original with us, while a number are borrowed from well known text-books and treatises, to the publishers of which we are greatly indebted for their use.

The chapters on the relations of ophthalmology to general medicine will be found to resemble in treatment the section devoted to that subject in the text-book on Diseases of the Eye edited by Drs. Hansell and Sweet, because they were both written by the same hand.

CASEY A. WOOD,

THOMAS A. WOODRUFF.

Chicago, March 1, 1904.

PREFACE TO THE SECOND EDITION.

The early exhaustion of the First Edition of this manual affords an opportunity for correcting a few errors in the text and adding to it several observations and illustrations that, it is believed, will increase the value of the book to students and practitioners.

Many new cuts have been prepared especially for this work, from original drawings and photographs, by the well-known Chicago author-artist, Dr. J. F. Burkholder.

C. A. W.

T. A. W.

Chicago, September 1, 1904.

TABLE OF CONTENTS.	PAGE
CHAPTER I.	
METHODICAL EXAMINATION OF THE EYE.	
Inspection of the eye—How to evert the lids— Has the patient "crossed eyes" or squint? —Has he ulcer of the cornea?—How to examine the eyes of children without hurt- ing them—The pupil reflexes—The oblique illumination with a lens—The tension or hardness of the eyeball—How to determine the visual acuity or amount of sight—Test types for distant and near vision—How to measure the field of vision with the perim- eter—Color vision and color blindness and how to test them.....	23-56
CHAPTER II.	
THE NORMAL, THE FARSIGHTED, THE SHORT- SIGHTED AND THE ASTIGMATIC EYE.	
The normal or emmetropic eye—The abnormal or ametropic eye—The differences between these lie mainly in their shape and size— How the eye focuses or accommodates— Presbyopia or old sight—The path of visual sensations from the retina to the brain—Hypermetropia or farsight, due to abnormally small eyes—Aphakia, absence or loss of the lens—Myopia or shortsight, in which the eyeball is enlarged—How abuse of the eyes causes the eye-coats to stretch—Astigmatism, or abnormal shape of the cornea or crystalline lens—The as- tigmatic chart—How to correct with lenses errors of refraction resulting from these abnormal conditions.....	57-80

CHAPTER III.

PAGE

THE MEASUREMENT OF AMETROPIA—THE FITTING OF GLASSES—THE OPHTHALMOSCOPE.

- Objective and subjective methods of measuring the refraction—The "test case" used for the subjective determination of ametropia—Fitting of glasses not an easy task—Symptoms of eye strain—The ophthalmometer, or measurer of corneal astigmatism—The ophthalmoscope and how to use it—Its value in the diagnosis of ocular disease—Why it should be in the hands of every physician—Skiascopy, retinoscopy or the "shadow test" the best objective means for measuring refractive errors—How to employ it in the various kinds of ametropia..... 81-102

CHAPTER IV.

THE COMMONER DISEASES OF THE EYELIDS.

- The anatomy of the lids—How they protect, lubricate and cleanse the front of the eyeball—The tarsus, the cilia and the Meibomian glands—"Black eye"—Styes—Chalazion or Meibomian cyst and how to remove it—Blepharitis—Eczema of the lid edges—Entropion—How to do a canthoplasty—Other operations for entropion and trichiasis—Ectropion and operations for its relief—Ptosis, or drooping of the upper lid, and how to treat it—Lagophthalmus — Symblepharon..... 103-136

CHAPTER V.	PAGE
THE COMMONER DISEASES OF THE CONJUNCTIVA.	
Anatomy—Hyperemia of the conjunctiva and its treatment—Acute conjunctivitis—The various infections of the conjunctiva and their bacterial causes—The pneumococcus, Koch-Weeks bacillus, streptococcus, staphylococcus, gonococcus, Morax-Axenfeld diplobacillus and other sources of conjunctivitis—"Pink eye"—The treatment of infectious diseases of the conjunctiva—Ophthalmia Neonatorum the commonest and most serious eye disease of infancy—How to treat it—Gonorrhoeal conjunctivitis in the adult.....	137 166

CHAPTER VI.

THE COMMONER DISEASES OF THE CONJUNCTIVA.
(Continued)

Follicular conjunctivitis and its treatment—Trachoma, the most serious form of granular lids—How it produces blindness—Its many complications—Treatment—"Spring" catarrh—Phlyctenular conjunctivitis and its treatment—Pterygium, its cause and treatment—Pinguecula.....	167-186
---	---------

CHAPTER VII.

THE COMMONER DISEASES OF THE CORNEA.

Anatomy and physiology—Ulcer of the cornea generally due to removal of protecting epithelium and subsequent infection—The pneumococcus—Deep ulcer—Hypopyon—Perforation of the cornea—Treatment—Serpent or spreading ulcer—Ring ulcer at	
---	--

the margin of the cornea—Neuroparalytic ulcer—Herpes of the cornea—Phlyctenular keratitis, a common disease of childhood—Treatment of the foregoing—Interstitial or parenchymatous keratitis—It occurs mostly in children and is due to syphilis or struma—Punctate keratitis, a sign of disease of the choroid or ciliary body—Opacities of the cornea and their treatment—Nebula, macula and leucoma—Artificial pupil—Optical iridectomy—Iridotomy—Tattooing the cornea—Conical cornea and how to treat it..... 187-230

CHAPTER VIII.

THE COMMONER DISEASES OF THE IRIS.

Anatomy and physiology—What produces the color of the iris—The pupil—The uveal tract—Acute iritis—Usually due to rheumatism or syphilis—Posterior synechia, or adhesions of the iris to the lens—How to distinguish iritis from conjunctivitis—Treatment of iritis very satisfactory if given early—Cyclitis or inflammation of the ciliary body..... 231-244

CHAPTER IX.

GLAUCOMA—HOW TO DISTINGUISH THE VARIOUS INFLAMMATORY DISEASES OF THE EYE.

Primary glaucoma—An affection of the intraocular drainage system—The acute form of the disease—Liable to be mistaken for supraorbital neuralgia—The practitioner should always be on the lookout for it—Symptoms of acute glaucoma

	PAGE
—Hardening of the eyeball—Chronic glaucoma—The lesions in this disease—Treatment—Scleritis and episcleritis—An easy method of diagnosing the commoner forms of inflammation of the eye—How to decide whether the inflamed eye is a serious or a simple matter.....	245-268

CHAPTER X.

THE COMMONER DISEASES OF THE LACHRYMAL APPARATUS.

The course of the tears from the ducts of the lachrymal gland to the inferior nasal meatus—The anatomy of the lachrymal apparatus—Difference between epiphora and lachrymation—Acute and chronic dacryocystitis practically always due to obstruction of the lachrymal passages—Diagnosis, symptoms and treatment of lachrymal stricture—Passing lachrymal probes—The lachrymal syringe—Extirpation of the sac and removal of the lachrymal gland.....	269-284
--	---------

CHAPTER XI.

CATARACT AND OTHER AFFECTIONS OF THE CRYSTALLINE LENS.

The crystalline is suspended from the ciliary body behind the lens, in front of the vitreous—Dislocation of the lens—Aphakia or absence of the lens—The various kinds of cataract—The senile variety the commonest and most important—Hard and soft cataract—The lens an epithelium structure within an unyielding cap-	
---	--

	PAGE
sule, grows heavier, larger and less transparent with age—Diagnosis of cataract—Operations for removal—Iridectomy—Contraindication for operation—Extraction of senile cataract—After treatment..	285-316

CHAPTER XII.

THE COMMONER INJURIES OF THE EYELIDS, CON-
JUNCTIVA, IRIS, CORNEA, LENS, SCLERA
AND CHOROID.

Injuries to the lids frequently seen—What constitutes a “black eye”—How to treat it—Incised and other wounds of the lids—Injuries of the conjunctiva—Symblepharon—Burns and other injuries of the cornea and how to manage them—Contusions of and blows upon the eyeball—Hyphemia—Iridodialysis or rupture of the iris—Dislocation of the lens—Deep injuries to the eye, such as rupture of the choroid—Rupture of the eyeball—Sympathetic ophthalmia may follow penetrating wounds, especially of the ciliary region—Injuries of the cornea and how to deal with them—The electro-magnet the most useful means for the extraction of iron and steel from the interior of the eyeball—Migratory, or sympathetic, ophthalmia due to infection of the second eye by microbes and toxins from the injured eye	317-340
--	---------

CHAPTER XIII.

PAGE

HOW TO PRESERVE THE EYESIGHT—THE FUNDAMENTALS OF OCULAR HYGIENE.

- A knowledge of the principles of ocular hygiene necessary to every well informed physician—Care of children's eyes—Stupid pupils often children that are half blind or half deaf—At what age shall a child be sent to school?—The building of school houses and the arrangement of the rooms—Measurements and lighting of the ideal or standard schoolroom—Window shades, blackboards, seats, desks and schoolbooks should be chosen with due regard to the pupils' eyesight—What colors should be used in painting the schoolroom?—The hygiene of adult eyesight—The illumination of offices, public buildings and private houses—The position of the reading lamp—When to avoid the use of the eyes for reading—Dotted veils a cause of eye-strain—Rules for artificial illumination 341-356

CHAPTER XIV.

THE COMMONER DISEASES OF THE OPTIC NERVE, ITS PERIPHERAL AND CENTRAL CONNECTIONS.

The retina an expanded layer of optic nerve tissue—The structure and important parts of the retina—The retinal circulation—The physiology of peripheral vision—The blind spot of Mariotte—The orbital and intracranial divisions of the optic nerve and their cerebral relations—The cortical

center for sight occupies the sides of the calcarine fissure in the occipital lobe—Eye signs of brain tumor—"Choked disk" and its meaning—Its value very great as a symptom of brain disease—Eye signs of meningitis—Blindness from epidemic cerebrospinal meningitis—Pseudo-glioma—Ocular symptoms of multiple sclerosis and tabes dorsalis—Argyll-Robertson pupil—Hereditary ataxia or Friedreich's disease	357-374
---	---------

CHAPTER XV.

OPHTHALMOLOGY IN GENERAL MEDICINE AND SURGERY.

Why the student of general medicine should study the eyesigns of disease—The extreme importance of ocular symptoms in general diagnosis—The eye symptoms (toxic amblyopia) set up by indulgence in tobacco and alcohol, by lead poisoning and by methyl alcohol—The treatment of toxic amblyopia—Ocular rheumatism—The eye signs of gout, gonorrhoea, measles, syphilis, dyspepsia and diseases of the reproductive organs—Affections of the eye in tuberculosis, simple anemia, leukemia, hemorrhages, nasal diseases and diseases of the ear.....	375-386
---	---------

CHAPTER XVI.

THE OCULAR COMPLICATIONS OF CERTAIN SYSTEMIC DISEASES.

The ocular lesions that accompany or follow smallpox, e. g., ulcer of the cornea—The

oculomuscular pareses of diphtheria—The eye complications of influenza, malaria, typhoid fever, rickets and diseases of the vascular system—Retinal pulsations in aortic insufficiency—Retinal embolism and thrombosis 387 396

CHAPTER XVII.

HEADACHE FROM EYE STRAIN—OCULAR HEADACHE—THE OCULAR SIGNS OF CERTAIN GENERAL DISEASES.

Headache from eye strain very common—Nearly always a frontal headache—Causes of ocular headache—How to distinguish an eye headache from others that resemble it—Treatment of it—Exophthalmic goitre, Graves' or Basedow's disease—The eye signs very important and valuable in diagnosis—The ocular signs in epilepsy—Migraine not an affection of the visual apparatus although it usually presents characteristic eye symptoms—The ocular signs of hysteria—Reversal of the color field—Hysterical amblyopia—Monocular diplopia—Hysterical photophobia and blepharospasm—Traumatic hysteria—The eye symptoms of Bright's disease—Albuminuric retinitis—The ocular signs of diabetes—Diabetic cataract—The commoner tumors of the eye—Glioma retinae 397-424

CHAPTER XVIII.

THE COMMONER DISEASES OF THE EYE MUSCLES. Anatomy and physiology—The rotation center of the eyeball—Six orbital and two

intraocular muscles—How to memorize their nerve supply as an aid to the diagnosis of cerebral and spinal lesions—Heterophoria and its meaning—The various forms of muscular imbalance—Tests for and treatment of heterophoria—Squint or strabismus—How it differs from paralysis of the eye muscles—Convergent and divergent squint—Symptoms and treatment—Tenotomy and advancement of the external ocular muscles—Paresis and paralysis of the eye muscles—Double vision and vertigo the chief symptoms—Syphilitic and rheumatic lesions the chief causes—Peripheral and central forms of the disease—Tabes and diphtheria—Treatment—Nystagmus and its causes.....	425-450
---	---------

CHAPTER XIX.

THE COMMONER PATHOGENIC BACTERIA THAT INVADE THE EYE.

Numerous bacteria, pathogenic and benign, inhabit the normal conjunctival sac—Slight traumatisms or local irritations permit them or their toxins to invade the tissues beneath the protecting epithelium—They constitute an important cause of ocular inflammations—The staphylococcus—The streptococcus—The gonococcus of Neisser the special cause of gonorrhoeal conjunctivitis in adults and in ophthalmia neonatorum—The pneumococcus the special bacterium of spreading ulcer of cornea—The Koch-Weeks bacillus responsible for “pink eye”—It is doubtful whether

CONTENTS

21

PAGE

the trachoma bacillus has been isolated—
Mixed infections—Toxins often as viru-
lent as the bacteria that excrete them—
The environment of much importance in
determining the virulence of bacteria.... 451-456

CHAPTER XX.

REMEDIES COMMONLY USED IN OPHTHALMIC
PRACTICE.

Local blood-letting—Leeches, natural and art-
ificial—The application of dry and moist
heat—This remedy mostly used in deep-
seated inflammation of the eye—The use
of cold—Moderately cold applications in
superficial ocular inflammation—Massage
of the lids over the eyeball—Subconjunc-
tival injections—How to irrigate the eye
—The use of the medicine dropper—How
to instill single drops—Poultices rarely
useful in eye diseases—The “rest cure” as
applied to the eyes—Protective glasses,
goggles and bandages—Their various
forms and how to apply them—Mydri-
atics and cycloplegics—Cocain, atropin,
euphthalmin and homatropin—Atropin
and other powerful cycloplegics—Miotics
and their uses—Holocain, cocain and
other local anesthetics—Silver nitrate,
argyrol and protargol—Zinc and copper
sulphates—Boric acid, formalin, bichlor-
ide, and other disinfectants—Dionin—Su-
prarenal capsule and its extracts—The
yellow oxide of mercury and its oint-
ments—The preparation of the patient in
ophthalmic operations 457-491

CHAPTER I.

METHODICAL EXAMINATION OF THE EYE.

Inspection of the eye.—How to evert the lids.—Has the patient “crossed eyes” or squint?—Has he ulcer of the cornea?—How to examine the eyes of children without hurting them.—The pupil reflexes.—The oblique illumination with a lens.—The tension or hardness of the eyeball.—How to determine the visual acuity or amount of sight.—Test types for distant and near vision.—How to measure the field of vision with the perimeter.—Color vision and color blindness and how to test them.

Just as one studies the conditions under which the healthy lungs and heart subserve their respective functions before proceeding to an investigation of the departures from health to which these organs are subject, so it is well to make a study of the normal eye. The physician should cultivate this habit of observation in the case of the visual apparatus particularly, because so much information as to its condition—whether normal or abnormal—can always be learned by simple inspection.

To be of the greatest value, *such an examination should be methodical and every case should be examined in the same order.* Of course, where the patient's condition is so obvious that it would be mere waste of time to follow out a program including all the parts of the eye, this rule may be modified; but it is the safest to run

over the whole ground, so far as possible, in the great majority of instances.

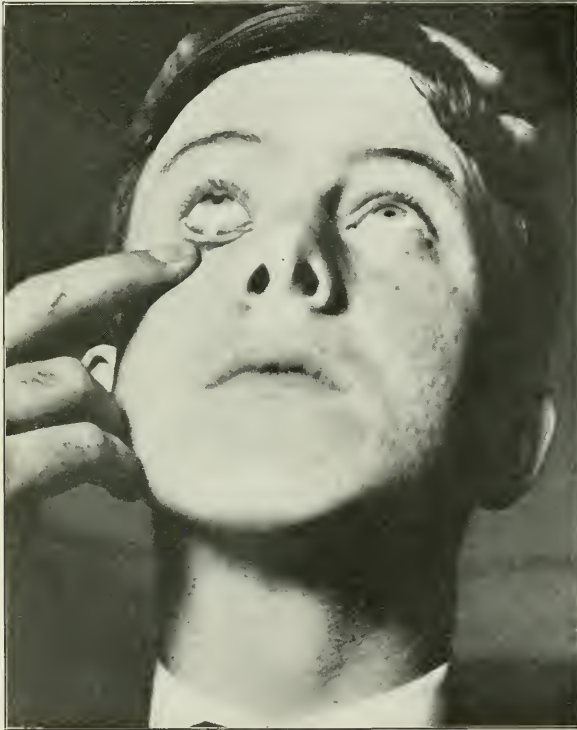The common and probably the best plan that can be adopted is that of proceeding from without inward, bearing in mind, meanwhile, as many as possible of those diseased conditions which one might expect to find in the particular locality under examination.

The objective examination of the eye should be begun by carefully inspecting the superficial structure and parts surrounding that organ. The patient is to be seated in a chair facing a window through which a good illumination can be obtained.

The lids are to be examined for any irregularity in their outline, for distended vessels, edema, thickening, redness or tumors (such as cysts) of the Meibomian glands (*Chalasia*)—and for scales, crusts or ulcerations along their margins (*blepharitis*). It should be noted if they are in close apposition to the eyeball, and whether their margins turn out (*ectropion*), or turn in (*entropion*), or if there is inability to close the lids (*lagophthalmus*), or drooping of the upper lid (*ptosis*).

The cilia or eyelashes should next be inspected to see if any are misplaced, or if they curve inward (*trichiasis*). The position and permeability of the **puncta** should be ascertained. Pressure should be made over the

lachrymal sac in the endeavor to squeeze out through the puncta any fluid (mucus or pus)



Everting the Lower Lid.

that may be retained therein. It should be noted if the conjunctival sac contain any secretion,

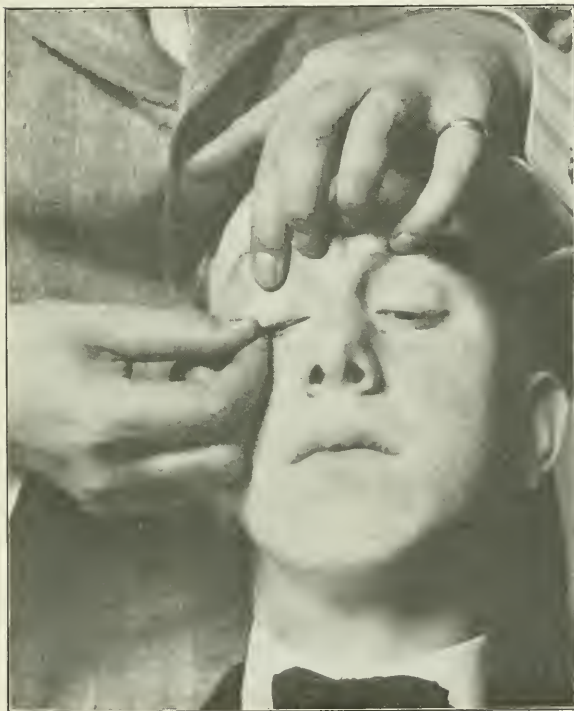and if so whether it is mucous or purulent; whether the tears accumulate in the corner of the eye, overflow and run down over the cheeks (*epiphora*).

For a thorough *examination of the mucous lining of the lids and eyeball (conjunctiva)*, the former should be everted and their inner surfaces inspected for any undue redness, roughness or other abnormality.

The **lower lid is everted** by placing the tip of the thumb upon the skin near its margin and drawing it downward, at the same time pressing backward, and telling the patient to roll the eyeball upward.

The **eversion of the upper lid** is somewhat more difficult, and is accomplished in the following manner. The patient is told *to look down during the whole time required for everting the lid*. The surgeon stands behind the operating chair. The forefinger of the left hand is placed upon the upper lid just below the eyebrow and the lid drawn by the finger tip up and away from the eyeball in such a manner that the cilia point upward. The eyelashes are then grasped by the thumb and forefinger of the opposite hand, without touching the globe. The patient is now directed to continue looking downward, *the lid is drawn down and away from the globe*, while the forefinger, which was in position

below the brow, is slipped to the upper margin of the tarsal cartilage and pressed downward. At

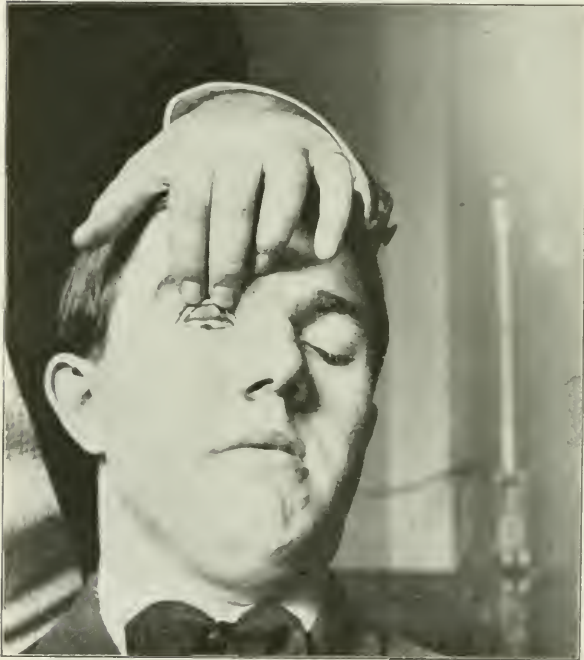

Everting the Upper Lid—First Act.

the same time the lid is quickly turned over the left forefinger nail.

The action of the levator palpebrae and or-

bicularis muscles in opening and closing the lids should also be noted, *at the same time* observing whether the size of the interpalpebral open-



Everting the Upper Lid—Second Act.

ing is normal or not. The eyeball should next be inspected for the purpose of determining the presence of hyperemia or inflammation. If the

congestion be superficial the conjunctival vessels alone are increased in number and size and the redness is most apparent in the retro-tarsal folds and gradually fades out as the cornea and the margins of the lids are approached. If it be deep seated the deep vessels in the sclera surrounding the cornea are enlarged, giving a pink or rosy hue to the area immediately encircling the cornea (*pericorneal injection*), indicating an inflammation of the cornea, iris or ciliary body.

Any edema of the conjunctiva (*chemosis*) should be noted. This does not, except in severe cases, reach the corneal margin, although it sometimes affects the whole of the ocular conjunctiva. The position of the eyeballs in the orbit should be observed, whether they are too prominent (*exophthalmus*) or sink into the orbit (*enophthalmus*). To decide whether there is any deviation of the visual axis, the patient is directed to look at the tip of a finger held about one foot in front of the eyes. If one eye turn in more than the other there is *convergence*, ("crossed eyes," *convergent squint*, *convergent strabismus*); if one turns out, there is *divergence* (*divergent squint*). If there be loss of motion in any direction, tested by asking the patient to closely watch the finger end as it is moved down and up, in and out, there

is *paralysis* of some one or more of the ocular muscles.

Inspection of the cornea will show any abnormalities present. By reflecting the image of



Placido's Disk for Examining the Cornea.

the window on the cornea (*corneal reflex*), any irregularity of its surface, as from an ulcer or foreign body, will be readily observed. Deep

scars resulting from old inflammations or ulcers will also cause a distortion of the image as reflected on the corneal surface. *Placido's disc*, which consists of alternate black and white circles having a hole at the center, may also be employed for detecting corneal inequalities. The patient is placed with his back to the window and the observer looks through the small hole in the center of the disc, at the same time re-



Method of Using Placido's Disk. (Lang.)

flecting the disc image on the cornea. If the patient looks in various directions the whole surface of the cornea can be examined and any distortion or breaking of the circles, as reflected

on the mirror-like surface of the cornea, will show an irregularity.

Ulcers and *abrasions* of the cornea will be more clearly demonstrated by instilling into the eye a drop or two of a two per cent solution of potassic fluorescein:

Fluorescein	gr. 8
Liq. potassæ	dr. ½
Aquæ dest.	oz. 1

This stains the local lesion a bright yellow-green and accurately maps out the disturbed area. Ulcers are usually replaced by scars of various density. When very faint and superficial the opacity is called a *nebula*, when somewhat denser it is a *macula*, and when very dense and white it is called a *leucoma*. The *sensibility of the cornea* may be tested by gently touching it with a piece of absorbent cotton twisted to a fine point.

A proper examination of the cornea may be rendered difficult and almost impossible by spasm of the lids (*blepharospasm*) due to various causes—inflammation, nervous reflex, or swelling of the lids. In such cases a few drops of a four per cent solution of cocain will usually overcome the difficulty. If it fails the lids will have to be separated by placing the thumbs near their margins and opening them by using gentle pressure, pushing them backwards toward the orbital margins, at the same time

keeping them in contact with the eyeball. Care must be taken that the thumbs are well applied to the lid edges or they will become everted and prevent all view of the parts to be inspected.

Any decided pressure upon the eyeball must be avoided owing to the danger of perforation that may ensue in case a deep ulcer of the cornea is present. In some cases it may be necessary (especially with children) to use a *retractor*



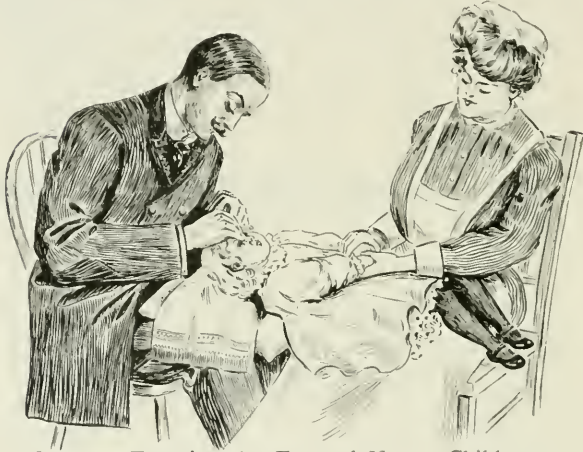A Lid Retractor.

in order to separate the lids, in which case care must be exercised not to scrape off a portion of the corneal epithelium. When force has to be used for this purpose the surgeon must remember that the secretion may suddenly squirt out and get into the observer's eyes.

In young children where much *difficulty is experienced in examining the cornea* the child should be laid across the nurse's lap in such a way that its legs are between her body and left arm, her right hand being used to control the child's hands. The examiner sits opposite with a towel or rubber sheet across his lap and places the child's head between his knees. In this way the child is prevented from kicking and struggling, and its head is held steady, leaving the

examiner's hands free to separate the lids, make the necessary examinations and apply the proper remedies.

In observing the anterior chamber its depth should be noted, remembering that it is more



How to Examine the Eyes of Young Children.

shallow than usual in early infancy and old age. The *aqueous humor* in the normal state is clear, but may be turbid and contain pus (*hypopyon*) or colored blood (*hyphema*) in diseased states.

The *iris* may be blue, brown, gray, or a mixture of yellow and green. Children at birth usually have irides of a bluish shade, which generally changes during the first few months of life. The color depends upon the amount of pigment in the stroma of the iris. The *pupil* is

round and, in health, about 4 mm. in diameter. Its size chiefly depends upon the amount of light admitted into the eye, being small when exposed to strong light, or when focused for near objects, and larger when the illumination is much diminished. The size of the pupil can be de-



A Pupilometer.

termined by a *pupilometer*. The *reaction of the pupil*, or, more correctly, the mobility of the iris, should be ascertained by directing the patient to look out, at a window, and then, shading both eyes with the hand, the pupil will be seen to dilate. When the hand is removed it will contract. Reaction of each pupil should also be tried separately. If this dilatation and contraction occur in the opposite eye *when it is covered* or blind, the pupils are said to react consensually.

The contraction of the pupils to accommodation should be tested by having the patient first look off into space in a moderately lighted

room and then direct the gaze at the point of a pencil or the end of the finger at a distance of about twelve inches. Normal reaction will show that the pupils contract when the gaze is directed at the near point. Failure of the pupil to react to light while reacting to accommodation is called the *Argyll-Robertson pupil*, and is an early

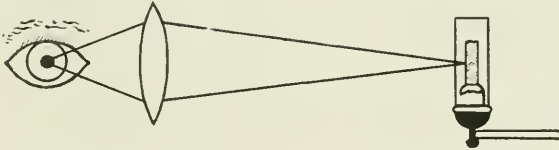


Convex Lens for Oblique Illumination of the Eye.

symptom of locomotor ataxia. Irregularity in the shape of the pupil is usually abnormal. In most cases it is due to adhesions of the iris either to the anterior capsule of the lens (*posterior synechia*) or to the cornea (*anterior synechia*).

Directly behind the pupil is the central portion of the lens.

Oblique Illumination.—The eye should next be examined by means of the oblique illumination. For this purpose it is necessary to have a darkened room. With the light from an ar-



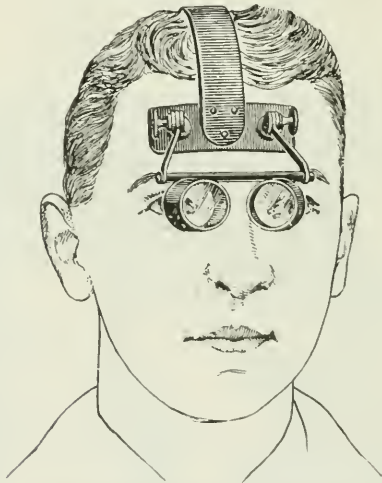Positions of Light and Lens in Oblique Illumination. gand burner or electric lamp placed about two feet to the side and a little to the front and



Method of Using the Oblique Illumination.

above the patient's eye, while he looks straight ahead, the rays are directed upon the cornea

by means of a biconvex lens which has a focus of three inches, that is, the lens is held at such a distance from the eye that the light pencil is focused exactly on the area under examination. The lens is held by its margin with its surface at right angles to the rays of light coming from the source of light. The eye is moved in various directions so that the whole surface of the cornea can be examined. To examine the iris and pupillary area the lens is held some-



Jackson's Binocular Loupe.

what nearer the eye. In this way abrasions, foreign bodies in or opacities of the cornea and changes in the iris are readily detected.

By this method opacities of the cornea or lens and those situated in the aqueous humor appear grayish with the black pupil as a background, and can be easily seen. Every physician should be provided with such a simple and effective means of diagnosis. Oblique illumination may be aided by means of a *corneal loupe*, a compound lens of high magnifying power. This is to be applied to the observer's eye with one hand, while the other directs the illuminating rays upon the corneal surface.

The tension or hardness of the eye is determined by palpating the globe (much as one would to detect fluctuation elsewhere) with the tips of the two index fingers. The patient is asked to look at his feet while the pressure on the eyeball must be directed downward and not backward, as the latter would press the eyeball back into the orbit and the necessary information would not be obtained.

The tension of one eye should be compared with that of the other, or with an eye which is known to be normal. When the tension is normal it is expressed by the sign T_n ; when it varies from the normal by $T + 1, + 2, + 3$, or $T - 1, - 2, - 3$, depending on the amount of increased or diminished resistance. Doubtful tension may be indicated by $T?$

In subjective examinations of the eye the answers given by the patient must, of course.

be relied upon. The questions should, consequently, be as simple and as brief as possible, and "control" queries should be instituted by repeating them when necessary. The amount and



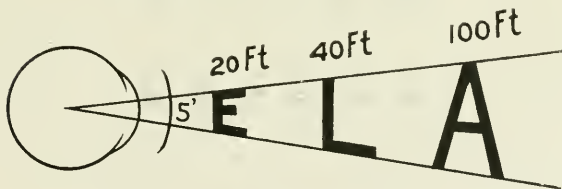
How to Find the Tension of the Eye-Ball.

kind of visual perception is divided into *Form sense*, *Light sense*, *Color sense*.

The Form sense, or the acuteness of vision, is the power the eye possesses of observing the shape, size and form of objects.

When a clear image of an object is desired, the individual looks directly at it so that the rays of light fall on the retina at the *macula lutea*, that being the point of most acute vision. This is called *central vision*. The acuity of central vision is tested for both distant and near objects.

To determine the distant vision the patient is placed six meters or twenty feet from and facing the test types, with his back to the window, if the illumination be from that source, although artificial light is usually employed and arranged in such a way that it falls directly upon the test letters. The letters used are of various sizes and are known as *Snellen's test types*. They consist of square letters so constructed as to subtend an angle of five minutes at the distance at which they should be seen



Relative Size of Snellen's Test Letters.

by the normal eye. Each part of the letter and each space are equal to one-fifth of the whole and subtend an angle of one minute.

200

Z

100

S A

70

P X E

50

K F O L

40

R B T V Z

30

N S P L H 4

20

F E O D G Z 3

10

P S L N H 4

80

C E Z F O D 3

Snellen's Test Types.

The reason the test types are situated twenty feet or six meters in front of the patient is that rays of light which enter the eye from this distance are practically parallel. The largest letter is of such a size that it should be read at



A Single Test Letter.

200 feet, or sixty meters, and those following decrease in size from above downwards, and should be read at 100, 70, 50, 40, 30, 20 feet, or their corresponding values in meters, respectively.

Each eye should be tested separately, and the result expressed by a formula in which V stands for vision. This is expressed by a fraction in which the numerator corresponds to the distance the patient is seated from the test types and the denominator the distance at which the letters should be read by the normal eye.

If the patient seated at twenty feet from the test type reads the letters numbered 20, then

$$V = \frac{20}{20}$$

or is normal. If he cannot read smaller letters than those numbered 50 (letters which should be seen by the normal eye at 50 feet)

$$V = \frac{20}{50}$$

If the patient seated at twenty feet is unable to read the large letter which should be seen at 200 feet, he walks toward the chart until the distance is reached at which he reads this largest letter. If, for example, it is ten feet, then

$$V = \frac{10}{200}$$

the numerator being the farthest distance from the chart at which he can read the largest letter.

When the patient's vision is so poor that he is unable to recognize the large letter at any distance, the distance is obtained at which he is able to count the examiner's fingers held against a black background. Suppose he is able to do this at ten inches or twenty-five centimeters, then $V =$ "counting fingers" at that distance. If he is unable to count fingers, the hand is moved in different directions in front of the eye, and the patient required to tell in what direction it is moved. If he is able to do this, $V =$ hand movements. If there is inability to distinguish hand movements, the eyes are alternately covered and uncovered, and if he is able to perceive the difference between light and darkness, $V =$ light perception (p. 1.).

If the patient is illiterate, test types are used in the form of E's, in which the openings are

D=48.

E

D=25.

Э W

D=20.

E W Э

D=15.

E W Э M

D=10.

W Э W E M

D=8.

Э E M Э W M

D=6.

E Э M M W E W

METRA.

Test Types for Illiterate Patients.

turned in various directions and the smallest row where he is able to detect the openings indicates the visual acuity.

In testing near vision the patient is seated in a good light and each eye is also tested separately. *Useful* test types consist of the various sizes of ordinary printer's type, technically called Jaeger's test types, the smallest corresponding to diamond print. More scientific and accurate are those corresponding with Snellen's distance types. The former are numbered 1, 2, 4, etc., according to the size of the type. If these are used and the patient reads the finest print at the ordinary reading distance, 10-13 inches, $V=J_i$; if he reads that numbered 4, $V=J_{iv}$, etc.

Accommodation.—When an eye is at rest rays coming from a distant object (20 feet) are practically parallel, and are focused on the retina. Rays from a point nearer than 20 feet are more divergent and are focused behind the retina, causing a blurred image. In order that these divergent rays may be brought to a focus on the retina the eye must so increase its refractive power that the image of a near object focuses exactly at the macula lutea and forms a clear and distinct picture. The change that in this way takes place is called the *accommodation*. It is brought about by a contraction of the ciliary muscle which relaxes the suspensory ligament and allows the crystalline lens to become

more convex. The lens is most elastic and flexible in early childhood. Each year it loses a certain amount of elasticity until about 60 years of age it fails to respond to the contractions

Corresponding to the "Schrift-Scalen" of Prof. E. JAEGER. *The numbers on the left approximate those calculated by Prof. SNELLEN.*

No. 1—Diamond.

For the three ensuing days I was in a state of anxiety to know what reception my letter might meet with; but in the mean time was frequently solicited by my wife to submit to any conditions rather than remain here, and every hour received repeated account of the decline of my daughter's health. The third day and the fourth arrived but I received no answer to my letter; the complaints of a stranger against a favorite nephew were no way likely to succeed; so that these hopes soon vanished like all my former. My mind however, still supported itself, though confinement and bad air began to make a visible alteration in my health and my arm that had suffered in the fire grew worse. My children, however, sat by

0.5

No. 2—Pearl.

to comfort, to strengthen her, to receive her last wishes, and teach her soul the way to heaven. Another account came—she was expiring, and yet I was debarred the small comfort of weeping by her. My fellow-prisoner, some time after, came with the last account. He bade me be patient—she was dead! The next morning he returned, and found me with my two little ones now my only companions, who were using all their innocent efforts to comfort me. They intreated to read to read to me, and bade me not to cry, for I was now too old to weep. "And is not my sister an

0.6

No. 4—Minion.

think of the rest of my family, and attempt to save my own life, which was every day declining for want of necessaries and wholesome air. He added that it was now incumbent on me to sacrifice any pride or resentment of my own to the welfare of those who depend on me for support; and that I was now, both by reason and justice, obliged to try to reconcile my landlord. "Heaven be praised!" replied I, "there is

The Jaeger and Snellen Test Type for the Reading Distance.

of the ciliary muscle at all and all power of accommodation is lost.

The distance between the point at which an eye can read print distinctly when in a state of rest (*far point*) and that where the maximum power of the accommodation is exerted (*near*

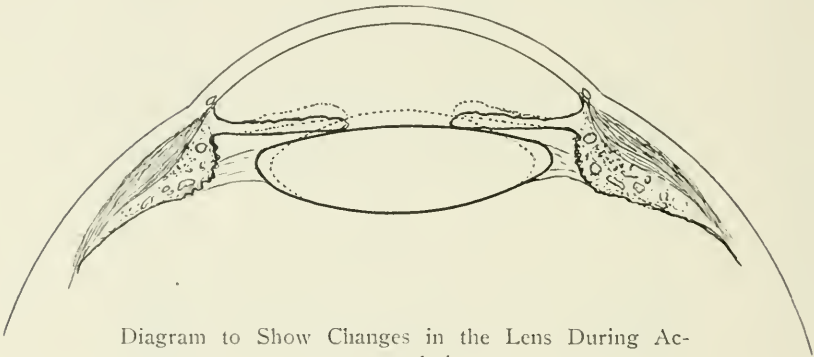
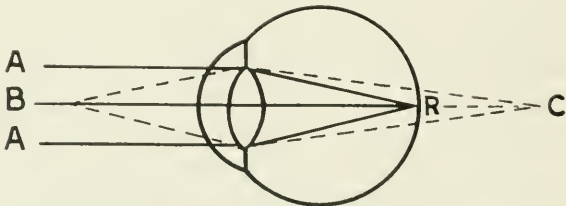


Diagram to Show Changes in the Lens During Accommodation.

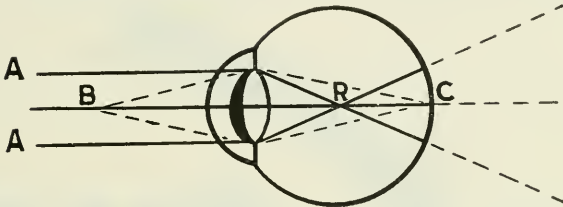
Dotted lines show increase in anterior surface during accommodation.



Eye, with Normal Refraction, at Rest.

point) is called the *amplitude, power or range of accommodation*.

Peripheral vision, that perceived by the



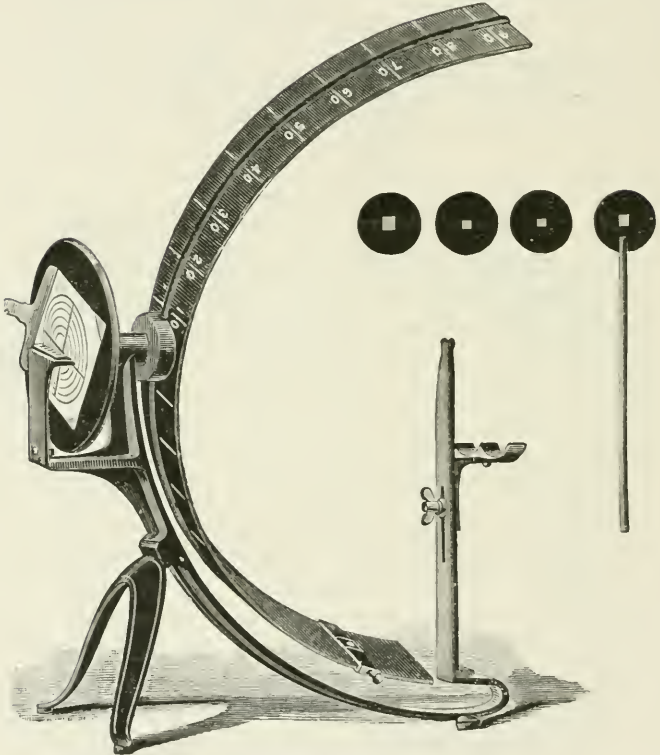
Eye, with Normal Refraction, During Accommodation.

retina remote from the macula lutea, is indistinct but it is important in enabling us to recognize objects in surrounding areas when the eyes are looking directly at an object. It enables us, for example, to guide ourselves while walking through crowds and to avoid other obstacles that may be in our way.

Field of Vision.—The space included in peripheral vision is part of the *field of vision*, which is measured by an instrument called the *perimeter*. The extent of the field of vision varies in the different meridians. Its outward limit is about 90 degrees, its downward about 60 degrees, its inward about 50 degrees and its upward about 55 degrees.

The **perimeter** consists of a semicircular arc or band which revolves upon its center so that it can be placed in the direction of any meridian. This arm is divided into degrees be-

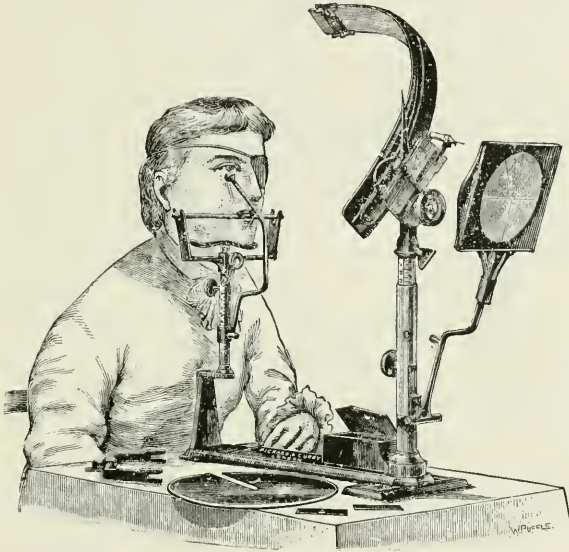
ginning with 0 at the center and extending to 90 degrees at either extremity. At the center of the semicircle is a small object (*fixation*



Perimeter for Measuring Fields of Vision.

point) for the eye to look at. The patient's head is supported by a chin rest, one eye is covered

and that under examination directed to look at the small object at the center of the semicircle. A small white object, about 10 mm. square, is then carried from the periphery along the inner



Method of Examination with the Perimeter.

surface of the arc. The point at which it first comes into view in each meridian denotes the limit of peripheral vision for that meridian. These points (marked on a chart), when joined by lines give the boundary of the field of

vision. If any defect is found in the visual field, the movable object will appear blurred or disappear entirely. This defect is known as a *scotoma*.

A physiological scotoma is present in every field of vision. It corresponds to the optic nerve entrance and is situated about 10 degrees to the outer side of the point of fixation and is known as the *blind spot of Mariotte*. Where a perimeter cannot be obtained the field of vision may be roughly taken with the hand in the following manner: The patient and the examiner face one another, the former with his back to the light. If the left eye is to be tested, the other eye is covered with a towel. The examiner closes his right eye and each looks into the other's eye at a distance of about three feet. The hand is then carried to the periphery of the field at an equal distance between the patient and himself. The hand is then moved slowly inward towards the visual axis and the patient is required to say when he sees the fingers moving. This is repeated in the various meridians of the field of vision. If the patient sees the fingers at the moment they are seen by the examiner, his field of vision is normal. If the fingers are not seen until they are nearer the visual axis than seen by the examiner there is some defect in the patient's field of vision.

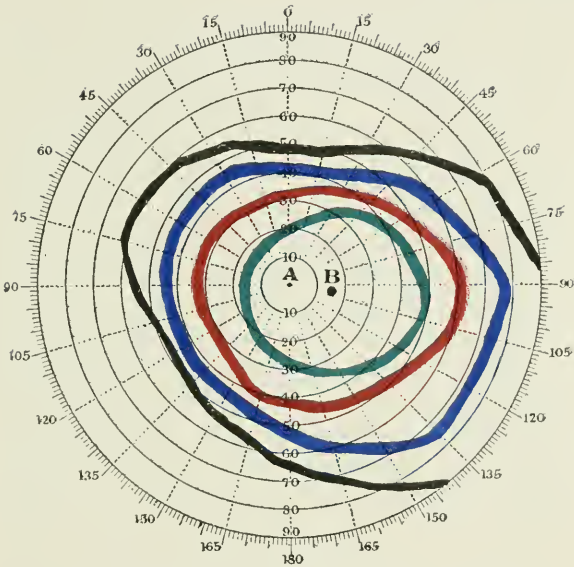


CHART OF THE VISUAL FIELDS:

A—Fixation Point. B—Blind Spot of Mariotte.

The heavy black line indicates the boundary of the field of White and the blue, red and green lines indicate the blue, red and green boundaries respectively.

The light sense is the power possessed by the retina of distinguishing different degrees in the intensity of illumination. It is measured by various instruments called *photometers*, as well as by tinted test types, chief among which are those invented by Bjerrum.


The color sense is the faculty of distinguishing light of different wave lengths.

The perception of color, as for form and light, is clearest at the macula. The sensitiveness of the retina varies for different colors as the periphery of the color field is approached. The field for green, also measured by the perimeter in the same way as white, is the smallest and then in order come red, yellow and blue. In disease of the brain, optic nerve, retina, etc., color perception is usually more easily dulled or destroyed than that for white. The field for color is determined on the perimeter in the same manner as the field for white, using a colored object in place of a white one.

Detection of Defects in the Color Sense.—

For the detection of defects in the color sense wools of various hues are employed, the method devised by Holmgren being the one in general use. A number of skeins of wool, comprising different shades of green, red and their confusion colors (gray and brown) are placed before the patient, who is first given a skein of

green colored wool. This is called the test skein and he is required to pick from the pile of wools in front of him the skeins of the *same*



Thomson's Color Stick and Skeins of Wool for Testing Color Blindness.

color, not the same *shade*, as the one he holds in his hand.

If there is any defect in his color vision the patient will select a number of the confusion colors (chiefly grays), with perhaps some green tints. If he accurately chooses all greens the investigation need proceed no further; he has normal

color sense—is not *color blind*. If, however, he fails he is given a *rose-colored* skein and again told to choose skeins of that color. He is now likely to match the rose with browns, purples, dark grays or even greens. Finally, *to find out what variety of color-blindness he has*, he is given a deep red skein when he will probably choose the dark browns and greens. The great majority of color blind people are defective in red and green and, consequently, are said to have red-green blindness, although all varieties, from simple green to total color blindness, exist.

With this test it is almost impossible for one who is color blind to escape detection. Thomson's modification of the Holmgren test is probably the most convenient. The person under examination should not be allowed to name the colors; only to select those colors resembling the test-skein in his hand.

Congenital color blindness is more common in men than in women, being in the proportion of about 4 per cent in the former and about 1 per cent in the latter. This form of the defect cannot be overcome, but frequently a color blind individual is able to distinguish to a certain degree the various colors although he does not see them as such.

Acquired color blindness is due to some or-

ganic changes in the optic nerve or visual centers, as seen in toxic tobacco or alcohol amblyopia, hysteria, optic nerve atrophy and other conditions.

CHAPTER II.

THE NORMAL, THE FARSIGHTED, THE SHORTSIGHTED AND THE ASTIGMATIC EYE.

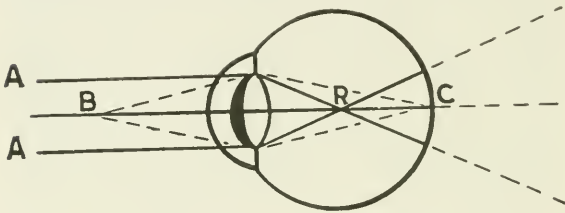
The normal or emmetropic eye.—The abnormal or ametropic eye.—The differences between these lie mainly in their shape and size.—How the eye focuses or accommodates.—Presbyopia or old sight.—The path of visual sensations from the retina to the brain.—Hypermetropia or farsight, due to abnormally small eyes.—Aphakia, absence or loss of the lens.—Myopia or short sight, in which the eyeball is enlarged.—How abuse of the eyes causes the eye coats to stretch.—Astigmatism, or abnormal shape of the cornea or crystalline lens.—The detection of astigmatism.—How to correct with lenses errors of refraction resulting from these abnormal conditions.

THE NORMAL OF EMMETROPIC EYE.

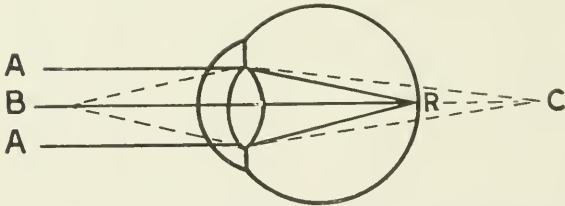
The normal or emmetropic eye is one in which, when the eye is in a state of rest, parallel rays of light coming from a distant point are focused on the retina. The emmetropic eye is 22 mm. (about an inch) in its antero-posterior diameter and this may be regarded as the standard or normal size-measurement with which to compare other eyes that differ from it in shape and size.

These rays, passing into the eye, have their course so altered by the structures which they encounter on their way to the back part of the eyeball—namely, the cornea, the anterior and posterior surfaces of the lens (called the refracting surfaces), the aqueous humor, the lens sub-

stance and the vitreous humor (called the refracting media)—that they become convergent and meet at the *fovea* on the retina, giving a clear image of the object looked at. This impression of the object is conveyed from the retina along the optic nerve to the visual centers, situated in the occipital lobe of the brain.



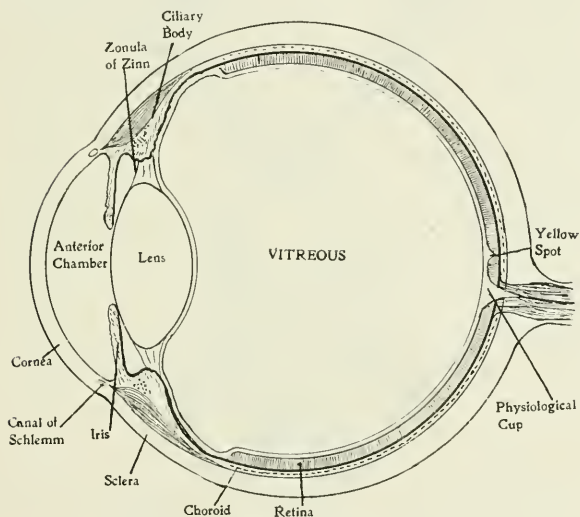
Rays of Light from a Near Object, B, Focus on the Retina, C, by the Aid of the Accommodation. Distant Rays Focus in Front, R.



Emmetropic Eye. Parallel Rays from a Distance. A.A, Focus on the Retina at R. Rays from a Near Object, B. Focus Behind the Retina, at C.

The mechanism of the eye is such that by means of the *accommodation* we are able to see near objects as distinctly as distant ones. The degree of accommodation is different for every

distance of the object. It is not suited for two different distances at the same time. If we look in the distance all objects nearer to the eye will appear blurred, and *vice versa*. In looking at distant objects with the normal eye no accommodation is required and the eye is said to be in a state of rest.



Vertical Section of the Eye Ball.

The *far point*, *punctum remotum*, of an eye is the distance at which objects are seen distinctly, while the *near point*, *punctum proximum*, is the nearest point at which an object can be brought to the eye and still be seen distinctly. The latter gradually gets farther away from the eye with age and the power to accom-

enced until about the fortieth year, when near work at that distance becomes slightly blurred and there is an inclination to hold the print farther from the eye, in order to read distinctly.

Presbyopia and the Use of a Lens.—The condition described is known as *presbyopia*, or *old sight*, and in order that we may still do comfortable near work the loss of accommodative power must be replaced by a glass, in the form of a convex lens of sufficient strength, to give clear vision for the ordinary reading distance.

For every year past forty the near point still further recedes and stronger convex glasses are needed to enable one to read and do close work with comfort. At about the sixty-fifth year the power of accommodation is practically in abeyance.

The following table shows the decline of the power of accommodation from the tenth to the

ACCOMMODATION (JACKSON).

Age.	Near point (inches).	Lens required.
10	2.81	
15	3.28	
20	3.94	
25	4.4	
30	4.9	
35	5.6	
40	7.	
43	10.	0:50
50	16	1.50
55	31.	2.25
60	78.	2.75
65	∞.	3.

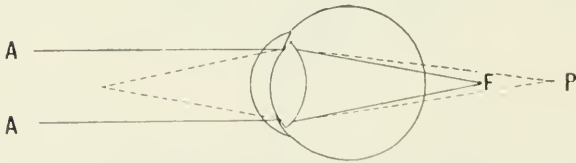
[This table is based upon an average and cannot be taken as absolutely correct for all cases of emmetropia.]

sixty-fifth year and the convex glass necessary to take the place of the lost accommodative power and bring the near point to the most comfortable working distance.

Abnormal refraction or ametropia is such that when the eye is in a state of rest, parallel rays of light come to a focus not on but at some point behind or in front of the retina and instead of presenting a clear image of the object looked at, vision is blurred and indistinct and *the eye has to exert its accommodative power to see clearly*, thereby causing fatigue and other symptoms of discomfort, setting up a condition known as *Asthenopia*.

Ametropia is divided into 1. *Hypermetropia*, 2. *Myopia*, 3. *Astigmatism*.

1. **Hypermetropia, or far sight**, is that condition in which, when the eye is at rest, parallel rays of light from distant objects come to



HYPERMETROPIC OR SMALL EYE.

Parallel rays of light, AA, from distance focusing behind retina at F. Dotted lines—rays of light from near object—focus still farther behind retina at P.

a focus at some point behind the retina, while divergent rays from near objects focus at a point still farther back of the retina.

In other words, *the hypermetropic eye is an eye that is smaller than it ought to be*—an undeveloped eye.

We have seen that in an emmetropic eye no accommodative effort is required to see *distant* objects distinctly and the accommodation is but slightly called upon when we wish to do near work. In far sight such is not the case, as the course of the rays of light entering the eye must be so altered by an increased effort of accommodation before they focus exactly on the retina and give distinct vision for distant as well as for near objects. A greater effort is required for the latter than for the former. The accommodation being constantly called upon the ciliary muscle is in a continual state of contraction and becomes hypertrophied. Such a condition of affairs leads to symptoms of discomfort not only in the eye, but in the structures surrounding it.

A slight amount of farsightedness may not cause any unpleasant symptoms, especially in youth when the general health is good and the eyes are not used for much near work. Children at birth are usually hypermetropic; this condition generally becomes less marked and may, as it often does, pass into a state of normal refraction.

The persistent and excessive demand made upon the accommodation for the purpose of giv-

ing clear and distinct vision frequently produces a sort of cramp of the ciliary muscle, causing pain and congestion in and around the eyes and an inability to use them for any length of time for near work.

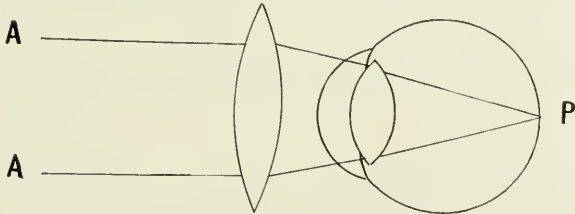
This is especially true of a farsighted eye, because a part of the accommodative power having already been used up in obtaining clear vision when looking in the distance, there is much less to fall back upon, and a *greater effort is required to see clearly when the eyes are called upon to do prolonged reading, sewing, book-keeping, etc.* The vision soon becomes blurred and the eyes have to be rested before the work can be continued.

If much near work is persisted in complaint is made of pain, fatigue, a sensation of weight, frontal headache and other symptoms of discomfort about the eyes. The conjunctiva becomes congested and frequently the margins of the lids are red and inflamed. Soon there is a feeling of sand in the eyes, with burning and smarting of the lids and eyeballs and an increased secretion of tears.

Where the strain is kept up for some time styes and other affections of the lids are frequently met with. When this strain is not relieved by appropriate treatment the effort even to see distant objects distinctly also causes marked discomfort until eventually the patient

is no longer able to use his eyes for any purpose, even for a few moments, with comfort. This condition is known as *Accommodative Asthenopia*.

A **farsighted eye**, as has just been noted, is a small eye and this abnormal state is due in the majority of instances to shortening of the antero-posterior diameter of the eyeball, to which is given the name *Axial Hypermetropia*. Less frequently it depends upon some deficiency in the curvature of the cornea or lens (*Curvature Hypermetropia*) or upon the absence of the lens (*Aphakia*). It is almost invariably a congenital and rarely an acquired condition.



HYPERMETROPIC EYE CORRECTED BY A CONVEX LENS

Parallel Rays AA, made more convergent and
Focus on the Retina at P.

For the correction of farsightedness it is necessary that parallel rays of light should be brought to a focus on the retina without the aid of the accommodation. This is accomplished by means of a *convex lens* in front of the eye, of sufficient strength to make the rays, as they

enter the eye, more convergent. The greater the amount of hypermetropia the stronger the convex lens must be.

When there is a spasm of the ciliary muscle (and this condition is more or less present in a large percentage of the cases) a variable amount of the error is *masked* and in some cases the cramp of the muscle is so great that the eye presents a condition of *false myopia*, due to the effort of accommodation being so great (in the endeavor to focus the rays on the retina) that it is overdone and the rays apparently focus in front of the retina.

In determining the true or total amount of far-sightedness the power of accommodation should be relaxed and the ciliary muscle paralyzed by the use of one of the many cycloplegics at our disposal, viz.:

Atropin sulph. gr. 4
Aq. dest. oz. 1

One drop into each eye three times daily for two days, or

Homatropin hydrobromate gr. 4
Cocain hydrochlorate gr. 4
Aq. dest. oz. $\frac{1}{2}$

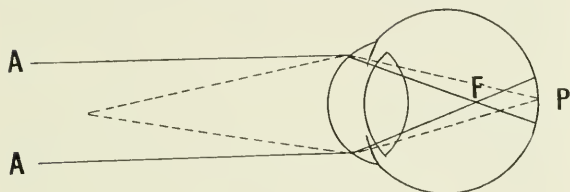
One drop into each eye every 10 minutes for one hour. In suitable cases full, but transient, cycloplegia occurs in an hour and a half after the first drop. Or

Scopolamingr. 1
 Aq. dest.oz. 1

One drop into each eye 3 times daily for two days.

Rest of the eyes from all near work is imperative in many cases.

2. **Myopia, or Short Sight, implies** a larger eye than normal (one that has slowly increased in size, usually as the result of strain) in which



MYOPIC OR LARGE EYE.

Parallel rays of light from a distance, AA, focusing in front of the retina at F. Rays from a near point R focusing on the retina at P.

parallel rays of light from a distant object come to a focus in front of the retina and then diverge to form a blurred image of the object.

Shortsight of moderate degree, unassociated with astigmatism, causes very few symptoms. The main complaint is the inability to see distant objects distinctly, but ordinary near work is performed with even less discomfort than in the farsighted eye. A refractive condition of this sort is suited for near work (about twelve to fourteen inches from the eye) because the mus-

cle of accommodation is required to make no undue effort to see objects distinctly at that distance.

We have seen that in a farsighted eye a very active accommodative power is necessary for the purpose of seeing both distant and near objects distinctly. In short sight such is not the case, for if the accommodation were active the rays of light would come to a focus at a point still farther in front of the retina and a more blurred image of the object would be produced. Therefore, in this error of refraction we have a poorly developed ciliary muscle, because the rays of light coming from an object situated at the near point will focus without the aid of accommodative power and give a clear and distinct image.

Moreover, the higher the amount of myopia the nearer to the eye will the near point be and the nearer to the eye will the patient have to hold the reading, sewing, etc. Hence, so long as the near point corresponds to the ordinary reading distance, *the shortsighted patient is able to perform the near work required of him without any marked symptoms*, and it is only when this point approaches too near the eye that discomfort is complained of.

Those who have myopic eyes are usually fond of reading, sewing, music, etc.; they rarely take an interest in outdoor sports, chiefly because they are not able to see distant objects distinctly. To

obtain a clear view of distant objects myopes frequently "squeeze up their eyes," i. e., pinch their lids together until these form a slit-like aperture and so cut off the confusing light rays, that otherwise enter the peripheral portions of the crystalline lens, and allow only the more direct ones to pass through its center. These latter make fewer *diffusion circles* when they reach the retina and so render the image clearer.

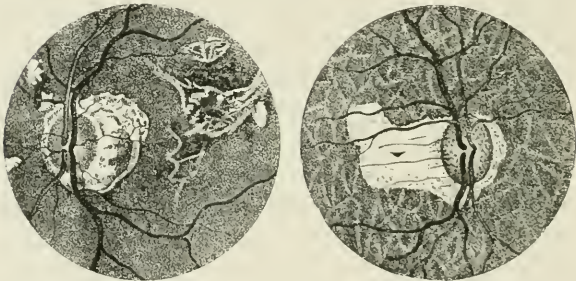
Myopia is in the majority of instances due to the antero-posterior diameter of the eyeball being too long (*axial myopia*). Less frequently it is caused by an increase in the curvature of the cornea or lens. It is frequently met with in old people who have beginning cataract, which often causes swelling of the lens. This is known among the laity as "second sight," because the patient has improved vision for reading and may even be able to read without spectacles, although at the same time he sees worse in the distance.

Shortsight is almost always an acquired condition, due in the majority of instances to excessive demands made upon the eye for near work in early childhood. It develops about the eighth year and either remains at a standstill or gradually increases in amount, constituting *progressive myopia*. The latter stage is largely determined by continued use of the eyes for near work, especially with poor illumination.

Heredity acts as a predisposing cause, the

children of myopic parents being more prone to myopia than those whose parents are hypermetropic. It is especially to be looked for in weak, sickly children, for whom outdoor games have few charms, and who are allowed to abuse their eyes with much reading, sewing, embroidery, music, etc.

The progress of shortsight depends upon a still further elongation of the globe in its antero-posterior diameter owing to stretching of the



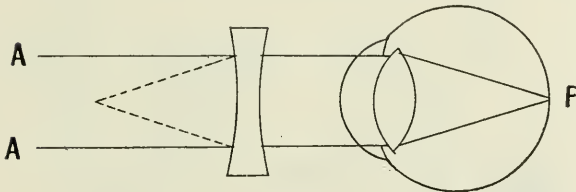
Background of the Eye in Progressive Myopia.
Choroidal Stretching with Myopia.

tunics of the eyeball at their weakest point—the posterior pole. This is mostly due to the pressure exerted by the lateral muscles in their endeavor to make the eyes converge for the working distance and to get binocular and comfortable vision.

As the disease progresses *all the tissues of the eye-coats are put upon the stretch* and

changes of a pathologic character take place within the eyeball. The vessels of the globe become congested, opacities form in the vitreous humor as the result of inflammation of the choroid, vision becomes considerably impaired and at last blindness may set in, owing to further implication of the parts necessary to the visual act.

The treatment of myopia consists in the prescribing of proper concave glasses for dis-



MYOPIC EYE CORRECTED BY A CONCAVE LENS.


The parallel rays, AA, are made divergent and focus on retina at P.

tance and near work, in order to bring the eye as near as possible to the normal condition of refraction. All close work should be restricted and the eye not allowed to become fatigued. The general health of the patient should be looked after.

No reading, sewing, or other near work, should be done except under good illumination and print should be held at the proper distance from the eyes.

The light used for near work should never be allowed to fall directly or indirectly upon the face, and to this end it should be placed behind, or above, the head and a little to the left, where it will fall upon the work to be done.

Print should not be too small and the patient



Poor Illumination. Light Shining Directly Into Eyes. must not be allowed to bend the head over his work, thus avoiding congestions of the vessels in the interior of the globe. If there is a tendency in the disease to progress *all* use of the eyes must be forbidden and, if in a child, he should be taken from school and obliged to lead an outdoor life.

3. **Astigmatism** is that condition in which there is an unequal curvature of the cornea or lens, but especially of the cornea, causing the




Another Example of Poor Illumination.

rays of light passing into the eye to come to a focus at two different points. It is divided into *regular* and *irregular*.

In irregular astigmatism the rays have different foci in the same meridian. This is us-

usually caused by irregularities of the corneal surface or changes in the lens substance. Corneal ulcers, leaving scars and facets on healing, is the common source of irregular astigmatism.



Position of the Head the Patient Must Assume in Uncorrected Myopia.

Vision is much impaired and can be very little improved by glasses.

In regular astigmatism one *principal meridian* of the cornea has a greater curve than the other. These two principal meridians are always at right angles to one another, the merid-

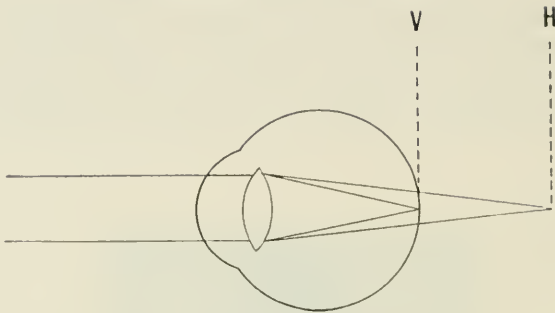
ian of greater curvature being usually situated in the vertical and that of less curvature in the horizontal meridian. When this is the case the astigmatism is said to be "with the rule"; when



Position of the Head When Myopia is Corrected by Glasses.

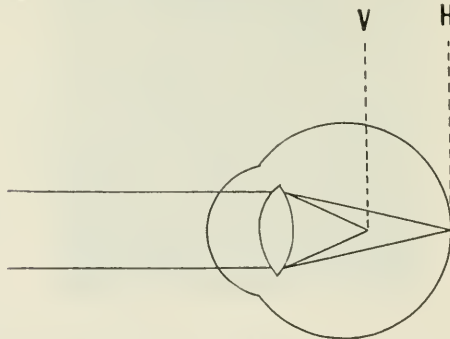
the reverse the astigmatism is said to be "against the rule." Regular astigmatism comprises—

1. The *simple form*, in which one meridian



Showing Path of Light Rays in Simple Hypermetropic Astigmatism.

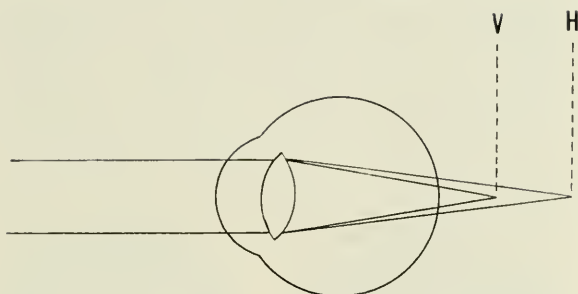
V, Rays of light in the vertical meridian focusing on the retina. H, Rays of light in the horizontal meridian focusing behind the retina.



Simple Myopic Astigmatism.

V, Rays of light in the vertical meridian focusing in front of the retina. H, Rays of light in the horizontal meridian focusing on the retina.

is ametropic while that at right angles to it is emmetropic. When the rays focus behind the

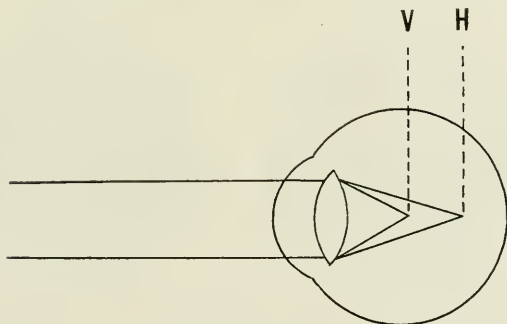


Compound Hypermetropic Astigmatism.

V, Rays in Vertical Meridian; H, Rays in Horizontal Meridian Focusing Behind Retina.

retina it is *simple hypermetropic*, and when in front of the retina *simple myopic astigmatism*.

2. The *compound form*, in which neither set

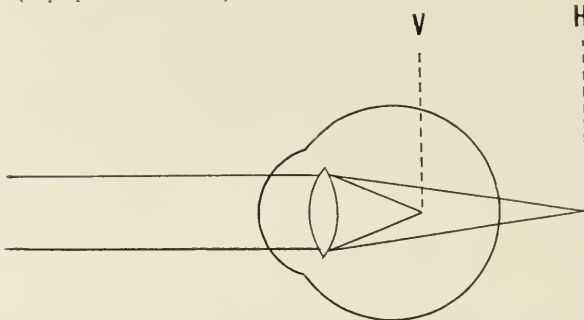


Compound Myopic Astigmatism. V, Rays in Vertical Meridian; H, Rays in Horizontal Meridian Focusing in Front of Retina.

of rays of light entering the eye focuses upon the retina, but does so either in front of or be-

hind the retina, according as it is a *compound hypermetropic* or a *compound myopic astigmatism*. In either form the rays have a different focusing point for the two principal meridians.

3. *The mixed form*, in which one set of rays of light entering the eye focuses at a point behind the retina (*hypermetropic meridian*) while those entering through the meridian at right angles focus at a point in front of the retina (*myopic meridian*).




Mixed Astigmatism. V, Rays in Vertical Meridian Focusing in Front of Retina; H, Rays in Horizontal Meridian Focusing Behind Retina.

Inasmuch as the majority of the forms of astigmatism are due to the *abnormal shape of the eyeball* it is usually congenital, but in some instances (after operation, injury, etc.) it may be acquired.

Astigmatism may be detected and its amount accurately measured by a number of

objective means, as set forth in the following chapter. A valuable *subjective* test for the presence of this defect is the *astigmatic chart*, one form of which is pictured in the text. It is sufficient for the patient to look, with each eye separately, at the figures on the chart. If



Test Figures for Detecting the Presence of Astigmatism.

astigmatism be present one or more of them will appear more blurred (or more distinct) than the others.

Astigmatism generally produces discomfort

when the patient attempts to use the eyes for reading, sewing, or other forms of near work. All the symptoms met with in *eye-strain* due to hypermetropia or myopia are more or less aggravated by the addition of astigmatism, even of low degree, especially if the patient be in a poor state of health and of a neurasthenic disposition. Distant as well as near vision may also be materially interfered with and rendered decidedly uncomfortable.

Astigmatism should be corrected with a cylindrical glass either alone (in simple astigmatism) or in combination with a spherical lens in compound or mixed astigmatism. The axis of the cylinder is placed in the meridian of greater corneal curvature in hypermetropic astigmatism and lesser corneal curvature in myopic astigmatism, *i. e.*, the meridian of normal refraction in simple astigmatism, and the meridian of least ametropia in compound astigmatism. *Even low degrees of astigmatism should be corrected in the majority of instances and glasses in the form of spectacles should be worn constantly.*

CHAPTER III.

THE MEASUREMENT OF AMETROPIA
THE FITTING OF GLASSES.
THE OPHTHALMOSCOPE.

Objective and subjective methods of measuring the refraction.—The “test case” used for the subjective determination of ametropia.—Fitting of glasses not an easy task.—Symptoms of eye strain.—The ophthalmometer, or measurer of corneal astigmatism.—The ophthalmoscope and how to use it.—Its value in the diagnosis of ocular disease.—Why it should be in the hands of every physician.—Skiascopy, retinoscopy or the “shadow test” the best objective means for measuring refractive errors.—How to employ it in the various kinds of ametropia.


Success in determining the amount of myopia, hypermetropia, or astigmatism in the eye or eyes of a patient, depends largely upon the ability to use properly at least *two methods of measurement*. It is by no means the simple process the optician or the jeweler would have us believe.

Assuming that there is no organic disease of the eye, particularly no opacities in the dioptric media—the cornea, lens and vitreous—the refraction should be first measured objectively, that is, with some instrument like the ophthalmoscope, or, better still, with the skiascope.

Having reached a conclusion, a “control” test should be made with test lenses, that is, with such concave, convex and cylindrical lenses (and

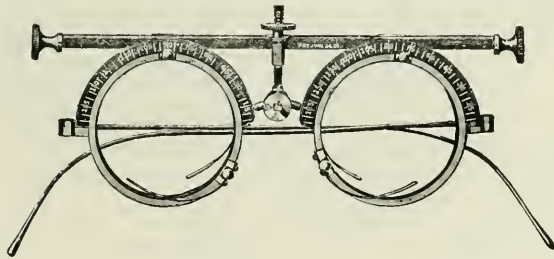
combinations of these) as are found in the "test case," that enable the patient to see best in the distance.

The difficulties that present themselves, when



Trial Case Containing Various Lenses Needed for Testing the Refraction of the Eyes.

an asthenopic patient is to be "fitted with glasses," are many. That one may solve these problems with most benefit to the patient, not only must the total refractive error be estimated for each eye separately by the foregoing methods, but



Spectacle Frames for Placing Test Lenses Before the Eyes.

the condition of the media and fundi, the state of the general health, the balance of the extrinsic eye muscles, the condition of the accommodation, as well as the amount and kind of eye work, must be taken into consideration.


In the same way the surgeon must decide whether a partial or full correction shall be worn, whether for the distance, for near work, or for both distance and near, or whether two different pairs of glasses (for distance and near) will be required. Will it be wise to keep the ciliary muscle paretic for a time, so that the accommodation is in abeyance while the patient gets accustomed to the new refractive condition

induced by the spectacles? Can the patient finally dispense with the lenses ordered, or can he, after wearing them for a time constantly, eventually use them only for reading, writing, etc.?

The improvement of defective vision is, in this country at least, less frequently our object in ordering glasses, than the relief of certain symptoms that have no particular relation to the eyesight. As a matter of experience, we know that most people under forty years of age who wear glasses do so *not* to enable them to see objects about them more clearly, *but to use their eyes without discomfort of some kind.*

It is for the relief of *eyestrain* chiefly that we order glasses and *this condition is found more commonly in farsightedness and astigmatism of low degree than it is in myopia.* Although the shortsighted person cannot, for instance, distinguish his friends across the street unless he wears glasses and is obliged to hold his book close to his eyes to read distinctly, he rarely suffers from eyestrain.

Among the numerous **symptoms** set up by ametropic eyes in their attempts to see normally are **headaches, pains in the eyes, fatigue of the eyes,** frontal or occipital "neuralgia," vertigo, insomnia, nervousness, spots or specks in front of the eyes (*muscae*), ear sickness and nausea.



An Ophthalmometer for Measuring the Amount of the Corneal Astigmatism.

Referred directly to the eyes or eyelids are burning, smarting, "drawing" and foreign-body sensations, lachrymation and "hot eye," not to mention actual organic alterations in the ocular tissues (ametropic choroiditis, cataract, granular lids, conjunctival hyperemia, styes and blepharitis) due to the chronic vascular changes set up by long continued efforts on the part of the muscular apparatus to bring about normal vision.

Occasionally this constant irritation of the central system is responsible for attacks of chorea, epilepsy, migraine, neurasthenia, "nervous" indigestion, "biliousness," and other disorders of the sympathetic system—symptoms that disappear when proper glasses are worn.

ASTIGMATISM AND THE OPHTHALMOMETER.

Corneal astigmatism is measured by an instrument called the *ophthalmometer*, whose efficacy depends upon the variation in the images of objects in the apparatus (*mires*) cast upon the abnormally shaped cornea. The various positions assumed by these images (as seen through a telescope) are registered and the amount of astigmatism calculated.

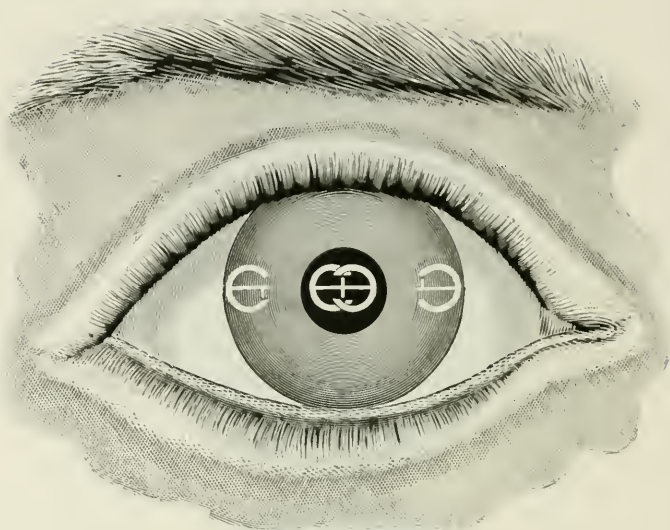
Use of the Ophthalmoscope.—Although it is not within the province of this elementary work to teach the use of the *ophthalmoscope*, the physician should be able to recognize the normal fundus through the dilated pupil. He should

also be in a position to detect those very evident, *gross* changes in the choroid, retina, optic nerve,




Test Objects (Mires) of the Ophthalmometer.

and optic media that so often furnish the best evidence of disease in other and distant organs.




The Test Objects (Mires) of the Ophthalmometer Reflected from the Surface of the Cornea.



The Loring Ophthalmoscope.

The ophthalmoscopic mirror is provided with



The Morton Ophthalmoscope,
a series of concave and convex lenses to neutral-

ize both the patient's and the observer's refractive errors, so that the background of the eye can be clearly seen.

In the first instance, after a careful inspection of the anterior parts of the eye, both without and with a lens and focal illumination, he should, holding the instrument against his own eyebrow with one hand and a $+20D$ glass with the other

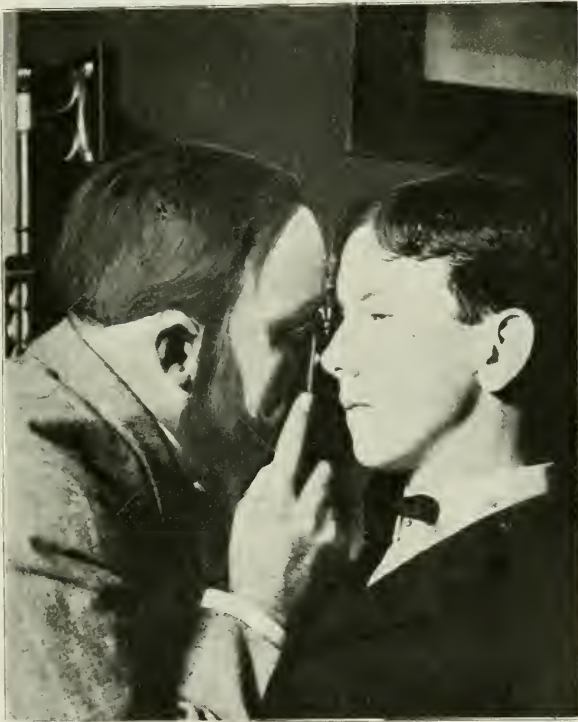

The Indirect Method of Using the Ophthalmoscope.

hand, focus the reflected light (from the concave mirror of the ophthalmoscope at a distance of about 40 cm. or 18 inches) upon the fundus through the (dilated) pupil.

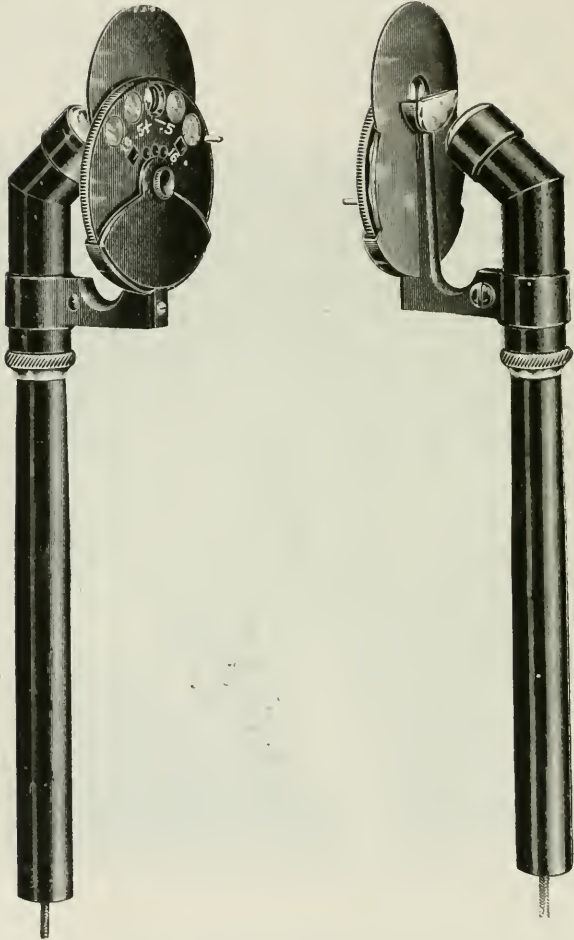
He will do this the more readily if a $+4.0D$ lens be placed in front of the eyehole of the mirror. This is the "*indirect*" method, which

gives an inverted image of the ocular fundus and an outline picture. It corresponds to the low power lens which we use in the preliminary examination of a microscopical section.



The Direct Method of Using the Ophthalmoscope.

Having taken this "bird's-eye view" of the background he now approaches the mirror as



The Electric Ophthalmoscope.

close as possible to the pupil of the patient so as to obtain a *direct and much enlarged detail picture* that may be likened to the examination of a slide with a high power.

No description or illustration of these methods will much avail the student; only patient practice with and study of normal and abnormal cases will make him an expert ophthalmoscopist.

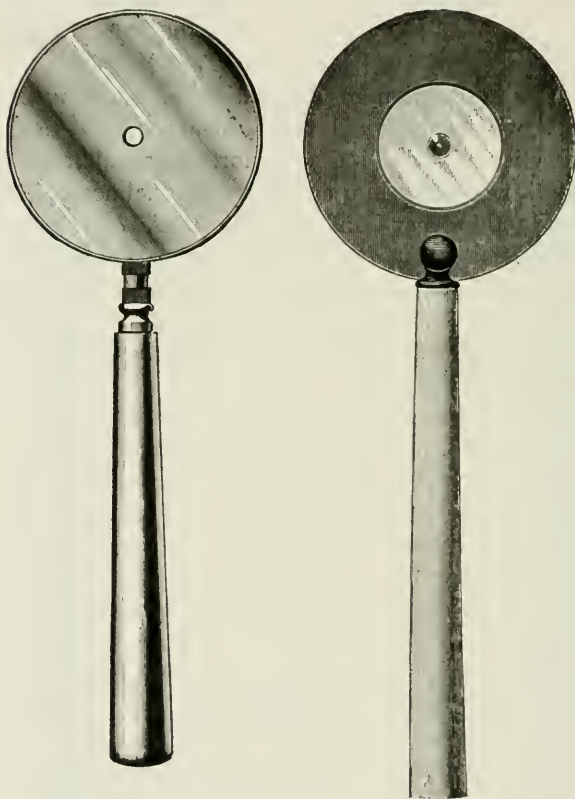
On the other hand, *an hour's use of the instrument every day or two for a month will enable him to employ the ophthalmoscope with precision in the diagnosis of most of those ocular changes with which every educated physician should be familiar.*

For bedside purposes the *electric ophthalmoscope* is the best. It is self-illuminating and by its use a patient can be readily examined in any position, without the necessity of a specially darkened room, movable gas-jet or other source of light—conditions requisite for an examination of the fundus with the ordinary ophthalmoscope.

Skiascopy, Retinoscopy or the Shadow Test.
—A ready means of determining not only the kind of refractive error but the amount of it is *retinoscopy, skiascopy or the shadow test*. Its ordinary use does not call for any considerable knowledge of physiologic optics nor does it need much practice.

By means of this *objective method* the result

is obtained independently of the observations of the patient under examination. The light

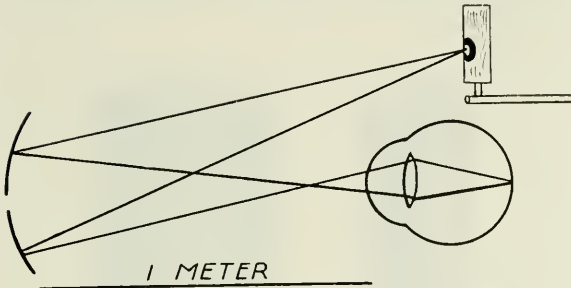


Mirrors (Plane and Concave) Used in Skiascopy.

from a gas-jet or electric lamp falls upon a concave or plane mirror and is reflected into the

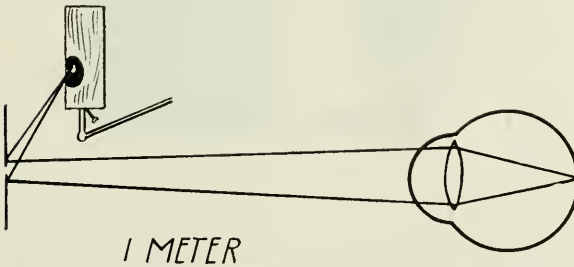
eyeball through the pupil. The retinal movements and shadows are observed as the mirror is rotated in various directions.

This method is especially useful where it is



Position of the Light in Using the Concave Mirror for Skiascopy.


not desirable to depend upon the statements or observations of the patient. It is particularly



Position of the Light in Using the Plane for Skiascopy.

valuable in dealing with children, illiterates, amblyopes, and others where an accurate subjective estimation of the full amount of the ametropia

is, for obvious reasons, difficult or impossible. It is, on the whole, the most satisfactory objective test we possess. Where it is possible, the skiascopic result should afterwards be verified by test lenses.



The Thorington Light-Screen.

In employing this test the examiner should be seated in a darkened room one meter, or about three feet, in front of and facing the patient, whose accommodation, if he be under forty years of age, should be paralyzed by means of a cycloplegic—atropin solution, or homatropin and cocain.

The light should be placed above and behind the patient's head, if a concave mirror is used; or it should be within five or six inches of the observer's eye, if the plane mirror. The source of light should be covered with a Thorington light screen, or asbestos chimney, provided with an iris diaphragm to regulate the amount of light falling upon the observer's retinoscope mirror.

The mirror with which the light is reflected into the eye has a small opening in its center (through which the observer looks), the edge of the mirror resting against the edge of the brow. The light is thrown from the mirror into the eye so that the red reflex of the fundus is seen by the observer as he looks through the hole in the center of the mirror.

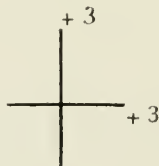
As the mirror is rotated in the principal meridians of the eyeball, a shadow will be observed within the area of the red reflex, moving in a direction contrary to or with the movement of the mirror, as the patient is hypermetropic or myopic. The shadow direction will also depend upon the sort of mirror used, whether it be concave or plane.

With a *concave mirror* the shadow moves *against* the movement of the mirror in emmetropia, in myopia of less than one diopter and in hypermetropia. It moves *with* the movement of the mirror in myopia of more than one diopter.

With a *plane mirror* the shadow moves *against* the movement of the mirror in myopia of more than one diopter and *with* it in emmetropia, myopia of less than one diopter and in hypermetropia.

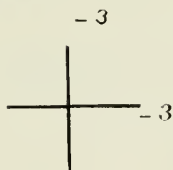
As soon as the direction of the shadow has been determined convex glasses, if the patient is emmetropic, myopic less than one diopter or hypermetropic, and concave glasses if the patient is myopic more than one diopter, should be placed in the spectacle frame in front of the patient's eye and increased in strength *until that glass is reached which reverses the movement of the shadow.*

The two principal meridians of the eyeball, usually the vertical and horizontal, should in this way be worked out separately. If the same lens reverses the shadow in each meridian we have simple hypermetropia or myopia, as the case may be. If it is a hypermetropia, say of three diopters, it is recorded as follows:



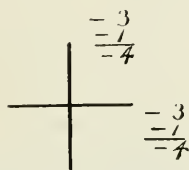
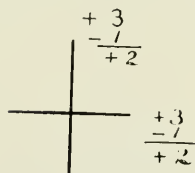
Skiascopy Results in Simple Hypermetropia.

If myopia, as follows:



Skiascopy Results in Simple Myopia.

As the observer is one meter distant from the eye under examination—the distance of the point of reversal of a myopic eye of one diopter—that amount should be subtracted from the result in hypermetropia and added to the result in myopia. In other words, in the skiascopic result, the hypermetropic eye is over-corrected and the myopic eye under-corrected one diopter in each meridian. The results should then read, to give the real state of things:




In the first instance the patient is farsighted to the extent of two diopters; in the latter myopic four diopters. If a spherical convex lens of $+2$ diopters, or a spherical concave of -4 diopters were placed in the trial frame before the eye, the full amount of the hypermetropia or myopia would be corrected and the correction would, in

each case, make the patient emmetropic and give him the best vision.

We have seen that in regular astigmatism the refraction in the two principal meridians is unequal. When, therefore, the point of reversal is found in one meridian, that at right angles to it is still uncorrected. The lenses should now be adjusted so that the shadow in this other meridian is reversed. The difference between the two meridians gives the amount of the astigmatism.

In the retinoscopic result the meridian of least error corresponds to the axis of the cylinder employed to correct it, and this, in the majority of hypermetropes, is in the vertical meridian, usually indicated by 90° ; while in myopia it is in the horizontal meridian (or at 180°).

In **simple astigmatism** the reversal of the shadows might be represented as follows:




Skiascopy Results in Simple Hypermetropic and Simple Myopic Astigmatism.

Adding -1 (the point of reversal of a myopic eye of one diopter at one meter) to each meridian the formula to be placed in the trial lens in front of the eye would read:

$$\begin{aligned} &+1\text{D cyl. ax. } 90^\circ \\ &-3\text{D cyl. ax. } 180^\circ \end{aligned}$$

In compound astigmatism the reversal of the shadows would be as follows:




Skiascopic Results in Compound Hypermetropic and Compound Myopic Astigmatism.

Adding -1 (the point of reversal of a myopic eye of one diopter at one meter) to each meridian the formula to be placed in the trial frame in front of the eye would read:

$$\begin{aligned} &+1\text{D sp.} +1\text{D cyl ax. } 90^\circ \\ &-3\text{D sp.} -1\text{D cyl ax. } 180^\circ \end{aligned}$$

In mixed astigmatism one meridian is myopic (usually the vertical) and that at right angles to it is hypermetropic (usually the horizontal) a concave lens, say of 2 D being used to get the reversal of the shadow in the former while a convex lens, say of 3 D is used for a like purpose in the latter meridian. The skiascopic result would read as follows:



Skiascopic Results and Correction in Mixed Astigmatism.

Adding $-1D$ (the point of reversal of a myopic eye of one diopter at one meter) to each meridian, the result should then read to give the real state of things:

The lenses to be placed in the trial frame before the eye may be either one of the following:

1. Using crossed cylinders, as follows:

-3 cyl. ax. 180°

$+2$ cyl. ax. 90°

2. Using a convex sphere and a concave cylinder:

$+2D$ sp.— $5D$ cyl. ax. 180°

3. Using a concave sphere and a convex cylinder:

$-3D$ sp.+ $5D$ cyl. ax. 90°

In mixed astigmatism the sum of the two results gives the amount of the astigmatism, because a convex or concave spherical lens placed in front of the myopic or hypermetropic meridian produces just as much more myopia or hypermetropia, as the case may be, in that meridian, and requires the addition of a concave or convex cylinder of such strength to correct it.

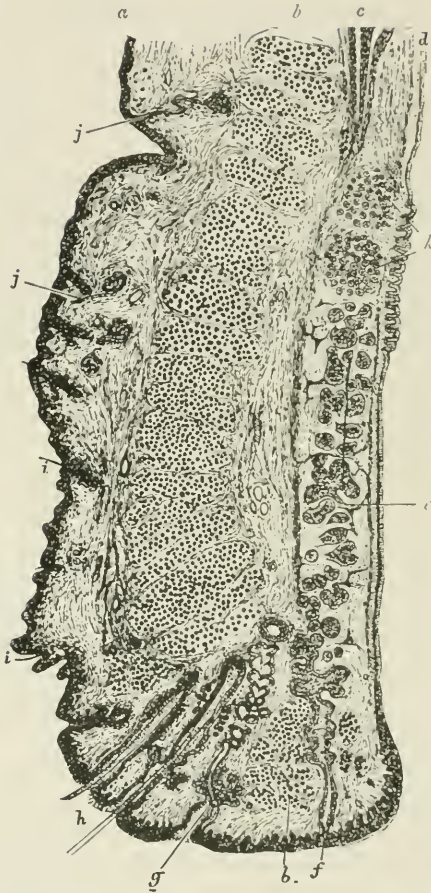
CHAPTER IV.

THE COMMONER DISEASES OF THE EYELIDS.

The anatomy of the lids.—How they protect, lubricate and cleanse the front of the eyeball.—The tarsus, the cilia and the meibomian glands.—“Black eye.”—Styes.—Chalazion or Meibomian cyst, and how to remove it.—Blepharitis.—Eczema of the lid edges.—Entropion.—How to do a canthoplasty.—Other operations for entropion and trichiasis.—Ectropion and operations for its relief.—Ptosis or drooping of the upper lid and how to treat it.—Lagophthalmus.—Symblepharon.

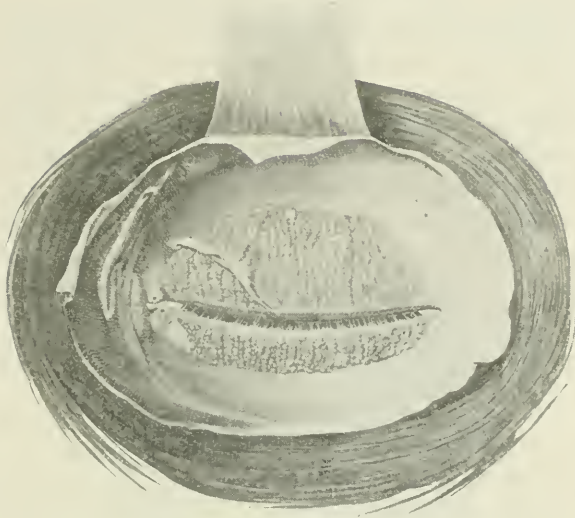
The eyeball is partially protected as well as cleansed by the eyelids. These are thin and loose folds of skin, whose inner aspect is covered by the conjunctiva. Between these are found connective tissue plates—the *tarsus*, or so-called tarsal cartilage—to stiffen them and to enable them to retain their form. The lids are closed by the powerful sphincter muscle—the orbicularis; they are opened chiefly by the *levator palpebræ superioris* above and by prolongations from the inferior rectus below.

The eyelashes, or cilia, in two or three rows, project from hair follicles at the outer margin of the lids. The union of the lids at the nose is called the inner canthus, where is also situated a small, reddish elevation—half skin, half conjunctiva—called the *caruncle*. The temporal junction of the lids is called the *outer canthus*. In each tarsus are some 20 or 30 tubules,



VERTICAL SECTION OF THE UPPER LID:

- a*, Skin; *b*, Orbicularis Muscle; *c*, Involuntary Muscle of the Lid; *d*, Conjunctiva; *e*, Tarsus;
f, Meibomian Gland; *g*, Sebaceous Gland;
h, Eyelashes; *i*, Small Hairs in Skin;
j, Sweat Glands; *k*, Posterior Tarsal Glands.



Meibomian Glands, Situated in the Tarsus of Both Upper and Lower Lids.

the ducts of simple, secreting follicles, called *meibomian glands*. These produce a lubricating material for the lid edges upon which they discharge their contents.

All the lid structures are well supplied with fat, lymphatic vessels and nerves. A constant mucous secretion from the various conjunctival and other glands moistens and lubricates the anterior ocular structures. The cornea particularly is kept clean and bright from this source, aided by the approximation of the lid edges in winking. This closure of the eye in a cleansing

fluid acts like a "window scraper"; it gently removes all deleterious matter from the front of the eyeball and pushes it towards the lachrymal puncta, whence it is drawn by the action of that curious suction apparatus, formed by Mueller's muscle, into the drainage system of the nose.

Ecchymosis constitutes what is popularly termed a "black eye." On account of the exposed location of the eye and the lax condition of the lid skin, contusion with discoloration is more frequent in this location than in any other region of the body.

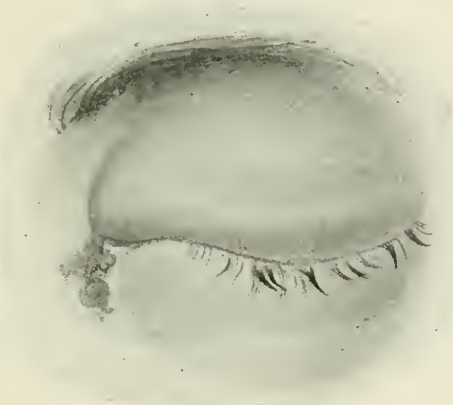
Treatment.—The ordinary black eye, if seen at once, is best treated by cold applications (cloths wet with iced water), or with an evaporating lead lotion:

Liq. plumbi subacetatis.....	dr. ʒ
Alcohol	dr. ʒ
Aq. destil.	pint ʒ

Where a definite blood-clot has formed within the palpebral tissues, the common practice of incising the skin and allowing the blood to escape or applying two or three leeches to the orbital margin is a good one. An antiseptic dressing should be subsequently applied. Unless treatment is resorted to within two days, no remedy will be of use. It is then best to cover up the discoloration with flesh-colored paint. We would advise every practitioner to keep on hand some water colors for this purpose. No production

of his artistic hand will be more appreciated than that which disguises such a noticeable blemish.

Edema is frequently seen, on account, also, of the laxity of the subcutaneous tissue of the lids. It follows congestion of the lids dependent upon injury to the head and local affections



Edema of the Lids, with Effusion of Serum.

of the lids themselves, such as styes, bites from insects, burns, etc. In some instances it is an important symptom of a diseased condition of the heart or kidneys.

Treatment should be directed to the cause. If the effusion is so great as to interfere with the opening of the lids the serum may be evacuated by puncture, followed by the application of a pressure bandage.

Stye or Hordeolum is a very common lid affection and may be regarded as a palpebral boil, situated at the root of an eyelash on the anterior lip of the lid margin. It begins as a small, hard, painful nodule, accompanied by redness and more or less edema of the whole



Stye, or Hordeolum. (Dalrymple.)

lid, usually running an acute course, going on to suppuration and rupturing in two or three days.

Styes frequently appear in crops and are recurrent. They are more often seen in young people and are often a sign of disturbance of the general health. In many instances they are a symptom of eye-strain resulting from an error of refraction.

Treatment.—In its earliest stage, before pus has formed, the stye may sometimes be aborted by pulling out the eyelash, which runs through it, and touching the swelling with

strong carbolic acid or tincture of iodin. If this fails, the point of a Beer's knife, or some similar instrument, should be pushed into the center of the tumor and its contents evacuated. Warm fomentations or hot stupes may be applied to relieve the pain and promote suppuration, and in a day or so a mild mercuric ointment should be rubbed over the diseased part.

Hydrarg. oxid flav.....gr. 2
Cosmolinoz. 1

This ointment promotes healing of the abscess and has a tendency to prevent a recurrence of the disease. Careful search should be made for errors of refraction which should be corrected by suitable glasses. The general condition often calls for attention in these cases, and treatment should be especially directed to digestive disturbances. Pil. calcii sulphid., gr. $\frac{1}{2}$ —1, three times daily, is often of great value.

Frequently, as in anemic girls, a course of iron, with proper diet and fresh air, is chiefly needed. A useful tonic in many instances is:

Tinct. ferri chlorid.....
Acid phosphoric dil.....aa. dr. 3
Tinct, rheidr. 1
Quinin sulphgr. 3
Liq. strychniæoz. $\frac{1}{2}$
Syr. simplicis. q. s. ad.....oz. 8

Take half a teaspoonful in water before meals.

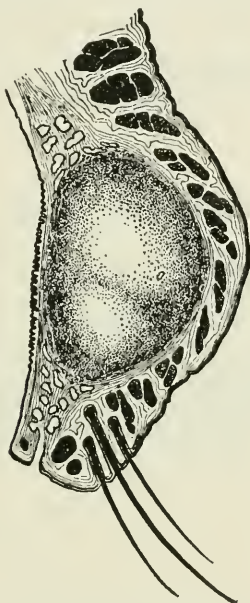
Chalazion.—Cyst of the lid. Meibomian Cyst. This is a small, hard, slow growing and slightly movable tumor imbedded in the tarsal cartilage. It is generally produced by the obstruction of a meibomian tubule, about thirty of which are found in each lid, having their openings along the palpebral margins. Its contents are usually gelatinous, in some cases cheesy, and



Chalazion or Meibomian Cyst.

occasionally (when infected) purulent. The tumor generally "points" towards the conjunctival surface of the lid, where its position is indicated by a purplish patch of discoloration, showing a thinning of the tarsus at this spot. Chalazia are mostly found in adults and several may

appear at the same time. Like styes they are frequently the result of errors of refraction, although in many cases no cause can be assigned for their occurrence. A chalazion differs from




Vertical Section Through a Chalazion of the Upper Lid. (Fuchs.)

a styne in that it develops in the lid proper and not along its margin.


Treatment.—The contents of the tumor should be evacuated, preferably from the conjunctival surface of the lid. The parts should first be anesthetized by means of:

Holocain hydrobromgr.	4
Cocain hydrochlorategr.	18
Ac. boricgr.	10
Aq. dest. q. s. ad.....oz.		1


A ring forceps is applied, with the ring blade over the chalazion, to control the lid and at the



Ring Forceps.



Curette.

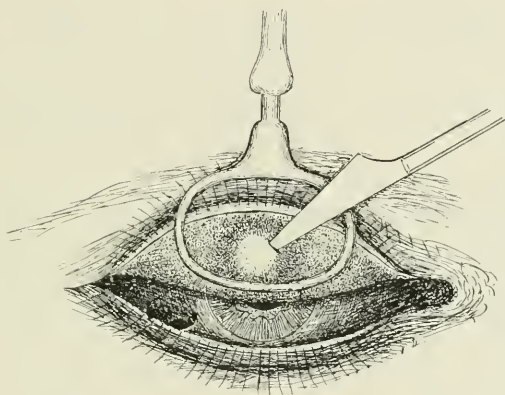


Beer's Knife

Instruments for the Removal of Chalazion.

same time to render the operation-field bloodless. The lid is then everted, and a crucial incision made with a Beer's or Graefe knife, involving the whole breadth of the tumor. The cyst contents are then evacuated by means of a small scoop or curette. This will effectually prevent its return. The patient should always be warned that after such an operation the removal of the cyst contents leaves a vacuum that is filled with a blood clot and the tumor appears as large as or larger than ever. In a few days, however, absorption begins and the tumor gradually disappears. Massage subsequently applied to the

lid for two minutes every two or three hours over the situation of the tumor will materially hasten absorption of its contents. In the first stages, and especially where the tumor is small, massage with mercurial ointments several times



Showing Method of Removing a Chalazion.

daily, continued for several days or weeks, will sometimes be followed by disappearance of the chalazion. Errors of refraction should be corrected by suitable glasses and all local sources of irritation, such as blepharitis or conjunctival catarrh, should be removed.

Xanthelasma is a flat, smooth *yellowish deposit* in the palpebral skin, due to alterations

in the superficial muscle fibres. It occurs as an irregular, round or oval patch, or patches, near the inner canthus and commonly affects the upper lids of *elderly females*. It is a *benign growth* which rarely calls for interference, except for cosmetic reasons, when the following may be used:

Hydrarg bichlor5i
Collodion5iii

Apply with a camel's hair brush.

An eschar forms in a few days, which finally falls off, leaving a faint scar. The X-rays also constitute an effective remedy.

Blepharitis Marginalis, called also *Tinea tarsi*, may or may not be a true eczema of the border of the lids. It is a very chronic affection, lasting often for years, and is frequently accompanied by chronic conjunctivitis. In such cases both affections should be treated together.

The chief sign of the disease is the formation of crusts or scales along the lid margin. These, when removed, expose a glazed, reddened or moist surface, and in many cases an ulcerated condition at the root of the lashes. The small crusts, which should not be mistaken for eggs of pediculi sometimes laid in this situation, adhere to the base of the cilia, which often become stunted and broken.

After a time the disease affects the root sheath

of the cilium, the bulb atrophies and the lids become more or less destitute of lashes. It is always bilateral, although one side may be in a more advanced stage of disease than the other. New lashes may grow; when they take a wrong direction they give rise to a condition called *trichiasis*.

Blepharitis is frequently found in poor, ill-nourished, strumous children. It also occurs in those whose occupations expose them to wind, dust, and other irritating influences. Errors of refraction and defects in the muscular balance of persons who constantly use their eyes for near work and in a bad light, are likely to cause suffering from the milder forms of this affection.

In the mild cases the symptoms are not, as a rule, urgent, but burning, smarting, a feeling of irritation and heat in the eye, always aggravated by exposure to wind and sun, are usually noticed. As the disease progresses the lid edges become thickened, the conjunctiva is involved and an added feeling of sand in the eyes, with sensitiveness (*photophobia*) to bright light is the result. After a time the eyes, having lost their hairy defenders, suffer from the entrance of dust and other foreign bodies.

Treatment should first of all be directed toward the removal of the crusts. Very few

patients persevere in this endeavor as they should, and it is, accordingly, often a wise measure to remove with the forceps every eyelash that harbors the scabby exudations. This prevents the reformation of the crusts, gives the remedies employed a better chance to reach the seat of the disease and set up healthy action in the parts affected.

The best way to remove the crusts is to soak them well with a hot 2 per cent solution of sodic carbonate. After removal of all scabs an ointment of yellow oxid of mercury should be thoroughly rubbed into the edges of the closed lids.

Hydrarg. oxid flav. gr. 2
Cold cream oz. 1


This may be done in the evening, shortly before retiring, while a boric acid solution should be applied several times during the day:

Ac. boric
Sodii bibor aa. gr. 15
Aq. rosæ dr. 2
Aq. dest. oz. 1

When the case is one of *eczema*, with moist crusts, swelling of the lids, and conjunctivitis, various measures have been advocated. Benzoated lard alone, or with the addition of oxid of zinc, is a useful application:

Zinc. oxid gr. 6
Adipis benzoat oz. 1

It goes without saying that patients suffering from blepharitis should avoid dust, heat and wind as much as possible and should wear protective glasses when they leave the house. They should not smoke themselves, nor allow their eyes to be irritated by remaining in a smoking-room. The general health is worth looking after; indeed, it may be that a strumous dia-



Entropion With Trichiasis. (Dalrymple.)

thiasis lies at the bottom of the disease, for which cod-liver oil, arsenic, iron, etc., may be necessary.

If a blepharitis be perpetuated by eye-strain, glasses or other proper treatment should be ordered, especially if there be any astigmatism present. Whatever the treatment may be, a complete cure is not, in the majority of cases, to be expected inside of several months.

Entropion is an inversion of the edge of the lid, with a turning in of the eyelashes. It may result from a spasmodic contraction of the orbicularis, as seen in old people with flabby lids or in whom the subdermal fat as well as other parts about the orbit have partially disappeared. A spasmodic entropion may follow any inflammatory condition of the eyeball.

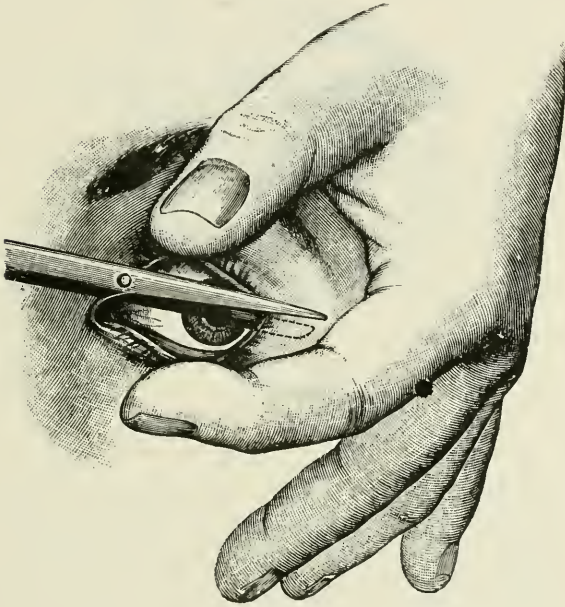
Entropion due to *cicatricial contraction* is a more serious condition. It may arise from burns or from other injuries, but is almost always caused by granular lids (*trachoma*). This disease first produces scarring (and contraction) of the palpebral conjunctiva and the subconjunctival tissues, followed by irregular atrophy and incurvation of the tarsus.

The eyelashes are secondarily affected, and some of them turn in, impinge upon and greatly irritate the cornea. If there be two regular rows of cilia, one is very apt, for a while at least, to retain its proper outward curve, while the other turns in upon the sensitive globe. Such a condition of affairs is termed *distichiasis*. When the curvation of the lashes is irregular, or if but a few of them are thus affected, the term *trichiasis* is employed to describe it.

In most of these cases the situation is made worse by a shortening and narrowing of the interpalpebral aperture (*blepharophimosis*); the lids are, then, too closely applied to the eyeball;

the patient cannot separate them widely enough, and all the symptoms are aggravated thereby.

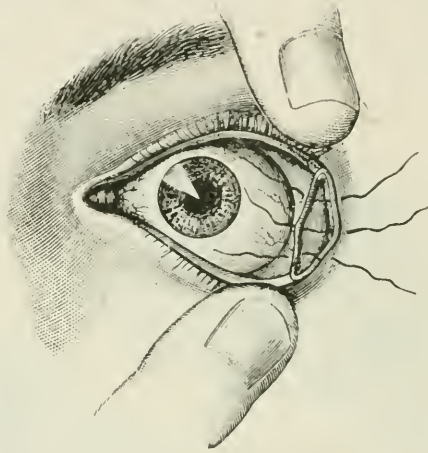
Treatment.—The spasmodic variety may be relieved by painting the skin with collodion or



Method of Operating for Canthoplasty.

by applying strips of adhesive plaster, to draw the lashes away from the eyeball. If these procedures fail, it must be treated like the cicatricial variety—by operative measures.

A simple operation called *canthoplasty* may be performed either alone or as an adjunct to other surgical measures. The external com-



Sutures in Canthoplasty.

missure is cut through in a horizontal line and directly outwards with a pair of straight scissors. The sharp-pointed blade of the latter is entered beneath the lids at the outer canthus, and the skin wound made a few millimeters longer than that in the mucous membrane. A preparatory subcutaneous injection of a few drops of cocain (4 per cent solution) will render this a comparatively painless operation.

The conjunctival edges are now separated

from the underlying tissues, and with three stitches are evenly joined to the margin of the skin wound. An antiseptic lotion, and the removal of the stitches, in from four days to a week, complete the case.

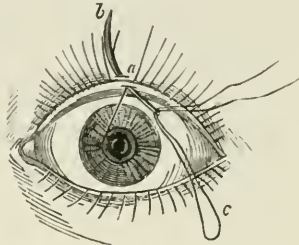


Epilation Forceps.

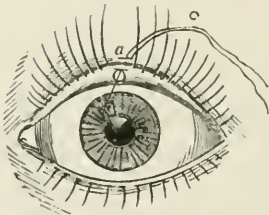
If the entropion be well marked, an efficient operation constitutes the best means of remedying *all* the evils attendant upon that condition, but in many cases it will suffice to do a canthoplasty and destroy a few troublesome cilia. Do not, however, temporize by pulling them out unless the patient positively refuses to undergo an operation. In that case remember that it is the fine, short, and colorless hairs, that do most damage, and are just the ones most likely to be overlooked, unless one have sharp eyes and use a magnifying lens to aid the vision. The pulling out of the lashes is termed *epilation*, and is practiced with special cilia forceps, having broad and smooth ends.

When they are not numerous the incurving hairs of trichiasis may be destroyed (and operation postponed or avoided) by one or both of the following measures:

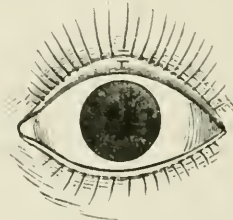
First—*Michel's method*, electrolysis. A platinum needle is connected with the negative pole of a 20-volt battery, and plunged accurately into the ciliary follicle, the positive pole being grasped by the patient. The action of the battery as evidenced by the disengagement of (hydrogen) gas from the neighborhood of the fol-



Passing of needle under the skin near the inverted eyelash.



Misdirected lash, caught in loop of the ligature.



Eyelash in corrected position.

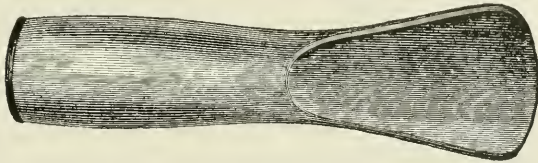
SNELLEN'S METHOD OF REPLACING AN INCURVED EYELASH.

licle, should be kept up for 60 seconds. Even with a previous injection of cocain this is a painful procedure.

Second—*Snellen's method*. Thread a sharp and small needle with both ends of a fine silk thread. Enter the former at the base of the cilium, push it underneath the palpebral skin, and bring it out six or eight millimeters from the lid margin. As the double thread is drawn through, ensnare the lash and draw it bodily into the substance of the lid.

When from one cause or another (usually from long standing trachoma or granular lids), the preceding measures are found or judged to be inadequate for the cure of the entropion and trichiasis, a more radical operation is necessary. A volume might be written in describing the various operations that have been devised for the relief of entropion.

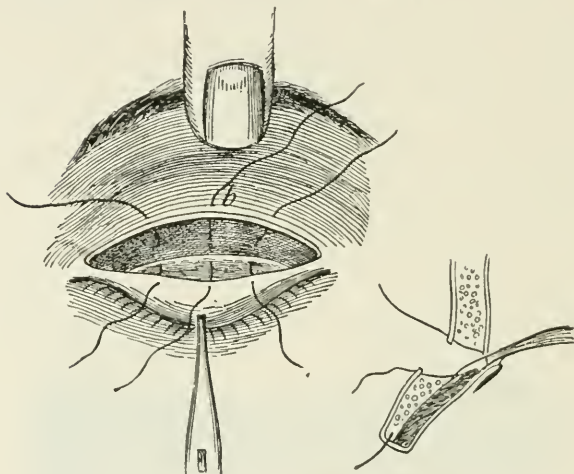
Holtz's operation for entropion is one of the best. He aims to make the upper and lower edges of a lid-wound adhere to the upper margin of the tarsus and so, by a sort of leverage action,



Lid Spatula.

draw the palpebral border with its incurved cilia upward and away from the globe. Ether or chloroform is given and a lid spatula may or may not be used.

An assistant now draws up and holds the skin of the (upper) lid firmly against the brow while the operator puts it on the stretch, with forceps, in the opposite direction. An incision is made horizontally from a point 2 mm above the inner canthus to a corresponding point above the outer commissure. If the skin be now left free this incision will be found to be *curved* and to cor-



Hotz's Operation for Entropion.

respond with the superior edge of the tarsus. The lower edge of the wound is now drawn down with forceps and the surgeon dissects some of the fibres of the orbicularis from the upper third of the tarsus. Three or four sutures are inserted, with a curved needle, first, into the up-

per edge of the wound, then through the upper edge of the tarsus and some of the tarso-orbital fascia just above it, and finally through the lower margin of the skin wound.

The bleeding having stopped the wound is cleared of clots and well irrigated. The ends of the threads are then firmly tied, binding both edges of the incision to the upper margin of the tarsal plate. Iodoform powder, or other dry dressing is now applied, the stitches being removed in two days or on the approach of suppuration.

Ectropion is a turning out of the *upper* or *lower lid*, or both, so that the conjunctival surface is exposed. It may be caused by (1) a cicatricial contraction due to burns, ulcers or wounds of the lids (*cicatricial ectropion*), or (2) to a chronic inflammation of the conjunctiva accompanied by hypertrophy. (3) It is prone to occur in old people in whom a portion of the orbicularis muscle becomes atrophied (*senile ectropion*). (4) The great majority of cases of ectropion are the result of spasm of the orbicularis due to local irritation (*spasmodic ectropion*). (5) In paralysis of the orbicularis muscle (seventh nerve) the lower lid becomes everted (*paralytic ectropion*). As a consequence, the tears flow over the cheek (*epiphora*) and produce excoriation of the skin and edge of the lid. This in its turn brings on edema of

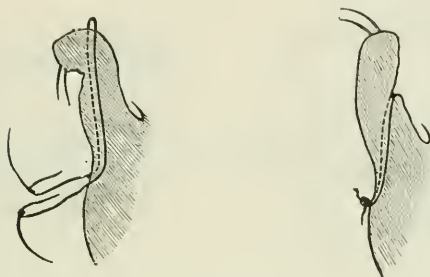
the parts, and chronic inflammation of the conjunctiva.

The treatment should be directed first towards the removal of the cause of the trouble. In the senile and spasmodic varieties the application of a suitable bandage at night will frequently relieve the condition. The relief of the paralytic variety depends upon the cure of the paralysis of the orbicularis muscle, although even in this form of the affection relief can also be afforded by the frequent application of a bandage.

In the great majority of cases operative measures are necessary for the cure of the condition. The excision of cicatricial tissue with transplantation of skin will afford ample opportunity for the exercise of the surgeon's best skill, and the rules to be observed do not differ from those in vogue in skin and mucous membrane regions elsewhere. For muscular ectropion many operative measures have been employed. One of the best of these—easy to perform—is that of *Snellen*.

Snellen's Operation.—One needle of a double-needled silk thread is entered where the everted conjunctiva is most prominent and brought out through the skin 2 cm below the lid margin. The other needle is passed in the same way, the points of exit in the skin being about 1 cm apart. Traction is now made upon the threads,

the mucous membrane is pulled *down* while the palpebral margin is assisted into place. The ends of the thread are tied over a piece of rubber, to protect the skin. Two, three or more sutures may be required. In the meantime any edema, conjunctivitis or other lid affection,

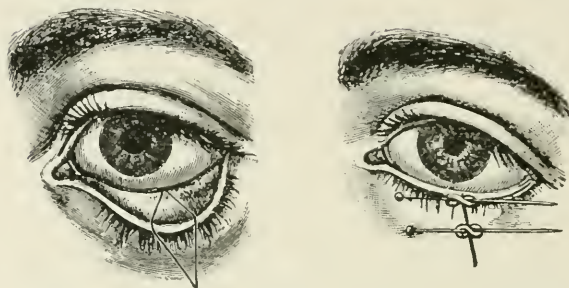


Snellen's Operation for Ectropion of Lower Lid.

should be treated, in the hope that the patient may eventually be able to get along without the stitches. If this simple means fails a cutting operation may be needed. That recommended by Adams is a good one.

Adams' Operation.—The palpebral margin is shortened by excising a wedge-shaped piece from the middle of the lid in its whole thickness, including the mucous membrane. The width of the piece taken away will depend upon the amount of shortening required. The edges of the wound are carefully brought together by harelip pins and silk sutures. Very accurate co-

aptation of the edges of the wound should be secured to avoid a defect at the border of the lid or an ugly scar in the skin. Another, and perhaps better plan, is to remove the wedge at the outer canthus.

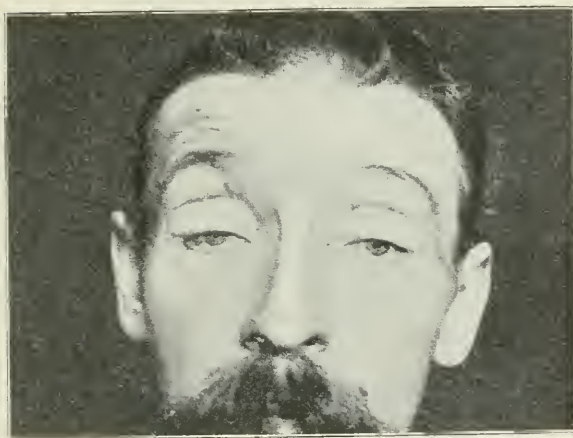

Adams' Operation for Ectropion of Lower Lid.

Ptosis.—Drooping of the upper lid. It may be *congenital* or *acquired*. *Congenital ptosis* is usually bilateral and is then due to either defective development or absence of the levator palpebræ superioris. With this anomaly there are often other congenital defects. It is sometimes hereditary.

Acquired ptosis, on the other hand, usually affects one side only. The commonest cause of this variety is paralysis of the third nerve, which supplies the levator palpebræ. One or more of the ocular muscles supplied by the same nerve are generally paralyzed at the same time.

First in order of causation come thickening and increased weight of the lid from disease (chronic conjunctival inflammation, trachoma, etc.) and, finally, wounds and adhesions of the lid to the globe (*symbblepharon*). Any of these forms of ptosis may be slight; they may be complete, in which case the lid covers the pupil



Ptosis, or Drooping of the Upper Lid.

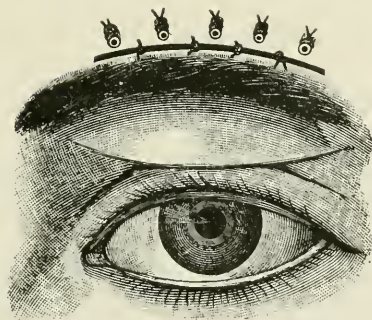
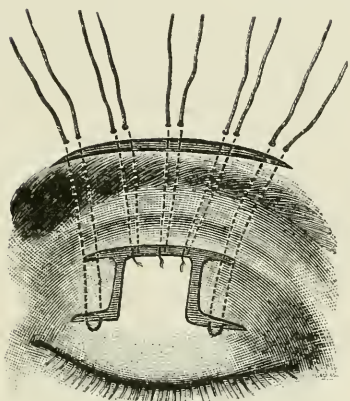
and directly interferes with vision. Attempts are generally made by the patient to raise the lid by bringing into action the occipito-frontalis muscle, causing a wrinkling of the skin of the forehead. In the endeavor to see distinctly the

patient throws the head backward, presenting a pose which is characteristic of this condition.

Treatment.—When attempts to remove the cause of the ptosis by electricity and other appropriate treatment fail operative interference is invoked. The usual method is to excise a horizontal, oval-shaped piece of skin from the lid. How to remove enough skin so that the shortening of the lid may allow of vision, and yet not so much as to prevent closure of the eye during sleep, is the problem.

A preliminary observation should be made by pinching up the palpebral skin with a pair of suitable forceps. The skin so grasped by the ptosis forceps is cut off by one sweep of a scalpel or snip of a stout pair of scissors. The edges of the wound are, after the arrest of bleeding, brought together by sutures. This procedure is suitable when the drooping is due to thickening of the lid. On the other hand, when the ptosis is the result of defective power in the levator, quite a different operation is called for, such as the following:

Pagenstecher's Operation.—No incision is made through the skin. The object aimed at is to provide a connection between the lid and the occipito-frontalis muscle by means of subcutaneous, cicatricial bands. A needle armed with a strong ligature enters the skin immediate-



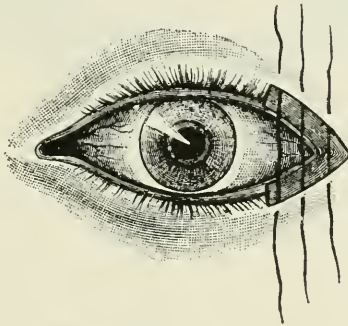
Panas' Operation for Ptosis.

ly above the eyebrow and is carried subcutaneously to its exit at the margin of the lid. It is reentered at this point and passed horizontally along the lid edge about 2 mm. The needle is then directed upward beneath the skin to again make its exit above the brow. Two or three such sutures are inserted and the ends drawn up and tied over a piece of rubber tubing at the eyebrow. The lower loops are then allowed to slowly cut their way through, by means of supuration (being tightened once daily), until they reach the eyebrow.

The Panas Operation.—An incision, 3 cm long, is made through the skin at the upper border of the brow to the bone. Another, 2 cm in length, is carried 2 mm below the superior orbital margin, the bridge of skin between the two incisions being thoroughly undermined. A tongue-shaped flap of skin and orbicularis muscle is cut from the lid below. This is drawn up under the bridge and stitched to the upper margin of the first incision by three sutures. As this may cause eversion of the lid two additional marginal sutures, passed through the tarso-orbital tissue only, are inserted.

Lagophthalmus.—This is a condition opposed to ptosis, due to paralysis of the orbicularis palpebrarum, in which the patient is unable to close his eyes. Literally translated it

means "*hare eye*," as that animal is said to sleep with his eyes open. The diagnosis is easily made if the patient be told to shut his eyes. When the disease is one sided, as it commonly is, these efforts are productive of a curious result, viz.: the eye of the affected side assumes the position it occupies during sleep, and is plainly seen to roll up under the unclosed lid. This is a fortunate position, as it serves to protect



Sutures in Tarsorrhaphy.

the cornea of patients suffering from this affection from the desiccating effects of the atmosphere, and from injury by dust and other foreign bodies.

Lagophthalmus is usually produced by paralysis of the *portio dura*, but it may also be due to any cause that brings about undue protrusion of the eyeball (*proptosis*), as *staphyloma corneæ*,

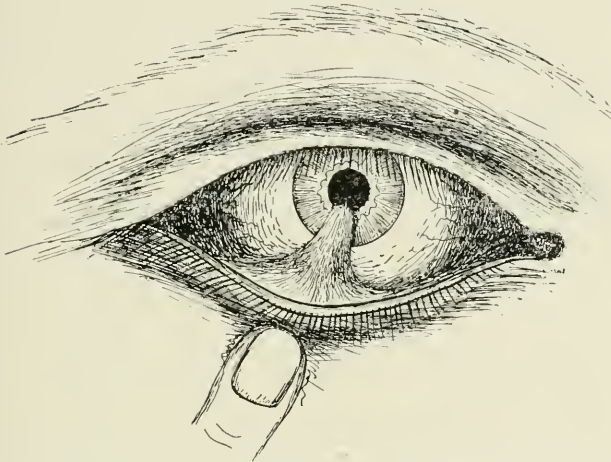
extreme myopia, Graves' disease, orbital and intraocular tumors, etc.

Treatment.—When possible the cause must be removed. The cornea should be protected from wind, dust, smoke, etc., by means of an eye shield. In paralytic cases, and in some of those due to the other causes mentioned, a simple operation, termed *tarsorrhaphy*, will be useful. By means of it the interpalpebral slit is both shortened and narrowed. A short strip of skin, the length of which will be determined by the effect desired, is removed from the margins of the lids at the outer canthus. The cilia with their bulbs are included in the excision, and the pared edges are sewed together.

Symblepharon.—This is a term applied to the abnormal union of the ocular with the palpebral conjunctiva. It may be partial or total and is most frequently produced by injury, usually burns by such escharotics as lime, molten lead, acids or strong alkalies, introduced into the conjunctival sac. Adhesion does not occur for several days or weeks after the accident, and it is extremely difficult to prevent it.

Treatment.—In slight cases the cicatricial bands are to be cut through, and the edges of the healthy conjunctiva united over the raw surfaces by sutures. In more extensive cases, simple separation of the adherent surfaces, is insufficient ;

the raw surfaces again unite in spite of all precautions. One or both separated surfaces must



Symblepharon, or Adhesion of the Lid to the Eyeball.

be covered by conjunctival flaps or with mucous membrane transferred from the lip or by skin from the arm.

CHAPTER V.

THE COMMONER DISEASES OF THE CONJUNCTIVA.

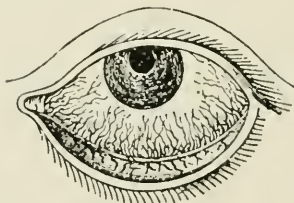
Anatomy.—Hyperemia of the conjunctiva and its treatment.—Acute conjunctivitis.—The various infections of the conjunctiva and their bacterial causes.—The pneumococcus, Koch-Weeks bacillus, streptococcus, staphylococcus, gonococcus, Morax-Axenfeld diplobacillus and other sources of conjunctivitis.—“Pink Eye.”—The treatment of infectious diseases of the conjunctiva.—Ophthalmia Neonatorum the commonest and most serious eye disease of infancy.—How to treat it.—Gonorrhoeal conjunctivitis in the adult.

Anatomy.—The front of the eyeball and the inner aspect of the lids are covered by a very important mucous membrane called the conjunctiva. The palpebral and *ocular* membranes meet above and below, at the fornix, where they are thrown into (*retrotarsal*) folds liberally supplied with bloodvessels and glands of various kinds. The bulbar segment is very thin, and is very loosely attached to the underlying sclera. The whole membrane is covered with pavement epithelium which is continued over the cornea and extends into the canaliculi to the lachrymal sac. It is thrown into a more or less plainly marked reduplication at the inner canthus, where it represents the third eyelid or nictitating membrane of the lower animals.

It is well to remember that the conjunctiva

is supplied by two distinct sets of bloodvessels, anterior and posterior, because of their value in diagnosing deep lesions of the eye from inflammations affecting only the conjunctiva.

A hyperemic condition of the conjunctiva is frequently met with and is chiefly confined to that part of the mucous membrane lining the lids. On everting the lids the conjunctiva is seen to be redder than normal and sometimes swollen, a condition better marked in the retro-tarsal folds. In some instances it presents a roughened and sandpapery appearance from the enlarged follicles. The redness eventually ex-



Hyperemia of the Conjunctiva. (Guthrie.)

tends to the ocular conjunctiva, where the sub-conjunctival vessels, especially in the upper and lower cul-de-sacs, are enlarged. No discharge is present, although the patient frequently complains of a gummy condition of the lids in the morning.

Where the condition is of long standing, particularly in old people, the conjunctiva takes on a dry and glazed appearance, and there is more

or less redness of the lid margins. The symptoms are generally a feeling of smarting and burning of the lids or eyeball, or both, and a sensation of sand in the eye, with some photophobia in a bright light, and, possibly, lachrymation in cold weather or when the eyes are exposed to the wind. Usually all the symptoms are increased towards evening.

Chronic hyperemia of the conjunctiva is very often due to uncorrected errors of refraction; it may also be set up by any condition of the eye which necessitates an effort to see distinctly, such as opacities of the lens or cornea. Its existence can frequently be traced to exposure to wind, dust, smoke and impure atmosphere. In many cases it is an extension of a chronic coryza, or is secondary to lachrymal obstruction. It may also mark the first stage of an acute or chronic inflammation of the conjunctiva.

Treatment demands removal of the cause. Errors of refraction should be corrected and all irritating influences removed. The patient should be made to work in good light, removed from a smoke or dust-loaded atmosphere, and the eyes should be protected from wind. Lachrymal obstruction or abnormal conditions of the nasal passages should be treated.

Cold fomentations applied to the closed eyelids three or four times a day are very soothing and grateful to the patient, especially if there

be sensations of smarting or burning. These should be applied in the following manner: A basin is filled with cold water at a temperature of about 40° F. The patient is instructed to fold a small face towel about twelve inches long and three or four wide, an end of which is grasped in each hand. While the face is held over the basin, with the eyes closed, the towel is dipped into the cold water and the dripping towel is applied to the closed lids, forehead and temples. This is repeated for a period of from three to five minutes. The application should be stopped if it makes the eyes or head ache.

In a few cases *very hot water* (applied in the same fashion) is more effective and more grateful than cold. Both may be tried and the more pleasant one adopted.

Following the application of cold (or hot) water several drops of a soothing, non-irritating solution should be instilled into the conjunctival sac. The following will be found to be very acceptable.

Acid. boric	dr.	1/2
Sod. bibor....	dr.	1/2
Aq. rosæ	dr.	2
Aq. destil., q. s. ad.....	oz.	2

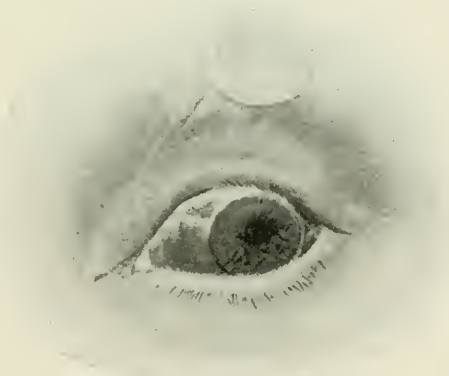If the lids are gummy or show a tendency to adhere in the morning a *little* simple ointment should be gently rubbed on the eyelashes just before retiring at night. Either simple lard

(without salt), benzoated lard, cold cream or cosmoline will act nicely. When the conjunctiva looks dry and glazed more stimulating lotions are indicated, such as

Zinci sulph.....gr. 1—2
 Aq. destil.....oz. 1

or brushing the lid with a ten per cent solution of argyrol, or one-fourth per cent silver nitrate two or three times a week is advised.

Subconjunctival hemorrhage. — Smooth, bright red patches, often involving from one-fourth to one-half the scleral surface, are not uncommonly seen on the eyeball. These discolorations are not accompanied by pain, or other



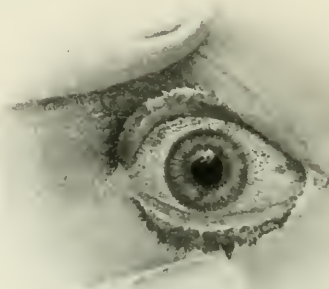
Subconjunctival Hemorrhage. (Ramsay.)

irritative signs. They often appear over night and are usually discovered, *not* by the patient, but by some member of his household. They

occasionally follow *sneezing, coughing, straining*, etc., are rarely of any pathological importance and do not call for treatment. These *sub-conjunctival bleedings* slowly disappear in the course of a week or ten days.

Acute Catarrhal Conjunctivitis may be regarded as an aggravated form of hyperemia of the conjunctiva, characterized chiefly by a mucopurulent discharge.

The disease usually begins with a sensation of smarting and burning of the lids and a feeling



Acute Catarrhal Conjunctivitis. (Ramsay.)

of sand in the eye. The discharge, at first serous, soon becomes mucopurulent and accumulates in the form of flakes in the retrotarsal folds. The lids stick together in the morning, while dried secretion is found adhering to the margin of the lids and to the eyelashes. The

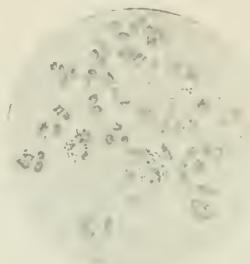
conjunctiva lining the lids is also seen to be slightly swollen and red. As evening approaches there is increased discomfort, accompanied by some photophobia in the bright sunlight or when in a lighted room. Lachrymation is usually present, the tears carrying off some of the discharge.

The conjunctival vessels on the globe are in most cases enlarged, but, in the milder types, there is no marked redness of the ocular conjunctiva, the thickening and redness being confined to the conjunctiva of the lids, particularly at the junction of the lids and the eyeball in the retro-tarsal folds. Sometimes there is a slight chemosis present, in which cases the nutrition of the cornea is liable to suffer, and ulceration may take place not only from pressure upon the vessels in that region but following infection from the discharge retained in the sulcus.

Acute Contagious Conjunctivitis.—A more severe and highly contagious form of acute catarrhal conjunctivitis is commonly known as "*pink eye*." Clinically its best name is *acute contagious conjunctivitis*.

It is met with usually in the spring and fall months, when, probably set up by wind and infected dust, it is frequently epidemic. In about two days after infection the ocular conjunctiva becomes deeply injected, giving it a bright red appearance; hence the name *pink eye*. The conjunctiva lining the lids is deeply red and swol-

len; the papillæ are prominent and present a succulent appearance, while the transition folds are thickened. The sensation of a foreign body in the eye, with burning and itching of the lids, is quite marked. The latter are stuck together in the morning. Photophobia and lachrymation are a source of discomfort to the patient and




Koch-Weeks Bacillus.

pain is sometimes present. From the accumulation of the discharge on the cornea the vision may become blurred. Slight hemorrhages are sometimes present on the ocular conjunctiva. The discharge, which is muco-purulent in character, is usually quite ropy, and sometimes becomes thick and purulent.

This affection is usually at its height at the end of the third day. It is sometimes accompanied by a rise in temperature and other constitutional disturbances. The symptoms gradually subside after a week or ten days, although

recovery may not take place until the end of two or three weeks.

Dust and other irritating substances, such as atropin, may also set up acute catarrhal conjunctivitis. It may accompany measles, scarlet fever and influenza. Many cases are undoubtedly due to the presence of micro-organisms. The pneumococcus of Fränkel has been isolated and cultivated by several observers, and this bacterium is justly regarded as an important factor in the causation of the affection. Staphylococci and streptococci are also found in the secretions of several forms of the disease. In acute contagious conjunctivitis a specific micro-organism has been isolated by Weeks which resembles the bacillus of mouse septicemia. A microscopical

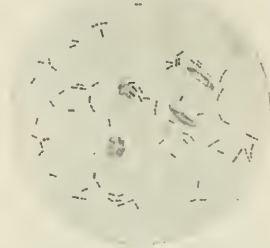


Staphylococcus Pyogenes Aureus.

examination makes a diagnosis of this form comparatively easy. The character of the discharge, which is thick and purulent, is useful in diagnosing the disease. *In every case of*

ocular inflammation with discharge the secretions should be examined bacteriologically.

Treatment.—In acute catarrhal conjunctivitis the cause should be searched for and all irritating influences removed. Mild, non-irritating antiseptics should be employed for cleansing purposes, such as solution of boric acid (gr. 15 to oz. 1), or bichloride of mercury 1-10,000. Cold applications should be used every two or three hours in the manner described in the treatment of hyperemia of the conjunctiva, to be fol-



Diplococcus of Morax-Axenfeld.

lowed by the instillation of four or five drops of the following solution:

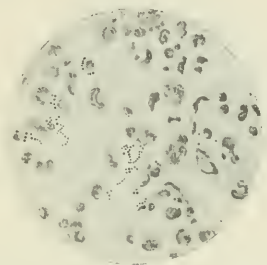
Acid. boric	gr. 15
Sodii bibor	gr. 15
Sol. hydrarg' bichlor (1-10,000)	
q. s. ad.....	oz. 1

At night a little pure lard or cold cream should be applied to the margins of the lids, or an ointment containing boric acid should be used:

Acid. boric gr. 10
 Lanolin oz. $\frac{1}{2}$
 Vaseline alb. oz. $\frac{1}{2}$

In the first stage a solution of adrenalin or suprarenalin, 1-10,000, is beneficial.

As the acute stage subsides more stimulating lotions may be used with advantage by the surgeon, especially a weak solution of nitrate of silver painted on the lids:

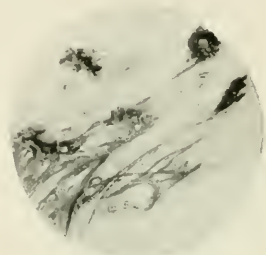


Streptococcus Pyogenes.

Argenti nitratis gr. 2
 Aquæ destillatæ oz. 1

In the acute contagious variety cold or iced applications should be applied every two hours. These are best employed as small pads of absorbent cotton or lint, kept cold on a block of ice and transferred to the closed lids every few minutes. They are to be discontinued as the acute stage subsides. The eyes should be irrigated every hour or two with an antiseptic solution: boric acid gr. 15 to the ounce, hydrarg bichlor

1-10,000; or with solution formalin 1-6,000. Painting the everted lids once a day or every other day with a 1-per-cent solution of nitrate of silver is indicated after the acute stage has somewhat subsided and when the discharge becomes thicker and more profuse. It should be applied well up in the retrotarsal folds. Protargol or argyrol, 10 to 20 per cent solutions,



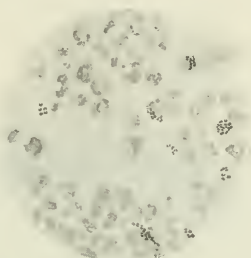
Pneumococcus.

may be used in lieu of the silver nitrate and is quite beneficial in many cases. It has the advantage of being less painful, but perhaps not as reliable as the silver salt.

Cold cream or vaselin should be applied to the lids at night. As the affection is *contagious* extreme care should be taken that no others are infected. The patient should, in severe cases, be isolated and no one allowed to use towels or handkerchiefs that have been handled by him or used on his inflamed eyes.

A laxative should be administered at the commencement of the disease.

Purulent Conjunctivitis.—It is difficult to draw a sharp line of distinction between the severe forms of acute catarrhal conjunctivitis and *simple blennorrhœa or purulent conjunctivitis*. In the latter, however, the chemosis is greater, while the discharge is more profuse and more purulent in character. The lids also become hard, tense and greatly swollen; the cornea is



Gonococcus.

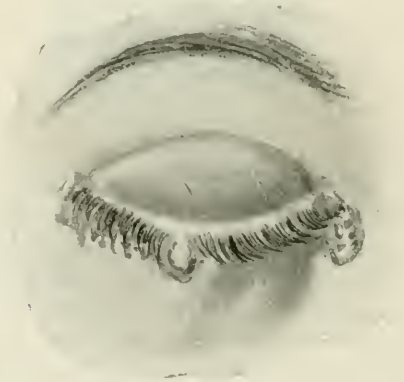more often infected and ulceration more frequently occurs. The inflammation permeates the deeper structures and the subconjunctival tissue is infiltrated with inflammatory exudates.

In the more serious cases of purulent conjunctivitis the *gonococcus of Neisser* is usually found, although a "mixed infection" with other pyogenic bacteria may constitute a danger more threatening to the eyesight than that presented by the gonococcus alone. In a minority of severe cases the latter germ cannot be found. This disease attacks particularly the new-born (*oph-*

thalmia neonatorum) and the adult (*gonorrhæal ophthalmia*). These examples of ocular infection will be described separately.

OPHTHALMIA NEONATORUM.

Ophthalmia Neonatorum is an acute infectious inflammation characterized by the presence of an abundant and copious discharge of pus, and is usually accompanied by infiltration of the subconjunctival tissue and distinctive lesions of the cornea.



Purulent Conjunctivitis from Gonorrhæal Infection.

The infection usually takes place during the passage of the child's head through the vagina, so that *the symptoms almost invariably show themselves during the first three days after birth*. If it occurs at a later period the infection is

probably not gonorrhœal but comes from soiled fingers, cloths, towels, sponges, etc. One eye is commonly affected one or two days before the other, although in some cases it is possible, if preventative measures are taken early enough, to prevent infection of the second eye. In the majority of cases, and especially in the severer forms, the gonococcus of Neisser is found to be present in the discharge.

There is usually a history of the mother having suffered from a leucorrhœa for some time previous to the birth of the child, or of the husband having recently had gonorrhœa or gleet.

There is a milder form, where the gonococcus is usually absent, that runs its course in from a few days to a week. In such cases the inflammation is not severe, and takes on the character of a simple, acute, catarrhal ophthalmia. The severe ophthalmia of the new-born begins with slight redness of the conjunctiva, accompanied by a small amount of discharge which accumulates in the corner of the eye. In a very short time the redness increases, and the lids are shiny and swollen—so puffed out that the upper lid falls down and covers the margin of the lower lid.

The palpebral skin shortly after becomes tense and hard and of a dusky red color, so that it is almost impossible to evert either lid. The conjunctiva is very red and much swollen, present-

ing a velvety appearance from the enlargement of the papillæ. This congestion rapidly extends to the ocular conjunctiva, which becomes intensely red and edematous (*chemosis*), overlapping the margin of the cornea so that the latter appears at the bottom of a pit surrounded by a hard rim of infiltrated and chemotic tissue.

The discharge, at first slight and yellowish in color, is soon very profuse, and of a cream-like consistency. It is secreted rapidly, accumulates in the cul-de-sac and flows from between the lids onto the cheek. In consequence of hemorrhages from the ruptured capillaries the discharge may assume at this stage a yellowish-green color from admixture with blood.

Sometimes a false membrane appears on the conjunctival surface which adheres closely to and is with difficulty stripped from the roughened conjunctiva. Occasionally this removal is followed by bleeding. As the disease progresses the lids are less tense and hard, and much of the swelling subsides.

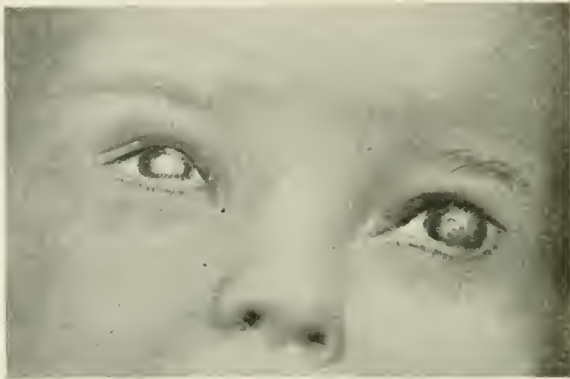The conjunctival surfaces of the lids remain thick and continue to be covered with granulations, while the ocular conjunctiva is thrown into folds. The discharge finally becomes thinner and less copious, although it is now frequently tinged with blood. The disease usually runs its course in about six weeks. The chief danger is to the eyesight. It is greatly to be feared that

the disease may affect the cornea, the vitality of which is always lowered, partly by strangulation of the vascular supply induced by the intense chemosis of the conjunctiva, and partly from direct infection. When this occurs the surface of the cornea first becomes hazy, dull and lusterless; this condition is soon followed by the formation of one or more small ulcers, usually at the limbus. These spread rapidly, their course depending in a great measure upon the resisting powers of the patient and the nature of the local infection, as shown by the amount of the chemosis, the character of the discharge, etc.

In the milder forms of the disease and in well-nourished babies resolution may occur with retention of good vision, even where corneal ulcer has formed, but in the more severe infections of unhealthy infants perforation of the cornea into the anterior chamber is a common sequel. The aqueous humor gushes out, the lens and iris coming forward into the opening thus made. If the perforation occur at the periphery of the cornea, the iris alone becomes entangled in the wound. Inflammatory exudates are now thrown out and the protruding iris is bound to the cornea; the opening heals and an *anterior synechia* results with a dense white scar at the site of the iridic hernia.

The cornea itself is sometimes rendered wholly

opaque, and, bulging forward under the influence of the increased intraocular pressure, constitutes an *anterior staphyloma*; or the eye may be rapidly destroyed from a panophthalmitis due to invasion of the deeper structures of the eye by the pyogenic microbes admitted through the corneal wound.



Corneal Scars and Staphyloma After Ophthalmia Neonatorum. (Ramsay.)

Treatment.—In a virulent inflammation which is followed by results so disastrous, the prophylactic treatment is of great importance. In these days of antiseptic surgery there is less danger of the child's eyes becoming infected than formerly. Where a discharge is known to exist, regular, daily cleansing of the vagina with an antiseptic solution before parturition should

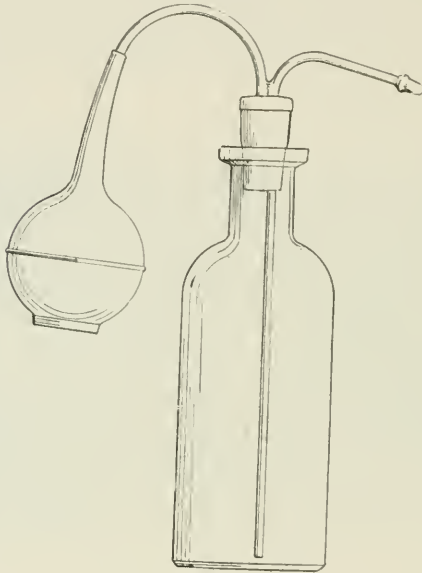
always be insisted upon. After the birth of the child the lids should be wiped dry with a piece of sterilized gauze, the eyes should be carefully opened and with a sterilized medicine dropper one drop of a two per cent solution of nitrate of silver should be carefully dropped into the conjunctival cul-de-sac.

This is the method of Credé, which, if it be carefully carried out, will greatly minimize the danger of infection. By this method Credé reduced the percentage of cases occurring in the Leipzig hospital from about 10 per cent to 0.2 per cent. Similar results have been obtained by others, until now this preventative treatment is almost universally carried out.

Cleanliness is the all important factor in the prevention as well as in the treatment of such an inflammation. Even if no vaginal discharge is present the child's eyes should be carefully looked after for some time after birth, and cleansing with sterilized water, or perhaps better still, with a mild antiseptic solution such as a saturated solution of boracic acid, will in many instances prevent much suffering. The attention of the nurse and the attendants should be drawn to the necessity for carefully cleansing their hands, using nothing but sterile cotton or gauze when wiping the infant's lids.

When the inflammation has actually set in, frequent irrigation and cleansing (if the lids are

hard and tense and the discharge is not profuse) of the conjunctival cul-de-sac should be carried out. A fountain syringe, undine or an Elwood



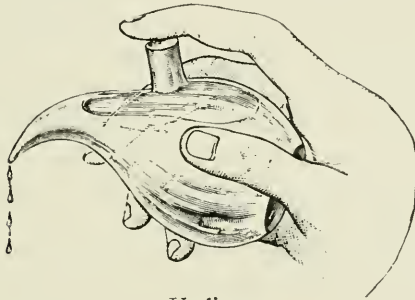
Irrigating Bottle.

irrigator should be filled with an antiseptic solution warmed to about 104° F.:

Acid. boricgr.	40
Sod. bicarb.gr.	40
Sol. hydrarg bichlor (1-10,000)	.oz.	4

The lids should be everted and the upper and lower cul-de-sacs thoroughly irrigated with the solution, stopping from time to time to wipe

away with pledgets of sterilized cotton any discharge adherent to the conjunctiva. This should be repeated every hour or two according to the severity of the case. Care should be taken when irrigating *that the nozzle of the irrigator does not touch the cornea*, or that the stream does not directly irrigate the corneal surface, on account of the danger of detaching a portion of the corneal epithelium, thus inviting infection of the



Undine.

cornea, the formation of an ulcer and the loss of the eye.

The application of agents directly to the eye, such as the use of pledgets of cotton in cleansing, is so often attended by danger from slight traumatism and subsequent infection that the practitioner should be the only one to evert the lids, make applications to them, or to use instruments of any kind about the inflamed eye. If he is not expert in these matters, it will be wiser

for him not to attempt direct medication at all, as he may do the child more harm than the applications will do good. This rule also holds good in the treatment of purulent ophthalmia in the adult.

If a fountain syringe is used it should be elevated not more than three inches above the level of the child's face (placed in a recumbent position), the nozzle of the irrigator being held about half an inch from the eye. In this way the upper and lower cul-de-sacs are gently washed out without danger of injury from too powerful a stream. The lids should be drawn with the fingers as far away from the cornea and globe as possible—first the upper and then the lower lid—and the stream directed *into* the upper and lower cul-de-sacs.

Together with the foregoing the use of *iced applications* should be carried out every hour or two for at least twenty to thirty minutes at a time. This should be done in the following manner: Take a square block of ice, perfectly flat on top and large enough to hold at least four compresses of lint about three inches square. The latter are laid upon the swollen lids and changed often enough to keep up a uniform degree of cold. These compresses should be merely damp; it is well to squeeze out any water they may have soaked up.

The *continuous* use of cold, or the application

of icebags is apt to chill the eye, to lower its vitality and to encourage the evils we most desire to avoid. An icebag is also apt to cause pain and discomfort from its weight, and its use is therefore not advisable.

As the disease advances the discharge becomes thicker and more copious, while the lids appear less glazed and tense. *Nitrate of silver* should now be applied once a day to the palpebral conjunctiva in from 2 to 4 per cent solutions. First, the lids should be carefully everted, thoroughly cleansed of all adherent discharge and then thoroughly dried. The silver solution is then applied to the conjunctiva by means of cotton twisted around a toothpick, any excess of the silver salt being washed off with a 5 per cent solution of sodium chlorid. Care should be taken not to touch the cornea with the swab, and the greatest gentleness should always be observed by both surgeon and nurse during all the applications to and manipulations of the inflamed eyes.

Protargol or argyrol (20 to 40 per cent) has been highly recommended in place of the solution of silver nitrate. It is applied in a similar manner, is less irritating and causes less pain than the silver nitrate and is quite as effective.

Should the cornea become cloudy a 1 per cent solution of atropin sulphate should be instilled into the interpalpebral space sufficiently often

to dilate the pupil. The iced compresses should be stopped and replaced by applications of heat in the form of moist applications at a temperature of 115° to 120° F. Warmed vaseline should be applied to the lid surface, previous to the application of the heat, in order to avoid scalding the skin.

These applications should be begun at a moderate temperature and the heat gradually increased. Any excess water should be wrung out of the cloths before applying in order to prevent excoriation of the skin by the hot fluid. When the discharge becomes profuse, in addition to the silver solution the following mixture, introduced by X. C. Scott, of Cleveland, is recommended:

Hydrastin sulphate	gr. 5
Acid boric	gr. 5
Sod. bibor.	gr. 5
Tr. opii deodor.	dr. ½
Aq. destil.	oz. 1

Mix and filter. Sig.—To be instilled into the eye every hour.

When the disease becomes complicated with corneal ulcer and the discharge is excessive, irrigation with formalin solution, 1-5,000 to 1-10,000 is also highly recommended. It is non-irritating and a very active destroyer of pyogenic bacteria. Various other solutions have been used with more or less advantage, proving prob-

ably that the good results are due not so much to the character of the solution as to the *mechanical cleansing* that is accomplished. Among these may be mentioned:

Potassium permanganate .. 1 part
Aq. dest4,000 parts

Or,

Hydrarg bichlorid 1 part
Aq. dest.....8,000 parts

Chlorin water is very efficient when much pus is secreted:

Chlorin water12 drams
Aq. dest..... 1 quart

Peroxid of hydrogen can also be used with advantage just before the irrigations. Following the irrigation it is good practice to insert between the lids a sterile ointment, of which vaseline is probably the most desirable.

When pressure is obviously exerted upon the eyeball from the hard, tense and swollen lids, a canthotomy will give relief.

The sound eye should be protected from infection, either by a bandage or by means of Buller's shield, although in infants the latter will be kept in position with difficulty.

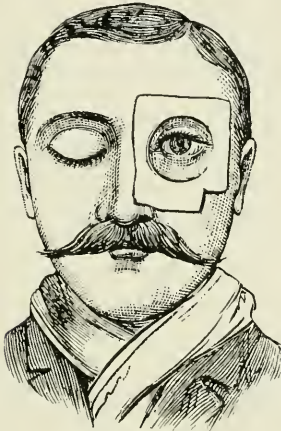The nurse and others in attendance upon the child must be impressed with the importance of faithfully carrying out the treatment as outlined if a favorable result is to be obtained and the eyesight preserved. They should also be warned

of the highly contagious nature of the discharge.

The *general health* of the patient must be carefully looked after. The majority of cases of ophthalmia neonatorum are recruited from the lower classes, or at least from the ranks of the improvident and careless, and the surgeon may expect that the feeding of the infant, and instruction of the mother in the management of sleep, bathing, dress, etc., will be especially required.

Gonorrhœal ophthalmia in the adult, like ophthalmia neonatorum, is due to direct infection of the conjunctiva by the discharge from a gonorrhœa or gleet. It is conveyed to the eye by means of the fingers, towels, etc. The gonococcus of Neisser is usually present in the discharge, which should always be carefully examined in suspected cases. In from one to three days after infection the lids become red and swollen, and the inflammation is accompanied by a watery discharge. The conjunctiva is red and turgid. The swelling rapidly increases, the lids become puffed, tense and hard, are with difficulty separated and cannot be everted, and the upper lid overrides the lower lid. The conjunctiva is of a dusky red color and soon becomes chemotic (edema), concealing the corneal margins and interfering with their nutrition. Pain is present from pressure of the swollen lids, and there is smarting and burning of the lids and a

feeling of foreign body in the eye. The discharge quickly becomes thick, purulent and tinged with blood. It wells up and runs over the margin of the lid on to the cheek. *The conjunctiva is thickened and thrown into folds,* and in some cases is covered with a thick, tenacious membrane, diphtheritic in character, which



Buller's Shield.

leaves a bleeding surface when removed. In a week or ten days these symptoms somewhat subside. The turgescence and tumefactions of the lids are less, and they become softer, the discharge less abundant. The pain is not now so marked, while the chemosis of the conjunctiva decreases, the membrane, however, presenting

a velvety appearance, owing to the hypertrophy of the papillæ, which bleed on the slightest touch. As the inflammation becomes less the swelling also goes down, leaving the conjunctiva of the lids roughened and covered with granulations. The secretion becomes thinner and gradually disappears, although the state of hyperemia remains.

During the stage of marked swelling and edema of the conjunctiva the vitality of the cornea is interfered with; it may become dull and lusterless, while corneal ulceration is liable to occur, terminating in its total destruction. In this case perforation usually takes place and the eye may eventually be lost from a panophthalmitis. On the other hand, a cicatrix may form at the point of perforation and a partial or total staphyloma of the cornea result.

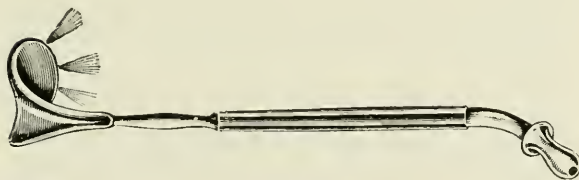
A milder form of purulent conjunctivitis may follow an infection from a leucorrhæal discharge that is due to causes other than gonorrhœa.

The prognosis of gonorrhœal ophthalmia is extremely grave; the symptoms follow one another rapidly, while vision is often impaired to a greater or less degree.

Treatment.—The sound eye should be at once protected by means of a Buller's shield. Iced applications should be applied almost continuously in the manner described in the treatment of ophthalmia neonatorum. The conjunctival

sac should be carefully irrigated every half hour with a saturated solution of boracic acid, permanganate of potassium 1-500, bichlorid of mercury, 1-10,000 or sol. formalin 1-5,000. The irrigant should be allowed to run well up into the conjunctival sac and all discharge washed away. As soon as the lids become less swollen and less tense and the secretion more profuse and purulent, local applications of nitrate of silver, 2 per cent, should be made once a day. Before the use of the silver salt, all discharge must be removed and the conjunctival surface wiped dry with absorbent cotton.

Protargol or argyrol, 20 to 40%, may be used in place of the silver nitrate, with equally good



Hollow Lid Retractor for Washing Out the Conjunctival Sac.

results. If the cornea becomes affected, hot should replace cold applications, while a 1 per cent solution of atropia sulphate should be instilled into the eye two or three times a day, or sufficiently often to dilate the pupil.

Hydrogen peroxid may also be used with advantage as a pus destroyer and cleanser. Where there is excessive edema of the conjunctiva scarification may be resorted to. Freely dividing the outer canthus will be of benefit in relieving the pressure on the cornea of the tense, swollen lids.

Numerous instruments have been devised for the purpose of irrigation and as a means of injecting solutions into the upper conjunctival sac, but *unless used with great care they may injure the cornea and set up ulceration.* Amongst these is the hollow lid retractor, which has openings in the blade through which the solution escapes. All dressings, absorbent cotton, etc., which come in contact with the eye should be burned, and great care must be exercised by the surgeon and nurse that none of the secretion squirts into their own eyes when an attempt is made to separate the lids. Their hands should be washed and scrubbed in an antiseptic fluid, such as corrosive sublimate 1-10,000, immediately after attending to the eye.

The bowels should be kept open and morphia given hypodermically if much pain is complained of.

CHAPTER VI.

THE COMMONER DISEASES OF THE
CONJUNCTIVA—CONTINUED.

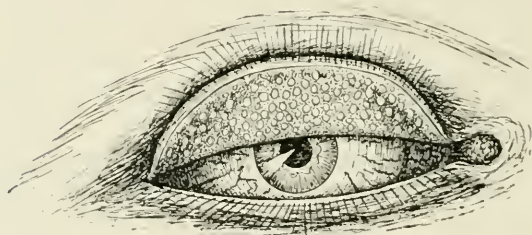
Follicular conjunctivitis and its treatment.—Trachoma; the most serious form of granular lids.—How it produces blindness.—Its many complications.—Treatment.—“Spring” Catarrh.—Phlyctenular conjunctivitis and its treatment.—Pterygium, its cause and treatment.—Pinguecula.

Follicular conjunctivitis is in reality a catarrhal conjunctivitis to which is added an overdevelopment or hypertrophy of the lymph follicles. The palpebral conjunctiva is covered with a number of pale, round, translucent granules, often arranged in rows parallel to the lid margin and more abundant in the lower than the upper lid. They are especially numerous at the junction of the palpebral with the ocular conjunctiva.

The milder forms are usually unattended by any marked symptoms, but in the more pronounced forms there is a mucoid secretion which accumulates during the night, and causes a glueing together of the lids in the morning. There is, also, a slight thickening with some injection of the palpebral conjunctiva. *The ocular conjunctiva is very little affected.* The patient commonly complains of photophobia and itching of the lids with a desire to rub them. In the

more severe types the symptoms are those of acute catarrhal conjunctivitis.

The disease occurs most frequently in *young people*, especially among those who have unhealthy surroundings and where many are crowded together, as in schools and asylums. It is probably not contagious, is confined to the conjunctiva proper, does not affect the deeper structure of the lid and thus differs from *tracho-*



Follicular Conjunctivitis.

ma. The disease is chronic in character and the follicles have a tendency to disappear in time without leaving any trace.

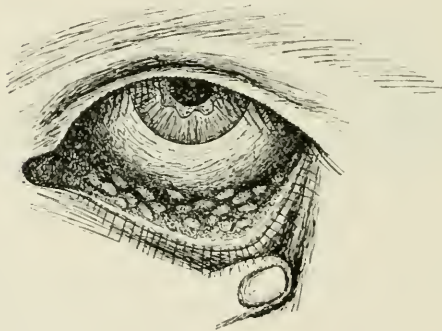
Treatment consists in relieving the symptoms by the application of cold compresses followed by a mild antiseptic lotion such as a saturated solution of boric acid, much the same as described under catarrhal conjunctivitis. A soothing and efficient lotion in such cases, to be instilled after the use of cold applications, is:

Dilute hydrocyanic acid.....	drop	1
Boric acid	dr.	1/2
Borax	gr.	40
Distilled water	oz.	2

The patient should be *removed from all unhealthy surroundings* and placed where he will receive plenty of fresh air. The general health should be improved when it is defective and, if necessary, all near work prohibited. Any existing error of refraction should be corrected. As adjuncts to this treatment many remedies have been recommended by different authorities, showing that they all are of some service. An ointment of sulphate of copper in vaselin (one per cent) applied to the lower conjunctival sac once a day has proved useful in many cases. A method of treatment which will prove satisfactory in the majority of instances and which is much less irritating is massage of the lid with the ordinary dilute citrine ointment, made with unrefined or brown cod liver oil instead of with the usual excipient, and this again diluted with from 30 to 50 per cent of refined cod liver oil. A small quantity of this salve should be placed in the lower cul-de-sac and then distributed over the anterior surface of the eyeball by having the patient rotate the globe in various directions. The upper lid is then gently massaged with the finger for from one to three minutes, the patient, meantime, turning the eyeball well down-

ward. The lower lid should be treated in a similar manner while the globe is rotated upward. This procedure should be carried out at least every other day at the beginning of the treatment, increasing the interval as improvement is noted. The surplus ointment (which is of a dark brown color) should not be washed off the lashes and lid edges for an hour or two after the rubbing because its local, mildly corrective action seems to be of value in these cases.

Trachoma is a very serious, contagious, in-



Trachoma Granules in the Early Stage.

tractable and destructive disease of the eye, characterized by the formation of minute nodular growths (granulations) in the conjunctiva which in time become absorbed, leaving cicatrices to mark the site of the new growths.

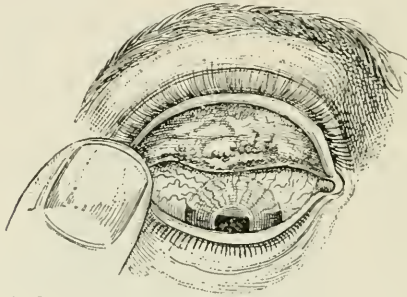
The *acute* form of the disease exhibits great swelling and injection of the palpebral conjunctiva and that portion of the membrane covering the globe, in which case the enlarged papillæ may be hidden by the swollen tissues. It is usually accompanied by discharge that is sometimes purulent in character. Ulcers, from infection, may form on the cornea, when lachrymation, pain and photophobia are prominent symptoms.

The *chronic* form of trachoma is more frequently met with and may set in without any marked discomfort, the patient complaining of nothing more distressing than itching, foreign body sensations or a slight smarting of the lids, these symptoms being aggravated when the eyes are exposed to wind, dust or prolonged use.

As the disease advances the symptoms gradually become more pronounced. On everting the lids their conjunctival surfaces will be found covered with a number of irregularly scattered granulations, more abundant in the upper lid and particularly in the retro-tarsal folds. These granulations are grayish white, somewhat resembling sago grains, are embedded in the conjunctiva and project above its surface.

The base of the granulation consists of connective tissue which eventually constitutes the cicatricial degeneration of the conjunctiva and indicates its locality. The disease, in the course

of months or years, finally involves the tarsal cartilage, the granulations disappear and deformity of the lids is a frequent result. This is due to the cicatricial contraction, producing *entropion*. The bulbs of the eyelashes become affected, so that they grow irregularly and a condition known as *trichiasis* results. After this atrophy of the granulations, the under surface of the lids again becomes smooth, but is shiny



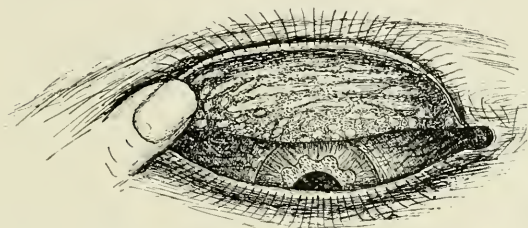
Typical Granular Lid and Beginning Scars, with Pannus.

and intersected by a number of whitish lines showing that the conjunctiva has been replaced by connective tissue.

As the disease still further advances other complications arise. The ocular conjunctiva becomes congested and a vascular condition of the cornea occurs, bringing about a condition called *pannus*, which is nothing more or less than the extension of the trachoma to the cornea. The upper portion of the cornea is generally the first

to suffer and is covered with vessels derived from the conjunctiva, which run between the epithelial layer and Bowman's membrane. The portion of the cornea affected is usually covered with a diffuse opacity, which may clear up entirely if the course of the disease is arrested.

If the disease progresses the whole cornea may present this same picture of vascularization and opacity and its surface may be covered with



Secondary Stage of Trachoma, Showing Cicatrices of the Conjunctiva.

a dense whitish membrane that may leave permanent opacities. In old-standing cases the weakened cornea may be unable to resist the intraocular pressure and, bulging forward, produce a *staphyloma*. As before stated, ulcers of the cornea may form, leaving cicatrices which permanently interfere with vision.

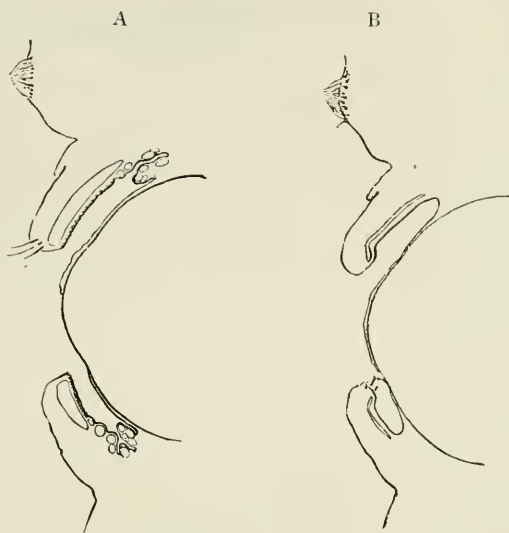
Trachoma is undoubtedly a *contagious disease* and is probably due to the presence of a micro-organism, that has not, as yet, been isolated, al-

though a number of authorities claim that certain bacteria present in the granulations are responsible for the ravages of the disease. It is very likely communicated from one person to another through the secretions transferred on towels, handkerchiefs, etc., especially among those who live in crowded tenement houses or in dwellings where the ordinary laws of hygiene are not observed. It is essentially a *dirt* disease.

Treatment.—In the acute variety *cold applications* should be used frequently every hour or two, followed by the instillation into the conjunctival sac of a solution of boracic acid, gr. 15 to oz. 1; solution of bichlorid of mercury 1-6000 or solution of formalin 1-4000. When the discharge is established and especially when it becomes excessive, the conjunctival surfaces of the lids should be painted with a one or two per cent solution of nitrate of silver, the excess being washed away or neutralized with a solution of common salt. A twenty per cent solution of protargol or argyrol may also be used with benefit.

In the early stages of the chronic form frequent irrigation of the conjunctival sac with mild antiseptic solutions should be resorted to. When the granulations are prominent they should be removed by expression, either by means of the thumb nail or, better still, using one of the several forceps devised for the pur-

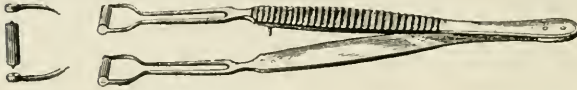pose; the roller forceps of Knapp being the most effective. The lid is everted and one arm of the forceps passed well into the cul-de-sac; the everted lid is then grasped and the forceps drawn away, the granulations being thus squeezed out. Another portion is then treated and the pro-



Schematic Section Through Lid and Eye-Ball.
A—Recent Trachoma. B—Old Trachoma.
(Fuchs.)

cedure repeated until all visible nodules are removed. As the operation is quite painful a general anesthetic should commonly be given. The conjunctival sac should then be irrigated with some mild antiseptic solution. Considerable re-

action follows but soon subsides under the frequent applications of iced cloths. If there is much discharge nitrate of silver or argyrol solution should be applied to the lids once a day or every second day. After this subsides astring-



Knapp's Roller Forceps.

ents should be used, either as solution or, better still, in the solid form. The best of these is the so-called *lapis divinus* gently applied to the everted lids every other day, any excess of the remedy being washed away. An ointment containing

Copper sulphategr. 10
 Vaselineoz. 1

Or,

Tanningr. 10
 Vaselineoz. 1

may be given to the patient to apply between the lids once or twice a day. Dusting the lids with tannic acid has proved useful in some cases.

Frequent cleansing of the conjunctivæ with non-irritating antiseptic solutions should also be carried out by the patient at home. One of the best of these is a 1-5000 solution of formalin.

In the early stages, when the granulations are excessive and prominent, massage of the lids with the yellow oxide of mercury ointment:

Hydrarg. oxid. flav.	gr. 5
Lanolin	oz. $\frac{1}{2}$
Vaselin	oz. $\frac{1}{2}$;

or the nitrate of mercury ointment made up with brown cod liver oil and diluted to the proper consistency with the refined cod liver oil:

Ungt. Hydrarg. nitratis made with

Cod liver oil (brown).....	parts 60
Cod liver oil	parts 40

has given good results in producing absorption of the granulations. The applications to the diseased lids should be kept up for a long time, many months elapsing, even in the mild cases, before the disease can be checked. Atropin should be used when corneal complications set in. The management of these will be considered later on.

For the *treatment of pannus*, especially when it has a tendency to spread over the whole cornea, excision of a strip of the conjunctiva (*peritomy*) surrounding the cornea is effective in order to destroy the blood vessels which supply it. This procedure has proved of benefit in some cases, although it cannot always be relied upon to entirely check the diseased process.

Excision of the entire fornix of the conjunctiva has been successful in many cases in checking the disease but it should be resorted to only when the disease is far advanced, i. e., in the stage of cicatrization.

Spring Catarrh is an affection of childhood and adolescence. It is active only in spring and summer and is apt to recur year after year. The palpebral conjunctiva usually presents a more or less velvety appearance and is covered with a bluish gray film, although in some cases this condition is absent. The ocular conjunctiva is injected and presents a peculiar thickening and grayish, elevated infiltrations at the corneal margin. There is considerable irritation, the patient complaining of itching and smarting with a desire to rub the eye. Lachrymation and photophobia in a bright light are, as a rule, also complained of. Discharge is rarely a symptom. The disease subsides with the advent of cold weather.

Treatment.—Very little can be done to cut short the attack. If possible the patient should be removed to a cooler climate or to cooler surroundings. Daily massage with a 2 to 10 per cent ointment of salicylic acid has been recommended and has proved to be beneficial in some cases, but no remedy can be relied upon to give the desired result.

Relief is best obtained by applying cold or iced compresses frequently during the day, followed by cleansing the conjunctival sac with a 15 grains to the ounce solution of boracic acid. Yellow oxid of mercury ointment (gr. 4 to oz. 1) should be applied between the lids on going

to bed. For the protection of the eyes from light, wind and dust, medium-tinted, smoked glasses or goggles should be ordered. The general health should be looked after and tonics prescribed if necessary. Allport reports a case cured by the X-rays.

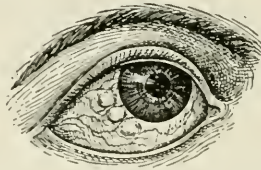
Phlyctenules of the conjunctiva are characterized by the formation of small elevations or pimples.

Symptoms.—This disease is one of childhood and usually sets in with smarting and burning of the eyes and excessive lachrymation. At the same time the patient exhibits an intense sensitiveness to light. The child buries its head in the mother's lap or in a pillow and seeks dark corners of the room to get away from the light. The lids are tightly closed (*blepharospasm*) and any attempt to open them is met with decided resistance. The photophobia and blepharospasm are due to the disease affecting the cornea, which usually becomes involved early in the disease.

Frequently accompanying phlyctenular conjunctivitis is an *eczematous eruption* behind the ears, on the face and at the corners of the mouth and nose. The cervical lymphatic glands are commonly enlarged. The child generally presents a strumous appearance. Blepharitis is frequently present and fissures are likely to form at the outer angle of the lids. The ocular conjunctiva is usually congested, especially when a num-

ber of phlyctenules are scattered over the conjunctival surface. Where there are only one or two pimples the injection is confined to a leash of blood vessels running to the phlyctenule.

The phlyctenule consists of a small, solid, reddish elevation, made up of a collection of lymphoid cells beneath the epithelial layer of the conjunctiva. In a short time the epithelium becomes destroyed and an ulcer forms. The phlyctenule usually appears on the conjunctiva in close prox-



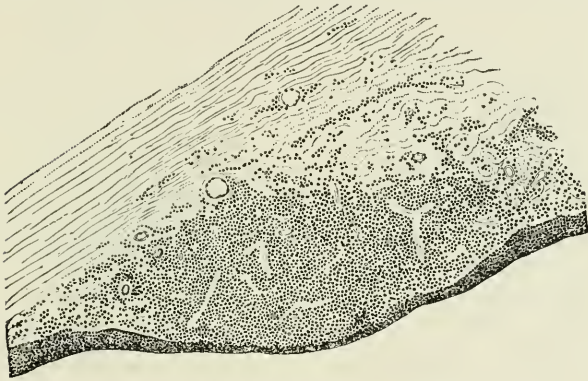
Phlyctenular Conjunctivitis. (De Schweinitz.)

imity to the corneal margin and as a rule the disease extends to the cornea forming ulcers, a description of which will be given later. Fresh attacks frequently occur, new phlyctenules appearing on other portions of the conjunctiva before the first outbreak has disappeared. As long as the disease is confined to the conjunctiva it is not serious, so far as interference with vision is concerned.

It is usually *found in children* of the poorer classes who are badly nourished and brought up

in unhealthy surroundings, and may be regarded as an eczema of the eye due to an attempt of nature to get rid, in an eruptive fashion, of some morbid blood product.

Treatment.—The *general health* should be carefully attended to. The *diet* should be regulated, giving the child plenty of fresh milk and eggs. Meat should not be allowed more than



Efflorescence at the Margin of the Cornea in Phlyctenular Conjunctivitis. (Fuchs.)

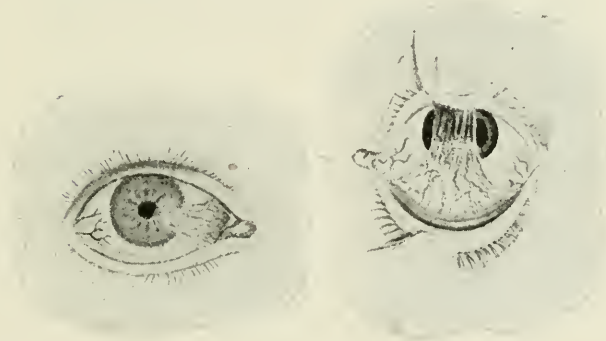
once a day and in the majority of cases it should be avoided altogether. Pastry, candy, and sweets of all sorts should be prohibited. The child should be kept in the open air, and, if possible, should have a healthier environment. Tinted glasses should be worn to protect the eyes from excessive light, from wind and from dust, but bandages should not be applied.

Small doses of calomel or gray powder should be given to regulate the bowels while tonics, especially arsenic and iron, are generally indicated. Syrup of the iodid of iron and cod liver oil are often required. The nasal passages usually require attention, as a chronic rhinitis is frequently present—another manifestation of the lowered condition of the general health.

The local treatment is important. If blepharitis be present all crusts should be removed from the margins of the lids, first softening them by bathing in warm soda water and then applying an ointment of the yellow oxid of mercury in vaselin, gr. 2 to 5 to the ounce. This should also be placed between the lids at night. The same ointment may be applied with benefit to the eczematous patches on the skin and at the angles of the mouth and nose. A weak solution of nitrate of silver ($\frac{1}{2}$ to 1 per cent solution) painted on the fissures at the outer angle of the lids, as well as on the excoriations at the angle of the mouth and nose, is also of benefit. The blepharospasm may be relieved by cold applications. Cleansing of the conjunctival sac with a solution of boracic acid (gr. 4 to oz. 1) will assist in keeping in check the congestion of the conjunctiva.

Pterygium.—Pterygium is a thickened, triangular fold of conjunctiva with its apex, or head, on the cornea and its body and base spread-

ing out, *like a fan*, towards either canthus. It is usually situated on the nasal side of the cornea but sometimes appears on the temporal side. It rarely appears above or below or in two situations at the same time. In the early stages it is highly vascular, with a tendency to advance slowly over the surface of the cornea towards its center, often as far as the pupillary area. In the latter case vision is permanently inter-



Usual Form.

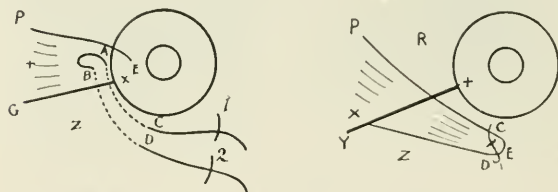
Pterygium.

Rare Form.

fered with. Later on, it ceases to grow, loses its vascularity and becomes thin, pale and atrophic. It is a cause of considerable disfigurement, acts as a nidus for bacteria, and, in a number of other ways, sets up a good deal of irritation. It is not safe to perform any operation that involves the opening of the eyeball while it is present.

Etiology.—It is usually found in subjects who are exposed to wind, dust and other irritating influences, especially in *farmers, motormen, cab drivers, sailors*, etc. The starting point of a pterygium is usually a small ulcer at the corneal margin, in which a fold of the conjunctiva becomes caught during the process of healing and is drawn into the healed area. This leaves a roughened surface at the limbus upon which foreign bodies readily lodge and from which the protecting epithelium is easily removed; there is a succession of ulcers and the growth advances apace.

Treatment.—The growth may be removed by some of the various operative measures at our



McReynold's Operation for Pterygium.

Fig. 1. Showing needles, 1 and 2, which enter the neck of the growth, *p, t, c*, at *a* and *b*, and then pass beneath the loosened lower segment of the conjunctiva, *x, y, z*, and emerge at *c* and *d*, below the cornea.

Fig. 2 shows the pterygium *p, t, c*, fixed by a single stitch, *c, d*, beneath the loosened lower segment of the conjunctiva, *x, y, z*. The former site of the growth, *p, x, z*, is now covered by the normal, smooth, but stretched, conjunctiva.

disposal. One of the best is that devised by McReynolds of Dallas, Texas, in which practically

no disfigurement remains after the operation. His method is described by the operator as follows:

1. Grasp completely the neck of the pterygium with strong but narrow fixation forceps.
2. Pass a Graefe knife through the constriction as close to the globe as possible, and then, with the cutting edge turned towards the cornea, shave off every particle of the growth smoothly from the cornea.
3. With the fixation forceps still hold the pterygium, and with slender, straight scissors divide the conjunctiva and subconjunctival tissue *along the lower margin* of the pterygium, commencing at its neck and extending towards the canthus, a distance of one-fourth to one-half of an inch.
4. Still hold the pterygium with the forceps and separate the body of the growth from the sclera with any small non-cutting instrument.
5. Now separate well from the sclera the conjunctiva lying below the oblique incision made with the scissors.
6. Take black silk thread armed at each end with small, curved needles and carry both of these needles through the apex of the pterygium *from without inwards*. The threads must be separated from each other by a sufficient amount of the growth to secure a firm hold.
7. Carry these needles downward beneath

the loosened conjunctiva lying below the oblique incision made by the scissors. The needles, after passing in parallel directions beneath the loosened segment of the conjunctiva until they reach the region of the lower sulcus, should then emerge from beneath the conjunctiva at a distance of about one-eighth to one-fourth of an inch from each other.

8. Now, with the forceps, lift up the loosened, lower segment of the conjunctiva and gently exert traction upon the free ends of the threads, which have emerged from below, and the pterygium will glide beneath the loosened, lower segment of the conjunctiva, and the threads may then be tightened and tied and the surplus portions of the thread cut off. *It is very important that no incision should be made along the upper border of the pterygium, because it would gape and leave a denuded space when downward traction is made upon the pterygium.**

Penguecula is a *small, yellowish-white elevation* in the ocular conjunctiva, usually situated near the corneal limbus towards the outer or inner canthus. It is composed of *thickened connective tissue* and is not a fatty deposit, as its appearance and name might suggest. It is an *innocent growth* and rarely requires removal.

* Ophthalmic Record, May, 1901.

CHAPTER VII.

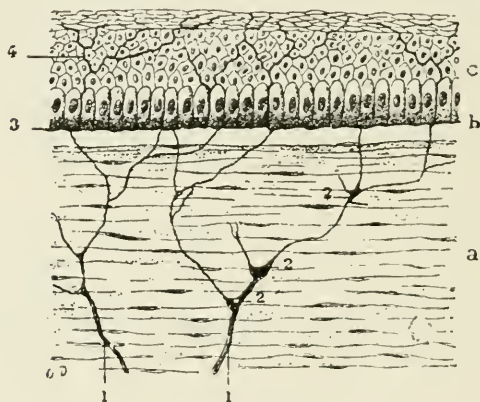
THE COMMONER DISEASES OF THE CORNEA.

Anatomy and physiology.—Ulcer of the cornea generally due to removal of protecting epithelium and subsequent infection.—The pneumococcus.—Deep ulcer.—Hypopyon.—Perforation of the cornea.—Treatment.—Serpent or spreading ulcer.—Ring ulcer at the margin of the cornea.—Neuroparalytic ulcer.—Herpes of the cornea.—Phlyctenular Keratitis, a common disease of childhood.—Treatment of the foregoing.—Interstitial or parenchymatous keratitis.—It occurs mostly in children and is due to syphilis or struma.—Punctate keratitis, a sign of disease of the choroid or ciliary body.—Opacities of the cornea and their treatment.—Artificial pupil.—Optical iridectomy.—Iridotomy.—Conical cornea.—How to treat it.

Anatomy and Physiology.—The cornea is attached to its scleral border much as a watch glass is set into its case. It forms a transparent front to the globe, is almost circular in shape and is covered by the same pavement epithelium that protects the conjunctiva. The sclero-corneal junction is known as the *limbus*. Here the sclera occasionally encroaches on the cornea so as to form a band or ring of opaque tissue. When it undergoes further changes (as it often does in old subjects and sometimes in young persons) it is called the *arcus senilis*.

In health no vessels are to be found in the cornea although fine, invisible capillary loops are arranged about the limbus from which, by


means of lymph channels, the cornea obtains most of its nutritive supply. The protective epithelium lies on Bowman's membrane, which separates it from the *true substance* of the cornea. The latter is composed of connective tissue arranged in layers that cross one another at right angles and are bound together by a sort of organic *cement*.



Nerve Supply of the Cornea.

- 1, Two afferent trunk nerves; 2, deep stroma plexus;
 3, sub-epithelial plexus; 4, intra-epithelial plexus;
 a, cornea proper; b, anterior or Bowman's
 membrane; c, anterior epithelium.

The *substantia propria* is traversed by canals or lymph spaces that indirectly connect with the ciliary vascular system and lymphatic vessels both inside and outside the globe. Beneath the proper substance of the cornea is *Descemet's*



Section of the Cornea.

membrane, a thin, tough and very elastic layer, which is lined by, and so forms the roof of the *anterior chamber*, a layer of hexagonal cells, the endothelium.

Corneal Ulcers are usually due to the entrance into the corneal substance of some one of the *microorganisms* productive of inflammatory conditions. The virulence of the infection depends upon the nature of the bacterium, whether it be the gonococcus, streptococcus, staphylococcus, pneumococcus or other germ.

In the earliest stage of ulcer one first notices a localized, hazy appearance of some part of the corneal surface, after which the epithelium covering this area breaks down, allowing one or more pathogenic microorganisms to penetrate into the corneal substance. Injury to the cornea in some form or other (commonly removal of the protective anterior epithelium) is usually the primary cause, even when the infection is secondary to a purulent or mucopurulent inflammation of the conjunctiva, tear passages or nasal mucous membrane.

Randolph has recently shown that *bacterial ptomaines* or *toxins* produce the same destructive effects as the bacteria themselves.

Once established, the ulcer may continue to be merely superficial and heal in a few hours, especially if no serious infection has taken place. In other cases it spreads in the anterior layer

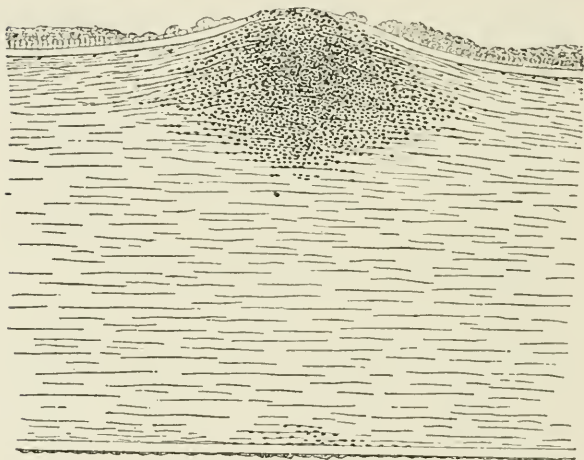
of the cornea towards the pupil or it remains near the periphery, following the sclero-corneal margin; or it may penetrate deeply into the substance of the cornea and perforate into the anterior chamber. With the exception of small, superficial ulcers, which are often nothing more than mere abrasions of the corneal epithelium without serious infection of the exposed surface, opacities of the cornea invariably follow ulcers in this situation.

Vision is often affected by the scar that forms in the cornea, the defective sight depending upon the situation and density of the cicatrix. Vision is greatly interfered with when the pupillary area is involved; it is unaffected when the opacity is situated elsewhere.

Owing to the fact that in old age the nutrition of the cornea is easily lowered, corneal ulcers are more common in advanced life than in early youth. As a result of their unsanitary surroundings and manner of living the poorer classes are more prone to ulcer of the cornea than the well-to-do. In the former the resisting powers of the cornea to the entrance of pathogenic microorganisms are insufficient and ulcers are liable to follow abrasions and other minor injuries of the cornea, especially in the presence of a previous infected conjunctiva.

The detection of corneal ulcer presents few difficulties if it is at all extensive, although small

and superficial ulcerations of recent origin are comparatively easily overlooked. In most cases there will be noticed a slight infiltration of the cornea, giving its surface a steamy appearance, while the epithelium will have lost its polished appearance, differing in this respect from a true scar, which is covered with normal epithelium.



Superficial Infiltration of the Cornea.

Again, if the reflection from a window be allowed to fall upon the affected cornea the image of the cross bars will appear broken or irregular. One of the surest means of detecting the presence of an ulcer is to allow a few drops of a two per cent solution of postassium fluorescein to flow over the surface of the cornea.

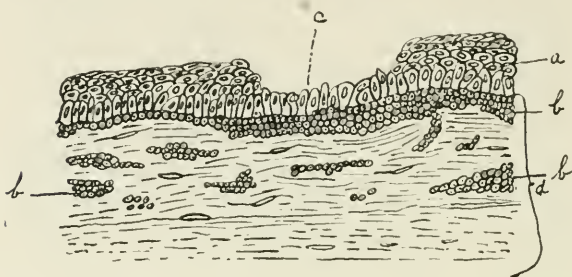
Fluorescein	gr.	8
Liq. potassæ	dr.	1
Aquæ dest. q. s. ad.....	oz.	1

This solution renders the denuded surface of the cornea green or greenish yellow and accurately maps out the limits of the ulcer.

Simple Ulcer, the most common variety of this affection, is usually due to a slight traumatism, for example, a cinder or other particle of foreign substance getting into the eye and abrading the corneal surface. The infection may be furnished by and be secondary to a diseased condition of the conjunctiva, either confined to the palpebral or ocular portion or affecting both. Some common examples of this are phlyctenular disease of the conjunctiva, follicular conjunctivitis, trachoma or acute conjunctivitis in any of its forms. Although this form of ulcer may extend into the cornea proper its tendency is to heal without further loss of substance.

If the ulcer be small and there is difficulty in its detection a drop of the two per cent solution of fluorescein just referred to will immediately reveal its existence. If it be large enough to be readily seen it will have a slightly scooped-out appearance with a grayish floor and a circumference surrounded by infiltration. There will be more or less circumcorneal congestion whose extent will depend in a great measure upon the situation and extent of the ulcer. It will then

be attended by *pain more or less severe, photophobia, blepharospasm and lachrymation*, while the pupil will be slightly contracted. When it



First Stage of Corneal Ulcer.

a, epithelial layer; *b*, collections of infiltrating round cells; *c*, destruction of protecting epithelium; *d*, proper substance of the cornea.

undergoes repair the depression fills up with new tissue which soon becomes covered with epithelium, leaving a whitish scar. The opacity becomes less dense, as time goes on, and in some instances disappears entirely.

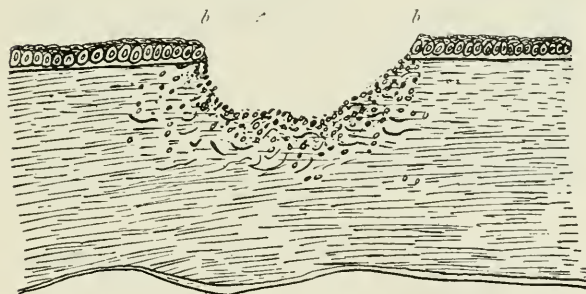
If the ulcer is situated near the periphery of the cornea, apart from the slight haziness (*nebula*) that is visible on oblique illumination of the corneal surface, vision is unaffected. It is only when the ulcer is situated in the pupillary area that sight is interfered with, the extent of which depends on the density of the cicatrix.

Treatment.—One drop of one per cent solution of atropin sulphate should be instilled into the conjunctival sac at once and continued once

or twice daily or often enough to keep the pupil dilated.

The application of hot water (as hot as can be borne) should be kept up every one to three hours, depending upon the amount of inflammation and pain present. This should be followed by washing out the conjunctival sac with a mild antiseptic lotion: boric acid solution, 3 per cent; solution hydrarg. bichlorid, 1 to 10,000; solution permanganate of potassium, 1 to 4,000, etc.

The eye should not be bandaged, but covered



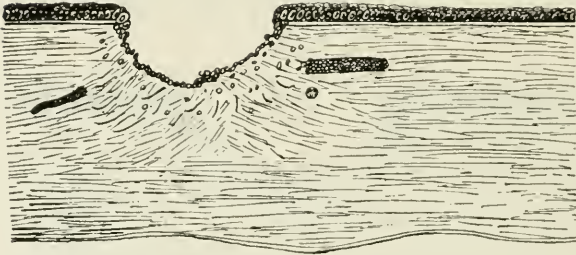
Second Stage of Corneal Ulcer.

The edges of the ulcer are at *b, b*, where the epithelium and anterior elastic lamina end. The bottom of the excavation is covered with tissue debris.

with an eye shade, a piece of sterilized gauze being placed between the eye and the shade. The cornea and conjunctival sac should be carefully examined, foreign bodies should be removed

and diseased lids treated with appropriate remedies. Tonics and other proper remedies should be given when the general health is at fault.

Deep ulcer is generally of the suppurative variety and is prone to involve the deeper layers of the cornea even to perforation of the latter. It follows, as a rule, injury to the cornea attended by infection from some pyogenic germ



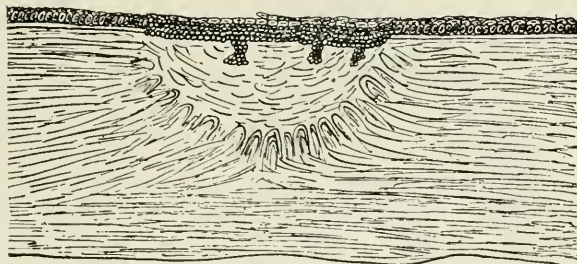
Third Stage of Corneal Ulcer.

Beginning of repair. The proliferating epithelium has covered the bottom of the ulcer. New blood vessels (dark spaces) forming near bottom.

accidentally present in the sac; or infection may occur during a purulent inflammation of the conjunctiva due to the presence of the gonococcus or other pus-microbe.

This serious disease is usually accompanied by severe pain in the eye and the frontal region, photophobia, lachrymation and congestion of the iris and ciliary body. Pus, fibrin with leuco-

cytes and some pyogenic microbes frequently form in the anterior chamber (*hypopyon*) changing their locality according to the position in which the head is held. When the patient



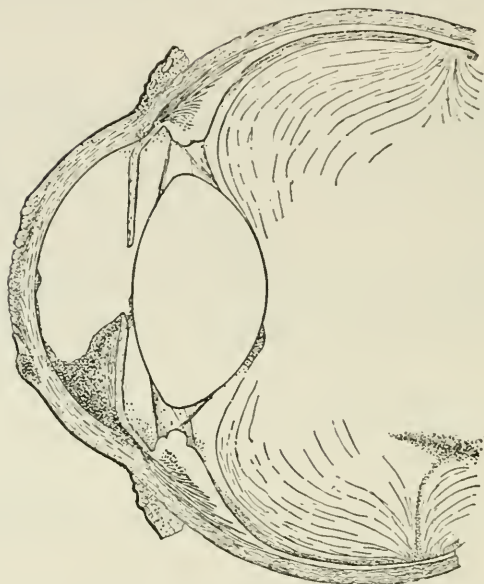
Fourth Stage of Corneal Ulcer.

Complete repair. The marginal epithelium has covered the scar, even extending into its substance.

holds the head upright the hypopyon is at the bottom of the anterior chamber and appears there as a grayish white streak or it may extend to the margin of the pupil. If the patient lies down the pus gravitates to the outer portion of the anterior chamber.

The amount of purulent liquid varies; sometimes it almost fills the anterior chamber, while at other times the amount is so small that it can only be detected on close examination. The quantity of pus in no way depends upon the extent and severity of the ulcer. This so-called

pus is often really sterile since it is not, as a rule, derived from the ulcer itself. The mem-



Corneal Ulcer with Hypopyon.

brane of Descemet forms a barrier that does not allow any foreign material to penetrate into the anterior chamber. The hypopyon is mostly made up of leucocytes derived from the iris, which wander from the bloodvessels of that structure and accumulate in the anterior chamber; sometimes the liquid of the hypopyon is very thick, at other times it is quite watery.

Deep ulcer is usually round and varies in size. Its floor is covered with pus; its edges are frequently swollen and surrounded by a grayish infiltration. It has no tendency to spread, but its chief disposition is to open into the anterior chamber. When *perforation* is about to occur actual bulging of Descemet's membrane into the cavity of the ulcer may be observed on close inspection.

When perforation takes place the aqueous humor gushes out; the iris is pushed forward and either becomes entangled in the corneal opening, or (especially if the perforation be peripheral) suffers prolapse.

If the ulcer is situated in the center of the cornea (pupillary area) out of reach of the iris, the anterior capsule of the lens becomes applied to the perforation wound. In either case plastic material is thrown out which glues the iris to the margins of the corneal opening, preventing the escape of more aqueous and allowing the anterior chamber to reform. The iris thus becomes incarcerated in the wound and an *anterior synechia* forms. The ulcer heals and in time a dense white cicatrix (*leucoma adherens*) is the result.

If a decided prolapse of the iris has taken place, we are likely to have bulging of the affected cornea (*anterior staphyloma*) of greater or less extent, due to the action of the intraocular pressure on its weakened walls.

Where a temporary adhesion has occurred between the anterior capsule of the lens and the edges of the perforation, reformation of the anterior chamber allows the lens to fall back into place. In that case a string of plastic material will be found joining the two surfaces. This ultimately breaks, leaving an opacity on the an-



Anterior Polar Cataract.

terior capsule at that point and giving rise to an *anterior polar cataract*.

Fortunately, perforation does not occur in all cases of deep ulcer because the deeper layers of the cornea, and particularly the membrane of Descemet, are tougher than the superficial layers and are better able to resist the destructive process that is going on. When it does occur its results are very disastrous, not only on account of the marked interference with vision but, also, as a result of the *entrance of pyogenic microorganisms into the interior of the eyeball*. The suppuration then extends to the internal struc-

tures and total destruction of the globe from panophthalmitis follows.

Treatment consists, first of all, in the disinfection of the ocular structures and especially of the discharges from a purulent or other form of conjunctivitis that may be present. The pupil is to be dilated with a few drops of a one per cent solution of atropia sulphate used sufficiently often to keep it in that condition. Even if no iritis is present, the atropin keeps the eye at rest by rendering the iridic and ciliary muscles inactive and thus checks the inflammation.

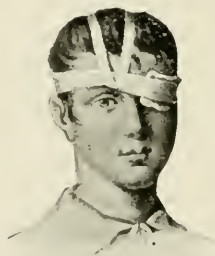Very hot applications, in the form of hot fomentations, hot water bags or hot steam, should be used every hour or two for 15 to 20 minutes at a time. These are to be applied as hot as they can be borne—at a temperature varying from 115 degrees to 120 degrees F. They may consist of hot water alone, hot chamomile tea or hot boracic acid solution (gr. 15 to the oz.). Hot applications not only stimulate the reparative powers of the tissues but are materially beneficial in relieving pain.

One effective method of application is as follows: A piece of sterilized gauze of several thicknesses is made into a pad large enough to cover the parts surrounding the eye. This is dipped into the hot water and wrung out so as to be moist (not wet) and applied to the ocular region. It must be changed frequently so that

it is always *hot*; it must not be allowed to get cool.

Gentle but frequent *irrigation* of the conjunctival sac and ulcer with a mild antiseptic solution is a very effective measure. One may use for this purpose boric acid, 15 grains to the ounce, or corrosive sublimate, 1 to 10,000. The eye should be protected from the wind, as well as from dust and other foreign particles by a shade.

If there is danger of perforation a bandage should be applied, firmly but not too tight, in which case it is well to place a small quantity of

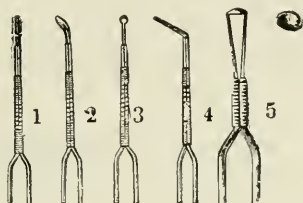


Pressure Bandage.

absorbent cotton at the inner canthus to act as a pad and as a means of securing uniform pressure over the eyeball. When there is discharge from the conjunctiva the pad is contraindicated.

When healing does not soon take place, or if the ulcer eats further into the corneal substance,

more active measures, looking to the removal or destruction of the pathogenic bacteria must be resorted to. The floor of the ulcer may be scraped with an ordinary spud such as is used for the removal of foreign bodies or, more effective still, the *actual cautery* may be employed.




Tips Used for Electro-Cautery of the Eye Tissues.

The outlines of the ulcer are first mapped out by instilling a two per cent solution of potassium fluoresceid, which stains the ulcer yellow green, and then a fine tip is used with the galvano-cautery and applied white hot to every part of the stained tissue. The end of a knitting needle, brought to a white heat and applied to the surface of the ulcer, makes a simple cautery. This may be repeated if necessary, but, if thoroughly done, is not usually required a second time.

If the perforation cannot be avoided it is anticipated by *paracentesis* of the anterior chamber through the floor of the ulcer. This may be done with a paracentesis needle, an ordinary Graefe knife or with a keratome. It is also in-

licated when great pain is present, and especially if there is increased ocular tension, both of which it relieves in a very short time. It is much better to produce an artificial perforation in this way than to allow it to occur naturally, since prolapse and incarceration of the iris in the wound may be prevented. The wound may be reopened as often as is necessary by passing a fine probe between the lips of the wound. If perforation does occur and the iris engages in



Paracentesis Needle.

the wound, an effort should be made to replace the former. If this is impossible the prolapsed portion should be drawn forward with forceps and cut off flush with the corneal surface; the iridic edges are then freed and replaced with a spatula.

Our efforts should always be directed, in these cases of serious ulcer, to prevent anterior synechiæ and staphyloma. If the perforation be near the periphery of the cornea, a solution of eserine may be used with advantage to contract the pupil and draw the iris away from the wound.

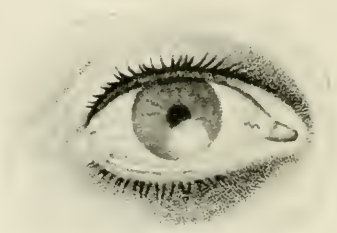
Spreading Ulcer is merely another form of purulent infection where the resulting ulcer tends to spread over the surface of the cornea

without involving its deeper layers. As in the other forms of infective ulceration we first have an abrasion of the epithelial surface (most likely to occur in those exposed to wind, dust and such deleterious influences) followed by inoculation from discharges due to diseased conjunctival or lachrymal apparatus, or nasal mucous membrane. Chronic conjunctivitis, dacryocystitis and ozena are not uncommon sources of the infection in sloughing ulcer. *The character of this ulcer depends chiefly upon the presence of the pneumococcus* (which will usually be found in the discharge), although mixed infections are not uncommon. Pain is not a prominent symptom, although it may be quite severe in some cases. Iritis may be present and the inflammation extend to the ciliary region, in which case there is a marked circumcorneal injection. The ulcer usually presents a dull gray or yellowish floor and undermined edges, with one or more breaks in various portions of the rounded margin. It is in the direction of these that the ulcer has a tendency to spread. The true margins of this ulceration are always surrounded by an area of infiltration more or less dense, and as the ulcer spreads over the surface of the cornea, the infiltrated edges slough off and form part of the central excavation.

In the majority of cases it is the *center of the cornea* that is first affected or, in any event, the

ulcer creeps in that direction. Hypopyon is usually present and the anterior chamber may become almost filled with pus. This process may go on until the whole cornea has become involved, leaving an opacity the density of which depends upon the severity of the disease.

In many cases the normal cornea is replaced by a dense white cicatrix (*leucoma*); in other



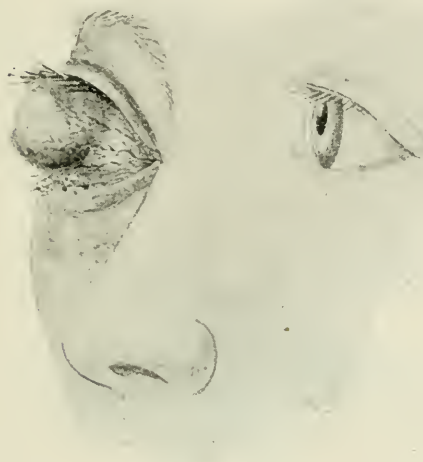
Leucoma, or Deep Scar of the Cornea.

cases the corneal tissue becomes softened and bulges (*staphyloma*) from the intraocular pressure. *Vision is very much interfered with.* Perforation is much less likely to take place than in deep ulcer. In some severe cases the whole cornea sloughs, followed by destruction of the globe from panophthalmitis.

When repair begins the surface becomes vascular and further extension of the ulcer is checked. The general health is usually affected in serpiginous ulcer.

Treatment.—This is much the same as in

deep ulcer—atrophia, hot fomentations and anti-septic solutions. In addition to these the administration of tonics (especially the tincture of the chlorid of iron in large doses with small doses of quinin) and regulation of the diet are called for. The spreading of the ulcer must be checked



Staphyloma, Following Ulcer of the Cornea.

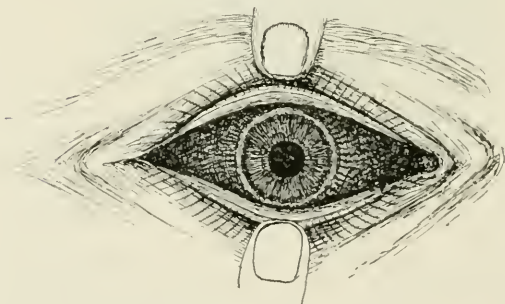
by cauterizing its surface and undermined margins. The actual cauterization, especially *the galvano-cautery*, seems to be the only means of arresting the disease in many cases. In the milder forms of the disease the pure tincture of iodine has a beneficial effect. Pure carbolic acid or 10

per cent solution of nitric acid has also been used with good results.

A wooden toothpick is dipped in either of these remedies and applied thoroughly to the cocainezied ulcer-excavation, after cleansing and staining with fluorescein. To be effective the toothpick should be soaked in the germicide fluid and *pricked into* the surface of the ulcer.

An incision through the floor of the ulcer should be resorted to if there is danger of perforation; sometimes paracentesis greatly assists the healing of the ulcer.

Ring ulcer is situated at and tends to *spread* .



Ring Ulceration of the Cornea.

around the margin of the cornea. It is more commonly met with in old people, especially in those whose general health is not of the best

and who have a chronic catarrh of the palpebral conjunctiva or a chronic dacryocystitis. It probably arises from an abrasion of the epithelium due to the lodgment of a foreign body at the corneal limbus, infection taking place from the conjunctival or other discharge present. A common form of this disease occurs in farmers, whose eyes are liable to injury from the flying stems and other parts of wheat or hay. An abrasion of the cornea is the result and infection follows.

It usually takes the form of a deep ulcer with infiltrated edges, that spreads along the corneal margin instead of extending towards the pupil as in ordinary serpiginous ulcer. The older ulcer may heal while the recent necrosis gradually extends, although destruction of the whole cornea may occur from interference with its nutrition, especially if the ulcer has already eaten completely around the sclero-corneal junction.

Treatment should be carried on actively, with atropin, mild antiseptic solutions and hot applications. The general health should be built up by the internal administration of iron, quinin, etc., and a nutritious diet. If there is danger of perforation a solution of eserin, $\frac{1}{4}$ to $\frac{1}{2}$ per cent, may be instilled into the conjunctival sac in order to contract the pupil and render prolapse of the iris less likely to occur. In such a case paracentesis through the floor of the ulcer

should be performed without delay. The early and thorough employment of the actual cautery is here indicated and it should be repeated if necessary.

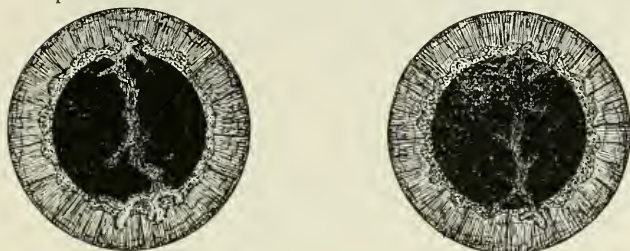
Neuroparalytic Keratitis.—The involuntary cleansing and moistening of the eyeball by winking (when the edges of the lids, acting like a rubber scraper, push secretions, dust, etc., towards the puncta where they are sucked into the nose) are indirectly brought about by the irritation of the cornea, either from drying of its surface or by the impact or contact of extraneous substances. When common sensation is destroyed, from paralysis of the ophthalmic branch of the fifth nerve, the eyeball is imperfectly cleansed and an infective keratitis may follow, resulting in ulcer, with hypopyon and loss of sight. A good example of this disease is the corneal ulceration *following removal of the Gasserian ganglion*. In paresis of the seventh nerve, when there is lagophthalmus and the patient is unable to close the eye owing to insufficiency of the orbicular muscle, in marked ectropion and after a loss of a portion of the lids practically the same form of corneal infection may occur.

Treatment consists in covering the eye with an eye-shade when anything interferes with the proper protection of the cornea, and the instillation of sterile castor oil or vaseline four times daily after washing out the sac with boric acid

solution. Atropin and a mild antiseptic solution should be applied when the disease shows itself, and the case treated as for spreading ulcer.

Various other forms of corneal ulcer are met with, but are more or less rare, in consequence of which they only require mention. Their treatment is based upon the lines already laid down.

Dendritic Ulcer derives its name from the peculiar branch-like form it assumes.



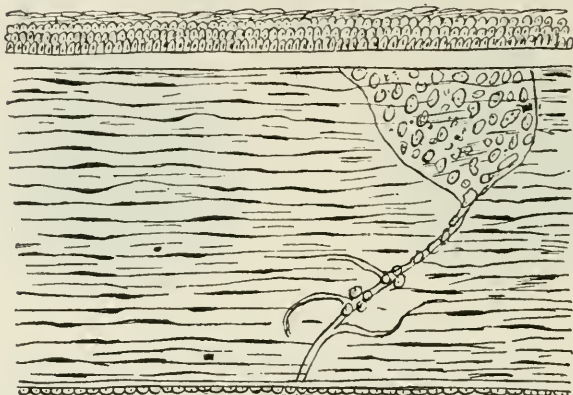
Dendritic Ulcer of the Cornea.

Herpetic Ulcer is the result of herpes zoster of the ophthalmic division of the fifth nerve, which is often seen with herpes of the face, lips and nose. Small vesicles occasionally form on the cornea; these, breaking down, are infected and eventually produce ulceration. The disease is accompanied by severe pain of a neuralgic character. The resulting corneal opacities often interfere greatly with useful vision.

Malarial Ulcer is sometimes seen in subjects suffering from malaria. There is loss of sensation in the area of the cornea occupied by the

ulcer, with severe pain and much circumcorneal injection. The treatment of the underlying disease is the chief indication.

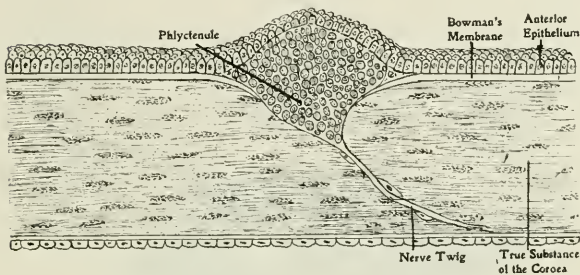
Phlyctenular keratitis or eczema of the cornea is an important and common disease of childhood and often occurs in conjunction with phlyctenular conjunctivitis (which is described



First Stage of Phlyctenular Keratitis.

under diseases of the conjunctiva), and depends upon the same causes for its origin. There first appears on some portion of the cornea (usually in the neighborhood of the limbus) a small, grayish elevation, which consists of an accumulation of lymphoid cells covered with epithelium. The epithelial covering breaks down in a very short time and leaves an ulcer. Several may

form in the same neighborhood and coalesce, or each heals, to be followed almost immediately by one of a similar nature. This may go on until the greater part of the cornea has been invaded. *Leashes of vessels* form and traverse the cornea



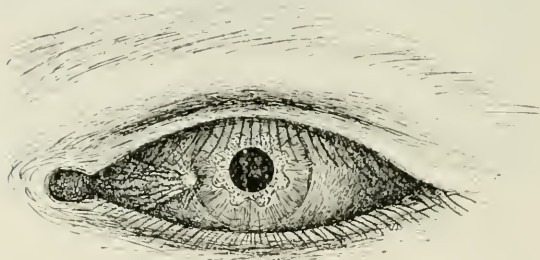
Second Stage of Phlyctenular Keratitis.

from the conjunctiva, extending to each ulcer, and if the disease is very extensive the whole cornea may be covered by a network of blood-vessels. Sometimes perforation into the anterior chamber takes place, followed by all the undesirable results accompanying such a condition.

This form of ulcer usually leaves permanent opacities of greater or less density. Relapses are frequent and the disease may last many months before a complete cure is obtained. This disease is usually accompanied by intense photo-

phobia, lachrymation and blepharospasm, from irritation of the nerve endings in the cornea. The child always seeks the dark corners of a room, or buries his head in a pillow or in his mother's lap, apparently to escape the light.

Spasm of the orbicularis muscles is probably the chief cause of this symptom, because a few drops of a 2 per cent solution of cocain instilled into the affected eye relieves the photophobia, when it would aggravate it under other condi-



Solitary Phlyctenule of the Cornea, showing the leash
blood-vessels.

tions. The lids are swollen and tightly closed; the little patient continually rubs his lids with his hands in the vain endeavor to relieve the pain or foreign body sensations from which he suffers. The conjunctival lining of the lids is red and in some cases presents a "raw-beef" appearance, while a troublesome fissure in the skin at the external canthus is not uncommon.

Eczematous patches are usually found on the face or about the ears; erosions of the same

kind may be seen at the angles of the mouth, and the alæ of the nose, and frequently there is suppuration of the middle ear. The mucous membrane of the upper air passages is congested and the extension of the inflammation through the lachrymal passages aggravates the disease. The profuse lachrymation and the consequent discharge of tears and mucus along the nasal duct into the nares make the child act and feel as if he had an acute coryza and furnish one of the best marked characters of the disease.

Treatment should be carried out as described under phlyctenular conjunctivitis. One or two drops of a 1 per cent solution of sulphate of atropia should be instilled into the eye sufficiently often to keep the pupil fully dilated. The photophobia (*blepharospasm*) is best relieved by the frequent (every hour or two) application of cold or iced cloths to the lids for five minutes at a time and will be found very grateful to the patient. The conjunctival sac may be flushed with solutions of boric acid, gr. 10 to the ounce, or corrosive sublimate 1 to 10,000, several times a day if the eczema of the skin of the lids is not extensive. It is well to avoid the use of watery solutions in the latter case. Milk may then be used to wash the face and lids. The fissures of the external canthus should be touched with a 1 per cent solution of nitrate of silver. An ointment of the yellow oxid of mercury, gr. 2-5 to

the ounce, should be placed between the lids at night and the same mixture applied three times daily to the patches of eczema about the face. It is well to introduce a small piece into the nose at the same time. Where the ulcers show a tendency to chronicity massage with a stimulating ointment is useful to promote healing:

Nitrate of mercury, made
 with cod liver oil.....60 pts.
 Cod liver oil.....40 pts.

The nasal mucous membrane should be treated with appropriate remedies.

A sine qua non is the *improvement of the general health*, particular attention being paid to a life in the open air, bathing and proper diet. As a rule meat should not be allowed; at most not more than once a day. Eggs and milk, especially the latter, should constitute the greater portion of the diet. Pies, cakes, candies and other sweets should be strictly prohibited. Plenty of outdoor exercise, especially, should be insisted upon, and if the child can be removed to more healthful surroundings and given a change of air and scene improvement usually soon follows. Internally, the administration of the syrup of the iodid of iron, liq. arsenicalis, cod liver oil, etc., is of the highest importance, first of all regulating the bowels with small doses of calomel or gray powder. The following formula will usually be found most helpful:

Liq. potass. arsenitis.....dr. $1\frac{1}{2}$
 Liq. potassædr. $1\frac{1}{2}$
 Aqua. dest.....q. s. ad. oz. 2

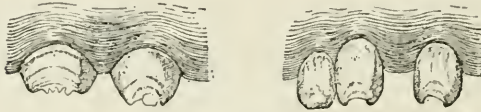
A teaspoonful in a tablespoonful of water, after eating, three times daily.

If the ulcers do not soon heal they should, after disinfection and under a general anesthetic, be touched with the *electro-cautery* or some other escharotic, one of the best being tincture of iodine.

Corneal abscess is an occasional result of infective ulcer; it is usually associated with the creeping or spreading variety, and hypopyon and iritis are almost invariably present. It is attended by severe pain, photophobia and blepharospasm, with much circumcorneal injection and tenderness. An abscess situated in the deeper layers of the cornea (*onyx*) is, strange to say, less likely to result in ulceration than a more superficial abscess, while absorption of its contents occasionally takes place.

Treatment.—Atropin and hot applications should be used, but if the abscess shows a tendency to spread or to go on to ulceration, treatment of a more active nature should be substituted. An incision should be made into the abscess cavity and its walls thoroughly scraped or cauterized (or both procedures adopted) and treated as a sloughing ulcer.

Interstitial Keratitis is, in the majority of instances, a *hereditary disease* of syphilitic origin, although some cases are probably evidence of a scrofulous taint. It usually occurs in children and young adults, girls being affected more commonly than boys. The patient shows other signs of hereditary syphilis or congenital struma, as seen, for example, in the flattened nose, the scars around the corners of the mouth, absence of the



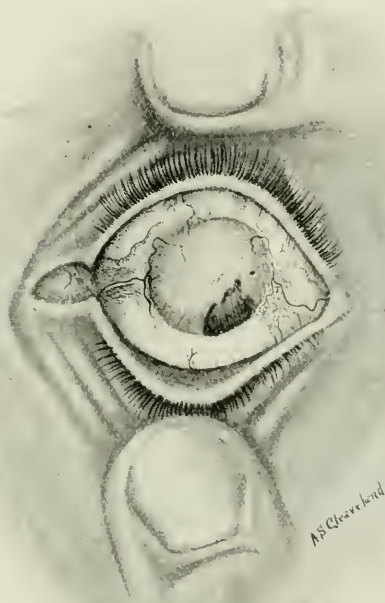
Hutchinson Teeth.

labio-nasal folds, and the "*pegged*" teeth described by Jonathan Hutchinson. This exudation is quite rare as a late manifestation of acquired syphilis. In some cases no cause can be assigned for its origin.

The disease commences with a faint opacity near the limbus, which gradually extends towards the center of the cornea, often clearing up from the margin as the central portion is involved. The deposit is evidently in the deep layers of the cornea and is practically never accompanied by loss of the protecting epithelium. It is a corneal exudate and has nothing to do with ulcer.

The whole cornea is eventually covered with a

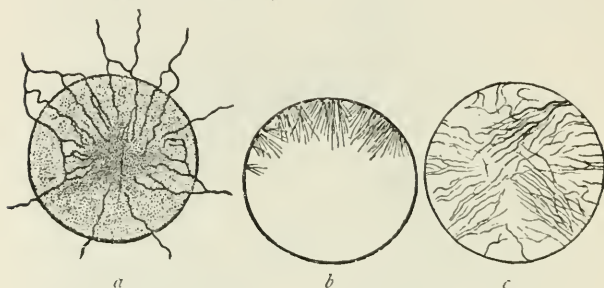
more or less dense, smooth and irregular opacity which may be so pronounced as to render the iris and pupil invisible. Vascularization of the deep layers of the cornea takes place and in



Interstitial Keratitis.

some instances is so marked as to give areas of greater or less extent a pinkish or yellowish hue.

There are known as "*salmon patches*." These new vessels, running in uniform, parallel rows, are derived from the deep conjunctival vessels and while in some cases are only recognized under oblique illumination or with a corneal loup, at others are clearly defined and can be recognized without difficulty. The empty tubes of the vessels can, years afterward, be distin-



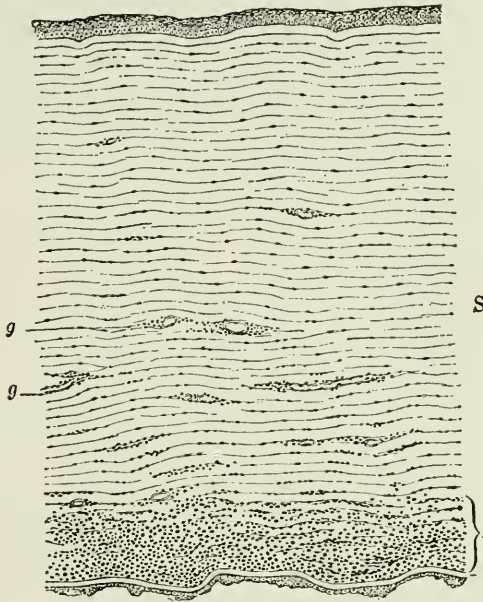
Bloodvessels in Various Corneal Affections.

- (a) Superficial blood vessels in pannus.
- (b) Deep lying blood vessels in a recent case of interstitial keratitis.
- (c) Deep lying blood vessels in an old case of interstitial keratitis.

guished with a dilated pupil, good illumination and the corneal loup (when no other corneal sign of the disease remains) as branched lines running in the deep layers of the cornea. They are known, from the observer who first describes them, as "*Hirschberg vessels*."

The *opaque exudates* may be absorbed completely in a few weeks or months, or they may

remain (especially over the pupillary area) for a much longer time, with more or less permanent impairment of vision. Sometimes the



Cross Section Through a Cornea with Interstitial Keratitis, showing infiltration in stroma (*s*) and transverse and longitudinal section of newly formed bloodvessels (*g g*) in the middle and deep layers of the cornea.

center of the cornea is first involved, the opacity extending towards the margin and the clearing gradually taking place from the center towards

the margin. As a rule there are but slight photophobia and lachrymation, even when there is marked injection of the region surrounding the margin of the cornea. When there is much pain, tenderness, photophobia and pericorneal injection, iritis or choroiditis (or both) may be suspected—in fact vision may be permanently damaged or even practically destroyed from an extension of the inflammation to the internal structures of the eyeball.

Both eyes are usually attacked—rarely both at one time. Indeed, the one first attacked is almost always well before a like process begins in the other. Relapses are not infrequent; the opacity may almost entirely disappear when a fresh attack develops that may be even more severe than the first. The disease commonly extends over many months, the acute stage lasting at least several weeks; then the opacity becomes so dense that the patient is practically blind, and walks about with great difficulty. Although the corneal opacity may never entirely disappear (haziness of the cornea remaining) the patient may be told that the densest opacity will ultimately clear up enough for useful vision, provided always that the internal structures of the eye have not been permanently damaged. Posterior synechiæ may follow here as elsewhere from an iritis, while patches of atrophy in the

choroid and opacities in the vitreous may result from the specific choroiditis.

Interstitial keratitis of non-syphilitic origin is usually less vascular and the opacity is apt to be less diffuse.

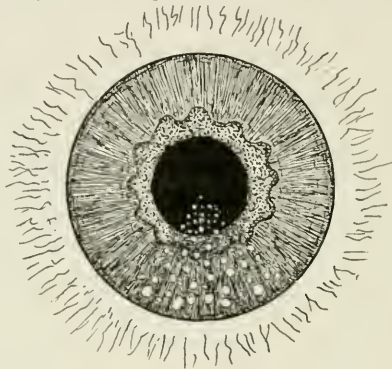
Treatment.—During the acute stages instillation of a 1 per cent solution of atropin should be made sufficiently often to keep the pupil dilated, while hot applications of chamomile tea, boric acid solution, etc., every one to three hours should be kept up as long as signs of capillary congestion are present. After the subsidence of the acute symptoms massage of the cornea with yellow oxid of mercury ointment, or the nitrate of mercury ointment with cod liver oil, should be systematically carried out for the purpose of hastening absorption of the opacity.

The patient's general health always requires attention. The alimentary canal should be regulated with small doses of calomel, gr. 1-10 to 1-4, given frequently until the bowels are acted upon. This should be followed by tonics in the form of tincture of iron, syrup of the iodid of iron, cod liver oil, etc. Even the purely syphilitic cases are not helped by the so-called anti-syphilitic remedies as much as by the agents just mentioned.

The patient should be given a nutritious diet, with plenty of milk and eggs, avoiding pastry, sweets and too much meat. The efficacy of out-

door exercise in the fresh air should be insisted upon.

Punctate Keratitis is a condition which occurs in inflammatory states of the uveal tract (iris, ciliary body and choroid) and consists of deposits of fine dots of lymph, mainly from the ciliary body, on the posterior surface of the cor-



Punctate Keratitis.

nea. It is merely one symptom of a deep seated disease and has nothing to do with an inflamed cornea. The dots are usually arranged in the form of a triangle with its apex pointing toward the center of the pupil. Sometimes the whole of the posterior corneal surface is so covered.

Superficial Punctate Keratitis is a much less serious affection. It occurs in the form of small grayish dots, or elevations, scattered irregularly towards the central portion of and in the superficial layers of the cornea. The con-

dition is usually preceded for a few days by and is associated with an acute catarrhal conjunctivitis. The eye shows signs of irritation, but not of pronounced character, which disappear in a few days.

Treatment.—Rest, atropia and hot applications.

Opacities of the Cornea have already been referred to as a frequent result of disease, *usually ulcer*, of that membrane. Generally speaking, one has to deal with a corneal *scar*, more or less thick or extensive, but they may be due to exudates into the corneal substance. A *faint opacity*, requiring the oblique illumination to see it distinctly, is called a *nebula*; a *macula* is a more distinct opacity, while a *leucoma* is a dense, white cicatrix, readily seen even at a distance from the patient. When, as a result of a perforating ulcer, the iris is attached to the healed scar tissue we have a *leucoma adherens*. Even a nebula, *if it occupy the area of the pupil*, reduces the vision considerably; *blindness*, as well as marked *disfigurement*, results from a central leucoma.

Treatment.—When the opacity is due to an exudate into the corneal tissue, or to a *faint* and recent cicatrix (*especially in children*) it may be removed entirely, or much reduced in density, by appropriate treatment. The most effective remedy is *massage with some stimulating oint-*

ment, preferably the "brown salve," as described on another page. *Irritants*, like oil of turpentine, calomel or tincture of opium, stimulate absorption of corneal deposits and may be used, once every day, with the massage. The Roentgen rays have also been recently used with considerable success. Old scars, especially in adults, are not much influenced by any form of treatment.

When the opacity is confined to the central area of the cornea and is not removed by the foregoing remedies, an *optical iridectomy* is indicated. The purpose of the operation is to make an *artificial pupil*.

Artificial pupil. An *optical iridectomy* is done for the purpose of enabling the patient to see through a part of the cornea more transparent than that opposite the pupil, which has been rendered unfit for visual purposes by a scar of or exudate into its central portion. The *best site* for the new pupil is that corresponding to the inner-lower quadrant of the cornea, as near the normal pupil as possible. Only a *small, marginal* section of the iris should be removed, through a corneal wound made with a *keratome*.

Another procedure, also intended to subserve the purpose of a new pupil is *iridotomy*.


Iridotomy is done when, after the removal of cataract or injury to the eye, the iris is drawn over the pupil and acts as an obstruction to

vision, just as a secondary membrane or a corneal scar would do. In *iridotomy* the fibres of the iris are cut through with de Wecker's forceps-scissors introduced through an opening in the cornea made by a keratome. The blades of the instrument are entered, closed, well within the anterior chamber, the sharper blade is pushed through the obstruction and with one snip of the blades an opening is made which, through the elasticity of the iridic fibres, opens and permits of vision.

A *similar opening* in the obstructing membrane may also be made with a *thin Graefc knife*, introduced through the cornea at the limbus and made to cut the stretched iris at the desired spot. Both procedures may be carried out under a local anesthetic.


Tattooing the Cornea.—When remedies fail to clear up the opacity on the corneal tissue, and particularly when the blemish is a broad macula or leucoma, the disfigurement may be disguised by tattooing it with ordinary *india ink*, or with colored pigments. After the eye has been cocaineized, a paste, made with sterile water and the best quality of india ink, is spread over the scar tissue with a medicine dropper. The pigment is now pricked into the cornea with a needle devised for the purpose. The ink paste is washed off the cornea from time to time, to note the effect of the operation. If, during this procedure, pain or

tenderness is complained of, the tattooing should be stopped and finished at a subsequent sitting. As the ink grains are in time absorbed this little operation should be repeated every two or three years.



Needles for Tattooing Corneal Scars.

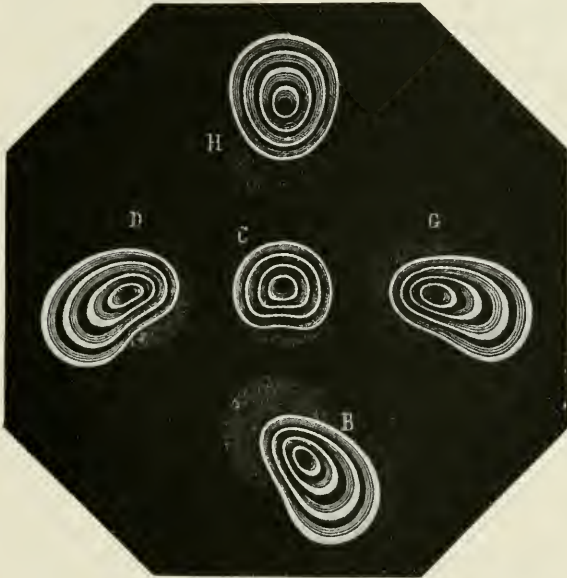
Conical cornea or **keratoconus** is rather a rare condition characterized by a slowly progressive protrusion of the cornea in the *shape*



Conical Cornea.

of a cone, the result of the intraocular pressure upon thin and weakened corneal tissue. At the apex of the cone is often observed a slight opacity. It is usually seen in young adults, generally of the *female sex*. If the patient look straight forward the deformity may be detected by a side view of the cornea at its temporal

aspect. Placido's disk, or the ophthalmometer, shows a marked distortion of the image indicating a high degree of *irregular astigmatism*. This anomaly is accompanied by a marked defect in vision which is but slightly improved by glasses.



Reflected Images of Placido's Disk in Keratoconus.

Treatment. Cylindrical glasses to some extent increase the visual power, but reduction of the cone by the use of the *galvanocautery* is the most reliable agent.

CHAPTER VIII.

THE COMMONER DISEASES OF THE IRIS AND CILIARY BODY.

Anatomy and physiology.—What produces the color of the iris.—The pupil.—The uveal tract.—Acute iritis.—Usually due to rheumatism or syphilis.—Posterior synechiæ, or adhesions of the iris to the lens.—How to distinguish iritis from conjunctivitis.—Treatment of iritis very satisfactory if given early.—Cyclitis or inflammation of the ciliary body.

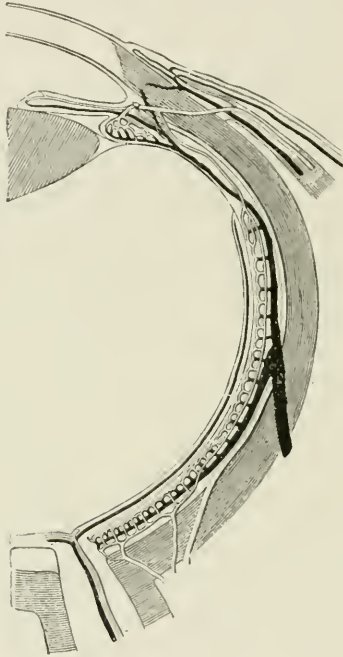
Anatomy and Physiology.—The *iris* is a circular, colored curtain suspended in front of the crystalline lens and pierced by an opening called the *pupil*. At its periphery it is attached to the ciliary body. It separates the anterior from the posterior chamber and regulates, by means of the expansion and contraction of the pupil, the amount of light admitted to the eye.

When fully contracted the pupillary margin of the iris lies on the anterior surface of the lens, but when the pupil is dilated it hangs (or floats) free in the aqueous humor.

The coloration of the iris depends not so much upon the actual color of the pigment (which is brown in every eye) on its anterior surface as upon the arrangement of the pigmentation.

Contraction of the pupil is brought about by the sphincter muscle, a narrow band of fibres encircling the pupil.

The dilation of the pupil is due (1) to paralysis of the *sphincter pupillae*, (2) contraction of the muscular coat of the iridic arteries and to



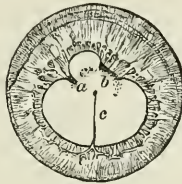
Bloodvessels of the Iris, Ciliary Body, Choroid Retina and Optic Nerve. (Fuchs.)

(3) unstriped muscular fibres that radiate from the margin of the pupil to the ciliary body. The last two sets of fibres are controlled by the

sympathetic, while the sphincter of the pupil is supplied by a third nerve.

The iris is structurally a spongy, elastic, connective-tissue membrane, abundantly supplied with vessels and nerves.

The pupil is closed until the 7th month of foetal life by a thin, semi-transparent membrane *which*



Remains of Pupillary Membrane. (Fuchs.)

occasionally persists, in part or whole, after birth, under the name persistent pupillary membrane. With the ciliary body and choroid (whose structure it closely resembles) the iris forms the uveal tract for providing nourishment to the interior of the eyeball.

IRITIS (INFLAMMATION OF THE IRIS)

Iritis usually sets in with a feeling of discomfort and aching in and around the eye which is soon replaced by pain, due to irritation of the ciliary nerves. The pain is not only in the eye itself but radiates usually over the brow and sometimes down on to the cheek. As the disease advances the pain becomes worse. It is especially severe at night, keeping the patient

awake, and in a short time becomes more or less constant.

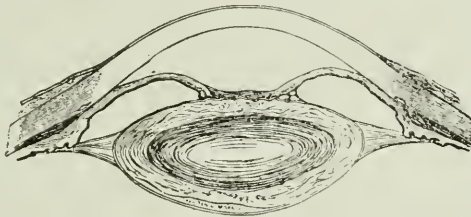
In the early stages the eye is reddened, the injection of the vessels becoming more pronounced as the inflammation increases; particularly is this the case in the scleral margin surrounding the cornea (*pericorneal zone*) which, assuming a pinkish hue at first, soon becomes of a dusky red color.

At the same time the eyeball becomes sore and tender to the touch. When the iritis is fully developed the eyeball is exceedingly sensitive, probably due to involvement of the ciliary body whose blood supply is intimately connected with that of the iris. *Lachrymation* and *photophobia* are now prominent symptoms. Discoloration, loss of luster and a swollen, muddy appearance of the iris surface are early manifestations of the inflammatory changes. A brown iris, for example, changes to yellow; a blue iris takes on a greenish hue, and so on.

The pupil becomes contracted and its usual reactions to light and accommodation are affected; slightly in mild cases, while it does not respond at all in the severe or pronounced cases. This defect in the normal expansion and contraction of the pupil may depend upon a number of causes: the engorgement of the iris vessels; spasm of the sphincter of the iris; exudates into the substance of the iris; or, as usually hap-

pens when improperly treated, adhesions that have formed with the anterior capsule of the lens.

Exudates are almost invariably present on the posterior and anterior surfaces and margins of the iris and are of a glue-like (plastic) consistency. This is what causes adhesions to form between the iris and lens (*posterior synechia*) and is the chief cause of blindness from iritis. The pupil is, thus, often bound down to the lens about its whole circumference (*ring sy-*

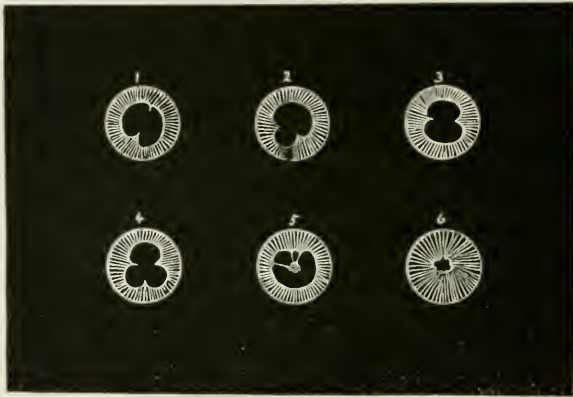


Iris Adherent to the Lens by Entire Pupillary Margin.
(Fuchs.)

nechia, exclusion of the pupil) so that it becomes immovable; or adhesions take place at various points along the pupillary margin, causing the pupil to dilate and contract irregularly when exposed alternately to deep shadow and strong illumination. This irregular dilation of the pupil is plainly shown when a mydriatic is instilled into the eye. Eventually the pupillary space may become covered with an exudate and,

if this be dense, vision is very seriously impaired. This condition is known as *occlusion of the pupil*.

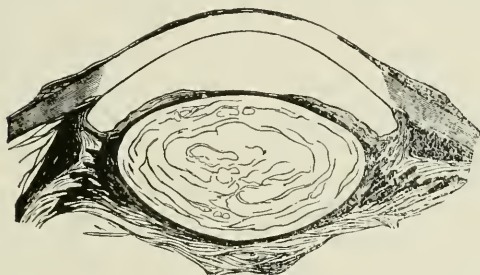
In the early stages the synechiæ may be broken down by the prompt use of an effective mydriatic, such as sulphate of atropin. When these adhesions are thus broken up dots of brownish



Some of the Deformities of the Pupil that May Result from Posterior Synechiæ. (Norris and Oliver.)

pigment are left on the anterior capsule in the locality where the adhesion had formed. Sometimes the synechiæ stretch as the pupil dilates, leaving a whitish thread or patch of exudate connecting the margin of the dilated pupil with the point of adhesion on the anterior lens capsule.

Vision is always more or less lowered—owing to cloudiness of the aqueous humor, deposits on the lens capsule and cornea or exudates into the pupil and even into the vitreous chamber. Interference with the focusing apparatus, due to congestion or inflammation of the ciliary body, is also one cause of a temporary interference with vision. Occasionally attacks of iritis are



Total Posterior Synechia—Posterior Surface of the Iris
Adherent to the Anterior Capsule of the Lens.

encountered in which pain and redness are either absent or are so slight as to pass unnoticed. In these instances impairment of sight is the only symptom complained of, although on examination synechiæ are found which have been gradually forming for some time. This form of the disease is known as *quiet iritis*.

Causes.—Syphilis is accountable for about 50 per cent of the cases, while about 25 per cent are the result of rheumatism. The remainder are due to a variety of causes, chiefly

injury, gout, diabetes, gonorrhœa, and, possibly, eye strain. Syphilitic iritis is usually a late manifestation of the second stage, in which small, yellowish gummata form, generally near the margin of the iris. As a rule an iritis due to syphilis is plastic in character and both eyes are affected.

Rheumatic Iritis.—Pain in this variety is usually severe, although in some cases it may be of the "quiet" variety. It may accompany an acute or subacute attack of rheumatism, or the ocular symptoms may be the only manifestations of the general disease. Repeated attacks are apt to occur and, as opposed to syphilitic iritis, may be confined to one eye at a time.

Gonorrhœal Iritis is rare and is more apt to occur as a sequel to gonorrhœal rheumatism. It is frequently accompanied by punctate keratitis, or serous iritis.

Serous Iritis is characterized by the formation of yellowish dots on the posterior part of the cornea (*punctate keratitis*), with cloudiness of the aqueous. In this variety the ciliary body is usually inflamed at the same time (*iridocyclitis*). The synechiæ that form are not so tenacious and are more easily broken down than in the other forms of iritis.

Iritis should not be mistaken for conjunctivitis, or vice versa. Such a mistake involves the eyesight of the patient. Recognized early, iritis is

usually a disease easily treated with good results. If neglected it often terminates in blindness. The following points of difference between these common forms of ocular inflammation will guard against a mistake in diagnosis:

IRITIS.

Pain. — Often severe; worse at night; felt in and above the eye.

Redness. — Especially marked as a zone about the corneal margin.

Pupil.—Contracted, sluggish or immobile; iris altered in color.

Vision.—Affected.

Lids.—Non-adherent.

Discharge.—Watery.

Photophobia.—Marked.

CONJUNCTIVITIS.

None, but some smarting, burning, and sensation of a foreign body.

More general.

Pupil and iris not affected.

Not affected.

Adherence of lids.

Mucous or mucopurulent.

None.

Treatment.—In all cases the dilation of the pupil is essential to prevent the formation of synechiæ or to break down those that have already formed. This is accomplished by means of one of the mydriatics at our disposal. The *sulphate of atropin* is probably the most useful, either in the form of ointment or solution. A few drops of a one per cent solution of atropin should be instilled into the conjunctival sac and repeated sufficiently often to paralyze the accommodation and to keep the pupil dilated. This may be aided or still further increased by adding to the atropin solution one or two per cent of hydrochlorate of cocain. Atropin not only

dilates the pupil and prevents dangerous adhesions to the lens, but it also relieves the congestion of the vessels both of the ciliary body and iris. It also applies the principle of the "rest cure" to the inflamed eye by paralyzing not only the ciliary muscle but the sphincter iridis.

Smoked protective glasses (No. 2 London smoke) should also be worn to protect the eye from the light and to ward off wind and dust if the patient is allowed to go out. *Hot applications* (as hot as can be borne) should be applied every hour or two in the form of moist pads, or hot chamomile tea. Dry heat in the form of a Japanese "hot box" often gives more relief to the pain and vascular congestion than moist heat.



Heurteloup's Artificial Leech.

As before mentioned *the pain of iritis is usually severe*, and in addition to the remedies just mentioned others are often needed. A valuable adjunct is a five per cent solution of *dionin*. Five or six drops, instilled at intervals of a minute into the eye, produce a serous exudation and

marked chemosis of the conjunctiva. This artificially produced swelling of the conjunctiva acts as a counter-irritant and gives great relief. When, towards night, the pains are severe and the pupil is slow in dilating, a blister (preferably cantharidal collodion) applied above the brow and to the temple, about noon so that full vesication is obtained about seven o'clock, frequently gives great relief.

The effect of this application is to "anticipate" the usual evening exacerbation and to prevent the nocturnal pains. In some cases, especially where the vascular congestion is very great, the abstraction of blood by means of the artificial leech, or by the application to the temple of two or three of the living animals, is the most effective remedy and is necessary before the patient experiences any relief from his sufferings. Antipyrin in ten-grain doses, or twenty grains of aspirin, and even morphin, are sometimes required to subdue the pains and permit the patient to sleep.

General treatment should be carried out when necessary by means of anti-syphilitic or anti-rheumatic remedies. It is well to begin treatment, no matter what the cause of the iritis, by opening the bowels with a dose of calomel followed by a saline. In addition to these systemic remedies the state of the general health often requires a course of iron, tonic doses of strychn-

nia, quinin or a combination of these. It must be remembered that iritis is a local manifestation of a general dyscrasia, may last many weeks or months and may require care during the whole of that period. If adhesions have formed benefit is often derived from the internal administration of potassium iodid in large and increasing doses as an adjunct to the use of atropia and cocain. Sub-conjunctival injections of normal salt solution have also been given with success in many of these cases.

INFLAMMATION OF THE CILIARY BODY.

Cyclitis frequently accompanies iritis, while the latter almost always complicates the former. The symptoms are those of iritis—severe pain, redness in the zone surrounding the cornea and marked tenderness in the same region. Although the exudates of cyclitis are sometimes plastic in character they are usually of the serous variety. The aqueous humor is then cloudy and on Descemet's membrane a number of yellowish dots (*punctate keratitis*) are found, arranged in the lower half of the cornea as a triangle, with its apex pointing towards the center of the cornea. Hypopyon frequently accompanies it. The anterior chamber is deep.

The inflammation in many cases extends to the choroid, and opacities frequently form in the vitreous chamber. The tension may be increased

in the acute form, although it is, later on, lowered, when the disease becomes chronic. Purulent cyclitis, as the result of metastasis or penetrating wounds, may occur, followed by destruction and disorganization of the eyeball.

Cause.—Cyclitis very rarely occurs of its own accord but usually follows an injury, as a complication of cataract operations, or (rarely) from germs carried from distant parts of the body.

Prognosis.—Cyclitis always involves serious impairments of vision. Secondary glaucoma is not an uncommon complication. In the purulent form detachment of the retina, changes in the vitreous humor, shrinking of the eyeball and total loss of vision practically always occur.

Treatment is that laid down for iritis. Cauterization of infected wounds, intraocular injections of mercuric bichlorid and the introduction into the anterior or posterior chamber, through the original or a second opening, of Haab's gelatin-iodoform rods may save the eye in some cases.

CHAPTER IX.

GLAUCOMA. HOW TO DISTINGUISH
THE VARIOUS INFLAMMATORY
DISEASES OF THE EYE.
SCLERITIS. EPI-
SCLERITIS.

Primary glaucoma.—An affection of the intraocular drainage system.—The acute form of the disease.—Liable to be mistaken for supraorbital neuralgia.—The practitioner should always be on the lookout for it.—Symptoms of acute glaucoma.—Hardening of the eyeball.—Chronic glaucoma.—The lesions in this disease.—Treatment.—Scleritis and episcleritis.—An easy method of diagnosing the commoner forms of inflammation of the eye.—How to decide whether the inflamed eye is a serious or a simple matter.

GLAUCOMA.

This disease is essentially due to a *damming or blocking of the drainage from the interior of the eye*. The chief lymph stream flows from the posterior chamber past the margin of the lens, through the zonula of Zinn, beneath the iris, through the pupil into the anterior chamber, thence through the loose tissue at the junction of the iris and sclera into the circular canal of Schlemm and from this space into the external lymph channels.

Obstruction to the steady escape of the intraocular fluids at any point in this drainage system or any undue increase of the fluids them-

selves may produce glaucoma. Probably the most important obstruction to the exosmosis is at the angle close to Schlemm's canal. There are two forms of the disease, whatever their cause: acute and chronic.

Primary Glaucoma is the name given to the variety that comes on without apparent, pre-existing disease of the eyeball.

Acute Glaucoma appears in inflammatory outbursts, attended by severe pain in and congestion and redness of the eyeball. Associated with these symptoms is temporary impairment of vision—usually the first symptom—the blurring lasting for a short time, then followed by the vision clearing again. It is also attended by loss of focusing power (accommodative asthenopia) and necessitates the frequent changing of the glasses, especially reading glasses, as it usually shows itself in persons over 40 years of age. During these periods the patient notices (*halos*) rings of various colors (as if one were looking through a glass that had been breathed upon) about gas jets or other flames. *The pupil is dilated and the anterior chamber becomes shallow.* These symptoms recur a number of times, each attack lasting longer than the one that precedes it.

Eventually the loss of vision becomes permanent. The pain, which is transient and slight at first, soon becomes severe and more constant. It

is referred not only to the eye itself but to the region surrounding the eye, radiating over the brow to the side of the nose and cheek and is very apt to be mistaken for facial or supraorbital neuralgia. The patient himself usually speaks of it as "a neuralgic attack."

As the disease advances the pain becomes almost unbearable and is not relieved even by morphia hypodermically or by the other analgesics commonly administered for trigeminal neuralgia. The eyeball, slightly congested at first, soon becomes plainly red and inflamed, especially in the zone surrounding the cornea (ciliary region) while the scleral vessels are dilated and tortuous. The cornea is hazy and has a "breathed on" appearance and finally becomes more or less insensible to the touch.

The field of vision is found to be contracted, especially on the nasal side. Central vision escapes during the first few outbreaks, but as the disease progresses the field becomes still further contracted until vision is entirely, or almost entirely, lost.

The tension of the eyeball is distinctly raised, especially at each of these attacks, often returning to normal during their subsidence, but finally the eyeball remains distinctly harder than normal.

In passing, it must be remembered that the proper method of determining the tension of


an eyeball is to palpate the globe much as one would a dropsical joint or an abscess. Standing in front of the patient, the tips of the forefingers resting on the upper lid, the patient being first directed to look downward, a gentle up and down motion should be made. It is well to compare the sensations thus obtained with the "feel" of one's own eyes.

The tension of an eye is recorded in the following manner: T_n = normal tension; $T_?$ = doubtful tension; T_+ = tension slightly raised; T_{+1} = tension considerably increased; T_{+2} = tension very much increased; that is, the eyeball is quite hard. On the other hand, if the tension is lowered or the eyeball softer or more yielding than normal it is recorded as T_- , T_{-1} , T_{-2} .

Usually the disease progresses until it ends in complete disorganization of the structures of the globe. The lens becomes opaque, the iris atrophies and hemorrhages take place in the interior of the eyeball. Bulging of the coats of the eyeball (staphyloma, ectasia), especially in the neighborhood of the ciliary body, frequently occur from the continuous increase of tension, until the eye feels and looks as if it were going to burst. Indeed, removal of the globe or its contents is often the only measure that gives the patient relief from his intense suffering.

On examining the interior of the eye with the

ophthalmoscope very little if any abnormality can be detected in the early stages, although during an attack pulsation of the arteries may be perceived if carefully looked for. If this be discovered one should suspect the onset of the disease and the globe should be examined for evidences of increased tension. In acute primary glau-

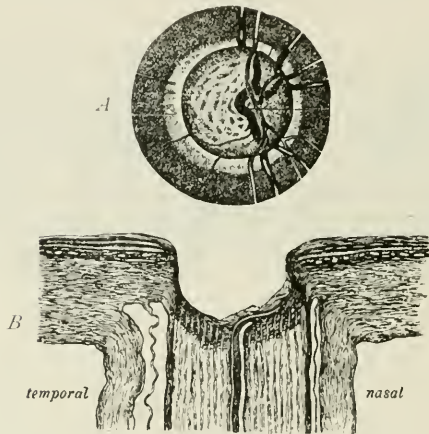


Physiological Excavation of the Optic Disk.

coma it is not until the disease is pretty well established that marked changes are seen in the fundus. During the attacks and late in the disease they are not always easy of detection on account of the cloudiness of the cornea, aqueous and lens, preventing a satisfactory view of the fundus. If, however, the background of the eye can be seen, "*cupping*" of the nerve head (optic disc) will generally be noticed in conjunction with the *pulsation of the arteries* referred to, especially at the margin of the disk.

Chronic Glaucoma, Simple Glaucoma.—In this variety of glaucoma the patient generally

complains of *very few symptoms* and the disease may progress for several months before the glaucomatous character of the affection is detected. There is, however, a dimness of vision which gradually grows worse. The patient gives a

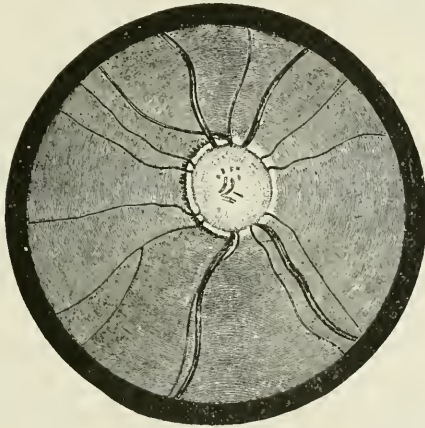


Cupping of the Disk in Glaucoma.

A Ophthalmoscopic picture; *B* excavation in nerve head. (Fuchs.)

history of having had many changes of glasses with the vain purpose of obtaining better sight, especially for near work. Instead of his vision becoming clearer it gets more and more obscured. The tension is finally found to be raised, even as high as $T+2$, although it may vary, for a time even reaching normal.

The morbid process advances so gradually that no changes in the external appearances of the eyeball are detected. The pupil is slightly dilated but it reacts promptly to light. The anterior chamber is of normal depth or only slightly shallower than it should be. On examination with the ophthalmoscope the media are found to be clear and a good view can always be obtained of the back part of the eye. Almost



Cupping of the Nerve Head in Glaucoma.

As Seen by the Ophthalmoscope.

without exception the mirror reveals a well marked *cupping of the optic nerve head*.

A glaucomatous cupping is to be distinguished from a physiological excavation (present in a great number of normal eyes) by the fact that the latter has shelving sides so that the course

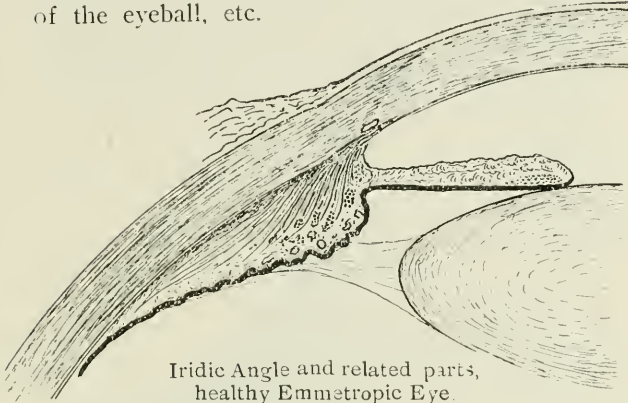
of the central vessels of the retina, as they issue from the depths of the optic tissue and spread out on the fundus of the eye, can be distinctly seen from the margin of the disk until they disappear at the bottom of the cup into the substance of the nerve. A glaucomatous cup has not only steep sides but overhanging edges, so that the vessels disappear just beneath the margin of the cup, as if they were cut off at that point, to reappear at the bottom of the excavation. *Pulsation of the arteries* can be readily detected.

From the pressure of the intraocular fluids upon it within the unyielding walls of the eye the optic nerve finally atrophies and presents a pale appearance instead of its normal pink color. Surrounding the optic nerve head is often seen a distinct ring of pallor, due to a choroidal atrophy which also sets in as another result of undue pressure.

Usually both eyes are attacked and, although the progress of the disease is slow, blindness eventually takes place (*absolute glaucoma*) if appropriate treatment is not applied.

Secondary Glaucoma, as the name implies, follows other ocular lesions, either injuries (mechanical, chemical or operative) or inflammation of some part of the eyeball. Perforating wounds, especially in the region of the ciliary body; iritis with extensive synechiæ directly obstruct-

ing the drainage of the eye; dislocation of the lens; perforating ulcers of the cornea; prolapse of the iris following cataract operations; swelling of the lens from injury to the capsule; tumors of the eyeball, etc.



Iridic Angle and related parts,
healthy Emmetropic Eye.

Retinal hemorrhages, with marked pain, congestion of the eye and total loss of sight, constitute a very grave form of the acute disease, called *hemorrhagic glaucoma*.

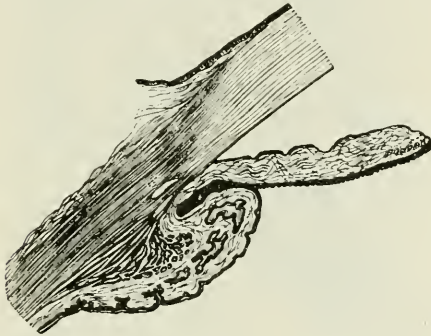
Etiology.—Primary glaucoma very rarely appears before forty years of age and occurs more frequently in women than in men. Grief, worry, shock, and abuse of the eyes are exciting causes. The use of mydriatics, especially atropia, after the age of forty is sometimes responsible for attacks in those predisposed to the disease and for this reason they should be used with caution in elderly people. Rheumatism and gout are predisposing causes.

Pathology.—As before mentioned, anything that unduly increases the amount of the normal intraocular fluids or interferes with their free exit from the eye may bring on an attack of glaucoma. In many excised eyeballs affected with glaucoma the periphery of the iris has been found adherent to the cornea so as to prevent the flow of the aqueous into the canal of Schlemm.

This *retention* theory of the disease is the one now generally accepted by the majority of authorities. Its usual occurrence late in life is explained by Priestly Smith on the ground that the crystalline lens (which grows in size as age advances) pushes the root of the iris into the angle of the anterior chamber and blocks the passage (filtration) of the lymph into Schlemm's canal. In the same way (according to this authority) small (or hypermetropic) eyes have small corneas and less space in the neighborhood of the angle of the anterior chamber and so are predisposed to attacks of glaucoma. In other words, the retention of the intraocular fluid is responsible for all forms of glaucoma. In the chronic variety the changes that take place are so gradual that complete closure of the angle of the anterior chamber does not occur. Though drainage through the lymph channels is more or less obstructed, they are not completely closed. As the disease advances and the obstruction is

not relieved by treatment, atrophy of the optic nerve from pressure takes place.

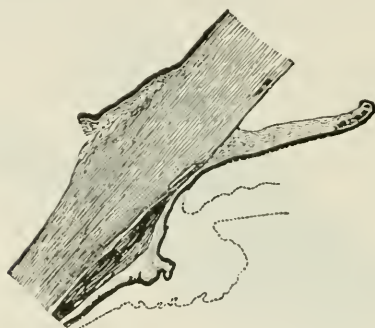
Treatment.—The acute inflammatory variety calls for prompt treatment which will, if given early, be wonderfully efficacious. The pains will be relieved, the vision will improve, and after the glaucomatous “storm” is over the eye may become almost, if not quite, natural again. This treatment is a broad and quite *peripheral iridectomy*. The operation should be performed up-



Blocked Iridic Angle in Recent Inflammatory Glaucoma. ward when possible, so that the resulting coloboma may be covered by the upper lid. This not only helps to hide the defect in the iris, but it largely prevents the unpleasant sensations that would be set up by the entrance of too much light into the interior of the eye.

The operation should be performed in the following manner: In the acute form, on account of the excessive amount of congestion

present, cocain or holocain is not readily absorbed and a general anesthetic is necessary. In the chronic variety a local anesthetic will be sufficient. The conjunctival sac having first been irrigated with a sterilized solution of boracic acid and all antiseptic precautions having been carried out, the wire speculum is introduced and, the eye being steadied by fixation forceps, an incision is made in the upper part of the cornea



Blocked Iridic Angle in Old Inflammatory Glaucoma
(Fuchs.)

about 1 mm. behind the sclero-corneal junction, with a keratome. The point of the instrument is first entered at right angles to the globe, the sclera is pierced, the handle is depressed and the point pushed in a direction parallel to the plane of the iris across the anterior chamber as deeply as necessary. As the aqueous begins to escape (almost as soon as the incision is com-

pleted) the knife should be withdrawn *slowly*, that there may not be a too sudden reduction in the tension, otherwise there is danger of intraocular hemorrhage or detachment of the retina.



The Operation of Sclerotomy.

The sharp point of the knife should be made to hug the posterior surface of the cornea during withdrawal, in order not to wound the lens or iris. The scleral opening should be wide and very peripheral. The fixation forceps is now

given to an assistant and, with his scissors in the right hand and his iris forceps in the left, the latter is entered closed and carried along the posterior corneal surface until the pupillary margin is reached. Here they should be opened, the pupillary margin of the iris grasped, pulled well out of the wound and a cut made with the scissors near one angle of the sclero-corneal wound. The mass of the iris is now drawn away from this incision and cut off along the whole of the sclero-corneal opening by several snips of the scissors. Finally, the remainder of the iris is drawn out and snipped off with one cut of the scissors, close to the cornea.

Some operators prefer *sclerotomy*. The pupil is first thoroughly contracted with eserin and an incision is made well within the sclera with a narrow Graefe knife, either in front of the iris (*anterior sclerotomy*) or behind the ciliary body (*posterior sclerotomy*). The point of the Graefe knife, edge up, is entered in the sclera (about 1 mm. behind the corneal limbus in anterior sclerotomy and about 7 mm. behind the limbus in posterior sclerotomy) and is directed downwards. The handle is depressed and a counter puncture is made, and by a to and fro motion the blade cuts its way upward. The section is not completed, but a bridge of scleral tissue about 2 mm. in width is allowed to remain. This prevents prolapse of the iris.

In sclerotomy a certain amount of drainage is assumed to take place through the scleral scar, and thus to relieve the intraocular pressure. The *peripheral iridectomy* relieves the choked canal of Schlemm.

Two things are especially to be remembered in connection with these operations: First, that operating on one eye is apt to *precipitate* (not produce) an attack in the other eye; and second, that the relief given to the intraocular pressure may be the cause of bleeding (into the anterior chamber and vitreous) from weak and (now) unsupported vessels. Vitreous hemorrhage is to be feared, as when it is extensive it may lead to final destruction of the eye. Bleeding into the anterior chamber is not of serious importance.

The non-operative treatment of glaucoma consists in the local application of drugs which contract the pupil (*miotics*) and in so doing relieve the obstructed drainage by dragging a portion of the iris away from the clogged "angle of filtration" and thus reduce tension. The advantage obtained from the use of miotics alone is but temporary and even this temporary benefit is seen only in the acute and subacute varieties and in the early stages of the disease, as in the later stages atrophic changes not only take place in the iris and render it incapable of contracting, but adhesions form at the angle of the an-

terior chamber between the peripheral portion of the iris and cornea and permanently close the "angle of filtration."

The miotic most commonly used to reduce intraocular tension is the sulphate of eserin (gr. $\frac{1}{2}$ to 1 to the ounce). On account of the pain in the eye and brow produced by eserin when instilled into the conjunctival sac it is commonly combined with equal parts of hydrochlorate of cocain, which also helps its absorption.

Eserin sulphate	gr.	$\frac{1}{2}$
Cocain hydrochlorat	gr.	$\frac{1}{2}$
Aq. dest.	oz.	1

One drop into the eye three times a day.

Stronger solutions of eserin may be used for instillation into the conjunctival sac (as high as $\frac{1}{2}$ per cent solutions) but they are apt to set up much conjunctival irritation and ciliary congestion and consequently are not so well borne by the patient. When eserin is the cause of too much discomfort to the patient a 1 per cent solution of the nitrate of pilocarpin may be substituted:

Pilocarpin nitratis	gr.	4
Aq. dest.	oz.	1

Massage of the eyeball with an ointment of 1-10 of 1 per cent of the sulphate of eserin is also especially useful in reducing the increased tension. This should be performed through the closed lids for a few minutes at a time daily or

every other day. The general health should be carefully looked after. Anti-lithemic remedies should be given when called for. Full doses of salicin should be ordered, or salicylate of sodium and colchicum, with, if possible, a sojourn in health resorts where appropriate mineral waters can be drunk. The diet should be regulated and any tendency to constipation relieved. The patient should avoid late hours; business cares and other sources of worry should be lightened as much as possible.

Episcleritis and Scleritis.—The subconjunctival tissue of the sclera is inflamed in the former, the sclera itself in the latter; but it is difficult to separate the one from the other. There are scleral injection, pain more or less severe, lachrymation, photophobia and swelling of a purplish color at the point affected—usually 3 to 4 mm. from the sclero-corneal junction. Tenderness may be present over the site of the inflammation.

The symptoms are apt to be more severe in scleritis, in which the tension of the eyeball may be increased, followed by staphyloma or ectasia of the anterior portion of the globe.

It is not a common affection and is likely to be mistaken for conjunctivitis and iritis. A little care will detect the circumscribed, reddish swelling or swellings which characterize the disease. After recovery, bluish or dark pigmented patches remain to indicate the site of the acute lesion.

It is more frequent in women than in men, is often obstinate and chronic and is nearly always found in individuals who have rheumatism or gout. The inflammation may extend to the uveal tract, setting up an iritis, cyclitis or chorioiditis.

Treatment.—Hot fomentations should be frequently applied (at least every two hours). A 1 per cent solution of sulphate of atropin should be used sufficiently often to keep the pupil well dilated.

Atropin sulphategr. 4
Aq. dest.oz. 1

Smoked protective glasses should be worn, with complete rest of the eye. When there is much pain with pericorneal injection the natural or artificial leech should be applied to the temple. The subconjunctival injection of normal salt solution, or 1-5000 solution of bichlorid of mercury, sometimes proves useful in obstinate cases. Pilocarpin sweats and iodid of potassium may be used with success, especially where the deeper structures of the eye are affected.

The rheumatic or gouty taint should be neutralized by salicylate of sodium, colchicum and other appropriate remedies. When the acute symptoms have been relieved, great benefit may be derived from massage of the eyeball with yellow oxide of mercury ointment or the nitrate of mercury ointment with cod liver oil.

An Easy Method of Diagnosing the Commoner Forms of Inflammation of the Eye.—

It happens that the reddened appearance presented by the eyeball (due to the engorgement of otherwise invisible vessels upon a background of the white sclera) is common to most inflammations of the eye. Not only in the superficial but in deep-seated ocular lesions as well, one or all the venous and arterial systems of the anterior segment of the globe become injected and more or less deeply tinge the otherwise whitish globe.

Taking this clinical observation as a starting point and combining with it careful inspection of the eye itself we may readily distinguish the various eye inflammations from one another, and from affections non-inflammatory in character, by means of the following scheme, drawn up after the plan pursued by Fenwick in his small work (1870) on medical diagnosis:

- (a) The eyeball is wholly or partially reddened, without discomfort or other symptom.
- (b) The eyeball is reddened and uncomfortable, but without actual pain.
- (c) The eyeball is red and distinctly painful.

(a) The eyeball is wholly or partially reddened without discomfort or other symptom. Practically one condition only is included under this heading, viz., subconjunctival hemorrhage. There is no discharge from the eye and close

inspection of it shows that the redness is localized as a *deep red, smooth, uniform patch*, obscuring the scleral vessels. Except in the recurrent type and in patients over 40 years of age (when Bright's disease or organic heart lesions may be suspected) it is an innocent condition.

(b) **The eyeball is reddened and uncomfortable, but there is no marked pain.** Here we have to deal with hyperemia of the conjunctiva, a foreign body in the cornea or conjunctival sac, phlyctenules of the conjunctiva, and most of the forms of infection of the conjunctiva popularly known as acute and chronic conjunctivitis. In *hyperemia of the conjunctiva* the lining of the everted lids looks redder and rougher than normal and than the ocular conjunctiva, there are slight smarting, burning and itching of the lids and, at times, a foreign body sensation. No secretion forms except a little at the inner canthus, which occasionally glues the lid edges together in the morning. *Foreign bodies in the cornea or in the sac* are always to be suspected when the patient complains of *constant scratching* and of that peculiar sensation, known to every layman, of a *corpus alienum*. The sac and cornea should be scanned with a magnifying lens when these symptoms are present. *Phlyctenules of or pimples on the conjunctiva* are commonly seen on the surface of the globe, surrounded by a patch of blood vessels. Their

diagnosis is extremely easy in the majority of cases, especially if the description of them already given be studied. In most of the forms of *acute and chronic conjunctivitis* there is no distinct pain, but smarting, burning and foreign body sensations (not constant) with a mucous or mucopurulent discharge, which is found on the lid edges and at the inner canthus in sufficient quantities to glue the lashes together so that they must be washed apart before the eyes can be opened after a night's sleep. The injection and swelling of the conjunctiva, and a loss of its transparency, is well seen on everting the lids and inspecting the posterior aspect of the globe. Only in long standing or very acute cases does the redness extend to the margin of the cornea. The tension of the eyeball is normal and the latter is rarely tender to the touch. A full account of the various forms of the disease has been already given.

(c) **The eyeball is red and painful.** These symptoms are common to iritis, glaucoma, phlyctenules of the cornea, ulcer of the cornea, scleritis and episcleritis, ocular neuralgia and gonorrhoeal infection of the conjunctiva.

In *iritis* the redness is at first confined to the corneal region of the ocular conjunctiva, although in a few days all the vessels of the globe are engorged. There are also marked photophobia and a copious flow of tears; the eyeball

is tender to the touch and the pain (in the eye and above it) becomes worse towards evening. The tension of the eye is rarely increased and the pupil is contracted.

Glaucoma is characterized by hardening of the eyeball associated with *attacks* of pain, neuralgic in character and usually extending along the course of the supraorbital nerve. The tension is markedly increased during these attacks. The vision is usually lowered, while there is but little secretion of any kind and but slight photophobia. The pupil is normal in size or dilated.

Phlyctenules of the cornea (phlyctenular keratitis) is a disease of childhood with symptoms so characteristic that it can hardly be mistaken for any other disease. Intense photophobia (blepharospasm), a copious, watery discharge from the eyes and the "snuffles" will serve to distinguish it from other inflammations of the eye occurring in childhood. *Ulcer of the cornea* can be easily detected, especially after instilling a few drops of a 4 per cent solution of cocain (to "quiet" the eye) and a small amount of fluorescein (to "stain" the ulcer), by the appearance of the local lesion.

Scleritis and episcleritis are comparatively rare affections and are known by the fact of the absence of severe pain and the occurrence of isolated, smooth, raised patches on the globe (entirely unlike the diffuse redness of other in-

flammatory diseases of the eye) of pinkish-red exudates. It is nearly always a rheumatic affection and when a cure occurs it leaves a slight purplish stain on the eyeball. There is little or no secretion in these affections. *Ocular neuralgia* rarely occurs without affecting other branches of the trigeminals. It may occasion *slight* reddening of the eye, but the latter is always unilateral, is not accompanied by lachrymation, mucous discharge or increased tension, nor does it affect the eyesight. *Gonorrhœal ophthalmia* is known by the great *swelling of the lids*, the profuse purulent discharge, intense injection and edema of the conjunctivæ, and the history of gonorrhœa.

CHAPTER X.

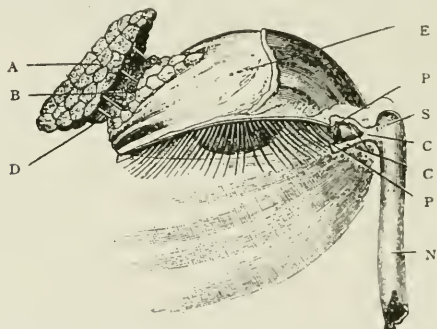
THE COMMONER DISEASES OF THE
LACHRYMAL APPARATUS.

The course of the tears from the ducts of the lachrymal gland to the inferior nasal meatus.—The anatomy of the lachrymal apparatus.—Difference between epiphora and lachrymation.—Acute and chronic dacryocystitis practically always due to obstruction of the lachrymal passages.—Diagnosis, symptoms and treatment of lachrymal stricture.—Passing lachrymal probes.—Slitting the canaliculi.—The lachrymal syringe.—Extirpation of the sac and removal of the lachrymal gland.

Anatomy and Physiology.—The lachrymal apparatus is sometimes divided into *secretory* and *excretory* portions. The former includes not only the lachrymal glands but the mucous glands of the conjunctiva. As a matter of fact, the moisture that commonly cleanses the ocular and conjunctival surfaces is contributed by the *mucous follicles of the conjunctiva*, while more copious supplies of tears are furnished by the *lachrymal gland*. The latter is of the salivary variety, divided into two lobes and situated in the orbital plate of the frontal bone. It secretes a slightly alkaline fluid containing much sodic chloride which is “sprayed” on the globe through a fan-shaped array of seven (to twelve) ducts opening at the upper-outer aspect of the superior sulcus.

Flowing over the eyeball, the lachrymal stream is directed by the lid edges in winking, to each *punctum lachrymalum*, placed about 6 mm. from the inner canthus in a whitish, elevated pit on the lid margin. Entering the *canaliculi* at right angles to the intermarginal surface the stream now assumes a course parallel to the lid margin and pours into the sac by separate openings.

The *lachrymal sac* is 12 mm. long by 6 mm. wide and opens directly into the *nasal duct*. The

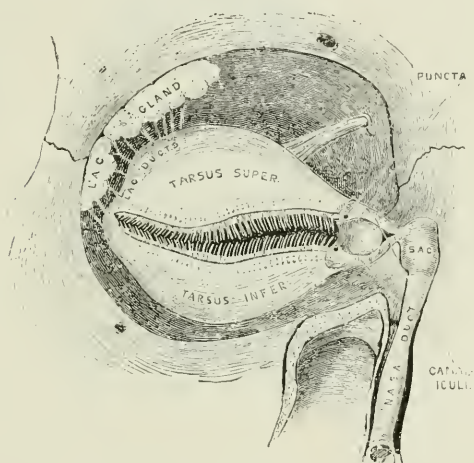


The Lachrymal Gland and Its Relations. (Schwalbe.)
a, superior portion of gland; *b*, inferior portion; *d*,
 lachrymal ducts; *c*, upper eyelid, skin partially
 removed; *p*, *p*, puncta; *c* *c*, canaliculi; *s*, lachrymal
 sac; *n*, nasal duct.

latter (about 21 mm. long and 4 to 6 mm. wide) passes downward, outward and backward and empties into the *inferior meatus* of the nose at its anterior third. The bony duct and sac are lined with fibrous tissue covered with columnar epithelium. The former is by no means uniform

in its diameters, being contracted where it leaves the sac and just before it enters the nose.

Epiphora is the name usually employed to designate a flow of tears over the lower lid margin. *Lachrymation* refers more particularly to an increase in the supply of tears. Anything which interferes with the drainage of the ex-



Lachrymal Apparatus. (Juler.)

ternal eye will produce epiphora; any cause which stimulates the formation of tears produces lachrymation. Among other causes of epiphora, besides lachrymation, may be mentioned: (1) Those that produce misplacement of the puncta, such as surgical and other wounds in the neighborhood, paralysis of the facial nerve (by which

the orbicularis loses its tone) and laxness of the palpebral tissues dependent upon senile changes; (2) obstruction at some point in the lachrymal canal or nasal duct. The last is the commonest and most important cause of epiphora, which will hereafter be considered merely as a symptom of this class of diseases.

Chronic dacryocystitis is a chronic infective inflammation of the mucous membrane lining the canaliculi and tear sac. This disease is usually chronic from the beginning and generally results from an obstruction of the nasal duct. There is a certain resemblance between inflammation of the urethra and the same affection of the tear passages, in that in both the infection is supplied from without, in the case of the latter from chronic maladies of the lid, such as blepharitis, trachoma, and such diseases of the nasal cavity as chronic rhinitis, nasal polypi, caries and syphilitic periostitis of the lachrymal bones. Moreover the inflammatory changes in both often end in organic stricture. The majority of cases of dacryocystitis occur in women of middle age, but it is sometimes met with in infants and young children, especially in those that exhibit a syphilitic or strumous taint.

Symptoms.—The main symptom is epiphora, increased by exposure to wind, dust and cold. There is always a hypersecretion of mucus mixed with some pus. For a time these ab-

normal secretions are carried along the nasal duct into the nose, but after a while the mucous lining of the canaliculi, sac, and nasal duct become involved; swelling and true hypertrophy of the lining membrane set in; distension of the sac takes place (forming the so-called *mucocele*)



Mucocele, with Dilated Lachrymal Sac.

and the muco-pus regurgitates through one or both puncta into the conjunctival sac, and may be seen as flocculi floating in the tear drops.

Diagnosis.—In all such cases, firm pressure made over the region of the sac at the inner canthus will expel the pent up muco-pus. Even before the enlargement of the sac becomes so pronounced as to show itself as a decided swelling

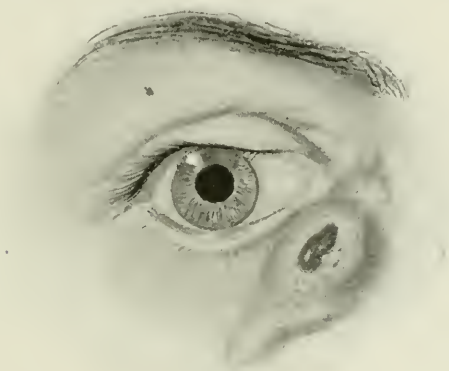in this region, this procedure will cause the mucopurulent fluid to issue from one or both puncta. This settles the point, and proves the existence of an obstruction in or below the lachrymal sac.

In the early stages of the disease the obstruction may be merely a swelling of the infected mucous membrane but, later on, when erosions occur in the mucous lining of the duct or when local ulceration eats into the submucosa, the cicatricial tissue resulting from the healing of these lesions and its subsequent contraction brings about an organic stricture that closely resembles an urethral stricture.

The practitioner will find the following a useful guide in the diagnosis of these cases. *When the sac is enlarged and pus can be squeezed out of the puncta an obstruction (stricture) is present; but if there be little or no cystic swelling and the secretion is mostly mucous the obstruction is a swollen mucous membrane (mucocoele).*

Another method of value is to inject through one or other punctum a few drops of a four per cent solution of cocain followed in five minutes by some colored fluid (1-5000 pyoktainin makes an excellent stain) and notice whether it passes into the nose. In cases of obstruction due to swelling of the duct lining only, the cocain reduces the edema, and the colored liquid reaches the nose where it is readily seen. In stricture no fluid can be injected into the nose.

A distended sac in these chronic cases is always liable to inflame and form an abscess—lachrymal abscess. When this happens the skin covering it becomes very much swollen and an erysipelatous blush surrounds the seat of the disease. There is considerable swelling of the lids and sometimes of the face, and it is accom-



Lachrymal Abscess and Fistula. (Dalrymple.)

panied by severe pain and tenderness. There is more or less constitutional disturbance and fever. If left to itself the pus points *below* the sac, the abscess opens on to the face and leaves an ugly fistula, which is often difficult to heal.

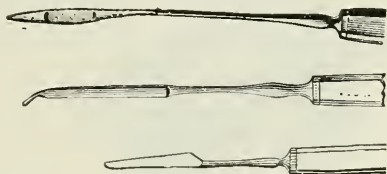
Operations of any nature should never be performed upon the globe during the existence of a chronic dacryocystitis, owing to the virulent

nature of the discharge and the great danger from infection of the wound and consequent loss of the eyeball.

Treatment.—If seen early we should try to prevent the formation of a mucocele and *to disinfect the sac, ducts and conjunctival sac*. Pressure should be made several times daily over the sac, its contents squeezed out and the lachrymal tract washed, through one of the puncta, with mild antiseptic solutions, such as boric acid gr. 20 to the ounce, or corrosive sublimate 1-10,000. A 10 to 20 per cent solution of argyrol or protargol, especially the former, is very efficacious at this stage of the disease. Sometimes, by dilating a punctum, a small (No. 4 or 5 Bowman) probe can be passed into the nasal duct through the intact canaliculus. If seen late, when abscess has formed and the skin over it is very thin, it is better to open the pus collection, reduce the swelling by appropriate applications and attend to the stricture subsequently. The scar left is then insignificant.

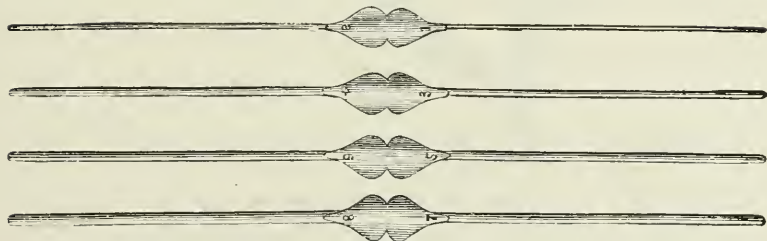
When an organic stricture is present palliative treatment is of little avail. The upper or lower canaliculus should be slit up well into the sac with a knife used for the purpose. Then the same knife, or another specially made for the purpose, must cut through the stricture into the nose. Slitting the canaliculus is performed with a probe-pointed canaliculus knife as fol-

lows: The surgeon should stand behind the patient's head. To open the lower canaliculus—the usual one—the punctum is everted and the point of the knife, edge upward, entered at right



Various Knives for Opening the Canaliculi and Dividing Strictures of the Nasal Duct.

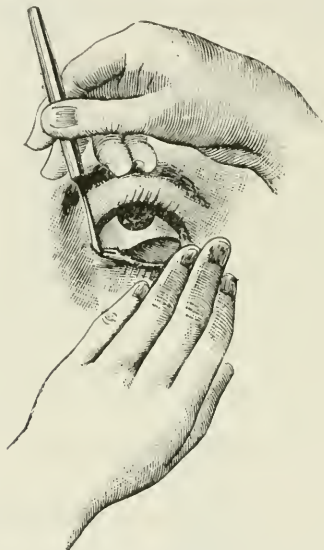angles to the lid margin. The palpebral skin is drawn towards the outer canthus with the disengaged hand and the handle of the knife depressed until it is almost horizontal. It is now pushed towards the sac until its nasal wall is



Lachrymal Probes.

felt. Keeping its point steadily in that position the handle of the knife is partially rotated so that the edge of the blade looks upwards

and slightly inwards. The handle is now carried up and slightly past the median line, cutting through the wall of the canal within the lid margin. The knife is again rotated to be used as a cutting probe. Having assumed this position

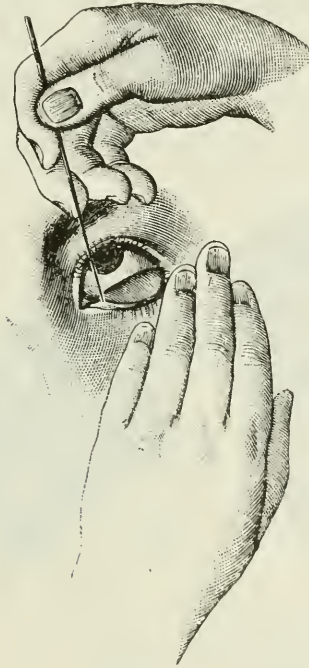


Slitting the Lower Canaliculus and Passing the Knife Through the Nasal Duct.

the handle almost touches the brow and the point is directed downwards, outwards and slightly backwards. It should then be passed down into the nasal duct, cutting through the stricture (or strictures) in one direction during its entrance. It should now be rotated ninety

degrees so as to cut its way out at right angles to the wound of entrance, and so withdrawn.

If the stricture be a very firm one, or if there be several points of obstruction, the incision may

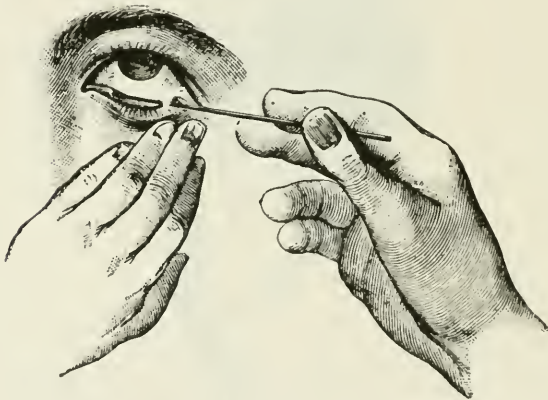

Passing the Probe Through the Lower Punctum.

be repeated two or three times so that the obstruction is divided in several directions. An anesthetic is usually necessary, and bleeding

from the nose should follow the operation, showing that an open communication exists between the conjunctival sac and the meatus. As large a lachrymal probe (number 10 or 11 Bowman) as possible should be passed immediately after the operation.

Passing the probe.—Stricture of the nasal duct is as difficult to *cure* as urethral stricture and, as in the latter case, it may be necessary to pass probes, as a complement to stricturotomy, two

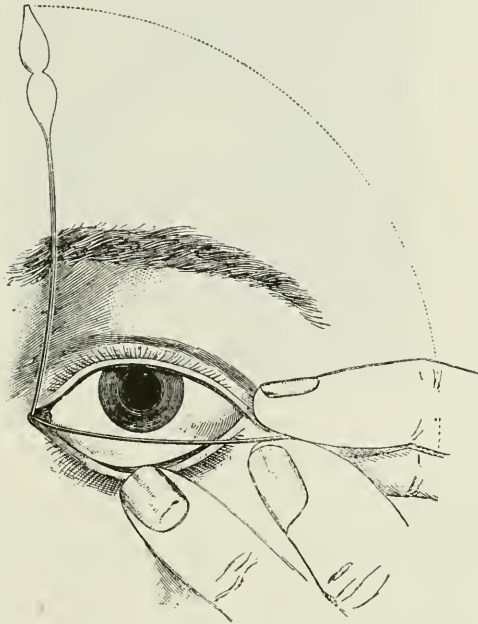


Passing the Probe Along the Lower Canaliculus.

or three times a week or oftener, for several months. Very often the patient gets great relief from the operation and the subsequent half dozen probings administered by the surgeon, but objects to the discomforts of this post-operative procedure and gives up treatment. The divided

stricture again slowly closes, purulent collections once more stagnate and decompose in the obstructed duct and sac, and the last state of the patient is worse than the first.

To avoid this *he should be taught to pass the probe himself* and instructed to keep it up at in-

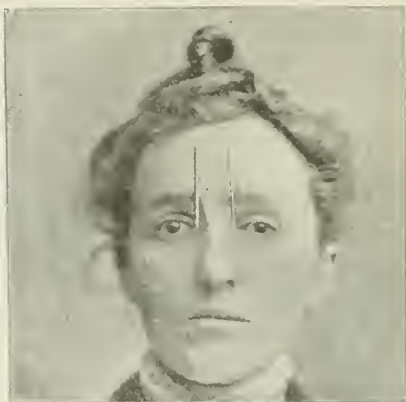

Passing the Probe Into the Lachrymal Sac and Nasal Duct.

creasing intervals for a year or more. Although the process is awkward to him for the first few

times the difficulty is soon overcome and in a short time he is enabled to pass it with ease.

The probes used in the dilation of lachrymal stricture are of all sizes and shapes. Those devised by Bowman, made of silver, answer most purposes. Passel along the open canaliculus un-




Probes in the Nasal Ducts.

til its point reaches the lateral wall of the sac, with the lid margin kept on the stretch, the probe is elevated and carried slightly past the median line until it, while almost touching the brow, points downwards, outwards and slightly backwards. It should now pass, *without employing undue force*, into the nose. As large a size as possible should be used and the probing should be done daily, while the patient should take lessons (usually five or six are enough) in passing the instrument himself. Care must always be

observed not to make a false passage, although when large probes are used this danger is insignificant. If persevered in, a complete cure of lachrymal obstruction when not due to disease of the bone (osteomata, syphilis and the like) can be confidently expected. A canaliculus once opened in the manner above described seldom or never closes, so that the natural drainage-function of the parts is destroyed. The operation should not on that account be lightly undertaken.

Lead or *silver styles* passed into the nasal duct, after the stricture has been divided, and left there for several days at a time is a method that has been practiced for many years with results that have never been very satisfactory. On



Style and Canula.

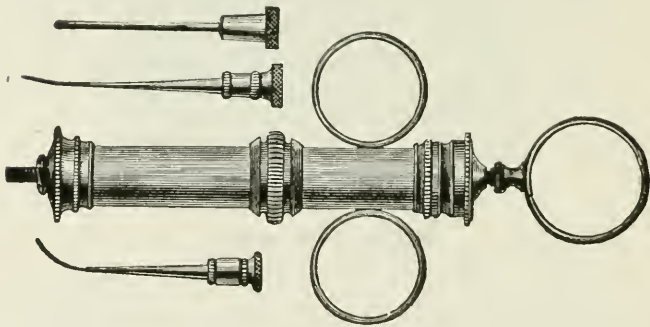
the other hand a *silver canula* left in the nasal duct, occasionally removed, cleansed and returned to its place, has proved of benefit in selected cases.

For most cases of epiphora systematic syringing of the passage through the puncta to the nasal meatus is sufficient in many instances to bring about a cure without having recourse to

probing or the cutting operation. In any case, partial or complete, of nasal duct obstruction, treatment, both ante- and post-operative, of the lining membrane of the tear passage is indicated. For this purpose boric acid lotion, with the addition of sulphate of zinc, makes a very good astringent application and is much used:

Acidi borici	gr.	15
Zinci sulphatis	gr.	1
Aq. dest., q. s. ad.....	oz.	1

Whatever the remedy, an Anel or Meyer syringe of the largest size should be used. The sac contents are first squeezed out, the point of



Lachrymal Syringe.

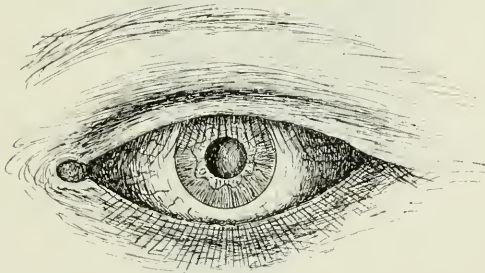
the syringe entered at the punctum, passed along to the sac, as in probing, directed downward and the nasal duct flushed into the nose. If the punctum be too small for the entrance of the syringe point, it must first be dilated with a fine Bowman's probe.

CHAPTER XI.

CATARACT AND OTHER AFFECTIONS
OF THE CRYSTALLINE LENS.

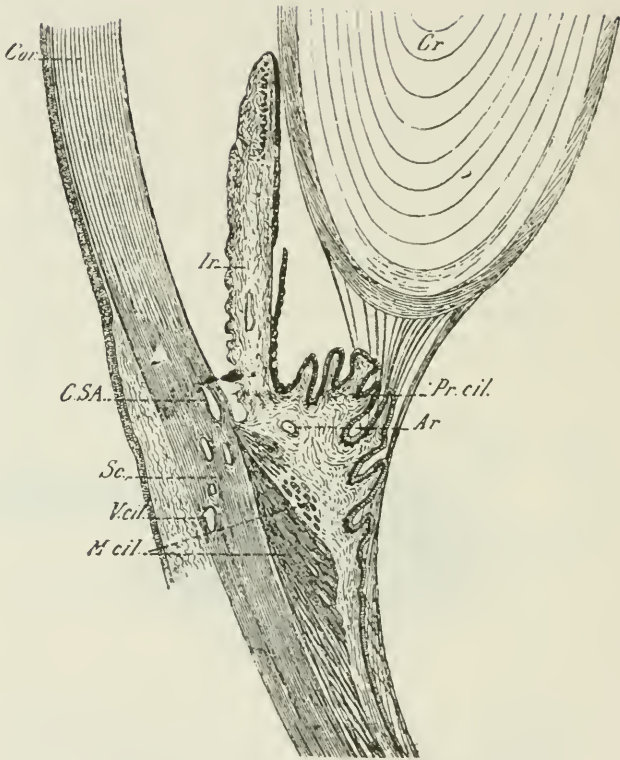
The crystalline is suspended from the ciliary body in front of the vitreous.—Dislocation of the lens.—Aphakia or absence of the lens.—The various kinds of cataract.—The senile variety the commonest and most important.—Hard and soft cataract.—The lens, an epithelial structure within an unyielding capsule, grows heavier, larger and less transparent with age.—Diagnosis of cataract.—Operations for removal.—Iridectomy.—Contraindications for operation.—Extraction of senile cataract.—After treatment.

Dislocation of the Lens.—The lens is beautifully suspended by means of the pectinate ligament, or zonula of Zinn, from the ciliary body,



Dislocation of the Lens.

and is so well poised that it readily withstands the influence of ordinary jars or injuries to the ocular region. But *severe blows*, delivered directly upon the globe may, particularly if the ligament be weakened by disease or if the



THE CRYSTALLINE LENS AND ITS CONNECTIONS.

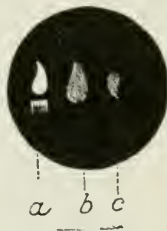Cor = Cornea. C S.A. = Canal of Schlemm. Sc = Sclera.
 V. cil. = Ciliary vein. M. cil. = Ciliary muscle.
 Ir. = Iris. Pr. cil. = Ciliary body.

vitreous be fluid, cause rupture of some of the suspensory fibres and the lens may thus become *dislocated*. When the zonula is torn to a slight degree only, the dislocation is correspondingly slight; but when the violence is considerable and directed towards the ciliary region, the lens may be torn entirely away from its fibrous supports and driven into the vitreous, the anterior chamber, or even through the burst sclerotic underneath the conjunctiva. In every case of dislocation there is more or less trembling of the unsupported iris (*iridodonsis*) when the patient is told to look in various directions, and this is diagnostic of the injury. After its dislocation (in consequence of interference with its nutrition) the lens grows hazy and may finally become quite opaque. If the pupil be dilated with homatropin, or better still with cocain and atropin, the new position of the dislocated lens may usually be accurately defined by means of reflected light and its contour easily determined.

The power of accommodation is, of course, lost when the lens is displaced, since the accident necessarily interferes directly with the mechanism of that act. For the reason given in the description of aphakia the eye becomes very hyperopic when the lens is no longer in the axis of vision. Its refractive effect on the rays of light entering the eye is then entirely wanting.

Treatment.—The best treatment of a *slightly* dislocated lens is to leave it alone, unless it becomes opaque and decidedly interferes with vision. Where the dislocation is very marked, or where the lens is loose and “bobs” up and down in a fluid vitreous, or where it is dislocated into the anterior chamber, it should be removed. The successful management of these cases requires some ophthalmological experience and the operation for the removal of such a lens usually calls for the exercise of considerable skill and dexterity.

Aphakia.—Whenever *the lens is absent*, whether as the result of operation, absorption,

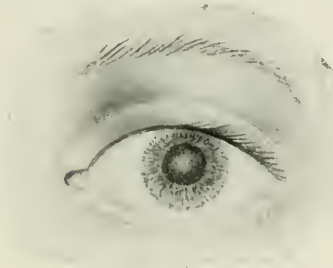

Images of Purkinje.

b. and *c.* Absent in aphakia. *a.* Reflection from the cornea. *b.* From the anterior surface of the lens. *c.* Inverted image from the posterior surface of the lens.

or dislocation, the condition is styled aphakia. The refractive power of the crystalline being equal to about ten diopters, the eye is made hyperopic to that extent, and after cataract operations, as is well known, this has to be taken

into consideration and suitable glasses ordered. Moreover, as aphakia necessarily involves a loss of accommodation power a second glass, for reading and other near work, is required in addition to the distance lens.



Nuclear Cataract.

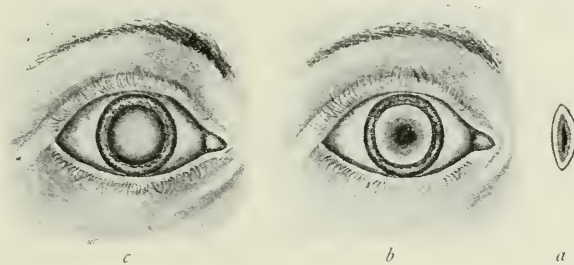


B



Cortical Cataract.

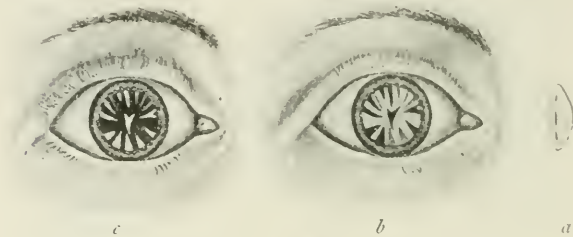
Cataract or opacity of the crystalline lens is the result of structural changes in the cells and fibres of which it is composed. Sometimes these alterations of structure are irregularly dis-



NUCLEAR CATARACT.

a. Section of lens, central position of opacity. *b.* Appearance by transmitted light. *c.* Appearance by oblique illumination.

tributed throughout the body of the lens, as in most cases of *senile cataract*; sometimes they are mainly central (*nuclear cataract*) and not infrequently they are confined to the periphery or cortex (*cortical cataract*). There is a great variety of cataracts, but the most practical division



CORTICAL CATARACT.

a. Section of lens, opacities beneath capsule. *b.* Opacities seen by transmitted light. *c.* Opacities seen by reflected light.

of them is into "*soft*" and "*hard*" cataracts. Speaking generally, the soft variety occurs in persons below thirty or thirty-five years of age, while the hard variety is found only in older patients.

Senile cataract (hard cataract).—This is the commonest as well as the most important form of the disease, the cortical variety being most frequent.

The normal lens gradually grows larger and denser as we grow older and exhibits other senile changes; the lenticular nucleus in particular becomes firmer, and with the rest of the lens ac-

quires a yellowish tint and transmits less light than formerly.

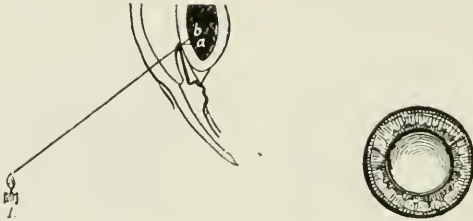When the pupil is widely dilated the grayish, translucent, outline of the whole crystalline is distinctly visible, both with the oblique illumination and by reflected light. While these alterations, attendant upon old age, may be regarded as more or less physiological, they are closely allied to true cataract. In the latter instance, however, delicate lines, or well defined streaks of opacity, best seen by reflected light with a dilated pupil, add themselves to the normal translucent gray of the lens. These commonly begin at the periphery or equator, and slowly invade both cortex and nucleus until the whole crystalline is involved.

The pictures made by progressive senile cataract, from the time when the first faint striæ appear until the cataract is complete, are often very pretty, and remind one of the geometrical shapes one sees when snow flakes are examined with a lens.

The time occupied by the process varies greatly, but may extend over many years. Some opacities remain stationery during life.

Symptoms.—Sight will not be much affected until the nucleus (in the area of the pupil) is involved. The patient then complains that images are distorted or multiplied (*polyopia*), or that there is a cloud, or floating body, before

the eyes. During this period (*incipient stage*) the sectors or streaks of opacity, when viewed through the dilated pupil, appear grayish by oblique illumination, and black with the reflected



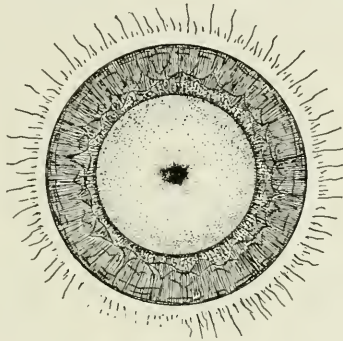
Shadow of iris, seen in front on immature cataract. (Fuchs.)

Shadow of iris upon the lens seen in cross-section. (Fuchs.)

light of the ophthalmoscope, the red reflex of the fundus showing through the clear portion of the lens. The fogginess increases very slowly until finally the visual acuity is reduced to the counting of fingers. In the early stages, before the opacity has completely invaded the periphery, vision is better in a dim light, because that moderate dilation of the pupil that occurs in a partially illuminated room, for example, permits the patient to see through some, as yet unaffected, peripheral parts of his lens. Occasionally a person blind in a bright light is able to read if he shades his eyes with his hand.

As the cataract advances the lens swells, becomes more convex, and the patient may be able to discard his reading glasses entirely (although

the affected eye always sees worse in the distance), owing to the increased refractive power of the crystalline. He then develops the condition commonly known as "*second sight*." When the cataract is ripe or mature the whole lens is opaque, and it can safely be removed from the capsule by operation without leaving any soft, lens matter behind. Such a cataract should have



Posterior Cataract as seen through dilated pupil. *a mother-of-pearl appearance by oblique illumination, and while the examination is being made (the pupil undilated) the iris should not cast a shadow on the lens surface. Shadows cast by the iris on the lens indicate that the anterior layers of the crystalline are still immature and transparent; the shadow being thrown on the opaque nucleus. There should also be no glittering sectors or facets brought to view as the patient is told to look in different directions during the examination.*

When an operation is undertaken on an im-

mature cataract the soft, glue-like portions of the unripe lens stick to the parts in the anterior chamber, and resist ordinary attempts to remove them. These small masses not only act as foreign bodies, producing irritation and inflammation of the iris, but transparent at first, finally become opaque, and lower the visual acuity.

In time the cataract becomes *hypermature*, or over-ripe. It may then shrink, or, becoming soft, semi-fluid, or of a milky consistency, allow the hard nucleus to sink to the bottom of the capsule cavity, showing there as a small amber-colored body (*Morgagnian cataract*). In such cases the iris loses its natural support, and an iridodonesis is the result. Sometimes the opaque lens takes on a dark brown color, and with the oblique illumination the pupil presents a black, almost normal appearance, although the cataract is mature (*black cataract*).

Cataract may remain stationary, and unless the opacity involves the central portion of the lens, vision may be very little impaired. Even when the opacity involves the pupillary area, it may take several years for the cataract to mature, and become favorable for removal.

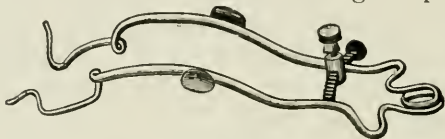
When both lenses are cataractous, the patient is doomed to go about in a state of practical blindness for months unless one or both cataracts are prematurely extracted or artificially ripened. One method of accomplishing the latter end is to perform a *preliminary iridectomy*,

combined with gentle massage, applied either directly to the lens or through the cornea, with a small spatula. In a month or six weeks the lens will often be found to be mature.

Another procedure is to wash out the soft matter of the unripe lens, at the time of extraction, by means of a small irrigator, using a stream of sterile, warm (102° F.), normal salt solution, or boric acid, two grains to the ounce of distilled water. Great care should be observed to use a scrupulously clean instrument, furnished with a rounded pipette (so as not to bruise the parts), and not to employ too powerful a current of fluid.

Iridectomy is performed in the following manner: the conjunctival sac having first been irrigated with an antiseptic solution (warm saturated solution of boric acid in 1-10,000 of bichlorid) and all other antiseptic precautions carried out, a few drops of a sterile, four per cent solution of cocain are, at intervals of a minute for five minutes, dropped into the eye. The wire speculum is now introduced, and the eye steadied by fixation forceps. The point of a keratome is entered at the upper sclero-corneal junction, at right angles to the globe; when the cornea is pierced the handle is depressed and the point pushed across the anterior chamber as deeply as necessary. The aqueous begins to escape as soon as the withdrawal commences, so that the sharp point of the instrument should be

made to hug the posterior surface of the cornea, else the lens may be wounded. The fixation forceps are now given to an assistant, and with the iris scissors in the right hand, the iris forceps are, with the left, introduced closed into the anterior chamber and carried along the posterior



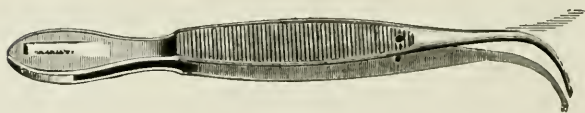
Lid Speculum.



Keratome.



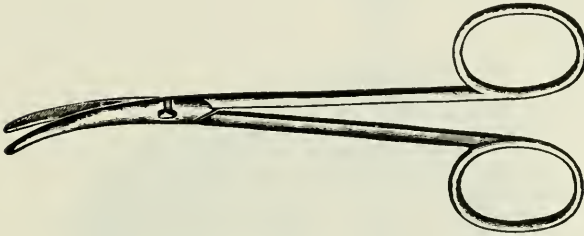
Fixation Forceps.



Iris Forceps.

corneal surface until the pupillary margin is reached. Here they are opened, the iris grasped, pulled out of the wound, and snipped off with one cut of the scissors close to the cornea. This part of the operation is the only one attended with pain. The discomfort may be somewhat


lessened by waiting a few minutes after the withdrawal of the keratome and allowing a drop of the cocain solution to flow over and into the wound of entrance. The patient should be told in advance that it may be painful, at the same



Iris Scissors.



Graefe Knife.



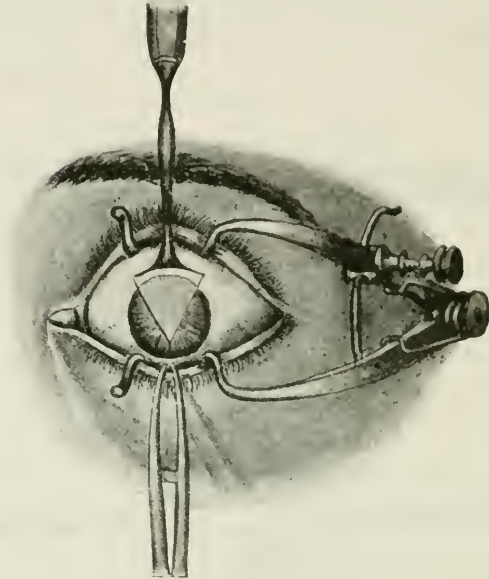
de Wecker's Iris Scissors.

time assuring him that the pain will not be severe and will last for an instant only.

Care should now be taken that the edges of the cut iris are replaced either with the repositor or, what is still safer, by gently stroking the cornea with a rubber spoon. The width of the corneal opening should be twice as wide as the

iris coloboma which, in this form of iridectomy, should be a small one.

Removal of Senile Cataract.—Before attempt-



Operation of Iridectomy.

Keratome within the anterior chamber. (deSchweinitz.)
ing the operation of extraction—the only efficient treatment of this form of cataract—certain important considerations must not be forgotten.

1. *The cataract must be mature.*
2. *The patient's health should be fairly good, else the healing process may be interfered with.*

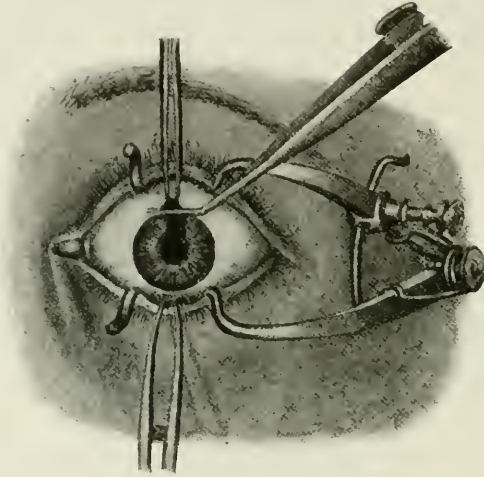
As hard cataract occurs in old people, who are not as a rule robust, we may have to deal with some patients who are not encouraging subjects for any kind of surgical treatment. It is wise to make the best of such cases and to improve their condition as far as it is capable of improvement. *Cough, constipation, and insomnia* are always serious complications and should be as far as possible relieved before the operation.

3. *The external eye should be examined.* Mucocele, blepharitis, conjunctival and corneal diseases should first be treated and, if possible, cured. If this is neglected, the abundant germs which these diseases supply are very likely to infect the corneal wound and lead to much dreaded complications.

4. *Corneal opacities* should be searched for, and if found, the patient should be warned that they form a bar to realization of perfect vision.

5. It is very important, in view of their ultimate effect upon the eyesight, that the presence or absence of *deep-seated disease of the eye* should be demonstrated. It would be very disappointing, after an operation entirely successful from a technical standpoint, to find that the patient had had all the while disease of the optic nerve, retina, etc., and was unable to see any better after the extraction than before it. In a case of *uncomplicated* cataract, then, the patient should have prompt perception of light—should

in other words be able to state at once when the hand is passed over the eye, between it and a



Operation of Iridectomy.
Excision of piece of iris. (deSchweinitz.)



1

2

3

Various Forms of Iridectomy.

1. Broad peripheral iridectomy. 2. Small iridectomy with ciliary border preserved. 3. Narrow iridectomy for optical purposes.
(de Schweinitz.)

good window light. In a dark room he should be able to see and *locate* a candle flame twenty feet away, or a faint light reflected from a mirror at a meter's distance and to point out its locality when it is moved in different directions. This "*projection of light*" test should never be neglected. It is really a test of the perceptive ability of the different sections of the retina, and fails when any considerable part of the latter is diseased.

The progress of an incipient or immature cataract can in a few cases be arrested if proper precautions be taken. All sources of strain should be removed from the eyes not only by the careful correction of any refractive error that may be present but by insisting upon ocular quiet. Excessive employment of the eyes for close work, or otherwise, in a poor light should especially be strictly prohibited. Exposure to wind, strong light and other influences that have a tendency to inflame the ocular tissues should be avoided. If the eyes are to be used at all, this should be done only under the most favorable conditions. Any disease of the eye itself should be treated by appropriate remedies. The general health should be carefully looked after; the digestive organs often require attention.

As before pointed out, in some cases of cataract the opacity is confined to the central portions of the lens (*nuclear*), with a clear zone

situated peripherally. In such cases vision is much improved when the pupil is dilated. This is best accomplished by the instillation of—

Euphthalmin	gr. 4
Cocain hydrochl.	gr. 4
Aquæ dest.	oz. $\frac{1}{2}$

Put one drop into the eye on rising and a second four hours afterwards. A harmless mydriasis results which lasts most of the day.

EXTRACTION OF SENILE CATARACT.

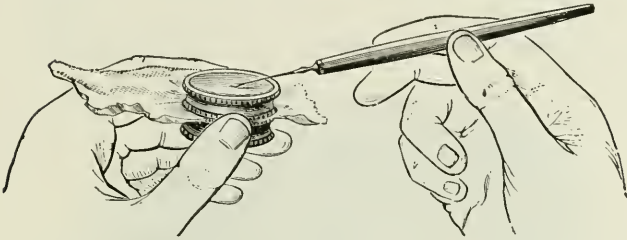
The day before the operation the bowels should be thoroughly moved by giving a dose of castor oil, an enema or by both remedies.

Preparation of the field of operation is more necessary in cataract extraction than, perhaps, in any other operative procedure on the eye. The directions given on page 486 should be strictly observed.

There are almost as many operations for cataract as there are operators, but the usual method of extracting senile cataract is the so-called *modified peripheral linear operation* of von Graefe. The instruments needed are a pair of fixation forceps, a wire speculum, a narrow Graefe cataract knife—whose well sharpened point pierces readily, and by its own weight, *the testing drum*, a pair of iris forceps, a metal or shell iris repositor, a pair of iris scissors, and a cystotome.

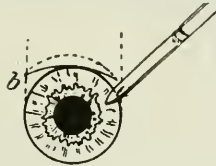
Examine them with a lens and be sure that

they are perfectly bright and clean and that the cutting instruments have a razor edge. One drop of a freshly prepared 5% solution of cocaine, or, better, this solution reinforced by a 1% solution of holocain, is dropped into the eye



Testing Drum.

every minute for five minutes. The speculum is introduced by sliding the upper branch under the upper lid; then the lower branch beneath the lower lid. It should not be opened too widely lest it cause pain. The patient should now be

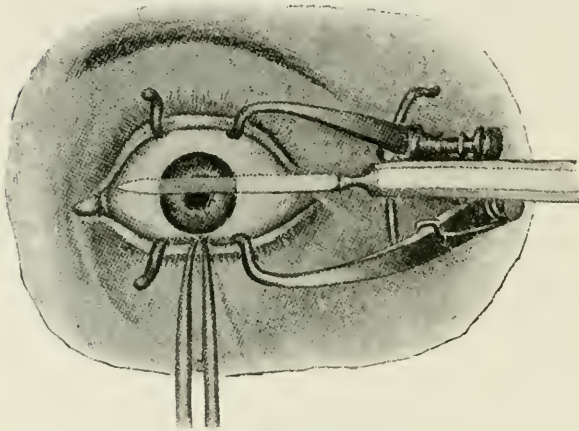


Graefe's Peripheral Linear Extraction.

warned not, under any circumstances, to "squeeze the lids together" during the operation. It would also be well to exercise him beforehand in looking up and down, in and out. Whether it be from "operation terror," or what

not, some patients cannot otherwise be induced to perform these simple acts at those critical moments when they are urgently called for. A little preliminary drill will be found useful in such cases.

The *first step* is the corneal incision. This should be made at the limbus in the upper cor-



The Incision in Cataract Extraction.

Puncture and counter puncture have been made. The section will pass in its whole extent exactly through the transparent margin of the cornea, the knife remaining in the same plane throughout. (deSchweinitz.)

neal semicircle, and will involve about two-fifths (better more than less) of the whole circumference. The patient looking up, the conjunctiva and subconjunctival tissues are grasped a short distance below the lower corneal margin. He

now looks down, and the point of the knife, edge up, is entered, and is directed downwards. The handle is depressed and a counter puncture is made, and, by a to and fro motion, the blade slowly cuts its way out towards the upper limbus.

The *second step*—the iridectomy—has already been described. When an iridectomy is to be made (in “simple” extraction it is omitted) it can be performed as the second step of the operation. In not a few cases, as before stated, it is preferable to do a “preliminary” iridectomy several weeks previous to the extraction operation, as a means of hastening the ripening of the



Cystotome.

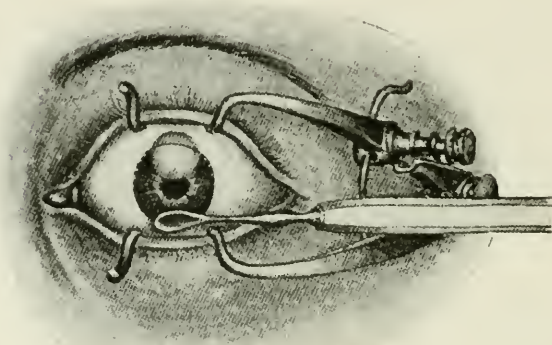
cataract. Some operators *always* prepare the patient for the actual extraction in this way. They believe that better results follow this plan.



Cataract Spoon.

The *third step* is the opening of the capsule to allow the escape of the lens. As soon as any bleeding stops the patient looks down, the surgeon again fixes the globe, the cystotome is introduced and crucial scratches are gently and carefully but firmly made through the anterior lens capsule on the cataract surface.

The *fourth step*. After the cystotomy the lens will probably present in the wound, and its complete delivery may be accomplished (the patient looking down) by gently pressing, midway between the center and the lower edge of the cornea, with the rubber or metal spoon usually attached to the other end of the cystotome handle.



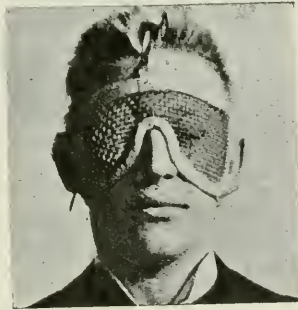
Cataract Extraction.

The lens is presenting in the wound. Capsulotomy has been performed. (deSchweinitz.)

The pressure should be directly backwards, and no attempt ought to be made to squeeze out the lens with even the slightest force. Loss of vitreous is apt to occur unless this precaution is observed. The opaque lens may, however, be "followed up" by the spoon as it emerges from between the lips of the wound. Here the fixation

forceps should be loosened, and the speculum had better be removed.

The *fifth step*. Masses of soft matter or pieces of capsule that have been left behind may be coaxed out by stroking the cornea from below upward, or, better still, they can be more thoroughly removed by *irrigating the anterior chamber* with a Lippincott irrigator—as just described. The pupil, which was before white, now becomes black and any remaining soft matter or capsule can be more readily seen. When the edges of the iris coloboma are in their proper places, and everything (iridic, lenticular or capsular remains, vitreous, blood clots, etc.) re-



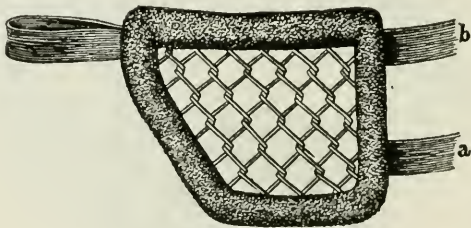
Shield for Protecting the Eye Operated On.

moved from between the edges of the wound the conjunctival sac should be irrigated with a warm boric acid solution and the lids gently closed, after placing well into the conjunctival sac a

small quantity of the ointment of the bichlorid of mercury (White), this being repeated at each dressing until the wound is thoroughly healed and all danger of infection is past, one or two drops of a one per cent solution of atropia sulphate having been previously instilled into the eye.

DRESSINGS AND AFTER-TREATMENT.


Dressings innumerable have been recommended after cataract operations. While it is well not to follow empirically any one plan, the



Mask After Cataract Extraction.

following will be found very useful. A piece of sterilized gauze with a thin layer of borated cotton is cut in circular form, having a diameter of from 2 to 2½ inches. The gauze side of this pad is evenly applied to the closed lids and is held in place by strips of zinc oxid adhesive plaster, about one inch in width. The first piece is applied over the brow; the second extends from the nasal extremity of the brow diagonally along the side of the nose to a point on the cheek

below the lower edge of the pad; the third extends from the outer extremity of the brow diagonally down the outer edge of the pad, to meet the lower end of the second strip on the cheek. This "*triangular*" bandage becomes firmly adherent in a few moments and has the advantage of not slipping or becoming displaced or being removed by the patient without considerable discomfort.



Papier Mache Mask.

The after treatment is important. During the twenty-four hours succeeding cataract extraction patients complain of smarting or occasional twitches of pain. These have no serious significance, and are usually relieved by an analgesic given at night. He should be kept on a soft diet. If the eye feels perfectly comfortable the dressing may be left in place until the third or fourth day. As a rule, however, the patient will be

more at ease if the bandage is removed and his closed lids are bathed cautiously, daily, with warm boric acid solution, and fresh dressings applied. In that case he is not tempted to rub his itching lids or brow, to the detriment of the healing process, as is sometimes the case when the eye remains untouched for several days. If all goes well, glasses for reading as well as for distant vision may be ordered in about six weeks.

Complications.—Continued dull pain after the first twenty-four hours, or excessive discharge, usually means mischief, and should lead to a removal of the bandage and a critical examination of the eye. These signs, when they occur during the first three or four days after the operation, point to the invasion of the corneal incision by microorganisms; later on—five or ten days—they mean iritis. In the first instance, purulent infiltration of the edges of the wound is indicated by a grayish yellow appearance along the edges of the wound in the cornea. As soon as it is discovered the eye should be well irrigated with hot boric acid solution and a 20 per cent solution of argyrol applied not only to the margins of the incision, but so as to flood the conjunctival sac. If this does not arrest the progress of the disease the actual cautery should be thoroughly applied to the line of infection. The hot irrigations should then be renewed every two or three hours, the argyrol being ap-

plied less frequently after the disease is under control. The secondary iritis has the signs and symptoms of the primary form, and should be treated like it.

Extraction without iridectomy has many advantages, in the preservation of a round, central and mobile pupil—a consummation devoutly to be wished. On the whole, this operation is more difficult to perform than that with iridectomy. Whether this drawback is offset by superior advantages in the way of better vision, a natural appearance of the pupil, etc., re-



Lamellar (soft) Cataract.

a, front view; *b*, sectional view.

mains a debated question. Probably it is better not to do exclusively either operation, and there certainly appears no reason why we may not employ the "simple" method for mature cataract in otherwise healthy eyes, adding the iridectomy when good and sufficient reasons call for it.

Soft cataract occurs in children and young adults. It presents a characteristic, uniform,

whitish appearance and, as a rule, has no distinct nucleus. The most important variety is the *lamellar* or *zonular* cataract. This is the ordinary cataract of infancy and childhood and is either congenital or forms soon after birth. It can easily be made out through the dilated pupil, both by oblique illumination and by reflected light. The opacity affects the lens in layers, does not extend to the periphery, and the visual acuity is sometimes nearly normal. Lamellar cataract is not progressive like the senile variety.

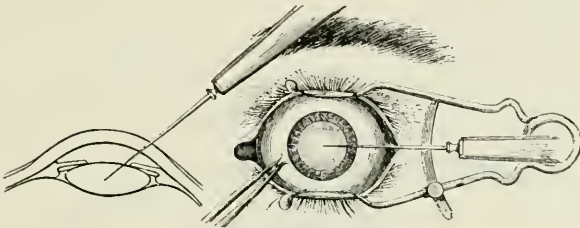
A history of infantile convulsions is almost always given by these patients; they nearly all have strumous teeth, that is to say, the enamel of the incisors and canines is likely to be absent from the crowns and upper halves. What the relation is, if there be any, between the cataract, the convulsions and the rachitic teeth it is difficult to say.

Traumatic Cataract.—In addition to the different forms of congenital and infantile cataract, *traumatic* cataract is of the soft variety. The injury brings about rupture of the anterior capsule; contact of the aqueous humor with the normal lens causes its fibres to swell, become opaque, project through the rent in the capsule and sometimes, as in the operation for discission, to become partially or totally absorbed.

Diabetic cataract is usually of the soft variety. The extraction of this form of cataract,

even when the diabetes is active, is not contra-indicated by the presence of the disease.

Treatment of Soft Cataract.—If, as in some cases of lamellar cataract, the patient's vision be sensibly improved by dilatation of the pupil, an optical iridectomy is indicated. If, however, with correction of optical errors this does not furnish




Needling of Soft Cataract.

a useful degree of sight, or if the cataract be *total*, needling or *discission* is called for. This operation is employed when absorption of the whole lens is the end in view.

The pupil having been previously dilated with weak atropin solution, cocain is instilled (or, in the case of quite young children, chloroform given) and a cataract needle passed through the cornea 2 mm. from the outer scleral junction. The point is now directed forwards to the center of the lens and a single vertical cut made in the capsule. The needle is at once withdrawn; little or no aqueous escapes and there is very little inflammatory reaction.

In a day or two a portion of the lens projects through the opening thus made. This, through the solvent action of the aqueous, is absorbed. Still another piece protrudes, goes through the same process, and so on, until in from three weeks to three months the whole lens has disappeared by absorption. Weak atropin drops should be used throughout and a bandage is generally advisable.

Some surgeons prefer, as soon as the lens mass comes forward into the anterior chamber, to remove it by the usual corneal section or by means

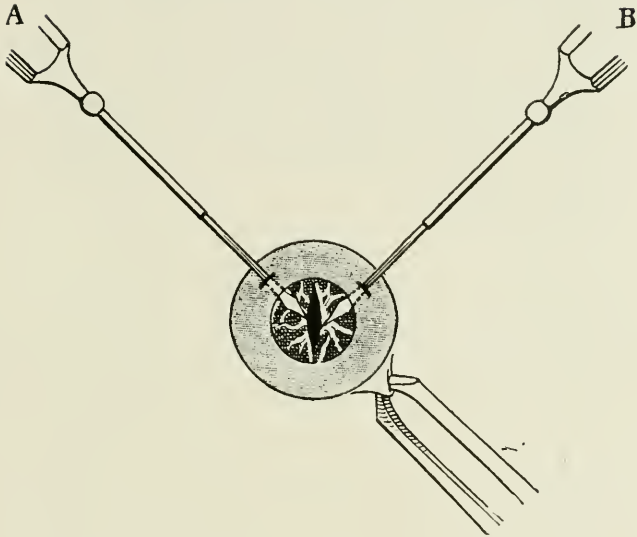


Syringe for Removing Soft Cataract by Suction.

of a specially constructed *suction syringe*, but the discission operation alone is generally safest and is usually all that is required, although it may have to be repeated.

Secondary Cataract; Capsular Cataract.—The posterior capsule is, of course, not removed in either of the cataract operations just described. It often happens that some of the lens substance

remains after extraction of the cataract; absorption of this takes place and vision gradually improves. In a certain percentage of cases, however, the posterior capsule becomes thickened and



Discission of Secondary Cataract With Two Needles.

vision in a few weeks or months, deteriorates to a considerable extent, the thickened capsule hanging like an opaque curtain behind the pupil and greatly interfering with vision. Similar changes may take place after a discission for soft cataract.

Treatment.—A central rent should be made in

this secondary cataract. This is best accomplished by introducing two discission or knife-needles—one in each hand—at the outer and inner corneal borders respectively, and having them meet in the center of the capsule. The handles of the needles are then simultaneously elevated so as to cut the desired opening. Even when the capsular cataract can be made out only with a lens, considerable increase in the visual acuity is attained by this operation of needling, and it is commonly resorted to. No reaction should follow.

CHAPTER XII.

THE COMMONER INJURIES OF THE
EYELIDS, CONJUNCTIVA, COR-
NEA, IRIS, LENS, SCLERA
AND CHOROID.

Injuries to the lids frequently seen.—What constitutes a “black eye.”—How to treat it.—Incised and other wounds of the lids.—Injuries of the conjunctiva.—Symblepharon.—Burns and other injuries of the cornea and how to manage them.—Contusions of and blows upon the eyeball.—Hyphemia.—Iridodialysis or rupture of the iris.—Dislocation of the lens.—Deep injuries to the eye, such as rupture of the choroid.—Rupture of the eyeball.—Sympathetic ophthalmia may follow penetrating wounds, especially of the ciliary region.—Injuries of the cornea and how to deal with them.—The electro-magnet the most useful means for the extraction of iron and steel from the interior of the eyeball.—Migratory ophthalmia due to infection of the second eye by microbes and toxins from the injured eye.

Injuries of the eyelids are quite common. They are mostly contusions, incised wounds and burns from hot water, acids or caustic alkalies.

On account of loose connective tissue in the lids, marked ecchymosis and swelling are liable to follow even slight injuries to any part of the orbital region or to blows upon and contusion of more remote parts of the head. Emphysema of the lids is occasionally seen after a severe injury in the neighborhood of the eye; when it appears, fracture of the orbit, and some communication with the air passages is to be sus-

pected. This may take place directly through the nose or indirectly by way of the frontal and ethmoid sinuses or the antrum of Highmore.

The ordinary "black eye" is usually not attended by any complications and except for the disfigurement which it causes the discoloration disappears in about two weeks.

Treatment.—If seen early iced compresses with lead lotion will do most good.

Acetate of lead	dr. 1
Alcohol	oz. 2
Distilled water, to make	oz. 8

Later on, pressure, hot compresses and massage are indicated. It is doubtful whether that universally applied remedy, a piece of cold beef, has any influence whatever on the present progress or future prospects of a black eye. At any stage of discoloration the lids may be painted with water colors for their cosmetic effect. Abscess rarely follows these injuries; when it does it should be treated in the usual way, opening it along the horizontal "creases" in the skin, to hide the subsequent scar.

Incised wounds of the lids are apt to produce a good deal of deformity unless their edges are carefully and promptly brought into position by sutures, to prevent the granulation tissue that readily springs up between the displaced margins of the wound.

Vertical wounds of the lids, particularly those that involve the orbicularis, are followed by still more gaping and consequent scarring than those running in a horizontal direction and they should, consequently, be sutured with care and accuracy. If this rule is strictly followed very little deformity follows even extensive wounds. If the fibres of the levator palpebræ are divided the cut edges of the muscle should be found and stitched together to prevent the disfiguring ptosis which would otherwise follow such an injury. Indeed, it may be said that to obtain the best result *all* wounds of the lids, it matters not in what situation, should be cleaned and their margins promptly and evenly brought together by fine silk sutures. The dressing should be dry iodoform gauze and a triangular bandage.

Lacerated wounds are often followed by sloughing, much scar tissue, and deformity of the lid. After complete healing has taken place and the hyperemia and swelling of the tissues have disappeared a plastic operation will usually remedy the defect.

Burns of the lids of the second or third degree should be cleansed with antiseptic solution, protected by non-irritating ointments, and their consequences treated by subsequent operation. Emphysema may be relieved by the application of a pressure bandage. The patient must be warned against blowing his nose.

Injuries of the Conjunctiva.—Foreign bodies, such as cinders, particles of sand and other forms of dust, frequently fly into the conjunctival sac. They are generally retained in the groove just behind the upper lid margin and are thence readily removed after eversion of the lid. Such minor accidents are usually attended by “foreign body sensations,” considerable pain, lachrymation and injection of the bulbar vessels, due to the rubbing of the particle against the surface of the cornea when the eye is opened or closed.

Wounds confined to the ocular conjunctiva, if slight, heal quickly and merely require cleansing and the application of a bandage to keep the eye closed. If they are extensive the edges of the wound should be brought together by *fine sutures* (to be removed in two days) and a bandage applied.

Burns of the conjunctiva from lime, caustic alkalis, acids or molten metals, ignited powder or steam occur quite frequently. They are followed by severe pain, as a rule, and inflammation of the parts involved. The edema of the neighboring conjunctiva is apt to be quite extensive. A grayish eschar soon forms which sloughs off and is replaced by granulation tissue. The most serious and most important sequel of this injury is the adherence of the lid to the globe or rather of the two opposing raw sur-

faces, constituting the condition known as *symblepharon*.

Treatment.—If seen immediately after the accident the pain can be temporarily relieved by a few drops of a 1 per cent solution of holocain, or 4 per cent cocain, and all foreign substances removed as quickly as possible. The conjunctival sac should be irrigated with a fountain syringe containing a chemical antidote (if the burn is due to lime, an acid or alkali) which will tend to neutralize or render insoluble the offending material. In the case of acids a solution of borax or bicarbonate of sodium, one per cent, is effective and is usually at hand.

When due to *strong alkalis* the irrigating fluid should be milk, sweet oil or a weak solution of vinegar. Subsequently cold applications should be applied to the closed lids and a mild antiseptic solution, such as a saturated solution of boric acid, should be instilled into the sac every two or three hours. If the burn is extensive, the conjunctival sac should be filled with warm sterilized vaseline, or some oily substance, which not only relieves the pain and other symptoms but adds a protective cover to the denuded surfaces. In this instance a supporting bandage should be applied to the eye and it ought not to be disturbed except to wipe off the discharge from the lid edges, applying more vaseline when required. *Symblepharon*, of greater or less de-

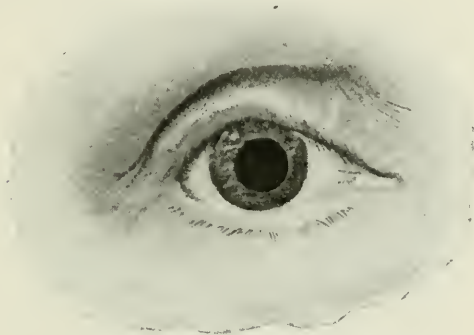gree, almost always forms and must be dealt with by operation.

Burns of the cornea usually accompany similar injuries to the conjunctiva and lids, and may end in impairment or complete loss of vision. Lime and fresh mortar are among the common causes of these distressing injuries and the scars that remain are exceedingly unsatisfactory to treat. In every workshop and in every building under repair or construction, in which lime is used, small tubes of vaseline or castor oil should be kept so that their contents may be *at once* pressed into an eye burned with lime, even before any effort is made to remove the injurious particles. By this simple means many a workman's eye might be saved.

Contusions of the Eyeball.—The ocular globe resembles a rubber ball, in that it is elastic and capable of a certain amount of compression without injury. As soon, however, as a blow is received strong enough to alter its shape so that the antero-posterior diameter is shortened, with, at the same time, lengthening of the equatorial diameters, the coverings of the eye are subjected to great strain, and there is disarrangement of the ocular contents and interference with its functions.

Among the common consequences of this traumatism are *paralysis of the sphincter of the iris (iridoplegia)*, dilatation of the pupil and its

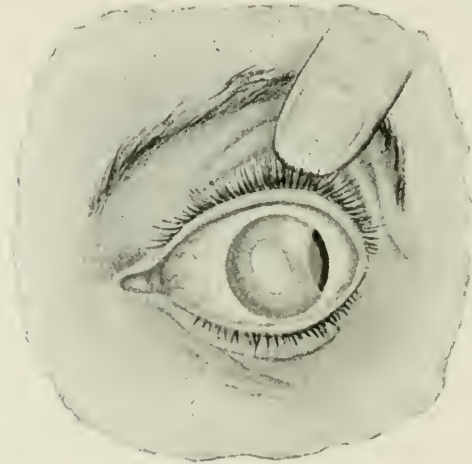
failure to contract to light (*traumatic mydriasis*), *paralysis of the ciliary muscle (cycloplegia)* and loss of the reflex contraction to accommodation. Either of these, or all of them, may follow blows or other injuries. The dilatation of the pupil may be complete and permanent or only certain portions of the sphincter may be affected, the pupillary dilation being irregular.



Traumatic Mydriasis, or Iridoplegia.

These conditions may, at first, be obscured by blood in the anterior chamber (*hyphemia*), usually from rupture of the iris vessels. This is commonly the case when the iris has been torn away from its ciliary attachment (*iridodialysis*). When it occurs an opening of variable size (sometimes multiple) forms at the periphery of the iris, the hemorrhage arising from the torn circular arteries of

the iris. The blood partially or completely fills the anterior chamber, making it impossible to estimate correctly the extent of the injury until it has been (in from two days to a week) wholly or partially absorbed. As a result of the rupture a second pupil is formed, through which the red reflex of the fundus can usually be seen with



Iridodialysis. (Berry.)

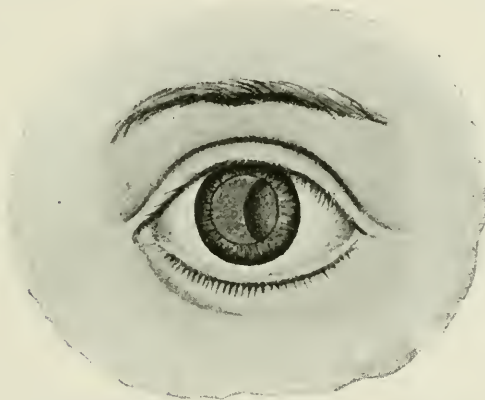the ophthalmoscope. Sometimes, as well, the margin of the lens and ciliary process can be plainly made out by means of the oblique illumination. This condition, often accompanied by double vision, is usually permanent, although a few cases have been reported of re-attachment of the iris to the ciliary body. Where separation

of the entire iris from the ciliary processes has taken place (*total iridemia*), the hemorrhage is usually severe.

Treatment.—Rest, cold applications and atropin are indicated.

Laceration of the capsule of the lens may follow contusion of the globe, in which case the aqueous humor invades the lens substance and a *traumatic cataract* is the result.

Dislocation of the lens is also met with after

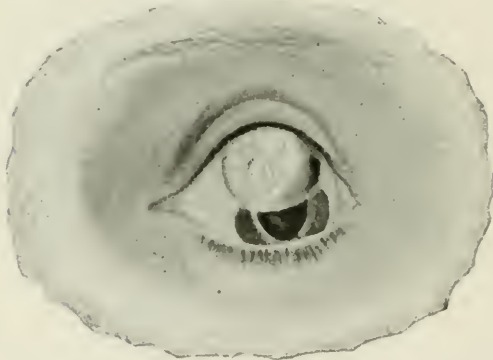

Partial Dislocation of the Lens. (Berry.)

severe contusion. The displacement may be partial or total, depending in a great measure upon the force of the blow and the extent of the rupture of its suspensory ligament—the zonula of Zinn.

When *partial* it is usually dislocated into the

space immediately behind the iris (*posterior chamber*). Sometimes its edge is found in the anterior chamber and is there observed as a dark rim, lying at the periphery of the pupil. When not cataractous the displaced lens then appears as an amber-colored body. Since the rays of light not only pass through the lens margin but through the aphakic pupil, as well, and come to a focus at different parts on the retina, diplopia is frequently present.



Dislocation of the Lens Beneath the Conjunctiva.

In *total dislocation* the lens either falls into the vitreous and disappears entirely, leaving a black pupil, just as after cataract extraction, or it is forced through the pupil into the anterior chamber. In either case, and especially if the lens becomes opaque (cataractous) much intra-

ocular disturbance takes place. The iris, as a consequence of losing the support of the lens, becomes tremulous (*iridodonesis*); the anterior chamber is deeper than normal and the pupil is more or less irregularly dilated.

Iridocyclitis and acute glaucoma, from the irritation of the ciliary processes and the blocking of the angle of the anterior chamber by the misplaced and swollen lens, are common sequelæ of a totally dislocated lens and the eyesight is lost unless promptly relieved.

Treatment.—The lens should in the majority of instances be removed as soon as the immediate symptoms, due to the injury, have subsided. Its extraction is, however, usually attended with a certain amount of difficulty on account of its liability to sink into the depths of the vitreous cavity. When it has primarily been dislocated into this chamber it may be left alone, if no symptoms of irritation develop, on account of the dangers and difficulties attending attempts to remove it—such as escape of vitreous and subsequent detachment of the retina. It is only when the reaction is particularly severe or when symptoms of acute glaucoma declare themselves that an attempt should be made to open the eyeball and extract the lens from the vitreous. The prognosis in such an event is not encouraging.

It may be well to mention other effects of

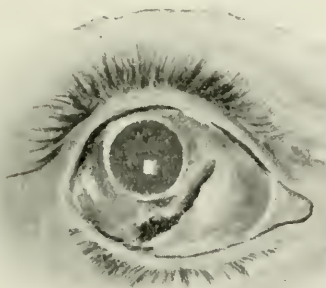
severe contusions, which can be detected only with the ophthalmoscope. Of these *commotio retinac; traumatic amblyopia*) is the most common. It is marked by a grayish infiltration and edema of the retina, especially in the macular region. Vision is impaired. The retina usually clears up in a few days and vision returns to normal—although a permanent defect may remain. In the severer types hemorrhages, from rupture of the choroidal vessels, may be present.

Treatment consists of rest, atropia and cold applications.

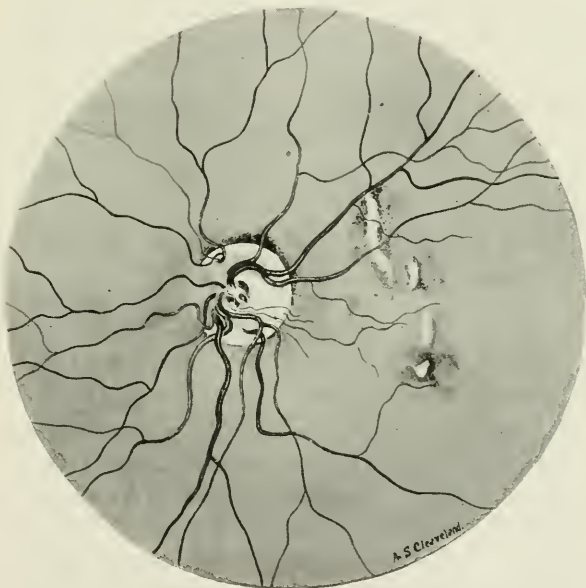
Rupture of the choroid is often obscured at first by hemorrhage but when this clears up the rent can be seen with the ophthalmoscope as a streak, yellowish in the early stages, white and bordered with pigment in a few weeks or months. It is usually crescentic in shape and situated near the papilla. The amount of visual impairment mainly depends upon the extent to which the macular region is involved.

Treatment consists in rest, protection of the eye from light, atropin and cold applications.

Rupture of the eyeball may occur from a severe contusion and is of very serious import, the majority of eyes being lost. The rupture usually takes place in the anterior segment of the globe and runs parallel with and close to the sclero-corneal margin on the upper nasal



Rupture of the Eyeball.




Rupture of the Choroid.

side. The conjunctiva may remain intact and beneath it protrude the iris, ciliary body, lens and vitreous, alone or together. If the conjunctiva be also ruptured the interior structures will be found completely prolapsed. Severe hemorrhage usually accompanies rupture of the eyeball.

Treatment.—The prolapsed parts should be cut away and the margins of the wound brought together with sutures. Cold compresses should then be applied in an endeavor to save the eyeball. No matter how carefully antiseptic precautions are carried out suppuration may take place and the eyeball require excision. Whenever the eyeball is opened and, in particular, when the ciliary body is wounded there is danger of *sympathetic or "migratory" ophthalmia*, endangering the second eye. Consequently one should always be on the lookout for early signs (*sympathetic irritation*) of this dreaded disease in the opposite organ, which may set in as early as two weeks or as late as many years after the primary injury. Enucleation of the injured eye should always be done if there be ground for suspecting sympathetic disease.

Injuries of the Cornea.—The lodgment of particles of dust, coal, sand, iron, steel, emery, etc., beneath the epithelium of the cornea is a common accident. Something flies into the eye and either sticks into the cornea or, more frequently, is imbedded by the rubbing of the eye by the patient

in his efforts to get it out. Infection is liable to take place if the foreign body is septic or if it is not removed promptly. The seat of the small wound is soon surrounded by a zone of grayish infiltration and a corneal ulcer is the result. When the foreign body is small and merely adheres to the epithelial layer, very little mischief may be looked for; it is easily removed, although it may be difficult to detect. When it becomes lodged in the deeper layers of the cornea, the mischief set up will in a great measure depend upon its size and the amount of infection that has taken place. Such injuries are, in many cases, followed by considerable reaction and subsequent ulceration.



Spud.

If the foreign body be a piece of iron or steel a rusty stain will be apparent and show the situation of the injury for some days after its removal. Considerable pain, photophobia and lachrymation are present and the patient usually complains of a feeling as if the foreign material were lodged beneath the upper lid.

Treatment.—Foreign bodies should be removed with as little delay as possible; if neglected their removal may occur spontaneously at the expense of an ulcerated cornea. The eye should be thoroughly anesthetized with a 4 per cent solution of cocain, the lids are separated with the fingers

of the left hand and *the foreign body picked out with a spud*. The seat of injury should then be thoroughly flushed with a solution of boric acid, 20 grains to the ounce, or 1:10,000 solution of bichlorid of mercury. If no infection has taken place the wound soon heals. The ulceration should be treated as described in the chapter on corneal ulcers.

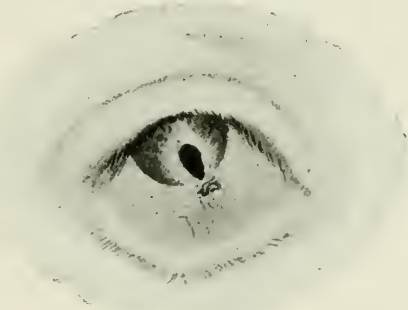If a foreign body penetrates all the layers of the cornea and projects into the anterior chamber it may be necessary to pass a keratome through the cornea into the anterior chamber and behind the foreign body, to act as a support to it during its removal.

The epithelium and anterior layers of the cornea may be abraded by scraping with the finger nail, a stick, branch of a tree, etc. If no infection takes place the wound heals readily, but to prevent infection the wound and conjunctival sac should be irrigated frequently with a solution of boric acid, or bichlorid of mercury, 1:10,000, or formalin 1:8,000. A solution or ointment of atropin one per cent, should be applied if much reaction is present.

Penetrating wounds of the eyeball, with or without retention of the foreign body, are always serious on account of the liability of the introduction of infectious material into the interior of the globe, there setting up a purulent inflammation (*panophthalmitis*), which is invariably followed by destruction of the ocular contents,

to say nothing of possible sympathetic inflammation of the other eye. The seat of injury may be either the cornea or sclera or may extend through both.

The injury affecting any segment of the globe

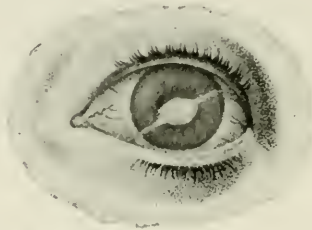

Prolapse of the Iris After Wound of the Eyeball.

may be incised, punctured or lacerated and may be caused by pieces of metal, chips of stone or wood or particles of glass. A traumatism of this character is frequently complicated by prolapse of the iris opacity of the lens or protrusion of a portion of the fluid contents of the globe. Large sized bodies, causing greater laceration, frequently destroy the eye at once. The reaction that follows is generally severe, especially if the wound is in the region of and involves the ciliary body (*danger zone*). It is accompanied by considerable ciliary injection, pain, photophobia and lachrymation, although the pain may be entirely wanting in some cases.

If the wound is small, and especially if it be

in the cornea, it usually heals quickly unless complicated by prolapse of some of the contents of the ocular cavity. If the injury has taken place through the cornea, which is usually the case, a rent may be discovered in the iris, or the iris may be found attached to the anterior capsule of the lens.



Incised Wound of Cornea, Iris and Lens.

When the lens is perforated there may be found either a small opacity corresponding to the point of perforation, or the whole lens may become cataractous, the latter condition being the more common consequence. If a missile enters and is retained in the anterior chamber it sinks to the bottom of that cavity. An exudation of inflammatory material may be thrown out, completely enveloping the foreign body, or, if the iris be injured, hemorrhage may obscure it and render it difficult of detection.


In some cases the point of entrance may be in the sclera; in which case it is usually situated at the upper part, not far from the sclero-corneal margin. When this occurs the wound will gape,

while a dark pigmented mass, consisting of a piece of iris or ciliary body or a bead of vitreous, protrudes between the lips of the wound. Usually such an injury is followed by severe reaction, although pain may be absent. If prolapse of the iris has taken place, the pupil will be elliptical in shape and a portion of the iris will be apparently wanting at the point corresponding to the prolapse.

It must be remembered that, owing to the hemorrhages or exudates about a foreign body that has penetrated the vitreous, it may be seen with difficulty, or not at all. Again it may pass entirely through the eyeball and become lost in the orbital cavity, or it may lodge in the coats of the eyeball and become encapsulated.

Perforating wounds of the sclera are more commonly followed by purulent inflammation than those of the cornea, on account of the injury to the ciliary body, which readily becomes infected. Prolapse of the vitreous is also more apt to occur in scleral wounds, thus presenting a favorable soil for the development and growth of microorganisms.

The danger in all penetrating wounds of the eye depends in a great measure on the condition and character of the body that produces the injury. It is very great if the missile be retained within the vitreous cavity. When the vitreous is cloudy and the posterior chamber cannot be satisfactorily examined with the ophthalmoscope,

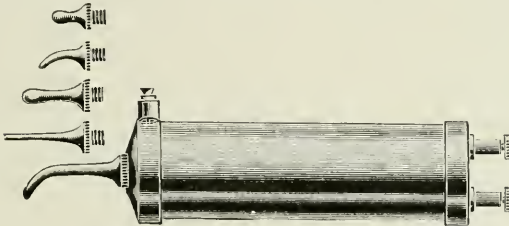


The Haab (giant) Electromagnet.

an attempt should be made *to locate it with the Roentgen rays*. A skiagram should at once be taken of the orbital region so that if a foreign body be present its size and position may be indicated. If the missile be a piece of iron or steel, it may, most satisfactorily, be extracted by means

of the *electro-magnet*. The best of these is the giant magnet of Haab. When this instrument is not available one of the smaller magnets will answer the purpose in most instances. If these means fail the question of removal of the eyeball presents itself.

Although cases are on record where particles of metal have been retained within the globe for years without causing trouble, they are always a source of danger not only to the eye within which they are lodged but to the opposite eye.



The Small, or Hand, Magnet.

Foreign bodies upon which the magnet has no effect, such as pieces of copper, stone and glass, should be removed by a pair of forceps introduced either through the original opening (which should be enlarged if necessary), or through another made for that purpose. Much loss of vitreous as a rule accompanies such a proceeding. If the procedure is unsuccessful enucleation of the eyeball is indicated.

Sympathetic ophthalmia is a plastic inflammation of the iris, ciliary body and choroid (uveal

tract) following an infection of the other eye set up by microorganisms introduced from without, as a result of perforating wounds of the globe.

The injured eye is called the *exciting eye*; its fellow is known as the *sympathizing eye*.

Symptoms.—At first there are signs of “irritation” only in the sympathizing eye. The patient complains of photophobia, lachrymation, blurring of the vision for near work and tenderness in the ciliary region. These symptoms eventually become marked as the disease progresses and to them are added intense injection of the zone surrounding the cornea, increased depth of the anterior chamber, while small grayish deposits appear on the posterior layer of the cornea (*descemetitis*, *punctate keratitis*). Iritis soon develops, the pupil is contracted and an exudate (serous at first—plastic later) fills the pupil and glues the iris to the anterior surface of the lens (posterior synechia). The tension of the globe increases in the early stages but diminishes as the inflammation becomes more severe and extends to the deeper structures of the eyeball. The anterior chamber is now shallow and the vitreous is filled with exudates owing to the extension of the inflammation to the choroid and retina. The iris changes in color and new vessels may be seen on its surface. The lens becomes opaque and detachment of the retina occurs from shrinking of

the vitreous. Finally, the eyeball, totally disorganized, undergoes atrophic changes and vision is entirely lost. This distressing and painful disease is usually slow in progress and it may take months before complete blindness follows the first symptoms.

In *mild cases* it may be arrested without total loss of vision. It sometimes happens that the inflammation in the exciting eye may be much less destructive than that which has been set up in the sympathizing eye, so that the vision of the originally wounded eye may eventually be better than that of the fellow eye. Sympathetic inflammation usually sets in from two to eight weeks after the penetrating injury, although a much longer period may elapse before any signs of inflammation show themselves.

It is more likely to occur in children and young adults than in old people. Even in its mildest form it is a serious disease on account of the impairment of vision, if not blindness, which follows it. Fortunately our present knowledge of antiseptics has been of great assistance in lessening its occurrence and it is met with much less frequently than formerly.

Pathology.—The most generally accepted theory of the production of this disease is that bacteria and their toxins (or both) are carried along the optic nerve of the exciting eye to the chiasma and thence to the other eye.

Treatment.—Very little can be done to cure but much to prevent this dreaded disease. An eye that has received a penetrating wound in the ciliary region is, generally speaking, too dangerous an organ to retain—it ought to be excised or eviscerated. The same is true of globes containing a foreign body that cannot be removed. When these wounded eyes are also blind there can be no worthy argument for their retention. When the disease is in progress, beyond the relief of pain and the administration of a supporting regimen and tonics, very little can be done. The intraocular injection of antiseptics (such as mercuric chlorid, formalin, etc.) and the passage of Haab's discs and rods of iodoform into the eyeball are worth trying, while the exhibition of potassic iodid, sodic salicylate and mercurial inunctions is of value, particularly in mild cases. No good now follows the removal of the exciting eye; moreover it must be borne in mind that after months of patient waiting the injured organ may be visually superior to the sympathizing eye.

CHAPTER XIII.

HOW TO PRESERVE THE EYESIGHT—
THE FUNDAMENTALS OF OCULAR
HYGIENE.

A knowledge of the principles of ocular hygiene necessary to every well informed physician.—Care of children's eyes.—Stupid pupils often children that are half blind or half deaf.—At what age shall a child be sent to school?—The building of school houses and the arrangement of their rooms.—Measurements and lighting of the ideal or standard school room.—Window shades, blackboards, seats, desks and school books should be chosen with due regard to the pupils' eyesight.—What colors shall be used in painting the school room?—The hygiene of adult eyesight.—The illumination of offices, public buildings and private houses.—The position of the reading lamp.—When to avoid the use of the eyes for reading.—Dotted veils a cause of eye-strain.—Rules for artificial illumination.

Surely it is quite as important to conserve the eyesight as to restore it. The application of those hygienic rules that have been formulated as the result of a study of ophthalmology is as necessary in the practice of the physician as regulating the dietary or any habit of his patient. Moreover, the family doctor will be constantly called upon to answer such questions as "What is the best light to use in reading?" "What do you think about the type of this school book?" "Would you advise us to send John to the kindergarten?"—all of which demand at least some acquaintance with ocular hygiene. It frequently

happens, also, that the physician is elected to serve as school trustee or as a member of the school board; how can he intelligently fill such an office unless he is acquainted with the requirements of modern school rooms, with all their details of lighting, seating, painting, etc.?—matters of vital moment when one considers that the eyes are the organs chiefly employed and involved in acquiring an education.

Infants' and children's eyes should never be exposed, even in sleep, to the glare of strong light, artificial or natural, and this is particularly imperative when the child is taken out in a perambulator or carriage. The eyes should then be protected by an awning or parasol lined with material that will not reflect the sun's rays upon the face.

They should not be encouraged to use their tender eyes for near work and their playthings ought to be large objects, easily seen. *Kindergarten and primary schools* should recognize this rule, so that the occupations of the child do not injure the eyesight. *No fine, difficult, or prolonged visual labor should be permitted* lest present eye strain be produced or a foundation for later myopia be laid. Sewing, map making, perforated card problems, much reading, intricate drawing *et hoc genus omne* should be banished from every primary school. As Pyle properly observes: "If a child has red eyes, holds its book close, complains of not being able to see at

a distance, looks at objects sideways or between partially closed lids, or squints or complains of headache, browache, or pain in the eyes, it is the parents' or teachers' duty to send it to a competent oculist. If the oculist decides that glasses are necessary, they should be put on at once in spite of any foolish prejudices, for they will save and promote the physical and intellectual development of the child and prevent many years of suffering and perhaps irreparable ocular disease."

The so-called "stupid" child is too frequently one who has defective eyesight or hearing, not detected by the parent or teacher, and in consequence appears inattentive to his studies; the adjective quoted might with greater justice be applied to his guardians.

The age at which a child should be sent to school depends largely upon the condition of his visual apparatus. If he has no ocular defects, is otherwise in good health and is never "crammed" or made to study out of school hours, half a day's schooling may be commenced at seven or eight years of age by the average child. The amount of work may be gradually increased until at ten he does a full day's work.

Children in poor health, especially if they exhibit ocular or aural defects or show a tendency to myopia, or present evidences of eye strain, *should have little or no systematic schooling before they are twelve years old.* That child will

be happier and a better citizen, as well as a more successful man of affairs, who develops into a fairly healthy, though imperfectly schooled, animal at twenty than if he becomes a learned, neurasthenic asthenope at the same age.

School houses should be located and built



Improperly Lighted Schoolroom.

The light is admitted from the right hand side.

(Norris and Oliver.)

with particular regard to the eyesight. Ocular defects are most numerous in poorly lighted, badly drained and improperly ventilated schools. The *window-space* should be at least *one square foot to every five of floor-space*. There should be no obstruction to the entrance of sunlight and the nearest buildings should be at least twice

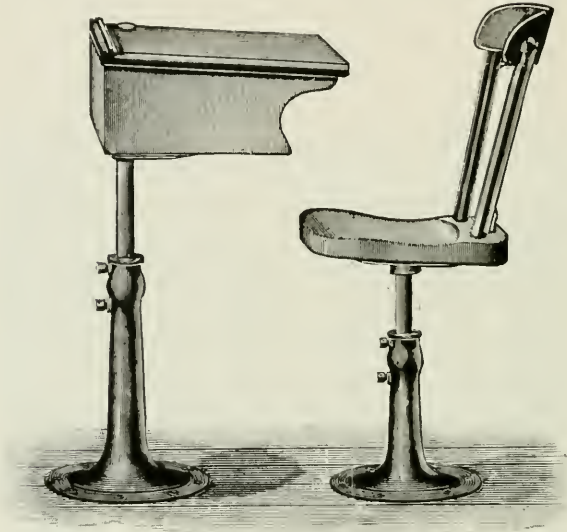
as far away as their heights. *Light should fall upon the pupils' desk from the left and rear* so that there never is any light thrown directly upon or indirectly reflected into their faces. In this way no shadows are cast by the hand and arm (of right handed pupils) upon the writing pad or paper. There should be no annoying cross lights, or windows in front. The top floors are best illuminated from overhead sky lights.



Schoolroom Properly Lighted from Left Side and Rear. (Norris and Oliver.)

Even on cloudy days *it should be possible to read fine (diamond) print in any part of the school room without the aid of artificial light*; indeed, no artificial light is ever used in the ideal school room. A north light is preferable, but

light from any direction can, at any time of the year, be regulated by shades and awnings, which are preferably of light colors—gray, buff, green




Adjustable Seat and Desk Showing Their Proper Relative Arrangement.

or blue. Risley, our chief American authority on this subject, gives the following *dimensions of the ideal school room*:

Length of room.....	32 feet
Width of room.....	24 feet
Height of ceiling.....	15 feet
Window space (linear measurement)	24 feet

From floor to window-sills
 (beveled) 3 feet
 Height of windows.....11 feet

The room accommodates 45 pupils, giving 256 cubic feet to each. The *walls and ceilings* as well as the woodwork should be of the same softly

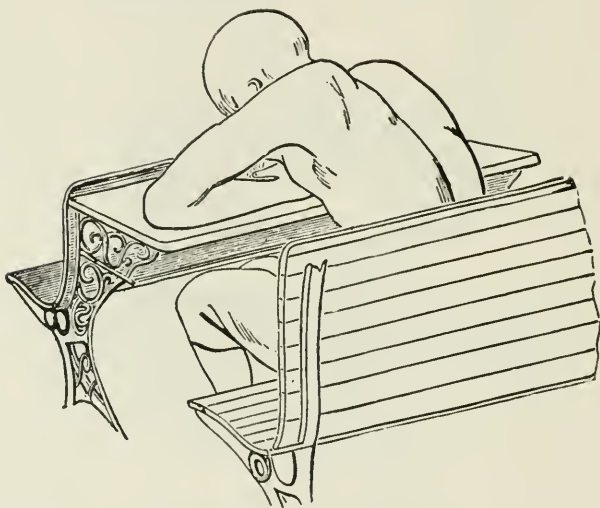


Proper Position of Student.

The pelvis is supported by the forward curve in the back of the seat.

reflecting colors as the window shades. The *desks* should be adjusted to the individual needs of the pupil and should be chosen with due regard to his comfort; the restless and uncomfort-

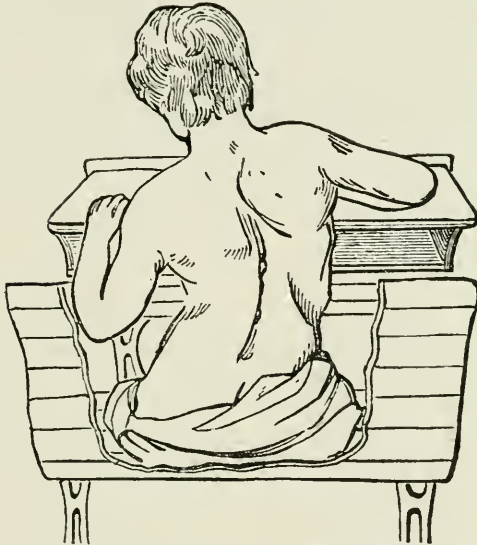
able pupil works the most mischief. If the seat is too high the child's feet are suspended in mid-air; if the desk is too high the elbows cannot rest without curving his spine out of shape, and the eye work is brought too near; if too low he stoops over his work, compresses the veins of his neck, brings on cerebral congestion and becomes, in addition, round shouldered.



Faulty Position in Writing.
Desk and seat too low.

Blackboards should be of slate, or painted a dull black, so as not to reflect the light falling on them. Most of us have realized the misery of the child straining his eyes in the attempt to

decipher, across the school-room, the not too plainly-written words or figures on greasy, shiny boards. Of course, they should never be placed between windows.



Faulty Position in Writing.
Desk too high or seat too low.

Regular medical examinations of the school children are urgently needed and are preferably made at the beginning of the school year. These investigations of the ocular and aural functions are easily made, so easily that the teachers can be readily instructed by the school physician how to carry them on. The plan advised by Dr. Frank

Allport, of Chicago, is an excellent one and has been adopted in many towns. Children with defective eyes and ears should be sent to an oculist or ophthalmic dispensary and should not be allowed to re-enter school until they have received proper advice and treatment.

School books should be easily read and ought to be small enough to be readily handled. For ocular reasons they should not contain smaller type than "10 point" (long primer). The lines should be at least one-tenth of an inch apart,

The conjunctival vessels on the globe are in most cases enlarged, but, in the milder types, there is no marked redness of the ocular conjunctiva, the thickening and redness being confined to the conjunctiva of the lids, particularly at the junction of the lids and the eyeball in the retrotarsal folds.

Properly Spaced.

The conjunctival vessels on the globe are in most cases enlarged, but, in the milder types, there is no marked redness of the ocular conjunctiva, the thickening and redness being confined to the conjunctiva of the lids, particularly at the junction of the lids and the eyeball in the retrotarsal folds. Sometimes there is a slight chemosis present

Improperly Spaced.

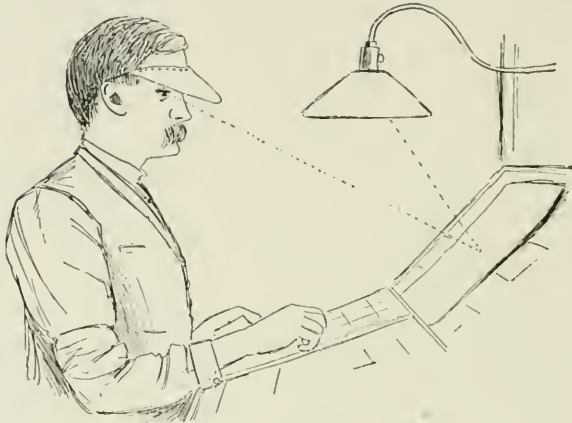
TYPE PROPERLY AND IMPROPERLY SPACED.

[The printed text of this book is an example of proper spacing]
they should not contain more than 60 letters nor be more than $4\frac{1}{2}$ inches long, so as not to fatigue

the muscles in consequence of undue rotation of the eyeballs. *The paper* used in books and magazines should not be, as it often is, so highly glazed that it acts as a mirror to reflect the light into the eyes. It is not always possible to accomplish this where "half tone" illustrations are frequently used with the text. In this book, for instance, a compromise has been effected by the *employment of a partially glazed, opaque paper*. The type should be distinct and the printing well done. Bad paper, poor ink and worse printing are too frequently encountered in our books and newspapers.

In adult life the hygiene of near work is also of prime importance. The enormous increase during the past twenty years in the amount and variety of work, which the full grown man and woman expect from the eyes, is largely responsible not only for the added need of glasses but for the great increase in the direct and reflex results of eye strain. If we expect to have comfort *and* to use our eyes to their fullest capacity we must select reading matter in large type, correctly spaced, printed with good ink in short columns, on unglazed paper. Other precautions are necessary, especially if the eyes are used constantly, as in the case of students, clerks, typewriters, bookkeepers, cashiers, sewing girls, etc. The reader or writer should sit upright and a little forward; the book, paper or other form of

near work (a heavy volume may be placed on an adjustable book-rest so that the top and bottom of the page are the same distance from the nose) must not be nearer than 12 inches nor more than



Improper Illumination.

20 inches distant. The illumination should be from over the left shoulder or to the left and above the head. If it is impossible to have a proper arrangement of the light, the latter, if an electric or other form of lamp, should be covered so that sufficient light is thrown upon the work to be done, and an eye shade ought to be worn by the worker.

Injurious Reading Habits.—*Reading while lying down (especially in bed when convalescent from an acute disease), in a railway train,*

on street cars, out-of-doors (by direct sunlight), by firelight, when tired or sleepy or when the eyes are fatigued or strained, is distinctly injurious. Fine sewing, embroidery, china painting, drawing, engraving, working on black goods and similar tasks should be performed only in the daytime by persons possessed of the strongest eyes and best health. Such work should also be interrupted with sufficient frequency. The *habit of wearing dotted or figured veils* is responsible for a good deal of eye strain. When they are used for protecting the face and keeping the hair smooth, or keeping the headgear in position, they should be thin, with a large, uniform mesh.

Artificial house and office lighting should follow the regulations applicable to school rooms. The *illumination should be of proper amount and quality and should shine upon the work to be done and NOT directly or by reflection into the eyes of the observer.* For the general illumination of any room the best light is that which imitates diffused daylight—the sort of illumination most satisfactory to the whole visual apparatus. If these facts be borne in mind any form of artificial light may, with proper modifications to suit individual requirements, be employed. The problems involved in many office buildings, stores, banks, etc., are not easy of solution but we may, perhaps, arrive at the best

light available by recollecting the following aphorisms:

(1) The electric arc light should never be used for indoor illumination; it is too brilliant, too dazzling and too *concentrated*; (2) owing to the heat evolved, the danger of fire, and the vitiation of the atmosphere by gas, electric lamps are preferable; (3) the Welsbach, or Auer light, is too powerful for near work. If hung well out of range it is a good light for large rooms and show windows; (4) the naked filament or wire light of the electric lamp gives an irregularly shadowed field of illumination upon the printed page or other near work; it should, in consequence, always be covered by a ground or porcelain glass when employed close at hand; (5) diffusion of this light, as well as that from incandescent mantles with gas of all sorts, has lately been accomplished by *prismatic globes or holophanes*, so disposed that the light rays are mostly deflected downwards; (6) apart from the heat and vitiated air engendered by it, there is probably *no better reading light than the old fashioned argand burner* (or "students' lamp") with gas or kerosene.

Lighting by means of prism batteries is of great value when, as in our crowded cities, the lower stories and rooms in buildings are rarely or never reached by direct daylight. These prisms are arranged as ornamental panes or as

canopies in front of the dark windows. For basements or cellars they are inserted in the pavement, with secondary screens below the sidewalk to assist reflection into the rooms beneath.

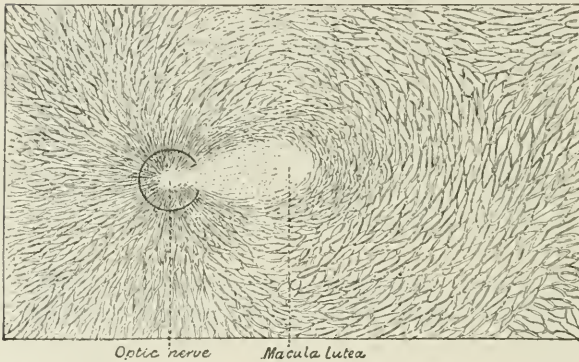
CHAPTER XV.

THE COMMONER DISEASES OF THE
OPTIC NERVE—ITS PERIPHERAL
AND CENTRAL CONNEC-
TIONS.

The retina, an expanded layer of optic nerve tissue.—
The structure and important parts of the retina.—
The retinal circulation.—The physiology of peripheral vision.—The blind spot of Mariotte.—The orbital and intracranial divisions of the optic nerve and their cerebral relations.—The cortical center for vision occupies the sides of the calcarine fissure in the occipital lobe.—Eye signs of brain tumor.—“Choked disk” and its meaning.—Its value very great as a symptom of brain disease.—Eye signs of meningitis.—Blindness from epidemic cerebro-spinal meningitis.—Pseudo-glioma.—Ocular symptoms of multiple sclerosis and tabes dorsalis.—Argyll-Robertson pupil.—Hereditary ataxia or Friedreich’s disease.

A clearer conception of the relations between ophthalmic signs and general disease will be possible if the student has at least a slight acquaintance with the anatomy and physiology of the optic nerve and retina. A few elementary facts will consequently be given regarding these important structures. In this and subsequent chapters will also be considered those diseases that most frequently involve the optic elements. **The retina** may be regarded as the intraocular expansion of the nerve of sight. It is spread out upon the background of the eye and serves the purpose of a sensitive plate upon which is

photographed the images of external objects. When the fundus oculi is observed with the ophthalmoscope we do not see the normal retina. It is a delicate, transparent membrane placed between the vitreous and choroid and extending forward to the *ora serrata*, where it joins the ciliary body. It is attached to the pigmented choroid only at the optic nerve entrance (papilla



Magnified View of the Innermost Layer of the Retina,
Showing the Bundles of Optic Nerve Fibres
Radiating from the Papilla.

or optic disk) and at the *ora serrata*; elsewhere it simply lies on the choroid or is feebly joined to it by its posterior layer of pigmented, hexagonal epithelium.

The most sensitive part of the retina lies directly in the axis of vision and is known as the *macula lutea* or yellow spot. At its center

is the *fovea*, a small depression that marks the *point of most acute vision*. This minute spot is always turned towards the objects which the normal eye "fixes," or looks directly at. The retina is supplied with blood almost entirely by the retinal artery which, with the accompanying vein, runs in the inner layers, the outer layers, next the choroid, being nourished by the chorio-capillary plexus. There are no vessels to be seen with the ophthalmoscope in the macular region.

The retinal circulation is a terminal one, there are no anastomoses with collateral branches (except with the ciliary vessels at the papilla), so that when thrombosis or embolism occurs the area supplied by the plugged artery is blind. The *structure* of the retina is a most complex one, which we shall not consider here. It will be sufficient to remember that the *rods and cones* compose the light-perception layer, and that the latter are longer than usual and are found exclusively at the fovea. Optic nerve *fibres* compose most of the papillary substance and do not perceive light. Hence we find with the perimeter that the disk corresponds to a blind area or *scotoma*, called in this instance the *blind spot* of Mariotte.

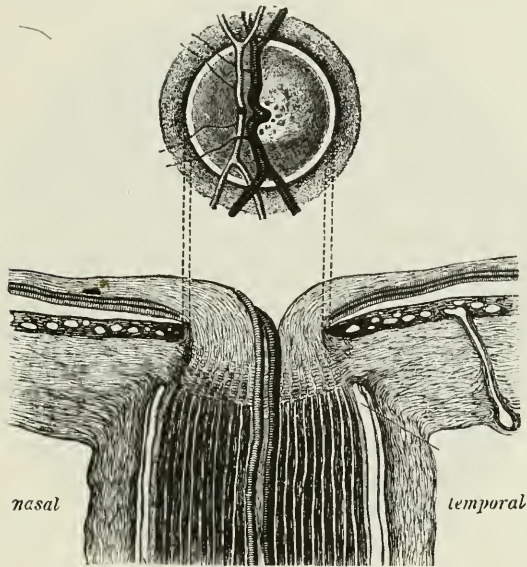
When light waves fall on the retina they bring about some chemical change in the so-called *visual purple* resident in the bacillary layer.

These impressions are carried to the brain and produce sensations of light. If they fall on corresponding points of both retinae a single image is the result; if they do not, double images (*diplopia, double vision*) are produced. The upper part of the retina sees objects in the lower part of the field of vision; the lower part perceives objects above the horizon. In the same way the nasal half of the retina perceives objects on the temporal side of the fovea, while objects towards the nose are seen by the temporal half of the retina. See the colored figure of the frontispiece.

The optic nerve proper is divided into *orbital* and *intracranial* portions. The nerve pierces the eyeball at the optic papilla, which is situated about 3 mm. to the inner side of the fovea. It is slightly elevated above and of a lighter color than the surrounding retina and presents a depression or *physiological cup*, where the central artery of the retina enters and the corresponding vein leaves the eyeball. These vessels pierce the nerve 2 cm. from the sclera and run between the nerve bundles to the centre of the disk, where they divide and subdivide dicotomously until their disappearance as minute capillaries.

At the *optic entrance* the *outer* layers of the sclera are continued as the outer nerve sheath, while the inner layers cross the nerves interlac-

ing with its bundles to form sieve-like openings—the *lamina cribrosa*. At this point the nerve loses its opaque medullary layer and becomes transparent. Occasionally, however, the latter

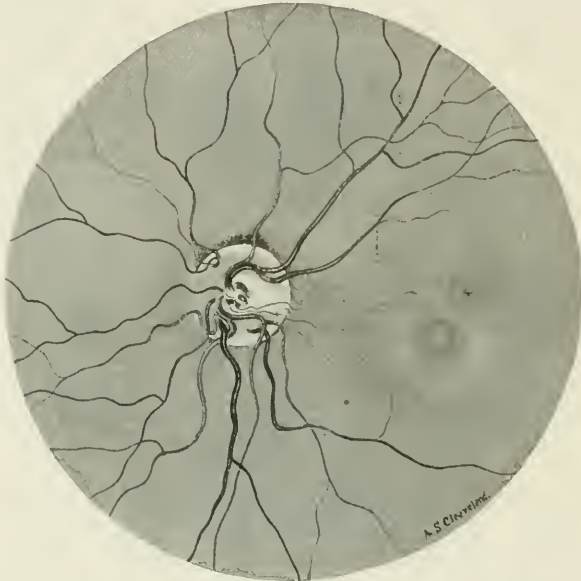

The Optic Nerve Entrance, Showing the Appearances by the Ophthalmoscope, and a Sectional View (Fuchs).

is retained and may be seen in the ocular fundus as a dazzling white sheaf of opaque nerve fibres.

The orbital part of the nerve is S-shaped to admit a free movement of the eyeball. It is

made up of nerve bundles separated by connective tissues and lymph spaces. Its envelopes are derived from the arachnoid, the pia mater and the dura mater. Between the last is the *intervaginal* lymph space, lined with endothelium and



Normal Background of the Eye as Seen by the
Ophthalmoscope.

communicating with the arachnoid and ventricular spaces in the brain.

An optic nerve from each eyeball joins its fellow at the chiasma, situated at the optic groove in the sphenoid bone. One-half of the fibres of

each nerve pass over, join the opposite nerve and proceed towards the occipital lobe as an *optic tract*. These wind around the crura cerebri, making connections with practically every central neuron and with one another, until they reach and form the parts surrounding the *calcarine fissure* of the occipital lobe, which is known as the *cortical center of cerebral vision*. Thus each retina is connected by nerve fibres with the great centers of both sides of the brain.

The temporal or outer half of the right retina and the nasal half of the left are supplied by right sided fibres; the nasal half of the right retina and the temporal half of the left retina are innervated from the left side of the brain. If one bears these facts in mind it will be of great assistance in the diagnosis of brain lesions—especially when the symptom *hemioptia* (or half sight) is present.

A good example of the mutual dependence of different portions of the body is found in *the relations that exist between the eye and the nervous system*. Disturbances of ocular function in the former as well as changes in the eye structure are often only symptoms of diseases of the brain and spinal cord. The development of the ocular nervous apparatus from the mid-brain might lead us to expect the part which the eye invariably plays in cerebral and spinal diseases—especially in diagnosis. Thus, the ocular

signs of tabes dorsalis are just as important from this standpoint as are the lightning pains, the absent knee jerks, the ataxic gait, lack of coordination, etc., to which our attention is so uniformly directed. Furthermore, the connection between the orbital vascular circulation, lymph channels and nerve supply and the general systems (of which they are a part) is so intimate that it is easy to understand why disease of the one so often affects the other.

Owing to the anastomosis at the Circle of Willis and to the fact that the cerebral supply does not altogether come from the internal carotid, cerebral hyperemia, hemorrhage, embolism and thrombosis present no distinctive eye signs. On the other hand, lesions and new growths of the meninges, cord and brain are often accompanied by changes within the eye. *In abscess of the brain*, mostly due to infectious emboli and purulent otitis media, "choked disk" may appear, but not so often as in central neoplasms; moreover the papillary swelling is less marked than in tumor. When abscess occurs at the base there are also exophthalmos, edema of the eyelids, photophobia and pain, followed by oculomotor paralysis and blindness. If recovery takes place defects in the visual fields, especially for colors, remain and the central vision is never entirely restored. Sometimes conjugate devia-

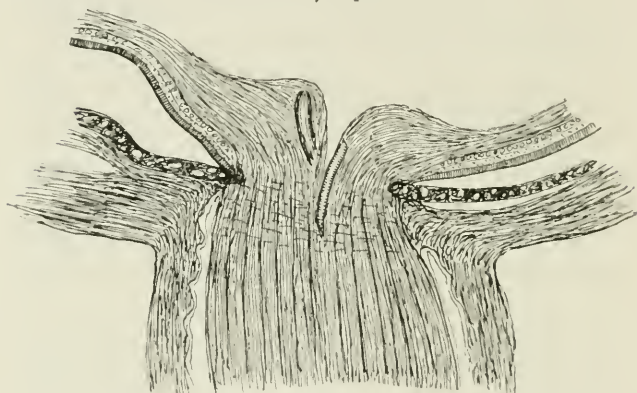
tion of the eyes and head toward the side of the abscess is noticed.

Brain Tumor.—The eye signs of cerebral tumor are very important and depend almost as much on its character and mode of growth as on its site. Neoplasms encroaching upon the neurons at the base of the brain, and in particular those situated in the cerebellum, are most likely to cause ocular symptoms. If the new growth develops gradually, slowly pushing the tissues to one side, not pressing upon them unduly, it may reach considerable size and even invade the region of the optic tract without setting up an optic neuritis or a muscular paresis. On the other hand, tumors that grow rapidly, especially those surrounded by an inflammatory zone are responsible for definite eye signs, even when they do not directly affect the great central neurons.

The cerebrospinal tumor-areas in order of importance from the standpoint of eye symptoms are probably the following: *The parts in and about the fourth ventricle*, other basal neurons, the cerebellum, the occipital lobes, the spinal cord, including the medulla, the frontal lobes, other superior convolutions, tractus opticus and chiasma, the meninges and, lastly, the corpus callosum.

Intermittent attacks of blindness, lasting only a few minutes but sometimes returning several

times a day, with regular but temporary contractions of the field of vision is *one of the early indications of tumor*. Although "choked disk" (optic neuritis with edema of the nerve head) is also found in cerebral hemorrhage, anemia from loss of blood, cerebral abscess, diabetes, albuminuria, etc., it is, *par excellence*, indicative of tumor of the brain, and sooner or later declares itself in about 70 per cent of all cases.



Section "Choked" Disk in Brain Tumor.

Its value in the diagnosis of the disease is therefore very great. It is almost always bilateral; *when one-sided the neoplasm is usually in the corresponding anterior lobe*.

If observed early the nerve-head will be found to be reddened, edematous and to project into the vitreous. In a few days the swelling increases and may measure six or more diopters

from its blurred base to its glass-like apex. The retinal vessels are tortuous, seem buried in the swollen tissue and become dilated to a considerable extent. Small hemorrhages appear in different parts of the optic mound to be followed shortly by white patches of degeneration. The papillary edema now subsides (it never entirely disappears in persistent *tumor cerebri*) and displays the signs of optic atrophy more or less marked. In this state it persists to the end. When the new growth, cerebral gumma for example, undergoes cure, snaky vessels and a muddy, infiltrated, pigmented nerve-head are all that remain to mark the intraocular process.

The anatomical causes of "choked disk" are somewhat obscure. It is now believed to be due sometimes to one condition, sometimes to a combination of conditions. At first it is undoubtedly a pure edema of the nerve-end within the eyeball, as a part of the inflammation process going on inside the cranium. Whether this initial swelling is due to the mechanical carriage of the increased subdural and arachnoid fluids along the corresponding channels of the nerve to the papilla, to the irritant (toxic) quality of that fluid (Leber and Deutschmann) or to both of these causes, it is followed, first, by an obstruction to the normal outflow of fluids through the disk, then by a true papillitis and,

later, by the secondary changes proper to inflamed connective and nervous tissue.

Central vision is not much disturbed at first, and the patient makes no complaint of defective eyesight, although narrowing of the visual field, with color defects, may be mapped out. If the patient live long enough blindness, more or less complete, may ensue. The discovery of a "choked disk" does not, unfortunately, throw much light on the size, site or nature of the tumor; these must be determined by other factors in the case. Occasionally we are helped to a diagnosis by additional eye symptoms. To this end Wernicke's sign and other pupillary reactions, the absence or presence of miosis or mydriasis, paresis of ocular muscles, etc., should be carefully noted.

Cerebral and Spinal Meningitis.—The eye symptoms are *not frequent* and depend upon the form of the inflammation. In diffuse *meningitis* of the cortex we may have hemianopia with preservation of the pupillary reaction to light. *In basilar disease the motor nerves are likely to be involved*, followed by pareses of the corresponding muscles, especially of the external rectus. In *tubercular meningitis, dilated pupils form a prominent sign* and in all of them the optic papilla becomes hyperemic, with some swelling and some appearance of new vessels in its substance and on its surface. Later, we have

a *post-neuritic atrophy*, resulting in contraction of the field of vision, color blindness and grave visual defects.

A very important sequel of the graver forms of meningitis, often *observed in children after epidemics of the cerebrospinal variety*, is a *plastic choroiditis*. The eye becomes red and injected, the iris is sluggish and discolored, the aqueous muddy and a yellow-white mass appears in the vitreous chamber. In cases of recovery from the general disease this yellowish mass is readily seen and forms one of the most striking signs of the affection known as "*pseudoglioma*." It has been mistaken for malignant neoplasms (especially before the glaucoma that attacks the patient in the second stage of tumor sets in), and as both diseases usually occur in young children the mistake is pardonable.

In cases of doubt small harm will result from enucleation, as the eye is blind. It is probable that this process in the eye is due to embolic deposits in the choroid similar to those found in the pia mater, both tissues being structurally alike. It must be remembered that "choked disk" (on the same side if the meningitis be a local one) is sometimes found in this form of meningitis.

Multiple Sclerosis; Sclerosis in Patches.—The ocular symptoms are here very important, because the degenerative foci are often found in

the optic nerve itself, as well as in the central neurons that take part in the visual act. The axis cylinders may remain intact for a long time and, like the deposits elsewhere in the brain and cord, rather inhibit (for a time at least) than destroy their functional activity and their conducting power. The effect upon sight is usually the result of a *partial retrobulbar neuritis* of one or both eyes; the patient complains of misty vision and this may be the first indication of a general disease. As the patches develop in other parts of the nervous system, sight becomes still more impaired and central scotomata (first for colors and then for white) become more marked.

Fundus changes are seen in about 20 per cent of all cases. The general *tremor* of this disease is represented in the eye by *nystagmus*, due to interference with the conduction-path between the motor areas and the nuclei of the ocular muscles and is more frequent in patchy degeneration than in other nerve lesions.

Tabes Dorsalis; Locomotor Ataxia.—The ocular symptoms of this disease are of more importance for diagnosis and prognosis than those attributed to any other organ. Sometimes they constitute the earliest and surest proof of its existence, and they must always be reckoned with. Whether the disease be syphilitic in origin or not, probably the most important sign is a reflex iridoplegia, known as the "*Argyll-Robertson*

pupil." The pupillary reaction to light is lacking, while its contraction on fixing a near object is preserved intact.

It is well to exercise care in eliciting this phenomenon, testing the light reflex in a dark room with focal illumination, the patient looking in the distance. The convergence-accommodation reflex should be tested in a partially darkened room the individual being asked, first, to gaze for several seconds at a distant object and then, suddenly, to fix the finger held 25 cm. in front of his face. A true *reflex iridoplegia* is also seen in general paresis, but it is so common in locomotor ataxia as to form presumptive evidence of the presence, or future onset, of the disease. It is sometimes present with loss of the cutaneous reflex contraction of the pupil. When these phenomena are noticed with miosis (or without mydriasis) the evidence is still more conclusive.

Of no less value in the diagnosis of tabes are oculo-motor paralytic symptoms; indeed it may be stated that every *temporary* paralysis of an eye muscle occurring in an otherwise healthy individual (especially in a man over thirty-five years of age) should arouse a suspicion of impending tabes. If the paresis disappears but recurs in a few weeks or months the probability is that it is the forerunner of locomotor ataxia. Dillmann found one or more eye muscles affected in forty-one per cent of tabes. The *external rectus* is most

liable to be paretic, then the levator palpebræ, while least frequently is the trochlearis. *Any or all of these paralyses, with or without treatment, may set in suddenly and disappear in a few days, or they may last for years.*

A peculiar form of *optic atrophy* is another characteristic of tabes. It appears as a progressive grayish discoloration, never preceded by swelling or hyperemia of the disk, first visible at the temporal half and gradually involving the whole of the nerve-head. The papilla seems to shrink, becomes excavated and assumes a uniform gray-blue hue, the white color of the lamina cribrosa showing through. If the disease attack a disk with a deep normal excavation it finally presents the picture, both clinical and ophthalmoscopical, of a simple chronic glaucoma.

Pure tabetic atrophy is never preceded by optic neuritis and one may doubt a diagnosis of uncomplicated locomotor ataxia where active congestion of the nerve-head is observed with the ophthalmoscope. Corresponding to the objective finding are the visual defects and the perimetric observations. The acuteness of vision is at first good and there are no central scotomata for colors or white. On the other hand there is a gradual and concentric narrowing of the field. It has been noticed that the rapidly progressive cases are those in which the color fields suffer out of proportion to white. On the other hand, when the optic

atrophy sets in early and blindness shortly follows, the other tabetic symptoms develop very slowly or there is a long arrest of the disease. Optic atrophy may set in during any stage of locomotor ataxia and it is found in about thirty per cent of all cases of tabes.

The treatment of these ocular symptoms is not encouraging, as cure or relief depends upon successful treatment of a disease that, although it usually lasts many years, has almost invariably a fatal termination.

Hereditary ataxia (Friedreich's Disease) is an anomaly of spinal development, and has little in common with tabes dorsalis. It usually affects several members of the same family and rarely presents any eye signs except nystagmic movements when an object is fixed. As nystagmus is not a part of tabes and is almost always present in hereditary ataxia, this symptom will serve to distinguish juvenile tabes from the former disease.

CHAPTER XV.

OPHTHALMOLOGY IN GENERAL MEDICINE AND SURGERY.

Why the student of general medicine should study the eye-signs of disease.—The extreme importance of ocular symptoms in general diagnosis.—The eye symptoms (toxic amblyopia) set up by indulgence in tobacco and alcohol, by lead poisoning and by methyl alcohol.—The treatment of toxic amblyopia.—Ocular rheumatism.—The eye signs of gout, gonorrhoea, measles, syphilis, dyspepsia and diseases of the reproductive organs.—Affections of the eye in tuberculosis, simple anemia, leukemia, hemorrhages, nasal diseases and diseases of the ear.

It must not be forgotten, in the study of ophthalmology, that there are few general diseases that do not, sooner or later, affect some part of the visual apparatus, or that do not cause ocular symptoms. On the other hand, many abnormal states of the eye (ocular strain for instance) induce pathologic states in other parts of the body.

Inasmuch as the eye contains examples of almost all the tissues found in the body alterations in these may present themselves as part of a general process. In other words, the morbid histology of the eye is not altogether a study apart, but is chiefly an application of the principles proper to general pathology. It is the purpose of this chapter to emphasize these truths and to insist that the neglect of the ophthalmologist to study other branches of medicine is as much to be deplored as the failure by the gen-

eral practitioner to recognize the ocular evidences of disease.

How few medical men intelligently employ the ophthalmoscope in the various forms of the so-called Bright's disease and in suspected brain tumor? How few make use of the perimeter, how few even determine the visual powers of the patient with test types? How few learn the many lessons taught by even simple inspection of the eye? It cannot be too much or too often insisted upon that these means of arriving at a diagnosis are *not* the especial property of the ophthalmologist; *they belong to the student of medicine in exactly the same sense and for the same reasons that does the stethoscope, the sphygmograph, or the hemometer.* The practitioner who ignores these aids to diagnosis is as culpable as the ophthalmologist who attempts to practice his specialty without keeping posted in general medicine.

A number of the commoner scrofulous, syphilitic, tubercular, rheumatic and gonorrhœal affections of the eye have already been described in these pages. We shall now proceed to consider the ocular signs of several additional constitutional diseases that we believe ought to be particularly studied by every practitioner of medicine.

Toxic Amblyopia.—The commonest form of poisoning productive of defective vision follows.

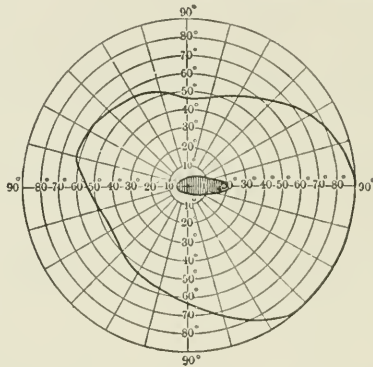
now and then, from the habitual abuse of ordinary (ethyl) *alcohol*, or *tobacco*, in any of its forms. As a rule the loss of sight results from the employment of both together. As we know, many who smoke and chew also drink; almost without exception the habitual drinker uses tobacco. The disease attacks mostly *men* who have an idiosyncrasy against these stimulants, who are above forty years of age and who suffer from chronic catarrh of the stomach.

Symptoms.—Both eyes are affected, *the patient complaining of foggy or misty vision*. He almost always applies for glasses to assist his failing sight and, as the disease is entirely painless and presents no external sign of disease, he rarely suspects the true cause of his visual defect. The acuity is lowered to at least $\frac{2}{5}$ or $\frac{2}{7}$ of normal and the reading of fine print is difficult or impossible with any glass.

There are also to be noted a well marked tobacco, or ethereal, odor to the breath, a general atonic condition, some insomnia, anorexia, and there may be dull frontal pain.

This condition is due to a central color (relative) *scotoma*, especially for *red and green*. The examination to determine this sign may be made with the *perimeter* or with a strand of red and green wool. Double a single thread between the thumb and finger of the right hand, holding it so that only a quarter

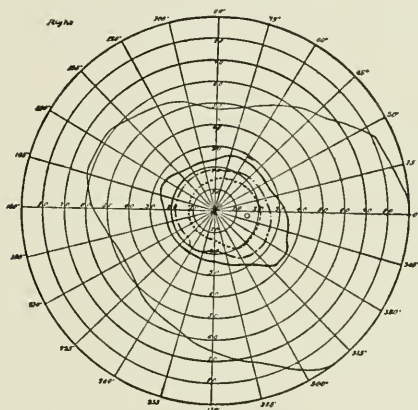
of an inch of the loop projects and is seen. Cover the patient's *left* eye with a bandage and ask him to look steadily at the pupil of the examiner's *right* eye at a distance of two feet. Now, interpose the small loop of red wool in the common line of vision at a point a few inches in front of the examiner's eye. In alcohol-tobacco amblyopia the patient will not *then* recognize the loop as red, or it will appear *redder* when



Field of Vision, Showing Central Scotoma for Red and Green in Alcohol-Tobacco Amblyopia.

removed an inch or two to the right, left, up or down from the line of sight, than it does when placed directly in front of the pupil. The same result will be obtained from the *green* wool, but probably not from *white*, blue or yellow, unless the disease is far advanced and the visual acuity has fallen below 1/10.

The *prognosis* is favorable. Taken in time a perfect recovery generally follows (1) total and immediate abstinence from tobacco and alcohol; (2) good food, fresh air, sufficient sleep, tri-weekly *Turkish baths*; (3) the administration of medicinal doses of iron and strychnia by the mouth, for which the following is an efficient formula.



Field of Vision in Chronic Lead Poisoning.

Quinin sulphate	gr. 5
Tincture of iron	oz. $\frac{1}{2}$
Dilute phosphoric acid	oz. $\frac{1}{2}$
Solution of strychnia	dr. 6
Tincture of rhubarb	dr. 1
Simple syrup, to make	oz. 8

A teaspoonful in water before meals; (4) the *hypodermic injection of increasing doses of*

strychnia daily or every other day. The diagnosis once correctly made this routine treatment can be prescribed with the assurance that, if faithfully followed, a cure may be confidently expected in from one to three months.

It must not be forgotten that occasionally overdoses of *quinin*, in susceptible patients, produces *complete and sudden blindness* (*quinin amaurosis*), followed by a partial restoration of vision.

More common still is *methyl alcohol* ("Columbia spirits," Jamaica ginger, bay rum, etc.) used as a beverage, followed by *blindness*, with much the same *ocular symptoms* that *quinin* exhibits. As a part of *chronic lead poisoning*, also, we may have progressive *optic nerve atrophy* and *ocular paresis*.

Rheumatism is responsible for many diseases of the eye, which play an important part in the general infection. Although the usual form in which the rheumatic poison manifests itself, viz. *iritis*, *scleritis* and *tenonitis*, sometimes accompanies or shortly follows the acute articular form, the most destructive and most protracted attacks more frequently come on after the system has been subject to the pathogenic organisms for months or years.

The eye diseases are more likely to occur with the relapses, although they may constitute the only evidence of a temporary return of the rheumatism. Often one is reminded by the occurrence

of a monocular iritis, without any other sign of rheumatism, of an attack of the disease affecting a single joint. *Excluding syphilis, gonorrhœa, gout and traumatism, an attack of iritis is almost certainly due to rheumatism.* The pain is usually more severe, the duration of the disease is longer, relapses are commoner and the effects of treatment less obvious than in the other varieties. Loss of sight, from the formations of posterior synechiæ and from cyclitis, is not uncommon in this form of iritis.

Inflammation of Tenon's capsule (tenonitis), due to rheumatism, presents a picture that reminds one of a rheumatic arthritis—swelling of the parts, chemosis, painful excursions of the globe, tenderness on pressure and some proptosis.

To the fact that the toxins or bacteria upon which rheumatism depends are not always destroyed or eliminated from the system at the time of the first attack are due the relapses characteristic of the disease. Again, a relapsing iritis, like a recurrent gouty or rheumatic joint affection, is especially to be feared, as it is often followed by infection of the deeper structures and, in the case of the eye, may lead to destructive cyclitis with permanent loss of vision.

Gout is also an occasional cause of these diseases of the eye. The probability, also, of its being the chief factor in producing glaucoma should not be forgotten.

Gonorrhœa, apart from the direct purulent infection of the conjunctiva and its grave consequences, already described, is of interest because it is not an uncommon cause of iritis of the rheumatic type. When this does occur it is likely to affect both eyes, to be associated with muddy aqueous or solid deposits in the anterior chamber and to recur with relapses of the gonorrhœa or with the revival of a gleet discharge.

Measles.—The early photophobia and peculiar injection of the scleral vessels in the early stage of this disease are an aid to the diagnosis. The latter sign may persist even after convalescence as a part of the conjunctivitis that occasionally remains. As a rule, however, the hyperemia and discharge disappear with the dermal and mucous membrane infection. Phlyctenules of the conjunctiva and cornea have been observed, with an occasional optic neuritis, but all of these, especially the last, are rare.

Syphilis.—*An important group of eye diseases resulting from general infection are the syphilitic affections, hereditary and acquired, of the eye.*

It is well to remember that syphilitic eye lesions almost always furnish valuable evidence of the nature of the process. For example, in lues the appearances and course of the *corneal infiltration*, of the choroidal exudates, of the *iridic inflammation*, of the *oculo-muscular pareses* are so significant of the underlying infection that they are

quite as valuable in establishing its presence as are the signs discoverable in any other organ.

Dyspepsia; Diseases of the Reproductive Organs.—Local diseases of distant parts may seriously affect the eyesight. This is, for example, true of the organs that compose the digestive tract and the reproductive system. Impaired nutrition and defective elimination are undoubted causes of asthenopia. As a matter of fact the visual act is in the main a muscular one and anything that lowers the general tone also weakens the ciliary and extrinsic muscles. In treating



Syphilitic Disseminated Choroiditis.

cases of muscular asthenopia, therefore, this should always be borne in mind, and tonics, regulation of the dietary and the employment of all measures tending to correct the digestive vice should be prescribed.

The same observations hold with *uterine* and

ovarian complications. The asthenopic symptoms (*kopiopia*), set up by these, do not disappear unless the former disappear. Buller has called attention to a common form of oculo-muscular fatigue that for this reason is sometimes incurable. The ophthalmologist will find that most eye symptoms are aggravated at the menstrual period. *Insomnia from any cause* is an effective bar to the relief of the accommodative fatigue, the photophobia, the eye-pains, the extrinsic muscular anomalies and the other ocular symptoms from which a certain class of patients suffer.

Tuberculosis.—Apart from the so-called lupus, that may attack any part of the eye, tubercle, in the true miliary form, is occasionally deposited in the iris and choroid. The value of this sign in general diagnosis is weakened by the fact that intra-ocular tubercle is seen only in the *late stages* of tuberculosis, after the whole system has been infected by the poison and has shown itself unmistakably in other organs.

Simple Anemia and Chlorosis.—These signs of a general blood change are almost always associated with insufficiency of accommodation—inability to read, fatigue of and pains in the eyes, etc. Deposits in the retina and choroid, and even neuro-retinitis with hemorrhages are also seen now and then.

The specific new formations in the lymph glands and spleen, particularly those that mark the so-called *leukemia*, furnish another example

of intoxication, with definite ocular changes. A bilateral retinitis, with numerous hemorrhages (resembling the albuminuric form), is the most important of these, due to fatty and other alterations in and about the minute capillaries. Fundus and vitreous changes have also been discovered in the advanced stages of the disease.

Acute and chronic hemorrhages (hematuria, melena, hematemesis, post-partum bleeding, severe epistaxis, etc.) are followed occasionally by a curious result which the older writers described as "amaurosis and amblyopia from loss of blood." Atrophy of the optic nerve may set in weeks or months after these accidents and end in complete blindness. The sudden disturbance of optic nutrition is responsible for such a serious sequel and the possibility of it should ever be borne in mind. This atrophy is often preceded by a mild *neuritis optica* with retinal patches and hemorrhages. In all likelihood there is previous systemic disease and some observers believe that the optic disease never occurs after these severe bleedings except in unhealthy subjects or only when blood is effused from the trunk of the central artery into the substance of the nerve.

One of the authors was consulted by a woman whose defective sight set in a few weeks after a prolonged and severe uterine hemorrhage. Both optic nerves were pale and muddy, there were traces of retinal hemorrhages and the blindness could not be otherwise explained.

Nasal Diseases.—There is a close connection between diseases of the nose and eye. This is seen in the *hyperemia* and inflammation of the *conjunctivæ*, with *epiphora* and inability to use the eyes with comfort, in many cases of acute and chronic rhinitis. The nose should never be neglected in making an ophthalmic examination. As before demonstrated, most cases of lachrymal sac disease, with its danger of conjunctival and corneal infection, are due to nasal inflammations. In children, phlyctenular keratitis and conjunctivitis are almost invariably associated with, if not caused by, nasal eczema. Pent up secretions in the frontal, sphenoid and maxillary sinuses, caries and necrosis of the ethmoid or sphenoid bone, may give rise to infra and supraorbital neuralgia, and, when the secretions resulting from these diseases break into the orbit, we find edema of the lids and conjunctiva, bulging of the eyeball, paralysis of the straight muscles, optic atrophy and loss of vision.

Diseases of the ear rarely produce eye symptoms, but one exception must be mentioned. Optic nerve inflammation may follow chronic purulent inflammations of the middle ear from disease of its bony walls and contents, with or without cerebral complications. *The importance of examining the fundus in all ear cases* where mastoid disease, with possible cerebral complications, is feared or suspected, cannot be overrated.

CHAPTER XVI.

THE OCULAR COMPLICATIONS OF CERTAIN SYSTEMIC DISEASES.

The ocular lesions that accompany or follow smallpox, e. g., ulcer of the cornea.—The oculomuscular pareses of diphtheria.—The eye complications of influenza, malaria, typhoid fever, rickets and diseases of the vascular system.—Retinal pulsations in aortic insufficiency.—Retinal embolism and thrombosis.

Smallpox.—Although pustules appear on the lids in 20 per cent of all cases, destructive lesions of the eye are comparatively rare and, when they occur, are generally found in the confluent variety. Palpebral abscess and furuncles, followed by entropion, ectropion and trichiasis, sometimes result, but the most dreaded of all the sequelæ are *pustules of the cornea* (usually at the sclero-corneal junction), which, becoming infected, spread and produce deep ulcer, with hypopyon and loss of eyesight. At first these resemble simple phlyctenulæ and, if kept clean, heal with but slight scarring. As proof of this, the serious form of variolous ulcer is a late manifestation, rarely developing until the end of the second or the beginning of the third week. The eyes should always be carefully watched and as strict asepsis and antisepsis observed as possible, because spreading ulcer (invariably due to secondary infection of the primary corneal pustule) may usually be prevented even if the conjunctiva

and corneal margins are involved by the pustules.

Diphtheria.—Both in cases where the infection is due to the diphtheria bacillus, as well as in examples of mixed poisoning, the eye symptoms are very important. By far *the most important sequela* are *pareses of the various eye muscles*. As these invariably set in from two to four weeks after the primary diphtheria has run its course, we may assume that they are the result of the bacillus toxins. It is characteristic of these muscular paralyses that they are generally incomplete, that they disappear spontaneously in from four to eight weeks and that they affect the ciliary muscle without implication of the iridic fibres. *Accommodative paralysis with widely dilated pupils* may attend mild attacks and patches on any mucous area, but it is the infective pharyngitis that is most frequently followed by ciliary paresis. Paralyses of the other eye muscles are rather rare. The authors have seen at least one case in which there was almost complete bilateral paresis of the external muscles supplied by the third nerve, closely resembling other post-diphtheritic paralyses. These are almost always peripheral in character and are due to an infective neuritis. Corte claims that *it matters not how serious the general diphtheritic attack may be, as long as the pupillary reaction to light is intact, recovery is probable, but if the pupils are immovable a fatal termination is certain*. Diph-

theria of the conjunctiva is often seen, either as a primary lesion or (more frequently) as a sequel to the disease in the pharynx, nose or larynx. Destruction of the cornea and loss of sight may follow this infection, as was well illustrated in the case of a child five years old, seen by the authors, where a patch appeared on the right upper lid in a severe case of nasopharyngeal diphtheria. A central ulcer of the cornea followed, in spite of all precautions, and a leucoma finally covered the entire pupillary area. A subsequent iridectomy gave $2/7$ of normal vision.

Influenza.—It is probable that ocular complications are rare in this disease and even when they do occur they are not characteristic of the *grippe*, but are observed in other acute infectious diseases. Prominent among these are outbreaks of acute glaucoma, serous iritis and affections of the optic nerve. The authors have observed two instances of optic neuritis that were probably sequels of influenza, one of them followed by progressive optic atrophy and blindness. In some instances paralysis of the ciliary and extrinsic muscles have followed *la grippe* where the disease also resembled diphtheria in its effect on deglutition and speech. In like manner iritis and dacryocystitis are described and attributed to influenza and, secondary to the meningitis of this disease, have been noted plastic uveitis and panophthalmitis.

Malaria.—Supraorbital and ciliary neuralgiæ are the most common eye symptom, modified or cured by the exhibition of quinin. In all cases of doubtful malarial disease of the eye, and particularly in the recurrent neuralgia of that organ, it is always well to examine the blood for the presence of the plasmodium malarizæ. Retrobulbar neuritis, as well as more peripheral infections of the optic nerve, shown by edema of the papilla, have been observed. Retinal hemorrhages, leaving deposits from pigment emboli, may be seen in the retina—just as they are found in the other organs—as the outcome of chronic malaria. Kipp has described malarial keratitis, attacking the superficial layers of the cornea, accompanied by anesthesia of the parts and characterized by tenderness of the nerve where it passes through the supraorbital foramen.

Typhoid Fever.—There are no eye affections characteristic of this disease. Probably the most common sequels are insufficiency of accommodation and convergence with, sometimes, mydriasis amounting to a paresis. These asthenopic symptoms, due to the general muscular weakness of convalescence, are observed just as they are during recovery from any other continued fever. Attempts to read are followed by blurring, mixing of the print, smarting, burning and pains in the eyes and head. The temptation to read, sew or even to write should be resisted at such periods.

and all forms of near work ought to be avoided until the patient has entirely recovered. It is sometimes necessary to order glasses to correct a latent astigmatism or hypermetropia that, previous to the attack, had given no trouble—a correction that may have to be worn for many months after the febrile symptoms have passed. The patient recently afflicted by typhoid or, for that matter, by any exhausting disease, should be warned not to read or sew in bed and even to avoid these occupations until there is complete restoration to health. During the period of stupor (accompanied by half-opened eyes) the cornea may become so dry that the protecting epithelium is removed and infection of the globe results. Probably the best prophylactic treatment of the eye during the somnolent stage is to wash out the sac and cleanse the lids every two or three hours with a one per cent solution of sodium chlorid, followed by the instillation of a small quantity of warm, fluid and sterile vaseline.

Rickets.—This nutritive vice is comparatively rare in native Americans, but imported examples of it are often seen, especially in the foreign-born children of our seaports and larger cities. *It is a common cause of congenital or lamellar cataract.* Whatever be its precise mode of development the majority of observers agree that it is associated with the general convulsions of rickets. Arlt claimed that it is a sort of “con-

cussion" cataract, but the immediate cause is more likely the violent nutrition-disturbances in the lens-system following spasms of the ciliary body and muscular coat of the vessels supplied to it. The *treatment* of this important form of "soft" cataract has already been given.

Diseases of the Vascular System.—The ophthalmic artery arises directly from the internal carotid. Its branch, the central artery of the retina, supplies the optic nerve, whose tissue it enters about $1\frac{1}{2}$ cm. behind the papilla. In this way the eye is intimately associated with most diseases of the heart, large vessels and brain structures. The venous and lymph streams are just as closely connected with the ventricles and other cerebral canals, and they constitute a portal through which general infection may find its way to and from the cranial cavity. It is thus easy to understand why eye symptoms are of especial value in the diagnosis of cerebral disease.

We know that diminished blood supply may lead to insufficient nutrition and, consequently, danger to the optic nerve; conversely, increased blood pressure in either arteries or veins commonly expresses itself in overfilled retinal vessels—a condition readily recognized with the ophthalmoscope. Moreover, changes in the intima, or walls, of the systemic capillaries can often be detected with greater ease and certainty by the mirror than by any other means.

It frequently happens that the first indication of these is discovered by the ophthalmologist on examining the eye-grounds. Some of them have already been mentioned and they include all such extensive vascular alterations as are found in *arteriosclerosis*, *atheroma*, *syphilitic changes*, *leukemia*, chronic toxic and other infectious diseases, *albuminuria*, fatty and other metamorphoses, as well as capillary hemorrhages. Bleeding from diseased arterioles or capillary veins reminds one of the warning given by de Schweinitz, that even *subconjunctival bleedings*, commonly insignificant should (particularly if recurrent and in subjects over forty years of age), give rise to a suspicion of general vascular disease, and a suitable systemic examination should follow. In *aortic insufficiency* there is practically always pulsation of the retinal arteries (alternating with filling of the veins) synchronous with the wrist pulse. This is due to a compensatory hypertrophy of the left ventricle and it may affect not only the arterial trunk and the primary branches, but the distension-wave may even reach the minutest capillaries.

Embolism of the central artery of the retina.—Distant diseases of the cardio-vascular system may be a cause of *ocular embolism and thrombosis*. The effect upon the eye structure depends upon the character of the original embolus. When this is infective, as in ulcerative

endocarditis, purulent affections of the lungs, uterus, etc., panophthalmitis or a destructive choroiditis may be set up. Non-infective embolism and thrombosis of the retinal and choroidal vessels are less serious, if more common.

Owing to the numerous anastomoses in the vascular choroid, vision is unaffected in choroidal embolism except at the point where the plug has lodged. *It is quite different with the retinal process.* The retinal arteries form part of a terminal circulation and the lodgment of a plug in an arteriole is followed by total loss of vision in the area supplied by that vessel. The perimeter marks with precision this territory, which does not recover its lost function as long as no blood passes the point of strangulation, or unless (in rare instances) a cilio-retinal vessel furnishes nutrition from the ciliary system. Fatty patches and cholesterin crystals appear later in the affected retina, and this stage of degeneration is likely to be followed by partial optic atrophy and even by progressive disease of the whole nerve. The embolus itself is occasionally seen with the ophthalmoscope and has been recognized at the autopsy.

When the parent vessel is occluded the branches appear empty, the veins are small and the disk is paler than usual. The whole fundus show a whitish edema except at the macula, where the coloration is preserved, marking what

is well known as a "cherry spot." The patient is stricken with sudden blindness, rarely accompanied by pain or shock, the disk becomes gray or white and the arteries are reduced to threads of connective tissue.

CHAPTER XVII.

HEADACHE FROM EYE STRAIN.—OCULAR HEADACHE.

EXOPHTHALMIC GOITRE. EPILEPSY. MIGRAINE.
THE EYE SIGNS OF HYSTERIA, ALBUMIN-
URIA, AND DIABETES. TUMORS
OF THE EYE.

Headache from eye strain very common.—Nearly always a frontal headache.—Causes of ocular headache.—How to distinguish an eye headache from others that resemble it.—Treatment of it.—Exophthalmic goitre, Graves' or Basedow's disease.—The eye signs very important and valuable in diagnosis.—The ocular signs in epilepsy.—Migraine not an affection of the visual apparatus although it usually presents characteristic eye symptoms.—The ocular signs of hysteria.—Reversal of the color field.—Hysterical amblyopia.—Monocular diplopia.—Hysterical photophobia and blepharospasm.—Traumatic hysteria.—The eye symptoms of Bright's disease.—Albuminuric retinitis.—The ocular signs of diabetes.—Diabetic cataract.—The commoner tumors of the eye.—Glioma retinae.

Few symptoms are of greater importance to the student or practitioner than headache, and none will more largely tax his diagnostic and remedial resources. Before he can properly decide to what class a particular headache belongs, he must have a practical knowledge of all of them. Ocular headache may be defined as that acute discomfort in and about the head that directly or indirectly results from organic or functional disorder of the visual apparatus.

The ocular element in all forms of headache is larger than is generally suspected. It is probably not less than forty per cent, while of all frontal headaches seventy-five per cent are due to eye-strain. In a previous chapter it was shown that the ciliary and other eye muscles always endeavor to bring about effective vision and that in abnormal states of the refraction, particularly, this constant effort results in symptoms, prominent among which is the headache in question. These attempts irritate not only the third nerve nuclei but the center for the trigeminus; the end filaments of the latter on the forehead suffer, so that there is not only a peripheral aching noticed by the patient but a duller pain referred to the eyeballs and the parts behind them. In the very chronic cases, also, the whole front of the head aches. The pains of eye strain are invariably bilateral.

The **exciting cause** of ocular headache is chiefly some form of near work that requires long continued use of the muscles of accommodation and convergence, such as reading, sewing, stenography, embroidery, drawing, painting, music, writing, cardplaying, typewriting, etc.

The *site* of the headache is very important. In the order of frequency this is supraorbital, deep orbital, fronto-occipital and temporal. *A unilateral, supraorbital headache or a hemi-*

crania of any kind is not commonly due to eye strain.

The pains do not always follow immediately upon indulgence in excessive near work; they are sometimes not noticed until the early morning. As a rule, however, the eyes and head commence to ache after a certain number of minutes or hours of close work with such regularity that the sufferer himself attributes it to some trouble with the eyes. Astigmatic, hypermetropic, and heterophoric patients also suffer when called on to use their eyes much for *distant* vision. An evening at the *theatre* or an afternoon spent in *shopping* is often responsible for an ocular headache, as these occupations reach the weak points in the ocular apparatus. In the latter case the necessity for keeping a lookout in all directions to avoid collisions with fellow-shoppers in a crowded store, with pedestrians on the pavement and with men, women and vehicles on street crossings, the close examination of fabrics—often in a poor light—all these efforts make large demands not only on the general nervous energy, but particularly on the extrinsic and intrinsic muscles of the eye. When the latter are handicapped by muscular anomalies or refractive errors, the shopper usually goes home with a headache. In the same way, riding in a *railway-train* or *street-car*, with the moving panorama viewed from the car window,

is especially trying to defective eyes. Doubtless *church, concert and theatre headaches* are also due to efforts made by abnormal eyes to stare at distant objects, while the cerebral centers are meantime further irritated by rebreathed air and unshaded lights.

Along with the headache are almost always other signs and symptoms that proclaim the ocular nature of the trouble. After reading for a time, *lines and letters run together* or become mixed up. The conjunctiva of the eyeball gets red from hyperemia of its vessels and the lids burn, smart and itch.

It must not be forgotten, however, in the **diagnosis of ocular headache**, that the eye, so far as symptoms and the results of inspection go, sometimes seems to be free from disease. There is an ocular headache, but no apparent disease of the eye. A patient may have a purely ocular headache although the vision is normal or even above normal, and although many of the asthenopic symptoms just detailed are wanting. It is, strange to say, usually the person with unusually good distant vision, or who at twenty years old has had it, who complains of eye-strain. The short-sighted person cannot distinguish objects in the distance, but he does not often suffer from headache.

Imbalance of the extrinsic muscles (heterotropia, heterophoria), in association with refra-

tive anomalies, is occasionally also a cause of ocular headache, and it is always desirable to apply the tests for this condition in the diagnosis of eye-strain.

The general practitioner must bear in mind that supraorbital headache also results from several forms of nasal "catarrh." Hypertrophic rhinitis, deviations of and growth from the septum, polypi, mucous and purulent collections in the frontal sinuses all produce frontal headaches. The chronic, frontal *headache of nasal disease differs from ocular headache* in that the former continues during the night, or gets worse when the patient takes "cold," while a purely ocular headache is not usually made worse by a simple coryza and ceases when the patient has retired and the lights in his room are extinguished; in other words, there is no headache when there is no ocular strain.

The various forms of supraorbital neuralgia may usually be detected by their periodicity, by the tenderness at the supraorbital notch and soreness of the skin along the course of the nerve, by their being almost always paroxysmal and unilateral and by the absence of asthenopic symptoms.

A class of practically *incurable ocular headache* is that arising from a combination of eye-strain, and organic disease of the retina, choroid, or ciliary body. The headaches from iritis, glaucoma,

and other acute diseases of the eye, are to be recognized by the presence of the affections themselves, a description of which is given in this treatise.

The *treatment* of ocular headache should be directed first of all to the relief of the eye-strain, especially the correction of the hyperopia, astigmatism or the accommodative anomaly, by means of glasses. *Any local inflammation should be allayed*; thus it not uncommonly happens that diseases of the lids may prevent a complete cure of the headache even after a correction of all refractive and muscular errors.

It should also be borne in mind that any departure from health may affect the eye and so act as a predisposing cause of ocular headache. Prominent among the conditions that intensify or invite ocular headache are *insomnia*, whatever be its origin, and one may be well assured that complete relief from the chronic pains in the head is very uncertain if the patient's sleep be disturbed or insufficient, even if the other factors in their production receive proper attention.

Dyspepsia in all its forms, but especially the toxic form, due to too much eating and too little exercise, is a frequent accompaniment of frontal headache and should receive quite as much attention as the purely ocular symptoms.

Excessive indulgence, in tobacco and alcohol

among male patients and tea and coffee among female sufferers should not be overlooked.

Of *local applications* the simplest, most effective and least harmful is the use of very hot or very cold fomentations. The patient may be allowed to try both hot and cold water, choosing the one that seems to him more useful or more grateful. Take a medium sized towel, folded to measure twelve inches long by four wide. Grasp an end in each hand and dip into a basin of cold (40° F.) or hot (130°F.-150°F.) water. Bending over the basin, press the dripping towel gently against the closed eyes, forehead and temples. Repeat the applications in this way every fifteen seconds for five minutes, stopping them if additional pain or discomfort be produced. Do this every hour, or oftener, while the headache lasts.

Soothing collyria relieve the headache, sometimes, by their action on the congested conjunctival vessels:

Borax	dr.	½
Boracic acid	dr.	½
Camphor water	oz.	½
Powdered suprarenal capsule...	gr.	10
Distilled water q. s. ad.....	oz.	2

M. Shake well, allow the mixture to stand for half an hour and drop into the eye, every hour or two, a few drops of the supernatant liquor. This eyewater decomposes readily unless it is kept in a cold-place.

Chloretone	Gm.	0.10
Borax	Gm.	0.50
Distilled water	Cc.	30.00

is another effective eyewater, to be used in the same way. The headache may often be dissipated by using the following mixture, to be rubbed over the forehead and temples; or a towel, wet with one part in ten of ice water, may be laid over the closed eyes and forehead while the patient is lying down:

Spirit of lavender, alcohol, of each 3 fluid-ounces; spirit of camphor, 1 fluid-ounce.

The following liniment is also effective:

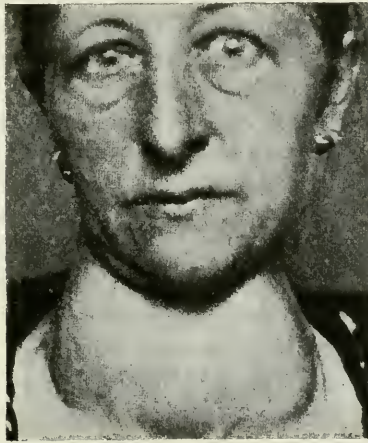
Chloroform	oz.	1
Camphor	dr.	2
Tincture of aconite	dr.	2
Oil of peppermint	gtt.	20
Alcohol	oz.	2

Shake well and apply every two or three hours.

Temporary relief of the pain may usually be obtained by the use of a weak, interrupted (or continuous) galvanic current, 3 to 5 ma., the positive pole applied to the nape of the neck, the negative, preferably by means of a double eye electrode, to the closed lids, for from two to ten minutes.

Exophthalmic Goitre, Graves' or Basedow's Disease.—This peculiar affection presents many eye signs, apart from the *exophthalmos*, that are extremely valuable for diagnostic purposes.

Sometimes one or more of these may be the only symptoms of the disease. Partial *abolition of the sensibility of the cornea* is present in many cases and may explain some of the other eye-signs. At any rate, we know that most of these phenomena may be produced artificially by



Exophthalmic Goitre. (Wilbrand and Saenger.)

instilling into the conjunctival sac of a normal subject, an agent that renders the cornea asensitive—a 5 per cent solution of cocain.

Graefe's sign is an important one. On looking slowly downward the upper lid edges of the patient suffering from Graves' disease will be found to lag behind the corneal margin on which they usually rest. They do not, as in normal

cases, maintain a uniform distance between the upper palpebral margin and the corneal junction, but show a portion of the white sclera. Sharkey found this sign absent in only 2 per cent of a large number of cases. Graefe attributed the phenomenon to spasm of Mueller's muscle, due to irritation of the sympathetic, but as the cocain experiment also produces it one may well believe that it is of purely peripheral origin and caused by loss of the corneal touch-sense. To this cause is also due the staring appearance (*Dalrymple's sign*) presented by the patient. This abnormal phenomenon is increased by the infrequent winking, *Stellwag's sign*, characteristic of the disease. Under normal conditions the individual winks about ten times per minute; it is reduced in exophthalmic goitre to five times and even to twice each minute.

The *exophthalmos*, apparently greater than it really is on account of the increased interpalpebral space, is the result of increased growth of the orbital contents and to edema and congestion of the retrobulbar vessels. A venous bruit or tremor can occasionally be heard when the stethoscope is placed over the closed lids. *Insufficiency of convergence, or the sign of Moebius*, is often noticed as a result, probably, of the stretching of the interni. Marked *epiphora* has also been noticed and it may be classed with

the sympathetic sweating so common in the disease.

Another peculiar phenomenon, known as *Becker's sign*, is pulsation of the retinal arteries and arterioles in the presence of normal or subnormal tension. Muscular pareses, as well as weakness of both internal and external eye muscles, forming a parallel to other muscular defects throughout the body, point to an autoinfection from the diseased thyroid gland, which acts like chronic toxemias elsewhere. Knies remarks that the exophthalmos resembles all the other symptoms of this strange affection in that it may occur in paroxysms, may diminish or increase or may remain permanent and uniform. Hulke reminds us that, on the whole, Graves' disease tends to get well and we have in it an example of an affection where recovery is almost certain if the patient live long enough.

Treatment.—The "rest cure" and, if that fails, partial thyroidectomy form the most effective method of dealing with the disease.

Epilepsy.—Sometimes we have a visual aura in this disease in the form of phosphenes, or as dazzling sparks and flames of light. Hughlings Jackson says that all colors from red to violet may flash before the eye as a premonitory symptom. The ophthalmoscope shows change in the caliber of the retinal vessels—usually dilation—and vigorous pulsation of the veins, just before

the occurrence of the convulsions. During the *status epilepticus* narrowing of the arteries has been observed with a return to normal conditions when the attack has passed.

The attacks of partial or total blindness, spoken of by authors as *epileptiform amaurosis* and experienced by the still conscious patient correspond to concentric contractions of the field of vision and the arterial and ciliary spasm so often elicited on examination. The perimeter is consequently of great value in the diagnosis of this disease and in cases of suspected malingering. The state of the pupil varies greatly in epileptic seizures and it cannot therefore be relied upon in diagnosis. Occasionally a case of idiopathic epilepsy recovers after the correction of a refractive error with glasses, or the relief of a muscular anomaly by means of prisms or operation, but whether this result is due to the purely psychic effect of the remedies or not is as yet undecided.

Migraine; Scintillating Scotoma; Amaurosis Partialis Fugax.—The attacks of this disease have certain affiliations with epilepsy but are not to be regarded as indicative of disease of the eye, although ocular disturbances form an important part of the symptom-complex. Apart from the scintillations, a "fortification" scotoma is the most common experience. This irregular, cloud-like appearance, usually edged with colors, shows itself in some part of the visual field and gradu-

ally spreads until the patient is blind. This is followed in its turn by severe, unilateral headache, lasting for a few hours or for a whole day, to be apparently relieved by vomiting. The attacks of migraine invariably become less frequent or less violent, until they disappear, with advancing years. The elasticity of the vascular walls diminishes with age, thus interfering with that spasm of the cerebro-cortical vessels upon which the disease probably depends. As in epilepsy, treatment directed to the eye occasionally relieves or cures this troublesome affection, but it is not to be relied upon.

Hysteria.—The ocular signs of this affection are probably the most constant, the most easily detected and the most conclusive signs both of *petite* and *grande hysteric* and a knowledge of the means by which the evidence can be obtained is of great value both to the ophthalmologist and the general practitioner.

Probably *the most important hysterical eye-sign* is the peculiar ciliary spasm. In hysterical spasm the eye acts as if it were under the influence of pilocarpin or eserin. The accommodation range is limited at both ends, and the patient reads or does other near work with difficulty; for these reasons, the condition has been called *hysterical insufficiency of accommodation, ciliary hyperesthesia, ciliary paresis or paralysis, and painful accommodation*. Every degree of

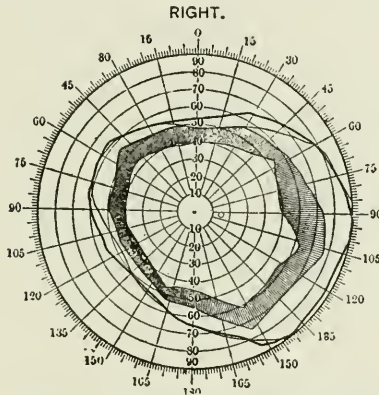
spasm may be present, just as one sees all degrees of hysterical muscle-contraction elsewhere in the body. The punctum proximum and punctum remotum may approach, or even coincide, and the patient reads fine print nearer the eye than usual, or at a fixed point. This, when it occurs, may be regarded as conclusive evidence of hysteria. As a rule, however, there is a marked, but incomplete spasm of accommodation—the near point for distinct vision being always nearer the eye than normal.

Hysterical spasm of the ciliary muscle usually produces false myopia (or hysterical near-sightedness) which, just like the axial variety, is improved by concave glasses. If there be a doubt as to the character of this short-sightedness, a single drop of a solution of atropia (1 per cent for patients under thirty-five years of age, $\frac{1}{2}$ per cent for those between thirty-five and forty-five) instilled into each eye, after meals, for two days, will disclose the true refraction.

Hysterical blindness, amblyopia or amaurosis, may be so marked that the patient has to be led about the room, or, more usually, it may pass unnoticed by the patient. It is not improper to regard the visual defect as due to an anesthesia of the perceptive elements of the retina in correspondence with that loss or perversion of sensation exhibited by the skin and mucous membrane in other phases of hysteria. This visual defect is

almost always present, and when the central acuity of sight, as determined by test-types, is nearly or quite normal it will be found on careful inquiry that peripheral vision, measured by the perimeter, is uniformly affected.

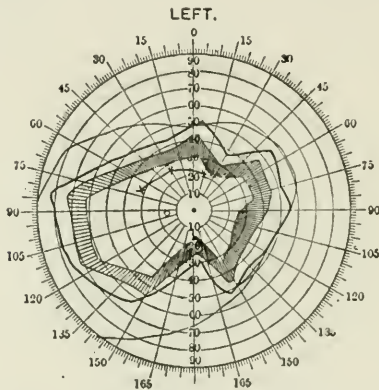
The *peculiarity* of an hysterical field is, that while in every other disease where peripheral limitations occur, the color field is affected in



Ring Scotoma in a Hysteropic Boy.

greater proportion than the field for white, in hysterical amblyopia the field is less affected for colors than for white. Even where the field for white is still the largest it can usually be shown (where there is no perimetric defect) that the visual field for red is larger than that for blue, and these measurements should always be taken in doubtful cases. This *reversal*

of the order and extent of the fields for white and colors is, when present, positive evidence of the existence of hysteria; it cannot be simulated, and is caused by no other ocular disorder. It is readily determined and possesses a diagnostic value equal to the anesthesia of the glottis and pharynx so frequently referred to as pathognomonic of this neurosis.



Ring Scotoma in a Hysteropic Boy.

Although contracture and spasm of almost every member of the oculo-muscular system have been observed in hysteria, many of these are differentiated from true paresis and insufficiencies with some difficulty. A few, however, are so evidently functional disorders, and their detection is so comparatively easy, that we do not hesitate to refer to them as hysterical stigmata with which every one should be acquainted.

Even before the days of modern Ophthalmology it was noticed that *spasm of the orbicular muscles* was frequently associated with amaurosis and amblyopia, although there was no apparent structural disease of the ocular apparatus. Such a state of affairs should make us suspect, and further examine the patient for, hysteria. All such forms of spasm of the orbicularis—*winking or blinking*, tonic, clonic, transitory or permanent, unilateral or bilateral—are probably hysterical. If central or peripheral excitants competent to produce the spasm can be excluded and if other hysterical stigmata be present the possibility becomes a certainty.

Monocular polyopia or diplopia is often noticed in hysteropes although this symptom will have to be developed in the majority of cases because the patient is unconscious of it as such.

It commonly appears to him as part of his visual defect. Tests should be made both in a lighted and darkened room. One eye being covered, a white match is held vertically three or four inches in front of the uncovered eye. The patient is then asked to observe whether the object appears double, as it is slowly moved from its first position to a point three feet away. In most cases the match will present a double image when held quite near the face; the images approach one another and become fused as they are removed, to separate again, more and more, until

the metre distance is reached. The match is again from this point gradually brought close to the eye when the same phenomenon, but in reverse order, will be manifested.

The second eye is similarly examined and finally the room is darkened and a further (control) test is made with a candle flame. Sometimes three or more images (polyopia) are observed, and it is usually possible to exclude one or more of these by carefully interposing a card so as to cover various segments of the pupillary area during the examination.

Hysterical Photophobia, not necessarily associated with spasm of the lid muscles, is a common experience in hysteria and, when present at all, may be so marked as to give rise to a suspicion of organic disease. The absence of all signs of vascular congestion is usually sufficient to exclude the latter. The patient often asserts that the light hurts the eyes even when these organs are covered with a heavy bandage, an exaggeration that should excite the suspicions of any one conversant with the hysterical character.

Pseudo-Paralytic Ptosis is another purely hysterical stigma. This rather unusual symptom, unlike organic paralysis, is almost always accompanied by other signs of hysteria, especially reflex photophobia and blepharospasm. The eye closes quickly when the hysterical lid is raised; slowly

in true paralysis. In unilateral hysterical ptosis, as Charcot observed, the eyebrow is lower on the healthy side; higher in true paralysis.

Traumatic Hysteria.—Suspicion should be aroused by the appearance of any of the symptoms above detailed if they show themselves after an injury, however trifling, if it be accompanied by mental shock. A majority, or a large minority, of examples of ocular hysteria belong to the so-called traumatic neurosis. It must not be forgotten that just as hysteria simulates most organic lesions it may also be present with them. Patrick has, among others, emphasized this important fact, and has reported cases illustrative of it. The eye is no exception to this rule, but fortunately organic alterations in the ocular structures as determined by the ophthalmoscope, perimeter, etc., usually speak for themselves, and present characters entirely unlike those of a purely functional affection.

It must be remembered, then, that most cases of hysteria present well-marked, easily detected eye-signs and symptoms; a few ocular symptoms, such as reversal of the relation of the color-fields and the field for white, the tonic form of blepharospasm and pseudo-paralytic ptosis, may be regarded as pathognomonic of hysteria; defects of vision (in the absence of refractive errors, accommodative anomalies and fundus lesions) are, generally speaking, hysterical if ac-

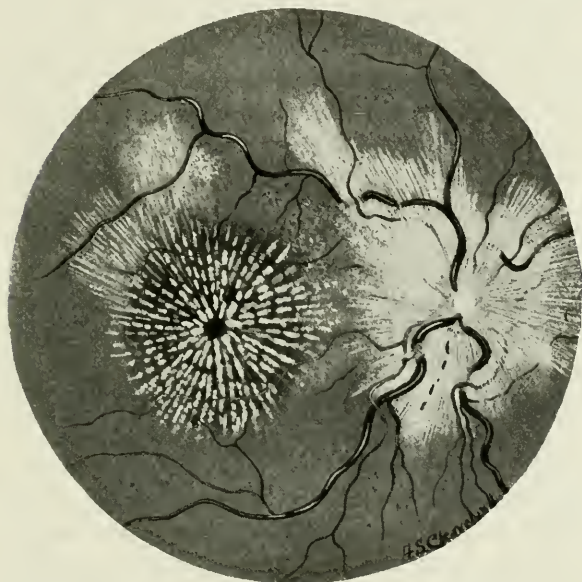accompanied by photophobia and any form of blepharospasm; no examination of a patient for hysteria should be regarded as complete without considering the condition of the ocular apparatus; where there is no conclusive external evidence of the neurosis present, the perimeter should be carefully used, the range of accommodation should be noted and the ophthalmoscope employed; ocular hysteria is common in children and men; organic diseases (traumatism especially) of the eye may accompany purely hysterical disturbances of the visual apparatus. The *treatment of ocular hysteria* is, first of all, that of the condition itself.

Often the purely eye symptoms can be relieved by glasses to correct the spasm or paresis of accommodation. Galvanism, or the mild faradic current, is of considerable benefit in most cases. Tinted glasses, to relieve the photophobia, and atropin, when there is pain or headache, will be found of use. Relapses of the eye symptoms often occur, just as they do in other aspects of the disease.

Bright's Disease; Albuminuria.—About 10 per cent of the cases of renal and other affections in which albuminous urine is found are uniformly associated with ocular changes. *Edema of the eyelids*, especially a temporary swelling of the lower lids on rising in the morning, is one of the earliest prodromata of albuminuria where anasarca is likely to occur. By far the most im-

portant eye manifestations, however, are alterations in the optic nerve and retina.

All degrees of hyperemia of the disk, from a simple congestion to a well developed "choked disk," are not uncommon in all forms of Bright's



Appearance of the Ocular Fundus in Albuminuric Retinitis.

disease. These occur alone or in conjunction with what may be regarded as the characteristic lesion in albuminuria, viz.: *whitish, degenerative patches arranged in stellate fashion about the macula*. They are first seen as linear streaks that grad-

ually arranged themselves, like the spokes of a wheel, about the fovea. Later on, other whitish areas appear in the background and they may coalesce, covering the vessels and marring the contour of the star-shaped picture around the macular region.

Associated with these alterations in the retina are eventually seen hemorrhages, usually on or about the disk. These may undergo absorption (leaving pigmented lines) to be followed by additional bleedings elsewhere in the fundus. The occurrence of retinal hemorrhages marks the gravest lesions in the general circulatory apparatus and is almost invariably followed in a few months by death.

In the advanced cases the diseased capillaries may be mapped out by the ophthalmoscope, which shows streaks along and thickening of their walls. This condition is not uncommon, but it is often masked by the retinal edema and the whitish patches. The vascular alteration is an endovasculitis, with degeneration of the intima and eventual occlusion of the lumen from thrombosis. The white patches consist of a fatty degeneration of Mueller's fibres and finally of most of the retinal tissues.

Although the lesions just spoken of occur in all forms of renal inflammation they are rare in the acute varieties, in fatty, sclerosed kidney, in large white kidney and in waxy kidney, unless

the last be affected (Bull) by fatty metamorphosis. Should the patient recover, as in the temporary albuminuria of pregnancy and scarlet fever, the early optic and retinal changes sometimes entirely disappear, but the injury to the nerve may finally lead to atrophy and blindness.

Owing to the comparative frequency of fundus changes in albuminuria, the ophthalmologist is sometimes the first to suspect the existence of the cardio-renal disease, especially as the general symptoms of albuminuria are so often ill-defined or are attributed by the patient to other sources.

Paralysis of the eye muscles is occasionally seen in the later stages of albuminuria when the brain changes (hemorrhages especially) occur about the nuclei of the oculomotor nerves. Finally, temporary blindness due to uremia and permanent loss of sight from detached retina are noted in albuminuric diseases.

Diabetes.—This sign of pancreatic or cerebral disease is frequently associated with marked alterations in the eye structures. If a decided glycosuria exist long enough and particularly if the patient reach middle life, *cataract is likely to occur*. Should lenticular opacities show themselves early their progress is usually rapid and there is a distinct swelling of the lens, with myopia or a decrease in the hyperopia.

Diabetic cataract is almost invariably bilateral, although one lens may exhibit greater opacity

than its fellow. It is probable that the circulation of glucose and other abnormal products in the blood affects first of all the ciliary vessels; then the nutritive supply to the lens, followed by opaque deposits in the crystalline. It is in the first stage of this form of cataract that one notices occasional clearing up of the opacities, should the patient recover wholly or partially from the initial disease. To this fact is probably due most of the so-called "cures" of cataract from massage, *cineraria maritima*, etc. Later in the disease, when organic changes have taken place in the crystalline structures themselves, these alterations continue to spread or they do not get any better even when the general cachexia disappears.

Another important result of the ocular invasion is disease of the optic nerve and retina resembling the so-called albuminuric retinitis, from which it is often difficult to distinguish the diabetic form. The appearance of retinal hemorrhages in diabetes (just as in Bright's disease) evidences extensive disease of the systemic capillaries and a fatal, probably an early, termination of the case.

A retrobulbar neuritis in diabetes has often been mentioned by authors. The central scotoma in such cases is for a time entirely relative and, if seen in alcoholics and smokers, makes it difficult to say whether it be due to the action of the


glycosuric poison or to the alcohol and nicotine. Later in the disease the red and green scotomata grow larger and the field for white becomes involved.

Knowing as we do the intimate relation existing between diabetes, early cataract, retinal hemorrhages (with or without optic neuritis), retrobulbar neuritis and optic atrophy, the urine of patients, suffering from these diseases, should always be examined at intervals for sugar. Eye changes are rare in *diabetes insipidus*.

Tumors of the eyeball and its appendages do not call for extended comment, because of their rarity. Tubercular growth (*lupus*), *epithelioma* and *carcinoma* of the conjunctivæ and lid skin are occasionally seen and, like similar growths elsewhere, call for prompt excision and treatment with the X-rays. The commonest intraocular neoplasms are *sarcoma* of the choroid or ciliary body and *glioma of the retina*.

Glioma or neuroepithelioma retinae is invariably seen in infancy, because it is probably congenital. It attacks one eye only and is very malignant, uniformly recurring even when enucleation of the globe is done early. In the first stage there is no pain or redness of the eyeball, but the nurse or parent is usually the first to notice *through the abnormally enlarged pupil a peculiar yellow-white reflex*. When the tumor extends towards the anterior portion of the vitre

ous the child gives evidence of pain, the superficial blood vessels are engorged, and the eyeball becomes hard. If allowed to progress still further the globe is plainly enlarged, the growth breaks through the sclera, involves the orbital tissues, the lids, and eventually protrudes upon the face—presenting a most horrible and distressing picture. Although death may result from extension to the brain it is quite as often due to exhaustion.



Glioma of the Retina, in the Second Stage, as Seen Through the Dilated Pupil.

The reason why thorough enucleation should be done as early as possible is that, occasionally, recurrence does not follow. If it does return, a complete exenteration of the orbit is advisable and this procedure should be repeated—so that a painless death may attend extension to the brain and thus save both parents and child the agony of that slow and painful termination that follows destruction of the facial tissues and metastases of the lungs, kidneys, liver, etc.

Intraocular sarcoma is a disease of *adult* life. Although its progress and termination, as well as

its treatment, are substantially those of retinal glioma, its first appearance can be properly diagnosed only with the ophthalmoscope. Subjects of it, however, usually assist in the diagnosis by



Fungating Sarcoma of the Eye. (Ramsay.)

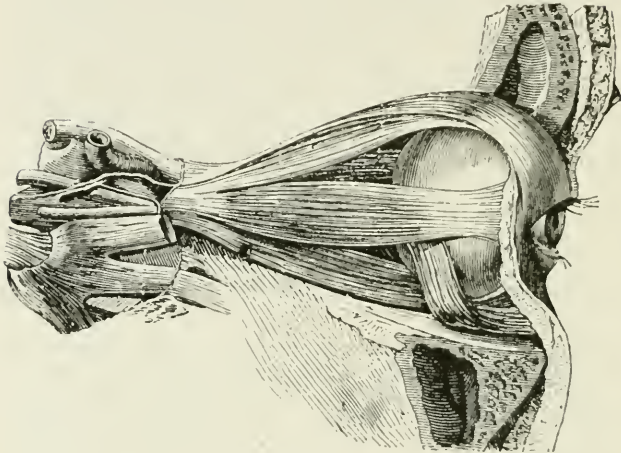
complaining of defects in the visual field and so draw the attention of the physician to the disease. Just as soon as possible after a thorough enucleation or orbital exenteration *the X-rays should be used for all cases of intraocular (and orbital) neoplasm* in the hope of further destroying the tumor cells.

CHAPTER XVIII.
THE COMMONER DISEASES OF THE
EYE MUSCLES.

Anatomy and physiology.—The rotation center of the eyeball.—Six orbital and two intraocular muscles.—How to memorize their nerve supply as an aid to the diagnosis of cerebral and spinal lesions.—Heterophoria and its meaning.—The various forms of muscular imbalance.—Tests for and treatment of heterophoria.—Squint or strabismus.—How it differs from paralysis of the eye muscles.—Convergent and divergent squint.—Symptoms and treatment.—Tenotomy and advancement of the external ocular muscles.—Paresis and paralysis of the eye muscles.—Double vision and vertigo the chief symptoms.—Syphilitic and rheumatic lesions the chief causes.—Peripheral and central forms of the disease.—Tabes and diphtheria.—Treatment.—Nystagmus and its causes.

The center about which the eyeball rotates is situated in the line of its visual axis, about 14 mm. behind the cornea. Six muscles turn (not draw) it in every possible direction, as well as give it a sort of *wheel motion* on its axis. If it were possible for them to operate separately we might regard the *external rectus* as rotating the globe directly outwards, the *internal rectus* as turning it directly inwards, the *superior rectus* as rotating it directly upwards, the *inferior rectus* as turning it directly downwards, while more complicated movements in various directions are effected by the combined action of these with the *superior* and *inferior oblique* muscles.

As a matter of fact, no movement of either globe—to say nothing of their combined movements—is effected by less than two or three muscles; probably every rotation is attended by the contraction or relaxation of all of them. The fourth nerve supplies the superior oblique,



External Muscles of the Eye. (Nimier and Despagnet.)
 the external rectus is supplied by the sixth nerve, while the other ocular muscles (including the *levator palpebrae superioris*, the *sphincter pupillae* and the *ciliary* muscles) are innervated by the *oculomotorius*—the third cerebral nerve.*

*A useful aid in remembering these innervations is the radical SO₄ (superior oblique, fourth nerve). Memorizing this fact, all one has to bear in mind is the sixth nerve supply to the *external rectus* and the third nerve to all the other muscles.

When a person, with head erect, looks at a distant object directly in front of him and in the horizontal plane, head and eyeballs are said to be in the *primary position*. This is accepted as a sort of standard with which to compare all other positions of the globe.

Orthophoria is the term applied to a perfect balance of all the external eye muscles.

Abnormal attitudes of the eyeball are taken in *heterophoria* (muscular insufficiency), *strabismus* (*squint or heterotropia*), *pareses* and *paralyses* of the muscles.

Heterophoria.—In this condition there is merely a *tendency* to abnormal rotation of the eyeball in some one direction. There is no *apparent* defect in fixation and probably there is none, or there is generally none, but *both eyes together look in the proper direction only by the exercise of constant effort*. We detect this condition only by applying tests for its presence. When the tendency is to excessive rotation inwards the condition is known as **esophoria**, excessive rotation outwards, **exophoria**, and of one eye upwards, **hyperphoria**. We may have combinations of these, as hyperexophoria and hyperesophoria.

The *causes* of these defects are mostly congenital and anatomical, i. e., a particular muscle may be either too short, too long, too much or too little developed; it may be imperfectly or

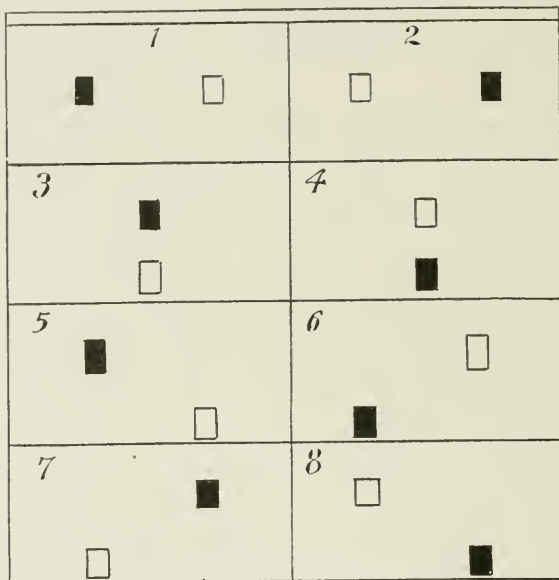
unduly innervated as compared with its antagonist or its fellow, in the work of so rotating the eye as to readily bring about binocular vision with the fellow eye.

Tests for Heterophoria.—In recording the rotating power of the muscles we should especially note their power of **abduction**, or simultaneously turning both globes on their axes outwards; their power of **adduction**, or turning both eyeballs inwards, as in ordinary convergence. In this connection there are also tests of the amount of muscular force resident in the vertical muscles—their **sursumduction**. Commonly these are determined by prisms, with their apices directed towards the globar attachment of the muscle or muscles whose rotating power we wish to register.

After a little instruction and a few trials we find that the (prism) convergence, or *adduction*, of the normal individual is about 30° , i. e., if the patient be placed in the primary position, facing a candle light at a distance of 20 feet, the double images of the light at first produced by a 30° prism, axis horizontal, in front of either eye, and with the apex towards the nose, can, after a little practice, be overcome so that he sees singly. Prism-divergence, or *abduction*, is normally about 9° , tested in the same way, with the apex towards the temple. Thus we find the relation of abduction to adduction to be about 1:3.

Sursumduction (right or left) is 2° to 3° only, the apex of the prism being directly upwards.

Perhaps the most important of all the tests is




Detection of Heterophoria.

The red glass is placed before the left eye and the red image is indicated by the black squares. 1. Esophoria. 2. Exophoria. 3. Right hyperphoria. 4. Left hyperphoria. 5. Right hyperesophoria. 6. Left hyperesophoria. 7. Right hyperexophoria. 8. Left hyperexophoria.

the *cover test*. Direct the patient, placed in the primary position, to look, as before, at a point of light twenty feet away. First cover one eye

with a card and then the other. When the first eye is uncovered it should not move out or in, up or down, to fix the distant light when the second one is covered. If it does, the surgeon notes the fact and determines whether it moves inward (*exophoria*), outward (*esophoria*), up or down (*hyperphoria*).

Numerous *phorometers* have been devised. These instruments *measure not only the amount*



The Wilson Phorometer.

of heterophoria, but the muscle rotating power, just described. One of the best of these is the Wilson phorometer, which combines the *Maddox rod* and the prism arrangement of the original Stevens phorometer.

Symptoms.—It has been found that most hete-

rophorias are indirectly due to errors of refraction (we frequently see esophoria associated with hypermetropia and exophoria with myopia), so that it is not strange that when the muscle defect is present its symptoms are merged with those resulting from the associated anomaly. Yet it is probable that some of the discomfort should be laid at the door of the muscular imbalance. Just as a small amount of hypermetropia or of myopia does not, as a rule, excite symptoms, so a few degrees of heterophoria, particularly defects of abduction or adduction, are of no clinical importance. In susceptible patients, or where the muscular strain is considerable, we notice especially *photophobia*, *headache*, *vertigo*, mental confusion, theatre and railroad fatigue, "car sickness," as well as other "panorama" symptoms—as Bennett calls them. In esophoria, where we find *excess* of convergent and *defect* of divergent power, the complaints are nearly always these distance symptoms; for opposite reasons exophoria is commonly responsible for symptoms attendant upon near work, as "mixing up" or "running together" of lines of letters or figures, the blurring or indistinctness of words, written or printed, fatigue on attempting to read, especially in the evening, etc.

Treatment.—Correct the ametropia by glasses, being careful to fully neutralize the astigmatism. Give the eyes as much rest as possible, not for-

getting meantime to improve the *tone* of the *general* muscular apparatus and so, with it, the power of the ocular muscles. Tincture of nuxvomica, three to five drops before meals, in a tablespoonful of beef, iron and wine, or similar excipient, often acts well as an effective muscular tonic. *Rhythmic (gymnastic) exercise* of the weak muscles with prisms is of considerable value in many cases, particularly of exophoria. This is continued a few minutes at a time, three times daily, for a month or two until the patient reaches a prism-convergence power, in the manner described, of 50° or 60° . When these expedients fail an operation, as for squint, is indicated. Prisms for the correction of small degrees of *hyperphoria* are often worn with considerable benefit. The wearing of prisms in esophoria or exophoria is of doubtful utility and temporary value.

Heterotropia, "Cross Eyes," Strabismus, Squint.—This affection has been called "true" or "concomitant" squint, because although the relation of the visual axes is not a normal one it is a *constant* relation—one eye moves about when the other does, and the visual lines always maintain the same angle in all positions taken by the two globes.

In *paralysis* of the muscles, on the other hand, the eyes may be "crossed," but on looking in various directions it will soon be noticed that

the visual lines do not preserve this constant relation to each other. One should always exercise the various *excursions* of both globes so as to determine whether or not a case of "squint" is



Convergent Squint. (Dalrymple.)



Divergent Squint. (Dalrymple.)

due to a paresis, or paralysis, of one or more muscles.

Strabismus.—The two most important and most common varieties of this disease are **convergent** and **divergent strabismus**. In the former instance, when one eye "fixes" an object the

other converges or turns in more than it should, and does not allow the image of the object looked at to fall on both foveæ. In the external form of squint the non-fixing eye diverges or "turns out." Usually one eye constantly fixes (and does the seeing) while the other squints. This is called *constant* or *unilateral* strabismus. Sometimes it seems to be a matter of indifference to the patient with which eye he fixes and which one squints; in which case the strabismus is termed *alternating squint*. When this occurs the patient is generally found to see equally well with, and the vision is normal or nearly normal in, either eye. Occasionally the patient squints only at times—*periodic* strabismus.

Tests for Strabismus.—Most cases of squint can be detected by directing the patient to look first at a near point—say 30 cm. in front of his nose—and then at some distant object. The cover test, as applied in heterophoria, also furnishes valuable and usually conclusive evidence in doubtful cases of slight or periodic squint.

Causes.—The optic centers of most individuals prefer *binocular* sight but, above all, they insist upon as clear images of objects as the visual apparatus can furnish. If one optic nerve receives and conveys to the cerebral neurons the sensation of a blurred image and the other, at the same time, transmits a clear or clearer image the mandate goes forth to suppress the less distinct im-

pression. This is done by sacrificing binocular vision; the defective eye turns in or out, up or down, according as convergent, divergent or sursumvergent power predominates. Now, the interni muscles being strongest in *hypermetropes* and *emmetropes* we find that squint in these persons is almost always *convergent*. *Myopes*, on the other hand, have relatively strong externi and weak interni; hence the strabismus of myopia is usually *divergent*.

There is no double vision in concomitant strabismus (ordinary squint) because the cerebral centers suppress the indistinct image of the squinting eye—just as when, in a "brown study," one's retina does not perceive surrounding objects.

Convergent strabismus usually sets in between the ages of one and five, when the child has begun to use its interni muscles for convergence. Most of us are born hypermetropic and that is, perhaps, the reason why most squinting children exhibit convergent strabismus. Divergent strabismus, on the other hand, is less frequent in this country owing to the comparative rarity of myopia. Shortsightedness is, as we know, a disease of late childhood and early adolescence; hence divergent squint develops later in life than the convergent variety.

The degree of squint is best measured by the *perimeter* or the *strabometer*. In using the latter

the patient's head is placed in the primary position; the instrument is then applied along the lower orbital margin of the squinting eye. The center of the pupil will now be found opposite a number which indicates in millimeters (or degrees) the amount of deviation. This observation is made for distant (20 feet) and near (10 inches) fixation. In using the *perimeter* the patient is placed as in measuring the field of vision, with the arm of the instrument horizontal in convergent or divergent squint; vertical in strabismus sursumvergens. A candle light is moved along the arm, from the center outward, until its reflection is seen by the surgeon upon the pupillary center of the squinting eye. The degree marked on the arm of the perimeter at this point is the size of the strabismic angle. This observation is taken both for the distant and the near point.

The *symptoms* of both convergent and divergent strabismus result from the associated refractive errors. Apart from the disfigurement this muscular anomaly causes little or no discomfort. For all practical purposes the patient is a one-eyed individual and there is no muscular strain.

Treatment.—First of all, after paralyzing the accommodation, the squinting child should be given, for constant wear, and in *spectacle frames*, such lenses as fully correct his refractive error. In addition, one drop of a two grains to the

ounce solution of atropia should be dropped into the fixing eye twice daily for two weeks, the eyes, meantime, being protected from light by tinted fronts. The patient may then be allowed to do a fair amount of near work if he have divergent squint, but none at all if he have convergent strabismus.

In the majority of these, the ordinary varieties of strabismus, great improvement or cure will follow such treatment if it be persisted in for six months. During this period the necessity for exercise of the binocular function of vision, by means of the *stereoscope*, or a special arrangement of this instrument called the *amblyoscope*, must not be forgotten. In other words, we desire not only *to have the child's eyes appear "straight,"* we wish to have him use both eyes together, so far as the vision of the defective eye will permit.

If the *cosmetic* or *visual results* are not satisfactory after patiently following the foregoing rules, a resort to operation is indicated. The following precepts will be of value, in most cases: (1.) If possible operate only on the squinting eye (2.) Use as an anesthetic a mixture of one per cent. holocain and four per cent. solution of cocain for tenotomies and a general anesthetic for advancement. (3.) Remember that the more a tendon is loosened from its connective tissue and other surroundings the greater the effect of a tenotomy. (4.) In *internal* squint, where the


convergence is not more than 15° - 20° , a *free* tenotomy of one internal rectus, or an advancement of one external rectus *without* tenotomy of the internus, is usually sufficient. (5.) Where the convergence exceeds 20° it is better to do an advancement of the external rectus *plus* tenotomy of the internal. (6.) Slight degrees of divergence call for a tenotomy of a single external rectus; marked deviations, for advancement of one or both interni, with or without tenotomy of the external. (7.) Exercise with



Worth's Amblyoscope.


the stereoscope, or some of its modifications, should be continued, after operation, for several months. (8.) When the squinting eye is amblyopic from corneal opacities, cataract, disease of the fundus, etc., and vision cannot be materially improved, the operation should be proceeded with at once—for cosmetic reasons. In such cases we have little or nothing to hope for from atropine, glasses or orthoptic exercise.

Tenotomy may be done in the following fashion: The eye, having been well cocainized, is



Tenotomy Hook.

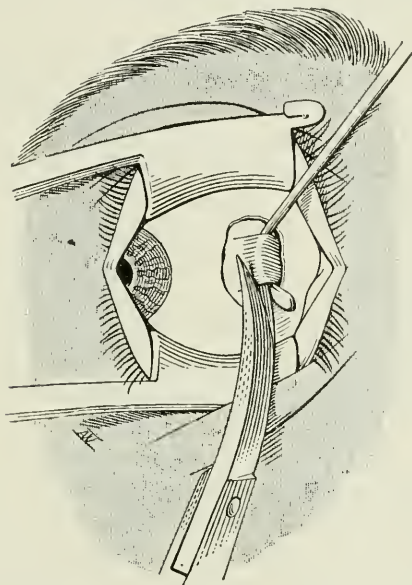
rotated by fixation forceps to the side opposite that on which the operation is to be done and is retained in position by the assistant. The conjunctiva and subconjunctival tissue immediately over the tendinous insertion are caught up by another pair of forceps and a fold of mucous membrane cut through by a pair of straight scissors at the lower edge of the tendon. A few drops of adrenalin solution (1-2000) is injected into the conjunctival opening, followed by a small quantity of cocaine. This not only gives a clearer



Scissors used in Tenotomy.

field for operation but renders subsequent acts painless. The points of the closed scissors are now passed into the conjunctival aperture, Tenon's capsule is opened and the tissues lying over

and on both sides of the muscle are undermined. Next, the strabismus hook is slipped into the opening and *beneath* the tendon; the latter is put on the stretch and divided *along the hook*, close to the eyeball.




Operation for Tenotomy.

As the last manœuvre requires a little care and some practice many operators believe that a more *certain* plan is to “buttonhole” the tendon at its center, to introduce the hook through the tendinous opening and sever tendon up and down

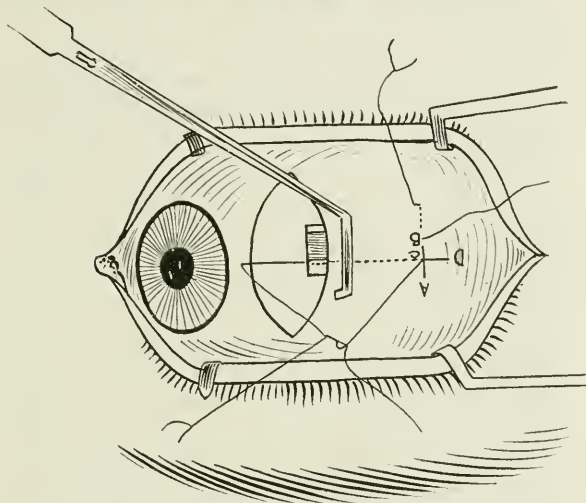
until the hook can be drawn freely towards the cornea. In either case this last act proves that the tendon is thoroughly divided. Finally, the curve of the hook should sweep both sides of the severed tendon so as to catch up and divide all remaining fibres.

Advancement of a tendon is generally done under ether or chloroform. There are many effective methods, but it will be sufficient to describe one only—a modification of Worth's. The conjunctiva and Tenon's capsule are divided in a vertical direction over the whole width of the tendon, and the latter is well stripped on all sides of its connective tissue. Wait a few minutes until adrenalin (momentarily) checks the bleeding, *i. e.*, give yourself a fair field for seeing just what you are doing. Grasp the tendon with a pair of Prince's advancement forceps. Exsect a piece of tendon between the forceps and the bulbar insertion. Place a suture, by means of *two* double-needled threads, at either margin of the tendon, behind the forceps, through conjunctiva, capsule and muscle, and tie them. Pass one needle of each double thread beneath the tendinous insertion, rotate the eyeball *towards* the wound of operation, remove the forceps, *advance* the main body of the muscle and tie all the tissues together in their new situation. A third suture may now be passed through the parts and tied as before. A handage is applied for one day. Some reaction

follows, to be combatted by cold boric acid fo-



Prince's Forceps.



Worth's Operation for Advancement of a Rectus Muscle.

The conjunctiva, Tenon's capsule and the distal end of the cut muscle are all grasped by Prince's forceps brought forward and attached by sutures nearer the corneal margin. The sutures are entered as shown in the cut.

mentations. The stitches may remain for four or five days.

Paresis and Paralysis of the Ocular Muscles, Ophthalmoplegia.—Although it is clinically useful to speak of these affections of the *muscles* it is well to remember that it is the *innervation* that is disturbed or abolished. If one bears in mind the nerve supply, paralytic diseases of the muscles resolve themselves into well defined groups.

Certain *symptoms* are common to all forms of ocular paralysis. The most important of these is *diplopia*—the patient has a sudden attack of double vision. This occurs in every instance where vision in both eyes is good and is due to the fact that images of objects do not fall on *corresponding* parts of both retinae. It is by the *relative position* of these double images—a somewhat difficult subject for the student—that most observers endeavor to locate the seat of the paralysis. *Vertigo*, and even *nausea* (the reflex effects of the diplopia) are frequently complained of. *Indistinct vision*, confusion of ideas and *headache* are not uncommon. The patient obtains at least temporary relief from these annoying symptoms by closing one eye or, if the images are not seen far apart, turns his head towards the paralyzed muscle. This latter sign often indicates which muscle is affected.

Paralysis of the External Rectus.—Sixth nerve paralysis. This is the commonest of the ocular pareses and is easily recognized. The

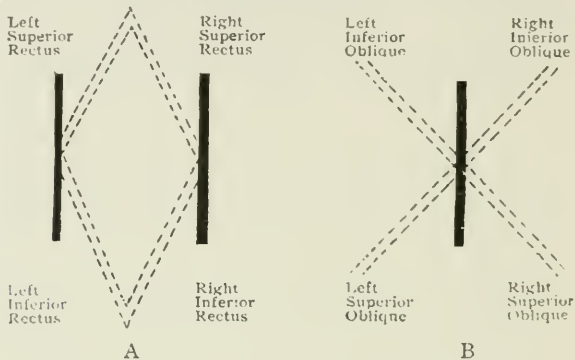
patient has double vision and the other symptoms just described and there is usually a *marked* convergence, the patient being unable to rotate the eye outwards to the normal extent. This last fact enables one at once to distinguish sixth nerve paresis from true convergent strabismus.

Oculo-Motor or Third Nerve Paralysis.—Any one, two, three, four, five (or all) of the muscles supplied by the third nerve may be paralyzed. Usually, however, there is *ptosis* from implication of the fibres supplied to the *levator palpebræ superioris* with *mydriasis* and *loss of accommodation* due to involvement of the sphincter muscles of the pupil and the ciliary muscle. The paralysis of the other muscles in this group can usually be made out by the loss of rotating power proper to each.

It must not, however, be supposed that it is always easy or possible to say just what muscle or muscles are affected, because of the *secondary contractions* and deviations that occur in *both* eyes, brought about by the efforts of the cerebral centers to accomplish single vision. Various diagrams and tables have been worked out to assist the student in this study by observing the positions and displacements of the two images in a parietic diplopia.

Causes of ocular paresis are chiefly *syphilis* and *rheumatism*, either of the nerves themselves or of the bony canals or periosteum that surround

them as they pass to the orbit from the central neurons whence they arise. If these organic deposits or growths undergo absorption before too great damage has been done to the nervous ele-



SCHEME FOR DETECTION OF PARALYSIS IN THE SUPERIOR AND INFERIOR RECTI AND OBLIQUES.

Dotted lines==False images (affected eye.)

Black line==True images (sound eye.)

A. Paralysis of Superior and Inferior Recti. False images situated between the true images. Diplopia crossed. The false images slanting away from (paralysis of Superior Recti) and towards (paralysis of Inferior Recti) the true image.

B. Paralysis of the Superior and Inferior obliques. True images combined in one line and situated between the false images. Diplopia homonymous. The false images slanting away from (paralysis of inferior obliques) and towards (paralysis of superior obliques) the true image.

ments a cure of the paresis results, but if, as the result of damage to any part of a nerve, changes occur in its structure, partial or total loss of function takes place.

When one nerve alone is affected the cause is *probably peripheral*, while a central lesion is to be suspected if more than one are involved. It was pointed out by von Graefe that when fusion of the double images by prisms is easy the lesion is more likely to be peripheral (and *not cerebral and spinal*) than when it is difficult or impossible to obtain and retain single vision. Paralysis of the external rectus is nearly always due to the rheumatic poison or to diabetes. It must be remembered in this connection that *diphtheria* sometimes produces ocular paralysis, especially of the ciliary muscle, and loss of the reading power (*cycloplegia*) with dilated pupil (*iridoplegia*). A more or less *transitory and recurrent* paresis of the ocular muscles is a rather frequent and premonitory sign of tabes dorsalis.

Prognosis.—Diphtheritic, and the early or primary, pareses of locomotor ataxia almost invariably get well, with or without treatment. So do most pareses that depend upon peripheral causes. Even if they are of central origin, and are due to syphilitic exudates that are themselves capable of absorption, the resulting pareses usually, though they do not uniformly, disappear. For obvious reasons the *later* tabetic paralysees remain, as do many others resulting from incurable central lesions.

Treatment.—It is proper, especially when the patient goes out, to cover the affected eye with a

shield, to guard against the nervous and other difficulties of double vision. Specific treatment should be given when it is indicated, and, even when there is no definite history of rheumatism or syphilis potassium iodide administered in gradually augmented doses, with large quantities of water, is useful as an alterative and absorbent in the majority of instances. It is usually desirable to supplement this medication with the hot pack or Turkish bath, the daily use of saline laxatives and the inunction of mercurial salve. Two weeks of this treatment should be given every month as long as improvement continues.

The faradic or the interrupted galvanic current is of value in paretic lesions, especially when the cause is peripheral, the negative pole being placed, daily, over the closed eyelids (or applied at the insertion of the muscle directly to the cocaineized sclera) for five minutes at a time. *Surgical interference*, as in squint, may be resorted to, in selected cases, when medical resources fail. In such operations advancement, with resection of a large portion of the tendon, is most likely to do good.

Nystagmus is a rather rare and curious symptom and may be described as a clonic spasm of the eye muscles due to a variety of causes. It is always associated with defective vision and is seen in *multiple sclerosis*, in albinos, and in many diseases of the optic nerve and retina. These spas-

modic jerkings of the eyeball may be vertical, horizontal, rotary, constant or occasional. Occasionally the patient is conscious of these oscillations, but as a rule his discomfort arises only from the imperfect sight. *Miners* are occasionally subject to the disease, due to the recumbent position and unusual excursions of their eyes, which they are required to continue for hours at a time. This form of nystagmus disappears when the patient relinquishes his work. *Treatment* is usually of little avail. It should be directed towards removal of the cause of the symptom—when that is possible.

CHAPTER XIX.

THE COMMONER PATHOGENIC BACTERIA THAT INVADE THE EYE.

Numerous bacteria, pathogenic and benign, inhabit the normal conjunctival sac.—Slight traumatisms or local irritations permit them or their toxins to invade the tissues beneath the protecting epithelium.—They constitute an important cause of ocular inflammations.—The staphylococcus.—The streptococcus.—The Gonococcus of Neisser the special cause of gonorrhoeal conjunctivitis in adults and in ophthalmia neonatorum.—The pneumococcus the special bacterium of spreading ulcer of the cornea.—The Koch-Weeks bacillus responsible for "pink-eye."—It is doubtful whether the trachoma bacillus has been isolated.—Mixed infections.—Toxins often as virulent as the bacteria that excrete them.—The environment of much importance in determining the virulence of bacteria.

In the secretions of the normal conjunctival sac a variety of microorganisms are found. Although a number of these bacteria (cocci or bacilli) are non-pathogenic in character both they and the pathogenic varieties are generally present. Almost all of them are capable of setting up an inflammation under favorable conditions. Just what constitutes a favorable condition it is not possible to say in every instance, but we do know that an abrasion or some irritation of the mucous membrane is the most favorable aid to microbic propagation and its pathologic results.

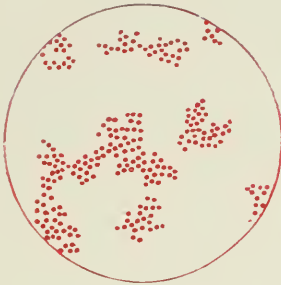
The following are the more common pathogenic microorganisms that have so far been

isolated in inflammatory affections of the eye and its appendages. Most of them have already been referred to and pictured in the chapters on the conjunctiva and cornea, but their importance in the causation of eye disease demands special mention. Reference to the colored diagrams accompanying this chapter will serve to fix their microscopic characters upon the memory of the student.

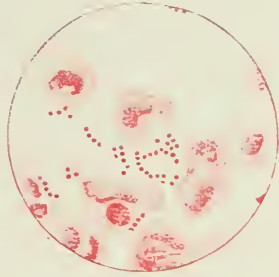
Staphylococcus pyogenes aureus.—This is one of the commonest pyogenic microorganisms found in the conjunctival sac. It may be regarded as the chief cause of all forms of irritation in that locality from the mildest hyperemia to the most severe inflammation. It appears as a round body, 0.7 to 0.9 μ in diameter. It occurs in clusters, and is readily stained with the ordinary aniline colors as well as by Gram's method.

The Streptococcus pyogenes is present in most purulent inflammations of the conjunctiva, especially in discharges from the lachrymal sac. It is also found as the active agent in many forms of corneal ulcer. Streptococci (as the name indicates) appear in chains, each coccus being about 1 μ . in diameter. It stains with the ordinary aniline colors.

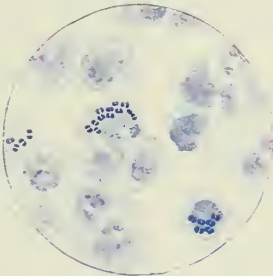
The Gonococcus (Neisser) is not easily demonstrated on account of its resemblance to various other cocci. They, however, grow readily in the ordinary media while the gonococci are diffi-



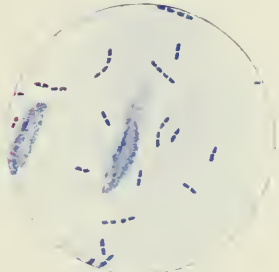
Staphylococcus
Pyogenes Aureus



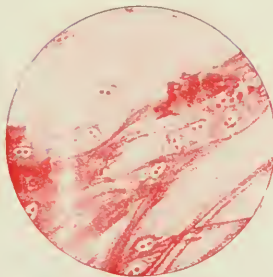
Streptococcus Pyogenes



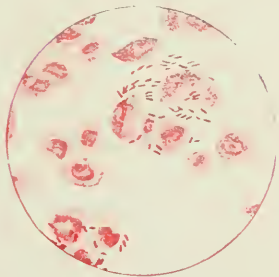
Gonococcus



Diplococcus of Morax-
Axenfeld



Pneumococcus



Weeks Bacillus

MICRO-ORGANISMS IN EYE DISEASES.

cult to cultivate. The gonococcus is stained by methylene blue, gentian violet and fuchsin. It is decolorized by the Gram method. It appears most commonly in the form of a diplococcus, the cocci being oval, with their flat surfaces opposed to one another. They are generally found within the leucocytes in the form of masses. These cocci are best cultivated in animal serum. This coccus is the special bacterium of adult *gonorrhoeal conjunctivitis*, and, in most cases, of *ophthalmia neonatorum*, particularly in that form of it that shows itself on or before the fourth day after birth.

The Pneumococcus.—This microorganism has been described by several observers as the *diplococcus lancetolatus Pneumoniae* (Talomon); *Micrococcus Pasteurii* (Sternberg); *Diplococcus pneumoniae* (Weichselbaum); the *Fränkel-Weichselbaum diplobacillus*; *Fränkel's pneumococcus*, etc. It is a short, oval (or lance-shaped) encapsulated coccus, usually seen in pairs or chains of from four to six cocci, with the outer ends pointed. It is stained by the ordinary aniline dyes and reacts well to Gram's stain. The pneumococcus is the bacillus found in a highly contagious form of conjunctivitis, in *serpiginous ulcer of the cornea*, and in panophthalmitis.

The Koch-Weeks bacillus is not readily separated from a large sized club-shaped bacterium that is frequently found with it. It is a small

bacillus, occurring in colonies, about 1 to 2 μ long and 0.25 μ thick. It resembles the germ of mouse septicemia and is stained not only by the Gram method but by the ordinary aniline dyes. It is readily found in the pus and mucus of the affected eyes, and is characteristic of that acute form of contagious conjunctivitis, commonly known as "*pink-eye*." It grows with difficulty in agar-agar, beef tea or any of the ordinary menstrua.

Trachoma microorganisms. A number of observers have described cocci which are held by them to be specific of trachoma, but as yet no satisfactory results have been reached from inoculation experiments. A diplococcus has been described by Michel and Sattler, but it is doubtful whether it is responsible for this serious disease.

The Diplobacillus of Morax and Axenfeld occurs commonly in pairs and sometimes in chains of three or four, each bacillus being about 2 to 3 μ in length and 1 to 1 $\frac{1}{2}$ μ in thickness. It is found in a well defined form of subacute conjunctivitis, accompanied by slight discharge, which usually runs a course of several weeks' duration.

It must not be forgotten (1) that *mixed infections* of any two or more of the foregoing bacteria may occur, (2) that the *amount and age of the microorganisms* may determine the sever-

ity of their action, and the virulence of the resulting infection, (3) that the *condition of the tissues attacked*, the resisting powers of the local vessels and the state of the general health may greatly modify the character of the inflammation set up by them, that (4) their toxins (and not the number or variety of the organisms) secreted by pathogenic bacteria, may be the chief or only cause of the lesions, and (5) that bacteria at one time inactive may, in combination with other germs or with a different environment than usual, become distinctly pathogenic.


CHAPTER XX.

REMEDIES COMMONLY USED IN OPHTHALMIC PRACTICE.

Local blood-letting.—Leeches, natural and artificial.—The application of dry and moist heat.—This remedy mostly used in deep-seated inflammations of the eye.—The use of cold.—Moderately cold applications in superficial ocular inflammation.—Massage of the lids over the eyeball.—Subconjunctival injections.—How to irrigate the eye.—The use of the medicine dropper.—How to instil single drops.—Poultices rarely useful in eye diseases.—The “rest cure” as applied to the eyes.—Protective glasses, goggles and bandages.—Their various forms and how to apply them.—Mydriatics and cycloplegics.—Cocain, atropin, euphthalmin and homatropin.—Atropin and other powerful cycloplegics.—Miotics and their uses.—Holocain, cocain and other local anesthetics.—Silver nitrate, argyrol and protargol.—Zinc and copper sulphates.—Boric acid, formalin, bichloride and other disinfectants.—Dionin.—Suprarenal capsule and its extracts.—The yellow oxide of mercury and its ointments.—Preparing the patient for ophthalmic operations.

Local Abstraction of Blood.—It is generally agreed that local blood letting is a valuable agent for the reduction of most *acute, deep seated* inflammations of the eye, such as iritis, iridocyclitis, glaucoma, choroiditis, etc. The pressure exerted upon the sensitive nerve-endings by the dilated blood vessels (and increased quantity

of blood in the congested tissues) is thereby removed and the severe pain which usually accompanies these abnormal conditions is often promptly relieved. Although there are several methods in use for the abstraction of blood in this neighborhood, such as scarification of the conjunctiva, opening an artery in the temple or the application of the *leech*, the last named is the most popular. One may use either the living animal or its substitute, the *artificial leech*. The latter is prefer-



Artificial Leech.

able, as it is not only more certain in its action and more agreeable to the patient, but the amount of blood abstracted can be easily regulated.

The **artificial leech** consists of a glass cylinder in which works a piston connected with a thumb screw. This is attached to the piston rod, by means of which it can be raised and lowered. The skin of the temple, half an inch from the

outer margin of the orbit, is the most desirable place for its application. Here the skin is first scarified, either with a small instrument containing a punch that cuts two crescentic wounds, or a number of small incisions are made with a fine scalpel. The end of the cylinder is then applied over the wound and the blood withdrawn by exhausting the air in the cylinder. At least half an ounce of blood should be withdrawn if a decided effect is to be produced upon the intra-ocular circulation.

Application of Heat.--Heat in eye surgery is generally applied in the form of *moist applications*.

Dry heat is sometimes used, but its action does not seem to be as effectual in promoting the absorption of the products of ocular inflammation as are moist forms. Various appliances and methods of applying *dry heat* have been recommended, all possessing their advantages and disadvantages. A simple and easy plan is to take an ordinary saucer and place it in the oven until it is too hot to handle. It should then be wrapped in a piece of flannel, which has also been well heated, and applied over the eye and surrounding parts, previously filling in the depression around the eyeball with warm cotton wool. The whole dressing should then be kept in place by a bandage.

Hot, Moist Applications can be applied by means of pieces of flannel, or gauze, of several thicknesses wrung out of water as hot as can be comfortably borne. They should not be too large, although of sufficient size to completely cover the front of the eye. They should be changed quickly as soon as they show signs of becoming cool.

Hot water may also be applied with a small towel, or ordinary wash cloth, folded about three inches wide by eighteen inches long. The patient is directed to hold one end of the towel in each hand and, dipping it into water as hot as can be borne, to apply it to the closed lids and parts surrounding the eye. It is applied to the ocular region and held there a moment, the application being repeated for the length of time desired. Hot applications to be of any therapeutic value should be applied every hour or two (depending upon the severity of the case) and for ten or fifteen minutes at a time. The temperature of the applications should be as high as can be endured, 115° to 125° F. On account of the danger of scalding, the skin of the lids and surrounding parts should be protected by anointing it with vaseline, or some simple ointment, previous to making the application.

Hot applications are valuable in most deep-seated inflammations of the eyeball to promote



Method of Applying Hot or Cold Applications to the
Eyes.

the absorption of exudates, for the stimulation of the circulation and for the *relief of pain*. They are especially indicated in iritis, cyclitis, keratitis and corneal ulcer.

Application of Cold.—Cold is a common and extremely useful application to the eye. The form of its application should depend upon the character and locality of the lesion. *Iced applications* are used in the severer forms of inflammation, when secretion is abundant, by means of gauze pads (7 or 8 thicknesses) or absorbent cotton about $2\frac{1}{2}$ inches in diameter. These pads are placed on the flat and smooth surface of a block of ice, which should be large enough to hold at least half a dozen, and the excess water wrung out before applying them to the eye. They must be *moist but not wet*, in order to avoid the disagreeable chilling of the surface of skin from the water running over the face. The pad should be changed frequently and, as it quickly absorbs the heat from the inflamed parts, ought to be replaced by another pad with as little delay as possible, so that the eye will not be exposed any longer than absolutely necessary during the procedure.

In the less severe inflammations cold may be applied in a manner similar to that described in moist hot applications, by means of a folded towel, using a basin of cold or iced water in place of the hot water. Cold or iced applica-

tions should not, as a rule, be used as long or as often as hot applications. In the milder forms of ocular inflammation five minutes is quite a sufficient length of time, although in the severe types of purulent conjunctivitis iced applications may be kept up for a longer period. Cold applications should not cause pain or discomfort to the eye; if they do they must be discontinued, or replaced by hot fomentations. The ice pack should never be applied to the eye.

Cold is generally employed in *superficial inflammations* of the eyeball and lids, especially in hyperemias and inflammations of the conjunctiva, purulent and otherwise, but is to be avoided when the cornea becomes affected. It is also indicated in most injuries of the globe.

Massage of the lids and eyeball is valuable in most chronic diseases of the lid borders and substance, in many subacute and chronic diseases of the conjunctivæ, and in a large proportion of ulcers of and deposits in the cornea. It is also employed for the temporary reduction of the increased tension of glaucoma. It is contraindicated in all conditions in which its use is followed by much injection of the eyeball, and especially where its use is followed by ocular congestion, photophobia or lachrymation.

Massage may be applied alone but is best used in conjunction with some oily remedy, or ointment, which should be made perfectly smooth

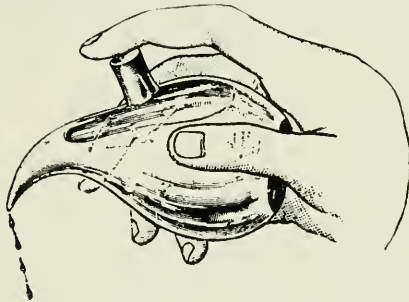
and of such a consistency that it is readily distributed over the conjunctival and bulbar surfaces. It is best applied with the pulp of the finger placed on the skin of the lid. The patient is told *to look down in massaging the upper lid* and upper portion of the eyeball, and *up in treating the lower lid* and lower portion of the eyeball. In each instance the other lid should be drawn away from the one undergoing massage.

If the cornea is to be treated the patient should be directed to look straight forward. The finger movements should be fairly rapid, and made at first in a circular fashion about the cornea as a center; then they ought to radiate from the pupil to the periphery of the sac in all directions. In no instance should they exert undue pressure upon the eyeball. The duration of the seances should not be more than three or four minutes each, and their frequency will vary from once daily to three or four times a week. The application should never produce severe pain or other marked discomfort, although this remedy usually causes a temporary congestion of the conjunctival vessels and a slight "foreign body" sensation, both of which should pass off within half an hour after the application.

The value of this remedial measure consists in emptying the palpebral ducts (meibomian and sudoriparous) as well as the blood and lymphatic vessels situated around the sclero-corneal margin

and the lymph spaces in the cornea, thereby promoting absorption of any exudates that may be present. At the same time the blood vessels are still further stimulated to contraction by irritation of the vasomotor system.

Subconjunctival injections of various agents, such as the normal salt solution, bichloride of mercury, cyanide of mercury, etc., are used in a number of affections of the eyeball, as for ex-

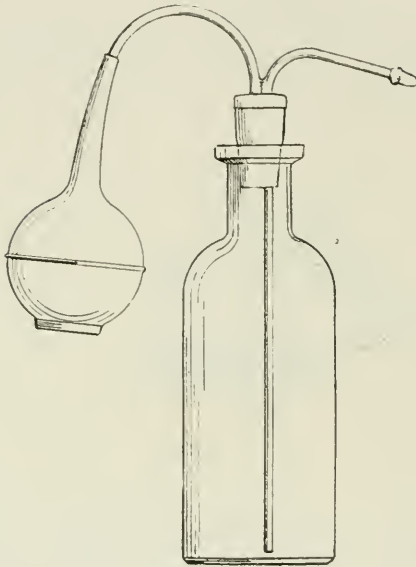


Undine.

ample iritis, corneal ulcers, infective keratitis and cyclitis, several varieties of choroiditis and retinitis, and panophthalmitis. The conjunctiva should be anesthetized with holocain or cocain, the point of the sterile hypodermic needle inserted near the margin of the cornea, well into the subconjunctival tissue, and a few (3 to 10) drops of the solution injected. The pain is not severe when mild salt, borax or boric acid solu-

tions are employed but it is quite severe when bichlorid, cyanid and strong (5% to 20%) sodic chlorid preparations are employed.

Irrigation of the conjunctival sac and the anterior surface of the globe for the removal of

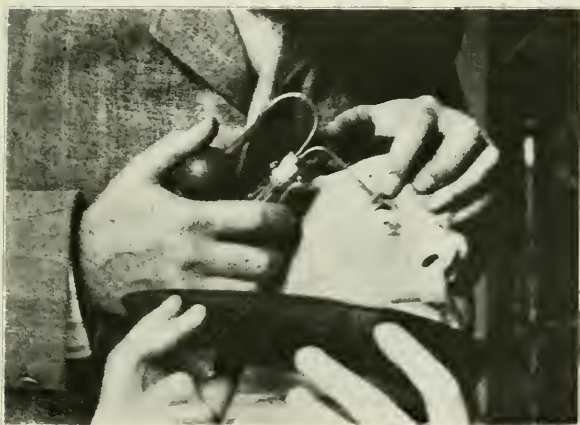

Irrigating Bottle.

discharge and other accumulations, is accomplished by means of weak solutions of any one of the antiseptics commonly used in ocular therapeutics, viz., bichlorid of mercury (1-10000), boric acid, borate of soda (4%), formalin 1 : 5000, or sterilized water. The lavage should be

copious and it is most effective when the solution is warm.

Of the many appliances at our command one of the most useful for the purposes of irrigation is the *undine*, although an ordinary *fountain syringe*, or a rubber tube syphon, will serve every purpose. Care should be taken that the

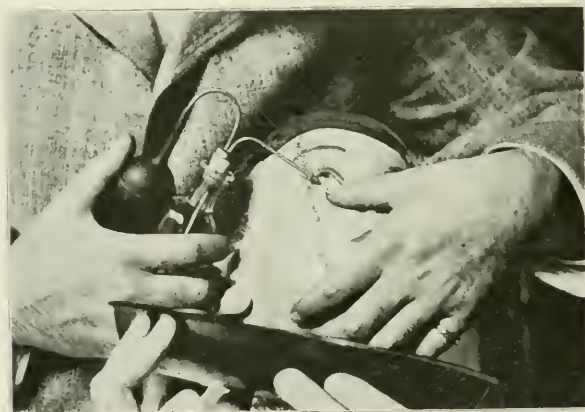

Irrigating the Upper Cul-de-sac.

stream of water which strikes the eye should not come with too much force and that the end of the pipette should not touch the cornea, or anterior portion of the eyeball, lest these parts be injured. Thorough flushing of the parts rather than the employment of force is the object of irrigation. The nozzle of the irrigating apparatus

should, consequently, *not* be directed at the globe; it ought to be held nearly parallel with the lid edges.

In irrigating the upper sulcus and upper aspect of the globe the patient looks down while the upper lid is gently drawn away from the eyeball. This exposes the upper cul-de-sac to the

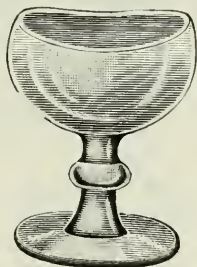


Irrigating the Lower Cul-de-sac.

cleansing action of the irrigating stream. To *cleanse the lower sac* the patient looks up, while the surgeon draws down the lower lid. The stream in most cases should be directed towards the inner canthus and not allowed to fall directly on the eyeball. If this precaution is not taken the patient will invariably resist, by closing the lids tightly, and difficulty will be experienced in

effecting a thorough irrigation. The ordinary *eye-cup* is also a useful means of washing out the conjunctival sac.

To apply solutions to the eyeball with a medicine dropper let the patient lie down, or, sitting up, hold his head slightly tilted to the right (to medicate or cleanse the left eye, to the left for the right eye) and slowly drop about ten drops of the solution upon the closed lids. A

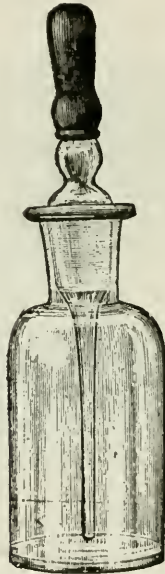

Eye Cup.

pool of the mixture will form at the inner canthus and gradually overflow into and bathe the eye from that point when the lids are opened. In this way the patient experiences no discomfort and will be able to rotate the eye-ball in all directions so that the irrigating fluid comes in contact with the whole surface.

Single drops are instilled with best results by forming a drop at the end of the pipette and simply touching the edge of either lid with it. If the remedy, eserin or atropin for instance,

is to chiefly affect the internal eye, the method of instillation should be different. In that case the upper lid-edge should be drawn away from the globe—the patient looking down—and the single drop applied to the raised margin beneath

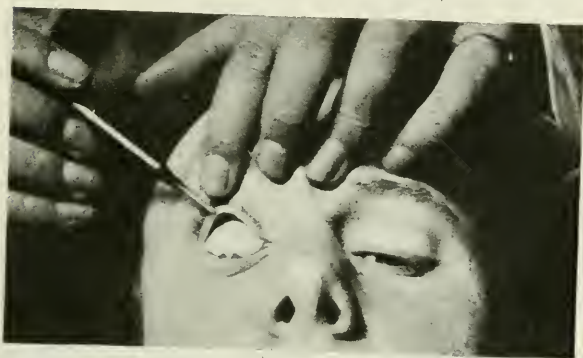

Bottle Fitted With Medicine Dropper.

the eye lashes. The watery solution flows over the upper palpebral surface to the upper sulcus, thence over the globar surface to the lower cul-de-sac and sac by which time it has been evenly distributed over the largest possible secreting

area, leaving little or none to flow through the puncta into the nose.

This consideration is of some importance when powerful remedies like duboisin, hyoscin, cocain, atropin, etc., are employed for long periods or in strong doses and one is desirous of avoiding their constitutional or toxic effects, or where,



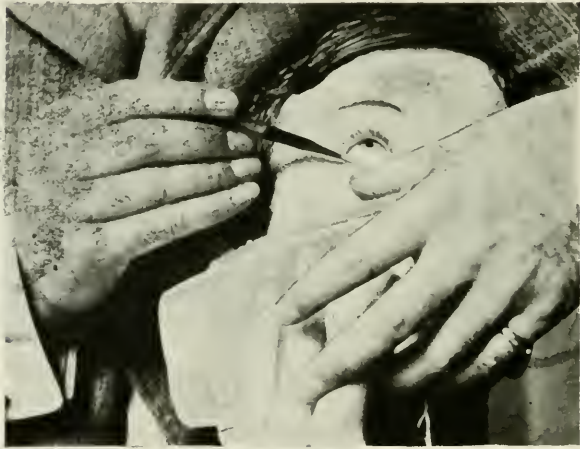Instilling Drops With a Dropper Into the Upper Cul-de-sac and Onto the Eyeball.

as in the case of homatropin and other expensive remedies, the fullest effect is required from the smallest dose or weakest solution. In both instances this plan serves to promote complete absorption and the *maximum local effect* of the instillation.

To insure slow and complete absorption of remedies it is a good plan to dissolve them in, or mix them with, some oily or fatty menstruum.

such as castor oil, vaselin, lard, etc. These oily solutions and ointments form most valuable applications in chronic diseases of the eye.

Poultices should *never* be used in inflammations of the eyeball. The practice of applying poultices of tea-leaves or bread, indulged in so frequently by the laity, generally aggravates in-



Dropping Solutions Into the Lower Cul-de-sac.

flamatory affections of the conjunctiva and cornea and may even convert a trivial and self-limited disease into a severe or serious one. They are occasionally of benefit in styes, abscesses and other local infections of the lids, but they should not be applied for long periods and should, as

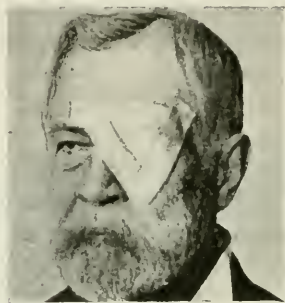
much as possible, be confined to the parts affected.

Rest of the eye is most effectually accomplished by paralyzing the accommodation with such cycloplegics as atropin, hyoscyamin, homatropin, and the wearing of tinted glasses, of which "London smoke" coquilles are generally the best. This ocular "rest cure" may also be accomplished by bandaging the eyes, or by placing the patient in a dark room, but neither of these procedures is desirable on account of the depressing effects on most patients. As a rule *abstinence from all forms of near work*, combined with an outdoor life, answers the demands of the majority of cases.

Protective glasses, goggles, eye-shades, dressings and bandages are used to guard against such outside influences (infective matter, wind, dust, strong artificial or natural lights, smoke) as are likely to irritate an inflamed or congested eye, or one that has been injured or operated on.

The triangular bandage is the one most frequently used by the authors. It consists of two layers of sterilized gauze, between which is placed a layer of absorbent cotton. These are together cut of the proper shape and size to cover the orbit, say, about two inches in diameter. It is laid smoothly upon the closed lids and held in place by three strips, each one inch wide, of zinc

oxid adhesive plaster. Number one is placed horizontally over the supraorbital edge, the second



The "Triangular" Bandage.

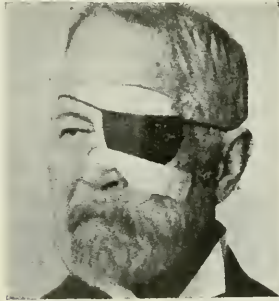
extends from the nasal extremity of number one obliquely downward and outward along the side



Lid Closed With Isinglass Plaster.

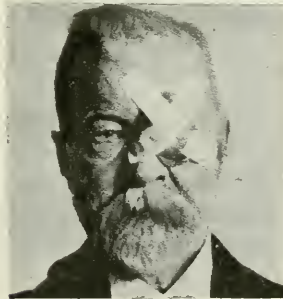
of the nose, while the third joins the temporal extremity to the lower end of the second strip

on the cheek. These adhesive strips keep the dressings securely in place. Unlike other band-



Protective Bandage.

dages there is little or no danger of its slipping off during the night, or as a result of the patient's

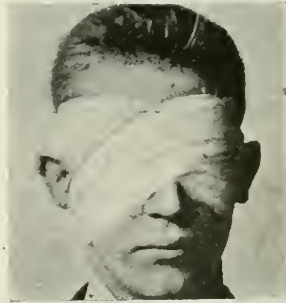

Snellen's Aluminum Shield, Kept in Place by Adhesive Strips.

efforts, as is apt to happen in the case of children.

The lids may be prevented from adhering or the lashes from sticking to dressings by applying any simple, non-irritating ointment to the palpebral margins or to the dressing itself.

Roller bandages, of gauze or muslin, from $1\frac{1}{2}$ to 2 inches wide and 5 or 6 yards long, are used in ophthalmic surgery, not only as a means of protection, but for applying pressure to the lids

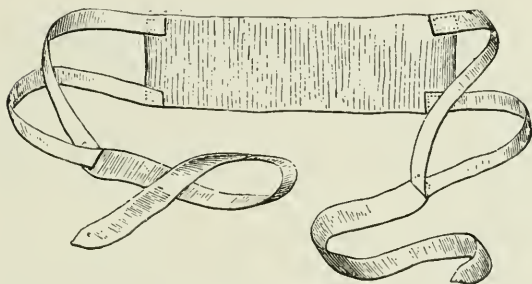


Roller Bandage for Both Eyes.

and eyeball. For the latter purpose the depressions about the globe should be carefully and evenly filled with absorbent cotton and the bandage applied firmly about the head.

The application of the bandage should begin on the forehead just over the affected eye. It ought then to be carried around the forehead across the opposite temple, obliquely down over the occiput under the ear of the affected side and thence obliquely across the eye dressing. It

should again be passed around the head but above the ear of the affected side, then *over* the forehead to the opposite temple and obliquely down the occiput, *under* the ear on the affected side and obliquely to the eye. This should be repeated, carrying the roller alternately above and below the ear on the affected side, until the bandage is firmly applied, fixing the dressing and keeping it from slipping.



Moorfield's Bandage.

The Moorfield bandage consists of a piece of linen, 3 inches wide by 7 inches long, with a notch of sufficient size in the center, into which the nose fits. Four tapes, one at each corner, are so arranged that loops are formed and surround the ears. The tape is then carried singly around the occiput and forward on the forehead.

Automobile and car drivers' glasses are made of cork and mica, celluloid and concave

glass, plain and tinted, for the protection of the eyes from wind and dust, that would otherwise injure the delicate corneal and other ocular tissues. They fit snugly about the orbit and are found in great variety at the optician's.

Mydriatics and Cycloplegics.—Mydriatics dilate the pupil; cycloplegics paralyze the accommodation. Many mydriatics are cycloplegics; most cycloplegics are mydriatics.

Cocain produces mydriasis but has a very faint effect on the accommodation. It also greatly assists the absorption of *any* local remedial agent (perhaps by widening the spaces between the corneal epithelium) and for this reason is often prescribed with eserine, atropin and other drugs whose action it increases.

Euphthalmin hydrochlorate is one of our most valued mydriatics and is particularly of use for dilating the pupil in making *ophthalmoscopic examinations*. Two or three drops of a 2% solution causes wide dilatation of the pupil in about half an hour. The mydriasis is more pronounced when it is combined with an equal amount of cocain:

Euphthalmin Hydrochlorate	gr. iv
Cocain Hydrochlorate	gr. iv
Distilled water	half a fluid ounce

This mixture has very little, if any, effect upon the accommodation and the mydriasis passes off within a few hours.

Homatropin hydrobromate is an effective cycloplegic and causes dilatation of the pupil in about fifteen minutes. Its effect lasts about thirty hours and many ophthalmologists use one drop of the following solution, in determining the refraction, every ten minutes for one hour. Complete cycloplegia occurs in from an hour and a half to two hours after instillation of the first drop:

Homatropin Hydrobromate.

Cocain hydrochlorate, of each 4 grains.

Distilled water, half a fluid ounce.

By far the most effective form of exhibiting homatropin and cocain as a *satisfactory and transitory cycloplegic*, in examining patients for glasses, is in *gelatine disks*. One of these, containing $1/50$ each of cocain and homatropin, placed every twenty minutes on the globe beneath the upper lid will effectually inhibit the accommodation at the end of an hour and a half. These disks, with full directions for use, are sold by the Messrs. Wyeth, Philadelphia. It must not be forgotten that whenever cocain is instilled into or applied to the eye the lids should be closed most of the time covered by the application.

Atropin Sulphate is commonly used as a cycloplegic in a one per cent. solution. The mydriatic effect of one drop of such a solution is apparent in about fifteen minutes while the cycloplegia generally lasts five or six days. It is con-

sequently of most use in young subjects, in patients where prolonged ciliary rest is required and, generally, when plenty of time is at the disposal of the individual as, of course, his eyes cannot be used for near work for a week or ten days after using atropia, while with homatropin mixtures work is possible after a day's rest. Atropin is also employed in those diseases where both complete and continuous mydriasis and cycloplegia are desired for a length of time, as in iritis, cyclitis, corneal ulcers, etc.

Duboisin, scopolamin, hyoscin and hyoscyamin are used in the same way, but in smaller doses than atropia.

Miotics (eserin, jaborandi extract, pilocarpin) produce spasm of the accommodation, contraction of the pupil and decrease of the intra-ocular tension.

Eserin Sulphate is the miotic most commonly used. It often induces painful contraction of the pupillary fibres and should be used in weak solutions whose effects may be painlessly increased by combining it with cocain:

Eserin sulph.....	gr. $\frac{1}{8}$ - $\frac{1}{4}$
Cocain mur.....	gr. 2
Distilled water	fluid oz. 1

Stronger solutions *may* be used but, as a rule, the weakest solution that will give the desired effect should be chosen. This remedy is most commonly used in glaucoma and *peripheral* ulcer of the cornea.

Pilocarpin is milder in action than eserin. The following is effective:

Pilocarpin hydrochlorate gr. 3
Distilled water fluid oz. 1

Local Anesthesia is generally sufficient to allow of painless operation on the eyes of adults and some children.

Cocain hydrochlorate is, on the whole, our best and most reliable local anesthetic. In from 2 to 10 per cent. solutions it produces sufficient anesthesia to render bearable, if not free from pain, almost all the operations on the tissues of and about the eyeballs. A few drops of the solution should be instilled every minute or two for 10 to 12 minutes before the operation. During the instillation of cocain the lids should be kept closed, on account of the drying and softening effect of the drug on the corneal epithelium, when the latter is exposed to the air.

Cocain Hydrochlorat. grs. 20 to 40
Distilled water 1 fluid ounce

Holocain hydrochlorate has, to some extent, displaced cocain as a local anesthetic on account of its negative effect on the corneal epithelium and its quicker action. It causes no dilatation of the pupil and it possesses antiseptic qualities. It is commonly used like cocain but in a much weaker solution:

Holocain hydrobromate gr. iv
Distilled water oz. i

Some operators use it in conjunction with cocain:

Holocain hydrobromategrs. 2
 Cocaine muriategrs. 10
 Distilled water..... half a fluid ounce

Silver nitrate is one of the most effective remedies we have, especially in infective inflammations of the conjunctiva. As a prophylactic in ophthalmia neonatorum, one drop of a 2 per cent. solution is dropped into the conjunctival sac at birth (Credé). It is also employed as a 2 to 5 per cent. solution, painting it on the palpebral conjunctiva, once every day during the stage of profuse discharge, in gonorrhœal and other purulent forms of ophthalmia. In chronic conjunctivitis of all kinds weaker solutions are used:

Silver nitrategr. i-ii
 Distilled wateroz. 1

Any excess of fluid should be washed out of the sac, after neutralizing it with a 2% solution of common salt.

Argyrol (Silver Vitelline) is one of a numerous array of substitutes (*argentamine, nargol, metallic silver, argol*) for silver nitrate which has appeared during the last few years. Few of them possess any of the merits of argentic nitrate.

Protargol and **argyrol** are probably an exception to this rule. When used in from 10 to 50

per cent. solution the latter salt is of value in purulent ophthalmia, chronic conjunctivitis and other affections where silver nitrate is indicated. It *possesses advantages over silver nitrate* in being non-irritating (in some cases it seems even to have a soothing effect upon the inflamed surfaces), it is not poisonous and it does not readily produce argyrosis.

Protargol is less irritating than nitrate of silver but more so than argyrol. It is employed where the nitrate is indicated in from 10 to 25 per cent. solutions.

Zinc sulphate, like *copper sulphate, alum, tannin, zinc chlorid and zinc acetate*, is an astringent and in the older text books is recommended in many external diseases, of the eye, especially in the chronic and subacute forms of these diseases. Tannic acid, gr. 5-30 to the ounce of glycerin, zinc sulphate mixed with the white of egg, and cupric sulphate in the form of crystals ("blue stone") are and were favorite applications for all varieties of "granular lids." Silver nitrate, as "*sticks*" of *lunar caustic* and *alum* as "*lapis divinus*" (fused rods of alum and copper sulphate) have long been popular caustics in the same affection. As a rule, however, the pain, lachrymation, asthenopia and local inflammation induced by these powerful astringents do not recommend them in the treatment of American patients.

Boracic acid (*boric acid*) and **Borax** are much used in ocular therapeutics because of their soothing and mildly antiseptic qualities. In a saturated solution (4 per cent.) boric acid or borax may properly be employed as a soothing collyrium in most of the simple infections and other mild external diseases of the eye. As effective but stronger antiseptics one must not forget **formalin** (solutions of one to five thousand), **chlorid of sodium** (one per cent.), **permanganate of potassium** (one-fourth of one per cent.) and **carbolic acid** (one-tenth of one per cent.). These are indicated especially as cleansing solutions for washing out, disinfecting, and removing discharge from the conjunctival sac.

Dionin, a most useful ophthalmic remedy, is a derivative of morphin. It relieves pain, induces local anesthesia, is a vasodilator and acts as a lymphagogue and counterirritant. It takes the place of that old remedy, blistering the forehead, lids and temples. It is instilled into the eye in the form of a 2 to 5 per cent. solution. Two drops dropped into the conjunctival sac every two minutes for ten minutes generally produces marked swelling of the conjunctiva. It is especially valuable in relieving the pain and other symptoms of iritis, keratitis, glaucoma and corneal ulcers. In iritis it not only assuages the pain but assists in dilatation of the pupil and helps to break down the posterior synechiæ that are the chief cause of

blindness in that disease. It may be used three or four times daily, if required.

Adrenalin, Suprarenalin, Hemostatin.—

These are extracts of *suprarenal capsule* and, like it, are powerful vaso-constrictors. One or two drops of any of these preparations causes marked anemia of the conjunctiva. They may be employed, as adjuncts to other remedies, in most inflammations of the iris and conjunctiva, but their use is contra-indicated in corneal ulcer. *Fresh* solutions of the suprarenal capsule should be used as it soon deteriorates. The following formulæ are useful collyria :

Suprarenalin (1:1000)	dr.	1
Distilled water	oz.	1
Adrenalin chlorid (1:1000)	dr.	1
Distilled water	oz.	1
Boric acid	gr.	10
Suprarenalin (1:1000)	dr.	1
Aq. camphoræ	oz.	½
Distilled water	oz.	1

Bichlorid of Mercury, unfortunately, cannot be used in solutions of sufficient strength to sterilize the conjunctival sac without inducing hyperemia of the conjunctival vessels. As an ointment, especially if made after the formula of Dr. J. A. White, of Richmond, Va., it is, however, available in the strength of 1:3,000 and acts as a non-irritating antiseptic.

Hydrarg. bichlorid	gr. $\frac{1}{6}$
Sodii chlorid	gr. $\frac{5}{6}$
Vaselin	oz. 1

Dissolve the mercury and the salt in a few drops of dilute alcohol and then add to the vaselin, which has previously been brought to a temperature of 212°F ., and stir until cool.

Yellow Oxid of Mercury is an old and reliable agent, employed in the form of ointment, for corneal ulcer, phlyctenular keratitis and conjunctivitis, chronic and subacute blepharitis and styes. It is also used with massage in corneal opacities, interstitial keratitis and other diseases in which massage is indicated. It is best used, once or twice daily, either to the lid edges, or a small piece of the salve should be inserted into the lower sulcus and distributed over the globar surface by gentle massage of the lids:

Hydrarg ox. flav.	gr. iv
Vaselin	
Lanolin, of each	$\frac{1}{2}$ oz.

Preparation of the patient for ophthalmic operations.—Generally speaking, the same rules that one follows in the surgery of other parts of the body apply with equal force to the ocular apparatus, and much the same precautions ought to be observed on the part of the surgeon. Especially if he is about to open the eyeball he should himself be clothed and cleansed as if he intended to do a laparotomy. All the *well known rules*

of asepsis and antiseptis should, with slight modifications, be observed in *every* ophthalmic operation.

As we have before stated, it is practically impossible to *sterilize* the eyeball and conjunctival sac, partly because of the favorable nidus for bacterial colonies presented by the retrotarsal folds, the follicles of the conjunctivæ, the lid edges and the lachrymo-nasal tract, and partly because the eye would be injured by antiseptics strong enough to act as effective germicides. It has been found that, on the whole, *mechanical lavage or irrigation with mild detergents or indifferent fluids* is the best antiseptic measure that can be employed. If we cannot safely kill, by means of powerful agents, the pathogenic bacteria that infest the ocular structures we can at least *reduce their numbers*, wash away their *toxins* and lessen their power for harm.

In preparation for major operations on the eye, particularly when instruments are introduced into the interior of the globe, as in cataract extraction, iridectomy, iridotomy, etc., it is well to prepare the ocular region the night before the operation. The eyebrow is shaved, the cilia cut off short and the skin about the orbit *scrubbed with an ethereal solution of soap* and warm water. The lids and lid edges are gently but thoroughly cleansed with cotton soaked in a warm, saturated solution of boric acid, the contents of the lachry-

mal sac squeezed out, the lids everted and they, with the retrotarsal folds, irrigated with some mild antiseptic used warm, such as 1:5000 formalin, a 4 per cent. solution of boric acid, or a 1 per cent. salt solution.

The nearest approach to complete sterilization of the field of operation with least irritation of the eye structures is attained by the use of an ointment suggested by Dr. J. A. White, (p.485), twenty-four hours before the operation. This bichlorid mixture may, with advantage, also be used immediately after the extraction, as an antiseptic dressing to the wound. We have never known it to irritate the ocular structures and it disappears by absorption a few hours after its application to the sac, which should be completely filled with it. Draw down the lower lid and apply it on a probe to the lower palpebral conjunctiva, the patient looking up meantime; or, the patient lying down, pour the warm and semi-fluid ointment into the lower sac, thus exposed, with a sterile spatula.

A light, sterile, gauze bandage is now applied, not to be removed until half an hour before the operation next day, when *the cleansing process should be repeated*, the second bandage remaining on the eye until the moment of operation. If the eye *now appears unduly hyperemic*, or if there is any discharge present, it is well to post-

pone the operation. Lippincott advises that the nasal cavities, those frequent sources of ocular infection, *be sprayed with 1:1000 solution of potassium permanganate* on the two dressing-occasions just mentioned.

Sterilizing the instruments. It is best to *boil for ten minutes all blunt instruments*, which, by the way, ought always to be bright and polished. Delicate, *cutting instruments* are injured by prolonged boiling. They should be first examined with a strong convex lens, to make sure that they are polished and void of rust-spots, that their cutting edges are keen and that they are free of dust. They are then immersed in

Carbolic acid	90 per cent
Glycerin	10 per cent

for 10 to 15 minutes and afterwards transferred to a pan of sterile water. The glycerin insures the removal of the acid by the water. Another method is to rub cutting instruments with gauze dipped in hot, one per cent soda solution, *to cleanse them thoroughly* and then to immerse them in 1% *formalin with absolute alcohol* for a quarter of an hour. They are then transferred to the operating pan until they are used. This is filled with sterile water which removes the excess of formalin-alcohol.

The position of the patient is important. Some operators prefer the sitting position *in an*

operating chair such as dentists use, but every valuable purpose is generally served by the employment of the ordinary surgeon's table—especially when a general anesthetic is given. A crescentic piece may be cut out of the table, corresponding to the right side of the patient's chest when he is in the prone position. The body of the operator occupies this semilunar space, and he is thus enabled (especially if he is not ambidextrous) to face his patient and manipulate his instruments to greater advantage.

Anesthetics. *The great majority of ophthalmic operations can be performed under local anesthesia.* Iridectomy made during an attack of glaucoma, when the eye is congested, enucleation and its substitutes, operations on the lids and most *operations on children* require a general anesthetic. Whether ether, chloroform, ethyl bromid, nitrous oxid or a combination of two or more of these is used will depend upon the views of the anesthetist. *Chloroform for children, ether for adults* is a good general rule.

The authors prefer for *local anesthesia* the following mixture.

Holocain hydrochlorate	gr. 5
Cocain hydrochlorate	gr. 25
Distilled water	oz. 1

In operations on the globe likely to be accompanied by bleeding *suprarenalin* or *adrenalin*, 1:1000, is used to insure a *temporary anemia*

and a better view of the operative field. It is possible that the employment of these hemostatics is often followed, later on, by an *increase of the hemorrhage*, but its value in permitting an unobstructed view in complicated procedures, like the advancement of an ocular tendon, overrides this subsequent disadvantage. *Suprarenal preparations*, as well as *holocain* and *cocain* solutions *readily decompose*; the latter should, therefore, always be freshly made and the former taken from a sealed bottle. When used on the same occasion they should be instilled, *drop by drop*, alternately every minute (usually four drops of each is sufficient) until full anesthetic and astringent effects are produced. The eyes should always be kept *closed* during the anesthetizing period, to prevent the *drying effects of cocain on the cornea*.

Local anesthesia by hypodermic or subconjunctival injection is best obtained from the use *Eucaïn "B"* in five per cent solutions. Unlike *cocain* and *holocain* this agent does not produce toxic effects when employed in this fashion. Under its influence operations on the lids and globe, otherwise quite painful, may be performed without resort to general anesthesia. The same can be said of lid operations under the *intra-tentaneous, local anesthesia method of Schleich*.

Artificial light is preferable to solar illumination for operations on the eye, because it is al-

ways to be depended upon, can be arranged to suit the operator and its brilliancy can be increased or decreased at will. A *covered hand lamp* is to be preferred and is to be held and regulated by an assistant.

The after treatment in eye operations has already been discussed in the chapter on cataract extraction. It may further be impressed upon the student that *post operative dressings* are generally *protective*, in which case a pad of sterile cotton faced with a single layer of gauze forms the best application. It is kept in place by a *gauze* or muslin *bandage* or by *strips* of *adhesive plaster*. When *pressure* is to be applied to the eyeball the ocular pad is made thicker and the bandage *firmly* covers the eye. A *mask* or *shield* may be adjusted over any dressing, to prevent injury to an eye recently operated on. Ointments, powders, solutions or other agents may also be applied to the dressing for their effect upon the ocular structures.

INDEX.

- Abduction, 429.
 Abscess, corneal, 217.
 Accommodation, 46, 58.
 — amplitude of, 49.
 — loss of, 445.
 — mechanism of, 46.
 — spasm of, 64.
 — testing the, 35.
 Accommodative asthenopia, 65.
 Adduction, 429.
 Adrenalin, 485.
 Advancement of a tendon, 442.
 Alum, 483.
 Amblyopia from lead poisoning, 380.
 — from methyl alcohol, 380.
 — from quinine, 380.
 — from tobacco and alcohol, 377.
 — hysterical, 410.
 — toxic, 376.
 — toxic, field in, 378, 379.
 — toxic, treatment of, 378.
 Amblyoscope, Worth's, 439.
 Ametropia, 62.
 — symptoms of, 84.
 Anemia and chlorosis in eye diseases, 384.
 Anesthetics in eye operations, 489.
 Aphakia, 65, 288.
 Application of heat and cold, 459.
 Aqueous humor, 34.
 Arcus senilis, 187.
 Argol, 482.
 Argyll-Robertson pupil, 370.
 Argyrol, 482.
 Artificial lights, 353.
 Asthenopia, 62.
 — accommodative, 65.
 — in hysteria, 409.
 — in typhoid fever, 390.
 Astigmatic, chart, 79.
 Astigmatism, 73.
 — against the rule, 75.
 — compound, 77.
 — compound, 100.
 — corneal, 73.
 — correction of, 80.
 — detection of, 78.
 — etiology of, 78.
 — irregular, 73.
 — mixed, 78, 101.
 — regular, 74.
 — simple, 75, 100.
 — with the rule, 75.
 Ataxia, hereditary, 373.
 Atropia, 479.
 — use of, 473.
 Automobile glasses, 477.
 Bacteria in eye diseases, 451.
 Bandages for the eye, 473, 474, 475.
 Basedow's disease, 404.
 "Black eye," 106, 317.
 — treatment of, 317.
 Blepharitis, 24.
 — marginalis, 114.
 Blepharophimosis, 118.
 Blepharospasm, 32, 179.
 — in hysteria, 413.
 Blindness, color, 56.
 — hysterical, 410.
 Blind spot of Mariotte, 53, 359.
 Boracic acid, 484.
 Bowman's membrane, 188.
 Bright's disease, eye signs of, 416.
 Buller's shield, 164.
 Canaliculus knife, 277.
 — slitting open the, 277.
 Care of children's eyes, 343.
 Care of the eyes, 341.
 Canthoplasty, 120.
 Caruncle, 103.
 Cataract, 285, 289.
 — after treatment of, 309.
 — anterior polar, 200.
 — black, 294.
 — capsular, 314.
 — complications, 310.
 — congenital, in rickets, 391.
 — cortical, 290.
 — diabetic, 312, 420.
 — dressings, 307.
 — extraction, 298.
 — traumatic, 312.
 — hard, 290.
 — hypermature, 294.

- incipient, 291.
- lamellar, 311.
- Morgagnian, 294.
- nuclear, 290.
- ripe, 292.
- secondary, 314.
- senile, 290.
- simple extraction, 310.
- soft, 290, 311.
- stationary, 294.
- suction syringe in, 314.
- zonular, 311.
- Canthus, inner, 103.
- outer, 103.
- Cautery of corneal ulcer, 203.
- Chalazion, 24, 110.
- Chamber, anterior, 34.
- anterior, bleeding into, 323.
- Chemosis, 29.
- Chiasma, 362.
- Choked disk, 366, 368.
- causes of, 367.
- Choroid, 358.
- rupture of, 328.
- Ciliary body, inflammation of, 242.
- Ciliary muscle, paresis of, 323.
- Cocain, 478, 481.
- Color blindness, acquired, 56.
- congenital, 56.
- detection of, 54.
- Color perception, 54.
- Color sense, 54.
- defects in, 54.
- Colors, field for, 54.
- Commotio retinac.*, 328.
- Conical cornea, 228.
- Conjunctiva, anatomy of, 137.
- bulbar, 137.
- burns of, 320.
- hyperemia of, 138.
- injuries of, 320.
- Conjunctivitis, acute catarrhal, 142.
- acute contagious, 143.
- follicular, 167.
- gonorrhoeal, 161.
- phlyctenular, 179.
- purulent, 149.
- Copper sulphate, 483.
- Coquilles, 473.
- Cornea, abscess of, 217.
- abrasion of, 332.
- anatomy of, 187.
- burns of, 322.
- conical, 228.
- deep ulcer of, 196, 211.
- dendritic ulcer of, 211.
- foreign body in the, 331.
- herpetic ulcer of, 211.
- injuries of the, 330.
- inspection of, 30.
- macula of the, 32.
- malarial ulcer of, 211.
- nebula of the, 32.
- opacities of, 225.
- ring ulcer of, 208.
- sensibility of, 32.
- simple ulcer of, 193.
- spreading ulcer of, 204.
- tattooing the, 227.
- ulcers of the, 32, 190.
- Corneal reflex, 30.
- spud, 331.
- Crédé method of prophylaxis, 155.
- Cyclitis, 242.
- Cycloplegia, 323, 447.
- Cycloplegics and mydriatics, 478.
- Dacryocystitis, chronic, 272.
- Descemet's membrane, 188.
- Descemetitis, 338.
- Diabetes, eye signs of, 410.
- Diagnosing the commoner forms of ocular inflammations, 262.
- Dionin, 240, 484.
- Diphtheria, eye diseases in, 388.
- Diplopia, 360.
- in hysteria, 413.
- Diplobacillus of Morax-Ax-enfeld, 454.
- Discission, 312, 315.
- Distichiasis, 118.
- Double vision, 360.
- Drainage of eye, 245.
- Duboisin, 480.
- Dyspepsia, eye symptoms in, 383.
- Ear and eye diseases, relations of, 386.
- Ecchymosis, 317.
- of lids, 106.
- Ectasia of eyeball, 248.
- Ectropion, 24, 125.
- Adams operation for, 127.
- cicatricial, 125.
- paralytic, 125.
- senile, 125.

- Snellen's operation for, 126.
- spasmodic, 125.
- Edema of lids, 107.
- Electrolysis for trichiasis, 122.
- Electromagnet, use of in eye surgery, 336.
- Embolism of central artery of retina, 393.
- Emmetropia, 57.
- Enophthalmus, 29.
- Entropion, 24, 118, 172.
- cicatricial, 118.
- Hotz' operation for, 123.
- operations for, 120.
- spasmodic, 118.
- Enucleation of the eyeball, 489.
- Epilation, 121.
- Epilepsy from eye-strain, 407.
- Epiphora, 26, 125, 271, 386.
- Episcleritis, 261.
- Eserin sulphate, 480.
- Esophoria, 428.
- Euphthalmin hydrochlorate, 478.
- Examination, objective, 24.
- of school children's eyes, 349.
- of the eyes of young children, 33.
- subjective, 39.
- Exophoria, 428.
- Exophthalmic goitre, 404.
- Exophthalmus, 29.
- Eye, tension of, 39.
- Eyeball, contusions of, 322.
- penetrating wounds of, 332.
- rupture of, 328.
- Eye-cup, 469.
- Eyelashes, 103.
- inspection of, 24.
- Eyelids, burns of, 319.
- emphysema of, 317.
- incised wounds of, 318.
- injuries of, 317.
- Eyesight, care of, 345.
- Far point, 48, 59.
- Far sight, 62.
- Field of vision in hysteria, 411.
- Fluorescein, 32.
- Formalin, 484.
- Form sense, 40.
- Fornix, 137.
- Fovea, 359.
- Friedreich's disease, 373.
- Fundus oculi, 358.
- Galvano-cautery, 207.
- General medicine, ophthalmology in, 375.
- Glaucoma, 245, 484.
- absolute, 252.
- acute, 246.
- chronic, 249.
- cupped disc in, 249.
- tension of eyeball in, 247.
- field of vision in, 247.
- from dislocated lens, 327.
- from la grippe, 389.
- hemorrhagic, 253.
- pathology of, 253.
- primary, 246.
- pulsating arteries in, 249, 252.
- secondary, 252.
- simple, 249.
- Glaucomatous cupping, 251.
- ring, 249.
- Glioma of the retina, 421.
- Goggles and other protective glasses, 473.
- Gonococcus, 149.
- in eye diseases, 451.
- Gonorrhea, eye signs of, 382.
- Gonorrhoeal ophthalmia, 482.
- ophthalmia in the adult, 161.
- Gout, eye symptoms of, 381.
- Graves' disease, 404.
- Halos, 246.
- Headache from eye-strain, 397.
- ocular, 397.
- ocular, causes of, 399.
- ocular diagnosis of, 398.
- ocular, treatment of, 402.
- Hemorrhage, subconjunctival, 141.
- Heterophoria, 428.
- symptoms of, 431.
- tests for, 429.
- treatment of, 432.
- Heterotropia, 433.
- Hirschberg vessels, 220.
- Holmgren's color test, 54.
- Holocain, 481.
- Homatropin hydrobromate, 479.
- Hordeolum, 108.
- Hutchinson teeth, 218.
- Hygiene of Eye, 341.
- of near work for the eyes, 351.
- Hyoscin, 480.

- Hyoscyamin, 480.
 Hysteria, eye symptoms of, 409.
 -- field of vision in, 412.
 -- polyopia in, 413.
 -- traumatic, 415.
 Hypermetropia, 62, 98.
 -- axial, 65.
 -- curvature, 65.
 -- etiology of, 65.
 -- masked, 66.
 -- symptoms of, 63.
 -- treatment of, 65.
 Hyperphoria, 428.
 Hypthemia, 34, 323.
 Hypopyon, 34, 197, 206.
- Illumination, oblique, 37.
 Influenza, eye diseases in, 389.
 Injurious reading habits, 352.
 Insomnia in eye diseases, 384.
 Instruments, sterilizing eye, 488.
 Iridectomy, 295.
 -- optical, 226.
 -- peripheral, 255.
 -- preliminary, 294.
 Irideremia, 325.
 Iridocyclitis, 238, 326.
 Iridodialysis, 323.
 Iridodonesis, 287, 327.
 Iridoplegia, 322, 447.
 -- reflex, 371.
 Iridotomy, 226.
 Iris, 34.
 -- anatomy of, 231.
 -- paralysis of, 322.
 -- prolapse of, 333.
 -- rupture of, 323.
 Iritis, 233, 484.
 -- diabetic, 237.
 -- from rheumatism, 380.
 -- gonorrhoeal, 238, 380.
 -- gouty, 237.
 -- plastic, 238.
 -- quiet, 237.
 -- rheumatic, 238.
 -- serous, 238, 338.
 -- syphilitic, 237, 381.
 -- traumatic, 237.
 Irrigation of conjunctival sac, 466.
 Irritation, sympathetic, 330.
- Jaeger's test types, 46.
 Japanese hot box, 240.
- Keratitis from malaria, 390.
 Keratitis, neuroparalytic, 210.
 -- phlyctenular, 212.
 -- punctate, 224, 238, 242, 338.
 -- punctate superficial, 224.
 -- interstitial, 218.
 Keratoconus, 228.
 Kindergarten work, effect of on children's eyes, 342.
- Lachrymal abscess, 275.
 -- apparatus, anatomy of, 269.
 -- probes, Bowman's, 282.
 -- canaliculi, 270.
 -- canula, 283.
 -- sac, distension of, 273.
 -- ducts, 269.
 -- gland, 269.
 -- probes, passing, 280.
 -- puncta, 106, 270.
 -- sac, 270.
 -- secretion, 269.
 -- style, 283.
 -- syringe, 284.
 Lachrymation, 271.
 Lagophthalmus, 24, 132.
 Lapis divinus, 483.
 Leech, artificial, 241.
 -- use of, 458.
 Lens, biconvex, 38.
 -- capsule, laceration of, 325.
 -- dislocation of, 285, 325.
 -- injury to, 334.
 Lenses, test, 81.
 Leucoma, 32, 206, 225.
 -- adherent, 199.
 Leukemia, retinitis in, 384.
 Levator palpebrae superioris, 103.
 Lid, eversion of lower, 26.
 -- eversion of upper, 26.
 -- retractor, 33.
 Lids, anatomy of, 103.
 -- examination of, 24.
 -- how to open, 32.
 Light projection, 301.
 -- sense, 53.
 Limbus, 187.
 Locomotor ataxia, 370.
 Loupe, corneal, 39.
- Macula, 225.
 -- lutea, 41, 358.
 Magnet, giant (Haab), 336.
 Malaria, eye diseases in, 390.

- Mariotte, blind spot of, 53, 359.
 Massage of eyeball, 463.
 McReynold's operation for pterygium, 185.
 Measles, eye symptoms of, 382.
 Medicine dropper, use of, 470.
 Meibomian cyst, 110.
 — glands, 104.
 Meningitis, cerebral and spinal, 368.
 — tubercular, 368.
 Migraine, 408.
 Miosis, 368, 371.
 Miotics, 480.
 Mirror, concave, 97.
 — plane, 97.
 Mucocele, 273.
 Mueller's muscle, 106.
 Muscles, eye, nerve supply to, 426.
 — — paresis of, 428.
 — — paralysis of, causes of, 445.
 — — paralysis of, symptoms of, 444.
 — — paralysis of, treatment of, 447.
 — — extrinsic, 425.
 Muscle, orbicularis, 103.
 — orbital, 425.
 — paresis of, 365.
 — paralysis of eye, 371, 388.
 — paresis of, hysterical, 409.
 Mydriasis, 445.
 — paralytic, 388.
 — traumatic, 323.
 Mydriatics and cycloplegics, 478.
 Myopia, 67, 99.
 — axial, 69.
 — curvature, 69.
 — etiology of, 69.
 — false, 66, 410.
 — organic changes in, 71.
 — progressive, 69.
 — symptoms of, 67.
 — treatment of, 71.
 Nargol, 482.
 Nasal diseases, ocular affections in, 386.
 Nasal duct, 270.
 — stricture of, 274.
 Near point, 48, 59.
 Nebula of the cornea, 225.
 Nervous system and eye, 363.
 Neuroepithelioma retinae, 421.
 Neuritis, retrobulbar, 370.
 Nystagmus, 370, 449.
 — in miners, 449.
 Oblique illumination, 37.
 Oculomotor paralysis, 445.
 Onyx, 217.
 Operations, eye, after treatment of, 491.
 — preparation of patient for, 486.
 Ophthalmia, migratory, 330.
 — neonatorum, 150, 453.
 — sympathetic, 330, 337.
 — sympathetic, exciting eye in, 338.
 — sympathetic, pathology of, 339.
 — sympathetic, sympathizing eye in, 338.
 — sympathetic, treatment of, 340.
 Ophthalmic artery, 392.
 Ophthalmometer, 86.
 Ophthalmoplegia, paralysis of eye muscles, 444.
 Ophthalmoscope, 86, 358.
 — direct method of examination, 93.
 — electric, 93.
 — indirect method of examination, 90.
 — lenses of, 89.
 Ophthalmoscopic mirror, 89.
 Optic atrophy after loss of blood, 385.
 — in tabes, 372.
 Optic chiasm, 362.
 Optic nerve, 392.
 — anatomy of, 357.
 — physiology of, 363.
 Optic neuritis, 365.
 — — in ear disease, 386.
 Optical iridectomy, 226.
 Ora serrata, 358.
 Orthophoria, 428.
 Pannus, 172.
 Panophthalmitis, 333.
 Papilla, 392.
 Paracentesis, 203.
 Paralysis of external rectus, 444.
 Pericorneal injection, 29.
 — zone, 234.

- Perimeter, 49.
 Phorometer for muscle testing, 431.
 Photometer, 53.
 Photophobia, hysterical, 414.
 Physiological, excavation, 251.
 — cup in optic nerve, 360.
 Pilocarpin, 481.
 Pinguecula, 186.
 "Pink eye," 143, 454.
 Placido's disc, 31.
 Pneumococcus, 205.
 — of Fraenkel, 145.
 — in eye diseases, 453.
 Polyopia, 291.
 — in hysteria, 413.
 Position, primary, 428.
 Potassic fluoresceid, 32.
 Presbyopia, 61.
 Projection, light, 301.
 Protargol, 482.
 Pseudoglioma, 369.
 Pterygium, 182.
 Ptosis, 24, 128, 445.
 — acquired, 128.
 — congenital, 128.
 — Pagenstecher's operation for, 131.
 — Panas operation for, 132.
 — pseudo-paralytic, 414.
 Punetum proximum, 59.
 — remotum, 59.
 Pupil, 34, 231.
 — Argyll-Robertson, 36, 370.
 — artificial, 226.
 — consensual contraction of, 35.
 — contraction of, 35.
 — dilated, 368.
 — exclusion of, 235.
 — occlusion of, 236.
 — reflexes, 35.
 — sphincter of, 232.
 Pupillary membrane, persistent, 233.
 Pupilometer, 35.
 Purkinje images, 288.
 Purple, visual, in retina, 359.
 — rods and cones of, 359.
 — visual purple of, 359.
 Retinal circulation, 359.
 — hemorrhage, 390.
 Retinitis, albuminuric, 417.
 — in diabetes, 420.
 Retinoscopy, 93.
 Retrotarsal folds, 137.
 Rheumatism, eye symptoms of, 350.
 Rickets, eye diseases in, 391.
 Rods and cones of the retina, 359.
 Salmon patches, 220.
 Sarcoma, intraocular, 422.
 Schlemm. canal of, 245.
 School books and eyesight, 344, 250.
 Sclera, perforating wound of, 335.
 Scleritis, 261.
 Sclerosis, multiple, 369.
 Sclerotomy, 258.
 — anterior, 258.
 — posterior, 258.
 Scotoma, 52, 370.
 — physiological, 52.
 — relative, 377.
 Scopolamin, 480.
 Second sight, 69, 293.
 Shadow test, 93.
 Short sight, 67.
 Sight, second, 292.
 Silver nitrate, 482.
 Skiagrams of eyeball, 336.
 Skiascopy, 93.
 — mirror in, 97.
 Smallpox, eye affections in, 387.
 Snellen's operation for trichiasis, 122.
 — test types, 41.
 Spring catarrh, 178.
 Squint, 428.
 — convergent and divergent, 435.
 — measurement of, 436.
 — or strabismus, 433.
 — or strabismus, causes of, 435.
 — symptoms of, 437.
 — tests for, 435.
 — treatment of, 437.
 Staphylococcus, 145.
 Staphyloma, 173, 248.
 — anterior, 154, 199, 206.

- Strabismus, convergent, 29.
 — divergent, 29.
 — or squint, 434.
 Streptococcus, 145.
 Sty, 108.
 Subconjunctival hemorrhage,
 141, 393.
 — injections, 465.
 Suprarenalin, 485.
 — capsule mixtures, 485.
 Sursumduction, 429.
 Symblepharon, 130, 134, 321.
 Synchia, anterior, 36, 199.
 — posterior, 36, 235, 338.
 — ring, 235.
 Syphilis, eye symptoms of,
 382.
- Tabes dorsalis, 363, 370.
 Tarsorraphy, 133.
 Tarsus, 103.
 Tattooing of cornea, 227.
 Tenonitis, 381.
 Tenon's capsule, inflammation
 of, 381.
 Tenotomy of a rectus muscle,
 440.
 Tension of eye, 39.
 Test types, distant, 41.
 — for near vision, 46.
 — for illiterates, 44.
 — Jaeger's, 46.
 — Snellen's, 41.
 Therapeutics, ocular, 459.
 Thorington light-screen, 97.
 Trachoma, 118, 170.
 — microorganisms of, 454.
 Trichiasis, 24, 118, 172.
- operations for, 122.
 Tuberculosis of the eye, 384.
 Tumor-areas, 365.
 — brain, 365.
 Tumors of the eyeball, 421.
 Typhoid fever, eye symptoms
 of, 390.
- Ulcers of cornea, 190.
 Undine, the, 467.
 Uveal tract, 233.
- Vascular system, diseases of,
 392.
- Vision, acuteness of, 40.
 — central, 41.
 — defects in field of vision,
 52.
 — distant, 41.
 — field of, 49.
 — extent of, 49.
 — near, 46.
 — peripheral, 49.
 Visual tract, 363.
- Weeks bacillus, 145, 453.
 Wernicke's sign, 368.
- Xanthelasma, 114.
- Yellow spot, 41, 358.
 Yellow oxid of mercury, 485.
- Zinc sulphate, 483.
 Zinn, zonula of, 285.

The Standard Medical Directory.

The Standard Medical Directory is issued in one imperial octavo volume of over 1,200 pages and consists of twelve complete parts comprising all divisions of Medicine as follows:

- I—MEDICAL COLLEGES with sketch of each.
- II [Section A]—DIRECTORY OF PHYSICIANS, arranged alphabetically by States and Towns, in the United States, Canada, Cuba, Mexico, and the Central American States—over 120,000 names, with college and year of graduation.
- II [Section B]—INDEX OF PHYSICIANS, arranged alphabetically by Names, with addresses.
- II [Section C]—LISTS OF PRACTITIONERS respectively of the Medical Specialties, with addresses.
- III—MEDICAL CORPS of the U. S. Army and Navy, Officers of the Marine Hospital Service, Pension Examining Surgeons, etc.
- IV—MEDICAL SOCIETIES, National, State and Local.
- V—MEDICAL LEGISLATION, including medical practice acts of all the States with synopses and rulings; also members of Health and Examining Boards, etc.
- VI—MEDICAL PUBLICATIONS, including all Medical Books in present use, Periodicals, Libraries, etc.
- VII—HOSPITALS AND SANITARIUMS.
- VIII—MINERAL SPRINGS with properties, etc.
- IX—ALL DRUGS AND MEDICINES, with properties, dose, form of administration, price, etc.
- X—MEDICAL AND SURGICAL PRODUCTS.
- XI—MANUFACTURERS of Medical Products.
- XII—LIFE INSURANCE COMPANIES.

Presenting the vast variety of information as above indicated in separate and distinct Parts, instead of scattering it through the entire volume, is an original feature which has won especially high commendation.

In Contents and Typography the "Standard" is universally recognized as pre-eminent.

1,200 pages, 8x11 in., price postpaid, \$10.00.

G. P. Engelhard & Co., Publishers, Chicago

"A Work of Common Sense Helpfulness."—Medical World.

BURDICK'S STANDARD MEDICAL MANUAL.

THE STANDARD MEDICAL MANUAL. A Hand-Book of Practical Medicine. By Alfred S. Burdick, M. D., Editor of the Medical Standard; Junior Professor of Practice of Medicine in the Illinois Medical College; Member of the American Medical Association, the Illinois State Medical Society, etc.

Though but recently issued Burdick's Medical Manual has already passed through five editions and with constantly increasing popularity. Its marked success is high tribute to the conscientious and intelligent endeavor of the author and may be ascribed to its evident

DISTINCTIVE ADVANTAGES:

1. It is new, up-to-date and the most recent work on Practice. It embodies in the best form the experience of the past and everything new of proven value.
2. It is concise. It is not laden with anything superfluous, but strips its subjects to the vital essentials and deals most fully with the diseases the average physician finds most prevalent in his community.
3. Special attention is given to treatment, which in every case is made full and complete. Of 17 pages on Typhoid Fever over half are on treatment; of 29 on Tuberculosis 14 on treatment; of 20 pages on pneumonia, 10 on treatment, and so with diphtheria, dysentery, bronchitis, epilepsy, etc. All methods of value are given, including the dietetic, mechanical, electrical, prophylactic, medicinal, etc.
4. The best Prescriptions are given from the experience of the most successful practitioners in America and Europe, and their proper and timely use explained.
5. The Commoner Ailments receive due attention, such as Backache, Headache, Boils, Styes, Stings and Bites, Burns, Corns, Bunions, Warts, etc., which in most works on practice receive but little if any notice.

Burdick's Medical Manual.

6. It is arranged for readiest reference, the names of diseases being arranged alphabetically and not by the usual hard-to-find method of disease characteristics.

7. The extensive Appendix includes such important subjects as Examination of the Urine and of Stomach Contents and as the Common Bacteria and their Recognition, Drugs and their Administration, Doses and Solubilities, Foods for the Sick, an Epitome of the National Formulary arranged therapeutically, etc.,

"Useful and valuable."—Louisville Medical Journal.

"A thoroughly practical work."—Louisville Journal M. and S.

"Of great value and very helpful."—Medical Fortnightly.

"An exceedingly practical work."—Canadian Jour. M. and S.

"A timely and forceful protest against therapeutic know-nothing-ism."—Chicago Clinic.

"Of greatest value as a guide to treatment, it does not slight the other essentials."—Cincinnati Lancet-Clinic.

"It presents in a convenient form and space the up-to-date aspects of medical practice along the most useful lines."—Peoria Medical Journal.

"The work is of very practical character and is calculated to be eminently helpful, especially to the busy general practitioner who does not want a treatise, but suggestive points at a moment's notice. The volume is very presentable in appearance and will doubtless find a place on many consultation shelves, not among the learned tomes that collect dust and are opened a few times a year, but among the books that are constantly at hand for ready reference."—Medical News, N. Y.

"Quite an unusual feature in a book on practice is the attention devoted to the minor ailments which are seldom taught in colleges and rarely mentioned in text-books, but which many times are the worry of the young man in medicine. There is given a large number of prescriptions, and the importance of diet, hygiene, hydrotherapy and other physiologic methods of treatment are dwelt on at length. It is a cleverly arranged work and it deserves the success which its value as a medical book entitles it to."—Buffalo Medical Journal.

A splendid Manual, which, it is believed, every physician will find invaluable.

Cloth, 900 Pages Octavo, \$4.00 postpaid.

G. P. Engelhard & Co., Publishers, Chicago

"For the Practitioner, Nurse and Student."

TULEY'S OBSTETRICAL NURSING.

OBSTETRICAL NURSING FOR NURSES AND STUDENTS. By Henry Enos Tuley, A. B., M. D., Louisville, Ky., Professor of Obstetrics, University of Kentucky Medical Department, Visiting Obstetrician to the John N. Norton Memorial Infirmary, Louisville City Hospital and the Home for Friendless Women; Member Alumni Sloane Maternity Hospital, New York, etc.

This book is an elaboration of the author's lectures at the Training School for Nurses connected with the John N. Norton Memorial Infirmary, Louisville, Ky.

Physicians will here find hints of the greatest value in their own practice or for communication to expectant mothers.

Trained nurses will find it almost indispensable for ready reference for the details of child-bed nursing.

Junior medical students and nurses' training school students will find it precisely adapted to their needs.

The various accidents and emergencies of the obstetrical period receive careful consideration and the duties of the nurse in every contingency are carefully pointed out.

Such important details as the care of the cord, the preparation of the patient for labor, preparation of room, obstetrical outfits, antiseptics, the making of abdominal girdles and breast binders, douches and injections, catheterization, diet, galactagogues, care of breast and nipples, infection, milk-leg, septic fevers, clothing, nursing and feeding the child, artificial respiration and many other subjects receive special consideration.

The volume is profusely illustrated, mostly from original drawings and photographs.

201 Pages, 5x8 in., Over 50 Illus., Cloth, Gilt Top, \$1.00

G. P. Engelhard & Co., Publishers, Chicago

"A Book on a Live Topic by an Authority."

OCHSNER ON APPENDICITIS.

HANDBOOK OF APPENDICITIS. By A. J. Ochsner, M. D., Professor of Clinical Surgery, College of Physicians and Surgeons, Medical Department of the University of Illinois, Chief-Surgeon of the Augustana Hospital, Chicago, etc.

This work by Dr. Ochsner may be counted as one of the most pronounced medical book successes of the decade.

Aside from the timeliness and intrinsic merit of the work, a further reason for its success may be found in the author's reputation as one of the most successful surgeons in the treatment of Appendicitis. The secret of his success is here told so plainly that it may be understood and applied by any physician.

The ten chapters include a history of the disease, Anatomy, Etiology, Classification, Symptoms, Differential Diagnosis, Non-Operative Treatment, Surgical Treatment, After-Treatment, and Complications.

Dr. Ochsner shows that the essentials of successful treatment are not necessarily surgical; that by appropriate medical or dietetic treatment the patient may often be tided over the critical acute attacks.

The book opens with a description of the anatomical arrangement and relations of the appendix and cecum, the physiological action of the bowel and how it may transform a simple pathological process in this region into a dangerous, often a fatal, condition.

The part devoted to treatment is, it is believed, epoch-making in this field of medicine. The description of the operative technic is so clear, so simple, that all ordinary difficulties are at once cleared up by their careful perusal. It is made even more clear by a large number of illustrations.

182 pages, 5x8 in. Illus., Cloth, Gift Top, \$1.00 net.

G. P. Engelhard & Co., Publishers, Chicago

"A Handbook by an Expert of International Reputation."

GOTTHEIL ON SYPHILIS.

SYPHILIS: ITS NATURE, DIAGNOSIS AND TREATMENT. By Wm. S. Gottheil, M. D., New York, Professor of Dermatology and Syphilography, New York School of Clinical Medicine. Profusely Illustrated.

It is believed this volume has proven the most convenient, practical and valuable working manual of the disease yet published. The author's qualifications for the discussion of the subject are unexcelled and he has prepared a book of great value.

After a brief historical introduction, syphilis is taken up in all its phases—primary, secondary and tertiary—and the lesions found in the different organs in each stage; then follow chapters on treatment, hopeful in tone and definite in statement.

The work cannot fail to be of special interest and value to the general practitioner who treats syphilis only occasionally and incidentally, and who may be called upon at any time to express an opinion, or advise measures for cases in which his opportunities for observation have been necessarily limited. And it must please and satisfy the physician who wants to bring his knowledge of this disease up to date without devoting much time to the study of much larger terms.

In the preparation of the text so much care and exactness has been exercised that the diagnosis will be greatly simplified and the methods of treatment and their application made very plain. The book is attractively printed on enameled paper giving lustrous effect to the numerous illustrations which depict every phase of syphilis.

210 pages, 5x8 in. Illus., Cloth, Gift Top, \$1.00.

G. P. Engelhard & Co., Publishers, Chicago

"A Vital Topic in Health and all Diseases."

BENEDICT ON DIET.

DIET IN HEALTH AND DISEASE. By A. L. Benedict, A. M., M. D., Buffalo, N. Y., Member American Gastro-Enterological Association, Medical Society State of New York, etc.

The important subject of dietetics has heretofore received scant attention at the hands of medical men, not because they lack interest in it, but because practical scientific books of convenient size and containing the essentials of the subject were not to be had.

Dr. Benedict's book makes good this deficiency. It simplifies the subject, laying down certain well-defined, underlying principles, and is couched in simple, straightforward language.

The introductory chapters deal with the Organic and Inorganic Principles in Foods and are followed by chapters on Dietetic Needs in Health (with specific facts as to Food values, average required daily ration, value of cooked vs. raw foods, comparative value of animal and vegetable foods, use of tea, coffee and liquors, frequency of eating, conditions of digestion, etc.), and on Dietetics of the Period of Growth (infant feeding to maturity), on Organotherapy, on Diet in Diabetes, Obesity, Leanness, Renal and Urinary Diseases, Anemia, on Diseases of the Alimentary Canal, Stomach, Intestines, in Fevers, Diarrhoea, Constipation, Hepatic Sclerosis, on Methods of Introducing Nutrition, etc., etc.

It is essentially a practical book, written for practical men and is free from theorizing, while rich in facts of incalculable daily value to the practitioner as material for advice in health or disease.

400 Pages, 5x8 in., Cloth, Gift Top, \$1.00

G. P. Engelhard & Co., Publishers, Chicago

"Disease and Treatment as Indicated by the Voice of Pain."

HILL ON PAIN.

PAIN AND ITS INDICATIONS. By Edward C. Hill, M. D., Professor of Chemistry and Toxicology, Denver and Gross Medical College.

Dr. Hill has written what may be considered an "encyclopedia of pain," enabling the physician to trace this symptom to its origin and then suggesting the indicated remedy or remedies. In doing this he has covered the whole field of medicine.

Certainly no disease of importance is omitted, so that the book is in reality a veritable vade mecum of medical practice.

In the briefest possible manner the important symptoms of each disease are described; then the indicated remedies are named, with their method of administration and dosage. There are hundreds of prescriptions, garnered from all sources, representing the successful methods of physicians from all parts of the world.

The amount of information which Dr. Hill has succeeded in crowding into this book of 325 pages is marvellous. There is no other like it and few, if any, so practically and universally helpful. Every physician should carry a copy of this book in his pocket or satchel for help in case of emergencies.

The following are some of the subjects discussed in the different chapters: Headache; Pain in the Ear and Nose; Pain in the Mouth and Throat; Chest Pain; Backache; Abdominal Pain; Pelvic Pain; Genito-Urinary Pain; Dermatalgia, etc.

Pain, from the standpoint of the patient, is the most important of symptoms. To recognize its cause and give relief is the first duty of the physician. This book will give the help desired.

325 Pages, 5x8 in., Cloth, Gilt Top, \$1.00

G. P. Engelhard & Co., Publishers, Chicago

'A Book of Emergency Information of Vital Interest.'

HEINECK'S ANESTHESIA.

GENERAL AND LOCAL ANESTHESIA. By Aime Paul Heineck, M. D., Adjunct Professor of Surgery, College of Physicians and Surgeons, Chicago. Attending Surgeon, Cook County Hospital. (New Revised and Enlarged Edition.)

The uncertainties and dangers usually attending the giving of anesthetics by practitioners having no special knowledge of the subject are so universally recognized as to account for the great popularity of this Manual by Dr. Heineck.

The subject is discussed in two chapters. The first—devoted to General Anesthesia—defines the uses of Chloroform and Ether; the Use of Anesthetics in Childbirth; for Diagnostic and Therapeutic Purposes; in Surgery; Selection of the Anesthetic as governed by the nature of the operation; Posture and Preparation of the Patient; Rules for Administration; Precautions Before and After; What to do in Cases of Accident.

In the second chapter local methods of Anesthesia are described with detail, such as Cocain, Eucaïn, the Schleich mixture, Ethyl Chlorid and Orthoform, also recent methods, such as Ethyl Bromid, etc.

"The study of its lessons cannot fail to aid in the proper and intelligent administration of anesthetics."—Northwestern Lancet.

"All theories and historical data are omitted, and only such details as experience has proved important are given."—Buffalo Medical Journal.

"The book abounds in many practical hints. * * The chapter on local anesthesia is excellent, practical and complete."—Medical News, New York.

"Every phase of the subject is taken up and fully described, including the treatment of the accidents that will sometimes ensue, despite the greatest care. It is a pleasure to welcome and recommend this special work on anesthesia, the first of its kind in the English tongue."—Cincinnati Lancet-Clinic.

234 Pages, 5x8 in., Cloth, Gilt Top, \$1.00

G. P. Engelhard & Co. Publishers, Chicago

"A Popular and Brilliant Work by a Recognized Authority."

ABRAM'S ON DISEASES OF THE HEART.

DISEASES OF THE HEART; THEIR DIAGNOSIS AND TREATMENT. By Albert Abrams, A. M., M. D., San Francisco, Consulting Physician for Diseases of the Chest, Mt. Zion Hospital and the French Hospital. Illustrated.

There are bigger books published upon diseases of the heart, but none better. It gives not only old ideas, but new ones not found in other similar works. The Contents include an Introduction and Chapters upon Diagnosis of Diseases of the Heart, their Treatment, Affections of the Pericardium, Endocarditis and Chronic Valvular Disease, Cardiac Neuroses, Affections of the Arteries and a valuable Addendum.

Dr. Abrams introduces some novel yet extremely valuable ideas which are winning recognition. These include a description of the Heart Reflex, discovered by himself, his method of measuring the heart tones and the use of the X-ray in diagnosis. A most valuable feature are the diagnostic and therapeutic tables which condense a fund of information so that it may be observed at a glance.

'From the first to the last there is not a word de trop. Every point is direct and practical.'—New Orleans Medical and Surgical Journal.

"We welcome this volume of Dr. Abrams', whose work stamps him easily among the foremost diagnosticians of the country."—Cincinnati Lancet-Clinic.

"The author has given much careful study to the actual bedside phenomena of heart disease, and he presents his findings in a clear and concise manner."—Denver Medical Times.

"This book shows careful and thoughtful consideration of clinical facts in a way that places it among the foremost works on diseases of the heart. It is superior to many of the so-called standard works like Gibson, Balfour, Broadbent and Loomis in arrangement and ready reference."—Medical Fortnightly.

172 Pages, 5x8 in., Cloth, Gift Top, \$1.00

G. P. Engelhard & Co., Publishers, Chicago

"The Latest and Best Hints on an Every-Day Problem."

HATFIELD ON CONTAGIOUS DISEASES.

ACUTE CONTAGIOUS DISEASES OF CHILDHOOD. By Marcus P. Hatfield, A. M., M. D., Professor Emeritus of Diseases of Children, Northwestern University; Professor of Diseases of Children Chicago Clinical School.

The author's wide experience both as practitioner and teacher has enabled him to prepare a book of special value upon a subject of lively interest to every practicing physician. It embodies not only the results of many years of practice, devoted largely to this field, but also the views of the later French and German authors. He avoids theories and gives special attention to the practical aspects of the subjects, viz., the diagnosis and treatment of these very common diseases.

The subjects considered are Scarlatina, Rubeola, Parotitis Epidemica, Pertussis, Varicella, Variola and Influenza.

"An admirable little work."—N. Y. Medical Journal.

"A succinct and clear account of the diseases of childhood."
—Medical Age.

"The author has admirably accomplished his task."—Chicago Med. Recorder.

"It is truly a book which lives close up to its motto, 'ever at hand.'"—Annals of Gynecology and Pediatrics.

"No one can read it without feeling that his perusal has impressed upon him many special points."—Canada Med. Record.

"The winnowing away of the two bushels of chaff in order that the busy reader may get the two kernels of wheat is the happy faculty of this writer."—Dr. A. C. Cotton in the Chicago Clinic.

140 Pages, 5x8 in., Illus., Cloth, Gilt Top, \$1.00

G. P. Engelhard & Co., Publishers, Chicago

"Presents the best of the New and the Old in Treatment."

WAUGH'S RESPIRATORY DISEASES.

THE RESPIRATORY DISEASES. By William F. Waugh, M. D., Professor of Practice of Medicine and Clinical Medicine, Illinois Medical College.

The distinguished author of this book has written in his usual brilliant style a work which will appeal to every practical man.

Among the subjects especially treated are Hay-Fever, Laryngitis, Coryza, Croup, Bronchitis, Asthma, Pulmonary Hyperemia, Hemoptysis, Bronchial-Pneumonia, Pleurisy, Lobar Pneumonia and Tuberculosis.

Dr. Waugh's ideas are original and full of common sense. He preaches a doctrine of therapeutic positivism which should gladden the heart of every earnest practitioner.

"Probably no reader of this volume will agree with its author in some opinions advanced with a good deal of emphasis and assurance; but if there is a practicing physician in the country who can peruse it without gaining valuable aids in the treatment of his patients, we pity him for his obtuseness or his obstinacy!"—Dietetic and Hygienic Gazette.

"The subject is presented in a most condensed form for practical use, and its pathology is of the latest modern variety. The therapeutic part is rich in new remedies and new uses of old ones, all of which have been carefully tested and verified by competent observers. The text is classically written in a most interesting manner, and the book should be in the hands of every general practitioner."—Medical Times.

"The descriptions of the symptoms of the diseases embrace the principal points upon which we rely in forming the diagnosis. The sections upon diagnosis contain the gist of the matter; but it is in the department of treatment where we find the distinctive features of the work. Although the author's dominant treatment is by means of alkaloids, he gives also other adjuncts in order to allay some of the symptoms."—Medical Summary.

221 Pages, Cloth, Gilt Top, \$1.00

G. P. Engelhard & Co., Publishers, Chicago

MOORE ON TYPHOID FEVER.

TYPHOID FEVER. By J. T. Moore, M. D., Professor of Practice of Medicine, Medical Department of Hamline University, Minneapolis, Minn.

This book discusses with sufficient detail the character, etiology and pathology of the disease, outlines the methods of diagnosis, points out the principal complications and tells how they should be avoided and treated and finally gives a clear, concise and logical chapter on treatment.

The subject-matter is thoroughly modern and embraces the latest researches in this field. The book contains the following chapters: History and Etiology; Histology and Pathology; Symptomatology; Complications and Sequelæ; Diagnosis and Prognosis; Treatment.

"An excellent review of the subject. It is primarily practical."—Med. Record (N. Y.).

"The book contains in brief compass all that is important and practical in our present-day knowledge of typhoid fever and is especially complete in the chapters on diagnosis and treatment."—Med. News (N. Y.).

155 Pages, 5x8 in., Cloth, Gilt Top, \$1.00

CROTHERS ON DRUG HABITS.

DRUG HABITS AND THEIR TREATMENT. By T. D. Crothers, M. D., Hartford, Conn.; Superintendent of the Walnut Lodge Hospital; Editor of the Quarterly Journal of Inebriety, etc.

Probably no other man in America is so competent to write a book on Drug Habits as Dr. Crothers.

Among the subjects considered are Alcoholism, the Opium and Morphin habits, Cocain, Chloral, Chloroform, Ether, Tea, Coffee, Arsenic, Eau de Cologne, Ginger, Paraldehyd and Gelsemium.

"To the author of this work is due the proper recognition of the disease of inebriety, as the possibilities of cure have been long emphasized by him and demonstrated in the institution under his care."—Louisville Jour. of Med. and Surg.


94 Pages, 5x8 in., Cloth, Gilt Top, \$1.00

G. P. Engelhard & Co., Publishers, Chicago

THE STANDARD FORMULARY.

THE STANDARD FORMULARY. By Albert E. Ebert, Ph. M., Ph. D., and A. Emil Hiss, Ph. G.

The great popularity of this work is evidenced by its having the most extensive sale of any book in the literature of pharmacy—over 40,000 copies to date.



While primarily designed for the use of pharmacists, it will be found a valuable work of reference by physicians, and quite indispensable to medical men who do their own dispensing. It contains over **5,000 Formulas** for Medicinal and other Preparations.

500 Pages, 6x9 in., Cloth, Price \$4.00 net.

G. P. Engelhard & Co., Publishers, Chicago

THE STANDARD FORMULARY.

This celebrated work, now in its tenth edition and fortieth thousand, is the most recent revised Formulary and covers every variety of remedy and preparation in possible demand. Its Formulas comprise the "survival of the fittest" in the practice of Dr. Ebert, covering a period of nearly a half century and of Prof. Hiss in his wide experience together with the best from Dietrich, Hager, Parrish, the U. S. Pharmacopeia, National Formulary, and the most reliable other sources in America and Europe.

The Volume is divided into Chapters as follows:

PART I.—PHARMACEUTICAL PREPARATIONS, 1,505 FORMULAS.

PART II.—HOUSEHOLD REMEDIES, 436 FORMULAS.—Comprising Ague, Asthma, Headache, Kidney, Gout, Dyspepsia, Eczema, and numerous other Remedies.

PART III.—PROPRIETARY AND PATENT MEDICINES, 468 FORMULAS.—Giving the approximate constituents of the principal patent medicines.

PART IV.—VETERINARY MEDICINES, 358 FORMULAS.—

PART V.—PERFUMES, ABOUT 800 FORMULAS.—Part V is a treatise in itself. It comprises: Perfumes, 268 Formulas; Skin Preparations, 215; Hair Preparations, 163; Mouth Preparations (Dentifrices, Washes, etc.) 92; Bath Preparations, 7.

PART VI.—SODA-WATER PREPARATIONS, 85 FORMULAS.—

PART VII.—MISCELLANEOUS PREPARATIONS, 1,000 FORMULAS.—Comprises Blackings, Cements, Inks, Fabric Cleaners, Polishes, and in fact everything under this head of household value.

"It is admirable, both in its scope and in its detail."—Albert B. Prescott, Ph. D., Dean School of Pharmacy, University of Michigan.

"The Standard Formulary fills a place not occupied by any other work."—Prof. Henry Trimble, Philadelphia, of the Philadelphia College of Pharmacy.

"What renders this book by all odds superior to anything else of the same kind is the trustworthy character of its contents."—Bulletin of Pharmacy, Detroit.

500 Pages, 6x9 in., Cloth, \$4.00

G. P. Engelhard & Co., Publishers, Chicago

"The Ancient in Medicine in Picture and Story."

PETERS' ANCIENT PHARMACY AND MEDICINE.

ANCIENT PHARMACY AND MEDICINE. By Dr. William Netter, from the German by Dr. Herman Peters.

Physicians, as well as pharmacists, will find this curious volume of absorbing interest. Its great popularity in the original German in Germany is fully equalled, if not surpassed, by the American translation which contains much matter referring to early pharmacy and medicine in America.

Here we find chapters on or reference to the Common Origin of Pharmacy and Medicine; Fetichism and Disease; Serpent Symbolism; Egyptian Medicine Pharmacy 3,500 years B. C.; Chinese, Sanscrit, Græco-Roman and Arabian Medicine in the Earliest Times; Medico-Pharmaceutical Conflicts; Medical Superstitions; Demon Possession; Incantations; Amulets; Witchcraft; Horoscopes; Tree Charms; Astrology and Disease; Charms against Fevers; Early Philters; the Male and Female Mandrake; Aphrodisiacs; Eber's Philter; Lucretius; Love Charms and Love Powders; Alchemic Theories.

Here are illustrations of Apothecaries' Shops dating back five hundred years; distilling apparatus from the earliest times; Alembics; Retorts; Demons of Disease, Love Charms; Male and Female Mandrake—over one hundred illustrations in all, covering all the prominent characteristics in ancient pharmacy and medicine.


"The work is so rich in quaint, old-world facts and fancies, with weird theories and grewsome practices of the alchemists, that one dislikes to put it down till having finished at least that portion which treats of the Middle Ages."—Druggists' Circular.

213 Pages, 5x8 in., Octavo, Illus., Cloth, \$2.00

G. P. Engelhard & Co., Publishers, Chicago



U. C. BERKELEY LIBRARIES



C049859203

