


QM22
Q3
1891
APP.
BIOL
LIB

UC-NRLF



B 3 889 202

QUAIN'S ANATOMY

E. A. SCHÄFER & G. D. THANE





THE LIBRARY
OF
THE UNIVERSITY
OF CALIFORNIA

PRESENTED BY
PROF. CHARLES A. KOFOID AND
MRS. PRUDENCE W. KOFOID

QUAIN'S
ELEMENTS OF ANATOMY

EDITED BY

EDWARD ALBERT SCHÄFER, F.R.S.
PROFESSOR OF PHYSIOLOGY AND HISTOLOGY IN UNIVERSITY COLLEGE, LONDON,

AND

GEORGE DANCER THANE,
PROFESSOR OF ANATOMY IN UNIVERSITY COLLEGE, LONDON.

IN THREE VOLUMES.

APPENDIX.

SUPERFICIAL AND SURGICAL ANATOMY.

BY PROFESSOR G. D. THANE,
AND
PROFESSOR R. J. GODLEE, M.S.

ILLUSTRATED BY 29 ENGRAVINGS.

Tenth Edition.

LONGMANS, GREEN, AND CO.
LONDON, NEW YORK, AND BOMBAY.
1896.

[All rights reserved.]

c Anat

THE ELEMENTS OF ANATOMY

BY WILLIAM HALLISTON, F.R.S.

REVISED BY JOHN HENRY HALL

IN THREE VOLUMES.

LONDON :

BRADBURY, AGNEW, & CO. LD., PRINTERS, WHITEFRIARS.

SUPERFICIAL AND SURGICAL ANATOMY.

BY WILLIAM HALLISTON, F.R.S.

REVISED BY JOHN HENRY HALL

PRINTED BY BRADBURY, AGNEW, & CO. LD., WHITEFRIARS, LONDON.

Third Edition

LONDON AND NEW YORK

1881

Q M 22
 Q 3
 1891
 Appendix
 Biol.
 Lib.

CONTENTS OF APPENDIX.

	PAGE		PAGE
SUPERFICIAL ANATOMY OF THE HEAD AND		SUPERFICIAL ANATOMY OF THE UPPER	
NECK	1	LIMB— <i>continued</i> .	
The Head and Face	1	The Wrist and Hand	39
The Neck	16	SUPERFICIAL ANATOMY OF THE LOWER	
SUPERFICIAL ANATOMY OF THE TRUNK	19	LIMB	42
The Chest	19	The Hip	42
The Abdomen	22	The Thigh	43
The Back	27	The Knee	45
TABLE OF LEVELS OF STRUCTURES IN		The Leg	47
THE TRUNK	32	The Ankle and Foot	48
SUPERFICIAL ANATOMY OF THE UPPER		ANATOMY OF THE GROIN : HERNIA	50
LIMB	35	Inguinal Hernia	51
The Shoulder	35	Femoral Hernia	57
The Arm	35	THE PERINEUM OF THE MALE	62
The Elbow	37	EXAMINATION OF THE PELVIC VISCERA	65
The Forearm	38	INDEX	67

CONTENTS OF APPENDIX

1. Introduction to the Appendix 1

2. The Appendix 2

3. The Appendix 3

4. The Appendix 4

5. The Appendix 5

6. The Appendix 6

7. The Appendix 7

8. The Appendix 8

9. The Appendix 9

10. The Appendix 10

11. The Appendix 11

12. The Appendix 12

13. The Appendix 13

14. The Appendix 14

15. The Appendix 15

16. The Appendix 16

17. The Appendix 17

18. The Appendix 18

19. The Appendix 19

20. The Appendix 20

21. The Appendix 21

22. The Appendix 22

23. The Appendix 23

24. The Appendix 24

25. The Appendix 25

26. The Appendix 26

27. The Appendix 27

28. The Appendix 28

29. The Appendix 29

30. The Appendix 30

31. The Appendix 31

32. The Appendix 32

33. The Appendix 33

34. The Appendix 34

35. The Appendix 35

36. The Appendix 36

37. The Appendix 37

38. The Appendix 38

39. The Appendix 39

40. The Appendix 40

41. The Appendix 41

42. The Appendix 42

43. The Appendix 43

44. The Appendix 44

45. The Appendix 45

46. The Appendix 46

47. The Appendix 47

48. The Appendix 48

49. The Appendix 49

50. The Appendix 50

51. The Appendix 51

52. The Appendix 52

53. The Appendix 53

54. The Appendix 54

55. The Appendix 55

56. The Appendix 56

57. The Appendix 57

58. The Appendix 58

59. The Appendix 59

60. The Appendix 60

61. The Appendix 61

62. The Appendix 62

63. The Appendix 63

64. The Appendix 64

65. The Appendix 65

66. The Appendix 66

67. The Appendix 67

68. The Appendix 68

69. The Appendix 69

70. The Appendix 70

71. The Appendix 71

72. The Appendix 72

73. The Appendix 73

74. The Appendix 74

75. The Appendix 75

76. The Appendix 76

77. The Appendix 77

78. The Appendix 78

79. The Appendix 79

80. The Appendix 80

81. The Appendix 81

82. The Appendix 82

83. The Appendix 83

84. The Appendix 84

85. The Appendix 85

86. The Appendix 86

87. The Appendix 87

88. The Appendix 88

89. The Appendix 89

90. The Appendix 90

91. The Appendix 91

92. The Appendix 92

93. The Appendix 93

94. The Appendix 94

95. The Appendix 95

96. The Appendix 96

97. The Appendix 97

98. The Appendix 98

99. The Appendix 99

100. The Appendix 100

SUPERFICIAL AND TOPOGRAPHICAL ANATOMY.

BY G. D. THANE AND R. J. GODLEE.

IN this section will be comprised, 1, a brief account of the external conformation of the body, including the relation of its anatomical constituents to its surface forms, and the mode of determining the position of deep-seated organs, such as the viscera, large vessels, and other important parts; and 2, the topographical and surgical anatomy of the inguinal and perineal regions.

SUPERFICIAL ANATOMY OF THE HEAD AND NECK.

THE HEAD AND FACE.

The **upper part of the cranium** is but thinly covered by the scalp, and the form of the head is almost exactly that of the skull. The bones can be readily examined by passing the hand over the head, and the following parts are thus to be distinguished:—In the middle line behind is the external occipital protuberance, from which the superior curved line proceeds outwards on each side towards the mastoid process; below this line the bone is obscured by the overlying muscles, except in the middle line, where the external occipital crest may sometimes be felt at the bottom of the *nuchal furrow* between the posterior muscles of the neck. Above the occipital protuberance, the lambdoid suture is often to be followed as a slight depression on the surface, owing to the projection of the occipital bone beyond the hinder part of the parietals. The lambda, corresponding to the central and highest point of this depression, is about two and a half inches (6—7 cm.) above the external occipital protuberance. Above the lambda there is usually a well-marked flattened surface at the region of the obelion (see Osteology, p. 83); and in front of this again the parietal bones often form in the neighbourhood of their junction a broad longitudinal ridge, in which the position of the sagittal suture is indicated by a slight median depression.

At the fore part of the lateral region of the head the temporal crest of the frontal bone becomes prominent, and leads down to the external angular process, the junction of which with the malar bone is marked by a distinct depression. Below this the outline of the malar bone can be followed, and from the hinder part of the latter the finger passes along the zygoma to its base in front of the ear. Higher up on the side of the head the lower temporal line on the parietal bone is frequently to be recognised, indicating the extent upwards of the temporal muscle. The margin of the orbit can be felt in its whole extent, and is found to be interrupted above, somewhat internal to the centre, by the supraorbital notch, unless this be converted into a foramen, when it is scarcely perceptible. Above the orbit is the variable superciliary ridge, small in the female and absent in the child; and above this on the forehead is the frontal eminence, which, like the parietal eminence, is most marked during childhood. In the infant, the anterior fontanelle is felt as a lozenge-shaped depression, leading forwards to the interval between the

two frontal, and backwards to that between the two parietal bones; the latter interval conducts to the triradiate posterior fontanelle, the lateral limbs of which are continued downwards along the upper margins of the occipital bone.

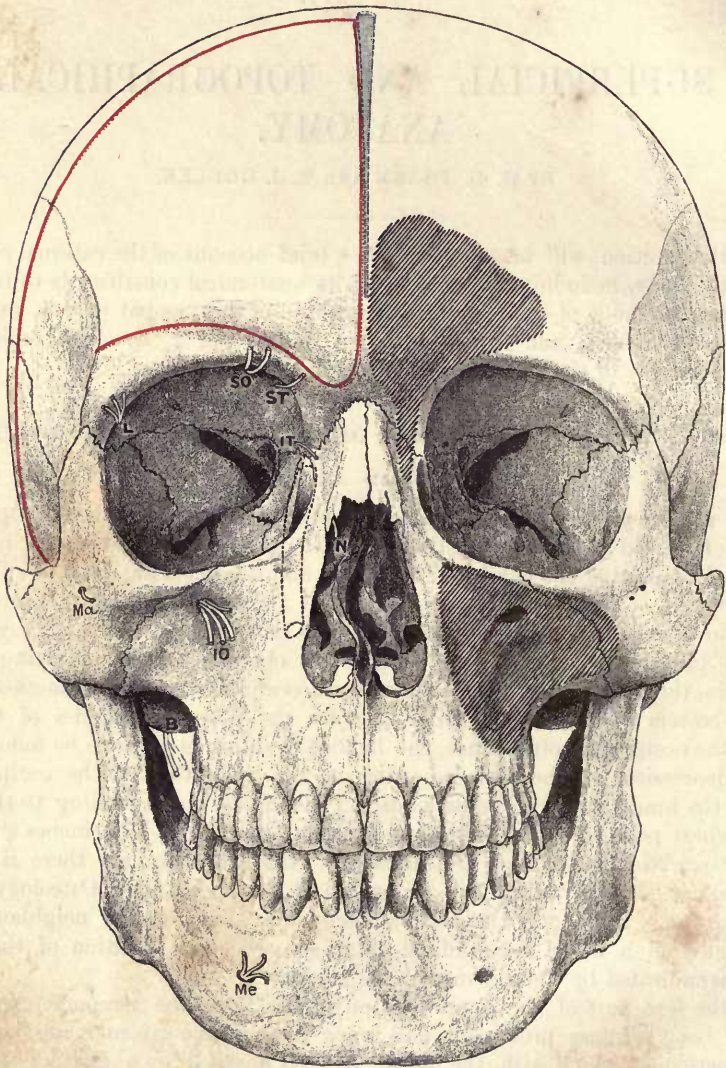


Fig. 1.—FRONT VIEW OF SKULL, SHOWING EXTENT OF CEREBRUM, AIR-SPACES, EXIT OF NERVES, &c. (G. D. T.)

The outline of the cerebrum is shown in red, and the position of the superior longitudinal sinus in blue. The frontal sinus with the infundibulum and the maxillary antrum are indicated by patches of shading, and the nasal duct with the lachrymal sac by a dotted line. The following letters refer to the nerves:—s o, supraorbital; s t, supratrochlear; i t, infraorbital; L, lachrymal; N, nasal; i o, infraorbital; M a, malar; B, buccal; M e, mental.

The **frontal sinuses** are contained in the lower part of the frontal bone, above the root of the nose and the inner ends of the eyebrows. In extent and capacity they vary greatly in different individuals; as a rule they are larger in the male than in the female, and are absent before the seventh year of life. In the adult

they may extend upwards as far as the frontal eminence, or fully two inches above the naso-frontal suture, and outwards over the orbit into the base of the external angular process; or they may exist only as slight recesses in the nasal portion of the bone. The dimensions of the sinuses are not necessarily related to the degree of prominence of the glabella and superciliary ridges, which are sometimes strongly marked without being excavated by the air-spaces; while on the other hand large sinuses not unfrequently co-exist with a comparatively flat lower frontal region, having apparently been formed by the recession of the inner table of the bone. The right and left sinuses are separated by a thin osseous partition, which is seldom defective; but they are often unequally developed, so that the septum deviates strongly from the median plane. In extreme cases one sinus may extend equally, or nearly so, in both halves of the frontal bone, the cavity of the opposite side being either rudimentary or wanting. The lower part of the sinus tapers into the *infundibulum*, a narrow passage which leads downwards and backwards through the fore part of the lateral mass of the ethmoid into the middle meatus of the nose. The infundibulum is deeply placed behind the

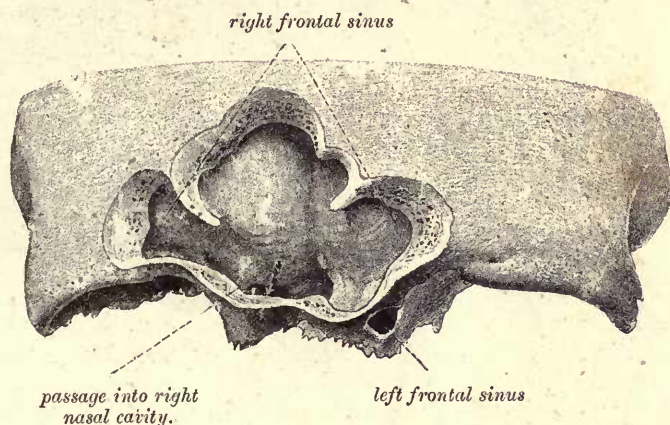


Fig. 2. —LOWER PORTION OF A FRONTAL BONE, SHOWING UNSYMMETRICAL DEVELOPMENT OF THE FRONTAL SINUSES. (From a photograph by G. W. B. Waters.) (G. D. T.)

nasal process of the superior maxillary bone, and near the inner wall of the orbit (*cf.* Osteology, fig. 66); its termination in the middle meatus is about on a level with the palpebral fissure.

Vessels and nerves of the scalp.—The supraorbital nerve and artery pass almost vertically upwards from the supraorbital notch, and more internally the frontal artery and supratrochlear nerve ascend over the margin of the orbit, while the large frontal vein descends in a similar position to the root of the nose. Posteriorly, the occipital vessels and great occipital nerve run upwards to the vertex, entering the scalp somewhat internal to a point midway between the external occipital protuberance and the mastoid process. The superficial temporal artery crosses the base of the zygoma immediately in front of the ear, and its anterior branch can frequently be seen, especially in old persons, running upwards and forwards with a tortuous course over the fore part of the temporal muscle towards the forehead.

Endocranial blood-vessels.—In contact with the inner surface of the cranial wall the superior longitudinal sinus is directed backwards along the middle line, extending from the lower part of the forehead to the external occipital protuberance.

It commonly deviates a little to one side, more frequently the right, especially in its hindmost part, as it descends over the upper portion of the occipital bone to its termination. From the latter spot the lateral sinus runs outwards and forwards, describing a slight curve with its convexity upwards, to the back of the ear on a level with the upper margin of the external auditory meatus, and then turns down-

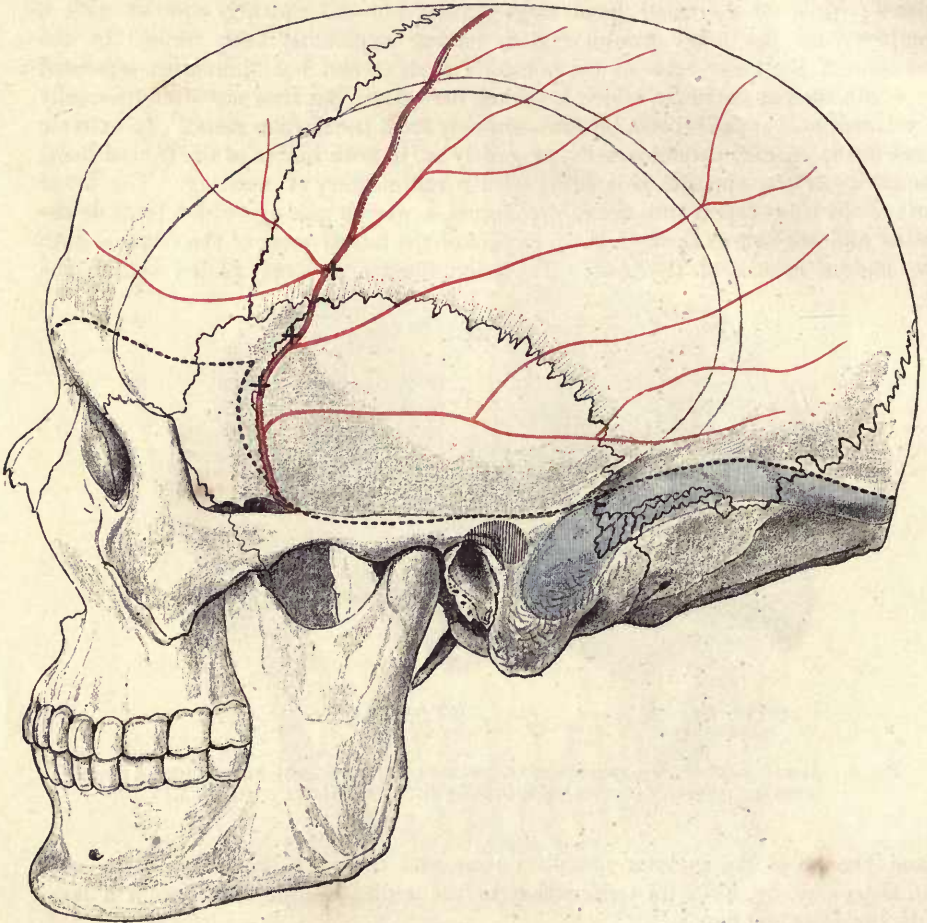


Fig. 3.—SIDE VIEW OF SKULL, SHOWING THE COURSE OF THE MIDDLE MENINGEAL ARTERY, LATERAL SINUS, &c. (From a photograph by G. W. B. Waters.) $\frac{2}{3}$. (G. D. T.)

The meningeal artery is represented in red and the lateral sinus in blue: the position of these was ascertained by drilling holes from the interior of the skull. The shaded area above and behind the external auditory meatus indicates the position of the epitympanic recess and mastoid antrum. The broken line represents the inferior limit of the cerebral hemisphere as traced on the surface of the skull. † † † indicate the points of intersection of vertical and horizontal lines respectively one inch, one inch and a half, and two inches behind the external angular process of the frontal bone, and above the upper border of the zygoma.

wards, following a course directed to the tip of the mastoid process as far as a point about 5 mm. beyond the level of the lower border of external auditory meatus. In the first part of its course the sinus usually lies altogether above a line drawn transversely from the external occipital protuberance to the centre of the opening of the ear, and the highest part of its arch, where the sinus crosses the postero-inferior

angle of the parietal bone, is from 15 to 20 mm. (in extreme cases even 25 mm.) above, and somewhat external to the mid-point of, this line. The distance of the descending part of the sinus from the posterior wall of the auditory canal is usually from 10 to 12 mm., but may be as little as 2 mm. The course of this part of the sinus corresponds roughly to the line of reflection of the skin from the pinna to the head posteriorly (Birmingham). The depth of the sinus from the surface of the mastoid varies from 1 to 15 mm., with an average of 7 mm.; and its breadth ranges from 5 to 15 mm. The sinus is often much wider in its mastoid than in its occipital segment. The right sinus is generally larger, projects more forwards, and approaches nearer to the surface than the left. The lateral sinus may be exposed by an opening in the bone immediately below the anterior part of the parieto-mastoid suture, or having its centre 25 mm. (1 inch) behind the highest point of the orifice of the osseous external auditory meatus.

The anterior and larger division of the middle meningeal artery runs upwards and backwards within the skull in the fore part of the temporal region, and would be reached at points equal distances, one inch, one inch and a half, and in most cases two inches, above the zygoma and behind the external angular process of the frontal bone. It will be remembered that the vessel in this part of its course is lodged in a deep groove, sometimes a canal, on the antero-inferior angle of the parietal bone. The ramifications of the posterior division of the artery are variable in number and position.

Cranio-cerebral topography.—*Extent of the cerebral hemisphere.*—The upper margin of the cerebral hemisphere extends from the lower part of the glabella nearly to the external occipital protuberance. It does not quite reach the middle line, being separated from its fellow by an interval which corresponds to the superior longitudinal sinus, and like that increases in breadth posteriorly, where it measures fully 1 cm. Owing to the lateral deviation of the sinus, the margin of the hemisphere commonly approaches nearer to the middle line on the left side than on the right. Below the sinus the mesial surfaces of the two hemispheres are nearly in contact, being separated only by the thickness of the falx cerebri. Inferiorly, the cerebral hemisphere reaches in front nearly to the eyebrow, at the side to the upper margin of the zygoma, and behind to the superior curved line of the occipital bone. The lower limit of the hemisphere is more precisely indicated by marking out its lateral margin, which consists of two parts—frontal and occipito-temporal. The frontal part begins internally close above the naso-frontal suture (which is felt at the bottom of the depression below the glabella), rises in an arch as it passes outwards, being about 8 mm. above the centre of the supraorbital border of the frontal bone, and crosses the temporal crest just below the deepest point of the hollow formed by the frontal bone immediately above the external angular process. From the temporal crest the frontal margin descends slightly in the fore part of the temporal fossa to a spot about 25 mm. behind the external angular process, where it meets the foremost part of the temporal margin in a receding angle, which corresponds to the stem of the fissure of Sylvius. The occipito-temporal division of the lateral margin begins posteriorly at the occipital pole of the hemisphere, which is placed a little (5 to 15 mm.) above and outside the external occipital protuberance, and then follows the arch of the lateral sinus, as described above, to the back of the ear. Crossing here the supramastoid crest, the margin is continued forwards about 6 mm. (varying from 3 to 9 mm.) above the roof of the external auditory meatus, and then on a level with the upper border of the zygomatic arch for about the posterior half of its length. Then curving gradually upwards, the border reaches its foremost point, corresponding to the temporal pole of the hemisphere, about 20 mm. above the zygoma and 15 mm. behind the external angular

process, and finally recedes slightly to meet the end of the frontal margin at the Sylvian notch.

Relations of the cerebral fissures and convolutions to the cranial wall.—The point of division of the Sylvian fissure is situated in the pterion, beneath or very near the spheno-parietal suture towards its posterior end. From this spot the posterior limb of the fissure runs backwards and somewhat upwards, at first following the line of the squamous suture, and then crossing the temporal area of the parietal bone as far

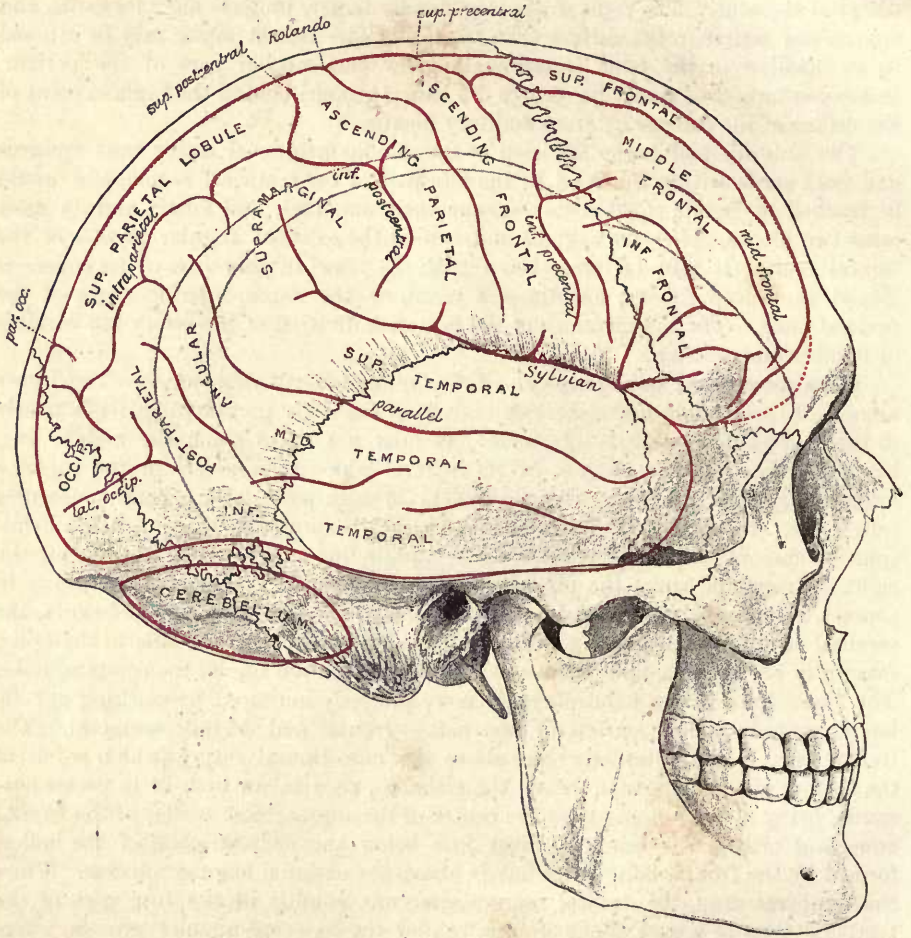


Fig. 4.—SIDE VIEW OF THE SKULL, SHOWING THE RELATIONS OF THE BRAIN TO THE CRANIAL WALL. 3. (G. D. T.)

as the inferior temporal line, beyond which its superior terminal branch ascends for a short distance beneath the parietal eminence. In the child the posterior limb of the fissure is distinctly above the line of the squamous suture. The anterior ascending branch of the Sylvian fissure runs from the hinder part of the spheno-parietal suture upwards and somewhat forwards, crossing obliquely the lower end of the coronal suture; and the horizontal branch is directed forwards in the line of the spheno-parietal suture. The parieto-occipital fissure is placed opposite the lambda, or often rather above that point, especially in young subjects. The fissure of Rolando is wholly beneath the parietal bone, its upper end being from 4 to 5 cm.,

and its lower end about 3 cm., behind the coronal suture. The superior precentral sulcus is from 2 to 3 cm. behind the upper part of the coronal suture; and the inferior precentral sulcus is a short distance (1 to 2 cm.) behind the lower part of the same suture. The inferior frontal sulcus about corresponds to the stephanion and the temporal crest of the frontal bone. The intraparietal fissure is very variable in position: its ascending or postcentral portions are approximately parallel to and about 15 mm. behind the fissure of Rolando; while its longitudinal portion runs backwards, with a slight inclination inwards, just above the parietal eminence, and at an average distance of 45 mm. from the median line anteriorly, 35 mm. posteriorly opposite the lambda. The parallel fissure lies mainly beneath the upper part of the squamous and the hinder part of the temporal area of the parietal bone, but its posterior end crosses the temporal lines and runs upwards for a short distance in the parietal lobe of the hemisphere under the superior division of the parietal bone: its position in the temporal part of its extent is indicated approximately by a line drawn from the marginal tubercle of the malar bone to the lambda. In the child, owing in great measure to the relatively small size of the squamous part of the temporal bone, the parallel fissure appears to be placed much higher, often reaching the level of the squamous suture.

From the foregoing determination of the situation of the fissure of Rolando and precentral sulci, it follows that the ascending frontal and the bases of the upper, middle, and lower frontal convolutions are placed beneath the anterior third of the parietal bone. The main parts of the superior and middle frontal convolutions correspond to the frontal region of the frontal bone, and of this area the superior frontal convolution may be said to occupy rather less than the inner half, and the middle frontal convolution rather more than the outer half. The centre of the frontal eminence is commonly over the middle convolution. The apex of the pars triangularis of the inferior frontal convolution corresponds to the antero-inferior angle of the parietal bone; and the pars orbitalis is covered by the temporal division of the frontal bone and the upper end of the great wing of the sphenoid. The whole of the parietal lobe is under cover of the parietal bone, the parietal eminence corresponding to some part of the supramarginal convolution; while the occipital lobe occupies the cerebral division of the occipital bone, and sometimes extends slightly beneath the adjacent part of the parietal bone. The temporal lobe lies for the most part beneath the squamous division of the temporal bone and the postero-inferior fourth of the parietal bone, its superior convolution being marked off from the rest by the line given above for the parallel fissure; but the anterior extremity of this lobe projects under the great wing of the sphenoid, while posteriorly the inferior temporal convolution is prolonged beneath the occipital bone to the occipital pole of the hemisphere.

Determination of the principal fissures on the surface of the head.—If a median line be drawn over the head from the nasion (centre of the naso-frontal suture) to the inion (external occipital protuberance), a point 1 cm. (or half an inch) behind the centre of this line will indicate with sufficient accuracy the spot where the fissure of Rolando meets the upper border of the hemisphere, and may be termed the *superior Rolandic point*. From 8 to 10 cm. farther back the lambda may be felt, or if that is not possible, a point should be taken on the nasio-inial line 6·5 cm. (or $2\frac{1}{2}$ inches) above the inion, and a line carried transversely outwards for a distance of 2 cm. from this spot will mark the parieto-occipital fissure.

On the side of the head, a line from the lowest point of the infraorbital margin to the centre of the aperture of the ear (Reid's *base-line*) is taken as the horizontal. This line is about parallel with the upper border of the zygomatic arch; and vertical lines are perpendicular to it. A spot on the base-line in the hollow between the tragus of the ear and the condyle of the lower jaw is known as the *preauricular point*. From the fronto-malar junction (p. 1) let a line be carried horizontally

backwards for 35 mm., and from the end of this a vertical line for 12 mm. upwards; the upper end of the latter line marks the spot where the anterior branches are given off from the Sylvian fissure, and may be termed the *Sylvian point*. A line drawn from the fronto-malar junction through the Sylvian point to the lower part of the parietal eminence will about lie over the posterior limb of the Sylvian fissure, and may be called the *Sylvian line*. The anterior ascending and horizontal branches of the fissure may be marked by lines 2 cm. long starting from the Sylvian point,

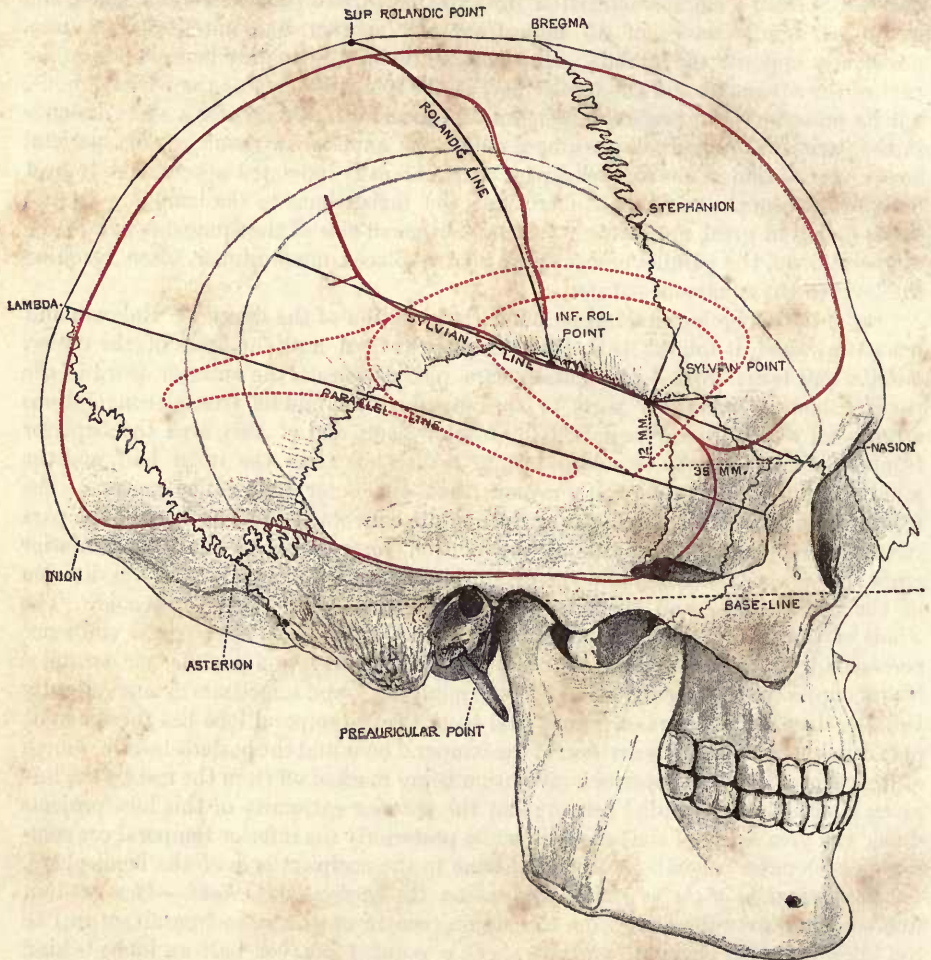


Fig. 5.—SIDE VIEW OF SKULL ON WHICH THE CHIEF POINTS AND LINES USED IN CRANO-CEREBRAL TOPOGRAPHY HAVE BEEN MARKED. §. (From a photograph by G. W. B. Waters.) (G. D. T.)

The contour of the cerebral hemisphere, with the Rolandic and Sylvian fissures, are marked by continuous red lines, and the outline of the insula and of the lateral ventricle by broken red lines.

the one directed upwards and forwards at right angles with the Sylvian line, and the other horizontally forwards.

On the Sylvian line, 25 mm. behind the Sylvian point, is the *lower Rolandic point*, the spot where the fissure of Rolando, if prolonged, would meet the Sylvian line. The lower Rolandic point is about 5.5 cm. (varying from 4 to 7) above the upper border of the zygomatic arch, on or slightly in front of a vertical line passing through the preauricular point. The *Rolandic line* may now be drawn between the

upper and lower Rolandic points, and gives the general direction of the fissure of Rolando. The line forms an angle (the *Rolandic angle*) anteriorly with the median line of about 70° (varying in individual cases from 64° to 75°); and if prolonged downwards it crosses the zygomatic arch about the middle (Le Fort). The fissure of Rolando is not quite so long as the Rolandic line, since the margin of the hemisphere does not quite reach the median line above, while below, the fissure of Rolando usually ends about 1 cm. above the Sylvian fissure or lower Rolandic point. The Rolandic line coincides most nearly with the upper part of the fissure, the inferior genu of which projects somewhat in front of the line a little below its centre, a spot which is placed from 5 to 15 mm. above the lower temporal line on the parietal bone.

The precentral sulci are situated about 15 mm. in front of the fissure of Rolando, with which they are nearly parallel; from the lower of these the inferior frontal sulcus arches forwards and downwards beneath the temporal crest of the frontal bone, which can be felt through the skin; and the position of the superior frontal sulcus may be indicated approximately by a line running forwards from the superior precentral sulcus slightly internal to the centre of the interval between the temporal crest and the median line of the forehead.

The postcentral sulci being also nearly parallel to, and about 15 mm. distant from, the fissure of Rolando, the average position of the longitudinal portion of the intraparietal sulcus may be marked by a line drawn from the centre of the Rolandic line to a spot 35 mm. external to the lambda, or 15 mm. from the end of the parieto-occipital line.

Lastly, the seat of the parallel fissure may be determined by the above-mentioned line from the marginal tubercle of the malar bone to the lambda.

Island of Reil, basal ganglia, and lateral ventricles.—The Sylvian point marks the position of the pole of the insula, and a spot on the Sylvian line 35 mm. behind this point will correspond to its posterior angle. The upper limit of the insula may then be indicated by a line, slightly convex upwards, drawn from its posterior angle to the upper end of the anterior ascending branch of the Sylvian fissure, and continued forwards for a distance of 15 mm. beyond the vertical passing through the Sylvian point; the lower limit by a line directed from the posterior angle downwards and forwards to a spot on the parallel line immediately below the Sylvian point; and the anterior limit by a line joining the anterior extremities of the two foregoing lines. The area of the insula thus marked out will serve as a guide to the position of the basal ganglia, which extend slightly beyond the limits of the island, and are circumscribed by a strongly-curved line corresponding to the outer border of the main part of the lateral ventricle. This line may be traced, beginning at the anterior extremity of the ventricle 1 cm. in front of the foremost point of the insula, and passing backwards in an arch, which follows the margin of the anterior horn and body of the cavity, an equal distance above the upper limit of the island to a spot 2 cm. behind its posterior extremity. Thence, the inferior horn runs forwards and downwards, to end about 1 cm. below the level of the parallel fissure and somewhat in advance of the coronal plane passing through the lower Rolandic and preauricular points. From the back of the loop thus indicated the posterior horn extends a variable distance towards the hindmost point of the hemisphere, which is placed a little higher than the occipital pole, beneath the occipital point of the skull.¹

¹ For more detailed information as to cranio-cerebral topography, reference may be made to the memoir by D. J. Cunningham, *Contribution to the Surface Anatomy of the Cerebral Hemispheres, with a Chapter on Cranio-Cerebral Topography*, by Victor Horsley. The subject is also fully illustrated by the series of models prepared under the direction of the former anatomist, showing the relations of the cerebral hemispheres *in situ* in a number of individuals of both sexes and at various periods of life, from infancy to old age.

The *cerebellum*, occupying the inferior occipital fossæ, is in contact with the cranial wall up to the lower margin of the transverse part of the lateral sinus. This vessel may occasionally have a lower position than that given on p. 4, and it is advisable, therefore, in operations upon the cerebellum, that the opening in the bone should be kept at least 1 cm. (half an inch) below the level of a line drawn from the external occipital protuberance to the centre of the external auditory meatus, while at the same time it should not extend farther forwards than a vertical line 35 mm. (one inch and a half) behind the latter spot. In this way both the lateral sinus and the occipital artery will be avoided (fig. 9).

Mastoid antrum.—The air-cells, which in the adult usually occupy the interior of the mastoid portion of the temporal bone, open into a small chamber termed the *mastoid antrum*. This is continuous anteriorly with the highest part of the

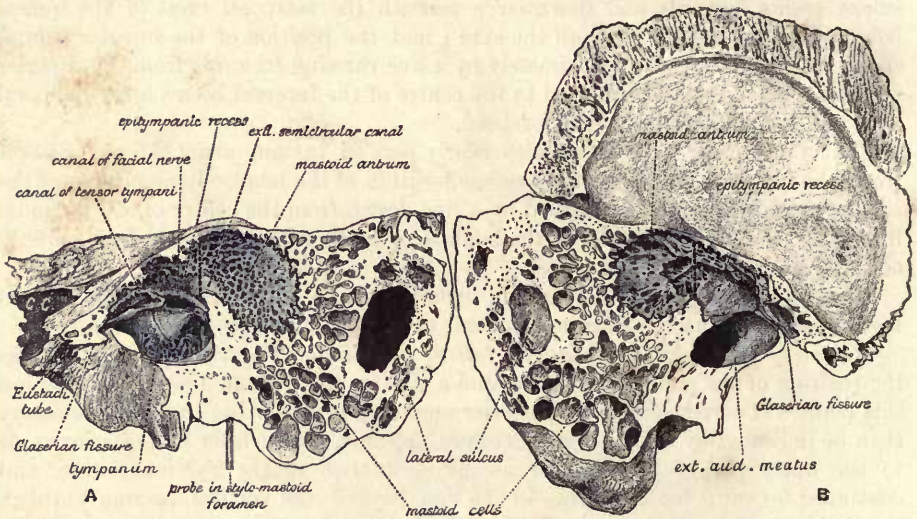


Fig. 6.—LEFT TEMPORAL BONE, DIVIDED BY A VERTICAL SECTION PASSING THROUGH THE TYMPANUM AND MASTOID ANTRUM: A, INNER PORTION; B, OUTER PORTION. Natural size. (From a photograph by G. W. B. Waters.) (G. D. T.)

The section is directed somewhat obliquely from before, backwards and outwards. The tympanic cavity and the antrum are coloured blue, and the division between the epitympanic recess and the antrum is indicated by a dotted line; *c. c.* carotid canal.

tympanic cavity or *epitympanic recess* (attic of the tympanum), and thus, through the Eustachian tube, the mastoid cells are put into communication with the external air. In form the mastoid antrum may be compared to the bulb of a retort, which is somewhat compressed in the transverse direction, and the truncated neck of which corresponds to the opening into the epitympanic recess (*aditus ad antrum*).

The dimensions of the antrum are subject to considerable variation, but in most cases it measures between 10 and 15 mm. longitudinally, about 10 mm. vertically, and from 4 to 6 mm. transversely. Its depth from the surface, *i.e.*, the thickness of its outer wall, varies from 7 to 14 mm. The bone here is commonly very hard and dense, but in the deeper part it is often more spongy, being excavated by cells in communication with the cavity. The entrance to the antrum from the epitympanic recess is rather triangular in form, with the base upwards and the lower angle broadly rounded off: its longest diameter is about 4 mm. both vertically and transversely. The lower margin of the opening is on a level with the upper wall of

the external auditory meatus; and the coronal plane in which the opening is contained, in consequence of the forward inclination of the bony meatus, is placed a little (about one-fourth of the horizontal diameter of the meatal opening) in front of the posterior margin of the external orifice of that canal. The epitympanic recess is situated above the anterior three-fourths of the orifice. Behind the entrance the floor of the antrum sinks, forming a hollow which does not usually extend below the level of the centre of the auditory meatus. The cavity is, however, continued into the mastoid cells, which are often of large size, and then as a rule reach to the tip of the mastoid process.

Superiorly, the antrum is separated from the middle fossa of the base of the skull by a thin plate of bone which continues backwards and upwards the tegmen

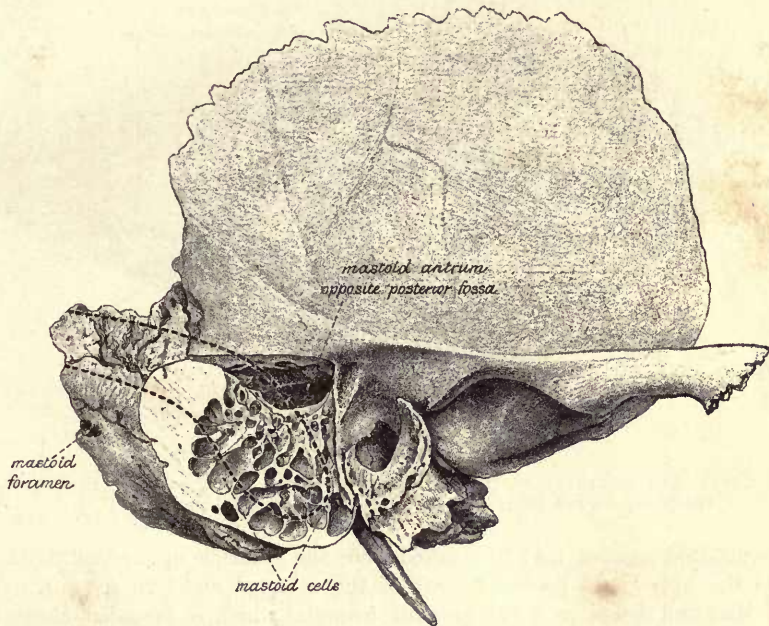


Fig. 7.—RIGHT TEMPORAL BONE, FROM WHICH THE SUPERFICIAL PORTION OF THE MASTOID DIVISION HAS BEEN REMOVED, EXPOSING THE MASTOID ANTRUM. Natural size. (From a photograph by G. W. B. Waters.) (G. D. T.)

The broken line indicates the position of the lateral sinus.

tympani. This sometimes presents small deficiencies, in which there is only a slender fibrous layer between the mucous lining of the cavity and the dura mater; and these two membranes are always united by connective tissue and vessels passing through the petro-squamosal fissure, as well as through minute apertures in the tegmen. In position, the roof of the antrum corresponds as a rule to the supra-mastoid crest externally, but not unfrequently it rises somewhat above that level, and in that case the upper part of the antrum may be overlapped by the lateral margin of the cerebral hemisphere, the inferior temporal convolution of which is received at this spot into a slight groove between the prominent tegmen internally and the lower border of the squamous temporal externally.

From the communication with the epitympanic recess the antrum extends backwards and outwards, so that it comes nearer to the surface behind than in front. Anteriorly, there is only a thin bony wall between the cavity and the deep part of

the auditory meatus. Posteriorly, it approaches the descending part of the lateral sinus, in some cases reaching close to the osseous lamina which forms the floor of the groove, but more commonly the two are separated by an interval of from 5 to 10 mm. occupied by mastoid cells. The sinus is usually nearer to the surface than the air-space. It will be remembered that the outer wall of the antrum is developed from the postauditory process of the squamo-zygomatic division of the temporal bone (see Osteology, p. 74); and there are generally in the adult some vestiges of the infantile masto-squamosal suture in the form of small clefts and canals which lead from the cavity to the exterior of the bone, and are occupied by connective tissue and veins.

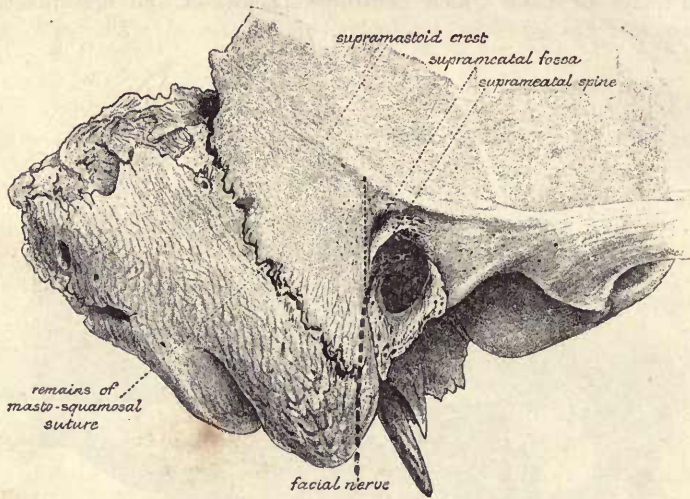


Fig. 8.—LOWER AND POSTERIOR PORTION OF RIGHT TEMPORAL BONE, SHOWING THE SUPRAMEATAL TRIANGLE, COURSE OF THE FACIAL NERVE, &c. Natural size. (G. D. T.)

The mastoid antrum may be reached from the exterior by perforating the bone close to the upper and posterior part of the external auditory meatus. In this region Macewen describes a *suprameatal triangle*,¹ which is bounded above by the supramastoid crest, below and in front by the postero-superior quadrant of the outer margin of the osseous meatus, and behind by a vertical line tangential to the hindmost point of that opening. The surface of bone included in the triangle is usually marked by a small depression—the *suprameatal fossa*, which is separated from the aperture of the meatus by a sharp prominent edge—the *suprameatal spine*. The perforation should be made within this area, at the site of, or close behind, the suprameatal fossa, and be directed inwards and slightly forwards, following the inclination of the external auditory meatus. The antrum will then be opened at its fore part, at a depth from the surface varying generally from 7 to 14 mm.; in extreme cases, and especially as the result of disease, this distance may be reduced to 3 mm., or increased to 18 mm., or even more. At the lower part of the entrance into the antrum the inner wall of the cavity presents a slight bulging over the external semicircular canal (fig. 6), which may be injured if the instrument is not checked as soon as the cavity is reached: the distance of the wall of the canal from the surface is mostly between 17 and 20 mm. (about three-quarters of an inch). Just below and in front of this, on the inner side of the epitympanic recess, is the arch of the facial nerve contained in its canal, the osseous wall of which is thin

¹ W. Macewen, *Pyogenic Infective Diseases of the Brain and Spinal Cord*, 1893, p. .

towards the cavity, and often defective in part. The nerve will best be avoided by not directing the perforation too much forwards. Between the semicircular canal in front and the lateral sinus behind, the air-spaces are in relation internally with the posterior fossa of the base of the skull, the thickness of the intervening bone ranging from 1 to 9 mm. The original perforation must be kept below the supramastoid crest in order to avoid opening the middle fossa of the skull; and it should not extend

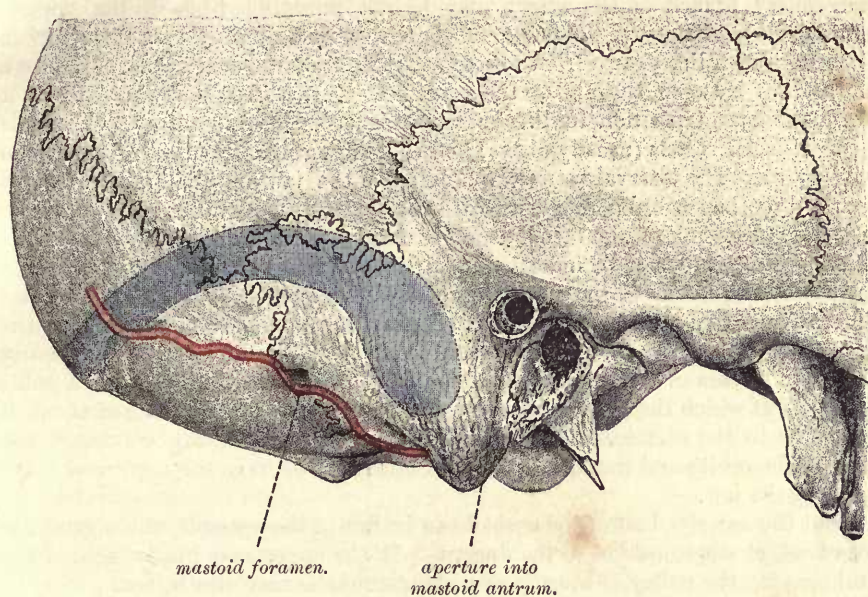


Fig. 9.—LOWER AND HINDER PART OF SKULL, IN WHICH AN OPENING HAS BEEN MADE INTO THE MASTOID ANTRUM, AND ON WHICH THE COURSE OF THE OCCIPITAL ARTERY AND LATERAL SINUS ARE INDICATED. (From a photograph by G. W. B. Waters.) † (G. D. T.)

backwards more than 2 mm. beyond the posterior boundary of the suprameatal triangle, or the lateral sinus may be endangered.

In the infant and child the mastoid antrum has nearly its full size, but its outer wall is relatively thin. The mastoid cells are, however, not usually developed before twelve years of age.

The face.—In the face proper, the nasal bones and the margin of the anterior nasal aperture are readily traced, and at the lower part of the latter, in the root of the septum narium, the anterior nasal spine is felt. In front of this opening the form of the upper and lower lateral cartilages can be distinguished, and the inner portion of the latter is more clearly made out by passing the finger into the nostril, by which means part of the cartilage of the septum, the lower margin of the upper lateral cartilage, and sometimes the tip of the inferior turbinate bone, can also be felt.

With the nasal speculum, if the parts be normal, the dull red mucous membrane of the floor of the nose and of the lower part of the septum may be seen, the brighter red inferior turbinate body for the greater part of or all its extent, and the inferior meatus for a variable distance. The anterior border and a small part of the inferior border, *i.e.*, the *operculum*, of the middle turbinate body may also be seen, and a very small part of the middle meatus. The fore part of the roof is visible, but the superior turbinate body rarely, and the superior meatus never. The back of the pharynx can be seen in a nose of moderate dimensions.

Below the base of the zygoma, the temporo-maxillary articulation is quite super-

ficial behind the upper part of the masseter, and from the condyle the posterior margin of the ramus of the lower jaw can be followed to the angle. The lower margin of the jaw can also be felt throughout, and ascending from its central point the anterior edge of the masseter. Immediately in front of the latter, the facial artery crosses the base of the jaw, and is readily found by its pulsation; the course of the vessel is roughly marked by a line passing upwards a little outside the corner of the mouth and continued by the side of the nose to the inner canthus of the eye. The coronary branch of the artery may be felt pulsating beneath the mucous membrane in each lip very near its free border. Stensen's duct runs generally in the direction of a line drawn from the lower margin of the concha of the ear to a point midway between the ala of the nose and the free margin of the lip, but it varies somewhat in position in different subjects; accompanying the duct are the transverse facial vessels (usually above) and the infraorbital branches of the facial nerve (below). The interval between the ramus of the jaw and the mastoid process is occupied by the parotid gland, a part of which extends forwards over the masseter muscle, and the trunk of the facial nerve is deeply placed beneath the gland; the position of the nerve may be indicated by a line running downwards and forwards from the anterior border of the mastoid process at the point where it meets the ear. A line carried downwards over the face, crossing the supraorbital notch and the interval between the two bicuspid teeth of the lower jaw, will be found to be nearly vertical and to pass over the infraorbital and mental foramina, thus forming a guide to the spots at which the largest cutaneous branches of the three trunks of the fifth nerve come to the surface. The infraorbital foramen is about 1 cm. below the margin of the orbit; and the mental foramen is midway between the upper and lower margins of the jaw.

About the anterior half of the eyeball can be felt in the aperture of the orbit: it gives a tense elastic sensation to the fingers. At the upper and inner angle of the orbital opening the pulley of the superior oblique muscle may also be felt.

When the eye is open the skin is drawn into the deep *superior palpebral sulcus* immediately above the upper lid, and forms a loose projecting fold between this furrow and the eyebrow. The corresponding *inferior palpebral sulcus* of the lower lid is much slighter, and often broken up: it is most distinct when the eye is directed downwards. Below this, another shallow groove, the *palpebro-malar sulcus*, runs round from near the inner canthus of the eye, following fairly closely the lower margin of the orbit. A small *external palpebral sulcus* is continued outwards from the outer canthus for about 3 mm., and forms a prolongation of the palpebral cleft when the eye is closed. Contraction of the outer part of the orbicularis palpebrarum gives rise to radiating furrows outside and below the eye, markings which are generally permanent in old persons.

The skin of the eyelid is very soft and thin; at the free margin of each lid it passes into the conjunctiva along the line of the eyelashes, and within this a sharp edge is formed, especially in the case of the lower lid, which is closely applied to the surface of the eyeball. The palpebral fissure is somewhat oval, or widely fusiform, in shape, but the margin of the upper lid is more arched than that of the lower. The fissure is also generally a little inclined from without inwards and downwards.

The whole length of the palpebral fissure is about 30 mm. (an inch and a quarter); its breadth is scarcely sufficient, unless when the eyes are unusually widely opened, to expose the whole of the cornea; but these dimensions, especially the latter, vary considerably in different persons, thus causing the eye to appear larger or smaller, although the size of the globe itself is relatively very constant. At the outer canthus, the lids meet in an acute angle; at the inner, the fissure is prolonged downwards and inwards for about 5 mm. between portions of the lid-margins, which are straight and rounded. The junction of the curved and straight portions of the

margin is marked by a slight elevation, the *papilla lacrimalis*, which is much better developed in the lower lid than the upper, and on drawing the lid forwards a minute opening, the *punctum lacrimale*, is seen on the summit of the papilla, leading into the canaliculus by which the tears are conveyed into the lachrymal sac. In the neighbourhood of the inner canthus the lids are separated from the eyeball by the *caruncula lacrimalis*, a red fleshy-looking portion of skin, which supports a few fine hairs, and by the fold of mucous membrane known as the *plica semilunaris*.

The lids can be readily everted, the lower one by simply pulling it downwards, the upper one by turning it over a probe, and the ocular and palpebral conjunctiva can thus be completely examined; the former is transparent and smooth, presenting only a few minute vessels in the healthy state; the latter is more or less red and velvety in appearance. The Meibomian glands are seen at the same time, appearing through the conjunctiva as lines of yellowish granules arranged perpendicularly to the edges of the lids; and along the latter the openings of their ducts are visible in the form of minute spots within the line of the eyelashes.

If the eyelids are drawn forcibly outwards, the internal tarsal ligament, or *tendo palpebrarum*, is made to project between the inner canthus and the margin of the orbit; and this band can also be felt as it is tightened during the act of winking. Behind the tarsal ligament, and reaching to a somewhat higher level, is the lachrymal sac; into the latter the canaliculi open, taking a course from the puncta lacrimalia, at first vertically, and then nearly horizontally, the one above and the other below the ligament. A knife entered immediately below the internal tarsal ligament will open the lower part of the lachrymal sac, and a probe may then be passed through the incision, in a direction downwards and slightly backwards and outwards, along the nasal duct into the nose.

Mouth and fauces.—On looking into the mouth, the teeth are seen, and by everting the lips, the outer surface of the gums may be inspected, and the alveolar processes can be examined with the finger. The smooth mucous membrane lining the lips is thus exposed, and in the middle line, passing from each lip to the jaw, is a thin fold termed the *frænum*; of these the upper one is the larger. On pulling the angle of the mouth outwards, the lining membrane of the inside of the cheek can be examined, and the papilla on which the duct of Stensen opens may be seen and felt opposite the second molar tooth of the upper jaw; with some difficulty a fine probe may be made to enter the aperture. A little farther back, if the mouth be alternately opened and shut, it is easy to distinguish the anterior borders of the masseter and temporal muscles, as well as the edge and inner surface of the ramus of the jaw.

By raising the tongue, the inner aspect of the gums and the floor of the mouth are brought into view. The under surface of the tongue is smooth, and is connected in the middle line with the floor of the mouth by the *frænum lingue*, a fold of mucous membrane similar to, but much larger than, the *fræna* of the lips; from this a fine line is continued forwards to the tip of the tongue. Somewhat less than half an inch external to the *frænum*, on each side, the ranine vein is clearly seen through the delicate mucous membrane; the corresponding artery is more deeply placed and does not come into view; an elevated and fringed line of the mucous membrane, *plica fimbriata*, lies superficially to these vessels, and may be followed, converging towards its fellow, almost as far as the tip of the tongue. Between the alveolar border and the tongue, on each side, is the *alveolo-lingual sulcus*, at the bottom of which the mucous membrane is raised into a well-marked ridge, directed obliquely forwards and inwards, over the sublingual salivary gland. Each ridge ends close to the middle line in a small papilla, and on this is seen, in the form of a minute spot, the opening of Wharton's duct, into which a fine probe may be easily passed.

On putting back the head, the mucous membrane covering the hard palate, and the soft palate come into view, as well as the uvula, the anterior and posterior pillars of the fauces, and the tonsils. The hamular process is plainly felt a little behind and internal to the last molar tooth; and just in front of this is situated the opening of the posterior palatine canal, through which the largest vessels and nerves of the palate issue. The pterygo-maxillary ligament is to be felt descending from the hamular process to the inferior maxilla, being contained in a more or less prominent fold of the mucous membrane, which passes between the jaws behind the extremities of the dental arches. Just in front of this, and immediately internal to the last molar tooth, the lingual branch of the fifth nerve runs inwards beneath the mucous membrane to the side of the tongue.

Between the posterior pillars of the fauces, a portion of the mucous lining of the hinder wall of the pharynx is seen; and if the finger be passed behind the tongue, there is no difficulty in feeling the greater part of the back of the pharynx and the epiglottis. By hooking the finger up behind the soft palate, the basilar process of the occipital bone is reached, and the posterior nares and adjacent parts may be explored. It is easy thus to distinguish the vault of the pharynx, the septum nasi, the posterior extremities of the middle and inferior turbinate bones, and the openings of the Eustachian tubes; and the finger may be made to pass some distance into the nasal fossæ. In this way also the upper four or five (in children six) cervical vertebræ may be examined, the anterior arch of the atlas being opposite the lower margin of the posterior nares, and the body of the axis corresponding to the soft palate. The part of the column which is accessible to a straight instrument introduced through the mouth is very limited, extending in the adult from the lower border of the axis to the middle or lower part of the fourth cervical vertebra; in the child, owing to the small depth of the face, it comprises the body of the axis and of the third cervical vertebra (Chipault).

By posterior rhinoscopy the upper parts of the posterior nares are seen, separated by the septum. They are in great part occupied by the posterior ends of the turbinate bodies, of which the most conspicuous is the middle; the superior is usually seen, but only the upper part of the inferior, the lower part of the latter, as well as the lower part of the septum, being concealed by the soft palate. On each side of the posterior nares are seen the Eustachian tube, the salpingo-pharyngeal and salpingo-palatine folds, and the lateral recess of the pharynx (fossa of Rosenmüller). By turning the mirror upwards, the vault of the pharynx, the pharyngeal tonsil and the median pharyngeal recess (bursa pharyngea) may also be examined. The septum appears whitish, the turbinate bodies are of an ash-grey colour, and the rest of the mucous membrane is of various shades of red.

THE NECK.

The front of the neck is divided into an upper, *suprahyoid*, *submaxillary*, or *hyo-mental region*, and a lower, *infrahyoid* or *hyo-sternal region*. The hyoid bone, which forms the boundary line between the two divisions, can be felt in the receding angle below the chin, and it may be examined by fixing the two great cornua between the fingers. The anterior bellies of the digastric muscles form the convex surface in the middle of the suprahyoid region, and outside this on each side the submaxillary gland is both to be felt and seen. The median prominence (*pomum Adami*) in the upper part of the infrahyoid region is due to the thyroid cartilage, and is strongly marked in men, especially those with deep voices, small or indistinct in women and children. Above the thyroid cartilage the finger sinks into the depression (*thyro-hyoid space*) between that and the hyoid bone; below the thyroid, the *crico-thyroid space* and the cricoid cartilage are recognised; and from the latter the finger passes on to the trachea. The rings of the trachea are, however, scarcely to be distinguished,

being obscured above by the isthmus of the thyroid body, and below by the muscles and the increasing quantity of fat as the air-tube recedes from the surface, the depth of the front of the trachea at the upper border of the sternum amounting to nearly an inch and a half (3.5 cm.).

The lower part of the epiglottis is placed behind the thyro-hyoid space, and still farther back is the upper aperture of the larynx. The rima glottidis is at a lower level, being opposite the middle of the short anterior margin of the thyroid cartilage. The lower border of the cricoid cartilage indicates also the termination of the pharynx and the commencement of the œsophagus.

Along the side of the neck, the sterno-mastoid muscle runs obliquely from the mastoid part of the temporal bone to the sternum and clavicle; its anterior border, forming the hinder boundary of the anterior triangle of the neck, is thick and prominent, and leads down to the strongly marked sternal head, which passes to the front of the manubrium and gives rise, with its fellow of the opposite side, to the deep *suprasternal notch* (*fossa jugularis*). The posterior border of the muscle is thin, and in its upper part does not show on the surface; inferiorly it becomes evident and is continued into the clavicular head, which is, however, broader and less salient than the sternal origin. A slight depression usually corresponds to an interval between the two heads, and the lower boundary of the depression is formed by the somewhat prominent inner extremity of the clavicle. A needle thrust backwards in this depression, and in contact with the end of the clavicle, would reach, on the right side, the bifurcation of the innominate artery, on the left, the common carotid artery as it passes into the neck.

The carotid arteries are situated just beneath the anterior border of the sterno-mastoid muscle, their position being indicated more exactly by a line drawn from the sterno-clavicular articulation to a point midway between the angle of the jaw and the tip of the mastoid process. The common carotid artery reaches upwards as far as, or slightly beyond, the upper border of the thyroid cartilage; above this level, the external and internal carotids are placed side by side, the external being the more anterior, until they pass beneath the posterior belly of the digastric muscle, the position of which may be indicated by a line drawn from the mastoid process to the fore part of the hyoid bone. If deep pressure be made in the situation of the great vessels opposite the cricoid cartilage, the prominent anterior tubercle of the transverse process of the sixth cervical vertebra (*carotid tubercle*) can be felt, and the common carotid artery may be compressed against it. This is a little below the spot at which the omo-hyoid muscle crosses the carotid artery, and indicates also the place where the inferior thyroid artery turns inwards, and the vertebral artery usually enters upon its course through the foramina in the transverse processes.

The lingual artery arises from the external carotid opposite the hyoid bone; it first forms a small loop with the convexity upwards, then passes forwards along the upper margin of the great cornu of the hyoid just below the level of the hypoglossal nerve and ranine vein, which are separated from it by the hyo-glossus muscle. At a slightly higher level, the occipital and facial arteries leave the external carotid, the former passing up to the transverse process of the atlas, which may be felt just below and a little in front of the tip of the mastoid process, the latter taking a winding course at first beneath and then above the submaxillary gland to the anterior border of the masseter muscle. The superior thyroid artery, arising below the lingual, runs downwards and inwards near the back of the thyroid cartilage, and sends its crico-thyroid branch across the crico-thyroid space.

The line of the internal jugular vein is just external to that of the carotid arteries; the facial vein, more superficial than the artery, courses from the anterior border of the masseter downwards and backwards, to join the main trunk about

opposite the thyro-hyoid space; the middle thyroid vein crosses the common carotid artery near the level of the cricoid cartilage, and the large inferior thyroid veins pass downwards deeply on the front of the trachea. More superficially placed, and often showing through the skin, are the anterior jugular vein near the middle line, and a communicating branch, frequently of large size, between the facial and anterior jugular veins, lying along the anterior border of the sterno-mastoid muscle. The right and left anterior jugular veins are generally connected by a cross branch of considerable size at the bottom of the suprasternal notch, close to the upper border of the manubrium, and the lower part of each vein is then directed outwards behind the origin of the sterno-mastoid, so that great care must be exercised, in order not to wound the vessel, in dividing this muscle for the cure of wry-neck.

The position of the tonsil corresponds externally to a spot slightly above the angle of the jaw.

Behind the sterno-mastoid muscle, between it and the trapezius, is the intermuscular space known as the posterior triangle of the neck; inferiorly, this gives rise to a broad depression, the *supraclavicular fossa*, in which the omo-hyoid muscle and the brachial plexus may be felt, and in thin persons seen. In the angle between the sterno-mastoid and the clavicle, the third part of the subclavian artery can be felt pulsating, and the circulation in the vessel may be arrested here by pressure directed downwards and backwards against the first rib. The subclavian artery, as it crosses the root of the neck, describes a curve with the convexity upwards, having its inner end behind the sterno-clavicular articulation, its outer end beneath the centre of the clavicle, and its mid-point from half an inch to an inch (1—2.5 cm.) above that bone. The left artery is more deeply placed at first than the right, and does not usually rise so high in the neck. The subclavian vein is placed at a lower level, and is, as a rule, entirely under cover of the clavicle. The pleura and lung ascend above the clavicle into the arch formed by the subclavian artery. The pulsation of the transverse cervical artery may frequently be distinguished a short distance above the clavicle.

The external jugular vein runs over the surface of the sterno-mastoid muscle in the direction of a line drawn from the angle of the jaw to the centre of the clavicle, and is covered only by the integument and the platysma, the fibres of the latter being nearly parallel to the course of the vein. The distance to which it reaches beyond the posterior edge of the sterno-mastoid below varies considerably. Near the clavicle the vein becomes considerably enlarged, being joined by some branches from the shoulder (transverse cervical and suprascapular), which, with the lower part of the trunk, generally form a more or less dense plexus over the third part of the subclavian artery.

About an inch (2.5 cm.) below the tip of the mastoid process, the spinal accessory nerve passes beneath the anterior border of the sterno-mastoid; emerging at, or slightly above, the middle of the posterior border of this muscle, it then continues its oblique course across the posterior triangular space, and sinks beneath the upper border of the trapezius on a level with the sixth or seventh cervical spine; under the latter muscle, the nerve runs downwards immediately internal to the vertebral border of the scapula. The great auricular and superficial cervical nerves also come out at the posterior border of the sterno-mastoid about the middle of its length, and are thence directed, the great auricular upwards to the ear, and the superficial cervical forwards to the front of the neck.

For the back of the neck, see p. 27.

SUPERFICIAL ANATOMY OF THE TRUNK.

THE CHEST.

On the front of the chest, the greater part of the thoracic wall is concealed on each side by the pectoralis major, the uppermost portion of the muscle extending over the inner half of the clavicle from which it arises, while inferiorly, it forms a prominent curved margin, which follows the direction of the fifth costal cartilage. The interval between the clavicular and sterno-costal portions can often be seen when the muscle is at rest, and always when it is put into action. Externally, the upper and lower borders of the muscle converge as it narrows to its insertion; the former is at first separated from the adjacent anterior margin of the deltoid by the *infraclavicular fossa*, but lower down the two muscles become closely united; the lower margin of the pectoralis major leaves the chest opposite the fifth rib (at which spot the lowest slip of the pectoralis minor often appears on the surface) and forms, as it passes upwards and outwards to the arm, the rounded anterior axillary fold, ending in the sharp tendon, which becomes apparent when the muscle is in action. The nipple is placed over the outer and lower part of the pectoral muscle, generally between the fourth and fifth ribs, about three-quarters of an inch (2 cm.) external to the junction of the bone and cartilage, and rather more than four inches (10 cm.) from the middle line; but its position varies considerably in different individuals, and it is not unfrequently, especially in fat persons and in females, at a much lower level.

Along the middle line, the sternum is subcutaneous at the bottom of the *sternal groove* or *furrow* between the great pectoral muscles. The furrow is interrupted towards the upper part by a slight, but distinct, transverse ridge, which marks the *sternal angle* formed by the union of the manubrium and the body of the sternum, and on each side of this the second costal cartilage, which projects forwards more than the others, continues the prominence outwards. Inferiorly, the sternal furrow opens out, as the pectoral muscles diverge from one another, exposing the lower end of the body of the sternum, a spot which marks the articulation of the seventh costal cartilage, and which is always to be readily felt, and usually distinctly seen, owing to the formation of the *infrasternal depression* (epigastric fossa, *scrobiculus cordis*) is a generally well-marked, although variable, hollow between the seventh costal cartilages and the upper ends of the recti muscles, and is placed over the ensiform process, which is itself seldom visible on the surface. It will be remembered that the upper margin of the sternum is on a level (during expiration) with the disc between the second and third dorsal vertebrae; the junction of the manubrium and body is opposite the fifth dorsal vertebra; and the xiphi-sternal articulation generally corresponds to the lower part of the ninth dorsal vertebra.

To the outer side of the pectoralis major, the ribs are covered by the serratus magnus. Of the digitations of this muscle, the first to appear, at the lower margin of the pectoralis major, is the one attached to the fifth rib; the following one, the sixth, is the largest and most prominent, and they become less marked below this. Below the pectoral muscle, the wall of the thorax is covered by the *rectus abdominis* internally, and the external oblique laterally, the pointed slips of the latter muscle being received between the digitations of the serratus magnus. More posteriorly, the *latissimus dorsi* ascends over the hinder part of the serratus, and, winding round the *teres major* muscle, forms the thick posterior fold of the axilla.

The ribs may generally be followed without difficulty over the front and sides of the chest; but only a very small portion of the first can be distinguished, as it is almost completely covered by the clavicle and scapula. The width of the intercostal spaces, and the form of the subcostal angle vary greatly in accordance with

the shape of the chest. Thus, in a long narrow chest the lower ribs slope very much downwards and are near to one another, the subcostal angle is narrow, and the lateral margin of the thorax reaches nearly, or in some persons quite, as far as the iliac crest. When the chest is broad the opposite conditions are found. The subcostal angle is on the average about 70° in the male and 75° in the female, but it may vary from 60° to 80° (Charpy).

The lungs.—The apex of the lung rises above the anterior end of the first rib and the clavicle into the neck, where it is placed behind the interval between the two heads of the sterno-mastoid, being covered immediately by the subclavian artery and scalenus anticus muscle. Its highest point is on a level with the neck of the first rib; and it projects very slightly, if at all, beyond the plane of that rib. The height to which it extends above the clavicle ranges in ordinary circumstances from half an inch to an inch (1—2.5 cm.), but sometimes it is as much as an inch and three-quarters (4 cm.), while in other cases the lung does not project at all above the bone. A resonant percussion-note may, however, always be obtained in the living subject for some distance above the clavicle, owing to the obliquity of the surface of the neck. The distance of the apex from the clavicle is actually diminished during inspiration, since that bone is then moved upwards with the anterior end of the first rib. There does not appear to be any constant difference in the extent upwards of the lung on the two sides, but it is not uncommon for the right lung to be somewhat higher than the left. From the apex, the anterior border of each lung inclines inwards behind the sterno-clavicular articulation and the manubrium, to the junction of the latter with the body of the sternum, where the two almost meet in the middle line; they then descend together, the right sometimes projecting a little to the left of the mid-line, as far as the fourth costal cartilage; from this point the margin of the right lung continues a nearly straight course to the level of the sixth chondro-sternal articulation (sometimes even to the lower end of the body of the sternum), while that of the left slopes outwards behind the fifth costal cartilage, in a direction which may be indicated with sufficient accuracy by a line drawn from the fourth chondro-sternal articulation of the left side to the spot on the chest-wall corresponding to the apex of the heart (see below).

The lower limit of the lung may be marked by a line, slightly convex downwards, carried round the side of the chest from the sixth chondro-sternal articulation to the tenth dorsal spine. In the mamillary line, the lung extends downwards to the sixth rib; opposite the posterior fold of the axilla, to the eighth rib; and in the scapular line (carried vertically downwards from the lower angle of the scapula, while the arms are against the sides), to the tenth rib. At the side of the chest the left lung often descends somewhat beyond these limits. This margin of the lung descends considerably in inspiration, and rises in expiration. The position of the great fissure in each lung may be ascertained approximately by drawing a line from the second dorsal spine to the sixth rib in the nipple-line; and the smaller fissure of the right lung extends from the middle of the foregoing to the junction of the fourth costal cartilage with the sternum.

The **pleura** reaches considerably farther downwards than the lung. Posteriorly, its lower margin corresponds most frequently to the head of the twelfth rib, or the eleventh dorsal spine; it is seldom higher than this, but often lower, in many cases extending as much as an inch (2.5 cm.) beyond the spot mentioned. Being directed at first horizontally outwards, its line then ascends gradually over the side of the chest, and passes behind the seventh costal cartilage to the sternum, from which point it slopes gradually inwards to reach the middle line at the level of the fifth cartilages. As the pleuræ of the two sides are almost symmetrical in front, the left extends considerably farther over the pericardium than the corresponding lung. At the side of the chest, the line of reflection of the pleura is generally from two to three

inches (5—7 cm.) above the lower margin of the thorax : towards the front, it is usually a little lower on the left side than the right.

The heart and great vessels.—The upper limit of the heart is represented by a line passing from the lower border of the second costal cartilage of the left side to the upper border of the third cartilage of the right side ; the lower limit by a line

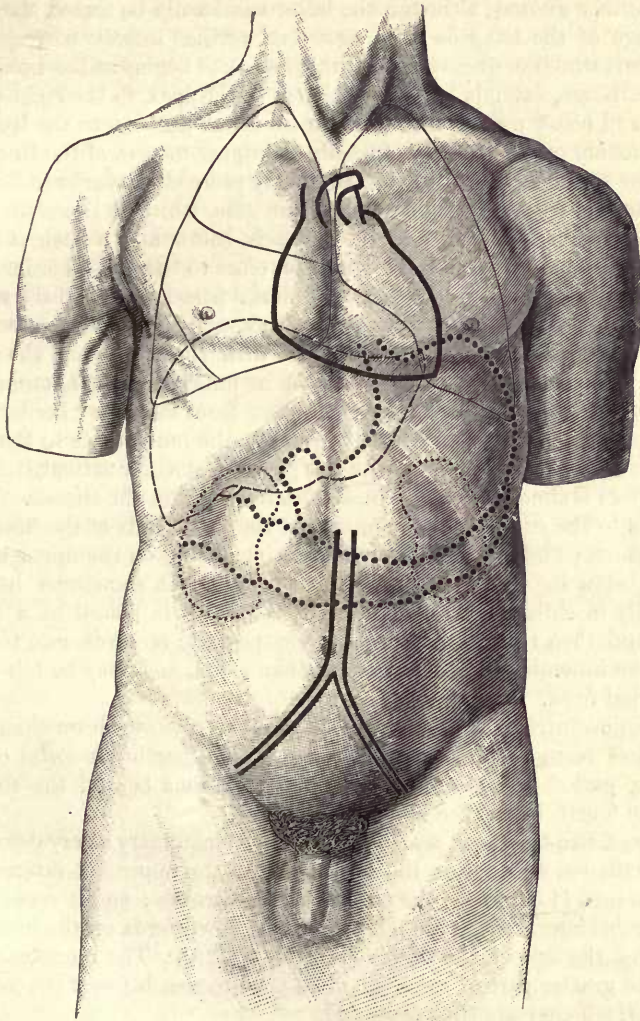


Fig. 10.—FRONT VIEW OF THE TRUNK, SHOWING THE RELATIVE POSITIONS OF THE PRINCIPAL THORACIC AND ABDOMINAL VISCERA, &c. $\frac{1}{2}$. (R. J. G. and G. D. T.)

The outlines of the lungs and their large fissures are indicated by thin lines ; the position of the heart and great vessels (superior vena cava, arch of aorta and pulmonary artery), as well as below the abdominal aorta and the common and external iliac arteries, by thick lines ; the liver is represented by a broken line ; the stomach and transverse colon by thick dotted lines ; and the kidneys by thin dotted lines.

drawn somewhat obliquely, and with a slight downward convexity, from the seventh chondro-sternal articulation of the right side to the apex, the latter point being in the fifth intercostal space, about three and a half inches (9 cm.) to the left of the middle

line, and generally about an inch and a half (4 cm.) below, and three-quarters of an inch (2 cm.) to the sternal side of the nipple. The right border of the heart is indicated by a line carried from the third to the seventh chondro-sternal articulation, and arching outwards to a distance of one inch and a half (4 cm.) from the middle line; the left border, by an oblique line, convex upwards, extending from the second left costal cartilage to the apex. The area thus marked out corresponds to what is known as the *deep cardiac dulness*, although the latter can hardly be traced above the third costal cartilage of the left side; the *superficial cardiac dulness* corresponds to that part of the heart which is uncovered by lung, and thus begins at the inner end of the fourth left cartilage, extends to the left almost to the apex, to the right as far as the middle line, and below merges into the dulness which answers to the liver.

The pulmonary orifice is placed opposite the upper margin of the third left costal cartilage, close to the sternum, whence the artery proceeds upwards to its bifurcation behind the second costal cartilage of the same side, which is therefore termed the *pulmonary cartilage*. The orifice of the aorta is below and a little internal to the pulmonary orifice, being behind the sternum, close to the lower border of the third left cartilage; from this spot the ascending aorta passes across to the right edge of the sternum opposite the second (*aortic*) cartilage, and the arch then returns to the left side, crossing the middle line about an inch (2.5 cm.) from the suprasternal depression. Opposite the middle point of the manubrium, the innominate and left common carotid arteries are arising close together from the upper border of the arch of the aorta, and they pass symmetrically upwards, the innominate to the back of the right, and the carotid to the back of the left sterno-clavicular articulation. The left subclavian artery is almost directly behind the left carotid in the thorax. The superior vena cava lies to the right of the arch, behind the inner ends of the first and second intercostal spaces; and the left innominate vein, resting on the upper border of the arch, is just below the upper margin of the sternum. It sometimes happens, however, especially in children, that the arch of the aorta is placed at a higher level than usual, and then the left innominate vein projects upwards into the neck. In other cases the innominate artery is longer than usual, and may be felt pulsating in the suprasternal fossa.

The auriculo-ventricular openings of the heart are lower down than the arterial orifices, the left being behind the inner end of the fourth left costal cartilage and the adjoining part of the sternum, while the right lies behind the sternum on a level with the fourth interspace and fifth cartilage.

Arteries of the thoracic wall.—The internal mammary artery descends behind the costal cartilages, and across the inner ends of the upper six intercostal spaces, about half an inch (1 cm.) from the margin of the sternum; and it occasionally gives off a considerable lateral costal branch which runs downwards on the inner surface of the ribs along the side of the thorax (Vol. II, p. 429). The intercostal vessels are lodged for the greater part of their extent in the grooves beneath the lower edges of the ribs, by which they are thus protected.

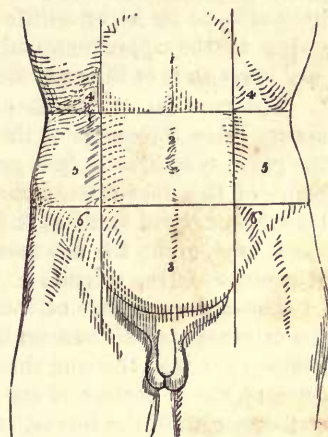
THE ABDOMEN.

The superficial limits of the abdomen are formed above by the lower margin of the thorax, and below by Poupart's ligament and the iliac crest on each side, the former corresponding, except in fat persons, to the curved inguinal furrow. The abdominal cavity, however, extends considerably beyond these limits, both upwards into the vault of the diaphragm, under cover of the lower ribs and their cartilages, and downwards into the hollow of the pelvis. The abdomen is arbitrarily divided into nine regions by two horizontal and as many vertical lines. Of the horizontal lines, one, called *infracostal*, is drawn across at the level of the lowest point of the tenth costal arch on each side, and the other, which may be termed *bi-iliac*, between

the most prominent points (laterally) of the two iliac crests. A horizontal plane containing the infracostal line usually cuts some part of the third lumbar vertebra, while the bi-iliac line lies in a plane passing through the body of the fifth lumbar vertebra about the middle of its anterior surface, and about an inch and a quarter below the highest point of the iliac crest. The umbilicus is generally from an inch and a quarter to an inch and a half (3—4 cm.) above the bi-iliac line. The vertical

Fig. 11.—OUTLINE OF THE FRONT OF THE ABDOMEN, SHOWING THE DIVISION INTO REGIONS.

1, epigastric region ; 2, umbilical ; 3, hypogastric ; 4, 4, right and left hypochondriac ; 5, 5, right and left lumbar ; 6, 6, right and left iliac.



distance between the infracostal and bi-iliac planes ranges from one and a half to four inches (4—10 cm.), with an average of two inches and three-quarters (7 cm.)¹. The vertical lines (*mid-Poupart lines*) are drawn upwards from the centre of Poupart's ligament on each side : above the bi-iliac line they nearly coincide with the lineæ semilunares, and are usually a little external to the outer borders of the recti.

Of the spaces bounded by these lines, the three central are called respectively, from above downwards, *epigastric, umbilical, and hypogastric*, and the lateral ones, right and left *hypochondriac, lumbar* or *lateral abdominal*, and *iliac*. The lowest portion of the hypogastric region, being covered with hair, is also referred to as the *pubes* or *pubic region* ; and the adjacent parts of the iliac and hypogastric regions together constitute what is known as the *inguinal region* or the *groin*.

The viscera which are contained in the several regions are shown in the following table :—

Epigastric region	{ The greater part or the whole of the left lobe, and part of the right lobe of the liver, with the gall-bladder, part of the stomach, including both orifices, the first and second parts of the duodenum, the duodeno-jejunal flexure, the pancreas, upper or inner end of the spleen, parts of the kidneys, and the suprarenal bodies.
Hypochondriac, right	{ The greater part of the right lobe of the liver, the hepatic flexure of the colon, and part of the right kidney.
Hypochondriac, left	{ Part of the stomach, with the greater portion of the spleen and the tail of the pancreas, the splenic flexure of the colon, part of the left kidney, and sometimes a part of the left lobe of the liver.
Umbilical	{ The greater part of the transverse colon, the third part of the duodenum, some convolutions of the jejunum and ileum, with portions of the mesentery and great omentum, and part of the right, or sometimes of both kidneys.
Lumbar, right	{ The ascending colon, part of the right kidney, and sometimes part of the ileum.
Lumbar, left	{ The descending colon, part of the jejunum, and sometimes a small part of the left kidney.
Hypogastric	{ The convolutions of the ileum, the bladder in children, and when distended in adults also, the uterus when in the gravid state, and behind, the sigmoid loop and upper part of the rectum.
Iliac, right	{ The cæcum with the vermiform appendix, and the termination of the ileum.
Iliac, left	{ The sigmoid colon, convolutions of the jejunum and ileum.

Abdominal wall.—The wall of the abdomen is formed at the front and sides mainly by muscles, and the forms to be recognized on the surface are for the most

¹ See D. J. Cunningham, *Delimitation of the Regions of the Abdomen*, Journal of Anatomy, xxviii, 1893.

part to be referred to these. Anteriorly, the rectus muscle extends on each side of the middle line from the pelvis to the thorax, its tendinous inscriptions producing transverse furrows, of which two are commonly to be recognized, one opposite, or just below, the tip of the ensiform process, and the other about midway between this and the umbilicus. In some cases the third may be distinguished about the level of the umbilicus. Between the two recti is a median groove (*abdominal furrow*) continued downwards from the infrasternal fossa, along the surface of the linea alba, as far as, or a little beyond, the umbilicus, where it gradually disappears owing to the approximation and eventual union of the muscles of the two sides. The lower ends of the recti are concealed by a small accumulation of fat.

The position of the umbilicus is subject to considerable variation, but it is always below the centre of the distance between the xiphi-sternal articulation and the pubic symphysis. It is generally on a level with, or slightly above, the highest point of the iliac crest, and opposite the upper part of the fourth, or the distance between the third and fourth lumbar vertebræ.

A line joining the two anterior superior iliac spines usually passes just above the promontory of the sacrum.

The convex surface of the side of the abdomen is formed by the fleshy part of the external oblique muscle, the outline of which can often be seen in front and below. Between this and the outer edge of the rectus there is a shallow depression over the upper portion of the linea semilunaris: this depression terminates above at the margin of the thorax, in the somewhat triangular *infracostal fossa*, the upper boundary of which is formed by the rounded ninth costal cartilage.

In the inguinal region, the superior set of glands may usually be felt lying along Poupart's ligament. The external abdominal ring is placed immediately above and external to the pubic spine, which can always be readily felt, as well as the common attachment of the outer pillar of the ring and Poupart's ligament. By invaginating the scrotum at some distance from the aperture, the finger may be passed through the ring into the lower part of the inguinal canal. The internal or deep abdominal ring is situated about half an inch (1 cm.) above Poupart's ligament, opposite a spot midway between the anterior superior iliac spine and the pubic symphysis; and the deep epigastric artery runs upwards close to the inner side of this opening, in the direction of a line inclining inwards towards the umbilicus. If the inguinal canal has been enlarged by the presence of an old hernia, the rings are almost opposite to one another, and the finger may be passed through them and can explore the surrounding parts in the interior of the abdomen.

The superficial epigastric vein is often seen through the skin, and it may frequently be observed to communicate with another vein (*v. thoraco-epigastrica*) that passes up into the armpit to join the axillary vein, especially if there be any obstruction to the return of the blood through the inferior vena cava.

Abdominal viscera.—The **liver**, which occupies the whole of the arch of the diaphragm on the right, as well as a part on the left side, is placed for the most part under cover of the ribs. In the right hypochondriac region, its lower margin just corresponds to the lower border of the thorax, but in the epigastric region, a part of both right and left lobes comes into contact with the abdominal wall; the margin of this part runs obliquely across the subcostal angle from the ninth right to the eighth left costal cartilage, and crosses the middle line about a hand's breadth below the xiphi-sternal articulation. The gall-bladder projects beyond this margin immediately internal to the ninth costal cartilage, and close to the outer edge of the rectus muscle, *i.e.*, opposite the infracostal fossa. The extent of the liver upwards, if traced on the surface of the body, is marked by a line crossing the body of the sternum close to its lower end, and rising on the right side to the level of the fifth chondro-sternal articulation, on the left to that of the sixth. A

little internal to the right mamillary line, it generally reaches as high as the fourth intercostal space, or nearly to the level of the nipple. On the left side it does not usually extend more than an inch and a half or two inches (4—5 cm.) beyond the margin of the sternum (see fig. 10). It must be borne in mind, however, that the liver is subject to great variations, not only in size, but also in position, both temporarily and permanently. Thus, it sinks with inspiration, and rises in expiration; it descends slightly on assuming the upright position; and it is frequently moved downwards by alterations in the shape of the chest. It is relatively very large in the infant and child, and extends across far into the left hypochondriac region. In adults, the margin of the liver is seldom to be felt below the ribs on the right side during health, unless the abdominal wall be unusually thin.

The **stomach** lies in the left hypochondriac and the epigastric regions, in the latter being partly covered by the liver and partly in contact with the abdominal wall. Its cardiac orifice is situated behind the seventh costal cartilage of the left side about an inch (2·5 cm.) from the sternum, and at a depth of about four inches (10 cm.) from the surface. The pyloric orifice is from three to four inches (8—10 cm.) below the xiphi-sternal articulation, and, when the stomach is contracted, in or immediately to the right of the median plane; but when the stomach is distended, the pyloric end moves considerably to the right. The pyloric orifice is much nearer to the surface than the cardiac. The fundus of the stomach is directed upwards into the left portion of the vault of the diaphragm, and reaches, under ordinary circumstances, to the level of, or somewhat higher than, the sixth chondrosternal articulation, or in the mamillary line to the fifth rib, being a little above (and behind) the apex of the heart. The great curvature of the stomach is directed at first to the left, and afterwards downwards, the latter part reaching, with a moderate degree of distension of the organ, about as far as the infracostal line.

Large intestine.—The transverse colon passes across in the upper part of the umbilical region, following closely the great curvature of the stomach. The cæcum is comparatively superficial in the right iliac region; the ascending colon and the hepatic flexure are deeply placed in the right lumbar and hypochondriac regions. The splenic flexure reaches a higher level than the hepatic, and is situated behind the stomach in the left hypochondriac region, while the descending colon occupies the hinder part of the left hypochondriac and lumbar regions. Deep pressure on the left side detects the sigmoid colon as it passes over the brim of the pelvis, in thin persons even when comparatively empty; if distended with fæces, it forms a distinct tumour in this situation.

Small intestine.—The intestines below the stomach are all covered more or less completely by the great omentum. The coils of the small intestine occupy the anterior part of the belly below the transverse colon, those of the jejunum being principally found above, those of the ileum below. The upper limit of the attachment of the mesentery, corresponding to the duodeno-jejunal flexure, is commonly between three and four inches (8—10 cm.) above the umbilicus and slightly to the left of the median line, while the lower end is, on an average, four inches (10 cm.) from the centre of Poupart's ligament of the right side, along a line directed upwards and somewhat inwards, following the course of the psoas muscle (Lockwood). The termination of the ileum in the large intestine corresponds generally to a spot on the anterior abdominal wall from one to two inches (3—5 cm.) internal to, and slightly above, the anterior superior iliac spine.

In children under ordinary circumstances, and in adults when it is distended, the **bladder** rises out of the pelvis into the hypogastric region, being closely applied to the anterior abdominal wall without the intervention of peritoneum for some distance above the pubic bones; if the distension be excessive, the bladder may reach nearly as far as the umbilicus.

The **kidneys**, being situated at the back of the abdominal cavity, are not to be felt under normal conditions, or at most the right is at times to be detected. They are lodged on each side mainly in the epigastric and hypochondriac regions. That of the right side usually extends slightly into the umbilical and lumbar regions; but on the left side the organ is frequently altogether above the infracostal plane.

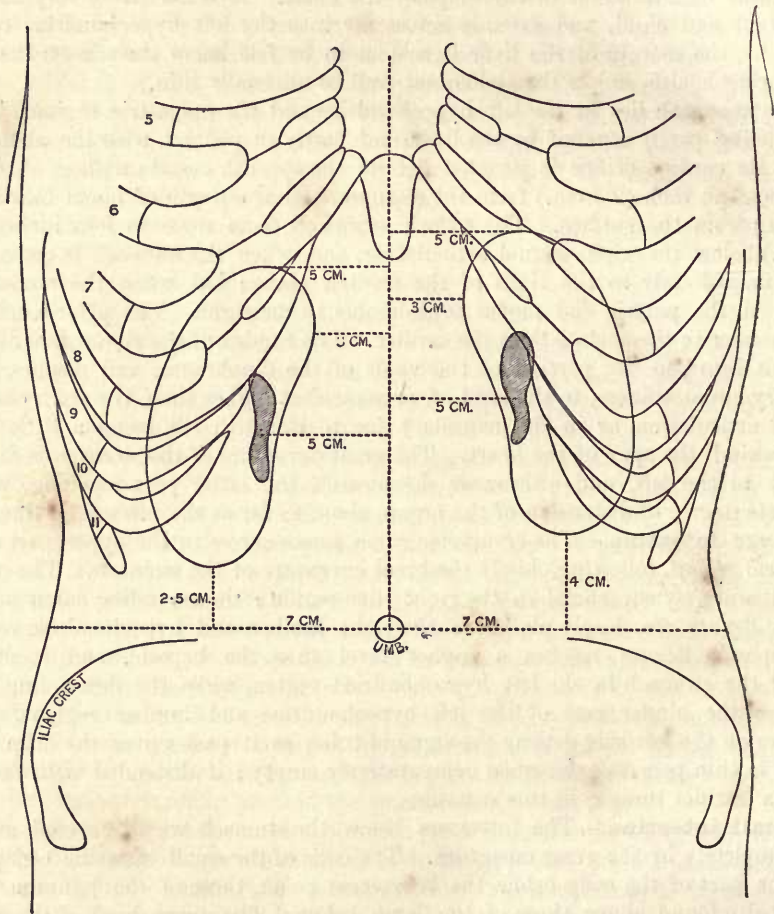


Fig. 12.—DETERMINATION OF THE POSITION OF THE KIDNEYS ON THE FRONT OF THE BODY: SCHEME.
(R. J. G. and G. D. T.)

The inferior pole of the kidney is about two and a half to three inches (6—7 cm.) from the median plane, and on the right side is about an inch (2—3 cm.) above the level of the umbilicus, while on the left side it is in the majority of cases about half an inch (1—2 cm.) higher. The length of the kidney being generally from four to four and a half inches (10—12 cm.), the position of the superior pole is indicated by a spot a corresponding distance above the level of the inferior pole, and about two inches (5 cm.) from the middle line. This spot is above the margin of the thorax, and is generally over the sixth or seventh costal cartilage, about the place where the interchondral articulation is formed between these cartilages. The shortest distance between the two kidneys, at the upper part of their mesial borders,

measures about two and a half inches (6 cm.): the hilum, which looks mainly forwards, is about two inches (5 cm.) from the median plane.

Like other abdominal organs, the kidneys are subject to considerable variations in size and position; and they are frequently found at a lower level than that just given. In the female they are situated as a rule slightly lower than in the male; and during childhood, when the kidneys are relatively of large size, they are at the same time lower and more symmetrically placed than in the adult.¹

The **pancreas** lies over the first and second lumbar vertebræ, from two and a half to five inches (6 to 12 cm.) above the umbilicus; and the **third part of the duodenum** crosses the spine at a lower level, often reaching nearly to the umbilicus.

Abdominal vessels.—The abdominal aorta commences rather above the midpoint between the infrasternal depression and the umbilicus, and passes downwards usually a little to the left of the middle line of the body, although its lower end often occupies a median position, or may even extend over slightly to the right. The bifurcation occurs on the average about three-quarters of an inch (2 cm.) below the umbilicus, and the direction of the common and external iliac arteries is indicated by drawing a line from this point to another midway between the pubic symphysis and the anterior superior spine of the ilium. The inferior vena cava lies just to the right of the aorta.

The cœliac axis arises opposite the lower part of the last dorsal vertebra, *i.e.*, between four and five inches (10—12 cm.) above the umbilicus; the superior mesenteric artery a very little lower; the two renal arteries from three and a half to four inches (9—10 cm.), and the inferior mesenteric about one inch (2·5 cm.) above the umbilicus.

THE BACK.

At the back of the neck, a slight median depression—the *nuchal furrow*, commencing immediately below the external occipital protuberance—descends over the ligamentum nuchæ, between the prominences formed by the complexus and trapezius muscles of the two sides. By pressing deeply in this furrow, the spine of the axis is readily felt, and generally also the spines of the third, fourth, fifth, and sixth cervical vertebræ less distinctly. The furrow disappears gradually towards the root of the neck, where the spines of the seventh cervical and upper one or two dorsal vertebræ become visible. The first spine to appear is usually that of the seventh cervical vertebra, but sometimes the sixth is long and comes to the surface: the most prominent is the first dorsal. They necessarily project more plainly when the neck is inclined forwards. Below these, the long *spinal* or *dorso-lumbar furrow* descends in the middle line between the elevations formed by the erector spinæ muscles covered on each side above by the trapezius and below by the latissimus dorsi. The furrow is deepest in the lower dorsal and upper lumbar regions, where the muscles are thickest and most fleshy; in the lower lumbar region and over the upper part of the sacrum, the erector muscles are tendinous, and give rise to a somewhat lozenge-shaped flattened area through which the groove is continued, becoming gradually shallower, to terminate at the spine of the third piece of the sacrum (last sacral spine) in the angle formed by the meeting of the right and left gluteus maximus muscles. A little above and external to this point, a slight depression indicates the position of the posterior superior iliac spine. At the bottom of the spinal furrow, the spines may be felt and counted, the middle dorsal ones generally with considerable difficulty in the erect position, but most of them are rendered very evident by

¹ See *Second Annual Report of Committee of Collective Investigation of Anat. Soc.*, 1890–91, by Arthur Thomson, *Journ. Anat.*, xxvi, 83; also F. Helm, *Beiträge zur Kenntniss der Nieren-Topographie*, Diss., Berlin, 1895.

bending the column forwards. The fourth lumbar spine is on a level with the highest part of the crest of the ilium: the third lumbar spine is generally somewhat higher than the umbilicus.

The spine of the scapula is easily felt beneath the skin, and may be traced outwards (very little upwards when the arm is hanging) to the acromion, which is represented on the surface by a depression in a muscular subject, or when the arm is raised. The lower border of the spine and the outer border of the acromion meet in the prominent *acromial angle*, which is always to be distinctly recognized on the surface; from this point measurements of the length of the arm are most conveniently taken. The vertebral border and the inferior angle of the scapula are seen, although covered for the most part by muscles, the former by the trapezius, the latter by the latissimus dorsi. The superior border cannot usually be distinguished, but the axillary border can be felt more or less distinctly through its thick muscular covering. With the arms hanging by the side, the upper angle of the scapula corresponds to the upper border of the second rib, or the interval between the first and second dorsal spines; the lower angle to the seventh intercostal space (sometimes the eighth rib) or the interval between the seventh and eighth dorsal spines; and the root of the spine of the scapula to the interval between the third and fourth dorsal spines. The vertebral border of the bone is at the same time nearly perpendicular.

At the inner end of the spine of the scapula, a distinct depression indicates the triangular tendon in which the lower fibres of the trapezius end; and a slight groove, which is seen at times passing upwards and outwards over the surface of the eminence formed by the erector spinæ, in the direction of a line from one of the lowest dorsal spines to the triangular tendon, marks the lower edge of the muscle. Immediately above the spine of the scapula is a convex surface formed by the thickest part of the trapezius covering the supraspinatus muscle; and above this, the sloping surface leading down from the neck to the shoulder is formed by the upper part of the trapezius, supported by the levator anguli scapulæ and by fat.

The lower ribs are to be felt through the latissimus dorsi, outside the edge of the erector spinæ; but it must be borne in mind that the twelfth rib is often very short and does not project beyond the margin of the erector muscle, so that the lowest rib that can then be felt is the eleventh. The ribs should, therefore, always be counted from above downwards, and not from below upwards.

The **lower end of the larynx and pharynx**, and the commencement of the trachea and œsophagus are about on a level with the interval between the sixth and seventh cervical spines. From this spot the **trachea** descends, at first in the middle line, and then inclining slightly to the right divides opposite the fourth dorsal spine into the two **bronchi**. The latter are thence directed outwards and downwards, the right usually more nearly in the line of the trachea, and the left becoming more transverse in direction, to the hilum of the lung, which they enter about the level of the fifth dorsal spine. In the lung the main prolongation of the bronchus descends, accompanied by corresponding pulmonary vessels, which are placed dorsally to the air-tube, about one and a half or two inches (4—5 cm.) from the median plane, towards the hinder part of the base of the lung.

Lungs and pleuræ.—The apex of the lung, corresponding to the neck of the first rib, extends up to the level of the seventh cervical spine. Mesially, the lungs touch the sides of the bodies of the vertebræ; and inferiorly, they reach down to the tenth dorsal spine, the pleura to the eleventh or even lower, as has already been described (p. 20).

The **œsophagus**, from its commencement, inclines at first somewhat to the left, but regains the middle line about the fifth dorsal vertebra; in its lower part it is deflected more considerably to the left, and it terminates at the cardiac orifice of the

stomach about on a level with the ninth dorsal spine. The **pyloric orifice of the stomach** is to the right of the twelfth dorsal spine.

Aorta.—The arch of the aorta reaches the left side of the vertebral column just above the fourth dorsal spine, and the descending aorta passes downwards, gradually

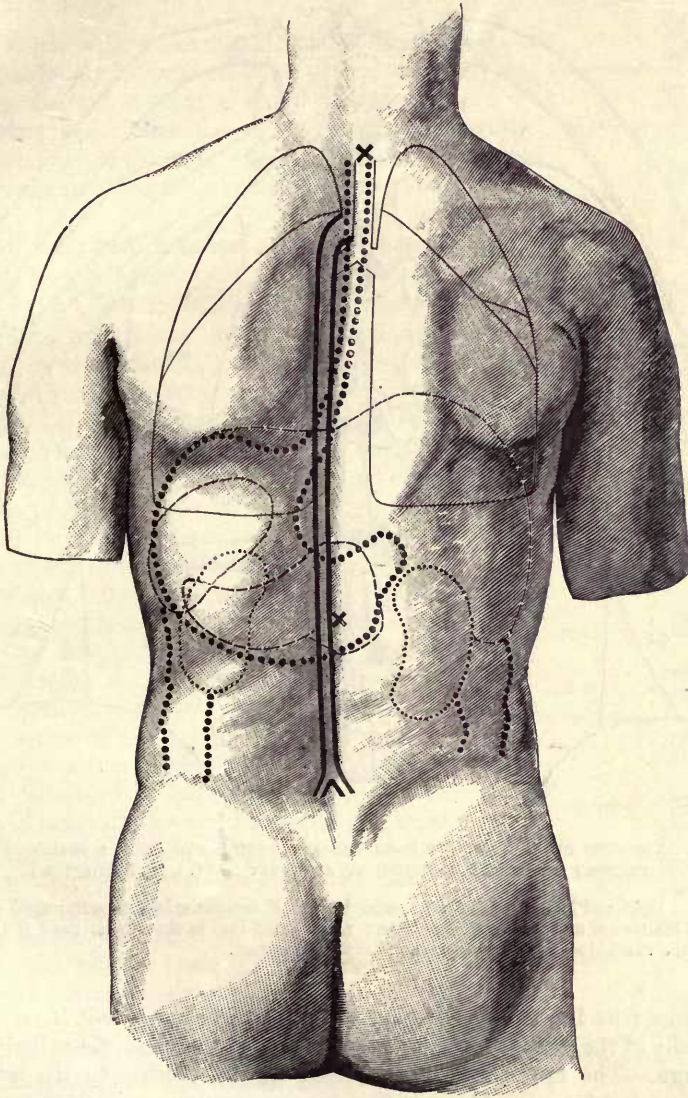


Fig. 13.—POSTERIOR VIEW OF THE TRUNK, SHOWING THE RELATIVE POSITIONS OF THE PRINCIPAL THORACIC AND ABDOMINAL VISCERA, &c. (R. J. G. and G. D. T.) $\frac{1}{2}$.

The several objects are indicated in the same manner as in fig. 10, the trachea and lungs by thin lines, the aorta by thick lines, the liver, pancreas and spleen by broken lines, the œsophagus, stomach, ascending and descending colon by thick dotted lines, and the kidneys by thin dotted lines; ×, ×, seventh cervical and first lumbar spines.

inclining to the front of the column, to bifurcate at a spot in, or close to, the median plane, on a level with the fourth lumbar spine. The celiac axis arises opposite the twelfth dorsal, the renal arteries opposite the first lumbar spine.

The convex surface of the **spleen** looks backwards and somewhat outwards. It

is placed beneath the ninth, tenth and eleventh ribs of the left side, being separated from them by the diaphragm, and at its upper part also by the lung. It lies very obliquely, its long axis coinciding almost exactly with the line of the tenth rib. Its highest and lowest points are on a level respectively with the ninth dorsal and first

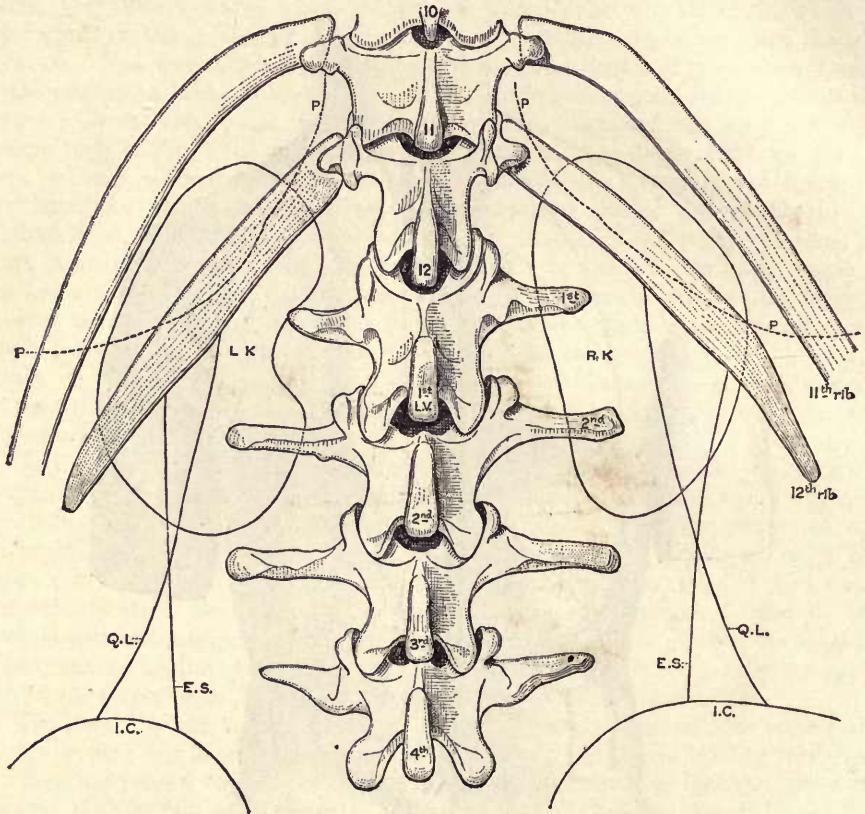


Fig. 14.—OUTLINE VIEW OF THE KIDNEYS FROM BEHIND, CONSTRUCTED FROM A SERIES OF HORIZONTAL SECTIONS THROUGH THE TRUNK OF AN ADULT MALE. (J. Symington.)

R.K., L.K., right and left kidneys; E.S., outer border of erector spinae muscle; Q.L., outer border of quadratus lumborum muscle; I.C., iliac crest; P.P., dotted line to show lower limit of costal pleura. In this case the two kidneys were nearly symmetrical in position.

lumbar spines; its inner end is distant about an inch and a half (4 cm.) from the median plane of the body, and its outer end about reaches the mid-axillary line.

Kidneys.—The upper end of the right kidney reaches to the level of the eleventh dorsal spine; the lower end is on an average one inch (2.5 cm.) above the iliac crest, and a little below the level of the second lumbar spine; the hilum is opposite the first lumbar spine. The last rib, when well developed, is sloped downwards and outwards at an angle of about 45° with the vertical, and crosses the posterior surface of the kidney in such a way that about one-third of the organ is under cover of the thoracic wall. The left kidney is, as a rule, about half an inch (1–2 cm.) higher than the right. In the female and child the kidneys are somewhat lower than in the adult male, and not unfrequently reach down as far as the iliac crest (*cf.* p. 26).

Colon.—The ascending and descending portions of the colon pass vertically along the outermost part of the right and left kidneys respectively ; the part of the

Fig. 15.—DIAGRAM SHOWING THE VARYING RELATIONS OF THE ROOT-ORIGINS OF THE SPINAL NERVES TO THE SPINES OF THE VERTEBRÆ. (After R. W. Reid.)

intestine which is in contact with the abdominal wall is placed immediately internal to a line carried vertically upwards from the central point of the iliac crest.

The **pancreas** crosses the spinal column opposite the twelfth dorsal and first lumbar spines, and the **third part of the duodenum** from the second to the third lumbar spine.

Spinal cord and origins of spinal nerves.—The lower end of the spinal cord in the adult corresponds generally to the interspace between the first and second lumbar spines, and is not subject to much variation in level ; but in the infant it reaches to the third lumbar spine. The cervical enlargement extends downwards to about the seventh cervical spine, and the lumbar enlargement corresponds mainly to the last three dorsal spines.

The relations of the origins of the spinal nerve-roots to the spinous processes of the vertebræ vary to some extent in different individuals, especially in the thoracic region, the range of any given dorsal nerve-root being about equal to the distance between three adjoining spines, or two interspinous intervals, as is shown in the accompanying diagram (fig. 15) constructed from the observations of R. W. Reid upon six subjects. The following rules will, however, serve to indicate with sufficient accuracy the average position of the several nerve-roots :—The second cervical nerve arises opposite the neural arch of the atlas, the third opposite the spine of the axis, and the fourth opposite the interval between the second and third cervical spines. The lower four cervical nerves arise each opposite the spine of the second vertebra above the place of exit of the nerve from the spinal canal. The origins of the upper six dorsal nerves are about on a level with the spines of the third, and of the lower six with the spines of the fourth vertebra above their respective places of exit. The lumbar nerves arise in the neighbourhood of the tenth and eleventh dorsal spines, and the sacral nerves between the eleventh dorsal and first lumbar spines.

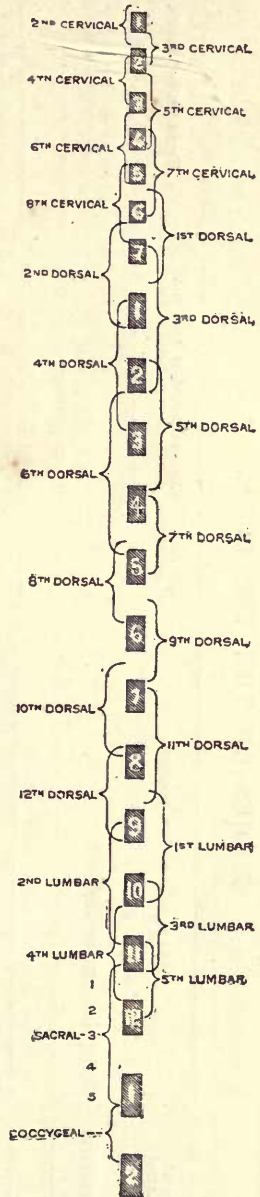


TABLE SHOWING THE LEVELS OF VARIOUS STRUCTURES IN THE TRUNK IN RELATION TO THE BODIES OF THE VERTEBRÆ.

Bodies of Vertebræ.	Origins of Spinal Nerves.	Objects, with average position.	Ribs and Cartilages divided by horizontal sections at middle of vertebral bodies.	Front Wall of Trunk.
1. and 2. cerv.	2. and 3. cervical.	Soft palate and mouth.		
3. cerv.	4. cervical.	Base of tongue. Upper end of epiglottis. Angle of lower jaw.		
4. cerv.	5. cervical.			
	6. cervical.	Hyoid bone. Superior aperture of larynx. Bifurcation of common carotid artery.		
5. cerv.	7. cervical.			
	8. cervical.	Thyroid cartilage, with rima glottidis.		
6. cerv.	1. dorsal.	Cricoid cartilage.		
		Lower end of pharynx and larynx. Beginning of trachea and œsophagus.		
7. cerv.	2. dorsal.	Arch of thoracic duct.		
1. dors.	3. dorsal.	Apex of lung. Summit of arch of subclavian artery. Acromio-clavicular articulation.	1. rib.	Outer end of clavicle.
		Upper angle of scapula.		
2. dors.	4. dorsal.	Bifurcation of innominate artery. Acromion.	2. 1. ribs.	Inner end of clavicle. Upper edge of manubrium.

3. dors.	5. dorsal.	Innminate artery and veins. Spine of scapula. Beginning of superior vena cava.	3. 2. 1. ribs ; 1 cart.	1. costal cartilage.
4. dors.	6. dorsal.	Highest part of arch of aorta. Root of spine of scapula. Lower edge of glenoid cavity.		
5. dors.	7. dorsal.	Arch of aorta.	4. 3. 2. ribs.	
		Bifurcation of trachea. Arch of azygos vein. End of arch of aorta.		
6. dors.	8. dorsal.	Right and left bronchi. Left pulmonary artery. Highest part of roots of lungs. Descending aorta.	5. 4. 3. 2. ribs ; 2. cart.	Junction of manubrium with body of sternum ; 2. chondro-sternal articulation.
		Highest part of heart. Division and right branch of pulmonary artery.		
		Ascending aorta. Pulmonary artery. Right and left auricles. Left bronchus.	6. 5. 4. 3. ribs.	
7. dors.	9. dorsal.	End of superior cava. Pulmonary orifice.		3. chondro-sternal articulation.
		Aortic orifice. Infundibulum of right ventricle. Both auricles.	7. 6. 5. 4. ribs.	
8. dors.	10. dorsal.	Left ventricle. Lowest part of roots of lungs.		
		Lower angle of scapula. Four cavities of heart. Both auriculo-ventricular apertures.	8. 7. 6. 5. 4. ribs ; 4. cart.	4. chondro-sternal articulation. Nipple.
9. dors.	11. dorsal.	Right vault of diaphragm. Orifice of inferior cava. Right auriculo-ventricular aperture.		
		Liver.	9. 8. 7. 6. 5. ribs ; 5. cart.	5. chondro-sternal articulation. 6. chondro-sternal articulation.
10. dors.	12. dors. 1. lumb.	Left vault of diaphragm and fundus of stomach. Lowest part of heart. Central leaflet of diaphragmatic tendon.		Xiphisternal articulation ; 7. chondro-sternal articulation.
		Cardiac orifices of stomach.	10. 9. 8. 7. 6. ribs ; 6. 7. cart.	Ensiiform process.
		Upper limit of spleen.		

TABLE SHOWING THE LEVELS OF VARIOUS STRUCTURES IN THE TRUNK IN RELATION TO THE BODIES OF THE VERTEBRÆ—*continued.*

Bodies of Vertebrae.	Origins of Spinal Nerves.	Objects, with average position.	Ribs and Cartilages divided by horizontal sections at middle of vertebral bodies.	Front Wall of Trunk.
11. dors.	2. and 3. lumbar.	Lower margin of lung posteriorly. Upper end of left kidney. Suprarenal bodies. Upper end of right kidney.	11. 10. 9. 8. 7. ribs ; 7. cart.	
12. dors.	4. and 5. lumbar.	Lower boundary of pleura behind. Foramen of Winslow. Pyloric orifice and first part of duodenum. Splenic flexure of colon.	12. 11. 10. 9. 8. 7. ribs ; 7. 8. cart.	
1. lumb.	1. sacral. 2. 3. 4. 5. sacral.	Beginning of abdominal aorta, and origin of cœliac axis. Pyloric orifice and first part of duodenum. Origin of superior mesenteric artery. Hepatic flexure of colon. Pancreas. Receptaculum chyli. Hila of kidneys. Renal arteries. Lower end of spleen.	12. 11. 10. 9. 8. ribs ; 8. cart.	
2. lumb.	coccygeal.	End of spinal cord. Head of pancreas. Duodeno-jejunal flexure. Lower end of left kidney.	11. 10. 9. ribs ; 9. cart.	
3. lumb.		Lowest part of liver. Lower end of right kidney. Third part of duodenum. Origin of inferior mesenteric artery. Infracostal plane.	(10. 11. ribs and cart. ?)	
4. lumb.		Bifurcation of aorta. Highest part of iliac crest.		Umbilicus.
5. lumb.		Beginning of inferior vena cava. Bi-iliac plane. Bifurcation of common iliac artery.		Anterior superior iliac spine.

SUPERFICIAL ANATOMY OF THE UPPER LIMB.

THE SHOULDER.

In the region of the shoulder, the outer part of the clavicle and the acromion process of the scapula can be distinctly felt beneath the skin, and the extremity of the former bone usually gives rise to a marked elevation at its junction with the acromion. The rounded prominence of the shoulder is formed immediately by the thick deltoid muscle, but it is also due in great measure to the large upper extremity of the humerus, which can be felt moving under the muscle as the arm is rotated. Close to the inner side of the shoulder-joint, and just below the clavicle, the coracoid process is to be recognized in the infraclavicular fossa (see below); and by pressing deeply in the axilla, when the arm is abducted, the lower margin of the glenoid cavity and the head of the humerus are also to be felt.

The adjacent margins of the deltoid and pectoralis major are closely united together at their lower parts, so that the division between the two muscles is not indicated on the surface; but superiorly, they are separated by a triangular interval of variable breadth, which gives rise to the well-marked *infraclavicular fossa*. By pressing deeply in this fossa, the axillary artery may be compressed against the second rib. The back of the shoulder is flattened, and sloped from within outwards and a little forwards, owing to the oblique position of the scapula; and the hinder portion of the deltoid, which is thinner than the anterior, is tendinous at its origin, and adheres closely to the subjacent infraspinatus muscle, so that the upper part of its margin is not indicated upon the surface. The infraspinatus is continued into the teres minor, and below the latter muscle is the thick teres major, with the latissimus dorsi winding round it, forming the posterior fold of the axilla. When the arm is abducted, the middle portion of the deltoid, being brought into action, is seen to present an irregular surface, the prominences corresponding to the separate fleshy portions of the muscle, and the depressions to the tendinous septa extending downwards from the acromion.

The course of the axillary artery is marked upon the surface by a line drawn from the mid-point of the clavicle to the inner border of the elevation formed by the coraco-brachialis muscle (see below). If the limb be raised from the side, the third part of the artery may be felt pulsating beneath the integument and fascia (the vein intervening) as it passes into the arm, being placed at the junction of the anterior and middle thirds of the space between the axillary folds. The artery may be readily compressed here against the humerus. The posterior circumflex vessels and the circumflex nerve are winding round the back of the humerus under cover of the deltoid, at the junction of the upper and the middle thirds of the muscle.

THE ARM.

The shaft of the humerus is for the most part thickly covered by the muscles of the arm, and can only be felt with difficulty; but just below the insertion of the deltoid the bone comes nearer to the surface, and from this spot the outer border, or the external supracondylar ridge, can be followed down to the outer condyle, along the bottom of a furrow over the external intermuscular septum, between the supinator longus and triceps muscles. The internal supracondylar ridge is less prominent, and not so readily felt.

Along the fore and inner part of the arm (when hanging naturally by the side) is the eminence formed by the biceps muscle, extending, with a slight inclination outwards below, from the anterior margin of the axilla to the elbow. Superiorly, this is continued into a narrow elevation produced by the coraco-brachialis muscle, which issues from between the anterior and posterior axillary folds. Two depressions, the *inner* and *outer bicipital furrows*, are found on the inner and outer

side respectively of the prominence of the biceps; along the outer of these the cephalic vein may generally be seen ascending beneath the skin; in the inner, which is better marked, are placed the basilic vein (in its lower half or less superficial to the fascia), the brachial vessels and the median nerve. The brachial artery

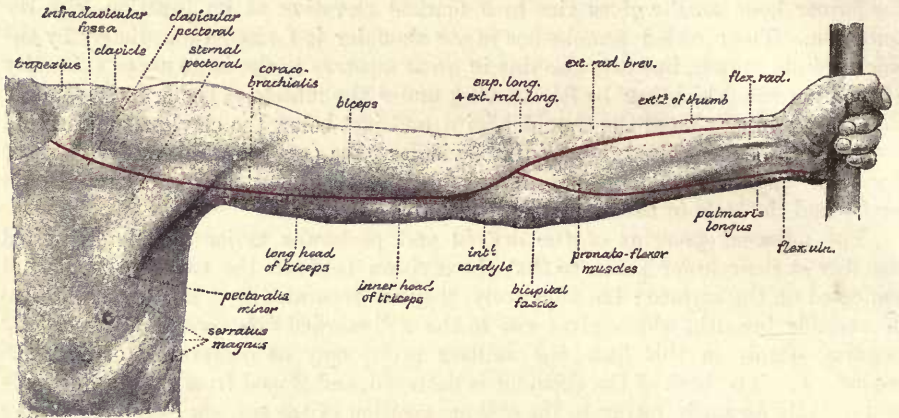


Fig. 16.—SUPERFICIAL ANATOMY OF THE UPPER LIMB: ANTERIOR VIEW. (From a photograph by G. W. B. Waters.) (R. J. G. & G. D. T.)

is usually overlapped to some extent by the margin of the biceps, but it can be felt pulsating throughout. Pressure should be applied to the vessel from within outwards in the upper half of the arm, from before backwards in the lower.

On the outer side of the biceps, a portion of the brachialis anticus comes to the surface, and beyond that the supinator longus and extensor carpi radialis longior form a prominence which descends to the forearm in front of the external condyle;

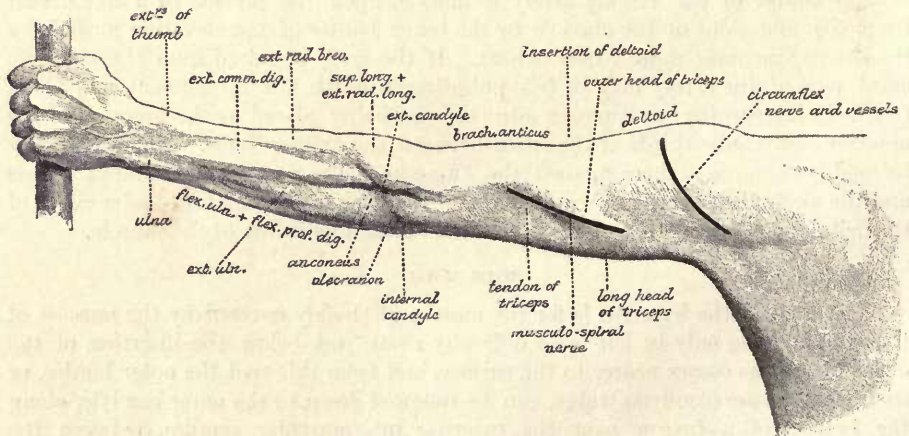


Fig. 17.—SUPERFICIAL ANATOMY OF THE UPPER LIMB: POSTERIOR VIEW. (From a photograph by G. W. B. Waters.) (R. J. G. & G. D. T.)

the supinator muscle shows very plainly if the elbow be forcibly flexed with the hand in a state of semipronation. On the inner side of the biceps, in the lower part of the arm, a smaller portion of the brachialis anticus is superficial, and between this and the triceps, the internal intermuscular septum can be felt, with the ulnar nerve close behind it, descending to the internal condyle.

The form of the back of the arm is determined by the triceps muscle, the three heads of which, together with the large tendon of insertion, are to be recognized when the muscle is called into play. The inner head is the least distinct; the outer head forms a large prominence immediately below the hinder border of the deltoid; the long head can be seen issuing from between the teres major and minor muscles, and descending along the middle of the back of the arm; while the tendon is represented by a depressed area, leading down to the olecranon process of the ulna. The musculo-spiral nerve begins to incline backwards immediately below the posterior fold of the axilla, and crosses the back of the humerus obliquely from within outwards in its middle third, being covered by the long and outer heads of the triceps muscle, and accompanied by the superior profunda vessels. At, or a little above, the junction of the middle and lower thirds of the arm, the nerve perforates the external intermuscular septum, and it then descends in front of the outer supracondylar ridge, and under cover of the supinator longus muscle, to the level of the external condyle, where it divides into the radial and posterior interosseous nerves. The former takes a straight course downwards to join the artery of the same name below the elbow; but the posterior interosseous is directed backwards across the outer side of the radius in its upper fourth, to gain the back of the forearm.

THE ELBOW.

At the elbow, the internal and external condyles come to the surface, and also the olecranon process of the ulna. The internal condyle, which, it will be remembered, is directed more backwards than inwards, is very prominent, and forms one of the most important bony landmarks of the limb. The external condyle, together with the common tendon of the extensor muscles of the forearm, gives rise, when the joint is extended, to a well-marked depression at the outer and back part of the elbow, between the supinator longus and extensor carpi radialis longior muscles externally, and the anconeus internally. In this hollow, when the muscles are relaxed, the head of the radius may be felt below the external condyle and the capitellum. If the elbow be semi-flexed, the condyle is slightly prominent; and in extreme flexion, the outer part of the triceps muscle is stretched over the capitellum of the humerus, which forms a rounded eminence to the outer side of the point of the elbow (olecranon), while the condyle itself is no longer visible. The olecranon is subcutaneous at its posterior surface, its upper end being entirely covered by the insertion of the triceps; its appearance necessarily varies with the position of the joint, as does also the distance between the process and the shoulder. A bursa is interposed between the bone and the skin.

At the bend of the elbow, the subcutaneous veins are more or less distinctly visible, according to the quantity of subcutaneous fat:—the median vein bifurcating into the median-basilic and median-cephalic, which join respectively the ulnar and radial veins to form the basilic and cephalic. The median-basilic and median-cephalic veins, diverging from each other, pass upwards on either side of the biceps tendon, which is seen, when the elbow is bent, descending from the lower end of the muscular belly into the interval between the two masses of forearm muscles. The sharp upper edge of the bicipital fascia may also be felt, and, when the muscle is forcibly contracted, seen, as it passes downwards and inwards between the median-basilic vein and the lower part of the brachial artery. The pulsation of the latter vessel may be felt, and often seen, as it passes obliquely downwards and outwards to a point a little below the middle of the bend of the elbow.

THE FOREARM.

From the olecranon, the sinuous posterior border of the ulna is to be followed down the forearm, corresponding to a superficial furrow between the ulnar flexor and extensor muscles of the wrist; the border becomes rounded off in the lower third, but a narrow strip of the bone is still subcutaneous, leading down to the styloid process. When the hand is supinated, the styloid process of the ulna is exposed at the inner and posterior part of the wrist; but if the hand be pronated, then the skin is stretched over the opposite (outer) part of the head of the ulna, which projects between the extensor carpi ulnaris and extensor minimi digiti muscles. Close below the outer condyle of the humerus the head of the radius may be felt moving beneath the muscles, more distinctly when the elbow is bent, as the forearm is alternately pronated and supinated. The upper half of the shaft of the radius is too thickly covered by muscles to be distinctly made out; the lower half is nearer to the surface, and can be readily examined between and through the surrounding muscles and tendons; at the lower end, the styloid process, which descends rather lower than the styloid process of the ulna, is superficial in front and behind, being covered externally by the tendons of the extensor ossis metacarpi and extensor brevis (ext. primi internodii) pollicis muscles; and the prominent tubercle on the outer side of the groove for the extensor longus pollicis (ext. secundi internodii) is also to be distinguished.

Along the inner and fore part of the forearm is the prominence formed by the pronato-flexor muscles, the great mass covering the ulna internally being formed by the flexor profundus digitorum beneath the flexor carpi ulnaris. A short distance below the internal condyle, a slight groove runs obliquely downwards and inwards across the muscles, caused by the prolongation of the fibres of the bicipital fascia. Near the wrist, the tendon of the flexor carpi ulnaris can be felt, passing down to the pisiform bone, and immediately external to the tendon the beating of the ulnar artery is perceptible: when the wrist is extended a groove marks the position of the tendon. About the centre of the front of the wrist the tendon of the palmaris longus descends, being the most prominent of all the tendons here, and a little external to this, the tendon of the flexor carpi radialis is also visible. It will however be remembered that the palmaris longus is often wanting. Outside the tendon of the flexor carpi radialis is a hollow in which the radial vessels are placed, and where the pulse is commonly felt: immediately internal to the tendon lies the median nerve.

Along the outer border of the forearm, the long supinator and radial extensor muscles of the wrist descend, becoming tendinous and smaller below the middle; and in the lower third of the forearm a smaller prominence, directed obliquely downwards, outwards and forwards, results from the presence of the extensor muscles of the thumb crossing over the long tendons. On the back of the forearm are the extensors of the fingers, the extensor carpi ulnaris, and the anconeus, all of which may be individually distinguished in thin persons.

Numerous cutaneous veins are seen on the forearm, arising principally from the network on the dorsum of the hand, and forming two main trunks, the posterior ulnar and the radial, which ascend respectively along the inner and outer borders of the limb, and incline forwards to their terminations in front of the elbow; in many cases another large vein is present (assisting or even replacing the radial vein), which turns round the outer border of the forearm below the middle to join the median vein. The subcutaneous veins of the lower part of the front of the forearm (also those of the palm) are small, and terminate in the median and anterior ulnar veins. It occasionally happens that the ulnar artery, having been derived from the brachial at a higher level than usual, descends over the pronato-flexor

muscles to the wrist, and in that case it would be felt pulsating beneath the skin in the neighbourhood of the anterior ulnar vein (Vol. II, p. 445).

The bifurcation of the brachial artery takes place opposite a spot a finger's breadth below the centre of the bend of the elbow. From this point, the radial artery runs downwards with a nearly straight course to the fore part of the styloid process of the radius, being covered by the supinator longus as far as the centre of the forearm, and superficial beyond this spot. The ulnar artery inclines, with a slightly curved course, inwards to the middle of a line drawn from the back of the internal condyle of the humerus to the outer side of the pisiform bone: this line indicates in its whole extent the direction of the ulnar nerve in the forearm, in its lower half that of the ulnar artery also. The latter is deeply placed beneath the muscles arising from the internal condyle till within an inch of the wrist.

THE WRIST AND HAND.

At the front of the wrist, on the inner side, the pisiform bone can be grasped between the fingers, and moved slightly from side to side; below this, and a little more externally, the hook of the ulnar bone can be felt with difficulty. On the outer side, a projection is felt just below and internal to the styloid process of the radius, formed by the tuberosity of the scaphoid bone, and close below this, the ridge of the trapezium is also to be distinguished. At the back of the wrist, on the inner side, the pyramidal bone can be felt, and slightly external to the middle line of the hand is a prominence, sometimes indistinct, but often very well marked, formed by the styloid process on the base of the third metacarpal bone at its articulation with the os magnum.

At the metacarpo-phalangeal articulation of the thumb the sesamoid bones can be felt; and on the dorsal aspect of the hand the metacarpal bones and the phalanges can be distinctly followed.

At the outer side of the wrist, when the thumb is extended, there is a deep hollow bounded by the prominent tendons of the extensor ossis metacarpi and extensor brevis pollicis anteriorly and the extensor longus pollicis posteriorly; the latter tendon may be followed down over the metacarpal bone and first phalanx of the thumb almost to its insertion. Beneath these tendons, and across the intervening hollow, the radial artery runs in its course from the front to the back of the wrist; its direction may be marked by a line drawn from the fore part of the styloid process of the radius to the upper end of the first interosseous space; and a considerable vein, ascending from the outer part of the hand, is usually to be seen through the skin over the position of the artery.

On the back of the hand, the tendons of the extensor communis digitorum and extensor minimi digiti may all be recognized, together with the connecting band between the innermost slip of the common extensor and the outer portion of the little finger tendon. In some cases the tendon of the extensor indicis may also be perceived on the inner side of the first slip of the extensor communis. Between the first and second metacarpal bones is the abductor indicis muscle, which forms a well-marked prominence when the thumb is brought to the side of the index finger, and below this is the adductor transversus pollicis muscle contained in the fold of skin passing across between the thumb and the outer margin of the palm.

The palm of the hand is concave in the centre, where the skin is tightly adherent to the palmar fascia, and raised on each side. The outer elevation (*thenar*) is formed by the outer group of the short muscles of the thumb; the inner (*hypothelar*) by the short muscles of the little finger. From the central hollow of the palm a slight groove is continued downwards to each of the fingers, corresponding to the prolongations of the palmar fascia. The palm is traversed generally by four more or

less regular lines, representing the folds or "flexures" produced in the skin by the movements of the principal joints of the hand. Two of these lines are directed nearly transversely, the others longitudinally. Of the transverse lines, one commences about the junction of the upper three-fourths with the lower fourth of the inner border of the palm, and runs outwards and then downwards to the cleft between the index and middle fingers; this is caused by bending the metacarpophalangeal articulations of the inner three fingers; the second starts nearly opposite the forego, at the outer border of the hand, and is directed inwards and some-

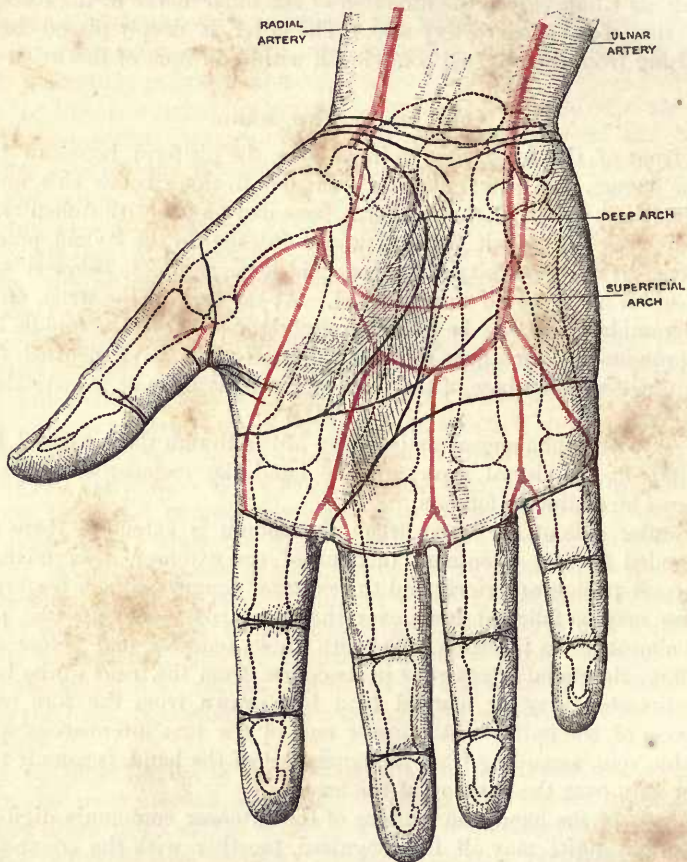


Fig. 18.—PALMAR SURFACE OF THE HAND, SHOWING THE CUTANEOUS LINES AND THE SITUATION OF THE CHIEF ARTERIES IN RELATION TO THE SKELETON. (G. D. T.)

what upwards across the middle of the palm; this results mainly from the flexion of the first joint of the index finger. The metacarpophalangeal articulations are placed about midway between these lines and the web of the fingers. Of the longitudinal lines, one, beginning near the centre of the wrist, curves outwards to join the upper transverse line, and is produced by the opposition of the thumb; the other runs downwards from the wrist through the centre of the palm to meet the lower transverse line opposite the middle finger, and is caused by the opposition of the fifth metacarpal bone. The four lines give rise to a figure resembling the letter M. At the wrist, two or three lines, directed rather obliquely, outwards and a little downwards, indicate the position of the principal folds formed during flexion

of the joint ; the radio-carpal articulation is placed about three-quarters of an inch above the lowest of these lines. There are three well-marked transverse grooves on each finger ; the lower and middle ones are nearly opposite the two interphalangeal joints ; the upper one, which is produced, as well as the transverse lines of the palm, by bending the metacarpo-phalangeal articulations, is placed nearly three-quarters of an inch (15 mm.) below the joint, and on a level with the web of the fingers. On the thumb, there are only two grooves, and the proximal, which is less distinct than the other, continues upwards the line of the radial border of the index finger, thus crossing obliquely the corresponding articulation.

The web of the fingers, containing the superficial transverse ligament, limits the interdigital clefts on the palmar side ; on the dorsum of the hand the clefts are continued upwards almost to the metacarpo-phalangeal joints.

The superficial palmar arch is placed beneath the palmar fascia about the centre of the palm ; its position may be indicated by a line carried from the outer side of the pisiform bone downwards, and then curving outwards across the middle third of the palm on a level with the upper end of the cleft between the thumb and index finger. From the convex side of the arch digital branches proceed, one to the ulnar margin of the little finger, and three which descend opposite the intervals between the fingers and bifurcate about half an inch above the clefts. The deep palmar arch rests against the metacarpal bones about a quarter of an inch nearer the wrist than the superficial arch, and the digital branches given off by the radial artery to the thumb and index finger are deeply placed in the palm, the collateral arteries of the thumb becoming superficial at the base of the first phalanx, that of the index finger issuing from behind the adductor transversus pollicis. The latter branch is not unfrequently derived from the radial artery at the back of the wrist, and may then be felt pulsating as it descends on the posterior surface of the abductor indicis muscle to its destination. The superficial volar artery is occasionally visible as it descends over the upper part of the thenar to the palm.

**SUPERFICIAL ANATOMY OF THE LOWER LIMB,
THE HIP.**

The region of the hip, gluteal region or buttock, extends from the subcutaneous iliac crest and the origin of the gluteus maximus muscle above to the fold of the nates below. The surface is formed posteriorly by the gluteus maximus, which is generally covered by a considerable quantity of fat, and laterally by the gluteus medius, together with, at the foremost part, the tensor vaginae femoris. The latter muscle may be recognized forming a distinct prominence below the anterior part of the iliac crest (fig. 20), especially if the thigh be abducted or rotated inwards. The fold of the nates is formed during extension of the hip by the drawing in of the skin below the level of the ischial tuberosity, and is directed horizontally outwards, crossing the oblique lower border of the gluteus maximus about its middle.

The iliac crest is represented on the surface, in muscular subjects, by a groove (*iliac furrow*), in consequence of the projection of the external oblique muscle

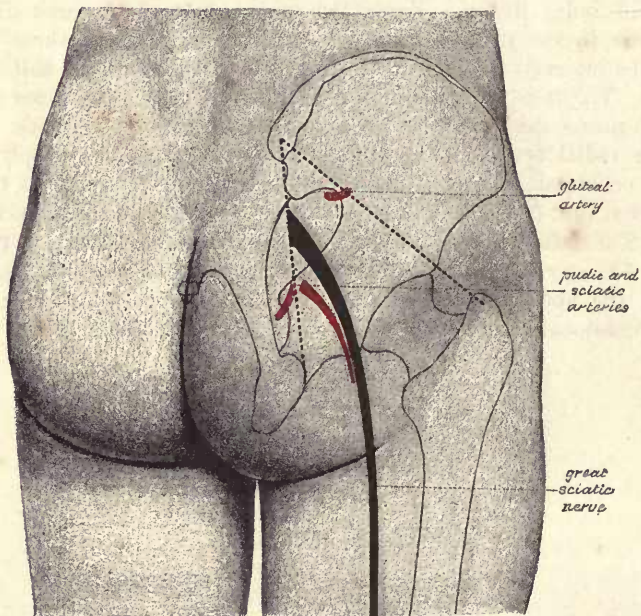


Fig. 19.—POSTERIOR VIEW OF THE HIP, SHOWING THE SITUATION OF THE BONES AND CHIEF ARTERIES, &c.
(R. J. G. & G. D. T.)

above, and, to a less extent, of the gluteus medius below. Traced forwards, this furrow terminates at the anterior superior iliac spine, which is always easily recognized; posteriorly, the furrow becomes less marked as the crest passes below the tendinous portion of the erector spinae, but a slight depression always indicates the position of the posterior superior spine. The latter point is on a level with the spinous process of the second sacral vertebra, and immediately behind the centre of the sacro-iliac articulation. From three to four inches (8—10 cm.) below the iliac crest, and somewhat in front of its central point, the great trochanter is to be felt, and in thin persons seen. The trochanter projects outwards farther than the iliac crest, but it does not usually appear as a prominence on the surface owing to the great thickness of the gluteus medius and minimus muscles, which occupy the hollow between it and the ilium. It is entirely covered by the aponeurotic insertion of the

upper part of the gluteus maximus, and its upper border, which is generally on a level with the centre of the hip-joint, is obscured by the tendon of the gluteus medius descending to its insertion on the outer side of the process. Immediately behind the great trochanter is a well-marked depression, where the lower portion of the gluteus maximus, after passing over the ischial tuberosity, becomes tendinous and sinks in to be inserted into the shaft of the femur.

Beneath the lower border of the gluteus maximus, the tuberosity of the ischium is to be felt, and when the hip is flexed this process is to a great extent uncovered by the muscle. A line drawn over the outer surface of the hip from the anterior superior iliac spine to the most prominent part of the ischial tuberosity is known as *Nelaton's line* (fig. 20), and will be found to pass over the top of the great trochanter and cross the centre of the acetabulum. It thus forms a guide to the natural position of the upper end of the femur, and is consequently of service in detecting dislocations of the hip and fracture of the neck of the bone.

If a line be drawn from the posterior superior iliac spine to the outer part of the ischial tuberosity, it will cross the posterior inferior spine and the ischial spine: the posterior inferior spine is nearly two inches (4 cm.), and the ischial spine about four inches (10 cm.), below the posterior superior spine: the sciatic artery appears in the buttock at the junction of the middle and lower thirds of this line. The gluteal artery leaves the great sacro-sciatic foramen beneath a spot corresponding to the junction of the inner and middle thirds of a line drawn from the posterior superior iliac spine to the great trochanter, when the thigh is rotated inwards. Between the gluteal and sciatic arteries, the great sciatic nerve leaves the pelvis, and it thence pursues a slightly curved course to a point midway between the great trochanter and the ischial tuberosity.

THE THIGH.

The thigh is separated from the abdomen in front by the curved *inguinal furrow*, at the bottom of which Poupart's ligament may be felt (except in fat people), more plainly in its inner than in its outer half, as it passes from the anterior superior spine of the ilium to the pubic spine: the band is relaxed, and becomes less distinct, on flexing and adducting, or rotating inwards, the thigh. From the pubic spine, the finger may be carried inwards along the pubic crest to the top of the symphysis, in the male passing over the spermatic cord, or downwards and backwards along the inner margin of the united pubic and ischial rami to the tuberosity of the ischium, thus tracing the boundary line between the thigh and the perineum. Externally, the thigh is not definitely marked off from the region of the hip.

Immediately below Poupart's ligament, a slight hollow is generally seen, corresponding to Scarpa's triangular space (Vol. II, pp. 252 and 487), in which, just internal to the centre, the femoral artery may be felt pulsating. Close below the innermost part of Poupart's ligament is situated the saphenous opening in the fascia lata, the upper end of which is about one inch outside the pubic spine. Through the lower part of this aperture, and about one inch and a half below Poupart's ligament, the internal saphenous vein passes back to join the femoral trunk, and above the vein is the spot where a femoral hernia first makes its appearance on the surface of the thigh. Over the opening, and for a short distance below it, the femoral or lower inguinal lymphatic glands may usually be felt through the skin, surrounding the upper end of the internal saphenous vein.

From the apex of Scarpa's triangle a depression is continued downwards along the inner part of the thigh, between the masses formed by the quadriceps extensor muscle in front, and the adductor muscles on the inner side. The sartorius muscle lies along this depression, and may be distinctly seen when it is brought into action by raising the leg across the opposite knee. The form of the rectus muscle may be

distinguished along the front of the anterior mass, and to its inner side, in about the lower half of the thigh, the vastus internus gives rise to a large prominence,

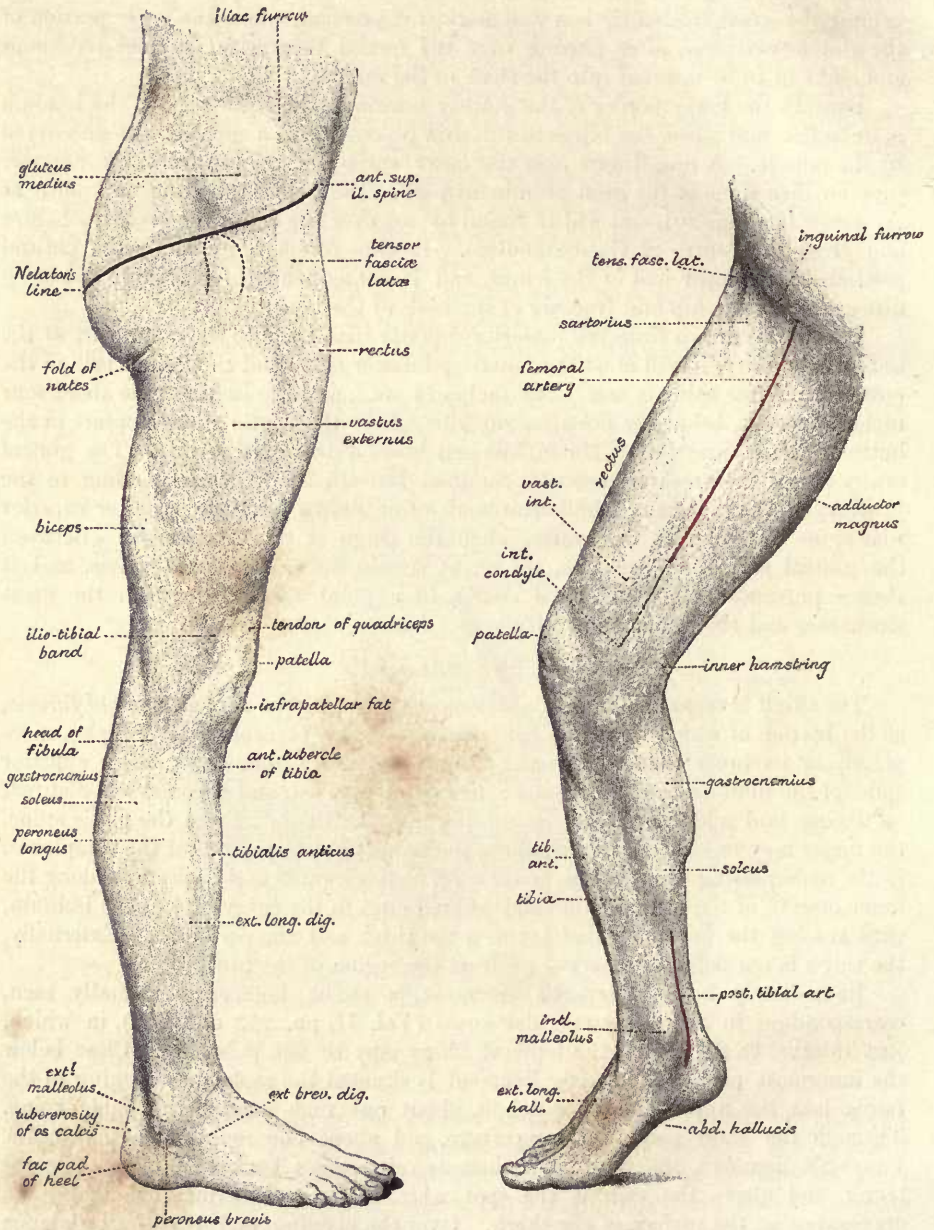


Fig. 20.—SUPERFICIAL ANATOMY OF THE LOWER LIMB: EXTERNAL VIEW. (From a photograph by G. W. B. Waters.) (R. J. G. & G. D. T.)

Fig. 21.—SUPERFICIAL ANATOMY OF THE LOWER LIMB: ANTERO-INTERNAL VIEW. (From a photograph by G. W. B. Waters.) (R. J. G. & G. D. T.)

increasing in size towards the knee, while on the outer side of the rectus, the vastus externus forms a broad convex surface, extending from the great trochanter above almost to the knee-joint below, and being continued backwards to the posterior

aspect of the limb. The surface formed by the vastus externus is often seen to be traversed by a longitudinal groove, due to the pressure exerted by the strong ilio-tibial band of the fascia lata as it descends from the insertions of the gluteus maximus and tensor vaginae femoris muscles to the outer tuberosity of the tibia. Of the adductor muscles, the only parts that are to be separately recognized are the strong tendon of origin of the adductor longus below the pubic crest, and the lower tendon of the adductor magnus which is felt distinctly, when the knee is bent, in the interval between the sartorius and vastus internus muscles, extending down to the adductor tubercle on the internal condyle of the femur. The adductors are not marked off on the surface from the hamstring group on the back of the thigh, nor are the latter muscles to be individually distinguished from one another until they become tendinous near the knee. Along the outer and posterior part of the thigh, however, the hamstring muscles are separated from the vastus externus by a well marked groove, corresponding to the position of the external intermuscular septum.

The whole of the shaft of the femur is deeply placed, and in fairly muscular subjects is not to be detected through its fleshy covering. It approaches the surface most nearly in the lower third of the thigh on the outer side, where it may be readily exposed in the interval between the vastus externus and biceps muscles. The head of the bone is situated close below Poupart's ligament, immediately external to its mid-point, and is occasionally, in thin subjects, to be felt in this position through the overlying muscles.

The subcutaneous veins of the thigh all join one trunk, the internal saphenous, which ascends from the hinder part of the inner side of the knee, with a gradual inclination forwards, to the saphenous opening. The extent to which this vein and its branches are to be perceived varies greatly with the amount of subcutaneous fat.

The position of the femoral artery is indicated by a line drawn from a point midway between the anterior superior iliac spine and the pubic symphysis to the prominent tuberosity on the inner condyle of the femur, the hip having been first slightly flexed and the thigh everted. At the junction of the upper three-fourths with the lower fourth of this line, the artery passes backwards through the opening in the adductor magnus muscle. Pressure is most conveniently applied to the vessel as it enters the thigh below Poupart's ligament, and it should be directed backwards so as to compress the artery against the pubis and the adjacent part of the hip-joint. Lower down, the pressure must be made in a direction backwards and outwards, as the artery lies considerably to the inner side of the shaft of the femur. At Poupart's ligament, the femoral vein is close to the inner side of the artery, and the anterior crural nerve is a little distance (a quarter to half an inch) from its outer side. The profunda, arising from the main trunk usually between one and two inches (3—5 cm.) below Poupart's ligament, follows a line almost identical with that of the femoral artery.

The small sciatic (posterior cutaneous) nerve lies immediately beneath the fascia along the middle line of the back of the thigh; and in the same line, but under cover of the hamstring muscles, is the great sciatic nerve.

THE KNEE.

On the inner side of the knee, the internal condyle of the femur and the corresponding tuberosity of the tibia produce a rounded surface, the most prominent point of which is formed by the tuberosity on the internal condyle. The interval between the two bones opposite the knee-joint is seldom to be seen, but is always easily felt. It can usually, however, be readily demonstrated by resting the

lower part of the leg on the opposite knee, when the inner tuberosity of the tibia projects beyond the inner condyle of the femur. On the upper part of the inner condyle, the sharp adductor tubercle and the insertion of the adductor magnus tendon are also to be recognized. The external condyle, although not generally prominent, is subcutaneous and readily felt; its tuberosity is comparatively little developed. The outer tuberosity of the tibia, on the other hand, forms a marked prominence at the outer and fore part of the knee, about an inch below the joint; and behind this, at a slightly lower level, viz., that of the tubercle of the tibia, the head of the fibula is distinctly felt at the outer and back part of the limb, where it generally corresponds to a depression, when the joint is extended, between the tendon of the biceps above and the peroneus longus muscle below: it often forms a prominence, however, when the knee is flexed. Anteriorly, the patella is subcutaneous, and its lateral margins are distinctly seen. When the extensor muscles are relaxed, the patella can be easily moved from side to side; but if these muscles are contracted, the patella is drawn upwards and pressed firmly against the end of the femur, and the ligamentum patellæ can then be followed down to the tubercle of the tibia: on each side of the ligament is a soft eminence produced by the infrapatellar mass of fat. When the knee is bent, the patella sinks into the hollow between the tibia and the femur, and the articular surface of the latter bone is in great part exposed; the trochlear surface can then be distinctly traced, although covered by the tendon of the extensor muscle. The upper and outer angle of this surface forms a useful landmark; and a line drawn from it to the adductor tubercle on the internal condyle marks the upper limit of the epiphysis of the lower end of the femur. There are generally two bursæ, a superficial one and a deep one, over the patella, and there is frequently another over the tubercle of the tibia (Vol. II, p. 242).

At the back of the knee is the ham, which is marked by a deep hollow when the joint is flexed, but by a slight elevation when it is extended. On each side are the tendinous hamstrings; internally the slender semitendinosus and the stronger semimembranosus are to be recognized, as well as the gracilis a little farther forwards; externally is the thick tendon of the biceps leading down to the head of the fibula. Immediately in front of the biceps tendon, when the joint is a little bent, the upper part of the external lateral ligament is to be detected; and between this and the outer margin of the patella, the lower end of the ilio-tibial band appears as a strong cord beneath the skin, running down on the outer side of the knee to the prominent external tuberosity of the tibia; while on the inner side, the sartorius tendon, with the subjacent tendons of the gracilis and semitendinosus, forms a slight elevation as it curves forwards below the inner tuberosity, to be inserted close to the tubercle of the tibia.

The external saphenous vein enters the lower part of the ham in the middle line of the limb, and perforates the fascia to join the popliteal vein; but it is not usually visible on the surface. The internal saphenous vein is generally seen on the inner side of the knee, and the nerve of the same name meets it behind the internal tuberosity.

The popliteal vessels enter the ham somewhat internal to the middle line above, and are then continued downwards over the centre of the back of the knee; the vein is more superficial than the artery, but both are very deeply placed. The upper articular vessels run transversely inwards and outwards immediately above the condyles of the femur; and the lower articular vessels are respectively just below the inner tuberosity of the tibia, and above the head of the fibula. The deep part of the anastomotic artery descends to the knee along the front of the adductor magnus tendon.

The internal popliteal nerve, continuing the direction of the great sciatic, and descending in the median line of the limb, is superficial to the vessels. The external popliteal nerve is at first under cover of the fleshy belly of the biceps, and then lies on the outer side of the ham, close behind the tendon of that muscle; it may be felt rolling beneath the finger as it crosses the outer side of the neck of the fibula, before entering the peroneus longus muscle; and it is sometimes to be seen giving rise to a slight elevation in this position.

The glands in the popliteal space are not to be felt unless they are enlarged.

THE LEG

Along the fore part of the leg, the anterior border of the tibia is to be followed downwards from the tubercle, constituting what is known as the shin. This border is sharp in the upper two-thirds of the leg, and describes a slight curve with the concavity outwards; in the lower third the border disappears, and the bone is concealed by the tendons of the anterior muscles. On the inner side of the shin, the broad internal surface of the tibia is subcutaneous below the sartorius, and leads downwards to the prominent internal malleolus. At the back of the latter process a sharp edge is felt, which is formed by the inner margin of the groove for the tendon of the tibialis posticus; the tendon itself covers the posterior surface of the malleolus, and is rendered prominent by inverting the foot. The head of the fibula is subcutaneous, as has been before mentioned; the shaft is surrounded by muscles, but it can be felt through them in the lower half at least of the leg, and it will be remembered that it is placed considerably farther back in the leg than the shaft of the tibia; near the ankle, a triangular portion of the bone comes to the surface, and is continued down to the external malleolus.

Along the concavity of the anterior edge of the tibia, the prominence formed by the fleshy belly of the tibialis anticus is seen, and external to this is the much less distinct and narrower extensor longus digitorum. The tendons of the muscles appear in the lower third of the leg, and between them also that of the extensor proprius hallucis; they are brought into view most distinctly by flexing the ankle and extending the toes. From the head of the fibula downwards, the peroneus longus and brevis muscles form an elongated swelling, from which the tendons can be traced descending behind the external malleolus. Posteriorly the elevation of the calf is formed by the gastrocnemius muscle, which terminates about the middle of the leg in the tendo Achillis; the inner head of the gastrocnemius is the larger, and descends lower than the outer. On each side of the gastrocnemius and tendo Achillis, a portion of the soleus comes to the surface; and the characteristic form of the gastrocnemius, depending upon the peculiar structure of the muscle (Vol. II, p. 262), as well as the extent and shape of the projecting portions of the soleus, are brought into view by raising the body on the toes. The tendo Achillis gradually becomes narrower as it approaches the heel, but it widens again a little as it passes over the tuberosity of the os calcis to its insertion. Between it and the malleolus, on each side, is a well-marked hollow, that on the outer side being the deeper; in the inner of these, the tendons of the tibialis posticus and flexor longus digitorum, and the posterior tibial vessels and nerve are superficial.

Both the external and internal saphenous veins are visible beneath the skin of the leg, together with numerous tributaries and communicating branches. The internal is the larger, and, after crossing in front of the internal malleolus, runs upwards just behind the inner border of the tibia; the external passes behind the outer malleolus and then ascends over the middle of the calf to the ham. Each vein is accompanied by the nerve of the same name.

The bifurcation of the popliteal artery takes place about two inches (5 cm.) below

the knee-joint, and on a level with the lower part of the tubercle of the tibia. The course of the anterior tibial artery is marked on the front of the leg by a line drawn from a point midway between the head of the fibula and the prominence of the outer tuberosity of the tibia to the centre of the ankle-joint. The intermuscular space in which the artery lies is also indicated by a depression which is seen at the outer border of the *tibialis anticus* when the muscle is called into action. The posterior tibial artery runs from the centre of the ham to the mid-point of a line drawn from the tip of the internal malleolus to the lower end of the inner border of the calcanean tuberosity; beneath this spot, the vessel divides into the internal and external plantar arteries. The posterior tibial artery is covered by the *gastrocnemius* and *soleus* for about two-thirds of its length, but in the lower third it is superficial, and may be felt pulsating in the interval between the *tendo Achillis* and the tibia. About three inches (7.5 cm.) below the knee, it gives off the large peroneal branch, which follows the direction of the fibula, and terminates behind the external malleolus.

THE ANKLE AND FOOT.

Of the two malleoli, the internal is usually the more prominent, but the external descends lower and also projects farther back, having its point, as a rule, about three-quarters of an inch (2 cm.) nearer to the heel than that of the internal malleolus. On the dorsum of the foot, the tarsal bones are not usually to be distinguished individually, but the head of the *astragalus* not unfrequently forms a considerable projection when the ankle-joint is extended; and if the arch of the foot is flattened, it often protrudes markedly on the inner side. Along the inner side of the foot, the tuberosity of the *os calcis* is first felt, and then, about an inch (2.5 cm.) below the internal malleolus, the *sustentaculum tali* of the same bone; in front of the latter, and about an inch and a half (4 cm.) from the malleolus, the tuberosity of the *navicular* bone is prominent, and to it the tendon of the *tibialis posticus* may be followed from the back of the internal malleolus; the finger next passes over the internal *cuneiform* bone, and recognizes the base of the first metatarsal bone as a slightly prominent ridge; from this, the shaft of the bone may be traced forwards beneath the skin to its expanded, and often unduly prominent, head, below which the *sesamoid* bones may be felt on the plantar aspect of the metatarso-phalangeal articulation. On the outer side of the foot, nearly the whole of the external surface of the *os calcis* is subcutaneous, and the peroneal spine of the bone may often be felt a little below and in front of the external malleolus. The anterior extremity of the *os calcis* may be distinguished when the foot is inverted, forming a marked prominence above the level of the *cuboid* bone, and in front of this, distant about two and a half inches (6 cm.) from the external malleolus, the projecting tuberosity at the base of the fifth metatarsal bone is easily felt.

The interarticular cleft of the ankle-joint is placed about half an inch (1 cm.) above the tip of the internal malleolus. The transverse tarsal articulation, at which *Chopard's* amputation is practised, runs from immediately behind the tuberosity of the *navicular* bone, outwards in front of the head of the *astragalus* and the anterior extremity of the *os calcis*, to end a little in front of the mid-point between the tip of the external malleolus and the tuberosity of the fifth metatarsal bone. The line of the tarso-metatarsal articulations is very irregular: commencing immediately behind the base of the first metatarsal bone, it passes at first transversely between that bone and the internal *cuneiform*, then turns sharply backwards for a full half-inch (15 mm.) to reach the cleft between the middle *cuneiform* and second metatarsal bones, next advances for about a quarter of an inch (5 mm.), and then is continued outwards, with a slight inclination backwards, between the outer three

metatarsal bones in front and the external cuneiform and cuboid bones behind, to its termination behind the tuberosity of the fifth metatarsal bone.

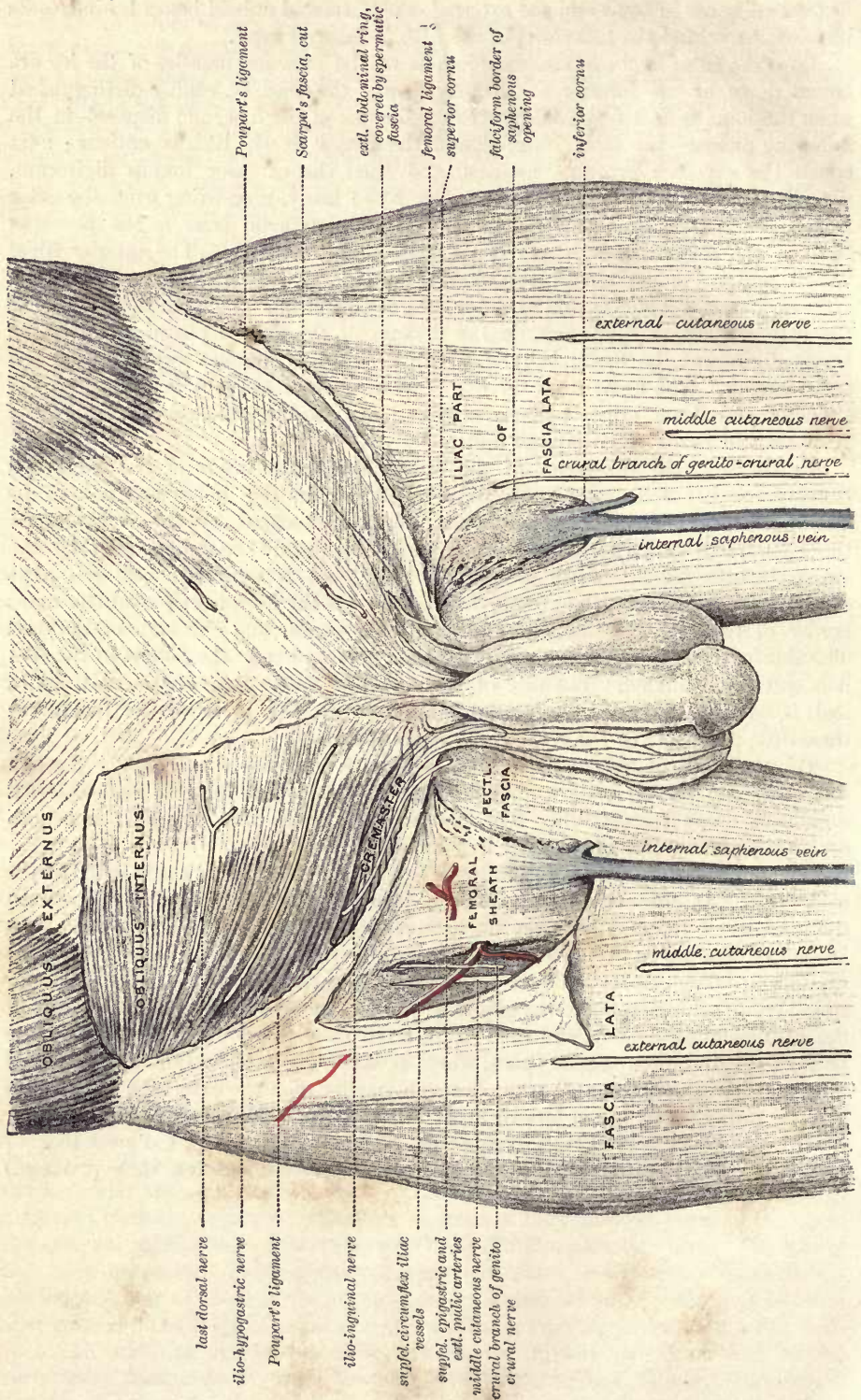
Over the front of the ankle, the tendons of the anterior muscles of the leg are bound down by the anterior annular ligament; they can be readily distinguished when the joint is flexed, spreading over the dorsum of the foot, and disposed in the following order:—the most internal and the largest is the tibialis anticus; next comes the extensor proprius hallucis, and then the extensor longus digitorum, dividing into its four slips for the smaller toes; lastly, proceeding from the outer side of the long extensor to the base of the fifth metatarsal bone is the peroneus tertius; the last named is, however, not unfrequently wanting. The anterior tibial vessels and nerve are placed, opposite the ankle-joint, between the tendons of the extensor proprius hallucis and extensor longus digitorum. Beneath the tendons of the extensor longus digitorum, on the dorsum of the foot, is placed the extensor brevis digitorum, the fleshy belly of which produces a distinct swelling over the tarsal region. The fleshy mass on the inner margin of the foot is formed by the abductor and flexor brevis hallucis muscles; and that on the outer border by the abductor and flexor brevis minimi digiti.

In the sole, the tuberosity of the os calcis and the heads of the metatarsal bones are easily felt, but in the intervening region the bones are not to be distinguished. The individual muscles are also obscured by the thickness of the integument and the manner in which the parts are bound together by the strong plantar fascia. When the arch of the foot is well developed the parts of the sole that rest on the ground in standing are the heel, a strip near the outer border of the foot, the heads of the metatarsal bones, and the ends of the toes. The skin over these parts is thick, hard, and smooth, but in the hollow of the foot it is soft and wrinkled. The sole of the infant is flatter than that of the adult, and is marked by lines similar to those seen in the palm of the hand, but these disappear more or less completely as age advances.

On the back of the foot, the arch or plexus of veins shows plainly through the skin, and its extremities may be followed into the internal and external saphenous veins respectively. The musculo-cutaneous and external saphenous nerves are not uncommonly visible through the skin.

The dorsal artery of the foot extends from the centre of the ankle-joint to the back of the first intermetatarsal space, and it may be felt pulsating midway between the tendons of the extensor proprius hallucis and extensor longus digitorum. Just before its ending it is crossed by the innermost slip of the extensor brevis digitorum. The external plantar artery runs from the bifurcation of the posterior tibial (p. 48) obliquely across the sole to within an inch (2·5 cm.) of the tuberosity of the fifth metatarsal bone, and then is directed more transversely inwards to the back of the first interosseous space, where it meets the termination of the dorsal artery. The internal plantar artery is much smaller than the external; its position may be indicated by a line drawn from the place of bifurcation of the posterior tibial to the under part of the metatarso-phalangeal articulation of the great toe.

The metatarso-phalangeal articulations are situated about an inch (2·5 cm.) behind the web of the toes.



last dorsal nerve
 ilio-hypogastric nerve
 Poupart's ligament
 ilio-inguinal nerve
 suprl. circumflex iliac vessels
 suprl. epigastric and extl. iliac arteries
 middle cutaneous nerve
 crural branch of genito-crural nerve

external cutaneous nerve
 middle cutaneous nerve
 crural branch of genito-crural nerve
 internal saphenous vein
 internal saphenous vein
 middle cutaneous nerve
 external cutaneous nerve

OBLIQUUS EXTERNUS
 OBLIQUUS INTERNUS

CREMASTER
 FEMORAL SHEATH
 PECTIL. FASCIA

Poupart's ligament
 Scarpa's fascia, cut
 extl. abdominal ring, covered by spermatic fascia
 femoral ligament
 superior cornu
 fatiform border of saphenous opening
 inferior cornu

ILIAC PART OF FASCIA LATA

FASCIA LATA

ANATOMY OF THE GROIN : HERNIA.

Two kinds of abdominal herniæ have such definite and important relations that the regions concerned require special notice in a work on anatomy. These are *inguinal herniæ*, which are associated with the spermatic cord in their passage through the abdominal wall, and *femoral herniæ*, which descend through the femoral canal on the inner side of the femoral vessels.

INGUINAL HERNIA.

The **inguinal canal**, through which the spermatic cord passes from the cavity of the abdomen to the scrotum, begins at the internal abdominal ring, and ends at the external ring. It is oblique in its direction, being nearly parallel with and immediately above the inner half of Poupart's ligament, and it measures about an inch and a half (3.5 cm.) in length. The external ring (Vol. II, p. 329) is immediately above and external to the pubic spine; the internal (*ib.*, p. 336) is midway between the anterior superior iliac spine and the pubic symphysis, and half an inch (1 cm.) above Poupart's ligament. In front, the canal is bounded by the aponeurosis of the external oblique muscle in its whole length, and at the outer end also by the fleshy part of the internal oblique; behind it is the transversalis fascia, together with, towards the inner end, the conjoined tendon of the two deeper abdominal muscles and the triangular fascia. Above the canal are the arched lower borders of the internal oblique and transversalis muscles; and below, it is bounded by Poupart's and Gimbernat's ligaments, which separate it from the sheath of the large blood-vessels descending to the thigh, and from the femoral canal at the inner side of those vessels. Below the internal ring, and separated therefrom by Poupart's ligament, is the external iliac artery, giving off its epigastric branch, which at first runs inwards, and then ascends close to the inner border of the opening (fig. 28).

The **spermatic cord**, which occupies the inguinal canal, is composed of the artery, veins, lymphatics, nerves, and excretory duct of the testis (*vas deferens*), together with a quantity of loose areolar tissue.

Coverings of the cord.—The coverings given from the constituent parts of the abdominal wall to the spermatic cord, besides the integuments, are, from the external ring the intercolumnar or spermatic fascia, the cremasteric muscle and fascia from the lower border of the internal oblique muscle, and a thin, funnel-shaped prolongation of the transversalis fascia from the edge of the inner ring (*infundibuliform fascia*). Beneath the last, the areolar tissue uniting together the constituents of the cord is continuous with the subperitoneal areolar layer.

Peritoneal fossæ.—When the lower part of the anterior abdominal wall is viewed from within, the peritoneum is seen to form a series of depressions, which are separated by more or less prominent folds. Thus, along the middle line is the *plica urachi* (*plica umbilicalis media*), which extends from the apex of the bladder upwards along the urachus to the umbilicus; a little outside this is the well-marked *plica hypogastrica* (*plica umbilicalis lateralis*), containing the obliterated hypogastric artery, and also extending from the bladder to the umbilicus; and still

Fig. 22.—ANATOMY OF HERNIA : SUPERFICIAL VIEW. (G. D. T.)

On the left side, only the skin and superficial fasciæ have been removed, exposing above Poupart's ligament the aponeurosis of the external oblique, with the spermatic cord emerging through the external abdominal ring, and below Poupart's ligament the fascia lata with the internal saphenous vein passing through the lower part of the saphenous opening and piercing the femoral sheath.

On the right side, the inguinal portion of the external oblique has been removed, bringing into view part of the internal oblique muscle and the cremaster; and below Poupart's ligament the iliac part of fascia lata has been detached from Poupart's ligament and reflected, so as to expose the front of the femoral sheath.

Fig. 23.—ANATOMY OF HERNIA : DEEP VIEW. (G. D. T.)

On the right side parts of the external and internal oblique muscles together with the cremaster have been taken away, so as to show the spermatic cord invested by the infundibuliform fascia lying in the inguinal canal. By the removal of a part of the front of the femoral sheath the femoral vessels have been exposed and the femoral canal opened. Gl., gland occupying the femoral ring.

On the left side parts of the two oblique muscles have been removed, and also a portion of the spermatic cord. Poupart's ligament has been divided, and the cut portions turned aside, thus exposing the deep femoral arch. Tr. F., triangular fascia; G. L., Gimbernat's ligament. The conjoined tendon on this side is very wide, and is prolonged outwards along the deep femoral arch as far as the internal abdominal ring.

more externally is a slight elevation, the *plica epigastrica*, over the epigastric vessels. The depressions are accordingly three in number on each side, viz., from without inwards, 1, the *fovea inguinalis lateralis*, on the outer side of the *plica epigastrica*,

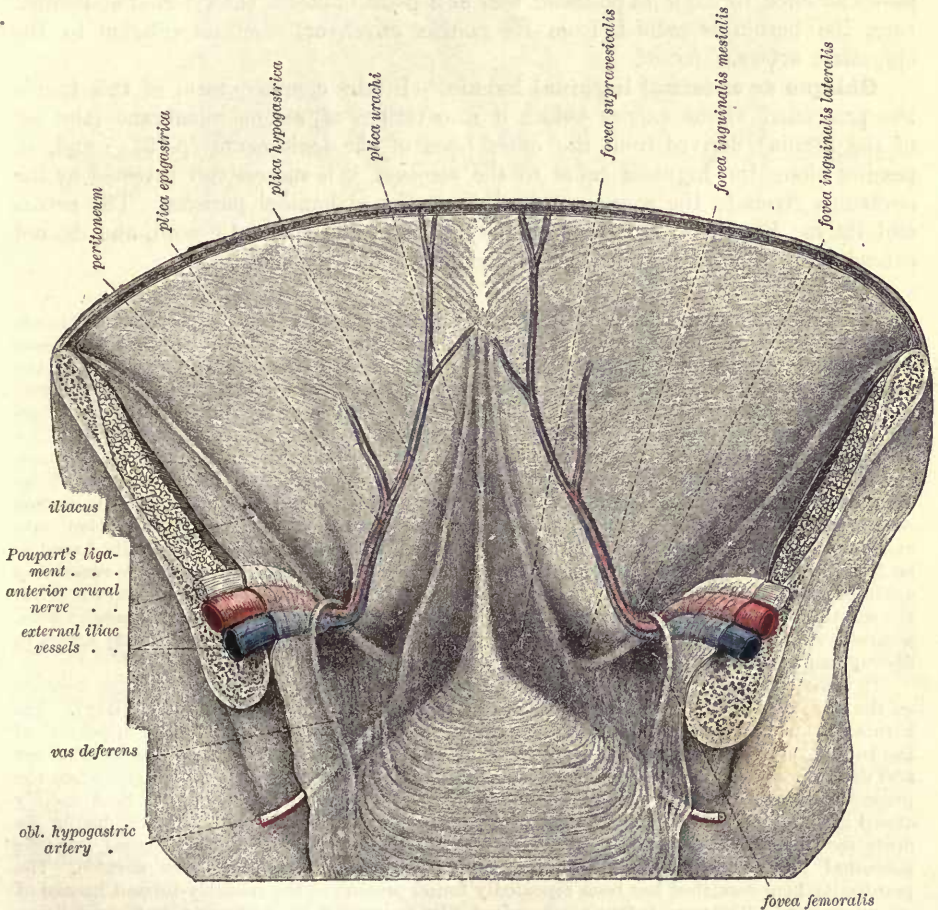


Fig. 24.—THE LOWER PART OF THE ANTERIOR ABDOMINAL WALL IN THE MALE VIEWED FROM BEHIND, SHOWING THE PERITONEAL FOLDS AND FOSSE. (After Joessel.)

the deepest part of which is opposite the internal abdominal ring; 2, the *fovea inguinalis mesialis* between the *plica epigastrica* and the *plica hypogastrica*; and 3, the *fovea supravesicalis*, between the *plica epigastrica* and *plica urachi*, immediately above and external to the apex of the bladder. Of these, the *fovea inguinalis mesialis* is the most strongly marked, and often extends inwards for some

distance beneath the plica hypogastrica over the back of the rectus muscle. Below the last fossa, and separated therefrom by the inner end of Poupart's ligament, there is often to be recognised another slight depression, the *fovea femoralis*, over the position of the femoral ring, to the inner side of the external iliac vein and the vas deferens, or the round ligament of the uterus, according to the sex.

FORMS OF INGUINAL HERNIÆ.—Two principal forms of inguinal hernia are described, which are distinguished according to the part of the canal which they first enter, as well as by the position which they bear with respect to the epigastric artery. Thus, when the hernia takes the course of the inguinal canal from its commencement, it is named *oblique*, because of the direction of the canal, or *external*, from the position of its neck with respect to the epigastric artery. On the other hand, when the protruded part, without following the length of the canal, passes at once through its posterior wall at a point opposite the external abdominal ring, the hernia is named, from its course, *direct*, or, from its relation to the epigastric artery, *internal*.

Oblique or external inguinal hernia.—In the common form of this hernia the protruded viscus carries before it a covering of serous membrane (the *sac* of the hernia), derived from the outer fossa of the peritoneum (p. 53); and, in passing along the inguinal canal to the scrotum, it is successively invested by the coverings given to the spermatic cord from the abdominal parietes. The hernia and its sac lie directly in front of the vessels of the spermatic cord, and do not extend below the testis, even when the tumour is of large size.

There are two other varieties of oblique inguinal hernia, in which the peculiarity depends on the condition of the process of peritoneum (*processus vaginalis*) that receives the testis when this organ descends from the abdomen. In ordinary circumstances the part of the peritoneal process connected immediately with the testis becomes separated after birth from the general cavity of that serous membrane by the obliteration of the intervening canal; and the hernial protrusion occurring after such obliteration has been completed, carries with it a distinct serous investment—the sac. But if this process of obliteration should not take place, and if a hernia should be formed, the protruded part is then received into the cavity of the *processus vaginalis*, which serves in the place of its sac. In this case the hernia is named *congenital*. It is thus designated, because the condition necessary for its formation only exists normally about the time of birth; but the same kind of hernia is occasionally found to be first formed in the adult, obviously in consequence of the *processus vaginalis* remaining unclosed, and still continuous with the peritoneum. The congenital hernia, should it reach the scrotum, passes below the testis; and, this organ being embedded in the protruded viscus, a careful examination is necessary in order to detect its position. This peculiarity serves to distinguish the congenital from the ordinary form of the disease.

To the second variety of inguinal hernia, in which the distinguishing character depends on the state of the *tunica vaginalis testis*, the name *infantile* has been applied (Hey). The hernia in this case is covered with a distinct sac, which is again invested by the upper end of the *tunica vaginalis*. The relative position of the two serous membranes (the hernial sac and the *tunica vaginalis*) may be accounted for by supposing the hernia to descend when the process of the peritoneum, which accompanies the testis from the abdomen, has been merely closed at the upper end, but not obliterated along the front of the cord. Hence during an operation in such a case, the hernial sac is met with only after another serous bag (the abnormal prolongation upwards of the *tunica vaginalis testis*) has been divided. The peculiarity here described has been repeatedly found present in the recently-formed herniæ of grown persons. The term *infantile*, therefore, like *congenital*, has reference to the condition of certain parts, rather than to the period of life at which the disease is first formed.

In the female, oblique inguinal hernia follows the course of the round ligament of the uterus along the inguinal canal, in the same manner as in the male it follows the spermatic cord. After escaping from the external abdominal ring, the hernia lodges in the labium pudendi. The coverings are the same as those in the male body, with the exception of the cremaster, which does not exist in the female; but it occasionally happens that some fibres of the internal oblique muscle are drawn

down over this hernia in loops, so as to have the appearance of a cremaster (Cloquet).

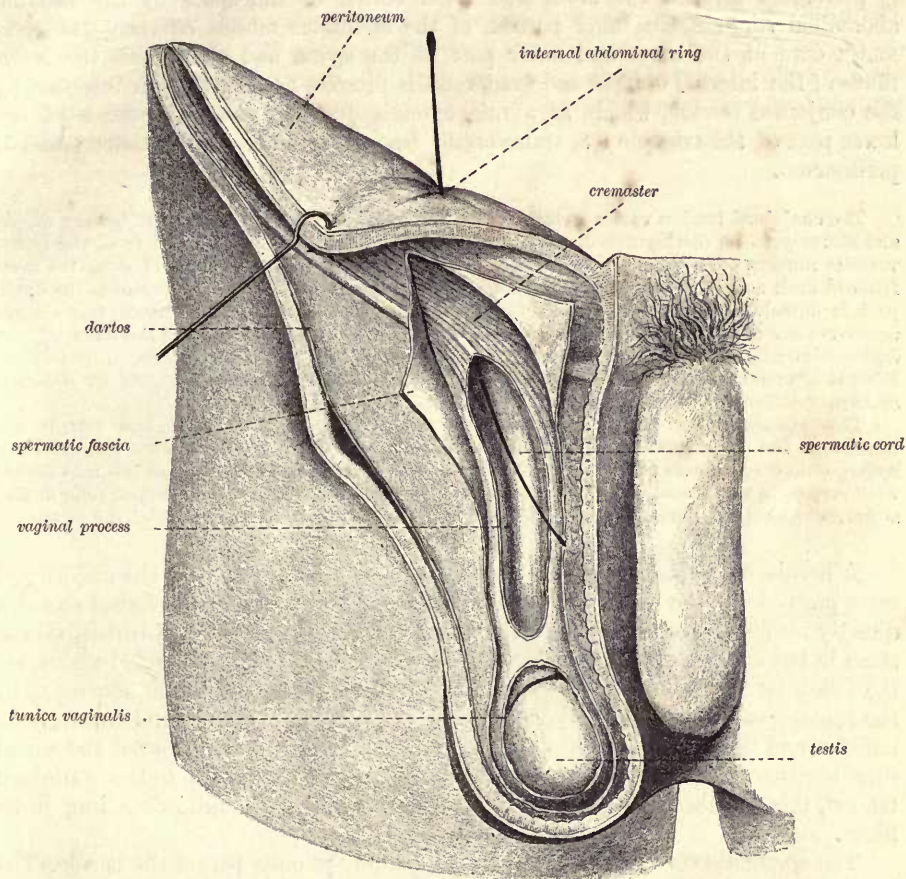


Fig. 25.—PERSISTENT VAGINAL PROCESS OF THE PERITONEUM. (After Joessel.)

The preparation is from a man 20 years of age. The tunica vaginalis is cut off from the vagina process, the tubular portion of which ends blindly a little above the testicle. In the inguinal canal the process becomes gradually narrower up to the internal abdominal ring, through which a probe is introduced into the cavity.

A strictly congenital inguinal hernia may occur in the female, the protruded parts being received into the little diverticulum of the peritoneum (canal of Nuck), which sometimes extends into the inguinal canal with the round ligament. But as this process of the peritoneum, in such circumstances, would probably not differ in any respect from the ordinary sac, there are no means of distinguishing a congenital hernia in the female body.

Direct or internal inguinal hernia.—Instead of following the whole course of the inguinal canal, in the manner of the hernia above described, the viscus in this case is protruded from the abdomen to the groin directly through the lower end of the canal, at the external abdominal ring. At the part of the abdominal wall through which the direct inguinal hernia finds its way, there is recognised on its posterior aspect a triangular interval, the sides of which are formed by the epigastric artery, and the margin of the rectus muscle, and the base by Poupart's ligament (fig. 28). It is commonly named the **triangle of Hesselbach**. The triangle measures about two inches (5 cm.) from above down, and an inch and a half

(3.5 cm.) transversely at its base. In this area the abdominal wall consists of, besides the integuments, 1, the aponeurosis of the external oblique muscle, which is perforated towards the lower and inner corner of the space by the external abdominal ring; 2, the inner portion of the cremaster muscle covering the spermatic cord at the lower and outer part of the space, and above this the lower fibres of the internal oblique and transversalis muscles passing to their insertion by the conjoined tendon, which, as a rule, extends over the inner two-thirds of the lower part of the triangle; 3, transversalis fascia; 4, subperitoneal tissue; and 5, peritoneum.

The conjoined tendon varies greatly in its development. In many cases it is very slight, and scarcely to be distinguished, while in others its deeper portion, derived from the transversalis muscle, covers the whole breadth of the triangle, reaching outwards along the deep femoral arch as far as the internal abdominal ring (fig. 23, left side). Sometimes the outer part is detached from the rest, and forms a band which has been designated *ligamentum interfoveolare* or *ligament of Hesselbach*, while to the remaining inner portion the name of *falsæ inguinalis* or *ligament of Henle* has been given. (See W. His, in *die anatomische Nomenclatur*, 1895, p. 121; and K. M. Douglas, *The Anatomy of the Transversalis Muscle and its Relation to Inguinal Hernia*, Journ. Anat., xxiv, 1890.)

The distance of the obliterated hypogastric artery from the middle line, and with it the breadth of the fovea supravesicalis, is also subject to variation. In most cases, however, the hypogastric cord ascends altogether behind the rectus muscle, and therefore an internal hernia will project in the mesial inguinal fossa. Only in rare cases does a hernia protrude in the supravesical hollow, between the obliterated hypogastric artery and the edge of the rectus.

A hernia emerging to the inner side of the epigastric vessels in the majority of cases protrudes in the inner part of the triangle of Hesselbach, and is forced onwards directly into the external abdominal ring. The coverings of such a hernia, taking them in the order in which they are successively applied to the protruded viscus, are the following:—The peritoneal sac and the subperitoneal tissue which adheres to it, the transversalis fascia, the conjoined tendon of the internal oblique and transversalis muscles, and the spermatic fascia derived from the margin of the external abdominal ring, together with the superficial fascia and skin. With regard to the conjoined tendon, this hernia may be covered by it, or may pass through an opening in its fibres.

The spermatic cord is commonly placed behind the outer part of the hernia. The hernial sac is not, however, in contact with the vessels of the cord, the investments given from the transversalis fascia to those vessels and to the hernia respectively, as well as the cremasteric fascia, being interposed.

But the spot at which an internal inguinal hernia passes through the triangle of Hesselbach is subject to some variation, and there is a second form of internal hernia which differs somewhat in its course and relations from the foregoing. In this variety the hernia protrudes to the outer side of the conjoined tendon, between that and the epigastric vessels. Such a protrusion passes through a considerable portion of the inguinal canal to reach the external ring, and has therefore a certain degree of obliquity, whence this variety is frequently termed *internal oblique inguinal hernia*. It is also known as *superior internal hernia*, the direct form being called *inferior internal*. As an internal oblique hernia passes outside the conjoined tendon, it has no covering derived from that structure, but it receives one from the cremaster in the same way as an external hernia.

Direct inguinal hernia is very rarely met with in the *female*. In the single case observed by Richard Quain, as well as in the few cases found recorded in books, the hernia though not inconsiderable in size was still covered by the tendon of the external oblique muscle.

FEMORAL HERNIA.

A femoral hernia leaves the abdomen at the groin, passing beneath Poupart's ligament, and over the anterior border of the hip-bone immediately at the inner side of the femoral vessels. It takes a downward course through the innermost compartment of the femoral sheath till it reaches the saphenous opening, when it turns forwards through the opening towards the front of the thigh, and is then bent upwards in the groin.

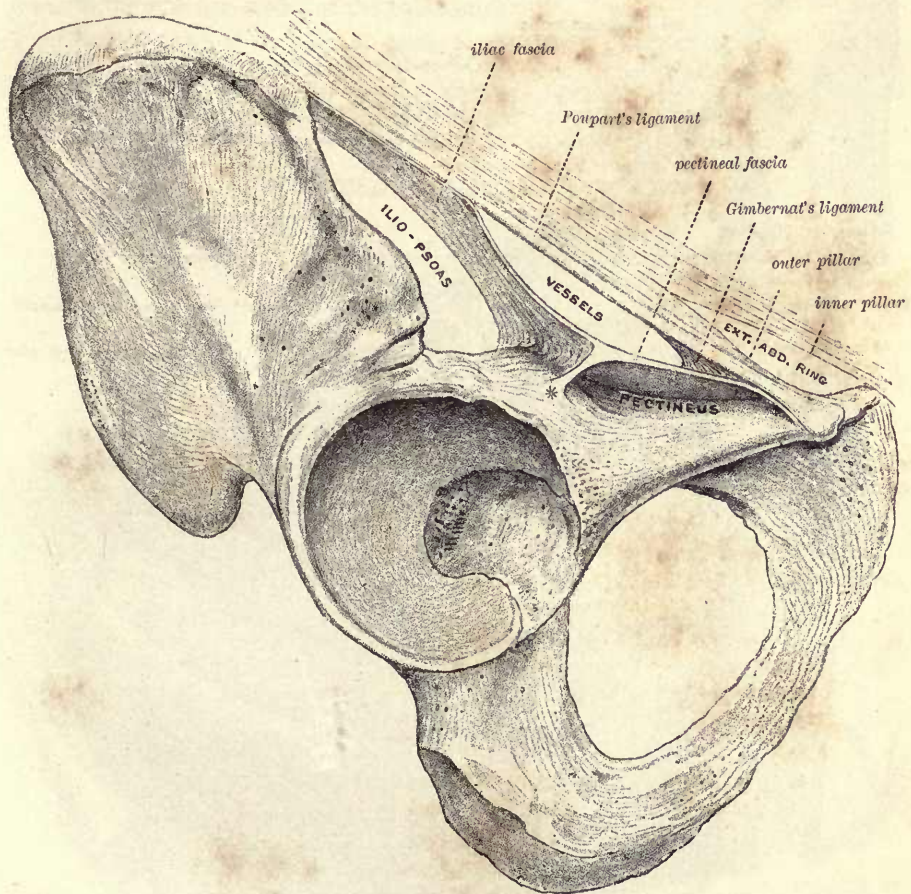


Fig. 26.—POUPART'S LIGAMENT AND THE NEIGHBOURING FASCIAE IN RELATION TO THE HIP-BONE. (G. D. T.)

The space between Poupart's ligament and the hip-bone is seen to be subdivided into three compartments by the fasciæ. Anteriorly is the vascular compartment, and posteriorly are the two muscular compartments—the larger one externally occupied by the ilio-pectineus, and the smaller one internally occupied by the upper end of the pectineus: the two are separated by * the ilio-pectineal intermuscular septum attached to the ilio-pectineal eminence.

The concave ilio-pubic margin of the hip-bone is bridged across in the recent state by Poupart's ligament or the (superficial) femoral arch (*ligamentum inguinale*), extending from the anterior superior iliac spine to the pubic spine. The intervening space, which is somewhat diminished at the internal angle by Gimbernat's ligament (*ligamentum lacunare*), is mainly occupied by the ilio-pectineus muscle and the external iliac vessels on their way into the thigh, and the upper end of the pectineus muscle.

These structures are invested by special fasciæ, which by their connection together subdivide the space into three chief compartments.

The **vascular compartment** (*lacuna vasorum*), situated in front of the others, is bounded anteriorly by Poupart's ligament and the continuation of the transversalis fascia into the front of the femoral sheath, with its thickening termed the *deep femoral*

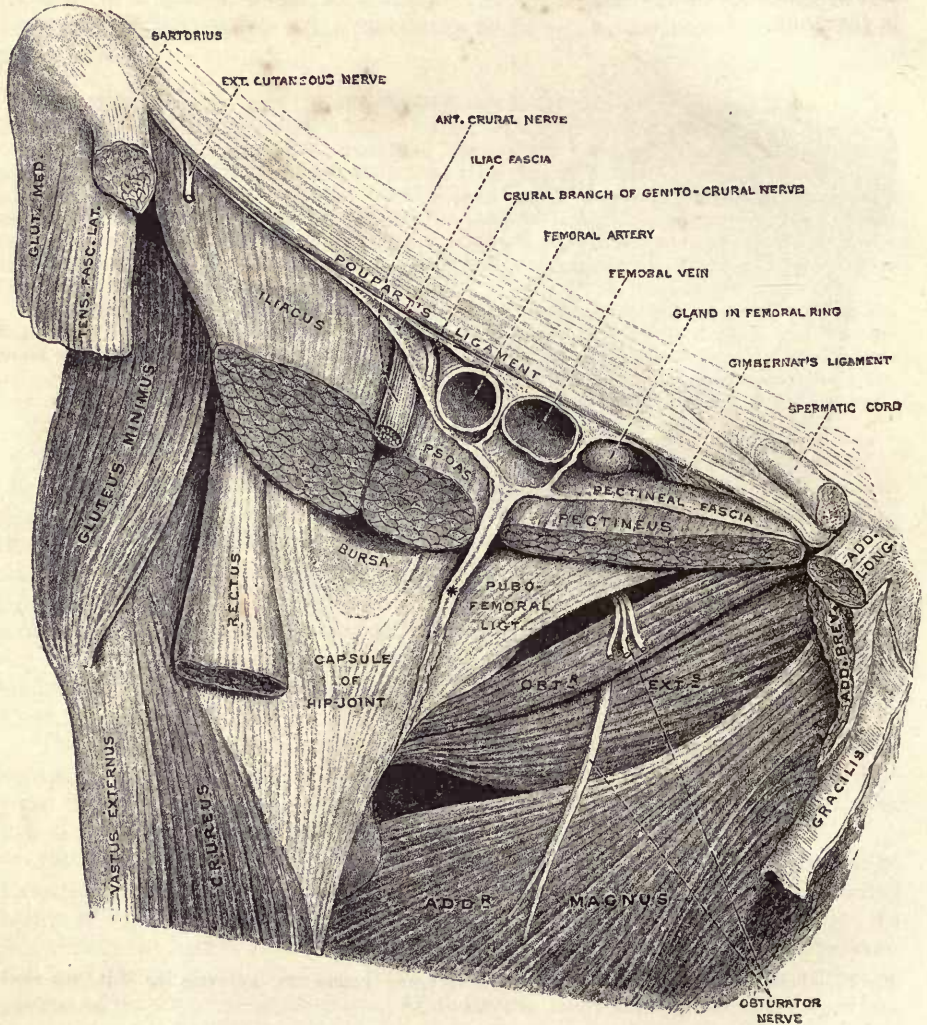


Fig. 27.—DISSECTION OF THE PARTS BENEATH POUPART'S LIGAMENT. $\frac{2}{3}$. (G. D. T.)

The femoral vessels, which are seen enclosed in the femoral sheath, have been divided close below Poupart's ligament. The fasciæ forming the back of the sheath, and the subjacent muscles have been divided at successively lower levels. * indicates the ilio-pectineal intermuscular septum attached to the capsule of the hip-joint along the inner part of its anterior surface.

arch (fig. 23); posteriorly by the continuous iliac and pectineal fasciæ. It allows of the passage into the thigh of the external iliac vessels and the crural branch of the genito-crural nerve, the vein being to the inner side, and the nerve to the outer side of the artery, while between the vein and Gimbernat's ligament is the interval known as the *femoral ring*. The **iliac compartment** (*lacuna musculorum*), the largest of

the three, is situated outside and behind the foregoing: it is bounded posteriorly by the ilium, anteriorly by Poupart's ligament and the iliac fascia, and internally is separated from the pectineal compartment by the ilio-pectineal intermuscular septum: it transmits the ilio-psoas muscle with the anterior crural and external cutaneous nerves. The **pectineal compartment**, lodging the upper end of the pectineus muscle, is between the pectineal fascia (or pubic portion of the fascia lata) in front and the superior ramus of the pubis behind. It extends only a short distance upwards beyond Poupart's ligament, being closed above by the attachment of the fascia to the superior border of the pubic ramus.

At the upper part of the pectineal fascia, immediately in front of its bony attachment, is a thickening formed mainly by bundles of transverse fibres, which are closely connected internally with, and in part derived from, Gimbernat's ligament. This is the *pubic ligament* of Astley Cooper, and is frequently spoken of as *Cooper's ligament*.

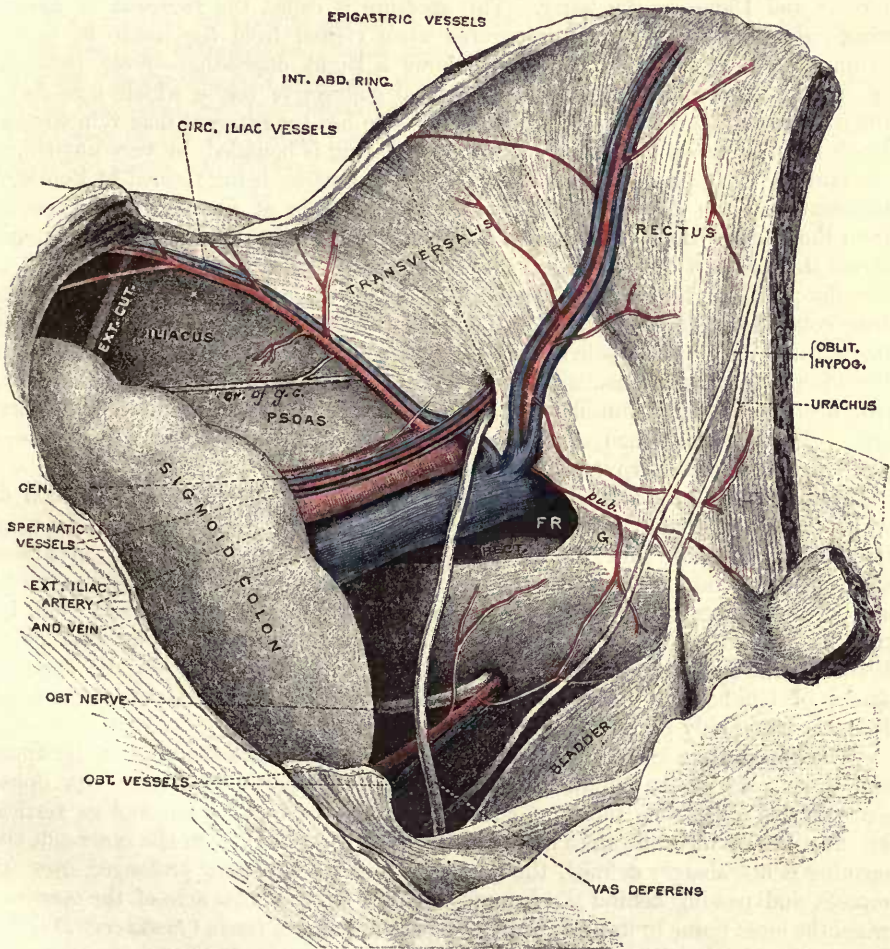


Fig. 28.—INNER VIEW OF THE GROIN, SHOWING THE INTERNAL ABDOMINAL AND FEMORAL RINGS. (Modified from Ellis.) (G. D. T.)

The peritoneum and subperitoneal tissue have been removed; and the rectus and transversalis muscles are seen covered by the transversalis fascia. The ilio-psoas muscle and external cutaneous nerve are covered by the iliac fascia.

F R, femoral ring; o, Gimbernat's ligament; PECT., pectineus muscle covered by fascia; pub., pubic branch of epigastric artery anastomosing with pubic of obturator.

The **femoral** or **crural sheath** (figs. 22 and 23), is a somewhat funnel-shaped structure surrounding the upper parts of the femoral artery and vein. It is wide above, but embraces the vessels closely below. It is continuous superiorly with the lining fasciæ of the abdomen, namely, with the transversalis fascia in front, and the iliac fascia behind. On removing its anterior wall, the sheath is found to be divided into three compartments by fibrous septa; the outer compartment containing the femoral artery, the middle, the femoral vein, and the inner being occupied merely by lymphatic vessels, a gland, and some fat. The inner compartment is about half an inch long, and from its being the passage through which the hernia descends, has been called the **femoral** or **crural canal**. The upper extremity of the canal presents an oval aperture towards the cavity of the abdomen, usually of sufficient size to admit the point of the forefinger: its size, however, varies in different persons, and it is larger in the female than in the male, its transverse diameter, which is the longest, being on an average 25mm. in the former, and 15mm. in the latter. This aperture is called the **femoral** or **crural ring** (*annulus femoralis*), and is covered when viewed from the inside by peritoneum, which at this spot frequently shows a slight depression—*fovea femoralis* (p. 54), and beneath that by the subperitoneal connective tissue, which here forms the *femoral septum* (Cloquet). On the outer side lies the external iliac vein covered by its sheath, but on the other three sides the ring is bounded by very unyielding structures. In front are the *femoral arches*, the *superficial* being formed by Poupart's ligament, and the *deep* by a variably developed bundle of fibres, which, springing from the under surface of Poupart's ligament outside the femoral vessels, extends across the fore part of the femoral sheath and, widening at its inner end, is fixed to the ilio-pectineal line behind Gimbernat's ligament. Behind the ring is the hip-bone covered by the pectineus muscle and the thickened upper part of the pectineal fascia; and on the inner side are several layers of fibrous structure connected with the ilio-pectineal line—namely, Gimbernat's ligament, the conjoined tendon of the two deeper abdominal muscles, and the transversalis fascia, with the deep femoral arch. The last-mentioned structures—those bounding the ring at the inner side—present more or less sharp margins towards the opening.

Relations to blood-vessels.—Besides the external iliac vein, the position of which has been already stated, the epigastric vessels are closely related to the ring, lying above its outer side. It not infrequently happens that an aberrant obturator artery descends into the pelvis at the outer side of the ring, or immediately across it; and in rarer cases this vessel passes in front of the ring to its inner side (Vol. II, p. 477). A pubic vein, also, has occasionally the same course; and the small pubic branch of the epigastric artery will be generally found ramifying on the superior aspect of Gimbernat's ligament. In the male, the spermatic vessels are separated from the canal only by the femoral arches.

The **saphenous opening** (*fossa ovalis*) of the fascia lata is placed at the upper and inner part of the thigh, immediately below Poupart's ligament. Its upper extremity is about one inch (2.5 cm.) external to the pubic spine, and its vertical extent measures from one and a half to two inches (4—5 cm.). On the inner side the opening is not sharply defined, the pectineal fascia being here prolonged over its muscle, and passing behind the femoral vessels. On the outer side of the opening, when the loose tissue in its area constituting the cribriform fascia (*fascia cribriformis*) has been removed, the iliac portion of the fascia lata forms a distinct crescentic edge known as the *falciform border*, which ends above and below in curved portions termed the *superior* and *inferior cornua*. Through the lower part of the opening the internal saphenous vein passes backwards to enter the femoral vein, and the inferior cornu curves sharply round in the angle between the two vessels to join the pectineal fascia internally. The superior cornu is thicker and less curved than the inferior:

it crosses over the upper and inner part of the femoral sheath to join Poupart's and Gimbernat's ligaments, its terminal portion being often distinguished as the *femoral ligament* or *Hey's ligament*. The femoral ligament crosses the antero-internal aspect of the femoral canal, and the closed extremity of that passage lies immediately behind the upper part of the saphenous opening.

Descent of the hernia.—When a femoral hernia is being formed, the protruded part is at first vertical in its course ; but at the lower end of the canal it bends forwards through the saphenous opening, and, as it increases in size, ascends over the iliac part of the fascia lata and the femoral arch. Within the canal the hernia is very small, being constricted by the unyielding structures which form that passage ; but when it has passed beyond the saphenous opening, it enlarges in the loose fatty layers of the groin ; and, as the tumour increases, it extends outwards in the groin towards the anterior superior iliac spine.

Coverings of the hernia.—The coverings of a femoral hernia in order from within outwards are, the peritoneum (which forms the sac), the septum femorale and the sheath of the femoral vessels. These two structures combined constitute a single covering, known as the *fascia propria* of the hernia (Cooper). It sometimes happens that the hernia is protruded through an opening in the sheath, which therefore in that event does not contribute to form the fascia propria. Lastly, the hernia is covered by the cribriform fascia stretching across the saphenous opening, the superficial fascia, and the skin.

THE PERINEUM OF THE MALE.

The perineum is the region which is included within the outlet of the pelvis, and which is traversed by the lower end of the rectum and by the urethra. It extends, therefore, from the apex of the subpubic arch in front to the tip of the coccyx behind, and from the ischial tuberosity of one side to that of the other. It is bounded on each side, at the fore part, by the conjoined rami of the pubis and ischium, and at the back part by the great sacro-sciatic ligament, together with a portion of the lower border of the gluteus maximus muscle. Its form is rather heart-shaped in consequence of the projection of the coccyx posteriorly; it measures about three and a half inches (9 cm.) from side to side, and about four inches (10 cm.) over the curved surface (three and a quarter inches in a straight line) from before back in the middle line. The perineal space is separated from the pelvic cavity above by the recto-vesical fascia and the levatores ani muscles; its depth is considerable (from two to three inches) at the posterior and outer part, much less (not exceeding an inch) at the fore part.

The perineal space is conveniently divided into two parts by a line drawn across from one ischial tuberosity to the other, and passing immediately in front of the anus. The anterior division is termed the *urethral part*, and is often referred to as the true perineum; the posterior division is called the *anal part*, or the false perineum.

The several muscles and fasciæ, vessels and nerves, which enter into the formation of the perineum have been fully described in the second and third volumes of this work, and it now only remains to give a short sketch of its superficial and topographical anatomy, with which may be included also the relations of the adjoining parts of the pelvic viscera.

Superficial anatomy.—The osseous portions of the boundaries of the perineum can be felt more or less distinctly through the skin, but the anterior portion of the subpubic arch is obscured by the presence of the penis, and the ischial tuberosities are at some distance from the surface, being covered by a thick layer of fat and, in the erect position, also by the great gluteal muscles. The sacro-sciatic ligament is scarcely to be distinguished beneath the gluteus maximus, except in very thin subjects. The lower part of the coccyx is very plainly felt. The anus is placed directly between the ischial tuberosities, its centre being about one inch and a half from the extremity of the coccyx.

The skin of the perineum is thin and provided with more or less abundant hairs; it is gathered into puckered folds round the anus, to which a farther irregularity is often given by swollen hæmorrhoidal veins. In front of the anus is a median ridge, the *raphé*, which runs forwards and is continued on to the scrotum and penis. Beneath this, the bulb of the urethra forms a slight median elevation, more perceptible in emaciated subjects. In such subjects, again, the fat in the ischio-rectal fossa does not reach the level of the ischial tuberosities so as to form a rounded surface sinking in towards the anus, as is the case in those who are well nourished. A fine white line round the anus indicates the point of junction of the skin and mucous membrane, and corresponds precisely to the division between the external and internal sphincters (Hilton).

One inch (2.5 cm.) in front of the anus is situated the central point of the perineum, which corresponds to the centre of the free border of the triangular ligament. Immediately in front of this, the bulb of the urethra commences, but the membranous part perforates the triangular ligament about half an inch farther forwards, and therefore one inch and a half (4 cm.) in front of the anus.

Topographical anatomy.—The superficial fascia of the perineum consists of

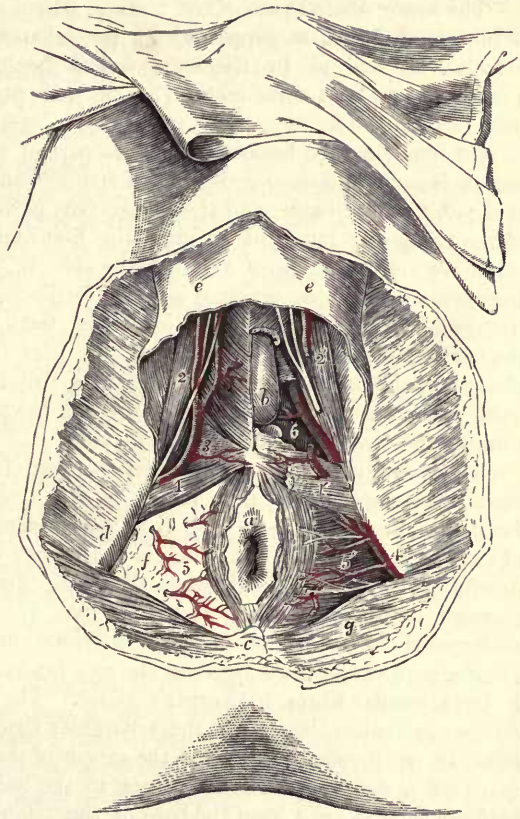
two layers, the more superficial of which is the ordinary subcutaneous fascia, and contains fat, especially in the posterior portion of the space, where it is very abundant and fills the ischio-rectal fossa. The deep layer or fascia of Colles is membranous, and is confined to the anterior part of the space; it is attached on each side to the rami of the ischium and pubis, and posteriorly to the base of the triangular ligament; it thus forms a somewhat triangular pouch in the fore part of the perineum, which may modify the course of an extravasation of urine or a collection of pus in this situation. The pouch is, moreover, subdivided posteriorly by a median septum, which extends from the back of the perineum to the scrotum.

The hinder part of the perineum is occupied in the centre by the lower end of the rectum, and between this and the ischial tuberosity on each side is a considerable hollow known as the ischio-rectal fossa.

FIG. 29.—DISSECTION OF THE PERINEUM IN THE MALE. (Allen Thomson.) $\frac{1}{2}$

The right side shows a superficial, the left a deeper view.

a, anus, with a part of the integument surrounding it; *b*, left half of the bulb of the corpus spongiosum, exposed by the removal of the bulbo-cavernosus muscle; *c*, coccyx; *d*, right ischial tuberosity; *e, e*, superficial perineal fascia; *f*, fat occupying the right ischio-rectal fossa; *g*, gluteus maximus muscle; *1*, on the right transversus perinei muscle, points to the superficial perineal artery as it emerges in front (in this case) of the muscle; *1'*, on the left side, on the surface of the triangular ligament, points to the superficial perineal artery cut short; *2*, on the right ischio-cavernosus muscle, points to the superficial perineal artery and nerves passing forwards; *2'*, on the left side, the same vessel and nerves divided; *3*, on the right half of the triangular ligament, points to the transverse perineal artery; *4*, on the left ischial tuberosity, points to the pudic artery deep in the ischio-rectal fossa; *5, 5'*, inferior hæmorrhoidal branches of the pudic arteries and nerves; *6*, on the left side, placed in a recess from which the inferior layer of the triangular ligament has been removed, in order to show the continuation of the pudic artery, its branch to the bulb, and Cowper's gland.



The **ischio-rectal fossa** is a hollow of an irregularly pyramidal shape. Its base is turned downwards, and measures about two inches (5 cm.) from before back, and one inch (2.5 cm.) from side to side. Its outer wall is nearly perpendicular, and is formed by the obturator internus muscle covered by its fascia below the level at which the rectovesical fascia is attached to it. The inner wall is oblique in direction and convex towards the fossa; it is formed by the levator ani muscle, covered by the thin anal fascia, and at the lower part by the external sphincter. Anteriorly, the fossa is limited by the base of the triangular ligament, and posteriorly by the gluteus maximus muscle and the great sacro-sciatic ligament. Its depth is about two inches (5 cm.) from the margin of the tuberosity at the hinder part, where it extends upwards to the ischial spine, the small sacro-sciatic ligament and the coccygeus muscle.

The pudic vessels and the dorsal and perineal divisions of the pudic nerve run forwards along the outer wall of the fossa, being embedded in the obturator fascia about an inch and a half (3·5 cm.) above the lower margin of the ischial tuberosity; the inferior hæmorrhoidal branches of these trunks run obliquely inwards and forwards from the hinder part of the fossa towards the anus; and anteriorly the superficial perineal vessels and the perineal nerve leave the shelter of the hip-bone and also enter the fat of the fossa.

The ischio-rectal fossa is often the seat of abscesses which burrow freely in the loose fat of the part, and frequently result in the formation of a fistula in ano, involving a communication with the bowel, sometimes above, but more frequently below, the external sphincter.

The lower dilated part of the rectum, which occupies the space between the two ischio-rectal fossæ, is supported by the levatores ani and the external sphincter muscles, as well as by the recto-vesical fascia. Its lateral wall is exposed for a distance of about three inches (7·5 cm.), its posterior wall for little more than an inch (3 cm.).

On removing the fasciæ of the fore part of the perineum the bulbo-cavernosus muscle is exposed covering the corpus spongiosum, the ischio-cavernosus covering the crus penis on each side, and the transversus perinei directed inwards over the base of the triangular ligament to meet the first-named muscle, as well as the external sphincter and its fellow of the opposite side, in the central point of the perineum. Between the bulbo-cavernosus, ischio-cavernosus, and transversus muscles is a small triangular space, in which a portion of the triangular ligament is exposed, and over the surface of the muscles (sometimes in part beneath or through the transversus) the superficial perineal vessels and nerves run forwards to the scrotum, while the small transverse perineal artery is directed inwards close to the transverse muscle towards the central point of the perineum.

The triangular ligament or deep perineal fascia, which occupies the subpubic arch, has a depth of an inch and a half in the middle line, but extends somewhat farther backwards on each side, at its attachment to the ischial ramus. It consists of two layers, the upper of which is continuous with the recto-vesical fascia. The membranous part of the urethra descends, first through the superior, and then through the inferior layer, about an inch from the pubic symphysis, and it is surrounded by the fibres of the constrictor urethræ muscle, which occupies the greater part of the space between the two layers. Near the urethra, also embedded in the muscular fibres, is Cowper's gland. The pudic vessels and the dorsal nerve of the penis enter the base of the triangular ligament and run forwards close to the bone, in small canals formed in the origin of the constrictor muscle, and the artery gives off here its considerable branch to the bulb, which is directed inwards about half an inch (1 cm.) from the base of the triangular ligament, and an inch and a half (3·5 cm.) in front of the anus.

Resting on the upper surface of the triangular ligament is the apex of the prostate, and this body is surrounded by its sheath, which is continuous on each side with the upper layer of the ligament; beneath the sheath is the large prostatic plexus of veins, derived mainly from the breaking up of the dorsal vein of the penis, which passes into the pelvis between the pubic symphysis and the triangular ligament. In the recess between the lateral part of the upper surface of the triangular ligament and the sheath of the prostate, the anterior part of the levator ani muscle is lodged.

Above the prostate, and at a depth generally of from two and a half to three inches (6—7 cm.) from the surface, is the bladder, the base of which projects backwards into the concavity formed by the rectum and overlaps the second part of

the bowel to a variable extent, according to the degree of distension of the bladder. Between the bladder and rectum are the vesiculæ seminales and the terminal portions of the vasa deferentia. When the bladder is full, the recto-vesical pouch of the peritoneum does not usually reach below a line an inch and a half from the base of the prostate.

In contact with the upper surface of the levator ani is the recto-vesical fascia, forming the deep boundary of the perineal space. It extends from the side wall of the pelvis downwards and inwards to the side of the rectum, to the bladder and prostate. Its line of attachment to the bladder on each side runs upwards and backwards immediately above the prostate, and external to the position of the vesiculæ seminales; and it is essential, in the operation of lateral lithotomy, that the bladder be opened entirely below this level. If the incision be carried through the fascia beyond this line, then the pelvic cavity will be opened, and extravasation of urine into the loose areolar tissue will probably follow.

EXAMINATION OF THE PELVIC VISCERA.

Rectal examination in the male.—On passing the finger into the rectum in the adult male, the constriction (*anal canal*) caused by the internal and external sphincters is first encountered, the internal sphincter extending one inch above the anal orifice. The soft mucous membrane of the bowel is then felt more or less doubled into transverse folds (folds of Houston, *plicæ transversales recti*): these are usually three in number, the largest being found on the front and right side of the bowel about three inches from the anus, and on a level with the extremity of the recto-vesical pouch of peritoneum, while another is placed on the left side about one inch higher; and the third, which is less constant, is on the left side, posteriorly, below the first. These folds are visible when the rectum is examined with the aid of a speculum, the body being placed in the genu-pectoral position. They sometimes render the introduction of the finger or an instrument beyond a certain point difficult or impossible. The columns of Morgagni (*columnæ rectales*) and the small folds of mucous membrane (valves of Morgagni) directed upwards which join them, with the enclosed recesses (*sinus rectales*), are not to be felt, but are easily seen with a speculum. The mucous membrane of the anal canal is thicker and drier than the velvety lining membrane of the bowel higher up. It often presents small polypoid projections from its surface.

Through the wall of the bowel numerous objects may be felt:—In front is the base of the triangular ligament, a little distance above which is the apex of the prostate. The outline of the prostate is readily made out, and above it the bladder may be felt if distended. The vesiculæ seminales are not to be recognized unless enlarged, and even then only their lower parts by a finger of average length.

Behind, after passing over the soft posterior part of the perineum (ano-coccygeal body), the tip of the coccyx is reached and the finger explores the hollow of the sacrum. From this there passes out on each side a resistant band consisting of the small sacro-sciatic ligament and the coccygeus muscle, which lead to the ischial spine.

On each side, the ischial tuberosity and the wall of the true pelvis are felt, and in this way the condition of the structures at the back of the acetabulum, in the neighbourhood of the cæcum, or of the large vessels may be determined.

This examination of the pelvis is easier in the infant, and is aided by bimanual examination, one hand being placed on the lower part of the abdomen. In the infant the parts felt are the same, except that the prostate is scarcely perceptible.

Rectal examination in the female.—In the female the anus is placed

slightly farther forwards than in the male, and is not so deeply sunk between the nates; the surrounding skin is usually destitute of hairs. Behind the rectum the parts to be felt are the same as in the other sex. In front, above the perineal body, the first part met with is the soft recto-vaginal septum; then the cervix and os uteri, and higher up the lower part of the body of the uterus. Any abnormality in the position of the organ or in the state of the pouch of Douglas can also be determined. At each side, besides the structures met with in the male, the resistance caused by the base of the broad ligament may be detected, the ovaries may be felt on bimanual examination, and the outline of the uterus more accurately determined.

Vaginal examination.—In a digital examination of the vagina, the passage is found to be small, and more or less obstructed by the hymen in the virgin, and the mucous membrane is rugose. In a woman who has borne children the parts are more capacious, there is no hymen, and the rugæ are no longer felt. The outline of the subpubic arch may be traced in front, and the region of the bladder explored; behind is the soft recto-vaginal septum; and on each side the pelvic wall may be examined, and the ovaries can easily be felt on bimanual examination. At the upper end of the vagina, and projecting from the anterior wall, is the cervix uteri, in which the os is to be felt as a transverse slit.

INDEX TO APPENDIX.

- ABDOMEN**, superficial anatomy of, 22
Abdominal aorta, 27, 34
 cavity, 22
 furrow, 24
 regions, 22
 lateral, 23
 viscera of, 23
 ring, external, 24, 51, 55, 56
 internal, 24, 51, 53
 vessels, 27
 viscera, 23, 24
 wall, 23, 56
Abductor. *See* **MUSCLES.**
Acetabulum, 43, 65
Acromial angle, 28
Acromio-clavicular articulation, 32
Acromion, 28, 32, 35
Adductor. *See* **MUSCLES.**
 tubercle, 45, 46
Aditus ad antrum, 10
Alveolar processes, 15
Alveolo-lingual sulcus, 15
Anal canal, 65
 fascia, 63
 part of perineum, 62
Anastomotic artery of thigh, 46
Anatomy, superficial. *See* **SUPERFICIAL ANATOMY.**
 topographical. *See* **TOPOGRAPHICAL ANATOMY.**
Anconeus muscle, 37, 38
Angle, acromial, 28
 of jaw, 14, 32
 Rolandic, 9
 of scapula, 28, 32, 33
 sternal, 19
 subcostal, 19
Angular process, external, 1
Ankle, superficial anatomy of, 48
Ankle-joint, 48
Annular ligament, anterior, 49
Annulus femoralis, 60
Ano-coccygeal body, 65
Antrum, mastoid, 10, 11, 13
Anus, 60, 65
Aorta, abdominal, 27, 34
 arch of, 22, 29, 33
 ascending, 22, 33
 descending, 29, 33
Aortic cartilage, 22
 orifice, 22, 33
Aperture of larynx, upper, 17, 32
Aperture, nasal, anterior, 13
Apex of bladder, 53
 of heart, 21
 of lung, 20, 28, 32
 of prostate, 64, 65
Aponeurosis of external oblique muscle, 51, 56
Appendix, vermiform, 23
Arch of aorta, 22, 29, 33
 azygos vein, 33
 femoral, deep, 58, 60
 superficial, 57, 60
 palmar, deep, 41
 superficial, 41
 of subclavian artery, 32
 subpubic, 62, 66
 of thoracic duct, 32
Arm, superficial anatomy of, 35
ARTERY or ARTERIES, aberrant obturator, 60
 anastomotic of thigh, 46
 articular of knee, 46
 axillary, 35
 brachial, 36, 37, 39
 of bulb, 64
 carotid, common, 17, 22, 32
 external, 17
 internal, 17
 cervical, transverse, 18
 circumflex, posterior, 35
 crico-thyroid, 17
 coronary, of facial, 14
 digital of hand, 41
 dorsal of foot, 49
 endocranial, 3
 epigastric, 24, 51, 53, 54, 55, 60
 facial, 14, 17
 femoral, 43, 45, 57, 60
 frontal, 3
 gluteal, 43
 hypogastric, 51, 56
 iliac, common, 27, 34
 external, 27, 51, 57, 58
 innominate, 17, 22, 32, 33
 intercostal, 22
 lateral costal, 22
 lingual, 17
 mammary, internal, 22
 meningeal, middle, 5
 mesenteric, superior, 27, 34
 inferior, 27, 34
 occipital, 3, 10, 17
 perineal superficial, 64
 transverse, 64
 plantar, 48, 49
 popliteal, 46, 47
 profunda of thigh, 45
 superior, 37
 pubic, of epigastric, 60
 pubic, 64
 pulmonary, 33
 radial, 38, 39
 renal, 27, 29, 34
 of scalp, 3
 sciatic, 43
 spermatic, 54, 56, 60
 subclavian, 18, 22, 32
 superficial volar, 41

- ARTERY OR ARTERIES—*continued.*
 supraorbital, 3
 temporal, superficial, 3
 of thoracic wall, 22
 thyroid, inferior, 17
 superior, 17
 tibial, 47, 48, 49
 transverse facial, 14
 ulnar, 38, 39
 vertebral, 17
 Articular arteries of knee, 46
 ARTICULATION OR ARTICULATIONS, acromio-
 clavicular, 32
 of ankle, 48
 chondro-sternal, 20, 21, 22, 24, 25, 33
 of elbow, 37
 of hip, 43
 interphalangeal, 41
 of knee, 45
 metacarpo-phalangeal, 40, 41
 metatarso-phalangeal, 49
 radio-carpal, 41
 sacro-iliac, 42
 of shoulder, 35
 sterno-clavicular, 18, 22
 tarsal, transverse, 48
 tarsometatarsal, 48
 temporo-maxillary, 13
 xiphisternal, 19, 24, 25, 33
 Astragalus, 48
 Atlas, 16, 31
 Attic of tympanum, 10
 Auditory meatus, external, 11, 12
 Auricles of heart, 33
 Auricular nerve, great, 18
 Auriculo-ventricular openings, 22, 33
 Axilla, folds of, 19, 35
 Axillary artery, 35
 Axis, 16, 27, 31
 coeliac, 27, 29, 34
 Azygos vein, 33
- BACK, superficial anatomy of, 27
 Basal ganglia, 9
 Base of bladder, 64
 of jaw, 14
 line of Reid, 7
 Basilar process, 16
 Basilic vein, 36, 37
 Bend of elbow, 37
 Biceps. *See* MUSCLES.
 Bicipital fascia, 37, 38
 furrows, 35
 Bifurcation of aorta, 27, 29, 34
 brachial artery, 39
 common carotid artery, 32
 common iliac artery, 34
 innominate artery, 32
 popliteal artery, 47
 posterior tibial artery, 48
 trachea, 33
 Bi-iliac line, 22
 plane, 23, 34
 Bladder, 23, 25, 53, 64, 65, 66
 Blood-vessels. *See* ARTERIES, VEINS.
 Body, ano-coccygeal, 65
 thyroid, 17
 turbinate, 13, 16
 Brachial artery, 36, 37, 39
 plexus, 18
 Brachialis anticus muscle, 36
 Broad ligament of uterus, 66
 Bronchi, 28, 33
 Bulb, artery of, 64
 of urethra, 62
 Bulbo-cavernosus muscle, 64
 Bursa, over olecranon, 37
 patella, 46
 pharyngea, 16
 over tubercle of tibia, 46
 Buttock, 42
- CÆCUM, 23, 25, 65
 Calf, 47
 Canal, anal, 65
 crural, 60
 of facial nerve, 12
 femoral, 51, 60, 61
 inguinal, 24, 51, 54, 55, 56
 of Nuck, 55
 palatine, posterior, 16
 semicircular, external, 12
 Canaliculi, lachrymal, 15
 Canthus, 14
 Capitellum, 37
 Cardiac dullness, deep, 22
 superficial, 22
 orifice of stomach, 23, 25, 28, 33
 Carotid artery. *See* ARTERIES.
 tubercle, 17
 Cartilage, aortic, 22
 costal, 19, 20, 21, 22, 24, 25, 26, 33, 34
 cricoid, 16, 17, 32
 of nose, 13
 pulmonary, 22
 of septum nasi, 13
 thyroid, 16, 32
 Caruncula lacrimalis, 15
 Central point of perineum, 62, 64
 Cephalic vein, 36, 37
 Cerebellum, 10
 Cerebral, convolutions, relations of, to cranium, 6
 fissures, relations of, to cranium, 6
 determination of, 7
 hemispheres, 5
 Cervical enlargement of spinal cord, 31
 vertebræ, 16, 27
 Cervix uteri, 66
 Chest, superficial anatomy of, 19
 Chondro-sternal articulations, 20, 21, 22, 24, 25,
 33
 Circumflex artery and nerve, 35
 Clavicle, 17, 18, 32, 35
 Clavicular head of sterno-mastoid muscle, 17
 Coccygeus muscle, 63, 65
 Coccyx, 62, 65
 Cœliac axis, 27, 29, 34
 Colles, fascia of, 63
 Colon, 23, 25, 31
 Columnæ rectales, 65
 Columns of Morgagni, 65
 Compartments, of femoral sheath, 60
 iliac, 58
 pectineal, 59
 vascular, 58
 Condyles of femur, 45, 46
 humerus, 35, 36, 37
 Congenital hernia, 54, 55
 Conjoined tendon, 51, 56, 60
 Conjunctiva, 15
 Constrictor urethræ muscle, 64

- Convolutions, cerebral, relations of, to cranium, 6
 Cooper, ligament of, 59
 Coraco-brachialis muscle, 35
 Coracoid process, 35
 Cord, spermatic, 43, 51, 54, 56
 coverings of, 51, 54
 spinal, 31, 34
 Cornua of falciform border, 60
 of hyoid bone, 17
 of lateral ventricle, 9
 Coronary branch of facial artery, 14
 Corpus spongiosum, 64
 Costal artery, lateral, 22
 cartilages, 19, 20, 21, 22, 24, 25, 26, 33, 34
 Coverings of spermatic cord, 51, 54
 direct inguinal hernia, 56
 femoral hernia, 61
 oblique inguinal hernia, 54
 Cowper's gland, 64
 Cranio-cerebral topography, 5
 Cranium, 1
 relations of cerebrum to, 6
 Cremaster muscle, 51, 55, 56
 Cremasteric fascia, 51
 Crest, external occipital, 1
 iliac, 22, 23, 28, 30, 34, 42
 pubic, 43
 temporal, 1, 7, 9
 supramastoid, 11, 12, 13
 Cribriform fascia, 60, 61
 Cricoid cartilage, 16, 17, 32
 Crico-thyroid artery, 17
 space, 16, 17
 Crural branch of genito-crural nerve, 58
 canal, 60
 nerve, anterior, 45, 59
 ring, 60
 sheath, 60
 Crus penis, 64
 Cuneiform bones, 48
 Curved line, superior, 1
- DELTOID muscle, 35
 Diaphragm, 33
 Digastric muscle, 16
 Digital arteries of hand, 41
 Direct inguinal hernia, 54, 55
 Dorsal artery of foot, 49
 nerve of penis, 64
 vein of penis, 64
 Dorso-lumbar furrow, 27
 Douglas, pouch of, 66
 Duct, nasal, 15
 of Stensen, 14, 15
 of Wharton, 15
 thoracic, arch of, 32
 Dulness, cardiac, deep, 22
 superficial, 22
 Duodeno-jejunal flexure, 23, 25, 34
 Duodenum, 23, 27, 31, 34
- ELBOW, superficial anatomy of, 37
 Eminence, frontal, 1
 hypothenar, 39
 parietal, 1, 6, 7
 thenar, 39
 Endocranial blood-vessels, 3
- Ensiform process, 19, 33
 Epigastric artery, 24, 51, 53, 54, 55, 60
 fossa, 19
 region, 23
 vein, superficial, 24
 Epiglottis, 16, 17, 32
 Epiphysis, lower, of femur, 46
 Epitympanic recess, 10
 Erector spinæ muscles, 27, 28
 External inguinal hernia, 54
 Extensor. *See* MUSCLES.
 Eustachian tube, 16
 Eyeball, 14
 Eyelid, 14
- FACE, superficial anatomy of, 1, 13
 Facial artery, 14, 17
 transverse, 14
 nerve, 14
 canal of, 12
 vein, 17
 Falciform border, 60
 False perineum, 62
 Falx inguinalis, 56
 Fascia, anal, 63
 bicipital, 37, 38
 of Colles, 63
 cremasteric, 51
 cribriform, 60, 61
 eribrosa, 60
 iliac, 58, 59, 60
 infundibuliform, 51
 intercolumnar, 51
 lata, 45, 59
 obturator, 63, 64
 palmar, 39
 pectineal, 58, 59, 60
 of perineum, deep, 63, 64
 superficial, 62
 propria, 61
 recto-vesical, 62, 64, 65
 spermatic, 51, 56
 transversalis, 51, 56, 58, 60
 triangular, 51
 Fauces, 15
 pillars of, 16
 Femoral arch, deep, 58, 60
 superficial, 57, 60
 artery, 43, 45, 57, 60
 canal, 51, 60, 61
 glands, 43
 hernia, 43, 51, 57, 61
 ligament, 61
 ring, 54, 58, 60
 septum, 60
 sheath, 57, 58, 60, 61
 vein, 45, 57, 60
 Femur, 45, 46
 Fibula, 46, 47
 Fingers, flexures of, 41
 Fissure or Fissures, cerebral, situation of, 6
 intraparietal, 7, 9
 of lung, 20
 palpebral, 14
 parallel, 7, 9
 parieto-occipital, 6
 petro-squamosal, 11
 of Rolando, 6, 7, 8
 of Sylvius, 6, 8
 Flexor. *See* MUSCLES.

- Flexure, duodeno-jejunal, 23, 25, 34
 hepatic, 23, 25, 34
 splenic, 23, 25, 34
 Flexures of palm, 40
 fingers, 41
 Floor of mouth, 15
 Fold or Folds, of axilla, 19, 35
 of Houston, 65
 of nates, 42
 peritoneal, 51
 salpingo-palatine, 16
 salpingo-pharyngeal, 16
 Fontanelles, 1, 2
 Foot, superficial anatomy of, 48
 Foramen, infraorbital, 14
 mental, 14
 sacro-sciatic, 43
 supraorbital, 1
 of Winslow, 34
 Forearm, superficial anatomy of, 38
 Fossa or Fossæ, epigastric, 19
 infraclavicular, 19, 35
 infracostal, 24
 ischio-rectal, 62, 63
 jugularis, 17
 middle of skull, 11, 13
 nasal, 13, 16
 ovalis, 60
 peritoneal, 51, 54, 60
 posterior, of skull, 13
 of Rosenmüller, 16
 supraclavicular, 18
 suprameatal, 12
 Fovea supravescicalis, 53, 56
 femoralis, 54, 60
 inguinalis lateralis, 53
 mesialis, 53, 56
 Frænum linguæ, 15
 of lips, 15
 Frontal artery, 3
 convolutions, 7
 eminence, 1, 7
 lobe of cerebrum, 7
 margin of cerebrum, 5
 sinuses, 2
 sulci, 7, 9
 vein, 3
 Fronto-malar suture, 1, 7
 Fundus of stomach, 25, 33
 Furrow, abdominal, 24
 bicipital, 35
 dorso-lumbar, 27
 iliac, 42
 inguinal, 22, 43
 nuchal, 1, 27
 spinal, 27
 sternal, 19
- GALL-BLADDER, 23, 24
 Ganglia, basal, 9
 Gastrocnemius muscle, 47
 Genito-crural nerve, 58
 Genu, inferior, of Rolandic fissure, 9
 Gimbernat's ligament, 51, 57, 58, 59, 60, 61
 Glabella, 3
 Gland or Glands, of Cowper, 64
 femoral, 43
 inguinal, 24, 43
 Meibomian, 15
 parotid, 14
- Gland or Glands—*continued*.
 popliteal, 47
 sublingual, 15
 submaxillary, 16
 Glenoid cavity, 33, 35
 Gluteal artery, 43
 region, 42
 Gluteus. *See* MUSCLES.
 Gracilis muscle, 46
 Groin, 23, 51, 57
 Groove, sternal, 19
 Gums, 15
- HAM, 46
 Hamstring muscles, 45, 46
 Hamular process, 16
 Hand, superficial anatomy of, 39
 Hard palate, 16
 Head of astragalus, 48
 clavicular, of sterno-mastoid, 17
 of femur, 45
 fibula, 46, 47
 gastrocnemius muscle, 47—
 humerus, 35
 metatarsal bones, 48, 49
 pancreas, 34
 radius, 37, 38
 sternal of sterno-mastoid, 17
 superficial anatomy of, 1
 of triceps muscle, 37
 of ulna, 38
- Heart, 21, 23, 33
 Hemisphere, cerebral, 5
 Henle, ligament of, 56
 Hepatic flexure, 23, 25, 34
 Hernia, 51
 femoral, 43, 51, 57, 61
 infantile, 54
 inguinal, 51, 54
 congenital, 54, 55
 direct, 54, 55, 56
 external, 54
 internal, 54, 55, 56
 oblique, 54
 internal, 56
 sac of, 54, 61
 Hesselbach, ligament of, 56
 triangle of, 55, 56
 Hey's ligament, 61
 Hip, superficial anatomy of, 42
 Hip-joint, 43
 Hook of unciform bone, 39
 Houston, folds of, 65
 Humerus, 35
 Hymen, 66
 Hyoid bone, 16, 32
 Hyo-mental region, 16
 Hyo-sternal region, 16
 Hypochondriac region, 23
 Hypogastric artery, 51, 56
 region, 23
 Hypoglossal nerve, 17
 Hypothenar eminence, 39
- ILEUM, 23, 25
 Iliac artery. *See* ARTERIES.
 compartment, 58
 crest, 22, 23, 28, 30, 34, 42
 fascia, 58, 59, 60
 furrow, 42
 part of fascia lata, 60

- Iliac region, 23
 spine, anterior superior, 23, 34, 42, 43, 51,
 57, 61
 posterior inferior, 43
 superior, 27, 42, 43
 vein, external, 54, 57, 58, 60
 Ilio-pectineal intermuscular septum, 59
 Ilio-psoas muscle, 57, 59
 Ilio-tibial band, 45, 46
 Ilium, 59
 Infantile hernia, 54
 Infraclavicular fossa, 19, 35
 Infracostal fossa, 24
 line, 22
 plane, 23, 34
 Infrahyoid region, 16
 Infraorbital foramen, 14
 Infrapatellar fat, 46
 Infrapinatus muscle, 35
 Infrasternal depression, 19
 Infundibuliform fascia, 51
 Infundibulum of frontal sinus, 3
 of heart, 33
 Inguinal canal, 24, 51, 54, 55, 56
 furrow, 22, 43
 glands, 24, 43
 hernia, 51, 54
 congenital, 54, 55
 direct, 54, 55
 external, 54
 internal, 54, 55
 oblique, 54
 internal, 56
 region, 23
 Ionion, 7
 Innominate artery, 17, 22, 32, 33
 vein, 22, 33
 Insula, 9
 Intercolumnar fascia, 51
 Intercostal spaces, 19, 21, 22, 28
 vessels, 22
 Intermetatarsal spaces, 49
 Intermuscular septum of arm, external, 35, 37
 internal, 36
 ilio-pectineal, 59
 of thigh, external, 45
 Internal inguinal hernia. *See* HERNIA.
 Interosseous nerve, posterior, 37
 Interphalangeal articulations, 41
 Intestines, 25
 Intraparietal fissure, 7, 9
 Ischial ramus, 43, 62, 63
 spine, 63, 65
 tuberosity, 43, 62, 65
 Ischio-cavernosus muscle, 64
 Ischio-rectal fossa, 62, 63
 Island of Reil, 9
 Isthmus, thyroid, 17

 JAW, lower, 14, 15, 32
 Jejunum, 23, 25
 Joint. *See* ARTICULATIONS.
 Jugular veins. *See* VEINS.

 KIDNEY, 23, 26, 30, 31, 34
 Knee-joint, 45
 Knee, superficial anatomy of, 45

 LABIUM pudendi, 54
 Lachrymal sac, 15
 Lacuna musculorum, 58
 vasorum, 58

 Lambda, 1, 6, 7
 Lambdoid suture, 1
 Larynx, 17, 28, 32
 aperture of, 17
 Lateral abdominal region, 23
 Lateral sinus, 4, 10, 12
 Latissimus dorsi muscle, 19, 35
 Levator. *See* MUSCLES.
 Leg, superficial anatomy of, 47
 Levels of structures of trunk, 32
 Ligament, annular, anterior, of ankle, 49
 broad, of uterus, 66
 of Cooper, 59
 femoral, 61
 of Gimbernat, 51, 57, 58, 59, 60, 61
 of Henle, 56
 of Hesselbach, 56
 of Hey, 61
 lateral, external, of knee, 46
 pterygo-maxillary, 16
 of Poupart, 22, 24, 43, 51, 55, 57, 58, 59,
 60, 61
 pubic, 59
 round, of uterus, 54, 55
 sacro-sciatic, 62, 63, 65
 tarsal, internal, 15
 transverse, superficial, of hand, 41
 triangular, 62, 63, 64, 65
 Ligamentum inguinale, 57
 interfoveolare, 56
 lacunare, 57
 patellæ, 46
 Limb, lower, superficial anatomy of, 42
 upper, superficial anatomy of, 35
 Line or lines, base, of Reid, 7
 bi-iliac, 22
 infracostal, 22
 mid-Poupart, 23
 nasio-inial, 7
 of Nelaton, 43
 of palm, 40
 of parallel fissure, 7, 9
 Rolandic, 8
 Sylvian, 8
 Linea semilunaris, 23, 24
 Lingual artery, 17
 nerve, 16
 Lips, 15
 Liver, 23, 24, 33, 34
 Longitudinal sinus, superior, 3, 5
 Lumbar enlargement of spinal cord, 31
 region, 23
 Lung, 18, 20, 28, 32, 34
 root of, 33

 MALLEOLUS, external, 47, 48
 internal, 47, 48
 Mammary artery, internal, 22
 Manubrium, 19, 20, 22, 32, 33
 Marginal tubercle, 7
 Masseter muscle, 14, 15
 Mastoid antrum, 10
 cells, 11, 12, 13
 process, 1
 Masto-squamosal suture, 12
 Meatus, external auditory, 11, 12
 middle, of nose, 13
 Median nerve, 36, 38
 vein, 37, 38
 Median-basilic vein, 37
 Median-cephalic vein, 37
 Meibomian glands, 15

Membranous urethra, 62, 64
 Meningeal artery, middle, 5
 Mental foramen, 14
 Mesenteric artery. *See* ARTERY.
 Mesentery, 23, 25
 Metacarpal bones, 39
 Metacarpo-phalangeal articulations, 40, 41
 Metatarsal bones, 48, 49
 Metatarso-phalangeal articulations, 49
 Mid-Poupart line, 23
 Morgagni, columns of, 65
 valves of, 65
 Mouth, 15, 32
 MUSCLE or MUSCLES, abductor hallucis, 49
 indicus, 39
 minimi digiti, 49
 adductor longus, 45
 magnus, 45, 46
 of thigh, 43, 45, 46
 transversus pollicis, 39
 anconeus, 37, 38
 biceps brachii, 35, 36, 37
 femoris, 45, 46, 47
 brachialis anticus, 36
 bulbo-cavernosus, 64
 coccygeus, 63, 65
 constrictor urethrae, 64
 coraco-brachialis, 35
 cremaster, 51, 55, 56
 deltoid, 35
 digastric, 16
 erector spinae, 27, 28
 extensor brevis digitorum, 49
 pollicis, 38, 39
 carpi radialis, 36, 37, 38
 ulnaris, 38
 communis digitorum, 39
 of fingers, 38, 39
 of forearm, 37
 indicus, 39
 longus digitorum, 47, 49
 pollicis, 38, 39
 minimi digiti, 38, 39
 ossis metacarpi pollicis, 38, 39
 proprius hallucis, 47, 49
 of thumb, 38, 39
 flexor brevis hallucis, 49
 minimi digiti, 49
 carpi radialis, 38
 ulnaris, 38
 longus digitorum, 47
 profundus digitorum, 38
 gastrocnemius, 47
 glutens maximus, 42, 43, 62, 63
 medius, 42, 43
 minimus, 42
 gracilis, 46
 hamstring, 45, 46
 ilio-psoas, 57, 59
 infraspinatus, 35
 ischio-cavernosus, 64
 latissimus dorsi, 19, 35
 levator anguli scapulae, 28
 ani, 62, 63, 64, 65
 of little finger, short, 39
 masseter, 14, 15
 obliquus abdominis, externus, 19, 24, 51,
 56
 internus, 51, 56
 obturator internus, 63
 omo-hyoid, 17, 18
 palmaris longus, 38

MUSCLE or MUSCLES—*continued.*
 pectineus, 57, 59, 60
 pectoralis major, 19, 35
 minor, 19
 peronei, 46, 47, 49
 quadriceps extensor, 43
 rectus abdominis, 19, 24, 55
 femoris, 43
 sartorius, 43, 46
 semimembranosus, 46
 semitendinosus, 46
 serratus magnus, 19
 soleus, 47
 sphincter ani, 62, 63, 64, 65
 sterno-mastoid, 17
 supinator longus, 35, 36, 37, 38, 39
 supraspinatus, 28
 temporal, 1, 15
 tensor vaginae femoris, 42
 teres, 35
 of thumb, short, 39
 tibialis anticus, 47, 48, 49
 posticus, 47, 48
 transversalis abdominis, 51, 56
 transversus perinei, 64
 trapezius, 28
 triceps, 35, 37
 vastus, externus, 44, 45
 internus, 44
 Musculo-cutaneous nerve, 49
 Musculo-spiral nerve, 37

NARES, posterior, 16
 Nasal aperture, anterior, 13
 cartilages, 13
 duct, 15
 fossa, 13, 16
 spine, anterior, 13
 Nasion, 7
 Nasio-nial line, 7
 Naso-frontal suture, 5
 Nates, fold of, 42
 Navicular bone, 48
 Neck, superficial anatomy of, 1, 16
 Nelaton's line, 43
 NERVE or NERVES, auricular, great, 18
 circumflex, 35
 cruial, anterior, 45, 59
 cutaneous, external, 59
 dorsal of penis, 64
 facial, 12, 14
 genito-cruial, 58
 hypoglossal, 17
 interosseous, posterior, 37
 lingual, 16
 median, 36, 38
 musculo-cutaneous, 49
 musculo-spiral, 37
 occipital, great, 3
 perineal, 64
 popliteal, 47
 pubic, 64
 radial, 37
 saphenous, external, 47, 49
 internal, 46, 47
 of scalp, 3
 sciatic, great, 43, 45
 small, 45
 spinal, 31, 32, 33, 34
 spinal accessory, 18
 superficial cervical, 18

NERVE OR NERVES—*continued.*

- supraorbital, 3
 - supratrochlear, 3
 - tibial, anterior, 49
 - posterior, 47
 - ulnar, 36, 39
 - Nerve-roots, spinal, 31, 32, 33, 34
 - Nipple, 19, 22, 33
 - Notch, supraorbital, 1, 14
 - suprasternal, 17
 - Nuchal furrow, 1, 27
 - Nuck, canal of, 55
- OBELION, I
- Oblique inguinal hernia, 54
 - internal, 56
 - Obliquus abdominis. *See* MUSCLES.
 - Obturator artery, aberrant, 60
 - fascia, 63, 64
 - internus muscle, 63
 - Occipital artery, 3, 10, 17
 - crest, external, 1
 - nerve, great, 3
 - protuberance, external, 1
 - Occipito-temporal margin of cerebrum, 5
 - Oesophagus, 17, 28, 32
 - Olecranon, 37
 - Omentum, great, 23, 25
 - Omo-hyoid muscle, 17, 18
 - Operculum of middle turbinate body, 13
 - Orifice, aortic, 22, 23
 - auriculo-ventricular, 22, 33
 - cardiac, 23, 25, 28, 33
 - of inferior vena cava, 33
 - pulmonary, 22, 33
 - pyloric, 23, 25, 29, 34
 - Origin of spinal nerve-roots, 31, 32, 33, 34
 - Os calcis, 47, 48, 49
 - Os uteri, 66
 - Ovary, 66
- PALATE, 16, 32
- Palatine canal, posterior, 16
 - Palm, 39
 - Palmar arch, deep, 41
 - superficial, 41
 - fascia, 39
 - Palmaris longus, 38
 - Palpebral fissure, 14
 - sulcus, external, 14
 - inferior, 14
 - superior, 14
 - Palpebro-malar sulcus, 14
 - Pancreas, 23, 27, 31, 34
 - Papilla lacrimalis, 15
 - Parallel fissure, 7, 9
 - Parietal eminence, 1, 6, 7
 - Parieto-occipital fissure, 6
 - Parotid gland, 14
 - Patella, 46
 - ligament of, 46
 - Pectineal compartment, 59
 - fascia, 58, 59, 60
 - Pectineus muscle, 57, 59, 60
 - Pectoral muscles, 19, 35
 - Pelvic viscera, examination of, 65
 - Penis, crura of, 64
 - Perineal artery. *See* ARTERY.
 - fascia, 64
 - nerve, 64

- Perineum, central point of, 62, 64
 - false, 62
 - anatomy of, 62
 - true, 62
- Peritoneal folds, 51
 - fossæ, 51, 54
- Peritoneum, 54, 56, 60, 61
- Peroneal spine, 48
- Peronei muscles, 46, 47, 49
- Petro-squamosal fissure, 11
- Pharyngeal recess, lateral, 16
 - median, 16
 - tonsil, 16
- Pharynx, 13, 16, 17, 28, 32
- Pillars of abdominal ring, 24
 - of fauces, 16
- Pisiform bone, 38, 39
- Plantar arteries, 48, 49
- Pleura, 18, 20, 28, 34
- Plexus, brachial, 18
 - prostatic, 64
- Plica epigastrica, 53
 - fimbriata, 15
 - hypogastrica, 51
 - semilunaris, 15
 - umbilicalis lateralis, 51
 - media, 51
 - urachi, 51
- Plicæ transversales recti, 65
- Point, preauricular, 7
 - Rolandic, inferior, 8
 - superior, 7
 - Sylvian, 8, 9
- Pomum Adami, 16
- Popliteal artery, 46, 47
 - glands, 47
 - nerves, 47
 - vein, 46
- Postcentral sulci, 9
- Pouch of Douglas, 66
 - recto-vesical, 65
- Poupart's ligament, 22, 24, 43, 51, 55, 57, 58, 59, 60, 61
- Preauricular point, 7
- Precentral sulci, 7, 9
- Process, alveolar, 15
 - basilar, 16
 - coracoid, 35
 - ensiform, 19, 33
 - external angular, 1
 - hamular, 16
 - mastoid, 1
 - styloid of third metacarpal, 39
 - radius, 38, 39
 - ulna, 38
 - transverse, of atlas, 17
 - of sixth cervical vertebra, 17
- Processus vaginalis, 54
- Profunda artery. *See* ARTERY.
- Promontory of sacrum, 24
- Prostate, 64, 65
 - sheath of, 64
- Prostatic plexus, 64
- Pterion, 6
- Pterygo-maxillary ligament, 16
- Pubes, 23
- Pubic branch of epigastric artery, 60
 - crest, 43
 - ligament, 59
 - portion of fascia lata, 59
 - rami, 43, 59, 63
 - region, 23

- Pubic spine, 24, 43, 51, 57, 60
 symphysis, 43
 vein, 60
 Pudic artery, 64
 nerve, 64
 Pulley of superior oblique muscle, 14
 Pulmonary artery, 33
 cartilage, 22
 orifice, 22, 33
 Pulse, 38
 Punctum lacrimale, 15
 Pyloric orifice, 23, 25, 29, 34
 Pyramidal bone, 39
- QUADRICEPS extensor muscle, 43
- RADIAL artery, 38, 39
 nerve, 37
 vein, 38
 Radio-carpal articulation, 41
 Radius, 37, 38
 Ranine vein, 15, 17
 Raphé of perineum, 62
 Receptaculum chyli, 34
 Rectal examination, 65
 Recto-vaginal septum, 66
 Recto-vesical fascia, 62, 64, 65
 pouch, 65
 Rectum, 23, 64, 65
 Rectus muscle. *See* MUSCLES.
 REGION or REGIONS, abdominal, 22
 viscera of, 23
 epigastric, 23
 gluteal, 42
 hyo-mental, 16
 hyo-sternal, 16
 hypocondriac, 23
 hypogastric, 23
 iliac, 23
 infrahyoid, 16
 inguinal, 23
 lateral abdominal, 23
 lumbar, 23
 of neck, 16
 pubic, 23
 submaxillary, 16
 suprahyoid, 16
 umbilical, 23
 Reid, base-line of, 7
 Reil, island of, 9
 Renal artery, 27, 29, 34
 Ribs, 19, 20, 25, 28, 30, 32, 33, 34, 35
 Rima glottidis, 17, 32
 Ring, abdominal, external, 51, 55, 56
 internal, 51, 53
 crural, 60
 femoral, 54, 58, 60
 Rolandic angle, 9
 line, 8
 point, inferior, 8
 superior, 7
 Rolando, fissure of, 6, 7, 8
 Root of lung, 33
 Roots of spinal nerves, 31, 32, 33, 34
 Rosenmüller, fossa of, 16
 Round ligament of uterus, 54, 55
- SAC of hernia, 54, 61
 lachrymal, 15
 Sacro-iliac articulation, 42
 Sacro-sciatic foramen, 43
 ligament, 62, 63, 65
 Sacrum, 65
 promontory of, 24
 Sagittal suture, 1
 Salpingo-palatine fold, 16
 Salpingo-pharyngeal fold, 16
 Saphenous nerves. *See* NERVES.
 opening, 43, 57, 60, 61
 veins. *See* VEINS.
 Sartorius muscle, 43, 46
 Scalp, vessels and nerves of, 3
 Scaphoid bone, 39
 Scapula, 28, 32, 33
 Scarpa's triangle, 43
 Sciatic, artery, 43
 nerve, great, 43, 45
 small, 45
 Serobiculus cordis, 19
 Scrotum, 54
 Semicircular canal, external, 12
 Semimembranosus muscle, 46
 Semitendinosus muscle, 46
 Septum, femoral, 60, 61
 intermuscular of arm, external, 35, 37
 internal, 36
 ilio-pectineal, 59
 of thigh, external, 45
 nasi, 13, 16
 recto-vaginal, 66
 Serratus magnus muscle, 19
 Sesamoid bones of foot, 48
 of thumb, 39
 Sheath, crural or femoral, 57, 58, 60, 61
 of prostate, 64
 Shin, 47
 Shoulder, superficial anatomy of, 35
 Shoulder-joint, 35
 Sigmoid colon, 23, 25
 Sinus, frontal, 2
 lateral, 4, 10, 12
 rectales, 65
 superior longitudinal, 3, 5
 Soft palate, 16, 32
 Sole, 49
 Soleus muscle, 47
 Space, crico-thyroid, 16
 intercostal, 19, 21, 22, 28
 thyro-hyoid, 16
 Spermatic artery, 54, 56, 60
 cord, 43, 51, 54, 56
 fascia, 51, 56, 60
 Sphincter muscles of anus, 62, 63, 64, 65
 Spinal accessory nerve, 18
 cord, 31, 34
 furrow, 27
 nerve-roots, 31, 32, 33
 Spine, iliac, posterior inferior, 43
 superior, 27, 42, 43
 anterior superior, 24, 34, 42, 43, 51,
 57, 61
 of ischium, 63, 65
 nasal, anterior, 13
 peroneal, 48
 pubic, 24, 43, 51, 57, 60
 of scapula, 28, 33
 suprameatal, 12
 Spines, vertebral, 20, 27, 28, 29, 30, 31, 42
 Spleen, 23, 29, 33, 34

Splenic flexure, 23, 25, 34
 Stensen's duct, 14, 15
 Stephanion, 7
 Sternal angle, 19
 furrow or groove, 19
 head of sterno-mastoid, 17
 Sterno-clavicular joint, 18, 22
 Sterno-mastoid muscle, 17
 Sternum, 19, 32, 33
 Stomach, 23, 25, 29, 33
 Styloid process of radius, 38, 39
 of third metacarpal bone, 39
 of ulna, 38
 Subclavian artery, 18, 22, 32
 vein, 18
 Subcostal angle, 19
 Sublingual gland, 15
 Submaxillary gland, 16
 region, 16
 Subpubic arch, 62, 66
 Sulcus, alveolo-lingual, 15
 palpebral, external, 14
 inferior, 14
 superior, 14
 palpebro-malar, 14
 Superciliary ridge, 1, 3
 Superficial anatomy of abdomen, 22
 of ankle, 48
 of arm, 35
 of back, 27
 of chest, 19
 of elbow, 37
 of foot, 48
 of forearm, 38
 of hand, 39
 of head and neck, 1, 16
 of hip, 42
 of knee, 45
 of leg, 47
 of limb, lower, 42
 upper, 35
 of perineum, 62
 of shoulder, 35
 of thigh, 43
 of trunk, 19
 of wrist, 39
 Supinator longus muscle, 35, 36, 37, 38, 39
 Supraclavicular fossa, 18
 Supracondylar ridges, 35, 37
 Suprahyoid region, 16
 Supramastoid crest, 11, 12, 13
 Suprameatal fossa, 12
 spine, 12
 triangle, 12, 13
 Supraorbital artery, 3
 foramen or notch, 1, 14
 nerve, 3
 Suprarenal bodies, 23, 34
 Suprascapular vein, 18
 Supraspinatus muscle, 28
 Suprasternal notch, 17
 Supratrochlear nerve, 3
 Suture, fronto-malar, 1, 7
 lambdoid, 1
 masto-squamosal, 12
 naso-frontal, 5
 parieto-mastoid, 5
 sagittal, 1
 Sustentaculum tali, 48
 Sylvian line, 8
 point, 8, 9
 Sylvius, fissure of, 6, 8

TABLE of levels of structures of trunk, 32
 Tail of pancreas, 23
 Tarsal articulation, transverse, 48
 bones, 48
 ligament, internal, 15
 Tarso-metatarsal articulations, 48
 Teeth, 15
 Tegmen tympani, 11
 Temporal artery, superficial, 3
 convolution, inferior, 11
 crest, 1, 7, 9
 line, lower, 1
 lobe of cerebrum, 7, 11
 muscle, 1, 15
 Temporo-maxillary joint, 13
 Tendinous inscriptions, 24
 Tendo Achillis, 47
 palpebrarum, 15
 Tendon, conjoined, 51, 56, 60
 Tensor vaginæ femoris, 42
 Teres muscles, 35
 Testis, 54
 Thigh, superficial anatomy of, 43
 Thenar eminence, 39
 Thoracic duct, arch of, 32
 Thyro-hyoid space, 16
 Thyroid arteries, 17
 body, 17
 cartilage, 16, 32
 veins, 18
 Tibia, 45, 46, 47, 48
 Tibial arteries, 47, 48, 49
 nerves, 47, 49
 Tibiales muscles, 47, 48, 49
 Tongue, 15, 32
 Tonsil, 16, 18
 pharyngeal, 16
 Topographical anatomy, cranio-cerebral, 5
 of groin, 51
 of mastoid antrum, 10
 of perineum, 62
 Trachea, 16, 28, 32, 33
 Transversalis abdominis muscle, 51, 56
 fascia, 51, 56, 58, 60
 Transverse ligament, superficial, of hand, 41
 process of atlas, 17
 of sixth cervical vertebra, 17
 tarsal articulation, 48
 Transversus perinei muscle, 64
 Trapezium, 39
 Trapezius muscle, 28
 Triangle of neck, anterior, 17
 posterior, 18
 of Hesselbach, 55, 56
 of Scarpa, 43
 suprameatal, 12, 13
 Triangular fascia, 51
 ligament, 62, 63, 64, 65
 tendon of trapezius, 28
 Triceps muscle, 35, 37
 Trochanter, great, 42, 43
 Trochlear surface of femur, 46
 True perineum, 62
 Trunk, levels of structures in, 32
 superficial anatomy of, 19
 Tubercle, adductor, 45, 46
 carotid, 17
 marginal, 7
 of radius, 38
 of tibia, 46, 48
 Tuberosity of femur, 45, 46
 of fifth metatarsal, 48, 49

Tuberosity of ischium, 43, 62, 65
 of navicular bone, 48
 of os calcis, 47, 48, 49
 of scaphoid, 39
 of tibia, 45, 46
 Tunica vaginalis, 54
 Turbinate bodies, 13, 16
 bone, inferior, 13, 16
 Tympanum, attic of, 10

ULNA, 38
 Ulnar artery, 38, 39
 nerve, 36, 39
 vein, 37, 38
 Umbilical region, 23
 Umbilicus, 23, 24, 28, 34
 Unciform bone, 39
 Upper limb, superficial anatomy of, 35
 Urachus, 51
 Urethra, bulb of, 62
 membranous part of, 62, 64
 Urethral part of perineum, 62
 Uterus, 23, 66
 broad ligament of, 66
 Uvula, 16

VAGINAL examination, 66
 Valves of Morgagni, 65
 Vas deferens, 51, 54, 65
 Vascular compartment, 58
 Vasti muscles, 44, 45
 VEIN or VEINS, azygos, 33
 basilic, 36, 37
 at bend of elbow, 37
 cephalic, 36, 37
 cervical, transverse, 18
 dorsal of penis, 64
 endocranial, 3
 epigastric, superficial, 24
 facial, 17
 femoral, 45, 57, 60
 frontal, 3
 iliac, external, 54, 57, 58, 60
 innominate, 22, 33
 intercostal, 22

VEIN or VEINS—*continued.*

jugular, anterior, 18
 external, 18
 internal, 17
 median, 37, 38
 median-basilic, 37
 median-cephalic, 37
 popliteal, 46
 pubic, 60
 radial, 37, 38
 ranine, 15, 17
 saphenous, external, 46, 47, 49
 internal, 43, 45, 46, 47, 49, 60
 of scalp, 3
 subclavian, 18
 suprascapular, 18
 thyroid, 18
 ulnar, 37, 38
 Vena cava inferior, 27, 33, 34
 cava superior, 22, 33
 thoraco-epigastrica, 24
 Ventricles, lateral, 9
 of heart, 33
 Vermiform appendix, 23
 Vertebrae, cervical, 16, 27
 bodies of, 19, 23, 27, 32, 33, 34
 spines of, 20, 27, 28, 29, 30, 31, 42
 Vertebral artery, 5
 Vesiculæ seminales, 65
 Vessels. *See* ARTERIES, VEINS.
 Viscera abdominal, 23, 24
 pelvic, examination of, 65
 Volar artery, superficial, 41

WALL of abdomen, 23, 56
 Web of fingers, 40, 41
 Wharton, duct of, 15
 Winslow, foramen of, 34
 Wrist, superficial anatomy of, 39

XIPHISTERNAL articulation, 19, 24, 25, 33

ZYGOMA, I
 Zygomatic arch, 7

THE END.

A LIST OF WORKS ON
MEDICINE, SURGERY
AND
GENERAL SCIENCE,
PUBLISHED BY
LONGMANS, GREEN & CO.,
LONDON, NEW YORK, AND BOMBAY.

Medical and Surgical Works.

ASHBY. NOTES ON PHYSIOLOGY FOR THE USE OF STUDENTS PREPARING FOR EXAMINATION. By HENRY ASHBY, M.D. Lond., F.R.C.P., Physician to the General Hospital for Sick Children, Manchester; formerly Demonstrator of Physiology, Liverpool School of Medicine. Sixth Edition, thoroughly revised. With 141 Illustrations. Fcap. 8vo, price 5s.

ASHBY AND WRIGHT. THE DISEASES OF CHILDREN, MEDICAL AND SURGICAL. By HENRY ASHBY, M.D. Lond., F.R.C.P., Physician to the General Hospital for Sick Children, Manchester; Lecturer and Examiner in Diseases of Children in the Victoria University; and G. A. WRIGHT, B.A., M.B. Oxon., F.R.C.S. Eng., Assistant Surgeon to the Manchester Royal Infirmary and Surgeon to the Children's Hospital; formerly Examiner in Surgery in the University of Oxford. Enlarged and Improved Edition. With 192 Illustrations. 8vo, price 25s.

BENNETT.—*WORKS* by WILLIAM H. BENNETT, F.R.C.S., Surgeon to St. George's Hospital; Member of the Board of Examiners, Royal College of Surgeons of England.

CLINICAL LECTURES ON VARICOSE VEINS OF THE LOWER EXTREMITIES. With 3 Plates. 8vo. 6s.

ON VARICOCELE: A PRACTICAL TREATISE. With 4 Tables and a Diagram. 8vo. 5s.

CLINICAL LECTURES ON ABDOMINAL HERNIA: chiefly in relation to Treatment, including the Radical Cure. With 12 Diagrams in the Text. 8vo. 8s. 6d. *

BENTLEY. A TEXT-BOOK OF ORGANIC MATERIA MEDICA.

Comprising a Description of the Vegetable and Animal Drugs of the British Pharmacopœia, with some others in common use. Arranged Systematically, and Especially Designed for Students. By ROBERT BENTLEY, M.R.C.S. Eng., F.L.S. With 62 Illustrations on Wood. Crown 8vo, price 7s. 6d.

COATS. A MANUAL OF PATHOLOGY. By JOSEPH COATS, M.D., Professor of Pathology in the University of Glasgow. Third Edition. Revised throughout. With 507 Illustrations. 8vo, 31s. 6d.

COOKE.—*WORKS* by THOMAS COOKE, F.R.C.S. Eng., B.A., B.Sc., M.D. Paris, Senior Assistant Surgeon to the Westminster Hospital.

TABLETS OF ANATOMY. Being a Synopsis of Demonstrations given in the Westminster Hospital Medical School in the years 1871-75. Tenth Thousand, being a selection of the Tablets believed to be most useful to Students generally. Post 4to, price 10s. 6d.

APHORISMS IN APPLIED ANATOMY AND OPERATIVE SURGERY. Including 100 Typical *vivâ voce* Questions on Surface Marking, &c. Crown 8vo, 3s. 6d.

DISSECTION GUIDES. Aiming at Extending and Facilitating such Practical Work in Anatomy as will be specially useful in connection with an ordinary Hospital Curriculum. 8vo, 10s. 6d.

DICKINSON.—*WORKS* by W. HOWSHIP DICKINSON, M.D. Cantab., F.R.C.P., Physician to, and Lecturer on Medicine at, St. George's Hospital; Consulting Physician to the Hospital for Sick Children.

ON RENAL AND URINARY AFFECTIONS. Complete in Three Parts, 8vo, with 12 Plates and 122 Woodcuts. Price £3 4s. 6d. cloth.

* * The Parts can also be had separately, each complete in itself, as follows:—

PART I.—*Diabetes*, price 10s. 6d. sewed, 12s. cloth.

„ II.—*Albuminuria*, price £1 sewed, £1 1s. cloth.

„ III.—*Miscellaneous Affections of the Kidneys and Urine*, price £1 10s. sewed, £1 11s. 6d. cloth.

THE TONGUE AS AN INDICATION OF DISEASE; being the Lumleian Lectures delivered at the Royal College of Physicians in March, 1888. 8vo, price 7s. 6d.

THE HARVEIAN ORATION ON HARVEY IN ANCIENT AND MODERN MEDICINE. Crown 8vo, 2s. 6d.

OCCASIONAL PAPERS ON MEDICAL SUBJECTS, 1855-1896. 8vo, 12s.

DUANE. THE STUDENT'S DICTIONARY OF MEDICINE AND THE ALLIED SCIENCES. Comprising the Pronunciation, Derivation, and Full Explanation of Medical Terms, together with much Collateral Descriptive Matter, numerous Tables, &c. By ALEXANDER DUANE, M.D., Assistant-Surgeon to the New York Ophthalmic and Aural Institute, Reviser of Medical Terms for "Webster's International Dictionary." 8vo, 21s.

ERICHSEN.—*WORKS by Sir JOHN ERIC ERICHSEN, Bart., F.R.S., LL.D. (Edin.), Hon. M. Ch. and F.R.C.S. (Ireland), Surgeon Extraordinary to H.M. the Queen; President of University College, London; Fellow and Ex-President of the Royal College of Surgeons of England; Emeritus Professor of Surgery in University College; Consulting-Surgeon to University College Hospital, and to many other Medical Charities.*

THE SCIENCE AND ART OF SURGERY; A TREATISE ON SURGICAL INJURIES, DISEASES, AND OPERATIONS. Tenth Edition. Revised by the late MARCUS BECK, M.S. & M.B. (Lond.), F.R.C.S., Surgeon to University College Hospital, and Professor of Surgery in University College, London; and by RAYMOND JOHNSON, M.B. & B.S. (Lond.), F.R.C.S., Assistant Surgeon to University College Hospital, &c. Illustrated by nearly 1,000 Engravings on Wood. 2 Vols. royal 8vo, 48s.

FRANKLAND. MICRO-ORGANISMS IN WATER, THEIR SIGNIFICANCE, IDENTIFICATION, AND REMOVAL. Together with an Account of the Bacteriological Methods Involved in their Investigation. Specially Designed for the Use of those connected with the Sanitary Aspects of Water Supply. By Professor PERCY FRANKLAND, Ph.D., B.Sc. (Lond.), F.R.S., Fellow of the Chemical Society; and Mrs. PERCY FRANKLAND, Joint Author of "Studies on Some New Micro-Organisms Obtained from Air." With 2 Plates and numerous Diagrams. 8vo. 16s. net.

GAIRDNER AND COATS. ON THE DISEASES CLASSIFIED by the REGISTRAR-GENERAL as TABES MESENTERICA. LECTURES TO PRACTITIONERS. By W. T. GAIRDNER, M.D., LL.D. On the PATHOLOGY of PHTHISIS PULMONALIS. By JOSEPH COATS, M.D. With 28 Illustrations. 8vo, price 12s. 6d.

GARROD.—*WORKS* by Sir ALFRED BARING GARROD, M.D., F.R.S., &c.; Physician Extraordinary to H.M. the Queen; Consulting Physician to King's College Hospital; late Vice-President of the Royal College of Physicians.

A TREATISE ON GOUT AND RHEUMATIC GOUT (RHEUMATOID ARTHRITIS). Third Edition, thoroughly revised and enlarged; with 6 Plates, comprising 21 Figures (14 Coloured), and 27 Illustrations engraved on Wood. 8vo, price 21s.

THE ESSENTIALS OF MATERIA MEDICA AND THERAPEUTICS. The Thirteenth Edition, revised and edited, under the supervision of the Author, by NESTOR TIRARD, M.D. Lond., F.R.C.P., Professor of Materia Medica and Therapeutics in King's College, London, &c. Crown 8vo, price 12s. 6d.

GRAY. ANATOMY, DESCRIPTIVE AND SURGICAL. By HENRY GRAY, F.R.S., late Lecturer on Anatomy at St. George's Hospital. The Thirteenth Edition, re-edited by T. PICKERING PICK, Surgeon to St. George's Hospital; Member of the Court of Examiners, Royal College of Surgeons of England. With 636 large Woodcut Illustrations, a large proportion of which are Coloured, the Arteries being coloured red, the Veins blue, and the Nerves yellow. The attachments of the muscles to the bones, in the section on Osteology, are also shown in coloured outline. Royal 8vo, price 36s.

HALLIBURTON.—*WORKS* by W. D. HALLIBURTON, M.D., F.R.S., M.R.C.P., Professor of Physiology in King's College, London; Lecturer on Physiology at the London School of Medicine for Women.

A TEXT-BOOK OF CHEMICAL PHYSIOLOGY AND PATHOLOGY. With 104 Illustrations. 8vo, 28s.

ESSENTIALS OF CHEMICAL PHYSIOLOGY. Second Edition. 8vo, 5s.

* * This is a book suitable for medical students. It treats of the subject in the same way as Prof. SCHÄFER's "Essentials" treats of Histology. It contains a number of elementary and advanced practical lessons, followed in each case by a brief descriptive account of the facts related to the exercises which are intended to be performed by each member of the class.

LANG.—**THE METHODICAL EXAMINATION OF THE EYE.** Being Part I. of a Guide to the Practice of Ophthalmology for Students and Practitioners. By WILLIAM LANG, F.R.C.S. Eng., Surgeon to the Royal London Ophthalmic Hospital, Moorfields, &c. With 15 Illustrations. Crown 8vo, 3s. 6d.

LANGTON. ABDOMINAL HERNIA. By JOHN LANGTON, F.R.C.S., Surgeon to St. Bartholomew's Hospital, Senior Surgeon to the City of London Truss Society, Member of the Council and Court of Examiners of the Royal College of Surgeons of England. With numerous Illustrations. [*In the press.*]

LIVEING.—*WORKS* by ROBERT LIVEING, M.A. & M.D. Cantab., F.R.C.P. Lond., &c., Physician to the Department for Diseases of the Skin at the Middlesex Hospital, &c.

HANDBOOK ON DISEASES OF THE SKIN. With especial reference to Diagnosis and Treatment. Fifth Edition, revised and enlarged. Fcap. 8vo, price 5s.

ELEPHANTIASIS GRÆCORUM, OR TRUE LEPROSY; Being the Goulstonian Lectures for 1873. Cr. 8vo, 4s. 6d.

LONGMORE.—*WORKS* by Surgeon-General Sir T. LONGMORE (Retired), C.B., F.R.C.S., late Professor of Military Surgery in the Army Medical School; Officer of the Legion of Honour.

THE ILLUSTRATED OPTICAL MANUAL; OR, HANDBOOK OF INSTRUCTIONS FOR THE GUIDANCE OF SURGEONS IN TESTING QUALITY AND RANGE OF VISION, AND IN DISTINGUISHING AND DEALING WITH OPTICAL DEFECTS IN GENERAL. Illustrated by 74 Drawings and Diagrams by Inspector-General Dr. MACDONALD, R.N., F.R.S., C.B. Fourth Edition. 8vo, price 14s.

GUNSHOT INJURIES. Their History, Characteristic Features, Complications, and General Treatment; with Statistics concerning them as they have been met with in Warfare. With 78 Illustrations. 8vo, price 31s. 6d.

LUFF. TEXT-BOOK OF FORENSIC MEDICINE AND TOXICOLOGY. By ARTHUR P. LUFF, M.D., B.Sc. (Lond.), Physician in Charge of Out-Patients and Lecturer on Medical Jurisprudence and Toxicology in St. Mary's Hospital; Examiner in Forensic Medicine in the University of London; External Examiner in Forensic Medicine in the Victoria University; Official Analyst to the Home Office. With numerous Illustrations. 2 vols., crown 8vo, 24s.

MUNK. THE LIFE OF SIR HENRY HALFORD, Bart., G.C.H., M.D., F.R.S., President of the Royal College of Physicians, Physician to George III., George IV., William IV., and to Her Majesty Queen Victoria. By William MUNK, M.D., F.S.A., Fellow and late Vice-President of the Royal College of Physicians of London. With 2 Portraits. 8vo, 12s. 6d.

NEWMAN. ON THE DISEASES OF THE KIDNEY AMENABLE TO SURGICAL TREATMENT. Lectures to Practitioners. By DAVID NEWMAN, M.D., Surgeon to the Western Infirmary Out-Door Department; Pathologist and Lecturer on Pathology at the Glasgow Royal Infirmary; Examiner in Pathology in the University of Glasgow; Vice-President Glasgow Pathological and Clinical Society. 8vo, price 16s.

NOTTER AND FIRTH. HYGIENE. By J. L. NOTTER, M.A., M.D., Fellow and Member of Council of the Sanitary Institute of Great Britain, Examiner in Hygiene, Science and Art Department, etc.; and R. H. FIRTH, F.R.C.S., Assistant Examiner in Hygiene, Science and Art Department. With 93 Illustrations. Crown 8vo, 3s. 6d.

OWEN. A MANUAL OF ANATOMY FOR SENIOR STUDENTS. By EDMUND OWEN, M.B., F.R.S.C., Senior Surgeon to the Hospital for Sick Children, Great Ormond Street, Surgeon to St. Mary's Hospital, London, and co-Lecturer on Surgery, late Lecturer on Anatomy in its Medical School. With 210 Illustrations. Crown 8vo, price 12s. 6d.

POOLE. COOKERY FOR THE DIABETIC. By W. H. and Mrs. POOLE. With Preface by Dr. PAVY. Fcap. 8vo. 2s. 6d.

POORE. ESSAYS ON RURAL HYGIENE. By GEORGE VIVIAN POORE, M.D., F.R.C.P. Crown 8vo, 6s. 6d.

QUAIN. A DICTIONARY OF MEDICINE; Including General Pathology, General Therapeutics, Hygiene, and the Diseases of Women and Children. By Various Writers. Edited by RICHARD QUAIN, Bart., M.D.Lond., LL.D.Edin. (Hon.) F.R.S., Physician Extraordinary to H.M. the Queen, President of the General Medical Council, Member of the Senate of the University of London, &c. Assisted by FREDERICK THOMAS ROBERTS, M.D.Lond., B.Sc., Fellow of the Royal College of Physicians, Fellow of University College, Professor of *Materia Medica* and Therapeutics, University College, &c.; and J. MITCHELL BRUCE, M.A.Abdn., M.D.Lond., Fellow of the Royal College of Physicians of London, Physician and Lecturer on the Principles and Practice of Medicine, Charing Cross Hospital, &c. New Edition, revised throughout and Enlarged. In 2 Vols. medium 8vo, cloth, red edges, price 40s. net.

QUAIN. QUAIN'S (JONES) ELEMENTS OF ANATOMY.

The Tenth Edition. Edited by EDWARD ALBERT SCHÄFER, F.R.S., Professor of Physiology and Histology in University College, London; and GEORGE DANCER THANE, Professor of Anatomy in University College, London. In 3 Vols.

* * The several parts of this work (which is now complete, with the exception of an Appendix on Superficial Anatomy) form COMPLETE TEXT-BOOKS OF THEIR RESPECTIVE SUBJECTS. They can be obtained separately as follows:—

- VOL. I., PART I. EMBRYOLOGY. By Professor SCHÄFER. Illustrated by 200 Engravings, many of which are coloured. Royal 8vo, 9s. [Ready.]
- VOL. I., PART II. GENERAL ANATOMY OR HISTOLOGY. By Professor SCHÄFER. Illustrated by 491 Engravings, many of which are coloured. Royal 8vo, 12s. 6d. [Ready.]
- VOL. II., PART I. OSTEOLOGY. By Professor THANE. Illustrated by 168 Engravings. Royal 8vo, 9s. [Ready.]
- VOL. II., PART II. ARTHROLOGY, MYOLOGY, ANGIOLOGY. By Professor THANE. Illustrated by 255 Engravings, many of which are Coloured. Royal 8vo, 18s. [Ready.]
- VOL. III., PART I. THE SPINAL CORD AND BRAIN. By Professor SCHÄFER. Illustrated by 139 Engravings. Royal 8vo, 12s. 6d. [Ready.]
- VOL. III., PART II. THE NERVES. By Professor THANE. Illustrated by 102 Engravings, many of which are Coloured. Royal 8vo, 9s. [Ready.]
- VOL. III., PART III. THE ORGANS OF THE SENSES. By Professor SCHÄFER. Illustrated by 178 Engravings. Royal 8vo, 9s. [Ready.]
- VOL. III., PART IV. SPLANCHNOLOGY. By Professor SCHÄFER and Professor JOHNSON SYMINGTON, M.D. With 337 Illustrations. Royal 8vo, 16s. [Ready.]

SUPERFICIAL AND SURGICAL ANATOMY.

By Professor THANE and Professor RICKMAN J. GODLEE, M.S.

(To be shortly published as an Appendix to the whole work.)

RICHARDSON. THE ASCLEPIAD. A Book of Original Research in the Science, Art, and Literature of Medicine. By BENJAMIN WARD RICHARDSON, M.D., F.R.S. Published Quarterly, price 2s. 6d. Volumes for 1884, 1885, 1886, 1887, 1888, 1889, 1890, 1891, 1892, & 1893. 8vo, price 12s. 6d. each.

SCHÄFER. THE ESSENTIALS OF HISTOLOGY: Descriptive and Practical. For the Use of Students. By E. A. SCHÄFER, F.R.S., Jodrell Professor of Physiology in University College, London; Editor of the Histological Portion of Quain's "Anatomy." Illustrated by more than 300 Figures, many of which are new. Fourth Edition, Revised and Enlarged. 8vo, 7s. 6d. (Interleaved, 10s.)

SCHENK. MANUAL OF BACTERIOLOGY. For Practitioners and Students. With especial reference to Practical Methods. By Dr. S. L. SCHENK, Professor (Extraordinary) in the University of Vienna. Translated from the German, with an Appendix, by W. R. DAWSON, B.A., M.D., Univ. Dub.; late University Travelling Prizeman in Medicine. With 100 Illustrations, some of which are coloured. 8vo, 10s. net.

SMALE AND COLYER. DISEASES AND INJURIES OF THE TEETH, including Pathology and Treatment: a Manual of Practical Dentistry for Students and Practitioners. By MORTON SMALE, M.R.C.S., L.S.A., L.D.S., Dental Surgeon to St. Mary's Hospital, Dean of the School, Dental Hospital of London, &c.; and J. F. COLYER, L.R.C.P., M.R.C.S., L.D.S., Assistant Dental Surgeon to Charing Cross Hospital, and Assistant Dental Surgeon to the Dental Hospital of London. With 334 Illustrations. Large Crown 8vo, 15s.

SMITH (H. F.). THE HANDBOOK FOR MIDWIVES. By HENRY FLY SMITH, B.A., M.B. Oxon., M.R.C.S. Second Edition. With 41 Woodcuts. Crown 8vo, price 5s.

STEEL.—WORKS by JOHN HENRY STEEL, F.R.C.V.S., F.Z.S., A.V.D., late Professor of Veterinary Science and Principal of Bombay Veterinary College.

A TREATISE ON THE DISEASES OF THE DOG; being a Manual of Canine Pathology. Especially adapted for the use of Veterinary Practitioners and Students. 88 Illustrations. 8vo, 10s. 6d.

A TREATISE ON THE DISEASES OF THE OX; being a Manual of Bovine Pathology. Especially adapted for the use of Veterinary Practitioners and Students. 2 Plates and 117 Woodcuts. 8vo, 15s.

A TREATISE ON THE DISEASES OF THE SHEEP; being a Manual of Ovine Pathology for the use of Veterinary Practitioners and Students. With Coloured Plate, and 99 Woodcuts. 8vo, 12s.

OUTLINES OF EQUINE ANATOMY; a Manual for the use of Veterinary Students in the Dissecting Room. Crown 8vo, 7s. 6d.

"STONEHENGE." THE DOG IN HEALTH AND DISEASE. By "STONEHENGE." With 84 Wood Engravings. Square crown 8vo, 7s. 6d.

THORNTON. HUMAN PHYSIOLOGY. By JOHN THORNTON, M.A., Author of "Elementary Physiography," "Advanced Physiography," &c. With 267 Illustrations, some of which are Coloured. Crown 8vo, 6s.

WALLER. AN INTRODUCTION TO HUMAN PHYSIOLOGY. By AUGUSTUS D. WALLER, M.D., Lecturer on Physiology at St. Mary's Hospital Medical School, London; late External Examiner at the Victorian University. Second Edition, Revised. With 305 Illustrations. 8vo, 18s.

WEICHSELBAUM. THE ELEMENTS OF PATHOLOGICAL HISTOLOGY, With Special Reference to Practical Methods. By Dr. ANTON WEICHSELBAUM, Professor of Pathology in the University of Vienna. Translated by W. R. DAWSON, M.D. (Dub.), Demonstrator of Pathology in the Royal College of Surgeons, Ireland, late Medical Travelling Prizeman of Dublin University, &c. With 221 Figures, partly in Colours, a Chromo-lithographic Plate, and 7 Photographic Plates. Royal 8vo, 21s. net.

WILKS AND MOXON. LECTURES ON PATHOLOGICAL ANATOMY. By SAMUEL WILKS, M.D., F.R.S., Consulting Physician to, and formerly Lecturer on Medicine and Pathology at, Guy's Hospital, and the late WALTER MOXON, M.D., F.R.C.P., Physician to, and some time Lecturer on Pathology at, Guy's Hospital. Third Edition, thoroughly Revised. By SAMUEL WILKS, M.D., LL.D., F.R.S. 8vo, 18s.

YOUATT.—WORKS by WILLIAM YOUATT.

THE HORSE. Revised and Enlarged by W. WATSON, M.R.C.V.S. With 52 Woodcuts. 8vo, 7s. 6d.

THE DOG. Revised and Enlarged. With 33 Woodcuts. 8vo, 6s.

General Scientific Works.

BENNETT AND MURRAY. A HANDBOOK OF CRYPTOGAMIC BOTANY. By A. W. BENNETT, M.A., B.Sc., F.L.S., and GEORGE R. MILNE MURRAY, F.L.S. With 378 Illustrations. 8vo, 16s.

CARNEGIE. LAW AND THEORY IN CHEMISTRY: A COMPANION BOOK FOR STUDENTS. By DOUGLAS CARNEGIE, sometime Scholar and Demonstrator in Chemistry of Gonville and Caius, Cambridge. Crown 8vo, 6s.

CLERKE. THE SYSTEM OF THE STARS. By AGNES M. CLERKE, Author of "A History of Astronomy during the Nineteenth Century." With 6 Plates and Numerous Illustrations. 8vo, 21s.

CLODD.—*WORKS* by EDWARD CLODD, Author of “*The Childhood of the World,*” &c.

THE STORY OF CREATION. A Plain Account of Evolution. With 77 Illustrations. Crown 8vo, 3s. 6d.

A PRIMER OF EVOLUTION: being a Popular Abridged Edition of “*The Story of Creation.*” With Illustrations. Fcp. 8vo, 1s. 6d.

CROOKES. SELECT METHODS IN CHEMICAL ANALYSIS (chiefly Inorganic). By W. CROOKES, F.R.S., V.P.C.S., Editor of “*The Chemical News.*” Third Edition, re-written and enlarged. Illustrated with 67 Woodcuts. 8vo, 21s. net.

CULLEY. A HANDBOOK OF PRACTICAL TELEGRAPHY. By R. S. CULLEY, M.I.C.E., late Engineer-in-Chief of Telegraphs to the Post Office. With 135 Woodcuts and 17 Plates, 8vo, 16s.

DU BOIS. THE MAGNETIC CIRCUIT IN THEORY AND PRACTICE. By Dr. H. DU BOIS, Privatdocent in the University of Berlin. Translated from the German by Dr. E. ATKINSON. With numerous Illustrations. 8vo, 12s. net.

GANOT. ELEMENTARY TREATISE ON PHYSICS; Experimental and Applied, for the use of Colleges and Schools. Translated and edited from GANOT’s *Eléments de Physique* (with the Author’s sanction) by E. ATKINSON, Ph.D., F.C.S., formerly Professor of Experimental Science, Staff College, Sandhurst. Fourteenth Edition, revised and enlarged, with 9 Coloured Plates and 1,028 Woodcuts. Large crown 8vo, 15s.

NATURAL PHILOSOPHY FOR GENERAL READERS AND YOUNG PERSONS; Translated and Edited from GANOT’s *Cours Élémentaire de Physique* (with the Author’s sanction) by E. ATKINSON, Ph.D., F.C.S. Eighth Edition, carefully revised; with 7 Plates, 624 Woodcuts, and an Appendix of Questions. Crown 8vo, 7s. 6d.

GOODEVE.—*WORKS* by T. M. GOODEVE, M.A., Barrister-at-Law; Professor of Mechanics at the Normal School of Science and the Royal School of Mines.

PRINCIPLES OF MECHANICS. New Edition, re-written and enlarged. With 253 Woodcuts and numerous Examples. Crown 8vo, 6s.

THE ELEMENTS OF MECHANISM. New Edition, re-written and enlarged. With 342 Woodcuts. Crown 8vo, 6s.

A MANUAL OF MECHANICS: an Elementary Text-Book for Students of Applied Mechanics. With 138 Illustrations and Diagrams, and 141 Examples taken from the Science Department Examination Papers, with Answers. Fcp. 8vo, 2s. 6d.

HELMHOLTZ.—*WORKS* by **HERMANN L. F. HELMHOLTZ**,
M.D., Professor of Physics in the University of Berlin.

ON THE SENSATIONS OF TONE AS A PHYSIOLOGICAL BASIS FOR THE THEORY OF MUSIC. Second English Edition; with numerous additional Notes, and a new Additional Appendix, bringing down information to 1885, and specially adapted to the use of Musical Students. By **ALEXANDER J. ELLIS**, B.A., F.R.S., F.S.A., &c., formerly Scholar of Trinity College, Cambridge. With 68 Figures engraved on Wood, and 42 Passages in Musical Notes. Royal 8vo, 28s.

POPULAR LECTURES ON SCIENTIFIC SUBJECTS. With 68 Woodcuts. 2 Vols. crown 8vo, 3s. 6d. each.

HERSCHEL. **OUTLINES OF ASTRONOMY.** By Sir **JOHN F. W. HERSCHEL**, Bart., K.H., &c., Member of the Institute of France. Twelfth Edition, with 9 Plates, and numerous Diagrams. 8vo, 12s.

HUDSON AND GOSSE. **THE ROTIFERA OR 'WHEEL ANIMALCULES.'** By **C. T. HUDSON**, LL.D., and **P. H. GOSSE**, F.R.S. With 30 Coloured and 4 Uncoloured Plates. In 6 Parts. 4to, price 10s. 6d. each; Supplement, 12s. 6d. Complete in Two Volumes, with Supplement, 4to, £4 4s.

* * * The Plates in the Supplement contain figures of almost all the Foreign Species, as well as of the British Species, that have been discovered since the original publication of Vols. I. and II.

JOUBERT. **ELEMENTARY TREATISE ON ELECTRICITY AND MAGNETISM.** Founded on **JOUBERT'S** "*Traité Élémentaire d'Électricité.*" By **G. C. FOSTER**, F.R.S., Quain Professor of Physics in University College, London; and **E. ATKINSON**, Ph.D., formerly Professor of Experimental Science in the Staff College. With 381 Illustrations. Crown 8vo, 7s. 6d.

KOLBE. **A SHORT TEXT-BOOK OF INORGANIC CHEMISTRY.** By **Dr. HERMANN KOLBE**, late Professor of Chemistry in the University of Leipzig. Translated and Edited by **T. S. HUMPIDGE**, Ph.D., B.Sc. (Lond.), late Professor of Chemistry and Physics in the University College of Wales, Aberystwyth. New Edition. Revised by **H. LLOYD-SNAPE**, Ph.D., D.Sc. (Lond.), Professor of Chemistry in the University College of Wales, Aberystwyth. With a Coloured Table of Spectra and 66 Woodcuts. Crown 8vo, 8s. 6d.

LARDEN. **ELECTRICITY FOR PUBLIC SCHOOLS AND COLLEGES.** With numerous Questions and Examples with Answers, and 214 Illustrations and Diagrams. By **W. LARDEN**, M.A. Crown 8vo, 6s.

LADD.—*WORKS* by **GEORGE T. LADD**, *Professor of Philosophy in Yale University.*

ELEMENTS OF PHYSIOLOGICAL PSYCHOLOGY: A TREATISE OF THE ACTIVITIES AND NATURE OF THE MIND FROM THE PHYSICAL AND EXPERIMENTAL POINT OF VIEW. With 113 Illustrations. 8vo, price 21s.

PSYCHOLOGY, DESCRIPTIVE AND EXPLANATORY: A Treatise of the Phenomena, Laws, and Development of Human Mental Life. 8vo. 21s.

OUTLINES OF PHYSIOLOGICAL PSYCHOLOGY. With numerous Illustrations. 8vo. 12s.

PHILOSOPHY OF MIND: an Essay on the Metaphysics of Psychology. 8vo, 16s.

LINDLEY AND MOORE. **THE TREASURY OF BOTANY, OR POPULAR DICTIONARY OF THE VEGETABLE KINGDOM:** with which is incorporated a Glossary of Botanical Terms. Edited by **J. LINDLEY, M.D., F.R.S.**, and **T. MOORE, F.L.S.** With 20 Steel Plates, and numerous Woodcuts. 2 Parts, fcp. 8vo, price 12s.

MARTIN. **NAVIGATION AND NAUTICAL ASTRONOMY.** Compiled by Staff-Commander **W. R. MARTIN, R.N.**, Instructor in Surveying, Navigation, and Compass Adjustment; Lecturer on Meteorology at the Royal Naval College, Greenwich. Sanctioned for use in the Royal Navy by the Lords Commissioners of the Admiralty. Royal 8vo, 18s.

MENDELÉEFF. **THE PRINCIPLES OF CHEMISTRY.** By **D. MENDELÉEFF**, Professor of Chemistry in the University of St. Petersburg. Translated by **GEORGE KAMENSKY, A.R.S.M.** of the Imperial Mint, St. Petersburg, and Edited by **A. J. GREENAWAY, F.I.C.**, Sub-Editor of the Journal of the Chemical Society. With 97 Illustrations. 2 Vols. 8vo, 36s.

MEYER. **OUTLINES OF THEORETICAL CHEMISTRY.** By **LOTHAR MEYER**, Professor of Chemistry in the University of Tübingen. Translated by Professors **P. PHILLIPS BEDSON, D.Sc.**, and **W. CARLETON WILLIAMS, B.Sc.** 8vo, 9s.

MITCHELL. **MANUAL OF PRACTICAL ASSAYING.** By **JOHN MITCHELL, F.C.S.** Sixth Edition. Edited by **W. CROOKES, F.R.S.** With 201 Woodcuts. 8vo, 31s. 6d.

MORGAN. **ANIMAL BIOLOGY.** An Elementary Text Book. By **C. LLOYD MORGAN**, Principal of University College, Bristol. With numerous Illustrations. Crown 8vo, 8s. 6d.

MOSSO. - FEAR. By ANGELO MOSSO. Translated from the Fifth Edition of the Italian by E. LOUGH and F. KIESOW. With 8 Illustrations. Crown 8vo, 7s. 6d.

* * * This book deals with much more than is conveyed by the title. It is, in fact, a series of essays on the expression of the emotions, dealing more especially with the painful emotions. Although the subject is treated in a measure scientifically, *i.e.*, physiologically, the book is not intended solely for the scientific public.

MUIR. THE ALCHEMICAL ESSENCE AND THE CHEMICAL ELEMENT: an Episode in the Quest of the Unchanging. By M. M. PATTISON MUIR, Fellow of Gonville and Caius College, Cambridge. 8vo. 4s. 6d.

ODLING. A COURSE OF PRACTICAL CHEMISTRY, Arranged for the use of Medical Students, with express reference to the Three Months' Summer Practice. By WILLIAM ODLING, M.A., F.R.S. With 71 Woodcuts. Crown 8vo, 6s.

OSTWALD. SOLUTIONS. By W. OSTWALD, Professor of Chemistry in the University of Leipzig. Being the Fourth Book, with some additions, of the Second Edition of Ostwald's "Lehrbuch der Allgemeinen Chemie." Translated by M. M. PATTISON MUIR, Professor of Gonville and Caius College, Cambridge. 8vo, 10s. 6d.

PAYEN. INDUSTRIAL CHEMISTRY; A Manual for use in Technical Colleges or Schools, also for Manufacturers and others, based on a Translation of Stohmann and Engler's German Edition of PAYEN's *Précis de Chimie Industrielle*. Edited and supplemented with Chapters on the Chemistry of the Metals, &c., by B. H. PAUL, Ph.D. With 698 Woodcuts. 8vo, 42s.

PROCTOR.—WORKS by RICHARD A. PROCTOR.

OLD AND NEW ASTRO-NOMY. By RICHARD A. PROCTOR and A. COWPER RANYARD. With 31 Plates and 472 Illustrations. Text. 4to, 21s.

LIGHT SCIENCE FOR LEISURE HOURS; Familiar Essays on Scientific Subjects, Natural Phenomena, &c. 3 Vols. crown 8vo, 5s. each.

THE ORBS AROUND US; a Series of Essays on the Moon and Planets, Meteors, and Comets. With Chart and Diagrams, crown 8vo, 5s. Cheap Edition, crown 8vo, 3s. 6d.

OTHER WORLDS THAN OURS; The Plurality of Worlds Studied under the Light of Recent Scientific Researches. With 14 Illustrations, crown 8vo, 5s. Cheap Edition, crown 8vo, 3s. 6d.

THE MOON; her Motions, Aspects, Scenery, and Physical Condition. With Plates, Charts, Woodcuts, and Lunar Photographs, crown 8vo, 5s.

UNIVERSE OF STARS; Presenting Researches into and New Views respecting the Constitution of the Heavens. With 22 Charts and 22 Diagrams, 8vo. 10s. 6d.

LARGER STAR ATLAS for the Library, in 12 Circular Maps, with Introduction and 2 Index Pages. Folio, 15s., or Maps only, 12s. 6d.

NEW STAR ATLAS for the Library, the School, and the Observatory, in 12 Circular Maps (with 2 Index Plates). Crown 8vo, 5s.

[Continued.]

PROCTOR.—*WORKS* by *RICHARD A. PROCTOR*—*continued.*

THE STUDENT'S ATLAS.

In 12 Circular Maps on a Uniform Projection and 1 Scale, with 2 Index Maps. Intended as a *vade-mecum* for the Student of History, Travel, Geography, Geology, and Political Economy. With a letter-press Introduction illustrated by several cuts. 5s.

OTHER SUNS THAN OURS :

a Series of Essays on Suns—Old, Young, and Dead. With other Science Gleanings, Two Essays on Whist, and Correspondence with Sir John Herschel. With 9 Star-Maps and Diagrams. Crown 8vo, 6s.

HALF-HOURS WITH THE

TELESCOPE : a Popular Guide to the Use of the Telescope as a Means of Amusement and Instruction. With 7 Plates. Fcap. 8vo, 2s. 6d.

THE SOUTHERN SKIES :

a Plain and Easy Guide to the Constellations of the Southern Hemisphere. Showing in 12 Maps the position of the principal Star-Groups night after night throughout the year. With an Introduction and a separate Explanation of each Map. True for every Year. 4to, 5s.

HALF-HOURS WITH THE

STARS : a Plain and Easy Guide to the Knowledge of the Constellations. Showing in 12 Maps the position of the principal Star-Groups night after night throughout the Year. With Introduction and a separate Explanation of each Map. True for every Year. 4to, 3s. 6d.

ELEMENTARY PHYSICAL GEOGRAPHY. With 33 Maps and Woodcuts. Fcp. 8vo, 1s. 6d.

LESSONS IN ELEMENTARY ASTRONOMY ; with Hints for Young Telescopists. With 47 Woodcuts. Fcp. 8vo, 1s. 6d.

EASY LESSONS IN THE DIFFERENTIAL CALCULUS : indicating from the Outset the Utility of the Processes called Differentiation and Integration. Fcp. 8vo, 2s. 6d.

THE STARS IN THEIR SEASONS. An Easy Guide to a Knowledge of the Star Groups, in 12 Large Maps. Imperial 8vo, 5s.

STAR PRIMER. Showing the Starry Sky Week by Week, in 24 Hourly Maps. Crown 4to, 2s. 6d.

ROUGH WAYS MADE SMOOTH. Familiar Essays on Scientific Subjects. Crown, 3s. 6d.

HOW TO PLAY WHIST : WITH THE LAWS AND ETIQUETTE OF WHIST. Crown 8vo, 3s. 6d.

HOME WHIST : an Easy Guide to Correct Play. 16mo, 1s.

OUR PLACE AMONG INFINITIES. A Series of Essays contrasting our Little Abode in Space and Time with the Infinities around us. Crown 8vo, 5s.

STRENGTH AND HAPPINESS. Crown 8vo, 5s.

STRENGTH : How to get Strong and keep Strong, with Chapters on Rowing and Swimming, Fat, Age, and the Waist. With 9 Illustrations. Crown 8vo, 2s.

THE EXPANSE OF HEAVEN. Essays on the Wonders of the Firmament. Crown 8vo, 5s. Cheap Edition, crown 8vo, 3s. 6d.

THE GREAT PYRAMID, OBSERVATORY, TOMB, AND TEMPLE. With Illustrations. Crown 8vo, 5s.

PLEASANT WAYS IN SCIENCE. Crown 8vo, 5s. Cheap Edition, crown 8vo, 3s. 6d.

[*Continued.*]

PROCTOR.—WORKS by RICHARD A. PROCTOR—continued.

MYTHS AND MARVELS OF ASTRONOMY. Crown 8vo, 5s.
Cheap Edition, crown 8vo, 3s. 6d.

CHANCE AND LUCK; a Discussion of the Laws of Luck, Coincidences, Wagers, Lotteries, and the Fallacies of Gambling, &c. Crown 8vo, 2s. boards, 2s. 6d. cloth.

NATURE STUDIES. By GRANT ALLEN, A. WILSON, T. FOSTER, E. CLODD, and R. A. PROCTOR. Crown 8vo, 5s.
Cheap Edition, crown 8vo, 3s. 6d.

LEISURE READINGS. By E. CLODD, A. WILSON, T. FOSTER, A. C. RUNYARD, and R. A. PROCTOR. Crown 8vo, 3s. 6d.

REYNOLDS. EXPERIMENTAL CHEMISTRY for Junior Students. By J. EMERSON REYNOLDS, M.D., F.R.S., Professor of Chemistry, Univ. of Dublin. Fcp. 8vo, with numerous Woodcuts.

PART I.—*Introductory*, 1s. 6d.

PART III.—*Metals and Allied Bodies*, 3s. 6d.

PART II.—*Non-Metals*, 2s. 6d.

PART IV.—*Chemistry of Carbon Compounds*, 4s.

SLINGO AND BROOKER. ELECTRICAL ENGINEERING FOR ELECTRIC-LIGHT ARTISANS AND STUDENTS. (Embracing those branches prescribed in the Syllabus issued by the City and Guilds Technical Institute.) By W. SLINGO and A. BROOKER. With 346 Illustrations. Crown 8vo, 12s.

SMITH. GRAPHICS; OR, THE ART OF CALCULATION BY DRAWING LINES, applied to Mathematics, Theoretical Mechanics and Engineering, including the Kinetics and Dynamics of Machinery, and the Statics of Machines, Bridges, Roofs, and other Engineering Structures. By ROBERT H. SMITH, Professor of Civil and Mechanical Engineering, Mason Science College, Birmingham.

PART I. Text, with separate Atlas of Plates—Arithmetic, Algebra, Trigonometry, Vector, and Locor Addition, Machine Kinematics, and Statics of Flat and Solid Structures. 8vo, 15s.

SORAUER. A POPULAR TREATISE ON THE PHYSIOLOGY OF PLANTS. For the Use of Gardeners, or for Students of Horticulture and of Agriculture. By Dr. PAUL SORAUER, Director of the Experimental Station at the Royal Pomological Institute in Proskau (Silesia). Translated by F. E. WEISS, B.Sc., F.L.S., Professor of Botany at the Owens College, Manchester. With 33 Illustrations. 8vo, 9s. net.

THORPE. A DICTIONARY OF APPLIED CHEMISTRY. By T. E. THORPE, B.Sc. (Vict.), Ph.D., F.R.S., Treas. C.S., Professor of Chemistry in the Royal College of Science, London. Assisted by Eminent Contributors. To be published in 3 vols. 8vo. Vols. I. and II. £2 2s. each, Vol. III. £3 3s.

TUBEUF. DISEASES OF PLANTS DUE TO CRYPTO-GAMIC PARASITES. Translated from the German of DR. CARL FREIHERR VON TUBEUF, of the University of Munich, by WILLIAM G. SMITH, B. Sc., Ph.D., Lecturer on Plant Physiology to the University of Edinburgh. With over 300 Illustrations. [In preparation.]

TYNDALL.—*WORKS* by JOHN TYNDALL, F.R.S., &c.

FRAGMENTS OF SCIENCE. 2 Vols. Crown 8vo, 16s.

NEW FRAGMENTS. Crown 8vo, 10s. 6d.

HEAT A MODE OF MOTION. Crown 8vo, 12s.

SOUND. With 204 Woodcuts. Crown 8vo, 10s. 6d.

RESEARCHES ON DIAMAGNETISM AND MAGNE-CRYSTALLIC ACTION, including the question of Diamagnetic Polarity. Crown 8vo, 12s.

ESSAYS ON THE FLOATING-MATTER OF THE AIR in relation to Putrefaction and Infection. With 24 Woodcuts. Crown 8vo, 7s. 6d.

LECTURES ON LIGHT, delivered in America in 1872 and 1873. With 57 Diagrams. Crown 8vo, 5s.

LESSONS IN ELECTRICITY AT THE ROYAL INSTITUTION, 1875-76. With 58 Woodcuts. Crown 8vo, 2s. 6d.

NOTES OF A COURSE OF SEVEN LECTURES ON ELECTRICAL PHENOMENA AND THEORIES, delivered at the Royal Institution. Crown 8vo, 1s. 6d.

NOTES OF A COURSE OF NINE LECTURES ON LIGHT, delivered at the Royal Institution. Crown 8vo, 1s. 6d.

FARADAY AS A DISCOVERER. Crown 8vo, 3s. 6d.

THE GLACIERS OF THE ALPS: being a Narrative of Excursions and Ascents. An Account of the Origin and Phenomena of Glaciers, and an Exposition of the Physical Principles to which they are related. With numerous Illustrations. Crown 8vo, 6s. 6d. net.


WATTS' DICTIONARY OF CHEMISTRY. Revised and entirely Re-written by H. FORSTER MORLEY, M.A., D.Sc., Fellow of, and lately Assistant-Professor of Chemistry in, University College, London; and M. M. PATTISON MUIR, M.A., F.R.S.E., Fellow, and Prælector in Chemistry, of Gonville and Caius College, Cambridge. Assisted by Eminent Contributors. To be Published in 4 Vols. 8vo. Vols. I. II. 42s. each. Vol. III. 50s. Vol. IV. 63s.

WEBB. CELESTIAL OBJECTS FOR COMMON TELESCOPES. By the Rev. T. W. WEBB, M.A., F.R.A.S., Vicar of Hardwick, Herefordshire. Fifth Edition, Revised and greatly Enlarged by the Rev. T. E. ESPIN, M.A., F.R.A.S. (Two Volumes.)

VOL. I. With Portrait and a Reminiscence of the Author, 2 Plates, and numerous Illustrations. Crown 8vo, 6s.

VOL. II. With Illustrations and Map of Star Spectra. Crown 8vo, 6s. 6d.

WRIGHT. OPTICAL PROJECTION: A Treatise on the Use of the Lantern in Exhibition and Scientific Demonstration. By LEWIS WRIGHT, Author of "Light: a Course of Experimental Optics." With 232 Illustrations. Crown 8vo, 6s.



U. C. BERKELEY LIBRARIES



C045804151

