


WSP


Microscopical

Soc.

Univ. of Calif. library







462.h

F893

HISTOLOGY
AND
HISTOCHEMISTRY OF MAN

by
Heinrich Frey

n. y.
appleton
1875

Q M 551
F 68

BIOLOGY
LIBRARY
G

HISTORICAL

LIBRARY OF THE UNIVERSITY OF MICHIGAN

PREFACE.

IF only in the eyes of those valued friends whose kindly interest in my work has oftentimes been as great a stimulus to sustained exertion in the laborious task of translation as it has been a solace in the usual and varied delays and disappointments of publishing, I feel that perhaps some justification of myself is necessary for the late appearance of this volume; so much later than either they or I had anticipated. The delay has in a great measure been due to my being obliged to recast a large portion of my first manuscript, in order to bring it down to a new and much enlarged and altered Fourth Edition of the original; commenced just as I had concluded my translation more than a year ago, and the "Proofs" of which I received as they were pressed off, and revised by the Author. The task accomplished, however, I now feel my regret at the delay lightened to a great extent by the consideration, that through it the value of the work is considerably enhanced, and that the latter now contains the most recently gathered matter from many important fields of investigation; passing, as it does, through the printer's hands, at the same time, with the last edition of the original.

As regards the work which I now present to my medical brethren in an English dress, and which has already been translated into French, any lengthy personal testimony to its value is unnecessary. The fact that it now appears for the *fourth* time in a new edition is a sufficient proof of the favour with which it is regarded as a handbook in Germany, where it was recommended to myself, when a student in that country, as the best work of its kind, by one of the fathers of Histology, my late valued and lamented teacher and friend, Professor Max Schultze. But I am aware this translation

leaves much to be desired; and yet to those critics thoroughly familiar with German literature, I feel but little apprehension in submitting it, confident that fully conversant with the varied difficulties of rendering German into English, they will be lenient to its faults and careful of censure. In undertaking the work I have been actuated by the desire to render accessible to my fellow-students, young and old, a good standard work, which has been a great aid to myself in dealing with a subject as yet but little studied in English-speaking countries, and especially in my own, and upon which we possess but few native manuals. I have been prompted, moreover, by the feeling that we all need to enter more fully into the spirit of other men's researches before we can deal fairly with their theories, or deduce any practical conclusions from their investigations. And I cannot but think that a greater effort should be made by all medical men who love progress, to vindicate the dignity of Pathological Histology as a science in this country, and to raise it above the complacent smiles of a large class appropriating to themselves the title of "the thoroughly practical," who, for the most part, ignorant of its most elementary principles, appear to regard it as merely the pet hobby of a few vague theorists and entirely unprofitable. General profit will only accrue to the practical surgeon or physician when, after patient toil, all are able to view the subject closely and from its many aspects. If my humble efforts to render this easier, by giving the English reader access to a compendium of the views of the greatest histologists arranged in a system, conduce, in however small a degree, to this desirable end, I shall deem my labour well bestowed.

In conclusion, I have to express my cordial thanks to Professor Emerson Reynolds for some valuable suggestions in regard to chemical terms in the first part of this work, the "Proofs" of which he was kind enough to read over.


A. E. J. B.

CONTENTS.

	Page
Introduction, §§ 1-6,	1
L THE ELEMENTS OF COMPOSITION AND OF STRUCTURE	
OF THE BODY, §§ 7-64,	11-64
1. ELEMENTS OF COMPOSITION,	11
A. Albuminous or Protein Compounds, §§ 8-14,	12
Albumen, § 10,	14
Fibrin, Fibrinogen, and Fibrinoplastin, § 11,	15
Myosin, Muscle-Fibrin, or Syntonin, § 12,	16
Casein,	17
Globulin, Crystallin,	17
Peptones,	17
Ferments,	18
B. Hæmoglobulin.	
Hæmoglobulin, Hæmatoglobulin, Hæmato-crystallin, § 13,	18
C. Histogenic Derivatives of the Albuminous Substances	
or Albuminoids,	21
Keratin, Mucin, Colloid, § 14,	21
Substances yielding Glutin, § 15,	21
Collagen and Glutin,	22
Chondrigen and Chondrin,	22
Elastic Material, Elastin,	23
D. The Fatty Acids and Fats, § 16,	23
Glycerin,	23
Formic Acid,	24
Acetic Acid,	24
Butyric Acid,	24
Capronic, Caprylic, Caprinic Acids,	25
Palmitic Acid, Tripalmitin,	25
Stearic Acid, Tristearin,	25
Oleic (Elaidic) Acid, Triölein,	25
Cerebral Matters, Cerebrin, and Lecithin, § 20,	28
Cholestearin, § 21,	30
E. The Carbohydrates, § 22,	30
Glycogen,	31
Dextrin,	32
Grape Sugar,	32
Inosite or Muscle Sugar,	33
Sugar of Milk,	33

	Page
F. Non-Nitrogenous Acids, § 23,	34
Lactic Acid, Paralactic Acid,	34
Oxalic Acid, Oxalate of Calcium,	35
Succinic Acid,	35
Carbolic Acid or Phenol,	36
Taurylic Acid or Taurolic,	36
G. Nitrogenous Acids, § 25,	36
Inosinic and Hydrotinic Acids,	36
Uric Acid, Acid Urate of Sodium and of Ammonium,	37
Hippuric Acid, § 26,	38
Glycocholic Acid, Glycocholate of Sodium, § 27,	39
Taurocholic Acid, Taurocholate of Sodium,	40
H. Amides, Amido Acids, and Organic Bases,	40
Urea or Carbamide,	40
Guanin, Hypoxanthin (Sarkin) Xanthin, § 29,	43
Allantoin,	43
Kreatin, Kreatinin, § 30,	44
Leucin, § 31,	45
Tyrosin, § 32,	47
Glycin, § 33,	48
Cholin (Neurin),	48
Taurin, § 34,	48
Cystin,	50
I. Animal Colouring Matters, § 35,	50
Hæmatin,	50
Hydrochlorate of Hæmatin, Hæmin,	50
Hæmatoidin,	51
Uroërethrin or Urohæmatin, § 36,	52
Black Pigment or Melanin,	52
Biliary Pigments, Bilirubin, Biliverdin, Bilifucsin, Biliprasin,	53
K. Cyanogen Compounds, § 38,	54
Sulpho-cyanogen (Rhodan), Sulphocyanide of Potassium,	54
L. Mineral Constituents, § 39,	55
Oxygen,	56
Nitrogen,	56
Carbonic Acid or Carbonic Dioxide,	56
Water, § 40,	56
Hydrochloric Acid,	57
Silicic Acid,	57
Calcium Compounds, § 41—Phosphate, Carbonate, Chloride, and Fluoride,	58
Magnesium Compounds—Phosphate, Carbonate, Chloride,	58
Sodium Compounds, § 43—Chloride, Carbonate, Phosphate, Sulphate,	61
Potash Compounds, § 44—Chloride, Carbonate, Phosphate, Sulphate,	62
Salts of Ammonium, Chloride, Carbonate,	62
Iron and its Salts, Protochloride, Phosphate,	62
Manganese,	62
Copper,	62

	Page
2. ELEMENTS OF STRUCTURE,	63
A. The Cell, §§ 45-58,	95
B. The Origin of the Remaining Elements of Tissue, §§ 59-64,	95
II. THE TISSUES OF THE BODY.	103
A. Tissues composed of Simple Cells with Fluid Inter- mediate Substance, §§ 65-85,	105
1. The Blood,	105
2. The Lymph and Chyle, § 82,	131
B. Tissues composed of Simple Cells, with a small amount of Solid Intermediate Substance, §§ 86-100,	137
3. Epithelium, § 86,	137
4. Nail, § 99,	160
C. Tissues belonging to the Connective Substance Group, §§ 101-155,	164
5. Cartilage, § 103,	166
6, 7. Gelatinous and Reticular Connective Substance, §§ 113-	
119,	187
8. Fatty Tissue, §§ 120-124,	198
9. Connective Tissue, §§ 125-139,	205
10. Tissue of Bone, §§ 140-149,	238
11. Dentine, §§ 150-155,	260
D. Tissues composed of Transformed, and as a rule Coher- ing Cells, with homogeneous, scanty, and more or less Solid Intermediate Substance, §§ 156-173,	273
12. Enamel Tissue, §§ 156-158,	273
13. Lens Tissue, §§ 159-161,	276
14. Muscle Tissue, §§ 162-173,	280
E. Composite Tissues, §§ 174-218,	305
15. Nerve Tissue, §§ 174-192,	305
16. Glandular Tissue, §§ 192-200,	344
17. The Vessels, §§ 201-211,	362
18. The Hair, §§ 212-218,	388
19. Combination of the Tissues, § 219,	298
III. THE ORGANS OF THE BODY,	401
A. Organs of the Vegetative Type, §§ 220-287,	403
1. Circulatory Apparatus, §§ 220-238,	403
2. Respiratory Apparatus, §§ 239-243,	448
3. The Digestive Apparatus, §§ 244-268,	458
4. The Urinary Apparatus, §§ 269-276,	514
5. The Generative Apparatus, §§ 277-287,	536
B. Organs of the Animal Group,	570
6. Bony Apparatus, §§ 288-289,	570
7. Muscular Apparatus, § 290,	573
8. Nervous Apparatus, §§ 291-300,	574
9. Sensory Apparatus, §§ 301-326,	603
INDEX,	665



MANUAL

OF THE

HISTOLOGY AND HISTOCHEMISTRY OF MAN.

INTRODUCTION

§ 1.

THROUGH the industry and perseverance of many talented investigators, human anatomy, as a science, had already reached an advanced stage of development so early as the close of the last century. As far as the dissecting knife could open up the structure of parts, these had been investigated in a manner sufficiently detailed for the requirements of the practical physician. And let us here offer the easy tribute of remembrance to the name of *Sömmerring*, which will ever be connected with this particular branch of study. That progress in development to be observed in all branches of natural science as a consequence of one of the nobler characteristics of human intellect, had also become manifest in anatomy. Out of a multitude of isolated facts general principles had been established. Anatomists had begun to recognise the significance of the occurrence over and over again, in the most dissimilar parts of the body, of certain definite structures, such as bone, cartilage, muscle, and nerves, but slightly or not at all modified in each, though taking a most important part in their formation. Here then, we have the origin of "GENERAL ANATOMY," the study of the structure of the body.

But again, bones, cartilages, muscles, and nerves were observed each to be made up of smaller parts, and it became necessary to resolve them into those ultimate elements of form of which they are composed, in such a manner as to be able to recognise the latter in various situations. Thus the conception of an "animal tissue" originated, and with it the consideration of tissues, or "HISTOLOGY," as a special branch of anatomical study. This, although the most important part, constitutes by no means the whole of general anatomy.

By tissues we understand organic masses, in so far as they are made up of more minute parts, and receive from these their physical, chemical, anatomical, and physiological characters.

The various arrangement and nature of these minute parts gives rise to the difference in what is termed the "texture" of the mass; they themselves are known as "tissue elements." But these constituents of form, these particles composing the tissues, are, in the marvellous con-

struction of the animal body, of such minuteness that the usual instruments of anatomical dissection are insufficient for their discovery and recognition, and we are therefore obliged to look around us for other assistance. On the other hand, a tissue, as such, may be investigated to a certain extent with the means at the disposal of an earlier epoch, when there is no question as to its further resolution or insight into its ultimate composition. Indeed, we see the rudiments of histology in the first discoveries of a period long gone by. But as these could only be of historic interest when we consider the vast strides that science has since made, we shall pass them over without further comment.

Fortunately for us, the science of general anatomy at the close of the eighteenth century numbered amongst its students a highly gifted man, through whose genius it underwent an amount of development greatly to be wondered at, when we consider the scanty aids to investigation of that period.

This man was *M. F. X. Bichat*, who died at Paris in the year 1802, at the early age of thirty-one, thus terminating a career memorable in the annals of medicine. Child of a stirring time, urged on by the great and celebrated philosophers of his day, and, we might add, inspired by that spirit of accurate investigation of which science of the present day is so proud, he founded a system of histology by the help of the anatomical knife, chemical analysis, and of pathological and physiological research, which his immediate successors were unable to improve upon to any considerable extent for lack of newer methods of examination.

With *Bichat* there commenced and reached its zenith an epoch in histological research which may be designated as that of *investigation without the microscope*—as that in which *the tissue-elements still remained veiled in obscurity*.

REMARKS.—*Bichat's* essays are to be found in a large work entitled *Anatomie générale appliquée à la physiologie et à la médecine*, which appeared in Paris in the year 1801, and was frequently reproduced afterwards.

§ 2.

The second epoch of histology may be termed that of *microscopical research*; as that of *penetration down to the elements of the tissues*. From this period our science took the name of Microscopical Anatomy, however inappropriate this term may be. Its first crude beginnings are lost in the clouds of a period far remote, in that age of reformative activity to which we owe the vigour of our modern intellectuality. In its scientific development it is the offspring of a maturer age, and the founders of the science of modern histology are many of them still alive.

Three nationalities contend for the honor of having been the first to discover the microscope—this instrument which has enabled us to penetrate into the regions of “The Minute.” These are the English, Dutch, and Italians. There can be but little doubt, however, that the first instrument of the kind was constructed by a Dutch optician of the name of *Z. Janssen*, about the year 1590; and that *Drebbel*, *Galilei*, and *Fontana*, are incorrectly stated to be the discoverers. This much, however, is incontestably proved, that many microscopes had been manufactured before the middle of the seventeenth century, and soon after came into use in scientific research.

Marcello Malpighi (1628–1694), and *Anton van Leeuwenhoek* (1632–

1723), are generally looked upon as the fathers of microscopical anatomy. The first of these made observations on the circulation of the blood, on the glands and lungs; the second, endowed with indefatigable industry, saw for the first time many of the constituents of the organs of the body, with tolerable distinctness too, although aided by very imperfect instruments. But the additions which *Leeuwenhoek* made to science, in keeping with the curiosity-loving spirit of the time, partook less of the nature of discoveries according to a definite principle, than of mere detection of strange and wonderful things, where the unaided eye had previously seen nothing. The infancy of microscopical anatomy is in fact represented in him. Indeed, the exertions of the Dutch seem just devoid of that which so characterised the investigations of the Frenchman *Bichat*, namely, that effort to combine units to a scientific whole. If we now associate with these two names those also of *Swammerdam* (1637-1685), and *Ruysch* (1638-1734), as the discoverers and developers of our present mode of injection, we shall have reached the close of the first epoch of histological study defined by the discovery of the microscope.

The instruments of that day were, however, most imperfect, so that *Leeuwenhoek* used simple lenses only. Hence, it is not surprising that in the hands of his successors, these microscopes, so difficult to manipulate, and so liable to deceive, became a frequent source of error. This explains the fact that *Bichat* preferred laying the foundations of his general anatomy without their aid.

After this there followed a long period of inactivity in histological research, reaching far into the nineteenth century, when the science received fresh impetus from the brilliant discoveries of our own schools.

REMARKS.—*Marcello Malpighii. Opera omnia. Lond. 1686; and Opera posthuma. Lond. 1697—...2.* The works of *Leeuwenhoek* may be found in the *Philosoph. Transact.*, and in his *Opera omnia. Lugd. Bat. 1722. Arcana naturæ detecta. Delph. 1695. Continuatio arcanorum naturæ detectorum. Lugd. Bat. 1722, &c.*

§ 3.

A new era in histological research was now ushered in by the discovery of achromatism in the middle of the last century, and by the construction of achromatic object-glasses for the microscope. The first of these are said to have been made by a Dutchman named *van Deyl*, and a German optician of the name of *Fraunhofer*, in the years 1807 and 1811. Thus the microscope was transformed from the clumsy and deceptive implement of the last century into the elegant and accurate instrument of the present day.

And now, in all the enthusiasm of novelty, the improved microscope became the means of adding discovery to discovery in the hands of many excellent German observers, so that an insight into the essential nature of the tissue-elements, and of their combination to form the various tissues, was gained in an inconceivably short time. It may suffice here, in speaking of the founding of modern histology, to mention the names of *Ehrenberg*, *Müller*, *Purkinje*, *R. Wagner*, *Valentin*, and *Henle*. Besides these, many others might be added, of younger observers, who have since distinguished themselves as developers and furtherers of the science.

Histology without the microscope had had a *Bichat* among its students; but the newer science was fortunate enough at its very outset to undergo, at the hands of *Th. Schwann*, the most searching and energetic elabora-

tion. By him the cell was proved to be the starting-point of all animal structures. He also indicated the mode of origin of the various tissues from the cell. It may be said that many points in relation to this fact were known before *Schwann's* time, and that he came to false conclusions in many things: but though this be true, the merit, nevertheless, remains with him of having been the first to make prominent this fundamental principle—the greatest discovery of histology—by an overwhelming multitude of facts in detail. *Schwann* may therefore be hailed as the founder of the science of “HISTOGENESIS,” or the study of the origin of tissues—one of the most important subjects which can come under our consideration, and one which has more recently undergone very extensive elaboration at the hands of *Reichert*, *Koelliker*, *Remak*, and others.

Another branch of histology, again, has gradually become distinct from the study of the nature of the textures in the normal state. This, which deeply affects pathology, is the consideration of the modifications which tissues undergo in diseased conditions. *J. Müller* may be looked upon as the originator of this particular line of study, known as “PATHOLOGICAL HISTOLOGY,” while more recently *Virchow* has become famous for his great efforts in the same direction. To these two may be added the well-known names of some of the disciples of the latter, as, for instance, those of *Recklinghausen*, *Rindfleisch*, and *Cohnheim*.

Like pathological, so is also “COMPARATIVE HISTOLOGY” indispensable for a scientific knowledge of the finer structure of the animal frame; and yet, in spite of numerous individual efforts, and the most ingenious researches, this branch is still in its infancy, owing to the immense amount of matter to be dealt with. To this particular field of investigation *Müller*, *Siebold*, *Koelliker*, *Leydig*, and others, have devoted their great talents with the happiest results.

REMARKS.—The microscope, its construction, way to work with it, &c., has become lately the theme of many literary effusions. We will only mention here one of the more important essays on the subject—*C. Robin, Du Microscope et des injections*, 2d ed., Paris, 1871. *Queckett*, “A Practical Treatise on the Use of the Microscope,” Lond., 1848. *W. Carpenter*, “The Microscope,” 3d ed., London, 1862. *H. Schacht*, “Das Mikroskop,” 3 Auf., Berlin, 1862. *L. Beale*, “How to work with the Microscope,” 4th ed.; and “The Microscope in Medicine,” just published. *H. Frey*, “Das Mikroskop und die mikroskopische Technik,” American Transl. —(2.) *Schwann's* works are to be found in an attractive little book, “Mikroskopische Untersuchungen über die Uebereinstimmung in der Struktur und dem Wachstum der Thiere und Pflanzen,” Berlin, 1839.—(3.) As to the rich literature of Histology, which is in its origin chiefly German (as this whole branch of anatomy is essentially the production of German industry), we shall only mention a few handbooks and other similar aids, and even these only sparingly. Among the older works which deserve mention are, *A. Koelliker*, “Handbuch der Gewebelehre des Menschen,” Leipzig, 1852. 5 Auf., 1857; and besides German works, *Todd and Bowman*, “Anatomy and Physiology of Man,” Lond., 1856. 2 vols. *L. Beale*, “The Structure of the Simple Tissues,” Last ed. *A. Ecker's* copper-plates in *Wagner's Icones physiologicæ*, may also be recommended.

§ 4.

In an earlier section we have seen that the study of the anatomical characters of tissues is the offspring of a comparatively late era of natural and medical science. But the chemistry of the tissues, or “HISTOCHEMISTRY,” is of more recent origin still. And in that an acquaintance with the composition of the different structures of the body can only be gained by the application to them of the facts of organic chemistry, so is histochemistry

in its progress dependent on the latter: in fact, it is only a special branch of the same.

Although in the infancy of chemical study a certain amount of notice had been taken of organic bodies, nevertheless, owing to the nature of the matter to be considered, they could only be dealt with (scientifically speaking) subsequently to the establishment of laws relative to inorganic substances and their combinations. And only after the latter, as the simpler had been studied, and that the more important laws of inorganic chemistry had been laid down, did it become possible to invade the more obscure field of organic chemistry with success.

It must be admitted, however, that important discoveries had been made by *Scheelé* (1742–1786) in the latter subject. Thus a number of vegetable acids, glycerin, uric acid, and cyanic acid, had all been brought to light. But these were only details, whose worth from a scientific point of view it remained for a later day to demonstrate. It was only with the introduction of quantitative analysis by *Lavoisier* (1743–1794), and after that his contemporary, *Priestley* (1733–1804), had discovered oxygen, that a new era in chemical science began to dawn—an epoch of exact research supervening upon the overthrow of phlogistic theory. From this point on it became possible to gain an insight into chemical combination by means of the balance—to recognise the elements of organic bodies, to place upon a sound basis the rules of equivalent and atomic weight, and establish a foundation for a system of stoichiometry.

And as in microscopical anatomy the improvement of instruments led within a short space of time to a more extended acquaintance with the subject, so do we see here in the province of chemistry the dawn of an era under the sun of *Lavoisier's* genius, in which, by a rapid succession of discoveries, the new science attained, within a short space of time, a wonderful degree of development and extensiveness.

It would be impossible, in the scope of such a work as the present, to bring in review the details of this progress in development, and we shall only mention a few points in regard to it of special interest.

The first impulse was given to the study of organic substances through the works of *Vauquelin* (1763–1829) and *Foucroy* (1755–1809). Much profit accrued also to zoochemistry through their labours in the investigation of the constituents of the urine, which were also ably handled by *Proust* (1755–1826). In the year 1815 *Gay-Lussac* (1788–1852) discovered cyanogen, an organic compound which conducts itself in combination much in the same way as an *organic* element. Thus he paved the way for the theory of organic radicals, to be further developed at the hands of future observers. Many other discoveries, both in organic and animal chemistry, were made about the same time by *Thenard* (1777–1857), and in 1823 *Chevreul* published his celebrated treatise on animal fats. Modern elementary analysis (brought to such a degree of perfection at a later date) was first opened up by *Gay-Lussac* and *Thenard*, and from that time on a knowledge of organic bodies, from a quantitative point of view, was rendered possible.

But under *Berzelius* (1779–1848), the greatest chemist of his time, the whole science now made the most brilliant advance, especially in the direction of organic analysis, which was pursued by him with all the accuracy of the present day. He was, in fact, the founder of the stoichiometry of organic bodies, and of the definite systematised zoochemistry we at present possess. Then the name of *Mitscherlich* (born 1796) must be

remembered as the discoverer of isomorphism. Among those who have lived in our own day, *Liebig* (1803–1873) may be said to have taken the place of the last-named Swedish philosopher. By his labours in the field of organic combination he has made himself celebrated, and has obtained, also in a wider circle than any other, a recognition of his genius by his imperishable popular essays on the science. He may be looked upon as the founder of the physiological chemistry and elementary analysis of the present day. Another important step towards an insight into the origin of organic substances in the body was made in 1823 by *Wöhler*, *Liebig's* talented coadjutor, through his well-known discovery of the composition of urea.

§ 5.

Study of the nature of the substances occurring in the animal economy, —their properties, constitution, transformations, &c.—constitutes what is termed “ZOO-CHEMISTRY.” The application of zoochemical facts to the elucidation of processes taking place in the system, the contemplation of the chemical features of life and significance which the elements of composition have in the same, includes, if not all, yet the chief objects of “PHYSIOLOGICAL CHEMISTRY.” That both these branches of study could only be carried on subsequent to the arrival at a certain degree of maturity of chemical science, is perfectly obvious, as has been already remarked, and requires no farther comment.

Again, the special application of the facts of physiological and zoochemistry to the tissues composing our frame, constitutes what is termed “HISTO-CHEMISTRY.” Its sphere lies in the consideration of the chemical constitution of the “structural elements,” and consequently also of the tissues. It is engaged with the substances occurring in the latter, their introduction, origin, and the significance they possess in the life of the *form* and *tissue-elements*; it traces their metamorphosis, decomposition, and elimination.

At present we can only boast of a very rudimentary histochemistry. In fact, we are met at all points by the most discouraging difficulties in this branch of study, owing to the nature of the subject to be dealt with. Compared with the extraordinary accuracy of anatomical analysis, through the aid of the microscope of the present day, the means at the disposal of the chemist for the separation of the unstable constituents of the tissues appear coarse and rude. While the histologist is able, for instance, to distinguish with ease, in the most ordinary form-element the cell, envelope, contents, nucleus, and nucleolus, the chemist is still unable to bring these several parts within the grasp of his analysis. Further, it is a rare thing with him to succeed in the analysis even of similar structural elements for themselves, even setting aside their ultimate composition; for, owing to the complex nature of most tissues, he has to deal with a mixture of several kinds of form-elements, which cannot be separated by chemical means.

After what we have just seen, too much must not be expected from the histochemistry of the present day. And yet we need not forget, in the contemplation of its necessary deficiencies, how much this special branch of science has produced. We must remember, farther, that without a knowledge of composition, true scientific study of histology is impossible, and the latter is in danger of degenerating into a mere toying with details of form. And as histochemistry, on the one hand, can only be based on a clear insight into the minute anatomical relations of the tissues, so does it form, on the other hand, the indispensable complement to histology.

Among those who have specially distinguished themselves in connection with this subject, we may mention the names of *Mulder, Donders, C. Schmidt, Lehmann, Schlossberger, Hoppe, and Kühne*. *Schlossberger* is the author of the first hand-book on histochemistry which scientific literature can produce.

§ 6.

In conclusion, we have only to give a brief sketch of the plan we shall pursue in the following pages. Histology and histochemistry combined, or the study of the finer structure and chemical composition of parts, constitutes the most important foundation for physiology and scientific pathology. The whole subject may be arranged, according to our views, into three great natural divisions.

In the first will be considered *the matters of which the human and animal body generally is composed*, with their histological and (as far as inseparable from these, and that a knowledge of them is indispensable for a proper comprehension of the whole) their physiological characters. Again, in another section of the same, the organised units of the body, the "*structural or tissue-elements*," will be brought in review, with their shape and composition, purposes and origin, ultimate destiny and origin, one from another: This constitutes "GENERAL HISTOLOGY AND HISTOCHEMISTRY."

In the second division—histology in the more restricted and real meaning of the word—*the various tissues, in their anatomical relations and composition*, will be brought under notice. Here also we shall consider the mode in which the form or structural elements of the first division are employed in the building up of certain masses. It stands to reason that here also the physiological characters of the tissues and their origin must still be frequently referred to.

A third division, finally, will be devoted to the consideration of *the more minute structure of the organs and systems of our body*, or the manner in which they are put together out of different tissues. This may be termed "TOPOGRAPHICAL HISTOLOGY."



Faint, illegible text at the top of the page, possibly a header or introductory paragraph.

Main body of faint, illegible text, appearing to be several paragraphs of a document.

7
Faint, illegible text in the lower middle section of the page.

Large area of faint, illegible text at the bottom of the page, possibly a concluding section or a list.



I.
THE
ELEMENTS OF COMPOSITION
AND OF
STRUCTURE OF THE BODY.

I. ELEMENTS OF COMPOSITION.

CHEMICAL investigation has gradually brought under our notice a number of bodies, some organic and some inorganic, which enter into the formation of the human frame as elements of composition. Owing to the rapid progress of science the tale of these increases year by year.

But these bodies are by no means laid down once for all in the organism to belong to the latter for the whole term of its existence, and to form permanent constituents of its fluid and solid portions. On the contrary, the material of which the animal body is composed is subject to continuous change, to constant transformations, or, in other words, is incessantly coming and going.

The substances of which our body is made up—those, namely, entering into the formation of tissues—consist, together with water and other mineral matters, of certain groups of organic principles. These are the albuminous, or, as they are called, the “protein substances,” and the nearer derivatives of the same, especially the gluten-yielding and elastic materials, with fatty matters and pigments. Thus we observe that the number of chemical compounds of which our frame is made up is primarily but small.

But owing to the fact that these do not continue long in their original condition, but undergo decay and metamorphosis, and must in consequence be changed, we have an extensive series of chemical mutations bound up with the exitus of matter. We need not be surprised, then, if, out of this limited number of histogenic substances, a whole host of mutation or decomposition products takes its rise. The introduction also of new material to make up for waste likewise introduces many chemical metamorphoses.

In considering, then, the elements of composition, all these points must be borne in mind. It belongs to the province of histochemistry to show by what processes alimentary matters are ultimately converted into the constituents of organs and tissues, or, in other words, to follow up the formation of histogenic substances. Again, it must deal as far as possible with the question as to the nature of the numerous products of decomposition. It should demonstrate also how and by what chemical processes the latter spring from histogenic substances; what is the relation of one to the other; how one mutation product takes its origin from another; and what part each plays in the occurrences of the economy, until it is finally cast out of the system. In this way only could we acquire a satisfactory knowledge of the chemical constitution and decay of our body.

But, unfortunately, the state of science at the present day does not admit of all these requirements being satisfied in the remotest degree.

We are, to be sure, tolerably well acquainted with the general interchange of matter which takes place in the system, but not so that in the individual organs. We are, indeed, justified in concluding that this interchange of material in the latter possesses varying degrees of intensity; that it increases during the action of the part, and decreases during rest; but we are possessed of almost no facts which would enable us to demonstrate with desirable accuracy the amount of this traffic, as it were, which goes on, even in a single tissue.

If in this way the destiny of many constituents of our body is veiled in obscurity, how much more so, then, their real chemical relations. Although of many substances we are able to say, "They are products of decomposition, residues, relics of broken down tissue, their sojourn in the body has no other significance," still, in dealing with others, great difficulties arise when it is to be decided to what side of metamorphosis they belong—to the formative or to the retrogressive. Of the sources of many products of decomposition we know nothing certain; and even the changes effected by chemical action are either but very unsatisfactorily understood, or not at all. Superfluous alimentary matter, so often present in the system, may possibly be hardly distinguishable in its derivatives from the matters resulting from metamorphosis of some constituents of the body itself. Finally, we are uncertain still in regard to many mineral substances, whether they are essential integral components of our body, or are only casually present in the latter.

Now it is, properly speaking, the theme of physiology to follow up this behaviour of material in detail, and to interpret its full significance for animal life; but histochemistry will be frequently obliged to enter upon physiologico-chemical research, for only in this way can a knowledge of the precise nature of the substances of which tissues and organs are composed be acquired.

Commencing with the axiom, that the physiological characters of a matter are in the first place dependent on its chemical constitution, we choose as an introduction to the elements of composition of the human body a section principally chemical.

A. Albuminous or Protein Compounds.

§ 8.

Absent from no organism, and taking part in the construction of all tissues, these matters, which constitute the most important materials of nutrition, appear of the highest significance in animal life; indeed, they may be regarded with all propriety as the chemical substrata of the latter. Their histogenic qualities come even more prominently before us in the embryonic body than in the mature; for in the latter, many parts consist of other than albuminous substances: for instance, of collagen, chondrigen, elastic matter, and fats; whereas, in the earliest periods of existence, protein compounds are everywhere present. Those matters just named, however, must also be looked upon as derivatives of the latter, produced by metamorphosis of albuminous principles.

The great instability and tendency to decomposition of all the members of this group cause the appearance of a considerable number of substances in the system, which in some cases participate still, though in a minor degree, in the formation of tissues, and are in others (having undergone some

further modifications) to be looked upon as effete, and no longer serviceable for any of the functions of life. As such, they may either circulate in the various juices of the body until eventually excreted, or may remain behind in the tissues in the character of dregs or sediment as it were.

All protein substances are of exceedingly complex composition. They contain, beside carbon, hydrogen, and oxygen, a large amount of nitrogen, and invariably sulphur. Phosphorus was also formerly supposed, though erroneously, to be present. Their true constitution is still quite obscure.

They all become swollen and puffy when placed in water, and enter into combinations with acids and bases, but whether in regular proportion is not yet known. They dissolve in alkalies, but probably with metamorphosis or decomposition, and may be thrown down from such solutions by the mineral acids. They likewise form combinations with acids, from which they may be again precipitated by means of the alkalies. The action of nitric acid causes them to assume a yellow hue, from the generation of an acid known as xanthoproteinic. *Millon's* reagent also, a solution of nitrate of mercury, containing nitrous acid, communicates a red colour to them, while iodine tinges them yellowish-brown. In concentrated hydrochloric acid they are dissolved, assuming at the same time a violet tint. The action of sugar and concentrated sulphuric acid upon the protein substances gives rise to a change of colour in them, at first to purple, and subsequently to more of a violet-hue (*Schultze*)—a reaction which they share with the acids of the bile and with elain. In watery solutions they bend a ray of polarised light to the left. Oxidizing agents, as well as dry distillation and putrefaction, develop in albuminous bodies a number of decomposition-products, such as formic, acetic, and benzoic acids, oil of bitter almonds, and also crystalline matters, as leucin and tyrosin. (See below.)

Most of the protein substances appear in the body under two isomeric modifications—firstly, in solution, or gelatinised, as in the greater number of fluids and tissues of the system; and—secondly, in a coagulated or insoluble state. They pass from the former into the latter condition in various ways, partly by boiling, partly by the action of strong acids, and finally, as the saying is, spontaneously. In the first modification the protein substances may be far more easily distinguished, one from the other by certain definite reactions, than when in the coagulated condition.

§ 9.

The complex composition of the principles under consideration, their indifferant nature, and great instability, account for the fact that, up to the present, their true constitution has remained utterly unknown. Indeed, we find a most discouraging obscurity resting over this most important of all groups of animal substances. So far is this the case that, in fact, we are not even able to enumerate the various albuminous principles with anything like certainty.

Again, the great instability of the protein substances gives rise to the appearance in the organism of a considerable number of decomposition-products, to whose nature and mode of origin we are still in most cases almost complete strangers. Among these may be reckoned, as far as we know at present, urea, uric, hippuric, and gallic acids; taurin, glycin,

leucin, tyrosin, sarkin, kreatin, kreatinin, glycogen, grape and milk sugar, inosit, and others besides. From a knowledge of these matters, it is not possible at present to arrive at any definite conclusions in regard to the constitution of the protein substances themselves; we may, however, set it down as being very complex. Owing to their great liability to undergo decomposition, farther, the protein compounds appear to be peculiarly fitted to act in the economy as ferments, *i.e.*, to effect a metamorphosis in other substances without at the same time acting through their chemical affinities. We shall refer again to these properties in § 12.

Turning now to the peculiarities of the protein compounds and their formative derivatives, especially important in histogenesis, we must bear the following points in mind:—

1. The fact that the substances in question are not crystallizable, but belong to the colloid group in the ordinary sense, as stated by *Graham*. This seems to constitute them peculiarly well fitted to assume the specific forms of tissue elements, and to preserve the same.

2. Their readiness to imbibe water, and to swell up in the latter into gelatinous masses, seems to render them suited for the formation of the watery, soft, and semi-solid matters of many tissues. Their capacity for gelatinisation appears greatest in slightly alkaline or acid water; in solutions of neutral salts less than in pure water.

3. The remarkable readiness manifested among the protein bodies to change from one modification to another, as well as from the liquid to the gelatinous or coagulated state, and *vice versa*, renders them capable of becoming deposited from the animal juices in the solid form, or, when previously so laid down, of undergoing re-solution and easy transport to other localities.

4. While gelatinised protein substances admit of the passage through them of crystallizable matters, they oppose the most determined resistance to the diffusion of colloid materials.

5. Albuminous principles manifest a readiness to intermix with other bodies, *e.g.*, fats, and phosphate of lime, and to retain these with obstinacy. They may therefore be regarded as the bearers of these substances.

6. On the other hand, true albuminous substances appear unfavourably constituted to form for any length of time unchanged the elements of composition of a tissue, owing to their great unstableness. They seem to impart to the textures into whose structure they enter, a certain aptness to undergo physical change, as may be strikingly seen in many instances. This is not the case, however, with many of their derivatives, whose liability to alteration appears to be far more limited—as, for instance, keratin, chondrigen, and elastic material. These being peculiarly suited for permanent tissues, serve for the formation of indifferent membranes, allowing the transudation of animal fluids, or including the same.

§ 10.

Albumen.

This most important of all the protein substances in the system, coagulates between 55° and 75° C. from its solutions in the form of flakes, and not spontaneously like fibrin. From very dilute solutions it can only be separated by a much more elevated temperature.

Like other protein matters it has two forms, a soluble and coagulated.

Of the first there are many varieties; but all these differences are probably dependent upon the admixture of other matters, such as alkalis or acids.

Soluble albumen is precipitated by alcohol, mineral acids, tannic acid, and the salts of most metals. A larger or smaller quantity is also thrown down by the passage through it of a stream of carbonic acid.

It becomes converted into the insoluble modification as already mentioned by boiling; further, by the action of most acids, without, however, being always precipitated. The alkalis likewise transform albumen into a very insoluble substance, but do not throw it down.

Albumen is not present in the animal juices in a pure state, but combined with a certain proportion of soda, saline water being the solvent. Such albumen has a weakly alkaline reaction, coagulates more in gelatinous masses than in flakes, and is, on the whole, more soluble than in the pure condition. A larger proportion still of soda may modify the coagulation of albumen by heat in many ways.

Coagulated albumen partakes of the same nature as the remaining protein substances in the same state.

Entering the body with the protein substances of the food, it appears as a constituent of blood, chyle, and lymph, and also of the fluids saturating various organs. Combined with some peculiar substances, it appears to form the medulla of nerves. To what extent it exists in the system in the coagulated form is a question difficult to answer in the present state of science. It can hardly be doubted, however, that it does so occur, and the finely granular contents of many animal cells are probably entirely or partially composed of it.

We are likewise at fault when asked to indicate the histogenic significance of albumen more in detail. It can hardly be doubted, however, that it is of very great importance, in that it is the first protein substance from which many of the others in the organism take their origin.

§ 11.

Fibrin, Fibrinogen, and Fibrinoplastin.

Fibrin has always been described as a substance which does not coagulate at boiling point, but, as the saying is, spontaneously, a short time after the animal fluids in which it is dissolved during life are poured out of the body.

It coagulates more rapidly at a moderately high than at a low temperature. The oxygen of the atmosphere has probably no accelerating effect upon the process, for in the interior of the body it is observed to take place in fluids which have come to a state of rest in closed cavities. The process may be retarded by the presence in the fluid of carbonic acid, or the addition of various alkaline salts, such as Glauber salt, for instance.

Coagulated fibrin can never be obtained pure, however; for, in the act of congelation, the numerous cellular constituents of the fluids in which it is contained become entangled in it. It offers, besides, many varieties for our consideration. In water acidulated with hydrochloric acid, it swells up, without, however, dissolving (*Liebig*); in contrast to syntonin obtained from muscle tissue (see below). Coagulated fibrin is dissolved in solutions of various alkaline salts—for instance, in nitrate and carbonate of potash, when the temperature is somewhat elevated—forming a substance similar to albumen. According to *Thenard*, further,

superoxide of hydrogen is rapidly decomposed by fibrin. Fibrin may be obtained from blood, chyle, and lymph, in small but variable quantity, also from serous transudations.

Let us now consider for a few moments the phenomena of coagulation of fibrin. Fluids in which this substance is contained become of a thickish or even jelly-like consistence soon after coming to a state of rest. Later, in consequence of progressive contraction of the fibrin, a certain quantity of the entangled fluid is squeezed out, and the coagulum becomes more or less solid as it decreases gradually in size. Under the microscope a homogeneous jelly is at first perceived; later on a tangle of usually very delicate threads or fibres (rarely broad), by which the cellular corpuscles of the fluid are caught. By many these fibres are regarded as the optical expression of folds or rugæ on fine membranous masses.

In regard to the origin of fibrin, it was for a long time generally supposed that it took its rise from albumen. And from the fact that its analysis showed a larger proportion of oxygen than is found in the latter, the hypothesis was advanced that fibrin is formed by a process of oxidation or putrefaction from albuminous substances.

Some years ago an interesting discovery was published by *A. Schmidt*, which completely upset all earlier theories as to the constitution of the material in question.

According to this observer, there exists no fluid fibrin at all in the animal fluids as long as in motion. It is first generated in the blood and other liquids by the chemical combination of two nearly related compounds, which have been named by the author "*fibrinogen*" and "*fibrinoplastin*." The first of these (also called *metaglobulin*) is dissolved in the plasma of the blood; the second (or *paraglobulin*), which, combining with fibrinogen, converts it into fibrin, exists, on the contrary, according to *Schmidt*, in the bodies of the coloured blood-cells, passing from these into the plasma. It is exceedingly similar to the globulin of these cells, (§ 12), or perhaps identical, and probably corresponded with the so-called "*serum casein*," (*A. Schmidt*). Lymph, chyle, pus, and many tissues containing cells (but not cartilage and tendon), and also fluids into which these cell-contents have passed,—as, for instance, the serum of the blood, synovia, humours of the eye, and saliva,—are all fibrinoplastic. Fibrinogen also, which is very like fibrinoplastin in its reactions—both may be precipitated from dilute solutions by conducting through them a stream of carbonic acid—appears widely distributed throughout the system, and is contained in almost all serous fluids, as well as those saturating connective tissue and muscle. The rapid mutation of matter which takes place in the moving juices of the body is supposed to be the obstacle to the formation of fibrin during life. *Schmidt* believes himself also justified in the conclusion that, on the chemical combination of these two "*mother substances*" to form coagulated fibrin, the alkalies, which previously held them in solution, are set free.

§ 12.

Myosin. Muscle-Fibrin, or Syntonin.

The contractile structures of the organism, the protoplasm of which the bodies of young cells are formed, with striped and smooth muscle-fibres, all consist of a series of albuminous substances remarkable for

peculiar reactions, as well as in almost all cases for the property of coagulating at comparatively low temperatures, ranging from 35° to 50° C.

One of these substances, the *myosin* of *Kühne*, coagulates after death, and is thus the cause of rigor mortis. Coagulated myosin is not soluble in pure water, but is readily so in such containing as little as ten per cent. of chloride of sodium. It may likewise be dissolved in dilute acids and alkalies. It has the same action upon superoxide of hydrogen as fibrin.

Beside myosin, the fluids with which muscle is saturated contain three other soluble albuminous matters, namely, an albuminate of potash, and two substances which coagulate,—one at 45° C., and another at 75° C.

From dead muscle, but also from other albuminous materials, a mutation product has been extracted by very dilute acids, to which the name of *muscle fibrin* or *syntonin* has been given by *Lehmann*. In contradistinction to the fibrin of blood, it is soluble in water containing 0·1 per cent. of hydrochloric acid, but not so in solutions of nitrate and carbonate of potash. It has no effect, moreover, upon superoxide of hydrogen.

Casein.

This protein substance, which is probably an albuminate of potash, does not pass from the soluble to the insoluble form spontaneously, like fibrin, but on coming into contact with the mucous membrane of the stomach. On being heated, liquids in which it is contained become covered with a thin pellicle, consisting of casein modified by the oxygen of the air. Casein is precipitated by acids in flakes, and in contradistinction to albumen by acetic acid. According to *Lehmann* it is not thrown down from milk by a stream of carbonic acid.

This substance forms the chief constituent of the milk of man and the mammalia, and the most important aliment for the infant. How far it is besides distributed through the system is still uncertain; its presence in alkaline fluids, however, is very probable. It is said to exist in the middle coats of arteries by *M. Schultze*.

Globulin. Crystallin.

By these names are known certain albuminous substances coagulating like albumen when heated. They require, however, a higher temperature, and then separate either in the form of a globular mass or milky coagulum. A solution of globulin, acidulated with acetic acid, is said to be precipitated by careful neutralisation with ammonia, and an ammoniacal solution by acetic acid. Globulin is entirely thrown down in fluids by a stream of carbonic acid.

Many things have in course of time received the name of globulin.

It is found in the lens, in blood-cells (?), in the plasma of the blood, as fibrinogen and fibrinoplastin (§ 11), and in exudations.

Peptones.

The albuminoids entering into the composition of tissues, as we have just seen, do not possess the power, when in watery solution, of passing through animal membranes. They are colloids in *Graham's* sense of the word (p. 14).

These, on being received into the body, partly from the animal and partly from the vegetable kingdom, are all converted by the processes of

digestion into what are termed *peptones*—*i.e.*, easily diffusible substances of very similar or identical constitution. These peptones are by no means so easily precipitated by reagents as the colloid albuminates. Thus, in contradistinction to the latter, they are *not* thrown down by boiling, by dilute mineral acids, or by acetic acid. On being precipitated by alcohol, they may be again dissolved by watery spirits of wine. A polarised ray of light is deflected by them strongly to the left.

Matters containing *collagen* and *chondrigen*, and also mucus, the consideration of which will soon occupy us, yield with greater or less certainty corresponding peptones.

Ferments.

It has been already noticed above (p. 14), that the instability of the albuminates permits of their ready conversion into what are termed ferments. By the action of such substances,—we believe them at present to spring in all probability from this source; the albuminous matters are converted into peptones. The ferments appear combined with water as constituents of the gastric, intestinal, and pancreatic secretions. Others of them, from the mouth and salivary glands, transform amydon, dextrin, and glycogen into grape sugar. A ferment in the pancreatic juice splits up the neutral fats into fatty acids and glycerin. Decomposing albuminous substances convert urea into carbonic acid and ammonia, &c. Thus the mutation of the most important substances in the body introduces a great chemical action in the same, and leads even to the assimilation of new albuminoids in the most extraordinary manner.

B. Hæmoglobulin.

§ 13.

Hæmoglobulin, Hæmatoglobulin, Hæmatocrystallin.

We have been recently made acquainted with a remarkable substance of still more complex constitution than the albuminates, which may very easily be resolved into an albuminous matter resembling globulin and into hæmatin.

From the red blood-cells of man and the vertebrates generally, a coloured crystalline substance may be obtained, namely, after destruction of the cells, containing iron, and of the greatest instability. Of this the blood-crystals so long known are composed (fig. 1). From the investigations of the Germans *Funke*, *Lehmann*, *Kunde*, *Teichmann*, *Bojanowsky*, *Rollett*, *Hoppe*, *Böttcher*, and others, we learn that the substance which thus crystallizes is by no means the same in all classes of vertebrates, but offers many differences for our consideration as regards solubility and crystalline form. The difficulties of dealing with it chemically are greatly enhanced by its liability to decomposition, and its admixture with other matters.

It may be obtained with greater or less ease in various ways: by first conducting a stream of oxygen through a mixture of blood and water, and then carbonic acid; then by evaporation of diluted blood, to which alcohol and ether have been added upon the glass slide of the microscope. Its separation is favoured by the presence of light according to the general opinion. Crystals may likewise be obtained by the freezing and

subsequent thawing of blood; by elevation of temperature to 60° C.; by electric discharges and the continuous current; by pumping out the gases of the blood; by the addition to the latter of various salts, such as sulphate of soda and those of the bile; and by the action of chloroform with free access of air. The blood of different animals crystallizes with varying degrees of readiness. In that of the guinea pig crystals are formed particularly rapidly. The blood of the splenic vein is also remarkable above that of all other localities for the freedom with which crystals are formed in it.

There appear to be further several kinds of hæmoglobin in the animal kingdom.

In the reddish blood of many of the invertebrate animals hæmoglobin has also been found.

The colouring matter of muscle is identical, according to Kühne, with that of the blood-corpuscles.

Blood-crystals are met with under various forms—such as prisms, tetrahedrons, hexagonal tables, and rhombohedrons. The first is by far the most universally encountered, appearing in man and the greater number of mammals (fig. 1, *c*), in which rhombic tables may also occur (*b*). The hæmoglobin of the mouse and guinea pig assumes the form of tetrahedrons (*d*). Hexagonal plates have up to the present been found in the blood of the squirrel only (*f*).

In the hamster or German marmot we find rhombohedrons (*e*). In fact, almost all blood-crystals belong to the rhombic system, with the exception of those of the squirrel, which belong to the hexagonal (*Rollet, von Lang*).

Hæmoglobin crystals are double-refracting and pleochromatic; observed in one aspect they are bluish-red, in another, scarlet.

They are insoluble in ether and alcohol, but dissolve in water, communicating to it a blood-red tint.

Watery solutions of hæmoglobin coagulate on being heated, owing to the production of an albuminous substance globulin, and hæmatin to be mentioned below. The same separation is brought about by the action of acids and alkalis.

Hæmoglobin combines with many gases, *e.g.*, oxygen, carbonic oxide, and nitrous oxide. Crystals obtained under free access of air contain oxygen in loose chemical combination, which is parted with in a vacuum, or when the former are heated. This is the *oxyhæmoglobin*




Fig. 1.—Crystals from the blood of man and some mammals. *a*, blood-crystals from human venous blood; *b*, from the splenic vein; *c*, crystals from the blood of a cat's heart; *d*, from the jugular vein of a guinea pig; *e*, from the hamster; and *f*, from the jugular vein of the squirrel.

of *Hoppe*, to which the statements made above in respect to blood-crystals refer.

A dilute solution of oxyhæmoglobin shows, as was discovered by *Hoppe*, two broad bands of absorption between the lines *D* and *E* of the solar spectrum (fig. 2, *a*) in the yellow and green part. Solutions of reduced




Fig. 2.—Appearances of solutions of h moglobin in the spectroscop. *a*, oxyh moglobin and nitroxy-h moglobin; *b*, carbonic oxide h moglobin; *c*, reduced h moglobin; *d*, h matin in acid solution; *e*, h matin in alkaline solution; *f*, reduced h matin. Solar spectrum with *Fraunhofer's* lines.

h moglobin, on the other hand, have only one absorption band between *D* and *E* (*e*), (*Stokes*).

Reduction of oxyh moglobin takes place easily. It may be brought about by the action of carbonic acid also.

Reduced h moglobin may also form crystals. They are of a deep purple colour, and far more soluble than those of oxyh moglobin.

The latter substance, in contact with carbonic oxide gas, parts with its oxygen, and absorbs the last named compound. In this way a crystalline compound of carbonic oxide with h moglobin is produced (*Hoppe*).

The combination of hæmoglobin with nitrous oxide (*Hermann*) conducts itself in a manner similar to its combination with oxygen.

C. Histogenic Derivatives of the Albuminous Substances or Albuminoids.

§ 14.

Keratin. Mucin. Colloid.

We come now to certain matters which receive in general but little attention. They are related to the protein compounds, and take their origin apparently from the latter within the body. They also are colloids. Their decomposition products are, in many respects, very similar to those of the albuminous substances.

In the older cells of horny tissue, of epithelium, of nails and hair, as well as in the analogous structures of animals, there exists a mixture or compound difficult to isolate in a pure state, and insoluble in water. It may contain up to five per cent. of sulphur, and is partially soluble in alkalies. Its decomposition products, among which leucin and a large quantity of tyrosin are found, indicate a close relationship with the protein substances. To this compound the name *keratin* has been given.

Under the name of *mucin* is known a substance, sometimes gelatinous, sometimes dissolved, which occurs in the secretions of the mucous membranes, in synovia and the vitreous humour of the eye, in the gelatin of *Wharton* of the umbilical cord, in several connective-tissue structures, and finally, in certain pathological products (mucous tissue). This substance does not coagulate on being heated. It is thrown down in flakes by acetic acid, and is not redissolved by an excess of the same. Alcohol produces a species of stringy coagulum in solutions containing mucin, but this dissolves again in warm water. In many other respects mucin resembles the protein compounds; its reaction with sugar and sulphuric acid is also the same. It appears to contain no sulphur, but is, on the other hand, rich in phosphate of lime (*Scherer*). Mucin, which is not diffusible, manifests fermenting properties. It appears to form a kind of peptone (*Eichwald*).

Colloid matter may also be mentioned here: a usually homogenous substance of some consistence, insoluble in acetic acid, but not, like mucin, precipitated by the latter. It is soluble, on the other hand, in alkalies. It is generally met with as a pathological product of the transformation of tissues (colloid degeneration), but also normally at certain periods of life, particularly in the thyroid gland of man.

§ 15.

Substances yielding Glutin.

From experience, we know that the important group of *glutin-yielding materials* takes its origin from protein compounds. These principles only occur in animal organisms, and constitute a large part of our body, in the form of interstitial matter in structures composed of connective tissue, of bone, and of cartilage. We understand by *glutin-yielding materials*, compounds containing nitrogen and sulphur, completely insoluble in cold water, but which may be rendered soluble by prolonged

boiling in the same—yielding then a principle which becomes gelatinous on cooling, known as glue. It is supposed that in these processes the composition of the materials under consideration is not essentially altered. Our knowledge of the chemistry of the formation of glue is not, however, at all satisfactory at present.

From allied protein substances these materials differ in their solubility in boiling water and subsequent gelatinisation. With the sugar and sulphuric acid test, likewise, they do not become red, but yellowish-brown. With nitric acid they assume a yellow colour, like albuminous materials.

All efforts to convert albuminous matters into gluten-yielding substances artificially, as well as the latter into one another, have up to the present proved futile.

Collagen and Glutin.

Collagen, or the substance converted into ordinary *glue* or *glutin* by boiling, has received but little attention, while glutin has been made the object of extensive investigation as regards its reactions. A solution of glue is not affected by mineral or acetic acids, or by alkalis; tannic acid alone gives a copious precipitate. Among the earthy and metallic salts, the chlorides of mercury and platinum, and basic sulphate of iron, precipitate glutin, but not acetate of lead. A polarised ray of light is bent to the left by a watery solution of the matter in question. With manganese and sulphuric acid it yields the decomposition products of albumen; with acids and alkalis, ammonia, leucin, glycine, and other compounds.

From glutin is formed the extensive group of connective-tissue structures, the organic substratum of bones and ossified cartilage. Consequently collagen is found widely throughout the body, entering into the composition of tissues of low physiological dignity. From the fact that, with one exception, that of leucæmic blood (*Scherer*), no glutin has as yet been found in the fluids of the body, we infer that collagen must spring from the protein substances. Connective tissue likewise, at an early embryonic period, yields no glutin, but appears to consist of a protein compound (*Schwann*). As to the mode in which the necessary changes here take place, the present state of zoochemistry does not admit of an answer being given.

Chondrigen and Chondrin.

Chondrin, or *cartilage-glue*—obtained from the cornea, from permanent cartilage, from bone cartilage before the commencement of ossification, and likewise from a pathological growth, enchondroma—is allied to glutin. Most acids, however, produce precipitates in a solution of chondrin, which are again dissolved by an excess of the reagent. The precipitate, however, caused by acetic acid does not redissolve. Watery solutions of chondrin possess greater power of left-sided polarisation than those of glutin. Heavy precipitates are also seen here on the addition of alum, sulphates of the protoxide and sesquioxide of iron, sulphate of copper, neutral and basic acetate of lead, nitrate of silver, and nitrate of mercury. Boiled with hydrochloric acid, or digested in gastric juice, chondrin yields, besides numerous other products, a sugar (cartilage sugar), as far as we know, non-crystallizable, but capable of fermentation. If this last statement be correct, chondrin may be regarded as a nitro-

genous glycosid, giving some indication as to the constitution of the albuminates. With sulphuric acid chondrin only yields leucin apparently. Of *chondrigen* but little is known.

As to the origin of chondrin from the protein substances, the same may be said as of gluten. In regard, however, to a transformation of chondrin into gluten during the process of ossification, spoken of by some, but rather improbable, the present state of chemistry permits of no definite conclusions being drawn.

It would appear that other matters nearly related to these two better known glue-yielding substances may also occur in the body.

Elastic Material, Elastin.

In numerous tissues of the body a substance destitute of sulphur is met with, which, unlike the gluten-yielding materials, is remarkable for its great insolubility and unchangeableness.

This *elastic substance*, even on prolonged boiling, yields no gluten, if completely free from connective tissue. It is likewise unaffected by acetic acid, whether warm or cold. It may be dissolved, however, by a boiling concentrated solution of caustic potash, and by cold sulphuric acid; also gradually, by saturated nitric acid with the formation of xanthoproteinic acid. Elastin is not coloured red by the test of sulphuric acid and sugar. As decomposition products under the action of the last-named acid, we find leucin, but neither tyrosin nor glycine.

Elastin, the definition of which presents many difficulties also to the microscopist, enters into the formation of fibres, plates, and limiting layers in connective tissue. It forms also in various organs possibly, both follicles and tubes, and capsules around animal cells, without being a constituent of the true cell-body itself.

The great unchangeableness of this substance, with its chemical inertness, seem to render it peculiarly fitted to include the fluids of the system, and to act at times as a filter for the same. Its great elasticity also serves many purposes.

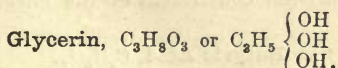
Its source is not as yet known with any degree of certainty. There can be hardly any doubt however that it has its origin from the protein compounds of the body.

D. The Fatty Acids and Fats.

§ 16.

Fatty acids appear in our body either free or combined with an inorganic base (fat-soap), or as a mixture of glycerin-ethers (neutral fats).

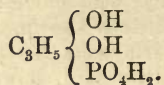
Let us glance for a moment at the latter:—



Glycerin, a triatomic alcohol, with the radicle *glyceryl* = C_3H_7 , is met with as a colourless, non-crystallizable syrup, miscible with water in all proportions.

Before going further, let us consider for a moment *glycerophosphoric*

acid, having the empirical formula $C_3H_9PO_6$. It is a bibasic ether-acid of glycerin.



Glycerophosphoric acid is to be found combined with various matters—in the yolk of the ovum, in cerebral substance, and in the bile. (Comp. § 20, Lecithin.)

The neutral fats, however—those glycerin ethers already mentioned above—are the compounds of most ordinary occurrence and greatest importance in the system.

From the fact that in our *tri*-atomic alcohol, 1, 2, or 3 atoms of H of the hydroxyl may be replaced by the acid radical, we have derived three series of fats known as *monoglycerides*, *diglycerides*, and *triglycerides*.

The neutral fats occurring naturally belong only to the last group—the triglycerides of many acids.

Glycerin finds its way into the body with the neutral fats of the food. It becomes free upon the saponification of these, and must again re-combine with the fatty acids on the formation of fats in the tissues, occurrences in regard to which we are still in the dark. The physiological decomposition products of glycerin are also still obscure.

§ 17.

The fatty acids of the system belong to two natural series, of which one is arranged after the formula, $C_nH_{2n}O_2$; the other $C_nH_{2n-2}O_2$.

Among the numerous monobasic acids of the first group, some of the *lower* or *fluid* fatty acids do not possess the characters of tissue elements, but rather those of decomposition products.

Formic Acid, CH_2O_2 .

Has been met with by *Scherer* and *Müller* in the fluids with which muscle, the brain, and the spleen are saturated; also in the thymus gland (*Gorup-Besanez*), in sweat in considerable quantity (*Lehmann*), and the blood of dogs after a prolonged sugary diet (*Bouchardat* and *Sandras*). It is also found pathologically in blood. Many of these statements appear, however, questionable.

Acetic Acid, $C_2H_4O_2$.

Is a constituent of the juices of muscle and the spleen (*Scherer*). Further, it is to be met with in the thymus gland, and has been observed in the perspiration. Acetic acid is also known as one of the ingredients of the gastric juice; it occurs probably also in the fluids of the brain. Finally, it appears as an occasional constituent of the blood after brandy potations.

Butyric Acid, $C_4H_8O_2$.

Appears in flesh and the juices of the spleen (*Scherer*); also in the milk, sweat, and secretions of the sebaceous follicles of many parts of the body, as, for instance, on the genitals: in the urine also (?). Its presence in blood seems doubtful (*Lehmann*). It is found also in the contents of the

stomach and intestines, as a product of the fermentation of hydrocarbons.

With glycerin as *tributylin*, = C_3H_5 $\left\{ \begin{array}{l} O.C_4H_7O \\ O.C_7H_7O \\ O.C_4H_7O \end{array} \right.$ it is a constituent of neutral butter fat.

Capronic, $C_6H_{12}O_2$. **Caprylic**, $C_8H_{16}O_2$. **Caprinic**, $C_{10}H_{20}O_2$. **Acids.**

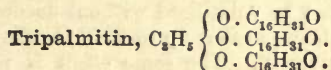
These are met with, in a free state, with glycerin, as constituents of butter, and possibly also of sweat.

Among the higher members of the group with which we are engaged, there occur several of these acids (usually *solid* at the ordinary temperature of the body) as constituents of the neutral fats, and consequently as histogenic compounds. They are introduced into the system with the fats of the alimentary matters as a rule. Their physiological decomposition probably results in the production of carbonic acid and water by oxidation, at the same time that the series is split up into lower members.

Palmitic Acid, $C_{16}H_{32}O_2$.

Palmitic acid is an element in almost all fats of the vegetable and animal kingdom. Its melting point is about $62^\circ C$. It crystallizes in glittering pearly scales.

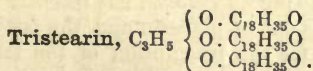
This acid forms with glycerin a compound occurring naturally and abundantly in human fat, as



Stearic Acid, $C_{18}H_{36}O_2$.

This is also a widely-spread constituent of the animal neutral fats, and is present in the human body. Here, however, it is exceeded in quantity by palmitic acid; but it preponderates, on the other hand, in more solid suety fats, as those of cows and sheep. Its melting point is higher than that of the preceding acids, being about $69^\circ C$. It crystallises in white silvery needles or scales.

Its neutral combination with glycerin is known as




Among the acids of the second group there is only one of any importance in the human economy, namely—

Oleic Acid (Elaidic Acid), $C_{18}H_{34}O_2$.

Pure oleic acid is met with as a fluid which stiffens into leaves at a temperature of $-4^\circ C$. It is scentless and tasteless, and cannot be volatilised without decomposition. Its salts are not crystallizable.

Elaidic acid is found as a most important constituent of the neutral fats of the body, combined with glycerin, namely, as



and also saponified with alkalis.

It is introduced into the body with the *neutral fats* of the food. Its physiological decompositions are probably manifold.

REMARKS.—It was formerly believed that *margaric acid* was the most widely-distributed of all animal fats. From the fact, however, that a mixture of equal parts of palmitic and stearic acids has naturally the same composition as margaric acid, $C_{17}H_{33}O_2$, some have denied the existence of the latter altogether, but incorrectly, for it has been produced artificially (*Becker, Heintz*). It is still a matter of doubt, however, whether it and *trimargarin* are constituents of the ordinary fats of the body.

§ 18.

In the foregoing section the constitution of the *neutral fats* which occur naturally, have been brought before our notice; we have also alluded to the different fatty acids of these compounds. It is not possible to separate one from the other, with any degree of accuracy, the individual neutral fatty combinations which occur here, so that our acquaintance with the latter is very unsatisfactory. They receive their peculiarities from the fatty acids of the combination.

Neutral fats, when pure, are colourless, without odour, and tasteless. Their reaction is neutral, they are lighter than water, and bad conductors of electricity. They are insoluble in water, but soluble in warm alcohol and in ether. They give rise to fatty stains upon paper, burn with brilliant flame, and cannot be volatilised without decomposition.

By the action of steam, heated up to $220^{\circ} C.$, the neutral fats are split up into acids and glycerin. The same effect is produced through the agency of ferments, as, for instance, putrefying protein compounds. Exposed to the air they greedily absorb oxygen, and with this and the combined action of ferments, become rancid, water being absorbed and glycerin and fatty acids set free. Further, by the action of alkalis in the presence of water, they are decomposed and converted into soapy compounds, in which process glycerin is set free, while the acid combines with the inorganic base.

It has been already remarked above, that the separation of the several neutral fats from the natural fats of the human body is not possible. Hence the questions in regard to their nature have been answered in various ways. *Berthelot*, following up *Pelouze*, has recently composed the neutral fats by artificial means out of glycerin and the fatty acids, and has thus opened up a new way for the recognition of the fatty matters occurring in the system. From the correspondence between their properties and those of the natural fats, many of these compounded neutral fats have been recognised as constituents of the body.

They are, therefore, all of them, combinations, in which the three atoms of H of the hydroxyls of the glycerin are replaced by the corresponding radicals of those fatty acids. Thus we have a compound corresponding with elaidic acid, *triolein*, a fluid at ordinary temperatures, and then holding two other solid crystalline neutral fats in solution, namely, *tripalmitin* and *tristearin*.* It is still doubtful whether we have here all the constituents of the mixture of neutral fats occurring in the system. In butter

* To these may be added probably *trimargarin*.

there exists a combination of butyric, caprinic, caprylic, and capronic acids, with glycerin.

According to the quantity of solid neutral fat dissolved in the triolein, are the animal adipose tissues soft, or hard and suety after death. During life, however, owing to the natural warmth of the body, they all remain soft, and more or less fluid. In one and the same animal, moreover, the adipose matter of many parts of the body may contain variable quantities of solid fats.

The neutral combinations of the latter occur widely distributed throughout the body. They are to be met with in nearly all fluids and tissues accompanying all the protein compounds and histogenic substances. Their amount is very variable. They appear in enormous quantities in the cells of fatty tissue, under the skin, in the orbit; around the heart and kidneys, and in bone; likewise in medullary nervous matter, together with some special compounds, now better known than formerly. Its constant presence in the tissues leaves no doubt as to the histogenic nature of fat. On the other hand, other tissues are frequently destroyed with fatty infiltration or generation, both physiological and pathological (fatty degeneration). The histogenic significance of the fats appears greatly heightened when we remember the fact that the hard crystalline combinations forfeit their crystallizability on becoming dissolved in triolein.

Under certain circumstances, solid fat separates from the natural fatty matters of the body on the cooling of the latter after death, in the form of needle-shaped crystals or groups of the same (fig. 3). These are known to the microscopist as margarin crystals.

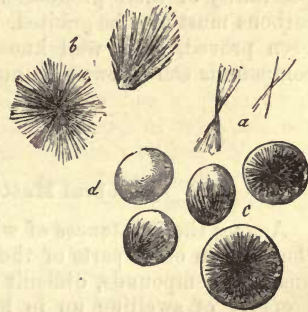


Fig. 3.—Crystals of margarin. *a*, single needles; *b*, larger groups of the same; *c*, groups of needles within fat-cells; *d*, a fat-cell quite free of them.

REMARKS.—The percentage of fats in different tissues is—in lymph, 0·05; in chyle, 0·2; blood, 0·4; cartilage, 1·3; bone, 1·4; lens, 2·0; liver, 2·4; muscle, 3·3; brain, 8·0; nerves, 22·1; spinal cord, 23·6; fatty tissue, 82·7; yellow marrow of bones, 96·0.

§ 19.

In considering the objects for which fat is designed in the human system, the following points may be borne in mind:—

1. The fats appear important, owing to their soft, fluid consistence at the ordinary temperature of the living body, as distributors of pressure, as pads and filling-up matters in various positions.

2. Large collections of neutral fats, as bad conductors, prevent to a certain extent loss of heat to the system.

3. They possess the somewhat subordinate property of rendering many hard tissues, such as epidermis and hair, pliant and soft, by saturating them. For this purpose the secretions of the sebaceous glands appear particularly designed.

4. Their want of affinity for water seems to render them peculiarly suited to separate from watery fluids in the form of granules and drops, and so give origin to the formation of elementary molecules and vesicles.

5. Owing to a certain chemical inertness in fat, the latter appears fitted for the formation of tissues which take but little active part in the chemical processes of the economy.

6. By the fermenting action of the protein compounds, but more by contact with the oxygen of the atmosphere, the fats become decomposed, and the fatty acids formed into other combinations, the final result of which is the production of carbonic acid and water. The heat which is evolved in this process constitutes them of the highest importance.

7. According to *Lehmann*, the fats possess the nature of ferments, in that with the protein compounds they lead to the generation of lactic acid in fluids containing sugar and starch. The energy of pepsin in the gastric juice is also said to be increased by the presence of fats.

8. Though the neutral fats are not soluble in the watery fluids of the body, their soapy combinations are, and are consequently of great importance for the distribution of fatty acids through the system.

The neutral fats are received into the body with food, although the possibility of their production also in the human organism from hydrocarbons must also be granted. That this takes place in many animals has been proved, as is well known, by *Liebig*. Their origin from protein compounds can likewise be no longer really doubted.

§ 20.

Cerebral Matters, Cerebrin and Lecithin.

Among the substances of which the brain and spinal cord are made up (but also in other parts of the animal body) there occur several peculiar, unstable compounds, difficult of analysis. They are remarkable for the property of swelling up in hot water into a substance like starch, for their solubility in warm alcohol and ether, and for their occasionally containing phosphorus. They were formerly erroneously designated as phosphorous fatty matters.

Cerebrin, $C_{17}H_{33}NO_3$.

Cerebrin, originally described by *Frémy* as cerebrie acid, and afterwards investigated by *Gobley* and *Müller*, is a white powder, seen under the microscope to be composed of roundish globules. It can only be dissolved in warm alcohol and ether, and is decomposed by boiling hydrochloric and nitric acids. It is insoluble in ammonia, caustic potash, and baryta water, and also in cold water; while in hot, as already mentioned, it swells up into a substance resembling boiled starch.

On being boiled with acids, cerebrin yields a species of sugar, and is therefore a glucoside. Its precise nature remains for further investigation.

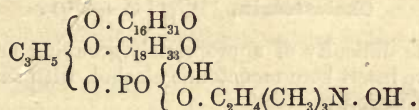
Lecithin, $C_{42}H_{84}NPO_9$.

This substance, first discovered by *Gobley*, is indistinctly crystalline. It resembles wax, may be easily melted, and is soluble in hot alcohol and ether. It enters into combination with acids and salts. In warm water it gelatinizes like cerebrin.

Lecithin is a substance easily decomposed. By prolonged boiling in spirits of wine, or better still, in acids or bases, as baryta water, it

may be split up into neurin, (*cholin*) = $C_2H_4 \left\{ \begin{array}{l} OH \\ N(CH_2)_3OH, \end{array} \right.$ palmitic and oleic acid, and glycerophosphoric acid.

Lecithin may be derived from glycerophosphoric acid, in which the two hydroxyl hydrogens of the glycerin are replaced by the radicals of palmitic and elaidic acids, at the same time that the neurin (half alcohol and half base) forms with the glycerophosphoric acid an ether-acid. Its formula is therefore



This substance, besides being found in nervous tissue, is also found in the yolk of the eggs of hens, in the blood-corpuscles, in bile, semen, and pus. There appear to be various kinds of lecithin in nature.

Protagon, a substance described some years ago by *Liebreich*, is simply a mixture of cerebrin and lecithin.

By *myelin*, as described by *Virchow*, we understand a substance of peculiar microscopic appearances occurring in different parts of the body, especially in those undergoing decomposition. It has a characteristic dull lustre (fig. 4), and is usually met with in masses of roundish, oval, filiform, looped, or lobulated figure, with double outline. Myelin is tinged slightly brown by iodine, while in concentrated sulphuric acid it becomes of a red, or at times violet, colour. It resembles cerebrin and lecithin in its property of absorbing hot water, and swelling up into a gelatinous mass, and also in its relations of solubility to alcohol and ether. Myelin drops, however, may be obtained from compounds of quite a different nature, as, for instance, from oleic acid and ammonia (*Neubauer*). Myelin is therefore chemically untenable as a special combination.

Another allied substance, known as *amyloid*, may be also mentioned here. This appears in peculiar homogeneous masses of dull lustre, and is probably a mixed degeneration product of many, especially glandular portions of the body (waxy or lardy degeneration). coloured of a peculiar reddish-brown or brownish-violet with a solution of iodine, which turns to violet usually on the subsequent addition of concentrated sulphuric acid, or, more rarely, to blue.

We turn finally to the *corpuscula amylacea*, round or bilobular structures of very variable size, which bear a strong resemblance to granules of starch, whence the name. They are sometimes laminated, sometimes not, and vary in their reactions, becoming violet under the action of iodine and sulphuric acid, but frequently blue or bluish with iodine alone. Thus they resemble amyllum in one respect, and cellulose in another, although we are not justified in referring them to either of these substances.

The corpora amylacea are to be found in the nervous centres of putrefying corpses, and, moreover, in quantity increasing with the advance of

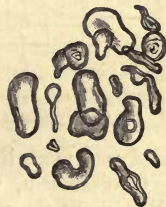

Fig. 4.—Different forms of myelin.

Amyloid matter is

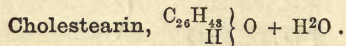


Fig. 5.—Corpuscula amylacea from the human brain.

decomposition. Besides, however, they may occur pathologically in the living body, *e.g.*, in the organs just mentioned, the brain and spinal cord, whose sustentacular connective tissue may contain them in abundance. They are met with also in the prostate of considerable size.

REMARKS.—*Strecker* in the *Zeitschr. für Chemie*, 1868, S. 437.

§ 21.



Sensible of the difficulty of appropriately grouping animal substances, for the present we insert here monatomic alcohol, with the distinct characters of a decomposition product.

This compound (fig. 6) has a very characteristic crystalline form; it is found, namely, in extremely thin, rhombic tables, whose obtuse angle is $100^{\circ} 30'$, and acute, $79^{\circ} 30'$, according to *C. Schmidt*. These are usually arranged overlapping each other, and are frequently broken at the corners.

Cholestearin is completely insoluble in water, but perfectly soluble in boiling alcohol, ether, and chloroform. It is dissolved in fats and ethereal oils; in the two combinations with soda of the biliary acids and in soap-water—important properties in regard to the occurrence in the human body of this otherwise insoluble substance.

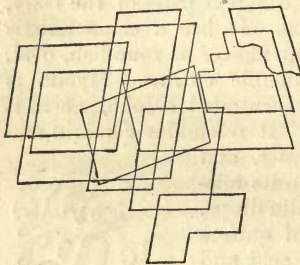


Fig. 6.—Crystals of cholestearin.

Treated with sulphuric acid, crystals of cholestearin become of a rusty or purple colour, beginning at the edges. In concentrated acid, on the other hand, they dissolve gradually, forming coloured globules. The addition of iodine to these reagents

produces more lively colours still.

Cholestearin, which has been recently met with widely distributed throughout the vegetable kingdom (*Beneke, Kolbe*), has no histogenic properties, its crystallizability seeming to render it but little fitted to enter into the structure of tissues. It possesses entirely the nature of a mutation product—whether of the fats or of azotised histogenic substances is still undecided. It is extensively distributed throughout the system, but is only excreted in minute quantities, so that some further decomposition still quite unknown to us may be inferred.

It is found in the blood, but in small amount, and in most of the animal fluids, especially in bile, but not in the urine. It is also met with in the substance of the brain, as a constituent of myelin, in pathological fluids and tumors, and in biliary calculi. Passing off with the bile, it is found in the excrements.

E. The Carbohydrates.

§ 22.

These substances bear this not very happily chosen name on account of their containing oxygen and hydrogen in the same proportions as in

water; they have therefore been regarded as hydrates of carbon. All have at least six atoms of the latter. Should they contain more, they are still complete multiples of six. They may be looked upon as derivatives of the six-atomed alcohols, and are divided according to their composition into three groups.

I. The *grape-sugar group* ($C_6H_{12}O_6$). These may be regarded from the way in which they conduct themselves as aldehydes of the six-atomed alcohols.

II. The *cane-sugar group* ($C_{12}H_{22}O_{11}$), may be looked upon as made up of anhydrites or ethers, formed of two molecules of the last, with the loss of one molecule of H_2O .

III. *Cellulose group* ($C_6H_{10}O_5$). The molecular proportions of these compounds are not yet ascertained. Most of them appear to possess a higher molecular weight than the last. They are likewise anhydritic derivatives.

All hydrocarbons are of neutral constitution; none are volatile; some are crystalline; some are insoluble; others easily soluble in water. The latter appear in the system usually in watery solution, or possibly entering into the composition of other substances as so-called glucosides.

The various hydrocarbons pass easily one into another, and in these processes many of the albuminous matters of the body play an important part as ferments. On being digested in dilute mineral acids, most of them are converted into grape sugar. The relation, further, of the hydrocarbons to the organic acids is of importance, many of them possessing the same empirical composition, and a part springing easily from the latter, as in the case of acetic and other fatty acids, and lactic acid. Their relations to alcohols must also be remembered.

The importance of the hydrocarbons in the vegetable kingdom is very great, produced as they are, with some exceptions (as, for instance, sugar of milk), by the plant; some of them are likewise of great histogenic worth here, especially cellulose. The case is quite otherwise in the animal organism, particularly in the bodies of the higher animals and man. The few hydrocarbons which here appear do not manifest tissue-forming qualities in the remotest degree, and are dissolved in the juices; on the contrary, they seem to be decomposition products of other materials, such as the protein compounds, or their source is the food taken into the body. By their physiological decomposition they yield, according to the commonly received theory, carbonic acid and water. It is still an undecided question how far they can pass into the higher members of the fatty acids, thus playing a part in the formation of fat, but that some of the hydrocarbons do so is certain.

In this group are included among several other substances three kinds of sugar, namely, *grape sugar*, *inosite*, and *sugar of milk*, as constituents of our body.

The sugars are generally sweet to the taste, soluble in water, and almost all crystalline. They undergo vinous fermentation with greater or less readiness quickly in the case of grape sugar; slowly, as in that of sugar of milk; or not at all, as in that of inosite.

Glycogen, $C_6H_{10}O_5$.

This compound, standing between amyllum and dextrin, was discovered by *Bernard*. It is met with as an amorphous substance, which

swells up in cold water, and is dissolved in warm, forming an opalescent fluid, manifesting strong right-handed polarisation. Glycogen becomes of a wine-red colour on the addition of iodine, or also brown and violet. It occurs in the tissue of the liver, and also temporarily in different embryonic tissues, as well as in the muscles of phytophagous animals. It may be converted in various ways into grape sugar, as, for instance, by boiling with dilute acids, by admixture with diastase, saliva, pancreatic juice, or blood. Glycogen is of great importance in the formation of hepatic sugar through the action of a ferment. Its hypothetical origin may be referred to the decomposition of some albuminous substance.

Dextrin, $C_6H_{10}O_5$.

This compound is soluble in water, and viscous when in concentrated solution. A polarised ray is deflected strongly to the right by its watery solution, which is coloured reddish-violet by the addition to it of iodine dissolved in iodide of potassium. It is converted readily into grape sugar by the action of dilute sulphuric acid, diastase, and saliva.

It is found in the contents of the intestine after starchy food, in the blood of phytophagous animals, in the liver of horses after feeding on oats, as well as in the muscles of the latter (*Limpricht*).

Grape Sugar, $C_6H_{12}O_6 + H_2O$.

Grape sugar (fig. 7) usually crystallizes indistinctly in crumb-like or warty masses; rarely in tables, which probably belong to the clinorhombic system. It is soluble in water, and in this form polarises light to the right. Grape sugar reduces sulphate of copper with a solution of potash, and, on being heated slightly, to the condition of suboxide, and forms a combination with chloride of sodium, which crystallizes in large four or six-sided pyramids. In the presence of other nitrogenous substances, as albumen and casein, and also of bases, it undergoes lactic, and later, butyric acid fermentation.

Grape sugar occurring in the animal kingdom, and springing from other carbohydrates in various ways, is formed from the latter, more particularly from amyllum, by the fermenting action of many glandular secretions, particularly those of the mouth, pancreas, and intestines within the body. It is absorbed in the digestive tract, and appears in the chyle and blood. It is generally supposed, from the fact of its disappearing rapidly in the latter, that it undergoes combustion with the formation of carbonic acid and water; but the intermediate products are unknown.

Besides this, the grape sugar found in dead hepatic tissue has a second significance already alluded to in speaking of glycogen.

Normal human urine is probably not entirely free from grape sugar; but the latter may be made to appear in considerable quantities in the urine of animals, by irritation of the medulla elongata (*Bernard*): irritation of other portions of the nervous centres, however, produces the same remarkable phenomenon. This substance occurs pathologically, and often in considerable

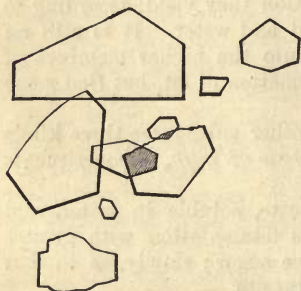


Fig. 7.—Tabular crystals of grape sugar obtained from honey.

quantity, in a peculiar disease known as *diabetes mellitus*. In this affection it is found in the urine and most opposite fluids of the body.

Inosite or Muscle Sugar, $C_6H_{12}O_6 + 2H_2O$.

This substance, discovered by *Scherer*, is identical with the phaseomannite first found in beans by *Vohl*, and subsequently, extensively distributed through the animal kingdom.

Inosite (fig. 8.) forms clinorectangular prisms, which lose at $100^\circ C$. two molecules of water of crystallization, efflorescing in the air. From its solution in boiling alcohol it separates in brilliant scales. It is easily dissolved in water, and undergoes fermentation with cheesy substances, generating so lactic and butyric acids.

The plane of polarisation is not affected by it, nor does it reduce sulphate of copper. On the other hand, when evaporated almost to dryness with nitric acid, and then treated with ammonia, it becomes of a lively rose-red colour on being again evaporated, especially when chloride of calcium is present.

Inosite is widely distributed throughout the body. It is met with in the juices of the muscle of the heart, in the muscles of dogs, in the pancreas and thymus (*Scherer*). It has been also found by *Cloëtta* in the lungs, kidneys, spleen, and liver, and finally, by *Müller* in the substance of the brain, and by *Holm* in the suprarenal capsules of the ox. Inosite may also pass off by the urine, as in diabetes and *Bright's* disease (*Cloëtta, Neukomm*).

It is, without doubt, a decomposition product of histogenic substances.

Sugar of Milk, $C_{12}H_{22}O_{11} + H_2O$.

This compound is distinguished from that just mentioned by its chemical composition, as well as its crystallization in oblique four-sided prisms (fig. 9), and lower degree of solubility in water. It polarises a ray of light also to the right, and reduces oxide of copper like grape-sugar. Sugar of milk, like inosite, is converted by cheesy and other ferments into lactic and butyric acids.

Milk-sugar is not found in the vegetable kingdom, but is a constituent of mammalian and human milk. Its quantity in this fluid stands in proportion to the amount of carbohydrates introduced into the system, and yet it is not absent in the milk of the carnivora after an exclusively fleshy diet, as *Bensch* has shown in confutation of *Dumas'* statements.

It has not yet been demonstrated in the blood of mammals with certainty, and appears not to exist there.

Sugar of milk, therefore, is probably generated by the (fermenting?)

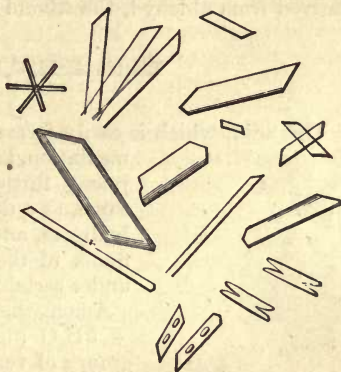


Fig. 8.—Inosite, from the muscle of the human heart.

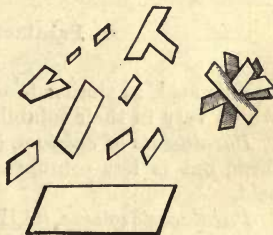


Fig. 9.—Sugar of milk.

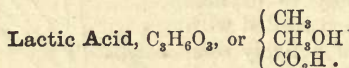
action of the mammary gland. There seem strong grounds for believing, further, that grape-sugar is the substance from which it is formed in this process.

F. Non-Nitrogenous Acids.

§ 23.

In considering the fats (§ 17), we have already been obliged to refer to two homologous series of acids, partly possessing histogenic properties. We now add here another series, having decidedly the nature of decomposition products.

In the first place may be mentioned two acids of the lactic-acid group, isomeric combinations, but differing in their constitution—the first being derived from aldehyd, the second from ethyl compounds.



This acid, which is easily formed from amyllum or sugary fluids by fermentation; or also from inosite, is found in the gastric juice; further, in the contents of the intestinal canal, as a decomposition product of ingested carbohydrates, and also in the brain, and various gland-fluids of the body (?). With bases it forms salts under certain circumstances.

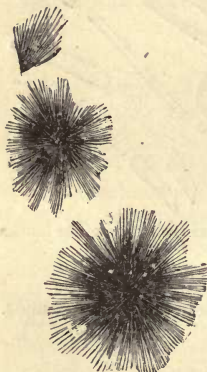
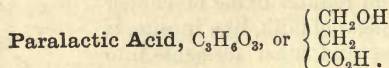


Fig. 10. — Lactate of lime in groups of fine needles.

Among these we have *lactate of calcium* $(C_3H_5O_3)_2Ca + 5H_2O$ (fig. 10), which crystallizes in brush-like groups of very fine needles.

Another salt, *lactate of zinc*, is of considerable diagnostic worth in the recognition of lactic acid. Its formula is $(C_3H_5O_3)_2Zn + 3H_2O$, and it crystallizes in four-sided obliquely-truncated prisms, which present a characteristic clubbed appearance while in process of formation.

In regard to the source of lactic acid in the body, there can be no doubt that, where it is not a product of fermentation, it is derived from the decomposition of histogenic substances.



This acid, so similar to ordinary lactic acid, differs from it in its salts, which vary in their solubility and amount of water of combination.

Paralactate of calcium, $(C_3H_5O_3)_2Ca + 4H_2O$, has the same crystalline form, but is less soluble than the corresponding salt of ordinary lactic acid.

Paralactate of zinc, $(C_3H_5O_3)_2Zn + 2H_2O$, is the same as the crystalline form, but easier of solution in water and alcohol than lactate of zinc.

Paralactic acid is to be found in muscle, on the death of which it becomes free, giving to its juices their acid reaction. It is also present in bile (*Strecker*).

§ 24.

Two other acids, from another series occurring in the human body must now be considered, namely, oxalic and succinic.

Oxalic Acid, $C_2O_2(OH)_2$.

This acid is found widely throughout the vegetable kingdom, and appears as an end product in the oxidation of most animal and vegetable substances. Oxalic acid forms with one atom of Ca *neutral oxalate of calcium*, almost the only one of its salts found in the human body.

Oxalate of Calcium, $C_2O_4Ca + 3H_2O$.

This compound is insoluble in water and acetic acid, but soluble in hydrochloric and nitric acids. On being roasted it is converted into carbonate of calcium. It crystallises in blunt, and at times also pointed, square octahedrons, which look like envelopes under low microscopic power (fig. 11).

Oxalate of calcium, a large amount of which is never met with in the body, is probably, in very minute quantity, a normal constituent of the urine. After a vegetable diet, and drinks containing a large amount of carbonic acid, this salt has been most frequently observed. It likewise appears in conjunction with disturbance of the respiratory functions, and may give rise to the formation of mulberry calculi. It is, further, met with in the gall-bladder and in uterine mucus (*C. Schmidt*).

The sources of oxalic acid may be manifold, as is indicated by its occurrence and origin. In the first place, it may spring from vegetable food, and, in the second, from the decomposition of various animal matters. In the latter respect its formation from the oxidation of uric acid must be mentioned (*Wöhler and Liebig*); also the fact that, on the injection of urates into the blood, the amount of urea and oxalic acid is increased in the urine (*Wöhler and Frerichs*).

Succinic Acid, $C_4H_6O_4$.

This compound, which originates in the oxidation of the fatty acids, as well as from the fermentation of different organic acids, crystallizes in colourless monoclinometric prisms (fig. 12), and is soluble in water and alcohol.

It was formerly supposed to occur, as has been already mentioned, only as a pathological constituent of the body, in encysted tumours and dropsical fluids, until demonstrated by *Gorup-Besanez* in a number of gland-juices, namely, those of the spleen, thymus, and thyroid. It has been, likewise, met with by *Meissner* and *Shepard* in the blood of phytophagous mammals, in human urine, and that of both carnivora and vegetable feeders, after fatty diet or the reception into the system of malic acid (*Meissner, Koch*).



Fig. 11.—Crystals of oxalate of calcium.

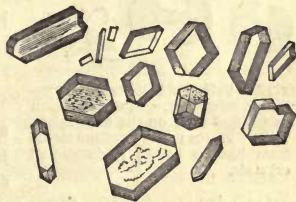


Fig. 12.—Crystals of succinic acid.

Carbolic Acid or Phenol, C_6H_5O .

The sources of this compound are manifold, as, for instance, the distillation of many organic substances and the oxidation of glue, also, which produces it in traces only. It possesses poisonous properties for the human body. It has been obtained from human and mammalian urine (*Staedeler*), and met with also in the same after reception into the stomach of benzol (*Schulzen* and *Naunyn*).

Taurylic Acid or Taurol, C_7H_8O .

This second compound, allied to the last, has been obtained from the same fluids, but not as yet in a pure state (*Staedeler*). It is, perhaps, identical with *kressol* discovered later.

G. Nitrogenous Animal Acids.

§ 25.

Although from organic chemistry we have learned how to produce a whole series of nitrogenous acids artificially, in a manner reminding us of the alkaloids, the number of such compounds occurring naturally in the human body is very limited, and none of them have up to the present been composed by art. They are not found in the vegetable kingdom at all.

None of these substances possess histogenic properties; all are—and in this respect they resemble animal bases—mutation products of histogenic matters or plastic alimentary materials. Owing to their complex constitution they give rise, under certain circumstances, to chemically interesting mutations. If we except two less-known acids which are met with in muscle and sweat, they are either constituents of the urine or the bile, forming essential elements of these secretions.

Inosinic Acid, $C_{10}H_{14}N_4O_{11}$.

This is a non-crystallizable acid, met with in the form of a syrupy fluid, whose constitution is not yet quite certain. It is a constituent of muscle-juice, and as such probably a mutation product of the fleshy fibre.

Hydrotinic Acid.

This is likewise a syrupy acid, recognised by *Favre* as a constituent of human sweat.

Uric Acid, $C_5H_4N_4O_2$.

Fig. 13.—Uric acid in its various crystalline forms. *a, a, a*, crystals such as are met with on the decomposition of urates; *b*, crystalline forms from human urine; *c*, dumb-bell crystals.

This bibasic acid, a derivative of ammonia, and of unknown constitution, appears to the unaided eye as a white powdery or scaly substance. Under the microscope the greatest variety in crystalline form may be seen in uric acid. By the splitting up of the salts of uric acid we obtain rhombic tables, or six-sided plates (fig. 13, *a, a, a*) resembling cystin. Precipitated very slowly, uric acid forms elongated right-angled tables, or parallelepipedic figures, or even right-angled, four-sided prisms with straight ends. The latter are often

grouped together in knots. Pyramidal or barrel-shaped pieces may also be found among other figures (*Schmidt, Lehmann*).

Uric acid, which has become deposited in urine (fig. 13, *b*), is discoloured by the pigmentary matters of this fluid, its crystals appearing yellow or brownish. The latter are met with as a rule either in the so-called "whetstone form," *i.e.*, as though they were transverse sections of strongly biconvex lenses, or in rhombic tables with blunt or rounded angles. Another very remarkable crystalline form is that known as the "dumb-bell" (*c*). This may be met with as a natural product, or may be produced artificially by the decomposition of urate of potassium (*Funke*).

Uric acid, whose acid properties are very feeble, requires about 14,000 parts of cold and 1800 parts of boiling water for its solution. With bases it forms salts, seldom neutral, and as a rule acid. Those of the first kind, which contain two atoms of base, are readily converted into the latter kind by the action of carbonic acid. They are, moreover, easier of solution than the acid salts, in which only one atom of base exists. Among the latter two of the most important alone need be mentioned, which are very difficult of solution in cold water.




Fig. 14.—Acid urate of sodium, *a*, needles, usually aggregated; *b*, spheroidal masses.

ACID URATE OF SODIUM, $C_5H_3NaN_4O_3$.

This salt forms short hexagonal prisms, or thick six-sided tables. It is usually found under the microscope in the form of rounded bunches of crystals (fig. 14). It also appears at times in strange spheroidal masses with beaded processes (*b, b*).

ACID URATE OF AMMONIUM, $C_5H_3(NH_4)N_4O_3$.

A compound crystallizing in fine needles, usually combined to form rounded tufts, in which the individual crystals are generally supposed to be smaller than in the preceding salt (fig. 15).

Both salts, as well as the acid itself, on being evaporated at a moderate heat with nitric acid, leave behind a reddish residue, which assumes a beautiful rose-red colour on the addition of ammonia, and on the subsequent addition of caustic potash an exquisite violet tint. This test, known as the murexide test, accurate for the detection of uric acid.

From its numerous decomposition products we are as yet unable to gain any sure insight into the true constitution of uric acid; its being the source, however, of urea, allantoin, and oxalic acid, and, according to *Strecker*, of glycin, renders it of great interest, and shows its importance.

Uric acid, as its name denotes, is a constant constituent of human urine. It is present in the latter, however, in far smaller quantity than urea, amounting only to about one per thousand, and combined with soda moreover. It is also met with, though in smaller proportion still, in the urine of carnivorous mammals. Traces only of it are found in the urine of phytophagous animals. Its amount in human urine appears to vary



Fig. 15.—Acid urate of ammonium.

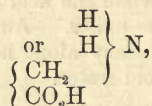
but little according to the nature of the food taken, but much in certain morbid conditions. Uric acid is besides a constituent of blood (*Strahl*, *Lieberkühn*, and *Garrod*). It is also found in the fluids with which many organs are saturated; as, for instance, that of the brain (*Müller*), of the kidneys and lungs in the ox (*Cloëtta*); and in man, of the spleen (*Scherer* and *Gorup-Besanez*).

Uric acid is a mutation product of azotised tissue-constituents, and as such is widely distributed throughout the animal kingdom. As to its mode of origin, we are unable to point it out, owing to our ignorance of the nature of the matter itself. The fact, already mentioned, that the injection into the body of this acid increases the amount of urea in the urine (*Wöhler* and *Frerichs*), seems to point it out as the source of the latter in the system: and the purely chemical decompositions of uric acid, also, which so frequently lead to the formation of urea, appear likewise to confirm this view.

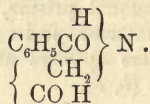
§ 26.

Hippuric Acid, $C_9H_9NO_3$.

Hippuric acid is a *glycin* (see below), *i.e.*, an amido-acetic acid = $C_2H_5NO_2$



in which one atom of the hydrogen is replaced by benzoyl (the radicle of benzoic acid), C_6H_5CO , thus—



This acid, which takes its name from its occurrence in the urine of horses, has the primary crystalline form of a vertical rhombic prism, and separates from hot solutions in small spangles, or large obliquely streaked four-sided pillars, which have two end surfaces (fig. 16). By slow evaporation from dilute solutions, crystals (*b*) may be obtained resembling in many respects those of phosphate of magnesium and ammonium, to be described presently.

Hippuric, which has much stronger acid properties than uric acid, may be dissolved in 400 parts of cold and easily in hot water. It is also soluble in alcohol, but only slightly so in ether. It forms with alkalis and alkaline earths crystalline salts soluble in water.

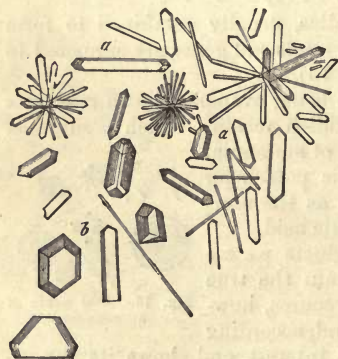


Fig. 16.—Crystalline forms of hippuric acid. *a, a, a*, prisms; *b*, crystals formed by slow evaporation, and resembling those of phosphate of magnesia and ammonium.

As to the numerous decomposition products of the acid with which we are engaged, the most characteristic is the transformation which it undergoes on being heated with acids and alkalis: it is split up, namely, into benzoic acid and glycin after taking up water (*Dessaignes*).

The same effect is produced by animal ferments in the presence of alkalies (*Buchner*).

Like the acids we have just been considering, hippuric is nowhere found in the vegetable kingdom. It is doubtful whether it exists in the blood of vegetable-feeding mammals and that of man (*Robin* and *Verdeil*). It appears in human urine in about the same quantity as uric acid, though in larger amount in certain diseased states of the system. The proportion of hippuric acid in the urine of phytophagous animals is greater, as, for instance, in that of the horse. Up to the present this acid has not been met with in the juices of the organism; it has, however, been found in the scales of a skin disease known as ichthyosis.

It is a fact of great interest, that benzoic, kinic, and cinnamic acids, oil of bitter almonds, and of tolu, introduced into the stomach, are excreted as hippuric acid through the kidneys.

Hippuric acid possesses the nature of a decomposition product of azotised substances of the body. The fact that on the oxidation of protein substances by permanganate of potash, a great quantity of benzoic acid is developed, is in favour of this view.

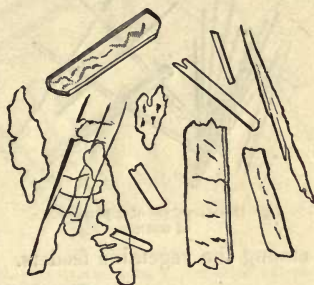

Fig. 17.—Crystals of benzoic acid.

§ 27.

Glycocholic Acid, $C_{26}H_{43}NO_6$.

This, which belongs to the bile, is of analogous constitution to hippuric acid, splitting up like the latter into glycin and a non-nitrogenous acid, known as cholic acid.

Let us consider this latter in the first place:—

Cholic, or *cholalic acid* of *Strecker*, $C_{24}H_{40}O_5$, crystallizes from ether with two equivalents of water of crystallization in rhombic tables; from alcohol with five molecules of water in tetrahedrons; or more rarely, in square octahedrons, which effloresce when exposed to the air. This acid is insoluble in water, but very soluble in alcohol and ether. With sulphuric acid and sugar it becomes of a purple-violet colour. The constitution and origin of cholic acid has not been fixed as yet.

Let us now return to *glycocholic acid*. This crystallizes in very fine needles, which may be heated to $130^{\circ} C$. without undergoing change. It is tolerably soluble in water, very easily so in alcohol and alkalies, but insoluble in ether. It may also be dissolved cold, and without decomposition, in many mineral acids, as, for instance, sulphuric and hydrochloric, but also in acetic acid. With sugar and sulphuric acid it gives the reactions of cholic acid. It is monobasic, and forms partly crystalline, partly amorphous salts, soluble in spirits of wine.

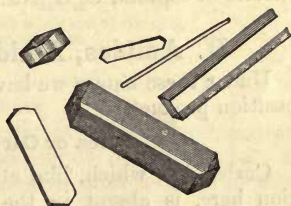


Fig. 18.—Crystals of cholic acid.

On being boiled with potash ley or baryta water it is split up with

absorption of water into cholic acid and glycin. Boiled with dilute mineral acids, on the other hand, it yields choloidinic acid, $C_{24}H_{38}O_4$, and glycin.




Fig. 19.—Crystals of glycocholate of sodium.

among the vegetable feeders.

Among its salts one in particular must be borne in mind, namely,

GLYCOCHOLATE OF SODIUM, $C_{26}H_{42}NaNO_6$.

(Fig. 19) a compound easily soluble in water, which, precipitated from its solution in alcohol by means of ether, crystallizes in large, brilliant white stellate groups of acicular crystals.

This acid forms an essential constituent of human, as well as most mammalian bile. It is combined with sodium, even

Taurocholic Acid, $C_{26}H_{44}NSO_7$.

This second acid is related very nearly, as regards its chemical constitution, with the foregoing. It splits up, however, into cholic acid; and (instead of glycin) taurin, an indifferent substance, containing sulphur, and no longer basic. This is the amide of isethionic acid or sulfethylenic acid = $C_2H_4 \begin{cases} NH_2 \\ SO_3H \end{cases}$.

Taurocholic acid, which is very easily decomposed, is non-crystallizable, but exceeds the last acid in its solubility in water and stronger acid properties. It dissolves fats, fatty acids, and cholesteinin with great readiness. With sugar and sulphuric acid it gives the same reactions as glycolic acid. Its combinations with alkalis are very soluble in alcohol and water, but insoluble in ether. Retained for a long period in contact with ether, they crystallize. They burn with a brilliant flame.

As regards the decomposition products of this acid, they are, as has been already mentioned, analogous to those of the foregoing. On being boiled with alkalis taurocholic acid splits up, on the absorption of water, into cholic acid and taurin; while, with the mineral acids, choloidinic acid besides taurin is produced, analogously to the previous case.

Combined with sodium taurocholic acid forms the second chief constituent of the bile of man and numerous mammals, namely, taurocholate of sodium, $C_{26}H_{43}NaNSO_7$.

H. Amides, Amido-Acids, and Organic Bases.

Under these names we have now to consider a series of further decomposition products.

Urea or Carbamide, CH_4N_2O , or $CO \begin{cases} NH_2 \\ NH_2 \end{cases}$.

Carbamide, which, like all the rest of the substances under consideration here, is absent in the vegetable kingdom, but which forms, on the other hand, the chief constituent of the urine of the human body, is of perfectly neutral reaction—corresponding in this respect with kreatin, glycin, and leucin—to be referred to presently. It crystallises in long four-sided pillars, terminating at either end in two facets (fig. 20). It is quite soluble in water and alcohol, but not so in ether.

Urea combines with oxygen acids, forming salt-like combinations, in which one molecule of water is always present ; thus it is with nitric and oxalic acid.

These two combinations are of particular importance in the recognition of urea, owing to their characteristic crystalline form.

Nitrate of urea, $\text{CO}(\text{NH}_2)_2, \text{HNO}_3$ (fig. 21, *a a*), crystallizes in pearly scales or glittering white leaves, which appear under the microscope in the form of rhombic or hexagonal tables.

Oxalate of urea, $2\text{CO}(\text{NH}_2)_2, \text{H}_2\text{C}_2\text{O}_4 + 2\text{H}_2\text{O}$ (fig. 21, *b b*), appears to the naked eye in the form of long thin leaves or prisms, found under the microscope to be made up of hexagonal tables as a rule, but also




Fig. 20.—Crystals of urea. *a*, four-sided pillars; *b*, indefinite crystals, such as are usually formed in alcoholic solutions.

of four-sided prisms. Both salts belong to the monoclinic system.

Urea combines also with metallic oxides and salts, as, for instance, with chloride of sodium.

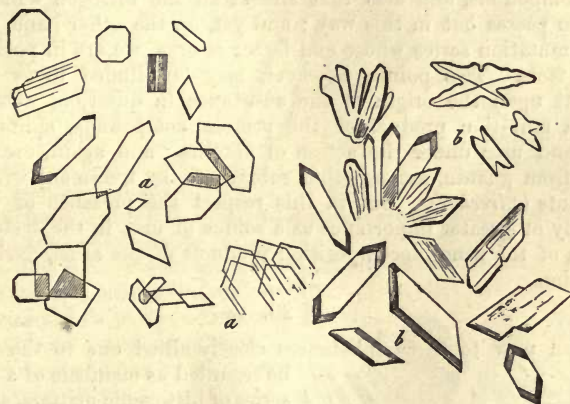


Fig. 21.—Crystals of combinations of urea with nitric and oxalic acid. *a a*, nitrate of urea; *b b*, oxalate of the same.

As regards its decomposition, urea may be artificially split up on absorbing water into carbonic acid and ammonia.

The same change is brought about by contact with animal matters undergoing putrefaction, such as protein compounds, or mucus, &c. It is owing to this fermentation that urine becomes after a time alkaline on being exposed to the air.

Urea may be obtained from other alkaloids, such as kreatin and allantoin, by treatment of the latter with alkalis ; further, by subjecting uric acid to the action of oxidising acids and caustic potash. Urea may be produced artificially in many ways besides.

Carbamide appears in human urine as the most important of all its solid constituents. It amounts to from about two and a half to three per cent.

of the fluid excreted, and is carried out of the body daily in considerable quantity. It is found likewise in the blood in very minute quantity (*Strahl* and *Lieberkuhn*, *Lehmann*, *Verdeil*, and *Dollfuss*), and in the chyle and lymph of mammals (*Wurtz*). It is also stated, but with uncertainty, by *Millon*, to be present in the aqueous humour of the eye. Further, it has been met with in the brain of the dog (*Staedeler*), and in normal sweat, according to *Favre*, *Picard*, and *Funke*. Under certain diseased conditions it may appear very widely distributed throughout the system.

Urea, like all allied substances, a decomposition product, and unfit, owing to its solubility, to take part in the formation of tissues—springs, as we know by experience, from the protein compounds of the system; from those albuminous substances entering into the constitution of tissues, as well as those received into the blood from the food, and superfluous there. Thus the amount of urea in the body is increased by muscular exertion and abundant fleshy diet; the introduction of many alkaloids into the stomach has the same effect, as, for instance, thein, glycin, alloxantin, and guanin. Finally, the injection of uric acid into the circulation causes an augmentation in the amount of urea excreted with the urine (*Wöhler* and *Frerichs*).

In regard to detail, we are still in the dark as to the formation of urea in the body. We do know that it is a decomposition product of the protein compounds, and also that almost all the nitrogen which leaves the system passes out in this way; and yet, on the other hand, as to the chemical mutation series whose end factor is urea, we are in possession of but few facts. Two points, however, may be alluded to as throwing some light upon the origin of the substance in question, namely, that kreatin, a mutation product of the protein compounds, splits up into sarkosin and urea under the action of alkalies; and again, urea may be obtained from guanin, among other substances, by treatment with oxidizing reagents (*Strecker*). But in this respect the presence of uric acid is probably of greater importance as a source of urea in the system—urea being one of the usual decomposition products of the same, derived from its oxidation.

§ 29.

We turn now to three substances closely allied one to the other, to be regarded as members of a mutation series of histogenic matters, and which possibly lead to the formation of uric acid in their further physiological transformation.

They are compounds very insoluble in water, but which dissolve readily in alkalies and acids, forming with the latter crystalline salts which are partly decomposed by water. All three evaporated with nitric acid, form yellow substances which, on the addition of potash without heat, assume a red colour, turning to a lively purple on the temperature being raised.

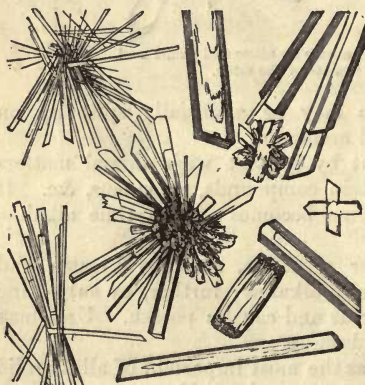

Fig. 22.—Crystals of chlorate of guanin.

Guanin, $C_5H_4N_2O$.

Guanin, discovered by *Unger* in guano, forms with hydrochloric acid a crystalline salt, met with in obliquely pointed needles or parollopipedic tables, belonging in general to the clinorhombic system (fig. 22). Some years ago *Strecker* obtained xanthin from the transformation of guanin. Guanin is not a constituent of urine, but is found in the pancreas.

Hypoxanthin (Sarkin), $C_5H_4N_2O$.

Hypoxanthin of *Scherer*, which is identical with sarkin, investigated subsequently by *Strecker*, is seen, by comparison of their respective formula, to be nearly related to guanin, as well as to the substance we are about to allude to, namely, xanthin. The crystalline forms of their nitric and hydrochloric acid salts (fig. 23) are characteristic, especially the first. Nitrate of sarkin, on rapid separation, forms rhomboidal plates; slowly deposited, it is met with in tufts of obliquely pointed flat prisms or rhomboidal crystals. Evaporated quietly, large darkly striped bodies like rock crystal are formed, besides smaller cucumber-shaped crystals. The chlorate crystallizes partly in bunches of four-sided bent prisms with curved surfaces, and partly in coarser, irregular, and darker prisms, grouped in pairs (*Lehmann*).

It has been found in human blood in the disease known as leucæmia, (*Scherer*); in the blood of the ox and horse; in muscle, in the heart, in the liver, spleen, thymus, and thyroid glands (*Scherer*, *Strecker*, *Gorup-Besanez*), and, finally, in the kidney and urine.

Xanthin, $C_5H_4N_2O_2$.

Xanthin, which differs from hypoxanthin in having one more, and from uric acid one less, atom of oxygen, forms a salt with nitric acid, which crystallizes in bunches of rhombic tables and prisms. Chlorate of xanthin occurs in glittering, six-sided tables (fig. 24).

Xanthin was formerly only known as a constituent of very rare urinary

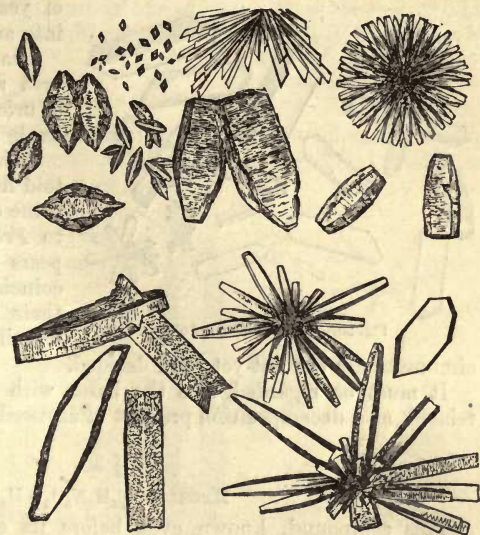


Fig. 23.—Crystals of nitrate of sarkin (upper half), and of chlorate (lower half).

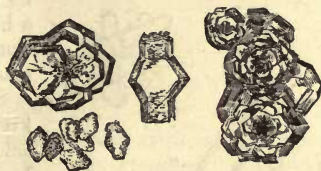

Fig. 24.—Crystals of nitrate of xanthin (above), and chlorate (below).

calculi; it has, however, been since found to occur very extensively, but in small quantities, in many different organs—in the brain, in glands and muscles, and in the urine.

Allantoin, $C_4H_6N_4O_3$.

This compound crystallises in glittering, colourless prisms, of rhombic fundamental form (fig. 25). It is difficult of solution in cold, but more soluble in warm water; not at all so in ether, on the contrary. Allantoin appears neutral, but combines with metallic oxides. Through the agency

of yeast-cells it may be split up into ammoniacal salts and urea.

Allantoin may be obtained with urea artificially on the oxidation of uric acid, by boiling with superoxide of lead.

It is a constituent of the allantoid fluid of the embryo, and the urine of young calves. According to *Frerichs* and *Staedeler*, it appears in the urine of mammals, coincident with disturbance of their respiratory functions, but whether in man under similar

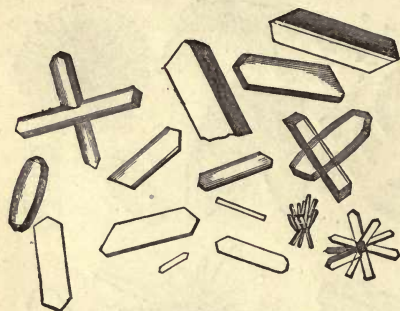

Fig. 25.—Crystals of allantoin.

circumstances has not yet been decided.

It must be regarded, like the bases with which it is physiologically related, as a decomposition product of azotised substances in the body.

§ 30.

Kreatin, $C_4H_9N_3O_2 + H_2O$.

This compound, known even before its constitution was accurately ascertained by *Liebig*, is of neutral reaction. It is soluble, in a minor degree, in cold, more so in hot water, and quite insoluble in pure alcohol and ether. It crystallizes in transparent rhombic prisms (fig. 26), loses its water of crystallization at $100^\circ C.$, and at a higher temperature melts with decomposition. With acids kreatin forms salts of acid reaction.

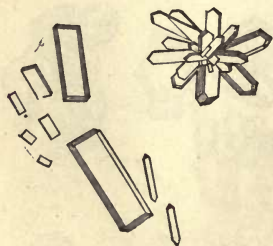
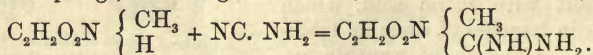


Fig. 26.—Crystals of kreatin.

Some of the decomposition products of kreatin are also of importance. Dissolved in acid and heated, it is transformed, with the loss of one molecule of water, into a closely-related substance, which also occurs naturally in the body; this is known as kreatinin, $C_4H_7N_3O$. Boiled with baryta water, kreatin passes into *urea*, CH_4N_2O (taking up a molecule of water), and another base, not yet met with naturally, known as sarkosin (methylglycocol), $C_2H_4(CH_3)NO_2$.

Kreatin springs, according to *Volkard*, from sarkosin and cyanamid =



This is looked upon as methyluramido-acetic acid (methylguanidin-acetic acid).

Kreatin is found (but only in small amount) in the juices of the muscles of man, and the vertebrates generally; also in the fluid saturating the brain (in the dog, according to *Staedeler*, together with urea), in the testes (!), and in the blood (*Verdeil* and *Marcet Voigt*). In the urine it is said by *Heinz* not to exist primarily, but to be formed secondarily from kreatinin.

Kreatin may be looked upon as a decomposition product of muscle and the substance of the brain, leaving the body through the kidneys. Perhaps the greater part of the kreatin which is formed in the body undergoes immediate decomposition, and is one of the sources of urea. This seems probable when we remember the mode in which it is split up by boiling with baryta water.

Kreatinin, $C_4H_7N_3O$.

This substance, nearly allied to kreatin, crystallizes in colourless oblique rhombic pillars belonging to the monoklinic system (fig. 27). In contradistinction to the compound last mentioned, kreatinin possesses strongly basic properties, and is readily soluble in water. With acids it combines to form crystalline and usually soluble salts.

Kreatinin may be obtained by treating kreatin with acids. A watery solution of kreatinin, on the contrary, becomes again transformed into kreatin.

Boiled with baryta water, it splits up into ammonia and methylhydantoin, $C_4H_6N_2O_2$. It is now looked upon as glykolylmethylguanidin.

Kreatinin is a constituent of the juices of muscle, and appears in the urine; here it is present in large quantities, and becomes transformed, as already remarked, into kreatin. *Verdeil* and *Marcet* state that they have found it, like the latter, in the blood:

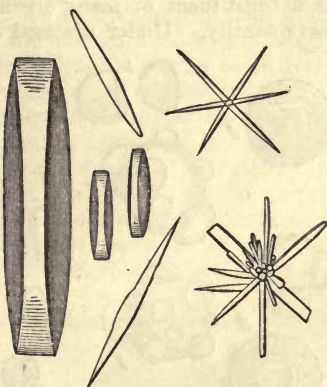


Fig. 27.—Crystals of kreatinin.

§ 31.

Leucin, $C_6H_{11}(NH_2)O_2$.

Leucin, or amidocaproic acid, is produced by the artificial decomposition of the protein compounds, gluten-yielding matters and elastin, by means of acids or alkalis. It is, likewise, met with as a product of the putrefaction of albuminous substances, like tyrosin, to be alluded to presently, and as such it was discovered many years ago by *Proust*.

Through the investigations of *Frerichs* and *Staedeler*, who showed it to be a physiological decomposition product widely distributed throughout the body, it has become of much interest. Contributions on the same point have also been made by *Cloëtta* and *Virchow*. Many of these statements, moreover, are confirmed by *Gorup-Besanez* and *Rudziejewsky*.

Leucin is met with as a crystalline substance, partly (but only rarely and when very pure) in delicate klinorhombic plates, partly in spheroidal lumps possessing a very characteristic appearance. They are either small globules (*a*), or hemispheres (*b b*), or aggregations of rounded masses (*c c d*),

and not rarely a number of segments of small spheres rest with their flat side upon a larger globe (*d e f*).

Leucin globules may be either unmarked (in which case they slightly resemble fat-globules), or they may present a concentrically laminated appearance (*g g g g*). They are frequently met with also with rough surfaces, as though eroded.

Leucin has no action upon vegetable colours, is *quite* soluble in water, hydrochloric acid, and alkalis, and slightly so in cold alcohol, while in ether it is insoluble. It may be volatilised by a cautious elevation of temperature. Rapidly heated, it fuses with decomposition. From its solutions it is not precipitated by most of the usual reagents.

In regard to the occurrence and significance of this substance in the human system, we must distinguish between leucin produced by the putrefaction of histogenic substances, and that formed physiologically in the living body.

The latter appears often, but not invariably, accompanied by tyrosin as a constituent of many organic fluids and gland juices, in greater or less quantity. Under diseased conditions it is often unusually abundant

in organs in which traces alone are to be found during health, as for instance in the liver.

It is present in the spleen, the pancreas, and its secretions, the salivary glands and saliva; in the lymphatic glands, the thymus and thyroid glands, and in the fluid saturating pulmonary tissue. In the healthy liver it is not to be found, or only so in traces, as is also the case with the brain. Muscle appears likewise to be destitute of leucin, though in the heart it may not unfrequently be found as a pathological product. It is at times present in large amount in the kidneys, and may pass into the urine (*Staedeler*).

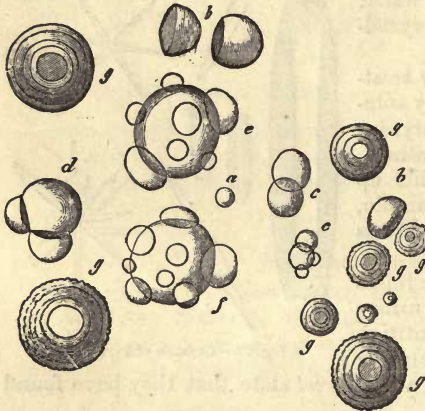


Fig. 28.—Spheroidal crystalline masses of leucin. *a*, a very minute simple spherule; *b*, hemispheroidal masses; *c*, aggregates of small globules; *d*, a large globule supporting two halves; *e f*, a large spheroid of leucin richly studded with minute segments; *g g g g*, laminated globules of leucin, some with smooth, some with rough surface, and of very various sizes.

These facts are of some physiological worth, in that they prove the existence in different organs of distinct series of mutations among their histogenic substances. Thus, leucin is no mutation product of muscle, but of many glandular structures. There can be no doubt, further, that as artificially, so also in the system naturally, does leucin spring from protein compounds, gelatin-yielding substances and elastin; its physiological origin from albuminates by the action of one of the ferments existing in the pancreatic juice has also been proved (*Kühne*).

Leucin is partially excreted with the glandular secretions, and appears in the intestinal canal, and probably undergoes further decomposition also in the body. It is a fact worthy of notice, that in the lymphatic and blood-vascular glands, there occurs besides leucin ammonia also, allowing of the hypothesis that leucin may be resolved there into ammonia and

volatile fatty acids (*Frerichs* and *Staedeler*)—a change which certainly takes place in the lower part of the intestinal canal.

§ 32.

Tyrosin, $C_9H_{11}NO_3$.

This substance is also an amido-acid, whose constitution, however, has not yet been fully ascertained. It possesses weak basic properties, and may be obtained like the foregoing, but in much smaller amount, from the artificial decomposition of protein matters. Not, however, like leucin, from that of elastin and gelatin-yielding substances. It is also produced by the putrefaction of protein compounds, and in especially large quantity from the decomposition of silk-fibrin and glue. Keratin and animal mucus also yield more tyrosin by far in their decomposition than the original protein matters. Thus we see it to be associated chemically with leucin, and it has been recently proved to be a physiological companion of the same as a constituent both of the normal and diseased body (*Frerichs* and *Staedeler*). Tyrosin, nevertheless, is not so extensively met with as leucin. It crystallizes in white silky needles (fig. 29, *a*) which are frequently arranged in very delicate, small, or large groups (*b b*). While leucin is *very* soluble in water, tyrosin is but little so, besides which it is insoluble in the pure state in alcohol and ether. It fuses with decomposition when heated, and combines in regular proportions with acids and bases. Warmed with concentrated sulphuric acid, there is found in it, beside other acids, a compound named *tyrosin-sulphuric acid*, which, like its salts, when mixed with chloride of iron assumes a beautiful violet colour (*Piria's* test).

This reaction with chloride of iron just mentioned resembles that of the salicyl compounds, although its nature has not yet been ascertained.

Without taking into account the tyrosin developed in the processes of putrefaction in the body, we find that it has similar physiological sources to the foregoing base. It is missed in the healthy liver like leucin, probably because it undergoes there rapid transformation into other compounds. In disease, however, it appears in this organ. Tyrosin which, as has been already mentioned, springs in smaller quantities from albuminous substances than leucin, and lacks besides the physiological sources of the latter from gelatin and elastin, as well as its solubility, is frequently missed where leucin occurs.

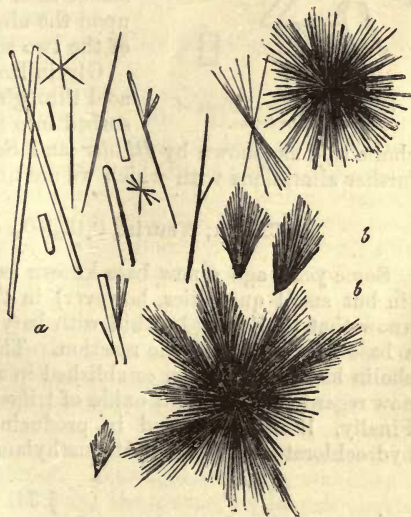


Fig. 29.—Acicular crystals of tyrosin. *a*, single crystals
b b, smaller and larger groups of the same.

Thus it has been found alone in no inconsiderable amount in the

spleen and tissue of the pancreas, as also in the digest of albumen in pancreatic juice.

The physiological significance of tyrosin is probably in general allied to that of leucin.

§ 33.

Glycin, $C_2H_3(NH_2)O_2$.

Glycin or *glycocoll*, or also *glutin sugar*, which is in reality amido-acetic acid, has not as yet been met with free in the system. It appears, however, on the splitting up of several animal acids, as *hippuric* and *uric*, and one of the biliary acids, namely *glycocholic*. It is also of interest as an artificial decomposition product of glutin and chondrin. It is obtained in greatest abundance by the decomposition of silk-fibrin (fibroin), in which it is present together with leucin and tyrosin. It may be artificially produced from chloracetic acid by the action of ammonia.

Glycin crystallizes in colourless rhombic pillars belonging to the monoklinometric system (fig. 30). These crystals bear a heat of $100^\circ C$. without losing any water, but at $178^\circ C$. they fuse, and are decomposed. Glycin is sweet to the taste, without alkaline reaction, soluble in water,

but almost insoluble in alcohol and ether. It forms acid salts with acids, and can combine with bases or even salts themselves. There must be some substance nearly related to glycin formed in the body, in all probability from glutinous matters (although at present we are unacquainted with it), which in combination with cholic acid constitutes glycocholic acid, and with benzoic, hippuric acid. This substance then becomes free in the form of glycin upon the absorption of water, and splitting up of the two acids.

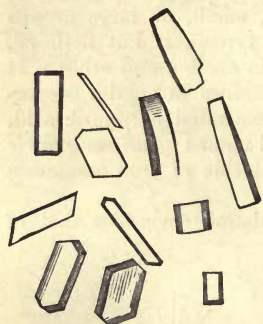


Fig. 30.—Crystals of glycin of different forms.

Glycin leaves the body partly with hippuric acid through the kidneys, and is partly reabsorbed into the blood as a component of glycocholic acid as (shown by *Bidder* and *Schmidt*) in order to undergo there further alterations with which we are unacquainted.

Cholin, **Neurin**, $C_5H_{15}NO_2$, or $C_2H_4 \left\{ \begin{array}{l} OH \\ N(CH_3)_3 OH \end{array} \right.$.

Some years ago a new base known as cholin was met with by *Strecker* (in but small quantities, however) in the bile of oxen and swine. We know that by boiling lecithin with baryta water *neurin* is obtained (§ 20), a base of strong alkaline reaction. The identity of this substance with cholin has recently been established in a very interesting way. *Neurin* is now regarded as hydrated oxide of trimethyl-oxethyl-ammonium (*Baeyer*). Finally, *Wurtz* succeeded in producing hydrochlorate of neurin from hydrochlorate of glycol and trimethylamin.

§ 34.

Taurin, $C_2H_7NSO_3$, or $C_2H_4 \left\{ \begin{array}{l} NH_2 \\ SO_3H \end{array} \right.$.

This substance, containing as much as 25.7 per cent. of sulphur, was

discovered long ago as a constituent of the bile. It crystallizes with the fundamental form of a right rhombic prism (whose lateral angles are respectively 111° and $68^\circ 16'$), in colourless six-sided prisms, with four and six facets on their extremities (fig. 31, *a*). From impure solutions it separates in irregular sheaf-like masses (*b*).

Taurin has no effect upon vegetable colours; it is tolerably soluble in water, but insoluble in alcohol and ether. The great stability of the substance is remarkable: even boiling in mineral acids in which it dissolves does not decompose it. Taurin is not precipitated from its solutions by tannic acid and the metallic salts. The sulphur it contains was for a long time overlooked; it is contained in it in a different combination to that which exists in cystin.

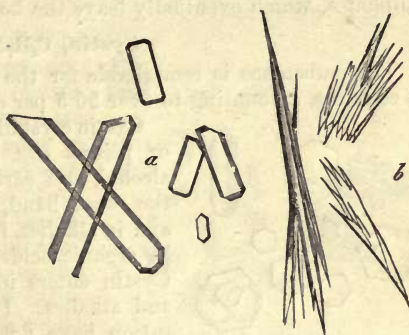
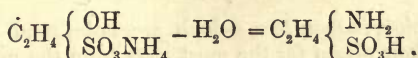


Fig. 31.—Crystals of taurin. *a*, well-formed six-sided prisms; *b*, irregular sheaf-like masses from an impure solution.

Taurin has recently been produced artificially. It is related to isethionic or sulfethylenic acid, $C_2H_4 \left\{ \begin{array}{l} OH \\ SO_3H \end{array} \right.$.

Isethionate of ammonium, when heated up to $200^\circ C.$, according to *Strecker*, yields taurin, with the loss of one molecule of water.



Thus taurin is an amido-sulfethylenic acid.

Kolbe obtained it also by the action of ammonia upon chlorethyl-sulphuric acid.

Taurin may be obtained by the splitting up of one of the two biliary acids, and contains all the sulphur of the bile. It also becomes free on the decomposition (commencing in the body) of this acid known as *taurocholic*, and appears thus in abnormal as well as putrid bile, and in the lower portion of the intestinal canal (*Frerichs*). It has been also met with by *Cloëtta* in the juices of renal and pulmonary tissue. As obtained from the latter source, it was formerly described by *Verdeil* as pulmonic acid. The suprarenal capsule contains it also (*Holm*), though the blood does not.

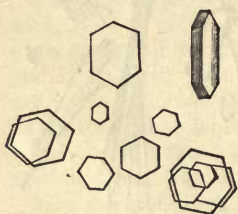
At present we are uncertain as to the origin of taurin; but it has all the nature of a decomposition product, and there can be hardly any doubt (from the fact of its containing sulphur) that it is derived from albuminous matters, a considerable quantity of the sulphur of the latter being present in it.

In regard to its farther changes, an observation has been made by *Buchner* of great physiological interest. Taurin, otherwise so stable, splits up by the action of a ferment (namely, the mucus of the gall-bladder) in the presence of alkalis, into carbonate of ammonium, sulphurous, and acetic acids. The latter acid, combined with an alkali, is changed into a carbonate, and the sulphurous acid in combination with sodium becomes later converted by oxidation into sulphuric acid, so that in

putrefying bile we meet with Na_2SO_4 . The circumstance that most of the bile poured out into the intestine is reabsorbed, as observed by *Bidder* and *Schmidt*, thus explains, at least partially, the origin of the sulphates, which eventually leave the body with the urine.

Cystin, $\text{C}_3\text{H}_7\text{NSO}_2$.

This substance is remarkable for the large quantity of sulphur which it contains, amounting to over 26.5 per cent.



32.—Crystals of cystin.

Cystin crystallizes in colourless hexagonal tables or prisms (fig. 32), and is insoluble in water, alcohol, and carbonate of ammonium. It is, on the other hand, readily soluble in mineral acids and in alkalis, from which it may be precipitated by organic acids, as, for instance, by acetic acid. Cystin enters into combination with both acids and alkalis. Its mutation products and constitution have not as yet been ascertained, nor do we know in what form sulphur is contained in it.

Cystin is of rare occurrence; it forms certain kinds of urinary calculi, and may also appear as an abnormal constituent of urine.

It was once met with in the liver (*Scherer*); likewise in the tissue of the kidneys of oxen by *Cloëtta*, but not invariably. The physiological relations of the substance are still quite obscure.

I. Animal Colouring-Matters.

§ 35.

The animal *colouring-matters*, which are not found in the vegetable kingdom, have their origin for the most part from the natural pigment of the blood, hæmoglobin (§ 13). They are met with either as artificial decomposition products, or occur in the living body.

Hæmatin, $\text{C}_{34}\text{H}_{34}\text{N}_4\text{FeO}_5$ (*Hoppe*).

This substance, as already mentioned, may be obtained from the red blood-corpuscles or hæmoglobulin, but only in a coagulated form.

According to *Hoppe*, hæmatin usually presents itself as an amorphous blue-black substance, which becomes of a reddish-brown on being triturated. It is insoluble in water and alcohol, but soluble in the latter if there be added to it a certain small amount of sulphuric or nitric acid. It may likewise be dissolved in a watery or spirituous solution of ammonia; and also in caustic alkalis in dilute watery or alcoholic solution. Such a fluid containing hæmatin is frequently changed to a greenish colour by the action of a large amount of potash—especially if it be boiled. Hæmatin, suspended in water, is decolorised by the action of chlorine with the formation of chloride of iron; the dried powder also becomes green by contact with chlorine gas. Dichroism is seen in alkaline, but not acid solutions of hæmatin; in a thin layer they appear olive-green, in a thick stratum red (*Brücke*).

With the aid of concentrated sulphuric acid, the iron it contains may be extracted from hæmatin, water taking its place in the combination (*Hoppe*).

Hydrochlorate of Hæmatin, Hæmin, $\text{C}_{34}\text{H}_{34}\text{N}_4\text{FeO}_5 \cdot \text{HCl}$ (*Hoppe*).

We are indebted to *Teichmann* for our acquaintance with this peculiar

crystalline element of the blood. Dried blood, treated with warm acetic acid, even when putrefaction has already set in, deposits regularly innumerable crystals of brown, dark-brown, or almost black colour, which appear either in the form of rhombic pillars (when they resemble hæmatoidin), or in needles, single or arranged in stellate groups (fig. 33.) The presence of chlorides of the alkalies is, as *Teichmann* very properly remarks, indispensable for the occurrence of this crystallization. Hæmin crystals are tolerably stable, do not decompose in the air, and are neither soluble in water, alcohol, ether, nor in acetic acid. They may be dissolved, however, in boiling nitric acid. Sulphuric acid likewise reduces them readily to solution, as also ammonia and weak potash. The latter, when concentrated, changes the colour of hæmin crystals to black, causing them at the same time to swell up. These crystals are of the greatest importance in a forensic point of view, as a means of proving the presence of small quantities of blood. *Kühne* obtained them from the colouring matter of muscle.



Fig. 33.—Crystals of hæmin.

Until a few years ago, the chemical constitution of hæmin was but very imperfectly known. We are indebted to *Hoppe* for the first accurate investigations of the subject. By him it was produced from pure hæmoglobin (see above), besides which he demonstrated that it might be again reconverted into ordinary hæmatin.

Hæmatoidin, $C_{17}H_{18}N_2O_3$, or $C_{34}H_{36}N_4O_6$ (?)

Blood which has left the vessels, and is stagnating in the tissues, undergoes gradually farther changes, by which a crystalline colouring-matter is formed, nearly allied to hæmatin, but destitute of iron. This, which is known as *hæmatoidin*, crystallizes in rhombic prisms (fig. 34), but also in acicular crystals (*Robin*). Under the microscope these appear red with transmitted light; with reflected, of a cantharidine green colour. Hæmatoidin is very soluble in chloroform, to which it communicates a golden yellow tint, and also in sulphide of carbon, which acquires from its presence a flame colour. Its crystals are likewise dissolved by absolute ether, but not by either absolute alcohol, water, ammonia, solution of soda, or dilute acetic acid: in concentrated acetic acid, however, they dissolve when warmed, communicating to the fluid a golden-yellow colour (*Holm*).



Fig. 34.—Hæmatoidin crystals.

Staedeler obtained unusually large crystals of this pigment, measuring as much as 0.45mm. from the ovary of the cow, by treatment with chloroform or sulphide of carbon (fig. 35). They appear under the microscope, in the first place, in the form of acute-angled triangular tables with one convex side, *a*. This curved border, however, may be replaced by

two right lines, giving rise to deltoïd tables (*b*). Again, two such

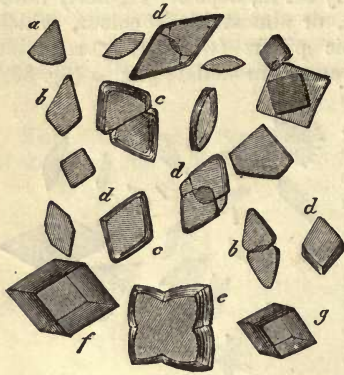


Fig. 35.—Very large crystals of hæmatoidin from the ovary of a cow, obtained by treatment with chloroform.

tables very frequently become fused together by their convex sides, or overlap each other (*bc*). We then have the rhombic tables usually ascribed to hæmatoidin (fig. 34); still showing indentations in most cases at the blunt angle of the rhombs, which gradually become obliterated (*dd*). It not unfrequently happens that two other crystals become associated with the two first, so that a four-rayed star is produced (*e*). These then give origin to four-sided tables on the filling up of the indentations at their corners, and each sometimes assumes eventually the appearance of an oblique dice, from its having gradually become thickened (*fg*).

§ 36.

Uroërythrin, or Urohæmatin.

In the urine a very small quantity of a red colouring matter is to be found, which gives to the fluid its yellow tint, and may colour the sediment of the same of a lively red. This substance is very unstable, and only obtainable with great difficulty, whence our imperfect acquaintance with its nature. The colouring matters of urine were first investigated by *Scherer*, and more recently by *Harley*. The latter obtained a red pigment almost insoluble in water, but freely so in warm fresh urine, giving to the latter a yellow tint, and to ether and alcohol, in which it is also dissolved, a beautiful red colour. *Harley* found this pigment to be ferruginous, and regards it as a species of modified hæmatin. Besides this, some other pigmentary matters were also met with by him.

A red pigment has been recently discovered by *Jaffe* in the urine, possessed of some spectroscopic peculiarities: it has been named by him *urobilin*, from the fact of its also occurring in bile and the excrements.

Blue and *violet* colouring matters, which may occasionally be met with in human urine, appear in but very small quantity. Under certain circumstances *indigo* has been observed here without having been taken up from without (*Sicherer*), while *indikan*, $C_{26}H_{31}NO_{17}$, or chromogen of indigo is, according to *Hoppe*, constantly present.

Black Pigment, or Melanin.

Black pigment is found in normal tissues in the form of very minute granules or molecules. It is a substance remarkable for its insolubility and unchangeableness. Melanin is not soluble either in water, alcohol, ether, dilute mineral acids, or concentrated acetic acid. It is dissolved in warm potash solutions, but only after some considerable time. The same takes place in concentrated nitric acid, by which the melanin is decomposed, however. Its ash contains iron.

The investigations in regard to the constitution of melanin which have

hitherto been made, must be received with reserve, for the substance is only to be obtained pure with the greatest difficulty.

Melanin, which with hæmatin is the only pigment in the body to which a certain amount of histogenic significance cannot be denied, appears, as a rule, forming the contents of polygonal or stellate cells. It is met with in greatest abundance in the interior of the eye. The large amount also in which it is met with in some of the lower vertebrate animals, as for instance in the frog, is remarkable.

As a pathological product, it (or something nearly allied to it) is frequently met with in great abundance in different organs, tumours, &c.

The source of melanin is usually, and probably correctly, supposed to be the colouring matter of the blood. This view is borne out by the nature of pathological black pigments, whose origin from hæmatin may in many cases be accurately traced.

We must be on our guard, however, not to confound the ordinary black pigment found in the human lungs with melanin. This consists of particles of carbon, charcoal, dust, or lamp-black, suspended in the air which is inspired. It is not met with in the lungs of infants or of wild mammalian animals.

§ 37.

Biliary Pigments.

Until very recently but little has been known of the colouring matter of the bile. It is characterised by its reactions with nitric acid. The latter, if it contain nitrous acid, or if concentrated sulphuric acid be added to it, produces in bile a peculiar play of colours,—green, blue, violet, red, yellow, following rapidly one upon the other.

Two kinds of pigment may be usually distinguished in bile: a brown, known as *cholepyrrhin* or *biliphæin*, and a green or *biliverdin*.

According to *Staedeler's* recent investigations, a whole series of probably characteristic pigments may be obtained from bile, although it is still a question whether they all exist in the latter when perfectly fresh.

BILIRUBIN, $C_{15}H_{18}N_2O_3$ (or $C_9H_9NO_2$?)

A red substance allied to hæmatin and hæmatoidin (but not identical with the latter), which may be obtained from its solutions in chloroform, sulphide of carbon, and benzol, in beautiful ruby-red crystals. These (fig. 36), when crystallized from sulphide of carbon, appear in clinorhombic prisms, with a basal surface, whose foremost angle is very sharply curved, and prism surface convex, so that a view of the basal surface presents an elliptical figure. Lying upon their convex surface these crystals have a rhombic form.

Bilirubin is insoluble in water, and nearly so in ether. It is soluble, on the other hand, in alkalis and in chloroform, communicating to the latter a pure yellow or orange-red colour; also in sulphide of carbon, which is tinged golden yellow by it. It possesses, further, the properties of a weak acid, and shows the play of colours just mentioned with nitric acid containing nitrous acid in the most

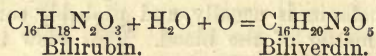


Fig. 36.—Crystals of bilirubin separated from sulphide of carbon.

marked degree. It is the most essential colouring matter of human bile and biliary calculi, and is probably derived from hæmatin; it is also found in the urine of persons suffering from jaundice (*Schwanda*).

BILIVERDIN, $C_{16}H_{20}N_2O_5$, or $(C_5H_9NO_2)_4$

This is a green colouring matter, which may, under certain circumstances, be obtained in a crystalline form. Its presence in fresh bile is still questionable, for it is probable that it absorbs water and passes into biliprasin, a coloring matter, to be presently alluded to. The relationship to bilirubin will be easily understood from the following formula:—



BILIFUSCIN, $C_{16}H_{20}N_2O_4$.

A non-crystallizable compound, soluble in water, containing soda or ammonia, communicating to it a brown colour. It is, to all appearances, of subordinate importance, and differs from bilirubin only in having one more molecule of H_2O .

BILIPRASIN, $C_{16}H_{22}N_2O_6$.

A green amorphous pigment, soluble in alkalis with a brown colour, in contradistinction to biliverdin, which, with the former, produces a green solution. The formula of this pigment corresponds to that of biliverdin + one molecule of H_2O . It occurs in biliary calculi and jaundiced urine.

BILIHUMIN, finally, is a name given by *Staedeler* to a dark earthy-looking substance, which, however, has not yet been obtained perfectly pure, so that its formula is not known. It may be obtained as the ultimate decomposition product of all the four biliary pigments like melanin.

REMARKS.—It may be well at this juncture to bestow a few words upon the extractive matters. Under this name we understand in zoochemistry, a set of substances which are partly present in the body naturally, and are partly the results of chemical manipulation. They manifest no characteristic peculiarities by which they may be recognised; they do not crystallize, nor combine in regular proportions with other matters, nor do they volatilise at definite temperatures. From this may be perceived the difficulty of dealing with these substances, either chemically or physiologically. Our chemical acquaintance with them is therefore very incomplete. Physiologically they are held to be decomposed materials, intermediate products in mutative processes, although in reality there is but little proof that this is the case. Several bases, acids, &c., already alluded to, have recently been separated from these compounds.

K. Cyanogen Compounds.

§ 38.

As a supplement to the consideration of the azotised decomposition products of the system, *cyanogen*, CN, and its combinations may be appended here.

Sulphocyanogen (rhodan), CNS. This ternary radical, whose compounds are remarkable for the beautiful red colour which they produce with salts of iron, forms with H what is known as hydrosulphocyanic acid $\left. \begin{array}{l} \text{CN} \\ \text{H} \end{array} \right\}$ S. Unlike other compounds of cyanogen, this is generated in the human body, and possesses but slight poisonous properties. It occurs in combination with potassium.

Sulphocyanide of potassium (rhodanide of potassium), $\left. \begin{matrix} \text{CN} \\ \text{Ka} \end{matrix} \right\} \text{S}$, is the only cyanogen compound met with in the human economy, and that in extremely small quantity. It is a constituent of saliva, in which it was discovered by *Treviranus*; its occurrence here, however, is not without exception.

The origin and relations of this compound are still entirely unknown.

Sulphocyanide of potassium gains in interest, moreover, when we remember that in the physiological mutation series no other cyanogen combinations make their appearance.

L. Mineral Constituents.

§ 39.

The number of mineral substances and inorganic compounds occurring in the human body is not inconsiderable. Our knowledge of these, however, is unfortunately far less perfect at present than the nature of the substances in question might lead us to expect. In respect to the combination of inorganic matters, we are—so far as the question turns upon their pre-existence in the various parts of the body, or to what extent they must be regarded as only produced by chemical manipulation itself—by no means as clear as might be desired. But greater obscurity still prevails in regard to the physiological relations of some of these substances. Granting, for instance, that no doubt can exist that in water we have before us the chief solvent and agent in saturation and gelatinization of the system, and that phosphate of calcium constitutes the most important hardening medium of the same, and so on, there remains still a considerable number of substances whose purposes in the body we are unable to ascertain with anything like certainty. It is likewise beyond our power at present to distinguish with precision between those inorganic compounds which occur as decomposition products in the economy, and those which possess histogenic properties. Finally, there are in all probability many mineral matters in the system which are only casual constituents of the same, introduced with the food.

It would lead us too far to detail here all the differences in amount between the ash constituents of the several tissues and organs of the body. The variation in this respect, according to age, is of such great interest, however, that a few points may be noticed in regard to it.

While, in the earlier periods of foetal life, the ash only amounts to 1 per cent. of the whole weight of the body, it rises later on to 2, and reaches in mature mammals so high as 3.5, 4, or even 7 per cent. In advanced age it is probable that this is still further increased (*Bezold* and *Schlossberger*).

Among the inorganic matters and compounds found in the body, the following must be specially borne in mind:—

(a.) *Gases*—oxygen, nitrogen, and carbonic acid.

(b.) *Acids*—carbonic, phosphoric, sulphuric, hydrochloric, hydrofluoric, and silicic. These, with the exception of the carbonic acid, diffused through fluids, and hydrochloric acid, found free as a constituent of the gastric juice, hardly ever occur in a free state in the body, but almost invariably combined with bases.

(c.) *Bases*—potash, soda ammonia, lime, magnesia, oxides of iron, manganese (and copper). These usually appear as salts, and yet we have free

alkalies, especially soda, combined with protein compounds, and also iron, in many animal substances, as, for instance, in hæmoglobin and melanin.

In regard to the gases just mentioned, they are found either in the cavities of the body, or diffused, or chemically combined in its various fluids.

Oxygen, O.

Oxygen occurs in the organic matters of the animal body in combination. It appears, however, also as an element in all the air cavities of the system. Finally, it is met with in all the fluids of the economy. In the blood oxygen is dissolved in very minute quantity, while the greater portion appears combined (though loosely) with the other constituents of the fluid. We need hardly remark that this element, from its strong tendency to combine with other substances, plays a most important part in the chemical and physiological life of the organism.

Nitrogen Gas, N₂.

Nitrogen, as is well known, occurs in combination in many organic matters in the body: it is also met with, however, in the air cavities of the latter, and in very small quantities dissolved in its various fluids.

Carbonic Acid, or Carbonic Dioxide, CO₂.

Carbonic acid appears partly in combination (especially with inorganic bases), partly free, either as a gas, or dissolved in the fluids of the body. As a gas, carbonic acid is present in considerable quantity in the gases expired from the lungs, and in various cavities containing air. Dissolved, it is a constituent (though in variable amount) of all animal fluids. It appears in abundance in the blood, moreover, partly free and partly combined. Carbonic acid, which is introduced into the economy in but small amount from without, is the most important end-product of many chemical mutation series in the body. It leaves the latter in large quantities through the lungs, and to a small extent with the exhalations of the skin.

§ 40.

Water, H₂O.

No inorganic compound is of such great importance for the existence of the organism, or occurs throughout all its parts in such abundance, as water: without it life is impossible. Setting aside that which occurs in hydrates and in crystals, water is necessary to the organism, in the first place, as a solvent for many of its constituents. By virtue of this property it renders an interchange of material possible. Dissolved in water, the alimentary matters are absorbed into blood and tissues, and by it effete substances are carried out of the body. In the preceding section we have already alluded to its power of absorbing gases.

The proportion of water to the whole weight of the body is in general very considerable; in the higher animals at a period of maturity it is, on an average, about 70 per cent., while in embryos it is still larger, ranging from 87 to 90 per cent. In the infant and in younger animals its amount gradually sinks, while that of solid organic and mineral matters undergoes constant increase (*Schlossberger, Bezold*). That the proportion of water in different parts of the body varies to an enormous extent is quite evident,

and will be alluded to later on more in detail. For the present it need only be remarked that, as water, on the one hand, renders possible all the chemical occurrences of the body by virtue of its solvent power, so, on the other hand, does it communicate to each tissue its individual stamp, from a physical or physiological point of view, as an imbibed matter. Its amount in the soft, semi-solid portions of our body appears disproportionately large, but even in the harder structures, such as bone, it is not inconsiderable.

Besides that which is generated within the body by oxydation from the H of organic substances, water is introduced into the body with food, both solid and liquid.

Hydrochloric Acid, ClH .

This acid is only found free in the gastric juice.

Silicic Acid or Silicon Dioxide, SiO_2 .

Very small quantities of silicic acid, either free or combined in salts, have been met with in human blood (*Millon*), saliva, urine, bile, and excrement, as well as in biliary and urinary calculi, bones, and teeth. But of all the tissues of the human body, the hairs, according to *Gorup-Besanez*, contain most of it.

Silicic acid is taken into the body with the food and drinking water, and passes out of the same, for the most part, immediately through the intestinal canal, while a portion of it is absorbed into the blood, and appears later in the secretions of the various glands.

The physiological or anatomical significance of silica in the human system is not known.

§ 41.

Calcium Compounds.

Lime, CaO , which next to soda is the most important inorganic base of the body, presents itself in many different combinations.

PHOSPHATE OF CALCIUM.

Phosphoric acid occurs, as is well known, under various modifications, of which, however, only the ordinary or tribasic acid appears in the system. The following are its calcium salts: (*a*), Acid phosphate of calcium, as it is called, $\text{CaH}_4\text{P}_2\text{O}_8$; (*b*), Neutral phosphate, CaHPO_4 ; and (*c*), Basic phosphate, $\text{Ca}_3\text{P}_2\text{O}_8$.

Basic, $\text{Ca}_3\text{P}_2\text{O}_8$, and *neutral* CaHPO_4 , phosphates of calcium.

The first of these is almost insoluble in water, but to a certain extent soluble in that containing carbonic or organic acids, as also in solutions of ammonium salts, chloride of sodium, and of animal gelatin. It is, as we have seen, the particular salt of calcium which occurs in the bones and teeth, and probably exists besides widely distributed throughout the animal body, while the acid salt is present in human urine.

Phosphate of calcium, which has its origin in general from the alimentary matters, appears in very variable amount in all the solid and fluid portions of the system. Wherever it is present in large quantities it is the most important hardening agent of the latter. Its deposits are almost always amorphous.

Phosphate of calcium has been shown to exist in the blood, urine, gastric

juice, saliva, semen, and milk, as well as in the juices of organs. Again, it invariably accompanies histogenic substances, as has been already mentioned, and appears with the same in the tissues and fluids of our body. It is present in bone in large quantities as the chief constituent of the hard material of this tissue known as bone earth. But in the enamel of the teeth, the hardest substance in the whole body, it exists in still greater quantity.

Phosphate of calcium must be regarded as an indispensable element of the tissues of the body; we must, therefore, ascribe to it histogenic properties.

CARBONATE OF CALCIUM, CaCO_3 .

This, like the preceding salt, occurs in the amorphous condition as hardening material in bones and teeth, but only in small amount. Besides this, it is met with in some of the animal fluids, as, for instance, the saliva, and in alkaline urine. It is also found in a crystalline form in the internal ear of man, constituting what are known as *otoliths*. It is met with more frequently still, however, in this state, in the bodies of the lower vertebrates, as, for instance, in frogs, deposited upon the membranes of the brain and spinal cord, and also on the anterior aspect of the spinal column, about the place of exit of the spinal nerves.

Otoliths (fig. 37) are small crystals of short, thick, columnar form, combinations of rhombohedrons and hexagonal prisms in their fundamental figure; among them may also be found pure rhombohedrons, or scalenohedrons.

The question as to what it is that retains carbonate of calcium in solution in the fluids of the body, has not yet been answered satisfactorily. It seems probable, however, that the carbonic acid diffused through the latter is the real solvent for the salt. Any other physiological purpose besides

that of a hardening medium of the second class, has not as yet been recognised for carbonate of calcium as it appears in the bodies of the higher animals.

Carbonate of calcium is partly taken up as such from without, and is partly formed in the body by the development of carbonic acid as a decomposition product (see above).

CHLORIDE OF CALCIUM, CaCl_2 .

Is of but subordinate significance, and has as yet been met with in the gastric juice only (*Braconnot*).

FLUORIDE OF CALCIUM, CaF_2 .

This salt is found in the enamel of the teeth and in small quantities in bone also; traces of it are also met with in the blood, milk, and urine, saliva, and bile, and in the hairs (*Nickles*). Fluoride of calcium is taken up from without as such.

§ 42.

Magnesium Compounds.

Magnesium appears under similar circumstances, combined with phos-

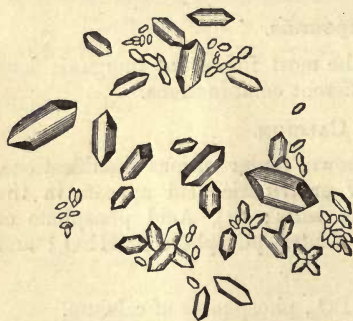

Fig. 37.—Otoliths consisting of carbonate of calcium.

phoric acid, like calcium, mentioned in the preceding section. Its amount, however, is everywhere smaller than that of calcium.

PHOSPHATE OF MAGNESIUM, $Mg_2P_2O_8 + 5H_2O$, or $MgHPO_4 + 7H_2O$.

We are not yet able to state which of these two salts it is which occurs in the body.—Like phosphate of calcium, the corresponding combination of magnesium is met with in all the fluids and solid portions of the body.—It is one of the hardening constituents of bones and the teeth, but only in a minor degree. The preponderance of phosphate of magnesium over the corresponding salt of calcium in muscle and the thymus gland (*Liebig*) is of interest. It is taken up as such from without, and is offered to the body in superabundance by a vegetable diet, so that the greater part of all that is received into the body passes through the intestinal canal unabsorbed.

PHOSPHATE OF MAGNESIUM and AMMONIUM, $MgNH_4PO_4 + 6H_2O$.

During putrefactive decomposition, or indeed with every generation of ammonia in the system, the latter combines with phosphate of magnesium to form a crystalline salt known as phosphate of magnesium and ammonium. This salt (fig. 38) is found in crystals of rhomboid fundamental form, and appears most generally in three-sided prisms bevelled at both ends on one of their edges; this form is known as the "coffin-lid crystal." Further varieties are produced by the bevelling of two polar opposed angles, or finally of the two remaining ones.

Crystals of phosphate of magnesium and ammonium are to be found in faecal matter, alkaline urine, and all putrefying animal substances.

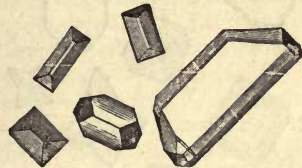


Fig. 38.—Crystals of phosphate of magnesium and ammonium.

CARBONATE OF MAGNESIUM

Is of very minor importance in animal life. It is met with in the urine of the vegetable feeders, probably as a bicarbonate $\left. \begin{array}{l} 2CO \\ MgH_2 \end{array} \right\} O_4$ also, perhaps, in bones. It is very difficult, namely, to determine whether it is the carbonate or phosphate of magnesium that exists in the latter, however.

CHLORIDE OF MAGNESIUM, $MgCl_2$.

This salt is said to be present in the gastric juice.

§ 43.

Sodium Compounds.

While the lime compounds appear, as a class, to possess in part the characters of hardening materials for the animal body, those of soda seem entirely devoid of these qualities as far as we know. On the other hand, however, they appear to play an important part in the chemical occurrences of the economy, although as yet we have not arrived at satisfactory conclusions in regard to all their purposes. It has been mentioned before (pp. 15–17) that soda is combined with the protein substances of the system, and retains the latter in solution; also that, combined with the two biliary acids, it forms the most important constituents of the bile (pp. 40 and 41).

CHLORIDE OF SODIUM, NaCl.

This salt, which is soluble in water, never meets with an opportunity for crystallization within the body, but may be found in crystals upon the surface of the latter under certain circumstances. These crystals (fig. 39) assume the form of dice, frequently marked with step-like depressions on their surfaces, or may be met with in the form of square prisms. Mixed with urea this salt crystallizes in the form of octahedrons, or, according to *C. Schmidt*, in tetrahedrons also.

Chloride of sodium, or common salt, is to be found in all animal fluids, and in all the solid parts of the body. Its amount in the juices is variable, but seldom exceeds 0.5 per cent. The fluid which saturates muscle is poorer than any in chloride of sodium. We see also, on the other hand, that though the animal juices may be at one time supplied with a larger quantity of the salt than at another, still the proportion in each fluid is tolerably constant, the surplus passing rapidly out of the body with the urine. The quantity of the substance in question is not less variable in the

solid portions of the system; the blood-cells are extremely poor, while cartilage is rich in it. An extremely interesting fact has been pointed out by *Bidder* and *Schmidt*, namely, that starving animals very soon cease to void chloride of sodium in their urine,—an indication that it is retained by the tissues and juices in the most determined manner as an indispensable ingredient in their composition. Some of the discoveries of pathology, also, bear out this conclusion, showing, as they do, that during the rapid formation of cells in exudations, the excretion of salt with the urine almost ceases, and that an extraordinary amount of chloride




Fig. 39.—Different crystalline forms of chloride of sodium.

of sodium is required for the plastic process (*Heller, Redtenbacher*). The experiences we have gathered from observation of domestic animals may also be alluded to here. In them the effect of a greater admixture of the salt in question with their food may be seen in the way it favours the whole process of assimilation (*Boussingault*).

All these facts seem to point to the conclusion, that chloride of sodium must be regarded as possessing the nature not only of an aliment, but also of a histogenic ingredient of animal tissue. But as to all the purposes in detail for which it exists in the body, we still possess but a scanty knowledge of them.

CARBONATE OF SODIUM, Na_2CO_3 , and NaHCO_3 .

Carbonate of sodium (the simple as well as the bicarbonate) appears very often in the products of the incineration of animal matters. It cannot be regarded as anything more than a calcination product in this case.

It is, however, present in several alkaline fluids, as, for instance, in blood, lymph, and the urine of vegetable feeders. In the blood it is the bearer of carbonic acid, and elsewhere the solvent for different protein substances.

PHOSPHATE OF SODIUM, Na_2HPO_4 , and NaH_2PO_4 .

Like potassium, to be alluded to presently, sodium forms three combinations with phosphoric acid, namely, basic phosphate of sodium, Na_3PO_4 ; neutral phosphate of sodium, with two atoms of base, Na_2HPO_4 ; and an acid salt with one atom of base NaH_2PO_4 . The first of these probably does not occur in the system, so that we have only to deal with the two last. Of these the neutral salt is the most common.

Phosphate of sodium is widely met with throughout the body. It has been found in the blood, the milk, the bile, the urine, and in the tissues. It is, perhaps, the bearer of the carbonic acid of respiration, and is, probably, the solvent for many matters, as, for instance, casein and uric acid. It probably plays an important part, also, in the formation of tissues, which is not yet fully understood.

SULPHATE OF SODIUM, Na_2SO_4 .

Like the sulphates of the alkalis generally, this salt is found in animal fluids, especially in urine, and in the excrements. In some of the most important secretions, however, it is not met with, as, for instance, in the gastric juice, the bile, and the milk. Like other sulphates, it cannot be said to possess any histogenic properties, but rather those of a decomposition product, the sulphur of the protein compounds and allied substances, forming sulphuric acid by oxidation, and displacing the carbonic acid of the soda salt.

In confirmation of what we have just stated, the facts may be adduced—first, that sulphates introduced into the body are rapidly excreted, and on the other hand, that after an abundant fleshy diet their amount in the urine increases (*Lehmann*); secondly, that the sulphur of taurin, as already mentioned (see above, p. 49), is set free under the action of ferments in the form of sulphurous acid which becomes subsequently converted into sulphuric acid by oxidation (*Buchner*).

§ 44.

Potassium Compounds.

These are of subordinate importance in the human economy, which fact may to a certain extent depend upon the nature of our food. Among the vegetable feeders, however, the serum of the blood still shows a preponderance of soda salts, and soda is also the base in their bile. But in many other portions of the system we find the most remarkable preponderance of potassium salts over those of sodium.

CHLORIDE OF POTASSIUM, KCl .

This compound is found together with common salt in animal fluids; in smaller quantity in man than in phytophagous animals. Its amount in the blood cells is however large (*C. Schmidt*), and in the juice of muscle it replaces chloride of sodium (*Liebig*).

CARBONATE OF POTASSIUM, K_2CO_3 .

Probably occurs with carbonate of sodium in some of the animal fluids, and in the urine of vegetable feeders in all probability as bicarbonate, KHCO_3 .

PHOSPHATE OF POTASSIUM, KH_2PO_4 , or K_2HPO_4 .

It is not yet decided in what form of combination with potassium ordi-

nary phosphoric acid occurs in the body, whether as an acid salt with one atom of base and two molecules of water, or a neutral as it is called, in which two atoms of base go to one molecule of water. The salt is met with in the juice of muscle (*Liebig*).

SULPHATE OF POTASSIUM, K_2SO_4 .

Appears in the body, probably, with the corresponding salt of sodium and under similar circumstances.

Ammonium Salts.

The physiological processes of the body are attended by but a comparatively small development of ammonia, so that in this respect they may be said to offer a contrast to putrefactive decomposition. The combinations of ammonium in the body are probably of various kinds; for the present, however, we are unable to enter into them very fully.

CHLORIDE OF AMMONIUM, NH_4Cl .

It is still an undecided question how far this or the carbonate appear in the economy.

CARBONATE OF AMMONIUM.

Is found in expired air, in decomposed urine, in blood, in the lymphatic glands and blood-vascular glands. The combinations which are here met with are the sesquicarbonate $(NH_4)_3H \left. \begin{array}{l} 2CO \\ \end{array} \right\} O_4$, and bicarbonate $NH_4.HCO_3$.

Iron, Fe, and its Salts.

This metal is extensively distributed throughout the body, and occurs probably in all its parts. It is met with in various forms also, being supplied to the system in great abundance with the food.

In some way not very fully understood at present, iron enters into the composition of the most important of all animal colouring matters, hæmoglobin (p. 18). Uroerythrin and melanin also contain iron (p. 52).

PROTOCHLORIDE OF IRON, $FeCl_2$.

This salt is said by *Braconnot* to be present in the gastric juice of dogs.

PHOSPHATE OF IRON, $Fe_2P_2O_8$.

Another compound of iron generally accepted, though perhaps on insufficient grounds, as occurring in the living body.

In regard to the presence of iron one thing is certain, namely, that all portions of the body supplied with blood must contain it. It has also been found in chyle, lymph, urine, sweat, bile, and milk, and finally in hair, cartilage, and other solid tissues.

Manganese, Mn.

This metal is introduced into the system in company with iron, and is met with here in minute quantity. It seems to be merely an accidental constituent. It is found in hair, and in biliary and urinary calculi.

Copper, Cu.

Copper has been noticed in the blood, bile, and biliary calculi of man. It is excreted by the liver.

2. ELEMENTS OF STRUCTURE.

A. The Cell.

§ 45.

THOSE anatomists of recent times who seek with the assistance of our improved microscopes an insight into the minute structure of the human and animal body, have all arrived at this conclusion, however widely their other scientific views may differ, that "the cell," *cellula*, is the most important of all the structural or form-elements of the system. This fact, although surmised by earlier observers, who recognised the structure in question under the name of "vesicle," was first firmly established by *Schwann*. Following up *Schleiden's* discoveries in vegetable anatomy, he showed the cell to be the starting-point, in the broadest meaning of the term, of the animal body (see above, p. 4). This is the greatest discovery ever made by the aid of the microscope.

Present-day investigation tends more and more to confirm the correctness of this proposition of *Schwann*, that the cell alone, and by itself, must be regarded as the primordial structural element of our frame, and that all the various other elementary parts to be found in the mature body are originally derived from the cell.

The first point, then, to be attended to here is, to obtain a correct impression of what is meant by a "cell," and what by a "structural element."

By "form constituents," "form elements," "elementary parts," or "structural elements," we do not by any means understand (as might be incorrectly inferred from the terms) the smallest particles of the body recognisable by the microscope in the shape of granules, vesicles, or crystals. A form-element is rather the last, or—contemplating the subject from another point of view, the first—anatomical unit: a combination of the most minute particles to form the smallest organic apparatus. Structural elements are the first representatives of organic activity; they are, consequently, physiological as well as anatomical units; they are "LIVING THINGS."

But what is the *cell*? This question cannot be answered in a word, but requires to be met with a somewhat detailed description.

The cell (fig. 40) is a microscopically small, primarily spheroidal body, which often assumes, however, other forms, and

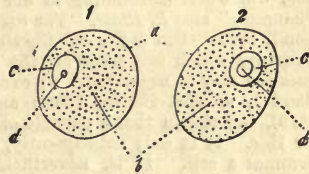


Fig. 40.—Two cells of round or oval form. *a a*, border of the cell; *b b*, cell body; *c c*, nuclei with nucleoli, *d d*.

which consists of a soft mass

including within it a peculiar structure. These parts require special names. The soft substance mentioned is known as the *cell-substance* or *cell-body* (*b b*), the central structure enclosed within it as the *nucleus* (*c c*), and a minute dot-like particle situated within the latter again as the *nucleolus* (*d d*).

The external boundary of the cell (*a a*) is in certain cases formed by the soft mass alluded to, or more frequently by a somewhat hardened stratum, the *enveloping* or *cortical layer*, or, finally, by a distinct independent pellicle separable from the cell-body, and known as the *cell-membrane*.

In regard to the latter, the views entertained respecting the animal cell have latterly undergone considerable change through the results of recent investigation. The presence of a special membrane was formerly considered necessary (*Schwann*) to the conception of a true cell; but the frequent absence of this envelope and its relatively small physiological significance has been since recognised (*Schultze*, *Brücke*, *Beale*).

But although its anatomical characters offer us the first and most important points in the definition of the cell, its physiological properties cannot be overlooked. By these the cell is constituted a living structure, endowed with special energies and the peculiarities of active vitality; with the power of absorption of matter, of transforming the same, and of excretion; with the capability of growth, of change of form, and of cohesion or fusion with similar organisms. The cell possesses further, undeniably—although there may be a variety of opinion as regards the extent of these powers in individual cases—the capability of vital motion, as well as of proliferation, or the generation of a progeny. The cell, we repeat it, is the earliest physiological unit, the first physiological apparatus: it has been called an “elementary organism” with propriety.

One of the most important facts established by recent scientific investigation is, that that mass from which the bodies of all the higher animals take their origin, namely, the ovum, has entirely the nature of a cell, so that, consequently, each such animal body, be it ever so complex in constitution, once consisted of one single cell. While in this respect the latter must be regarded as the starting-point of animal life, naturalists again have brought to light creatures of such simple organisation that their whole body is formed of nothing more than one independent cell, and whose whole existence is included within the narrow circle of cell-activity. Among such may be reckoned those animals known as gregarines. Finally, single-celled plants have been discovered by botanists, as single-celled animals by anatomists: and even still more rudimentary organisms have been met with.

REMARKS.—Compare the work of this author, “*Mikroskopische Untersuchungen über die Ubereinstimmung in der Struktur und dem Wachsthum der Thiere und Pflanzen* ;” also *L. Beale*, “*The Structure of the Simple Tissues of the Human Body*,” Lond. 1861. But is the cell the simplest “elementary organism,” *i.e.*, the simplest structure which can meet all the requirements of the lowest grade of life? This question may be negatived. An excellent observer, *E. Häckel* (*Generelle Morphologie*, Band 1, s. 269, Berlin, 1866; and *Biologische Studien*, Heft 1, s. 77, Leipzig, 1870), has shown that a particle of protoplasm, or “*cytode*,” as he terms it, suffices for this. It is only subsequently, after the generation of a nucleus that the whole becomes a cell. It is, nevertheless, a deeply significant fact, that the building stones of the bodies of higher animals are never represented by “*cytodes*,” but always by cells.

§ 46.

Turning now to the more detailed analysis of cells, the first point to be borne in mind is, that the latter, in the earlier portions of their existence, manifest a certain amount of uniformity, whether as the cells of young embryos or those of later life. Again, that in the course of further development they may assume, as mature and senescent structures, the most diverse shapes, as well as acquire an entirely different body, so that they not unfrequently take on an appearance which may remove them very far, nay, even so far as to be unrecognisable from the plan of a cell, given in the foregoing section.

1. Directing our attention, then, in the first place, to the size of cells, we find them, in the human body as well as almost everywhere in the animal kingdom, to be within microscopic measurement. The smallest, such as we find, for instance, among the blood-corpuses, have a diameter of only 0.006–0.007 mm. (millimeters), while the largest typical cell of our body, namely, the ovum, may attain a breadth of more than 0.23 mm. Between these extremes the greater number of cells range in diameter from 0.011 to 0.023 mm. Those of 0.07–0.115 mm., such as occur, for instance, in fat and nerve tissue, must be looked upon as very large. Thus we observe that the most important structural element of our body is of remarkable minuteness, as usually met with.

2. If we next turn to the shape of the cell, we are struck likewise with its extreme variability. The fundamental form (fig. 40) is, however, spherical or spheroidal.

From this primary form two others, easily derived, are produced by compression and flattening in two opposite directions; these are the *flattened* and the *tall narrow cell*.

Flattened cells springing from the spherical primary form by compression are met with, in the first place (fig. 41), as disks, such as may be seen in human and mammalian blood-corpuses; or they may become, by a further increase of superficial extent, flat or scaly structures (fig. 42) such as those, for instance, of the epithelium of many parts of the body.

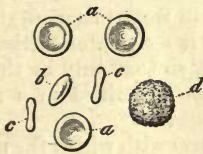


Fig. 41.—Diskoid cells of human blood, *a, a, a*. At *b*, half side view; close by at *d*, colourless corpuscle.

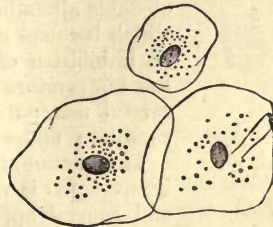


Fig. 42.—Flattened scaly epithelium cells from the human mouth.

That there may exist every gradation between flattened cells and the spheroidal species appears self-evident, and needs no farther comment.

If the elements in question undergo, on the other hand, lateral compression, the resulting form may be either more or less cylindrical or conical, and the *tall narrow cell* is produced (fig. 43). We shall see later on, in our consideration of the several tissues, that many modifications of

this figure may appear. The *fusiform cell* may be regarded as one of these; besides being narrowed, it is fined off at either end to a point (fig. 44).

The fusiform cell usually gives off at either end a thread-like process; but such filaments may occur in greater number in many animal cells, and on their part undergo further ramification. It is in this way that the *stellate cell* (fig. 45) is produced—one of the most remarkable forms in which the structure in question can meet the eye.

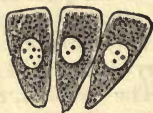

Fig. 43.—Tall, narrow cells, as found in what is known as cylinder or columnar epithelium.

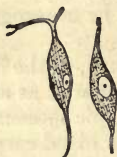

Fig. 44.—Fusiform cells from immature connective tissue.

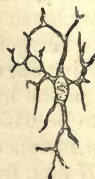

Fig. 45.—Stellate cell from a lymphatic gland.

3. But far more important than either shape or size is the substance of the cell-body: in this the greatest variety is observed.

Let us, take in the first place, young cells (fig. 46): here we perceive that the body is made up of a more or less soft, usually viscid and slimy mass, containing in a transparent cementing medium a variable amount of albuminous and fatty granules (*a-g*). This primordial cell-substance is known at the present day by the name *protoplasm* (*Remak* and *Schultze*) borrowed from botany. It has also received from *Beale*, *Koelliker*, and *Dujardin* respectively, the names *bioplasm*, *cytoplasm*, and *sarcodæ*. The chemical peculiarities of this protoplasm have been already referred to in § 12, and we shall be obliged presently to enter somewhat minutely upon the consideration of its vital properties. It will suffice to remark here, that it consists of an extremely unstable albuminous compound, insoluble in water, but which becomes gelatinous (or in some instances shrinks) on imbibition of the latter: it coagulates further at a low temperature and at death, so that only by the most careful manipulation can it be examined in a normal condition under the microscope.

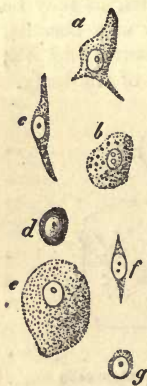

Fig. 46.—Different kinds of cells with nuclei and protoplasm; half diagrammatic.

The amount of this protoplasm with which the nucleus is enveloped is very variable, and consequently the size and general appearance of cells. Our woodcut represents from *a* to *d* elements with a medium amount of this substance; *e*, a larger proportion. Other cells are observed to possess but a very small quantity of protoplasm, as *f* and *g*, without having lost the capability, however, of increasing in substance and subsequently fulfilling all the purposes for which cells in general are designed. As far as we know at present, a cell can never again be formed from a nucleus which has quite lost its protoplasm.

But if we turn now to mature or senescent cells, we frequently find that the protoplasm of an earlier period of existence is replaced by

matters of completely different characters; thus the body of the blood-corpucle is found to be made up of a transparent yellow gelatinous substance (fig. 47); in old scaly cells also, such as are met with on the surface of many mucous membranes (fig. 48), the protoplasm is replaced

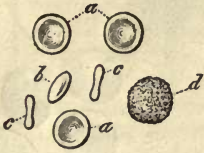

Fig. 47.—Human blood-corpucle.

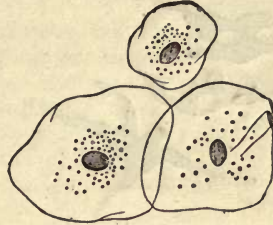


Fig. 48.—Old epithelium cells from the human mouth.

by a hard substance, poor in water, and almost destitute of granular matter, —a metamorphosed albuminous material, to which the name of *keratin* has been given.

Such cells, however, as those in both instances cited, are no longer capable of supporting a prolonged existence, they have lost their active vitality with their protoplasm.

Again, there are cells still more frequently met with which contain other substances as formed deposits in their protoplasm (fig. 49).

Setting aside for the present those cells into whose bodies foreign matters, such as granules of carmine (*a*), or blood-corpucle and fragments of the same (*b*), have penetrated from without (remarkable objects which will be considered at greater length presently), we frequently meet with globules and drops of *neutral fats* laid down in the original cell-mass (*d*), which may gradually coalesce, supplanting the protoplasm until but a small remainder of it is left. Besides such fatty matters, molecules of brown *biliary pigment* are to be seen in other cells, as, for instance, in those of the liver (*c*).

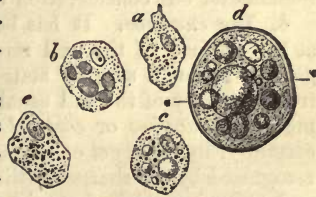

Fig. 49.—Cells with deposits of foreign matter in their protoplasm (half diagrammatic). *a*, a lymph corpucle with granules of carmine imbedded in it; *b*, another of the same, with included blood-cells and fragments of the latter; *c*, an hepatic cell, containing fat globules and granules of biliary pigments; *d*, a cell with fat globules and distinct membrane; *e*, another, with granules of melanin.

Cells also which have become the receptacles of melanin granules (p. 52) present the most peculiar appearance. This pigment may be present in such abundance that the whole body of the cell becomes black throughout (fig. 50). The occurrence of *crystals* in the interior of animal cells is less frequent. They are, however, to be met with as acicular formations, already alluded to (p. 27), and appear in the interior of fat cells on the *post mortem* cooling of corpses, within the membranes of the former (fig. 51). But while the appearance of these is by no means rare, there are other crystalline deposits which are only encountered in minute quantity, and under abnormal pathological conditions. Matters which assume the crystalline form in such watery solutions as exist in the animal economy, must be regarded generally as unfitted to take part in the con-

struction of tissues. The rarity of crystals as cell-contents is thus explained by this law, as it may be called, to which, with all the varie-

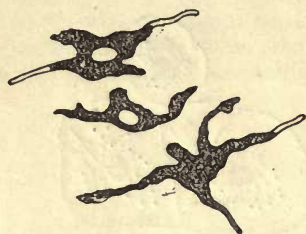


Fig. 50.—Stellate cells containing black pigment.




Fig. 51.—*a*, *b*, Crystals of margaric acid; *c*, the same contained within fat cells; *d*, a cell from adipose tissue destitute of crystals.

ties of cells in the different groups of the animal kingdom, there are but few exceptions.

§ 47.

Among the further characteristics of the animal cell there now only remains for our consideration the envelope and nucleus.

4. *The envelope.* It has been already remarked that the protoplasm at the surface of the cell rarely remains so soft as in the interior. In general terms it may be stated that a hardening of the non-granular or free periphery of the cell usually takes place by contact with surrounding media (*enveloping or cortical layer* of protoplasm). This hardening is certainly, in numbers of cases, exceedingly slight, so that it is only to be recognised by the sharper outline of the cell: it can also be easily overcome, and softening again brought about by the very brief action of external agencies. In other cases, however, it is greater; the transparent, tough layer increases in thickness, and may be brought into view as distinctly separable from the richly granular protoplasm of the interior, by the action of water and other reagents.

It is such appearances that have been over and over again accepted as proofs of the existence of cell-membranes, especially when, through a rent in the cortical layer, the contents have been observed to protrude. And in fact, this hardened peripheral layer of protoplasm does lead us on to the cell-membrane as it becomes gradually more and more independent, and assumes different chemical properties.

But no one is able to define where this cortical layer of protoplasm ends, and where the membrane of the cell begins—a point essayed on all sides in the case of animal cells at an earlier period of histological study.

Occasionally, at some distance from the shrunken cell-body such a covering with double contour may be recognised (fig. 49, *d*). But its presence cannot be doubted for an instant, when, either mechanically, as, for instance, by rupture and squeezing out of the contents, or by chemical reagents which dissolve the latter, the membrane is successfully isolated. Those fat-cells already mentioned (fig. 51, *a*) allow of the fluid fat (*b*) being pressed out in drops, when such a membrane (*c*) becomes recognisable. The same may be seen when the contents have been

extracted by alcohol. These membranes exist in many cellular formations of the body beyond question. Their purposes appear chiefly anatomical, in that the consistence requisite for many animal tissues is, as we know by experience, greater than could be yielded by the soft protoplasm of the cell-body alone.

Where, however, the individual cells are widely separated by considerable quantities of solid intermediate substance, or where just the reverse is the case, and they are suspended in a liquid, forming a fluid-tissue, this membrane is probably absent as a rule. Such cells are those of dentine tissue and of bone, as also the cellular elements of the blood, the lymph, and the liver (fig. 52).

The membranes of cells are usually transparent, and, as far as we can see with our present optical instruments, structureless and without openings or pores. Attention has, however, been lately directed to certain cells in which pores may be distinguished by means of the microscope—a circumstance into which we shall have to examine more closely further on.

It is probable, also, that in isolated cases this cortical layer or envelope covers only certain portions of the body of the cell.

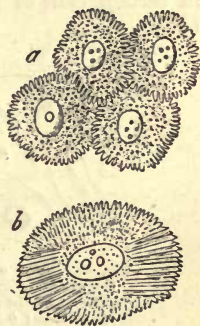
As a rule, we find the demarcation of a cell such that a smooth contour encloses the figure; but it may happen that the granular contents produce a rugged appearance on the surface, which leads us involuntarily to the distinction between *smooth edged* and *granulated* cells (fig. 53, *a d*). Both of these differences are, however, of minor importance. Again, owing to a partial exit of the matter contained within, the cell, which had been up to that time perfectly smooth, may assume a wrinkled appearance; while, on the other hand, the reverse may take place with a granulated cell through the imbibition of water; it may swell out and become a smooth rounded object.

Attention has lately been directed by *M. Schultze* to a remarkable appearance in the borders of young cells, and especially those of flat epithelium; their surface, namely, is completely covered with points, ridges, and prickles, as they might be named (fig. 54), which fit in among those of the neighbouring cells "like the bristles of two brushes which have been pressed against one another." The appropriate name of "*spinous* and *furrowed*" cells has been given to these.

5. If we now turn to the analyses of the nucleus, with its adjuncts, we meet with a certain variability in it likewise. First, the difference in size of the various animal cells brings with it very considerable fluctuation in the diameter of the nucleus; proportionately less, of course, than that of the cell itself. We may accept 0.0011–0.075 mm. as a medium diameter for the nuclei of animal cells; but at the same time, it must be borne in mind that some may be found

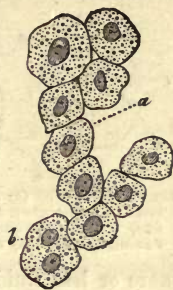
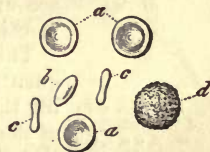
Fig. 52.

Fig. 53.—*a b c*, Smooth-edged diskoid blood-corpuscles, with one granulated white cell (*d*) whose nucleus is obscured.Fig. 54.—Spinous or furrowed cells. *a*, from the undermost layers of the human epidermis; *b*, a cell from a papillary tumour of the human tongue (copied from *Schultze*.)

much smaller, even down to 0.006 mm., and less, whilst other cells again possess nuclei whose diameter may reach 0.023-0.045 mm. The position of this nucleus in the animal cell is at one time central, at another excentric.

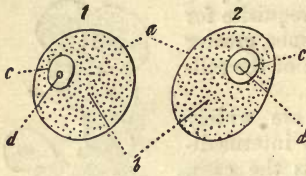


Fig. 55.—Two cells (a) with vesicular nuclei at c, which show a smaller or larger nucleus at d. The nuclei themselves lie excentric in the body of the cell, b.

The fundamental form of the object under consideration, as it is met with in the earliest formative cells of embryonic tissue, and frequently enough in those of more mature parts of the body, appears to be that of a vesicular body approaching the spherical figure (fig. 55, c c), with more or less fluid, and, it may be added, homogeneous, transparent contents and strong cortex, which latter shows, under the strongest microscopes of the present day, a double contour as optical expression of its thickness. Thus we see that the nucleus possesses an analogous structure to the cell, which is endowed with a membrane, and one of whose components it is.

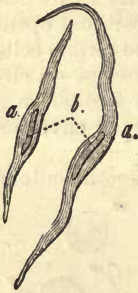

Fig. 56.—Two cells of involuntary muscle, a a, b, the rod-like homogeneous nuclei.

In the interior of this hollow nucleus, or, as it has been named, *nuclear utricle*, or *vesicle*, may be discovered, single or double, a roundish formation, almost a mere speck on account of its minuteness: this is the *nucleolus* already mentioned (d d).

This fundamental form, however, of the nucleus is frequently enough exchanged subsequently for another, altering thus its original appearance, although the variations of the nucleus may be stated as a rule to be less in proportion than those of the cell itself. We find, for instance, in turning to the consideration of some of these changes of figure, that it may become elongated, as in those cells which enter into the composition of unstriped muscle (fig. 56, b), or diskoid, as seen in the tissue of nail (fig. 57). Ramifications of nuclei have also been met with in certain cells of lower organism, but not as yet in those of the human body.




Fig. 57.—Cells of nail tissue. a a, view from above, with the granular nucleus; b b, side view of the cell, with the flattened levelled nucleus.

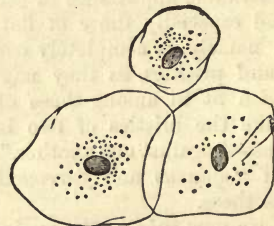


Fig. 58.—Flat epithelial cells, with completely homogeneous smooth-edged nuclei.

On the other hand, the nucleus may exchange the original vesicular condition of an earlier period for solid contents, as is the case, for instance, in the superficial epithelial cells of the mouth (fig. 58), or for perfect homogeneity, so that even the envelope of the nucleus is no longer to be

distinguished. This latter form is seen in the cells of involuntary muscle just mentioned (fig. 56, *b*). In such cases the nucleoli are frequently invisible.

It often occurs also that elementary granules are laid down in the nucleus, giving to it, when in large quantities, a rugged appearance, and precluding the possibility, further, of the nucleolus being distinguished. It is thus that the so-called *granular nuclei* have their origin. Again, there are cells whose nuclei may be obscured by an enveloping drop of oil. The former may be seen on treating the blood-corpuscles of the lower vertebrates with water (fig. 59), while the latter are of frequent occurrence among certain cartilage cells.

It is not always that we are able to make out the object in question in the interior of animal cells: it is often hidden from view, as for instance, in the living cell. We have already mentioned in a previous section that a rich deposit of elementary granules also, or pigment molecules, may obscure the nucleus (fig. 60). The same may be the case if the cell-body be occupied by a quantity of fatty matter; but very close scrutiny will always reveal the nucleus to the observer after a time. On the other hand, there are cells in which such a covering up of the nucleus cannot be thought of, in which the contents appear perfectly clear, and yet in which we can by no means in our power render the nucleus visible. The

coloured blood-corpuscles of mature mammalia and human beings belong to this category (fig. 61); likewise the cells of the more superficial layers of the epidermis which clothes the external surface of the human body (fig. 62). But of both these we know that they possessed nuclei at an earlier embryonic period. There are, consequently, certain cells in our system whose nuclei disappear usually at some period of their existence. We may also remark here and there in tissues whose cells are as a rule destined to retain their nuclei for the whole life of the animal to whose body they belong, an isolated cell without a nucleus among its complete companions; but it must be looked upon as a rare anomaly. All such non-nucleated cells are moreover incapable of existing for any length of time, and are simply on their way to dissolution as far as we know at present.

In contrast to the kind of cell just mentioned, we meet with others in which two or even a greater number of nuclei exist. The first case (fig. 63) is seen with comparative frequency, and in very dissimilar tissues: cells with many nuclei are rare, and found principally in the medulla of bones, where they may contain ten, twenty, or even forty nuclei, and

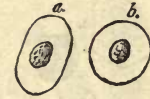

Fig. 59.—Two blood-cells of the frog, *a b*, with granular nuclei, as they present themselves after treatment with water.

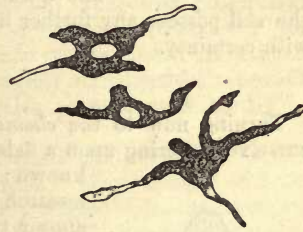


Fig. 60.—Stellate cells filled with black pigment. In two of the same we can recognise the nucleus, but in the third the latter is hidden by the quantity of melanin granules contained in the cell-body.

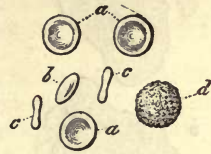

Fig. 61.—Coloured human blood-corpuscles, *a b c*.

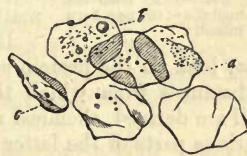

Fig. 62.—Epidermis cells without nuclei.

at times attain enormous proportions (fig. 64). Such conditions are invariably coincident with a process of proliferation in the cell, and will be treated of more minutely when discussing the latter. We must distinguish this truly double or multiple nucleus from another deceptive appearance of two or several more in one animal cell. There are, namely, cellular formations in various fluids of the system, as in the blood (the white or colourless blood-corpuscles) lymph, chyle, mucus, pus, &c.—we will call them *lymphoid* cells—which contain originally a simple nucleus; which when mature may often, under the action of reagents, such as dilute acids, for instance, be made to break up into several pieces, so that the observer is deceived into the belief that he has before him cells with several nuclei.

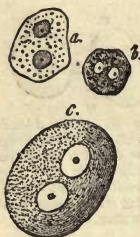

Fig. 63.—Cells with double nuclei. *a*, from the liver; *b*, from the choroidea of the eye; *c*, from a ganglion.

The question as to whether the body and nucleus of the cell possess any further finer texture, cannot at present be answered with certainty.

§ 48.

Turning now to the *chemical constitution* of the animal cell, we find ourselves entering upon a field of histochemical inquiry of which little is known: here more than elsewhere does microscopical research in the investigation of the elements of form appear to be far in advance of chemical analysis. In order to follow up this line of inquiry with any hope of success, we should be able to separate the cell from its surroundings, *i.e.*, from elements of tissue; to take it asunder, or resolve it into its various parts, *i.e.*, nucleus, cell-body, membrane, and subject these separately to chemical analysis. Unfortunately this is for the present impossible, and thus the existence of a great gap in our knowledge is more than sufficiently explained.

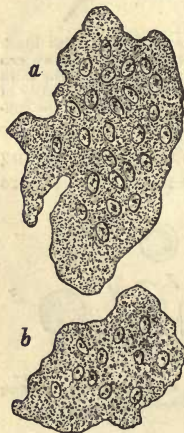

Fig. 64.—Multinuclear "giant-cells" from the medulla of the new-born infant.

We are in general only able to state so much; that the still very obscure group of protein compounds or albuminous principles, with its numerous members and modifications, with certain of the histogenic descendants of the latter, play the chief part in the constitution of the animal cell.

Besides these, as in all other parts of the system, we find as further constituents, water, and moreover usually in considerable amount; also certain mineral matters, and probably also everywhere fats.

But though, after what has just been remarked, we may look on the protein matters, and their immediate derivatives, as those substances from which the materials for the production of the animal cell are derived, chemical investigation teaches, on the other hand, that the various parts of the latter must be composed of modifications of these, in that nucleus, cell-body, and membrane (when the latter is present) generally display different reactions. Not unfrequently we are obliged to own our knowledge of the composition of animal cells as comprehended in these few and general propositions only. In some other cases, however,

and under favourable circumstances, it is possible to penetrate somewhat more deeply into the chemical constitution of these most important of the elements of form.

Let us first, then, inquire into the constitution of the *cell-body*. We have already seen in one of the preceding sections that this is originally formed of protoplasm. In speaking of the latter we described it as a tough, viscid, or mucoid substance, consisting of a peculiar albuminous compound, which coagulates at death, and also when heated up to a certain point; which becomes further swollen up or gelatinised by the action of water, but not dissolved. This is about all we know at present of this important compound protoplasm. The granules which lie embedded in the homogeneous substances of the latter in greater or less quantity, consist partly of coagulated albuminous matters, partly of neutral parts, and more rarely of pigments, especially melanin. That mineral constituents are also present need hardly be remarked.

In many cells the protoplasm is transformed gradually into various other modifications of the protein compounds. Thus, instead of it the mature blood-corpuscle is composed of watery hæmoglobin, the formative cell of the fibres of the lens likewise of an albuminoid known as globulin. Other cells again contain mucin or allied substances, as for instance colloid, and it often occurs that the original cell-body is converted by a loss of water into one of the more solid modifications of the albuminoid group, for instance into keratin, found in the older cells of epidermis and nail tissue, &c. However imperfect our knowledge at present may be, it must still be considered of importance to know for certain that those more remote descendants of the albuminoids, as we meet them, for instance, in gluten and elastin (§ 15), never form the proper body of an animal cell.

Ferments, also, are probably of frequent occurrence in the bodies of cells. Thus we find minute molecules of pepsine in the protoplasm of the glandular cells of the stomach, and allied matters in the elements of the intestinal glands.

We have also hydrocarbons presented to us in hepatic cells in the form of granules of glycogen (§ 16).

Deposits of neutral fats are likewise of extremely common occurrence here. Granules and globules appear at first in the various kinds of cell-substance, gradually forming in some cases large drops, which may eventually displace almost the whole of the latter. And although it cannot be doubted that most of these fatty compounds are taken up into the body of the cell from without, it must still be regarded as extremely probable that a formation of fat can be brought about in the cell itself by the splitting up of its proper albuminous body.

With the exception of the salts of lime, formed deposits of inorganic substances do not occur in the bodies of cells.

In turning now to the consideration of the chemical constitution of the *surface of the cell*, we must remember that very generally the enveloping layer of protoplasm has been hardened, now more, now less, through con-

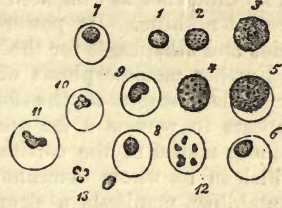


Fig. 65.—Lymphoid cells, 1-4, unchanged; 5, the nucleus and membrane; the same at 6, 7, and 8; 9, the nucleus begins to divide, also at 10 and 11; 12, it has broken up into six pieces; 13, free nuclei.

tact with surrounding substances. As to the composition of this layer, as to its difference as compared to the softer protoplasm within, we know at present nothing. Its power of resisting the action of reagents, such as acids and alkalies, is for the most part very limited.

Further metamorphosis of this superficial layer leads on through intermediate stages to the formation of the proper "cell wall." This appears to possess a far greater power of resistance, in that the albuminous matter of the cortical layer has been converted into a substance, which in its whole demeanour as regards various reagents, and in its immutability, manifests a strong resemblance to, if not accordance with, elastin. Even years ago it was asserted by *Donders*, that the membranes of all animal cells consisted of elastin; and although this expression of that most excellent observer may be somewhat exaggerated, nevertheless the capability of changing into a cell membrane possessed by the cortical layer of protoplasm, gives support to the proposition that elastic matter (elastin) may take its rise from the protein substances, although the minutæ of the process of transition are not yet known.

Passing on, finally, to the constitution of the *nucleus*, we have to distinguish between the envelope and contents of this originally vesicular body. The contents, formed of a pellucid fluid, appear to be composed of some soluble modification of protein matter; for we can frequently produce a precipitate of small granules in it, by the action of alcohol, acids, &c., as, for instance, in the nuclei of ganglion cells, and that of the ovum. The envelope consists comparatively seldom of matter which does not resist the action of acetic and other allied acids, as, for instance, in the nuclei of the cells just mentioned. Usually—and this is the means for the recognition and distinguishing of the nucleus, long in use empirically among histologists—the envelope of the latter and the remaining substance is not acted on by such acids. Now, although the substances in question correspond in the last respect with the elastic material of many cell-membranes, they yet differ from them most distinctly in their greater or less degree of solubility in alkalies. This has been very properly pointed out by *Kölliker* to be a distinguishing feature between the nucleus and membrane of the cell.

The chemical transformations which the nucleus undergoes during the life of the cell are manifold, as, for instance, when it becomes solid, or exchanges its vesicular nature for a granular one. The tendency, further, of certain nuclei to deposit fats round about themselves is very striking, a process which can go so far that, as is the case in certain cartilage cells, finally, instead of a nucleus, nothing but a drop of oil can be distinguished. It is also remarkable that pigments are seldom seen in the nuclei of cells. Those of the epidermis of dark parts of the skin, however, appear to be tinged by some brown colouring matter.

The *nucleolus*, owing to its minuteness, has almost completely escaped chemical investigation hitherto. It is supposed, from its refracting properties, to consist of fat.

Great uncertainty still prevails as to how far the products of the decomposition of histogenic matters (already discussed in a former section), which are found in the fluids saturating cellular tissue, are originally constituents of the cell-body. It is also impossible to state, even in the most favourable cases of simple cellular tissue, what products of decomposition belong to the different parts of the cell, what to the

body, and what to the nucleus, as in the case of the hepatic and contractile fibre-cells.

If, as would appear from all this, our knowledge of the composition of the cell is very unsatisfactory from a *qualitative* point of view, how much more so when we glance at it from the *quantitative* side of chemistry! In fact, we are unable to give the quantitative analysis of any single form of cell in the body.

§ 49.

In regard to *phenomena of vitality* observed in cells, they would appear, in the first place, to be of the vegetative type—consisting in processes of *absorption* of matter, *transformation* and *excretion* of the same, *growth* and *proliferation*. Again, the vitality of the cell is manifested in the most striking manner by the extraordinary phenomena of *contractility* which have recently been met with among the corpuscular elements of the animal body.

Contractile cells have long been known—one might say as curiosities—in the bodies of lower animals. Comparatively recently they have been recognised also as existing very widely distributed among the same, and some animals are known of such simple structure that almost the whole mass of the body consists of them. But we have also gradually become acquainted with an ever-increasing number of the same kind of cells in the bodies of the higher animals, likewise endowed with the power of vital contractility. Besides this, such a property could no longer be doubted after the recognition of the fact that a widely-spread species of muscular tissue, known as unstriped, as also the heart (at least at an earlier period of embryonic life), had consisted of such cells entirely. Taking with all this the fact that, up to the present, this vital contractility has been observed in the cells of all but a few tissues, such as, for instance, those of the nervous system, we are almost warranted in concluding that, at an earlier period of their existence, *all* cells are endowed with this power of contraction; that is to say, as long as they consist of protoplasm alone, and before they are enclosed in a distinct cell-membrane, and that this power is dependent probably on some property inherent in the latter substance.

Let us take a somewhat nearer glance at this wonderful phenomenon of cell-life in individual cases.

If we take a frog in whose eye inflammation has been produced by the action of nitrate of silver applied to the cornea, we find after a few days that the aqueous humour becomes milky. A drop of this fluid, placed with extreme care under the microscope, will often show us the cells sketched in fig. 66 (pus-corpuscles). These seldom or never appear of simple spheroidal figure, but almost always under a variety of jagged shapes, whose points and angles are engaged in an incessant change of form, usually very sluggish, but at times somewhat energetic. We are able to

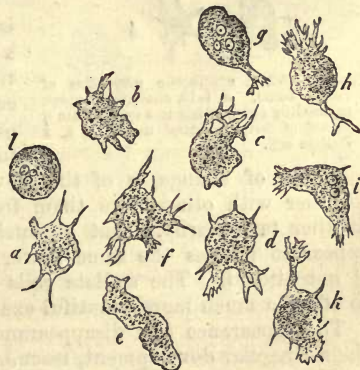

Fig. 66.—Contractile lymph-cells from the *humor aqueus* of an inflamed eye of a frog.

of simple spheroidal figure, but almost always under a variety of jagged shapes, whose points and angles are engaged in an incessant change of form, usually very sluggish, but at times somewhat energetic. We are able to

recognise also, that certain thin, thread-like processes, consisting of a clear structureless substance, extend themselves rapidly from the main mass (*a*), while others much broader (*b d f*) commence an extensive ramification (*g h k*). Should the branches of neighbouring processes come into contact with one another, they coalesce at the point of contact, forming net-like figures or broad flat meshes, which gradually assume the dark appearance of the rest of the body of the cell. Other prolongations of the protoplasm, on the contrary, have in the meanwhile receded and disappeared in the body of the cell. At times the most extraordinary intermediate forms of the cell result from these changes (*i e*). All this time a slow circulation of the granules lying in the protoplasm may be observed, the nucleus moving about passively with them. It is only on the death of the cell that this extraordinary movement ceases, and that the former assumes the round shape (*l*), formerly supposed to be the only one in which the pus-corpuscle ever appeared.

The species of cell just mentioned, our "lymphoid cell" (p.72), is found widely distributed throughout the bodies of vertebrate animals, and has received different names, according to the region in which it is met with, as, for instance, the "white blood-corpuscle," the "lymph and chyle corpuscle," the "mucous corpuscle," &c.

Does it undergo the same changes of form in the human and mammalian body generally?

This question may be answered in the affirmative; but, owing to the much smaller size of the cell in the latter, and the rapid cooling of the preparation, the demonstration of vital contractility is attended with more difficulty. The series of changes sketched in fig. 67 may be followed (*a*, 1-10) on the white corpuscles of the blood; but the energy of the movement is greatly increased if the natural warmth of the fluid be kept up artificially.

Another instance of change of figure is depicted in fig. 68, which represents a small portion of living connective tissue from the body of the frog. The cells known as connective-tissue corpuscles put forth here very long and thin filiform processes (*a b c*), but the

Fig. 67.—White contractile corpuscles of human blood. *a*, 1-10, changes of shape succeeding one another in a cell, within a period of forty minutes' duration; *b*, a stellate cell.

sequence of change is of the slowest kind. These processes meeting together with others like them from neighbouring cells, fuse into one another temporarily. But all such connective-tissue corpuscles do not appear to possess the same power of motion, for at *d* and *e* the form is not altered. The stellate cells of corneal tissue are said, however, to afford a much more beautiful example of vital change of form.

The appearance and disappearance of these protoplasm processes, and their irregular development, resemble in the most striking manner those wondrous variations in figure observed to take place in the body of one of the naked rhizopods, the amœba, which consists entirely of protoplasm; and we may, therefore, with perfect propriety, adopt the name "amœboid motion" for the phenomena under consideration.

It is very easy to convince one's self, with the aid of the microscope, that the amœba is able to take up solid particles into its body from the

surrounding medium in which it floats. The mode in which the little animalcule slowly effects a change of position in the field by means of its contractility may also be recognised. It is observed, namely, to put out a process in one direction, into which the rest of the body gradually streams, as it were, until finally this process has become the body of the organism. The interesting discovery also was made a few years ago, that these two properties are not exclusively confined to the elementary organisms just mentioned, but exist in the less independent amœboid cells of the bodies of higher animals. Thus we see that tiny molecules of pigmentary matters, such as cinnabar, carmine, indigo, and aniline, or the oil-globules of milk, are taken up into the bodies of the amœboid cells of blood, of lymph, and of pus,—some

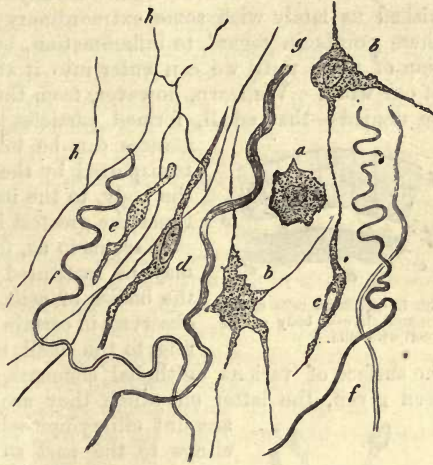


Fig. 68.—Living connective tissue from the frog's leg. *a b c d e*, various forms of connective-tissue corpuscles; (*a-c*, contractile); *f*, fibres, and *g*, bundles of the same; *h*, elastic network.

of them while lying at rest being reached and embraced, as it were, by processes of the protoplasm, and so received into the body of the cell (fig. 69, *a*). But what is thus brought about artificially with comparative difficulty, takes place readily and extensively in the living body. Closely-packed in the narrow interstices of organs, amœboid cells receive into their substance even larger formed masses; these may, however, be forced into the soft protoplasm from without. In the interior of such cells we find at times conglomerations of animal colouring matters, fragments, or even perfect examples of blood-corpuscles, which have left the general circulation (*b*), objects which were regarded as enigmatical in former times, when the cell was supposed to possess an imperforate membrane.

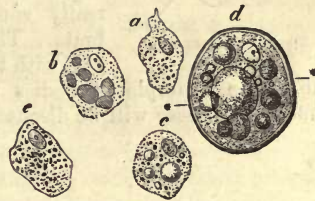


Fig. 69.—*a*.

With the power of receiving matters into its body there coexists in the cell another of expelling the same. After a certain time the contractile protoplasm works the granules, or fatty molecules as the case may be, towards its surface, and finally discharges them from the body of the cell completely.

This wandering of amœboid cells through the interstices of living parts was discovered years ago by *Recklinghausen*. The readiest mode of studying the phenomenon for ourselves is by taking a drop of some fluid containing cells from the body. In the tissues of the system the cells wander on with a continual change of shape through fine narrow interstices (usually compressed somewhat into elongated figures), and traverse thus in a short space of time comparatively large distances.

Both of these—the reception of matters into their interior, and the locomotive propensities of cells—furnish us with an insight into a new world of liliputian life. Owing to these properties, the amœboid cells of such animal fluids as lymph, mucous and serous exudations, may wander out from deep or remote organs in any direction. *Cohnheim* has furnished us lately with some extraordinary results of his observations on these points in regard to inflammation, but we will defer the consideration of them until we can enter into it at greater length in another part of our work. We learn, however, from these—and the possibility cannot be denied—that small, formed particles of zymotic and infecting substances can be taken up by amœboid cells, and transported by the latter to distant localities in the body, to the imminent danger of, and with at times the greatest injury to the system.

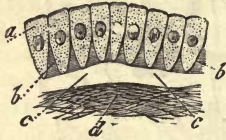

Fig. 70.—Ciliated cells of the mammal. *a-d*, body of the cell with cilia.

It seems to us, further, as though a comparison may be instituted between this contractility of the bodies of cells, and another kind of motion observed in certain appendages of the latter. We refer to the small, hair-like formations attached to the surface of various epithelial elements, to which the name cilia has been given, the latter on which they are placed being termed on this account ciliary epithelia (fig. 70). As long as life clings to the part so long are these delicate hairs engaged in a constant and rapid undulating movement. But we will consider this “ciliary motion” more fully further on.

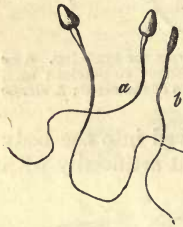


Fig. 71.—Human spermatozoa.

The nucleus, also, or parts formed from it may, although exceptionally, become contractile in animal cells. But up to the present we are acquainted with really contractile nuclei only among the invertebrata. The spermatozoa of vertebrates, however (fig. 71), with their wonderful power of rapid progression, afford an example of bodies which have their origin perhaps in the nucleus. These will be discussed more at length presently.

§ 50.

Let us now contemplate among the vegetative phenomena of cell-life the *growth* of this element.

Like all other organic structures the animal cell possesses the capability of growth, of increase in size, by means of the introduction of new particles among those already composing its body, or, as it is the custom to say, by “intussusception.” And in that the most extended use is made of this property throughout the system, we see consequently that in size, newly formed cells are much smaller than those already arrived at maturity. The enlargement of cells, however, takes place very unequally in the several tissues; in some they usually increase but moderately in size, as, for instance, in certain epithelia, while in others, as in the elements of unstriped muscle, they may undergo an enormous augmentation in volume. These latter are the contractile fibre cells already so frequently referred to. Certain cells, also, as, for instance, those of fatty tissue and cartilage, are often much more minute in the advanced embryo, or infant, than in the same tissue in the adult human body,—a fact established many

years ago by the Dutch investigator *Harting* with the aid of the microscope.

A satisfactory physical analysis of cell-growth is not possible in the present state of science, and we can only here and there at most seize on certain items of the process.

If its surroundings afford the growing cell sufficient room for operation, and if those elements lying next to it are separated from it by considerable intervals of soft, yielding matter, it increases uniformly in all directions, and preserves its primary spherical form. But if, on the other hand, growing cells are crowded closely together, owing to this increase in size the various members of the crowd must come into contact eventually, and consequently a mutual flattening of each individual element ensue on account of their softness. It then depends, of course merely upon mechanical moments, whether they will assume the flattened shape, and become squamous, or take on the elongated form.

We meet, however, often enough with cells increasing in size, in tissues of soft consistence, which are difficulties in the way of such an explanation as that just given of the law of growth of cells, where the deposition of new molecules does not progress with uniformity, and in consequence the cell becomes fusiform or pyriform, losing its original figure altogether. If these additions to the substance of the cell take place only at very limited points, they give rise not unfrequently to the formation of long processes in varying number.

We cannot, however, hope to have attained much by this mode of explanation of the shapes assumed by cells; for, just as the many species of plants and animals possess each one its own special stamp, so do the various kinds of cells of our body possess their own peculiar specific characters whose origin mocks every kind of analysis we can apply.

But not alone does the body of the cell grow, but the nucleus and nucleolus also undergo an addition to their bulk, though in a minor degree. The nucleus, on account of its similarity in nature to the cell, may be supposed to increase in the same manner; and, in fact, we often remark, besides the general enlargement, an irregular growth through which the spheroidal body may become flat, elongated, and narrow, or columnar, &c. The increase in size of the nucleolus is probably least of all, although it can be distinguished in ganglion cells, and many others, as, for instance, in the primitive ovum.

In contrast to these cells there exist others in which, on account of the growth or senescence of the body, the nucleus previously present disappears—is, in fact, dissolved.

Thus the nuclei of the most superficial, or, in other words, the oldest and largest cells of the epidermis vanish; and again the formative white blood-corpuscle is endowed with a nucleus, which is absent in the red cell later on, at least among human beings and mammals.

Should the cell have developed around itself a more or less sharply defined cortical layer of protoplasm, or an independent wall, this may become increased in superficial extent by the deposit in it of new molecules produced in the body of the cell.

The envelopes, also, of growing cells frequently become thickened, besides by a constant deposit of solid matter on their internal surfaces. We shall have to take all these points into consideration below when considering cartilage cells.

Other phenomena of growth which lead to a relinquishing of the

cellular nature and individuality of the cell will come under our notice lower down.

§ 51.

All structures of the body—the tissue elements, and, in the case in point, the cells—show a transmutation of the matters of which they are composed (p. 11); they present for our consideration an “*interchange of material*” in connection with them.

Simple microscopic investigation even affords us many proofs of this, by showing that, beside the growth of the cell, its contents may become eventually of a different nature from an optical point of view. Thus we see, in glancing at embryonic processes in the first place, that the formative cell of tissues exchanges its previously homogeneous or finely granular contents for more specific materials, in that, instead of the granules of the yolk, fat globules, pigmentary matters, and blood-pigments, &c., may make their appearance in its body. The same interchange of matter is also seen in the mature animal system; the white formative blood-corpuscles are transformed into red cells. The neutral fats, which, enveloped in a thin layer of protoplasm, form the contents of the so-called fat-cells, may disappear from the body of the latter in consequence of prolonged fasting or exhausting disease, and be replaced by watery protoplasm, or, as it was formerly expressed, by a “serous fluid.” Again, in the interior of the epithelial cells of the small intestine, certain fat globules may be observed after every meal, which, in the course of a few hours, have regularly disappeared again. And, indeed, we might bring forward many other examples.

One more example of cellular transmutation may be mentioned here as a recent discovery.

In the inactive submaxillary gland are to be found cells which contain, besides a small amount of protoplasm expanded peripherally and a nucleus, a large drop of mucus. By the action of a continued electric stimulus, these gland-cells may be made artificially to discharge the mucin, and on doing so, are found to be granular throughout, and, freed of the gelatinous substance, smaller. In a few hours the whole cell-body is observed to be formed entirely of protoplasm.

Now, although we are in this way able to see, one might almost say, with the naked eye, the transmutation of matter in the cell, nevertheless great difficulties arise so soon as the question turns upon a more detailed analysis of the same; and this it is which causes the advance to appear so inconsiderable which has been hitherto made in a field of inquiry so important for general physiology. The very knowledge of the fact, also (first observed by *Graham*), that crystalloids, but not colloids, can pass through the envelopes and body of the cell, which consists of colloid matter, renders it difficult to comprehend how the nourishment and growth of the latter take place, although it may explain, on the other hand, the mode of excretion of the products of decomposition.

When we are questioned as to the vigour with which this interchange of matter takes place in the animal cell, we are only able to offer conjectures. In the first place, different parts of the cell may be endowed with different degrees of transformative energy. The membrane, for instance (if the cell have acquired one), appears to be endowed with less than the other portions, and to be the most stable of the whole, especially when it consists of tough and indifferent elastic matter. On the other hand, everything

points to the conclusion that, as in the growth of the cell, so also in its transmutative functions, the body takes the most prominent part, for in it the most important alterations are observed to take place. The nucleus seems to stand between the inert membrane and active body of the cell in point of energy in the metamorphosis of matter.

Of the amount of transmutation in large groups of cells of particular tissues we know just as little. There are physiological facts, however, which would lead us to the conclusion that those tissues to which we ascribe the highest physiological dignity—as, for instance, those of the muscular and nervous systems—possess this power to a very considerable extent; so that we may look on the cells of unstriped muscle and of ganglia as structures possessing the capability of rapid renovation of their substance. But the coming and going of material must be still more rapid in those numerous cells which clothe the interior of the glands of our body, from all we know of the processes of secretion. On the other hand, we find certain kinds of cells whose transformative abilities are probably very inconsiderable, as, for instance, those of old laminated epithelia and of nail-tissue (so closely related to that of the epidermis), and the cells of cartilage. In respect to many other cellular structures, we are not even able to form likely conjectures.

The consideration of the means employed by nature to bring about this transmutation of matter in the animal cell, is likewise bound up with many difficulties.

Among these agencies, however, may be reckoned, in the first place, the property of imbibition inherent in histogenic materials; and, secondly, great stress must be laid upon the processes of endosmosis always accompanying cell-life. And in that chemical processes are incessantly at work in the interior of the cell, and are often of considerable energy; in that constant series of transmutations follow one upon another here, and that the contents of the element change their nature very frequently; in that fluids of different constitution pass over the surface of the cell finally, the phenomena of diffusion must be very various.

Looking somewhat more closely into the vital actions of the cell-substance, we find them to be of two kinds: "egotistical," or occurring in the interests of the proper nutrition of the latter; and again of another nature, for the attainment of greater ends no longer confined to the narrow purposes of cell-life. The latter are to be observed in gland cells.

The mode of action of these is two-fold, with transitions from one to the other. Certain cells only receive into their bodies substances which existed previously in the blood, and which pass through them without undergoing change, into the ducts of the gland, to form the peculiar secretion of the latter. Thus, in the case of the gland-cells of the kidney, for instance, we find them simply allowing of the passage through them of certain constituents of the blood, namely, urea, uric and hippuric acids, and several salts. It is probable, also, that the cells with which serous sacs are lined admit of the transudation, in a similar manner, of the fluids with which they are moistened and lubricated. On the other hand—to return to the gland-cells—we find a considerable number of glandular organs which do not constitute simple apparatuses for the filtration of constituents of the blood, but which receive, on the contrary, certain matters into their interior in order to transform them—to cause them to enter into new combinations, or to split them up into new compounds, and so on. The tendency to refer all this chemical change to the

action of fermenting matters in the cell-body, or to some properties inherent in the nucleus, seems natural. Thus, we see that the action of the hepatic cell gives rise to the formation of the bile acids and glycogen. In the gland-cells of the functioning mamma sugar of milk must be produced from some of the hydrocarbons it receives, or from albuminous matters. In the cells of the salivary glands of the gastric and intestinal follicles and of the pancreas, ferments are generated which do not exist as such in the blood, and which impart to the secretions of the organs in question their peculiar physiological properties.

Now, these operations engaged in by the gland-elements are repeated again in the proper or egotistical nutrition of individual animal cells. It seems probable that in many cases constituents of the blood simply enter animal cells in order—perhaps after undergoing very slight modification—to become constituents of the latter. This is borne out by the fact that the cells are principally built up, as it were, of albuminous compounds. On the other hand, we frequently observe considerable transmutation to take place, by means of which matters received acquire another nature. Thus the protein compounds of laminated epithelium are converted gradually into keratin, the albuminous substances of other cells are transformed into mucin, and again the fatty soaps of the blood assume the form of neutral fats on entering the cells of adipose tissue—a metamorphosis of which but little farther is known.

But the metamorphosis of matter taken up into the cell becomes especially striking in the case of the formation of pigments. Here we behold the white blood-cell generating in its interior a colouring matter and becoming a red corpuscle; in the same way granules of black pigment or melanin are developed in the bodies of many originally colourless cells, when they are known as pigment cells.

The question as to what matters are generated by the cell itself, and what are received into it from without already formed, is in many cases difficult, and frequently impossible, to answer.

Now, as to the retrograde metamorphosis of the components of the cell, as to the liquefaction and discharge of the products of decomposition, we know at present but very little. The most purely cellular tissues usually exist in too small quantity to admit of chemical investigation. But occasionally, under favourable circumstances, a few conclusions may be drawn on these points. Thus the products of decomposition of striped muscle may most probably be regarded as similar to those of involuntary fibre, judging from their chemical and morphological relationship; and in the contractile fibre-cell of the latter we suppose the albumen to be transformed into kreatin, kreatinin, hypoxanthine, inosinic acid, inosite, and the paralactic acid.

In concluding this section, it may be remarked that *Schwann* has designated those phenomena connected with the chemical transmutations of the cell as “metabolic occurrences,” and speaks of a “metabolic force” inherent in cells.

§ 52.

The interchange of material going on among animal cells, as a study, (however scanty our knowledge of it may be), has made us acquainted with the elaboration of amorphous matter, and with the excretion of fluids containing the products of decomposition or the earlier substance of cells in solution. It has also brought under notice a number of formations

of much deeper import in histology, in which material supplied by the cell-body solidifies and assumes definite forms, a process of the greatest importance in histogenesis, and upon which great stress was laid many years ago, especially by *Koelliker*.

The formations to which we refer may be regarded at one time as produced by secretions from the surface of the protoplasm; at another by metamorphosis of peripheral layers of the latter. In fact, both these processes are merged into one another so frequently that no great stress need be laid on their separation.

These *solid formed structures*, although of greater significance in the bodies of the lower animals than in the human, appear nevertheless to play no unimportant part in our organisation, although the distinctions between the processes by which they are formed are still obscure.

In one of the foregoing sections the cortical layer of the protoplasm of cells was described, as also the cell-wall, which was recognised as an envelope differing chemically from the rest of the element.

When such membranes attain a certain degree of thickness and independence as regards the body of the cell, they are known as *cell-capsules*.

The best examples of such capsular membranes are to be found among the elements of a very widely spread tissue, cartilage (fig. 72).

The cartilage cell proper (*b*), consists of a nucleus (*a*) imbedded in transparent contractile protoplasm. On the surface of the latter a chemically different layer is gradually formed, which is at first thin and delicate, but eventually attains considerable thickness (*c*) by the deposit on its internal surface of laminae of new matter. Not unfrequently a distinctly concentric marking may be observed in the capsule, as optical expression of this successive formation within it of laminae. Again, much may be learned from the action of water upon the body of the cell, under which the latter shrivels up and becomes widely separated from the capsule (3).

It is probable that the thick tough envelope known as the chorion (fig. 73), which invests the primitive ovum cell, is of analogous nature to the cartilage capsule. This has recently been discovered to possess a very peculiar structure; it is marked, namely, by very delicate radiating lines, which are the optical expression of extremely fine passages or canaliculi, known as the "*pore-canals*" of *Leydig*. These which are also present in vegetable cells are undoubtedly of the deepest significance in cell-life.

As related to these capsular structures enveloping whole cells, other formations may be mentioned which are only *partial*, occurring on the free surface of epithelial cells. They are to be found, for instance, among the columnar epithelial cells of the mammalian intestine, with their delicate *pore-canals*, discovered many years ago almost simultaneously and independently of one another, by *Funke* and *Koelliker*.

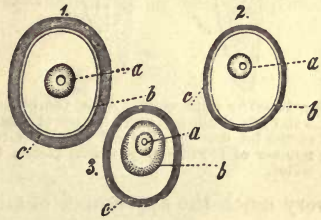


Fig. 72.—Diagram of three cartilage cells with capsules. *a*, nucleus; *b*, cell-body; *c*, capsules.

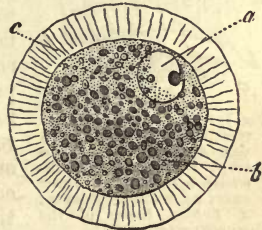


Fig. 73.—Ovum of the mole (copied from *Leydig*). *a*, nucleus; *b*, cell-body; *c*, thickened capsule traversed by pores.

It had long been known that the free surfaces of the columnar cells in question were covered with transparent borders. These, however, were held to be the optical expression of thickened cell-membranes. We now know, however, beyond doubt, that each cell is topped by a kind of lid as it were. In this fine streaks or pore-canals may, as a rule, be distinctly recognised (figs. 74 *a*, 75 *b*); seen from above, also, the cells are observed to be finely dotted (fig. 74 *b*). At times, however, the markings on the borders of the cells are not distinguishable, or only very indistinctly

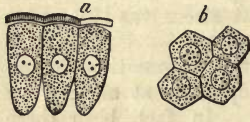

Fig. 74.—Columnar cells from the small intestine of the rabbit. *a*, side view of cells with thickened raised lids traversed by pores; *b*, view from above, in which the orifices of the pores appear like dots.

so. This transparent lid may be loosened from the surface of the cells

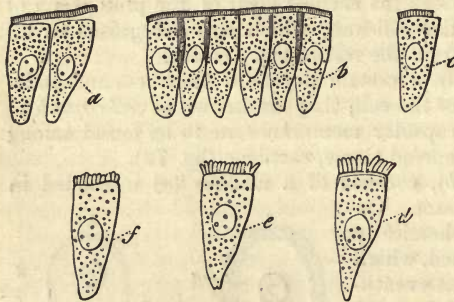


Fig. 75.—The same cells. At *a*, the border is loosened by water and slight pressure; *b*, natural condition; *c*, a portion of the lid destroyed; *d e f*, the latter is resolved into a number of rod-like or prismatic pieces, by maceration in water.

by the action of water or pressure; either in the form of one continuous band (figs. 74 *a*, 75 *a*), or, only specially attached to each cell (figs. 75 *c-f*). Then again, the delicate substance of the lid, composed of some unstable albuminous matter, splits up frequently on imbibing water, or under slight pressure, into a number of rod-like pieces, which may give to the columnar epithelial cells in question

very much the appearance of ciliated elements.

§ 53.

The nature of this cell-border on the free surface of the columnar epithelia just mentioned, leaves no room to doubt that the layer is produced by the cell itself, and not deposited on its membrane from without in some way or other.

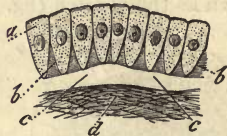

Fig. 76.—Diagram of a mucous membrane covered with columnar epithelium. *a*, the cells; *b b*, interstitial substance between their lower ends; *c c*, transparent layer; *d*, fibrous tissue of the mucous membrane.

But many other formations leave us less certain as to their origin. These may occur lying beneath cells, or again, on the exterior of large collections of the latter, in which case they represent continuous layers, capsules, sacs, blind follicles, tubes, &c., formations which all correspond in their structureless transparent appearance, and usually in their insolubility, and in consisting of some material allied to, if not identical with elastin.

Thus, underneath the coatings of epithelial cells which cover different mucous membranes of the body, a transparent layer may frequently be observed with varying degrees of distinctness (fig. 76 *c c*). This is the so-called *intermediate membrane* of Henle or *basement membrane* of the English investigators, Todd and Bowman. There appear in like manner transparent laminae underneath the epithelium, clothing the anterior and posterior surfaces of the cornea.

In our opinion, the latter glass-like subepithelial strata have nothing to do with the cells of this tissue, they are more probably modified limiting layers of the connective tissue of cornea and mucosa.

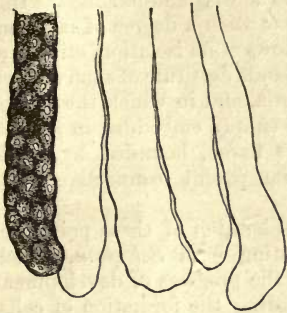


Fig. 77.—Glands from the large intestine of the rabbit; one follicle with cells and four glands, of which only the *Membrana propria* has remained completely stripped of cells.

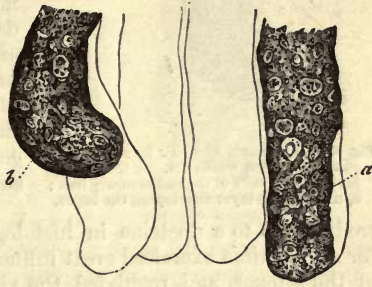

Fig. 78.—Follicle from the large intestine of the guinea-pig. Gland at *a*, with *Membrana propria* partially visible; at *b*, the contents have escaped through a slit in the latter membrane.

As we have just remarked, there occur, enveloping certain groups of cells, homogeneous layers, constituting, especially among the glandular structures, what is known as the *Membrana propria*, i.e., a transparent tunic investing the gland and determining its shape, as well as that of its several parts, and on this account of much importance. Of these membranes are formed the vast multitude of follicular glands, having the shape of long narrow pouches (figs. 77, 78 *a*), whilst in the no less widely distributed group of racemose glands the latter are replaced by numbers of flask-shaped saccules packed closely together (fig. 79).

But also around aggregations of embryonic cells, destined later on to become definite structures, similar transparent envelopes are to be found, as, for instance, around the rudimentary human hair, as pointed out by *Koelliker* (fig. 80).

Such homogenous membranes have been regarded by some as produced by the solidification of a secretion from the cells themselves,—a theory which is not at all weakened by the fact of the separation of the transparent envelope from the cells by which it is formed, nor that it outlasts the elements from which it has had its origin. It is, however, difficult to explain why in an aggregation of cells identically the same, only those situated externally should possess the power of generating such a secretion.

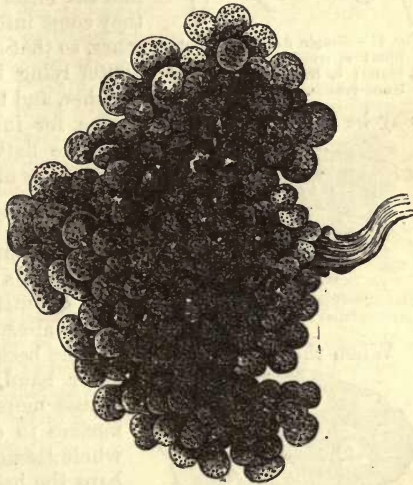


Fig. 79.—A human racemose gland (*Brunner's*) with saccules of the *Membrana propria*.

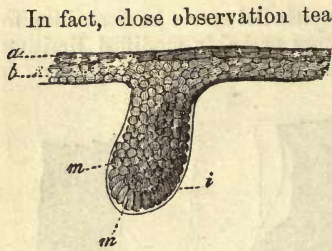


Fig. 80.—Rudiments of a hair from a human embryo sixteen weeks old. *a b*, cuticular layers; *m m*, cells of the rudimentary hair; *i*, mucous layer enveloping the latter.

In fact, close observation teaches here also that the structures in question are merely modified, limiting layers of the fibrous tissue of the cutis. And although, in most glandular organs this may arrive at such a degree of independence as allows of its isolation, still there are other glands destitute of such a membrana propria, and in which the groups of cells are simply embedded in a pit in the mucous tissue, bounded by homogeneous transparent connective substance.

The consideration of these points introduces us to a doctrine in histology originating with *Schwann*, which for a long time exercised great influence over the progress of development of the science, and regulated the views regarding the formation of cells.

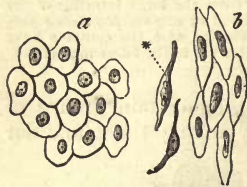


Fig. 81.—Simple flattened epithelium; *a*, from a serous membrane; *b*, from the lining of blood-vessels.

We refer to his theories respecting “cytoblastema,” or the “ground-substance” of tissues, which, when occurring between cellular elements is known as “intercellular substance.”

If we direct our attention to portions of the body consisting mainly of cells, we frequently find the latter so closely crowded together that they come into immediate contact one with the other, so that at first nothing is to be seen of the matter lying between them which holds them together, and to which the name of *tissue-cement* may be given. This is the case, for instance, in some of the epithelia, such as the flattened species, which line the internal surfaces of serous cavities and blood-vessels (fig. 81).

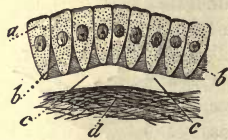

Fig. 82.—Columnar cells with intercellular substance, *b c*.

Again, layers of cells are to be found in which a connecting medium is apparent between the several elements of the tissue, though perhaps only in small quantity, as, for instance, in columnar epithelium already mentioned (fig. 82).

When the cells of a simple tissue become more widely separated on the

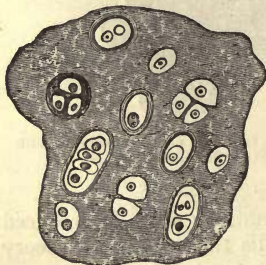


Fig. 83.—Cartilage cells of various forms with homogeneous intercellular substance (diagrammatic).

other hand, the intercellular substance increases more and more in amount, and commences to determine the consistence of the whole tissue. Cartilage supplies us with perhaps the best example of this (fig. 83).

This intercellular substance is of many kinds, both as to appearance and composition. Thus we meet with it, for instance, perfectly transparent—its most usual form—without granules, &c., as between the cells of epithelium. In many species of cartilage it is milky white; in others finely streaked to a greater or less extent.

Another kind of cartilage, known as the “elastic” or “yellow,” presents a most peculiar appearance: in it the intercellular matter is made up of a tangle of irregularly interlacing bands and fibres (fig. 84).

Chemically, intercellular substance may either appear as a fluid containing albuminous matters in solution (blood, lymph), or as a jelly composed of gelatinised protein compounds (many foetal tissues), or as coagulated metamorphosed albuminous substances (epidermis, nails), or as glutin-yielding tissue, such as chondrin (in permanent cartilage), or finally as elastic material (in elastic or yellow cartilage).

Now, by *Schwann* this intercellular substance was regarded as the primary structure in which he supposed the cells subsequently to take their origin,—a view which was favoured for a very long time by the greater number of histologists.

The fact, however, that in the earlier periods of foetal life no intercellular substance is found between the cells of growing tissue, seems to point to another conclusion (especially when viewed in the light of present-day science), namely, that the matrix is a product of the secretion of the cell itself, or a metamorphosed peripheral portion of the cell-body, the contribution of each element fusing, of course, into the common mass.

And, indeed, there are appearances in cartilage which admit of no other explanation. Thus, we not unfrequently remark that the peripheral capsular layers surrounding the cells like a halo, blend into the adjacent intercellular substance without any sharp line of demarcation. But the appearances presented by sections of cartilage which have been treated with certain reagents are of far greater importance even (fig. 85). Here the apparently homogenous matrix of fig. 83, for instance, is resolved into systems of thick capsules, which encircle the various cartilage cells, or groups of the latter touching each other at their circumference. We shall refer to this again further on.

But if blood, lymph, and chyle be numbered among the tissues of the body—which may be reasonably done—their fluid intercellular substance is certainly of other origin, *i.e.*, not produced by the corpuscles. The cellular elements of lymph have rather wandered actively out of the lymphatic glands in part, and have been partly carried out with the currents of the fluid, just as a stream may sweep away portions of its banks, and transport them to a greater or less distance.

§ 54.

In a former section we have already considered the question, how far the growth of parts depends upon a simple enlargement of cells already present, and how far upon an increase in the number of the cellular elements of which the part is composed. We have seen that the last-named mode of growth is the rule: cellular structures increasing in volume, usually show a multiplication of their elements. The cell, like all organic formations, is a transient structure, and in all probability invariably endowed with a term of existence far shorter than that of the body generally, and which may be named in many cases exceedingly brief when compared with the latter. It stands to reason, then, that it must either possess the capability of proliferation,—of reproducing similar structures to itself, of generating a progeny,—or whole families of cells

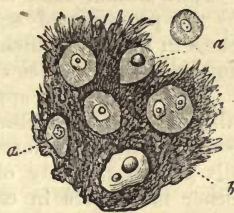


Fig. 84.—Fibro-reticular cartilage from the human epiglottis.

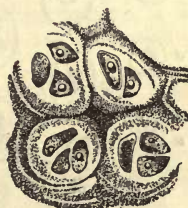

Fig. 85.—Thyroid cartilage of the pig treated with bichromate of potash and nitric acid.

must be produced independently of those originally present by a species of spontaneous generation in the tissues themselves.

That animal cells really possess the property in question, is indicated by the processes of segmentation which have been long known to take place in them, to which attention was directed many years ago by *Remak*, and which have since then been observed over and over again.

Division of cells appears invariably to depend upon the vital contractility of their protoplasm, and to be an impossibility so soon as the cell-body becomes transformed into other substances. It is, therefore, essentially a vital property of young cells. The process of segmentation may either take place in cells destitute of membranes, or in those contained within capsules. Owing to this the occurrence is variously modified. When the division takes place in membraneless elements, the whole structure is constricted until separation into two halves occurs; while in those which possess an envelope or capsule, the latter remains unaffected by the process which divides the cell within it. The last variety is known as "endogenous multiplication or cell growth."

1. Division of naked cells, or, as it may be called, free segmentation, can be observed accurately in the white corpuscles of the blood of young mammalian animals and embryonic birds. In the first (fig. 86) we usually find a round nucleus (*a*) in a spheroidal cell. When segmentation is about to take place, the former becomes somewhat elongated, and is shortly after observed to be marked by a slight transverse constriction, the whole cell assuming at the same time an oval form (*b*). This transverse furrow on the nucleus then deepens more and more until the latter is finally divided into two pieces (*c*), which at first lie very close together, indicating their origin, but soon begin to separate from one another (*d*). On this the body of the cell undergoes the same constriction (commencing either at one side, or regularly all round), which causes the cell to assume a form likened at times

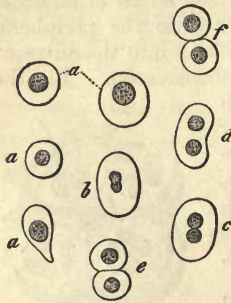

Fig. 86.—Blood-corpuscles from a young deer embryo. *a a a*, spheroidal cells; *b-f*, segmentation of the same.

to a double leaf (*e*). Later on there only exists a narrow band of connection between the two portions of the body (*f*), which is finally completely severed, giving rise to the formation of two cells. By subsequent growth these rapidly attain the typical dimensions of such elements. In the embryonic chick, an easily obtainable object, the nucleoli may be first seen to undergo the process of division within the nucleus. This fact has been improperly denied by some in connection with embryonic blood (*Billroth*).



Fig. 87.—A cell from the frog undergoing segmentation into three portions (after *Remak*).

But the process of segmentation does not always occur with the regularity of the example just cited. Thus, in the frog division is described by *Remak* as occurring in such a manner as to produce from a single corpuscle three, four, or six cells. In other respects, however, and as regards nucleus and body, the process is similar to that of simple cleaving (fig. 87).

Those very remarkable formations known as "giant cells" (*Riesenzellen*) (fig. 64, p. 72) are produced by multiplication of the nuclei without corresponding segmentations of the body.

§ 55.

2. Passing on now to the consideration of segmentation in cells endowed with a wall or capsule, we find perhaps the best example in the cellular elements of cartilage. Endogenous growth in the cells in question does not take place with the same simplicity as in the process just referred to, and is a phenomenon the details of which are not yet fully known; so that in the following description much that is hypothetical must be advanced to supply points upon which we possess no certain information yet (fig. 88).

The nuclei of naked cells enveloped in secondary capsules (*b*) are found at first to possess a single nucleolus (1). On the commencement of the process of division this becomes double (2); upon which a transverse furrow may be recognised in the nucleus (3); by the deepening of this furrow the latter is eventually divided into two segments (4); which then recede from one another, thus initiating the constriction of the cell-body (5); on the completion of the latter act (6), two perfectly distinct cells (7) are found within the capsule, which has remained throughout entirely passive. These new elements are known as "daughter cells," while the original cell, or, more correctly speaking, the capsular membrane of the same, has received the inappropriate name of "mother cell," or parent cell.

Now, if this sketch be correct, the only difference existing between the simple division described at (1), and the latter, consists in the presence of a capsule, so that in a blood-corpuscle of a mammalian embryo, if we imagine it endowed with an envelope, we have precisely the same plan of segmentation as that of cartilage cells.

But the division of the latter does not by any means always stop here; in both daughter cells the same process of segmentation may be repeated until the capsule includes four of them (8), around which capsular formations are eventually developed (*e*). So by a repetition over and over again of the same acts, whole generations of new cells may be produced within a common capsule (9).

On the fusion of this envelope of the parent cell with the surrounding intercellular substance, the daughter cells may eventually appear to lie free in the matrix. Part of the cartilage cells which have multiplied on the above plan assume an apparently free condition in this way.

Others again remain permanently enclosed in the parent capsule.

The ovum, after fertilisation has taken place, presents to us a similar process of cell-division, of the utmost anatomical and physiological moment, known as yolk-segmentation (fig. 89). The mode in which this takes

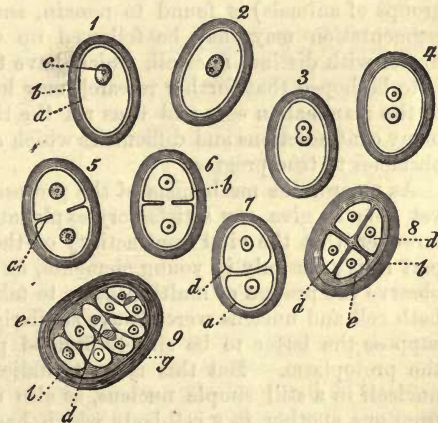


Fig. 88.—Plan of dividing cartilage cells. *a*, body of cells; *b*, capsules; *c*, nuclei; *d*, endogenous cells; *e*, subsequent formation of capsules around the latter.

place in the mammalia is, unfortunately, not yet conclusively ascertained. The primordial nucleus of the ovum, however, known as the

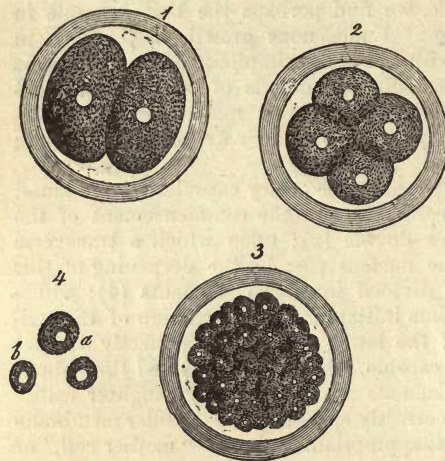


Fig. 89.—Segmentation of the mammalian ovum (half-diagrammatic). 1, Yelk cleft in two; 2, further subdivided into four spherules (cells) with nuclei; 3, a large number of nucleated cells; 4, *a b*, separate corpuscles.

germinal vesicle, seems first to disappear; after this two transparent spots are seen, two new nuclei, and around each, half of the cell-body or yelk, by which name the latter is known here (1). By further subdivision, four cells are formed from these two segments (2); and from these again eight, and so on, until finally, in consequence of repeated segmentation, the capsule of the ovum contains a multitude of small nucleated cells (3, 4). From the latter the first rudiments of the embryonic body are formed: from them spring all normal and pathological form-elements; they are the most important and highly destined cells in the whole system.

Throughout the whole animal kingdom this segmentation of cells is observed in the ovum. Those cases are particularly instructive in which the original nucleus of the egg (germinal vesicle) (seen among some low groups of animals) is found to remain, and in which the phenomena of segmentation may then be followed up with the greatest ease on the nuclei with distinct nucleoli, which have taken their origin from it. It is to be hoped that further research may lead to the same results in regard to the mammalian egg, and thus rid the theories of yelk-segmentation of many contradictions and difficulties which at present offer such unpleasant obstacles to true progress.

As regards the mechanism of the process of segmentation, science is not yet able to give any satisfactory explanation. There can be no doubt, however, that the vital contractility of the cell-body plays an important part in it; for only in young elements, *i.e.*, containing protoplasm, do we observe the process of multiplication to take place. Were it the case that both cell and nucleus were always similarly affected by the act, we might suppose the latter to be simply divided passively by the constriction of the protoplasm. But this is contraindicated by the occurrence of two nucleoli in a still simple nucleus, as also of two nuclei widely separated from one another in a cell-body which has as yet undergone no change (fig. 86 *c*).

One fact, adduced from extended observation, is of great importance, namely, that the whole process of division may be, and usually is, completed very rapidly, probably within the space of a few minutes. This enables us to comprehend the enormous proliferation of cells which we not unfrequently meet with in pathological processes. It also explains the fact that cells engaged in the act of segmentation are comparatively rarely met with, even where the liveliest plastic processes are going on in an organ.

§ 56.

The question now arises, whether in the two processes of segmentation of animal cells just described, the entire act of multiplication of the elementary parts in question is contained, or whether the cell may not produce similar elements in other ways.

A kind of gemmation has been observed on the nuclei of both normal and pathological cells. This was found years ago, by *Koelliker*, to take place in the large colourless cells of the spleen of young mammals (fig. 90). In these, from three to five or more nuclei may be recognised clinging together, displaying a peculiar modification of the process of

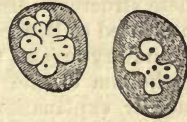


Fig. 90.—Colourless blood-cells from the spleen of a kitten.

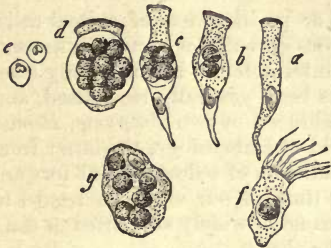


Fig. 91.—Supposed formation of pus-corpuscles in the interior of epithelial cells, from the human and mammalian body. *a*, simple columnar cell from the human biliary duct; *b*, another with two pus-corpuscles; *c*, with 4, and *d*, with many of the latter; *e*, the latter isolated; *f*, a ciliated cell from the human respiratory apparatus, containing one pus-corpuscle; and (*g*), a flattened epithelial cell from the human bladder, with a large number of the same.

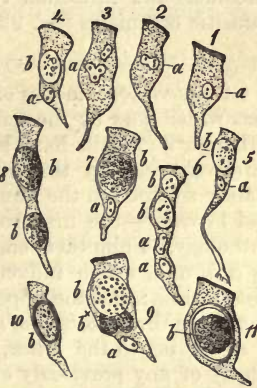

Fig. 92.—Psorospermia in the interior of epithelial cells from the small intestine of the rabbit. 1, Simple epithelial cell; 2 and 3, nuclear multiplication; 4 and 5, columnar elements with single psorospermia cells; 6, with two; 7, with a large contained body; 8, with two, without the cell nucleus; 9, division of contained body; 10 and 11, cells with perfect psorospermia (the latter are marked by *b*, the cell nuclei by *a*).

division in the nucleus. I have myself observed something similar in modified columnar epithelium from the small intestine of the rabbit (fig. 92, 3).

Gemmation, as a mode of multiplication of whole cells, has not yet been met with in the human body or that of the higher animals.

Of late years another remarkable process, apparently of cell formation, has been observed, in which the proto-plasm of the original cell becomes transformed into one or more new cells, possessing completely different characters from the cell-body from which they have had their origin.

It is thus that pus-corpuscles are supposed to be produced in the interior of different epithelial cells of the human body under inflammatory conditions (*Remak, Buhl, Eberth*, and others).

Fig. 91 will give some idea of the case in point. Here we have ordinary columnar cells (*a*) containing two (*b*) or four (*c*) pus-corpuscles, the regular nuclei remaining visible. Such cells may also be encountered in-

cluding a still larger number of pus-corpuses, and altered in their shape on that account (*d*).

On being liberated from the cells in which they have been contained, these structures display all the characters of pus-corpuses (*e*). But even in ciliated cells, such as are to be met with in the mucous membrane of the respiratory organs, these pus-cells may be found (*f*), as also in the flattened epithelium of the bladder (*g*). Such things are, however, capable of another explanation. Pus-corpuses, elements whose vital contractility is beyond a doubt (§ 49), may have wandered into the epithelial cells from without. Such an immigration of strange elements has been proved to take place recently into the cells of some morbid growths (*Steudener*).

The same appearances are presented farther by psorospermia, peculiarly puzzling single-celled structures, which are frequently to be found in the bile-ducts and intestinal canal of rabbits, and which are looked upon as parasitic organisms (fig. 92).

§ 57.

Of the various modes of reproduction or proliferation of animal cells, that which goes by the name of endogenous growth has been long known, although its details have been variously interpreted. But it is only comparatively recently that segmentation has been generally recognised, and mainly so through the numerous proofs adduced by two observers, *Remak* and *Virchow*—the first from the wide field of embryology, the latter from pathology. From them emanated a contradiction of a doctrine put forward by *Schwann*, which influenced for a long time all our views in regard to histogenesis; and the opposition soon became so widely supported as completely to throw *Schwann's* theory into the shade.

According to the latter, animal cells are formed free, that is, independently of any previously existing. "There is," says he, "either in those cells already present or between them, a structureless substance, the cell-contents or intercellular substance; this matter (cytoblastema) possesses in itself, to a greater or less extent, according to its chemical constitution and degree of vitality, the power of giving rise to new cells. The genesis of cells represents in organic nature what crystallization does in inorganic."

In the first place, says *Schwann*, there springs up in this cytoblastema a minute corpuscle, namely, the nucleolus, and owing to the attraction of this body for surrounding molecules of matter, layers of these are precipitated, as it were, around it, giving rise to the nucleus. By a repetition of the process, a second layer is deposited upon the latter, which, though differing from the surrounding medium, is not yet sharply defined, but becomes so later. This deposit, hardening externally, forms the substance and wall of the cell. At the commencement the newly formed envelope lies closely round the nucleus—the cavity of the cell, and with it the entire structure, being still small, but the wall increases subsequently in size, and the whole obtains finally its specific contents.

To this was added later another theory, according to which the nucleus of certain cells is enclosed, in the first instance, by the future specific contents, and then only, around this mass, containing in its interior the nucleus (the so-called "enveloping sphere"), is formed a wall by solidification of part of the deposit, which brings the whole structure to completion.

For many years these two modes of origin of the animal cell appeared to be proved beyond all doubt, and the sole differences of opinion which

existed were as to the prevalence of one or other of them. The occurrence of free nuclei was taken as conclusive evidence of the pre-existence of these structures, although all were obliged to admit that they might have been liberated by destruction of the body of the cell. And, indeed, the occurrence of cells in such fluids as lymph, mucus, and pus, appeared to be capable of most plausible explanation by means of this theory of free origin; and proliferation of already existing cells, which could not rightly be denied, was yet regarded as exceptional. 'Tis true that this spontaneous generation (*Urzeugung*) of animal as compared with vegetable cells, which spring from others already in existence, presents a strange contrast between the construction of the animal and vegetable systems. But, on the other hand, the rapid development of pathological histology based on *Schwann's* work, seemed to give weight to the theoretical views of this talented man in this department also. The organisation of exudations, the formation of tumours, &c., were interpreted in this manner, to the support of the theory of spontaneous origin.

On *Remak's* demonstrating in a most elaborate manner that no spontaneous formation of cells takes place in the embryos of mammalia, but that all new elements have their origin solely from division of previously existing ones, this theory of the *generatio æquivoca* of animal cells became untenable, as regards the construction of the embryonic body at least. Great exertions were also made by *Virchow* to prove that for the growth of pathological tissues also (a far more difficult and obscure subject), spontaneous generation of the cell need not exist; and giving up all earlier theoretical conclusions, he conducted his case with the happiest results. A review, likewise, of the earlier investigations touching the cellular tissues of the healthy mature body, showed likewise a scarcity of free nuclei at those points where cells were being formed anew, and led to another easy interpretation, also, of the existence of cells without membranes. And now that earnest search began to be made for those already mentioned examples of cell multiplication which had been up till then so rarely met with, they were found to exist in far greater number than was at first supposed.

This, then, may be regarded a turning-point in histological science. Histologists, as a rule, have now abandoned the theory of the origin of cells without parents, accepting in its stead that of formation alone from others previously existing,—though, indeed, still to a certain extent in the light of an article of scientific faith, it must be confessed. The proof, namely, that spontaneous generation of cells in the system does not exist, is not even in the present day capable of being established by facts. And, indeed, it is probable that we never shall be able to adduce proof that such spontaneous generation does not take place in the midst of some of the more inaccessible tissues of the living body.

And now at the present moment, remembering the former state of science, and how for decades these theories of *Schwann* were clung to generally, and with an amount even of wantonness, we would inculcate caution. And though everything now seems to point to the conclusion that spontaneous generation of animal cells does not take place, nevertheless, it seems desirable, for many reasons, that the old view should still have its defenders as well as the new its opponents. Thus will science be compelled to put forth all her energies for the accumulation of that so indispensable material "facts," in order to set her dogmas upon a firm foundation, and histology can only gain by it.

§ 58.

Now, as to the decay of animal cells, we find their destinies to be very various.

Firstly, the existence of a cell may terminate purely mechanically; it may be rubbed or peeled off from its bed. Thus we see the superficial scale-like cells of the epidermis becoming dry and hard, and losing their nuclei; at the same time that their previously secure connections, by means of a cementing substance, become loosened, allowing of their easy separation. The same is the case, also, with the nucleated surface cells of certain laminated epithelia of mucous membranes, as, for instance, of those of the mouth. Such a separation also takes place from some of the more simple or even single-layered epithelial coatings, although not to the same extent as was formerly supposed. Thus mucus carries off some of the cells of the locality in which it is produced.

This mode of destruction, however, is the most rare, the cell passing on more frequently through changes in its consistence and composition to decay.

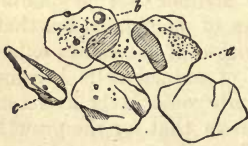

Fig. 93.—Detached cells of epidermis from the human skin.

The most usual way, probably, in which cells are destroyed, is that of solution of their bodies, and in the case of those possessing membranes, rupture of the latter, with escape of the contents, and eventual liquefaction of the nucleus, if such have been present. In this manner it is that blood-corpuscles are supposed to disappear, as also the cells which clothe the cavities of glands, and those in which spermatozoa are developed. Digested in the slightly alkaline fluids of the system, the matter of which the dying cell is composed is often transformed into a substance resembling if not identical with mucus. These occurrences, taking place in the gradual decay of the cell, are of interest from another point of view,

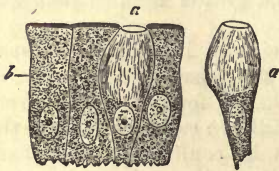


Fig. 94.—Cylinder epithellum from the human intestinal villi (after *Schulze*). *b*, normal cell; *a*, another in process of transformation into mucus.

namely, from the fact of their having been misinterpreted by the adherents of the older theorists, who reversed the order of things to the support of their own peculiar view.

We occasionally meet among the more delicate epithelia with both modes of decay side by side. Thus, of those cells of the intestine covered by a thickened border, some are cast off, whilst others first undergo decomposition with solution of the upper part of the membrane of the cell and escape of the contents (fig. 94, *a*).

Another change to which the body of the cell is liable, is into colloid matter, a much more stable substance than mucin, which, in contradistinction to the latter, is not precipitated by acetic acid. The connective tissue cells of the *plexus choroidæ*, and the cellular elements of the thyroid gland, are specially subject to this degeneration.

But, again, through far different chemical transformations, so to speak, can the cell meet the destiny of all organic things, its dissolution being at the same time hastened. There are usually two kinds of deposits of foreign matter to be found in the bodies of cells, which may make the latter incapable of further existence, and, curiously enough, of substances widely

distributed throughout the system, and which constitute the normal contents of the cells of other tissues. These are (1), neutral fats, deposits of which, for instance, cause the destruction of numerous cells of the *Graafian* follicle during the formation of the *corpus luteum* in the ovary (fig. 95, *a*). The same effect is produced by these fats on the gland cells of the mamma during secretion; (2), by salts of calcium (phosphates and carbonates) in the process which is termed calcification. We meet the latter very frequently in the cells of many cartilages. Inhaled molecules of charcoal may also accelerate the decay of the epithelial cells of the lungs.

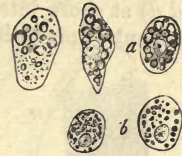

Fig. 95.—Modes of degeneration of animal cells. *a*, cells of the *Graafian* follicle filled with fat; *b*, epithelial elements of pulmonary alveoli, replete with pigment.

It belongs to the province of pathological histology to show that the same modes of decay are largely met with in the pathological processes of the system, namely, those of mucous and colloid metamorphosis, of fatty and calcareous degeneration; likewise that forms of degeneration appear in diseased states of the tissues which do not exist in the normal; as, for instance, the amyloid (§ 21), and the peculiar withering of cells in tuberculation.

B. The Origin of the Remaining Elements of Tissue.

§ 59.

Now, it is from these cells of which we have been speaking, and the substance to be found between them, that the remaining elementary parts of the animal body take their rise.

But, first of all, let it be borne in mind that it is by no means possible everywhere to define sharply between cells and many other elementary parts. Though we have seen, in the preceding pages, that a large number of the various cells preserve their cell-nature unchanged, or with but slight modifications, from the commencement to the end of their existence, still we have also become acquainted with some very striking transformations in their bodies, owing to which they may assume the most anomalous forms. To these may be reckoned the fibre-cells which make up the unstriped muscle of the human body and of all vertebrates. Here the cell has become a fusiform fibre owing to its unsymmetrical growth, and the nucleus also, though to a minor extent, has taken part in the process of elongation. While in this example of increase in the length of the cell the nucleus has also become elongated, still, in other similar enlargements, it may preserve its originally oval shape. This is the case in those long transparent cylinders consisting of globuline, which form the fibres of the crystalline lens.

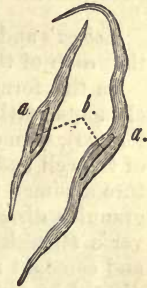

Fig. 96.—Contractile fibre-cells.

On the other hand, in some structures multiplication of the nucleus may accompany excessive elongation of animal cells to form tissue elements. This may be observed in a very abundant tissue of the body, namely, in striped muscle.

The elements of the latter are long cylindrical fibres (fig. 97, 1), of varying thickness, which possess certain contents (2, *a*) enclosed within a

structureless sheath. This contained substance is seen, with varying degrees of distinctness in different cases, to be marked by fine longitudinal lines combined with transverse striation, and to be studded with nuclei (*d d*) at short intervals; these nuclei are surrounded each with a small amount of protoplasm.

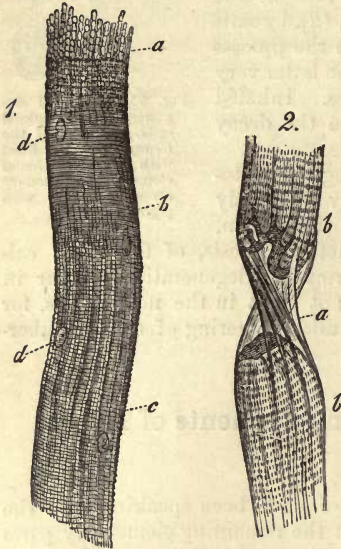


Fig. 97.—1. Fibre of striped muscle split up into primitive fibrillæ, *a*; more distinctly striped at *b*; longitudinal lines more visible at *c*; nuclei, *d d*. 2. A fibre, *b b*; torn through, with empty sheath partially separated, *a*. (Copied from *Bowman*).

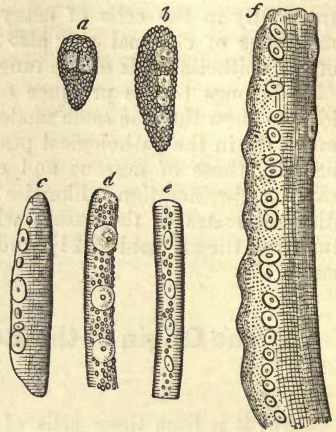


Fig. 98.—Stages of development in the formative cell of the striped muscle fibre of the frog. (After *Remak*.)

Lebert's and *Remak's*, as well as more recent investigations, have shown that each of these fibres has its origin in a single cell.

In the formative cells of frog's muscle (fig. 98), (the usual nucleated elements, with granular protoplasm, of which the body of the embryo is formed), segmentation may be recognised as elsewhere (*a*). By the growth of the cell and multiplication of the nucleus by division, the whole structure assumes the appearance sketched in fig. 98, *b*. Later on the dark granules disappear from the elongated cell, and the characteristic transverse streaking commences (*c d e*). Finally, by continuous elongation and constant multiplication of the nuclei, the cells take on the form indicated by *f*, where the longitudinal lines are commencing, and the muscle-fibre has almost reached its full development. The origin of the nuclei in fig. 97 (1), is thus cleared up. But it must not be supposed, as was formerly the case, that the structureless sheath (*b*) corresponds to the cell-membrane; it is rather a matter deposited externally on the fibre.

§ 60

From what we have seen of the mode of development of striped muscle-fibres in the preceding section, it is clear that many cells may undergo considerable transformation without in the least forfeiting their individuality.

But it is otherwise in the construction of some tissues, in which the various cells commence to cohere and fuse more and more into one another, losing eventually, in many instances, their independence completely. By such series of metamorphoses (and they occur widely throughout the animal system, and are therefore of the greatest importance) networks of cells, tubes, fibres, and such like, may be formed. The changes in question are of the most various kind, but cannot be described in all cases with desirable accuracy. It will suffice, however, to take a few of the better known as examples.

The finest tubes in the circulatory system, namely, the capillaries (fig. 99, *A*, *a b*, and *B*, *a*), are found by ordinary examination to be made up of a delicate transparent membrane, in which nuclei are imbedded at intervals. Until a few years ago, this was generally thought to be the entire structure of the capillary tubes, whose development was explained in the following manner. Formative cells were supposed to fuse together, the cavities of the cells to become the lumen of the tube by opening into one another, and the walls of the cells with their nuclei to supply the delicate transparent nucleated membrane of the vessel.

From the German investigators—*Hoyer*, *Auerbach*, *Eberth*, and *Aeby*—we have recently learned, however, the true structure of the capillaries, and the incorrectness of the former views entertained with regard to them.

By treatment with a solution of nitrate of silver, namely, this fine membrane may frequently be resolved into extremely thin nucleated formative cells of considerable size, terminating in laps and processes (fig. 100), by which the cells adhere to one another at their edges, and, taking the hollowed form of the lumen, thus produce the vessel.—It is the action of light on the silver at the junction of the elements which makes their boundaries visible.—Thus we see that the lumen has not had its origin in the cavities of coalescing cells, but is rather an intercellular space.

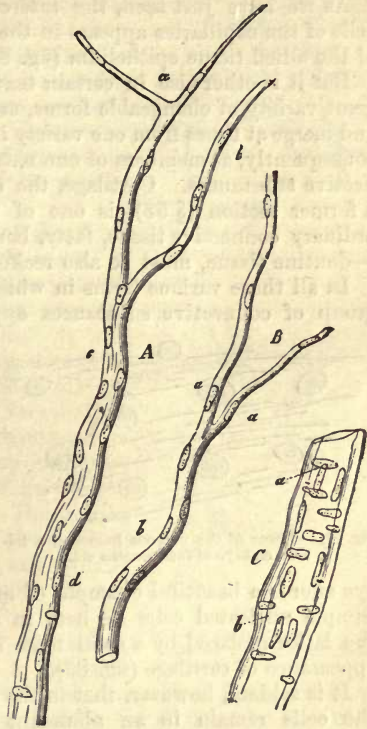


Fig. 99.—Small blood-vessels from the pia mater of the human brain. *A*, a twig, *c*, terminates above in two delicate capillaries, *a b*; *B*, a similar vessel, with capillaries, *a*; *C*, a stronger twig, with longitudinal and transverse nuclei.

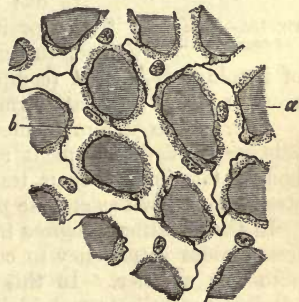


Fig. 100.—Capillary vessel from the lung of a frog, after treatment with dilute solution of nitrate of silver. *a*, nuclei; *b*, boundaries of the cells.

§ 61.

As we have just seen, the intercellular matter between the formative cells of the capillaries appears in the most minute quantity, reminding us of the allied tissue epithelium (fig. 81).

But it is otherwise in certain textures which, though appearing under great variety of changeable forms, are yet connected by intermediate links, and merge at times from one variety into another. These must be regarded, consequently, as members of one natural group, and are known as the connective substances. Cartilage, the consideration of which occupied us in a former section (§ 53), is one of these; further, colloid, reticular, and ordinary connective tissue, fatty, bony, and—nearly related to the latter—dentine tissue, must be also reckoned as belonging to them.

In all those various forms in which the members of this widely-spread group of connective substances appear, we meet with cells imbedded

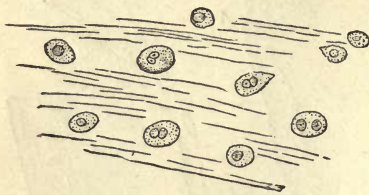


Fig. 101.—Tissue of the vitreous humor of a human embryo of four months old.

in more or less abundant intercellular substance. The cells, however, display very different characters in different instances, and no less so the intercellular substance, which may be found either in the form of mucoid jelly, fibrous, and more solid substance, or of hard stony matter.

The vitreous humor of the foetal eye affords a beautiful example of an extremely simple texture (fig. 101). Simple nucleated cells lie here in a watery jelly. If we can imagine the latter replaced by a solid mass of chondrin, we have the well-known appearance of cartilage (fig. 83).

It is seldom, however, that in the group of tissues under consideration the cells remain in an abundant intercellular substance, so slightly matured, as in cartilage. Crowded together, they may perhaps increase in size, and, retaining their spherical shape, become filled with neutral fats, as is the case with fat-cells which have this origin, as far as is known at present. But, as a rule, the formative cells of the connective-tissue group abandon the spheroidal form, and grow irregularly.

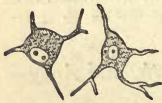

Fig. 102.—Stellate cells of connective tissue.

At one time they become fusiform by extension in two opposite directions, as we have seen in a similar case, though on a far larger scale, among the elements of involuntary muscle (comp. fig. 96, p. 95); at another they assume more or less of a stellate form (fig. 102).

And, just as certain connective-tissue cells may become fat-cells, so at this stage of development many pigments may be laid down in their bodies, terminating their transformations. It is in this way that the structures known as stellate pigment-cells are formed (fig. 50, p. 68).

In their further progress in development, connective-tissue cells manifest, besides a tendency to continuous elongation, an inclination to fuse with one another. In this way, by the cohesion of the processes of adjoining cells, extremely delicate cellular networks are formed (fig. 103), whose meshes are occupied by a mucoid jelly. But this latter may again disappear, and be replaced by totally different matters, as, for instance, by lymph-corpuscles. As they grow older, also, connective-tissue cells, tense and full when young, may shrink and decrease very considerably in volume.

But, as already mentioned, the variety which the intercellular substance

of connective tissue presents for our consideration is not less considerable than that existing among the cells themselves. Consisting originally of albuminous matters (consistently with its origin from the protoplasm of the cells), it commences later on, as its solidity increases, to contain gluten, or more properly, collagen. In bone again, and in dentine, it attains a high degree of hardness and firmness by the reception into its composition of large quantities of the salts of lime.

It is not, however, changes alone of this kind in consistence and composition which are to be met with in the intercellular substance of the connective-tissue group. Even if it escape solidifications of the species just described, it still manifests a great tendency to become streaky or banded, or finally to break up into fibrillæ. Again, between all these varieties no very distinct boundaries exist; and in the neighbourhood of banded or fibrillated portions, we may encounter more or less of a residue, as it were, of unchanged homogenous intercellular substance. The fibrillæ alluded to are sometimes found in the form of extremely fine isolated threads, but are usually arranged in bundles. They are known as connective or cellular-tissue fibrillæ.

Fig. 104 is designed to represent the latter. In the preparation, which is from a structure intermediate between true cartilaginous and connective tissue, we find simple cartilage cells scattered among bundles of fibres. In fig. 105 also we have these fibres (*f*), (grouped in bundles at (*g*)), between stellate connective-tissue cells (*a-e*).

But this metamorphosis of the formerly homogenous intercellular mass into collagenic fibres is not the only one met with in connective tissue. Another kind of thread-like element, consisting of a material with far greater power of resistance to reagents (comp. § 15), is formed by the transformation of intercellular matter, and is known as the elastic fibre (fig. 105, *h*). It also is liable to vary much, both as regards strength and the occurrence or absence of branches (fig. 106).

However, this appearance of elastic matter in the form of fibres is not the only one it makes in connective tissue. The intercellular matter may be transformed, at the boundaries of the tissues in question, towards the cells and cellular networks, and likewise at their surfaces, &c. (but still retaining its homogenous appearance), into limiting layers of divers kinds, formed of a substance identical with, or optically and chemically the same as elastin. These have frequently been erroneously taken for cell-membranes and other peculiar envelopes.

Thus in the course of development of connective substance, a whole

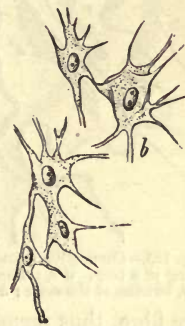
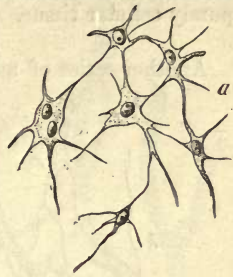
Fig. 103.—Cells from the enamel organ of a human fetus at four months.

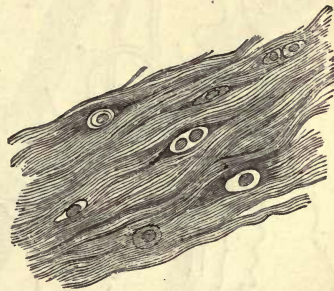


Fig. 104.—Fibrous cartilaginous substance from a ligamentum intervertebrale of man.

series of the most striking transformations takes place in an originally purely cellular tissue.

§ 62.

Another series of metamorphoses which may be mentioned here leads,

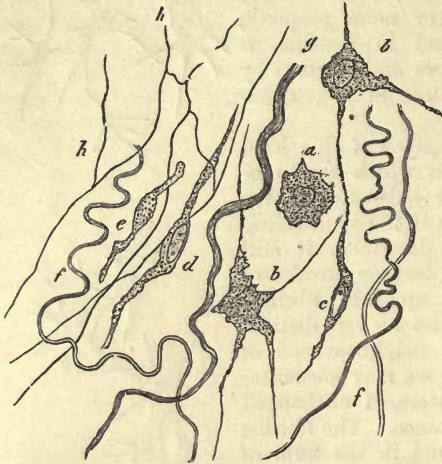


Fig. 105.—Connective tissue from between the muscles of the leg of a frog. *a-c*, connective-tissue cells; *f*, fibrillae; and *g*, bundles of the same; *h*, network of elastic fibres.

it is supposed by a process of fusion, to the formation of many of the final ramifications of nerve-fibres.

But the mode of origin of the unbranched nerve-fibres situated in the middle of nervous trunks (fig. 107, 1) is still, it must be granted, a most obscure point.

Nerve-fibres are usually observed to divide in binary order when near their termination (fig. 108). At such points (at least apparently) are situated stellate cells, with usually three processes (fig. 107, 2 *a*¹, *b*¹, *b*²), one of which is united by fusion with the upper unbranched portion of the fibre, thus preparing the way for ramification of the latter.

The neurilemma, or primitive sheath, a structureless tube which envelops the mature nerve-fibre (fig. 108), is probably, as in the case of the sarcolemma of muscle elements, laid down from adjoining structures.

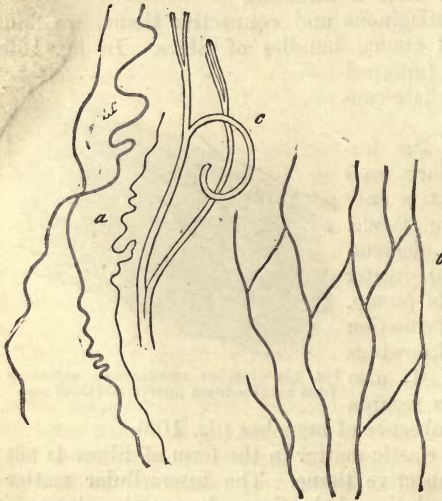


Fig. 106.—Elastic fibres from the human body. *a*, simple and of the finer kind; *c*, a thick one, branching; *b*, fibrous network.

§ 63.

The physiological relations of the remaining tissue elements originating in the metamorphosis of cells, dealt with in the second division, are so very various that they must, for the most part, be reserved for future consideration. In muscle-fibres and nerve-tubes we have tissues of the highest physiological dignity, while the great group of connective substances takes but a low rank as investing or supporting tissues for the system. The capabilities of transmuta-

tion are very various in the different tissues derived from the cell; but at present our knowledge of the details of this subject is very imperfect. Muscles and nerves, we are aware, are remarkable for the energetic

transformation of material which goes on in them, although the nature of the processes is only known as regards the striped fibre. In contrast to this, many connective-tissue parts are remarkable for the great permanence of the substances of which they are constituted, especially when they are only scantily supplied with blood-vessels, and possess numerous elastic fibres. In other structures of the same kind a very rapid transmutation of material may take place, when a large amount of blood passes through them, or when they are finely canalised, as for instance, in the case of bone. On the other hand, all connective-tissue structures display an enormous degree of energy in a formative direction under conditions of pathological irritation, and are thus of great worth in the plastic processes of the diseased body, considerations which will occupy us again in a subsequent section.

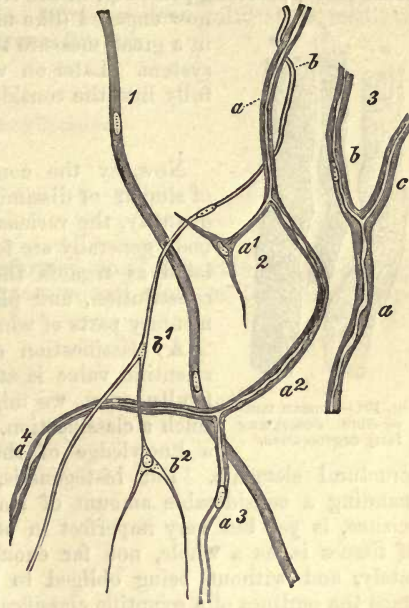


Fig. 107.—Development of nerve-fibres in the frog.

In regard to the products of transmutation much has been already said. We refer the reader to pp. 21, 22 for the glutin-yielding substances; to pp. 40-50 for the alkaloids. The voluntary or striped muscles, consisting of albuminates, yield as decomposition products, kreatin, kreatinin, hypoxanthin, inosinic and lactic acids, and inosite.

Of the physiological decay of the form-elements, and the regeneration and length of existence of the same, we know very little, excepting in the case perhaps of striped muscle-tissue. The duration of many of them, as for instance, of elastic fibres and allied structures, is probably long, for in their case we have only remaining the processes of solution and degeneration, mechanical attrition being excluded (comp. p. 94). The three kinds of transformation, by pigmentation, deposit of fat (fig. 109), and of cal-

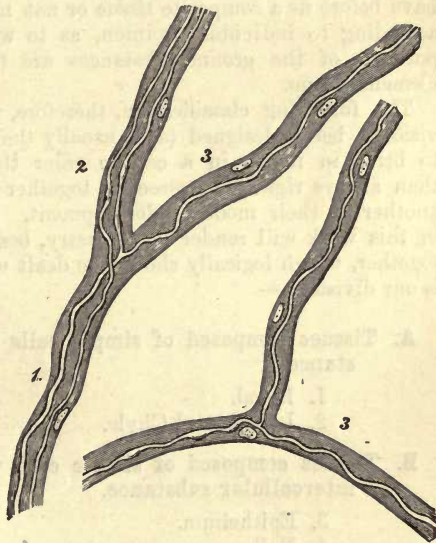


Fig. 108.—Small branching nerve-fibres, *a* and *b*, from the mesentery of the frog, surrounded by thick envelopes studded with nuclei; 7, the trunk; 2 and 3, the branches.

careous matters in cells, may at least be partially regarded as physiological processes, but belong probably, in the elementary parts with which we are now engaged (like many other modes of degeneration), in a great measure to the pathological changes of the system. Later on we shall be obliged to enter more fully into the consideration of this subject.

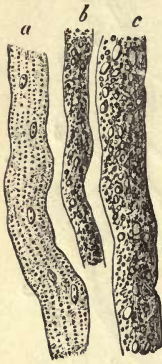

Fig. 109.—Human muscle-fibre undergoing fatty degeneration.

§ 64.

Now, by the combination of structural elements of similar or dissimilar kinds, and in larger or smaller quantity, the various tissues of the human and animal body generally are formed. These are naturally regulated as regards their anatomical texture, chemical constitution, and physiological properties, by the elementary parts of which they are composed.

A classification of tissues that shall have any scientific value is still a matter of the greatest difficulty—nay, we might almost say, of impossibility. Such a classification, namely, can be founded only on a knowledge of the mode of development of the structural elements. But histogenesis, unfortunately, although commanding a considerable amount of material in many branches of our science, is yet but very imperfect in others. The history of the origin of tissues is, as a whole, not far enough advanced to enable us accurately, and without being obliged to resort to many hypotheses, to trace the outlines of a scientific classification of the various tissues. Even that apparently easy and accurate division into simple and composite textures cannot be strictly adhered to, and the question whether we have before us a composite tissue or not must, in many cases, be decided according to individual opinion, as to whether certain metamorphosed portions of the ground-substances are to be considered as structural elements or no.

The following classification, therefore, is only to be accepted as provisional, being designed (as is usually the case in artificial systems) more to bring in review in a certain order the materials to be considered, than always rigidly to associate together parts probably related to one another in their mode of development. The practical objects aimed at in this work will render it necessary, besides, to consider many things together, which logically should be dealt with separately. The following is our division:—

- A. Tissues composed of simple cells with fluid intercellular substance.
 1. Blood.
 2. Lymph and Chyle.
- B. Tissues composed of simple cells with a small amount of solid intercellular substance.
 3. Epithelium.
 4. Nail.

C. Tissues composed of simple or transformed cells (in some cases cohering), situated sometimes in homogeneous, sometimes fibrous, and, as a rule, more or less solid intermediate substance (Connective-tissue Group).

5. Cartilage tissue.
6. Colloid do.
7. Reticular connective-substance.
8. Adipose tissue.
9. Connective do.
10. Bone do.
11. Dentine do.

D. Tissues composed of transformed and, as a rule, non-cohering cells, with scanty homogeneous and more or less solid intermediate substance.

12. Enamel tissue.
13. Lens do.
14. Muscle do.

E. Composite Tissues.

15. Nerve tissue.
16. Gland do.
17. Vessels.
18. Hairs.

II.

THE

TISSUES OF THE BODY.

THE
THE
THE

II. THE TISSUES OF THE BODY.

A. Tissues composed of Simple Cells with Fluid Intermediate Substance.

1. The Blood.

§ 65.

In the blood-vessels of our body, a closed system (except in the case of the spleen) of intercommunicating canals, into which, however, the lymphatic and lacteals discharge their contents, there exists an extremely complex fluid, "the blood," which is constantly in motion during life. And just as on the one hand no pause takes place in its continuous circulation while life remains, so on the other hand is this fluid unceasingly engaged in a lively interchange of matter. The walls of the blood-vessels being formed of membranes permeable to endosmotic currents, and processes of filtration further occurring in glands, the blood is constantly being robbed by the organs and tissues of certain of its constituents in the form of watery solutions, while other substances similarly dissolved are rendered back to it again. It receives also bulky additions of other complex fluids in the shape of lymph and chyle poured into it.

Notwithstanding this coming and going of material which constitutes the blood the centre of the vegetative processes of life, the fluid in question is always singularly unvarying, both in regard to chemical and anatomical composition, any deviations from the normal standard being rapidly compensated.

Human blood is a thickish, opaque fluid with a peculiar faint odour, alkaline reaction, temperature of about 38° C., and a red colour,—light cherry-red in the arteries, but somewhat deeper in the veins. The amount of blood contained in any one body cannot be estimated at present with anything like accuracy, and we find statements on this point very various as regards the human system. It appears probable that the weight of the blood averages in man about a twelfth or thirteenth of that of the whole body.

REMARKS.—Compare *Nasse's* article "Blut" in the *Hundwörterbuch der Physiologie*, Bd. i. p. 75, and *Milne Edwards, Leçons sur l'anat. et la physiol. comparée*, Paris, 1857, tome i. p. 36; as also the various handbooks of histology.

§ 66.

If we examine the anatomical composition of the blood with the aid of a high microscopic power, we find it to be made up of a transparent

colourless fluid, the *plasma*, or *liquor sanguinis*, in which two kinds of cells are suspended, namely, the "red blood-cells" and the "colourless," or "lymph-corpuscles" of the blood (lymphoid-cells) (fig. 110). The first occur in great preponderance, and are the cause of the red colour of the blood, while the latter generally represent but a small fraction of the number of cells contained in the whole mass of the fluid in question. Besides these, we also meet in human blood with conglomerations of minute pale granules, measuring 0.0011–0.0022 mm. (*Schultze*).

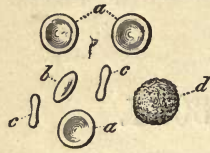


Fig. 110.—Human blood-cells. From above, *a a*; half side view, *b*; seen completely from the side, *c*; lymph-corpuscles, *d*.

The *coloured blood-cells* discovered long ago by *Malpighi*, and which have since then received very different names, such as "blood-granules," "blood globules," "blood-disks," "blood-corpuscles," and "blood-vesicles," appear in human blood as circular formations, with a yellowish tint, and sharp and delicate contour. They display among themselves but little variety either in size or otherwise. Their number in a drop of blood is enormous; it may be accepted as being about five millions to the cubic millimeter. *C. Schmidt* estimates their specific gravity at 1.088–1.089, *Welcker* at 1.105. The diameter of the cell in the blood of the male averages 0.0077 mm., with extremes of from 0.0039 to 0.0024 mm.

With very accurate focus the living blood-corpuscles lying in the plasma present in their centre a clear colourless space, and also at a spot in their interior a slight shading of more or less semicircular outline, situated at that side of their border opposite to that from which the light is thrown on the field (fig. 111, *a*).

The reason of this appearance becomes clear so soon as the cells are set in motion. Far from preserving their circular form, in rolling over the glass plate of the microscope, they appear when standing on their edge (*c c*) like thin biscuit-shaped rods, with thickened bevelled ends, and constriction in the middle. In thickness they are about 0.0018 mm.

From what we have just seen, there can be hardly any doubt that the form of the cell is in reality that of a biconcave disk with bevelled, swollen edges. The volume of the human blood-corpuscles has been estimated by *Welcker* to be 0.000000072 cub. millim, the weight 0.00008 milligram, and the superficial extent 0.000128 square millim. Its body is composed of a completely homogeneous substance of a yellowish colour by transmitted light; this deepens to a rather reddish tint at points where any two cells overlap one another. Should they commence to form larger aggregations, they then begin to show the red colour of the blood itself.

§ 67.

In order to make ourselves better acquainted with the further nature of the blood-corpuscles, it is necessary to observe the effects of certain external agencies upon it. If we expose a drop of blood on the glass plate of the microscope for a short time uncovered, and allow it to evaporate, the form of the cell changes (fig. 111, *b*). With a decrease in size down to from 0.0059 to 0.0052 mm., it becomes irregularly angular, lumpy, and frequently stellate, the pointed portions coming out as dark dots in the object. We have here to deal with a shrinking together of the body of the cell depending on a loss of water, a process the interpretation of which in human blood presents many difficulties owing to the

minuteness of the object. If the blood dry up rapidly in very thin layers, the corpuscles have usually a round smooth outline, with a distinct projecting central portion (fig. 111, *c*).

If water be added to a drop of human blood, a completely different picture is presented to the eye of the observer. Far from becoming knobbed and jagged, the cell preserves its circular smooth-edged aspect, but the clear central portion is no longer recognisable, and the yellowish border stands out no more in relief (fig. 111, *a*). Close observation teaches that the swelling up of the cell commences at the border, and that the encroachment of the swollen portion it is which causes eventually the two depressions in the centre of the blood-corpuscle to disappear. As soon as a cell so treated begins to roll, the important difference caused by the loss of its biconcave discoid figure becomes evident. We find the corpuscle from every point of view spherical; it has swollen out into a globule with diminution in diameter, down to 0.0061–0.0057 mm. Under the continued action of water this globule grows paler and paler (*a* to the right) whilst the surrounding fluid acquires a yellowish tinge. Some cells are very rapidly decolorised, others resist the action of the water for a longer period. At last the corpuscle becomes so perfectly decolorised that it can only be recognised by high magnifying power and in a shaded field; it is there seen as a very delicate, completely smooth-edged structure of extreme paleness. During the whole procedure no nuclei make their appearance.

The employment of many watery solutions, such as those of sugar, gum arabic, common salt, &c., produces an effect on the cells similar to that of evaporation. But if these reagents be gradually diluted a degree of concentration is at length reached, at which no further change of form in the cell can be observed. If the solutions be still further diluted, we observe eventually the same effects produced as those of pure water, namely, a puffing out and bleaching of the cell until it becomes invisible. It is most interesting to mark on one and the same cell the changes produced by the alternate addition of various fluids one after the other,—changes from the stellate wrinkled to the spherical tense form, and back again, or *vice versa*.

All observations which have been made up to the present teach the absence of nuclei, and present to us the blood-corpuscle as a structure whose substance rapidly absorbs and parts with water, in the first instance swelling up and acquiring greater volume, and in the second shrinking together. We see, further, that the colouring matter of the cell-body is soluble in water. Now, if we apply the results thus obtained to the corpuscle as it circulates in the blood, we have in it an element which must, indeed, engage in a lively interchange of matter with the fluid of the plasma, but

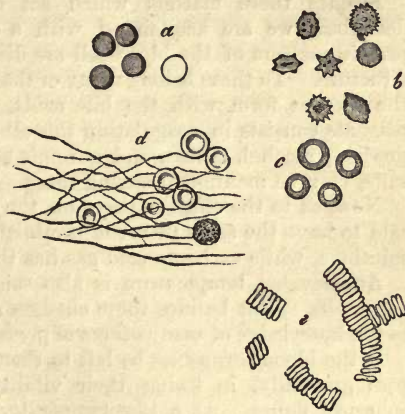


Fig. 111.—Human blood-cells; *a*, after the action of water; *b*, in evaporating blood; *c*, dried up; *d*, in coagulated blood; *e*, arranged one over another in rouleaux.

which, at the same time, undergoes neither a considerable variation in volume nor loss of its colouring matter. It may be roughly stated to be composed of a soft gelatinous substance which swells up in an excess of water.

Besides these matters which act on the cell in the manner just described, we are acquainted with a number of others in which the protein matters of the blood-cell are dissolved, and with them the whole structure. To these belong many of the mineral acids, and the salts which the alkalis form with the bile acids. The action of another series of reagents consists in coagulating the albuminous matters of the blood-corpuscles; alcohol, tannic, and chromic acid, kreasote, and certain metallic salts, may be mentioned among these.

Now, as to the effect of gases on the shape of the blood-cell, oxygen is said to have the same power of diminishing its size possessed by saturated solutions, while carbonic acid gas has the contrary effect.

An elevated temperature is also said to diminish the bulk of blood-corpuscles. But besides these changes already long known, we have come to the knowledge of many others of great interest within the last few years.

If the blood-corpuscles be left to themselves in defibrinated blood, they pass gradually, in losing their vitality, from the disk-shaped to the spherical figure. At a low temperature many days may elapse before this transition is completed.

An electric discharge causes the cells to assume a rugged appearance, coarsely granular at first, but finer later on. Soon after the corpuscle takes on again the form of a smooth spheroid, and finally loses its colour (*Rollett*).

If a living blood-cell be warmed up to about 52° C., a wonderful change comes over it (fig. 112); it becomes rapidly marked by a varying number of deep indentations; shortly after this the formation of a series of bulb-like processes takes place, which either separate at once, or remain for a time in connection with the rest of the cell-body by means of slender filiform styles (*a*).

Owing to this, the most singular appearance of beaded rods is produced; globules are found with caudal appendages, &c., while the portions which have become free immediately engage in the most lively molecular motion (*Beale, Schultze*).

By none of these modes of treatment are we enabled conclusively to demonstrate the presence of a membrane on the blood-cell of adult human beings; besides which, the changes just mentioned, produced on them by an elevation of temperature, can hardly be reconciled with the supposition of such a structure. We are likewise never able to recognise any of those phenomena of vital contractility in the mature blood-corpuscle, which appear in so many other cells of the system.

Attention has been rather recently directed to some interesting differences between the blood-cells of different regions of the circulatory system. According to *Lehmann's* discoveries, the blood of the vena porta contains the ordinary so mutable corpuscles, whilst in that of the hepatic vein cells of anomalous constitution are to be found; these are smaller, more swollen, approaching the spheroid form, and having

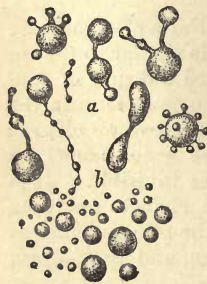


Fig. 112.—Human blood-corpuscles heated up to 52° C.

nothing of the usual central depressions; they resist for a comparatively long space of time also the action of water. Similar cells also make their appearance in the spleen (*Funke*). They are looked upon by some as young newly-formed blood-corpuscles.

REMARKS.—Beale in the "Quarterly Journal of Microscop. Science," 1864. Transact., p. 32.

§ 68.

The study of the coloured cells of the blood of other vertebrates, as a means of controlling the results obtained in the investigation of those of human blood, is of great interest, and a chapter of comparative histology which cannot, therefore, be completely passed over here.

The blood-corpuscles of mammalia present almost unexceptionally the form of biconcave disks (fig. 113, 1), and the only slight variations in them are those of size. Thus the cells of the elephant, which are the largest, attain a diameter of about 0.0095 mm., those of apes correspond with the human cells, and in many other mammals they are smaller than our own, as, for instance, in the horse, 0.0056 mm., and rabbit, 0.0080 mm. The blood-cells, however, of some of the ruminants, as of the lama, alpaca, and camel, show striking deviations, being oval disks of 0.0081 mm. Of nuclei, we see just as little in the coloured elements of mature mammal blood as in those of our own.

Such elliptical blood-cells, however, become the prevailing form in the succeeding classes of vertebrates, manifesting, moreover, striking variations in size; and the nucleus, which we have missed up to this, now takes its place as a regular constituent of the cell. It is only in a low order of fishes, the cyclostomata, that the circular figure of the mammal cell is found again; and the lowest of all vertebrates, the extraordinary *Amphioxus lanceolatus*, possesses completely anomalous blood, no longer red in colour, and reminding us of that of invertebrates: it need detain us no longer here.

The corpuscles of birds have an average length of 0.0184–0.0150 mm., and transverse diameter amounting to the half of this (*a a*) (fig. 113, 3).

Seen from the side, instead of the biconcave disk, they present a bulging out in the central portion of each surface. The nucleus, which in uninjured cells is either not at all visible, or only so as a slight clouding, appears on proper manipulation, *e.g.*, desiccation, or the action of water, &c., as a dark structure with rough contour, elongated figure, and diameter of

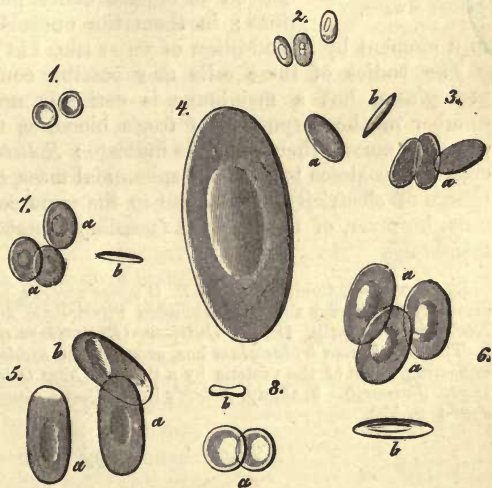


Fig. 113.—Coloured blood-corpuscles. 1, From the human being; 2, camel; 3, dove; 4, proteus; 5, water salamander; 6, frog; 7, cobitis; 8, ammocoetes. At *a*, views in profile; *b*, from the edge (mostly after *Wagner*).

0.0050–0.0043 mm. (in the hen). The nucleus usually occupies the middle portion of the cell, but lies occasionally excentric.

Again, we find the blood-cells of scaly amphibia, of tortoises, lizards, and snakes, also oval, but somewhat broader and longer than those of birds. In length they range from 0.0182 to 0.0150 mm.; but the central boss is somewhat less prominent. The cells of the osseous fishes also are small, and but slightly oval (fig. 113, 7, *a a b*), measuring 0.0182–0.0114.

In the naked amphibia and fishes with transverse mouth, the oval or elliptical blood-corpuses show the most astounding dimensions. The length of those of rays and sharks is 0.0285–0.0226 mm.; of toads and frogs (fig. 113, 6, *a a b*), on an average 0.0226 mm.; of tritons (fig. 113, 5, *a a b*), 0.0325–0.0225 mm.; and of salamanders, 0.0445–0.0375 mm. The diameters of the cells of the *ichthyoida* (Fischlurche) are even considerably larger, so that a powerful eye can just recognise them, without a microscope, as minute dots; as, for instance, in the cryptobranchus, in which their length is 0.0510 mm., and proteus (fig. 113, 4), where they are 0.0570 mm.

Finally, the cyclostomata (fig. 113, 8) possess, as we have already remarked, red cells, having the form of small round biconcave disks (*b*) with a diameter of about 0.013 mm.

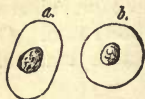

Fig. 114.—Two blood-cells from the frog. *a*, *b*, with granular nuclei as they come to view under the action of water.

All these cells conduct themselves towards reagents in a similar manner to those of man; but many of the effects produced on them are naturally clearer and sharper owing to their larger proportions. In this respect the corpuscles of the frog may be particularly noticed as objects easily procurable for first observations; in them the nucleus can be rendered visible

in a moment by the addition of water (fig. 114).

The bodies of these cells may possibly contain a certain amount of protoplasm, but a membrane is certainly not present on the greater number of the corpuscles of frog's blood, as the spherical segmentation observed among them seems to indicate: *Rollett's* discovery also, that two cells may coalesce to form one spheroidal mass, on being subjected to a discharge of electricity, would lead to the same conclusions. Some isolated cells, however, of frog's blood (possibly senescent) do possess a distinct membrane.

REMARKS.—1. Comp. Besides *R. Wagner's* works, which opened the way to farther discoveries (Beiträge zur vergleichenden Physiologie des Blutes, Leipzig, 1833; und Nachträge, Leipzig, 1836. *Gulliver* (Proceedings of Zool. Society, 152, 1842). 2. The *Amphiuma tridactylum* has, according to *Riddell*, the largest of all blood-cells, exceeding those of the proteus by a third. (*New Orleans, Med. and Surg. Journ.*, 1859. *January*). 3. Comp. *Robert's* in the *Quart. Journ. of Microscop. Science*, 1863, *Journ.* p. 170.

§ 69.

Whilst the coloured blood-corpuses present in beings of the same kind the greatest uniformity and correspondence (with the exception of those extraordinary typical deviations in the vertebrates), and must be looked upon as the fully developed and completed cells of the blood, which undergo no further kind of perfecting in the system, but rather decay at a later period by rupture and solution, the nature of the second cellular element of this fluid, namely, the *colourless blood-cell* or so-called *lymph-corpusele* (lymphoid cell), is completely different. We have here

to deal with cells engaged in the process of formation, with all the differences incident to their various stages of development. We have possibly also to deal with others engaged in retrograde metamorphoses. We meet, therefore, in one and the same body several kinds of these cells. But let us look to their characters.

The colourless cells of human blood appear when at rest, or in a lifeless condition, of spheroidal form, and varying considerably as to size. Small examples measure on an average only about 0.0022, while those of larger dimensions may be of the same size as the red corpuscles. They usually, however, exceed the latter in magnitude, ranging from 0.0077 to 0.0120 mm. As the result of measurements made on those of my own blood, I have found their usual diameter to be 0.0091 mm.

The appearance of these cells is finely granular, but the granules show usually no molecular motion. Under high magnifying power, however, this may be seen as in other lymphoid cells. Their contour is also more or less rugged. In most cases the molecules of protoplasm are very small and delicate, but in some isolated specimens we find considerably larger, dark particles, consisting of fat, imbedded in the interior. These have been probably taken up from without (fig. 116, 4). The nucleus, enveloped in the smaller cells by a thin layer only of protoplasm, is in many cases not to be seen without the aid of reagents.

In some it may be rendered visible by the simple addition of water: this, however, causes a change in its appearance, and the cell is at the same time puffed out to a certain extent, and acquires a smoother and more delicate contour. The action of acetic acid, also, brings it rapidly into view. Thus treated, the nucleus is not unfrequently smooth (fig. 116, 6), but it is usually more or less rugged (7, 8), containing in its interior a nucleus. In form it is roundish or elongated, and frequently irregular, especially after the prolonged action of acetic acid. The diameter of the nucleus is mostly about 0.0077-0.0052 mm. It may frequently appear reniform (9), and in other cases consists of two or three portions lying in contact with one another (10, 11). In consequence of the prolonged action of the reagent just mentioned, these three portions may become separated from one another by considerable intervals. Finally, we meet with cells whose nuclei have in this manner been split up into four, five, six (12), or even seven fragments. In addition to all this, it must be borne in mind that some isolated lymph-corpuscles are destitute of nuclei, so that the variety met with in the colourless blood-cell is not inconsiderable.

Compared with coloured cells, the white are somewhat less sensitive towards reagents. Observation of floating blood-cells teaches likewise that the colourless corpuscles roll about with less ease, adhere more frequently, and in general change their position with more sluggishness than the

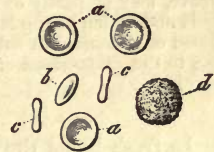

Fig. 115.—Coloured blood-corpuscles from the human being, *a* to *c*; *d*, a colourless cell or so-called lymph-corpuscle.

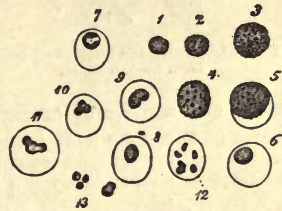

Fig. 116.—Human colourless blood-corpuscles. From 1 to 3, ordinary unchanged cells; 4, one rich in fat granules; 5, commencement of the action of water; appearance of the nucleus from 8 to 11; 12, the nucleus divided by the action of acetic acid into six pieces; 13, free nuclei.

others, which has been set down to a certain clamminess of their surface. Again, they are specifically lighter than their red companions. In a drop of blood copiously diluted with water they gradually collect on the surface. We will refer again, lower down, to their position in whipped as well as coagulated blood, as the best proof of their lower specific gravity.

REMARKS.—1. It is now many years since *Wharton Jones* first demonstrated finely and coarsely granular lymph-corpuscles in the blood of the most different vertebrates. (*Philosoph. Transact.* 1846, *Part II.* p. 63.) 2. Whilst the red blood-cell of the human being is incapable, owing to its characteristic peculiarities, of being confounded in any way with other cells of the body, it is quite another matter with the colourless corpuscles. In many fluids of the system, containing protein matters in solution, we meet with very similar, or more correctly, identical cells;—in chyle, in lymph, mucus, pus, and saliva; to distinguish these from the others is impossible. There can be hardly any doubt, also, that the deviations from the typical form mentioned above, may be partly owing to differences in age; but to determine which are old cells and which young is hardly possible. These colourless elements exist also in the blood of animals, but subject to less variation as to size than the coloured. According to the dimensions of the latter, they may be the largest or smallest of the two species.

§ 70.

In fresh blood the red cells give no signs of an active change of form, and are only remarkable for their elasticity and extensibility. The white corpuscles, on the other hand, belong, in almost every case, to the class of *contractile cells* already mentioned (§ 49); and can retain this power of motion for many days in blood which is preserved cool. In cooled preparations, however, these changes of figure can only be recognised with difficulty, and take place but slowly (fig. 117). But the whole scene is changed if the normal temperature of the body be artificially maintained during examination (fig. 118).

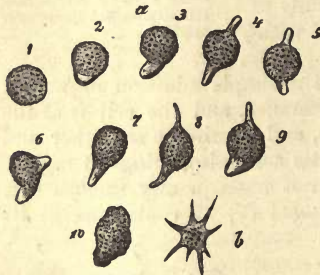


Fig. 117.—Contractile lymph-corpuscles from human blood.

We can then distinguish a lively development of frequently very long processes, and wonderful configurations of the lymph-corpuscle. The latter creeps at the same time hither and thither over the glass plate, and takes up small particles of any matter in the neighbourhood into its interior, such as cinnabar, carmine, or milk-globules, &c. But for this it is requisite that the lymph-corpuscle have attained a certain magnitude; smaller ones put forth but inconsiderable processes, and do not alter their position, while the most minute, measuring perhaps 0.0050 mm., do not even possess the power of varying their shape.

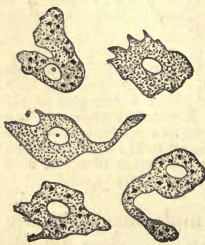

Fig. 18.—The same elements at the natural temperature of the body; some of them contain particles of colouring matters.

These changes of form and locality of the lymph-corpuscle may be also very easily seen in the blood of cold-blooded animals: the frog and salamander afford excellent examples.

The number of white blood-cells compared with the coloured is always inconsiderable, and in the human being as a rule very small; to a thousand of the latter we find at most two or three

colourless corpuscles. Their number is smallest during the hours of fasting, when it may fall to about from 2 or 3 per thousand to 1000:0·5.

Old age, also, is usually accompanied by a decrease in the comparative number of lymph-corpuscles. On the other hand, their quantity increases on the introduction of food into the system, and especially after an abundant meal of animal substances. Finally, we are told that during pregnancy, and at an early age, as well as after severe hæmorrhages, the number of these cells is greater than usual,—facts which all indicate a lively formation of blood going on at those particular periods.

We find, also, that the proportions of both species of cell are not the same in the various parts of the circulatory system. It is especially worthy of note, that the streams of blood flowing from the liver and spleen are uncommonly rich in colourless cells, so that of these we may reckon 5, 7, 12, 15, and more, to each thousand of red. Under certain pathological conditions, also, the relative proportions of both forms may vary very much. In that strange disease, more nearly investigated by *Virchow*, which is known by the name of leucæmia, the white corpuscles may make their appearance in such multitudes as nearly to equal the red in number, so that we may sometimes count to every five or three red, one white cell. Indeed, it appears that the lymph-corpuscles may in some cases attain a numerical preponderance over the coloured elements.

It is a very interesting study to watch the passage of both species of blood-cell through the vessels of a living animal. For this purpose the thin web of a frog's foot (fig. 119), or tail of a tadpole, may be chosen. Here we see the red corpuscles hurrying on swiftly and easily, and often passing one another in the race, while the white cells advance with far less rapidity, owing to their adhesiveness, and not unfrequently remain clinging to some point on the internal surface of the vessel. Here, again, we may convince ourselves of the elasticity and extensibility of the red corpuscle, which appears at one moment diminished in breadth, for instance, or indented at the point where it squeezes past a neighbour, the next taking on its old form on again arriving in the unimpeded stream.

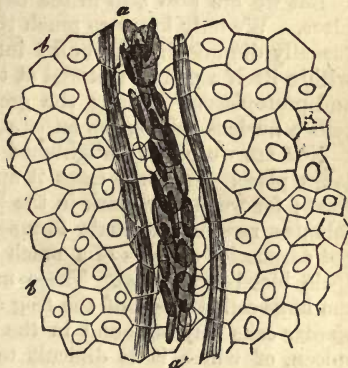


Fig. 119.—A stream of blood in the web of a frog's foot. *a*, the vessel; *b*, epithelial cells of the tissue.

But these passive variations in shape are met with to a far greater extent in the red corpuscles of circulating mammalian blood, which present to our view all kinds of forced changes of form so long as the fluid is in motion, immediately returning, however, to the well-known disk-shaped figure at the moment it attains a state of rest (*Rollett*).

§ 71.

If we now inquire into the origin of the colourless cells of the blood, there can be but little doubt as to that of a certain number of them at least. They are simply the cells of the chyle and lymph-systems, and, as

we shall presently see, have been partly washed passively out of the glands of the latter, partly have migrated actively from the same. They may come likewise from the tissue of the spleen and medulla of bones, carried off from these organs by the stream of venous blood flowing from them.

And touching their further significance, they have been for many years regarded, and we may now say rightly so, as cells which are destined to pass into red corpuscles, and thus to cover the loss of the latter according to the rate of their decay. The colourless cells serve to replace the red therefore.

This conjecture has, moreover, been confirmed by a remarkable discovery of *Von Recklinghausen*, that frog's blood, collected in a vessel and kept from evaporation, while the air about it is renewed several times daily, will show, in from eleven to twenty-one days, a transformation of the colourless corpuscles into the characteristic red cells of that animal. How many or how few of the uncoloured cells undergo this change in the living body is a question, however, which cannot at present be met by scientific facts. The statements made on this point must necessarily vary greatly, depending as they do on the hypothesis as to the amount of chyle and lymph streaming daily into the blood, as well as on the still completely unknown length of existence of the coloured blood-cells. It seems highly probable, however, that a large number of these colourless elements never attain this state, and pass to decay without being transformed into red cells.

But we are also still in the dark as to how this change exactly takes place. We only know so much that the white corpuscle is transformed (usually diminishing in bulk) into a circular flat plate, and generates within itself a yellow material at the same time that it loses its nucleus and protoplasm. Among the groups of vertebrates in whose coloured cells a nucleus occurs, the latter structure is permanent.

Nor are we better enlightened as to the region in which this change takes place. In some cases it appears to be over the whole circulatory tract; for we may remark in the blood of the three lower classes of vertebrates, rare intermediate forms—that is, besides the usual nucleated, red corpuscles—others of a much paler colour, with round or oval figure (pale blood-corpuscles). These may be readily recognised, especially in the large-celled blood of the frog and salamander (2). Then, again, very similar cells may be found in the blood of the human and mammalian spleen, of which it is difficult to say whether they still belong to the lymph-corpuscles, or are already red blood-cells. Finally, similar intermediate cells are met with, according to *Bizzozero* and *Neumann*, in the medulla of bones, especially in the red species of medulla.

REMARKS.—1. See *Von Recklinghausen* in the *Archiv. für mikrosk. Anatomie*, Bd. ii. § 137. 2. Comp. *Wharton Jones'* work.

§ 72.

Though, from an anatomical point of view, blood may appear a tolerably simple tissue, with fluid intercellular substance, physiologically it is a fluid of very complex constitution. In it we have the very focus of vegetative activity, the stream upon which all the traffic of the system takes place as it were. In it we must expect to find matters which serve as well for the formation of tissues as for nutrition. These, however, may still exist in several varieties of combination not met with in the tissues. The most diverse products of metamorphosis also pass through the blood on their way to excretion. We can hardly be surprised, then, that almost

all the most important substances in the system, with which we were made acquainted in a former part of the work, are represented in the blood. Many gaps, however, still exist in our knowledge on this particular branch of physiology, owing to the difficulty of the subject.

The matters which may at present be looked upon with more or less certainty as constituents of the blood are the following:—1. From the *albuminous* group—hæmoglobin, albumen, the two constituents of fibrin, namely, fibrinogen and fibrinoplastin, near to which we place globulin, obtained by the splitting up of the latter. Casein is not found, nor are the glutinous substances or elastic matters.—2. Of the solid *fatty acids* (usually saponified, more rarely as neutral fats), stearic, palmitic (and margaric?) acids, to which oleic may be added. Of the volatile fatty acids, we find butyric, with lecithin and cerebrin from the brain.—3. Of the carbohydrates, grape sugar, whilst sugar of milk and inosite are missed.—4. Of non-nitrogenous and nitrogenous acids, we find lactic and succinic (?), whilst others, as, for instance, oxalic, benzoic, and gallic acids, are absent.—5. Of amides, amido acids, and bases, urea, kreatin (?), kreatinin (?), hypoxanthin (?), and xanthin (?); whilst, on the other hand, other allied matters, as leucin, tyrosin, glycin, taurin, are not contained in it.—6. Of extractives; and finally,—7, numerous mineral constituents, among which we find, beside water—of bases, lime, magnesia, potash, soda; and of metals, iron, copper, manganese (?); of acids, carbonic, phosphoric, sulphuric, hydrochloric, and silicic; and finally, of gases, carbonic acid, oxygen, and nitrogen.

A chemical analysis of this kind of the whole mass of the blood, is of but little worth, however; at most it only adds a few facts to chemical statistics. Such an enumeration of its constituents only renders evident that in it are contained the most important alimentary matters, as well as many of the products of transmutation of our body.

Owing to the abundance of elements of composition which it contains, the first and most important point to be made out is—1. What substances enter into the composition of the red corpuscles, and in what proportions do they exist there? 2. Of what are the colourless cells composed? 3. Of what materials does the intercellular matter of the blood, the so-called plasma, consist? 4. Since we must expect that some of the ingredients of the blood exist in the cellular elements as well as in the fluid, we ought to determine in what relative proportions they appear in the cells and in the plasma.

In this way alone could we gain anything like a satisfactory insight into the chemical constitution and physiological properties of the blood, or ascertain what the blood-cell chemically is, and of what nature the fluid is in which it is suspended, and with which it is constantly engaged in interchange of material.

Do we now ask how far the requirements just stated are to be looked upon as met by the present state of science, we must bear the following points in mind:—Firstly, all efforts to isolate the white from the red corpuscles of the blood have been hitherto unsuccessful. We are completely in the dark, therefore, as to the composition of the former, and can never, on the other hand, obtain the red perfectly free from the presence of the colourless elements,—a source of error which is, however, but considerable in analysing human blood, owing to the small number of the latter contained in it. Then, again, it is only occasionally possible to make an analysis, which is then but approximate, of the blood-cells in

a fresh state as they exist in the blood, namely, loaded with water. This is an evil which renders all earlier analyses useless, from the fact that chemists were compelled to reckon the whole amount of water contained in the blood to the plasma alone, which was quite incorrect, as, instead of that, it should have been distributed, of course, between the latter and cells. The plasma, according to this mode of calculation, appeared to have a naturally large proportion of water, while wide play was given to the theories in regard to the constitution of moist, moving blood-cells.

§ 73.

Some years ago the proportion of moist cells in the blood was ascertained by *Hoppe*. It is necessary to have for this analysis blood which coagulates unusually slowly, so that the sinking cells may have already disappeared at the time of operation from the uppermost layer of the fluid. If we now ascertain the proportion of fibrin contained in a certain quantity of this plasma freed from cells, and likewise in a given quantity of blood, it is easy to find the amount of blood-plasma by a simple calculation, and likewise by subtraction that of the moist corpuscles.

The following is the composition of horses' blood according to *Hoppe*:—

1000 parts contain—

Plasma,	673·8
Moist corpuscles,	326·2

1000 parts of blood-corpuscles contain—

Water,	565
Solid constituents,	435

1000 parts of plasma contain—

Water,	908·4
Solid constituents,	91·6
Fibrin,	10·1
Albumen,	77·6
Fats,	1·2
Extractives,	4·0
Soluble salts,	6·4
Insoluble do.,	1·7

From the foregoing analysis we see that the proportion of water in the cells is not quite $\frac{2}{3}$ ths, while in the plasma it is $\frac{1}{5}$ ths, with which the differences in specific gravity agree (cells = 1·105 plasma = 1·027–28 in the human being). We shall presently find that the solid constituents of the blood-corpuscle consist principally of hæmoglobin, a matter which is entirely absent from the plasma, whilst fibrin and albumin are substances belonging particularly to the latter.

§ 74.

If we now turn to the consideration of the *composition of the blood-cells*, that of the colourless elements must be passed over, in that they cannot be isolated as already remarked. The little which might be said of them, besides, can be more appropriately brought forward when we are discussing lymph and chyle.

Red cells, as they appear in human and all mammalian blood, are structures destitute of a nucleus, consisting of a homogenous yellow gelatinous substance, in which a lively interchange of matter may be recognised. All substances, accordingly, which are contained in the blood-cell, must be so in a state of gelatinisation or solution, if we deny the presence

of a membrane on the cell. The elements of composition belonging to the red corpuscle are numerous.

In the first place, the *cell-body* consists of hæmoglobin (§ 13), as was already mentioned, divisible into two substances—an albuminous and pigmentary, known respectively as globulin (§ 12) and hæmatin (§ 35). The first of these, however, has only been obtained in an impure state, as both bodies defy perfect separation from one another. It appears in the cell in far larger proportion than the colouring matter; for instance, 1000 parts of blood-corpuscles from the horse contain 360·4 of solid constituents, of which 19·9 consist of hæmatin and 321·1 of globulin.

Blood-crystals, which were discovered first by *Funke* in the blood of the splenic vein, have already been discussed (§ 13).

The crystallizing substances of blood-cells are not by any means always identical, a fact which is indicated by the greater or less readiness with which crystallization commences in the blood of various species of animals, and which is further corroborated by the varieties in the crystalline form (figs. 120, 121).

The colouring matter of blood is, on account of its composition, into which iron enters, one of the most remarkable substances of our body. Not being met with either in the plasma or the fluids compensating the blood for loss, namely, lymph and chyle, it must be formed by the chemical activity of the blood-cell by a process still unknown to us. It is not always contained in the same amount in the corpuscles, which we might at once infer from the variation in intensity of the tint of isolated cells, which are at one time yellow, another of a paler hue. The difference in the colouring properties of certain kinds of blood when mixed with water points to the same conclusion.

Fibrinoplastic matter (*Schmidt*) has also been met with in the blood-cell, and, it appears, in no inconsiderable quantity; besides which, lecithin, cerebrin, and cholestearin (§ 21) (*Hoppe, Hermann*) have been met with here. A proposition first made by *Berzelius*, that the “fatty



Fig. 120.—Crystals of hæmoglobin, from the guinea pig (above); from the horse (lower half).

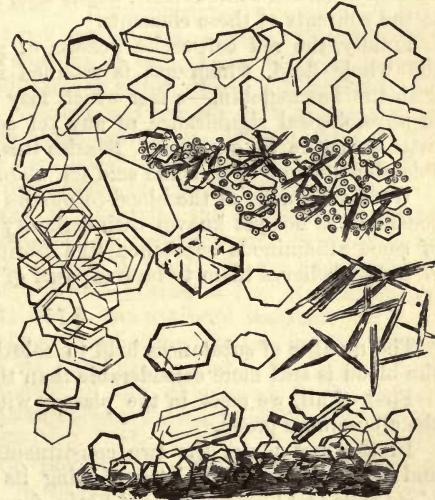

Fig. 121.—Hæmoglobin from the squirrel, crystallizing in the hexagonal system.

matters containing phosphorus" found in the blood might possibly belong to the cell, was subsequently shown by *Lehmann* to be quite correct. The cells of venous blood, moreover, appear to be richer in these cerebral substances than those of arterial blood.

Of the products of decomposition of the blood-corpuscle but little is as yet known, except that hæmatoidin (§ 35) may be regarded as a transformation product of blood-cells breaking down in the living body; as also bilirubin (§ 37), and in all probability cholestearin.

As far as these matters generated by the transmutative power in the cell do not rapidly leave the latter, or undergo further metamorphosis immediately, they appear in the uninteresting form of the so-called extractive matters (p. 54, remarks).

Finally, the nature of the mineral constituents, proper to the cell in contradistinction to those of the plasma, is of great interest,—an aspect of blood analysis first brought under notice by *C. Schmidt*. Among the salts of the blood-cell there appear some which are soluble in water, but in smaller quantity than if the cell were simply saturated with plasma. Further, the cell appears to be poorer in chlorine, but richer in phosphoric acid than the plasma; it likewise shows a much larger proportion of potash, and on the other hand a considerably smaller one of soda than the latter fluid. Thus, we find in it principally the phosphates of the alkalies, together with chloride of potassium, whilst chloride of sodium preponderates in the liquor sanguinis. The latter is, moreover, richer in phosphatic earths than the cell.

Now, since iron is not met with in the intercellular fluid (*C. Schmidt*), all of this metal which exists in the blood must be contained in the cells. Copper, also, and manganese (whose presence in the blood, however, must be still regarded as doubtful), ought also, according to analogy, to belong to the contents of these elements.

Finally, the red corpuscles possess of gases almost all the oxygen of the whole fluid, which gas is retained in loose chemical combination with the hæmoglobin,—a fact which may be looked upon as the greatest in physiological significance of any yet adduced in connection with the little structure in question. Besides this, the corpuscles contain a considerable amount of carbonic acid (*A. Schmidt*).

What the nuclei of the blood-corpuses of the lower vertebrate animals consist of is not yet known with certainty; it is generally supposed to be of some albuminous substance like fibrin, although a recent observer, *Brunton*, believes them to be composed of mucin.

§ 75.

The number of substances held in solution by the *intercellular fluid* of the blood is still more considerable than those contained in the cell.

First of all, we meet in the plasma with several matters belonging to the albuminous group.

In the first place, the two constituents of fibrin, namely, fibrinogen and fibrinoplastin, the latter finding its way into this fluid from the blood-cells (§ 11). Coagulated fibrin formed from these appears in the proportion of about 4 in 1000 parts of liquor sanguinis, but is liable to vary considerably as to quantity, even in the healthy subject.

Albumen (serum albumen), which, as previous analyses have shown, is contained in far larger proportion in liquor sanguinis than fibrin, is very probably held in solution by salts.

Besides this, another matter belonging to the albuminoid group is generally present, namely, the "serum-casein" of *Panum*; yet, as we have already seen (§ 11), it is probably nothing else than *Schmidt's* fibrinoplastin.

As to the fats contained in serum, very little is at present known. They occur for the greater part in the state of soap, and dissolved; more rarely suspended in the form of fine molecules. Should they become unusually abundant in the latter form, a cloudy opalescent appearance may be communicated to the blood, although this is more frequently the effect of a molecular precipitation of some albuminate. Moreover, it appears to be the ordinary fatty acids which enter into the composition of the serous fats, and we are warranted in accepting the presence of oleic, palmitic, stearic (and margaric?) acids here (§ 17). Further a peculiar substance, cholestearin, already mentioned (§ 21), is to be found in small quantity in the plasma.

Turning now to the remaining and better known constituents of plasma, which may be regarded for the most part as products of decomposition, we find their number very considerable, owing to the nature of the fluid. The following notes may be said to contain almost all that is at present known about them.

Among the organic acids the existence of lactic acid in healthy blood is not yet entirely beyond doubt, but it has been found in the latter under abnormal conditions. Blood may also contain formic acid from the group of fluid fatty acids. Acetic acid has been remarked after indulgence in alcohol (§ 16), and succinic in the blood of phytophagous mammals (§ 24).

The non-existence of taurocholic and glycocholic acid in the plasma is again of the highest physiological importance, whilst, on the other hand, uric acid is met with; the existence of hippuric remains doubtful (§ 26). Among the organic bases we must accept urea, kreatin, kreatinin (?); hypoxanthin, and probably also xanthin, as being many of them present in the fluid under normal conditions, a series which will probably be enlarged in the next few years. Leucin and tyrosin only appear pathologically; they may occur in the blood during diseases of the liver. In addition to these substances we have grape sugar also (belonging to the group of hydrocarbons) as a constituent of plasma (*Bernard* and *C. Schmidt*): it is partly introduced as such into the system, and partly formed in the liver. This substance, as *Lehmann* and *Bernard* have shown, is not to be found at all, or only in traces, in the blood of the vena porta, whilst that of the hepatic vein is rich in it. Milk sugar, on the contrary, is probably absent; inosite has not been observed.

Finally, there exists an unknown colouring matter in the liquor sanguinis, which gives rise to its pale yellow tint. The pigmentary matters of the bile are absent here, on the other hand, in its normal condition (at least usually). As to the extractives, their amount in the plasma is greater than in the cells.

Now, when we come to consider the mineral matters of the plasma, we find them essentially different in quantity from those of the blood-corpuses. The proportion of chlorine is more considerable here than in the cell, but that of phosphoric acid, on the other hand, smaller; and whilst the amount of potash exceeded that of soda in the cell, the case is completely reversed in plasma, the quantity of soda salts, and more especially of chloride of sodium, preponderating in the latter.

Further, the liquor sanguinis contains bicarbonate of soda, a small

quantity of silicic acid, and probably also traces of fluoride of calcium. Salts of ammonia are also present, in all probability, in healthy living blood, though in very small amount. Iron, as was already mentioned, is missing in the plasma.

In conclusion, the plasma, like all animal fluids, contains absorbed gases,—small quantities of O and N, and a larger amount of CO₂; besides this, carbonic acid appears in double chemical combination; loosely combined, it represents the second acid atom of bicarbonate of sodium, and is besides united in a subordinate manner with the phosphate of the latter (§ 43). In fixed combination it is supposed to constitute the first acid atom of carbonate of sodium.

REMARKS.—Volatile fatty acids belonging to the higher members of the series appear to be not entirely absent; witness the peculiar odour of fresh blood. This odour may be due to the presence of butyric acid, although the latter has not yet been proved to exist in the blood.

§ 76.

In the foregoing section we have had an example of the mean composition of the blood. But it stands to reason that the latter must be subject to great variation in the proportions of its constituents, according to age, sex, and other circumstances—according to the species of food, and state of the secretions, even in our healthiest days. However, these considerations belong more to physiology than to histochemistry. The blood of men is generally supposed to be richer in cells than that of women. The amount of corpuscles decreases also with increasing age, and is in the earlier periods of life smaller than in the adult body. The proportion of cells, further, sinks with bad nourishment, and also in consequence of great loss of blood. Of the solid constituents of the intercellular fluid, we know that the fibrin is subject to greater variation as to quantity than the albumen. The latter, however, occurs in far greater proportion than fibrin, and must, in fact, be looked upon as the most important constituent of the plasma for the support and formation of the tissues.

But the difference in the various kinds of blood of one and the same body is a subject of much more importance. Blood being the general nutritive fluid, enters everywhere into an interchange of matter with the tissues; it gives up certain substances, and receives others back again. And in that the chemical constitution of the several tissues and organs is different, and also their series of transmutations, the composition of the blood must be considerably modified in the various regions of the circulatory system. For instance, we will find blood flowing from the secreting breast of a woman of a different nature from that which returns from supplying the substance of the brain. But these deviations are still more remarkable in the glands and lungs. The blood which enters the kidney must be richer in urea, uric and hippuric acids, and certain mineral constituents, than that which leaves it by the renal vein. Blood which flows from the lung has given off carbonic acid and water, and, on the other hand, received oxygen; and so on.

Owing to the crude state of blood-analysis, this productive field of inquiry has up to the present day yielded but little. We are even now hardly able to ascertain anything accurately; thus the difference between arterial and venous blood, and that also between the blood of the vena porta and hepatic vein: again, in what respect the fluid contents of the splenic artery differ from that of the corresponding vein.

1. *Arterial and venous blood.* The usual manner of examining these is to compare blood taken from a vein of the skin with that from an artery, consequently only one kind of venous blood. It is generally supposed that arterial blood coagulates more rapidly on the whole, and is richer in fibrin, extractives, water, and salts, than the venous, but does not come up to the latter in its amount of albumen and fats. However, we must not give too much weight to this. According to *Lehmann*, the smaller veins contain more fibrin and water, but less cells, than the arteries. The same observer found that the corpuscles of arterial blood have more hæmatin and salts, but far less fats, than those of the venous fluid. Again, arterial blood possesses, in comparison to the remaining gases, more oxygen, while venous is richer in carbonic acid: the corpuscles of the first of these appear red, those of the latter more or less greenish. Venous blood is dichroic, when in thick layers it is dark red, and in thinner green (*Brücke*). A solution of reduced hæmoglobin manifests the same dichroic properties, whilst oxyhæmoglobin is monochromatic.

2. Blood from the *vena porta* and *hepatic vein*. It has been already remarked above (§ 70) that fewer colourless cells appear in the vena porta than in the hepatic vein. The cells, likewise, of the latter seem to differ from those of the remaining kinds of blood, and especially from those of the *V. portæ* (§ 67). Finally, no fibrin separates from the blood of the hepatic vein, according to *Lehmann* (a statement which is, however, questioned), while the vena porta does yield ordinary fibrin. This investigator directed his chemical inquiry towards the blood of horses and dogs, and obtained as a result a much greater richness in cells in the fluid of the hepatic vein, together with a considerable decrease in the quantity of water, consequent on the secretion of the bile. Further, the amount of albumen here is said to be smaller than in the vena porta. In conclusion (according to *Lehmann*), the blood of the hepatic vein is poorer in salts and fats, richer, on the contrary, in extractive matters, and especially so in grape sugar. The coloured cells of the hepatic vein are, besides, remarkable chemically for their abundance of solid constituents, but the amount of fat, salts, and iron in them has at the same time undergone diminution.

3. Blood from the *splenic artery* and *vein*. We have already referred to the blood of the splenic vein as that which, anatomically speaking, deviates most from the usual standard of this fluid, in that it possesses a very large contingent of colourless corpuscles (§ 70), and contains intermediate forms between the two species of cells. It is, further, remarkable for the more spherical figure of its cells, and the readiness with which crystallization takes place in it, as we have seen in section 13. *Funke* directed attention also to a somewhat modified form of lymph-corpuscle in this blood; it is of larger size, and filled with fine dark granules. The only real chemical difference, however, which could be distinguished by this observer between this peculiar kind of blood and the ordinary kind of the splenic vein, was a decrease in the amount of fibrin.

4. *Menstrual blood.* This blood, which is poured out from the turgid, and probably lacerated, vessels of the uterine mucous membrane of women, at intervals of four weeks, during the whole time they are capable of bearing, is remarkable, at least frequently, for a deficiency of fibrin. It is supposed that the latter has either coagulated already within the uterus, or is prevented from undergoing this change by the admixture of mucus when passing through the internal genital parts. But we are still in want here

of a satisfactory chemical analysis. Microscopical examination shows the fluid to be contaminated with the form-elements of mucus.

REMARKS.—1. Gray "*On the Structure and Use of the Spleen*," London, 1854, pp. 144 and 147. Here we find the abundance of colourless elements corroborated. Attention is also directed to the constant occurrence of dark pigment granules, or small elongated crystalline formations, which are occasionally contained in cells. 2. According to Gray, *loc. cit.* p. 152, the blood of the spleen is poorer in cells, but, on the other hand, richer in water, fibrin, albumin, and fat, than other blood. We shall have to discuss, later on, the occurrence in it of other peculiar matters, in considering the organ in question.

§ 77.

This is probably the most suitable place to consider more closely the varieties in colour in arterial and venous blood, already mentioned.

The colour of the blood (a body-colour) is produced, as we have already seen, by the presence of multitudes of coloured cells suspended in the usually colourless intercellular fluid. Without taking the subordinate differences into account, the tint of arterial blood is a light or cherry red, while that of the veins is of a darker or bluish red tinge (*modena*).

The following is all that is known at present of the cause of these variations in colour.

It has long been known that certain gases produce a change in the colour of blood. From time immemorial the light tint of the arterial fluid has been ascribed to the action of oxygen, and the darker shade of veins to that of carbonic acid. The correctness of this theory is easily proved by conducting a stream of these gases separately into a quantity of blood. A stream of oxygen causes the latter to become of a light cherry red, and carbonic acid makes it dark. Besides this, blood which has stood for a long time exposed to the air is always much lighter in colour on the surface than deeper down.

A solution of hæmoglobin is similarly affected by a stream of either of these gases.

But this solution, freed from formed elements, is transparent; it has the appearance of a "lac colour."

If we allow blood to freeze, it displays, on being again cautiously thawed, the same transparent colour. The microscope discloses the bodies of the cells, but decolorised. The hæmoglobin has passed from them in solution into the plasma. Such lac-coloured blood conducts itself in respect to its colouring properties very similarly to the artificial hæmoglobin solution of the chemist, and is exactly the same as the latter after complete destruction of the cells. Its transparency is much greater than that of normal blood with its coloured cells, and it appears with reflected light darker than the latter.

The more red cells, then, the blood contains, the darker and more opaque is it; the less it possesses of such elements, the lighter and more transparent does it become, seen by transmitted light.

The form, also, of the cells has a very great influence on the tint of the blood. All agents which cause the red corpuscles to shrivel, as, for instance, a concentrated solution of common salt, also render the blood paler in appearance, as seen by reflected light, whilst all reagents which produce an expansion of the cell, such as water, give rise to a darkening of the whole fluid. Such blood increases also in transparency, as might be expected.

It has been maintained by *Nasse* and *Harless* that a change of form is produced in the red cells by the action of carbonic acid and oxygen gas, the latter decreasing its size, the former causing it to swell out. This has been doubted by others, but has again received support from recent observers.

Many other things may also act on the colour of the blood, modifying it; for instance, an abnormal preponderance of colourless elements may produce a lighter tint in the fluid. Thus leucæmic blood often appears strikingly changed.

§ 78.

Sinking of the blood-cells.—The coloured blood-corpuseles possess, as has been already mentioned, a considerably greater specific gravity than the intercellular fluid—about as 1.105:1.028 in man. They would always, therefore, sink rapidly to the bottom in a vessel containing blood, or indeed in any quantity of the same in a state of rest, in obedience to the laws of gravity, were it not that the rapid coagulation of the fibrin renders this in most cases impossible. This gravitation, however, of the cells does to a certain extent take place in blood coagulating slowly. But the process may be distinctly followed up in blood deprived of the power of coagulation, by being beaten up or mixed with other reagents. Here we may perceive, after a considerable time, the commencement of a separation of the whole mass of blood into two portions—a superficial, almost colourless, transparent layer of fluid, and a red mass of coloured cells, occupying the floor of the vessel. Microscopical examination shows that the second element of form, the lymphoid cell, has taken no part in this gravitation, being a lighter body. Comparison of examples shows, also, that this sinking of the red cells commences sometimes rapidly, and often after some little time.

The position which the blood-corpuseles of human beings and mammalia (but not those of the other classes of vertebrata) take up in this state is peculiar. Instead of floating about singly in the fluid, as was the case during life, they now lie together with their broad surfaces in contact with one another, forming aggregations (fig. 122, *e*) like rouleaux of coins. If we follow up this formation of rolls, which begins even in a drop of blood freshly taken from a vessel, and observe it from its commencement on under the microscope, the process is seen to be initiated by the coming together of pairs of cells, which then cohere by their broad surfaces. From this on, the rouleau grows rapidly by the addition of new members, and it frequently comes to pass that other little columns, or rouleaux, range themselves with the first-formed at various angles, giving rise to the formation of dendroid, and often almost net-like figures. The addition of water at this stage of the process dis-

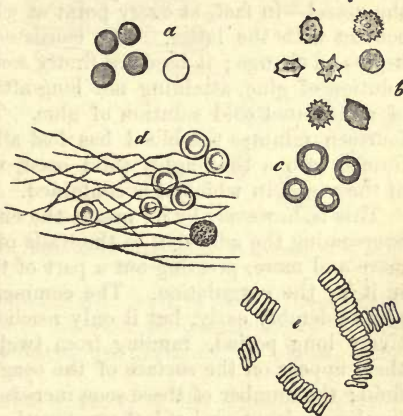


Fig. 122.—Human blood-cells; *e*, formation of rouleaux.

members the rouleaux, in that the several cells swell out and assume the spherical form, and thus again separate from one another. On this account the roundish corpuscles of the blood of the hepatic and splenic vein show no such columnar grouping.

The cause of this formation of columns is still unknown. The explanation of the phenomenon through the adhesiveness of the intercellular fluid or surfaces of the cells does not suffice.

At all events, it favours the descent of the coloured cells essentially, for the little structures thus united must be able to overcome better than when isolated the resistance offered to their gravitation by the fluid. If rouleaux have once been formed, the same settling down makes itself again rapidly evident in blood which has been re-agitated.

REMARKS.—It is a striking fact that, on the addition of anything which renders the intercellular substance more dense, as, for instance, of concentrated solution of sugar, the settling down of the blood-cells is accelerated, although just the contrary might be expected.

§ 79.

Coagulation of the blood.—The consistence of the blood begins very rapidly to change a few minutes after it has been obtained from the vessels—it coagulates, namely. This process commences much more slowly within the vessels of the corpse, or in sanguineous effusions in the interior of the living body. The latter may preserve their original consistence for many weeks.

Now, as regards the phenomenon itself—first of all, we remark the commencement of this change in blood taken from the living body in from two to five minutes. The first step in the process is the formation of a thin pellicle of the greatest delicacy on the surface of the fluid, which soon acquires greater thickness and solidity, so that it may be at length lifted off with the point of a needle.

Commencing thus on the surface of the fluid, this formation of membrane extends itself gradually along the sides and down to the bottom of the vessel—in fact, at every point at which our sample of blood comes in contact with the latter. The consistence of the blood so enclosed then begins to change; it becomes firstly somewhat thickish, like a half-cooled solution of glue, attaining not long after the consistence of stiff jelly, or of a saturated cold solution of glue. Then, at the end of from seven to fourteen minutes the blood has lost all its fluidity, and has been transformed into a thoroughly solid mass, whose form is determined by that of the vessel in which it is contained.

This is, however, by no means the end of the process. The solid jelly, overcoming the adhesion to the walls of the vessel, contracts subsequently more and more, pressing out a part of the fluid which has been entangled in it by the coagulation. The commencement of this contraction takes place tolerably early, but it only reaches its termination after a comparatively long period, ranging from twelve to forty-eight hours. At first there appear on the surface of the coagulum a few drops of a transparent fluid; the number of these soon increases, upon which they coalesce, forming larger drops, and at last run together into a layer of fluid which covers the surface of the coagulated mass. Whilst the coagulum thus progressively contracts to a smaller volume, similar layers of fluid to that on the surface collect under the latter, as well as along the edges and floor of the vessel, until the mass which at first adhered closely to the

cup, so that the latter could be turned upside-down without its falling out, commences to float in the expressed liquid.

From this on, the process only undergoes a quantitative alteration—that is, a continuous contraction of the lump causes it to decrease more and more in size, at the same time that an ever-increasing quantity of fluid is being pressed out of its interstices. When the whole process is at an end, we have a larger or smaller coagulum, sometimes soft and sometimes hard, floating in a varying amount of transparent fluid, which has, like the plasma, a slight yellowish tint. The coagulated mass having contracted uniformly, preserves the figure of the vessel, and forms a diminutive cast of the same, appearing in an ordinary porcelain basin plano-convex, and in a test-tube cylindrical. Its colour is that of the blood,—of a darker red, however, at the lower and internal portions than on the surface, where it is light.

This red lump has received the name of the *crassamentum* or *placenta sanguinis*, while the fluid in which it swims is known as the serum, or *serum sanguinis*.

Now, how are these two portions of the coagulated blood related to that which circulates in the living body, to its cells and intercellular substance?

We must remember, in the first place, that the latter is a fluid containing the two constituents of fibrin in solution. And as in other cases, so also after withdrawal of the blood from the system, these combine to form coagulating fibrin, by which, in that the fibrinogen is sufficient, the whole fluid, together with its cells, is entangled by the solidifying mass; just as a solution of glue retains, on cooling, any particles which may have been suspended in it—to make use again of this ordinary simile. By the progressive contraction of the gelatinous mass, a part of this now defibrinated intercellular fluid is expressed in ever-increasing proportion from its meshes, whilst the blood-cells remain behind entangled. From this we see that the liquor sanguinis consists of intercellular fluid deprived of its fibrin, or is, in other words, defibrinated plasma. The *crassamentum* must consequently be formed of the

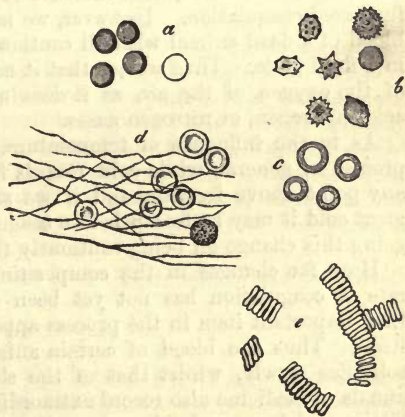


Fig. 123.—Human blood-cells; coagulated fibrin at *c*, with included corpuscles.

blood-corpuscles entangled in coagulated fibrin. And, in fact, microscopical examination of thin sections of the *placenta sanguinis* shows us the unchanged cells embedded in a homogenous, fibrinous, or plaited substance (fig. 123, *d*).

Of course a more or less considerable quantity of the intercellular fluid must still remain entangled in the cake of blood.

According to what has just been remarked, serum shares with the plasma its transparency, light yellowish colour, and chemical characters. Its specific gravity must, however, be somewhat lower, and may be stated at between 1.026 and 1.029. It not unfrequently happens that a

certain number of the red corpuscles escape being entangled in the coagulum, appearing as a kind of reddish sediment in the lower strata of the serum.

When a quantity of blood is beaten and whipped up, the fibrin deposits around the instrument used, and the former remains fluid. In such defibrinated blood the sinking of the red corpuscles mentioned in § 78 may be best observed.

§ 80.

The process of coagulation of blood, moreover, displays much variety. The consideration of each several point connected with it in detail, however, would lead us too far here; we will only, therefore, touch on some of the most important matters of interest.

As regards the rate at which the changes take place, we find that they may be hastened or retarded. Retardation is easiest produced, as a rule. The coagulation of blood is accelerated by setting the fluid in rapid motion, as, for instance, by means of whipping or beating. The blood of men is said to coagulate in general more slowly than that of women. Further, arterial blood solidifies more rapidly than venous, whose greater amount of carbonic acid exercises a retarding influence on the process.

Again, atmospheric air accelerates the clotting of blood, which explains the fact that, the finer the stream of blood flowing from the orifice of a vessel, or the flatter the dish in which it is caught, the more rapidly does it become solid. *Hewson's* experiences, also, are in harmony with this, who found that air injected into the vessels of a living animal frequently furthered coagulation. However, we may prevent the access of air to the blood of a dead animal with all caution, without being able to preserve it in a fluid state. Thus we see that it may coagulate without the influence of the oxygen of the air, as it does also in an atmosphere of carbonic acid, hydrogen, or nitrogen gases.

As to the influence of temperature, we find that warmth favours the process in general, while cold retards it. Coagulation may take place at any point above freezing, and if we subject fluid blood to the action of great cold it may be frozen before coagulation sets in, subsequently undergoing this change on being cautiously thawed.

How far changes in the composition of the blood may influence the rate of coagulation has not yet been sufficiently accurately ascertained. One important item in the process appears to be the nature of the fibrin itself. Thus the blood of certain animals, as, for instance, of the horse, solidifies slowly, whilst that of the sheep does so more rapidly. The annals of medicine also record extraordinary cases of extremely late coagulation, which are probably only to be explained likewise by some modification in the constitution of the fibrin.

The character, also, of the *crassamentum* is liable to vary greatly; sometimes it is uncommonly small and hard, sometimes large, soft, and fragile. Poorness in corpuscles may cause the first of these states, an increase in the latter the second, in that a superabundance of cells—other things being equal—must be looked on as a hindrance to the contraction of the fibrin, whilst in an opposite state but slight resistance to it is offered. A larger proportion than usual of water in the blood gives rise also to a softer coagulum.

Beside all this, there occur also very incomplete cases of coagulation where the process remains stationary in one of its earlier stages; indeed,

we see that very soft fragile clots may subsequently become again fluid. Finally, in some portions of the system the blood does not undergo this change at all, as, for instance, in the hepatic vein, and also possibly the menstrual blood of the female (p. 121). The blood of persons struck by lightning, and of those dead of asphyxia, has been found fluid *in toto*.

If in the moment of coagulation the coloured cells have already disappeared from the uppermost layers of the fluid, the coagulum does not present the usual red colour, but is yellowish white in its superior portion, then known as the *crusta phlogistica s., inflammatoria*. Microscopic examination of the latter shows the absence of red corpuscles in the coagulated fibrin, and, on the other hand, the lymph-corpuscles which are specifically lighter imbedded in the lower part of this light coloured stratum. And in that a quantity of cells usually hinders the contraction of the fibrin, the latter shrinks with much more energy in this uppermost layer, which is poor in the former, than in the parts of the cake which are of a deeper red. This explains the fact, that the *crusta phlogistica* generally forms a concave disk depressed in the centre, and smaller than the red part of the placenta lying underneath it.

This buffed portion then is produced, on the one hand, by the more than usually rapid gravitation of the red cells, or on the other by delay in the coagulation of the fibrin. Thus we meet it as a normal appearance in the blood of horses. It is met with frequently, likewise, in the human being as a pathological phenomenon, and especially during inflammatory diseases of the respiratory apparatus; but also under more normal conditions, as, for instance, in the blood of pregnant women.

Owing to our ignorance in regard to the protein substances, this phenomenon of coagulation cannot be at present explained. Since the earliest days of medicine, however, there has been naturally no lack of efforts to do so. The cooling of the mass of blood, its coming to a state of rest, or the action of oxygen on it, have all been looked upon as the causes of the process. Recently *Brücke* has entered the lists in defence of an old theory formerly held by *A. Cooper* and *Thackrah*, namely, that the blood is retained in a fluid state by contact with the internal surface of the living heart and blood-vessels. *A. Schmidt* also ascribes to these surfaces the property of retarding coagulation.

This is the present (but let us hope temporary) state of our knowledge on this point.

§ 81.

If we now ask, at the conclusion of this long inquiry into the nature of the blood, How much is known at the present day of the conditions during life of its two species of cells? we must allow that the results of all research so far are but very unsatisfactory.

The red cells are the vehicles for the oxygen of respiration, and appear to generate hæmoglobin within them, and to contain fibrinoplastic matter.

The physiological destruction of these cells takes place, firstly, in the blood passing through the vessels of the liver, taking a part there in the production of the bile, as is indicated by the solvent power of the alkaline salts of the biliary acids (p. 108), as also the near relationship between hæmotoidin (§ 35) and bilirubine (§ 37).

Again, we meet with another species of decay of the blood-cells in the more quiescent blood of the spleen, where they form small aggregations, which are transformed gradually into dark pigmentary masses. Forced

into the amœboid lymph-cells of the splenic tissue, the corpuscles and their fragments may give rise to the formation of those cells containing blood-corpuscles observed in the spleen. The same may also take place possibly in the medulla of bones.

We may mention here another circumstance for the discovery of which we are indebted to *Stricker*, namely, that by impeded circulation and increased pressure the red cells of the blood are forced through the uninjured walls of small vessels (capillaries and veins). Thus partly uninjured, partly divided into small beads, in consequence of being obliged to squeeze through, they reach the exterior, and are found in the neighbouring tissues and adjacent lymphatic passages according to *Hering*. In the first position they probably decay very rapidly, while their occurrence in the latter explains, at least partially, the presence of red blood-corpuscles in the lymph, already long known.

It is only seldom that under normal conditions blood escapes into the tissue of any living organ from lacerated vessels; but we have one case, that of the ruptured *Graafian* vesicle. Such extravasations, however, are not of unfrequent occurrence pathologically. In both these cases we meet

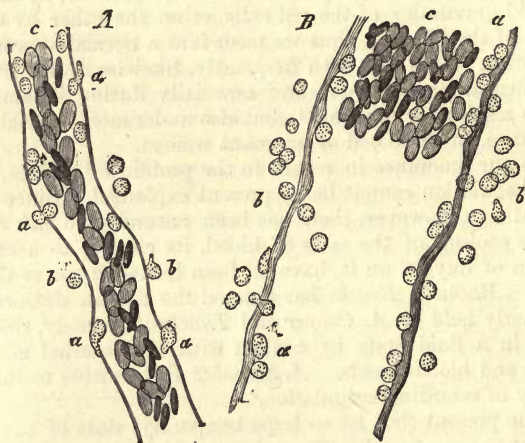


Fig 124.—Blood-vessels of the frog's mesentery, eight hours after irritation had been set up, showing emigration of lymphoid cells. *A*, a large capillary, shows at *a*, the mode of escape of cells, at *b*, some already escaped. *B*, a vein; *a*, the lymphoid cells closely applied to the walls, and making their way through; *b*, external to the vessel; *c*, coloured blood-corpuscles.

with destruction of the coloured elements after coagulation, and production from them of hæmatoidin crystals. In such effusions of blood, also, we may again meet with those cells already mentioned containing blood-corpuscles.

The colourless cells derived from the medulla of bones, the spleen, and lymphatic glands, are now looked upon, and indeed rightly, as serving to replace the loss of the red corpuscles (§ 71).

But in what proportion these undergo transformation into the latter is not yet ascertained, and is dependent upon the length of existence of the red cells, still completely unknown. However, we cannot doubt that such a metamorphosis of white corpuscles into red does take place very extensively after severe losses of blood, where a rapid reparation occurs.

But these lymph-corpuscles have yet another destiny.

Like the red cells, they also (but by virtue of their vital contractility) pass through the uninjured walls of the vessels (fig. 124) in the healthy as well as the diseased body; in some cases re-entering the lymphatic circulation, in others penetrating into various tissues (§ 49). Now it is probable that partly, at least, from this source the wandering lymphoid cells of connective tissue have their origin. These we will make the subject of later consideration. Under conditions of inflammatory irritation such an exit from the blood-vessels in the vicinity of the affected part takes place on a large scale (*A. Waller, Cohnheim*), and the pus-corpuscles appearing at this spot are, in part, nothing but the lymphoid cells of the blood which have emigrated.

Finally, touching the origin of the blood in the embryo, we may premise by stating that we are but partially acquainted with this chapter of histogenesis.

But in order properly to comprehend the process, we must first render ourselves familiar with the broader and more important outlines of embryology generally.

By the processes of segmentation in the impregnated ovum a cellular material is formed which represents the germ, *i.e.*, that spot at which the body of the coming being is to be built up. It is first disposed in the form of a membrane which, according to *Remak's* admirable investigations (recently questioned, however), may be distinguished as made up of three layers of cells arranged one over the other, from each of which certain distinct tissues and organs have their origin. Thus we have a key to a scientific classification of the tissues of the body.

For the present it need only be borne in mind that the upper stratum bears the name of the "*corneous*," the lowermost that of the "*intestinal gland*" layer (Darmdrüsenblatt). The derivatives of each of these will be met with presently. From the intermediate leaf known as the "*middle germinal*" layer very many structures take their origin; thus, the whole of the large connective-substance group, the voluntary and unstriped muscles, the vascular and lymphatic systems with their accessory organs and contents, including the tissue under present consideration, the "*blood*."

The first formation of blood then takes place at a very early period in foetal life. But the primary blood-cells are not related in any way to the characteristic corpuscles of later times, they are nothing but what are known as the ordinary *formative* or *embryonic* cells of which originally the most widely different structures of the body may consist.

The first appearance of the primary blood-cells corresponds with that of the heart and larger vessels immediately adjoining it. Both of the latter are said not to be originally hollow, but solid aggregations of cylindrical form, consisting of cells. Now the destiny of these cells entering into the formation of the cylinders is various; the peripheral become adherent to one another, or unite more closely still to represent the primitive walls of the heart and vessels, while between the most internal, bordering on the axis, fluid gradually accumulates in such quantity as eventually to immerse the cells completely.

From this moment on we may with propriety speak of blood in the embryo, in that the fluid in the rudimentary heart and vessels represents a scanty plasma, and the cells suspended in it the primitive blood-corpuscles.

At first the latter appear, as has been already mentioned, in the form of plain spherical cells, with finely granular protoplasm, vital contractility, and frequently vesicular nuclei, within which nucleoli may be seen. They

are still destitute of hæmoglobin, which gives them their characteristic peculiarities at a later period of their existence. Their size is also very various, exceeding frequently that of the cells of fully developed blood. Their average diameter in the embryo of fowl is, according to my observations, about 0·0128 mm.

Little by little the cell becomes clearer, and the characteristic yellow tinging with hæmoglobin commences, this substance being developed by the body of the former. Such coloured nucleated cells range in their diameter in the human being and in mammals, from 0·0056 to 0·0160 mm. (*Paget, Kölliker*).

Whilst this transformation of embryonic cells into blood-corpuses is proceeding with the further development of the circulatory system, the blood must of course contain, at the same time, both kinds of cells, the coloured as well as the more advanced, besides immature colourless ones.

During the earlier periods of foetal life, however, rapid multiplication of the red cells by means of division takes place, as was first observed by *Remak*. This may easily be followed in the embryonic chick.

The process begins here with division of the nucleolus, then follows that of the nucleus, which generally splits into two portions, and only very seldom, according to *Remak*, into three or four. Sometimes such a nucleus will divide anew, but it requires a very close search to discover in the chick cells engaged in more than the usual binary division. Finally, the contractile body of the cell is seen to undergo constriction in the middle until the two portions part company. The extreme delicacy of these blood-cells frequently gives rise to artificial appearances, for instance, of cells which are furrowed in the middle, and only contain a nucleus in one-half, or others whose two portions containing nuclei are held together by a long, thin, connecting thread. In the foetal chick it is just in these periods of formative life in which the liveliest increase of blood takes place, that this process of division (which may, as it appears, pass over very rapidly) can be best observed. Later on, at a more advanced stage of development, it ceases altogether, according to *Remak's* and our own observations.

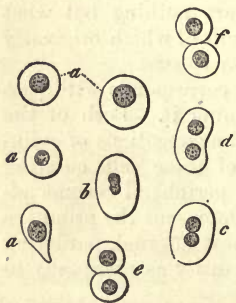


Fig. 125. — Blood-cells from the early embryo of the deer. The more spherical cells at *a a a*; multiplication of the same from *b* to *f*.

We owe much to *Kölliker* for his profound investigations in regard to the blood of the mammalia. Of the correctness of his views I convinced myself years ago in embryonic deer (fig. 125), as well as later on in rabbits and the human embryo. Here also the same process of division may be recognised. According to *Remak*, multinuclear cells occur also frequently. To me the nuclei always appear granular. Moreover, the act of division is liable to temporary variations, it appears. Thus in rabbit embryos of 9 mm. long I have only remarked a very small number of cells engaged in division, while the process could be often recognised in much larger ones. The further destiny of these in general still larger cells (though they may vary considerably as to dimensions), consists in this, that they take on more and more the spherical form, lose their inequality as to size, and assume the typical shape; the nucleus disappears at the same time in mammals. Even at a very early period

isolated examples of such fully formed, yet extremely delicate cells may be observed among the spherical and nucleated of a still earlier stage of development. Thus the embryos of the rabbits which I have examined, of about 9 mm. long, showed $\frac{1}{4}$ th to $\frac{1}{6}$ th of the whole number already without a nucleus, and presenting the characteristic form of the blood-cell. *Kölliker* found in sheep embryos of 8.6 mm. long no such mature blood-corpuseles, and *Paget* missed them also completely in a human fetus 9 mm. in length. According to the first of these investigators, they are still uncommonly rare in foetal sheep of 20 mm., while they constitute by far the largest proportion of the cells in the young of the same animal measuring 29 mm. In human embryos of the third month they only amount to about from $\frac{1}{3}$ th to $\frac{1}{4}$ th of the whole mass of the blood. Sheep embryos, on the other hand, of 11 to 29 mm. show a fall in the number of nucleated cells to a very small fraction.

The continued multiplication of red cells, which goes on naturally after the process of division has ceased, appears to be carried forward in the foetus, as in the adult, by the lymphatic glands, the medulla of bones, and by the spleen. Very early the characteristic lymph-corpuseles, derived from the latter sources, may be seen among the other coloured cells. That the liver takes part in the formation of blood, as has been supposed, appears very doubtful.

REMARKS.—Much has been adduced within the last few years in regard to the exit through the walls of vessels of the cellular elements—an occurrence of the highest significance in pathological and physiological questions, and especially in inflammation.

2. Lymph and Chyle.

§ 82.

While describing the foregoing tissue we mentioned that certain of the constituents of the blood are constantly passing from the capillary vessels into the surrounding tissues in the form of watery solutions.

This escape of fluid is indispensable for the nutrition of the various parts of the body, the organs as well as tissues, in that in these solutions various alimentary materials are contained. Now the latter, we know, are different in the several tissues; they are specially adapted, for instance, to the wants of bone, of the brain, of muscle, and so on. Then the fluids of the tissues become gradually quite different as to chemical composition by the loss of various materials of nutrition in particular parts of the body.

But to these fluids are also added the results of the interchange of matter going on in the tissues; the products of their decomposition; and these are also, as has already been remarked in the chapter on general chemistry, again different in the several organs. Here, then, we have a new source of variety in constitution of the several tissue-juices of the body.

Now for the carrying off of the latter, as far as they do not immediately return to the stream of the blood by processes of diffusion; the body is supplied with a special system of fine canals which communicate by means of their main outlets (already long known) with the circulatory apparatus. Their mode of commencement is only partially understood at present.

This system of canals is known as the *lymphatic* or *absorbent* system.

and the colourless fluid found in its vessels which has been strained off from the blood-capillaries, as "*lymph*."

Now the latter, although it may appear pretty much the same to the observer's eye in the various regions of the body, cannot possibly have identically the same composition everywhere from what we have just seen above. On the contrary, it will always be found to differ according to the nature of the tissue or organ from which it flows, and to be, therefore, a fluid of more variable constitution than the streams of blood belonging to the several regions of the circulatory system.

There is, however, in our body one portion of the lymphatic system which serves other purposes, at least, at certain times. The lymphatic canals namely, of the intestinal mucous membrane contain in the fasting state a fluid possessing all the usual characteristics of lymph. During digestion, however, there enters by the radicals of this system of canals a mixture of albuminous substances and fats taken up from the alimentary matters. We now find the passages charged with a whitish, opaque, and frequently milky fluid, to which, owing to its appearance, the name "*milk-juice*" or "*chyle*" has been given. These particular vessels are then spoken of as *lacteals*.

§ 83.

Both these juices contain, suspended in a *plasma* or *fluid intercellular substance*, a considerable number of *cells* all possessing the same nature (lymphoid cells); these are known, from the mode of their occurrence, as *lymph* and *chyle corpuscles*. They were first discovered by *Leeuwenhoek* and *Mascagni*.

In all essential particulars they correspond with the colourless cells of the blood, already discussed at (§ 69); nay more, they are identical with them. The cells of the lymph and chyle, namely, pass into the blood, and circulate there as white corpuscles. Besides these, there are other immeasurably small molecules to be seen, especially in the chyle, as also larger elementary granules, while in some particular regions, especially of the lymphatic system, isolated red blood-cells may be observed.

The cells in both fluids display much variety as to size and other relations, and no regular law seems to govern their distribution, although one or other form of cell may at times gain the ascendancy in this or

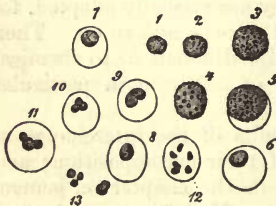


Fig. 126.—Cells from lymph. From 1 to 4 unchanged; at 5 the nucleus and envelope appear, also at 6, 7, 8; at 9 the nucleus commences to divide, as also at 10 and 11; at 12 it has separated into six pieces; at 13 we have liberated nuclei.

that region. It is a fact of great interest, further, and one which may be especially clearly recognised in the chyle absorbents, that either none at all, or very few of these corpuscles are to be seen in the finest radicals, when on the point of leaving the wall of the intestine; but that they become all at once very numerous in the fluid after the passage of the latter through the mesenteric glands. The same may be observed in other parts of the lymphatic system.

Now as to the cells themselves, more particularly, they may be said to have been already considered when speaking of the blood. They are the same formations, namely, with like diversity as to size, as to the body of the cell and its contents, with the same kind of nuclei and endowed with the like vital contractility as the colourless corpuscles of that fluid.

But while the cells of lymph and chyle are everywhere alike, the contrary is the case with the remaining elementary particles of these fluids.

On microscopical examination the chyle of mammiferous animals displays a certain amount of turbidity—the cause of its white colour to the eye—produced by innumerable minute dust-like particles suspended in it, and not by small globules of fat with which this fluid was formerly supposed to be so richly filled. These particles (as is usually the case with substances in a minute state of division suspended in fluid), are engaged in a peculiar tremulous or restless movement, termed the *molecular motion of Brown*. The more opaque and milky the chyle appears, the more numerous are these molecules found to be. They decrease in number again in the larger passages of the lymphatic system, and are completely absent in the clear lymph of fasting animals. Eventually these particles flow from the absorbents into the blood through the *ductus thoracicus*, and may form in it transient constituents of the plasma. As to ascertaining their magnitude, with any approach to accuracy, we must confess our utter inability to do so, owing to their extreme minuteness.

These dust-like molecules consist, we are told by *H. Muller*, of neutral fats enclosed in a wondrously delicate layer of a coagulated protein substance (albumen). Owing to this they do not coalesce, as free fat globules would do, nor do they on the addition of water. But if chyle be evaporated to dryness, the particles do unite on the subsequent addition of water, as also when acetic acid is mixed with the fluid. They are dissolved by ether, to the action of which the albuminous envelope seems to present no obstacle. We will see further on that these fatty particles represent the fats of the food absorbed from the intestinal tract.

Besides these, larger and less clearly defined elementary granules of 0.0002 – 0.0011 mm. in size are to be found in the chyle, partly scattered and partly in groups. They appear to be the wreck of lymph corpuscles, and probably occur in the blood also (§ 64) (*Hensen, H. Muller*).

Finally, we have blood corpuscles again brought before us in both lymph and chyle. Some of these, doubtless, gain access to our preparations from wounded blood-vessels, and the admixture may be completely avoided by careful dissection. On the other hand, such red cells may be found almost always in the *ductus thoracicus* of many animals, as, for instance, in that of the dog. The lymph of the spleen further appears to be very rich in red cells (*Thomsa*), as also that of the liver (*Hering*). From this there would appear to be but little doubt that in isolated cases lymph-corpuscles may undergo transformation into red cells before entering the circulation. For my own part, I believe, I have observed intermediate forms in the thoracic duct of the rabbit, between the two species of cells; they are also to be seen in the blood of the splenic vein (§ 76), and in the medulla of bones. On the other hand, the possibility of a migration of red cells from the blood-vessels into the lymphatics through the walls of the former (§ 81), *Hering*, must be allowed.

§ 84.

Now, the question as to the *source* of these lymph and chyle cells, is one of the utmost importance for the histology of the present day.

And since their spontaneous generation in both fluids could not any longer be allowed, and that they were found to be either entirely absent, or only to occur with extreme rarity in the commencement of the absorbents, while immediately after the passage of the fluid through the lymphatic

glands they were met with, the possibility of their origin in these so-called glands was recognised even years ago. This view received support, also, from the discovery that the contents of the latter is the same as that of the lymphatic vessels. In the mucous membrane of the digestive tract there occur also small lymphatic glands, known as "*Peyer's patches*," and hence the origin of the few isolated lymph-corpuscles found in the smaller branches of the chyle vessels, leaving the intestinal tube.

And, in fact, the cells of lymph and chyle are the corpuscles of these organs which have penetrated into the hollow interstices of the lymph-nodes, and have been carried off by the stream of fluids. These points if borne in mind will render the description of the lymphatic glands more easy of comprehension, in discussing which we shall have to consider the origin of the cells in question in the latter organs.

How far these cells are capable of undergoing multiplication in the lymph and chyle streams, is also a matter worthy of our consideration. At present we are in possession of no reliable facts bearing upon this point.

§ 85.

However important it might be to determine the *amount* of these fluids in the body, even approximately, science possesses at present no certain data to go upon in regard to their quantitative analysis. We can only, so far, conjecture that the amount of both must be very considerable, and that, as through the lacteal system, so also through that of the lymphatics, an extensive intermediate circulation exists.

If we now turn to the *chemical constitution* of these two fluids, we have at present but very insufficient analyses to go upon. Hitherto it has not been possible to investigate chyle and lymph in a manner adequate to the requirements of histology. We cannot yet even accurately determine the composition of the moist lymph-cell. All the rough analyses, too, which have hitherto been made, display enormous differences, owing to the difficulty of obtaining large quantities of lymph and chyle in a pure state, and to the changeable nature of both liquids.

As to the cells, they consist of various modifications of albuminous compounds, the enveloping layer showing different reactions to those of the nucleus and protoplasm of the body of the cell, which encloses molecules of a coagulated albuminoid, and of fats: it is soluble, namely, in dilute acids, while the nucleus is not.

Lymph is a more or less clear, alkaline, watery liquid, whose specific gravity is not yet known. In it may be found, again, those protein substances which are likewise present in the plasma of the blood namely, the two constituents of fibrin, with albumen and its modifications. The former give rise here, also, to the coagulation of the fluid when collected in a vessel. And yet a difference exists between the fibrin of lymph and that of blood in the manner in which it solidifies. Lymph, namely, does not usually coagulate in the corpse, but subsequently on being drawn off, and only after frequently very long continued exposure to the oxygen of the atmosphere. As far as is known at present, from ten to twenty minutes appear necessary; but even an hour may pass over before it takes place (*Nasse*). The lymph-clot retains also, as was the case with that of the blood, the form of the vessel in which it solidifies, but is naturally much smaller on account of the much smaller number of cells

which it contains. Another peculiarity frequently observed, and which I myself am in a position to verify, is also very striking; the coagulum, namely, may become red on exposure to the air, a change of colour probably depending upon the generation of the pigmentary principles of the blood through the action of the atmospheric oxygen.

The amount of fibrin seems, moreover, to be liable to considerable variation.

The albumen of lymph exists, like that of the plasma of the blood, in combination with soda as albuminate of sodium. Casein is missed, as in the blood also.

The fatty matters, individually but slightly known, appear partly as neutral fats and partly saponified with soda. Their amount, like that of albumen, seems to vary considerably. Besides these, lymph contains also grape sugar and urea. As to the extractives which are here met with in no small amount, their nature has not been investigated.

Chloride of sodium is very strongly represented among its mineral constituents, as well as the carbonates of the alkalis; besides which, the usual combinations of phosphorus and sulphuric acid of the system all occur in lymph. Finally, iron also makes its appearance here.

Although the proportion of water in this fluid always remains larger than that in the liquor sanguinis, it is still subject to very considerable variation.

Lymph contains no oxygen, or only traces of it; it does, however, possess nitrogen in small amount, and carbonic acid seems to be present in great abundance. A portion of the latter is held in loose combination, another portion can only be displaced by acids.

On the whole, it would seem that lymph possesses a composition allied to that of the plasma of the blood, both of them apparently containing exactly the same proportion of salts (*Nasse*). But in general it may be stated to be richer in water and extractives, but poorer in albumen, fats, and salts than the liquor sanguinis.

Not long since analyses were undertaken by *C. Schmidt*, in which, for the first time, the coagulum and serum of lymph were separately treated.

The lymph to be analysed was obtained from the neck of a foal, which had been previously well fed with hay: it showed the following composition:—

1000 parts of lymph contain			
• Serum, 955·2		
Coagulum, 44·8		
1000 parts of coagulum contain:—		1000 parts of serum contain:—	
Water, 907·3	Water, 957·6
Fibrin, 48·7	Albumen, 32·0
Albumen, } 34·3	Fats and fatty acids, 1·2
Fats and fatty acids, } 34·3	Other organic matters, 1·8
Other organic matters, } 34·3	Salts, 7·4
Salts, 9·7		

In regard to the mineral constituents, *Schmidt* observed a similar, though less marked, contrast between cells and plasma, as in the blood (comp. § 75).

Now, as to the chemical constitution of the *chyle*, we find it slightly alkaline. Owing to its greater richness in fatty matters also it is more cloudy or milky than the fluid last mentioned, and in general richer in solid constituents, so that its specific gravity lies between 1·012 and 1·022.

It partakes of the same peculiarity as lymph, in coagulating some considerable time after it has been collected from the body; it does so, however, with much greater rapidity on the addition of a certain amount of blood (*A. Schmidt*). We have already mentioned (§ 11) that the fibrinogen of the latter fluid has its origin in the red blood-corpuscles. The coagulum of chyle may also subsequently become red on exposure to the air. Its fibrin generally contracts much less, and remains more gelatinous, at the same time that it possesses greater solubility.

Albumen, an important constituent, as we would be led to expect from the nature of chyle, appears in considerable, but, according to the kind of food, variable quantity. We have already mentioned its partly forming the envelopes on the minute molecules of this fluid; but another portion of it is present in the form of solution in water.

The amount of fats, also, in chyle, though necessarily subject to great rise and fall, is far larger than in lymph. Primarily, whilst in the finest vessels all of them are found as neutral compounds suspended in a state of the most minute division, later on saponified fats make their appearance, as observation with the microscope teaches us, by means of which we see the formation of fat-globules in a clear fluid on the addition of an acid (*H. Muller*).

Again, we find that grape sugar and urea are contained in this fluid. It may also have lactic acids in its composition, according to *Lehmann*.

Chyle contains, also, a by no means inconsiderable proportion of extractive matters and the ordinary mineral compounds, such as the alkaline salts, with chloride of sodium in large quantity. Further, minute quantities of the earthy salts and iron have been found in it.

A rather old analysis of *Rees* (1) may serve as a clue to the composition of the chyle, beside which we give one of lymph by the same author.

Chyle obtained from the <i>ductus thoracicus</i> of a young donkey seven hours after having been fed on peas and beans (after <i>Rees</i>).	From the extremities of the same animal.
Water,	902·37
Fibrin,	3·70
Albumen,	35·16
Watery extract,	12·33
Alcoholic do.,	3·32
Fats,	36·01
Salts,	7·11
	965·36
	1·20
	12·00
	13·19
	2·40
	Traces
	5·85

Strangely enough, the most recent experimenter on chyle, *C. Schmidt*, arrived at completely different results in his analysis of that from the thoracic duct of the foal. According to this observer, the composition of both fluids, of lymph and chyle is exceedingly similar, except that the latter showed a somewhat larger proportion of iron, whilst the amount of fat found in it was extremely small.

The following is the composition of the chyle obtained from the thoracic duct of a healthy foal, which had been fed three hours before with meal-pap and hay:—

1000 parts contained

Serum,	967·4
Coagulum	32·6

In 1000 of coagululum of the chyle :—	In 1000 of serum of ditto :—
Water, 887·6	Water, 958·5
Fibrin, 39·0	Fibrin,
Free fat, 1·5	Free fat, 0·5
Fatty acids of the soaps, 0·3	Fatty acids of the soaps, 0·3
Albumen	Albumen, 30·9
Sugar and other organic } 66·0	Sugar and other organic } 2·3
matters, }	matters, }
Hæmatin, 2·1	Hæmatin,
Mineral constituents } 5·5	Mineral constituents } 7·5
without iron, }	without iron, }

As yet we know but little as to the *first appearance* of lymph-cells in the embryo. But from the fact alone, that lymph-corpuscles may be observed in foetal blood at an early period, we may infer that they occur also largely in the lymph.

REMARKS.—*London, Edinburgh, and Dublin Philosophical Magazine*, Feb. 1841. Comp. also Nasse's article "Chyle," p. 235.

B. Tissues composed of simple cells, with a small amount of solid intermediate substance.

3. Epithelium.

§ 86.

By *epithelium* we understand a tissue formed of closely associated cells, which clothes, in layers of greater or less thickness, the external and internal surface of the body, canals of exit and even numerous completely closed cavities of the system. It is only through the nearer acquaintance with the history of its development that we have been enlightened as to its true nature. And for this we are indebted to the searching investigations of *Remak*, from which we learn that at an early period of development the flat rudimentary embryo is bounded above and below by two strata of cells, the *corneous* and *intestinal glandular* layers. From the first of these the epithelium of the external surface takes its origin, and from the second that of the digestive tract. But the cells of these two layers play a further part in the construction of numerous other organs.

Thus we find that it is not alone the outer clothing of the body, the skin, with its manifold reduplications, which bears these epithelial layers of cells, but the mucous membrane also with which it is continuous, the glands of the intestinal tube, the internal surfaces of the respiratory and generative apparatus, and even parts which have completely ceased to communicate with these primordial epithelial layers; as, for instance, the cavities in the brain, the spaces and bounding surfaces in the eye and auditory organs: these all possess this characteristic covering. Owing to the fact that the secreting gland-cells having the same origin as the epithelia, we frequently find transitions from one kind of cell into the other in the interior of those organs.

The epithelium extends, however, still further throughout the body. The strata of cells enclosed between the corneous and intestinal glandular layers, namely, the so-called *middle* or *intermediate* layer, becomes, with

advancing development, the seat of various cavities which acquire subsequently on their inner surface a clothing of epithelium. It is in this exceptional manner that the epithelia of serous cavities and lining membranes of the heart, with the blood and lymphatic vessels, have had their origin.

The elements of epithelium are pale, transparent cells, with distinct nuclei, only absent in the older cells of many kinds of tissues. The size of these cells is liable to vary greatly; it lies between 0.0074 and 0.056 mm.; that of the nucleus is less so, whose diameter may be stated on an average to be from 0.0045 to 0.0091 mm. The appearance of the latter may be vesicular, homogenous, or granular.

It has already been remarked that the surfaces of the body are clothed with layers of epithelium of varying thickness. The depth of the tissue, in fact, changes to a most extraordinary extent in the several localities of the system. Whilst some strata of epithelial cells may attain a height of 2 mm. and upwards upon the external skin of the human body, so that they were recognisable to earlier generations of anatomists without the aid of the microscope, they may yet decrease in thickness in other places, forming thin coatings of only a few layers of cells, invisible to the unaided eye. Finally (and this is the case over by far the greatest portion of the surface of the body), this tissue may consist of one single extremely delicate layer of cells.

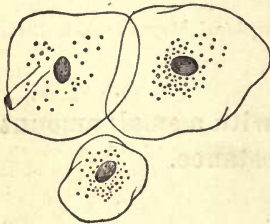


Fig. 127.—Flat epithelium cells from the human mouth.

The most important feature which this so widely-distributed tissue presents for our consideration is the *variety of form* which it displays, which has led to the recognition of several distinct species of epithelium. It is comparatively seldom—and in the human body over very limited areas—that epithelial cells preserve the original typical form of the cell, namely, the *spheroidal*. We generally find either one or other of the changes affecting the spherical body already considered (§ 46), *i. e.*, flattening or lateral compression, so that it usually appears, with modifications in particular instances, either as a flattened, squamous, or narrow cylindrical cell.

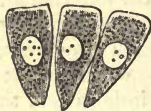

Fig. 128.—Cylinder or columnar epithelium from the large intestine of the rabbit.

We must therefore distinguish between 1, the *flattened* or *pavement epithelium* (fig. 127) and 2, *cylinder* or *columnar epithelium* (fig. 128).

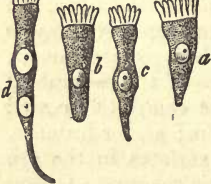

Fig. 129.—Various forms of ciliary cells from vertebrata.

Other modifications of this tissue may arise from the free surface of the cells bearing minute hair-like appendages, as we have already mentioned. Thus a third special form is produced, the *ciliary epithelium*, fig. 129. In man and the higher animals it is almost exclusively upon the cylindrical cells that these supplemental structures occur.

Again, in certain regions of the body the cell is found to possess peculiar contents, namely, granules of black pigment or melanin, with which its body may be charged.

In human beings and mammalia it is only the more flattened cells of the epidermis which have these exceptional contents. They represent what used to be described by histologists as *polyhedral pigment cells*

(fig. 130). According to our way of thinking they should be called *pigmentary epithelia*.

The extremely variable depth of this tissue just mentioned leads to further variety. Besides epithelium, in which many layers are placed one over the other, forming a heavy coating (fig. 131), we find others made up of but one single stratum of cells (fig. 132); and between the *densely laminated* and *non-laminated* species there exist many intermediate forms, in which only a few strata are to be seen, disposed one over the other. It must be borne in mind, from this on, that it is only the flattened epithelia which are capable of becoming laminated to any remarkable extent; but that they need not necessarily everywhere take on this form.




Fig. 130.—Pigmentary flattened epithelium (the so-called polyhedral pigment cells) of the sheep.

§ 87.

The most widely distributed variety of the tissue under consideration is the *flattened* or *pavement* epithelium. Overlooking its more limited occurrence in certain regions, it is met with on the external skin, on many mucous membranes, in serous sacs (true and false), as well as on the internal surfaces of the vessels of the circulatory system. Its thickness is subject to the greatest variation, so that, at one time strongly laminated, it represents the strongest of all epithelia; at another it displays merely a delicate coating of cells of the simplest kind.

Simple pavement epithelium (1), in the first place, forms the internal coating of the cavities of the heart, as also of the blood and lymphatic vessels. (2.) It makes its appearance, further, in the true serous sacs on synovial membranes (bursæ, sheaths, and capsules for the joints). (3.) Again, within the eye, on the posterior surface of the cornea and anterior of the iris; on the internal surface of the capsule of the lens; within the auditory apparatus, namely, on the periosteum of the internal ear, the inner surface of the semicircular canals and vestibule. To what extent gland ducts possess such a lining need not for the present be discussed. We find sometimes a simple and sometimes slightly laminated pavement epithelium in the canals of exit of the sweat and ceruminous glands. The infundibuli of the lung are likewise lined by the same species of cell. (4.) Finally, the greater part of the ventricles of the brain in the adult is covered with a species of pavement epithelium instead of the ciliated cells of early life.

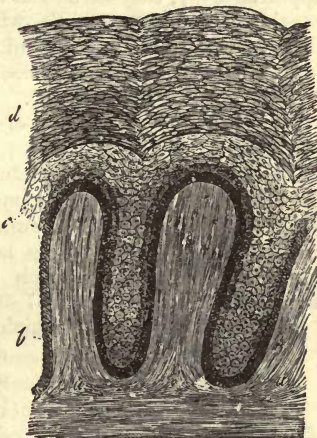

Fig. 131.—Vertical section of the skin of a negro. Thick laminated epithelium lying on the elongated papillæ of the dermal tissue (a), with younger cells at b and c, older at d.

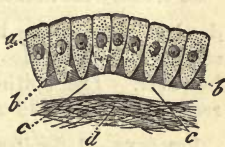

Fig. 132.—Simple coating of cylinder epithelium on a mucous membrane. Fibrous tissue of mucous membrane at d; cells at a.

The elements of this tissue consist of pale flat cells (fig. 133) placed closely together, and without any apparent intercellular matter. They are frequently destitute of granular contents, but display at times very minute dust-like molecules. Such is the indistinctness of limitation in the cells, in

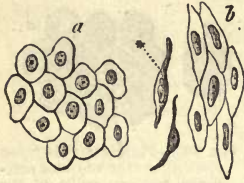

Fig. 133.—Simple pavement epithelia. Serous membrane at *a*; from a vessel at *b* with lateral view.

certain instances, that their outlines may not be apparent, or they may seem to fuse into one another. Their boundaries usually become visible, however, in the form of dark lines, on treatment with a dilute solution of nitrate of silver.

These cells possess distinct nuclei, sometimes granular, sometimes smooth-edged, in the interior of which one or more nucleoli are usually visible. Their form is twofold; in one instance they may be broad, with a polyhedral outline (*d*) and diameter of 0.0226–0.0090 mm., while the round nucleus is 0.0075–0.0057 mm.; in another their shape is more or less lanceolate, and length—0.0226–0.0455 mm.—with a similarly narrowed nucleus (*b*). In side view such cells may present a very peculiar appearance (*b*); they then seem to possess the form of short fibres, thickened considerably in the middle, where the nucleus is situated. The first of these species of cells is found lining serous sacs, the latter clothing the internal surface of blood-vessels and lymphatics; but here again there exists much variety (*Legros*). In the arteries we find long and narrow cells, while the endothelium of veins is made up of shorter and broader elements.

The thickness of these structures, and with it that of the whole covering, must, as we have already mentioned, present much variety. Where but a small amount of flattening has taken place, the depth of the cell and thickness of the whole layer is generally about 0.0055 mm. and upwards, whilst strata which have undergone more compression may sink in depth to only 0.0037–0.0032 mm.

Those tall cells, again, which occur in the hollows of the brain also deserve special notice as peculiar elements; also those of the choroid plexus. The latter (fig. 134) are likewise thicker and rounder, giving off one or more pointed processes, and containing, besides the nucleus, as a rule, one or several granules of a dark brown substance, which is, moreover, absent in the younger cells.

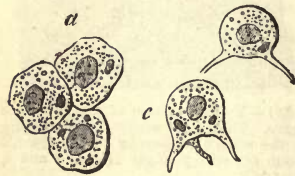


Fig. 134.—Epithelial cells from the human choroid plexus. *a*, cells from above; *b* and *c*, side views of the same.

Pavement epithelia are very delicate structures which undergo rapid decay in the dead body. In the living subject, on the other hand, they probably constitute more durable tissues, with but little power of rapid regeneration however. The epithelia of the lung are perhaps an exception in this respect. The mode of their regeneration is not yet known.

REMARKS.—1. See *Henle's Allg. Anat.* p. 226, &c. *Luschka*, *Die Structur der serösen Häute*. Tübingen, 1851. 2. We refer our readers to the special chapter on the vascular system for the rest. 3. Those views which were formerly entertained on this point, and which taught of the existence of a laminated pavement epithelium on the surface of connective tissue, were based on deceptive appearances. However, at an early embryonic period the surfaces of cartilages do seem to be clothed with a layer of cells similar to those of epithelium. We will refer to this again. 4. Comp. the paragraph on the respiratory apparatus for the epithelium in question.

§ 88.

The simple pavement epithelia just referred to pass, without any sharp line of demarcation, into the more or less strongly laminated species, through certain intermediate forms. Thus, on the internal surface of the tympanum and dura mater, and external surface of soft skin, we find an epithelium formed of several layers, but still thin; of these the more superficial are recognised as formed of larger and flatter cells.

The anterior surface of the cornea of mammals affords an interesting example of a moderately laminated epithelium. Here we find from seven to nine layers of cells laid one over the other. The counting of them, however, is not in all cases easy. In some of the strata we observe flattened cells, and in others call bodies, generally of round figure, but often assuming other forms under the influence of lateral pressure. The undermost layer consists of naked elements, greater in height than in breadth, and having each a full, plump nucleus (perpendicularly elongated cells).

The lining of the urinary apparatus is still less markedly laminated. The uppermost layer is formed of a single stratum of cells of different sizes, with vesicular nuclei. Their under surface displays a varying number of grooves with ridges and prominences situated between them. Applied to these depressions, we find the rounded ends of columnar cells belonging to a second layer. Then follows a third stratum of more irregularly shaped elements, at one time cylindrical, at another, more or less fusiform, next to which, finally, a fourth and terminating layer of small polygonal cells may be recognised (*Linck, Henle*).

The pavement epithelium of many mucous membranes of the body often displays much stronger and even very considerable lamination, as for instance, that of the conjunctiva of the eye, the entrance to the nares, the cavity of the mouth and pharynx, as well as the œsophagus down to its connection with the stomach, the vocal cords, and finally, the mucosa of the female genitals, as far up as the uterus.

For a closer examination of these typical formations, the mouth may be recommended as peculiarly adapted (fig. 135). In the deepest layers, seated immediately upon the fibrous tissue of the mucous membrane, we meet with strata of soft small cells of roundish, or at times more oval figure, with a diameter of only about 0.0075 or 0.0114 mm., and vesicular

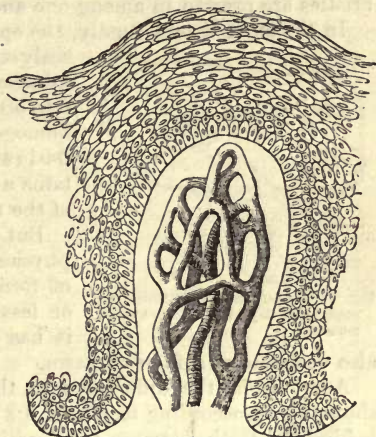


Fig.—135.—A papilla from the gum of a child, showing the vascular net-work and lamination of the epithelium.

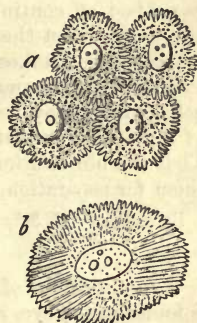


Fig. 136.—The so-called spinous or furrowed cells. At *a*, from the undermost layers of the human epidermis; at *b*, from a papillary tumour of the human tongue.

nuclei of 0.0056 mm. in size, or less. All these cells display under high microscopic powers a very peculiar structure (fig. 136). Their whole surface namely is covered with prominent ridges and spines (*a*), by mean of which neighbouring cells are attached to one another, "like two brushes whose bristles are pressed in among one another" (*Schultze*).

In the outer layers, finally, the epithelial cells (fig. 136) appear as thin scaly structures, without either grooves or prominences, and of considerable size (0.0425–0.0750 mm.), with more or less oval and homogeneous nuclei of from 0.0090 to 0.0114 mm. Here the body of the cell contains a few granules usually in the vicinity of the nucleus.

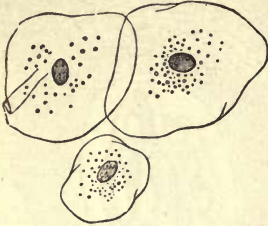


Fig. 137.—Epithelial cells from the uppermost layers of the human mouth.

But the cell has also changed in its physical condition. Instead of the softness of former days, it now manifests a greater or less degree of hardness and brittleness; it has become horny, as the saying is: it is also destitute of soft protoplasm.

Apart from the differences in thickness which the whole bed may show (being, according to *Henle*, 0.2 mm. on the palate, and on the gums, behind the teeth, between the papillæ, 0.4 mm.), the cells of the locality just mentioned seem to differ but slightly.

The persistence of epithelium, already considered in speaking of the simplest pavement cells of closed cavities, appears to be the same in the urinary apparatus; in the thickly laminated coatings of other mucosæ it is well known not to obtain. Here we have to do with a tissue undergoing rapid repair, in that a certain quantity of the most superficial cells is rubbed off continually, forming a regular constituent of the mucus of the part, whilst the deeper cells advance to the surface, and a process of cell-formation takes place in the undermost strata in order to cover the loss of the desquamating cells of the surface. The multinuclear epithelial cells which may be observed, by no means unfrequently, in deep parts of the strata, are evidence in favour of such a process of cell-formation. That the obliteration of the spines and ridges in senescent cells prepares them for separation, is very probable.

REMARKS.—*M. Schultze* in *Virchow's Archiv*, bd. 30, s. 260.

§ 89.

A modification of the pavement epithelia we have just been discussing is found in the eye, in the so-called "polyhedral pigment cells" of the uvea. These are epithelial cells, partly laminated to a small extent, and partly not, and moderately flattened, which occur in the eye in the form of a delicate mosaic. They have peculiar contents as a rule, made up of numerous elementary granules of the black colouring matter, melanin, already described (p. 52).

These cells are met with on the internal surface of the choroidea in an unbroken but single layer, which becomes suddenly laminated in the vicinity of the *ora serrata* of the retina, at the same time that the individual elements decrease in size. Thus arranged, they are found covering the ciliary processes, and in the human eye the posterior surface of the iris as far as the edge of the pupil.

The granules of black pigment are sometimes elongated, sometimes

rounded, and usually appear darker the smaller they are, in any one individual. They are probably crystalline. The tint of the molecules is by no means exactly the same in different mammals. In man, where the granules are small, it is seen to be brownish black, but in many of our mammalia, as in the pig and calf, it is jet black. The size of these particles remains always considerably below 0.0023 mm. Answering to their minuteness, they show, on becoming free in water, the liveliest molecular motion, a phenomenon which may, however, be remarked in the substance of uninjured cells when strongly swollen under the action of imbibed water.

The pigmentary epithelium itself (fig. 138) appears on the choroid as a simple bed of closely crowded cells, of a beautiful polyhedral, usually hexagonal figure, running at times through whole groups (a) with the greatest regularity. And yet they may be found indefinitely angular; and some unusually large cells are frequently octagonal (b). The diameter of most of these cells is on an average 0.0014–0.0204 mm., and their thickness 0.0090 mm.

The quantity of molecules of melanin contained in the transparent thick and tenacious contents of the cell is by no means everywhere the same. We meet some cells (and they are the most suitable for examination) in which the amount of black elementary particles is but small, so that the nuclei and membranes, always very delicate, may easily be distinguished. In such specimens the nucleus is found to be 0.0055–0.0075 mm. in size, either round or more or less oval, and always smooth-edged. It has usually one or more nucleoli. But much oftener the amount of molecules in the pigment cells is far more considerable, so that the nucleus only glistens through as a clear speck. Should the particles remain somewhat distant from the external surface of the cell-body, such groups of cells appear at first sight as though separated by narrow intervals of transparent intercellular substance. Finally, cells are encountered, in which, such is their richness in pigmentary particles, the nucleus is completely hidden.

A side view of these pigment cells (easily obtainable, owing to the small amount of flattening present in the structure) shows that only in one-half of them, namely, that directed towards the retina, do these melanin granules occur, a transparent contents occupying the other half. The nucleus is situated in the latter, or at the junction of the clear and dark portions (fig. 139, b).

In conclusion, we may remark that cells with two nuclei are also encountered here, but are of rare occurrence.

At the boundaries of the choroid, near the *processus ciliares*, the laminated cells are smaller and less clearly polygonal, while they have become far richer in pigment, so that the nucleus can only be rendered visible in general by squeezing the cell-body. The lining of the back of the iris is of precisely similar nature.




Fig. 138.—So-called pigment cells from the choroides of sheep. At a, a mosaic of hexagonal cells; at b, a larger octagonal.

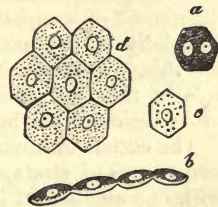


Fig. 139.—Cells from the choroid of the calf. a, cell with two nuclei; b, a side view of ordinary cells, moderately filled with pigment; c, some which are only supplied with but a scanty amount of pigment particles; from the neighbourhood of the tapetum.

With those mammals in which the choroidea forms a tapetum, the epithelial cells of the same undergo an interesting modification, being here destitute of the pigment molecules of the contents. On the boundaries may be found certain intermediate forms, with very scanty colouring matter (fig. 139, *c d*); besides which some isolated black cells are encountered among the colourless ones of the tapetum. In albinos, where the pigment fails completely in the eye, all these cells with which we are now engaged are completely bleached, appearing in the form of a very delicate pavement epithelium. This interesting fact may be verified on any white rabbit. The more markedly laminated epithelia have no pigment cells in man, but such may make their appearance in other mammals, as, for instance, in the conjunctivæ of the horse (*Bruch*).

REMARKS.—1. This layer of cells belongs, however, as we learn from the history of development, not to the *Uvea*, but to the *Retina*.

§ 90.

The region in which pavement epithelium is most strongly laminated, though indeed with certain modifications, is the external surface of the body.

The surface of the cutis, which appears quite smooth to the unaided eye, is covered, nevertheless, by a number of minute prominences known as the *papillæ tactus* (fig. 140, *a, a, a*). These, together with the depressions between them, are covered with very numerous layers of cells lying one over another (*b c d*). Of course, the latter naturally possess a far greater depth in the intervals between the papillæ than on the apices of the latter, in that the surface of all the strata collectively, or the epidermis, is tolerably even.

But apart from these inequalities, produced by the ridges of the cutis, the thickness of the whole clothing of cells is very different in the various parts of the body. It may range from 0.04–3 mm. and upwards, the more superficial layers of flattened cells being subject to the greatest change, the deeper, smaller, and rounder, to least of all (*C. Krause*). The unequal pressure which the various portions of the skin experience, differences of occupation, and consequent use of certain parts of the body, especially of the hands and feet, account, at least in a great measure, for this. And yet it has long been known that the epidermis on the sole of the foot, even in the fœtus, is much thicker than that of any other region of the body.

The cuticle of human beings and other mammalia may be divided into two groups of strata, into a superficial and a deep, which are continuous with one another, at one time gradually, at another with a tolerably sharp line of demarcation. The first (*d*) is usually termed the *epidermis* in the more precise meaning of the word, while the second has received the name of the *Malpighian* layer, or *rete mucosum* (*b, c*). By a certain amount of maceration, these may be separated from one another. From the fact that the deeper strata fill up the intervals between the papillæ, they must naturally possess here quite a different depth from that the points of the latter, as already mentioned. Hence their appearance is rendered more or less sieve-like or reticulated, which has given rise to the name generally employed by the older anatomists.

In these deepest layers we encounter not free nuclei, but small cells of about 0.0075–0.0090 mm. in size, of roundish or oval form, in which case

their diameter is greater, and may rise to 0.0114 mm. The outlines of these cells are very delicate and difficult to distinguish; they contain a more or less granular, and frequently yellow nucleus, 0.0045–0.0075 mm. in diameter, whose shape is either roundish or oval. Then there follow a considerable number of strata of cells lying one over the other, in which, however, the latter become gradually larger, ranging from 0.0181 to 0.0280 mm. A polyhedral flattening is apparent at the same time, and the cells seem to increase in superficial extent, their nuclei becoming paler and assuming more of a lenticular form. All these layers of the rete Malpighii contain the same spinous and ridged cells already described as occurring in strongly laminated mucous epithelium (fig. 141 *a*). But besides these younger epithelial elements, lymphoid cells which have wandered out of the blood-vessels are encountered in varying frequency (§ 81). They may be distinguished by their brilliant border, irregular outlines, and very small size. Finally, we come to the smooth-edged cells of the horny or outermost layers, or epidermis in the more restricted meaning of the word, whose diameter is 0.0285–0.0450 mm. From below upwards they become more and more like flattened scales, formed of a transparent and solid substance, without any immediately recognisable membrane (fig. 142). Though in this respect they resemble the most superficial cells of laminated mucous epithelia, they still differ from these in possessing no nuclei.

This absence of a nucleus is, however, immaterial, for in young embryos all, even the most superficial scales, are nucleated, as also those on the adult body, at spots where the skin is of a soft texture, and naturally moist.

Now, as the layers of the epidermis lying one over the other present a dull white or brownish appearance, they must, more or less, damp the deep red colour, due to its great vascularity, of the cutis lying underneath, and, moreover, in a degree proportionate to their thickness.

We are taught this also by experience. In those localities, namely, where the tint of the skin is reddest, the epidermis is very thin, as on the lips and cheeks. It attains, on the contrary, in the sole of the foot and, with many individuals, in the palm of the hand, a great thickness, combined with a progressive decrease in the red flesh colour, until at last at those points where the cuticle is thickest nothing but the tinge of the epidermal layers is apparent. This is also seen in weals.

It is well known that the skin of Europeans presents at certain points a brownish tint, lighter in blonde individuals than in brunettes. Among

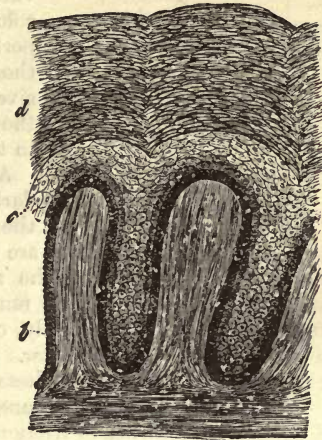


Fig. 140.—Skin from a negro's leg. At *a*, the papillae of the cutis, upon which the cells of the epidermal layers may be observed; *a*, older, and *b* and *c* younger, strata.

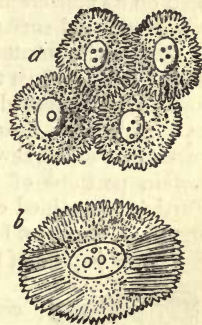

Fig. 141.—So-called spinous or ridged cells. *a*, from the deeper layers of human epidermis; *b*, cells from a papillary tumour of the human tongue.

these points may be reckoned the nipple and areola of the breast, the scrotum, the labia, and the vicinity of the anus, as well as the more individual cases of freckles and moles. Now, this colouring, which is only found in isolated portions of the bodies of those belonging to the white human races, appears most extensively in the multifarious shades of skin of the remaining varieties of our species, down to the deep black of many tribes of negroes.

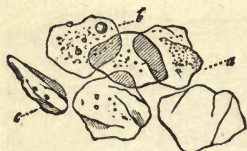

Fig. 142.—Cells from the human epidermis. *a*, from above; *b*, cell with a globule of fat lying upon it; *c*, another in half profile.

As far as has hitherto been ascertained, these darker tints (in which the fibrous tissue of the cutis is never affected) are dependent

on three conditions, which are combined in the specially marked cases: namely, on a tinging of the nucleus with a usually diffuse pigment; secondly, on a similar but much slighter colouring of the whole contents of the cell; and finally, on the deposit in the body of the cell of a granular pigmentary matter. It is principally the deeper layers of the cuticle which take part in these changes (fig. 138 *b c*).

Like the mucous membranes, epidermis suffers considerable loss by desquamation, owing to friction, washing, the pressure of clothes, &c., so that it may be looked upon as a rather transient tissue.

REMARKS.—When these tints of the skin are less intense, we usually find that it is merely the deepest and most recently formed layers of cells which contain nuclei of a slightly brownish colour. But if the hue of the skin deepens, that of the nuclei becomes intensified to a chestnut brown or brown black. The contents, however, of the cell are now no longer free, but slightly tinged with brown. Finally, in the undermost layers of the cuticle we find cells with granular colouring matter also, which vary in shade from yellow to brown, or even from this to the black of melanin. Here, then, we have epidermal cells containing melanin also in the human subject.

§ 91.

We now turn to another form of the tissue we are engaged in considering, known as *cylinder* or *columnar* epithelium, occurring in the human body on its mucous membranes. This is the epithelium of the digestive tract, whose internal surface is clothed by it from the cardiac end of the stomach to the anus in uninterrupted course, where it terminates with a sharp line of demarcation against the epidermis. Further, it is found in the larger excretory ducts of those glands pouring their secretions into the intestinal tube, as, for instance, those of the pancreas of the liver and gall-bladder. The passages of exit likewise, from the mamma and lachrymal glands, as well as certain portions of the generative system, are lined with the same cells. Further, a modified cylinder-epithelium is found on isolated portions of the organs of sense, as, for instance, on the regio olfactoria of the nose, and on the broad papilla of the frog's tongue. We shall have to refer to this again.

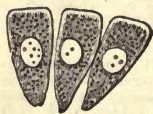

Fig. 143.—Cylinder epithelium from the large intestine of the rabbit; in profile.

This species of epithelium consists of a single layer or coating of tall narrow cells, set up perpendicularly on their ends, which either possess the same breadth throughout, or are broadest at their free extremities (fig. 143), while at the opposite end they are narrowed down more or less to a point. In many of these cells the nucleus lies about in the middle, in others it is situated lower down. Externally, we find here also a polyhedral accommodation where the cells come into contact, so that cylinder epithelium, observed from above, often presents the appear-

ance of an extremely delicate mosaic, similar to that of pavement epithelium. But the fields are smaller, and the nuclei lie deeper than the edges of the cell.

Below, the pointed portions of the cell, separate at times from one another (fig. 144), in which case the transparent intercellular-substance becomes visible with considerable distinctness (*b*).

But where the cells remain broad below, or serve to clothe strongly curved surfaces (fig. 145), they lie in contact with one another throughout their whole length.

The nuclei of cylinder cells are roundish and smooth, supplied also with nucleoli. The body of the cell is seldom quite transparent, but usually delicately granular and slightly clouded. The membrane is generally very thin and fine laterally, and is probably absent on certain portions of the free base of the cell, or rather replaced by a soft boundary layer; at times, however, it is met with apparently thickened by a transparent layer of the cell-contents lying beneath it, containing no granules (fig. 143).

Both as to size and form, our cells are subject to numerous variations.

Many appear tolerably short, while others are long, and at times also run out into long processes below. Many of them again are broad, so that the nucleus may be seen surrounded by the membrane at no inconsiderable distance (fig. 143), whilst others remain much narrower. In the latter case the envelope surrounds the nucleus closely, or appears bulged out by the latter. Finally, we meet with cells which contain double nuclei.

The relation of length to breadth in the cells of the human small intestine, is as 0.0182–0.0270 mm. to 0.0057–0.0090 mm. at its upper end, while at the openings of the biliary and pancreatic ducts the cells are narrower, with the same length. *Henle* has seen unusually slender ones in the human stomach.

§ 92.

As has already been remarked in the general section (§ 50), cylinder-cells may display strange deviations from the characters just mentioned, especially those in the small intestine of man and other mammals.

The thickness of the border pierced with minute pores (fig. 146 *a*, 147) is, in the rabbit, from 0.0017 to 0.0025 mm., and the number of lines crossing it from 10 to 15.

This secretion of the cell consists, as we have already mentioned, of a coagulated protein substance, differing from the membrane, and offering but small resistance to the action of water, on the application of which transparent drops rapidly well from it. Whether these pores

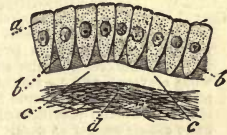


Fig. 144.—Cylinder cells of a mucous membrane, arranged perpendicularly (diagrammatic). *a*, the cells; *b*, the intermediate matter; *c*, basement layer; *d*, the fibrous tissue of the mucous membrane.

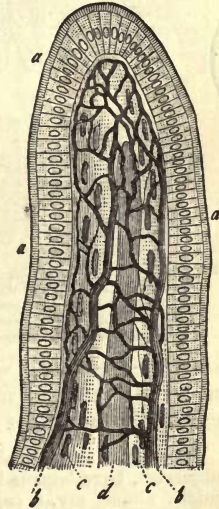


Fig. 145.—An intestinal villus clothed with cylinder cells. *a*, cylinder epithelium with border; *b*, vascular network; *c*, longitudinal bundles of muscular fibres; *d*, chyle vessel in the centre.

really pass through a regular cell-membrane or no has not yet been ascertained. Cells which have puffed out under the action of water show clearly the presence of a lateral membrane at least.

However, it is not alone the cylinder cells of the small intestine, but also those of the gall-bladder and larger biliary ducts, which possess these thickened lids perforated by canaliculi (*Virchow, Friedreich*); the same structures are said to have been encountered in the large intestine and other localities.

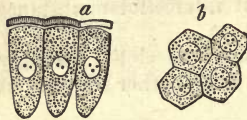


Fig. 146. — Cylinder-epithelium from the small intestine of the rabbit. *a*, the cells in profile, with the thickened border somewhat elevated and traversed by pores; *b*, view of the same from above, in which the orifices of the little canals appear as dots.

Columnar cells containing melanin have neither been met with in man nor any other mammal.

Cylinder epithelium appears to undergo in general but moderate physiological renovation. The older views, according to which a

frequently repeated stripping of larger surfaces took place, have long since been recognised as erroneous.

Among these cylinder cells, but also between the elements of ciliary epithelia and the soft slimy epidermis of the lower vertebrates, are to be found certain peculiar elements which have been named "goblet-cells" (*Becherzellen*) (fig. 148 *a*).

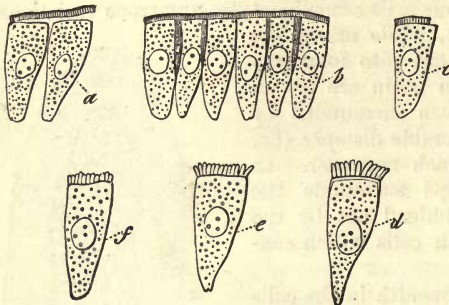


Fig. 147.—The same cells. At *a*, the border has been loosened by the action of water and slight pressure; *b*, view of the cells in the normal condition; *c*, a part of the thickened border is destroyed; *d e f*, the latter resolves itself into separate columnar or prismatic pieces.

They are sometimes disposed without order, but at other times possess a certain regularity of arrangement. They have usually the form either of a plump, or more or less slender flask or wide-mouthed goblet, and are destitute of membrane on their free surface. The nucleus and protoplasm of these elements is displaced towards the lower pointed extremity, while the other half is occupied by a slimy

substance, granular when in a fresh condition, but transparent in specimens subjected to maceration. We look upon them as decaying cells engaged in a process of slimy metamorphosis.

REMARKS.—The goblet-cells in question, known many years ago to various observers, have become lately the object of general attention, and have evoked, one might almost say, a superabundance of treatises. This is no place to enter upon a criticism of those works, but it may be observed that they regard the matter from three different points of view: 1. Goblet-cells are epithelial elements engaged in slimy metamorphosis. 2. They are independent formations, not derived from the ordinary epithelial cells. 3. They do not exist in the living body, and are purely artificial productions

§ 93.

We turn now to the last modification of this clothing tissue represented in *ciliated* epithelium. We understand by ciliated epithelium, a coating of cells, sometimes single, sometimes laminated, which bear on their free ends a varying number of small hair-like bodies endowed with a power of motion; these are the cilia. The fully developed cell is usually presented to us

in the form of a cylinder, less frequently as a more rounded or flattened body. The undeveloped elements, lying deeper down in the tissue spoken of as laminated ciliary epithelium, are rounder, and destitute naturally of the characteristic cilia.

The columnar cells of ciliated epithelium (fig. 149) manifest the same diversity of form, and the same difference of length, as those of the simple tissue. The free edge of the cell sometimes presents a darker contour than the side walls. Its substance is at one time transparent, at another, finely granular, but always tolerably pale. The number of cilia, as we have already mentioned, is liable to vary, and ranges, probably, between ten and thirty. In mammalian animals and man the cilia appear somewhat flattened, and terminate above slightly blunted, although some observers speak of their being pointed. The size of these minute hairs is subject to variation among the higher animals. In the first place, those attached to any one cell are not necessarily all of the same length; and again they are met with of larger or smaller proportions in different localities. The gigantic magnitude which they attain in many of the lower groups of animals is never seen here. The largest cilia, of from 0.0226 to 0.0340 mm., are found in the human subject upon very large-sized cylinders, measuring 0.0445–0.0560 mm., which clothe the upper part of the passage of the epididymis (Kölliker).

In other situations the cilia are smaller, as for instance in the *coni vasculosi* of the testicle (0.0114 mm.), but their length is still less in the epithelial cells of the respiratory organs, namely, 0.0056–0.0038 mm. The length of the cells themselves ranges in the human body from 0.0285 to 0.0570 mm. The cilia are of a delicate and perishable nature, and consequently decay rapidly a few hours after death. At times, however, they remain exceptionally in a very perfect condition even for days in the bodies of the warm-blooded animals.

Ciliated epithelium is found in the following parts of the human body:—

It clothes the mucous membrane of the respiratory tract, commencing at the base of the epiglottis, after which it covers the whole larynx, with the exception of the vocal chords. Here it is slightly laminated, forming a bed of from 0.0056 to 0.0992 mm. in depth. It likewise extends over the trachea and bronchi with decreasing lamination, until at last the very smallest tubes are covered with a single layer of minute elongated ciliated cells, 0.0135 mm. high (Kölliker).

The organs of smell also possess a laminated ciliated epithelium, commencing about at that point at which the cartilaginous nose terminates. It is from 0.0451 to 0.0992 mm. in thickness. The *regio olfactoria* alone, in the more restricted application of the term, is an exception to this with its epithelium, which will be considered more at length in discussing the apparatus. Moreover, it is not only the main cavities which are lined with these cells, but the adjacent ones also connected with the organ.

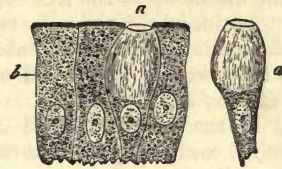


Fig. 148.—Goblet-cells from the epithelium of an intestinal villus from the human subject, treated with Muller's fluid (Schulze). a, goblet-cells; b, cylinder-cells.

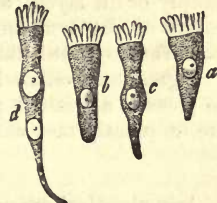


Fig. 149.—Ciliated cells from the mammal. a b, simple forms; c, narrow elongated cell; d, one still more so, with double nucleus.

Simple ciliated cells are also met with covering the mucous membrane of the female generative apparatus from about the middle of the neck of the uterus up to the free edge of the fimbria.

Again, in the male, the *vasa efferentia, coni vasculosi*, and the passage of the epididymis, down to about its middle, are clothed with similar cells, which become larger and support longer cilia as we advance downward (*Becker, Kölliker*).

In the new-born child it would appear the cavities of the brain and spinal cord still possess throughout a lining of ciliated cells. This is only partially the case, however, in the adult. Thus, we find these cells in the central canal of the cord, at the posterior end of the fourth ventricle, in the *aquæductus Silvii*, and in the lateral ventricles. The remaining parts of these regions are lined by simple pavement epithelium of more or less rounded cells, in the adult individual. The *plexus choroidei* and *telæ choroideæ* are covered by that modified rounded pavement epithelium mentioned already in an earlier section (§ 88), though in the embryo they are clothed with ciliated cells.

In conclusion, we find a stratum of flattened epithelium cells, arranged simply or in layers, and covered with cilia, in the *Eustachian* tube and cavity of the tympanum, which gives way on the surface of the latter, however, to a multilaminar pavement epithelium.

Pigmentary ciliated cells are unknown. Ciliated epithelium appears to possess a limited physiological power of renovation. "Goblet-cells" are frequently met with among them (*Schulze*).

§ 94

Any chemical examination of epithelium to meet adequately the requirements of present day histology would have to undertake the analysis of cells and intercellular substance, as well as that of the nucleus, body, and envelope of the latter, should it be present. It would have to show also what the changes in chemical constitution are which the young cell passes through in laminated epithelium, while undergoing transformation into the scale-like formations of the older and more superficial layers.

But these theoretical requirements cannot be responded to, in that we possess no means of isolating the several portions of epithelial tissue from one another, and can only subject the whole mass in the form of a mixture to analysis. In spite of all this, however, so much is certain, that epithelium is a tissue which, in its simpler forms and younger layers, is made up of cell-bodies, consisting frequently of protoplasm, while in epithelia of greater thickness the superficial layers undergo chemical transformation to a considerable degree, owing to which they become hard, dried, and more consistent, *i.e.*, become converted into corneous matter or keratin (§ 14), or, as the saying is, become horny.

Many non-laminated pavement epithelia, together with cylinder and ciliated cells, display the ordinary characters of elements formed of unstable protoplasm, the action of water even causing changes in the cell, such as puffing, expulsion of spherical drops, and bursting of the envelope. On the other hand, numbers of simple pavement epithelia resist the action of both cold and hot water, and are affected only by acids and alkalies, earlier or later, after which the protoplasm is changed, though a portion of it may remain unaltered around the nucleus. The latter usually offers a determined resistance to the action of acetic acid.

The bearing of the deeper or younger cells of laminated epithelia agrees

with the description just given, while the more superficial scale-like formations, at one time nucleated, at another not so, give the reactions of keratin.

This represents, naturally, a mixture of substances; it forms the nucleus, contents, envelope of these elements, and the scanty intercellular matter; the residue after treatment with water, alcohol, and ether.

This mixture is then insoluble in cold as well as boiling water, and (if not contaminated with other elements of connective tissue) yields no gluten on boiling; nor is it acted on by acetic acid. Even to sulphuric acid, in which it becomes puffy, it offers a certain amount of resistance. With hydrochloric and sulphuric acid it gives the reactions of the protein substances.

Its conduct toward alkalis is, however, of the greatest importance: with them keratin enters into combination, at the same time that it puffs out or becomes gelatinous, and is subsequently dissolved on the addition of water. If to such a solution of keratin acetic acid be added, certain products of the decomposition of the albuminoid group are precipitated.

The swelling up of this tissue before solution, as it occurs both in cold and heat, has much interest for the anatomist (fig. 150). In order to produce this appearance, we treat the epidermis either with a very strong caustic solution, and then with water, or we employ from the commencement more dilute reagents. On this the older cells become puffed out into spheroids (1 *b-f*, 2 *b*, *c*), lose their flattened figure, and again assume, in the most striking manner, their original cellular character, the contents beginning to dissolve in the imbibed fluid, and the envelope to become sharply defined. At the same time, also, the stratification of the epithelial beds becomes distinctly visible, so that in this respect likewise alkalis may be of the greatest service to microscopists. Later on the nucleus is

attacked (1 *b-d*), and then the intercellular matter. Finally the envelope is dissolved, but only if the cell be not one of those which have been completely converted into horny matter. Very old squamous elements possess, on the other hand, a membrane which reminds us in its great capacity for resistance to alkalis, of the substance of the elastic tissues. The addition of acetic acid produces in the cell which has gelatinised in the manner described, a precipitate of decomposed protein substances already mentioned (1 *g*, 2 *d*).

After what has just been remarked, there can be hardly any doubt that keratin partakes of

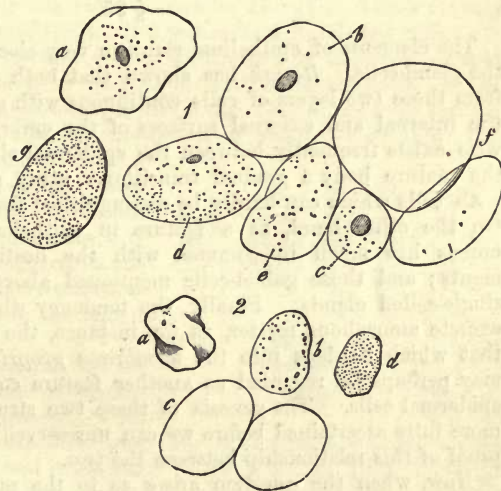


Fig. 150.—1. Epithelial cells. At *a*, an unchanged flat cell from the mouth; from *b* to *f*, the same kinds of cells after treatment with caustic soda, some containing nuclei (*b c d*) and some not; *g*, on the addition of acetic acid, after treatment with caustic soda. 2. Epidermal cells. *a*, unchanged; *b*, commencing action of the soda; at *c*, after prolonged action of the same; *d*, on the addition of acetic acid.

the nature of a mixture, so that its present analyses are almost worthless. We may take, for instance, those quantitative ones of *Mulder* and *Scherer*, which apply to the epidermis of the sole of the human foot.

	(Scherer.)		(Mulder.)	
C	51.036	50.752	C	50.28
H	6.801	6.761	H	6.76
N	17.225	17.225	N	17.21
O	} 24.938	25.262	O	25.01
S			S	0.74

The amount of sulphur (0.74 per cent.) in *Mulder's* analysis appears strikingly small, while it is found to rise to between 2 and 5 per cent. in the keratin of other tissues. As to the form in which it is contained in the latter we know nothing. It is, however, only loosely combined. The proportion of ash rises to about from 1 to 1.5 per cent. The salts obtainable are chlorides of sodium and potassium, sulphate and phosphate of calcium, phosphates of magnesium and of iron, besides which silicates are also contained in the epidermis.

The pigmentary cells possess the same characters as all the other epithelial formations. Those of the eye correspond in their delicate constitution with the non-laminated epithelia. In regard to the melanin with which they are charged, comp. § 37. Finally, we are still quite ignorant as to what the matter is with which the nuclei of epidermal cells, of dark spots of the skin, are coloured.

§ 95.

The elements of epithelium stand in very close genetic relationship to the gland-cells. *Remak* has shown that both tissues have their origin from those two layers of cells continuous with one another, which clothe the internal and external surfaces of the embryonic body. There likewise exists frequently between the epidermal elements and gland-cells of the mature body a gradual transition: many glands, namely, are lined with cells which can hardly be distinguished from those of the epithelia. On the other hand, as a feature in epithelial life, the formation of mucus has much in common with the destiny of certain gland elements; and those goblet-cells mentioned above (§ 92) may be named single-celled glands. Finally, the tendency which they both display to excrete amorphous matter, as for instance, the thickened cell-border or that which hardens into the *membrana propria* or *basement membrane*, may perhaps be regarded as another feature common to the gland and epidermal cells. The genesis of these two structures, however, must be more fully ascertained before we can unreservedly adduce it as additional proof of this relationship between the two.

Now, when the question arises as to the purposes which epithelium serves in the body, and why all the surfaces of the latter are clothed with such a continuous cellular coating, we must confess ourselves in a difficulty in ascribing to each species its particular properties.

If we look for a physiological significance in our tissue, it may be said to have its basis in all probability in the relation of the latter to the processes of transudation, diffusion, and absorption of the economy; and

we may perhaps regard epithelium as the regulator of these processes spread over the parts where they take place.

As a purely cellular tissue untraversed by blood-vessels, epithelium presents to us many sides of cell-life in the most beautiful manner, such as multiplication, growth, and change of form. That the whole vegetation of the epithelial cells is dependent upon the vessels of their connective-tissue substrata is easy to conceive, though we meet with epithelia on non-vascular portions of the body, as for instance on the cornea and capsule of the lens. But of the direction of the interchange of matter in our tissue we know nothing, either of that in ordinary epithelium, or the modified forms of it, where in the interior of the cells a formation of melanin and other pigments takes place. That this alteration of material in laminated epithelium is only undertaken with any degree of energy by the younger cells which still possess soft contents, is more-over not difficult to understand. It is also probable, on the other hand, that this interchange of material has ceased entirely in the more superficial scales of laminated epithelia which have undergone horny metamorphosis: in these also decomposition commences very late.

Then the cylinder epithelial cells of the small intestine are made the media for much transfer of matter, and moreover, not in their own egotistical interest, and for their own special support: through them, namely, the absorption of fats with the other constituents of the chyle takes place. Here again we are reminded of many kinds of gland-cells.

Attention has likewise been directed within the last few years to the penetration into the interior of epithelial cells of minute coloured particles, which had been introduced into the circulation of the lymph and blood, and, indeed, of red blood-corpuscles also (1). These we may observe in the goblet-cells of the small intestine and in ciliated cells.

We are obliged for the present to explain the fact of the occurrence of mucous and pus corpuscles, as well as of contractile elements, in the interior of cylinder and pavement epithelium (fig. 151) in the same manner (§ 56). It is manifest that a penetration of small bodies into open goblet-cells might take place without difficulty. But, besides, we find these lymphoid-cells within the epithelial stratum, between the columnar elements of the intestine, engaged in migrating from the connective-tissue of the mucous membrane into the lumen of the tube.

Epithelium may, in general, be set down as a tissue capable of undergoing no further development. No doubt from the earliest rudiments, from the cells of the corneous and intestinal glandular layer, many other tissues, and some of them of high dignity, take their origin in the construction of the embryonic body, as we shall see in some of the succeeding chapters. But not so in the mature body: its epithelial cells are only able to reproduce similar structures, and not other elements, such as, for instance, fat-cells or connective-tissue corpuscles.

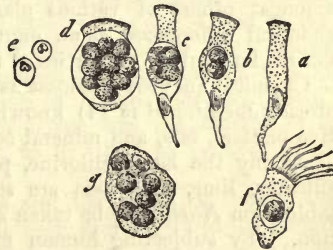


Fig. 151.—Occurrence of mucous and pus-corpuscles in the interior of epithelial cells. *a-a*, cylinder cells of a biliary duct; *e*, free pus-corpuscles; *f*, ciliary cells of the respiratory tract; *g*, flat cells from the urinary passages.

The destruction of epithelial cells is brought about, first, by solution, next, by mechanical attrition. This naturally deprives the system daily of a certain quantity of albuminoid matters, though in an altered condition.

REMARKS.—The question as to a connection between epithelial cells and the elements of connective substances and of nerve-tissue, must be discussed in a future section.—1. I have convinced myself of the presence of granules of cinnabar in the cylinder cells of a frog's intestine, three days after their injection into the circulation.

§ 96.

Owing to their composition decaying epithelia are of the greatest importance in the formation of *mucus*. The consideration of these tissues must, therefore, extend itself over fluids likewise.

We understand by mucus a coating of a rather thick semifluid substance, more or less stringy and tenacious, which covers the surfaces of all mucous membranes in varying quantity, and endows the latter with their usual moistness and smoothness. It must also be regarded, owing to its consistence, as well fitted to form a protecting medium against chemical action, and it is probably not indifferent, besides, to the interchange of gases.

Mucus is without odour and tasteless, and variable in its reactions. It is found sometimes transparent, sometimes more opaque, white or yellowish. Microscopical examination discloses to us in it the cast off epithelial and gland-cells of the locality in which it is formed, but in variable number; and besides these a small cell, the so-called *mucus-corpuscle*, whose appearance, size, and bearing repeats the colourless blood-cell completely, as well as the elements of chyle and lymph, and whose origin, as far as is at present known, may be very various. It may spring not only from epithelial cells, but also from those of connective tissue and lymphatic organs. To these are added the cells of the glandular formation of the part from which the liquid is obtained. Again, owing to its viscosity, mucus entangles usually a number of very minute air-bubbles. From all this it would appear that mucus is a most variable substance. From an anatomical point of view it is only a mixture of many dissimilar matters, and amongst others of various gland juices, which endow it further with chemical differences, as an expression of which we recognise the multifarious fermenting properties of the several kinds of mucus.

Chemical analysis discloses as a solid constituent a peculiar substance already mentioned (§ 14) known as *mucin*. Besides this we find extractive matters, fats, and mineral constituents.

Among the latter chlorine, phosphoric, sulphuric, and carbonic acid, silicates, lime, and soda are said to exist in mucus. The following table from *Nasse* may be taken as an example of its quantitative composition. By subjecting human mucus, which had been coughed up, to analysis, he obtained the following results:—

Water,	955.52
Solid constituents,	44.48
	<hr/>
Mucin (and a trace of albumen),	23.75
Extractive matters,	9.82
Fats,	2.89
Mineral constituents,	8.02

Of all these components mucin alone requires further consideration. It appears in mucus under two forms: as an insoluble substance, merely gelatinising in water, and which remains behind on a filter; and as a soluble matter which may be filtered. Now, in that the reactions of both are the same, we are warranted in supposing that mucin in a pure state is insoluble, and has probably acquired its solubility by admixture with other compounds, especially alkalies,—an hypothesis which appears to receive further support from its parallelism with many protein matters in this respect.

Synovia also reminds us of mucus (*Frerichs*). We meet it as a clear, colourless, or straw-coloured fluid of slimy consistence and alkaline reaction, in which the microscope reveals to us the epithelial cells of the capsule of the joint, which have been shed, as well as lymphoid corpuscles. The use of this liquid is, as is well known, to retain the parts entering into the formation of the joint in a moist and slippery condition.

Synovia, strangely enough, has farther the same constituents as mucus, in addition to which albumen is also present. Of salts we find, chloride of sodium, basic phosphates of the alkalies, sulphates of the alkalies, phosphatic earths, and carbonate of calcium.

The two following analyses of *Frerichs* may serve as an example of its composition per cent. The first applies to the synovia of an ox fed in the stall, while the second is that of one in pasture:—

	I.	II.
Water,	969.90	948.54
Solid constituents,	30.10	51.46
	<hr/>	<hr/>
Mucus with epithelium,	2.40	5.60
Albumen and extractives,	15.76	35.12
Fats,	0.62	0.76
Salts,	11.32	9.98

According to this, it would appear as though the friction of the surfaces of the joints induced by exercise were of importance in the formation of synovia, for we find it during inactivity, watery, less viscid, and poorer in mucin. At the same time, however, its quantity is far more considerable. Again, on energetic bodily exertion the quantity of this fluid decreases considerably, and the amount of mucin increases, with its oiliness or thickness. The contents of bursæ and the sheaths of tendons appear, also, according to *Virchow*, to be allied to synovia in composition.

Now, as to the formation of mucus and the origin of mucin particularly, the older views, which referred both exclusively to the secretion of special glandular organs, the so-called mucous glands, can no longer obtain, in that the proportion of the fluid stands in no relation to the frequency or rarity of those glands; and in that synovial capsules, which have none of the latter, nevertheless secrete mucus. Epithelial cells, however, appear to stand in close relation to the origin of mucin, beside which the elements of the glands themselves, without doubt, play a part in the formation of mucus. There seems, indeed, much probability in the supposition, that an alkaline fluid transuding through the capillaries of mucous membranes macerates the cast-off cells, aided by the natural

warmth of the body, and thus transforms their contents into mucin (*Simon, Frerichs*). If this mode of explaining its origin be correct, mucin must represent in numerous cases a physiological transformation product of epithelial tissue.

§ 97.

To what extent epithelial cells are endowed with the property of vital contractility, when young and still soft, we are for the present unable to state. But a most remarkable movement is met with on the other hand in ciliated epithelia, which has been named *ciliary motion* (*Motus vibrato ius*). This phenomenon, known from the earliest epochs of microscopic research, has been recently very closely studied, but unfortunately with but small results. For although its wide distribution throughout the animal kingdom has been recognised, and ciliary motion not long since observed in low vegetable organisms, we are still completely in the dark as to its mechanism and object. The elucidation of points of this kind regarding it are rendered thus difficult by the fact, that the phenomenon of ciliary motion is met with in very varied extent throughout the animal kingdom, parts which are ciliated in one class being no longer so in another group; thus, for instance, none of these cells can be found among any of the arthropoda.

Ciliary motion, a simultaneous and regular swinging of all the minute hairs, appears, as seen on the edge of a fold of membrane, somewhat like to the undulation of a shaken cloth, or the flickering of a candle flame. Seen from above it frequently reminds us of the waving of a field of corn moved by the wind, or when it takes place in a tube of extreme fineness, of the current of a brook in the sun light. All these comparisons, however, are perhaps hardly adequate to express the peculiarity of the appearance.

Small particles suspended in water—as, for instance, blood-corpuscles and pigmentary granules—are driven along by the movements of the cilia at the edge of a membrane possessing them in one definite direction, and apparently with great rapidity when the action is energetic, and the magnifying power great. In reality, however, this rapidity is much less than it seems, but still by no means inconsiderable, for an interval of an inch may be traversed by one of these particles in a few minutes. Even a shred of a ciliated stratum of cells may be driven along by the motion of its own particular cilia, if it be not altogether too large, while a smaller piece, or single detached cell, may whirl itself through the water in a lively manner, simulating in a most deceptive way the motions of the infusoria.

However, in a fresh state, and when the cilia are endued with great vital energy, the motions of the hairs follow so rapidly in succession, that the latter are not seen, nor can the phenomenon be recognised as a rule. Several vibrations are usually observed to take place in the course of a single second.

For the closer examination of the phenomenon that moment is most suitable at which the movement of the cilia has become slower and weaker, owing to the approaching death of the cells, and when each individual little hair may be observed for itself. The mode in which it is carried out is not always the same, so that the motion has been classified into four varieties (*Purkinje* and *Valentin*), namely, into (1), the *hook-like* (*hakenförmige*), in which each cilium makes the movement of a

finger which is alternately bent and extended ; (2), the *funnel-shaped* (trichterförmige), in which the upper portion of the hair describes a circle in swinging, and the whole a cone, whose apex is formed by the firmly attached base of the cilium ; (3), the *oscillating*, in which the whole hair sways more like a pendulum from side to side ; and (4), the *undulating*. In this the hair executes a movement like the lash of a whip moderately wielded, or the tail of a spermatozoon. Of all these forms of ciliary motion the first appears to be by far the most frequent (2).

This movement appears quite independent of the circulatory and nervous systems. Destruction of the latter or interruption of the stream of blood causes no cessation of its activity. The cilia, also, of detached cells persist in their oscillation still, as we have already remarked. Should they, however, become separated from their cells they cease to manifest vitality, and soon disappear completely in the water surrounding them. Ciliary motion, farther, is of longer duration than the life of the animal, but with extraordinary differences. Sometimes it only lasts a short time, especially among birds, and also mammals, where it continues about until the cooling of the corpse, whilst among cold-blooded animals it may be observed for days (3).

Elevation of temperature increases the energy of this movement, until finally at from 44° to 45° C. coagulation commences. On the other hand, cold has a retarding and finally destructive influence, while agents which do not act chemically do not disturb it in the least. Thus it continues unimpeded in serum, milk, and also in urine. Water accelerates ciliary motion at first, but subsequently puts an end to it rapidly, owing to its action on the very delicate cell. The addition of bile produces an injurious effect on it also, while that of alkalies, acids, alcohol, and such like, put an end to it for ever. A very interesting discovery was made not long since by *Virchow*, that ciliary motion which has come to a state of rest under normal conditions may be again excited by the application of dilute solutions of soda and potash (4). The influence of gases on the phenomenon has also been lately investigated by *Kühne*. It appears that like protoplasmic contractility, to which they are akin, the motions of the cilia require oxygen for their support, and that hydrogen causes them to cease. They may be again set agoing by the introduction of a stream of oxygen into the medium in which the cells are immersed. Acidulation also with carbonic acid has a retarding influence on the ciliary motion, counteracted again by alkaline vapours. The retarding effects of alkaline vapours can also be met by acid ones.

There seems to be an inclination to bring this ciliary motion physiologically to bear upon the transport of small bodies, and to ascribe to it, for instance, the power of forwarding mucus from the nose and lungs, and the ovum from the ovary into the uterus. But these are surely only incidental objects of ciliary motion, which receive their just value when we take into consideration the fact that coatings of ciliary cells occur in completely closed cavities. That the little hair-like appendages may effect a change of locality of the whole body, however, of lower organisms, or induce a motion in the water in contact with the surface of the latter, or, finally, a rotation of alimentary matters in their digestive tract, &c., is beyond doubt.

REMARKS.—1. The discovery of ciliary motion appears to have been made by *A. de Heyde*, in the year 1683 ; and the Dutch *Coryphæi* of former days were also acquainted with it. But the most accurate studies, dating from 1830, in which this

subject was first treated with effect, were made by *Purkinje* and *Valentin*, comp. *De phænomeno generali et fundamentali motus vibratorii continui in membranis cum externis, tum internis animalium plurimorum et superiorum et inferiorum ordinum obvi comment. phys. Vratislaviae*, 1835.—2. According to *Englemann's* varying observations, this swinging of the cilia depends upon two motions of unequal length,—upon a longer one produced by the contractility of the protoplasm, and a shorter one caused by elastic resistance. Currents of fluid passing over ciliated surfaces do so in the direction of the last of these, in which also the cilia stiffen after death.—3. Under certain circumstances, difficult to explain, the ciliary motion may persist for one or two days after the death of a mammalian animal.—4. As *Koelliker* has demonstrated, the same peculiarity is displayed by the spermatozoa.

§ 98.

Now, as to *the origin of epithelium* in the embryo, we must enter here at somewhat greater length upon the consideration of the relations of parts briefly touched on already at § 86, in order to obtain a clear conception of its development.

As we have already seen, the rudimentary embryonic body according to *Remak* (1.) consists of three layers of cells, of the so-called leaves or germinal plates. These are known as the superior or the *corneous*, the *intermediate* or *middle* germinal, and the inferior or *intestinal glandular* leaf or plate. From these the various tissues and organs of the body take their rise.

The corneous plate produces, first of all, the epithelium, with the nails and hair which are closely allied to it, and beside these the crystalline lens, a decidedly epithelial organ. The cellular elements, likewise, of the various glands of the skin, together with those of the mammary and lachrymal organs, take their origin from the same layer. Finally, the axial portion of the corneous plate enters into the construction of the nervous centres (brain and spinal cord) as well as the internal portions of the higher organs of sense. That the peripheral nerves also originate in the axial part of the corneous plate primarily, is at least probable. (2.) The significance, consequently, of the corneous plate is very great, physiologically the highest in the body.

Thus a large part of the epithelium described in former sections, the epidermis, including those layers of cells which clothe the openings of the larger passages of the body, takes origin from this source, and appears as laminated epithelium, with a horny substance devoid of vitality. The pigmentary pavement epithelium also, of the eye, together with the internal coating of the cavities of the nervous system, are also derived from this superior plate.

The second, or *intestinal-glandular* plate, supplies the epithelia of the digestive apparatus, as well as the cellular constituents of all the glands in connection with the latter, including the lungs, liver, and pancreas. Its epithelial formations appear principally in the form of the cylinder-cell, either naked or ciliated.

We must now finally devote a few moments to the *middle germinal* plate, and inquire after its contributions to the epithelia. This middle stratum of the rudimentary embryos supplies material for a great many structures. First of all, for the formation of all the tissues of support in the system, the whole group of connective substances; for the building up of muscle; for the blood and lymph, together with the so complicated system of vessels which contains both; and finally, for the so-called lymph or blood-generating glands (including the spleen). The cutis

vera containing the vessels of the dermis, with the connective tissues of mucous membrane and true glands, take their rise from this source.

It is evident that the changes must be very great in the middle layer which produce from it such structures.

To many of these changes we shall have to refer again in subsequent pages, but for the present our attention must be principally directed to the formation of numerous cavities in the middle plate appearing in the course of its development. Thus it is that the serous sacs originate, as also the bursæ and sheaths of tendons. Thus is formed the most intricate of all systems of canals, namely, that of the blood and lymphatics. Together with this formation of cavities, also, we must expect besides to find a whole series of epithelial coatings springing up.

The latter have much about them that is peculiar. If we except the more circumscribed laminations as they appear in synovial membranes, they almost always consist of a single layer of thin flat scales (§ 87) without the transient nature of the two other forms of epithelium. Further, as observation of the circulatory system teaches, such an epithelial tunic may acquire sufficient strength by cohesion of its cells, as to fit it to form the chief part of the finer and more minute canals of the former. But these epithelia of the intermediate germinal plate do not possess the power of yielding in continuous transition the secreting cells of glands, nor are they able to develop any physiological function similar to glandular activity. On the other hand, they are remarkable for the great ease with which the fluids of the blood transude through them, which is far from

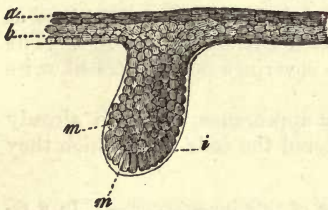


Fig. 152.—Skin, with rudiments of a hair, in a human embryo of sixteen weeks old. *a*, the superficial layers of cells of the epidermis; *b*, the deeper; *m m*, cells of the rudimentary hair; *i*, transparent membrane clothing them.

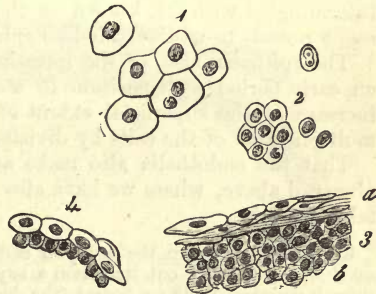


Fig. 153—Epidermis from the neighbourhood of the head of a sheep-embryo of 4 in. in length. 1, epidermal cells of the most superficial layer; 2, from deeper lamina; 3, vertical section of the same; 4, cuticle from the free edge of the eyelid.

being the case with the epithelial structures of the corneous layer. If we are asked for another contrast, it is to be found in the nonvascularity of the subjacent tissue of this last species of epithelium compared to the great vascularity of the other two kinds.

This intermediate species has been termed *false epithelium*, or *endothelium*, by *His*.

As regards the epithelium of the corneous layer, *Koelliker* found the epidermis in the human embryo of five weeks old to consist already of two laminae of nucleated cells: a superficial, made up of delicately-edged polyhedral elements of 0.0275-0.0451 mm., with round nuclei, measuring 0.0090-0.0136 mm.; and a deeper layer, in which the cells

were smaller, about 0.0068–0.0090 mm. in diameter, with nuclei of only 0.0034–0.0045 mm. From this we see that the epidermis, properly so called, and the rete Malpighii, are each formed originally of one layer of cells. Later on in the fourth month these are slightly laminated, the whole epidermis consisting of three or four strata (fig. 152, *a b*). From this on the lamination becomes stronger by degrees. Let us take, for example, the epidermis of a foetal sheep 4 inches long (fig. 153). This consists of six or seven layers of cells (fig. 153), of which the most superior (*a*) are transparent, and measure 0.0156–0.0206 mm., with nuclei 0.0052–0.0066 mm., whilst the deeper (*b*) are only 0.0104–0.0124, the nuclei preserving the same dimensions as in the more superficial laminae. In the superficial strata are found scattered cells with a double nucleus (fig. 153, 1), and division of the latter may be remarked at times in those lying deeper (2). The epithelium on the free edge of the eyelid shows in this embryo but two layers of cells (4). I have found the epithelium of the cornea also in a human foetus four months old 0.0205 mm. thick, and consisting of two upper and two lower layers of cells.

With the further growth of the foetal body, the thickness of the epidermis and the number of its laminae increase more and more, and the most superficial of the latter already resemble the scaly non-nucleated structures of later years, before the close of the second half of intra-uterine life.

Desquamation of the cuticle commencing in embryonic life, produces upon the body of the child a coating of a greasy whitish substance, intermingled with fat, known as the *vernix caseosa*, in which the microscope reveals to us the scale-like epidermal cells.

The epithelia, also, of the intestinal glandular plate likewise evince at an early period a disposition to assume their characteristic forms. The increase of the superficial extent of these coverings necessitates likewise multiplication of the cells by division.

That the endothelia also make an early appearance has been already observed above, where we have also considered the cells from which they take their rise.

REMARKS.—1. Comp. the work on embryology of this investigator.—2. In a recent work *His* points out that from a superior germinal plate the nervous system, animal muscles, Wolffian bodies (the kidneys and sexual glands), take their rise together with the epidermal structures and cells of external glands. A subsequently formed inferior plate gives origin to the sympathetic system, unstriped muscles, epithelia, and glands of the mucous membranes. These two plates constitute his “*archiblast*.” Between them the “*parablast*” is then inserted, from which connective tissue and blood are formed. For the present we prefer adhering to *Remak's* views.

4. Nail.

§ 99.

Like the epidermis and the hair, to be considered farther on, the *nails* have long been placed by anatomists among the horny tissues. And, indeed, they represent nothing more than a peculiarly modified cuticle for the part of the skin lying underneath. But the transformation proves to be less on microscopic investigation than we might have expected from the physical constitution of the tissue.

The nail is a hard, flat and arched body of rounded quadrangular

shape. It is more strongly doubled down at the sides than in the middle; and at the anterior free edge is thicker than posteriorly.

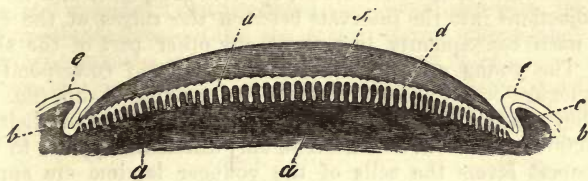


Fig. 154.—Nail and matrix in transverse section. *a*, the matrix with the ridges of the cutis; *b*, side portion of the same, forming the groove of the nail; *c*, rete Malpighii; *e*, horny layer; *d*, rete Malpighii of the nail, dipping in between the papillæ of the matrix; *f*, the horny substance of the nail.

Of the edges only the anterior is exposed, while the lateral ones are concealed in a fold of the skin (fig. 154, *b*) which commences at the point of the finger as a flat groove, and becomes deeper and deeper behind. The posterior portion of the nail finally disappears in a very deep furrow of about 4.5 mm. in depth (fig. 154, *a* left), in which a considerable proportion of the whole nail is contained, known as the "root" (fig. 155, *l*), while the lateral grooves have received the name of "the fold," and the portion of skin concealed by the nail, that of "the matrix" (fig. 154, *a*; 155, *a*).

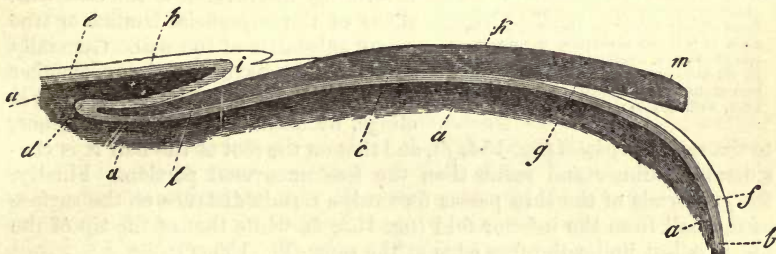


Fig. 155.—Nail and matrix divided vertically and longitudinally. *a*, the matrix, forming at the left hand side the deep fold for the root; *l*; *k*, the horny part of nail; *m*, its anterior free edge; *f*, epidermal layer on the point of the finger; *g*, its termination towards the nail; *b*, rete Malpighii of the same, which becomes that of the nail at *c*, and of the fold of the nail and root at *d*; while at *e*, it is continuous with that of the dorsum of the finger; *h*, epidermal layer on the dorsum of the latter; *i*, termination of the same towards the nail.

The nail, which determines, roughly taken, the form of the matrix in conjunction with the lateral fold, is so closely adherent to the first of these that, like the rete Malpighii on other parts of the fibrous tissue of the cutis, it can only be separated from it by maceration or boiling.

If we examine the surface of a matrix so exposed, we find it marked by a number of longitudinal ridges. These, as *Henle* has demonstrated, commence at the posterior border of the matrix as from one pole, and, in the middle portions, pass directly forwards to the anterior edge, while at the sides they maintain a course convex externally. On these ridges are situated, more or less isolated, the papillæ of the cutis. Fig. 154, *d*, represents the former, of which from 50 to 90 may be reckoned on one matrix. They are arranged much closer together under the root of the nail than elsewhere, but are, at the same time, much less elevated there. Both parts of the matrix are usually

sharply defined one against the other by a curved line, which is visible through the nail as the edge of the so-called *lunula*.

Now, as we have already remarked, the rete *Malpighii* dips down with jagged projections into the intervals between the ridges of the cutis; it conducts itself consequently just as at any other part of the skin (fig. 154, *d*). The young cells of which it is composed correspond also in their histological constitution with those of the external skin (fig. 156, *f*). In size they range between 0.0090 and 0.0160 mm., and their nuclei between 0.0065 and 0.0075 mm. The only difference appears to be, that in the deepest layers the cells of the younger laminae are apparently more or less oval. According to *C. Krause*, the nuclei of such nail cells contain, in negroes, the same dark brown pigment as the skin itself (§ 90); a fact of much interest. Cells with a double nucleus are not unfrequently met with here also (*g*). That the rete *Malpighii* of the nail is continuous with the younger cells of the epidermis in the furrow, and at the point of the finger, hardly requires to be mentioned, and may be seen in fig. 154, *c*, and 155, *b*.

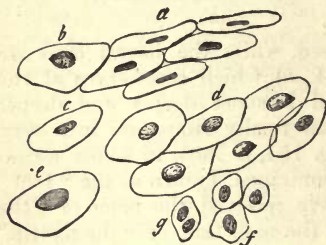


Fig. 156.—Tissues of the human nail, mostly after treatment with caustic soda. *a*, cells of the superficial layer in profile; *b*, one seen from above; *c*, half profile; *d*, a number of cells, of polyhedral outline, in contact with one another; *e*, a cell whose nucleus is about to disappear; *f*, cells from the undermost part of the rete *Malpighii*; *g*, one of the same kind, with double nucleus.

Now, while the cells of the deeper layers have but little about them that is striking, the reverse is the case with those of the superficial laminae or true horny substance of the nail. Generally speaking, we have only to remember that the under surface of the horny layer clings, by means of slight indentations, to the rete *Malpighii* (fig. 154, *f*), and that on the root of the nail it is considerably thinner and softer than the free uncovered portion. Finally, the epidermis of the skin passes forwards a certain distance on the surface of the nail from the inferior fold (fig. 155, *i*), while that of the tip of the finger is lost under the free edge of the same (fig. 155, *f*).

Sections of this horny substance give no clue to its texture without further treatment; for we have to deal with a brittle, hard, and tolerably transparent mass, which appears, to a certain extent, split up and torn by the edge of the knife. If we subject such a section, however, to the action of sulphuric acid, or, still better, to that of caustic soda or potash, the whole of it swells up in a very remarkable manner (especially when warmed) into the most beautiful epithelial tissue (fig. 156, *a-e*). At first the cells are marked off one against the other, as flattened polyhedra (*d*); but eventually they separate from one another, under the continued action of the reagent. Their size is usually 0.0375-0.0425 mm.

But though they correspond so far with epidermis cells, the elements of nail-tissue possess one distinguishing characteristic (if the chemical action of the reagents have not gone too far), in the form of a rounded granular nucleus, a delicate lenticular structure, seen in fig. 156, *b, c, d, e*, from above, as compared with the side view at *a*. Its diameter lies between 0.0075 and 0.0090 mm.

§ 100.

The nails of the human being differ from the epidermis in their greater hardness and solidity, but correspond very essentially with the latter in their chemical relations. Like the scales of the cuticle, they yield on treatment with alkalis *keratin*, already mentioned (§ 94).

Analyses of the substance of human nail-tissue have been frequently made; of those available we will only quote the following, from *Scherer* and *Mulder* :—

	<i>Scherer.</i>	<i>Mulder.</i>
C, . . .	51.09	51.00
H, . . .	6.82	6.94
N, . . .	16.90	17.51
S, } . . .	25.19	{ 2.80
O, } . . .		{ 21.75

According to these, the proportion of sulphur in the keratin of nail-tissue appears more considerable than that of the epidermis, in which it only amounts to 0.74 per cent. (p. 152). The proportion of mineral constituents was found to be 1 per cent.

The tissue of nail, like that of the cuticle, is nourished by the blood-vessels of the matrix and furrow, and shows, in our condition of culture, a constant and tolerably lively growth, exceeding by far the loss of substance induced by the ceaseless wear and tear going on at the free edge. It appears, however, that with those who do not pare their nails, as, for instance, the Chinese, the growth of the former reaches a limit eventually, for those talon-shaped nails, of about two inches in length, sometimes met with, do not increase any more, according to *Hamilton*. According to *E. H. Weber*, the free edge is cast off at times in children in the form of a crescentic strip. Some interesting experiments were made by *Berthold* in regard to the amount of growth of the nail, or, what is the same thing, into the length of existence of a horny cell of the latter. Regeneration takes place, according to this observer, more rapidly in infancy than at an advanced age, and in summer than in winter; a nail, which requires during the warm part of the year 116 days for its complete renovation, consuming 152 days in the latter process during the winter. The nails also of different fingers, as well as those of corresponding members on the right and left hands, are said to be dissimilar in growth also.

The mode in which they grow is as follows :—The deeper cells of the rete *Malpighii* preserve their position, whilst the horny lamina is pushed forward over the softer layer of cells covered by it, by the constant production of new elements at the posterior border of the root, which become transformed into scales. That the nail anteriorly is considerably thicker than behind is explained by the fact that the more superficial cells of the rete mucosum are also transformed on the surface of the matrix into horny laminae, which unite with the under surface of the completed corneous portion of the nail, strengthening the latter, and naturally pressed forward with it.

Now, just as there is a normal physiological renovation of the nail, so do we find that the latter may be completely regenerated after having been lost in an abnormal manner, provided that the matrix have preserved its integrity. If the latter have suffered, an ill-formed nail is produced.

And further, in that the nail is dependent for its growth on the vessels of the matrix, it is easy to conceive how many affections combined with

disturbances in the circulation of the latter may lead to its malformation. The nails, likewise, are shed from the extremities among rabbits, as *Steinrück's* well-known experiments have shown, after division of the sciatic nerve. The fact also observed by *Koelliker* is very interesting, namely, that in those cases in which we find thickening and malformation of the nails of elderly individuals, the capillaries of the anterior portion of the matrix may be impervious, owing to a deposit in them of fatty granules.

Finally, as to the first appearance of the nail in the embryo, we find its rudiments in the third month of inter-uterine existence in the form of a fold in the usual situation, which is clothed with the ordinary cells of the embryonic skin. Then in the fourth month, under the embryonic epidermis, and above the rete *Malpighii* of the matrix, a layer of new cells is seen, destined to become the horny cells of the future nail. Later on, more of the same kind of strata are deposited on these, so that the corneous layer, although still soft, acquires considerable thickness. At the end of the fifth month the coating of simple epidermal scales has disappeared from over the nail, and the latter lies freely exposed. In the nail of the new-born child we may still recognise its cellular nature without the aid of reagents, but after the first year the cells are of the same constitution as in the adult body.

C. Tissues belonging to the Connective-Substance Group.

§ 101.

Having discussed the epithelia, we now turn to the consideration of another natural group of textures, namely, the *connective-substance group*, one of the most important, but at the same time most difficult chapters of histology.

This name has been given by the greater number of investigators of our day to a series of tissues, all of which probably take their origin from the so-called middle embryonic plate, and start from the same rudiments. They usually, however, in the course of their farther development in various directions, become separated further and further from one another, taking on the most diverse forms, as well from a chemical as anatomical point of view. Thus, in the mature organism, there occur in the connective-substance group masses which appear at the first glance to be separated by a very wide gap. Among these may be reckoned *cartilage, mucoid or gelatinous tissues, reticular connective-substances, ordinary connective tissue, fatty tissue, bone, and the substance composing teeth or dentine.*

The near relationship, however, of all these different tissues is not to be denied.

In the first place, we often see,—though the typically marked varieties of these several tissues may differ widely from one another,—intermediate forms, as, for instance, between gelatinous and ordinary connective tissue, and between the latter and cartilage; so that a sharp line of demarcation cannot possibly be drawn between the various members of the series.

Again, in many regions of the body, these several tissues merge one into another, as, for instance, in the case of those just mentioned.

Further, a substitution or replacement of one tissue by another equivalent one has been remarked, and moreover of threefold nature.

In the first place, comparative histology teaches that the different forms which belong to this group of connective tissues replace each other frequently enough. What is in one animal, for instance, ordinary connective tissue appears in another in the form of reticular substance, cartilage, or bone. The cartilage of some organs in one being is replaced in the same parts of another by bone, or bony tissue by dentine, and so on.

But in one and the same organism also typical development brings with it a substitution of one member of the connective-substance group for another. There, for instance, where in the embryonic state gelatinous tissue existed, the latter is found transformed into connective tissue or fat at a later epoch; cartilage with its derivatives takes on the form of bony substance.

Finally, we encounter every kind of this substitution in the richest abundance in pathological research, brought about by formative activity of a system modified by disease. Almost every member of the group of connective tissues may be replaced by very nearly any other, firstly by immediate metamorphosis, then again more particularly by reconstruction from the offspring of the original tissue.

Now, while we thus have sufficient examples of relationship on anatomical territory, all the tissues of this group are also found to correspond in another respect, namely, from a physiological point of view. Their significance in the actions of the healthy body is of a more subordinate kind, although they make up an enormous proportion of it. They represent, as is usually said, tissues of lower vital dignity, certain connecting, enclosing, or supporting matters in our system, or a kind of widely distributed framework, in whose interspaces other tissues, as, for instance, muscles, nerves, vessels, and gland-cells, lie imbedded. The name, therefore, "connective-substance," formed after that of "connective-tissue" proposed by Müller, appears in many respects a suitable one. The term "sustentacular tissue" applied to it by Kölliker might also be recommended.

However, though connective-substance takes but little part in the physiological occurrences of the mature and healthy body, as we have just said, it loses this character of quiescence and indifference in the numerous transformations and luxuriant growths of the diseased body, and becomes on the contrary the most active tissue of the whole system. We are indebted to Virchow for having brought out, by an extensive series of observations, that it is principally from the tissues of the connective-substance group that most of the pathological new formations take their rise, "so that the connective-tissue with its equivalents may be regarded as the common germ-bed of the body."

REMARKS.—Science has to thank Reichert for having in the year 1845 placed our views as regards connective-tissue on a firm basis.

§ 102.

Now, although it is comparatively easy to sketch the first outlines of the connective-substance group, definition in individual cases, and the arrangement of the various forms of tissue by means of the history of their development, is attended at present with the greatest difficulty.

Indeed, the requirements of histology on these points can be only but very imperfectly satisfied in the present state of science. In the first place, there still exist great gaps, and then the earlier and more extensive

memoirs on the subject—as, for instance, those of *Virchow*, *Donders*, and others—are no longer serviceable in the present condition of histology. And, finally, owing to the difficulty of investigation, and a certain amount of weariness produced by unprofitable discussions, the connective-tissues have recently been somewhat neglected by microscopists.

The following are about all the features we can pronounce as histologically characteristic of the group of connective substances:—

The embryonic rudiments of all the tissues in question consist originally of aggregations of more or less spheroidal formative cells, without any membrane, and enclosing vesicular nuclei. Between these a soft, homogeneous intercellular substance, consisting of albuminous matter, begins to be formed, be it as a product of the cells, or as a transformed portion of the cell-bodies. This appears later on in considerable though varying abundance. Subsequently the cells as well as the intercellular matter commence to take on other forms. As a rule, the ground-substance or matrix undergoes more or less a division into fibrous or stringy masses or a transformation into fibrillæ, while the cells become stunted, or on the other hand develop into spindle-shaped or stellate elements, which again may unite to form a cellular net-work. Calcification likewise of the intercellular substance is a typical occurrence in some of the tissues under consideration.

And with these anatomical changes we find besides corresponding chemical metamorphoses. As we have just said, the ground-work of connective-substance consists originally of protein matter or near derivatives of the same. A substance nearly allied to, or identical with, mucin (p. 21), also makes its appearance here very frequently. Almost everywhere the chemical constitution of earlier days is missed, more remote descendants of the protein group appearing, namely, the glutinous substances (p. 22), and amongst them usually gluten or more rarely chondrin: local transformation of the ground-substance into elastic material (p. 23) may also take place. In the cell-body also the original protoplasm may be replaced by other matters, such as pigments, fats, &c.

Now, as we have already remarked, a classification of the tissues belonging to this group must be looked upon as a doubtful matter, owing to the intermediate forms and transitions which are constantly encountered. We will, however, distinguish between—1. *cartilaginous*; 2. *gelatinous and reticular connective-substance*; 3. *fatty tissues*; 4. *ordinary connective tissue*; 5. *bony tissue*; and, 6. *dentine*.

5. Cartilage.

§ 103.

By cartilage we understand a compact tissue (appearing very early in the embryo, often rapidly maturing and as often rapidly decaying), which is widely distributed throughout the body, and formed of cells situated in an originally homogeneous intercellular substance. The specific gravity of cartilage in keeping with its solidity is considerable, amounting, according to *W. Krause* and *Fischer*, to 1.095 and 1.097 for that of the joints and the ear. The flexibility and elasticity of cartilage is by no means inconsiderable when in thin pieces or plates; but thicker pieces are brittle, and snap easily.

According to the regions in which they occur, anatomists have divided cartilages into *articular*, or such as clothe the extremities of

bones entering into the formation of joints, and *membranous*, or such as serve for the formation of cavities, in that they strengthen and solidify the walls of the latter.

Another classification based on the length of existence of the tissue might be said to be natural. We meet, namely, early in intra-uterine life and very widely distributed, a cartilaginous skeleton, the greater part of which disappears in the normal process of development at an early period, being destined to give place by decay to another tissue, namely, bone, whilst only a small portion is retained throughout the whole of life. The first of these is *temporary*, the second *permanent* cartilage (1).

There is, however, a third and more rational classification, which is based on the histological texture of the cartilage or that of its intercellular substance.

The latter appears originally in all cartilages, homogeneous, transparent, or slightly clouded. This transparent constitution may last the whole life through, when such cartilages are known as *hyaline*, and represent the typical form of the tissue (fig. 157). These may be recognised by the unaided eye, from their appearing in thin slices, transparent as water, while in larger or thicker masses they present a bluish-white or at times milky appearance.

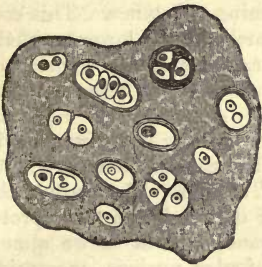


Fig. 157.—Hyaline cartilage.

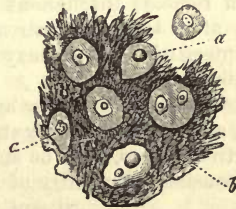


Fig. 158.—Reticular cartilage, from the human epiglottis.

Cartilaginous tissue is, however, liable to undergo in the course of time many kinds of anatomical metamorphoses even of the intercellular substance, which in some cases commence very early, in others however delay a long time in making their appearance. At one time again, they affect but small portions of a cartilage, and at another extend themselves over the whole of the latter. If they appear early and spread throughout whole cartilages, they produce special modifications of the latter and are specially named.

Thus intercellular substance may undergo a coarsely granular clouding, or become streaky and banded, or be transformed into fibres of various kinds. At one time we perceive a partial change into parallel bands and fibres unacted on by acetic acid; at another, meet with an interlacing of dark elastic fibres, or remark in the matrix the characteristic, delicate

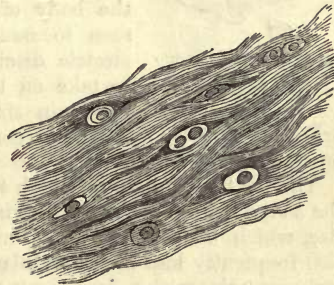


Fig. 159.

fibrillæ of connective tissue paling under the action of this reagent. The two last-named varieties have given rise to the distinction between the *elastic* or *reticular* cartilages (fig. 158), and the *connective tissue* or *fibro cartilage* (fig. 159). Parts which have undergone metamorphoses of the intercellular substance of this kind lose the bluish-white appearance of hyaline cartilage, and become opaque and either yellow or white.

REMARKS.—Correctly speaking, this division is not good, in that we are unable to draw any distinct line between *permanent* and *temporary* cartilage, and the question is only as to differences of degree. Comparative anatomy teaches likewise that the temporary cartilages of one group of animals may be permanent in another, and *vice versa*. Finally, it is very frequently the case that late in life bony growths are formed at the expense of the so-called permanent cartilage.

§ 104.

The cells of cartilage manifest no less an inclination to change than the intercellular substance. And though in very young tissue these elements present nothing very striking in their appearance, yet they may become very characteristic structures through subsequent transformation.

In its rudimentary condition growing cartilage presents itself as a simple aggregation of nucleated formative cells (flattened somewhat where they are in contact with one another), between which close scrutiny enables us to detect thin streaks of a homogeneous glistening substance. This condition remains throughout life among the cartilages of lower animals. Soon after this these streaks become broader, and within a short time the interstitial matter may attain proportions as great as represented in fig. 160.

The cartilage cells now appear round, oval, or more or less crescentic in form, and frequently very strongly flattened. Their dimensions, exclusive of extreme cases, may be stated at 0.0182–0.0275 mm. The body of the cell consists frequently of a homogeneous or delicately granular protoplasm without a membrane, and in it we almost always find a simple vesicular nucleus, measuring from 0.0075 to 0.0144. According to *Rollett*, this protoplasm becomes clouded in a peculiar manner on being heated up to 73–75° C.

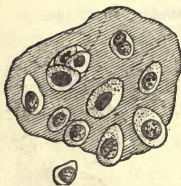

Fig. 160.—Cells of an embryonic temporary cartilage from the pig.

Under the action of reagents, and even of water, the body of the cells of many cartilages may be seen to assume jagged or stellate forms. Violent electric discharges also cause the cells in question to take on the same forms, with a simultaneous decrease in size (*Heidenhain, Rollett*). They are also probably endowed with vital contractility; but this has not yet been proved beyond doubt.

The further changes to which the cell (fig. 161) is liable apply less to the shape (which generally remains one of those mentioned) than to the size, which increases, and at times to a very great extent. The nuclei also frequently lose their vesicular nature, becoming solid while they remain smooth, or else assuming a granular appearance. Deposition of fats in the body of the cell may also commence early.

Another appearance, which is remarked not unfrequently in many mature cartilages, though to a variable extent, is also of great significance. Halos or rings of a sometimes homogeneous, sometimes laminated, sub-

stance, surround isolated cells or groups of the same, at one time very distinct, at another blending in their peripheral portions into the matrix (fig. 161). These are the long-known *cartilage-capsules*, which we have already considered in a former part of our work (p. 87).

We are here met by the important questions: how have these capsules originated? what is their relation to the cell and intercellular substance? and what is the source of the latter?

The opinions of histologists on the points in question have varied from the earliest days of microscopy in the most marked way. It was long ago supposed, under the belief in the spontaneous generation of cells and the doctrine of blastema, that the intermediate substance was gradually insinuated between the cells (§ 102), and that the cartilage-capsule was formed of a modified layer of the latter around the cell: consequently, that the capsule was deposited externally upon the cell-body. On the other hand, some, while they allowed the origin of the apparently homogeneous intercellular substance to be that just stated, still looked upon the cartilage capsule as a product of secretion from the cell, fusing at its periphery with the matrix. According to a third view (1), the capsule, as well as the intercellular substance, is a material supplied by the cartilage cells. But it is still a subject of controversy whether the capsule and groundmass are to be looked upon as a secretion of the cells, which has become solid, or a part of the body of the latter, which has undergone metamorphosis; or, again, whether, as a rule, this intercellular matter is to be considered structureless or the reverse. The last of these three views is, in our opinion, the only one tenable at the present day (2).

We are able, indeed, by means of certain reagents, to demonstrate with complete certainty that the so-called intercellular substance of many cartilages is only apparently structureless (fig. 162). This is seen to be the case in the frog, while it is less distinctly evident and more difficult of demonstration among mammals. It is, in fact, by a process of repeated formation of capsules that the matrix is produced and increased in quantity. The whole ground-work of cartilage consists of nothing but a number of large systems of capsules, which have become fused into one another. Each cartilage cell, therefore, takes a part in this process. In many cases these concentric laminae in the capsule appear in section of exactly the same refractive power, and consequently it was formerly supposed that the intercellular substance of cartilage was homogeneous and structureless. But if, on the other hand, the youngest layers in the system presents different optical bearings (which occurs, as we know, not unfrequently), the term cartilage-capsule is usually applied to them.

But although so much is, in our opinion, certain, yet the problem as to whether these capsules are the products of secretion of the cell-body

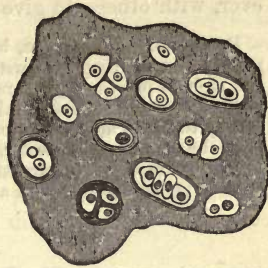


Fig. 161.—Diagram of well-developed old hyaline cartilage, with various kinds of cells.

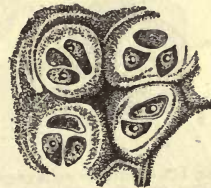

Fig. 162.—Thyroid cartilage from the pig, after treatment with chlorate of potash and nitric acid, showing the intermediate substance resolved into the portions belonging to each cell.

or are the transformed outer portion of the latter, is not yet capable of solution, in the present state of our knowledge. We are inclined, however, with others, to give the preference to the latter view.

REMARKS.—1. There are, besides, instances in which this origin of the intercellular matter may be recognised without any trouble. As *Remak* has very correctly shown, the xiphoid process of the rabbit affords a suitable object. Here the cells may be seen surrounded by broad halos.—2. *Remak* may, to a certain extent, be numbered among these. The observations of *Heidenhain* also are of importance. He succeeded, with the help of warm water, and the action of potash with nitric acid, in resolving the structure of the apparently homogeneous intercellular substance of frog's cartilage. I myself have arrived at the same result on repeating the experiment.

§ 105.

The segmentation of its cells, or, as the usual expression is, *endogenous cell-formation* (fig. 163), is no less characteristic of cartilage. This process has already been described in § 55: we refer the reader to what was there stated. We mentioned there also that all the phases of this process of segmentation had not yet been placed beyond doubt by observation. Thus we still require satisfactory proofs of stages 2, 3, 5, and 6, which have not yet been observed, owing perhaps to the rapidity of the process.

As we have already seen, two (7), four (8), or indeed whole generations of so-called daughter-cells (9), may lie in the interior of a capsule.

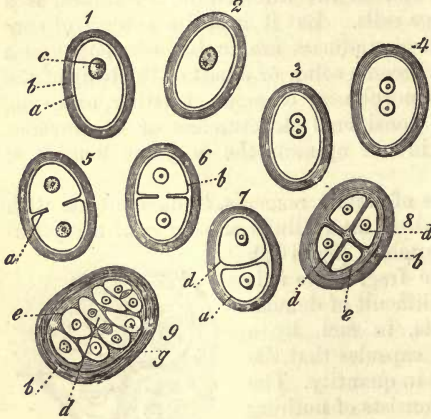


Fig. 163.—Cartilage-cells engaged in the act of segmentation (so-called endogenous multiplication). *a*, body of the cell; *b*, capsule; *c*, nucleus; *d*, endogenous cells; *e*, subsequent formation of capsules on the exterior of the latter; *f*, external portion of the capsule, which fuses with ground-substance of the cartilage. Diagrammatic.

costal cartilages of elderly individuals, we have the best opportunity of observing these latter very much enlarged, and constituting the so-called *mother* or *parent cells*: they may attain a diameter of from 0.113 to 0.226 mm. These again may enclose whole swarms of daughter-cells. The formation of laminated envelopes may then take place subsequently on the daughter-cells which have sprung up within the original capsule (8, 9), and these may appear in course of time to lie free in the tissue (after that the parent capsule has become fused with the ground-substance) undergoing probably later on the same process of segmentation over again. Thus the cartilage be-

comes very rich in cells, showing the important part endogenous multiplication plays in the formation of the latter tissue.

This explains the fact that growing cartilages, in which no kind of regeneration of cells can be discovered, nevertheless acquire gradually a great number of cartilage elements. And, in fact, on searching through cartilage tissue, we frequently meet with spots where the cells still appear as though jammed against one another, and flattened at the point of contact

(fig. 161), and whose partial origin in the manner just mentioned is at least very probable.

In many cartilages besides, which are on their way to dissolution, and where a lively change of tissue is commencing again, there often occurs a very extensive segmentation of cells. This is especially the case where in the fœtus the production of bone begins at the expense of, and together with, softening of the cartilages. It was formerly supposed that other tissue elements (medullary cartilage cells), allied to lymphoid corpuscles, could spring from the daughter-cells. These were then believed to take part in the formation of other tissues, such as the bony, fatty, and connective. We shall refer again to this in dealing with osteogenesis.

§ 106.

The nature of cartilage, as that of a very early formed and rapidly senescent tissue, explains the fact that, in examining, not alone the mature or aged body, but also the foetal in part, we encounter a series of changes in the tissue in question, which, occurring more rarely in other parts, are usually looked upon there as pathological occurrences, but which may here be set down for the greater part as normal processes, and must, therefore, be discussed here.

The transformations which may affect the cell and ground-substance in various ways are more especially three—*fatty infiltration*, *calcification*, and *softening*. They occur principally, but not exclusively, in hyaline cartilage.

Fatty deposit may commence, as, for instance, in the human costal cartilages, even in infancy (fig. 164 *a, b*). We first remark very small isolated globules of oil, which either lie separately in the body of the cell or grouped around the nucleus. On their becoming more numerous, they coalesce, forming drops of greater magnitude, which either lie in the cavity of the cell, without order, or, more frequently still, they so envelope the nucleus that it cannot be recognised without the aid of reagents. Thus it was that that view, held by earlier authors, originated, namely, that the nucleus could itself be transformed into an oil-globule. Should the process advance very far, almost the whole cavity of the cell may eventually be occupied by one large drop of oil, or a swarm of globules.

Calcification of cartilaginous tissue is essentially different from true ossification, that is, from the formation of genuine bony substance containing peculiar cells, although both processes were formerly confounded with one another.

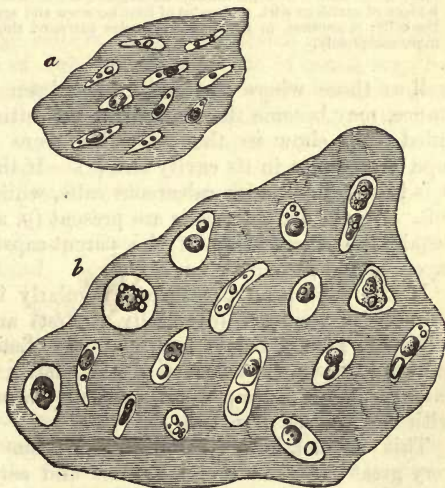


Fig. 164.—Costal cartilage of an infant, transversely cut. *a*, a portion from the circumference; *b*, from the interior.

We now know that cartilage hardly ever becomes bony tissue, but on being calcified, it has rather attained the end of its course, and neither grows nor is further developed in any other manner. In this form it may exist for a longer or shorter period, and, in many of the lower animals, the whole life through, or, more frequently still, it may undergo a rapid re-solution, in order to make way for the formation of true osseous tissue.

We are indebted to *Bruch*, but more even to *H. Müller*, for having first enlightened us as to the right way of viewing these processes.

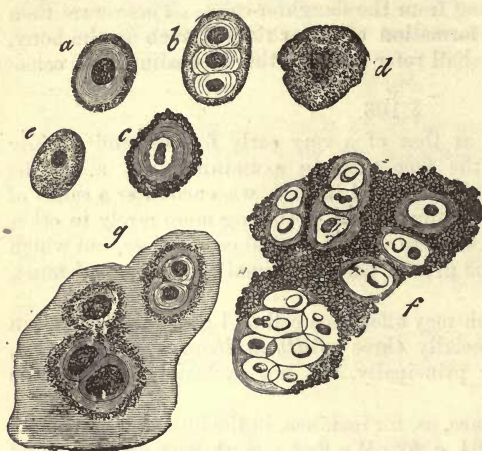


Fig. 165.—Diagrammatic sketch of calcified cartilage. *a*, A capsule with thick walls and shrivelled contents; *b*, another, with daughter-cells; *c*, with very thick walls; *d*, very markedly calcified; *e*, cell with a thin membrane undergoing calcification; *f*, a piece of cartilage with molecules of lime between and around the cells; *g*, another, in which the granules surround the cell more completely.

In some rare cases it is the cells (*a-e*) which are first affected by calcification (fig. 165), but more commonly the ground-mass (*f*). Later on, we see both parts equally attacked by it, or perhaps the process may confine itself principally to the intercellular substance. This process consists in the deposit of either finely granular, or, what is more rare, of coarser crumbs and molecules of the salts of lime. The tissue becomes, owing to this, more and more opaque, until, finally, it is so in an extreme degree.

Touching the cartilage-cells, those whose capsules are apparent, still as well as those where the latter have been merged into the ground-substance, may become the seat of the deposition of lime-salts. Thinly capsuled cells show us the molecules more on the interior of the envelope, or perhaps in its cavity also (*e*). If the capsule be stronger (*a, b, c*), it is impregnated with calcareous salts, while the real cell usually remains soft. When daughter-cells are present (*g*, above), we frequently remark, beside the calcification of the parent-capsule, a deposit of salts in the layers of the secondary envelopes.

If the deposition take place regularly in the ground-substance, the granules of lime are (especially at first) arranged in groups around the cells (fig. 165, *g*, below, and 166, *a*). Later on their amount increases more and more in the rest of the matrix (fig. 166, *b, c, d*) until at last they may appear heaped up, molecule on molecule, in the closest contact with one another (fig. 165, *f*).

This calcification of cartilaginous tissue occurs in the first place to a very great extent in the embryonic and earlier periods of life, appearing there in the falsely-called ossification of cartilage. Cartilage of this kind soon becomes dissolved.

On the other hand, this same process appears subsequently as an ordinary occurrence in the so-called permanent cartilage of later life; for instance in that of the ribs and larynx. Calcified masses of the last kind

may again undergo solution at certain points, and show a new formation of bone in the spaces which have thus been formed. But they may also (and this is most frequently the case) remain in this same condition to the end of life.

It is not alone in hyaline and streaky cartilage that calcification is met with; it appears also, though less frequently, in the reticulated species.

Softening, the last of these transformative processes, may affect either calcified or the soft and still unchanged tissue.

In the latter it occurs in the first place very extensively in the temporary cartilaginous portions of the skeleton, during fetal life, or in early infancy, but may appear likewise in older permanent cartilage, though not as a regular occurrence. The first step of the process is a kind of colloid softening of portions of the matrix, taking place at isolated points in the intercellular substance, attacking the walls of the capsules situated here in its further progress, and forming cavities into which the cartilage cells or their descendants find entrance. In consequence of this process of liquefaction, a system of canals may be formed, which may either open externally towards the perichondrium, or enter into communication with the passages of a neighbouring portion of bone containing vessels, which soon make their way into the interior of the cartilage, and may be recognised there. In the mass which fills up these sinuses in the cartilage, we have the before-mentioned medullary cells (p. 171).

The process of liquefaction of a portion of already calcified cartilage-tissue is of a precisely similar kind.

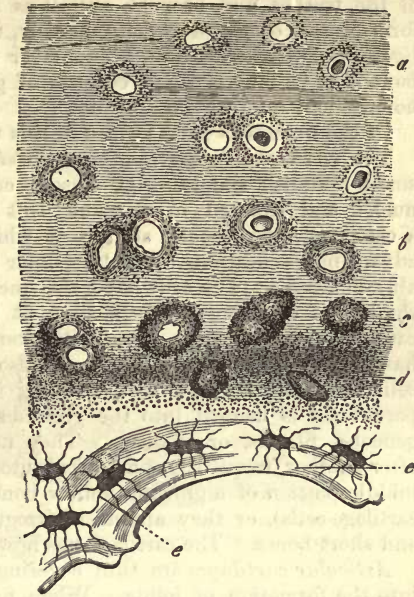


Fig. 166.—Cartilage from symphysis of a woman one hundred years of age, undergoing calcification. *a*, cartilage-cells surrounded with scattered molecules of lime-salts; *b*, *c*, *d*, more copious deposit in the intercellular substance, and around the cells; *e*, true bony tissue.

§ 107.

In inquiring now into the mode of occurrence of the several varieties of cartilage, the following facts as regards the human body may be remembered.

Hyaline cartilaginous matter (partially fibrous, softened, or calcified, however, after a certain age) forms the rudimentary skeleton in the fœtus, that is, the several portions of the vertebral column, of the thorax (not excepting the clavicle), of the shoulders, of the pelvic bones, and in addition, many of those of the head. In the adult this hyaline texture remains in the cartilages, clothing the ends of the bones entering into the formation of articulations (with the single exception of the maxillary). It remains in the cartilages of the nose, and the larger ones of the larynx, namely, the thyroid

and cricoid, but only partly in the *c. arytenoidea*. Again, in the half rings of the trachea and bronchi, as well as in the costal cartilages, and ensiform process of the sternum. Finally, in the symphyses, and equivalent *ligamenta intervertebralia*, a thin layer immediately in contact with the bone is to be found, which consists of genuine cartilaginous matter with homogenous intercellular substance.

Of the numerous parts formed of this tissue some deserve special notice.

The *rudimentary cartilaginous skeleton* of the foetus presents at first small roundish simple cells, closely crowded together, with vesicular nuclei, and situated in a scanty soft ground-substance. Should such a cartilage have reached an age at which it is about to fall a prey to advancing ossification, the intercellular matter is seen to have considerably increased. The cells have also increased in size, especially towards the line of commencing ossification, at the same time that their capsules cannot be said to have become thickened. Endogenous multiplication has produced here a large increase also in their number. The daughter cells so formed are now, as the saying is, free, in that the capsule of the parent-cell is merged into the ground-substance, which is either homogeneous, fibrous, or streaky. They now lie either in long rows one after another, frequently compressed into an obliquely oval form, as in the middle portion of a growing hollow bone (in the so-called "direction" of cartilage-cells), or they appear in irregular groups, as in the epiphyses and short bones. The cartilage has now become vascular besides.

Articular cartilages are thin coverings for the ends of bones entering into the formation of joints. When firmly united to the bone at their under surface, they represent the remainder of the original rudimentary cartilage, which has not given way to the encroachments of ossification. Their superficial portions, lying free in the cavity of the joint, contain small but strongly flattened cartilage cells measuring 0.0113–0.0178 mm., crowded one over the other, in a way that reminds us (when seen in vertical section) somewhat of laminated epithelium. Further down, or at a greater depth, we see the cells in the growing substance separated somewhat more widely from one another. They lose at the same time the flattened appearance, becoming taller and larger, increasing to 0.0156–0.0282 mm. and upwards, with nuclei of from 0.0065–0.0090 mm. At first they are piled without arrangement in heaps over one another; but deeper in the vicinity of the bone, they group themselves into long rows, perpendicular to the surface of the latter. The remainder is made up of beds of calcified matter. In the large cells of articular cartilage, daughter-cells are frequently present, while fatty globules are occasionally, but rarely met with.

The *costal cartilages* have been frequently described by histologists as the best examples of hyaline structure, but incorrectly so on account of their various transformations. In the new-born infant there appear in a completely homogeneous ground-substance (fig. 167) beds (*a*) of small cells (parallel with the surface) like rents in the matrix, which have a delicate outline, and which contain nuclei of about 0.0056 mm. in diameter. The length of these cells is 0.0095–0.0150 mm.

Their contents are either quite transparent or dotted with a few very minute oil-globules of about 0.0018 mm., or even less in diameter. More internally we encounter a number of generally narrow oval cells, sometimes reniform or wedge-shaped, placed in every position as regards one another, while in the deepest portions of the costal cartilages, the largest and

broadest cells (*b*) are to be found, some of oval or spherical form, and diameter of 0.0169–0.0282 mm. Capsules are either not at all visible, or only so in the form of delicate halos, and within the latter we find at most one pair of so-called daughter-cells.

If we now examine the same cartilage in an adult or older individual (fig. 168), we remark, particularly in the internal portions, isolated whitish or white spots, where the tissue presents a silky gloss or appearance like asbestos, in the midst of the more transparent ordinary ground-substance (*a*). Under the microscope we find the tissue to be here fibrous (*c*), and indeed most regularly so; we see stiff, crowded bundles of

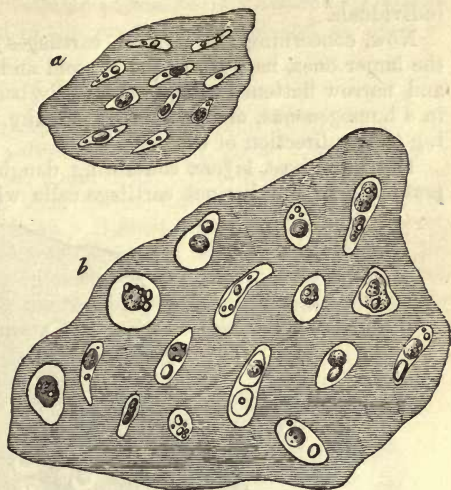


Fig. 167.—Costal cartilage from the infant in transverse section. *a*, external portion lying next the perichondrium; *b*, internal portion.

fibres running parallel with one another, and becoming lost in the neighbouring ground-mass. These do not pale on treatment with acetic acid. Again, in many localities the intercellular substance appears granular and clouded, in others cleft or further split up into bundles (*b*).

Here also, in transverse sections, we meet with small flattened cartilage cells, close under the surface, arranged in several layers, and without any capsules or so-called daughter-cells. They lie in the usual manner with their long axis parallel to the edge of the cartilage. Deeper down the cells, which are still in general of but small dimensions, take up an irregular position, becoming gradually broader and larger. We may meet with some towards the centre, measuring 0.0750–0.1150 mm. At the same time, the position of the elements either remains irregular, or they may be more or less arranged in radiating lines. Here we find the daughter-cells also more numerous (*d*, *e*, *f*).

The cells found in the portions which have become fibrous may be enormously large, attaining in some cases a diameter of 0.1423–0.2256 mm. They are of roundish, oval, or elongated form, with whole swarms of endogenous cells, 20, 25, or 30, or even 60, as *Donders* once saw.

Capsules are of very ordinary occurrence around the cells in the more internal portions of the costal cartilages. They are of varying but generally considerable thickness (*f*), and appear at one time distinctly marked off externally, at another blending into the surrounding ground-substance. In other cartilage cells this capsule system cannot be distinguished optically from the surrounding matrix (*d*), or has developed into fibres (*e*).

The large amount of fat which (commencing at birth) has been gradually accumulated here, is also very remarkable. Here may be seen larger or smaller globules, which coalescing—especially in the neighbourhood of the nucleus—may frequently envelope the latter, so that we have apparently to do with a drop of oil in its place.

Again, processes of liquefaction and calcification, as well as incipient ossification, are of common occurrence in the costal cartilages of elderly individuals.

Now, concerning the hyaline cartilages of the *larynx*, we observe in the larger ones, namely, in the thyroid and cricoid, many layers of small and narrow flattened cells, immediately beneath the perichondrium, lying in a homogeneous, or occasionally streaky intercellular substance, according to the direction of the cells.

The innermost layers, containing daughter-cells, on the other hand, present large and distinct cartilage cells with thickened walls. In older

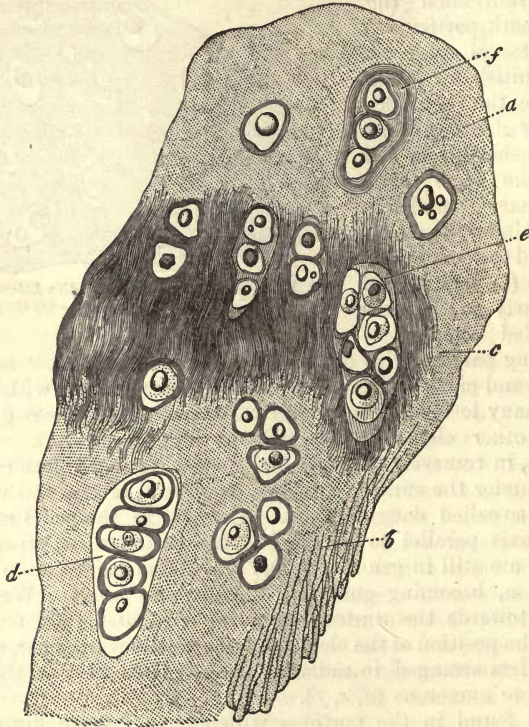


Fig. 168.—Transverse section of the costal cartilage of an old man. *a*, homogeneous ground-substance, which has become striated at *b*, and has broken into fibres at *c*; cartilage-cells may also be seen, possessing for the most part thickened capsules. At *d* and *e*, two large parent-cells with numerous offspring; another at *f*, with well-developed laminae in the capsule.

subjects the intermediate matter may be fibrous or banded; deposit of fats in the cells is also of frequent occurrence here. Between these two portions, again, is situated a thin layer of larger cells, whose intermediate substance appears granularly clouded (*Rheiner*). Calcified portions, with finely granular calcareous matter, are also very commonly met with in older individuals; and true ossification is also seen. The half rings of the trachea correspond with these two cartilages in all essential particulars of texture.

The texture of the arytenoid cartilages is of great interest, constituting as it does an intermediate form between that just mentioned and

elastic cartilage. In some parts, namely, these are homogeneous, and then in others again the intercellular substance is traversed by elastic fibres. The latter may be seen in the *processus vocalis*, and at times in the tips.

§ 108.

Elastic, reticular or fibro-reticular cartilages (fig. 169), which are remarkable for their rather yellowish tint and great opacity, spring from the hyaline cartilage of the fœtal body. The development of their elastic fibrillation reminds us thus of the formation of the chondrin-yielding fibres of hyaline cartilage. It must be remembered, however, that it is a process which belongs to the earlier periods of life, whilst the appearance of fibres containing chondrin is an occurrence of a later time. In young bodies the originally homogeneous constitution of the cartilage may remain at particular points, especially in the vicinity of some of

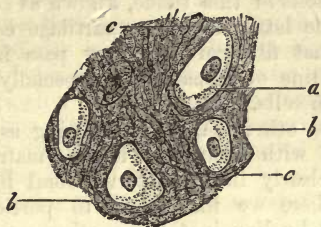


Fig. 169.—Reticular cartilage from the ear of the calf. *a*, cells; *b*, intercellular substance; *c*, elastic fibres of the latter.

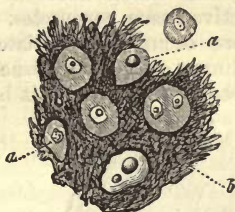


Fig. 170.—Fibro-reticular cartilage from the human epiglottis.

the cartilage cells. The fibres are at one time thin and delicate, at another dark and irregularly bordered, with a very intricate course, reticulated or tangled like the fibres of felt. Wherever this fibrillation is very strongly pronounced, the cells may be concealed to a great extent, as, for instance, in the epiglottis (fig. 170), and pinna of the human ear. The proportion of intercellular substance to the cells is also subject to great variation, to such an extent at times that the latter may in one instance be separated from one another only by narrow belts, or, on the other hand, by a large quantity of interposed matter. The fibres are those belonging to the elastic series, with the characteristic power of resisting the action of reagents. They take their rise through an immediate metamorphosis of the homogeneous blastema without the intervention of cells, as is indicated by the fact that in the human arytenoid cartilages the homogeneous ground-substance is immediately continuous with the fibrous.

The cells of reticular cartilage, which vary greatly as to form and size, are easier of isolation than those of the hyaline tissue. They are usually scattered without any definite arrangement, although we may find in the peripheral portions of the epiglottis small narrow elements, as in permanent hyaline cartilage. The cells of reticular cartilage, farther, are often remarkable for possessing less definite capsules and a less marked tendency to the production of daughter-cells. The nuclei, which are either smooth (in which case they contain a nucleolus), or granular, occur therefore single as a rule, or more rarely in pairs. In the body of the cell or round about the nucleus fat may also be met with here.

Among the cartilages of the human body which have a thoroughly solid reticular intercellular substance, may be numbered certain portions of the respiratory apparatus, namely, the epiglottis, the cartilages of *Wrisberg* and *Santorini*, the *Eustachian* tube and pinna of the ear. Further, as having a partially fibrous blastema, the arytenoid cartilages and intervertebral ligaments.

§ 109.

We have now to enter on the consideration of a third species of this tissue, namely, of the *connective-tissue* cartilage, or, as it has been less happily termed, *fibro-cartilage* (fig. 171). This may be looked upon as a hyaline cartilage whose abundant matrix has developed into fasciculi of connective-tissue, or as a solid species of the latter, through which cartilage cells are scattered. The fact is that it is usually a mixture of connective-tissue and cartilage. Like connective-tissue, it contains elastic fibres as well as the cells of this tissue, known as connective-tissue corpuscles. Between the latter and many cartilage cells there occur intermediate forms, so that fibro-cartilage may pass into ordinary connective-tissue without any line of demarcation, especially at those points at which it becomes poor in cells.

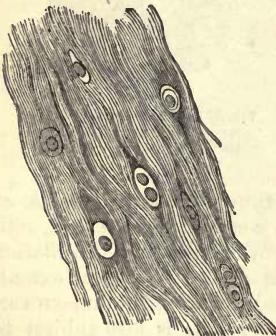


Fig. 171.—Fibro-cartilage from a human *Ligamentum intervertebrale* (half diagrammatic).

On the other hand, its bearing as a cartilage, with connective-tissue matrix, appears clearly in the intervertebral ligaments, where we find close to portions which are hyaline in texture other points where the matrix is obscurely fibrous, and continuous with a substance which is evidently connective-tissue.

Fibro-cartilage, which is brought especially into use in the construction of joints, appears to the unaided eye of whitish or slightly yellow colour, and to possess a texture sometimes solid and sometimes rather soft. It is more extensible, further, than ordinary cartilage.

Under the microscope we find, instead of the homogeneous matrix of hyaline cartilage, connective-tissue with fibres sometimes more indistinct than at other times, when they may be very sharply defined. The bundles are usually crossed in all directions confusedly. They may, however, preserve some definite direction on the other hand, while their optical and chemical bearing is quite that of ordinary connective-tissue (see below). As to the cartilage cells, their proportion is in general but small, and frequently, indeed, very inconsiderable, so that they require to be searched for. The size, further, of the cells is also small, and their whole constitution simple, the outline being usually very delicate, and the nucleus, as a rule, single. Cells with two nuclei are rare, and those containing daughter-cells apparently do not occur at all. Fatty infiltration likewise, which is so common in other species of cartilage, is here of rare occurrence. The position of the cells is also liable to variation. They are either without arrangement or crowded together in small groups, or again, arranged one after another in rows. The latter position corresponds with the direction of the fibres of the tissue.

Connective-tissue cartilages possess vessels, but only in small number; but as to the presence of nerves, we are as yet unable to state anything certain.

Among them the cartilages of the eye-lids may be reckoned, of which the upper appears to be richer in cells than the lower, which has but few of the latter (*Gerlach*); further, the *c. triticeæ* of the larynx, which may, however, consist of hyaline substance (*Rheiner*); then the *c. inter-articulares*, as well as the so-called *labra cartilaginea* of certain joints, with the cartilaginous knots found in tendons. As a rule, it seems to be part of the composite character of the fibro-cartilages, that structures formed of pure connective-tissue may be transformed at points into the varieties of the tissue in question by the imbedding of cartilage cells. This is the case in the terminal portions of tendons where they are inserted into bone, as well as many parts of their sheaths (*Kölliker*).

Finally, fibro-cartilage, springing, moreover, continuously from the hyaline, appears in the symphyses and so-called half-joints, which have their origin in the liquefaction of the central portion of solid masses connecting bones (*Luschka*).

Among the latter, those most worthy of consideration are the sym-

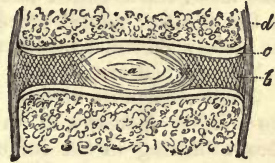


Fig. 172.—Diagram of a vertebral symphysis divided vertically. At *a*, the pulpy centre; at *b*, the fibrous ring; at *c*, the cartilaginous covering of the body of the vertebra; *d*, the periosteum.

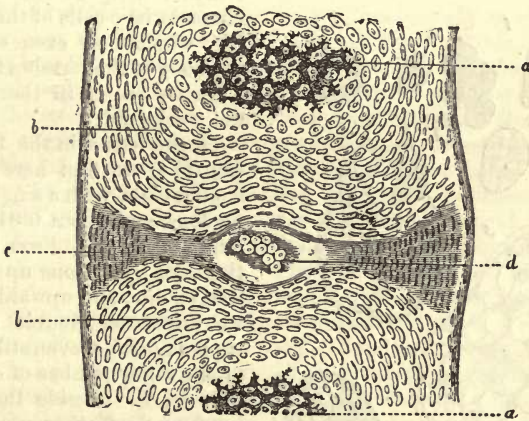


Fig. 173.—Vertical section through the bodies, the last dorsal and first lumbar vertebra of a human embryo at ten weeks. Body with calcified cartilaginous tissue, *a*; and unchanged, *b*; at *c* the fibrous ring developing, consisting of elongated cells (?), and with a cavity containing transparent cells at *d*, which becomes the pulpy nucleus of the infant.

physes of the vertebra, so frequently the subject of investigation, the so-called *ligamenta intervertebralia*, about which *Luschka* has imparted to us such valuable information.

They present themselves as solid connecting plates between the bodies of the vertebra (fig. 172), taking their rise continuously (at least at their circumference) from a layer of hyaline cartilage which clothes the surfaces of the bone (*c*). They each consist of a fibrous ring externally (*b*),

that is, of concentric portions of fibrous tissue crossing each other perpendicularly and obliquely. This ring has sometimes the character of simple connective-tissue, sometimes that of an elastic or fibro-cartilage. The central portion is soft, and often possesses a cavity containing a jelly-like mass, the so-called *gelatinous* or *pulp nucleus* (*a*). This is made up in the adult of ragged processes of the peripheral fibrous cartilage, which lie closely crowded together, leaving in their midst a cavity filled with gelatinous matter.

While the pulp nucleus resembles more and more the fibrous ring as its solidity increases at an advanced period of life, it shows a very different bearing in the infant and foetus. Here (fig. 173), at an earlier embryonic epoch, the origin of the nucleus is quite manifest. It takes its rise, namely, from the exuberant growth of the residue of a rudimentary foetal structure, the *chorda dorsalis* (*Luschka*). This latter, which persists among the lowest animals for a part of, or the whole of, life, presents itself as a cylindrical rod blunted before and fining off to a point posteriorly. It passes from the base of the skull down to the lower end of the vertebral column in the place of the bodies of the bones making up the latter.

It consists of a tissue which may be perhaps classed among the cartilages, formed of transparent cells crowded close together, and enclosed in a homogenous envelope. The *chorda dorsalis* disappears almost entirely with the formation of the cartilaginous base of the skull and vertebral column. However, in the intervertebral ligaments there remains a space filled with the characteristic cells of the notochord (*d*), which may even extend into the body of the vertebra themselves. Thus we see it in the embryo of ten weeks old.

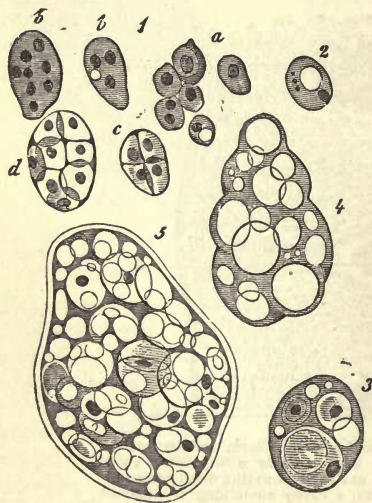


Fig. 174.—Descendants of the cells of the *chorda dorsalis* in a foetus of five months old, and in an infant. 1, Cells from the foetus of five months; 2, single cell from the infant; 3, another, with daughter-cells; 4 and 5, a structure which has taken its rise from a very much enlarged parent-cell, with nucleated cells and many transparent globules of albuminous nature.

In the foetus in the fifth month (fig. 174) we find here again very similar cells, with a single vesicular nucleus, and about 0.0136–0.0180 mm. in diameter. From these (1, *a*) there are gradations up to some of 0.0413 mm. and upwards, in which we encounter double and quadrupled nuclei, or even still more (*bb*), or the same number of endogenous cells (*c*, *d*). Beside these, springing from the further growth of such parent-cells very large bodies are met with, measuring up to 0.1128 mm., of tough constitution and transparent appearance. They are partly filled with distinct daughter-cells, but principally with extremely numerous transparent globules of a metamorphosed albuminous substance.

In the still infantile body we meet with the same structures with a tough envelope (the thickened parent capsule), which may attain a

diameter of 0.0226 mm. (4.5). Other smaller bodies of this kind (3) still bear clearly the characters of large parent-cells.

These gelatinous collections of cells exist throughout the first year after birth, and then appear to fall a prey to the centrifugal growth of the fibrous ring encroaching on them.

§ 110.

In the *chemical* investigation of cartilage, the variations corresponding to the different forms in which the tissue makes its appearance should be taken into account. It ought to be ascertained (*a*) of what substances the cartilage cell, with its several parts, consists; (*b*), what matters enter into the composition of the system of capsules and the substance cementing them together; (*c*), how far the youngest layers immediately surrounding the cells differ from the older ones, which form the apparently structureless matrix; (*d*), how far the composition of the latter changes according as it remains homogeneous or becomes granular, and likewise on the appearance of elastic fibres in it. In chemical examination we should be able to follow up (*e*) the changes which the composition of cartilage undergoes in the physiological metamorphoses of the tissue; and, finally, the fluid saturating the latter should come within the range of inquiry, and we should look in it for the products of the transformations going on in the tissue. Unfortunately, however, these requirements cannot be met by any means in the present state of science.

If cartilage be treated microchemically, we immediately recognise the fact that it belongs to the tissues which are not very mutable. In cold water it shows but little sensibility, with the exception of the bodies of the cells, which rapidly shrink up (§ 104). Acetic acid has the same action upon the latter, but, like other weak acids, has no effect on the whole. Even sulphuric acid and strong solutions of potash are resisted for a remarkably long time by the cells of cartilage (*Donders* and *Mulder*). The latter may be obtained in an isolated condition by maceration in hydrochloric acid (*Virchow*). With sugar and sulphuric acid the cells assume a red colour, while the intermediate substance of hyaline cartilage becomes yellowish red (*Schultze*). The nuclei also appear difficult of solution as a rule. It is otherwise, however, with the intermediate substance. This may be dissolved by long-continued boiling in water, after from twelve to forty-eight hours, and yields chondrin: it consists, therefore, of what is known as chondrigen. The microscopic examination of the dissolving tissue during this process is a matter of some interest. The cells resist the solvent action in the most determined manner, and are, therefore, not formed of chondrigen or any of the other glutinous compounds. It is no proof to the contrary that they are subsequently dissolved. Again, the laminae of the capsules immediately adjacent to the cells resist the action of boiling water longer than the rest of the ground-substance. They do not, therefore, possess the same composition, though they may be said to yield chondrin.

The same difference also is manifest in the granules of chondrigenous cartilage.

The granular clouding of the ground-substance does not disappear on treatment with acetic acid or ether, but does so in a warm solution of potash, and on heating in dilute, hydrochloric, and sulphuric acids.

These granules especially are coloured red when heated with *Millon's* reagent (*Rheiner*). The fibres of hyaline cartilaginous tissue yield chondrin likewise, as far as we can gather from investigations which have been made up to the present.

From all this we learn that hyaline cartilage is a tissue yielding chondrigen with cells of a different constitution, with which we are not more nearly acquainted.

§ 111.

Now, concerning elastic or reticular cartilage, we may obtain from it, that is, from the residue of hyaline matter which it still contains, a small quantity of chondrin, but only after long-continued boiling. The elastic fibres, which must take their rise from a metamorphosis of the chondrigen, manifest here the same characteristic insolubility as elsewhere. It is only after digestion in potash of many days' duration that they become jelly-like and break down into granules, which are dissolved on the addition of water. Whether the cells of reticular cartilage are more soluble than those of the hyaline species, as has been stated, but without sufficient foundation, requires more accurate investigation.

Passing on then to fibro-cartilage, we find that its ground-substance gives the same reactions as connective-tissue, and is transformed likewise into gluten by boiling. The latter is not, however, chondrin, but the ordinary gluten of connective-tissue (p. 22). The semi-lunar cartilages of the knee-joint are said to be most difficult of solution.

At present we know nothing of the fluid with which cartilaginous tissue is saturated. But the so variable proportion of mineral matters which are found in the latter seem to point to a variation also in its composition. Leucin, glycin, and cartilage-sugar may probably be regarded as physiological products of the transformation of the tissue in question. Comp. §§ 31, 33, and 22.

The percentage of water in this tissue is reckoned at 54–70 per cent., and the fats, which are entirely absent in no cartilaginous structures from the very earliest periods, are found to vary naturally very considerably. Their proportion, according to most observers, is about from 2 to 5 per cent., but which of their varieties occurs in the tissue of cartilage has not yet been ascertained.

There now only remain for consideration the mineral constituents. The proportions of these are very differently stated, which is, most probably, dependent on the imperfect methods of calcining which have been resorted to. Phosphate of calcium and magnesium, with chloride of sodium, carbonate of sodium, and sulphates of the alkalies, have been mentioned as occurring here.

We may set down a few results here which have been obtained in one and the same animal as examples of the relative proportions of mineral constituents. *Schlossberger* found that the ashes yielded by the nasal cartilages of an old rabbit amounted to 3·51 per cent., those of the ear to 2·30 per cent., while those of the ribs rose to 22·80 per cent. *Hoppe* again obtained from the costal cartilage of a suicide aged 22, 2·20 per cent., and from that of the knee-joint, 1·54 per cent. of ash.

The observations which have been made on the costal cartilages of the human being teach that the proportion of inorganic constituents is increased in one and the same cartilage by age. The following analysis, with the exception of the fifth, have been all made by *Bibra* :—

A child of six months,	2·24	per cent. of ash.
A child of three years,	3·00	„
A girl of nineteen years,	7·29	„
A woman of twenty-five years,	3·92	„
A man of twenty years,	3·40	„
A man of forty years,	6·10	„

§ 112.

The cartilages of the adult body may be regarded as the residue of a tissue very widely distributed through the system at an early period of intra-uterine existence, which has for the greater part given way to the subsequent formation of bone (§ 103). In many structures, therefore, this tissue manifests a remarkable degree of transitoriness. And even those cartilages which persist in the body up to its maturity show a certain inclination to undergo anatomical metamorphosis, that of softening, of fibrillation, of calcification, and even of ossification; in other words, to pass through subsequent processes which in the so-called temporary cartilages had taken place at an earlier epoch (§ 106).

For the rest, cartilaginous tissue, which is, as a rule, non-vascular, possesses but a small amount of transformative power over the matters which it receives; and such as it is, its bearings are unfortunately still very obscure. The nutrition of the tissue occurs in two ways. Some cartilages are clothed with a fibrous membrane, the perichondrium, whose vessels supply the nutritive materials. For all this it is a strange fact that, in the interior of the cartilage, the tissue appears most highly developed—thus at the point most remote from the blood-vessels. How far, and whether indeed the tissue can further grow at all from the *perichondrium*, has not yet been ascertained. Other portions of the tissue in question, which enter into the structure of joints, possess no perichondrium, and depend on the vessels of the adjacent bone for their nutriment.

According to all this, we have in cartilage to deal with an aggregation of simple cells, whose intercellular substance is its only essential peculiarity; on which also the physical properties of the tissue, its solidity, hardness, and pliancy, depend. It is owing specially to this latter quality that cartilage is of such importance to the system; it adapts to form supports for other parts, to strengthen the walls of membranous canals, &c., to clothe the ends of bone, forming a layer peculiarly suitable for articulations through its hardness, smoothness, and small liability to wear and tear. Finally, it presents itself as a very strong connecting matter for joining bones together.

Although non-vascular, cartilages may undergo the same changes as other vascular portions of the body, under conditions of inflammatory irritation. Energetic segmentation of its cells has been remarked, as well as increase in size of the capsule and deposit of fats in the body of the cells. The intercellular substance may also split up into fibres and fasciculi, or break down altogether. Calcification or transformation of the whole into a substance more or less like connective-tissue may also occur (*Redfern, Virchow*). These changes are, in many cases, brought about by but a repetition of the process described in § 106.

The substance of cartilage is not regenerated, however, so that two fractured portions of the latter can only be united again by a connective-tissue cicatrix. But an accidental new formation of cartilage is by no means of rare occurrence. In the first place, it may start from cartilage already

present (*ekchondrosis*), or a cartilaginous tumour may spring up in places where cartilage does not normally appear, as, for instance, in bone or glandular structures (*enchondroma*). In the latter, and not unfrequently in the same tumour, we meet with the several varieties of cartilage as regards its cells and interstitial substance; islands of the true tissue are sometimes separated from one another by fasciculi of connective-tissue.

It now remains for us to consider the *first appearance of cartilage in the embryo*, and the changes which take place in it subsequently. On this point much valuable information has been contributed by *Schwann*, *Kölliker*, *Bruch*, *Heidenhain*, and others.

The histological development of cartilage takes place at a very early period of intra-uterine life, as is indicated by the original simplicity of the tissue, and its similarity to the first cellular rudiments of the organs and various other parts of the system, namely, the embryonic cells. The first anatomical rudiments of cartilage, that is, of the temporary tissue, appear at the commencement whitish and clouded, without differing in texture from the neighbouring structures. Its characteristic features begin, however, to be developed very early.

Originally these primitive cartilage cells lie closely crowded together, and there is hardly the slightest trace of intermediate matter. The latter, however, soon makes its appearance somewhat more distinctly.

Thus, in the embryos of sheep, of 6-7 mm. in length, *Kölliker* found cartilage cells measuring 0.0135-0.0226 mm., and the intercellular substance still very scanty. In larger embryos even, as those of the pig, of 2 inches long and upwards, the ground-substance is still much less in quantity than the cells, in which latter the production of daughter-cells is beginning. Fig. 175 represents this process. In other fœtuses of the same animal, measuring $3\frac{1}{2}$ inches long, the intercellular substance amounts to only about one-fourth of the whole volume, according to *Schwann*. At the same time, the tissue is so soft that, on the slightest pressure, the cells separate from one another, and float about in the surrounding fluid. Later on, the proportion of the intercellular substance increases more and more, while the cells enlarge, and endogenous multiplication reaches

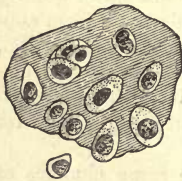

Fig. 175.—Cartilage cells from the body of a vertebra of a fœtal pig, of 2 inches in length.

in many cartilages a high degree of activity. But during the growth of a cartilage, the number also of the cells it contains increases by segmentation of those previously existing. The stronger capsules, presenting different optical characters from the surrounding medium, are only found at a later period of development. Deposition of fats also (at least in the cartilages of many new-born infants) may also be found commencing (comp. fig. 165). The formation of bands and appearance of chondrin fibrillation occurs at a much later period.

Great interest attaches to the discovery made by *Schwann*, and afterwards confirmed by *Hoppe*, that the ground-substance of foetal cartilage does not consist originally of a matter yielding chondrin, or indeed of any material which stiffens, like gluten, on cooling.

All the statements just made refer, in the first place, to hyaline cartilage: the primary form of reticular and of fibro-cartilage, however, is also included. The latter consist originally also of a homogeneous ground-substance, in which the metamorphosis into fibres commences sooner or later, and continues in some parts even after birth.

6 and 7. Gelatinous and Reticular Connective-Substance.

§ 113.

Under the name of *gelatinous* or *mucoïd tissue* and *reticular connective-substance* combined, we shall now consider a second series of tissues, liable to great variation, and belonging to the group of connective-substances. This classification, however, can only be said to have a provisional value: it remains for more accurate histogenic investigation to show, at some future time, whether the mode of development of the different tissues placed together here justifies or modifies our method of arrangement.

Gelatinous and reticular connective-substance appear at the first glance separated by a wide gap from cartilage. Whilst in the latter we have to deal with a tissue made up of round cells held together by a solid glutinous intermediate matter, the plan of the tissues with which we are now engaged is completely different. They are all of them more or less soft, partly swollen up into a glutinous condition, or in other rarer cases even present themselves in the liquid form.

Only in exceptional cases do their cells preserve their spherical form: they present themselves, as a rule, in most characteristic figures, radiated and stellate, and united with each other by means of simple or branched processes, forming networks of cells (figs. 177 and 178).

The system of meshes so formed varies as to its contents very considerably, apart from the differences in the size of its meshes.

In a certain number of the tissues which may be reckoned in this category, the network formed by these elements is occupied by a structureless, watery jelly, containing mucin or some allied substance, when we term it a *gelatinous* or *mucoïd tissue* (fig. 177).

A second and more extensive group shows us these interstices, instead of being occupied by a mucoïd mass, filled rather with innumerable granular cells, which correspond exactly with the elements of lymph. We have thus presented to us the most widely distributed species of *reticular connective-substance* (fig. 178). It has been named "cytogenous connective-substance" by Kölliker, and by His "adenoid substance."

Another series of connective matters belonging also to this group in our opinion, encloses, in a usually narrow-meshed and delicate cellular network, another kind of contents, *e.g.* chiefly, nervous elements (fig. 179), or also, though much more rarely, masses of

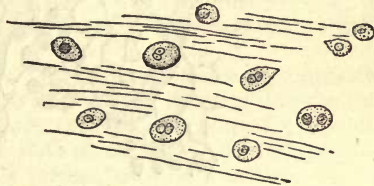


Fig. 176.—Gelatinous tissue with roundish cells from the vitreous humour of a human fetal eye.

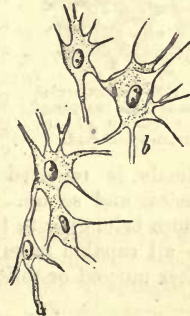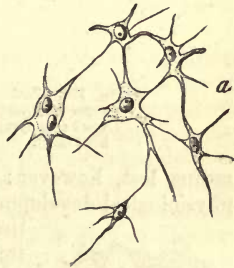


Fig. 177.—Gelatinous tissue with stellate cells, from the enamel organ of the human embryo.

fat. This may be designated for the present as *sustentacular nervous matter*, and is a species which has, up to the present, been investigated least of all.

The fibrous character of most of the tissues enumerated here is by no

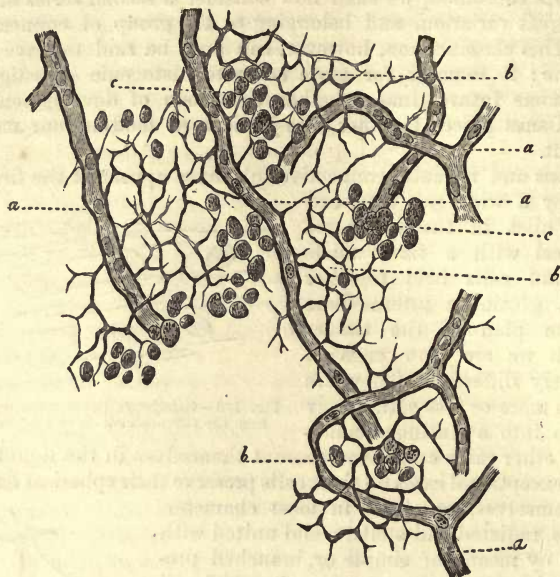


Fig. 178.—Reticular connective-substance with lymph corpuscles from Peyer's follicle of the adult rabbit. *a*, capillaries; *b*, reticular framework; *c*, lymph cells (most of the latter have been removed by brushing).

means lost, however; for we frequently see, whether in the course of physiological development or as a pathological occurrence, many of these tissues, the mucoid as well as the reticular, becoming transformed into ordinary fibrous tissue, in that the cellular network obtains coatings of filaments while the gelatinous intercellular matters, or as the case may be, lymphoid corpuscles, decrease and finally disappear.

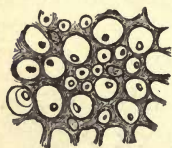


Fig. 179.—Sustentacular tissue from the posterior column of the human spinal cord.

Then, again, we recognise that other substitution already mentioned section 101, in different groups of animals. Thus, for instance, the reticular connective-substance in one organ of certain animals is replaced by ordinary fibrillated connective-tissue in other species, and so on. Finally, it seems probable that any of the other tissues belonging to this so widely distributed connective-substance group are all capable more or less of reproducing from their cellular offspring either mucoid or reticular tissue.

§ 114.

We have just seen that by *gelatinous* or *mucoid tissue* is understood a cellular structure, characterised by possessing a very soft and watery intercellular substance, containing either mucin or some matter very

similar to it, and which is thus distinguished from gluten-yielding cartilage and regular connective-tissue. The amount of this interstitial substance is usually considerable, so that all the physical properties of the tissue are determined by it. In this respect cartilage and gelatinous tissue resemble each other, though, on the other hand, they may differ widely as regards consistence.

The cells in a soft interstitial substance of this kind are originally of spheroidal figure, and when imbedded in a completely homogeneous mass may be regarded as the simplest form of gelatinous tissue—one which is, however, but extremely rarely permanent, and which is destined to undergo, as a rule, further transformation. The cells, in such cases, are metamorphosed into fusiform and stellate structures, displaying a strong inclination to unite with one another, and in the intercellular substance there commences to make its appearance a streakiness and fibrillation.

In general, mucoid tissue may be said to be a species of connective-substance standing low in the group, and as such it enters into the composition of temporary embryonic structures under normal conditions, which do not attain in this form a state of maturity. In fact, we have to do with foetal tissues. The cells further, while still in their simplest form, may be so compressed by the superabundant interstitial matter that they cease to exist, the latter only remaining over. It is, however, more usual to meet with an ascending metamorphosis in other of these textures, by which they are developed into ordinary soft connective-tissue. The points of distinction, consequently, between the two cannot be very definitely laid down.

The parts of the human body which are looked upon at the present day as belonging to this group of tissues are the following:—the vitreous humour of the eye; the gelatin of *Wharton* of an early period of life; certain substances filling up the interior of the rudimentary ear; the enamel organ of the rudimentary teeth; and the soft, formless connective-tissue of intra-uterine life, which has not yet developed collagen. But in animals gelatinous tissue is more permanent. Thus the *sinus rhomboidalis* in the spinal cord of birds is formed of it, and the formless connective-matter of fishes. It appears also widely distributed among the lower animals. The bodies of the acalophæ are chiefly made up of it (*Virchow* and *Schultze*).

Whilst in the mature body no gelatinous tissue is to be found, with the exception of that small quantity known as the vitreous humour, it may be produced anew under abnormal conditions by development from another member of the group of connective-tissues, as, for instance, from fatty tissue in cases of emaciation. Tumours formed of mucoid tissue are known as myxomas (*Virchow*).

§ 115.

The simplest form of this gelatinous tissue to be found is in the *corpus vitreum* of the eyes of embryos and very young individuals.

The surface of the latter is originally covered with a vascular network, which is obliterated, however, very early. If we examine the structure in a foetus at about the end of the fourth month (fig. 180), we find it to consist of an abundant and completely colourless, homogeneous, and somewhat viscid ground-substance, which becomes stringy on the addition of acetic acid. In this are imbedded, at tolerably

regular intervals, a rather scanty proportion of cells, either quite spherical or spheroidal, which may take on other distorted forms, however, owing to their soft consistence and the semi-fluid nature of the surrounding medium. They resemble enlarged colourless lymphoid cells, &c., and are granular, either coarsely or finely so, but usually to no great extent, so that they are not very opaque. Their membrane opposes a certain amount of resistance to the action of acetic acid, and the nucleus appears more or less granular, showing in its interior a nucleolus. We also meet with round, oval, reniform, and double nuclei, which have always their special nucleoli, indicating probably a multiplication of cells here.

The size of these cells is 0.0104, 0.0156–0.0182 mm., while the simple nuclei have an average diameter of 0.0052 mm.

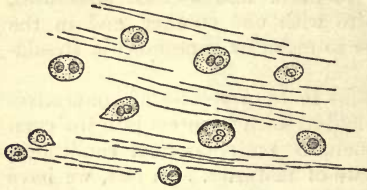


Fig. 180.—Structure of vitreous humour in a four months' foetus.

Fusiform and stellate cells are not entirely absent in the true *corpus vitreum*, but are found principally in the *membrana hyaloidea* in connection with the formation of the vessels of that part, as *Kölliker* justly observes.

The same is found to be the structure of the vitreous humour of the infant, while, according to the general opinion, the cells undergo decay in the first years of childhood, so that in adults the *corpus vitreum* is composed of the intercellular substance alone; a view which is opposed by *O. Weber*. According to this observer, namely, the cells of the mucoid substance remain in all cases, though more scanty towards the centre than at the periphery.

Examined chemically by *Berzelius*, *Lohmeyer*, and *Virchow*, the corpus vitreum was found to contain more than 98.5 per cent. of water, and among the solid constituents an abundance of inorganic matter, chiefly made up of chloride of sodium. Among the organic matters we find traces of albumen. According to *Virchow* a substance allied to mucus is also to be found here, to which the semi-fluid gelatinous nature of the structure is due. The vitreous humour is now regarded as composed of a certain quantity of mucin gelatinised in a large amount of saline fluid. The following analysis by *Lohmeyer* is given for the purpose of showing more clearly the composition of the substance in question.

1000 parts of vitreous humour contain:—

Water,	986.400
Membranes,	0.210
Albuminate of sodium (and mucin?)	1.360
Fats,	0.016
Extractives,	3.208
Chloride of sodium,	7.757
Chloride of potassium,	0.605
Sulphate of potassium,	0.148
Phosphate of calcium,	0.101
Phosphate of magnesium,	0.032
Phosphate of iron,	0.026
Lime earths,	0.133

Mucin was not looked for, but urea was found by *Millon* and *Wöhler*, but not by *Lohmeyer*.

The vitreous humour is the most posterior of the refracting media of the eye. Its refractive index is (taking water to be 1.3358) 1.3506 in the human being (*Krause*). If destroyed it is not regenerated.

REMARKS.—Besides the German literature, comp. *Bowman, Lectures on the Parts, &c., of the Eye*, London, 1849, p. 100.

§ 116.

Again we find gelatinous tissue presented to us in a higher state of development (setting aside the tissues of the membranes of the ovum), in the first place in the enamel organ, then in the gelatin of *Wharton*, and finally in the formless connective-substances of embryos.

Here we find universally, in a transparent gelatinous substance, fusi-

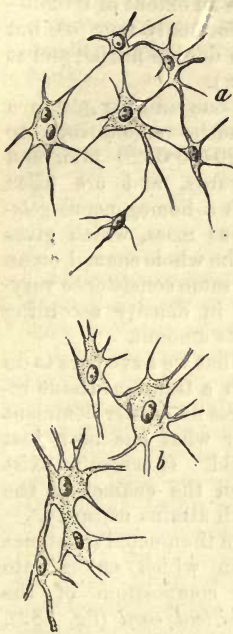


Fig. 181.—Cells from the enamel organ of a fetus four months old. At *a*, small; at *b*, larger and more highly developed stellate cells.

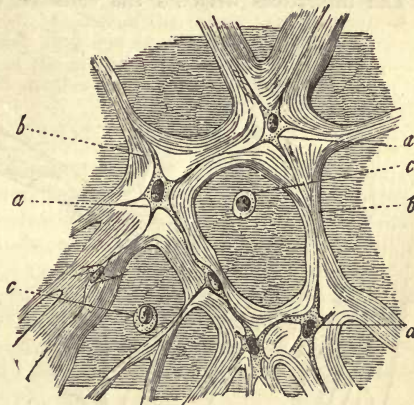


Fig. 182.—Tissue of the gelatin of *Wharton* in transverse section; from the cord of an embryo of four months. *a*, a net-work of branching cells; *b*, condensation of the ground-substance forming bands; *c*, unchanged, roundish, formative cell.

form and stellate cells, known since the days of *Schwann*. These form with their processes a cellular net-work, and lie at first somewhat closely together, but after a while separate more widely one from another, a deposit of the condensed intercellular substance forming around them. Thus we have a system of reticulated bands within which the cellular net-work still exists. The meshes enclose a soft and gelatinous mass in which may be distinguished isolated unchanged formative cells.

The substance, however, of which the enveloping bands are composed commences early to present the appearance of being longitudinally streaked. This gradually becomes more evident until the whole assumes a fibrous condition, on which the mass is transformed into ordinary connec-

tive-tissue fibrillæ. Elastic fibres make their appearance also by the transformation of the same substance (see below, with connective-tissue). The cells again frequently take on a more elongated, narrowed form. If the whole series of transformations passes over them to its conclusion, which is by no means always the case, what is known as formless connective-tissue is formed.

After this general description, let us subject the *enamel organ* and *umbilical cord* to nearer examination. The first of these covers the germ of the rudimentary tooth during intra-uterine life and the earliest years of infancy.

Its tissue (fig. 181) consists of delicate stellate cells with distinct nuclei. The latter are vesicular in the embryo of four months, measuring 0.0066–0.0090 mm., whilst the cell with its processes shows an extent of 0.0260–0.0385 mm. The number of these latter is at times only four (*a*), but often far greater (*a, b*). There occur also cells with double nuclei, and at times a species of segmentation is observed (*b*, below).

The interstices between the cells so united to one another attain a breadth amounting to 0.0204–0.0320 mm. and upwards, and are filled with a homogeneous gelatinous mass, which gives to the whole enamel organ the same consistence varying in density according to its amount.

That we have here to do with a transient tissue requires no farther comment after what has been just stated. It ceases to exist when the enamel of the tooth attains maturity.

In the mucoid substance again which enters into the composition of the *umbilical cord* (fig. 182), namely, the gelatin of *Wharton*, cells exactly similar to those encountered in the enamel-organ are to be found.

But this cellular network (fig. 182, *a*) becomes enveloped at a very early period by a clear and deli-

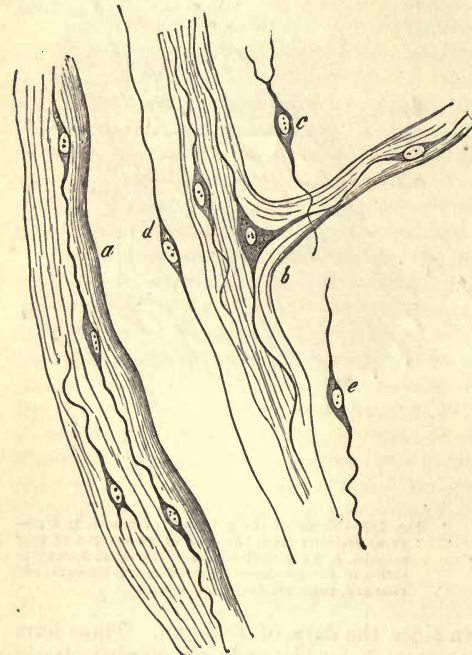


Fig. 183.—Tissue of the umbilical cord a short time before birth, with well-developed connective-tissue fibrillation. *a, b*, bands of the latter with their corpuscles in the axis; *c, d, e*, isolated cells.

cately streaked intermediate substance (*b*), and in the continuous system of meshes still remaining, we meet with the same structureless mucoid jelly. Here may be found also spherical cells (*c*) as they appear in the same stage of development of structureless connective-substance. They are contractile, and migrate (*Koester*). The bands of condensed ground-matter enveloping the cellular net-work (fig. 183, *a, b*) are subsequently transformed into fibrillæ of connective-tissue, and between these there

appear elastic fibres (at least in animals). The network also shows increase of the distance between individual cells, a development of long filiform processes, and the bodies of the former, in which, however, a nucleus is still apparent, become smaller as the processes are extended (*c, d, e*).

For the rest this cellular network displays at a later period much variety (*Weismann*). In its power of resistance towards reagents it reminds us of elastic matter, whilst, on the other hand, it is rapidly acted on by alkalies in contradistinction to the latter.

We have before us here, then, a connective-tissue transformation which is far advanced when at birth the death of the tissue takes place.

The soft, structureless connective-tissue of early life has just the same nature. In its meshes likewise, as *Schwann* has shown, the same rounded cells are to be found, which possibly become fat-cells eventually. The banded portions of both these tissues yield originally no gluten on being boiled.

REMARKS.—The origin of the enamel organ appears indeed to be peculiar, in that it takes place from epithelium (comp. chapter on the teeth). Of the truth of this statement we are assured by *Kölliker*, after due examination of the development of the teeth. Further investigation of the matter is desirable, however, considering the great histological interest which attaches to the subject, and the difficulty of such embryological research.

§ 117.

Having now concluded the consideration of gelatinous tissue, we turn to another member of the so very varied group of connective-substances, namely, to the *reticular*—the *adenoid* of *His*, or *cytogenic* of *Kölliker*.

Here we encounter similar networks of radiated connective-tissue cells (subject, however, in individual cases to much variation), which are metamorphosed into fibres or fasciculi of more or less extensive course, and may receive also coatings of a streaky or fibrillated intermediate substance. The spaces, however, incompletely enclosed by them, are not filled with mucoid jelly, but by structural elements, by innumerable lymphoid cells, such as are found in lymph, chyle, &c.

A considerable number of organs possess a tissue of this kind. For instance, the framework of the lymphatic glands is composed of it, as well as that of those lymphoid organs so nearly related to the latter, namely, the tonsils, thymus gland, and follicles which are met with, isolated or in groups, imbedded in the intestinal tube and conjunctiva. The *Malpighian* corpuscles also of the spleen consist of reticular connective-substance. The latter again, although presenting many varieties, forms, among the higher animals, the mucous membrane of the small, and partly of the large intestine; and, finally, it is met with, strongly modified, in the pulp of the spleen.

Here also we encounter again certain peculiarities, already frequently mentioned. In the first place, we see in such organs the peripheral portions undergoing further changes in their reticular connective-substance, through which the latter may eventually become converted into ordinary fibrous tissue. Further (and this is the case, for instance, in the intestines of the lower animals), the reticular substance may be replaced by the latter. Finally, it may spring from ordinary connective-tissue under pathological conditions, on the other hand, or become transformed into the latter.

As elements we meet with stellate cells (fig. 184), whose nuclei have smooth borders and a nucleolus, and measure, on an average,

0.0059-0.0075 mm. They may, however, be met with more or less granular. They are enclosed in a thin layer of a clear substance, forming the body of the cell, which is spread out peripherally into a varying number of pale radiating processes. These are primarily about 0.0023 mm. in diameter, becoming, after a short course, three or four times as fine. A secondary formation of branches is observed on these processes rather frequently, which pass off usually more or less at right angles. Further, there are generally formed, by the union of such processes of adjacent cells, small knots, in which naturally no nuclei are to be seen. The meshes thus formed are usually of roundish or delicate polyhedral figure (fig. 185), with a breadth of 0.0114-0.0226 mm. The latter may, however, be much less, or, on the other hand, more considerable; and meshes are found in certain parts of far greater length and extent still.

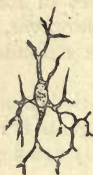

Fig. 184.—A cell from the reticular connective-substance of a lymphatic gland, strongly ramified.

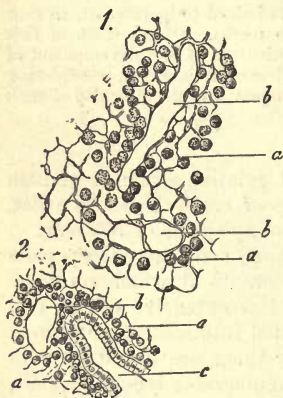


Fig. 185.—From a lymphoid follicle of the vermiform appendix of the rabbit. 1. Reticular tissue, with the system of meshes, *b*, and remains of the lymph cells, *a*. Most of the latter have been removed artificially.

swellings at the corresponding points in the network. The appearance of such portions has given origin to the mistake of confounding this cellular network with which we are engaged with an interlacement of elastic fibres. Fig. 186 gives a good idea of the structure of such a portion of tissue. In it we may recognise also the characteristic relations of the reticular connective-substance to the blood-vessels. Such a network, namely, is always traversed by blood-vessels, in contradistinction to gelatinous tissue, which is either very poor in the latter or entirely non-vascular. Round these vessels there is woven a secondary investing tunic, a microscopic *adventitia* (*a*), formed by the union of neighbouring cells with their processes and membranous expansion of the latter.

This shrinking together of nucleus and cell-body may, moreover, give place, under conditions of irritation, to a speedy increase in size again, when we find, after a short period, the former plump appearance of both restored.

In other modifications of the cellular network a strong expansion

The whole of this delicate network, in the fresh state, is very soft and fragile, and only to be rendered perfectly visible on that account by hardening treatment of the tissue and removal of the lymph-corpuscles. The connective-tissue cells withstand boiling, but are, on the other hand, rapidly acted on by alkalis and acetic acid.

The genesis of this network of cells, and of the lymph corpuscles enclosed in it, still requires further investigation.

§ 118.

The description of the cellular network of reticular connective-substance just given, applies to its usual appearance in the system at an early age. But we frequently encounter in more mature bodies a certain change in the tissue—a shrivelling-up of the body of the cell and nucleus—so that these chief central knots are only evident as slight

of the ramifications of the processes may be observed, by which the latter become, not unfrequently, membraniform. We likewise obtain views of isolated, more or less fusiform cells, joining to form fibres, which might be mistaken for elastic were they not acted on by alkalis. Finally, we sometimes see—and in this the bearing of gelatinous tissue is repeated—the cellular network enveloped in thin layers of an intermediate substance, sometimes more or less streaky, and sometimes fibrillated, which may be continuous with ordinary connective-tissue. The matter so deposited is, without doubt, a product of the cells themselves, and may be regarded in the same light possibly as that laid down in cartilage (§ 104).

The mucous membrane of the small intestine supplies a very good

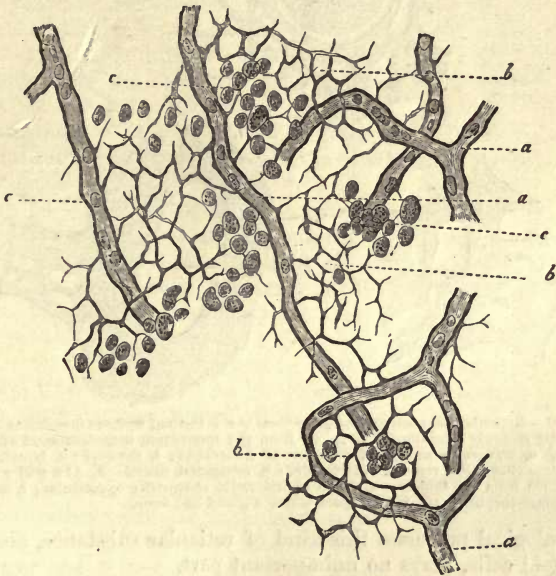


Fig. 186.—Reticular connective-substance with lymph-cells, from a Peyer's patch of the full-grown rabbit. *a*, capillaries; *b*, reticular sustentacular tissue; *c*, lymph-cells. Most of the latter removed by brushing.

example of the changeable character of reticular connective-substance, as well as its gradual transition into ordinary fibrous tissue. If we examine the tissue, for instance, in the sheep, from the immediate neighbourhood of a lymphoid follicle (fig. 187, 1), it still presents its customary reticulated appearance (*b*), but even at a short distance the banded network may be met with very much thickened and irregular (*2*).

Very usually, however, we find, especially around glandular cavities, a more homogeneous and nucleated connective-substance (*3, d*), which may nevertheless assume the old reticular nature at points (*3, b*).

In the large intestine we find an intermediate form between reticular connective-substance and ordinary fibrous tissue, with a usually small proportion of lymphoid cells.

We have now to enter on the consideration of the finest and most delicate species of this tissue, that of the so-called pulp of the spleen, which takes its rise continuously from the ordinary net-like sustentacular matter of the *Malpighian* corpuscles of this organ.

In hardened preparations it consists of a fine network of pale, delicately-contoured, and very slight fibrillæ, which may be, however, partially expanded into membranous processes at points. Here and there we meet with pale oval nuclei in these. The meshes of this framework, measuring 0.0226-0.0068 mm., are occupied, in the first place, by lymphoid cells, but also by coloured blood-corpuscles.

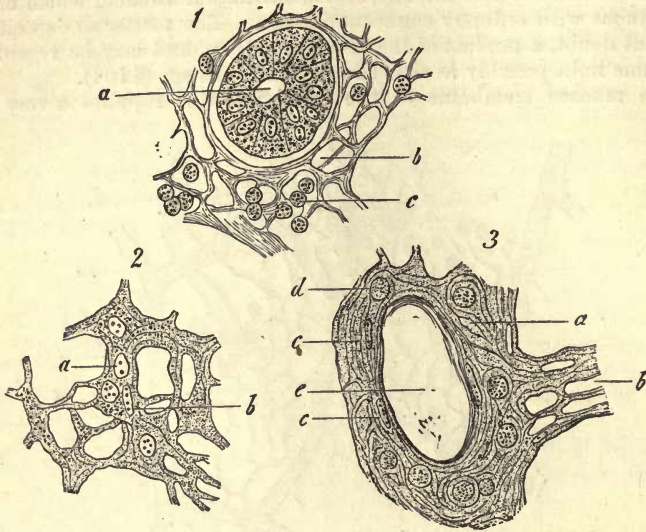


Fig. 187.—Reticular connective-substance from the intestinal mucous membrane of the sheep; strongly magnified. 1. Taken from the immediate neighbourhood of a follicle. *a*, transverse section of a follicle of *Lieberkühn*; *b*, network; *c*, lymph-cells. 2. Somewhat more remote. *a*, rounded; *b*, elongated, nuclei. 3. At a still greater distance from the follicle. *a*, tissue of indefinite character; *b*, reticular; *c*, nuclei; *d*, lymph-corpuscles; *e*, vacant space where a gland had been.

In pathological processes this kind of reticular substance, also containing lymphoid cells, plays no unimportant part.

Apart from enlargement of the organs consisting of it, as the lymphatic glands, the tonsils, *Peyer's* patches, and the spleen, we also recognise new growths of the tissue in question in other parts, at the expense of the framework of fibrous tissue, as, for instance, in the liver, kidney, and stomach.

§ 119.

We turn now to a formation about which far less is known than of ordinary reticular connective-tissue, namely, the delicate *sustentacular substance* of the *nervous centres* and the *retina*. That it originates from the middle germinal plate, the source of the other members of this series, appears, besides, doubtful, so that its position among the connective-tissues may require to be altered in consequence. Although long ago the presence of such a framework in the substance of the brain and spinal cord was here and there allowed, it was a long time, nevertheless, before the present views regarding it were generally recognised. Moreover, we are met by the impossibility of drawing any very sharp line between the tissue in question and the nervous form-elements of grey matter. We cannot wonder, then, that *Bidder* and his pupils suppose this substratum of con-

nective-tissue to exist in large quantity in the nervous centres, while other investigators deny almost completely the presence of any other than nervous form-elements in those organs.

Wherever the connective-tissue framework is well developed, and to a certain extent pure, as is the case in the "ependyma" (so named by *Virchow*) of the ventricles of the brain, and in the matter lining the central canal of the cord, it occurs as a more or less homogeneous or streaky or fibrillated mass, in which ordinary radiated or fusiform cells are seen to be imbedded.

This substance, whose connective-tissue character cannot conveniently be doubted, is continuous then with the sustentacular substance of the white and grey mass,—a far more difficult subject for investigation—namely, with the so-called "nerve-cement" or "neuroglia" of *Virchow*.

If we examine a portion of the white substance of the brain which has been hardened artificially, we see how the fibres are separated from one another by bands of such a substance.

This may be either homogeneous or streaky; and in it are situated, at intervals, round or oval nuclei, smooth in contour, and measuring 0.0093–0.0075 mm. We learn also, from side views, that these septa, seen in the transverse section, are continued further between the nervous cylinders as membraniform prolongations, so that in this way a regular system of tubular compartments is formed. The elements of form of which the latter is composed appear to be cells with radiating processes, spreading out into membraniform prolongations and investing masses.

But the sustentacular tissue of the grey matter of the nervous centres, though much more abundant, is far more fragile and difficult to elucidate. In fresh preparations it is found usually as a rather granular complementary matter, filling up the interstices between the nervous fibres and cells. It sometimes contains but a few, sometimes, however, very many, nuclei with smooth contour, and measuring 0.0090–0.0075 mm. In successfully-treated preparations (fig. 189) we recognise, with the aid of extremely powerful lenses, a wondrously fine and dense network of the most delicate fibrillæ, which take their rise from knots, in each of which one of these nuclei lies imbedded, not unfrequently enveloped in a thin layer of protoplasma. Here again we may have before us a network of stellate cells in this porous spongy tissue. But the pre-existence of such a network, though very probable, is not yet capable of proof, and the possibility of the tissue before us being an artificial fabric must be admitted.

This porous supporting substance, with its cellular equivalents, is, moreover, traversed at points by definite fibres of connective-tissue.

The connective-matter of the retina appears precisely the same, the supporting fibres of which are known under the name of *Müller's fibrillæ*.

In that extraordinary fatty organ, the so-called thymus gland of hibernating animals, which occurs in many of the Mammalia, we meet with a similar dense network of the finest fibres in hardened preparations.

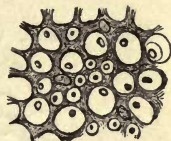


Fig. 188.—Connective-tissue sustentacular matter from the posterior pillars of the human spinal cord, surrounding sections of the nerve-fibres.



Fig. 189.—Spongy tissue from the grey substance of the human cerebellum, obtained by treatment with very dilute chromic acid.

The sustentacular connective-tissue of the nervous centres is reproduced in a number of pathological growths. These have been named "glioma" by *Virchow*.

8. Fatty Tissue.

§ 120.

Fatty tissue, with a specific gravity of 0.924 (*W. Krause and L. Fischer*), consists of large roundish cells measuring 0.0340–0.1300 mm., and nuclei of 0.0076–0.0090 mm., whose thin envelope is usually completely occupied by one single oil globule. These fat-cells usually lie heaped together in considerable groups (fig. 190), and occur in parts formed of connective-tissue of loose texture, the so-called formless species. They generally constitute the complementary substance of the cavities in the latter, which diminishes frequently in quantity between the individual cells of such a group.

Fig. 190.—*a*, Human fat-cells completely filled with oil, lying in groups together. *b*, free drops; *c*, empty envelopes.

The thin membrane is completely obscured by the dark outlines of the fatty contents, so that cells of this tissue display much similarity to free drops of fat. They show sharply defined dark edges with transmitted light; but when reflected, their silvery border appears whitish or yellowish white. But, on the other hand, the close crowding to which they are subjected frequently leads to a flattening of adjacent cells at the points of contact, so that they assume a polyhedral form, which does not take place with free drops of oil (fig. 190, *b*), which coalesce when pressed one against the other, like those drops of grease seen floating on the surface of soup.

Careful examination directly of completely filled fat-cells may lead to the conclusion that they possess a membrane, but does not enable us to discover it. For this certain treatment is required. Thus, by increasing pressure, we may cause the very tense membrane to rupture, on which the flaccid empty envelopes of large cells are seen as thin structureless saccules (fig. 190, *c*). We may likewise extract the contents from the uninjured envelope chemically, by treatment with alcohol and ether. In such cells artificial colouring is

necessary before the nuclei can be seen.

But the fat-cells may deviate more or less from the fundamental form just described. Their contents consist of a mixture of oily and solid neutral fats, always, however, of one which is fluid and soft at the ordinary temperature of the living body. In warm-blooded Vertebrates the cooling of the corpse brings about, not unfrequently, in such as are rich in solid fats, a congelation of the contents. The fat-cells lose, in such a case, their round plump figure and delicate outline, and become rough,



Fig. 191.—Human fat-cells occupied by crystals. *a*, Single needles; *b*, larger groups; *c*, cells with groups of the latter in the interior; *d*, an ordinary fat-cell without crystals.

angular, and knotty. On being warmed, they assume, however, their former smooth appearance once more.

Again, we meet with peculiar appearances in those cells in which a part of the solid fat of the contents has become crystalline (fig. 191, *c*). In such, groups of needle-shaped crystals, either single, double, or in greater number, are to be found. These were declared formerly, quite arbitrarily, by microscopists, to be composed of margarin or margaric acid. Such cells have long been known. Eventually, the whole contents may be converted into such a crystalline mass (*Kölliker*).

Such cells are the result of the cooling of the corpse, and are not found in the warm living body.

REMARKS.—1. *Todd and Bowman's Physiol. Anat.*, vol. i. p. 80. 2. Fat-cells mounted in glycerin usually show these crystallisations.

§ 121.

These normal cells just described—*i.e.*, those surcharged with fat—have little instructive about them. There can be but little doubt that here also the oil globule is enveloped in a thin coating of protoplasm with a peripheral nucleus. This will be easily understood after examination of those cells, poor or almost entirely deprived of fatty contents, the *serum cells* of early observers (fig. 192, 2, *b*), small structures found in emaciated subjects. Here we find an abundant, probably watery, protoplasm in the place of the fat. Let us examine such cells somewhat more minutely.

Instances are met with, in the first place, in which a considerable fat globule is separated from the delicate outline of the envelope by a thin interposed layer of fluid (1, *a*, *b*), in which the nucleus (*c*, *d*), situated at the circumference, may be discovered. The latter is smooth in outline, and at times vesicular. In such cases we not unfrequently observe a darker yellowish tint than usual in the fatty contents, which intensifies the more the latter decreases in quantity; so that adipose tissue which has undergone this change strikes even the unaided eye on account of its yellowish-red appearance. When such fat-cells are crowded together, they frequently give rise to an uncommonly delicate structure resembling hyaline cartilage surcharged with fatty globules.

Owing to the progressive disappearance of fat from these cells, we not unfrequently find an oil globule decreasing more and more in size (*f*). In others, this decreasing globule may become divided into

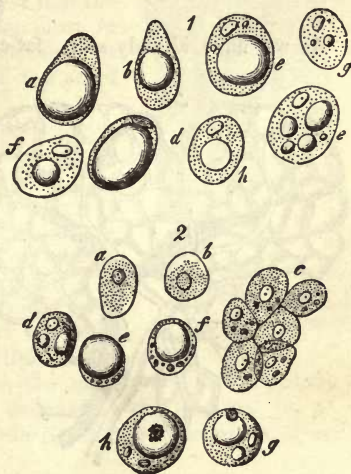


Fig. 192.—Cells incompletely filled with fats. 1. From the subcutaneous cellular tissue of a lean human subject, in which the amount of fatty contents is on the decrease. *a*, with a large, *b*, with a smaller oil globule; *c* and *d*, the nuclei visible; *e*, a cell with separate globules; *f*, with a single small drop; *g*, almost free of fat; and *h*, without fat and with a globule of an albuminous substance in the interior. 2. Cells of fatty tissue from the neighbourhood of the kidney of a sheep embryo, measuring 10 inches. They are becoming filled more and more with fat; *a* and *b*, isolated cells without the latter; *c*, a collection of the same; *d-h*, cells with increasing deposit of fatty contents.

several drops of different sizes, and frequently very diminutive (*e*, *g*). Finally, we meet with cells from which (*h*) all the fatty glomerules of the contents have vanished, and in which the whole cavity is occupied by a homogeneous liquid.

With the decrease of the fat the nuclei become more apparent as essential constituents of the cells. If the envelope, in other respects, preserve its original thinness, the whole structure is very delicate in contour and easy to examine. Sometimes the disappearance of the fat is accompanied by another process—namely, segmentation of the nuclei of the different elements, until the old envelope is filled with several nuclei and cells (*Flemming*). The same is seen in inflammation of adipose tissue.

REMARKS.—The fact that the nucleus always reappears in cells which thus lose their fats, allows of no other explanation than that in the completely-filled cells of ordinary fatty tissue it is likewise present. Portions of this tissue prepared with carmine, and mounted in Canada balsam after their water has been extracted, reveal the presence of a nucleus also.

§ 122.

As we have already seen, fat-cells are found accompanying formless,

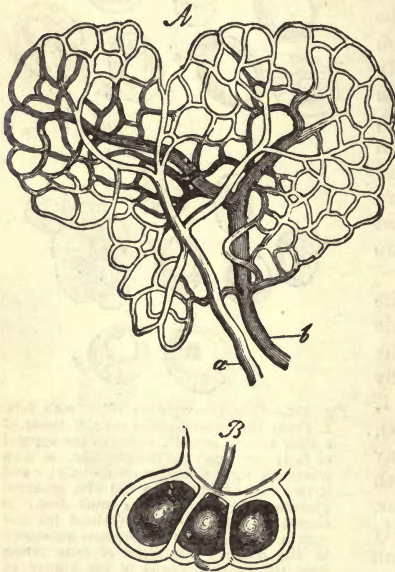

Fig. 193.—A. Capillary network of a pellet of fat. *a*, the arterial; *b*, the venous branch. B. Three fat-cells enclosed in the meshes of the capillary network.

soft connective-tissue, whose interstices and cavities they occupy. Here they form closely crowded pellets of fatty tissue, which are traversed by a very complex network of capillaries (fig. 193, A), in each mesh of which a single cell is situated (B). The energetic interchange of matter which takes place at times among these cells is thus easily accounted for by the great vascularity of the structure.

Fatty tissue, which forms a large proportion of any well-nourished body, is found, first of all, in subcutaneous connective-tissue, constituting here the *panniculus adiposus*, and in numerous other smaller and irregular collections chiefly along the course of the blood-vessels. Its amount varies, however, according to the region of the body. Thus large collections of cells are to be found under the skin of the foot, of

the palm of the hand, of the buttocks, of the female mammary gland, &c., while the eyelid is quite destitute of fat. Further, we meet with an abundance of adipose tissue around the synovial capsules of joints very frequently, as well as in the orbit, where it is never absent, even in cases of the greatest emaciation. Again, in the medullary canal of compact bones, where it constitutes the yellow marrow of the part. We may mention also, among the points in the interior of the body

whose connective-tissue is usually occupied by rich assemblages of fat-cells, the neighbourhood of the kidney, the omentum, and the surface of the heart.

Again, the quantity of these collections of fat-cells, which, as a moderately developed *panniculus adiposus*, imparts to the body its usual plump, smooth appearance, is subject to great variation. It is usually larger in proportion in the bodies of women and children than in men, and during childhood than at an advanced age. We know also how great the differences in the amount of fats are in well-fed and lean individuals. A body in good condition may part with all its adipose tissue in consequence of continued fasting, wasting disease, or a dropsical infiltration of the connective-tissue, and regain it all again rapidly with the return of health. The fact that we frequently find in very lean corpses a preservation of the cells, although their contents have disappeared, seems to point to the conclusion that the latter are more or less permanent structures, in which, on subsequent return to embonpoint, the fluid contents can be expelled by the deposit of fat.

In exaggerated degrees of obesity, such as may be produced in domestic animals by cramming, we meet with fat-cells in situations in which they do not otherwise occur; for instance, in the soft connective-tissue between the fibres of voluntary muscles (fig. 194), where it may, to a certain extent, impair the functions of the organ. The same is the case in muscular parts which have not been used for a long time. But we must discriminate between such fatty infiltration of muscle and fatty degeneration, in which the structure is destroyed by a deposit of the substance in question in the interior of the fibre.

By fatty tumours or *lipomas* we understand new formations of connective-tissue loaded with oil globules.

Adipose tissue is to be found in the bodies of all vertebrate animals, but in very varying quantity and with different anatomical distribution.

REMARKS.—Collections of adipose tissue on the exterior of synovial capsules force the latter inwards at times in folds, producing thus the *glandulae mucilaginosæ* of Havers.

§ 123.

In the fat-cells we have the receptacles for the physiological deposit of the neutral fats of the body. Their repletion with the latter must be looked upon, further, as the normal state at a certain period of life, while poverty in this respect must be designated as an abnormal condition. Why these cells above all others possess the power of taking up fat is a question we are still unable to answer.

We have already considered (pp. 26–28) the neutral fats of the human body, and referred to the unsatisfactory state of our acquaintance with them at present: it would be superfluous, therefore, to enter again on the subject at this place.

As we have seen there, the fatty substances of the system consist of

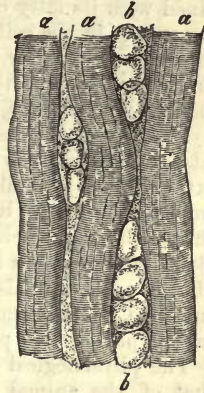


Fig. 194.—Muscle with fatty infiltration. *a*, three muscle fibres; *b*, fat-cells in the interstitial connective-tissue.

tripalmitin and tristearin, held in solution by another oily neutral fat, triolein. The more of the solid fats there are contained in the latter, the higher stands the liquefying point of the compound, and the easier does it congeal after death into a hard suety mass. In keeping with this there exist also differences between the various portions of the body. The consistence of the fats of various groups of animals differs likewise. In this respect the adipose tissue of the Carnivora and Pachyderms corresponds most nearly to that of the human being, whilst that of the Ruminants and Rodentia appears to be much more solid. The fatty tissue of Cetaceans and fishes is, on the other hand, of an oily nature, a necessary condition on account of their living in water. Combined with its fatty contents there exists, besides, a still unknown colouring matter in the cell occasioning its yellowish tint. It is retained with considerable tenacity by the residue which still occupies the envelope after the greater part of the fat has left the latter, and communicates to it a reddish yellow tinge, as already remarked (§ 121).

Now, as to the *chemical constitution* of the cells which contain these fats, the following is all that is at present known on the subject. After extraction of the oily contents by means of ether and hot alcohol, the empty cell remains behind in a flaccid condition. Its membrane is not affected by acetic acid, but treatment with the latter causes the exit of globules of oil from it, an effect produced likewise by the action of sulphuric acid, and also by an elevation of temperature. Further, the envelope offers a more or less determined resistance to the action of caustic potash, and probably consists of a material allied to elastin.

The physiological significance of adipose tissue corresponds partly to that of the animal fats in general. It is well adapted, through the contents of its cells (fluid at the normal temperature of the body), for the distribution of pressure and for acting as padding. Further, it is suitable for the filling up of certain interstices between portions of the body which require a yielding material of the kind. Again, owing to its bad conducting powers, it must restrain the giving out of heat, and consequent cooling of the body. The fatty contents, besides, of these cells, like other fats, undergo decomposition through the atmospheric oxygen, especially when they leave the cavity of the cell and return to the blood, the ultimate results of which process (after many intermediate products have been formed) are the generation of carbonic acid and water, accompanied by the evolution of heat.

The neutral fats of the tissue we are considering have their origin in the oily constituents or matters adapted to fatty metamorphosis of our food. This seems indicated by the rapid deposition of fats which takes place under good nourishment. But an important physiological question here arises. The fats of the alimentary matters enter the radicals of the lacteals in a neutral form, are met with saponified in the blood, and again as a neutral combination in the interior of the cell. What now becomes of the glycerin which is set free in the animal juices by this saponification, and whence comes the same organic body on subsequent resolution of this soapy compound? In regard to these points we possess at present but few facts (§ 18). That the protoplasm of the cell-bodies plays an important part in the processes cannot, therefore, be maintained without question. Just as little is known also about the series of changes produced in the elaboration of fats from albuminous substances and hydro-carbons.

§ 124.

The *development* of fat-cells in the embryo, and the nature of the tissue at an early age, is partially understood. The former takes place along the course of the blood-vessels (early or late according to the locality) (*Flemming, Toldt*), possibly by the metamorphosis of roundish cells bearing more of an embryonic character (*Virchow, Frey, Rollett*), or from connective-tissue cells (*Flemming*). There is no doubt, however, that later in life a formation of fat-cells does take place frequently in connective-tissue by metamorphosis of its cells.

Reserving the consideration of its development in the hollows of rudimentary bone, we will here discuss the formation of fat-cells in formless connective-tissue.

This takes place possibly from the spheroidal cells which occupy the interstices of rudimentary formless connective-tissue (fig. 195, *c, c*). By the segmentation of the former, groups spring up, which fill up these spaces at a later period.

According to *Valentin's* statements, which, however, neither *Gerlach* nor myself have been able to verify, there may be seen isolated adipose cells, but still destitute of fat, in the sole of the foot and palm of the hand of very young human embryos—*e.g.*, of fourteen weeks old.

At a later period (fig. 196, 2), the fatty tissue presents very peculiar appearances. Spheroidal cells (*a, b*) of considerable size, containing vesicular nuclei, and finely granular contents, lie crowded together in the usual characteristic manner (*c*), squeezed into polyhedra, and enclosed in the well-known vascular network. As yet, however, they contain no oil globules. The cells of a 10-inch sheep's embryo are about half as large as those in the full-grown animal, while the nuclei are on an average 0.0066 mm. Now commences (apparently) the very interesting and gradual process by which the cell is filled with fatty matters, which may be ob-

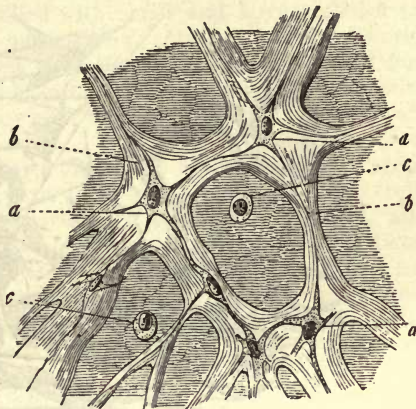


Fig. 195.—Tissue of the gelatin of Wharton, serving at the same time to explain the development of formless connective-tissue. *a*, connective-tissue corpuscles; *b*, fasciculi of connective-tissue; *c*, spherical formative cells, possibly passing into fat-cells.

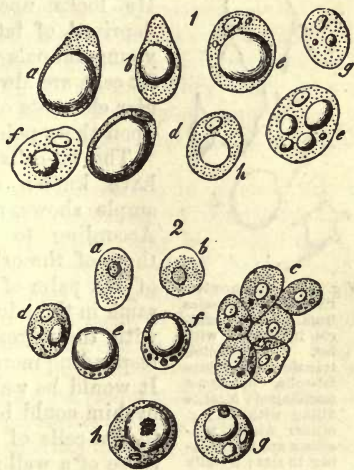


Fig. 196.

served in a number of cases at various stages in its progress. It repeats in fact, inversely, the appearances presented in the mature body by the cells whose fatty contents are diminishing (§ 122). We first see isolated globules of oil appearing (*d*), which become more nume-

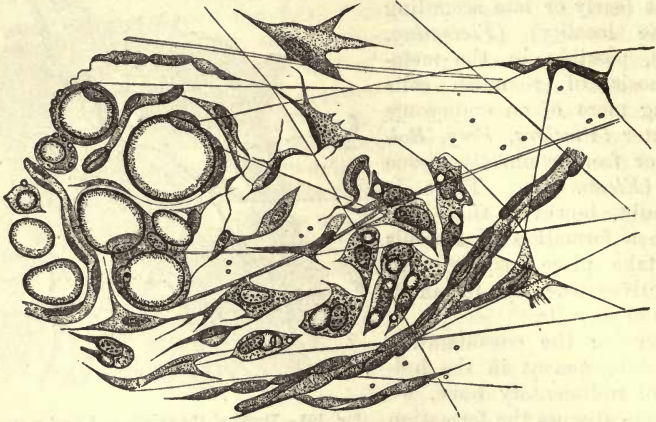


Fig. 197.—Adipose tissue from a young rabbit. In the middle may be seen connective-tissue cells; to the right, similar structures filled with fat. Fat-cells to the left (*Flemming*).

rous (*g*), and subsequently run into one another, forming larger drops (*e, f, h*), while the original finely granular contents of the cell decrease more and more. This deposit of fat, moreover, commences sometimes early, sometimes late, in the different classes of Mammals. These appearances, however, are explained in a completely different manner by *Flemming*, the most recent observer of note. He looks upon these cells also as elements partly deprived of fat, and supposes that in embryos and young animals which have been richly fed (fig. 197), fat-cells are always formed subsequently from the cellular elements of connective-tissue. The final decision upon these points must remain for future investigation.




Fig. 198.—Connective-tissue corpuscles from a human muscle infiltrated with fat, undergoing transformation into fat-cells. *a*, almost unchanged; *b*, cells filling with fat; *c*, others whose processes are diminishing in size; *d*, fully developed adipose tissue cells.

The fat-cells of an early period of life are, as we have known since *Raspail's* day, and as our example shows, much smaller than in the mature body. According to *Harting's* very careful measurements, those of the orbit in the infant are about half, those of the palm of the hand, about a third as large as the same in the adult. *Harting* concludes from this, that with the increase in volume of an organ only a corresponding increase in the size of the cells takes place. It would be well if the interesting question proposed by him could be accurately answered, namely, whether the fat-cells of a lean body are generally smaller than those of a well-fed and plump one.

This near relationship existing between the cells of fatty and connective tissue is confirmed by further observation. As *Virchow*, *Wittich*, and *Förster* state, atrophied organs

are often enveloped in and traversed by tracts of fatty tissue. We have already alluded to the same kind of transformation between the elements of muscle (fig. 194). Here (fig. 198) may be seen all the transitions from connective-tissue corpuscles to fat-cells in the loose connective-tissue situated in fleshy substance. We see the first of these (*a*) becoming gradually filled with small and large globules (*b*), which commence to fuse with one another. Owing to this, cells originally fusiform become expanded gradually (*c*) into the spherical form of the fat-cell. Here, then, we have fat-cells springing from connective-tissue corpuscles, an occurrence which has also been observed by *Förster* in the formation of lipomas.

The question also as to whether fat-cells may again undergo retrograde development into ordinary fusiform and stellate connective-tissue cells, may be answered in the affirmative. Thus *Kölliker* observed, after disappearance of the fatty matter of the subcutaneous cellular tissue, the so-called serous fat-cells (§ 121) become transformed into such connective-tissue corpuscles. The same may be seen under similar circumstances around the hilus of the kidney and under the pericardium, where the fatty tissue is transformed into a regular mucoid tissue (*Virchow*).

9. Connective-Tissue.

§ 125.

Under the name of *connective-tissue* is understood a substance widely distributed throughout the body, consisting, like those structures already considered, of cells or their rudiments and intercellular matter. The latter, however, is here glutin-yielding, and indeed affords almost always collagen, except in rare and exceptional cases, such as the cornea, where chondrin is obtained from it. It is likewise characterised by its tendency to break up into fibres, which latter process has already taken place, more or less, in every well-developed connective-tissue, giving rise to connective-tissue *fibrillæ* and *fasciculi* in a structureless substance. Again, there appear in this tissue elastic elements besides, which have originated in the metamorphosis of the intercellular matter. They enter into the formation of fibres, networks of the latter, fenestrated membranes, terminal layers around fasciculi of connective-tissue and interspaces, which may harbour cells.

Now, although it is thus possible to characterise in a few words the peculiarities of most parts of the body consisting of connective-tissue, and though, from this point of view, the latter may be looked upon, in many cases, as only a higher stage of development of that substance, described in a previous section as gelatinous tissue, still we must remember that many parts formed of this tissue differ more or less from this plan which we have just given, and may deviate even so far as to be beyond being recognised as belonging to it. Connective-tissue appears indeed in such a variety of forms that its limits are rather difficult to define, and every histologist of the present day gives the name connective-tissue to things which are frequently very remote from what was considered such at an earlier microscopic epoch.

If we now inquire, in order to obtain a clue through the difficulties of the coming description, what these modifications are, the following points may be noticed.

We have, in the first place, one species of this tissue which is characterised by the scanty development of its interstitial matter, while the greater part of it consists of abundant fully-developed connective-tissue corpuscles, either in the form of simple cells or of cellular networks. In this there is no sign of fibrillation, as a rule. The cells may retain their ordinary homogeneous contents, or may become filled with granules of melanin, thus giving rise to the so-called stellate pigment cells. As long as the corpuscles are assembled together without order, the homogeneous intermediate substance shows no tendency to divide in any definite direction; but where, in other parts composed of this tissue, the cells are arranged in rows, one after another, the intercellular substance undergoes a change, and becomes scissile in the direction indicated by the position of the cells: it divides into bands and leaves.

Both arrangements of the cells now lead gradually on to fully-developed connective-tissue, in that the intercellular matter becomes cleft, shreddy, and finally fibrillated. At the same time (and we are here introduced to a new variety of the tissue), the corpuscles either preserve their original cellular character, or are diminished down to their nucleus merely. No less liable to variation is the proportion of these cells and their residue in the different structures formed of connective-tissue. Finally, the elastic elements, whose multifariousness has already been referred to above, display the greatest diversity of form, and in the relative frequency with which they occur.

The present state of our acquaintance with the nature of connective-tissue, however, leaves much still to be desired. In the first place, we are unaware here and there of the limits of the tissue; and then again the mode of development of parts consisting of it requires a more thorough investigation in many cases than it has yet received. Finally, the nature of the tissue opposes many obstacles to investigation; for instance, the so-called fibrillæ of connective-tissue obscure, as a rule, all the other elements, so that the latter can only be recognised after treatment of the whole with strong chemical reagents. But these give rise to great changes, especially in the cells, and the distorted structures seen by their aid are very different things from the normal living connective-tissue cells. In regard to the latter our knowledge is still very insufficient.

REMARKS.—In the earlier days of modern histology, connective-tissue was described as a substance composed of fine transparent fibres, crossing one another partly, and in part collected together in bundles, but having no farther and especial cellular elementary parts. The latter were first noticed much later.

§ 126.

We now turn to the consideration of the elements of typical connective-tissue, and shall, in the first place, describe that part of it which has been longest known and is most characteristic—namely, the glutin-yielding fibre. The latter is met with in the form of a very delicate, extensible, and, at the same time, elastic thread, transparent, and having a thickness of about 0.0007 mm., and without branches.

These *primitive fibrillæ* of connective-tissue (fig. 199) are at times grouped in very varying number, in *strands* and *bundles* of extremely dissimilar strength, but may be separated from one another either by simple mechanical dissection or by the action of chemical agents (*Rollett*), and this with tolerable ease and in considerable length. The elasti-

city of the fibre often gives rise to a peculiar delicately wavy or undulating course in the fasciculi of the tissue, which gives to many parts the appearance, recognisable even without the microscope, of being made up of bands, or transversely ribbed. The interlacement of the bundles is besides liable to variation. They frequently pass through the same plane alongside of one another, in which case there usually appears a considerable amount of homogeneous residual interstitial matter, as a pale thin lamella, through which the several fasciculi are connected with one another.

In other cases, again, the bundles are arranged parallel to one another, and at the same time rather densely, so that the residue of unchanged intercellular substance is greatly diminished, as, for instance, in a tendon. Finally, the bundles may be woven together more confusedly, though at times also with a certain amount of regularity and rectangular arrangement, but so that no particular direction in their course appears to be the predominant one—as, for instance, in the sclerotic coat of the eye. From this we see that parts formed of connective-tissue may differ most essentially in appearance, consistence, &c.

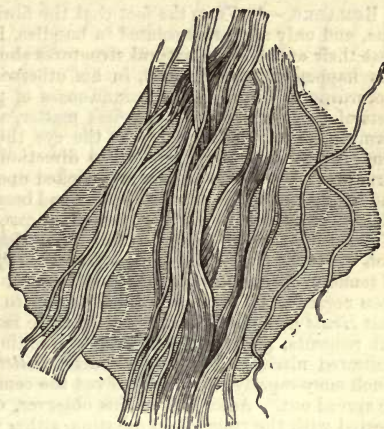


Fig. 199.—Bundles of connective-tissue lying in an abundant interstitial matter. To the left are seen a few isolated fibrillæ.

Connective-tissue bundles possess, according to the number of fibrils contained in them, a greater or lesser diameter. And as these may again be associated to form thicker cords, they can be distinguished as *primary*, *secondary*, and *tertiary fasciculi*.

An important question now arises, namely, whether these aggregations of fibrillæ are naked and without any envelope, or whether the whole strand is not encased in a homogeneous sheath of condensed substance. The first of these may be looked upon in general as the most probable state of the two. And yet we may distinguish in many places bundles which are enclosed in an envelope, sometimes thick, and sometimes of great delicacy. These occur especially where the connective-tissue is loosely arranged, as, for instance, in subcutaneous cellular tissue, or, more distinctly still, at the base of the brain. The membranes so formed, moreover, may have preserved the ordinary glutin-yielding nature, or have undergone subsequently a metamorphosis into elastic matter (see below).

Acetic acid has come greatly into use as an important reagent in the investigation of the tissue in question. The fasciculi of connective-tissue, namely, which, owing to their nature as collagenic structures, are to a certain extent remarkable for their insolubility, lose very rapidly their fibrous appearance under the action of the acid, and become clear and transparent, swelling up at the same time very considerably. In tissue rendered clear in this manner, which is not unfrequently marked by a transverse striping together with the puffing out of the bundles, the elastic fibres and networks now make their appearance in the most beautiful way, beside which we are also able to recognise the changed connective-

tissue corpuscles. The relative proportions also of elastic parts may be estimated by the aid of this reagent, and without the microscope; for a connective-tissue which has a great abundance of the former as components is rendered but little clearer by this treatment.

That no solution of the fasciculi takes place is easy of demonstration; for on carefully washing out a small portion of tissue which has been acted on by the acid, the fibrillæ again become visible.

REMARKS.—1. From the fact that the fibrillæ of connective-tissue are so extremely fine, and only appear associated in bundles, it is not strange that at a time not long past their existence as natural structures should have been completely denied. This has happened with *Reichert*, in his otherwise so important and stimulating work. According to his view, the ground-mass of parts composed of connective-tissue consists of homogeneous, structureless matter, which has a tendency to shrink together, forming folds, which convey to the eye the impression of fibrillæ. It has also a tendency to split up in the same direction. Now, although, in former times, the structure of connective-tissue was looked upon to too great an extent as uniform, and the residues of intercellular substance had been frequently overlooked, still every unprejudiced inquirer into the true state of the case may satisfy himself of the untenableness of *Reichert's* theory. A portion of living tissue even shows the fibrillæ, and examination with the polarisation apparatus teaches their presence also. On transverse sections of tendons, for instance, we may also remark a finely-punctated appearance, which has been regarded by many observers as due to the ends of divided fibrillæ. 2. After that *Henle* had shown that fibres could be isolated by alternate treatment with different reagents, producing shrinking or swelling, as, for instance, with dilute and concentrated nitric or hydrochloric acid, *Rollett* found that steeping in lime-water (or, much more rapidly, baryta) dissolved the cementing substance, so that the fibres could be spread out. According to this observer, connective-tissue resolves itself, on being treated with the reagents in question, either immediately into fibrillæ or into bundles, which only divide into the latter on prolonged maceration. Based on these facts, *Rollett* proposes to distinguish two forms of fibrillation in connective-tissue. For the first of these, tendon affords an example. In the same category he reckons also the bundles of the sclerotica of the aponeuroses, the fibrous ligaments of joints, the dura mater, and the inter-articular ligaments.

Among the tissues which show the second form of resolution are the cutis, conjunctiva, subcutaneous cellular tissue, submucosa of the intestines, and *tunica adventitia* of vessels. In our opinion, the question here only turns upon quantitative differences.

§ 127.

By means of the reagents mentioned in the previous section we are enabled also to recognise the elastic elements imbedded in the connective-tissue, which is rendered clear by the former. These are all alike in their power of resisting not only the action of acids, but also that of potash ley, however much the form in which they appear may vary. The latter is the most important agent for their recognition.

Elastic fibres are of the commonest occurrence. They are met with at one time fine, at another of no inconsiderable thickness; sometimes simple, sometimes branched.

The most delicate elastic fibres (fig. 200, *a*) were formerly known by the name of nucleus fibres (*Gerber* and *Henle*), being erroneously supposed to arise from the fusion of fusiform elongated nuclei. They are frequently met with as constituents of connective-tissue in many parts of the body, as, for instance, in that of loose texture lying under the skin. Their diameter may be the same as that of the connective-tissue fibril, but their dark contour and far more tortuous course, their irregularly-twisted, cork-screw-like or hooked appearance, renders their recognition easy. Their peculiar appearance is the result of their elasticity, as well as of the manner in which they have been cut, combined with the swelling up of

the connective-tissue under the action of the acetic acid. Whether these finest fibres are all solid or may not be hollow in part, we are not yet able to state.

By the occurrence of branches on such very fine fibres, and their ever-increasing ramification (the diameter of the tubes reaching at times 0.0014–0.0022 mm.), an elastic network is at length formed (*b*). This again varies considerably as regards the breadth of its meshes. It usually maintains with its principal fibres the same direction as the bundles of the connective-tissue.

From these elastic threads we now find transitions to even broader and thicker forms (*c*), which are decidedly solid, and which, contrasted with the so extensible fibrils of lesser magnitude, display

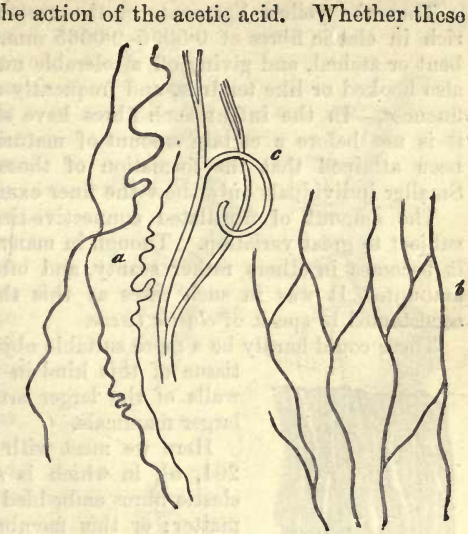


Fig. 200.—Elastic fibres from the human being. *a*, unbranched, fine, and finest; *b*, a network of fine elastic fibrils; *c*, a thicker one with branches.

often a considerable degree of brittleness, so

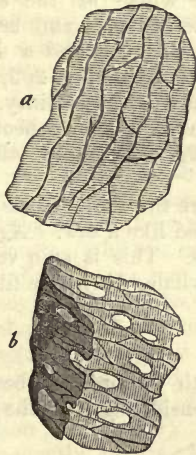


Fig. 201.—From the middle coat of the carotid artery of an ox. *a*, a membrane with a network of the finest elastic fibres; *b*, a similar membrane fenestrated at intervals.

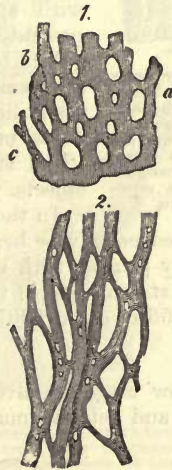

Fig. 202.—From the middle and external coat of the aorta. 1. An elastic membrane (from the ox) fenestrated to a great extent (*a*), and with thick bands between the various holes, *b*, *c*. 2. A network of broad elastic fibres from the whale, which are partly pierced with minute foramina.

that, in many instances, we can only obtain by dissection short fragments of the formations in question.

Thus the yellow ligaments of the vertebral column are uncommonly rich in elastic fibres of 0.0056–0.0065 mm., which are usually met with bent or arched, and giving off a tolerable number of branches, which are also hooked or like tendrils, and frequently attain a remarkable degree of fineness. In the infant such fibres have still but a small diameter, and it is not before a certain amount of maturity of the mammal body has been attained that the formation of these broader fibres takes place. Smaller individuals only show the finer examples.

The amount of fibrillated connective-tissue found amongst these is subject to great variation. Though in many localities tolerably abundant, it becomes in others rather scanty, and often excessively diminished in amount. It was in such cases as this that earlier investigators were accustomed to speak of *elastic tissue*.

There could hardly be a more suitable object for the study of an elastic tissue of this kind in all its peculiarities, than the walls of the larger arteries, especially those of the larger mammals.

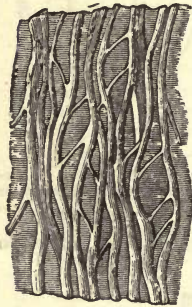


Fig. 203.—A very dense network of broad elastic fibres from the middle coat of the aorta of an ox. The fibres are connected by a homogeneous intermediate substance of a membranous structure.

Here we meet with thin elastic membranes (fig. 201, *a*), in which is seen a network of very fine elastic fibres embedded in homogeneous intermediate matter; or this membranous ground-substance may be pierced with holes of various kinds (fig. 201, *b*), (the fenestrated tunic of *Henle*). We likewise encounter very simple elastic tunics without embedded fibres (fig. 202, 1), which are also studded with apertures (*a*), the whole of the substance presenting the appearance of bands and broad irregular fibres (*b*, *c*). Between such and a dense interlacement of broad elastic fibres (fig. 202, 2), it is often difficult to distinguish with certainty. Those dense networks which have a homogeneous interstitial substance, as in fig. 203, afford still better objects.

In those localities where the elastic fibres are very broad, their edges may be here and there jagged like a saw. Again they are frequently pierced with very minute holes. This is seen very generally in the external coat of the aorta of the whale, where the fibres may measure 0.0056 or even 0.0075–0.0088 mm.

§ 128.

Having now made ourselves acquainted with the ordinary bearings of elastic fibres and nets, we must turn to the consideration of the limiting

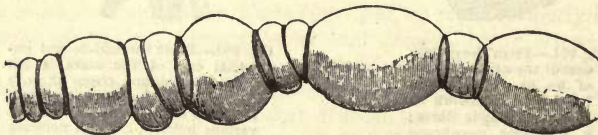


Fig. 204.—A connective-tissue bundle from the base of the human brain, treated with acetic acid.

layers of many connective-tissue bundles, which have sprung from a metamorphosis into elastic substance of some matter situated around them.

The bundles of connective-tissue which pass from the arachnoid to the larger vessels on the base of the brain (fig. 204), with other isolated fasciculi in the loose cellular tissue under the cutis and certain serous membranes, and that of tendons even, show us a very interesting example of the artificial production of figures extremely like annular or spiral elastic fibres, and which have even been taken for them. To demonstrate this, acetic acid is employed or prolonged maceration in water.

In the first place we meet with fasciculi in which the elastic envelope is puffed out and stretched by the action of the reagent, but remains uninjured, the consequence of which may be twofold as to appearance. Firstly, the gelatinised substance of the connective-tissue may be puffed out at intervals into globules, so that annular or at times spiral indentations arise (fig. 205, 1, 2, *c*), or the puffing may be more one-sided, in which case the furrows appear clearer and more distinctly spiral (4). All these furrowings are characterised by their delicate outline, which is never double. Further, we may besides recognise the presence of the envelope on the cut end of a bundle (2 *d*), or when it has become separated from the contents, in consequence of the penetration of fluid (1 *a*).

It frequently occurs, however, that a number of transverse rents are produced in this elastic envelope, in consequence of which the substance of the connective-tissue may swell out in globules, while each portion of the envelope becomes more and more shortened by the pressure, a contraction ensuing, which is rapidly increased by the

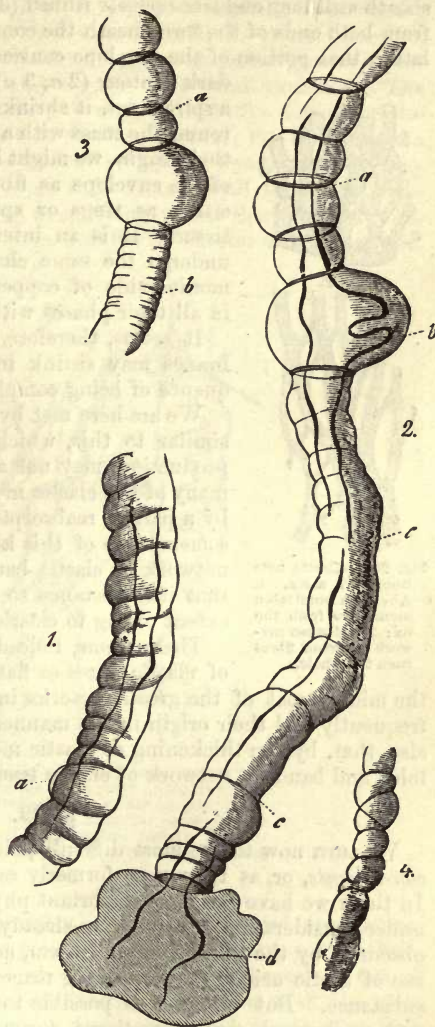


Fig 205.—Bundles of connective-tissue from the base of the human brain, after treatment with acetic acid. Some of them have more or less developed elastic fibres in their interior. 1. A bundle whose envelope is not torn, but obliquely wrinkled; a small portion of the latter is separated for a short distance at *a*. 2. A bundle with annular shrunken portions of the sheath at *a*, a more strongly pronounced puffing of the substance of the connective-tissue at *b*, and a longer portion of the wrinkled envelope at *c*, from the cut end of which, at *d*, the contents are protruding. 3. A bundle with annular fragments of the envelope at *a*, and a larger portion of the latter at *b*, more strongly wrinkled. 4. A smaller bundle with uninjured varicose sheath.

elasticity of the membrane. Thus we remark at first the fragment of the sheath still long and transversely ribbed (3 *b*), but soon, and especially when from both ends of the torn sheath the contents swelling out press upon the latter, that portion of the envelope contracts into a fine narrow ring with a dark contour (2 *a*, 3 *a*); more rarely, in consequence of a spiral rent, it shrinks into a filiform structure passing round the mass with a spiral course. Did we not know their origin, we might look on these shrunken fragments of the envelope as fibres of a coarser kind, encircling either as rings or spirals the bundle of connective-tissue. It is an interesting fact that fibres of cotton undergo the same changes, under the action of ammonio-oxide of copper, which may here be observed in all their phases with the most perfect ease.

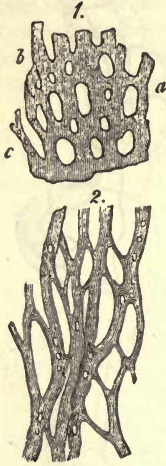


Fig. 206.—Elastic nets from the aorta. 1. An elastic fenestrated membrane from the ox; 2. A distinct network of broad fibres from the whale.

It seems, therefore, beyond doubt that elastic membranes may shrink into filiform structures in consequence of being completely rent.

We are here met by the question, whether something similar to this, which we have found as an artificial production, may not also occur as a normal process in many of the elastic membranes of the body,—whether, by a partial reabsorption or rending of its substance, a membrane of this kind may not be converted into a network of elastic bands and fibres, at the same time that its substance so fenestrated diminishes greatly in extent owing to elasticity.

There seems, indeed, to be no doubt that networks of elastic fibres or flat bands, as we meet with them in the middle coat of the greater arteries in large mammals (fig. 206), have frequently had their origin in the manner just described. It is probable also that, by the thickening of elastic membranes at particular points in folds and bands, a network of elastic tissue may be formed (fig. 203).

§ 129.

We turn now to the most difficult point in this subject, to the *cellular constituents*, or, as they were formerly called, *connective-tissue corpuscles*. In them we have the most important physiological elements of the tissue under consideration. As we have already remarked, these cells are usually obscured by the fibrillæ around them, and only come into view after the use of acetic acid and other strong reagents, amid the gelatinised ground-substance. But where it is possible to obtain a view of the still living and unchanged connective-tissue corpuscle, it is very far removed in appearance from those which have been acted on by reagents.

Besides the true connective-tissue cells, all the structures we are engaged in considering appear to contain a second element, the *lymphoid cell*, which has migrated from the blood-vessels. The cells of connective-tissue might, therefore, be classed with propriety into *fixed* and *wandering*.

Let us turn now to the living tissue.

An excellent spot for obtaining living connective-tissue was pointed out not long ago by *Kühne*: this is in those thin transparent lamellæ which occur between the muscles of the leg of the frog.

In one of these (fig. 207), we may see in the extremely soft ground-

substance, which is gelatinous and transparent, first of all the fibrillæ and fasciculi of the connective-tissue (*f, g*), as well as a network of extremely delicate elastic fibres (*h*). Then the expected cells (*a-e*) are observed, though not so close together as in our plate, but at rather greater intervals. All of them are naked, and appear in several varieties. The most usual form in which they are met with is that of a delicate protoplasmic structure in which no nucleus can be discerned, but in its place a darker spot (*a*). The cells in question send off several processes which may attain considerable length, and come into contact with those of neighbouring cells (*b*). By very strong magnifying power there may be seen, beside these longer processes, a large number of shorter and paler ones,

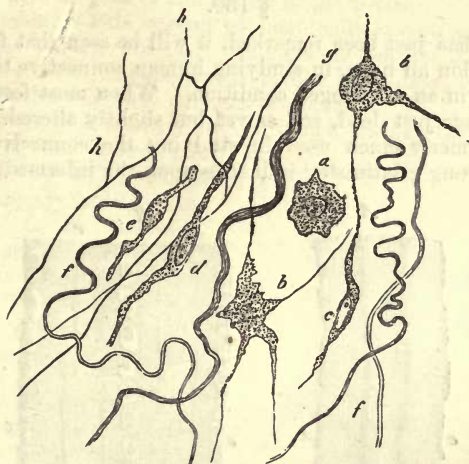


Fig. 207.—A portion of living connective-tissue, cut out from between the muscles of the frog's thigh (strongly magnified). *a*, a pale contracted cell with a dark lump in the interior; *b*, ramified corpuscles; *c*, a similar corpuscle with vesicular nucleus; *d* and *e*, motionless, coarsely granular cells; *f*, fibrillæ; *g*, bundles of connective-tissue; *h*, elastic fibrous network.

giving to the contour of the structure a regularly jagged appearance. Other connective-tissue corpuscles preserve generally a more even outline, and contain a vesicular nucleus (*b* above, *c*). By their processes, few in number, they are connected with one another, as well as with the cells belonging to the first variety. Finally, there appear other cells of a third form, remarkable for the opacity of their protoplasm. They are usually fusiform (*d, e*), and contain a vesicular nucleus.

With the exception of the last mentioned and more coarsely granular cells, connective-tissue corpuscles are endowed with the power of very slow but unmistakable vital contractility, their form changes, processes commence to make their appearance, elongate and unite with those of neighbouring cells, and become again disunited. Nothing can be seen of pre-formed paths for these processes; the almost mucoid consistence of the intercellular substance allows of free play to their motion in all directions.

In other organs also, and in the bodies of many different animals, the same contractile corpuscles of connective-tissue have been observed, so

that we are probably dealing with a peculiar property inherent universally in these elements.

Let us now return for a moment to the connective-tissue corpuscles we were observing in the frog. It is only necessary to add a drop of water to the preparation to produce a great change in the nucleus, and greater in the protoplasm, which contracts around the latter to a kind of fine network. Acetic acid has even a more lasting effect. It causes the nucleus to appear darkly and clearly in the shrunken protoplasm, and gives rise to a distinctly marked halo around the cell. This boundary line encircling the corpuscle formed of altered intermediate substance may simulate a membrane upon it.

§ 130.

After what has just been remarked, it will be seen that for the present we must abandon all hope, in studying human connective-tissue, of meeting these cells in an unchanged condition. When most fortunate, we can only obtain them just dead, and as yet but slightly altered. Acetic acid, which was formerly much used in studying the connective-tissue cells, exercises a strong gelatinising influence upon the intermediate substance,

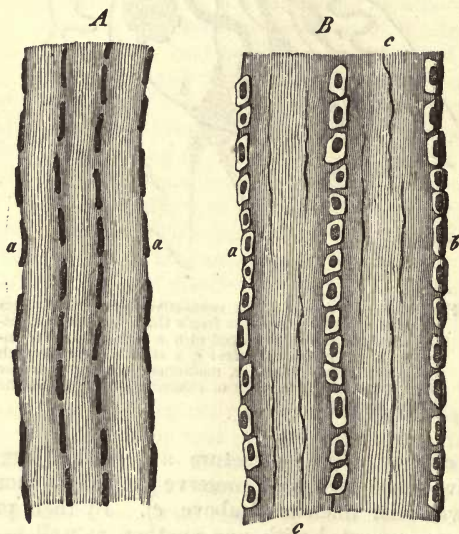


Fig. 208.—Tail tendon of a young rabbit. *A*, the tendon stretched, magnified 200 times. *B*, a less tense tendon enlarged 300 diameters; *a*, cells of the tendon filled with fat at *b*; *c*, fine elastic fibres.

by which the cellular elements are distorted and assume the most extraordinary forms. This reagent has been the cause of numerous errors, and has regulated for many years our views in regard to connective-tissue.

Now, what is known at the present day of these elements?

We must confess not much. Something we have, however, gained from more accurate investigation. The connective-tissue cells of the mature body are frequently (though not invariably) flattened structures, nucleated plates displaying still some protoplasm in the neighbourhood of the nucleus as a rule, but so thin at their borders as to require

the closest scrutiny in order to make out their boundaries at all. The recognition of them is rendered, moreover, difficult by their not lying all in the same plane as a rule, but at very variable intervals, and their being bent and squeezed into the greatest variety of shapes besides by their position.

Many years ago *Henle* had remarked peculiar flattened nucleated cells (like epithelial elements) lying in rows between the bundles of which tendons are made up. *Ranvier*, an excellent French observer, has directed attention to the same in the tail tendons of the rodents, falling into the error, however, of taking them for tubular elements curled on themselves.

Fig. 208 will give an idea of the nature of the parts.

But how variable is this system of bent cells investing imperfectly the surface of the tendon bundle! Immoderate tension converts them into extremely delicate long nucleated bodies like fibres, while, on the part relaxing, the flat cells may curl and warp anew.

It is not the tendons alone, however, which display these flat cells: their presence in the cornea also was maintained by an excellent observer, *Schweigger-Seidel*, whose early death is to be lamented. They have been accurately described by *Flemming* as occurring in soft formless connective-tissue in their usual strange, jagged, crumpled shape. His drawings, our fig. 209, are very faithful.

In spite of every effort, however, we are still as regards the connective-tissue cell but very imperfectly enlightened. Let us not forget this fact.

In order to convey a clear idea of what we have just stated, we repeat fig. 210 in illustration as we close the section. In this we have connective-tissue corpuscles as they are seen altered by the action of acetic acid. At *a*, *b*, *b*, and *c*, *d*, *d*, we perceive tolerably simple cells from foetal connective-tissue: *i-e*, on the other hand, are purely artificial productions, distortions which have more than once played a part in the history of both normal and pathological histology.

Thus it was formerly maintained that the formation of elastic fibres took place from those narrow elongated structures, connected with one another by long thin processes. But although the appearance of the latter under the microscope, as well as their bearing under treatment with strong mineral acids, is the same, still they differ from elastic fibrous networks in being destroyed by strong alkaline leys, while the latter resist the action of the same (*Koelliker*).

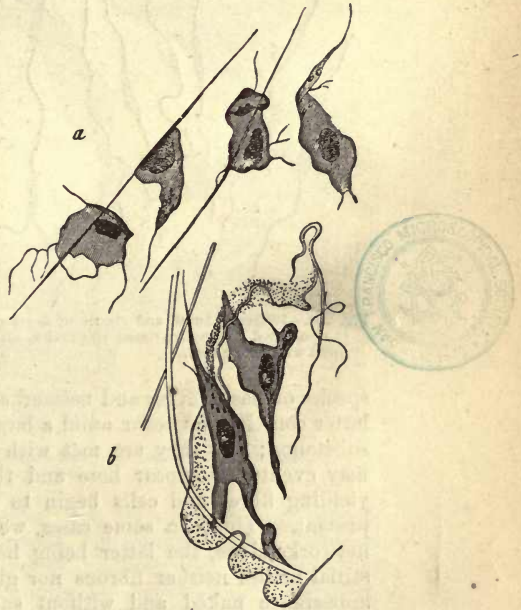


Fig. 209.—Cells from the formless connective-tissue of a young rabbit just born (*a*), and of a mature Guinea-pig (*b*).

In many structures formed of connective-tissue it is probable that

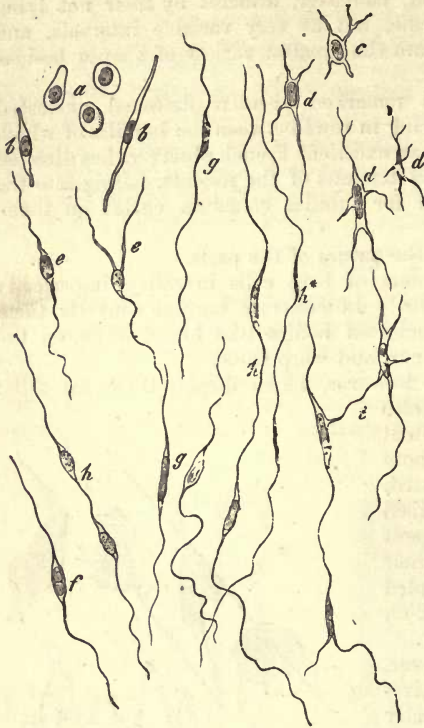

Fig. 210.—Different forms and stages of development of the so-called connective-tissue corpuscles, after treatment with acetic acid.

the protoplasm becomes more and more expended in the production of the intermediate substance, until the latter, either fibrillated or streaky, appears as though only nuclei alone instead of cells were left in existence.

The total disappearance also in many parts of the connective-tissue cells present in the embryo, may be bound up with the development there of numerous elastic elements. This has been remarked in the ligamentum nuchae of mammals (*Koelliker*).

§ 131.

We now turn to the mode of occurrence of connective-tissue.

The numerous portions of our body consisting of this tissue offer for our consideration fibrous and generally fibrillated intermediate substance, cellular elements, the connective-tissue corpuscles, and wandering lymphoid cells, and also the various

species of elastic fibres and networks. In some structures a few only of the latter constituents occur amid a large quantity of fibrillated intermediate substance; but they are met with more abundantly in other parts, and may eventually appear here and there in such excess that the glutin-yielding fibres and cells begin to be obscured or actually cease to be present. Thus, in some cases, we find elastic membranes and fibrous networks alone, the latter being held together by a membranous interstitial matter neither fibrous nor glutinous. They may also make their appearance naked and without such a cementing medium. In that numerous intermediate forms exist, however, between them, the latter cannot be classed as a tissue distinct from the true connective-tissue.

Associated with these essential form-elements of connective-tissue we sometimes find other incidental constituents, such as cartilage-cells (§ 109), fat-cells (§ 122), smooth muscle fibres (in which the *Tunica dartos* of the scrotum is very rich), blood and lymph vessels, nerve fibres, &c. Here, then, we have, in consequence of these additions which differ exceedingly from one another, a new ground for variableness in parts formed of connective-tissue.

These latter appear either as yielding substances, filling out the spaces between organs or portions of organs, as loose enveloping masses,

and paths for vessels and nerves, or they may constitute formed structures, membranes, cords, or solid envelopes. Accordingly, we distinguish two kinds of this tissue, the *formed* and the *formless*,—a division which is, generally speaking, well based, although it must not be forgotten that there are in many places transitions from the formed to the formless, and *vice versa*, and that, therefore, nature has drawn no sharp bounding line between the two species. As a rule (which is not without exceptions, however), the first of these is a soft slimy matter, the latter a more solid substance.

Formless connective-tissue, or, as it has been named when occurring in large quantities, *loose* or *areolar tissue*, possesses besides a homogeneous, gelatinous, and almost mucoid ground-substance, connective-

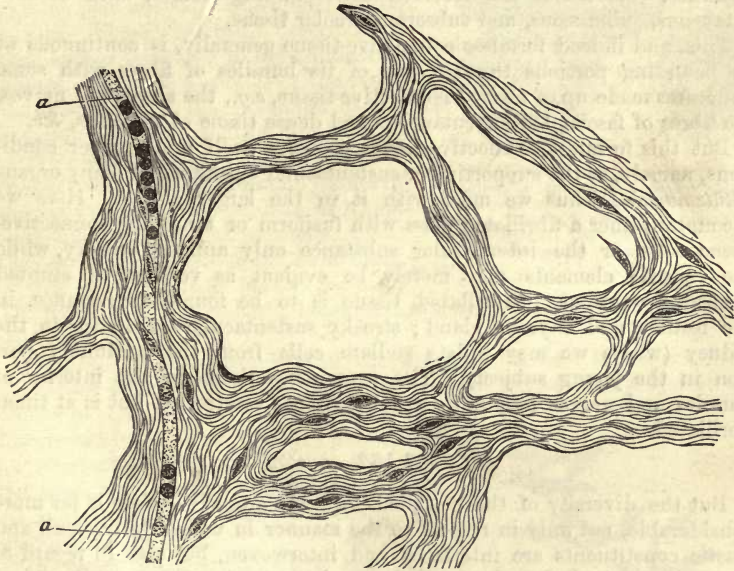


Fig. 211.—Formless or areolar connective-tissue from the large omentum of man.
a, a, a capillary vessel.

tissue fasciculi, elastic fibres and cells, but in very varying proportions. The interlacing of these fasciculi (in general rather loose, so that the whole remains on that account yielding and extensible) is either retiform, or several of the bundles lie longitudinally together, embedded in and held together by the soft formless substance. By the heaping up of fat-cells within this loose tissue it is opened up, and a number of communicating spaces are produced with septa between them. These are the cells of older anatomists, which procured for the tissue the designation cellular, a name which has given way to the histological nomenclature of the present day. We may also succeed mechanically, as for instance by inflation with air, in producing a more or less artificial separation of this substance, which is saturated during life with small quantities of a watery transudation similar to synovia, § 96. These “cells” or loculi appear also pathologically on the accumulation of large quantities of fluid or the entrance of air.

In all this we see a resemblance between the structure in question and gelatinous tissue. And, indeed, the greater part of this areolar tissue existed at an earlier embryonic period in the form of a reticular mucoid substance. The elastic fibres also are no less subject to variation, for we meet both with fine and medium-sized specimens; their amount, however, is but moderate. The connective-tissue cells proper are situated either between the fasciculi in the form of fusiform or stellate elements, or in the softer interstitial mass. Here also we encounter lymphoid corpuscles, which may wander through the mucoid substance by virtue of their vital contractility; and yet we are unable to recognise any preformed paths for them.

According to its occurrence in more considerable amount in several localities, this tissue has received corresponding names, such as subcutaneous, submucous, and subserous areolar tissue.

This, and indeed formless connective-tissue generally, is continuous at its bounding portions through one of its bundles of fibres with some structures made up of formed connective-tissue, *e.g.*, the sheaths of nerves, the fibres of fasciæ, the subcutaneous and dense tissue of the cutis, &c.

But this formless connective-tissue presents itself under other conditions, namely, as the supporting or sustentacular substance of many organs (*Stützmasse*). Thus we meet with it in the larger glands. Here we encounter either a fibrillated mass with fusiform or ramifying connective-tissue cells, or the intercellular substance only appears streaky, while the cellular elements may merely be evident as very much stunted nuclear formations. Fibrillated tissue is to be found, for instance, in the testicle and thyroid gland; streaky sustentacular substance in the kidney (where we may isolate stellate cells from the medullary portion in the young subject). The supporting tissue in the interior of muscles and nerves frequently appears striped or streaky, but is at times fibrillated.

§ 132.

But the diversity of the so-called *formed* connective-tissue is far more considerable, not only in respect to the manner in which its fasciculi and elastic constituents are interlaced and interwoven, but also in regard to its texture. And though, as a rule, we have to do with a well-marked typically developed connective-tissue, yet there occur not unfrequently very peculiar varieties. A few of these may here be mentioned.

We have, first of all, certain connective-tissue structures, in which the cells are exceedingly stunted, and seen as though only the nucleus had been left over, and in which the intermediate substance is either homogeneous or streaky, but not fibrillated. Radiated corpuscles and elastic fibres are absent, either totally, or only give very slight indications of their presence.

The tissue of the dental pulp apparently belongs to this class. And yet we may have to do with a species of gelatinous or mucoid tissue here, in that the interstitial matter does not become clear on the addition of acetic acid.

Again, the sheath or *perineurium* of the smaller nerves consists of a transparent substance, through which are scattered long oval and apparently naked nuclei, measuring about 0.0075–0.0114 mm. If we pass on from these to somewhat more considerable branches, we find the ground-substance of the envelope becoming stringy and fibrillated, while, instead of nuclei, we

find connective-tissue corpuscles, until, finally, in the larger nervous trunks, the perineurium assumes an exquisitely fibrillated character, and discloses a rich network of elastic fibres.

Further, a similar homogeneous nucleated tissue encloses, as an external capsule, the nerve-cells in the ganglia (fig. 212, A). Not unfrequently we have opportunity of remarking how, from this connective-tissue acting thus as an envelope to the cells, flat bands pass off (*dd*). There is a pressing necessity here, however, for closer investigation.

Later on we shall have to inquire into the nature of the so-called fibres of *Remak*, in considering the nervous system, pale nucleated threads of mixed nature. Some structures described as such appear to belong to the connective-tissues, and to be a species of the latter similar to that of the envelopes of the ganglion cells just mentioned.

We meet with very peculiar masses of connective-substance in certain tissues of the body of vertebrate animals, in which (like many of the flat epithelia, § 89) the cells are filled with granules of black or the nearly allied *brown pigment*. The particles of this melanin, however, are smaller than those in the epithelial cells.

Connective-tissue corpuscles of this kind, the stellate pigment cells of an earlier epoch (fig. 213), are found in the human body almost exclusively confined to the eye. Among the lower vertebrates, however, they may attain an enormously wide distribution throughout the body, so that we encounter them in all parts formed of connective-tissue, for instance, in the frog.

In these vital contractility has been observed, and the power of wandering from one situation to another. Thus they may penetrate from the connective-tissue between the cells of the epidermis, by virtue of this power.

Fig. 214 represents the changes of form in one of these migrating cells.

In the human eye, the number of melanin cells of this kind is either very considerable, while the proportion of intermediate matter is moderate (the latter being at the same time homogeneous more or less), or the cells occur more isolated amid fibrous typical connective-tissue.

A case of the first kind is to be found in the choroid. In it we encounter a dense network of these cells, of stellate or fusiform figure, with oval nuclei, and a varying number of processes, which elongate themselves frequently into extremely thin filaments, appearing at times tangled: through these the cells are connected with one another. The size of the latter is about 0.0226–0.0452 mm. Altogether this reminds us of the

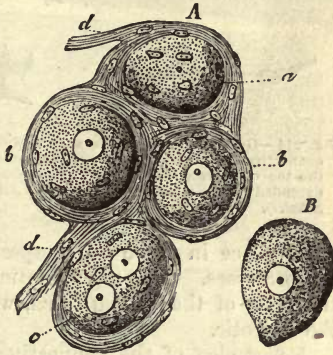


Fig. 212.—A portion of a human sympathetic ganglion. A, four ganglion cells surrounded by homogeneous nucleated connective-tissue; a, without a nucleus; c, containing two of the latter. This tissue, *bb*, passes off into the fibres *dd*. B, a cell without an envelope.

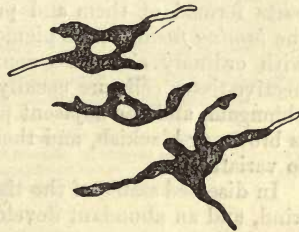


Fig. 213.—Pigmentary connective-tissue corpuscles (so-called stellate pigment cells), from the *lamina fusca* of the mammal eye.

cellular networks of many of the colourless connective-tissue corpuscles,

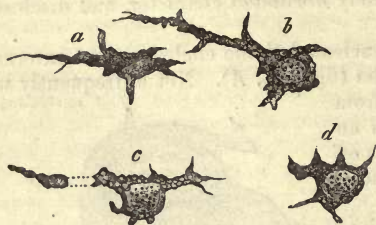


Fig. 214.—Gradual change of form in a pigimentary connective-tissue corpuscle; from the epidermis of the toe of a water-salamander. The observation extended over a space of 45 minutes.—(After F. E. Schulze).

with which indeed it most completely corresponds in the body of the infant, where the body of the cells have not yet become filled with granules of melanin.

This uncoloured state of the choroid cells only persists in certain exceptional cases, until late in life, through absence of pigment. Thus among albinos, of which we have always a good example in white rabbits. As a rule, it will be found that, soon after birth, the deposit of granules

takes place in these cells, especially in their body and thicker part of the processes. This pigmentation spreads likewise from the *choroidea* to the cells of the *lamina fusca*, which is situated between the latter and the sclerotic.

A part also of the connective-tissue cells of the iris, of dark but not blue-eyed individuals, is likewise effected by it. But the colouring matter appears here to be, as a rule, lighter, and of a clearer brown.

If we examine the pigimentary connective-tissue cells of adult animals or human beings (fig. 213), we are struck by their irregularity of form, which may be explained by the hindrance to their further development through the deposit of melanin. For the same reason, the nucleus remains here broad and oval, whereas in better-developed cells it usually becomes long and narrow.

It is a point of special interest in viewing the stellate pigimentary cells as modified connective-tissue corpuscles, that there exist gradations between parts formed of them and purely fibrous structures. This is the case in the *lamina fusca*, whose pigimentary cells are continuous towards the sclera with ordinary colourless connective-tissue corpuscles. Pigimentary connective-tissue cells are usually found also in the *pia mater* of the medulla oblongata, and the adjacent portions of the cord, in adults. Their colour is brown or blackish, and their quantity and distribution, moreover, liable to variation.

In diseased states of the tissues we may likewise find transitions of this kind, and an abundant development of pigimentary cells.

§ 133.

Many widely different parts are reckoned among the *formed* connective-tissues. 1. We commence with the *cornea*. No connective-tissue structure has so frequently been the subject of research as it.

The cornea (fig. 215) presents for our consideration on its anterior aspect, the laminated epithelium of the conjunctiva (*d*), while the posterior surface is clothed with a layer of simple pavement cells (*e*), a so-called endothelium. Under each of these layers we come next upon a transparent structureless membrane or lamella, of which that on the anterior surface is not easy of isolation, whilst that on the posterior aspect appears stronger and easier to separate, as has long been known.

The first of these, the *lamina elastica anterior* of *Bowman* (which is, however, said to have an extremely dense fibrillated texture, by *Rollett*

and *Engelmann* (*l*), has a thickness of from 0.0068–0.0090 mm. in man. It is soluble in boiling water. It is, however, by no means sharply defined against the tissue of the cornea lying underneath. The second layer (*c*), which bears the name of the *membrane of Demours* and *Descemet*, and is 0.006–0.008 mm. in the central portions, and 0.01–0.012 at the border (*H. Müller*), is separable in various ways from the cornea. It has a considerable amount of elasticity, so that it rolls up upon itself on loosening. At its circumference it is lost on the anterior aspect of the iris, as the *ligamentum pectinatum iridis*. Now, between these two transparent membranes is found the true tissue of the cornea (*a*), which has been the subject of such extended research, and whose structure is still far from being satisfactorily elucidated. It is formed of intercellular matter and a system of canals containing cells. The first is continuous peripherally with the fibrillated connective-tissue of the conjunctiva, but also, and to a greater extent, with that of the sclerotic.

This ground-mass of the cornea presents transparent, flat bands of 0.0282–0.0090 in breadth, and 0.0045–0.0090 mm. in thickness, which are, for the most part, so arranged

in respect to the surface, that a regularly laminated structure is the result, though, at the same time, a crossing of the bands may be remarked frequently enough, especially on the anterior surface and periphery of the cornea. Owing to the fact that these can be demonstrated either as hanging together in lamellæ or separable one from the other, the cornea has been declared at one time to be laminated, at another to be fibrous, or both at once, as a combination of both views. As far as we know at present, the cornea may be likened to a compressed network of flat bands, matted in layers, a view which is farther borne out by its double refracting properties with polarised light (*His*). Reagents, as, for instance, permanganate of potash, employed by *Rollett*, or a 10 per cent. solution of common salt, by *Schweigger-Seidel*, show it to be made up of the finest fibrillæ however, held together by a homogeneous intermediate substance, which may also be recognised on fresh corneal tissue, and, better still, in that

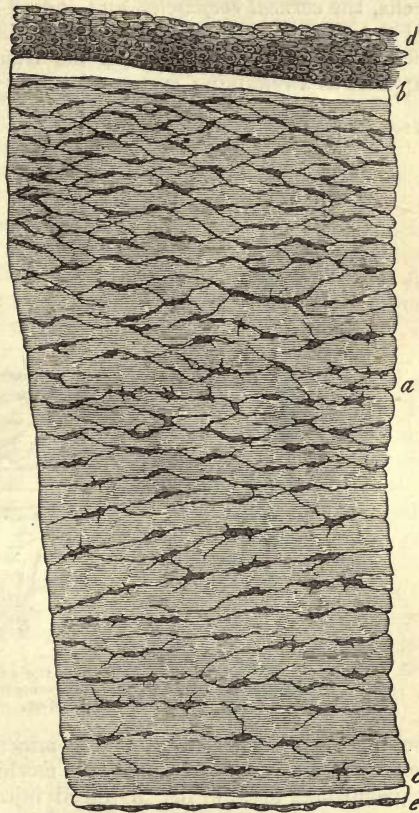


Fig. 215.—The cornea of the infant in vertical section, but much shortened. *a*, corneal tissue; *b*, anterior; *c*, posterior transparent layer; *d*, laminated scaly epithelium; *e* single layer of epithelial cells.

which is shrivelled. Swelling up of the tissue, on the other hand, renders these delicate fibres invisible in a moment. The system of canals (fig. 216, *a*) has been erroneously taken by many to be a system of retiform cells, the *corneal corpuscles*, and indeed it is deceptively like something of the kind when treated with dilute acids. It always occupies with its accessories the spaces between the bands of the ground-substance, and appears as a ramifying system of tubes, capable of isolation by means of

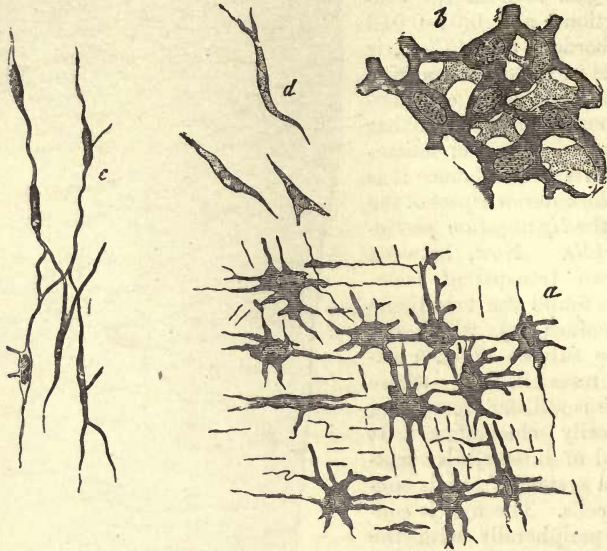


Fig. 216.—Corneal corpuscles. *a*, from the ox, as seen from the surface; *b*, from an infant (surface); *c*, side view of the same from a child four months old; *d*, from small embryos of the human being and ox.

boiling and maceration in strong mineral acids. That it is in reality hollow is indicated by the fact that morbid growth and deposits of fat and pigment take place in it. Artificial injection of the cornea by puncture (*Bowman*, *Recklinghausen*, *Leber*, *C. F. Müller*, *Schweigger-Seidel*), generally gives rise to a rupture of the tissue (*Rollett*), and produces various appearances in it. The canal-work of the so-called corneal corpuscles appears also to be capable of being filled however (*Boddaert*). This system of canals, which possesses probably a modified parietal layer (extremely extensible, and certainly not everywhere continuous), has far wider meshes in the adult than in the infant or foetus.

Seen from the surface, its characters are those of a network possessing widened radiating nodal points of considerable magnitude (fig. 216), while, in profile, it presents longitudinal and usually fusiform enlargements, running parallel with the bounding lines of the cornea. The former stand in communication with one another by means of fine passages, and at times also with those of the deeper or more superficial series, through ascending or descending lines. These stellate enlargements are, therefore, flattened in a direction perpendicular to the surface of the cornea.

As to the size of these points or of the *corneal corpuscles*, their length is stated at 0.0135–0.0180 mm., and breadth at 0.0102–0.0124 mm. Their processes have a diameter of about 0.0023–0.0007 mm.

The average distance of the corneal corpuscles from one another is 0.0226–0.0452 mm.

After the customary treatment of the cornea with dilute acetic acid, we may recognise in these nodal points nuclei of 0.0090–0.0113 mm. in size (fig. 216, c). And in that, as a rule, the substance of the body of the cell reaches as far as the limiting lines of the space, we have the appearance of a stellate cell clothed with a membrane. The use also of a dilute solution of nitrate of silver for obtaining the like views has been recommended (*Recklinghausen*).

But we are obliged to turn to the cornea in a condition as far as possible unchanged, in order to gain a correct view of the state of things. Here we see the tissue studded with membraneless stellate cells extending their processes in all directions, and frequently forming a cellular network through union of the latter. This network, in our opinion, lies within the system of canals already mentioned. Very elegant objects illustrating the nature of this cellular network may be prepared with chloride of gold.

The contractile lymphoid wandering cells of connective-tissue parts (already mentioned, p. 77), were discovered several years ago by *Recklinghausen* in the cornea of frogs and mammalia also, travelling, as he supposed, through the passages of this structure. This discovery, confirmed on all sides, has led to a multitude of other observations and experiments, which have unveiled most interesting features in cell-life of the widest significance. If we place the excised cornea of one frog in the lymph-sac of another, we may demonstrate this immigration of lymph corpuscles into the corneal tissue (*Recklinghausen*). We have already considered the power these cells possess of taking up molecules of colouring matter into their protoplasm. This may easily be brought about by injecting granules of pigmentary substances either into the circulation or into a lymph-sac in a frog. The same injection produces similar occurrences among mammals. Fed in this way, the lymph corpuscles leaving the blood pass into the corneal tissue, in small numbers indeed, into that which is healthy, but in great quantities, on the other hand, in a cornea which has been inflamed through an irritant (*Cohnheim*). But all of these cells, which now go by the name of pus corpuscles, have not the same source, *i.e.*, from the circulation. There must be a new formation in the interior of the corneal tissue itself (*Hoffmann* and *Recklinghausen*, *Norris* and *Stricker*), about which, however, we have but insufficient information at present.

We will add but one word more on the structure of the cornea at an early period of life.

In the embryo (fig. 216, a), the so-called corneal corpuscles show but few processes, and the nuclei enclosed in them appear vesicular. Division may also be observed among them. The network formed of these is extremely dense as it is first seen (b), and the intermediate substance, originally very scanty, increases in proportion later on. It is still completely homogeneous and without any cleavage. Double refraction is also absent. The formation of the two transparent limiting membranes also takes place very early.

REMARKS.—The literature to which investigations of the cornea have given rise is very extensive, and frequently very contradictory in its statements. Among the newer works we may mention, beside those of the Germans, *Toynbee*, *Philosophical Transactions for the year 1841*, Part 2, p. 179; *W. Bowman*, *Lectures on the Parts*

concerned in the Operation on the Eye and on the Structure of the Retina and Vitreous Humour, Lond. 1840.

§ 134.

The following parts are further reckoned among the *formed* connective-tissues.

2. The *tendons*. They consist (with a sp. gr. of 1.117, *Krause* and *Fischer*) of a solid and but slightly elastic tissue formed of longitudinally arranged cylindrical connective-tissue bundles of a distinctly fibrous nature. These are combined to form stronger cords, and are separated from similar bundles by layers of loose connective-tissue, in which the few blood-vessels of the structure are situated. The tendons contain also longitudinal rows of connective-tissue cells. Portions of them may possess cartilaginous deposits. They are

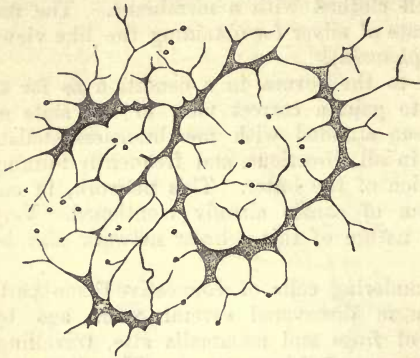


Fig. 217.—Transverse section of the tendon of the tail of a young rat.

connected with the neighbouring structures by means of ordinary formless connective-tissue, or the latter may be condensed around them into a kind of vaginal envelope, the synovial sheath of the tendon. We have already considered the mucoid fluid which collects in the latter when speaking of synovia (p. 155).

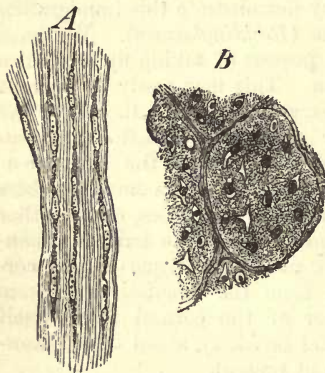


Fig. 218.—From the tendo Achillis of a foetal pig 8'' in length. A, the fusiform cells and fibrous intermediate matter in profile; B, transverse section (spirit of wine preparation).

The more minute structure of these parts is by no means easy to make out, and has given rise to much controversy.

If we examine a transverse section of an infant's tendon which has been previously dried and subsequently softened, we remark a number of angular and jagged figures connected with one another by means of from two to four processes, presenting thus the appearance of a cellular network (fig. 217).

Side-views of the tendons display under proper treatment longitudinal rows of *Henle's* or *Ranvier's* flat cells (fig. 208). These are not, however, rolled up into tubes, as the French investigator erroneously supposed, but only lightly curved, enclosing the connective-tissue bundles incompletely.

Turning again to the transverse sections, we may discern in each of the apparently cellular interspaces (*Henle*) these transversely divided cellular elements, at least faintly. They are, moreover, frequently curved and crumpled.

If we turn to a still earlier or embryonic period (fig. 218), we find in side views (*A*) narrow, fusiform, connective-tissue corpuscles without membranes, and with elongated nuclei 0.0188–0.0023 mm. in length, and 0.0038 mm. in breadth. These are arranged in longitudinal rows, and are divided from those beside them by narrow deposits of fibrillated intercellular substance measuring about 0.0068–0.0045 mm. Transverse sections (*B*) show, on the other hand, the outlines of the cells contained in irregular roundish or jagged interstices. Thus both views correspond.

In the adult we find a strongly marked increase in the connective-tissue fibrous matter. The jagged interstices in transverse sections are separated from one another by intervals of 0.0668–0.0890 mm. (2). In longitudinal view of the stretched tendon the rows of cells are seen as extremely thin rod-like structures, displaying the greatest differences according to the tensivity of the tendon (*Ranvier*). If we examine, on the other hand, a tendon in vertical section, no longer on the stretch, but gelatinised and constricted at points by the action of acetic acid (as was formerly done as a rule), we then see narrow twisted structures measuring 0.0451 mm., and reminding us at the first glance of nuclei. These appear to extend themselves into long thin elastic fibres.

These deceptive appearances were formerly often seen and described.

But that all tendons contain those flattened cellular elements I doubt very much from recent investigations.

REMARKS.—1. The so-called sesamoid cartilages imbedded in certain tendons belong to these. Here we meet with aggregations of cartilage cells generally simple, lying in a ground substance of connective-tissue. 2. If we destroy the interstitial matter formed of connective-tissue by means of concentrated mineral acids, we have remaining a figure corresponding to the cellular network in question. This appears to be the contents of the system of interspaces enclosed in such a modified bounding lamina. For further particulars on this point we must refer to the headings cornea, bone, and dentine. Transverse sections of dried tendons present a very peculiar appearance during the action of acetic acid on them. A number of sinuous band-like figures, namely, appear with fusiform connective-tissue corpuscles and fragments of the most delicate elastic fibres. These are the edges which have turned over on account of the swelling up of the mass, therefore the side view of the sections of the bundles.

§ 135.

3. The *ligaments* have a similar structure to that of tendons, with the exception of those which are elastic.

4. *Fibro- or connective-tissue cartilage*, which might be treated of here with an equal right as when considering cartilage, owing to the nature of its intermediate substance, has been described already with the latter tissue (§ 109.)

5. The large group of *fibrous membranes*. These are remarkable for the close interweaving of their frequently very strong bundles of connective-tissue, which cross and recross each other. Their elastic elements may correspond to those of the tendons, but are frequently more numerous, and display a greater breadth of fibre. The proportion of blood-vessels in their composition is but small. Among the fibrous tissues we generally reckon—

a. Such closely-woven whitish envelopés as occur frequently in the form of external coverings to the internal organs of the body. Thus the sclerotica of the eye, with its densely interlacing connective-tissue bundles; the *dura mater* of the brain and spinal cord, with its numerous elastic fibres; the fibrous part of the pericardium. Then, again, other fibrous

envelopes, as those of the testicle, the kidneys, the spleen, the penis, and clitoris. There is generally a considerable richness in elastic fibrillæ here also. This tissue may, besides, be continuous internally towards the organ, with a banded or plaited network, in which smooth muscular fibres appear sometimes as farther form-elements. This arrangement may be seen in the cavernous portions of the urino-genital apparatus in the lymphatic glands and spleen.

b. The fasciæ, which run externally into formless connective-tissue, and likewise penetrate between the muscle fibres internally, in the form of thin plates. At one time they have more the texture of tendon; at another the elastic fibres gain the preponderance, to such an extent, in certain cases, that abundant networks of the broadest fibres may occur.

c. The perineurium, or, as it is usually called, the neurilemma, likewise continuous externally with formless connective-tissue, and passing inwards between the nervous fibres in a more homogeneous form. It consists, on the larger nervous trunks, of regular bundles of connective-tissue lying side by side, parallel with the course of the nerve. The undulating arrangement of these it is which gives to the structure its glistening plaited appearance. Beside these we find numerous elastic fibres. The structure of the sheath continues thus down to the smaller nervous branches, only decreasing in quantity; here its substance loses more and more the fibrillated character, and fusiform connective-tissue corpuscles make their appearance at considerable intervals, until finally, in the smallest ramifications, we find only a transparent homogeneous membrane with single nuclei imbedded in it. There is, therefore, a gradual transition here from a fully-developed connective or fibrous tissue into a very plain connective-tissue substance.

d. Periosteum and perichondrium. The first of these is a strong membrane clothing the outer surface of bone, which, on account of its supplying the bone with nutrition, is traversed by a multitude of blood-vessels. Its external layers show a large proportion of connective-tissue, and its internal, or those lying nearer the bone, more of the fine elastic fibrous networks considered already. Its connection with the bone is effected by means of the blood-vessels sinking from it into the latter, while, externally, it merges into formless connective-tissue. Whenever processes of mucous membrane extend over the surfaces of bony cavities, it is the custom to speak of a coalescence of the former with the periosteum, although this cannot be demonstrated. Perichondrium, except that it is the enveloping membrane of cartilage, is similar in structure. It is rich in blood-vessels, which are destined for the supply of the former (§ 112). In reticular cartilage we may remark the elastic fibres of its intermediate substance passing continuously into similar elements of this connective-tissue tunic.

6. The *serous membranes*. In these, bundles of connective-tissue are discovered intersecting each other in all directions, but they may appear as though converted on the free surface into a more homogeneous layer. Besides these, we encounter also, in tolerable abundance, and at times even in large quantity, networks of fine elastic fibres in them. Here the amount of blood-vessels is inconsiderable. Underneath, towards the organ enclosed, this structure passes into a loose formless connective-tissue, the so-called sub-serous, whilst the free surface is clothed with flattened epithelium springing from the middle germinal plate (§ 98). Theoretically, the serous membranes were formerly held to be completely closed sacs,

which had been doubled in by the organs which they invest. But this is by no means always the case, and only so at most in those which have received the names of true serous sacs, among which may be reckoned the *pericardium*, *pleura*, *peritoneum*, and *tunica vaginalis propria* of the testicle. The *arachnoidea*, which has also been numbered among these, has no parietal layer.

The synovial capsules of joints only possess also the requisites of a serous membrane on their lateral portions, namely, a layer of connective-tissue clothed by epithelium, while the floor and roof of the cavity are formed of the naked articular cartilage.

But some other cavities, arranged also in this category, are even more imperfectly defined, namely, the synovial bursæ and sheaths of tendons. Here we have frequently to deal, not with a regular wall, but with an extremely soft connective-tissue, saturated with fluid, gradually becoming more solid externally, instead of a distinct cavity. But in those situations where the sheaths and bursæ in question are more sharply defined, we may encounter at points a simple flattened epithelium on the connective-tissue forming the walls of the cavity.

The formation of these "true" and "false" serous sacs is explained by the occurrence of those cavities in connective-tissue mentioned at § 98. By the formation in the middle germinal plate of larger hollows of this kind, which become more and more defined, we pass gradually from the mucoid sheath to the true serous sac. The sub-arachnoid spaces may be looked upon to a certain extent as intermediate forms.

The same serous exudation which saturates formless connective-tissue retains the surfaces of these cavities moist and slippery. Its amount is normally but very small. We have already met with this fluid in greater abundance in the form of synovia (p. 155).

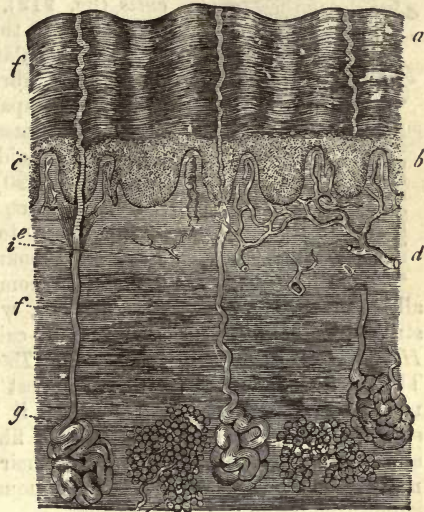


Fig. 219.—Human skin in vertical section. *a*, superficial layers of the epidermis; *b*, *rete Malpighii*. Underneath the latter is the corium, forming papillæ at *c*, and passing below into the subcutaneous connective-tissue, in which collections of fat-cells may be seen at *h*; *g*, sweat glands with their ducts, *e* and *f*; *d*, vessels; *i*, nerves.

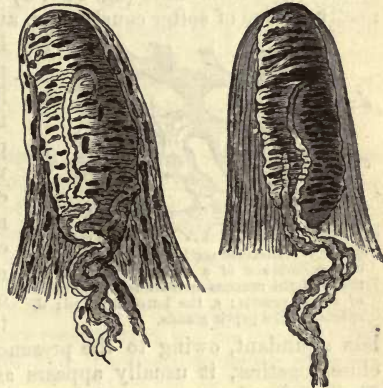


Fig. 220.—Two tactile papillæ of the skin freed of epithelium. Here may be seen the connective-tissue entering into their composition, with the tactile corpuscles in the interior and the nerves ending in the latter.

§ 136.

7. Whilst the serous membranes are poor in blood-vessels, as we have

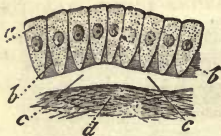


Fig. 221.—Diagram of a mucous membrane clothed with columnar cells. *a*, the cells; *b*, *b*, the intermediate substance between their lower extremities; *c*, transparent layer or basement membrane; *d*, mucous membrane tissue formed of fibrous connective-substance.

just seen, we have to deal, in considering the *cutis* (fig. 219), with a structure very different from them in this respect. The latter consists of a very vascular tissue, made up of densely interwoven fibrillated bundles of connective-tissue, accompanied by very numerous elastic fibres. It possesses connective-tissue and emigrated lymphoid corpuscles also. In the papillæ alone (fig. 220) and on the surface does its fibrous character become less strongly marked, giving place to a more homogeneous appearance on account of the interweaving of the filaments becoming so intimate as to get rid of

all interstices (*Rollett*). Here, then, we may accept the presence of a structureless limiting layer, the so-called intermediate membrane of *Henle*, or *basement membrane* of *Todd* and *Bowman* (comp. p. 84). The *cutis* is covered by the strongest bed of epithelium in the body, namely, by the epidermis. Further, it is rich in nerves, contains many small bundles of smooth muscular fibres, possesses lymphatic canals, and is traversed by the hairs and their follicles as well as the ducts of numerous glands. Below it is continuous with the soft fatty subcutaneous connective-tissue (fig. 219, *h*).

8. The tissue of the *mucous membranes*, which is also very vascular, has a similar structure to that of the corium, if it do not consist, as in the small intestine especially, of reticular connective-substance containing lymphoid cells. We have already considered (at § 88, 91, 93) the various kinds of epithelium which may be found clothing it, all having their origin from the lower or intestinal glandular plate of the embryo. The true mucous membrane (fig. 221, *d*) consists of interlacing bundles of connective-tissue of softer constitution and looser texture, however, than those

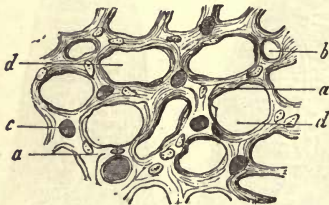


Fig. 222.—Transverse section through the mucous membrane of a rabbit's stomach. *a*, tissue of the mucous membrane; *b*, sections of empty vessels; *c*, the latter injected; *d*, spaces for the peptic glands.

in the *cutis*. The proportion of elastic matter here is liable to variation, but is smaller than in the skin. Superficially, as well as in the various prominences of the tissue, *e.g.*, in the villi, papillæ, and folds, the fibrous character becomes fainter, so that we not unfrequently have here, as in the *cutis*, a transparent layer (*c*). But the mucous membrane tissue in different organs varies to a certain extent. In those parts, for instance, where it is

less abundant, owing to the presence of a large number of glands lying close together, it usually appears as a more or less streaky or slightly fibrillated substance containing nuclei (fig. 222). On its deep aspect it is continuous with the submucous connective-tissue, which is remarkable in many parts, and more especially in the digestive tract, for its strong texture and white appearance, and which constitutes the *tunica nerved* of older anatomists. The mucous membranes, which are in general very vascular, possess a varying number of lymphatics and nerves.

At certain points they contain no glands, but in most cases the latter occur in such quantities that the groundwork of connective-tissue is completely thrown into the background owing to their amount, as has been already remarked. As an instance of such extreme richness in glands, we may take the mucous membrane of the stomach (figs. 222 and 223). Attention has been recently directed to the occurrence of smooth muscle fibres in many of these membranes, to which we must ascribe considerable physiological importance. We shall refer to this again.

9. The so-called *vascular membranes* of the brain and eye, the *pia mater* and *plexus chorioidea*, and choroid, also belong to the connective-tissues. In all these we find a multitude of blood-vessels supported by soft connective-tissue. The latter appears under different forms. One of these, that of the choroid of the eye, has been already described (p. 219). The *plexus chorioidei* show in the infant a completely homogeneous substance, in which round non-ramified cells are imbedded. In the adult also the whole bears in general the character of an undeveloped streaky connective-tissue (*Häckel*). In the *pia mater*, on the other hand, we have the fibrillated form of the latter.

10. Finally, connective-tissue tunics are found widely distributed throughout the *vascular system*. The endocardium may be reckoned among these, also the external coat of the vessels, or so-called *tunica adventitia*, and most of the middle and internal layers of the arteries, veins, and lymphatics. Great variety is met with here, however. Together with structures of fibrillated connective-tissue, with a larger or smaller proportion of elastic fibres, are found, especially in arteries, membranes which, without having any bundles of the former, present in a homogeneous ground substance elastic networks alone, of either fine or coarse, or sometimes very thick fibres. They may also occur homogeneous without fibres. Thus we find a gradual transition from connective-tissue membranes to purely elastic ones.

11. In other parts also we encounter a preponderance of *elastic* elements, with a sometimes slight, sometimes great, decrease, and at other times almost complete disappearance of the fibrillated interstitial connective-tissue. This is the case in the various ligaments and membranes of the larynx, the trachea, the bronchi, and tissues of the lungs. Externally also, around the œsophagus, is found a principally elastic layer, and connecting the latter with the tubes of the respiratory apparatus. Beside other more limited occurrences, we may reckon also to this category the *ligamenta flava* of the spinal column and *ligamentum nuchæ* of some mammalian animals.

§ 137.

All connective-tissues of the living body are, as has been already remarked, saturated by small quantities of an animal fluid, in which we may suppose the matters of nutrition and decomposition to be contained. This, arriving by the blood-vessels and exuding from them, gives up its



Fig. 223.—Vertical section of the mucous membrane of the human stomach. *a*, papillæ of the surface; *b*, peptic glands.

surplus to the radicals of the absorbents contained in the tissue (§ 82). Unfortunately, the amount of this fluid is too small to allow of our obtaining it for chemical analysis, so that its composition still remains unknown. Conclusions as to the constitution of the normal fluid drawn from analysis of those abnormal collections met with in formless connective-tissue in œdema, appear to us inadmissible.

In the serous sacs and cavities likewise we meet with a very similar fluid, in varying but usually small quantity, which might be named a watery exudation from the intercellular fluid of the blood, containing, on analysis, albumen, extractive matters, salts, and at times also fibrin (1). Up to the present, the only fluid contents of any of the true serous sacs that have been examined, under completely normal conditions, are those of the *pericardium* in the case of executed criminals (*Gorup-Besanez* and *Lehmann*). The results varied. The first of these investigators obtained in two cases a fluid of weak alkaline reaction and yellowish colour.

1000 parts of pericardial fluid consist of —

	1.	2.
Water,	962·83	955·13
Solid constituents,	37·17	44·87
Albumen,	21·62	24·68
Fibrin,	—	0·81
Extractive matters,	8·21	12·69
Salts,	7·34	6·69

Lehmann, on the other hand, only obtained 8·79 of albumen, 0·93 of other organic matters, and 0·89 of mineral constituents, per thousand. For synovia (comp. p. 155). The intercellular matter of connective-tissue, together with the fasciculi of the latter, consists of a glutin-yielding material. The composition of the cells is, on the other hand, still enveloped in obscurity, while in the elastic elements we may recognise elastin. The intermediate substance of the cornea alone is an exception, in that it yields chondrin. This short notice includes all that was formerly, and is to a great extent at present known of the composition of connective-tissue.

In the embryonic state this tissue possesses, according to *Schwann's* investigations, repeated subsequently by *Schlossberger*, a ground mass, from which no glutin can be obtained on boiling, and which appears to belong rather to the protein group. This corresponds also with investigations made on the constitution of pathologically formed immature connective-tissue, so that we see a parallel between recently formed connective-tissue and undeveloped cartilage (§ 112). But in that the fully developed tissue, after it has been chemically cleansed, may be converted to a greater or less extent into glutin by boiling, there must take place between the embryonic period and that of maturity some transformation of the albuminoid intermediate substance into a collagenic one. Of the intermediate steps we know nothing, and as to the manner also in which this change takes place we have at present but hypotheses to offer; for we have not as yet been able, as is well known, to effect an artificial transformation of the protein substances into glutin or glutinous matters. The chemical constitution likewise of those undeveloped and not yet fibrillated portions of connective-tissue already mentioned has, with the excep-

tion of the cornea, remained undiscovered: the latter also in the fœtus, it appears, yields no chondrin.

The ground substance of connective-tissue remains unchanged in cold water, alcohol, and ether, and swells up into a jelly-like mass under the action of acetic acid, which only dissolves it to a certain extent when warm, and after a considerable lapse of time. Potash, on the other hand, commences to dissolve it even when cold. By boiling in water this intercellular matter is converted into glutin (§ 15), but whether *in toto* is still an unsettled question. The time necessary for this is liable to variation, according to the quality of the connective-tissue on which we are working. As to the process also by which the collagenic tissue is transformed into glutin, we are as much in the dark here as elsewhere. And if in the analysis of portions of connective-tissue the same results per cent. have been obtained as in the case of the glue prepared from the latter by boiling, it only speaks for the imperfection of the chemical manipulation. It is, in fact, impossible to elucidate with any degree of accuracy the constitution of this intercellular matter, in that we possess no means of separating it from the numerous form elements entangled in its substance, namely, connective-tissue corpuscles, elastic fibres, &c., without even taking into account other accidental and unessential tissue elements, such as blood-vessels, fat cells, &c. The substance cementing the fibrillæ together is soluble in permanganate of potash (*Rollett*), 10 per cent. solutions of common salt and in baryta and lime water; these take up from tendinous tissue an albuminous substance giving the reactions of mucin (*Rollett*).

The composition also of connective-tissue corpuscles is but to a small extent known, on account of our being obliged to base almost all our conclusions on microchemical reactions. Their nuclei show the usual resistance to acetic acid, and the protoplasm—it appears in the tendon-cells of the mature body to be reduced to a minimum—though it may become greatly changed by the action of water alone, still offers to that of acids considerable opposition. It holds out against concentrated mineral acids for a period in which the connective intermediate substance is softened into a pulp or dissolved (2). Hot solutions of potash, on the contrary, dissolve the whole cell rapidly, and are thus of importance in the demonstration and diagnosis of elastic elements. The latter only admit of nearer investigation in those parts in which they are met with in great preponderance, as in the ligamentum nuchæ, and to this is due the slight acquaintance we possess with elastic matter in general (§ 15).

Those homogeneous elastic membranes of large vessels already discussed (§ 127), as well as the structureless intermediate substance of many elastic fibrous networks, resemble in their microchemical bearing ordinary elastic fibrous tissue. The homogeneous envelopes of certain of the connective-tissue bundles appear still to consist of glutinous substance, in that they give way to the action of caustic alkaline solutions, while in other instances they are decidedly composed of elastic material (comp. § 128). The transparent limiting layers of connective-tissue membranes likewise are liable to the same variation in composition. *Descemet's* membrane on the cornea is elastic, while the anterior transparent lamina of the latter and the *basement membranes* are of glutinous nature.

These facts just stated are, however, of interest in another way. They show that elastic matter represents a product of the subsequent transformation of glutin-yielding intermediate substance, and, moreover, of that

form from which collagen as well as chondrigen is produced: comp. what has been already stated in regard to elastic cartilage (§ 108).

Analysis of organs wholly formed of connective-tissue has been undertaken comparatively rarely up to the present. The proportion of water in the tendons amounts according to *Chevreul* to 62·03, in the cornea to 73·94–77·82 per cent. (*His*). The latter has, therefore, 26·06–22·18 of solid matters, of which in one case 20·38 were converted into gluten on boiling, and 2·84 was found to be made up of organic non-glutinous substance. The latter may be referred to the corneal cells and their processes, as well as the membrane of *Descemet*. Together with these were found besides 0·95 per cent. of mineral constituents, of which 0·84 were soluble in water.

REMARKS.—1. According to *A. Schmidt* “fibrinogen” is almost always one of the components of such exudations. 2. We can thus isolate connective-tissue passages with their terminal layers, and remains of cells in the interior, by means of sulphuric, hydrochloric, or nitric acids. Prolonged boiling also in alcohol acidulated with hydrochloric acid, and subsequent maceration in water, leaves the protoplasm of the cells still remaining, while the interstitial substance undergoes solution, and the elastic fibres crumble up.

§ 138.

Connective-tissue forms a large part of the ordinary investing and sustentacular substances of the body. It connects organs with one another, envelopes them, and fills out interstices between them and between their divisions: it fixes parts against one another, forms passages for vessels and nerves, and cavities for collections of fat cells, &c. This so widely-distributed tissue, then, comes under our consideration, as regards its physical properties, mainly for the building up of our body. Loosely interlaced as regards its fasciculi, connective-tissue presents itself in the form of a yielding extensible substance. But, on the other hand, we usually encounter a more dense and intimate interweaving of its fibres, especially in formed connective-tissue; so that a greater or less degree of solidity is attained, as opposed to the extensibility of that formless species. The plentiful occurrence in it of elastic elements has also a great influence on the physical qualities of the tissue.

On the other hand, we encounter structures formed of connective-tissue which play a part in the chemical processes of the system, owing to their great vascularity or abundant exudatory activity, as, for instance, the skin and mucous membranes. This depends, however, properly speaking, upon the contained blood-vessels.

It is usually supposed, though without sufficient data for proof, that the transformative capacities of connective-tissue in regard to the matters passing through it are in general but small. We are led to infer this by the passive part which the tissue takes in the assimilative revolutions of the body, or its slight inclination to decay, and by the poorness in vessels of many parts formed of it.

This interchange of matter, however, be it great or small, is still completely veiled in obscurity as regards its nature. The fact that glycine and leucine (§ 35 and 31) are products of the artificial decomposition of gluten, while elastic material yields the last of these only, may give us some slight point to hold by in the present helpless state in which we find ourselves.

Some years ago, from the connective-tissue theory of *Donders* and *Virchow*, an idea sprung up that the cellular networks of its cor-

puscles, supposed to be supplied with membranes, constituted a hollow system of canals, like that to be met with in bone, for the conducting of certain definite nutritive fluids through the tissue, forming thus a *plasmatic* circulation. Based on this view, the name of *sap canaliculi* was given by *Koelliker* to these passages. But there was no physiological necessity for supposing that this must be the case in connective-tissue, in that it does not occur in cartilage. Besides, the system of interstices in parts formed of connective-tissue would appear but little suited for the fulfilment of such an object, frequently stopped as they are by cells, and compressed by the intermediate substance. Communications between these interspaces and the vascular systems do not occur, either with the blood-vessels or lymphatics, although this erroneous doctrine still permeates histology.

The question now arises, which of the elements of form are to be looked upon as physiologically the most active and important in connective-tissue masses? Here also as anatomically the decision must be in favour of the cells, so long as the latter possess even a small remnant of their body. On the other hand, connective-tissue structures, in which the cellular elements no longer exist, and where alone dense networks of elastic fibres remain, must be looked upon as tissues endowed with a minimum amount of life; for instance, the ligamentum nuchæ.

Among the transformations of senescent connective-tissue we must now bestow a few words on *calcification*, occurring in a similar manner to that in cartilage, and by no means rarely. Bony tissue may likewise take the place of the former, but much more seldom by direct transition of one tissue into the other as by a neoplastic process, corresponding to that which takes place in the embryo, where the newly-produced bony mass takes up the place of the vanishing connective-tissue. We shall be obliged to refer again to this question in considering osseous tissue.

We are now met by another difficult question, namely, how far connective-tissue cells may become transformed into the elements of other tissues not belonging to this group. It appears plain that, with their power of vital contractility, no great distinction can be made between them and the cellular elements of unstriped muscle. And yet there have been long and indeterminable controversies as to what are muscle and what connective-tissue cells in certain organs, *e.g.*, the lymph glands and the ovary. We have already stated (§ 98) that the so-called endothelia must take rise from the cellular elements of connective-tissue. On the other hand, there appears to be no transition into the cells and offspring of the corneous and intestinal glandular plates, and there seems further (if we except the neuroglia and many portions of the higher organs of sense) to be no true connection between these tissues. It is true that such intercommunication has been frequently asserted to take place, as, for instance, in the intestinal villi by *Heidenhain*. Here long processes of the cylinder-epithelial cells are stated to be united with those of the connective-tissue corpuscles of the sustentacular substance of the villus. These statements have not, however, been corroborated.

The contractile and wandering lymphoid cells of connective-tissue have been already dealt with in a former section. That they generally take their rise from the derivatives of the middle germinal plate in enormous numbers there can be no doubt.

It is a striking fact, ascertained by *Virchow*, that connective-tissue,

which usually appears so quiescent and indifferent in the adult body, displays during pathological processes a new and mighty vigour of growth.

Simple inflammatory irritation alone gives rise to a rapid swelling-up of the cells contained in the interstices of the tissue. In the dull protoplasm of these we may remark division of the nuclei also, in non-vascular parts like the cornea, as well as in vascular structures (*Stricker and Norris*).

We have already seen (p. 129) that pus corpuscles (lymphoid cells) may frequently accumulate in the passages and interstices of connective-tissue (fig. 224) in great quantities, owing to such irritation, arriving there partly from the circulation. But others originate in the tissue itself; and it has been by some maintained now for many years, with the utmost certainty, that the parents of these are the connective-tissue corpuscles.

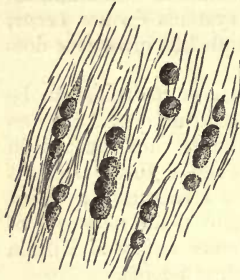


Fig. 224.—Pus corpuscles in the interstices of tendinous tissue; from the tendo Achillis of the rabbit.

But the mode of this origin requires nearer investigation than it has as yet received. It is possible that the membraneless connective-tissue cell may divide into these lymphoid elements by simple or double nuclear segmentation.

Owing to its wide distribution throughout the body, connective-tissue plays the most important part in pathological neoplastic processes. Loss of substance in the organs of the middle germinal plate is replaced by it (cicatrical tissue) just as it may take the place physiologically of degenerated organs. Luxuriant growth of this structure causes an increase in quantity of the sustentacular substance of glands and other parts, as well as thickening of membranes, and so on. Numerous new formations, in the form of tumours, from the simple wart up to the supporting tissue of the most dangerous cancerous growths, consist of it. Tumours consisting of pure connective-tissue, with a more or less dense texture, have been given the name of *fibromas*. The starting-point of these is in most cases ordinary or physiological connective-tissue, with an undoubted participation of lymphoid cells.

The appearance of such a pathological connective-tissue is very variable. Beside the most fully developed texture, such as only formed connective-tissue can show, we meet with structures of a softer species allied to the so-called formless kind. We encounter also appearances such as are presented by the young embryonic tissue. Thus, wherever a rapid development of the tissue is taking place, soft fusiform and stellate cells in close juxtaposition are observed, or there may be merely round and very primitive elements with scanty intermediate matter to be seen. It appears, also, that nucleated formative cells without a membrane may coalesce owing to their abundant protoplasm, forming more or less homogeneous multi-nuclear masses. This must have been the origin of the many alleged exudations with spontaneous generation of nuclei spoken of in former days. We leave the rest to the hand-books of pathology, and pass on in the next section to the origin of the tissue.

§ 139.

The first indication of the formation of connective-tissue is the appearance at an early foetal period of delicate embryonic cells (fig. 44, p. 66), crowded together, without any membrane, and containing vesicular nuclei. These are held together by a small amount of an albuminous intercellular substance, so that connective-tissue and cartilage commence both of them with extremely similar primary forms. This first condition of rudimentary connective-tissue, however, is only very transient.

The further transformations take place with equal rapidity, and are of different kinds in the various connective-tissue structures. If these remain poor in blood, as, for instance, the tendons, the cells preserve their original crowded position, but become fusiform (fig. 225). If, on the other hand, they become vascular, as is the case with subcutaneous cellular tissue, an outpouring of a plasmatic fluid containing albumen and mucin takes place: the formative cells separate from one another, and assume frequently stellate figures (fig. 226).

But even already all these cells have undergone metamorphosis. Their processes have broken up into a number of the most delicate fibrillæ, which are at first straight, and contain abundant granules of protoplasm between them. Later on the latter withdraw more towards the middle of the cell, and the original cell-

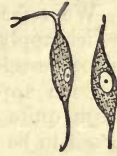

Fig. 225.—Fusiform cells from embryonic connective-tissue.

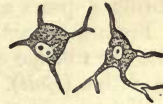

Fig. 226.—Stellate cells from the same.

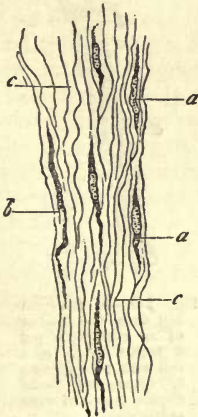


Fig. 227.—Soft connective-tissue from the neighbourhood of the tendo Achillis of a human embryo of two months old.

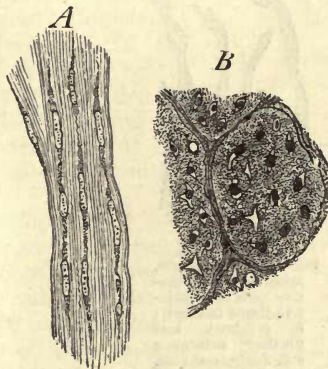


Fig. 228.—From the tendo Achillis of a pig embryo 8" long. A, the fusiform cells and their fibrous intermediate matter in profile; B, transverse section (spirit of wine preparation).

body diminishes to a corresponding degree in volume. The fibrillæ then assume gradually a more and more wavy character, and are converted into an ordinary bundle of connective-tissue fibrillæ (the interstitial molecules disappearing at the same time) (*Breslauer and Boll*), or into single fibril (*Kutznetzoff and Obersteiner*). From personal observation we

are inclined to accept this as the correct view, although *Rollett* supposes the connective-tissue fibres to have their origin independently of the cell.

The fasciculi, according to this, spring from the metamorphosis of the original cell-body, or, if we prefer an expression of *M. Schultze's*, are produced by "the formative agency of the protoplasm."

We refer the student to figs. 227, 228, 229, and 230, almost all of which apply to the development of solid connective-tissue masses poor in blood-vessels and intermediate fluid.

Such appearances were known long ago to *Schwann*, who interpreted them quite correctly. Later on the connective-tissue fibrillæ were supposed to be formed by a metamorphosis of the intercellular substance,—a theory for which at last even *Koelliker* declared himself.

At the present day, when the absence of an envelope on the connective-tissue cells is looked upon as certain, and the intercellular substance is regarded as at least in many cases a metamorphosed external part of the cell-body, as in cartilage (p. 167), the relationship of the cell-body to the fibrillæ appears again such as indicated by *Schwann*.

From the length of mature connective-tissue bundles, it may be inferred that the fibrillæ of adjacent cells unite in a longitudinal direction in their formation (*Boll*).

We turn now to the inquiry, what is the further destiny of the so much impoverished formative cell of connective-tissue?

It appears to vary in different ways.

In some cases this cell persists, separates from its product the fasciculus, and is transformed into that frequently flattened, sometimes smooth-edged,

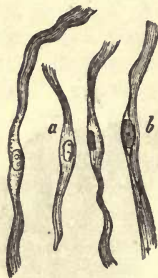


Fig. 229.—*a*, Fusiform, apparently formative cells of connective-tissue fasciculi; *b*, cell-body and fibrillar substance still distinguishable.

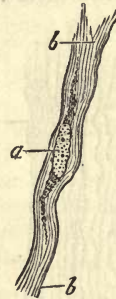

Fig. 230.—A fusiform cell from the tendon of an embryonic pig 8 inches long. *a*, a cell with protoplasm; *b*, connective-tissue fibrillæ (spirit of wine preparation).

sometimes jagged element with which we have become acquainted through the investigations of *Kühne*, *Ranvier*, *Flemming*, and *Boll*, as the cell of mature connective-tissue (comp. § 129).

Again, the nucleus remains behind with a small (fig. 230) or frequently almost imperceptible residue of protoplasm. This is the case in those connective-tissue structures we have already considered, in which apparently naked nuclei are met with in the fibrous mass (§ 132, for instance.)

Thirdly, the nucleus seems, in some cases, to disappear early with its scanty remainder of protoplasm, by commencing fatty degeneration (*Boll*),

so that we may only meet with fasciculi intermixed with elastic elements, but without a trace of the original formative cell (comp. fig. 201-203).

We must still leave it an open question, whether lymphoid cells which have wandered out of the foetal blood-vessels may not be transformed into formative cells of connective-tissue. It seems, however, probable.

The mode in which elastic fibres have their origin, though comparatively easy to observe, has been long a subject of controversy. And although the manner of their separation from the interstitial substance remains up to the present completely unexplained, still there can be no doubt that they originate independently of the connective-tissue cells.

In § 136 we spoke of the ligamentum nuchæ of the adult mammal as a mass abounding in elastic fibrous networks, and in which no corpuscles are to be found. Now, it was from this tissue in question that Müller, and subsequently Hentle and Reichert, obtained proof of this.

If we examine the ligamentum nuchæ of very small fetuses, we observe the same to consist of numerous spindle-shaped cells arranged longitudinally, and of an intermediate substance without any elastic elements. Later on (fig. 231, A), we recognise exactly similar fusiform cells, with considerable sized nuclei and short pointed extremities (a). Between these there appears an indistinctly fibrous matter (b). Even here nothing is seen of the elastic elements until the whole has been treated with boiling potash (B), when the cells are destroyed, and a network of extremely fine elastic fibres becomes visible.

If we continue our research on older embryos, we find these fusiform cells becoming thinner and longer until they gradually disappear. In the new-born animal only traces of the latter are to be seen. The elastic networks increase in density in the same proportion, and their fibres in strength. The bundles of connective-tissue also become more apparent in the ligamentum nuchæ (Koelliker).

The above sketch of the development of connective-tissue will, no doubt, receive, through continued research, many additions, the more so as our acquaintance with the subject must be looked upon as being merely in its commencement.

If we inquire into the mode of appearance of connective-tissue in the body, we find that it may be classed into a *primary* and *secondary*. The primary is from a metamorphosis of the cells of the middle germinal layer. The secondary, also from the same embryonic layer (never from the corneous and intestinal glandular leaf), takes place usually from other members of the connective-tissue group, most probably from lymphoid corpuscles. As an instance of secondary formation of connective-tissue, we may cite the process of the production of bone to be described in the following section.

In pathological novogenesis, also, the formation of the tissue takes

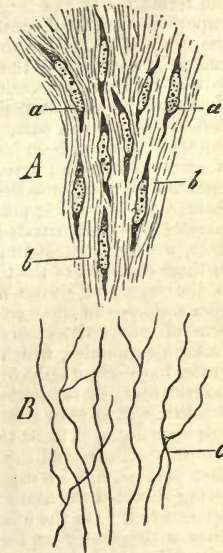


Fig. 231.—From the ligamentum nuchæ of an embryonic pig 8 inches long. A, lateral aspect; a, fusiform cells in fibrillated ground substance, b; B, elastic fibres, c, rendered visible by boiling in potash. (Spirit of wine preparation.)

place in the same manner as has been described above for the normal structure. But that many subordinate peculiarities may make themselves evident here must be granted.

REMARKS.—We should be obliged to overstep the bounds of a work of this kind by a great deal did we enter more minutely, or in a manner which could be regarded to any extent as exhaustive, upon this still unsettled question as to the origin of connective-tissue. In the year 1839, its mode of origin was held by *Schwann* to be the following:—Cells, originally spheroidal, took on the fusiform figure, and, becoming further elongated, underwent a splitting up of their substance into fibrillæ, commencing at their extremities, thus giving rise on the metamorphosis of the latter into the so-called bundles of connective-tissue. As to the destiny of the nuclei of these formative cells, it remained unexplained, and the development of elastic fibres from other cells was looked upon as probable. *Henle*, however, appeared soon after as propounder of a new theory of origin, in consequence of renewed investigation. According to his view, connective-tissue consists of an originally nucleated blastema, in which the nuclei are arranged with regularity, and the ground substance splits up into bands following their direction. By a fibrillar metamorphosis of the latter, the ordinary fasciculi are produced. At the same time, the nuclei are supposed to become elongated into fusiform bodies, which may subsequently unite, forming fine elastic fibres (Kernfasern). No personal investigations have been published by him as to the formation of the larger elastic filaments. In 1845, *Reichert* brought out a very important work for the history of connective-substance. In this he taught that between the original cells of embryonic connective-tissue an intercellular matter gradually makes its appearance, the former coalescing with this to form a homogeneous mass, so that in that the nuclei are still recognisable; we have arrived at about the same starting-point as that maintained by *Henle*. Later on, the nuclei were supposed by him to disappear in part, while the occurrence of fusiform cells was denied, and the objects which had been held to be such were declared to be (together with the fibrillæ of connective-tissue) artificial products, as already mentioned. Elastic fibres were regarded as transformations of the ground substance. In the year 1851, however, there came a turning-point, through the works of *Virchow* and *Donders*. These investigators demonstrated, with the scanty aids to research of the time, in the first place, the persistence of nucleated cells, and laid, with perfect justice, the chief stress on these elements of the tissue. They fell, however, into a dangerous error in regard to the origin of elastic fibres, in that they supposed the latter to take their origin from a change in these cells. According to both observers, the latter never take the form of connective-tissue bundles, but enter into the construction of stellate and fusiform corpuscles, which may unite to form elastic tubes and fibres. The latter, as a rule, have origin only from such cells (a point long defended by *Koelliker*). True connective-tissue is intercellular substance. This view, supported by *Virchow* and *Donders*, was at once attacked by *Henle* in the most determined manner; the stellate cells were declared to be the transverse sections of interstices between the bundles of connective-tissue, and the whole to be an optical illusion. Now, although *Henle*, we must confess, has in many respects gone too far, still he is entitled to praise for having directed attention to errors in the theory just mentioned as that of *Virchow* and *Donders*. On the other hand, this new theory, sometimes unchanged, and sometimes with greater or less modification, was received (and further developed by observation of the normal as well as diseased tissues) by a number of new adherents of the two men just named. The formation of bundles of connective-tissue from cells, in the sense in which *Schwann* spoke of it, has only been supported (among men of any note) by *Koelliker*, up to the year 1861, when he too gave it up; all others have regarded the fasciculi and fibrillæ as metamorphosed intercellular substance. Again, a new era was initiated by a paper by *M. Schultze* in *Reichert* and *Du Bois-Reymond's Archiv*. 1861, p. 13. In this he proclaimed the formative cell of connective-tissue to be membraneless, like other young cells.

10. The Tissue of Bone.

§ 140.

Bony or *osseous tissue* is a member of the group of connective-substances, by no means springing in the first instance and immediately from the cells of the middle germinal plate. It is rather formed

secondarily from metamorphosed descendants of cartilage or connective-tissue cells, and may therefore be regarded as the most complex structure of this group. It consists of a network of stellate ramifying spaces containing cells, and an abundant intermediate substance of homogeneous nature. The latter is remarkable for its extreme hardness and solidity, and renders the whole the most resistant of all the more widely spread tissues. Its specific gravity in the compact substance of hollow bones is 1.930; in the spongy, 1.243 (*Krause and Fischer*). As the name expresses, the occurrence of this tissue is in the human body normally confined to the bones, if we except a thin coating on the roots of the teeth. Its distribution, however, among the vertebrates, presents considerable variety.

As is well known, bones are divided by anatomists according to their form,—into the *long* or *cylindrical*, the *flat* or *tabular*, the *short* or *irregular*. Again, in accordance with their texture,—into the *compact* (in which the tissue has the appearance of a solid continuous mass), and the *spongy* or *cancellated*, in which the osseous substance, occurring in the form of bands and plates, encloses a system of cellular intercommunicating cavities. The cylindrical bones display a compact texture, except in their terminal portions or epiphyses, whilst those belonging to the short or irregular class are formed of spongy tissue, with the exception of their superficial layers. In tabular bones we encounter spongy substance or diploë clothed externally by laminae of a very hard tissue known as vitreous layers (*Glastafeln*).

The great hardness of osseous tissue does not admit of the usual methods of examination being applied to it, and we are obliged either to have resource to plates which have been sawed out and ground thin, or we must extract from the tissue its solid mineral constituents, after which the decalcified remainder (*bone-cartilage*, as it has been inappropriately

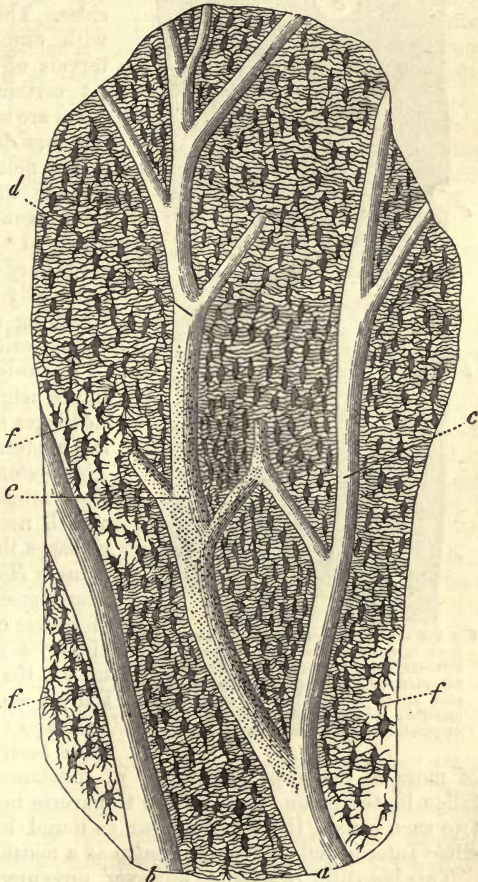


Fig. 232.—Perpendicular section through a human phalanx. At *a* and *b*, two medullary canals with branches, *c* and *d*; *e*, the orifices of canaliculi appearing as dots; *f*, osseous cells filled with air.

named) or *ossein* permits of being cut up owing to its cartilaginous consistence.

In vertically cut plates of compact substance from long bones (fig.

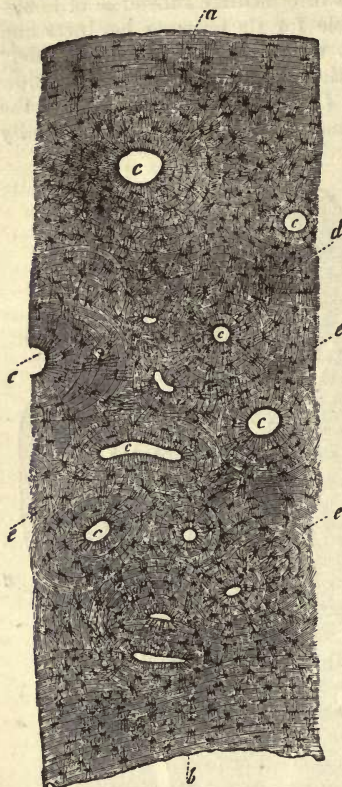


Fig. 233.—A portion of a human metacarpal bone in transverse section. *a*, external, *b*, internal, surface with their respective general lamellæ; *c*, transverse sections of *Haversian* canals surrounded by their special lamellæ; *d*, intermediate lamellæ; *e*, bone corpuscles with their ramifications.

227) we may recognise the following points. The whole is traversed by a system of canals formed of longitudinal passages connected in a reticular manner with one another (*a*, *b*, *c*, *d*), and having an average diameter of 0.1128–0.0149 mm., with extremes on both sides. These run more or less parallel with one another, separated by intervals of about 0.1128–0.2802 mm. At certain intervals also connecting tubes are seen passing between these at one time directly transverse, at another rather more obliquely. If the section include the whole thickness of the bone, some of these canals may be observed to open freely into the medullary cavity internally, as well as externally towards the periosteum, widening as they do so into funnel-shaped orifices.

Towards the ends of the long bones, in the neighbourhood of their articular cartilages, certain bends in the course of the medullary canals may be observed. This system of passages is destined for the admission into the bone of the blood-vessels necessary for its nutrition. The passages themselves are known by the name of *Haversian* or *medullary canals*. Transverse sections, as fig. 233, have of course quite a different appearance. Here we see, at corresponding distances, the severed ends of the longitudinal canals in the form of rounded apertures (*c*, *c*); or should the section have been made somewhat obliquely,

of more or less oval deficiencies of substance. Again, if the cut have fallen in the plane of one of the transverse intercommunications between two such canals, the latter appear as round holes connected by an open slit. Intermediate forms occur also as a matter of course.

This beautiful regularity, however, presented by the central portion of a long bone, is more or less at an end in other than compact osseous tissue. In the external crust of tabular bones, the *Haversian* canals generally run in a direction parallel with the surface; in most cases also radiating from a central point. In the short bones also there is usually one preponderating direction in their course.

In the bands and septa of spongy osseous tissue, this system of medullary canals is far less strongly developed, the latter frequently opening into the cancellous spaces with funnel-shaped enlargements.

Several *Haversian* canals may often be seen also uniting with their enlarged ends to form a small medullary cavity, between which and the larger kind many intermediate forms exist.

REMARKS.—Beside the German works on the subject, compare *Tome's* article, "Osseous Tissue," in the *Cyclopædia of Anatomy and Physiology*, as well as the excellent treatise of *Tomes* and *De Morgan* in the *Phil. Transact. for the year 1853*, part i. p. 109.

§ 141.

The hard homogeneous osseous tissue between these *Haversian* canals has a laminated structure, explained by the mode of origin and formation of the mass in successive portions. These *lamellæ* are united in the most intimate manner with one another, but may be separated in macerated bone which has been deprived of its mineral constituents.

The systems of laminae, however, are of two classes. In one of these the leaves affect the whole thickness of the bone, in the other they are arranged round the individual *Haversian* canals. We may designate the first as *general* or *fundamental*, the others as *special* or *Haversian lamellæ*.

Nowhere can this be better seen than in a transverse section of the middle portion of a hollow bone, such as we have in fig. 233. The general lamellæ are here distinguishable as a system of concentric layers traversing the whole thickness of the piece: commencing internally (*b*) around the central medullary canal of the bone, whose walls they form (medullary lamellæ); then usually less distinct in the middle portion (*d*), with numerous interruptions (intermediate lamellæ), and on the other hand appearing in the most distinct manner again externally towards the periosteum (*d*) (periosteal lamellæ). Of course these stratifications belong to one and the same system of lamellæ. The number and the thickness of the individual leaves is subject to variation. The latter amounts to 0.0077–0.0156 mm. and upwards. The special lamellæ surround the *Haversian* canals in varying number—from 6–18, with extremes in both directions (*c*). Their thickness is, on an average, 0.0065–0.0127 mm., and their arrangement is, as a rule, more or less concentric, the most internal of them constituting the walls of the *Haversian* canals. The latter are not unfrequently situated eccentrically in their systems of lamellæ. Should this be the case to any great extent, the latter may be incomplete towards one side, and it occasionally happens also that the systems of two *Haversian* canals are enclosed again in secondary lamellæ (*Tomes* and *De Morgan*). The strength of these systems further round the canals is very variable. Those of the latter, which have a medium calibre, usually possess the strongest. In the heavier cylindrical bones of the human skeleton, the *Haversian* canals usually lie so close together that their concentric lamellæ almost entirely obscure the intermediated ones; not so, however, in the smaller bones of the metacarpus and fingers, where the distance between them remains greater, as is the case generally among other mammals.

If we prepare a longitudinal section of the compact substance of a long bone, the extended network of the *Haversian* canals will be seen surrounded by lines running parallel with their contour, and at the same distance from one another as those concentric ones of the transverse section. Thus the lamellæ appear to be a system of tubes of considerable length, disposed one within the other, and placed, as a rule, per-

pendicularly, only that the horizontal passages of communication are enveloped by corresponding lamellæ. The latter may be best seen, though seldom, in the horizontal canals occurring in transverse sections, cut through in their length.

In other parts of the skeleton this beautiful regularity is less marked. Thus we see, even in the epiphyses of the cylindrical bones, that these systems of lamellæ are much less developed, that the medullary canals are enclosed within an inconsiderable number of the latter, while the more internal general lamellæ are entirely missing. In spongy osseous tissue the laminated texture is rather more apparent in thick bands and plates, while it disappears more and more as the latter diminish in volume. In the outer layers of flat bones the general lamellæ, as well as the *Haversian* canals with theirs, run parallel to the surface. The same may be remarked with both systems in the compact layer covering the short bones. The great energy of the formative process in young bone often effects a re-resolution of already perfect tissue, commencing in one of the *Haversian* canal-systems (fig. 234, *a*). This produces irregularly-bounded cavities of varying size, with eroded edges, and lamellæ appearing as though gnawed away at points. *Tomes* and *De Morgan*, who first directed attention to this, have given to these the name of "*Haversian spaces*."

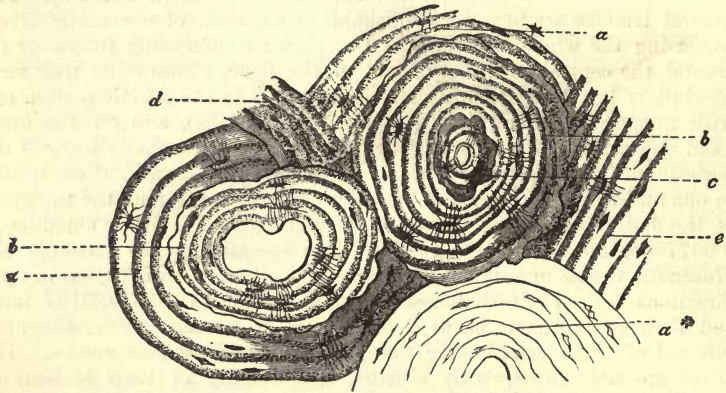


Fig. 234.—Transverse section of a human phalanx. *a*, *Haversian* system of the ordinary kind; *a a*, two others which have undergone re-absorption in the interior (*b b*), thus giving rise to *Haversian spaces*, which are filled anew with lamellæ; *c*, another such system, in which re-absorption has taken place for the third time, with subsequent deposit of new bony matter; *d*, irregular, and *e*, ordinary intermediate lamellæ.

Such a cavity may be subsequently filled up by a new system of special lamellæ, its characteristic outline nevertheless betraying its origin (*b b*). Indeed, as I myself saw, some years ago, in a human phalanx, one of these systems occupying an *Haversian space* may undergo re-absorption for the second time from the centre, with a tertiary formation of concentric lamellæ in its interior (*c*). *Haversian spaces* of this kind are of no very rare occurrence. When present in large number, they may impart to the bone considerable irregularity of texture.

§ 142.

Osseous substance, which may be numbered among the double refracting tissues, as the polarisation microscope teaches, has a rather homoge-

neous, but by no means very transparent appearance: it is, on the contrary, tolerably dull and opaque. If we employ very strong magnifying powers, we remark at times, with tolerable clearness, a finely-dotted appearance in the mass. Owing to this, many histologists (*Todd* and *Bowman*, *Tomes* and *Koelliker*) look upon the texture of the tissue as being granular, which is denied by others (*Henle* and *Gerlach*). It appears more than probable, however, that the transverse sections of the finest of the canaliculi, though they do not entirely produce this appearance, do play some part in it.

In transverse sections, likewise, we may distinguish on every *Haversian* lamella, with more or less distinctness, an external and more deeply shaded, and an internal and much lighter part—a difference the significance of which is doubtful.

Attention has been directed rather recently to a peculiar system of fibres in the ground-mass of osseous tissue, namely, to the *perforating* fibres of *Sharpey* (fig. 235), (*Sharpey*, *H. Müller*, *Koelliker* (2), *Gegenbaur*). They are to be found in human bone and that of other mammals, but more frequently still in that of amphibia and fishes, appearing with a certain irregularity and variableness.

Those systems of lamellæ which are formed by the periosteum, namely,

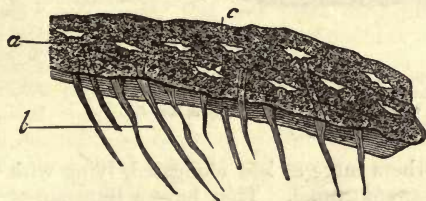


Fig. 235.—*Sharpey's* fibres (*b*) of a periosteal lamella, from the human tibia. *a* *c*, osseous cell-cavities.

the general lamina, as well as the more superficial of the *Haversian* system, are pierced by the fibres in question, sinking into them from the periosteum "like the leaves of a book by a nail which has been driven through them." They are frequently enlarged at one end into a funnel shape, but may also be pointed or branched,

&c. In certain localities they enter into the construction of a network, sometimes wide and sometimes narrow, in its meshes. In the hollow bones of amphibia and mammals (fig. 236) this system of fibres consists of longitudinal columns (*b b*), from which radiating systems of branches (*c c*) pass off, piercing the lamellæ in the direction of the periosteum, as well as towards the *Haversian* canals.

In the substance of these fibres, but especially in their nodal points, we may encounter osseous corpuscles. *Sharpey's* fibres are connected with the periosteum; they are the residue of connective-substance, *i.e.*, of bundles of connective-tissue dating from the period of the formation of those lamellæ. The cells contained in their cavities have the significance of connective-tissue corpuscles also (*Gegenbaur*). The chemical bearing also of these mostly calcified fibres agrees likewise with this view. In keeping with their origin from the periosteum, they must be absent in the systems of leaves, filling up the *Haversian spaces* (fig. 234).

The most important elements of osseous tissue, however, are the *cells* of the latter, imbedded in it in the greatest abundance, and situated in the enlarged and radiating nodal points of a highly-developed *system of canaliculi* traversing the hard osseous substance.

With these, therefore, we must occupy ourselves before passing on to anything else.

This system of canals, whose finer branches are called canaliculi (Kalk-

kanälchen), while the wider spots or nodal points bear the name of *lacunæ* (Knochenhöhlen), was formerly held to be the source of deposit of the bony earths—an erroneous view, which has perpetuated itself in one of the names just mentioned.

The *lacunæ* (fig. 237) appear in fresh moist bone as oval lenticular

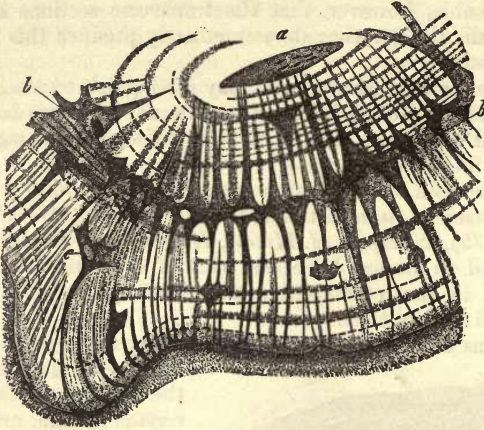


Fig. 236.—Transverse section of the metatarsus of an ox (after Gegenbaur). *a*, Haversian canals; *b*, transversely cut columns of Sharpey's system of fibres, whose branches, *c*, are partly in connection with osseous corpuscles.

cavities, sometimes short and at others more or less elongated, lying with one broad surface towards an *Haversian* canal. They have a transparent

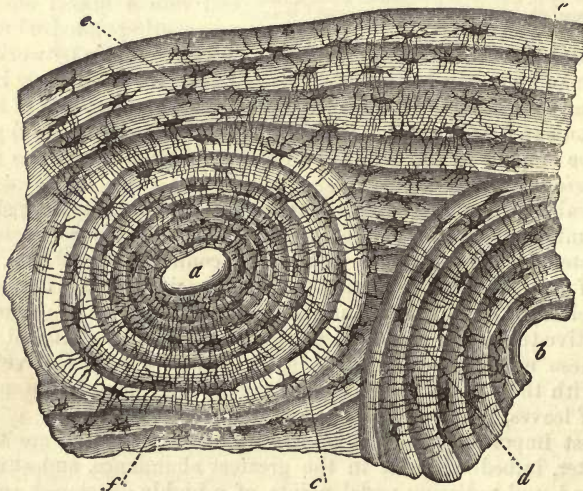


Fig. 237.—Transverse section of a human bone. *a b*, two divided *Haversian* canals, surrounded by special lamellæ *c d*; *e, f*, the general lamellæ.

appearance, and vary considerably in figure. In length they range from 0.0181 to 0.0514 mm, in breadth from 0.0068 to 0.0135 mm., and in

thickness from 0.0045 to 0.0090 mm. In transverse sections they usually lie in the middle of the lamellæ, at times also between the same, with their long axis parallel to the limiting edge of the lamella. General and special lamellæ display but little difference in this respect. The processes of the lacunæ, fine tubules of 0.0014–0.0018 mm. in diameter, can only be followed up for a short distance, when they disappear in the ground-substance.

But we gain a far more perfect insight into the arrangement of these lacunæ and canaliculi from sections of dried bone, in which the former are filled with air, and are brought out with great sharpness, appearing dark or black with transmitted and white with rejected light, and constituting now the most striking form-elements in microscopical investigation of the tissue, catching every eye (figs. 232, 233, 234, 237). From these jagged lacunæ the canaliculi take their rise in enormous numbers; traversing the ground-substance in an irregular radiating course, and with many ramifications, and inosculating in great numbers with the processes of neighbouring lacunæ. The canaliculi likewise of one system of lamellæ may pass over into another adjacent to it.

If we follow up these fine passages in a transverse section (fig. 238, *a*), we see them in the first place converging towards an *Haversian* canal, and opening into the latter (*b*). Again, we can easily make out, in the internal general lamellæ bounding the great medullary canal, the orifices of other canaliculi, and also in the peripheral periosteal leaves a third mode of exit externally under the periosteum.

In longitudinal section (fig. 232), we see the lacunæ surrounding the medullary canals and some of their processes opening into the latter in a more or less horizontal direction. Those spots are specially instructive at which the wall of an *Haversian* canal is exposed which has been opened longitudinally. Here the numerous orifices of the canaliculi may be observed, giving to the surface a dotted appearance (fig. 232, *e*). The other bones also show the same relations as those just described, with very many modifications of course as to number and position.

A glance at this so highly developed system of lacunæ and canaliculi, with its multitude of free openings, explains the fact that a thin section of bone rapidly fills with air on drying, and on being subsequently placed in oil or very liquid Canada balsam, that the air is again displaced by the latter. It is an object well worthy of microscopical examination this gradual expulsion of the air by the advancing oil. In microscopical preparations put up in Canada balsam, we have not unfrequently an opportunity of observing both conditions of the lacunæ and canaliculi. At one point we see the air retained, at another it has been replaced by the Canada balsam. The whole may be injected likewise with coloured liquids (*Gerlach*).

The question as to whether the walls of this complicated system of canals are formed of a substance differing from the remaining ground-mass, or whether the system merely represents a series of lacunæ

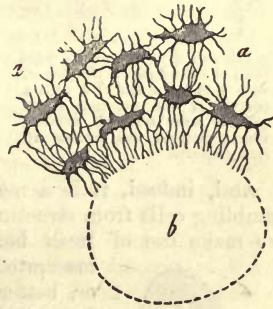


Fig. 238.—Lacunæ (*a, a*) with their numerous ramifications opening into a transversely-cut *Haversian* canal.

possessing no regular internal layers, is one which has been frequently discussed, but not yet conclusively answered.

A method of isolating from the ground-mass by means of alkalis or concentrated mineral acids, a something corresponding to these lacunæ and canaliculi, has been known for many years past. The structures so laid bare have been looked upon by some as being a soft cellular network, by others as made up of the lining layers just mentioned of the system of canals.

And not alone from fresh bone do we succeed in isolating the reticular mass in question, but also from that in which all the softer tissue must have been destroyed by maceration; even in bony masses which have been made use of for turning, it may be separated, as *Neumann* has shown; so that for our own part we must declare ourselves on the side of those who maintain the existence of an independent calcified wall.

We have now taken a survey of the canalisation of bony tissue, but have not yet become acquainted with the cellular elements imbedded in the lacunæ. These "bone-cells," as they are called, were for a long time overlooked, owing to the practice so much in vogue amongst former anatomists of examining principally macerated osseous structures. But after some earlier observers had given it as their opinion that nuclei were to be seen here and there in the lacunæ, general attention was directed to the cells of osseous tissue by *Virchow*.

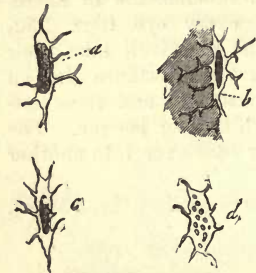

Fig. 239.—Figures resembling cells from the diaphysis of the femur, with nuclei at *a* and *c*; *b*, with a portion of the softened intercellular substance; *c*, another whose nucleus has broken up into granules.

And, indeed, it is a matter of slight difficulty to obtain bodies resembling cells from structures belonging to this class. For this purpose we make use of fresh bone (fig. 239), which has been either simply macerated in hydrochloric acid or subsequently boiled;

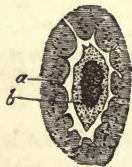

Fig. 240.—Bone-cell from the fresh ethmoid bone of the mouse; tinged with carmine.

or, better still, which has been boiled for a short time in a solution of soda after having been previously treated with the acid just mentioned. In the now soft and almost liquid intercellular substance (*b*) we see structures similar in form to the figures of the pre-existing lacunæ, with shorter or longer processes, definite walls, and each with an oval or elongated and more or less sharply defined nucleus, and measuring on an average 0.0074 mm. The most striking objects are to be obtained by cautiously squeezing and moving the glasses between which the tissue is placed, when some of the cells may be freed from the intercellular matter clinging to them (*a-d*).

These "isolation products" were regarded by some as stellate cells with remarkably resistant envelopes, in that the persistence of cell-body invested with an ordinary membrane, or even completely naked, was out of the question after boiling in caustic soda.

But careful observation of fresh bone will lead to other conclusions. Under cautious treatment, aided by carmine tincture, we may recognise in the lacunæ (fig. 240, *a*) small, membraneless, indistinctly oval cells (*b*), with small projections, at times very short, which are directed towards the openings of the canaliculi. They are possessed also of elongated

nuclei. How far this structure (corresponding to the connective-tissue corpuscle) resembles in this condition the cell of the living tissue, remains for future investigation,—whether the contractile protoplasm does not protrude filiform processes into the canaliculi. In fig. 239, then, we have the walls of the lacunæ isolated, together with the cell-body.

In what has just been described we may trace a very important parallel between the “bone-cell” with its “wall-system,” and the connective-tissue corpuscle with its bounding layer, as also with the cell and capsule of cartilage.

REMARKS.—1. *Tomes* (*l. c.* p. 848) obtained extremely fine granules on crushing calcined bone. *Koelliker* goes so far as to suppose the ground-substance of bone to be made up of an intimate intermixture of organic and inorganic compounds in the form of closely-united fine granules. 2. The fibres in question were discovered by *Sharpey* in the year 1856 (see 6th ed. of *Quain's Elements of Anatomy*: edited by *Sharpey* and *Ellis*, Lond.). Their nature and occurrence were then investigated, especially among the higher animals and human beings, by *H. Müller*, and among the lower classes of Vertebrata by *Koelliker*. A calculation made by *Harting*, from which it appears that a square millimetre contains about 910, gives some idea of the vast number of bone-corpuscles in osseous tissue.

§ 143.

Turning now to the *composition* of bone, we must bear in mind that the medullary receptacles, whose multifarious contents cannot be removed, must be taken with the proper substance of the former, namely, cells and ground-mass.

Fresh bones from human beings and the higher classes of Vertebrata have a rather small proportion of water, especially their compact tissue, in which it amounts to 3–7 per cent., whilst in spongy tissue it may rise to from 12 to 30 per cent. (*Stark*). Young bone is richer in water than the mature tissue.

Dry osseous tissue consists of about from 30 to 45 per cent. and upwards of glutinous material, rendered hard by a large amount of the so-called *bony earths*, a mixture of inorganic salts. Beside this, there is present a small but varying amount of matters not convertible into gluten, which may be set down as derived from the bone-cells, the systems of walls belonging to the lacunæ and canaliculi, as well as from the contents of the medullary cavities which have not been removed.

The glue obtained by boiling, from bone deprived of its salts (which, as has been mentioned, appears soft and cartilaginous on the loss of its earths, and is called in that state ossein or bone-cartilage), is gluten (p. 22), as is also the case with connective-tissue.

The occurrence of small quantities of chondrin is of great interest also, as indicating residual traces of the original cartilage (*Müller*, *Simon*, *Bibra*). Secondarily formed bone springing from the periosteum is probably entirely free from chondrin (see below).

Bony earths are a mixture of various salts, whose bases are lime and (in a subordinate degree) magnesia, combined with phosphoric and carbonic acids, and a small amount of fluorin.

Basic phosphate of calcium (p. 57) appears in by far the greatest quantity, although subject to great variation, according to age, the nature of the food, and the part of the skeleton we examine. It is still a question whether this is the only combination occurring in bone. The carbonate

is found taking a far more subordinate position, and the amount of fluoride of calcium is still less. The admixture, finally, of magnesia appears quite inconsiderable in comparison to the abundant occurrence of the lime salts; it is supposed generally, and rightly, to occur in the form of a phosphate.

Besides these, we meet with alkaline salts, with phosphoric acid, in fresh bone; also chlorine (sulphuric acid?), iron, manganese, and silica, which may be set down as belonging to the nutritive fluid saturating the tissue.

By means of calcining, the organic substratum may be removed from bone without destroying its form. But when thus treated, the tissue loses all cohesion, and breaks up into a white powdery mass on being handled. If we accept it as a fact that no equivalent combination of phosphate of calcium with gluten exists, that the proportion of bony earths in the several bones varies considerably, and that the mineral constituents may be extracted from osseous tissue without the slightest injury to its texture, we must see that the combination of bony earths with the so-called bone-cartilage is probably only mechanical. And yet the granular deposit of lime-salts in cartilage undergoing calcification, compared with the diffuse deposit in true osteogenic tissue from the very commencement, is somewhat puzzling.

The following are the results of two analyses, by *Heintz*, of the compact tissue of a female tibia:—

	1.	2.
Phosphate of calcium, .	85·62	85·83
Carbonate of calcium, .	9·06	9·19
Fluoride of calcium, .	3·57	3·24
Phosphate of magnesium, .	1·75	1·74

As is usually admitted, the bony earths vary, first of all, according to the portion of the skeleton in one and the same body subjected to analysis. Thus *Rees* obtained as a maximum 63·50 from the temporal, and the smallest amount from the scapula, namely, 54·51 per cent. (2). *Bibra* found the highest figures in the femur, and the lowest in the sternum, the numbers being respectively 69 and 51 per cent. Compact osseous tissue is in general richer in bony earths than the spongy kind, probably because the latter can be but imperfectly freed of the soft parts enclosed in it.

Further, the same portion of bone is said to change with age; for at an early period it appears to be richer in organic material than at a later. Thus *Bibra* found in the femur of a fœtus seven months old, 59·62 per cent. of bony earths; in that of an infant of nine months, 56·43; in that of a child at five years, 67·80; in a man of twenty-five years old, 68·97; in a woman of sixty-two, 69·82; and in another of seventy-two years of age, 66·81.

It is an interesting and not yet satisfactorily explained fact, that fossil bones are very rich in fluoride of calcium. The latter may rise as high as 10 or even 16 per cent. of the ash in quantity.

REMARKS.—1. The theory of the transformation of chondrigen into collagen during the process of ossification (p. 22), which formerly occupied the attention of chemists and physiologists to a great extent, has almost lost all worth since the investigations of *Bruch* and *H. Müller* on the subject. We now know that cartilage is not metamorphosed into bone, but is dissolved, so making room for the development of osseous

tissue. The particles of chondrogenous substance are probably decomposed and absorbed, while new albuminous material is separated from the circulation and transformed into collagen just as in connective-tissue. 2. *Rees* (*London and Edinburgh Phil. Mag.* 1838) arranged the following series in relation to the matter in question (but possibly based on insufficient research)—temporal bone, humerus, femur, radius, ulna, fibula, tibia, ilium clavicle, ribs, vertebrae, metatarsus, sternum, and scapula. *Bibra* found, however, a different sequence.

§ 144.

Owing to their hardness and solidity, the bones are peculiarly well adapted for the mechanical construction of the body, excelling by a great deal cartilage in this respect. They serve to protect internal organs, and form systems of levers to be worked by the muscles.

By the deposit of bony earths the flexible bone cartilage is rendered hard, in order to bear the weight of the body without bending. There remains at the same time, however, a certain amount of elasticity and cohesion, which enables osseous tissues to withstand very strong blows, &c., without any breach of continuity. An increase in the proportion of mineral constituents gradually imparts to bone a greater brittleness and fragility. This may be very clearly seen in the difference between the bone of infants and that of very old individuals in a normal state, while in pathological conditions it may be more strongly marked.

The bones take part also, to a great extent, in the chemical occurrences of the organism, owing to the lively interchange of matter going on in them. And though this is as yet but imperfectly known, both as to its amount and direction, still most physiological facts compel us to regard it as by no means inconsiderable, though subject to great rise and fall. Among these facts relative to the energy of the processes going on in bony tissue may be mentioned the whole vegetative life of the same, the frequent regeneration of its substance, the healing of fractures, &c. The well-known experiment of placing a metal ring round a bone in a young animal, which is found at a later period to be imbedded in the interior, teaches us also the great transformations going on in bony tissue, for which, however, the best proof is to be found in the mode of development of the latter. Moreover, there is not necessarily any destruction of tissue bound up with this interchange of material. The rapid coming and going of matter may be also demonstrated chemically. It is easy to conceive that where there is such abundance of phosphate of calcium, a deficiency in the supply of this salt will result in an inadequate hardening of the bone (*Chossat*). On the other hand, the well-known experiments of feeding with madder have lost in recent times in scientific significance; for only the new osseous tissue formed during the absorption of the red colouring matter (*i.e.*, the most external ground lamellæ under the periosteum, as well as the internal layer of the medullary canals) become coloured (*Lieberkühn, Koelliker*).

The so wondrously complicated system of canaliculi and lacunæ has been looked upon by some as a physiological apparatus presiding over this energetic interchange of material, as a system of vessels for the plasma, which receives with its minute openings nutritive fluids from the exudations of the blood-vessels of the medullary canals and surfaces of the bone, conducting them through the whole tissue, so that every smallest part of the ground-substance participates in the transmission of nutritive matter, organic as well as inorganic (*Goodsir, Lessing, Virchow*). The circulation, however, of a nutritive fluid through this system of canals, so frequently interrupted by the bone-cells, appears questionable, at the same

time that we do not wish to deny its significance in the processes of nutrition taking place in bone.

REMARKS.—1. On this experiment, performed in the last century by *Duhamel*, comp. *Flourens (Annal. de Scien. Nat., 2 série, tome 13, p. 97)*. 2. *Goodsir (Anatomical and Pathological Researches, Edinburgh, 1845, p. 66)*.

§ 145.

Osseous tissue, as has been already mentioned, is not one of the primary formations; it belongs rather to those appearing late in the human body, and is missing at a period in which the development of most of the remaining tissues is far advanced.

Its nature is consequently quite different from that of cartilage, whose place it is destined to take to a great extent. For the rest, this tissue is developed within very different spaces of time in the various localities of the body.

Its origin, or the theory of the *process of ossification*, is one of the most difficult chapters of histology, and one in regard to which there is the greatest variety of opinion at the present day.

Now, in that all the bones of the skeleton are moulded first in cartilage, with the exception of some of those of the head, and that this substance appears to the unaided eye to be transformed into osseous tissue, nothing could be more natural than the idea that this actually took place,—that bony masses were developed by a transformation of cartilage,—a view which was held by microscopic histologists even until comparatively recently.

But the investigations of *Sharpey, Bruch, Baur, and H. Müller*, soon made it clear that this older theory is incorrect,—that the cartilaginous mass may undergo calcification, but does not generally become bony tissue, dissolving rather, and so making room for the advancing formation of bone (p. 172). The latter always comes about in a simple way. New generations of stellate cells make their appearance in a ground-substance, at first soft, and soon becoming diffusely calcified, representing thus osseous tissue.

REMARKS.—For a very long time endeavours were made to elucidate, by means of the microscope, the manner in which this metamorphosis of the non-vascular non-laminated cartilage, containing round cells, could take place into laminated bone with its stellate cells, and especially the mode of transition of the latter elements of cartilage into those of bone. In the history of this branch of science we find three different views as regards the last point, springing up one after another, and taking the field against each other. According to one of these, the nucleus of a cartilage cavity spreads out and becomes stellate, forming thus a bone corpuscle. From the second theory we gather that the whole cartilage cell undergoes this transformation. A third view, which appeared for a time to reign supreme, originated with *Schwann* and *Henle*. According to it, the bone-corpuscle is formed by an uneven thickening of the wall of the capsule of the cartilage cell. Indeed, the appearance of stellate, shrunken, true cartilage cells within their capsules, as well as the cellular nature of the bone-corpuscle by *Virchow*, seemed to give weight to this theory. *Koelliker's* discoveries also of the nature of rachitic bone supported it likewise. But in the year 1846, *Sharpey (Quain's Anatomy, fifth edit., by Quain and Sharpey, part 2, p. 146, Lond., 1846)*, and shortly after him *Koelliker*, declared that true bone takes its origin in the human being and vertebrates also from connective-tissue substrata of a membranous nature, explaining first of all the growth of bone from the periosteum, and next that of a number of osseous structures not previously laid down in cartilage, the so-called secondary formations. Thus it was that two modes of origin of osseous tissue were supposed to exist by many,—first, by a transformation of cartilage already present; and again, by the metamorphosis of a substratum of connective-tissue, although *Sharpey* maintained the latter mode of origin to be exclusively that also of the bones even previously moulded in cartilage. The following is an

outline of the view which formerly obtained in regard to the supposed metamorphosis of cartilage:—During the process of ossification, bony earths are deposited in the cartilage; the cells of the latter change, according to the third theory mentioned above, into bone corpuscles; while their secondary envelopes fuse into the intercellular substance, forming thus the ground-mass of the bone. The origin of the medullary cavities and canals was set down to a process of absorption and resolution in the tissue undergoing this change. The formation of the lamellæ remained more or less unexplained, and that of the canaliculi was but unsatisfactorily touched on. We owe much to *Bruch, Baur*, and more than all, to *H. Müller* (*Zeitschrift für wissenschaft. Zoologie*, Vol. 3, p. 147), for having shown this view of the supposed transformation of cartilage into bone to be erroneous, working on *Sharpey's* premises.

§ 146.

Now, although from the foregoing section we must perceive that bone is not formed by an immediate transformation of cartilage, nevertheless, in order to comprehend rightly the process of ossification in portions of the skeleton preformed in the latter, a knowledge of the texture prevailing in the same is indispensable. Reference has already been made (§§ 106 and 107) to the calcification and softening, as well as to the arrangement and nature of the cells of cartilage. The various groupings of the latter are represented in fig. 241, *g*, and 242 (above).

Cartilage shows further, previous to the commencement of ossification, blood-vessels, which spring up at an early period of foetal life, and are of course of importance in the changes about to take place. They grow from the perichondrium in tufts into the softening tissue. Around them a soft immature connective-tissue is formed, and thus canals are produced. This is the so-called *cartilage medulla*, whose cellular constituents were formerly looked upon as descendants of the cartilage cells (although no one had ever seen the transition). The boundary of the medullary canals in the cartilage is always sharply and suddenly defined against the cells of the latter (fig. 241).

Those broad irregular vessels just mentioned require further examination, both as regards their course and the structure of their walls.

In the condition just described, cartilage is prepared for calcification and the formation of bone, closely following on it. The latter commences, as is well known, at certain definite spots, the *points of ossification*, or

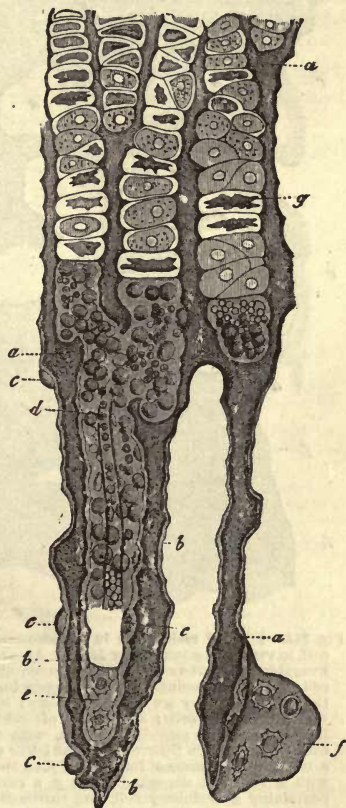


Fig. 241.—Vertical section from the edge of the ossifying portion of the diaphysis of a metatarsus, from a foetal calf 2' long; after *Müller*. *a*, ground-mass of the cartilage; *b*, of the bone; *c*, newly-formed bone-cells in profile, more or less imbedded in intercellular substance; *d*, medullary canal in process of formation with vessels and medullary cells; *e*, *f*, bone-cells on their broad aspect; *g*, cartilage capsules arranged in rows, and partly with shrunken cell-bodies.

(more correctly speaking) of calcification in this case. Several of these points, or *bony nuclei* as they have also been named, may occur in one bone, without, however, necessarily springing up simultaneously. In tubular bones the point of ossification of the diaphysis is mostly situated in the interior of the middle; and in double, flat, and short bones, in the centre. Single bones have two or more such bony nuclei. From the circumference of the latter the process of ossification now advances by

degrees farther and farther into the cartilage. The latter, therefore, displays a difference of texture according to its proximity to the bone nucleus.

In the examination of such portions of cartilage from the neighbourhood of one of the latter, much difficulty was formerly experienced owing to an opacity very difficult to be overcome due to the granules of lime. This it is which has rendered it so difficult to acquire a correct knowledge of osteogenesis. We have, however, rather recently learned from *H. Müller* a mode of overcoming this obstacle by the employment of chromic acid, in which the preparations are placed.

The deposition of the calcium salts, further, displays much variety. In those places where the cartilage cells lie close together, in small groups or singly (fig. 237), they are more completely enclosed in the lime granules than when arranged in rows as in fig. 236, where small

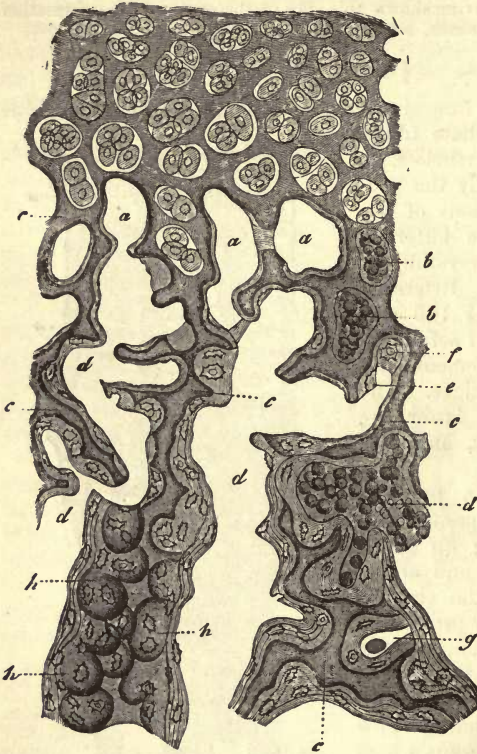


Fig. 242.—Edge of ossification in a phalangeal epiphysis from a calf, in vertical section; after *Müller*. Above, the cartilage, with irregularly scattered cartilage capsules containing large daughter cells. *a*, small medullary spaces, appearing in some cases as though closed, they are sketched empty; *b*, some of the latter with medullary cells; *c*, residue of calcified cartilaginous tissue; *d*, larger medullary spaces, with thinner or thicker osseous deposits on their walls, in the latter case it is laminated; *e*, bone-cell in process of formation; *f*, an open cartilage capsule with a bone-cell deposited in it; *g*, a cavity partly filled up, containing a medullary cell, and surrounded externally with osseous tissue; *h*, apparently closed cartilage capsule with bone-cells in its interior.

bridges of the ground-substance often remain soft.

§ 147.

The calcified cartilage commences now to undergo a rapid process of liquefaction, beginning around the passages containing vessels by which it is now traversed. This gives rise to the formation of numerous medullary spaces. As a matter of course, the so much softer capsules are

the first to fall a prey to this re-resolution. If we still keep to the diaphysis of the cylindrical bones, we see the walls of the capsules of one row, as well as the small amount of intercellular matter between them, becoming dissolved, by which long narrow cavities with wavy contour are produced (fig. 241, *d*). Then again, owing to the fact that other neighbouring parts of the ground-mass of the cartilage become a prey to advancing liquifaction, numerous communications are formed between adjacent sinuses (*d*, above). If we now turn to an epiphysis (fig. 242) or a short bone, we are struck by the fact that the re-resolution takes place irregularly in all directions, starting from the bone already formed. The consequence of this is, that the medullary sinuses form a system of irregular tortuous cavities, the tracing of which is a matter of difficulty, and whose arms not unfrequently simulate closed medullary spaces, when the entrance has come away in making the preparation (fig. 242, *a* [to the right and above], *b*.)

The contents of the cavities formed in this manner are of great importance, supplying the substratum for future processes, or, as we might express it generally, constituting the fœtal medulla.

The latter (fig. 244), a soft reddish substance, shows moderately small

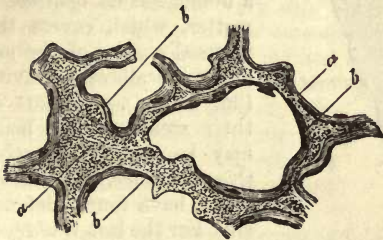


Fig. 243.—Transverse section from the upper portion of the femur of a human embryo of eleven weeks old. *a*, residue of cartilage; *b*, coating of osseous tissue.

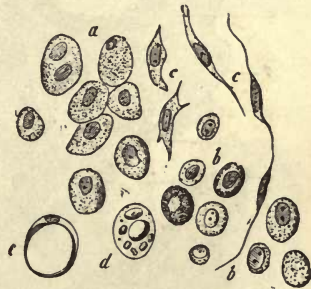


Fig. 244.—Medullary cells of cartilage. *a*, from the humerus of a human fœtus of five months old; *b*, from the same bone of an infant; *c*, fusiform cells; *d*, formation of the fat cells of the medulla; *e*, a cell filled with fat globules.

roundish cells, measuring 0.0129–0.0257 mm. (*a*), of a very primitive appearance, reminding one of embryonic elements or lymphoid cells. They possess more or less granular contents and a single or double nucleus. These are held by some to be either immediate or more remote descendants of the cartilage cells, which have found their way into the cavities, commencing with the absorption of the capsules, there undergoing segmentation, and thus producing new generations. However, though we do not wish to deny the possibility of such an origin, the greater part of these (perhaps contractile) cells of the cartilage medulla has certainly another source. They are young formative-cells, entering the cartilage cavities with the advancing blood-vessels of the internal layers of the perichondrium and periosteum (*Gegenbaur, Frey, Rollett, Stieda*). They may be regarded as emigrated lymphoid cells of the blood.

The further destiny of these cells is very various. Some of them become fusiform (*c c*), and form very early-scattered connective-tissue fibres, which traverse the tissue, which probably contains mucin. Other cells preserve the old lymphoid form. In the red medulla the latter are to be seen the

whole life through. Others again, it is supposed, become filled with neutral fats after increasing in size, thus constituting the fat-cells of the yellow medulla eventually (*e*). This last view, however, requires confirmation.

But other of these cells have a higher destiny: they become the *generators of the osseous tissue*. *H. Müller* supposed this to take place immediately, the roundish lymphoid cell becoming transformed into a bone-cell; but *Gegenbaur* recognised an intermediate form, a modification of the medullary cell, to which he gave the name "osteoblast" (figs. 245, 246).

There is but little difficulty in recognising that the irregular medullary cavities are lined by these cells in a manner similar to the arrangement of epithelium (fig. 245, *c*).

Crowded together (fig. 246, *b, b*), round, polygonal, or more or less cylindrical in form, with single or multiple nucleus, and considerable variation as to size, these osteoblasts secrete externally a thin layer of a homogeneous opalescent matter, which covers the internal surface of the undulating walls of the cavity (fig. 245, *d*), or a part of their membraneless body may be continuous with this substance. Both these views have found defenders. For the last *Waldeyer* has entered the lists, followed by *Rollett* and *Stieda*; and for the first, *Gegenbaur*, *Landois*, *Koelliker*. We must declare ourselves inclined to look on *Gegenbaur's* interpretation of the appearances presented as the more correct, although

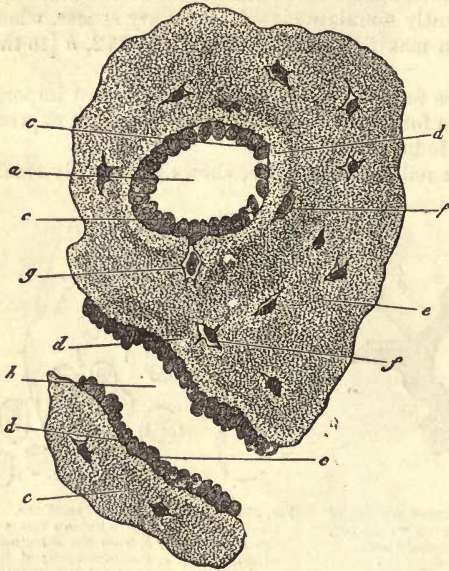


Fig. 245.—Transverse section from the femur of a human embryo of about eleven weeks old. *a*, a medullary sinus cut transversely, and *b* another longitudinally; *c*, osteoblasts; *d*, newly-formed osseous substance of a lighter colour; *e*, that of greater age; *f*, lacunæ with their cells; *g*, a cell still united to an osteoblast.

we do not regard the difference of views as anything essential.

But this layer of osteoblasts supplies not only the material for the ground-substance of the osseous tissue, but the cells of the latter likewise. Advancing from the ranks of these osteoblasts, either single and entire cells or parts of the same sink themselves into the newly-formed lamella (fig. 245, *g, f*, fig. 246, *c*), where they may be recognised in every stage of growth up to the stellate form, on assuming which they are not unfrequently connected by means of their processes with contiguous cells. They are, however, larger and poorer in ramifying processes than the structures of a later period.

These processes are repeated over and over again. On the completion of the first homogeneous lamella with its contained cells, there follows the formation of a second with new cells, and so on, and the stratum becomes thicker and thicker, assuming a laminated appearance in conse-

quence of its deposition in successive portions. This is the beginning of the laminated formation of bony tissue.

We are still in uncertainty as to the mode of formation of the canaliculi during these processes.

The characteristic peculiarity of osseous substance soon makes its appearance now,—namely, its calcification; not in granules moreover, but by a more diffused deposit of bone earths, communicating to the whole to a certain extent a translucent appearance. The organic substratum of these layers is probably from the very commencement collagenous matter.

Naturally enough, the irregular form of the medullary sinuses, and continuous re-solution of the still remaining portions of cartilage, give rise to very different appearances in the osseous tissue first formed, as we may see in fig. 241, or more strongly marked still in fig. 242.

A transverse section, also, through the middle portion of the femur, discloses the same irregular structure, the bone consisting principally of longitudinal septa connected by means of transverse bridges (fig. 243).

Here, then, we have a contrast to the regular texture of completed bone.

Those points are of special interest, as explaining the former error of supposing a direct transition of cartilage cells into bone corpuscles, where the ruptured cavity of a cartilage cell has been made use of as a receptacle for the deposit of one or more bone corpuscles with the accompanying ground-substance. Here one, two, or three of the latter elements may appear to be contained in the interior of a closed capsule, owing to the ease with which the opening of the latter may be overlooked (fig. 242, *h, f*; fig. 241, *e*).

But sometimes almost all the septa of a preparation of osseous tissue have this same extraordinary appearance, so difficult of description, which may be better understood by a glance at fig. 242 (to the left, below).

By the gradual liquifaction of the remaining portions of cartilaginous

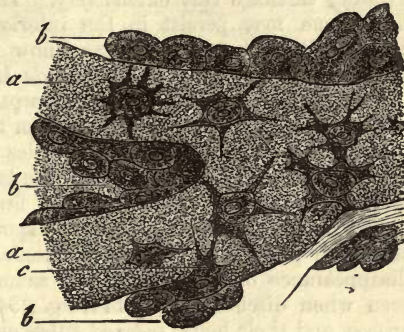


Fig. 246.—Osteoblasts from the parietal bone of a human embryo thirteen weeks old (after *Gegenbaur*). *a*, bony septa, with the cells of the lacunæ; *b*, layers of osteoblasts; *c*, the latter in transition to bone corpuscles.

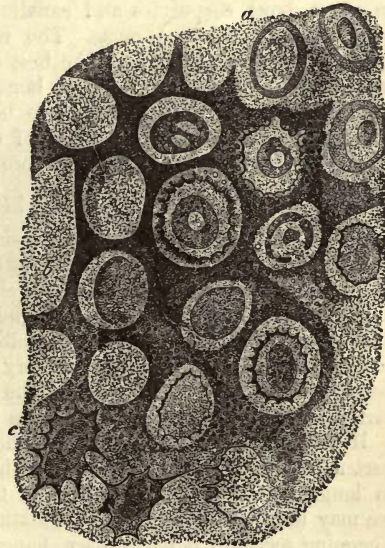


Fig. 247.—Section of the frontal protuberance of the calf (after *Gegenbaur*). *a*, hyaline, and *b*, calcified cartilage; *c*, bone corpuscles.

substance, and the consequent acquisition of new spaces for the growing bony tissue, which lays down additional layers of progressively increasing thickness, at the same time that the canaliculi are being more and more developed, the new osseous substance takes the place of the pre-existing cartilage very extensively. That a residue of the original calcified tissue may persist in the interior of fully-matured bone appears certain, although at present we know nothing definite as to the extent to which it may do so (*Tomes and de Morgan, Müller*).

That a rapid and extensive re-absorption takes place in the formed bone will be seen later on. But apart from this re-resolution of calcified osteoid tissue on a large scale, there is besides another hidden process in osseous tissue, by which older portions of the latter are dissolved, and new masses laid down in their place. This is first of all borne witness to by the nature of the medullary cells in old spongy bone, as compared to those of the same parts in younger individuals. And that there is an incessant disappearance of material of the same kind at a late period has been seen when discussing at § 141, fig. 234, the formation of the *Haversian* spaces, and their being re-lined subsequently by new lamella of bony substance.

A direct transformation, however, of cartilage into osseous tissue does likewise occur, though as a rare exception. In such cases we remark certain jagged cartilage lacunæ in the calcified tissue (fig. 247, *b*), which have arisen from a peculiar mode of thickening of layers on the internal surface of the capsules. Later on the granular calcification becomes diffuse (*c*), the jagged processes of adjacent cells unite to form passages; in short, bone corpuscles and canaliculi (*c*) are produced. In these the cells lie in twos or threes. The frontal protuberance of calves and tracheal rings of birds afford the best examples of transformations of this kind (*Gegenbaur*). In rachitic bone, also, as has long been known, isolated spots of this kind are to be found with the same transitions going on in them. In the antlers of deer undergoing ossification similar changes probably take place to a more marked extent.

§ 148.

There still remains for our consideration the formation of osseous tissue in parts of the body where cartilage is not previously laid down, to be again dissolved in order to make way for the former. Under this head we shall have to discuss, first, the origin of bone from the *periosteum*, and again the ossification of the so-called *secondary bones*.

The first of these, a process very extensively met with, and in its beginnings frequently preceding the ossification which takes place in cartilage, is the source of the increase in thickness of bones.

Holding still to the example of the cylindrical bones, we know by experience that the latter increase with the growth of the body, not only in length, but also considerably in thickness. The increase in length, we may here mention, is a continuation of the process treated of in the foregoing section: it takes place, namely, at the expense of the epiphysis and articular cartilages, whose deeper portions become calcified and then dissolved to make room for the advance of osseous substance. During this time the cartilage also grows upwards by division of its cells and accumulation of its ground substance. The increase in thickness takes place in the following way:—New layers of bone are formed under the clothing periosteum, which envelope the mass within in a series of tubes.

It is hardly necessary to add that each newly formed ring must be larger than the older one formed before it. And the growing bone also becoming lengthened, each of these osseous tubes is likewise longer than the preceding.

The importance of the periosteum in the formation of bone has been further proved by *Ollier* through a series of remarkable experiments. Detached portions of this membrane, whether still in connection with the remainder of the structure or completely separated from it, have the power of generating again a complete bone; and not only in this case, but even when transplanted to other parts of the body, or from one animal to a second of the same species. But the deeper layer of the periosteum must be carefully preserved in doing this,—a precaution which we will presently understand.

If we now turn to the histology of the process (fig. 248), we must first recall to mind the structure of the fibrous periosteum (p. 226), which is more vascular at an early period than later on. The latter consists internally (*Blastème sous-périostale* of *Ollier*) of a mass of young connective-tissue, not fibrous, but formed of fusiform and stellate cells (*b*). Under this appears the stratum of *Gegenbaur's* osteoblasts (*c*), which generate the osseous tissue here, as in the interior of calcified cartilage, and in the same manner. Both processes, the intracartilaginous as well as the periosteal, are therefore identical. The newly-formed bone (fig. 248, *c*) is irregular, and jagged towards the still soft external layers, and is traversed in the interior by sinuses, giving it a spongy texture. These are filled with medullary cells, and covering the latter with osteoblasts, and become eventually *Haversian* canals. Thus the osteoblasts, as in the intracartilaginous formation of bone, give rise also to the production of the special lamellæ of the *Haversian* passages (*a*). Bundles of connective-tissue which penetrate this new layer of bone ossify immediately, and are known later as *Sharpey's* fibres (§ 142).

During all this, however, the secondary formation of the great medullary cavity introduces new changes into the young osseous tissue. When we remember the large dimensions of the former, it is easy to conceive the great quantity of the latter which must undergo re-resolution in its production.

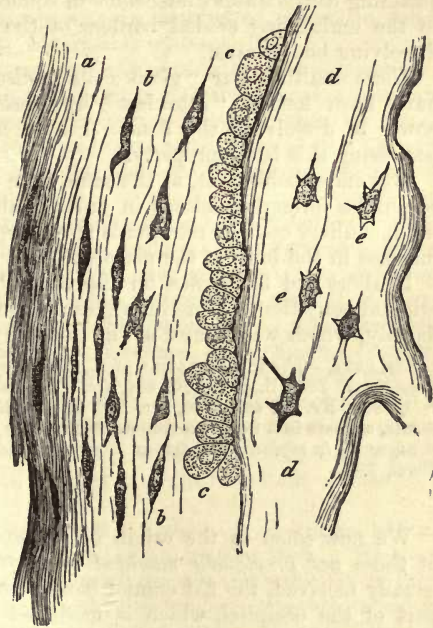


Fig. 248.—Formation of secondary bone. Longitudinal section of the femur of a well-grown fetal sheep. *a*, the internal layer of the periosteum, consisting of connective-tissue; *b*, younger stratum, or *Ollier's* layer of the periosteum; *c*, layer of osteoblasts; *d*, newly-formed osseous tissue; *e*, lacunæ and cells.

If we remember, also, that the cavity in question of a fully grown bone occupies more space than is taken up by the entire bone at an earlier period of life, we see that the whole of the primitive osseous tissue must have fallen a prey again to absorption, and the mature bone consist of osseous substance formed only from the periosteum. The layers supplied by the latter are the general lamellæ, as is easy of comprehension, and as may be seen in every section (fig. 233). Of course, from what has just been stated, it will be remarked that the oldest of them that are present become eventually medullary lamellæ, bounding the great medullary cavity.

In regard to the details of this process of re-resolution, to which we have been obliged to allude so frequently, but little was known until very lately. From *Koelliker's* very extensive investigations, it would appear that modified multinuclear cells spring from *Gegenbaur's* osteoblasts, attaining considerable dimensions in some cases: these are closely applied to the undulating eroded borders of the "lacunæ of *Howship*" of the dissolving bony tissue.

These multinuclear "giant cells" (discovered, to be sure, years ago) have been named "ostoklast" by *Koelliker*, who ascribes to them a power of dissolving the bone. I have not the faintest belief in their possessing this latter property.

It is improbable that, at the same time that this takes place, the bone-corpuscles formerly enclosed in ground-substance are set free, and, becoming medullary cells by retrograde metamorphosis, provide for the necessary increase in the bulk of the marrow.

In short and flat bones, on the other hand, a certain amount of the original bony tissue, sometimes greater, sometimes less, remains,—of that, namely, which was formed at the expense of the cartilage.

REMARKS.—The investigations of *L. Ollier* are to be found in the *Journ. de la physiologie*, Tome ii. p. 1, 170, 468, and T. iii. p. 88, as well as in the *Gazette médicale*, 1859, Nr. 37, and 1860, Nr. 12. A résumé of these works, with new experiments, appears in a new two-volume work of the same author, *Traité expérimental et clinique de la régénération des os et de la production artificielle du tissu osseux*. Paris, 1867.

§ 149.

We now come to the origin of *secondary* bones, or, better expressed, of those *not previously moulded in cartilage*. To these belong, as is usually received, the flat cranial bones, with the exception of the under part of the occipital, which is modelled first in cartilage; further, the upper and lower jaw, the nasal, lachrymal, and palate bones, the vomer, zygoma, and, finally, the inner leaf of the wings of the sphenoid and *Cornua sphenoidalia* (*Koelliker*). These spring up outside of the primordial skull from circumscribed spots, which spread out subsequently, gaining rapidly in superficial extent. Here we first meet with a (true) osseous nucleus, which grows out in all directions, forming a network of bony bands and needles (*Kalkbälkchen* and *Kalknadeln*), which are lost in the adjacent soft tissue. It is easy to recognise here, also, the similarity of the osteogenetic process to that in other parts of the system, and to see that these bony bands are covered by a layer of osteoblasts (fig. 246).

Much difference of opinion still prevails as to the nature of this original tissue, as also of that of the corresponding subperiosteal stratum; one party regarding it as an undeveloped connective-tissue substance, and not

cartilage (*Koelliker*), and another as a kind of fibro-cartilage (*Reichert*). The latter view is decidedly incorrect: we have before us most unmistakably a young and undeveloped connective-tissue, with fusiform and stellate cells.

The diffuse calcification now advances superficially, as has just been remarked, accompanied by a border of osteogenic tissue, so that the full size and ultimate form of such a secondary bone is only attained gradually, in contradistinction to the cartilaginous preformations of the first kind.

In order now that the bone may increase in thickness, a deposit of osseous substance takes place from the periosteum on both surfaces, and so the compact external layers are formed, which present at first all the porous characters of newly-formed periosteal bony tissue. The deposit of osteogenic matter from the medullary spaces resembles the process as it occurs in bones previously modelled in cartilage.

These observations tend to show what energy exists in the growth of osseous tissue, an energy in which may be manifested afresh in fully developed bone, especially under abnormal conditions.

But though these processes, as we see them in the development of cylindrical bones, are so far clear, we must not think that a solution internally and a deposit externally alone takes place: there is something more, namely, an interstitial and expansive growth ("a growth by intussusception"), such as is to be observed in almost all tissues. (*R. Volkmann*).

But highly developed connective-tissue may also, under certain circumstances, be transformed directly into bony substance. The flat cranial bones of embryonic birds (fig. 249) present to us most unmistakably, according to *Gegenbaur*, a process of this kind. Here a network of connective-tissue bundles is seen (*c*), in part still soft and fibrillated and in part granularly calcified (*d*). Later on these bands of hardened tissue become broader, are now diffusely calcified, while the cells enclosed in them remind one of bone-corpuscles. A layer of osteoblasts (*b, e*) is also demonstrable here, which deposits that stratum of bone clothing the connective-tissue framework. That we have to do here with an occurrence which, taken generally, has been already discussed in referring to the formation of *Sharpey's* fibres, is quite apparent.

The conversion of tendons into osseous tissue is well known to take place largely as a physiological occurrence in mature birds. Here we encounter, at first, a simple calcification of the connective-tissue, so that, on depriving the part of its bony earth, the tendinous texture is again presented to us unchanged. Later on, however, true osseous substance makes its appearance, with a small number of lacunæ, lamellæ, and *Haversian* canals. It was formerly supposed that here a direct transformation took place from tendinous into osseous tissue (*Lieberkühn*), but this is an error. There appear, rather, in the calcified tendon, spaces containing vessels which correspond to the medullary sinuses of cartilage, and are filled with a soft mass. From these cavities the deposit of a solid substance takes place, which becomes calcified at once, "resembling true bone more or less" (*H. Müller*). Remnants of calcified connective-tissue are left, however, in these ossified tendons.

Regeneration of osseous tissue occurs pathologically, with great frequency, on the fracture of various bones,—for the repair of breaches of continuity and replacement of lost substance, whether it have been thrown off by a pathological process or removed by surgical instruments;

further, in uninjured bones a luxuriant growth may occur, in the form of hypertrophies, exostosis, and osseous tumours. In most of these cases

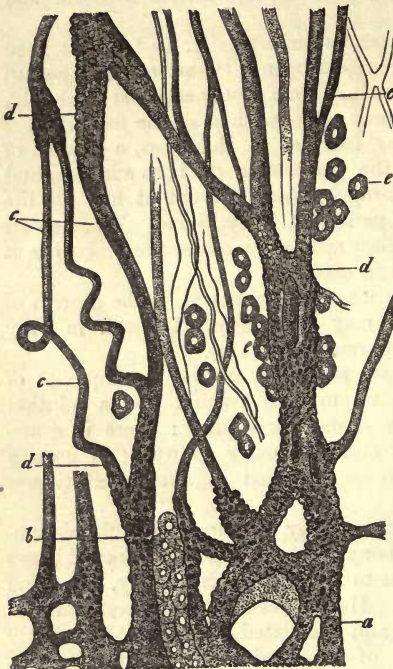


Fig. 249.—From the edge of the frontal bone of a chick undergoing ossification (from *Gegenbaur*). *a*, network of osseous bands; *d*, granularly calcified, and *c*, soft connective-tissue; *b*, *e*, osteoblasts.

the production of the new tissue takes place from the periosteum in the manner described. Without this, however, we may be satisfied of the great importance of the membrane in the production of bone from *Ollier's* experiments (p. 257). But while the medullary tissue remains inactive in the normal formation of bone, as was ascertained by the investigator just mentioned, it may, under abnormal conditions, become transformed into a more or less solid connective-tissue on its exterior—into a species of endosteum, and generate bone-like matter. The latter is rarely developed in soft parts remote from bone. The formation of true osseous tissue independent of bone is very circumscribed. It takes place, however, far on in life in cartilage, and at its expense, when the processes of foetal ossification are repeated; likewise in parts formed of connective-tissue, when a growth similar to that from periosteal osteogenic substance is the starting-point.

Masses of bone formed pathologically have frequently a porous character at first, resembling the normal tissue, but may also be compact, and endowed with a high degree of solidity.

The occurrence of re-resolution of normal osseous tissue is by no means rare in disease. It takes place with previous decalcification, in the same way as physiological absorption in growing bone.

REMARKS.—From the fact that bones not previously modelled in cartilage are in many cases developed before those others become ossified which are thus pre-formed, we may perceive that the designation "secondary" has not been very happily applied to them. An attempt has been made, therefore, to replace it by the names "tegumentary or overlaying bone" (*Deck- or Belegeknochen*). The whole thing has lost considerably in histological worth, however, according to the latest observations in osteogenesis.

11. Dentine.

§ 150.

Before entering upon the description of dentine (1), it will be necessary first to devote a few words to the consideration of the teeth, the greater part of which it forms.

A tooth may be divided into three distinct parts,—into the *crown*, which lies exposed; the *neck*, enclosed in the gum; and the *root*, buried

in the alveolus. It is hollow internally, traversed by a canal which, commencing above in the crown, terminates below at the point of the root by a free opening. In the incisor and canine teeth this cavity is single, and is divided in the others according to the number of their roots. It is filled with a peculiar connective-tissue, very vascular, and largely supplied with nerves, which is called the *pulp*. The nutrition of the whole organ takes place from this as from the *Haversian* canals of bone.

From a histological point of view the tooth may be regarded as made up of three kinds of tissue (fig. 250),—of a coating on the root, called the *cement*, *i.e.*, a bony substance; then of a layer covering the crown, known as the *enamel* (see next section); and finally, of a mass situated internally, the proper tissue of the tooth surrounding the cavity just mentioned. This has received the names of the "*ivory*," "*dentine*."

The latter possesses a hardness exceeding that of bone, and must be looked upon as a species of the latter without bone-corpuscles, and with a more regular course in its canaliculi. It appears white, in thin sections, with a satiny lustre frequently, as long as the system of canals is filled with air and is not occupied by a fluid.

These passages or *dental canaliculi* appear, in dried sections containing air, as extremely numerous and fine dark tubes of from 0.0011–0.0023 mm. and upwards. They maintain a tolerably parallel course, side by side, perpendicular to the surface of the cavity of the tooth. This is consequently vertical in the middle of the crown (fig. 250), oblique at the sides of the latter, becoming horizontal below towards the root (2). In transverse section the middle and under portions of a tooth display a radiating arrangement of the canaliculi.

If the latter become filled with fluid, they blend into the ground-substance and are rendered partly or altogether invisible, reminding us of what takes place in bone under similar circumstances.

They correspond farther with the canaliculi of bone in having a special lining layer, which is, however, thicker than in the latter. In macerated dentine this layer appears on sections in the form of tubes projecting beyond the surface. The latter may be easily isolated by the softening action of acids, as well as boiling of the tooth-cartilage or treatment with alkalis, on which they are presented to us as intercommunicating structures (*Koelliker, Hoppe, Neumann, Frey, Waldeyer*).

In suitable sections of dentine we may likewise see the canals transversely opened (fig. 251).

If we now examine into the more minute arrangement of the canaliculi in thin leaves of dentine containing air, we find their number to be greater in that portion of tissue surrounding the central cavity, and in the crown, than in the root. We remark also in the whole course of one of these tubes,

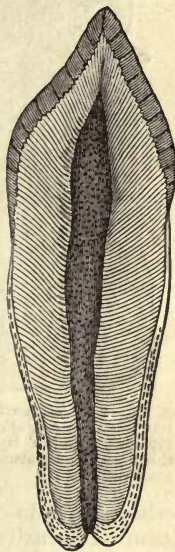


Fig. 250.—A human incisor, with the cavity in the axis surrounded by dentine, which latter is covered above by enamel, below by cement.

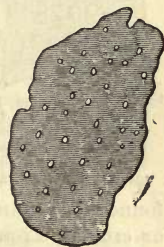

Fig. 251.—Softened dentine, with transversely cut canaliculi.

from within outwards, usually three, or sometimes only two, undulating curves (known as the lines of *Schreger*), and within these again a number of very small jagged or spiral bends, of which about two hundred may be seen in the length of a line (*Retzius*).

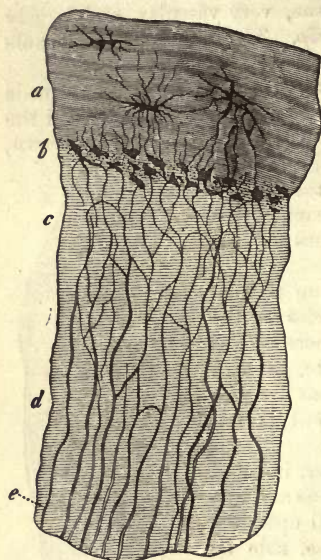


Fig. 252.—External portion of human dentine *d*, with coating of cement *a*; at *b*, the granular or *Tomes'* layer of the first of these, with interglobular spaces; *c* and *e*, canaliculi

perhaps (?) into the enamel (fig. 253, *c*). We will meet with these again. Internally, this system of canals terminates by free openings in the cavity of the tooth.

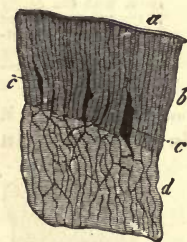


Fig. 253.—External portion of dentine, *d*, from the crown of a tooth, with its layer of enamel *b*. *a*, enamel cuticle; *c*, interstices filled with air.

Like the canaliculi of bone, those of dentine (fig. 252, *e*) are observed to divide over and over again, and to communicate through their branches; though in other respects they differ, owing to their more regular course.

In the internal portions of the dental tissue a number of divisions take place at acute angles, and in rapid succession, with decrease in the size of the branches. This becomes more rare externally, gaining again in frequency in the most superficial portions. Thus from one canal a whole system may be produced.

We encounter further, in many cases, intercommunications between adjacent canaliculi by means of oblique branches (*c*). This may lead eventually to the formation of a regular network in the external portion of the tissue (fig. 253). Here some of the canaliculi join down into the cavities of a granular layer situated at that part (*b*), and a third set advances beyond the limits of the dentine into the cement (fig. 252, *a*), or

The ground-substance of dentine, finally, is a homogeneous substance which may be split into bands artificially after maceration. The direction in which this cleavage takes place is determined by the course of the canals.

In addition to these elementary and essential features of the tissue in question may be added some of minor significance. For instance, a certain system of irregular cavities, of extremely variable size, named by *Czermak* "interglobular spaces" (fig. 152, *b*), exists normally in this tissue, the interstices between the projections of a number of more or less spheroidal masses aggregated in the ground-substance, known as "dentine globules." The cavities in question are found, very numerous and small, principally under the cement covering, or *crusta petrosa*, of the root. They here enter into the construction of the so-called granular layer of *Tomes*, and may be confounded with lacunæ, more especially as they receive into them the terminations of canaliculi. These interstices, however, contain no air during life but a soft organic mass.

Larger globules of dentine may make their appearance internally on the boundary wall of the central cavity of the tooth, communicating to it here, as has been very well said, a "stalactitic" appearance. In the crown we may frequently recognise concentric tracings running more or less parallel to the surface, probably pointing to a kind of lamination which may hereafter find its explanation in histogenesis. These are the so-called "contour-lines" of Owen.

We have already remarked that dentine may be regarded as a species of bone. Comparative histology also teaches us that the osseous tissue of many bony fishes supplies intermediate forms between bone and dentine, and that in no inconsiderable number of these the latter appears in the place of osseous tissue (*Koelliker* (3)).

REMARKS.—1. Beside the German works of *Henle*, *Gerlach*, and *Koelliker*, comp. *Todd* and *Bowman* (Vol. 2). Further, *R. Owen—Odontography*, etc. Vol. 1; Lond. 1840-45. *J. Tomes—A Course of Lectures on Dental Physiology and Surgery*. Lond. 1848; and *Philos. Transact. for the year 1856*, p. 515. *Beale*. The structure of the simple tissues. 2.

In the many-pointed crowns of the back teeth the direction of the canaliculi is the same as if every knob were the crown of a simple tooth. Between the many roots on the so-called alveolar surface, as *Purkinje* has very happily named this part, the perpendicular course of the middle portion of the crown is again re-established. 3. Subsequently to *Quekett's* having directed attention to this in certain fishes (*Catalogue of Surgeons of England*, Vol. 2), the above-mentioned German investigator proved the frequent and extensive occurrence of this interesting relation.

§ 151.

The *pulpa dentis* is the unossified remainder of the papilla existing in the embryonic tooth (see below). It is a kind of undeveloped soft connective-tissue, possibly belonging to the mucous or gelatinous species, containing numerous cellular elements of elongated or round form. The intermediate substance, which is not rendered clear by acetic acid, is

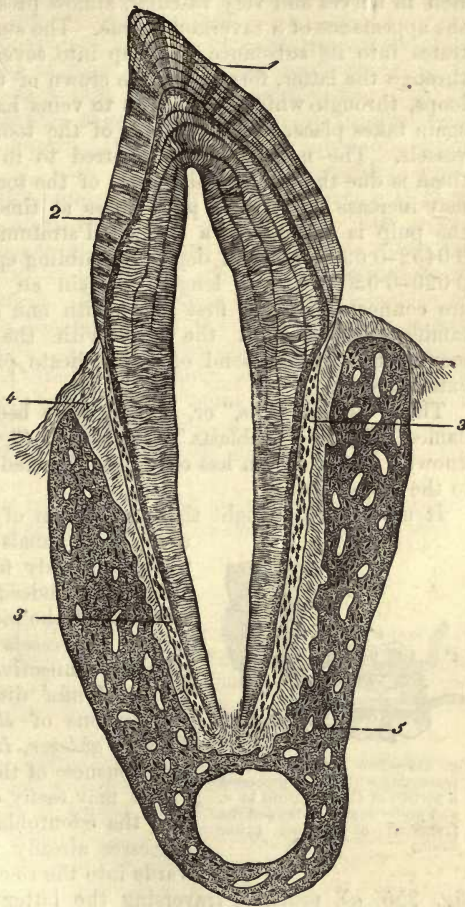


Fig. 254.—Premolar tooth of the cat (after *Waldeyer*). 1, enamel with cross and parallel streaks; 2, dentine with so-called lines of *Schreger*; 3, cement; 4, periosteum of alveolus; 5, bony tissue of the lower jaw.

indistinctly fibrous, and devoid of elastic elements. The pulp is further rich in nerves and very vascular, almost presenting in transverse section the appearance of a cavernous tissue. The small arterial stem which penetrates into its substance splits up into several branches, which advance through the latter, forming in the crown of the tooth numerous capillary loops, through which transitions to veins having a similar course back again takes place. The nutrition of the tooth is presided over by these vessels. The nerves will be referred to in a subsequent section. To them is due the great sensitiveness of the tooth, which, as is well known, may increase to intense painfulness at times. The external surface of the pulp is covered by a laminated stratum of narrow cylindrical cells, 0.0452-0.0902 mm. in depth, resembling epithelium. These elements, 0.020-0.030 mm. in length, contain an elongated nucleus. They are connected in the first place with one another by means of their ramifications, and in the next with the deeper-lying cellular elements: finally, they send off soft delicate processes, single or multiple, externally.

The "dentine cells," or, as they have been more recently and better named, the "odontoblasts" (*Waldeyer*) (fig. 255, *b*), have been long known; but attention has only been directed gradually to their relations to the dental tissue.

It used to be thought that the system of canaliculi was nothing but a series of canals possessing no formed contents, and only filled with a nutritive fluid (*Lessing*). Indeed, dentine appeared to present one of the most beautiful examples of a system of vessels for plasma in the whole group of connective-substances.

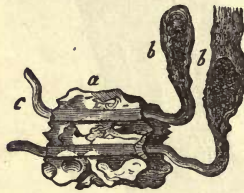


Fig. 255.—Two dentine cells, *b*, traversing with their processes a portion of the canaliculi at *a*, and projecting at *c* beyond the fragment of dentine. (After *Beale*.)

But *Tomes'* discoveries, confirmed by the observations of *Beale*, *Koelliker*, *Neumann*, *Frey*, *Waldeyer*, *Hertz*, and *Boll*, showed the erroneousness of this older view.

We may easily convince ourselves, namely, that the odontoblasts protrude those of their processes already mentioned as directed outwards into the so-called canaliculi of the tooth (fig. 255, *a*), probably traversing the latter with their ramifications in their whole length; at least, they may be still seen in the crown of the adult tooth. It would appear also as though these fibres of *Tomes*, or "dental fibres," filled up the whole lumen of the passages.

It has been supposed that the structures resembling canaliculi, isolated by means of maceration, are nothing but these ramifications of the dentine cells. This, however, is not correct; for even after processes which must have destroyed all the softer parts of the tooth, after the most active decomposition, canaliculi endowed with a special wall may be laid bare (*Neumann*).

This wall can just as little be looked upon as the calcified membrane of dentine cells and their processes as in the corresponding elements of bone. It is here also, as in bone, a modified bounding layer of the ground-substance, so that we are correct in speaking of "dental sheaths" (*Neumann*, *Waldeyer*, *Boll*).

Tomes' view of the matter is of great interest: he refers the great sensitiveness of the dentine to the soft fibres of these cells. We shall

have to discuss this point at greater length in a future section, when considering the termination of the nerves of the pulp.

In passing, it will be convenient to touch here on the nature of the *cement*, or *crusta petrosa*, of the teeth. This commences at the termination of the enamel as a thin layer clothing the root (figs. 250 and 254), increasing in thickness below until it attains its greatest thickness at the point of the latter. It is, however, nothing but simple osseous tissue (fig. 252, *a*), and, like this tissue, generally greatly inferior in hardness to dentine and still more so to enamel. It is not always sharply defined against the ivory of the tooth. Its ground-substance is sometimes homogeneous and sometimes streaked: when very thick it may also appear faintly laminated, but it rarely comes to the formation of *Haversian* canals. No bone-cells at all are found in the cement around the neck of the tooth, and they only become numerous towards the point of the root. Their size and shape, and the number of their ramifications, which is often considerable, are more liable to variation than those of ordinary bony tissue. Some of these ramifications are united with the canaliculi of the tooth which have penetrated as far as the cement; others form anastomoses with adjacent cells (fig. 252, in the middle of *a*).

These lacunæ must not be confounded with clefts which are frequently to be met with in the cement of old teeth in the form of irregular, branching interstices.

§ 152.

Dentine, whose specific gravity is 2.080 according to *C. Krause*, contains, notwithstanding its hardness, several per cent. of water: some analyses give 10 per cent. It consists, like bone, of a gluten-yielding substratum, rendered hard by a considerable excess of calcium and also magnesium salts.

The organic substratum, determining the form of the structure, is collagenic matter without any admixture of chondrin. An interesting observation has been made in regard to the walls of the canaliculi, namely, that though they may be isolated by means of the stronger acids and alkalies, they remain for a time undissolved in a *Papin's* digester, in which the ground-substance is transformed into gluten (*Hoppe*), showing that these canals are not formed of gluten-yielding matters. We have thus a similar condition of things as in the lacunæ of bone and their ramifications. The dentine globules also are not convertible into gluten, and their substance offers even a more determined resistance to the action of acids than the other portions of the tissue.

The bony earths of dental tissue consist of a considerable proportion of phosphate of calcium, with a smaller quantity of carbonate, and also—taking a more subordinate place—fluoride of calcium and phosphate of magnesium. The carbonate of calcium appears to be subject here to more variation in amount than in bone. Fluoride of calcium was originally determined by *Berzelius*, and *Bibra* made the interesting discovery that the dentine of many mammals is comparatively very rich in phosphate of magnesium.

Beside these, many other salts and mineral constituents are met with in the teeth, and also a small proportion of fat.

The bony earths, taken quantitatively, amount in human dentine from

71 to 78 per cent., while the collagenic substratum of the tissue (the so-called *tooth cartilage*) ranges about from 20 to 29 per cent.

The following two analyses of *Bibra* may be taken as an example. They refer to the dried dentine of human molar teeth. The first of these was from an adult male; the latter from a woman twenty-five years of age.

	1.	2.
Organic collagenic substratum,	27.61	20.42
Fat,	0.40	0.58
Phosph. and fluoride of calcium.	66.72	67.54
Carb. of calcium,	3.36	7.97
Phosph. of magnesium,	1.08	2.49
Other salts,	0.83	1.00

As to the softer *crusta petrosa*, any distinction from dentine is doubtful. The investigations which have taken place up to the present show somewhat more organic substratum yielding gluten. Its nature is otherwise similar to that of dentine. *Bibra* obtained from that of the human teeth, 29.42 (inclusive of some fat) of organic substance, and 70.58 of mineral constituents.

§ 153.

The *development* of the teeth (1), as productions of mucous membrane, is, even in its coarser outlines, a most difficult chapter in embryology.

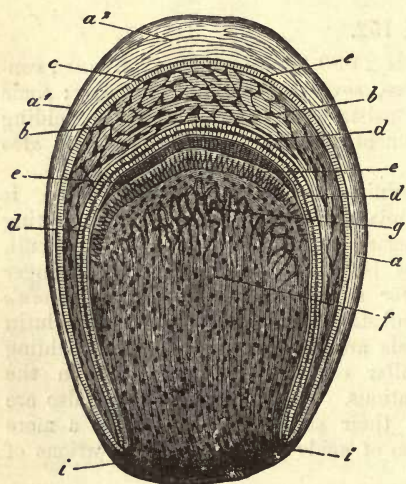


Fig. 256.—Dental sac of a human embryo at an advanced stage of development, partly diagrammatic. *a*, wall of the latter, formed of connective-tissue, and with its outer stratum *a*¹, and inner *a*²; *b*, enamel organ with its papillary and parietal layers of cells *c*; *d*, the enamel membrane and enamel prisms; *e*, dentine cells; *f*, dental germ, and capillaries *g*; *i*, transition of the connective-tissue of the wall of the follicle into the tissue of the dental germ.

From the fourth month on of intra-uterine life, we remark in the human embryo preparation for the formation of the future milk-teeth. This takes place on the edges of the jaws, by the formation of closed follicles, from the floor of which a papilla projects into the cavity, destined to produce the dentine of the structure, and, moreover, in the first place, that of the crown, while the remainder enters into the formation of the pulp. These papillary structures, which resemble in form the crown of the future tooth, are called the "tooth" or "dental" germs."

In fig. 256 we have a sketch of one of these follicles from a tolerably mature embryo, with its but ill-defined wall of connective-tissue (*a*) and dental germ (*f*) containing numerous capillaries (*g*). The latter is covered by a peculiar structure,

in the form of a cap, hanging down over its sides (*b*). This has been named the "enamel-organ," on account of its presiding over the production of the enamel, as we shall see presently. Its concave inferior surface is lined by a layer of narrow cylindrical cells (*d*) covering the dental

germ, while its convex external aspect is covered by a similar coating of smaller cells (*c*).

But though all is so far tolerably clear, we are now met by the difficult question, so variously answered at different times, as to how these several structures take their origin.

Recent investigations, and the researches of *Tiersch* and *Koelliker*, supported at a later date by those of *Waldeyer* (with which my own subsequent observations correspond), seem to point to the following conclusions.

The parts which are contained in the dental sac are of various origin. The dental germ corresponds to a papilla of the mucous membrane, which becomes enclosed in the parietal portion of the follicle as with a sheath of the latter. Both these structures have their origin from the proper tissue of the mucous membrane of the foetal jaw.

The enamel organ, on the other hand, is a production, by reduplication, of the mucous epithelium, which covers the dental germ, just as a papilla of the mucous membrane is covered by cuticular tissue. But the mass which has grown down into the gum has (in the phase in which we see it in fig. 256) become completely separated, by the closing in above, from its original source of origin.

In order really to understand these relations, we must look back to a much earlier period of foetal existence.

Originally, before any trace of either dental germ or tooth sac is to be seen, the edges of the jaws, which are marked with a slight groove known as the "dental groove," are covered by a thick ridge of epithelium, just over the spots where the future structures are to be formed. This latter has been named the "dental ridge" (2) by *Koelliker* (see fig. 257, 1 *a*, 2 *a*).

The epithelium soon after commences to grow down from the dental groove into the substance of the mucous membrane, in the form of a leaf-shaped process, which becomes curved downwards and inwards, appearing sickle-shaped, in vertical transverse sections. To this the

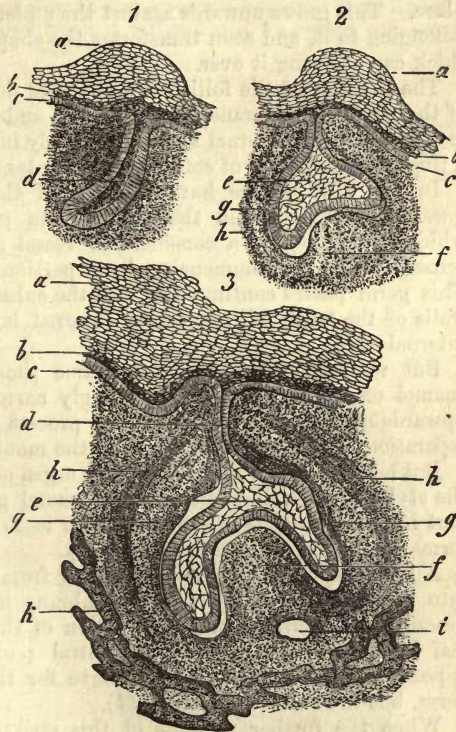


Fig. 257.—Development of the teeth from *Thiersch's* preparations of embryonic pigs (vertical transverse sections of the upper jaw). 1, 2. From a small embryo: the right and left halves of the maxilla. *a*, dental ridge; *b*, younger layer of epithelium; *c*, the deepest; *d*, enamel germ; *e*, enamel organ; *f*, dental germ; *g*, inner, and *h*, outer layer of the growing tooth sac. 3. From an older embryo: *d*, the style of the enamel organ; *f*, blood-vessel severed; *k*, bony substance. The remaining letters as in 1 and 2.

name of "enamel germ" has been given (1 *d*). Its walls are formed of narrow cells arranged perpendicularly, and its interior is taken up by small round cells.

Later on may be seen how various parts of this enamel germ (3) increase in breadth at their deepest half, at those spots where the development of the several dental papillæ is to take place, thus preparing the way for the formation of the individual enamel organs (2 *d*). It is the small round cells of the interior just mentioned which principally occasion this enlargement, in that they gradually become transformed into the already well-known non-vascular gelatinous tissue (fig. 181) with stellate elements (2 *e*).

After this the formation of the dental germ or tooth papilla (2 *f*) takes place. This grows upwards against the under surface of the enamel organ belonging to it, and soon transforms the shape of the latter into that of a thick cap covering it over.

The parietes of the follicle are now laid down from the adjacent tissue of the mucous membrane, but gradually and but ill-defined, and soon we may recognise an external and more closely interwoven stratum (2 *h*), and a thick internal layer of softer and looser texture (2 *g*).

In fig. 257 (3) we have represented the stage of development in question. At *f* is seen the dental germ projecting upwards, beneath which the lumen of a considerable vessel appears which has been cut across (*i*), and the commencing bony portion of the upper jaw-bone (*k*). This germ passes continuously into the substance of the still unfinished walls of the tooth follicle, whose external layer is to be seen at *h*, and internal at *g*.

But we recognise also, at the same time, that the style (*d*) of the enamel organ (*e*) has become strongly narrowed, owing to the growth upwards of the walls of the sac,—a process which is destined to effect a separation of the enamel organ from the mouth.

But before this the formation of an organ of the future takes place from the style, namely, of the *secondary* enamel germ. This plays the same part in the rudiments of the permanent teeth as its predecessor did in the formation of the milk-teeth (*Koelliker*).

A leaf of epithelium is seen to spring from this style, and to sink down into the tissue of the mucous membrane in a manner similar to that described as occurring in the formation of the first enamel organ. This leaf lies beside the latter in a central position. From this it would appear that the permanent teeth have for their formation a new dental germ, but the old enamel organ (4).

When the further progress of this striking and interesting series of changes leads to the obliteration of the stalk-like connecting bands of epithelium between the summit of the enamel organ and the epithelium of the jaw, we arrive at the phase of development presented to us in fig. 256: the parietal portions of the tooth sac have closed over the enamel organ, covering it in.

REMARKS.—1. Literature is very rich in essays on the development of the teeth. Compare (beside the older and more recent German writings) *Goodsir*, in the *Edinburgh Med. and Surg. Journ.*, 1838, No. xxxi. 1; *Huxley*, in the *Quart. Journ. of Microsc. Science*, vol. iii. p. 149, vol. x. p. 127, and vol. xix. p. 166; *Magiôt*, *Études sur le développement et la structure des dents humains*, Paris, 1856; and also *Comptes rendus*, 1860, p. 424; *Guillot* in the *Annal. des scienc. nat.*, 2 Série, Tome ix. p. 227; *Jolly* in the same, 3 Série, Tome ii. p. 151; *Robin et Magiôt* in the *Journ. de la physiologie*, Tome iii. p. 1, 300, 663, and Tome iv. p. 60; as also in the *Gaz. méd. de Paris*, 1860–61, in many places. 2. For a long time *Goodsir's*

description was held to be correct. According to him, the first item in the development is the formation of a groove in the edges of the jaws, taking place in the human embryo during the sixth week. In this the twenty-teeth germs of first dentition take their rise. He supposed hollows to be formed around these by the subsequent development of septa between the several dental germs, and that these underwent later on a closure above. This theory of *Goodsir* was attacked most vigorously, at a later date, in the works of French histologists,—*Guillot*, *Magitot*, and *Robin*. According to the latter, the tooth sacs, dental germs, and remaining parts, are developed, in the first instance, within the sub-mucous connective-tissue, quite independent of epithelium and mucosa. 3. *Huxley* was the first to declare the whole enamel organ to be of epithelial origin. 4. In the fifth month of intra-uterine life there may already be seen new follicles, situated above the germs of the milk-teeth in an oblique position. They become, however, more vertical later on, and lie behind and beneath the milk-teeth. Their ossification is spread over the earlier years of infancy. Since the histogenic occurrences in both cases are similar, it will suffice if we confine ourselves in the text to the consideration of the milk-teeth.

§ 154.

The connective-tissue envelope of the tooth sac (fig. 258, *a*) consists (as we have already seen in the previous section), at an early period, of two layers, an external (a^1) and an internal (a^2). The first of these presents a great denseness in its fibrous texture; the latter, rich in cellular elements, preserves a softer and more gelatinous character. The inner surface of the dental sac assumes a more or less homogeneous aspect, and to such an extent sometimes that a hyaline terminal layer has been spoken of.

The occurrence of villous projections of this inner layer, which are directed towards the surface of the enamel organ, is of great interest. They appear to be equivalent to the ordinary vascular papillæ of a mucous membrane (1). A complex vascular network, which receives its blood from the vessels of the jaws and gums, traverses the whole parietal portion of the dental sac, and may be seen forming loops in the projections just mentioned.

The enamel organ presents for our consideration, upon its concave under surface, a coating of epithelial cells already long known. The latter are narrow, cylindrical, and nucleated; in length 0.0226–0.0338 mm., and in breadth 0.0451 mm. The whole of this layer was formerly called the *enamel membrane*.

The epithelium, on the other hand, which clothes the external convex surface of the enamel organ (*b*), was only generally recognised at a later date. It consists of low cells, measuring in man 0.0113 mm. (2).

The last-named coating, however, does not by any means everywhere possess the same thickness: it forms, rather, numerous small bud-like

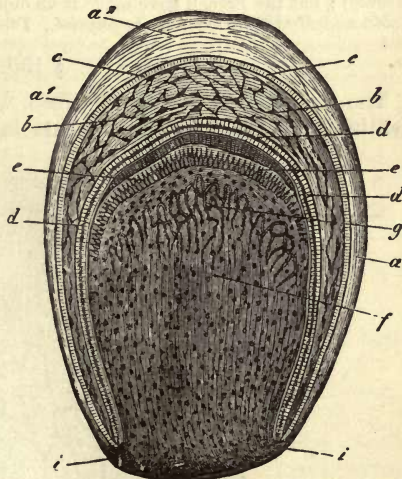


Fig. 258.—Dental sac of a tolerably mature human fœtus, partly diagrammatic. *a*, fibrous wall of the sac with its external stratum a^1 , and internal a^2 ; *b*, enamel organ, with its papillary and parietal cells *c*; *d*, enamel membrane and enamel prisms; *f*, dental germ with its capillaries *g*; continuation of the connective-tissue of the parietes into that of the dental germ.

growths towards the follicle, especially at that portion covered by the gum. These interdigitate with the vascular tufts just referred to.

We have already considered, in § 116, the gelatinous non-vascular tissue enclosed in the cellular tunic of the enamel organ, so that we refer the reader again to what was there remarked.

The dental germ (*f*) appears to be formed of an undeveloped connective-tissue, of a finely granular dull mass, containing a multitude of roundish nuclei and cells of like shape, or more or less fusiform. It is, moreover, highly vascular, the capillaries being recognisable at a short distance from its surface, forming numerous terminal loops (*g*, and fig. 258). Numerous nerves are also formed in it subsequently, whose origin calls for more accurate investigation, as also the question as to the occurrence of lymphatic vessels.

The dental germ is covered by delicate cells arranged in strata, now more or less cylindrical, now of irregular figure (fig. 258, *e*; 259). These are the *dentine cells* or *odontoblasts*, whose nature and position in the perfect tooth has already been treated of in § 151. They correspond to the osteoblasts of *Gegenbaur*, which we have seen in the bony tissue (§ 147). These cells, taken as a whole, have been described as the "ivory or dentine membrane."

REMARKS.—1. These villous projections were first seen by English investigators (*Huxley*, *Goodsir*, *Todd*, and *Bowman*, *ll. cc.*), and then more accurately described at a later date, principally by *Robin* and *Magitot*. 2. The epithelium on the outer surface of the enamel organ was also first recognised by English observers (*Nasmyth*, *Huxley*); but the French have made it an object of closer study; comp. *Guillot*, *l. c.*, *Robin* and *Magitot* (*Journ. de la physiol.*, *Tome 4*, p. 71).

§ 155.

The dental germ is now destined, with the odontoblasts, to produce dentine. To this end the elements in question send out long filiform

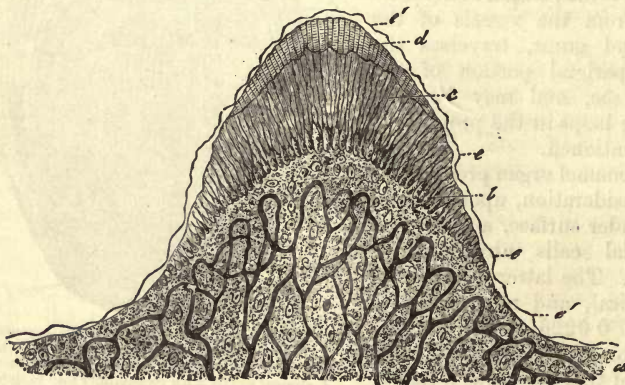


Fig. 259.—Vertical section of the dental germ of a human molar tooth with incipient calcification. *a*, vascular germ; *b*, ivory cells, and dentine *c*; *d*, enamel; *e*, so-called *membrana praeformativa*.

processes externally, which constitute the soft dental fibres of *Tomes*, already known to us from § 151. Between them a homogeneous substance then makes its appearance, whose origin must be accepted as being similar to that of the intercellular matters of the connective-tissue

group. This is converted into dentine by a diffuse calcification similar to that of the so nearly allied osseous tissue; while the walls of the canaliculi of the teeth are formed by the bounding laminae of the mass surrounding the fibres of *Tomes*.

The following sketch may be accepted as tolerably faithful as far as we are acquainted with the course of development, so difficult to follow.

Young dentine cells (fig. 259, *b*; fig. 260) present themselves as membraneless nucleated structures closely crowded together, and of irregular jagged form, and united one with another by means of short processes. Externally, they send off single or multiple prolongations, which form interlacements by means of side branches with the processes of adjacent cells. The odontoblasts eventually become

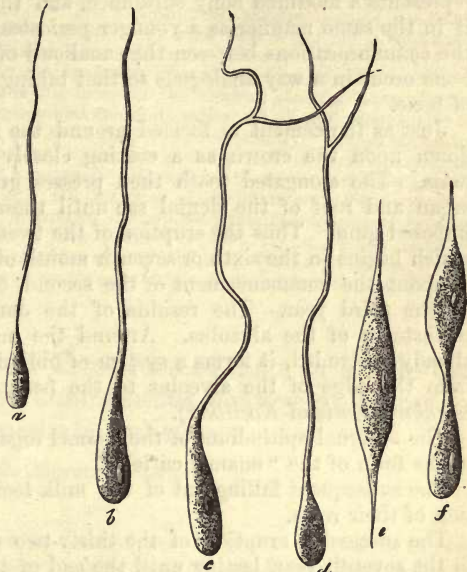


Fig. 260.—Dentine cells after *Lent*. At *a* and *b*, simple filiform processes, which become converted into canaliculi; *c*, *d*, specimens of the latter with branches; *e*, fusiform cell; and *f*, one of the latter undergoing division.

longer and narrower, and the more peripheral portions of their processes attain a considerable length. Thus are formed the soft fibres of *Tomes*.

The calcification already mentioned commences at the apex of the dental germ, in the tissue just described, in the form of a single, or frequently, at first, of several separate thin plates. This plate has been named the "dental cup" (*Zahnscherbchen*) (fig. 259, *c*). On the further superficial extension of this structure the calcified layer spreads down over the sides of the dental germ, in which, with the commencement of calcification, the vascular network has already reached its fullest development.

But, owing to the continued production of the fibres of *Tomes*, of the canaliculi and the ground-substance, through the agency of the still soft ivory cells below the dental cup, and the progressive calcification of the ground-substance, the thickness of the dental germ decreases more and more, although it has grown considerably in length.

This increase in length leads eventually to the formation of the root, which is changed into ivory exactly in the same way as the crown, and becomes calcified externally.

The production of the cement commences before the passage of the teeth through the gums, as soon as the root is developed. But the bony mass in this case arises, it is supposed, from a growth of the inferior portion of the dental sac, the latter becoming converted into osteogenic substance, as in the growth of the periosteum, and undergoing diffuse calcification. Osteoblasts and bundles of connective-tissue are also to be

seen here, the latter reminding us of *Sharpey's* fibres (§ 142) in the way in which they ossify. According to this description, both parts have a similar or identical nature to that of osseous tissue. Dentine represents a modified bony substance, and the cement is deposited upon it in the same manner as a younger periosteal layer upon an older, while the communications between the canaliculi of the tooth and those of the bone occur in a way analogous to that taking place in concentric growth of bone.

Just as the cement is formed around the root, so is the enamel laid down upon the crown as a coating closely adherent to the subjacent mass. The elongated tooth then presses gradually against the enamel organ and roof of the dental sac until these disappear with the superimposed gum. Thus the eruption of the twenty milk teeth comes to pass, which begins in the sixth or seventh month of an infant's life, terminating at about the commencement of the second, or sometimes in the middle of the third year. The residue of the dental follicle persists as the periosteum of the alveolus. Around the milk teeth, which have been already protruded, it forms a system of obliquely ascending fibres passing from the edge of the alveolus to the neck of the tooth (*ligamentum circulare dentis* of *Koelliker*).

The external epithelium of the enamel organ may, perhaps, persist also in the form of the "enamel cuticle."

The subsequent falling out of the milk teeth is preceded by re-absorption of their roots.

The successive eruption of the thirty-two permanent teeth commences in the seventh year, lasting until the end of the second decade, when the wisdom teeth make their appearance.

The cause of the falling out of the teeth at an advanced age has not yet been sufficiently cleared up. It is probable, however, that a narrowing of the canaliculi, and degeneration of *Tomes'* fibres, prepares the way for the decay of the organs.

The origin of dental caries requires also further investigation. In it we remark in succession, softening and destruction of the enamel membrane and enamel, of the dentine in its ground-substance, and of the dental sheaths and fibres. In this process vibriones and filiform fungi make their appearance.

The so-called tartar of the teeth consists of albuminates and allied matters from the fluid of the mouth, together with a large proportion of phosphates. The former amount, according to *Berzelius*, to 21, the latter to 79 per cent.

Hypertrophies of various external portions of the teeth are of frequent occurrence: they generally affect the cement or dentine, or both together.

There likewise occurs frequently enough a new formation of dentine on the internal surface of the tooth and an ossification of the pulp. To compensate for the wear and tear of the crown also, produced by chewing, and also of loss of substance on the external surface through disease, there are new layers of dentine laid down by the pulp on the interior of the central cavity.

Teeth which have been drawn may again become attached, and healed in their alveoli on being replaced.

The formation of teeth in strange localities occurs also as a rarity, especially in the ovary, but occasionally in other situations.

REMARKS.—1. Here we meet with two different views, as in considering bone and connective-tissue. According to one of these, dentine arises from the odontoblasts in the form of an intercellular substance produced by the latter; according to another, a direct calcification of these cells takes place. The latter theory has been defended recently, principally by *Waldeyer*:—"The formation of dentine consists in a transformation of part of the protoplasm of the ivory cells into a glutinous substance, which becomes subsequently calcified, after which the other unchanged part of the body of the cell remains over in the hardened mass in the form of soft fibres." 2. Besides diffuse calcification, the laying down of the *dentine globules* takes place at this period. These are small spheroidal calcified bodies, which are supposed to be partly permanent (p. 262), and partly to disappear subsequently. *Hoppe* maintains that they are not simple concretions of the bony earths with an organic collagenic substratum, as has been already mentioned. He was unable to convert their organic substratum into gluten by boiling. He is rather of the opinion of *Hannover*, that their nature is cellular. In the interstices incompletely calcified appearing between them, again we have the "interglobular spaces" touched on in section 150. 3. See *Trans. of the London Pathol. Society*, vol. vii., p. 185. Earlier numbers also of this periodical contain other important works of the same author on the diseased states of the teeth.

D. Tissues composed of Transformed and as a rule Cohering Cells, with homogenous, scanty, and more or less solid Intermediate Substance.

12. Enamel Tissue.

§ 156.

Enamel, which in the human subject is confined to the teeth, as also among the higher animals, and which is, as we shall find further on, a decidedly epithelial production, presents a glistening white appearance like porcelain, but may also be met with of a more or less yellow or bluish tint. Its surface appears at first quite smooth, but by the help of a lens we may usually discover a number of delicate grooves encircling the crown, of which *Retzius* counted 24 to the 1 mm., and which become more frequent down below near the edge of the cement. Like the osseous coating of the dentine, the enamel is thinnest at the neck of the tooth, where it is sharply defined against the cement. From this point upwards it becomes stronger, attaining its greatest thickness in the middle of the crown (comp. fig. 250, p. 261). Examined with polarised light, enamel displays much more double refracting power than either dentine or cement (*Hoppe, Valentin*).

From the examination of finely ground sections, or of small portions of enamel macerated in acid, we gather, that the tissue (fig. 261) consists of long polyhedral fibres or pillars, closely crowded together, and held thus by a scanty amount of some cementing substance.

These are called "enamel columns or prisms." They generally extend through the whole thickness of the enamel layer, resting with one end on the dentine, while the other assists in forming the surface of the former. It is possible, however, that shorter prisms also occur, which terminate at a greater or less distance from the dental tissue. Their transverse diameter lies between 0.0034 and 0.0045 mm., and

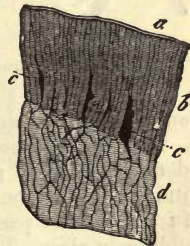


Fig. 261.—Vertical section of enamel, with subjacent dental tissue, from the human tooth. *a*, enamel cuticle; *b*, enamel prisms; *c*, interstices between these latter; *d*, dentine with its tubes.

their direction roughly taken corresponds to that of the canaliculi of the tooth.

If a transverse section of the enamel layer be made, the cut prisms appear like a delicate tessellated pavement of four or six sided plates, reminding one of epithelium (fig. 262).

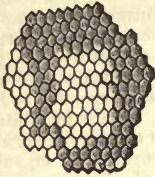


Fig. 262.— Transverse section of human enamel prisms.

Finally, the enamel is coated and protected by an extremely hard and resistant homogeneous membrane discovered by *Nasmyth* (fig. 261, a). This is the so-called "enamel cuticle" or *cuticula dentis* (*Koeliker*). Its thickness is about 0.001–0.0013 mm.

§ 157.

Nearer inspection discloses to us many peculiarities in the texture of enamel.

Owing to the fact that certain groups of the prisms project deeper into the surface of the dentine than others, the latter becomes rough and uneven. Further, a question arises whether the prisms do not increase in breadth externally, since the internal surface of the layer appears to be less extensive than superficial, and since no considerable interstitial substance can be detected; or whether a certain number of the prisms, shorter than the others, may not terminate at some distance from the surface of the subjacent dentine. The occurrence of such short pillars has been supposed by many, although it is hardly possible to decide the question owing to their unsteady course. *Czermak* states, however, that he has often observed a widening of the columns externally.

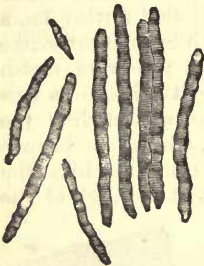


Fig. 263.—Pieces of human enamel prisms.

The latter (fig. 263) display as a rule, in varying clearness and distance, a transverse linear marking, which may be partly dependent perhaps upon the progressive laminar calcification of the structure (*Hannover, Hertz*).

Finally, as to the direction of the individual prisms, we find it very variable; owing to their undulations and different bends, whole groups of them may intersect others. Thus in longitudinal sections, the prisms are cut through, in part longitudinally, in part transversely and obliquely, and so communicate a streaky appearance to the surface.

Enamel possesses no special nutritive canals. But a system of accidental cavities is met with in it (fig. 261, c), which vary greatly in magnitude, and are sometimes simple, sometimes branched, mostly elongated in a direction parallel to that of the prisms: they may, however, run obliquely also. They are usually situated in that portion of the enamel tissue nearest to the cement. But rents and cracks resulting from the grinding of sections may give rise to the same appearances. Finally, it seems probable that some of *Tomes'* fibres penetrate with their canaliculi from the dentine into the substance of the enamel, as already mentioned, and run here for a short distance between the prisms, either sinking into the cavities or coming to an end among the prisms.

REMARK.—Comp. *Tomes'* work (*Phil. Transact.*), p. 522.

§ 158.

This substance enamel, now under consideration, is the hardest and densest in the body, and admirably suited for the protection of the subjacent dentine. In this respect, however, the prisms are excelled by the enamel cuticle.

As far as we know of the *chemical constitution* of this tissue, it is the poorest in water of any in the system, and most rich at the same time in inorganic constituents. For every 2, 4, or 6 per cent. of organic matter which retains the form of the prisms after treatment with acids, but which yields no gluten on boiling (*Hoppe*), we find 81-90 per cent. of phosphate, 4-9 of carbonate, and more than 3 per cent. of fluoride of calcium (according to *Berzelius*); also 1.5-2.5 of phosphate of magnesium. We shall take as examples the two following analyses of *Bibra*, of which the first refers to the enamel from the molar tooth of an adult man, and the latter to that from a woman of twenty-five years of age:—

	1.	2.
Organic substratum,	3.39 (?)	5.97
Fat,	0.20	traces
Phosphate and fluoride of calcium,	89.82	81.63
Carbonate of calcium,	4.37	8.88
Phosphate of magnesium,	1.34	2.55
Other salts,	0.88	0.97

Partially developed enamel is naturally far richer in organic constituents. The substratum of organic matter found in the *enamel cuticle* is remark-

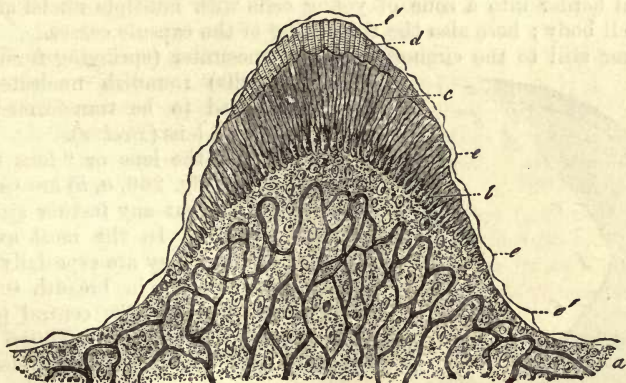


Fig. 264.

able for its power of resisting acids and alkalis. It yields, moreover, no gluten (*Koelliker*).

The *development* of enamel takes place, as has long been known, from the cells clothing the concave surface of the enamel organ (fig. 258, *c*), and in such a way that each future prism corresponds to a cell. The process is, however, still a matter of controversy, although everything seems to point to the conclusion that a calcification of the bodies of the cells takes place.

As we are already aware, the latter at first appear in the form of cylindrical structures, with vesicular nuclei and very delicately granular contents, and of about the same breadth as the prisms. Later on, as the

calcification of the dentine is commencing, we may remark the surface of the latter covered with already hardened but still short prisms (fig. 264, *d*). Not seldom we encounter appearances as if over these prisms there were superimposed a special cuticle, the so-called *membrana præformativa* (fig. 264, *e*). Such a membrane does not in reality exist however, and the whole is only a deceptive appearance produced by the youngest layer of enamel which is undergoing development, and which may often be raised off in the form of a membrane (after the decalcification of the whole) from the fully formed tissue beneath.

13. Lens Tissue.

§ 159.

The *crystalline lens* (1) consists of a capsule enclosing a tissue formed of extremely fine transparent fibres or tubules. The latter have had their origin from the cells of the corneous embryonic plate, and the whole structure bears a decidedly epithelial character.

The *capsula lentis* (fig. 265, *a*) is a perfectly transparent membrane, apparently structureless, and only under very high magnifying power finely streaked. It is much thicker anteriorly than posteriorly (about 0.0135–0.0068 mm.). The inner surface of the anterior half of the capsule is lined with flattened epithelium of simple nucleated cells, already mentioned § 87. These measure from 0.0169 to 0.0226 mm. in diameter (fig. 265, *b*, and 269, *d*).

In the neighbourhood of the *zonula Zinnii* this epithelium passes at its external border into a zone of young cells with multiple nuclei and but little cell body; here also the thickening of the capsule ceases.

Nearer still to the circumference we encounter (springing from these formative cells) roundish nucleated elements, destined to be transformed into the fibres of the lens (*Becker*).

The *fibres* of the lens or "lens tubes" (*Linsenröhren*) (fig. 266, *a, b*) are pale and transparent, without any further structure in their interior. In the most external layers of the lens they are especially transparent, and measure in breadth 0.0902–0.0113 mm., while in the central portion of the organ they are finer (0.0056 mm.), but more distinctly bounded and clearer.

The fibres at the periphery (*d*) possess a viscid homogeneous contents, probably enclosed in a very delicate envelope, and deserve, therefore, rather the name of tubes.

Those of the interior (*b*), on the other hand, have become more solid, and not unfrequently present a serrated appearance along their border, a condition of great significance, for the adhesion of the several tubes one with another, especially among fishes, where these edges are regularly toothed.

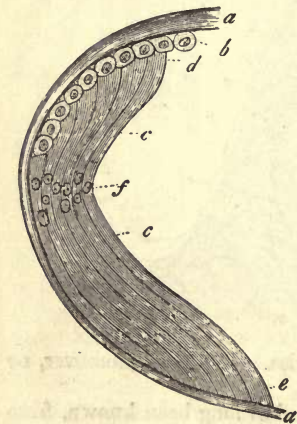


Fig. 265.—Diagrammatic sketch of the human lens. *a*, the capsule; *c*, the fibres of the lens, with widened ends, *a*, applied to the anterior layer of epithelium *b*, and abutting behind against the capsule *c*; *f*, the so-called nucleus zone.

As may be seen even from side views, the fibres of the lens are not

As may be seen even from side views, the fibres of the lens are not

cylindrical, but more or less flattened (fig. 266, *a*). This is, however, most evident when we take the transverse section of a dried lens (fig. 267) for our object. Here we find the several tubes most delicately marked out as compressed hexagonal figures, measuring 0.0113–0.0056 mm. in breadth.

Looking now to the arrangement of the fibres (fig. 265), we find them placed meridionally, passing from the middle portion of the anterior half of the capsule over the equator of the organ to a corresponding point on the posterior half. Their broad surfaces are always directed outwards, and their borders are closely applied to those of adjacent fibres. Owing to the latter union being the stronger of the two, whole layers of fibres can be peeled off from the lens in the form of delicate concentric lamellæ, which follow at the surface of the organ the greater curves of the latter, while within they are more circular.

In perpendicular sections of hardened lenses the fibres (fig. 265, *c*) are seen to spring up with a broad extremity (*d*) under the epithelial coating (*b*) of the anterior wall, and then, pursuing their curved course, to end in a similar manner by insertion into the posterior half of the capsule (*e*), which is devoid of cells (2). In following up this course of the fibres, we remark in the neighbourhood of the equator of the organ, in each, a beautiful rounded vesicular nucleus (*f*), about 0.0074–0.0129 mm. in diameter.

A glance through the transparent tissue down upon this arrangement of the nuclei, the "nucleus zone," of *H. Meyer*, is one which well repays the observer for the trouble of preparation. The statement, however, that each fibre of the lens possesses only one nucleus is not correct in all cases (see below): in a fetus of eight months old I myself have seen them with two or three, most distinctly visible (fig. 270).

We must not, however, picture this nucleus zone to ourselves as a diaphragm occupying the equatorial plane; it resembles far more a leaf attached at the periphery, which is continued inwards in an undulating course, at regular distances from the rays of the "lens star," to be referred to immediately (*von Becker*.)

The cloudy organ of the infant (fig. 268) presents for our consideration a very peculiar arrangement in its structure in the relations of the so-called "lens stars." In the centre of the anterior surface (*a*), namely, we perceive three bands meeting together at an angle of 120°, forming a three-rayed star or inverted Y. On the posterior wall, either a similar figure reversed is met with or that of a four-rayed star (*b*). In the first case the arms of the posterior Y occupy a position in relation to the anterior as though turned on their axis to the amount of 60°. Later on in life each of these rays subdivides at acute angles into regular series of branches, giving rise to complicated stellate figures.

The microscope teaches us that within such a ray and its system of

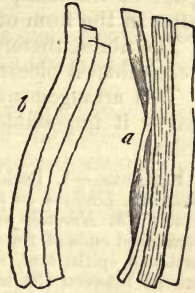

Fig. 266.—Fibres of the human lens. *a*, from the circumference; and *b*, from the more central part.



Fig. 267.—Transverse section of the fibres of a dried lens.




Fig. 268.—Lens from an infant. *a*, the anterior; *b*, the posterior surface.

branches there exists no lens fibres, their place being occupied by a tenacious homogeneous mass. Thus we see that the organ in question is divided by a system of partitions, springing with its layers from a central space in the lens; in that this substance can be followed through the latter in the form of septa.

The fibres, therefore, form in each half of the lens some three or four wedge-shaped pieces.

This arrangement naturally determines the course of the fibres, and makes it impossible that any one of them should actually reach both poles.

REMARKS.—1. Beside German handbooks on histology and monographs, comp. *Bowman, Lectures on the parts concerned in the operations of the eye, etc., London, 1849; Th. Nunnely in the Journ. of Microsc. Science, 1853, p. 136.* 2. These broadened ends of the fibres of the lens may simulate when in transverse section a flattened epithelium, without nuclei however. It was formerly supposed that there existed between the lens and capsule a small quantity of a clear thick fluid, the *humor Morgagnii*. This is not, however, present in the living eye, and is the result of a post-mortem change, produced by the decomposition of the so delicately constituted peripheral fibres and epithelium. The latter swells up before bursting into a number of spherical globules (fig. 269, e).

§ 160.

Turning now to the *composition* of the tissue of the lens, that of the capsule, in the first place, is at present but insufficiently known. The latter gelatinises in acetic acid and solutions of the alkalis, without, however, becoming clouded or dissolved. Even after two days' boiling, also, it is not converted into gluten. It offers prolonged resistance to the action of alkalis, but is, on the other hand, gradually dissolved in the mineral acids (*Mensonides*). Thus we have the reactions, to a certain extent, of most of the transparent elastic membranes. On the other hand, according to *Strahl's* statements, each capsule may be dissolved by boiling for several hours in water, yielding a substance which does not give, however, the reactions of gluten.

The composition of the nuclei and walls of the lens fibres is not as yet known. In their interior is contained a concentrated solution of a peculiar and very unstable protein substance known as crystallin (§ 12, p. 17). Owing to its close relationship to albumen, all reagents which cause the latter to coagulate produce clouding in the tissue of the lens, and when suitably employed may render the structure of the latter more distinct. In this respect chromic acid has gained great repute. Besides this, the lens contains a not inconsiderable proportion of fats, and, according to older analyses, of extractive matters also. For the human lens *Berzelius* obtained the following percentage, of

Water,	58.0
Protein matter,	35.9
Walls of the fibres, &c., remaining on the filter,	2.4
Extractive matters,	3.7

The proportion of fats in the human lens was found to be 2.06 per cent. (*Husson*); among them cholestearin is present (*Lohmeyer*). The amount of mineral constituents met with is only 0.35 per cent. The clouding of the lens after death depends upon some change in composition not yet understood.

The specific gravity of this organ in the human being is, according to *Chenevix*, 1.076 in the external layers, while that of the more dense

nucleus may reach 1.194. The index of refraction amounts, in the external strata, to 1.4071 according to *Krause*; in the middle to 1.4319, and in the central to 1.4564.

§ 161.

The lens is developed from a doubling-in of the superficial layer of cells coating the embryonic body or the corneous layer, which has been already discussed in considering the epidermis.

But even at a very early period it appears as a structure completely separated from the layer just mentioned. It is hollow in the interior, and has very thick walls, which are bounded by a transparent membrane. These walls are formed of several strata of elongated cells. From them, possibly, the excretion of the homogeneous substance has taken place, which subsequently solidifies into a capsule for the whole organ. In our

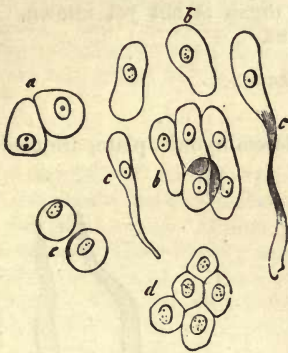


Fig. 269.—*a-e*, Cells from the lens of a fetal pig two inches long. *a*, original cells; *b*, other elongated specimens; *c*, some more so still, passing into the form of tubes; *d*, epithelium of the lens of a human embryo at eight months; *e*, cells from the so-called humor Morgagnii.

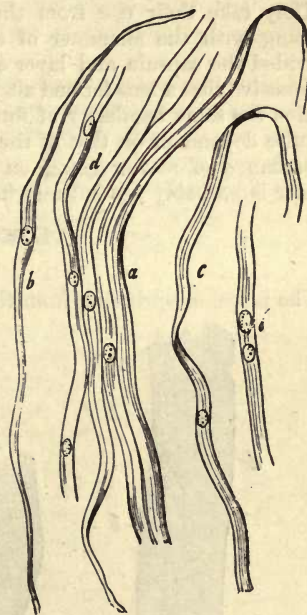


Fig. 270.—Fibres from the lens of a human fetus at eight months. *a*, fibres with one nucleus; *b*, another, which still shows its cellular character; *c*, flattened form, as seen from the side; *d*, fibres with two or three nuclei.

opinion, however, the capsule is a modified deposit from the adjacent connective-tissue. These cells gradually fill up, it is supposed, with their descendants, the central cavity, and become developed in most cases into lens tubes or fibres, while a certain remainder only, preserving their original characters, constitute the epithelium of the capsule seen on its anterior internal surface.

In young embryos we have an opportunity of studying the fibres of the lens in process of development (fig. 269, *a-e*).

In more advanced fetuses, as for instance in the human towards the

last months, the fibres are quite similar to what are found in the adult (fig. 270, *a*, *c*), at times, however, still preserving the cellular character (*b*). Not very unfrequently we encounter also lens fibres with double or even triple nucleus (*d*). The further production of these tubes probably takes place by a process of segmentation of the immature cells in the zone situated at the border of the epithelium of the capsule (§ 159), the new elements being laid down over the older ones. That the process and the growth of the lens extend far beyond the period of intra-uterine life is almost a matter of certainty.

At an early period the capsule of the lens is enclosed in a vascular membrane, which forms a part of the well-known system of envelopes of the organ under the name of the *membrana capsulo-pupillaris*.

After birth the number of the fibres of the lens is multiplied with the growth of the body, but their diameter is not increased.

They take their rise from the epithelial cells of the capsule, and, in keeping with the character of epithelial structures, can be regenerated provided the capsule and layer of cells be preserved. It is not difficult to conceive that a lens formed after the capsule has once been opened never attains the same regularity of form as the first structure, seeing its figure is quite dependent on that of the capsule. The amount and nature of the interchange of matter going on in this organ is not yet known. The former is probably not entirely insignificant.

14. Muscle Tissue.

§ 162.

The muscles, springing from the middle embryonic plate, are made up

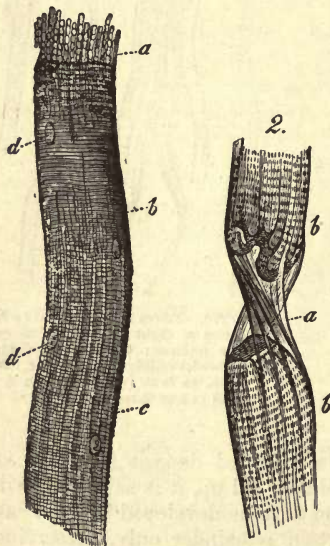


Fig. 271.—Striped muscle-fibres.

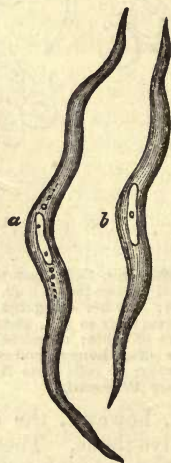

Fig. 272.—Elements of smooth muscle, from the rabbit.

of a soft reddish fibrillated tissue, which is remarkable for the property it possesses of contracting when its motor nerves are excited. This peculiarity is characterised by the term *irritability*. As we are taught by

physiology, the contraction of muscular tissue is of two kinds, voluntary and involuntary.

Viewed from a histological point of view, muscles may be divided into those which are made up of long transversely striated fibres as elementary structures (fig. 271), and those built up of smooth or unstriated fusiform elongated cells (fig. 272). Dependent on these differences we speak of *striped* and *smooth* muscle.

This anatomical difference, however, seems at first sight much greater than it is in reality.

In the first place, we encounter many intermediate forms between these two species of muscular tissue in the animal world; and, secondly, the history of development has recently shown that both elements have an origin extremely similar, namely, each form a single cell (§ 59). The element of the unstriated tissue preserves this character throughout life, the striped fibre forsakes its original nature in the greater complication of its development.

In conclusion, we need only remark that the voluntary muscles of our body consist of striated fibres (the heart, however, also, among those organs which are involuntary), whilst those muscles withdrawn from the influence of the will are composed of smooth fibres. The expressions, therefore, of "smooth" and "involuntary," or "striped" and "voluntary," do not correspond exactly in the human body. The specific gravity of the first of these was settled by *Krause* and *Fischer* to be 1.058, that of the latter 1.041.

§ 163.

The elements of unstriated muscular tissue (fig. 273) were formerly held to be long, pale, band-like fibres (*i*), displaying at intervals several likewise elongated nuclei. It remained for *Koelliker's* quickness of perception to recognise in these fibres a series of elongated cells arranged linearly one after the other, and in the year 1847 to introduce to the notice of histologists the "contractile fibre-cell" (*c-h*),—a great step towards a proper comprehension of the structure of this tissue, so difficult of investigation.

We usually meet with the *smooth muscle-cell* in the form of a long (*d-f*) band, which may at times possess extremely great length (*g*), and which generally runs off to a point at both ends. It is often short however (*e*). Its medium length is about 0.0451–0.0902 mm., short cells measuring often 0.0282 mm., and very long specimens 0.2256 mm. and upwards. Its breadth lies between 0.0074 and 0.0151 mm.

Further, it appears pale and homogeneous, either completely colourless or tinged slightly yellow, and without recognisable difference between the envelope and contents. Not unfrequently we may remark a row of granules, the residue of the earlier protoplasm, extending from each pole of the nucleus into the body of the cell (fig. 272, *a*); small dust-like molecules of the same may also cloud the otherwise clear substance of the cell. Finally, as a sign of retrograde metamorphosis, we find fat granules in varying quantity and size (fig. 273, *h*).

The contractile fibre-cell may present a very characteristic appearance, principally due to its nucleus, which appears under the action of strong acid as a tolerably pale, long, cylindrical rod, more or less rounded at both ends. Again, this nucleus is met with quite homogeneous, without any difference of contents and envelope, and apparently without any nucleus. Its medium length is 0.0226 mm., and breadth 0.0023–0.0029 mm. Its

situation is generally at an equal distance from both ends and in the axis of the cell, as may be best seen in transverse sections of previously dried muscle (*k*); from which, also, we

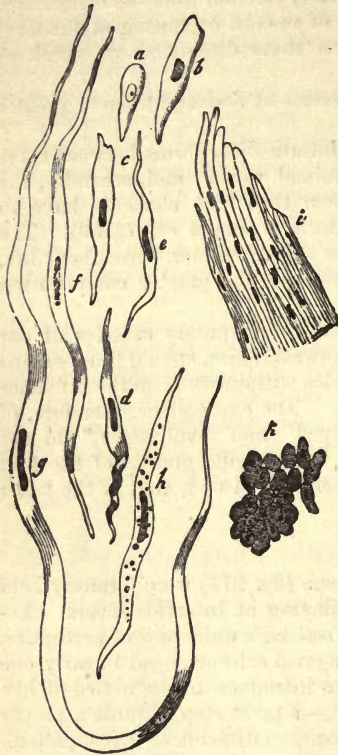


Fig. 273.—Smooth muscle fibres from the human being and other mammals. *a*, a formative cell from the neighbourhood of the stomach of a foetal pig ten inches long; *b*, another more developed; *c-g*, various forms of contractile cells from the human body; *h*, one of the latter, containing fat granules; *i*, a bundle of smooth muscle fibres; *k*, a transverse section through one of these from the aorta of the ox, with several nuclei in the plane of the cut.

may convince ourselves of the cylindrical form of most of the fibres. In most cases the nucleus is only single; but two, three, or even four, may occur in one cell (*Remak*, *Koelliker*, *G. Schwalbe*),—a circumstance of great importance in tracing the relationship of these to striated muscle fibres.

It is only very lately that, by the aid of more advanced technical knowledge, we have been enabled to render visible in many nuclei, single or multiple (1-4), granules of round form and glittering appearance, which have probably the significance of nucleoli. Their diameter is 0.0009-0.0002 mm. (*Hessling*, *Frankenhäuser*, *Arnold*, *Schwalbe*).

Under the polarising microscope the contractile fibre-cell is found to be double refracting and positive to the axis (*Valentin*).

But though this cell appear thus singular in a state of maturity, it bears in the embryonic body a less striking character; the nucleus is then round and vesicular (*a, b*). Whether this original constitution may not persist in many parts of the body is a question incapable at present of being answered. Besides this, it is impossible to indicate any very certain features of distinction between the fusiform cells of connective-tissue, which are likewise endowed with vital contractility, and the elements of smooth muscle. The many controversies which have taken place in the last few years as to whether we are to admit the presence

of contractile muscle cells in this part and that, or no, must be judged accordingly.

On the other hand, the singly nucleated contractile fibre-cells may acquire striated contents, and thus approach nearer to the elements of voluntary muscle.

Among such may be reckoned the elements of the muscle of the heart of lower vertebrates (*Weismann*), of the bulbus aortæ of the salamander and proteus (*Leydig*); but probably not the fibres situated under the endocardium of the ruminants, of pigs and horses, bearing the name of the fibres of *Purkinje*.

Smooth unstriated muscle is to be found throughout the whole digestive tract, from the inferior end of the œsophagus down nearly to the

termination of the rectum; it is met with also in the mucous membrane itself, as the so-called *muscularis mucosæ*, in the form of thin layers and small bundles. The organs of respiration are likewise supplied with this tissue: thus, it is seen in the posterior wall of the trachea, in the circular fibres of the bronchi and their branches, and perhaps also in the pulmonary vesicles. The walls of blood-vessels possess it also, especially in the middle layer of their coats. These contractile cells make their appearance too in the cutis: firstly, in the form of small groups, as in the hair follicles, the sebaceous and sudoriferous glands; and then again forming more or less continuous layers, as in the *tunica dartos* of the scrotum, the mamma, and areola. The human biliary apparatus only shows tissue in the walls of the gall bladder (*Henle, Eberth*). Further, the tissue is distributed throughout the urinary apparatus. It occurs in the calyces of the kidneys in the form of continuous strata, and also in the pelvis of the latter organ, in the ureters and vesica. Again, in the form of scattered elements along the urethra and over the surface of the kidney. In the male organs of generation also it is extensively met with: thus, in the *tunica dartos*, between the *tunica vaginalis communis* and *propria* of the cord, *epididymis*, *vas deferens*, seminal vesicles, prostate, *Cowper's* glands, and *corpora cavernosa*. Also in the female: thus, in the ovaries, in the *Fallopian* tubes, and uterus, which latter organ presents to us during pregnancy the greatest accumulation of the tissue in question which exists in the body. Again, in the round (*Koelliker*) and broad ligaments (*Luschka*), and in the *corpora cavernosa*. Further, smooth muscular fibres are supposed to exist in the envelope and in the septa within the spleen and lymphatic glands of mammals. Finally, they occur in the organs of vision as sphincters and dilators of the pupil; also in the choroid, in the ciliary and orbital, as well as eyelid muscles (*H. Müller*).

§ 164.

The second species of muscular tissue, namely, *the striped or striated*, is to be found in all the muscles of the trunk and extremities, —those of the ear and external parts of the eye, with the exception of the muscles mentioned in the preceding section. It enters further into the construction of many internal organs, as the tongue, pharynx, upper portion of œsophagus, larynx, genitals, termination of the rectum, and diaphragm. Finally, it presents itself, modified to a certain extent, in the heart.

As elements, we here meet with long cylindrical and strongly flattened fibres (fig. 274, 1), which do not, as a rule, give off branches. They have a thickness of from 0·0113 and 0·0187 mm. up to 0·0563 mm. in the human body. To these the name of "muscle fibres" or "primitive bundles" has been given. The human primitive bundle, which is, owing to its greater thickness, of a yellower tint than the smooth element, displays, in contrast to the latter, a most striking and characteristic texture under high magnifying power.

It consists of an envelope and contractile contents. The first of these, called usually the "sarkolemma" or "primitive sheath," is a transparent, homogeneous membrane, which, on account of its high degree of elasticity, always remains closely adherent to the included mass in all the changes of form which take place in the latter (fig. 274, 1). The primitive sheath may be demonstrated apart from chemical aid by simply breaking the continuity of the contents (2 a), or also, as is strongly recommended, by treatment of the living fibre with water, on which the

membrane becomes raised up in blebs by endosmosis. Preparations also of the muscles of naked amphibia which have lain in spirit frequently afford very good objects, in which the envelope is observed widely separated from the included mass.

On the internal surface of the sarkolemma are situated a series of roundish or oval nuclei (1 *d*) 0.0074–0.0113 mm. in length. More minute examination of the muscle fibres of naked amphibia (fig. 275) with very high magnifying powers shows the nuclei (*c*) to be vesicular, with tolerably thick, and therefore doubly contoured walls, and to contain one or two nucleoli. In fresh tissue the nucleus lies closely enveloped in a fusiform cleft. The apices of the latter are occupied by a homogeneous clear substance. This is the remainder of the original protoplasm, which has not been consumed in the formation of the fleshy matter of the fibre. This, taken as a whole, has been named the "muscle

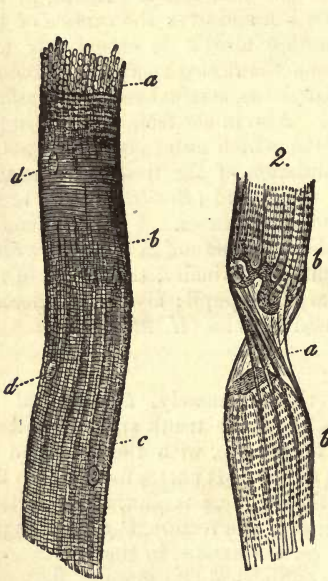


Fig. 274.—1. Striated muscle fibre with a breaking up into primitive fibrillæ *a*; more distinct striation at *b*, and longitudinal lines at *c*; *d*, nuclei. 2. A fibre, *b*, torn through at *a*, with the sheath partially empty and visible.

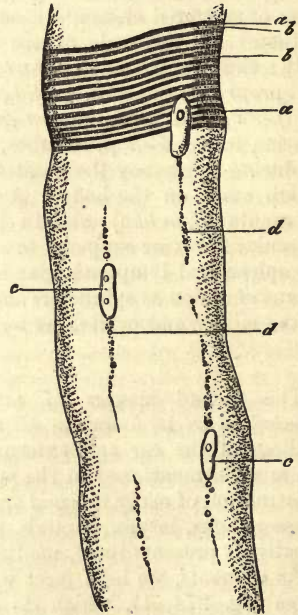


Fig. 275.—A muscle fibre from the frog, magnified 800 times. *a*, dark zones with sarcous elements; *b*, lighter zones; *c*, nuclei; *d*, interstitial granules. (Alcohol preparation).

corpuscle" (*M. Schultzze, Welcker*), and is looked upon as equivalent to a cell.

In fig. 275 we may remark filiform streaks springing from these muscle corpuses, and dotted with fat granules throughout, as also is the degenerated body of the cell. These we shall have again to take into consideration below.

The number of these nuclei or muscle corpuses is not inconsiderable; their position is sometimes without arrangement, sometimes alternating. In the fibres of the heart alone do there exist, beside the circumferential nuclear formations, others which occupy the axis. But among the lower

animals, as for instance in the frog, the nuclei lie at every depth in the fibre.

The contents enclosed in the sarkolemma, or the fleshy substance of the muscle (fig. 274, 1), is of extremely complex and delicate texture. It presents, but in varying degrees of distinctness, a longitudinal (*c*) and transverse striation (*d*), affecting the whole thickness of the fibre.

In many dead muscles the longitudinal marking may be observed with the greatest clearness in many fibres, appearing in the form of very delicate but distinct parallel lines, traversing the whole length of the element.

The distance of these from one another varies between 0.0011–0.0022 mm. In many cases the lines run continuously for a considerable distance, but more frequently only make their appearance at intervals in the fleshy mass, and, after running a short course, disappear again.

On transverse sections of a fibre we may frequently observe the substance of the contents projecting in the form of fine fibrillæ or bands (1, *a*), bounded by the linear marking.

The objects, however, which we obtain by the action of certain reagents on the muscle fibres are extremely peculiar,—a method of treatment much in use. Those which have been macerated in cold or boiled in hot water, such also as have been subjected to the prolonged action of alcohol, bichloride of mercury, chromic acid, and, more than all, of bichromate of potash, are often seen split up in the most beautiful way into long fine fibres of 0.0011–0.0022 mm. in breadth (fig. 276).

Owing to this circumstance, it has been supposed by many that the fibres of muscle are made up of fine elementary

threads or “muscle fibrillæ,” as they have been named; the muscle fibres are also known, on this account, as “primitive bundles.”

The theory in question has had among its defenders a number of men whose opinions should have great weight. Among these we may mention *Schwann*, *Valentin*, *Henle*, *Gerlach*, *Koelliker*, *Leydig*, *Welcker*, *Schön*.

REMARKS.—Comp. beside *Henle's* work, *Bowman* in the *Phil. Transact.* 1840, Part 2, p. 69, and 1841, Part 1, p. 457; also the two articles by the same, “Muscle” and “Muscular Motion,” in the *Cyclopædia*, vol. iii. p. 506 and 519; and in the work edited in conjunction with *Todd*, vol. i. p. 150.

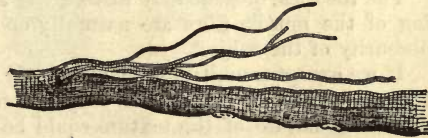

Fig. 276.—A muscle fibre after the continued action of bichromate of potash for twenty-four hours, showing its partial resolution into fibrillæ.

§ 165.

The *transverse striation* of muscle is also subject to much variation, and it is a matter of great difficulty to gain a proper conception of it, owing to the minuteness of the object and the obstacles in the way of correct focus. In the first place, we meet with dark, sharply defined, and continuous lines, running parallel to one another, whether in a straight or undulating course. Their distance from one another likewise lies between 0.0011 and 0.0023 mm. Again, these transverse striæ may be interrupted, ceasing for a certain distance. The contour of the whole fibre is at the same time quite smooth. In other muscle fibres, markings not so dark, but much broader, are seen, regular cross-bands, so that the whole appears to consist of a double system of dark and light transverse zones. Finally,

though seldom, the transverse lines may become separated from one another, the lateral outlines of the fibre becoming indented; so that the whole conveys to us the impression that it is about to break up into a number of plates. Coincident with the more distinct appearance of transverse striation, the longitudinal marking usually decreases in clearness.

When treated with certain reagents the peculiarities of the tissue in this case also are forcibly brought before us. Thus, acetic acid causes the longitudinal lines to vanish, while the transverse remain a certain time still visible. In very dilute hydrochloric acid, and also in the acid gastric juice, the muscle fibre is resolved into a number of thin disks, while at the same time that it swells up, and commencing solution sets in, the longitudinal markings becoming completely destroyed. These disks often separate from one another in the most regular manner imaginable (fig. 277, 4, 5). Carbonate of sodium has a similar action, but does not produce swelling of the tissue; chloride of calcium also, which, however, gives rise to a shrinking and transverse wrinkling in the fibre, and not unfrequently causes the appearance in its interior of transverse rents. Now, as in the former cases, we believed ourselves warranted in accepting with certainty the fibrillated composition of the muscle fibre, so ought we now, seeing these effects produced by the chemical reagents just named, to look upon the latter as made up of a number of disks or plates arranged one over another (1).

The theories broached by histologists as to this peculiar double marking of the muscle fibre are naturally enough very various, owing to the obscurity of the subject.

If we except a multitude of manifestly incorrect efforts at explanation, there remained for many years only two modes of viewing the matter, by which the nature of the texture could be interpreted, at least in its most important features. Hence both of the views in question found assailants and defenders.

According to the first of these theories, already mentioned in the preceding section, the fibrillæ are the pre-existing essential elements of the fleshy mass, and remarkable for their jointed structure (fig. 277, 2). Owing to the fact that the transverse markings of all the fibrillæ occur at the same intervals and lie one beside the other, a striped appearance is communicated to the whole fibre (1). It is not difficult to see that the appearances presented may be thus tolerably well explained, and why it is that we sometimes remark a longitudinal and sometimes transverse striation to preponderate. On the other hand, the occurrence of disks, with absence of the longitudinal lines, is difficult of interpretation.

The second theory, which has gained for itself in recent times a considerable circle of adherents, and which we believed also, with certain modifications, to be correct, originated with that excellent English investigator *Bowman*. Among those who supported it, with greater or less modification, the names of *Harting*, *Haeckel*, *Leydig*, *Keferstejn*, *Margo*, may be mentioned.

According to this theory, the muscle fibre consists essentially of an aggregate of small particles (*Fleischprismen*, *Fleischtheilchen*), or *sarcous elements*, which, united in a transverse direction and clinging together, give the appearance of a disk or thin plate (*Bowman's Disk*, fig. 277, 3, 4, 5), and, arranged longitudinally, that of a fibril (1, 2). Both, however, fibrils as well as disks, it was held, are not the optical expression of a pre-existing composition of the kind, which is entirely absent in the

fresh, living muscle fibre; they rather indicate a tendency, on the part of the muscular element, to split up in one of these two directions (2). It must be allowed, however, that the tendency to break up into fibrillæ in a longitudinal direction is greater than in the transverse into disks, the latter being of rarer occurrence than the primitive fibrillæ.

The supposition of the existence of these sarcous elements, connected longitudinally and transversely with one another, necessitates of course the presence of a uniting medium between them. And when we remember the completely opposite effect of the two reagents already mentioned, that, for instance, very dilute hydrochloric acid resolves the muscle fibre into plates, while alcohol and bichromate of potassium convert it into fibrillæ, we must look for two kinds of cementing substance,—one for the agglutination forming longitudinal fibrillæ, and another different one uniting the flesh prisms in a transverse direction and forming disks.

The quantity of transverse cement (probably more or less gelatinous) is far smaller than that of the probably fluid longitudinal. The latter is remarkable for its great capacity for contraction and swelling out. In conformity with this, we sometimes find the dark transverse zones placed far closer to each other than at other times.

Here arose the very important question, how the closer relation of the sarcous elements to the transverse lines of the fibre was to be represented.

We frequently remark (and especially regularly after slight treatment with acetic acid) the transverse striation to be made up of dark zones, refracting the light very strongly, alternating with clearer belts of less refracting power. The latter are the layers of the longitudinal cement, swollen up and rendered clear; while the darker zones represent the sarcous elements, united together by an agglutinating medium, and forming disks. Accurate study of the effect of water acidulated with hydrochloric acid showed how the clear transverse zones become more distinct with the rapidly-commencing swelling up of the longitudinal cementing medium preceding solution; that a muscle fibre might then break up into disks, each of the latter consisting (like a voltaic element with its zinc and copper plate) of




Fig. 277.—1. A muscle fibre with primitive fibrillæ and transverse striation strongly marked, taken as the fundamental form. 2. Isolated fibrillæ strongly magnified. 3. Sarcous elements united, forming a disk (diagrammatic). 4. Plates of human muscle after treatment with hydrochloric acid. 5. A human fibre after prolonged treatment with hydrochloric acid, with dark (c) and light (d) zones and nuclei (a, b). 6. Two pointed fibres from the human *biceps brachii*. From one of them the interstitial connective-tissue is prolonged over the end.

a darker and clearer portion (fig. 277, 5, c, d) (3); it showed further, that the clear part underwent solution by degrees, while the dark zone remaining over occasionally presented to view the sarcous elements of a disk, as though in the act of separation from one another.

The improved and greatly increased magnifying power of our new microscopes has since rendered it no longer difficult to obtain a view of the fleshy prisms and of the fibrous structure of many muscles (fig. 278). The lamprey, and, better still, the lower amphibia (*Proteus*, *Siredon*), afford very good objects, owing to the large size of their sarcous elements. However, the same may be recognised in the smaller particles of the muscles of frogs, mammals, and human beings (4).

The prisms appear now as cylindrical or hexagonal prismatic particles, of greater height than breadth. Their length in the proteus (fig. 278, 1, a) is 0.0017 mm., in the frog (fig. 280) 0.0013 mm., in the pig (fig. 278, 2, a) and in man 0.0011–0.0012 mm. Standing one beside the other, they form the dark transverse zones, and are almost in actual contact with one another as a rule, owing to the scanty amount of interposed cement (fig. 278, 2, a; fig. 279, a).

Those spots are particularly instructive where the sarcous elements of a

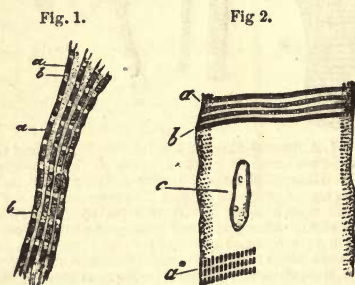


Fig. 278.—Two muscle fibres from the proteus, 1 and fig. 2, magnified 1000 times. (The first was an alcohol preparation, the latter treated with acetic acid of 1.01 per cent.). a, sarcous elements; b, clear longitudinal cement. At a, the sarcous elements are more separated from one another, and the transverse cement is visible. c, nucleus.




Fig. 279.—Krause's transverse disks, a, a. 1, a muscle fibre without, 2, one under strong extension; both highly magnified (Martyn); 3, a fibre from the dog immediately after death.

transverse row appear somewhat distant from one another (fig. 278, 1 below, 2, a*).

In our description so far of the structure of the muscle fibre, we have intentionally followed up the historic course of the opinions held regarding it, in order to facilitate the comprehension of the most recent investigations by the reader.

From the newest researches we learn that our earlier views were incomplete. But still the field of inquiry is so exceedingly wide, the matters to be dealt with lie so near the verge of invisibility, and the composition of the fleshy mass is so very unstable, that the views of present-day observers differ widely.

In the first place, the *transparent* transverse zone is traversed by a very fine dark line. This was referred to by the English observer *Martyn* with others, and the second edition of this hand-book, in the year 1862.

Later on, its nature was made the subject of more extended research by *Krause*, so that we may name it the "transverse plate of the transparent zone" of *Krause*. This cross-line (fig. 279, *a*) may be recognised without great difficulty in the living muscles of mammals and the naked amphibia. It is to be seen very distinctly in the muscle fibres of insects, after previous stretching, attaining a thickness at times of 0.0008 mm. After the action of very weak acetic acid it is the source (at least very frequently) of the transversely striated marking of the muscle fibre of the vertebrates.

Krause holds a very peculiar view in respect to the structure of muscle (fig. 280). He regards the dark cross-line just mentioned as the optical expression of a delicate transverse partition springing from the sarcolemma, which divides the interior of the muscle fibre into a number of diskoid compartments built up one over the other. The contents of such a compartment, then, would consist from below upwards of (1) half of a transparent transverse zone; (2) of a dark zone occupying the middle (*i.e.*, of a transverse disk of sarcous elements); and (3) of another half of a transparent cross zone (see fig. 280). *Krause* believes also in the existence of a delicate lateral membrane, investing closely the sides of the sarcous elements and ends of its transparent appendages, and uniting with the transverse membrane. In this way he supposes the elementary structures of the striped fibres to be formed—the so-called "muscle caskets." In longitudinal rows they constitute the fibrillæ. This author also believes the clear longitudinal and transverse cementing medium to be liquid, and that during contraction the layers of fluid flow from the end surfaces to the sides.

Almost at the same time, however, *Hensen* observed the dark transverse zone to be divided in its middle by another transparent cross-line of weaker refracting power (fig. 281, *a*). This is now known by the name of the "middle-disk" of *Hensen*. The views regarding its nature are very various. By some (*Krause*, *Heppner*) it is regarded as an optical illusion, while others (*Merkel*, *Engelmann*) maintain its presence in the living fibre. The last view, of course, does away with the pre-existence of the sarcous elements. They would have to consist either of three portions,—two dark terminal, and a central transparent,—or could only be products of coagulation, assuming a homogeneous constitution after death, composed of the dark matter of the transverse zone and middle disk.

Finally, minute granules have been remarked, arranged in rows, at each side of *Krause's* transverse lines (*Flögel*, *Merkel*). These rows have been named "accessory disks" (*Engelmann*) (fig. 282).

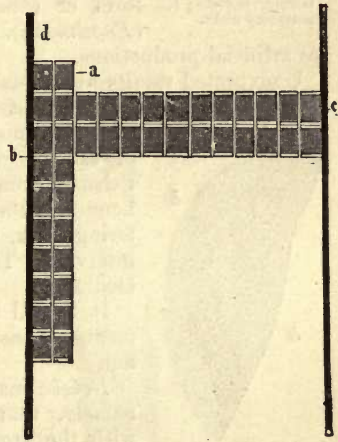


Fig. 280.—"Muscle caskets," *a*; *b*, fibrilla forming transverse disks at *c*; *c*, sarcolemma.

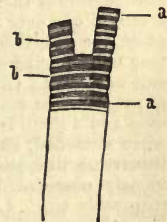


Fig. 281.—Muscle-fibre of the lancelet (*amphioxus*). *a*, the "middle disk" of *Hensen*; *b*, transparent transverse zone (alcohol preparation).

This does not appear to be the place for entering more deeply into the subject.

The structure of striped muscle fibres will probably remain a matter of controversy for many years to come. We look, however, upon the cross-lines of *Krause* as fully substantiated. But as to the existence of lateral membranes, and the theory of the "muscle caskets" dependent on it, we do not believe in it any more than in the fluidity of the cementing medium. As regards the *middle disks*, we have not yet come to any definite conclusion. We look upon the *sarcous elements* as pre-existing in some form or other, and not as products of coagulation (*Engelmann*). In our opinion the longitudinal fibrillæ are artificial productions.

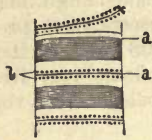


Fig. 282.—Portion of dead muscle fibre, after *Engelmann*. *a*, transverse disks; *b*, accessory disks.

Unexpected results were obtained some years ago by a method of treatment practised by *Cohnheim*, namely, the preparation of transverse sections of frozen muscle. In these may be recognised groups of sarcous elements, like a mosaic of small particles of from three to six-sided figures. Between and bounding these is a trellis-work of transparent glittering lines, which become broader only at irregular intervals. These belong to the transverse cementing medium.

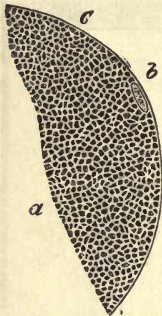

Fig. 283.—Transverse section of a frozen frog's muscle. *a*, groups of sarcous elements; *b*, a nucleus; *c*, clear cement.

It is still a matter of uncertainty whether the elements of unstriped muscle possess sarcous elements or not.

Brücke made a very interesting discovery long ago, namely, that *Bowman's* sarcous elements, together with the cross-lines of *Krause* and middle disk, are double refracting, and are positively monaxial, while the cement deposited between them is single refracting. The first are "anisotropic," the latter "isotropic." The correctness, however, of *Brücke's* statement has been since questioned by *Rouget* and *Valentin*.

REMARKS.—1. The slight inclination of the fibrillæ to separate from one another (when no reagents are made use of) seems also to point to this conclusion. 2. "The muscle fibre is therefore just as little a bundle of fibrillæ as a pillar built up of disks arranged one over the other. Should a total separation in both directions really take place, the result would necessarily be a breaking up into fleshy prisms." "And if we tear off a fibril from a muscle fibre we take away from every disk a sarcous element, and vice versa" (*Bowman*). 3. *Dobie* (*Annal. of Nat. Hist.*, Feb. 1848) also discriminated in the same manner long ago between the darker sarcous elements of *Bowman* and a second system of clearer portions situated between them. Muscle fibres, when stretched, show, according to *Martyn* (*Beale's Archives*, Vol. iii. p. 227), another transverse line passing through the centre of each clear zone. The same was previously observed by *Amici*, *Koelliker*, and others. I myself have remarked it frequently too. 4. They may assume very large proportions, also, in the crawfish. Here they were found by *Häkel* to vary from 0.0020 to 0.0099 mm. in height; and he was able to isolate them in a gelatinous condition as long as 0.0114 mm. He looks upon them as hexagonal prisms. *Amici's* observations are also of great interest. According to him, the elongated prismatic elements of the muscle of the common house-fly, separated by a distinct cement or clear zone from one another, assume during contraction a marked obliquity of position. This I can corroborate myself. Further, according to *Schönn*, there is a dark spot visible in each sarcous element.

§ 166.

The occurrence in its substance of certain *foreign molecules*, partly consisting of fat, is another peculiarity of the muscle fibre. These are known as the "interstitial granules of *Koelliker*," although described long ago by *Henle*.

They are not always distinct in human muscle, but when present are encountered in rows parallel to the direction of the fleshy fibres.

In the muscle of the frog they appear with greater distinctness (fig. 284, *d*), and are often uncommonly numerous also, resisting, further, the

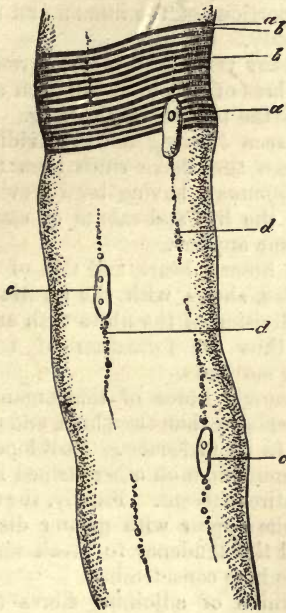


Fig. 284.

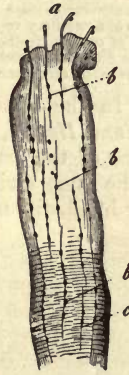

Fig. 285.—Muscle fibre from the leg of a frog, after prolonged treatment with dilute hydrochloric acid. From the cut surface very fine fibres are seen projecting, *a*; with granules, *b*; the latter are distributed along the whole fibre.

action of water acidulated with hydrochloric acid entirely. Here they commence at the poles of the nuclei, and appear as though situated in a system of canal-like interstices, occupied by nuclei, granules, and fat molecules (*Koelliker*), which, under ordinary circumstances, are filled up with the well-known protoplasm. When coagulated, these masses may form a series of extremely delicate fibres (0.0006 mm. thick) and project from the cut end of a muscle fibre which has been treated with water containing a trace of hydrochloric acid (fig. 285). The fibres contain fat molecules, partly externally, and partly in the interior. *Leydig*, *Böttcher*, and *O. Weber*, erroneously regard these structures, together with the nuclei of the muscle, as a network of stellate connective-tissue cells with tubular processes traversing the substance of the muscle-fibres.

On transverse sections of muscles which have been dried and subsequently moistened (fig. 286, *a*), we see these rows of fat granules as a number of dark dots, as long as the molecules remain in the section,

but as small round openings on their falling out. But, besides these, the sarcous elements appear, under low magnifying power, more or less distinctly, in the form of extremely fine pale dots.

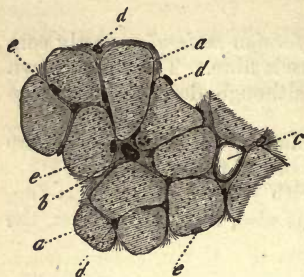


Fig. 286.—Transverse section of the human *biceps brachii*. *a*, muscle fibres; *b*, section of a large vessel; *c*, a fat-cell in a considerable connective-tissue interstice; *d*, section of a capillary vessel in the thin septum of connective-tissue between two muscle fibres; *e*, nuclei of the latter lying close to the sarcolemma.

§ 167.

We now come to a special modification of striped muscular tissue, namely, that formed of *branching* or *reticulated* fibres. These are of frequent occurrence in the lower animals, but are, as far as we know, at present confined to but limited portions of the human and mammalian body.

For many years past the occurrence of muscle fibres of this kind has been recognised in the tongue of the frog. Here they are seen dividing and subdividing at acute angles. In the same organ of man they have since been found by *Biesiadecky* and *Herzig*, as also by *Rippmann*, having been previously observed in some of the mammalia. In the lips and snouts of many of these animals the same variety of the tissue appears.

On the other hand, the muscle of the human heart, and that of other vertebrates, shows with the greatest frequency division of the fibres with anastomoses; thus the formation of regular muscular networks.

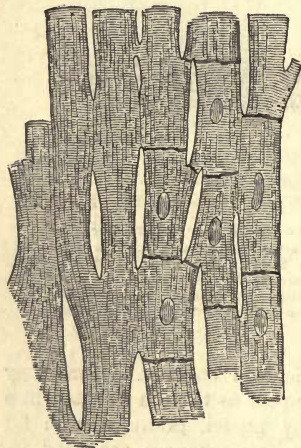


Fig. 287.—Muscle fibres from the heart, after *Schweigger-Seidel*. To the right the boundaries of the cells and the nuclei are to be seen.

The muscle fibres of this organ (fig. 287) are smaller than elsewhere, and richer likewise in fat molecules. Envelopes are less apparent than on other striped fibres, or are entirely absent. Finally, the transverse striæ appear with greater distinctness, and the tendency to break up into fibrillæ is here considerable.

The union of adjoining fibres (*a*, *b*) is effected as a rule by short (*c*) and usually slender branches, which leave the stem now obliquely, now more transversely, so that a regular network is produced, very important in the mechanism of the motions of the heart.

According to *Koelliker's* statements, each ramifying muscular element of the heart corresponds to a stellate cell, and the whole to a cellular network. *Weismann*, however, declares that his investigations have led him to other conclusions. According to him, the muscle bands consist (and it is easy to convince ourselves of the fact), in fishes and amphibia, of simple elongated fusiform and sometimes branching cells, associated together. The same is the case in the embryos of the higher vertebrates.

In the latter, however, they become, later on, more closely united to form the common mass of the band. But even here it is possible to

render visible the boundaries of the individual cells artificially (*Aeby, Eberth, Schweigger-Seidel*).

In the other transversely striped muscles of the body it is the exception to find branching fibres.

REMARKS.—The retiform connections of striped muscle fibres were described by *Leuckart* and myself many years ago, and probably for the first time, as occurring in arthropods, and noted later as of frequent occurrence among invertebrate animals. In the year 1849 they were again brought to light by *Koelliker*, having been previously seen by *Leeuwenhoek*.

§ 168.

The fibres of striped muscle are arranged parallel to one another (with exception of those of the heart), and appear prismatic, owing to their mutual contact (fig. 288, *a*). Their direction is that of the long axis of the muscle. Between them is situated a very small quantity of interstitial connective-tissue, in which the nutrient capillaries (*d*) and nerves of the part are contained.

Several of these muscle fibres are usually united to form a bundle varying in thickness from 0.5 to 1 mm., and separated from the surrounding bundles by a stronger layer of connective-tissue. Such *primary* fasciculi are then combined to form *secondary*, which present themselves in very varying thickness.

The connective-tissue envelope and uniting substance of muscle is known under the name of "perimysium," two kinds of which are recognised, namely, an external, enveloping the whole structure, the *perimysium externum*, and a continuation of the latter between the fibres, the *perimysium internum*.

Fat-cells (*c*) may also be met with in the connective-tissue of muscle, becoming more numerous in obese bodies, or in muscles which have remained long unused. Seen from the side, they are arranged in rows one after the other (fig. 289, *b*). They may eventually interfere with the ability of the fibres to perform their work.

Bands of smooth muscle also, although they seldom form such bulky muscles in the human body as the first formation, are nevertheless put together in a similar manner in bundles, wherever they are crowded and collected in large numbers together. On the other hand, contractile fibre-cells appear frequently enough in the body in very small aggregations, hidden and obscured by an excess of connective-tissue, so that they can only be discovered amid the latter with difficulty. Consequently, we may distinguish between *pure* and *mixed* unstripped muscle (*Koelliker*).

The vascularity of muscle is very considerable, and the arrangement of its vessels characteristic (fig. 290). The arterial stems entering the

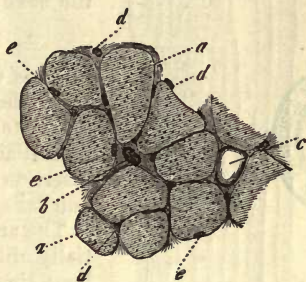


Fig. 288.

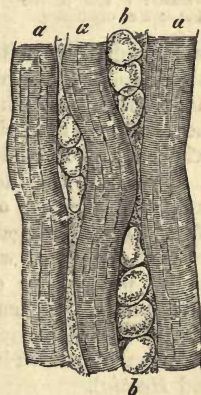


Fig. 289.—Human muscle showing fat-cells. *a*, muscular fibre; *b*, rows of fat-cells.

muscle (*a*), send off to the fibrillæ short transverse branches, which are then broken up into a delicate capillary network (*c*, *d*), whose longitudinal tubes pass between the muscular fibres, and communicate with one another at long intervals by means of short cross twigs. Thus, a long-meshed capillary network is formed within which the muscle fibre is situated. The proper fleshy substance of the latter receives none of these capillaries. As to the venous vessels, their course corresponds precisely to that of the arterial.

The nerves met with here will be considered in the next chapter.

§ 169.

As is well known, muscles are united very closely with their *tendons*, and in such a manner that the latter, in their course, appear to be either the immediate prolongation of the muscle fibres, or, the insertion of the latter into the substance of the tendon takes place at an oblique angle.

The arrangement of the tissues is, however, essentially alike in both cases. Yet for all this it was a long time before conclusive results could be arrived at here, owing to the want of suitable modes of manipulation.

With a rectilinear insertion of the tendon, there appears to be no sharp boundary between the fleshy substance and that of the connective-tissue, so that a casual observer would be warranted in supposing

Fig. 290. — Capillary network of a striped muscle. *a*, arterial vessel; *b*, venous; *c* and *d*, the network of capillaries.

an immediate transition of one tissue into the other (fig. 291). On the other hand, a completely different appearance is presented, where the insertion of the fleshy fibres is oblique, namely, a sudden termination of the latter, so that simple agglutination of two tissues was supposed to exist here by *Koelliker*.

Weismann, on the other hand, succeeded in demonstrating in every case, with the help of strong solutions of potash, the sharp termination of muscle fibres against the tendinous tissue. He showed them to be covered also here with sarcolemma (fig. 292, *b*), and to end rounded (*a*, *b*), pointed, or obliquely truncated, and so on. They are merely cemented to the tendinous bundle (*c*, *d*) at this point, although most securely. Other macerating fluids may be made use of with similar results, and even immersion in glycerine may produce the desired effect (*Biesiadecky* and *Herzig*).

We are now met by the important question as to the length of the contractile fibres of muscles.

Do they traverse the latter in their whole extent, or do they terminate before they have done so?

It was formerly supposed that each muscle fibre was of the same length as the muscle to which it belonged. More recently, however, the interesting discovery was made by *Rollett*, that many of the fibres are not obliged to pass through the whole extent of the muscle in order to end in a tendinous bundle, but that the termination of the strongly pointed fibre

may take place rather in the middle of the muscle (fig. 277, *b*). Continuous with its end, and playing the part of a tendon to a certain extent, we find interstitial connective-tissue. These statements were then subsequently corroborated by *E. H. Weber*, *Biesiadecky*, and *Herzig*, *Aeby*, and *Krause*, who met with rounded and pointed forms of termination besides.

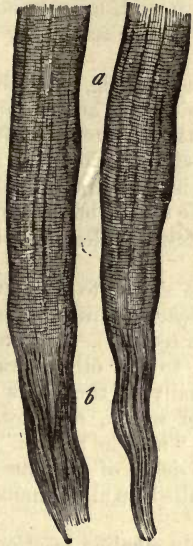


Fig. 291.—Two muscle fibres (*a*), with apparent transition into the connective-tissue bundles of the tendon (*b*).

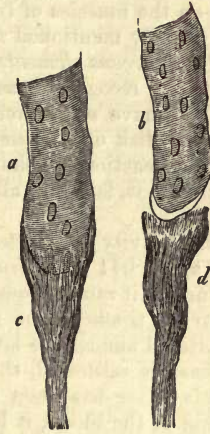

Fig. 292.—Two muscle fibres (*a*, *b*) after treatment with solution of potash. One of them is still connected with a tendinous bundle (*c*), the other loosened from its attachment to one of the latter (*d*).

We can also convince ourselves that the opposite end of the fibres may terminate in like manner. *Krause* is of opinion that no muscle fibre exceeds 4 c. m. in length, and that those which are apparently longer consist of two fusiform elements adhering together (?). Further investigation appears desirable here. In short muscles the fibres probably traverse, as a rule, the whole length of the muscle. In the longer muscles of the frog, also, we may convince ourselves that this does in reality take place (*Koelliker*, *Weismann*, *Kühne*).

REMARKS.—The views which were formerly most widely held may be arranged under two heads. According to the first of these, the fleshy mass was directly continuous with the tendinous bundles; to the second, that the muscle fibre, terminating abruptly, was embraced externally at its end by the fibres of the tendon, in the same way that the finger of one hand may be grasped by the tips of those of the other.

§ 170.

In examining muscular tissue chemically, we should be able to separate its essential constituents, such as the striped fibres and contractile cells, from those which are mere accessories, namely, connective-tissue, vessels, and nerves. Further, we should be able to determine what organic and what inorganic substances enter into the composition of fibre and cell, and how they are distributed over nucleus, envelope, and

contents. Finally, we should analyse the fluid saturating muscles, with its nutritive matters and products of decomposition resulting from the energetic transformative processes going on in the tissue.

Zoochemistry, however, of the present day is unable to meet these requirements of physiology; and yet, muscle is one of those tissues which has received most attention to this end. In the year 1847, *Liebig* presented us with his elaborate treatise, and, more recently, *Kühne* has essentially furthered our acquaintance with the subject by his elegant experiments on the muscles of frogs.

From the already mentioned *microchemical* bearing, we gather that the substance of the *sarcous elements*, of the longitudinal and of the transverse cement, is to be recognised as three distinct materials with separate reactions. We have still, then, the nucleus, insoluble in acetic acid, dark transverse disk of *Krause* (also of resistant nature), and the sarcolemma, with its reactions so similar to elastic tissue (but greater solubility in alkalies); so that, taken in all, there is very considerable complexity to be coped with.

The specific gravity of striated muscle is stated to lie between 1.055 (*C. Krause*) and 1.041 (*W. Krause* and *Fischer*), while the proportion of water contained in it ranges from 78 to 72 per cent. (1). This water belongs first of all to the tissue of the fibres, then to the other structural constituents scattered among the latter, and finally, to the fluids with which the whole mass is saturated, the amount of which, however, is not yet known. This latter has been named the "muscle plasma." Like the plasmatic fluid of the blood, it loses, on the death of the muscle and consequent "spontaneous" coagulation as it is called, an albuminous substance, and becomes "muscle-serum" (*Kühne*).

The juice of living muscle has a distinctly alkaline reaction (*Du Bois-Reymond*); that of the dead tissue, or that affected by rigor mortis, is acid (*Liebig*).

From the solid constituents of muscular tissue, which amount to somewhere about 20 per cent., we have first a varying quantity of *glutinous* matter to deduct, which belongs to the commingled connective-tissue. About from 0.6 to 2 per cent. of glutin may be obtained from fresh muscle.

The fresh tissue then contains, to the amount of 15-18 per cent., a series of *albuminous matters*, partly soluble and partly insoluble, with which we are still but imperfectly acquainted. These are in the first place constituents of the juices of the tissue, then again of the fleshy fibres of the latter. The soluble members of the group are for the most part remarkable for their coagulation at a low temperature (35-50° C.), a property which is to be met with only in those of the contractile substances of the system.

Kühne has obtained the spontaneously coagulating albuminous substance of the plasma from the muscles of frogs, and has named it *myosin* (§ 12). It is the congelation of the latter which communicates to the fibre of muscle its cloudy appearance on rigor mortis setting in. The coagulum of myosin is insoluble in water, but soluble in solutions of common salt, which contain less than 10 per cent of *ClNa*, likewise in dilute acids and alkalies.

Three other albuminous substances, besides, may be obtained, according to the same observer, from muscle serum, namely, the so-called albuminate of potash, a second material, coagulating at 45° C., and a third, which requires 75° C., before the latter process takes place in it.

If, on the other hand, muscle be treated with a very dilute solution of hydrochloric acid (1 : 1000), another modification of the albuminate group is obtained, from the members of the latter contained in it, namely, *syntonin*. This body was formerly named "muscle fibrin," until *Liebig* prove its difference from fibrin. It may be obtained, moreover, by a similar process, from other albuminous matters, and is probably also formed physiologically by the action of the acid gastric juice during digestion.

The quantity of syntonin varies very much in the muscles of different animals (*Liebig*), and we are taught further, by the microscopic control of the fibre engaged in solution, that we have here to deal, not with a simple, but with a compound matter, consisting of three substances,—first, the longitudinal cementing medium, which falls the first prey to the solvent action of hydrochloric acid, and then the sarcous elements and transverse cementing substance, which are probably not simultaneous in their solution. Besides these, there remains over in the sarcolemma a slimy granular residue with fatty molecules.

Neither nucleus nor sarcolemma yield any of this syntonin. The first affords no glutin (*Scherer, Koelliker*), but consists of a substance nearly allied to elastin, but differing from it in its smaller power of resistance to reagents; the latter resists the action of dilute hydrochloric acid for days in the most determined manner (fig. 277, 5, a, b), but gives way on the other hand to strong alkaline solutions.

Like all other tissues, muscle contains *fat*, but in most variable quantity. A certain proportion of it may be set down to the cells of the nerves and fat-cells of the fleshy mass, but a certain amount belongs to the fibres themselves.

By means of washing and expression, about 6 per cent. of constituents, soluble in cold water, may be extracted from the dead muscles of the mammalia. They are of very various nature and great physiological interest. In the liquid so obtained, which is of reddish colour, opaque, and of strongly acid reaction, we encounter, in the first place, a not inconsiderable proportion of soluble albuminoids, amounting in the fresh tissue to 2–3 per cent.

We obtain in the first place, then, the red *colouring matter* of the muscular fibres in solution, which is identical with that of the blood (*Kühne*), and with which the tissue is saturated during life. The tint of striped muscular tissue is more intense than that of unstriped fibres, and is, as a rule, only present, with any degree of markedness, among the higher vertebrates, whilst the flesh of the lower members of this group appears in general but slightly reddened, or even quite pale.

Besides this, the juice of muscle contains, as shown by *Liebig*, a series of important products of decomposition, which were known to earlier investigators as "extractives." Among these there appear, in the first place, several azotised substances. The first of these is *kreatin* (p. 44), whose amount is usually small, existing, it is generally supposed, in largest quantity in the heart. It varies also in different species of animals, and is more abundant in lean than in fat bodies, and likewise after muscular exertion. A hundred parts of fresh human muscle contain, according to *Schlossberger*, 0·06 of kreatin (in the horse, 0·07, according to *Liebig*), while the heart yields 0·14 per cent. The next of the series is *kreatinin* (p. 45) (nearly allied to the last), which appears to occur in smaller quantity than the last. Its occurrence, however, appears doubtful

from *Neubaur's* investigations. Then we find *hypoxanthin* (p. 43). *Strecker* states the amount of the last of these to be only 0.022 per cent. in the fresh flesh of oxen. In addition to these, a fourth substance, *xanthin* (p. 43) is supposed by *Scherer* and *Staedeler* to exist in the flesh of mammals. A new substance, discovered by *Weidel* in *Liebig's* extract, may also be mentioned here, to which the name of *carmin* has been given. *Urea* is not usually present in human muscle; *tyrosin* and *leucin* are also absent (2). The muscles of embryonic pigs of two inches long, however, contain, besides *kreatin*, a moderate amount of *leucin*.

In muscular tissue also there is a peculiar species of spurious sugar, which has been named *inosite* (p. 33), and which has up to the present only been met with in the substance of the heart. According to *Valentiner*, it appears to be a normal constituent of the muscles of drunkards (3). *Staedeler* met with it also in the muscles of dogs. *Meissner* has likewise demonstrated the presence of a kind of sugar, "*muscle sugar*," peculiar to muscle, in the flesh of the five classes of vertebrata, although as yet no one has succeeded in obtaining it in a pure state. It is a matter of some interest, further, that the embryonic muscle fibre, as well as the contractile fibre-cell, both contain glycogen (*Rouget*, *Bernard*, and *Kühne*); but it appears also to be regularly present at a later period (*O. Nasse*).

In that the muscles of phytophagous mammals contain *dextrin*, the occurrence of this muscle sugar is easily explained.

The series of *organic acids* is no less considerable. In the first place, we have 0.6–0.7 per cent. of *paralactic acid* (p. 34)—the source, apparently, of the acid reaction of dead muscle. It was formerly supposed with *Liebig* that it was a component of every living muscle also, but *Du Bois-Reymond* showed later that the plasma of quiescent or moderately active muscle has a neutral or weakly alkaline reaction, and only becomes acid when the structure has been called on for immoderate exertion. On the other hand, after the death of the muscle, which is ushered in by rigor mortis, the fluid of its parenchyma becomes rapidly acid by virtue of the presence of free lactic acid. As to the particular constituent of the muscle from which this acid has its origin, we are at present unable to answer anything with certainty.

Besides this, we meet with *inosinic acid* (p. 36), according to *Liebig*, about which but little is known, and which appears also in very small quantity. *Schlossberger*, however, was unable to discover it in human flesh. Further, muscle juice contains of the volatile fatty acid group *butyric*, *acetic*, and *formic acids*. *Uric acid* was only once met with by *Liebig*.

Finally, the *mineral constituents* of muscle (of the tissue as well as contained fluid) are very peculiar. The same compounds as those occurring in the plasma of blood are certainly met with, but in completely different proportions. While in the latter the combinations of soda preponderate, muscle tissue shows the greatest poverty in soda, and an excess of potash. In contrast also to the plasma of blood, the phosphatic salts exceed in muscle the combinations of chlorine by a large amount, the greater part of the phosphoric acid being united with potash, and the proportion of chloride of sodium appearing but very inconsiderable. In conclusion, among the combinations of phosphoric acid with earths, we find the magnesium phosphate exceeding in amount the corresponding salt of calcium. Iron is also contained in flesh in a small quantity. The absence of sulphates is rather remarkable.

When the question is started, Where are we to suppose these mineral constituents to exist, whether in the fibre or its nutritive fluid? the following fact may be borne in mind, that the proportion of salts soluble in water which are present in flesh is very considerable. The former amount, according to *Chevreul*, to 81, and to *Keller*, to 82.2 per cent of the whole ash, while the quantity of phosphate of calcium is stated to be 5.77, and that of magnesian phosphate 12.23 per cent. Of course a larger proportion of potash compounds must occur in the fluid of muscle than in the fibre itself, whereas the latter is richer in phosphatic earths.

Living muscle contains, further, *carbonic acid* and *oxygen gases*. The latter is absorbed by it so long as its vitality exists, while carbonic acid is generated within it as a product of decomposition, whether blood be conveyed through it or no. The amount, moreover, of the latter increases with the use of the muscle, which appears to be one of the most important sources of this ultimate product of mutation in the body.

Smooth muscles, with the contractile substance of their cell body and their nuclei, manifest less complication than those formed of striated fibres, but appear on account of their smaller bulk less suitable objects for chemical investigation. Their composition appears, moreover, to be the same as that of the striped tissue. Syntonin has naturally been obtained from them also (*Lehmann*). Further, in their juices albuminous substances have been found—kreatin, hypoxanthin, lactic, acetic, formic, and butyric acids. Here also the potash combinations predominate.

REMARKS.—1. *Bibra* states the proportion of water in the human muscle to be only 72-74 per cent., as opposed to the usual figures, 77-78. 2. Among the fishes we find the muscular tissue of the plagiostoma to contain enormous quantities of urea (*Staedeler* and *Frerichs* in *Erdmann's Journal*, Bd. 73, p. 48, and Bd. 76, p. 58). 3. The same observers found, further, a substance very similar to inosite in the muscles of the plagiostoma; this is named "*scyllit*."

§ 171.

In regard to the many physiological and physical properties of the tissue, a few points only need be touched on here.

Quiescent living muscle displays a high degree of extensibility, returning almost completely to its original length as soon as the extending force is suspended; it has slight, but very perfect elasticity. The active fibre is still more extensible, *i.e.*, its elasticity has undergone diminution. The dead muscle fibre possesses much less capability for being extended, and return to its original length does not take place.

The living structure possesses electromotor properties, and presents the so-called "muscular stream," in the study of which *Du Bois-Reymond* has lately done so much. We cannot here enter upon its differences during quiescence and activity of the muscle. The latter ceases to possess electromotor properties so soon as its vitality is at an end.

The most important property, however, of the living muscle fibre (striped and smooth) is, that it contracts on stimulation of the motor nerves terminating in it, decreasing in length, and enlarging it in a transverse direction. The nature of this peculiar property inherent in muscle—whether it be itself capable of being excited, or only through the medium of the nerves which end in it—has been now for many years the subject of physiological controversy.

The kind of contraction, again, varies according to the histological elements with which we are engaged. In striped fibres we observed it to commence almost simultaneously with the application of the excitant to the nerves of the part, ceasing very rapidly again on cessation of the stimulus, and giving way to relaxation. The reverse may be observed in smooth muscle. Here an appreciable interval of time is remarked between the application of the stimulus and contraction, while the latter outlasts the action of the excitant for some moments; the fibre reassuming gradually a condition of quiescence. This is evident in the motions of whole groups of animals, and also in those of individual organs, as in the iris of birds, made up of striped fibres in contrast to that of human beings and mammals generally, in which the former are smooth. With us it is the striated fibres alone which obey the influence of the will in their rapid and precise action.

In the rectilinear muscle, with the aid of the microscope, we see during contraction the longitudinal striæ become less distinct, and eventually disappearing, while the transverse markings become clearer and clearer. It would naturally be a great point achieved could we ascertain precisely how the elementary particles of the active fibre are affected by this, and especially how the dark zones behave in relation to the clear. It appears, however, as though the former approached each other, while the clear zones decreased in height. These points are, however, still too doubtful for us to be able to draw any great conclusions from them. We regard it as not improbable, however, that the sarcous elements may be relatively immutable, as compared with the particularly contractile longitudinal cementing medium. According to *Amici's* observations on the muscles of the common fly, the elongated fleshy particles appear to assume an oblique position at the moment of contraction. This we have ourselves seen.

According to the most recent observer, *W. Engelmann*, the seat of the contracting force is exclusively the dark (*anisotropic*) layer. The transparent (*isotropic*) transverse zone is either contractile in a minor degree, or only elastic probably, like the dark transverse disk of *Krause*. While the volume of the muscle casket enclosed between two of the latter does not become appreciably lessened, the dark transverse zone at the moment of contraction increases in bulk, the clear becomes less voluminous; the first swells, the last shrinks, so that an overflow of fluid takes place. Besides this the first becomes clearer and softer, the latter darker and more solid.

The sarcolemma, owing to its elasticity, follows the changes of form in the fibre, tightly investing the latter throughout. That the transverse striæ are not produced by wrinkles across its substance was recognised long ago. The motor nerves will be referred to in a future chapter.

It is a matter of far greater difficulty to obtain a view of the contractile fibre-cell, or unstriated fibre, in the moment of contraction. According to *Heidenhain*, each element (at least among invertebrate animals) becomes likewise simultaneously and evenly thicker in all its parts, with a corresponding decrease in length.

As to the rigor mortis connected with the death of muscle, on which an albuminous substance contained in the latter undergoes coagulation, while its reaction becomes acid, the microscope has added but little to our knowledge. The dead fibre appears more rigid and dull, and less transparent than during life.

§ 172.

Turning now to the *development* of the tissue, we find *smooth* muscle to take its rise from the simple transformation of round formative cells with spheroidal vesicular nuclei of the middle germinal plate. These elements change into contractile fibre-cells by growth in two opposite directions, during which the nucleus assumes its before-mentioned elongated configuration (p. 281). Fig. 273 (*a, b*) represents two such embryonic cells from the wall of the stomach of a foetal pig two inches long.

Touching now the striated structures, it was for a long time supposed, in accordance with *Schwann's* view, that the fibre was always produced by a fusion of formative cells arranged in rows, whose united membranes went to form the sarcolemma, while the nuclei persisted, and the combined contents of the cells took on the characteristic form of fleshy matter through further metamorphosis.

But this view is, as we now know for certain, quite erroneous. The muscular fibre, far from being a result of the fusion of a series of cells, is nothing more than a single elongated filiform cell, in which the nucleus has undergone division and multiplication, and the contents metamorphosis, and which has attained gigantic dimensions in proportion to the length of the striped muscle. We have already referred to this mode of development (for the discovery of which we are indebted to *Lebert* and *Remak*) in discussing the growth of the tadpole (p. 96).

In the mammalia and human beings the same is to be observed. Here we may follow up, in young embryos, the steps in development of the tissue, which are essentially similar.

Thus in the human foetus, at about the sixth or eighth week, very narrow membraneless and fusiform cells, often only 0.0025–0.0036 mm. in breadth, are met with as elements of the rudimentary muscle of the hands and feet. They are formed of very delicate protoplasm, with a single or double vesicular nucleus, and attain a length of 0.14–0.18 mm. (*Koelliker, Frey*).

The same is to be seen in mammalian embryos at corresponding stages of development. In those of the sheep, measuring 27–9 mm. in length (fig. 293), we may obtain from the diaphragm and abdominal muscles fusiform cells 0.28–0.38 mm. long, and 0.0045–0.068 mm. in breadth. These show a vesicular nucleus 0.0077–0.0104 mm. in diameter, and incipient transverse striation in the central portion (*a, b*). These nuclei range in number from two to four, but other cells further advanced possess many more of the latter (*c*), and increase in transverse diameter to double or even more (*d*). As a rule, their axis remains unaffected by the transverse striation, and in it we see the original protoplasm. In somewhat older animals the muscular fibre is 0.0129–0.0156 mm. in thickness, and so long that it can no longer be isolated in its entire length, although the pointing of one end (*e*), or blunt rounding off of the same (*f*), may be easily found. The number of nuclei now becomes greater and greater, and the process of division is observed as an ordinary occurrence (*e, f, g*). Sometimes the position of the former is central (*f, g, i*) and sometimes peripheral (*h*). The axis of the fibre generally remains free from transverse marking (*f, h, g*), while at its circumference the longitudinal cleavage commences to manifest itself. The tendency among muscles of this kind to break up into thick discs under the action of water (*i*) is a point of much interest.

Fœtal muscle, as already remarked, contains glycogen, but at first, before the embryonic cells have begun to undergo their characteristic transformation into fibres, this substance is entirely absent, according to the

interesting investigations of *Bernard* and *Kühne*. In smooth nucleated fibres it presents itself as a granular matter deposited around the nucleus. *Rouget*, however, asserts that it only occurs diffusely. Later on, with the development of the transverse striæ and appearance of the characteristic muscular structure, the fibre is infiltrated with glycogen, which persists until birth, disappearing rapidly on the commencement of respiration.

As yet we have not said one word as to the origin of the structureless envelope, the *sarcolemma*. In earlier years, supposing the formative cell to be endowed with an envelope, this sarcolemma was looked upon very generally as being the metamorphosed cell-membrane of the former. But now that we have convinced ourselves that no such envelope exists upon the formative cell, such a view can no longer be entertained. At the present we find two theories very generally held in regard to this point. According to one, the sarcolemma is a hardened secretion from the cell, of the same nature as the so-called cuticular formations; according to the other (and we are inclined to favour this view) this structureless sheath is a connective-tissue formation laid down on the muscle fibre from without, which may be compared to the elastic bounding layers of many connective-tissue structures.

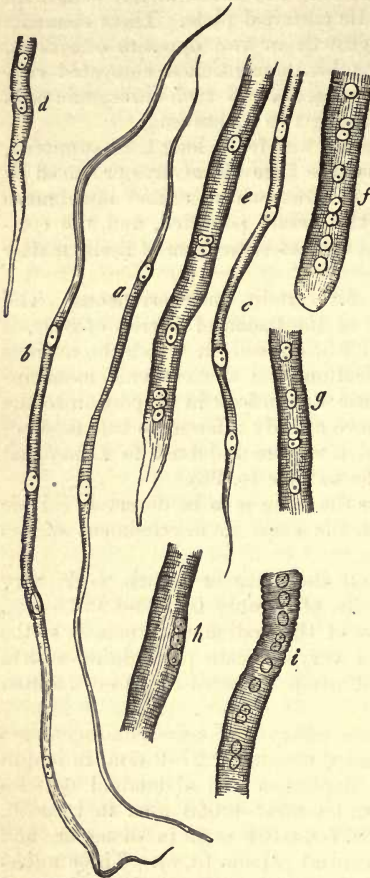


Fig. 293.—Development of striped muscle fibres: from a fetal sheep. *a, b*, very long fusiform cells with two or three nuclei and commencing striation; *c, d*, portion of a somewhat more mature fibre, with numerous nuclei and considerable diameter; *e, f, g*, fibres still further developed, with nuclei in the axis; *h*, nuclei beneath the envelope; *i*, a fibre breaking up into thick discs.

That the end of the muscle fibre can be separated with its envelope from the tendon, as we have seen at p. 294, appears to us to be no very weighty objection to this view. Do we not also see elastic fibres separating themselves from connective-tissue bundles? and yet they have both the same origin.

The branching muscular elements of the heart correspond, we are assured by *Koelliker*, each to a metamorphosed stellate cell, and the whole to a cellular network. *Weismann*, however, is opposed to this theory from his own observations. In his opinion the muscular bands consist (and of

this we may convince ourselves very easily), in fishes and amphibia, of aggregations of simple elongated fusiform and at times branching cells. The same is the case in the embryos of the higher vertebrates. In the latter, however, these cells unite more intimately at a subsequent period to form the common substance of the band. But we may still render the boundaries of the various cells visible here also by artificial means (*Eberth*).

§ 173.

Let us now turn to the growth of muscle.

Embryonic muscular fibres, as we have already mentioned in the previous section, are considerably finer than those of the infant, and their diameter in the latter is far less than in the adult.

According to *Harting's* accurate measurements, the muscle fibres of the adult appear about five times as thick as at the time of birth. This increase in length and breadth is brought about by the reception of new particles between those already present in the fleshy substance, or, as it is the custom to say, by intussusception.

But the fibres of growing muscle become not only larger, but their number also increases, as was demonstrated beyond gainsaying by *Budge*, by experiments on the sural muscles of a frog's leg. We are indebted to *Weismann* also for further interesting information on the same point. According to the last-named observer, the growth of the muscles of frogs takes place only in part through increase in thickness of the fibres originally present; there occurs, besides, a considerable augmentation of the number of the latter by a process of longitudinal division. This process is ushered in by an active proliferation of the nuclei or muscle corpuscles (*Muskelkörperchen*) in the old fibre, so that we soon meet with regular columns of the former arranged one over the other, while the fibre itself becomes flattened and widened. Subsequently to this the fibre splits into two threads, in each of which the process just described is repeated, so that out of one old muscle element a whole group of new ones eventually takes its rise. Each of the new fibres then attains its typical diameter through that growth from within, which has already been referred to.

In full-grown frogs, also, during their winter torpidity, we may see a lively regeneration, with fatty degeneration of the previously existing muscle fibres (*Wittich*). In this case, likewise, the same process of multiplication was observed by *Weismann*.

Great interest attaches further to a discovery made by *Lenker*, that an extensive destruction of human muscle fibres takes place during typhus fever, combined with rapid multiplication of the muscle corpuscles and connective-tissue cells. This is due to a peculiar degeneration, and is followed by energetic regeneration of the elements on recovery. The process is probably the same as that observed in the hibernating frog.

This luxuriant growth of the muscle corpuscles takes place, besides, in other states of irritation of the tissue.

From these facts, few though they be, we may infer that muscle fibres are by no means so persistent structures as was formerly tacitly agreed to.

The uterus of pregnant women offers us a good opportunity of setting on foot interesting investigations as to the nature of the growth of the elements of unstripped muscle. As is well known, the organ in question

increases enormously in volume at certain times, a fact which depends chiefly on changes in its muscular tissue. The contractile fibre-cells become enlarged to 7-11 times their original length, and to 2-5 of their breadth (*Koelliker*). Besides this, there takes place, according to the same observer, a reproduction of cells also.

After parturition a decrease in the size of the contractile cell begins to be apparent, with which it returns in about three weeks to its original dimensions. Fatty infiltration of the substance of the latter during this period is of frequent occurrence, and we may also accept as a certainty the resolution of a certain number of the muscular elements also.

That there really may be such a thing as a physiological hypertrophy of the striped fibres can hardly be doubted any longer since *Auerbach's* discoveries.

In hypertrophied hearts it was stated by *Hepp* long ago that thickening up to four times their original size took place in the fibres. It would appear, however, that there is really only a multiplication of the fibres here (perhaps by longitudinal division).

Pathological hypertrophies, however, of unstriped muscle, amounting even to the formation of tumours, are of frequent occurrence. They affect parts which are richly supplied with this tissue,

such as the œsophagus, stomach, and uterus. Their genesis requires to be made the subject of more accurate investigation than has as yet been the case. That a transformation of connective-tissue cells into contractile elements takes place is at least probable (*Aeby, Arnold, Koelliker*).

Finally, we meet with an atrophy of muscle fibres or disappearance of the same. In the first place, this is encountered as a more or less normal phenomenon in old age. Then, again, it appears more frequently under pathological conditions as a diminution in the diameter of the fibre (as in paralysis of various members), combined, to a certain extent, with fatty degeneration of the fibre or development of interstitial fat-cells.

The latter (fig. 294) have been already discussed (§§ 122 and 169). If this latter process proceed to too great length, it may possibly interfere at last with the functions of certain portions of muscle through pressure, as, for instance, in the heart. The deposit of small molecules of fat in the interior of fibres is of frequent and normal occurrence when the quantity of the former does not become too great. Thus we meet with it in the muscle of the heart, and in the frog in the muscles of the extremities (§ 166).

In a greater degree it must be looked upon as a phenomenon of retrograde development (fig. 295), of pathological significance. But, on carefully searching through healthy muscles, we will always encounter certain fibres containing a considerable amount of fat granules of this kind, and not unfrequently also a diminution in thickness, so that it is

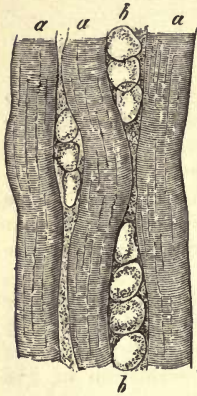


Fig. 294.—Human muscle studded with fat-cells. *a*, muscular fibre; *b*, rows of fat-cells.

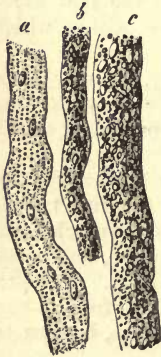

Fig. 295.—Fatty degeneration of human muscle fibres. *a*, low degree; *b*, a higher; *c*, the highest degree.

probable that a physiological decay with fatty degeneration also takes place to a limited extent.

Calcification of this tissue is rarely seen.

Neoplasia of striped muscle, at points where it did not previously exist, is of very unfrequent occurrence. A certain number of those few cases which have been up to the present recorded have reference, strange to say, to the testicle and ovary. Here there can hardly be any doubt of the development of muscle fibres from connective-tissue cells, however we may suppose their source to be from the muscle corpuscles in the intramuscular new formation.

Though it was formerly believed that wounds of muscles could be repaired by connective-tissue alone, numerous recent observations have proved the power of regeneration inherent in the tissue. The mode of this new formation of muscle is a matter, however, about which much difference of opinion still exists.

E. Composite Tissues.

15. Nerve Tissue.

§ 174.

The form-elements of the nervous system (1) are structures of two different kinds, namely fibres and cells, imbedded in a ground-work of connective-tissue. The first of these, known under the several names of "nerve fibres," "nerve tubes," and "primitive fibres" of the nervous system, make up almost exclusively the white substance of the neural apparatus. The last, to which the names of "nerve or ganglion cells" have been given [also "ganglion corpuscles" ("Ganglienkörper")], are found mixed up with the first described elements, in the grey matter.

The "groundwork" of connective-tissue presents itself in the first place in the form of a highly developed fibrillated structure, more frequently, however, as a more or less homogeneous connecting substance (perineurium), or, finally, as an extremely delicate tissue containing cells and nuclei, as in the nervous centres.

Nerve-fibres (fig. 296) are met with either as dark-bordered threads, the *medullated*, or pale, the *non-medullated*. They are simple unbranched fibrils, except at their origin and termination, and vary to an extraordinary extent in thickness, measuring from 0.0225 down to 0.0018 mm. and less. Owing to their appearance not being the same in all cases, we distinguish between *broad* or *coarse* fibres (*a* and *b*) of 0.0226 mm. (more usually of 0.0113–0.0056 mm.), and *fine* or *narrow* fibres, whose diameter may fall to 0.0045–0.0018 mm. (*c*, *d*, *e*).

Dark-edged nerve fibres consist of three parts,—namely, of a very delicate envelope of connective-tissue, the "neurilemma" or "primitive sheath;" of an albuminous portion extending down the centre, the so-

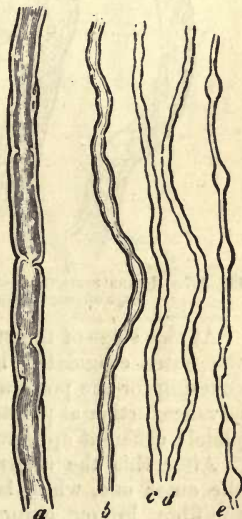


Fig. 296.—Nerve fibres from the human being. *a*, a coarse specimen; *b*, medium-sized fibre; *c*, *d*, *e*, finer still.

called "axis cylinder;" and of another portion situated between the envelope and the latter, a mixture of albuminous substances, cerebral matters, and (?) fats, the "medullary sheath" or neural medulla" (Nervenmark). Of these three, which cannot be demonstrated on the perfectly fresh fibre, but only by round-about modes of treatment, the axis cylinder must be looked upon as the most essential and only indispensable structural constituent.

The appearance of *broad* nerve fibres in a recent state is that of threads formed of some completely homogeneous transparent or milky mass. It is rare, however, that we obtain a view of them in this state, owing to the exceedingly rapid changes which take place in the contained matter. All the more customary modes of preparation (if we desire to isolate the fibres) bring the latter before us in a form which has already undergone change, or has "coagulated," as the saying is. This congelation, however, is met with in various stages of completeness (fig. 296, *a, b*; fig. 297).

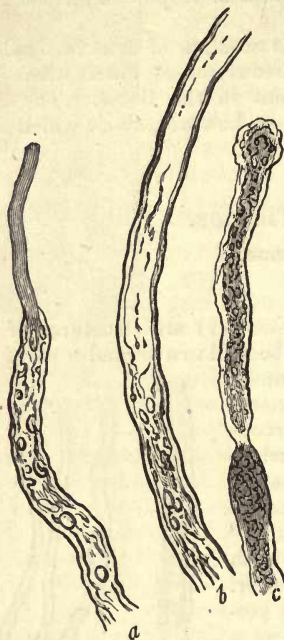


Fig. 297.—Human nerve fibres at an advanced stage of coagulation.

When isolated with as great rapidity and care as possible, the nerve fibre presents to our view a dark border, and closely applied to this internally a second and finer bounding line (fig. 296, *a, b*; fig. 297, *b*, above).

Later on, these two lines or "double contours" are not quite parallel, and the internal one is no longer continuous throughout. The thin layer interposed between the two lines on each side of the fibre appears homogeneous (fig. 296, *a, b*) or granular.

At this stage of transformation the nervous fibre may remain stationary, the outer coagulated layer acting to a certain extent as a protecting covering for the portion situated more internally, or, the congelation may advance further at points, and the nerve fibre may frequently present a completely different appearance at various parts of its course (fig. 297, *b*).

After this the internal line becomes separated more and more from the outer one, while between the two, and also in the central part of the fibre, lumpy, granular, or globular masses are formed (*a, b*), until eventually the whole appears transformed into a sometimes coarse and sometimes finely granular substance (*c*), and the entire nerve tube has become dark (2).

REMARKS.—1. Literature is very rich in information on this subject. 2. Neural medulla which has escaped from its sheath displays precisely the same changes ("Myelin" of Virchow.)

§ 175.

The existence of an envelope on the nervous tube is easily inferred

from the fact that the latter can be isolated in a considerable part of its length, in spite of the soft nature of its contents. This *neurilemma* may be seen not unfrequently as a short empty tube, at points where the included mass has been displaced (fig. 297, *c*). It may likewise be demonstrated by means of chemical reagents, which completely or partially dissolve the substance contained within it (fig. 298, *a, c*). Neurilemma consists either of elastin or some material nearly allied to it, and is usually encountered among the higher vertebrates and in the human body as a completely homogeneous and very delicate membrane, either with or without nuclei. Among the lower orders of vertebrates, and on the peripheral ramifications of human nerves, it may be found thickened and supplied with numerous nuclei.

To what extent this sheath exists among the elements of the nervous system is a more difficult question, and one which cannot at present be answered with certainty. Thus, in the branches of many of the cranial nerves it is absent; and in the terminal peripheral ramifications not unfrequently. Its demonstration, moreover, on very fine medullated nervous tubes is a matter attended with some difficulty. Finally, the fibres of the brain and spinal cord are destitute of this sheath.

The *axis cylinder* of *Purkinje*, or *primitive band* of *Remak*, cannot be recognised in the fresh nervous tube on account of its delicacy and soft consistence. It is frequently missed also in many simply coagulated fibres, owing to the fact that it also has undergone a granular metamorphosis.

It appears, however (and upon this we would lay greatest stress), at the point of origin (fig. 298, *g*), as well as at the terminations of the nerve tubes, where the medullary sheath fails. It is likewise to be seen in many nerve fibres, coagulating in the ordinary manner, as a pale homogeneous band-like structure, about a fourth or third of the breadth of the former, projecting from its cut end (fig. 297, *a*, above).

Certain chemical reagents again may be employed for its demonstration to great purpose. Among these are several substances, in the first place, which are well known to render the protein bodies hard, without dissolving or producing any particular effect on the fats; these are, for instance, chromic acid, chromate of potash, and chloride of mercury (fig. 298, *b*). Again, there are reagents which are employed for the same ends on account of their power of dissolving the fats, but not the albuminates; of these we may mention alcohol and boiling ether (*a*). Sometimes we obtain specimens in which the axis cylinder projects from the cut end "like the wick from a candle." One of the best aids, however,

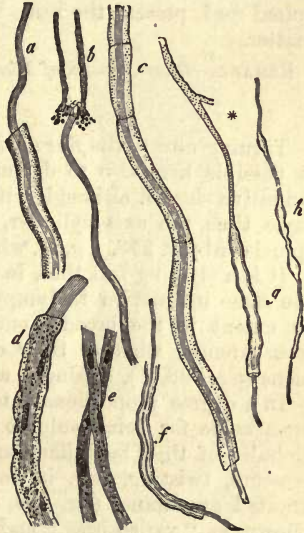

Fig. 298.—Nervous fibres of various kinds. *a*, a broader one from the frog after treatment with absolute alcohol, showing the axis cylinder and neurilemma; *b*, another, with axis cylinder, after treatment with bichromate of potash; *c*, a fibre from the same animal, treated with collodium, showing the axis cylinder and neurilemma; *d*, a non-medullated fibre from the *petromyzon* with the axis cylinder and nucleated envelope; *e*, a non-medullated fibre from the olfactory of the calf; *f, g, h*, fine fibres from the human brain with axis cylinders; the fibre *d* (copied from *R. Wagner*) unites above with the process of a ganglion cell.

in the demonstration of the structure in question, is collodium, recommended by *Pflüger*. Under its action the axis cylinder makes its appearance almost instantaneously throughout the whole length of every fibre, frequently bent over strongly to one side (*c*). Tinction with carmine may also be employed, and aniline (*Frey*) or chloroform (*Waldeyer*).

Very instructive objects, as regards the nature of the structure just described, may be prepared from transverse sections of nervous trunks previously artificially hardened (*Reissner*). In these we recognise the envelope of each tube, its axis cylinder as a small central formation, and between the two the medullary sheath. In the latter may be seen an irregular concentric marking, first observed by *Lister* and *Turner*, which is probably the optical expression of lamination in the medullary substance. Transverse sections also, through the white substance of the spinal cord, present the same views of the axis cylinder, and medullary matter.

REMARK.—*Quart. Journ. of Microsc. Science*, 1860, p. 29, pl. 2.

§ 176.

Turning now to the *fine dark-edged nerve fibres* (fig. 296, *c, d, e*), we find it possible here also to demonstrate in many cases the presence of the primitive sheath, although with greater difficulty. We recognise at the same time the axis cylinder, especially in the fibres of the brain and spinal cord (fig. 298, *f, g, h*), where the primitive sheath is no longer present.

It is a striking fact that, in these fine nervous tubes, we do not remark the same inclination to lumpy or granular coagulation as is seen to such an extent in the broader ones; we find them rather preserving their transparency, whether their contour appear double, as in larger specimens (fig. 298, *f*), or single, as in the more minute (fig. 296, *c, d, e*).

In a degree proportionate to their thinness, these fine nerve tubes are remarkable for being subject to a displacement, and the formation into globules of their medullary substance under the action of water, or from pressure, twisting, &c., in consequence of which they often present a knotted appearance (fig. 296, *c, d, e*, and 298, *h*). These swellings are known as "varicosities," and are nothing, we repeat it, but artificial productions, which do not exist in the living body.

Next in succession to these dark-edged medullated fibres, we come now to a second species, namely, to the *pale or non-medullated*.

This is the primary form of all the fibrous neural elements in the embryos of man and the vertebrates.

In the family of the petromyzon, a lowly organised fish, this non-medullated pale appearance of the fibre, presenting simply an axis cylinder, persists throughout life (fig. 298, *d*). But even in the bodies of the higher vertebrates, and human beings also, the nerve tubes may still preserve this original embryonic condition in various positions; thus, in the *nervus olfactorius*, as soon as it enters the nose.

While there can be but little doubt as regards the nature of the fibre-elements in the olfactory nerves, it is quite a different matter in the course and distribution of the sympathetic. Here we encounter in the human body and among the higher vertebrates, together with medullated tubes, the so-called fibres of *Remak* (ganglionic nerve fibres), which may even preponderate. These are transparent sometimes; flat bands of about 0.0038–0.0068 mm. in breadth and 0.0018 mm. in thickness (fig. 299, 300, *b*). Their appearance is usually homogeneous, while at intervals

an elongated oval or fusiform nucleus may be remarked, measuring about 0.0068–0.0113 mm. in length. At times, also, these flat fibres are split up, though imperfectly, into fibrillæ (fig. 299, *b*).

As to the nature of these fibres of *Remak*, whether they are composed of connective-tissue, or are (as was supposed by their discoverer, and with him by *J. Müller*) nervous elements, are points which, in the annals of histology, have been the subjects of controversy for years past. The existence of similar pale nerve elements among the lower animals and in the petromyzon, and among the embryonic and olfactory fibres of the higher animals, seems to point to the conclusion that they are of nervous nature, and, indeed, the general opinion grows stronger from year to year that this is the case. They are just nerve-fibres destitute of medullary sheath, and in which the axis cylinder is enclosed within a nucleated

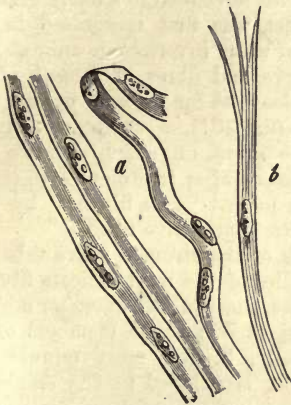


Fig. 299.—*Remak's* fibres from the calf *a*, simple flat nucleated bands; *b*, a fibre split above into fibrillæ.

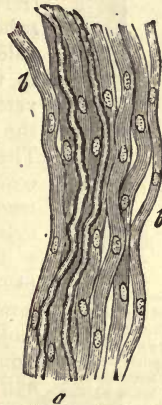

Fig. 300.—A small nervous branch from the sympathetic of a mammal. Two dark-bordered nerve tubes, *a*, among a number of *Remak's* fibres, *b*.

neurilemma. On the other hand, it must be granted that young immature connective-tissue may present precisely the same appearance. The nucleated envelope of many ganglion cells is also a difficult point for us, which will be discussed in the next chapter.

In some small trunks of the sympathetic system (fig. 300), the proportion of these pale fibres (*b*) is so large, and the number of the medullated tubes is so small, that it is difficult to conceive what would be the object of such an enormous amount of enveloping connective-tissue for so few nervous fibres.

In the nerves of the spleen of fully developed mammals twigs have been found of 0.45 mm. in thickness, which contain nothing but *Remak's* fibres.

The question whether this variety in the appearance of the nerve-fibres corresponds to a *difference in their functions* or energies must be generally negatived. The nerves of voluntary muscle and those of the skin have, for instance, the same kind of fibres. The preponderance, however, of narrow dark tubes in the sympathetic is certainly remarkable, but the same occur in great abundance in the brain and spinal cord. Transitions from broad to narrow fibres are also numerous, and in the sympathetic

system as well as in the olfactory nerves, as has just been mentioned, pale, non-medullated, nucleated fibres are to be found.

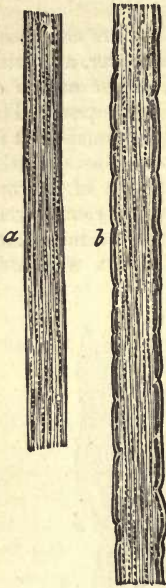


Fig. 301. — Fibrillated structure of the axis cylinder (after *Schultze*). *a*, a strong axis cylinder from the spinal cord of the ox; *b*, a nerve fibre from the brain of the electric ray.

But our position is far more difficult when we are asked for an answer to the question, whether, in what has been just described as the texture of the nerve tubes, their whole structure has been given, or whether they possess a further and more complex constitution.

For many years past there has been no lack of efforts (and some very daring) to prove the latter to be the case. Only one point, however, of any great importance has been ascertained, through the improved optical auxiliaries to our investigations, namely, that the axis cylinder is made up of *extremely delicate fibrillæ*, imbedded in a finely granular substance. This fact was first recognised in the pale nervous tubes of many invertebrate animals, and in the olfactory nerve and fibres of *Remak* of the vertebrates. It is also true for the axis cylinders of the nervous centres (fig. 301), according to *Schultze*. These extremely fine fibres, on which delicate varicosities may be remarked after treatment with certain reagents, have been named "axis fibrillæ" by *Waldeyer*, and by *Schultze* "primitive fibrillæ."

The axis cylinders of the stronger nerve tubes appearing thus as bundles of the most delicate fibres of immeasurable fineness, those of less diameter must be looked on as collections of smaller members of the same, until eventually, in the most minute axis cylinders, the number is reduced to one single primitive fibril (1).

Later on we shall see that the primitive fibrilla (which call, however, for closer observation as to their nature) make their appearance naked, and separated one from the other in the termination of numerous fibres, and also constitute important fibrous elements in the nervous centres.

REMARKS.—1. The importance of the facts but briefly mentioned in the text entitles them to more extended consideration. It was *Remak* who first pointed out, years ago, this remarkable complication in regard to the axis cylinder of the *craw-fish*. In the gangliated cord of the latter are to be found, besides others, unusually thick nerve fibres, whose axis cylinders consist of bundles of above a hundred of the finest fibrillæ, only 0.0004 mm. in diameter. This was subsequently corroborated by *Häkel*, *Leydig*, *G. Walter*, and *Waldeyer*, with discoveries of similar composition in the nerves of other invertebrate animals. *M. Schultze* observed the same structure in the axis cylinders of the *olfactorius* and nervous centres of vertebrates. As to the further points of interest in regard to the structure of the nervous tubes, we have already referred (p. 308) to the concentric markings to be seen in the medullary substance on transverse section of the latter. It seems to depend on lamination, but this view has been opposed by *Frommann*. According to *Klebs*, the axis cylinder is immediately surrounded by a fluid substance,—the "periaxial fluid." Years ago *Stilling* also described as very complicated, the structure of the nerve fibre, working with very high microscopic powers, and preparations made in chromic acid. Compare *Lockhart Clarke* in the *Quart. Journ. of Microsc. Science*, 1860, p. 165. More recently still *Frommann* and *Grandry* have described a transverse striation on the axis cylinder after treatment with nitrate of silver. *Roudanowsky* informs us further that the axis cylinder is knotted, and gives off branches at right angles which anastomose with those of neighbouring fibres.

§ 177.

We now turn to the *cellular elements* or the *ganglion corpuscles*, whose appearance is very characteristic, with the exception of many in the brain and spinal cord, where their boundaries are difficult to define. They may be divided into those *without processes* (fig. 302) and those *with processes* (fig. 303). To the first-mentioned species the term "apolar" has been applied, and to the latter "unipolar," "bipolar," or "multipolar," according to the number of their ramifications.

In every variety of size, from 0.0992 mm. down to 0.0451–0.0226–0.0018 mm. and even less, we meet with these cellular bodies of spherical, oval, pear-shaped, or renal form. In these are situated spheroidal vesicular nuclei of 0.0180–0.1090 mm., with a round slightly lustrous nucleolus of 0.0029–0.0045 mm. Another round point, frequently visible in the interior of the latter—either granular or clear—has been given by *Mauthner* the name of *nucleolulus* (fig. 308). Not unfrequently the nucleolus is double, but the nucleus is seldom so. The latter, unlike most nuclear formations, gives way comparatively rapidly to the action of concentrated acetic acid.

The contents of these cells, probably a species of protoplasm, appears as a tough doughy mass, with numerous minute granules of a protein substance, and in addition to these, fat molecules, soluble in alcohol and

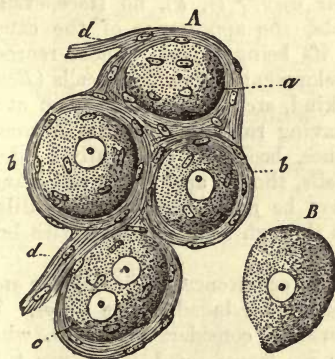


Fig. 302.—Ganglion cells from a mammal. *A*, Cells with connective-tissue envelope, from which *Re-mak's* fibres take origin, *d, d*; *a*, a non-nucleated cell; *b, b*, two cells with single nuclei; and *c*, one with two of the latter structures. *B*, A ganglion cell destitute of envelope.

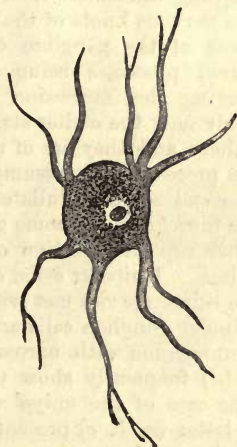


Fig. 303.—Multipolar ganglion cells with protoplasm processes, from the grey substance of the human brain.

ether, and, not at all unfrequently, particles of yellow, brown (fig. 303), or black pigment (fig. 305, 4). The latter substances offer a most determined resistance to the action of alkalis.

All these ganglion cells, the central as well as the peripheral, are destitute of distinct membranes. In the grey matter of the nervous centres they are imbedded in that fibrillated sustentacular substance already mentioned at p. 197. In the peripheral ganglia, on the other hand, of man and the vertebrates, they are usually enclosed in envelopes

of a non-fibrillated nucleated tissue (fig. 302, A), from which they may be isolated in the form of membraneless corpuscles (B).

According to recent investigations, the internal surface of each of these corpuscles is lined in man and the vertebrate animals with delicate flattened epithelium or endothelium, resembling that of the blood-vessels (*Fränzel, Koelliker, Schwalbe*) (1).

What is the nature of this enveloping nucleated tissue?

Here we meet with a great variety of opinions. It was formerly set down as being *in toto* a connective-tissue structure, but *Beale* and *Remak* ascribe to it a nervous character. Be this as it may, the distinct origin of *Remak's* fibres from these systems of capsules is very remarkable.

REMARKS.—1. This was noticed years ago by *Robin* and *R. Wagner* in the case of the ganglion cells of the electric ray. *Remak* too was aware of the presence of this cellular lining.

§ 178.

The *processes* and *ramifications* of the ganglion cells serve, in the first place, possibly as connections between neighbouring cells (commissural fibres), and, in the next place, they certainly go to form the axis cylinders of different nerve fibres. For the investigation of these very difficult points the lower orders of vertebrates, and especially fishes, are to be recommended, in which the dissection is rendered easy by the small amount of enveloping connective-tissue (1). The following points may be noticed in the nervous knots of the burbot [*Gadus lota* (2)] (fig. 304).

Some of the ganglion cells appear *apolar* (*i, k*), no trace even of ruptured processes being discoverable, the appearance of the capsule conveying the impression rather of its being closed. These represent possibly only the earlier stages of development of ramifying cells (*Beale*).

Others, and they are of a smaller kind, are *unipolar*, giving off at one end a process which assumes, after having run for a certain distance, a darker and more medullated appearance, becoming eventually a *narrow* nerve fibre (*f*). On some ganglion cells, though apparently unipolar (*e*), another ruptured portion of fibre may be recognised on the mutilated envelope. Unipolar cells, continuous through their processes with broad nerve tubes, are not met with.

Bipolar ganglion cells are of frequent occurrence. The smaller are in communication with narrow, the larger with broad, nerve fibres. The first (*d*) frequently show us pale fibres of considerable length, which, in the case of the unipolar cell, become transformed into nerve tubes. The latter (*a, b, c*) present to us the fibre as a dark medullated tube, extending as far as the extremity of the cell (*a*). Here the medullary matter spreads out in a thin layer, investing the body of the latter (3) and may persist in that situation even after the rest of it has escaped from the cut end of the nervous tube (*b, c*).

Such bipolar origins as at *h* are of rare occurrence, as also the appearance of two ganglion cells on one and the same nervous tube, as at *g*.

Our diagrams show also that the enveloping neurilemma or capsule of the ganglion cell is continuous with the connective-tissue primitive sheath of the nerve tube. In the peripheral ganglia of fishes, multipolar cells do not occur. Even those with three processes are very rare (*Stannius*).

The recognition of corresponding structural relations in the human being and among the mammalia is of much greater difficulty, owing to the larger proportion of interstitial connective-tissue, and mutilated

ganglion cells are also of frequent occurrence here. Nor dare we form conclusions in regard to the mammal body from what is found in the fish.

The existence, however, of apolar, unipolar, and bipolar ganglion cells, cannot be denied in this case also after candid consideration, although we are still in the dark as to the relative frequency of the various forms.

Multipolar cells must be looked upon as peculiar to many peripheral ganglionic masses, as also to the terminal expansion of the optic nerve in the retina. They were discovered by *Remak* in the sympathetic.

The same species of, and possibly also exclusively, multipolar ganglion cells, occur likewise in the grey matter of the brain and spinal cord (fig. 305); those apolar specimens which are found here, or such as have only one or two processes, being probably mutilated cells (*Wagner, Schröder van der Kolk*). These cells, which contain either a pale substance alone (2), or, besides this, brown and black pigmentary particles (4), possess a very variable number of ramifications, ranging from 4 to 20 and upwards (1-4). The latter appear, under high magnifying power, partly as broad or narrow processes of the finely granular cell body (2, c), and partly homogeneous (1, a). Some of these ramifications split up eventually, with repeated subdivision (4), into fibres of extreme fineness. Others, acting as commissures (2, c; 3, b), are supposed to combine the ganglion cells to a physiological unit (4). Finally, axis cylinders are seen arising from them (fig. 305, 1, a, b; 3, c; and 298, g*).

It is at present impossible to trace any connection between the variation in the ganglion cells just described, and a difference in function in each or any.

REMARKS.—1. In older histological works of the year 40, apolar ganglion cells alone were recognised. *Purkinje*, it is true, had seen the processes of ganglion cells in 1838, but had not recognised their significance. Subsequently to *Helmholtz's* and *Will's* discovery of the one-sided origin of fibres among the invertebrate animals, *Koelliker*, was the first to demonstrate its occurrence among the vertebrates. Great progress was next made in this direction in the year 1847, through the discovery, by *Wagner* and

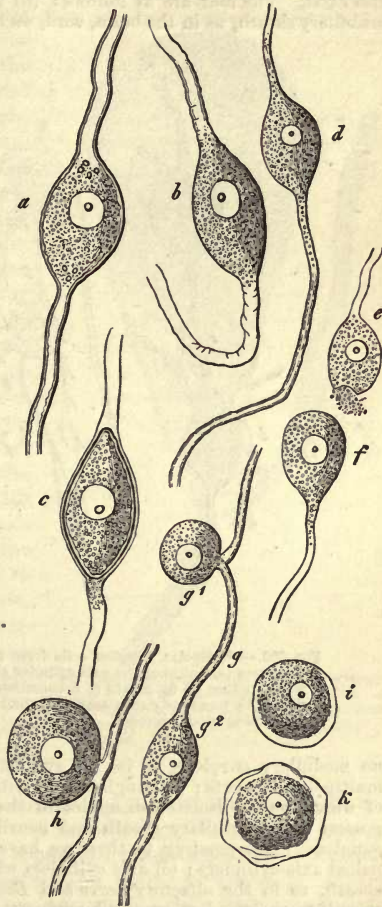


Fig. 304.—Nerve cells from the peripheral ganglia of *Gadus lota*. a, b, c, Bipolar connected with broad nerve fibres; d, similar cell produced into a narrow fibre; e, another of the same kind, from which a nerve fibre has been torn off; f, a unipolar cell with narrow tube; g, two bipolar (g-1, g-2) peculiarly united to fine nerve tubes; h, another bipolar cell; i, k, two apolar ganglion cells.

Robin, of bipolar cells in the ganglia of fishes. 2. *Phil. Trans for the year 1863*, vol. cliii. part ii. p. 543. 3. In his excellent treatise (*Observationes de retinae structura penitiori*) *M. Schultze* divides ganglion cells into four classes, and, as far as our own observation goes, they may be so classed with propriety, though intermediate forms also exist. The four are as follows: (a) those that have neither neurilemma nor medullary sheath, as in the brain, cord, and retina; (b) such as have neurilemma, but




Fig. 305.—Multipolar ganglion cells from the human brain. 1, a cell, one of whose processes (a) becomes the axis cylinder of a nerve fibre (b); 2, a cell (a) connected with another (b) by means of a commissure (c); 3, diagram of three cells (a) connected by means of commissures (b), and running into fibres (c); 4, a multipolar cell containing black pigment.

no medullary envelope, as in the sympathetic and other peripheral ganglia with multipolar elements; (c) ganglion cells with medullary envelope, but no neurilemma, of which we see isolated examples in the *N. acusticus*; and, finally, those which possess both medullary sheath and neurilemma, as in the bipolar cells of spinal ganglia. Corresponding to these we have four species of nerve fibres, namely, (a) naked axis cylinders; (b) axis cylinders with neurilemma, but without a medullary sheath, as in the olfactory nerve and *Remak's* fibres; (c) axis cylinders without a primitive sheath, but supplied with an envelope of medullary substance, as for instance in the white matter of the nervous centres; and finally, (d) axis cylinders surrounded by both medulla and primitive sheath, the usual form. 4. Strange to say, the existence of commissural fibres between the central ganglion cells is stoutly denied by *Deiters*. I myself have seen them most certainly many years ago, and believe in them still.

§ 179.

Here also, as in the consideration of the nerve tubes, the question arises, Does the description of the ganglion cell just terminated give us its complete structure, or does it possess a finer texture?

At present the extremely various views on the subject supply us with but very inadequate materials for replying to this query conclusively. Thus the nerve fibre, *i.e.*, the axis cylinder, has been stated to spring from the nucleus or nucleolus. Among the various observations made on this

point there are doubtless some few which are correct (always excluding those based on optical illusions), but they are probably the exception (1).

One discovery made by *Beale* some years ago, on the other hand, we do look upon as correct, having satisfied ourselves further by personal observation. It applies to the ganglion cell of the tree frog (fig. 306). Here may be seen, namely, making its exit from the interior of the pear-shaped or round structure, at its pointed end, a straight fibre, in which a nucleus (*c, e*) is not unfrequently visible. This is surrounded by the coils of one or more *spiral fibres*, which also contain nuclei. These spring from the surface of the cell-body in close spiral turns (*d, d*), which increase in girth as they proceed on their way round the straight fibre, until they eventually attain a straight course themselves, and pass on as *spinal fibres* with their own special sheath (*f*). The first mentioned fibre, which, as has been already mentioned, springs from the interior of the cell-body (whether from the nucleus or no we are unable to say with certainty), is of nervous structure. *Beale* maintains also that the spiral have the same character, though they appear to us to be, as a rule, of elastic nature. But we are far from denying the possibility that, when two fibres spring from the one pole of a ganglion cell, one of them may encircle the other spirally. *J. Arnold* maintains that these cells possess a much more highly complicated structure.

Deiters mentions having found a double mode of arrangement in the ramifications of the cells of the nervous centres (fig. 307). The greater number of the processes is formed, namely, by prolongations in various directions of the protoplasm composing the body of the cell. These "*protoplasm processes*" then undergo repeated subdivision, giving off branches in all directions, until they finally dip into the sustentacular matter in the form of the most extremely delicate fibrillæ.

From these protoplasm ramifications we can distinguish at a glance one peculiarly long process (*a*), which springs either from the cell itself or from one of the first and broadest prolongations of its body. This process never gives off branches, and becomes clothed later on with a medullary sheath; it is known as the "*axis cylinder process*." Of the correctness of this we may easily convince ourselves.

Beside these just mentioned, other very fine fibres may be recognised (*b, b*), leaving the protoplasm ramifications at right angles. In these *Deiters* supposes (without, however, giving any reason for his opinion), that we have before us a second system of extremely fine axis cylinders.

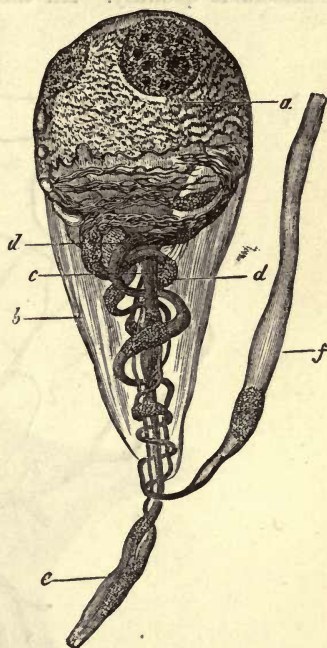


Fig. 306.—Ganglion cells from the sympathetic of the tree frog (from *Beale*). *a*, cell-body; *b*, envelope; *c*, straight nervous fibre; *d*, spiral fibres; *e*, continuation of the former; and *f*, of the latter.

According to *Schultze's* recent investigations, both forms of processes of these central ganglion cells (fig. 308) possess a fibrillated texture, more apparent in the axis cylinder processes (*a*) than in the protoplasm ramifications (*b*), in which latter a granular interstitial substance is present in considerable quantity. All these primitive fibrillæ may be followed up

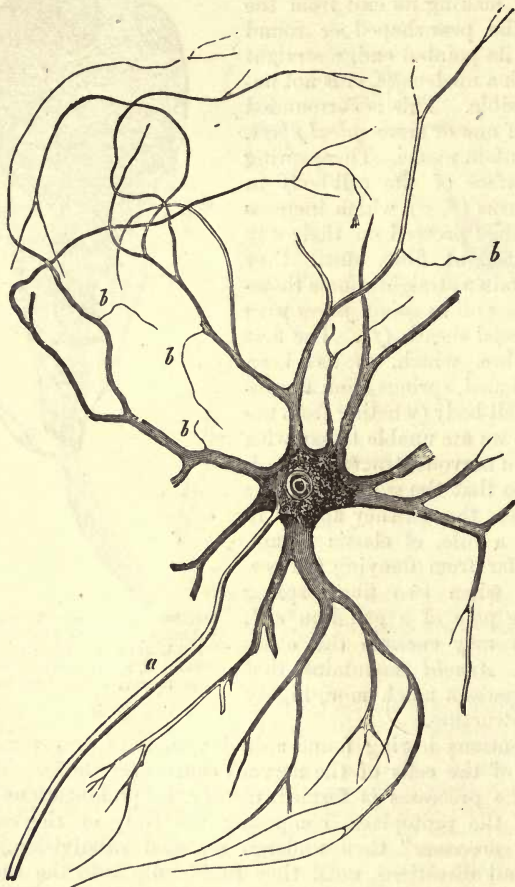


Fig. 307.—Multipolar ganglion cell from the anterior cornu of the spinal cord of the ox, with an axis cylinder process (*a*), and other protoplasm processes with their ramifications, from which the finest fibres take origin (after *Deiters*).

into the body of the ganglion cell, and may be easily recognised there, especially in the external portions, imbedded in a finely molecular mass. Their course is a complicated one, sometimes diverging on entry, and sometimes giving rise to an interlacement of crossing and re-crossing fibrillæ. Connection with the nucleus or nucleolus does not take place. Whether we have here the true origin of the primitive fibrillæ, or whether the latter merely undergo a re-arrangement here,—that is, that, arriving from remote localities through the various

protoplasm processes and penetrating the body of a cell, they are collected together in the latter, and pass out as an axis cylinder,—are questions still undecided.

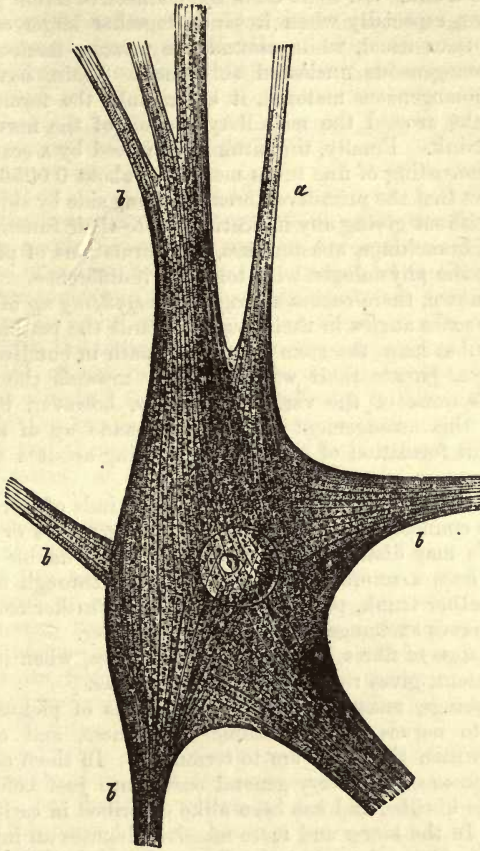


Fig. 308.—Ganglion cell from the anterior cornu of the spinal cord of the ox (after *Schultze*). *a*, axis cylinder; *b*, processes sent off by the cell.

REMARKS.—See *Beale's* treatise in the *Phil. Trans. for the year 1863*, part ii. p. 543. Many other German observers agree with us in our view of the probably elastic nature of the spiral fibres.

§ 180.

Having become acquainted with the two kinds of form-elements of the nervous system, let us now turn to the consideration of *their general arrangement* in the *peripheral nervous apparatus*.

The nerves of the brain and spinal cord, differing in their white colour from those of the sympathetic system, which are usually grey or greyish red, become clothed with a delicate envelope at their exit from the nervous centres. This covering receives another addition from the *dura mater* of connective-tissue bundles in its passage through the latter, and, thus strengthened, constitutes what was formerly known as “neurilemma,” but which we will designate from henceforth “perineurium” (1).

Internally this perineurium extends between the bundles of nerve-fibres, which, as in muscle, may be divided into *primary* and *secondary*, and in which the tubes are already arranged in the series in which they eventually leave the trunk. In some cases the connective-tissue preserves its fibrous character, especially when it binds together larger collections of nervous tubes than usual, while around the primary fasciculi it appears rather as a homogeneous nucleated substance. Again, having become modified to a homogeneous material, it enters into the formation of the primitive sheaths around the medullary portion of the nerve-tubes contained in the trunk. Finally, the latter is traversed by a scanty network of capillaries, consisting of fine tubes measuring about 0.0056 mm.

From the fact that the primitive fibres run along side by side unchanged in the nerve, without giving any indications as to their functions by their appearance, all branchings, anastomoses, and formations of plexuses, may be regarded by the physiologist with tolerable indifference.

As is well known, there occurs a progressive *splitting up* of the nervous trunks at very acute angles in their course towards the periphery. Thus, the primitive tubes leave the stem or common path in bundles, and, bending off sideways, pursue their way separately towards the organs they supply. The actions of the various nerves is, however, by no means determined by this arrangement; but in one made up of sensitive and motor fibres, this formation of branches may bring about a separation of the latter.

Anastomoses, for the interchange of different kinds of fibres for anatomical ends, are connections between neighbouring nerves or branches of the latter. We may distinguish between simple and double anastomoses also. In the first, a number of nerve-tubes pass through a connecting branch into another trunk, pursuing in this their further course; in the second, both nerves exchange fibres with one another.

This interchange of fibres between adjacent nerves, when it takes place to any great extent, gives rise to the so-called *plexus*.

These branchings, anastomoses, and formations of plexuses, are continued down to nerves of microscopic minuteness, and even in the organs within which the latter are to terminate. In them especially the formation of plexuses is a very general occurrence just before the final radiation of the fibrillæ, and has been alike described in earlier and more recent times. In the larger and more massive plexuses an interchange of single primitive fibres alone is to be observed; while in the finer, or, as they have been called, the terminal plexuses, repeated divisions of the nervous tubes and retiform intercommunications between their branches have been met with.

In its whole course, from its central origin until towards its peripheral distribution, the nerve fibre does not change its character in the least, and its diameter but to a slight degree.

With the progressive division of the nervous trunk, however, certain modifications of the connective-tissue sheathing make their appearance. This latter, namely, decreases in amount from the stem towards the branches, and appears no longer fibrillated on the finer twigs, but only streaky, until, finally, in the terminal filaments, we find nothing but a homogeneous nucleated mass. This simplest form of perineurium may be seen on little twigs which only contain a few primitive fibres. Even single nervous tubes may course through a tissue for a considerable distance in a clothing of this kind, until they terminate finally with loss of

the latter. In such cases the connective-tissue envelope is perineurium and neurilemma at the same time. These facts, however, are variously viewed, some regarding this simplified perineurium as a thick primitive sheath.

The trunks and branches of the sympathetic system are essentially the same in structure as those just described, except that in them *Remak's* fibres (already mentioned at § 176) make their appearance in great numbers.

REMARKS.—This name was first applied by *Robin* to the envelopes composed of simple connective-tissue of the finest twigs.

§ 181.

From time immemorial anatomists and physiologists have been occupied with the question, how the nervous fibres terminate peripherally. In older times, of course, before the introduction of microscopic analysis, conjecture alone could be formed on this point. It was supposed that the nervous twigs broke up into finer and finer fibrils, which became fused finally with the tissue of the organ they supplied.

With the aid of the microscope, about the thirtieth year of this century, it was already a matter of no difficulty to follow the progressive sub-division of the smaller branches down to their finest twigs, and to recognise here and there the course of the latter through the tissue, as well as the formation of the plexuses and minutest anastomoses already mentioned (§ 180).

At that time many observers maintained that they had found a looped termination, and, moreover, in the most different organs. They supposed that two neighbouring fibres were always united at the periphery in the form of a wider or narrower loop, or, what is but another mode of expressing the same thing, that each nerve tube, on arriving at the periphery, became doubled on itself, and took its course back again to the nervous centre, from whence it came. This theory of terminal loops, which held good for motor and sensitive fibres alike, led however to great physiological difficulties.

We now know, from a series of newer and more accurate investigations, that these loops are of frequent occurrence among the peripheral ramifications of nerves, but that they possess no terminal significance, since the nerve fibre in this curved course has not yet arrived at its final destination. This theory of the looped termination of nerves has, therefore, disappeared from histology.

As far as we know at present (though our knowledge on the subject is still in a most unsatisfactory condition), nervous fibres terminate without any medullary substance—first of all in the form of simple or ramifying *axis cylinders*, and, in the next place, in the form of *primitive fibrillæ*. The final disappearance of the fibre, moreover, is frequently seen to take place in special "terminal structures" or "end corpuscles." These are either *complex* or *single-celled*.

§ 182.

It was for some time supposed that an insight of the mode of termination of the *motor nerves* in *striped muscle* (fig. 309) had been gained with tolerable correctness through the labours of *R. Wagner* and *Reichert* (1). It was believed that the motor nerve tube ceased on the striped fibre after repeated sub-division in the form of pale terminal filaments. On account

of this repeated splitting-up of the primitive fibres further, a considerable number of terminal filaments could be formed from a few of the latter (2).

So far the difficulty of following up the nerves is but small, if we take, for instance, the platysma of the frog.

But experience teaches that this repeated division of motor nerve fibres is peculiar to the lower orders of vertebrate animals. In fishes also it may give rise to the formation of more than one hundred terminal filaments from one such; and primitive fibres are by no means rare, which supply upwards of fifty muscular fibres.

Among the higher orders of vertebrata, on the contrary, this splitting up becomes less and less frequent, so that its occurrence is only exceptional among the mammalia. The number of muscle and nerve fibres becomes almost the same,—a fact of great physiological importance.

If we examine one of the thin transparent muscles of a frog, we find without any difficulty the small trunks of the nerves, which have entered the substance of the latter, lying sometimes obliquely, sometimes parallel to its fibres, and giving off numerous branches and anastomotic twigs. In human and mammalian muscle likewise a plexiform interchange of fibres between adjacent twigs may be observed.

At the points of division of the latter, and especially when they have attained a considerable degree of fineness, and contain but few primitive fibres, we not unfrequently perceive the manner in which a nerve-fibre suddenly breaks up into two or more branches, with a contraction generally at the point where the latter part from one another. These branches possess the same medullated appearance as the parent stem, and pass onwards, according to the character of the whole nerve, more or less divergent. Deceptive appearances, however, are matters of possibility here.

At those points, however, where, in the further course of their ramifications, the nerve fibres come to lie either singly or in extremely small number together, traversing thus the muscle in a usually oblique direction (309, *a*), their further subdivision may be most distinctly observed.

This most frequently occurs by division into two threads, more rarely into three or four. The latter may either correspond to one another in breadth, or are unlike in that respect (*a* below and in the centre). Contractions at the points of division may not be present, or if so, only slightly marked; or again, they may be very strongly pronounced. But complete solution of continuity, to such an extent that the empty primitive sheath alone remains, is always an artificial production. The axis cylinder, on the other hand, divested entirely of medullary sheath, appears frequently as a natural formation.

The division of this axis cylinder is for the rest hardly anything more than the separation of the original primitive fibrillæ into two new fasciculi of smaller diameter.

In consequence of this repeated division, the nerve fibres (which possessed at the outset a medium diameter of 0·0142–0·0113 mm. and a double contour) become gradually reduced in calibre down to 0·0056 mm., and lose their double outline (*b*).

Finally, however, we observe the terminal twigs of 0·0045–0·0038 mm. in breadth approaching the single muscle fibres in the form of free axis cylinders having lost their dark medullated appearance, and apparently ending here in two short branches.

It was formerly believed that we had here in these pale fibres the true termination of the nerves, while it still remained a matter of uncertainty,

owing to the difficulty of investigation, whether this took place externally on the sarkolemma, or after perforating the latter in the interior of the fleshy substance.

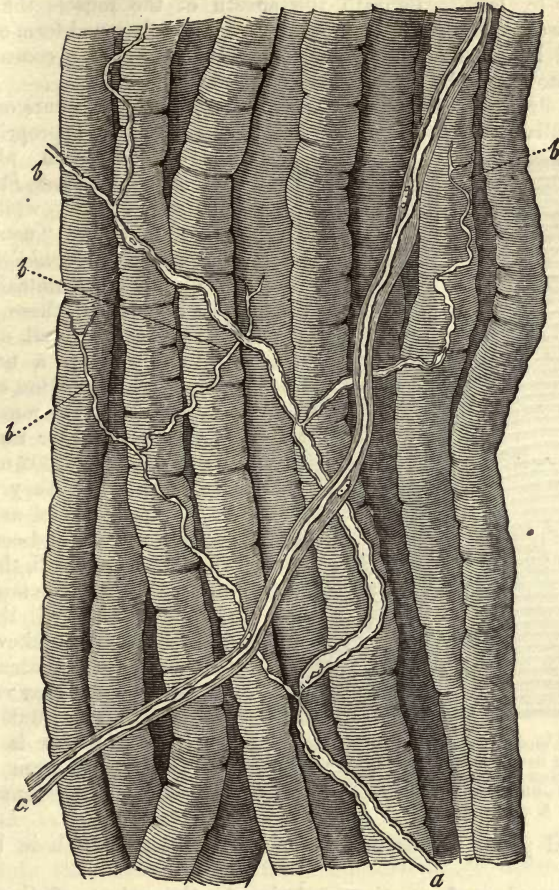


Fig. 309.—Distribution of nerves in a voluntary muscle from the frog. *a*, a nerve fibre destitute of neurilemma, showing repeated subdivision down to apparently terminal filaments *b*, *b*; *c*, an undivided nerve fibre with a thick envelope.

From a whole series of recent investigations, among which those alone of *Beale*, *Kühne*, *Margo*, *Koelliker*, *Krause*, *Rouget*, *Engelmann* (3). need here be mentioned, the conclusion has been arrived at that this early view is likewise untenable, and that the true ending of the fibres takes place far beyond these apparently terminal twigs.

But in what form and where this final cessation of the fibre is situated, whether within or external to the sarkolemma, is a point about which considerable difference of opinion still prevails.

Beale, *Krause*, and *Koelliker* believe the fibre to terminate externally, while the other observers are of the opinion that it perforates the sarkolemma; and we believe rightly.

In fact, we may see, on examination of the muscular fibres of verte-

brates (fig. 310), that the dark-edged primitive fibre (*a, b*) approaches the muscle fibre (*g*, left), enclosed within a loose nucleated sheath (*c, d*), and pierces the sarkolemma, while the neurilemma becomes continuous with the latter (*c*, left). Beneath the sheath of the muscle the terminal filament swells up into a finely granular mass of a flattened form containing nuclei (*f*, left). This merges at its edges (*e, e*), and concave under surface, into the fleshy substance of the fibre (4).

To this structure in which the fibre ends, and which occurs only singly in mammalian muscle fibres, has been given the very appropriate name

of "terminal plate" by *Krause, Rouget, Engelmann*, and others; while *Kühne* calls it the "neural eminence" (*Nervenhügel*).

In the mammalian body, in which these terminal plates are well developed, and occupy a not inconsiderable portion of the surface of the muscle fibre, their diameter ranges from 0.0399 to 0.0602 mm., while in thickness they vary.

Their nuclei are smooth, clear, oval, and contain one or two nucleoli, thereby differing from the more opaque formations of the neurilemma, and likewise from those of the muscular fibres. In diameter they range from 0.0049 to 0.0099 mm. Their number is liable to variation; from four to twenty being found in one plate.

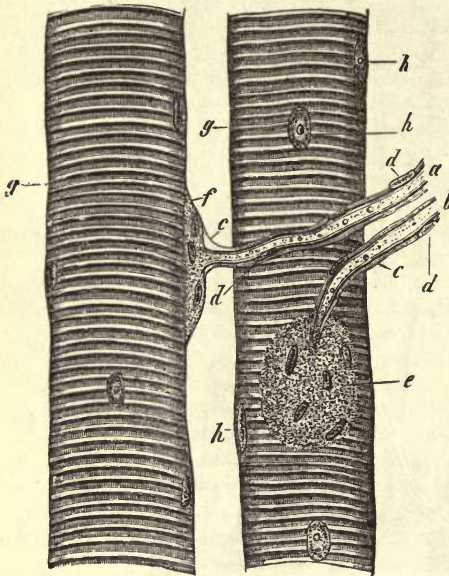


Fig. 310.—Two muscular fibres from the psoas of the Guinea pig, showing terminations of nerves. *a, b*, the primitive fibres with their transition into the terminal plates *e, f*; *c*, neurilemma with nuclei *d, d*, continuous with the sarkolemma *g, g*; *h*, muscle nuclei.

Terminal plates of the same kind are to be met with in birds and reptiles.

But a number of questions relative to the nature of these *neural eminences* must for the present be left unanswered, and perhaps for a long time still; for instance: Do we see in them the whole of the ultimate distribution of the fibre? Does the finely granular substance of which they are composed take its origin from a transformation of the axis cylinder, or does the latter end within them, and, if so, in what form? On these points there is no lack of variety of opinion.

According to *Krause*, we may recognise a pale, single, double, or triple fibre (axis cylinder) within the terminal plate, ending with a swelling or knob upon it. A very fine and somewhat tortuous fibre was also remarked in the same situation by *Schönn*. But from *Kühne's* researches, which from our own observations we are inclined to regard as correct, we learn that the structure is far more complicated. On its entrance into the terminal apparatus (fig. 311), the axis cylinder of the nerve fibre divides, and spreads out with further ramification into a peculiar pale

formation, bounded by undulating lines and truncated processes. This is the "true terminal plate." The nuclei and finely granular substance of the "neural eminence" are situated beneath this structure, adjacent to the fleshy mass of the fibre (5). *Engelmann* also speaks of an arborescent arrangement of branches of the axis cylinder lying in the granular substance of the neural eminence.

Now if, as would appear to be the case, the distribution of the nerve fibre be confined to the immediate mass of the terminal plate, the extremities of the muscle fibre must remain without nervous supply, in that the former is set into the latter at about its middle. But the fleshy matter manifests contractility at the extremities also!

The bearing of the terminal portions of the nerves supplying the muscles of the lower orders of vertebrates, of naked amphibia and fishes, present new difficulties in this so uncertain, but physiologically so important subject. Here we find that those complex multinuclear terminal plates are no longer present. In the frog, the nerve tube, on arriving at the fibre, not unfrequently breaks up into a multitude of dark-edged fibrils, forming thus the "terminal tuft" of *Kühne*. These having pierced the sarkolemma, course along within the muscle fibre as intra-muscular axis cylinders with isolated nuclei, and eventually become merged, to all appearance, in the fleshy mass. Whether we have to deal here with simple uninuclear terminal plates (*Krause, Waldeyer*) (of which, in that case, several would seem to be present in one muscle fibre), or whether this system of intramuscular axis cylinders may not represent in the frog the true terminal plate of *Krause*, mentioned above, are questions which must be determined by future research.

According to *Krause*, these terminal plates are to be found also in the heart of the rabbit.

Taken from other sources, the results which have been obtained on inquiry into the nature of the final terminations of nerve fibres are essentially different.

REMARKS.—1. *J. Müller* and *Brücke* appear to have been the first who observed division in the nerve fibres supplying muscle, in the year 1844. 2. Thus *Reichert* counted 7-10 afferent nervous fibres in the thin platysma of the frog, containing about 160-180 muscular fibres. These split up, eventually, with progressive ramification, into 290-340 terminal filaments. 3. With regard to the final distribution of nerves, modern literature is very rich. Compare, besides the works of Continental investigators—of *Kühne, Rouget, Koelliker, Engelmann*, and others—*Beale (Proceedings of the Royal Soc., vol x. p. 519; Phil. Transact. for the year 1861, p. 611; and 1862, Pt. 2, p. 889; also his Archives of Med., No. 11, p. 257; and in the Quart. Journ. of Micros. Science, 1863, p. 97; Proceedings, p. 302; and lastly (1864), Transact., p. 94.* 4. This is most beautifully seen in the group of small spider-like animals, the tardigrades. Here, where many years ago the terminations of the nerves, *i.e.*, the neural eminence or terminal plate, had been recognised by *Doyère*, the naked nerve fibre applies itself to the likewise membraneless muscle fibre, and both masses become fused one into the other at the point of contact. If we now suppose both nerve and muscle fibre enclosed in their sheaths, we obtain the same relation of parts as in the mammal body. 5. According to *Rouget*, the neural

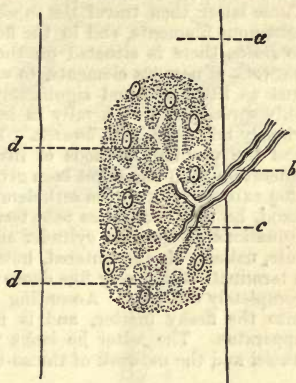

Fig. 311.—A muscle fibre from the lizard, *a*; *b*, nerve fibre; *c*, dichotomous division in the terminal plate, with transition into the true terminal structure of *Kühne*.

eminence is not the true terminal structure. The nerve fibre, he says, becomes forked (among the arthropods) at the summit of the eminence, giving off two fibrils. These latter then travel the substance of the terminal plate, and breaking up into numerous filaments, end in the fleshy mass of the muscular element. 6. According to *Beale*, there is situated on the exterior of the sarkolemma a very fine nucleated network of nervous elements, to which formation this English investigator ascribes just as little terminal significance as elsewhere in the body, in that the nerves are only spread out peripherally in loops. A similar view of the subject had been previously taken by *Schafhausen*. The statements of such a man as *Beale*, however, and the peculiar methods of investigation made use of by him, deserve more consideration than has as yet been given them. *Koelliker's* views, as regards the termination externally upon the sarkolemma, correspond with those of *Beale*. On the other hand, he only recognises pale terminal fibres in the frog, which he regards as continuations of the axis cylinder and primitive sheath, and which probably end, as a rule, naked. He encountered, however, some isolated cases, which seemed to indicate a termination in a very fine dense network. *Margo's* views, on the other hand, are completely different. According to him, the nerve pierces the sarkolemma, sinks into the fleshy matter, and is in communication here with a peculiar terminal apparatus. The latter he looks upon as formed of the greater part of the muscle nuclei and the network of the so-called interstitial granular threads (§ 166).

§ 183.

Turning now to unstriped muscular tissue, we find it far more difficult to recognise in it the final distribution of the nerve fibres than in the tissue we have just been considering. Division occurs here also, as has been seen, for instance, in the stomach of the frog and rabbit by *Ecker*; in the heart of amphibia and nerves supplying the uterus of rodentia by *Kilian*.

In the mesentery of the frog (fig. 312), moderately treated with acetic acid, we may observe in the narrow medullated nerve fibres enclosed in a thickened envelope several repeated dichotomous divisions, until at last the branches penetrate the walls of the part and are removed from further observation. These fibres are enclosed, as was before indicated, in a thick nucleated envelope.

But what becomes of these nervous elements on arrival in the unstriped muscular tissue?

This is a question which for a long time remained without any satisfactory answer. It is true that years ago plexuses or networks of pale delicate filaments had been met with, with nuclear structures at the expanded nodal points, and that this network was held by many to be a terminal structure, which view seemed strengthened by the fact of the occurrence of a similar nervous end-formation in the electric organs of the ray.

But not long ago an important discovery apparently was made by *Frankenhäuser*, subsequently confirmed by *Lindgren*, and more recently still through the most comprehensive researches by *Arnold*. This was that the nerve fibres of smooth muscle penetrate to the nucleus of the contractile cell in the form of a fine terminal filament, the primitive fibrilla, and end probably in the nucleolus.

From *Arnold's* experiences it would appear that the nervous twigs supplying unstriped muscle consist partly of medullated and partly of non-medullated fibres, in varying proportion. We encounter the latter as fine or broad threads, measuring in diameter 0·0018–0·002 mm., and showing at intervals small nuclei. Externally, in the connective-tissue covering the muscle, these nerves are arranged in the form of a wide-meshed network, in which, as *Beale* has pointed out, ganglion cells are to be found at certain points in the muscles of the vascular system. To this the name "ground plexus" has been given (1).

From this plexus are given off, in the first place, medullated nervous fibres, which assume, after a longer or shorter course, the form of pale longitudinally striated bands of 0.0041–0.0050 mm. in diameter, containing at intervals nuclei of the same dimensions. These bands become gradually narrowed down until we meet them as the nucleated fibres, 0.0018–0.0023 mm. in diameter, which have been already mentioned.

From these, again, is formed a second network with tolerably broad rhomboidal or elongated meshes, whose nodal points show nuclei with distinct nucleoli. Pale fibres, however, are also given off directly from the "ground-plexus" to the muscle cells. This the "intermediate network" (fig. 313) lies immediately upon the layers of muscular tissue, or between the latter. From it there pass off small fibres which penetrate between the muscle fibres. These are only supplied with nuclei

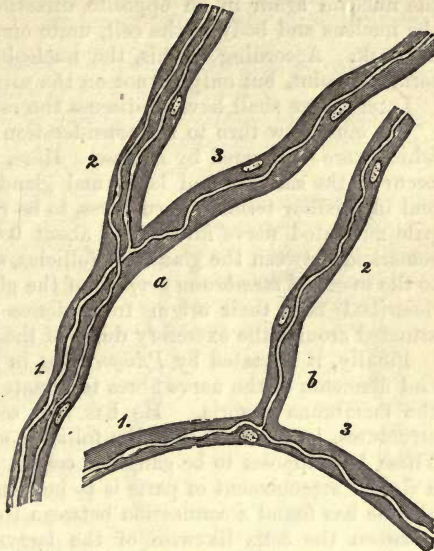


Fig. 312.—Two narrow branching nerve fibres (a, b) from the mesentery of the frog, surrounded with a thick nucleated envelope. At 1, the trunks; at 2 and 3, the branches.

at the commencement, and become rapidly smaller, so that after repeated subdivision they are reduced to threads of 0.0005–0.0003 mm. in thickness. On the latter, as well at their point of division as elsewhere, there occur elliptical, round, or otherwise shaped swellings or granules.

The last-mentioned fine fibres unite once again to form a new, but this time very close-meshed network, the "intramuscular," whose varicose fibrillæ occupy the narrow passages between the contractile cells.

Finally, leaving this intramuscular interlacement, dark straight fibres of extreme fineness pass off, which are at the very most 0.0002 mm. in thickness. These penetrate into the contractile cells, and advancing to the nucleus, terminate, according to *Frankenhüuser*, in the nucleolus. The number of terminal filaments which enter any one muscle cell corresponds with the number of granules occurring in the nucleus (§ 163).

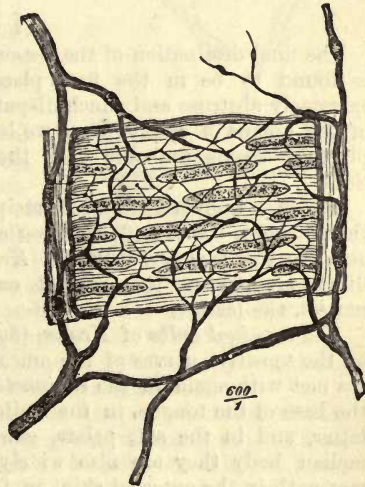


Fig. 313.—Ramification of nerves and termination in the muscular tunic of a small artery of a frog; from *Arnold*.

Arnold believes, however, that in very many cases these fibrillæ leave the nucleoli again in an opposite direction, and after having traversed the nucleus and body of the cell, unite once more with the intramuscular network. According to this, the nucleolus would appear to be not the terminal point, but only a knot on the ultimate filament.

Later on we shall have to discuss the reticulum of the *corneal nerves*.

We must now turn to the consideration of the *nerves supplying glands*, which were discovered by *Krause*. Here, besides dark-edged fibres which occur in the salivary and lachrymal glands of mammals, and come to an end in peculiar terminal structures, to be referred to again; besides these, pale nucleated nerve fibres, only about 0.0020 mm. in diameter, may be remarked between the glandular follicles, and applied, with dual division, to the so-called *membrana propria* of the gland element. These fibres just described take their origin from dense networks of medullated tubes situated around the excretory ducts of the lobules.

Finally, it is stated by *Pflüger* that in the salivary glands the delicate end filaments of the nerve fibres terminate in the gland-cells after piercing the *membrana propria*. He has also seen the processes of multipolar structures, lying external to the follicles, coming to an end in the same. These he supposes to be ganglion cells. The same observer states that a similar arrangement of parts is to be seen in the pancreas. In the liver also he has found a connection between the nerve fibres and gland cells. Between the cells likewise of the lacrymal gland, a radiation of fine terminal fibres has been described by *Boll*. We regret being obliged to express our incredulity as regards the correctness of all these statements; in our opinion, the termination of the nerve filaments in glands is still unknown.

REMARKS.—*Philos. Trans. for the year 1863, part ii. p. 562.*

§ 184.

The final destination of the *sensory nerve fibre*, to which we now turn, is found to be in the first place a special *terminal structure*—the extremely abstruse and much-disputed question of their bearing in most of the organs of special sense we leave out of the question—in the next place, it seems probable that the fibre may end with free ramifications.

The best known anatomical recipients of the sensitive nerves are—(1) the *Pacinian bodies*; (2) the *tactile corpuscles* of *Wagner* and *Meissner*; and (3) the *terminal bulbs* of *Krause*. The first of these, the oldest discovery, present the greatest complexity of structure; the last or newest, the least.

The *terminal bulbs* of *Krause* (fig. 314) are found in the human being on the sensitive nerves of the mucous membrane and in the skin. They are met with again in the *conjunctiva bulbi*, in the mucous membrane at the base of the tongue, in the fusiform and circumvallate papillæ of the latter, and in the soft palate, *glans penis* and *clitoris*. In the mammalian body they are also widely distributed. They have been also met with in the external skin, as, for instance, in that of the mouse, and they occur on the volar aspect of the Guinea-pig's toes. Their nature, moreover, is the same in the mammalia as in our own frame.

The form of these structures in the mammal is egg-shaped (1, *a*), 0.0751–0.1409 mm. in length, and (2 *a*) about one-fourth as broad. In man and the monkey they are more rounded, their diameter being from

0.0322 to 0.0751 mm. Some isolated bulbs may attain, however, much greater dimensions, and twisted or indented forms are also met with.

The terminal bulb of *Krause* consists of a transparent nucleated envelope, containing a soft, homogeneous, slightly lustrous substance.

The nerves connected with it (*c*) undergo subdivision into branches more or less frequently repeated (1*, 2). Thus from one primitive fibre from 6 to 10 terminal corpuscles may be supplied. On entering the latter, the primitive fibres of medium size until there (about 0.0046–0.0075 mm.) become immediately still finer, constituting then the pale, non-medullated end filament or axis cylinder (1 *b*). The latter is 0.0039–0.0029 mm. in thickness, passes through the axis of the structure, and ends towards its upper pole with a slight button-like swelling about 0.0046 mm. across.

The terminal bulbs of the human conjunctiva (2) frequently present sinuosities and twists on the primitive tube as it is about to enter or has already entered the former. These may be present to such an extent as to form a regular convolution, especially in the interior of the corpuscle. Within the latter itself, or before its entrance, a splitting of the nerve tube may take place; beside which many varieties are to be seen as regards its bearing.

The number of these formations also seems to vary considerably. In 1 □''' of the conjunctiva of the calf *Krause* noticed 13 terminal bulbs.

Structures allied to the latter were also met with by *Krause* in the glans clitoridis, and in smaller number in the penis.

These "*genital nerve-corpuscles*" lie in the tissue of the mucosa at the bases of the papillæ of the mucous membrane. In size and form they vary, some of them attaining a diameter 0.1439, or even 0.2001 mm. As a characteristic of these genital nerve-corpuscles, constrictions may be mentioned which occur in varying number on the surface, and communicate to the whole a mulberry-like appearance. They appear to be the recipients of sexual sensation, for which reason *Finger* proposes giving them the name of "*sensual corpuscles*" (Wollustkörperchen).

The same observer has described another kind of structure similar to the end-bulbs, as present in the racemose glands of mammalia. These, the "*end capsules of the gland nerves*," have a somewhat elliptical form, and consist of a number of concentrically laminated membranes, from four to eight of which may be observed in each, and which are studded with numerous nuclei. In the interior is to be seen the minute cylindrical end-bulb, which is not unfrequently of sigmoid figure, and whose axis is occupied by an almost immeasurably fine lustrous terminal fibre. The latter springs from a dark-edged nerve tube.

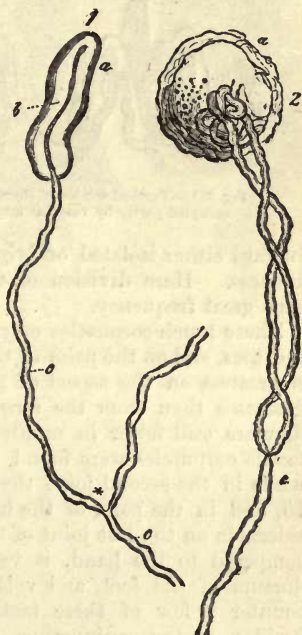


Fig. 314.—Terminal bulb. 1. From the conjunctiva of a calf. 2. From that of a human being. *a*, Bulb; *c*, nerve fibre ending in (1) an axis cylinder (*b*).

§ 185.

Another modification, to a certain extent, of these end bulbs of *Krause* is presented to us in the *tactile* or *touch corpuscles* of the skin (fig. 315).

The nervous network supplying the latter give off primitive fibres towards the bases of the so-called tactile papillæ (p. 234), which pass

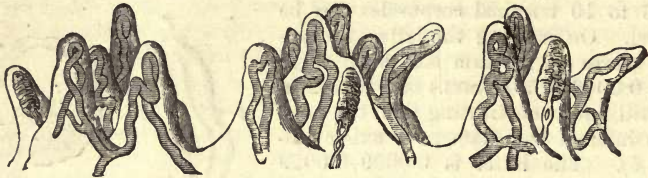

Fig. 315.—Vertical section of three groups of tactile papillæ of the human index finger, occupied partly by vascular loops, and partly by tactile corpuscles.

forward either isolated or lying together in small fasciculi of microscopic fineness. Here division of the nervous tubes, at acute angles, occurs with great frequency.

These touch-corpuscles may be found on the volar aspect of the fingers and toes, and on the palm of the hand and sole of the foot. Their number is greatest on the aspect of flexion of the last joints of the fingers, and decreases then from the second to the first. In the palm of the hand they are still fewer in number. Thus in the \square''' to 400 papillæ, 108 tactile corpuscles were found by *Meissner* on the last joint of the finger, while in the second joint the latter only amounted to 40, on the first to 15, and in the palm of the hand to 8. Their amount is also most considerable on the last joint of the toes. Here, however, the proportion, as compared to the hand, is very small. On the back of the hand, the dorsum of the foot, and volar surface of the forearm, we may also encounter a few of these tactile corpuscles. *Krause* has found them, besides, in the conjunctiva. Finally, they are to be met with in the nipple and skin of the lips, though in but moderate number. In the latter regions intermediate forms between them and the terminal bulbs have been described. Among the mammals they have only been recognised in the ape, in the palm of the hand, sole of the foot, and skin of the lips (*Meissner, Krause*).

Size and form are liable to considerable variation. In the *vola manus* they measure upwards of 0.1115 mm. with a breadth of 0.0451–0.0563 mm. Smaller specimens may only reach 0.0451–0.0377 mm. Those of greater dimensions are usually oval; those of smaller, mostly of rounder figure.

These structures are situated in the axis and apex of the tactile papillæ, but excentrically in those which are in any degree complex. Only the latter are exceptionally supplied also with vascular loops (fig. 315; in the middle a double papilla). Otherwise those which contain tactile corpuscles are non-vascular.

The touch corpuscle consists of a capsule formed of a homogeneous substance enclosing a finely granular soft matter best seen in transverse section.

In the capsule, further we may remark numerous elongated bodies arranged transversely or obliquely. We shall refer to these again pre-

sently. They communicate to the whole structure a characteristic transversely striated appearance.

The nerve fibres (fig. 316) pass out towards these bodies either singly, or, as is more frequently the case, double: at times, also, they are trebled or quadrupled. They are enveloped in simple neurilemma (fig. 316), which is continuous with the capsule. They are dark-edged, 0.0045 mm. and less in breadth, and enter the base of the touch-corpuscle, or at times also its side.

The mode in which they end, however, is difficult to determine. At times a peculiar twining of the nerve tubes around the tactile corpuscle may be remarked, or they may be seen to run for a greater or less distance straight along the latter. They all finally pass into the interior of the corpuscle, however, but in what manner they end there is still unascertained. In all probability they spread out in the form of pale non-medullated fibres or axis cylinders, like those of the terminal bulb. That the transversely arranged nuclear bodies, already mentioned, are connected with the termination of the fibrillæ appears extremely improbable.

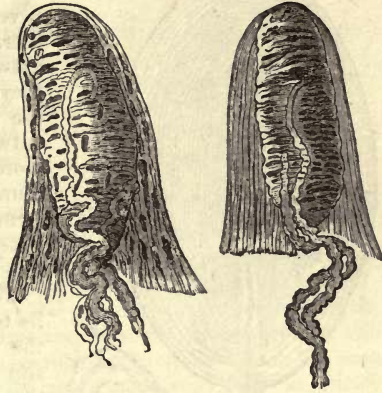

Fig. 316.—Two human tactile papillæ from the volar surface of the index finger. In the interior we have the tactile corpuscles, into whose tissue the nervous fibres may be seen entering.

§ 186.

We turn now, in conclusion, to the *Pacinian bodies*, which may be likened to a terminal bulb enveloped in numerous concentric capsules of connective-tissue.

As they come under our notice they are elliptical structures, sometimes more elongated than at others, and measuring from 1 to 2 mm. in length. To the unaided eye they appear translucent, and marked towards the axis with a streak. In man they occur regularly on the nerves supplying the palm of the hand and sole of the foot, but with especial frequency on those passing to the tops of the fingers and toes. Their total number, in these parts taken together, has been estimated at from 600 to 1400. According to *Rauber*, they are met with also, but with less frequency and constancy, at many other points in the body: thus on the dorsum of the foot and back of the hand, beneath the skin of the arm, forearm, and neck; on the intercostal nerves, and all the articular nerves of the extremities. They are likewise to be found on many nerves supplying bone, and in the interior of the muscles of the hand and foot; further, in the nerves of the parts of generation, and finally on the plexuses of the sympathetic system, round about the abdominal aorta. Again, they are encountered among the mammalia, especially on the sole of the foot, and with exquisite distinctness, and in greater or less number, in the mesentery of the cat. *Pacinian* bodies are also found in birds as well as in mammals, although modified to a certain extent.

The laminae of the capsules are looked upon as formed of connective-tissue, consisting of an either homogeneous or somewhat fibrillated

ground substance, in which elongated nuclei or cells are imbedded. On the internal surface of these membranes a mosaic marking, like

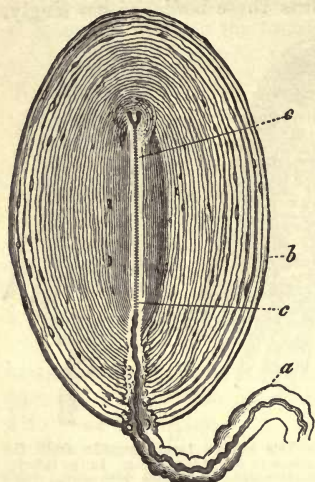


Fig. 317.—Pacinian bodies from the mesentery of a cat. *a*, a nerve with its perineurium forming the stalk; *b*, the system of capsules; *c*, axial canal or internal bulb, within which the nerve tube ends forked.

epithelium, has been recently remarked by *Hoyer* after treatment with nitrate of silver. These systems of capsules, further, are traversed by a scanty vascular network. The individual laminae of which they are composed follow the contour of the whole corpuscle, and are not so thick outwardly as within, where they appear more condensed, and where they surround in shorter curves the canal or internal bulb occupying the axis. The latter consists of a soft nucleated connective substance.

The internal bulb (*c*) is rounded off at its termination. Its walls, like those of the capsules, are continued at the opposite extremity into a stalk (*a*), by which the *Pacinian* body is attached like a berry to the nerve.

This style consists of ordinary longitudinally marked connective-tissue, and is formed by the perineurium of the afferent nervous fibre.

The diameter of the latter is 0.0142–0.0113 mm. and less. It presents the usual medullated appearance, and so reaches the corpuscle, at whose inferior pole it makes its entry into the central canal, occupying the axis of the latter. On entering the central passage the fibre loses its dark border, as is the case in the terminal bulb of *Krause*; it then becomes considerably diminished in size, and comes to an end as a pale terminal filament or axis cylinder of distinctly fibrillated constitution. The latter traverses thus the whole internal bulb, and ends at the roof of the latter (*c*, above) with a slight button-like swelling.

Division of the nerve fibre before its entry may occur; and not unfrequently do we see, too, the pale terminal fibre splitting into two or three branches, divisions in which the axial canal may also participate.

Very rarely two nerve fibres are seen to enter the same corpuscle, and terminate singly or doubly in a single internal bulb (*Koelliker*).

Many other variations besides those mentioned here must be passed over.

That these *Pacinian* bodies are connected with the sensory-nervous apparatus can hardly be a matter of earnest doubt any longer, since the discoveries of *Wagner*, *Meissner*, and *Krause*.

REMARKS.—These wondrous structures were known even long ago, but they received but little attention. The old German anatomist *Vater* observed, more than a century ago, that the nerves of the skin of the palm of the hand and sole of the foot were studded not unfrequently with small oval swellings, to which he gave the name of *papilla nervæ*. Later on, in the year '30, after having been completely forgotten for some time, they were again discovered by *Pacini* of Pistoja, and noticed also at the same time in France. They were, however, specially brought into notice through a monograph by *Henle* and *Koelliker*, which appeared in the year 1844.

These two observers gave the corpuscles the name of *Pacinian* bodies, without any idea of their previous discovery by *Vater*. This name has been retained by some, while by others the structures are designated as *Vater-Pacinian* corpuscles.

§ 187.

Having finished the consideration of these terminal bodies, let us now turn to the question as to how the remaining wholly sensible nerves end, one of the most obscure subjects in minute nervous anatomy, and one about which much uncertainty still prevails.

It is quite obvious that centripetal nerves must occur in voluntary muscle as recipients of muscular sensation. Our acquaintance, however, with them, is still very slight.

With a view to throwing some light on this point, the platysma of the frog was subjected by *Koelliker* to minute investigation, being peculiarly well suited for this purpose. Here there is to be seen—possibly springing from the division of a single broad nerve tube—a slight nervous ramification, confining itself almost entirely to the anterior surface of the muscle. The narrow nervous twigs of the same are, at their commencement, still dark-edged, but become paler as the branching progresses, and are seen later on as fibrils clothed with a loose neurilemma studded with nuclei. Eventually they terminate, after the loss of this envelope, in the form of extremely fine still branching filaments. The latter measure less than 0.0023 mm. in diameter. At intervals in their course, as well as at the nodal points of their division, small structures like nuclei are to be observed. Retiform connections among the fibres appear to occur only as exceptions.

In connection with other nerves, however, to which a sensory nature may be ascribed with greater or less probability, terminal networks of various kinds, formed of pale fibres, have been described. *Arnold* the younger, for instance, mentions such an one on the surface of the conjunctival mucous membrane, and *Billroth* another on the mucous membrane of the pharynx of the water salamander. Again, *Koelliker* speaks of one in the mucous membrane of the small intestine of the frog, and confirms *Billroth's* statements as regards the pharynx of the last-mentioned animal.

Similar terminal networks of pale fibres have also been described by *Armann* and *Ciaccio* as occurring in the cutis of the frog, and, many years ago, as existing in the tail of the tadpole. *Klein* has also met with the same networks, and described them as occurring very widely throughout the body of the same animal.

For many years past we have known of certain isolated instances of their occurrence in the skin of mammals, and *Schöbl* has recently demonstrated their presence here in great abundance.

There can be no longer any doubt that the most superficial terminations of sensible nerves frequently penetrate into the epithelial layers of their organs.

But their ultimate arrangement is still very variously explained. The fact is, that at the present time our modes of investigation are still too imperfect to admit of our settling the matter conclusively.

Some suppose them to end in a terminal plexus, so that we would only have an intermixture simply of epithelial cells and nerve fibres. Others, again, state that the latter penetrate into the cells and end in the nucleoli. Thirdly, many support the view that there exist certain peculiar

structures imbedded in the epithelium, in which the nerve fibres terminate. These are known as *Langerhans' cells*. A few more points may be mentioned in regard to these views.

A few years ago an excellent observer, *Hensen*, stated that in the tail of the tadpole the terminal filaments penetrated into the nucleoli of the epithelial cells. His observations gained greatly in interest through the further investigations of *Frankenhäuser* and *Arnold* (§ 183). But these statements have not since been confirmed, and must now be declared incorrect: this we maintain against *Lipmann*, who asserts that very delicate nerve fibrillæ may be seen to terminate in the nucleoli of the posterior epithelial cells of the cornea.

We must also confess our disbelief in *Joseph's* theories with regard to a similar ending of the nerves in the cells of bone, and to *Lavdowsky's* with respect to those of the cornea.

But, on the other hand, we have since learned from the beautiful investigations of *Hoyer* and *Cohnheim*, that very fine nerve-fibres or primitive fibrillæ do terminate in the epithelium of the corneal conjunctiva. Of this there can be no doubt.

The cornea possesses several distinct plexuses of these nerve fibres. From the most superficial, which lies close under the *lamina elastica anterior* (fig. 318), and which consists of bundles of delicate primitive

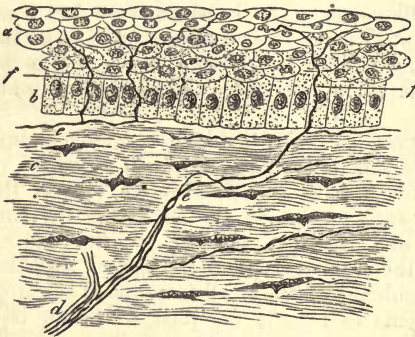


Fig. 318.—The cornea of a rabbit in vertical section after treatment with chloride of gold. *a*, the older; *b*, the younger epithelial cells of the anterior surface; *c*, corneal tissue; *d*, a nerve twig; *e*, finest filaments or primitive fibrillæ; *f*, their splitting up and termination in the epithelium.

fibrillæ, there arise at intervals isolated twigs (*e*), which perforate this anterior boundary layer of the cornea perpendicularly. Arrived at the external surface of the latter, they break up into a tassel of primitive fibrillæ, and form a "sub-epithelial plexus" of the most delicate threads (*b*, below), with elongated meshes radiating from the centre of the cornea (*Guinea pig*).

From this horizontal end-plexus a number of primitive fibrillæ are given off as side branches, which ascend

vertically in the epithelium, sending out twigs in various directions, and terminating as such in the superficial epithelial layers. The same arrangement almost is to be seen in the human cornea.

According to *Klein*, two very dense webs of the most delicate nerve fibres are to be found in the epithelium, a deep and a terminal, which is very superficial, only covered by about two layers of cells.

In the year 1868 *Langerhans* pointed out fine non-medullated nerve fibres passing in between the cells of the *rete Malpighii*, partly uniting here with elongated oval cells measuring 0.0088–0.0033 mm., and partly passing on farther upwards with subdivision. This arrangement was confirmed as existing in the cornea of the rabbit by *Podcopaëw*.

A similar arrangement of terminal nerve filaments had, however, been found before this in the mucous membrane of the tongue by *Freyfeldt-Szabaföldy*; and *Luschka* made the same discovery in regard to the lining

membrane of the human larynx. *Kisseleff* appears to have seen similar things in the mucous membrane of the frog's bladder, and recent investigations by *Morano*, *Klein*, *Elin*, and *Chrschtschonovitsch*, show that the same arrangement of non-medullated filaments exists in the epithelium of the conjunctiva, mouth, and of the vagina, sometimes with, sometimes without the corpuscles of *Langerhans*.

The mode of termination of the nerves in the pulp of the teeth (already mentioned, p. 269), has also been recently followed up.

Nervous twigs have long been known to exist in the walls of this structure. They may be easily seen here, and consist of dark-bordered fibres whose diameter is 0.0038–0.0067 mm. These run upwards parallel to each other, and then form an elongated nervous network by the branching of their fasciculi.

By the binary subdivision of these nervous twigs immense numbers of very delicate silky primitive fibrillæ are formed, according to *Boll*, which resemble elastic fibres in some degree, but which are never seen to join in a reticulated manner. These pass in between the odontoblasts (p. 270) to reach the inner surface of the dentine, where they probably sink into the dental canaliculi. Thus the latter contain a double system of fibres, composed partly of *Tomes'* dental fibres (p. 270), and partly of these nerve fibres. The well-known sensitiveness of the tooth depends upon the latter.

§ 188.

We now turn to one of the most difficult subjects in nervous histology, and one which is still the theme of much controversy—namely, *the structure of the ganglia*.

In regard to the relation of the nerve fibres to the cells even in the bodies of fishes, where research is attended with least difficulty, considerable difference of opinion still exists. But this is the case to a far greater extent in man and the higher vertebrates, where the difficulty of obtaining good and serviceable objects is very great. Besides, it would be hardly prudent to make use here of analogy to too great an extent, and to apply those discoveries, which have been made in the body of the fish, to the human organisation without due caution,—in that we are not able to estimate, with any certainty, the whole physiological connection between nerve fibres and cells in general. On the other hand, it is no less dangerous to take isolated observations, which have been with difficulty made on the human and mammal body, and, generalising from these, to dash off with bold strokes plans of the organisation of the nervous knots, which dazzle us for a time by an apparent physiological consistency, it is true, but which may be subsequently recognised as entirely incorrect.

At first sight we recognise investing the nervous ganglia an envelope of connective-tissue of varying thickness, a modified perineurium, consisting partly of fibrillated connective-tissue alone, and partly of the latter intermixed with *Remak's* fibres. This fibrous mass, in which the blood-vessels of the ganglion are situated, extends also into the interior of the organ, which is, however, chiefly made up of ganglion cells packed closely together.

The nervous trunk or trunks entering the knot (fig. 319, *b*) are divided in the latter into fasciculi, which conduct themselves in various ways. Some of them, namely, traverse the structure directly, or with but little deviation from the straight line (*k*), while others are resolved into primitive fibrillæ (*l*), which continue their course through the ganglion, twist-

ing and winding in every possible direction between the cells of the latter. Eventually, however, they become again united into bundles, which associate themselves with those which passed through in a straight line. In this way are formed the stem or stems which leave the ganglion (*d, e*).

The nerve fibres entering the knots have, on this account, been classed into "direct" and "tortuous," terms which will still be found appropriate. There exist, however, as might be supposed, many intermediate forms between the two modes of arrangement.

It used formerly to be believed that the relation of the fibres to the cells within the ganglion was only that simply of close proximity. This view, however, was found to satisfy the requirements of the physiologist just as little as that which held that the nerve-fibres ended in loops, and was finally abandoned on the discovery of the origin of the fibres.

Confining ourselves for the present to the *spinal ganglia* (fig. 319), we

find that a number of investigators have observed an extraordinary arrangement in these structures in the fish, namely, that all the nervous fibres of the posterior root of the ganglion are interrupted in their course within the latter by a cell,—the broader fibres usually by a larger, the finer by a smaller element.

The corresponding ganglia of mammals and man, however, present but rarely such bipolar cells (*h*). Here some of the processes may take an opposite course, as in the fish, or both pass out below towards the periphery (*a*). As a rule, we meet with nerve cells here which only give off one process towards the circumference (*f*), which may subsequently divide into two fibres, according to *Remak*. Finally (and it is in the spinal ganglia of the smaller mammalian animals that we obtain the most characteristic objects), isolated apolar cells are to be found (*i*), probably but undeveloped forms of the first kinds. It appears, nevertheless, undeniable that a certain number of the nerve-tubes entering the spinal ganglia may pass through the latter without being connected in the least with its cells. How many do so is not yet determined.

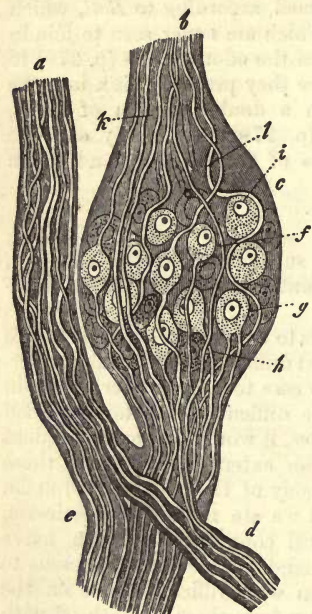


Fig. 319.—A spinal ganglion from the mammal *c* (diagrammatic). *a*, anterior or motor, *b*, posterior or sensitive root; *d, e*, efferent nervous trunk; *k*, direct, and *l*, tortuous fibres; *f*, unipolar, *g* and *h*, bipolar, and *i*, apolar ganglion cells.

The ganglion cells found in the *sympathetic knots* (fig. 320, *d, e, f*) appear to be somewhat smaller as a rule, but not so much so that we should feel ourselves justified in placing a distinction between *sympathetic* cells and *cerebro-spinal* on this account.

The nervous fibres are some of them broad, but for the most part fine tubes (*a, b, c*). Besides these, there may be seen in the sympathetic ganglia, and sometimes in considerable quantity, those formations known as *Remak's fibres*

Finally, turning to the relation of the two kinds of structural elements

to one another,—in the first place, apolar ganglion cells (*f*) are to be met with, but whether their number is a large one or no, we are unable to determine. Secondly, unipolar cells (*e*) are encountered, giving off a delicate nerve fibre, which is distributed peripherally. Again, we meet with bipolar ganglion corpuscles, whose two nerve tubes take a course at one time opposed to each other, at another in the same direction. It is one of the many things also for which we are indebted to *Remak*, that he has pointed out besides, the existence in the sympathetic of a fourth form among these elements, namely, the multipolar cell. Taking their rise from the latter (*d*), we see from three to twelve processes which, by rapid ramification, may soon increase threefold (*d**). The amount of these is dependent on the number of nervous trunks in connection with the sympathetic knot, and into which the processes are continued in the form of nerve tubes: thus it is greater in the solar plexus than in the ganglia of other parts of the cord.

According to the observer just mentioned, the processes of unipolar and bipolar cells of sympathetic ganglia undergo division likewise.

§ 189.

Beside these larger ganglia just described, we have to consider a multitude of smaller, and also most minute nervous knots, which have only recently been recognised, owing to their frequently microscopical dimensions. We find them, on the one hand, containing numerous ganglion corpuscles, or, again, with but few of the latter. Their number is quite surprising throughout the body. They seem to belong, more or less, to the sympathetic system, supplying principally the smooth and involuntary muscles with their fibres.

Among these may be numbered groups of ganglion cells, which are found in the ciliary muscle of the eye, on the branches of the circular plexus to be found in the same (*C. Krause, H. Müller*). Several small twigs from the ciliary nerves, likewise penetrating into the choroid coat, form there, in the deeper portions of the latter, a delicate plexus, in which scattered ganglion cells and small aggregations of the same have been remarked (*H. Müller and Schweigger, Sämisch*).

Other small nervous knots were discovered also, many years ago, by *Remak* on the branches of the *N. glossopharyngeus*, distributed to the pharynx and tongue; but those on the twigs of the *Lingualis*, supplying the last-named organ, are still more minute. The nervous twigs, likewise distributed to the walls of the larynx and bronchi, as well as the interior of the lungs, bear also similar ganglia upon them.

Another series of extraordinary ganglia is to be met with in the muscle of the heart, presenting itself in man and the mammalia imbedded in the sub-

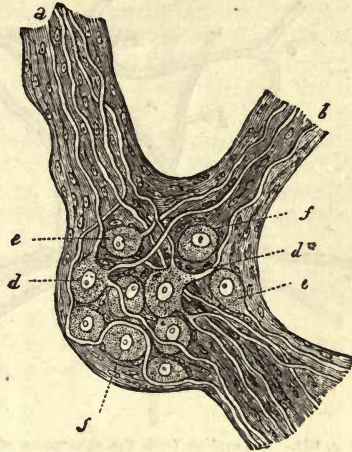


Fig. 320.—Sketch of a mammalian sympathetic ganglion. *a, b, c*, nervous trunks; *d*, multipolar cells; *d**, some of the latter with a dividing nerve fibre; *e*, unipolar, and *f*, apolar cells.

stance of both ventricles and auricles (*Remak*). The most carefully studied have been those of the frog, where they are situated in the septum between

the auricles, and at the union of the latter with the ventricles. They are said only to contain unipolar cells.

These ganglionic plexuses are also encountered in great abundance in the walls of the alimentary canal. Here attention was first directed to them by a discovery of *Meissner's*, which initiated a series of further investigations.

The first of these ganglionic and nervous plexuses extends in the human and mammalian intestine from the stomach downwards through the submucosa. Its peripheral branches probably contain, for the most part, motor elements for the *muscularis mucosæ* and some few

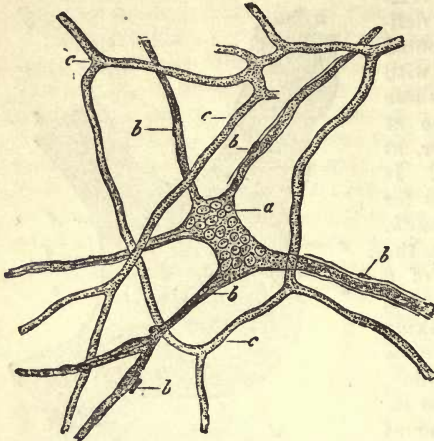


Fig. 321.—A ganglion from the submucosa of the small intestine of a suckling ten days old. *a*, ganglion; *b*, nervous twigs given off by the latter; *c*, injected capillary network. This preparation had been macerated for a very long period in pyroligneous acid.

sensible fibres for the mucous membrane.

This *submucous ganglion plexus*, as seen in the infant (figs. 326 and 322, 1), has narrow meshes, but in the adult broader and more irregular ones. The number of twigs given off from it is variable (fig. 321, *b*),

and the ganglia differ also greatly as to size and shape (fig. 321, *a*; 322, 1, *a*). The smaller cells of the latter are entangled in the meshes of a nucleated perineurium which clothes (fig. 321, *b*; 322, *c*) likewise the efferent trunks and commissures, consisting of fine pale nerve fibres (322, 2). These cells are said to be unipolar, apolar, and bipolar: multipolar do not appear to exist here.

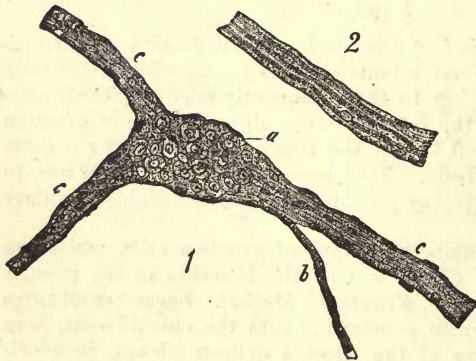


Fig. 322.—1. A large ganglion from the small intestine of a suckling ten days old. *a*, ganglion with its cells; *b*, *c*, efferent nervous trunks with pale nucleated fibres in a fresh state. 2. Small nervous twig of the same nature from a boy five years of age, showing three primitive fibres. After treatment with pyroligneous acid.

Here, between the circular and longitudinal layers of the latter, a second nervous apparatus, no less remarkable, is to be found—namely, the so-called *plexus myentericus* (fig. 323), for the discovery of which we are indebted to *Auerbach*.

Reaching from the pylorus to the rectum, it is seen as a regular and

delicate interlacement of nerves, woven, as it were, round the intestinal tube (*a*), and having polyhedral meshes.

At each nodal point in these there is always situated an aggregation of ganglion cells (*b*), sometimes large, sometimes small, but usually causing but a moderate thickening of the cord. Two adjacent ganglia, also, may be connected by means of a band formed of cells, beside which form the most characteristic examples of annular ganglia and commissures are also to be met with. Though liable to variation to a certain extent, according to the different species of animals, the whole formation is usually very much flattened everywhere. Here again we also meet with smaller ganglionic bodies, pale and very fine nerve fibres, and a nucleated perineurium, beside which apolar cells are to be observed, with others giving off two or three processes.

From this plexus in question innumerable delicate nervous twigs are sent off to the circular and longitudinal muscular fibres of the alimentary canal, presiding over the peristaltic action of the latter.

The genito-urinary apparatus, also, is no exception in the occurrence of such small nervous knots. Thus they have been seen by *Remak* in the

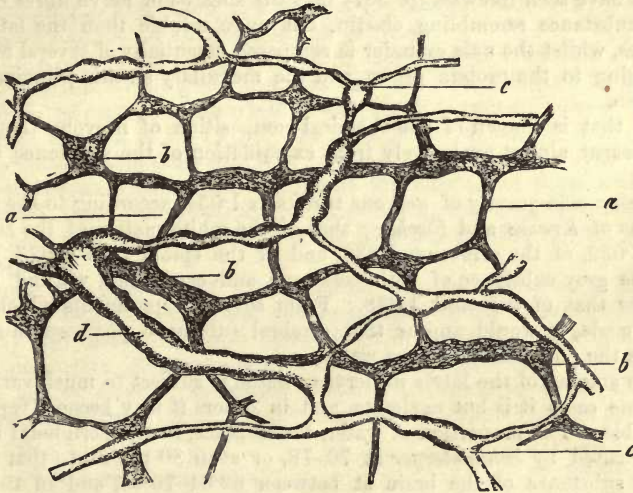


Fig. 323.—From the small intestine of the Guinea pig (after *Auerbach*). *a*, nervous interlacement; *b*, ganglia; *c*, lymphatic vessels.

bladder of the pig, and in other mammals by *Meissner*. In the same organ of the frog they may be recognised with great ease also (*Manz, Klebs.*)

In the corpora cavernosa of the male organ of generation these knots were found between the years 1830 and 1840 by *J. Müller*. They are also present in the nerves of the human and mammalian uterus, and in the connective-tissue around the vagina, as well as in the submucosa of the latter.

Remak and *Manz* mention ganglionic plexuses around the muscular gland-ducts of birds also.

In the lachrymal and salivary glands of mammals, finally,—therefore, in organs which elaborate large quantities of secretion under nervous stimulus, very complicated nervous networks of dark-edged fibres, richly studded with ganglia, have been met with by *Krause*.

§ 190.

Of the *chemistry* of nervous tissue, but little is known on account of its anatomical peculiarities; for, in the first place, the most massive nervous apparatus, namely, the cerebro-spinal, which is on account of its bulk most frequently the object of chemical research, has a very complex structure, and in it together with a ground-work of connective-tissue, we have to deal with nerve tubes and ganglion cells which cannot be separated. On the other hand, but little has been done to elucidate the nature of the *albuminous substances* of the neural apparatus, and much obscurity still hangs over the so-called *cerebral matters* (§ 20).

The living nerve displays, while at rest, a neutral reaction which becomes acid at death. The same change is produced, also, according to *Funke*, by over excitement of the fibre. This is but a repetition of what takes place in muscle under similar circumstances (§ 170).

From the anatomical study of the various parts of ganglion cells, we know that the latter are made up of albuminous compounds, in which fatty molecules and granules of pigment may be present (§ 178).

We have seen likewise (p. 307) that the sheaths of nerve fibres consist of a substance resembling elastin, but more soluble than the latter in alkalis, whilst the axis cylinder is composed essentially of several matters belonging to the protein group, and the medullary sheath principally of cerebrin.

All that is known of the chemical composition of nervous tissue has been learnt almost exclusively from examination of the substance of the brain.

The specific gravity of nervous trunks is 1·031, according to the observations of *Krause* and *Fischer*; that of the white matter of the cerebellum 1·032, of the cerebrum 1·036, and of the spinal cord 1·023, whilst for the grey substance of both cerebrum and cerebellum we find 1·031, and for that of the cord 1·038. From several experiments which have been made, it would appear that cerebral substance possesses in a high degree the power of absorbing water.

The amount of the latter in nervous tissue is subject to much variation. In some cases it is but moderate, and in others it may become very considerable. The proportion of water, for instance, in the peripheral nerves is estimated by *Schlossberger* at 70–78, or even 80 per cent., that in the white substance of the brain at between 69·64–70·68, and in the grey matter 84·84–86·64, showing that the latter is richer in aqueous constituents. In the infant the brain is still poorer in solids. In the spinal cord the percentage of water is lower, being, according to *Bibra*, 66 per cent. Of course this water is distributed over both the tissue and the nutritive fluids saturating the latter.

As already mentioned, nervous matter consists of several *albuminous bodies* of cerebral substances (lecithin and cerebrin), together with *mineral constituents*. Finally, it contains certain decomposition products.

Touching the *albuminous matters*, we are here more than elsewhere in the dark as regards their nature. Our slight unacquaintance with the chemical constitution of nerve cells only permits of our accepting the presence of one or more members of the group in general, but gives no indication as to what substance or substances occur specially.

The reactions of the axis cylinder are those of an albuminoid substance in a coagulated condition. But how far other albuminous matters may

occur in nervous tissue, apart from a small amount of it in a soluble form, is still uncertain. Quantitatively it is impossible to analyse them on account of being obliged to include the primitive sheath, and other tissue elements. The amount, besides, of residue insoluble in ether varies considerably, from 9 to 14 per cent.

As soluble in ether, we obtain further the so-called cerebral substances *lecithin* and *cerebrin* (§ 20), and likewise *cholestearin* in considerable quantity (§ 21). The amount of these matters, further, has been found to be far greater in the white substance of the brain than in the grey, and they may, therefore, be regarded as essentially constituents of the nervous medulla, although we do not possess any satisfactory explanation of the manner in which they occur here being insoluble in water.

From the fact that *lecithin* (which exists in great quantity in the brain), yields, besides *neurin* (§ 33), and *glycerophosphoric acid* (§ 16), *palmitic* and *oleic acid* also, we may infer that the fatty acids and fats, upon which such stress used formerly to be laid, were possibly only products of the decomposition of the former.

Cholestearin, which occurs in cerebral tissue in large quantities (amounting, according to *Von Bibra*, to a third of the matters soluble in ether), has the nature likewise of a decomposition product.

Turning now to the quantity of these matters soluble in ether, we find their proportion in the grey substance, in which much water is contained, to be 5-7 per cent.; in the white tissue, which is poorer in the latter, on the other hand, it is 15-17 per cent., and rises still higher in the spinal cord. Considerable difference may be observed, also, between the various parts of the same brain. In the infant the amount of these matters is very small, there being, besides, no difference in this respect between the white and grey tissue. In the fetus they are present in still smaller quantity.

Among the products of transformative processes going on in nervous tissue, may be reckoned *formic* and *lactic acid* (found in the brain), and possibly also *acetic acid*, also *inosit*, *kreatin*, *leucin* (in the ox), *xanthin* and *hypoxanthin* (*Scherer*), *urea* (in the dog), and *uric acid*.

The ash of cerebral substance amounts, according to *Breed*, to 0.027 per cent. of the fresh tissue. In a hundred parts of the former he found:—

Free phosphoric acid,	9.15
Phosphate of potassium,	55.24
„ of sodium,	22.93
„ of iron,	1.23
„ of calcium,	1.62
„ of magnesium,	3.40
Chloride of sodium,	4.74
Sulphate of potassium,	1.64
Silica,	0.42

The preponderance of potash and magnesia over soda and lime recalls to mind the state of things in muscle.

§ 191.

Turning now to the application to neural physiology of the points regarding the structure of the nervous apparatus, which have just been described, we see in the first place, in the two kinds of structural elements, a contrast between merely conducting fibres and cells which are endowed

with higher functions, with those of perception, and of directing voluntary and reflected motion. Thus we find the latter structures in the grey matter of the brain, spinal cord, and ganglia, to which we have long been compelled by experience to ascribe reflex functions. They are met with, also, at some other points where their significance is not yet quite apparent, as, for instance, among the terminal ramifications of some of the higher nerves of sense.

With regard to the nerve tubes, we have learned from the last section that their varieties of form and thickness do not go hand and hand with functional differences. Thus the sensitive roots of the spinal nerves contain fibres which differ in no respect from those of the motor roots. In the sympathetic system we meet with *Remak's* fibres, whose nervous nature would seem to be almost beyond doubt, and to these the most analogous formations are the nerve tubes of the olfactory nerve. The fine medullated nervous fibres can with as little right be looked upon as a special sympathetic form, presiding over peculiar functions, as was formerly maintained by *Volkmann* and *Bidder*; for numbers of intermediate grades between coarse and fine tubes are met with at points where there can be no suspicion of sympathetic influence. In this respect the accurate microscopical analyses of recent times has greatly modified the sanguine expectations of an earlier epoch.

On the other hand, some important aids to physiology have been acquired through the knowledge of the finer anatomy of the nerve fibre. All observers concur in regarding the continuity of the nerve tube as certain,—a point necessarily accepted as indispensable by the physiologist, likewise in respect to the isolated course of the latter. Thus we see everywhere the same state of things; the nerve fibre taking an uninterrupted course through the long interval between the nervous centre and the place of its final termination, although this course may be modified somewhat by the insertion of a ganglion cell. The question as to what part of the nerve tube is to be looked upon as the really active, *i.e.*, conducting medium, may perhaps be answered in favour of the axis cylinder, in that it is frequently the only portion present at the origin of the nerve fibre, and probably always at its ultimate termination, whilst the medullary and primitive sheath enclosing it are here absent. At those contracted portions of the fibre, also, which are seen at points where branches are given off, the axis cylinder may present itself for a short distance divested of its usual medullary envelope. The theory of the termination of the nerves in loops having been shown to be incorrect, has given further support anatomically to the theory of isolated conduction. The separate termination of the nerve fibre, whether single or with many ramifications, is also consistent with the views of the physiologists of the present day. The splitting up by which, as we have seen in the nerves supplying muscle, a primitive fibre may become resolved into a multitude of branches, must be looked upon as an ingenious provision of nature for obtaining as highly nervous a periphery as possible, both sensitive and motor, with comparatively thin nervous trunks. This arrangement seems certainly to have the character of something belonging to a lower order of creation, for the higher we ascend in the animal kingdom, the more do the numbers of tubes and muscle fibres become alike, as we have already remarked above. An acquaintance with the terminal apparatus of motor nerves is, also, another important advance recently made. Regarded from a physiological aspect, *Krause's* and *Kühne's* discovery of

muscular substance, excitable though free of nerves, has done much towards the adjustment of that very old controversy in regard to whether there be such a thing as muscular irritability. The termination of sensory nerves in special anatomical structures, such as the *Pacinian* bodies, or *Krause's* tactile corpuscles, is also of great interest.

To return to the ganglion cells: there seems to be among them just as little coincidence between their anatomical variety and physiological difference as among the nerve tubes. The physiological significance, further, of the apolar nervous cells, is still unknown to us; even the fact of their existence has in it something strange to the physiologist. The unipolar cell, also, which is looked upon as the starting-point of the fibre proceeding from it, should be connected with the cells adjacent to it by commissures. The physiological purpose for which bipolar cells exist is likewise veiled in obscurity. The most comprehensible are the multipolar elements with their efferent nervous fibres.

But, although we are at present unable to understand many things in the texture of the ganglion, nevertheless, important points in relation to the motions of organs have been gained by an acquaintance with the smaller ganglionic plexuses discovered in such surprising numbers. We refer to the submucous ganglionic networks, and *plexus myentericus* of the digestive apparatus.

Living nervous substance, further, has, like muscle, electromotor properties.

As to the amount of interchange of matter which goes on in the nervous elements, we are still in the dark. That it is probably considerable, is indicated by the fact that a fatigued nerve regains, after a certain period of rest, its original power of functioning, and also that ligature of the arteries of a part brings about a rapid paralysis of the motor and sensible nerves supplying the same. The scanty notes of the preceding section likewise contain all that is at present known of the nature of this interchange of matter.

As to the question, further, how far an anatomical change goes hand in hand with the chemical, or, in other words, how far the nerve tubes and cells may be regarded as persistent structures, or, on the other hand, only destined for a short existence as transitory formations, we are unable to give any answer. The corpuscles and fibres present themselves in far too great variety of form in the adult body for us to be able to separate young, mature, and older elements from one another.

§ 192.

The *mode of development* of nervous tissue in the embryo is one of the most obscure chapters of modern histology.

That the brain and spinal cord, together with the internal portions of the higher organs of sense, formed from the first of these, are productions of the so-called corneous layer of *Remak*, is an ascertained fact. They take their rise, in other words, from the cells of the upper cellular layer nearest the embryonic axis.

On the other hand, the point of origin of the ganglia and peripheral nerves is still unknown to us. We are still unable to determine whether, as is very probable, these parts are productions of the corneous embryonic leaf, or whether, according to one view which is held, they have not originated independently in the middle germinal plate, and only become subsequently connected with the nervous centres. The connection of

the ends of nerves with tissues at the periphery, such as the muscle fibres which, as far as we know at present, have had their origin from the middle germinal plate, is a great theoretical difficulty.

The usual but unsatisfactory view which is held regarding *ganglion corpuscles* is that they are metamorphosed formative cells.

By the enlargement of these, and their subsequent acquisition of a characteristic finely granular contents, the ganglion cell is arrived at. When their further growth takes place regularly we have the apolar element, and the structure with processes when the former is unequal. Through these latter adjacent cells may be connected, and from them nerve fibres are given off. It is possible that multiplication by segmentation may take place in already formed nerve cells in the fetal body, but the subject requires closer investigation.

The formation of *nerve fibres*, which has been already touched on in the general part of our work (p. 100), was formerly supposed generally to be brought about by the fusion of cells in such a way that (in the case of the non-ramifying nerve tube) connection took place between the individuals of a series of fusiform or cylindrical elements.

The nervous trunks of man and the mammalia have not that white appearance in early foetal life which characterises them at a later date; they are on the contrary grey and translucent, the more so the younger the embryo. At first we only remark on teasing them out the individual formative cells of fusiform, or simply elongated figure, and with vesicular nuclei. Later on we may succeed in splitting off rows of these from the main structure in the form of pale fine nucleated bands. These are the first nerve fibres whose pale non-medullated appearance reminds us of *Remak's* elements; their medium breadth is 0.0029–0.0056 mm.

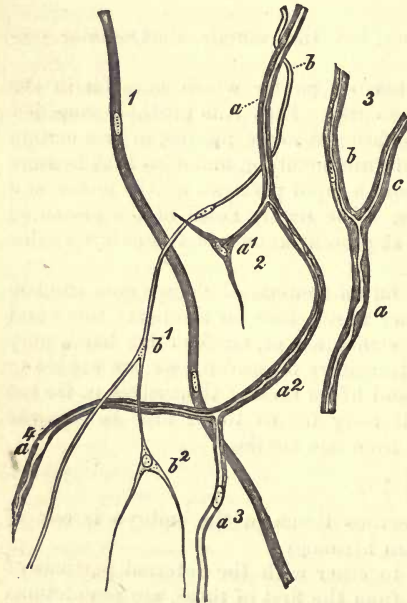


Fig. 324.—Development of nerve fibres; from the tail of a tadpole. 1. A pale still non-medullated fibre with two nuclei. 2. More advanced tubes partly filled with medullary matter. *a*, a fibre, with which a stellate formative cell (*a*¹) is connected at its side, while lower down, where the fatty contents gradually give way to a paler (*a*²), its division into two branches (*a*³ and *a*⁴); *b*, a fibre which is united to two stellate cells (*b*¹ and *b*²). 3. A nerve tube still more developed, at *a*, the stem at *b*, and *c*, the branches.

been received into histology.

The formation of *branches* on nerve fibres was supposed to take place

In the older nerves we may perceive the specific contents of the primitive tubes, advancing gradually from the central towards the peripheral portions, the axis cylinder arising in all probability first, and the fatty medullary mass being deposited subsequently between it, and the primitive sheath formed of the membranes of the cells.

These, then, are the usual views on the subject based upon *Schwann's* outlines, which have

by the fusion of stellate formative cells (provided usually with three processes), with the terminating portion of the already formed fibres, the latter growing by the addition at their periphery of new cells. The tail of the tadpole and electric organ of the torpedo were put forward as suitable objects for the recognition of these points. And, indeed, here we have the best opportunity at this great distance from the central organs of coming upon younger and younger specimens of nervous branches.

In the tail of the tadpole (fig. 324) we encounter isolated nerve tubes, which bear all the characters of *Remak's* fibres, showing nuclei situated one behind the other (1). Others (2 *b*) without any thickened envelope appear dark and medullated in the upper part, while below they become finer, and are continuous with the peripheral formative cells (*b*¹ *b*²), which radiate with their pointed processes in the surrounding tissues. Again we may meet, and by no means unfrequently, with nerve fibres possessing thickened envelopes (2 *a*) and dark medulla, which is continued below into a progressively paling fibre (2 *a*³ and *a*⁴) resembling an axis cylinder.

Now, although we do not yet possess a satisfactory knowledge on these points, nevertheless we have acquired enough material to demonstrate the untenableness of these earlier views.

Bidder and *Kupffer*, in their inquiries into the origin of the spinal cord, found that the formation of nerve tubes from one row of cells occurs neither in the white substance of the organ, nor in the roots of the spinal nerves. In place of these fibrillæ only are observed, without nuclei and cells. These, the axis cylinders of the future, according to the authors in question, grow simply outwards towards the periphery. The envelopes appear to be formed for themselves subsequently, from new tissue elements appearing between these fibrillæ.

The late excellent observer *Remak* also maintained, many years ago, quite a different mode of origin for the ramifications of nerves in the tail of the tadpole from that described in the text. According to him, the branching rudiments of the cutaneous nerves appear everywhere to be prolongations from the spinal ganglion.

According to *Hensen*, also, the nervous ramifications in this well-trodden locality are present from the commencement all the way down to the periphery, in the form of fine, lustrous forked fibres (axis cylinders) without a sign of nuclei. It is only subsequently that the mode in which they become sheathed in thin, pale, and extremely elongated cells, can be recognised, until eventually the axis cylinder lies in the interior of a nucleated envelope, the stellate cells spoken of taking no part in the process.

Besides a great instability in their contents, owing to which the latter may assume the appearance of a chain of separate drops, the newly-formed nerve tubes are remarkable for their great fineness as contrasted with corresponding elements in the mature body. The increase in thickness of the whole nervous trunk is sufficiently explained by the augmentation in the diameter of the individual primitive fibres. According to *Harting*, their thickness in the median nerve of a fetus at four months is only 0.0024 mm., while in the infant and adult they measure respectively, on an average, 0.0103 and 0.0164 mm. The number of primitive tubes, at these three periods, were estimated by him at 21.432, 20.906, 22.560.

It is a well-known fact that nerves, on being severed, cease to fulfil their functions, but after a certain time has elapsed regain their powers. The separated ends, namely, heal rapidly; yes, and even after a tolerably

long piece has been cut out from a nervous trunk, connection is again restored by means of new tissue.

According to the early observations of *Waller*, which have been since confirmed by others, that part of the nerve situated at the distal side of the cut degenerates down to its ultimate ramifications, with coagulation and subsequent absorption, until eventually the neurilemma alone remains, which also disappears completely after a certain time, according to the same investigator. From this we infer that a new formation of nervous fibres must take place in order to effect connection with the central portion. This last view is opposed by *Lent*, who asserts that a new filling-in of medullary matter into the primitive sheath supervenes upon the union of the two cut ends. According to *Hjelt*, finally the severed nerve fibres only degenerate in part completely, being replaced by neoplasia, whilst other primitive tubes are capable of a regeneration subsequent to their reunion. *Lent*, again, has observed a very interesting multiplication of nuclei in the primitive sheath. But the whole question, as regards the origin of the newly-formed interposed tissue, is worthy of being made the subject of renewed research in the present state of histology.

Whether regeneration of ganglion cells takes place is still uncertain. Pathological new formation of nervous elements in other neoplasms is of rare occurrence, as are also nervous tumours or neuromas. The latter may consist of tubes or grey matter

In atrophied nerves a decrease in the thickness of the primitive tubes is manifest, and, instead of a continuous medulla, a number of fat globules and granules are presented to us.

16. Glandular-Tissue.

§ 193.

The definition of what we understand by a gland was, until comparatively recently, a matter of considerable difficulty, so that a talented anatomist, more than thirty years ago, was fully justified in expressing

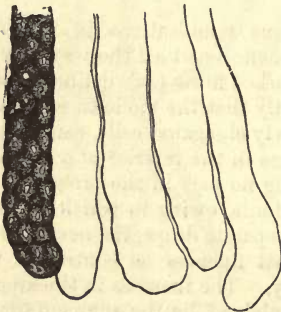


Fig. 325.—Glands from the large intestine of the rabbit. A follicle filled with gland cells; four others without cells, showing the *membrana propria*.

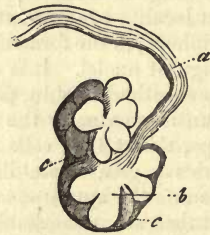

Fig. 326.—A racemose so-called mucous gland from the rabbit's œsophagus. *a*, the duct; *b*, the follicles; *c*, the investing connective tissue.

himself thus:—"That *class* of structures called glands is one of those careless productions of an infant science, to define which, set it upon a firm basis, and support it there, requires all the care and pains which the latter can bestow in its present state of maturity."

In the earlier days of anatomical study a round form, soft consistence, and great vascularity, sufficed to gain for an organ the name of "gland." Later on, however, the physiological requisites for the proper conception of a gland became more prominent. And first of all, that the latter abstract from the blood matters which are not to be made use of for its own nutrition, but which tend to benefit the whole system, either by being cast out of the body as decomposed material to be gotten rid of, or turned to account in the economy as specially prepared by the gland. Thus, the latter came to be looked upon as a secreting organ, great stress being laid, consequently, on its efferent duct. Finally, it was recognised that there are many completely closed organs from which no secretion is ever given off, and to which, nevertheless, we cannot deny the right to be called glandular structures. This was subsequent to comparative anatomy having shown the comparatively small weight to be given to the duct as the distinguishing mark of glands.

Recent microscopical analysis has supplied us with characteristic signs by which, in general, a gland may be diagnosed, although there remain certain points relating to structure about which doubt still exists.

The history of development likewise has also afforded most important information here. From it we learn that the physiologically important parts of true glands, namely, their secreting cells, all take origin either from the corneous or intestino-glandular embryonic leaves. No truly glandular organs spring from the middle germinal plate.

Finally, owing to our extended knowledge of the nature of the lymphatic apparatus, we are now enabled to class with the latter as *lymphoid* organs a series of parts springing from the middle embryonic leaf, which used formerly to be reckoned among the glands.

Let us now return to the histological characters of glands. These organs consist of two kinds of structural elements (figs. 325 and 326) (1) of a fine structureless *transparent membrane*, known as the *membrana propria*, which determines the form of the organ as well as that of its sub-divisions, and (2) of the contents of the latter, the so-called *gland cells* (figs. 325, 327, and 328). As a third indispensable factor, we find on the external surface of the homogeneous membrane a *vascular network* (fig.

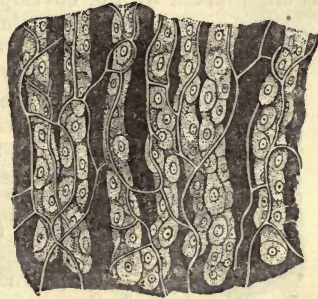

Fig. 327.—Gastric glands from the dog, filled with cells, and interlaced by a vascular network.

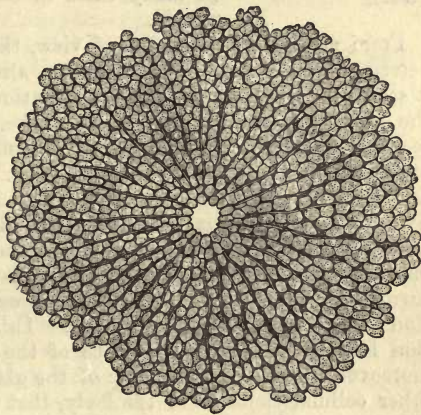


Fig. 328.—Lobule from the liver of a boy ten years old.

327), from the contents of which the materials of the secretion of our organ are abstracted.

Of the three requisites of a gland the blood-vessels and cells are never absent, and the homogeneous membrane only rarely so.

Besides these, we have to take into account the *nerves* distributed to the organ, the *lymphatics*, connective-tissue, and at times also muscular envelopes; and, finally, as a frequent occurrence, a special and often tolerably complicated *excretory duct*.

§ 194.

The *membrana propria*, when such a structure exists, presents itself in the form of a homogeneous envelope, at one time immeasurably thin, at another thickened frequently up to 0.0011, or more rarely 0.0023 mm. It is often mixed with or enveloped in an extra layer of connective-tissue until a tunic of 0.0045–0.0090 mm. results. As an exception, we may perceive between these two strata a layer of unstriped muscle, as in the large sweat glands of the axilla. At times, also, as, for instance, in the sebaceous glands, we find the *membrana propria* replaced by an undeveloped connective-tissue. In other cases there appears (fig. 329) imbedded in it a web of flattened connective-tissue cells containing nuclei (parotid, submaxillary, and lachrymal gland).

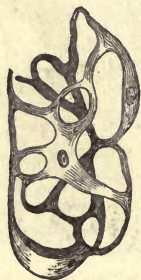

Fig. 329. — Web of flat stellate connective-tissue cells isolated by maceration from the *membrana propria*. From the submaxillary gland of the dog, after Boll.

The structureless *membrana propria* manifests further a considerable amount of distensibility and strength, and likewise of power of resistance to the action of weak alkaline solutions and acids, so that these may be made use of with good effect for its demonstration. At present we are not acquainted with its chemical constitution; it is probably formed in many cases of some substance closely allied to elastin.

From an anatomical point of view, this covering may be regarded as determining the form of the organ as already mentioned, physiologically it serves for the filtration and transudation of the plasma. In respect to the histology of the structure, it has been supposed to be a substratum secreted by the first aggregations of rudimentary gland cells on their exterior, and hardened in that situation. This process was looked upon as having taken place at an early period in existence, the membrane outliving many generations of gland cells. But another recent view appears to us far more worthy of acceptance, namely, that the gland-membrane is only the transformed, and more or less independent limiting layer of the surrounding connective-tissue, and represents therefore a contiguous portion of the middle germinal plate. This theory offers an easy explanation for the presence or absence of the *membrana propria*. It seems, moreover, to be a characteristic of the gland cells, in contradistinction to other cellular elements of the body, that they do not generate externally definite formed products.

The shapes under which the *membrana propria* or limiting layer of connective-tissue presents itself to us, are, as has been already remarked, very various. Three varieties may be generally recognised, and corres-

ponding to these, three forms of glands, which are, however, here and

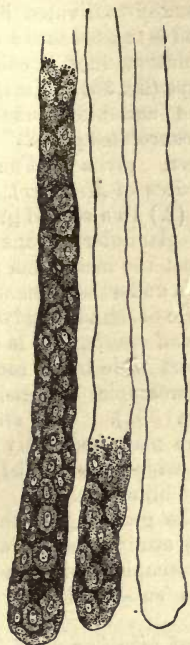

Fig. 330.—Simple tubular glands from the mucous membrane of the human stomach.



Fig. 331.—A convoluted gland from the conjunctiva of the calf.



Fig. 332.—The vesicles of a racemose gland (Brunner's) from the human being.

there blended one into another, and also make their appearance at one time as *simple*, at another as very *complex* apparatuses.

(1.) In the first form (fig. 330) the envelope presents itself as a narrow passage of very variable length, almost always closed at one end and open at the other, discharging itself either independently or in connection with other structures of the like nature in the form of a very complex apparatus. An envelope of this kind is known as a *gland tubule*, and such glands are named *tubular*. Of these two kinds are recognised, namely, the *simple*, where the whole organ consists entirely of one microscopically small sac; and the *complex*, where several or very many of these tubuli are combined to form a new anatomical unit, or if we prefer another view, where the tubules are sub-divided. They may even form a retiform combination of tubes. If the latter attain great length, as is the case in two compound glands of the human body, the testicle and the kidney, they may be regarded as a special variety under the name of *gland tubes* (fig. 333, a-e).

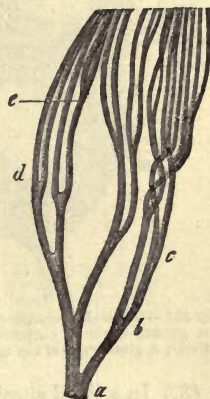


Fig. 333.—Branching uriniferous tube from the kidney of a kitten. a-e, progressive subdivision at acute angles.

Another peculiar species of tubular glands is presented in those in




Fig. 334.—One of Brunner's racemose glands from the human being.

which the upper and usually undivided blind end is twisted into a convolution like a coil of rope (fig. 331). To these the suitable name of "*convoluted glands*" has been given (*Knauel-drüsen* of Meissner).

(2.) In a second group of glandular organs we meet the *membrana propria* under the elementary form of the so-called *open gland vesicle*, that is of a short wide blind sac of microscopic dimensions (fig. 332). This structure may frequently be

very aptly compared to a short-necked flask with a wide body, whilst in other cases it is more like a spheroidal berry or short blind gut.

In this case the most characteristic points are the grouping of these vesicles together. Such a group (which frequently attains considerable dimensions) may form a complex gland still of microscopical minuteness, or may be associated with other aggregations as a sub-division of an organ (figs. 326 and 334).

These aggregations are known under the names of *lobuli* or *acini* (1). From these open vesicles a multitude of glands is built up, as, for instance,

the so-called *racemose*, which, with all their variety of general figure and difference of size are really under the microscope, comparatively speaking, very uniform as to structure.

No very sharp line, however, can be drawn between these last described and the tubular species. If the walls of the latter be not smooth, namely, and the *membrana propria* bulges outwards in the form of spheroidal projections, and that a certain division of the sac is combined with this, we have as a consequence intermediate forms which may with equal right be said to belong to either species of gland.

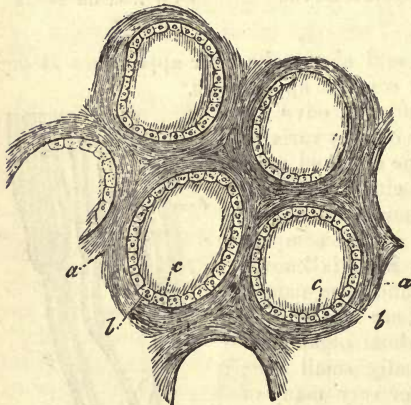


Fig. 335.—Glandular capsules from the thyroid of a child. a, ground-work of connective-tissue; b, the capsule itself; c, gland cells of the latter.

(3.) In a third species of glands we find a bounding layer of connective-tissue in the form of a *roundish capsule*, closed on all sides, and frequently of considerable size (fig. 335). Capsules of this kind get rid of their contents either by rupture of their walls, known as *dehiscence*, by

which they are, without exception, destroyed, or the cavity remains closed during the whole of life, the contents exuding through the parietes. To the first of these species the glandular elements of the ovaries belong; to the second, those of the thyroid body. In man, however, we never meet with a whole gland formed of one closed capsule by itself, as is the case with the tubular follicles. The few organs in our body which may be numbered with the last species, are composed of a multitude of elements of this kind imbedded in a connective-tissue ground-work.

REMARKS.—The word “acinus” is also made use of to designate the gland-vesicle, so that it is as well, perhaps, to avoid the term entirely.

§ 195.

The second, and more important elementary structures of the organs with which we are now engaged, are the *gland cells*. These are derived from the corneous and intestinal glandular embryonic leaves, and in keeping with their origin, never completely lose their epithelial characters.

In the bodies of many of the lower animals the significance of these gland cells appears in the most striking way. The interesting discovery, namely, has been made, that in them there exist glandular organs which consist of but one single cell only.

Within the cavities of glandular organs these cells are either packed closely together without order, filling out the former, or they clothe their internal surfaces like epithelium. Not unfrequently, when so arranged, their figure is polyhedral. They may also occur either arranged in one single layer, or forming a double lamina.

At the outlets of glands these cells are continuous with those of the neighbouring epithelial formations, and frequently without any sharp line of demarcation, so that the latter may be looked upon as having become gradually transformed into glandular elements. Indeed, we meet with

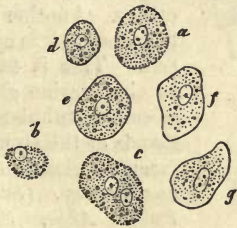

Fig. 336.—Cells from the peptic glands of man. *a*, cell without a membrane; *b*, a nucleus enveloped in a residue of the body of the cell; *c*, a cell with two nuclei; *d-g*, cells with sharper contour and decrease in the number of granules usually contained in such.

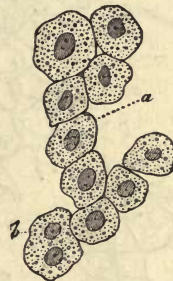

Fig. 337.—Human hepatic cells. *a*, one with a single nucleus; *b*, another with two of the latter.

many glandular organs whose cells are but little different, at least anatomically, from those of the epithelia.

The different species of cells which are met with in the latter have their

counterparts again among those lining glands. On account of the physiological calls made on them, however, they require greater volume than

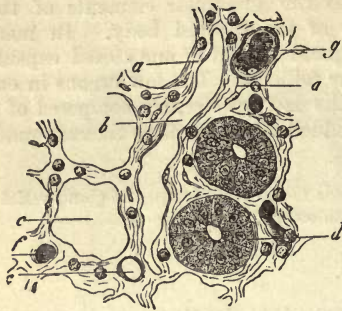


Fig. 338.—Transverse section through the mucous membrane of the small intestine of a rabbit (near the surface). *a*, reticular connective substance containing lymph cells; *b*, lymph canal; *c*, transverse section of a follicle of *Lieberkühn*; *d*, another of the latter with its cells *in situ*; *e*, *f*, *g*, blood-vessels.

simple epithelial elements. For this reason we miss among them the extremely flattened scales of many pavement epithelia, and meet, on the other hand, as a rule, more cubical forms, which display, however, considerable diversity to the manner in which they are fitted in among their neighbours. Ciliated gland cells are never met with in the human body, if we except those of the gland-follicles of the uterus, and are but of rare occurrence elsewhere. Deposits of melanin likewise are never seen here, although granules of yellow and brown pigment are not so rare.

Small spheroidal or completely spherical cells, first of all are to be found for instance in the ovary, clothing its capsules and larger ones in the sebaceous glands of the skin and *meibomian* of the eyelids. The gland cell may frequently resemble very closely, when seen from above, one of the elements of flattened epithelium, its body having become widened out. It is in this form that the cells lining the peptic glands of the stomach are presented to us (fig. 336), and also those of the liver (fig. 337), with many others. Another species is the more or less cylindrical cell. This is to be seen in the uterine glands, the so-called tubular mucous glands of the stomach, and racemose glands of mucous membranes (*Schlemmer*, *Puky Akos*, *Schwalbe*), and in *Lieberkühn's* follicles of the small intestine (fig. 338, *d*). In the latter, according to *Schulze*, the most exquisite examples of "beaker cells" are to be seen between the ordinary columnar elements.

Small spheroidal or completely spherical cells, first of all are to be

found for instance in the ovary, clothing its capsules and larger ones in the sebaceous glands of the skin and *meibomian* of the eyelids. The gland cell may frequently resemble very closely, when seen from above, one of the elements of flattened epithelium, its body having become widened out. It is in this form that the cells lining the peptic glands of the stomach are presented to us (fig. 336), and also those of the liver (fig. 337), with many others. Another species is the more or less cylindrical cell. This is to be seen in the uterine glands, the so-called tubular mucous glands of the stomach, and racemose glands of mucous membranes (*Schlemmer*, *Puky Akos*, *Schwalbe*), and in *Lieberkühn's* follicles of the small intestine (fig. 338, *d*). In the latter, according to *Schulze*, the most exquisite examples of "beaker cells" are to be seen between the ordinary columnar elements.

The gland cell may frequently resemble very closely, when seen from above, one of the elements of flattened epithelium, its body having become widened out. It is in this form that the cells lining the peptic glands of the stomach are presented to us (fig. 336), and also those of the liver (fig. 337), with many others. Another species is the more or less cylindrical cell. This is to be seen in the uterine glands, the so-called tubular mucous glands of the stomach, and racemose glands of mucous membranes (*Schlemmer*, *Puky Akos*, *Schwalbe*), and in *Lieberkühn's* follicles of the small intestine (fig. 338, *d*). In the latter, according to *Schulze*, the most exquisite examples of "beaker cells" are to be seen between the ordinary columnar elements.

Another species is the more or less cylindrical cell. This is to be seen in the uterine glands, the so-called tubular mucous glands of the stomach, and racemose glands of mucous membranes (*Schlemmer*, *Puky Akos*, *Schwalbe*), and in *Lieberkühn's* follicles of the small intestine (fig. 338, *d*). In the latter, according to *Schulze*, the most exquisite examples of "beaker cells" are to be seen between the ordinary columnar elements.

This is to be seen in the uterine glands, the so-called tubular mucous glands of the stomach, and racemose glands of mucous membranes (*Schlemmer*, *Puky Akos*, *Schwalbe*), and in *Lieberkühn's* follicles of the small intestine (fig. 338, *d*). In the latter, according to *Schulze*, the most exquisite examples of "beaker cells" are to be seen between the ordinary columnar elements.

and racemose glands of mucous membranes (*Schlemmer*, *Puky Akos*, *Schwalbe*), and in *Lieberkühn's* follicles of the small intestine (fig. 338, *d*). In the latter, according to *Schulze*, the most exquisite examples of "beaker cells" are to be seen between the ordinary columnar elements.

and in *Lieberkühn's* follicles of the small intestine (fig. 338, *d*). In the latter, according to *Schulze*, the most exquisite examples of "beaker cells" are to be seen between the ordinary columnar elements.

In the latter, according to *Schulze*, the most exquisite examples of "beaker cells" are to be seen between the ordinary columnar elements.

the most exquisite examples of "beaker cells" are to be seen between the ordinary columnar elements.

are to be seen between the ordinary columnar elements.

to be seen between the ordinary columnar elements.

between the ordinary columnar elements.

columnar elements.

elements.

elements.

elements.

elements.

elements.

elements.

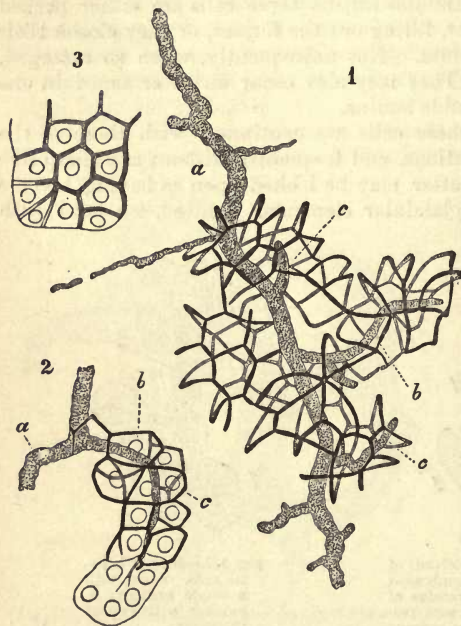


Fig. 339.—Gland capillaries from the pancreas of a rabbit, filled with Berlin blue (after *Saviotti*). 1 and 2, a large excretory duct; *b*, that of an acinus; *c*, finest capillary passages; 3, an acinus with cells, and gland capillaries only partially filled.

We have recently been made acquainted with the fact that in certain glands there exist two

kinds of cellular elements, as, for instance, in the submaxillary and peptic glands of many mammals. We shall refer to these again.

Differences in gland cells have also been remarked corresponding to their conditions of activity and rest, *e.g.*, in the glands of the stomach and submaxillary of many mammals, &c.

Finally (*en passant*), between the hepatic elements, and later still between those of several racemose glands, a system of the most delicate canals has been met with, to which the name of "gland capillaries" has been given. Fig. 339 will give some idea of the nature of these.

Turning now to the size and further composition of the gland cell, we observe great diversity, especially in the former. Those elements, for instance, clothing the internal surface of the ovarian vesicles, possess a diameter of only 0.0074–0.0090 mm., while the roundish polyhedral cells of the racemose mucous glands measure 0.0068–0.0113 mm., those of the peptic glands 0.0226–0.0326 mm., and those of the liver almost as much, &c. In these cells are to be found single, or not unfrequently double, nuclei of from 0.0056 to 0.0090, at one time vesicular, and at another more homogeneous. At a later period, in the more mature cell, these may, however, become dissolved. The contour of such elements is usually very delicate, and their contents are of various kinds; this we shall again refer to.

§ 196.

The delicate constitution of the cells in question, together with the lively interchange of matter which is carried on through their agency, tends to render the existence of a certain number of them very transitory, showing again another parallel with many epithelial elements. But while we are able to demonstrate the briefness of the existence of many cells with all the certainty desirable, we have no facts to support us in other cases, nay, we even have observations which point to the very opposite conclusions as regards them. Thus the hepatic (fig. 337) and renal cells are known to be comparatively permanent elements.

Here again, as among the epithelia, mechanical wear and tear takes place also, the stream of fluid which flows towards the outlet of the gland carrying off with it greater or smaller quantities of the cellular lining. If we observe, for instance, the stratum of mucus which covers the coats of the stomach while digestion is going on, especially among phytophagous animals, we may frequently discover extraordinary numbers of peptic cells swept away in the gastric juice which wells up from below. The sebaceous secretions of the skin contain likewise cellular elements derived from the glands, from whence they emanate. In other organs, however, such as the kidney, lachrymal, and sweat glands, the cells appear to be washed away to a smaller extent, and in the bile hepatic cells are never to be found.

The transient nature of these elements is manifested again in another way. They are destroyed, namely, to form the secretion of the gland to which they belong. Without taking into account such peculiar changes as lead to the origin of spermatozoa within the cells of the seminal tubules, we find the most ordinary mode of decay to be in physiological fatty degeneration, as it may be expressed, of the elements of glands. Here the cells are observed to be destroyed by the generation within them of fatty contents, undergoing subsequently a process of solution by which the latter are liberated, and appear as constituents of the glandular secretion. This is found to take place in the sebaceous glands

of the skin, in the mamma during lactation, in the *Meibomian* and ceruminous glands, as well as many of the sudoriferous organs.

Thus we see the saccules of sebaceous glands (fig. 340, *A*) clothed on their internal surface with cells (*a*), which may be regarded as a modified prolongation of the *Malpighian* layer of the skin, but which differ from the latter in being to a certain extent rich in fatty granules (*B*, *a*). By a further deposit of fat within the cell the latter is increased in size (*B*, *b-f*), and becomes detached from the *membrana propria* (*A*, *b*), so that in the cavities of the organ cells of 0.0377-0.0563 mm. are met with—elements in which the amount of fat is very considerable. The latter presents itself either in the form of innumerable granules (*B*, *b*), or several globules of oil (*c*) enclosed within the membrane of the cell, or, one large drop communicates to the latter the appearance of an ordinary fat cell (*d*). The nuclei of these elements are gradually destroyed, apparently, as also their envelopes, at least frequently. Thus the secretion of sebaceous glands contains, in the first place, free fatty globules, and in the next place, those cells loaded with oily matters just described.

Fig. 340.—Saccule of a sebaceous gland. *a*, gland cells, clothing the walls; *b*, those which have been cast off, filled with oil globules, and occupying the lumen of the sac; *B*, the cells under higher magnifying power; *a*, smaller specimens belonging to the parietal layer, and poor in fat; *b*, larger, with abundance of the latter; *c*, a cell in which several oil globules have coalesced to form larger drops; and *d*, one with a single fat globule; *e*, *f*, cells whose fat has partially escaped.

varying size, held together by some agglutinating matter. At one time they are seen to possess envelopes and nuclei, at another to be without either. There can be no doubt that in these structures are presented to us the gland cells which have been shed, and having undergone fatty degeneration, are now in process of solution.

Soon after delivery the milk contains innumerable milk globules as they are called (*a*), that is, small drops of oil enclosed in a delicate film of coagulated casein. These bodies are of very different diameters, measuring from 0.0029 to 0.0090 mm. In this case the increased energy of secretion has led to rupture of the gland cells while still within the organ.

In those situations where the gland cell possesses a finely granular body consisting of albuminoid matters, we find it a matter of greater difficulty to convince ourselves of the destruction of the former in the formation of the secretion. We usually meet, however, in the mucous and peptic glands of the stomach with a certain number of liberated

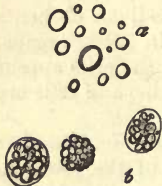

Fig. 341.—Form elements of human milk. *a*, milk globules; *b*, colostrum corpuscles.

molecules, as well as naked nuclei, and even broken down cells, so that the destruction of numerous cellular masses cannot well be denied. Such cellular debris has long been known; at an earlier epoch, however, by reversing the order of things, a view of its nature was taken which favoured the theory of the spontaneous origin of cells.

Another, and it appears equally widely-spread destructive process, is met with in the metamorphosis by which mucin is formed. Ordinary albuminous cells made up of the usual protoplasm occupy the parietal portion of the glandular sac, while larger elements containing mucus, and which have had their rise in the first form, are situated in the more central part. By the solution of the latter the mucus of the gland is produced. This is found to take place, for instance, in numerous small mucous glands, such as the labial of man and the rabbit, those of the larynx of the latter animal and the dog, in the submaxillaris of many mammalia, beginning with the dog and cat, and finally, in the sublingual of the dog.

We shall have to consider these points at greater length among other things in the third part of our work, in referring to the salivary glands.

The reverse of all this takes place in other glandular organs, as, for instance, in the kidney, where the cells allow the secreted matters to pass through their membrane, repeating again what occurs among the epithelia.

The question as to how gland cells are regenerated calls for renewed investigation. There can be but little doubt, however, that a process of segmentation takes place among them, for in many organs the occurrence of cells with two nuclei is of great frequency (fig. 336, *c*; and 337, *b*).

§ 197.

The *vascularisation* of glands in keeping with their extreme vegetative energy is very perfect. The form of the vascular networks is liable, however, to great variation, being determined by the shape of the glandular elements. Thus racemose glands are found to possess around their spheroidal vesicles corresponding bag-shaped capillary networks (fig. 342), like those of fat



Fig. 342.—Capillary network from a racemose gland (the pancreas).

lobules. On the other hand, tubular or follicular glands are supplied with a system of capillaries arranged in more elongated meshes or loops along their walls (fig. 327 and 343), not dissimilar at times to the mode of arrangement of the minute vessels in striated muscle. Around the outlets alone when crowded together do the meshes again assume a circular form (fig. 343 above, and 344 *c*). The vascular network of the

liver (fig. 345), is extremely dense surrounding the cells (comp. fig. 328), partly with roundish and partly with more or less radiating loops.

With the exception of the latter anomalous organ, we never find the capillary networks situated actually among the groups of cells themselves, but external to the *membrana propria* or envelope of connective-tissue.

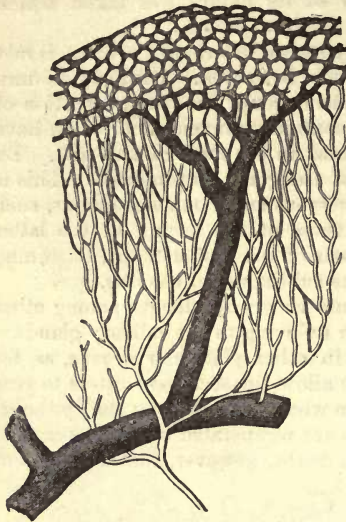

Fig. 343.—Network of blood-vessels from a peptic gland of the human stomach.

In those cases in which the vessels penetrate into the interior through the enveloping structures, as in *Peyer's glands* and lymphatic knots, the part is improperly termed a secreting organ, and belongs rather to the lymphatic formations.

The energetic transformation of material which takes place in glands, appears as a rule to necessitate the presence in them of *lymphatics*, an acquaintance with the nature of which has recently been gained with greater accuracy than was previously possible. The testicle and thyroid gland (fig. 344, *d*, and 346, *d-f*) may be mentioned as examples.

With the consideration of the *nervous supply* of glands, we come to one of the most obscure points in histology. The nerves here met with consist partly of *Remak's fibres*, and partly of medullary elements. Their distribution is in the first place to the blood-vessels of the organ, then to the excretory ducts and secreting elements of the latter. As a rule, but few and scattered nerves

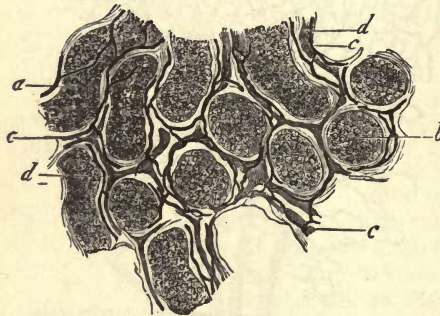


Fig. 344.—From the testicle of the calf. At (*a*) the seminal tubules are seen somewhat from the side; at (*b*) transversely; *c*, blood-vessels; *d*, lymphatic passages.

can be recognised in glands, but that several of the latter, as, for instance, the lachrymal and salivary, are richly supplied with them has already been mentioned in a previous section (§ 189).

Unstriped muscle may also be an important element in the structure of glands. Thus, without taking into consideration the muscular structures around the efferent ducts, we may see in the first place narrow bundles, ascending between the individual glands, as, for instance, in the mucosa of the stomach, or the same may be observed in the connective-tissue enveloping the several sub-divisions of the organ, as in the prostate and *Cowper's glands* (*Koelliker*). The wall of the organ again may be muscular, as best seen in the large sweat glands of the axilla.

The *excretory passages* of glandular organs must now be specially described. We have already seen that these are not indispensable to the

proper conception of a gland, and even in cases in which the latter possesses an outlet, there may be as yet no trace of a special canal for the carrying off of the secretion of the part.

All simple follicular glands belong to the latter order, in which the form of cell changes just before the outlet is reached, but the termination of the follicle itself is not clearly defined. In those cases only in which several of the latter are united in one common, short, and widened terminal portion, can we speak of such a canal, as in those peptic glands of the stomach, in which the portion common to the several tubules (*Stomach cell* of *Todd and Bowman*) is marked by the difference of its columnar cells (fig. 347, *a*). The straight portion of the tubules of convoluted glands may be looked upon as an excretory duct, as it passes from the convolution towards the outlet, although neither the structure of the wall nor the cellular lining is altered in the least; the diameter, however, decreases at first. On the other hand, among complex tubular glands,

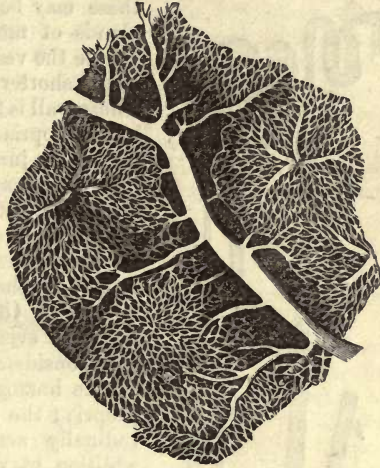


Fig. 345.—Network of vessels in the rabbit's liver.

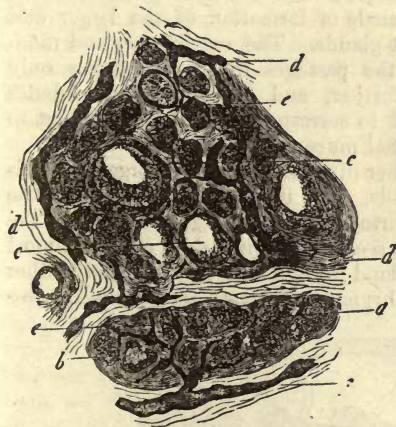


Fig. 346.—From the thyroid of the infant. *a*, crypt of gland filled with cells alone; *b*, incipient colloid metamorphosis of the contents; *c*, the latter far advanced; *d* and *f*, large lymphatics; *e*, small lymphatics.

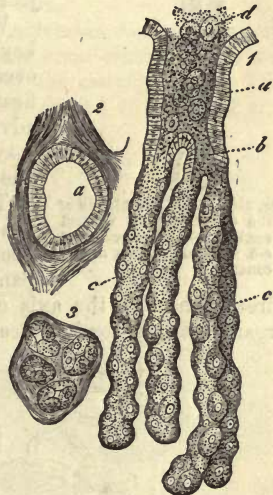


Fig. 347.—A compound peptic gland from the dog. *a*, wide orifice of exit (*stomach cell*) clothed with columnar epithelium; *b*, point of division; *c*, single follicles lined with peptic cells; *d*, contents passing out. 2. The orifice (*a*) in transverse section. 3. Section through the several glands.

such as the kidney, we find an elaborate system of excretory ducts lined

with clear, low, cylindrical cells, traversing the whole organ (fig. 348, *a-d*). We shall refer to this again.

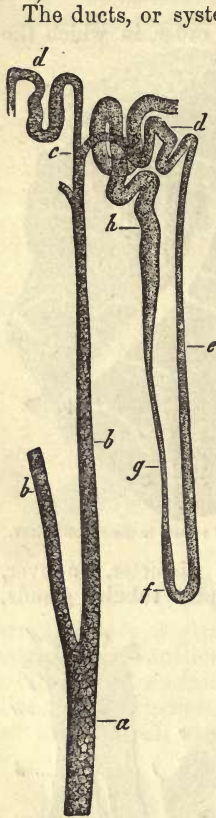


Fig. 348.—From the kidney of the Guinea-pig, in vertical section. *a-d*, excretory; and *e-h*, secreting portion of the canal.

The ducts, or systems of ducts of racemose glands, however, are recognised by all. The most simple forms in which these may be seen are to be found in the small glands of mucous membranes (fig. 349). Here we see the vesicles making up a lobule, continued into a shorter or longer passage of small diameter, whose wall is formed by a prolongation of the membrana propria. Among very small glands of this nature the junction of two tubes, such as that just described, may constitute the whole duct of the organ (fig. 326). But in others the matter is not so simple, and in the larger mucous glands the common canal of exit from a group of lobules formed by the confluence of their ducts is but a branch of the true common passage. In the latter, or even in a branch of the first order of any considerable gland, we no longer find the simple homogeneous structure of the membrana propria; the walls are here composed of longitudinally arranged connective-tissue fibres, in addition to which an external stratum of looser texture may be remarked. They are lined, likewise, within with a layer of epithelium cells. The length and breadth of these passages is subject to much variation.

What has just been described may serve as a key to the mode of formation of the larger and even largest glands. The subdivision and ramification of the passages in the latter has only advanced further, and the groups of lobules may be said to correspond to a certain extent to the individual mucous glands.

The further diversity of form of organs of this kind depends, also, in a great measure on the peculiar course of these passages. Thus, in the pancreas we see the principal duct passing almost directly through the axis of the gland towards its apex. Many other organs, also, as, for instance, the lachrymal and mammary glands, are pos-

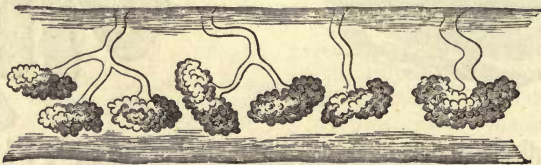


Fig. 349.—Small mucous glands, some of whose ducts unite in a common outlet.

sessed of several outlets: the union of the final twigs to form one common canal may be said in this case not to have taken place.

In regard to the texture, in these instances we have presented to us in

the finer ramifications the state of things already seen in the smaller mucous glands. The more considerable and terminal passages, however, acquire a tougher internal tunic, rich in elastic elements, which is enveloped in the external coat. Between these two layers there is interposed, further, in one class of glands a muscular sheath, consisting, when only slightly developed, of longitudinally arranged unstriated fibre-cells, as in the mamma and *Cowper's* glands. When more highly developed it is made up of an external longitudinal and internal transverse layer, to which may be added another still more internal of longitudinal fibres (*vas deferens*). The tunic situated internal to these, formed of connective-tissue, is gradually converted into a mucous membrane clothed with cylinder cells, and in it again minute mucous glands may appear (biliary and pancreatic ducts).

§ 198.

Turning now to the individual glands, the following points may be borne in mind:—

1. Among the *tubular glands* of the human body may be reckoned *Bowman's* of the regio olfactoria, *Lieberkühn's* of the small intestine, the so-called follicles of the large intestine, the peptic and mucous glands of the stomach, and the glands of the uterus. These all consist of follicles of varying length, formed of a simple membrana propria. Their length, which depends on the thickness of the mucous membrane, ranges from 0.2256 to 2.2558 mm. and upwards. In breadth they differ considerably; in *Bowman's* glands the diameter being 0.0323–0.0564 mm., in *Lieberkühn's* 0.0564 mm., the large intestine 0.0564–0.1128 mm., and those secreting the gastric juice 0.0323–0.0457 mm.

The number of these glands is often very considerable, so that they may cover the whole surface of the mucous membrane when crowded together, —as, for instance, the follicles of *Lieberkühn* of the cat (fig. 350.) The tubes usually remain undivided, but in many glands, as those of the stomach and uterus, each may be split into two or three branches. The cells contained within them are partly flattened and round, partly cylindrical.

Among the *convoluted glands* we have the smaller and larger sudoriferous organs, the ceruminous glands of the ear, and the tubules occurring in the conjunctiva at the edge of the cornea in many mammals. It is seldom that, as in the latter situation, they possess a simple membrana propria. In most the wall is stronger, this membrane being again enclosed within a layer of

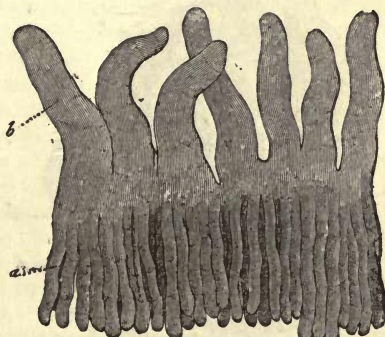


Fig. 350.—*Lieberkühn's* glands from the cat (a), surmounted by intestinal villi (b).

connective-tissue, between which structures muscular elements may be interposed as a middle tunic, e.g., the large sweat glands of the axilla. In this manner the walls may attain a thickness of 0.0045–0.0094, or even 0.0135 mm. The breadth of the very long tubules of a convolution varies from 0.0451 to 0.0992, or even 0.1505 mm., and that of the whole of the latter from 0.2 to 6.7 mm.

The efferent duct is at first narrow, later on expanded somewhat, and loses its walls on penetrating the strata of the epithelium. The cells

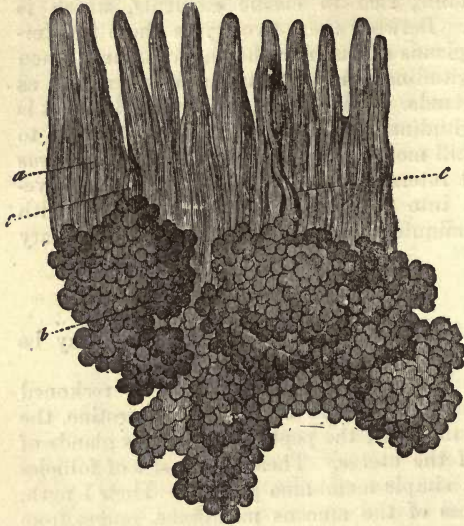


Fig. 351.—Brunner's glands from the human duodenum. *a*, villi; *b*, bodies of the glands situated in the submucous tissue, which empty themselves through their ducts between the bases of the villi.

lining these glands are usually roundish and flattened, and possess a more or less fatty contents.

The complex tubular glands present either a homogeneous membrane, as in the kidney, or this is replaced by connective-tissue, as in the testicle. The seminal tubules of the latter have a diameter of about 0.1128 mm., and the uriniferous tubes of the former range from 0.2 and 1.2 to 0.0377 mm. and upwards. These cells are polyhedral, calling to mind the appearance of flattened epithelium.

The physiological purposes served by the several kinds of tubular glands are exceedingly various.

2. The *racemose glands* constitute a very large group of organs, varying greatly both as to size, the character of the secretion yielded by each, and their physiological significance. To these belong the many small glands

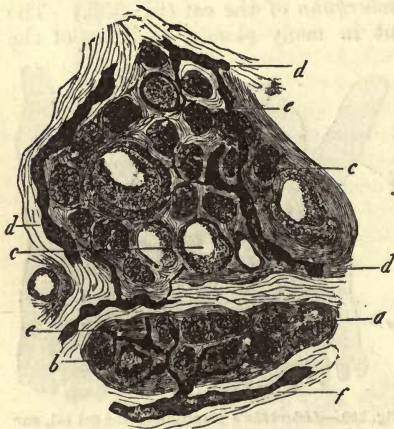

Fig. 352.—From the thyroid of the infant. *a-c*, glandular spaces.

of the mucous membranes of the body. They occur with very different degrees of frequency; often as, for instance, in the mouth and in the duodenum, they are very densely crowded together (fig. 351).

In different situations they are known under special names, as in the last case, where they have obtained that of *Brunner's glands*. The sebaceous glands of the skin, likewise, with those modified forms of them known as the *Meibomian* of the eyelids, belong to this same category. At the commencement of their development the first of these present themselves as

simple flask-shaped follicles, which are subsequently converted by sacculation of their walls into smaller or larger racemose organs.

Among the larger glands of this group may be reckoned the lachrymal, the various salivary glands, the pancreas, the mammary, *Cowper's* and *Bartholini's* glands in the organs of generation, as well as that aggregation

of these structures known as the prostrate. The lungs might also be added here on account of their structure and development. The gland vesicles, almost always formed of a delicate *membrana propria*, vary in size from 0.1128 to 0.0451 mm., with extremes in both directions. The contents consists either of rounded, or more or less cubical cells. Some of them are filled with a fatty secretion. We have already considered their efferent ducts in the foregoing section.

3. Turning, finally, to those glands consisting of *entirely closed* roundish cavities, the thyroid (fig. 352) may be taken as the type. Here we find a number of short glandular spaces of roundish form in a groundwork of connective-tissue, having a diameter of 0.1128–0.0564 mm. and less, and consisting of a fibrous wall (without any distinct *membrana propria*) with a coating of small round cells. In the *Graafian* vesicle of the ovary, which is opened by rupture, and destroyed after expulsion of the ovum and remaining contents, we have another more complicated capsule, also imbedded in abundant, dense fibrous tissue. The interior is lined by minute, round, nucleated cells, in the midst of which lies the primitive ovum.

§ 199.

As to the *composition* of glandular-tissue, to which we will now devote a few lines, it is one of the most neglected subjects in histology. Even of the nature of the *membrana propria* we know but little: its substance, however, is no albuminous one. It consists rather of some material difficult of solution, and offering a tolerably prolonged resistance to the action of weak acids and alkalis, reminding us of the bearing of the transparent membranes of the eye. Its power of resisting concentrated alkalis is sometimes also considerable, in which cases this gland-envelope may consist of elastin, an important point when we take into account its indifferent nature and stability, and the great secretory energy of the organ. In other cases this membrane is not so durable, and we have not the slightest clue as to its composition. It need hardly be remarked that at those points where, instead of a transparent homogeneous membrane, a layer of connective-tissue presents itself, bounding the subdivisions of the organ, we have to deal with a glutin-yielding substance.

The gland cells, the most important parts of the organ in question,—those, in fact, which constitute them glands,—have but little remarkable about them excepting the contents of their bodies. Their membranes consist, for the most part, of a matter which gives way even to the weaker acids, but sometimes of a material possessing much greater power of resistance, thus reminding us of many of the so closely allied epithelia. The nuclei present the same peculiarities here as elsewhere.

The matters, however, contained in these gland cells vary with the species of secretion to be produced. Thus, for instance, we meet with materials in the cells of the liver which are subsequently found free in the bile,—such as fats, pigments, and glycogen, which leads to the formation of sugar, and is carried off with the blood of the hepatic vein. In the cells of the mammary gland, further, we have the butter fats of the milk; in those of the sebaceous glands, the fatty matters observed on the skin; in the gastric cells, the pepsin found in the juices of the stomach, and so on. Mucin also is contained, together with other substances, in those cells held to be the generators of mucus.

Now, although the components of the secretions present themselves

first as constituents of the gland cells, we find, nevertheless, that they differ among themselves in two particulars.

In the first place we remark, that in a certain number of the organs in question these substances are only abstracted from the blood to sojourn simply in the body of the cell for a longer or shorter space of time. This is the case, for instance, with the constituents of the sweat glands and kidneys, in which we are unable to demonstrate any notable chemical metamorphosis through the agency of the cell. The latter may, however, be evident, though in a minor degree, in other glands, for instance in the female breast, in which an albuminous substance is transformed into casein, and, we suppose, grape sugar into sugar of milk. Such instances are connecting links between the first case and another, in which the cell produces, by the disintegration and rearrangement of the matters it receives, completely new and peculiar substances, as may be seen in the liver, in the production of the bile acids.

Another difference concerns the cell itself, as we know already. This may either be cast off after the generation of its specific contents, setting free the latter (sebaceous, milk, and peptic cells), or the contents may escape from its uninjured body, while it itself remains as a permanent structure (renal and hepatic cells).

Finally, the "egotistical" mutation of matter of glandular tissue, *i.e.*, that which takes place in the interest of its own proper nutrition, must give rise to the generation of the more general decomposition products of the system. Thus, according to *Staedeler* and *Frerichs*, leucin has been found in exceedingly small quantity as a very general transformation product in glands, seldom in larger amount, as in the pancreas. Other bases, such as tyrosin, taurin, cystin, hypoxanthin, xanthin, and guanin, appear more rarely. Inosit and lactic acid may also be met with, and uric acid, though with less frequency. These matters are partly discharged with the secretions of the glands, and partly taken up again into the circulation.

Later on, in considering the salivary glands, we shall see the control which the nervous system possesses over the chemical action of these organs.

§ 200.

Turning now to the *development* of glands, it will be remembered that the epithelial nature of these structures has already been touched on. The mode of origin is the best proof of this. It is well known that a whole series of glandular organs is derived from the external cellular layer of the foetal body from the so-called *corneous leaf*. They commence in the form of nodulated prolongations downwards of the epithelial cells, in which at first no trace exists of either central cavity or gland-membrane. This latter is subsequently formed on the exterior of the aggregation of cells as a deposit. The size of this mass is increased by division of the cells of which it is composed, while the connective-tissue surrounding it becomes eventually the envelope of the gland. Among the structures so formed may be mentioned the sweat, mammary, and lachrymal glands.

The *sweat glands* (fig. 353, *a*) are developed, according to *Koelliker*, after the fifth month of intra-uterine life. Commencing as small flask-shaped growths formed of the rete *Malpighii* cells, they advance deeper downwards through the skin in the following months, becoming eventually curved, in a gradual manner, at their lower end. Then a trace of the central passage and external outlet becomes apparent. The *sebaceous*

glands also, the first rudiments of which may be observed somewhat earlier than in the preceding case, are likewise solid lateral growths of the undermost cells constituting the rudiments of the embryonic hair follicle, and possess the same flask-like form. The cells in their interior begin very early to undergo that so characteristic fatty infiltration with which we are already acquainted, at the same time increasing in volume. Then by continuous growth they gradually form those vesicular lobules met with in the fully matured structures. The *mammary glands*, again, are developed in a manner precisely similar, from the fourth and fifth month on. Around the several aggregations of cells (fig. 354) an external connective-tissue envelope may be seen, a doubling in of the skin. But it is only at the period of puberty and pregnancy that the organ attains a state of perfect development.

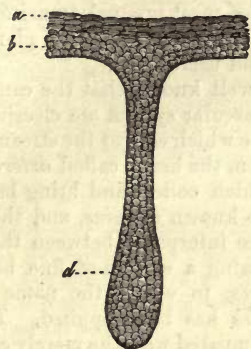


Fig. 353.—Sweat glands of a fœtus at five months. *a*, superficial, *b*, deeper layer of the epidermis; the rudiments of the gland are formed by the exuberant growth downwards of the latter.

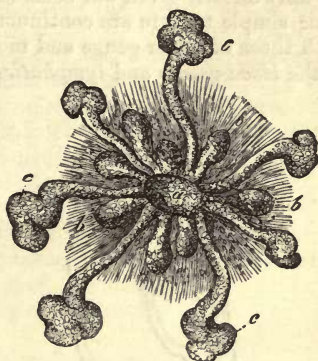


Fig. 354.—The mammary gland from a tolerably mature embryo, after Langer. *a*, the middle nodulated portion with shorter excrescences; *b*, and longer.

As to the germ-producing glands, the ovaries and testicles, as far as concerns their cellular elements, we are still, unfortunately, in the dark in spite of numerous investigations.

Besides those just mentioned, there are a great number of organs of the same nature, whose development takes place on a precisely similar plan, from the so-called intestinal glandular embryonic plate. Among these may be reckoned the glands of the digestive apparatus and the larger organs connected with the latter, *e.g.*, the liver, pancreas, and lungs. Here, instead of the cells of the corneous layer, we have before us the elements of the glandular leaf arranged over the surface of the tube as intestinal epithelium. The mode of formation of these, however, is but imperfectly known, as, for instance, that of the peptic glands and follicles of the large intestine. The follicles of *Lieberkühn* appear, on the other hand, to consist, from the very commencement, of hollow duplicatures. The first rudiments of *Brunner's* glands, however, as well as those of the remaining racemose mucous glands, are formed of solid masses of cells. The salivary glands seem to be formed on an analogous plan of development, except that a far more extensive proliferation of the cells takes place, producing roundish aggregations of the form of the vesicles of the organ. The pancreas commences also in a hollow duplicature, whose clothing of cells gives rise by a similar process to the various lobules and

vesicles of the organ. The formation of the lungs is carried out on a similar plan.

17. The Vessels.

§ 201.

Of a special *vascular tissue*, or tissue peculiar to vessels, we can only speak in a very limited sense. The most internal layer alone consists everywhere of a series of flattened cells of a peculiar kind, cemented together at their edges, and resembling very closely epithelium. The walls of the finest and most simple tubes are composed solely of these cells. All the remaining coats, on the other hand, which strengthen the walls by being laid down around them (and they are seen very early) are formed of muscular and elastic tissue, of structures, therefore, to which we have already given our consideration. But in that the fine tubes with their simple texture are continuous through the most gradual transitions with those of wider gauge and more complex structure, a general glance at the *blood-vessels* and *lymphatics* will be found useful.

It is well known that the canals of the vascular system are classified into those which convey the stream of blood from the heart, called *arteries*, those which collect and bring back the same known as *veins*, and those which are interposed between these two, forming a system of fine hair-like tubes, to which the name of *capillaries* has been applied. The latter, compared with the merely conducting veins and arteries, constitute the most important part, physiologically, of the whole, in that through their delicate walls the interchange of matter between the blood and organic fluids, as well as secretion, takes place.

The capillary vessels present for our consideration, as a rule, a wall quite distinct from the neighbouring structures. For those so constituted we would retain the name of *capillaries*. In other and rarer instances, this tube containing the blood is fused with the adjacent tissues, the fluid, as it were, flowing through grooved passages, in which case we have the *capillary canal*. Finally, recent observations seem to teach that in the pulp of the spleen the finest streams of blood actually flow through membraneless interstices. These latter are known as *capillary lacunae*.

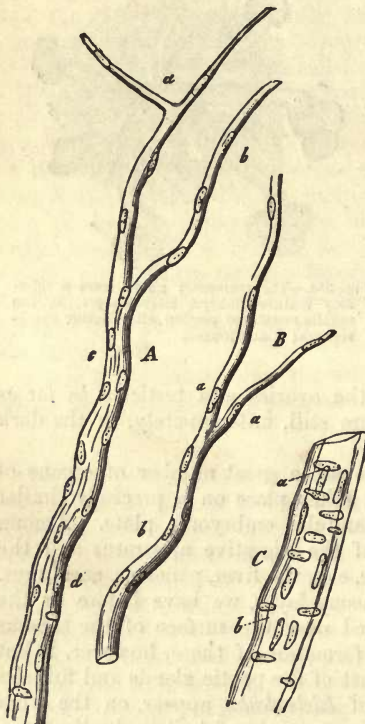


Fig. 355.—Fine blood-vessels from the pia mater of the human brain. *A*, a small branch, which divides above into two delicate capillaries, *a*, *b*, and which consists below (*d*), of two tunics; *B*, a similar tube, with branches; *C*, a vessel of greater calibre, with a double membrane, the internal (*a*) showing longitudinally arranged, and the external (*b*), as well as intermediate, transverse nuclei.

Capillaries of the smallest calibre, which do not, however, occur in all

parts of the body, are tubes just sufficiently large to permit the passage through them of a single blood corpuscle, which can even be compressed in its course. The diameter of the lumen may be stated consequently at 0.0045–0.0068 mm., whilst other and more considerable tubes attain a breadth of 0.0113 mm. and upwards.

These canals (355, *A*, *B*) were supposed, until very recently, to have an extremely simple texture. As a rule, their walls are perfectly transparent and structureless, and endowed with remarkable elasticity and extensibility. Chemically, they resemble the sarcolemma of muscle fibres and primitive sheath of nerves, displaying a considerable power of resisting the action of many strong reagents. In the walls of these tubes rounded or oval nuclei are to be seen, 0.0056–0.0074 mm. in diameter, in which nucleoli may be remarked. These are arranged irregularly one behind the other at considerable intervals (*A*, *a*, *b*, *B*, *a*), but at times at more regular distances (*A*, *a*, *B*, *b*). In larger branches, measuring perhaps 0.0113 mm. and upwards, the latter arrangement is the rule; otherwise the structure remains the same, except that such tubes may attain considerable thickness, amounting to 0.0018 mm. The long axis of the nuclei corresponds to that of the vessel; they are consequently said to be longitudinally *oval* in figure.

§ 202.

This view just mentioned of the nature of the walls of capillaries was held for many years with unquestioning tenacity, no expedient having as yet been hit upon by which the structure of the transparent nucleated membrane of which they consist could be farther resolved.

However, all at once the analysis of structure was accomplished through the discoveries of *Auerbach*, *Eberth*, and *Aeby* following in the footsteps of *Hoyer*. From them we learned the usefulness of very dilute solutions of nitrate of silver in rendering visible, in the most exquisite manner, the delicate contour of cells (whether those of epithelium or smooth muscle) in the form of dark lines. The transparent nucleated membrane in question is formed of flat cells, often peculiarly bordered, and having a single nucleus (figs. 356 and 357); they are united closely with one another at their edges, and curved towards the lumen of the vessel. The tube thus formed is endowed, moreover, with vital contractility (*Stricker*).

These cells, further, extend continuously into the more considerable and even the largest trunks, though to a certain extent modified. This may easily be recognised. Here they were known even to the earlier histologists, their contour being plainly visible without any further treatment. They were described as the epithelia of the arteries, veins, and cardiac cavities (§ 87), and we may add, with perfect correctness, for these lining cells of the vascular system are members of the epithelium group of the middle germinal layer (pp. 158, 159), the *endothelia* of *His*. Another name has been proposed for them also by *Auerbach*, namely, *perithelium*. It may be found more convenient, how-

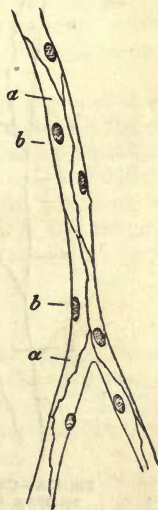

Fig. 356. — Capillaries from the mesentery of a Guinea-pig after treatment with solution of nitrate of silver. *a*, cells; *b*, nuclei of the same.

ever, if, for the future, we make use of the term *primary vascular membrane* in referring to this cellular tube.

In regard to the cells themselves, they are presented to us according to the breadth of the tube, either under a more or less fusiform or polygonal form. The first variety (fig. 356), bounded by delicate serrated or undulating lines, have a length of 0.0756–0.0977 mm., and breadth of 0.0099–0.050 mm. Such elements are to be found forming the walls of the finest capillaries, arranged either parallel to the axis of the vessel, or more rarely obliquely, as regards the latter. In transverse sections of the vessels two or three, or less frequently four of them, may be remarked.

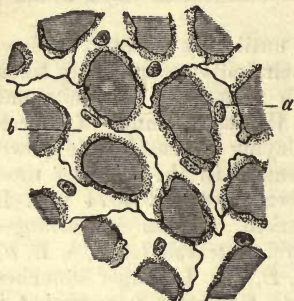

Fig. 357.—Capillary network from the lung of the frog treated with solution of nitrate of silver. *b*, vascular cells; *a*, nuclei of the same.

In many of the finest vessels portions of the tube are formed of one single cell alone, its two edges meeting around the lumen. Such cases may be found among the capillaries of the brain, the retina, the muscles, and the skin.

Capillaries of larger calibre are made up of cells of the second variety. We encounter here either regular polygons, as, for instance, in the *chorio-capillaris* of the cat and *iris* of the bird's eye, or more irregular

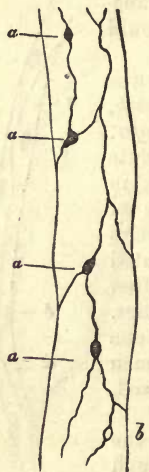


Fig. 358.—Capillary vessel from the mesentery of the frog treated with nitrate of silver. Between the vascular cells at *a*, *a* and *b*, the "stomata" are to be seen.

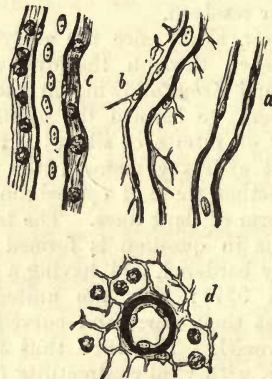


Fig. 359.—Capillaries and finer trunks from a mammal. *a*, capillary from the brain; *b*, from a lymphatic gland; *c*, a somewhat stronger branch, with a lymphatic sheath, from the small intestine; and *d*, transverse section of a small artery of a lymphatic gland.

plates (fig. 357), in many instances giving off long processes. In the transverse section of the vessel we may have two or four of these. In size they are naturally subject to great variation, and may attain a diameter at certain points of 0.0749–0.01737 mm. The interdigitation of their

processes presents a most peculiar appearance under the microscope. Between these cells, however, may be observed a greater or smaller number of roundish marks of varying size, sometimes in the form of a dark spot (fig. 358, *a, a*), sometimes in that of a ring (*b*).

These have been hitherto held by many to be preformed openings or "stomata," and to account for the exit of white and coloured blood corpuscles (p. 128).

The recent investigations of *Arnold* also have confirmed the correctness of this view.

Now, whilst we believe that in many parts of the body the whole of the capillary vessel is represented in this cellular tube just mentioned, there are some localities in which the latter is enveloped in a delicate homogeneous membrane, probably the first indication of the *tunica intima*. There are again places in which the surrounding connective-tissue forms an external envelope for all capillaries, even the most minute,—in fact, an *adventitia capillaris*, which may be regarded as equivalent to the *tunica cellulosa* of larger trunks. Thus we find the capillaries of the brain (fig. 359, *a*) enclosed in a homogeneous nucleated membrane, and those of lymphoid organs (*b*) closely invested in reticular connective substances. Again, other more considerable, but still capillary vessels, may be enveloped loosely in a layer of connective-tissue (*c*), and the space thus left between the latter and the vessel may serve the purpose of a lymphatic passage. We shall refer again to these *lymph sheaths*, and only stop to remark here, that every adventitial tissue of a blood-vessel containing lymphoid cells, must not be regarded as one of the latter. Another circumstance also may frequently give rise to the deceptive appearance of such a sheathing, namely, that a blood-vessel is often bounded on each side by lymphatic canals; this is most commonly seen in uninjected preparations.

Now, although in those cases just described the capillary wall is easy of recognition in its own individuality, there are others in which the cells of the tube become so intimately united with the adjacent tissues, that they are either totally inseparable from the latter, or only so with the help of the stronger reagents at our disposal, although treatment with nitrate of silver naturally renders them visible. This is the texture of the capillary canal as found, for instance, in the *membrana pupillaris* of the foetal eye, the skin, and other strong fibrous structures.

§ 203.

Passing on now from these finer forms to the *larger* trunks, we meet again with those layers already known to us, namely, the epithelial, and the intima enveloping it, and finally the external fibrous coat. The latter appears in the form of longitudinally striated connective-tissue, with vertically arranged nuclei or connective-tissue corpuscles.

Very soon, however, even in extremely fine trunks, especially as we pass towards the artery, between the two internal membranes and the external coat, a thin layer of transversely arranged contractile fibre cells may be observed, whose nuclei we may easily detect. The latter are spoken of as *transversely oval*. There can be now no doubt but that in this we have before us the first rudiments of the middle or muscular coat of the larger trunks.

Once more to recapitulate: we see first (*a*) the layer of flattened cells, then (*b*) the longitudinally streaked internal coat, then (*c*) the transverse

muscular elements as middle coat, and finally (*d*) the external envelope of connective-tissue.

Vessels of this kind can by no means be called any longer capillaries ;

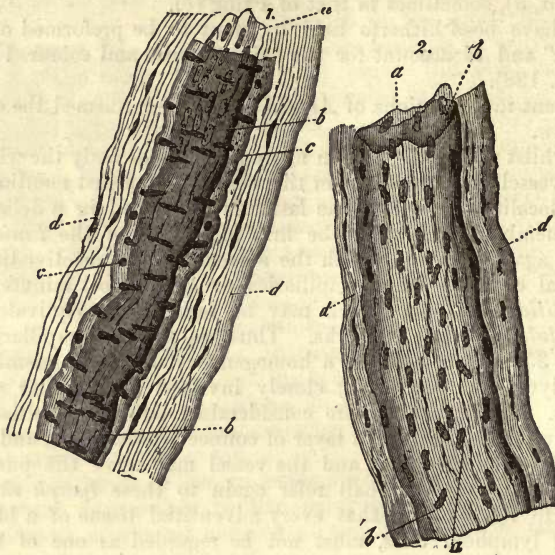


Fig. 360.—Two considerable vessels from the *pia mater* of the human brain. 1. A small arterial twig. 2. A venous twig; *a*, *b*, internal; *c*, middle; and *d*, external layer.

they bear from henceforth far more the character of fine *arterial* and *venous* branches. According to their nature in this respect, they offer certain differences for our consideration, and besides, a series of others of a more local or individual kind.

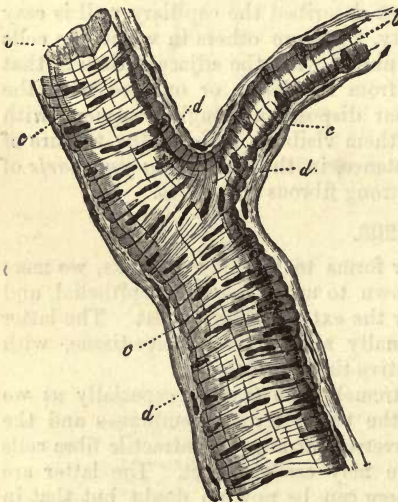


Fig. 361.—An arterial branch. At (*b*) the homogeneous internal layer destitute of nuclei; (*c*) middle tunic formed of contractile fibre cells; *d*, the external connective-tissue tunic.

Taking vessels of about 0.0282–0.04512 mm. in diameter (fig. 360), only two membranes are to be distinguished in a *venous* branch (2) of this kind. In the first place an inner (*a*, *b*), in the form of a tolerably resistant elastic tunic, remarkable for its tendency to form smaller or larger longitudinal folds, and studded with numerous nuclei. The latter on treatment with silver are seen to be the nuclear formations of the vascular cells, which are smaller here than in the capillaries, presenting also a broader and more rhomboidal figure. It is still a matter of uncertainty whether these are again clothed in a thin longitudinally marked

coat or not. The second layer (*d*) presents itself in the form of a streaky fibrous tissue envelope with elongated nuclei and connective-tissue corpuscles.

If we compare with this an *arterial* branch (1), we find again the two coats (*b* and *d*) just described; but between the inner membrane and outer tunic of connective-tissue there now appears a layer of transversely arranged contractile fibre cells lying side by side (*c*), whose elongated nuclei present themselves in transverse sections of the vessel as encircling the latter. This tunic is of varying strength. In other arterial twigs it may appear with greater distinctness, either as a single or multiple layer. Fig. 361 represents this in a side view, and fig. 359, *d*, the transverse section of a small artery with laminated muscular coat, and an *adventitia* consisting of reticular connective-tissue. The epithelium cells are narrower here than in the veins, but much more elongated in the direction of the vessel, and fusiform.

§ 204.

Thus far is it possible to subject the blood-vessel as a whole to microscopical analysis. Larger tubes must be examined in their various parts, either by rending the walls, peeling off layers with a forceps, the vessel having been slit up, or by preparing sections of the previously dried or hardened wall.

The further changes from the next in order to those occurring in the formation of the largest vessels, consist in this, that all the layers, with the exception of that formed of endothelial cells, which remains single, commence to become more and more laminated, especially the internal and middle, thus collectively bringing about an increase in the whole thickness of the vessels. The internal strata preserve in their systems of membranes arranged in laminae one over the other their elastic character, presenting every variety of elastic tissue in longitudinal arrangement. The middle coat is transformed into a system of laminae of smooth muscle fibres, connective and elastic tissue, with a transverse direction. The external tunic, finally, becomes thicker and thicker in its connective substance with an ever increasing development of elastic networks. Fig. 362 represents at (1) the umbilical artery of a fœtus of eight months old in transverse section, and at (2) a large artery from the adult similarly cut, and gives us for the present an idea of the arrangement of parts in question. The distinction between the different coats becomes, however, less and less apparent at the same time. We must, however, bear in mind that the coats of veins are thinner than those of arteries of corresponding calibre, a circumstance which depends upon the minor development in them of the middle tunic. The endothelial cells of venous vessels preserve everywhere the same short broad figure already mentioned in the foregoing §.

Small veins, merely higher grades of development of such a vessel as that represented in fig. 360 (2), commence much later to acquire a muscular layer than arteries of the same magnitude. A venous vessel, for instance, of 0.23 mm. in diameter offers for our consideration an internal membrane in which may be observed elastic longitudinal interlacements, a few laminae of muscle-fibres in the middle coat, intermixed with elastic networks and layers of connective-tissue, and, finally, an external thicker coat, formed of fibrillated connective-tissue and elastic fibres.

In *medium-sized veins* the internal coat consists of either one or several

laminae, longitudinally streaked and studded with nuclei and fusiform cells, and a stratum of elastic membranes and fibrous networks arranged longitudinally, between which the elements of smooth muscle may even be insinuated. The middle tunic is formed of obliquely-crossed fibrous

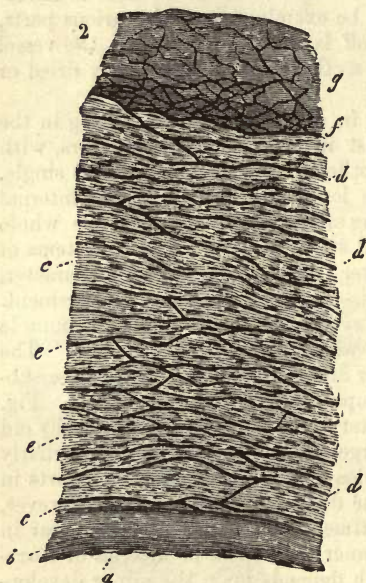
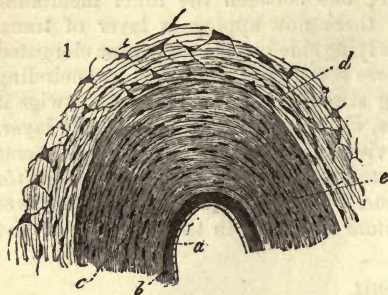


Fig. 362.—Transverse sections of arteries. 1. The umbilical of a human foetus eight months old. *a*, epithelium; *b*, layers of the internal coat; *c*, the muscular layers of the middle coat without any intermixture of elastic elements; *d*, external covering, made up of colloid tissue. 2. A large artery from the adult; *a* and *b*, as in fig. 1; *c*, the line of demarcation between the inner and middle coats; *d*, elastic, and *e*, muscular laminae of the middle coat; *f*, the external tunic traversed by elastic networks; at *f*, below, the latter are highly developed.

tissue, with elastic networks, whose fibres take the same direction, and also of unstripped muscle cells. Between these there appear, however, elastic membranes, whose fibres maintain a longitudinal course. The middle layer of vessels of this kind is, as a rule, much weaker than that of arteries, but is rich in muscular elements. The strong external coat is formed of connective-tissue with elastic interlacements. Unstripped muscle may, however, also occur.

The largest veins of all, finally, present a similar arrangement of their internal laminae, except that the latter have no unstripped muscle fibres, while the middle layer remains comparatively undeveloped, or may in rare cases be entirely absent. The muscle elements of the latter when present are scanty, and accompanied by abundant connective-tissue, whose fibres are obliquely arranged. Elastic fibrous networks of longitudinal direction are also present still. A strange peculiarity has been remarked here in the usually strongly developed external layer of many veins, namely, the occurrence of a large amount of longitudinally arranged muscle, which generally occupies the internal portion of the former in varying strength: it is mixed with fibres of connective-tissue taking an oblique course. There are certain veins, indeed, which show an excessive development of these muscular elements, as, for instance, those of the pregnant uterus; in others they are

entirely absent, as in the sinuses of the dura mater.

The valves of veins, which are covered with endothelium, consist mainly of connective-tissue interspersed with elastic fibres.

In small arteries the internal and external layers remain comparatively

unchanged. The former, however, may frequently acquire the characters of a reticular elastic tunic, owing to incipient absorption at certain points; this is the so-called *fenestrated* membrane (§ 127). Condensation may also lead to the formation of an elastic network stretched in the direction of the axis of the vessel. The middle layer consists of several strata of transverse unstripped muscle-fibres, laid one over the other. In the outer, finally, the connective-tissue becomes fibrillated, and the corpuscles of the latter unite to form fine elastic fibrous networks.

We must be permitted here to refer, in a few words, to the *umbilical arteries* (fig. 362, 1). These are remarkable for the extraordinary development of their muscular middle coat (*c*). As *tunica adventitia* we find (*d*) a reticular connective substance, already seen in the gelatin of *Wharton* (p. 191). The arteries of the ovaries likewise have very strong muscular tunics. The latter may attain an enormous pitch of development in the branches supplying the so-called *corpus luteum*.

Trunks of *more considerable* magnitude, of about 2 mm. in diameter, for instance, show in their internal coat an increase of elastic tissue, in addition to which longitudinally striated layers may occur. There are likewise interposed between the greatly thickened laminae of muscle fibres imperfectly developed membranes of elastic nature, with webs of elastic fibres holding an oblique course; the latter attain also, in the outer tunic, a high pitch of development. In vessels of larger diameter still these elastic networks are developed more and more, especially internally, towards the *tunica media*.

Turning now, finally, to the *largest arterial trunks* of the body (fig. 362, 2), we find, in the first place, that the internal layer (*b*) has increased in thickness by multiplication of its elastic laminae. These latter present themselves, in keeping with the variability of elastic tissue, either in the form of membranes or of membranous networks stretched in the long axis of the vessel, or again as fenestrated coats. More internally, close to the epithelial layer, may be seen laminae, either homogeneous or longitudinally striated, in which, as for instance in the ascending aorta, networks of stellate cells exist, lying one over the other, as was discovered by *Langhans* and confirmed by *Ebner*. In the middle coat (*d, e*) the membranous character of the obliquely running elastic webs becomes more and more marked. The latter may be very thick, or, again, fine and delicate, and the whole present a fenestrated appearance, owing to absorption of the interstitial connecting substance. As a rule, these membranous elastic layers, whose number may amount to from thirty to fifty and upwards, are interleaved with tolerable regularity with the laminae of the muscular substance (*e*). The latter presents itself in varying degrees of perfectness, and is frequently but slightly developed, which may depend upon the high degree of development of the elastic intermediate layers: its direction, likewise, is by no means always the same. In the outer portions of the middle tunic fibrillated connective-tissue is also to be found (*Schultze, von Ebner*). In the most external coat (*g*) the elastic networks are frequently more and more strongly marked at its inner portion (*f*), so that among the larger mammals, as, for instance, in the whale, they furnish one of the strongest examples of elastic tissue that can be met with. As an exception, smooth muscle may also make its appearance in the internal coat of human arteries. Corresponding muscle elements to those we have described as occurring in the external layers of the veins appear to be entirely absent in the arteries of the human body.

Commencing even in the smaller twigs, the blood-vessels are supplied

with arteries for the nutrition of their walls. These are known as the *vasa vasorum*, and are distributed, for the most part, to the middle and external coats, and especially to the latter, in which they are tolerably numerous. They are here arranged like those of formless connective-tissue, except that they form narrower meshes. Later on they appear in

the middle layer, where they have been seen in arteries to form vascular networks of fine tubes, with elongated oblique meshes (*Gerlach*).

The *nerves* of arteries derived from the sympathetic and cerebro-spinal system are distributed in the larger trunks to the middle and external tunics. As a rule, the arteries seem to be richer in nerves, on account of their thicker middle layer, than the veins, but the greatest variety exists in this respect. All that is necessary has already been remarked in respect to the termination of the nerves of vessels in § 183.

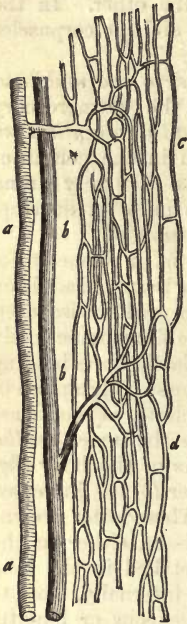


Fig. 363.—Vessels of striped muscle. *a*, artery; *b*, vein; *c* and *d*, extended capillary network.

§ 205.

We must now turn to the more careful consideration of the *capillaries* as to the most important subdivision of the vascular system.

We have already seen that no sharp boundary can be drawn between these vessels and the arteries and veins, in that the most imperceptible transition exists from one to the other. But one thing is characteristic in the capillaries, namely, that their tubes no longer decrease in calibre from the giving off of branches, and that they form among themselves, in the various organs supplied by them, networks of tolerably regular size and shape (fig. 363, *c*, *d*). The diameter of the vessels so connected is, however, by no means the same in the various organs,

and the finest are not presented to us in every locality. The brain and retina possess the most delicate. Their transverse diameter in these organs

may be stated at 0.0068–0.0065 mm., or, in some cases, even so low as 0.0056 mm. In muscle they appear to be somewhat larger, measuring 0.0074 mm. Those of the connective-tissue of the skin and mucous membranes, again, are still larger. In most glands, as, for instance, the liver, kidneys, and lungs, the diameter of the capillaries lies between 0.0091 and 0.0135 mm. The largest of all vessels of this kind are to be found in bony tissue, where they measure as high as 0.0226 mm. It must be borne in mind, however, that, owing to the elasticity of the capillary tube,

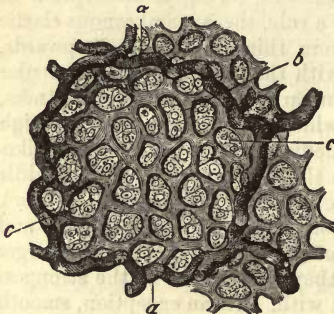


Fig. 364.—A pulmonary alveolus from the calf. *a*, large blood-vessel; *b*, capillary network; *c*, epithelium cells.

and its variation in diameter according to the amount of blood contained in it, these measurements can only be regarded as approximate.

In other vertebrates, likewise, the size of the capillaries must be greater to correspond with the larger diameter of the blood corpuscles.

Touching now the distances between the tubes, and the greater or less vascularity of a part depending thereon, the most remarkable variety prevails. The lungs, the glands, the mucous membranes, and the skin are the most vascular of all structures; whilst other parts, such as the serous and fibrous membranes and the nervous trunks, are very poor in vessels. The vascular networks of the lungs (fig. 364) and of the retina (fig. 365) afford examples, although the latter membrane cannot be reckoned among those poorest in blood in the body.

Finally, we know of tissues which contain no blood-vessels, such as the cornea, the lens cartilage, the epithelial structures, and nails. It is easy to conceive that, owing to the minuteness of the elements of form, only considerable groups of the latter can be surrounded by the capillary networks in organs with a small amount of vascularity. But even in those parts most abundantly supplied with blood the capillary tube always lies external to the elementary structure, and never penetrates into the interior; at the very most, is each individual form element surrounded with a single loop, as in the case of the fat cell (§ 122) and muscle fibre (§ 168). The forms under which capillary networks present themselves are very numerous, and at the same time frequently so characteristic of the various parts to which they belong, that the practised eye can often recognise an organ from a section of its substance which has been injected.

These forms are chiefly determined by the texture of the part and the grouping of its structural elements,

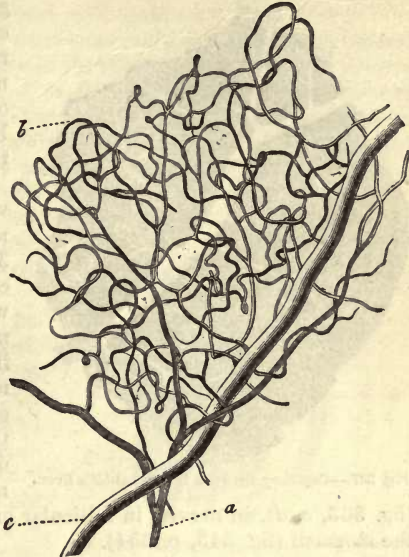


Fig. 365.—Vessels from the human retina. *a*, arterial; *b*, capillary network; *c*, venous twig.

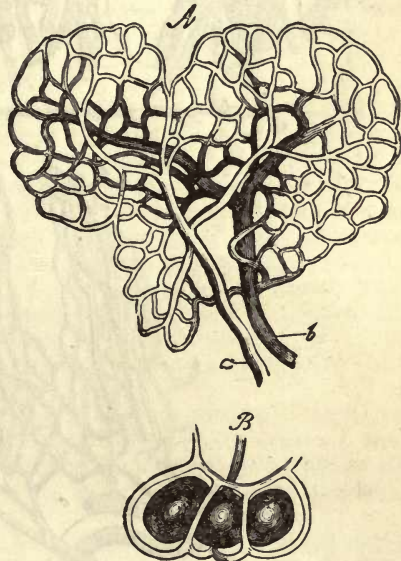


Fig. 366.—Vessels from about fat cells. *A*, an arterial twig at *a*, and venous at *b*, with round capillary network of a fat globule. *B*, the capillaries of three free cells of the latter.

as well as the shape of the latter (fig. 366, *A, B*). Thus, around certain globular structures, such as fat cells and the terminal vesicles of racemose glands, we find *bag-like* nets of vessels, and also about the outlets of follicular mucous membranes a circular interlacement of the latter.

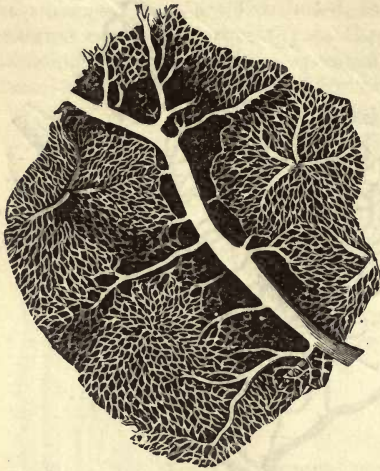


Fig. 367.—Capillary network from a rabbit's liver.

(fig. 363, *c, d*), in nerves, in follicular or tubular glands, such as those of the stomach (fig. 343, p. 354).

The cells of an hepatic lobule, which have a radiating arrangement, as depicted in fig. 328, p. 345, produce also a radiating course in the capillaries of the network of the part, which is primarily bag-like (fig. 367). Again, in those parts whose structural elements are elongated and regularly grouped, we find the meshes of the vascular web likewise much drawn out, as it were, and very narrow, as, for instance, in muscle

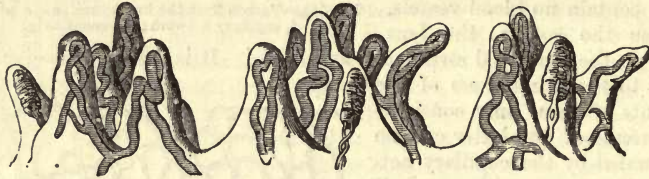

Fig. 368.—Capillary loops from the sensitive papillæ of human skin.

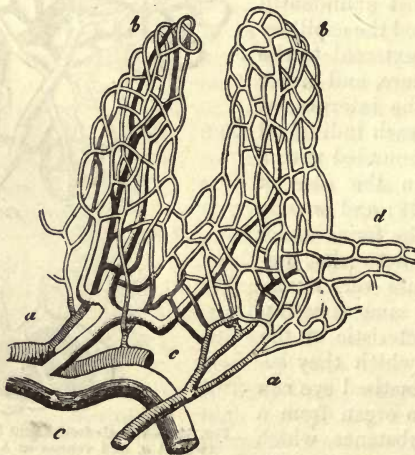


Fig. 369.—The vascular loop network of an intestinal villus. *a*, arterial twig; *b*, capillary net with its circular arrangement around the outlet of the *Lieberkühn's* follicle at *d*; *c*, venous branch.

It is easy to conceive also that each form of network may make its appearance with ever so many different modifications.

On account, for instance, of the narrowness of the space in such conical protuberances as the sensitive papillæ of the skin and papillæ of the mucous membranes, regular *capillary loops*, as they are called, may be formed (fig. 368). Again, if these cones attain much greater dimensions, as in the villi of the small intestines, an arrangement of capillaries is brought about which is known under the name of the *loop network*, a further complication of the former. In this case we see, passing between the two or more principal vessels of the sling, a finer set of tubes holding a transverse course (fig. 369, *b*).

Finally, in this sketch may be included the *glomerulus*, as it is called, of the kidney, an arrangement of vessels peculiar to, and characteristic of, that organ (fig. 370). Here we find a minute arterial twig (*b*), microscopically small indeed, suddenly curled upon itself in a manner similar to the inferior portion of a sweat gland (*c*). Within the convolution it may divide into branches to a certain extent, as in man and the mammalia, or remain single, after which an efferent vessel makes its appearance (*d*), which at a short distance from the glomerulus is resolved into a capillary network (*ef*).

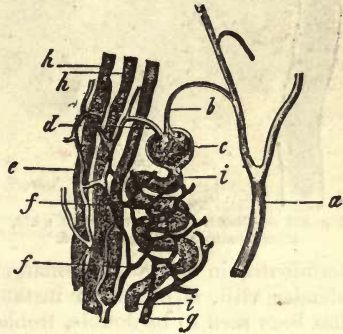


Fig. 370.—Glomerulus from a pig's kidney (half diagrammatic). *a*, arterial branch; *b*, the twig supplying the convolution; *c*, glomerulus; *d*, efferent vessel; *ef*, capillary network emptying itself into a venous twig at *g*; *hi*, urinary tubules.

§ 206.

The *lymphatic system* is an appendage of the circulatory, designed to bear back into the blood those nutritive fluids, impregnated with the products of decomposition of the tissues, which have transuded into the interstices of organs from the capillaries. It likewise takes up, during the period of digestion, by means of its radials terminating in the mucous membrane of the small intestine, that fluid known as chyle, which has been already referred to (p. 131). Owing to the fact, therefore, that the lymphatic system is only destined for the conveyance of these matters into the circulation, it is entirely wanting in vessels corresponding to the arteries. It consists rather of a set of vessels corresponding to the capillary part of the circulation, and of drainage tubes taking their rise from those which may be compared to the veins.

Lymphatic vessels are widely distributed throughout the body, but occur most abundantly in vascular parts. They have, however, been missed up to the present in certain portions of the body well supplied with blood. They are not found in such non-vascular tissues as the epidermis, nails, and cartilages.

The mode of origin of lymphatics was for a long time veiled in the deepest obscurity, owing to the fact that the numerous valves of the larger trunks offered the most determined resistance to injection, and that the colourless nature of the contents of the finer tubes rendered their immediate recognition almost impossible. Further, it is only certain specially transparent parts that allow of the latter being seen at all. That

portion of the system presiding over the absorption of the chyle is, however, on account of its dark fatty contents during digestion, more favourable for observation, and was in fact the only point, a few years ago, at which the relations of the vessels in question could be studied with any success.

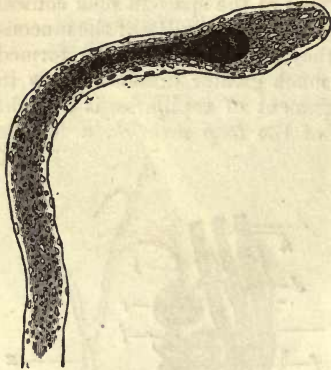


Fig. 371.—Villus from the intestine of a kid, after treatment with acetic acid.

In the first place, then, let us take a glance at the lacteals.

If we choose for examination the intestinal villi of a mammal which has been fed some hours before with rich fatty food, such as that of a young sucking animal (fig. 371), which best answers our purpose, we shall see, in the central portion of each villus traversing its axis, a passage filled with minute fatty molecules, and dark on that account. This duct frequently terminates in a rounded enlargement or bulb, and is usually single in slender villi, although in instances in which the latter are broader it has been seen to be double, treble, or quadruple.

Minutely examined, this vessel (fig. 372, *d*), which has a diameter of 0.0187–0.982 mm., is seen to possess a thin homogeneous, but distinct wall. Above, it terminates blind, without the interposition of any finer system of canals, and may be expanded at its end to a diameter of 0.0300 mm. in some cases. This axial vessel has been supposed by some to be merely a deficiency in the connective-tissue substance of the villus, but this is incorrect. Years ago I had frequently met with the villus half torn through, and the uninjured wall of the axial canal thus isolated. The results of artificial injection (§ 208) have since corroborated this explanation of its nature. Around this chyle radicle the capillaries of the loop network (*b*), mentioned in section 205, are coiled with a thin layer of unstriated muscle-cells interposed: a fact of great interest.

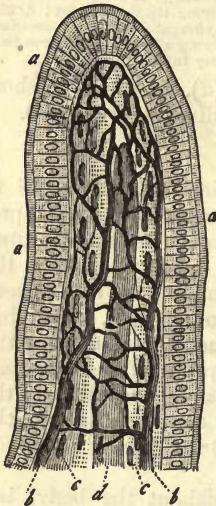


Fig. 372.—Intestinal villus. *a*, the thick border of the cylinder epithelium; *b*, capillary network; *c*, longitudinally arranged smooth muscle fibres; *d*, chyle radicle in the axis.

Lymphatic radicles were observed also, many years ago, by *Koelliker* in the tail of the tadpole.

Their appearance as they occur here is very variable. They most usually present themselves, however, in the form of tubes much finer than in the preceding case, measuring in diameter 0.0045–0.0113 mm., and consisting of a thin homogeneous wall, which is nucleated and studded with a multitude of minute saccules.

They are arranged as a whole in the form of a tree, with branches passing off at acute angles, and do not present the reticulated appearance of the blood capillaries. The terminal tubules seem to end in delicate filiform processes, directed towards similar ramifications belonging to stellate formative cells.

§ 207.

That difficulty of filling the peripheral portions of lymphatics owing to their valves, already mentioned in the preceding section, we have recently learned to overcome. The following is the method usually employed, known as *Hyrtl's* method of puncture:—A fine cannula is passed into such parts as are supposed to contain lymphatics, and through this the injection fluid is gently forced. The extensive researches of *Teichmann* have greatly increased our knowledge as regards this branch of study, beside which other contributions have been made by *Ludwig* and his pupils, *Tomsa*, *Zawarykin*, and *MacGillavry*, as well as by *His*, *Frey*, *Langer*.

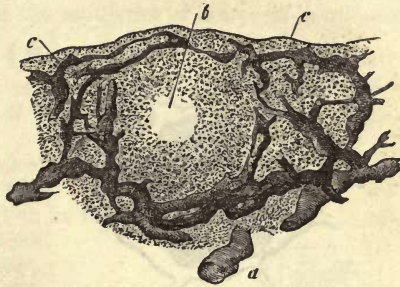


Fig. 373.—Vertical section through the mucous membrane of the conjunctiva of the ox, from the lower lid. *a*, large lymphatic vessel; *b*, follicle; *c*, superficial lymphatic canals.

As far as is known at present, the radicals of absorbents, the peripheral lymphatic canals, occupy the interstitial connective-tissue of the various organs, or are at least always situated in its course.

They are seen here either in the form of networks, reminding us of the peripheral portions of the circulation, or they begin in blind passages which are subsequently united in a reticular manner.

The first form is met with, in general, where the surface of an organ is smooth, or in the interior of the latter (figs. 373, 374, 375, 377); the second in parts of the body where the surface is covered by round or tufted appendages (figs. 371, 376).

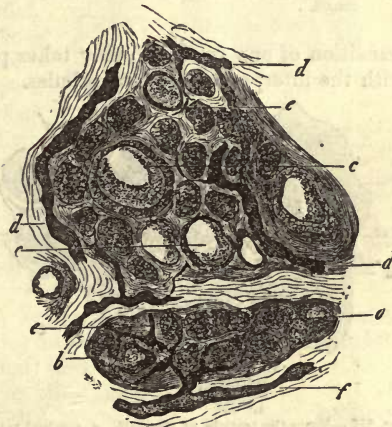


Fig. 374.—From the thyroid gland of the infant. *a*, *c*, glandular spaces; *d*, *f*, larger and terminal lymphatics.

The arrangement of the canals, however, in the various regions of the body is variable enough, and we miss everywhere that beautiful regularity to be seen among the capillaries of the blood-vessels.

The diameter of lymphatic canals is in general much more considerable than that of the capillaries, ranging from 0.0113 to 0.0451. Only for short distances, however, do they preserve anything like the same diameter of lumen. As a rule, these vessels present strong dilatations and sudden constrictions, down to about 0.0027 mm. and less; and so on. The whole may present frequently a jagged or knotted appearance, difficult of description (fig. 373, 374), but which to a practised eye is unmistakable.

The amount of lymphatic vessels varies in the different organs, and

indeed frequently, to a considerable extent, in regard to the various parts of the same.

As to their relation to the blood-vessels one thing is certain, that a

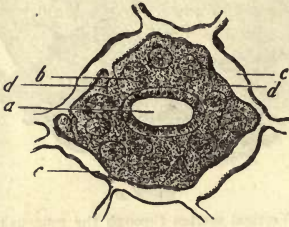


Fig. 375.—Surface of the vermiform appendix of the rabbit. *a*, a depression; *b*, outlets of the follicles of *Lieberkühn*; *c*, lymphatic network; *d*, descending canals.

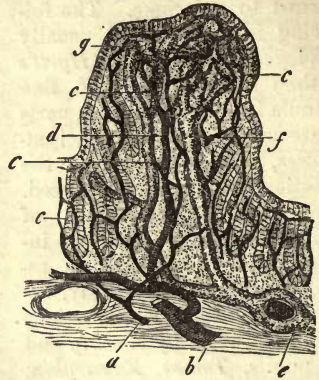


Fig. 376.—Papilla from the colon of the rabbit. *a*, arterial; *b*, venous twig; *c*, capillary network; *d*, descending vein of the papilla; *e*, lymphatic vessel; *f*, lymphatic canals of the papilla; *g*, blind termination of the latter.

transition of one into the other takes place nowhere, neither directly nor with the interposition of fine tubules.

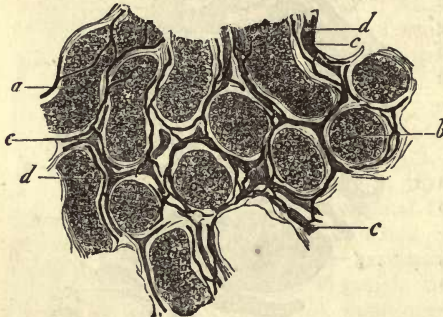

Fig. 377.—From the testicle of the calf. *a*, seminal tubules in side view; *b*, more obliquely seen; *c*, blood vessels; *d*, lymphatic canals.

In many instances we may see lymph canals surrounded externally by capillaries (fig. 372, 376). In other cases tubes of both kinds run, with greater or less regularity, side by side (fig. 377).

Finally, a stream of lymph may be taken up by the adventitia of a blood-vessel, enveloping the latter as with a sheath (fig. 376, *e*). Thus we see that the arrangement of the structures in question is very various.

A few moments must now be devoted to the consideration of that ensheathing of blood-vessels in lymph streams which has just been mentioned.

It has been the custom to speak of this as of frequent occurrence among the lower orders of vertebrates, such as reptiles. It has been denied, however, that it takes place at all in the frog by *Langer*, who has given the matter his closest attention. In the higher animals and in man it may appear, without, however, being anything but an accidental occurrence, except, perhaps, in particular portions of the body.

We have recently learned from *His* that the blood-vessels of the nervous centres, the brain and spinal cord, are loosely enveloped in a sheath of streaked connective-tissue in a vast number of cases. This arrangement of parts is seen among arteries, veins, and capillaries alike,

and has been named by *His* the *perivascular canal system*. This observer is inclined to regard it as belonging to the lymphatic system, in which he is perhaps right. The merit of having first discovered these rests, however, with *Robin*, who, several years previously, had maintained the presence of lymph sheaths around the capillaries of the parts in question.

§ 208.

Having discussed the disposal of the lymphatics, let us now turn to the consideration of the nature of their peripheral portions, a point of great importance.

Are they, in the first place, vessels,—that is, endowed with a special wall like that of blood capillaries?

This has recently been declared to be the case by *Teichmann* (1), after the most extensive researches, aided by injections, and also by *Koelliker*, who investigated the matter in the tail of the tadpole (§ 206).

Another view, which has found numerous defenders within the last few years, is, however, directly opposed to this. According to it, the peripheral circulation is only lacunal, *i.e.*, takes place within the interstices of connective-tissue (2) (*Brücke*, *Leydig*, *His*, *Ludwig*). For my own part, I have for many years looked upon the lymphatics as bounded alone by connective-tissue, which is, however, condensed and membranous, and encloses the space completely, playing the part of a sheath. Indeed, it was impossible, until very recently, to make out anything but a homogeneous boundary layer around the lymphatic passage (fig. 378, *b*).

By means of the new reagent, however, dilute solution of nitrate of silver, this apparently homogeneous limiting layer of connective-tissue has been resolved into a series of united, smooth, and nucleated cells or endothelia, allied to those of the blood-vessels (fig. 379).

But while in the blood capillaries this wall maintains its independence in regard to the adjacent tissue, it fuses here with the latter, so that only as an exception, and where the surrounding substance is of loose texture, can it be isolated.

The peripheral lymphatics, whose structure is represented in fig. 380, are, according to this, in contrast to the blood-vessels, by no means regular vessels, but canals (p. 372). In the last-mentioned woodcut, also, we see that here, as in the blood-vessels, gaps or *stomata* occur between the cells.

A communication between the lymphatic system and the cavities of serous sacs, namely, of the peritoneum and pleuræ, by means of orifices

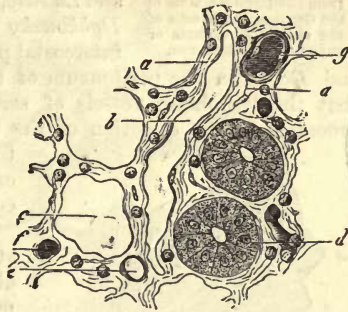


Fig. 378.—From the small intestine of the rabbit. *a*, reticular connective substance with lymph cells; *b*, lymph cavity; *c*, space for a follicle of *Lieberkühn*; *d*, one of the latter with its cells; *e*, *f*, capillary in transverse section; *g*, thicker trunk.

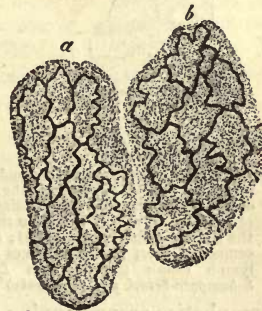


Fig. 379.—Cells from a lymphatic passage. *a*, elongated plates; *b*, broader specimens.

opening into the former, has been recognised within the last few years by *Recklinghausen*, *Ludwig*, *Dybkowski*, *Schweigger-Seidel*, and *Dogiel*, corroborating the suppositions of the older observers, as, for instance, those of *Mascagni*.

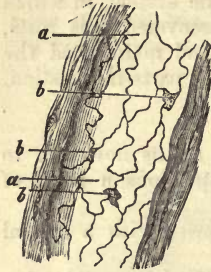


Fig. 380.—A lymphatic canal from the large intestine of the Guinea-pig. *a*, cells of the vessel; *b*, stomata or gaps between the latter.

Recklinghausen was the first to point out that the *centrum tendineum* of the rabbit's diaphragm is studded with openings whose diameter exceeds that of the red blood-cells, and through which formed particles, such as milk globules and granules of cinnabar, can make their entry, passing into the lymphatics of the diaphragm. This interesting discovery has been confirmed by *Schweigger-Seidel* and *Ludwig*, in respect to the locality mentioned, and *Dybkowski* observed the orifices in question in the intercostal pleura of the dog, and *Schweigger-Seidel*

and *Dogiel* in the peritoneum of the frog. The fact was also recognised that the lymphatic vessels of serous membranes give off short lateral processes in the direction of the surface (fig. 381, 2, *b*), which are seen

to open into the cavities, spoken of by orifices, situated between the epithelial cells [fig. 381, 1 and 3, *a*, *a* (3)].

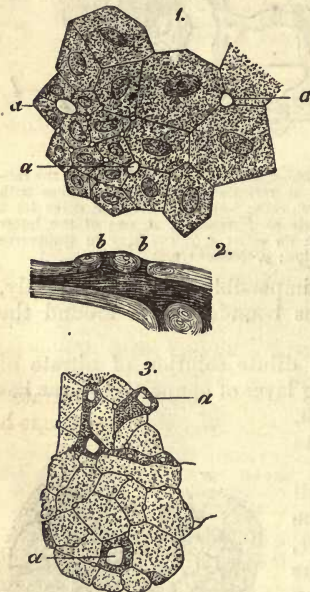


Fig. 381.—1, Epithelium from the under surface of the *centrum tendineum* of the rabbit. *a*, pores; 2, epithelium of the mediastinum of the dog; *a*, pores; 3, section through the pleura of the latter animal; *b*, free orifices of short lateral passages of the lymph canals (copied from *Ludwig*, *Schweigger-Seidel*, and *Dybkowski*).

Turning now from these finest lymphatic passages to the larger canals, we observe that the latter have at the commencement a precisely similar texture, while their arrangement varies to a great extent, being frequently retiform (fig. 382). Here also the walls are formed of nucleated cells alone. The occurrence of scattered nodal and ampullar enlargements is the first striking feature in regard to these canals while still of medium size. In larger trunks the former are more frequently to be seen, in addition to which valves similar to those of veins also present themselves.

It is only trunks of this kind that can with perfect correctness be called *lymphatic vessels*. In them at times (however, in smaller branches also), the walls commence to become more and more independent, and to appear distinct from the surrounding tissues. Here also the relation to the blood-vessels is very different. As a rule, to be sure, lymphatic and blood-vessels run along side by side, but not very rarely we encounter larger

lymphatics accompanying a great arterial branch in pairs. They eventually may lead to an ensheathing of the blood-vessel in a lymph stream, but the latter is of less frequent occurrence than is usually supposed.

The appearance of new external layers in addition to the cellular tube is a point requiring closer investigation.

Koelliker tells us that twigs of only 0.2256–2609 mm. may be possessed of three tunics. Around the cellular coat a longitudinally fibrillated elastic membrane is to be found, as serosa, then a media consisting of contractile fibre cells and elastic fibres, which is covered by an adventitia of longitudinal fibrous tissue.

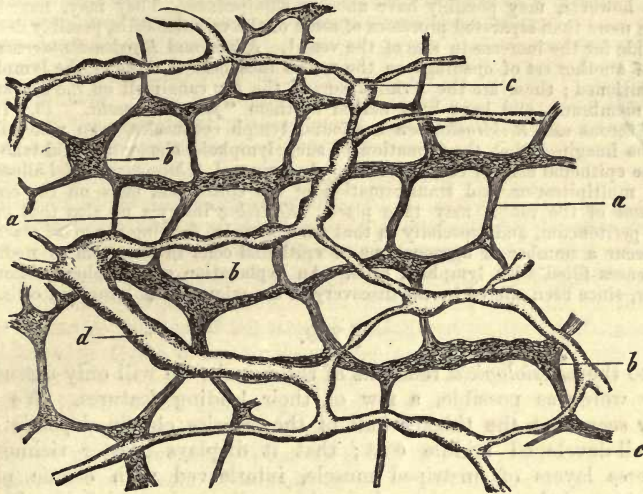


Fig. 382.—Lymphatics from between the longitudinal and transverse layers of muscle in the small intestine of the Guinea-pig. *c*, fine, and *a*, larger canals; *ab*, plexus myentericus of *Auerbach*.

In still larger absorbent vessels the structure is similar. They correspond in this respect with the veins, as is well known.

In the thoracic duct the epithelium presents itself enclosed in several layers of fibrous membranes, upon which an elastic network is laid down, its elongated meshes arranged in the long axis of the vessel. The next or middle coat consists of connective-tissue, coursing with its fibres in the direction of the tube, after which we come upon transverse muscular fibres. The adventitia presents for our consideration, besides ordinary connective-tissue, scattered bundles of unstriped muscle arranged in a reticular manner. According to *Koelliker*, the serosa has a thickness of hardly 0.0135–0.0226, and the media of 0.0564 mm.

The relations of these canals to the lymphatic glands, on their arrival in the latter, we reserve for the third part of our work.

REMARKS.—(1.) *Teichmann* was of opinion that the foundation of the whole lymphatic system consisted of structures resembling stellate cells (*Saugaderzellen*). He regarded them as metamorphosed cells which had preserved their envelope, and which, united through their processes, thus formed the "lymphatic capillaries." (2.) Among the views in question great variety may be observed. Many have simply accepted the membraneless interstices of interstitial or other connective tissue as the commencement of the absorbent system. The extensibility of this tissue was supposed to lead to the formation of clefts or openings into the neighbouring parts on increased pressure, artificial or natural (*Brücke* and *Ludwig*). *Recklinghausen*, in his article "Die Lymphgefäße und ihre Beziehung zum Bindegewebe," Berlin, 1862, appears to have arrived at peculiar results in his investigations. According to him (and the merit of the discovery rests with him), all lymphatic radicles are clothed with that epithelium already mentioned. They are, however, says he, related to those formations of connective-tissue so well known from *Virchow's* works as con-

nective-tissue corpuscles. *Recklinghausen* does not mean, however, that a system of hollow cells is formed of these, but rather a series of fine clefts as it were (*Saftkänälchen*) traversing the tissue, in which elementary spheroidal (connective-tissue) cells are lodged. This view, however, has met with the greatest opposition, and is, we are convinced, incorrect. In order to account for the transition of these "sap-canal" into the larger lymphatic radicals, which are lined with cells, *Recklinghausen* points to the *stomata* already mentioned in the text. Many of these small figures, however, may possibly have another significance. They may, namely, be nothing more than separated processes of some of the vascular cells, possibly designed to provide for the increase in size of the vessel. *Klein* and *Burdon-Sanderson* both speak of another set of openings on the serous sacs besides those of the lymphatics just mentioned; these are the terminations of the sap canaliculi on the free surface of the membrane, and have been named by them "*pseudo-stomata*." (3.) In the fluid of serous sacs *Recklinghausen* has found lymph corpuscles, from which fact it might be imagined that the formation of such lymphoid elements could take place from the epithelial cells of these cavities. *Ludwig* and *Schweigger-Seidel* allow that such a multiplication and transformation of the epithelium cells on the *centrum tendineum* of the rabbit may take place. *Koelliker* informs us also that on the human peritoneum, and especially in that part, namely, forming the great omentum, there occur a number of aggregations of epithelial cells in the form of nodulated excrescences filled with lymphoid cells. An explanation of this phenomenon has, however, since been offered by the discovery of the migration of lymphoid cells.

§ 209.

As to the *physiological* relations of the vessels, we will only discuss, in as few words as possible, a few of their leading features. We have already seen that the thicker wall of the arteries chiefly depends upon the well-developed middle coat; that it displays greater richness in transverse layers of unstriped muscle, interleaved with elastic plates, while veins of the same calibre have thin walls, owing chiefly to thinness in the *tunica media*, while the *tunica adventitia* is strongly developed. We have likewise seen that in the smaller veins the muscular elements soon disappear completely, whilst in the very smallest arteries, even down to their termination in the capillaries, these contractile fibre-cells are distinctly visible. The capillaries themselves are entirely destitute of muscular tissue, but possess, according to *Stricker*, vital contractility (§ 202).

The circulation of the blood takes place, as is well known, with pulsations through the arterial vessels, and evenly through the veins and capillaries. The pressure of the blood upon the walls of the arteries is very considerable, exceeding at least tenfold that upon the internal surface of veins, and increasing, besides, more and more with the ramifications of the former.

The walls of the larger vessels, in keeping with their texture, possess a slight but very perfect elasticity, that is, they can be stretched by a small amount of force, returning subsequently to their original form. It must be borne in mind, too, that the vascular tubes are always largely distended with blood, so that the elasticity of their walls also exercises a certain amount of pressure on the columns of fluid enclosed by them. If we consider this centred in the arteries, whose expansion under increasing pressure is much less than that of the veins, we have in them a system of elastic tubes charged with blood, into which, at every contraction of the heart, a new quantum of the latter is forced. The pulsation of arteries is an undulation produced in the walls of the latter by this pumping in of fresh quantities of fluid, and is gradually destroyed as it advances toward the periphery by the resistance of the vessels, which are undergoing an ever-increasing ramification. Owing to this the capillaries

are not reached by it. This undulating motion of the artery does not constitute the propulsive force of the circulation; its only effect is to accelerate the course of the stream of blood. The advance of the latter is occasioned rather by the difference of pressure prevailing in arteries and veins, each contraction of the heart forcing a new mass of blood into the distended arterial tube, and each diastole abstracting a certain quantity from the venous trunks, and receiving it into the auricle.

The course of the circulation is in general very rapid, the time consumed in the completion of its circuit amounting on an average to about half a minute. The rapidity is greatest in the arteries, equalling in the carotid of the horse 400 millimetres in the second, while in the veins it is considerably less, being only 250 mm. in the second, as seen in the jugular of the same animal. In the following section we shall see that the flow of blood through the capillaries is very slow, the length of the latter being also very considerable. This sluggishness depends probably upon the narrowness of the arterial canals, compared with the much greater extent of surface in the capillaries, and the consequent increase of friction to the column of blood. The subsequent decrease in the superficial extent of the bed of the stream, consequent on the confluence of the capillaries to form veins, explains the comparative acceleration which again becomes evident in the latter in the flow of the blood, which still remains, however, as has been already remarked, far more tardy than that in the arteries.

The question now arises, What have (together with the elastic materials) the muscular elements of vessels to say to the motion of the streams in the vascular system?

We know that the arterial walls, which are rich in these, contract considerably under electric and mechanical irritation, as well as under the action of cold and many chemical reagents. Consequently, we cannot deny the presence of vital contractility in the arteries, and, from their allied structure, in the veins also. The general opinion is, that the muscular tissue of the vascular system is perpetually in a state during life of slight tonic contraction, which supports the elastic action of the remaining elements, entering into the composition of the wall. In that here, also, as everywhere else, the action of the muscles is under the influence of the nervous system, we must expect to find certain vessels narrowed by the increased contraction of their muscles, and expanded on relaxation of the latter. The regulating action, then, of vascular muscles on the amount of blood contained in certain parts cannot be denied. Experimental nervous physiology has shown, besides, that section of the nerves supplying the vascular system gives rise to expansion of the arteries (*Bernard* and others). We have to thank this observer for our acquaintance with the striking fact that irritation of the sympathetic nerves supplying the arteries of the submaxillary gland causes decrease in their calibre, so that the blood passing through the organ is found to be dark, while only a small amount of viscid saliva is secreted. Stimulation, on the other hand, of the cranial nerve which enters the gland, namely, the chorda tympani, produces a completely opposite effect, bright red blood streaming rapidly through the part, and a copious watery secretion being poured out. Other organs also, such as the parotid, kidney, and stomach, manifest the same antagonism in the actions of expanding and contracting nerves. In them, likewise, we observe that the enlarged vascular territory contains during the process of secretion bright red blood.

Finally, the *capillaries*, supplied likewise, it would appear, with nerves, constitute the most important part of the whole vascular system. Through the membranes of which they are formed takes place the interchange of matter between the plasma of the blood and the organic juices: from them are exuded those fluids which appear afterwards as glandular secretions. We have already learned (§ 205) that upon the richness in capillaries of any organ or tissue depends the energy of its transformative power. The variety in the matters given out from and received into the several portions of the capillary system, may partly depend upon a different molecular constitution of the walls of the vessels; partly on difference in composition of the blood of various regions of the vascular system, as well as the changeable nature of the organic fluids. The form of the afferent and efferent vessels of capillary networks is also certainly of importance. It will suffice here to point to the retarding effect of the glomerulus of the kidney (fig. 370) on the stream of blood traversing the organ. The different amount of pressure in the several parts of the capillary system produced by this is, however, probably the most important moment in the processes taking place here.

We have already referred (§ 81) to an occurrence of great vital importance, which has only been recognised very recently, namely,—the passage of colourless as well as red blood corpuscles through the uninjured walls of vessels,—the contractility of the vascular cells appearing to provide for the closure of each successively formed aperture.

We turn now to the question, so frequently discussed, as to the existence of the so-called *vasa serosa*, or plasmatic vessels. Are there in the system capillaries of such small calibre that they do not admit, in the normal state, of the passage of blood-cells through them, and consequently only serve for the transmission of the liquor sanguinis? Such vessels do not exist, although it was formerly supposed that such was the case, and that a non-vascular organ could rapidly acquire capillaries when in a state of irritation by the enlargement of these to such an extent as to allow of the passage of blood-cells. Long ago attention was directed by *Henle* to the presence in the substance of the brain of fine filiform tubes communicating with ordinary capillaries. These were afterwards discovered to be merely fine vessels which had been unnaturally stretched, and thus narrowed (*Welcker*). Here and there efforts have, indeed, been made to maintain the transition of capillaries into plasmatic passages or “sap-canals” (*Coccius, Eckard, Heidenhain*), but without success. However the hypothesis of such an intermediate system of vessels between capillaries and lymphatic radicles may recommend itself on account of its convenience, observation does not support anything of the kind.

§ 210.

The *circulation* of the blood in the living body is one of the most beautiful spectacles which the microscope can reveal. The readiest mode of seeing this is to examine the transparent parts of cold-blooded vertebrates, such as the web of the frog’s foot or the tail of the tadpole. The embryos of fishes and birds, the wing of the bat, the mesentery of previously narcotised small mammals, &c., will serve the same purpose.

Taking, for instance, the first-named portion of the frog’s body (fig. 383), we see in the larger arterial and venous branches of the web the blood streams coursing in opposite directions, with a rapidity magnified natu-

rally in proportion to the strength of the lens employed. In the minute arteries the characteristic pulsation may be recognised, while in the capillaries a sluggish and more even flow is observed. The blood in the veins is seen also to move along steadily, but again slightly increased in pace. In the large tubes the oval blood-cells are driven along end foremost, sometimes side by side, or one over the other, and in the more considerable arterial twigs are frequently seen twisting and whirling in rapid motion. The internal surface, however, of such a vessel, of somewhat considerable calibre (*a*), is not touched by the rapidly-moving red corpuscles. In contact with it we observe a clear colourless layer, in which, in the case of veins scattered, white corpuscles may be discovered, which advance much more slowly and lazily than their hurrying companions, and sometimes even adhere to the wall of the vessel for a considerable time. In the arteries, on the other hand, this colourless stratum of fluid consists, according to *Conheim*, of liquor sanguinis, almost entirely free of cells. Thus, a distinction may be drawn between a rapid *axial* and lazy *parietal* stream. In the finest vessels and capillaries this peripheral layer disappears on account of the narrowness of the tube, and instead of the helter-skelter which goes on in the arteries, a more quiet, measured progression commences. At last the coloured and colourless blood-corpuscles glide along singly one after the other, sometimes closely packed, sometimes separated by considerable intervals. The former, which are smooth and pliant, as well as endowed with a high degree of elasticity and extensibility, are driven through the finer canals with greater ease than the latter, which are not unfrequently arrested in their progress owing to their roughness and adhesiveness. As soon, then, as the compression exercised upon it is removed, the red corpuscle returns to its primary form again. In certain cases some of the capillaries appear completely devoid of cells for the time being, and transmit plasma alone. It seems almost superfluous to remark here that, in the normal condition, a continuous transition of the arteries into the veins takes place through the capillaries. In this exquisite spectacle a great number of subordinate variations may be observed beside those already mentioned. But the moving coloured cells of the mammal are liable to even greater changes, according to *Rollett's* interesting observations. They assume continually (of course passively) the most diverse forms, and only appear exceptionally in their normal shape. This they assume again on the blood coming to a state of rest.

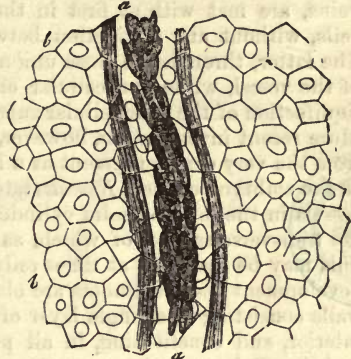


Fig. 383.—Stream of blood in the web of a frog's foot, after *Wagner*. *a*, the vessel; *b*, the epithelium cells of the adjacent tissue.

The *rapidity* of the capillary circulation can only be estimated approximately. The red cell of the frog traverses about the fourth or fifth of a line in a second, while the lymph-corpuscle requires for the same distance about ten or fifteen times as long. It is only the great shortness of the capillaries, of which we have already spoken, which renders possible the rapid circulation of the whole mass of the blood through the body.

§ 211.

As to the *development* of the vascular system, we know that it takes place from the middle embryonic plate. According to an old and widespread theory, the heart and the earliest trunks which appear in the rudiments of the embryo, namely, the arch of the aorta and primitive veins, are met with at first in the form of solid cylinders composed of cells, without any distinction between the axis and peripheral portion. The latter, through the close union of its cells, becomes the primary wall of the vessel, while the cellular elements in the axis constitute, on the liquification of the intercellular substance, the first blood corpuscles (§ 81). More recent investigation, however, has shown that the heart is developed from the very commencement as a hollow organ (*Schenck, Hensen, Klein*). In the embryonic chick, *Remak* states that he has recognised the first blood-vessels in the form of solid cylinders 0.0282–0.0451 mm. in breadth; in the transverse section of which, as a rule, from three to eight formative cells may be seen, but at times only two. At a more advanced stage of development these cylinders are observed to be hollow and tubular, their walls consisting of a single layer of formative cells projecting far into the interior, and constituting, in all probability, the endothelium of a later period. Subsequently great stress was laid here also upon the hollow rudiment.

The vessels of a later period were long supposed to be developed after another fashion, namely, from the fusion of simple rows of cells with subsequent investment in other cells.

This is almost identical with the mode of development which, since the days of *Schwann*, has been regarded as that of the capillaries.

The latter, as the older theory goes, are formed by the melting down of the central portion of formative cells, which, arranged in rows one after the other, and united in this position, are converted into a tube by opening into one another. In this case the membrane of the cell becomes the wall of the vessel, and the nucleus remains with it, as is always seen.

The formation of non-branching capillary tubes was believed to occur in the following manner:—It was supposed that fusiform cells, arranged one after the other, became united by means of their processes, the difference in the diameter of the cell, and its ramifications, gradually disappearing later. The cellular tubes so formed were then supposed to receive their blood by becoming connected with the previously existing vessels.

But owing to the fact that such unbranched tubes but seldom occur in any length, and that a retiform arrangement of tubules is the rule, the stellate cell was regarded as playing an important part in the production of ramifications among rudimentary capillaries. This also has since been shown to be incorrect. The lumen of the capillary vessel is an intercellular space.

Seeing, then, that these older views are no longer tenable, let us inquire what have recent observations done towards showing the true mode of development of the blood-vessels.

Let us take first that of the earliest rudimentary vessel in the foetus, which is of considerable size, as is well known.

The first-formed vessels in the chick spring, according to *Klein*, from cells of the middle germinal layer, whose contents become fluid until the enlarged and watery cell-body is contained within a cortex of protoplasm supplied with a nucleus. From such cells the primary wall of the vessel takes its origin with the endothelium tube and first blood-corpuscles.

A cell of this kind, then, swells up into a vesicle, while at the same time its nucleus undergoes segmentation. Some of these nuclei presenting great regularity of arrangement throughout the protoplasm cortex (*endothelium vesicle* of *Klein*), the latter may be regarded as made up of not yet separated endothelial cells. These are to be seen later more distinctly.

From the endothelial wall further yellow-coloured and white cells spring, by a process of gemmation, —the *first blood corpuscles*. The genesis of these cells, therefore, appears now under a new light (§ 81).

In other of these formative cells the inner portion of the protoplasm is said to assume a red colour, and to divide itself over the new nuclei formed by segmentation to form blood-corpuscles. Finally, coarsely granular cells are said to undergo a precisely similar process of transformation.

Thus, we see that both the walls of the vessels and the first blood corpuscles take their origin from the same cells, “the brood-cells” (*Brutzellen*) of *Klein*.

But how is the vascular tube formed from these separate endothelial vesicles?

The first of the vesicles become elongated and sacculated. They may, however, only at first send out laterally solid buds of protoplasm which subsequently become hollowed. Now, by the union of all these, one with another, the first vascular tubes are formed.

Even the largest vessels and the heart itself appear to have a similar origin.

We have before us, then, protoplasm tubes which gradually divide into endothelial cells by a process of segmentation of the nuclei. This agrees very perfectly with an old-established fact, namely, that only from a certain stage of development on, does the nitrate of silver solution produce the well-known mosaic appearance in the walls of capillaries.

Very early it may be remarked in the chick that the growing arteries receive a clothing of flat stellate cells forming an embryonic *adventitia*.

The further development of vessels, but more especially of new capillaries from those already present, agrees most beautifully with all this. On this point we have lately had some very excellent observations by *Arnold*, with some not quite so recent.

An object formerly much studied has recently received much attention.

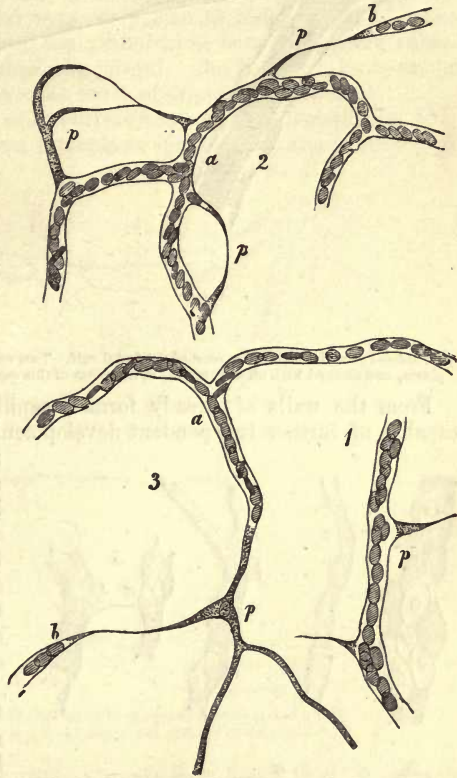


Fig. 384.—Development of fine capillaries in the tail of the tadpole. P, P, protoplasm sprouts and cords.

also, namely, the tail of the tadpole. Here (fig. 384) a rapid formation of capillaries, from some already present, may be observed to take place, as has long been known, by a species of budding.

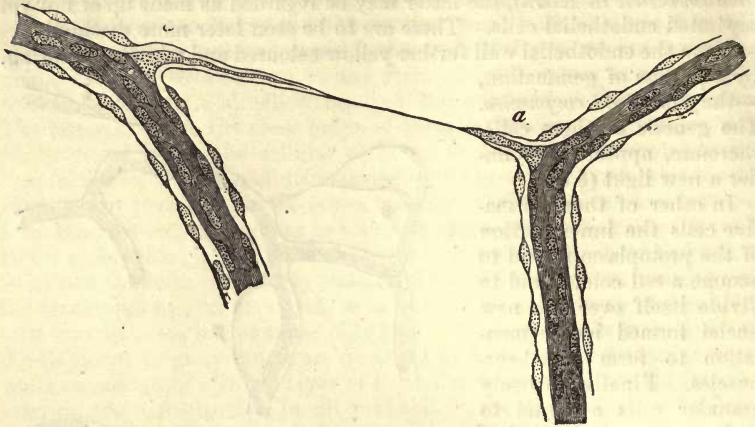


Fig. 385.—From the *vitreous humour* of the foetal calf. Two vessels connected by a "cord" of protoplasm, and clothed with an adventitia. *a*, insertion of this cord into the primary wall of the vessels.

From the walls of already formed capillaries protoplasm is supplied capable of further independent development (*p, p*). By the growth of these sprouts and threads are produced to which we have just alluded. These, again, are converted into cords by fusion one with another, and the axial portion of each thread becoming fluid subsequently, tubes of protoplasm are formed.

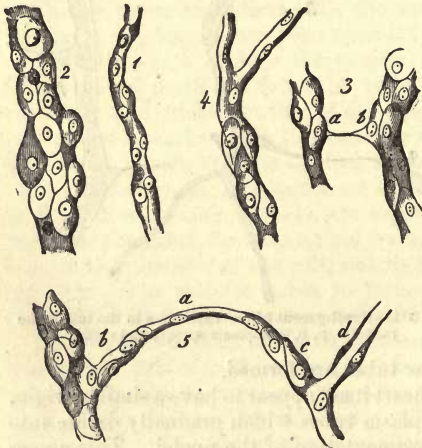

Fig. 386.—Vessels from the *membrana capsulo-pupillaris* of an embryonic pig, $\frac{24}{100}$ inches long, overlaid with round adventitial cells. 1, a fine vessel with a single one of the latter; 2, with numbers of the same; 3, three vessels. *a, b*, connected by a transverse thread; 4, clothing of cells only on the undermost portion; 5, a vessel with rounded cells *b*, connected by a transverse branch *a* (which acquires to the right at *c*, a new clothing of cells) with another tube *d*, which shows the adventitial cells in profile.

foetal calf. Here, however, numerous adventitial cells are also present.

The next woodcut also (fig. 386), which appeared in the first edition of this work, represents the same thing.

But with this further transformation of the walls a formation of new nuclei goes hand in hand. The latter are at first small and not sharply defined, but become larger and more distinct later on. From these two constituents, then, nuclei and protoplasm, the vascular or endothelium cells already mentioned are formed by a species of segmentation (*Arnold*).

In fig. 385 we have represented something similar in the formation of vessels in the corpus vitreum of the

The vessels frequently undergo, subsequently, further development, both in regard to form, size, and texture. Those of the gravid uterus present a peculiar periodical increase in size. Others, as, for instance, those of the cornea towards the close of foetal life and after birth, suffer extensive obliteration. During this process *His* observed the formation of stellate bodies resembling ramifying pigment cells.

Pathological neoplasia of vessels is of frequent occurrence. It was formerly supposed, however, that they were formed independently of the normal vessels already present, the pathological tubes becoming subsequently united to those physiologically formed. But there can be no doubt that the pathological have the same mode of origin as the normal.

Thus, in the regeneration of a tadpole's tail we may remark (fig. 387, *a, b, c, d*) the same long known protoplasm sprouts and threads again. If

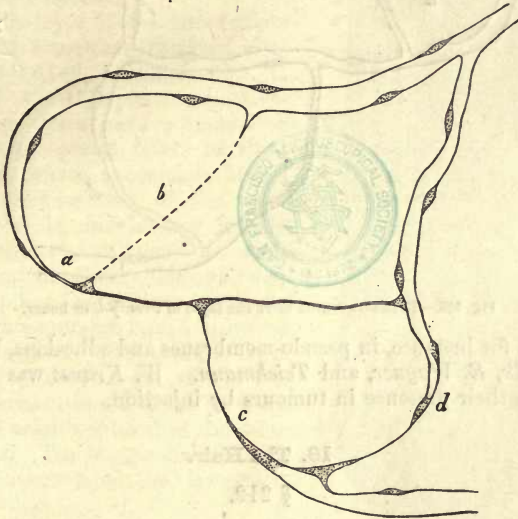


Fig. 387.—Development of capillaries in the regenerating tail of a tadpole after *Arnold*. *a, b, c, d*, sprouts and cords of protoplasm.

we look at the same vascular region twenty-four hours later, it presents the appearance figured in fig. 388. The protoplasm thread, *d*, has become converted into a pervious capillary tube; *a, b*, and *c* have become wide protoplasm cords.

It appears, however, that a new formation of vessels may take place in another manner. According to *Thiersch*, if a wound be made in the tongue of mammals, a number of *wall-less* passages are observed between the arteries and veins at a certain stage of the healing process, which carry the blood. Some of these lacunar passages become later on converted into true vessels, the neighbourhood probably supplying vascular cells, while the greater number are destroyed. Hereafter, in speaking of the spleen, we shall have to consider similar lacunar blood streams as existing in it.

Vascular tumours, known as *angiomas*, present a different structure. We refer the student to the handbooks of pathological anatomy.

As to the development of the *lymphatic* vessels we possess very little information at present. There can be but little doubt, however, that the

fine canals in the tadpole's tail have a similar origin to the blood capillaries.

The pathological new formation of lymphatic vessels has been remarked,

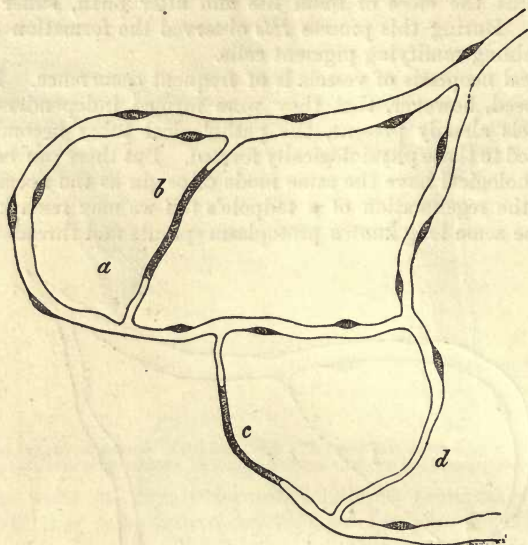


Fig. 388.—The same region after the lapse of twenty-four hours.

however, as, for instance, in pseudo-membranes and adhesions, by *Schröder van der Kolk*, *E. Wagner*, and *Teichmann*. *W. Krause* was the first to demonstrate their presence in tumours by injection.

18. The Hair.

§ 212.

The *hairs* are productions of the corneous embryonic plate. They are filiform appendages, composed of a modified epithelial tissue, and are of rather complex structure. In hairs we have to distinguish between the *shaft* (fig. 389, *l*), which projects beyond the skin in the greater part of its length, and terminates above in a point, the *root* or lower portion which is concealed in the skin, and ends in a flask-shaped duplicature of the latter, called the *hair follicle* (*a*), and the *bulb*, which is the thickened and rounded terminal portion (*b*). The latter, hollowed out below, is seated on a papilla (*i*) rising from the floor of the follicle. Between the follicle and the proper hair is found a complex encasing *sheath*, which is divided into an *external* (*c*) and *internal* portion (*d*).

It may be found most convenient if we commence our observations with the most deeply seated portions of the structures in question, for in them we have the source from whence the latter spring, and can observe the earliest forms under which the tissue makes an appearance. In this way we shall be best enabled to comprehend the further transformations which take place until eventually the texture of the shaft is arrived at.

The *hair follicle* (*a*) is a reduplication of the cutis vera of variable length and oblique direction. In some cases, when the hairs are long,

it may project downwards into the subcutaneous cellular tissue. Its form is in general cylindrical; not seldom, however, it is narrowed at its lower end. It consists, like the corium, of fibrous connective-tissue, in which several layers may be observed. To this one or several bundles of unstriated muscle are attached externally, the *arrectores pili* of *Eylandt*. The outermost layer of the follicle, which may be extremely thin when the surrounding tissue is densely interwoven, is seen to be made up of longitudinally arranged connective-tissue bundles with fusiform nuclei lying in the same direction. The thickness of this layer usually ranges between 0.0036 and 0.0070 mm. In it a complicated network of capillaries is to be seen, and nerves have been in some instances also observed.

The middle layer of the hair follicle is in general somewhat thicker, measuring from 0.0149 to 0.0233 mm. It consists of undeveloped connective-tissue, whose fibres have a transverse direction, with several layers of elongated nuclei, whose appearance brings to our recollection that of the well-known nuclei of involuntary muscle fibres (*Koelliker*), although no such elements can be clearly demonstrated here. A capillary network is also to be seen here, whose meshes have a direction chiefly transverse. This middle layer commences at the bottom of the follicle, but terminates above on arriving at about the neighbourhood of the sebaceous glands. The human hair follicle, further, is surrounded by lymphatic vessels.

Finally, the whole induplication is enclosed in a transparent structureless membrane (fig. 389, *b*; fig. 390, *g*) finely striated internally, which may be looked upon as a modified limiting membrane or hyaline coat. Like many structures of the same nature, it manifests great power of resisting the action of acids and alkalis. Between this layer and the middle, in the large tactile hairs of some mammals, there is situated, according to *Leydig* and *Odemius*, a highly-developed cavernous vascular plexus, which terminates above in a circular venous sinus (*Dietl* and *Schöbl*).

According to the more recent investigations of *Wertheim*, however, the hair follicle is not, as has been up to the present generally supposed, rounded off at its termination in the manner represented in our fig. 389. It is continued down through its external and middle layers into a cord of connective-tissue, which becomes at first enlarged "like a cup," and then narrowed into a kind of "stalk." Preserving the direction of the

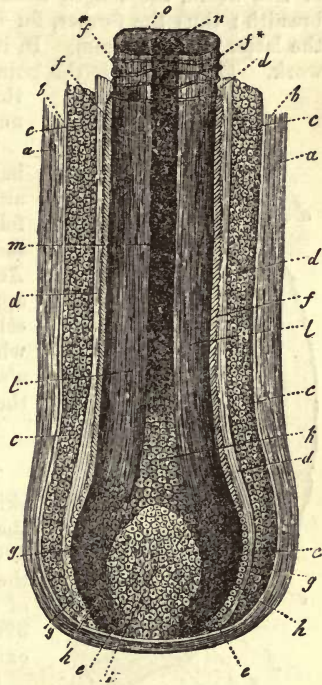


Fig. 389.—Human hair and follicle. *a*, fibrous follicle; *b*, transparent internal layer of the latter; *c*, the external, and *d*, the internal root-sheath; *e*, transition of the external sheath into the hair bulb; *f*, hair-cuticle, seen at *f** in the form of transverse fibres; *g*, the lower portion of this structure; *h*, cells of the hair-bulb; *i*, hair papilla; *k*, cells of the medullary part; *l*, cortical portion; *m*, medulla containing air; *n*, transverse section of the latter; *o*, cortex.

follicle, or bending off more at right angles, this cord pursues a downward course to a greater or less distance, and eventually becomes continuous, together with other of its companions, with a strong bundle of connective-tissue down below.

Rising from the fundus of this follicle, we next see the *papilla* of the hair (*i*), consisting of a species of undeveloped nucleated connective-tissue with a slight intermixture of fibres. This structure may be regarded as a modified tactile papilla of the skin. Its shape is either conical or more or less ovoid, the length from above downwards always exceeding the breadth; thus the former, for instance, may amount to 0.2256 mm., and the latter to 0.1128 mm. In its interior is contained a fine capillary network. This papilla is the point from which the hair is developed, and that also from whence the latter receives its nutritive supply.

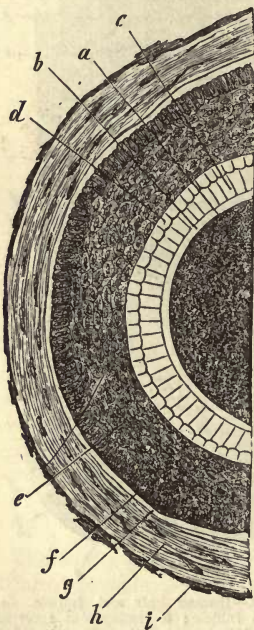


Fig. 390. — Transverse section of a human hair from the head, with its follicle. *a*, the hair; *b*, cuticle of the same; *c*, the inner; and *d*, the outer layer of the so-called internal root-sheath; *e*, the external root-sheath; *f*, its peripheral portion formed of elongated cells; *g*, hyaline membrane of the follicle; *h*, middle layer; and *i*, external layer of the latter.

internally appear to be elongated in a radial direction, recalling to mind the state of things seen in the *Malpighian* layer of the skin. Just as this outer root-sheath is continuous above with the rete mucosum, so is it continued on reaching the fundus of the follicle (fig. 389, *e*) into the cellular mass of the hair-bulb (*h*). In some cases, however, it does not extend so far.

The *internal root-sheath* is distinguished from the duller mass of the

The presence of nerves, on the other hand, has not been remarked in the papillæ of hair, although in man the external layer of the follicle contains isolated fibres, which are seen here and there to undergo division. According to recent observations, these latter appear to be connected with peculiar terminal cells situated in the external root-sheath, which, as we have seen before (§ 187), are also to be found in the *rete Malpighii* of the skin (*Langerhans*).

§ 213.

The hair follicle being a portion of the skin which has been folded in, as it were, the external root-sheath (fig. 389, *c*; and 390, *e, f*) represents the undermost layer of the *rete Malpighii*. As to the precise nature of the internal root-sheath (fig. 389, *d*; and 390, *c, d*), on the other hand, there still exists considerable difference of opinion.

If the entrance of the follicle be closely examined, the deeper layers of cells of the adjacent skin are seen descending as *external root-sheath* into the sac, and lining its walls. The number of layers of these small rounded and nucleated cells varies with the strength of the hair (fig. 389, *c*; 390, *e*; and 391, *c*). The cells themselves are about 0.0074–0.0113 mm. in diameter. Those of the most internal stratum are more or less flattened, while those situated more ex-

outer by its lighter and more transparent appearance: it is, besides, thicker (fig. 389, *d*; 390, *c*, *d*). Two strata of large cells may be remarked in it. The external (fig. 390, *d*; 391, *a*) (the root-sheath of *Henle*) consists of transparent ovoid cells without nuclei, between 0.0377 and 0.0451 mm. in diameter. Between these may be observed small narrow clefts, which can be rapidly increased in size by pressure, &c., owing to the brittle nature of the whole mass. Within this, again, there appears either a single or double layer of cells first seen by *Huxley* (fig. 390, *c*; and 391, *b*). These elements are likewise transparent and polyhedral, owing to pressure one against another. Their axis parallel to that of the hair is short, while their radial diameter exceeds that of the elements composing *Henle's* layer (fig. 390, *c*, *d*). The most important point of distinction between them, however, is that the cells of *Huxley's* layer possess small narrow nuclei, bringing to our recollection the appearance of nail-cells seen from the side (p. 162, fig. 156).

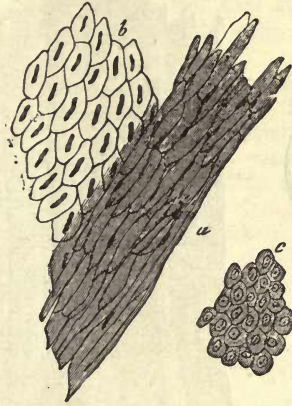

Fig. 391.—Cells of the root-sheaths. Internal root-sheath, with *Henle's* layer, *a*; and *Huxley's*, *b*; *c*, cells from the external sheath.

Below, towards the fundus of the hair follicle, the internal sheath consists of only one layer of nucleated cells, which may be continuous with the peripheral elements of the hair-bulb. Above, towards the outlet of the follicle in the neighbourhood of the sebaceous glands, it ends, however, with a sharp, jagged border.

§ 214.

We come now to the proper *hair*, into the bulb of which, as it rests on and overlays the papillæ, the cellular strata of the external and internal root-sheaths are continued.

In the hair-bulb (fig. 392, *h*), throughout its whole substance, with the exception of a thin coating, the same small, round, and densely-crowded cells are to be seen as those which form the external root-sheath (fig. 393, *a*). Their contents are either colourless molecules, or there appear in them (at one time in small quantity, at another in larger proportion) granules of pigment varying in tint with the colour of the hair.

Above, however, the nature of these cells is changed, and in many hairs a contrast is distinctly seen, owing to the metamorphosis, between the axial and peripheral portion; we then speak of the *medullary mass* (fig. 392, *k*) and *cortical substance* (*l*).

In the first place, the cells of the latter become ovoid, while the nucleus still preserves its original spherical form. Higher up we find these cells transformed, through flattening, into a plate of 0.0451 mm. and upwards in length, whose nucleus has become likewise long, narrow, and rod-like (fig. 393, *b*). Higher still, where the stem has attained the hard horny consistence of the shaft, the cells acquire the nature of thin and flat oval plates, with irregular outline (*c*, *d*), with an increase in length to about 0.0751 mm., the transverse diameter sometimes falling to 0.0045 mm. Their nuclei are either changed into very thin filiform

spindles, or finally disappear completely. The union, however, of these

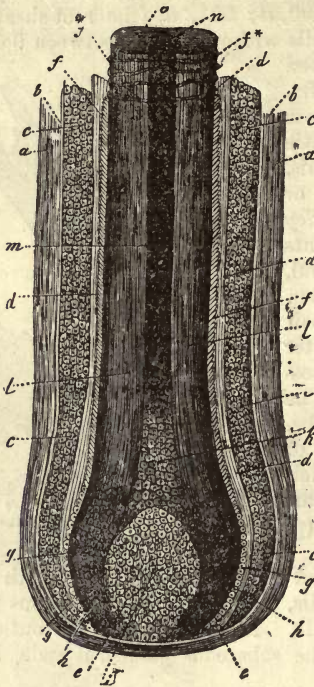

Fig. 392.

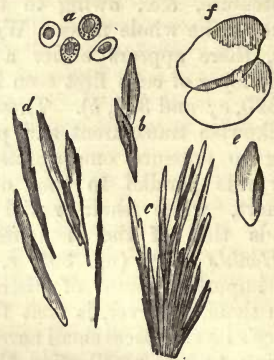


Fig. 393.—a, Cells of the hair bulb; b, from the first part of the shaft; c, cortical substance treated with sulphuric acid, resolved into separate plates at d; e and f are cells from the haircuticle.

hair-scales, forming the cortical portion, is so intimate that not the slightest indication of their existence appears in the fresh hair (fig. 392, *l*). Even by mechanical means we can only split off rows of them in the form of rough splinters. Chemically, however,—namely, by the aid of sulphuric acid,—we are enabled quickly and easily to render visible the elements of the structure by the solution of the matter cementing them together.

Looking upon the cortical mass as a whole, we find it saturated with a colouring matter varying according to the tint of the hair. Together with this the latter is marked with definite longitudinal streaks, which either represent the borders of adjacent hair-scales, or depend upon the disposition in rows of the pigmentary molecules, which in darker hairs may make their appearance in large and broad groups.

Finally, the hard dry consistence of the shaft of the hair favours the entrance of air-bubbles, which frequently occupy small elongated cavities in the interior of the hair-plates. We shall meet again with a far larger accumulation of air in the medullary mass.

§ 215.

In the preceding section the presence, from the lower part of the root up, of a peculiar thin enveloping layer, was noticed. This, as it ascends, is known as the *cuticle of the hair*. Close observation of the bulb at its base (fig. 392) shows us that, from that point on, at which its cells cease to be continued into the external root-sheath, the structure becomes

clothed with a double layer of small pale nucleated cells (*g*). Taking the hair higher up, we see the peripheral layer of these cells assuming more a short thick figure, even after they have lost their nuclei. They extend as far as the upper part of the follicle, where they terminate. From the fact that they are frequently met with loosened from the hair and clinging to the internal root-sheath, they have been regarded by some as representing the cuticle of the latter.

But the cells of the internal layer, which are not lost as we ascend, are of greater importance. These remain fixed to the shaft throughout its whole length, and communicate to it a peculiar transversely striated appearance. The cells assume, at the upper portion of the bulb, a more elongated form and a position more and more oblique as regards the surface of the latter. Losing their nuclei and becoming more and more flattened (fig. 392, *f*), they are gradually transformed into a series of obliquely-placed thin and transparent scales (fig. 393, *e, f*) of 0.0377–0.0451 in diameter, which overlap each other like roofing tiles, the lower lying with their free edges upon those above.

Thus originates that series of delicate irregularly undulating or jagged lines which are seen passing across the surface of the fresh hair (fig. 394; and 392, *f*f*), connected in a reticular manner with one another by means of other obliquely coursing lines (1). We sometimes succeed in detecting these cells, on the outline of the hair, owing to their upper free edge projecting from the shaft in the form of small ridges. To show them properly, we have recourse to the action on the tissue of solutions of soda, or, better still, of sulphuric acid.




Fig. 394.—Cuticle from the shaft of the human hair. One specimen shows the medullary mass, the other not.

There still remains for consideration the *axial* or *medullary mass* of the hair (2). This is, however, no essential constituent of the structure in question, in that it is not to be found as a rule in downy hairs, and is frequently absent in part or entirely in those of the head. It presents itself in the form of a streak in the centre of the stem, occupying about a fourth of the thickness of the latter (fig. 392, *m, n*; 394).

Whilst at the boundary between the bulb and commencement of the shaft the external cells become elongated, and the transformation into the characteristic hair-plates commences, those situated internally assume a more or less angular form as they become arranged in several layers and increased in size until they may measure 0.0151–0.0226 mm. These soon lose their nuclei and dry up (fig. 392, *k*). On the other hand, small cavities are found in great number and most extensively in the contents of the cells, which become filled with corresponding bubbles of air, presenting, owing to their tiny proportion, the appearance of fatty or pigmentary molecules (fig. 392), which they were long supposed to be. They communicate to the medullary substance of white hair a silvery appearance with reflected light, whilst in coloured hair, whatever be its tint, the white axial portion shines through. By suitable treatment we are able to expel the air from the medulla in the same manner as from a thin section of bone, when, on subsequent drying, it rapidly fills again.

REMARKS.—On the upper edges of the cuticular cells becoming more everted the transverse lines appear with greater distinctness. Hairs which have been torn out

frequently display an extensive folding back of the cells towards the bulb, giving rise to the appearance of encircling fibres. 2. The medullary portion of the hair is the only part about which there exists at present any considerable difference of opinion. The presence in it of air was first pointed out by *Griffith* in the *Lond. Med. Gazette*, 1848, p. 844. On this point no doubt can be entertained. *Steinlin* held the medullary mass to be a process of the papilla of the hair, consisting of cells, and extending into the shaft. The lower part is, according to him, vascular, and made up of soft cells, while above, the vessels become obliterated, and the cells shrink, making room for the accommodation of air, so that the medulla might be said to be formed from the dried papilla. *Reichert* supposes the dried remainder of the papilla to occupy the interior of the medulla in the form of a delicate axial thread, and likens it to the "pith of a feather." In some of the mammalia such an extension of the papilla into the shaft of the hair does take place, and even far up into the latter, but in man it is doubtful that this occurs. The representation given in the text is that most generally received, and probably the simplest expression of observation. It is likely also that many communications exist between the residual cells, which explain the rapid readmission of air.

§ 216.

The hairs, like cuticle and the nails, are numbered among the so-called *horny tissues*, in that from them all, by treatment with alkalies, that mixture of metamorphosed albuminous matters can be obtained, to which the name of *keratin* (p. 21) has been given. The complex structure of the hair, however, renders this analysis of less value than that of the two other more simple tissues.

Microchemical reaction shows that, in the hair and its envelopes, the young recently-formed cells are still composed of ordinary albuminous materials, so that even the more feeble attacks made by acetic acid and dilute solution of the alkalies are capable of destroying their membranes, and, soon after, the nuclei in the case of the latter reagents. This is the case with the rete mucosum of the hair follicle, the external root-sheath, and also the root of the hair. On the other hand, we are met by a most striking insensibility to the action of chemicals in the cellular layers of the internal root-sheath and cuticle of the hair, with the exception of the most internal portion of both tissues bordering on the bulb. We find that even concentrated sulphuric acid and alkaline solutions have no action on the cells, even when the latter are treated for a considerable time with these fluids. The latter do not even produce any amount of swelling up in the elements, so that we have at all events peculiar kinds of combination before us in these tissues.

The action of sulphuric acid on those dry and horny cellular plates which form the cortical portion of the hair, causes them to separate readily from one another, while alkalies produce a swelling up of the cortical mass, and solution of the whole when dilute and at an elevated temperature.

The cells likewise of the medullary mass can be recalled from the shrunken condition in which we find them in the mature hair to their original tense round form by these reagents.

The transparent internal layer of the follicle, finally, manifests, as has been already mentioned, all the insensibility of the elastic hyaline membranes.

The solubility of hair in solutions of soda and potash, with previous swelling up, repeats, as we have already stated, what takes place with epidermis and nail tissue under similar treatment. The products of the combustion of hair also are similar to those of the latter. An analysis of *Van Laer's* will serve as an example:—

C	.	.	.	50·65	per cent.
H	.	.	.	6·36	„
N	.	.	.	17·14	„
O	.	.	.	20·85	„
S	.	.	.	5·00	„

The amount of sulphur, 4–5 per cent., seems considerable.

But little is known at present of the nature of that diffused colouring matter which saturates the cortical tissue of the hair, or of the granular pigment of the structure. Those fatty matters which may be extracted in varying amount from hairs appear to contain the ordinary neutral combinations found in other parts of the system. They probably have their origin, for the most part, in the sebaceous glands.

The ashes of hair amount to from 0·54 to 1·85 per cent. They consist of salts soluble in water, together with phosphate and sulphate of calcium, silicates and oxide of iron (0·058–0·390 per cent.) Manganese, although formerly stated by *Vauquelin* to exist in the hairs, has not been found by chemists of a later period. That the presence of iron has anything to say to the tint of the latter is very improbable.

§ 217.

Hairs are to be found on almost every part of the human body. They are missed, however, on the upper eyelid, the lips, the palm of the hand and sole of the foot, the last joints of the fingers and toes, the inner surface of the prepuce, and on the glans penis. Their size, further, is liable to considerable variation, as we may see from the range in their diameter from 0·15 mm. and upwards down to even 0·0153 mm. A distinction is always made between the very pliant downy hairs (*lanugo*) and those which are stronger, sometimes pliant and sometimes stiff. No sharp distinction, however, can be drawn between them. The thickest are those of the beard and pubis. The length of the free portion also varies extremely, ranging from 1–2''' among the smaller downy hairs, to 4–5', as on the heads of women. Many hairs, notwithstanding their thickness, remain exceedingly short; this is the case in the eyebrows (*supercilia*), eyelashes (*cilia*), and bristles at the entrance to the anterior nares (*vibrissæ*). The straightness or curliness of hairs depends upon the form of their shaft. In the first instance, the transverse section of the latter is round; in the second, oval, or even reniform.

Hairs are found either singly, in pairs, or small groups. The oblique direction of the follicles also brings with it great variety of position in the various localities (*Eschricht*). In the several parts of the body the number of hairs likewise is found to vary considerably, so that, while on the scalp 293 have been counted to the square inch, the same superficial extent of the chin has only shown 39, and on the anterior aspect of the leg, 13 (*Withof*). It is hardly necessary to remark that, together with this variation, many individual differences present themselves.

The structures we are engaged in considering are remarkable for their great strength and elasticity. They will support a considerable weight without breaking, and return almost to their original length again on removal of the extending force, if the latter have not been altogether too great. Owing to their dry and horny composition, they belong to the most durable of all the tissues of the body; witness the hairs of mummies. They absorb moisture greedily from without—in the first place, aqueous

vapour from the atmosphere; and again, through the bulb, from the fluids of the neighbourhood. It is upon this property that the interchange of matters which takes place in hairs is dependent. The latter appears to be by no means inconsiderable, as we may infer from the rapidity with which hairs in some instances turn grey. The appearance of air within the medulla follows upon a process of drying up which takes place there. The shaft of the hair, however, is also saturated with the oil of the sebaceous secretions. As *Henle* very properly remarks, we may recognise the physiological condition of the skin from the state of the hairs; their brittleness on the one hand, and softness, pliancy, and glossy appearance on the other.

The growth and the nutrition of these structures takes place in a manner exactly similar to that of the nails (p. 164). Multiplication of cells takes place by segmentation at the lowest and softest part of the bulb, kept up by supply of material through the blood-vessels of the follicle, and more directly through those of the papillæ. And just as the growth of nails can be accelerated by paring the free edge, so does cutting of the ends of the structures in question favour their rapid production, as is seen in the beard after frequent shaving. On the other hand, when both these tissues are left in the natural state, uncut, they seem eventually to reach a point at which they cease to grow. We have already seen that the nail may be completely reproduced so long as its bed remains uninjured. The same is the case with the hair if its follicle remain intact. This regeneration is called into play extensively during the earlier periods of life; and even later on, renewal takes place, to supply the loss of large numbers of hairs which is sustained by the healthiest body yearly, owing to disappearance of their roots. The hair destined to be cast off is seen to be swollen at its lower end, and to be destitute of the earlier excavation for the papilla. This is the "hair-knob" (*Haar-kolben*) of *Henle*. Later on, loosening from the papilla, the whole hair splits, and breaks up into a number of shreds, and becomes like a brush. *Pincus* estimated the average daily loss of hairs from the heads of young men to be, under normal conditions, from 38 to 108.

The phenomena of growth observed accurately by *Berthold* in relation to the nails have also been studied as regards the hairs. The latter grow more rapidly at night than during the day, and in the warmer than in the cold seasons of the year. They are also produced more quickly when frequently cut. Thus the hairs of the beard when shaved every twelve hours, show a growth in the year of 12"; when cut every twenty-four hours, only 7½"; and when shaved every thirty-six hours, only 6¾".

§ 218.

From the extensive researches of *Valentin* first, and then *Koelliker*, we learn that the *first rudiments* of the hairs are formed in the human embryo at the end of the third and beginning of the fourth month, appearing first on the forehead and eyebrows (fig. 395). Here we find nodulated or mamillated aggregations of cells (*m*) 0.0451 mm. in length, belonging to the rete mucosum (*b*), which sink gradually into the cutis by a process of proliferation, pushing the adjacent part of the latter before them. These cells increase rapidly in number, so that the collection soon becomes larger and more flask-shaped. Around the latter there may now be remarked a thin homogeneous transparent membrane (*i*), probably the hyaline internal layer of the future follicle, about which the corium is

gradually transformed into the peripheral portion of the follicle. Up to this stage the development of sweat glands and hairs is identical (§ 200).

Although at the commencement the whole aggregation of cells appears solid, and of the same nature throughout, a distinction soon makes itself evident between an axial and peripheral portion. From the first is formed the hair and its internal root-sheath, from the second the external sheath. The cells of the last-named stratum are elongated transversely, while those of the axial portion of the rudimentary hair increase in a longitudinal direction. This is the state of the parts in the eighteenth week of intra-uterine life, at which time the agglomeration of cells has attained a length of 0.226–0.0451 mm.

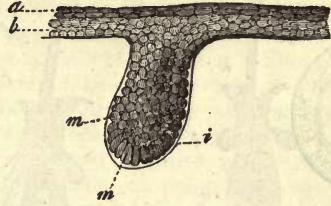


Fig. 395.—First rudiments of a hair from the human embryo at sixteen weeks. *a, b*, layers of the cuticle; *m, m*, cells of the rudimentary hair; *i*, hyaline envelope.

Soon after, a new division in this internally somewhat club-shaped mass,—broad below, and more or less pointed above,—commences; the outer layer, namely, with its cells, is transformed into the clear transparent internal root-sheath, whilst the axial part, which becomes the bulb and shaft of the hair, remains dark. At this period, also, the papilla may be clearly seen.

The true hair thus commenced is at first short, and surrounded by a very strong internal root-sheath, but without any recognisable medullary substance. It then gradually increases in length, passes between the undermost cells of the epidermis, and perforates the latter either immediately or after turning on itself, and taking an oblique course for a certain distance.

The other hairs are developed in a manner exactly similar, but later. At the end of the sixth or commencement of the seventh month, most of them have made their appearance through the epidermis. The hairs, so appearing by perforation of the cuticle, are thin and light-coloured.

In regard to the regeneration of hairs it must be remembered that many of the downy ones are cast off during intra-uterine life, and become mixed up with the waters of the ovum. After birth, however, this change of hairs increases in amount, the new appearing in the place of the old. Even at an advanced age this regeneration does not cease in man. Among the mammals, as is well known, a very extensive renewal of hair takes place periodically. In regard, however, to these processes there still exists considerable difference of opinion.

It was *Koelliker* who first observed the regeneration of hairs in the eyelids of the infant (fig. 396). From his statements it will be seen, in the first place, that the bulb of the old hair separates from its papilla, from which the rudiments of a new structure are produced in the form of a conical mass (*A, m*).

Above this, consequently, lies the loosened hair (*de*), horny down to the very bulb. This rudimentary structure (*B*) is transformed into hair bulb (*f*) and shaft (*bh*), with inner root-sheath (*g*), in a manner precisely similar to that we have already seen in the formation of hair in the embryo. The inner root-sheath of the old hair disappears from the commencement, and the new-comer drives its point by the side of the first, which is displaced, through the outlet of the follicle occupying the whole of the latter as soon as its former occupant falls out. *Koelliker* has also

stated that with this process there takes place, further, a growth downwards of the follicle into the cutis, but this view is combated by other observers.

This mode of explaining the regeneration of the hair from the old papilla, from what we and others have seen, is, we consider, quite correct. Whether it includes all that occurs at the time of change, is another question.

According to *Stieda's* statements, on the other hand, the papillæ of those hairs which are about to be cast off degenerate. A residue of those indifferent formative cells, however, from which, as we have seen, the specific tissue of the hair is formed (§ 214), remains behind in the fundus of the follicle, commences then to grow downwards into the cutis, and becomes cupped by pressing down upon a new papilla rising and formed from the latter. From this cellular mass covering the papilla the new hair takes its origin.

That the whole structure—follicle, outer root-sheath, and hair—may be newly formed under normal conditions, at a later period of life, appears probable;

Fig. 396.—From the eyelid of a child of a year old, showing new formation of hairs at the bottom of the sacs. *A*, early, *B*, later stage of development. *a*, external, *g*, internal root-sheath; *d*, bulb, and *e*, shaft of the old hair; *i*, sebaceous follicles; *k*, ducts of sweat-glands; *c*, funnel-shaped pit at base of the new rudimentary hair which is seen at *m*, fig. *A*, to be still quite homogeneous; whilst in fig. *B* the bulb *f*, stem *b*, and point *h*, may be recognised.

indeed, *Wertheim* believes such an occurrence to be the rule in the change of hair in the human being. This requires, however, more careful investigation.

Pathological neoplasia of hairs and follicles, on the other hand, does occur without doubt under the most extraordinary circumstances. Hairs are met with on mucous membranes, but only extremely rarely; again, on the internal surface of follicular tumours or cysts in the skin and ovaries, in which case the wall of the cyst has been found to have assumed a similar constitution to the outer skin, and to contain not only hair and sebaceous glands, but also sweat glands. Transplantation of hairs, together with their follicles, succeeds likewise.

Search among the follicles often brings us into contact with hairs destined to fall out. These have parted from the papilla upon which young cells and pigmentary matters are to be seen. The appearance of their roots is also altered; they seem as though broken up into fibres resembling in figure the end of a broom, and are, like the whole hair, paler and free of pigment. Beneath these the root-sheaths and follicles are narrowed for a greater or less distance, and in the latter small newly-formed hairs may be met with.

§ 219.

The tissues we have been engaged in describing up to the present, are combined in various ways, and under great variety of outward form, to

produce the several *organs* and *apparatuses* of the body. These organs, whose performances are dependent on the individual qualities of the various tissues of which they are composed, present far greater difficulties, as regards their classification, than the tissues themselves (§ 64),—the more so, as we are unable accurately to define what is precisely meant by an organ. If we compare the many apparatuses of the body, we find the greatest differences existing as regards their construction. Some of them are formed in the simplest manner of one single tissue, as, for instance, the nails, the lens, the vitreous humour. Their performances, in such cases, may also agree with the physiological energy of the tissue. Other organs, however, are combinations of several, of many, nay, even of most, of the tissues of the body. It will suffice to point, by way of example, to the organs of vision. Thus, here, as in the classification of tissues, the systematic worth of the terms simple and compound seem to recommend them for use. This principle of division, however, can be by no means so strictly adhered to here, owing to the multitude of organs, as was the case in dealing with the tissues.

It is a common mode of classification among anatomists to group the organs of the body in particular *systems*. By this we understand the arrangements of parts together, which are found to be identical or similar as regards the finer composition of their tissues. Thus the present divisions into nerves, muscles, osseous, and vascular systems have been arrived at. We also speak, however, of a digestive and generative system, where this similarity of texture in the various parts making up the whole by no means exists. Thus in the many manuals which treat of these subjects the greatest differences as regards classification may be observed.

It may be found most expedient, then, if we base the third section of this work upon the principle of physiological classification, and make use of the old division of organs, into those which take part in the *vegetative* occurrences of the body, and those belonging to the *animal* side of life. It cannot be denied, however, that this classification will not everywhere hold good; for in the wonderful linking of parts one with another there occur many intermediate forms. Thus nerves and muscles make their appearance in apparatuses belonging to the vegetative sphere, blood and lymphatic vessels, and glands in animal organs, and so on.

Starting from this point, then, we come to another mode of grouping parts, namely into *apparatuses*, that is, a combination of a number of organs for the carrying out of some one physiological purpose. A system and apparatus may correspond, as in bony, muscular, and nervous portions of the body, but do not necessarily. Thus from one point of view there is such a thing as a digestive and respiratory apparatus, but not a digestive and respiratory system. The following is our classification of organs:—

A. Belonging to the Vegetative Group.

1. Circulatory apparatus.
2. Respiratory apparatus.
3. Digestive apparatus.
4. Urinary apparatus.
5. Generative apparatus.

B. Belonging to the Animal Group.

- 6. Bony apparatus or system.
- 7. Muscular apparatus or system.
- 8. Nervous apparatus or system.
- 9. Sensory apparatus.

Having been obliged, in speaking of the different tissues, to refer frequently to their arrangement in the formation of various organs, or their constitution within composite apparatuses, the discussion of this third part, or Topographical Histology, will be very irregular as regards the several parts. The chief object to be kept in view will be the description of the finer structure of organs, with reference to that, in the microscopical relations of the same which could not before be brought under notice.

A. Belonging to the Vegetable Group.

- 1. Respiratory apparatus.
- 2. Digestive apparatus.
- 3. Excretory apparatus.
- 4. Reproductive apparatus.

III.
THE
ORGANS OF THE BODY.



III. THE ORGANS OF THE BODY.

A. Organs of the Vegetative Group.

1. Circulatory Apparatus.

§ 220.

As we have already considered the blood and lymphatic vessels in the second part of our work (§§ 201-211), we shall here be engaged merely with gleanings from what has been previously referred to. Thus we have to describe the *heart*, the *lymphatic glands* and *lymphatic organs*, with the *spleen*, as well as the remainder of the so-called blood-vascular glands.

The *heart*—the muscular central organ of the circulatory system—consists of the pericardium, a serous sac (which has been previously referred to, p. 226) of muscle, and of the so-called endocardium. The latter is analogous to the *T. intima* of larger vessels (§ 204), while the fleshy mass of the organ corresponds to the muscular layers of the latter. Many modifications, however, are apparent.

The *pericardium* corresponds in its texture to many of the true serous sacs. It presents for consideration a thick parietal and thin visceral portion. The latter is connected with the fleshy mass of the organ by means of that connective-tissue known as subserous, and shows especially in the grooves of the heart, but at times also over nearly its whole surface, collections of fat cells (p. 198).

The *vessels* of this structure have nothing special about them, and the *nerves* of the parietal layer are supplied, according to *Luschka*, by the right vagus (*ramus recurrens*) and phrenic. The *epithelium* has been already dealt with at p. 139, and the fluid contents of the sac at p. 230.

We have likewise considered the striated muscle of this involuntarily acting organ while speaking of muscle generally at p. 292.

The connection of the reticularly united muscular fibres one with another (fig. 397) is very peculiar. They are not, as in other striped

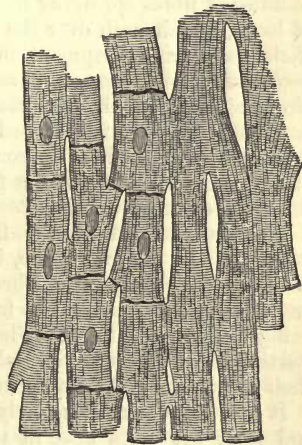


Fig. 397.—Muscle-fibres from the heart, after *Schweigger Seidel*. To the right the boundaries of the cells and the nuclei are to be seen.

muscle, collected into bundles, excepting the *trabeculae carneae, m. pectinati* and *papillares*. The single fibres lie rather closely crowded side by side, held together by a small quantity of connective-tissue.

As is well known, the strength of the fleshy mass varies much in the different divisions of the heart. It is most massive in the left ventricle, thin in the two auricles, and weakest in the right of these. The course which the fibres take is also very complicated, for which reason we shall confine ourselves to only a few of the chief points of interest as regards it.

The course of the fibres of the heart, which is different in the auricles and ventricles, may be divided into longitudinal and circular. This distinction, however, can only be made with accuracy as regards the auricles, and not the ventricles. It is a remarkable fact, further, that some of the muscular fibres are common to the two auricles, and another to the two ventricles, while each of these four parts possesses also its special fibres.

The starting-points of the fibres of the heart are usually held to be the two annular masses of fibres which encircle the *ostia venosa* of the ventricles, known as the *annuli fibro-cartilaginei*. They consist of very strong connective-tissue, with very delicate elastic fibres. Sometimes their tissue assumes a similar appearance to that of the perichondrium at its transition into true cartilaginous tissue.

From these rings the fibres take their origin, and return, after travelling round the cavities of the organ, to be inserted into them again, thus forming loops. In consequence of this, both auricles and ventricles must contract towards these points, the bases of the ventricles, during systole of the organ.

In the auricles we encounter in the first place, as most internal layer, bundles of fibres springing from the *ostium venosum*, and forming a series of loops, which arch over the cavity, producing a kind of dome. From their peculiar development in the right auricle they give rise to the *m. pectinati*. This layer is enveloped by another stronger one, formed of circular fibres, which is in the first place distinct for each of the auricles, and then specially developed on the anterior aspect of the organ, it includes both of them in common. Finally, surrounding the openings of the veins we find circular fibres, continued to a certain distance over the walls of these vessels.

The arrangement of the fibres of the ventricles, however, is more complex. In the first place, it may be remarked that the left ventricle possesses a special set of fibres. The right has likewise its own, which are, however, so arranged as to strengthen the muscular mass of the left, being produced into it. Finally, fleshy fibres are to be seen, which, starting from the left ventricle and returning to the same, surround in their course the right cavity in loops.

It may be remarked, namely, that from the fibrous ring of the left side, and from the aorta also, in the whole circumference of the ventricle, a number of longitudinal fleshy fibres take their origin, which descend on the one wall in its outer portion, and bending round at the apex of the heart, return in the inner surface of the opposite wall to the *annulus fibro-cartilagineus*. Owing to the oblique course of these fibres, they cross each other at the apex of the left ventricle, forming there the so-called vortex of the heart. In the right ventricle, likewise, we meet with an origin of fibres from the *annulus fibro-cartilagineus*. There one limb of the loop pursues a course in a similar manner down to the apex of the right

cavity, but passes then, not into the opposite wall of the same, but into the wall of the left ventricle, arriving eventually at the left fibrous ring, where it terminates.

Besides this peculiar arrangement of the fibres, which is, however, on the whole a longitudinal one, there is also a circular set. This takes its rise from the left *annulus*, and surrounds the wall of the left ventricle in figures of eight, while other fleshy bundles arising in the same region envelope the right chamber in simple loops. These different masses of fibres lie between the longitudinal. From the right *annulus* also, though in much smaller number, similar fibres take their rise, encircling the wall of the left ventricle in the same kind of simple loops. Finally, we have another set of circular fibres, which, springing from the right *annulus*, return to be inserted into the same, encircling in their course the *conus arteriosus*.

The musculæ papillares are formed both from the longitudinal and transverse fibres.

In conclusion, we must devote a few lines to those peculiar structures, discovered in the year 1845 in the hearts of horses, cows, sheep, and pigs, which have been named, in honour of the discoverer, the fibres of *Purkinje*.

These present themselves as flat grey jelly-like threads, spread out in a reticular manner, immediately under the endocardium, on the internal surface of the ventricles. They penetrate further into the musculæ papillares, and stretch across various depressions in the walls of the heart.

Purkinje's fibres (which were subsequently found to exist in the hearts of deer and goats) are structures whose significance is far from being understood as yet. We may see that they consist of rows of round or polygonal nucleated bodies, ranged side by side, or one over the other, which have received the name of "the granules." Between these is noticed a plexiform or reticulated arrangement of the so-called "interstitial substance." The latter consists of thinner or thicker fibres of striped muscle, which can be followed into the substance of the heart. Those cell-like bodies which lie in the interstices also frequently present a transverse and longitudinal striation, and may unite finally with the surrounding striped network to form stronger muscular fibres.

For our own part we look upon the whole as a strange complicated interlacement of cardiac or endocardial muscle fibres, which have remained stationary at an embryonic stage of development. We refer the reader to the genesis of the latter (§ 172).

§ 221.

All the cavities of the heart, with their inequalities and projections, are clothed with an *endocardium* of varying thickness. This structure is thinnest in the ventricles, where it is presented to us in the form of a delicate membrane, and thickest in the *atrium sinistrum*, where it forms a tough lining.

It consists of several layers. As a substratum may be recognised an elastic lamina with abundant elastic fibrous networks, and corresponding poorness in connective-tissue. Internally appears a specially dense lamella of an elastic network supporting a coating of simple endothelium (p. 139).

The external layer contains, besides, in the ventricles, smooth and transverse muscle fibres; but in the auricles only a few scattered contractile fibre-cells are to be found (*Schweigger-Seidel*).

The *valves* between the auricles and ventricles (*valvulae tricuspidales* and *mitrales*) are duplicatures of endocardium, with a strong middle layer of fibrous tissue, derived principally from the fibres of the *annulus fibro-cartilagineus*, and expansions of the tendons of the *museuli papillares*.

On one aspect they are clothed with the strong endocardium of the auricle, on the other by the thinner of the ventricle.

Under the first of these endocardia muscular bands are prolonged into the valves from the muscular substance of the auricle penetrating to various depths (*Gussenbaur*).

Finally, the whole is covered with simple endothelium. The semilunar valves also of the arteries have a similar structure, except that the middle layer is thinner.

The *blood-vessels* of the heart present in its muscular substance the most typical form of the elongated mesh-work (p. 370). Several capillaries pass immediately and together into one strong venous root. The ready outflowing of the blood is thus better provided for than elsewhere. The endocardium is only provided with vessels in its undermost connective-tissue layer. A few may also be seen in the auriculo-ventricular valves, but none in the semilunar (*Gerlach*).

The heart is supplied with *lymphatic vessels* in considerable number, and according to *Eberth*, *Belajeff*, *Wedl*. The two leaves of the pericardium, as well as the endocardium, contain dense networks of coarser or finer trunks. In the interior of the auricles they appear more scanty than in the ventricles. In the *chordæ tendineæ*, on the other hand, they are not to be found, and in the semilunar and auriculo-ventricular valves are only present in small number. The fleshy substance of the heart does not appear to be so richly supplied with them as was formerly supposed by *Luschka*.

The *nerves* of the heart have their origin from the cardiac plexus, which is itself made up of branches from the *vagus* and *sympathetic*.

The course of the numerous nervous stems is alongside of the blood-vessels until they spread out in the auricles and ventricles. The auricles are poorer in nerves than the ventricles, of which the left is the most richly supplied. The nerves of the heart appear more or less grey, and consist of fine medullated tubes with an intermixture of *Remak's* fibres. They terminate for the greater part in the muscle, while some of them may be traced into the endocardium. All efforts to elucidate the mode of ultimate termination here have hitherto proved futile in man and the *mammalia* generally. The occurrence of numerous microscopically small ganglia is also peculiar. The latter appear on the nerves imbedded in the substance of the heart, especially in the neighbourhood of the transverse groove and *septum ventriculorum*.

Physiology, as is well known, has brought to light the interesting fact that these two kinds of fibre elements are entirely different in function. Whilst the *sympathetic*, namely, preside over the contraction of the muscle, having their chief centres of energy in the ganglia just referred to, so that the heart continues to pulsate after removal; the *vagus* filaments exercises a completely opposite influence, causing, when stimulated, an interruption to the motor power of the *sympathetic* elements, and to such an extent also that the heart comes to a standstill in a condition of *diastole* (*E. Weber*). It is possible that the fibres of the *vagus* may terminate in the cardiac ganglia, *i.e.*, in their cells.

Regarding the *composition* of the muscle of the heart, *vide* chemistry of

muscular tissue (§ 170, p. 295). The occurrence in it alone of inosite is a fact of great interest.

The structure of the arteries and veins has been already discussed in §§ 203 and 204, that of the capillaries in §§ 201 and 202.

§ 222.

We now turn to the consideration of those peculiar bean-shaped and very vascular organs, the *lymphatic glands* or *lymph-nodes*, which occur in the bodies of the higher vertebrates, interrupting the course of the larger absorbent vessels. They are met with in greatest number on the lymphatic trunks of the intestines, and at those points where superficial and deeper sets of vessels join. It not unfrequently comes to pass that one single vessel is in this way interrupted over and over again by such nodes, and it is probable that every trunk in its course from the periphery to the *ductus thoracicus* has at least one such. In those lymph-nodes, which are not very minute (fig. 380, *a*), we usually find several lymphatic twigs penetrating into their interior from the convex border. These are the *vasa afferentia* (*f, f*). From the other side either one or more vessels (in the first case of greater calibre), make their exit, known as the *vasa efferentia* (*h*). This takes place as a rule at a point where a kind of depression may be observed, and where the larger blood-vessels enter the organ. This spot, when the depression is present, is named the *hilus* (*h*). It is entirely absent, however, in many glands.

The internal arrangement of the lymph-nodes is a point most difficult to determine, and it is only very recently that any satisfactory insight has been gained into their minute structure. We

learn, besides, from recent observations, that the organs in question display considerable variety, both as regards volume, compared with the size of the mammal body, and also their locality; so that the structure, for instance, of a large lymph-node from an ox, and a small one from a rabbit or Guinea-pig, exhibits great difference. Were this axiom allowed its due weight, we should be spared many unprofitable controversies.

In those lymph-nodes which are not altogether too small we can distinguish a reddish grey *cortical portion*, consisting of round bodies, the *follicles* (*d*), and a darker spongy *medullary portion*, composed of the tubes and reticular prolongations (*e*) of these follicles.

Each lymphatic gland is enclosed in a thicker or thinner fibrous envelope (*a*), moderately vascular, and consisting of ordinary connective-tissue cells, fibrillated interstitial substance, and elastic elements. A continuous layer of muscular tissue does not occur in this envelope. The outer

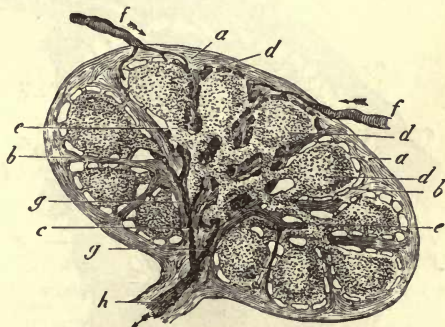


Fig. 398.—Section of a small lymphatic gland, half diagrammatically given, with the course of the lymph. *a*, the envelope; *b*, septa between the follicles or alveoli of the cortical portion; *c*, system of septa of the medullary portion, down to the hilus of the organ; *e*, lymph-tubes of the medullary mass; *d*, different lymphatic streams which surround the follicles, and flow through the interstices of the medullary portion; *g*, confluence of these passing through the efferent vessel; *h*, at the hilus of the organ.

portion of the tissue in question merges into a formless connective-tissue mass, not unfrequently very rich in fat-cells.

Internally the capsule gives off a very extensive system of either simple or extremely complicated septa (*b, b, c*), which divide the interior of the organ into a number of intercommunicating cavities by splitting up and again becoming united. These spaces are occupied by the proper lymphoid tissue.

The *septa* correspond in structure with the tissue of the capsule. They consist of fibrous connective-tissue, intermixed with smooth muscular fibres. These latter are found in certain cases in large number, as in the inguinal, axillary, and mesenteric glands of the ox (*His*). According to *Schwartz*, the muscular fibres at the line of junction of the medullary and cortical portions have a principally radiating arrangement. The partitions of which we are speaking usually spring from the interior of the capsule, with broad bases, between the rounded ends of the follicles, descend perpendicularly between the latter, and undergo a change below, where, as we shall soon see, the lymphoid tissue presents likewise a different arrangement. At the transition from cortical to medullary substance a general splitting up and subdivision of these connective-tissue plates take place, the latter decreasing greatly in thickness. But no follicle is completely ensheathed at its under surface in this system of septa. On the contrary, either one or several gaps, or even wide deficiencies, are left, through which the follicular tissue comes into immediate contact with

the medullary substance. In the same way the partitions passing inwards between adjacent follicles may be interrupted by massive bridges, as it were, of lymphoid tissue, by which these are connected one with another.

§ 223.

By means of this arrangement of partitions just mentioned, the cortical portion of each lymph-node is divided into a smaller or larger number of usually roundish bodies (fig. 399, *b, c*) known as the *follicles*. These, however (figs. 398, *d*, and 399), do not come into contact with the surface of the septum; there remains rather a remarkable

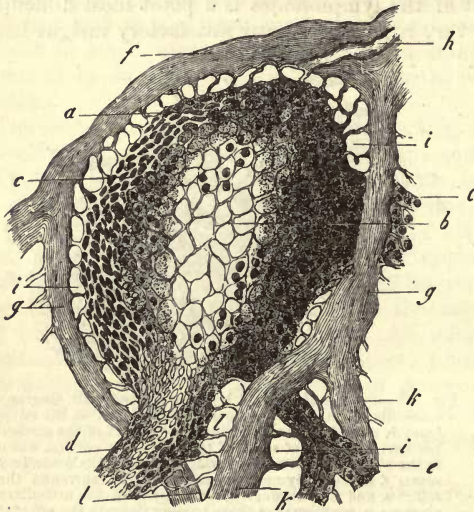


Fig. 399.—Follicle from the lymphatic gland of a dog in vertical section. *a*, reticular sustentacular substance of the more external portion; *b, b, c*, of the more internal, and *c*, of the most external and finely webbed part on the surface of the follicle; *d*, origin of a thick lymph-tube; *e*, the same of a thinner one; *f*, capsule; *g*, septa; *h*, division of one of the latter; *i*, investing space of the follicle with its retinacula; *j*, vas afferens; *l*, attachment of the lymph-tubes to the septa.

interspace, of greater or less breadth, between the two, called usually the *investing space of the follicle* (fig. 399, *i*).

The follicles themselves may be either closely crowded together or more or less widely separated, and are arranged sometimes in a single layer, and

sometimes bedded in several rows one over the other. Owing to this, the depth of the whole cortical portion in the different lymphatic glands is liable to great variation.

Further, the diameter of the follicles varies according to the species of animal, and also the region of the body. It may range from 0.3760 to 1.1279, or even 2.2558 mm., and upwards.

The form of these constituents of the organ is generally roundish, bulging greatly towards the circumference of the gland. Exceptions, however, are frequently met with here also. When closely crowded, the follicles of the cortical portion exhibit usually a certain amount of accommodation towards each other, leading to a more or less definite polyhedral flattening of each. Besides this, the fact that the follicles are pointed at their internal portion, which is directed towards the centre,

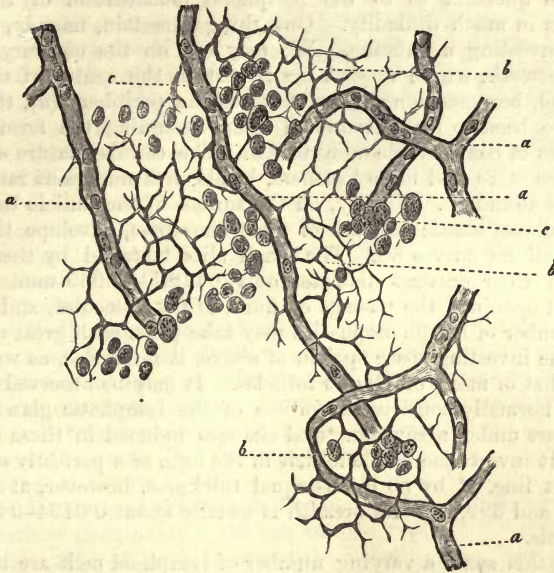


Fig. 400.—Reticular connective substance from a *Peyer's* follicle of an old rabbit, which may also be made use of as exemplifying the structure of the follicles of lymph-nodes. *a*, the capillaries; *b*, reticulated sustentacular matter of connective-tissue with shrunken cell-bodies; *c*, lymph-cells.

is quite apparent in most cases, so that the whole presents a somewhat pear-shaped form (fig. 398). More distinctly pronounced variations may be met with when in the cortical portion of a lymph-gland several rows of follicles are crowded one over the other.

With the tissue of the follicles (fig. 400) we have already been made acquainted (§ 117, p. 195). It consists of reticular connective-tissue, formed of the well-known cellular network, in all directions continuous, with roundish polyhedral or irregularly shaped meshes. It is, however, liable to vary greatly, both as to the bodies of the cells, the number and strength of their processes, and the breadth of the meshes formed by the interlacement of the latter. These differences depend upon the age and turgescence of the lymph-gland, and also upon its state as regards health and disease.

If a lymphatic gland from a new-born child be examined closely, it will be seen that in some part of each nodal point in this network there is a distinct cell-body, with a plump nucleus measuring 0.0045–0.0056 mm. in diameter. The breadth of the meshes is 0.0097 and 0.0160 mm., but may rise to 0.0139–0.0226 mm. The cellular nature of the network, however, may at other times be far less evident.

In the adult we most usually meet with either a rudimentary shrunken nucleus, or indeed none at all, in the but slightly thickened nodal points. The openings of the meshes may be stated on an average to be 0.0113–0.0194 mm. The septa may be fine or coarse, and vary in many respects.

In the mammalian body the same appearances are presented in the sustentacular matter, and similar varieties of the latter.

Now, though the structural relations just mentioned are easy of recognition, the question as to the peripheral demarcation of the follicle involves us in much difficulty. One thing is certain, namely, that they have no investing membrane. We may see, on the contrary, that the cellular network, whose meshes are largest in the centre of the follicle (fig. 399, *b*), becomes more dense towards the periphery (*a*), the meshes which have been so far of roundish figure assuming the form of longitudinal slits of considerable minuteness. The cellular nature of the network is also more and more lost here, bands with numerous ramifications being most abundant. Finally, on the surface of the follicle these fibres, arranged like an elastic network of great denseness, envelope the former, following all its curves (*c*). The small slits bounded by them usually measure in their greatest diameter only 0.0081–0.0065 mm. Through these small openings the passage of fluid, of fat molecules, and also of a certain number of lymph-corpuscles may take place with great ease.

As to the investing space spoken of above, it resembles, as we shall see later on, that of many of *Peyer's* follicles. It may be observed surrounding every normally constituted follicle of the lymphatic glands, though it disappears under many structural changes induced in these organs by disease. It invests the whole follicle in the form of a perfectly continuous transparent line, of by no means equal thickness, however, at all points (fig. 398; and 399, *i*). Its breadth is usually about 0.0194–0.0303 mm. and upwards.

Within this space a varying number of lymphoid cells are to be seen. If these be removed by brushing, a second tissue element then presents itself, occupying the investing space, namely, a system of solid fibres (*i*), which, springing from the internal surface of the capsule and sides of the partitions, take a radial course towards the surface of the follicle, to be inserted into the narrow meshed cellular network situated here. Thus, taking their rise from the capsule and the surfaces of the septa, they hold the follicle stretched and tense, as embroidery is fastened within a frame. In consequence of this, collapse of the delicate follicular network is prevented, and the fine slits in the surface of the latter are retained in an open condition,—provisions of importance as regards the lymph-stream and the whole life of the organ. The retinacula in question present themselves either in the form of non-nucleated, coarse or fine fibres, or bands, usually giving off branches at an acute angle; or there may occur in the nodal points of the former nuclei showing that we have to do with a system of cells. Here again we have presented to us the various forms of that so varied group, the reticular connective-tissues.

§ 224.

We now turn to the *medullary portion* of the lymphatic glands.

This may be looked upon in its complex nature as a continuation of the cortical septa and the substance of the follicles with their investing spaces and retinacula.

Under microscopical analysis many varieties are observed to exist in the nature of this portion of the gland, according to the age of the animal from which the latter has been taken. Thus it is more fully developed in younger, as a rule, than in older bodies, in which it appears more or less degenerated. It is observed to differ also, to a certain extent, according to the species of animal examined. Finally, the medullary substance of the lymph-nodes belonging to the interior of the body, and especially to the digestive tract, as a rule, displays a higher degree of development than those situated more superficially, as the inguinal and axillary glands.

Let us commence with the *septal system*, formed of connective-tissue. This (fig. 401, *c*), supposing it to be moderately developed, is the continuation of the interfollicular partitions, and consists of fine, but dense, connective-tissue plates and bands, uniting with one another at acute angles at intervals, or dividing in the same way one from another. Eventually, in the neighbourhood of the hilus, *i.e.*, of that point at which the efferent vessels leave the organ (*b*), the connective-tissue septa converge and unite to form a common fibrous mass. The latter again exhibits in its amount the greatest variety imaginable. Whilst in many of the internal lymph-nodes it is extremely insignificant, or even almost entirely absent, it may attain enormous thickness in others, especially those lying less deeply, encroaching upon the lymphoid tissue of the medullary substance.

To this massive fibrous structure, arising from the union of the septa, the name of the *connective-tissue nucleus* (*Frey*), or *hilus-stroma* (*His*) has been given.

Turning to the essential, *i.e.*, lymphoid portion of the medullary mass (*e*), we find it to be made up of cylindrical tubular elements, which, connected with one another in a reticulated manner, give rise to a peculiar spongy tissue, whose interstices correspond to prolongations inwards of the cortical investing spaces. We shall speak of these cylindrical elements for the future as the *lymph-tubes* ("medullary tubes" of *His*) and of the system of lacunæ between these, under the name of *lymph passages of the medullary substance* (cavernous passages).

Let us now glance, in the first place, at the lymph-tubes (figs. 402,

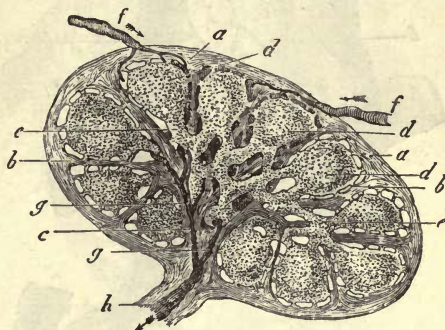
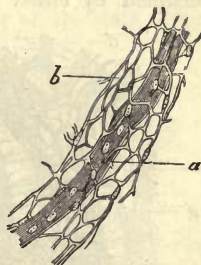


Fig. 401.

Fig. 402.—Lymph tube from the mesenteric glands of a dog. *a*, capillary, *b*, reticular connective substance forming the tube.

403, 404). These vary extremely in thickness, besides which one and

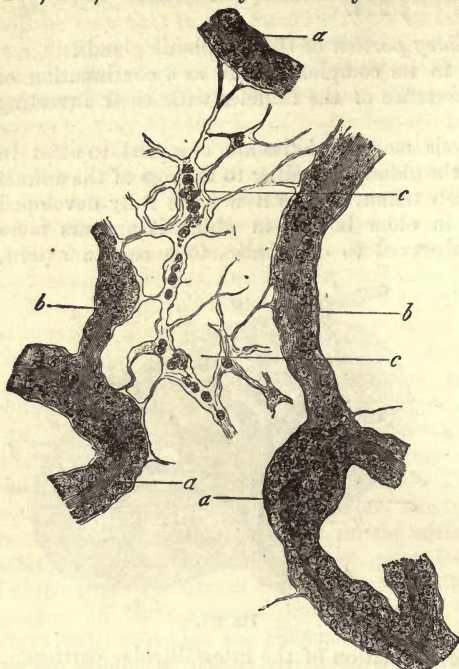


Fig. 403.—Lymph tubes (*a, a*) from the medullary portion of the pancreas *Asellii* of the rabbit, with simple vessels and their branches, *b, b*. Between them is to be seen a strongly stretched cellular network *c*.

occupied by either an arterial twig, a capillary (figs. 402, *a*; 403), or

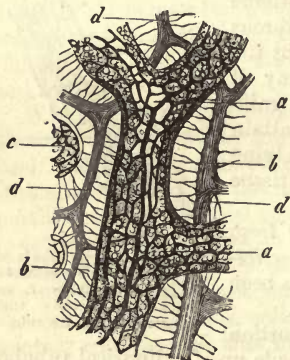


Fig. 404.—From the medullary substance of the inguinal gland of the ox (after *His*). *a*, Lymph-tube with its complicated system of vessels; *c*, portion of another; *d*, septa; *b*, retinacula stretched between the tube and the septa.

as the rabbit (fig. 403, *a, b*), the external surface may become more or less membranous and homogeneous, resembling a hyaline glandular

the same tube may exhibit at different parts of its course very different diameters. Fine lymph tubes may measure 0.0361 mm., or even considerably less, across, whilst others show a thickness two or three times as great. Even in the smaller mammals some may be met with of 0.0902–0.1263 mm. in diameter. In the large lymph-nodes of the ox tubular elements of the medullary substance may be encountered presenting a still greater diameter.

If we now pass on to the structure of the lymph-tubes, we have the most striking picture presented to us on filling the blood-vessels artificially; all the lymph-tubes, namely, are traversed by blood-vessels, so that they appear like lymph-sheaths around the latter. According to their strength, we find the axis

occupied by either an arterial twig, a capillary (figs. 402, *a*; 403), or a small venous branch. If, as is the case in larger animals, the lymph tubes are of considerable thickness, their vascular system is more complicated, as is seen in fig. 404, *a*. Here also an arterial or venous twig passes through the axis, while the peripheral portion is traversed by interlacing capillaries belonging to the axial vessel and forming elongated meshes.

The tissue of the lymph-tubes is again reticular connective substance; a cellular or banded network (fig. 402, *b*), which surrounds the blood-vessels and takes the place of an adventitia.

In thick lymph-tubes also the reticular character may be recognised in their interior. The surface likewise is often observed with the greatest distinctness to have mesh-like slits. In finer tubes, as also in those of the smaller animals, such

tube to a certain extent. This variety, in the demarcation of the formations in question, is explained by the changeable nature of reticular connective substance.

We are now met by the questions, whence come these lymph tubes? *what is their origin, and what becomes of them?*

It is comparatively easy to recognise the origin of the lymph-tubes from the follicles (fig. 405). They spring from the under surface of the latter (*d, e*), and it appears always several of them together. The sustentacular matter of the follicle becomes the banded network of the lymph-tube, and the blood-vessel of the latter enters the follicle at this point. At this under surface the septal system is very frequently extremely imperfect; comp. fig. 401.

Passing on now to the consideration of the second question, namely, *What becomes of the lymph tubes?* nothing would seem more natural

—bearing in mind the parallelism of the latter with the blood-vessels—than that they should converge towards the hilus of the organ, forming eventually by their confluence, and on separating from the latter, the *vas efferens*; and, indeed, this utterly incorrect view of the state of parts has been put forward by some. More accurate observation, however, of the medullary portion of the gland convinces us that no such thing takes place, but that the network of the tubes, just as it took its rise on the one hand from follicles, so is it on the other hand continuous (subject to many variations certainly) with other follicles (fig. 401). Consequently, in this highly developed reticular arrangement of the lymph tubes of the medullary substance, we have nothing but a *very complicated system of intercommunications between the follicles of the lymphatic nodes.*

Recognising now the medullary mass as a network of lymph-tubes, we must, of course, expect to meet with a corresponding system of interstices. Throughout these lacunæ (sometimes in the greater part of them (fig. 388, *b*), sometimes only in some few) the system of connective-tissue septa with which we have been already made acquainted extends. But, as was before observed, in regard to the parti-

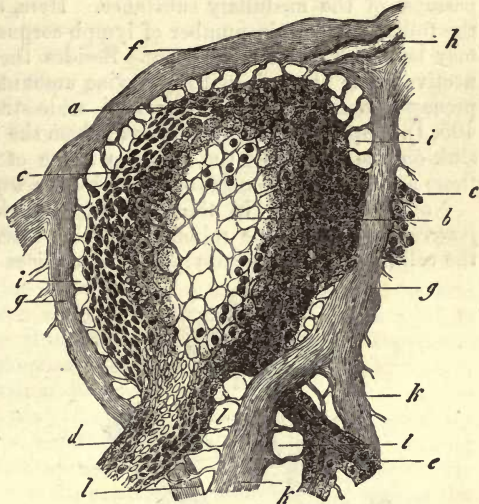


Fig 405.

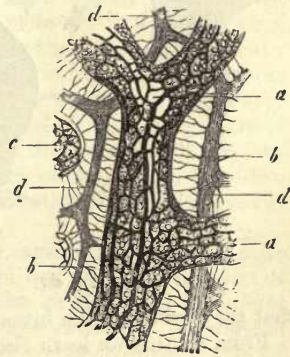


Fig. 406.

tions in the cortical portion, the septa do not come into contact with the lymphoid substance here either. On the contrary, we find,—as in the first case, so here also,—the lymph-tubes and septa, or, where the latter are absent, the lymph-tubes alone, separated from one another by a narrower or broader interval analogous to the investing space of the follicle.

There now remains for consideration the contents of these reticulated passages of the medullary substance. Here, as in the investing space of the follicles, a certain number of lymph-corpuscles are to be found, which may be removed with a brush. Besides these, we observe that a connective-tissue network, with a varying amount of nodal points, nuclei, and processes, occupies the passages with wide straggling meshes (fig. 406, *b*; 405, *l*). Springing on the one hand, from the septa of the gland, its fibres sink on the other into the reticular tissue of the lymph-tube, or, where there are no septa, connect one lymph-tube with another.

Not unfrequently in the mesenteric glands, as for instance in the *pancreas Asellii* of the rabbit, some very interesting points in regard to the cellular network occupying the interstices of the medullary substance

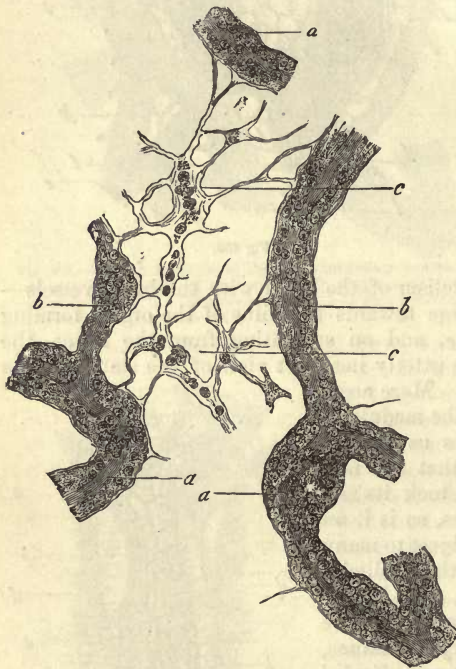


Fig. 407.

may be observed (fig. 407, *c*). The bodies of the cells appear tense and swollen: they have, moreover, no membrane. Their processes or ramifications are likewise thickened and broad. Within both the bodies and their processes, besides soft-looking nuclei, isolated lymph corpuscles are to be seen (*W. Müller, Frey*), which may have come there either by immigration or possibly by generation on the spot. The possibility of this latter alternative remains, however, still a matter of uncertainty.

If we follow up the reticular interstices of the medullary substance to the boundary of the latter, we have no difficulty in recognising the fact (especially if we carry our eye along one of the partitions) that they lead into the investing spaces of the follicles (fig. 405). From all this we learn that the lymph-nodes are formed of a system of cavities (imperfectly bounded by septa) which are occupied by lymphoid matter—in the cortical portion by the follicles, and in the medullary by the lymph-tubes—but always so arranged that the lymphoid substance does not come into contact with the fibrous septal system. Thus we have both a series of spaces, encasing, as it were, the follicles, (investing spaces), and a system of intercommunicating passages enveloping the

lymph-tubes (the lymph-passages of the medullary portion. Throughout this extremely complicated cavity in the larger lymph-glands, then, a network of fibrous bands and cells extends, springing from the lymphoid substance on the one hand, and is attached to the septa on the other, holding the whole lymphoid sustentacular matter in a tense condition.

We must now turn to the more active portions of our organ, namely, the blood and lymph streams.

§ 225.

Artificial injection of the *blood-vessels* of lymph-nodes is a matter of but slight difficulty. It shows us that the organs in question receive their supply of blood from two different sources of unequal importance. The larger arterial twigs in the first place pass into the septa and glandular tissue through the hilus without exception, while the smaller branches penetrate through the capsule into the interior. The last mode of supply, however, is probably not always present, though others are wrong who assert that it does not exist at all.

Passing through the hilus in the first place then, one or several small arterial trunks are seen which give off their first branches while within the connective-tissue situated here. With the connective-tissue a small number of these branches pass into the system of septa within, ramifying with further division towards the periphery. Most of the arterial twigs, however, penetrate into the lymph-tubes of the medullary substance, and pursue their way within the offsets of the latter. Among the smaller lymph-tubes, such as those of the *pancreas Asellii* of the rabbit and Guinea pig, as well as the mesenteric glands of man, each of the former contains, as a rule, but one single axial vessel, either a small artery vein or capillary. In lymph-tubes of greater diameter several of these may be met with, or, as is the case in the inguinal glands of man and lymph-nodes of the ox, these elements of the medullary substance contain within them a thick arterial or venous axial vessel, and a long-meshed capillary network around it (fig. 406), whose tubules have a medium diameter of 0.0046-0.0090 mm., and form a most delicate interlacement about the central vessel. Passing from the more external lymph-tubes, these twigs, together with their capillaries, enter the follicles, and occupy a considerable portion of its space, terminating eventually in a very loose and rather irregular capillary network. The latter exhibits at the periphery of the follicle where it is most highly developed as a rule, numbers of loops on the tubes from the union of which the venous radicals take their origin, which lie more internally. These, on leaving the follicles, penetrate into the lymph-tubes, and return (imitating the arrangement of the arteries) through these to the hilus.

The second source of supply of blood is the capsule of the lymph-node which is traversed by arterial venous and capillary vessels. The first of these appear in the bases of the interfollicular partitions as horizontal twigs, which divide finally into finer branches encircling the various follicles. The veins of the capsular tissue have a similar course.

Internally the greater number of these capsular vessels sink into the septa, communicating there with others coming from the hilus.

Other twigs (rarely arterial or venous, but usually capillary) enter the follicular tissue itself, taking a course through the stronger retacula of the investing space or through the partitions.

We shall find later on that other organs, such as the spleen, liver, and

kidneys, exhibit a similar connection between the vessels of the parenchyma and capsule.

For the recognition of the *course of the lymph*, also, we require the aid of artificial injection. This may be successfully performed through the *vas afferens*, though not easily. On the other hand, it may be very easily effected by *Hyrtl's* method of puncture beneath the capsule. The true course of the lymph through the gland was, however, first ascertained by myself in the year 1860, and shortly afterwards by *His*.

The *afferent lymphatic vessels* (fig. 408, *f, f*) enter the organ either singly or, as is the case with larger nodes, in greater number. Their walls are thin, and they exhibit considerable variety of diameter and richness in valves. There may also be one or several efferent vessels leaving the glands. They have a similar structure to the last.

Their point of exit may be a depression like the hilus, although not necessarily, so that the distinguishing of afferent and efferent vessels from one another is not always an easy matter.

If we cautiously force in some injecting fluid through one of the vessels leading into the organ, the first portion to fill is a series of spaces under the capsule, closely communicating with one another, and surrounding the follicle: this is effected with great ease. Perpendicular sections show that the fluid penetrates also into the interior by keeping along the sides of the follicles, and in the middle of the stream the banded network of the interfollicular septa is seen distinctly.

What is here produced artificially is effected by nature also. A few hours after a meal of fatty food, the cortical portion of the mesenteric glands is filled by white chyle in a manner precisely similar.

It requires but a slight acquaintance with the lymph-nodes to convince one's self that the injection fluid, in fact, on first entering the organ, finds its way into the investing spaces of the follicle, and, filling these, occupies those circular networks on the surface of the latter which have been already mentioned above as being 0.0162-0.0323-0.0483 mm. in breadth.

Close inspection shows farther that the afferent lymphatic vessel, from that point at which it enters the capsule, loses its independent wall by the fusion of the outer layers of the latter with the connective-tissue of the capsule. In this way it opens into the investing space, either in the form of a simple or branched passage. Thus the effects of injection are easily explained.

It may be mentioned, as a modification of this arrangement, that the afferent lymphatic tubes sometimes first pass for a certain distance

through the interfollicular partitions before opening into the lymphatic spaces of the gland.

Let us bear in mind farther that the investing spaces of the organ are immediately continuous with the network of interstices of the medul-

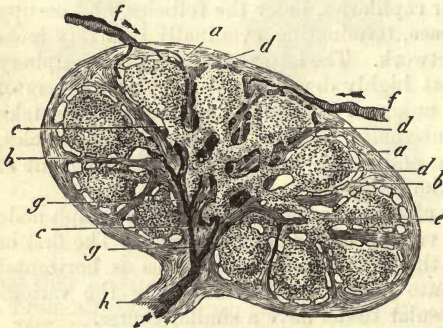


Fig. 408.

lary substance (§ 224), so that there can be no doubt as to the farther course of the injection fluid: it fills namely this network of lymph passages also, while the lymph tubes of the medullary substance remain colourless so long as only slight pressure is used.

From the mode of termination of the injection we perceive that the *vas efferens* must take its rise from the passages of the medullary portion of the gland, in that it is at last filled by the fluid employed. It is also possible at times to drive the liquid back through the *vas efferens* into the lymph node by overcoming the opposition of the valves. Retrograde injections of this kind impel the matter used first into the reticulated passages between the lymph-tubes of the medulla, and from thence further on into the investing spaces of the follicles.

The confluence of these medullary lymph streams, however, to form a branch of the *vas efferens* is a point very difficult of detection (fig. 409).

The latter vessel which leads into the connective-tissue at the hilus undergoes there further division into branches, as has been already remarked. These may vary greatly according to the size of the gland, and the greater or less development of the fibrous nucleus of the latter. Enclosed within the partitions of the medulla, the last branches of the *vas efferens* (*e*) are observed to course along in the form of tubes of various calibre, whose walls are, as a rule, fused with the surrounding connective-tissue (*f*).

Finally, on penetrating further into the gland we observe that the partitions which contain such ramifications of the *vas efferens* become subdivided more and more, forming series of diverging bands, so that the lymph stream is no longer enclosed within an envelope, and exhibits all the reticular characters and irregular limitations (*d*) characteristic of the hollow cavities of the medulla. In fact, there can be no doubt that we have before us the origin of the *vas efferens* from the cavernous portion of the medulla of the gland.

It may be remarked, further, that the vasa efferentia on their exit from the lymph nodes present much variety of appearance, depending upon the size of the organ and the development of the connective-tissue nucleus in the neighbourhood of the hilus. Thus in the hilus of the large mesenteric glands of the ox a regular plexus of peculiar, very tortuous, and knotted vessels has been seen by *Koelliker*, and *Teichmann* also gives drawings of exceedingly complicated vasa efferentia.

From the foregoing description, then, the following conclusions may be drawn. The vessel leading into the gland pierces its capsule in the form of a canal, and opens into the investing spaces of the follicle. These lead then into the lymph passages of the medullary portion, from the confluence of which the radicals of the vasa efferentia enclosed within the substance of the converging partitions are formed.

From this we see that really independent lymphatic vessels do not

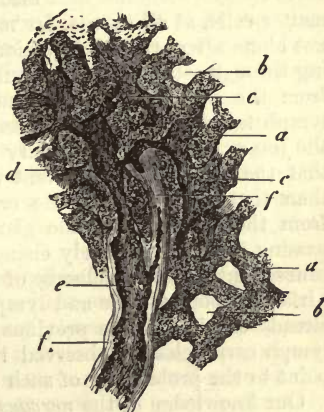


Fig. 409.—From the medullary substance of an inguinal gland of a large dog. *a*, lymph tubes; *b*, empty reticulated passages of the medulla; *c*, the same filled; *d*, transition into the commencement of a twig of the *vas efferens*; *e*, the latter coursing along within a fibrous septum *ff*.

exist in the glands in question, and that the views entertained to the opposite effect are incorrect, as those of *Teichmann*, for instance.

On the other hand, that older and so widely held view to which we ourselves subscribed for many years can no longer be supported in its integrity, namely, that only lacunar circulation takes place within the lymph nodes. The lymphatic canals, namely, traversing the capsule are, as we may easily convince ourselves, lined with peculiar flat epithelium-like cells (fig. 410), already dealt with in considering the vascular system (§ 208). The investing spaces are likewise lined in the same manner, not only on the surfaces of the septa and the retinacula connected with them, but those of the follicles themselves (*His*). It is still a matter of uncertainty whether the lymph passages of the medulla possess a similar lining or no. This

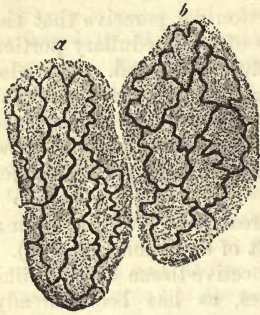

Fig. 410.

matter calls, at all events, for more accurate investigation; for we find—not alone after artificial injection, but also from the stream of lymph passing through—that small granules of colouring matters or fats penetrate from the periphery towards the centre of the follicles, and also into the lymph tubes. They are also seen in the cellular network passing across the interstices of the medullary portion of the gland. We know, farther, that the lymph of the afferent vessels is not unfrequently poorer in cells than that which leaves the organ. From this fact we may infer that from the substance of the gland lymph corpuscles are yielded to the passing fluid. The lively change of shape of the cells of the latter, and consequent power of change of locality (§ 40), as well as the trellis-like surface of both follicle and lymph tube—the fact, finally, which has been already considered in a previous section, that cellular networks containing lymph corpuscles are observed in the passages of the medulla,—all these point to the probability of such an addition being here made to the fluid.

Our knowledge of the *nervous supply* of the lymph glands is at present extremely scanty. Some fine nervous twigs have been observed by *Koeliker*, in the larger nodes of the human body, to pass in with the arteries into the medullary portion; beside which *Remak's* pale nerve fibres have also been observed in the glands of the ox.

REMARKS.—1. No doubt can any longer prevail as to the perviousness of the lymph glands to small solid granules. And although, after tattooing, molecules of pigmentary matter are laid down in these organs, the fact can be explained in a manner quite reconcilable to this view. Every one who has ever injected lymph nodes with any granular matter, and afterwards essayed to brush it out, knows very well with what tenacity the granules cling to parts of the surface of the investing space. That lymphoid cells possess the power of taking up molecules of pigmentary matter into their bodies has already been remarked at p. 77. Why it is that *Virchow* still doubts the possibility of the passage of pus cells, or even granules of cinnabar, through lymph glands, is to me somewhat incomprehensible.

§ 226.

It has been long supposed, and rightly so, from physiological experiences, that a lively interchange of matter takes place in the lymph nodes between the blood and the lymph. The same is taught us by the changes produced in the glands in question in morbid states of the juices of the

body, manifested by inflammatory appearances and swellings of these organs.

Thus we see that the lymphatic glands of man are liable to vary much in structural appearance, which must be partly attributable, no doubt, to the metamorphoses accompanying increasing age.

Among the latter may be reckoned the partial transformation of the connective-tissue framework into fat cells, and degeneration of the reticular connective substance into ordinary fibrous tissue, with consequent gradual obliteration of the whole organ.

A third change observable in lymph nodes is true pigmentation. This affects principally the bronchial glands, and is almost invariably to be met with after a certain age, though with varying degrees of intensity. It may be due to the irritation of inflammation in the pectoral organs. Small granules of melanin (p. 52) are formed by the gradual metamorphosis of the colouring matter of the blood. But though this may be accepted as one source of black pigmentary molecules, the latter have a very different origin, most probably, in many other cases. They are, namely, particles of carbon in a state of the most minute division, given off as soot from lamps, &c., and inspired and conveyed from the lungs into the lymphatic glands (*Knauff*). But between these two kinds of molecules we are at present unable to distinguish with any certainty. They lie utterly without order, partly within the lymph corpuscles, and in peculiar lumpy masses, and partly in the ground-work of the septa and walls of the vessels. In some instances the follicles appear to be the parts most affected, in others the lymph tubes of the medulla. A slight amount of this "melanosis" communicates to the bronchial glands a mottled appearance, while strongly marked it may cause the whole organ to appear uniformly black.

The effect on the lymphatic glands of inflammation of neighbouring parts is most evident. The meshes become narrower in the framework; the bodies of the cells of the same become plump, their nuclei undergo division, while great distension of the capillaries is also observed,—in fact, the whole gland acquires more or less the appearance it presented at an earlier age. Later on the reticular framework may grow luxuriantly, the distinction between medulla and cortex ceases to be apparent, the lymphatic system of canals disappears, and the whole organ becomes incapable of functioning.

The *development* of the lymphatic glands in the embryo, as well as their nature, was until quite recently entirely unknown. That their origin, together with the whole vascular system, was from the middle germinal plate, is all that was known about them. This had been demonstrated years ago by *Remak*. The labours of *Sertoli* and *Orth*, however, have recently thrown some light upon the subject as regards these points. According to the interesting, but by no means exhaustive treatise of the first of these observers, there may be seen in the mesenteric glands of the ox, in the first place, a system of lymphatic canals at that spot where the connective-tissue nucleus or hilus-stroma of *His* is to be found. Around this system a quantity of connective-tissue, rich in lymph corpuscles, is gradually developed, from which the cortical substance, in the first place, takes its rise, and then the lymph tubes of the medulla. The investing spaces and cavernous passages of the medulla make their appearance subsequently, as well as the capsule, septa, and reticulated tissue connected with the latter.

As to the *composition* of the lymph glands but little is known. They contain a certain amount of leucin as a product of decomposition, according to *Städeler*, and may also, it appears, contain uric acid, tyrosin (?), and xanthin (?) *Krause* and *Fischer* state the specific gravity of the organs in question to be 1.014 in the human being.

§ 227.

Nearly related to the organs we have just been considering, we find others which consist partly of single follicles, and partly of a number of the latter crowded together closely, and held thus by a peculiar connecting substance. These are mostly situated in the mucous membranes or submucous tissue. Among these may be reckoned, as occurring in the human being and mammalia, the so-called *trachoma glands* or *lymphoid follicles of the conjunctiva*, the *lingual follicular glands*, and *tonsils*, certain irregularly occurring *follicles of the gastric mucous membrane* (lenti-

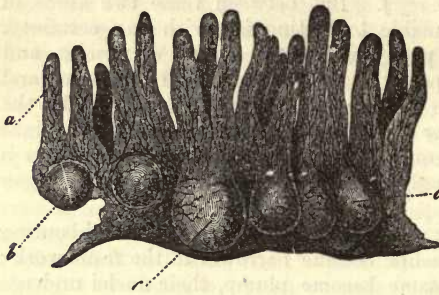


Fig. 411.—Vertical section of a Peyerian gland from the small intestine of the rabbit. a, villi; b, c, follicles.

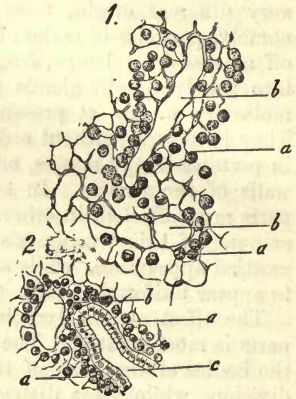


Fig. 412.—Reticular sustentacular tissue between the follicles of the vermiform appendix of the rabbit. 1. Deeper portion in horizontal section. a, framework; b, lymph canals. 2. Superficial portion; a, b, as in 1; c, depression in the mucous membrane lined with cylinder epithelium.

cular glands), and the *solitary* and *agminated glands* of the intestine, or *Peyer's patches* (fig. 411).

That large massive organ, the thymus, may also be mentioned as presenting a similar structure.

This whole group, including the lymphatic glands themselves, may be named with propriety the group of *lymphoid organs*. In addition to them we have, finally, the *spleen*, though no doubt a modified form.

In all those organs first mentioned, which belong to the mucous membranes, we find the follicle as the essential structure. It corresponds in its structure to the analogous elements of the lymphatic glands, and consists of a reticular substance enclosing lymph corpuscles (comp. fig. 400 and 412). This presents not unfrequently in its interior a loose and open-meshed appearance, whilst more superficially the network becomes denser, and further outwards still, on the surface, exceedingly close, just as we

have seen it in the lymph-nodes (§ 223). The vascularity of these mucous follicles is liable to vary to a considerable extent. In some of them, such as those of the conjunctiva, the capillaries only occur sparsely, in the form of very open interlacements; while in other cases we observe an extremely complex and delicate network, the tubes having, to a certain extent, a radiating arrangement when viewed in transverse section. Fig. 412, sketched from such a preparation of one of *Peyer's* patches from the rabbit, will serve as an example of the latter form.

These rounded follicles, sometimes spherical and at others vertically elongated, are situated either in the tissue of the mucous membrane itself, or when of considerable length, they project down into the submucosa. Their upper portion [the cupola (fig. 414, *d*)] may be covered by a thin layer of mucous tissue [conjunctival follicle (fig. 415)], but may also advance so far forwards as to be covered merely by an epithelial coating lying directly on the reticulated sustentacular tissue [tonsil *Peyer's* follicles (fig. 413)].

In the middle equatorial region [“mesial or equatorial zone” (fig. 414, *e*)] the follicle is connected to a greater or less extent with the adjacent parts; sometimes with the neighbouring mucous tissue, which in that case presents, for a certain distance, the same reticular character, containing also lymph corpuscles, and at other points with abutting follicles. Thus we see, for instance, in the vermiform appendix of the rabbit—a portion of the intestine consisting entirely of crowded oval follicles—that the latter are regularly united in the neighbourhood of their equator by bands of lymphoid tissue (fig. 412), whilst the whole lower half of the follicle (the base) exhibits the same continuous investing space as in the lymph nodes. The analogy, however, is even more perfect than might be inferred at first sight, for careful observation teaches that here also a system of fibrous septa exists, which, springing from the submucosa, passes under the follicles, and sends up partitions perpendicularly between them. These spaces are even lined by the same characteristic endothelial cells, as those seen in the lymph nodes, according to *His*.

Should these extensive investing spaces be absent, the follicles of each group are usually united to one another by means of reticular lymphoid tissue. The latter, in contradistinction to that of which the follicle itself is composed, exhibits a much closer texture, so that under the microscope it appears as a dense and non-transparent layer, within which the more

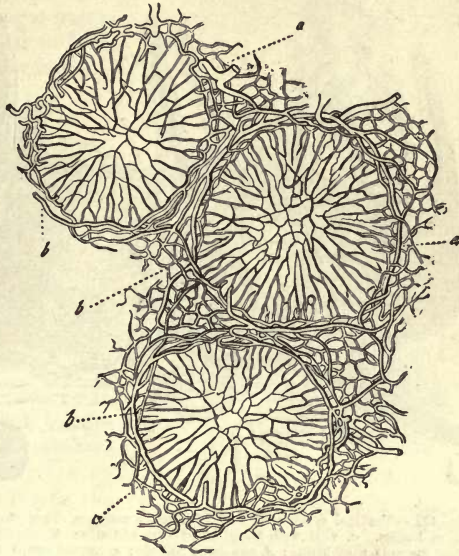


Fig. 413.—Transverse section through the equator of three *Peyer's* patches of the same animal, *a*, the capillary network; *b*, of the larger circular vessels.

loosely woven follicles are observed to lie. This condition of parts may be seen in the tonsils and conjunctival follicles.

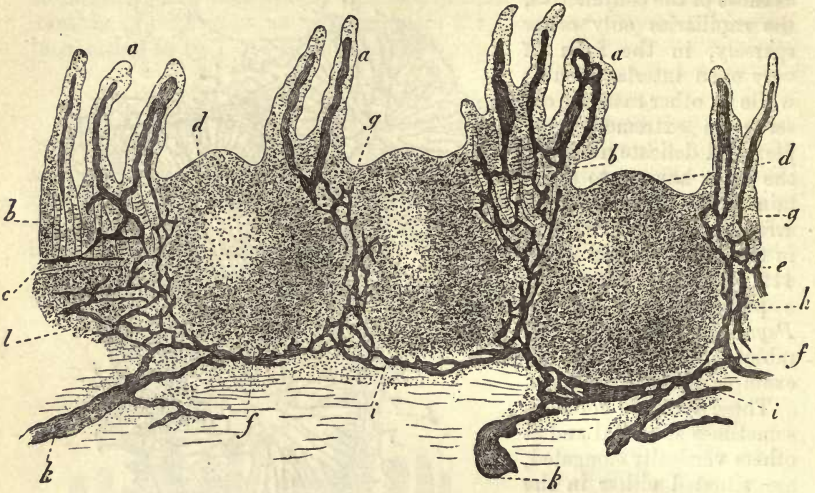


Fig. 414.—Vertical section of one of *Peyer's* patches from the human being, injected through the lymphatics. *a*, villi with their absorbent radicles; *b*, glands of *Lieberkühn*; *c*, muscular coat of the mucous membrane; *d*, cupola of follicle; *e*, mesial zone; *f*, base; *g*, passage of the chyle-radicles of the villi into the true mucous membrane; *h*, reticulated arrangement of the absorbents about the mesial zone; *i*, course of the latter at the bases of the follicles; and *k*, their confluence to form the lymphatics of the submucosa; *l*, follicular tissue of the latter.

When this arrangement prevails the investing spaces cannot be said to be entirely wanting, they are rather converted into a system of narrow passages, which interlace upon the surface of the follicle "like the net upon the surface of a child's toy Indian rubber ball."

The view that holds these passages around the follicle to be lymphatic canals is shown to be correct by injection (fig. 415). We observe that, from the surface of the mucous membrane, and mostly from the neighbourhood of the follicle generally, *e.g.*, in many of *Peyer's* patches, from the adjacent villi (fig. 414, *a*); and in the case of the conjunctival follicles from the mucous membrane, especially on the surface of the band of union (fig. 415, *c*); that lymphatic vessels which take the place of the *vas afferens* of the nodes are conducted to the surface of the follicle, either simply (fig. 415), or with a certain amount of complex interlacement (fig. 414, *g*). Arrived here, they open into either the investing space or its retiform equivalent (fig. 414, *h, i*; 415, *c*).

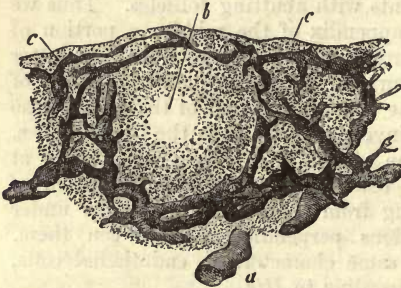


Fig. 415.—Trachoma gland from the ox in vertical section and with injected lymphatic canals. *a*, sub-mucous lymphatic vessel; *c*, distribution of the same to the passages of the follicle *b*.

Those submucous lymphatic vessels, which take on such a variety of forms (fig. 414, *k*; 415, *a*), are the conduits corresponding to the *vasa efferentia* of the lymph nodes; in short, the parallel between these

latter and the follicles of the mucous membrane is almost complete. The latter may be regarded as *small lymphatic glands occurring in mucous membranes*, with which view the similarity of the pathological changes occurring in them to those observed in lymphatic glands, is in perfect accordance.

§ 228.

The *thymus gland*, a double organ whose function is unknown, and which is, as far as we are at present aware, similar to a lymph node in structure, exists in full development only during the earlier periods of life, falling, later on, more and more a prey to fatty degeneration. Thus it is only exceptionally to be recognised in the bodies of older individuals.

The first point which we observe in the structure of the organ is that, besides being exquisitely lobulated, it possesses a very vascular fibrous envelope. Owing to the fact that the latter invests the internal mass but very loosely, the glandular tissue of each half of the organ may, after severance of the blood-vessels, be disentangled from it in the form of a band-like skein. The latter consists everywhere of a venous and arterial twig of accompanying lymphatic vessels, and a peculiar gland-duct, known as the *central canal*, upon which are situated, externally, the lobes and lobuli of the gland. When dissected out, the whole is of considerable length (fig. 416, 1). The central canal, which, according to *His*, has in the calf a diameter of only 0.7444 mm., is twisted up into a kind of spiral in the natural state, and the lobes are in close contact with one another.

If we proceed with our analysis, we find that each lobe is made up of a number of smaller lobuli, and the latter, enclosed within a vascular envelope of connective-tissue, are again composed of smaller polyhedral structures, flattened one against the other, whose diameter is 0.5640–1.1128

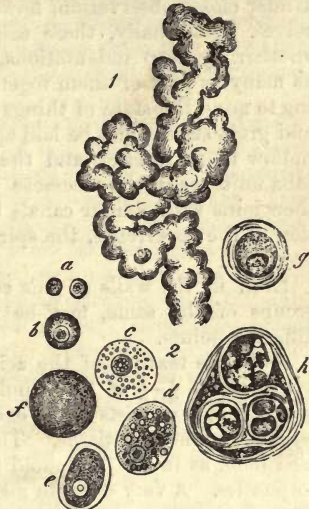

Fig. 416.—1. Upper portion of the thymus of a fetal pig of 2" in length, showing the bud-like lobuli and glandular elements. 2. Cells of the thymus, mostly from man; *a*, free nuclei; *b*, small cells; *c*, larger; *d*, larger, with oil globules, from the ox; *e*, *f*, cells completely filled with fat at *f*, without a nucleus; *g*, *h*, concentric bodies; *g*, an encapsulated nucleated cell; *h*, a composite structure of a similar nature.

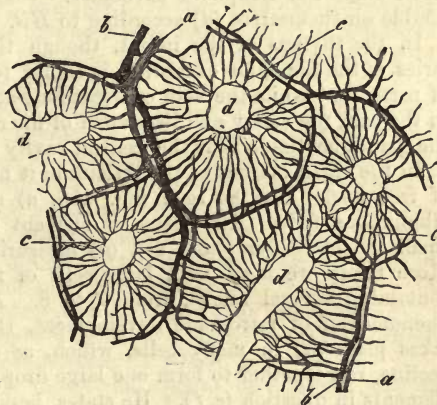


Fig. 417.—Portion of the thymus of a calf (after *His*), showing the arterial, *a*, and venous rings, *b*; the capillary network, *c*; and the cavities of the acini, *d*.

mm., or, in the calf, 1.1128–2.2256 mm.

These are the elements of the gland, the so-called *granules* or *acini* of the thymus. At first sight they remind us forcibly of lymphoid follicles. Under closer observation, however, important differences manifest themselves. Externally, these acini of the thymus are separated from one another by deep indentations, whereas, internally, they become united, as many as fifty of them together, to form a medium-sized lobe—recalling to mind the state of things observed in the racemose glands. Then—and great stress must be laid upon this point—the thymus element appears hollow in its interior, and the cavities of the thick-walled acini of each lobe unite, as in the racemose glands, to form its common passage. This then joins with similar canals belonging to other lobes, until, by a repetition of the occurrence, the spiral central canal of each half of the organ is produced.

Even in the walls of this common duct, bulgings or attached acini, or groups of the same, may be remarked, so that its thickness varies at different points.

As to the texture of the acinus, we find that the central cavity, occupying about $\frac{1}{4}$ – $\frac{1}{3}$ of the whole diameter, is bounded by a layer of soft tissue. This consists of an exceedingly dense network of stellate cells of reticular connective-tissue. The narrow meshes of this structure are occupied here, as in the lymphoid follicles, by an immense number of lymph corpuscles. A very delicate membrane, richly supplied with blood-vessels, covers its surface. The blood-vessels, farther, which traverse the follicular tissue, are also very numerous, and possess the well-known adventitia (§ 202). With the exception of a few stronger twigs, these are for the most part capillaries of 0.0063–0.0068 mm. in diameter. Injection of these brings out their arrangement in the most instructive manner.

From the larger vessels of the central band smaller twigs are given off to the lobuli. Here they eventually form (in the calf) delicate circular and arched groups of arterial and venous branches (fig. 417, *a, b*) around the individual acini. Springing from these the capillaries are seen internally (*c*) taking a convergent course, and forming a most exquisite network amid the lymphoid substance. Close to the central cavity they double on themselves (*d*) according to *His*.

In the thymus of the infant, though the arrangement of the capillaries is the same, an exception is so far to be seen to this arrangement of parts, that while the vein courses along at the periphery of the acinus as in the calf, the artery and its system of finer tubes occupies the interior of the glandular tissue near the central cavity in a manner wholly different.

In the small meshes of the reticulum it has been asserted that numbers of free nuclei may be seen (fig. 416, *a*) suspended in an acid, viscid, albuminous fluid. The essential element is, however, beyond doubt a small nucleated lymphoid cell (*b*) measuring 0.0074 mm. in diameter. More rarely we meet with large cells of from 0.0046 to 0.0023 mm., containing several nuclei, from 2 to 8. *Ecker* mentions further, as a phenomenon of retrograde development, that a deposit of fat globules takes place (*d*) in many cells, which, as soon as the organ is on the decline, run together to form one large drop, filling the whole body of the elements in question (*e, f*). He states, besides, that in older cells he has not unfrequently observed an absence of nuclei (*f*).

But there are other structures to be met with here which are by no means connected with the involution of the thymus; these are the so-called *concentric bodies*.

Around certain single cells, namely, which appear not unfrequently to be undergoing fatty metamorphosis, or again, about a group of the latter, we notice the formation of dense concentric layers, which may be seen on closer examination to be composed of flat nucleated cells, like pavement epithelia (*Ecker, Paulitzky*), reminding us of the formations in epithelial cancer, so well known to pathologists.

The smaller examples of these bodies (*g*) are formed of a group of cells, sometimes filled with granules, sometimes with fatty matter, and in some cases still possessing nuclei; which is surrounded by the thick laminated rind alluded to; they may attain a diameter of 0.0169–0.0208 mm. The larger structures of this kind (*h*), measuring 0.0593 mm., are formed by a repetition of the process enclosing several of these smaller corpuscles.

As regards the *lymphatics* of the thymus, we are still comparatively ignorant. That the chief stems accompany the arteries and veins through the central band, has been already remarked above; but besides these there are finer lymphatic vessels to be seen. These are found in the interstitial connective-tissue of the lobes, according to *His*, in the form of delicately walled tubes, only coursing round the latter. They are even stated by that observer to open into passages about 0.0226 mm. in breadth, filled with lymphoid cells, which spring from the centre of the acinus. Through these tubes a communication exists, according to *His*, between the central cavity and the lymphatic vessels, by means of which the cellular elements can pass into the latter.

From the fact, however, that up to the present no one has succeeded, by puncture, in filling lymphatic vessels around the acini of the thymus, (and my own numerous experiments also teach me that it cannot be done); and as the discoveries of more recent date, relating to lymphoid organs, do not seem favourable to the supposition of such an arrangement of parts as *His* describes, the matter would seem to call for closer investigation.

The final distribution of *nerves* in this organ is still enveloped in obscurity.

As to the *composition* of the thymus (whose specific gravity is stated at 1.046 by *Krause* and *Fischer*), analyses have been made by *Simon* and *Friedleben*. The former of these obtained from the organ of a calf three months old, about 77 per cent. of water, *circa* 4 of an albuminous substance, traces of fat and 2 per cent. of salts.

The thymus of the calf is further stated by *Gorup, Frerichs, Staedeler*, and *Scherer*, to contain large quantities of leucin, also hypoxanthin and xanthin, volatile fatty acids, such as acetic and formic; also succinic and lactic acids. The mineral constituents consist principally of phosphates and chlorides of the alkalis, with a preponderance of phosphoric acid and soda. The proportion likewise of the magnesian exceeds that of the lime salts. Sulphuric acid is only present in small traces. The presence of salts of ammonia is a fact of some interest (*Frerichs* and *Staedeler*). On the whole, its composition has some resemblance to that of muscle.

The development of the thymus was first explained by *Simon*, whose statements were subsequently corroborated by *Ecker*.

In the mammal, as far as has up to the present been ascertained, it appears first in the form of an elongated and closed sac lying in front of the carotids, which is filled with cells and granular contents. By a bulging of the walls of this, numerous rounded prominences are formed, in which we have the first indication of the future lobes. By a repetition of the process the capsule of the glands is eventually formed. A subse-

quent liquefaction of the central portion gives rise eventually to the formation of the central cavities. From fig. 416, 1, representing the gland of a foetal pig two inches long, in course of development, we may obtain some idea of the process, and understand better the structure of the gland at the period of maturity.

The retrograde development of the gland takes place with decrease of volume by the formation, as has been already remarked, of fat cells at the expense of the tissue, by which we are reminded of a similar metamorphosis in the lymph nodes (§ 226). That fatty degeneration of the gland cells also occurs, has been asserted, as we have already said, by *Ecker*. The time at which the retrograde process begins appears to vary; it lies between the eighth and twenty-fifth years.

§ 229.

We have still to consider in conclusion one other organ belonging to the lymphoid series, namely, the *spleen*.

Owing to the great difficulties attendant on the study of this organ, it remained until a comparatively recent date the subject of but brief and unsatisfactory research. But, lately, through the labours, especially, of *Gray*, *Billroth*, *Schweigger-Seidel*, but more than all of *W. Müller*, we have been made acquainted with the leading peculiarities of its structure. In the latter it resembles a lymph node, even more strongly than the thymus. In fact, the spleen may be regarded, as I myself expressed it many years ago, after careful consideration of the subject, as a lymph gland in which the system of lymphatic passages is replaced by the blood-vessels; it might be named, perhaps, with propriety a *blood lymph gland*.

The organ presents, in accordance with this view beside, a *fibrous envelope* with a system of *trabeculae* or *septa*, and a sheath-like formation of connective-tissue around the vessels, a soft glandular *parenchyma*. The latter is of two kinds; it presents itself, in the first place, in the form of *lymphoid follicles*, and in the next as a brownish red friable mass, known as the *pulp of the spleen*. The first of these correspond to the elements of the same name found in the lymph nodes; the latter is more or less a modified species of the medullary substance.

Beneath the serous covering, which may be isolated from the organ in the ruminant body, the fibrous envelope or *capsule* of the spleen appears. In man, on the contrary, this tunic is closely adherent to the investing peritoneum. It is seen, under the microscope, to be made up of a dense interlacement of connective-tissue fibrillæ, with a preponderance of fine elastic fibres, and contains also unstriped muscular elements. The latter are present in large numbers in many of the mammalia, as, for instance, in the sheep, dog, pig, horse, and hedgehog, especially in the deeper portions of the envelope. In other animals of this class they do not make their appearance in such quantities, as, for example, in the ox; while in man the contractile fibre cells are present in but small proportion.

The capsule which invests the whole spleen is folded in at the point of entry of the vessels and nerves,—the so-called *hilus*,—and is continued further inwards in the form of sheaths to the various vessels. It accompanies the ramifications of the latter (more strongly developed and massive around the arteries than the veins) down to their finest twigs. It exhibits, however, considerable variety in the various species of animals, a point to which we shall be obliged to refer again further on.

Besides the sheaths of the vessels, and continuous with them, we meet

with another prolongation of the fibrous envelope of the spleen directed inwards in the form of a system of septa. In the nature of the latter, as regards the spleen of the several mammalian animals, extraordinary variety has been observed. Just as was the case in the lymph nodes, it is but very slightly developed in the spleen of smaller mammals, as, for instance, in that of the mouse, the squirrel, the Guinea pig and rabbit, while in larger animals, as in horses, pigs, sheep, and oxen, it attains a high pitch of development. In man, and in the dog and cat, on the other hand, it is but moderately marked, reminding us of the lymph nodes again. The more numerous the trabeculæ in any spleen the harder is the organ found to be.

From the whole internal surface of the fibrous envelope there spring a multitude of fibrous cords and bands, varying as to their distance from one another, and as to the angle at which they are given off. Their diameter is about 0.1128–0.1279, or even 2.2556 mm. These *trabeculæ* of the spleen traverse the organ in all directions, uniting and again branching in the most irregular manner. They form, when in a state of perfect development, a very complicated sustentacular tissue. On the other side they are connected with the sheaths of the vessels, or continuous with the latter, especially the veins (*Tomsa*).

Within the innumerable irregular spaces,—formed by the intercommunication of these trabeculæ,—the glandular tissue of the spleen is contained. When the system of septa is fully developed, therefore, the spleen of the larger animals acquires necessarily a complexity of structure, rendering the recognition of its nature of great difficulty. On this account the spleen of smaller animals is the most suitable object for investigation, as was also the case with the lymph nodes.

In its more minute structure the tissue of the trabeculæ resembles that of the capsule. Here we find, again, a closely woven whitish connective-tissue, with nuclei and elastic fibres; in addition to these, also, longitudinally arranged muscular elements. The latter present themselves, either in all the septa, as in the case in the spleen of pigs, dogs, and cats (*Koelliker, Gray*), or, as is stated by many, only in the smaller trabeculæ. Thus it is in the ox and sheep (*Koelliker, Ecker, Billroth*). In man the number of muscle fibres is small.

§ 230.

Now, in the cavities already described in the preceding section, amid this system of trabeculæ, the *glandular* or *lymphoid portion* of the gland is contained. This consists, as we have already remarked, of a network of cords or bands, the *pulp tubes* analogous to, but not identical with, the lymph tubes of the medullary portion of the true lymphatic glands. In this, and connected with it, a number of lymphoid follicles are imbedded, discovered some centuries ago by *Malpighi*, and named in honour of him *Malpighian corpuscles* (*Milzkörperchen, Milzbläschen*).

In many respects these are exceedingly like the follicles of lymphatic glands. They are not, however, grouped peripherally to form, as in the latter, a cortical portion, but occur scattered throughout the whole of the pulp. Their relation and connection to the arterial part of the vascular system is very peculiar, calling for a few moments' consideration.

It is only rarely that, as among the ruminants, the splenic artery makes its entry into the spleen as one single trunk: it generally divides into several branches before doing so. Each of the latter then preserves in

the interior of the organ its own individuality as regards its ramifications. Soon after there commences a most extensive division and subdivision of

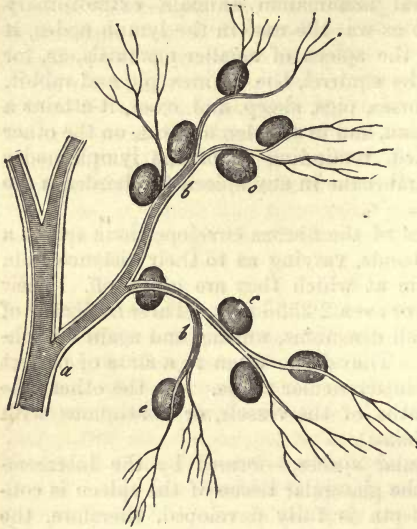


Fig. 418.—From the spleen of a pig. *a*, an arterial twig invested with its sheath, showing its twigs, *b*, and attached Malpighian corpuscles, *c*.

the vessels, until, finally, the latter, greatly diminished in size, form a series of terminal groups, which have been long compared to the hairs of a paint-brush. But a more appropriate comparison has been made between these "*Penicilli*" and the branches of a willow tree divested of its leaves. Fig. 418 gives a tolerable representation of the arrangement referred to.

Drawing such a branch out of the tissue of the spleen, we may recognise on it the follicles of which we have been speaking. They are of a whitish colour, and hang on the fine arterial twigs like grapes on their stalk. They are either attached by their border to the artery, or the latter traverse their interior; or, finally, the

angles of division of such a series of branches may be surrounded by numbers of them for a considerable distance. In form they are sometimes spheroidal, sometimes more or less elongated.

Such spleen corpuscles are to be found in all the mammalia, although presenting much variety. In the human organ, however, they are less distinct as a rule than elsewhere; and in bodies which have suffered from protracted illnesses they were formerly supposed not to exist, while in those in which death had occurred suddenly they were said to be always recognisable, even without the microscope; as also in youthful corpses (*von Hessling*). For this reason they were looked upon even years ago as integral portions of the human spleen.

If we follow up the disposal of the vessels commencing at the hilus, we soon remark that it is liable to vary greatly in different animals. The sheaths of these tubes also are no less subject to variation. Though very imperfectly developed in the Guinea pig, rabbit, squirrel, and marmot, they attain a high degree of development in other animals, as, for instance, in the dog and cat. There the arteries enter the spleen in several branches, each of the latter accompanied by a vein and one or two nerves. Both artery and vein while passing in receive a sheath, but not in the same way. Around the artery the latter is loose, and only runs for a short distance unchanged, undergoing rapidly a peculiar lymphoid transformation. The vein, on the contrary, is accompanied for a much greater distance by a tight investment, closely united to its walls. On the smaller venous twigs the latter resolves itself into a few bands of connective-tissue, which sink into the septa of the spleen. Deviations from this general plan are to be seen in the ruminants and the pig.

In man the arteries and veins arrive in the spleen, already divided into

from four to six branches. Down to twigs of about 0.2030 mm. they are contained in a common sheath, possessing a thickness of about 0.2256 mm. at its commencement. This investing formation then becomes gradually finer and finer, until reduced to a thickness of 0.1128 mm., enveloping in this state arteries having a diameter of 0.2256 mm., and veins of 0.4512 mm.

The arterial twigs with their sheaths then separate by degrees from the accompanying veins, and ramify independently. But about the venous tube the simple sheath extends somewhat farther still, becoming eventually split up into fibres, continuous with the trabeculæ of the organ (*W. Muller*).

These sheaths exhibit the same minute structure, farther, as the trabeculæ.

At those points, however, at which the arterial separates from the venous twig, the structure of the tunic of the former changes its nature. Its fibrous tissue is transformed into reticular lymphoid connective substance, together with which a decrease in its amount goes hand in hand. The advancing metamorphosis also, commencing externally, attacks eventually the proper tunic of the artery. Progressing still, this transformation, this construction of "lymph sheaths" gradually leads to more or less circumscribed swellings of different shapes, and these finally to the *Malpighian* corpuscles of the spleen (fig. 419, *a*). In fact, the latter, with their varied configuration sometimes roundish, in other instances elongated more or less, and possessing a diameter of 0.2256–0.7444, or on an average 0.3609 mm., take their origin from the infiltrated sheaths of the arteries, from which they can be by no means sharply defined.

Arterial twigs of 0.1579 and 0.0993 mm. in diameter, down to those of only 0.0203, are usually seen to possess this metamorphosed sheath, and may all acquire a great increase of size by its formation.

Owing, however, to the fact that the position of the artery is by no means always the same as regards this infiltrated sheath, further variety may be noticed. The former, namely, may pass either through the axis of these elongated masses or more laterally. In those parts, also, converted into follicles, we meet, at one time, with an eccentric course in the arterial twig, at another with a more central one.

This position, further, has an effect on the texture of the various parts of the sheath. In the lower degrees of transformation we usually meet with an ordinary loosely woven connective-tissue with lymph cells in its interstices. The same is the case with the sheaths of

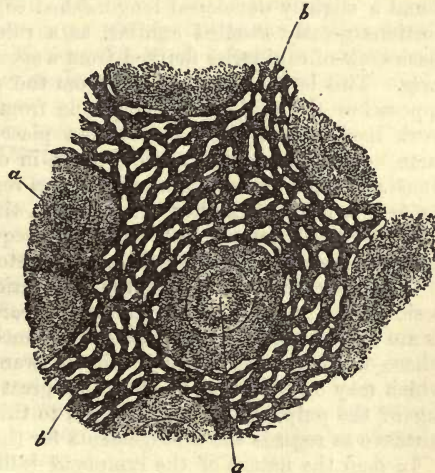


Fig. 419.—Section of the spleen of a rabbit. *a*, *Malpighian* corpuscle; *b*, sustentacular matter of the pulp, with the interspaces filled with venous blood.

the arterial twigs passing along the borders

of follicles. When, however, these take a course through a swollen point, or even eccentrically, or through a *Malpighian* corpuscle, the transformation usually goes farther, leading to the formation of a tissue nearly allied to lymphoid tissue. Whilst in the lower degree of lymphoid infiltration the sheath alone is affected, and not the proper adventitia, in the more advanced stages of the same the latter is drawn more and more within the circle of lymphoid metamorphosis.

Turning now to the follicle, we find the sustentacular tissue framework denser and more resistant peripherally, while within it possesses wider meshes, and is more delicate. At times the internal is marked off from the more cortical portion by a circular line, as in the rabbit, Guinea pig, and marmot. This arrangement, however, calls for closer investigation.

Here also, as in the lymph nodes, we may distinguish in some of the expanded nodal points distinct nuclei. The external demarcation of a *Malpighian* follicle is never produced by a homogeneous membrane enclosing it, but always by reticular connective-tissue, even at those points where by its denser texture its surface is sharply defined against the adjacent structures. In other cases the follicle is continuous, as to its delicate framework, with the surrounding tissue of the pulp, without any sharp line of limitation existing between them.

Entangled within the meshes of all these different portions, there appear, beside free (?) nuclei (*Müller*), a host of ordinary *lymph cells*, possessing as a rule but a single nucleus. Some of them, however, are multinuclear when very large. Beside these there occur, although in no great number, elements formed of colourless granular matter, or again containing molecules of a deep yellow or brown pigment.

As regards the *vessels* of those portions which have become infiltrated, and converted into follicles, there are also capillaries to be considered, besides those arterial twigs already referred to. Veins, on the other hand, are entirely absent. In parts but slightly infiltrated, is to be found a slightly developed long-meshed capillary network, whereas those portions greatly swelled exhibit, as a rule, a far more highly developed meshwork of capillaries derived from a special and rather variable arterial twig. This latter either springs from the artery of the follicle itself, or approaches the *Malpighian* corpuscle from without. The capillary network itself varies also; in the first place, in different follicles of the same organ, and in the second place, in different animals. It is sometimes met with presenting a more or less regular radiating arrangement of its capillaries with arched anastomoses, the tubes having a diameter of 0.0029–0.0081 mm. But far more frequently the disposal of these minute vessels is irregular both as to anastomosis, division, and diameter.

Observing the texture of the capillaries more closely, we recognise beside those presenting the ordinary appearance, with an adventitia, such as are seen, for instance, in reticular connective substance (§ 202), others whose walls are exceedingly delicate wanting the double contour, but which may on the other hand exhibit great richness in nuclei. In speaking of the pulp we shall refer again to this point, which is of great importance as regards the arrangements for the circulation in the spleen.

In man the nature of the lymphoid infiltration, and the mode of formation of follicles, is similar to that just described, although the transformed arterial sheaths, and their local thickenings, may display considerable variety. We must not forget, however, that we are obliged to undertake our researches into the nature of the human spleen under

much more unfavourable circumstances than when dealing with animals, namely, long after the death of the individual, and not unfrequently in cases where death has been produced by protracted illness. Nevertheless, we may easily satisfy ourselves as to the infiltration of the arterial sheaths, the local thickenings giving rise to follicular masses, and the analogous arrangement of the finer blood-vessels.

§ 231.

On passing beyond the lymphoid infiltrated investments, and also the follicles, the arterial twigs continue their course for a certain distance ramifying in the manner already described, but without any intercommunication among their branches.

Finally, they are resolved into a multitude of straight capillaries which anastomose only to a very small extent with one another. These are of rather fine calibre, and are not unfrequently very tortuous also. They pass on,—taken as a whole,—eventually into the finest vascular passages of the pulp.

Among the various mammals, however, the minute structure of these capillaries differs considerably. In the pig, the dog, the cat, and the hedgehog, most of them are (according to *Schweigger-Seidel, Müller*) enveloped in elliptical swellings of the adventitia. These "*capillary husks*," as they have been named by *Schweigger-Seidel*, which are of great frequency among the capillaries of the spleens of birds (*Müller*) consist of a pale, soft, and very finely granular mass, in which numerous delicate nuclei are imbedded. Their dimensions in the dog, cat, and hedgehog, are 0.0451–0.0600 mm. in breadth, and 0.0902–0.1489 mm. in length. The capillaries, enclosed either singly or in greater number in these husks, present the same two-fold constitution of their walls, already described in the foregoing section. Other capillaries of the same animals just mentioned do not, however, show these husks, and correspond thus with capillaries of man and the rest of the mammalia.

The latter present for the most part a strong wall, as far as their transition into the vascular passages of the pulp, while some of them are seen to be more delicate, more richly nucleated, or as though formed of single apparently distinct vascular cells.

Great variety, however, is seen among the lymphoid adventitiæ of such capillaries. They may appear to be made up of a delicate mass of connective substance, with round or elongated nuclei in the nodal points or interstices, but may also become thicker, obtaining a more or less fibrillated coat of connective-tissue externally, with a more loosely reticular portion internal to it, in whose interstices lymphoid and fusiform cells are situated; thus reminding us of the "*capillary husks*" between which and these there are intermediate forms.

In possession of these points regarding the structure of the capillaries, we may now at last turn to the consideration of the pulp. This is found to be a very soft red mass, occupying all the interstices of the organ between the partitions, vascular sheaths, follicles, and those other constituents already described. Its coarser and more minute structure is only recognisable after artificial hardening.

The pulp is made up of a *network* of irregularly formed *cords* and *bands* of a medium diameter of 0.0677–0.0226 mm. (fig. 420, *b*), which bound a system of spaces and cavities varying again according to the species of animal, but in every case designed for the reception of the

venous blood. The former or pulp tubes, like the lymph tubes of the lymphatic nodes, spring, in the first place, in great number, and with gradual transitions from the surface of the follicles. Here, as in the rabbit, Guinea-pig, hedgehog, and marmot, they may be, for the most part, concentrically arranged, the interspaces bounded by them naturally corresponding in direction. A similar origin of the pulp cords from the lymphoid infiltrated arterial sheaths as well as from the adventitiæ of the last ramifications of the arteries, may also be recognised. Eventually they are inserted into the fibrous trabeculæ of the interior.

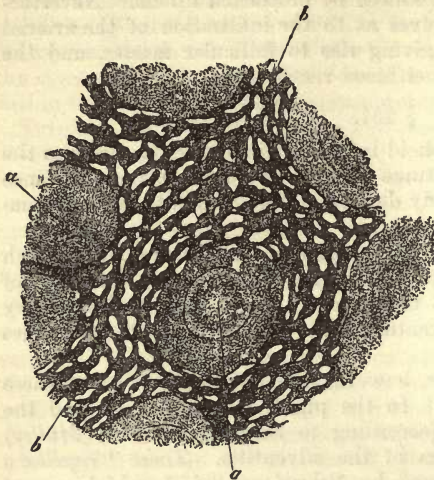


Fig. 420.

The tissue of the *pulp tubes* or *pulp cords* is a modification of the *reticular* connective species, and is of very delicate texture (fig. 421). It presents everywhere a reticulum usually of extremely fine fibres, but also of somewhat more expanded bands. In some of the nodal points nuclei appear

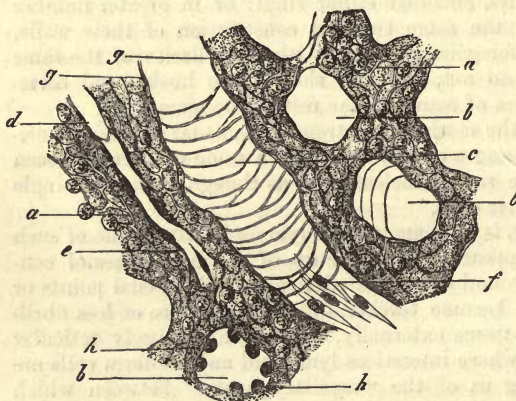


Fig. 421.—From the pulp of the human spleen. The preparation has been brushed out (combination). *a*, pulp cords with delicate reticulated sustentacular substance; *b*, transverse section of hollow venous canals; *c*, longitudinal section of the same; *d*, capillary in a pulp tube, dividing at *e*; *f*, epithelium of venous canals; *g*, side view of the same; and *h*, transverse section.

to be imbedded, although, owing to the great delicacy of the tissue, doubt still exists as to whether they are actually imbedded, or only adherent externally. If we now follow up the connections of this network towards the follicles or thickened points of the arteries, we recognise the fact that the reticulated tissue of the pulp is continuous with the coarser and tougher sustentacular matter of these parts; intermediate forms exist-

ing between the two kinds. If we now examine with special care the numerous venous passages, and the limitations of the pulp cords towards them, we soon convince ourselves here also of the reticular character of the tissue in question. If successful in obtaining a view of the floor of one of these venous passages, as at *c*, we will soon come to the conclusion—and to this *Henle* was the first to direct attention—that the tissue

of these pulp elements is composed of a network of fine circular fibres anastomosing at acute angles, which constitutes the boundary of the blood stream.

These venous passages are clothed with a peculiar species of vascular cells. The latter are, as regards form, fusiform elements (fig. 421, *f, g, h*), and present in man round and projecting nuclei. They lie in the long axis of the venous path, crossing, consequently, at right angles the meshes of the cellular network. They are non-adherent to one another—a peculiarity of the utmost importance—and on this account may easily present clefts between them if the venous passage be subjected to a more than ordinary distending force. Here, then, the distinctly impervious walls of other venous canals do not exist. The vascular cells in question have long been known, from the fact of their extending back into the larger venous trunks, but they were only recognised a few years since in the venous pulp passages by *Billroth*. They are to be seen with great distinctness in the human spleen.

In the small meshes of the network of the pulp cords are entangled the same lymphoid cellular elements in pairs or singly, which we have already mentioned when speaking of the follicles and metamorphosed sheaths of the vessels. Pigmentary cells, and even free aggregations of pigment granules, golden yellow, brownish, or black, occur with such frequency in many spleens, that even to the unaided eye the colour of the pulp presents great variety.

In addition to these elements a certain number of coloured blood corpuscles are regularly met with, at one time unchanged, at another twisted, distorted, and altered. In preparations which have been carefully managed, moreover, the important fact may be noticed with comparative ease, namely, that these corpuscles are situated in the meshes of the tissue of the pulp perfectly free, that is, unenclosed by any capillary walls.

On leaving the blood stream they undergo, in fact, changes of various kinds; they shrink, they become fissured, and are thus converted into those pigmentary molecules of different kinds already alluded to.

But the most remarkable feature in this decay of the red elements, is the production of those cells of the spleen containing coloured corpuscles, known now for many years. These structures, which were a puzzle to the observers of early times, and to which have been given consequently the most various signification, have been already considered at pp. 77, 78. Here, as in other organs, the vital contractility of the membraneless bodies of the lymphoid cells enables them to take up into their interior, not indeed the whole blood corpuscle, perhaps, but fragments of its substance. That the lymphoid cells of the spleen possess this power of contracting, I saw myself very clearly some years ago in water salamanders and frogs.

Later still the phenomenon was observed most extensively among mammals also, by *Cohnheim*, and in the embryos of the latter animals by *Peremeschko*. In conclusion, we would point out that, owing to the

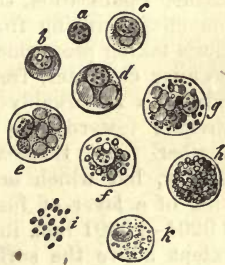

Fig. 422.—Cells from the spleen of man, the ox, and horse. *a-d*, from man; *a*, free nuclei; *b*, ordinary cell (lymphoid corpuscle); *c*, nucleated cell with a blood corpuscle (?) in the interior; *d*, with two such; *e*, the same from the ox with several; *f*, a cell from the latter animal with fat-like granules; *g-h*, from the horse; *g*, a cell containing several fresh blood corpuscles and granules, as in the last figure; *h*, cell with an agglomeration of granules; *i*, the same, free; *k*, a cell containing small colourless molecules.

incomplete nature of the walls of the venous passages, these cells, containing blood corpuscles in every stage of development, may make their way into the stream occupying these passages, and thus become elements of the splenic blood.

Besides these, *Funke* and *Koelliker* mention, as farther elements of the splenic pulp in young and sucking animals, other small yellowish nucleated cells, which they hold to be young blood corpuscles in process of development. Our own experience does not enable us to offer any remarks on this point.

§ 232.

We have still to consider the *course of the blood-vessels* and of the *lymphatics* in the organ with which we are engaged, and to glance at the *arrangement of its nerves*.

Commencing with the veins, we find them liable to vary greatly in different mammals. They are remarkable for their large calibre and great distensibility, even when the distending force is but very small, a peculiarity which explains the rapid physiological and morbid congestions with which this organ is affected.

Among the ruminants,—as, for instance, in the sheep and ox,—the *vena lienalis* enters the organ as a single trunk, parting with its *adventitia*, and soon after its *media*, to the surrounding connective-tissue sheath, and then divides into wide branches, which send off a number of lateral twigs, whose walls consist above of a very thin membrane, so that these appear on section as interstices in the parenchyma of the spleen. In their further ramification, these vessels present an arborescent appearance, the branches springing from them at right and acute angles, and no anastomosis taking place among them. Thus the whole arrangement assumes a peculiar character, from the fact that these venous ramifications (whose calibre is remarkably great), breaking up rapidly into finer twigs, are directed towards the numerous *Malpighian* follicles in greater or less number. All these venous tubules are possessed of walls of extreme tenuity, but which are usually entire nevertheless. They consist, as a rule, of a layer of fusiform cells, 0.0029–0.0079 mm. in breadth, and 0.0201–0.0501 mm. in length, whose elongated nuclei project to a small extent above the surface of the cell. Externally the finer twigs are enveloped in the reticular tissue of the pulp already mentioned.

Venous branches of this kind have been named by *Billroth* “capillary veins,” or “cavernous splenic veins.” They are met with in all the mammalia, though presenting much diversity as regards arrangement, by which again the form of the pulp-cords is also modified.

Whilst among the ruminants these cavernous veins pursue their course with acute angled division, and without anastomosis, they break up into branches among other animals, more or less, at right angles, in the primary dendroid ramifications, and communication amongst the twigs of the latter takes place, so that eventually, and by degrees, a regular network of like-sized venous canals, or more or less expanded passages, is formed. This reticular arrangement is seen, for instance, in the spleen of the rabbit, the Guinea-pig, the marmot, and likewise in man. In certain cases the spleen of the infant displays with peculiar beauty this retiform intercommunication of venous canals, and in such instances the lateral twigs springing from ensheathed trunks assume almost immediately a net-like character. I myself was the first to establish, in the year 1860,

their venous nature by means of injections, and it was from my preparations that *Billroth* became acquainted with them. Their diameter is, on an average, 0.0169–0.0226 mm., with extremes of 0.0113 and 0.0282 mm., and their structure precisely the same as in the sheep. A spleen of this kind, on the whole, presents, in regard to its pulp, great similarity to the medullary mass and medullary passages of lymphatic glands.

Here too, as in the sheep and all other mammals, the walls gradually assume a more and more interrupted character, by separation of their vascular cells, and thinning down of their cribriform substratum, so that clefts leading into the bounding pulp-cords are formed. Finally, diminished to 0.0158–0.0099, all the cavernous veins conduct the blood everywhere into the venous radicles with their fissured walls and defective vascular cell-lining.

§ 233.

Having now followed the cavernous venous passages down to their finest subdivisions, the lacunar venous radicles, bounded only by the tissue of the pulp, we next come to the important question so much discussed within the last few years, namely, *How does the blood from the ultimate ramifications of the arterial system find its way into the radicles of the venous?*

Many observers, among whom *Gray*, *Billroth*, and *Koelliker* may be mentioned, believe that fine terminal capillaries open immediately into the cavernous veins without having formed previously any true network. *Schweigger-Seidel* supposes the transition to take place through peculiar vessels formed of fusiform cells alone. The views, however, of *Key* and *Stieda* are quite different. According to them, there exists between the capillary ramifications of the arterial system and the cavernous veins an extremely dense network of most delicate capillary vessels with distinct walls, in whose tiny meshes the lymphoid cells are entangled, and which, in broad terms, constitute the pulp.

Many of these views are based upon the appearances produced by incomplete injection or improper interpretation of preparations good enough in themselves.

Thus it not unfrequently happens that we believe we see direct openings of capillaries into veins, which prove, on closer inspection, to be in almost all cases optical illusions.

We do not wish, however, to characterise these immediate transitions as impossible. We have, indeed, ourselves, during a long study of the subject, met with appearances hardly capable of any other interpretation; but their number was extremely small, so that the conclusion that they were only exceptional was forced upon us. Our own studies, therefore, compel us to dissent from the opinion of *Gray*, *Billroth*, and *Koelliker* on this point.

Key and *Stieda*, on the contrary, have determined the true mode of transition, but have mistaken an extremely dense reticulum of very delicate lacunar passages for a network of capillaries possessed of distinct walls.

The fact is, that the passage of the arterial blood of the spleen into the veins of the latter takes place in man and the mammalia generally in small streams, having no special bounding walls. The blood traverses the network of the pulp and interstices of the lymphoid cells contained in the latter in the same manner—if we may be allowed the comparison—as the water of a swelling river finds its way through the pebbles of its

bed. These interstices have been named the *intermediate pulp-passages*.

We have to thank *W. Müller* for being the first to place the existence of these lacunæ beyond doubt, although such an arrangement of parts had been already pointed out here and there. Our own observations on the spleens of the sheep, rabbit, Guinea-pig, mouse, mole, and human being, have led us to the same conclusions on the subject as those arrived at by the gentleman just mentioned.

To understand correctly, however, the nature of these pulp-passages, it will be necessary to return for a moment to those ultimate ramifications of the *arteria lienalis* already dealt with in section 230. There we considered fully the capillaries of the simply infiltrated arterial sheaths of the lymphoid swellings on the latter and of the *Malpighian* corpuscles. In all these parts, either the usual structure of the capillary tube was presented to us, or a modified and much thinner wall indicative of its approaching transformation.

But all these capillaries to which we referred make their way into the pulp of the spleen, becoming merged, after a shorter or longer course, in the wall-less passages of the tissue, either single or branching. We not unfrequently meet with spleens whose pulp must be said to be rich in

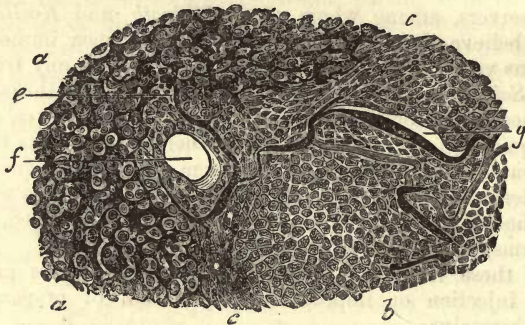


Fig. 423.—From the spleen of the hedgehog (after *W. Müller*). *a*, pulp with its intermediate streams; *b*, follicle; *c*, bounding layer of the same; *g*, its capillaries; *e*, transition of the same into the intermediate interstitial pulp-streams; *f*, transverse section of an artery at the border of the *Malpighian* corpuscle.

long capillaries, which occupy the axes of the pulp-cords in a way reminding us of the lymph tubes.

As to the mode now in which these capillaries run out, the following points may be recognised (fig. 423). The walls of the little vessels become, as they are about to run out, finer and thinner without exception, besides which they appear delicately granular, as well as richly studded, with nuclei imbedded in their substance. Subsequently we notice a regular fibrillation commencing in the tissue of the wall, the nuclei, with the portion of tissue adjacent, developing into separate bands and fibres, pale in colour, which are inserted continuously into the reticulum of the pulp. We are often uncertain, indeed, for some distance, whether we have still before us the passage of a capillary on the eve of termination, or a canal-like interstice of the pulp. Naturally, at these points, the matters injected into the capillaries find their way into the adjacent portions of the pulp.

Now, the latter, as the reader is already aware, is formed of a very narrow-meshed retiform sustentacular substance, whose interstices are occupied by lymphoid cells. Between these latter, and along the fine bands of the reticulum, we find that the injection (*a*) passes further into the pulp. If glue have been employed, the mass hardens subsequently in the form of thin but irregularly defined shell-like fragments around the lymph corpuscles of the pulp, broader at one spot than another. The diameter of each stream varies from about 0.0032 to 0.0090 mm., and is of course affected by the amount of force exercised in injection. The great distensibility of the spleen observed during both health and disease, and which is sufficiently known to every one who has devoted any time to its artificial injection, is in a great measure owing to this capacity for dilatation of the intermediate pulp-passages.

It was the contemplation of such appearances under the microscope which led to the view supported by many recent observers, that there exists in the pulp an intermediate network of very delicate capillaries, bounded by special walls. At the same time, the reticulum of the pulp was erroneously held to be formed of the collapsed canals of this net.

It is quite obvious that a slowly increasing pressure will fill a larger and larger portion of this system of interstices in the pulp. Thus we see the *Malpighian* corpuscles encircled by rings of the reticulated passages; and eventually the matter employed for injection may advance into the more superficial portions of the same, and give rise there to the same appearance of retiform interlacement.

But, finally, the injection (*b*) advances from the pulp (fig. 424, *a*) into the radicles of the veins (*c*) already known to us from the preceding section. To its progress there are no obstacles, from the fact that the radicles of the veins are nothing else than interstices found in the tissue of the pulp; and, therefore, enclosed by the same reticulated tissue which had been filled through the capillaries.

If, for the control of these artificial injections, other naturally filled spleens be carefully examined, in which the red blood-cells have been preserved by certain modes of treatment, and the whole hardened, we will observe that at the terminal portions of the capillaries these coloured elements are prolonged in wall-less passages between the lymph corpuscles, and at other points arranged together in similar rows and groups, which coalesce to form the wall-less radicles of the veins.

Thus seeing that both artificial and natural injection point to the same conclusions, we may venture to sum up as follows: the blood from the arterial capillaries is emptied into a system of intermediate passages, which are directly bounded by the cells and fibres of the network of the pulp, and from which the smallest venous radicles with their cribriform walls take origin.

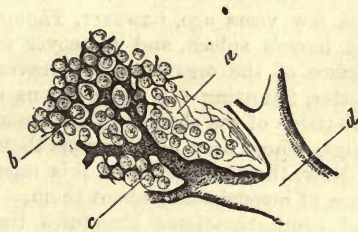


Fig. 424.—From the spleen of the sheep (double injection). *a*, sustentacular network of the pulp; *b*, intermediate pulp-passages; *c*, their transition into the venous radicles with their imperfect limitation; *d*, venous twig.

§ 234.

As regards the *lymphatics* of the spleen, it was for some time believed, from the results of injection, that it only possessed such vessels on its surface. These are situated underneath the serosa, and are arranged in a very complex network, in the ox, sheep, and pig, formed of valved vessels of considerable size (*Teichmann, Billroth, Frey*). In the first animals mentioned these vessels may be easily injected, and are seen then to present a number of bead-like dilatations at various points.

From the fact that during injection of the external vessels the matters employed for that purpose could not be forced into any deeper lymph passages in the parenchyma of the spleen, and that it had been already ascertained that the *Malpighian* corpuscle is not possessed of anything corresponding to the investing space of the lymph follicle, the spleen came to be regarded as an organ analogous to the lymph nodes, but in which the internal lymphatic passages are replaced by venous canals. The well-known participation of the organ in the life of the blood, the entrance of lymphatic cells into the venous stream, and the very probable destruction of multitudes of red corpuscles within the organ, all seem to justify its being declared a *blood lymph gland* (*Frey*).

Of course, the denial just mentioned of the existence of internal lymphatics led to contradictions of the older views, based upon the stated entrance of absorbent tubes at the hilus of the organ, together with the arteries and veins (*Ecker, Koelliker*, and others). While the superficial lymphatics, namely, were found to contain a pellucid fluid, those of the interior were stated to be filled with a coloured liquid reddened by the presence of blood-cells.

A few years ago, however, *Thomsa* demonstrated lymphatic vessels in the horse's spleen, and moreover in communication with those of the surface of the organ. They traverse partly the banded sustentacular matter, following the ramifications of the veins, and partly the connective-tissue of the sheaths of the vessels, together with the stronger arterial twigs, whose finer ramifications they completely ensheath eventually.

Now, the statements of this talented observer have not the slightest trace of inconsistency about them. Here, as elsewhere, we find muscular and connective-tissue structures traversed by lymphatic passages, and, owing to the lymphoid transformation which comes over these sheaths continuous on the other hand with ordinary connective-tissue, the lymph cells may be supplied to the fluid from such localities.

But when *Thomsa* states, further, that the final ramifications of the internal absorbents conduct eventually into the follicles and pulp, and there clothe the individual lymph corpuscles and agglomerations of blood-cells with ring-like passages, we cannot rid ourselves of the greatest doubt upon the point, nor avoid regarding what he has observed as probably the result of extravasation into a tissue we know to be so fragile. We can hardly conceive it possible, that beside the almost ubiquitous blood stream, unconfined by a definite wall, a similar lymph stream could have room to exist, and such an extensive peripheral mixture of lymph and blood would be without any analogy in all that has as yet been observed in the body in the two systems.

But whichever view is correct, the significance of the spleen as a blood lymph gland is by no means shaken.

The *nerves* of the spleen having their origin from the *plexus lienalis* of

the sympathetic, consist principally, and not unfrequently almost exclusively of pale elements already known under the name of *Remak's* fibres. They enter at the hilus, and pursue the same course as the ramifications of the arteries. The number of nerves supplying the organ is very considerable as a rule, but their mode of termination, judging from *Koelliker* and *Billroth's* observations in the sheep and ox, is still uncertain. Division of their trunks was observed by *Koelliker*, and *Ecker* probably saw terminal resolution. According to *W. Müller*, finally, there occur at certain points of the splenic nerves groups of cells like ganglion corpuscles: once only did he succeed in tracing a fibre into a capillary sheath in the spleen of a pig. We are tempted to ascribe to the structures in question a similar significance as the end capsules of *Krause* on the gland nerves (p. 327).

§ 235.

The spleen, whose sp. gr. is 1·058 (*Krause* and *Fischer*), contains 18–30 per cent. of organic matter, and an average of 0·5–1 per cent. of mineral constituents (*Oidtmann*).

That organic fluid of acid reaction, which saturates the tissue of the spleen, contains, according to *Scherer*, *Frerichs*, *Staedeler*, *Cloëtta*, and *Gorup*, a large number of interesting substances.

Among these may be named inosite, volatile fatty acids,—*e.g.*, formic, acetic, and butyric, also succinic, lactic, and uric acids. Among the bases we find, in the normal human spleen, considerable quantities of leucin, and a moderate, that is comparatively large amount of tyrosin (*Frerichs* and *Staedeler*). Xanthin and hypoxanthin are also encountered in the organ. Beside these, *Scherer* succeeded in obtaining non-carbonaceous pigments, a very interesting albuminous substance rich in iron, and much iron combined, it appears, with acetic and lactic acids. The peculiar constitution of the veins must provide for the passage of these matters into the circulation, but up to the present no analysis of the blood of the splenic vein has come upon them there (comp. p. 121).

Special attention has been bestowed by *Oidtmann* upon the mineral constituents, and among them he has found chlorine, phosphoric, sulphuric, and silicic acids, potash and soda (the latter preponderating), lime, magnesia, iron, manganese, and copper.

Turning, then, to the *physiological significance* of the spleen, so frequently a subject of debate, it is supposed to play an important part in the economy of the blood. It is believed to be concerned, namely, in the destruction of the blood-cells on the one hand; on the other, in the reproduction of the same. The first of these views may be defended, but not incontrovertibly proved in the present state of science; for although, in many spleens, the blood-cells are certainly very extensively destroyed, still a doubt exists whether this is anything more than an accidental occurrence. The second theory appears, however, more capable of proof. According to it the spleen may be regarded as analogous in function to the lymphatic nodes, producing the colourless cells of the pulp, which, on finding their way into the blood, are known there as white blood corpuscles, and which possibly, in part at least, undergo ere they leave the cavernous portions of the tissue of the spleen a transformation into coloured cells. The amount of blood in the organ, further, is influenced in various ways by its fibrous and muscular elements. The elasticity of the former opposes to every expansion an amount of resistance varying with the volume of

the contained blood, while the periodical activity of the muscular elements presided over by their nervous systems leads to the expulsion of the fluid contents of the spleen towards the point of least resistance, namely, the veins and lymphatic vessels, and so to a decrease of volume in the organ.

In support of the theory that the spleen is a species of accessory or modified lymphatic gland, providing for the reproduction of colourless blood-cells, we have, in the first place, the parallelism which exists in the changes taking place in both these organs in certain diseases, then the greater richness of the blood of the splenic vein in white elements (§ 70), and, finally, the analogous structure of the spleen and lymph nodes. This latter point, namely, that of similarity of structure between the spleen and lymphatic glands, is most easily demonstrable in the lizard and snake, in which a definitely enclosed stream of blood is seen to flow between certain follicular masses (*W. Müller*).

Gray's view is that the spleen serves the purpose of a reservoir for a certain quantity of the blood. *Schiff*, on the other hand, regards the organ as an auxiliary to the digestive apparatus, yielding to the pancreas its power of digesting albuminous matters.

The *origin* of the spleen, as far as at present known, is from a special aggregation of cells belonging to the middle germinal plate, and quite unconnected with the digestive organs. These cells are subsequently metamorphosed into the various tissues of which the organ is composed. The first rudiments are remarked at the end of the second month. According to *Remak*, the appearance of the *Malpighian* corpuscles is very early, but *Koelliker* believes, on the contrary, that it is only towards the end of intra-uterine life that they are formed.

Other conclusions, however, on these points have recently been arrived at by *Peremeschko*. According to him the spleen is developed as an *offshoot of the pancreas*. The envelope and trabeculæ, as well as the fine reticulated tissue of the pulp, is first formed; then the lymphoid cells, with numerous red blood corpuscles, make their appearance, at first in but small number; then, from the rapid increase in number of the lymphoid elements, numerous collections of the latter are formed in the sheaths of the arteries, giving rise, at a very early embryonic period, to the *Malpighian* corpuscles.

The numerous morbid changes in structure taking place in this organ require more careful attention than has up to the present been accorded to them, owing to insufficient acquaintance with the minute structure of the part. Among these a great increase of volume in the organ, associated with an excess of white corpuscles or leucæmia, has awakened much interest.

§ 236.

Pending a more satisfactory classification, impossible in the present state of histology, we shall for the present associate with the lymphoid parts a series of other organs whose functions are still a problem, and as to whose structure much doubt still exists on many points. These are the *thyroid gland*, the *supra-renal body*, and the *pituitary body*. For the present we may retain for them the old name of *blood-vascular glands*. In many cases they have already reached or passed their full development, as met with in the adult body, and are engaged in retrogression or processes of decay.

The *thyroid gland* is found to be made up of closed vesicles of roundish form embedded in vascular connective-tissue (fig. 425, *a*, *b*). These appear, at first sight, like closely grouped granules of 0.5641–1.1279 mm. in diameter, rounded or flat, and of a reddish-yellow colour. They are

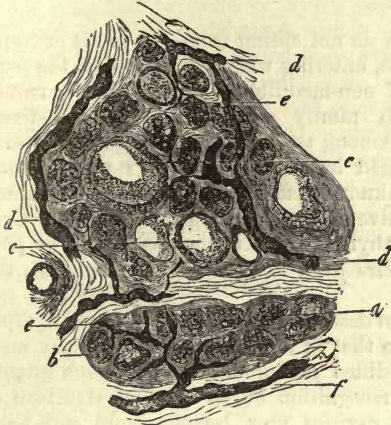


Fig. 425.—Two lobules from the thyroid of an infant. *a*, small glandular vesicles and their cells; *b*, the same with incipient colloid metamorphosis more strongly marked at *c*; *d*, coarse lymph canals; and *e*, fine radicals of the same; *f*, an efferent vessel of considerable size.

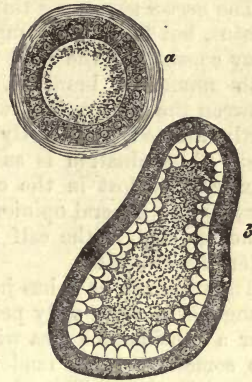


Fig. 426.—Colloid metamorphosis. *a*, glandular vesicle from the rabbit; *b*, incipient colloid metamorphosis from the calf.

again arranged in small lobules, and these in larger lobes, the consideration of which we leave for descriptive anatomy.

The stroma is made up of ordinary fibrillated connective-tissue of tolerably loose texture, mixed with elastic elements. The gland vesicles, 0.0501–0.1026 mm. in diameter, possess a limiting membrane formed of rather delicate homogeneous connective-tissue, which is enveloped externally in a dense round network of capillaries. The latter of a diameter of about 0.0072–0.0115 mm. in the dog, and 0.0088–0.0115 and 0.0114 mm. in the calf, are arranged in meshes of an average breadth of 0.0201–0.0226 mm. Their internal surface (fig. 426, *a*, *b*) is clothed with low cylindrical cells about 0.0196 mm. in height and 0.0113 mm. in breadth. These resemble epithelium, and contain nuclei of about 0.0086 in diameter (*Peremeschko*). The cells separate very easily from the walls in consequence of decomposition, and on their solution the nuclei become free. In the embryo the cavity of the round gland capsule is represented at first by a finely granular substance, in which cells and nuclei are embedded. Later on the growing cavity is usually seen to contain a homogeneous, transparent, and almost fluid substance, known as colloid matter (p. 21). By it the whole interior of the gland capsule is completely filled in the fully developed animal.

The recent researches of *Frey* and *Peremeschko* have made us acquainted with the *lymphatic vessels* of the part. The whole envelope of the organ is covered by knotted trunks, which take their origin from a network of very complicated canals, situated in a deeper layer of the former. This latter network is formed around the secondary lobules of the gland by the reticular intercommunications of these canals (fig. 425. *f*).

From the peripheral network formed of canals burrowing through the connective-tissue of the capsule, lateral ramifications are given off, which penetrate into the interior, and gradually enclose the primary lobes in complete rings, or more or less perfect arches (*d, d*). From these a few fine terminal passages with blind ends (*e*) are seen sinking in between the different vesicles.

The *nerves* supplying this organ do not spring from the vagus or hypoglossus, but from the sympathetic, entering with the vessels of the part. They consist for the most part of non-medullated fibres, forming trunks with numerous branches, which ramify amid the connective-tissue between the lobes and lobules. Among them may be seen ganglion cells, partly isolated, and partly arranged in groups of from 2 to 5. Their mode of termination is as yet unknown, except so far that fine terminal filaments are lost in the connective-tissue bounding the vesicles. Contrary to the general opinion, the thyroid gland cannot be said to be poor in nerves, nay, in the calf it appears even to be richly supplied with the latter (*Peremeschko*).

The structure, as it has just been described, undergoes, however, a rapid change, even at an early period, so that in the infant, even, we may meet over a considerable area with modified glandular tissue, in such quantities sometimes as to render the recognition of its original structure of some difficulty. The glandular cavities now become more and more filled with a homogeneous transparent and semifluid substance (fig. 425, *b, c*), a product of the transformation of the gland cells to which the name *colloid matter* has been given (fig. 426). Later on in life the cavities just described undergo in the human being a great increase in volume through increase of the colloid matters, and most unmistakably at the expense of the interstitial connective-tissue, which suffers compression. An extreme degree of colloid accumulation leads not unfrequently in man to a considerable enlargement of the whole organ, constituting that condition known as *goitre*, the *glandular struma* of *Ecker*.

This progressive colloid metamorphosis, in which small whitish semi-transparent points may be seen even with the naked eye, gives rise to compression of the interstitial connective-tissue, and with it of the lymphatic canals embedded in it. In consequence of this the absorbent apparatus decreases more and more in efficiency, while the blood-vessels, which remain pervious for a longer time, continue to supply material for a continuation of the colloid metamorphosis. Further accumulation of this substance leads to obliteration of the gland vesicles, the connective-tissue disappearing, and the cavities opening into one another. If we now examine a portion of the gland in which the process has advanced to this stage, each lobe appears as a pale yellow coloured jelly-like mass, enveloped in a network formed of the dwindling and half-macerated connective-tissue bundles. Finally, it may come to pass that a whole lobe is metamorphosed into a pellet of colloid matter. Hand in hand with these changes anatomical transformations take place in the gland cells, the latter becoming filled with the same substance, and finally undergo solution.

The views regarding the functions of the thyroid gland are still only hypothetical. The fluid which may be pressed out of its substance contains leucin, hypoxanthin, as well as volatile fatty acid, and lactic and succinic acids. The specific gravity of the organ has been set down by *Krause* and *Fischer* at 1.045.

From *Remak's* investigations as to its origin, it would appear that the thyroid springs in the form of a saccule from the middle line of the anterior wall of the pharynx, and is formed consequently in the same manner primarily as the glands of the intestine. Soon after, however, it becomes completely separated from the pharynx, and out of the single vesicle two sacs are formed by division, which assume a lobulated appearance from indentations and constrictions which are eventually developed on them. In the thickened walls of these sacs solid aggregations of cells are subsequently formed, which are developed later on into the gland vesicles of the organ, becoming invested with an envelope of connective-tissue, within which a certain amount of fluid collects among the elements. The large main vesicle on each side appears, likewise, to give origin to glandular elements, by undergoing constriction at various points, and seems thus to work its own obliteration. According to *Peremeschko*, we not unfrequently encounter division of the gland capsules as phenomena of growth. The thyroid gland is probably at its greatest pitch of development in the new-born infant, and becomes very sluggish in growth a few weeks after birth.

§ 237.

The *suprarenal bodies* (*glandulæ suprarenales*) have, on the other hand, a different origin from the last, namely, from the middle germinal plate. These are double organs, in regard to whose functions we are totally in the dark. Enclosed in a capsule they present considerable variety of substance, both from an anatomical and physiological point of view, and we may distinguish a cortical and medullary portion. The cortical substance is marked with radiating streaks in different animals, varying in colour from a brown or reddish, down to a whitish yellow, and is of a tolerably firm consistence. Contrasted with this the lighter greyish red or whitish medullary portion is less resistant. In man a dark narrow boundary zone may be observed between these two portions, usually yellowish brown, but at times greenish or blackish brown. After death this breaks down rapidly, and becoming fluid, causes the loosening of the medullary part of the organ from the rest.

The *envelope* (fig. 427, *c*) consists of connective-tissue with elastic elements. Externally it merges into formless areolar tissue, containing fat cells. Internally it gives off those numerous fibrous processes which traverse the organ, and in their ultimate arrangement form a framework within which the cells are enclosed.

Let us now glance at the *cortical substance* of the suprarenal bodies.

Those band-like processes just mentioned are tolerably strong, and take a slightly convergent course inwards, giving to the cortex, which in man is about 0.6767–0.1279 in thickness, a fibrous appearance, distinctly visible even to the unaided eye. From these numerous bundles of connective-tissue coming off, laterally intercommunicate with others also given off from the internal surface of the envelope, giving rise to a large number of glandular cavities. Near the surface of the organ these latter are generally short, but soon attain considerable length as they follow the course of the septa, assuming a columnar figure (fig. 427, *a, b*; 428, *a*). In transverse section, however, these rows of cells do not always appear round, but not unfrequently present to our view oblong, reniform, and crescentic configurations. Again, in profile, we may easily make out that such gland cylinders divide and give off branches at acute angles.

Further inwards still the cavities of the cortical portion become shorter and shorter, assuming, consequently, a more rounded form. From this point on there commences, in the strong and but slightly altered septa of connective-tissue, a rapid fibrillation, the fibres converging so that the further we advance towards the centre of the organ, the smaller do the interstices become. In the nodal points of this network we find nuclei, the general arrangement of parts resembling in many respects what we have already met with in lymphoid reticular connective substance (*Joesten*).

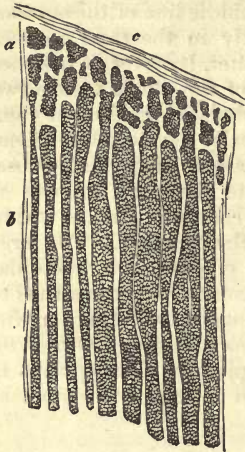


Fig. 427.—Cortical portion of the human suprarenal body in vertical section. *a*, small, and *b*, larger gland cylinders; *c*, capsule.

already alluded to, contain large quantities of brown pigmentary granules.

While the more internal and smaller meshes enclose but a few cells, the elongated and radiating compartments contain multitudes of them (fig. 428). The latter cavities are, besides, traversed by minute fibrous bands, forming a reticulum.

As to a *membrana propria*, each agglomeration of cells was formerly supposed to be enveloped in one, in the same manner as a glandular crypt (*Ecker*); but this covering certainly does not exist in our opinion.

Elucidation of the structure of the delicate *medullary substance* is attended with great difficulties.

We see, however, that at the inner border of the cortical portion the fine fibres of the framework, though very closely arranged, approach each other still more, and are inserted eventually into processes of a mass of tough connective-tissue, which occupies the centre of the organ enveloping the stronger blood-vessels, and especially the large veins.

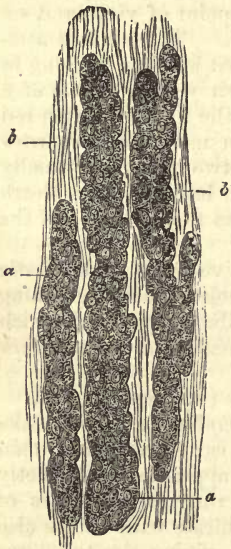


Fig. 428.—Cortical portion of human suprarenal body under high magnifying power. *a*, gland cylinders; *b*, interstitial connective-tissue.

Enclosed within this fine sustentacular substance of the medullary portion of the organ, a number of large oval cavities are to be seen. These exceed in size those of the cortex, but do not possess the same radiating arrangement; they lie rather with their broad surfaces towards the centre and surface of the organ. In man these medullary cavities appear to be generally smaller and rounder than in other animals.

These interstices are likewise occupied by naked cells, with beautiful vesicular nuclei and finely granular bodies. Fatty molecules are present, however, in this case in but small quantity. The dimensions of the cells (0.0180–0.0350 mm.) exceed those of the cortical elements. Owing to their softness, also, they accommodate themselves one to another. From the fact of their form being somewhat that of a thick angular plate, they recall to mind, when seen from the side, the appearance of columnar epithelium. It is a point worthy of note that, while the cells of the cortical portions of the organ are but slightly affected by the action of bichromate of potash, the bodies of these which are now under consideration acquire a deep tinge of brown from immersion in a solution of this salt (*Hentle*).

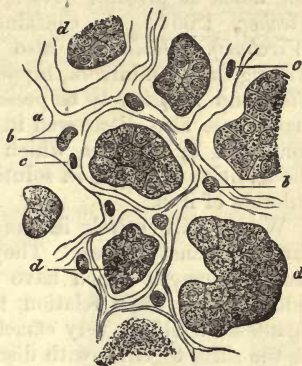


Fig. 429.—Transverse section through the cortical substance of the human suprarenal body. *a*, framework of connective-tissue; *b*, capillaries; *c*, nuclei; *d*, gland cells.

The *blood-vessels* of the suprarenal body offer many peculiarities for our consideration. They are very abundant in this organ. Multitudes of small arterial twigs, partly from the aorta and partly from the phrenic, celiac, lumbar, and renal trunks, penetrate into the interior of the suprarenal body with numerous ramifications, and break up there into a network of capillaries, whose elongated meshes are arranged in the direction of the radiating bands of tissue within the organ. These small tubes have a diameter of about 0.0059–0.0074 mm., and follow the course of the connective-tissue processes which traverse the cortical substance. The meshes formed by them, measuring about 0.0451–0.0564 mm. in length, and 0.0293–0.0201 mm. in breadth, invest eventually the many agglomerations of cells already alluded to. The medullary portion appears to have no true capillaries, and the cortex is certainly destitute of venous twigs.

On entering the medulla the arterial capillaries become larger, and form, by anastomosis, a number of vessels of considerable calibre. These, then, continue to join one with another at acute angles, maintaining, as a rule, the direction of the capillaries of the cortex. Thus the whole of the medulla becomes occupied, to a great extent, by an uncommonly highly developed venous network of tubes, measuring 0.0200–0.0293 mm. and upwards, with interspaces between them of 0.0200–0.0345 mm. The union of these vessels produces larger, which empty themselves into the usually single large venous trunk, situated in the centre of the organ. Thus we find the cortical portion traversed by a delicate arterial interlacement, and the medulla occupied by a coarse venous network.

As regards the *lymphatics* of the organ, we possess at present no reliable information.

The chief interest, however, which attaches to the medulla is owing to its great richness in nerves (*Bergmann*) which are arranged here in many mammals in a highly intricate plexus of microscopic minuteness, in which, according to *Holm*, ganglion cells may be recognised. Owing to this it has been surmised that the suprarenal body has some connection with the nervous system. The final termination of the nerves is still unknown. The cortical portion often appears to be utterly devoid of nerve fibres.

As regards the *composition* of the suprarenal body, we only possess a few notes at present. Its specific gravity is, according to *Krause* and *Fischer*, 1.054. It contains leucin and myelin in large quantities (*Virchow*). *Holm* has also met with inosite and taurin in the ox. Among the graminivora, hippuric and taurocholic acids are also stated by *Cloez* and *Vulpian* to be present in the organ in question (?) Another matter was also discovered in the medulla by *Vulpian*, and its presence confirmed by *Virchow*, which became red on exposure to the air and on the addition of iodine in solution, and blackish blue under the action of chloride of iron.

We are still entirely in the dark as to the *physiological* significance of the suprarenal bodies. They are, however, liable to undergo many morbid changes, which have recently become the subject of much consideration in their relation to the so-called *Morbus Addisonii*. This manifests itself in very emaciated subjects as a very deep discoloration of the skin, together with disorganisation of the suprarenal bodies. The tingeing of the skin is produced by the presence in the deeper layers of cells of the *rete mucosum* of either a diffuse or very finely molecular pigment of a yellowish or yellowish brown colour. That peculiar colouring matter in the boundary zone between the medullary and cortical portion of the organ which we have already considered above, is very possibly connected with this very obscure and enigmatical phenomenon.

The suprarenal body is developed at the same time as the kidney, but independent of it, from an aggregation of cells in the middle germinal plate. It is a curious fact, that during the earlier portion of intra-uterine existence these bodies at first exceed in magnitude the urine-secreting organs. At about the twelfth week in the human subject they are about equal the latter in size, and from that on they remain more or less stationary. The histogenesis of these organs, however, is not yet quite settled.

§ 238.

The pituitary body, or *hypophysis cerebri*, was formerly supposed to be a glandular structure, but was subsequently classed among the nervous organs.

Present in all five classes of vertebrata, but smallest in man and the mammalia, it consists in the latter of two portions or lobes. In the smaller posterior part, which is greyish in colour, we meet in a connective-tissue substratum with fine isolated nerve tubes, cells resembling ganglion corpuscles, a quantity of sustentacular connective-tissue, with fusiform cells and blood-vessels, but no glandular elements.

The anterior lobe, much larger and redder, has by no means the same structure. It is traversed by a canal according to *Peremeschko*, and, as was found many years ago by *Ecker*, it possesses great similarity with the so-called blood-vascular glands. Here we encounter, within a connective-tissue framework very richly supplied with blood-vessels, roundish or oval glandular cavities, measuring in man and among the mammalia 0.0496–0.0699 mm. These are occupied by cells of about 0.0140 mm. in diameter, with tolerably large and finely granular bodies. Here also we find, according to *Ecker* and *Peremeschko*, a colloid metamorphosis of the cells, like that which takes place in the thyroid gland. The canal, whose form is very various in different animals, is lined among the latter with flattened cells, which in man are ciliated. It is continuous with the

cavity of the infundibulum. Behind the canal the glandular tissue assumes a somewhat different character. Here we remark, besides, a finely granular mass and free nuclei, cells, whose bodies seem poor in granular substance. Colloid vesicles are also to be found here; the framework is formed of a somewhat more highly developed connective-tissue than elsewhere.

The pituitary body is richly supplied with interlacing capillaries, 0.0050 mm. in diameter, the anterior portion being most vascular (*Peremeschko*).

Some years ago an extraordinary little organ, of roundish figure, and about 2 mm. in diameter, was discovered by *Luschka*, which, owing to its position on the tip of the coccyx, he named *coccygeal gland*. The structure of this body, as described by the discoverer, resembles, if we except several peculiarities, in general that of the blood-vascular glands, namely, the hypophysis cerebri and suprarenal capsules. The subsequent researches of *Henle*, *Krause*, and *Koelliker*, have not shown any essential inaccuracies in his description.

Like the pituitary body, the coccygeal gland is placed at one extremity of the sympathetic chain; and, like the suprarenal capsule, it is rich in nervous elements. As glandular elements, it is stated to contain round vesicles and simple and branching follicles, imbedded in a tolerably solid connective-tissue interspersed with numerous elongated nuclei.

The coccygeal gland, which is very vascular, receives its blood from a branch of the *sacralis media*.

The accuracy of this description has, however, been recently questioned by *J. Arnold*, in toto. According to him, the organ does not contain glandular elements, but belongs rather to the vascular system, being composed of a multitude of saccules communicating with the arterial twigs of the part (fig. 430, *b, c*). When strongly marked these may form a system of convoluted diverticula, recalling to our minds the glomeruli of the kidney, and possessing always the same structure as the walls of arteries, with a strongly developed external layer of longitudinal muscle fibres (*h, i*). Groups of these saccules may open immediately into the arterial twigs (*a*), and are like them filled with blood; they may, however, owing to the fineness of the afferent and efferent blood-vessels (*d, e, f*), appear to be completely closed on all sides. These statements have, however, been again questioned. The glandular structure of the organ has once more been insisted on, the cells supposed by *Arnold* to be

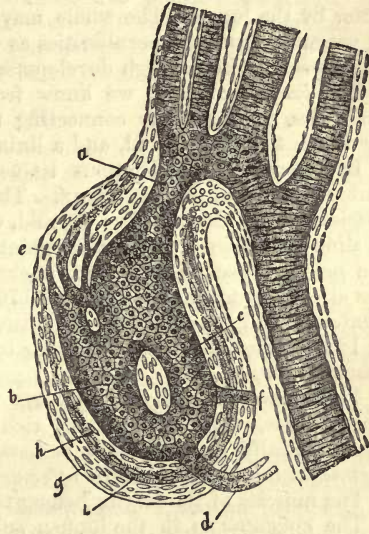


Fig. 430.—Vascular diverticulum, *b, c*, of the coccygeal gland lined with endothelium; *a*, afferent, *d*, efferent arterial twig; *e, f*, branches which break up into a capillary network; *h, i*, muscular tissue; *g*, envelope (after *Arnold*).

endothelium, are regarded now as covering vessels situated in its interior.

The so-called *ganglion intercaroticum*, which was found by *Luschka* to be very similar, as regards its microscopical appearance, to the coccygeal gland, has also been declared by *Arnold* to have the same peculiar vascular structure as the latter.

2. Respiratory Apparatus.

§ 239.

The *respiratory apparatus* is made up of a *system of branching canals* for the entrance and exit of air, and a *proper* respiratory part. The first of these is represented by the larynx trachea and its ramifications, the latter by the lungs. The whole may be compared to a racemose gland. It presents important peculiarities as well physiologically as anatomically, and especially in the high development of its elastic tissue.

The *larynx* consists, we know from descriptive anatomy, of several *cartilages*, the *ligaments* connecting these one with another, the *muscles* by which they are moved, and a lining of *mucous membrane*.

In describing cartilaginous tissue we have already referred to the various cartilages of the larynx. These afford examples of the different species of this tissue. The thyroid, crycoid, and arytenoid are formed of hyaline substance. At certain points in the latter, however, namely, in the *processus vocalis* and apex, a change into elastic cartilaginous tissue has already commenced (§ 107, p. 176). The cartilages of *Wrisberg* and *Santorini*, and the epiglottis, are entirely formed of the latter tissue (§ 108, p. 180), while the *c. triticea* appear to be principally composed of fibrous tissue (§ 109, p. 181).

The *ligaments* of the larynx are either almost entirely composed of elastic fibres, or are at least very rich in them (p. 229). Those in which the essentially elastic nature is best marked are the vocal cords, the *ligamenta thyreo-arytænoidea inferiora*.

The muscles of the larynx belong to the striped class (§ 164, p. 103).

The *epiglottis* is in the human subject covered on its anterior surface with a strongly laminated epithelium 0·2 or 0·3 mm. in depth, and on its posterior aspect with a much thinner bed, only 0·06 or 0·1 mm. The lower part of the latter is lined with laminated ciliary epithelium 0·15 mm. or even more in thickness.

The *mucous membrane*, which, especially in its deeper portions, is rich in elastic tissue, presents as a rule a smooth surface and tough texture.

At certain points, however, it presents larger or smaller papillæ, as on the true vocal cords. Its most superficial layer contains lymph corpuscles embedded in it close under the epithelium. These may be present in such number as to give rise to regular lymphoid follicles, single or grouped.

Finally, it is studded with numerous racemose mucous glands, either scattered or crowded together in certain situations. The bodies of these glands may lie embedded in depressions in the subjacent cartilage. It is by these organs that the mucus of the larynx is secreted. Their excretory canal appears thick-walled, and the acini are frequently elongated and clothed with low columnar cells.

From the base of the epiglottis and false vocal cords the *epithelium* (with the exception of that clothing the true cords, which is of the

laminated flattened species) consists of a slightly laminated layer of ciliated cells (1) (p. 149). Among these are scattered a certain number of beaker cells, which are also present in the trachea and its ramifications, according to *Gegenbaur* and *Knauff*.

The *nerves* supplying the larynx are branches of the *vagus*, namely, the *laryngeus superior*, composed of fine medullated fibres principally sensitive, and the *l. inferior*, formed of broad filaments, and essentially motor. Their ramifications have in many cases microscopically small ganglia connected with them. They are distributed to the muscles, the perichondrium, and the mucous membrane. Their terminal plexuses may be recognised in the latter, but not the ultimate ending of their primitive fibrillæ.

Nothing unusual is to be seen in regard to the *blood-vessels*. The *lymphatics* are numerous, and are arranged in the mucosa and sub-mucous layer in a superficial and deep network, which are not, however, sharply defined against one another in all cases (*Teichmann*).

§ 240.

The *trachea*, with its branches the *bronchi*, may be described as a ramifying tube, consisting of a strong fibrous tissue, in whose anterior wall lie embedded the *annuli cartilaginei*. Thus the fibrous tube presents in the first place perichondrium, and then the *ligamenta interannularia* connecting the half rings of the trachea one with the other, and finally closing the cartilaginous canal behind the *membrana transversa*. The latter is strengthened internally under the mucous membrane by a thick layer of muscular bundles, running for the greater part transversely.

The fibrous tissue of which the canal is principally formed possesses besides an abundance of elastic fibres (p. 229).

The *tracheal cartilages* belong to the hyaline species (§ 107), and have nothing remarkable about them.

The *muscular substance* of the wind-pipe is made up of smooth fibres (§ 163). It is about 0·8–1·2 mm. thick. The great abundance of elastic tissue present throughout the whole respiratory apparatus, allows also of the formation of beautiful elastic tendons, through which these muscles are attached to the perichondrium on the extremities of the *annuli cartilaginei*. External to these transverse muscular fibres there are frequently, though not invariably, found a number of scattered longitudinal bundles which take their rise from the fibrous wall of the canal (*Koelliker*).

The *mucous membrane* of the trachea, 0·13 or 0·15 mm. in thickness, contains a multitude of racemose mucous glands, in some instances small and simple, in others large and complex, in which case the body of the organ reaches deeper into the wall of the tube. The larger glands are situated partly between the rings of the trachea, and partly in the posterior wall, in which a regular layer of them presents itself.

The surface of the mucous membrane is clothed with *ciliated* epithelial cells, of 0·0594 mm. in height, interspersed with beaker cells.

The trachea is also richly supplied with *blood-vessels* and *lymphatics*. The latter are arranged in a superficial layer of minute canals, measuring in diameter 0·0678 mm., lying in the mucosa, and taking principally a longitudinal direction, and a deeper set of much larger tubes 0·0941 mm. in diameter. The course of these stronger trunks is, at least, partly transverse (*Teichmann*). The *nerves* of the part which are supplied by the sympathetic and inferior laryngeal require closer study.

§ 241.

We turn now to the consideration of the *lungs*.

These organs may, as regards form, be compared to racemose glands. This resemblance is also seen in their mode of development. The excretory canals are represented by the bronchial ramifications, and the *acini* by the air-vesicles. Besides these numerous blood-vessels, lymphatics, nerves, and connective-tissue structures enter into their composition.

The two bronchi, which, as is well known, divide again into two before their entry into the roots of the lungs, continue to sub-divide with the factor two, and at acute angles, on entry into the organ, so that a multitude of ever decreasing canals is soon formed. The cartilaginous supports lose from this on the character of rings, and assume rather the form of irregular plates and scales, which are no longer confined to the anterior wall, but for the rest, as far as their texture is concerned, differ in no respect from those of the trachea. The last traces of cartilaginous plates are only lost

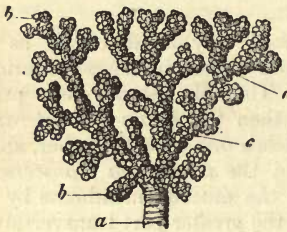


Fig. 431.—A portion of the lung of an ape (*Cercopithecus*) filled with quicksilver (after F. E. Schulze). *a*, end of a bronchial twig; *c*, alveolar passage; *b*, infundibula.

layer which, as we have seen in the foregoing section, exists in the trachea, forms around the bronchial passages a continuous tunic. It may be

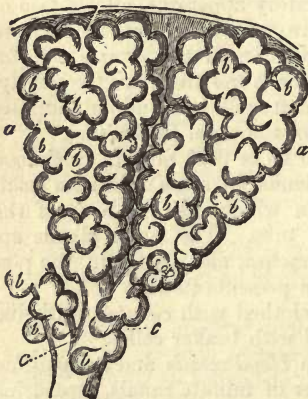

Fig. 432.—Two primary pulmonary lobuli or infundibuli (*a*) with the air-vesicles, *b*; and terminal bronchial tubes, *c*; which also bear some of the pulmonary vesicles, *b*.

in bronchial twigs of extreme fineness, *Gerlach* having found them in those of only 0.23 mm. diameter. The walls of these tubules present, but in decreasing strength, of course, the same fibrous layer that we have already seen in the trachea, and a mucous membrane with ciliated cells, which loses gradually its laminated structure, until there only remains at last but one single layer, 0.0135 mm. in height, of dwarfed cells (p. 149). *Racemose mucous glands*, likewise, present themselves here until we pass into canals of extreme fineness. The smooth muscular layer which, as we have seen in the foregoing section, exists in the trachea, forms around the bronchial passages a continuous tunic. It may be followed here, likewise, down to the very finest tubes, and is present possibly even in the neighbourhood of the air-vesicles, but is certainly not to be found on the latter. In the very finest tubes the mucous membrane and external fibrous layer become eventually fused into one single thin coat, made up of a homogeneous membrane surrounded externally by elastic fibres.

Owing to this progressive sub-division, together with which small lateral twigs are given off from the larger bronchi, a very complex system of branching passages is produced.

At the end of the last bronchial twigs (fig. 431, *a*), tubes of 0.3–0.2 mm. in diameter, we come upon the true respiratory part of the organ. This consists, in the first place, of thin-walled round canals of 0.4–0.2 mm. across. To these the name of *alveolar*

passages has been given by *Schulze* (fig 431, *b*; 432, *c*). They are subdivided again at acute angles, and end finally in peculiar dilatations (431, *b*; 432, *a*). These are the so-called *primary pulmonary lobules*. They are of short conical figure, and have received from *Rossignol* the name of *infundibula*.

These primary lobuli correspond, to a certain extent, with the primary lobules of the racemose glands, and are like them made up of terminal vesicles, as a rule roundish, but polyhedral when strongly distended. They are always met with on the surface of the organ in this form.

There is, however, a difference between the two. While the saccules, namely, of every genuine racemose gland remain more or less distinct from one another, the analogous parts of the respiratory organs, to which the names *air cells*, *pulmonary vesicles*, *alveoli*, or *Malpighian cells*, have been given, are far less isolated. They appear to be rather saccular dilatations in the walls of the primary lobules, in which no further canals are to be discovered, all the alveoli, on the contrary, opening

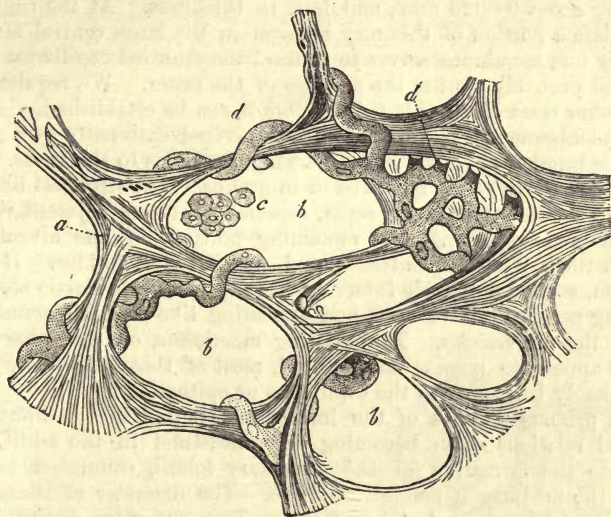

Fig. 433.—Transverse section through the substance of the lung of a child of nine months (after *Ecker*). *b*, a number of air vesicles enveloped in elastic fibrous networks which, together with a thin structureless membrane, form the walls of the same; *d*, a portion of the capillary network of the part, with its tendril-like tubes projecting into the cavities of the alveoli; *c*, remains of epithelium.

directly into a common cavity. In the adult body, moreover, absorption of the walls between the several air cells of an *infundibulum* may take place (*Adriani*).

The side walls of the alveolar passages are also thickly covered with numbers of similar pulmonary vesicles (fig. 431, *c*, *c*).

In sections of pulmonary tissue (fig. 433) the more or less round or oval form of the vesicles may be recognised in the open spaces of varying size brought into view (*b*), agreeable to the description just given.

The diameter of the alveoli is generally stated as ranging between 0.1128 and 0.3760 mm. Their great elasticity admits, of course, during life, of their dilatation to a great degree, so that, as we would expect, the vesicles are, at the end of inspiration, much larger than during expiration.

Complete collapse or distension of the air cells, however, never takes place under normal conditions in the lung. The possibility of this is precluded by the situation of the organ. This, namely, is hermetically sealed up within the cavity of the chest. On account of its distensibility, therefore, it follows all the motions of the thorax in inspiration, most accurately lying in contact with every part of the internal surface of the latter. Then, on account of its elastic nature, and aided by the muscles of its air passages, it contracts with every expiration as much as is admitted of by the walls of the chest. It never, however, goes so far as entire collapse, which is only reached naturally when the cavity of the thorax is laid open, on which it at once takes place.

If we now inquire into the texture of this elastic alveolus, which is constantly expanding and contracting during life, we will find a few points elucidated by fig. 433. The walls of the air vesicles, as continuations of the finest bronchial ramifications, present for our consideration, in the first place, an extremely delicate membrane of connective-tissue, measuring about 0.0023 mm., and less, in thickness. At the right side of the plate a portion of this may be seen in the large central alveolus. This very fine membrane serves to connect the crowded capillaries of the walls, and probably clothes the surfaces of the latter. We require, however, further research on this point before it can be established.

This membrane of the air cells is then covered externally by a greater or smaller number of elastic fibres, varying greatly as to thickness. They present themselves either scattered or in groups. The strongest fibres are to be seen in the interalveolar septa, especially between adjacent vesicles, closely packed together. The remaining portions of the alveolus are poorer in them than the entrance, and especially the fundus. Here are to be seen, scattered at wide intervals, the most delicate elastic elements, measuring perhaps 0.0011 mm., and appearing like reticular connections between the air vesicles. The limiting membrane, on the other hand, does not appear to possess many nuclei, most of those which are to be seen probably belonging to the capillaries or epithelia.

These primary lobules of the lung, best studied in the infant, the structural relations often becoming very indistinct in the adult, enter again into the formation of the secondary lobuli, connected together through the medium of connective-tissue. The diameter of these latter may be roughly estimated at 1 or 2 mm. They are more distinctly seen in the adult than in the infant, in the form of polygonal fields on the surface of the organ, marked out by the deposit between them of black pigment.

By the aggregation of these lobuli the larger lobes are gradually formed, the consideration of which belongs to descriptive anatomy.

It is a curious feature in the existence of the interstitial connective-tissue of the lung, that there is usually a certain amount (frequently very large) of black pigment deposited in it. The walls of the air vesicles, also, may likewise be affected in the same way; besides which, molecules of this substance are met with in the protoplasmic bodies of the smaller epithelial cells of the respiratory tubes, and in certain rounded corpuscles connected with the mucus of the part. We have already referred to the pigmentation of the bronchial glands (p. 418).

It was for a long time supposed that this pigmentation resulted from a deposit here of true melanin. But from the fact of its not being present in the lungs of wild animals, while in man, living in an atmosphere of

smoke, and loaded with soot, it is found in large quantities, it was inferred that the true origin of the pigmentation must lie in the inspiration of particles of carbonaceous matter. This view seems to be confirmed, farther, by observations made on the organs of those engaged in occupations which necessitate their breathing an air charged with suspended dust of various kinds, as, for instance, those of coal miners, whose lungs may be found to be perfectly black. It was also discovered that large fragments of wood charcoal often make their way into the air vesicles, and that the lungs of animals, when confined in sooty chambers, become quite black (*Knauff*). That a deposit of genuine melanin, however, does also take place in the lungs and air passages, as well as in the bronchial glands, is beyond doubt, but we are unfortunately unable as yet to distinguish between the two kinds of particles.

REMARKS.—A distinction between “*anthrakosis*” and “*melanosis*” of the respiratory organs may be made. The cells which we have given in fig. 95, frequent constituents of the sputa, are in many instances genuine melanin cells; but in other cases which may be set down as more the rule, the contractile body of the cell has taken up fine carbonaceous particles from without. We must confess, however, that the deposit of these matters in the interstitial connective-tissue of the lung and parenchyma of the bronchial glands is still a subject of great obscurity.

§ 242.

There now remain for our consideration but a few more structural relations in dealing with the lung. There are the arrangement of its blood and lymphatic vessels, epithelium of the air vesicles, nerves, and serous covering.

The *blood-vessels* of the organ receive their blood, as is well known, from two sources: firstly, from the bronchial; secondly, from the pulmonary arteries. The first of these serve the subordinate purpose of yielding nourishment to the tissue of the organ; the second are set apart for the requirements of respiration. The distinction between the two, however, is by no means sharp.

The *arteria pulmonalis* divides and subdivides, following the ramifications of the bronchi, and arrives thus with its twigs between the lobuli. Here a further splitting up occurs until very fine tubes are formed, which penetrate into the elastic band-work between the pulmonary vesicles (fig. 434), often sub-dividing still further in their course here. At the same time, the most extensive anastomosis takes place, so that imperfect or even complete rings are formed (*b*). From these a multitude of capillary tubes is given off to form the *respiratory capillary network*, which clothes the walls of the air-vesicles, only separated from the atmospheric air by the most delicate membrane.

This network (*a*) is remarkable for the great regularity and small size of its meshes. It may be reckoned among the densest, as also the most regular occurring in the body. The peculiar form of its wide capillaries is also striking. The diameter of the latter is about 0.0056–0.0113 mm..

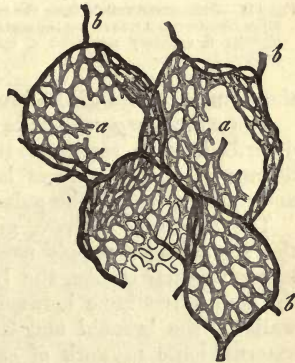


Fig. 434.—The respiratory capillary network of a horse's lung, injected after Gerlach's method. *b*, the end branches of the *arteria pulmonalis* encircling more or less the several pulmonary vesicles; *a*, the capillary system.

being sufficient to allow of the easy passage of the blood-cells. When the pulmonary vesicle is contracted, or but very slightly distended, they appear too long for the extent of surface to be covered by them, and project in the form of loops and tendril-like convolutions, pushing before them a portion of the delicate lining membrane of the alveolus (fig. 433, *d*).

But when the air-cells are strongly distended, these capillaries assume a much straighter direction, while the loops and projections into the vesicles disappear in a corresponding degree.

In muscle, also, which is constantly undergoing change in length, we find the same provision of nature. When contracted the longitudinal tubes of its capillary network assume a spiral course; when relaxed, on the other hand, they appear straight.

As to the walls of the capillaries, there is nothing remarkable about them. They are usually nucleated, and may easily be resolved into the well-known vascular cells (fig. 356, p. 363).

The meshes bounded by these tubes are very close, even in lungs which have been previously inflated (figs. 433, 434, 435). They may be more or less round or angular. They have a diameter of from 0.0393 to 0.0293 mm. That in the uninflated organ the meshes will be found much smaller than in the inflated, owing to their shrinking together, is quite evident.

The capillaries, further, of adjacent alveoli intercommunicate very extensively.

But the fine twigs of the pulmonary artery also, curious to say, form in another situation a wide-meshed capillary network, namely, under the pleura. Here they communicate with

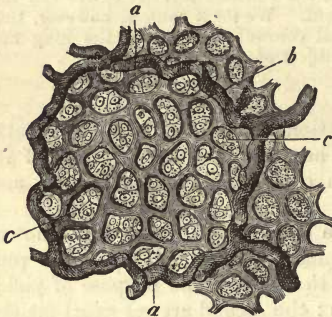


Fig. 435.—Pulmonary vesicle from the calf. *a*, large blood-vessels traversing the septa of the alveoli; *b*, capillary network; *c*, epithelial cells.

the terminal tubes of the bronchial arteries.

The *pulmonary veins* take their origin from the capillary networks just described, with scattered twigs in the interalveolar septa. The confluence of these produces larger trunks, which accompany the bronchi and ramifications of the pulmonary artery back to the root of the organ.

The *bronchial arteries*, giving off as a rule a single branch to each of the air passages, supply numerous twigs in the root of the lung to the larger vascular trunks, the lymphatic glands of that neighbourhood, and the connective-tissue between the lobuli and under the pleura. In the walls of the bronchi and their ramifications they are resolved into an external loose network of capillaries for the muscular tissue of the part, and an internal and much denser for the mucous membrane. In the latter, however, there is, besides, another coarser and more superficial capillary network, which does not appear to communicate in any way with that of the bronchial arteries. It belongs to the respiratory system proper, and may be injected easily from the *vena pulmonalis*, with difficulty from the *arteria pulmonalis*, and not at all from the bronchial arteries. From this we may infer that its radicals spring from the respiratory capillary network (*Henle*).

The arrangement of the *bronchial veins*, further, is peculiar. These pro-

ably only receive the blood returning from the thick walls of the larger bronchi, and from the lymphatic glands and pleura around the root of the organ. The finer and internal venous radicals, on the other hand, coming from the smaller divisions of the air passages, and which correspond to the distribution of the bronchial arteries, empty themselves into the branches of the pulmonary veins.

Lymphatics, as has long been known, are present in the lungs in considerable number. They may be divided into two classes: into superficial (arranged in retiform interlacements immediately under the serous covering of the organ); and into deep, which may be traced outwards along the air passages into the bronchial glands. Both of these sets of vessels communicate freely, however, with one another.

Not long since *Wywodzoff* was fortunate enough to succeed in injecting the radicals of the lymphatics in the walls of the alveoli in the lungs of the dog and horse, and *Sokorsky* also in the first named animal and in the cat. In these walls are found lacunæ, which are enlarged opposite the meshes of the capillaries. They cross the capillaries, without, however, forming sheaths of any kind around them. Soon after, however, the lymphatic canals as they pass away commence to occupy the adventitia of the blood-vessels.

We now come to the consideration of the *epithelium* of the air-cells—still a subject of controversy, and which has been recently the object of the most earnest investigation.

Turning then, in the first place, to the lung of the frog, we find the arrangement of parts of the simplest kind (fig. 436). The whole respiratory portion of the organ is lined with a single continuous layer of flattened nucleated epithelial cells.

But the lungs of the mammalia and man present greater difficulties.

Here we must first study the structure of the parts at an early period of existence, if we would understand it in the adult body.

In the mammal fœtus we likewise find a continuous epithelium lining both pulmonary vesicles and alveolar passages, and entirely the same in both. Its elements are flat polyhedral cells, with nucleus and protoplasm.

After birth, however, several changes become rapidly apparent, consequent upon the commencement of respiration. Only a small portion of the epithelium preserves its former character. Over the projections of the capillaries, and all other prominences, we can find much larger pale cells without protoplasm or nucleus in many cases.

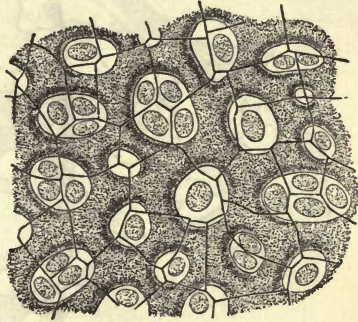


Fig. 436.—A portion of an air-cell from the lung of a frog.

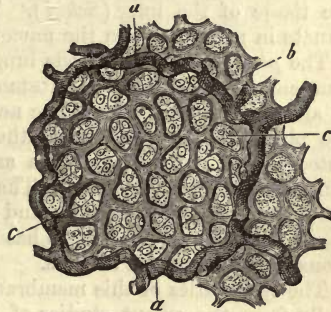


Fig. 437.

Fig. 437, after an old drawing, represents the original cells in the meshes of the capillary network of a young animal.

The condition of parts, on the other hand, in the mature mammal, is given in fig. 438. Here large non-nucleated plates are seen, with remnants of the original small cells, and a trace of the protoplasm and nucleus with them, at their points of contact and corners (*Schulze*).

The *nerves* of the organs of respiration spring from the anterior and posterior pulmonary plexus. They are derived partly from the sympathetic and partly from the vagus, and take the same course, to a great extent, as the ramifications of the bronchi or the pulmonary arteries.

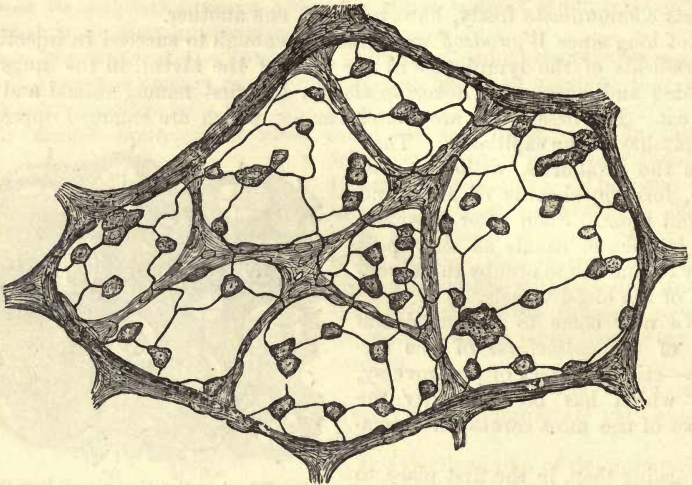


Fig. 438.—Epithelium from the base of an infundibulum situated immediately under the pleura. From a fully-grown cat; treated with nitrate of silver.

The pulmonary veins and bronchial arteries are not accompanied to the same extent by nervous twigs. On the external surface of the bronchi there are to be found, in connection with the latter, numerous small ganglia (*Remak*). The same are seen on the finer ramifications of the nerves in the tissue of the lung (*Schiff*). These nervous filaments appear to terminate in many cases in the mucous membrane of the bronchi.

The *pleural covering* of the lung and thorax presents, as far as epithelium and connective-tissue substances are concerned, the ordinary texture of all serous membranes. The nerves of the structure are derived from the phrenic, vagus, and sympathetic (*plexus pulmonalis*). Those distributed to the pulmonary pleura are stated by *Koelliker* to have scattered ganglion cells among them. The vascularity of the membrane is low, the capillaries being very fine, and forming wide meshes. The pulmonary pleura receives its vessels, as has been already mentioned, from the pulmonary and bronchial arteries.

The lymphatics of this membrane are to some extent well known, especially from the recent studies of *Dybkowsky*. In the dog they are only evident in the movable portions of the parietal layer, *i.e.*, in the intercostal spaces, and upon the *sterno costalis* muscles, but not upon the ribs. On the mediastinal portion they are only seen at those spots where collections of fat-cells exist.

The lymphatic network is very dense, and may be divided into two layers separated from one another by fibrous tissue. The superficial canals traverse the interstices of a reticulated layer of connective-tissue, the substratum of the serosa. Here their walls, composed of vascular cells, are covered solely by the epithelium of the membrane between whose cells those orifices already described in section 208, fig. 381, 2, 3, are situated.

Absorption from the cavity of the pleura is effected through the agency of the respiratory movements in the intercostal spaces, and the varying amount of tension to which the connective-tissue in which these canals are situated is subjected thereby. The contents of the networks formed by the latter are received by valved vessels running along the ribs towards the vertebral column and by the mammary twigs.

§ 243.

Turning now to the *composition* of the pulmonary tissue, we find that only of the products of decomposition occurring in the fluids with which it is saturated is anything really known. *Cloëtta* obtained inosite, taurin, and leucin from the lung of the ox. The human lungs, also, were found to contain leucin in considerable quantity. In the fœtus the organ yields glycogen (*Bernard, Rouget*).

The *development* of the lungs (fig. 439, 1) takes place very early in the same way as the large glands connected with the intestinal tube, namely, in the form of two hollow processes (*c*) attached by one stalk (*a*) to the anterior wall of the pharynx. This body is hollow from the very commencement. Both the internal and middle germinal plate are here represented, the former in the cellular layer (*c*), the latter in the fibrous wall of the part (*b*). From the cellular layer the epithelium of the respiratory tract is derived, while in the external investing mass we have the rudiments of all the fibrous and cartilaginous portions of the air-passages, bronchi, and lungs. From these blind tubes of the glandular plate an ever-increasing number of new sacculi (*d*) are now given off into the surrounding substance by means of cell-multiplication, so that the arborescent arrangement of the respiratory canals becomes more and more marked, as the enveloping layer decreases progressively in proportion. At the

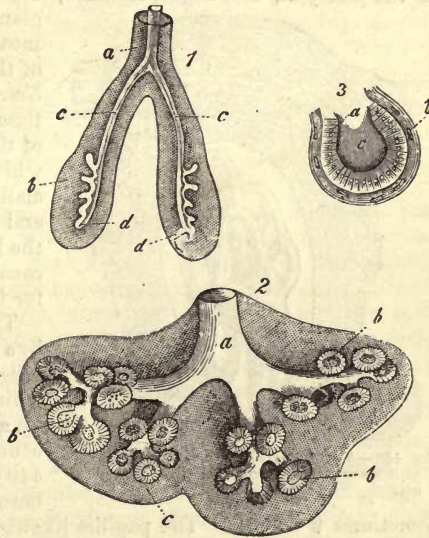


Fig. 439.—Development of the lungs. 1. Plan of the formation of the whole organ. *a*, common canal (the future trachea) dividing into (*c*) the two bronchi, with their incipient bud-like saccules, (*d*); *b*, the surrounding fibrous mass. 2. Ramifications farther advanced, from the lung of a human fœtus about four months old. *a*, the tube; *b*, lobulated dilatations lined with cylinder epithelium, from which the infundibula are formed apparently. 3. The same strongly magnified. *a*, cylinder epithelium; *c*, cavity; *b*, the investing fibrous layer, the remainder of *b*, fig. 1.

ends of the branches (2, *a*) there then appear round vesicular dilatations (*b*), lined with cylindrical cells (3, *a*), which by a process of gemmation are resolved into a number of finer loculi, from which then the infundibula or primary lobules are derived, and in all probability also their air-vesicles by a further sacculation of their walls.

The pulmonary tissue is subject to many *changes*. One senile metamorphosis consists in the disappearance of parts of the alveolar walls, and confluence of the air vesicles to form larger cavities, with consequent destruction of the capillaries contained in the interalveolar septa.

The occurrence of new growths here is an obscure subject, especially as regards their point of origin. This may probably be the nuclei of the vascular cells, or the epithelium of the lung.

3. The Digestive Apparatus.

§ 244.

The digestive apparatus consists of the *mouth* with its *teeth*, already described §§ 150 and 156, the *tongue*, and attached *salivary glands*, then of the *pharynx*, *oesophagus*, *stomach*, *large* and *small intestine*, the large

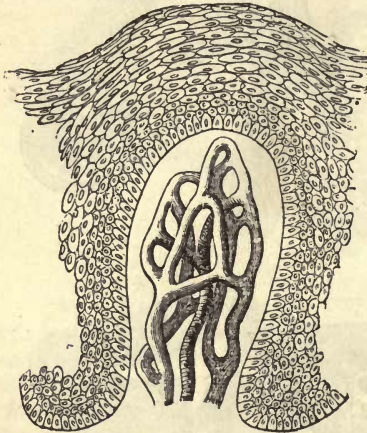


Fig. 440.—A papilla from the gum of an infant, with its vascular network and epithelial covering.

glands emptying their secretions into the upper portion of the last of these, namely, the *pancreas* and *liver*. Almost every variety of tissue takes part in the formation of this extensive group of organs, in which the *glandular elements* especially are pre-eminently important, and are found from the upper to the lower aperture of the alimentary canal forming a mucous covering for the whole internal surface.

The *cavity of the mouth* is lined by a mucous membrane of the texture roughly described already (§ 136), which is marked on its free surface by a multitude of closely crowded conical and filiform papillæ (fig. 440). The thickness of this membrane varies, its maximum being sometimes 0.45 mm. The papillæ likewise differ greatly in length, ranging from 0.23 mm. to 0.45 mm. The strongly laminated epithelial layer consists of flattened cells (fig. 444), which we have already considered at greater length at p. 141. At the opening of the mouth they are continuous with the cells of the epidermis.

This mucous membrane itself is rich in elastic fibres, and presents a network of connective-tissue bundles. It is denser towards the surface, upon which a homogeneous transparent limiting layer may be seen. In the papillæ here, as in those of the external skin, and still more in the villi of the intestine, the connective-tissue loses its fibrous character more or less, and presents itself in a rather undeveloped form.

Below, the mucous membrane gradually merges into submucous tissue. The latter is in some localities a solid fibrous mass, as in the case of the gum, and in others soft and elastic, with loose texture, as on the floor of

the mouth. In this substance are to be found globular groups of fat cells and the bodies of mucous glands.

The last named organs (fig. 442) present themselves in large numbers in the mucous membrane of the mouth. They measure in diameter from 4.5 and 2.3 down to 0.5640 mm., or even lower, and are usually situated in a row underneath the true mucosa, where they may be so closely

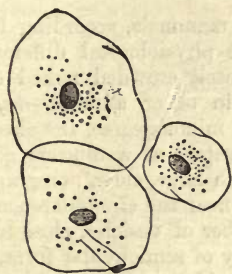


Fig. 441.—Epithelial cells from the most superficial layers of the mucous membrane of the human mouth.

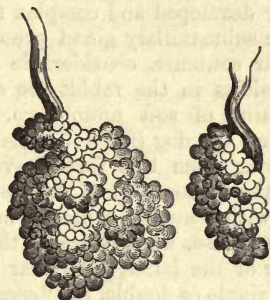

Fig. 442.—Racemose mucous glands from man (so-called palatal glands).

crowded as to form a regular special glandular stratum. From this their short and more or less straight ducts penetrate the mucous membrane, and open on the surface. Their structure is as elsewhere: for which see sections 198 and 197.

In certain localities these little glands, which play an important part in the production of the mucus of the mouth, are particularly numerous, and then receive special names. Such are the *labial*, *buccal*, and *palatal*. The first of these, which are very numerous, form, at some little distance from the red margin of the lip, a regular group. They are most numerous in the under lip (*Klein*). Their cells usually present themselves in the form of numerous low, clear, columnar elements, but slightly coloured by carmine, as was very correctly described by *Puky Akos*. According to *Heidenhain*, however, there occur also (in man and the rabbit) other smaller elements, richer in protoplasm, from the transformation of which the first take their rise. The little palatal glands, likewise, are arranged in a thick pad under the mucous membrane of the soft palate.

The *vascularity* of the mucous membrane of the mouth is very great, the capillaries forming a close network. In the papillæ we encounter either a single loop or congeries of vessels (fig. 440). We are still to a great extent in the dark as to the *lymphatics*. So much is known, however, that they interlace along the lips, the inner surface of the cheeks and the tongue, and covering the glands of the mouth, form interlacements, which communicate with the vessels of adjacent parts (*Teichmann*). The final distribution of the *nerves* of the mouth is a point on which even less is known. *Krause* observed end-bulbs upon them (§ 184), in the furrows of the mucous membrane on the floor of the mouth, near the tongue, in the soft palate, and in the tissue of the membrane, at the edge of the red margin of the lips, but not always in the papillæ. *Elin* states, on the other hand, that both in the hard and soft palate of the rabbit, fine nerve filaments penetrate into the epithelium, and (§ 245) terminate in ramifying cellular bodies (§ 187).

§ 245.

Until very recently, the *salivary glands* received but little attention from a histological point of view, but a step in the right direction has lately been made in the interesting studies of *Pflüger*, *Gianuzzi*, and *Heidenhain*, followed by a number of other observers.

These organs may from their form be regarded, to a certain extent, as highly developed and complex mucous glands.

The submaxillary gland presents in various mammals, according to its cellular contents, considerable and important physiological differences. Its vesicles in the rabbit are occupied by closely crowded naked cells, consisting of soft protoplasm. The organ in other animals—as, for instance, the dog (fig. 443), the cat, and in a minor degree, the sheep—departing from this form, have all the characters of a mucous gland. Here the greater part of the vesicle is filled with large, clear, non-granular cells, with a nucleus which is usually situated near the circumference (*a*). Besides these, we may see in the greater number of vesicles, close to the border of the latter, a peculiar element usually of semicircular form, and either single or double, the “*crescent*” of *Gianuzzi* (*c*). At first this appears to be a granular mass of protoplasm with imbedded nuclei, but after being subjected to a particular kind of treatment, it may be recognised to be a collection of small highly compressed cells. Other saccules contain protoplasm cells alone (*b*). These *crescents* reach the highest stage of development in the submaxillary of the cat.

The first of these elements—we shall give them the name of *mucous cells*—present, after maceration, the most remarkable irregularity of outline. They may, however, discharge their mucous contents, as we shall see later on, and then present protoplasm only.

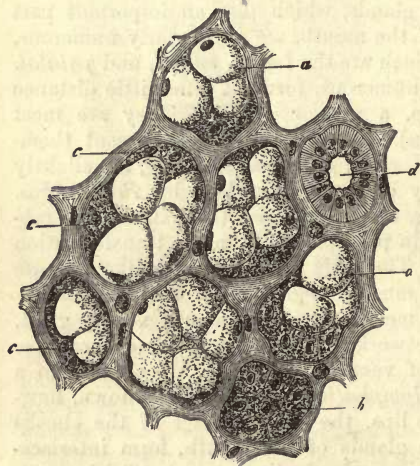


Fig. 443.—Submaxillary gland from the dog. *a*, mucous cells; *b*, protoplasm cells; *c*, “*crescent*” of *Gianuzzi*; *d*, transverse section of an excretory duct with its special columnar epithelium.

Intermediate forms teach us that these mucous cells are not specifically different from those of the *crescent*, or *border cells*, but only so on account of their having become altered and undergone mucous metamorphosis. In newly born animals they are not yet to be found. The submaxillary glands of man, likewise (specific gravity of 1.041, according to *Krause* and *Fischer*), contain the same mucous cells, which require, however, closer investigation.

For a long time it was maintained that the submaxillary gland possessed, most unquestionably, a structureless *membrana propria*. More recent investigations, however, have shown that the boundary layer is only formed of greatly flattened cells of stellate figure, which probably belong to the connective-tissue group (*Heidenhain*, *Koelliker*), § 194.

We have already referred (p. 350, fig. 339) to a network of fine secreting tubules or canaliculi, which have been met with in the acini of many racemose glands. These are also to be found in the submaxillary glands (*Pflüger*, *Ewald*, and others). Even uninjected, they can be recognised as a network of clear, somewhat lustrous, streaks of 0.002-0.003 mm. in diameter.

How far a recently observed connective-tissue reticulum (*Boll*), which traverses the acinus, has anything to say to these secretion tubules, or is connected with the wall cells of the membrana propria, are points which require closer investigation.

The walls of the excretory duct are made up of connective-tissue. A thin layer of muscular cells, difficult of recognition, has been stated by *Koelliker* to occur here; these have not, however, been found by others (*Eberth*, *Henle*). The epithelial lining consists of a single layer of cylinder cells (*d*), in whose bodies we may recognise distinct and persistent longitudinal markings (*Pflüger*) underneath the nucleus.

The vascular networks are, as in most racemose glands, round. The capillaries lie loosely about the glandular vesicles, while their tubes of supply and overflow accompany the ramifications of the ducts.

The recent investigations of *Gianuzzi* have made us acquainted with the lymphatics of the salivary glands of the dog. Here they appear as clefts in the interstitial connective-tissue between the lobuli and vesicles, as well as around the lobes of the organ. They are stated, also, to

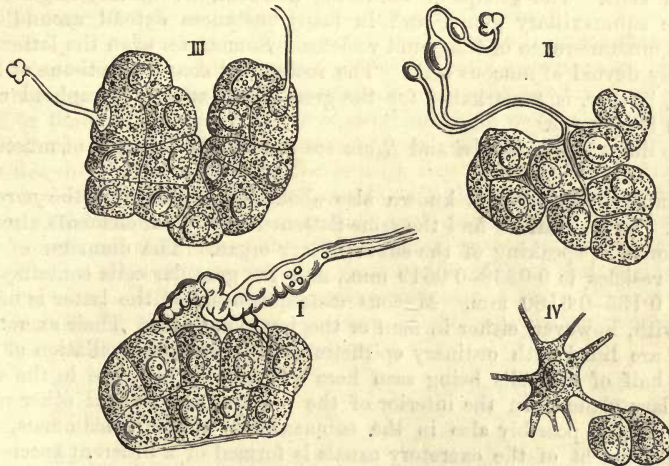


Fig. 414.—Mode of termination of the nerves in the submaxillary gland of the rabbit, after *Pflüger*. In I. and II. the nerves penetrate into the gland vesicles, and end between the cells of the latter. In III. the termination of a nerve fibre in the nucleus of a gland cell is observed. IV. the same, with a "ganglion cell."

ensheath the venous and arterial twigs before becoming developed into regular lymphatic vessels.

The mode of termination of the nerves of the submaxillary gland is very remarkable and important, though not, perhaps, in some cases ascertained beyond all doubt. After some earlier studies by *Krause*, *Reich*, and *Schlüter*, the point was taken up and pursued with much vigour by that excellent observer, *Pflüger*, taking the rabbit as subject

(see § 183). The following are the conclusions drawn from his investigations. In the first place, medullated nerve fibres make their way as far as the gland vesicles, then pierce the membrana propria of the latter (fig. 444, I.), and so get between the cells of the gland. The terminal filaments, however, advance still further (II.), penetrating into the very body of the cells, and end in the nuclei of the latter (III.)

The nerve fibres, further, are connected with multipolar cells declared by *Pflüger* to be ganglion corpuscles. These are situated on the external aspect of the membrana propria (IV.), sending their processes from thence into the protoplasm of the gland cells.

Pflüger describes, finally, another set of fibres which become resolved into pencils of the most delicate primitive fibrillæ, which become fused eventually with the bodies of the epithelial cells lining the ducts. These it is which produce that longitudinal striation beneath the nucleus already spoken of.

For the present we defer giving any opinion as to these statements, but must just remark that we have never been able to find anything of the kind, and have already described the ganglion corpuscles alone as connective-tissue cells, entering into the structure of the walls of the gland vesicles.

But little attention has, up to the present, been given to the texture of the *sublingual glands*. From *Heidenhain* we learn that in the dog they appear to be very similar in structure to the submaxillary, and to have likewise two kinds of cellular contents, mucous elements surrounded by border cells. The groups of the latter, however, are usually larger than in the submaxillary gland, and in many instances extend around the whole circumference of the gland vesicles. Sometimes even the latter are entirely devoid of mucous cells. The interstitial connective-tissue of this gland, farther, is remarkable for the great abundance of lymphoid cells which it contains.

The ducts of *Bartholini* and *Rivin* are completely destitute of muscular fibres.

Comparatively little is known also about the structure of the *parotid gland*. In its wall we find the same flattened multipolar elements already mentioned in speaking of the submaxillary organ. The diameter of the gland-vesicles is 0.0338–0.0519 mm., and the granular cells contained in them 0.135–0.0180 mm. Mucous metamorphosis of the latter is never met with, however, either in man or the lower animals. Their excretory ducts are lined with ordinary epithelium, none of that fibrillation of the lower half of the cells being seen here which is to be found in the submaxillary gland. In the interior of the parotid, and several other racemose glands, possibly also in the submaxillary of many mammals, the commencement of the excretory canals is formed of a different species of cells, the so-called "centro acinal" cells first discovered by *Langerhans* in the pancreas (see below). These are flat elements resembling vascular epithelium usually of spindle or more rarely stellate figure. They bound an axial canal of the acinus more or less perfectly. According to *Pflüger* the termination of the nerves is the same, as in the submaxillary gland of the rabbit.

The development of the salivary glands is on the same plan as the racemose. They commence to be formed in the human embryo in the latter half of the second month. They are then seen as solid aggregations of cells from which they are developed by gemmation. At the third month they are already pretty well marked.

§ 246.

The *saliva*, as found in the human mouth, is a very complex mixture of the secretions of different organs connected with that cavity. In the first place of the matters produced by the numerous little mucous glands already described § 244, then of those secreted by the parotid submaxillary and sublingual glands. Under certain circumstances, also, the secretions of the mucous membranes of the nose and lachrymal gland are likewise mixed with it. We shall first enter upon the consideration of the variety of composition of this fluid as a whole, and then turn to what has up to the present been ascertained in regard to the individual secretions from a physiological and chemical point of view.

The saliva, taken as a whole, is a colourless, slightly clouded, and somewhat viscid fluid without either odour or taste. Its reaction is generally alkaline or neutral, more rarely acid. Its sp. gr. ranges between 1·004 and 1·009.

Under the microscope this fluid is found to contain cast-off epithelium, and at times gland cells which have been washed out of their original position. As a third and never absent element, we meet with great numbers of what have been named *salivary corpuscles* (mucous corpuscles). The latter present the same appearances as lymph cells which have become swollen in water. Within their bodies, as long as they are uninjured, a lively movement of small molecules may be perceived. This motion was always regarded as of the ordinary molecular species, until lately, when *Brücke* came forward to oppose the theory.

Turning to the chemical analysis of the secretion, we find that it contains between five and ten parts per 1000 of solid constituents. Among the organic matters the most important is a ferment combined with alkalis or lime, called by *Berzelius ptyalin* insoluble in alcohol, slightly so in water. It has not yet, however, been obtained in a pure state. Besides this, leucin is probably present (?) also mucin, extractive matters, fats, and combinations of the fatty acids with the alkalies. Urea has also been found as an abnormal or pathological constituent. The inorganic compounds are chlorides of the alkalies, small quantities of phosphates of the alkalies and earths, carbonates, some oxide of iron, and besides,—at least in man,—sulphocyanide of potassium (comp. § 38). We insert here an analysis by *Frerichs*, as a specimen of its quantitative composition. The saliva of a healthy man contains:—

Water,	994·10
Solid constituents,	5·90
<hr/>	
Epithelium and mucus,	2·13
Fat,	0·07
Mucin and traces of alcoholic extract,	1·41
Sulphocyanide of potassium,	0·10
Chloride of sodium, chloride of potassium, phosphates of the alkalies, and earths, and oxide of iron,	2·19

The saliva contains of gases small quantities of nitrogen and oxygen (the latter in far greater quantities than other secretions), and abundance of carbonic acid.

The amount of saliva secreted is, of course, liable to variation. *Bidder*

and *Schmidt* have estimated it at 1500 grammes in man, but also at a lower figure.

Its action and use are, in the first place, the same as water; further, as a slimy fluid it lubricates the various matters taken into the mouth, causing them to pass the more easily into the cesophagus; and then again its action on starch ($C_6H_{10}O_5$) is chemical, transforming the latter into dextrine ($C_6H_{10}O_5$) and grape sugar ($C_6H_{12}O_6$). It is the ptyalin alone which here acts as a ferment.

Let us now turn to each of the secretions in succession of which the saliva is composed, taking first the *mucus of the mouth*. The amount of this is inconsiderable, if we are to judge from experiments on animals. It was found by *Bidder* and *Schmidt* to contain water to the amount of 99 per cent. In the mucus of the mouth we find, likewise, an abundance of form elements, flattened epithelium cells, and salivary corpuscles.

Of all these secretions, that with which we are best acquainted is the saliva obtained from the *submaxillary gland* of the dog. As was shown many years ago by *Ludwig*, the secretion of this fluid is presided over by the nervous system. From a whole series of experimental studies, partly undertaken by *Ludwig* and his pupils, partly by *Koelliker* and *Müller*, *Czermak*, *Bernard*, *Eckhard*, *Adrian*, and *Heidenhain*, we have become acquainted with the following points of interest. The submaxillary gland receives, first of all, branches from the facial nerve, mixed with a small contingent of the trigeminus: this is the continuation of the *chorda tympani*. In the second place, a number of filaments of the sympathetic enter the organ with the arteries. Finally, it receives nervous offsets from the submaxillary ganglion, which run with the chorda through the organ, and are excited by reflex action from the tongue through the lingualis.

Irritation of the chorda tympani gives rise to the secretion of a large quantity of a strongly alkaline and non-viscid fluid, whose proportion of water is about 99 per cent. Together with this the gland becomes filled with a larger quantity of blood than usual; the pressure in the veins is increased, and the whole mass of the blood, leaving the organ, presents a bright red colour (*Bernard*), while the temperature of the latter rises about $1^{\circ} C$. (*Ludwig* and *Spiess*). That this secretion is independent of the increased influx of blood is clear from the fact, that after interruption of the flow through the carotid, as well as in a head severed from the body, it may be induced by stimulation of these nerves.

Stimulation of the sympathetic salivary nerves, on the other hand, has quite a different effect (*Czermak*, *Eckhard*). Here the circulation is considerably retarded, and the venous blood leaving the organ is of a dark red colour. A small quantity only of a very viscid, cloudy, and strongly alkaline secretion issues from the excretory duct, containing solid constituents in the proportion of from 1.6 to 2.8 per cent.

In the saliva given off after stimulation of the chorda, mucin has been found with various albuminous substances. After irritation of the sympathetic it is also very rich in mucin. As far as we know, neither of these secretions of the submaxillary gland have any action on the food, with the exception of a slight power of producing sugar manifested by the sympathetic saliva of the dog.

The form elements appearing in these two kinds of saliva of the submaxillary are of great interest. Many years ago numerous pellets of colloid matter were noticed by *Eckhard* in the sympathetic secretion of

the dog. These are entirely absent, it is stated, in the chorda saliva.

The fluid excreted by the submaxillary gland contains farther, as was observed by *Heidenhain*, in the first place, cast-off mucous cells; either those of the gland vesicles intact, or changed by maceration and swollen up, the result of which is the production of a multitude of peculiar round and very pale masses, like drops of some viscid substance. Besides these, *saliva corpuscles* are present in the secretion, *i.e.*, small lymphoid cells in various stages of development, and which have wandered out with the fluid.

When one of the two secretory nerves of the submaxillary gland is irritated uninterruptedly for a considerable period, the number of these salivary corpuscles becomes naturally increased. Another effect of this proceeding is further seen, as was pointed out by *Heidenhain*, in an extraordinary transformation of the interior of the gland (fig. 445). In the greater number of the vesicles the mucous cells are found to have entirely disappeared, irregularly granular nucleated elements, smaller than the original cells, occupying their place. The explanation is simply this, that these cells have parted with their mucus, and have again become filled with protoplasm (*Ewald, Rheiner*).

In *man* the saliva of the submaxillary gland contains a large quantity of mucin dissolved in an alkaline fluid, together with a sugar-forming ferment and sulphocyanogen (§ 38), which latter is also found in the sublingual and parotid secretions. In the saliva of the lower animals, on the other hand, this compound is not to be found.

The secretion of the *sublingual gland* has, up to the present, excited but little attention. According to *Heidenhain*, the organ is presided over by the same nerves as the submaxillary gland in the dog, namely, the facial and sympathetic. Stimulation of the chorda tympani causes here also an increased flow of the secretion.

The saliva of the sublingual gland is an extremely tenacious and completely transparent substance, which can hardly be called a fluid. Its reaction is alkaline, and its percentage of solid constituents about 2.75.

The product of the *parotid* finally may be increased by irritation of one of the cranial nerves, namely, the lesser superficial petrosal, a branch of the facial (*Ludwig, Bernard*). Stimulation of the sympathetic also has the same effect (*Eckhard, von Wittich, Nawrocki*). The fluid thus obtained has a much less alkaline reaction than that of the submaxillary gland. It is always thin, and never in the least viscid. The secretion of the parotid, further, has no reaction on mucin, and contains from five to six per cent. of solid constituents (*Ordenstein*); also albumen, and, as already mentioned in the human subject, sulphocyanogen combined with

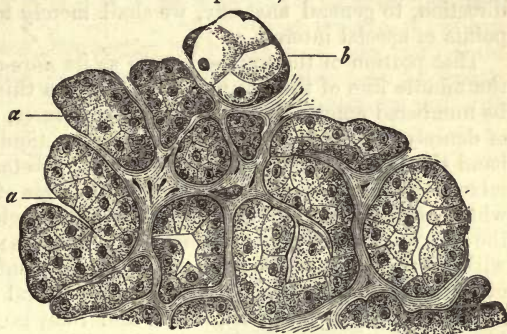


Fig. 445.—Submaxillary gland of the dog with its contents. *a*, modified by strongly stimulating the chorda tympani; *b*, unchanged residue; after *Heidenhain*.

potash or soda. According to *Ordenstein*, the sugar-forming ferments appear in the corresponding fluid obtained from the dog (*Bidder* and *Schmidt, Bernard*).

§ 247.

The *tongue* is an organ essentially muscular, but covered by a mucous membrane which, over the greater portion of the anterior part of the dorsum, is studded with a multitude of highly developed papillæ supplied with nerves, the *gustatory papillæ*, which constitute the whole an organ of sense.

Leaving the greater portion of the description of its striped fibres, which have a partly perpendicular, partly longitudinal, and partly oblique direction, to general anatomy, we shall merely touch here on one or two points of special interest.

That portion of the tongue known as its *fibro-cartilage*, which occupies the middle line of the organ in the form of a thin vertical septum, cannot be numbered among the cartilaginous structures, seeing it merely consists of densely interwoven bundles of connective-tissue. At either side of this band the two *genioglossi* pass up into the substance of the tongue, intermixed, as their fibres diverge, with the fibres of the *transversus linguæ*, which cross the former more or less at right angles. The greater part of the substance of the organ is formed by these two muscles. The *hyoglossus*, with its two portions, the first of the muscles entering into the formation of the border of the tongue, passes to the lateral portion of the organ in manner similar to the genioglossus, and likewise crossed by the external fibres of the transversus on each side. The *styloglossus* sends its weaker internal division between the genioglossus and hyoglossus and as far as the fibro-cartilage. Its longer external band passes forwards on the external surface of the hyoglossus, intermixing behind the frænum and anterior to the foremost extremity of the sublingual gland, with the fibres of its fellow of the opposite side. Besides these there are longitudinal bundles of muscular fibres coursing from the root to the tip of the tongue, partly on the dorsum and in part near its inferior surface. The latter are the most numerous, and go by the name of the *lingualis* muscle. They are strengthened anteriorly by fibres from the external division of the styloglossus. Their course is between the geno- and hyoglossus muscles towards the tip of the tongue, where their fibres diverge, some passing upwards and others still forwards. The superficial layer of bundles (*lingualis superior*) is spread out over the whole dorsum of the organ under the mucous membrane. Those muscle bundles which are lost in the mucous membrane, such as the ascending fibres of the genioglossus in the middle line, and of the hyoglossus in the lateral portions of the organ, may be seen to bifurcate at acute angles, and terminate in the connective-tissue in conical points.

The most important part, however, of the tongue is the mucous membrane itself. This is covered over with the flattened epithelium of the mouth (§ 90), and is, with the exception of having papillæ, in no essential feature different from other mucous membranes. Its connective-tissue substratum is tolerably strong, and interspersed with numerous elastic fibres. It is also extremely vascular.

In the gustatory portions there is no submucous tissue, its place being taken by a closely woven layer of fibrous tissue, the undermost portion of the substance of the mucous membrane.

§ 248.

While the mucous membrane on the under surface of the tongue is quite smooth and destitute of papillæ, the dorsum of the organ is covered from the *foramen cœcum* to the tip with innumerable *gustatory papillæ*. Of these, as is well known, there are three species, although between each kind there exist a number of intermediate forms. These three species are named respectively the *filiform*, *fungiform*, and *circumvallate*.

The *papillæ filiformes*, *s. conicæ* (fig. 446), are found in by far the greatest number of all. They consist of a conical base bearing on its apex a number of thin pointed papillæ, the whole presenting a tufted appearance. The number of the latter varies from 5 to 15 and upwards. The point most worthy of note here is the high degree of development to which the epithelial layer may attain. Very horny in texture, it presents itself in long filiform and frequently bifid shreds on the end of the papillæ, causing the latter to appear considerably increased in length. Together with these, examples of the same kind of papillæ are met with whose epithelial covering is very delicate.

The vascular supply consists of single capillary loops for each of the conical papillæ, with one arterial and one venous twig for each group. The mode of termination of the nerves is not yet ascertained. The papillæ are most strongly developed along the middle of the dorsum of the tongue, decreasing in size near the edes and tip. In these situations they are in many instances arranged in rows, enveloped in a common sheath of epithelium.

The second form, the *papillæ fungiformes*, *s. clavatæ* (fig. 447), are found scattered over the whole surface of the tongue among the latter variety, but most numerous towards the tip. They are remarkable for their thick conical form and smooth surface, and absence of tufts, together with diminution in the thickness of their epithelial coat. They are elevated above the surface of the tongue with a somewhat constricted neck, and terminate above in round and blunted bulbs. The whole surface of the latter (*A*) is studded with numerous conical accessory papillæ (*p*), which are covered again by the epithelial coating of the tongue (*A*, *e*, *B*, *e*). In this species the

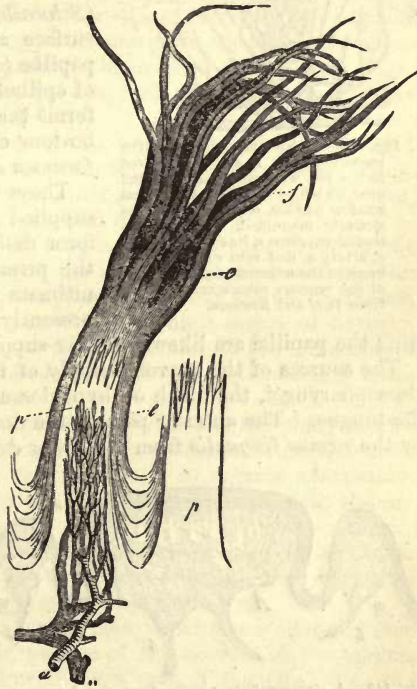


Fig. 446.—Two filiform papillæ from man, the one (*p*, left) with, the other (*p*, right) without epithelium. *e*, epithelial covering, ending above in long tufted processes, *f*; vascular portion of the papilla, with its arterial twig *a*, and vein *v*. Copied from *Todd and Boremann*.

vascular loops are far more numerous than in the first form. The nerves enter the papillæ as tolerably strong twigs: the mode of their ultimate termination, however, is still undecided. According to *Krause*, terminal bulbs may be found here (§ 184).

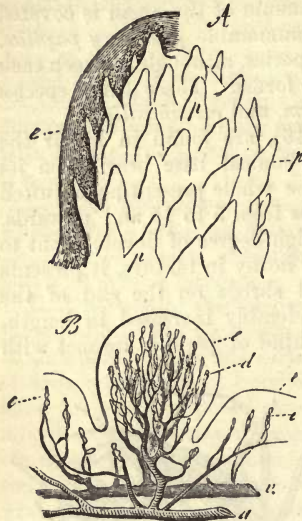


Fig. 447.—Fungiform papilla, from the human tongue. A, a papilla covered to the left with epithelium, *e*, and over its whole surface with conical smaller papillæ, *p*. B, another, less strongly magnified, with its epithelial envelope *e*, its capillary loops *d*, artery *a*, and vein *v*; *e*, vascular loops in the adjacent simple papillæ of the mucous membrane. Copied from *Todd* and *Bowman*.

In the third form, finally, the *papillæ vallatæ*, *s. circumvallatæ* (fig. 448), we have the largest of all these organs, and probably also the most important, as far as the sense of taste is concerned. In man and the mammalia generally they present many varieties. Their number is small but variable, amounting to from 10 to 15. They are arranged at the root of the tongue in a V-shaped figure. Each of the projections (*A*) is surrounded by a circular ridge of epithelium (*B*), into which racemose glands empty themselves (*Schwalbe*), and supports on its broad surface a multitude of conical accessory papillæ (*c*) overlaid with a smooth stratum of epithelium (*a*). That eminence which forms the apex of the V-springs from the bottom of a deep groove known as the *foramen cæcum linguis*.

These little organs are abundantly supplied with nerves (*b b*). The latter form delicate interlacements, from which the primitive tubes are given off whose ultimate distribution will be referred to presently. The annular folds also encir-

cling the papillæ are likewise richly supplied with nerves (*B, b*).

The sources of the nervous supply of these parts are the trigemini and glossopharyngei, the ninth or hypoglossus being simply a motor nerve of the tongue. The anterior part of the dorsum of the organ is innervated by the *ramus lingualis* from the lower division of the fifth nerve, and by

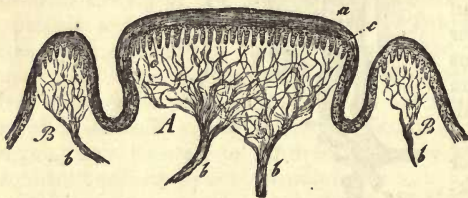


Fig. 448.—A circumvallate papilla from the human tongue A, with accessory papillæ *c*, its epithelium *a*, and nervous twigs *b*. B, the ridge running round the papilla, with its nerves *b*. Copied from *Todd* and *Bowman*.

the *chorda tympani*, while the posterior portion is supplied by the lingual branch of the glossopharyngeus, which sends its ramifications into the circumvallate papillæ. On both of these nerves small ganglia are to be seen. It seems hardly probable that the filiform papillæ, clothed as they are with a large

amount of horny epithelium, should be the recipients of the sense of taste (*Todd* and *Bowman*). The two other forms seem to preside over the latter as well as the sense of touch.

The *lymphatics* of the tongue have been carefully studied by *Teichmann* and *Sappey*. According to the former, the mucous membrane, and

still more so the submucous tissue, is very abundantly supplied with absorbent canals, while the muscular substance is only traversed by regular vessels. In the roots also of the filiform papillæ is to be found a capillary network, from which cæcal prolongations are sent off into the papillæ themselves.

The development of the tongue in the embryo commences as early as the sixth week of intrauterine life, in the form of a thick ridge, which seems subsequently to become stationary as regards its growth. The papillæ are said to be rudimentarily formed in the third month.

REMARKS.—1. Compare *Todd* and *Bowman*, vol. i. p. 437-2. Much variety is to be seen in the form of the filiform papillæ. It is not uncommon also to meet with a thread-like fungus, the *leptothrix buccalis*, in great quantity among and upon these papillæ.

§ 249.

Behind the foramen cæcum the mucous membrane presents to the unaided eye a more or less smooth appearance. Here the laminated epithelial stratum merely covers a series of small simple papillæ, each supplied by a single vascular loop.

In this locality a number of different varieties of secreting organs make their appearance. In the first place, even anterior to the foramen cæcum, small scattered mucous glands present themselves, which form more posteriorly under the circumvallate papillæ, and towards the root of the tongue a thick continuous glandular layer.

On the under surface of the tongue also, near its tip, are to be found two other racemose glandular masses of considerable magnitude. These empty themselves by several ducts at either side of the frænum (*Blandin*, *Nuhn*). Their functions are, however, still unknown.

From the posterior fourth of the tongue on, finally, the tissue of the mucous membrane, commences to undergo at points a *lymphoid* metamorphosis. This may be absent in many mammals, but attains in others, on the other hand, as for instance in the pig, a high degree of development. In the latter animal this process may advance to the formation of follicles in the larger papillæ imbedded in a densely reticulated connective substance (*Schmidt*).

This metamorphosis of the mucous tissue (by which the pharynx also may be affected) leads, as it advances, to the formation of larger and more sharply defined lymphoid organs, varying greatly as regards distribution and structure. They are largely met with among the mammals, and are not absent in man.

Among these may be numbered the *lingual follicles* or *follicular glands* of the mouth, the *tonsils*, and, at the top of the pharynx, the *pharyngeal tonsils*, structures discovered some years ago by *Koelliker*.

The *lingual follicles* (fig. 449) occur in man sometimes scattered, sometimes crowded, upon the posterior portion of the dorsum of the tongue, from the circumvallate papillæ down to the root of the epiglottis, and from one tonsil across to the other. They consist of a depression of a greater or less depth (3·5 mm. and upwards), implicating the whole of the mucous membrane, so that, beside flattened epithelium, accessory papillæ may also exist within the reduplicated portion.

Each crypt or depression is enveloped in a thick stratum of reticular connective substance, entangled in which innumerable lymphoid cells are to be found. This stratum extends to immediately beneath the epithelial tunic. In it, and distinguished by their looser and wide meshed frame-

work, and consequently lighter shade, a number of small lymphoid follicles may be observed, measuring in diameter from 0.28 to 0.56 mm. These are sometimes sharply defined, sometimes less distinctly so. Other of these crypts, however, are quite destitute of these follicles. Most usually we find these lingual crypts encased in a strong fibrous capsule. This, however, is also often absent in less distinctly defined examples.

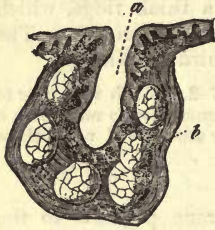

Fig. 449.—Plan of a lingual follicle. *a*, hollow reduplication of the mucous tissue with its papillae; *b*, lymphoid portion of the walls with several follicles.

Among and beneath these lingual follicles are generally scattered a great number of racemose glands, whose ducts open partly in the immediate neighbourhood of the crypt (but on the surface of the mucous membrane), and partly within its cavity. In many mammals these lingual follicles are entirely absent, as in the tongue of the rabbit, sheep, and dog. In others they are formed upon the same plan as in man, for instance, in the horse, pig, and ox.

The *blood-vessels* and *lymphatics* are of the same description as those in the tonsil, to which we refer the reader for minutiae.

The *tonsils* or *amygdalæ*, the largest lymphoid organs of the mouth, are to be found in man and most of the mammalia, presenting, however, considerable variety of structure in the latter. In some of these, moreover, as in the Guinea-pig, the rat, and the mouse, they are entirely absent. The form of the organ, as it appears in the rabbit and hare, is from its simplicity very instructive. Here we find a simple depression surrounded by a thick stratum of lymphoid structures containing small lymph-follicles. The boundary of the organ, externally, is a fibrous capsule. Numerous minute racemose mucous glands lying adjacent, send off their ducts, partly external to the depression, and partly through the lymphoid mass, to empty themselves into the latter. In this case, therefore, these organs show all the characters of a lingual follicle.

As a rule, however, the tonsils present a far more complicated structure. They are generally made up of groups of such bodies as those we have just described as representing the tonsils in the hare. These are collected together in greater or less number, their follicular ducts opening either singly on the surface or converging like the corresponding portions of a racemose gland to form passages of greater magnitude. These latter may then discharge their contents, either independently of one another, or, pursuing the same system of confluence, may eventually, as in the tonsil of the ox, give origin to one large excretory duct. Between these two extremes many intermediate forms are met with.

Each pit is enveloped in a thick lymphoid layer external to the flattened epithelial lining and mucous membrane papillæ often present. This layer, enveloped in dense fibrous tissue, extends as far as the epithelium or its immediate vicinity. As a rule, but not invariably, it contains within a loose tissue a number of follicles.

The latter present, both as to number and distinctness of demarcation against the denser interstitial tissue around, considerable variety. Their diameter, in most mammals, is on an average about 0.28 or 0.51 mm. In the dog they may even attain greater magnitude, reaching 0.9-1.4 mm. The large tonsils of the pig, further, are unusually rich in follicles.

Here also are to be met with, as might be expected, numerous racemose mucous glands, playing an important part in the construction of the

tonsils, and as varied in the arrangement of their excretory ducts as those of the lingual follicles. They discharge their contents, namely, either into the caecal depression of the organ or free on the surface of the tonsil.

The frequent inflammatory affections to which the amygdalæ are subject in adult human beings, render them rather dubious objects of research, for which reason specimens obtained from young children should be preferred. The ordinary arrangement of the openings in the adult was found by *Schmidt* to be either a separate duct for each pit (fig. 450, *b*) or a collection of the latter to form one large canal (*a*). The surface of the organ presented the usual mucous membrane papillæ, but the depression only showed traces of them. He frequently encountered, also in the immediate neighbourhood of the tonsils, a few scattered crypts with lymphoid walls, in which follicles were imbedded, resembling greatly the blind follicles of the tongue (*d*).

This extension, just mentioned, of lymphoid tissue from the fundus of the crypt up to the under surface of the epithelial covering, may be readily seen in the tonsils and lingual follicles of the calf. In some spots even this covering appears not to be completely continuous throughout. Taking this arrangement of parts into consideration, it does not seem unwarrantable to suppose that from out the meshes of this superficial reticular tissue, lymph cells may be set free, constituting, when surrounded by the watery secretion of the mouth, those saliva corpuscles so enigmatical as to their origin. This view may be the more safely accepted now that we are acquainted with the amoeboid powers of motion of the lymph cells (§ 49).

If the mucus welling from the orifices on the tonsils of a newly killed calf be examined, the abundance of saliva corpuscles to be met with there (*Frey*) will strike every eye.

The *blood-vessels* (remarkable for the number of highly developed veins among them) form, with their ramifications, a dense network of coarse and fine tubes, which becomes more delicate as it approaches the surface, where it sends off loops into any papillæ which may be present. As soon as follicles commence to make their appearance in this lymphoid layer, the vascular network is restricted to the smaller space of the interfollicular connective-tissue, so that it becomes more dense still. In the follicle itself, however, a very delicate network of radially arranged capillaries is now to be seen, very similar to that already encountered in the follicles of *Peyer's patches*.

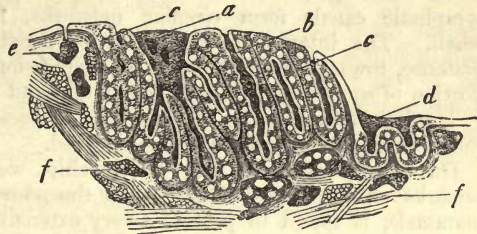


Fig. 450.—Tonsil of an adult (after *Schmidt*). *a*, large excretory passage; *b*, a simple one; *c*, lymphoid parietal stratum with follicles; *d*, a lobule strongly resembling a lingual crypt; *e*, a superficial, *f*, a deeper mucous gland.

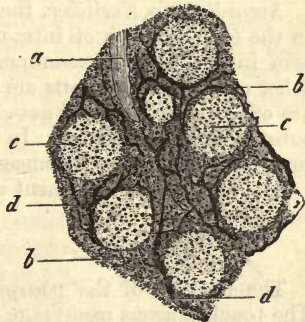


Fig. 451.—From the tonsil of the fig. 450. *a*, depression in the mucous membrane; *b*, lymphoid tissue; *c*, follicle; *d*, lymphatic vessel.

Passing on to the *lymphatic canals* of the tonsils (fig. 451) (*Frey, Th. Schmidt*) we find in the neighbourhood of the capsule and in the latter itself, considerable vessels, with valves and knotty dilatations. From these branches are given off, internally, some of which encircle, at considerable distance, the bodies of the racemose mucous glands, and some reach the base and external surface of the different divisions of the tonsils. Here they enter into the formation of a network of canals, with greatly dilated nodal points, and some of them penetrate upwards into the tissue connecting the follicles (*b*). In the latter situation they are remarkable for their extreme fineness and arrangement in dense but irregular networks. Around the follicles themselves (*c*), these lymphatic canals form circular networks, their calibre being rather small. The interfollicular lymphatics penetrate, to a greater or less distance, towards the surface of the depression which occupies the axial portion of each division of the tonsil, and end here eventually, blind.

The lymphatics of the lingual crypts possess in all salient points the same arrangement as these just mentioned.

On account of their near relationship, we will here append a few remarks on the lymphoid organs of the *pharynx*. The latter, in many mammals, is found to present a very extensive lymphoid infiltration of the mucous membrane. In man, the arch of the pharynx is possessed of follicular glands and a pharyngeal tonsil, composed of a number of the latter. This is situated at the point at which the mucous membrane comes into contact with the base of the skull. It is a mass several lines in thickness, which extends from the opening of one Eustachian tube to the other. In structure it resembles the tonsils.

The same organ is to be found among the mammalia, as in the pig, sheep, ox, and dog. Other animals, however, are not possessed of it, as, for instance, the hare (*Schmidt*).

According to *Koelliker*, the first rudiments of the tonsils may be seen in the fourth month of intra-uterine life, in the form of a simple depression in the mucous membrane of the mouth. A month later, several other additional little pits are evident, and the lymphoid infiltrated walls are of considerable thickness. The follicles appear subsequently in the substance of the latter. In the new-born child they may be already present, but in many instances this is not the case.

The mode of development of the lingual crypts is in its broad outlines the same.

§ 250.

The muscles of the *pharynx* are made up of striped fibres (§ 164). The tough mucous membrane of the lower portion is covered with simple papillæ clothed with laminated flattened epithelium. The upper part (*fovea*), on the other hand, is quite destitute of these, and is covered in the infant with ciliated epithelium, while in the adult body the latter is replaced by the flattened species. This portion of the pharynx, farther, is that most abundantly supplied with glands. These are, in the first place, of the racemose mucous species, and then lymphoid organs mentioned in the preceding section. The mucous membrane of the pharynx is very vascular, besides being abundantly supplied with lymphatic canals. Interlacements of delicate nerve-fibres have also been seen in it (*Billroth, Koelliker*).

We now turn to the *œsophagus*, which, in its strong external longitu-

dinal layer of muscular fibres, as well as its fine internal transverse tunic, shows a gradual substitution of contractile fibre cells for the striped tissue, of which the upper portion of the tube is composed. In the superior third of the latter the first species of muscle alone is to be found. Then, on the entry of the œsophagus into the thorax, contractile fibre cells begin to make their appearance, either scattered or in groups, first among the transverse bundles, and later, in the longitudinal tunic. After this they become more and more numerous, so that from about the middle of the tube on the muscle tissue usually appears to be made up entirely of the smooth variety of cells (*Welcker* and *Schweigger-Seidel*) remaining so throughout the whole of the digestive tract.

The mucous membrane loosely adherent to the muscular tunic beneath is thrown into a multitude of rugæ, and contains numerous simple papillæ covered by strongly laminated epithelium. In the upper part of the œsophagus large numbers of isolated bundles of vertically arranged contractile fibre cells are scattered through it, and lower down a continuous longitudinal *Muscularis mucosæ* presents itself, occupying the deeper

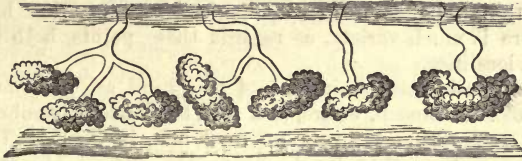

Fig. 452.—œsophageal glands from the human subject.

portion of the membrane (*Koelliker, Hentle, Klein*). The latter (at least in the new-born child) is formed of distinct lymphoid tissue (*Klein*).

The glands of the œsophagus (fig. 452 and 453) occurring, it would appear, in varying numbers, sometimes scanty, sometimes abundant, are of the small racemose species, two or three of their excretory ducts frequently joining to form one common canal. At the extreme end of the human œsophagus, about the cardiac opening, are to be found small structures, extending not quite down to the sub-mucosa; these are the cardiac glands of *Cobelli*. Here they form an elevated ring about 2 mm. in height.

The *blood-vessels* are arranged in a moderately loose network of capillaries, and the *lymphatics* also in a retiform interlacement with small meshes, the tubes measuring about 0.0200 or 0.0699 mm. in diameter, and lying for the most part parallel with the axis of the œsophagus. These latter are situated in the deeper strata of the mucosa, and in the submucous connective-tissue. The arrangement of the nerves here appears to be similar to that in the pharynx.

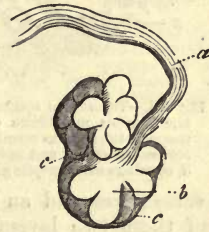

Fig. 453.—A small racemose œsophageal gland from the rabbit.

§ 251.

We now come to the description of the stomach (*ventriculus*), which, on account of the physiological importance of the organ, must necessarily be more minute than that of the last mentioned parts, its mucous membrane calling for our special attention.

The *serous covering* of the viscus presents the ordinary structure of

membranes of this kind (p. 226); the *muscular substance*, consisting of longitudinal, transverse, and oblique fibres, belongs to the involuntary species (§ 163).

The *mucous membrane* of the stomach is clothed from the cardiac orifice on (where the flattened epithelium of the œsophagus terminates with an irregular boundary line) with columnar epithelium (§ 91), which is continuous from that point on throughout the whole extent of the intestinal tube. The cells are of the long and narrow species (about 0·6323–0·6226 mm. in length and 0·0045–0·0056 in breadth). In profile they are seen to possess a cell-membrane, of which the free base of many of them is probably quite destitute during life (*Schulze*). Younger and smaller epithelial elements may also be seen between the undermost pointed extremities of these cylinders.

The surface of the gastric mucous membrane is by no means smooth, but on the contrary very uneven, with prominences varying in height from 0·0751 to 0·1128 and 0·2 mm. The latter possess either a tuft-like form or that of intersecting folds, bounding a multitude of smaller or larger depressions into which the peptic glands discharge their contents. Orifices at the summits of these eminences, on the other hand, never occur. There is much variety, as regards these points, both in different animals and localities.

Still more considerable eminences of this kind are to be found at the pyloric end of the stomach, where, as a rule, the mucous membrane attains its greatest thickness, measuring up to 2 mm. in depth. Towards the cardiac end, on the other hand, where the surface is smoother, the membrane decreases greatly in depth, falling down to from 1·1128 to 0·5640 mm.

The proper tissue of the mucous membrane is, owing to the enormous number of glands imbedded in it, but very scanty. As a rule, it presents itself in the form of a soft nucleated connective-tissue of loose texture (fig. 454). It varies, however, considerably in different classes of animals. Beneath the glandular layer is situated a stratum about 0·0564 or 0·1128 mm. in thickness, consisting of fibrous connective-tissue and intersecting muscle fibres. In this two layers may be recognised—an internal, formed principally of transverse fibres, and an external or longitudinal coat. The relative thickness of these two layers varies greatly in different portions of the stomach (*Schwartz*). Then from this laminated muscular substance there ascend small bundles of contractile fibre-cells between the glandular follicles. These *musculares mucosæ*, whose beginnings we have already seen in the œsophagus, persist now from this on, with certain variation of arrangement as might be supposed, and form integral elements of the digestive mucous membrane.

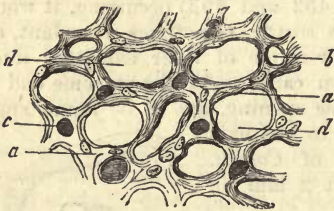


Fig. 454.—Transverse section through the gastric mucous membrane of the rabbit. *a*, tissue of the mucous membrane; *b*, transverse sections of empty and injected blood-vessels; *c*, openings where peptic glands were situated.

These *musculares mucosæ*, whose beginnings we have already seen in the œsophagus, persist now from this on, with certain variation of arrangement as might be supposed, and form integral elements of the digestive mucous membrane.

This constitution, however, of the mucous membrane may give way to another. There may appear, namely, between the bands of connective-tissue a greater or smaller number of lymph-corpuscles, pointing to an intermediate form of tissue between that of the gastric

mucous membrane, and the reticular lymphoid substance of the mucosa of the small intestine.

The almost innumerable glands of the stomach are of two kinds, not always easy to distinguish from one another, however. These are the *peptic* and *gastric mucous glands*.

The first of these are those blind tubules, already mentioned in section 198, which are closely crowded together, and occupy the whole thickness of the gastric mucous membrane in vast numbers (fig. 455, *b*). The fact that in the neighbourhood of the pylorus in the rabbit about 1894 may be counted upon 1 □ mm. of surface, will give some idea of their abundance. Their length, which corresponds to the depth of the mucosa, is on an average about 1.13 mm., but may fall to the half of this, as well as exceed it by more than double. Their transverse diameter ranges from 0.0564 to 0.0451 mm. In children the tube is shorter and of smaller calibre.




Fig. 455.—Vertical section of the human gastric mucous membrane. *a*, ridges; *b*, peptic glands.

The openings of these tubuli, which may be either grouped together or parted by regular intervals from one another, are roundish orifices considerably decreased in size by the columnar epithelium cells with which they are lined, and which are arranged in a radiating manner (fig. 456).

Both chemically and mechanically there may be easily demonstrated a *membrana propria* on all the tubuli, formed by a condensation of the soft loose connective-tissue of the mucosa in which flat stellate cells have been met with. In the human subject this is only slightly wavy in outline (fig. 457), but in many animals it is on the contrary markedly sacculated, as, for instance, in the dog. The blind end of the tube, which is usually more or less bulbous, is that at which it attains its greatest calibre, while towards its opening it is generally somewhat contracted. Double tubuli, although of rare occurrence, may frequently be simulated by the crossing of the extremities of adjacent tubuli. Treatment with alkali will generally, however, bring out the true arrangement of parts.

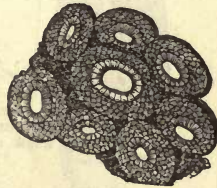


Fig. 456.—Surface of the stomachal mucous membrane, with scattered openings of the peptic glands, showing also the cylinder epithelium lining the latter.

Only on very limited portions of the human stomach are deviations from the arrangement of the peptic cells just described to be met with. Thus a very narrow band of compound tubules is to be found around the cardiac extremity, of which fig. 460, 1, taken from the same region of the dog's stomach, will give an idea. From a common excretory duct of greater or less length (*a*) 4, 5, 6, or 7 gland tubules spring.

Such compound peptic follicles appear to exist in much greater abundance among the mammalia.

As regards the contents of these peptic glands the earlier views may be summed up as follows. Columnar epithelium lines the depressions to a greater or less distance (fig. 460, *b*). Intermediate cellular

elements then make their appearance, and after them the specific gland or peptic cells (fig. 457). The form of these when isolated is more or less cubical (fig. 459). They are of considerable size, and almost completely fill the gland tubule.

In man they had only been met with in a more or less decomposed




Fig. 457.—Three stomach glands from the human being, partly filled with peptic cells.

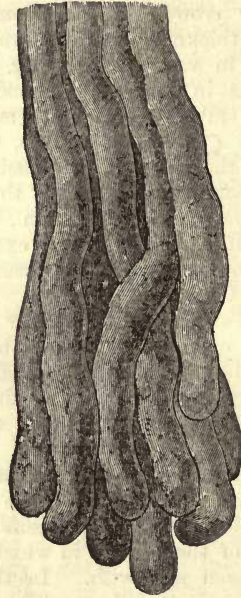


Fig. 458.—Peptic glands from the human stomach after treatment with alkalis.

condition (b). In suitable objects (a, c-g) they appear roundish or indefinitely angular, 0.0323–0.0187 mm. in diameter. They present a delicate boundary layer (e, f, g), or are quite membraneless (a, c), and are composed of protoplasm which becomes clear in acetic acid, surrounding a nucleus 0.0074 mm. in diameter, within which a nucleolus may be recognised.

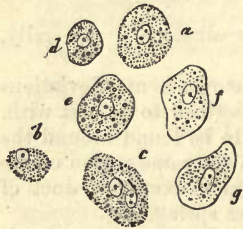


Fig. 459.—Different forms of peptic cells from man.

Of late years, however, this older view of their nature has been shown to be quite incomplete. Recent investigations by *Heidenhain* and *Rollett* have adduced much that is new, but the extreme difficulty of the subject has prevented definite conclusions being drawn on all points.

The conclusions drawn from our own personal observations are as follows:—The peptic gland consists of several parts: with *Rollett* we distinguish four.

(1.) The first is the entrance portion; sometimes deep, sometimes shallow, in one instance wide, another very narrow. This is the "stomach cell" of English writers, the "Magengrübchen" of the Germans. This depression is lined with the ordinary slender columnar epithelium of the surface of the stomach. The nucleus lies far down in the cells, and is of elongated oval figure (fig. 461, *a*).

(2.) The second is the undermost portion of the stomach cell, or, if we prefer a term made use of by *Rollett*, the "inner intermediate portion of the peptic gland." Here (*b*) the cells, without departing from their

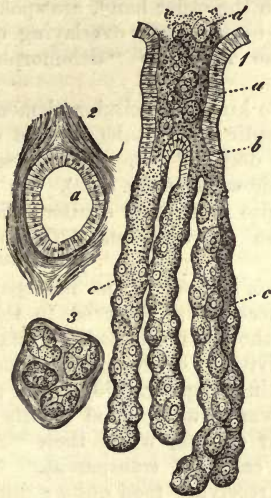


Fig. 460.—A compound peptic gland from the dog. *a*, wide entrance ("stomach cell") lined with columnar epithelium; *b*, division; *c*, the several tubules lined with peptic cells; *d*, protrusion of the contents of the peptic follicle. 2. The opening, *a*, in the transverse section. 3. Transverse section through the several glands.

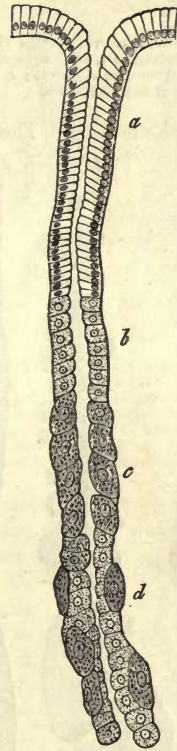

Fig. 461.—A peptic gland from the cat in side view. *a*, "stomach cell;" *b*, inner; *c*, outer intermediate portion; *d*, the gland tubule with its two kinds of cells.

epithelial character, are broader, lower, and more granular. The nucleus, a round structure, takes up about half the height of the cell. The lumen of this part is usually strikingly narrowed.

(3.) The third part now is the "outer intermediate portion" of *Rollett* (*c*). It consists of a continuous layer of peptic cells. Externally these are in contact with the membrana propria, and internally they bound the axial canal. We have not been able to find any

other kinds of cells here, although others are stated by *Heidenhain* to exist. We are supported in this by *Rollett*.

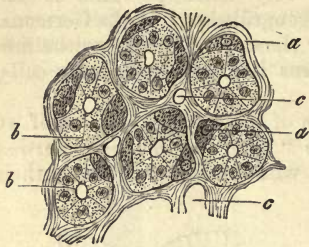


Fig. 462.—Transverse section through the peptic gland of a cat. *a*, peptic cells; *b*, internal cellular elements; *c*, transverse section of the capillaries.

(4.) Finally, we come upon the true gland tubule (*d*). Here the picture is entirely changed. The lumen is bounded by a continuous layer of a special kind of cell, which in many places comes in contact with the membrana propria. External to this layer, and as if imbedded in it, we find our old friends the peptic cells, sometimes few, sometimes in large number. The innermost cells have been named by *Heidenhain* "chief cells," and by *Rollett* adelomorphous cells. The peptic elements, on the other hand, are spoken of by the first observer as "overlying cells," and by the latter as "delomorphous" cells.

lomorphic cells. The peptic

elements in the true peptic gland tube may be easily seen in the dog and cat. Transverse sections also show them (fig. 462). In other mammals also essentially similar relations are likewise to be seen (*Heidenhain*, *Rollett*).

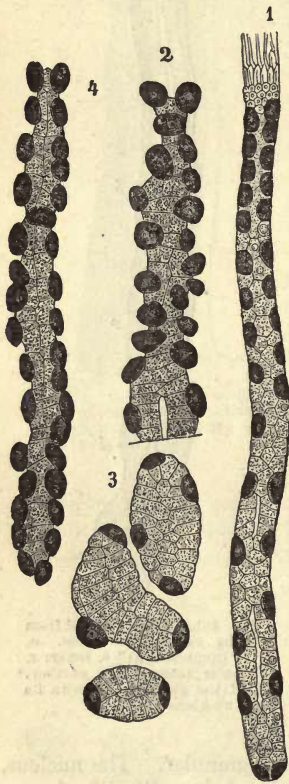


Fig. 463.—Peptic glands from the dog, after *Heidenhain*; the peptic cells darkened with aniline blue. 1. From a fasting animal. 2. A portion swollen up in the first period of digestion. 3. Transverse and oblique section of the same. 4. Gland follicle at the end of the period of digestion.

Heidenhain's observations in regard to the differences to be observed in the appearance of the peptic glands in the states of rest and activity are of great interest further.

In a fasting dog (fig. 463, 1) the gland tubules appear shrunken, and usually regular in their outline, while their "adelomorphous" cells are transparent. Some hours after receiving food quite a different appearance presents itself (2, 3). The peptic glands appear swollen, and their walls bulged out at points, the adelomorphous cells are enlarged and clouded with a finely granular contents. Later on all this swelling up has disappeared (4). The adelomorphous cells are much diminished in volume, but still very rich in granular matter.

Which kind of cell now produces the gastric juice, the peptic or adelomorphous? or does one species of cell yield the pepsin and the other the acid?

These questions cannot at present be answered. We are inclined to ascribe the greatest importance to the peptic cells, and with *Rollett* to regard them as contractile elements.

§ 252.

There is beside those just mentioned another species of gastric glands, discovered many years ago in the pig by *Wasmann*. Here we have tubes with blind endings and hollow down to the latter, which are clothed internally not by peptic cells, but columnar elements like those of epithelium. The tube itself becomes opaque on treatment with acetic acid. These (fig. 464) are the *gastric mucous glands* (*Koelliker*). They have since been recognised as occurring very widely in the stomachs of the mammalia, and may be met with either simple (fig. 464, 1) or compound (2). In the dog, cat, rabbit, and Guinea-pig they are met with near the pylorus in large numbers. They are arranged in a narrow zone in the neighbourhood of the pylorus in man also, but in the form of compound glands (*Koelliker*).

Very accurate observations have lately been made by *Ebstein* on the stomach of the dog. Here the ordinary columnar epithelium of the surface of the stomach is continued down to a considerable depth into the sometimes simple, sometimes compound tube (fig. 465, *a*). The under portion or blind end presents, on the other hand, lower cellular elements rich in fine granules and clouded (*b, b*). These resemble in many respects the adelomorphous cells of the peptic glands.

They also manifest the same differences in the fasting and digesting animal, which were pointed out by *Heidenhain* (previous §) in the latter.

As regards the composition of the two kinds of stomachal gland cells some observations were made some years ago by *Frerichs*. They are composed of an albuminous substance, and a finely granular matter, pepsin (see below), which may be dissolved out with water. Besides this they contain a certain amount of fats, and among them cholestearin. The ashes, amounting to 3-3.5 per cent., consist of earthy phosphates, traces of phosphates of the alkalis, and sulphate of calcium.

That their contents have anything to do with the formation of gastric juice has not yet been proved, although some suppose them to have.

The existence, in the human stomach, of those ordinary *racemose glands* which are of such frequent occurrence in most mucous membranes, is denied, and as a rule with justice. They are, however, constant in the pylorus, in the form of minute organs imbedded in the mucosa itself. In man they are grouped together in longitudinal bands of from 5 to 7 (*Cobelli*).

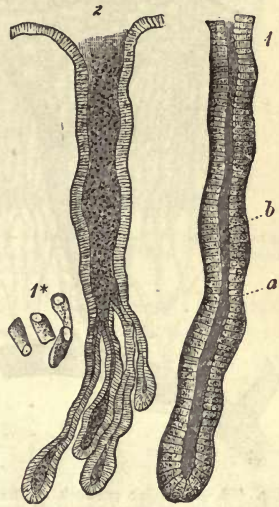

Fig. 464.—Stomachal mucous glands. 1. A single gland tube, from the cardiac end of the pig's stomach, lined with columnar cells. *a*, the cells; *b*, the axial passage. 1*, isolated cells. 2. A compound gland from the pylorus of the dog.

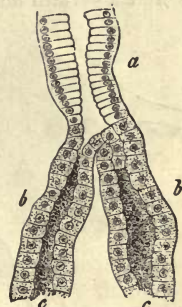


Fig. 465.—From a stomachal mucous gland of the dog. *a*, uppermost portion of the canal of exit; *b*, commencement of the true gland tube.

The *lymphoid follicles* of the gastric mucous membrane have long been known under the name of the *lenticular glands*. They are not always to be found in man, but are of rather exceptional occurrence, varying greatly in number, also, wherever they are present.

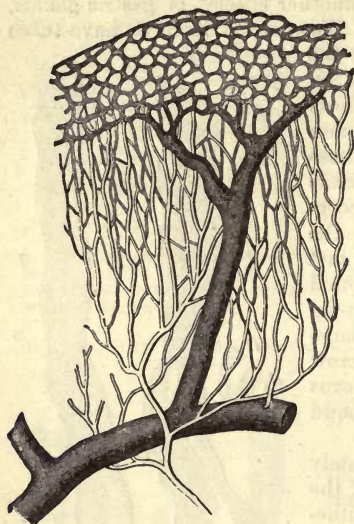

Fig. 466.—Vascular network of the human gastric mucous membrane (half diagrammatic). A fine arterial twig breaks up into a long-meshed capillary network, which passes again into a round-meshed around the openings of the glands. From this latter the vein (the large dark vessel) takes its origin.

that may be present (fig. 466, above). It is from this last portion of the vascular apparatus alone that the transition of arterial into venous blood takes place. The radicals of the veins are more or less scattered, so that a certain amount of resistance is offered to the flow of blood into

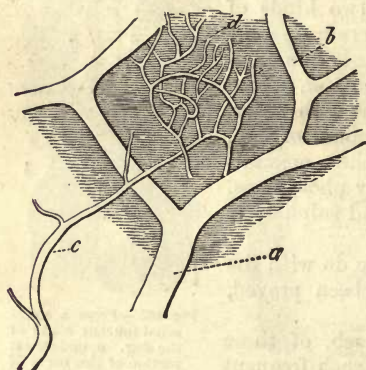


Fig. 467.—From the stomach of the dog. *a*, a vein; *b*, its branches; *c*, an arterial twig breaking up into a capillary network (*d*) for the peptic glands.

with the venous radicals, that part formerly erroneously supposed to be devoted to absorption.

The *vascular system* of the stomachal mucous membrane (fig. 466), upon which the secretion of the gastric juice and absorption of the fluid contents of the stomach is dependent, is very characteristic (§ 197). The arteries undergo division immediately on arriving in the submucosa, so that they arrive at the under surface of the true mucous membrane in the form of very fine twigs having an oblique course (figs. 466 and 467, *c*). Here, with but slightly diminished calibre, they are finally resolved into a delicate network of capillaries (fig. 467, *d*), whose tubes of 0.0070–0.0038 mm. are woven around the peptic glands forming elongated meshes (figs. 466 and 468). Thus they advance as far as the surface of the mucosa, where the orifices of the glands are surrounded in a circular mesh-work, and loops are prolonged into any papillæ

that may be present. These venous twigs, then, become very rapidly developed into trunks of considerable calibre, which traverse the mucous membrane perpendicularly downwards to empty themselves eventually into a wide-meshed network lying horizontally underneath the latter (figs. 466 and 467, *b*, *a*). This arrangement persists, as a rule, throughout the various species of mammals, with slight modifications, affecting principally the surface of the mucous membrane.

In the long-meshed network of capillaries we have before us that portion of the vascular system presiding over the secretion of the organ, and in the round meshed network

As regards the *lymphatics* of the stomach, only the deeper were known until quite recently.

According to *Teichmann*—with whose views my own observations are in perfect harmony—there exists beneath the peptic glands a network of lymphatic canals, about 0.0305–0.0501 mm. in diameter, which communicate with a deeper wide meshed network of passages of larger calibre, measuring transversely, from 0.1805 to 0.2030. From these latter the true, valved lymphatic vessels are then developed, which gradually perforate the muscular tunic to follow subsequently the two curvatures of the stomach.

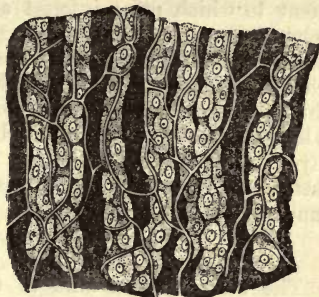

Fig. 468.—Undermost half of peptic glands from the dog, with their long meshed capillary networks.

For many years this was supposed to be the true arrangement of parts, and numerous efforts were made to prove that the superficial veins of the stomachal mucous membrane presided over the absorption of the organ.

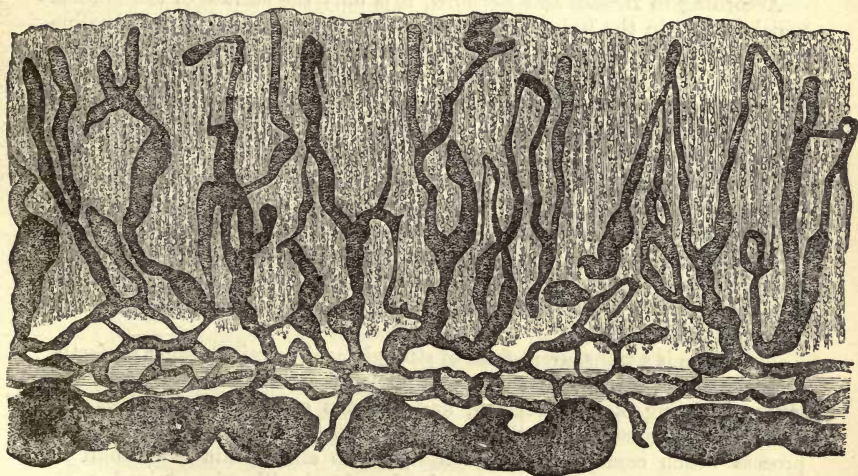


Fig. 469.—Lymphatic vessels in a vertical section of the mucous membrane of the stomach of an adult man (original drawing by *Lovén*).

But quite recently this difficulty has been got over at the hands of an excellent Swedish observer, *Lovén*, whose dexterity we may thank for the injection of these passages, and that of the highly developed lymphatic apparatus, whose radicals ascend almost to the surface of the mucous membrane. The arrangement of these will be easily understood from fig. 469, and no further explanation need be given.

The *nerves* of the stomach, derived from the vagus and sympathetic, are arranged in the submucous tissue in a plexus studded with numerous minute ganglia (*Remak, Meissner*). The greatest obscurity, however, still remains as to the ultimate termination of the fibres.

The development of the stomach is a subject in the history of development to which great interest attaches. We will, however, occupy ourselves only with its accessory organs. These, the tubular glands, commence in the form of pointed processes, springing downwards from the intestinal glandular germinal plate, which become gradually hollow, beginning at the openings. It is a point worthy of notice, that these glands are for a long time entirely unconnected with the subjacent loose fibrous intestinal layer; and it is not until the fifth month of intrauterine life that the latter sends up tufted processes between the gastric tubuli to form the mucosa of the part (*Koelliker*).

§ 253.

The mucous membrane of the non-functioning stomach is pale in colour, and more or less completely covered by a quantity of either slightly acid or alkaline slimy matter of considerable viscosity. This is the secretion elaborated by the gastric mucous glands. In it may be seen, under the microscope, beside cast-off columnar epithelium, numerous peptic cells escaped from the peptic tubuli, and frequently, also, a number of more or less broken down structures of the same nature, naked cells, and free nuclei surrounded by particles of the original cell contents.

According to *Brücke* and *Bernard*, it is only the surface of the mucosa which is acid in the living animal, the deeper portions having an alkaline reaction. After death the whole becomes rapidly acid owing to diffusion.

On the introduction of food into the stomach, or under the influence of other chemical or mechanical excitants of the gastric mucous membrane, the condition of things is immediately changed. Owing, probably, to some reflex action not yet understood, although indicated in many ways, an increased influx of blood into the intricate vascular interlacements of the mucosa takes place. The veins become distended, and contain brighter blood, and the whole surface appears to the unaided eye of a more or less rose-red colour, in addition to which phenomena the temperature rises. Coincident with these changes the *gastric juice* commences to well up from the tubules, bearing with it numerous peptic cells from the lining of the latter.

This juice is a transparent fluid of strongly acid reaction, either perfectly colourless or of a pale straw tint. It takes up certain constituents of the mucous coating of the stomach, and extracts subsequently various fermenting substances from the granular contents of the peptic cells, a process which commences while the juice is still within the tubuli in which the peptic cells are contained. It is likewise mixed with whatever saliva may have been swallowed. It cannot then be a matter of surprise that the gastric juice possesses a specific gravity of 1·001, 1·005, and 1·010.

The proportion of solid constituents in this secretion is, as a rule, small but variable. Thus, in the sheep, it contains, according to *Bidder* and *Schmidt*, 1·385, and in the dog, 2·690 per cent., while, according to the last named observer, that of the human female only contains 0·559 per cent. The nature of the fluid also would lead us to expect considerable variety also in one and the same individual.

The two most important of these constituents are a free acid and peculiar fermenting substance, which possesses in the presence of the former, and only then, a great amount of energy.

The *acid* in question has given rise to much debate regarding its

nature. It has been held at different times to be either *lactic* or *hydrochloric*, without taking into account a number of other ill-founded theories. The matter has been at last set at rest, however, by *C. Schmidt*, in favour of the latter view. Lactic, acetic, and butyric acids may, however, be present as decomposition products, the first being indeed a very frequent constituent of gastric juice. 0.02 per cent. of hydrochloric acid was discovered by *Schmidt* in the gastric juice of a female, and 0.305 per cent. by *Bidder* in that of the dog.

The *ferment* found in the gastric juice is known as *pepsin*. It was many years ago made the object of very extended investigation by *Schwann* and *Wasman*, and since then by many other observers, but can hardly be said to have ever been obtained completely pure. Its proportion generally amounts to about, on an average, 1 per cent. *Bidder* and *Schmidt's* analyses give 1.75 for the dog, 0.42 for the sheep, and for man only 0.319 per cent. At present but little is known of pepsin as about all the other fermenting substances of the animal economy. We are aware, indeed, that it occurs in a soluble form, is precipitated by alcohol without losing its digestive power on subsequent re-solution in water, whilst elevation of temperature above 60° C. destroys this for ever. This pepsin, as has been shown by *Frerichs*, is the granular matter seen in the contents of the peptic glands. It appears to possess almost unlimited digestive properties in the presence of an adequate amount of dilute acid, so that there seems to be an inexhaustible store of it in the mucous membrane of the stomach.

The *mineral constituents* of the gastric juice are, chlorides of the alkalis; phosphatic earths, and phosphate of iron (*Bidder* and *Schmidt*). Among the first we find a great preponderance of common salt, and besides chlorides of potassium, of calcium, and of ammonium also. We shall take an analysis by the two last named observers as an example of the proportions of the various salts. The percentage in the gastric juice of the dog was as follows: Chloride of sodium, 0.251; of calcium, 0.062; of potassium, 0.113; of ammonium, 0.047; phosphate of magnesium, 0.023; of calcium, 0.173; of iron, 0.008.

Just as the peptic cell is able to produce pepsin from an albuminous substance, so also does it yield hydrochloric acid by the splitting up possibly of the chlorides. This process, however, is probably carried on only at the undermost portion of the gland tubule, *i.e.*, near the orifice (*Brücke*), the source of the watery fluid with its salts being the long-meshed capillary network of the peptic glands.

The amount of gastric juice poured out is naturally very variable, owing to the periodical nature of the functions of the stomach, and therefore necessarily difficult to determine. It is stated by *Bidder* and *Schmidt* to be at all events very considerable. A dog of about a kilogramme weight produces, in the course of a day, about 100 grammes, with extremes in both directions. *Schmidt* estimated the amount secreted hourly in the body of a woman at the enormously high figure of 580 grammes.

The *use* of this fluid is to dissolve the albuminous matters taken into the stomach, and to convert them into *peptones*, *i.e.*, modifications of these substances which neither coagulate at boiling point or under the action of mineral acids, nor combine with metallic salts to form insoluble compounds (*Lehmann*). They transude, on the other hand, with great readiness through animal membranes, a property of the utmost import-

ance, which undigested albumen does not possess. In contradistinction to the latter, then, these peptones might be designated as albuminates capable of being absorbed. Owing, however, to the extreme difficulty of the subject, there still exists up to this very hour a great difference of opinion among physiologists as to the nature of peptone, in spite of the exertions of very excellent observers (*Brücke, Meissner*).

§ 254.

The *small intestine*, with its serosa and well-known double layer of muscle fibres, presents, as regards its mucous membrane, a far more

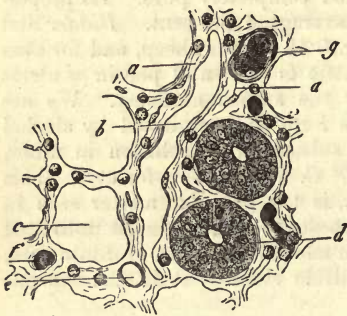


Fig. 470.—From the small intestine of the rabbit. *a*, tissue of the mucous membrane; *b*, lymphatic canal; *c*, an empty transverse section of a gland of *Lieberkühn*; *d*, another of the same occupied by cells.

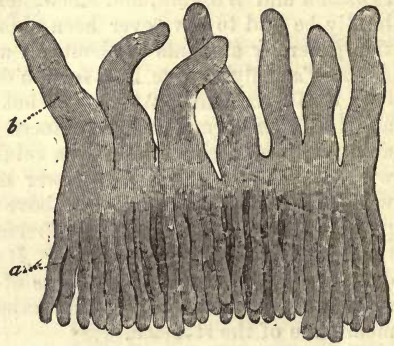


Fig. 471.—Vertical section of the mucous membrane of the small intestine of a cat. *a*, the glands of *Lieberkühn*; *b*, villi.

complicated structure than that of the stomach. This membrane, in the first place, is thrown out into a multitude of crescentic duplicatures, known as *valvulae conniventes Kerkringii*, and is covered in the next by innumerable small conical processes, the *villi intestinales*. By this arrangement of valves and tufts, an enormous increase of surface is obtained. We find, further, in the tissue of the mucosa, two forms of glands, namely, the *racemose mucous glands* of *Brunner*, and the *tubular* of *Lieberkühn*, to which may be added the *lymphoid follicles*, either single or in groups, known as the *solitary* and *agminated* glands of *Peyer*.

But the *tissue* of the mucous membrane itself (fig. 470), is also different in texture from that of the stomach. Thinner, and supplied with the *muscularis mucosæ*, it no longer presents the character of ordinary fibrous tissue, as does that of the stomach as a rule. It consists rather of reticular connective-tissue, containing, entangled in its interstices and meshes, an abundance of lymphoid cells, and only assuming a more or less homogeneous membranous structure towards the gland cavities and towards its free surface, whilst at other points, as, for instance, near the surface of large vessels, it appears to be made up of longitudinal fibres. This tissue of the mucous membrane varies also to a certain extent, according to the different species of animals.

The *villi* commence on the intestinal aspect of the pylorus, flat and low at first, and increasing gradually in height until they assume a conical or pyramidal form, which merges step by step, as we progress downwards, into a slender tongue-like figure. They stand tightly packed

one against the other (fig. 471, *b*), so that, according to *Krause's* estimate, about from 50 to 90 spring from 1 □ mm. in the jejunum, and duodenum, and in the ileum from 40 to 70, giving for the whole extent of the small intestine, according to his calculation, 4,000,000. Their height varies from 0.23 to 1.13 mm. and upwards. Their breadth also differs, naturally, according to their form. Transverse sections show them to be either cylindrical or leaf-shaped.

All these villi are clothed with peculiar columnar epithelial cells, already referred to (p. 147), which present on their free surfaces a thickened border, perforated by pores or fine canaliculi (fig. 472, *a*).

Between these cells (fig. 473, *b*) may be observed—not unfrequently distributed with tolerable regularity—those “goblet cells” which have been already brought before our notice (§ 93). In number they vary with the species and the individual.

We also encounter here, as in the stomach, small roundish structures lying between the internal extremities of the columnar epithelium cells. These may be regarded as destined to replace the latter as they successively perish.

Under the epithelial layer we next come upon the framework of the structure in the form of reticular connective-substance with entangled lymphoid corpuscles and nuclei in some of the nodal points of its not unfrequently long meshed network.

The recognition of the true nature of the surface of the villus is attended with considerable difficulty. Nevertheless, we may see that here also it preserves the same retiform character, although the bands may in many instances become broader and flatter, and the interspaces between them decrease in size until they become merely small apertures, so that the effect almost of a homogeneous membranous limiting layer may be given.

This tissue of the villi is traversed in the first place by a vascular network (*b*), next by a lymphatic canal (*d*), occupying the axis of the structure, and lastly, by delicate longitudinal bundles of unstriped muscular fibres (*c*). For the discovery of the latter we are indebted to *Brücke*, although anterior to his researches on the subject, distinct contractility had been recognised in the intestinal villi in the living or recently killed animal, producing numerous wrinkles on the surface of the process (*Lacauchie*, *Gruby*, and *Delafond*). These bundles of muscle fibres may be traced down through the mucous membrane into the *muscularis* of the latter.

The *vascular networks* of the intestinal villi (figs. 474, 475) occupy invariably the peripheral portions of the latter, and are supplied in the smaller mammalia each by a small arterial twig or pair of the same (*a*),

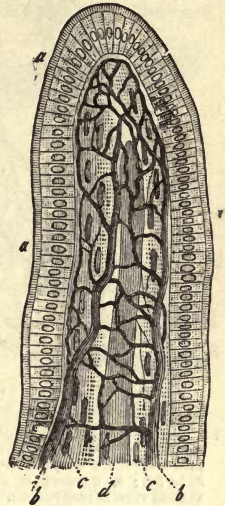


Fig. 472.—An intestinal villus (after *Leydig*). *a*, columnar epithellum with thickened border or cuticular membrane; *b*, capillary network; *c*, longitudinal muscular bundles; *d*, axial chyle radicle.

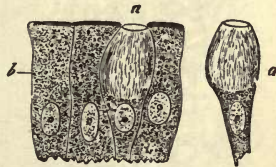


Fig. 473.—Epithelial cells from a human intestinal villus (after *Schulze*). *a*, goblet cells; *b*, ordinary elements.

which ascend at one side, bend over at the apex, and follow the opposite wall in returning, as venous vessels (*c*). Between these afferent and efferent vessels a capillary network exists, sometimes exceedingly complex, sometimes very simple in its arrangement (*b*).

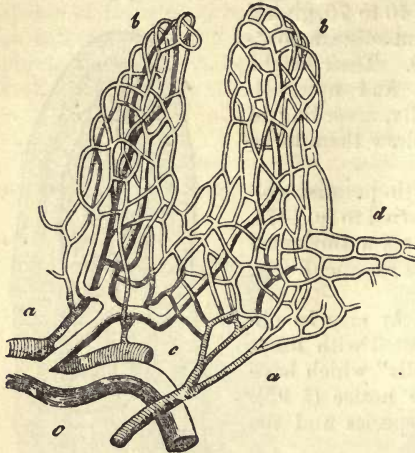


Fig. 474.—Vascular system of an intestinal villus in the rabbit. *a*, the arteries (shaded), breaking up first into a capillary network around the glands of Lieberkühn (*d*); *b*, network of capillaries in the villus; *c*, venous vessels (unshaded).

It not unfrequently happens that a system of capillaries is first given off by the arterial twig to supply the glands of Lieberkühn (*d*), opening at the base (fig. 474, *a* to the right) of the villus, which system is simply continuous with that of the latter (*b* to the right).

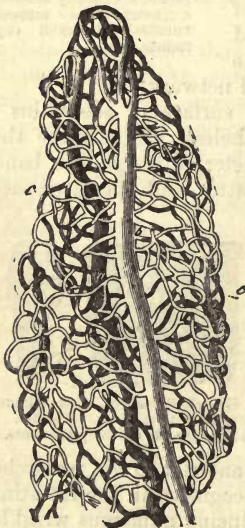
The diameter of the arterial vessel may rise to 0.226–0.0282 mm., that of the vein to 0.0451 mm. In calibre the capillaries measure on an average 0.0074 mm., and their arrangement is usually in elongated meshes. The disposal in loops of the arteries in their transition into

veins may be absent, a capillary network being interposed between the two vessels at the summit of the villus.

We have already alluded (p. 374) to the cæcal *chyle canal* of the intestinal villus. When the latter is more than usually broad there may be two or even several of these blind tubes, but when small and slender they are only single. The chyle canal occupies the axis of the villus, and presents itself, under ordinary treatment (fig. 472, *d*), in certain cases quite distinctly as a tube formed of a homogeneous non-nucleated membrane, on an average 0.023 mm. in diameter. On treatment with a solution of nitrate of silver, however, this tube is easily shown to be composed of a layer of those jagged-edged vascular cells already so frequently alluded to. It may be seen with great clearness when injected artificially, and also in the villi of animals killed while engaged in digesting an abundance of fatty food (fig. 476).

§ 255.

Fig. 475.—Vascular network from the intestinal villus of a hare, with its arterial branch *b*, capillaries *c*, and venous branch *a*.



Turning now to the glandular elements of the small intestine, we shall commence with the least important, namely, with the *racemose mucous glands* (fig. 477, *b*), known commonly as *Brunner's*. They are confined to the duodenum, and begin close to the stomach, closely crowded together into a regular adenous layer

seated immediately under the mucosa. Thus they extend as far as the orifice of the *ductus choledochus*, and from that point on appear more rarely. Among the mammalia much variety is observed as regards these organs. When only slightly developed, as is frequently the case, they are confined to the neighbourhood of the pylorus, forming a complete zone just behind it. The diameter of these glands ranges from 0.23 to 2 mm. The branches of the excretory ducts present a complicated series of twists unlike other glands of the same kind (*Schwalbe*). The acini are round, elongated, or even tubular, and measure from 0.0564 to 0.1421 mm. The excretory canals of these glands, considerable in calibre (fig. 477), ascend obliquely upwards, slightly bent, discharging their contents at the base of the villi (fig. 477, *c*).

Both excretory duct and gland vesicle are, strange to say, lined by the same species of cells. These are low columnar elements, whose nucleus is situated low down in the body, and which are but very slightly coloured by carmine. They are unlike the contents of the follicles of *Lieberkühn* soon to be described.

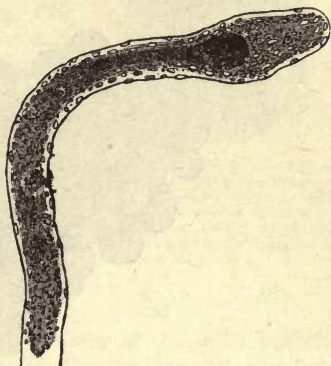

Fig. 476.—Very slender villus from the intestine of a kid, killed while engaged in digestion: without epithelium, and showing the absorbent vessel in the centre filled with chyle.

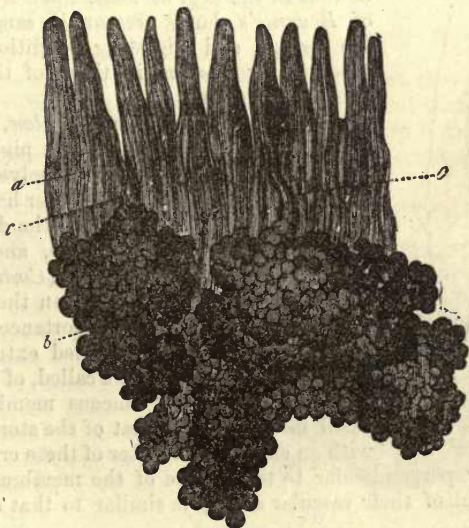


Fig. 477.—Brunner's glands from the duodenum. *a*, villi; *b*, bodies of glands; *c*, excretory canals opening between the villi.

That same network of extremely delicate gland canaliculi we have already spoken of as occurring in many racemose organs (§ 195), as well as in the salivary glands (§ 245), is to be found also in the glands of *Brunner*, according to *Schwalbe*. The *membrana propria*, which is here

completely closed, and contains imbedded nuclei; sends no processes into the interior of the gland vesicles.

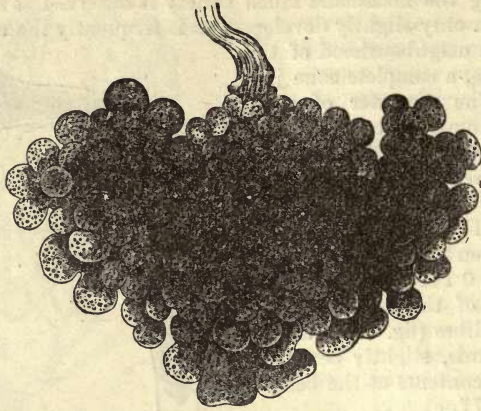


Fig. 478.—One of Brunner's glands from the human being.

These organs appear to be richly supplied with lymphatic vessels of large size, which penetrate between their vesicles and lobules.

The secretion of these glands appears to be peculiar. According to *Schwalbe*, the contents manifest considerable similarity to those of the stomachal mucous glands already alluded to (§ 251). *Heidenhain* tells us that in the dog, at least, the cellular elements of Brunner's glands present the same changes in the fasting and digesting condition that were observed by *Ebslein*, in those of the stomachal mucous membrane.

According to *Budge* and *Krolow*, the contents of these organs convert (in the pig) starch into dextrin and grape sugar, and dissolve fibrin at 35° C., but have no effect, on the other hand, on either coagulated albumen or fat. In the dog and horse the secretion is rather viscid, and contains a considerable amount of mucus (*Costa*).

The crypts of *Lieberkühn*, on the other hand, are glands of far greater importance. They are to a certain extent a modified extension of the mucous glands, as they are called, of the stomach.

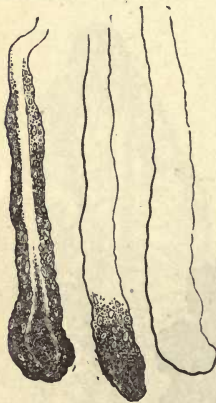

Fig. 479.—Lieberkühn's glands from the cat, with broken down cellular contents.

The whole of the mucous membrane of the small intestine, like that of the stomach, is beset with an enormous number of these crypts crowded

closely together perpendicular to the surface of the membrane (fig. 479). The arrangement of their vascular supply is similar to that of the peptic glands.

The length of these crypts is less than that of the gastric tubuli, ranging from 0.3767 to 0.4512 mm., with a breadth of 0.0564–0.0902 mm. Their membrana propria is hardly distinguishable from the surrounding connective-tissue. It is delicate, and the outline of the tube is consequently smooth. At its blind end we may either find a dilatation or decrease in calibre.

The contents of these crypts, unlike those of *Brunner's* glands, consist of delicate columnar nucleated cells, with widened base, which rest on the *membrana propria*. These, together with the open axial canal, may be seen in every transverse section (fig. 470, *d*). According to *Schulze*, between these cells other goblet cells may present themselves, a point worthy of note.

In suitable preparations (fig. 480) the orifices of the glands are to be seen at varying distances from one another, lined with columnar epithelium, which passes in through the entrance of the tube. At those points at which the villi are very crowded, the orifices of these glands of *Liebekühn* surround their bases in rings.

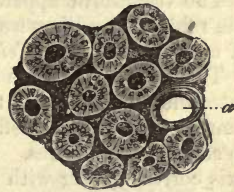


Fig. 480.—Openings of the glands of *Liebekühn* in the mouse. At (*a*) an empty opening, in the other cases each is filled with columnar cells, placed with their long axis towards the centre.

§ 256.

We now turn, finally, to the *lymphoid follicles* of the small intestine. These occur with greater frequency here than in the stomach, which fact is explained by the greater similarity of their tissue to that of the mucosa of the small intestine. As has been already mentioned, they are in the first place met with scattered over the whole length of the small intestine as *glandulæ solitariae*. These are roundish, opaque, white bodies of very unequal size, ranging from 0.2 to 0.4 and 2.2 mm. In some subjects they are very scantily represented, or even entirely absent, while in other cases they appear in multitudes. In situation and structure they correspond with the agminated glands into which they may merge without any sharp boundary. At parts of their periphery they are continuous with the circumjacent connective-tissue.

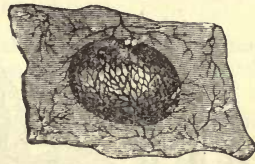


Fig. 481.—One of *Peyer's* glands from the rabbit.

By the agmination of these follicles it is that *Peyer's patches* or *plaques* are formed (figs. 481, 482), which occur in man, as in all mammalia, in the greatest abundance, but in very various degrees of development. In some cases they are made up of from 3 to 7 follicles only, but more frequently of from 20 to 30. Again, when large, they may contain up to 50 or 60 of the latter.

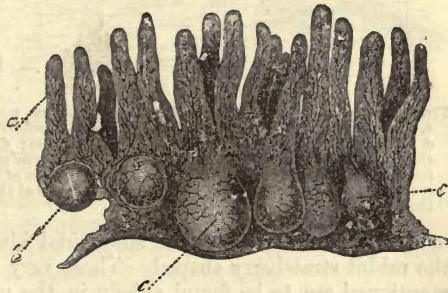


Fig. 482.—Vertical section through one of *Peyer's* glands from the rabbit. *a*, villi; *b*, bodies of glands rounded off above; *c*, others, apparently open above.

Peyer's patches are found principally in the small intestines, and always at the free side, or that opposite to the mesenteric attachment of the viscus. They appear, as a rule, first at the end of the jejunum, and become more frequent in the ileum.

But although this is the usual mode of distribution, it is not without

exceptions, especially in the occurrence of isolated *Peyer's* glands in the colon.

The vermiform appendix of man, and to a greater extent also that of the rabbit, may likewise be said to be one large *Peyer's* gland, composed of crowded follicles (*Teichmann, His, Frey*).

The number of these agminated glands to be found in the human small intestine varies from 15 to 50 and upwards. The diameter of such a group cannot, of course, be definitely laid down, varying, as it does, from 7 mm. to several centimetres. The form they assume is usually oval, their long axis corresponding with that of the intestine.

Subjecting the *glandule agminatee* to close inspection, we find in longitudinal sections that, although the form of the follicles may be similar in one and the same group, nevertheless it is liable to vary to a large extent, both in different animals, and according to the locality in the intestine we choose for examination.

Beside spheroidal follicles, namely (fig. 483), we meet with others more or less elongated, presenting somewhat the figure of strawberries. But in other instances the follicles may be so increased in vertical diameter as to present on section an outline resembling that of the sole of a shoe. In

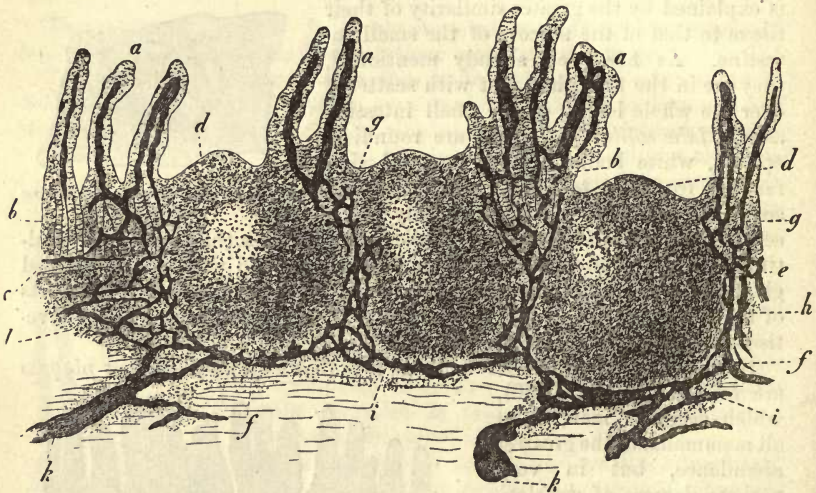


Fig. 483.—Vertical section of one of *Peyer's* plaques from man, injected through its lymphatic canals *a*, villi, with their chyle passages; *b*, follicles of *Lieberkühn*; *c*, muscularis of the mucous membrane; *d*, cupola or apex of follicles; *e*, mesial zone of follicles; *f*, base of follicles; *g*, points of exit of the chyle passages from the villi, and entrance into the true mucous membrane; *h*, retiform arrangement of the lymphatics in the mesial zone; *i*, course of the latter at the base of the follicles; *k*, confluence of the lymphatics opening into the vessels of the submucous tissue; *l*, follicular tissue of the latter.

man they are usually of the spheroidal kind; in the small intestine of the rabbit strawberry shaped. Those very much elongated examples just mentioned are to be found chiefly in the under portion of the ileum of the ox and vermiform appendix of the rabbit.

The follicle, however, may be of what shape it will, we can always distinguish three portions in it, namely, the summit or *cupola*, the *mesial zone*, and the *base*. The cupola (*d*) projects into the intestinal tube; the base (*f*) descends to a greater or less depth into the submucous connective-tissue; and the mesial zone (*e*) serves to connect together all

the follicles of one gland by means of a tissue entirely similar to their own. It is also continuous, without any line of demarcation, with the adjacent infiltrated retiform tissue. It is at its level that we usually find the *muscularis mucosæ* (*c*) which opens in each case to allow room for the follicles (*Frey*).

We must now turn to the nearer consideration of the cupolæ. These are surrounded by annular ridges of mucous membrane, containing follicles of *Lieberkühn* (*b*), and are continuous downwards into the mesial zones, supporting on their free surface, either ordinary or, what is more frequently the case, somewhat modified irregular villi (*a*). The actual summits of the follicles, however, are quite destitute of villi. They are, in fact, so freely exposed that each lymph follicle appears to the naked eye as a little pit on the surface of the plaque.

The ridges around the follicles may, however, as in the plaques of the colon, be quite bare of villi. In the *processus vermiformis* of the rabbit, also, the surfaces of the rings may be increased greatly in breadth (fig. 484, *b*), so that only a narrow entrance (*a*) to the follicles is left.

If we turn now to the finer structure of the elements of *Peyer's* patches, we find it to be exactly that of other lymphoid follicles. Their sustentacular tissue is a species of retiform connective substance, traversed by capillaries in which innumerable lymph cells are entangled (pp. 195 and 420). Many of the nodal points in this network contain in young individuals full-bodied nuclei, met with in adults, on the other hand, in a shrunken condition. At the mesial zone this reticular tissue is continuous with the similarly constituted connecting lymphoid layer, and through this with the closely related tissue of the mucous membrane.

The sustentacular matter in the interior of the follicles is very loosely interwoven, while externally it assumes a denser texture.

At two spots it becomes exceedingly densely reticulated and distinct; in the first place on the surface of the cupola, which is, like the villi, covered immediately by columnar epithelium, and then at the peripheral portion of the base. This latter in some of *Peyer's* glands is surrounded by a continuous investing space, which corresponds to the investing spaces of the lymphatic glands (§ 223). In many animals the resemblance is increased by the interposition of perpendicular fibrous septa

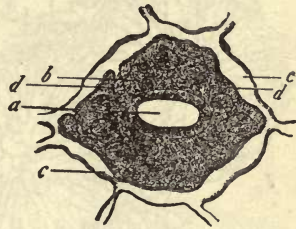


Fig. 484.—From the surface of the *processus vermiformis* of the rabbit. *a*, narrowed entry to the cupola of a follicle; *b*, mouth of crypts in the broad ridge of mucous membrane; *c*, horizontal lymphatic network; *d*, descending lymph canals.

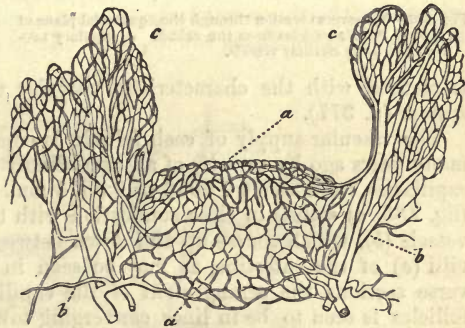


Fig. 485.—Vertical section through an injected *Peyer's* follicle of the rabbit, showing the capillary network of the same; the large lateral vessels, *b*, and those of the villi, *c*.

between adjacent investing spaces, which are lost at the level of the mesial zone.

In other *plaques*, instead of these continuous investing spaces, the surface of the base is covered by numerous fine lymphatic canals, like a child's toy ball with a net. In the connecting layer, between the mesial zones, a network of similar passages may likewise be recognised.

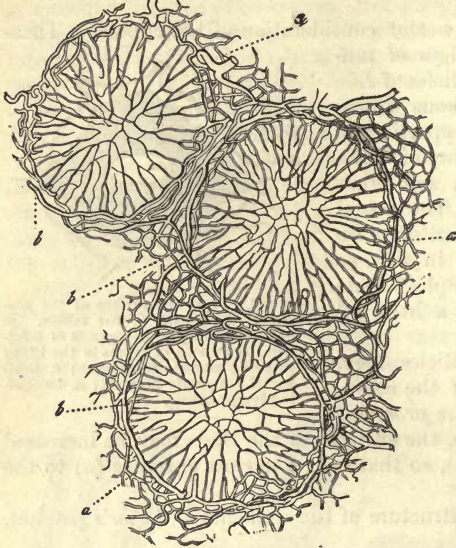


Fig. 486.—Transverse section through the equatorial plane of three of Peyer's follicles from the rabbit. *a*, capillary network; *b*, large circular vessels.

The walls of these passages, then, are made up of very small-meshed lymphoid reticular substance.

In the actual follicles themselves, however, no such passages exist.

We have only to add, that the superficial lymphatic canals of the mucous membrane, of the smooth as well as villous annular ridges, all sink down to empty themselves into these lymph passages of the connecting layer already mentioned; also that, at least, a part of the investing spaces around the follicles

is clothed with the characteristic vascular epithelium of the lymphatic system (p. 377).

The vascular supply of each follicle is composed (as was demonstrated many years ago by myself) of an exceedingly complex network of delicate capillaries, from about 0.0056 to 0.0074 mm. in diameter. This network (fig. 485, *a*) stands in close connection with the large arterial and venous vessels (*b*), which course up and down between the follicles supplying the villi (*e*) of the intestine, as may be seen in vertical sections. In transverse sections the arrangement of the capillaries in the interior of the follicles is seen to be in lines converging towards the centre (*a*), starting from circular vessels externally—an object of extreme beauty under the microscope.

§ 257.

The *nervous apparatus* of the small intestine is exceedingly complicated, deriving its roots from the ventral divisions of the vagus and sympathetic. It consists of a double plexus of microscopic ganglia connected above with the nerves interlacing in the walls of the stomach.

In the submucosa we first meet with the plexus of *Remak* and *Meissner*, remarkable for its highly developed knots. From this pale nucleated fibres are given off, principally to the muscularis of the mucous membrane, and muscular bundles in the villi, and to a minor extent to the surface of the membrane as sensory elements. We are still lacking in observations on these points, however.

Externally this submucous plexus is connected with the remarkable and no less developed *plexus myentericus* of *Auerbach*. The latter, with its regularly flattened ramifications, but more minute ganglia, is situated between the internal transverse and external longitudinal muscular tunic of the gut. These it supplies with its numerous twigs, forming first a secondary plexus of threads, 0.001–0.005 mm. in thickness, each of which possesses from 3 to 6 of the finest nervous filaments (*L. Gerlach*), leaving no doubt as to the motor nature of the latter, although we are still in the dark as to the ultimate termination of the fibres.

We may form some estimate of the extent to which the nervous system of the intestines is developed, from the fact that about 100 ganglia, belonging to the submucous, and over 2000 to the myenteric plexus, are to be found in 1 \square " of the intestine of the rabbit.

The following is the general arrangement of the *vessels* of the intestine. (On arriving in the walls of the latter, a few small twigs are given off

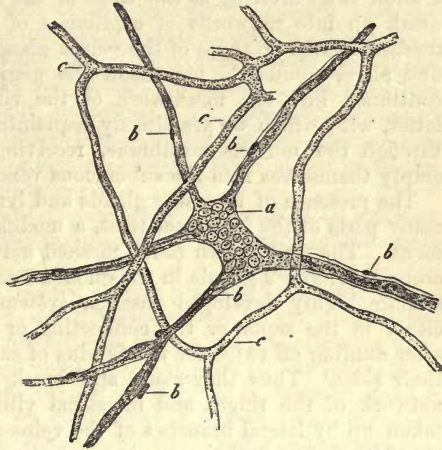


Fig. 487.—A ganglion from the submucous tissue of a human infant. *a*, nervous knot; *b*, radiating twigs; *c*, capillary network.

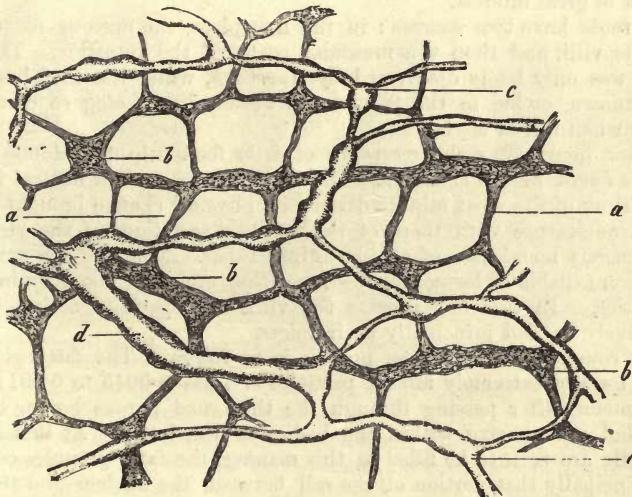


Fig. 488.—From the small intestine of the Guinea-pig. *a*, *plexus myentericus*, with its ganglia; *b*, *c*, fine, and *d*, larger lymphatic vessels.

to the serous covering of the part, after which the vessels break up in the muscular tunics into the usual well-known capillary network with elongated

meshes, whose long axes correspond with that of the contractile elements. The submucosa is from this supplied further with another network of capillary tubes of somewhat greater calibre than the first (*Frey*).

The chief supply, however, is to the mucous membrane itself. Here arterial twigs arriving at the bases of the crypts of *Lieberkühn* gradually break up into networks of capillaries of medium calibre, with oblong meshes, similar to those of the peptic glands. These are disposed, in the first place, around the mouths of the glands in delicate rings, and then continued into the mesh-work of the villi. The veins arising in the latter, with which we are already acquainted, descend directly downwards through the mucous membrane, receiving but few lateral twigs, and empty themselves into the submucous venous network.

The presence of racemose glands and lymphoid follicles necessitates, in many parts of the intestinal tract, a modification of this vascular arrangement. The well-known round-meshed network, for instance, is met with around *Brunner's* glands in the duodenum. Then *Peyer's* patches require a more highly developed vascular system. Here little arteries ascend, either in the septa, or the connecting or junction layer of the follicles, after sending off twigs for the fundus of each of the latter, as well as for their sides. Thus they reach and break up into the terminal capillary network of the ridges and intestinal villi. From thence the blood is taken up by lateral branches of the veins arising here, which descend by the side of the arteries, receiving also an addition from the follicles.

§ 258.

Through the exertions of *Teichmann*, *His*, *Frey*, and *Auerbach*, we have recently become accurately acquainted with the nature of the *lymphatic apparatus* of the small intestine. This is from many points of view of great interest.

Its roots have two sources: in the first place, the mucous membrane with its villi, and then the muscular coats of the intestine. The last source was only lately discovered by *Auerbach*, while the first has long been known, owing to the fact of the vessels here being so distinctly visible when full of chyle.

A few hours after the reception of fatty food into the stomach, the matters found in the small intestine are found to contain neutral fats in a condition of the most minute division, a physical change brought about by the admixture with them of the bile and secretions of the pancreas and mucous membrane of the intestinal tubes. The fats are now in a condition capable of being absorbed, and they are soon taken up in large quantities. In this last process the villi are especially active, if not exclusively so, and principally their apices.

The commencement of the process is as follows: The fatty globules in the form of extremely minute particles of from 0.0045 to 0.0011 mm. in diameter, after passing through the thickened porous border on the epithelial cells, arrive within the bodies of the latter. At first only a few cells are seen to be filled in this manner, the fatty granules occupying principally that portion of the cell between the nucleus and the free end. The number of cells, however, presenting this fatty infiltration soon becomes greater and greater, and the fat-molecules penetrate past the nucleus into the pointed and attached half of the columnar elements. In the further progress of this process the granules of fat pass through the apices of the cells into the tissue of the mucous membrane beneath,

either filling the whole apex of the villus in such myriads as to give it the appearance of being diffusely infiltrated, or else ranging themselves in long streaks, which may be mistaken for fine canals charged with fatty globules, as they course along between the lymph cells and connective-tissue fibres. In the third stage of the process we remark that the minute fatty molecules have penetrated through the walls of the chyle radical into its lumen, entirely filling the latter, so that this element of the intestinal villus, at other times so difficult of detection, becomes distinctly visible, as has been already mentioned. The concluding phase of the whole act is especially instructive; here we see the columnar epithelial cells and tissue of the mucous membrane again freed of fat, while the chyle vessel is still full (fig. 476, p. 487).

That this is the true course of the process may be confirmed by artificial injection of the lymphatic canals in the mucous membrane of the small intestine.

The radicles of the chyle or lacteal system (fig. 489) are easily recognised in the villi of the gut as blind canals, which in our opinion (in which we are supported by *Teichmann* and *His*), are not continuous with the actual tissue of the villus. According to the form of the latter, they present themselves either single (*a*) or double (*b*), or even in greater number (*c*). In the last case we either find a looped communication between them in the apices of the villi, or the vessels end separately. Towards the roots of the villi we not unfrequently encounter transverse connecting branches.

On arriving in the mucous membrane after leaving the villi, the lacteal vessels descend through the former between the follicles of *Lieberkühn*, either directly or subsequent to the formation of a superficial horizontal

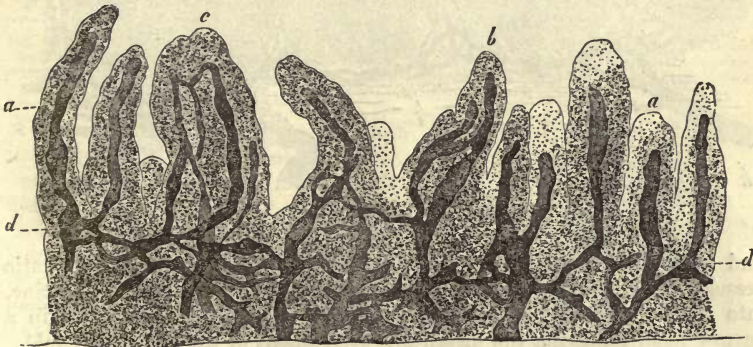


Fig. 489.—Vertical section of the human ileum. *a*, villus, with one chyle canal; *b*, another with two; *c*, another with three; *d*, absorbent canals in the mucous membrane.

network, which lies at the bases of the villi, and encircles with its meshes the mouths of these glands of *Lieberkühn*.

At the boundary between the mucosa and submucosa, and in the latter, a network (*d*) is formed by the intercommunication of these chyle canals. These latter may be of considerable calibre, as in the sheep and rabbit, or small, as in man and the calf. They accompany the network of blood-vessels also here, and in some cases form sheaths around the latter. As a whole, moreover, much variety is met with among them, depending on the thickness of the mucous membrane and species of animal chosen for observation.

The arrangement of the lacteals is modified wherever *Peyer's* plaques occur (fig. 490). Those lymphatic passages (*a*), returning from the modified villi of the circular ridges of these localities, form around the tubular glands (*b*) of the villous ridges a network (*g*), which is continuous with another system of intercommunicating passages (*h*) formed in the reticular substance encircling the mesial zones of the follicles. The latter open either into simple investing spaces enveloping the basal portions of the follicles, and precisely similar to those of the follicles in a lymph gland (in the rabbit, sheep, and calf for instance), or (the case in man, the dog, and cat) these spaces are replaced by a system of separate canals (*i*), interlacing around the bases of the follicles like those we have already considered in § 227.

From this set of passages, or from the simple investing space, as the case may be, the efferent lymph vessels finally take their rise.

Returning now to the system of canals of the submucous tissue, we

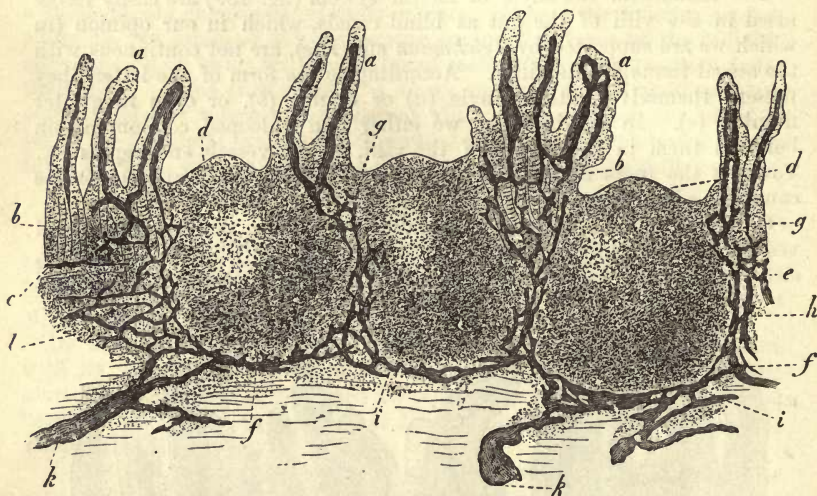


Fig. 490.

find springing from it a certain number of regular knotted lymphatic vessels, which empty themselves, after piercing the walls of the intestine, into the subserous lymphatic trunks. These latter are arranged in a narrow band following the mesenteric attachment of the gut (*Auerbach*).

The submucous lacteal network communicates, moreover, by means of another set of passages with a second plexus of lymphatic vessels lying between the longitudinal and transverse layers of muscle of the part. This (fig. 488, p. 493), to which the name *interlaminar network* has been given by *Auerbach*, accompanies the plexus myentericus situated here also, with which we are already acquainted. It collects all the lymph from the muscular substance of the intestinal tube, from a series of very densely reticulated lymph canals of exceedingly small calibre, which are found singly in the longitudinal tunic, but bedded one over the other in the transverse layer. This interlaminar lymph net is connected finally with the subserous trunks by efferent vessels.

In this complex arrangement there is most undoubtedly a double pro-

vision made for the escape of the chyle, as *Auerbach* very correctly remarks, and during the peristaltic action of the bowel, also, the latter fluid is able on this account to give way to the pressure in many directions.

In conclusion, we have only to state, as regards the *development* of the small intestine, that in man the villi make their appearance in the third month of intra-uterine life. They are then apparent as wart-like excrescences. Further, we would point to the fact, that the crypts of *Lieberkühn*, unlike the gastric tubuli, are present from the commencement as pits in the mucosa, and that the follicular structure of *Peyer's* glands is apparent in the seventh month. The cells of the intestinal mucous membrane, and of *Lieberkühn's* follicles, contain glycogen in the fœtus (*Rouget*).

§ 259.

The mucous membrane of the *colon* corresponds in most essential particulars with that of the small bowel, except that it is quite destitute

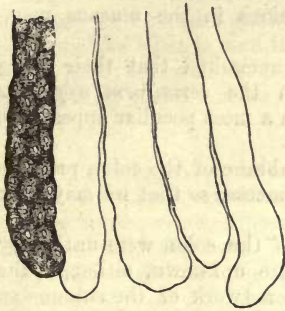


Fig. 491.—Tubular glands from the rabbit's colon. One tube filled with cells, the others sketched without them.

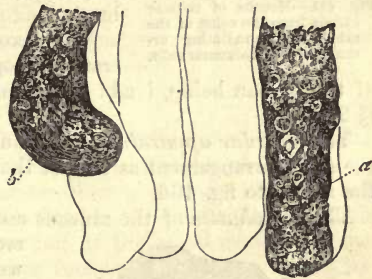

Fig. 492.—Tubular gland from the colon of a Guinea-pig. At *a*, a tube is seen with *membrana propria* apparent at certain points; at *b*, the contents are escaping through a rent in the latter.

of those important appendages the villi. Its substratum, also, is far poorer in lymph cells than that of the small intestine, and approaches more in character to ordinary fibrous connective-tissue.

The epithelium consists of columnar cells similar to those of the ileum, but lacking pores in the but slightly thickened border. Goblet cells are also met with here (*Schulze*).

Its muscular tunic resembles that of the mucosa of the stomach (§ 251), and exhibits the same variety in the relative development of its two layers (*Schwartz, Lipsky*). Imbedded in it we find a great number of tubular glands, the *tubuli of the colon*, and a variable number of *lymphoid follicles* like those already met with in the small intestine.

The tubuli of the colon (fig. 491) are merely modifications of the follicles of *Lieberkühn* from which they are gradually developed.

They present themselves in the form of simple undivided tubes with tolerably smooth and even walls, and a

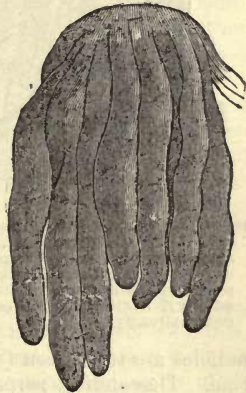

Fig. 493.—Tubuli from the colon of the rabbit, treated with caustic soda.

length which varies between 0.4512 and 0.5640 mm. and upwards, the transverse diameter lying between 0.0902 and 0.1505 mm. Moreover, they are just as crowded as the gastric and jejunal tubuli, and are found in every part of the large intestine, including the processus vermiformis.

They contain a viscid, and at times somewhat fatty mass (fig. 491 and 492, *b*), consisting of nucleated gland cells (measuring 0.0151–0.0226 mm.) made up of granular protoplasm. These present the appearance when seen on the surface of flattened epithelium, from the fact of their being accommodated to one another, but are found on section of the gland to be columnar.

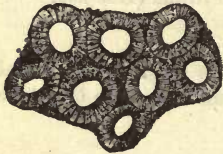

Fig. 494.—Mouths of tubular glands from the colon of the rabbit, with radiating arrangement of columnar cells.

Here also goblet cells may be encountered (*Schulze*). The mouths of these glands are of the ordinary kind, lined with columnar epithelial cells converging towards the lumen (fig. 494).

The *lymphoid follicles* are, as a rule, larger than those of the small intestine. Their cupolæ project from depressions in the mucous membrane.

We have already remarked that their being crowded together, in the *vermiform appendix* of the human being, lends to the latter organ a most peculiar appearance (§ 255).

The *vascular apparatus* of the mucous membrane of the colon presents the same arrangement as that of the gastric mucosa, so that we may refer the reader to fig. 466.

The *lymphatics* of the mucous membrane of the colon were until very recently quite unknown, although the well-known network of the submucosa had been discovered long before. We are now certain of their existence in the mucous membrane of phytophagous and carnivorous animals, and it is highly probable that they are not absent in man.

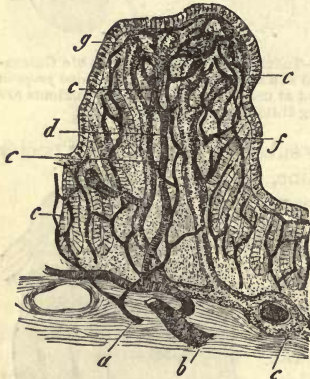


Fig 495.—Papilla from the colon of a rabbit, in vertical section. *a*, arterial; *b*, venous twig of the submucosa; *c*, capillary network; *d*, descending venous twig; *e*, horizontal lymphatic vessel ensheathing an artery; *f*, lymph canal in the axis; *g*, caecal extremity of the same.

Though the surface of the colon is, as a rule, quite smooth, we find its upper fourth in the rabbit thickly studded with broad projections comparable to the intestinal villi.

These papillæ, however (fig. 495), in contradistinction to the villi of the small intestine, are just as densely crowded with tubular glands as the other portions of the mucous membrane of the colon.

In the axial portion of these prominences one or more blind lymphatic radicles are to be seen (*f, g*), precisely similar to those of the small intestine. Descending perpendicularly, and twined about by a vascular network (*a-d*), they pass into the loose mesh-work of the submucous lymphatic vessels. In other animals the smooth mucous membrane of the colon is traversed partly by perpendicular caecal canals, and partly by a wide-meshed net-work. These lymphatic vessels, which do not by any

means attain the same degree of development as those of the small intestine, have been traced down into the rectum.

The lymphatic apparatus, on the other hand, attains in the vermiform appendix of man the most remarkable degree of perfection, as was first shown by *Teichmann*. The external ramifications of the absorbent vessels in the walls of the colon presents the same arrangement as in the small intestines, and the same complicated distribution is evident as in the muscular tunic of the latter.

The *nervous supply* of the large intestine is derived from a wide-meshed submucous plexus beset with ganglia. The plexus myentericus presents the same peculiarities here as in the jejunum and ileum.

No further reference need be made to the *muscular* and *serous* coats of the large intestine.

At the anus the columnar epithelium suddenly ceases, where the epidermal cells commence, with a sharply defined line of separation.

Close to the termination of the gut below, a certain admixture of voluntary or striped muscle fibres presents itself among the unstriated elements like what is seen in the œsophagus.

The mode of development of the mucous membrane of the colon is the same as that of the mucosa of the stomach (*Koelliker*).

§ 260.

The physiological significance of the crypts of *Lieberkühn*, and tubular glands of the large intestine, is still a point of considerable obscurity.

They are, however, supposed to secrete what goes under the name of the *intestinal juice* (*succus entericus*),—a fluid in the production of which the glands of *Brunner*, in the upper portion of the small intestine, must also take a part. The secretion requires further examination before we can pronounce upon its composition with any certainty.

By a very ingenious mode of procedure, we have recently learned how to obtain pure intestinal juice from the *small intestine* of dogs (*Thiry*). This is then found to be a thin, strongly alkaline secretion of a light wine colour, and sp. gr. of 1·0125. It possesses about 2·5 per cent. of solid constituents, of which nearly 2·5 per cent. is albumen, and 0·3 per cent. carbonate of sodium. It dissolves fibrin as long as alkaline, but neither raw flesh nor boiled albumen are acted on by it. Moreover, it is said neither to convert starch into grape sugar, nor to decompose the neutral fats. This, however, is denied by *Eichhorst*, as regards the secretion of the small intestine. The amount of this fluid poured out appears to be very great.

The secretion of the tubular glands of the large intestine has also an alkaline reaction. The vermiform appendix is nothing but one large absorbent apparatus.

§ 261.

The *pancreas*, to which we now turn, exhibits, as regards its structure, many points of similarity to the salivary glands. Its vesicles are roundish, measuring 0·0564–0·0902 in diameter. The *membrana propria* is studded over at certain points with nuclei, showing that here also, as in other kinds of racemose glands, the construction, probably, out of flat stellate cells.

The investing vascular network (fig. 496) is of the ordinary round form of the whole of this group of organs.

The numerous lymphatics require closer attention than has, up to the present, been bestowed upon them.

The gland vesicles of the pancreas are clothed with cubical cells. In the full-grown rabbit these present in their inner half, or that next the lumen of the gland, fatty particles, while the middle portion in which the nucleus lies, and external to the latter, is clear.

The excretory canals possess rather thin walls without muscular elements, in which are embedded, at the lower portion, a number of small racemose mucous glands seated in the mucosa.

If we examine closely in animals the clothing of columnar cells, we find that from the beginning they are not particularly high. But in the branches they decrease more and more in length, until, finally, in the gland vesicles we meet with flattened epithelium, reminding us, in many respects, of vascular endothelium. These are the centro-acinal cells of which we have already spoken in considering the salivary glands (§ 245). They were first seen here by *Langerhans*.

By careful injection of the excretory canal-work, the same system of extremely fine secreting tubules may be brought to view in the pancreas (fig. 297), as that to which we have already so frequently alluded (*Langerhans, Saviotti*).

As regards the nerves nothing certain is known. According to *Pflüger* their mode of termination is the same as in the salivary glands.

The *development* of the pancreas takes place very early from the posterior wall of the duodenum in the form of a small saccule or bud.

As far as the composition of the alkaline reacting tissue of the gland is concerned, nothing is known. Its sp. gr. is, according to *Krause* and *Fischer*, 1.047. A series of very interesting decomposition products, however, have been met with in the fluid saturating the gland; in the first place leucin in large quantities, and a considerable amount, comparatively, of tyrosin (*Virchow, Staedeler, and Frerichs*); further, guanin and xanthin

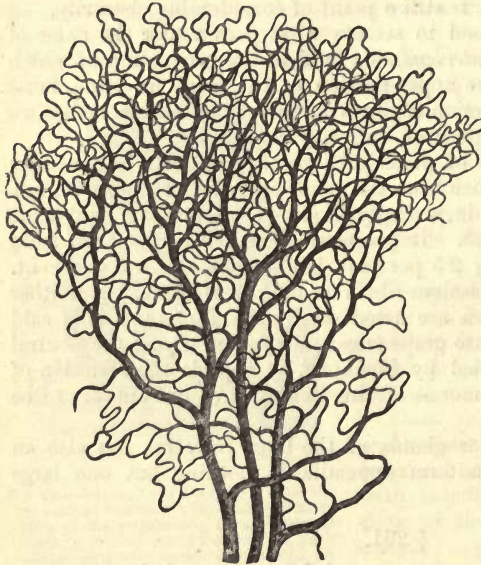

Fig. 496.—Vascular network of the pancreas from the rabbit.

(*Scherer*), sarkin or hypoxanthin (*Gorup*), lactic acid, (and in the ox) inosite (*Boedeker* and *Cooper Lane*). Among these leucin (and tyrosin?) have been remarked in the secretion of the gland, with which they find their way into the intestinal canal.

In a state of rest, or, more properly speaking, of slow secretion, the gland in question appears pale. When, on the other hand, it is actively functioning, from about the fifth to the ninth hour after the reception of

food into the stomach, it is of a deep red colour. In this condition bright scarlet blood flows from the veins of the organ, while in the inactive state the capillaries contain a dark fluid.

The secretion of the gland or *pancreatic juice* (*succus pancreaticus*) has been obtained from the living animal. So obtained, it is a strongly alkaline viscid fluid (*Bernard*), while that collected from a permanent pancreatic fistula is a very thin liquid (*Ludwig* and *Weinmann*). In the first albumen was digested (*Bernard*, *Corvisart*), starch was transformed into grape sugar, the neutral fats (after first forming an emulsion) were split up into glycerine and free fatty acids. In the latter form the first of these properties was absent. The thick liquid, whose percentage of water is about 90, is secreted by the gland when the latter is of a deep red colour from increased vascularity; the thinner liquid containing about 95-98 per cent. of water when it is pale.

The amount of fluid secreted is greatest within the hours before mentioned during digestion. It varies, however, to a great extent at other times, so that calculations as to the amount produced daily are found to differ considerably.

The most essential constituents of the fluid consist, in the first place, of an albuminoid substance, which separates, in a gelatinous form on cooling below freezing point, from the thicker kind of pancreatic juice, but not from the thinner fluid; then, again, of a ferment occurring in both forms of the fluid, which converts starch very rapidly into grape sugar. Further, as *Corvisart* has pointed out, there is present in the first modification of the fluid another ferment which digests albumen, and whose action does not cease on neutralisation, or even weak acidulation of the secretion (*Kühne*). Finally, there is a third fermenting substance, which effects that peculiar decomposition of the fats already mentioned. The change also alluded to produced in the albuminates is of great interest, namely, a process of disintegration, with the formation of an albumen peptone, as well as considerable quantities of leucin and tyrosin (*Kühne*). A gelatin peptone has also been so obtained (*Schweder*).

The constituents of pancreatic juice obtained by incineration, and amounting to 0.2-0.75 and 0.9 per cent., are lime, earths, magnesia and soda, chlorides of sodium and calcium, phosphates of sodium, calcium, and magnesium, sulphates of the alkalies, and traces of iron combined with

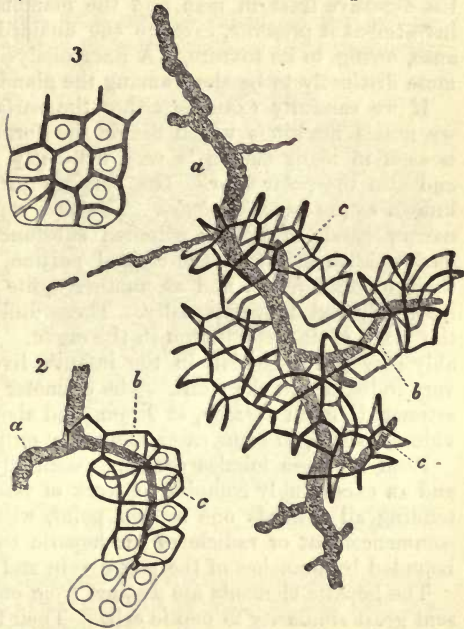


Fig. 497.—Gland tubules from the pancreas of the rabbit, after *Saviotti*. *a*, strong excretory canal; *b*, the same of an acinus; *c*, delicate capillary passages between the cells.

phosphoric acid (*Bernard, Frerichs, Bidder, and Schmidt*). Sulphocyanide of potassium is not present in the secretion of the pancreas.

§ 262.

We come now to the *liver*, the largest of all the glands connected with the digestive tract in man and the mammalia. Underneath its fibrous investment it presents, even to the unaided eye, a most peculiar appearance, owing to its texture. A finer analysis of the latter shows it still more distinctly to be alone among the glands of the body.

If we carefully examine either the surface or a section of the liver, we notice markings which divide the former into regular fields. This is seen in many mammals very distinctly, but especially so in the pig and also the polar bear. The portions included in these markings are known as the *hepatic lobules*. They are separated from one another by narrow bands of lighter coloured substance, and are at one time of a dark reddish brown in the central portion, and of a lighter hue nearer their circumference, and at another quite the reverse, appearing light internally and dark externally. These differences depend entirely upon the state of the circulation in the organ. In man this marking is tolerably easy of recognition in the infant's liver, but is, on the other hand, very indistinct in the adult. The diameter of the lobules may be roughly estimated, on an average, at 9 mm., and about a third more in larger individuals, while, in some cases, they may only measure 1·1 mm.

Each of these lobules consists essentially of innumerable gland cells, and an exceedingly complex network of vessels passing among them, and tending all towards one central point, where their confluence forms the commencement or radicle of an hepatic twig, while externally they are bounded by branches of the portal vein and biliary canals.

The hepatic elements are distinct from one another (fig. 498), and present great similarity to peptic cells. Their form is more or less irregularly polygonal, owing to their mutual accommodation. In diameter they are, on an average, about 0·0226–0·0180 mm., with extremes up to 0·0282 mm. and down to 0·0113 mm. Their nuclei, which are oval, and contain nucleoli, have a diameter of 0·0056–0·0074 mm. Each cell usually contains one of them (*a*), but may in some cases be possessed of two (*b*). The substance of which the hepatic cells are composed is of viscid consistence, and presents a greater or less number of fine elementary granules embedded in it. The cells are entirely destitute of membranous covering, and the whole structure, when isolated, is seen to be possessed of the power of amoeboid motion, very distinct, though slow (*Leuckart*).

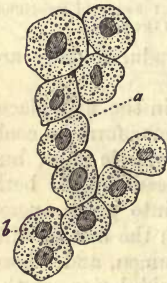

Fig. 498.—Hepatic cells of man. *a*, with one nucleus; *b*, a cell with two of the latter.

Besides these just mentioned, other matters are frequently met with in the contents of the hepatic cells, which, when present in small quantities, may be regarded as normal constituents, while their appearance in greater amount denotes a morbid condition of the cell. These are, in the first place, molecules of a brown or yellowish-brown pigment (biliary colouring matter), and, secondly, fatty globules of varying sizes (fig. 500). The latter, chiefly in the form of very fine fatty molecules, are found normally in sucking animals and children, and

may be called into being artificially by the administration of very rich fatty food to an animal. In very well marked specimens considerable masses of fat are to be seen filling the whole of the cell, and completely obscuring its nucleus. The cells in such cases are often increased in size. Amongst adults, and especially after habitual indulgence in rich food, such fatty livers are of frequent occurrence.

But besides this fatty infiltration, as it may be called, of the hepatic cells, which the latter are well able to tolerate, regaining their previously normal condition as soon as freed from the oily molecules, there is also a true fatty degeneration, a morbid change of the whole element into lardy matter, which leads to its entire destruction.

The arrangement of the cells of the lobules is very remarkable. They are placed in long rows side by side and connected with one another at points, without by any means being fused together. This arrangement, in elongated groups, may be frequently recognised among hepatic cells which have been scraped off the cut surface of the liver (fig. 498), but more clearly in delicate sections of the lobules, as in fig. 499, in which a radiating arrangement of the bands of elements is perfectly manifest, especially in the more internal part, while externally this is more or less lost, the cells being disposed with greater irregularity.

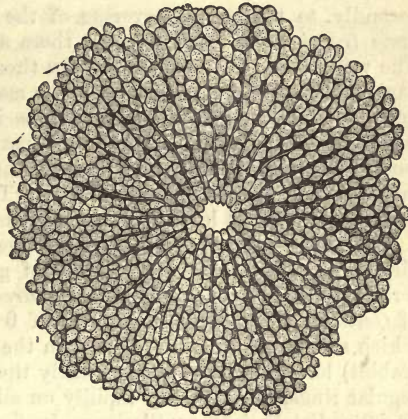


Fig. 499.—Hepatic lobule from a child ten years old (copied from Ecker), with the central hepatic vein in transverse section.

In the human and mammalian liver generally, the cells of such a band are arranged in a single row, only doubled at certain points. Much variety exists, however, in the mode of grouping.

These so-called lobules, which do not, however, like the well-known divisions of racemose glands, open into an excretory duct, but are placed on a twig of the hepatic vein, are separated one from the other (at those points at which they are seen sharply defined) by distinct septa of connective-tissue, which may be isolated from about the lobules in the form of regular capsules. This mesh-work of connective-tissue is derived, in the first place, from the so-called capsule of *Glisson*, i.e., that sheath of cellular tissue which clothes the blood-vessels and bile ducts, entering the organ at the *porta hepatis*, and again from the connective-tissue covering the whole organ. In the normal condition of the human liver this septal connective-tissue, dividing lobule from lobule, is very scanty, while, in a certain peculiar affection of the organ, known as cirrhosis, it becomes hypertrophied.

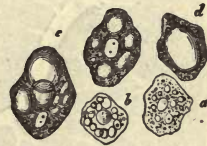

Fig. 500.—Cells from a fatty liver. *a, b*, filled with small oily particles and globules *c, d*, with larger drops.

§ 263.

In order to gain a farther insight into the structure of the organ, it will

be necessary, in the first place, to consider the arrangement of its *blood-vessels*.

The vascular system of the liver possesses this peculiarity, that it receives its blood from two sources, namely, from the hepatic artery and portal vein. The last of these conveys a much larger proportion of blood to the organ than the former, which takes part less in the elaboration of bile than in the nutrition of the hepatic tissue. Its branches, accompanying the divisions of the portal vessels and bile ducts, are distributed, in the first place, as *vasa nutrientia* to the coats of both (*rami vasculares*); and, secondly, to the serous covering of the liver, as far as which they penetrate (*rami capsulares*), forming there a wide-meshed capillary network. The veins derived from these empty themselves into the ramifications of the portal vessels, so that the latter may be injected from the hepatic artery, and *vice versa*, if the canula be inserted into the portal vein the injection may be driven into the hepatic artery. Finally, a few very small twigs (*rami lobulares*) sink into the peripheral portion of the capillary network of the hepatic lobules. Through these the hepatic artery takes some part, at least in the production of the bile.

The *portal vein*, with whose course we take it for granted the reader is already acquainted from the study of general anatomy, forms, with its terminal branches, the *venæ interlobulares* of *Kiernan*, or *venæ periphericæ* of *Gerlach*. These are fine tubes of 0.0338–0.0451 mm. in diameter, which surround the lobules either in the form of short (in man) or long (rabbit) loops, or, as is pre-eminently the case in the pig, in the form of regular rings, breaking up rapidly on all sides, either into finer branches or immediately into capillaries. In fig. 501 we have a representation of what takes place here: a twig of the portal vein is seen passing through the middle, and giving off on either side the *rami-interlobulares*, which terminate eventually in a capillary network after encircling the lobules.

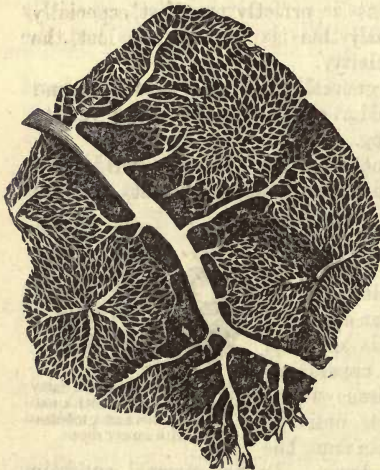


Fig. 501.—Rabbit's liver injected, showing a portal branch, the *venæ interlobulares*, the capillary network, and a *vena intralobularis* in the centre of a lobule.

This network, the most highly developed which exists in the body, consists of vessels from 0.0090 to 0.0126 mm. in diameter, whose delicate walls can only with difficulty be demonstrated. The meshes formed by these are very dense, measuring only from 0.0226 to 0.0451 mm. They are either rounded, square, or triangular in figure, and lie, for the most part, with their long axis, often rather indistinctly directed, towards the centre of the lobules.

In the interior of the latter the capillaries either form, by their rapid confluence, a single hepatic venous radicle, or, what is more frequently the case, two or more such. These may, in some instances, be met with in much larger numbers. The hepatic twigs are situated in the centre of the lobules; they are from 0.5640 to 0.0677 mm. in diameter (*Gerlach*), and have been

named by *Kiernan*, on account of their position, the *venæ intralobulares*, by *Gerlach* *venæ centrales*. On their exit from the lobules these vessels join together to form larger trunks. The latter are intimately connected with the parenchyma of the organ, so that they remain gaping even when emptied. From the fact that the veins of the liver do not possess valves, the whole hepatic circulation may be just as easily injected from them as from the portal vessels.

§ 264.

So far we have only discussed those points of structural arrangement of the liver which are easily recognisable, and may be therefore regarded as permanent additions to histological knowledge.

Far different is it now, however, when we come to deal with questions as to the nature of the sustentacular substance of the interior of the lobules, with the relations of the veins to the finest biliary ducts, as well as the disposal of the radicles of the lymphatic system in the parenchyma of the gland.

From the fact that the two networks—that formed by the intersection of bands of hepatic cells and that of the circulation—are closely interwoven one with another, many suppose that the hepatic cells are simply entangled in the meshes of the capillary network.

Nevertheless, if very fine sections of a properly hardened liver be carefully brushed with a camel's hair pencil, there remains, after removal of the hepatic cells, an exquisitely delicate reticulated framework, composed of homogeneous membranous bands, which separate the rows of gland cells and blood stream from one another. In this network may be seen, in the first place, the nuclei of the capillaries, and then, small isolated nuclei, which present themselves in a shrunken condition in the adult (fig. 502).

In the liver of the infant, or foetus, in the later months of utero-gestation, this fine transparent membranous structure may be seen at certain points to be double. One of its layers corresponds to the walls of the capillaries, and in some instances has been resolved into those vascular cells so well known (p. 363) (*Eberth*). Its other lamina, on the other hand, invests the bands of hepatic cells as they intersect each other.

From this it would appear to be beyond doubt that a thin homogeneous layer of sustentacular connective-substance envelopes the various rows of hepatic cells. This layer is often of the most extreme delicacy, but may be seen with comparative ease to be continuous at the periphery of each lobule with the interlobular connective-tissue.

Here then we have the long sought for *membrana propria* of the hepatic cells presenting itself. To it belongs indubitably the second and smaller series of nuclear formations, which appear at an early period in greater abundance, as a system of connective-tissue corpuscles, frequently exhibiting distinct cell bodies.

While at first these two membranes, namely, the sustentacular connec-

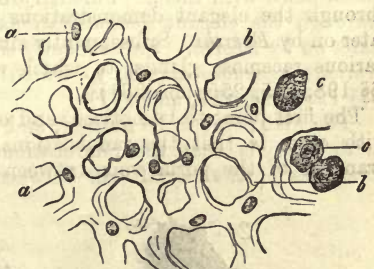

Fig. 502.—Sustentacular tissue from the liver of the infant. *a*, homogeneous membrane with nuclei; *b*, filiform folds in the former; *c*, isolated hepatic cells, remaining after brushing.

tive-substance of the gland and the walls of the vessels, appear quite distinct from one another, they assume the appearance, later on in older animals, of being fused into one single lamina. That this, however, is probably not the case, will be seen further on when we come to consider the arrangement of the lymphatic streams.

For our acquaintance with these important points, in regard to the structure of the liver, we are indebted for the most part to the exertions of *Beale* and *E. Wagner*.

§ 265.

The arrangement of the ultimate *radicles of the bile ducts* in the interior of the lobules, and their relations to the secreting cells, is a subject fraught with difficulty for the microscopic anatomist, and one which for a long time baffled every attempt at elucidation, owing to the imperfection of the earlier methods of treatment of the hepatic tissue. It is no wonder, then, that here extensive use was made of hypothesis, and that many theories as to the arrangement of parts sprung up only to be abandoned again. At last success attended the efforts of some to demonstrate distinctly the finest bile ducts. The first successful observers in this interesting field of discovery were *Gerlach*, *Budge*, *Andréjevic*, and *MacGillavry*. The results of their investigations were all very similar, and our own experiences, as well as those of *Chrzonszczewsky* (arrived at by means of a peculiar method of treating the hepatic tissue), are in exact accordance with them. Further progress in this direction was made again through the elegant demonstrations of *Hering*, confirmed and amplified later on by *Eberth*. Subsequently similar passages were discovered in the various racemose glands, to which we have already frequently referred (§§ 198, 245, 255, and 261).

The first point to be noticed, and one which has long been recognised with ease, is that the ramifications of the bile ducts accompany the branches of the portal vein between the hepatic lobules. From these,

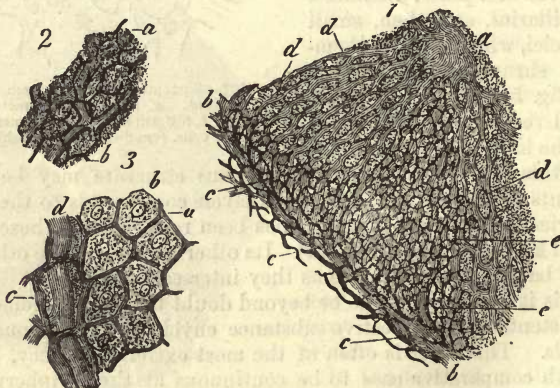


Fig. 503.—Biliary capillaries from the rabbit's liver. 1. A part of a lobule; *a*, *vena hepatica*; *b*, portal twig; *c*, bile ducts; *d*, capillaries; *e*, biliary capillaries. 2. Biliary capillaries (*b*) in their relation to the capillaries of the vascular system (*a*). 2. Biliary capillaries in their relation to the hepatic cells; *a*, capillaries; *b*, hepatic cells; *c*, bile ducts; *d*, capillaries of the blood-vessels.

then, another set of fine thin-walled biliary canals take their rise (fig. 503, 1), which invest the further ramifications of the *vena portæ* (*b*) with delicate networks (*c*) in their course between the lobules.

More internally still these tubules are continuous with an exquisitely delicate mesh-work of the finest tubes, known as the *biliary capillaries* (*d*). These are passages of extremely small calibre, measuring in the rabbit only 0.0025–0.0018 mm. Arranged in a dense network (*3 a*), they pass between the hepatic cells (*b*) in such a way that the surface of each of the latter comes in contact with them at various points.

The meshes are cubical, so that the network presents the same appearance from almost every point of view. The breadth of each mesh is, on an average, 0.0144–0.0201 mm. in the rabbit, and corresponds as a rule with that of the gland cells. The whole is characterised by the wonderful delicacy of arrangement, and the regular way in which this third and finest network is interwoven with the two others formed by the blood capillaries and bands of gland cells.

These biliary capillaries have been known for many years past to exist in many mammals, among which the rabbit appears to be best suited for their demonstration. They have recently, however, been discovered in the other three classes of vertebrata also (*Eberth, Hering*).

The questions now arise—Do the biliary capillaries possess independent walls, or are they simply lacunar passages; and what relation do they maintain to the hepatic cells?

For our own part, we would with *MacGillavry*, as formerly, so still answer the first question in the affirmative, having always held the opinion that the biliary ducts do possess independent walls. Isolation of the latter has, however, up to the present been impossible, but the significance of this fact seems of minor importance when we consider the great delicacy of all the component tissues of the part. Again (*2*), the interlacement of the blood capillaries (*a*) is seen to take place in such a peculiar manner through the network of the biliary capillaries (*b*), and in many localities the latter present such regularity when injection has been successfully accomplished, that the existence of a system of lacunæ of this kind between cells endowed with vital contractility seems highly improbable. Further, we may at times encounter points, at the junction of injected and uninjected portions of tissue, at which the amount of granules of colouring matter of the former diminish in the latter in a way that permits of our following on the network of biliary capillaries a little farther by the thin lines of coloured fluid, until they appear eventually in the tissue around the several hepatic cells quite destitute of coloured contents. Under very high magnifying power, also, the empty network may be seen clearly, presenting great regularity, the canals of the same calibre throughout, with no enlargements at the nodal points, and sharply contoured. Sometimes we are even so fortunate as to obtain a section so thin that it is almost entirely formed of a network of bands of hepatic cells only one tier thick; and here, along the middle of each band, some of these biliary passages may take their course, maintaining the axis, and lying quite free and uncovered by other rows of cells. An appearance of this kind is easily explained, if we accept the presence of a special wall to each canal, but is, on the other hand, difficult to account for if the passages be regarded as lacunar. The existence of these walls has been since recognised by both *Eberth* and *Koelliker*.

The next question is: How are these biliary ducts related to the hepatic cells?

On this point the opinions of histologists have until recently been very

much divided owing to the obscurity of the subject. Many (as, for instance, *Andréjevic* some years ago) supposed the bodies of the hepatic cells to be always interposed between the blood and biliary capillaries, so that these two could never come into contact one with another. *MacGillavry*, on the other hand, believed in the interlacement and weaving together of both networks in such a way as to render this possible.

The discoveries of *Hering* and *Eberth*, however, have since given support to the first view, which, from our own researches, we are also led to believe to be the correct one.

But in order to understand this fully, we must examine not only the complex liver of the mammal, but the gland also in a simpler form, as it

presents itself in other vertebrate animals, among which we would reckon for the case before us not only fishes and amphibia, but also birds.

Let us take, then, first of all the liver of the amphibia, which is especially instructive. Here we find—as, for instance, in the common ringed snake—that the bands of cells and networks of these bands are made up (as is shown in fig. 504, 1) of rouleaux of gland cells, bounded externally by blood-vessels, and convergent towards a fine biliary duct running through the axis of each rouleau. One of the latter is in transverse section comparable to an ordinary tubular gland clothed with unlaminate epithelium, and possessed of a very narrow lumen, each blood capillary being separated from the bile ducts by the full height of the hepatic cells (*Hering*). The livers of the batrachia, also, present a similar arrangement of parts. A side-view (2) discloses between each two rows of hepatic cells a long bile-duct holding the axis of the bands formed by these rouleaux, while external to the latter the blood-capillaries are situated. Nearer the circumference of the organ biliary ducts of greater calibre are to be found clothed with low

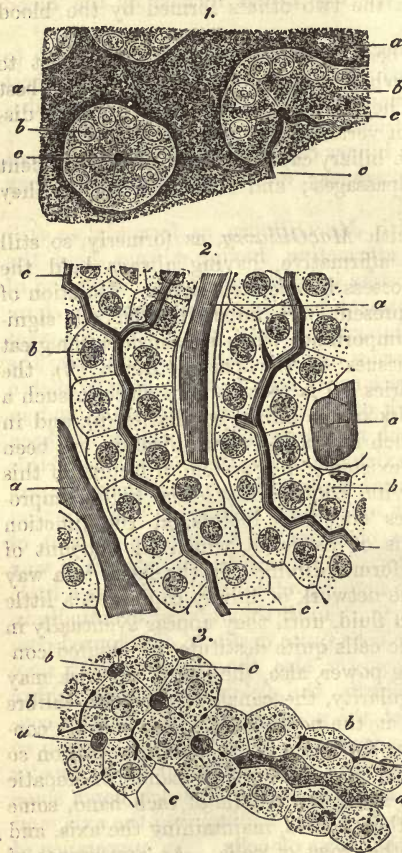


FIG. 504.—Ultimate radicles of biliary ducts in the liver. 1. From the common snake (after *Hering*). 2. From the salamander (after *Eberth*). 3. From the rabbit. *a*, blood-vessels; *b*, hepatic cells; *c*, biliary capillaries.

columnar epithelium which has taken the place of the hepatic cells.

Among the lower orders of vertebrate animals lateral branches on the bile ducts are seen, but sparsely, and the existence of blind terminations to

these (although liable to be simulated by imperfectly injected canals), cannot be denied in our opinion.

It is only when we ascend to birds, that we meet with a higher development of this system of lateral branches.

Among those mammals, on the other hand, which have been hitherto made the subject of research, it is in many cases found in an extremely high state of development in the form of that exceedingly complex network of biliary capillaries, represented in fig. 503. Here the surface of each hepatic cell comes in contact with one or more biliary ducts. But even still, and though presenting complex and various modifications, the fundamental plan, as seen in fig. 504 (3), remains distinct. The biliary (*c*) and blood-capillaries (*a*) never come into actual contact; they are always separated from one another by a whole or fraction of an hepatic cell (*b*). In the lower vertebrates several hepatic cells combine to enclose the former, while higher up the scale the contact of fewer, and at last of two, is sufficient for their formation.

Finally, we are met by the inquiry, What is the nature of the delicate wall of the biliary duct?

The cuticular border of the epithelial cells in the terminal ramifications of the bile ducts, is pointed out by *Eberth* as its probable source. Just as the cell secretion or cuticular formation becomes thickened and perforated by pores towards the larger branches, as already mentioned (§ 92), so does it, as we advance upon the biliary capillaries, acquire greater delicacy, forming eventually the walls of the biliary capillaries at the points of contact of the hepatic cells.

§ 266.

There are still left for our consideration the larger biliary ducts, the lymphatics, and nerves of the organ.

Resembling to a considerable extent the ramifications of the portal system, in their course and mode of confluence, the bile ducts present for our consideration a homogeneous membrane with a clothing of small low cells from the *ductus interlobularis*, which has been already mentioned in the preceding chapter. In the larger trunks, instead of homogeneous walls, fibrous coats and long cylindrical epithelial cells make their appearance, upon whose surface a porous cuticular border may be recognised with increasing distinctness, as we advance from within outwards. In those passages of large size, which have already left the parenchyma of the liver, a mucous membrane and external fibrous layer are to be seen composing their walls. It was formerly supposed that, besides these, a series of longitudinal contractile fibre cells entered into the structure of the tube: this has not, however, been since confirmed.

The coats of the gall bladder are formed, according to *Henle*, of layers of connective-tissue alternating with muscular laminae, consisting of unstriped fibres which cross each other in all directions. The mucous membrane is marked by beautifully regular folds, and is covered by the same coating of nucleated columnar cells met with in the small intestine. These latter are also endowed with the same power of absorbing fats as those of the intestine.

The bile ducts possess also numerous follicles and racemose glands. The first are to be found in the larger canals, as in the *ductus choledochus cysticus* and hepatic duct with its larger branches: they are arranged sometimes irregularly, sometimes in rows. The racemose mucous glands

are but sparsely found in the gall bladder and inferior portion of the cystic duct, but make their appearance in the upper portion of the canal, and *ductus choledochus* and *hepaticus* (fig. 505, *a*). In the wider passages of the latter, with a diameter of about 0·7 mm., is to be found another series of simple caecal formations, some of tubular, some of flask-like figure. In that network of fine passages situated in the transverse fissure of the liver they occur also (*b*); likewise in those ducts arranged around the larger

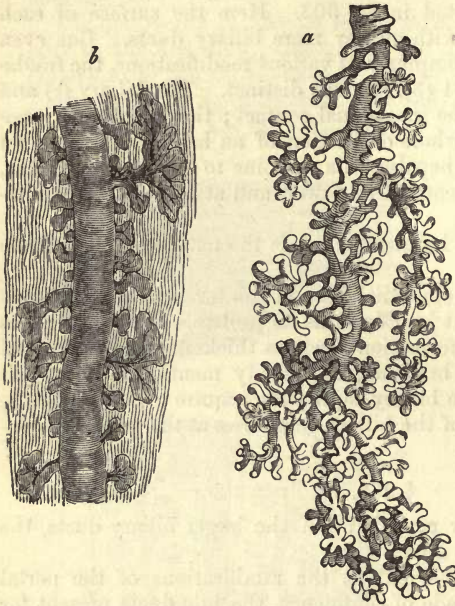


Fig. 505.—*a*, bile-duct glands from the hepatic duct of the human liver; *b*, injected twig of the biliary plexus of the fossa transversa (after Henle).

branches of the portal vein within their sheaths, and finally in the lateral twigs given off from the branches lying in the longitudinal fissure of the organ. These appendages have by some been supposed to be imperfectly developed mucous glands, but by the majority of histologists they are regarded now as blind ramifications of the bile ducts or receptacles for the bile (*Beale, Koelliker, Riess*). According to this last view they would be numbered among the *vasa aberrantia* of *E. H. Weber*. We understand under this name, passages of 0·02–0·7 mm. in diameter, which leaving the substance of the liver, undergo sub-division into smaller branches in a connective-tissue stroma. They are to be

found in the *ligamentum triangulare sinistrum*, and the fibrous bridge across the inferior vena cava. They are partly disposed in a retiform manner, and some of them terminate with bulbous dilatations.

The numerous *lymphatics* of the liver consist of a series of superficial vessels, and another situated more deeply communicating with the first.

The first lying in the deepest layer of the peritoneal covering of the organ, is made up of a complex unlined network of fine canals, whose larger efferent vessels pass off in various directions. Those on the convex surface of the liver take their course towards the ligaments of the organ, and do not meet with lymphatic glands until their entrance into the thorax. Those from the under surface of the viscus, on the other hand, empty themselves into lymph nodes in the neighbourhood of the transverse fissure and the gall-bladder.

The deeper *lymphatic* vessels enter with the portal veins, hepatic arteries, and bile ducts, into the interior of the organ, enveloped in a fibrous prolongation of *Glisson's* capsule, and follow all the ramifications of the latter canals. In their course they invest the branches of both ducts and blood-vessels with a delicate network of tubes, and arrive thus at the periphery of the lobules, still in the form of distinct vessels. Here

they merge, either as distinct vessels or interlobular lacunæ, into a very remarkable network of lymphatic passages, traversing the whole lobule in every direction. Every blood capillary, namely, is ensheathed in a lymph stream, whose external boundary is without doubt formed by the delicate fibrous sustentacular membrane of the hepatic cell bands; so that each of the cells of such a band bounds, with a portion of its surface, the interlobular lymph stream. We are indebted to *MacGillavry* for the discovery of these perivascular lymphatic spaces (§ 207). These facts we have confirmed by personal observations, and *Biesiadecky* has recently succeeded in demonstrating that the same arrangement of parts prevails in the human liver. Incautious injection of the biliary capillaries frequently results in rupture of the latter, and communication between them and the lymphatic interlacements, giving rise to appearances which have led at least several observers into the error of regarding the latter as biliary networks.

The nerves of the liver, springing for the most part from the *plexus celiacus*, and consisting of both *Remak's* fibres and other dark, fine, or broader filaments, spread themselves along the course of the bile-ducts, along the hepatic arteries and its ramifications, as far as its interlobular branches, along the portal and hepatic veins and serous covering of the organ (*Koelliker*). The mode of their ultimate termination is still very obscure.

§ 267.

Turning now to the *composition* of the liver, older and rougher analyses of its tissue (whose sp. gr. is stated by *Krause* and *Fischer* at 1·057) give, beside about 70 per cent. of water for man, soluble albumen, coagulated protein matters, glutinous substances, fats, extractives, and about 1 per cent. of mineral constituents.

In addition to these, a number of interesting mutation products have been found in the liver. As far as we know at present, glycogen, grape sugar, inosite (in the ox), lactic acid, uric acid, hypoxanthin, xanthin, and urea have been met with here. Kreatin and kreatinin, on the other hand, have not been found, nor leucin and tyrosin, of which the first is at the most only present in traces in the healthy liver (§ 31 and § 32). Cystin has also been found in the organ under morbid conditions.

None of these matters are present in the bile, and must consequently return into the circulation.

The *mineral constituents* are, in the first place, phosphates of the alkalies, which appear in large quantities, the salts of potassium preponderating, while phosphate of calcium and magnesium, chlorides of the alkalies and sulphates are present in but small amount. Iron, manganese, and copper (p. 62), with traces of silicates, have also been found.

Accurate observation has shown that the tissue of the liver, which is of soft consistence during life, possesses also an alkaline reaction, while in the dead animal it reacts acid.

The glandular elements, or hepatic cells, are composed of richly albuminous protoplasm, containing frequently glycogen. This latter compound vanishes from the cells of starving animals. Glycogen, which is neither found in the vegetable kingdom nor in the blood, must be regarded as a product of cell life. Through the agency of a ferment also existing in the cell, this substance is converted first into *dextrin*, as an

intermediate step, and then into *grape sugar*. Its amount in the living cell is so small that we are unable actually to prove its presence there, but immediately after death it increases considerably in quantity. Besides this, fatty matters are encountered in the glandular elements, and frequently also biliary pigment in the form of granules. The hepatic cell, however, fabricates besides several other substances of great importance in the formation of bile, as we shall see presently in considering this secretion. It is not improbable that the formation of glycogen, and certain of the constituents of bile, are only different portions of one and the same mutative chemical process.

The fatty matters of hepatic tissue still await accurate analysis.

§ 268.

The *bile*, an exceedingly decomposable secretion, is, as it flows immediately from the liver, a clear and rather thin fluid of alkaline reaction. Its colour is sometimes reddish yellow, as in the carnivora, and sometimes greenish, as in the case of the vegetable feeders. Whatever its tint be at the outset, it always turns to green on exposure to the air. To the taste it is sweetish bitter, leaving little aftertaste. During its sojourn in the gall-bladder its characters become changed, its alkalinity appears more marked, it receives an admixture of mucus, the colour deepens to brown, and it becomes more concentrated. The sp. gr. of human bile is usually accepted as 1·026–1·032.

The fluid is usually completely homogeneous, without either granules or fat globules; nor do hepatic cells make their appearance in it, owing to the small calibre of the biliary capillaries.

The most important and essential constituents of bile are the compounds of sodium with two peculiar acids, and the pigmentary substances.

These two acids, *taurocholic* and *glycocholic*, have been already considered (§ 27). From the fact that they are absent from the blood, we are forced to the conclusion that they are generated in the liver. Their mode of origin, however, is still a matter of great obscurity.

For a long time the greatest uncertainty prevailed as to the nature of the *colouring matters* of the bile. It was not until after *Staedeler's* beautiful investigations were published that any progress was made in this direction (p. 53). Fresh bile appears to contain only two of those pigmentary matters discovered by this chemist, namely, the more essential *bilirubin* and *biliverdin*.



Fig. 506.—Crystals of bilirubin obtained from its solution in sulphide of carbon.

Bilirubin (fig. 506) may be obtained from slightly acidulated bile by agitation with chloroform. That it is nearly allied to hæmatin, and has its origin in the destruction of the pigment of the blood-cells in the parenchyma of the liver, can hardly be doubted, although we were obliged at p. 50 to negative the question of identity of the two substances. The peculiar crystalline form of this pigment is also against our accepting it as identical with hæmatin, its crystals assuming a whetstone figure.

Very small crystalline bodies, made up of bilirubin in irregular and sometimes stalk-like masses, may be met with in the bodies of the hepatic cells at times.

The enormous colouring power possessed by this pigment is also a point of great interest. Diluted to a million times its volume, it is still capable of communicating a distinctly yellow tinge to a layer of fluid two inches deep. Again, as is well known, a very small quantity in the blood of jaundiced persons imparts a yellow colour to their skin and conjunctiva.

The pigment of fresh green bile is probably biliverdin, nearly allied to the last. It is also developed in the other species of bile on their becoming green. Dissolved in alkalis, it gradually assumes a brown tint.

In decomposing bile, another brown colouring matter is also to be found, which, on the addition of acid, assumes a green colour. This is probably biliprasin.

We have already referred, as far as necessary, to the mode of generation of the various colouring matters (§ 37).

Another colouring matter, also present in the urine, has likewise been recently discovered in this fluid, to which the name of *urobilin* (§ 53) has been given (*Jaffe*).

Besides these constituents, neutral fats are also present in the bile, also combinations of fatty acids with alkalis, lecithin, with its two decomposition products, glycerophosphoric acid and neurin or cholin, cholestearin (p. 30), and mineral matters. The latter consist principally of chloride of sodium, some carbonate and phosphate of sodium, phosphate of calcium and magnesium, as well as traces of iron, copper, manganese (p. 62). Fresh bile contains no sulphates; these are, however, produced in it by incineration and by the processes of putrefaction, from taurin, which contains sulphur (p. 49).

Of gases, the bile contains (dog) a small amount of oxygen, abundance of carbonic acid, and some nitrogen (*Pflüger*).

The proportion of these matters in the bile is usually higher than in the other digestive fluids, but varies greatly, according as the bile remains for a longer or shorter time in the gall bladder, where it undergoes a loss of water by absorption. The percentage of solid constituents in the human bile is generally estimated at from 9 to 17 (*Frerichs, Gorup*). That from the ox contains from 7 to 11 per cent., that obtained directly from the livers of dogs, cats, sheep, only about 5 per cent. (*Bidder and Schmidt*). The bile of the Guinea-pig is still richer in water. The organic matters in man amount, according to *Frerichs*, to about 87, or, according to *Gorup*, to 93 per cent. of the dried residue. Among these the combinations of sodium, with the two biliary acids, appear to preponderate greatly, while the proportion of fats and of cholestearin is much less considerable. The percentage of mineral constituents is stated by *Gorup* to be about 6.14 of the whole solid residue.

The secretion of bile in the normal conditions of the system is continuous, but liable to vary considerably. It depends, in the first place, on the nature of the alimentary matters taken into the system, being most abundant after a meal of flesh mixed with fat, while it decreases after purely fleshy food, and is still less after an exclusively fatty diet. A draught of water also increases its amount, and after the introduction of food into the system, the quantity elaborated becomes larger and larger for several hours.

The quantity of bile produced in twenty-four hours varies in many animals, and has besides been estimated differently by several observers for one and the same animal. From 1000 to 1800 grammes is supposed

generally to be about the average amount secreted by the adult human being daily; though we must admit that this statement is based upon very uncertain data.

As to the use of bile in the processes of digestion, we know that it possesses no fermenting power over the albuminates, but precipitates on the contrary albuminous substances from their acid solutions whether digested or undigested. It has the same effect on pepsin. It is still a debated question, whether it possesses the power of transforming starch into sugar. It saponifies the free fatty acids, and forms an emulsion with fat, thus facilitating its absorption by the intestinal villi (*Bidder* and *Schmidt*, *Wistinghausen*).

Besides this, as *Bidder* and *Schmidt* have shown, the greater part of the bile, in fact almost all its water, as well as $\frac{7}{8}$ ths of its solid constituents, is again taken up into the circulation by absorption from the intestines; but nothing farther is known as to what changes its constituents undergo there. In a changed state the pigmentary matters pass through the intestine, together with a small quantity of cholestearin, and occasionally some taurin. The products of the metamorphosis of choleic acid are also met with, namely, choloidinic acid and dyslisin. Neurin also and glycerophosphoric acid also partake of the nature of decomposition products.

The *development of the liver*, although still a knotty point in histology, has been cleared up to a great extent by the important discoveries of *Remak*. From these it would appear that the organ springs very early from the cells of the so-called gland layer in the form of two saccules, clothed externally by a fibrous envelope, derived from the walls of the intestine, and which has been pushed before the growing saccules. From the most internal cells of these primitive bile ducts, solid groups of elements are produced by a process of division, the "hepatic cylinders," which advance in their farther growth into the external enveloping layer, dividing in their progress, and branching with the formation of networks. Those cells of the originally external envelope, which have become as it were entangled within the meshes of the network formed by the hepatic cylinders, are gradually converted into fibrous or connective tissue, vessels and nerves, while the secreting elements of the gland are to be found in the cells of the hepatic cylinders. It is a fact of great interest, first pointed out by *Bernard*, that at an early period of intra-uterine existence the liver contains no glycogen, although this is to be found in the placenta, the epidermal cells, and epithelium of the intestine, as well as in the passages of the glands developed from the latter, and also in muscle (§ 170). With the development of the liver the disappearance of glycogen commences at one point early, at another later, continuing until birth.

4. The Urinary Apparatus.

§ 269.

The urinary apparatus consists, as is well known, of two glands: the *kidneys* (designed to secrete the urine), and a system of excretory passages made up of the *ureters*, which terminate in a common reservoir, the *bladder*, and the *urethra*, by which the fluid is eventually carried off from the latter.

The *kidney*, *Ren*, a large bean-shaped organ with a smooth surface, is covered by a thin but strong fibrous envelope, the *tunica propria*, which is continued on to the external surface of the infundibula at the hilus,

where the ureter leaves the gland, and its nutrient blood-vessels enter.

The substance of the kidney presents for consideration two portions, namely, the *cortical* or external, which is of a brownish red colour, and indistinct structure to the naked eye, and an internal paler *medullary portion* of fibrous appearance. The latter is marked by fine lines converging towards the hilus, and consists in most mammals of a single conoid mass with the apex towards the hilus, but in the case of the human being and pig this is divided into from 10 to 15 sections, whose bases lie towards the cortical part of the organ, their apices being directed towards the hilus. To these the name *Malpighian* or *medullary pyramids* has been given. Between them the cortical substance is prolonged inwards in the form of septa, known as the *columnæ Bertini*, while both portions of the organ contain interstitial sustentacular connective-tissue.

Notwithstanding their want of similarity in appearance, both portions of the kidney consist of glandular elements resembling each other in many particulars. These are long branching canals or tubes, known as the *uriniferous tubes* of *Bellini*. In the medullary part of the organ, however, they pursue a straight course diverging slightly or running nearly parallel, and dividing at very acute angles; while on their arrival in the cortex they commence to turn and twist upon themselves, and intertwining one with another (fig. 507, *e*), terminate eventually in a blind dilatation (*d*) which envelops a peculiar congeries of vessels (*c**, *c¹*).

The difference of texture observed in both portions of the organ is thus explained.

This is all that was known until recently about the structure of the kidney, and much difference of opinion existed, besides, as regards the relations of the blood-vessels to the several elements of the organ.

We owe much to *Henle* for having given a new impetus to the study of the histology of this organ some years ago by his interesting discoveries. He found, namely, that the medullary substance contains, besides the well-known straight tubes, with acute-angled division, which open into the pelvis of the organ, a series of finer canals arranged in loops, whose convexities are directed towards the apex of the medullary pyramids and which on arrival at the limits of the latter are continued into the cortex.

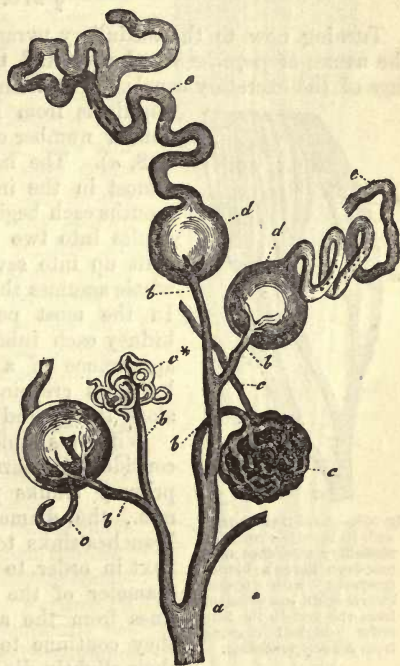

Fig. 507.—From the cortex of the human kidney. *a*, arterial twig giving off branches; *b*, to the congeries of vessels *c**, *c¹*; *c*, efferent vessel of the latter; *d*, dilatations on the ends of convoluted uriniferous tubes, *e*.

But *Henle's* work on the subject, besides elucidating much that was most useful, led to incorrect conclusions as to the structure of the cortex. It served, however, a great purpose in provoking a series of farther investigations, and thus through individual exertions the views on the structure of the organ have undergone since a most salutary change.

REMARKS.—(1.) Among the older essays on the subject which may be said to extend up to the year 1862, we shall only mention, beside the German works of *Gerlach*, *Ludwig*, and *Koelliker*, those of *Bowman* in the *Phil. Trans. Act. for the year 1842*, pt. i. p. 57, and *Johnston's* article "*Ren*" in the *Cyclopaedia* vol. iv. p. 231.

§ 270.

Turning now to the medullary pyramids, whose apices have received the names of *papillæ renales*, we find the latter studded with the openings of the excretory canals. The number of these oval orifices for each papilla is from 10 to 30. They correspond to a similar number of trunks of the gland tubes (fig. 508, *a*). The latter are, however, very short, and almost in the immediate neighbourhood of their mouths each begins to divide usually at very acute angles into two or three branches. These again split up into several more (*b*, *c*, *d*, *e*) until the whole assumes the appearance of a bunch of twigs. In the most peripheral groups in the human kidney each tube presents to a certain extent the appearance of a runner with somewhat knotted branches creeping for a greater or less distance along the ground (*Henle*).

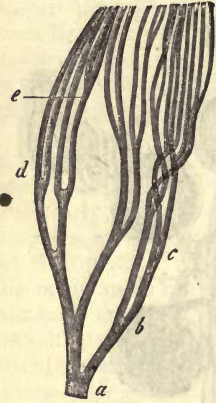


Fig. 508.—A uriniferous tube with its branches from the medullary substance of a new-born kitten's kidney (prepared with hydrochloric acid). *a-e*, divisions from the first to the fifth order (original drawing from *Schweigger-Seidel*).

With this rapid sub-division the canals become considerably narrower. While the mouths and primary trunks possess a calibre of 0.3–0.1985 mm., the diameter even of the first series of branches sinks to 0.1985–0.0990 mm., and in the next in order to 0.0510–0.501 mm. This is the diameter of the uriniferous tubes at about two lines from the apex of the papillæ, and which they continue to maintain throughout the rest of their slightly divergent course through the medullary substance.

Further division is now no longer remarked, or if seen is only exceptional.

The increase in bulk of the medullary pyramids towards the cortical portion of the organ is partly explained by this division and subdivision of the uriniferous tubes, but only partly so. Another factor in this enlargement of the bases of the pyramids is the system of narrow, looped, uriniferous tubes (*Henle*), which appear here in addition to those opening at the papillæ, and to which the name of *canals of Henle* has been given (*Koelliker*). These, from 0.04, to 0.02 mm. in diameter, pass in great numbers out of the cortex into the medullary portion, and are here doubled back upon themselves sooner or later (*i.e.*, at a greater or less distance from the papillæ), forming regular loops. Thus they return to the cortex, becoming wider in their course back again. In order now to prevent all misunderstanding in the rather complicated explanation of the arrangement of parts about to follow, we shall apply to those limbs of the looped canals

which leave the cortex of the kidney the term *descending*, and to those curving back again that of *recurrent tubes*.

In fig. 509 we have a representation of these looped canals (*d*) lying between the widely separated tubes (*b*, *c*). It shows likewise the inequality in the distances from the papillæ, at which the smaller tubes turn on themselves.

It seems hardly necessary to remark that the number of looped tubes increases the nearer we approach the cortex of the organ. This is shown by transverse sections of the medullary pyramids taken at varying heights. Near the apices of the papillæ but few cross-sections of the looped tubes of *Henle* are to be seen around the wide openings of the straight canals. But nearer the bases of the pyramids of *Malpighi* the small lumina of the former become more and more numerous. Again, while the open uriniferous tubes are at first arranged close to one another, surrounded by circles of the orifices of the looped canals, we meet them further outwards with larger intervals between them, which are occupied by cross-sections of the tubes of *Henle* in great numbers. But it is not only a difference in diameter which distinguishes these two systems of uriniferous tubes from one another: the glandular epithelium in the open canals is of a species entirely distinct from that in the looped, and the so-called *membrana propria* presents several points of difference, though of a less marked kind.

The short trunks of the open canals have at their commencement no *membrana propria*; they are simply bounded by the fibrous framework of the apex of the papillæ. Further on a delicate, transparent, limiting membrane begins to be apparent. This remains throughout the ramifications thin and fine, presenting always a single outline under the microscope. The case, however, is quite different with the looped canals (fig. 510, *a*, *b*, *c*). Here the *membrana propria* is stronger and thicker, and exhibits under high magnifying power a double contour.

In the short primary trunks of the open canals we find an epithelial lining continuous with that covering the surfaces of the papillæ. But the cells here are clearer, and of the low columnar type, with broad bases turned towards the walls of the tube. A considerable lumen is still left, however, for the height of the cells is only 0.0300–0.0201 mm. They remain thus as far as the branches of the first and second order (*Henle*). The last system of branches which run, as

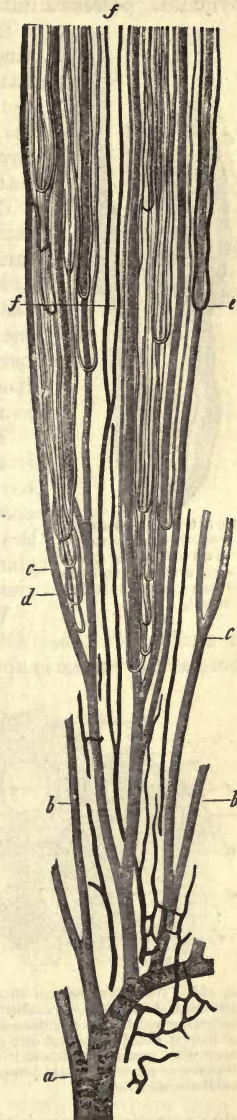


Fig. 509.—Vertical section through a medullary pyramid of the pig's kidney (half diagrammatic). *a*, trunk of uriniferous tube opening on the tip of a pyramid; *b* and *c*, branches of the same; *d*, looped tubes, or *Henle's* canals; *e*, vascular loops; and *f*, branches of the *vasa recta*.

we have seen, undivided for long distances towards the bases of the pyramids, possess a lining of gland cells only 0.0158 mm. high.

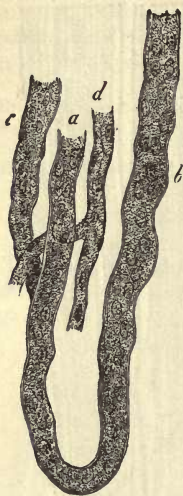

Fig. 510.—Looped canals from the renal pyramid of an infant. *a, b*, the two arms; *c*, another tube; *d*, capillary blood-vessel.

The gland cell of the looped canals is, on the other hand, in the descending arms and curves, a very flat pavement element, presenting great similarity to the endothelium of the vascular system (§ 87). Its nucleus also, as in the latter, projects slightly beyond the surface (fig. 511, *d*). The resemblance to these vascular cells is really very striking.

The recurrent tubes, however, of *Henle's* loops commence sooner or later to enlarge, and from this on the lining cells assume a different character. Instead of clear, flattened elements, the ordinary cubical gland-cells with distinct nuclei and granular protoplasm present themselves, with not unfrequently ill-defined boundaries between each one and its neighbour. Hence the recurrent arm becomes cloudy or granular in appearance, and its lumen decreases in diameter.

These points are very well seen in fig. 511, which is taken from the kidney of the infant. Here may be recognised, at *a*, the transverse sections of the open canals; at *b*, the clear, flat, epithelial cells of the descending tubes; and at *c*, the granular clouded gland elements of the recurrent arm of the looped uriniferous canals.

We must, of course, expect to find the number of sections of tubes filled with dark gland-cells, increasing more and more as the cortex is approached.

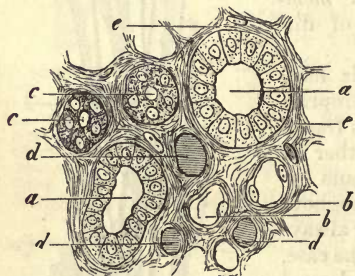


Fig. 511.—Transverse section through a renal pyramid of an infant. *a*, collecting tube with columnar epithelium; *b*, descending arm of a looped canal with flat cells; *c*, recurrent arm with granular epithelial elements; *d*, transverse section of a blood-vessel; *e*, fibrous sustentacular tissue.

The clearest insight into the arrangement of parts, just described, is to be obtained from preparations in which the open canals have been injected from the ureter with one colour, and the blood-vessels of the medulla with another.

Above, at the termination of the medullary substance and commencement of the cortex, the distinctive differences between the two species of tubes disappear more and more, as far as diameter and epithelial lining are concerned. But even here injection from the ureter exhibits the peculiarities of the two systems; for, though the open canals are easily filled, the urine-secreting looped tubes remain, as a rule (unless special modes of treatment be adopted), completely devoid of the fluid injected. The upper portion of the medullary substance assumes, on injection of the blood-vessels, a deep red hue for a considerable depth. This is the *boundary layer* of *Henle*. Its deeper colour is due to the presence of numerous tufts of radiating vessels.

§ 271.

Turning now to the *cortical substance* of the kidney, we find just as peculiar and complex an arrangement of parts as in that portion we have been considering.

In vertical sections (fig. 512) we observe that it consists of tubes twist-

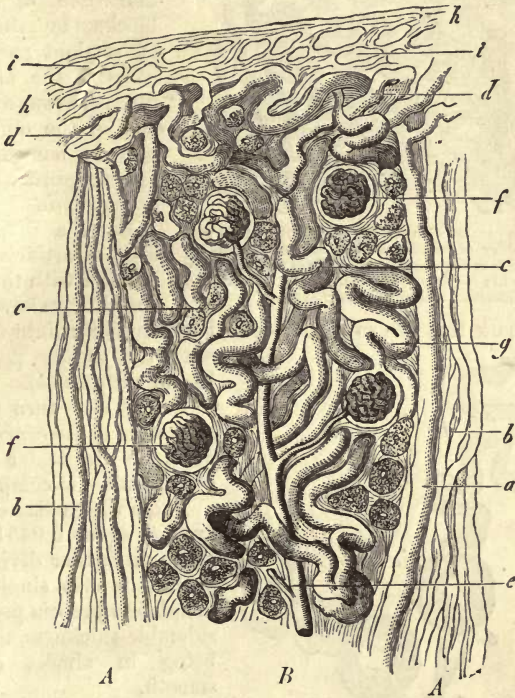


Fig. 512.—Vertical section through the cortical portion of the kidney of the infant (half diagrammatic). *A A*, medullary processes; *B*, true cortical substance; *a*, collecting tube of the medullary process; *b*, finer tubes of the latter; *c*, convoluted tubes of the cortical substance; *d*, peripheral layer of the latter; *e*, an arterial twig; *f*, glomeruli; *g*, transition of uriniferous tube into one of *Bowman's capsules*; *h*, envelope of the kidney with its lymphatic interstices.

ing and intertwining in all directions (*B*); but that, besides these, it is traversed from within outwards by cylindrical bundles (*A*) of about 0.2707–0.3158 mm. in diameter, at regular and short intervals. These bundles or cords are made up of canals of different calibre, which, in some instances, become narrowed in their course outwards, where they are lost in convolutions immediately under the surface, forming there a narrow stratum of convoluted tubes (*d*). This cortical stratum of convoluted elements, consequently, is interrupted at intervals by the bundles of straight uriniferous tubes (fig. 512, *A*), in about the same way that a board is pierced by groups of closely-standing nails driven through it.

These bundles, although discovered long ago, have only very recently received particular attention. They have been given by *Henle* the name of "*pyramid processes*," and by *Ludwig* that of "*medullary radii*."

We shall presently take into consideration their significance and bearing as regards the canals of the medullary substance.

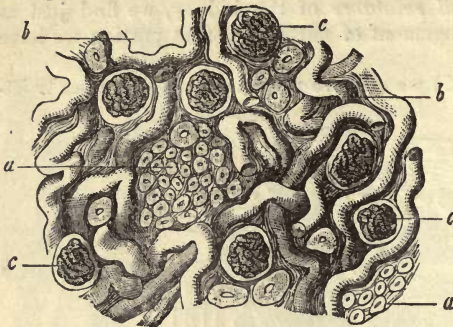


Fig. 513.—Section parallel with the surface of the cortical portion of the kidney of an infant (half diagrammatic). *a*, transverse section of the uriniferous canals of the medullary processes or radii; *b*, convoluted tubes of the true cortical substance; *c*, glomeruli and capsules of *Bowman*.

Here we remark that the so-called cortical pyramids run into one another with the greater part of their lateral surfaces (*b*).

Let us now turn to the consideration of the *convoluted tubes* of which the greater part of the cortical mass is composed.

Those whose diameter is on an average about 0.0451 mm., undergo no farther division; their outline is also single, and the *membrana propria* possesses considerable thickness, their outline being in almost every case smooth.

The cells of the convoluted tubes are also very characteristic in appearance. Their bodies are made up of granular cloudy protoplasm, in which fatty molecules are often imbedded, increasing its opacity. In diameter they range between 0.0099 and 0.0201 mm. (*Schweigger-Seidel*). Should the preparations have been treated by the method most generally in use at present, namely, that of maceration in hydrochloric acid, the convoluted tubes will probably appear dark, without any indication of a lumen, and not unfrequently without

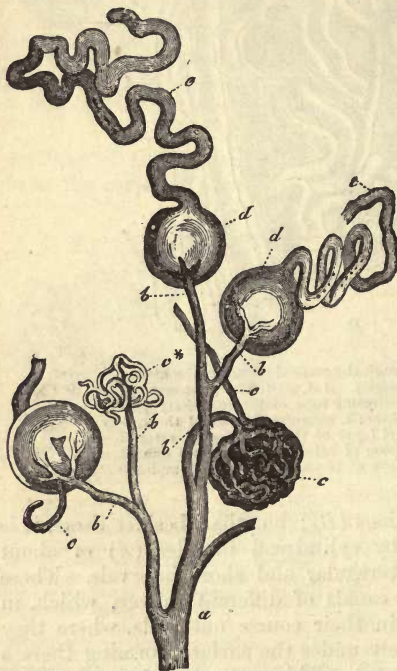

Fig. 514.—From the cortical portion of the human kidney. *a*, arterial twig giving off the afferent blood-vessel (*b*) of the glomerulus (*c**, *c'*); *c*, efferent vessel of the latter; *d*, capsule of *Bowman* opening into a convoluted uriniferous tube of the cortex *e*.

any distinct marking off of one gland cell from the other.

The mode of termination of the uriniferous tubes is a point in regard

to which, at an earlier epoch, the most erroneous views were held. They were supposed by some to end blind in the cortex, and by others to be continuous one with another by means of loops (*Huschke, J. Müller*). It was, to be sure, remarked that a peculiar congeries of vessels, known as the glomerulus of *Malpighi* was enveloped in a capsule, but its connection with the uriniferous tubes was denied in the most decided manner by the discoverer, *J. Müller*.

In the year 1842, however, this connection was demonstrated by *Bowman*, who seems thus to have advanced the histology of the organ by several decades.

Let us now turn for a moment to the mode of termination of the tubes in these capsules, known either in connection with *Bowman's* or *J. Müller's* names.

It is not unfrequently seen that, on arrival in the neighbourhood of the capsules, the uriniferous tubes (fig. 514) execute a series of very rapid undulations, more or less in one plane. Further, that immediately before opening into the capsule (*d*) there occurs pretty commonly a constriction on each tubule, more or less marked, and for a greater or less distance (fig. 515, *d*), and that the limiting membrane of the latter runs continuously into the apparently homogeneous tunic of the capsule. The latter has, as a rule, a diameter of about 0.1415–0.2256 mm., and spheroidal figure. It may, however, present itself of an elliptical or laterally widened form, or even heart-shaped.

In a very thin superficial layer of the cortical substance, the *cortex corticis* of *Hyrtil*, neither capsules nor glomerules are to be found. They are, however, very numerous in the cortex. Their number, as estimated by *Schweigger-Seidel*, appears to be, in the kidney of the pig, about 6 to every cubic millimetre, or 500,000 for the whole cortical portion of the organ.

It is generally held by many observers, among whom *Bowman*, *Gerlach*, and *Koelliker* may be mentioned, that those capsules situated deeper in the kidney are of greater magnitude than the others, and that those nearest the boundary, between the cortex and medulla, have the greatest diameter of all.

The most difficult point to determine in regard to *Bowman's* capsules, is the relation to them of the vascular glomerulus and the cellular lining of the interior.

It was at one time supposed that the vessels simply perforated the wall of the capsule, and that the glomerulus lay naked within the cavity of the latter. Other observers, as *Koelliker*, for instance, supported the view as far as regarded the perforation, but believed the glomerulus to be covered over by the cells lining the capsule. Another theory is, that the knot of vessels is received into a depression in the capsule, somewhat in the same way as the lungs are received into the pleura. From my own investigations I am inclined to accept the last view as correct, besides which, it is easiest reconciled with the history of the development of the part (*Remak*). It must, however, be admitted that the membrana

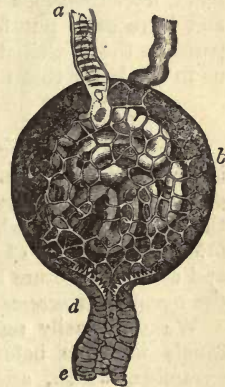


Fig. 515.—From the kidney of the common snake (after *Ecker*). *a*, vas afferens; *c* glomerulus; *b*, vas efferens; *d*, cessation of ciliated cells at the point of exit of the uriniferous tube *e*.

propria of the capsule is excessively thin over the glomerulus, and more like a homogeneous connective-substance or delicate boundary layer of the whole.

Turning our attention now particularly to the epithelial lining, we at once recognise the fact that the thick granular gland cells of the convoluted tubes become transformed, at the entrance to the capsule, into delicate pavement epithelial elements (fig. 515, *e*), which line the whole internal surface of the capsule, and may be easily rendered visible by the aid of a solution of nitrate of silver (fig. 516, *g*). Among the lower vertebrates a number of ciliated cells are arranged around the entrance of the capsule, a most fragile species of ciliated epithelium (fig. 515, *d*).

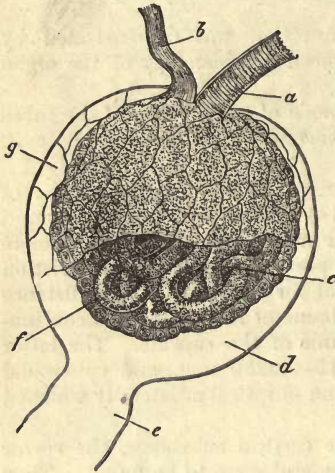


Fig. 516.—A glomerulus from the rabbit. *a*, vas afferens; *b*, vas efferens; *c*, glomerulus; *d*, undermost portion of capsule without epithelium; *e*, neck; *f*, epithelium of the glomerulus; and *g*, that of the internal surface of the capsule after treatment with nitrate of silver.

But the cellular layer said to exist over the glomerulus, is far more difficult of recognition, and has not as yet been satisfactorily demonstrated. Nuclei are easily seen in this situation, but the borders of cells are not to be made out in the adult. From the fact that distinct cells are seen upon the glomerulus in the fœtus, it has been supposed that they may have become fused together into one homogeneous nucleated membrane (*Schweigger-Seidel*). Other observers, on the other

hand, have described here a complete covering of distinctly separate cells, and have even put forward statements in regard to their size as compared to the epithelial cells of the capsule. Our own experience inclines us to the belief that they are correct in their views (fig. 516, *f*).

§ 272.

From the preceding section we have learned that the convoluted tube is an important element of the cortex, and takes its origin from the capsule of the glomerulus. Leaving the destination of its other end for the present undecided, let us turn our attention in the meantime to those other constituents of the cortical portion of the organ whose position and coarser structure have been already touched on (§ 270); we allude to the *pyramid processes* or *medullary radii*.

We may easily satisfy ourselves that, in these bundles of straight canals we have before us some of the open tubes of the medullary pyramids, which, after passing through the so-called boundary layer, arrive either singly, or, more rarely, in twos, in each of the processes, and traverse the latter from below upwards, nearly to the surface of the kidney. These passages, remarkable for their considerable calibre (fig. 517, *a*), have received the appropriate name of *collecting tubes* (*Ludwig*). They are lined by transparent low columnar epithelium, which we have already seen in the last branches of the open medullary canals; this is, however, less characteristic here than in the situation just alluded to.

Each of these collecting tubes is accompanied by a number of smaller passages. These, as we shall see presently, are the descending and recurrent arms of the looped tubes of *Henle*, which are consequently elements of the cortex both before and after traversing the boundary layer.

But what becomes of the collecting tubes on their arrival at the surface of the kidney?

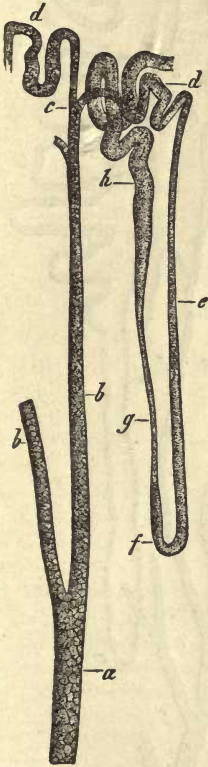


Fig. 517.—Vertical section from the kidney of the Guinea-pig (hydrochloric acid preparation). *a*, trunk of a collecting tube; *b*, branches of the same; *c*, further subdivision; *d*, convoluted canal (intercalated portion); *e*, descending arm of a loop tube; *f*, loop; *g*, recurrent arm; and *h*, continuation as convoluted uriniferous tube of the cortex.

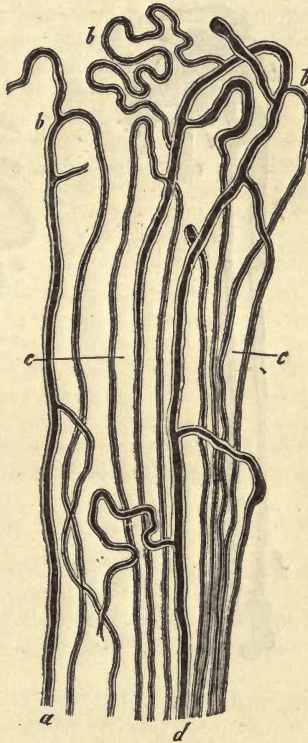


Fig. 518.—The upper portion of a medullary ray from the kidney of the pig; *a* and *c*, so-called collecting tubes; *b*, their arched branches and continuation at *c* into the descending arms of the looped canals.

Maceration in acid (fig. 517) enables us to convince ourselves that on their arrival here they give off numerous branches, and eventually break up into arching, and, not unfrequently coiled tubules (*d*). The latter may present in smaller animals a rugged appearance, not seen in larger creatures. These are the “intercalated portions” of *Schweigger-Seidel* or “connecting canals” of *Roth*.

The same result is obtained when the passages of the gland have been

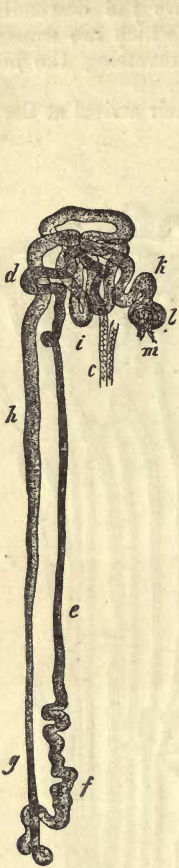


Fig. 519.—Vertical section from the kidney of the mole (hydrochloric acid preparation). *c*, terminal branch of collecting tube; *d*, portion of a convoluted uriniferous tube; *e*, descending arm of the looped canal; *f*, loop; *g*, *h*, recurrent arm and continuation into a convoluted tube at *i*; *k*, neck of the latter; *l*, *Bowman's* capsule; *m*, glomerules.

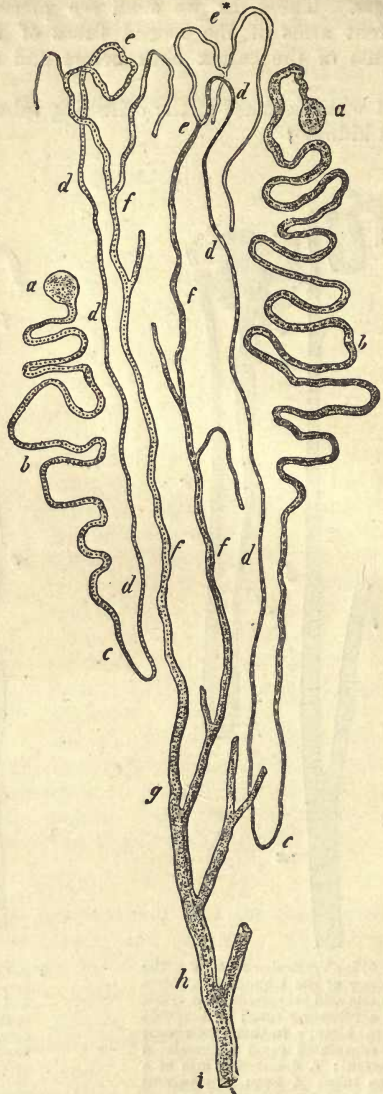


Fig. 520.—Diagram representing the course of the uriniferous tubes, based on the arrangement as seen in the kidney of the mole. *a*, *Bowman's* capsule; *b*, convoluted uriniferous tube; and *c*, recurrent arm of loop; *d*, descending arm; *e*, convoluted passages; *f*, collecting tubes joining to form one large, open uriniferous canal, *g*, which communicates with another canal, *h*; *i*, main trunk opening on the papilla.

artificially injected through the ureter with success, as may be well seen

in the dog and pig, for instance. In the latter animal the breaking up of the collecting tubes into arching ramifications (*b*) is easily recognisable.

It appears, moreover, that loops of communication never occur between the ramifications of one collecting tube and those of another, although we might sometimes be easily led to believe otherwise in thick sections of injected kidneys.

It was such deceptive appearances which tempted *Henle*, after he had been successful in filling the renal tubuli so far, through the ureters, to the conclusion that the terminations of the strait canals which open at the apices of the papillæ lay before him; and farther, that a system of tubes, distinct from these open passages, and in no way communicating with them, is formed by the convoluted uriniferous canals, capsule of glomerulus, and looped tubuli of the medulla.

Both modes of procedure mentioned above, namely, that of maceration in acid, and that of complete artificial injection, show that series of passages, of various forms, spring from the arches just mentioned, and also earlier still from the collecting tube itself. These it is (fig. 518, *c*) which, arriving in the medulla, somewhat decreased in size (fig. 517, *h, g*), form there the *descending arms of the looped tubes of Henle* (fig. 517, 519, *e, f*).

Here, then, we have the origin of the descending portion of the loops.

If we now follow it still farther—to repeat a former description—we find it (fig. 519, *e*) advancing into the medullary substance for a greater or less distance, and then curving round on itself (*f*), pursuing the same course back again to the medullary process (*g, h*). At the same time its diameter increases, as already stated, and its lining of cells changes in character. Arrived here it turns off sideways, sooner or later, to become a *convoluted tube of the renal cortex* (*i*), terminating eventually as such in one of *Bowman's* capsules.

We now have the whole intricate course of the uriniferous tubes before us.

In some few instances we may be fortunate enough to succeed in driving the injection fluid as far as the capsules.

It seems almost superfluous to add another diagram (fig. 520) for the purpose of once more tracing the course which the secretion must take from the glomerulus outwards.

From *Bowman's* capsule (*a*) the fluid escapes into the convoluted tube (*b*), which, after numerous twists and curls in the cortex, arrives in the medullary substance, where it pursues a straight course (*c*). Lined by its own peculiar epithelium, it traverses the medullary pyramid in a direction more or less directly downwards, then forms a loop (*c*), and returns to the cortex (*d*). The recurrent arm so formed alters sooner or later in character: it becomes wider and more tortuous (*e*), and, together with other similarly constituted tubes, empties itself into the collecting canal (*f*), which uniting with adjacent passages of the same order at acute angles (*g, h*), pours out the urine finally at the apex of the papilla (*i*). Many efforts have been made

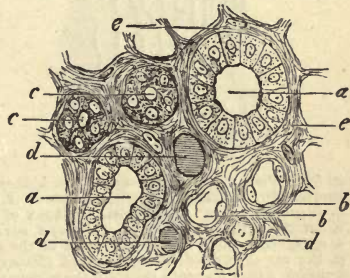


Fig. 521.

to ascertain the length of this very tortuous passage through which the

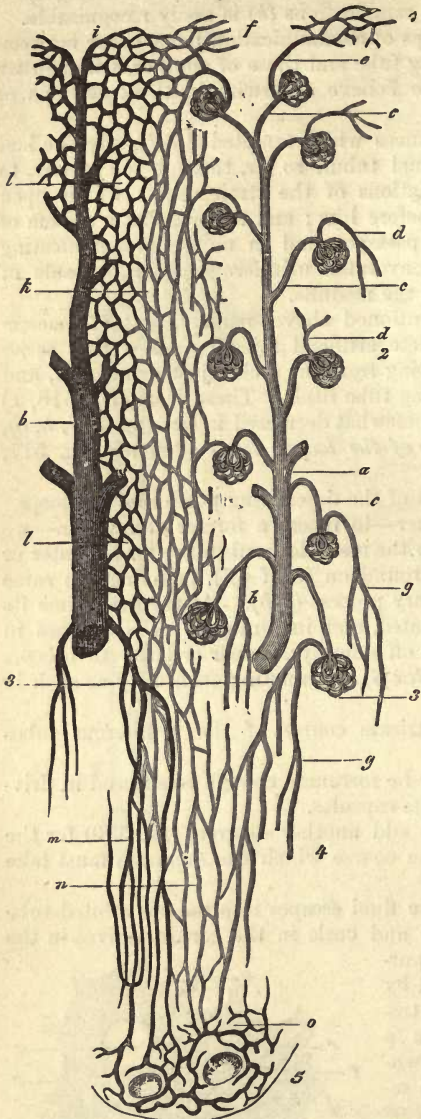


Fig. 522.—Plan of the circulation of the kidney (much shortened). 1. External portion of cortex. 2. Cortex. 3. Boundary layer. 4. Medulla. 5. Apex of papilla. *a*, arterial twig; *b*, vein; *c*, *vas afferens*; *d*, *vas efferens*; *e*, *vas efferens* and *f*, capillary network of the surface; *g*, the *vas efferens* of a deeper-seated glomerulus; *h*, *arteriola recta*; *i*, venous radicle of the surface; *k*, capillaries of the medullary process; *l*, of the convoluted tubes; *m*, *venulae rectae*; *n*, medullary capillaries; *o*, network around the openings of the uriniferous tubes.

urine must flow, and, from the calculations of *Schweigger-Seidel*, it would appear that, from *Bowman's* capsule to the tip of the papilla is about 26 mm. in the Guinea pig, 35–40 in the cat, and about 52 mm. in man.

Turning now to the *sustentacular substance* of these very intricate glandular passages, we find that it consists of a small but by no means unvarying amount of fibrous stroma throughout the whole organ. In the cortex it consists of partitions composed of connective-tissue elements, with homogeneous or streaky intercellular matter, which is somewhat more abundant in the neighbourhood of the adventitial lamina of the larger blood-vessels and *Bowman's* capsules. At the surface of the organ, also, this stroma presents itself as loose areolar tissue, and is continuous here with the capsule of the kidney. The sustentacular substance is somewhat firmer in the *medullary rays* than elsewhere. It appears to attain its highest degree of development, though this is always but of a very low order, in the medullary substance (fig. 521, *e*). It may be well seen in sections of kidneys hardened in alcohol or chromic acid, the sections having been well brushed out, and by the aid of maceration in hydrochloric acid the stellate connective-tissue cells may be isolated very clearly, as has been shown by *Schweigger-Seidel*.

§ 273.

We have now to consider the *blood-vessels* of the organ, which exhibit considerable peculiarity of arrangement.

As a rule both arterial and venous trunks enter the human kidney at

the hilus, having previously divided, after which their subdivision is continued immediately within the organ. Here, after giving twigs to the fibrous envelope of the organ, they pierce the latter external to the infundibulum, each arterial twig being usually accompanied by a large venous branch.

In this way they advance between the several medullary pyramids as far as the bases of the latter. At this point both kinds of vessels give off curving branches, forming imperfect arches among the arteries, but, on the other hand, complete anastomotic rings on the veins.

From these arterial arches those branches spring which bear upon them the *glomeruli* of the cortical substance (fig. 522, *a*). They pass in general through the axial portion of those blocks of cortical tissue, bounded on either side by medullary processes (the cortical pyramids of *Hentle*), giving off towards the periphery the afferent vessels of the glomeruli (fig. 523, *a, b*; 512, *e, f*; 522, *a, c*).

Each of these vasa afferentia subdivides at an acute angle within the glomerules of man and the mammalia (fig. 524, *b, c'*), and gives origin, after coiling and twisting there, to the vas efferens, by the union of the small branches so

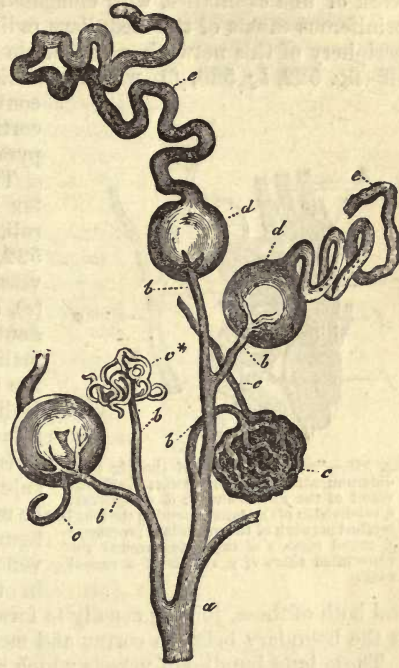


Fig. 523.

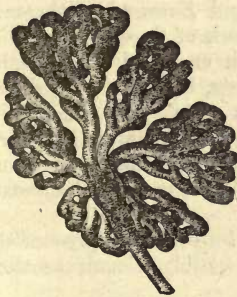


Fig. 524.—Glomerulus from the pig's kidney.

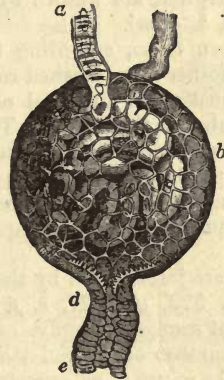


Fig. 525.

formed (fig. 522, *d*; 526, *d*; 527). In the lower vertebrates, as for instance in the adder (fig. 525), the vas afferens (*a*) commences to curl

upon itself without undergoing division (*c*), leaving the capsule as an efferent vessel (*b*).

In man and the mammalia this efferent vessel breaks up into a network of fine capillaries, with elongated meshes surrounding the straight uriniferous canals of the medullary radii (fig. 522, *k*; 526, *e*). From the periphery of this network a multitude of somewhat wider tubes is given off (fig. 522, *l*; 526, *f*), which encircle with their rounded meshes the convoluted uriniferous tubes (*i*) of the cortical substance proper (or cortical pyramids (*Stein, Key*), and others).

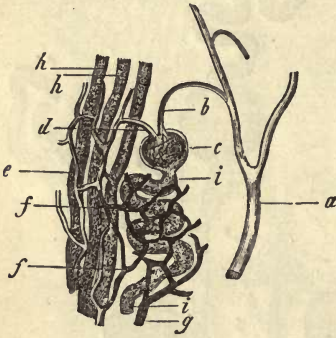


Fig. 526.—From the kidney of the pig (half diagrammatic). *a*, arterial twig; *b*, afferent vessel of the glomerulus; *c*, *a*, *vas efferens*; *e*, subdivision of the latter, forming the long-meshed network of the medullary processes; *f*, round meshes of capillaries around the convoluted tubes *i*; *g*, radicle of a venous twig.

The most external layer of the cortex is destitute of *Malpighian* glomeruli. It receives its capillaries (fig. 522, *f*) principally from the efferent vessels of the superficial glomeruli (*e*), and to a smaller extent, and undoubtedly in only some of the mammalia, from certain terminal twigs of the arteries supplying the *Malpighian* bodies, which pass forward directly to this layer of the cortex.

Immediately underneath the capsule microscopic venous radicals may be recognised (*i*) in the form of stellate figures (*stellulae Verheyenii*). Other venous twigs take their origin deeper in the cortical tissue (fig. 522, *b*),

and both of these, joining usually to form larger trunks, empty themselves at the boundary between cortex and medulla into the venous arches.

Those long bundles of vessels which appear in the medullary substance at its boundary, between the uriniferous tubes, running from thence downwards, and either communicating with each other in loops, or forming a delicate network around the mouths of the uriniferous canals, at the apex of the papillæ, are known by the name of the *vasa recta* (fig. 509, *e, f*, and 522, *h, g, m*).

Between these, according to *Ludwig* and *Zawarykin*, there is interposed another large meshed capillary network of finer tubes (*n*). This is a continuation of the oval network which encircled the straight uriniferous tubes of the cortex. There still exists, however, great difference of opinion as regards the origin of the *vasa recta*. In our opinion they partake partly of the arterial, partly of the venous nature; but in many, though not the greater number of cases, more of the latter than of the former springing from the capillary network of the cortical substance (fig. 527, *f*).

They are joined then by the *vasa efferentia* of the deeply-seated glomeruli (fig. 522, *g*; 527, *e, f, b*), which possibly constitute their most important source of supply.

The number of arterial twigs, on the other hand, is quite inconsiderable as far as we have ourselves observed, which are given off from the branches bearing the glomerules, but before the latter are formed, and which sink as arteriolæ rectæ into the vascular portion of the medulla (fig. 522, *h*; 528, *f*).

As we have already remarked, the subdivision of stronger trunks to

form these vasa recta gives rise in many instances to vascular tassels or bundles.

The confluence of the returning, straight venous vessels (fig. 522, *m*), takes place in a manner precisely similar. They commence partly as loops and partly as capillaries of the medulla. Others, too, spring from a special capillary network of larger tubes, situated at the apices of the papillæ (*o*). They empty themselves finally into the arching veins, already mentioned above, as lying at the boundary between cortex and medulla.

All earlier efforts to inject the *lymphatics* of the kidney, by the method of puncture, were unattended with success, and it was not until *Ludwig* and *Zawarykin* had invented a peculiar mode of procedure that it was effected. The kidney chosen to be operated on was that of the dog.

The lymphatic canals of the parenchyma occupy the interstices of that areolar tissue which we know to exist immediately under the capsule of the organ (fig. 512, *i*). Here they communicate externally with other vessels of the fibrous envelope, and penetrate internally through interstices in the connective-tissue stroma, passing between the uriferous tubes and around the capsules of *Bowman* and finer blood-vessels towards the deeper portion of the organ. But though intercommunication between the lymphatics of the cortex exists very freely, the fine absorbent vessels of the medullary processes can only be filled with some difficulty, and still later those of the medulla itself. The whole arrangement, indeed, resembles, to a great extent, that of the lymphatics of the male generative glands, the testes, to be referred to again below. The canals collecting the lymph in the cortex take precisely the same course as the blood-vessels towards the hilus. They only commence to present valves in the vicinity of the latter, where several very large trunks may be seen.

The *nerves* of the kidney belonging to the sympathetic system, and springing from the plexus renalis, enter with the arteries of the organ. Their course and mode of termination, as well as their relations to the processes of secretion, are however entirely unknown.

The *development* of the organs, as investigated by *Remak*, takes place from the lowest part of the intestinal tube, in the form of hollow buds, composed of a portion of the intes-




Fig. 527.—A deeply-seated glomerulus, *m, m*, from the kidney of the horse. *a*, arterial twig; *a f*, *vas afferens*; *m*, glomerulus; *e f*, *vas efferens* of the latter, dividing at *b* into branches for the uriferous tubuli of the medullary substance.

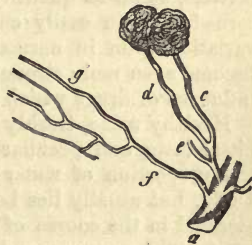


Fig. 528.—From the boundary layer of the human kidney. *a*, arterial twig; *c*, branches of the same bearing at *c* and *d*, as vasa afferentia, two glomeruli; *e*, another branch (*arteriola recta*) breaking up into long capillary meshes of the medullary substance.

tinal germinal plate, with an external fibrous layer, consequently in the same manner as the lungs (§ 243). Subsequently the uriniferous tubes are developed from this system of cavities, in the form of solid bands of cells, which become hollow at a later stage of development, acquiring at the same time a *membrana propria*. The results of *Kupffer's* observations, however, would seem to point to different conclusions. According to him the organs in question are first developed in the form of saccules, on the passages of the primordial kidneys or *Wolffian* bodies.

§ 274.

From the investigations of *Frerichs*, it would appear that the kidney (whose sp. gr. is placed by *Krause* and *Fischer* at 1·044 for the medulla and 1·049 for the cortex) contains from 82 to 83·70 per cent. of water. Of the 18–16·30 per cent. of solid constituents, albumen seems to be the largest in amount. The proportion of fatty matter is from 0·1 to 0·63 per cent. The tissue of the organ is alkaline here also during life, and acid after death (*Kühne*). As to the composition of the gland elements, we know that the *membrana propria* partakes of the nature of the elastic substances, while the contents and whole substance of the cells must be looked upon as albuminous. The fatty molecules observed in the cell bodies explain the amount of adipose matter found in the organ, which varies considerably.

The decomposition products of the kidney found in its juices are of some interest. Among them appear inosite, hypoxanthin, xanthin, and at times leucin in considerable abundance (*Staedeler*). Further, in the dog kreatin is to be found (*M. Hermann*), in the ox, cystin and taurin (*Cloëtta*). Most of these matters probably pass off in the urine.

The *urine* is designed to carry off from the body the greater part of all the water received into it, as well as the principal products of the decomposition of histogenic substances, and also the excess of albuminous matters received into the system as food. Finally, it eliminates all mineral constituents set free in the interchange of material in the animal economy, together with any excess of salts which may be present in the alimentary matters. Taking all this into consideration, and especially that its composition is materially influenced by the nature of the alimentary matters, as far as quantity, wateriness, and chemical constituents are concerned, we can easily conceive that it must be subject to considerable variation even in normal states of the system, a variation which may become even more strongly marked under pathological conditions, or the influence of drugs which are partly eliminated through the kidneys.

Healthy urine, freshly secreted, is a light yellow fluid of acid reaction, bitter taste, and peculiar odour. Its sp. gr. varies greatly, according to the proportion of water contained in it, and may range from 1·005 to 1·030, but usually lies between 1·015 and 1·020. The amount of urine secreted in the course of the day varies also. It usually exceeds somewhat 1000 grammes, and may rise and fall between 1200 and 1800.

On cooling a light cloud is generally found in animal urine, consisting of mucus secreted by the urinary passages, especially the bladder, together with the characteristic flattened epithelium of these parts, and a few mucous corpuscles.

The acid reaction which human urine exhibits when just voided, depends not upon the presence of one or more free acids, for such are not to be found in it, but upon acid salts, and especially on phosphate of sodium.

The following are the principal constituents of urine, as far as the present state of science enables us to enumerate them with any certainty: urea, kreatin, and kreatinin, xanthin, and hypoxanthin, uric, hippuric, and oxalic acids, extractives, colouring matters, indican, and salts. Grape sugar is probably also constantly present in the urine (*Brücke*), as well as oxalic acid (combined with lime), phenol, and tauroi (*Stædeler*). The whole amount of solid ingredients varies much in the course of the day, ranging from 40 to 70 grammes.

Urea (§ 28) is found in the large proportion of from 2·5 to 3 per cent. in normal urine, or to the amount of from 25 to 40 grammes per diem. This can, however, only be regarded as an approximate estimate. Its quantity is not increased by muscular exertion (*Voit*), contrary to an old and widely-spread theory. But under a diet consisting largely of animal food, it rises in amount ranging from 52 to 53 grammes, and after purely vegetable food or complete abstinence, its quantity becomes considerably diminished, and may only amount to about 15 grammes, or even less, per diem (*Lehmann*). Copious draughts of water and excretion of the latter through the kidney also increases its amount. Urea is the most important end product of the nitrogenous tissue elements, and consequently of the albuminous substances introduced into the system with the food. It appears in many cases to be derived from uric acid, a fact not only supported by the nature of its chemical constitution, but also by the observations of *Wöhler*, *Frerichs*, and *Zabelin*, that the injection of uric acid into the circulation increases the amount of urea excreted with the urine. Kreatin, however, has also been regarded as one of its sources. The introduction, also, of certain other bases into the body occasions likewise, it is believed, a rise in the quantity of urea eliminated. These are glycerin, guanin, and alloxantin.

Uric acid (§ 25) presents itself, on the other hand, in far scantier amount than urea. In round numbers its proportion may be stated as about 0·1 per cent., and its quantity for the whole day from 0·5 to 0·9 grammes, descending even so low as 0·2 grammes. Under similar conditions to those alluded to in discussing urea, its amount rises and falls analogously, though not, perhaps, to the same degree. It is contained in large quantities in the urine of the lower order of mammals. It frequently presents itself in very large quantities during fevers, accompanied by great disturbance of the functions of respiration, a fact which lends additional support to the theory already alluded to, that the formation of uric acid is but a preliminary step to the formation of urea. As to where it is generated, we know as little as of urea. The products of its physiological decomposition are, besides urea, allantoin (§ 29), oxalic, and carbonic acids. *Strecker's* discovery, also, that the decomposition of uric acid gives rise to glycin, promises farther light on this subject. Uric acid is supposed to exist in the urine in combination with soda, held in solution by acid phosphoric acid. The sparing solubility of its salts is the cause of those sediments in the urine observed so frequently on the cooling of the latter in a saturated condition. The rose-coloured or brick dust precipitates so formed consist of urate of sodium.

The appearance, further, of one of the decomposition products of uric acid in the urine is of great interest; this, oxalic acid occurs combined with ammonia (*Schunk*, *Neubauer*).

Hippuric acid (§ 26) appears, under normal conditions, to occur in but small quantities in human urine, and to have a double origin. In the

first place, it possesses the nature of a decomposition product of the nitrogenous constituents of the body, which is indicated by the production of benzoic acid and oil of bitter almonds by the oxidation of albuminous matters. This source, however, is not its greatest, for, after a purely fleshy diet, its amount sinks to a minimum. In the next place, it takes its origin from vegetable food, which yields the unnitrogenous constituent of the acid. Consequently, its amount is much increased in man by a vegetable diet. It is also very abundant in the urine of the herbivora, while again, that of the calf is quite free from it so long as sucking (*Wöhler*). It has been already mentioned that benzoic acid, oil of bitter almonds, cinamic and kinic acids, and oil of tolu, when taken into the stomach, are eliminated by the kidneys as hippuric acid (§ 26).

The nitrogenous part of hippuric acid, which, on combination with water, separates in the form of glycin (§ 33), is originally a product of the decomposition of the glutin-yielding tissues in all probability. We are not yet sure, however, in what way its construction takes place, or, in other words, how hippuric acid is generated. It was supposed, some years ago, that the process was carried on in the circulation of the liver (*Kühne* and *Hallwachs*). It has been shown, on the other hand, more recently by *Meissner* and *Shepard*, that the acid is probably formed in the kidney itself exclusively.

Oxalate of calcium, as already stated, is possibly constantly present in very small quantity in normal urine; at all events, it appears very commonly there. The frequent appearance of oxalic acid, also, coincidently with the decomposition of uric acid, is a point of some interest (p. 35). Kreatin may likewise play a part here. Of one point, however, we are certain, that oxalic acid may take its origin from vegetable aliment.

Carbolic and taurylic acids (p. 36) are also possibly constant constituents of human urine (*Staedeler*).

We now come to two substances with all the characters of decomposition products of nitrogenous tissues, namely, of muscle and nervous matter; we allude to *kreatin* and *kreatinin* (§ 30). The latter is always to be found in human urine (*Neubauer*, *Munk*), in which kreatin may also be present. Both bases are almost invariably to be met with in the urine of dogs (*Voit*, *Meissner*). In considering this subject, sufficient weight must be given to the fact that kreatin is converted into kreatinin by the action of acids, whilst the latter may be transformed into the former by contact with alkaline solutions. Their presence, then, in acid or alkaline urine must be judged accordingly. The amount of these two substances increases greatly under an abundantly fleshy diet. Injected also into the blood they are eliminated with the urine (*Meissner*). In starving animals, likewise, in which combustion of their own muscular tissue is going on, the quantity of both alkaloids is found to rise (*Voit*, *Meissner*). Muscular exertion, on the contrary, produces no effect on their generation. It is an interesting fact, that the urine of dogs whose ureters have been ligatured, and which has consequently been secreted under high pressure, contains no urea, but an abundance of kreatin (*M. Hermann*).

Xanthin and *hypoxanthin* are likewise present in minute quantity in human urine. The first is also to be found in the renal secretion of dogs after moderate muscular exertion (*Meissner*).

As regards the existence of *grape sugar* as a normal constituent of urine

which is maintained by *Brücke* and denied by others, no definite conclusions can be come to upon the point.

The *extractive matters* of the urine are partly derived from the products of mutative processes in the tissues of the body, and partly from the alimentary substances introduced into the latter. Their daily amount varies from 8 to 20 grammes and upwards. From *Lehmann's* researches it would appear that they are most abundant after vegetable food, and appear in small amount under a meat diet.

We have already referred to the unsatisfactory state of our acquaintance with the colouring matters of the urine (§ 36). It is a point of interest, however, that *indican* and indigo-chromogen have been proved to exist here by *Hoppe* and *Jaffe* working on *Schenck's* and *Carter's* method (§ 36). This explains the fact that blue crystals of *indigo (uroglauclin)* may be obtained by treating urine with the mineral acids, and that these crystals are found at times in the latter. *Indigo-carmin* has also been met with here. From the circumstance that *indican* is not present in the rest of the body according to *Hoppe's* investigations, and that it is found in the urine of the lower mammals as well, we may conclude that it is generated by the kidney.

The *mineral matters* of the urine are, owing to the nature of the fluid, very variable in their amount. The latter may be set down at from 10 to 25 grammes for the twenty-four hours. They consist of *chlorides of the alkalies*, and indeed almost entirely of compounds of soda, especially of *chloride of sodium*, which is present in from 1 to 1.5 per cent., amounting in the day, on an average, according to *Bischoff*, to 14.73 grammes, but falling sometimes as low as 8.64, or rising again as high as 24.84 grammes. Chloride of sodium, which is introduced, as is well known, into the system with the food, is a constant constituent of the body. Both the perspiratory glands and kidneys take part in its elimination. There are many points of interest attached to this process.

If the blood and tissues of the body be saturated with chloride of sodium, all the absorbed salt is again excreted by the organs mentioned. If, on the other hand, the body have previously suffered a deprivation of the salt excretion does not follow upon its ingestion, until the system has recovered its normal percentage of chloride of sodium. If, however, all supply of the latter be cut off, as is the case in starvation or existence on food devoid of saline ingredients, it still continues to be eliminated, but in much smaller and ever decreasing quantity (*Voit*), until, after some days, albumen begins to make its appearance in the urine (*Wundt*)—a proof of incipient disintegration of the blood.

The amount of *chloride of potassium* and *ammonium* in the urine is small on the other hand.

Urine contains, farther, certain *phosphatic salts*, and especially acid phosphate of sodium with *phosphate of calcium* and *magnesium*. As is well known, the corresponding combination of potash (§ 170) is to be found in muscle, while the phosphates of the earths are combined with some of the histogenic substances, and especially albumen. The brain likewise contains phosphorus as one of the ingredients of lecithin. According to the nature of the alimentary matters, phosphoric acid appears in greater or less abundance. It does not, however, fail to be excreted when the system ceases to be supplied with it (*Bischoff*).

The amount daily eliminated by the kidneys has been estimated by *Breed* at from 3.8 to 5.2 grammes. Its rise and fall is to a certain extent

proportional to that of urea, which likewise originates in the splitting up of some of the albuminates.

Among the urinary salts we also find *sulphates of the alkalies*, amounting in the day to 2.094 grammes (*Vogel*). These are augmented by animal food, and diminished, on the other hand, by vegetable diet (*Lehmann*). From the fact that, as a rule, no sulphates are introduced into the body with the food, those which appear in the urine must be looked upon as developed in the decomposition of histogenic substances having sulphur as an ingredient. This latter element is also cast out of the economy as a component of taurin, as well as of those particles of horny tissue constantly being shed from the surfaces of the body.

The secretion of the kidney possesses likewise traces of *iron* and *silicates*, and small quantities of *ammonia*; further, *nitrogen* and *carbonic acid gas*, both free and in combination, together with a trace of *oxygen*.

Among the *abnormal* and *occasional* constituents of urine, we have (without taking into account casual matters) *albumen* in many diseases and disturbances of the circulation. Then again, *hæmoglobin*, as, for instance, after poisoning with phosphorus or injection of biliary acids into the blood, causing destruction of the red corpuscles of the same. *Grape sugar* is found in diabetes, and *inosite* likewise, as also in *Bright's* disease. *Lactic acid*, too, is frequently to be found in normal urine and after acid fermentation. Besides these *fatty matters*, *butyric*, *succinic*, *benzoic*, and *biliary acids* (§ 27), present themselves here; also the *pigmentary matters* of the bile (§ 37), *cystin* (partly in solution and partly in crystalline concretions), *leucin*, and *tyrosin* (in various diseases). *Allantoin*, likewise (§ 29), a product of the artificial decomposition of uric acid, which occurs also in the liquor amnii of ruminants and urine of sucking calves, was met with by *Frerichs* and *Staedeler* in the urine of dogs suffering from obstructions to respiration. It was found also by *Meissner* in abundance after fleshy food or injection into the circulation of kreatin. Cats fed in the same way excrete it also.

According to an old and, we believe, correct view, urine, when exposed for several days to the air, undergoes a process of acid fermentation, by which, as has just been observed, lactic and acetic acids are produced, increasing its acid reaction, and during which crystals of free uric acid, coloured by the pigments of the urine, are deposited. This view, however, is stated by some later observers to be incorrect. According to them, the acid reaction of the urine becomes less marked the longer it stands, the acid phosphate of sodium is converted into a neutral combination, and acid urates and free uric acid are produced. The latter are then thrown down (§ 25).

Later on, another, an alkaline fermentation, is frequently observed, in which urea is split into carbonic acid and ammonia (§ 28). Coincident with this, the urine becomes somewhat decolorised, extremely foetid and turbid, and deposits a whitish sediment, while a light pellicle forms upon its surface. The former consists of crystals of ammoniaco-magnesian phosphate (§ 42), and of urate of ammonium (§ 25). This process of alkaline fermentation may take place, on the other hand, almost immediately after the urine has been voided, or even during its sojourn in the bladder.

§ 275.

We now come to the question, how far the secretion of urine is to be

regarded as merely consisting in an elimination of matters from the blood which already existed there?

From the fact that some of the most important and best known constituents of the urine had been met with in this central fluid (§ 75), the agent in so many of the exchanges of matter going on in the system, it was for a long time supposed that the secretion of the fluid in question was analogous to the process of filtration, and so essentially dissimilar to the formation of bile in the liver. But though the statements of *Zalesky*, that urea and uric acid are generated by the kidneys, have been shown to be incorrect, still many circumstances point to caution as regards the acceptance of this old view. Thus, for instance, the acid nature of the urine, the transformation of benzoic into hippuric acid in the kidney itself (*Meissner* and *Shepard*), and the fact that albumen does not transude under ordinary circumstances. It seems extremely probable, indeed, that the process of excretion of urine partakes both of the nature of secretion and filtration.

When we consider the structure of the kidney, as described above, the question also naturally presents itself—Which of the two vascular apparatuses, the glomerulus or the network investing the uriniferous tubes, presides over the excretion of the fluid?

When we remember that the kidney and glomerulus go hand and hand among the vertebrates, we must be inclined to ascribe to this portion of the vascular system the greatest importance, even though the gland cells of the convoluted tubes do possess the power of secretion, and represent something more than a mere passive epithelial lining, which is hardly to be doubted. It is only the straight canals running from the external surface of the medullary rays to the points of the papillæ, which present the latter in our opinion.

If we bear in mind that in man and in the mammalia the *vas afferens* breaks up into branches in the glomerulus, besides being arranged in convolutions, and that these branches combine again to form a smaller *vas efferens*,—that a retardation of the blood must be brought about in the convolutions of the glomerulus, owing to the greater area to be traversed by it, will be clear; and that this sluggishness must be succeeded by rapid circulation in the narrow efferent vessel, giving way again to a second and more clearly marked retardation in the capillary network around the uriniferous tubes, is also plain. This narrowness of the *vas efferens* produces, then, a greater or less degree of obstruction to the blood in the glomerulus, and, consequently, to an increase of lateral pressure, far exceeding that of the second capillary system; it favours thus excretion. The blood in the capillary network, on the other hand, investing the uriniferous tube, flows certainly under smaller pressure, and appears partly to possess the power of absorption, and to rob the urine as it passes of some of its water again (*Ludwig*). The peculiar disposal, further, of the derivatives of the *vas efferens*, first around the passages of the medullary ray, and subsequently around the convoluted tubes of the cortex, seems to indicate some physiological purpose beside all this.

The progress of the urine towards the openings on the papillæ takes place without any muscular aid, merely through the *vis a tergo* produced by the continuous secretion behind pushing forward the columns of fluid in the uriniferous tubes. Besides this, in the ureters the gravitation towards the bladder comes in aided by the contraction of the muscular walls of the ureter (*Engelmann*). Owing to the well-known anatomical arrange-

ment of parts below, a return of the urine from the bladder into the ureters is just as difficult as from the latter into the papillæ.

§ 276.

The urinary passages commence in the *calyces renales* at the *pelvis* of the organ. In these parts we find an external fibrous tunic, a middle layer of smooth muscular fibres crossing each other in various directions, and but slightly developed in the calyces, and then an internal mucous membrane with a smooth surface and laminated epithelium of peculiar flattened cells, to which we have already referred (p. 141). Here we also meet with either tubular or racemose mucous glands in man and the larger mammals. They are not so frequently seen in man as in other animals, as, for instance, in the horse.

The *ureter* presents the same structure, except that its muscular tunic is stronger, consisting of an external longitudinal and internal circular layer of fibres, to which is added, lower down, a third and most internal layer of longitudinal elements. Under the epithelial lining the blood-vessels are arranged in a dense network of delicate tubes. In the fibrous covering of the ureter in the rabbit a nervous plexus, almost destitute of ganglion cells, is to be found. The mode of termination of the nerves is not yet known.

As is well known, the ureters terminate in a round diverticulum known as the bladder or *vesica urinaria*, piercing its walls obliquely. The structure of the bladder is similar to that of the ureters. Its external surface is in part covered by a serous membrane, the peritoneum. Its muscular coats, however, attain a much greater degree of strength here than in the ureter, and are no longer arranged with the same regularity, consisting for the most part of obliquely running muscular bundles, interlacing in a retiform manner. At the neck of the organ these fibres are disposed in a thick circular fasciculus, the *sphincter vesicæ*, besides which they form, externally, on the anterior wall and summit, longitudinal masses, to which the term *detrusor urinæ* is applied. However, much variety is to be observed in the arrangement of the muscular tissue. Within the organ the mucous membrane presents a smooth surface and characteristic flattened epithelium. A few scattered mucous glands of small size may be found in the fundus and around the neck. Here also a complicated network of capillaries lies close under the epithelium. The manner in which the nerves of the bladder terminate is just as obscure as in the ureters.

The female urethra is lined by a mucous membrane thrown into heavy longitudinal folds and covered with papillæ. It is studded also, in the neighbourhood of the bladder, with a number of mucous glands of either simple or complex structure, the largest of which are known by the name of glands of *Littre*. The muscular substance of the part, which is of considerable thickness, consists of separate longitudinal and oblique bundles of fibres; the epithelium is of the flattened species. The vascularity of the walls is very considerable, the vessels having a plexiform arrangement.

5. The Generative Apparatus.

§ 277.

The generative apparatus of the female consists of the *ovaries*, the *Fallopian tubes*, opening into a diverticulum called the *uterus*, the *vagina*, and external *genital organs*. Finally, the *mammary gland* is connected with the reproductive functions of the female.

The *ovary* (fig. 529), the most important part of the whole, is a very remarkable organ.

It may be divided into two portions, namely, into a kind of *medullary substance*, *i.e.*, non-glandular and very vascular connective-tissue, and into a *glandular parenchyma* enveloping the latter. The first has been named the *vascular*, the external layer the *parenchymal zone* by *Waldeyer*.

Taking the former of these first, we find it commencing at the so-called *hilus* of the organ (the *hilus stroma* of *His*), at which spot large blood and lymphatic vessels enter and leave the part. Traversed in all directions by innumerable blood-vessels, this fibrous nucleus presents itself as a spongy red mass, comparable to cavernous tissue.

From it a number of centrifugal bands of fibrous tissue are sent off into the gland parenchyma, where they form septa, and coalesce again peripherally, giving rise, by their close intermixture, to an external boundary layer (fig. 530, *b*). It was formerly held that this last might be divided

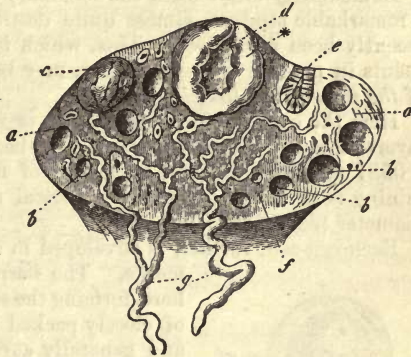


Fig. 529.—The ovary. *a*, stroma; *b*, mature Graafian follicle; *c*, a larger one; *d*, a fresh corpus luteum with thick lining*; *e*, an old corpus luteum; *g*, veins with their first branches, *f*, within the organ.

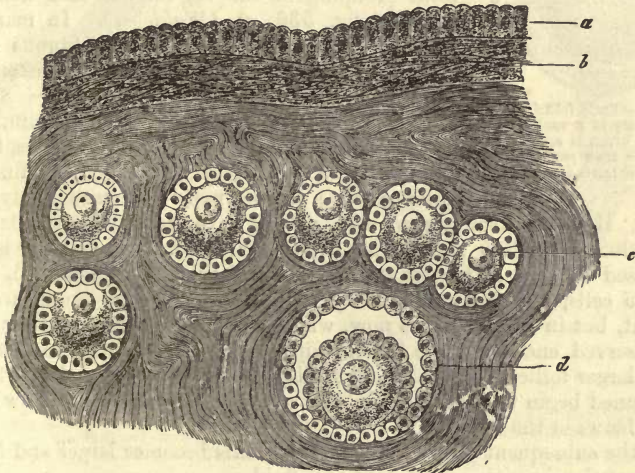


Fig. 530.—Ovary of the rabbit. *a*, germinal epithelium (supposed *serosa*); *b*, cortical or external fibrous layer; *c*, youngest follicles; *d*, a somewhat better developed and older one.

into an internal lamina of very dense texture, the *albuginea*, and an external serous membrane covering the latter. This condition of parts does not exist, however. The surface of the ovary uncovered by peritoneum is coated with a layer of low columnar cells (*a*) (*Pflüger*, *Waldeyer*). To this the suitable name of germinal epithelium has been given.

Having now dwelt for a moment on the general anatomy of the ovary, let us commence a more particular consideration of its finer structure with that of the glandular portion.

Immediately underneath the boundary layer just mentioned is situated a remarkable stratum, almost quite destitute of vessels, which has only recently been recognised. This, which is composed of glandular constituents in process of development, may be called the *cortical zone* or *zone of the primordial follicles*.

Here the essential elements of the organ lie closely crowded in several layers, namely, the young ova (*c, d*),—beautiful globular structures about 0.0587 mm. in diameter, consisting of naked granular protoplasm containing fatty molecules and a spherical nucleus of about 0.0226 mm. in diameter (fig. 531, 1).

Each egg-cell, further, is enveloped in a mantle of small nucleated elements. The narrow interposed septa which exist here, forming the stroma of the ovary, are composed of closely-packed fusiform connective-tissue cells, and generally surround each ovum, including its covering of small elements, with a species of special tunic, bounded towards the ovum by a homogeneous limiting layer or *membrana propria*. This then constitutes the so-called follicle of the ovary in its earlier form. In this description we have followed the appearances presented in the ovary of the rabbit; but in the organs of other animals, as, for instance, the dog and cat, a more or less racemose grouping of the egg-cells is met with frequently (fig. 536, *c*), (*Waldeyer*). In man and the larger mammals the connective fibrous tissue is more abundant, and the ova more distant one from the other.

Turning now from this external stratum, with its enormous number of germinal structures, to the more internal portion of the ovary, we find the follicles as we proceed more and more highly developed.

Here we encounter some which may have even attained a diameter of 0.0902 or 0.1805 mm. The ovum contained within them is also increased in size, and is enveloped in a distinct membrane (2). The minute cells, situated within the latter and around the ovum, are also present, but in several layers now, while a system of capillaries may also be observed encircling the follicle with a small number of vessels. In other larger follicles (fig. 530, *d*), the layers of the smaller elements just mentioned begin to separate from one another, producing a narrow interspace between the two.

In the subsequent growth of the follicle this becomes larger and larger, filling at the same time with a watery fluid.

A follicle at this stage may measure from about 0.3835 to 0.4512 mm. in diameter. On the internal surface of its walls, now supplied by a well-developed capillary network, may be noticed at some one point an enlarged ovum increased to 0.1805 mm. transverse measurement, containing within it a nuclear vesicle of 0.0609 mm. and nucleolus of 0.0135. The tough capsule of the cell is also increased in thickness to 0.0063 mm., and the whole ovum is enclosed within a mass of small cells arranged in layers

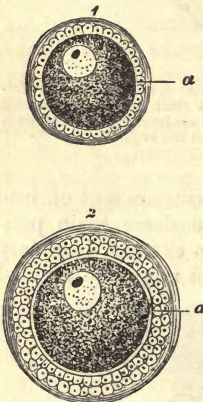


Fig. 531.—Early follicle from the ovary of a rabbit. In 1, the ovum is seen without the *zona pellucida*, *a*; in 2, the latter begins to be apparent.

which cover also, peripherally, the whole internal surface of the follicle as an epithelial lining.

Finally, the ovarium (fig. 529) generally contains a limited number of mature follicles, varying from 12 to 20, which, from the fact of their having been discovered at the end of the seventeenth century by an anatomist of the name of *De Graaf*, have received the name of the *Graafian follicles*. These vary in diameter, according to the maturity and size of the animal, from 1 to 8 mm. (*b, c*).

Fig. 532 represents such a follicle with its wall (*d, e*), its epithelial lining (*c*), the ovum (*a*) embedded in the thick epithelial mass (*b*), and enlarged cavity.

In the walls of the follicle, or, as it has been named, the *theca* or *membrana folliculi*, two laminae may be distinguished, an internal and external. Within the first of these the ramifications of the capillaries take place, while the external contains the branches (*e*) of the larger vessels. The outer layer is composed of the same elements as the remaining sustentacular matter of the organ, namely, of fibres of connective-tissue and very densely crowded fusiform cells.

Owing to the fact that the blood and lymphatic vessels of the tissue form around the external layer of the *membrana folliculi* a series of open sinuous cavities, the follicle may be separated with ease, and in a perfectly uninjured condition, from its surroundings. In the internal lamina of the wall we then observe that the capillaries enter the latter in lines con-

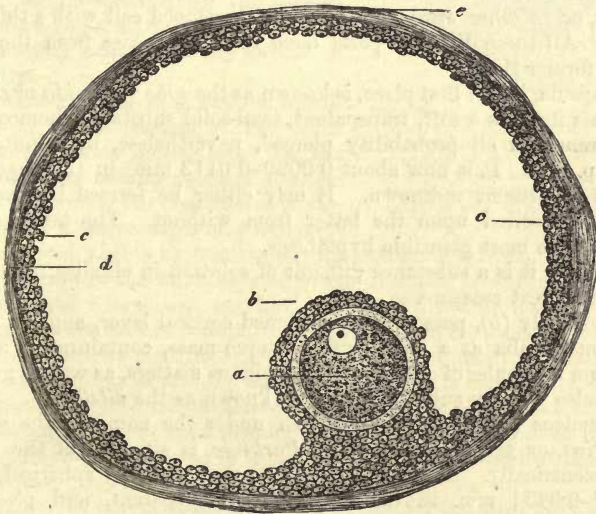


Fig. 532.—Mature follicle. *a*, ovum; *b*, layer of epithelium enveloping the latter and lining the cavity of the follicle; *c*, *d*, fibrous wall; *e*, external surface of the follicle.

verging towards the centre of the follicle, forming internally a very dense network with circular meshes. Like embryonic tissue this layer is particularly rich in cells of different forms and dimensions. Besides smaller ones resembling lymphoid elements, we find another kind of larger cells, roundish or polygonal in figure, and measuring about 0.0226 mm. in diameter. These are, in part, situated in the intervals between the vessels,

and partly around the latter, enveloping them in a manner which reminds one of the mode of formation of the walls of vessels already described (§ 211), (*His*).

The *Graafian* follicle is distended by that fluid, the commencement of whose formation we have already alluded to above. It is transparent, alkaline in reaction, and contains albumen. It is known as the *liquor folliculi*. The round nucleated cells covering the internal surface of the cavity, in ill-defined layers, are known, taken as a whole, as the *formatio* or *membrana granulosa*: the elements measure individually about from 0.0074 to 0.0113 mm. The breaking down or solution of the latter may account for the presence of albumen in the fluid. The point at which this stratum attains its greatest depth, in order completely to surround the egg (*cumulus proligerus* of embryologists, *cumulus ovigerus* of *Koelliker*), was formerly supposed to be at that aspect of the follicle nearest to the periphery of the organ. More accurate and recent observation has, however, shown this view to be erroneous, and that the ovule is attached to that side of the follicular cavity, as a rule, which is most remote from the surface of the ovary (*Schrön.*, *His*). It may, however, be found in the first position (*Waldeyer*).

The mature ovum (fig. 533, 1, 2) is still of great minuteness, and therefore not easy to find. In order the better to investigate its nature we are obliged, in the first instance, to free it from the elongated cells of the *membrana granulosa*, fixed upon it in a radiating manner (2, c). It is then found to be a spherical structure from 0.28 to 0.1379 mm. in diameter, or, in other words, a beautifully developed cell with a thickened capsule. All these different parts have received names from the anatomists of former times.

The capsule, in the first place, is known as the *zona pellucida* or *chorion*. It presents itself as a soft, transparent, semi-solid substance, homogeneous in appearance, in all probability pierced, nevertheless, by minute pores (fig. 73, p. 83). It is now about 0.0090–0.0113 mm. in thickness. Its origin is at present unknown. It may either be formed by the ovum itself, or deposited upon the latter from without. The latter, in our opinion, is the most plausible hypothesis.

Chemically it is a substance difficult of solution in alkalis, resembling elastin in a great measure.

The cell body (*b*), possessing a hardened cortical layer, appears in man and the mammalia as a more or less opaque mass, containing in a viscid substratum molecules of coagulated albuminous matters, as well as granules and globules of fatty substances. It is known as the *vitellus*.

The nucleus (1, c), generally known under the name of the *vesicula germinativa*, or germinal vesicle of *Purkinje*, is situated in the mature ovum excentrically. It is a very delicate and perfectly spherical vesicle of 0.037–0.0451 mm. in diameter, quite transparent, and presents a round and highly refracting nucleolus (*d*), from 0.0046 to 0.0068 mm. in diameter. The latter has received the name of the *macula germinativa*, or germinal spot of *Wagner*.

Let us now turn to the blood and lymphatic vessels of the ovary.

We have already been obliged to refer to the *blood-vessels* in the foregoing description. They arrive at the hilus in the form of large arterial and venous twigs, the former taking a very tortuous spiral course on their way thither. Arrived in the stroma they break up into numerous branches, so that the medullary substance of the latter is, in reality, a

mass of vessels. The interstitial tissue is extremely scanty, consisting merely of intersecting bands of fusiform cells, which turn off from the middle muscular tunic of the arteries. Intimately united to this interstitial substance are to be found the venous walls which gape on being cut through.

For this reason the whole tissue of this so-called hilus stroma has been regarded as composed of the modified walls of vessels, themselves traversed again by smaller vessels (*His*), recalling to mind the structure of the *corpora cavernosa* (*Rouget*). From this it would appear that the spindle cells of the medullary substance are muscular elements (§ 163, p. 283), in keeping with which view the fresh stroma of the ovary has been observed to possess the power of contractility by both *His* and myself.

Further, numerous pencils of vessels are seen to penetrate from the periphery of the stroma of the hilus between the internal follicles towards the surface of the organ. In this course they supply follicles, as mentioned above, with a dense network of vessels. Prolongations of the latter, however, penetrate still further towards the zone of cortical cells, doubling on themselves, for the greater part, before their arrival in the latter, which remains almost entirely devoid of vascularity.

But besides being very rich in blood-vessels, the whole stroma of the hilus possesses numerous *lymphatics*. In the latter, which are similar in their arrangement to the veins, the characteristic vascular cells of these passages may be everywhere rendered visible by treatment with nitrate of silver.

Their relation to the follicles is of special interest, however. The latter having attained a large size, and having pressed forwards towards the surface, may be seen in this position to be surrounded by a dense network of lymphatics, situated principally in the external lamina of the wall of the follicle. According to *His* the apex of the latter is completely destitute of lymphatics, as also of blood-vessels. Smaller follicles also, as soon as their internal tunic has been developed, are found to present an investing network of lymph canals, even long before they have reached the surface of the organ.

The numerous *nerves* of the ovary springing, for the most part, from the genital ganglia, as has been shown by *Frankenhauser* (§ 279), contain medullated and non-medullated fibres, and enter the organ with the arteries. Their ultimate distribution is still obscure.

Lying between the ovaries and *Fallopian* tubes a trace of the *Wolffian* bodies may be seen on either side of the uterus, in the form of a few small tortuous canals, situated in the *ala vesperilionum*. To this the name of the *parovarium* has been given. The tubules are composed of a fibrous wall, epithelial lining, and transparent contents.

The chemical composition of the ovary still awaits accurate investiga-

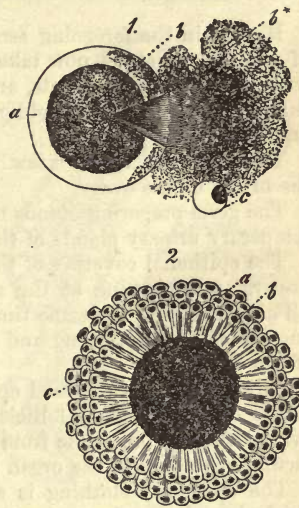


Fig. 533.—Egg of a mammal. 1, one in which a rent has been made in the *zona pellucida* (*a*), allowing the escape (*b**) of a portion of the yolk, *b**; *c*, the pre-germinal vesicle with germinal spot, *d*; 2, mature ovum covered with radiating epithelial cells, *c*; with the chorion, *a*; and yolk, *b*.

tion. Its sp. gr. in the human female is, according to *Krause* and *Fischer*, 1.045. Chemical analysis, on the other hand, of the ova of the mammalia is not practicable, owing to the minuteness of the objects to be dealt with.

REMARKS.—See *Waldeyer's* beautiful monograph, "Eierstock und Ei," Leipzig, 1870. The best work which has, up to the present, appeared on the subject.

§ 278.

Having in the foregoing section become acquainted with the structure of the ovary, let us now take up the question, Whence are the follicles with their cellular contents, and especially the ovum? For an answer to this query we shall be obliged to follow up the development of the organ.

The following is the view which obtains most generally in regard to the origin of the ovary.

The germ-preparing glands of the female spring from the sides of those temporary urinary glands of the embryo known as the *Wolfian* bodies.

The epithelial covering of the *Wolfian* bodies is observed very early to undergo a thickening at the spot in question in the embryonic chicken (*Waldeyer*). At the same time a small cellular growth makes its appearance here also, springing and projecting from the connective-tissue mass of the organ.

Now, from the thickened epithelium covering this projection the rudiments of the *Graffian* follicles and ova are formed, as well as the later ovarian epithelium, while from the connective-tissue the vascular sustentacular substance of the organ takes its rise.

The epithelial clothing is soon observed to contain (not only in the chick, but also in the mammal embryo) certain enlarged cells or *primordial ova*.

The further changes consist in an intermixture of the fibrous and epithelial constituents. Fig. 534 gives a representation of what now takes

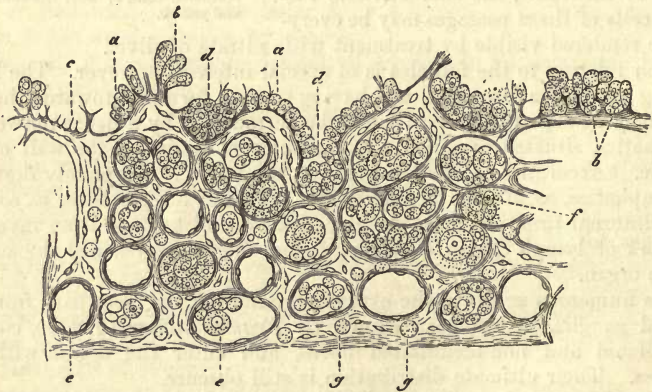


Fig. 534.—Vertical section of the ovary of a human fetus 32 weeks old (after *Waldeyer*). *a*, germinal epithelium; *b*, younger egg-cells, the "primordial ova" contained in this; *c*, increasing band of fibrous connective-tissue; *d*, epithelial cells in process of being folded in; *e*, youngest follicles; *f*, ova and germinal epithelial cells in groups; *g*, lymphoid cells.

place. The connective-tissue processes increasing rapidly in length, the aggregations of cells become smaller and smaller, and contain one or

several primordial ova. In this way, follicles are eventually formed in their most rudimentary form.

On the external side of the *Wolfian* body this epithelium dips down to form a groove. From this, again, a canal is formed subsequently, the canal of *Müller* (*Waldeyer*), and from it the Fallopian tube and uterus are developed.

Several very important points have recently been brought forward by *Pflüger* in regard to the follicles, which enable us the better to comprehend some statements made long ago by *Valentin* and *Billroth*, which had almost sunk into oblivion. These have since been confirmed by many other observers, among whom may be named *Borsenkorp* and *Spiegelberg*, *His*, *Letzerich*, *Langhanns*, *Frey*, *Koelliker*, and *Waldeyer*.

According to *Pflüger's* investigations the *Graafian* follicles are secondary formations. He asserts that they take their origin from oblong or irregular aggregations of cells by a process of constriction affecting the latter at various points. To these collections of cells the name of *primordial rudimentary follicles*, or, more briefly expressed, "ova chains" (*Eisträngen*), has been given (fig. 535). They contain besides peripheral cells of small size and pale colour (the elements of the future *membrana granulosa*), the *primordial ova*. These are situated in the axis of the group, and may be distinguished by their greater magnitude and granular protoplasm. Their existence, therefore, anterior

to the formation of the follicle, is a point about which there can be but little doubt. These cell-groupings are sometimes enclosed in a homogeneous *membrana propria*, giving rise to regular tubular structures, as in the cat. This may be absent in other cases, as in the calf. The arrangement of newly-formed follicles which, instead of occurring singly, appear still in groups, or ranged like beads on a string (*Follikelketten*), is thus easily understood as regards the mode of their development. The primordial ovum possesses farther vital contractility, and multiplies by segmentation (*Pflüger*).

It is only at certain points, however, that at this period we come upon these "ova chains," which explains the fact of their having so long remained undiscovered.

Pflüger states that he has satisfied himself that in the kitten, four weeks after birth, the period for finding these primordial tubes is already passed. But towards the time of casting their young the formative energy awakes afresh in the ovary of the mammal, and not only are

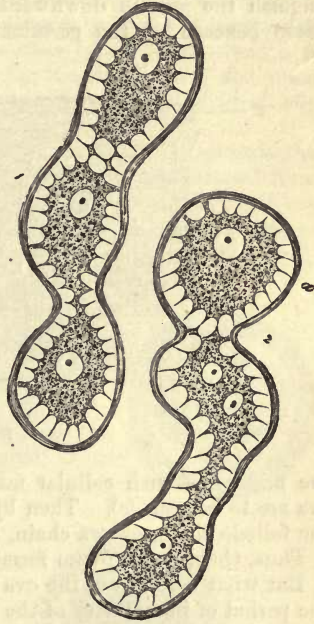


Fig. 535.—Chains of follicles from the ovary of a calf. 1, containing ova in process of development; and, 2, showing gemmation to form *Graafian* follicles.

there formed both ova and *Graafian* follicles, but the manner in which the process is carried on is the same as before,—“ova chains” appear anew.

The origin of these remarkable structures is a question of great interest. *Pflüger* was the first to point out that they were probably derived from in-growth of the epithelium on the surface of the ovary, in the form of tap-root like processes, and *Waldeyer* has since proved his supposition to be correct.

In suitable preparations (fig. 536) it is a matter of no difficulty to distinguish the growth downwards into the connective-tissue sustentacular tissue beneath of the germinal epithelium at certain points (*b*). In

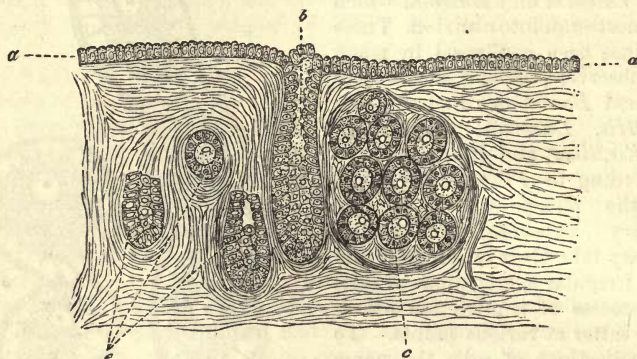


Fig 536.

the middle of such cellular masses certain large elements or primordial ova are to be seen (*c*). Then by constriction at the surface of the organ the follicle chain, or ova chain, represented in fig. 535, is produced.

Thus, then, is the ovum formed.

But what becomes of the ova? Their destiny is twofold,—one during the period of immaturity of the animal, another all through the period of generative activity.

In the first period it would appear that both follicle epithelium and ovum are frequently destroyed by fatty degeneration (*Slavjansky*). In very young and healthy mammals, moreover, I myself have not unfrequently observed an extensive colloid metamorphosis of the whole contents of the follicles.

But the destiny of the ovum is quite different in the mature animal. Here containing the material for the construction of a new individual, it is destined to become free by bursting of the *Graafian* follicle.

It was formerly believed that the stimulus of connection with the male was requisite, as a rule, to bring about this rupture. Hence those who held this view regarded the *Graafian* vesicles as persistent structures, of which only a certain limited number ever really did burst during the reproductive period of female existence.

Recent investigation, however, has thrown quite a new light on this subject. We now know that the expulsion of an ovum takes place with every menstruation in the human female. It is, therefore, independent of sexual intercourse, since this occurs in virgins as well as in married women. Amongst the lower animals the period of heat, or rutting, is that in which either one or more ova are liberated.

When a *Graafian* vesicle arrives at this epoch of its existence it undergoes a further increase in size, owing to continuous proliferation of the cells of the internal membrane of the follicle and accumulation of fluid within it. It now gives rise to a prominence on the surface of the ovary, from the fact of its being tense and swollen, and no longer situated in the stroma of the organ, but merely covered by a thin layer of connective-tissue.

Finally, there comes a moment at which the wall of the follicle becomes so stretched and distended that it must succumb to the forces acting on it, and it ruptures. The rent always takes place at the point of least resistance, and consequently in the external surface of the ovary, which is only covered by a thin fibrous envelope. For the reception of the ovum at this time the *ostium abdominale* of the *Fallopian* tube is closely applied to the surface of the ovary.

The ovum now commences its journey down the tube towards the uterus, in which it arrives after some days. After it has escaped from the *Graafian* follicle, the inherent energies of the encapsuled cell are aroused by the penetration of spermatozoa into its yolk, and the process of segmentation commences (fig. 537, 1), which has been already described. This process continuing for some time (2), a mulberry-like aggregation of cells is formed (3), which constitutes the material for the construction of the new individual. This process was formerly very generally supposed to be preceded by the disappearance of the nucleus of the ovum or so-called germinal vesicle; but from recent observation it would appear that this does not take place, but that by its division it is bound up with segmentation of the cell in the usual manner of endogenous growth.

But when impregnation does not take place, the ovum is destroyed within the generative organs by a process of liquification or solution. This is what occurs in by far the greater number of cases with the egg of the human female. And if we take into consideration the number of menstruations which occur during the whole time that a woman is capable of bearing, we shall gain some idea of the number of follicles requisite to supply the ova. This is, nevertheless, exceeded by far by the enormous production of the latter.

We have now to consider the destiny of the ruptured and emptied *Graafian* vesicle (fig. 538). The latter, soon after the fulfilment of its functions, is to be found filled up with cicatricial connective-tissue, constituting what is known under the name of the *corpus luteum*, after which it gradually disappears entirely in the stroma of the organ.

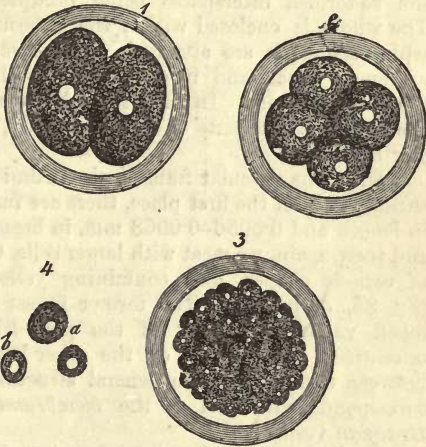


Fig. 537.—Division of the mammal ovum (half diagrammatic). 1. The yolk divided into two globules (cells) with nuclei. 2. Quadripled. 3. A large number of nucleated cells. 4. *a*, *b*, isolated cells.

If we examine a recently ruptured follicle very minutely, we notice in many instances the internal tunic projecting into the cavity on either side in folds (fig. 538, *d**). These folds consist of young exuberant cell-growths, and contain in their axes fasciculi of hard ill-developed fibrous tissue. On the coming in contact of the apices of the folds a peculiar system of septa is formed of the latter, the cells constituting the yellow substance of the *corpus luteum*.

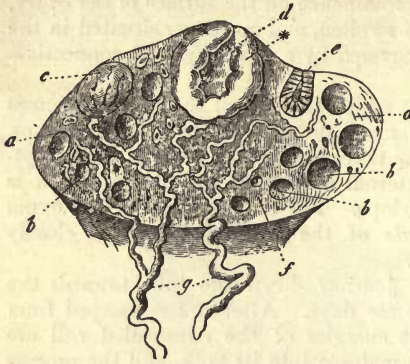


Fig. 538.

If, again, a completed corpus luteum (of a cow, for instance, *His*) be closely examined, it is found to have a peculiar radiating structure, produced by filamentous bands passing out from a central fibrous nucleus, the so-formed interspaces being occupied by a soft yellow substance. The whole is enclosed within the external membrane of the follicle to which the septa are attached. The vascularity of the corpus luteum is extremely great, and it contains, like the rest of the ovary, numerous lymphatic vessels. In fact, this yellow mass may be numbered among the most vascular parts of the whole body, so highly developed is its capillary network.

Beside this vascular framework we find two forms of cells in the yellow substance. In the first place, there are fusiform elements, 0·0338–0·0451 in length and 0·0056–0·0068 mm. in breadth, with oval elongated nuclei; and then, again, we meet with larger cells, 0·0226–0·0451 mm. in diameter, of various shapes, and containing yellow fatty granules within them (fig. 95, *a*, p. 95). The former invest at all points the highly developed vascular network of the part like the cells of a rudimentary *adventitia*. The latter, on the other hand, occupy the narrow meshes between these. Thus the general structure of the mature corpus luteum corresponds with that of the *membrana interna* of a fully developed *Graafian vesicle*.

The yellow body, however, does not long remain in this condition of exuberant growth. It soon begins to undergo a process of retrograde development, diminishing at the same time in magnitude (fig. 538, *e*). This change commences in all probability in a decay of the afferent arterial tubes, which are now found to possess enormously thickened walls (*His*). For some time we may still recognise, besides the vanishing yellow mass, the remains of the fibrous septal system, and external follicle membrane, distinguished by its dark brown pigments contained in cells. This colouring matter is laid down along the course of the vessels, and is possibly metamorphosed hæmoglobin.

As soon as this pigment has been absorbed, the yellow substance, formerly so abundant, melts gradually away with the adjacent ovarian tissue, until it is no longer recognisable.

The time consumed in this retrogressive process varies considerably. When pregnancy does not supervene upon menstruation, the changes mentioned follow one another in rapid succession. But if gravidity takes

place, the process is carried on with greater tardiness: the yellow body increases in magnitude, remains for some months at a high degree of development, and only recedes after four or five months. At the end of pregnancy it has not yet disappeared. These differences appear to be occasioned by the continuous increase of vascularity in the organs of generation in the latter case, compared with the more transitory excitement in the first instance. The corpora lutea have been classified, owing to this, into *true* and *false*.

§ 279.

We now turn to the consideration of the *Fallopian* tubes and uterus.

The first of these may be divided into two portions, namely, an upper and more or less tortuous half of greater diameter, known as the *ampulla* of *Henle*; and an inferior and much narrower half, which leads into the uterus, the *isthmus* of *Barkow*. They present an external layer of connective-tissue belonging to the peritoneum, and beneath this a muscular tunic, consisting of longitudinal involuntary fibres, on the outside, and transverse fibres within. The cells of this coat, largely intermixed with connective-tissue, are extremely difficult to isolate. During pregnancy this is somewhat easier. The mucous membrane of the tubes is entirely destitute of glands. In the isthmus it is covered with small longitudinal folds; in the ampulla with a series of very considerable ones, which are supplied, as I find in the pig, with a very complex network of looped vessels, and almost close the lumen completely. Its ciliated epithelium (p. 150), which extends as far as the external surface of the fimbriæ, moves in a ciliary wave directed towards the uterus. As in the mucous membrane of the uterus, so also here do we miss those goblet cells described by *Schulze*.

The *uterus* or *womb*, although it undergoes numerous changes during the earlier periods of existence, owing to the processes of menstruation and pregnancy, is nevertheless in many points similar in structure to the *tuba Fallopii*. Its muscular tissue is, however, of greater strength, and its mucous membrane contains glands.

The fleshy mass of the uterus consists of transverse, oblique, and longitudinal bundles of smooth muscular fibres, interlacing in every conceivable direction (p. 283). To a certain extent we may distinguish three layers, of which the middle is the thickest. Around the neck of the womb the fibres are arranged in transverse bundles, so as to form a regular *sphincter uteri*. In this neighbourhood the contractile fibre-cells are particularly difficult to isolate if the organ is not in the gravid condition.

In the mucous membrane of the uterus (which is closely adherent to the muscular tissue, and exchanges with it many of its elements of form), we find both in the body and cervix a network of stellate and fusiform cells similar to those of the framework of lymphoid organs (*Henle*, *Lindgren*).

Those bands of smooth muscular fibres which extend into it appear to terminate in its deeper strata. The mucous tissue of the vaginal portion was found by *Lindgren* to be traversed by vertical bands of elastic fibres, connected with one another in arches near the surface. The body and parts of the neck also of the uterus present ciliated epithelial elements, described at a very early period as simple columnar cells without cilia.

But the lower portions of the cervix are lined by the same flattened epithelium met with in the vagina (p. 141).

The surface of the mucous membrane varies also according to locality. In the fundus and body it is smooth and destitute of papillæ, while numerous transverse folds of *plicæ palmatæ* occur in the cervix, and many mucous papillæ in its lower portion, with vascular loops in their interior. These are particularly abundant about the os, and are met with throughout the vagina.

The same diversity is manifest in the occurrence of the *glands*. In the fundus and body of the organ they are crowded together, subject to variations, in this respect, in different individuals. These *glandulæ utriculares* are found in the form of either branching or undivided tubes, about 1.13 mm. in length, and 0.0451–0.0751 mm. in breadth. They may, however, exceed in both directions. They are lined internally by columnar cells, and resemble in many respects the mucous glands of the stomach (§ 252), or crypts of *Lieberkühn* of the intestine, though frequently convoluted at their inferior extremities. They are either entirely destitute of a *membrana propria*, or the latter is only present towards the mouth of the gland. In the pig the uterine glands are clothed within by ciliated epithelium, as was pointed out many years ago by *Leydig*. More recently the same species of epithelium has been found by *Lott* in these glands, in various other mammals. In the cervix they are no longer to be found (*Henle*), but are replaced by numerous depressions in the mucous tissue, lined with columnar cells, which appear between its folds. These have been by some included among the glands of the organ.

Both these structures, but especially the latter, preside over the secretion of the alkaline mucus of the uterus. Not unfrequently the little pits just mentioned become occluded, and in consequence distended with mucus. They then present themselves in the form of small round vesicles, known as the *ovula Nabothi*.

The large *arterial tubes* of the uterus, which is very vascular, are chiefly situated in the external and middle muscular coats. The capillary networks are to be found in the mucous membrane, the coarser in the deeper portions of the latter, the more delicate near the surface: they are rather irregular as to their arrangement, however. Both kinds of vessels are possessed, in the mucosa of the body of the uterus, of very delicate walls, while in that of the cervix the latter are extremely thick (*Henle*). The radicles of the veins are wide, and the walls of the latter are intimately connected with the tissue of the organ. They occur in the form of a dense plexus, especially in the middle layer of the muscle substance, and are entirely without valves. The arrangement here, as in the ovary, was pointed out by *Rouget* to be similar to that of the *corpora cavernosa*.

Lymphatics were long ago observed in the gravid uterus, principally in the outer portions of its walls, but those of the mucosa remained for a long while unknown. Here they were found, however, by *Lindgren*, arranged (in the cervix) in retiform and arched passages, ending under the surface of the mucous membrane, either blind or in loops, and passing from thence into a deeper wide-meshed network of larger canals. The *portio vaginalis* possesses just the same kind of vessels. The mucous membrane of the body of the organ requires further observation.

The *nerves* of the uterus have been very carefully investigated by *Franckenhäuser*. They are derived from the genital or spermatic ganglia, and through these from the so-called *plexus uterinus magnus* and *p. hypogastrici*, to which branches of the sacral nerves are given off.

On the posterior wall of the neck of the uterus is situated a ganglionic mass of considerable size, the *ganglion cervicale* of *Lee*. From this most of the nerves supplying the organ take their rise beside vaginal and vesical twigs. Only a very small number come from the *p. hypogastricus*. The course of the nerves in the walls of the organ usually corresponds with that of the blood-vessels; it is, however, very hard to follow. In regard to the ganglia found here, we refer to § 189. The termination also of the filaments in the muscular substance has been likewise dealt with in § 183.

In the *ligamenta lata* bundles of unstripped fibres are to be found between their two layers. The round ligaments are, however, still more richly supplied with these elements, besides which they contain voluntary fibres. On the other hand, the *lig. ovarii* are but slightly muscular.

During *menstruation* the uterus becomes looser in texture and increased in volume owing to a great influx of blood into it at this time. At the same time, the glands of the mucosa increase considerably both in length and breadth. A discharge of blood takes place also from the gorged capillaries of the mucous membrane, the walls of the latter being either ruptured in the act, or, by the passage, as some believe, of red corpuscles through the uninjured walls. The blood of menstruation, which is poured out at the external genitals (p. 121), is found besides to contain a large admixture of cast-off uterine epithelium.

During *pregnancy* the uterus undergoes a considerable increase in volume, affecting principally the muscular layers, and, as microscopical analysis has shown, consisting in a remarkable growth of the contractile fibre-cells (§ 173) (which may now be easily separated from one another) as well as in a multiplication or neoplasia of the same, at least at the commencement of the period.

Both the blood-vessels and lymphatics, as might be expected, participate also in this increase in size.

It is also an interesting fact, that the nerves of the uterus becomes thicker and grayer at the same time through thickening of their perineurium, while the individual fibrillæ present a darker outline than before, so that they can now be followed farther into the parenchyma (*Kilian*). That the number of primitive fibrillæ actually becomes larger is a matter greatly to be doubted.

We must now bestow a few words on the most important of all the changes which take place here, namely, the metamorphosis of the mucous membrane. Already before the arrival of the ovum in the cavity of the uterus this structure becomes thicker, softer, and more vascular. Further, its fibrous elements gaining in number, and the uterine glands increasing to four or five times their original length, a separation takes place between it and the inner surface of the uterus. Covering the ovum, now it is known as the *decidua*. After parturition a new mucous membrane and new glands are formed on the surface of the uterine cavity, a regeneration of which neither of the two tissues are capable under normal circumstances. The involuntary fibres of the womb undergo, about the same time, fatty degeneration, retrograde development, and partial destruction.

§ 280.

The *vagina*, an elastic tube, is to a certain extent a continuation, as far as structure goes, of the generative organs situated higher up. In it we find a layer of muscular fibres internal to a thick envelope of connective-tissue, loose without and dense within, and containing numerous elastic elements. This muscular coat consists of a layer of longitudinal fibres internally, and another of circular fasciculi externally. The mucous membrane of the part presents ridges and protuberances which go by the name of *columnæ rugarum*, besides which it is possessed of numerous papillæ, similar to those of the cervix uteri, lying underneath its flattened epithelium. It appears to be quite destitute of mucous glands, and its secretions have an acid reaction.

The *hymen* is nothing but a duplicature of mucous membrane rich in nerves and vessels.

The *vascular system* of the vaginal wall has a different arrangement for each of the three layers of the latter, and is remarkable for the high degree of development of the venous networks. But little is known, on the other hand, of the *lymphatics* of the part, but scattered lymphoid follicles have been met with in the vaginal mucous membrane of both man and the mammalia, and considerable patches have been observed to present an infiltration with lymph-cells. The *nerves* by which it is supplied are derived from the sympathetic and *plexus pudendus*. In man their termination in papillæ has not been recognised, although their fibres are seen to divide; but in the rabbit the vaginal tunics are supplied with terminal bulbs and *Pacinian* bodies (*Krause*). See p. 333.

The external female genitals consist of the *clitoris* and *labia majora* and *minora*.

The *clitoris* is possessed of a prepuce or fold of mucous membrane continuous with that covering the glans, in which situation it is supplied with numerous papillæ. Its corpora cavernosa and *bulbi vestibuli* are analogous to the cavernous portions of the male organ (see below).

The *labia minora*, or *nymphae*, are also small duplicatures of mucous membrane. They present numerous papillæ and very vascular connective-tissue without any fat cells. In them, as in the external parts of generation, numerous sebaceous glands, without hairs, are to be found.

The *labia majora*—folds of skin padded with fat—present on their internal surface all the characters of a mucous membrane, while externally their structure is that of the skin. On their outer surface they are covered with hairs, into whose follicles numbers of sebaceous glands pour out their secretions.

The *vestibulum* and opening of the vagina contains many ordinary racemose mucous glands, of which the largest, attaining a diameter of 15 mm. are known as the glands of *Bartholin* or *Duverney*, which open with tolerably long excretory ducts into the vestibule. They correspond to *Cowper's* glands in the male generative apparatus. They are lined with low columnar epithelial cells, and filled with a transparent mucoid secretion of viscid consistence.

The *blood-vessels* of the part, with the exception of those of the corpora cavernosa have nothing remarkable about them. The *lymphatics* require closer study, as also the *nerves* which spring from the *plexus pudendus* of the sympathetic. The latter are stated by *Koelliker* to terminate in certain papillæ of the clitoris in a manner similar to their arrangement in

the tactile corpuscles. These observations have been since confirmed by the discovery of the presence in this organ of end bulbs, as they are called, and other mulberry-shaped terminal structures allied to them, the *genital bodies* (*Wollustkörperchen* of *Krause*, *Finger*). *Pacinian* corpuscles have also been found in the labia majora, where they merge into the nymphæ, and in the præputium clitoridis (*Schweigger-Seidel*).

§ 281.

The *mammary glands*, which only attain their full development in the female body and corresponding secretory power, belong to the great group of racemose organs, as has been already remarked (p. 358). They are peculiar, however, in that each organ does not empty itself eventually into one single excretory duct. In either breast the milk is poured out by from eighteen to twenty canals or *galactophorous ducts* as they are called, each of which belongs to one of the primary lobes, or, better expressed, glands. Having already frequently referred to the nature of racemose glands, we need only remark here, that in this particular instance the end vesicles (formed of a homogeneous *membrana propria*) are more sharply defined one from the other, also that their form is spherical or pear-shaped, each having a diameter of between 0.1128 and 0.1872 mm. (fig. 539, 1, 2, a). Their *membrana propria* presents, as in other allied glandular organs, a network of flattened stellate cells (*Langer*). Both the lobules and lobes are enveloped in fatty connective-tissue, which gives to the breast its usual smooth rounded appearance. The former are also invested in the characteristic *vascular networks* of racemose glands. Of the *lymphatics* of the organ but little is known at present, and the *nerves* of the interior have but rarely been the objects of research. The influence of the latter on the process of secretion has likewise never been demonstrated experimentally. The interior of the vesicles is lined finally

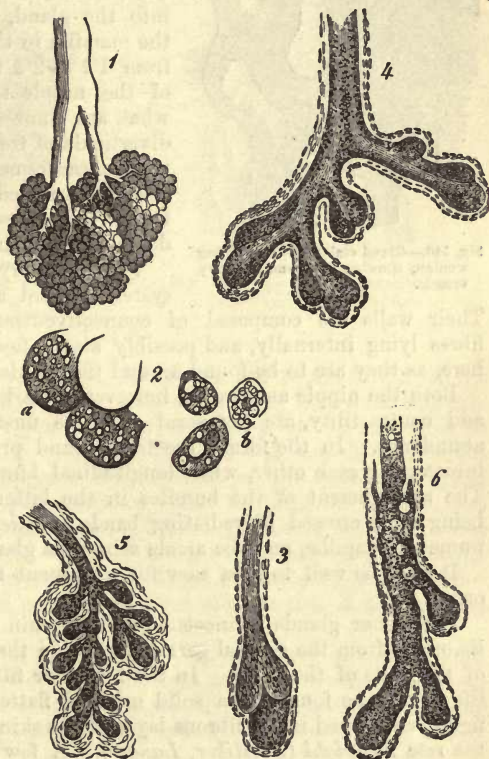


Fig. 539.—The mammary gland; for the most part after *Langer*.
1. A lobule, from the interior of the gland of a pregnant woman.
2. a, vesicle; b, gland-cells. 3. Ducts from an infant. 4. Galactophorous duct from a boy 9 years old. 5. The same from a girl of 15. 6. The same from a grown man.

by ordinary cubical or polygonal cells about 0.0113 mm. in diameter (fig. 540).

It is an interesting fact, that here also that well-known network of very delicate tubules already mentioned (§ 195) may be rendered visible by injection, between the cells in the interior of the acini (*Gianuzzi* and *Falaschi*). According to *Langer*, however, no fibrous network can be discovered within the gland vesicles.

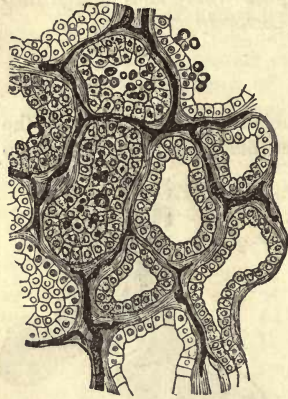


Fig. 540.—Gland vesicles from suckling woman, showing cells and capillary vessels.

The excretory ducts terminate amid the wrinkles of the mamilla with orifices about 0.7 mm. in diameter. Following them up into the gland, we find them traversing the mamilla in the form of tubes measuring from 1.1 to 2.2 mm. across. At the base of the nipple they become dilated into what are known as the *sacculi lactiferi*, diverticula of from 4.5 to 6.8 mm. in transverse measurement. After this they then become narrowed again to 2.2–4.5, and continue their course with rapid ramification down to the ultimate vesicles.

The excretory canals of the lactiferous system present a lining of columnar cells. Their walls are composed of connective-tissue and a layer of elastic fibres lying internally, and possibly also a few muscular elements occur here, as they are to be found around the lobules (*Henle*).

The excretory canals of the lactiferous system present a lining of columnar cells.

Both the nipple and areola, however, remarkable for their dark colour and contractility, are possessed of these unstriped muscular fibres in abundance. In the former are to be found principally transverse bands intersecting each other, while longitudinal bundles are of less frequency. The arrangement of the bundles in the latter is chiefly circular, these being again crossed by radiating bands (*Henle*). The mamilla contains numerous papillæ, and the areola sebaceous glands.

It may be well to turn now for a moment to the *development* of the organ.

Like other glands connected with the skin (§ 200), the mamma takes its origin from the corneal germinal plate in the form of a growth inwards of the cells of the latter. In the fourth or fifth month of intra-uterine life it may be found as a solid mass of flattened globular or knobbed figure, enveloped in the fibrous layer of the skin, and consisting of cells of the rete *Malpighi* (*Koelliker*, *Langer*). A few weeks later (fig. 541) we remark that the knobbed process (*a*) has given off new solid buds (*b*, *c*) through cell proliferation. These are the first rudiments of the ducts of the primary lobes, and are destined to further gemmation (*c*). Up to the time of birth (fig. 539, 3), however, the rudimentary vesicles have not been formed. During all this time the border is always more highly developed than the central portions, as we might infer from the diskoid figure of the gland, and this continues to be its condition until the end (*Langer*). The ducts of the mammary gland of the infant present fibrous walls lined with small cells. At their ends we find solid aggregations of cells of irregular shape, the formative material for farther ramification.

Even during childhood, and in girls (fig. 539, 4) as well as boys (5), the development of terminal vesicles has not yet begun; the canals con-

tinue to present the same structure as before. The female breast is, however, at this period in a more perfect state than the male.

At the commencement of puberty the formation of a considerable number of gland-vesicles takes place in the female breast, and with tolerable rapidity, causing the organ to assume its well-known shape. But even still, and throughout the whole term of virginity, the gland does not attain

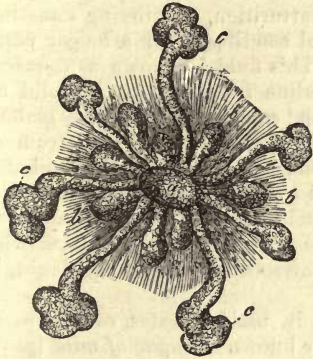


Fig. 541.—The mammary gland from a mature foetus, after *Langer*. *a*, central knobbed mass with smaller internal *b* and *c*, larger external buds.

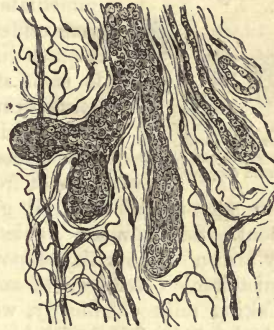

Fig. 542.—Degenerated mammary gland from woman 90 years of age.

anything like its full development, for which the supervention of the first pregnancy is requisite. In this state of maturity it remains throughout the whole period of fecundity, decreasing, however in size when at rest, and losing some of its vesicles. Finally, with the decline of the reproductive powers a retrograde development of the mammary gland takes place, with gradual disappearance of all its terminal vesicles, and destruction of the smaller ducts, until eventually nothing but fatty tissue is to be found in its place. It is represented in this condition in fig. 542. Here the canals only are to be found; everything else has disappeared. The interstitial connective-tissue appears rich in elastic fibres (*Langer*).

The mammary gland of the male (fig. 539, 6), with very rare exceptions, never attains the same degree of development as in the female. In it we generally find nothing but a system of ducts, varying greatly in size, no trace of terminal secreting vesicles being apparent (*Langer*).

§ 282.

Milk is an opaque bluish or yellowish-white fluid, without odour, sweetish to the taste, with a slightly alkaline reaction, and a sp. gr. usually of about 1.028–1.034. When kept in a state of rest it separates into two strata—an upper, thick, fatty, and white (cream); and a lower of much thinner consistence. Some considerable time after this a process is set up, in which its alkaline reaction is changed for an acid by the conversion of sugar of milk into lactic acid. As a consequence of this, the casein contained in the fluid coagulates, a change which is also effected by contact with the mucous membrane of the stomach (p. 17).

Anatomically, milk consists of a transparent fluid, in which innumerable fatty globules are suspended: it is therefore an emulsion.

These *globules* (fig. 543, *a*), present the usual optical characters of oil drops, and an average diameter of 0.0023–0.0090 mm. Under ordinary circumstances they do not coalesce, but do so readily on the addition of acetic acid, showing that each particle possesses a very delicate membrane of some protein substance, probably casein.

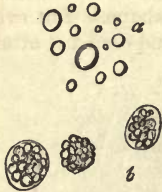

Fig. 543.—Form-elements of human milk. *a*, globules; *b*, colostrum corpuscles.

The microscopic appearance, however, of milk, which is secreted in the last days of pregnancy, and immediately after parturition, continuing sometimes, even under abnormal conditions, for a longer period, is quite different. This fluid is known as *colostrum*. It is of strong alkaline reaction, rich in solid constituents and salts, and contains, besides fatty globules, other bodies to which the name of colostrum *corpuscles* has been given. These (*b*) are spherical structures of from 0.0151 to 0.0564 in diameter, consisting

of an agglomeration of oil globules, held together by some species of cement. Sometimes a nucleus may be found in them, besides which they are endowed with the power of contractility, sluggish no doubt, but unmistakable (*Stricker, Schwarz*).

Taking milk chemically, we find in it, besides water, *casein* (p. 17), *neutral fats* (p. 26), and a kind of sugar known as *sugar of milk* (p. 33); further, *extractives* and *mineral constituents*, free *carbonic acid*, and *nitrogen*, gases, and small quantities of *oxygen* (*Hoppe*). Even blood and bile pigments may also be abnormally present.

Casein is generally supposed to occur partly in combination with soda, dissolved in the watery portion of the milk, and partly, as we have already remarked, coagulated in the form of delicate membranes around the milk-globules. The amount of phosphate of calcium present in this fluid is quite remarkable. Albumen also appears to exist in milk, but in colostrum it is undoubtedly present. The *neutral fats* of the milk consist first of the ordinary fatty matters, and then of those which, on saponification, set free *butyric, capronic, caprylic, and capnic acids* (p. 25). We have already spoken of them in detail in an earlier section. The *sugar of milk* is found in solution, as also the *extractives* and the majority of the *mineral ingredients*. The latter consist of chlorides of sodium and potassium, of combinations of phosphoric acid with the alkalis and earths, and of soda and potash with casein; iron is also present. The insoluble salts usually preponderate.

The name "fairy's milk" (*Hexenmilch*) has been applied to a peculiar milky secretion produced by the mammary glands of infants for some days after birth.

In the quantitative analysis of human milk we must bear in mind that it varies considerably according to age of the individual, and nature of food indulged in by the latter. These variations are much more decidedly marked in many of the mammalia. The following is an analysis of *Simon's*:—

1000 parts contain—

Water,	880.6
Casein,	37.0
Sugar of milk,	45.4
Fatty matters,	34.0
Extractives and salts,	3.0

The proportion of casein in woman's milk is, according to *Simon*, about 3·5 per cent. on an average; that of fats, 2·5–4 per cent.; of sugar of milk, between 4 and 6 per cent.; of salts (among which phosphatic earths predominate), 0·16–0·20 per cent.

The average amount of milk secreted daily by the human female, during the period of lactation, is somewhat over 1000 grammes. About 50 or 60 grammes may be produced by one breast in two hours (*Lampérière*).

The use of milk is, as is well known, for the aliment of the infant. It is secreted at the expense of the nutritive material of the mother's blood, and may be designated as the prototype of all aliment.

If we compare the ingredients of milk with those of the plasma of the blood (p. 115), we find that the mineral constituents of the latter may have simply transuded into the former, somewhat in the same manner as that in which they find their way into the urine. But the three series of organic substances are not to be found as such in the blood, or, if so, only in small amount. To the first of these, casein and sugar of milk belong, the sources of which may be regarded as albumen and grape sugar; to the third the fatty matters. All this seems to indicate an inherent power in the mammary gland of causing a species of fermentation, as also of producing within its cells a part, at least, of the oily matters found in the milk.

The mode in which the secretion of the mammary gland is produced in the interior of the vesicles is similar to that in which the sebaceous matter of the skin is formed. The gland-cells become enlarged by the generation within them of oil globules (fig. 539, 2, *b*), and are in this way physiologically destroyed, at least in many cases, although the membraneless body of the contractile gland-cell no doubt frequently enough simply discharges its fatty contents. During the less active formation of the colostrum these cells, or fragments of them, are carried off in the watery portion of the milk. The gland-cell of the suckling woman is regarded by us as a very transitory structure.

§ 283.

The male *generative apparatus* consists of *two testicles*, enclosed in the *scrotum*, and invested with their several tunics; of the *excretory ducts*, emptying themselves into the urethra; of the *copulative organ*; and, finally, of *accessory structures*. Among the latter we have the single *prostatic gland*, a pair of glands known as *Cowper's*, and the *vesiculæ seminales*.

The *testis*, with its accessory *epididymis*, is a gland consisting of a multitude of fine and very tortuous tubules, known as the *tubuli seminiferi*. The whole is covered by a fibrous investment, to which the name of *tunica albuginea*, *s. propria testis* (p. 227), has been given,—a tough, whitish membrane of considerable thickness. It is again contained within another sac, the *tunica vaginalis propria*, a serous investment, whose internal portion (*t. adnata*) cannot be distinguished from the albuginea. Finally, the testicle and spermatic cord are enveloped in the *t. vaginalis communis*, a strong bag, composed of a serous and fibrous portion, which contains, around its junction with the vaginalis propria and epididymis, a number of contractile fibre-cells (*Koelliker*). Upon this coat the striped fibres of the *cremaster* muscles are situated externally. This vaginalis communis is connected without with the muscular tunic of the scrotum,

the *dartos* (p. 283), by formless connective-tissue. Finally, the whole is covered by a thin layer of true skin quite destitute of fat.

If we seek to remove the albuginea, we observe that numerous but imperfect fibrous septa are given off by the latter, and penetrate into the interior of the gland.

These partitions, which divide the parenchyma into lobules (fig. 544, *b*)

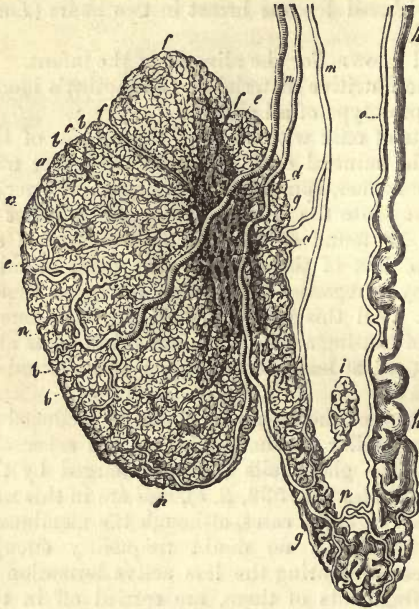


Fig. 544.—The human testicle, after *Arnold*. *a*, testicle divided into lobuli *b*; *c*, tubuli recti; *d*, rete vasculosum; *e*, vascula efferentia; *f*, coni vasculosi; *g*, epididymis; *h*, vas deferens; *i*, vas aberrans of *Haller*; *m*, branches of the internal spermatic artery, with their arrangement in the gland *n*; *o*, artery of the vas deferens, anastomosing at *p* with the last named vessel.

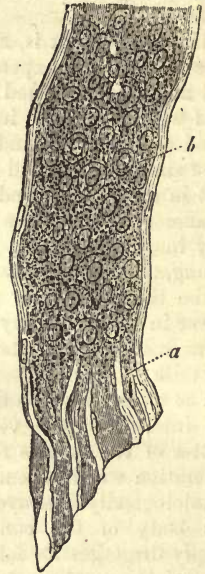


Fig. 545.—Seminiferous tube from a human testicle. *a*, membrane; *b*, cells.

of conical form, whose apices are directed inwards and upwards, converge in the superior part of the organ, to be inserted into a dense wedge-shaped mass known as the *corpus Highmori*, whose base is attached to the albuginea.

Each of these lobules is made up of several extremely long seminiferous tubules, about 0.1128–0.1421 mm. in diameter, folded on themselves several times. These may be seen to divide frequently, and anastomose, and to terminate, not blind, but in the form of slings and loops. At the apices of the lobules the seminiferous tubules, becoming rapidly narrowed, open into a straight passage, which goes by the name of the *tubulus rectus* (*c*), and which penetrates the *corpus Highmori* (lined with low columnar cells), and forms what is called the *rete testis* (*d*), by intercommunication with the vessels of the same kind. From this network the larger tubes, or *vascula efferentia* (*e*), take their rise. Their number is from 9 to 17, and their course at first straight until they pierce the albuginea, after which they become again very tortuous, and are arranged in a series of conical lobes, known as the *coni vasculosi* (*f*), which form the *caput epididymis*.

They then gradually combine to form one single wide canal (*g, g*) 0.3767-0.45 mm. in diameter; which turns and twists upon itself still further in forming an elongated body known as the *corpus* and *cauda epididymis*.

By degrees this tube, of which the epididymis is composed, becomes less tortuous and of greater calibre, its diameter amounting on an average to 2 mm. It is now known as the *vas deferens* (*h*). Frequently before this it receives the addition of a short coecal branch, the *vas aberrans* of *Haller* (*i*).

Turning now to the structure of the seminal gland, we find in the first place that it presents a sustentacular substance. This is found in the form of fibres of connective-tissue (fig. 546, 1, *d*), radiating from both septa and capsule throughout the whole organ. In this connective-tissue numerous cells and nuclei are encountered in young animals: its bands vary in thickness; in the calf from 0.0564 to 0.0113 mm.

These bundles of connective-tissue (*Mihalcowicz*) are enveloped in those flat membraneous cells of which we have already spoken (§§ 130, 223), and to which we shall again have occasion to refer in considering the arachnoid. These cells cover like a membrane both seminal tubules and blood-vessels, leaving, however, chinks between them, which serve a purpose in the lymphatic circulation.

In the human and mammalian testicle besides a number of peculiar cellular elements, undergoing pigmentary and fatty metamorphosis, the "interstitial cells," are met with, at times in great abundance. They are usually arranged in bands, their diameter being in the cat 0.014-0.020 mm. They may envelope the vessels like a sheath.

The interstices of this sustentacular substance are occupied by the *seminiferous tubules* (figs. 545, 546, 1 *a*; 547, *a, b*) whose diameter is on an average from 0.1128 to 0.1421 mm. By the aid of the microscope we learn that the membrana propria is represented by a coat (sharply defined from the interstitial connective-tissue) of tough texture, and fibrous or banded structure, containing elongated nuclei (fig. 545, *a*; 546, 1 *a, b*, 2 *a, b*). Its thickness ranges from 0.0046 to 0.048 mm. In man this wall is particularly well marked.

It consists, according to *Mihalcowicz*, of several layers of flattened cells united with one another in the form of a membrane. The most internal layer is quite impervious; but the external is open and net-like.

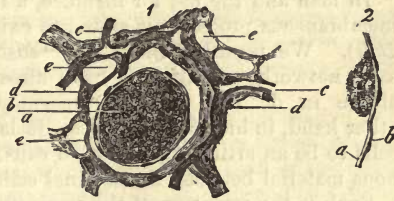


Fig. 546.—From the testis of a calf. 1. Transverse section of a seminiferous tubule. *a, b*, walls of the latter; *c*, capillary network; *d*, connective-tissue framework; *e*, lymphatic canals. 2. Side view of the wall of a seminiferous tube; *a* and *b*, wall.

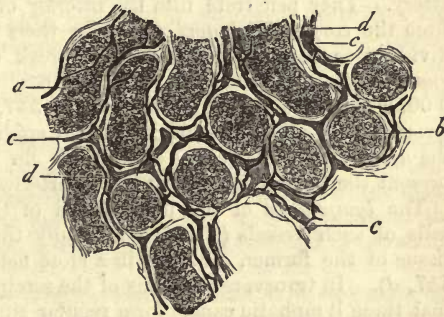


Fig. 547.—From the testis of the calf. *a*, seminiferous tubules in profile; *b*, in transverse section; *c*, blood-vessels; *d*, lymphatics.

The interior of these tubes is filled with cells, of which the most peripheral may cover the membrana propria in a manner similar to epithelium. They are usually roundish or polygonal, and from 0.0113–0.0142 mm. in transverse section. They are composed in young subjects of a finely granular, rather pale substance (containing yellow pigment in man), which becomes charged in the course of years with an ever-increasing number of fatty granules. These cells of the testes have been observed even in embryos to be endowed with contractility, and to possess the power of amoeboid change of form (*La Valette St George*).

Recently, however, a more complex structure has been ascribed to the seminal tubes.

In man and the ox, for instance, a framework of flat stellate cells with membranous processes is stated to exist in their interior (*Sertoli, Merkel, Boll*). We regarded these, the "sustentacular cells" of *Merkel*, as the same network to which we have already had such frequent occasion to allude in dealing with the racemose glands. *Mihalkowicz*, on the other hand, in his excellent work, declares this appearance of sustentacular cells to be an artificial production caused by the coagulation of an albuminous material between the seminal cells.

Such is the structure of the seminiferous tubes as far as the rete testis, in which for the time being their external fibrous tunic is fused into the connective-tissue of the *corpus Highmori*. The tubes, which leave the latter as they increase in size, obtain an additional layer of smooth muscular fibres, which is further strengthened lower down in the body of the epididymis by two coats of longitudinal fibres, an external and an internal. This arrangement we shall again meet with in the vas deferens.

We have already (p. 150) alluded to the peculiar *ciliated epithelium* of the epididymis.

The *blood-vessels* of the testes are branches of the internal spermatic artery. They penetrate into the interior of the organ-form without, and from the *corpus Highmori*, and take their further course along the septa dividing as they go. Finally, they break up into a long-meshed, rather loose capillary network of somewhat contorted vessels, from 0.0128 to 0.0056 mm. in diameter (fig. 546, 1, c; 547, c), which invests the seminiferous tubes. The vascularity of the epididymis, which is supplied by the *arteria vasis deferentis Cooperi*, is no less considerable. The veins present the same arrangement as the arteries.

The *lymphatics* of the parenchyma of the organ, lined by the special cells of such vessels (*Tommasi*), occupy the soft interstitial connective-tissue of the former, arranged in a close network of canals (fig. 546 1, c; 547, d). In transverse sections of the seminiferous tubes, it may be seen that these lymphatic canals form regular rings around the latter, of passages from 0.0128 to 0.0292 mm. in diameter, and strongly dilated at the points of junction with each other. Steady injection at last drives the fluid employed through the external cellular layers of the walls of the seminiferous tubes. The most internal layer alone is entirely impervious (*Mihalkowicz*). The blood-vessels, also, are here and there ensheathed in lymph streams.

From the rings just mentioned other lymphatic canals are given off to the numerous connective-tissue septa of the lobules. Under the albuginea, also, they are arranged in a very complex network of wide canals, and then penetrate the former in the form of wide-valved intercommunicating passages, most highly developed on the dorsum of the organ. Finally,

they unite with the lymphatics of the epididymis and tunica vaginalis to form several main trunks, which then take their course along the spermatic cord.

The *nerves* of the testis spring from the internal spermatic plexus; as to their ultimate mode of termination, however, nothing is at present known.

In connection with the epididymis we have to consider several structures, and in the first place the so-called *hydatids* of *Morgagni*. These present themselves under two forms, seen in some cases together. The first kind is a petiolate vesicle seated upon the anterior surface of the head of the epididymis. Its style is usually solid and fibrous, while the vesicle contains a clear fluid, cells, and nuclei. But the second form is far more frequently met with. In it we have a knobbed flattened structure with hardly any stalk, and either simple or divided into lobes. Its position varies, and it sometimes communicates with the passage of the epididymis.

Finally, at the posterior edge of the testicle, between the head of the epididymis and the vas deferens, a small flattened structure presents itself, composed of several loosely connected whitish nodules. Each of the latter consists of the convolutions of a tube terminating at each end in a blind dilatation. The interior of these is filled with a clear fluid, and lined with pavement epithelium whose cells are in process of decay. This body is known as the *corps innominé* of *Giraldès*, or organ of *Giraldès* (*Koelliker*), or *parepididymis* (*Henle*). In the infant, and up to the age of ten years, this structure is encountered in complete development; later on, it degenerates.

Referring to the history of development, we find some light is thrown upon the nature of these accessory structures.

The testis, like the ovary (§ 278), is developed at the inner side of the *Wolffian* bodies. Here, however, the germinal epithelium never attains that degree of perfection we have observed in the female embryo. The genesis of the seminiferous tubules is not yet fully ascertained. According to *Waldeyer*, they are formed, not from the germinal epithelium at all, but from the glandular passages themselves of the primordial kidney.

From the canals of the *Wolffian* body, then, which are insignificant in the female generative system (a mere trace remaining in the mature body as the parovarium), the epididymis is formed, while the duct of the organ is gradually converted into the vas deferens. The other remnants of the *Wolffian* bodies, then, give rise to the organ of *Giraldès*, and the structure known as the *vas aberrans*.

But beside the duct of the *Wolffian* body, we find at a very early age the rudiments of a second canal, that of *Müller*, already alluded to in speaking of the female generative system. This has, however, a different destiny in each sex. While in the female it becomes converted into the *Fallopian* tube and uterus—therefore into very important parts—in the male generative system it degenerates almost completely. The last trace of its upper portion alone is to be seen as the hydatid of *Morgagni*, just referred to; while its most inferior portions form by their junction the so-called *uterus masculinus*, or *vesicula prostatica* of anatomists.

The composition of the tissue of the testicle, whose sp. gr. is 1.045 (*Krause* and *Fischer*), still awaits investigation. Glycogen was found by *Kühne* in the organ in the dog.

§ 284.

In the foregoing section a microscopical analysis of the contents of the seminiferous tubes in the state of rest, not of activity, has been presented to us. During the whole period of virility in man, however, and in the rutting season of animals, these glandular tubes generate another kind of contents, namely, *semen* or *sperma*).

Human semen, as secreted by the testis, is a whitish slimy fluid destitute of any odour, and of high sp. gr. Its reaction is either neutral or alkaline. Semen, however, as discharged *in coitu*, has received additions from the accessory glands of the generative organs, and so undergone considerable modification. It reacts strongly alkaline, and has a peculiar odour, which has been aptly compared to that of freshly sawn bone. Besides this, it is more fluid and transparent. Shortly after being ejected it coagulates, forming a thick gelatinous mass, which becomes again liquid after some time.

A glance at fresh human semen under the microscope shows innumerable thread-like form elements engaged in the most lively motion. To these several names have been given,—such as *seminal filaments*, *seminal animalcules*, and *spermatozoa* (fig. 548). Suspended in a homogeneous fluid they are seen to consist of two portions, namely, an anterior wider end known as the *head*; and a long filiform process posteriorly, to which the term *tail* has been applied.

The form of the head (*a*) is oval, or, more correctly speaking, pear-shaped; the broadest end being posterior, at the insertion of the tail. Its length is, on an average, 0.0045 mm., and its breadth about half as much. When the head is seen in profile (*b*), we remark that, like the corpuscles of the blood, it is greatly flattened. Seen from the surface it appears broad, with sharp but not dark outline, but viewed from the side it is narrow, and presents a broad dark border. Its thickness lies probably somewhere about 0.0018–0.0013 mm. (*Koelliker*). The hindermost division of the structure, the filiform process (*a*, *b*) commences with a constricted neck, succeeded by a somewhat thickened portion, gradually becoming thinner and finer, until at last it attains such a pitch of tenuity as to baffle microscopic analysis. It may be followed to a length of about 0.0451 mm.

For a long time it was supposed that the spermatozoa only consisted of these two parts, and that they were quite homogeneous throughout, without any distinction between envelope and contents. More recent observations, with the aid of the stronger systems of lenses of the present day, would seem to place this view in question. The reports, however, of *Valentin*, *Grohe* and *Schweigger-Seidel* on the subject do not yet entirely agree.

From the able researches of the last-named observer it would appear that the tail of the spermatozoon (fig. 549) may be divided into two portions, often sharply defined one from the other, and different in diameter and in chemical and optical characters: these are, first, the middle portion (*b*), as it is called; and, secondly, the delicate terminal filament (*c*). In those instances in which the head of the human spermatozoon possesses the length mentioned above, of 0.0045 mm., the middle portion

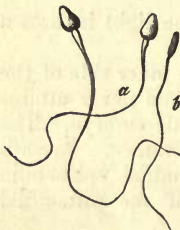

Fig. 548.—Human spermatozoa. *a*, view of the broad surface; *b*, in profile.

is 0.0061, and the terminal filament 0.0406. Both the head and middle portion appear rigid, leaving the end fibre alone movable. That a difference exists between envelope and contents in the spermatozoa, as maintained by *Grohe* and *Schweigger-Seidel*, we do not think has been yet clearly proved.

Throughout the whole animal kingdom semen is possessed of certain definite form-elements. But though the prevailing shape of these spermatozoa is filiform in all animals, nevertheless they present extremely interesting and considerable varieties of appearance, reminding us of the similar though much less markedly characteristic peculiarities of the red blood-cells (§ 68). The narrow limits of our work, unfortunately, do not permit us to enter deeper into this very interesting subject; but we cannot relinquish it without pointing to the probable safeguard against hybrid impregnation which exists in these strongly-marked peculiarities,—a kind of aid to the persistence of distinct species. Besides this, in many animals this motion has been missed, while in others a lazy amœboid change of form only could be observed.

From a chemical point of view the spermatozoa of the mammalia consist of a resistant metamorphosed albuminous substance, rich in lime, which approaches in quality to elastin. They withstand for a very long time the process of putrefaction, and even oppose a determined resistance to the action of the mineral acids, dissolving, on the other hand, but still very slowly, in caustic alkalis (*Koelliker*). Owing to the large proportion of mineral ingredients in the spermatozoa, they preserve their form, although subjected to a red heat.

The composition of pure semen,—that is, the secretion of the testicle,—was studied many years ago by *Frerichs*, especially that of the carp, but also of the cock and rabbit. In his observations he found the fluid neutral, resembling a dilute solution of mucus, and containing a certain amount of albumen. Chlorides of the alkalis, and small quantities of phosphates and sulphates of the same, were present in its residual ash, as also phosphate of magnesium.

The dry substance of the spermatozoa contained 4.05 per cent. of a yellow matter like butter, probably containing phosphorus, and, we may now add (?), probably also cerebrin and lecithin. Besides this, 5.21 per cent. of ash constituents, among which lime and phosphoric acid presented themselves.

Pure semen from the horse has 18.06 of solid ingredients; that of the bull 17.94, of which the metamorphosed protein substance of the spermatic filaments amounts to 13.138 per cent. lecithin (?) to 2.165, and mineral matters to 2.637 per cent. (*Koelliker*).

Semen, as discharged from the urethra, is richer in water, from the addition of the secretions of the accessory glands: that of man was found by *Vauquelin* to contain, on the whole, only 10 per cent. of solid matters.

The substance which causes semen to coagulate after emission, named long ago by *Vauquelin* "spermatin," appears to be an albuminate of sodium (*Lehmann*).

The development of the spermatozoa was formerly supposed to take place from peculiar cells in the seminiferous tubules. But the process was first accurately described by *Koelliker*. At the time when semen first begins




Fig. 549.—Spermatozoa of the sheep, after *Schweigger-Seidel*. a, head; b, middle portion; c, tail.

to be formed (puberty in man, rutting season in animals), most of the glandular epithelium cells of the seminal tubules undergo division, by which act a multitude of delicate, pale, and transparent elements of spherical form are produced, with vesicular nuclei of 0.0056–0.0079 mm. in diameter, sometimes single, sometimes ranging from 10 to 20. These cells vary in diameter between 0.0113 and 0.0074.

From them the seminal filaments are supposed to be developed, and, moreover, from the nuclei. At first it was thought that, in the interior of each of these vesicular nuclei, a seminal element took its rise; but *Koelliker* asserted later that the whole nucleus becomes converted into a spermatozoon. This he stated to take place by its becoming elongated and flattened, and dividing into an interior dark and posterior lighter portion, and sending out at one end a filament destined to increase more and more in length, while the nucleus itself assumed gradually the characteristic form of the head.

The spermatozoa so formed were supposed to lie eventually within the cells, in number corresponding to the original number of nuclei. Their arrangement there was stated to be regular when more than a few were present, namely, with their heads close to one another and the tails likewise parallel, bent according to the amount of space left to contain them. A small number of these formative cells were supposed to rupture before leaving the testis, setting free the spermatozoa; but by far the largest proportion of the latter to be liberated in the epididymis.

But these theories, the correctness of which was for some time believed to be beyond doubt, have been since found to be untenable, and the genesis of the spermatozoa is at the present day a point of great obscurity.

Henle was the first to point out, some years ago, another order of things from that just mentioned. He found, namely, two kinds of cells in the seminiferous tubuli,—one with coarsely and another with finely granular, sharply-defined, nuclei. He supposed the head to take its origin from the latter, which project beyond the surface of the cells; further, that the filamentous process does not spring from the interior of the cell. In the last view he is supported by *Schweigger-Seidel*. This observer regards the spermatozoon as a single ciliated element formed by the metamorphosis of a whole cell. The nucleus, he believes, is transformed into the head, and the middle portion to be derived from the remainder of the cell-body, while the terminal filament represents a cilium. According to *Henle*, cells with rolled-up filaments never occur as normal structures in the seminiferous tubes, which is also denied by both *Schweigger-Seidel* and *La Valett-St George*, with whom we also entirely agree.

From our own, but, we must confess it, rather hasty, observations (fig. 550), the process of the formation of spermatozoa appears to be as follows:—The nucleus of the primary seminal cell (*a*) advances to the periphery (*b*). Then the formation of the caudal appendage commences (*c*). The nucleus then passes beyond the original boundary of the formative cell, clothed in a thin layer of protoplasm (*d*). Later still, the nucleus, with this covering of protoplasm, forms the head of the seminal element, while the appendage of the cell-body grows out into a long thread (*e*). Finally (*f*),

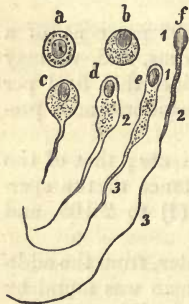

Fig. 550.—Mode of formation of spermatozoa in the mammal. 1, head; 2, middle portion; 3, terminal filament.

we have the head or nucleus (1), the middle portion or remainder of the cell-body (2), and the filament, the elongated cilium (3).

§ 285.

The most striking and important peculiarity of the seminal elements, and one recognised as such ever since their discovery, consists in their movements. These, which were in olden times accepted as a proof of their independent individual life (whence the name "spermatozoa") appear to be very nearly allied to the phenomena of ciliary motion (§ 99), and, like the latter, baffle at present all explanation.

If semen be taken from the seminal tubes of some freshly slaughtered mammal, it will be found, as a rule, that the movements in question have not yet commenced. But if a drop of the fluid, immediately after emission from the urethra, be placed upon a glass slide under the microscope, innumerable spermatozoa are observed moving in all directions in the utmost confusion.

Closer inspection shows us that the individual elements of the semen execute a series of movements, consisting in alternate flexion and extension, and undulating motions like those of the lash of a whip, by means of which the whole structure is propelled from place to place. Though tempted for a moment to compare this with the independent hurrying to and fro of a host of infusoria, we very soon observe the most marked points of distinction. We miss, in the first place, the spontaneity of the latter organisms,—that swimming in definite directions and avoidance of obstacles which characterise their movements; also that momentary acceleration and slackening in pace. The rate of progression moreover of the spermatozoa is by no means very great, several minutes being consumed in advancing even the distance of an inch. Like the motions of the cilia, those of the seminal filaments commence, after a time, to decrease in rapidity and the structure dies. We remark the intensity of the whip-like undulations of the fibre growing less and less, until at last the movements of the latter cease to propel the spermatozoon any farther, and all evidences of life become extinct.

Let us now consider the conditions of these movements. Their duration, in the interior of the male organs of generation or in emitted semen, varies in these different classes of animals. In birds they cease most rapidly, often within a quarter of an hour. Among the mammalia they persist for a much longer period, at times almost for a whole day. Thus in human semen, after pollution, the spermatozoa may be observed still to retain the power of motion sixteen or twenty hours after emission. Among the Amphibia they last much longer, and in fish longer than in any other animals. Here they may be seen under favourable conditions four days after the discharge of the semen (*Wagner*). We are thus reminded again of ciliary motion. If the temperature be reduced to below freezing-point, the movements of the spermatozoa cease; but even after remaining four days in a congealed state they may regain their power of locomotion on being warmed. Cooled down to -17 C. , they die; as also on being heated up to $+50\text{ C.}$ (*Mantegazza*).

As to the effects of the addition of other fluids to the semen, we find that indifferent matters of a certain average concentration,—as, for instance, solutions of sugar, urea, glycerine, and neutral salts of the alkalis and earths,—may be added without arresting the motion of the spermatozoa, while very dilute solutions cause their destruction. Very concentrated fluids also prevent by their viscosity any play or motion in the filaments.

The same mechanical obstacles to the motions of the spermatozoa are presented by matters which become simply gelatinous in water; such as vegetable mucous. Those re-agents, also, which act chemically on either the seminal filaments or fluid,—as, for instance, mineral acids, metallic salts, acetic acid, tannic acids, ether, alcohol, and chloroform,—all bring the lively movements of the former to an end. They may be best examined in serum, white of egg, and vitreous humour; as also in the contents of the vesiculæ seminales, prostate, and *Cowper's* glands, as the natural ingredients of the semen. In the secretions of the internal female organs of generation their motions are for a long time preserved. Here they may be observed, in the mammalia, wandering hither and thither for days, under the favouring influence of the animal heat of the parts. The acid mucous of the vagina, as well as the transparent and viscid secretion of the cervix, are said to put an end to the movements of the spermatozoa. Urine, when neutral or slightly alkaline, has no very great effect upon the latter; but when strongly acid or alkaline, its action is very well marked. In alkaline milk or mucus the phenomenon of motion is quite evident, while saliva has the same effect on it as water. This is peculiar, bringing all movement rapidly to an end; but it is preceded by increased activity for a short time, during which the spermatozoa hurry about with great rapidity, striking and lashing with their tails. Soon, however, they come to a state of complete rest, when the under end of the filament is usually observed to be folded round the upper portion, like the lash round the stock of a whip. It is an interesting fact that such motionless spermatozoa may be again called into activity by surrounding them with saturated solutions, such as those of sugar, white of egg, and common salt, and also, when in too strong solutions, by subsequent addition of water,—an indication of the important part which endosmosis plays in the phenomenon.

We have already seen in an earlier section that the caustic alkalis have a most stimulating action on the ciliary motions: the same has been observed by *Koelliker* to be the case with the elements of semen.

Recent research has shown that the spermatozoa penetrate into the interior of the ovum in order to impregnate it, moreover,—in the mammalia in considerable number. This entrance appears here, as among all the vertebrates, to be effected by the efforts of the spermatozoa, and carried out by the movements of their thinner portion. A special opening (*micropyle*), to admit them, has not yet been demonstrated in the *zona pellucida*, but those radiating lines seen on the envelope of the ovum may possibly represent, as pore-canals (§ 52), such passages for the spermatozoa which may be enlarged by the latter. These, on penetrating into the yolk, become motionless, and soon after break down and become fluid.

§ 286.

Turning now to the thick-walled *vasa deferentia*, it will be remembered that they take their origin gradually from the passages of the epididymis, and are therefore possessed of a similar structure to the latter. They are made up of an external fibrous investment, then a muscular coat of considerable thickness, composed of three laminae (already mentioned in speaking of the epididymis), an external strong and internal weak layer of longitudinal fibres, together with a middle tunic of circular bundles, which is the strongest of the three. The mucous membrane with which they are lined is covered by columnar cells, 0.0501 mm. in height. Near

the lower end of the vas deferens is a fusiform dilatation, the "ampulla" of *Henle*, from which a number of blind diverticula, leaving the main tube, pass at very acute angles upwards into its walls.

In this expanded portion of the canal the mucous membrane differs from elsewhere: it is thicker and rugose, and presents a number of pits and saccules. In the walls of the ampulla further vermiform glands present themselves, filled with polyhedral cells, and containing molecules of a yellow and brown pigment (*Henle*). The nerves of the vas deferens possess ganglion cells, and are medullated. Their mode of termination is not yet known.

The thin-walled *vesiculæ seminales* have also a similar structure. They are, in fact, little else than highly-developed diverticula of the same stamp as the ampulla of the vas deferens, but branching. They are partly designed as receptacles for the semen as it is secreted, and partly as secreting organs themselves. Their walls are supplied with scattered bundles of smooth muscular fibres. Within them we find a transparent fluid which coagulates into a gelatinous substance on exposure to the air, becoming subsequently liquid again. This is manifestly the same matter as the semen discharged from the urethra (§ 284). According to *Gerlach*, the rugose mucous membrane with which they are lined contains numerous compound mucous glands, which are stated by *Henle* to be of the tubular kind, and by *Klein* to be only pits. Their structure is otherwise similar to that of the ampulla.

The *ejaculatory ducts* correspond also in structure with the last-named organs.

Their calibre decreases greatly in their course through the prostate. In the more dilated portions their mucous membrane presents similar folds, tubular mucous glands, and yellow and brown pigment granules, as the ampulla and *vesiculæ seminales*. Within the prostate the muscular layer of the ejaculatory duct gives place to cavernous tissue (*Henle*), and the mucous membrane becomes thinner, smoother, and loses its glands.

The *prostate*, the largest of all the organs connected with the male generative organs, is an aggregation of glands belonging to the racemose type, but presents, besides, many peculiarities. With *Henle* we may consider it as divided into three portions, namely, the two sphincters of the bladder, the internal formed of unstriped fibres, and the external with an increasing number of striped elements; and finally, the body of the gland just mentioned. Besides a fibrous tunic with an admixture of muscle elements, the prostate is enveloped in a tough yellowish membrane, consisting chiefly of smooth muscular fibres. This latter sends off into the interior of the glandular mass a number of processes forming a massive framework, and making up a considerable portion of the whole organ. The separate elements of the gland, in number varying from 15 to 20, appear to be of the racemose kind. In them we find pear-shaped vesicles of 0.1254-0.23 mm. in diameter, lined with columnar epithelial cells. The ducts of the gland are fine, surrounded by a muscular coat, and lined with the same columnar epithelium: they empty themselves singly, in the neighbourhood of the *colliculus seminalis*, into the urethra.

The vascularity of the organ is considerable, its vesicles being enveloped in capillary networks. The lymphatics and mode of termination of the nerves of the prostate which present ganglion cells are still unknown.

The secretion of the prostate is probably allied to that of the *vesiculæ seminales*. In both we find an albuminous matter freely soluble in acetic acid.

Those concentrically laminated concretions known as *prostatic calculi* are composed of this substance. In old men almost every prostate contains some of these bodies, which are often seated in the excretory ducts.

The *sinus prostatica* or, as *E. Weber* has named it, the *uterus masculinus*, is a slender saccule, from 7 to 14 mm. in length, lying in the substance of the prostate. Like the *colliculus seminalis* it is lined with laminated epithelial plates, has a fibrous wall intermixed with muscle elements, and is enveloped in a thin layer of cavernous tissue. It opens at the summit of the *colliculus seminalis* between the two orifices of the ejaculatory ducts.

Cowper's glands are small, round, and more or less lobulated bodies, a few lines broad. They possess a fibrous envelope, containing some isolated bundles of striped muscle, and present the usual structure of racemose glands. In their lobules, which are separated from one another by connective-tissue mixed with contractile fibre-cells, we find small gland vesicles lined with columnar cells. The somewhat wide ducts of the lobes are clothed with flattened cells. In the interior of the organ they unite to form a number of large passages, which give to a transverse section of the organ an appearance as though sacculated. Subsequently, however, they combine at acute angles to form one single trunk.

§ 287.

There still remain to be considered the *urethra* and *copulative organ* of the male.

The first of these consists, as is well known, of three portions,—the *pars prostatica*, passing through the prostate gland; the *p. membranacea*, a middle portion, made up of an independent membrane; and a third compound part, which is the longest of the three, and named *p. cavernosa*. This latter belongs to the penis, in which it is enveloped in a spongy body, the *corpus cavernosum*, s. *spongiosum urethræ*, which forms with its anterior extremity the *glans penis*. Associated with this spongy mass are two other structures of a similar nature, the *corpora cavernosa penis*, which, together with an external covering of skin and several voluntary muscles (*m. m. ischiocavernosi* and *bulbo-cavernosi*), make up the copulative organ of the male.

The urethra of man presents for consideration, internally, a mucous membrane, covered in the prostatic and membranous portion with flattened or transition cells, but lower down with cylinder epithelium (§ 91). This mucosa is invested, again, in a fibrous tunic, rich in elastic elements and of looser texture, in whose interstices a cavernous tissue is formed (*Henle*). External to this, again, is a layer of involuntary muscular tissue formed of longitudinal fibres internally, and transverse externally.

The three portions must, however, be considered separately.

The first thing which strikes the observer in the *prostatic* portion is the prominence of the *colliculus seminalis*, to which we have already referred in speaking of the ejaculatory ducts and prostate. It is covered by a longitudinally wrinkled mucous membrane, and consists of elastic tissue (intermixed with bundles of contractile fibre-cells), which bears all the characters of cavernous substance. This spongy tissue is near the surface displaced at certain points by glands similar to those of the prostate, situated partly in the mucosa and partly deeper (*Henle*). The mucous membrane of the *pars prostatica* is seen to be arranged in fine intersecting folds, chiefly, however, longitudinal: it contains glandules identical with those just mentioned.

In the middle or membranous portion of the passage under the mucous membrane a long-meshed cavernous tissue again presents itself. The organic muscular layer, on the other hand, is weaker, and covered by bundles of the *musculus urethralis*, which consists principally of transversely arranged bundles of striped fibres.

But the unstriped muscular tissue of the *pars cavernosa* is even less developed still. Here the mucous membrane is covered with cylinder cells, which give place to a covering of flattened epithelium at a greater or less distance from the mouth of the urethra.

The last-named portion of the urethra contains farther little depressions or pits, the *lacunæ Morgani*, which are not glandular in their nature; also isolated small and ill-developed racemose glandules, known as glands of *Littre*, whose vesicles and ducts are lined with cylinder epithelium. These do not appear to exist in the *pars membranacea* (*Henle*).

Just a few words in regard to the *skin* of the penis. This is thin and loose down to the free edge of the prepuce, and is possessed of fine downy hairs, which decrease in length below, and into whose follicles sebaceous glands empty themselves. Its very elastic subcutaneous areolar tissue presents longitudinal bundles of involuntary muscle-fibres, prolongations of the *tunica dartos* of the scrotum, and is quite devoid of fat-cells. This subcutaneous tissue invests the whole organ down to the base of the glans: it is known as the *fascia penis*. At the root of the member it is condensed into an elastic band—the *ligamentum suspensorium penis*.

The connective-tissue binding the two laminae of the foreskin together manifests the same distensibility, but is destitute of fat: it is intermixed with muscular elements.

The surface of the glans is covered by a delicate membrane, closely adherent to the cavernous tissue beneath. This membrane is possessed of very numerous papillæ arranged in rows converging towards the crifice of the urethra, and obscured by the flattened epithelium covering of the part. On the *corona glandis* we may frequently observe larger papillæ, measuring from 0.9 to 0.5 mm., and appearing as white specks through the membrane or bulging out the latter.

The internal leaf of the foreskin, smooth and without wrinkles, presents all the characters of a mucous membrane. It is quite destitute of hair and convoluted glands, but is supplied with numerous tufted papillæ.

On the inner surface of the prepuce are situated a number of sebaceous follicles, known as *Tyson's* or *Littre's* glands. These occur in varying number and form, and are found at times also upon the surface of the glans, especially in the vicinity of the frænum. Their secretion mixes with the epidermal scales of the part when shed, and so assists, though, in a very minor degree, in producing that tallowy substance, known as the *smegma preputii*, which collects sometimes underneath the foreskin.

Each of the *corpora cavernosa* is enveloped in a fibro-elastic tunic, containing but few muscular elements, the *tunica albuginea, v. fibrosa*, from which innumerable bands and septa are given off internally, consisting of ordinary and elastic connective-tissue fibres, with a number of muscular elements. These bands, then, undergo repeated subdivision, and unite in every conceivable way; so producing a system of cavities communicating with one another, like those of a sponge, and lined throughout with vascular cells or endothelium. Thus a peculiar venous receptacle is formed for the blood.

The several cavernous bodies in man resemble each other, as a rule, in

structure. The description just given, however, refers more particularly to the *corpp. cav. penis*. These are separated from one another anteriorly by an imperfect partition. But, besides these, there is another cavernous body, the *bulb of the urethra*, quite distinct from them, and remarkable for having a thinner envelope, more delicate trabeculæ, smaller receptacula, and a larger proportion of elastic fibres. The interstices in the spongy tissue of the *glans* are even narrower still.

The reservoirs just mentioned are constantly filled with blood, but become overcharged with the same at intervals, effecting that change in the male organ known as *erection*.

In order to understand this phenomenon clearly, it will be necessary to review first of all the whole arrangement of vessels and circulation of the cavernous organs. In doing this we shall adhere to the description given in a very excellent work by *Langer*.

The *corpora cavernosa* of the penis only receive a few inconsiderable twigs from the dorsal artery; they are chiefly supplied by the *arteriæ profundæ* which run close to the septum. These are enclosed in a sheath

connected with the cavernous cellular network, and give off gradually numerous anastomosing twigs to the cavernous substance which run along within the trabeculæ, and take a tortuous course in the quiescent state of the organ.

The modes in which these vessels merge into the cavities of the venous spongy tissue are several.

In the first place, they decrease rapidly in diameter towards the surface of the corpora cavernosa, and more so still in the vicinity of the septum. Here we find true capillary networks of somewhat large-sized tubes at the point of transition. These constitute, as *Langer* expresses it, the "superficial cortical network," and (fig. 551, 1, *a*) communicate with a "deeper system of wide venous canals" (*b*), "the deep cortical network."

An immediate transition of fine arterial twigs (2, *a*) into

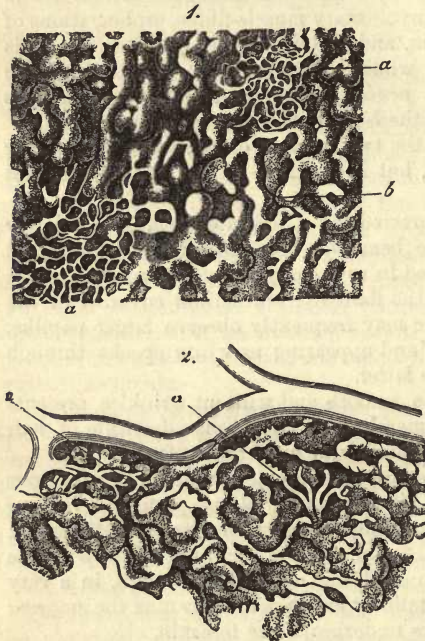


Fig. 551.—From the peripheral portion of the corpus cavernosum penis, under low magnifying power. 1. *a*, network, known as the superficial; *b*, the deep. 2. Connection of arterial twigs (*a*) with the canals of the deeper cortical network (copied after *Langer*).

of turgidity in the peripheral system of lacunæ.

Direct communication of terminal arterial twigs takes place also with the deeper venous receptacles of the interior, a remarkable funnel-shaped opening being evident at the point of transition ("*Zapfen*").

The trabeculæ of the interior of the corpora cavernosa contain also

wide-meshed capillary networks, which probably empty themselves likewise into the venous cavities of the part.

Finally, the coats of the *arteria profunda* are supplied with a meshwork of capillary vessels. These gather themselves together to form venous twigs, also to be seen here, which empty themselves into a network of venous spaces surrounding the artery.

The so-called *arteriæ helicinæ*, brought into notice by *J. Müller*, and the subject of such frequent controversy, used to be supposed to terminate, after many contortions and tendril-like convolutions, partly with blind sacculæ in the cavernous spaces projecting into the latter. The appearances which led to these conclusions were, however, artificial (*Rouget, Langer*), produced in part by imperfect injection, partly by the constriction caused by severed elastic trabeculæ.

The conveyance of the blood out of this system of lacunæ is effected, in the first place, in the dorsal portion of the organ, by short venous passages, which spring from the deeper cortical network, and empty themselves into the dorsal vein of the penis (so-called *venæ emissariæ*). Again, by the *venæ emissariæ inferiores*, which come from the interior of the cavernous system, and make their exit near the urethral furrow; lastly, by the *venæ profundæ* of the crura of the corpora cavernosa.

In the spongy portion of the urethra we find a venous network internally around the tube, consisting of long meshes connected with the venous lacunæ. In the bulb alone do we encounter a direct entrance of arterial twigs into the lacunæ: the transition in other localities takes place through the medium of capillary networks, as seen, for instance, in the mucous membrane of the urethra.

In the spongy part of the glans, where the lacunar system is more or less replaced by genuine venous vessels, the connection between arteries and veins is everywhere effected through the medium of capillary interlacements (*Langer*).

The *lymphatics* of the male urethra, connected with those of the bladder, are arranged in complicated networks, which, with longitudinally arranged meshes, open directly into the lymphatic canals of the glans penis. The latter are numerous, but thinner than those of the urethra (*Teichmann*). They interlace in the uppermost layer of the skin in the form of wide passages, seen in greatest numbers in the glans, and less highly developed in the prepuce and other portions of the organ (*Belajeff*). The larger trunks derived from these course along the dorsum of the penis, and are received partly into the true pelvis, partly into the glands of the groin.

The *nerves* of the penis are derived partly from the cerebro-spinal system (*n. pudendus*), partly from the sympathetic (*plexus cavernosus*). The latter are stated to supply the cavernous tissue alone; the first the skin, and mucosa besides. The skin of the glans is peculiarly rich in nerves. Many years ago *Krause* discovered terminal bulbs in this situation, and since then genital nerve-corpuscles (p. 327) have been also observed. *Tomsa* mentions also a second and more simple mode of termination of the nerves of the glans. *Pacinian* corpuscles also were found by *Schweigger-Seidel* behind the glans, in the neighbourhood of the dorsal artery of the penis.

In regard to the *theory of erection* of the penis, *Koelliker* endeavoured, many years ago, to explain it as effected by a relaxation of the muscular tissue of the corpora cavernosa under the influence of the nervous system.

This would naturally allow of the distension with blood of the small receptacles of the cavernous substance. Later *Eckbart* found in the dog fibres running from the *plexus ischiadicus* to the *hypogastricus*, which he showed to be the erection nerves. *Lovén* found that during irritation of these a bright red stream of blood spurted from a small arterial twig suddenly on being opened; the pressure of the blood, at the same time, in the vessels of the penis continuing much less than in the carotid. Here, then, we have before us a relaxation of the walls of the smaller arteries brought about by stimulation of a nerve similar to that produced in the heart by irritation of the vagus.

But, besides this, no doubt hindrance to the exit of the blood from the organ increases the erection. This is possibly brought about by the *m. transversus perinæi* (*Henle*) preventing the return through the roots of the penis. Also by the position of the *venæ profundæ* in the corpora cavernosa, and the fact that the veins of the *plexus pudendalis* possess numerous projections of smooth muscles.

B. Organs of the Animal Group.

6. Bony Apparatus.

§ 288.

Although we have already referred at some length, in the second part of our work, to the *bony apparatus* or *osseous system* in dealing with the tissues of which bones are composed, there still remain some complementary considerations which must occupy us for a few moments. These are, in the first place, the *mode of connection* of the various portions of the skeleton with one another; secondly, the *vessels* and *nerves* of bone; and thirdly, the *substance* with which the cavities of the latter filled up.

The ways in which bones are joined together are, as is well known, very various. While in the embryo the connecting masses are, in all probability, almost universally solid, but a small number of them remains so at a later period. In such instances they are known to anatomists as examples of *synarthrosis*, a mode of connection represented in *sutures* and *symphyses*. In other rudimentary masses of this kind a process of liquifaction in the interior gives rise to the formation of cavities, while the peripheral cells of the mass are transformed into the tissue of a capsule, with its epithelial cells, &c. This mode of connection is designated as *diarthrosis*, or jointed union. If, as is often the case with symphyses, the process of liquifaction should cease at an early period, we have what has been called half joints (*Luschka*). The latter are usually somewhat ill-defined, and are variable in nature: no synovial capsule is to be recognised in their interior.

In regard now to the several media of articulation between bones, the suture is united by what is incorrectly named suture-cartilage, which is nothing less than a fine band of whitish fibrous connective-tissue. Symphysis is effected by hyaline, or fibrous cartilage and connective-tissue. Here the ends of the bones are clothed with a layer of hyaline substance, which, covered externally by connective-tissue, completes the union; or this cartilage passes gradually, more and more, into a fibrous mass, which may at certain points give way to pure connective-tissue. We have already referred to this texture, in speaking of fibrous cartilage, in § 109, where the intervertebral disks were fully described. The *symphysis pubis* and *sacroiliaca* are half joints, as also almost invariably the points of union of

the costal cartilages with the sternum from the second to the seventh rib. We not unfrequently meet in the symphyses with a layer of calcified cartilaginous tissue in the vicinity of the bone. The further consideration of these parts must be left to works on descriptive anatomy.

As regards the joints, we have already considered their cartilages (§ 107), and in § 109 their *labra cartilaginea*, sometimes present.

Under the cartilaginous coverings of bones forming joints we very generally find a layer of peculiar undeveloped osseous tissue. It is, on an average, 0.27 mm. in thickness (*Koelliker*), and consists of a yellowish and usually fibrous solid mass, which presents, however, neither *Haversian* canals nor bone corpuscles. Instead of these, we observe in thin sections cartilage capsules filled with air.

A description of the tissue of the *synovial capsules* will be found in § 135. The latter are very vascular, and are richly supplied, apparently, with lymphatics (*Teichmann*). They are strengthened externally by the addition of strong fibrous tissue. Their epithelial lining has been already discussed, as far as it occurs, in § 88, and the synovia itself in § 97. For a description of the *inter-articular cartilages*—those disks of connective-tissue cartilage attached laterally to synovial capsules, and interposed between the heads of bones forming joints—compare § 109. The *ligaments* of joints consist of connective or fibrous tissue (§ 135).

From the frequent deposit of fat-cells in the connective-tissue enveloping synovial capsules, it is often found, as already alluded to in § 122, that collections of the former are protruded into the cavity of the joint in the form of duplicatures. These are most usually met with in the knee and hip joints, and are known there as the *glands of Havers*. The appearance, however, of very vascular fringed folds of synovial tissue is of far more frequent occurrence, and encountered in almost all joints. These are usually destitute of fat-cells, and present occasionally a few cartilage elements intermixed with those of the connective-tissue. They have been given the name of *plicæ vasculosæ* (1), and are represented also in the half joints, according to *Luschka*, although devoid of vessels in those situations.

REMARKS (1).—The structures in question are frequently covered with smaller processes, leaf-shaped or membranous, and sometimes of the strangest shapes. From these the loose cartilages found at times in the interior of joints are derived, though not exclusively. They consist of more or less calcified cartilage, and occur most frequently in the knee. Compare *Virchow*, "Die krankhaften Geschwülste," Bd. i. 5, 449.

§ 289.

As regards the *blood-vessels* of bone, we have to bear in mind, in the first place, that the periosteum (§ 135) is very vascular. It is supplied by a number of large vessels, which pierce it, however, for the most part, only on their way to supply the osseous tissue beneath. It is possessed, further, of finer vessels proper to itself, which are arranged in rather complex capillary networks.

In order the better to comprehend the arrangement of the vessels of osseous tissue, let us first take one of the tubular bones as an example. As we have seen above, numerous vessels from the periosteum are given off to the openings of the *Haversian* canals (§ 140), and are there arranged in a long-meshed network of tubes of considerable size, which often assume characters different from those of true capillaries, and belonging rather to the smaller veins and arteries. Beside this, we always meet with a large single or double canal in the diaphysis of such a bone, the *foramen nutri-*

tium, into which an arterial twig is sent which makes its way eventually into the central medullary canal as the *arteria nutritia*. The latter then divides into an ascending and descending branch, which again break up into a capillary network, including the fat-cells of the medulla in its loops (see below), and giving off a series of vessels which enter the internal opening of the *Haversian* canals to anastomose with those coming from the periosteum. In the epiphyses, also, the supply of blood is partly from without, through small vessels derived from the periosteum, or larger twigs entering through the more numerous nutritive foramina of these portions; and partly from within, through close connection with the vessels of the medullary canals of the diaphysis. These vessels, then, are situated, in the first place, within the *Haversian* canals, and again distributed through the medullary cavities.

The course of the veins is analogous to that of the arteries. One set of venous vessels convey the blood out of the part through the larger and smaller nutrient canals; another set of branches return to the periosteum by the peripheral openings of the smaller medullary canals.

Turning now to the other kinds of bones—to the short and tabular, namely,—we find that they present the same arrangement of vascular supply as the epiphyses, with the exception of the flat bones of the head. Through the many openings, namely, on their surfaces, small arteries and veins make their entrance and exit: their terminal branches are found, however, more in the medullary cavities than the scanty *Haversian* canals. The flat bones of the cranium, on the other hand, are supplied by numerous fine arterial twigs, which enter through holes in the two vitreous plates, and break up in the cavities of the diploë into capillaries interlacing amongst themselves. The veins, however, present themselves, as was discovered by *Breschet*, in quickly-branching wide bony canals, in the form of very thin-walled tubes traversing the diploë in various directions, and emptying themselves partly into the external veins of the head, and partly into those of the dura mater. The cartilage covering the ends of bones is quite destitute of vessels.

The existence of *lymphatics* in osseous substance has not been demonstrated to a certainty.

The *nerves* with which bones are supplied present the same arrangement as the blood-vessels. The periosteum is very richly supplied with them; but the greater proportion simply pierce this membrane to reach the osseous tissue beneath,—so that, in fact, but a small number properly belong to it itself. In this respect, however, the periosteum varies greatly, according to locality: in some spots it appears to be quite without nerves, while in others it is richly supplied. The nerves consist of broad and medium-sized fibres which split up before their termination.

One set of nerves enter the bone with the blood-vessels which pass through the periosteum, by means of the *Haversian* canals: these are very fine. Other stronger twigs find their way into the interior through the foramina nutritia. From thence they are distributed to the larger medullary cavities. Their ultimate termination is still a matter of doubt. Many of the short and flat bones are, according to *Koelliker*, very highly innervated. Most of the nerves are derived from the cerebro-spinal system.

The *capsules* of the joints are also very rich in nervous supply, while the ligaments are but scantily furnished with sentient elements.

The cavities of the bones are filled up with a substance known as the *marrow*. This presents itself under two forms, with intermediate varie-

ties. In the long bones it is met with as a yellow mass, found under the microscope to be made up of scanty bundles of connective-tissue interspersed with fat-cells (fig. 552, *d*, *e*). Chemical analysis shows it to be composed of neutral fats to the amount of 96 per cent., according to *Berzelius* (comp. §§ 122 and 147). In the epiphyses, on the contrary, and in flat and short bones, the medulla is a reddish or red mass of soft consistence, made up usually of bundles of connective-tissue similar to those of the last variety (but in smaller quantity), with an ever-decreasing number of fat-cells containing, on the other hand, numerous small contractile lymphoid elements, with granular contents and distinct nuclei. These latter, 0.0090–0.0113 mm. in diameter, are identical with the cells figuring in plate 552, *b*, from the medulla of an infant. Like them, they were formerly supposed to be descendants of the cartilage medullary cells (§ 147).

On the surface also of the yellow variety of medulla, cells of this kind are to be met with here and there.

An interesting point, in regard to these lymphoid cells of the medulla of bones, has recently been noticed by *Neuman* and *Bizzozero* in the osseous tissues of man and other mammalia. This is the transformation of the former into red blood corpuscles, reminding us of the formation of embryonic blood. The possibility of immigration of these into the vessels of the medulla is suggested.

Another kind of element is also to be found in the medulla of bones, and, moreover, at all periods of life, namely, large isolated membraneless multinuclear cells, known as *myeloplaxes* (p. 258). According to *Berzelius*, red medullary substance from the diploë contains 75.5 per cent. of water, traces 24.5 of solid constituents, protein compounds, and salts, but merely of fatty matters.

7. Muscular Apparatus.

§ 290.

The structures we are now about to consider briefly have been already described in the second portion of our work in dealing with muscular tissue (§§ 162–173). The structure of the *tendons* formed the subject of § 134, belonging as they do to the connective-tissues, among which the *fascias* also are included. In § 109 the fact was also mentioned, that at those points where tendons are inserted into bone, deposits of cartilage cells are not unfrequently met with between the bundles of fibres, of which the structure is chiefly composed, thus giving rise to a kind of fibro-cartilage. That the same cartilaginous tissue may be developed in the interior of tendons was also remarked in the same place. Here, then, we have the source of *sesamoid cartilages*, whose place again may be taken by analogous osseous formations known as *sesamoid bones*.

The *blood-vessels* of the tendons can be only found with great difficulty, nay, further, small sinews are entirely destitute of them, and are supplied entirely by a wide-meshed network contained in the connective-tissue in

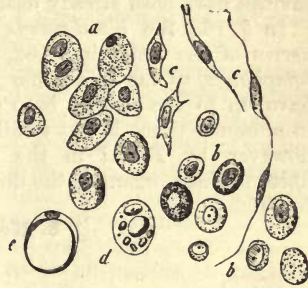

Fig. 552.—Medullary cells of cartilage. *a*, from the humerus of a human foetus at five months; *b*, from the same bone of an infant shortly after birth; *c*, stellate and fusiform cells from the first; *d*, formation of the fat-cells of the marrow; *e*, a cell filled with oil

which they are enveloped. Large tendons contain in their superficial layers isolated vessels; while those of greatest magnitude are supplied with blood-vessels as far as their internal laminae, while that portion farthest from the surface remains non-vascular.

The *mucous* or *synovial sheaths* of the tendons, *vaginae synoviales* have been already described in speaking of the latter. The *synovial sheaths of muscles* have also a similar structure, as likewise the *bursae mucosae*. Most of these are, however, by no means shut serous sacs, as was formerly supposed: this is only in some measure the case here and there. The same may be said of the epithelial lining of simple flattened cells (§ 87): it is only met with in portions of the capsules, in the walls of which, further, a sprinkling of cartilage cells may be met with. The contents of all these cavities have been already dealt with in considering the synovia (p. 155).

In § 168 the *blood-vessels* of the muscles are dealt with, and the *nerves* of the latter in § 182, with the nervous system generally. The *lymphatics*, as far as we may judge from the scanty observations which have up to the present been made upon the subject, present themselves in muscular tissue in but small number (*Teichmann*). They were found, however, by *Tomsa* in the interstitial connective-tissue between the fibres of these organs in the dog: another superficial set, also, is described by *His*.

8. Nervous Apparatus.

§ 291.

The greater part of the nervous system has already come under consideration in an earlier portion of our work (§ 174–192): there still remain, however, the *brain* and *spinal cord*.

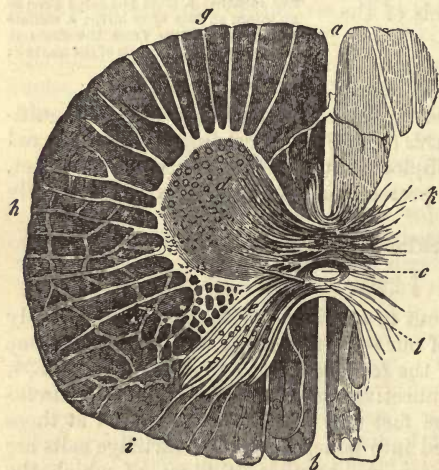


Fig. 553.—Transverse section of the spinal cord of a calf (after *Ecker*). *a*, anterior, *b*, posterior median fissure; *c*, central canal; *d*, anterior, *e*, posterior cornua; *f*, *substantia gelatinosa* of *Rolando*; *g*, anterior column with motor roots; *h*, lateral column with connective-tissue partitions; *i*, posterior column with sensitive roots; *k*, anterior, and *l*, posterior transverse commissure.

gradually closed in to form the foetal spinal cord. It is lined within by ciliated epithelial cells (§ 93).

The circumferential *white* substance presents deep indentations both

before and behind, the anterior (*a*) and posterior median fissures (*b*), so that its two halves are only connected at the bottom of the anterior fissure by a white band (*k*), the white commissure or *commissura anterior*. The isthmus, however, contains besides a band of grey substance, known as the *posterior commissure* (*l*). The white matter of the cord may be considered as consisting of three imperfectly defined symmetrical longitudinal bands,—the *anterior* (*g*), *lateral* (*h*), and *posterior* (*i*) columns.

In the cervical portion of the spinal marrow the latter most internal and posterior portion constitutes what is known as the band of *Goll*, to which we will again refer in speaking of the medulla oblongata.

At the junction of lateral and anterior columns the *motor* roots of the spinal nerves penetrate as far as the anterior cornu; while the entrance of the *posterior sensory* roots takes place in a similar manner at the point of union of the middle and hinder columns.

Looking at it from a histological point of view, the whole spinal marrow may be said to be supported interstitially by a lowly-organised vascular connective-tissue, and to be composed of nervous fibres and ganglion cells imbedded in this framework. In the white substance, however, we find fibrous nerve-elements alone, but in the grey, besides these, ganglion cells. There are, however, so many difficulties still connected with the investigation of the more minute arrangement and combination of these nerve-elements, that, with the brain, the spinal cord may be said to be one of the most obscure and unsatisfactory fields of modern histological research. One of the obstacles to advance in this direction is, that we are unable here to draw any sharp line of distinction between nervous and connective-tissue constituents (see § 119). One school of histologists believe that connective-tissue constitutes a very large portion of the substance of the spinal cord, while quite the opposite view is held by another party.

REMARKS.—(1.) Literature is very rich in treatises on the structure of the spinal cord. Besides numerous Continental essays by *Stilling* and *Wallach*, *Schröder van der Kolk*, *Koelliker*, *Reissner*, *Deiters*, *Gerlach*, may be mentioned those of *Lockhard*, *Clarke*, *Philos. Transact.* 1851, p. ii. p. 607, and p. iii. p. 347; and *Beale's Archiv. of Medic.* 1858, p. iii. p. 200. Further, in the *Proceed. of Roy. Soc.* vol. viii. No. 27; and *Philos. Trans.* 1858, p. i. p. 231, and 1859, p. i. p. 437. *J. Dean's Microscopical Anatomy of Lumbar Enlargement of the Spinal Cord, Cambridge (U.S.)* 1861. *W. Hendry in Micros. Journ.* 1863, p. 41.

§ 292.

We shall now consider the *neuroglia* or *connective-tissue sustentacular substance* of the spinal cord, whose chief peculiarities have been already touched on in a former section (§ 119).

In it we have a framework, as it were, for the medulla, in contact with the pia mater externally, and continuous throughout the whole cord, though of by no means of the same structure in the different divisions of the latter.

We find it in its simplest form surrounding the central canal as a ring merging imperceptibly at its periphery into the grey matter. To this several names have been given, such as “central ependymal thread,” “grey central nucleus,” “gelatinous central substance.” It presents itself here as a soft substance of homogeneous, streaky, or even at certain points finely fibrous appearance. Filiform processes from the epithelial cells of the axis canal project into it, as also connective-tissue ramifications of the pia mater from both fissures of the cord. Cellular elements may also be

recognised as entering into the composition of this ependymal tissue. They appear to have been formerly incorrectly described as nerve-cells, of which, as well as of nerve-fibres, this tissue is entirely destitute.

The *substantia gelatinosa* of *Rolando*, mentioned in the preceding section, presents also purely connective-tissue characters. It is remarkable for its richness in cellular elements. Some very few nervous constituents may be observed in it in the form of scattered fibres.

But the sustentacular substance in the grey matter of the cord is far less pure: it is mixed up with nerve-fibres, ganglion cells, with their various processes, and blood-vessels. It forms here a finely porous spongy tissue, referred to already at § 119, of the most delicate texture, with numerous free nuclei or (if the latter still retain a thin layer of protoplasm) with the equivalents of small cells.

The connective-tissue framework of the white substance, however, attains a greater degree of massiveness. In transverse section (fig. 554) it appears homogeneous or streaky, dotted at its nodal points with nuclei, and forming so a lace-work as it were, in whose meshes the transverse sections of the nerve tubes are to be seen; while in longitudinal cuts a more or less regularly tubulated appearance is presented by the slice, which may also show oblong deficiencies of substance.

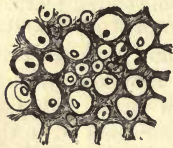


Fig. 554.—Sustentacular connective-tissue from the posterior column of the human spinal cord, showing the nerve-fibres in transverse section.

Towards the periphery of the cord the sustentacular substance is again much more highly organised, and is free from nerve-fibres (*Bidder*, and *Kupffer*, *Clarke*, *Koelliker*, *Frommann*). Lastly, the pia mater covers the surface of this grey cortical layer.

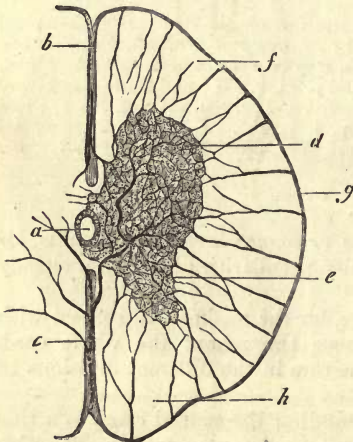


Fig. 555.—Transverse section in the dorsal region of the medulla spinalis of the cat. *a*, Central canal; *b*, anterior, *c*, posterior fissure; *d*, anterior cornu; *e*, posterior cornu; *f*, *g*, *h*, white columns, with their wide-meshed capillary networks.

Turning now to the *blood-vessels* of the cord (fig. 555), it may be usually observed in transverse sections that from the branches of the *art. med. spin. anter.* two twigs are given off in the anterior fissure, which pass into the substance of the spinal marrow, and that a third twig, corresponding to them, lies in the posterior fissure (*b*, *c*). Other finer arterial tubes are conducted into the white substance (*f*, *g*, *h*) by the radiating bands of connective-tissue of the pia mater. It is from these principally that the capillary interlacements of the white matter are supplied, which are here particularly large meshed, and composed of very delicate tubes.

The capillary network of the grey substance is much more dense (*d*, *e*).

It is chiefly derived from the arteries of the fissures just named, but is connected at all points of its periphery with the vessels of the white substance.

Of the veins, two are specially striking in the neighbourhood of the central canal (*Clarke, Lenhossek*).

Some years ago the arrangement of the capillary network of the cord was very minutely studied by *Goll*. The widest meshes were found by him in the anterior columns, the finest in the lateral, while those of the posterior columns lay between the two. But the densest capillary interlacings of all are to be met with in the grey matter in those situations where many ganglion cells are collected together. Finally, the restiform bodies are remarkable for having meshes of capillaries as small as those of the grey substance.

It has been already mentioned (§ 207) that throughout the whole spinal cord and brain, all the blood-vessels, including arteries, veins, and capillaries, are invested with a loose sheath of connective-tissue. A watery fluid found within the latter has been regarded by some as lymph. The existence, however, of this system of *perivascular canals* of *His* is not yet firmly established, and has lately been the subject of very earnest controversy.

§ 293.

Having now discussed the connective-tissue groundwork of the cord, let us turn to its nervous elements.

The *white substance*, as has been already remarked, consists entirely of fibres. These present all the characters of central structures (fig. 556, *f, g, h*), *i.e.*, they are not supplied with the same primitive sheath as the peripheral tubes, so that in many cases we are only able to obtain them in broken fragments. In the finer specimens further there seems to be a tendency to varicosity (§ 176), and we may easily recognise their axis cylinder. Their diameter may be roughly estimated at from 0.0029 to 0.0090 mm., showing, that besides very fine elements, broader ones also exist. It appears beyond doubt, further, that these central fibres divide, although we are confined to conjecture at present as to the frequency of the occurrence.

Passing on to the *arrangement* of the nerve fibres in the white columns of the cord (fig. 557), we have to discriminate between bundles which hold a *longitudinal*, a *horizontal*, and an *oblique* course. The greater proportion of fibres belong to the first of these classes (*l, m, n*), and are often unmixed with bundles having any other direction. Their course in the peripheral portions of the cord is regularly parallel, while in the vicinity of the grey matter they generally may be observed to interlace, and to be collected in small fasciculi.

Further, and in this we have probably an important physiological fact, certain regular differences in the diameter of those nerve fibres of the white columns are manifest.

In the first place, the more internal, lying close to the grey matter,

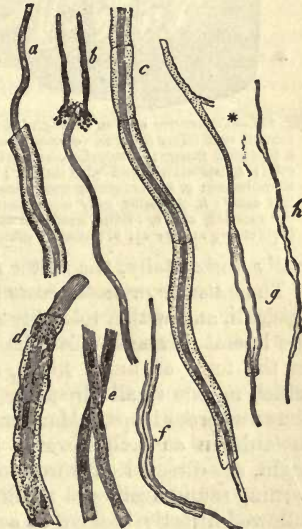

Fig. 556.—Different kinds of nerve fibres, *f, g, h*, central; the fibre *g*, as axis cylinder, is continuous above, with the process of a ganglion cell.

are remarkable for their small diameter, as compared with their fellows situated more externally. One spot in particular presents very fine fibres, namely, close to the inner angle of the lateral column, where the anterior and posterior cornua meet.

Very characteristic differences in diameter are also apparent, if we compare the chief masses of fibres of the various columns. The anterior (*l*) possess the broadest, and consist principally of such. Those bundles of the lateral column in the vicinity of the grey matter are made up of very fine elements. Further out towards the periphery a stronger series is to be found occurring with great regularity (*m*), and intermixed more externally still with small fasciculi of finer fibrillæ. The fibres of the posterior column, compared with those of the anterior, are distinctly smaller in diameter. But in the bands of *Goll* we meet with the most delicate filaments of all disposed with the utmost regularity.

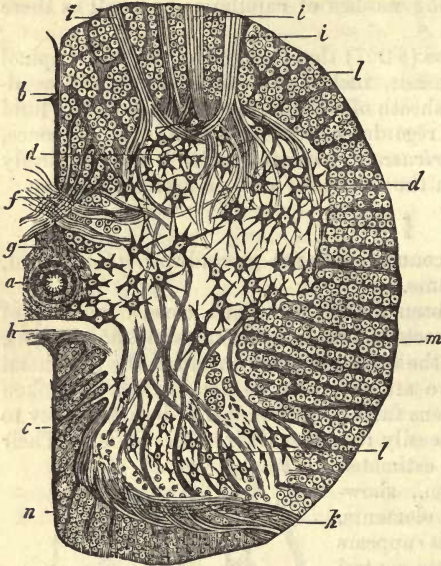


Fig. 557.—Transverse section through the under half of the human cord (after *Deiters*). *a*, central canal; *b*, anterior; *c*, posterior fissure; *d*, anterior cornu, with large ganglion cells; *e*, posterior cornu with smaller; *f*, anterior white commissure; *g*, sustentacular substance around the central canal; *h*, posterior grey commissure; *i*, bundles of the anterior, and *k*, of the posterior spinal nerve roots; *l*, anterior; *m*, lateral; *n*, posterior column.

really horizontally, the motor root-bundles take an oblique course.

The *anterior* or *motor roots* pass through the white substance in several fasciculi, and with a tolerably straight course, separating the anterior from the lateral columns. In this way they arrive at the anterior cornu still in the form of broad fibres, and then break up into delicate elements, which radiate in all directions, and in various planes, forming at the same time numerous loops. Many take their course along the surface of the cornu inwards, in an arch towards the anterior longitudinal fissure. Others, again, are directed outwards towards the boundary of the lateral column, turning round again and running inwards. Other bundles, again, may be followed directly backwards as far as the base of the posterior cornu.

In order the better to understand their further destiny, let us accompany these nervous fasciculi into the anterior cornu, and in the very first place inquire into the complicated structure of the *grey matter*.

In the delicate spongy mass, of which its sustentacular tissue is composed, we see, in the first place, an inextricable maze of fine and extremely delicate *nerve filaments*. Then, in the *anterior cornu* large multipolar

ganglion cells (*d*) are observed, imbedded in the sustentacular substance of the part. These are not unfrequently tinged with brown pigment, and vary considerably both in shape and in the number of their processes. They are specially numerous at the apex of the anterior cornu, where they usually form several dense clusters as it were. Here they are separated from one another by interposed broad nerve fibres. Other scattered multipolar cells, however, are met with singly, and especially towards the surface of the grey substance. In the most internal portions of the cord also, near the axis, as also at the base of the posterior cornu, we find them still presenting precisely the same essential characteristics, though decreased in size.

The numerous processes of these ganglion corpuscles spread themselves out in all directions, and, as a rule, are soon lost to view by dipping into other planes. As observed by *Deiters*, whose statements we here follow in regard to many points, these processes may penetrate into the radiating septa of connective-tissue running through the white substance; others, also, may be regularly looped around bundles of nerve fibres in certain cases (*Clarke, Deiters*).

These groups of multipolar ganglion cells have been very commonly described as connected with one another by means of some of their ramifications, and great stress has been laid upon the importance of the latter as commissures. It cannot be denied, however, that a deplorable misuse has been made of this supposed existence of connecting fibres (fig. 305, p. 314), and it is only extremely rarely that a perfectly unmistakable view can be obtained of them. Thus, in the works of many authors it is openly confessed that, with all their efforts, they were never successful in obtaining a sight of anything of the kind (*Goll, Koelliker*). Others even deny the existence of such commissures altogether (*Deiters*). Others, again, are able to state that they have observed them, but in rare instances (*Reissner*). Our own experience coincides with that of the latter. Even *Dean*, a very sound observer, who is, notwithstanding, somewhat too profuse with such commissural processes, only speaks of them as exceptions.

A second widely received axiom in the anatomy of the spinal cord, is that other processes of the ganglion cells become the axis cylinders of the nerve fibres of the anterior roots. This also is asserted on many sides with great certainty to be quite easy to see, whereas it is a matter of the greatest difficulty in reality to obtain even one clear instance of it, some observers honestly confessing their ill fortune in this respect (*Goll*). As a rule, under favourable conditions, one such process may perhaps be observed uniting with one of the motor root-bundles (*Clarke, Dean, Gerlach, Frey*).

Deiters, a recent and very thorough investigator, has added much to our stock of knowledge on this very abstruse subject of the relations of the central ganglion cells. We have already referred to his important and repeatedly confirmed discovery (§ 179), that the ramifications of the ganglionic bodies are of two kinds (fig. 558). In the first place, wide branching processes of protoplasm (*b*) present themselves, and then for every cell another smooth undivided one (*a*), the *axis cylinder process*. This observer, nevertheless, states that only in exceptional cases was he able to follow up the latter for any distance in a section of the spinal cord.

As may be seen in our plate, there also spring (usually at right angles) from the broad protoplasm processes of the cell, a number of other very delicate fibrillæ. These *Deiters* regards as a system of *secondary axis*

cylinders for the most delicate nerve fibres, as we have already briefly stated (p. 315). But probably the end filaments of all these tree-like processes eventually acquire the same constitution.

The fact that both species of processes, namely, the branched protoplasm and the axis cylinder, may be observed to be marked with fine lines, indicating fibrillation (*Schultze*), has been already alluded to (p. 316, fig. 308).

The cells also situated close to the central canal, and those as far back

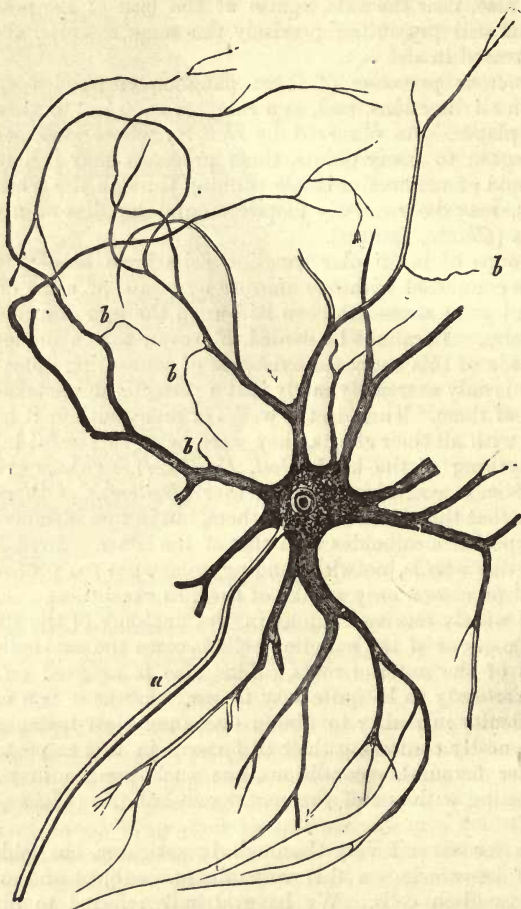


Fig. 558.—Multipolar ganglion cells from the anterior cornu of the spinal cord of the ox. *a*, axis cylinder process; *b*, finest filaments springing from the ramifying protoplasm processes.

as the base of the posterior cornu, present the same remarkable structure recognised by *Deiters*. The destiny of these “protoplasm processes.” however, is by no means settled as yet. According to *Gerlach* they first break up into a delicate, dense network of nervous nature, from which the nerve fibres then spring, or (if we prefer the converse) into which they sink after previous ramification.

Going further backwards still, regularly into the *posterior cornu* (fig.

557, 1), we encounter smaller cells, in many cases fusiform and of delicate consistence. In them also one process becomes an ordinary, though thin axis cylinder, beside which may be seen again ramifying protoplasm processes with lateral derivation of the finer axis cylinders of the second order. In size and shape these cells also vary considerably, larger examples resembling in a great measure those of the anterior cornu. These corpuscles of the posterior cornu have been set down as the source of the fibres of the sensitive roots, and been designated as sensory elements, although at present we are possessed of no really complete proof of the correctness of this view: *Gerlach* reckons them, moreover, among the motor ganglion corpuscles.

At the base of the posterior cornu, internally, almost throughout the whole length of the cord, other small groups of cells are to be seen (the pillars of *Clarke*, or nuclei of *Stilling*, according to *Koelliker*). The elements, collected here, are of medium size, round, and ramifying. Very little is as yet known about them. According to *Gerlach*, further, they are not possessed of an axis cylinder process. Their ramifications merely sink into the dense neural network of the grey substance.

The proper ganglion cells of the posterior cornu possess, as a rule, in the opinion of the last-named observer, processes only, which merge into that nervous reticulum just spoken of. From the latter, then, the sensory fibres of the posterior roots arise.

From all this it would appear that the mode of origin of the motor and sensory nerve fibres is entirely different.

The delicate neural network alluded to is only observed to be absent in the immediate neighbourhood of the axial canal, and in the *substantia gelatinosa* of *Roland*. It may be easily distinguished from the elastic reticulum of the neuroglia by certain reactions according to *Gerlach*.

§ 294.

Turning now to the *posterior roots* of the cord (*k*), we find far greater complication than among the motor bundles of the spinal nerves. Our knowledge, therefore, of the nature of their arrangement is necessarily more scanty than of the latter. The remarkable diminution, besides, in diameter which the sensitive nerve fibres undergo on entering the grey matter, renders the tracing of them very difficult.

It is stated by some (*Koelliker*) that the external portion of the posterior root-bundles passes directly through the posterior column into the grey substance. Another, and moreover larger part is said, on the other hand, to pursue a rather devious curving course through the hinder column, bending round subsequently in order to pierce from the side the convex border of the posterior cornu, which is turned towards the middle line. From this the fasciculi advance towards the anterior cornu, passing partly into the anterior commissure, and partly in among the posterior group of motor ganglion cells; or, again, penetrating at times as far as the anterior portion of the lateral column, where they are lost. The first-mentioned bundles are said to pass forwards, partly as separate longitudinal fasciculi, tending at the same time with radiation towards the centre, in order to arrive at the pillars of *Clarke*, as they are called, without becoming connected with cells. Some of them reach the anterior cornua and commissure.

Commenting on these statements, *Deiters* showed later that it is always the greater part of the posterior root which takes this curved course through the posterior column, and enters the cornu from it. Here

we see the *substantia gelatinosa* of *Roland* traversed in its whole circumference by separate fasciculi of very delicate fibres, which advance later into the base of the posterior cornu in part, or, taking another direction, enter the pillars of *Clarke*. Other bands of fibres may be observed to pass forwards through the latter, disappearing eventually in the grey matter beyond. Others, again, are said to enter the posterior commissure, and many, probably, the grey matter of the anterior.

So far, then, it appears at least possible, that all the fibres of the posterior root penetrate into the grey matter. And in that they here probably pass between sensory ganglion corpuscles, we might expect a (direct or indirect) connection with the latter. An immediate turning in of a portion of the posterior root into the posterior column in order to pursue a course towards the brain ("sensory fibres" of *Schröder van der Kolk*) appears for many reasons very unlikely.

According to *Deiters* the three white columns—mainly composed of the conducting portions of the cord—may be regarded as springing from the grey matter, and the system of the ganglion cells as interpolated between them and the roots of the spinal nerves.

Accepting this as correct, the ganglionic cell system would appear to possess the significance of a provisional central point, from which the neural tract, altered in direction, and in all likelihood simplified, takes its course onward to the cerebrum. It must, however, be designated as a mere point of histological dogma if *all* the fibres of the roots be stated to have such a connection with ganglionic corpuscles. Whether the very fine protoplasm processes of the latter, discovered by *Deiters*, are commissures between the ganglionic cells; whether after further isolation, and increase in breadth, they become the axis cylinders of the nerves of the white columns; whether for the formation of one of the latter axial structures, several of these very delicate fibrillæ first combine, or whether, as *Gerlach* maintains, the latter form a network of filaments of the most extreme tenuity,—are all questions to which science is unable at present to give satisfactory answers. The same want of facts is felt in regard to the existence of a connection between motor and sensitive cells.

It is generally supposed that the anterior columns serve as conductors between the motor nerves and the brain, and the posterior between the latter and the sensory nerves, while the lateral cords partake of the nature of both.

We shall now conclude this extremely unsatisfactory description with a brief mention of the two *transverse commissures* of the spinal cord.

If we examine the most anterior of these bands (*f*) closely, we shall soon convince ourselves that a number of genuine nerve fibres exist in it, enclosed in sustentacular connective-tissue, and intersecting each other at various angles. In the medulla spinalis of the calf and ox, in which the relations of parts may be very clearly seen (*Deiters*), the transverse intersecting bundles advance even into the white substance of the anterior column. They arise in the grey matter on one side, and after descending and again ascending to a certain extent in their course, arrive in the fibrous substance of the anterior column on the opposite side. No connection with ganglion cells can be demonstrated with certainty. Many have argued from this a total decussation of the motor nervous tracts in the spinal cord; but, perhaps, without sufficient grounds. At certain points, also, in the grey portion of the anterior commissure, fine nerve fibres may be observed to pass across from one side of the cord to the other.

In the posterior commissure (*h*), likewise, we have a connective-tissue

framework, intersected by a number of nervous bands, of great fineness however. The latter, it is stated by some, may be seen to be connected in part with the lateral columns, in part with the posterior or sensitive nerve roots, and in part to be lost in the grey substance at the junction of the anterior and posterior cornua.

§ 295.

We come now to the consideration of the *medulla oblongata*, whose complicated structure involves us in far greater difficulty even than that of the *medulla spinalis*. The earlier investigations of *Stilling*, *Schröder van der Kolk*, *Koelliker*, *Lenhossek*, *Clarke*, and *Dean*, all led to different conclusions. But considerable light has since been thrown upon the subject by *Deiter's* observations, and later still by *Meinert's* studies.

In order to recall to the mind of the reader the rough anatomy of the *medulla oblongata*, it may be remarked, in the first place, that this connecting link between cord and cerebrum has one of its numerous peculiarities impressed upon it through the central canal. The latter, namely, opens out gradually into the *sinus rhomboideus* or *calamus scriptorius*, and is continued as the *fourth ventricle* upwards. From this alone it is evident that a most essential change in position of the various columns and collections of grey substance must take place; parts situated close to the central canal, at a lower point on the cord, must now be displaced laterally.

But while this spreading out takes place on the dorsal aspect of the cord, the anterior fissure begins to close in to form the *raphe* (fig. 559, *r*).

Besides these changes we now remark a number of different parts visibly distinct from one another even externally, and known by special names. At either side of the anterior median line the *pyramids*, with their remarkable decussation, are first seen. Then external to them, and bounded on both edges by ascending fibres, the (inferior) *olivary bodies* appear. Adjoining these we next observe the so-called *lateral columns* (*funiculi laterales*), and behind them (later on quite external) the *corpus restiforme* of each side, or *funiculus cuneatus*, with the *f. gracilis* in the cervical portion of the cord,—a prolongation of the band of *Goll*.

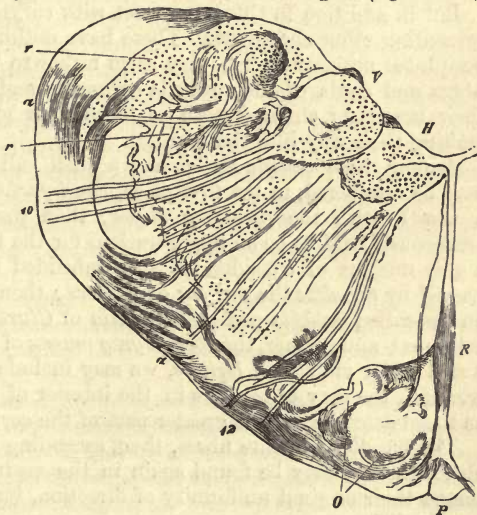


Fig. 559.—Transverse section of the *medulla oblongata* (after *Dean*). *R*, raphe; *O*, olivary bodies; *H*, hypoglossus; and *V* vagus; *r*, posterior cornu; *a*, arched fibres; 12, hypoglossus and 10, vagus nerves.

The *medulla oblongata* is covered above and anteriorly by the *pons Varolii*, and at either side may be seen to be connected with the cerebellum by means of thick cords known as the *crura cerebelli*. These may be

divided into two portions, namely, the *crura cerebelli ad medullam oblongatam* and *ad pontem*. The pedunculi cerebrii connect it with the cerebrum. Finally, numerous nervous trunks spring from the medulla oblongata.

Turning now from this mere outline sketch to the structure as seen with low magnifying powers, the full peculiarity of the medulla oblongata soon strikes us.

The *cornua* of the central grey mass, as found in the medulla spinalis, become rapidly changed here, the alteration of shape commencing at the point of junction of anterior and posterior cornu, and spreading from thence further and further. Instead, namely, of the continuous grey substance of another part of the cord, the cineritious matter here assumes the appearance of a series of bands or network, through which nerve fibres take their course (*formatio reticularis*).

This metamorphosis then gradually extends, affecting eventually the white columns also almost throughout the whole medulla oblongata.

Here and there, however, masses of grey matter still remain undisturbed, which are known as the *nuclei* of the medulla oblongata; these give rise to further peculiarities.

Such nuclei are of two kinds. From one set of them the nerves springing from the medulla oblongata seem to take their rise primarily: these are the *nerve nuclei* of *Stilling*. A large number of them may be recognised, as we shall see later on. They have nothing absolutely new in them as compared with the spinal cord, and are equivalent to the sources of origin of the spinal nerves.

But in addition to these, we meet with collections of ganglionic matter presenting other characters. These have nothing to do with the origin of peripheral nervous tracts; they seem rather to be the points at which the fibres and cords of the medulla oblongata end provisionally, previous to their becoming changed both as to number of fibres and direction, and making their way into the brain.

Among these *specific nuclei*, as we shall call them for shortness' sake, may be numbered, in the first place, the *inferior olives* (*olivary bodies*, in a word), with the *accessory olives*; then the *superior olives*, formerly erroneously held to be an upper nucleus for the trigeminus by *Stilling*, and a grey nucleus of considerable size imbedded in the lateral column, and named by *Schultze* the *nucleus of Deiters*; then, again, the *pyramid nuclei* and so-called *ganglia post-pyramidalia* of *Clarke*, situated in the posterior columns; and further, the *special grey masses* of the *pons Varolii*. Taking a still wider view with *Deiters*, we may include here the *corpus dentatum cerebelli*, the grey collections in the interior of the *crura cerebelli*, as well as those constituting the greater part of the corpora quadrigemina.

The bundles of white fibres, then, ascending from the medulla spinalis, although they may be found again in the medulla oblongata, preserve no longer their original uniformity of direction, but pursue, in many cases, a totally different course.

Besides the latter fasciculi, there appears in the medulla oblongata another very peculiar and complicated system of nerve tubes,—that of the *transverse, arched, and circular fibres* (*a, a*). This was named, many years ago, the *zonal* by *Arnold*. In the raphe a very complex group of these intersecting fibres exists, but grey matter presents itself here also.

If, in addition to all this, we remember the root fibres of the afferent and efferent nerves, we cannot but be struck with the truly labyrinthine complexity of the medulla oblongata.

§ 296.

Let us now endeavour, as far as the scope of our manual will permit, to clear up some of the difficulties connected with this most complicated arrangement of parts in the medulla oblongata.

And first, as regards the grey substance.

In the upper portions of the spinal cord we may remark, in transverse sections, that at the external angle of contact of the two cornua, at one particular spot, the grey matter is prolonged outwards into a pointed process. This has been named by *Jacobowitsch* the *lateral accessory cornu*, and by *Clarke* and *Dean* the *tractus intermedio-lateralis*. It attains, in its passage into the medulla oblongata, a higher degree of development, and assumes, at the same time, a decidedly retiform appearance, bands of fibres from the lateral columns occupying its meshes. We shall see later on what great importance this lateral region of the medulla oblongata possesses, being, as it is, the origin of a special system of nerves commencing with the spinal accessory.

This is the beginning of the *formatio reticularis*.

Advancing further through the medulla oblongata towards the brain, we find this reticulated and banded mass encroaching more and more upon the anterior and base of the posterior cornu. This change gradually advances so far that the whole of the upper portion of the medulla may be regarded as a meshwork of grey matter, traversed by bundles of white nerve fibres. The grey substance is, in fact, spread out almost to the periphery, and is connected with the grey nuclei situated there. From the fact, however, that the most internal portions of grey matter, *i.e.*, those originally surrounding the axis canal, remain for the most part unchanged, they may present an appearance liable to deceive, namely, as though they alone were the prolongations of the cornua of the spinal cord.

That in this very extensive bandwork of grey matter, as well as in the nuclei, we should encounter ganglion cells of the greatest variety of form, and in certain cases of remarkable size, with primary and secondary axis cylinders, will excite no wonder. And that the tracts of this grey reticulum should also give origin to part of the cranial nerves might likewise be expected.

The reader will also understand very easily, from the foregoing description, that the posterior cornu suffers the most displacement from the opening out of the central canal, and that it must now lie much more to the side than formerly.

We have already mentioned, in the preceding section, the separation of the posterior band of *Goll*, and its transformation into the *funiculus gracilis*.

In it likewise, and about it, the grey reticulated mass becomes more and more expanded, pressing down the remainder of the posterior column. Thus the fourth ventricle obtains a lining of grey matter almost over its entire floor. The sustentacular substance, also formed more exclusively of connective-tissue, which surrounded the central canal, experiences here a great increase in quantity likewise, and plays, later on, an important part in the formation of the *aquæductus Silvii*, the third ventricle, and *infundibulum*.

Leaving for the present the grey matter of the medulla oblongata, let us now take a preliminary survey of another very important series of parts, let us inquire into the origin of the *ten cranial nerves*.

A most important discovery was made in regard to these by *Deiters*. Besides the two modes of origin, corresponding to the anterior and pos-

terior roots of the spinal nerves, the medulla oblongata was found by him to possess an additional one, namely, from a third lateral tract. This commences so low down as the upper part of the spinal cord (with the farther development of the so-called lateral accessory cornu) as a narrow, separate, nervous bundle.

To these three systems of roots all the nerves of the medulla oblongata may be referred.

(a.) From the lateral system several nerves spring. The first of these is the *accessorius*, which is soon followed by the *vagus* and *glossopharyngeus*. This place of origin of the lateral system is originally nothing but a special division of the anterior cornu for the accessory nerve. To this there is soon added a portion of the posterior sensitive cornu (which may be followed up as far as the pons), so that the nerves springing from this lateral part may be of mixed nature.

The *facialis* and *acusticus* also, as well as the anterior root of the *trigeminus*, take their origin likewise from this lateral tract of the cineritious substance. This surprising relation, however, is explained by the fact, that each of them again splits up into a sensitive portion (*acusticus*), and a motor (anterior root of *trigeminus* and *facialis*).

(b.) The sensitive portion of the *trigeminus*, on the other hand, is derived from the posterior root system. The fibres of the latter are likewise collected, from the first spinal nerves on, into longitudinal tracts, which do not, however, leave the medulla oblongata as separate sensitive bundles, as in the cord, but unite to form this root.

(c.) Besides the *hypoglossus*, the *abducens*, *trochlearis*, and *oculomotorius*, all correspond to the anterior spinal roots.

As to the *nuclei*, already mentioned, of the numerous nerves arising here, those of the hypoglossus and accessory first appear most inferiorly, appertaining to the deepest portion of the anterior cornu, and situated in the neighbourhood of the central canal. These are collections of multipolar motor ganglion cells in the cineritious substance, which, as has been already mentioned, is split up here and reticulated. Then there make their appearance successively on the floor of the fourth ventricle and around the aqueduct of *Silvius*, similar spots for the *vagus*, *glossopharyngeus*, *abducens*, *trochlearis*, and *oculomotorius*.

Let us turn again, for a few moments, to the nucleus for the hypoglossus. Its large multipolar ganglion cells present, like those of the anterior cornu of the grey matter of the spinal cord, protoplasm ramifications and an axis cylinder process, which probably becomes eventually a fibre of the hypoglossus (*Gerlach*). It was at one time generally supposed that a complete decussation of the hypoglossal fibres took place here. This is, however, more probably only partial (*Clarke*, *Dean*, *Deiters*). The arrangement, as found by *Gerlach*, is as follows:—In the first place, a set of delicate fibres, lying posteriorly, passes across from one hypoglossal nucleus to the other, and may be regarded as commissural between the nuclei themselves. Other fasciculi, again, lying more anteriorly at the bottom of the raphe, and of greater diameter, decussate, as proper roots of the hypoglossal nerves, with the fibres of the opposite side, pursuing their course in the trunk of the side opposite to that on which they took origin.

The external portion of the posterior cornu likewise remains almost unchanged in its grey substance, and the connection between it and the motor nucleus of the middle line is still continuous and diffuse. It gives origin to the sensitive *trigeminus* root and the *acusticus*, which does not,

as was formerly supposed, spring from a collection of large cells in the *crura cerebelli ad medullam oblongatam*, but rather from small cells of the posterior cornu and of the raphe (*Deiters*). It likewise gives origin to the sensitive portion of the *vagus* and *glossopharyngeus*.

Finally, there still remain in the reticulated grey substance some remote unbroken masses. Towards these the motor portion of the trigeminus advances, a part of whose root constitutes what is known as the "sounding-rod" (*Klangstab*) of *Bergmann*. (*Stilling, Lenhossek, Deiters*.) Further, the *facial nerve* arises in this neighbourhood. Upon it a sudden bend was discovered by *Deiters* at a spot corresponding to the *eminentia teres* in the fourth ventricle. This observer does not regard the nucleus of the last-named nerve as situated near the *abducens*, as his predecessors believed it to be (*Stilling, Clarke, Dean*), but rather in the vicinity of the motor nucleus of the trigeminus. Finally, the motor portion of the *vagus*, discovered by *Deiters*, takes its origin here also.

§ 297.

Turning now to the question: What becomes of the continuation of the three columns of the spinal cord on arrival at the medulla oblongata? the first point that appears quite evident is that a prolongation of all the nerve fibres of the whole cord into the latter cannot take place. We have to do here rather with a continuation of the fibres in question under a simplified form, and in reduced number,—a modification which is most probably effected through the interposition of ganglion cells in a manner similar to that found in the spinal cord.

The decussating portions of the pyramids were formerly supposed by *Schröder van der Kolk* to be derived from the anterior columns, but erroneously, for the latter particularly, preserve for a considerable distance into the medulla their original straight course and shape. It is true, that in the lower portion of the latter they become displaced by the extrusion of the decussating fibres of the pyramid; but when these cease to pass across, they assume again their old position, and continue their course augmented by fibres of the hypoglossus, and probably also of the *vagus*, as longitudinal cords lying at either side of the raphe, and extending far under the pons.

But the anterior column becomes considerably modified during this course. In the first place, it is traversed by circular fibres springing for the most part from the posterior columns. Again the grey substance commences even very early to make inroads into it. It is characterised here, as in the spinal cord, by the great breadth of its nerve fibres.

Beneath the *pons Varolii*, however, fine and also very delicate fibres begin to take the place of the latter. Here we observe an interpolation of ganglion cells in the usual way, so that the apparent continuation of the anterior column under the pons is in reality a second system of filaments springing from these, and passing into the cerebrum, and partly also into the cerebellum.

The lateral columns, which have likewise, though incorrectly, been described as the source from whence the decussating fibres of the pyramids spring (*Koelliker, Lenhossek*) form the *funiculus lateralis* of the medulla oblongata, and extend, at least in part, probably as far as the cerebrum. They, too, are affected by the general complication of the medulla oblongata.

The reader has not yet forgotten the *formatio reticularis* appearing in the angle of junction of the two cornua of grey matter. A part of this is

regarded by *Deiters* as derived from a change in the lateral column, that is to say, some of the fibres of the latter terminate provisionally in the cells of this formation.—The fibres passing off from these ganglionic bodies centripetally we shall meet again in dealing with the formation of the pyramids.—The remaining portion of the lateral column advances now unchanged for a certain distance towards the brain. It begins, however, very soon to be encroached upon by the reticulated cineritious mass already alluded to; besides which, a special nucleus, named after *Deiters*, is developed in the lateral column as mentioned before, containing somewhat small ganglion cells. Like the other so-called specific nuclei of the medulla oblongata, this may be regarded as a central point for arrival of one and departure of another system of fibres on its way to the brain. The first of these belongs to the lateral column, while the latter forms a zonal system of fibres, the *stratum zonale Arnoldi*, which pursues its course into the cerebellum. Whether other efferent fibres preserve the original direction of the lateral column towards the cerebrum is still an undecided question.

Other collections of ganglionic substance in the neighbourhood of the lateral columns, are the inferior olivary bodies, which also receive, in all probability, some circular fibres from these. Again we meet with cineritious substance in the accessory olive, and at the point of departure of the *crus cerebelli ad medullam*; also in the superior olivary bodies. The latter appear, moreover, to be fed by fibres coming from the lateral column, and to give off a zonal system of fibres which (lying in the lower mammals anterior to, and in man within the pons) is known as the *corpus trapezoides*.

As regards the *posterior columns*, they were for a long time supposed, and again incorrectly, to pass directly into the cerebellum as the *crura cerebelli ad medullam*. The direction of both these sets of fibres, it is true, is the same, and this explains the mistake; but the fibres of the posterior columns are in their farther course replaced by quite a different species.

From the posterior column of the spinal cord, as we have already seen, its internal portion becomes distinct as the band of *Goll*, which then forms the *funiculus gracilis* of the medulla, while its remaining portion is known as the *funiculus cuneatus* in its further course.

Both these bands become mixed internally with grey matter (*ganglia postpyramidalia* of *Clarke*), and increase consequently in size to a considerable extent. Here also the white substance of the posterior column, consisting of fine nerve tubes, diminishes in a corresponding degree more and more, coming to an end provisionally in the grey matter just mentioned, as well as in the adjacent parts of the posterior cornu. From this it again starts in the form of a system of circular fibres. Thus it may be said that the posterior column disappears entirely as regards its original position.

The fibres arising from it secondarily appear destined to augment in part the pyramids (see below), but also to enter partly and gradually into the formation of the *crura ad medullam* (seemingly a direct continuation of the posterior columns). Again, some of them penetrate into the olivary bodies, decussating to arrive at the opposite side, none passing straight into the olive of their own half. These fibres thus constitute the chief source of supply to these specific nuclei of the medulla oblongata.

The *pyramids*, remarkable for the fineness of their nervous tubes, are, according to *Deiters*, no direct continuation of the white cords; they represent rather one of those numerous secondary systems of fibres which

spring from the cells of the formatio reticularis, which receives fibres both from the lateral and posterior cords. This explains the increase in volume also supervening upon the formation of the pyramids. After their decussation the latter advance into the brain through the crura cerebri, strengthened by additional bundles of fibres, but augmented no farther by grey matter. Here they are said to reach as far as the *corpora striata*, *nuclei dentati*, and even the cortical portion of the hemispheres.

The *olivary bodies* (i.e., inferior) are, as is well known, very characteristic organs of the medulla oblongata. Their grey substance forms in man a peculiar corrugated capsule, the *corpus dentatum olivæ*, which encloses a white nucleus on all sides except internally. In the spongy sustentacular tissue of this cineritious substance we find, according to *Clarke* and *Dean*, small yellowish cells from 0.0156 to 0.0189 mm. in diameter with rounded body, and the so often mentioned two species of processes. Between these small bundles of the most delicate nerve-filaments take their course.

It has been supposed by many that there exists some relationship between the olivary bodies and the hypoglossal nerves—that they are in some way “auxiliary organs” for the latter; but this is not the case. It is true that the roots of these motor nerves, so remarkable for the size of their fibres, pass by the organs in question, a few even through them in part, but no connection with their elements takes place.

Deiters' researches, which we here quote, have led him to the conclusion that those very delicate fibres received into the olivary bodies, to terminate provisionally in their cells, are derived, as has been already mentioned, in each case from the posterior columns, each olive obtaining, however, fibres from both sides of the cord. A new system of fibres then springs from these cells, which passes partly into the brain, partly into the cerebellum. Thus we see that the olivary bodies also belong to those interpolations in the very complicated chain of the central organs, and are related both to the cerebellum and pons. Besides, they are traversed by numerous fibres of the circular and transverse systems. Further, they are embraced round their external border by a set of zonal fibres springing from the posterior columns. At the summit of the olivary bodies posteriorly, the so called *accessory olivary nuclei* of *Stilling* present themselves, having a similar texture to the former, while higher still, above the abducens and facialis, and external to the first of these nerves, another body of similar structure is to be found on each side, known as the *superior olive*; this is not absent in man, but is buried in the pons. It likewise possesses a zonal system of fibres. It was formerly supposed to be connected with the facial or acoustic nerves of its own side.

Let us now turn our attention for a moment to the *crura* or connecting bands of the medulla oblongata.

The *crura cerebelli ad medullam oblongatam* are, without doubt, in part processes of the latter continued into the little brain. Their fibres consist for the most part of prolongations to the *stratum zonale* of *Arnold*, springing, in the first place, from the olivary bodies, and probably also from the nucleus of *Deiters* in the lateral column, and from the corpus trapezoides. *Meinert*, however, states that a sensory band from the *funiculus gracilis* and *cuneatus* passes into the cerebellum, and a motor from the latter downwards back into the cord again.

The fibre bundles of the *crura cerebelli ad pontem* possess quite a different significance. Apart from the fact that they connect similar portions

of the two halves of the cerebellum as commissural systems, they conduct no new fibres into the interior of the organ, but, on the contrary, convey fasciculi of nerve fibrils springing from the cerebellum further upwards into the cerebrum.

Now, it seems very improbable that the whole mass of fibres conveyed through the first-named crura into the cerebellum, terminate provisionally there, to escape again through another set of processes by the last-named crura. It is far more likely that only a *portion* of the mass takes this circuitous route through the cerebellum, while the rest passes directly into the cerebrum. Thus we have in the cerebellum a most complicated accessory apparatus. Its abscision, moreover, in keeping with this view, disturbs certain connections to a great extent, but does not completely put an end to them.

The *blood-vessels* of the medulla oblongata have the same arrangement as those of the spinal cord.

As elsewhere, the white substance found in the medulla oblongata is traversed by an open network of capillaries, whose elongated meshes are seen according to the direction of the fibres, either in profile, or in transverse section. The collections of grey matter, on the other hand, are much more vascular, and supplied by a denser interlacement of capillaries. The very closely intercommunicating capillaries of the cineritious capsule of the human olivary bodies present a peculiarly beautiful appearance; they are partly supplied by vessels from without, and partly by another set of larger tubes, situated in the white nuclei. We shall speak of the *lymphatics* further on (§ 300) in their proper place.

§ 298.

Turning from the medulla oblongata to the neighbouring parts of the brain, we find that less and less is known of their structure the farther we advance.

In the foregoing section we have had frequent occasion to touch upon many points relating to the *pons Varolii* and cerebellum, so that they may now be first described.

In regard to the *pons Varolii* we have already remarked, in the preceding section, that in it we have before us collections of grey matter with the white cords of the medulla passing through it. Further, it contains a series of well-marked transverse fibres.

The *cerebellum* consists essentially of collections of white nervous tissue, cineritious matter only presenting itself on the roof of the fourth ventricle, in the corpus dentatum, the so-called roof nucleus of *Stilling*, and in the layer covering the surface of the convolutions.

Into and out of it, as we know, the *crura cerebelli ad medullam* conduct bands of fibres of the medulla oblongata. In the same way further elements leave it through the (§ 297) *crura cerebelli ad pontem*. Finally, the *crura cerebelli ad corpora quadrigemina* connect the organ with the brain.

The whole of the cerebellum presents, likewise, that very delicate sustentacular connective-tissue already mentioned (§ 119). It is especially highly developed in the cortical layer.

The *nerve fibres of the white substance* of the cerebellum are stated to present a similar arrangement and diameter at almost all points; the latter is, on an average, 0.0045, but may range from 0.0027 to 0.0902 mm. (*Koelliker*).

The *cineritious substance* is only to be found, in small amount, on the

roof of the fourth ventricle. Here we encounter ganglion cells of considerable size, varying from 0.045 to 0.067 in diameter, and of brownish tint, disseminated through the white substance (*substantia ferruginea superior* of *Koelliker*).

The *nucleus dentatus* of the cerebellum is of great interest on account of its relationship to the specific nucleus of the same name in the olivary bodies. In its plicated capsule of grey matter numerous ganglionic corpuscles of medium size (0.018–0.036 mm.) are to be met with disposed in three layers,—an external and an internal of fusiform cells, and middle of multipolar elements. The bodies of these also are coloured, as a rule, with pigment. Between them a maze of fibres is to be seen.

Our knowledge of the course of the fibres in the cerebellum is at present exceedingly imperfect. Nervous bundles of the *crura cerebelli ad med. oblong.* are said to advance as far as the crumpled plate of grey matter of the *corpus dentatum*, and to terminate in its ganglion cells provisionally. Then, again, efferent fibrous bands are stated to make their way out of the organ, at that point where the corrugated capsule of grey substance is imperfect, passing into the *crura cerebelli ad corpora quadrigemina* (*Rutkowsky*). The fasciculi of the last-named *crura*, however, have also been described as radiating from the *corpus dentatum* towards the surface of the cerebellum; they are said to connect this cortical layer with the so-called corona radiata fibres (*Stabkranzfaserung*) of the hemispheres of the cerebrum (§ 299). But the bundles of fibres of the *crura cerebelli ad medullam oblongatam* are also described as entering the roof nucleus of *Stilling*, and spreading from thence to the cortex. Some speak also of a system of arching fibres here (similar to those we shall have to consider presently in the hemispheres of the cerebrum), serving to connect adjacent convolutions of the cortex with one another.

In short, the whole matter is still very obscure.

The *cortical layer* of the cerebellum has, to be sure, been recently made the subject of very earnest study, and, to some extent, the older and newer investigations have thrown a light on the subject.

And first, as regards its coarser structure, it presents two layers,—an internal of a rusty brown colour, and an external grey. The first of these is not so deep as the latter.

It was at one time supposed (*Gerlach, Hess, Rutkowsky*) that the nerves of the white substance undergo repeated division, radiating at the same time in a brush-like manner, and forming eventually, with further subdivision, a retiform plexus of fibres of only 0.0023 mm. in thickness, in whose course the numerous nuclear structures of the rust-brown layer are interpolated (*Gerlach*). This view, however, has not since been confirmed.

The *rust-brown stratum*, which has a thickness of from 1 to 0.5 mm. (least at the bottom of the sulci), is by no means sharply defined against the white matter beneath it. In it we find densely aggregated those nuclear structures already mentioned, which also occur in the white stratum (the “granules” of *Gerlach*). These are of rounded form and diameter of about 0.0067 mm. on an average; each presents also one or two nucleoli (fig. 561, below). Whether we have before us cells or nuclei here is a point very difficult of decision. One fact, however, in regard to them can hardly escape even the superficial observer, namely, that they possess considerable resemblance to certain elements of the retina, *i.e.*, those of the granular layers of the latter.

Many of these elements present very fine filiform processes, of which

two are often exactly opposite one another. As a rule the latter are only visible for a very short distance from their point of origin.

Two species of these elements are recognised by *Schulze*. In the first place, smaller ones of 0.0067 mm. in diameter, and smooth edged, which, on treatment with bichromate of potash, acquire great brilliancy of outline, and are seen to possess one or two small nucleoli and the filaments just mentioned; in the second place, larger elements, 0.0090 mm. in diameter, which have distinct nucleoli. These show no polar filaments, but have frequently attached to them small shreds of the fibrous sustentacular substance, to which latter they probably belong, while the first form of cell is, by this observer, set down as nervous, and analogous to the granules of the retina.

There is, however, great difference of opinion upon this point; and some very weighty authorities, among whom *Koelliker*, *Stieda*, and *Deiters* may be mentioned, look upon the whole as part of the spongy tissue of the sustentacular substance, and deny any connection with nerve-fibres ascending from below. This view we ourselves also are inclined to regard as the most correct.

A set of small ganglion cells has been described by *Koelliker* and *Schulze* as occurring at the border of this stratum, which give off a number of ramifying processes; and *Meinert* speaks of a layer of tangentially coursing nerve fibres, with similarly arranged fusiform cells here. We have already alluded to this above.

Turning now to the most external of these two cortical strata, the *grey* or *cellular layer*, as it is called, we find its most striking elements to be large ganglion cells (fig. 560), discovered many years ago by *Purkinje*.

Fig. 560.—A ganglion cell of *Purkinje*, from the human cerebellum. *a*, cell; *b*, pointed process; *c*, antler-like ramifications, with delicate branches, *f*; *d*, axis cylinder; *e*, nerve fibre (*d* and *e*, completed from the dog).

They lie chiefly in the inner portion of the stratum, but are by no means abundant (fig. 561), and form but a single row. Internally they give off one process only of a different appearance from themselves (fig. 560, *b*). According to *Gerlach* this breaks up into the fine network of the rusty-brown layer, already alluded to, with its interpolated nuclei, which would be a very peculiar arrangement of the nervous fibres. But although others have expressed their concurrence in this view of *Gerlach's* (*Hess*, *Rutkowsky*), it must, nevertheless, be declared

as incorrect. The process mentioned remains undivided (*d*), and, becoming clothed with a layer of medullary substance (*e*), may be regarded as the ordinary axis-cylinder process of the central ganglion cells (*Deiters*, *Koschewnikoff*, *Hadlich*, *Boll*).

Externally—that is, directed towards the surface of the cerebellum—these large ganglion cells send off several (generally two) characteristic protoplasm processes through the so-called “molecular layer of *Hess*.” These then give origin to regular systems of branches, thin at first, and running down to the most delicate terminal filaments finally (*c*, *c*, *f*, *f*). Taken as a whole, they present somewhat the appearance of a stag’s antlers. Commissural union of one cell with another, by means of these processes, does not occur. On the contrary, the discovery of *Hadlich* (if it be confirmed) is of great interest (fig. 561), namely, that these finest filaments of the arborescent system of ramifications (*a*) bend over on arriving near the surface of the cortex in shorter or longer arches, and run inwards again through the grey layer in the direction of the granular layer of the rust-brown stratum. Before they reach this, however, they sink into a very delicate filamentous network, according to *Boll*, which is spread through the whole of the grey matter. This network would correspond, then, to that described by *Gerlach* in the interior of the spinal cord. From it then, in the granular layer stronger nerve-fibres are said to arise.

The nerve fibres of the white internal portion of the cerebellar convolutions pass outwards to the grey covering layer, interlacing at the same time. They pass into the rust-brown layer, radiating like hairs of a paint-brush. Here most observers state (we believe correctly) that they undergo extensive subdivision, so that only very fine twigs reach the under surface of the large, remarkably formed ganglion cells. They appear at last to terminate in the fine neural network of *Gerlach*. The axis-cylinder processes, on the other hand, of these strange ganglion corpuscles pass inwards towards the white substance.

The nervous plexus of the rust-brown layer is continuous, with rapid diminution in the thickness of its fibres through the internal third of the molecular layer.

The framework of the grey layers is formed of ordinary spongy sustentacular tissue (*Koelliker*, *Rutkowsky*), with those scattered nuclear elements of which, according to *Schulze*, two kinds may be distinguished.

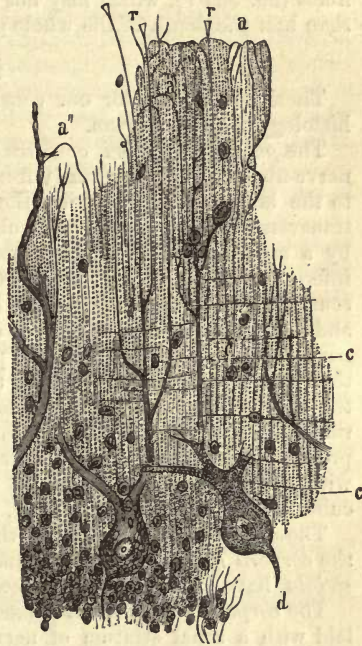


Fig. 561.—Section through the cortex of the human cerebellum (after *Hadlich*). Two ganglion cells of *Purkinje*; below them a part of the granular layer. At *r*, sustentacular fibres; *a*, the looped filaments of the delicate ramifications of the ganglion cells; *c*, finest tangential nerve fibres.

In the outer portion of the cineritious substance is to be found another very interesting textural arrangement, again reminding us of the retina (see below). A homogeneous connective-tissue boundary layer, lying underneath the pia mater, and corresponding to the grey peripheral lamina of the spinal cord, gives off internally, converging sustentacular fibres (fig. 561 *r*), which may not unfrequently be followed through more than half the depth of the whole grey matter (*Bergmann, Schulze*).

§ 299.

There now remain for our consideration a few points in regard to the histology of the *cerebrum*.

The *pedunculi cerebri*, or *crura cerebri ad pontem*, consist of masses of nerve-fibres, which pass partly from the medulla oblongata and cerebellum to the brain, and partly from the latter into the medulla possibly. In transverse section each crus is observed to be divided into two portions by a crescentic band of grey matter, the *substantia nigra*. The most inferior of these ("the base") is crescentic, and the upper ("the cap") round. According to *Meynert*, it is motor fibres from the *corpus striatum* and lenticular nucleus, or *nucleus dentatus*, which pass through this lower part of the peduncles serving the purposes of voluntary motion. Through the "cap," or upper portion, on the other hand, other fibres, arising in the optic thalamus and quadrigeminal body, descend, which preside over the reflex motions. Under the microscope the white matter of the crura presents the ordinary central nerve-tubes and grey ganglionic corpuscles, with numerous processes, which ramify largely, and pigmentary molecules in their interior (fig. 305, 4, p. 314).

Those structures which go by the name of the *cerebral ganglia*, namely, the *corpora quadrigemina*, *thalami optici*, *nucleus dentatus*, and *corpora striata*, have up to the present received but little attention.

The *corpora quadrigemina* possess, like the *thalami*, a white layer overlaid with a zonal stratum of nerve-fibres. Underneath them the *crura cerebelli ad corp. quad.* simply pass on to reach the cerebral hemispheres. They are therefore incorrectly so called, for they are much more *crura cerebelli ad cerebrum*. Laterally, there enter the *corp. quad* from below the two lemnisci springing from the motor part of the medulla oblongata, and traceable back to the same. Each of the ganglia sends off two cords, the quadrigeminal arms, which are said to pass into the system of the corona radiata. In the anterior of the quadrigeminal bodies a root of the optic nerve, coming from the *corpus geniculatum internum*, is said to terminate. The achievements of histology in this field are still very insignificant. Small cells have been recognised in the internal grey substance with larger multipolar and fusiform ganglion corpuscles. The latter are to be found in the deeper layers of the anterior bodies about the aqueduct of *Sylvius* (*Meynert*).

The *optic thalami*, we take it for granted, are already familiar to our readers as regards form. Their posterior end has received the name of the *pulvinar*. Internally to it is situated the *corpus geniculatum internum*, more posteriorly; and externally the *c.g. externum*. Into the latter a portion of the optic tract passes on its way to the pulvinar. The cap of the *crus cerebri* is intimately connected with the *thalamus*. These are then the newest views of *Meynert*; but some years ago, *J. Wagner* came to different conclusions in regard to the optic tract, and they will be probably modified still by subsequent observations. An abundant corona radiata

of fibres further springs from the external border of the thalamus. As to the histology of the part, we possess but very little satisfactory information. Cells are to be found here which appear to differ from the large multipolar elements, most of them being fusiform. The pulvinar presents nothing remarkable about it. In the external geniculate body the cells are frequently pigmented; the internal contains fusiform elements.

We pass on now to the *corpora striata* and *nucleus dentatus*.

Both these present a grey surface. In them terminate fibres from the *bases* of the *crura cerebri*. Externally, both ganglia send fibres to the corona radiata (*Stabkranz*). The grey matter of both ganglia presents for the most part great uniformity of structure. In it we meet with larger and smaller multipolar ganglion cells and small elements, measuring 0.005–0.01 mm. The neuroglia is similar here to that in the cortex of the cerebrum.

In respect to the *nuclei amygdalæ* and *claustrum* we are in want of trustworthy observations.

Turning now to the *corona radiata*, we find that it consists in the first place of fibres which, without having touched one of those ganglia, ascend directly through the *crura cerebri*, and then of the radiations of the ganglionic masses. These great masses of fibres are probably connected with the intellectual functions.

The *corpus callosum*, on the other hand, has nothing to do either with the peduncles of the brain or the corona radiata. It is a purely commissural system of fibres, radiating extensively in the hemispheres of the cerebrum, as also is the anterior commissure. Besides these, there are well developed systems of fibres which connect various parts of the brain on the same side, as, for instance, the fibres of the surface which unite the gyri one with the other "associating fibres."

The white substance of the hemispheres consists of medullated fibres of about 0.0026–0.0067 mm. in diameter. At the surface only of the larger ganglionic masses, and towards the cortex is the non-medullated species to be found.

The nerve-fibres are grouped together in bundles invested with a covering of connective-tissue cells (*Golgi, Boll*).

The *cortex of the hemispheres* may be divided into several layers, not distinctly marked off, however, against one another at all points. Their number, also, has been variously estimated by several observers, among whom may be mentioned *Koelliker, Stephany, Berlin, Arnutt, Meynert, Henle, and Stieda*. This is easily conceivable, and it is probable that it varies also in the different lower mammals.

We regard the cortex in man as divisible into six laminae, but would mention that our material has been in the last few years very insufficient. We were unable to procure brains fresh enough for our object.

(1.) The uppermost layer (*Koelliker*) consists of a series of horizontal transverse and oblique fibres, probably of nervous nature.

(2.) The next—the *first*, of *Meynert* (fig. 562, 1), is among the mammals deeper than in man, and is composed chiefly of neuroglia with a few scattered nervous elements. Two forms of the latter have been described—in the first place, namely, small cells of 0.009–0.010 mm. in diameter, and of polygonal or pyramidal figure giving off processes; and secondly, networks of the most delicate nervous fibrillæ of unknown nature.

(3.) A layer of crowded small multipolar nerve cells usually of pyramidal form (2).

(4.) A deep stratum in which much larger many-rayed ganglion cells,



Fig. 562.—The fine layers of the human cerebral cortex, after Meynert.

0.025-0.040 mm. in diameter, are met with at wide intervals. These present roundish or oval nuclei. Usually from the apex of the cell one process passes outwards, and three others from the broader part inwards. They may be seen to be of fibrillated structure. The middle one of these basal processes is in contrast to the others, which ramify, an "axis-cylinder process" (*Meynert, Koschevnikoff*), and is prolonged into one of the nerve-fibres of the corona radiata. (3.) The smaller cells of the third layer are also said to present the same arrangement likewise.

(5.) A layer of closely packed, roundish, smaller cells 0.008-0.010 mm. in diameter, with hardly recognisable processes (4).

(6.) A lamina, consisting of fusiform cellular elements, measuring 0.030, from whose apices filiform processes spring (5).

These last ramifications are not supposed to have anything to do with the corona radiata, but are connected, in all probability, with "associating fibres" of *Meynert*. The multipolar ganglion cells of the fourth layer are stated by this observer to be motor, the elements of the fifth resembling the "granules of the retina" (see below), possess sensitive properties. This is all, in our opinion, purely hypothetical.

A discovery has recently been made by *Gerlach* which seems important. The cortex of the cerebrum presents, namely, in the first place, a wide-meshed network of medullated fibres in whose interstices ganglion cells are situated. Here we find, besides that very delicate network of extremely fine fibres already

met with in the grey matter of the spinal cord (§ 293). Nay, further, the ramifying cellular processes are also seen here sinking into the latter. But though the cortex presents this general plan of structure, there are nevertheless local deviations from it.

In the first place, at the point of the posterior lobe, in the neighbourhood of the *sulcus hippocampi* (a spot investigated long ago by *Clarke*), a number of anomalous white streaks present themselves in the cortical portion. *Meynert* regards this part as made up of eight layers. The first two of these conform to Nos. 1 and 2 of our fig. 562. The third stratum lacks the large pyramidal cells, but presents in their place granules. Under these there appear, as fourth layer, those scattered pyramidal cells already mentioned, but very sparsely and at great intervals from one another. As a fifth layer, we find granules again, as in the third. The sixth resembles the fourth in having again scattered pyramidal bodies. On this there follows another granular layer. The eighth and last layer, finally, consists of ordinary fusiform cells (fig. 562, 5).

The *cornu ammonis* presents the same difference of appearance. It was first studied by *C. Kupffer* in the brain of the rabbit, and later by *Arndt* and *Meynert* in the human being.

According to the first of these observers, the structure is complicated, but allied to that of a cerebral convolution. The *cornu ammonis* presents under its most superficial layer of nerve fibres another so-called molecular stratum of grey matter, which contains in its deeper portions a series of closely-packed ganglion cells, one set of whose ramifying processes is directed towards the centre, thus constituting a deeper streaked grey lamina. Under this we next come upon a reticulated, then a second molecular, and finally a stratum formed of closely-crowded "granules."

According to *Meynert*, the grey cortical layer of the *cornu ammonis* in man may be regarded as a thin covering layer without granules. At one point alone—namely, at the apex of the *fascia dentata*—do these "granules" appear in any great abundance.

We turn now to the *bulbus olfactorius*, a remarkable piece of cerebral substance, but ill developed in man. In many mammals it is, as is well known, quite hollow. Its walls consist, if we will, of two groups of laminae, an *inner white* and an *external grey*. The latter becomes more and more highly developed as we approach the ethmoidal cells.

Into the first the root bundles from the neighbouring parts of the brain enter. Of these there are two—first a strong root coming from the external side, of which one-half seems to be a continuation of the anterior inferior convolution of the brain, while the other thinner portion can be followed into the *corpus callosum* (*Walter*); second, an internal weaker root of the bulb, consisting of three bundles of fibres, one from the *corpus striatum*, another from the *chiasma nervorum optitorum*, and the last from the *pedunculus cerebri*. In many points, however, *Clarke's* views differ essentially from this sketch.

If we now examine the walls from within outwards, the very complex structure of the central organs presents itself to us here also.

The cavity is lined with delicate ciliated epithelial cells, whose filiform root processes penetrate into the strongly developed neuroglia of the sub-stratum, with its roundish cellular equivalents. This latter is traversed again at a slight depth by a set of fine longitudinal but medullated nerve-fibres, which are a continuation of those of the root-bundles. Next to, and probably derived from them, is to be found a stratum of nervous elements

arranged in a plexus (*Clarke*), presenting very fine tubes as a rule, and nuclear elements of the sustentacular substance between the perpendicularly descending nerve-fibres. The sustentacular tissue presents itself here in a very pure state, but at the same time, of extreme delicacy. It contains numerous nuclei, and among them some of considerable size, which belong, according to *Walter*, to small bipolar ganglion cells. Besides this, it presents a layer of large multipolar ganglionic corpuscles, with widely branching protoplasm processes. The whole reminds us considerably of the cortical layer of the cerebellum (§ 298). Below, or, more properly speaking, externally, the walls of the bulb acquire a very obscure character from the transformation of the grey matter. Here we encounter, namely, spheroidal pellets of a granular nucleated substance, lying in spongy tissue, from which the peculiar pale peripheral olfactory fibres are given off. These we have already alluded to, and shall consider again in dealing with the organs of smell.

The *pineal gland*, or *conarium*, is a very puzzling organ, which probably, like cartilage, undergoes early changes. It has been by some supposed to have some relationship to the lymphatic glands (*Henle*). It presents in a connective-tissue framework, roundish, sometimes complete, sometimes incomplete cavities. These are occupied by two kinds of cellular elements, namely, larger, provided with long, thick, ramifying processes, forming a delicate "reticulum," and smaller, which give off processes in the adult, but not in the infant just born (*Bizzozero*).

Numerous peculiar concretions occur here also, known as the *acervulus cerebri*, a full description of which we reserve for the following section, where we shall consider them in connection with the choroid plexus.

The *hypophysis cerebri* has been already disposed of, with the other members of that obscure group of "blood vascular glands" (§ 238) to which it belongs.

In respect to the *composition* of the brain and spinal cord we have already mentioned all that is necessary to be borne in mind, in the second part of our work (§ 190). We have also alluded there to the extremely imperfect state of our knowledge on the subject.

§ 300.

We now come finally to the *membranes* investing the brain and spinal cord, of which there are three. In the first place, there is the *dura mater* externally, a strong fibrous coat (p. 225); then in the middle the *arachnoidea*, with all the characters of a serous membrane (p. 226); and finally, the *pia mater*, a delicate internal membrane, immediately in contact with the nervous substance of the brain and cord (p. 229).

The *dura mater* has been already dealt with, as regards its structure generally, in another chapter. It is rich in elastic fibres. Its relations to the brain and spinal cord are somewhat different. The latter is contained within it as in a tube, which hangs down in the spinal canal (lined throughout with periosteum), loose at either side and behind, and only attached anteriorly by a band of connective-tissue to the ligamentum longitudinale posterius. The matter which occupies the cavity so resulting is a soft colloid tissue, containing connective-tissue corpuscles and fat cells. Without taking into account the well-known venous plexuses traversing it, the latter is rich in small and extremely delicate blood-vessels.

Within the cranium, on the contrary, the *dura mater* is intimately connected with the periosteum, or, more properly speaking, it plays the part

of the latter with its external portion, which is more vascular and of less dense texture than the internal laminae. In the spinal cord it is very scantily supplied with vessels. The dura mater is very rich in *lymphatics*. Some of these run along side by side with the blood-vessels, while others ensheath the latter. It appears very probable, further, that they open into the cavity between the dura mater and arachnoid. The same seems to occur also on the external surface of the first-named membrane (*Michel*). As yet no nerves have been found in the dura mater of the cord, in contrast to that of the brain, which receives twigs from the sympathetic and trigeminus. The mode of termination of these nervous elements, which have been observed to undergo subdivision, has not yet been sufficiently cleared up. They appear to end in the blood-vessels and bones.

The dura mater is separated from the next membrane underneath it by what is known as the "*subdural space*."

The second membrane, the *arachnoidea*, was formerly described as forming a shut serous sac, but erroneously so; the parietal leaf being usually represented as fused together with the outer layer of the dura mater, since it could not be demonstrated separately. It presents for our consideration a very thin delicate membrane on the spinal cord, investing the pia mater quite loosely, and only connected with the latter and with the nervous roots by means of numerous bands of connective-tissue, varying according to locality. Consequently there is left a considerable interspace between it and the pia mater, known as the *sub-arachnoid space*. But the relations of this envelope on the brain are different in some respects. Here we find it for the greater part firmly adherent to the pia mater, the latter, however, dipping in between the convolutions, while the arachnoid stretches across the depressions between the same, and also those larger ones situated at the base of the brain. In this way a great number also of smaller sub-arachnoid spaces are produced. In regard to the connective-tissue of the arachnoid *Key* and *Retzius* have recently made some admirable observations. The retiform fibrillated bundles are covered with flat connective-tissue cells, similar to those we have already considered in speaking of connective-tissue (§ 130), the lymphatics (§ 223), and the testes (§ 283). These are united to each other to form a kind of membrane, and fill up the interstices of the various layers. Under the action, further, of nitrate of silver solution they present the well-known mosaic appearance of the "endothelial cells" (§ 98, &c.)

Within these spaces situated under the arachnoid of the brain and cord, and communicating more or less with one another, as well as within the ventricles of the brain, we find what is known as the *cerebro-spinal fluid*. This contains, besides, about 99 per cent. of water, small quantities of albuminate of sodium, extractives, and the ordinary salts of the body (*C. Schmidt, Hoppe*).

The number of *capillaries* encountered in the arachnoid is extremely small. Nerves, on the other hand, are not uncommon, but whether they actually end here is a point not yet decided. The outer surface of the arachnoid and internal of the dura mater are covered with a slightly laminated flattened epithelium (p. 141).

We come now, finally, to the third and last of the coverings, the *pia mater*. In it we have before us a delicate connective-tissue tunic. Here also we find those flat membranous cells just referred to, with connective-tissue bundles and elastic fibres. The whole, however, is a continuous and

unbroken envelope. The *pia mater* is completely closed (*Key, Retzius*). It appears, moreover, much thinner on the brain than on the cord.

In it, as is well known, innumerable blood-vessels present themselves, penetrating for the most part into the nervous matter. We have already considered (§ 292) this point in speaking of the spinal cord. In the brain their arrangement is analogous. The *pia mater*, further, is richly supplied with well-developed lymphatic canals.

Between the *pia mater* and the brain, or spinal cord, there does not exist any appreciable space. The "epispinal" and "epicerebral" spaces described by *His* are artificial productions. After personal observation, we do not hesitate for a moment to declare this statement of *Key* and *Retzius* as entirely correct. *Boll* is also of the same opinion.

We now turn to a very interesting and important point, as bearing upon the lymphatics of the central organs, namely, the nature and relations of the walls of the vessels entering the substance of the brain.

These are loosely invested in a sheath, which, lying next the *tunica media*, opens out into the subarachnoid space with a kind of funnel-shaped dilatation. Owing to this arrangement, the sheaths may be artificially injected from the subarachnoid space far into the interior of the brain and spinal cord. Injections, however, which penetrate under the *pia mater*, or into the actual nervous tissue of brain or cord, are the result of ruptures. There are no such things as "perivascular" spaces, *i.e.*, passages between the adventitial coat and the adjacent neuroglia; if anything of this kind present itself, it is an artificial production.

Another very interesting discovery has also been made by *Key* and *Retzius*, *viz.*, that nerve-trunks and ganglia are also invested with a similar dural sheath and arachnoid envelope, and which can be artificially filled in the same way. Here, again, then, we have the "subarachnoid" space.

We glance now finally at the *Pacchionian granulations*, small round masses of connective-tissue, met with as normal structures principally along the course of the longitudinal sinus.

Key and *Retzius* have made some remarkable statements in regard to these.

They say that if fluid be injected into either the subdural or subarachnoid space, it makes its way easily into the venous sinuses and venous ramifications of the dura mater. *The entrance takes place through the spongy tissue of these granulations.* We naturally look for further observations on this point.

The two entrances to the cavities of the brain, the posterior and anterior

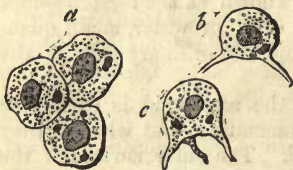


Fig. 563.—Epithelial cells from the human choroid plexus. *a*, the cells from above; *b*, the same in profile.

transverse fissures, are closed by the stretching across them of the *pia mater* (*telæ choroideæ*). From their inner side, especially in the anterior transverse fissure between the cerebrum and cerebellum, a leaf-like process with large vessels penetrates into the ventricles of the brain, to form there the *plexus choroidei*. This is nothing but a network of vessels (§ 136) embedded in homogeneous, colloid, or, later on, streaked

connective-tissue containing cells. On its free surface, as far as this exists, we find those peculiar rooted epithelial cells (fig. 563) already described, § 87. The ventricles, however, receive no further covering of

pia mater than this: on their surface the ill-developed connective substance of the ependyma appears under the epithelial covering (§ 119).

This deepest membrane of brain and spinal cord is also the most highly innervated of all. The *nerves* here form dense plexuses, not only in the course of the vessels, but also in the connective-tissue itself. According to *Koelliker*, they even penetrate, in part, into the substance of the brain along with the finer arterial twigs. The nerves supplying the pia mater spring, in the first place, from the posterior roots of the spinal cord (*Remak*); and, secondly, in all probability, from the cranial nerves also, as well as from the carotid and vertebral plexuses of the sympathetic. It would appear also that, from the surface of the brain and spinal cord, delicate filaments may likewise be given off in the opposite direction to the pia mater (*Bochdalek, Lenhossek*). The choroid plexus is quite destitute of nervous supply.

The *blood-vessels* of the cerebral substance have in so far an analogous arrangement to those of the cord, that they form larger meshed networks in the white matter than in the grey.

The mode in which they are disposed in the cortex of the cerebellum was found by *Gerlach* to be different in the three layers,—the white, the rust-coloured, and the grey. In the first is seen a loose network of vessels with long meshes fitting closely to the fasciculi of the nerve-tubes. But the densest capillary network is found in the rust-coloured layer. Its meshes, roundish or polygonal, branch off inwards with greater rapidity, but enclose, on the other hand, the larger ganglionic corpuscles of the grey stratum externally. The meshes of the latter are less dense, and are arranged in the direction of lines radiating from the centre of the cerebellum. The most external boundary lamina of the grey layer is quite devoid of capillaries. The latter terminate here in the form of loops. The larger vessels supplying the brain enter, for the most part, with the processes of the pia mater, which dip in between the convolutions from the surface. Here they give off regular twigs at right angles to their course, which may be traced pretty far into the cortical grey matter, forming there, by lateral subdivision, the capillary networks just mentioned. Other larger branches ramify in the white substance.

Not less delicate, and rather similar in frontal section to that of the cortical-portion of the cerebellum, is the arrangement of vessels in the olfactory bulb, as seen in the rabbit, for instance.

Between the two olfactory lobes runs a large vessel, sending off on either side fine branches, with the greatest regularity, into the grey matter, while the outer aspect of the lobes is similarly supplied by other twigs. From these a dense network is formed in the grey substance, with elongated meshes externally, and very small round ones internally. After this we then come upon the large and long meshed capillary network of the white internal layer.

We have still left for consideration the *sabulous matter* of the brain (fig. 564), which is found in the choroid

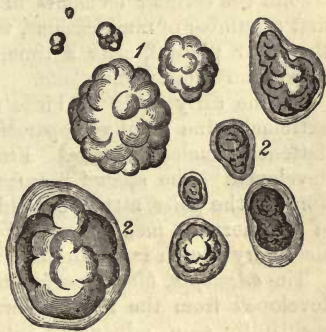

Fig. 564.—Concretions from the human brain: 1. from the pineal gland, 2. from the choroid plexus; with their envelopes of connective-tissue.

plexus and pineal gland. It consists of very irregular granules, ranging in diameter from 0.0113 to 0.5638 mm. of flattened or more generally spheroidal, or at times most fantastic shape. These masses, formed of concentrically arranged layers of carbonate of calcium, with phosphate of calcium and magnesium combined with an organic substratum, are usually imbedded in bundles of connective-tissue, in which they present a dark outline. Their occurrence is almost entirely confined to the human brain, and much doubt exists as to their histological significance.

Turning now to the *origin* of the central organs *in the embryo*, it will be remembered that both brain and cord are developed from the so-called corneous germinal plate, that is, from that portion of it bordering on the middle long axis of the embryo, and named, accordingly, by *Remak* the *medullary plate*. Properly speaking, it is more the province of embryology than of histology to follow up the transformation of this portion of the germ into a groove, and the subsequent closure of the latter. This much, however, may be mentioned here, that at an early period the still wide central canal of the spinal cord is lined by a layer of grey substance composed of small cells of round form. These elements gradually become increased in number at the spot where the anterior cornu exists later on, and from this point the nerve fibres of the anterior roots make their exit. The white portions of the cord are developed later on, but their mode of origin and relation to the grey substance requires further investigation. The fibres of the sensitive roots are formed at the same time with the development of the posterior column. Both the lining epithelium and subjacent layer of sustentacular tissue are distinctly visible at an early period: the former is originally thick, and made up of several layers.

At present we possess but a very fragmentary knowledge of the histogenesis of the *brain* and its appendages. The important question, likewise, as to the origin of the connective-tissue framework of the nervous centres is especially difficult to answer.

Two species of cells were found by *Boll*, even at a very early period, in the cortical layer in the embryonic chick,—one with vesicular nuclei and sharply defined body, the other with bodies hardly distinguishable from the surrounding protoplasm.

From the first species the ganglion corpuscles are developed; from the second the cellular elements of the sustentacular substance. From the first a number of ramifications, with varicose fibres, may be seen to spring; the latter present, after a time, halo-like rings of the peculiarly constituted neuroglia around them.

In the early brain of birds the white substance presents bundles of extremely fine fibrillæ, separated by long rows of roundish, polygonal, flattened, nucleated cells. From the first the sustentacular matter is developed. The second, formed of spindle cells with two long varicose fibres at the poles, attract around them, later on, a number of the granules of the nervous medulla, and by the fusing together of the latter the medullary sheath is produced.

The *envelopes*, *blood-vessels*, and *lymphatics* of the brain and cord are developed from the middle germinal layer. The blood-vessels may be beautifully seen, advancing into the substance of the brain and spinal medulla, in the form of bud-like excrescences from the envelopes, and spreading out and uniting in their interior (*His*).

9. Sensory Apparatus.

§ 301.

The *skin* in man (fig. 565), the organ presiding over the *sense of touch*, consists of the *cutis vera* (below, *c*), the *cuticle* (*a, b*), the subcutaneous areolar tissue (*h*), nerves (*i*), vessels (*d*), sudorific (*g, e, f*), and sebaceous glands, hairs and nails.

All these parts have been already separately considered in speaking of the several tissues. For the *cutis*, see p. 228; the *epidermis*, p. 144; the subcutaneous areolar tissue, and the collection of fat cells occurring in it, §§ 120–123. The nerves, as far as their course and mode of termination is known, were discussed in §§ 185 and 187. The two species of glands occurring in the skin have been already spoken of generally, at §§ 198 and 196, in describing glandular tissue. Hair has been dealt with in § 212, and the nails in § 99.

The *thickness* of the *cutis* varies in different parts of the body, ranging from 0.45 to 3.38 mm. It is thinnest in the eyelids, the glans penis and prepuce, and inner surface of the labia majora. In the face, the scrotum, and areola of nipple it becomes thicker, varying from 0.68 to 1.13 mm., and on the forehead it is 1.50 mm. Its average depth, on most parts of the surface of the body lies between 1.69 and 2.26 mm. On the sole of the foot, the nates and back, and often, likewise, in the palm of the hand, it attains the greatest thickness. In males it is stronger than in females, and in children under seven years of age it is hardly half as deep as in the adult (*C. Krause*).

The *epidermis* also, already considered at greater length in another place, varies much in different localities, and, moreover, in a much higher degree than the *corium*. This variation affects principally its corneous layers; while the soft strata of cells underneath only range from 0.1128 to 0.0347 mm. or so; the horny portion may vary from 0.0347 to 2.26 mm. Its average thickness, in most regions, was fixed by *C. Krause* at 0.0751–0.1735 mm. The *epidermis* attains the greatest strength in the palm of the hand and sole of the foot, [in both of which situations, as has been known from the earliest days of histology, this inequality may be noticed even in the embryo.

The *tactile papillæ* of the skin have been already described in § 136. They are to be found over the whole extent of the latter, but present con-

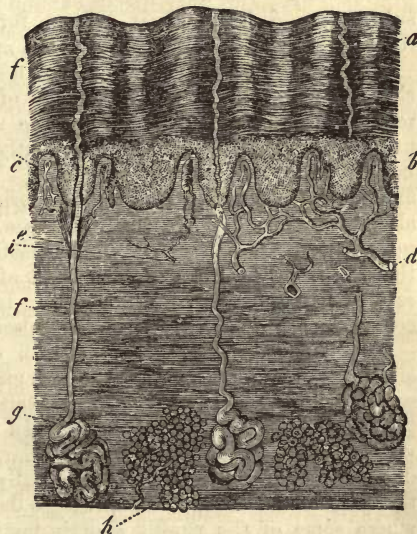


Fig. 565.—Vertical section of human skin. *a*, superficial laminae of the epidermis; *b*, rete Malpighii. Below this the corium is seen forming papillæ at *c*, and merging into subcutaneous areolar tissue underneath; *g*, sweat glands, and their ducts *e* and *f*; *d*, vessels; *i*, nerves.

siderable variety among themselves as to position, size, and shape (fig. 565). In certain localities—as, for instance, in the palmar aspect of the hand—they are frequently aggregated in small groups arranged along the ridges of the corium.

At other spots the grouping is more irregular, and the papillæ are sometimes found widely scattered, at others crowded together. Their size also varies greatly. The longest, rising to 0·1505, or even 0·23 mm., are to be found on the volar aspect of the hand, the sole of the foot, and nipple. The most usual length of the papillæ is 0·1128–0·0564 mm.; but small examples, such as those found, for instance, in the face, may not measure more than 0·0451–0·0377, or even less. The largest of them are conical or tongue-shaped, but the smaller are truncated, or merely slight elevations. Besides the simpler papillæ, there exist also compound, that is, broader excrescences, running into two or more, rarely three, points (fig. 566 in

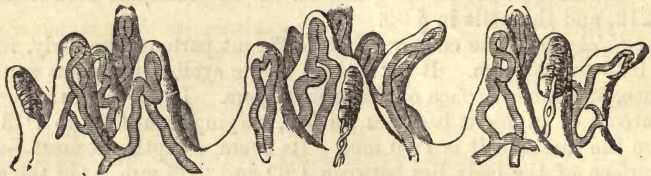

Fig. 566.—Three groups of tactile papillæ from the skin of the human index finger, in vertical section. Some are supplied with vascular loops, some with tactile corpuscles.

the middle). We have before spoken of their apparently homogeneous substratum, § 136. Their surface, further, is thrown into ridges and furrows, giving to the whole a toothed appearance (*Meissner*).

We have already said as much as necessary in regard to the muscular elements of the skin § 163. Bands of these pass, as we have learned recently from *J. Neumann*, from the upper part of the cutis into the panniculus adiposus, dividing frequently in their course, and sending off both vertical and horizontal bundles. There occur, besides, both above and below the perspiratory glands, horizontal muscular branches, especially in the hairy part of the scalp: these probably belong to the *arrectores pili* (§ 212). Finally, beneath the tactile corpuscles, especially those of the scalp, and on the extensor aspect of the limbs, are to be found other sets of bands of unstriped muscle. In different individuals, however, considerable variety exists in this respect.

The *vascular network* of the skin commences in the subcutaneous areolar tissue in the form of round meshes enclosing the fat cells, and capillary interlacements around the hair follicles and convoluted ends of the perspiratory ducts (fig. 567, *c*). In the corium itself, we encounter a very complicated plexus of fine capillary tubes, 0·0074 to 0·113 mm. in diameter. These spread out horizontally, and supply the greater part of the papillæ with loops on an average 0·0090 mm., except at those points where some of the papillæ contain tactile corpuscles, in which case they are without vessels (§ 185).

The *lymphatics of the skin*, known to earlier observers as very dense networks, have recently been closely studied by *Teichmann*, and more so still by *Neumann*.

In the corium these present a system of tubes possessing independent walls, and arranged in two different dense networks, a deeper, of coarser canals with wider meshes; and a more superficial, of finer passages with

closer meshes. The lymphatics of the cutis vera do not contain valves, which first appear in the subcutaneous areolar tissue.

The arrangement of these vessels varies much in the different localities. Here and there blind-ended offshoots of varying thickness are met with. In the papillæ of the skin the lymphatics present sometimes single tubes, sometimes loops.

The several complementary structures of the skin, as the hairs with their sebaceous follicles and the sweat glands, all possess their own special lymphatic vessels; even the fat lobules are surrounded with looped canals. The lymphatic vessels are very highly developed in the subcutaneous areolar tissue.

The various parts of the body present considerable difference as to the number of these vessels to be found. The parts which seem to be most richly supplied with them are the scrotum, labia majora, palms of the hands, and soles of the feet.

The arrangement of the *nerves* of the skin in plexuses, which constitute the latter one of the apparatuses of special sense, has been before touched on in the second part of our work. We refer to §§ 185 and 187 for a description of the several modes of termination of the nerves,—in the first place in the tactile corpuscles, and then at other points. In § 184 the scattered observations on the occurrence of the end bulbs of *Krause* are mentioned.

The *development of the epidermis* in the embryo has been already treated of at p. 159. The *cutis* still consists entirely, according to *Koeliker*, in the fourth and fifth month of human intra-uterine life, of collections of round and fusiform formative cells, and has a thickness of 0·0135–0·0226 mm. In the third month the subcutaneous areolar tissue may be distinguished, and both layers are of about the same depth. Both together, including the cuticle, measure 0·1353 mm. A month later the first lobules of fat may be remarked, and in the sixth month the papillæ make their appearance, the corium having attained a thickness of 1·13 mm. and upwards. In the new-born infant the panniculus adiposus is particularly strongly developed.

§ 302.

The glandular structures which lend to the skin the character of a secretory organ are of two kinds, *perspiratory* and *sebaceous*.

The *sweat glands* (*glandulæ sudoriferæ*, figs. 565 and 567) have been before dealt with, as far as relates to the differences of size and structure observed among them (p. 357).

The convoluted portion with which they commence is situated either in the deeper parts of the corium, or more generally in the subcutaneous areolar tissue, deeper than the hair follicles, and surrounded by the fat-cells of the panniculus adiposus. The excretory duct, long or short, according to the thickness of the corium, perforates the latter, passing between the papillæ into the epidermis. In this course it frequently twists and turns spirally, especially in the cuticle. The mouths of these ducts, on the surface of the skin, are of microscopical minuteness, with the exception of those on the palm of the hand and sole of the foot, which are wider and funnel-shaped. Here they appear as rows of small dots upon the ridges of the skin, whereas in other localities they present themselves in irregular groups. Internally the glands in question are lined sometimes with a single, sometimes double layer of round or poly-

gonal gland-cells of rather small size, ranging from 0.0113 to 0.0157 mm. in diameter, and containing in their interior, as a rule, molecules of a brownish pigment and of neutral fats.

The space in the axis of the tube is filled either with a more or less

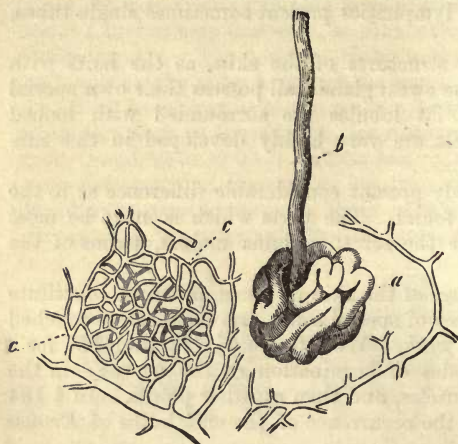


Fig. 567.—Sudorific gland from the human being. *a*, convoluted portion surrounded by the radicals of venous vessels; *c*, basket-like plexus of capillaries from around a convoluted, with arterial twigs; *b*, excretory duct.

transparent fluid, destitute of granular matter, or, as is the case with the larger convoluted glands, with a thickish matter, rich in molecules of fats and albuminous substances, which has its source in a bursting of the gland-cells, and in some instances nearly resembles the fatty secretions of the allied ceruminous glands of the ear or racemose sebaceous follicles. The blood-vessels are disposed around the convolutions of these organs in delicate basket-like capillary networks, *c, c*. Apart from a dense network of nerves surrounding the

capillaries of the sudorific glands (*Tomsa*), no special *secretory nerves* are known for the organ, although the agency of the nervous system in the mechanism of absorption is very probable.

Sudorific glands occur over the whole surface of the human skin whether covered with hair or no, with the exception of a few limited spots. They are liable, however, to vary considerably, both in regard to grouping, size, and number, in different localities. On the ridges of skin in the palm of the hand and sole of the foot they are arranged with regularity in rows. It is most usual, however, to find them in small irregular groups, separated from one another by small tracts of skin quite free of glands. On the lip they extend as far as the red edge, and on the nose to the entrance of the nostrils; on the penis, again, as far as the border of the external skin of the prepuce; and on the pudenda to the limits of the outer integument. Over the whole body almost, the smaller species of glands alone present themselves, while the large tubules of more complex constitution appear in the axilla only, crowded together and forming a regular stratum. We are indebted to *Krause* for some very interesting calculations in regard to the number of the sudorific glands in different localities. Whilst on the back of the neck, back, and nates, 417 on an average may be found in \square ", the cheeks, for instance, have 548; the inner surface of the thigh and leg, 576; the forearm externally, 1093, internally, 1123; the breast and belly, 1136; the forehead, 1258; the dorsum of the hand, 1490; the palm, 2736; and the sole of the foot, 2685. Thus, computing for the whole surface of the body, this observer estimates the total number of these glands at 2,381,248. No doubt this is subject to great variation, according to the individual. The mode of origin of the glandulæ sudoriferæ has been referred to before at p. 360.

The thickish fatty nature of the secretion of the axillary glands hardly warrants the application to them of the term "sudorific" with any degree of propriety; they require some special name just as much as the glands of the external ear.

Recently a ring of very large sweat glands, lined with columnar epithelium, has been described as surrounding the opening of the anus by *A. Gay*, by whom they are named the "*circumanal glands*."

The *glandulæ ceruminosæ*, closely crowded together, are seated in the cartilaginous portion of the external auditory meatus. They present the same structure as the ordinary sweat glands, with convolutions of 0.23-1.69 mm. in diameter, but differ from them in possessing short, almost straight and never spiral, excretory ducts. The gland-cells of the convoluted portion contain granules and drops of fatty matters with molecules of a brownish pigment, which communicate to the secretion its well-known colour.

The *cerumen auris*, a yellowish, thick, and bitter substance, presents under the microscope, beside epidermal scales, granules and globules of an ordinary yellow fat, molecules of a brown pigment just mentioned (either separate or aggregated), and large cells filled with oil globules, which in the opinion of *Koelliker* may be derived from the sebaceous glands of the neighbourhood.

According to an analysis of *Berzelius*, the cerumen of the ear contains, besides epidermal scales, a soft fat, a yellowish substance soluble in alcohol, and bitter to the taste, but which has nothing to do with the constituents of bile (*Lehmann*), extractive matters, potash, and lime salts. *Pétriquin* found also a potash soap here. In fact, potash is almost the only alkali present in the cerumen; only traces of soda and lime are to be found.

§ 303.

Part of the water contained in the skin is continually exuding through the hard, dry, epidermal scales over the whole surface of the human body. This process, which, although varying in intensity at times, may nevertheless be regarded as a constant one, is known as *perspiration*. The sources of this moisture are in the first place the blood-vessels of the papillæ, and the transuded tissue fluid of the latter, and then the aqueous contents of the passages of the sweat glands, which also exhale fluid from their surface. How much is to be set down to these sources respectively is still a matter of doubt. According to *C. Krause* the largest proportion by far is derived from the bodies of the papillæ. We are indebted to this observer for the discovery that horny epidermis is almost impervious to water in such a condition that it will form drops, but permeable to all gases.

In contrast to this constant and purely physical process of evaporation of the water of the skin, there is another, which is only periodically active, namely, the *generation of sweat*, the efflux of water in the condition of drops from the innumerable orifices of the sudorific glands, in which the small isolated globules form by confluence larger drops upon the greasy surface of the skin. Both processes, however, are frequently merged into one another.

The amount of water which the body loses through the skin varies naturally at different periods. It may be estimated, according to *Krause*, at from 8 to 9 hundred grammes per diem on an average, with extremes

as high as 550 to 1500. We see, then, that the excretion of water through the kidneys (§ 274) exceeds that of the skin in general, and further, that but a small amount of the products of decomposition escape through the latter. The amount of moisture eliminated by the skin is, however, far more than that exhaled from the surface of the lungs, which is only from 5 to 7 hundred grammes in twenty-four hours. Further details on this subject may be left to physiologists.

The *chemical* analyses which have been hitherto made of the watery secretions of the skin have been directed partly to the fluid exhaled over the surface of the body, and condensed there in drops again; partly to the water welling from the perspiratory glands themselves in the form of drops; and lastly, towards both together. To this mixture, then, the term sweat is generally applied.

The *sweat* (*sudor*) always contains an admixture of cast-off epithelial scales and fatty molecules, which last are derived partly from the sebaceous matter of the skin, partly from the contents of the convoluted glands. Otherwise the secretion is quite devoid of form elements of every kind.

It is a clear, colourless fluid, normally of acid reaction when fresh, but becoming, after some time, neutral or even alkaline. Its taste is usually salty, and smell more or less intense, and dependent on the presence of volatile fatty acids.

The proportion of solid constituents is small but variable, decreasing relatively with the amount of water excreted: it may be stated at 0·5–2 per cent. of the latter. They consist of both organic and mineral matters. To the first belong several members of the volatile fatty acid series (p. 24), and prominent among them *formic*, *butyric*, and *acetic* acids. The presence also of *metaceton*, *capronic*, *caprylic*, and *caprinic* acids is at least probable. But there can be no doubt that we have here to deal with a very variable fluid, which is indicated, among other things, by the different odour of the perspiration of various parts of the body, as well as of different races of men, such as that of Europeans and negroes. According to *Favre's* observations, further, a peculiar acid may be demonstrated in sweat, which he has named *hydrotinic acid* (p. 36).

Recent observation has shown also that sweat, even under normal conditions, contains *urea*, to the presence of which substance the rapid change in the reaction of the secretion, combined with the development of ammonia, may be ascribed. In morbid conditions of the system also, induced by impairment of the functions of the kidneys, this compound may be excreted largely by the skin. Among the other widely diffused animal bases none have been demonstrated here as yet.

Neutral fat is likewise a constant constituent, and *cholestearin* has also been met with (*Schottin*). *Leube* also met with a peculiar albuminous substance here.

Under abnormal conditions the *biliary pigments* may also appear in the sweat.

The *mineral matters* found here consist, besides iron and phosphate of calcium (derived from the epithelial cells), principally of chlorides of the alkalis, and above all of sodium; then, again, small quantities of phosphates and sulphates of the alkaline salts. Finally, free carbonic acid is met with here, and salts of ammonia, due to decomposition.

§ 304.

The *sebaceous glands* (fig. 568), small structures included in the racemose class, are to be found likewise almost everywhere over the whole surface of the skin, although less extensively distributed than the sweat tubules.

Their secretion is essentially a fatty one (fig. 569); its mode of origin has been already treated of at § 196.

The sebaceous glands, always seated in the corium itself, and never in the subcutaneous areolar tissue, are, as a rule, associated with the presence of the large and small hairs of the body, into whose follicles they empty themselves, either singly, doubly, or in greater number. While in relation to the larger hair follicles they appear but as lateral appendages to the same with the downy hairs, the case is altered, the hair follicles of the latter seeming but appendages of the glandular organs. In addition to these sebaceous glands connected with hairs, the "hair-follicle glands," there exist others found only on bald parts of the body, which pour out their secretion directly on the surface. The naked parts of the skin are almost, without exception, destitute of them, such as the palm of the hand, sole of the foot, and last joints of both fingers and toes. On the whole these are not widely distributed, and only occur in certain parts of the sexual organs, namely, on the prepuce and glans penis (known there as the glands of *Tyson*), and on the labia minora of the female.

The structure of the sebaceous glands, which range in diameter from 0.2 to 2.2 mm., is very different in different cases. When small and simple their form is that of a wide, shallow sac. Others, again, are found at whose lower ends isolated buds commence to present themselves, which become more and more frequent, acquiring eventually in some cases a flask-like form (fig. 569, *A*), and in others a more globular shape. These gland vesicles, whose length is consequently very various, differ also considerably in transverse measurement, ranging from 0.0564 to 0.0751 mm., or even 0.2256 mm. The largest are observed on the nose, scrotum, mons veneris, and labia majora. The envelope of the vesicles and excretory passage is not, as is the case with most glands, a transparent structureless membrane, but consists of streaky con-

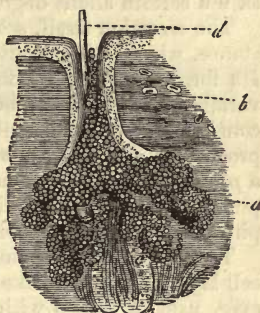


Fig. 568.—A sebaceous gland. *a* the gland vesicles; *b*, excretory duct; *c*, the follicle of a downy hair; *d*, shaft of the latter.

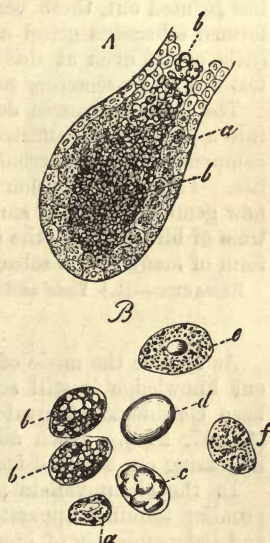


Fig. 569.—*A*, the vesicle of a sebaceous gland. *a*, the gland cells next the wall; *b*, cast-off elements filling cavity of the vesicle, and containing oily matters. *B*, the same cells more strongly magnified. *a*, small elements belonging to the walls, and poor in fat; *b*, larger richly filled; *c*, a cell with large confluent globules; *d*, another with a single drop of oil.

nective-tissue. As a rule we find no blood-vessels about the body of the gland. The process of secretion in the latter appears to be of a very low order, but active enough to meet all the functional requirements of the organ, which is designed to communicate to the hairs and surface of the skin a certain slight degree of oiliness.

The secretion itself, *sebum cutaneum*, when fresh, is a thickish oily substance, which stiffens after some time like lard which has been heated. Its form-elements (*B*), found together with cast-off epidermal scales in variable amount, have been described at p. 352. Chemically the mass consists—apart from slight differences dependent on locality—of a large proportion of *neutral fats* in addition to *soapy materials*, *cholestearin*, and a *protein substance*. Among its inorganic constituents the chlorides and phosphates of the alkalis appear in small proportion, but the earthy phosphates in considerable amount.

The *development* of the sebaceous follicles takes place from the external cell-layer of the skin like the sudorific and mammary glands; it is, however, usually linked with that of the first rudiments of the hairs, and may be remarked in the fourth or fifth month of foetal existence.

At first these glands present themselves in the form of solid buds on the rudimentary external root sheaths (p. 390), primarily of globular figure, and subsequently flask-like. These buds are produced by proliferation of the formative cells of that sheath just mentioned. As *Koelliker* has pointed out, there very soon commences in the axis of this simply formed sebaceous gland a fatty degeneration of its contents, so that the little organ, even at this early period, already exhibits the characteristic features of its secretory process.

The further changes destined to convert this simple flask-shaped sac into a plain or complicated racemose gland begin, on the other hand, at a comparatively late period, namely, in the later months of intrauterine life. They depend upon a multiplication of the peripheral cells causing new gemmation at the surface,—a process which is not completed at the time of birth, and by the continuation of which the complicated lobulated form of many of the sebaceous glands is gradually perfected.

REMARKS.—(1.) *Todd* and *Bowmann*, vol. i. p. 424.

§ 305.

As regards the mode of termination of the *gustatory nerves of the tongue* our knowledge is still scanty and unsatisfactory. The organ itself has been considered at greater length in speaking of the digestive apparatus (§§ 247, 248). Much advance, however, has been made of late years in increasing our stock of facts relating to this question.

In the circumvallate papillæ of the human and mammalian tongue, peculiar terminal apparatuses were discovered almost at the same time, and independently of one another, by *Lovén* and *Schwalbe*, for which the name of "*gustatory buds*," chosen by the first of these observers, recommends itself most. The term "*taste-cups*," proposed by *Schultze*, appears less suitable. Here, again, *Engelmann* and *Wyss* both found, independently of each other, an analogous gustatory organ on the side of the root of the tongue in the rabbit, a plicated body presenting similar "*gustatory buds*" represented in our woodcut. This is known as the "*papilla foliata*."

These papillæ foliatae also occur in the human tongue. They are seated immediately before the bases of the pillars of the *arcus glossopalatinus*,

are several millimetres across, and present five longitudinal clefts, which contain numerous gustatory buds (*Krause*).

The crown and side walls of the circumvallate papillæ, with the internal surface of the surrounding ridge of mucous membrane, are clothed with a thin layer of the ordinary flattened epithelium of the tongue. Now it is principally the side walls of the papillæ (fig. 570), but

not unfrequently the inner aspect likewise of the encircling ridge (the crown of the papillæ never), which presents the terminal structures just mentioned. These are pear-shaped or bud-like organs which traverse the whole thickness of the epithelial covering, and present,

according to the animal examined, a plump, or slender figure. Their number is, as a rule, considerable. In length they attain in the tongue of the ox, 0.1717; in man, 0.0810-0.0769; in the deer, hare, and dog, 0.0729 mm.; in the rabbit, 0.0575 mm.

Their walls consist of flattened lanceolate cells (fig. 571, 2 a) arranged side by side like the staves of a cask, or the sepals of a flower bud. Above these supporting or encasing cells converge; below they are narrowed into ribband-like processes, which sink into the tissue of the mucosa, and are to all appearance connected with the elements of the same.

The apices of the gustatory buds (1) perforate the epithelial covering, and lie naked and free. Here we may observe small round holes arranged with considerable regularity, and formed by the borders of either several, or perhaps two, or even of one single cuticular cell. Through these openings delicate terminal filaments may project (*Schwalbe*).

A second species of cell (2 b) is now found in the interior of the gustatory bud, enclosed within the cortical lamina of encasing cells. These elements appear in the form of longitudinal bundles, and are known as "gustatory cells." A fusiform nucleated body becomes narrowed above into a thin rod or spike, and is fined off below into a thread-like process. The ends of such rods project at times to a greater or less extent from the openings of the gustatory buds, while the end filaments below, on which varicosities may be observed, penetrate into the tissue of the mucous membrane.

Underneath the gustatory buds the latter is seen to contain a plexus of pale and medullated nerve fibres. Immediately under the epithelial covering pale single or dividing terminal filaments present themselves.

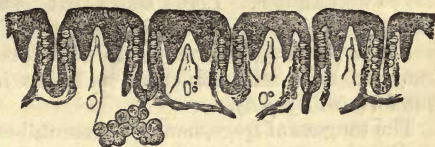

Fig. 570.—From the lateral gustatory organ of the rabbit. The gustatory ridges are represented in vertical transverse section (after Engelmann).

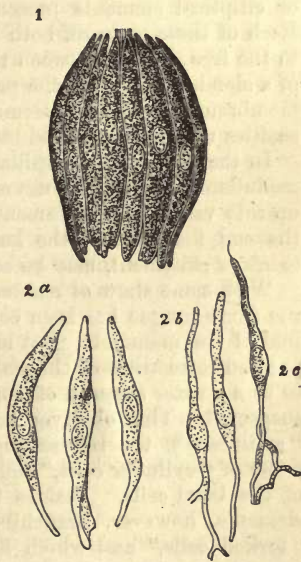


Fig. 571.—1. Gustatory bud from the rabbit. 2 a, encasing cells; 2 b, rod-cells; 2 c, a rod-cell with fine terminal thread.

Their appearance is the same as that of the terminal filaments of the gustatory cells. Fusion with the latter fibres has not been yet observed, however. The hidden position of the gustatory buds within the narrow grooves formed by the elevations of the papillæ seems to have some significance in regard to the persistence of after-taste sensations.

The mode of termination of the nerves of the *papillæ fungiformes* is not so well known. *Lovén* states that he has found a gustatory bud in the centre of the crown of each in the rat. *Krause* also mentions the same.

A few years ago some points of interest in regard to what we now know to be similar structural relations in the tongue of the frog were put forward by *Key*.

The tongues of frogs, namely, present, besides a narrower form of papilla, another broader species, reminding us of the *p. fungiformes* of mammals. On these we can better study the structural arrangement of such parts.

The side walls of these broad papillæ are clothed with columnar cells, the edges of the crown with ciliated epithelia. The surface itself of the crown, on the other hand, is covered by one of the other varieties of epithelial elements destitute of cilia. In the first place, columnar cells are to be seen giving off processes below, which anastomose with one another, forming thus a kind of network in which here and there imbedded nuclei may be recognised.

But between these cylinder cells, and at different heights, smaller roundish or elliptical elements present themselves, with relatively large nuclei. Each of these gives off both above and below a process; the first ascends to the free surface between the columnar epithelial elements in the form of a slender rod, while the process extending downwards into the mucous membrane is but an extremely delicate filament, on which minute varicosities may be recognised characteristic of the finest nerve fibrillæ.

In the axis of each papilla is a nervous twig, consisting of a few broad medullated tubes. At the end of the twig the latter axis cylinders split up into very delicate filaments, likewise varicose. They resemble greatly the end filaments of the last species of cell mentioned, and, according to *Key's* statement, may be seen to be directly connected with the latter.

With some show of reason, this coating of the crown of the papillæ of the frog's tongue has been compared to a superficially unfolded gustatory bud of the mammal. But more recent investigation by *Englemann* has put the correctness of this comparison again in question, and has revealed to us a greater amount of complexity in structure here than was at first suspected. This observer notices, in addition to his "bowl-cells" (the "cylinders"), the rod-bearing structures of *Key*, to which he gives the name of "cylinder cells," and whose nervous nature he denies, as also that of the bowl cells. Besides these, he speaks of another peculiar set of elements, however, branching both above and below, which he calls "forked cells," and which he regards as the terminal structures of the gustatory nerves, with whose axis-cylinders the ultimate ramifications of their inferior processes are continuous.

§ 306.

The *organ of smell*, to the consideration of which we now pass on, consists, as is well known, of the two *nasal fossæ* and *accessory cavities* in connection with the latter. Besides being a sensory apparatus, this organ also serves as a passage for the respiratory system, and a canal for the reception of the tears.

But the whole of this organ does not participate in the perception of odours. It is only the upper portions of the two greater cavities which preside over the reception of this particular kind of impressions; the other parts are either accessories in the process, or merely endowed with ordinary sensation through twigs of the trigeminus nerve.

That portion of the organ designed for the perception of odours corresponds to the distribution of the olfactory nerves. It consists generally of the upper part of the septum, the superior, and portion of the middle turbinated bones. It is remarkable for its yellow or brownish tint, better seen in the mature than in the newly born animal, and but slightly pronounced in man. It is further liable to vary in extent in different individuals, especially of the human species. To this tract the appropriate name of *regio olfactoria* has been given (*Todd and Bowman*). The older name of *Schneiderian* membrane may be retained for the remainder of the mucous surface not endowed with perceptive power.

The bony boundaries of the organ of smell need not be described, nor its cartilages, which consist of hyaline tissue.

The external skin of the nose is thinly clothed with epidermis, and contains, together with a few sweat glands, a large number of sebaceous glands of considerable size (§ 198). In the anterior nares strong hairs are to be found, known as *vibrissæ*, designed to prevent, to a certain extent, the entrance of foreign bodies. Internally, the coating of flattened epithelial cells extends for a certain distance from the entrance, and then gradually gives way to a slightly laminated ciliated species already alluded to, which extends from thence throughout all the cavities of the organ. Here, also, we find beaker-cells, except in the *regio olfactoria* (*Schultze*).

The *Schneiderian* membrane, which is very vascular in the greater cavities, differs much in structure in particular localities. In the accessory cavities it is thinner, and so intimately connected with the surface of the bone, that its submucous tissue plays the part of periosteum to the latter. In the nasal fossæ proper, the mucosa attains, on the contrary, greater, and at certain points, very considerable thickness. Here it is richly supplied with *racemose mucous glands*, which only occur very sparingly in the adjacent cells. It presents, also, in this region, a dense plexiform arrangement of blood-vessels, especially of veins, to which is due the great tendency of the nose to bleed. The mode of termination of the sentient nerves of the nose is still unknown.

REMARKS.—Compare *Todd and Bowman*, *l.c.* vol. ii. p. 1, and *Schultze*. Untersuchungen über den Bau der Nasenschleimhaut, namentlich die Structur und Endigungsweise der Geruchsnerven bei dem Menschen und den Wirbelthieren. Halle, 1862.

§ 307.

The *regio olfactoria* (fig. 572, left) offers for our consideration a very remarkable and extremely delicate tissue, whose constituents are peculiarly liable to suffer early from decomposition. For our present acquaintance with its nature we are particularly indebted to *Schultze*, and before him, for many points, to *Eckard* and *Ecker*. Apart from difference of colour, it may be distinguished from the surrounding membrane by its greater thickness, and dissimilarity in the species of glands it contains, as well as in not possessing ciliated epithelium.

The glands in question (*D*) have been named by *Koelliker* after their discoverer *Bowman* (§ 189). They belong to the tubular species, and

remind one of the follicles of *Lieberkuhn*. In the central portion of the regio olfactoria they present themselves in great number, becoming more scattered towards the edge, and finally disappearing. Their form is that of an elongated tube, somewhat twisted below, and of varying calibre, generally narrowing greatly at the mouth (*d*). Internally they are lined with rather large gland-cells, containing usually a considerable quantity of small yellow or brown pigment molecules, which fact explains, to a certain extent, the peculiar tinge of the olfactory region. These glands of *Bowman*, whose existence was formerly erroneously denied, are to be found in all the lower mammalia (2), and are not absent in man, although they take the form here of a kind of transition to ordinary racemose glands (*Frey, Schultze*). The secretion of *Bowman's* glands, as regards its composition and physiological significance, has not yet been made the subject of investigation.

Thus, we find the olfactory region in the lower mammals and human infant (*Schultze*). In the adult, also, spots quite destitute of cilia are to

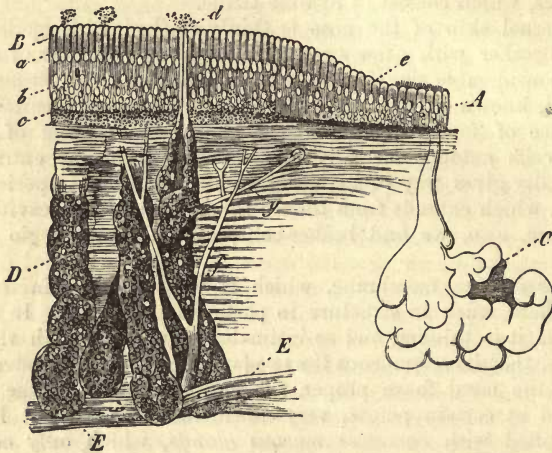


Fig. 572.—The olfactory region of the fox in vertical section (after *Ecker*). *B*, columnar epithelium; *a*, line of nuclei; *b*, of olfactory cells; *c*, of pigmented layer. *A*, adjacent ordinary ciliated epithelium; *e*, boundary between the two. *C*, ordinary racemose mucous gland. *D*, glands of *Bowman*, with excretory ducts, *d*. *E*, a branch of the olfactory nerve; *f*, ascending twig ramifying at *g*.

be found, which vary, however, considerably in extent. But, under certain circumstances, the whole regio olfactoria has been observed to be clothed with ciliated columnar cells (*Gejenbaur, Leydig, and H. Müller, Welcker, Luschka, Henle, with Ehlers*).

When we take into consideration the varying acuteness of the sense of smell in different individuals, and also that frequently recurring catarrh may induce changes of structure, this need not surprise us.

At the border of the regio olfactoria the ordinary ciliated epithelium gradually terminates (fig. 572 *A*), giving place to a no longer laminated covering of long cylindrical cells (*B*). These (fig. 572, *B*; 573, 1 *a*, 2 *a*) dwindle down below into thread-like processes, which descend into the subjacent connective-tissue, where they become widened again, and undergoing division, unite by means of their branches with one another. In this way a network of fibres, or rather of more or less homogeneous bands,

is formed. Between these cylindrical elements there remain naturally interstices, which serve for the reception of another species of cell, to be referred to again immediately. The occurrence of particles of yellowish or brown pigment, either in the upper broader portion of the columnar cells (fig. 573, 2 *a*), or deeper down below their nuclei (fig. 572, *c*), is peculiar; these granules may not unfrequently be seen also in the widened portions of the processes (fig. 539, *c*). The former is the case in man and many of the mammalia. Like the contents of the glands of *Bowman*, these coloured particles communicate to the locality in which they are situated a peculiar tint.

Between these decidedly epithelial elements (and moreover, in all vertebrate animals) a second species of cell presents itself (fig. 573), different in shape and composition, and of nervous nature. These cells consist of a fusiform body (fig. 573, 1 *b*, 2 *b*), situated deeper down, however, than the bodies of the first kind, containing a vesicular nucleus and finely granular contents. From both poles of each of these nervous structures, as they are held to be, these olfactory cells, a process is given in opposite directions. The descending (fig. 573, 1 *d*, 2 *d*) is of extreme delicacy, and liable to undergo early decomposition. At intervals it is studded with minute varicosities, recalling to mind those of very fine nerve tubes (§ 176). The ascending process (1 *c*, 2 *c*) is, on the other hand, thicker and less knotted, presenting a more or less smooth outline. It has the form of a slender cylinder or rod, 0.0018 or 0.0009 mm. in diameter, reminding us of one of the elements of the retina, to be referred to presently.

These rods mount up between the columnar epithelial cells to the surface of the mucous membrane, terminating here in various ways. In the frog and allied amphibians (in which they may be easily seen), they are surmounted at their free extremity (fig. 573, 1 *e*) by a set of delicate hairs of considerable length, in a certain number of which ciliary motion has been observed, while others, generally the longest, remain quite stiff. These two kinds of "olfactory filaments" appear to be linked together by intermediate forms. In other amphibia and birds very similar, and in certain cases, even longer hairs are to be found, either in large numbers or single (*Schultze*); none have been observed among the fishes. In man, and the rest of the mammalia also, we may seek in vain for these paradoxical cilia. Here we only remark small appendages, about from 0.0023 to 0.0045 mm. in length, seated on the extremities of each rod (fig. 573, 2 *e*), and projecting beyond the ends of the columnar cells; these, however, are only artificial productions.

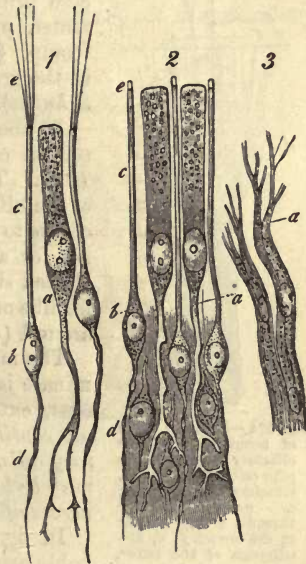


Fig. 573.—1. Cells from the *regio olfactoria* of the frog. *a*, an epithelium cell dwindling below into a ramifying process; *b*, olfactory cells, with descending fibres *d*, peripheral rods *c*, and long cilia, *e*. 2. Cells from the same locality in man. The letters and description are the same here, only that little (artificial) appendages appear at *e*, upon the tips of the rods. 3. Nerve-fibres of the olfactorius from the dog, breaking up at *a* into fine fibrillae.

In order the better to understand the nature of these remarkable olfactory cells, we must now make ourselves acquainted with the arrangement of the branches of the first cerebral nerve.

In one of the foregoing sections (§ 299) we have already described the olfactory lobes, and seen that the nerves of scent take their origin from peculiar lumpy masses in the lower surface of the latter, in the form of bundles of pale fibres. A few dark-edged fibres, which have been met with by *Remak* and *Schultze* in the olfactory nerves, are probably derived from anastomosis with the trigeminus.

The true olfactory fibres are pale elements, 0.0045–0.0074 mm. in thickness, enclosed within a nucleated sheath. The contents of the latter are not constituted by a single axis cylinder, however, but, as was found by *Schultze*, by a bundle of extremely delicate varicose primitive fibrillæ, 0.0023–0.0002 mm. in diameter, presenting a secondary nucleus formation (comp. § 175). Similar fibres are to be found in the grey matter of the bulbus olfactorius (*Walter, Schultze*).

In the mucous membrane of the regio olfactoria several other bundles may be recognised (fig. 572, *E, f*). These spring at acute angles from branches of the olfactory twigs, and give origin in their further course to the true (complex) nerve tubes. The latter are for a short distance enclosed within their nucleated sheaths, until eventually the delicate varicose fibrillæ of the interior stream out free into the tissues around (*Schultze*).

The mode in which these filaments ultimately terminate is not yet fully ascertained. It seems, however, extremely probable that the varicose fibrillæ are continuous with the descending fibres of the olfactory cells, so that these bodies, with their narrow rods, may be looked upon as the terminal structures of the nerves of smell.

In fig. 574 we have given a diagram of the probable arrangement of parts here, which appears very nearly allied to the mode of final distribution of the gustatory nerves in the tongue of the frog (§ 305).

The fact, however, cannot be concealed, that the most recent observations by *Exner* on the structure of these parts have pointed to other conclusions.

According to him there is no such very sharp line of distinction between the two species of elements of the regio olfactoria, the olfactory and columnar epithelial cell; they are, he says, connected by intermediate forms.

Further, underneath these cells there exists a ("subepithelial") band-work of protoplasm, whose interstices are filled with nuclei. Into this (in man) thin network the ramifications of both kinds of cells sink from above, and become fused. From below, also, the olfactory fibres ascend into it. Thus we have in it an intermediate nervous plate.

The course of development of the olfactory organs in the embryo,

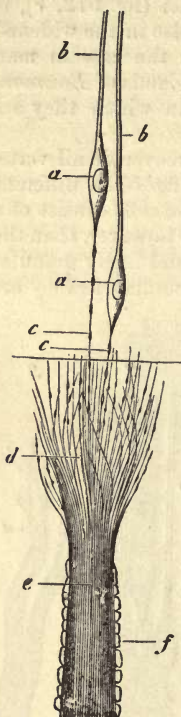


Fig. 574.—Probable mode of termination of the olfactory nerves in the pike (after *Schultze*). *a*, olfactory cells; *b*, rods; *c*, deeper varicose threads; *e*, axis fibrillæ in the sheath *f*; *d*, distribution of the latter. At — missing connection with the corresponding fibres, *c*.

although followed up in its broader outlines, has not been minutely investigated up to the present.

REMARKS.—(1.) In many of the mammalia we meet with peculiar structures, known as the organs of *Jacobson*. These consist of tubes, with cartilaginous walls, and are situated in the substance of the palate; they open into the duct of *Stenson*. In these is contained a branch of the olfactory nerves. In their texture they resemble much the regio olfactoria (*C. Balogh.*).—(2.) *Bowman's* glands may be made out with comparative ease.—(3.) Those delicate fibrillæ which spring from the inferior end of the olfactory cells, and those which are derived from the spreading out of the olfactory nerves, resemble each other in the most complete manner in every respect. But the difficulties connected with investigation in this direction have hitherto rendered it impossible to demonstrate a direct transition of one into the other. On this account we have marked the gap between the two with a line.

§ 308.

The organ of sight is made up of the eyeballs and a series of other accessory structures. These consist of membranous parts, as the eyelids, of glands, especially the *lacrimal*, and of muscles.

The *bulbus oculi* (fig. 575) is formed almost entirely of a system of

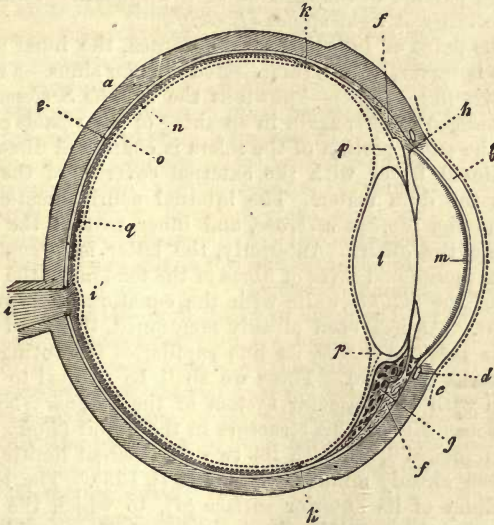


Fig. 575.—Transverse section of the eye, after Helmholtz. *a*, the sclerotic; *b*, cornea; *c*, conjunctiva; *d*, circulus venosus iridis; *e*, tunica choroides and membrana pigmenti; *f*, ciliary muscle; *g*, processus ciliaris; *h*, iris; *i*, optic nerve; *j*, colliculus opticus; *k*, ora serrata retinae; *l*, lens; *m*, membrana of Descemet; *n*, membrana limitans retinae; *o*, membrana hyaloidea; *p*, canal of Petit; *q*, macula lutea.

capsules. Its posterior and larger segment is constituted by the opaque *sclera* (*a*), while the anterior and smaller division is made up by the transparent *cornea* (*b*). Internally it is lined by a system of blackened membranes—the *uvea*, consisting of the *choroid* (*e*), the *ciliary processes* (*g*), the *ciliary muscle* (*f*), and diaphragm, or *iris* (*h*). The cavity of this hollow globe is filled with various refracting media. These, among which the *cornea* may be numbered as the most anterior, are the fluid of the chambers of the eye (anterior to *l*), the crystalline lens (*l*), and the vitreous humour (behind *l*). The greater part of the cup-shaped expansion of the optic nerve, or *retina* (*i*), is covered by the latter.

Besides these parts, we have in the eye a complicated vascular *system*, derived almost exclusively from the ophthalmic artery. This may be considered as consisting of several divisions, with separate afferent and efferent vessels, but communicating one with another. These are (*a*) the system of the retina, (*b*) the ciliary system, and (*c*), as far as the globe of the eye is covered by the conjunctiva, the conjunctival system.

REMARKS.—(1.) Compare *Bowman*, Lectures on the parts concerned in the operations of the eye, &c. London, 1840.

§ 309.

The *sclerotic*, the *hard*, or *white tunic* of the eyeball, belongs to the large group of fibrous membranes. Like these it consists of a dense interlacement of connective-tissue bundles, intermixed with numerous fine elastic fibres, which appear in greatest number on the internal concave surface. The mode in which these bundles are interwoven is peculiar—one set anastomosing around the entrance of the optic nerve, and radiating from thence meridionally towards the edge of the cornea, while another set is arranged parallel to the equator of the eyeball. Thus the fasciculi intersect each other at right angles (*Loewig*).

Close to the point of insertion of the cornea, the inner surface of the sclerotic coat is traversed by a complicated circular sinus—a regular plexus of venous twigs (fig. 575, *d*)—known as the *canalis Schlemmii*, to which we shall be obliged to refer again in speaking of the vessels of the choroid. Posteriorly, the outer portion of the sclera is connected directly by means of its meridional fibres with the external covering of the optic nerve, derived from the *dura mater*. The internal neurilemmatic substance of the nerve, and the *lamina cribrosa*, and inner part of the sclerotic, also merge one into the other. Anteriorly, the latter is strengthened by the addition to its meridional layer of fibres of the tendons of the *recti* muscles, while those of the *obliqui* unite with the equatorial fasciculi in the posterior segment. As has been already mentioned, this hard membrane of the eyeball is *poor in vessels*, its fine capillaries presenting rather large-meshed networks (*Brücke*). These we shall be obliged to refer to again in connection with the vascular system of the bulbus. Nerves are said to have been met with in this structure in the rabbit (*Rahm*).

The *cornea* (fig. 576, *a*), with its two transparent limiting membranes (*b*, *c*), has been already minutely described (§ 133). The laminated flattened epithelium of its anterior surface (*d*), to which the name of *conjunctival layer of the cornea* has been given, was also considered, and also the simple cellular covering of the posterior surface (*e*), (§§ 87 and 88).

The peculiar chondrin-yielding tissue of the cornea becoming somewhat changed towards the periphery, is continuous with the ordinary collagenic connective-tissue of the sclerotic, more particularly with its meridional fasciculi. At its edges the membrane of *Descemet* undergoes a peculiar transformation into streaky membranous masses, which are then disposed in various ways. The most external pass partly into the posterior wall of the canal of *Schlemm*, and are in part lost in the ciliary muscle of the choroidea; the internal break up eventually into bands and cords, which pass across the anterior chamber, disappearing in the tissue of the iris. They thus constitute the *ligamentum pectinatum* of the latter (see below).

In adults the cornea appears almost completely destitute of *blood-vessels*. At the border alone a narrow row of them, from 1·1 to 2·3 mm.

in diameter, may be observed, being the last trace of a more extensive vascular covering of the anterior surface of an earlier period of existence. Here we find either a single or double row of fine capillary loops, derived from the anterior ciliary arteries. The calibre of the capillaries is from 0.0090 to 0.0045 mm. They reach as far inwards as the fibrous portion of the conjunctiva extends over the edge of the cornea. Among the lower mammals they usually form a broader zone, in which case they are joined by deeper, finer capillaries, springing from the vessels of the sclerotic. The latter accompany the nervous twigs, supplying the part and end likewise in loops.

Whether the cornea is possessed of *lymphatics* or not is a question still undecided, in spite of very extended research. We have already seen, in § 133, that this very peculiar tissue of the cornea is traversed by a system of passages containing contractile wandering cells, and remarkable for their great dilatibility, and which seem also to possess a species of modified lining membrane. We have also stated that this set of canals is capable of being injected artificially, when, either strongly distended "corneal tubes" present themselves, or finer passages (*Bowman, Recklinghausen, Leber, Schweigger-Seidel, and Lavdowski*). But the fact that from them the lymphatics of the conjunctiva may be eventually filled does not seem a conclusive proof that they are of lymphatic nature.

The *nerves* of the cornea, so frequently the subject of study, are derived almost exclusively from the ciliary branches, and have two modes of termination,—they end, namely, either in the epithelium or in the proper tissue of the cornea. They spread from the border of the latter into its substance in considerable number, the adult cornea presenting about 60 (of a diameter of 0.02–0.055 mm.), while that of the infant has only from 30 to 34 (*Sämisch*).

Close to the edge of the cornea these thicker or thinner twigs, as the case may be, are observed to contain delicate, but clearly-defined primitive fibrillæ of from 0.0045 to 0.0023 mm. in diameter. Their perineurium is rich in nuclei.

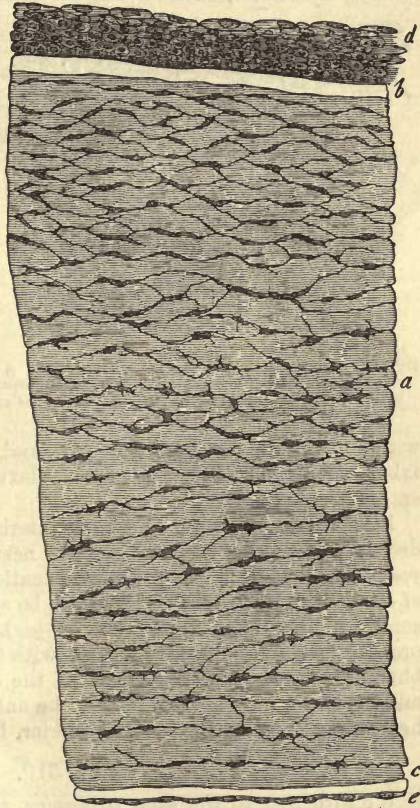


Fig. 576.—Vertical section of the cornea of an infant (shortened considerably, however). *a*, corneal tissue; *b*, anterior; *c*, posterior transparent lamina; *d*, laminated, flattened epithelium of the anterior; and *e*, single layer of the posterior surface.

Rapidly decreasing in size, the nerve fibres quickly lose their medullary sheath, and are then suddenly found, at a greater or less distance from the border of the cornea, in the form of filaments, reduced in diameter to 0.0009 mm., which, under the action of certain reagents, are seen to be varicose. The bundles of fibres run in a direction towards the centre and anterior surface of the cornea, and in their course divide and subdivide over and over again, forming by intercommunication a nervous plexus at the nodal points, of which nuclei may be observed. At the same time, an increase of the number of the fine fibrillæ unmistakably takes place, while, on the other hand, the perineurium is no longer to be seen.

Of these nervous plexuses there are several, lying one over the other. The most anterior, with its delicate bundles of fibres, was looked upon by

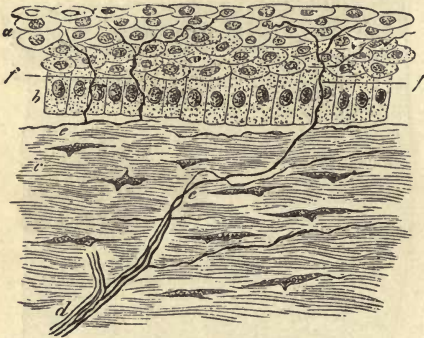


Fig. 577.—Vertical section of the cornea of a rabbit. *a, b*, epithelium; *d*, a nervous twig; *e, f*, sub-epithelial distribution of fine varicose nerve fibrillæ; *f*, distribution and termination in epithelium.

earlier observers (*His*) as a terminal network of the nerves. From it, however (fig. 577), bundles of fibres are again given off, which pierce the anterior surface of the cornea (*Hoyer, Cohnheim*), and, splitting up into tassels, form that sub-epithelial interlacement already mentioned (§ 177), whose perpendicularly ascending fibres terminate in the epithelium (*Cohnheim*).

At its border this last interlacement receives other twigs, which enter the cornea

with the minute vessels of that part, and, ascending more or less abruptly, takes part in the formation of the plexus, and extend also as far as the anterior surface.

Besides these sensory nervous interlacements, the cornea possesses deeper plexus-like ramifications of nerves. *Kühne* maintained, many years ago, that in the frog the termination of the varicose end filaments of these in the epithelial cells might be seen; but this has not been since confirmed (*Koelliker, Engelmann, Hoyer*). Here also the primitive fibrillæ probably terminate, in part at least, with free ends. They are to be found but rarely in the posterior layers of the cornea, in larger numbers in the middle, and tolerably abundant in the anterior portions. A plexus, seated here under the *lamina elastica* anterior, has been described by *Hoyer*.

§ 310.

We turn now to the *uvea* or *tunica vasculosa*, with its various constituents, mentioned above, and find the arrangement of parts much more complex than in the structures just dealt with.

The choroid is usually described as consisting of an external *fibrous coat*, and an internal single layer of pigmentary *flattened epithelium*, which latter belongs, properly speaking, to the retina, as we learn from the history of its development. In fig. 578 we have the latter figured again; but it has been already described, at greater length, in § 150. As we shall have to refer to these cells again in speaking of the retina, we shall, for the present, say no more about them.

Apart from this cellular coating, the uvea consists of several layers, not in all cases, however, distinctly defined one against the other.

First, and most internally, we find a *transparent limiting layer*, smooth, and only 0.0006–0.0008 mm. in the fundus of the eye-ball, but thicker, and presenting a more uneven internal surface anteriorly.

The next stratum is the *choriocapillaris*, an extremely dense network of nucleated capillaries (already spoken of in § 311), imbedded in a simple connective-tissue. This stratum extends to the ora serrata.

The third layer, the *proper choroid*, consists of a network of ramifying stellate, or irregularly jagged connective-tissue cells, with thread-like processes of varying length. These cells are remarkable for the great avidity with which they take up dark black pigmentary matters (fig. 579). We have already considered them under the name of "*stellate pigment cells*" in speaking of connective-tissue, p. 219. But what particularly characterises this layer further is the great abundance of arterial and venous vessels found in it. The first present a strongly developed muscular tunic. Longitudinal bundles of involuntary muscular fibres also occur in the posterior segment of the choroid accompanying these arterial vessels (*H. Müller*), and lymph cells likewise (*G. Haase*).

Externally the choroidal tissue is continuous, in the form of a soft, brownish connective substance with the sclerotic, and is known here as the *lamina fusca* or *suprachoroidea*.

Anteriorly, as is well known, the choroid is continuous with the *corpus ciliare* and its numerous *ciliary processes* projecting inwards. These structures are likewise clothed with the same flattened pigmentary epithelium. Here, however, the latter has become laminated, or at least double-layered (p. 143).

On and within the corpus ciliare, whose tissue resembles that of the choroid (although pigmentary cells are fewer in it), and which also possesses the same delicate limiting membrane as the latter, a peculiar involuntary muscle presents itself, the *tensor choroidea*, or *musculus ciliaris* (fig. 573, *f*), for the discovery of which we are indebted to *Brücke* and *Bowman*, while many important points, in regard to its nature, were subsequently put forward by *H. Müller*. This muscle, which has been so frequently the subject of investigation, was formerly held to be nothing but simple connective-tissue, under the name of the *ligamentum ciliare*.

It springs (fig. 580), at the line of union between the cornea and sclerotic coat, from the fibrous tissue which forms the internal wall of the canal of *Schlemm*, and its distribution is to the tissue of the ciliary body. Its fasciculi, closely crowded, maintain from this point of origin a radiating or meridional course backwards, and are lost in the external portion of the corpus ciliare. Here it is separated from the sclera by a thin prolongation of the so-called *suprachoroidea* (*Henle, Schultze*). Internally, that




Fig. 578.—Polyhedral pigment cells from the choroid of the sheep. *a*, mosaic of six-sided cells; *b*, a larger octagonal example.

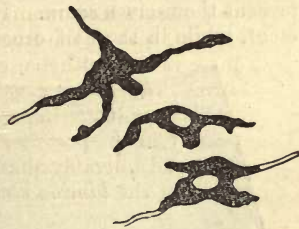


Fig. 579.—Pigmentary connective-tissue corpuscles (so-called stellate pigment cells), from the lamina fusca of a mammalian eye.

is to say, towards the ciliary processes, this tough muscular plate breaks up into a long, fan-shaped, wide-meshed network of thin bands (*b*), in which, at last, the direction of the fasciculi changes gradually from being meridional externally to equatorial in its inner portions, forming so the circular

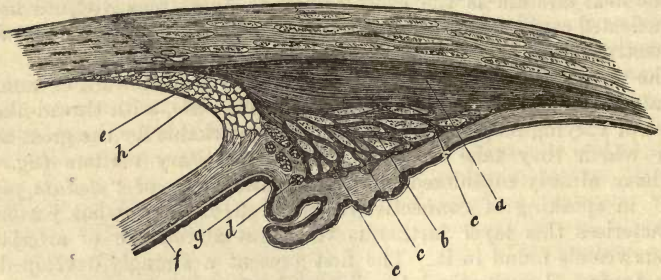


Fig. 580.—Section through the ciliary region of the human eye (after Ivanoff). *a*, radiating bundles of the ciliary muscle; *b*, deeper bundles; *c*, circular network; *d*, annular bands of Müller; *e*, tendon of ciliary muscle; *f*, muscles on the posterior side of the iris; *g*, muscles on the ciliary border of same; *h*, ligamentum pectinatum.

network. Finally, internally (*d*) the so-called “ring muscle” of Müller makes its appearance. This is formed of tolerably strong fascicles, the anterior quite independent, the posterior taking their rise from the muscular structure just mentioned.

This, then, is the arrangement of the ciliary muscle of man, but among the other mammalia it is thoroughly retiform (*Flemming*). It is strongest amongst the beasts of prey, weaker among ruminants, and especially so in the rodents. Although there still exists much difference of opinion in regard to many minor points relating to the functions of this muscle, it is commonly agreed that it plays an important part in the accommodation of the eye.

In the *iris* or *diaphragm* the connective-tissue cells of the whole uvea present themselves again. In blue eyes, however, they are devoid of pigment, while in those of other deeper tints they are more or less crowded

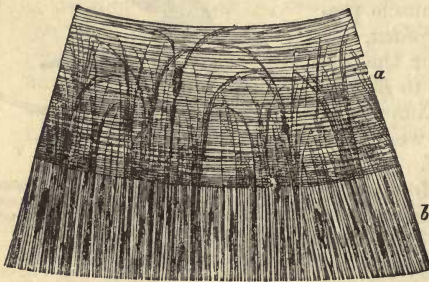


Fig. 581.—Surface view of the human iris (after Ivanoff). *a*, the sphincter; *b*, dilator of the pupil.

with either lighter or darker yellowish, brownish, or even black granules. Between these cells the ground substance is no longer homogeneous, but streaky and broken up into fibrillæ, in fact, it has become genuine fibrous connective-tissue.

The muscular character of the iris has been long recognised. In the first place, we encounter around the central aperture, but

more towards its posterior aspect, a muscle known as the *sphincter pupillæ*. This is composed of a system of circular bundles of smooth muscular tissue, of about 0.8–1 mm. in breadth in man (fig. 581, *a*). From this sphincter other separate bundles of contractile fibre cells take their rise (as

may be seen in the eye of any white rabbit), which, seated likewise in the back part of the iris, radiate outwards through the tissue of the latter.

Not so, however, in man.

The dilator appears, to be sure, here also to be a continuation of those circular fasciculi of the sphincter. At first, still in the neighbourhood of the latter, we may recognise separate arched interwoven bundles partly in the circular muscle, partly behind it. After passing beyond the limits of the circular muscle, however, these radiating bands unite to form a completely continuous muscular plate, with regular layers of fibres forming the posterior wall of the iris (*b*). At the ciliary border, at last, a circular layer is formed by the interweaving of thicker and thinner bundles springing from the muscular plate (*Iwanoff, Jeropheeff, Merkel*). The muscular substance of the iris, however, is not connected with the ciliary muscle.

The radiating fibres, then, just mentioned, constitute the *dilatator pupillæ*.

It is a fact of great interest, that the muscular tissue of the iris, which in man and the mammalia is composed of involuntary fibres, consists in birds and scaly amphibia of transversely striated fibres.

At its circumference the diaphragm of the eye receives another element of tissue on its anterior surface, in the form of the so-called *ligamentum pectinatum iridis* (*Huek*), (§ 309).

The fibres of the latter, originating in a transformation of the membrane of *Descemet*, as we have already seen, and covered at first with the normal epithelium of this coat, commence near the border of the cornea as a fine network, which is changed at the edge of the latter into a plexus of stronger bands. These pass free across the peripheral portion of the anterior chamber, and so reach the anterior surface of the iris, in whose tissue they are lost. The ligamentum pectinatum encloses a circular space crossed, of course, by bands of fibres known as the "canal of *Fontana*" (fig. 580, at *h*).

In regard to the nature of these fibrous masses much difference of opinion still exists. From their chemical reactions they would appear in man to be allied to the elastic tissues, without, however, possessing the same power of resistance to reagents, while among the mammalia they manifest rather the constitution of connective-tissue. In birds, again, they give the reactions of elastic tissue.

In all probability there was originally a cellular network here.

On its posterior surface the iris is covered by a laminated coating of pigmentary epithelium cells, and on its anterior aspect by a single layer of colourless polyhedral and roundish elements. These latter are continued in single rows over the bands of the ligamentum pectinatum.

Reserving the arrangement of the vessels of the uvea for the next section, let us turn now to the nerves of the same. These, the *nervi ciliares*, are distributed principally to the iris and ciliary muscle. Their number is from 14 to 18, and they spring for the greater part from the lenticular ganglion.

After piercing the sclera, these twigs advance through the external layer of the vascular membrane of the eye to the ciliary muscle, giving off in this course a few twigs to the choroid itself. The latter form superficial and deep plexuses, whose fibres are found to be partly medullated, partly pale, and among them small ganglia are formed by collections of nerve cells (*H. Müller, and C. Schweigger, Sämich*).

But the nervous supply of the ciliary muscle is much more abundant. Before their entrance into the latter the ciliary nerves have undergone repeated subdivision. Within the muscle they then form a ganglionic annular plexus, the *orbiculus gangliosus*, in which, according to *Krause* and *H. Müller's* observations, ganglia are to be found.

This plexus supplies twigs to the *tensor choroideæ*, besides those branches to the cornea already mentioned, p. 619, the iris, likewise, is innervated by it.

In the latter structure, twigs made up of medium-sized and fine dark-edged fibres may be observed to course inwards from the whole periphery, dividing as they go dichotomously. Converging while still in the peripheral portion of the iris, they commence the formation of an extremely complex nervous plexus, presenting rows of transversely anastomosing twigs. From this, then, in the first place, recurrent branches are given off towards the ciliary border, and then others directed more inwards. These, again, form an irregular network of nerve fibres,—about 0·0045–0·0023 mm. in diameter, at first medullated, but later on losing their medulla,—which at many of the nodal points presents triangular expansions. This plexus is then prolonged farther into an interlacement of the finest species of filaments, only 0·0020–0·0018 mm. in diameter. It is still an unsettled point whether this is a terminal network or not.

While this nervous interlacement just described belongs more particularly to the posterior wall of the iris, another is spread over its anterior surface. Its broader elements are probably sensory.

Finally, a plexus is found traversing the substance of the sphincter, whose fibres are at first still medullated, but later on pale in appearance.

REMARKS.—(1.) A very peculiar appearance is frequently to be found in the eyes of some mammals. This proceeds from the *tapetum lucidum*, a colourless glittering spot situated behind the choriocapillaris, between the most internal lamella of the choroid containing its capillaries and the middle coat, in which the larger vessels are contained. Among the ruminants, in the horse and elephant, &c., it consists of a delicate and regularly undulating arrangement of connective-tissue bundles, which, from the uniformity of their disposal in wavy lines, gives rise to a play of prismatic colours. In the carnivora, and in seals also, it consists, on the contrary, of smooth, blunt-angled nucleated cells. The cell-substance of these presents, according to *Schultze*, a very remarkable structure. It consists, namely, of extremely fine-pointed double-refracting crystals, arranged in groups within the cell. Each of these groups reflects the light from a particular angle of incidence into another, producing colour. Over the tapetum the epithelial cells are usually devoid of pigment molecules.

§ 311.

The *vascular system* of the uvea (fig. 582) has been the subject of much study both in earlier and later times. It has been lately investigated in the most thorough manner by *Leber*.

Owing to its extreme complication, it will require a very minutely detailed description, during which, however, we shall have an opportunity of referring again to the blood-vessels of the sclerotic and cornea already noticed cursorily (§ 309).

The choroid, corpus ciliare, and iris, all receive their supply from the *ciliary arteries* as they are called. Of the latter, those springing directly from the *ophthalmica* are known as the *posterior*, those given off from the arteries supplying the recti muscles as the *anterior*.

The first break up again into the *short* and *long posterior* ciliary vessels.

1. The *short posterior* ciliary arteries (*a, b*), three or four in number,

advance to the back of the bulb and split up there into a large number of twigs. Besides the hinder part of the sclerotic coat and point of entrance of the optic nerve (see below), they supply only the choroidea proper, about 20 small branches lying in the outer layer of the latter. Moreover, these are distributed chiefly to the back part of the choroid coat, and reach neither the iris nor ciliary processes. They are, however, connected at certain points both with the long posterior and the anterior ciliary vessels. Their end branches spreading out internally, break up finally into the capillary network of the *choriocapillaris* (*d, d*).

This capillary network, whose tubes measure from 0.0090 to 0.0113 mm. in diameter, is one of the most dense in the body, especially at the back of the eyeball, whereas, anteriorly, the meshes gradually increase in size. Its tubes (fig. 583) radiate from numerous central points, which are either arterial or venous terminal twigs. In the

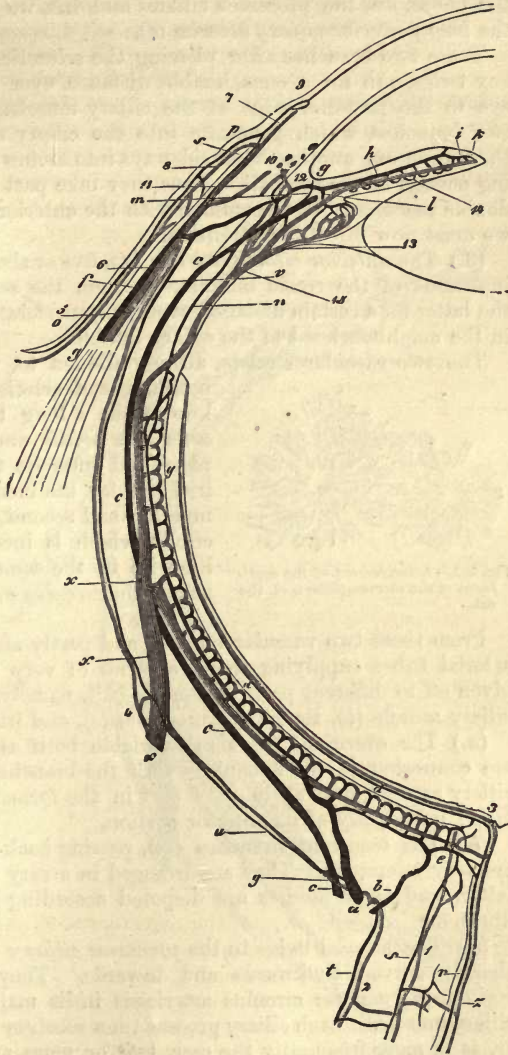


Fig. 582.—Diagram of the arrangement of the vessels of the eye-ball (after Leber). *a*, large, and *b*, small twig from a short posterior ciliary artery; *c*, long posterior; *d*, *choriocapillaris*; *e*, arterial collar around the optic nerve, and branches of the same to the latter; *f*, anterior ciliary artery; *g*, large circle of the Iris; *h*, artery of the same; *i*, small circle of the Iris; *k*, capillary network of the *sphincter pupillae*; *l*, artery of the ciliary process; *m*, artery of the musculus ciliaris; *n*, recurrent branch to the choroidea; *o*, posterior conjunctival vessel, and *p*, anterior; *q*, arterial branch to the border looped network; *r*, arteria centralis retinae; *s*, artery to the internal sheath of the optic nerve; *t*, artery to the external sheath of the same; *u*, twig from the short ciliary vessels to the sclerotic; *v*, twig from anterior ciliary artery to same; *x*, vein of one of the vortices; *y*, posterior *vena ciliaris*; *z*, central vein of the retina; *1*, vein of the internal sheath of optic nerve; *2*, of the outer sheath of same; *3*, vein and artery of the choroid which enter the optic nerve; *4*, vein of the sclerotic opening into the trunk of a vortex; *5*, anterior ciliary vein; *6*, its branches to the sclerotic; *7*, vein to the border looped network; *8*, anterior, and *9*, posterior conjunctival vein; *10*, venous ciliary plexus (canal of *Schlemm*); *11*, connection of the same with the anterior ciliary vein; *12*, vein of the ciliary muscle running into the plexus ciliaris; *13*, vein of the ciliary process; *14*, vein of the iris; *15*, vein of the ciliary muscle emptying into a vortex trunk.

Fig. 582.—Diagram of the arrangement of the vessels of the eye-ball (after Leber). *a*, large, and *b*, small twig from a short posterior ciliary artery; *c*, long posterior; *d*, *choriocapillaris*; *e*, arterial collar around the optic nerve, and branches of the same to the latter; *f*, anterior ciliary artery; *g*, large circle of the Iris; *h*, artery of the same; *i*, small circle of the Iris; *k*, capillary network of the *sphincter pupillae*; *l*, artery of the ciliary process; *m*, artery of the musculus ciliaris; *n*, recurrent branch to the choroidea; *o*, posterior conjunctival vessel, and *p*, anterior; *q*, arterial branch to the border looped network; *r*, arteria centralis retinae; *s*, artery to the internal sheath of the optic nerve; *t*, artery to the external sheath of the same; *u*, twig from the short ciliary vessels to the sclerotic; *v*, twig from anterior ciliary artery to same; *x*, vein of one of the vortices; *y*, posterior *vena ciliaris*; *z*, central vein of the retina; *1*, vein of the internal sheath of optic nerve; *2*, of the outer sheath of same; *3*, vein and artery of the choroid which enter the optic nerve; *4*, vein of the sclerotic opening into the trunk of a vortex; *5*, anterior ciliary vein; *6*, its branches to the sclerotic; *7*, vein to the border looped network; *8*, anterior, and *9*, posterior conjunctival vein; *10*, venous ciliary plexus (canal of *Schlemm*); *11*, connection of the same with the anterior ciliary vein; *12*, vein of the ciliary muscle running into the plexus ciliaris; *13*, vein of the ciliary process; *14*, vein of the iris; *15*, vein of the ciliary muscle emptying into a vortex trunk.

neighbourhood of the ora serrata this peculiar arrangement of vessels is no longer preserved.

(2.) Turning now to the sources of blood for the anterior portions of the choroidea, the processus ciliares and iris, we find besides the anterior the *long posterior ciliary arteries* (*c*).

These two branches after piercing the sclerotic, and without giving off any twigs, run for a considerable distance over the vascular coat of the eye to the posterior edge of the ciliary muscle. Here each splits into two branches, which penetrate into the ciliary muscle (*m*), and parting there from one another bend sideways into arches embracing a corresponding portion of the eye-ball. Thus they take part in the construction of a double vascular collar in common with the anterior ciliary arteries to which we must now direct our attention.

(3.) The *anterior ciliary arteries* (*f*), five or six in number, piercing the insertions of the rectic muscles, lie upon the sclera, and running along the latter for a certain distance, eventually perforate it with many branches in the neighbourhood of the ciliary muscle.

The two vascular circlets, already alluded to, which are derived from both kinds of arteries, are—first an anterior, known for a long time past, the *circulus arteriosus iridis major* (*g*), which is complete, and encircles the outer portion of the iris, but for the most part within the ciliary muscle; and second, a posterior and external circlet which is incomplete, and imbedded likewise in the same muscle. This may be named the *circulus arteriosus musculi ciliaris* (*Leber*).

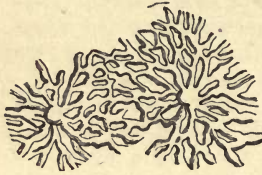

Fig. 583.—Arrangement of the capillaries of the choriocapillaris of the cat.

From these two vascular circlets, and partly also immediately from the arterial tubes supplying them, a series of very important branches are given off to different parts of the eye-ball, namely, to the choroid (*a*), the ciliary muscle (*b*), the ciliary processes (*c*), and iris (*d*).

(*a*.) The *choroidal twigs* (*n*), variable both as to number and calibre, are connected in the first place with the branches of the posterior short ciliary arteries, and again take part in the formation of the chorio-capillaris: principally of its anterior portion.

(*b*.) The recurrent branches (*m*), passing back into the *ciliary muscle*, are very numerous. They are arranged in a very fine network within the latter, and their meshes are disposed according to the direction of its fibres.

(*c*.) The arterial twigs to the *processus ciliares* (*l*) are very short tubes, sharply curved backwards and inwards. They enter the structures, springing from the *circulus arteriosus iridis major*, after traversing the ciliary muscle. Each ciliary process then receives either one special twig, or, as is more frequently the case, two or more are supplied to it by one such rootlet. In each process itself the arterial vessels split up rapidly, and subdivide into a considerable number of fine tubes, which form with arches of anastomosis a beautiful and characteristic network. From the latter then spring the venous radicles of the part.

(*d*.) The vessels supplying the *iris* (*h*) are all derived from the *circulus arteriosus iridis major*, and extend beyond the outer border of the latter in considerable number. Their direction is more or less towards the anterior surface, and convergent towards the pupil. Giving off lateral

Branches they form a long and wide-meshed capillary network. Near the opening of the iris a certain number of these tubules enter into the construction of a new vascular circlelet, the *circulus arteriosus iridis minor* (i), but the greater proportion of them bend back in loops, and merge into venous radicles after supplying the sphincter of the pupil.

§ 312.

The *veins* derived from this very complex arterial system do not correspond to its vessels (fig. 584).

The uvea is possessed of two sets of venous canals; of different degrees of importance however. The greater proportion of blood from this membrane is taken up, namely, by a moderate number of large trunks, the *venæ vorticosæ* (x) while the anterior ciliary veins (5) at the foremost part of the choroid, and especially in the ciliary muscle, play but a subordinate part in draining these parts. Veins, corresponding to the posterior ciliary arteries do not exist.

Let us first, then, direct our attention to the *venæ vorticosæ*.

These are situated in the external layer of the choroid, and are arranged in stellate figures or vortices, numerous wide venous trunks converging towards a central point. Of these vascular stars from four to six well-developed examples may be distinguished in addition to some others less perfect in form and poorer in radii. These several systems are connected together by transverse twigs. The blood of the choriocapillaris is conducted into them by fine veins

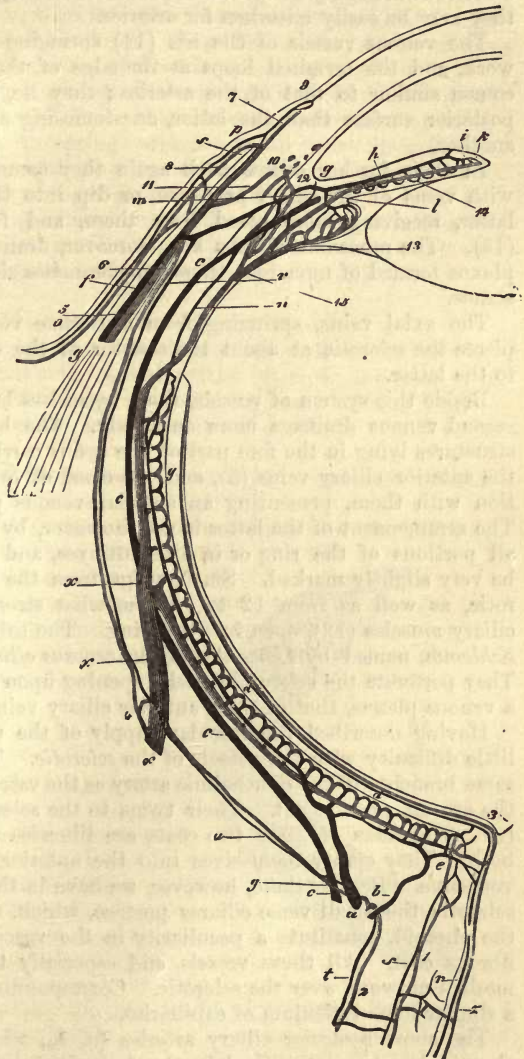


Fig. 584.

passing from behind from the fundus of the bulb, while that from the foremost portion of the choroid, as well as the ciliary body and iris, is also received into them.

In the *iris* and *ciliary processes* numerous frequently anastomosing venous radicles take their rise. Crowded close together, they unite at very acute angles to form larger branches, which reach the choroid after further intercommunication, and diverging here in groups empty themselves into the adjacent *venæ vorticosæ*. Owing to their slender make they may be easily mistaken for arteries.

The venous vessels of the iris (14) springing from the capillary network, and the terminal loops at the edge of the pupil (*h*), maintain a course similar to that of the arteries; they lie, however, nearer to the posterior surface than the latter, anastomosing also frequently with one another.

In their further course back again they communicate either directly with veins of the ciliary processes, or dip into the furrows between the latter, receiving more blood from them, and from the ciliary muscle (15). The *processus ciliares* are, moreover, drained by a regular venous plexus formed of numerous transverse branches situated within their substance.

The axial veins, springing from the *venæ vorticosæ* of the choroid, pierce the sclerotic at about the equator of the eye-ball to run external to the latter.

Beside this system of vessels, there is, as has been already remarked, a second venous drainage more anteriorly. The blood from some of the structures lying in the fore part of the eye is carried off, namely, through the anterior ciliary veins (5), and the canal of *Schlemm* (10) in connection with them, presenting an annular venous plexus (*Rouget, Leber*). The arrangement of the latter is not, however, by any means the same in all portions of the ring or in different eyes, and its retiform nature may be very slightly marked. Small twigs from the inner part of the sclerotic, as well as from 12 to 14, somewhat stronger branches from the ciliary muscles (12), open into this ring. The tubes, leaving the canal of *Schlemm*, named by *Leber* the *plexus venosus ciliaris*, are very numerous. They perforate the sclera obliquely, opening upon its external surface into a venous plexus, that of the "anterior ciliary veins."

Having described the vascular supply of the uvea, we shall have but little difficulty with the vessels of the *sclerotic*. This tunic is fed by the same branches of the ophthalmic artery as the vascular membrane, namely, the art. cil. post. et ant. Their twigs to the sclerotic are seen at (*u*) and (*v*). The veins of these two coats are likewise more or less common to both. They empty themselves into the anterior ciliary veins and *venæ vorticosæ*. Besides these, however, we have in the posterior part of the sclerotic the small *venæ ciliares posticæ*, which, receiving no blood from the choroid, constitute a peculiarity in the vascular arrangement of the fibrous coat. All these vessels, and especially the veins, form a wide-meshed network over the sclerotic. Corresponding to them we find also a similar loose reticulum of capillaries.

The short posterior ciliary arteries (*a, b*), whose distribution to the choroid has been described in the foregoing section, have peculiar and important relations in the neighbourhood of the entrance of the optic nerve into the eye-ball. They are (*e*) connected, namely, with the vascular supply of the retina (see below), which is otherwise a perfectly

distinct system of vessels. Two twigs from the posterior ciliary arteries form a ring around the nerve, sending off one set of small branches in between the fibres of the latter, and another externally to the choroid. In this way provision is made for indirect communication between the two circulations. In addition to this there is also a direct communication, however, consisting in arterial and fine venous twigs and capillaries, which pass directly from the choroid into the optic nerve.

The conjunctiva of the sclerotic is supplied by the vessels of the lids and lachrymal gland; it is, therefore, also independently provided. Its arteries are represented at (*o*) and (*p*). Near the border of the cornea only are they connected with those of the sclerotic.

Here, namely, the end branches of the scleral vessels communicate with one another in arches. From the latter, then, in the first place, recurrent loops are seen to spring, which course back through the conjunctiva, anastomosing with the proper vessels of that membrane. Further, there arise partly from these loops, and partly also from the terminal twigs of the anterior ciliary arteries themselves, the branches for that capillary network already mentioned (§ 309) situated round the border of the cornea. This is drained by the anterior ciliary veins to which we now turn.

These (5) receive their blood from four different sources.

(1.) The radicles springing from the border network of the cornea, which form a polygonal network encircling the latter, in the form of a ring from 4 to 7 mm. in breadth, lying upon the sclera. This is known as the episcleral venous network, and from it twigs of the ciliary veins take their rise (7).

(2.) In its whole extent the venous network just mentioned is reinforced from the capillaries of the sclerotic itself (6).

(3.) Into the ciliary veins, also, the efferent vessels of the canal of *Schlemm* (11), as well as those of the ciliary muscle (12), empty themselves.

(4.) Finally, we have venous twigs springing up in the neighbouring portions of the conjunctiva and corresponding to the arterial connecting arches, which unite with them.

§ 313.

The refracting media of the eye, situated behind the cornea, consist of the *aqueous humour*, the *lens*, and the *vitreous humour*.

Of these the *lens* (fig. 585), with its capsule, have been already described in speaking of the tissue of which it is composed (p. 276). The vitreous humour was also alluded to in connection with gelatinous tissue (p. 190).

There remains then for our consideration, in the first place, the *aqueous humour*. With it both chambers of the eye are filled. According to *His* it passes easily through the tissue of the cornea, and we know that when evacuated it is very rapidly replaced. The aqueous humour is an alkaline fluid of a sp. gr. of 1.003–1.009. It

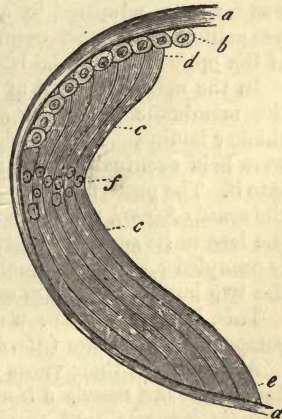


Fig. 585.—Diagram of the structure of the lens. *a*, capsule; *b*, epithellum; *c*, lens fibres; *d*, anterior; and *e*, posterior end; *f*, nuclear zone.

possesses no form elements, but is simply water containing 1-1.5 per cent. of solid matter in solution, which is secreted, probably, by the vessels of the ciliary processes and iris. The solids dissolved in the humour aqueous are albumen in combination with soda, urea according to *Millon* (p. 42), extractives, and mineral substances. Among the latter chloride of sodium is the chief.

We avail ourselves here of an analysis of *Lohmeyer's*, in which he gives the following average composition of the fluid, as found in the eye of the calf:—

Water,	986.870
Albuminate of sodium,	1.223
Extractives,	4.210
Chloride of sodium,	6.890
Chloride of potassium,	0.113
Sulphate of potassium,	0.221
Earthy phosphates,	0.214
Lime earths,	0.259

The refracting index of the human aqueous humour stands, according to *Krause*, at 1.3349. The exponents of refraction for the vitreous humour, lens, and cornea, are all mentioned with their respective tissues.

The fact that puncture of the *vitreous humour* causes the escape of some fluid, but not of all contained in it, seems to indicate (apart from its finer texture), the presence of some structure within it of membranous or septal nature. But this is still a matter of great obscurity. The existence of a system of concentric lamellæ, or of vertical partitions arranged like those of an orange, radiating from a centre, has been supposed by many from what they have observed in artificially hardened eyes. Neither of these views, however, has been confirmed.

But the presence of an external envelope, of the *membrana hyaloidea*, was for years admitted by all. This is an extremely delicate, structureless pellicle lying loose upon the retina, and only attached at the entrance of the optic nerve to the latter, and anteriorly to the ciliary body.

In the neighbourhood of the *ora serrata* it was formerly supposed that the *membrana hyaloidea* split into an interior delicate and posterior thicker lamina. These, increasing gradually in distance from one another, were held eventually to be inserted into the capsule of the lens and fused into it. The posterior leaf was known as the true *hyaloidea*, and the anterior the *zonula Zinnii*, while the passages enclosed within them, which encircle the lens in its equator, received the name of the *canal of Petit*. The latter is occupied either by a small amount of fluid during life (*Koelliker*), or the two lamina come into contact (*Henle*).

This, however, has been denied, within the last few years, by the most competent authorities (*Merkel, Iwanoff*).

According to their views there is no such thing as a special *membrana hyaloidea*, but merely a *limitans* of the retina, while anteriorly the *zonula ciliaris* becomes well marked as a special layer. *Schwalbe*, however, opposes this view in favour of the old idea.

The zone of *Zinn*, closely united to the ciliary processes, is indented by them, presenting somewhat the appearance of a ruff, inserted with its wavy border into the capsule of the lens. Although to the naked eye it appears formed of a strong transparent membrane, it presents under the microscope a system of very pale, stiff fibres, holding a meridional direc-

tion, best seen near the lens. These were discovered by *Henle*. They are some of them very fine, some stronger, as though made up of bundles of the first, and are often connected together in a retiform manner. In many points this membrane resembles certain kinds of connective-tissue, although we are unable to discover at the nodal parts the usual nucleus of the connective-tissue corpuscle. The fibres resist also, with great obstinacy, the action both of alkalis and acids.

§ 314.

The *retina* of the eye consists primarily of an expansion of the optic nerve; but, besides this, it contains other form-elements of various kinds, presenting a very complex structure. The extraordinary delicacy of this membrane, combined with its liability to rapid decomposition, render it one of the most difficult objects of histological investigation. For this reason the controversies, in regard to its structure, are still far from being set at rest, in spite of very extensive and thorough study, aided by the discovery of the action of chromic, and later of osmic acids, on such tissues.

Of the later observers who have largely added to our knowledge of the structure of the retina, *H. Müller* deserves to be first mentioned. More

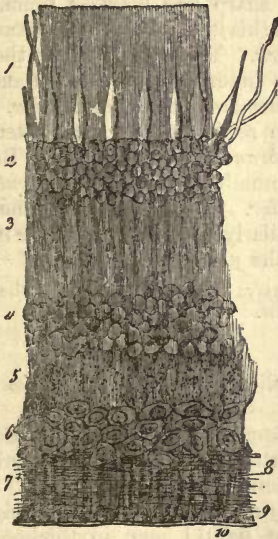


Fig. 586.

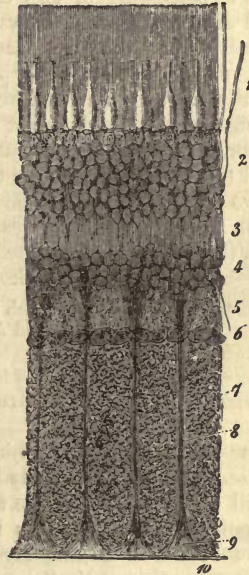


Fig. 587.

Vertical sections of the human retina. Fig. 586, half an inch from the entrance of the optic nerve. Fig. 587, close to the latter. 1, layer of the rods and cones (*columnar layer*), bounded underneath by the *membrana limitans externa*; 2, external granular layer; 3, intergranular layer; 4, internal granular layer; 5, molecular layer; 6, layer of the ganglion cells; 7, expansion of optic fibres; 8, sustentacular fibres of *Müller*; 9, their attachment to the *membrana limitans interna*; 10, the latter.

recently still, the master-mind of *Max Schultze* has swept away many of the difficulties which hung about this subject, on which he was justly regarded as the highest authority at the time of his lamented death, which took place on the 16th of January 1874.

The depth of this nervous coat, at the point of entrance of the optic nerve, where it is greatest, is from 0.38 to 0.23 mm. Anteriorly it thins off to about half of this, and at its foremost edge it is still 0.09 mm. in thickness. Here it ends with an undulating border, the *ora serrata*. External to the point of entrance of the optic nerve, and about 3.4 mm. from the centre of the latter, a yellow spot, the *macula lutea*, may be observed, an oval patch about 3.4 mm. long and 1.13 mm. in breadth, tinged with diffuse yellow pigment. In its centre it presents the *fovea centralis*, an irregular depression corresponding to a great decrease in thickness of the retina. The *macula lutea* is the point at which sight is clearest.

The retina (figs. 586 and 587) consists of the following layers, in succession from without inwards: (1) the layer of the *rods* and *cones* (columnar layer, 1.1); (2) the *membrana limitans externa* (between 1 and 2); (3) *external granular* layer (2.2); (4) the *intergranular* layer (3.3); (5) the *internal granular* layer (4.4); (6) the so-called *molecular* layer (5.5); (7) the *ganglionic cell* layer (6.6); (8) the *expansion of the optic nerve* (7.7); (9) of the *membrana limitans interna* (10.10); we add finally (10) of the *pigmentary* layer.

We have recently been brought to consider this chaos of textural elements as consisting of two essentially different constituents, although it is still difficult to draw everywhere a sharp line between them. The retina possesses in the first place (and in this it resembles the central nervous system) a *connective-tissue framework*. This springs up in the outer part of the retina, soon attaining, at the inner side of the rod and cone layer, considerable development as the *membrana limitans externa*. From this it spreads itself throughout all the retinal strata lying internal to this, and terminates by forming the *membrana limitans interna*. Between these two membranes are stretched a number of vertical *sustentacular* septa, the *radial* fibres, or fibres of *Müller*. The remainder of the retina—and in this is included a system of similarly *radiating* or *oblique* nervous fibrillæ—may probably be reckoned to the *nervous tissue*.

REMARKS.—Literature is very rich in new essays upon the structure of the retina. The last are those of *H. Müller* and *M. Schultze*.

§ 315.

We turn now, first of all, to the delicate *sustentacular tissue* of the retina.

For our acquaintance with this we are especially indebted to *M. Schultze*, and any one who has thoroughly investigated the subject with an unbiassed mind will be forced to concede the correctness of his views.

The point from which this framework of the retina starts (fig. 588, A) is a modified bounding layer, about 0.0011 mm. in thickness, the transparent *membrana limitans interna* (*l*). Anteriorly it is stronger than posteriorly. Its internal surface is smooth, but not so the external, from which a series of sustentacular fibres (*e*) take origin, which traverse almost the whole thickness of the retina, perpendicularly to its internal surface. These are known as the radiating fibres of *Müller*. Absent in the *macula lutea*, they increase in quantity anteriorly. They spring from the *membrana limitans interna* with a delicate triangular flat or conical pedicle, or with several extremely fine fibrils, which unite at very acute angles (*e*, below). In their course they give off numerous branches, by which they are connected one with another in a retiform manner. In addition

to these stronger bands, and passing into them without any sharp line of distinction, we find at certain points, but especially in the molecular (*g*) and intergranular layer (*d*), an extremely delicate porous or *spongy tissue* (*e*), like that already met with in the grey matter of the nervous centres. This (neuroglia) has been regarded by some as an artificial product, formed by the coagulating action of the chromic acid on some of the fluids of the tissue (*Henle*).

The spongy substance in question is so delicate in man and many other mammals, that with weak microscopic power we are only able to make out a dotted mass, perhaps adherent to the fibres of *Müller*. Very strong lenses, on the other hand, reveal its reticulated structure and connection with the sustentacular bands, whose outline on that account is by no means smooth. In different portions of the retina, however, this sustentacular matter presents much variety. In some of the nodal points nuclei are to be seen, so that here again we have the cellular equivalents of the grey matter of brain and spinal cord. In the internal granular layer the fibres of *Müller* are observed to be possessed invariably of elongated nuclei (*e'*).

The sustentacular matter we are considering extends as far as the internal surface of the so-called rod-layer (*columnar*).

Here we find a repetition of the relations already seen at the internal surface of the retina, although less marked, namely, a fusing together of the fibres of *Müller* to form a cribriform limiting membrane. To this (*a, a*), which usually presents itself in vertical section as a sharply defined line, the name of *membrana limitans externa* has been given (*Schultze*). But the name is unfortunately selected, for many of these bands of *Müller* apparently terminate before reaching it, in the first place—namely, in the intergranular layer, or even deeper still; and then, again, as very recent observations show, the connective-tissue sustentacular matter does not cease at the *membrana limitans externa*. It extends

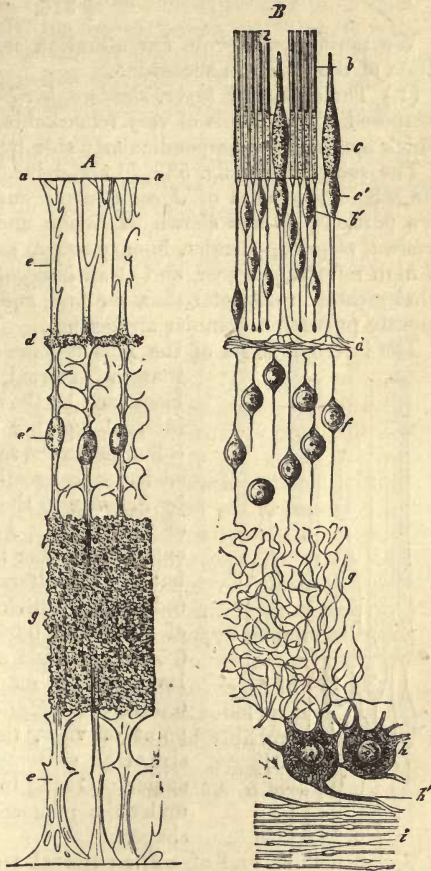


Fig. 588.—Diagram of the retina, after *Schultze*, with its connective-tissue portion. *a*, *Membrana limitans externa*; *c*, radiating, or *Müller's* sustentacular fibres, with their nuclei *e'*; *d*, framework of the intergranular, and *g*, of the molecular layer; *i*, *membrana limitans interna*.

further outwards still as a system of delicate envelopes, the consideration of which we must reserve for a future section.

§ 316.

We must now devote our attention more particularly to the several strata of the retina in succession.

(1.) The *columnar layer, stratum bacillosum* or *membrana Jacobi*, is composed of two kinds of very remarkable elements—the *rods* and *cones*, which are arranged perpendicularly side by side.

The *rods, bacilli* (fig. 589, *b*) are delicate cylinders extending through the whole thickness of *Jacob's* membrane. They consist invariably of two portions, as was shown by *Braun* and *Krause*, after *Müller*,—of an *external member*, slender, homogeneous, and transparent, and possessed of high refracting power, and of an *internal member*. The latter is somewhat greater in diameter than the first, and paler in outline; it not unfrequently presents a granular appearance.

The internal joints of the rods become more deeply dyed by carmine than the external, which, on the other hand, are blackened by the action of osmic acid, while the internal member remains for a long time quite colourless in the same. The reagent just mentioned has come greatly into use since its application by *Schultze* to the investigation of the structure of the retina. According to this observer, the external member is double refracting in the frog, but not the internal. The length of the whole rod in man, which is greatest in the posterior part of the eye, is 0.0600 mm.; more anteriorly it is 0.0501 mm., and at the *ora serrata* about 0.0399. Its thickness may be stated at from 0.0016 to 0.0018 mm. (*Müller*). Regarded from a chemical point of view, these structures appear to consist of an extremely perishable albuminoid substance. Owing to this, they present themselves under the microscope in the greatest variety of shapes.

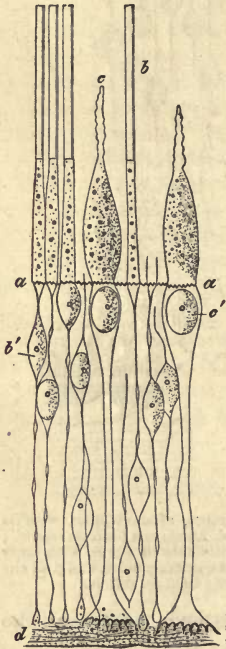


Fig. 589.—Rods and cones from the equatorial portion of the retina, after *Schultze*. *a*, *Membrana limitans externa*; *b*, rods; *c*, cones; *b'*, rod granule; *c'*, cone granule; *d*, intergranular layer.

The external truncated end of the column is in contact with the pigmentary epithelium of the choroid. In the three first classes of the vertebrates the cells of the latter form around the external members of the rods (and also of the cones) complete pigmentary sheaths.

This may also be seen among the mammalia, but slightly marked however. From the under surface of these cells filiform prolongations of their bodies extend downwards between the rods (and cones), like pencils of very fine hairs.

The inner members of the rods extend somewhat beyond the *limitans externa* in the form of very fine points, easily broken off, and which are prolonged into filaments of the most extreme delicacy. Under careful treatment with certain reagents, the latter are found to present varicosities, similar to those so characteristic of nervous filaments. Each of these bacillary threads traverses the external granular

layer perpendicularly,—or in other words, in a direction convergent towards the centre of the eyeball. Eventually it terminates in a body known as its “granule” (*b'*). We shall be obliged to refer to it again.

The rods of the retina, like the cones, belong to those few tissue elements of the animal body, which manifest characteristic differences among the various classes of living creatures. In the eyes of naked amphibians, such as frogs, toads, and salamanders, they are enormously large.

The great tendency to change after death, manifested by the rods, renders it a difficult point to decide how far many other structural peculiarities recently described by numerous observers really exist in the living retina.

The first point to be borne in mind is, that the internal member of the column is not found to be homogeneous among all the mammalia. In connection with the larger rods of the batrachia (fig. 590, 2, 3), of fishes (4), and even of birds (1), we meet—namely, with remarkable lenticular bodies of hemispherical or plano-parabolic figure, whose flat sides are applied to the bases of the external members (*a, a*). These structures are extremely rapid in decomposition (*Schultze*). They have been named “bacillary elipsoïds” (*Stäbchen elipsoïde*) by *Krause*.

It has been long known (but the process has been recently more fully investigated by *Schultze*) that the *external halves* of the rods may resolve themselves (fig. 591, 5) into a number of transverse plates, or if the process of decomposition have progressed farther, into thin disks, resembling slightly those of the muscle fibres.

The transverse markings are, in man and the mammals, about 0.0003–0.0004 mm. distant from one another (*Schultze*).

The *external members* of the rods present further, as has been known for years (*Hensen, Schultze*), a peculiar longitudinal striation. Transverse sections in the frog show that this is produced by a longitudinal grooving, running to the extent of internal cleavage.

However—and here we tread upon very uncertain ground—the internal joints of the rods in man, and many mammals (fig. 591, 1, 3), present superficial longitudinal striation too. This is, perhaps, directly continuous with the longitudinal cleavage rifts of the external members. It appears to correspond to a delicately grooved connective-tissue investing lamina, which would therefore represent an outward prolongation of the *membrana limitans externa*. Quite recently this has been named by *Schultze* the “fibre-basket.” According to this observer, however, the *internal joint* of the rod presents, likewise, a fibrillated structure, and, moreover, in the *interior*.

We shall now enter somewhat further into the consideration of the various views entertained upon this very obscure subject.

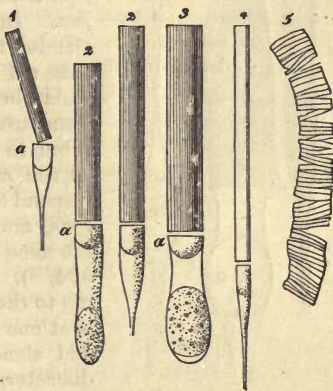


Fig. 590.—Structure of the rods of the retina. 1, From the hen; 2, from the frog; 3, from the salamander; 4, from the pike, showing external and internal members, and in the latter the lenticular bodies referred to in the text; 5, resolution of the external portion of a column into disks, from the frog (after *Schultze*).

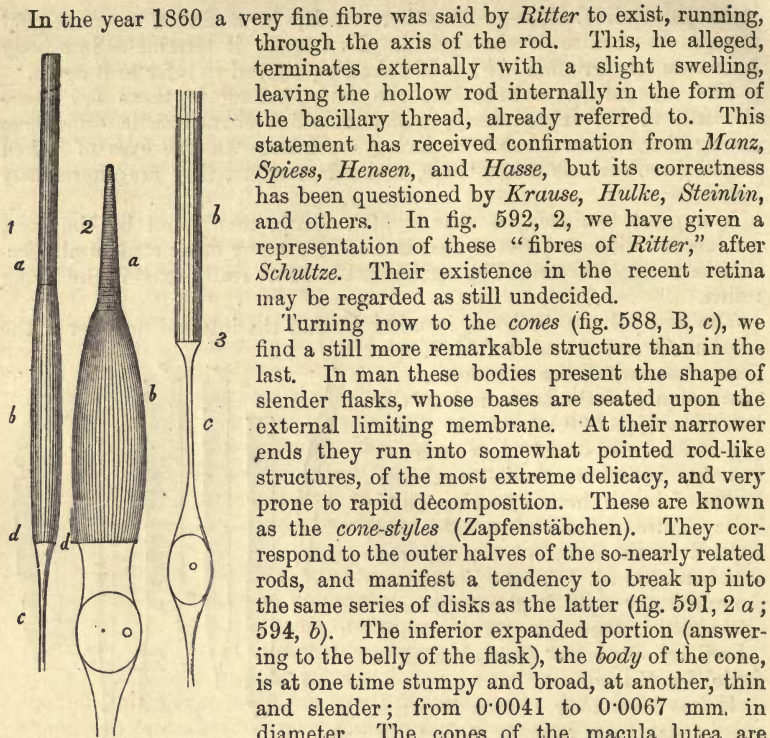


Fig. 591.—Fibrillar coating of rods and cones. 1. Rods. 2. Cones (of man). *a*, External; *b*, internal joint; *c*, bacillary threads; *d*, *limitans externa*. 3. Rods (from the sheep). The fibrillae here overtop the internal joint. The external member is missing (after *Schultze*).

intervening between the two. This body consists of a small oval or pyriform cell, possessing both nucleus and nucleolus, and belonging to the external granular layer of the retina. The whole length of the cones is, as a rule, somewhat less than that of the rods, and sometimes considerably so, as in the retina of the pig (*Schultze*).

In regard to the proportion of rods and cones in the human retina, much difference has been remarked according to locality. In the macula lutea, where the sense of sight is most acute, cones alone are to be found, as was discovered by *Henle* (fig. 593, 1). Around this spot the cones are still crowded, so that they are only encircled by single rows of rods (2). Further forwards and externally they occur more rarely, and are surrounded by several rings of rods (3). The number of the latter, therefore, in the whole retina, exceeds by far that of the cones.

The rods and cones of the ape tribe are similar in all points to those of the human being.

In most of our domestic animals, likewise, such as the ox, sheep, pig,

horse, and dog, the same variety in the distribution of both elements of the retina may be observed.

Strange to say, however, the retina of the bat is, according to *Schultze*, quite destitute of cones (although this is indeed denied by *Krause*). The same is the case with the hedgehog, the mouse, the Guinea-pig, and mole, as well as many nocturnal and burrowing animals.

In the cat we find but ill-developed cones, while in rabbit and rat traces merely of them exist (*Schultze*). Whether, as appears probable, the retina of the whale is quite without cones, is a point which requires further investigation.

The eyes of bony fishes approach those of man in many respects; their cones are of considerable size. In rays and sharks rods alone are to be found.

The case is quite different in birds and the naked amphibia. In the first of these cones are present in large numbers, reminding us of the yellow spot in the human eye. In the lizard and chameleon, on the other hand, rods are entirely absent; perhaps also in the snake.

The cones of the bird's retina are remarkable for peculiar spheroidal structures at the junction of style and body, more or less imbedded in the latter. They are glittering in appearance, and occupy the whole breadth of the cone, so that no ray of light can pass them by. They are usually of a yellow or red tint, but rarely colourless. In owls (nocturnal fowl, as every one knows) the long rods become again so prominent, and the cones so few in number, that the ordinary structure of the bird's retina is reversed. Red spheroids are never found here, and those yellow present become paler near the ora serrata.

Globules similar to those just mentioned are to be met with also among the scaly amphibia. In the cones of the tortoise they are red, yellow, or colourless; in lizards yellow.

Among the naked amphibia we find a few very small cones standing amid a host of colossal rods.

The former present either colourless or pale yellowish globules at the point of union of style and body.

The "twin cones," as they are called, discovered some time ago by *Hannover*, present to us another remarkable modification of these structures. These are united to each other by their lateral surfaces, remaining on the other hand quite distinct as regards their styles and bodies. They are frequently met with in bony fishes; but even in birds and amphibia may be found interspersed with the simple cones (*Schultze*).

They are probably the result of an uncompleted process of longitudinal segmentation of the simple elements (*Steinlin, Dobrowolsky*).

Those peculiar lenticular bodies already mentioned as occurring within

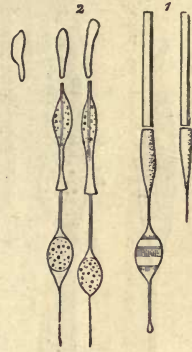


Fig. 592.—Structure of the rods of the retina. 1. From the Guinea-pig; a, with internal and external member; b, still in connection with a transversely striped granule. 2. Macerated rods from *Macacus cynomolgus*, with altered external and internal members, and the "fibres of Ritter" in the axes of the latter (after *Schultze*).

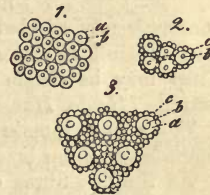

Fig. 593.—The stratum bacillosum viewed from without. a, cones; b, cone-styles; c, ordinary rods. 1. From the yellow spot; 2. from the border of the same; 3. from the middle of the retina.

the substance of the internal members of the rods, close to their junction with the outer halves (ellipsoids of *Krause*), are of not very infrequent occurrence in apes (fig. 594, *b*), frogs, and water newts (*Schultze*). The human cones possess them also (*Dobrowolsky*).

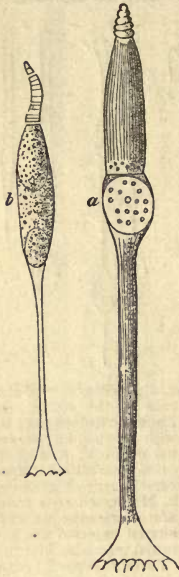


Fig. 594. — *a*, human cone with decomposed external member, and an apparently fibrous internal half; *b*, the same from *Macacus cynomolgus*, showing division into plates of the style, and lenticular structure in the body.

(2.) Having already devoted sufficient time to the consideration of the *membrana limitans externa* in the foregoing §, we shall now turn to the next stratum.

(3.) The *external granular layer, stratum granulosum externum* consists of, besides the sustentacular connective-tissue, several strata of small cells, whose scanty body merely covers thinly their nuclei (fig. 595, *A* between *a* and *d*). The whole bed ranges in thickness from 0.0501 to 0.0600 mm. over the greater part of the retina, but decreases in depth both towards the ora serrata and near the axis of the eye. The cells of which this layer is made up are connected both with the rods and cones, and have consequently been classed into *cone granules* (fig. 589, *b'*) and *rod granules* (*c'*). The former are somewhat pyriform or roundish oval in shape, and are remarkable for their size (0.0090–0.0120 in length, 0.0041–0.0061 mm. in breadth): they also possess both a large nucleus and nucleolus. They are never marked by those dark transverse lines discovered recently by *Henle*, which are only to be seen on the rod granules. We have already described these bodies as applied to the bases of the cones, so that nothing more need be said here. The second species of granules are smaller (0.0045–0.0079 mm.) oval, and generally more numerous than the last. They are rarely applied immediately to the bases of the rods, but are, as a rule, connected with the latter by a shorter or longer filament as the case may be. Those dark transverse zones, already alluded to, which are observed on them (fig. 592, 1), are still difficult to interpret. They are possibly *post-mortem* appearances. They may be single or multiple, but are usually double on each rod granule (*Henle, Hasse, Schultze*).

There now remain for our consideration the *nervous fibre elements* of the inter-granular layer.

As the fine fibres coming from the extremities of the rods enter the corpuscles above, so do they leave the same at their opposite end, and descending perpendicularly enter the inter-granular layer. Here they appear to terminate with a fusiform or button-shaped swelling, exceeding the ordinary varicosities in magnitude (fig. 595, *B*; fig. 589). But in reality they have a longer course. Thus *Hasse* has in many cases seen a delicate filament leaving this swelling, and losing itself in the inter-granular layer. He looks, therefore, upon the little body as “an interpolated ganglion cell.”

According to *Schultze's* observations, extremely delicate filaments may be seen very distinctly to spring from these small swellings (at least in birds and amphibia), and taking a horizontal course to become lost in the tangle of the inter-granular layer.

The fibres which descend perpendicularly from the cone granule through the external granular layer (fig. 589), differ from the rod fibrillæ in their greater thickness (reaching 0.0029 mm.) though still of great delicacy. They traverse the layer just mentioned in a straight course, coming likewise to an end at the outer surface of the stratum intergranulosum in a conical swelling. In this course they present considerable resemblance to axis cylinders, and give indications of being made up of the most delicate axis-cylinder fibrillæ (comp. § 176). *Schultze* states (the expansion on the fibres having been recognised, however, before by *Müller* and *Henle*) that in the stratum intergranulosum he has distinctly seen a splitting up of those cone fibres into extremely delicate fibrillæ, whose course from that on is horizontal (fig. 595, B, d). *Hasse*, on the other hand, never observed more than three of these processes, one single in the middle, and one at either side. He regards this expansion as triangular and smooth. The central process, he believes, moreover, he has followed up in a perpendicular course into the inter-granular layer.

It seems almost superfluous to remark that the external granular layer is only composed of rod corpuscles when the retina is destitute of cones.

Finally, this layer appears to possess no connective-tissue cells.

§ 317.

Passing on now to the consideration of the remaining layers of the retina, we take the next in succession.

(4.) The *stratum intergranulosum* or *intergranular layer* (fig. 595, A, B, d, d) which is about 0.010 mm. thick, is crossed, as we know already, by the radial fibres of *Müller*. The finely dotted substance of the intergranular layer, which presents the appearance of being streaked

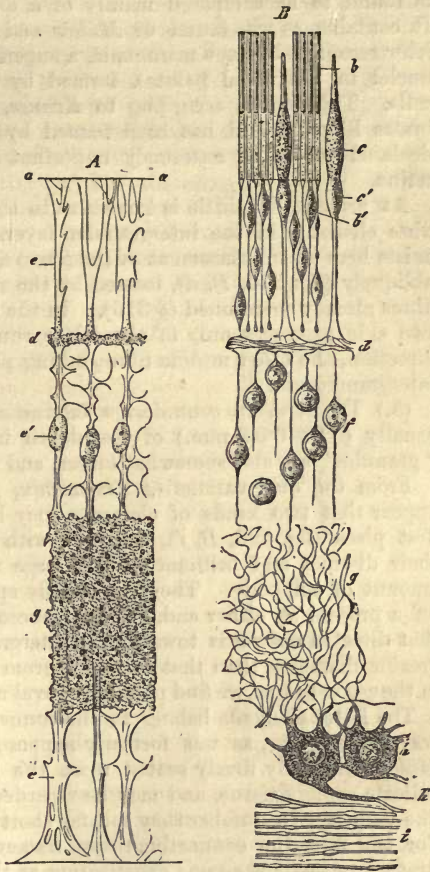


Fig. 595.—Diagram of the retina, after *Schultze*. B. neural constituents; b, rods with external and internal members; c, cones with style and body; c', cone granule; d, expansion of the cone fibre forming very delicate fibrillæ in the intergranular layer; d', granules of the internal granular layer; e, maze of very delicate filaments in the molecular stratum; f, ganglion cells; g, their axis-cylinder process; h, nerve-fibre layer.

perpendicularly by the fibres of *Müller* (when seen in vertical section) is found to be composed mainly of a dense connective-tissue network. It contains, as was found by *Müller* and *Schultze* in fishes, and as *Koeliker* recognised in the mammalia, a superficially expanded network (with nuclei in the nodal points), formed by the union of flattened stellate cells. This exists, according to *Krause*, as a single layer in all vertebrates likewise, and has been named by him *membrana fenestrata*, and declared to be an extremely important "boundary structure" for the retina.

At present but little is known as to the arrangement of the nervous fibre elements in the intergranular layer. According to *Schultze*, there exists here an interlacement of the finest fibrillæ running horizontally and obliquely (fig. 596, *B, d*), formed by the splitting up of the rod and cone fibres already mentioned (§ 316). In the opinion of *Hasse*, however, the two side processes only of the latter run a short distance in an oblique direction, the other middle fibre sinking perpendicularly into the stratum intergranulosum.

(5.) The *stratum granulosum internum* or *internal granular layer* is usually (0.03–0.04 mm.) of less depth in man than the external. Its "granules" are also somewhat larger, and more distinct in outline.

From the observations of *Vintschgau*, *Müller*, and *Schultze*, it would appear that two kinds of elements may be distinguished here. In the first place (fig. 596, *B, f*), we meet with roundish cells remarkable for their distinct and brilliant outline, large nuclei with nucleoli, and small amount of cell-body. They are usually spoken of as bipolar, *i.e.*, giving off a process at either end. These processes are extremely delicate, but that directed outwards towards the intergranular layer is of considerably greater diameter than that springing from the opposite pole (*Schultze*)—in the second place, we find pale-edged oval nuclei with large nucleoli (*A, e*).

The latter elements belong to the connective-tissue of the part. They are not, however, as was formerly supposed, imbedded in the fibres of *Müller*, but only firmly seated upon the latter, enveloped in masses of delicate spongy tissue, and may be regarded as the central points of cell-like bodies. In number they fall far short of the first species of granule. For the rest, the connective-tissue framework of the internal granular stratum presents the same constitution as that of the external.

Here also we are ignorant of the course of the nerve fibres. As in the last layer treated of, so here strong fibres, corresponding to the axis cylinders of the cones, are wanting in the *stratum granulosum externum*. We can only expect to find here primitive fibrillæ, or plexuses of the same. The fine threads which spring from both poles of the "granules," giving to the latter the appearance of small bipolar ganglion-cells, are probably fragments of such. After a short course, however, they are lost to sight. In some instances such a thread, springing from a cell situated high up, extends upwards into the inter-granular layer. Again, springing from cells seated low down near the *molecular layer*, filiform processes may be seen which sink into the latter.

(6.) The *stratum moleculare*, or *finely granular layer* (*Bg*), presents very much the appearance of the delicate molecular matter already encountered in the grey substance of the brain and spinal cord. Under high microscopic power, it is found to be made up of fine spongy tissue. As has been before mentioned (§ 315), this layer (in man 0.03–0.04 mm. thick) is traversed vertically by the fibres of *Müller*. It appears to contain a

complete maze (*B, g*) of the most delicate nerve fibrillæ (*Schultze, Steinlin, Hasse*), which, there is every reason to believe, spring from the bipolar cells of the internal granular layer and from the ganglion cells.

(7.) The *stratum cellulosum*, or *layer of the ganglion corpuscles*, is the next in order. It lies next the inner surface of preceding layer, but is indistinctly marked off against the latter. Its pale, delicate, membraneless cells (fig. 586, 587, 6; 596, *B, h*) are of different sizes, and may measure, when particularly large, 0.0377 mm. in diameter. They belong, partly at least, to the multipolar class, like those of the brain and spinal cord, and appear also to possess a fibrillated structure (§ 179, fig. 308). It is probable, also, that their ramifications have the same relations here as in the nervous centres. One of them directed inwards, the axis-cylinder process (fig. 596, *B, h'*) appears to be continuous with one of the horizontal optic fibres (*i*) of the *stratum fibrillosum* (*Corti, Rehak, Koelliker, H. Müller, Schultze, Hasse*, and others), while protoplasm processes, on the other hand, are given off externally (*g*), and it is supposed undergo repeated subdivision here, forming in the delicate spongy tissue of the molecular layer a tangle of the most delicate, and probably varicose filaments.

Finally, commissural processes have been stated to exist between adjacent ganglion cells (*Corti, Koelliker*); but this has lately been again questioned by many.

The depth of the stratum cellulosum (figs. 586 and 587, 6) varies in the most interesting way, according to locality. It is greatest opposite the yellow spot, where several rows of cells, sometimes from 6 to 10, may be observed lying one over the other. Here it may present a thickness of 0.0999 mm., except in the fovea centralis, where it is much less. With the distance from the macula lutea the ganglionic layer decreases more and more in depth, until but two rows of cells are to be seen, and then gradually one alone. In the vicinity of the ora serrata, finally, the ganglionic corpuscles are only met with singly, and with an ever-increasing interval between them.

In the middle portion of the retina the quantity of sustentacular con-

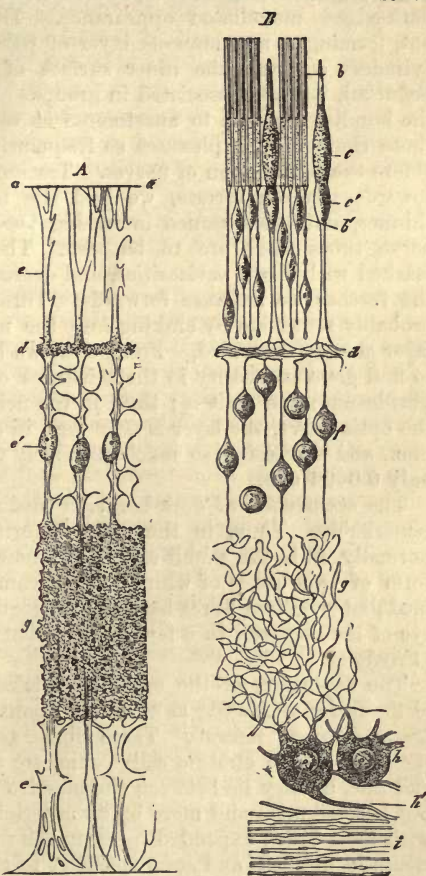


Fig. 596.

nective-tissue found between these cells is small, while anteriorly the fibres of *Müller*, becoming more and more numerous as we advance in that direction, form regular compartments for their accommodation.

(8.) We turn now to the *expansion of the optic nerve*, the *stratum fibrillosum*. The nerve tubes of the opticus, which, with *Schultze*, we believe to be possessed of no primitive sheath, and which must consequently be of the same nature as the nerve tubes of the centres, lie in the trunk of the former in bundles, separated by interstitial connective-tissue. Here they are to be seen as dark fibres 0·0045–0·0014 mm. in thickness, and frequently varicose; and in this form they pass through the lamina cribrosa. In their passage through the funnel-shaped opening in the sclerotic, and as far as the *colliculus nervi optici* (i.e., that slight eminence projecting internally at the point of entrance of the nerve), they lose this dark-edged medullated appearance. Here they commence to spread out, forming a membranous layer of pale fibres, that is, of naked axis cylinders covering the inner surface of the retina (*Bowman*, *Remak*, *Schultze*), but still associated in groups. Diverging now more and more, the bundles are seen to anastomose at very acute angles, forming one of those characteristic plexuses so frequently to be met with immediately before the termination of nerves. Tracing up this expansion of the fibres towards the ora serrata, we find the fasciculi becoming thinner and thinner, and the distance increasing between them. Finally, scattered nerve tubes alone are to be seen. These are extremely delicate and marked with slight varicosities, and decrease in number more and more the further we advance forwards. Throughout the whole retina they probably terminate by sinking into the multipolar ganglion cells of the layer already described. From what we have just seen we should expect to find great inequality in the thickness of various parts of the stratum fibrillosum; and so it is; thus, in the neighbourhood of the entrance of the optic nerve, the layer is 0·29 mm. in depth, sinking rapidly to 0·099 mm., and decreasing so much anteriorly that close to the ora serrata it is only 0·0026 mm.

The occurrence of dark-bordered medullated fibres in some retinae is remarkable. Thus, in the eyes of certain of the rodentia they exist normally, as in the rabbit and hare, where they present themselves in the form of two bands of white fibres streaming into the retina. The same medullated retinal fibres have not unfrequently also been observed in the eye of the dog, and in a few cases in that of the ox (*H. Müller*) and man (*Virchow*).

The expansion of the optic fibres takes place between the extremities of the fibres of *Müller*, as they are about to be inserted into the *membrana limitans interna*. These fibres, as we have already remarked in speaking of the stratum cellulosum, are at the fundus of the eye narrow and fine, as they lie between the massive bundles of fibres situated here, but become more and more bulky anteriorly, thus affording extra support with their broad expanded bases to the nerve fibres, where the latter decrease in number, and seem specially to require it.

(9.) The *membrana limitans interna* has been already described above.

§ 318.

There now remains for our consideration the special structure of two spots in particular in this complicated structure, the retina; these are the macula lutea and ciliary or anterior border.

The *yellow spot*, or *macula lutea* (fig. 597), from the fact of its being the most sensitive portion of the retina, and also from its peculiar texture, possesses for the histologist the highest interest.

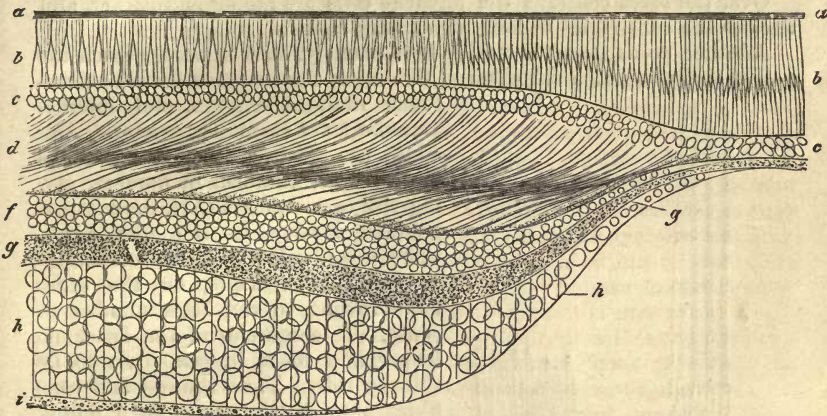


Fig. 597.—Diagram of the macula lutea and fovea centralis of the human retina, in vertical section (after *Schultze*). *a*, pigmentary; *b*, columnar; and *c*, external granular layer; *d*, inferior fibrous portion of latter; *f*, internal granular layer; *g*, molecular stratum; *h*, stratum cellulosum; *i*, layer of optic fibres.

If we examine the different layers of this locality (in which the sustentacular matter is in general but ill developed), in order from within outwards, we remark that the layer of the optic fibres (*i*) disappears very early, so that even at a considerable distance from the fovea centralis the stratum of the ganglion corpuscles is in contact (its six or seven layers of cells (*h*) accommodated to one another like epithelium with the *membrana limitans interna*. The latter stratum, also, is much thinned, as it passes into the fovea centralis, so that only about three rows of cells (*h*) are to be seen at the border (*H. Müller*). These, moreover, are for the most part bipolar over the macula lutea (*Merkel, Schultze*). The central portion of the fovea is destitute of ganglion cells according to *Schultze* (and before him *Bergmann*). The molecular layer (*g*) diminishes likewise considerably in depth here, and in the very centre possibly disappears. This is certainly the case with the internal granular layer (*f*).

The remarkable change in the proportion existing between the rods and cones as we approach the macula lutea, and in the latter itself, has been already alluded to (§ 316). In fig. 597, *b*, we see that here the rods fall in number more and more, until eventually, in the yellow spot, cones alone are to be found (*Henle*), which increase regularly in length towards the centre of the fovea, up to upwards of 0.100 mm., diminishing at the same time in thickness.

We must now deal with these facts, however, somewhat more in detail.

In man the bodies of the cones, in most parts of the retina, present a diameter of 0.007–0.006 mm., falling, however, at the edge of the macula lutea to 0.005–0.004 mm. More towards the centre of the latter, where rods no longer exist (fig. 598, *a, b*), they become still narrower, and in the fovea centralis their diameter is only 0.002–0.0025 mm., probably only 0.0028–0.0033 mm. when quite fresh (*Schultze*, with *H. Müller* and *Welcher*). Here, then, we have cones almost of the same thickness as

the rods. The cone styles sink at the same time, perhaps, to 0.0009 and 0.001 mm. in diameter, while the cone fibres, on the other hand, preserve their original thickness.

Over the fovea centralis the pigment cells are higher and darker, and enclose the cone styles in long pigmentary sheaths.

Another point deserves notice here, namely, that as we approach the yellow spot the retina increases in thickness, the distance between mem-

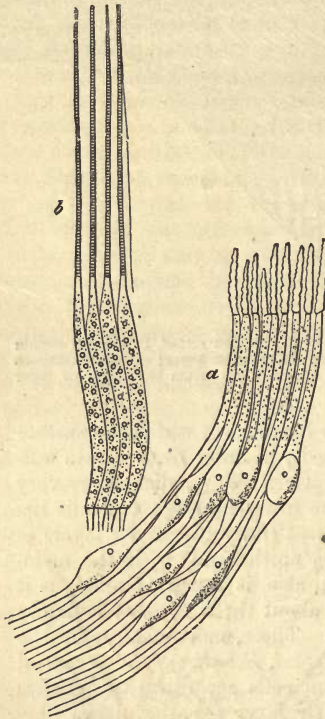


Fig. 598.—Cones from the human macula lutea and fovea centralis. *a*, with half decomposed external member; *b*, with resolution of the latter into disks (after *Schultze*).

brana limitans externa and internal granular layer becoming greater. And while the thicker cones increase, the slender rods diminish in number, giving rise to a change also in the external granular layer. In the first place, there are absolutely fewer corpuscles necessary here, while, on the other hand, owing to the large number of cones, the corpuscles of the latter no longer find room in one plain to lie side by side. Thus, the rod and cone fibres present themselves as a purely fibrillated stratum beneath the granules, the latter no longer lying upon the intergranular layer as in other parts of the retina. In this deeper portion of the layer in question, which is destitute of granules, and which has received from *Henle* the name of *external fibre layer*, the bacillary and cone fibres commence to abandon their perpendicular arrangement more and more as we approach the inner part of the fovea centralis. Here they may be observed to run obliquely downwards and outwards (*Bergmann, H. Müller*), and in the centre of the fovea almost horizontally (fig. 597, *d*), so that it is only after a long course that the cone fibre reaches at last the intergranular layer. At the same time the fibrillated half of the external granular layer increases in thickness about the periphery of the yellow spot, but becomes rapidly thinner in centre of the fovea itself (*Schultze*).

According to the latter's observations, farther, it is not only the internal surface of the fovea turned towards the vitreous humour that is concave, but also the opposite side facing the membrana limitans externa. Owing to this the choroidal ends of the fovea cones are inclined towards each other, and consequently more approximated than would be possible were they still arranged perpendicularly,—a circumstance which bears upon the delicate sensitiveness of this region. The adjacent portion of the retina also takes part in this peculiar curvilinear arrangement of the light-perceiving elements.

Let us now turn to the ciliary edge of the retina.

Anteriorly towards the ora serrata the thickness of the latter decreases

more and more, its nervous constituents commence to disappear, while the sustentacular matter gains the preponderance. The optic fibres cease gradually to constitute a separate layer, the ganglion cells appear at wider intervals, the granular layers become shallower, and the rods and cones shorter &c. (*Müller, Merkel, Schultze*). Finally, the nervous elements disappear entirely from the membrane, leaving behind reticula of connective-tissue fibres, which give way in their turn to a nucleated and eventually non-nucleated homogeneous substance. This becomes, then, still thinner, until, about 2 mm. from the ora serrata, the retina terminates by fusing with the membrana hyaloidea. This is the relation of parts as described by *Ritter*, while other observers seem to have come to different conclusions on the point. Thus *Koelliker* states that the membrana limitans extends in the form of a system of cylindrical cells decreasing in height, over the ciliary processes (intimately united to them and to the *zonula Zinnii*) as far as the external border of the iris. *Brücke* and *H. Müller*, on the other hand, suppose them to reach as far as the edge of the pupil.

Schultze found several forms of these cells, but did not observe any transition into the fibrous matter of the *zonula Zinnii* (§ 313). He regards the cells as corresponding to the radiating sustentacular fibres.

The *blood-vessels* of the retina (fig. 584) are derived from the arteria and vena centralis, enclosed within the optic nerve. They thus constitute a separate vascular system of the bulb, which forms, however, connections in the manner described in § 312 with the vessels of the ciliary system (*e*). From the splitting up of the artery just mentioned is formed a delicate wide-meshed network of capillaries 0.0056–0.0045 mm. in diameter (fig. 599, *b*). This vascular plexus lies chiefly in the internal portion of the retina, but extends, however, as far as the internal granular layer. It was formerly supposed by many that at the ora serrata this retinal system of vessels communicate with that of the choroid; but this is not really the case (*H. Müller, Leber*). In the yellow spot numerous capillaries are to be seen, but no vessels of any size.

The optic nerve itself only receives small twigs from the *art. cent.*, but, on the other hand, numerous branches from the internal sheath (fig. 584, 1), and a few from the external sheath.

A highly developed network of this kind does not, however, occur in the retina of all mammalia. In the horse, for instance, we only find a narrow belt of delicate radiating vessels around the entrance of the optic nerve. The retina of the hare and rabbit, also, only presents a narrow vascular zone corresponding, as a rule, with that of the medullated

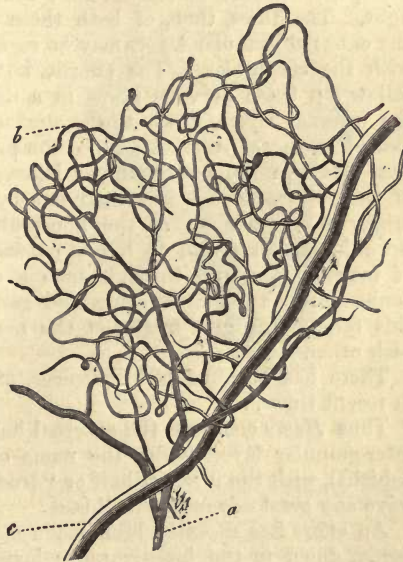


Fig. 599.—Vessels of the human retina. *a*, arterial; *c*, venous twig; *b*, capillary network.

nerve fibres. At the edge of this zone the most exquisite recurrent capillary loops may be seen. In birds, amphibia, and fishes the retina is even entirely devoid of vessels, but the *membrana hyaloidea* is fed by a network which probably also supplies the retina (*Hyrthl, H. Müller*).

The question now arises at the conclusion of this long description of the retina, *What is the arrangement and connection of its nervous elements?* and here we have only hypotheses to offer. That the rods and cones may be regarded as the terminal perceptive elements of the membrane is to our mind a point upon which there can be now but very little doubt. Bacillary cells, besides, we know have recently been recognised as the terminal structures of other nerves of special sense. Another question arises here also from which we cannot refrain, although a physiological one, namely, *What are the relative purposes of the rods and cones?*

We have learned from the foregoing description, that the point at which the power of perception is most intense, the *fovea centralis*, presents only cones in the human eye. Mammals of more nocturnal habits (§ 316) have, on the other hand, rods alone throughout the whole retina. It is to be remembered, also, that towards the external border of the retina the nervous fibrous mass undergoes considerable and progressive diminution.

The probability has been pointed out by *Schultze*, that the latter structures are endowed with the powers of perceiving quantitative differences in light and in distance, while the cones, besides possessing both these, are sensible to colours also, that is, to qualitative differences in light. The fibres, then, of both these retinal structures, which traverse the external granular layer, may be regarded as nervous elements together with the corpuscles. The efforts, however, of earlier investigators to follow up these nervous fibres in a direct perpendicular course through the internal layers, down to the stratum of the ganglion cells, are to be looked upon as fruitless. Since the provisional ending of both rod and cone fibres in the inter-granular layer, consequently in the very middle of the retina, has been pointed out by *Schultze*, and also the apparent origin of another set of the finest fibrillæ pursuing an altered course inwards, it seems vain to hope to demonstrate, with our present modes of investigation, and through such a complicated system of fibres, the connection between the cones and ganglion cells and optic fibres. In this respect the grey matter of the nervous centres and retina resemble each other.

There has been no lack, however, of other views regarding the retina in recent times.

Thus *Henle* contrasts the external half of the membrane, as far as the inter-granular layer, under the name of "*mosaic stratum*" (*musivische Schicht*), with the internal half or "*true nervous layer*." We fail to perceive any great advantage in this.

An effort has recently been made also by *Krause* to prove that the retina, down to the inter-granular layer, his *membrana fenestrata*, is by no means of nervous nature. Apart from anatomical considerations, he bases his views upon the fact, that some weeks after section of the optic nerve, the nerve fibres and ganglion cells of the retina may be observed to have undergone fatty degeneration, but the whole rod and cone apparatus to remain unaltered.

As to the *composition* of the retina we know but little. Some investigations by *C. Schmidt* have brought into notice a substance contained in

it, giving the reactions neither entirely of albumen nor of glutinous bodies, but exhibiting properties to some degree intermediate between the two.

§ 319.

Before passing on from the globe of the eye, we must bestow a few words upon its *lymphatic vessels*.

From *Schwalbe's* investigations it would appear that the lymph formed in the ball of the eye is carried off in three directions. That produced in the iris and ciliary processes is collected, in the first place, in the anterior chamber. This with the absorbents of the conjunctiva and corneal tissue may be said to belong to the first part, or *anterior lymphatic circulation* of the eye.

All the lymphatic spaces situated behind the ciliary processes empty their contents in two other directions. Those of the sclerotic and choroid open near the points of exit of the *venæ vorticosæ*, while the absorbents of the retina, on the other hand, are independent of these, and leave the globe of the eye through the optic nerve. Here, then, we have what we may call a *posterior lymphatic circulation*.

Let us consider this *posterior lymphatic* circulation first (fig. 600). Both the sclerotic and choroid seem destitute of special lymphatic vessels. Instead of these the shell-like interspace between the two coats appears to possess the nature of a lymph receptacle. This occupies the position of the supra-choroidea, as is well known (§ 310). To this receptacle, which is crossed by connective-tissue networks, the name of "*perichoroidal space*" (*p*) has been given by *Schwalbe*, who describes it as lined by endothelium. From this (at about the height of *m.r.* in our figure) that communication with "*Tenon's space*" (*t*) takes place which has been already alluded to. The latter lies between *Tenon's* sheath and the external surface of the sclerotic. The oblique intercommunicating canals invest, as a rule, the *venæ vorticosæ* like sheaths. This lymphatic space of *Tenon* is continuous behind with the "*supravaginal*" (*spv*) of *Schwalbe*, which latter invests the external optic nerve sheath "like a sheath." In it, also, there is apparently a lining of endothelial cells.

By *Key* and *Retzius* it was found (§ 300), that from the subdural space of the cranium another space between the external and internal sheath of the optic nerve may be injected, and that from this the perichoroidal interval may be filled, which would seem to show that the latter is a prolongation of the first. Between the internal sheath and the connective-tissue immediately investing the optic nerve fibres, injection

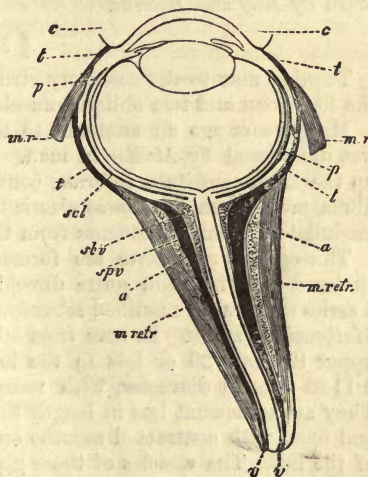


Fig. 600.—Posterior lymphatic circulation in the eye of a pig (diagram after *Schwalbe*). *c*, conjunctiva; *m.r.* recti muscles; *m. retr.* retractor bulbi; *a*, layer of fat; *v*, external sheath of optic nerve; *t*, "*Tenon's*" space opening behind into the "*supravaginal*," *spv*; *sbv*, "*subvagal*" space between the internal and external optic nerve sheath; *p*, "*perichoroidal*" space communicating by oblique passages with *Tenon's* space.

fluid may also be driven, and moreover from the subarachnoidal space of the brain. *Schwalbe*, however, states that his "subvaginal" space (*shv*) between the internal and external optic sheath does not communicate with the perichoroidal interval.

The lymphatics of the retina are said to invest the capillaries and veins like sheaths in the adventitial layers, but to pass along side by side with the arteries. They enter the optic nerve, as already stated above. We are still in want of details here.

Turning now to the *anterior lymphatic circulation*, we have already remarked that the anterior chamber is regarded as a reservoir for the lymph produced in the iris and ciliary processes.

In the first place, according to *Schwalbe*, the lymphatic fluid passes by a series of slits out of the canal of *Petit* into the posterior, and from thence into the anterior chamber.

But the supply flowing from *Fontana's* space, through the system of slits in the ligamentum iridis, is of more importance still. This space receives the lymph of the ciliary processes and iris apparently.

At the border of the membrane of *Descemet* the opening into the circular canal of *Schlemm* takes place, according to *Schwalbe*. This may be filled with even very slight pressure, and, whether we deny it the nature of a venous vessel or not, certainly does communicate with the venous system.

This reminds us of a similar arrangement of parts described in the brain by *Key* and *Retzius*.

§ 320.

Turning now to the accessory structures of the eye, we may pass over the four recti and two oblique muscles as requiring no farther description.

Many years ago an analogue to the *orbital muscle* of many mammals was discovered by *Müller* in man. This is a greyish-red mass, closing up the *fissura orbitalis inferior*, consisting of bundles of unstriped muscle fibres, most of which possess elastic tendons. It is supplied by pale, non-medullated nervous filaments from the sphenopalatine ganglion.

The *eyelids*, *palpebre* are formed of the *tarsal cartilages* (§ 109), enclosed in a thin skin quite devoid of fat. Imbedded in this cartilage a series of peculiar modified sebaceous glands is to be found, known as the *Meibomian* glands. In man from 30 to 40 of these may be counted in the upper lid, and 20 or less in the lower. In form they are tubes about 0.1128 mm. in diameter, with round vesicles attached along the sides. They are somewhat less in length than the tarsal cartilages are in height, and open with contracted mouths on the posterior edge of the free border of the lid. The vesicles of these glands are enveloped in a beautiful network of medium-sized capillaries. Their contents, with the exception of a laminated lining of flattened cells in the excretory duct, is the same as that of the sebaceous glands of the skin (§ 304).

The secretion of the *Meibomian* glands is a thick, whitish-yellow matter containing much fat, and hardening on exposure to the air. It is known as the *sebum palpebrale*, and serves to keep the free border of the lid in a greasy condition.

The *orbicularis palpebrarum* muscle belongs to the striped class. Associated with it, however, are membranous layers of smooth fibres, forming reticulated fasciculi (*H. Müller*), and constituting a *m. palpebralis sup.* and *inf.*

The posterior surface of the eyelids, and anterior portion of the sclerotic, with the cornea, are covered by a thin, soft, mucous membrane, known as the *conjunctiva*. This is generally divided into the *c. palpebrarum*, the *c. bulbi*, or that passing from the latter to the ball of the eye; and the inferior part, the *c. scleroticæ* and *corneæ*. The latter portion, however, deserves no longer the name of mucous membrane, from the fact of its being represented merely by a laminated flattened epithelial covering.

The substratum of the palpebral conjunctiva is formed of reticulated connective-tissue containing lymphoid cells (*Henle*). This *Stieda* asserts to be separated from the epithelial layer by a homogeneous elastic membrane. The epithelium in the cleft between the lids, derived from the cuticular layer of the skin, was formerly erroneously supposed to be ciliated (*Henle*). It consists, on the contrary, of several layers of pavement cells.

Numerous depressions, pits, and clefts, of the most diverse forms, which occur in this mucosa, are, strange to say, lined by a kind of columnar epithelium, producing the deceptive appearance of true glands; indeed, such were described here by *Henle*. Among the ordinary epithelial elements of the part there occur also, in the conjunctiva palpebrarum, those structures known as beaker cells (*Stieda*). We also meet here with tactile corpuscles, according to *Krause*, the terminal structures of the nerves of sensation (§ 185). The conjunctiva bulbi is a continuation, not only of the epithelial cellular layer, but also of the subjacent connective-tissue. The first extends over the whole cornea (§ 292), but not so the latter, which is lost at the periphery of the cornea in the tissue of the same, after having become very thin. The *plica semilunaris*, finally, is a duplicature of the conjunctiva bulbi, and contains in its *caruncula lachrymalis* ordinary sebaceous glands. Scattered fasciculi of unstriped muscle also occur here (*H. Müller*).

The *glands* of the conjunctiva are of various kinds.

In man, and in certain of the mammalia, in the first place, small racemose glandules are to be found, known generally as mucous glandules ("accessory lachrymal glands" of *Henle*). They are situated in that portion of the conjunctiva passing from the tarsus to the bulb, and are seen to the number of 42 in the upper, while from 2 to 6 only occur in the lower lid. They are irregularly scattered, imbedded in the mucous membrane or sub-mucous tissue. They are most crowded in the transition fold. The contents of their acini, which are about 0.0564 mm. in diameter, present fatty particles.

Among the ruminants, but not in man, there occurs, as was discovered some years ago by *Meissner*, a second very interesting form of gland in the conjunctiva of the eyeball, and particularly in that part encircling the cornea below and internally. This belongs to the convoluted tubular class (fig. 601) like the sweat glands of the skin, but each gland opens with a bulbous dilatation. The number of such convoluted glandules, however, is very small, only amounting in each eye to from 6 to 8.

At the outer border of the cornea of the pig another third species of gland was found by *Manz*. In this form we have simple, round, or oval sacs, measuring 0.067–0.2 mm. in diameter, made up of



Fig. 601.—A convoluted gland from the conjunctiva bulbi of the calf (after *Manz*).

concentric layers of connective-tissue, and containing cells and a granular matter. They have been named by histologists, after their discoverer, the glands of *Manz*.

In addition to these secreting organs of the conjunctiva we meet with

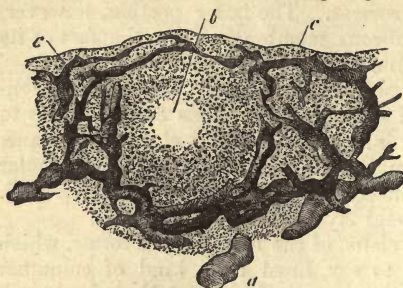


Fig. 602.—Trachoma gland from the ox, with injected lymphatic canals: vertical section. *a*, submucous lymphatic vessel; *c*, splitting up of the same round the follicle, *b*.

lymphoid follicles, or, as they have been named by *Henle*, *trachoma glands* (fig. 602). They are to be found in man, in numerous mammals, and in several birds. They usually occupy, but not in all animals, the inner angle of the eye, especially in the transition fold of the under and third lid, or *plica semilunaris*, and are sometimes scattered, sometimes aggregated. An enormous collection of them, strongly resembling one of *Peyer's* patches, may be observed in the under eyelid of the ox (*plaque of Bruch*). In the human conjunctiva they are only met with irregularly and sparsely scattered.

The structure of these bodies is that of other lymphoid follicles (*Frey*, *Huguenin*). Their vascular network is thin and irregular (§ 227). Around them, even without injection, lymphoid lacunæ may be recognised.

As regards the *blood-vessels* of the conjunctiva bulbi, we find its capillary supply derived from branches of the palpebral and lachrymal arteries, as well as twigs given off from the anterior ciliary vessels (comp. § 312). The capillary system of the palpebral conjunctiva is much more dense and more extensive.

The *lymphatics* of the conjunctiva were discovered many years ago by *Arnold*, and have been since observed by *Teichmann*. A delicate zone of the same, about 0.9 mm. broad, encircles the cornea, and is continuous peripherally with the network of wider canals of the sclerotic conjunctiva.

The trachoma glands are likewise rich in lymphatic vessels, as may be learned from injection (*Frey*).

In *Bruch's* plaque in the ox (fig. 602) knotted lymphatics of considerable size, ranging from 0.377 to 0.1511 mm., may be observed traversing the submucosa

Fig. 603.—Termination of the nerves of the conjunctiva in end-bulbs. 1. From the calf. 2. From man.

obliquely or perpendicularly (*a*). These form, at the under surface of the follicle, a very complicated network of canals 0.0744–0.1128 mm. in breadth, and give off other finer vessels, 0.02 mm., which are also arranged in a retiform manner, ascending through the narrow-meshed

connecting layer of the follicle, and forming, on their part, a net-like covering (*c*) around the same (*b*). The most superficial part of this network, namely, that underlying the epithelial layer, runs more or less horizontally beneath the latter, giving off numerous fine terminal twigs of 0.0282–0.0113 mm. in diameter, which ascend still farther for a short distance, and then end blind under the epithelial covering.

The *nerves* of the conjunctiva (fig. 603, *c*) terminate, in the first place (as has been shown by *Krause*), in man and other mammalia in those *end-bulbs* (*a*), already described (§ 184). Again, as we have learned from *Cohnheim's* and *Hoyer's* interesting discovery, the *corneal nerves* extend into the overlying epithelium, or so-called conjunctiva corneæ (§ 309). For the rest we refer the reader to § 184.

The *lacrimal glands*, whose sp. gr., according to *Krause* and *Fischer*, is 1.058, consist of aggregations of racemose glands, which, as far as the shape of both lobuli and vesicles, and their nucleated cells, composed of finely granular protoplasm, is concerned, present nothing peculiar for our consideration. Their excretory canals, 7 to 10 in number, made up of fibrous tissue lined with columnar epithelium, perforate the conjunctiva. In the walls of these we meet again with those flattened stellate cells already alluded to, § 194 (fig. 329). The nerves of the organ are supposed to penetrate through the limiting structures of the acini, and terminate between the gland cells in the same manner as in the sub-maxillary gland (*Boll*). The arrangement of the *capillaries* here is as usual in such structures.

The structures composing the apparatus for carrying off the tears are not alike throughout. In the lacrimal canals the tissue of the mucosa is rich in elastic fibres, while in the lacrimal sac and duct a reticulated connective substance, containing lymphoid cells, presents itself (*Henle*). From the lining membrane of the nose small mucous glands extend upwards, and occur not only in the wide nasal duct, but also in the mucosa of the canaliculi (*R. Maier*). In regard to the species of epithelium lining the lacrimal passages there still exists much diversity of opinion. Non-ciliated columnar cells are stated to occur throughout them by *Maier*. *Henle*, on the other hand, mentions having found flattened epithelium in the canaliculi, ciliated in the lacrimal sac and nasal duct, merging into the flattened formation of the nose.

We turn now to the *tears*, the secretion of the lacrimal glands, which, with a small quantity of aqueous humour, which exudes through the cornea, bathe the front of the eye. This fluid has a strong alkaline reaction and slightly saltish taste. Chemical analysis, instituted long ago by *Frerichs*, shows about 1 per cent of solid matters (0.9–1.3 per cent.) Among these albumen appears in combination with soda (the "lachrymine" of earlier investigators), together with traces of fats, extractives, and mineral matters. Of the last chloride of sodium is the most important, phosphates of the alkalis and earths appearing in but small amount. Under ordinary circumstances the tears are carried off by the canaliculi into the nose, but when the secretion is too abundant it overflows the lower lid. The psychical significance in the human being of tears has long been recognised.

§ 321.

The *development* of the eye, to which we will only devote a few words here, takes place from three different portions of the rudimentary embry-

onic body. The first trace is seen in the form of a hollow stalked process of the anterior portion of the brain, the *primary optic vesicle*, which is destined in its farther development to transformation into the *retina* and *pigmentary epithelium* of the *choroid*, while the pedicle becomes the optic nerve. We have already seen that the lens springs from that portion of the *corneous germinal layer* which lies over the rudimentary eye, growing inwards in the form of a thick-walled hollow sphere (comp. § 161). Besides the latter, and underneath it, there presses into the primary optic vesicle the vitreous humour, a production of the *middle germinal layer*, *i.e.*, of the dermal tissue of the head. These two organs thus double in the optic vesicle into itself, after which, as in the serous sacs, two lamellæ of formative cells may be distinguished, a thicker internal one, the future retina, and an external thin layer destined to form the pigmentary epithelium. We now have before us what is known as the *secondary optic vesicle*. The *fibrous layer* of the *choroid*, the *ciliary body* and *muscle*, the *iris*, *sclerotic*, and *cornea*, all spring from the adjacent portions of the middle germinal layer of the rudimentary embryonic head.

That the *whole retina*, with the exception of the pigmentary epithelium, takes its rise from the internal lamella of the secondary optic vesicle, is a fact observed long ago by *Remak* and *Koelliker*, which has been confirmed more recently by *Babuchin* and *Schultze*. The first elements to be recognised, according to *Babuchin*, are the rudiments of the fibres of *Müller*, in the form of fusiform cells, terminating at either end in the limiting membranes (external and internal) which are formed from them. After the fibres of *Müller* the ganglion cells are next developed, and then the stratum fibrillosum. The molecular and inter-granular layers, as well as that of the rods and cones, appear almost simultaneously; the first-mentioned layer, however, precedes the others somewhat in formation, and the stratum bacillosum brings up the rear. The rods, cones, and cone-bodies are produced, according to *Babuchin*, in the tadpole as processes or outgrowths from cells. They thus constitute with their cells ("granules" or "corpuscles") an inseparable whole.

The development of the central portion of the retina, moreover, hurries on in advance of that of the periphery (*Babuchin*, *Schultze*).

A number of delicate hemispheroidal growths were recognised by *Schultze* in the chick projecting from the outer surface of the *membrana limitans externa*. These are stated by him to be developed later on into rods and cones.

The outer halves or members of the rods, which also undoubtedly belong to the internal wall of the secondary optic vesicle, are formed much later than the inner members.

In connection with the late development of the rods there is a point of much interest mentioned by *Schultze*. Animals which are born with closed eyes—as, for instance, cats and rabbits—do not at birth possess those retinal elements, while in man and the ruminants they are already fully developed when born.

The external layer of the so-called secondary optic vesicle is formed by a single row of perpendicular, and originally elongated, but later more or less cuboid cells, which become eventually flattened. This is gradually transformed into pigmentary epithelium, as has been already remarked, by the absorption of molecules of melanin. This layer is generally reckoned among the laminae of the choroid, whereas it belongs in reality to the retina.

The histogenic occurrences in connection with the development of the *coroid*, *iris*, and *sclerotic* require further investigation. The rudimentary *chrnea* has been already alluded to, § 133, and the mode of origin of the fibres of the *lens* has been dwelt upon in the section quoted above.

The *lachrymal glands* are developed in the same manner as most other racemose secreting organs; their cellular constituents springing from the corneous germinal plate. The *Meibomian* follicles are developed at rather a late period.

§ 322.

We come now, finally, to the consideration of the *organs of hearing*, the last of the apparatuses of special sense which shall occupy our attention.

On each side of the head we have an *internal ear*, consisting of the *labyrinth*, which receives the impressions of sound, a *middle ear* for the conducting of the waves of sound; and an *external ear*, separated from the last by the *tympanum*.

We will commence our description with the latter.

The *outer ear* is made up of the pinna and *external auditory meatus*. The texture of its cartilage has been already described § 108. The external skin, likewise, which is here closely attached to the latter, and which is quite destitute of fat, except in the lobe of the ear, needs no farther notice. In the pinna of the ear we find numerous downy hairs, and often considerable sebaceous follicles (§ 304), as well as small sudoriferous glands (§ 302), especially on the posterior aspect. The peculiarities of the glandulæ cerminosæ of the outer passage, in which sebaceous follicles are also present, have been likewise dealt with in an earlier portion of our work (§ 302). The muscles of the pinna belong to the striped class (§ 164).

The *membrana tympani* consists of a fibrous plate clothed externally by the cutis, and internally by the mucous membrane of the middle ear. Through the so-called *annulus cartilagineus* it is continuous with the adjacent periosteum. The coat derived from the skin presents a thin fibrous layer, quite devoid of glands and papillæ, which may be found, however, in its immediate neighbourhood. The fibrous plate consists of an external lamina of radiating fibres, and an inner sheet of circular bundles. The elements are those of ill-developed connective-tissue, exhibiting flat anastomosing bands with connective-tissue corpuscles (*Gerlach*), and perhaps also a few smooth muscle fibres (*Prussak*). The *mucous membrane* of the inner surface possesses likewise a very thin fibrous portion, and usually a covering of simple flattened epithelium. The latter extends also into the several depressions of the tympanum, and into the mastoid cells. The rest of the cavity of the tympanum is lined with doubly laminated ciliated epithelium. The *vascular network* of this diaphragm consists of several portions (*Gerlach*) of an external web formed of radiating elongated meshes of fine tubes belonging to the dermal layer, an internal with rather small meshes supplying the mucous membrane, while the middle fibrous layer of the tympanum, which was formerly said to be devoid of vascularity, presents a third set of vessels according to *Kessel*. *Lymphatics* are also present here in large numbers, and *nerves* likewise, but the mode of termination of the latter has not yet been ascertained.

The whole of the middle ear, with its various parts and adjoining cavities, is lined by the same thin, vascular, probably glandless, mucous mem-

brane. In the *Eustachian* tube its ciliated cells are of the columnar kind interspersed with beaker cells (*Schultze*).

The *vascular system* of the tympanic cavity is remarkable for presenting a few very slightly ramifying arterial feeding tubes, forming but a very ill-developed arterial capillary network. The venous portion, on the other hand, is highly developed. Here we meet with considerable vessels forming strong networks. The circulation of the cavity is characterised by being very rapid, and subject to small pressure (*Prussak*).

The *lymphatics* of the cavity resemble those of the tympanum (*Kessel*).

The *nerves* require closer attention. On the tympanic branch numerous ganglia have been observed, formed of larger or smaller collections of cells, or even of single elements between the medullated fibres (*Krause*). Numerous nervous networks are also found here.

The *small bones* of the ear consist of compact osseous substance, presenting numerous *Haversian* canals (*Rüdinger, Brunner*). Between the hammer and ambos only is there a joint. The first of these is covered as far as it is united to the tympanum (*i.e.*) on its short process, and the so-called handle with a thin coat of hyaline cartilage (*Gruber*).

The union of the short process of the ambos (which is clothed with cartilage) with the side of the cavity is effected by strong connective-tissue, that between ambos and stapes by a symphysis of hyaline cartilage, with a diaphragm of fibrous tissue in the middle. The cartilaginous borders of the foot of the stirrup, and of the foramen ovale, are joined by strong connective-tissue (*Brunner*).

The muscles of the ossicular auditus are of the striped kind (§ 164).

We conclude this section with a glance at the *Eustachian* tube.

Its cartilage has been already considered, § 108. Its mucous membrane bears a double layer of ciliated epithelium, and contains racemose mucous glands, varying in size and position, however, in different localities. The gland vesicles are lined with columnar cells. The mucous tissue may in parts be infiltrated with lymphoid cells (*Rüdinger*). A nervous plexus with groups of ganglion cells is also to be seen in the *Eustachian* tube (*Krause*).

§ 323.

The *internal, and proper organ of hearing*, consists of the *vestibule, semicircular canals, and cochlea*. The whole is occupied by certain membranous bags and canals, containing a watery fluid; in these the auditory nerves terminate, surrounded by the fluid. The distribution of these nerves is twofold,—first, to the ampullæ and sacculi of the vestibule, and then to the spiral plate of the cochlea.

Both the vestibule and internal surface of the semicircular canals are lined with periosteum. The transparent serous fluid with which they are filled is known as the *perilymph*, or *aquila Cotunii*. According to *Schwalbe*, they may be injected from the subarachnoid space of the brain through the *porus acusticus internus*. The periosteum, with the mucous membrane of the cavity of the tympanum, constitute the *membr. tympani secundaria*, resembling in their structure, as a whole, the true drum of the ear in many respects.

The walls of the *sacculus hemiellipticus* and *rotundus* and *c. semicircularis membranacei*, with their *ampullæ*, suspended in the perilymph, but always attached at definite points to the periosteum, consist of an external undeveloped connective-tissue, composed of stellate corpuscles, and an internal elastic transparent layer, containing numerous nuclei. In

the membranous semicircular canals, which lie excentrically, that is, attached to the convex aspect of the long passages (*Rüdinger*), this elastic lamina is maintained by the same observer to project in the form of numerous tufts into the lumen. These, however, appear to be in man pathological products (*Lucae*). Again, internally these present a thick covering of epithelium (0.0068 mm. deep), made up of pavement cells, from 0.0090 to 0.0180 mm. in diameter. From the usually numerous blood-vessels of these walls a second watery fluid is secreted, known as *endolymph*, or *aquila vitrea auditiva*, which fills the space contained within them.

The *otolithes* (fig. 604), enclosed within a special membrane, present themselves in the form of white specks at those points where the terminal filaments of the auditory nerves are spread out in the sac of the vestibule. These are probably small columnar crystals, whose size varies to a remarkable extent, their diameter ranging from 0.0090 to 0.0020 mm. and less. A few of them are also contained within the membranous semicircular canals. They consist principally of carbonate of calcium, but leave behind, according to the observations of many investigators, an organic substratum, after having been treated with acids.

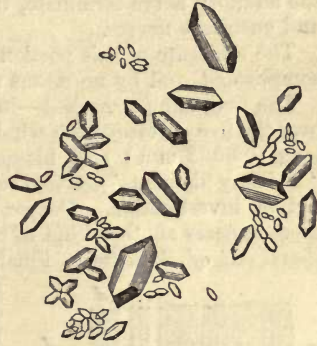


Fig. 604.—Otolithes, consisting of carbonate of calcium (after Funke).

§ 324.

There now remains for our consideration *the mode of distribution of the acusticus* to the two sacs of the vestibule and the membranous ampullæ. The nerve fibres for the sacculus hemiellipticus and ampullæ are derived from the *n. vestibuli*; those for the sacculus rotundus from the so-called *n. sacularis minor*, a branch of the cochlear division of the auditory. They enter the duplicatures of the walls, which are especially distinct and prominent in the ampullæ, projecting into the cavity in the form of partitions. Here they divide into branches, and run towards the internal free surface of the walls, still ramifying in their course. All the nerve fibres are, however, confined to this projection, known as the *septum nerveum*; none of them extend into the adjacent parts of the ampullæ.

It was formerly supposed, from the early investigations of *Valentin* and *Wagner*, that the filaments of the auditory nerve were arranged in terminal loops. The incorrectness of this view, however, is now generally recognised; and we know that the ends of the nerves undergo still farther subdivision. It was *Schultze*, however, who first arrived at definite conclusions here in regard to the arrangement of parts, which latter is of the highest interest, manifesting as it does such close relationship to the mode of termination of the higher nerves of special sense (fig. 605). These conclusions were not drawn from investigation of the structure of the human ear, but from that of rays and sharks.

If the *septum nerveum* be very minutely examined, its projecting margin (*crista acustica* of *Schultze*) presents on either side a thick covering of soft pultaceous matter, resembling, in transverse section, the cap of a

mushroom. Under the microscope we may easily recognise the fact, that the ordinary simple pavement epithelium of the internal ear has given way to another species, namely, to a deeply laminated, whose uppermost elements (*a*), which are cylindrical in shape, and dotted with yellowish granules, have a strong resemblance to the cells met with in the regio olfactoria (§ 307).

It is between these cylinders on the septum nerveum that the fibres of the auditory nerve terminate, in a manner similar to that of the olfactory and gustatory nerves.

The structure of this portion of the organ of hearing is, however, very complicated, and by no means as yet fully understood.

The first thing remarked—in fishes, such as young tritons (*Schulze*)—over the free surface of the whole yellow layer, is a multitude of extremely long (0.0902 mm.) stiff filaments, projecting beyond the surface (the “auditory filaments”), whose relation, however, to the cells below requires farther investigation. Deeper down, seated on the fibrous substratum, there appears another kind of cell (*b*), supported upon an expanded base (*basal cell of Schulze*). Finally, we meet with small colourless cells in

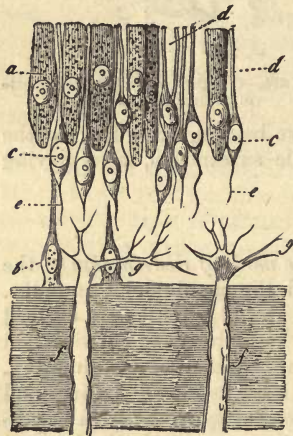


Fig. 605.—From the *crista acustica* of the ampulla of *Raja clavata* (after *Schulze*). *a*, cylinder cells; *b*, basal cells; *c*, fibre cells, with an upper rod-like process *d*, and lower filiform *e*; *f*, nerve fibres, passing into pale axis cylinders at *g*.

great number, which give off a process at either pole of their rounded or fusiform bodies (*c*); these are the *fibre cells of Schulze*. The superior process (*d*) is the thickest, and of rod-like form, ending on the surface of the complex epithelial stratum, with truncated extremity. The inferior (*e*) is thinner, and dips down towards the connective-tissue substratum. The nerve fibres (*f*) appear at first sight to terminate at the border of the fibrous layer, under the epithelial covering, but only merge here into pale axis cylinders, which enter the latter (*g*), and after splitting up into a large number of branches, disappear eventually from view. It is not improbable, although not yet proven, that these terminal fibres are continuous with the inferior processes of the fibre cells (*Schulze*). *Schulze* maintains, and possibly with perfect right, that the divided non-medullated axis cylinder is prolonged directly into the long hairs already mentioned.

The same structural relations, with shorter hairs, however, have been observed in the otolith sac of fishes.

Statements have also been made to the same effect as regards other vertebrates; but the opinions of investigators still differ widely.

The two nervous projections of the human vestibular sacculæ, or *maculæ acusticæ*, as *Hentle* calls them, are less marked than the *septa nervea* of the ampullæ, but are wider, and present a larger surface on the other hand.

These maculæ acusticæ were very accurately described some years ago by *Odenius*. In the utriculus a complicated plexus of nerves spreads out towards the surface through the connective-tissue substratum, terminating finally in delicate axis cylinders, which penetrate into the epithelial layer.

The arrangement of nervous elements in the *sacculus rotundus* varies in some points, though in the main the same.

In approaching the macula, the low cylindrical elements covering the walls of the sacculæ are observed to give place to long, columnar, distinctly nucleated cells, with yellowish contents, above whose free border filaments are seen to project.

Minute examination reveals that of these very decomposable elements there are at least two forms, probably corresponding to the cylinder and fibre cells of *Schultze*. These were also seen and sketched by *Koelliker* in the saccus hemiellipticus of the ox years ago. One species present long, narrow fusiform bodies without nuclei, but bearing on their ends those filaments 0·0221–0·0226 mm. long, which, as we have already seen, project beyond the surface of the nerve epithelium. These auditory filaments were discovered long ago by *Schultze* in mammals, and from *Odenius* we learn that they are also to be found in the septum nerveum of the human ampullæ.

The connection of these filamentous bodies with the axis cylinders, which certainly penetrate into the epithelium, requires, however, further proof in our opinion.

§ 325.

Let us turn now finally to the consideration of the *cochlea* (fig. 606).

This spiral canal, which performs in the human ear two and a half turns, is divided into two passages, which have long been known as the *scalæ*,—the upper, named *scala vestibuli* (*V*), and the lower, *scala tympani* (*T*),—by a spiral plate, the *lamina spiralis* (*q-i*). Besides these, it presents also a third and more important intermediate space, the *canalis cochlearis* of *Reissner* (*C*).

The *lamina spiralis* (from *q* to *i*) consists of an internal bony and an external soft or membranous portion. The first of these, an outgrowth from the modiolus or central pillar, is about half the breadth of the whole leaf. It is not, however, alike in all the turns, being broadest in the first, and becoming gradually narrow as it ascends, until it finally terminates in the last half in a hook, *hamulus*.

This osseous spiral plate, *lamina spiralis ossea*, presents two lamellæ of compact bony tissue—the upper facing the *scala vestibuli*, the lower the *scala tympani*, and between these, porous tissue, through which run the freely intercommunicating passages for the transmission of vessels and nerves. Near the junction with the membranous portion these passages unite to form a single fissure, bounded by the two osseous lamellæ, both of which terminate together here likewise.

The membranous portion is directly and horizontally prolonged outward from the bony partition. It is known as the *lamina spiralis membranacea*, or *membrana basilaris*. It presents about the same breadth throughout (0·45 mm.), and is attached to the inner surface of the outer wall of the cochlea.

But as we first learned from *Reissner* and *Koelliker*, there springs further, within the *scala vestibuli*, and near the line of junction of the *lamina ossea* with the *membranacea* (*a*), another membrane (*R*), which ascending obliquely upwards and outwards reaches the inner surface of the external wall of the cochlea, where it is attached. This is known as the membrane of *Reissner*.

Thus, a narrow passage is cut off from the *scala vestibuli*, lying external

to it, and holding, of course, a spiral direction likewise. In cross-section it is almost triangular. This is the *canalis cochlearis*, already mentioned above (C). Its three sides are consequently formed, below, by the lamina spiralis membranacea (tympanic wall), above, by the membrane of *Reissner* (vestibular wall), and externally by the parietes of the cochlea. Above, at the hamulus, the *canalis cochlearis* ends in a blind sac ("Kuppelblind-

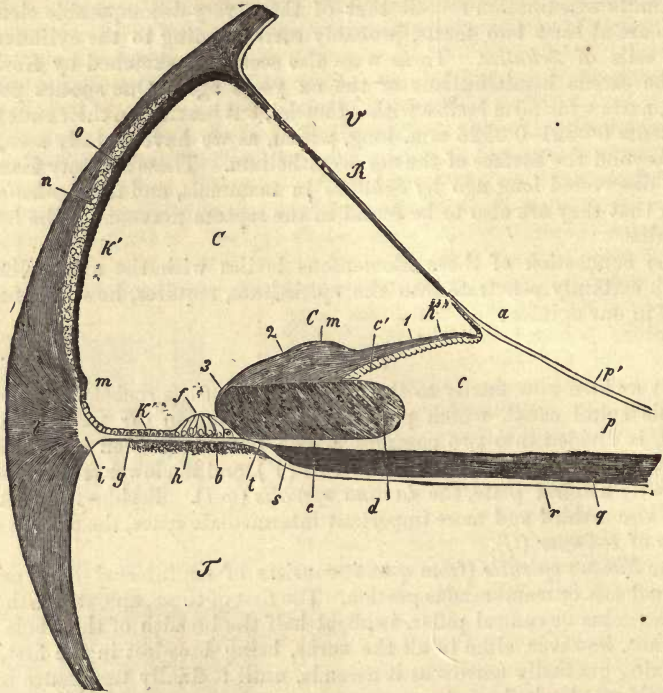


Fig. 606.—Vertical section through the tube of the cochlea and adjacent parts from a fetal calf at an advanced period. V, *Scala vestibuli*; T, *Sc. tympani*; C, *canal of the cochlea*; R, *membrane of Reissner*, with its attachment (a) to a projection on the so-called *habenula sulcata* (c); b, *connective-tissue layer*, with a *vas spirale* on the under surface of the *membrana basilaris*; c', *teeth of the first row*; d, *sulcus spiralis*, with thickened epithelium, which extends to the *organ of Corti* (f), still in process of formation; e, *habenula perforata*; Cm, *membrane of Corti* (1, its inner and thinner; 2, its middle thicker portion; 3, its external end); g, *zona pectinata*; h, *habenula tecta*; k, *epithelium of the z. pectinata*; k', *external wall of the cochlea*; k'', *habenula sulcata*; l, *ligamentum spirale* (i, transparent portion of the same, connecting it with the *zona pectinata*); m, slight elevation; n, *cartilaginous plate*; o, *stria vascularis*; p, *periosteum of the zona ossea*; p', *transparent external layer of the latter*; q, *bundles of cochlear nerve fibres*; s, *point of termination of the medullated nerve fibres*; t, *position of the axis cylinders in the hab. perforata*; r, *tympanic periosteum of the zona ossea*.

sack") (*Hensen, Reichert*), and below also practically, in a vestibular sac ("Vorhofs' blind sac"), although there does exist a communication between it and the *sacculus rotundus* (*Hensen, Reichert, Henle*). This is a short and fine tubule, opening at right angles into the lower end of the *canalis cochlearis*, in the same way as does the *oesophagus* into the stomach. We name this the *canalis reuniens*. The latter, like the two blind sacs, is only lined with cubical epithelial cells, and is destitute of the acoustic nerve fibres present elsewhere.

Both *scala tympani* and *scala vestibuli* are lined by a fibrous coat. The *membrane of Reissner* is also formed of fibrous connective-tissue

covered underneath, but not above, with a single layer of epithelium. The outer wall of the canalis cochlearis is likewise formed by a coat of periosteum overlaid with similar cells (*h'*). In it, also, may be recognised a peculiar eminence (*m*), a layer of cartilage situated higher up (*n*), and a vascular streak (*o*).

The floor of the canalis cochlearis, *i.e.*, the upper surface of the lamina spiralis membranacea, exhibits a very complex structure; while the under surface, or that facing the scala tympani, presents nothing remarkable for our consideration, with the exception of the so-called *vas spirale* (*b*), enveloped in a thin coating of connective-tissue.

The very important structures to be seen here were in part discovered by Corti, who was succeeded by Reissner, Claudius, Böttcher, Schultze, Deiters, Koelliker, and Hensen (without mentioning many others), by whom the wonderful arrangement of parts was further and further unveiled, at the same time that its complexity was rendered so evident as to baffle all hopes of arriving at anything like definite conclusions for the present.

According to Corti, the membranous spiral plate may be divided into two zones,—an *internal zona denticulata*, and an *external z. pectinata* (*g*).

The zona denticulata has been again subdivided into two portions, namely, into the *habenula interna*, or *sulcata* (*c*), or *labium superius* of the *sulcus spiralis*, and into the *h. externa*, *s. denticulata* (*e, h*).

The first of these presents itself as a high eminence, the *crista spiralis*, projecting into the canalis cochlearis with comb-like ridges and grooved external border. The furrow is known as the *semicanalis* or *sulcus spiralis* (*d*). The whole structure results from the peculiar disposal of the periosteum

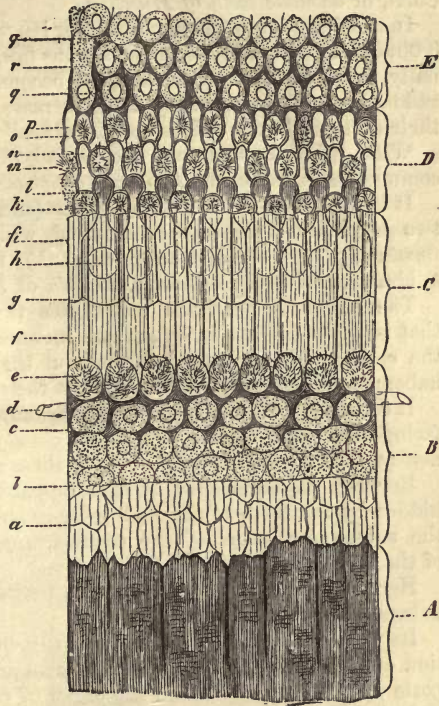


Fig. 607.—The organ of Corti from the dog, after Waldeyer, seen on its vestibular aspect, the membrane of Reissner and the so-called *membrana tectoria* having been removed. *A*, *Crista spiralis*; *B*, epithelium of the *sulcus spiralis*; *C*, pillar heads of the fibres of Corti; *D*, *lamina reticularis*; *E*, external epithelium of the *membrana basilaris*; *a*, cells of the *sulcus spiralis* shining through the acoustic teeth; *b*, corresponds to the outer boundary line of these teeth; *c*, cuticular meshwork between the internal epithelial cells; *d*, *vas spirale*; *e*, internal hair cells; *f*, heads of the internal pillars, or fibres of Corti; *g*, their head plates; *g*, boundary line between the external and internal pillars; *h*, heads of the external pillars shining through the head plates of the internal fibres of Corti (the clear circle is the optical transverse section of the external fibre or pillar); *i*, phalangeal head-plate of the external pillar or the first phalanx; *k*, *m*, *o*, first, second, and third rings of the *lamina reticularis*, with the hairs or filaments of the first, second, and third rows of hair or tufted cells; *n* and *p* are the second and third phalanges; *r*, supporting cells (*Hensen*); *g*, cuticular network between the epithelial cells or the framework of *Deiters*.

of the spiral bony plate. Under the microscope it is seen to be made up of simple, either homogeneous or streaked, connective-tissue, with imbedded cells and scattered capillaries. For the rest, this eminence decreases, both in height and breadth, as we ascend through the canal of the cochlea.

Upon the upper surface of this peculiar pectiniform structure (fig. 607, A) a number of not less remarkable longitudinal and bifurcating ridges present themselves. These are the *teeth of the first order of Corti*, or *acoustic teeth of Huschke*.

In the first turn of the cochlea their length is 0.0451 mm., and diameter 0.0090–0.0113 mm.; these dimensions fall, however, as we ascend. Internally, towards the modiolus, they become shorter and shorter, ceasing suddenly; while externally they increase in length, overhanging with their extremities the sulcus spiralis already mentioned.

With this last structure the second division of the zona denticulata commences, namely, the *habenula denticulata* or *externa*, as it is called.

It is again subdivided by *Koelliker* (and, indeed, unnecessarily so) into two secondary divisions,—an internal, which he calls the *habenula perforata* (fig. 606, e); and an external (h), the *habenula tecta*. The latter is identical with the *habenula arcuata* of *Deiters*.

The *habenula perforata* constitutes the floor of the sulcus spiralis, that is, of its *labium inferius*, and increases in breadth as the summit of the cochlea is approached throughout the turns of the canal, while the *habenula sulcata* becomes narrower at the same time.

It consists of simple connective substance, and is covered on its surface facing the canal of the cochlea by closely set row of longitudinal eminences, 0.0226–0.01128 mm. broad; these are the apparent teeth of *Corti*.

Between the outer ends of these apparent teeth, which are completely hidden by the teeth of the first order in the first, but only partially so in the subsequent turns of the cochlea, small slits exist for the passage of the cochlear nerves (fig. 608, h).

Here, then, we have the boundary between the *habenula perforata* and *habenula tecta* or *arcuata*.

Its wall, or the *membrana basilaris* (fig. 608, a, b) (formed by a prolongation outwards of the *habenula perforata* and tympanal periosteum), supports upon its upper surface the organ of *Corti*,—a structure of the most remarkable kind, whose physiological significance is as yet by no means understood (figs. 607, 608). This is also known as the *papilla spiralis*,—a name proposed by *Huschke*, and employed after him by *Hensen*.

In this extraordinary organ may be distinguished two species of form elements, namely, peculiar fibres and no less characteristic cells.

The first of these, the *fibres* or *pillars of Corti*, consist of two rows of band or pillar-like elements standing upon the surface of the *membrana basilaris*, which is somewhat thinned here, and converging obliquely above, where they meet with pointed extremities. Collectively they present the appearance of a puffy elevation, holding a spiral course through the coils of the cochlea. The whole being hollow, has not inaptly been likened to a tunnel.

Thus, in the organ of *Corti*, we have to distinguish between *internal* (n, m) and *external* (o) *pillars*. Both kinds of elements are not present, however, in the same number. Two of the external pillars may usually be counted to three of the internal (*Claudius*).

The internal pillars, separated from one another by narrow clefts, all spring up in the same line, external to the holes in the *habenula perforata*. They rest upon the membrana basilaris with a slightly expanded base (*n*), which covers a mass of nucleated protoplasm. This is a remnant of the original formative cell of the pillar.

The upright portion of our internal pillar becomes, at first, somewhat narrowed (down to 0.0034–0.0045 mm.), but terminates above in a

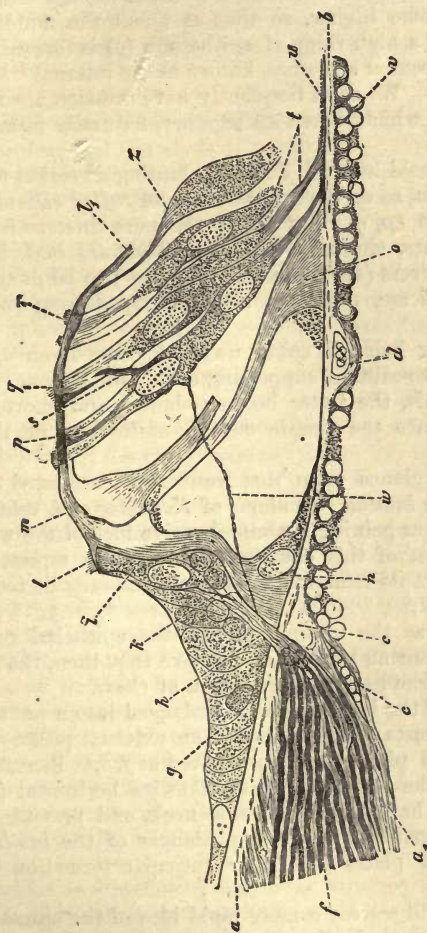


Fig. 608.—Vertical section of the organ of Corti from the dog, after Waldeyer. *a*, *b*, homogeneous layer of the so-called *memb. basilaris*; *a'*, vestibular layer; *v*, tympanal, with nuclei and protoplasm; *a*, *tubium tympanicum* of the *crista spiralis*; *a'*, prolongation of the tympanal periosteum of the *lamina spiralis ossis*; *c*, thickened commencement of the *memb. basilaris* near the point of perforation of the nerves *h*; *d*, and *e*, blood-vessels; *f*, the nerve; *g*, epithelium of the *sulcus spiralis internus*; *i*, internal or tufted cell, with basal process *k*, surrounded with nuclei and protoplasm (of the "granular layer"), into which the nerve-fibres radiate; *n*, base or foot of the inner pillar of the organ of Corti; *m*, "head" of the same united with the corresponding part of an external pillar whose under half is missing, while the next pillar, *o*, presents both middle portion and base; *p*, *q*, *r*, the three external hair cells; *t*, bases of two neighbouring hair or tufted cells; *z*, a so-called supporting cell of Hensen; *l* and *l'*, *lamina reticularis*; *u*, nerve-fibre, terminating in the first of the external hair cells.

bulbous swelling 0.0054 mm. in diameter (*m*). Into a depression on the outer aspect of the latter, the upper end or "head" of the external pillar of Corti (*o*) (0.0079 mm. across) fits.

This external pillar springs, with a similar expansion, from the membrane upon which it rests, and presents here also the same nucleated protoplasm as the internal. These protoplasmic cell-residues taken collectively, are known as the "granular layer."

The form of the external pillar is allied to that of the internal, although by no means quite the same. A glance at fig. 608 will render any further description unnecessary.

These remarkable structures are composed of a transparent homogeneous substance, offering but slight resistance, however, to the action of reagents.

But the *cellular elements* of the organ of Corti are no less remarkable.

Commencing from within from the *sulcus spiralis*, we may observe that the epithelial cells become higher, so that at about the middle of the internal pillars of Corti a high ridge of epithelium (*g*) is formed. Here, then, we come upon a peculiar structure, known as the internal "hair cell" or tufted cell of *Deiters*. We shall frequently have occasion again to refer to the cells in question, which, taken all together, naturally form a spiral row.

Now, just as the internal hair cell lies in a slanting direction upon the internal pillar covering it, so do the *external hair* or *tufted cells* or cells of Corti of earlier observers (*p, q, r*), of which there are three or four rows, cover the external pillars, similarly inclined. They are said, however, by the most recent observers (*Gottstein* and *Waldeyer*) to be double cells, and the pillars of Corti are, probably, also developed from such twin cells likewise.

External to the outer hair-cell spiral we next come upon columnar epithelial elements, the so-called "supporting cells" of *Hensen* (fig. 608, *z*; 607, *r*). Beyond this, the latter become shorter and shorter, until they gradually merge into the simple cubical epithelium of the *zona pectinata* (fig. 606, *k*).

Let us now bestow a glance upon that wonderful fenestrated *covering membrane*, known as the *lamina reticularis* of *Koelliker* or *l. velamentosa* of *Deiters*, essential to our gaining a comprehensive idea of the whole.

In fig. 608 the position of this covering membrane is represented in side view from *l* to *l'*, but its remarkable structure can only be recognised from above, as in fig. 607.

From as far inwards as the internal pillars, the epithelial cells give off a cuticular annular limiting border (*c*). Above this, then, the internal hair-cells (*e*) reach the same height as the organ of Corti.

Each internal pillar of the latter, then, is prolonged into a pretty broad horizontal plate, which rests upon the top of an external pillar. In fig. 607 these internal "head plates" are represented at *f, i*. Beneath them lie the head plates of the external pillars, likewise horizontal (607, *l*; 608, *m*). These plates have a long narrow neck, and present an oar-shaped figure. They constitute the first phalanges of the *lamina reticularis*. In these head plates the latter cuticular formation has its commencement.

A glance at fig. 607 will convey a more rapid idea of the annular condition of this *lamina reticularis* than any description, however minute (*k, m, o*). With the first phalanx we are already acquainted. At *n* and *p*, the second and third rows of phalanges are to be seen. *K, m, o*, indicate the tufts of hairs of the three spiral ranks of the so-called external hair cells. Finally, at *E*, descending again, we come upon the external epithelial cells of the *membrana basilaris*. But between these also further prolongation of this cuticular mesh-work may be recognised. This is the so-called "*terminal framework*" of *Deiters* (*q*).

The *zona pectinata* (fig. 606, *g*), *i.e.*, the external portion of the lam.

spiral. memb. commences at the outer border of the organ of *Corti*, and remains—one might almost say happily—free from further accessory structures. Formed of the two periosteal laminae of the memb. basilaris it presents a perfectly smooth under surface towards the scala tympani, while the upper appears finely streaked as if fibrillated. The outer border of the *zona pectinata* reaches the bony wall of the cochlea (fig. 606, *i*). Here opposite a low bony ridge (*m*), which *Huschke* has named the *lamina spiralis accessoria*, it unites with the so-called *ligamentum spirale* (*l*). The latter, a vascular mass, consists of an upper fibrillated portion, and an under cellular part facing the scala tympani (*Hensen*).

§ 326.

There still remain for our consideration the *epithelial lining* of the *canalis cochleæ*, and the *mode of termination of its nerves*.

In the fœtus this canal (fig. 606, C), is originally lined throughout with epithelial cells (*Koelliker*). These present themselves as a single layer of pavement elements, except in two localities, namely (1), at the sulcus spiralis (*d*), and so-called habenula sulcata, and (2) in the position of the organ of *Corti* (*f*). In the first of these positions the cell-layer is stratified and overlaid with a membrane, the membrane of *Corti* (*Cm*). At the spot indicated by (*b*), the epithelial mass forms a ridge which supplies, according to *Koelliker*, material for the formation of the organ of *Corti*, of the hair-cells, and as a cuticular structure of the lamina reticularis also.

If the membrane of *Corti* be closely examined in the full-grown animal, it will be found to present (in the ox, for instance) a thickness of 0.045 mm., and finely fibrous appearance. It commences upon the habenula sulcata at about the same spot as that at which the membrane of *Reissner*, already mentioned, arises. Its mode of termination externally is still a matter of controversy. According to *Hensen*, *Gottstein*, and *Waldeyer*, it reaches to the organ of *Corti*, terminating very much thinned in the neighbourhood of the external hair-cells. It rests immediately upon the lamina reticularis.

The *epithelium* of the fully developed *canalis cochleæ* consists, upon the membrane of *Reissner* of a layer of large flat pavement cells. Smaller and thicker cells are to be found on the outer parts of the canal and *zona pectinata*, as far as the neighbourhood of the organ of *Corti*, where large spheroidal, and at last perpendicularly elongated elements present themselves the "supporting" (*Stützzellen*) of *Hensen*. Under *Corti's* membrane, upon the habenula sulcata, it probably only occurs, on the other hand, interruptedly, and in the sulcus spiralis *Hensen* only found a single layer.

The cochlea is supplied by numerous *capillary networks* situated in the periosteum and lamina spiralis. Above the so-called *ligamentum spirale*, especially, may be seen a peculiarly vascular streak, the *stria vascularis* of *Corti* (fig. 606, *o*). Within the *lamina spiralis* the bony tissue and nervous ramifications are traversed by a complex network, which communicates with a spiral vessel situated upon the under surface of the plate, *i.e.*, that facing the scala tympani.

As regards *lymphatic spaces*, in the internal ear, we have only to remark that injections from both subdural and subarachnoidal spaces of the encephalon penetrate into the labyrinth (*Key*, *Retzius*).

Turning now to the distribution of the *cochlear nerve*, the first point to

be observed is that bundles of fibres, made up of medullated tubes 0.0034 mm. in thickness, radiate from the modiolus into the lamina spiralis ossea, forming a dense plexus in its complicated passages. At one particular spot, namely, at the point of exit from the bony portion of the spiral plate, there is imbedded (as was first observed by *Corti*) in the course of the primitive fibres a ganglion cell (*ganglion spirale of Corti*). Preserving their plexiform arrangement, the nerve fibres still pursue a course outwards, passing eventually through the apertures in the habenula, after having dwindled down to non-medullated axis cylinders. Arrived now in the canalis cochlearis they present themselves as extremely delicate pale fibrillæ.

From this on two different sets of fibres may be distinguished, namely (a), one for the internal, and (b) one for the external hair cells.

The axis cylinders of the internal set (0.0015-0.002 mm. thick) are supposed to penetrate into the apices of the internal hair cells (fig. 608). The external, which are much finer, to pass across the "tunnel" of the organ of *Corti*, about midway between floor and roof (*Gottstein, Waldeyer*) to unite with the external hair cells (*w*). These views are, however, still but very feebly supported.

While we leave the greater part of the *development of the organs of hearing* to the special works on embryology, we may here mention a few general facts on the subject in conclusion.

The labyrinth makes its first appearance as a vesicular structure, known as the *labyrinthine* or *auditory vesicle*, a multilaminar infolding of the *corneous layer* (*Remak*), which subsequently receives from the middle germinal plate a fibrous, and then over that a cartilaginous covering in the form of a capsule.

The *semicircular canals* and the *canalis cochlearis* are then formed from the auditory vesicle as secondary outgrowths.

The *canalis cochlearis*, at first only a slight eminence, grows out into a curving horn, which acquires in its further development the spiral passage (*Koelliker*). The two *scala*, that of the tympanum and that of the vestibule, are tertiary formations produced by the liquefaction of the connective-tissue adjoining the canalis cochlearis.

INDEX.

- Acetic acid, 24
 Acids (fatty), 23
 nitrogenous, 36
 non-nitrogenous, 34
 Acinus of glands, *vid.* Glandular Tissue
 of thymus, *vid.* CIRCULATORY APPARATUS
 Acoustic teeth, *vid.* SENSORY APPARATUS
 Addison's Disease, relation to supra-renal
 bodies, *vid.* CIRC. APP.
 Adenoid Connective-Tissue of *His*, 193
 Agminated glands, 420
 Air-cells of lungs, *vid.* RESPIRATORY APP.
 Albumen, 14
 of several organs, *vid.* latter
 Albuminous Compounds, 12
 albumen, 14
 casein, 17
 composition of, 13
 crystallin, 17
 ferments, as, 14, 17
 fibrin, 15
 fibrinogen, 15
 fibrinoplastin, 15
 globulin, 17
 hæmoglobulin, 18
 histogenic derivatives from, 21
 chondrin, 22
 chondrigen, 22
 collagen, 22
 colloid, 21
 elastin, 23
 glutin-yielding substances, 21
 glutin, 22
 keratin, 21
 mucin, 21
 myosin, 16
 peptones, 17
 properties of, 13
 syntonin, 16
 Amides. Amido-Acids, Organic Bases, 40
 allantoin, 44
 cholin (neurin), 48
 cystin, 50
 glycin, 48
 guanin, 43
 hypoxanthin, 43
 kreatin, 44
 kreatinin, 45
 leucin, 45
 neurin, 48
 relations and constitution of, 40
 sarkin, 43
 taurin, 48
 tyrosin, 47
 urea, 40
 nitrate of, 41
 oxalate of, 41
 xanthin, 43
 Ammonium Salts, 62
 carbonate of, 62
 chloride of, 62
 urate of (acid), 37
 Amœboid cells, *vid.* Cells
 Amœboid motion, *vid.* Cells and Blood
 Amyloid degeneration of cells, *vid.* Cells
 Amyloid matter, 29
 Anatomy, general, 1
 study of same with microscope, 2
 without latter, 2
 APPARATUSES OF BODY, 399
 bony,
 circulatory, 402
 digestive, 458
 generative, 536
 muscular, 573
 nervous, 574
 respiratory, 448
 sensory, 603
 urinary, 514
 Aqua *Cotunii* (perilymph) of internal ear,
 vid. SENS. APP.
 vitrea auditiva (endolymph) of internal
 ear, *vid.* SENS. APP.
 Arachnoid of brain, *vid.* NERV. APP.
 Areola of breast, *vid.* GEN. APP.
 Arrector pili, muscle of hair follicle, *vid.*
 Hair
 Arteriæ helicinæ of cavernous organs, *vid.*
 GEN. APP., male
 Arteries, *vid.* VESSELS
 Arteriola rectæ of the kidneys, *vid.* URINARY
 APP.
 Articulations, *vid.* BONY APP.
 cartilages of, *vid.* BONY APP.
 Auditory filaments, *vid.* SENS. APP.
 Auerbach's plexus myentericus, *vid.* Nerv.
 Tiss. and DIGEST. APP.
 Auricles of heart, *vid.* CIRC. APP.
 Axial canal of spinal cord, *vid.* NERV. APP.
 Axial stream of blood-vessels, *vid.* VESSELS
 Axis cylinder, *vid.* Nerve Tiss. and NERV.
 APP.
 Axis-cylinder process of ganglion cells, *vid.*
 Nerve Tiss. and NERV. APP.
 Axis fibres, *vid.* Nerve Tiss.
 Axis fibrillæ, *vid.* Nerve Tiss.
 Bacillary layer of retina, *vid.* SENS. APP.
 granules, *vid.* SENS. APP.
 Bacilli (rods) of retina, *vid.* SENS. APP.
 Bartholin's glands, *vid.* GEN. APP. (female)
 Basement membrane (intermediate mem-
 brane), *vid.* Cells
 Bases, organic, *vid.* Amides, &c.
 Beaker cells, *vid.* DIGEST. APP. and Epithe-
 lium
 Bellini, tubes of, *vid.* URIN. APP.

- Benzoic acid, 38
Bichat, X., 2
 Bile, *vid.* DIGEST. APP.
 Biliary capillaries of liver, *vid.* DIGEST. APP.
 Biliary passages, *vid.* DIGEST. APP.
 glands of, *vid.* DIGEST. APP.
 Biliary pigments, 53
 Bilifuscin, 54
 Bilihumin, 54
 Biliprasin, 54
 Bilirubin, 54
 Biliverdin, 54
 Bladder, *vid.* URIN. APP.
 Blood, 105
 amount of, in body, 105
 analysis, chemical (present state), 115
 anatomical, 105
 cells, conditions of, during life, 127
 coloured or red (human), 106
 compared with those of lower animals, 109
 composition of, 117
 differences of, in vena porta and vena hepatica, 108
 effects of electrical discharges on, 107
 of gases on, 122
 of heat on, 108
 of several reagents, 107
 number of, 106
 origin of, 114
 passage of, through walls of uninjured vessels, 128
 rouleaux of, 123
 shape of, 106
 size of, 106
 volume of, 106
 weight of, 106
 colourless, white, pale, 110
 amœboïd motion of, 112
 composition of, 134
 number (normal) compared with red and in leucæmia, 113
 nuclei of, 111
 origin of, 113; from bone medulla, spleen, and lymphatic glands, 128; in the embryo, 129.
 passage of, through walls of vessels, 129
 segmentation of, 129
 transformation of, into red cells, 114, 128
 circulation of red and white corpuscles in living vessel, 113
 coagulation of, 124
 buffed coat, 127
 causes of, theories, 127
 crassamentum, 126
 crusta phlogistica, 127
 variations in process of, 126
 composition of (chemical), 114
 arterial of, 121
 intercellular fluid of, 118
 menstrual of, 121
 splenic artery and vein of, 121
 venous of, 121
 vena porta and hepatica of, 121
 corpuscles, *vid.* Cells
 crystals, 117
 development of, in embryo, 129
 gases of, 118-120
- Blood, odour of, 105
 physical properties of, 105-106
 plasma of, 106
 temperature, 105
 Blood-vascular glands, *vid.* CIRC. APP.
 Blood-vessels, *vid.* VESSELS
 of organs, *vid.* same
 Bodies of cells, *vid.* Cells
 Bone, *vid.* Oss. Tiss.
 canaliculi of, *vid.*
 cartilage, *vid.*
 earths, *vid.*
 lacunæ of, *vid.* } Oss. Tiss.
 Bones of ear, *vid.* SENS. APP.
 BONY APPARATUS, 510
 Articulation (modes of), 570
 diarthrosis, 570
 sutures, 570
 symphyseis, 570
 synarthrosis, 570
 Cartilage of, 570
 ill-developed osseous tissue underneath, 170
 Formation of, 570
 Half-joints, 570
 Haversian glands, 571
 Medulla (conversion of cells of, into red blood corpuscles), 573
 Myeloplaxes, 573 and 71
 Nerves of, 572
 Plicæ vasculosæ, 571
 Vessels of, 571
 Boundary layer of *Henle* in kidneys, *vid.* URIN. APP.
Bowman's glands of olfactory regions, *vid.* SENS. APP.
 Brain, *vid.* NERV. APP.
 Breast, *vid.* GEN. APP. (fem.)
 Bronchi, *vid.* RESPIR. APP.
Bruch's agminated follicles (plaques) of conjunctiva, *vid.* SENS. APP.
Brunner's glands, *vid.* DIGEST. APP.
 Buccal glands, *vid.* DIGEST. APP.
 Bulb of eye, 617
 Bulb olfactory, 597
 Bulb of urethra, 566
 Butyric acid, 24
- Calcification of cells, *vid.* Cells
 Canal, semicircular, of ear, *vid.* SENS. APP.
 Canal of *Petit* of eye, *vid.* SENS. APP.
 Canal of *Schlemm* of eye, *vid.* SENS. APP.
 Canaliculi of bone, 243
 Canalis cochlearis, *vid.* SENS. APP.
 Canals, *Haversian*, 240
 Capillaries, *vid.* VESSELS
 Capillary canals, *vid.* VESSELS
 Capillary vessels, *vid.* VESSELS
 Capillary looped networks, *vid.* VESSELS
 Caprinic acid, 25
 Capronic acid, 25
 Caprylic acid, 25
 Capsula lentis, *vid.* Lens Tiss.
 Capsule of cells, *vid.* Cells
 Caput epididymis, *vid.* GEN. APP.
 Carbohydrates, 30
 Cardiac ganglia, *vid.* Ganglia
 Carotid ganglion, *vid.* Ganglia
 Cartilages, 166
 articular, 167, 174
 calcification of, 171
 capsules, 169

Cartilages—

- cells, 163
 - fatty infiltration of, 171
 - cells of (medullary), 171
 - segmentation of, 170
 - chemical analysis of, 183, 184
 - classification of, 167
 - connective-tissue, *vid.* fibro-cartilage
 - early appearance of, 186
 - ekchondroses, 186
 - elastic, 179
 - enchondroma, 186
 - fibro, 180, 225
 - colloid nuclei of intervertebral ligaments, 182
 - fibro-reticular, 179
 - hyaline, 166
 - portions of adult bodies still consist of it, 173, 174
 - preformation of foetal skeleton in, 173
 - intercellular substance, 169
 - source of, 169
 - liquefaction of, 173
 - medulla of, 251
 - membraniform, 167
 - neoplasmata of, 186
 - permanent, 167
 - respiratory apparatus, of, 176, 448
 - reticular, 179
 - significance of, in adult and foetal body, 185
 - temporary, 167
- Casein, 17
- Cauda epididymis, *vid.* GEN. APP.
- Cavernous passages of lymphatic glands, *vid.* CIRC. APP.
- Cells, 63
- amœboid motion in, 75
 - body of, 64
 - material of, 66
 - calcification of, 95
 - capsule of, 83
 - casting off of, 94
 - chemical constitution of, 72
 - ciliated, the, 78
 - colloid metamorphosis of, 94
 - component parts of, 66
 - containing red blood-corpuscles, *vid.* CIRC. APP.
 - contractile, 75
 - cytoblastema, 87
 - decay of, 94
 - derivatives of, *vid.* Cells, as parent of other structures
 - division of, 88
 - envelope, 64
 - structure of, 68
 - enveloping sphere of, 92
 - fatty metamorphosis of, 95
 - flattened, 65
 - formed products of, 82
 - basement membranes, 84
 - ground substance, 86
 - intercellular substance, 86
 - intermediate membrane, 84
 - membrana propria, 85
 - tissue cement, 86
 - fusiform, 66
 - generation of, within larger and older cells, 94
 - giant (multinuclear), 71
 - granulated, 69

- Cells, growth of, 78
 - interchange of material of, 80
 - mature, 66
 - membrane of, 64
 - multinuclear, 71
 - multiplication of, 88
 - networks of, *vid.* Cells, as parent of other structures and, 98
 - nucleolus, 64, 70
 - nucleus, 64, 69
 - absence of, 71
 - gemmation of, 91
 - ova, perfect examples of, 64
 - parent, 89
 - parents of other structures as, 95
 - of cellular networks, 98
 - of connective substances, 98
 - of connective-tissue fibres, 89
 - of elastic fibres, 89
 - of nerve fibres, 100
 - of smooth muscle fibres, 95
 - of striped muscle fibres, 96
 - of vascular cells, 97
 - physiological properties of, 64
 - decay of, 101
 - pore canals of, 83
 - protoplasm of, 66
 - deposit of strange matters in, 67
 - psorospermia in, 92
 - reception of solid particles into interior of, 77
 - Renak's* discoveries concerning, 93
 - ridged, 69
 - segmentation of, 88
 - of naked cells, 88
 - of encapsuled, 89
 - of parent, 89
 - of daughter, 89
 - of yolk, 90
 - senescent, 66
 - shape, 65
 - single-celled organisms, 64
 - size of, 65
 - smooth-edged, 69
 - solution of, 94
 - spheroidal, 65
 - spinous, 69
 - spontaneous generation of (*Schwann*), 92
 - stellate, 66
 - tall narrow species of, 66
 - tuberculisatio of, 95
 - vital properties of (amœboid motion), 75
 - wandering of, through the body, 78
 - significance of latter process in inflammation, 79
- Cellular networks, *vid.* Cells, as parent of other structures
- Cement, *vid.* Dent. Tiss.
- Central organs of NERV. SYS. (brain and cord), *vid.* NERV. APP.
- Cerebellum, *vid.* NERV. APP.
- Cerebra ganglia, *vid.* NERV. APP.
- Cerebrum, *vid.* NERV. APP.
- Cerumen, *vid.* SENS. APP.
- Ceruminous glands, *vid.* SENS. APP.
- Chemistry of tissues, 5
 - physiological, 6
 - chloride of ammonium, 62
 - of calcium, 58
 - of iron, 62
 - of magnesium, 59
 - of potassium, 61

- Chloride of sodium, 60
 Cholestearin, 30
 Cholic acid, 39
 Cholin (neurin), 48, and Nerve Tiss.
 Chondrigen, 22
 Chondrin, 22
 Chorda dorsalis, *vid.* Cartilage
 Choriocapillaris, *vid.* SENS. APP.
 Choroid coat of eye, *vid.* SENS. APP.
 Chorion (zona pellucida) of ovum, *vid.* GEN. APP.
 Chyle, *vid.* Lymph vessels, *vid.* VESSELS
 corpuscles, *vid.* Lymph in intestinal villi, *vid.* DIGEST. APP.
 Ciliary arteries, *vid.* SENS. APP.
 Ciliary motion, *vid.* Epithelium
 Ciliary muscles, *vid.* SENS. APP.
 Ciliary nerves, *vid.* SENS. APP.
 Ciliary processes, *vid.* SENS. APP.
 Ciliated cells, *vid.* Epithelium
 CIRCULATORY APPARATUS, 403
 Blood-vascular Glands, 440
 carotid gland (ganglion intercaroticum), 448
 coccygeal gland, 447
 structure of, 447
 vessels of, 447
 pituitary body, 446
 glandular structure of anterior lobe, 446
 suprarenal body, 443
 Addison's Disease, 446
 blood-vessels of, 445
 composition of, 446
 cortical substance of, 443
 development of, 443
 envelope of, 463
 lymphatics of, 445
 medullary substance of, 444
 pathological changes in, 446
 thyroid, 440
 colloid metamorphosis of, 442
 composition of, 442
 development of, 443
 goitre in, 442
 lymphatics of, 441
 nerves of, 442
 stroma of, 441
 vesicles of, 441
 Heart, 403
 auricles of, 405
 endocardium of, 405
 fibres of *Purkinje* of, 405
 ganglia, 406
 muscular substance of, 403, 292
 nerves of, 403, 406
 pericardium of, 403
 valves of, 406
 vessels of, 406
 Lymphatic Glands, 407
 follicles of, 407
 of cortical layer, 407
 of medullary mass, 407
 investing spaces of, 408, 410
 structure of, 408
 hilus-stroma of, 411
 lymphatic passages of, 415
 epithelial lining of, 417
 lymph tubes of, 411, 412
 origin of, 413
 termination of, 413
 CIRCULATORY APPARATUS—
 Lymphatic Glands—
 medullary substance of, 407
 nerves of, 418
 nucleus of, *vid.* hilus-stroma
 septa of, 408
 substance of, 411
 vas afferens of, 407
 vas efferens of, 407
 vessels of, 414
 Lymphoid Organs, 420
 lenticular follicles of stomach, 420
 lingual follicles, 420
 lymphoid follicles, 420
 investing spaces of, 421
 lymphatic passages of, 422
 structure of, 420
 lymphoid glands, 420
 agminated, 420
 solitary, 420
 spleen, 426
 arteries of, 427
 capillaries of, 431
 capillary husks, 431
 cavernous splenic veins, 434
 cells containing blood corpuscles, 43
 composition of, 439
 development of, 440
 envelope of, 446
 follicles of, 430
 gradual formation of same, 431
 intermediate pulp passages of, 436
 lymphatics of, 438
 lymphoid portion of, 427
 Malpighian corpuscles of, 427
 morbid changes in, 440
 nerves of, 438
 penicilli, 427
 pulp, 427
 pulp tubes, 432
 pulp cords, 432
 septa, 427
 trabeculae, 427
 transition of arterial into venous
 circulation in, 435
 vascular sheaths of, 429
 veins of, 434
 venous system of, 434
 wall-less passages of, 435
 thymus, 423
 acini of, 424
 central canal of, 423
 composition of, 425
 concentric bodies of, 424
 degeneration of, 425
 development of, 425
 granules, 424
 lobules, 423
 lymphatics, 425
 vessels, 424
 tonsils, 420
 trachoma glands, 420
 Circulus arteriosus iridis major and minor,
 vid. SENS. APP.
 Circulus arteriosus musculi ciliaris, *vid.*
 SENS. APP.
 Clitoris, *vid.* GEN. APP. (fem.)
 Coagulation of nervous matter, *vid.* NERV.
 APP.
 Coccygeal gland, *vid.* CIRC. APP.
 Cochlea, *vid.* SENS. APP.
 Cochlear nerve, *vid.* SENS. APP.

- Cohnheim's* fields in transverse sections of muscle, *vid.* Mus. Tiss.
 observations on wandering of white blood-corpuses, 129
- Collagen, 22
- Colliculus seminalis, *vid.* GEN. APP.
- Colloid matter, 21
- Colloid metamorphosis of thyroid gland, *vid.* CIRC. APP.
 of cells, *vid.* Cells
- Colloid nucleus of intervertebral ligament, *vid.* Cart.
- Colon, follicles of, *vid.* DIGEST. APP.
- Colostrum, *vid.* GEN. APP. (fem.)
 corpuscles, *vid.* GEN. APP.
 formation of, *vid.* Gland. Tiss.
- Colouring matters (animal), 50.
- Columnar layer of retina, *vid.* SENS. APP.
- Commissures, ant. and post. of spinal cord, *vid.* NERV. APP.
- Conarium (pineal gland), *vid.* NERV. APP.
- Concentric bodies of thymus, *vid.* CIRC. APP.
- Cone granules, *vid.* SENS. APP.
- Cones of retina, *vid.* SENS. APP.
- Coni vasculosi, *vid.* GEN. APP.
- Conjunctiva of eye, *vid.* SENS. APP.
- Conjunctival glands, *vid.* SENS. APP.
- Connective substance, its origin from cells, *vid.* Cells, parents of other structures cytogenous, *vid.* Gelat. Tiss.
 reticular, 187
 sustentacular of nervous system and retina, 188, 196
- Connective-tissue, 205
 bundles
 elastic limiting layers of, 210
 primary, secondary, and tertiary, 207
 cartilage, *vid.* fibro-cartilage
 cells, *vid.* corpuscles
 cornea of eye, 220
 canal work of, 222
 corpuscles, 222
 elastic laminae of (ant. and post.), 220
 epithelium of, 220
 tissue of, 220
- corpuscles, 212
 amoeboid motion of, 213
 immigration of, into tissue of cornea under inflammatory irritation
Cohnheim's and *v. Recklinghausen's* experiments, 222
 in an inanimate state, 214
 stellate pigmentary, 219
 change of form of, 219
- cutis vera, of, 228
- dental pulp, of, 218
- elastic, elements of, 208
 nucleus fibres, 208
 origin of, in embryo, 237
 structures of respiratory organs, 229
 tissue, so-called, 210
- fasciae, 226
- fibres, *vid.* Cells, as parents, and, 205
- fibrillae, 205
 more closely considered, 206
- fibromata, 234
- fibrous membranes, 225
- formed, 219
- ligaments, 225
- ligamentum flavæ of spinal col., 229
- ligamentum nuchæ, 229
- mode of occurrence, of, 216
- Connective-tissue, loose areolar, 217
 mucous membranes of, 228
 neurilemma, 226
 origin of, in the embryo, 235
 perichondrium, 226
 perineurium, 226
 periosteum, 226
 physiological purposes of, 232
 plasmatic circulation (suppositious) in, 223
 relationship to other tissues, 233
 serous membranes of, 226
 subarachnoid spaces of, 227
 subcutaneous, 218
 submucous, 218
 subserous, 218
 suppuration in, 234
 synovial bursa of, 227
 sheaths of, 227
 tendons of (in the infant), 224
 (in the adult), 224
 tunics of blood and lymph vessels, 229
 varieties of, 205
 vascular membranes of (pia mater and choroid plexus), 229
- Contour (double) of nerves, *vid.* Nerve Tiss.
- Contour lines of dentine, *vid.* Dental Tiss.
- Contractility, vital, of cell, *vid.* Cells
- Convolved glands of conjunctiva, *vid.* SENS. APP.
- Copper, 62.
- Cord, spinal, *vid.* NERV. APP.
- Cornea, *vid.* Con. Tiss. and SENS. APP
- Corneal tubes, *vid.* SENS. APP.
 nerves, *vid.* SENS. APP.
- Corneous layer of epiderm's, *vid.* Epithelium, and SENS. APP.
- Cornification of flattened epithelium, *vid.* Epithelium
- Cornu ammonis, *vid.* NERV. APP.
- Cornua of spinal cord
 accessory of medulla oblongata
 corpuscles, *vid.* Con. Tiss.
 germinal layers (*epiblast*, *mesoblast*, and *hypoblast*)
 layer of epidermis
- Corpora cavernosa, *vid.* GEN. APP. (male)
- Corpora quadrigemina, NERV. APP.
- Corpora amylacea, 29
 quadrigemina, *vid.* Nerv. Tiss.
- Corps inomine of testicle, *vid.* GEN. APP. (male)
- Corpus ciliare of eye, *vid.* SENS. APP.
- Corpus dentatum of cerebellum, *vid.* NERV. APP.
 of olivary body, *vid.* NERV. APP.
- Corpus epididymidis, *vid.* GEN. APP.
- Corpus *Higmorei* of testicle, *vid.* GEN. APP. (male)
- Corpus luteum, *vid.* GEN. APP. (female)
- Corpus striatum, *vid.* NERV. APP
- Corpus vitreum, 189
- Cortex corticis of kidney, *vid.* URIN. APP.
- Cortis fibres in cochlea, *vid.* SENS. APP.
 cells of, *vid.* same.
 organ of, *vid.* SENS. APP.
- Cowper's glands, *vid.* GEN. APP.
- Crura cerebelli
 ad corpora quadrigemina
 ad medullam oblongatam
 ad pontem, *vid.* SENS. APP.
- Crura cerebri ad pontem, *vid.* SENS. APP.

Crusta petrosa, *vid.* Dent. Tiss.
 Crystallin, *vid.* Globulin, 17
 Cumulus proliigerus of ovary, *vid.* GEN. APP.
 (female)
 Cuticula of hair, *vid.* Hair
 Cyanogen compounds, 54
 Cystin, 50
 Cytoblastema, *vid.* Cells
 Cytogenic connective-tissue of *Koelliker*, 193

Daughter cells, *vid.* Cells
 Decidua of uterus, *vid.* GEN. APP. (female)
 Dehiscence of glands, *vid.* Gland. Tiss.
 of ovarian follicles, *vid.* GEN. APP.
 (female)
Deiter's cells, *vid.* SENS. APP.
 Dental tissue, 260
 cement, 264
 composition of, 265
 formation of, 271
 lacunæ of, 265
 crusta petrosa, 265
 dental canaliculi, 261
 cup, 271
 fibres, 264
 follicles, 266
 germ, 266
 groove, 267
 ridge, 267
 dentine, 261
 cells, 254
 composition of, 265
 contour line, 263
 globules, 262
 ground-substance, 262
 interglobular spaces, 262
 enamel, 261
 germ, 268
 membrane, 269
 organ, 266
 odontoblasts, 264
 layer of, 270
 pathological conditions of, 272
 pulpa dentis, 263
 teeth, 260
 development of, 266
 tooth 260
 crown of, 260
 germ, *vid.* dental germ
 neck, 260
 root of, 260
 Tomes' fibres, 264
 layer, 262
 Dental germ, *vid.* Dent. Tiss.
 Dental cells, *vid.* Dent. Tiss.
 Dentine, *vid.* Dent. Tiss.
 Diarthrosis, *vid.* BONY APP.
 DIGESTIVE APPARATUS, 458
 Colon, 497
 blood-vessels of, 498
 development of mucous coat, 499
 lymphatics of, 498
 lymphoid follicles of, 497
 tubuli of, 497
 Intestine (small), 484
 development of, 497
 glands of, 486
 Brunner's, 486
 Lieberkühn's, 488
 racemose, *vid.* *Brunner's*
 juices of, 499
 lymphatics of, 495

DIGESTIVE APPARATUS—

Intestine (small)—

lymphatics of, arrangement in mucous membrane and sub-mucous tissue, 496
 in *Peyer's* plaques, 496
 Auerbach's interlamina plexus of, 496
 in villi and muscular tunic, 495
 radicles of, 495
 lymphoid follicles of, 489
 agminated, 489
 base, 490
 cupola, 490
 form of, 490
 mesial zone of, 490
 parts of, 490, 491
 Peyer's plaques, 489
 position of, 489
 ridge of mucous memb. of, 491
 structure of follicles, 491
 mucous membrane of, 484
 nervous apparatus of, 492
 Auerbach's plexus myentericus, 494
 Remak's and *Meissner's* sub-mucous plexus, 492
 succus entericus, 499
 valvulæ conniventes, 484
 vascular supply of, 493
 villi, 484
 capillary network of, 485
 chyle radicles of, 486
 structure of, 485

Liver, 502

bile, a secretion of, 512
 bile, composition of, 512
 gases of, 513
 pigments of, 53, 513
 quantity of, 513
 secretion of, 513
 uses of, 514
 bile ducts, 506
 glands of, 510
 bile capillaries, 506
 relation of, to cells, 507
 walls of, 509
 cells, 502
 arrangement of, 502
 contents, 502
 cuticular border of, 509
 cirrhosis of, 502
 composition of tissue of, 511
 development of, 514
 gall bladder, 509
 vasa aberrantia of, 510
 lobules of, 502
 arrangement of vessels in, 504
 capillaries of, 504
 demarcation of, 504
 sustentacular tissue of, 505
 lymphatics of, 510
 nerves of, 511
 vena hepatica, 504
 vena intralobularis, 504
 vena interlobularis, 504
 vena porta, 504

Mouth, 458
 glands of, 459
 buccal, 459
 lingual, 459
 palatal, 459
 lymphoid organs of, 469

DIGESTIVE APPARATUS—

- Mouth—
 mucus of, 464
 mucous membrane of, 458
 submucosa, 458
- Esophagus,
 glands of, 472
 lymphatics of, 473
 nerves of, 473
 vessels of, 473
- Processus vermiformis, 499
- Pancreas, 499
 development of, 500
 juice of, 501
 composition of, 501
 nerves of, 500
 secreting tubules of, 500
 structure of, 500
- Pharynx, 472
 lymphatics of, 472
 lymphoid organs of, 472
 vessels of, 472
- Saliva, 463
 composition of, 463
 uses of, 464
- Salivary glands, 460
 parotid, 462
 secretion of, 465
 effect of irritation of nerves on, 465
- submaxillary glands, 460
 blood-vessels of, 461
 border cells of, 465
 crescents of, 465
 excretory ducts of, 461
 lymphatics of, 461
 mucus of, 465
 nerves of (termination of), 461
 secretion of, 464
 corpuscles of, 465
 effect of nerve irritation on, 464
 varieties of cells of, 460
- sublingual glands, 462
 secretion of, 465
- Stomach, 473
 cells, 477
 development of, 482
 glands of, 475
 cells of, 475
 adelomorphous, 478
 delomorphous, 478
 membrana propria of, 475
 mucous of, 479
 peptic, 475
 racemose, 479
 juices of, 482
 action of, 482
 composition of, 482
 mucous membrane of, 474
 muscularis mucosæ, 474
 lenticular follicles of, 480
 lymphatics of, 481
 nerves of, 481
 peptones of, 483
 serous covering of, 473
 vascular system of, 480
- Tongue, 466
 development of, 469
 fibro-cartilage of, 466
 glands of, 469
 lingual follicles, 469
 lymphatics of, 468
 mucous membrane of, 469

DIGESTIVE APPARATUS—

- Tongue—
 mucous membrane of, lymphoid infiltration of, 469
 muscular substance of, 466
 nerves of, 468, and SENS. APP.
 papillæ of, 467
 circumvallate, 467
 filiform, 467
 fungiform, 467
- Tonsils, 470
 lymphatics of, 471
 vessels of, 470
- Diglycerides, 24
- Dilatator pupillæ, *vid.* SENS. APP.
- Disks, *vid.* Mus. Tiss.
- Ductus ejaculatorii, *vid.* GEN. APP.
- Ductus thoracicus, *vid.* Vessels
- Dura mater, *vid.* NERV. APP.
- Duverney's glands, *vid.* GEN. APP. (female)
- Ear (internal), *vid.* SENS. APP.
- Ekchondroses, *vid.* Cartilages
- Elain, *vid.* Triolein, 26
- Elaidic acid, 25
- Elastin (elastic material), 23
- Elementary parts of body, 63
- Elements of composition of body, 11
- Enamel of teeth, *vid.* Enamel Tiss.
- Enamel columns, *vid.* Enamel Tiss.
- Enamel cuticle, *vid.* Enamel Tiss.
- Enamel fibres, *vid.* Enamel Tiss.
- Enamel germ, *vid.* Dent. Tiss.
- Enamel membrane, *vid.* Enamel Tiss.
- Enamel organ, *vid.* Dent. Tiss.
 tissue of, *vid.* Gelat. Tiss.
- Enamel prisms, *vid.* Enamel Tiss.
- Enamel tissue, 273
 columns, 273
 cuticle (membrana præformativa), 276
 composition of, 275
 development of, 275
 fibres of, 273
 prisms of, 273
- Enchondroma, *vid.* Cartilages
- End-bulbs, *vid.* Nerv. Tiss.
- End-capsules of gland nerves, *vid.* Nerv. Tiss.
- Endocardium, *vid.* CIRC. APP.
- Endogenous cell growth, *vid.* Cell
- Endolymph of internal ear, *vid.* SENS. APP.
- Endothelium, *vid.* Epith. and Vessels
- Envelopes of fine nerve twigs, *vid.* Con. Tiss. and Nerve Tiss.
- Envelopes of the central organs of nervous system, *vid.* NERV. APP.
- Ependymal thread of spinal cord, *vid.* NERV. APP.
- Epidermis, *vid.* Epith.
- Epididymis, *vid.* GEN. APP. (male)
- Epithelium, 137
 Cells (varieties of), 138
 action of alkalies upon, 151
 beaker, *vid.* goblet
 ciliated, 138
 columnar, 138
 flattened, 139
 goblet, 143
 occurrence of mucous and pus-corpuscles in, 153
 pavement, 138
 pigmentary, 138
 ridged, 141, 142

Epithelium—

- Cells, relationship to gland cells, 152
 - spinous, 141, 142
- Ciliated, 143
- Ciliary motion of, 156
- Columnar, 146
 - thickened border of, 84, 147
 - pore canals in, 84, 147
- Composition of, 150
- Development of, 137
- Endothelium, 159
- Epidermis, 144
 - corneous layer of, 144
 - cornification of, 150
 - Goblet cells in, 150
 - Keratin of, 151, 152
 - Laminated, 139
 - Mucus of, 154
 - Pavement, 139
 - Physiological significance of, 152
 - Rete *Malpighi*, 144
 - Synovia a secretion of, 155
- Erection of penis, *vid.* GEN. APP.
- Eustachian* tube, *vid.* SENS. APP.
- Extractives, 54 (note)
- Eyelids, *vid.* SENS. APP.
- Faries' milk, 554
- Fallopian* tubes, *vid.* GEN. APP.
- Fats, 23
 - cerebral, 23
 - neutral, 26
 - of several organs and tissues, *vid.* same purposes of, 27
- Fat-cells containing serum, *vid.* Fatty Tiss.
- Fat-cells poor in fat, *vid.* Fatty Tiss.
- Fatty acids, 23
- Fatty degeneration of muscle, *vid.* Mus. Tiss.
- Fatty metamorphosis of cells, *vid.* Cells
- Fatty tissue, 198
 - blood-vessels of, 200
 - development of, in embryo, 203
 - distribution of, through the body, 200
 - fat cells, 198
 - deprived of fatty matter, and containing serum, 199, 200
 - formation of, from connective-tissue corpuscles, 203
 - fatty tumours, 201
 - panniculus adiposus, 200
 - physiological purposes of, 202
 - Fatty tumours, 201
- Fermentation of urine, *vid.* URIN. APP.
- Ferments, 14, 17
- Fibre-cell contractile, *vid.* Muscle Tiss.
- Fibres (elastic), *vid.* Cells, as parent of tissues and Con. Tiss.
- Fibrin, 15
 - coagulation of, 16
- Fibrinogen, 15
- Fibrinoplastin, 16
- Fibroma, *vid.* Con. Tiss.
- Fibro-cartilage, *vid.* Cartil. and Con. Tiss.
- Fibro-reticular cartilage, *vid.* Cartil.
- Fluoride of calcium, 53
- Follicles,
 - of colon, *vid.* DIGEST. APP.
 - Graafian*, *vid.* GEN. APP. (female).
 - of lymphatic glands, *vid.* CIRC. APP.
 - lymphoid, *vid.* CIRC. APP., and several organs
 - Malpighian*, *vid.* CIRC. APP.

- Follicular rudiments of ovary, *vid.* GEN. APP. (female)
- Forked cells, *vid.* SENS. APP.
- Form elements of body, 63
- Form, change of, in amoeboid cells, *vid.* Cells
- Formatio granulosa of ovarian follicle, *vid.* GEN. APP. (female)
- Formatio reticularis of med. oblong., *vid.* NERV. APP.
- Formic acid, 24
- Fovea centralis of retina, *vid.* SENS. APP.
- Fundamental lamellæ of bone, *vid.* OSS. Tiss.
- Gall bladder, *vid.* DIGEST. APP.
- Ganglia of different organs, *vid.* same
 - cardiac, *vid.* CIRC. APP.
 - cells of, *vid.* Nerve Tiss.
 - apolar, *vid.* Nerve Tiss.
 - bipolar, *vid.* Nerve Tiss.
 - multipolar, *vid.* Nerve Tiss.
 - unipolar, *vid.* Nerve Tiss.
 - ramifying in anterior cornu of spinal cord, *vid.* Nervous App.
 - cerebral, *vid.* Nervous App.
 - corpuscles, *vid.* Nerve Tiss.
 - structure, *vid.* Nerve Tiss.
- Ganglion intercaroticum, *vid.* CIRC. APP.
- Ganglion spirale of *Corti*, *vid.* SENS. APP.
- Ganglionic cell layer of retina, *vid.* SENS. APP.
- Ganglionic plexuses
 - of submucosa of intestine, and of muscular tissue, *vid.* Nerv. Tiss. and DIGEST. APP.
- Gegenbaur's* osteoblasts, *vid.* OSS. Tiss.
- Gelatinous and Reticular connective substance, 187
 - forms of, 187
 - mucoïd of enamel organ, 191
 - of vitreous humour of eye, 189
 - composition of, 190
 - of gelatin of *Wharton*, 191
 - neuroglia, 197
 - reticular, 187, 193
 - forms of, 194
 - where found, 193
 - sustentacular of Nervous System and Retina, 187, 190
- GENERATIVE APPARATUS (female)
 - Constituents of, 526
 - Corpus luteum, 545
 - degeneration of, 546
 - formation of mode of, 546
 - structure of, 546
 - true and false, 547
 - Decidua, 549
 - Fallopian* tubes, 547
 - Formatio granulosa, 540
 - Hymen, 550
 - Mammary glands, 557
 - areola of, 552
 - development of, 552
 - excretory ducts of, 552
 - nerves, 551
 - nipple, 552
 - sacculi lactiferi, 552
 - structure of, 551
 - in male, 553
 - in child, 552
 - in mature body, 553
 - in virgin, 553
 - vascular supply of, 551
 - Milk, 553

GENERATIVE APPARATUS (female)—

- Milk, colostrum corpuscles of, 554
 composition of, 554
 corpuscles of, 553
 globules, 553
 mode of generation of, 555
 purposes of, 555
- Ovary, 540
 blood-vessels of, 540
 cortical zone, 538
 development of, 542, from *Wolffian*
 bodies
 germinal epithelium, 537
Graafian, follicle of, 539
 bursting of, 545
 cumulus proligerus (ovigerus), 540
 liquor folliculorum, 540
 membrana granulosa, 540
 membrana follicula, 539
 theca folliculi, 539
 hilus stroma of, 537
 lymphatics of, 544
 medullary substance of, 537
 nerves of, 544
 sustentacular matter of, 537
- Ova chains, 543
- Ovum (ovule), 540
 chorion of, 540
 destiny of, 545
 discharge of, 545
 germinal vesicle of, 540
 germinal spot of, *Wagner*, 540
 macula germinativa, 540
 vitellus (yolk), 540
 segmentation of, 545; and Cells
- Parovarium, 541
- Primordial follicles, 543
- Primordial ova, 542
- Pudenda, 550
 blood-vessels of, 550
 clitoris, 550
 genital corpuscles of, 551
 glands of *Bartholin*, 550
 of *Duverney*, 551
 nerves of, 551
 nymphæ, 550
 vestibulum, 550
- Purkinje's* vesicle, 540
- Uterus, 547
 arteries of, 548
 during menstruation, 549
 pregnancy, 549
 glands of, 548
 lymphatics of, 548
 nerves of, 549
- Vagina, 550
 nerves of, 550
 vascular supply of, 550
- Wolffian* bodies, development of ovary
 from, 542
- Zona pellucida, 540
- Zone of primordial follicles, 540
- GENERATIVE APPARATUS (male), 555
- Constituents of, 555
- Colliculus seminalis, *vid.* Urethra, 566
- Corps innominé, *vid.* Testis, 555
- Couper's* glands, 566
- Ductus ejaculatorius, 565
- Erection, theory of, 570
- Epididymis, 555
 caput of, 556
 cauda of, 557

GENERATIVE APPARATUS (male)—

- Epididymis, corpus, 557
 vasa aberantia, 557
- Hydatids of *Morgagni*, 559
- Littre's* glands, *vid.* Penis
- Organ of *Giraldès*, 559
- Parepididymis, 559
- Penis, 566
 corpora cavernosa, 567
 arteriæ helicinae of, 569
 lymphatics of, 569
 nerves of, 569
 vessels of, 568
 erection of, 570
 glands of *Tyson*, 567
 of *Littre*, 567
 skin of, 567
 structure of, 566
- Prostate, 565
 calculi of, 566
- Semen, 560
 composition of, 561
- Smegma preputii, 567
- Spermatozoa, 560
 composition of, 560
 development of, 561
 movements of, 563
 penetration of into ovum, 564
 structure of, 560
 under actions of reagents, 563
- Testis, 555
 coverings of, 555
 coni vasculosi of, 556
 corpus *Higmoreani*, 556
 development of, 559
 lymphatics of, 558
 nerves of, 559
 rete testis, 556
 structure of, 557
 sustentacular tissue of, 557
 tubulus rectus, 556
 vasa efferentia, 556
 vessels of, 558
- Tyson's* glands, *vid.* penis, 567
- Uterus masculinus, 566
- Urethra, 566
 colliculus, seminalis of, 556
 Vasa deferentia, 564
 Vesiculæ seminales, 565
- Germinal layers of embryo, 129, 137
- Germinal vesicle of *Purkinje*, *vid.* GEN.
 APP. (fem.), Ovum
- Germinal spot of *Wagner* of ovum, *vid.* GEN.
 APP. (fem.)
- Giant cells (of medulla of bone), *vid.* Cells
 and BONY APP.
- Giraldès*, organ of, *vid.* testis, GEN. APP.
 (male)
- Glandulæ agminatæ, 429
- Glandular Tissues, 353
 Composition of, 359
- Glands, 353
 acini of, 348
 blood-vessels of, 353
 capsules shut, 348
 cells of, 345
 part taken by, in secretion, 351
 transitoriness of, 351
 varieties of, 349
 compound, 349
 debiscence of, 349
 excretory passages of, 354

Glandular Tissues—

- Glands, general comparison of, 359
lobules of, 348
lymphatics of, 354
membrana propria of, 345
 anatomically, 348
 physiologically, 348
 structure of, 348
muscular elements, 354
nerves, 354
 simple, 349
 tubular, 349
vesicles, 348
 shut, 348
- Gland capsules, *vid.* Gland. Tiss.
Gland cells, *vid.* Gland. Tiss.
Gland nerves, *vid.* Nerv. Tiss. end capsules of, 327
Gland tubules, *vid.* Gland. Tiss.
Gland vesicles, *vid.* Gland. Tiss.
- Globulin, 17
Glomerulus, *vid.* Vessels
Glutin, 22; glutin-yielding substances, 21
Glycerin, 23
Glycerophosphoric acid, 24
Glycin, 48
Glycocholic acid, 39
Glycogen, 31
Goitre of thyroid gland, *vid.* CIRC. APP.
Goll, band of, in spinal cord, *vid.* NERV. APP.
Graftian follicle, *vid.* Ovary, GEN. APP.
Granular layer of retina, *vid.* SENS. APP.
Granules of cerebellum, *vid.* NERV. APP.
Granules of retina, *vid.* NERV. APP.
Grape sugar, 32
Ground lamellæ, *vid.* General Lamellæ
Ground substance, *vid.* Cells
Growth of cells, *vid.* Cells
Guanin, 43
Gustatory buds, *vid.* SENS. APP.
Gustatory cells, *vid.* SENS. APP.
Gustatory organ, (tongue), *vid.* SENS. APP.
Gustatory papillæ of tongue, *vid.* DIGEST. APP.
- Habenula interna (sulcata) externa (denticulata) perforata and tecta of the cochlea, *vid.* SENS. APP.
- Hæmatin, 50
Hæmatoglobulin, 18
Hæmatocrystallin, 18
Hæmatoidin, 51
Hæmin, 50
Hæmoglobulin, 18
- Hair, 388
 arrectores pilorum, 389
 bulb, 388
 structure of, 391
 composition of, 349
 development of, in embryo, 396
 follicle, 388
 layers of, 389
 muscles of, 389
 growth of, 396
 Henle's layer, 391
 Huxley's layer, 391
 papilla of, 390
 physiological purposes of, 395
 regeneration of, 397
 roots of, 388
 root-sheath, 388

Hair--

- root-sheath, external, 390
 internal, 390
 shaft, 388
 cortical portion of, 391
 cuticle of, 392
 hair scales of, 392
 medulla of, 393
 structure of, 391
- Hair bulb, *vid.* Hair
Hair follicles, *vid.* Hair
Hair scales, *vid.* Hair
Haversian canals, *vid.* Oss. Tiss.
Haversian glands (so called) of bones, *vid.* BONY APP.
Haversian lamellæ, *vid.* Oss. Tiss.
Haversian spaces, *vid.* Oss. Tiss.
Heart, *vid.* CIRC. APP.
 ganglia of, *vid.* CIRC. APP.
 muscle of, *vid.* CIRC. APP.
 nerves of, *vid.* CIRC. APP.
 valves of, *vid.* CIRC. APP.
 vessels, *vid.* CIRC. APP.
- Hemispheres of cerebrum, *vid.* NERV. APP.
Hemispheres of cerebellum, *vid.* NERV. APP.
Henle's investigation on structure of kidney, *vid.* URIN. APP.
Henle's layer of inner root-sheath, *vid.* Hair
Hepatic vein, blood of, *vid.* Blood.
Hilus stroma of ovary, *vid.* GEN. APP. (fem.)
Hilus stroma of lymphatic glands, *vid.* CIRC. APP.
- Hippuric acid, 33
 in urine, *vid.* URIN. APP.
- Histochemistry, 4
Histogenesis, 4
Histology, 1
 comparative, 4
 general, 1
 pathological, 4
 topographical, 7
- Humor aqueus of eye, *vid.* SENS. APP.
Humor vitreus of corpus vitreus, *vid.* Gelat. Tiss.
Huxley's layer of internal root-sheath, *vid.* Hair
- Hydrochlorate of hæmatin, 50
Hydrochloric acid, 57
Hymen, *vid.* GEN. APP. (fem.)
Hypophysid cerebri, *vid.* CIRC. and NERV. APP.
Hypoxanthin (sarkin), 43
- Indican, 52
Indigo, 52
Infundibula of lung, *vid.* RESP. APP.
Inosinic acid, 36
Inosite, 33
Intercellular substance, *vid.* Cells
Interchange of material of cells, *vid.* Cells
Interglobular spaces, *vid.* Dental Tiss.
Intergranular layer of retina, *vid.* SENS. APP.
Intestinal glandular germinal layer, 129, 137, 349
Intestinal juice, *vid.* DIGEST. APP.
Intestinal villi, *vid.* DIGEST. APP.
Investing spaces of lymph follicles, *vid.* CIRC. APP.
Investing sphere, *vid.* Cells
Iris, *vid.* SENS. APP.
 nerves of, *vid.* SENS. APP.

- Iron, 62
in different organs and tissues, *vid.* same
in hæmoglobin, 18
in hæmatin, 50
in melanin, 52
phosphate of, 62
protochloride of, 62
salts of, 62
- Ivory, *vid.* Dental Tiss.
- Joints, *vid.* BONY APP.
- Keratin, 21
Kerkring's folds of intestines, *vid.* DIGEST. APP.
- Kidney, *vid.* URIN. APP.
- Kreatin, 44
Kreatinin, 45
- Lachrymal glands, *vid.* SENS. APP.
Lachrymal passages, *vid.* SENS. APP.
- Labial glands, *vid.* DIGEST. APP.
- Lacteals, *vid.* VESSELS
- Lactic acid, 34
- Lamellæ of bone, *vid.* OSS. TISS.
- Lamina elastica anterior of cornea, *vid.* CON. TISS.
- Lamina fusca (supra-chorioidea) of eye, *vid.* SENS. APP.
- Lamina spiralis of cochlea, *vid.* SENS. APP.
Lamina spiralis accessoria of cochlea, *vid.* SENS. APP.
- Larynx, *vid.* RESP. APP.
- Lateral accessory cornu of med. obl., *vid.* NERV. APP.
- Lenticular glandules of stomach, *vid.* DIGEST. APP.
- Lens, tissue of,
capsule, 276
composition, 273
development, 279
fibres or tubes, 276
arrangement of, 277
membrana capsulo pupillaris, 280
relation of, to corneous germinal layer, 279
stars, 277
- Lens capsule, *vid.* Lens Tiss.
Lens tubes, *vid.* Lens Tiss.
Lens stars, *vid.* Lens Tiss.
- Lecithin, 28
- Leeuwenhoek, A. van,* 2.
- Leucæmia, *vid.* Blood
- Leucin, 45
- Lieberkühn's* follicles of small intestine, *vid.* DIGEST. APP.
- Ligamenta ciliare (ciliary muscle), *vid.* SENS. APP.
- Ligamenta flava of spinal column, *vid.* CON. TISS.
- Ligamenta intervertebralia (symphyses of vertebral bodies), *vid.* Cartil. TISS.
- Ligaments, *vid.* CON. TISS.
- Ligamentum nuchæ, *vid.* CON. TISS.
- Ligamentum pectinatum iridis, *vid.* SENS. APP.
- Ligamentum spirale of cochlea, *vid.* SENS. APP.
- Lime compounds, 57
- Limiting layers on connective-tissue bundles, *vid.* CON. TISS.
- Lingual follicles, *vid.* DIGEST. APP.
- Lipoma, *vid.* Fatty Tiss.
- Liquor folliculi of ovary, *vid.* GEN. APP.
- Liver, *vid.* DIGEST. APP.
cirrhosis of, *vid.* DIGEST. APP.
cells of, *vid.* DIGEST. APP.
lobules of, *vid.* DIGEST. APP.
sustentacular substance of, *vid.* DIGEST. APP.
- Loosening of cells, *vid.* Cells
- Lungs, *vid.* RESP. APP.
alveoli of, *vid.* RESP. APP.
infundibula of, *vid.* RESP. APP.
vesicles of, *vid.* RESP. APP.
- Lunula of nail, *vid.* Nail Tiss.
- Lymphatic circulation, *vid.* VESSELS
- Lymphatic glands (nodes), *vid.* CIRC. APP.
of various organs, *vid.* same
- Lymphatic canals, *vid.* Vessels
- Lymphatics of several organs, *vid.* same
- Lymphatic passages of lymphatic glands, *vid.* CIRC. APP.
- Lymphatic vessels, *vid.* Vessels
- Lymphatic radicles, *vid.* Vessels
- Lymphatic vessels in intestinal villi, *vid.* VESSELS and DIGEST. APP.
- Lymphatic vessels in tadpole's tail, *vid.* VESSELS
- Lymph (and Chyle), 131
amount of, in system, 134
blood-corpuscles in, 133
cells of, 132
first appearance of in embryo, 137
source of, 133
composition of lymph and chyle, 134-136
elementary granules of, 132
molecules of, 133
physiological significance of, 131
- Lymph corpuscles, *vid.* Lymph
- Lymph corpuscles of blood, *vid.* Blood
- Lymph corpuscles as elements of reticular connective substance, *vid.* Gelat. Con. Sub.
- Lymph nodes (glands), *vid.* CIRC. APP.
- Lymphoid cells, *vid.* Lymph
- Lymphoid follicles of conjunctiva (trachoma glands), 420 and SENS. APP.
- Lymphoid organs, *vid.* CIRC. APP.
- Lymph sheaths of vessels, *vid.* VESSELS
- Lymph tubes of lymphatic glands, *vid.* CIRC. APP.
- Macula germinativa of ovum, *vid.* GEN. APP. (female)
- Macula lutea of eye, *vid.* SENS. APP.
- Malpighi, M.,* 2
- Malpighian* glomerulus of kidney, *vid.* URIN. APP. and VESSELS
- Malpighian* corpuscles or follicles of spleen, *vid.* CIRC. APP.
- Malpighian* pyramids of kidney, *vid.* URIN. APP.
- Malpighian* cells of lungs, *vid.* RESP. APP.
- Mammary glands, *vid.* GEN. APP. (fem.)
- Manganese, 92
- Manz's* glands of conjunctiva, *vid.* SENS. APP.
- Margaric acid, 26
- Margarin, 36
- Medulla of nerve fibres, *vid.* NERVE TISS.
- Medulla oblongata, *vid.* NERV. TISS.
- Medulla spinalis, *vid.* NERV. APP.
- Medulla of bone, *vid.* BONY APP.
fetal, *vid.* Osseous Tiss.
- Medullary canals of bone, *vid.* OSS. TISS.

- Medullary pyramids of kidney, *vid.* URIN. APP.
- Medullary radii of kidneys, *vid.* URIN. APP.
- Medullary sheaths of nerves, *vid.* Nerv. Tiss.
- Medullary spaces of bone, *vid.* Oss. Tiss.
- Medullary substance of lymphatic glands, *vid.* CIRC. App.
- Meibomian* glands of eyelids, *vid.* SENS. APP.
- Melanin, 52
in the lungs, *vid.* RESP. APP.
- Membrana capsulo pupillaris, *vid.* SENS. APP.
- Membrana Descemetica of cornea, *vid.* Con.-Tiss.
- Membrana fenestrata of retina, *vid.* SENS. APP.
- Membrana follicularis of ovary, *vid.* GEN. APP.
- Membrana granulosa of ovary, *vid.* GEN. APP.
- Membrana hyaloidea of eye, *vid.* SENS. APP.
- Membrana limitans, ext. and int., of retina, *vid.* SENS. APP.
- Membrana propria of glandular structures, *vid.* Cells and Gland. Tiss.
- Membrana tympani, *vid.* SENS. APP.
- Membrana tympani secundaria, *vid.* SENS. APP.
- Menstrual blood, *vid.* Blood
- Metabolic force of cells, 82
- Microscope, invention of, 2
- Middle germinal layer, 129
- Milk, *vid.* GEN. APP. (female)
- Milk globules, *vid.* GEN. APP.
formation of, *vid.* Gland. Tiss.
- Milk receptacles, *vid.* GEN. APP. (female)
- Mineral constituents of body, 55
of several organs and fluids, *vid.* same
- Molecular layer of retina, *vid.* SENS. APP.
- Molecules foreign in muscle fibres, *vid.* Mus. Tiss.
- Monoglycerides, 24
- Morgan* and *Tomes*, *vid.* *Tomes*
- Morgagni's* hydatids, *vid.* GEN. APP.
- Mother cells, *vid.* Parent Cell
- Motus vibratorius, *vid.* Epithelium
- Mouth, *vid.* DIGEST. APP.
- Mouths, open, of lymphatics, 378
- Mucin, 21
- Mucous glands of stomach, *vid.* DIGEST. APP.
- Mucous membranes, *vid.* Con.-Tiss.
- Mucous sheaths of muscles, *vid.* Mus. Tiss.
- Mucous sheaths of tendons, *vid.* Con.-Tiss.
- Mucus, 154
corpuscles, presence of, in interior of epithelial cells, 91, 153
- Müller's, H.*, radiating sustentacular fibres of retina, *vid.* SENS. APP.
- Muscle bundles, *vid.* Mus. Tiss.
- Muscle fibres, *vid.* Mus. Tiss. and Cells as parents of tissues
- Muscle fibrillæ, *vid.* Mus. Tiss.
- Muscle fibrin, *vid.* Mus. Tiss.
- Muscle Tissue, 280
composition of, 293
constituents, 298
contractile fibre-cells, 281
striped, 283
structure of, 282
in mature animal, 282
in embryo, 282
where found, 283
contraction of, 299
decay of, 303
- Muscle Tissue—
development of, 301
growth of, 303
mode of union of, with tendons, 294
muscle sugar, 33, 298
myosin, 296
neoplasia of, 305
pathological changes in, 304, 305
perimysium, 293
physiology of, 299
plasma of, 296
ramifying fibres of, 292
arrangement of, in bundles, 292
rigor mortis of, 300
sarkolemma, 302
smooth, 281
striped, 283
accessory disks, 289
cementing matter, 287
Cohnheim's mosaic, 290
disks of *Bowman*, 286
fibres of, 283
fibrillæ of, 285
fleshy substance of, 285
foreign deposits in, 291
middle disk of *Hensen*, 289
muscle, caskets of, 289
muscle, corpuscles of, 284
primitive bundles, 283
primitive sheath, 283
sarkolemma, 283
formation of, 302
seen with polarised light, 290
transverse plate of transparent zone of *Krause*
transverse marking on, 285
zones transparent and dark, 288
syntonin, 16, 297
unstriped, 281
vessels of, 291
voluntary and involuntary, 281
- Muscle caskets, *vid.* Mus. Tiss.
- Muscle corpuscles, *vid.* Mus. Tiss.
- Muscles, lymphatics of, *vid.* MUS. APP.
nerves of, *vid.* Nerv. Tiss.
plasma of, *vid.* Mus. Tiss.
- Muscle sugar (inosite), 33, and Mus. Tiss.
- MUSCULAR APPARATUS, 573
Blood vessels, 574
of tendons, 573
Lymphatics of, 574
Mucous bursæ, 573
Mucous sheaths, 573
Sesamoid bones, 573
Sesamoid cartilages, 573
- Muscular elements, *vid.* Cells, parents of other structures, and Mus. Tiss.
- Myelin, 29
- Myeloplaxes, *vid.* BONY APP.
- Myosin, 16, and Mus. Tiss.
- Nail, 160.
cells, 162
composition of, 163
embryonic development of, 164
lunula of, 162
matrix of, 161
root, 161
- Nerve fibres, *vid.* Cells, parents of other structures, and Nerv. Tiss.
- Nerve loops, *vid.* Nerv. Tiss.
- Nerve sheath (perineurium), *vid.* Nerv. Tiss.

- Nerve Tissue, 305
 axis, cylinders of, 307
 fibrillar structure of, 310
 cellular elements of (corpuscles), 311
 apolar, unipolar, bipolar, &c., 316
 body (structure of), 311, 319
 envelopes of, 311, 312
 processes (axis, cylinder, protoplasm)
 315
 purposes of, 312
 spiral, 315
 composition, 338
 constituents of, 338, 339
 development of, in embryo, 341
 elements, cellular and fibrous (general
 arrangement of, in nervous centres),
 317
 fibres, *vid.* Nerve Fibres
 ganglia, structure of, 333
 course of nerves through, 334
 most minute, 335
 perineurium of, 333
 spinal, 334
 sympathetic, 334
 ganglion cells or corpuscles, 305
 ganglionic plexuses, 336
 myenteric (plexus) of *Auerbach*, 336
 submucous, 336
 medulla (nervous), 306
 coagulation of, 306
 nerve fibres (varieties of), 305
 anastomoses of, 318
 coarse, 305
 double contour of medullated, 306
 fine dark-edged, 305
 medullated, 305
 neurilemma of, 307
 non-medullated, 308
 perineurium, 318
 primitive fibrillæ, 310
 primitive sheath, 306
Remak's, 308
 structure of, 307
 sympathetic, 319
 termination of (motor), 320
 in glands, 326
 in loops (supposed) 319
 in neural eminences, 322
 in non-medullated fibres, 320
 in salivary glands, 326
 in special terminal structures, 320
 in striped muscle, 322
 in terminal plates, 322
 in unstriped muscle, 324
 transverse sections of, 308
 nerve tubes, *vid.* Nerve Fibres
 physiology of, 339
 plexuses, 318
 repair of nerves after section, 343, 344
 sensory nerves, 326
 terminal structures, 326
 bulb of *Krause*, 327
 end capsules of gland nerves, 327
 genital corpuscles, 327
Pacinian bodies, 329
 tactile corpuscles of skin, 328
 termination of simply sensitive
 nerves, 331
 in corneal epithelium, 332
 in dental pulp, 333
 varicosities, 308
 Nerve tubes, *vid.* Nerve Tiss.
- Nerves of several organs and tissues, *vid.*
 under same
 NERVOUS APPARATUS, 574
 Cerebellum, 590
 cortical layer of, 591
 grey layer of, 592
 ganglion cells of, 592
 nerve fibres of, 590
 nucleus dentatus of, 591
 rust brown layer of, 591
 granules of, 591
 Cerebrum, 594
 arachnoid of, 599
 blood-vessels of, 601
 cerebral ganglia, 594
 cerebro-spinal fluid, 599
 cornu ammonis, 597
 corpora quadrigemina, 594
 corona radiata, 595
 corpus striatum, 594
 crura cerebri ad pontem, 94
 development of central organs, 602
 dura mater, 598
 hemispheres, 595
 cortex of (structure of, &c.), 595
 membranes of, 598
 olfactory bulb, 597
 optic nerves (origin of), 594
Pacchionian granulations, 600
 pedunculi cerebri, 594
 "base" of, 594
 "cap" of, 594
 pia mater, 599
 pineal gland, 598
 pituitary body, 598, and *CIRC. APP.*
 plexus chorioidea, 600
 sabulous matter in, 601
 subarachnoid spaces, 599
 substantia nigra, 594
 thalami optici, 594
 Medulla Oblongata, 583
 blood-vessels of, 590
 columns of spinal cord in, 586
 cranial nerves arising from, 586
 crura cerebelli ad med. oblong., 589
 ad corp. quad., 590
 ad pontem, 589
 formatio reticularis of, 585
 lateral accessory cornu of, 585
 lateral nervous tract of, 586
 nuclei of (specific, &c.), 584
 olivary bodies of, 589
 pyramids of, 589
 several constituents of, 583
 systems of fibres of, 585
 structure of, 585
 tractus intermedio lateralis, 585
 Pons *Variolii*, 590
 Spinal Cord, 577
 anterior cornua, 578
 multipolar ganglion cells of, 578
 processes of ganglion cells, 578
 anterior nerve roots of, 578
 axial canal, 574
 bands of *Goll* of, 578
 blood-vessels of, 576
 columns of, 574
 commissures of, 574
 ependymal thread of, 575
 ganglion cells, 582
Goll's bands, 578
 grey matter and cornua, 574

NERVOUS APPARATUS—

- Spinal Cord, nervous elements of, 577
 arrangement of, in white substance, 577
 differences in thickness of, in several columns, 577
 horizontal, 577
 longitudinal, 577
 oblique, 577
 neuroglia, 575
 perivascular canals, 577, 365
 posterior cornua, 581
 posterior roots, 581
 relation to cornua, 581
 substantia gelatinosa of *Rolando*, 574
 sustentacular substance of, 575
 of grey and white matter, 576
 transverse commissure of, 582
- Nervous nuclei of med. oblong., *vid.* NERV. APP.
- Nervous plexuses, *vid.* Nerve Tiss.
- Nervous tracts (lateral) of med. oblong., *vid.* NERV. APP.
- Nervous tracts of spinal cord, *vid.* NERV. APP.
- Neural eminence, *vid.* Nerve Tiss.
- Neurilemma (primitive sheath), *vid.* Nerve Tiss.
- Neurin (cholin), 48, and Nerve Tiss.
- Neuroglia, *vid.* Gel. Tiss. and NERV. APP.
- Neutral fats, *vid.* Fats
- Nitrogen, 56
- Non-vascular organs, 371
- Nose, cavities and accessory cavities of, *vid.* SENS. APP.
- Nucleus, *vid.* Cells
- Nucleus fibres, *vid.* Con. Tiss.
- Nucleus fibrous of lymphatic glands, *vid.* CIRC. APP.
- Nucleolus, *vid.* Cells
- Nymphæ, *vid.* GEN. APP. (female)
- Odontoblasts (dentine cells), *vid.* Dent. Tiss.
- Œsophagus, *vid.* DIGEST. APP.
- Oleic acid, *vid.* Elaidic acid
- Olfactory nerves (ramification and termination of, in *regio olfactoria*), *vid.* SENS. APP.
- Olfactory cells of *regio olfactoria*, *vid.* SENS. APP.
- Olfactory filaments, *vid.* SENS. APP.
- Olfactory bulbs, *vid.* NERV. APP. and SENS. APP.
- Olfactory organs, *vid.* SENS. APP.
- Olfactory roots, *vid.* NERV. APP.
- Olivary bodies, *vid.* NERV. APP.
- Ollier's* views on functions of periosteum in formation of bone, 257
- Openings (free) of lymphatics, *vid.* 378
- Optic nerve, *vid.* SENS. APP.
 expansion of same to form retina, *vid.* SENS. APP.
 origin of, *vid.* NERV. APP.
- Ora serrata of retina, *vid.* SENS. APP.
- Orbital muscles, *vid.* SENS. APP.
- Organs of the body, 403
- Organ of *Giraldès*, *vid.* Corps innominé
- Organs of Hearing, *vid.* SENS. APP.
- Organ of Sight, *vid.* SENS. APP.
- Organ of Smell, *vid.* SENS. APP.
- Organ of Taste, *vid.* SENS. APP.
- Organ of Touch, *vid.* SENS. APP.

Osseous Tissue, 238

- bone cartilage, 239
 bone cells, 246
 bone earths, 247
 canaliculi, 243
 cartilage before ossification, 251
 cartilage medulla, 251
 classification of bones, 239
 composition of, 247
 development of, 250
 dotted appearance of, 243
 formation of, from periosteum, 256
 glutin-yielding substratum, 247
 growth of, 256
Haversian canals of, 240
Haversian spaces of, 242
 lacunæ, 244
 lamellæ, 241
 formation of, 254
 fundamental, 241
 general, 241
 special (*Haversian*), 241
 subsequent absorption of, in newly-formed bone, 256
 medulla (fœtal), 253
 medullary canals, 240
 medullary spaces (formation of), 252, 253
 neoplasia (pathological) of, 260
 ossein, 240
 ossification, 250
 direct, of cartilage, 256
 direct, of connective-tissue, 259
 points of, 251
 osteoblasts, 254
 ostoklasts, 258
 physiological purposes of, 249
 preformation of, in cartilage, 250
 regeneration of, for repair, 259
 regeneration from periosteum, 260
 secondary bones, 256
Sharpey's fibres, 244
- Ossein (bone cartilage), *vid.* Oss. Tiss.
- Ossification process, *vid.* Oss. Tiss.
- Osteoblasts, *vid.* Oss. Tiss.
- Osteogenesis, *vid.* Oss. Tiss.
- Ostoklasts, *vid.* Oss. Tiss.
- Otoliths, *vid.* SENS. APP.
- Ova chains, *vid.* GEN. APP. (female)
- Ova primordial, *vid.* GEN. APP. (female)
- Ovarial follicles, *vid.* GEN. APP. (female)
- Ovary, *vid.* GEN. APP. (female)
- Ovigerms, *vid.* GEN. APP. (female)
- Ovum (ovulum), *vid.* Cells and GEN. APP.
- Oxalic acid, 35
- Oxygen, 56
- Oxyhæmoglobin, 20
- Pachionian* granulations, *vid.* NERV. APP.
- Pacinian* corpuscles, *vid.* Nerv. Tiss.
- Palatal glands, *vid.* DIGEST. APP.
- Palmitic acid, 25
- Palpebræ, *vid.* SENS. APP.
- Pancreas, *vid.* DIGEST. APP.
- Pancreatic juice, *vid.* DIGEST. APP.
- Panniculus adiposus, *vid.* Fatty Tiss.
- Papilla spiralis (of organ of *Corti*), *vid.* SENS. APP.
- Papillæ circumvallatæ of tongue, *vid.* DIGEST. APP.
- Papillæ filiformis (conicæ) of tongue, *vid.* DIGEST. APP.

- Papillæ fungiformis (clavatæ) of tongue, *vid.* DIGEST. APP.
- Papillæ renales, *vid.* URIN. APP.
- Papillæ of skin, *vid.* SENS. APP.
- Papillæ of tongue, *vid.* SENS. APP.
- Paralactic acid, 34
- Paraovarium, *vid.* GEN. APP. (female)
- Parent cells, *vid.* Cells
- Parapitidymis, *vid.* GEN. APP. (male)
- Parietal stream of blood-vessels, *vid.* VESSELS
- Parotid gland, *vid.* DIGEST. APP.
- Parotid saliva, *vid.* DIGEST. APP.
- Pavement epithelium, *vid.* Epithelium
- Pedunculi cerebri, *vid.* NERV. APP.
- Penicillii of splenic artery, *vid.* CIRC. APP.
- Penis, *vid.* GEN. APP. (male)
- Pepsin, 18, and DIGEST. APP.
- Peptic gland cells, *vid.* DIGEST. APP.
- Peptones, 17, and DIGEST. APP.
- Perichondrium, *vid.* Cartilage and Con. Tiss.
- Pericardium, *vid.* CIRC. APP.
- Perilymph (aquula *Cotunii*), *vid.* SENS. APP.
- Perimysium, *vid.* Mus. Tiss.
- Perineurium, *vid.* Con. and Nerve Tiss.
- Periosteum, *vid.* Con. Tiss.
functions in ossification, *vid.* Oss. Tiss.
- Perithelium (endothelium), *vid.* Epithelium and VESSELS
- Perivascular canal system in spinal cord and brain, *vid.* NERV. SYSTEM
- Perspiration, *vid.* SENS. APP.
- Petit*, canal of, *vid.* SENS. APP.
- Peyer's* glands, 420, and DIGEST. APP.
- Pharynx, *vid.* DIGEST. APP.
tonsil of, *vid.* DIGEST. APP.
- Phenol, 36
- Physical properties of blood, *vid.* Blood
- Pia mater, *vid.* Con. Tiss. and NERV. APP.
- Pigmentary epithelium, *vid.* Epithelium
- Pigmentary metamorphosis of cells, *vid.* Cells
- Pigment cells (polyhedral), *vid.* Epithelium stellate, *vid.* Con. Tiss.
- Pineal gland, *vid.* NERV. APP.
- Placenta sanguinis, *vid.* Blood
- Plasmatic vascular system, *vid.* Vessels
- Pleura, *vid.* RESP. APP.
- Plexus chorioidea of brain, *vid.* Con. Tiss. and NERV. APP.
- Plexus myentericus, *vid.* NERV. APP. and DIGEST. APP.
- Plexus (formation of), *vid.* Nerv. Tiss.
- Plica semilunaris of eye, *vid.* SENS. APP.
- Plicæ vasculosæ, *vid.* BONY APP.
- Pons *Varolii*, *vid.* NERV. APP.
- Pore canals of cells, *vid.* Cells
- Potash compounds, 61 and 62
- Primitive fibrillæ
of con. tiss. *vid.* Con. Tiss.
of muscles, *vid.* Mus. Tiss.
of nerves and axis cylinders, *vid.* Nerv. Tiss.
- Primitive sheath (sarcolemma) of muscle, *vid.* Mus. Tiss.
- Processus ciliares of eye, *vid.* SENS. APP.
- Processus vermiformis, *vid.* DIGEST. APP.
- Prostate gland, *vid.* GEN. APP. (male)
- Prostatic vesicle (uterus masculinus) *vid.* GEN. APP. (male)
- Prostatic calculi, *vid.* GEN. APP. (male)
- Protagon, 29
- Protein bodies, *vid.* Albuminous Compounds
immediate derivatives of, 15
remote derivatives of, 21
- Protoplasm, 66
- Protoplasm processes of ganglion cells, *vid.* Nerve Tiss. and NERV. APP.
- Psorospermia in interior of columnar epithelium, 91
- Pudenda, *vid.* GEN. APP. (female)
- Pulpa dentis (dental germ), *vid.* Dent. Tiss.
- Pulp tubes of spleen, *vid.* CIRC. APP.
- Purkinje's*, germinal vesicle of, *vid.* GEN. APP. (female)
fibres of heart, *vid.* CIRC. APP.
- Pus corpuscles in interior of epithelial cells, 91, 153
emigrated lymphoid cells, 129, 91, 153
in connective tissue, 234
- Pyramids, *vid.* NERV. APP.
- Pyramid processes of kidney, *vid.* URIN. APP.
- Pyramids, decussation of, *vid.* NERV. APP.
- Recklinghausen, von*, on formation of red blood cells, 114
- Regeneration of several tissues, *vid.* same.
- Regio olfactoria, *vid.* SENS. APP.
- Reisner's* membrane of cochlea, *vid.* SENS. APP.
- Remak's* views on cell theory, *vid.* Cells
Remak's fibres, *vid.* Nerve Tiss.
- RESPIRATORY APPARATUS, 448.
- Bronchi (structure of), 450
Composition of pulmonary tissue, 457
- Larynx, 448
cartilages of (structure of), 176
lymphatics of, 449
nerves of, 449
structure of, 448
vessels of, 449
- Lungs, 450
air-cells of, 451
alveoli (structure of), 451
arrangement of vessels in, 453
development of, 453
epithelium of, 455
infundibula of, 451
lobes of, 450
lymphatics of, 455
pigmentary deposit in, 452
vesicles, 451
- Neoplasms in, 458
- Nerves of, 456
- Pathological changes in, 458
- Pleura, 456
absorption from cavity of, 457
- Trachea, 449
several parts (nerves, lymphatics, vessels), 449
- Rete *Malpighi*, *vid.* Epithelium
- Rete testis, *vid.* GEN. APP. (male)
- Retina, *vid.* SENS. APP.
- Rhodanide of potassium, 55
- Ridged and spinous cells, *vid.* Cells
- Rods of retina, *vid.* SENS. APP.
- Rolando* (substantia gelatinosa of), *vid.* NERV. APP.
- Rod granules of retina, *vid.* SENS. APP.
- Roots of hair, *vid.* Hair
- Root sheaths (int. and ext.), *vid.* Hair

Sacculi lactiferi, *vid.* GEN. APP. (fem.)
 Sacculus ellipticus, *vid.* SENS. APP.
 Sacculus rotundus, *vid.* SENS. APP.
 Saliva, *vid.* DIGEST. APP.
 Salivary glands, *vid.* DIGEST. APP.
 Sarcous elements, *vid.* Mus. Tis.
 Sarkolemma, *vid.* Mus. Tis.
 Sarkin, *vid.* Hypoxanthin
 Scala media tympani and vestibuli of cochlea, *vid.* SENS. APP.
 Sclerotic of eye, *vid.* SENS. APP.
 Schlemm, canal of, *vid.* SENS. APP.
 Schneiderian membrane, *vid.* SENS. APP.
 Schwann, Th., 3
 Schwann's sheath of nerve fibre, *vid.* Nerve Tis.
 Sebum cutaneum, *vid.* SENS. APP.
 formation of, 351 and 2
 Sebum palpebrale, *vid.* SENS. APP.
 Segmentation of cells, *vid.* Cells
 Semen (sperma), *vid.* GEN. APP. (male)
 Semicircular canal, *vid.* SENS. APP.
 Seminal filaments, *vid.* GEN. APP.
 Seminal tubules, *vid.* GEN. APP. (male)
 Seminal vesicles, *vid.* Versiculæ Seminales
 Semicanalis (sulcus) spiralis of cochlea, *vid.* SENS. APP.
SENSORY APPARATUS, 603
 Organs of Hearing, 653
 development, 664
 external ear, 653
 Eustachian tube, 654
 ossicula auditus, and muscles of, 654
 pinna, 653
 tympanum, 653
 internal ear, 654
 cochlea, 657
 canalis cochlearis of *Reissner*, 657
 epithelium of, 663
 termination of nerves in, 663
 canalis reuniens, 658
 Corti, cells of, 660
 Corti, fibres (pillars) of, 660
 heads of, 661
 Corti, organ of, 659
 external and internal pillars of, 660
 hair or tufted cells of, 662
 habenula externa and interna, 659
 habenula perforata and tecta, 660
 lamina spiralis, 657
 lamina spiralis accessoria, 663
 ligamentum spirale, 663
 membrane of *Reissner*, 657
 scala tymph. and vestib., 657
 sulcus spiralis, 659
 teeth of first order, 660
 zona denticulata, 659
 zona pectinata, 662
 endolymph (aquula vitrea auditiva), 655
 nerves, acoustic, distribution of, 655
 in fishes and mammals, 656
 otoliths, 653 and 58
 perilymph (aquula, *Cotrenii*) 654
 sacculus ellipticus and rotundus, 654
 semicircular canals, 654.
 septem nerveum, 655
 auditory filaments, 656
 crista acustica, 655
 fibre cells of *Schultze*, 656

SENSORY APPARATUS—

Organs of Hearing—
 internal ear, vestibule, 654
 Organs of Sight, 617
 aqueous humour, 629
 bulbus oculi (various parts of), 617
 vascular system of, 618
 canal of *Petit*, 630
 ciliary arteries, *vid.* Iris (below).
 cornea, 618 and 220
 conjunctiva of, 618
 lymphatics of, 619
 nerves of, 619
 vessels of, 619
 conjunctiva of eye, 649
 glands of—
 Bruch's plaques, 650
 convoluted, 649
 lymphoid, 650
 lymphatics of, 650
 nerves of, terminating in epithelium, 650
 palpebral, 649
 plica, semilunaris of, 649
 vessels of, 650
 development of eye, 651
 iris, or diaphragm of eye, 622
 ciliary arteries, 624
 dilator pupillæ, 623
 ligamentum pectinatum iridis, 623
 nerves of, 623 and 624
 sphincter pupillæ, 622
 vascular system of iris and choroid, 624
 circulus arteriosus iridis major, 626
 cir. art. irid. minor, 626
 cir. art. muscul. cil., 626
 vessels of choriocapillaris, 625
 lachrymal glands, nerves or lymphatics of, 651
 lens, 629
 lymphatics of eye, 647
 Meibomian glands, 648
 muscles of eye, 648
 palpebre, 648
 retina, 631
 composition of, 647
 blood-vessels of, 645
 fovea centralis, 632
 layers of, *vid.* strata
 macula lutea, 632
 structure of, 643
 medullated retinal fibres, 644
 membrana fenestrata of *Krause*, 646
 membrana limitans exter., 633
 membrana limitans interna, 632
 ora serrata, 632 and 644
 properties of several constituents, 646
 radiating fibres of *Müller*, 632
 stratum bacillosum, 634
 bacillary ellipsoids, 635
 constituents of, in different animals, 634
 cones, 635
 of macula lutea, 637
 supposed functions of, 646
 cone granules, 636, 638
 cone styles, 636
 cone twins, 637

SENSORY APPARATUS—

Organs of Sight—

- retina, 634
- fibres of *Ritter*, 636
- rods, 634.
- supposed functions of, 646
- rod granules, 635
- stratum bacillosum, 634
- stratum cellulosum of, 641
- stratum fibrillosum of, 642
- stratum granulosum ext. of, 638
- stratum granulosum int. of, 640
- stratum intergranulosum of, 638
- stratum moleculare of, 640
- sclerotic, 618 and 625
- canal of *Schlemm* of, 618
- vessels and nerves of, 618 and 628
- sebum palpebrale, 648
- tears, 651
- uvea (tunica vasculosa), 621
- choroid (structure of), 621
- transparent limiting layer of, 621
- lamina fusca, 621
- memb. choriocapillaris, 621
- musculus ciliaris, 621
- processus ciliaris, 621
- suprachorioidea, 621
- tensor chorioidea, lig. cil., 621
- veins of, 627
- vena vorticosæ, 628
- vitreous humour, 630
- membrana hyaloidea of, 630
- with its relations to zone of *Zinn* and canal of *Petit*
- zonula *Zinnii*, 630
- Organs of Smell, 612
- nose (cavities of, and accessories), 612
- regio olfactoria, 613
- epithelium of, 614
- glands of *Bowman* of, 614
- olfactory cells of, 615
- olfactory filaments of, 615
- olfactory nerve, 615
- supposed termination of, 616
- structure of, 613
- Organs of Taste, 610
- gustatory buds of, 610
- gustatory cells of, 611
- gustatory nerves (termination of), 610
- in papillæ of tongue, 610
- papillæ foliatæ of, 610
- papillæ of frog's tongue, 612
- bowl cells of, 612
- cylinder cells of, 612
- forked cells of, 612
- Organ of Touch (Skin), 603
- blood-vessels of, 604
- cutis (thickness of), 603
- development of, 603
- epidermis (thickness of) 603
- development of, 605
- glands of, 605
- ceruminous, 607
- cerumen of, 607
- circumanal, 607
- sebaceous, 609
- development of, 610
- sebum cutaneum of, 610
- structure of, 609
- sweat, 605
- sweat (composition of), 606

SENSORY APPARATUS—

Organ of Touch—

- glands, sudorific, where found, 608
- lymphatics of, 604
- papillæ of, 603
- perspiration from, 607
- Septum nerveum, *vid.* SENS. APP.
- Serum sanguinis, *vid.* Blood
- Sesamoid bones, *vid.* MUS. APP.
- Sesamoid cartilages, *vid.* MUS. APP.
- Shafts of hair, *vid.* Hair
- Sharpey's* fibres, *vid.* Oss. Tiss.
- Sheaths of nerves, *vid.* Nerve Tiss.
- Sillicic acid, 57
- Skin (as tactile organ), *vid.* SENS. APP.
- secretions, *vid.* SENS. APP.
- Small intestine, *vid.* DIGEST. APP.
- Smegma preputii, *vid.* GEN. APP.
- Sodium compounds, 40, 59.
- carbonate of, 60
- chloride of, 60
- glycocholate of, 40
- phosphate of, 61
- sulphate of, 61
- taurocholate of, 40
- Solitary glands of intestine, *vid.* 407 and DIGEST. APP.
- Special lamellæ (*Haversian*) of bone, *vid.* Oss. Tiss.
- Sphincter pupillæ, *vid.* SENS. APP.
- Spinal ganglia, *vid.* Nerve Tiss.
- Spinous (and ridged) cells, *vid.* Cells
- Spiral fibres of ganglionic nerve cells, *vid.* Nerve Tiss.
- Spiral (so-called) elastic, *vid.* Con. Tiss.
- Spleen (&c.), *vid.* CIRC. APP.
- Splenic blood, *vid.* Blood
- Spontaneous generation of cells, *vid.* Cells
- Stearic acid, 25
- Stellulæ *Verheyenii* of kidney, *vid.* URIN. APP.
- Stomach, *vid.* DIGEST. APP.
- Stomach, juices of, *vid.* DIGEST. APP.
- Stomachal glands, *vid.* DIGEST. APP.
- Stratum bacillosum of retina, *vid.* SENS. APP.
- cellulosum of retina, *vid.* SENS. APP.
- fibrillosum of retina, *vid.* SENS. APP.
- granulosum (internal and external) of retina, *vid.* SENS. APP.
- intergranulosum of retina, *vid.* SENS. APP.
- moleculare of retina, *vid.* SENS. APP.
- Struma (goitre), *vid.* CIRC. APP.
- Subarachnoidal spaces, *vid.* Con. Tiss.
- Sublingual gland, *vid.* DIGEST. APP.
- Sublingual saliva, *vid.* DIGEST. APP.
- Submaxillary gland, *vid.* DIGEST. APP.
- Submaxillary saliva, *vid.* DIGEST. APP.
- Submucous ganglionic plexus of *Remak* and *Meissner*, *vid.* DIGEST. APP.
- Substantia gelatinosa of *Rolando*, of spinal cord, *vid.* NERV. APP.
- Substantia nigra of brain, *vid.* NERV. APP.
- Succus entericus, *vid.* DIGEST. APP.
- Succus gastricus, *vid.* DIGEST. APP.
- Sudor (sweat), *vid.* SENS. APP.
- Sugar of grape, 32
- Sugar of milk, 33
- Sulcus (semicanalis) spiralis of cochlea, *vid.* SENS. APP.
- Sulphocyanogen, 54

- Suprachorioidea (lamina fusca) of eye, *vid.*
SENS. APP.
- Suprarenal body, *vid.* CIRC. APP.
- Sustentacular substance (nervous), *vid.* Gelat.
Tiss. and NERV. APP.
- Sweat, *vid.* SENS. APP.
- Sweat glands, *vid.* SENS. APP.
- Sympathetic cord, *vid.* Nerve Tiss.
- Sympathetic fibres, *vid.* Nerve Tiss.
- Sympathetic glands, *vid.* Nerve Tiss.
- Symphyses, *vid.* BONY APP.
- Symphyses of vertebræ, *vid.* Cart. Tiss.
- Synovia, 155
- Synovial sheaths of tendons, *vid.* Con. Tiss.
- Syntonin, *vid.* Musc. Tiss.
- Systems of the body, 399
- Tactile corpuscles, *vid.* SENS. APP.
- Tannin, 48
- Taurochloric acid, 40
- Taurylic acid, 36
- Tears, *vid.* SENS. APP.
- Teeth, *vid.* Deut. Tiss.
- Tendons (vessels of), *vid.* Con. Tiss.
- Tensor chorioidea (ciliary muscle), *vid.*
SENS. APP.
- Terminal plates, *vid.* Nerve Tiss.
- Terminal structures of nerves, *vid.* Nerve
Tiss.
- Testis (testiculus), *vid.* GEN. APP. (male)
- Thalami optici, *vid.* NERV. APP.
- Theca of ovarian follicle, *vid.* GEN. APP.
- Thymus gland, *vid.* CIRC. APP.
- Thyroid gland, *vid.* CIRC. APP.
- Tissues, 1
simple, 102
cement of, *vid.* Cells
classification of, 102, 103
composite, 103
elements of, 1
- Tomes and De Morgan's Haversian spaces,*
vid. 242 and Oss. Tiss.
- Tome's layer of dentine, vid.* Dental Tiss.
- Tongue, *vid.* DIGEST. APP.
follicular glands of, 420
glands of, *vid.* DIGEST. APP.
muscles, *vid.* Mus. Tiss.
papillæ, *vid.* DIGEST. APP.
- Tonsils, 420, and DIGEST. APP.
- Touch corpuscles, *vid.* SENS. APP.
- Trachea, *vid.* RESP. APP.
- Trachoma glands, 420, and SENS. APP.
- Tractus intermedio lateralis of med. oblong,
vid. NERV. APP.
- Tractus olfactorius, *vid.* NERV. APP.
- Tractus opticus, *vid.* NERV. APP.
- Tributyryn, 25
- Triglycerides, 24
- Trimargarin, 26
- Triolein, 26
- Tripalmitin, 25
- Tristearin, 25
- Tubæ Fallopii, *vid.* GEN. APP. (female)
- Tuberculation of cells, *vid.* Cells
- Tubuli seminiferi, *vid.* GEN. APP.
- Tubuli uriniferi, *vid.* URIN. APP.
- Tympanum, *vid.* SENS. APP.
- Tyrosin and crystals, 47
- Tyson's glands, vid.* GEN. APP. (male)
- Umbilical artery, *vid.* VESSELS
- Umbilical cord (tissue of), *vid.* Gelat. Tiss.
- Ureter, *vid.* URIN. APP.
- Urethra (female), *vid.* URIN. APP.
- URINARY APPARATUS, 514
Bladder, 536
Kidney, 514
arteriolaræ rectæ, 528
Bellini's tubes of, *vid.* tubuli uriniferi
boundary layer of *Henle*, 518
blood-vessels of, 526
arrangement of, in superficial layer
of cortex, 528
composition of, 530
convoluted tubes of, 520
structure of, 520
termination of, in glomerulus, 521
cortex corticis of, 521
cortical pyramids of, 520
cortical substance of, 515
development of, 529
glomeruli of, 527
capsule of, 521
vasa afferentiæ of, 527
vasa efferentiæ, 527
Henle's investigations, 515, 516
looped tubes of *Henle*, 516
lymphatics of, 529
Malpighian pyramids of, 515
medullary pyramids of, 515
medullary radii of, 519
collecting tubes of, 522
relation to ascending and descend-
ing arms of looped tubes, 525
minute anatomy of, 522
nerves of, 529
open tubes of, 516
structure of, 517
papillæ renales, 516
pyramidal processes, 519
stellulæ *Verheyenii* of, 528
straight tubules of, 519
sustentacular substance of, 526
tubuli uriniferi of, 515
differences in med. and cort., 515
general sketch of course from glomer-
ulus outwards, 525
vasa recta, 528
- Urinary passages, 536
bladder, 536
calyces, 536
pelvis, 536
ureter, 536
urethra (female), 536
- Urine, 530
constituents of, 531
abnormal, 534
occasional, 534
proportion of, 531
fermentation of, 534
physiology of, 535
- Urorethrin, 52
- Urohæmatin, 52
- Uterine glands, *vid.* GEN. APP.
- Uterus, *vid.* GEN. APP.
- Uterus masculinus (vesicula prostatica), *vid.*
GEN. APP. (male)
- Uvea of eye, *vid.* SENS. APP.
- Vagina, *vid.* GEN. APP.
- Valves of vessels, *vid.* VESSELS
- Valvulæ conniventes, *Kerkringii*, of small
intestine, *vid.* DIGEST. APP.
- Varicosities of nerves, *vid.* Nerve Tiss.

- Varolii* pons, *vid.* NERV. APP.
 Vas aberrans *Halleri*, *vid.* GEN. APP. (male)
 Vas afferens and efferens of lymphatic glands,
vid. CIRC. APP.
 Vas deferens of testicle, *vid.* GEN. APP.
 Vasa aberrantia of liver, *vid.* DIGEST. APP.
 Vasa afferentia and efferentia of the glomerulus of kidney, *vid.* URIN. APP.
 Vasa recta of kidneys, *vid.* URIN. APP.
 Vasa serosa (plasmatic vessels), *vid.* VESSELS
 Vasa vasorum, *vid.* VESSELS.
 Vascula efferentia of testicle, *vid.* GEN. APP.
 Vascular cells, *vid.* Cells, parents of other structures, and VESSELS
 Vascular convolutions, *vid.* VESSELS
 Vascular membranes, *vid.* Con. Tiss.
 Vascular nerves, *vid.* VESSELS, and 324
 Vascular Tissue, *vid.* VESSELS
 Veins, *vid.* VESSELS
 Venæ interlobulares of liver, *vid.* DIGEST. APP.
 Venæ intralobulares (central vein) of liver, *vid.* DIGEST. APP.
 Venæ vorticosæ of eye, *vid.* SENS. APP.
 Vernix caseosa of infant, 160
 Vesicula prostatica (uterus masculinus) *vid.* GEN. APP.
 Vesiculæ seminales, *vid.* GEN. APP.
 VESSELS (Vascular Tissue), 362
 Arteries, 362
 nerves of, 370 and 324
 structure of, 369
 umbilical, 369
 Blood-vessels, 362
 Capillaries, 362
 development of, 385
 lymph sheaths of, 365
 structure of, 363
 Capillary canals or lacunæ, 362
 Capillary system, 370
 convolutions, 373
 glomerulus, 373
 loops, 373
 networks, 371
 elongated, 372
 looped, 373
 round, 372
 Circulation of blood, 382
 axial and parietal stream, 383
 rapidity of, 383
 Development of early, late, 384
 pathologic, 387
 Ductus thoracicus, 279
 Lymphatic system, 373
 commencement of, in villi, 374
- Vessels—
 Lymphatic system—
 in other organs, 374
 in tadpole's tail, 374
 larger vessels of, 378
 Lymphatic canals, 373
 communication of, with serous sacs, 377
 development of, 377
 pathology of, 388
 relation of, to blood capillaries, 376
 texture of finer tubes, 377
 Perivascular canal system, 377
 Physiological relations of larger vessels, 382
 of capillaries, 382
 Plasmatic vessels, 382
 Primary vascular membrane, 364
 Vasa serosa or plasmatic vessels, 382
 Vasa vasorum, 370
 Vascular cells (perithelium endothelium), 363
 Veins, 362
 structure of, 366
 valves of, 363
 Vestibule of ear, *vid.* SENS. APP.
 Vestibulum vaginæ, *vid.* GEN. APP.
 Villi intestinales, *vid.* DIGEST. APP.
 Vitellus (yolk) of ovum, *vid.* GEN. APP.
 segmentation of, *vid.* Cells
 Vitreous humour, *vid.* SENS. APP.
- Wagner's* germinal spot on ovum, *vid.* GEN. APP.
 Water, 56
 proportion of, in tissues and organs, *vid.* same
Wharton, gelatin of, *vid.* Gelat. Tiss.
Wolfian bodies (primordial kidneys), *vid.* GEN. APP.
- Xanthin, 42
- Yolk (vitellus) of ovum, *vid.* GEN. APP. and Cells
 segmentation of, *vid.* Cells
 Yellow spot of retina, *vid.* SENS. APP.
- Zinn*, ligament of, *vid.* SENS. APP.
Zona denticulata of cochlea, *vid.* SENS. APP.
Zona pectinata of cochlea, *vid.* SENS. APP.
Zona pellucida (chorion) of ovum, *vid.* GEN. APP.
Zonula Zinnii of eye, *vid.* SENS. APP.
 Zoochemistry, 6

NEW YORK MEDICAL JOURNAL.

JAMES B. HUNTER, M. D., Editor.

This old and popular monthly journal, now in its twentieth volume, has greatly-increased facilities for placing monthly before the Profession the latest movements and discoveries in medicine, thus enabling the active practitioner, whose time for reading is limited, to keep pace with every advance in the art and science of his calling.

A competent staff of experienced writers will cooperate with the editor in gleanings medical news and information from every source, and thus keeping the JOURNAL in the front rank of Medical Literature.

Among the prominent features of the NEW YORK MEDICAL JOURNAL are the following:

Original Communications from the leading men of the Profession; articles which are widely quoted, and which leave their impress on the medical literature of the age.

Clinical Reports of Extraordinary Cases, occurring in public and private practice. These records are of much interest, and of great practical value to the Profession.

Notes of Practice in Metropolitan Hospitals, giving the most recent methods of treating medical and surgical cases adopted by the leading men of the day.

Reports of the Progress of Medicine in the various departments—Obstetrics and Diseases of Women, Surgery, Therapeutics, Ophthalmology, etc.

Proceedings of Societies, in which all the leading questions of the day affecting the Medical Profession are thoroughly discussed.

Translations, prepared expressly for the JOURNAL, from the latest German, French, Italian, and other foreign medical periodicals.

Impartial Reviews and Notices of all recently-published works on medicine and kindred subjects, constituting an invaluable guide to those wishing to enlarge their libraries.

A new volume of the NEW YORK MEDICAL JOURNAL begins with the numbers for January and July each year. Subscriptions may commence from any date.

Terms, Four Dollars per Annum.

The JOURNAL will be sent on trial for

Three Months for One Dollar.

A specimen copy will be sent on receipt of twenty-five cents.

Very favorable Club Rates made with any other journals.

Remittances, invariably in advance, should be made to the Publishers.

Subscribers to the NEW YORK MEDICAL JOURNAL can have any FOREIGN OR AMERICAN MEDICAL JOURNALS at a liberal discount. Commutation rates furnished on application.

D. APPLETON & CO., 549 & 551 Broadway, N. Y.

THE POPULAR SCIENCE MONTHLY,

(Established May, 1872.)

Conducted by Prof. E. L. YOUMANS.

THE POPULAR SCIENCE MONTHLY was started to promote the diffusion of valuable scientific knowledge, in a readable and attractive form, among all classes of the community, and has thus far met a want supplied by no other periodical in the United States.

The great feature of the magazine is, that its contents are not what science *was* ten or more years since, but what it *is* to-day, fresh from the study, the laboratory, and the experiment: clothed in the language of the authors, inventors, and scientists themselves, which comprise the leading minds of England, France, Germany, and the United States. Among popular articles, covering the whole range of NATURAL SCIENCE, we have the latest thoughts and words of Herbert Spencer, and Professors Huxley, Tyndall, and R. A. Proctor. Since the start, it has proved a gratifying success to every friend of scientific progress and universal education; and those who believed that science could not be made any thing but dry study are disappointed.

The press all over the land is warmly commending it. We subjoin a few encomiums from those recently given:

"That there is a place for THE POPULAR SCIENCE MONTHLY, no one can doubt who has watched the steady increase of interest in scientific investigation manifested in this country, not only by a select class, but by the entire community."—*New York Times*.

"A journal which promises to be of eminent value to the cause of popular education in this country."—*New York Tribune*.

"It is, beyond comparison, the best attempt at journalism of the kind ever made in this country."—*Home Journal*.

"The initial number is admirably constituted."—*Evening Mail*.

"We think it is not too much to say that this is the best first number of any magazine ever published in America."—*New York World*.

"It is just what is wanted by the curious and progressive mind of this country, and ought to be widely circulated."—*New York Evening Post*.

"It is the first successful attempt in this country to popularize science in the pages of a monthly."—*N. Y. School Journal*.

"Not the less entertaining because it is instructive."—*Philadelphia Age*.

"THE MONTHLY has more than fulfilled all the promises which the publishers made in the prospectus of publication."—*Niagara Falls Gazette*.

"It places before American readers what the ablest men of science throughout the world write about their meditations, speculations, and discoveries."—*Providence Journal*.

"This is a highly-auspicious beginning of a useful and much-needed enterprise in the way of publication, for which the public owe a special debt of obligation to Messrs. D. Appleton & Co."—*Boston Gazette*.

"This new enterprise appeals to all who are interested in the laudable effort of diffusing that information which is best calculated to expand the mind and improve the conditions and enhance the worth of life."—*Golden Age*.

"Just the publication needed at the present day."—*Montreal Gazette*.

"This new magazine, in our estimation, has more merit than the whole brood which have preceded it."—*Oswego Press*.

"In our opinion, the right idea has been happily hit in the plan of this new monthly."—*Buffalo Courier*.

"This is one of the very best periodicals of its kind published in the world. Its corps of contributors comprise many of the ablest minds known to science and literature. It is doing a great and noble work in popularizing science, promoting the growth of reason, and leveling the battlements of old superstitions reared in the childhood of our race before it was capable of reasoning."—*The American Medical Journal*, St. Louis, Mo.

"This magazine is worth its weight in gold, for its service in educating the people."—*The American Journal of Education*, St. Louis, Mo.

"This monthly enables us to utilize at least several years more of life than it would be possible were we obliged to wait its publication in book-form at the hands of some compiler."—*The Writing Teacher and Business Advertiser*, New York.

THE POPULAR SCIENCE MONTHLY is published in a large octavo, handsomely printed on clear type, and, when the subjects admit, fully illustrated. Each number contains 128 pages.

Terms: \$5 per Annum, or Fifty Cents per Number.

Postage free to all Subscribers in the United States, from January 1, 1875.

A new volume of the POPULAR SCIENCE begins with the numbers for May and November each year. Subscriptions may commence from any date. Back numbers supplied.

Now Ready, Vols. I., II., III., IV., and V., of *The Popular Science Monthly*, embracing the Numbers from 1 to 30 (May, 1872, to October, 1874). 5 vols., 8vo. Cloth, \$3.50 per vol. Half Morocco, \$6.50 per vol.

For Sale, Binding Cases for Vols. I., II., III., IV., and V., of *The Popular Science Monthly*. These covers are prepared expressly for binding the volumes of THE POPULAR SCIENCE MONTHLY as they appear, and will be sent to Subscribers on receipt of price. Any binder can attach the covers at a trifling expense. Price, 50 cents each.

D. APPLETON & CO., Publishers,
549 & 551 Broadway, New York.

DESCRIPTIVE CATALOGUE
OF
MEDICAL WORKS.



D. APPLETON & CO.,
PUBLISHERS AND IMPORTERS,

549 & 551 BROADWAY, NEW YORK.

1875.

CATALOGUE
OF
MEDICAL WORKS.

ANSTIE.

Neuralgia, and Diseases which resemble it.

By FRANCIS E. ANSTIE, M. D., F. R. C. P.,

Senior Assistant Physician to Westminster Hospital; Lecturer on *Materia Medica* in Westminster Hospital School; and Physician to the Belgrave Hospital for Children; Editor of "The Practitioner" (London), etc.

1 vol., 12mo. Cloth, \$2.50.

"It is a valuable contribution to scientific medicine."—*The Lancet* (London).

BARKER.

The Puerperal Diseases. *Clinical Lectures
delivered at Bellevue Hospital.*

By FORDYCE BARKER, M. D.,

Clinical Professor of Midwifery and the Diseases of Women in the Bellevue Hospital Medical College; Obstetric Physician to Bellevue Hospital; Consulting Physician to the New York State Woman's Hospital; Fellow of the New York Academy of Medicine; formerly President of the Medical Society of the State of New York; Honorary Fellow of the Obstetrical Societies of London and Edinburgh; Honorary Fellow of the Royal Medical Society of Athens, Greece, etc., etc., etc.

1 vol., 8vo. Cloth. 526 pages. Price, \$5.00.

"For nearly twenty years it has been my duty, as well as my privilege, to give clinical lectures at Bellevue Hospital, on midwifery, the puerperal and the other diseases of women. This volume is made up substantially from phonographic reports of the lectures which I have given on the puerperal diseases. Having had rather exceptional opportunities for the study of these diseases, I have felt it to be an imperative duty to utilize, so far as lay in my power, the advantages which I have enjoyed for the promotion of science, and, I hope, for the interests of humanity. In many subjects, such as albuminuria, convulsions, thrombosis, and embolism, septicæmia, and pyæmia, the advance of science has been so rapid as to make it necessary to teach something new every year. Those, therefore, who have formerly listened to my lectures on these subjects, and who now do me the honor to read this volume, will not be surprised to find, in many particulars, changes in pathological views, and often in therapeutical teaching, from doctrines before inculcated. At the present day, for the first time in the history of the world, the obstetric department seems to be assuming its proper position, as the highest branch of medicine, if its rank be graded by its importance to society, or by the intellectual culture and ability required, as compared with that demanded of the physician or the surgeon. A man may become eminent as a physician, and yet know very little of obstetrics; or he may be a successful and distinguished surgeon, and be quite ignorant of even the rudiments of obstetrics. But no one can be a really able obstetrician unless he be both physician and surgeon. And, as the greater includes the less, obstetrics should rank as the highest department of our profession."—*From Author's Preface.*

On Sea-sickness.

By FORDYCE BARKER, M. D.

1 vol., 16mo. 36 pp. Flexible Cloth, 75 cents.

Reprinted from the NEW YORK MEDICAL JOURNAL. By reason of the great demand for the number of that journal containing the paper, it is now presented in book form, with such prescriptions added as the author has found useful in relieving the suffering from sea-sickness.

BARNES.

Obstetric Operations, *including the Treatment of Hæmorrhage.*

BY ROBERT BARNES, M. D., F. R. C. P., LONDON,

Obstetric Physician to and Lecturer on Midwifery and the Diseases of Women and Children at St. Thomas's Hospital; Examiner on Midwifery to the Royal College of Physicians and to the Royal College of Surgeons; formerly Obstetric Physician to the London Hospital, and late Physician to the Eastern Division of the Royal Maternity Charity.

WITH ADDITIONS, by BENJAMIN F. DAWSON, M. D.,

Late Lecturer on Uterine Pathology in the Medical Department of the University of New York; Assistant to the Clinical Professor of Diseases of Children in the College of Physicians and Surgeons, New York; Physician for the Diseases of Children to the New York Dispensary; Member of the New York Obstetrical Society, of the Medical Society of the County of New York, etc., etc.

Second American Edition. 1 vol., 8vo. 503 pp. Cloth, \$4.50.

"Such a work as Dr. Barnes's was greatly needed. It is calculated to elevate the practice of the obstetric art in this country, and to be of great service to the practitioner."—*Lancet*.

Bellevue and Charity Hospital Reports.

The volume of Bellevue and Charity Hospital Reports for 1870, containing valuable contributions from

ISAAC E. TAYLOR, M. D., AUSTIN FLINT, M. D., LEWIS A. SAYRE, M. D., WILLIAM A. HAMMOND, M. D., T. GAILLARD THOMAS, M. D., FRANK H. HAMILTON, M. D., and others.

1 vol., 8vo. Cloth, \$4.00.

"These institutions are the most important, as regards accommodations for patients and variety of cases treated, of any on this continent, and are surpassed by but few in the world. The gentlemen connected with them are acknowledged to be among the first in their profession, and the volume is an important addition to the professional literature of this country."—*Psychological Journal*.

BENNET.

Winter and Spring on the Shores of
the Mediterranean; or, the Riviera, Mentone, Italy, Corsica, Sicily, Algeria, Spain, and Biarritz, as Winter Climates.

BY J. HENRY BENNET, M. D.,

Member of the Royal College of Physicians, London; late Physician-Accoucheur to the Royal Free Hospital; Doctor of Medicine of the University of Paris; formerly Resident Physician to the Paris Hospital (ex-Interne des Hôpitaux de Paris), etc.

This work embodies the experience of ten winters and springs passed by Dr. Bennet on the shores of the Mediterranean, and contains much valuable information for physicians in relation to the health-restoring climate of the regions described.

1 vol. 12mo. 621 pp. Cloth, \$3.50.

"Exceedingly readable, apart from its special purposes, and well illustrated."—*Evening Commercial*.

"It has a more substantial value for the physician, perhaps, than for any other class or profession. . . . We commend this book to our readers as a volume presenting two capital qualifications—it is at once entertaining and instructive."—*N. Y. Medical Journal*.

BENNET.

On the Treatment of Pulmonary Consumption, by Hygiene, Climate, and Medicine, in its Connection with Modern Doctrines.

By JAMES HENRY BENNET, M. D.,

Member of the Royal College of Physicians, London; Doctor of Medicine of the University of Paris, etc., etc.

1 vol., thin 8vo. Cloth, \$1.50.

An interesting and instructive work, written in the strong, clear, and lucid manner which appears in all the contributions of Dr. Bennet to medical or general literature.

"We cordially commend this book to the attention of all, for its practical common-sense views of the nature and treatment of the scourge of all temperate climates, pulmonary consumption."
—*Detroit Review of Medicine.*

BILLROTH.

General Surgical Pathology and Therapeutics, in Fifty Lectures. A Text-book for Students and Physicians.

By DR. THEODOR BILLROTH.

Translated from the Fifth German Edition, with the special permission of the Author, by

CHARLES E. HACKLEY, A. M., M. D.,

Surgeon to the New York Eye and Ear Infirmary; Physician to the New York Hospital; Fellow of the New York Academy of Medicine, etc.

1 vol., 8vo. 714 pp., and 152 Woodcuts. Cloth, \$5.00; Sheep, \$6.00.

Professor Theodor Billroth, one of the most noted authorities on Surgical Pathology, gives in this volume a complete résumé of the existing state of knowledge in this branch of medical science. The fact of this publication going through four editions in Germany, and having been translated into French, Italian, Russian, and Hungarian, should be some guarantee for its standing.

"The want of a book in the English language, presenting in a concise form the views of the German pathologists, has long been felt; and we venture to say no book could more perfectly supply that want than the present volume. . . . We would strongly recommend it to all who take any interest in the progress of thought and observation in surgical pathology, and surgery."
—*The Lancet.*

"We can assure our readers that they will consider neither money wasted in its purchase, nor time in its perusal."—*The Medical Investigator.*

CARPENTER.

Principles of Mental Physiology, with their Applications to the Training and Discipline of the Mind and the Study of its Morbid Conditions.

By WM. B. CARPENTER, M. D., LL. D., F. R. S., F. L. S., F. G. S.,

Registrar of the University of London; Corresponding Member of the Institute of France and of the American Philosophical Society, etc., etc.

"Among the numerous eminent writers this country has produced, none are more deserving of praise for having attempted to apply the results of Physiological Research to the explanation of the mutual relations of the mind and body than Dr. Carpenter. To him belongs the merit of having scientifically studied and of having in many instances supplied a rational explanation of those phenomena which, under the names of mesmerism, spirit-rapping, electro-biology, and hypnotism, have attracted so large an amount of attention during the last twenty years. . . . We must conclude by recommending Dr. Carpenter's work to the members of our own profession as applying many facts, that have hitherto stood isolated, to the explanation of the functions of the brain and to psychological processes generally."—*The Lancet.*

COMBE.

The Management of Infancy, *Physiological and Moral. Intended chiefly for the Use of Parents.*

BY ANDREW COMBE, M. D.

REVISED AND EDITED

BY SIR JAMES CLARK, K. C. B., M. D., F. R. S.,
Physician-in-ordinary to the Queen.First American from the Tenth London Edition. 1 vol., 12mo. 302 pp.
Cloth, \$1.50.

"This excellent little book should be in the hand of every mother of a family; and, if some of our lady friends would master its contents, and either bring up their children by the light of its teachings, or communicate the truths it contains to the poor by whom they are surrounded, we are convinced that they would effect infinitely more good than by the distribution of any number of tracts whatever. . . . We consider this work to be one of the few popular medical treatises that any practitioner may recommend to his patients; and, though, if its precepts are followed, he will probably lose a few guineas, he will not begrudge them if he sees his friend's children grow up healthy, active, strong, and both mentally and physically capable."—*The Lancet.*

CHAUVEAU.

The Comparative Anatomy of the *Domesticated Animals.*

BY A. CHAUVEAU,

PROFESSOR AT THE LYONS VETERINARY SCHOOL.

Second edition, revised and enlarged, with the coöperation of S. ARLOING, late Principal of Anatomy at the Lyons Veterinary School; Professor at the Toulouse Veterinary School. Translated and edited by GEORGE FLEMING, F. R. G. S., M. A. I., Veterinary Surgeon, Royal Engineers.

1 vol., 8vo. Cloth. 957 pp., with 450 Illustrations. Price, \$6.00.

OPINIONS OF THE PRESS.

"This is a valuable work, well conceived and well executed by the authors, MM. Chauveau and Arloing, and well translated by Mr. Fleming. It is rather surprising how few works exist, in any language, in which the anatomy of the commoner animals, domestic and otherwise, is given with any approach to detail. Systematic works there are in abundance, but, if the student be desirous of ascertaining any particular point, such as the position and branches of the pneumogastric or sympathetic nerves, or the homologue of a given muscle in several different animals, he may search all day ere he find it. The work before us appears to be well adapted to meet this difficulty.

"The illustrations are very numerous, and Mr. Fleming has introduced a large number that are not contained in the original work.

"Taking it altogether, the book is a very welcome addition to English literature, and great credit is due to Mr. Fleming for the excellence of the translation, and the many additional notes he has appended to Chauveau's treatise."—*Lancet (London).*

"The want of a text-book on the Comparative Anatomy of the Domesticated Animals has long been felt. . . . The descriptions of the text are illustrated and assisted by no less than 450 excellent woodcuts. In a work which ranges over so vast a field of anatomical detail and description, it is difficult to select any one portion for review, but our examination of it enables us to speak in high terms of its general excellence. . . . The care and attention with which hipptomomy has been cultivated on the Continent are illustrated by every page in M. Chauveau's work"—*Medical Times and Gazette (London).*

DAVIS.

Conservative Surgery, *as exhibited in remedying some of the Mechanical Causes that operate injuriously both in Health and Disease. With Illustrations.*

By HENRY G. DAVIS, M. D.,
Member of the American Medical Association, etc., etc.

1 vol., 8vo. 315 pp. Cloth, \$3.00.

The author has enjoyed rare facilities for the study and treatment of certain classes of disease, and the records here presented to the profession are the gradual accumulation of over thirty years' investigation.

"Dr. Davis, bringing, as he does to his specialty, a great aptitude for the solution of mechanical problems, takes a high rank as an orthopedic surgeon, and his very practical contribution to the literature of the subject is both valuable and opportune. We deem it worthy of a place in every physician's library. The style is unpretending, but trenchant, graphic, and, best of all, quite intelligible."—*Medical Record*.

ECKER.

The Cerebral Convolutions of Man,
represented according to Personal Investigations, especially on their Development in the Fœtus, and with reference to the Use of Physicians.

By ALEXANDER ECKER,
Professor of Anatomy and Comparative Anatomy in the University of Freiburg.

Translated from the German by Robert T. Edes, M. D.

1 vol., 8vo. 87 pp. \$1.25.

"The work of Prof. Ecker is noticeable principally for its succinctness and clearness, avoiding long discussions on undecided points, and yet sufficiently furnished with references to make easy its comparison with the labors of others in the same direction.

"Entire originality in descriptive anatomy is out of the question, but the facts verified by our author are here presented in a more intelligible manner than in any other easily-accessible work.

"The knowledge to be derived from this work is not furnished by any other text-book in the English language."—*Boston Medical and Surgical Journal*, January 20, 1873.

ELLIOT.

Obstetric Clinic. *A Practical Contribution to the Study of Obstetrics, and the Diseases of Women and Children.*

By the late GEORGE T. ELLIOT, M. D.,

Late Professor of Obstetrics and the Diseases of Women and Children in the Bellevue Hospital Medical College; Physician to Bellevue Hospital, and to the New York Lying-in Asylum; Consulting Physician to the Nursery and Child's Hospital; Consulting Surgeon to the State Woman's Hospital; Corresponding Member of the Edinburgh Obstetrical Society and of the Royal Academy of Havana; Fellow of the N. Y. Academy of Medicine; Member of the County Medical Society, of the Pathological Society, etc., etc.

1 vol., 8vo. 458 pp. Cloth, \$4.50.

This work is, in a measure, a *résumé* of separate papers previously prepared by the late Dr. Elliot; and contains, besides, a record of nearly two hundred important and difficult cases in midwifery, selected from his own practice. It has met with a hearty reception, and has received the highest encomiums both in this country and in Europe.

"The volume by Dr. Elliot has scarcely less value, though in a different direction, than that of the Edinburgh physician (Dr. Duncan, 'Researches in Obstetrics')."—*Lancet*.

"There is no book in American obstetrical literature that surpasses this one."—*Edinburgh Medical Journal*.

"It ought to be in the hands of every practitioner of midwifery in the country."—*Boston Medical and Surgical Journal*.

"It has no equal in the English language, as regards clinical instruction in obstetrics."—*American Journal of Obstetrics*.

FLINT.

Manual of Chemical Examination of the Urine in Disease. *With Brief Directions for the Examination of the most Common Varieties of Urinary Calculi.*

By AUSTIN FLINT, JR., M. D.,

Professor of Physiology and Microscopy in the Bellevue Hospital Medical College; Fellow of the New York Academy of Medicine; Member of the Medical Society of the County of New York; Resident Member of the Lyceum of Natural History in the City of New York, etc.

Third Edition, revised and corrected. 1 vol., 12mo. 77 pp. Cloth, \$1.00.

The chief aim of this little work is to enable the busy practitioner to make for himself, rapidly and easily, all ordinary examinations of Urine; to give him the benefit of the author's experience in eliminating little difficulties in the manipulations, and in reducing processes of analysis to the utmost simplicity that is consistent with accuracy.

"We do not know of any work in English so complete and handy as the Manual now offered to the profession by Dr. Flint, and the high scientific reputation of the author is a sufficient guarantee of the accuracy of all the directions given."—*Journal of Applied Chemistry*.

"We can unhesitatingly recommend this Manual."—*Psychological Journal*.

"Eminently practical."—*Detroit Review of Medicine*.

FLINT.

The Physiology of Man. *Designed to represent the Existing State of Physiological Science as applied to the Functions of the Human Body.*

By AUSTIN FLINT, JR., M. D.,

Professor of Physiology and Microscopy in the Bellevue Hospital Medical College, and in the Long Island College Hospital; Fellow of the New York Academy of Medicine; Microscopist to Bellevue Hospital.

In Five Volumes. 8vo. Tinted Paper.

Volume I.—*The Blood; Circulation; Respiration.*

8vo. 502 pp. Cloth, \$4.50.

"If the remaining portions of this work are compiled with the same care and accuracy, the whole may vie with any of those that have of late years been produced in our own or in foreign languages."—*British and Foreign Medico-Chirurgical Review.*

"As a book of general information it will be found useful to the practitioner, and, as a book of reference, invaluable in the hands of the anatomist and physiologist."—*Dublin Quarterly Journal of Medical Science.*

"The complete work will prove a valuable addition to our systematic treatises on human physiology."—*The Lancet.*

"To those who desire to get in one volume a concise and clear, and at the same time sufficiently full *résumé* of 'the existing state of physiological science,' we can heartily recommend Dr. Flint's work. Moreover, as a work of typographical art it deserves a prominent place upon our library-shelves. Messrs. Appleton & Co. deserve the thanks of the profession for the very handsome style in which they issue medical works. They give us hope of a time when it will be very generally believed by publishers that physicians' eyes are worth saving."—*Medical Gazette.*

Volume II.—*Alimentation; Digestion; Absorption; Lymph and Chyle.*

8vo. 556 pp. Cloth, \$4.50.

"The second instalment of this work fulfils all the expectations raised by the perusal of the first. . . . The author's explanations and deductions bear evidence of much careful reflection and study. . . . The entire work is one of rare interest. The author's style is as clear and concise as his method is studious, careful, and elaborate."—*Philadelphia Inquirer.*

"We regard the two treatises already issued as the very best on human physiology which the English or any other language affords, and we recommend them with thorough confidence to students, practitioners, and laymen, as models of literary and scientific ability."—*N. Y. Medical Journal.*

"We have found the style easy, lucid, and at the same time terse. The practical and positive results of physiological investigation are succinctly stated, without, it would seem, extended discussion of disputed points."—*Boston Medical and Surgical Journal.*

"It is a volume which will be welcome to the advanced student, and as a work of reference."—*The Lancet.*

"The leading subjects treated of are presented in distinct parts, each of which is designed to be an exhaustive essay on that to which it refers."—*Western Journal of Medicine.*

Flint's Physiology. Volume III.—*Secretion; Excretion; Ductless Glands; Nutrition; Animal Heat; Movements; Voice and Speech.*

8vo. 526 pp. Cloth, \$4.50.

"Dr. Flint's reputation is sufficient to give a character to the book among the profession, where it will chiefly circulate, and many of the facts given have been verified by the author in his laboratory and in public demonstration."—*Chicago Courier.*

"The author bestows judicious care and labor. Facts are selected with discrimination, theories critically examined, and conclusions enunciated with commendable clearness and precision."—*American Journal of the Medical Sciences.*

Volume IV.—*The Nervous System.*

8vo. Cloth, \$4.50.

This volume embodies the results of exhaustive study, and of a long and laborious series of experiments, presented in a manner remarkable for its strength and clearness. No other department of physiology has so profound an interest for the modern and progressive physician as that pertaining to the nervous system. The diseases of this system are now engaging the study and attention of some of the greatest minds in the medical world, and in order to follow their brilliant discoveries and developments, especially in connection with the science of electrology, it is absolutely necessary to obtain a clear and settled knowledge of the anatomy and physiology of the nervous system. It is the design of this work to impart that knowledge free from the perplexing speculations and uncertainties that have no real value for the practical student of medicine. The author boldly tests every theory for himself, and asks his readers to accept nothing that is not capable of demonstration. The properties of the cerebro-spinal, nervous, and sympathetic systems are treated of in a manner at once lucid, thorough, and interesting.

Although this volume is one, perhaps the most important one, of the author's admirable series in the Physiology of Man, it is nevertheless complete in itself, and may be safely pronounced indispensable to every physician who takes a pride and interest in the progress of medical science.

Volume V.—*Special Senses; Generation.*

8vo. Cloth, \$4.50.

"The present volume completes the task, begun eleven years ago, of preparing a work, intended to represent the existing state of physiological science, as applied to the functions of the human body. The kindly reception which the first four volumes have received has done much to sustain the author in an undertaking, the magnitude of which he has appreciated more and more as the work has progressed.

"In the fifth and last volume, an attempt has been made to give a clear account of the physiology of the special senses and generation, a most difficult and delicate undertaking. . . .

"Finally, as regards the last, as well as the former volumes, the author can only say that he has spared neither time nor labor in their preparation; and the imperfections in their execution have been due to deficiency in ability and opportunity. He indulges the hope, however, that he has written a book which may assist his fellow-workers, and interest, not only the student and practitioner of medicine, but some others who desire to keep pace with the progress of Natural Science."—*Extracts from Preface.*

FLINT.

On the Physiological Effects of Severe
*and Protracted Muscular Exercise. With Special ref-
erence to its Influence upon the Excretion of Nitrogen.*

By AUSTIN FLINT, JR., M. D.,

Professor of Physiology in the Bellevue Hospital Medical College, New York, etc., etc.

1 vol., 8vo. 91 pp. Cloth, \$2.00.

This monograph on the relations of Urea to Exercise is the result of a thorough and careful investigation made in the case of Mr. Edward Payson Weston, the celebrated pedestrian. The chemical analyses were made under the direction of R. O. Doremus, M. D., Professor of Chemistry and Toxicology in the Bellevue Hospital Medical College, by Mr. Oscar Loew, his assistant. The observations were made with the cooperation of J. C. Dalton, M. D., Professor of Physiology in the College of Physicians and Surgeons; Alexander B. Mott, M. D., Professor of Surgical Anatomy; W. H. Van Buren, M. D., Professor of Principles of Surgery; Austin Flint, M. D., Professor of the Principles and Practice of Medicine; W. A. Hammond, M. D., Professor of Diseases of the Mind and Nervous System—all of the Bellevue Hospital Medical College.

"This work will be found interesting to every physician. A number of important results were obtained valuable to the physiologist."—*Cincinnati Medical Repository*.

HAMILTON.

Clinical Electro-Therapeutics. (*Medical
and Surgical.*) *A Manual for Physicians for the
Treatment more especially of Nervous Diseases.*

By ALLAN McLANE HAMILTON, M. D.,

Physician in charge of the New York State Hospital for Diseases of the Nervous System;
Member of the New York Neurological and County Medical Societies, etc., etc.

With Numerous Illustrations. 1 vol., 8vo. Cloth. Price, \$2.00.

This work is the compilation of well-tryed measures and reported cases, and is intended as a simple guide for the general practitioner. It is as free from confusing theories, technical terms, and unproved statements, as possible. Electricity is indorsed as a very valuable remedy in certain diseases, and as an invaluable therapeutical means in nearly all forms of NERVOUS DISEASE; but not as a specific for every human ill, mental and physical.

HAMMOND.

Insanity in its Relations to Crime.
A Text and a Commentary.

By WILLIAM A. HAMMOND, M. D.

1 vol. 8vo. 77 pp. Cloth, \$1.00.

"A part of this essay, under the title 'Society versus Insanity,' was contributed to *Putnam's Magazine*, for September, 1870. The greater portion is now first published. The importance of the subject considered can scarcely be over-estimated, whether we regard it from the stand-point of science or social economy; and, if I have aided in its elucidation, my object will have been attained."—*From Author's Preface*.

HAMMOND.

A Treatise on Diseases of the Nervous System.

By WILLIAM A. HAMMOND, M. D.,

Professor of Diseases of the Mind and Nervous System, and of Clinical Medicine, in the Bellevue Hospital Medical College; Physician-in-Chief to the New York State Hospital for Diseases of the Nervous System, etc., etc.

FOURTH EDITION, REVISED AND CORRECTED.

With Forty-five Illustrations. 1 vol., 8vo. 750 pp. Cloth, \$5.00.

The treatise embraces an introductory chapter, which relates to the instruments and apparatus employed in the diagnosis and treatment of diseases of the nervous system, and five sections. Of these, the first treats of diseases of the brain; the second, diseases of the spinal cord; the third, cerebro-spinal diseases; the fourth, diseases of nerve-cells; and the fifth, diseases of the peripheral nerves. One feature which may be claimed for the work is, that it rests, to a great extent, upon the personal observation and experience of the author, and is therefore no mere compilation.

This work is already universally popular with the profession; their appreciation of it may be evidenced by the fact that within two years it has reached the fourth edition.

"That a treatise by Prof. Hammond would be one of a high order was what we anticipated, and it affords us pleasure to state that our anticipations have been realized."—*Cincinnati Medical Repertory*.

"This is unquestionably the most complete treatise on the diseases to which it is devoted that has yet appeared in the English language; and its value is much increased by the fact that Dr. Hammond has mainly based it on his own experience and practice, which, we need hardly remind our readers, have been very extensive."—*London Medical Times and Gazette*.

"Free from useless verbiage and obscurity, it is evidently the work of a man who knows what he is writing about, and knows how to write about it."—*Chicago Medical Journal*.

"This is a valuable and comprehensive book; it embraces many topics, and extends over a wide sphere. One of the most valuable parts of it relates to the Diseases of the Brain; while the remaining portion of the volume treats of the Diseases of the Spinal Cord, the Cerebro-spinal System, the Nerve-Cells, and the Peripheral Nerves."—*British Medical Journal*.

"The work before us is unquestionably the most exhaustive treatise, on the diseases to which it is devoted, that has yet appeared in English. And its distinctive value arises from the fact that the work is no mere *raffaciamento* of old observations, but rests on his own experience and practice, which, as we have before observed, have been very extensive."—*American Journal of Syphilography*.

"The author of this work has attained a high rank among our brethren across the Atlantic from previous labors in connection with the disorders of the nervous system, as well as from various other contributions to medical literature, and he now holds the official appointments of Physician to the New York State Hospital for Diseases of the Nervous System, and Professor of the same department in the Bellevue Hospital Medical College. The present treatise is the fruit of the experience thus acquired, and we have no hesitation in pronouncing it a most valuable addition to our systematic literature."—*Glasgow Medical Journal*.


HOFFMANN.

Manual of Chemical Analysis, *as applied to the Examination of Medicinal Chemicals and their Preparations. A Guide for the Determination of their Identity and Quality, and for the Detection of Impurities and Adulterations. For the use of Pharmacutists, Physicians, Druggists, and Manufacturing Chemists, and Pharmaceutival and Medical Students.*

By FRED. HOFFMANN, PHIL. D.

One vol., 8vo. Richly Illustrated. Cloth. Price, \$3.

SPECIMEN OF ILLUSTRATIONS.



"This volume is a carefully-prepared work, and well up to the existing state of both the science and art of modern pharmacy. It is a book which will find its place in every medical and pharmaceutical laboratory and library, and is a safe and instructive guide to medical students and practitioners of medicine."—*American Journal of Science and Arts.*

In America this work has already met with general and unqualified approval; and in Europe is now being welcomed as one of the best and most important additions to modern pharmaceutical literature.

Send for descriptive circular. Address

D. APPLETON & CO., 549 & 551 Broadway, N. Y. City.

HOLLAND.

Recollections of Past Life,

By SIR HENRY HOLLAND, Bart., M. D., F. R. S., K. C. B., etc.,
President of the Royal Institution of Great Britain, Physician-in-Ordinary to the Queen,
etc., etc.

1 vol., 12mo, 351 pp. Price, Cloth, \$2.00.

A very entertaining and instructive narrative, partaking somewhat of the nature of autobiography and yet distinct from it, in this, that its chief object, as alleged by the writer, is not so much to recount the events of his own life, as to perform the office of chronicler for others with whom he came in contact and was long associated.

The "Life of Sir Henry Holland" is one to be recollected, and he has not erred in giving an outline of it to the public.—*The Lancet*.

"His memory was—is, we may say, for he is still alive and in possession of all his faculties—stored with recollections of the most eminent men and women of this century. . . . A life extending over a period of eighty-four years, and passed in the most active manner, in the midst of the best society, which the world has to offer, must necessarily be full of singular interest; and Sir Henry Holland has fortunately not waited until his memory lost its freshness before recalling some of the incidents in it."—*The New York Times*.

HOWE.

Emergencies, and How to Treat Them.

The Etiology, Pathology, and Treatment of Accidents, Diseases, and Cases of Poisoning, which demand Prompt Attention. Designed for Students and Practitioners of Medicine.

By JOSEPH W. HOWE, M. D.,

Clinical Professor of Surgery in the Medical Department of the University of New York;
Visiting Surgeon to Charity Hospital; Fellow of the New York Academy
of Medicine, etc., etc.

1 vol., 8vo. Cloth, \$3.00.

"This work has a taking title, and was written by a gentlemen of acknowledged ability, to fill a void in the profession. . . . To the general practitioner in towns, villages, and in the country, where the aid and moral support of a consultation cannot be availed of, this volume will be recognized as a valuable help. We commend it to the profession.—*Cincinnati Lancet and Observer*.

"This work is certainly novel in character, and its usefulness and acceptability are as marked as its novelty. . . . The book is confidently recommended."—*Richmond and Louisville Medical Journal*.

"This volume is a practical illustration of the positive side of the physician's life, a constant reminder of what he is to do in the sudden emergencies which frequently occur in practice. . . . The author wastes no words, but devotes himself to the description of each disease as if the patient were under his hands. Because it is a good book we recommend it most heartily to the profession."—*Boston Medical and Surgical Journal*.

"This work bears evidence of a thorough practical acquaintance with the different branches of the profession. The author seems to possess a peculiar aptitude for imparting instruction as well as for simplifying tedious details. . . . A careful perusal will amply repay the student and practitioner."—*New York Medical Journal*."

HUXLEY AND YOUMANS.

The Elements of Physiology and
Hygiene. With Numerous Illustrations.

BY THOMAS H. HUXLEY, LL. D., F. R. S., and
WILLIAM JAY YOUMANS, M. D.

New and Revised Edition. 1 vol., 12mo. 420 pp. \$1.75.

A text-book for educational institutions, and a valuable elementary work for students of medicine. The greater portion is from the pen of Professor Huxley, adapted by Dr. Youmans to the circumstances and requirements of American education. The eminent claim of Professor Huxley's "Elementary Physiology" is, that, while up to the times, it is trustworthy in its presentation of the subject; while rejecting discredited doctrines and doubtful speculations, it embodies the latest results that are established, and represents the present actual state of physiological knowledge.

"A valuable contribution to anatomical and physiological science."—*Religious Telescope.*

"A clear and well-arranged work, embracing the latest discoveries and accepted theories."—*Buffalo Commercial.*

"Teeming with information concerning the human physical economy."—*Evening Journal.*

HUXLEY.

The Anatomy of Vertebrated Animals.

BY THOMAS HENRY HUXLEY, LL. D., F. R. S.,

Author of "Man's Place in Nature," "On the Origin of Species," "Lay Sermons and Addresses," etc.

1 vol., 12mo. Cloth, \$2.50.

The former works of Prof. Huxley leave no room for doubt as to the importance and value of his new volume. It is one which will be very acceptable to all who are interested in the subject of which it treats.

"This long-expected work will be cordially welcomed by all students and teachers of Comparative Anatomy as a compendious, reliable, and, notwithstanding its small dimensions, most comprehensive guide on the subject of which it treats. To praise or to criticise the work of so accomplished a master of his favorite science would be equally out of place. It is enough to say that it realizes, in a remarkable degree, the anticipations which have been formed of it; and that it presents an extraordinary combination of wide, general views, with the clear, accurate, and succinct statement of a prodigious number of individual facts."—*Nature.*

JOHNSON.

The Chemistry of Common Life.

Illustrated with numerous Wood Engravings.

By JAMES F. JOHNSON, M. A., F. R. S., F. G. S., ETC., ETC.,

Author of "Lectures on Agricultural Chemistry and Geology," "A Catechism of Agricultural Chemistry and Geology," etc.

2 vols., 12mo. Cloth, \$3.00.

It has been the object of the author in this work to exhibit the present condition of chemical knowledge, and of matured scientific opinion, upon the subjects to which it is devoted. The reader will not be surprised, therefore, should he find in it some things which differ from what is to be found in other popular works already in his hands or on the shelves of his library.

LETTERMAN.

Medical Recollections of the Army of
the Potomac.

By JONATHAN LETTERMAN, M. D.,

Late Surgeon U. S. A., and Medical Director of the Army of the Potomac.

1 vol., 8vo. 194 pp. Cloth, \$1.00.

"This account of the medical department of the Army of the Potomac has been prepared, amid pressing engagements, in the hope that the labors of the medical officers of that army may be known to an intelligent people, with whom to know is to appreciate; and as an affectionate tribute to many, long my zealous and efficient colleagues, who, in days of trial and danger, which have passed, let us hope never to return, evinced their devotion to their country and to the cause of humanity, without hope of promotion or expectation of reward."—*Preface.*

"We venture to assert that but few who open this volume of medical annals, pregnant as they are with instruction, will care to do otherwise than finish them at a sitting."—*Medical Record.*

"A graceful and affectionate tribute."—*N. Y. Medical Journal.*

LEWES.

The Physiology of Common Life.

By GEORGE HENRY LEWES,

Author of "Seaside Studies," "Life of Goethe," etc.

2 vols., 12mo. Cloth, \$3.00.

The object of this work differs from that of all others on popular science in its attempt to meet the wants of the student, while meeting those of the general reader, who is supposed to be wholly unacquainted with anatomy and physiology.

MAUDSLEY.

The Physiology and Pathology of the
Mind.

By HENRY MAUDSLEY, M. D., LONDON,

Physician to the West London Hospital; Honorary Member of the Medico-Psychological Society of Paris; formerly Resident Physician of the Manchester Royal Lunatic Hospital, etc.

1 vol., 8vo. 442 pp. Cloth, \$3.00.

This work aims, in the first place, to treat of mental phenomena from a physiological rather than from a metaphysical point of view; and, secondly, to bring the manifold instructive instances presented by the unsound mind to bear upon the interpretation of the obscure problems of mental science.

"Dr. Maudsley has had the courage to undertake, and the skill to execute, what is, at least in English, an original enterprise."—*London Saturday Review*.

"It is so full of sensible reflections and sound truths that their wide dissemination could not but be of benefit to all thinking persons."—*Psychological Journal*.

"Unquestionably one of the ablest and most important works on the subject of which it treats that has ever appeared, and does credit to his philosophical acumen and accurate observation."—*Medical Record*.

"We lay down the book with admiration, and we commend it most earnestly to our readers as a work of extraordinary merit and originality—one of those productions that are evolved only occasionally in the lapse of years, and that serve to mark actual and very decided advances in knowledge and science."—*N. Y. Medical Journal*.

Body and Mind: *An Inquiry into their Connection and Mutual Influence, especially in reference to Mental Disorders; an enlarged and revised edition to which are added Psychological Essays.*

By HENRY MAUDSLEY, M. D., LONDON,

Fellow of the Royal College of Physicians; Professor of Medical Jurisprudence in University College, London; President-elect of the Medico-Psychological Association; Honorary Member of the Medico-Psychological Society of Paris, of the Imperial Society of Physicians of Vienna, and of the Society for the Promotion of Psychiatry and Forensic Psychology of Vienna; formerly Resident Physician of the Manchester Royal Lunatic Asylum, etc., etc.

1 vol., 12mo. 155 pp. Cloth, \$1.00.

The general plan of this work may be described as being to bring man, both in his physical and mental relations, as much as possible within the scope of scientific inquiry.

"A representative work, which every one must study who desires to know what is doing in the way of real progress, and not mere chatter, about mental physiology and pathology."—*The Lancet*.

"It distinctly marks a step in the progress of scientific psychology."—*The Practitioner*.

MAUDSLEY.

Responsibility in Mental Diseases.

By HENRY MAUDSLEY, M. D.,

Fellow of the Royal College of Physicians, Professor of Medical Jurisprudence in University College, London, etc., etc. Author of "Body and Mind," "Physiology and Pathology of the Nervous System."

1 vol., 12mo. 313 pp. Cloth, \$1.50.

"This book is a compact presentation of those facts and principles which require to be taken into account in estimating human responsibility—not legal responsibility merely, but responsibility for conduct in the family, the school, and all phases of social relation in which obligation enters as an element. The work is new in plan, and was written to supply a widely-felt want which has not hitherto been met."—*The Popular Science Monthly*.

MARKOE.

A Treatise on Diseases of the Bones.

By THOMAS M. MARKOE, M. D.,

Professor of Surgery in the College of Physicians and Surgeons, New York, etc.

WITH NUMEROUS ILLUSTRATIONS.

1 vol., 8vo. Cloth, \$4.50.

This valuable work is a treatise on Diseases of the Bones, embracing their structural changes as affected by disease, their clinical history and treatment, including also an account of the various tumors which grow in or upon them. None of the *injuries* of bone are included in its scope, and no *joint* diseases, excepting where the condition of the bone is a prime factor in the problem of disease. As the work of an eminent surgeon of large and varied experience, it may be regarded as the best on the subject, and a valuable contribution to medical literature.

"The book which I now offer to my professional brethren contains the substance of the lectures which I have delivered during the past twelve years at the college. . . . I have followed the leadings of my own studies and observations, dwelling more on those branches where I had seen and studied most, and perhaps too much neglecting others where my own experience was more barren, and therefore to me less interesting. I have endeavored, however, to make up the deficiencies of my own knowledge by the free use of the materials scattered so richly through our periodical literature, which scattered leaves it is the right and the duty of the systematic writer to collect and to embody in any account he may offer of the state of a science at any given period."—*Extract from Author's Preface.*

MEYER.
Electricity in its Relations to Practical
Medicine.

By **DR. MORITZ MEYER,**
Royal Counsellor of Health, etc.

Translated from the **Third German Edition, with Notes and Additions.**
A New and Revised Edition,

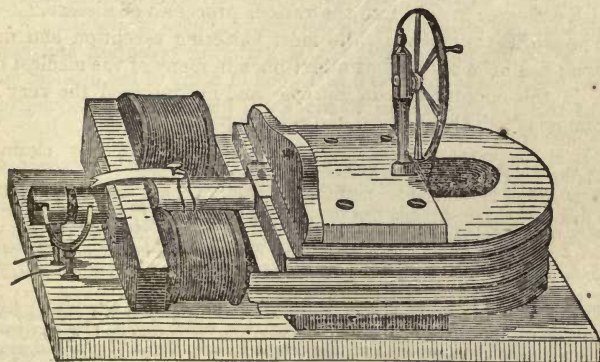
By **WILLIAM A. HAMMOND, M. D.,**

Professor of Diseases of the Mind and Nervous System, and of Clinical Medicine, in the Bellevue Hospital Medical College; Vice-President of the Academy of Mental Sciences, National Institute of Letters, Arts, and Sciences; late Surgeon-General U. S. A., etc.

1 vol., 8vo. 497 pp. Cloth, \$4.50.

"It is the duty of every physician to study the action of electricity, to become acquainted with its value in therapeutics, and to follow the improvements that are being made in the apparatus for its application in medicine, that he may be able to choose the one best adapted to the treatment of individual cases, and to test a remedy fairly and without prejudice, which already, especially in nervous diseases, has been used with the best results, and which promises to yield an abundant harvest in a still broader domain."—*From Author's Preface.*

SPECIMEN OF ILLUSTRATIONS.



Saxton-Ettinghausen Apparatus.

"Those who do not read German are under great obligations to William A. Hammond, who has given them not only an excellent translation of a most excellent work, but has given us much valuable information and many suggestions from his own personal experience."—*Medical Record.*

"Dr. Moritz Meyer, of Berlin, has been for more than twenty years a laborious and conscientious student of the application of electricity to practical medicine, and the results of his labors are given in this volume. Dr. Hammond, in making a translation of the third German edition, has done a real service to the profession of this country and of Great Britain. Plainly and concisely written, and simply and clearly arranged, it contains just what the physician wants to know on the subject."—*N. Y. Medical Journal.*

"It is destined to fill a want long felt by physicians in this country."—*Journal of Obstetrics.*

NIEMEYER.

A Text-Book of Practical Medicine.

With Particular Reference to Physiology and Pathological Anatomy.

By the late Dr. FELIX VON NIEMEYER,
Professor of Pathology and Therapeutics; Director of the Medical Clinic of the University of
Tübingen.

Translated from the Eighth German Edition, by special permission of
the Author,

By GEORGE H. HUMPHREYS, M. D.,
Late one of the Physicians to the Bureau of Medical and Surgical Relief at Bellevue Hospital for
the Out-door Poor; Fellow of the New York Academy of Medicine, etc.,

and

CHARLES E. HACKLEY, M. D.,
One of the Physicians to the New York Hospital; one of the Surgeons to the New York Eye
and Ear Infirmary; Fellow of the New York Academy of Medicine, etc.

Revised Edition. 2 vols., 8vo. 1,528 pp. Cloth, \$9.00; Sheep, \$11.00.

The author undertakes, first, to give a picture of disease which shall be as lifelike and faithful to nature as possible, instead of being a mere theoretical scheme; secondly, so to utilize the more recent advances of pathological anatomy, physiology, and physiological chemistry, as to furnish a clearer insight into the various processes of disease.

The work has met with the most flattering reception and deserved success; has been adopted as a text-book in many of the medical colleges both in this country and in Europe; and has received the very highest encomiums from the medical and secular press.

"It is comprehensive and concise, and is characterized by clearness and originality."—*Dublin Quarterly Journal of Medicine.*

"Its author is learned in medical literature; he has arranged his materials with care and judgment, and has thought over them."—*The Lancet.*

"As a full, systematic, and thoroughly practical guide for the student and physician, it is not excelled by any similar treatise in any language."—*Appletons' Journal.*

"The author is an accomplished pathologist and practical physician; he is not only capable of appreciating the new discoveries, which during the last ten years have been unusually numerous and important in scientific and practical medicine, but, by his clinical experience, he can put these new views to a practical test, and give judgment regarding them."—*Edinburgh Medical Journal.*

"From its general excellence, we are disposed to think that it will soon take its place among the recognized text-books."—*American Quarterly Journal of Medical Sciences.*

"The first inquiry in this country regarding a German book generally is, 'Is it a work of practical value?' Without stopping to consider the justness of the American idea of the 'practical,' we can unhesitatingly answer, 'It is!'"—*New York Medical Journal.*

"The author has the power of sifting the tares from the wheat—a matter of the greatest importance in a text-book for students."—*British Medical Journal.*

"Whatever exalted opinion our countrymen may have of the author's talents of observation and his practical good sense, his text-book will not disappoint them, while those who are so unfortunate as to know him only by name, have in store a rich treat."—*New York Medical Record.*

NEUMANN.

Hand-Book of Skin Diseases.

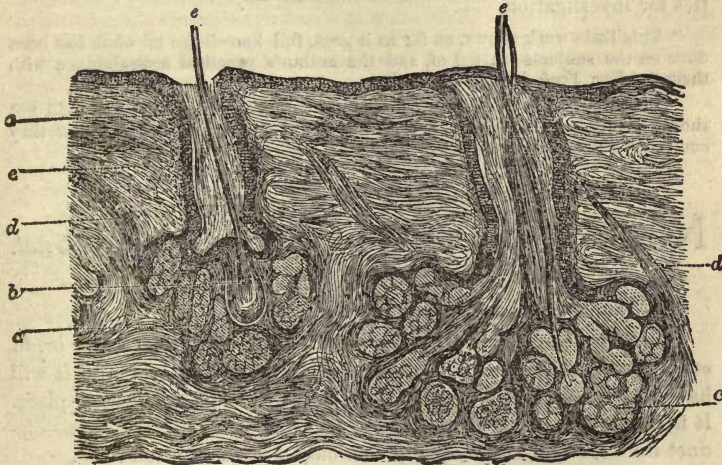
By DR. ISIDOR NEUMANN,
Lecturer on Skin Diseases in the Royal University of Vienna.

Translated from advanced sheets of the second edition, furnished by the
Author; with Notes,

By LUCIUS D. BULKLEY, A. M., M. D.,
Surgeon to the New York Dispensary, Department of Venereal and Skin Diseases; Assistant
to the Skin Clinic of the College of Physicians and Surgeons, New York; Mem-
ber of the New York Dermatological Society, etc., etc.

1 vol., 8vo. About 450 pages and 66 Woodcuts. Cloth, \$4.00.

SPECIMEN OF ILLUSTRATIONS.



Section of skin from a bald head.

Prof. Neumann ranks second only to Hebra, whose assistant he was for many years and his work may be considered as a fair exponent of the German practice of Dermatology. The book is abundantly illustrated with plates of the histology and pathology of the skin. The translator has endeavored, by means of notes from French, English, and American sources, to make the work valuable to the student as well as to the practitioner.

"It is a work which I shall heartily recommend to my class of students at the University of Pennsylvania, and one which I feel sure will do much toward enlightening the profession on this subject."—*Louis A. Duhring.*

"I know it to be a good book, and I am sure that it is well translated; and it is interesting to find it illustrated by references to the views of co-laborers in the same field."—*Erasmus Wilson.*

"So complete as to render it a most useful book of reference."—*T. McCall Anderson.*

"There certainly is no work extant which deals so thoroughly with the Pathological Anatomy of the Skin as does this hand-book."—*N. Y. Medical Record.*

"The original notes by Dr. Bulkley are very practical, and are an important adjunct to the text. . . . I anticipate for it a wide circulation."—*Silas Durkee, Boston.*

"I have already twice expressed my favorable opinion of the book in print, and am glad that it is given to the public at last."—*James C. White, Boston.*

"More than two years ago we noticed Dr. Neumann's admirable work in its original shape; and we are therefore absolved from the necessity of saying more than to repeat our strong recommendation of it to English readers."—*Practitioner.*

NEFTEL.**Galvano-Therapeutics.** *The Physiological and Therapeutical Action of the Galvanic Current upon the Acoustic, Optic, Sympathetic, and Pneumogastric Nerves.*

By WILLIAM B. NEFTEL.

1 vol., 12mo. 161 pp. Cloth, \$1.50.

This book has been published at the request of several aural surgeons and other professional gentlemen, and is a valuable treatise on the subjects of which it treats. Its author, formerly visiting physician to the largest hospital of St. Petersburg, has had the very best facilities for investigation.

"This little work shows, as far as it goes, full knowledge of what has been done on the subjects treated of, and the author's practical acquaintance with them."—*New York Medical Journal*.

"Those who use electricity should get this work, and those who do not should peruse it to learn that there is one more therapeutical agent that they could and should possess."—*The Medical Investigator*.

NIGHTINGALE.**Notes on Nursing:** *What it is, and what it is not.*

By FLORENCE NIGHTINGALE.

1 vol., 12mo. 140 pp. Cloth, 75 cents.

Every-day sanitary knowledge, or the knowledge of nursing, or, in other words, of how to put the constitution in such a state as that it will have no disease or that it can recover from disease, takes a higher place. It is recognized as the knowledge which every one ought to have—distinct from medical knowledge, which only a profession can have.

PEREIRA.**Dr. Pereira's Elements of Materia Medica and Therapeutics.** *Abridged and adapted for the Use of Medical and Pharmaceutical Practitioners and Students, and comprising all the Medicines of the British Pharmacopœia, with such others as are frequently ordered in Prescriptions, or required by the Physician.*

Edited by ROBERT BENTLEY and THEOPHILUS REDWOOD.

New Edition. Brought down to 1872. 1 vol., Royal 8vo. Cloth, \$7.00; Sheep, \$8.00.

PEASLEE.

Ovarian Tumors; *Their Pathology, Diagnosis, and Treatment, with reference especially to Ovariectomy.*

By E. R. PEASLEE, M. D.,

Professor of Diseases of Women in Dartmouth College; one of the Consulting Physicians to the New York State Woman's Hospital; formerly Professor of Obstetrics and Diseases of Women in the New York Medical College; Corresponding Member of the Obstetrical Society of Berlin, etc.

1 vol., 8vo. Illustrated with many Woodcuts, and a Steel Engraving of Dr. E. McDowell, the "Father of Ovariectomy." Price, Cloth, \$5.00.

This valuable work, embracing the results of many years of successful experience in the department of which it treats, will prove most acceptable to the entire profession; while the high standing of the author and his knowledge of the subject combine to make the book the best in the language. It is divided into two parts: the first treating of Ovarian Tumors, their anatomy, pathology, diagnosis, and treatment, except by extirpation; the second of Ovariectomy, its history and statistics, and of the operation. Fully illustrated, and abounding with information the result of a prolonged study of the subject, the work should be in the hands of every physician in the country.

The following are some of the opinions of the press, at home and abroad, of this great work, which has been justly styled, by an eminent critic, "*the most complete medical monograph on a practical subject ever produced in this country.*"

"His opinions upon what others have advised are clearly set forth, and are as interesting and important as are the propositions he has himself to advance; while there are a freshness, a vigor, an authority about his writing, which great practical knowledge alone can confer."—*The Lancet.*

"Both Wells's and Peaslee's works will be received with the respect due to the great reputation and skill of their authors. Both exist not only as masters of their art, but as clear and graceful writers. In either work the student and practitioner will find the fruits of rich experience, of earnest thought, and of steady, well-balanced judgment. As England is proud of Wells, so may America well be proud of Peaslee, and the great world of science may be proud of both."—*British Medical Journal.*

"This is an excellent work, and does great credit to the industry, ability, science, and learning of Dr. Peaslee. Few works issue from the medical press so complete, so exhaustively learned, so imbued with a practical tone, without losing other substantial good qualities."—*Edinburgh Medical Journal.*

"In closing our review of this work, we cannot avoid again expressing our appreciation of the thorough study, the careful and honest statements, and candid spirit, which characterize it. For the use of the student we should give the preference to Dr. Peaslee's work, not only from its completeness, but from its more methodical arrangement."—*American Journal of Medical Sciences.*

"Dr. Peaslee brings to the work a thoroughness of study, a familiarity with the whole field of histology, physiology, pathology, and practical gynecology, not excelled, perhaps, by those of any man who ever performs the operation."—*Medical Record.*

"If we were to select a single word to express what we regard as the highest excellence of this book, it would be its *thoroughness.*"—*New York Medical Journal.*

"We deem its careful perusal indispensable to all who would treat ovarian tumors with a good conscience."—*American Journal of Obstetrics.*

"It shows prodigal industry, and embodies within its five hundred and odd pages pretty much all that seems worth knowing on the subject of ovarian diseases."—*Philadelphia Medical Times.*

"Great thoroughness is shown in Dr. Peaslee's treatment of all the details of this very admirable work."—*Boston Medical and Surgical Journal.*

"It is a necessity to every surgeon who expects to treat this disease."—*Leavenworth Medical Herald.*

"Indispensable to the American student of gynecology."—*Pacific Medical and Surgical Journal.*

"There is not a doubtful point that could occur to any one that is not explained and answered in the most satisfactory manner."—*Virginia Clinical Record.*

"The work is one the profession should prize; one that every earnest practitioner should possess."—*Georgia Medical Companion.*

"Dr. Peaslee has achieved a success, and the work is one which no practical surgeon can afford to be without."—*Medical Investigator.*

SAYRE.

A Practical Manual on the Treatment of Club-Foot.

By LEWIS A. SAYRE, M. D.,

Professor of Orthopedic Surgery in Bellevue Hospital Medical College; Surgeon to Bellevue and Charity Hospitals, etc.

1 vol., 12mo. New and Enlarged Edition. Cloth. \$1.00.

"The object of this work is to convey, in as concise a manner as possible, all the practical information and instruction necessary to enable the general practitioner to apply that plan of treatment which has been so successful in my own hands."—*Preface*.

"The book will very well satisfy the wants of the majority of general practitioners, for whose use, as stated, it is intended."—*New York Medical Journal*.

SMITH.

On Foods.

By EDWARD SMITH, M. D., LL. B., F. R. S.,

Fellow of the Royal College of Physicians of London, etc., etc.

1 vol., 12mo. Cloth. Price, \$1.75.

Since the issue of the author's work on "Practical Dietary," he has felt the want of another, which would embrace all the generally-known and less-known foods, and contain the latest scientific knowledge respecting them. The present volume is intended to meet this want, and will be found useful for reference, to both scientific and general readers. The author extends the ordinary view of foods, and includes water and air, since they are important both in their food and sanitary aspects.

STROUD.

The Physical Cause of the Death of Christ, and its Relations to the Principles and Prac- tice of Christianity.

By WILLIAM STROUD, M. D.

With a Letter on the Subject,

By SIR JAMES Y. SIMPSON, BART., M. D.

1 vol., 12mo. 422 pp. Cloth, \$2.00.

This important and remarkable book is, in its own place, a masterpiece, and will be considered as a standard work for many years to come.

The principal point insisted upon is, that the death of Christ was caused by rupture or laceration of the heart. Sir James Y. Simpson, who had read the author's treatise and various comments on it, expressed himself very positively in favor of the views maintained by Dr. Stroud.—*Psychological Journal*.

SIMPSON.

The Posthumous Works of Sir James

Young Simpson, Bart., M. D. In Three Volumes.

Volume I.—*Selected Obstetrical and Gynæcological Works of Sir James Y. Simpson, Bart., M. D., D. C. L., late Professor of Midwifery in the University of Edinburgh. Containing the substance of his Lectures on Midwifery. Edited by J. WATT BLACK, A. M., M. D., Member of the Royal College of Physicians, London; Physician-Accoucheur to Charing Cross Hospital, London; and Lecturer on Midwifery and Diseases of Women and Children in the Hospital School of Medicine.*

1 vol., 8vo. 852 pp. Cloth, \$3.00.

This volume contains all the more important of the contributions of Sir James Y. Simpson to the study of obstetrics and diseases of women, with the exception of his clinical lectures on the latter subject, which will shortly appear in a separate volume. This first volume contains many of the papers reprinted from his *Obstetric Memoirs and Contributions*, and also his *Lecture Notes*, now published for the first time, containing the substance of the practical part of his course of midwifery. It is a volume of great interest to the profession, and a fitting memorial of its renowned and talented author.

"To many of our readers, doubtless, the chief of the papers it contains are familiar. To others, although probably they may be aware that Sir James Simpson has written on the subjects, the papers themselves will be new and fresh. To the first class we would recommend this edition of Sir James Simpson's works, as a valuable volume of reference; to the latter, as a collection of the works of a great master and improver of his art, the study of which cannot fail to make them better prepared to meet and overcome its difficulties."—*Medical Times and Gazette.*

Volume II.—*Anæsthesia, Hospitalism, etc.* Edited by Sir WALTER SIMPSON, Bart.

1 vol., 8vo. 560 pp. Cloth, \$3.00.

"We say of this, as of the first volume, that it should find a place on the table of every practitioner; for, though it is patchwork, each piece may be picked out and studied with pleasure and profit."—*The Lancet (London).*

Volume III.—*The Diseases of Women.* Edited by ALEX. SIMPSON, M. D., Professor of Midwifery in the University of Edinburgh.

1 vol., 8vo. Cloth, \$3.00.

One of the best works on the subject extant. Of inestimable value to every physician.

SWETT.

A Treatise on the Diseases of the Chest.

Being a Course of Lectures delivered at the New York Hospital.

By JOHN A. SWETT, M. D.,

Professor of the Institutes and Practice of Medicine in the New York University; Physician to the New York Hospital; Member of the New York Pathological Society.

1 vol., 8vo. 587 pp. \$3.50.

Embodied in this volume of lectures is the experience of ten years in hospital and private practice.

SCHROEDER.**A Manual of Midwifery.** *Including the Pathology of Pregnancy and the Puerperal State.*

By Dr. KARL SCHROEDER.

Professor of Midwifery and Director of the Lying-in Institution in the University of Erlangen.

Translated from the Third German Edition,

By CHAS. H. CARTER, B. A., M. D., B. S. Lond.,

Member of the Royal College of Physicians, London, and Physician Accoucheur to St. George's, Hanover Square, Dispensary.

With Twenty-six Engravings on Wood. 1 vol., 8vo. Cloth.

"The translator feels that no apology is needed in offering to the profession a translation of Schroeder's Manual of Midwifery. The work is well known in Germany and extensively used as a text-book; it has already reached a third edition within the short space of two years, and it is hoped that the present translation will meet the want, long felt in this country, of a manual of midwifery embracing the latest scientific researches on the subject.

TILT.**A Hand-Book of Uterine Therapeutics and of Diseases of Women.**

By EDWARD JOHN TILT, M. D.,

Member of the Royal College of Physicians; Consulting Physician to the Farringdon General Dispensary; Fellow of the Royal Medical and Chirurgical Society, and of several British and foreign societies.

1 vol., 8vo. 345 pp. Cloth, \$3.50.

Second American edition, thoroughly revised and amended.

"In giving the result of his labors to the profession the author has done a great work. Our readers will find its pages very interesting, and, at the end of their task, will feel grateful to the author for many very valuable suggestions as to the treatment of uterine diseases."—*The Lancet*.

"Dr. Tilt's 'Hand-Book of Uterine Therapeutics' supplies a want which has often been felt. . . . It may, therefore, be read not only with pleasure and instruction, but will also be found very useful as a book of reference."—*The Medical Mirror*.

"Second to none on the therapeutics of uterine disease."—*Journal of Obstetrics*.

VAN BUREN.**Lectures upon Diseases of the Rectum.***Delivered at the Bellevue Hospital Medical College. Session of 1869-'70.*

By W. H. VAN BUREN, M. D.,

Professor of the Principles of Surgery with Diseases of the Genito-Urinary Organs, etc., in the Bellevue Hospital Medical College; one of the Consulting Surgeons of the New York Hospital, of the Bellevue Hospital; Member of the New York Academy of Medicine, of the Pathological Society of New York, etc., etc.

1 vol., 12mo. 164 pp. Cloth, \$1.50.

"It seems hardly necessary to more than mention the name of the author of this admirable little volume in order to insure the character of his book. No one in this country has enjoyed greater advantages, and had a more extensive field of observation in this specialty, than Dr. Van Buren, and no one has paid the same amount of attention to the subject. . . . Here is the experience of years summed up and given to the professional world in a plain and practical manner."—*Psychological Journal*.

VAN BUREN AND KEYES.

A Practical Treatise on the Surgical

Diseases of the Genito-Urinary Organs, including Syphilis. Designed as a Manual for Students and Practitioners. With Engravings and Cases.

By W. H. VAN BUREN, A. M., M. D.,

Professor of Principles of Surgery, with Diseases of the Genito-Urinary System and Clinical Surgery, in Bellevue Hospital Medical College; Consulting Surgeon to the New York Hospital, the Charity Hospital, etc.; and

E. L. KEYES, A. M., M. D.,

Professor of Dermatology in Bellevue Hospital Medical College; Surgeon to the Charity Hospital, Venereal Division; Consulting Dermatologist to the Bureau of Out-Door Relief, Bellevue Hospital, etc.

1 vol., 8vo. Cloth, \$5.00; Sheep, \$6.00.

This work is really a compendium of, and a book of reference to, all modern works treating in any way of the surgical diseases of the genito-urinary organs. At the same time, no other single book contains so large an array of *original* facts concerning the class of diseases with which it deals. These facts are largely drawn from the extensive and varied experience of the authors.

Many important branches of genito-urinary diseases, as the cutaneous maladies of the penis and scrotum, receive a thorough and exhaustive treatment that the professional reader will search for elsewhere in vain.

Both to the specialist and the general practitioner the work commends itself as one of inestimable value.

The work is a marvel of conciseness, and very rarely is so much condensation accomplished without loss of any valuable points of detail. A glance at the table of contents will give an idea of the scope of the volume, but only a careful perusal of the work will convince the reader that full justice has been done to all the various branches of this highly-interesting class of diseases.

The work is elegantly and profusely illustrated, and enriched by fifty-five original cases, setting forth obscure and difficult points in diagnosis and treatment.

"The first part is devoted to the Surgical Diseases of the Genito-Urinary Organs; and part second treats of Chancroid and Syphilis. The authors 'appear to have succeeded admirably in giving to the world an exhaustive and reliable treatise on this important class of diseases.'"—*Northwestern Medical and Surgical Journal*.

"It is a most complete digest of what has long been known, and of what has been more recently discovered in the field of syphilitic and genito-urinary disorders. It is perhaps not an exaggeration to say that no single work upon the same subject has yet appeared, in this or any foreign language, which is superior to it."—*Chicago Medical Examiner*.

"The commanding reputation of Dr. Van Buren in this specialty and of the great school and hospital from which he has drawn his clinical materials, together with the general interest which attaches to the subject-matter itself, will, we trust, lead very many of those for whom it is our office to cater, to possess themselves at once of the volume and form their own opinions of its merit."—*Atlanta Medical and Surgical Journal*.

VOGEL.

A Practical Treatise on the Diseases
of Children. Second American from the Fourth
German Edition. Illustrated by Six Lithographic
Plates.

By ALFRED VOGEL, M. D.,

Professor of Clinical Medicine in the University of Dorpat, Russia.

TRANSLATED AND EDITED BY

H. RAPHAEL, M. D.,

Late House Surgeon to Bellevue Hospital; Physician to the Eastern Dispensary for the Diseases
of Children, etc., etc.

1 vol., 8vo. 611 pp. Cloth, \$4.50.

The work is well up to the present state of pathological knowledge; complete without unnecessary prolixity; its symptomatology accurate, evidently the result of careful observation of a competent and experienced clinical practitioner. The diagnosis and differential relations of diseases to each other are accurately described, and the therapeutics judicious and discriminating. All polypharmacy is discarded, and only the remedies which appeared useful to the author commended.

It contains much that must gain for it the merited praise of all impartial judges, and prove it to be an invaluable text-book for the student and practitioner, and a safe and useful guide in the difficult but all-important department of Pædiatrica.

"Rapidly passing to a fourth edition in Germany, and translated into three other languages, America now has the credit of presenting the first English version of a book which must take a prominent, if not the leading, position among works devoted to this class of disease."—*N. Y. Medical Journal*.

"The profession of this country are under many obligations to Dr. Raphael for bringing, as he has done, this truly valuable work to their notice."—*Medical Record*.

"The translator has been more than ordinarily successful, and his labors have resulted in what, in every sense, is a valuable contribution to medical science."—*Psychological Journal*.

"We do not know of a compact text-book on the diseases of children more complete, more comprehensive, more replete with practical remarks and scientific facts, more in keeping with the development of modern medicine, and more worthy of the attention of the profession, than that which has been the subject of our remarks."—*Journal of Obstetrics*.

WALTON.

The Mineral Springs of the United States and Canada, with Analyses and Notes on the Prominent Spas of Europe, and a List of Sea-side Resorts. An enlarged and revised edition.

By GEORGE E. WALTON, M. D.,

Lecturer on Materia Medica in the Miami Medical College, Cincinnati.

1 vol., 12mo. 390 pages, with Maps. Price, \$2.00.

The author has given the analyses of all the springs in this country and those of the principal European spas, reduced to a uniform standard of one wine-pint, so that they may readily be compared. He has arranged the springs of America and Europe in seven distinct classes, and described the diseases to which mineral waters are adapted, with references to the class of waters applicable to the treatment, and the peculiar characteristics of each spring as near as known are given—also, the location, mode of access, and post-office address of every spring are mentioned. In addition, he has described the various kinds of baths and the appropriate use of them in the treatment of disease.

EXTRACTS FROM OPINIONS OF THE PRESS.

" . . . Precise and comprehensive, presenting not only reliable analyses of the waters, but their therapeutic value, so that physicians can hereafter advise their use as intelligently and beneficially as they can other valuable alterative agents."—*Sanitarian*.

" . . . Will tend to enlighten both the profession and the people on this question."—*N. Y. Medical Journal*.

" . . . Contains in brief space a vast amount of important and interesting matter, well arranged and well presented. Nearly every physician needs just such a volume."—*Richmond and Louisville Medical Journal*.

" . . . Fills this necessity in a scientific and pleasing manner, and can be read with advantage by the physician as well as layman."—*American Jour. of Obstetrics*.

UNIVERSITY OF VIRGINIA, June 9, 1873.

GENTLEMEN: I have received by mail a copy of Dr. Walton's work on the Mineral Springs of the United States and Canada. Be pleased to accept my thanks for a work which I have been eagerly looking for ever since I had the pleasure of meeting the author in the summer of 1871. He satisfied me that he was well qualified to write a reliable work on this subject, and I doubt not he has met my expectations. Such a work was greatly needed, and, if offered for sale at the principal mineral springs of the country, will, I believe, command a ready sale. Very respectfully yours,

J. L. CABELL, M. D.

WELLS.**Diseases of the Ovaries; *Their Diagnosis and Treatment.***

By T. SPENCER WELLS,

Fellow and Member of Council of the Royal College of Surgeons of England; Honorary Fellow of the King and Queen's College of Physicians in Ireland; Surgeon in Ordinary to the Queen's Household; Surgeon to the Samaritan Hospital for Women; Member of the Imperial Society of Surgery of Paris, of the Medical Society of Paris, and of the Medical Society of Sweden; Honorary Member of the Royal Society of Medical and Natural Science of Brussels, and of the Medical Societies of Pesh and Helsingfors; Honorary Fellow of the Obstetrical Societies of Berlin and Leipzig.

1 vol., 8vo. 478 pp. Illustrated. Cloth, Price, \$4.50.

In 1865 the author issued a volume containing reports of one hundred and fourteen cases of Ovariotomy, which was little more than a simple record of facts. The book was soon out of print, and, though repeatedly asked for a new edition, the author was unable to do more than prepare papers for the Royal Medical and Chirurgical Society, as series after series of a hundred cases accumulated. On the completion of five hundred cases he embodied the results in the present volume, an entirely new work, for the student and practitioner, and trusts it may prove acceptable to them and useful to suffering women.

"Arrangements have been made for the publication of this volume in London on the day of its publication in New York." French and German translations are already in press.

WAGNER.**A Hand - book of Chemical Technology.**

By RUDOLPH WAGNER, Ph. D.,

Professor of Chemical Technology at the University of Wurtzburg.

Translated and edited, from the eighth German edition, with extensive additions,

By WILLIAM CROOKES, F. R. S.

With 336 Illustrations. 1 vol., 8vo. 761 pages. Cloth, \$5.00.

Under the head of Metallurgic Chemistry, the latest methods of preparing Iron, Cobalt, Nickel, Copper, Copper Salts, Lead and Tin, and their Salts, Bismuth, Zinc, Zinc Salts, Cadmium, Antimony, Arsenic, Mercury, Platinum, Silver, Gold, Manganates, Aluminum, and Magnesium, are described. The various applications of the Voltaic Current to Electro-Metallurgy follow under this division. The preparation of Potash and Soda Salts, the manufacture of Sulphuric Acid, and the recovery of Sulphur from Soda Waste, of course occupy prominent places in the consideration of chemical manufactures. It is difficult to over-estimate the mercantile value of Mond's process, as well as the many new and important applications of Bisulphide of Carbon. The manufacture of Soap will be found to include much detail. The Technology of Glass, Stone-ware, Limes, and Mortars, will present much of interest to the Builder and Engineer. The Technology of Vegetable Fibres has been considered to include the preparation of Flax, Hemp, Cotton, as well as Paper-making; while the applications of Vegetable Products will be found to include Sugar-boiling, Wine and Beer Brewing, the Distillation of Spirits, the Baking of Bread, the Preparation of Vinegar, the Preservation of Wood, etc.

Dr. Wagner gives much information in reference to the production of Potash from Sugar residues. The use of Baryta Salts is also fully described, as well as the preparation of Sugar from Beet-roots. Tanning, the Preservation of Meat, Milk, etc., the Preparation of Phosphorus and Animal Charcoal, are considered as belonging to the Technology of Animal Products. The Preparation of Materials for Dyeing has necessarily required much space; while the final sections of the book have been devoted to the Technology of Heating and Illumination.

NEW MEDICAL WORKS IN PRESS.

Hand-Book of the Histology and Histo-
Chemistry of Man. By Dr. HEINRICH FREY, of Zurich. Illustrated with
500 Woodcuts.

Clinical Lectures on Diseases of the
Nervous System. Delivered at the Bellevue Hospital Medical College, by
WM. A. HAMMOND, M. D. Edited, with Notes, by T. M. B. Cross, M. D.

Acne ; its Pathology, Etiology, Prognosis, and Treatment. By L. DUNCAN
BULKLEY, A. M., M. D., New York Hospital.

A monograph of about seventy pages, illustrated, founded on an analysis of two hundred
cases of various forms of acne.

Compendium of Children's Diseases, for
Students and Physicians. By Dr. JOHN STEINER.

Diseases of the Nerves and Spinal Cord.
By Dr. H. CHARLTON BASTIAN.

D. APPLETON & CO.,
549 & 551 BROADWAY, NEW YORK.

THE NEW YORK MEDICAL JOURNAL.

JAMES B. HUNTER, M. D., Editor.

Published Monthly. Volumes begin in January and July.

"Among the numerous records of Medicine and the collateral sciences published in America, the above Journal occupies a high position, and deservedly so."—*The Lancet (London)*.

"One of the best medical journals, by-the-by, published on the American Continent."—*London Medical Times and Gazette*.

"A very high-class journal."—*London Medical Mirror*.

"The editor and the contributors rank among our most distinguished medical men, and each number contains matter that does honor to American medical literature."—*Boston Journal of Chemistry*.

"Full of valuable original papers, abounding in scientific ability."—*Chicago Medical Times*.

"We know no other periodical that we would rather present as a specimen of American skill and intelligence than the NEW YORK MEDICAL JOURNAL."—*Franklin Repository*.

Terms, \$4 per Annum. Specimen Copies, 25 Cents.

THE POPULAR SCIENCE MONTHLY.

Conducted by Prof. E. L. YOUMANS.

Each Number contains 128 pages, with numerous Descriptive and Attractive Illustrations.

Published Monthly. Volumes begin in May and November.

Terms, \$5 per Annum, or Fifty Cents per Number.

THE POPULAR SCIENCE MONTHLY was started to promote the diffusion of valuable scientific knowledge, in a readable and attractive form, among all classes of the community, and has thus far met a want supplied by no other periodical in the United States.

The great feature of the magazine is, that its contents are not what science *was* ten or more years since, but what it *is* to-day, fresh from the study, the laboratory, and the experiment; clothed in the language of the authors, inventors, and scientists themselves, which comprise the leading minds of England, France, Germany, and the United States. Among popular articles, covering the whole range of NATURAL SCIENCE, we have the latest thoughts and words of Herbert Spencer, and Professors Huxley, Tyndall, and R. A. Proctor. Since the start, it has proved a gratifying success to every friend of scientific progress and universal education; and those who believed that science could not be made any thing but dry study, are disappointed.

The press all over the land is warmly commending it. We subjoin a few encomiums from those recently given:

"A journal which promises to be of eminent value to the cause of popular education in this country."—*New York Tribune*.

"It is, beyond comparison, the best attempt at journalism of the kind ever made in this country."—*Home Journal*.

"The initial number is admirably constituted."—*Evening Mail*.

"In our opinion, the right idea has been happily hit in the plan of this new monthly."—*Buffalo Courier*.

"Just the publication needed at the present day."—*Montreal Gazette*.

New York Medical Journal and Popular Science Monthly, - - - - -	\$8 00
New York Medical Journal and Appletons' Weekly Journal of Literature, Science, and Art, - - - - -	7 00
Appletons' Weekly Journal and Popular Science Monthly, - - - - -	8 00
New York Medical Journal, Popular Science Monthly, and Weekly Journal, - - - - -	11 50

Payment, in all cases, must be made in advance.

Remittances should be made by postal money-order or check to the Publishers,

D. APPLETON & CO.,

549 & 551 Broadway, New York.

5

THIS BOOK IS DUE ON THE LAST DATE
STAMPED BELOW

AN INITIAL FINE OF 25 CENTS
WILL BE ASSESSED FOR FAILURE TO RETURN
THIS BOOK ON THE DATE DUE. THE PENALTY
WILL INCREASE TO 50 CENTS ON THE FOURTH
DAY AND TO \$1.00 ON THE SEVENTH DAY
OVERDUE.

Biology Library

MAR 24 1950


AUG 7 1950

OCT 22 1957

LD 21-95m-7,'37

8

U.C. BERKELEY LIBRARIES



C026151832



