



3 1761 04210 7003

LIBRARY

Department of Pathology and Bacteriology
UNIVERSITY OF TORONTO

NO. 64 CATALOG

week to any member in good standing during
the Collegiate year.

- II. Members shall neither retain nor obtain books during the Summer vacation.
- III. Any person injuring, destroying, or retaining a book, will be charged with the value of it, and will be punishable by suspension.
- IV. The General Committee may, at their discretion, refuse the loan of any volume.



ANATOMICAL PLATES

ARRANGED AS A COMPANION VOLUME FOR

"THE ESSENTIALS OF ANATOMY"

23A


(BY WILLIAM DARLING AND A. L. RANNEY)

AND FOR

ALL WORKS UPON DESCRIPTIVE ANATOMY

COMPRISING

FOUR HUNDRED AND THIRTY-NINE DESIGNS ON STEEL BY PROF. J. N. MASSE, OF PARIS, AND
NUMEROUS DIAGRAMMATIC CUTS SELECTED OR DESIGNED BY THE EDITOR
TOGETHER WITH EXPLANATORY LETTER-PRESS



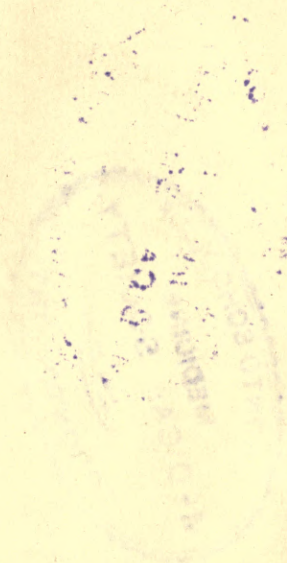
AMBRIDGE L. S. BANTLEY, A.M., M.D.

*Adjunct Professor of Anatomy and late Lecturer on Genito-Urinary Surgery at the
Fellow of the New York Academy of Medicine. Member of the Medical Society of the County of New York. Author of
"A Practical Treatise on Uterine and Gynaecological Diagnosis," etc.*



NEW YORK
G. P. PUTNAM'S SONS
27 AND 29 WEST 23D STREET
1881

412576
31.5.43



COPYRIGHT

1881

By G. P. PUTNAM'S SONS

EDITOR'S PREFACE.

THE editor feels much gratification in being enabled to present to the profession of the United States an American edition of the beautiful "Anatomical Atlas" of Professor J. N. Masse, of Paris. As a teacher of Anatomy, he has felt the want of such a work to recommend to his pupils; and, recalling to his mind the difficulties he encountered himself, as a student, in the cultivation of anatomical science, he is enabled to form a just estimate of the value of such an atlas. There are, it is true, already in existence many valuable anatomical atlases. These are, however, not only too voluminous and too expensive to supply the wants of the great body of the profession, but, as it has been observed, ~~that the different parts of the same organ being often represented in different cuts, the student, from his being obliged, in consulting them, to refer to different plates, becomes confused, and is unable to form a correct idea of the true structure of the organ, which he studies.~~ Again, from their size, they are only suited for consultation at home; they cannot be carried into the anatomical theatre and the dissecting-room, which, in the opinion of the editor, is a great objection against the form of this anatomical atlas enables the student to make it his constant companion. He places it before him as he listens to the demonstration of the professor in the lecture-room; and, on his return home, on his examining the plates, ~~the subjects of which he has heard demonstrated, the lesson taught by his teacher is forcibly recalled to his mind.~~ In the dissecting-room, the atlas serves as a guide to the student in the prosecution of his dissections; it not only teaches him how to expose the organs, the structure of which he is investigating, but the engravings so clearly exhibit them to his eye, and the text furnishes such satisfactory information as to the name and locality of every part of the structure he has unveiled, that the necessity for the assistance of a demonstrator is, in a great measure, obviated. To the physician or surgeon who has no means of referring to the *dead subject*, this atlas will be found an invaluable work for reference. When the former wishes to refer to the position of any particular viscus, and to study its relations, or when symptoms depending on nervous connection arise in disease which he cannot explain, referring to this atlas, all his difficulties are removed. When

the latter prepares himself for the performance of a surgical operation, and when in vain he attempts to recall to his mind surgical relations long since seen, and now only confusedly remembered, referring to his atlas, the vision of the past is recalled to the mind in all its original freshness, and with confidence he is enabled to perform his operation. Such being the fact, invaluable as the possession of this atlas is to the medical student, it is, if possible, still more valuable to the country physician and surgeon; and, from the very low price at which it is furnished, we are much mistaken if it does not obtain an extensive circulation.

The editor at first thought that he could improve the original text of Masse by re-writing the descriptions of the plates, and greatly extending them; but, having done this in several instances, he found that descriptions, so conducted, would require several pages of letter-press. By so extending the text, one of the great advantages of the work would be destroyed, that of having the description and the plate placed on opposite pages, and he therefore altered his original intention.

The execution of this work may be considered as a proud trophy to the arts of the United States. The engravings on steel, by Mr. Ormsby, are most excellent. Although Masse's Atlas is justly considered one of the most beautiful works ever published in Paris, the most critical must admit that, in so far as the engraving is concerned, the American edition is, to say the least of it, fully equal to the edition executed by the Parisian artists.

The diagrammatic cuts which the editor has scattered throughout the volume are intended to make certain points in anatomy plain which would otherwise be obscure even in an accurate representation of the parts. To the intelligent student, such a drawing often renders the perfect comprehension of a part possible, which was previously beyond his grasp in spite of plates or dissection. For some of these, the editor is indebted to the skill of friends in the profession, or to other authors; but most of them are either entirely original, or so modified from old designs as to have lost their original appearance.

The use of *numbers* as guides to the text, in place of having the names printed upon each individual structure, is not, in the opinion of the editor, a disadvantage. While it does not assist a rapid review of a figure, but rather hinders it, this fact alone is the best proof of the advantage of the system. Plates must be *studied*, and not merely glanced at, to be of value to the student; and anything which tends to break up a bad habit, so easily formed and so common among beginners, should be encouraged rather than deprecated.

The Messrs. Putnam have fixed the price of this work at about one-third the cost of the original work of Masse, and which makes this, by far, the cheapest atlas now in print. Such liberality should, and we have no doubt will, be met with a corresponding support and patronage on the part of the profession and the medical schools of the country.

wants and ministering to the pleasures of man. Every means must be employed to acquire knowledge; and we must be grateful to every variety of talent which furnishes us with those means. If it be true that dissecting manuals and directions as to the mode of exposing organs placed at the beginning of anatomical descriptions are useful, it is equally true that pupils almost never consult them. An exact and accurate design of an organ will quickly and clearly point out the preparation necessary for its exposition. In this point of view, it is our opinion that the *ATLAS* will form a necessary complement to works on descriptive anatomy. To the physician, anatomy is not only a science, it is also an art; and this art, which constituted the glory of Dessault, of Boyer, of Dupuytren, like all others, must be learned. With regard to dissection, the directions are tedious and fatiguing; a single sketch shows both the end and the means. *Longum iter per praecepta, breve per exempla.*

It is often remarked that we retain the recollection of objects in proportion to the amount of trouble we have had in discovering them. It would be nearer the truth to say that we retain them so much the better, the better they have been prepared and seen. The object which is *only* sought for does not meet the eye, and leaves no trace in the mind. It is with pain and sorrow that one sees a number of pupils daily waste pre-

INTRODUCTION.

THE interest which is attached to every department of human knowledge has caused the means for its diffusion to be greatly increased. Art has rendered to anatomical science, in particular, most invaluable aid. Our museums are, with justice, proud of the wax preparations of Laumonier, of Dupont, and of the elder Guy, their rival. Anatomy owes much, also, to painting; and we take great pleasure in here offering a tribute of respect and our sincere thanks to M. Leveillé, a young artist whose skillful pencil, always directed by an acquaintance with the subject, is destined to render to our science important assistance. We are happy to have it in our power to state that the engravings are a faithful representation of his drawings, and contribute much to the value of our work.

The dead body, without doubt, is the true source from which the physician should derive his knowledge. It is nature herself that he must observe and understand. But he must know how to study her; and, in her absence, it is useful to preserve her image. The arts are brethren, and ought mutually to assist each other in satisfying the

cious hours in searching for organs which they never display in a proper manner; so that, after much trouble, they cannot but read with ennui the description of an organ badly prepared, imperfectly seen, and, consequently, difficult or impossible to be recollected. An *ATLAS*, which the student can carry with him into the dissecting-room, and place by the side of his subject, will be a powerful means of diminishing his labour and increasing its value.

When the subject is not before us, it is tedious to read over a long, intricate, and dry description. Study will become easy, however, when we have before us a drawing which we have compared with the original, and whose accuracy we have tested. Students will appreciate this benefit, especially when the season of anatomical instruction has expired, and the time of examination draws nigh. When this period arrives, which excites fears even in the minds of the best prepared, they want to review in a few days, even in a few moments, an infinity of topics. Then they become excited; they wish to run over the multiplied springs and wheel-work of the human machine; but the scalpel is too slow; it rivets attention on some objects, and causes others to be neglected. The student, under these circumstances, abandons the dead body, which only allows itself to be interrogated by slowness and patience, and has recourse to the large atlases. It is often a

difficult matter for him to procure these; and even if one should be at hand, he is obliged to run over the numerous designs, in which are separately represented the different elements of the same organ. This kind of dissection is generally tedious, fatiguing, and, at such a time, unprofitable. An atlas, to be valuable, must have precision. Too great a number of figures only produce prolixity and confusion.

We have endeavoured to combine accuracy with precision. In order to be up to the present state of the science, we have deemed it our duty to consult the different atlases, and especially to examine minutely the discoveries of Scarpa, Arnold, Breschet, Cruveilhier, &c.; but, in availing ourselves of these valuable resources, we have always had our sketches taken from nature. Aponeurology, a part of anatomy still new, has been treated with care, and in detail. Neurology, that other department of anatomy so difficult and so important, has cost us much labour, and we flatter ourselves that our pains will not be useless. We have profited by the researches we made some time ago on the anatomy of the nervous centres, as well in regard to position as to structure, and we believe that pupils will, at last, advance with assurance into the study of this curious world of thought.

The methodical arrangement of the classic authors is often the reverse of the order that must be pursued in dissection; so that it may become

necessary to begin a description at the end, and to finish it at the beginning. The order that we have followed in general is that of nature, of dissection, and of the anatomy of relation; but as we have been obliged to sacrifice it, in some instances, to the arrangement of the designs, we add, at the end of the Atlas, a table, which refers to each figure in the order of preparation.

We have been careful to represent the entire organs. For instance, to display the facial nerve, it is not necessary to make a particular drawing of its superficial portion, and then to make five or six more to exhibit its deeper branches. Memory requires conciseness of system. The mind, distracted among several objects, without order, and fatigued by the difficulties incurred in seeking them out, catches at and retains nothing more than unconnected and confused ideas.

It would be a strange error to suppose that we have thought of withdrawing, for a single moment, the student from the study of nature herself. We have only aimed at rendering her study more prompt and more useful; and, at the same time, we have endeavoured to facilitate the remembrance of many important and various objects when they are no longer present to the sight.

It is with the same view that we now publish a Synoptic Anatomy. By this sort of recapitulation, the essential divisions, the order, the connexion of facts, and their harmony with each other, are

exposed, and the mind is allowed to embrace the whole of a science, at the same time that it renders it easy for it to recover each fact which has come within its comprehension. The new inquiries on aponeurology, on the nerves, on the structure of the nervous centres, which are not found registered in classic works, not admitting of being described under the synoptic form, have compelled us to give concise descriptions, which elsewhere we have placed in connexion with the engravings of the Atlas.



CONTENTS.

OSTEOLOGY.

- Pl. 1. Frontal—Parietal.
 Pl. 2. Cranium in general.
 Pl. 3. Occipital—Sphenoid—Temporal.
 Pl. 4. Parietal—Ethmoid.
 Pl. 5. Vertebra.
 Pl. 6. Superior Maxillary—Palato-Nasal—Os Unguis—Os Malæ—Vomer—Inferior Turbinate Bone—Inferior Maxillary Bone, and Os Hyoides.
 Pl. 7. Different sections of the Face—Teeth.
 Pl. 8. Vertebral Column in general—Ribs—Sternum—Thorax in general—Clavicle.
 Pl. 9. Bones of the Hand—Femur—Patella—Tibia—Fibula.
 Pl. 10. Scapula—Humerus—Ulna—Radius.
 Pl. 11. Sacrum—Coccyx—Ilium—Pelvis in general.
 Pl. 12. Bones of the Leg—Bones of the Foot.
 Pl. 13. Five diagrammatic figures.

ARTHROLOGY.

- Pl. 14. Articulation of the Lower Jaw—Articulation of the first two Vertebra with each other and with the Os Occipitis.
 Pl. 15. Articulations of the Pelvis.
 Pl. 16. Articulation of the Vertebra with the Ribs (Vertebro-costal and Costo-transverse)—Articulations of the Ribs with the Sternum (Sterno-costal)—Articulations of some Ribs with each other.
 Pl. 17. Articulation of the anterior part of the first two Vertebra with each other and with the Os Occipitis, viewed from behind—Articulation of the Vertebra in general.
 Pl. 18. Sterno-clavicular Articulation—Articulations of the Shoulder—Articulations of the Elbow Joint.

Pl. 19. Tibio-tarsal Articulation—Articulation of the Foot.

Pl. 20. Coxo-femoral Articulation, or Hip Joint—Articulation of Knee—Tibio-fibular Articulation.

Pl. 21. Ulna-radial Articulation—Radio-carpal Articulation—Articulations of the Hand.

MYOLOGY.

- Pl. 22. Muscles of the Head.
 Pl. 23. Muscles of the Tongue—Muscles of the Velum Palati—Muscles of the Larynx.
 Pl. 24. Muscles of the Supra-hyoid and Infra-hyoid, and lateral regions of the Neck—Muscles of the Pharynx—Muscles of the Tongue.
 Pl. 25. Muscles of the Eye—Pterygoid Muscles—Superficial Muscles of the Neck.
 Pl. 26. Muscles of the Chest and Abdomen.
 Pl. 27. Diaphragm—Psoæ, Quadratus Lumborum, and Iliacus Internus Muscles.
 Pl. 28. Muscles of the Genital Organs of the Female—Triangularis Sterni—Deep Muscles of the anterior part of the Neck—Inguinal Canal, viewed from before.
 Pl. 29. Muscles of the Abdomen—Muscles of the Genital Organs of the Male.
 Pl. 30. Superficial Muscles of the posterior part of the Trunk.
 Pl. 31. Muscles of the Shoulder and Arm.
 Pl. 32. Deep Muscles on the posterior part of the Neck—Intercostal, Supra-costal, and Transverso-spinalis Muscles.
 Pl. 33. Deep Muscles of the posterior part of the Trunk.
 Pl. 34. Superficial Muscles on the anterior part of the Fore-arm—Deep Muscles on the anterior part of the Fore-arm.
 Pl. 35. Muscles on the anterior and inner part of the Thigh.
 Pl. 36. Muscles on the posterior part of the Lower Extremity.

Pl. 37. Superficial Muscles on the posterior part of the Fore-arm—Deep Muscles on the posterior part of the Fore-arm—Muscles of the Hand.
 Pl. 38. Muscles of the Leg and Foot.
 Pl. 39. Sections of the Arm, Fore-arm, Thigh, and Leg—Fasciæ of the Abdomen.

APONEUROSIS.

Pl. 40. Fasciæ of the Neck, Axilla, and Eye.
 Pl. 41. Deep Muscles of the Leg and Foot.
 Pl. 42. Fasciæ of the Fold of the Groin, Pelvis, and Perineum.

SPLANCHNOLOGY.

Pl. 43. The Eye and its Appendages.
 Pl. 44. Bosom, or Mamma—Tongue—Skin, Nails, and Hair.
 Pl. 45. Fasciæ of the Upper and Lower Extremity.
 Pl. 46. Cartilages of the Nose and Nasal Fossa.
 Pl. 47. Pharynx, seen from behind—Larynx, Trachea, and Bronchial Tubes.
 Pl. 48. Salivary Glands—Buccal and Pharyngeal Cavities.
 Pl. 49. Organs of Hearing.
 Pl. 50. Pleura and Lungs—Right and Left side of the Heart.

Pl. 51. Stomach—Duodenum—Liver and Biliary Apparatus.
 Pl. 52. Peritoneum.
 Pl. 53. Heart.
 Pl. 54. Cardiac and Pyloric Orifices of the Stomach—Intestine.
 Pl. 55. Bladder, Urethra, and Prostate Gland—Testicle and Appendages.

Pl. 56. Genital Organs of the Male.
 Pl. 57. Small Intestine, and Cæcum, laid open—Biliary Apparatus and Pancreas—Spleen—Kidney and Supra-renal Capsule.
 Pl. 58. Genital Organs of the Female.

ANGEIOLOGY. ARTERIES.
 Pl. 59. Vertebral Artery—Arteries of the Brain—Thoracic Aorta and its Branches.
 Pl. 60. External Carotid, Lingual, Internal Maxillary, Internal Carotid, Ophthalmic, &c., Arteries.
 Pl. 61. Heart, Arteria Innominata, Carotid and Subclavian, &c.
 Pl. 62. Diagrammatic cuts of Arteries.
 Pl. 63. Arteries of the Axilla, Arm, and Hand.
 Pl. 64. Inferior Mesenteric, and Right and Left Colic Arteries.

Pl. 65. Superior Mesenteric Artery.
 Pl. 66. Coeliac Axis and its Branches.
 Pl. 67. Diagrammatic cuts of Arteries.
 Pl. 68. Abdominal Aorta and its Branches.
 Pl. 69. Arteries of the Lower Extremity.
 Pl. 70. Internal Pudic Arteries in the Male—Internal Pudic Arteries in the Female.
 Pl. 71. Internal Iliac Artery and its Branches—Perforating Arteries of the Thigh.
 Pl. 72. Arteries of the Leg and Foot, viewed in front—Scapular Arteries—Arteries on the posterior part of the Arm, Fore-arm, and Hand.

ANGEIOLOGY. VEINS.

Pl. 73. Superficial Veins of the Upper Extremity.
 Pl. 74. Superficial Veins of the Head and Neck—Subclavian Veins—Vena Cava Superior.
 Pl. 75. Vena Cava, Superior and Inferior—Subclavian Veins—Vena Azygos—Veins of the Uterus.
 Pl. 76. Diagrammatic cuts of Sinuses of Dura Mater.
 Pl. 77. Diagrammatic cuts of Veins and Thoracic Duct.
 Pl. 78. Vena Porta.
 Pl. 79. Organs of Circulation in a Fœtus.
 Pl. 80. Veins of the Spine.
 Pl. 81. Superficial Veins of the Abdomen, of the Lower Extremity, and of the Genital Organs.
 Pl. 82. Sinuses of the Dura Mater—Veins of Bones.

ANGEIOLOGY. LYMPHATIC VESSELS.

- Pl. 83. Posterior and deep Lymphatic Vessels and Ganglia of the Lower Extremity.
- Pl. 84. Anterior and deep Lymphatic Vessels and Ganglia of the Lower Extremity.
- Pl. 85. Superficial Lymphatic Vessels and Ganglia of the Lower Extremity, and lower half of the Abdomen.
- Pl. 86. Lymphatic Vessels and Ganglia of the Abdominal Viscera.
- Pl. 87. Lymphatic Vessels of the Upper Extremity.
- Pl. 88. Thoracic Duct—Receptaculum Chyli—Lumbar Plexus.
- Pl. 89. Lymphatic Vessels of the Thoracic and Abdominal Viscera.
- Pl. 90. Lymphatic Vessels and Ganglia of the Axilla, Head, and Neck.

NEUROLOGY.

- Pl. 91. Corpus Callosum—Fornix—Plexus Choroïdes, &c.
- Pl. 92. Brain and Origin of the Cranial Nerves.
- Pl. 93. Dura Mater.
- Pl. 94. Third and Fifth Ventricles—Upper portion of the Lateral Ventricles—Upper surface of the Corpus Callosum and Cerebellum—Vertical section of the Cerebrum in the Median Line.
- Pl. 95. Cerebrum, viewed from below—Plexus Choroïdes—Fornix, &c.
- Pl. 96. Different sections of the Cerebrum, Medulla Oblongata, and Nodus Cerebri.
- Pl. 97. Different sections of the Cerebellum—View of the interior of the Ventricles—Preparations of the Medulla Oblongata.
- Pl. 98. Different preparations of the Medulla Spinalis, Medulla Oblongata, and Nodus Cerebri.
- Pl. 99. Transverse sections of the Cerebrum—Vertical section of a Lateral Lobe of the Cerebrum.

- Pl. 101. Lateral Ventricle of the Cerebrum—Cerebellum, viewed from below—Fasciculus of re-enforcement of the Medulla Oblongata, &c.
- Pl. 102. Cervical Plexus (superficial portion).
- Pl. 103. Deep portion of the Cervical Plexus—Brachial Plexus.
- Pl. 104. Facial Nerve—Auditory Nerve—Jacobson's Nerve.
- Pl. 105. Deep Nerves of the Upper Extremity.
- Pl. 106. Superficial Nerves of the Upper Extremity.
- Pl. 107. Intercostal Nerves, and branches of the Lumbar Nerves.
- Pl. 108. Nerves of the Lower Extremity.
- Pl. 109. Lumbar Plexus—Cranial Nerve and its Branches.
- Pl. 110. Nerves of the posterior part of the Body.
- Pl. 111. Sacral Plexus—Sciatic Nerve, &c.
- Pl. 112. Passage of the Cranial Nerves through the Foramina at the base of the Cranium—Nerves of the Eye.
- Pl. 113. Fifth pair of Nerves—Glosso-pharyngeal, Hypoglossal, &c.
- Pl. 114. Structure of the Brachial Plexus—Deep Cervical Nerves, Supra-scapular, Circumflex—Nerves of the Fingers.
- Pl. 115. Olfactory Nerve—Fifth Pair—Ganglion of Meckel, or Sphenopalatine—Otic Ganglion—Laryngeal Nerves.
- Pl. 116. Great Sympathetic (lower portion).
- Pl. 117. Diagrammatic cuts of Nerves (optic).
- Pl. 118. Diagrammatic cuts of Motor Oculi and Trigemini.
- Pl. 119. Diagrammatic cuts of Facial and Auditory.
- Pl. 120. Diagrammatic cuts of Auditory and Glosso-pharyngeal.
- Pl. 121. Diagrammatic cuts of Pneumogastric.
- Pl. 122. Diagrammatic cuts of Spinal Accessory, and Hypoglossal.
- Pl. 123. Great Sympathetic (upper portion).
- Pl. 124. Eighth Pair.



OSTEOLOGY, PLATE 1.

Fig. 1. FRONTAL BONE (anterior surface).

1. Mesial line, on which we see the trace of the original division of the bone.—2. Frontal eminence.—3. Superciliary ridge.—4. Portion of the curved temporal ridge, to which the fascia of the temporal muscle is attached, and below which the temporal fossa is situated.—5. Nasal notch, from the centre of which the nasal spine passes off.—6. Orbital arch, which presents at its inner third the supra-orbital notch, through which a small artery and a branch of the ophthalmic division of the fifth pair of nerves pass, and, at its extremities, the external and internal angular processes are situated.

Fig. 2. FRONTAL BONE (posterior surface).

1. A portion of the sagittal groove, which terminates anteriorly in the frontal spine.—2. Frontal fossa.—3. The convex cerebral surface of the orbital plate.

Fig. 3. FRONTAL BONE (inferior surface).

1. Ethmoidal fissure, having in front the nasal spine, and the openings of the frontal sinuses; on the sides, portions of cellules, among which are two small grooves, 4 and 5, which contribute to form the internal orbital * foramina, through which the nasal division of the ophthalmic branch of the fifth pair of nerves and a small blood-vessel pass.—2. Orbital plate.—3. Lachrymal fossa.—4'. Depression for the pulley of the superior oblique muscle.—5'. Surface which articulates with the sphenoid bone (on either side).

Fig. 4. PARIETAL BONE OF THE RIGHT SIDE (external surface).

1. Parietal protuberance.—2. Temporal ridge, a continuation of the ridge seen in Fig. 1 (4).

* Called the *anterior* and *posterior ethmoidal foramina*.

OSTEOLOGY, Pl. 2.

Fig. 1. HEAD VIEWED FROM THE LEFT SIDE AND FROM BEFORE.

1. Temporal fossa.—2. Tempo-parietal suture.—3. Spheno-parietal suture.—4. Fronto-parietal, or coronal suture.—5. Spheno-temporal suture.—6. Zygomatic fossa.

Fig. 2. HEAD VIEWED FROM BELOW.

1. Arch of the palate and the point of union of four sutures, where the point of a scalpel can touch five bones, viz., the two upper maxillary, the two palatine, and the vomer.—2. One of the posterior openings of the nasal fossa, separated from the opening of the opposite side by the vomer.—3. Pterygoid fossa.—4. Pterygo-maxillary fissure.—5. Zygomatic fossa, bounded by the arch of the same name.—6. Foramen ovale.—7. Petro-sphenoidal suture.—8. Foramen lacerum medium.—9. Foramen caroticum externum.—10. Jugular fossa.—11. Petro-occipital suture.—12. One of the condyles of the occipital bone.—13. Foramen magnum.

Fig. 3. BASE OF THE CRANIUM VIEWED FROM ABOVE.

1. Crista galli: there is seen, in front, the foramen cecum; on the sides, the ethmoidal grooves.—2. Suture of the frontal bone, with the lesser wings of the sphenoid.—3. The lesser wing of the sphenoid, at the internal extremity of which is seen the optic foramen, and beneath which there is placed the sphenoidal fissure, or, as it is called, the foramen lacerum orbitale.—4. Sella turcica, bounded by the four clinoid processes and by the cavernous grooves.—5. Foramen rotundum.—6. Foramen ovale.—7. Foramen spinosum.—8. Foramen lacerum medium.—9. Basilar groove.—10. Meatus auditorius internus.—11. Foramen lacerum jugulare.—12. Anterior condyloid foramen.—13. Lateral groove, lodging lateral sinus.

Fig. 1.



Fig. 2.




Fig. 3.

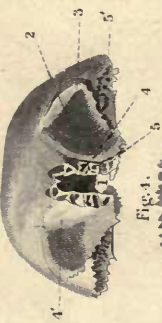

Fig. 4.



Fig. 3.

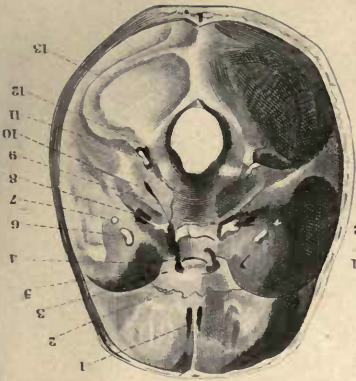


Fig. 1.

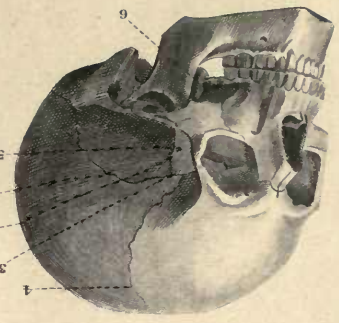
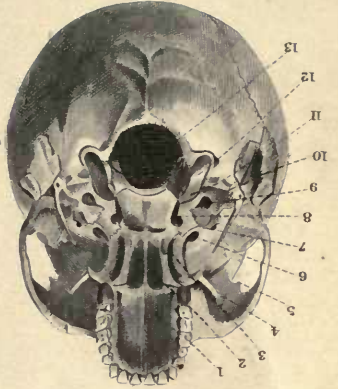


Fig. 2.







OSTEOLOGY, Pl. 3.

Fig. 1. OCCIPITAL BONE (external surface).

On the median line there are seen, 1. The external occipital protuberance.—2. The external occipital crest.—3. Foramen magnum.—4. The inferior surface of the basilar process. On each side, 5. The upper semicircular line; 6. The lower semicircular line.—7. The condyle, before and behind which are seen the condyloid fossæ.

Fig. 2. OCCIPITAL BONE (internal surface).

1. Portion of the sagittal or longitudinal sinus, which is continuous with, 2. The lateral sinus.—3. Internal occipital crest.—4. Superior occipital fossa.—5. Inferior occipital fossa.

Fig. 3. SPHENOID BONE (upper surface).

1. Pituitary fossa, or sella turcica, which lodges the pituitary body.—2. Carotid or cavernous groove.—3. Quadrilateral plate, which limits posteriorly the sella turcica.—4. Lesser wing of the sphenoid, or the process of Ingrassias, at the base of which is found the optic foramen and the anterior clinoid process.—5. Greater wing of the sphenoid.—6. Sphenoidal fissure.—7. Foramen rotundum.—8. Foramen ovale.—9. Foramen spinosum.

Fig. 4. SPHENOID BONE VIEWED FROM BEFORE.

1. The beak or rostrum process of the sphenoid.—2. Opening of the sphenoidal sinus.—3. Portion of the greater wing, called orbital process, and which contributes to form the outer wall of the orbit.—4. Portion of the greater wing, named temporal process, and which contributes to form the temporal fossa.—5. Pterygoid process.—6. Hamular process.—7. Sphenoid process.—8. Vidian canal.—9. Foramen rotundum.

Fig. 5. TEMPORAL BONE (external surface).

1. Portion of the temporal fossa.—2. Zygomatic process.—3. Portion of temporal curved ridge.—4. Glenoid or articular cavity.—5. Meatus auditorius externus.—6. Mastoid process; and, 7. Mastoid foramen.

Fig. 6. TEMPORAL BONE (internal surface).

1. Petrous portion.—2. Meatus auditorius internus.—3. Styloid process.—4. Portion of the groove for the lateral sinus.

OSTEOLOGY, Pl. 4.

Fig. 1. PARIETAL BONE OF THE RIGHT SIDE (internal surface).

1. Groove which lodges the middle meningeal artery and its branches.—2. Portion of the groove which lodges the lateral sinuses.

Fig. 2. ETIMOID BONE (upper surface).

1. Crista galli.—2. Cribriform plate of the ethmoid, grooved for the reception of the olfactory nerve, perforated with foramina, which give passage to the branches of this nerve.—3. A small groove, which articulates with the frontal bone, and forms one of the internal orbitary foramina* by which the nasal branch of the ophthalmic division of the fifth pair of nerves enters the cranium.

Fig. 3. ETIMOID BONE (inferior surface).

1. Perpendicular plate of the ethmoid.—2. Middle turbinated bone.

Fig. 4. ETIMOID BONE (viewed from behind).

1. Crista galli.—2. Perpendicular plate.—3. The cribriform plate, arranged in the shape of a cross.—4. Posterior ethmoidal cells.

Fig. 5. ETIMOID BONE (viewed from before).

1. Crista galli.—2. Perpendicular plate.—3. Anterior ethmoidal cells.

Fig. 6. ETIMOID BONE (external surface).

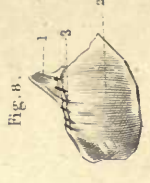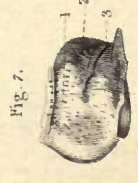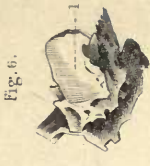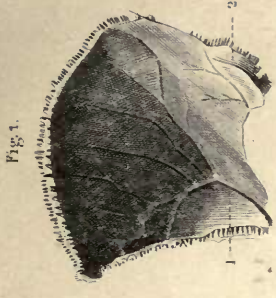
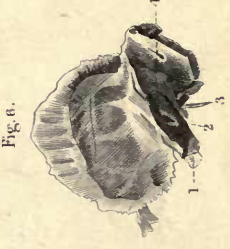
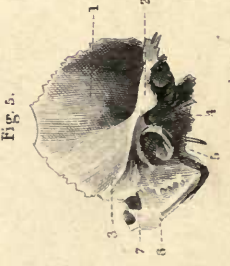
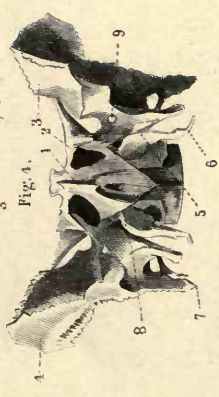

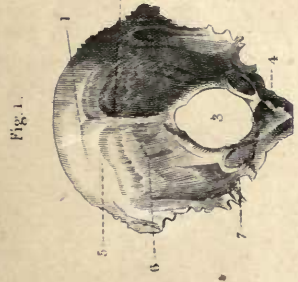
1. Os planum, or lamina papyracea, constituting, in a great measure, the inner wall of the orbit.

Fig. 7. ETIMOID BONE (internal surface).

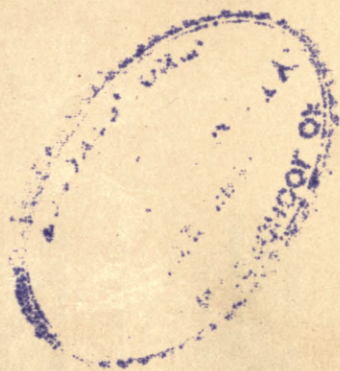1. Superior turbinated bone.—2. Superior meatus.—3. Middle turbinated bone.

Fig. 8.—1. Crista galli.—2. Perpendicular plate.—3. The cribriform plate, with its foramina cut ver-
tically.

* Called the anterior ethmoidal foramen.







OSTEOLOGY, PL. 5.

Fig. 1. ATLAS (upper surface).

1. Articular facette.—2. Anterior arch.—3. Posterior arch.—4. Transverse process and its foramen.—5. Vertebral foramen.

Fig. 2. ATLAS (lower surface).

1. Articular facette.—2. Small facette, which articulates with the odontoid process of the axis.

Fig. 3. AXIS (anterior surface).

1. Body.—2. Odontoid process.—3. Articular facette.—4. Transverse process.

Fig. 4. AXIS VIEWED FROM THE RIGHT SIDE.

1. Body.—2. Odontoid process.—3. Articular facette.—4. Transverse process.—5. Spinous process.

Fig. 5. A CERVICAL VERTEBRA (upper surface).

1. Body, and, 2. The lateral ridges.—3. Transverse process, bifurcated, and perforated by a hole.—4. Articular processes.—5. Vertebral lamina.—6. Spinous process, bifurcated.

Fig. 6. A DORSAL VERTEBRA VIEWED FROM THE RIGHT SIDE.

1. Body, and, 2. Costal articular semi-facette.—3. Vertebral pedicle.—4. Upper articular process.—5. Transverse process, with its costal articular facette.—6. Spinous process.

Fig. 7. A LUMBAR VERTEBRA (upper surface).

1. Transverse process.—2. Upper articular process, and its apophyseal tubercle.—3. Spinous process.

Fig. 8. A LUMBAR VERTEBRA VIEWED FROM THE RIGHT SIDE.

1. Lower articular process.

OSTEOLOGY, PL. 6.

Fig. 1. UPPER MAXILLARY BONE OF THE LEFT SIDE (external surface).

1. Ascending or nasal process.—2. Nasal notch.—3. Lower wall of the orbit.—4 and 5. Infra-orbital groove and foramen.—6. Canine fossa.—7. Malar process.

Fig. 2. PALATE BONE (external surface).

1. Groove which contributes to form the posterior palatine canal.—2. Orbital process.—3. Sphenoidal process.—4. Notch which contributes to form the sphenopalatine foramen. This surface articulates with the upper maxillary bone.

Fig. 3. PALATE BONE (internal surface).

- 1 and 2. Portions of the inferior and middle meatus.—3. Orbital process.—4. Sphenoidal process.—5. Portion of the sphenopalatine foramen.—6. Tuberosity of the palate bone. This surface contributes to form the nasal fossæ.

Fig. 4. PALATE BONE VIEWED FROM BEHIND.

1. Posterior border.—2. Orbital process.—3. Tuberosity of the palate bone.—4. Palatine process.

Fig. 5. OS NASI VIEWED ON ITS OUTER SURFACE.

- Superiorly, the rough scabrous process by which it is articulated to the nasal process of the frontal bone is distinctly shown.

Fig. 6. OS UNGUIS* VIEWED ON ITS OUTER SURFACE.

- This surface is seen divided by a small spine; to the right of which the smaller grooved division is placed. This groove, joined to a corresponding groove formed on the orbital edge of the nasal process of the upper maxillary bone, forms the fossa for lodging the lacrymal sac. The larger division, placed to the left of the spine, forms a part of the inner wall of the orbit, and is called orbital process.

Fig. 7. MALAR BONE OF RIGHT SIDE (external surface).

1. Malar hole.—2. Orbital process.

Fig. 8. VOMER.—1. Upper border.—2. Wings, with a groove between them for the trostrum of the sphenoid bone.

Fig. 9. INFERIOR TURBINATED BONE.

Fig. 10. INFERIOR MAXILLARY BONE (external surface).

1. External oblique line.—2. Mental foramen, the lower orifice of the dental canal.—3. Condyle.—4. Coronoid process.—5. Sigmoid notch.

Fig. 11. RIGHT HALF OF THE INFERIOR MAXILLARY BONE (inner surface).

1. Internal oblique line.—2. The alveolar foramen, the upper orifice of the dental canal.

Fig. 12. HYOID BONE (anterior surface).

1. Body.—2. Great cornu.—3. Little cornu.

* The *lachrymal bone* (called os unguis from its resemblance to a finger-nail).



Fig. 2

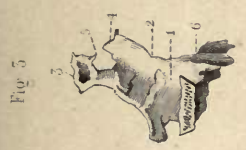

Fig. 5




Fig. 4

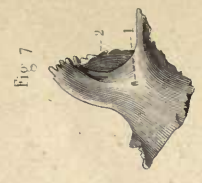

Fig. 7



Fig. 6



Fig. 5

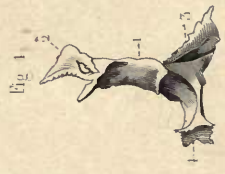

Fig. 1



Fig. 9

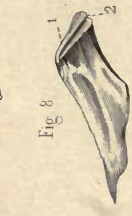

Fig. 8

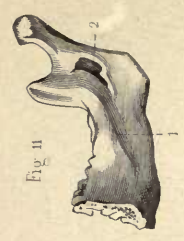

Fig. 11

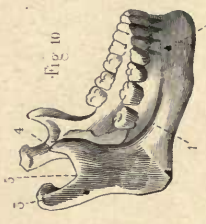


Fig. 10

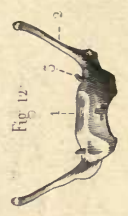

Fig. 12

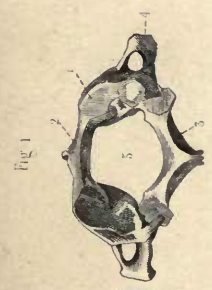


Fig. 1

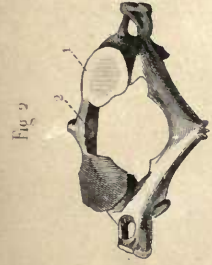


Fig. 2

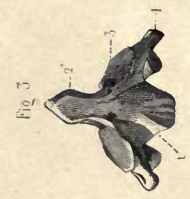

Fig. 3

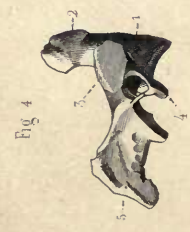

Fig. 4

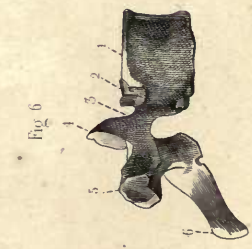


Fig. 6

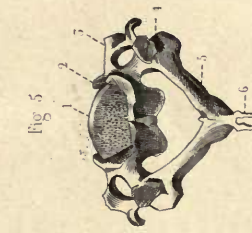


Fig. 5

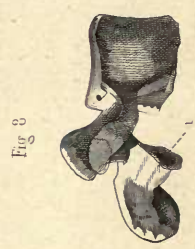

Fig. 8

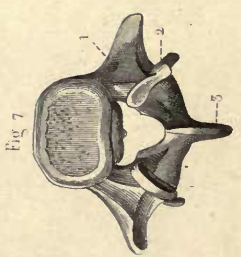


Fig. 7





Fig. 1. VERTICAL SECTION OF THE HEAD, INTENDED TO SHOW THE OSSEOUS PORTION OF THE SEPTUM OF THE NASAL FOSSÆ.

1. Perpendicular plate of the ethmoid bone, which, in connexion with the vomer, forms the septum narium.*—2. Vomer.—3. Sphenoidal sinus.

Fig. 2. VERTICAL SECTION OF THE HEAD, INTENDED TO SHOW THE EXTERNAL WALL OF THE NASAL FOSSÆ.

1. Upper turbinated bone, beneath which is seen the superior meatus; and behind the meatus, 2. The sphenoidal sinus.—3. Middle turbinated bone, beneath which is the middle meatus.—4. Inferior turbinated bone, beneath which is the inferior meatus.—5. Frontal sinus.

Fig. 3. POSTERIOR OPENINGS OF THE NASAL FOSSÆ AND THE ARCH OF THE PALATE.

1. Posterior border of the vomer, which separates the nasal fossæ.—2. Pterygo-palatine foramen.—3. Vidian or pterygoid foramen.—4. Pterygoid fossa.—5. Scaphoid fossa.—6. Inner plate of the pterygoid process.—7. External plate.—8. Crucial suture of the arch of the palate, and the place where the point of a scalpel can touch five bones: the two palate, the two upper maxillary, and the vomer.

Fig. 4. VERTICAL AND TRANSVERSE SECTION OF THE NASAL FOSSÆ.

It presents, 1. The upper turbinated bone.—2. The superior meatus.—3. Middle turbinated bone; and, 4. The middle meatus, which communicates with the maxillary sinus.—5. The lower turbinated bone; and, 6. The inferior meatus.

Fig. 5. The outer table of both maxillary bones removed to show the teeth in their sockets.

Fig. 6. The outer table of both maxillary bones removed to show the teeth of the first and second dentition.

Fig. 7. The teeth of both maxillary bones are seen in front, and the four incisors and the two canine teeth of each jaw are very plainly shown.

Fig. 8. The teeth of the left side of each jaw are displayed, and especially the canine, the bicuspidati, and the large molar teeth.

* Although the perpendicular plate of the ethmoid bone and the vomer are only described in this *fig.* as forming the septum narium, were it not from the elevated spine which arises from the junction of the palatal processes of the upper maxillary and palatine bones, it would be inferiorly imperfect. On this spine the lower edge of the vomer rests, and by it, below the vomer, the septum is formed.

Fig. 1. VERTEBRAL COLUMN ENTIRE, SEEN FROM THE LEFT SIDE.

1 and 2. Two semi-facettes, which articulate with the head of the rib.—3 and 4. Two foramina, each resulting from the union of two vertebæ.—5. Cervical region and its corresponding curve.—6. Dorsal region and its corresponding curve.—7. Lumbar region and its corresponding curve.—8. Sacrum.

Fig. 2. STERNUM.

1. Middle part of the sternum, and the trace of the union of the two pieces of which it was originally composed.—2. Upper extremity, or manubrium of the sternum.—3. Fourchette, or semilunar notch of the sternum.—4. Surface which articulates with the clavicle.—5. Xiphoid appendix, or ensiform cartilage.

Fig. 3. FIRST RIB (*upper surface*).

1 and 2. Tubercles for the attachment of the scapular muscles.—3. Groove for the subclavian artery.—4. Head of the rib.—5. Tubercle and angle blended together.

Fig. 4. SECOND RIB (*upper surface*).

Fig. 5. MIDDLE RIB.

1. Head of the rib.—2. Neck.—3. Tubercle.—4. Angle.

Fig. 6. THE TWELFTH RIB, HAVING NEITHER ANGLE NOR TUBERCLE.

Fig. 7. THE CHEST ENTIRE.

Its component parts are: behind, 1. The dorsal region of the vertebral column; before, 2. Sternum, and, 3. The costal cartilages; 4 and 5. On each side, the twelve ribs.—6. Line of union of a rib, with its corresponding cartilage.

Fig. 8. LEFT CLAVICLE VIEWED FROM BELOW.

Fig. 9. LEFT CLAVICLE VIEWED FROM ABOVE.

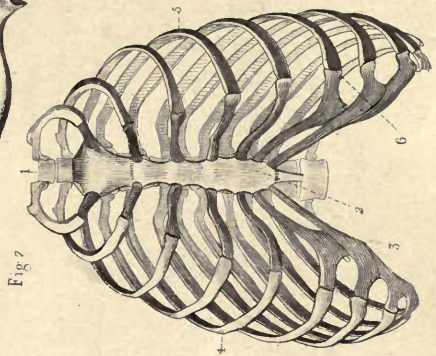
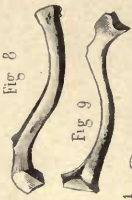
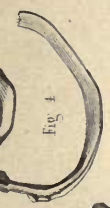
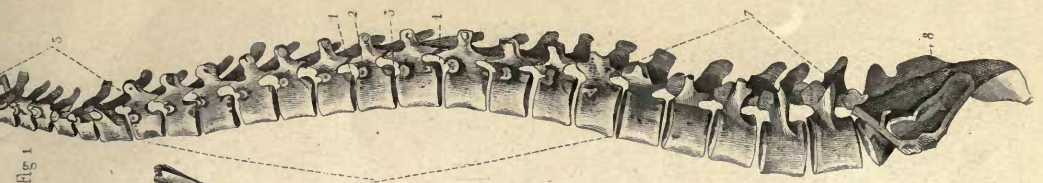
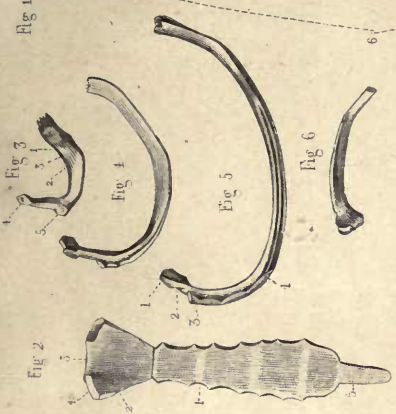

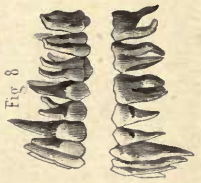
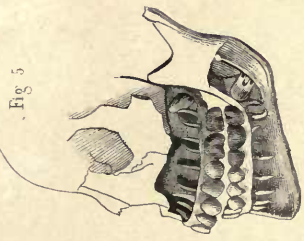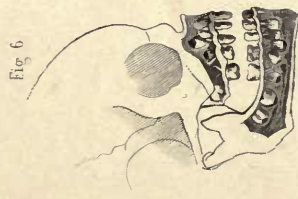
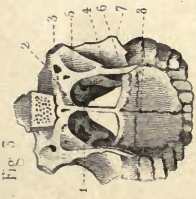
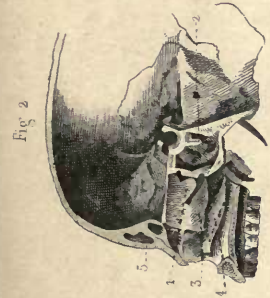
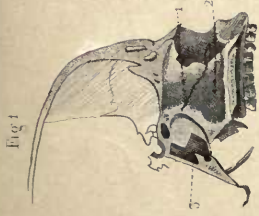





Fig. 1. BONES OF THE CARPUS VIEWED FROM BEHIND.

These bones are arranged in two rows. In the first row are, 1. Scaphoid.—2. Semilunar.—3. Cuneiform.—4. Pisiform. In the second row are, 5. Trapezium.—6. Trapezoid.—7. Magnum.—8. Unciform.

Fig. 2. BONES OF THE HAND VIEWED IN FRONT.

1. Bones of the carpus.—2. Second metacarpal bone. The last three are parallel to it; the first is separated from it.—3. First phalanx of the index finger.—4. Second phalanx.—5. Third phalanx. The thumb has no middle phalanx.

*Fig. 3. THE BONES OF THE HAND VIEWED FROM BEHIND.**Fig. 4. PATELLA VIEWED IN FRONT.**Fig. 5. PATELLA VIEWED FROM BEHIND.*

1. Articular facette.

Fig. 6. Femur (anterior surface).

1. Head of the femur.—2. Neck.—3. Trochanter major — 4. Trochanter minor.—5. Anterior part of the femoral trochlea.

Fig. 7. Femur viewed from behind.

1. Digital cavity of the trochanter major.—2. Oblique line which unites the two trochanters.—3. Attachment of gluteus maximus.—4. Linea aspera of the femur, on which is seen the hole for the principal nutritious artery of the bone.—5. Internal tuberosity.—6. External tuberosity.—7. Internal condyle.—8. External condyle.

*Fig. 8. Upper extremity of the femur viewed from above.**Fig. 9. Lower extremity of the femur viewed from below**Fig. 10. Tibia viewed in front.*

1. Spine of the tibia.—2. Internal tuberosity.—3. External tuberosity.—4. Anterior tuberosity.—5. Crest of the tibia.—6. Internal malleolus.

Fig. 11. Fibula of right side viewed in front.

1. Head of the fibula.—2. Lower extremity, which forms the external malleolar process.—3. Articular facette.

Fig. 1. Scapula (posterior surface).

1. Supra-spinous fossa.—2 and 3. Spine of the scapula, and acromion process.—4. Infra-spinous fossa.—5. Coracoid process.—6. Coracoid notch, through which the supra-scapular nerve passes.

Fig. 2. Scapula (anterior surface).

1. Sub-scapular fossa.—2. Spine of the scapula, terminating in the acromion.—3. Coracoid process.

Fig. 3. External or axillary border of the scapula.

1. Axillary border, or inferior costa.—2. Glenoid cavity, surmounted by the coracoid process (4).—3. Acromion process.

Fig. 4. Humerus viewed in front.

1. Head and neck of the humerus.—2. Lesser tuberosity.—3. Greater tuberosity.—4. Bicipital groove.—5. Anterior surface of the humerus.—6. Coronoid cavity.—7. Internal condyle.—8. Trochlea, or pulley of the humerus.—9. Small head of the humerus.—10. External condyle.

Fig. 5. Humerus (posterior surface).

1. Anatomical neck.—2. Surgical neck.—3. Posterior surface.—4. Cavity for the reception of the olecranon.

Fig. 6. Upper extremity of the humerus, composed of the head and the two tuberosities.

Fig. 7. Lower extremity of the humerus, composed of the trochlea and internal condyle, the small head and external condyle.

Fig. 8. Ulna and radius in relation with each other, and viewed from behind.

1. Ulna.—2. Radius.

Fig. 9. Brachial extremity of the ulna viewed in front.

1. Great sigmoid cavity.—2. Small sigmoid cavity.

Fig. 10. Brachial extremity of the ulna viewed from without.

1. Olecranon process.—2. Coronoid process.—3. Lesser sigmoid cavity.

Fig. 11. Brachial extremity of the ulna viewed from within.

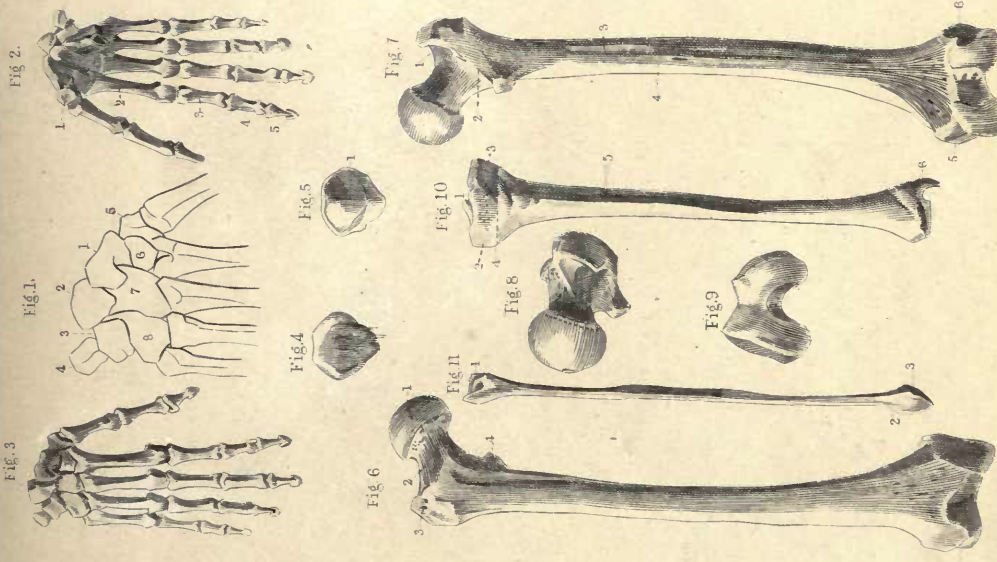
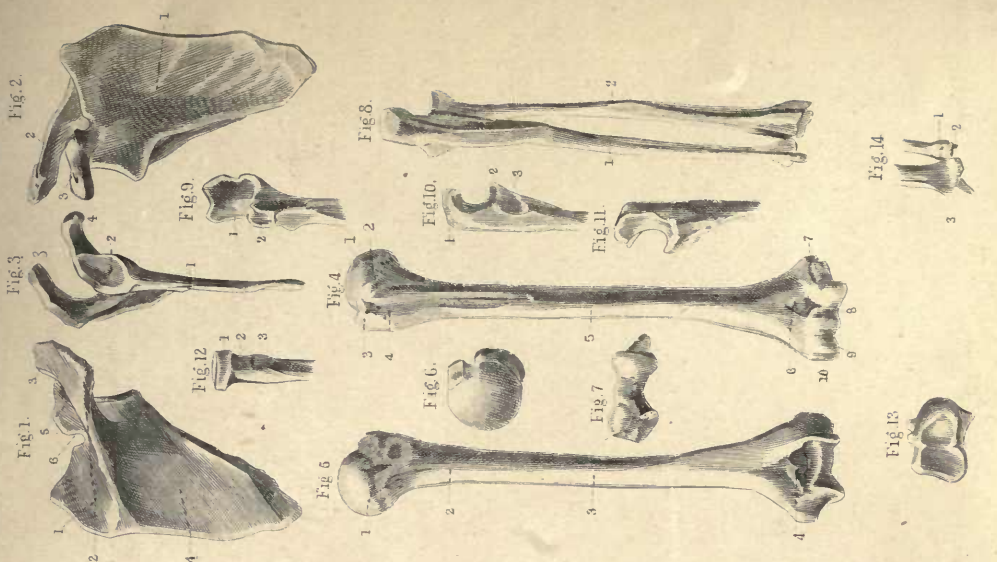
Fig. 12. Brachial extremity of the radius.

1. Head of the radius.—2. Neck.—3. Bicipital tuberosity.

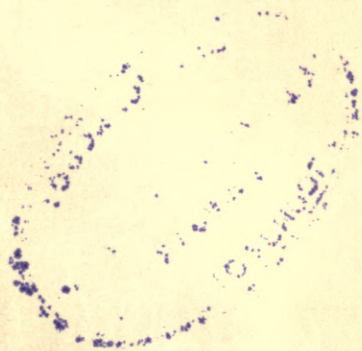
Fig. 13. Carpals of the radius viewed from below. This figure shows the articular facettes formed on it for the reception of the scaphoid and semilunar bones of the carpus.

Fig. 14. Carpals of the two bones of the forearm viewed from below.

1. Head of the Ulna.—2. Styloid process of the ulna.—3. Styloid process of the radius.







OSTEOLOGY, PL. 11.

Fig. 1. SACRUM (*anterior surface*).

1. One of the ridges which mark the point of union of two of the original pieces of the sacrum.—2. One of the anterior sacral foramina.—3. Alee of the sacrum.—4. Articular process of the sacrum.

Fig. 2. SACRUM (*posterior surface*).

1. Ridge of the sacrum.—2. One of the posterior sacral foramina.—3. Upper orifice of the sacral canal.—4. Lower orifice.

Fig. 3. COCCYX (*anterior surface*).—1. Horn of the coccyx.

Fig. 4. OS INNOMINATUM (*external surface*).

1. Dorsum of the ilium.—2. Upper curved line, which indicates the extent of the origin of the gæuteus medius muscle.—3. Lower curved line, which marks the extent of origin of the gæuteus minimus muscle.—4. Posterior superior spinous process of the ilium, forming the posterior limit of the crest of the ilium.—5. Posterior inferior spinous process of the ilium.—6. Great ischiatic notch.—7. Spine of the ischium.—8. Small ischiatic notch.—9. Tuberosity of the ischium.—10. Cotyloid cavity.

Fig. 5. OS INNOMINATUM (*internal surface*).

1. Internal iliac fossa.—2. Articular portion, composed of a surface invested with cartilage, and a tuberosity intended for ligamentous attachments.—3. Crest of the ilium.—4. Anterior superior spinous process of the ilium.—5. Anterior inferior spinous process of the ilium.—6. Ilio-pectineal eminence and surface of the pubes.—7. Body of the pubes and its articular surface, contributing to form the symphysis pubis.—8. Point of union of the descending ramus of the pubes, and the ascending ramus of the ischium.—9. Obturator foramen.

Fig. 6. PELVIS IN GENERAL.

It is formed, behind, by the sacrum and coccyx; on the sides, by the ossa innominata.

1. Ilio-pectineal eminence.—2. Horizontal ramus of the pubis.—3. Arch of the pubis.—4. Superior opening, or brim of the pelvis.

OSTEOLOGY, PL. 12.

Fig. 1. UPPER EXTREMITY OF THE TIBIA VIEWED FROM ABOVE.

1. Spine of the tibia.—2. Internal articular facette.—3. External articular facette.

Fig. 2. LOWER EXTREMITY OF THE TIBIA VIEWED FROM BELOW.

There is here seen an articular facette, consisting of two portions, viz., a horizontal and a vertical.

Fig. 3. THE TWO BONES OF THE LEG VIEWED IN FRONT AND IN THEIR NATURAL POSITION.

They present, below, the cavity into which the astragalus is received, formed on either by the two malleolar processes.

Fig. 4. BONES OF THE LEFT LEG VIEWED FROM WITHOUT.

Fig. 5. BONES OF THE TARSUS VIEWED FROM ABOVE.

These bones form two rows. In the first row are seen, 1. Astragalus.—2. Calcaneum. In the second row are seen, 3. Scaphoid.—4. First cuneiform.—5. Second cuneiform.—6. Third cuneiform.—7. Cuboid.

Fig. 6. RIGHT TARSUS VIEWED FROM WITHOUT AND FROM ABOVE.

1. Great process of the os calcis.—2. Calcaneo-astragaloid hollow.

Fig. 7. RIGHT TARSUS VIEWED FROM WITHIN.

1. Small process of the calcaneum.—2. Head of the astragalus, which joins the scaphoid.

Fig. 8. CALCIS (*upper surface*). 1, 2.—Articular surfaces.

Fig. 9. BONES OF THE FOOT VIEWED FROM ABOVE.

This figure presents successively, 1. Bones of the tarsus.—2. The five bones of the metatarsus.—3. The first five phalanges.—4. The second phalanges of the last four toes.—5. The last five phalanges. The great toe has no middle phalanx.

Fig. 10. BONES OF THE RIGHT FOOT VIEWED FROM BELOW.

1. Internal tuberosity of the calcaneum process of the os calcis.—2. External tuberosity.



Fig. 4

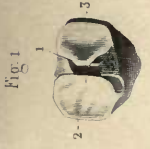

Fig. 1

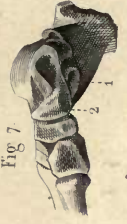

Fig. 7



Fig. 6



Fig. 2



Fig. 8




Fig. 5

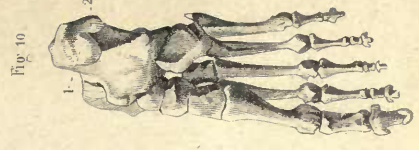

Fig. 10

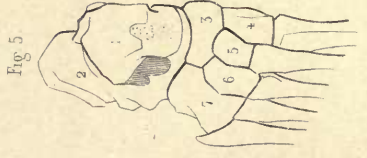

Fig. 5

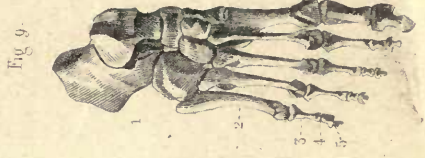

Fig. 9

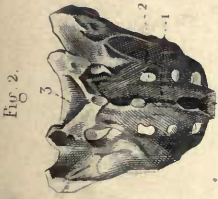

Fig. 2

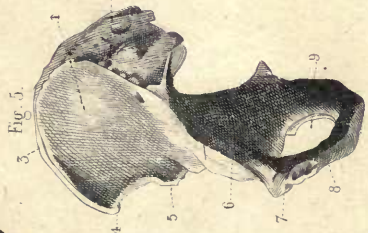


Fig. 5

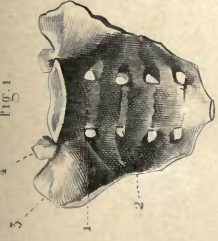


Fig. 1

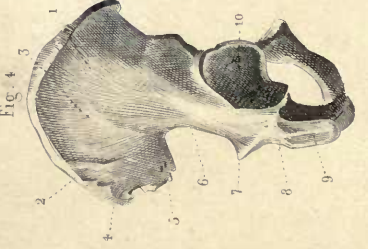

Fig. 4



Fig. 3

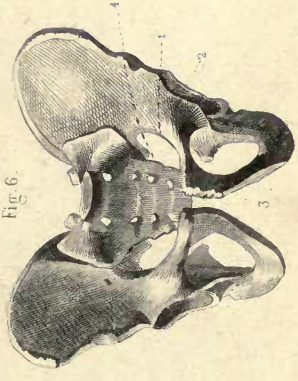



Fig. 6



Pl. 13.

Fig. 1. A DIAGRAM TO SHOW THE CARPAL ARCH (modified from Holden).

1. Trapezium.—2. Scaphoid.—3. Pisiform.—4. Unciform.—5. The anterior annular ligament of the carpus, underneath which the flexor tendons pass.

Fig. 2. A DIAGRAM TO SHOW THE RADIO-CARPAL AND INTER-CARPAL ARTICULATIONS (modified from Holden).

1. Pisiform.—2. Cuneiform.—3. Semilunar.—4. Scaphoid.—5. Unciform.—6. Os magnum, showing its globular head.—7. Trapezoid.—8. Trapezium.—A. Metacarpal bone of little finger.—B. C. D. Metacarpal bones of three other fingers.—E. Metacarpal bone of thumb, separated from the rest.—*a.* Line of radio-carpal articulation.—*b.* Line of inter-carpal articulation.

Fig. 3. A DIAGRAM TO SHOW THE HORIZONTAL PLANE OF THE ANKLE-JOINT AND THE CANAL OF THE TARSUS.

1. Tibia.—2. Fibula.—3. Astragalus.—4. Os calcis.—5. Tunnel of the tarsus, for the inter-osseous ligament between the astragalus and os calcis.

Fig. 4. THE COMPARATIVE OBLIQUITY OF THE NECK OF THE FEMUR.

1. In the child.—2. In the adult.—3. In old age.

Fig. 5. A DIAGRAM TO SHOW THE CONSTRUCTION OF THE NASAL ARCH (horizontal section).

N. N. The nasal bones.—S. M. The superior maxillary bone.—F. The spine of the frontal bone.—E. The perpendicular plate of the ethmoid. Thus, four bones help to sustain a weight when balanced upon the bridge of the nose; hence its wonderful strength, when the lightness of the nasal bones is considered.

Fig. 6. A DIAGRAM TO SHOW THE OBLIQUITY OF THE PELTS TO THE SPINAL COLUMN (modified from Holden).

It will be seen that the brim of the pelvis lies 54° below the horizontal line drawn from the center of the upper surface of the sacrum, or 144° from a perpendicular dropped through the line of gravity of the spinal column. In the female, the total angle is about 140°. In both sexes, the line of gravity passes through the acetabulum, when the subject is in the erect posture.

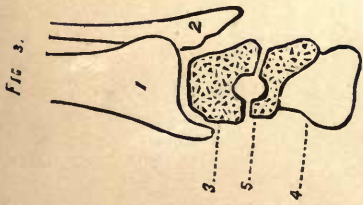


Fig. 1.

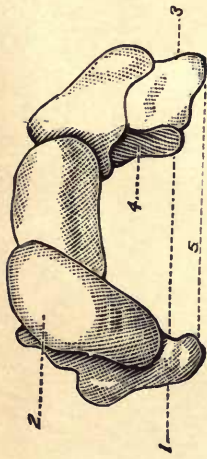


Fig. 4.




Fig. 2.

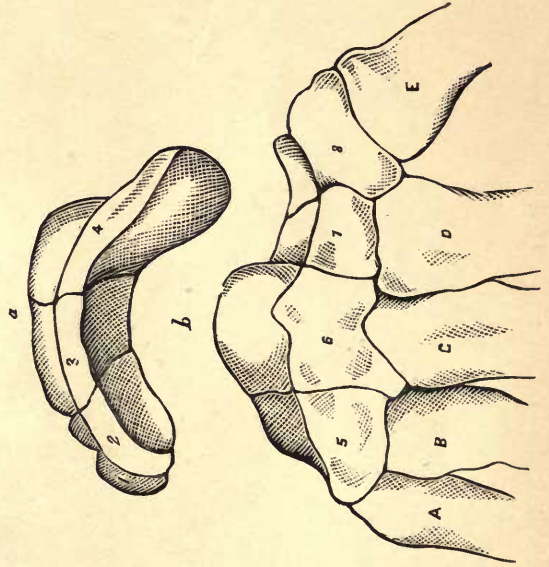
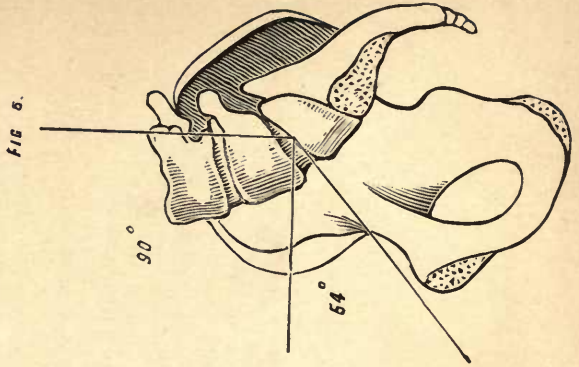
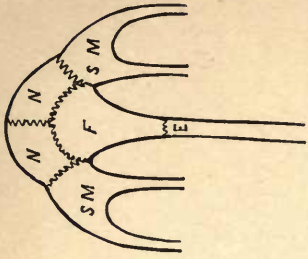
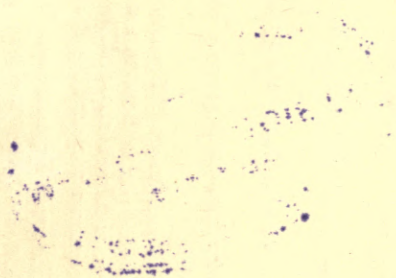

Fig. 5.







ARTHOLOGY, PL. 1.

Figs. 1, 2, and 3. These three figures represent the temporo-maxillary articulation.

Fig. 1.—1. External lateral ligament.—2. Stylo-maxillary ligament.

Fig. 2.—1. Internal lateral ligament.—2. Stylo-maxillary ligament.

Fig. 3. THE JOINT VIEWED FROM WITHOUT, AND OPENED.

1. The inter-articular fibro-cartilage.—2. The stylo-maxillary ligament.

Fig. 4.—1. Anterior occipito-atloid ligament, composed of a middle band strong and narrow, and of a posterior band weaker and broader.—2. The upper part of the anterior common vertebral ligament.

Fig. 5.—1. Occipito-axoid ligament.—2. The upper part of the posterior common vertebral ligament.

Fig. 6 presents the posterior half of the foramen magnum, and a portion of the vertebral canal, separated from the anterior half.

1. Posterior occipito-atloid ligament.—2. One of its borders, forming part of a foramen for the passage of the vertebral artery.—3. Membrane which connects the first two vertebrae, occupying the situation of the first of the ligamenta subflava.

ARTHOLOGY, PL. 2.

Figs. 1, 2, 3, and 4. ARTICULATIONS OF THE PELVIS.

Fig. 1.—1. Termination of the anterior common vertebral ligament, which extends from the third cervical vertebra to the sacrum.—2. Some fibres forming the anterior membrane of the sacrum.—3. Anterior sacro-coccygeal ligament.—4. Ilio-lumbar ligament.—5. Sacro-vertebral ligament.—6. Anterior sacro-iliac ligament.—7. Great, or posterior sacro-sciatic ligament.—8. Lesser, or anterior sacro-sciatic ligament.

Fig. 2.—1. Lower portion of the common supra-spinous ligament.—2. Posterior sacro-coccygeal ligament.—3. Ilio-lumbar ligament.—4. Posterior sacro-iliac ligament.—5. Sacro-spinous ligament.—6. Great, or posterior sacro-sciatic ligament.—7. Lesser, or anterior sacro-sciatic ligament.

Fig. 3. SYMPHYSIS PUBIS VIEWED IN FRONT.

1. Fibres of the anterior pubic ligaments crossing each other.—2. Superior ligament.—3. Inferior triangular ligament.—4. Obturator membrane.—5. Foramen for the passage of the obturator vessels and nerves.

Fig. 4. SYMPHYSIS PUBIS SEEN FROM BEHIND.

Fig. 1.

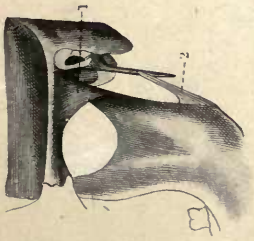


Fig. 2.

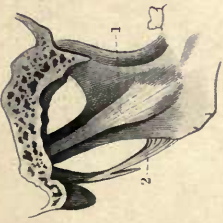

Fig. 3.

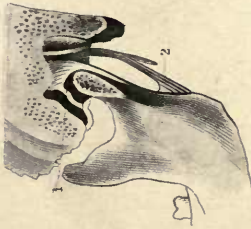

Fig. 4.

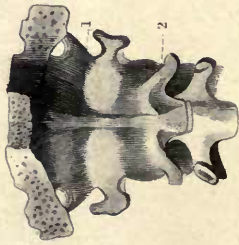


Fig. 6.

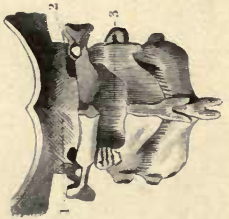


Fig. 5.




Fig. 1.

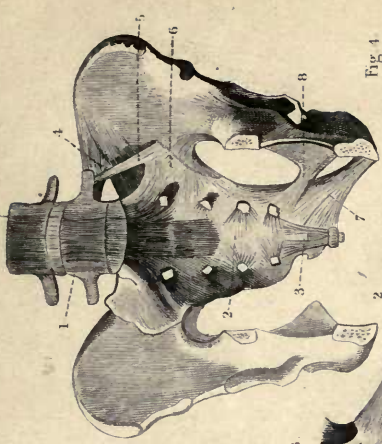


Fig. 3.

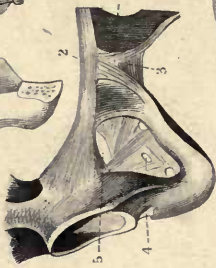
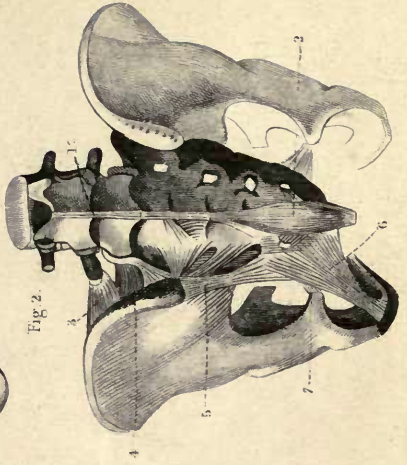

Fig. 4.



Fig. 2.







ARTHROLOGY, Pl. 3.

Fig. 1. COSTO-VERTEBRAL ARTICULATIONS.

1. One of the inter-vertebral substances. The fibres are seen crossing each other, and extending from one vertebra to another.—2. Stellate ligament of the costo-vertebral articulation.—3. Interosseous ligament of a costo-vertebral articulation.

Fig. 2. COSTO-TRANSVERSE ARTICULATION.

1. Portion of the common supra-spinous ligament.—2. Posterior costo-transverse ligament.—3. Anterior costo-transverse ligament.—4. Inferior costo-transverse ligament.

Fig. 3. A vertebra, and the posterior portion of a rib, sawed horizontally, to show, 1 and 2. The anterior costo-transverse ligaments.

Fig. 4. CHONDR0-COSTAL AND CHONDR0-STERNAL ARTICULATIONS, VIEWED IN FRONT.

1. A costal cartilage.—2. Line of union of this cartilage with the rib.—3. Anterior ligament of a chondro-sternal articulation.—3'. Anterior membrane of the sternum, formed by the crossing and union of the anterior ligaments.—4. Chondro-xiphoid ligament.—5 and 6. Ligaments which unite the cartilages of the sixth, seventh, and eighth ribs at their middle.—7 and 8. Ligaments which unite by their anterior extremity the cartilage of the seventh to the cartilage of the eighth rib, and the cartilage of the latter to that of the ninth.

Fig. 5. CHONDR0-STERNAL ARTICULATIONS, VIEWED FROM BEHIND.

1. A chondro-sternal cartilage.—2. A posterior ligament.—3. Membrane on the posterior surface of the sternum.

ARTHROLOGY, Pl. 4.

Fig. 1.—1. The deep bundle of the occipito-axial ligament.—2. One of the odontoid ligaments.—3. Transverse ligament, composed of two bundles.—4. The upper part of the posterior common vertebral ligament.

Fig. 2. ARTICULATION OF THE BODIES OF THE VERTEBRÆ.

1. Middle portion of the anterior common vertebral ligament.—2 and 3. Lateral portions of the same ligament.—4. One of the stellated ligaments of the costo-vertebral articulations.

Fig. 3. Vertebral canal, laid open to bring into view, 1. The posterior common vertebral ligament.

Fig. 4. THE UPPER SURFACE OF A VERTEBRA.

1. Fibrous portion of the inter-vertebral substance.—2. Gelatinous portion of the same.

Fig. 5. The vertebral canal, laid open to bring into view the ligamenta subflava, attached to the laminae of the vertebrae.

1. One of the ligamenta subflava.

Fig. 6. A portion of the common supra-spinous ligament.—2. One of the inter-spinous ligaments.

Fig. 1

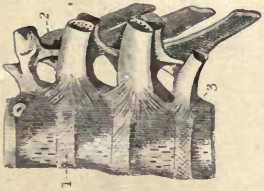


Fig. 2

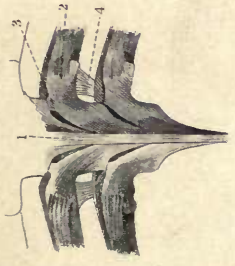


Fig. 5

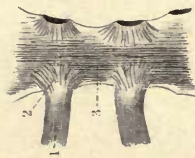


Fig. 4

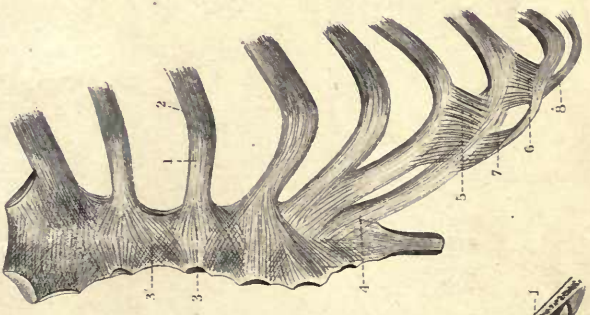


Fig. 3

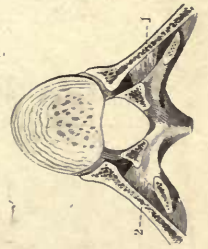


Fig. 1

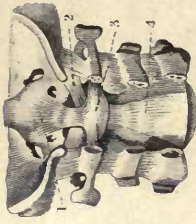


Fig. 3



Fig. 5

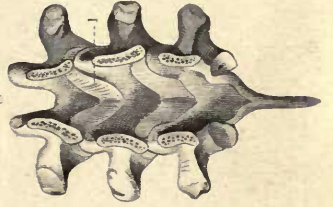


Fig. 2

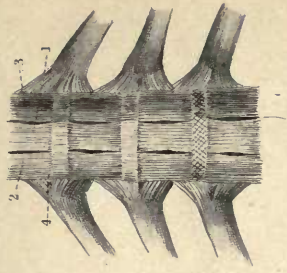


Fig. 4

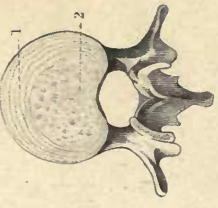
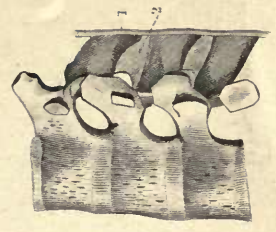



Fig. 6





ARTHOLOGY, Pl. 5.

Fig. 1. STERNO-CLAVICULAR ARTICULATION VIEWED FROM BEHIND.

1. Posterior ligament.—2. Fibres extending from one clavicle to the other, constituting the inter-clavicular ligament.—3. Costo-clavicular ligament.

Fig. 2. STERNO-CLAVICULAR ARTICULATION VIEWED IN FRONT

1. Anterior ligament.—2. Inter-clavicular ligament.—3. Costo-clavicular ligament.—4. Joint opened, and displaying the inter-articular fibro-cartilage.—5. One of the anterior stellated ligaments.

Fig. 3. SCAPULO-CLAVICULAR AND SCAPULO-HUMERAL ARTICULATION.

1. Acromio-clavicular articulation.—2 and 3. Coraco-clavicular ligament, composed of the conoid and trapezoid ligaments.—4. Coraco-acromial ligament, or ligamentum proprium antertus.—5. Coracoid ligament, or ligamentum proprium posterius.—6. Tendon of the biceps, surrounded by a sort of capsular.—7. Capsular ligament of the scapulo-humeral articulation, or shoulder joint.

Fig. 4.—1. Glenoid cavity.—2. Glenoid ligament.—3. Tendon of the biceps, continuous with the glenoid ligament.

Fig. 5. ELBOW JOINT VIEWED IN FRONT.

1. Anterior ligament, composed of fibres passing in various directions, and continuous with the lateral ligaments.—2. Annular ligament of the radius.

Fig. 6. ELBOW JOINT FROM BEHIND.

1. Posterior ligament, composed of many bundles.—2. External lateral ligament.

Fig. 7. ELBOW JOINT VIEWED FROM WITHOUT.

1. External lateral ligament.—2. Part of the posterior ligament.

Fig. 8. ELBOW JOINT VIEWED FROM WITHIN.

1. Internal lateral ligament.—2. External lateral ligament.

* Often called the *transverse* or *supra-scapular* ligament.

ARTHOLOGY, Pl. 6.

Fig. 1. ANKLE JOINT VIEWED IN FRONT.

1. Anterior and inferior peroneo-tibial ligament.—2. Anterior ligament of the ankle joint.—3. Internal lateral ligament.—4. External and anterior lateral ligament.—5. External and middle lateral ligament.

Fig. 2. ANKLE JOINT VIEWED FROM BEHIND.

1. Posterior and inferior peroneo-tibial ligament.—2. Fibres extending between the malleoli, and serving to strengthen the joint.—3. Posterior ligament.—4 and 5. Fasciculi of the internal lateral ligament.—6. External and posterior lateral ligament.—7. External and middle lateral ligament.—8. Small internal ligament, uniting the os calcis to the astragalus.—9. Posterior calcaneo-astragaloid ligament.

Fig. 3. DORSAL LIGAMENTS OF THE TARSUS AND METATARSUS.

1 and 2. Fasciculi of ligamentous fibres, situated in the hollow between the calcis and astragalus, and uniting them to each other.—3. Calcaneo-scaphoid and calcaneo-cuboid ligaments, resembling the letter Y.—4. Upper calcaneo-cuboid ligament.—5. Scaphoid bone, from which proceed ligaments to the calcis, to the three cuneiform bones, and to the cuboid.—6. One of the dorsal ligaments of the cuneiform bones.—7. Ligament extending from the internal cuneiform to the first metatarsal bone.—8. Second metatarsal bone, from which proceed three ligaments to the cuneiform bones.—9. Cuboid bone, from which proceed ligaments to the third, fourth, and fifth metatarsal bones.—10. Ligament from the third cuneiform to the third metatarsal bone.—11. One of the ligaments which unite the tarsal extremities of the metatarsal bones.

Fig. 4. PLANTAR LIGAMENTS OF THE TARSUS AND METATARSUS

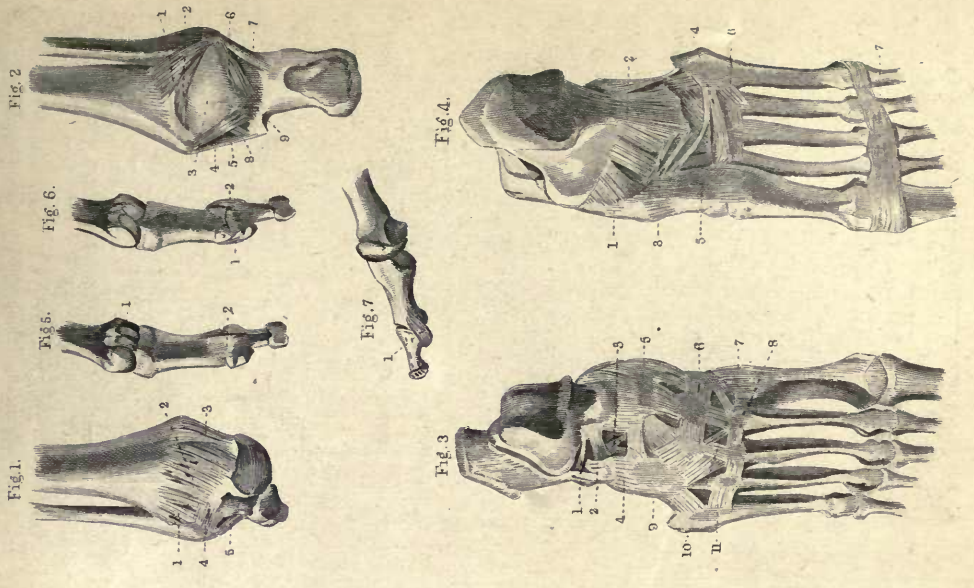
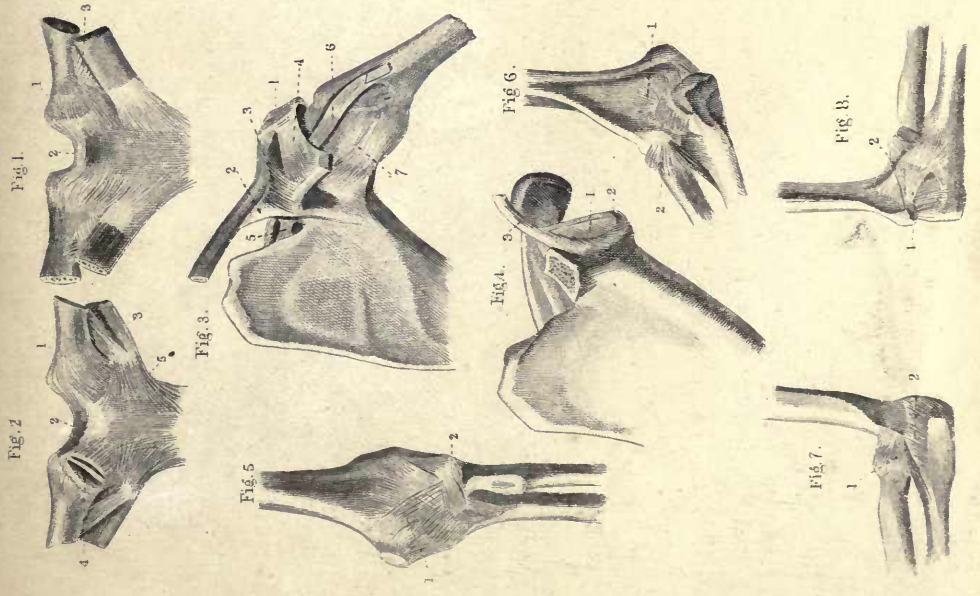
1. Calcaneo-scaphoid ligament.—2. Calcaneo-cuboid ligament.—3. Various ligamentous fasciculi, some of which are a continuation of the tendon of the tibialis posticus.—4. Common transverse ligamentous fasciculi.—5. Ligament from the internal cuneiform to the first metatarsal bone.—6. One of the transverse ligaments which unite the tarsal extremities of the metatarsal bones.—7. Common transverse ligament of the digital extremities of the metatarsal bones.


Fig. 5.—1. Sesamoid bones of the metatarso-phalangeal articulation of the great toe.—2. Anterior ligament of a phalangeal articulation.


Fig. 6.—1 and 2. Lateral ligaments of a phalangeal articulation.

Fig. 7.—1. Lateral ligament of a phalangeal articulation

* The superficial (5) being called the *deltoid* ligament.







ARTHIROLOGY, Pl. 7.

Fig. 1. COXO-FEMORAL ARTICULATION (or hip joint).

1. Ilio-femoral ligament.—2. Capsular ligament.

Fig. 2. HIP JOINT WITH THE CAPSULAR LIGAMENT REMOVED.

1. Tendon of the rectus femoris, continuous with this ligament.—3. Inter-articular, or round ligament.

Fig. 3. KNEE JOINT.

1. Tendon of the triceps extensor cruris.—2. Ligamentum patellæ.—3. Internal lateral ligament of the patella.—4. Internal lateral ligament of the knee joint.—5. External lateral ligament anterior fasciculus.—6. External lateral ligament outer fasciculus.

Fig. 4. KNEE JOINT FROM BEHIND.

1 and 2. Tendons of the gastrocnemii divided.—3. Tendon of the semi-membranosus divided, from which proceed three fasciculi.—4. Tendon of the popliteus.—5. Posterior ligament.—6. Posterior border of the internal lateral ligament.—7. External lateral ligament.

Fig. 5. KNEE JOINT LAID OPEN.

1. Ligamentum patellæ divided and turned downward.—2. A small synovial bursa.—3 and 4. External and internal condyles of the femur.—5 and 6. Anterior and posterior crucial ligaments.—7 and 8. The semilunar fibro-cartilages.

Fig. 6. UPPER EXTREMITY OF THE TIBIA VIEWED FROM ABOVE.

1 and 2. Anterior and posterior crucial ligaments divided.—3. Internal fibro-cartilage.—4. External fibro-cartilage.

Fig. 7. PERONEO-TIBIAL ARTICULATIONS VIEWED IN FRONT.

1. Interosseous ligaments.—2. Opening which gives passage to the anterior tibial vessels.—3. Anterior and superior peroneo-tibial* ligament.—4. Anterior and inferior peroneo-tibial ligament.

* Another name for *tibio-fibular* ligament.

ARTHIROLOGY, Pl. 8.

Fig. 1. ARTICULATIONS OF THE TWO BONES OF THE FORE-ARM WITH EACH OTHER.

1. Interosseous ligament.—2. Round ligament, or the ligamentous cord of Weitbrecht.—3. Annular ligament of the radius.—4. Anterior and inferior radio-ulnar ligament.

Fig. 2.—1. Upper extremity of the ulna.—2. Annular ligament which surrounds the neck of the radius.

Fig. 3. Lower extremity of the two bones of the fore-arm viewed from below, to show the triangular ligament (1).

Fig. 4. Anterior ligaments of the lower extremity of the fore-arm, of the carpus and metacarpus.

1. Anterior and inferior radio-ulnar ligament.—2. Anterior ligament of the wrist joint.—3. Radio-carpal, or external lateral ligament.—4. Ulna-carpal, or internal lateral ligament.—5. Pisiform bone, from which proceed numerous ligaments.—6. Os magnum, from which ligamentous fibres proceed to most of the bones of the carpus and metacarpus.—7. Capsular ligament of the trapezium and first metacarpal bone.—8. One of the palmar ligaments, which unite the upper extremities of the last four metacarpal bones.—9. Common transverse palmar ligament.—10. Lateral ligament of the metacarpo-phalangeal articulation of the thumb.

Fig. 5. Posterior ligaments of the lower extremity of the fore-arm, of the carpus and metacarpus.

1. Posterior ligament of the wrist joint.—2. Radio-carpal, or external lateral ligament.—3. Ulna-carpal, or internal lateral ligament.—4. Posterior carpal ligaments.—5. One of the posterior ligaments of the carpus and metacarpus.—6. Ligament passing from the trapezium to the second metacarpal bone.—7. One of the dorsal ligaments, which unite the last four metacarpal bones.

Fig. 6. This figure shows the lateral ligaments of the metacarpo-phalangeal articulation, and the phalangeal articulations of one finger

Fig. 7. Shows, 1 and 2. The anterior ligaments of the phalangeal articulations of a finger.

Fig. 8. Shows the lateral ligaments of the metacarpo-phalangeal and phalangeal articulations.

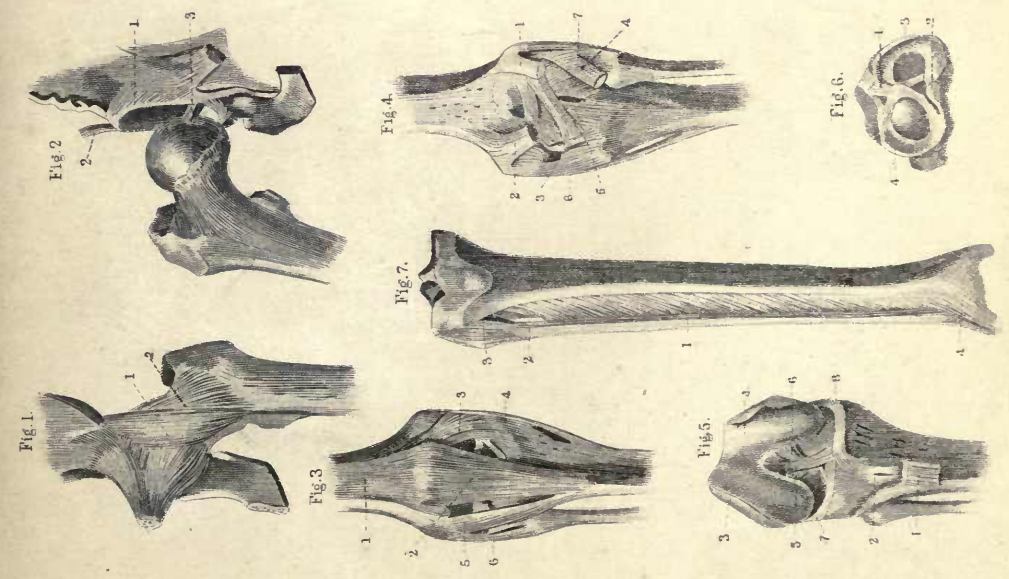
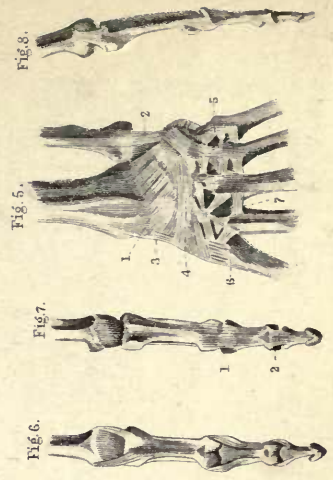
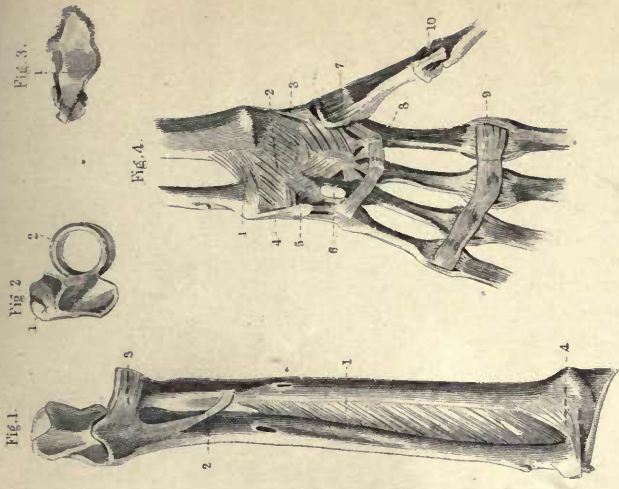


Fig. 1. HEAD VIEWED ON THE LEFT SIDE, AND SHOWING THE SUPERFICIAL MUSCLES.

1. Epi-cranial aponeurosis, being the tendon which unites the frontal and occipital bellies of the occipito-frontales.—2 and 3. Frontal portion of this muscle, and its prolongation, the pyramidalis nasi.—4. Occipital portion.—5. Auricularis superior.*—6. Auricularis posterior.—7. Auricularis anterior.—8. Orbicularis palpebrarum.—9. Triangularis nasi.—10. Levator labii superioris alæque nasi.—11. Levator labii superioris.—12. Zygomaticus minor.—13. Zygomaticus major.—14. Caninus, or levator anguli oris, being the upper portion of the same fasciculus whose lower portion forms, 15. The triangularis, or depressor anguli oris.—16. Quadratus menti, or depressor labii inferioris.—17. Levator menti.—18. Orbicularis oris.—19. Buccinator.—20. Masseter.

Fig. 2. HEAD VIEWED ON THE LEFT SIDE.

1. Temporalis.—2. Corrugator supercillii.—3. Superior oblique and its pulley.—4. Levator palpebræ superioris.—5. Triangularis nasi.—6. Depressor alæ nasi or myriformis.—7. Orbicularis oris, cut through.—8. Caninus, continuous with the triangularis or depressor anguli oris.—9. Quadratus menti, or depressor labii inferioris.—10. Buccinator, pierced by the parotid, or Steno's duct.

* 5, 6, and 7 are also called *atrolleus*, *atrahens*, and *retrahens*.

Fig. 1. The anterior part of the head has been separated from the vertebral column, and the pharynx and the posterior part of the velum palati and the posterior part of the larynx.

1. Levator palati.—2. Circumflexus palati.*—3. Azygos uvulæ.—3'. Palato-glossus.—4. Tonsil.—5. Palato-glossus.—6. Palato-pharyngeus.—7. One of the posterior cricoarytenoid muscles.—8. Arytenoides, consisting of fibres crossing each other, and of a fasciculus passing transversely.

Fig. 2. This figure shows the upper muscles of the velum on a larger scale.

1. External pterygoid muscle.—2. Levator palati.—3 and 4. Circumflexus* palati of both sides.—5. Azygos muscle, composed of two fasciculi, called the palato-staphylini.—6. Upper extremity of the muscle called the palato-pharyngeus.

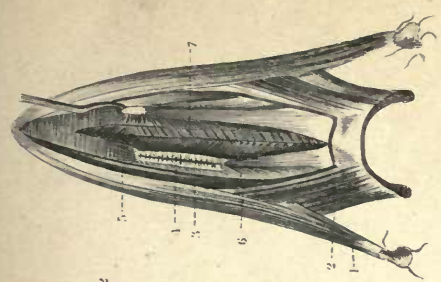
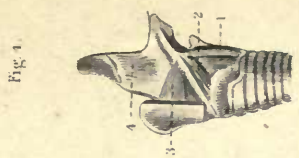
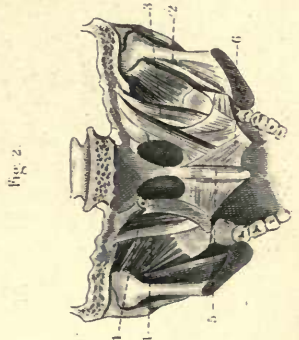
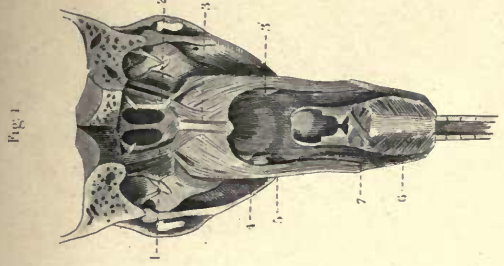
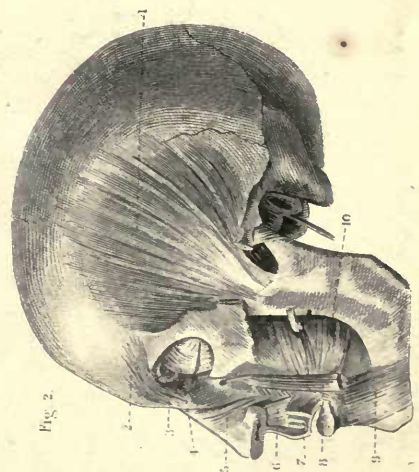
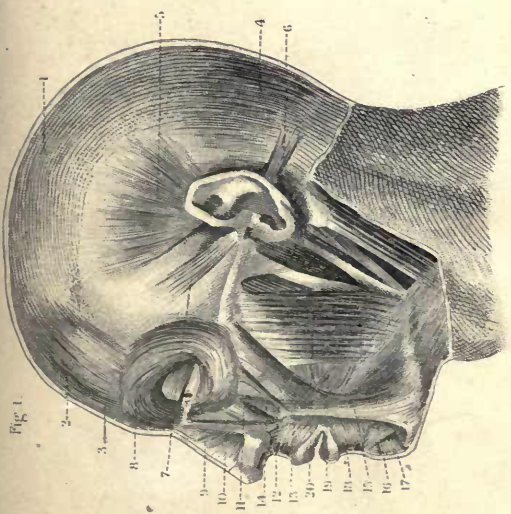
Fig. 3. THE TONGUE, AS SEEN ON ITS LOWER SURFACE.


1. Stylo-glossus muscle.—2. Hyo-glossus.—3. Lingualis.—4. Lower extremity of one of the genio-glossi of one side, detached from the genial process.—7. The groove which separates the two genio-glossi muscles.


Fig. 4. A LARYNX FROM WHICH A PORTION OF THE THYROID CARTILAGE HAS BEEN REMOVED, VIEWED LATERALLY.

1. Crico-arytenoides posticus.—2. Crico-arytenoides lateralis.—3. Thyro-arytenoides.—4. Some fibres constituting a small muscle, called the aryteno-epiglottideus.

* Called, from its action, the *tensor palati*.







MYOLOGY, PL. 3.

Fig. 1. MUSCLES OF THE SUPRA AND INFRA-HYOID REGIONS (right side.)

1. Anterior belly, and, 2. Posterior belly of the digastricus.—3. Mylo-hyoid.—4. Stylo-hyoid.—5. Stylo-glossus.—6. Stylo-pharyngeus.—7. Sterno-hyoid.—8. Omo-hyoid.—9. Thyro-hyoid.—10. Sterno-thyroid.—11. Scalenus anticus.—12. Scalenus posticus.

Fig. 2. MUSCLES OF THE TONGUE (right side.)

1. Styloid process of the temporal bone.—2. Stylo-hyoid.—3. Genio-hyoid.—4. Stylo-pharyngeus.—5. Stylo-glossus.—6. Hyo-glossus.—7. Lingualis.—8. Genio-hyo-glossus.

Fig. 3. MUSCLES OF THE PHARYNX, SEEN ON THE RIGHT SIDE AND FROM BEHIND.

1. Lower portion of the thyro-hyoid muscle.—2. Raphé of the muscles of the pharynx viewed from behind.—3. Styloid process.—4. Stylo-pharyngeus muscle.—5. Superior constrictor.—6. Middle constrictor.—7. Inferior constrictor.—8. Buccinato-pharyngeal aponeurosis, or pterygo-maxillary ligament.—9. Buccinator.—10. Parotid duct.—11 and 12. Stylo-glossus and hyo-glossus muscles, cut through.—13. Posterior fibres of the genio-glossus, continuous with the superior constrictor of the pharynx.—14. Genio-hyoid.

MYOLOGY, PL. 4.

Fig. 1. RIGHT EYE AND ITS MUSCLES.

1. Superior rectus.—2. Inferior rectus.—3. Inter-nal rectus.—4. Superior oblique, passing through its pulley.—5. Inferior oblique.

Fig. 2. RIGHT EYE VIEWED BEHIND, WITH THE FOUR STRAIGHT MUSCLES STRETCHED OUT, AND THE TWO OBLIQUE MUSCLES CONTINUOUS BEHIND BY MEANS OF THEIR APONEUROSES OF INSERTION.

Fig. 3. This figure shows the pterygoid muscles of the left side.

1. External pterygoid muscle.—2. Internal pterygoid.

Fig. 4. SUPERFICIAL MUSCLES OF THE NECK (left side).

1. Platysma myoides.—2. Some muscular fibres continuous with those of the platysma myoides, forming the musculus risorius Santorini.—3. Sterno-cleido-mastoid.—4. Trapezius.—5. Splenius.—6. Triangular space, forming an important surgical region, bounded in front by the sterno-cleido-mastoid, behind by the trapezius, and below by the clavicle.

Fig. 3.

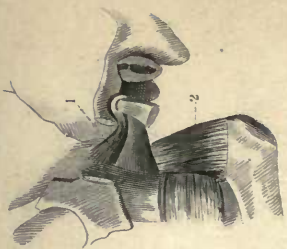

Fig. 1.



Fig. 2.

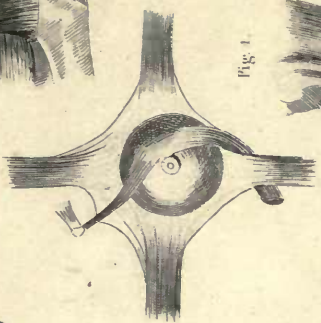


Fig. 1.




Fig. 1.

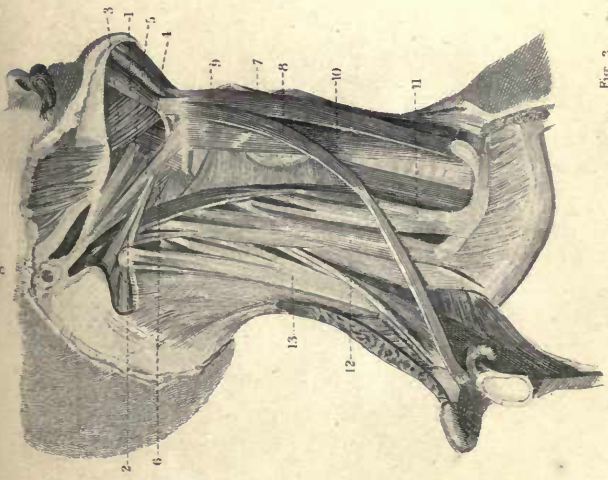


Fig. 3.

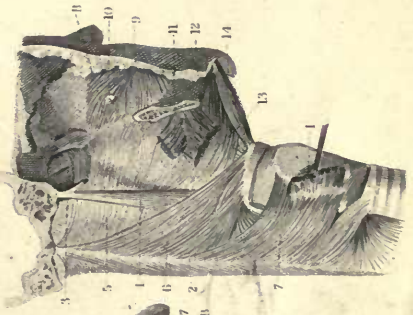
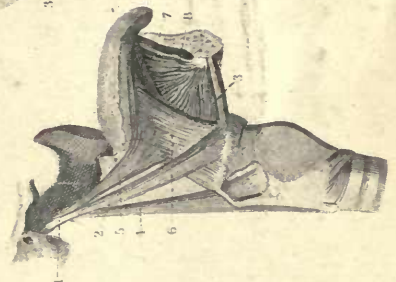

Fig. 2.






MYOLOGY, PL. 5.

THE MUSCLES SITUATED ON THE ANTERIOR OF THE TRUNK.

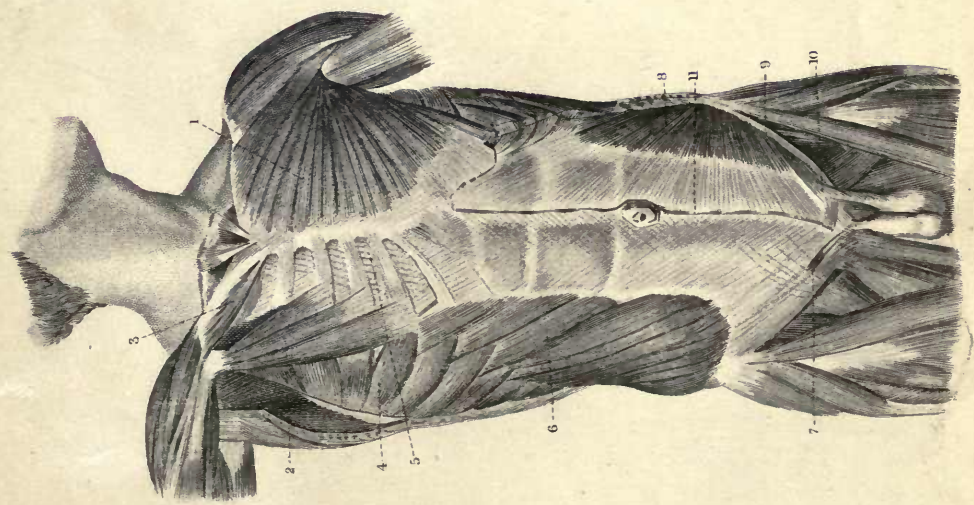
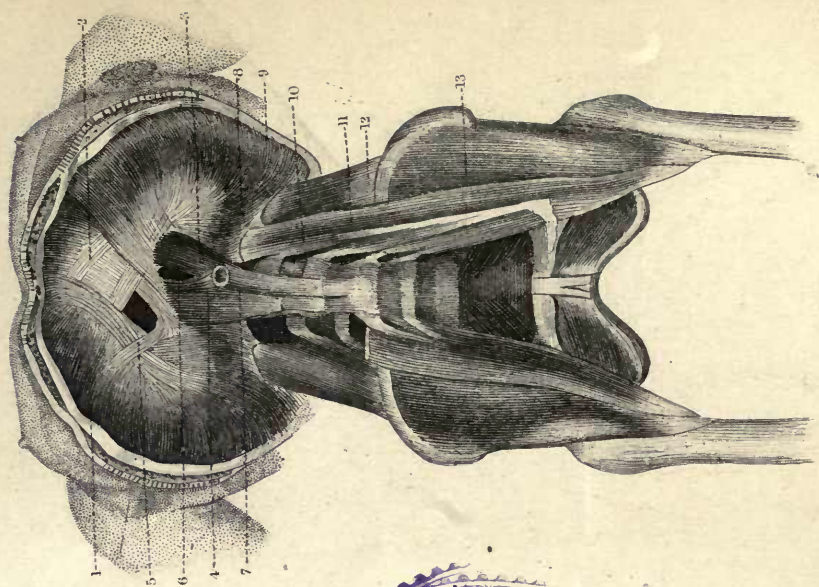
1. Pectoralis major, separated from the deltoid by a small space.—2. Pectoralis minor.—3. Subclavius.—4. Serratus magnus.—5. An internal intercostal muscle.—6. Obliquus externus abdominis.—7. External abdominal ring.—8. Obliquus internus abdominis.—9. Tendon of the obliquus externus, turned down.—10. Cremaster.—11. Linea alba.



MYOLOGY, PL. 6.

- Fig. 1. Diaphragm.—2. Cordiform tendon.—3 and 4. Crura of the diaphragm.—5. Opening for the passage of the vena cava ascendens.—6. Oesophageal opening.—7. Aortic opening.—8. Arch for the passage of the psoæ muscles.—9. Ligamentum arcuatum.—10. Psoæ parvus.—11. Psoæ magnus. 12.—Quadratus lumborum.—13. Iliacus internus.





MYOLOGY, PL. 7.

Fig. 1. MUSCLES CONNECTED WITH THE FEMALE GENITAL ORGANS.

1. Erector clitoridis.—2. Constrictor vaginae.—3. Transversalis perinei.—4. Sphincter ani.—5. Levator ani.—6. Clitoris.—7. Meatus urinarius.

Fig. 2. TRIANGULARIS STERNI.

Fig. 3. This figure displays the muscles situated on the anterior part of the cervical portion of the vertebral column.

1. Rectus capitis anticus major.—2. Rectus capitis anticus minor.—3. Rectus capitis lateralis.—4 and 5. Inter-transversales cervicis.—6. Scalenus anticus.—7. Scalenus posticus.

Fig. 4. INGUINAL CANAL VIEWED IN FRONT.

1. Tendon of the external oblique, divided above the fold of the groin, and turned downward and outward.—2. Inter-columnar fascia.—3. Lower border of the internal oblique.—4. Cremaster, whose fibres are seen descending in loops on the spermatic cord.

MYOLOGY, PL. 8.

Fig. 1. MUSCLES OF THE ABDOMEN.

1. Obliquus internus abdominis, whose tendon is divided into, 2. An anterior lamina, divided and turned outward: this portion, with the whole of the tendon of the external oblique, passes before the rectus, and into, 3. A posterior lamina, which extends only to the lower fourth of the rectus muscle, and which, with the tendon of the transversales, passes behind the rectus.—4. Transversalis abdominis, whose tendon is divided into, 5. An upper lamina, which passes behind the rectus muscle, in connexion with the posterior lamina of the obliquus internus, and into, 6. An inferior lamina, which, at the point where the posterior lamina of the obliquus internus terminates, passes in front.—7. Pyramidalis.—8. Rectus.—9. Linea alba.

Fig. 2. MUSCLES CONNECTED WITH THE MALE GENITAL ORGANS.

1. Erector penis.—2. Acceleratores urinae, united by a raphé.—3. Transversus perinei, consisting of two fasciculi.—4. Sphincter ani.—5. Levator ani.

Fig. 1.

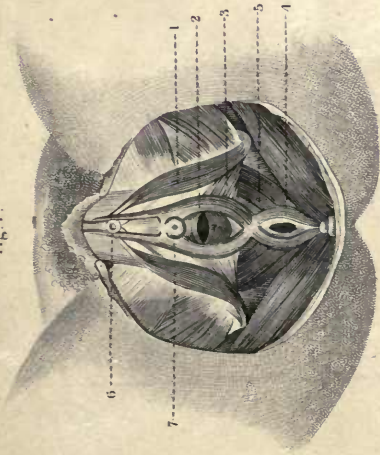


Fig. 3.

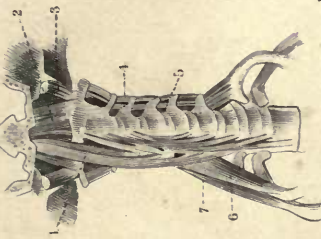


Fig. 2.




Fig. 4.

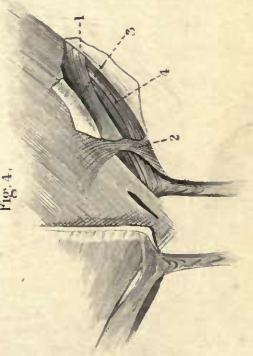


Fig. 1.

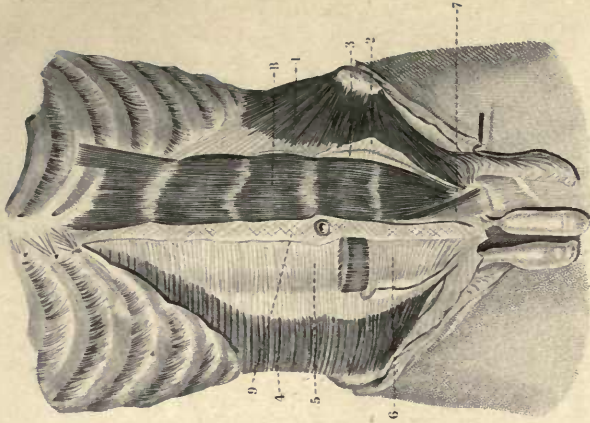
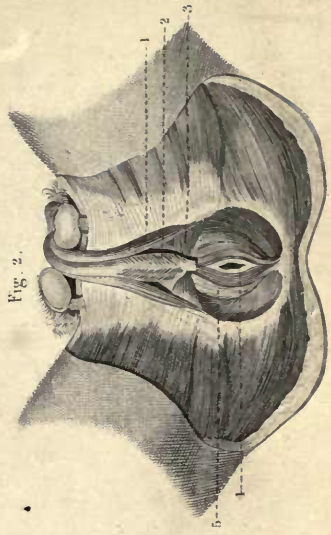



Fig. 2.





THE SUPERFICIAL MUSCLES SITUATED ON THE POSTERIOR PART OF THE TRUNK.

1. Trapezius.—2. Latissimus dorsi.—3. Teres major.—4. Rhomboideus.—5. Levator anguli scapulae.—6. Splenius.—7. Upper portion of the complexus.—8. Sterno-cleido-mastoid.—9. Deltoid, raised up

Fig. 1.—1. Deltoid muscle: its tendon is continuous with the brachial aponeurosis.

Fig. 2. POSTERIOR MUSCLES OF THE SHOULDER.

1. Supra-spinatus.—2. Infra-spinatus.—3. Teres minor.—4. Teres major.—5. Extremity of the latissimus dorsi.

Fig. 3. MUSCLES ON THE ANTERIOR PART OF THE SCAPULA AND ARM.

1. Sub-scapularis.—2. Biceps flexor cubiti.—3. Coraco-brachialis.—4. Brachialis anticus.—5. Extremity of the pectoralis major.—6. Teres major.—7. Internal portion of the triceps extensor cubiti.—8. Aponeurotic expansion of the biceps flexor cubiti, which becomes blended with the fascia of the forearm.

Fig. 4.—1. Lower extremity of the deltoid, embraced by the brachialis anticus, 2.

Fig. 5.—1. Portion of the deltoid.—2. Triceps extensor cubiti.—3. Middle, or long portion of the same muscle.—4. Outer portion.—5. Inner portion.—6. Anconeus.

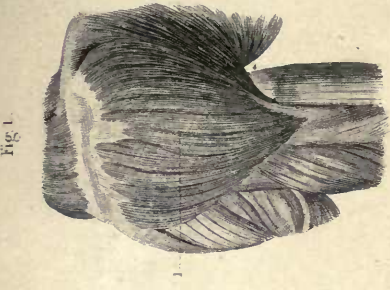
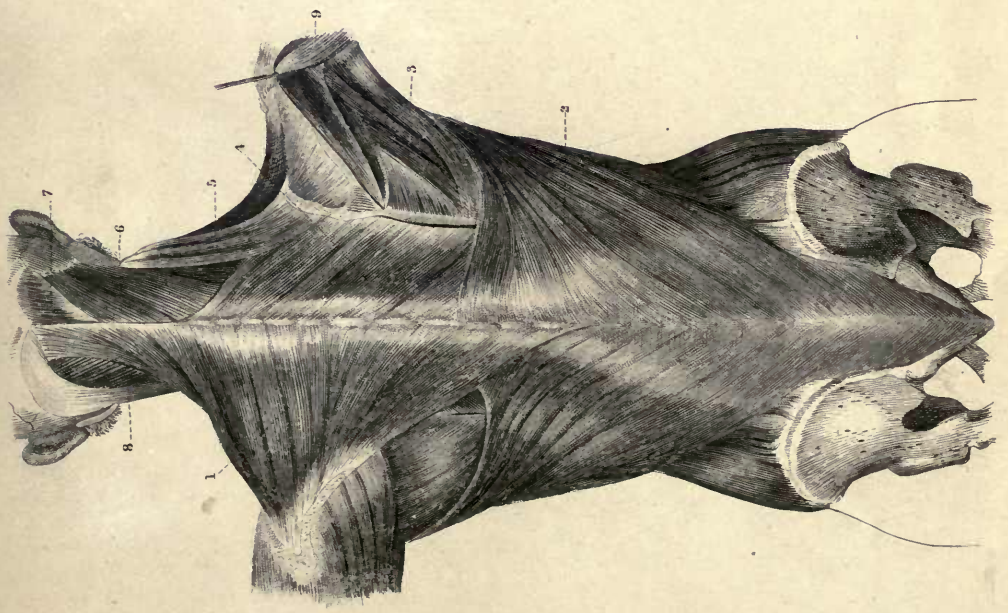


Fig. 1.

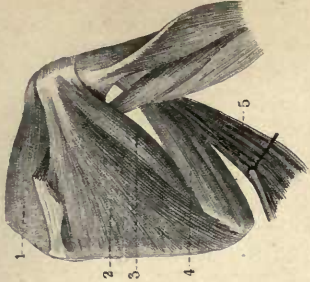


Fig. 2.




Fig. 3.

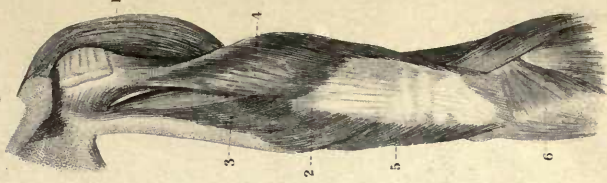


Fig. 5.



Fig. 4.



Fig. 1.—1. Splenius, occipital portion.—2. Cervical portion of the same muscle.—3. Complexus.—4. Trachelo-mastoideus.

Fig. 2. DEEP MUSCLES OF THE POSTERIOR PART OF THE NECK.

1. Complexus.—2. Trachelo-mastoideus.—3. Obliquus capitis inferior.—4. Obliquus capitis superior.—5. Rectus capitis major.—6. Rectus capitis minor.

Fig. 3. This figure represents several vertebrae, and the posterior part of the corresponding ribs. It ought to be examined after the various fasciculi which compose the sacro-spinalis.

1. One of the supra-costal muscles, shown in its relations with, 2. An external intercostal muscle.—3. An internal intercostal muscle.—4. Five fasciculi of the transverso-spinalis muscle, arising from a single transverse process, and going to be inserted, successively, and in the order of position, into the lamina of the vertebra above, into the union of the lamina with the spinous process of a second vertebra, into the base of the spinous process of a third, into the middle of the spinous process of a fourth, and into the summit of the spinous process of a fifth vertebra.

DEEP MUSCLES ON THE POSTERIOR PART OF THE TRUNK.

1. Serratus posticus superior.—2. Serratus posticus inferior.—3. Fascia which extends from the serratus posticus inferior to the splenius.—4. Splenius: its occipital and its cervical fasciculus are distinct.—5. Sacro-lumbalis.—6. Longissimus dorsi.—7. Thoracic portion of the transverso-spinalis.—8. Trachelo-mastoideus.—9. Transverso-spinalis, being merely a portion of No. 6.—10. Complexus.—11. Spinalis dorsi of Winslow, formed by fasciculi extending from the spinous processes of the upper lumbar to the spinous processes of the lower dorsal vertebrae.*

* The divisions and subdivisions which some anatomists adopt in their descriptions of the posterior spinal muscles are, in the opinion of the Editor, of no practical value, and only tend to complicate and render difficult what is really very simple. Craveilhier, discarding the numerous subdivisions of anatomists, considers the long muscles of the back as three in number, viz., the sacro-lumbalis, the longissimus dorsi, and the transverso-spinalis; and Chaussier, with more propriety and simplicity, considers all of these as forming only one muscle, which he names the sacro-spinal muscle: a muscle which, from its action, may, with much propriety, be called the *erector spinæ*.

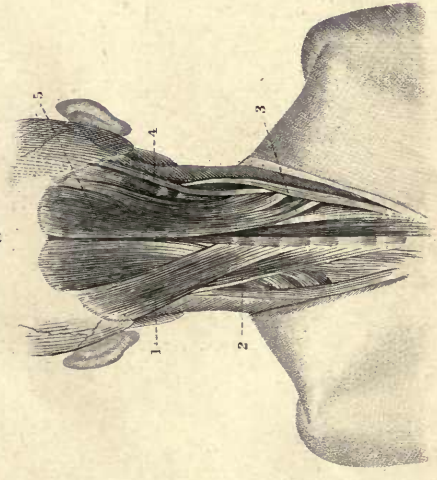
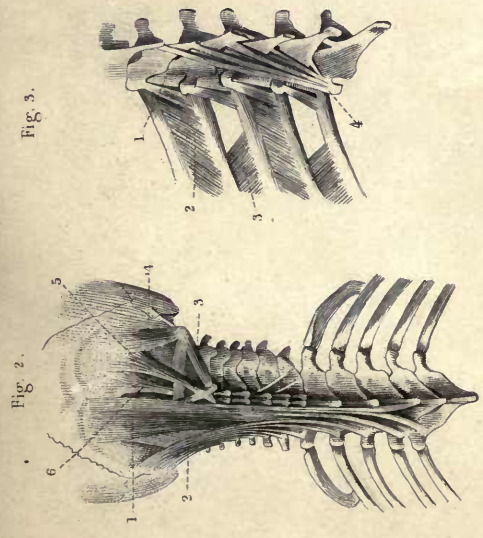
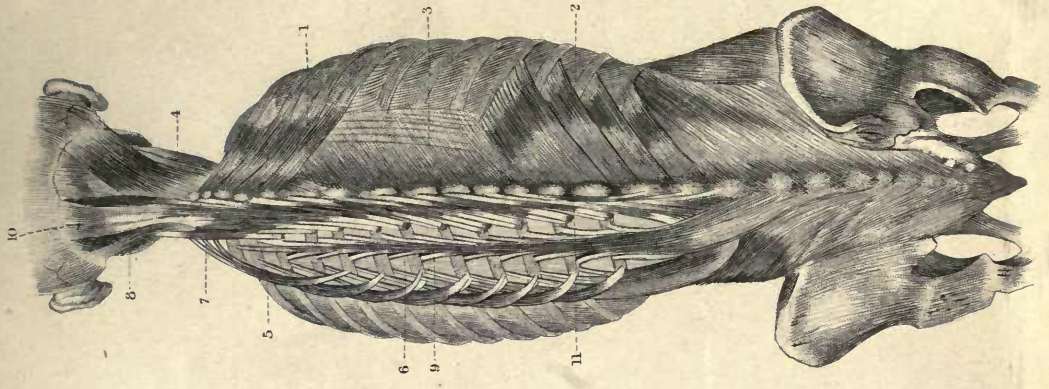




Fig. 3.

Fig. 2.

Fig. 1.





MYOLOGY, PL. 13.

Fig. 1. SUPERFICIAL MUSCLES SITUATED ON THE ANTERIOR PART OF THE FORE-ARM.

1. Pronator radii teres.—2. Flexor carpi radialis.—3. Palmaris longus.—4. Flexor carpi ulnaris, having its upper extremity traversed by the ulnar nerve, 7.—5. Supinator radii longus.—6. Flexor digitorum sublimis.—7. Ulnar nerve.

Fig. 2.—1. Flexor digitorum sublimis.—2. One of the tendons of this muscle, split, to allow the passage of the corresponding tendon of the flexor profundus.—3. Supinator radii longus.—4. Lower part of the brachialis anticus.—5. Tendon of the biceps.—6. Anterior annular ligament of the carpus.

Fig. 3. DEEP MUSCLES SITUATED ON THE ANTERIOR PART OF THE FORE-ARM.

1. Flexor digitorum profundus.—2. Flexor longus pollicis.—3. A small fasciculus of the same muscle.—4. Pronator quadratus.—5 and 6. Supinator longus and brevis.

MYOLOGY, PL. 14.

Figs. 1, 2. MUSCLES SITUATED ON THE ANTERIOR AND INNER PART OF THE THIGH.

1 and 2. Psoas magnus and iliacus internus, divided.—3. Sartorius.—4. Tensor vaginae femoris.—5. Rectus femoris.—6. Vastus externus, or external portion of the triceps extensor cruris.—7. Pectineus.—8. Adductor longus.—9. Gracilis.

Fig. 2.—1. Triceps extensor cruris: the rectus femoris is divided.*—2. Adductor brevis.—3. Adductor magnus.—4. Obturator externus.

* By the term triceps extensor cruris we understand one muscle, which is formed by the rectus femoris, the vastus externus, and vastus internus of anatomists. What is described as the crureus is merely a portion of the vastus. All of these muscles are inserted into the tibia through the intervention of the patella and its ligament, and hence the propriety of considering them as forming only one muscle.

Fig. 2.

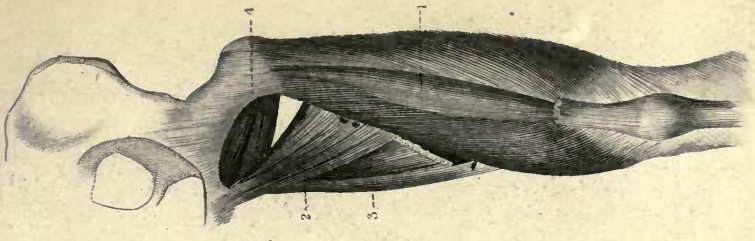


Fig. 1.

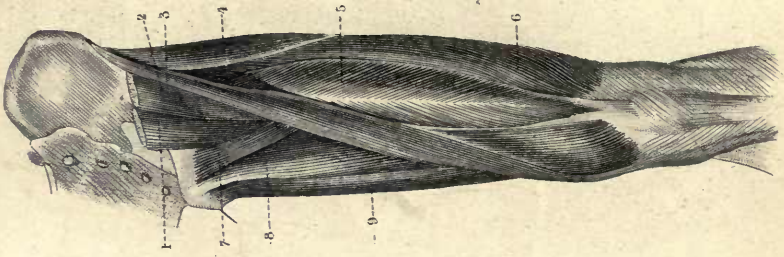


Fig. 1.

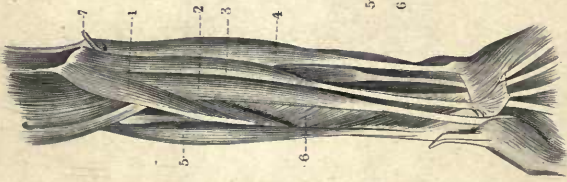


Fig. 2.

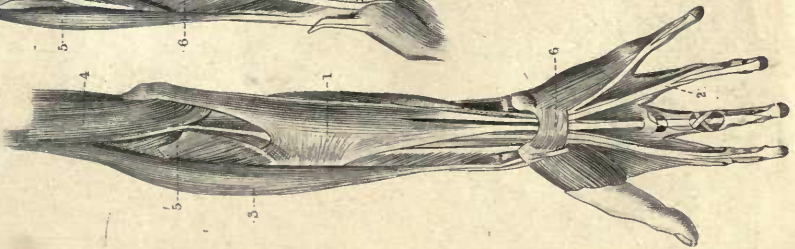
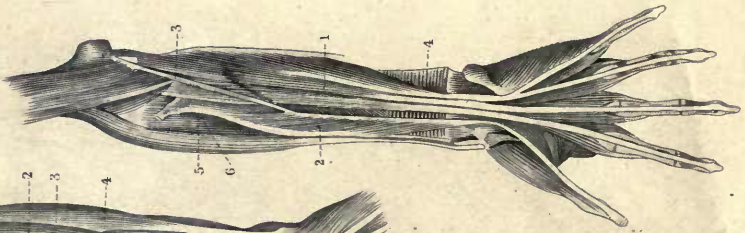



Fig. 3.





Figs. 1, 2, 3. MUSCLES SITUATED ON THE POSTERIOR PART OF THE LOWER EXTREMITY.

Fig. 1.—1. Gluteus maximus.—2. Fascia covering the gluteus medius.

Fig. 2.—1. Gluteus medius.—2. Pyriformis.—3. Tendon of the obturator internus, above and below which are seen the fibres of the gemellus superior and of the gemellus inferior.—4. Quadratus femoris.—5. Tendon of the gluteus maximus, divided.

Fig. 3.—1. Pyriformis, divided.—2. Gluteus minimus.—3. Obturator internus, accompanied above and below by the gemelli.—4. Quadratus femoris.—5. Adductor magnus.—6. Biceps flexor cruris.—7. Semi-tendinosus.—8. Semi-membranosus.—9. Internal head of the gastrocnemius, by the side of which is seen its external head.

Fig. 1. SUPERFICIAL MUSCLES ON THE POSTERIOR PART OF THE FORE-ARM.

1. Extensor communis digitorum.—2. Extensor minimi digiti.—3. Extensor carpi ulnaris.—4. Anconeus.—5. Extensor carpi radialis longior and brevior, whose tendons pass beneath the tendon of the extensor pollicis longus muscle.—6. Posterior, or dorsal annular ligament.

Fig. 2. DEEP MUSCLES ON THE POSTERIOR PART OF THE FORE-ARM.

1. Supinator radii brevis.—2. Anconeus, raised up.—3. Abductor longus pollicis.—4. Extensor brevis pollicis.—5. Extensor longus pollicis.—6. Extensor proprius indicis, whose tendon becomes blended with the corresponding tendon of the extensor communis.

Fig. 3.—1. Tendons of the long muscles of the thumb, viz., flexor longus, extensor longus brevis, and abductor longus pollicis.—2. Tendon of the palmaris longus.—3. Tendon of the flexor carpi ulnaris.—4. Abductor brevis pollicis.—5. Opponens pollicis.—6. Flexor brevis pollicis.—7. Adductor pollicis.—8. Palmaris brevis.—9. Adductor minimi digiti.—10. Flexor brevis minimi digiti.—11. Opponens minimi digiti.

Fig. 4. This figure displays the dorsal interosseous muscles, beneath the lower extremity of which are seen passing, 1, 2, and 3, the palmar interossei

Fig. 1.

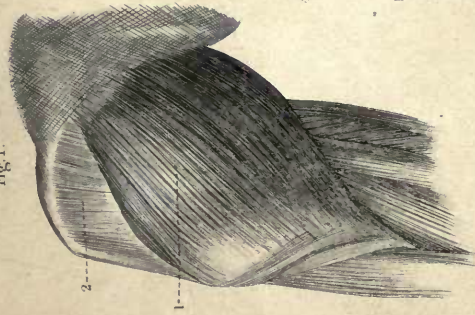


Fig. 3.

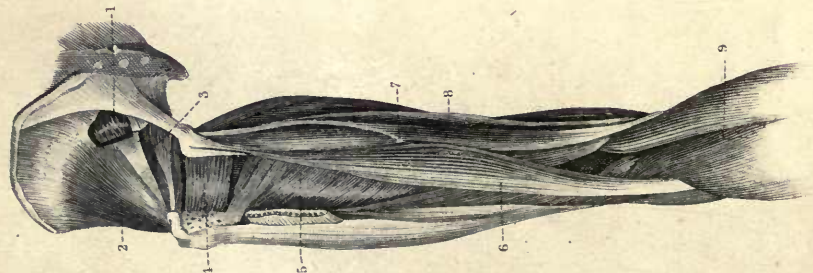


Fig. 2.

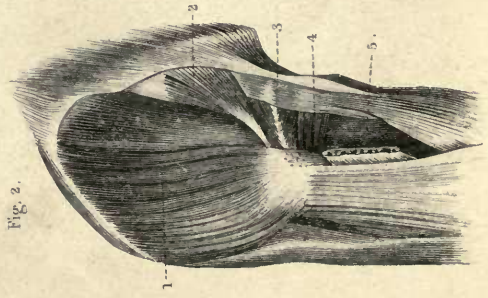


Fig. 4.




Fig. 1.

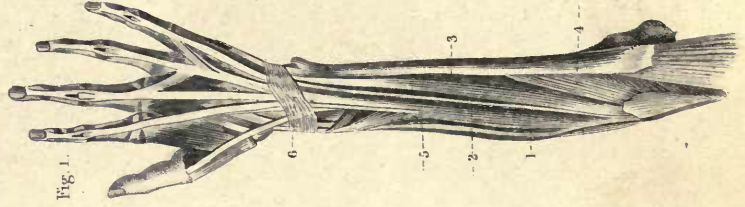


Fig. 2.

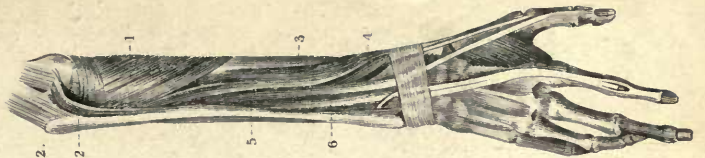
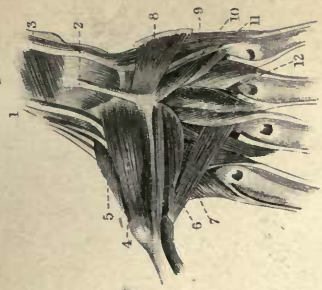




Fig. 3.







MYOLOGY, PL. 17.

Figs. 1, 2, 3. MUSCLES OF THE LEG AND FOOT.

Fig. 1.—1. Tibialis anticus.—2. Extensor proprius pollicis.—3. Extensor longus digitorum pedis.—3'. Peroneus tertius.—4. Peroneus longus.—5. Peroneus brevis.—6. Extensor brevis digitorum.—7. Tendon of the peroneus tertius.—8. Tendon of the peroneus brevis.—9. Tendon of the peroneus longus.—10. Dorsal annular ligament of the tarsus.

Fig. 2.—1 and 2. Heads or origins of the gastrocnemius, divided near their upper extremities.—3. Plantaris.—4 and 5. Heads of the gastrocnemius, divided near their lower extremities.—6. Tendo Achillis.—7. Soleus.—8. Popliteus.

Fig. 3.—1. Flexor brevis digitorum.—2. Adductor pollicis.—3. Flexor brevis pollicis.—4. Adductor minimi digiti.—5. Flexor brevis minimi digiti.

APONEUROLOGY, PL. 1.

Figs. 1, 2, 3, and 4 are perpendicular sections of the extremities, with a view to show the aponeurotic sheaths of the muscles, and the relations of these sheaths with the bones, the vessels, and the nerves.

Fig. 1. SECTION OF THE RIGHT ARM NEAR THE LOWER THIRD OF THE DELTOID.

Fig. 2. SECTION OF THE FORE-ARM AT ITS MIDDLE.

Fig. 3. SECTION OF THE RIGHT THIGH AT ITS MIDDLE.

Fig. 4. SECTION OF THE RIGHT LEG AT ITS UPPER THIRD.

Fig. 5. SUPERFICIAL FASCIA OF THE ABDOMEN.

1. Superficial fascia of the abdomen.—2. Prolongation of this fascia on the thigh.—3. Its continuity with the dartos.—4. Accessory suspensory ligament of the penis, formed by the superficial fascia.

Fig. 6.—1. Superficial fascia, turned down.—2. Reflected layer of the superficial fascia, becoming attached to the crural arch.—3. Tendon of the external oblique.—4. External abdominal ring, through which the spermatic cord passes.—5. Fibres called the inter-columnar fascia, which strengthen this ring by connecting its pillars.—6. Linea alba.—7. Ventral aponeurosis.



Fig. 1.

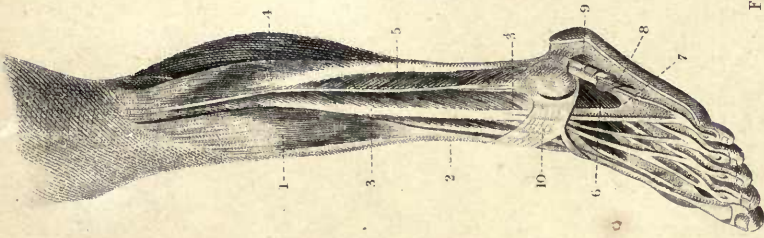


Fig. 2.

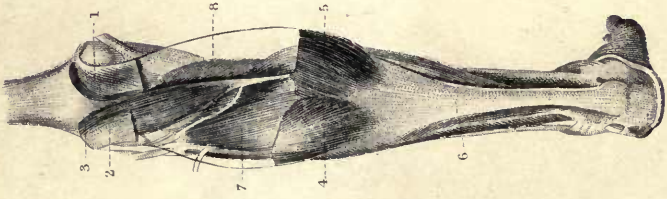


Fig. 3.

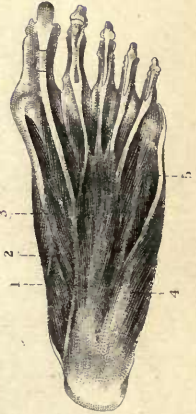

Fig. 2.

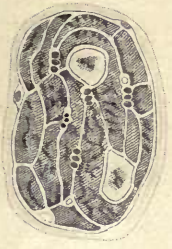

Fig. 1.

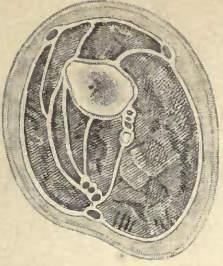


Fig. 3.

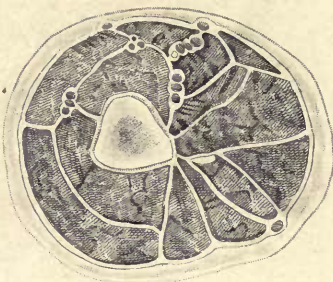


Fig. 4.

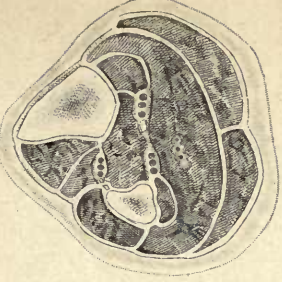


Fig. 6.

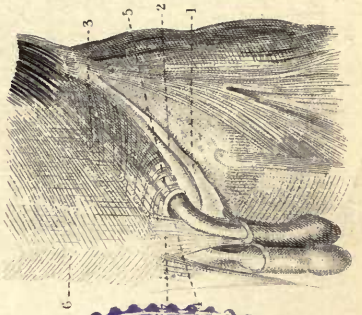

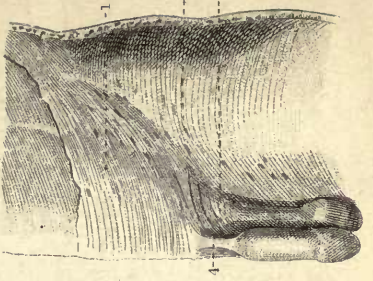


Fig. 5.



APONEUROSIS PL. 2.

Fig. 1. FASCIÆ OF THE NECK. The platysma myoides is in this figure raised with the fascia superficialis, which connects it to the muscle of the opposite side.

1. Superficial layer of the cervical fascia.—2. Masseteric fascia.—3. Parotid fascia: a continuation of the cervical fascia.—4. Supra-clavicular fascia: a continuation of the cervical.—5. Superficial portion of the cervical fascia, extending over the pectoralis major.—6. External jugular vein, lying immediately on the sterno-cleido-mastoid, and seen through the superficial layer of the cervical fascia.

Fig. 2. FASCIÆ OF THE NECK.

1. Middle portion of the cervical fascia.—2. Superficial layer of this fascia divided.—3. Middle layer, passing under the sterno-cleido-mastoid, and becoming blended with the tendon of the omo-hyoid, and forming above, 4, the sheath of the great vessels of the neck.
5. Sterno-cleido-mastoid, divided.—6. Portion of the cervical fascia, becoming attached to the lower jaw, and separating.—7. The parotid gland, and, 8. The submaxillary gland.

Fig. 3. FASCIÆ OF THE NECK.

1. Superficial portion of the cervical fascia, divided.—2. Sterno-cleido-mastoid, divided.—3. Middle layer of the cervical fascia.—4. Deep layer of this fascia, extending into the chest, and becoming attached to the lower border of, 5. The thyroid body.

Fig. 4. PREVERTEBRAL APONEUROSIS.

1. Prevertebral aponeurosis.—2. Scalenus anticus, forming a projection behind this aponeurosis.—3. Clavicle sawn through.—4. Sterno-cleido-mastoid, divided.

Fig. 5. FASCIÆ OF THE AXILLA.

1. Pectoralis major, divided.—2. Pectoralis minor.—3. Aponeurotic fasciculus, to which are attached, above and below, 4 and 4'. Infra-clavicular fascia.—5. Suspensory ligament of the axilla.

Fig. 6. FASCIÆ OF THE EYE.

- 1 and 2. Fasciæ of the eye, continuous with the tarsal fibro-cartilages.—3. Aponeurotic lamina connecting the muscles of the eye, composed of one lamina in the interval between the muscles, but dividing into two lamella along their courses to form their sheaths.—4. Aponeurotic lamina immediately investing the sclerotic, and terminating near its union with the optic nerve.—5. Optic nerve.

MYOLOGY, PL. 18.

Figs. 1, 2, 3, and 4. MUSCLES OF THE LEG AND FOOT.

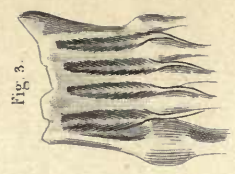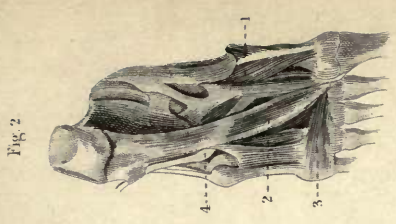
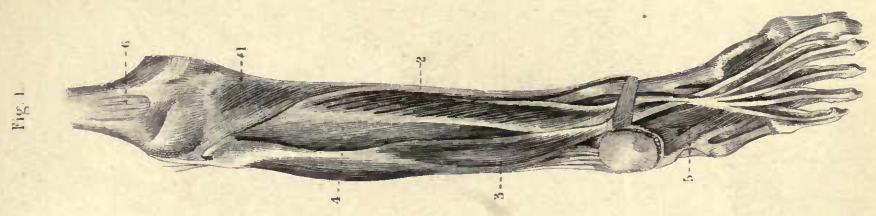
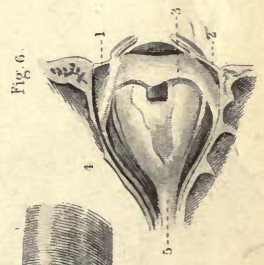
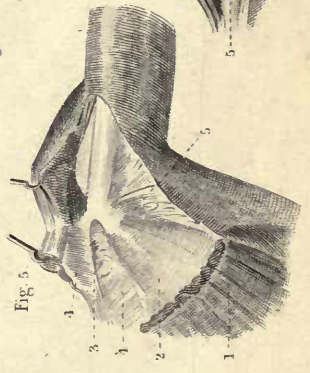
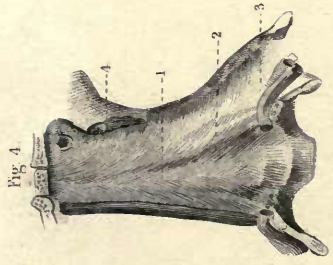
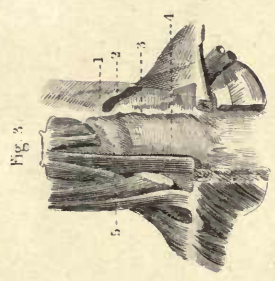
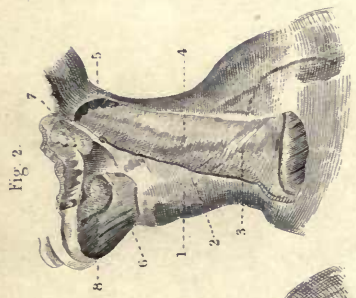
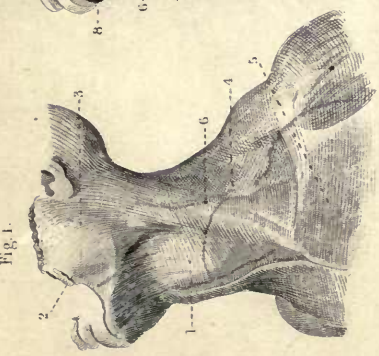
- Fig. 1.*—1. Popliteus.—2. Flexor longus digitorum pedis.—3. Flexor longus pollicis.—4. Tibialis posticus.—5. Flexor accessorius.—6. Tendon of the semi-membranosus.


Fig. 2.—1. Flexor brevis pollicis.—2. Adductor pollicis pedis.*—3. Transversus pollicis pedis.—4. Tendon of the peroneus longus.

Fig. 3. This figure represents the four dorsal interosseous muscles.

Fig. 4. This figure represents the four plantar interosseous muscles.

* This is called by Cruveilhier the abductor pollicis; but, for the reasons stated in the note, which may be referred to in the Editor's edition of Cruveilhier's Anatomy, p. 288, we give it the name which it generally receives from anatomists, viz., adductor pollicis pedis.





SPLANCHNOLOGY, PL. 1.

Fig. 1. THE EYE AND ITS APPENDAGES

1 and 2, Puncta lachrymalia.—3. Ocular portion of the conjunctiva.—4. Membrana nictitans.—5. Caruncula lachrymalis.

Fig. 2. It presents the tarsal cartilages, united at their extremities, 1 and 2, by fibrous tissue.—3 and 4. Meibomian glands.

Fig. 3—1. Lachrymal gland.—2. Lachrymal sac, on the external wall of which is seen the tendon of the orbicularis palpebrarum muscle.—3. Nasal duct, opened from lachrymal sac into the lower meatus of the nostril.—4. Inferior meatus.

Fig. 4. BALL OF THE EYE VIEWED SIDWAYS.

1. Optic nerve.—2. One of the recti muscles: the tendons of these muscles become blended with the sclerotic coat of the eye.

Fig. 5.—1. Sclerotic, cut away near the insertion of the optic nerve, to show, 2. The choroid coat, on the external surface of which are seen the ciliary nerves.—3. Ciliary ligament, at which the choroid coat *appears* to terminate.—4. Iris.

Fig. 6. AN EYE, FROM WHICH THE SCLEROTIC COAT AND THE CORNEA HAVE BEEN REMOVED, SEEN IN FRONT.

1. Ciliary ligament.—2. Iris.—3. Pupil.

Fig. 7. IRIS VIEWED FROM BEHIND.

1. Folds of the choroid coat, called the ciliary processes.—2. Pigmentum nigrum, covering the posterior surface of the iris, constituting the uvea.—3. Pupil.

Fig. 8. VERTICAL SECTION OF EYE OF THE FÆTUS MAGNIFIED.

1. Optic nerve.—2. Arteria centralis retinae.—3. Sheath of the optic nerve, continuous with the sclerotic.—4. Sclerotic.—5. Transparent cornea.—6. Union of the sclerotic and transparent cornea.—7. Choroid.—8. Ciliary ligament, continuous with the anterior part of the choroid.—9. Ciliary processes, continuous with the choroid coat, and, in fact, formed by it.—10. Iris.—11. Pupil.—12. Retina.—13. Vitreous body.—14. Hyaloid membrane.—15. Hyaloid canal, containing a large artery.—16. Division of the hyaloid membrane into two layers, which enclose the crystalline lens.—17. Space between these two laminae and the crystalline lens, constituting the canal of Petit.—18. Crystalline lens, formed of a central nucleus, the liquor Morgagni, and of its proper capsule.—19. Anterior chamber of the eye, containing the aqueous humour, enclosed in its proper membrane.—20. Posterior chamber.

APONEUROSIS, PL. 3.

Fig. 1. FASCIA TRANSVERSALIS.

1. Rectus abdominis muscle.—2. Tendon of the external oblique muscle reflected down.—3. External portion of the fascia transversalis.—4. Internal portion.—5. Upper orifice of the inguinal canal.

Fig. 2 and 3. GROIN (FASCIE).

Fig. 2—1. Suspensory ligament of the penis.—2. Crural arch.—3. Gimbernat's ligament.—4. Cruriiform fascia.—5. Internal saphena vein.

Fig. 3—1. Aponeurotic layers, lying immediately upon the femoral vessels.—2. The fasciform border of the fascia lata, corresponding to the termination of the internal saphena vein

Fig. 4. ILIAC FASCIAE, &c., &c. (right side of the pelvis).

1. Tendon of the external oblique.—2. Ilio-pubic band, or ligament of Hesselbach.—3. Fascia iliaca.—4. Tendon of the psoas parvus.—5. Ligament of Cooper.—6. Femoral vessels divided, on a level with the crural ring.

Fig. 5. SUPERFICIAL PERINEAL FASCIA.

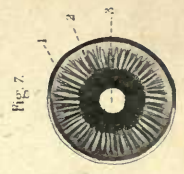
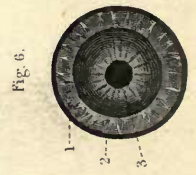
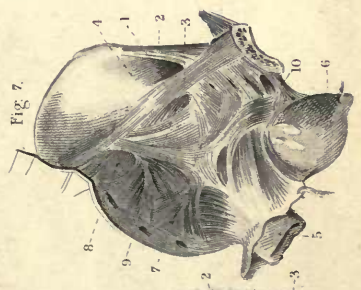
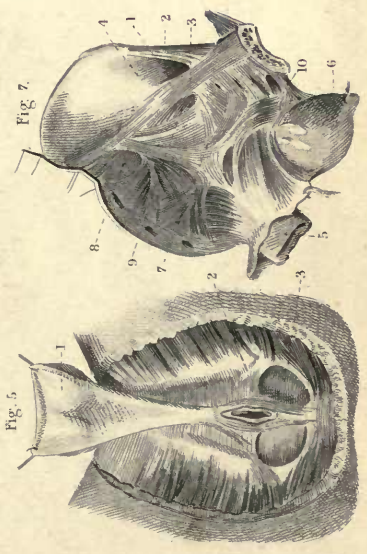
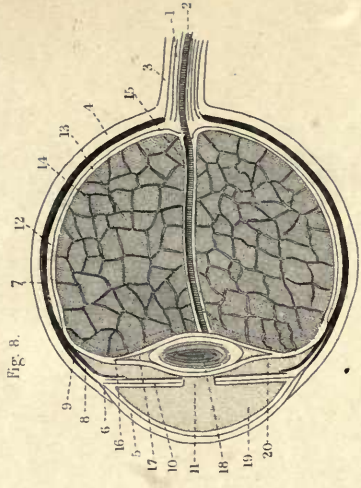
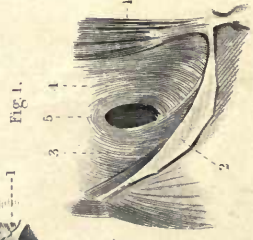
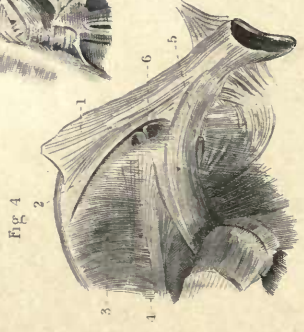
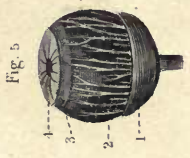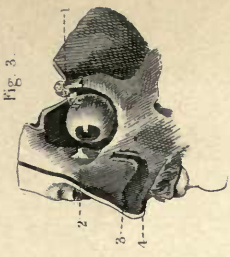
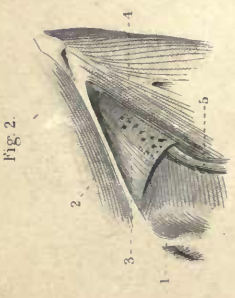
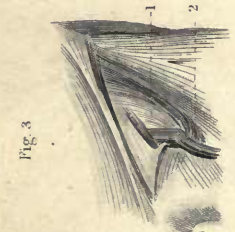
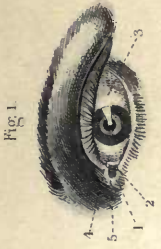1. Testicles drawn up to show the posterior prolongation of the dartos.—2. Superficial perineal fascia.—3. Excavation, the bottom of which is formed by the levator ani.

Fig. 6. DEEP PERINEAL FASCIA.


1. Superficial perineal fascia divided.—2. Deep perineal fascia, or the ligament of Carcassone.—3. Foramina for the passage of the dorsal vessels and nerves of the penis.—4. Bulbous portion of the urethra, divided.

Fig. 7. FASCIA PELVICA.

1. Crural ring.—2. Gimbernat's ligament.—3. Cooper's ligament.—4. Iliac fascia, forming the external border of the crural ring.—5. Rectum reflected down.—6. Bladder reflected down.—7. Pelvic fascia, composed of fasciculi passing in various directions.—8. Opening for the passage of the gluteal vessels.—9. Opening for the passage of the obturator vessels and nerve.—10. Anterior ligament of the bladder, formed by the pelvic fascia.







SPLANCHNOLOGY, PL. 2.

Fig. 1. THE MAMMA, OR ORGAN OF LACTATION

1. Skin.—2. Areola.—3, 3, 3. Masses of fat, some of which adhere to the skin, others are connected with the lobules of the mammary gland.—4. Mammary gland.—5. Nipple.—6. Lactiferous ducts.—7. Ampulla of one of these ducts.

Fig. 2. STRUCTURE OF THE SKIN VIEWED THROUGH A MICROSCOPE, ACCORDING TO BRASCHET.

1. Dermis.—2. Epidermis arranged in layers.—3. Papillæ arranged in pairs, forming the ridges of the skin.—4. Nerves of the papillæ.—5. Sudoriferous glands emerging between two papillæ.—6. Sudoriferous gland and duct seen entire: the duct opens in the interspace between a pair of papillæ.—8. Apparatus for the secretion of the colouring matter of the skin, terminating in a number of small ducts.—9. Colouring and epidermic matter gradually deposited in layers to form the epidermis.—10, 10. Absorbent vessels.—11. Blood vessel.

Fig. 3. THUMB CUT VERTICALLY.

1. Nail.—2. Epidermis continuous with the nail.—3. Dermis.—4. Groove of the dermis, in which the posterior extremity of the nail terminates.—5. Subcutaneous adipose tissue.—6. Ungual phalanx.

Fig. 4. END OF A THUMB FROM WHICH THE EPIDERMIS HAS BEEN REMOVED.

1. Matrix of the nail.—2. Papillary body of the nail.—3. White spot desitute of papillæ.

Fig. 5. VERTICAL SECTION OF A HAIR TAKEN FROM THE MUZZLE OF AN OX, ACCORDING TO GAULTIER.

1. A hair split.—2. Membrane of the follicle.—3. Blood-vessel entering the follicle by its orifice.—4. The same vessel dipping down in the follicle to reach the base of the hair.—5. The cavity of the hair, with its base resting on a small reddish conoid body.—6. The root of the follicle, formed by nervous filaments.—7. Small hairs.—8. Sebaceous follicles, which supply the entrance of the bulb of the hairs.

Fig. 6. THE TONGUE (*dorsum*).

1. Foramen cœcum.—2. Calliciform papillæ, arranged in the form of the letter V.—3, 3, 3. Conical papillæ.—4, 4, 4. Lines formed by filiform papillæ.—5. Glands at the base of the tongue.—6, 6, 6. Glosso-epiglottic ligaments.

Fig. 7. TRANSVERSE VERTICAL SECTION OF THE TONGUE.

1. Envelope of the tongue.—2. Median cartilage.—3. Genio-hyo-glossi muscles.—4. Proper vertical fibres.—5, 5. Vertical fibres continuous with the preceding fibres, and with those of the genio-hyo-glossi muscles.—6. Dots, representing longitudinal fibres cut.—7, 7. Transverse fibres.

APONEUROLOGY, PL. 4.

Fig. 1. FASCIAE OF THE UPPER EXTREMITY.

1. Fascia covering the deltoid.—2. Brachial aponeurosis.—3. Aponeurosis of the fore-arm.—4. Fasciculus which passes from the biceps to the fascia of the fore-arm, and strengthens it.—5. Palmar fascia.—6. Palmaris brevis.

Fig. 2.—1. Dorsal annular ligament of the carpus.—2. Dorsal fascia of the hand.

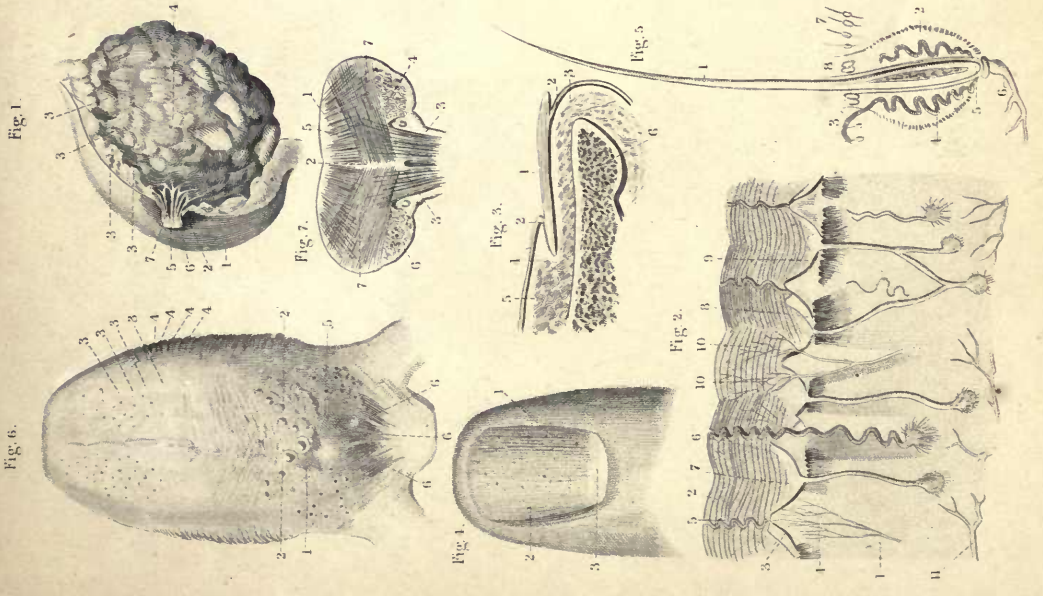
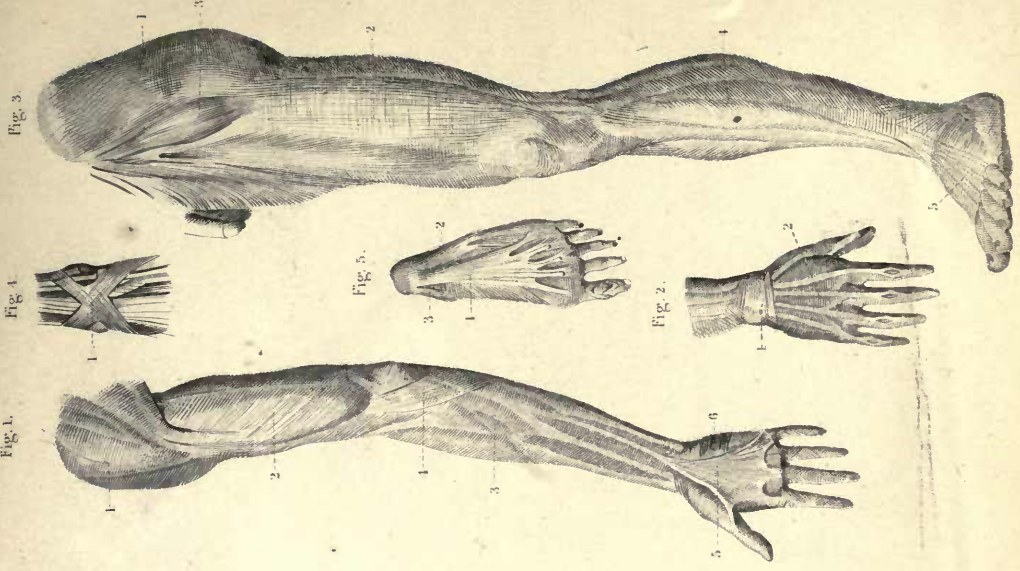
Fig. 3. FASCIAE OF THE LOWER EXTREMITY.


1. Fascia of the gluteus maximus.—2. Fascia lata.—3. Fascia of the tensor vaginæ femoris.—4. Aponeurosis of the leg.—5. Dorsal fascia of the foot.

Fig. 4. Annular ligament of the instep, formed of two bundles crossing each other.

Fig. 5. PLANTAR FASCIAE.

1. Middle fasciculus and its terminating bands.—2. External fasciculus.—3. Internal fasciculus.





SPLANCHNOLOGY, PL. 4.

Fig. 1. CARTILAGES OF THE NOSE.

1. Lateral cartilage.—2. Outer branch of the cartilage of the opening of the nostril.—3. Cartilage of the ala of the nose.—4. Skin of the ala of the nose.

Fig. 2. CARTILAGE OF THE OPENINGS OF THE NOSTRILS.

1. Outer branch.—2. Inner branch.

Fig. 3. LATERAL CARTILAGE OF THE NOSE SEPARATED.

Fig. 4. CARTILAGE OF THE SEPTUM.

1. Caudal prolongation.

Fig. 5. VERTICAL SECTION OF THE NASAL FOSSÆ TO SHOW THE CARTILAGE OF THE SEPTUM.

1. Perpendicular plate of the ethmoid.—2. Vomer.—3. Cartilage of the septum.—4. Upper wall of the nasal fossæ.—5. Orifice of the sphenoidal sinus, situated in the nasal fossæ.—6. Sphenoidal sinus.—7. Lower wall of the nasal fossæ.

Fig. 6. OUTER WALL OF THE NASAL FOSSÆ, THE TURBINATED BONES, AND MEATUSES.

1. Upper turbinated bone, and, 2. Upper meatus.—3. Middle turbinated bone, and, 4. Middle meatus: it presents the orifice of the maxillary sinus.—5. Inferior turbinated bone, and, 6. Inferior meatus.—7. Orifice of the Eustachian tube.

Fig. 7. THE TURBINATED BONES CUT TO SHOW THE COMMUNICATION OF THE MEATUSES.

1. Posterior ethmoidal cells, communicating with the upper meatus, near which is seen, 2. The sphenoidal sinus.—3. Anterior ethmoidal cells, communicating with the middle meatus, which latter also communicates with, 4. The frontal sinus, and with, 5. The maxillary sinus.—6. Inferior meatus, communicating with, 7. The lachrymal canal, and presenting behind, 8. The Eustachian tube.

SPLANCHNOLOGY, PL. 5.

Fig. 1. PHARYNX OPENED FROM BEHIND. It is removed from the vertebral column.

1. Internal pterygoid muscle.—2. Stylo-pharyngeus muscle.—3 and 4. Posterior openings of the nasal fossæ.—5. Velum palati and uvula.—6. Anterior pillar, and, 7. Posterior pillar of the velum, forming, with the base of the tongue, 8. The amygdaloid fossa.—9. Posterior opening of the mouth.—10. Base of the tongue.—11. Upper opening of the larynx.—12. Posterior surface of the larynx.—13. Commencement of the trachea.

Fig. 2. THYROID CARTILAGE.

1. Oblique line.—2. Great cornu.—3. Small cornu.

Fig. 3. CRICOID CARTILAGE.

Fig. 4. ARYTENOID CARTILAGE VIEWED FROM BEHIND.

Fig. 5. EPIGLOTTIS.

Fig. 6. LARYNX, CUT VERTICALLY, AND VIEWED FROM WITHIN.

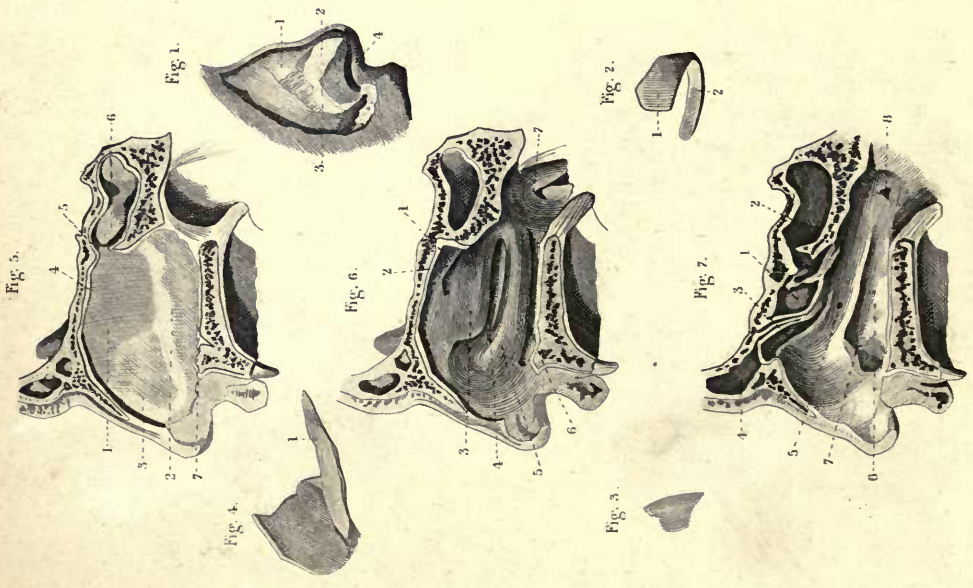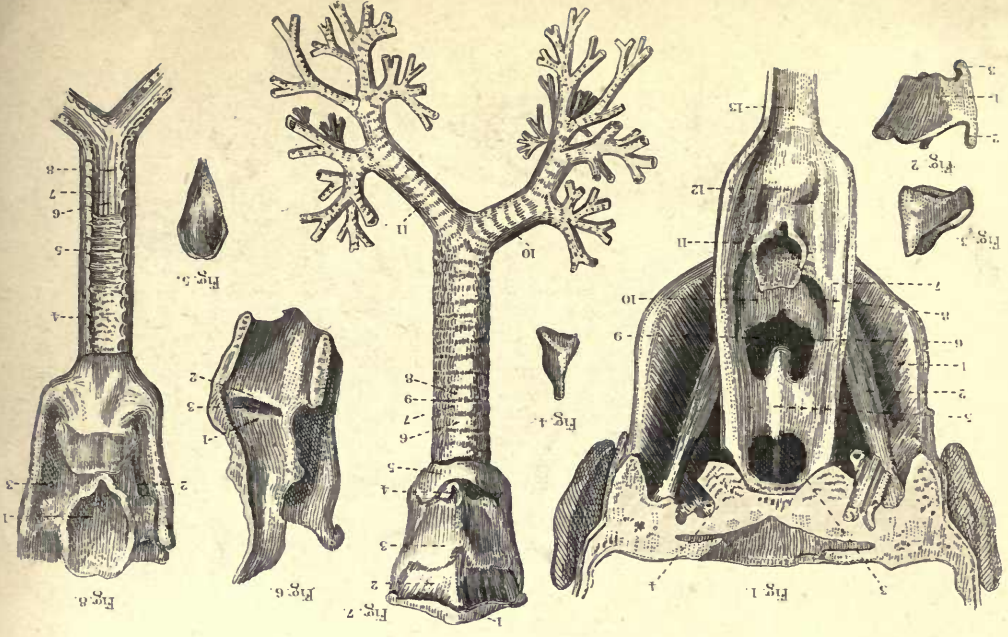
1. Upper ligament of the glottis of the left side.—2. Inferior ligament of the glottis. These ligaments form the chordæ vocales.—3. Ventricle of the larynx, called saccula laryngea.


Fig. 7. LARYNX, TRACHEA, AND BRONCHIAL TUBES, VIEWED IN FRONT.

1. Hyoid bone.—2. Thyro-hyoid membrane.—3. Thyroid cartilage.—4. Crico-thyroid membrane.—5. Cricoid cartilage.—6. Trachea.—7 and 8. Two cartilaginous rings.—9. Membrane which separates them.—10. Right bronchus and its divisions.—11. Left bronchus.

Fig. 8. LARYNX, TRACHEA, AND COMMENCEMENT OF THE BRONCHI, VIEWED FROM BEHIND.

1. Upper opening of the larynx.—2 and 3. Lateral grooves of the larynx.—4. Fibrous membrane of the trachea, interspersed with small glands, beneath which is seen, 5. The muscular fibres; beneath this last are seen, 6 and 7. Small fibrous bands, which fold, 8. The mucous membrane seen between them.—





SPLANCHNOLOGY, Pl. 6.

Fig. 1. SALIVARY GLANDS.

The body of the jaw-bone cut near the symphysis, on the right side, and at its union with the ramus. The tongue is drawn out of the mouth.

1. Sterno-cleido-mastoid.—2. Masseter.—3. Parotid gland and the duct of Steno.—4. Accessory gland, adherent to Steno's duct.—5. Glands around this canal near its termination.—6. Genio-hyo-glossus muscle.—7. Mylo-hyoid muscle, divided.—8. External portion of the sub-maxillary gland.—9. Internal portion of this gland.—10. Duct of Wharton.—11. Sub-maxillary ganglion, which inosculates with the lingual nerve.—12. Sub-lingual gland, and duct of Rivinus.

Fig. 2. VIEW OF THE MOUTH.

The right side of the lower jaw sawn near the symphysis, and removed. The right cheek is removed, and the pharynx opened on the same side.

1. Arch of the palate.—2. Velum palati.—3. Uvula.—4. Posterior pillar.—5. Anterior pillar of the velum palati.—6. Tonsil.—7. Tongue.—8. Epiglottis, beneath which is seen the upper opening of the larynx.



SPLANCHNOLOGY, Pl. 7.

Fig. 1. PINNA OF THE EAR INVESTED WITH INTEGUMENT.

1. Helix.—2. Groove of the helix.—3. Antihelix.—4. Fossa navicularis.—5. Tragus.—6. Antitragus.—7. Concha.—8. Lobule.

Fig. 2. PROPER MUSCLES OF THE PINNA.

1. Process of the helix, from which proceeds a ligament and the anterior auris muscle.—2. Great muscle of the helix.—3. Small muscle of the helix.—4. Muscle of the tragus.—5. Muscle of the anti-tragus.

Fig. 3. CARTILAGE OF THE PINNA (internal surface).

1. Transverse muscle of the pinna.
- Fig. 4. EXTERNAL EAR, PINNA, AND MEATUS AUDITORIUS EXTERNUS.

1. Pinna, viewed in profile and from behind.—2. Osseous portion of meatus auditorius.—3. Cartilaginous portion.—4. Membranous portion.

Fig. 5.—1. Bony ring of the tympanum, distinctly seen in the fetal skull.—2. Membrana tympani.

Fig. 6. INNER WALL OF THE TYMPANUM.

1. Osseous projection of the aqueduct of Fallopius.—1'. Continuation of the aqueduct of Fallopius.—2. Fenestra ovalis.—3. Promontory.—4. Fenestra rotunda.—5. Canal for the tensor tympani muscle.—6. Eustachian tube.—7. Orifice of the mastoid cells.—7'. Mastoid cells.—8. Canal of the pyramid.

Fig. 7. BONES OF THE EAR.

1. Malleus.—2. Incus.—3. Orbicular.—4. Stapes.—5. Base of the stapes.

Fig. 8. MUSCLES OF THE TYMPANUM.

1. Tensor tympani.—2. Laxator tympani.—3. Stapedius.

Fig. 9. INTERNAL EAR OR LABYRINTH.

1. Fenestra ovalis.—2. Wall of the vestibule, into which the fenestra ovalis leads.—3. Fenestra rotunda, which leads into the scala tympani of the cochlea.—4. Superior semicircular canal.—5. Inferior semicircular canal.—6. Horizontal semicircular canal.—7. Cochlea.

Fig. 10. COCHLEA, WHERE THE OUTER WALL HAS BEEN REMOVED TO SHOW THE GYRATIONS.

1. Lamina gyrorum.—2. Lamina spiralis.—3. Scala tympani.—4. Scala vestibuli.

Fig. 1.

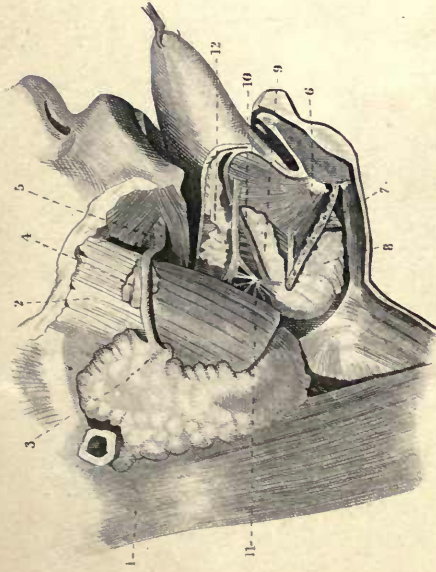


Fig. 2.


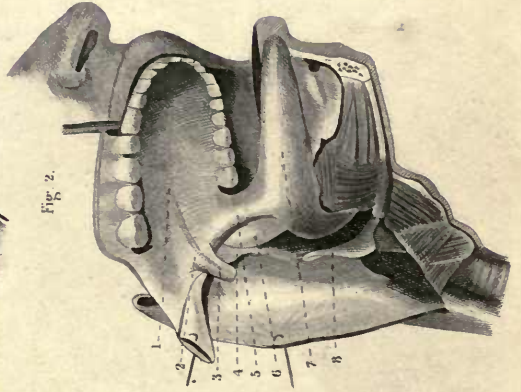


Fig. 1.



Fig. 2.

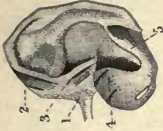

Fig. 3.

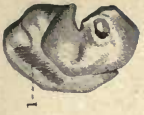

Fig. 7.

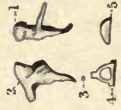

Fig. 5.

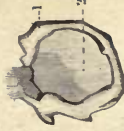

Fig. 4.

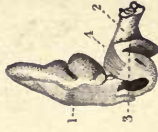

Fig. 8.



Fig. 9.



Fig. 6.

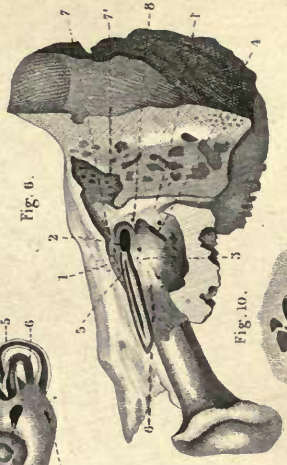



Fig. 10.





SPLANCHNOLOGY, PL. 8.

Fig. 1. RIGHT SIDE OF THE HEART SEEN IN FRONT (proper fibres).

1. Right auricle, above which is seen the vena cava superior.—2. Right ventricle.—3. Pulmonary artery.

Fig. 2. LEFT SIDE OF THE HEART SEEN IN FRONT (proper fibres).

1. Left auricle and pulmonary veins.—2. Left ventricle.—3. Aorta.

Fig. 3. Vertical section of the chest, with a view to show the course of the pleuræ.

1. Heart and pericardium.—2 and 3. Tissue of the two lungs.—4. The pleura of the right side, traced from the junction of the ribs and costal cartilages, is seen, after investing these cartilages, to be reflected on the posterior surface of the sternum, and to form, with the pleura of the left side, behind this bone, 5, the anterior mediastinum; it then invests the pericardium, 6, the anterior part of the root of the lung, the entire surface of the right lung, 7, the posterior part of the root of the lung, from which it is reflected to invest the sides of the vertebral column, so as to form, with the pleura of the opposite side, 8, the posterior mediastinum, in which is seen the œsophagus and numerous vessels; it then invests the internal surface of the ribs, and returns to its point of departure, 4, thus forming a shut sac.

Fig. 4. LARYNX, TRACHEA, PERICARDIUM, AND LUNGS VIEWED IN FRONT.

1. Larynx.—2. Trachea.—3 and 4. Lungs.—5. Pericardium.—6. Vena cava superior.—7. Arteria innominata.—8. Primitive carotid artery of the left side.—9. Left subclavian artery.

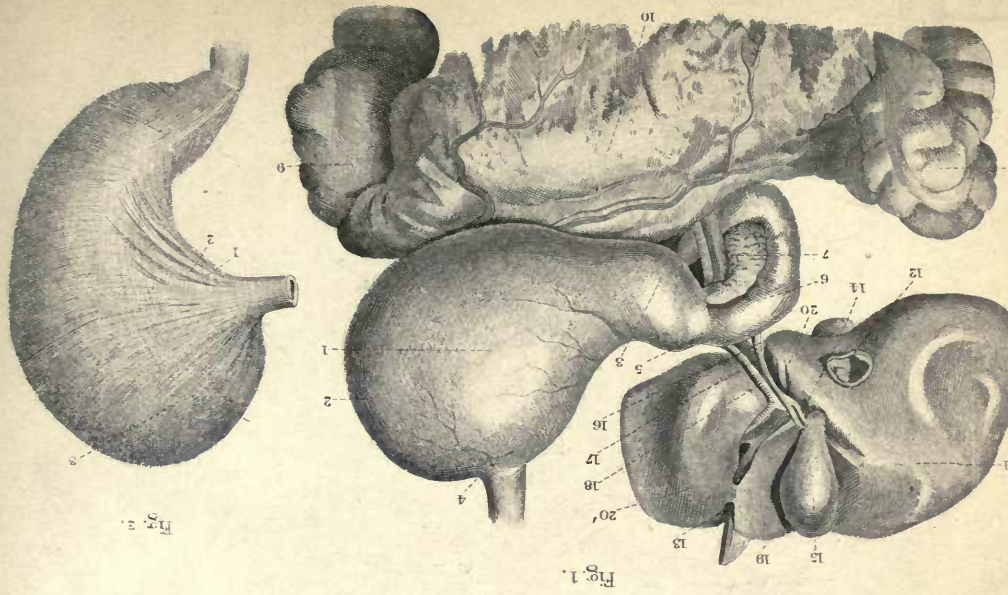
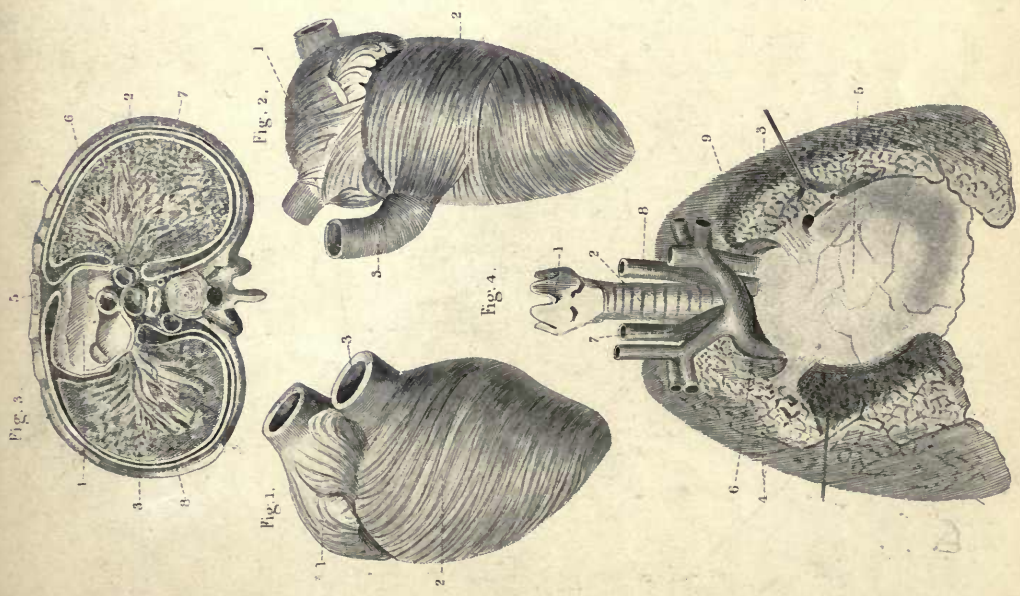
SPLANCHNOLOGY, PL. 9.


Fig. 1. THE STOMACH AND THE DUODENUM VIEWED IN FRONT, AND THE LIVER FROM BELOW.

1. Stomach.—2. Great cul-de-sac.—3. Small cul-de-sac.—4. Cardiac orifice, or cardia.—5. Pyloric orifice.—6. Duodenum.—7. Head of the pancreas, defined by the vena porta and superior mesenteric artery, which also define the extent of the duodenum as they pass in front of it.—8 and 9. Portions of the large intestine.—10. Portion of the great omentum.—11. Lower surface of the great lobe of the liver.—12. Course of the vena cava inferior.—13. Longitudinal fissure, or fissure of the umbilical vein, containing the remains of this vein, now converted into the round ligament.—14. Transverse fissure, containing the sinus of the vena portæ, branches of the hepatic artery and hepatic duct.—15. Gall bladder, terminating in the cystic duct, which unites with the hepatic duct to form, 16. The ductus communis choledochus.—17. Trunk of the vena portæ.—18. Hepatic artery.—19. Lobulus quadratus.—20. Lobulus Spigelii.—20'. Left lobe.

Fig. 2. STOMACH, FROM WHICH THE MUCOUS MEMBRANE HAS BEEN REMOVED, TO SHOW THE ARRANGEMENT OF ITS FLESHY FIBRES.

1 and 2. Small fibrous bands, from the œsophagus to the small curvature.—3. Muscular fibres passing in various directions.





THE PERITONEUM. The abdomen is opened on the right side. The peritoneum, traced from, 1, the umbilicus, invests, 2, the anterior wall of the abdomen, and passing from thence it is reflected on the lower surface of, 3, the diaphragm, and forms, 4, the suspensory ligament of the liver; at 5 the peritoneum is reflected from the diaphragm on this latter organ, and covers, 6, its superior surface.—7 represents the gall bladder, and a part of the inferior surface of the liver. As the peritoneum passes from the liver to the stomach, it forms, 8, the anterior layer of the gastro-hepatic omentum; as it passes from the stomach to the spleen, it forms, 9, the anterior layer of the gastro-splenic omentum. It enters, in the form of a cul-de-sac, 10, the foramen of Winslow; the anterior wall of this cul-de-sac is formed by the reflected portion of the anterior layer of the gastro-hepatic omentum, while the posterior layer is formed by the process of the peritoneum, which enters by the foramen of Winslow. These two layers separate at, 11, the small curvature of the stomach, and come together again at, 12, the great curvature, and form, 13, the gastro-colic, or great omentum. This is reflected upon itself, and terminates by dividing at, 14, the transverse colon (cut through). The two layers cover the colon, the one above the other below, and then, in reuniting, form, 15, the transverse meso-colon. The two layers separate above, 16, the duodenum. The upper layer covers, 17, the pancreas, and ascends to the foramen of Winslow, and of itself forms, after this division, the posterior wall of, 18, the cavity of the omentum. The lower layer, 19, reaches, 20, the small intestine, invests it, and forms, 21, the mesentery. After having formed the mesentery, it turns upon itself, goes down and covers, 22, the sigmoid flexure of the colon, and, 23, a part of the rectum; is reflected from the rectum to cover the upper part of the posterior wall of the vagina, so as to form, 24, the posterior ligament of the uterus. It then surrounds, 25, the womb, and forms, on each side, 26, the broad ligaments (one of these ligaments is cut). From the womb, it passes on the posterior wall of, 27, the bladder, forming, 28, the anterior ligaments of the uterus, returns to the umbilicus (its point of departure), surrounding the urachus and umbilical arteries, as it forms, 30, the superior ligaments of the bladder.

Fig. 1. HEART VIEWED IN FRONT.

1. Right auricle.—2. Right appendix auriculæ.—3. Vena cava superior.—4. Vena cava inferior.—5. Left auricle.—6. Left appendix auriculæ.—7 and 8. Pulmonary veins.—9. Auriculo-ventricular furrow, in which are seen the coronary vessels.—10. Groove which separates the two ventricles.—11. Right ventricle.—12. Pulmonary artery.—13. Left ventricle.—14. Aorta.

Fig. 2. RIGHT SIDE OF THE HEART LAID OPEN SO AS TO DISPLAY THE INTERIOR.

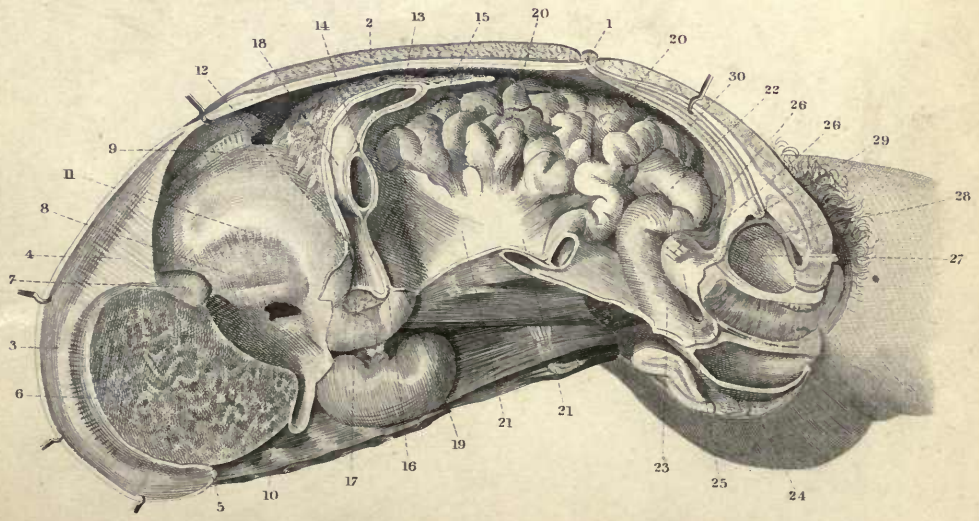
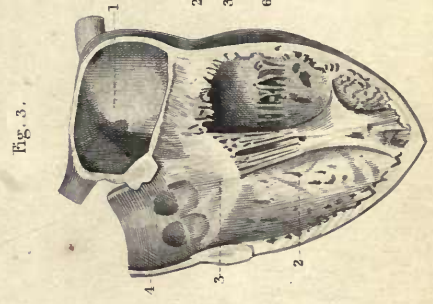
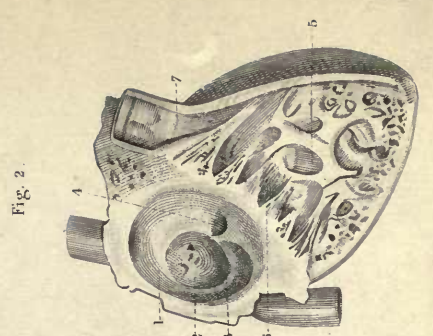
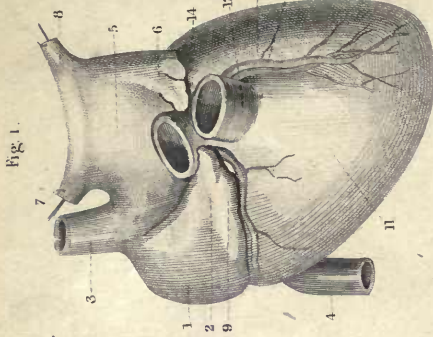
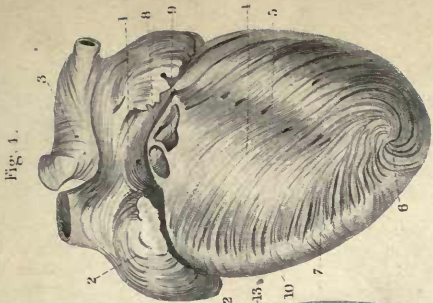
1. Cavity of the auricle.—2. Fossa ovalis.—3. Eustachian valve.—4. Orifice of the great coronary vein.—5. Cavity of the ventricle presenting the various orders of columnæ carnea. —6. One of the folds of the tricuspid valve.—7. Pulmonary artery, with two of its sigmoid valves.


Fig. 3. LEFT SIDE OF THE HEART LAID OPEN.

1. Cavity of the auricle, at the upper part of which are seen the pulmonary veins.—2. Cavity of the ventricle.—3. Mitral valve.—4. Aorta, at the origin of which are seen two sigmoid valves.

Fig. 4. HEART, WITH ITS SEROUS MEMBRANE AND FAT REMOVED TO DISPLAY THE MUSCULAR FIBRES.

1. Fibres common to the two auricles.—2. Proper fibres of the right auricle.—3. Proper fibres of the left auricle.—4. Fibres common to the two ventricles.—5. Foramina, which give passage to the coronary vessels.—6. Point of the heart where the common fibres, superficial at first, are seen to collect in a spiral form, enter into the interior of the wall of the heart, and become deep seated.—7. Raphe, where the common superficial fibres, anterior and posterior, are seen to cross each other, and become deep seated.—8 and 9. Orifices of the pulmonary artery and aorta.





SPLANCHNOLOGY, PL. 12.

Fig. 1. A portion of the internal surface of the œsophagus and stomach.

1. Smooth mucous membrane of the œsophagus.
- 2. Surface of the stomach.—3. Line of separation of the œsophagus and stomach, marked by inequalities corresponding to the cardiac orifice.

Fig. 2. VALVE OF THE PYLORUS.

- Fig. 3.*—1. Convolutions of the small intestine.—2. Cœcum, receiving the small intestines, and presenting the appendix vermiformis.—3. Ascending colon.—4. Transverse colon.—5. Descending colon.—6. Sigmoid flexure of the colon.—7. Commencement of the rectum.—8. One of the appendices epiploicæ of the large intestine.

SPLANCHNOLOGY, PL. 13.

Fig. 1. PROFILE VIEW OF THE BLADDER FROM THE RIGHT SIDE.

1. Muscular fibres passing in various directions.—1'. Neck of the bladder.—2 and 3. Ureters.—4. Urachus.—5. Vesicula seminalis.—6. Prostate gland.—7. A portion of the urethra.

Fig. 2. THE LOWER PART OF THE BLADDER, AND THE URETHRA OPENED FROM ABOVE AND FROM BEFORE.

1. Trigone vesicale, bounded by the urethra, and by, 2 and 3. The openings of the ureters.—4. Vesicula seminalis.—5. Prostate.—6. One of Cowper's glands.—7. Verumontanum, or urethral crest, where the two orifices of the ejaculatory ducts and the ducts of the prostate enter the urethra.—8 and 9. Two small cavities, known under the name of the lacunæ of Morgagni.

Fig. 3. GENITAL ORGANS: ENVELOPES OF THE TESTICLE.

1. Skin of the scrotum.—2. Dartos.—3. Lamella, which descends from the circumference of the external abdominal ring.—4. Muscular fibres of the cremaster, forming the tunica erythroides.—5. Fibrous coat.—6. Tunica vaginalis, or serous coat.—7. Testicle, enveloped in the tunica albuginea.—8. Epididymis.—9. Vas deferens.—10. Artery which accompanies it.—11. External abdominal ring.—12. Inguinal canal laid open: the spermatic cord is seen passing beneath the obliquus internus.

Fig. 4. TESTICLE CUT VERTICALLY.

1. Substance of the testicle, as if divided by bands.—1'. Tunica albuginea.—2. Tubuli seminiferi.—3. Corpus Highmorianum.—4. Ducts passing from the corpus Highmorianum, and going to, 5. The globus major of the epididymis.—6. Body of the epididymis.—7. Globus minor.—8. Vas deferens.

Fig. 3.

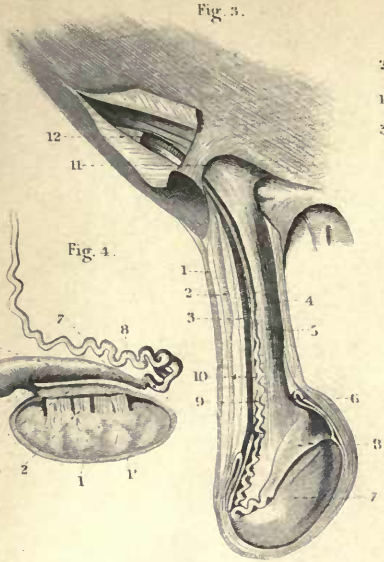


Fig. 4.

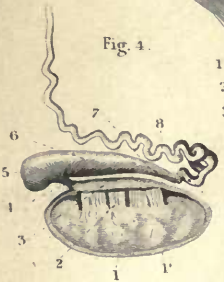


Fig. 2.

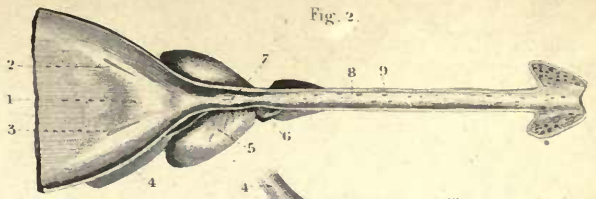


Fig. 1.

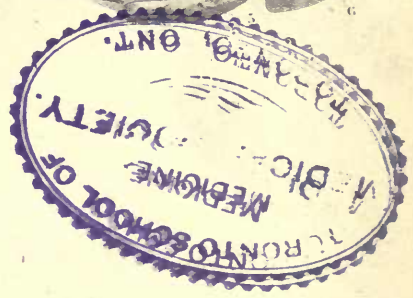
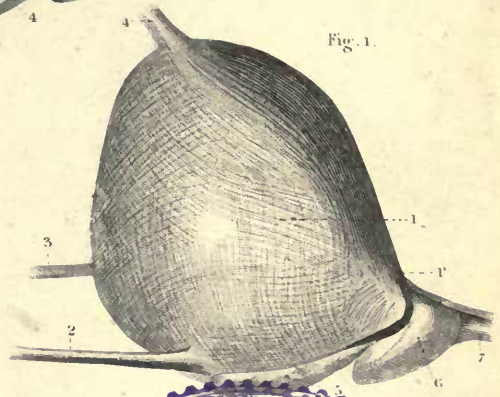


Fig. 3.

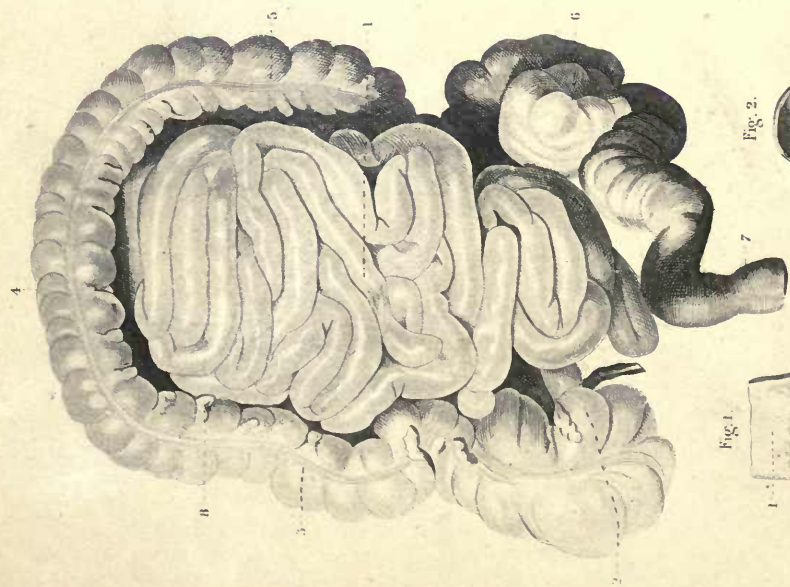
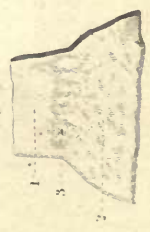


Fig. 2.



Fig. 1.





SPLANCHNOLOGY, PL. 14.

GENITAL ORGANS. Pelvis divided in the median line, and laid open from the right side.

1. Vertebral column.—2. Termination of the large intestine.—3. Bladder.—4. Ureter.—5 and 6. Vasa deferentia.—7. One of the vesiculæ seminales, opening into the vas deferens to form, 8. The ductus ejaculatorius communis.—9. Prostate.—10. Membranous portion of the urethra.—11. Triangular ligament.—12. One of Cowper's glands.—13. Urethra.—14. Bulb of the urethra.—15. Glans penis.—16. Septum scroti: the right testicle and its envelopes have been removed.—17. Skin of the penis.—18. Prepuce.—18'. Frænum preputii.—19. Corpus cavernosum, cut so as to show its membrane, its structure, and its artery.—20. Septum pectiniforme of the corpus cavernosum.

SPLANCHNOLOGY, PL. 15.

Fig. 1. PORTION OF THE SMALL INTESTINE OPENED TO SHOW THE VALVULÆ CONNIVENTES, OR THE VALVES OF KERRINGIUS.

Fig. 2. CÆCUM LAID OPEN.

1. Lower extremity of the small intestine.—2. Appendix vermiformis.—3. Orifice of this appendix.—4. Opening of the small intestine in the cœcum.—5 and 6. Segments of the ilio-cæcal valve, or the valve of Bauhin.

Fig. 3. SPLEEN.

1 and 2. Fissures which are sometimes observed upon its borders.—3 and 4. Two of the vascular apertures, by whose union is formed the fissure of the spleen.

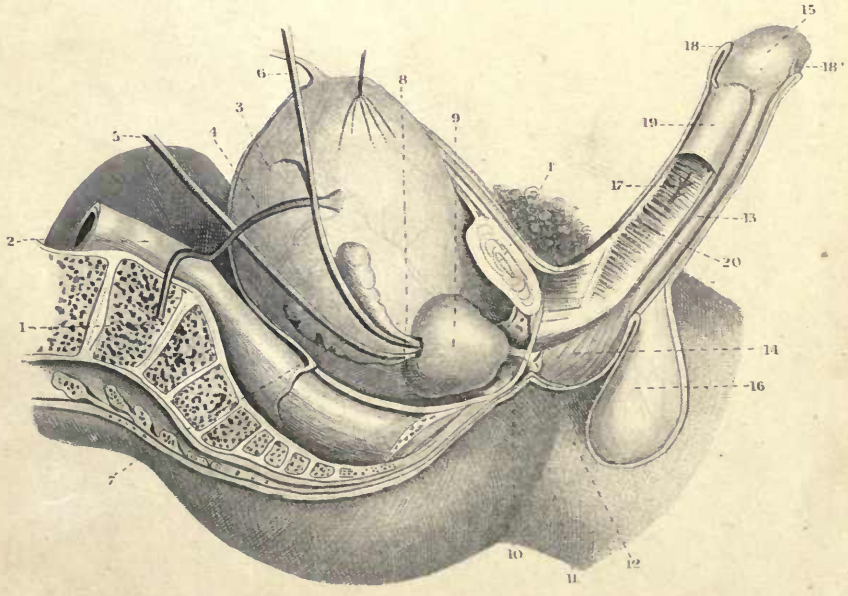
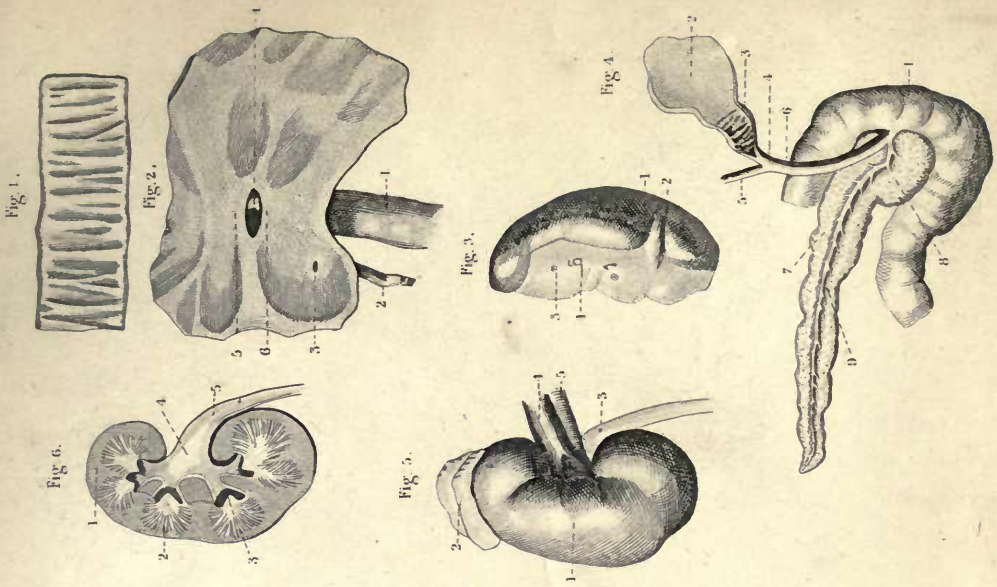
Fig. 4. BILIARY AND PANCREATIC DUCTS VIEWED IN FRONT.


1. Duodenum.—2. Gall bladder laid open.—3. Small valvular folds.—4. Cystic duct.—5. Hepatic duct.—6. Ductus communis choledochus.—7. Pancreas.—8. Head of the pancreas.—9. Pancreatic duct, or the canal of Wirsung.


Fig. 5.—1. Supra-renal capsulæ.—2. Kidney.—3. Ureter.—4 and 5. Renal artery and vein.

Fig. 6. KIDNEY CUT THROUGH THE MIDDLE.

1. Cortical substance.—2. Cone of tubular substance, terminating by a papilla which is embraced by a calyx.—3. A calyx laid open.—4. Pelvis.—5. Ureter.







SPLANCHNOLOGY, Pl. 16.

Fig. 1. GENITAL ORGANS OF THE FEMALE.

1. One of the broad ligaments of the uterus.—2. Round ligaments.—3. Round ligament, terminating in a pes anserinus.—4. Ovary and its ligament.—5. Fallopian tube, terminating in its fibrillated extremity.—6. Body of the womb.—7. Neck.—8. Os Tince.

Fig. 2. THE POSTERIOR HALF OF THE UTERUS AFTER A PERNICULAR TRANSVERSE SECTION OF IT HAS BEEN MADE.

1. Cavity of the body of the uterus: it is continuous with, 2. The cavity of the Fallopian tubes, and, 3. The cavity of the neck. In this last cavity there is seen an arborescent projection, called the arbor vitæ of the womb.—4. Ligament of the ovary.

Fig. 4. WOMB DIVIDED INTO TWO LATERAL HALVES: THE LEFT HALF IS HERE SHOWN. THE BLADDER, THE URETHRA, THE VAGINA, AND THE RECTUM ARE OPENED.

1. Bladder.—2. Utrachus.—3. Anterior ligament of the bladder.—4. Urethra.—5. Rectum.—6. Lacunæ at the inferior extremity of the rectum.—7. Fallopian tube.—8. Ovary.—9. Uterus: the peritoneum is seen to envelop it, and to pass from thence on the bladder and on the rectum.—10. Vagina.—11 and 12. Anterior and posterior pillars of the vagina.—13. Clitoris.

Fig. 5. EXTERNAL GENITAL ORGANS.

1. Mons Veneris.—2. Labium major.—3. Labium minus at its upper extremity it divides into two folds, one of which terminates below the clitoris; the other unites with a similar fold of the labium minus of the opposite side, to form a sort of prepuce to the clitoris.—4. Clitoris, of which only the anterior extremity is seen.—5. Vestibule.—6. Meatus urinarius.—7. Entrance of the vagina.—8. Fourchette.—9. Fossa navicularis.—10. Anus.—11. Perineum.

Fig. 6.—1 and 2. Labia minora.—3. Clitoris, root, body, and glans.—4. Suspensory ligament of the clitoris.—5. Corpus cavernosum, in its course to terminate in the glans clitoridis

ANGIOLOGY, Pl. 1.

Fig. 1. ARTERIES OF THE CEREBRUM, CEREBELLUM, &c., &c.*

1. Anterior lobe of the brain.—2. Posterior lobe.—3. Fissure of Sylvius.—4. Pons Varolii.—5. Cerebellum.—6. Medulla oblongata.—7. Trunk of the internal carotid artery, cut.—8. Posterior communicating artery.—8'. Artery of the choroid plexus (one part of the middle lobe is removed).—9. Anterior cerebral artery.—10. Anterior cerebral artery after it has become united to the corresponding artery of the opposite side by the, 11. Anterior communicating artery.—12. Vertebral artery.—13. Posterior and inferior cerebellar artery.—14. Basilar artery.—15. Anterior and inferior cerebellar artery.—16. Superior cerebellar artery.—17. Posterior cerebral artery, anastomosing with the internal carotid by means of the posterior communicating artery. Between it and the superior cerebellar artery is seen the third pair of nerves.

Fig. 2. VERTEBRAL AND CERVICALIS PROFUNDA ARTERIES. A LATERAL VIEW OF THE VERTEBRAL COLUMN, AND A PORTION OF THE BASE OF THE CRANIUM.

1. Portion of the subclavian artery.—2. Common trunk of the vertebral artery and of the cervicalis profunda.†.—3. Vertebral artery in the canal formed by the transverse processes.—4. Vertical curve of this artery.—5. Horizontal curve.—6. Vertebral artery within the cranium.—7. Basilar artery and its branches.—8. Cervicalis profunda.—9 and 10. Anastomoses between this artery and the vertebral.—11. End of the transversospinalis muscle.

Fig. 3. ARCH AND THORACIC PORTION OF THE AORTA. THE RIBS HAVE BEEN SAWN THROUGH NEAR THE VERTEBRAL COLUMN.

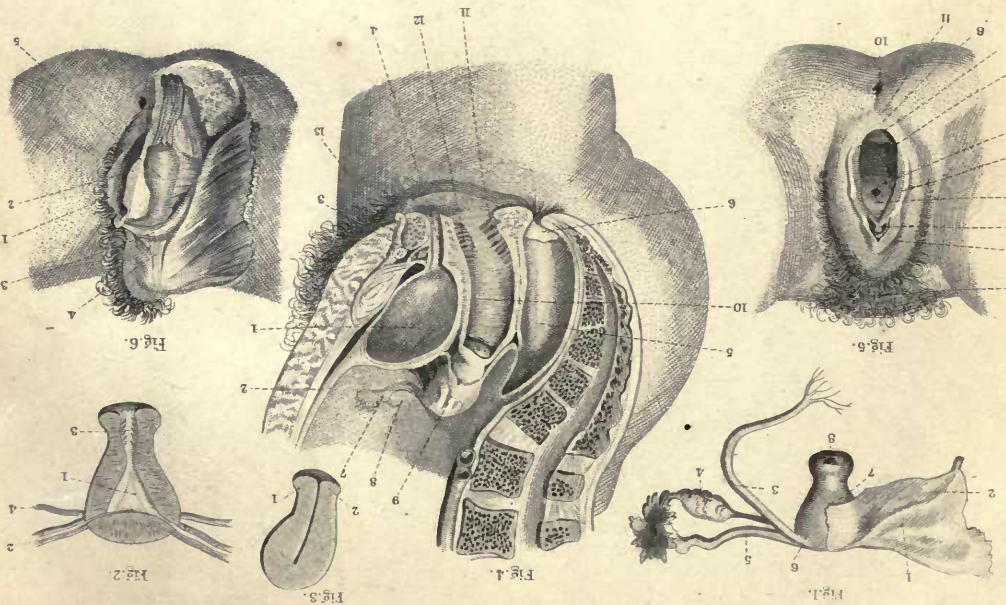
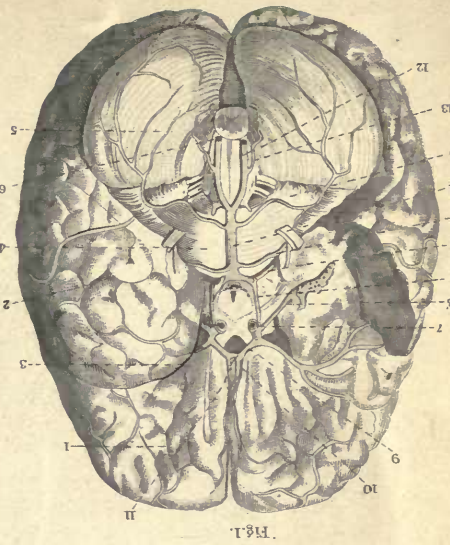
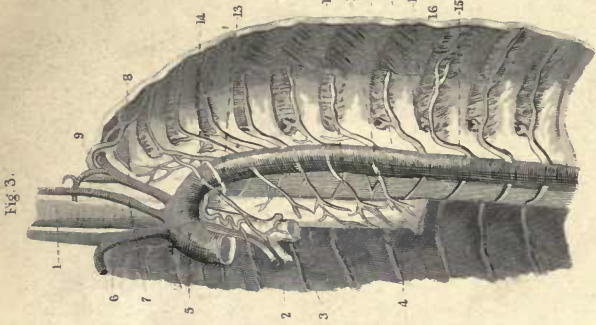
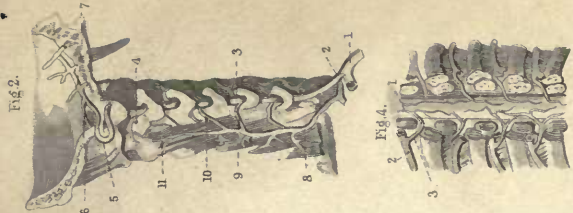
1. Trachea.—2 and 3. Bronchi.—4. Œsophagus.—5. Arch of the aorta.—6. Arteria innominata.—7. Primitive left carotid.—8. Left subclavian.—9. Superior intercostal, arising from a common trunk with the inferior thyroid.†.—10. Thoracic aorta.—11 and 12. Œsophageal arteries.—13 and 14. Bronchial arteries.—15. One of the inferior intercostal arteries.—16. Infercostal branch.—17. Dorsal branch.—18. Spinal branch.


Fig. 4. SPINAL ARTERIES. The body of the vertebræ is removed, and the vertebral canal is opened in front.

1. Spinal marrow, with its membranes in the vertebral canal.—2. An intercostal artery.—3. A spinal artery entering through an intervertebral foramen, and furnishing branches to the walls of the canal, to the spinal marrow, and to its membranes.

* See diagram of circle of Willis (Plate 63).

† The cervicalis profunda does not arise in common with the vertebral artery, as here described; on the contrary, it arises as an independent branch, and usually comes off from the subclavian artery, as it lies under cover of the scalenus anticus. ‡ This is not its usual origin.





ANGEOLOGY, Pl. 2.

Fig. 1. LINGUAL ARTERY. The inferior maxilla is sawn through.

1. Os Hyoides.—2. Ilio glossus, divided to show the course of the lingual artery.—3. Stylo-glossus muscle.—4. Genio-glossus.—5. External carotid artery.—6. Lingual artery.—7. Dorsal artery of the tongue.

Fig. 2. INTERNAL MAXILLARY ARTERY.* The right side of the cranium has been removed, all the upper part of the inferior maxilla, the external table of the rest of the bone, and the outer wall of the orbit.

1. External carotid artery.—2. Occipital artery and its mastoid branch.—3. Posterior auricular and the stylo-mastoid branch.—4. Superficial temporal and the anterior auricular branches.—5. Middle temporal artery.—6. Internal maxillary artery, which gives off the meningea media, which enters the cranium by the foramen spinosum, and the meningea parva, which enters by the foramen lacerum jugulare.—6'. Division of the middle meningeal artery.—6'', 6'''. Anterior meningeal branches, furnished by the ophthalmic artery.—6''', 6'''. Divisions of the posterior meningeal within the cranium.—7. Inferior dental.—7'. Same artery in the dental canal.—8. Masseteric.—9. Pterygoid.—10. Buccal.—11. Facial, anastomosing with the buccal.—12. Alveolar and posterior dental branches.—13. Infra-orbital.—13'. Same artery, as it appears on the face, passing through the infra-orbital foramen.—14, 14. Deep temporal.—15. Internal maxillary in its passage through the pterygo-maxillary fissure.

Fig. 3. INTERNAL MAXILLARY ARTERY ENTERING THE SPHENOIDAL FORAMEN, WHICH NAME IT TAKES

1. Pterygoid process.—2. Infra-orbital artery.—3. Palatine.—4. Vidian, or pterygoid.—5. Pterygo-palatine

Fig. 4. OPHTHALMIC ARTERY. The outer wall of the orbit is removed, and the carotid canal laid open.

1. Anterior dental artery in its canal.—2. Posterior dental branches.—3. Internal carotid.—4. Ophthalmic.—5. Arteria centralis retinae.—6. Lachrymalis.—7. Muscular branch.—8. Supra-orbital.—9. One of the long ciliary arteries.—10. An anterior ciliary artery.—11. Ethmoidal arteries.—12. Palpebral.—13. Termination of the ophthalmic artery in the frontal and nasal branches.

Fig. 5. OPHTHALMIC ARTERY, THE EYE BEING REMOVED.

1. Ophthalmic.—2. Inferior muscular branch.—3.—Superior palpebral.—4. Inferior palpebral.

* See diagram on Plate 57.

ANGEOLOGY, Pl. 3.

HEART, ARCH OF THE AORTA, ARTERIA INNOMINATA, CAROTID AND SUBCLAVIAN ARTERIES,* &c., &c.

The sternum is sawn through, and the thorax is opened on the left side.

1. Heart.—2. Left coronary artery.—3. Right coronary artery.—4. Pulmonary artery, cut through.—5. Arch of the aorta.—6. Arteria innominata.—7. Right primitive carotid.—8. Left subclavian artery.—9. Division of the arteria innominata into the right primitive carotid and right subclavian.—10. Division of the primitive carotid into external and internal carotid.—11. Superior thyroid artery and its principal branches.—12. Lingual artery.—13. Facial artery.—14. Inferior palatine artery.—15. Submental artery.—16. Inferior coronary artery.—17. Superior coronary artery.—18. One of the branches of the lateralis nasi.—19. Occipital artery.—20. Posterior auricular artery.—21. Ascending pharyngeal artery.—22. Division of the external carotid artery into internal maxillary and superficial temporal.—23. Transverse facial artery.—24. One of the anterior auricular branches.—25. Middle temporal artery.—25'. The arteria cervicalis ascendens, a branch of the inferior thyroid artery.—26. Vertebral artery.—27. Place where the vertebral artery enters the canal of the transverse processes.—28. Superior intercostal artery.—29. The supra-scapular artery.—30. The transversalis colli artery.—31. Internal mammary artery.—32. Anterior mediastinal artery.—33. Superior phrenic artery.

* See diagrams on Plate 62.

Fig. 2.

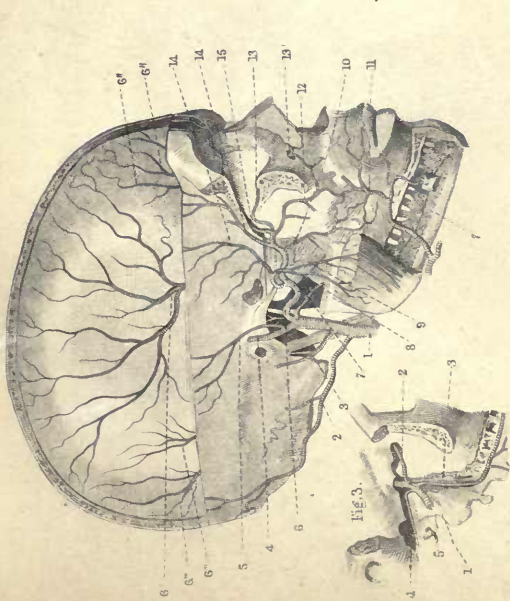
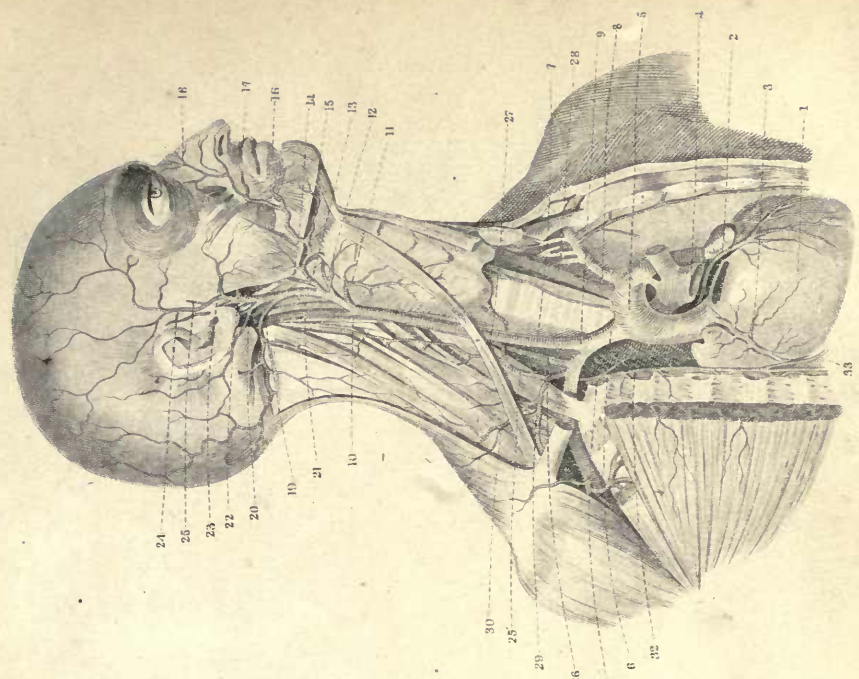
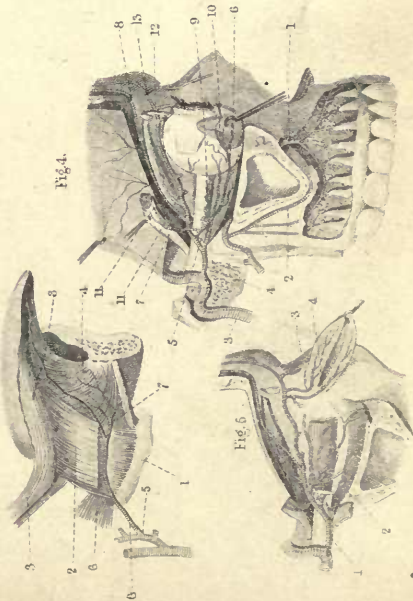


Fig. 1.






Fig. 1. A DIAGRAM OF THE CAROTID ARTERIES AND THE BRANCHES OF THE EXTERNAL CAROTID (after Wilson).

1. The common carotid.—2. The external carotid.—3. The internal carotid.—4. The carotid foramen in the petrous portion of the temporal bone.—5. The superior thyroid artery.—6. The lingual artery.—7. The facial artery.—8. The mastoid artery.*—9. The occipital artery.—10. The posterior auricular artery.—11. The transverse facial artery.—12. The internal maxillary artery.—13. The temporal artery.—14. The ascending pharyngeal artery.

Fig. 2. A DIAGRAM OF THE ARTERIES OF THE BASE OF THE BRAIN—THE CIRCLE OF WILLES (after Wilson).

The branches of the arteries have references only on one side, on account of their symmetrical distribution.

1. The vertebral arteries.—2. The two anterior spinal branches, uniting to form a single vessel.—3. One of the posterior spinal arteries.—4. The posterior meningeal artery.—5. The inferior cerebellar artery.—6. The basilar artery, giving off its transverse branches to either side.—7. The superior cerebellar artery.—8. The posterior cerebral artery.—9. The posterior communicating branch of the internal carotid artery.—10. The internal carotid artery, showing the curvatures it makes within the skull.—11. The ophthalmic artery divided across.—12. The middle cerebral artery.—13. The anterior cerebral arteries connected by, 14. The anterior communicating artery.

* More often a branch of the superior thyroid artery.

Fig. 3. A DIAGRAM OF THE LARGE VESSELS OF THE THORAX AND THEIR RELATIONS (after Wilson).

1. The ascending aorta.—2. The arch.—3. The thoracic portion of the descending aorta.—4. The arteria inguinata dividing into, 5, the right carotid, which again divides at 6 into the external and internal carotid; and 7, the right subclavian artery.—8. The axillary artery; its extent is designated by a dotted line.—9. The brachial artery.—10. The right pneumogastric nerve running by the side of the common carotid, in front of the right subclavian artery, and behind the root of the right lung.—11. The left common carotid, having to its outer side the left pneumogastric nerve, which crosses the arch of the aorta, and, as it reaches its lower border, is seen to give off the left recurrent nerve.—12. The left subclavian artery, becoming axillary, and brachial in its course, like the artery of the opposite side.—13. The trunk of the pulmonary artery connected to the concavity of the arch of the aorta by a fibrous cord, the remains of the ductus arteriosus.—14. The left pulmonary artery.—15. The right pulmonary artery.—16. The trachea.—17. The right bronchus.—18. The left bronchus.—19, 19. The pulmonary veins. 17, 15, and 19, on the right side, and 14, 18, and 19, on the left, constitute the roots of the corresponding lungs, and the relative position of these vessels is carefully preserved.—20. Bronchial arteries.—21, 21. Intercostal arteries; the branches from the front of the aorta above and below the number 3 are pericardiac and œsophageal branches.

FIG. 1.

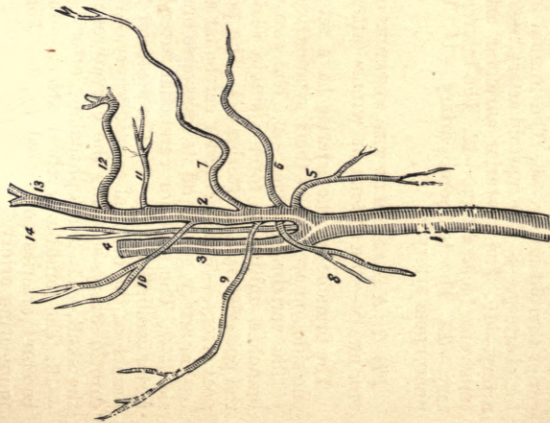


FIG. 2.

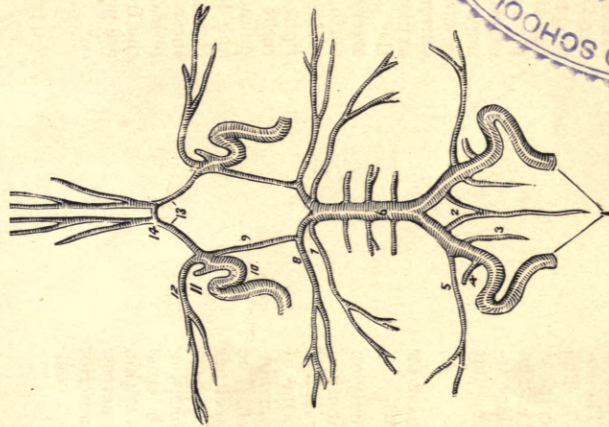
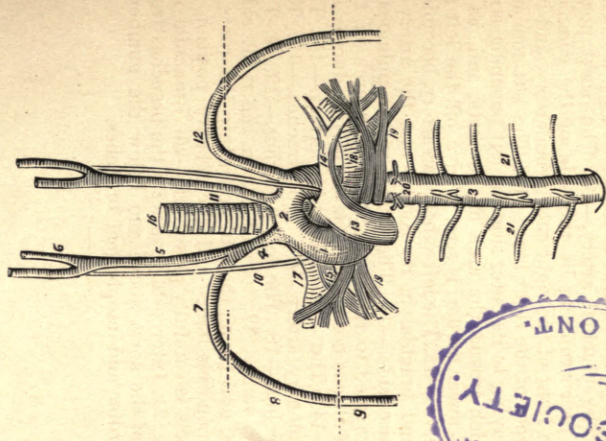


FIG. 3.



ANGEIOLOGY, PL. 5.

Figs. 1 and 2. ARTERIES OF THE AXILLA, ARM, AND HAND.

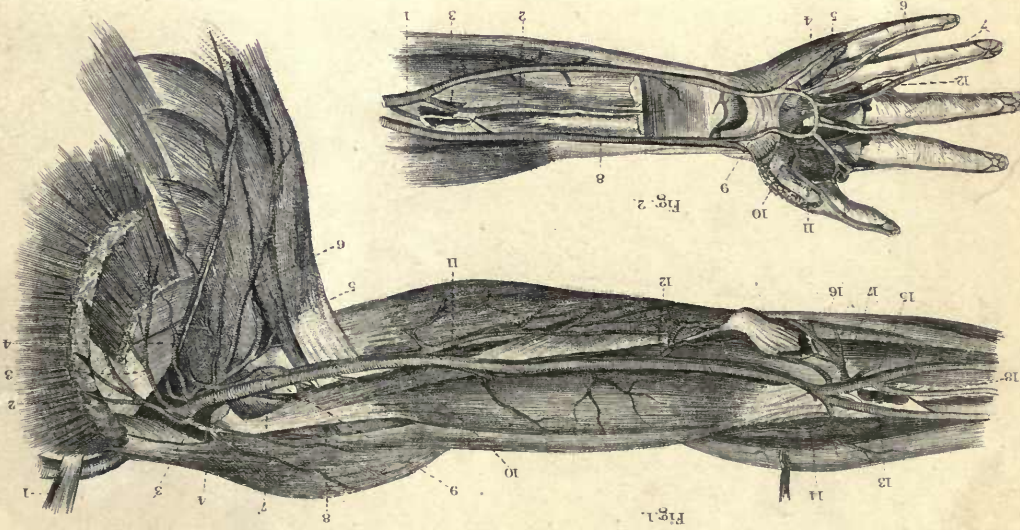
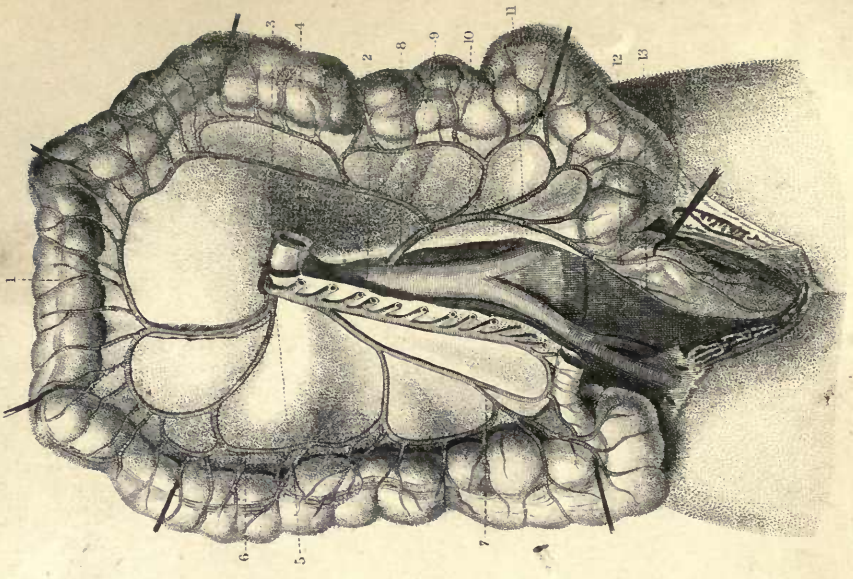
Fig. 1. Scalenus anticus muscle, behind which passes the subclavian artery.—2 and 3. Anterior thoracic arteries.—3'. Acromial artery.—4. External mammary artery.—5. Posterior branch of the subscapular artery.—6. Anterior branch of the same artery.—7 and 8. Anterior circumflex artery.—9. Posterior circumflex artery.—10. Brachial artery.—11. Superior profunda artery.—12. Inferior profunda.—13. Radial artery.—14. Anterior radial recurrent.—15. Ulnar artery.—16. Anterior ulnar recurrent.—17. Posterior ulnar recurrent.—18. Interosseous artery.

Fig. 2.—1. Ulnar artery.—2. Anterior interosseous.—3. Posterior interosseous.—4. Superficial palmar arch.—5. One of the collateral branches of the fingers.—6 and 7. Two digital arteries.—8. Radial artery.—9. Superficialis volæ.—10. Deep palmar arch.—11. A posterior perforating artery.—12. One of the anterior perforating arteries.

ANGEIOLOGY, PL. 6.

RIGHT AND LEFT COLIC ARTERIES. The small intestine is here removed.

1. Large intestine.—2. Aorta.—3. Superior mesenteric artery.—4. One of its branches for the small intestine, cut near its origin.—5. Superior right colic artery, or colica media, a branch of the superior mesenteric artery.—6. Arch formed by the middle colic artery.—7. Inferior right colic, or colica dextra.—8. Inferior mesenteric artery.—9. Superior left colic.—10. Middle left colic.—11. Inferior left colic [these three branches are often described as forming the colica sinistra].—12 and 13. Superior hæmorrhoidal arteries.





SUPERIOR MESENTERIC ARTERY. The small intestines are drawn downward and to the left, the large intestines are raised upward and to the right.

1. Small intestines.—2. Cæcum.—3. Appendix vermiformis cæci.—4. Ascending colon.—5. Transverse colon.—6. Superior mesenteric artery, giving off from its convexity the arteries of the small intestines, which form a sort of network before they reach the intestine.—7. Superior right colic artery.—8. Middle colic [both 7 and 8 form really the middle colic arteries].—9. Inferior colic, or colica dextra.

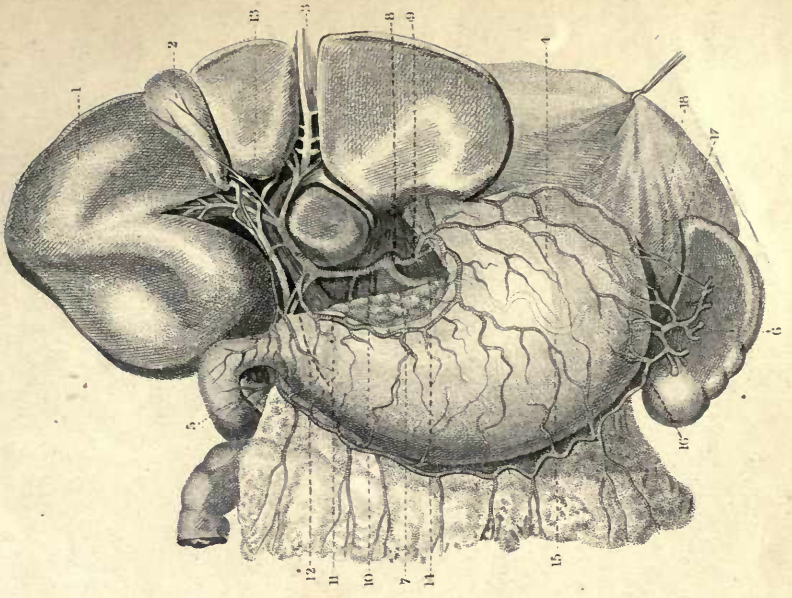
CELIAC AXIS.*

The liver is elevated so as to show its lower surface.

1. Liver.—2. Gall bladder.—3. Cord, or, as it is called, the rounded ligament, the remains of the umbilical vein.—4. Stomach.—5. Commencement of the duodenum.—6. Spleen.—7. Pancreas.—8. Celiac axis.—9. Coronary artery of the stomach, giving origin to the œsophageal branches, and passing along the small curvature of the stomach.—10. Hepatic artery.—11. Pyloric artery.—12. Gastro-epiploica dextra, passing down behind the duodenum, and along the great curvature of the stomach.—13. Cystic artery.—14. Splenic artery.—15. Flexuous line, showing the course of the splenic artery behind the stomach.—16. Gastro-epiploica sinistra.—17 and 18. *Vasa brevia.*

* See diagrammatic figure in Plate No. 67

Pl. 66.



Pl. 65.

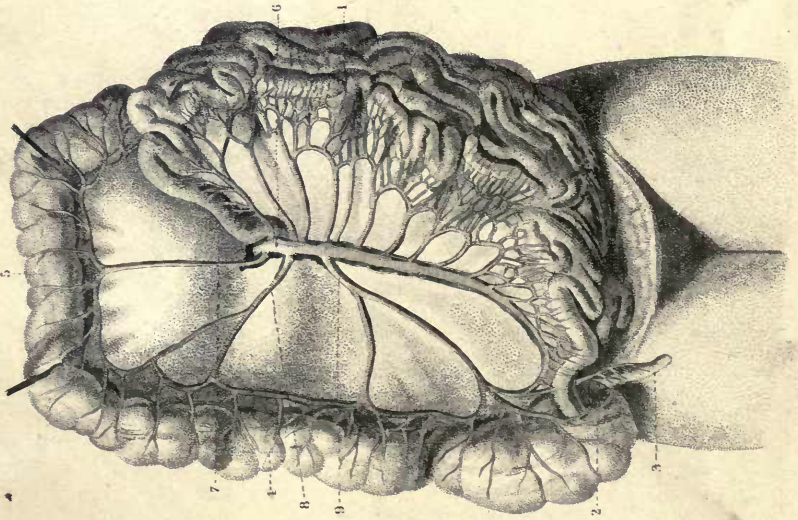




Fig. 1. A DIAGRAM OF THE INTERNAL MAXILLARY ARTERY, ITS DIVISIONS AND BRANCHES (after Wilson).

1. The external carotid artery.—2. The trunk of the transverse facial artery.—3, 4. The two terminal branches of the external carotid.—3. The temporal artery; and 4. The internal maxillary, the first or *maxillary portion* of its course; the limit of this portion is marked by an arrow.—5. The second, or *pterygoid portion*, of the artery; the limits are bounded by the arrows.—6. The third or *pterygo-maxillary portion*. The branches of the maxillary portion are, 7. A tympanic branch.—8. The arteria meningeae magna.—9. The arteria meningeae parva.—10. The inferior dental artery. The branches of the second portion are wholly muscular, the ascending ones being distributed to the temporal, and the descending to the four other muscles, the two pterygoids, the masseter and buccinator. The branches of the pterygo-maxillary portion of the artery are, 11. The alveolar or superior dental artery.—12. The infra-orbital artery.—13. The posterior palatine.—14. The sphenopalatine or nasal.—15. The pterygo-palatine.—16. The Vidian.* The remarkable bend which the third portion of the artery makes as it turns inwards to enter the pterygo-maxillary fossa.

Fig. 2. A DIAGRAM OF THE RIGHT SUBCLAVIAN ARTERY AND ITS BRANCHES (after Wilson).

1. The arteria innominata.—2. The right carotid.—3. The first portion of the subclavian artery.—4. The second portion.—5. The third portion.—6. The vertebral artery.—7. The inferior thyroid.—8. The thyroid axis.—9. The superficialis cervicis.—10. The profunda cervicis.—11. The posterior scapular or transversalis colli.—12. The supra-scapular.—13. The internal mammary artery.—14. The superior intercostal.

Fig. 3. A DIAGRAM OF THE ABDOMINAL AORTA AND ITS BRANCHES (after Wilson).

1. The phrenic arteries.—2. The coeliac axis.—3. The gastric artery.—4. The hepatic artery, dividing into the right and left hepatic branches.—5. The splenic artery, passing outward to the spleen.—6. The suprarenal artery of the right side.—7. The right renal artery, which is longer than the left, passing outward to the right kidney.—8. The lumbar arteries.—9. The superior mesenteric artery.—10. The two spermatic arteries.—11. The inferior mesenteric artery.—12. The sacra media.—13. The common iliacs.—14. The in-

ternal iliac of the right side.—15. The external iliac artery.—16. The epigastric artery.—17. The circumflex ili artery.—18. The femoral artery.

Fig. 4. A DIAGRAM OF THE ILLAC ARTERIES AND THEIR BRANCHES (after Wilson).

1. The aorta.—2. The left common iliac artery.—3. The external iliac.—4. The epigastric artery.—5. The circumflex ili.—6. The internal iliac artery.—7. Its anterior trunk.—8. Its posterior trunk.—9. The umbilical artery giving off (10) the superior vesical artery.—11. The internal pudic artery passing behind the spine of the ischium (12) and lesser sacro-ischiatric ligament.—13. The middle haemorrhoidal artery.—14. The ischiatic artery, also passing behind the anterior sacro-ischiatric ligament to escape from the pelvis.—15. Its inferior vesical branch.—16. The ilio-lumbar, the first branch of the posterior trunk (8) ascending to anastomose with the circumflex ili artery (5) and form an arch along the crest of the ilium.—17. The obturator artery.—18. The lateral sacral.—19. The gluteal artery, escaping from the pelvis through the upper part of the great sacro ischiatic foramen.—20. The sacra media.—21. The right common iliac artery cut short.—22. The femoral artery.

Fig. 5. A DIAGRAM OF THE BRANCHES OF THE COELIAC AXIS (after Wilson).

1. The liver.—2. Its transverse fissure.—3. The gall bladder.—4. The stomach.—5. The entrance of the oesophagus.—6. The pylorus.—7. The duodenum, its descending portion.—8. The transverse portion of the duodenum.—9. The pancreas.—10. The spleen.—11. The aorta.—12. The coeliac axis.—13. The gastric artery.—14. The hepatic artery.—15. Its pyloric branch.—16. The gastro-duodenalis.—17. The gastro-epiploica dextra.—18. The pancreatico-duodenalis, anastomulating with a branch from the superior mesenteric artery.—19. The division of the hepatic artery into its right and left branches; the right giving off the cystic branch.—20. The splenic artery, traced by dotted lines behind the stomach to the spleen.—21. The gastro-epiploica sinistra, anastomulating along the great curvature of the stomach with the gastro-epiploica dextra.—22. The pancreatica magna.—23. The vasa bravia to the great end of the stomach, anastomulating with branches of the gastric artery.—24. The superior mesenteric artery, emerging from between the pancreas and the transverse portion of the duodenum.

Fig 1.

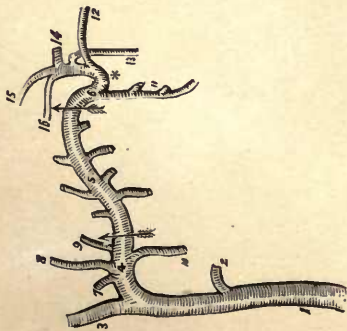


Fig 3.

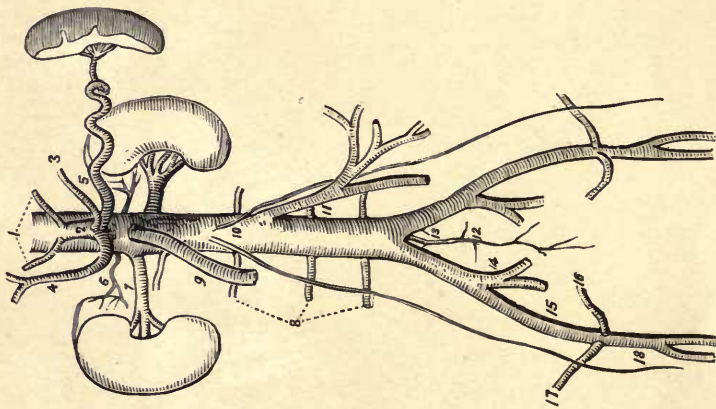


Fig 2.

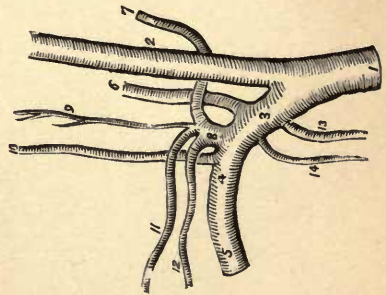
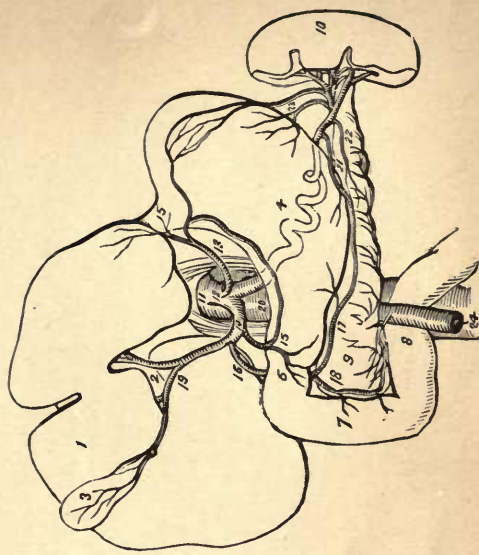


Fig 4.

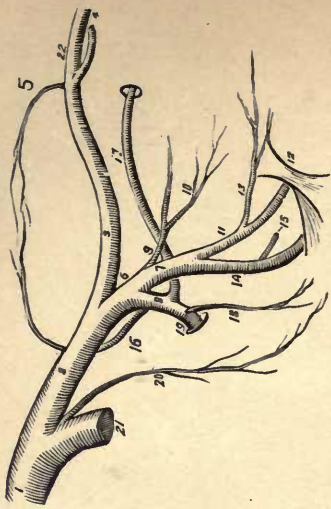

Fig 5.



ANGEIOLOGY, PL. 10.

ARTERIES OF THE ABDOMEN.*

1. Diaphragm.—2. Kidney.—2'. Supra-renal capsule.—3. Aorta.—4. Cœliac axis (cut).—5. Superior mesenteric artery (cut).—6. Inferior mesenteric artery (cut).—7. Superior capsular artery; the middle comes from the aorta, the inferior from the renal artery.—8. Renal artery.—9. One of the spermatic arteries.—10. One of the lumbar arteries.—11. One of the phrenic arteries.—12. Middle sacral artery.—13. Division of the aorta into the primitive iliacs.—14. Division of a primitive iliac artery into the external and internal iliacs: the latter is frequently named the hypogastric artery.—15. Circumflex iliac.—16. Epigastric artery.

* See diagrammatic figure in Plate No. 67.

ANGEIOLOGY, PL. 11.

Fig. 1. ARTERIES OF THE THIGH.

1. Sartorius, cut.—2. Ring of the adductor magnus, through which the femoral artery passes.—3. Superficial femoral artery.—4. Superficial epigastric.—5. Profunda.—5', 5'', 5'''. Perforating arteries.—6. Internal circumflex artery.—7. External circumflex.—8. Great, or superficial muscular artery.—9 and 10. External pudic arteries.—11. The termination of the femoral in the popliteal artery.

Fig. 2. POPLITEAL ARTERY, AND THE ARTERIES ON THE POSTERIOR PART OF THE LEG

1. Popliteal artery.—2 and 3. Arteries which supply the gastrocnemii, the muscles here cut, and their bellies removed.—4 and 5. Superior internal articular arteries.*—6. Superior external articular artery.—7. Inferior internal articular artery.—8. Inferior external articular artery.—9. Division of the popliteal artery into, 10. Anterior tibial artery, and, 11. Peroneo-tibial artery.†—12. Peroneal artery.—13. Posterior tibial artery.

Fig. 3. SOLE OF THE FOOT.

1. Posterior tibial artery.—2. Internal plantar artery.—3. External plantar.—4. Plantar arch.—5. Perforating artery.—6. One of the collateral branches.—7. Division of a collateral into two branches.—8. Anastomosis of one of those branches with a neighbouring branch, and, 9. Division of this anastomosis into two digital branches.—10. Anastomosis of two digital branches.—11. Termination of two digital branches in the form of an arch, and the arterial plexus which results from it.

* The upper internal articular artery, indicated in this *fig.* by 4, is frequently wanting. Anatomists in general, even when this branch is present, describe only one internal articular, viz., the vessel designated by *fig.* 5.

† Anatomists frequently describe the popliteal artery as dividing, at its termination, into the anterior and posterior tibial arteries; ‡2, the peroneal artery, being considered a branch of the posterior tibial.

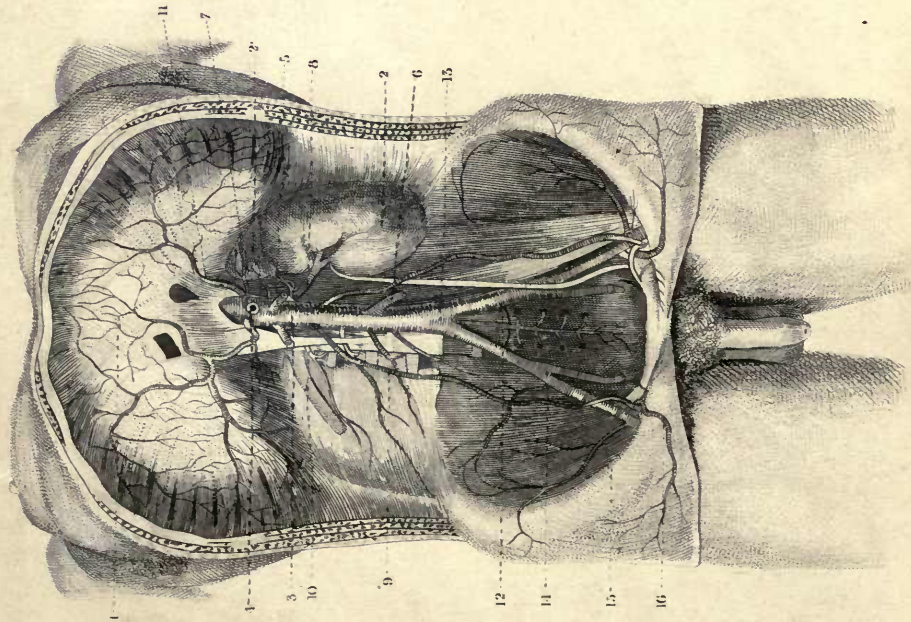


Fig. 1.

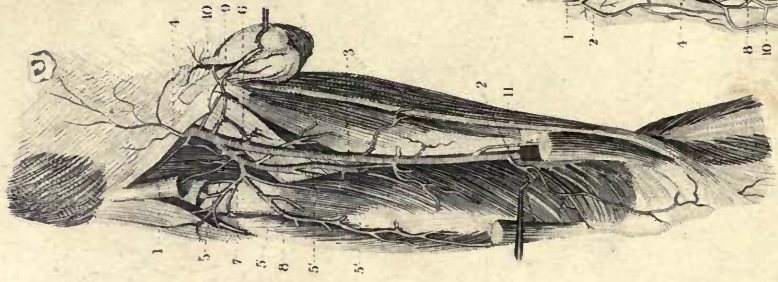


Fig. 3.

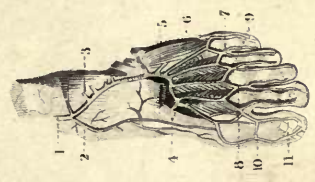
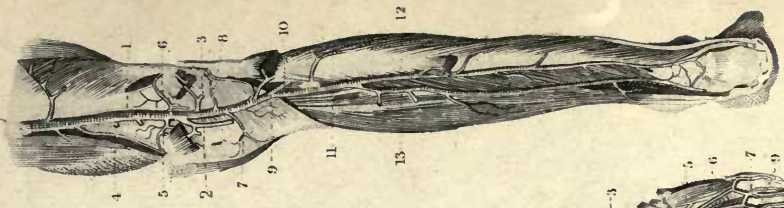


Fig. 2.



ANGEOLOGY, PL. 12.

Fig. 1. INTERNAL PUDIC ARTERIES IN A MALE.

1. Gluteus maximus, cut.—2. Great sacro-sciatic ligament, cut.—3. Small sacro-sciatic ligament.—4. Sphincter ani.—5. Transversus perinei.—6. Erector penis.—7. Accelerator urinae.—8. Urethra, enclosed in the corpus spongiosum urethra.—9. Dartos.—10. Trunk of the pudic artery.—11 and 12. Inferior hæmorrhoidal arteries.—13. Perineal branch.—14. Deep artery of the penis.—15. Arteria transversalis perinei.—16. Arteria dorsalis penis.—17. Artery of the corpus cavernosum.

Fig. 2. INTERNAL PUDIC ARTERIES IN A FEMALE.

1. Gluteus maximus muscle.—2. Sphincter ani.—3. Constrictor vaginae.—4. Meatus urinarius.—5. Clitoris.—6. Pudic artery.—7 and 8. Inferior hæmorrhoidal arteries.—9. Inferior, or perineal branch.—10. Superior branch, or branch of the clitoris.—11. Dorsal artery of the clitoris.—12. Artery of the corpus cavernosum.

ANGEOLOGY, PL. 13.

*Fig. 1. ARTERIES OF THE PELVIS.**

1. Termination of the aorta.—2. Middle sacral artery.—3. A lumbar artery.—4. Primitive iliac.—5. External iliac.—6. Circumflex iliac.—7. Epigastric.—8. Remains of the umbilical artery of the fœtus, converted into a ligament.—9. Obturator.—10. Vesical.—11. Ilio-lumbar.—12 and 13. Lateral sacral arteries.—14. Gluteal artery.—15. Middle hæmorrhoidal.—16. Internal pudic.—17. Sciatic.

Fig. 2. The obturator artery, dividing outside the pelvis into two branches, which encircle the obturator foramen.

Fig. 3. THE GLUTEAL AND SCIATIC ARTERIES WITHOUT THE PELVIS.

The gluteus maximus and medius muscles are divided and turned aside.

1. Gluteal artery.—2. Branch to the gluteus maximus.—3, 4, and 5. Deep branches, situated between the gluteus medius and minimus.—6. Sciatic artery.—7 and 8. Internal pudic artery.—9. Internal circumflex, a branch of the profunda femoris.—10 and 11. Two perforating arteries of the arteria profunda femoris.

* See diagrammatic figure in Plate No. 67.

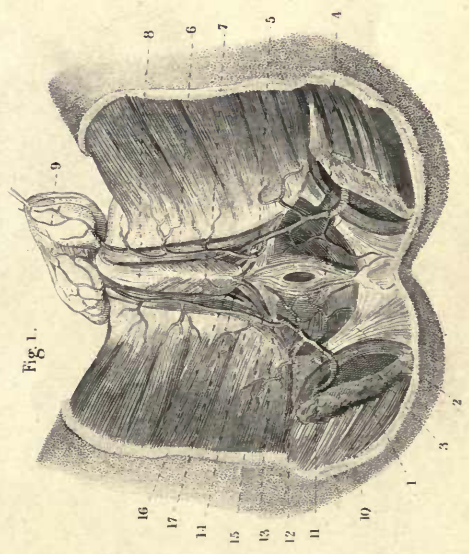
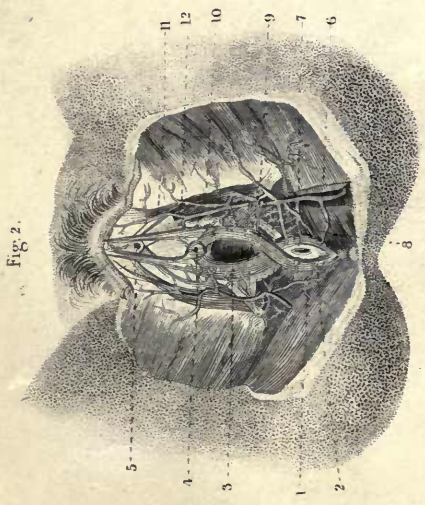
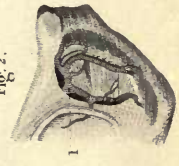
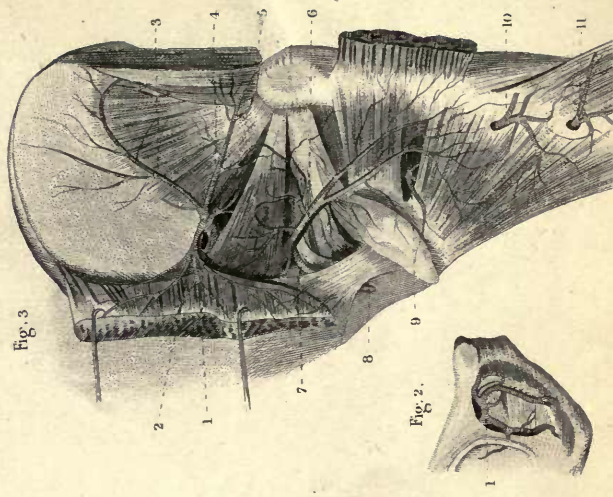
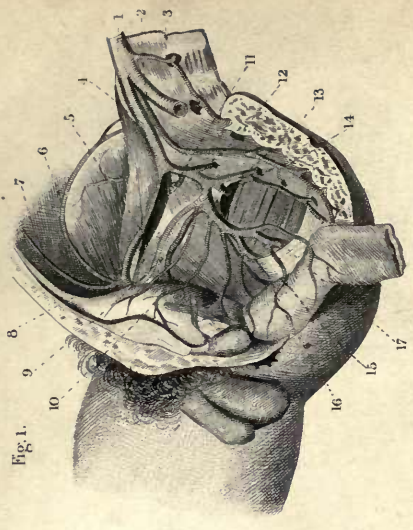


Fig. 1. SUPERFICIAL VEINS OF THE UPPER EXTREMITY.

1. Axillary vein.—2. Cephalic vein.—3. Superficial radial vein.—4. Median cephalic.—5. Basilic vein.—6. Posterior ulnar.—7. Anterior ulnar.—8. Median basilic.—9. Median vein.

Fig. 2.—1. Superficial radial vein.—2. Cephalic vein of the thumb.—3. Posterior ulnar.—4. Vena salvatella.

Fig. 3. VEINS AT THE BEND OF THE ARM.

1. Opening made in the brachial aponeurosis, which permits us to see the brachial artery and its accompanying veins, and the median nerve situated on its inner side.—2. Cephalic vein.—3. Superficial radial vein.—4. Median cephalic.—5. Basilic vein.—6. Posterior ulnar.—7. Anterior ulnar.—8. Median basilic.—9. Median vein.

Fig. 1. SCAPULAR ARTERIES.

1. Levator angulæ scapulæ.—2. Rhomboideus.—3. Supra-spinatus.—4. Infra-spinatus.—5. Teres major and latissimus dorsi.—6. Internal portion of the triceps extensor cubiti; the other two portions are removed.—7. Anconeus, cut.—8. Posterior scapular artery, the terminating branch of either the cervical superficialis, or of the transversalis colli.—9. Supra-scapular artery, or transversalis humeri.—10. Posterior branch of the sub-scapular artery.—11. Posterior circumflex artery.—12. Superior profunda.—13. Posterior interosseous artery.—14. Posterior radial recurrent.—15. Branch of the posterior muscles of the fore-arm, a division of the posterior interosseous artery.

Fig. 2.—1. The arteria interossea perforans, formed by the arteria interossea media, which perforates the interosseal ligament immediately above the pronator quadratus, and which supplies the muscles on the lower and back part of the fore-arm, and also the back of the carpus.—2. Carpal portion of the radial artery, passing beneath the extensor muscles of the thumb, and entering the first interosseous space.—3. Arteries of the carpus.—4. Collateral artery of the first interosseous space, commonly called the artery of the metacarpus.—5. Collateral artery of the third interosseous space, communicating at its upper extremity with, 6. A posterior perforating; at its lower extremity with, 7. An anterior perforating artery.

Fig. 3. ANTERIOR TIBIAL AND ARTERIA DORSALIS PEDIS.

1. A branch of the superior external articular artery.—2. Anterior tibial artery.—3. Anterior tibial recurrent artery.—4. External malleolar artery.—5. Internal malleolar.—6. Tarsal artery.—7. Metatarsal artery.—8. Collateral artery of the second interosseous space.

Fig. 3.

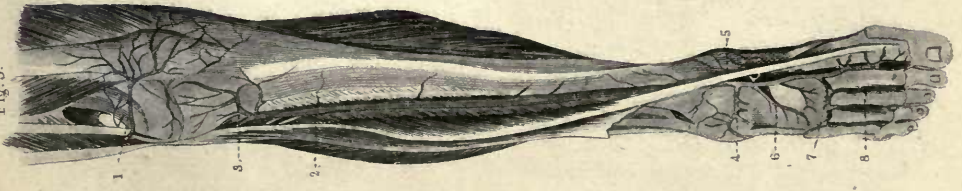

Fig. 1.

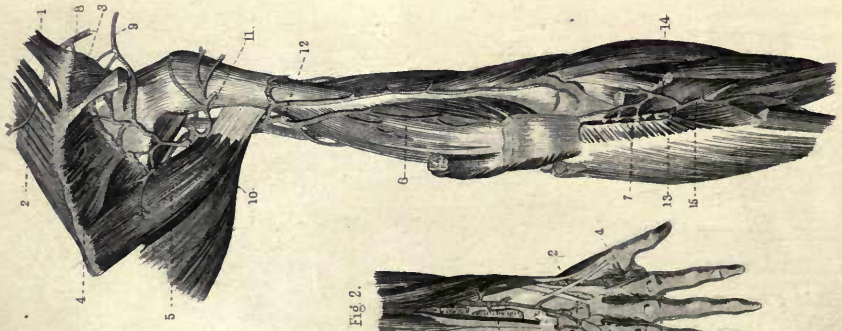


Fig. 2.

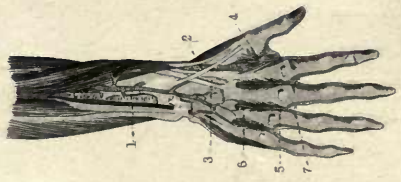


Fig. 1.

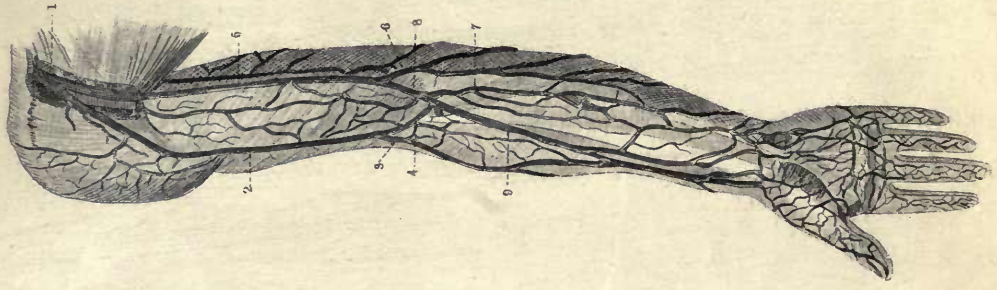


Fig. 3.

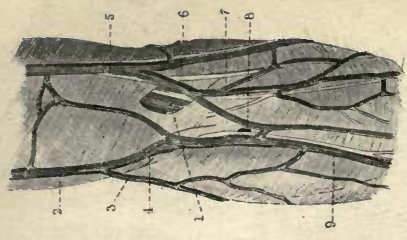
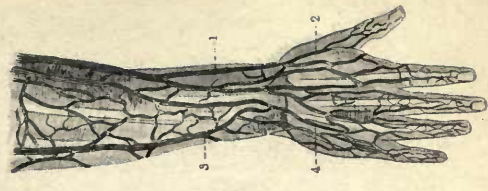


Fig. 2.



ANGEOLOGY, Pl. 16.

SUPERFICIAL VEINS OF THE HEAD AND NECK, SURCLAVIAN VEINS, VENA CAVA SUPERIOR, &c.: THE THORAX IS OPENED.

1. Pericardium, opened.—2. Right auricle.—3. Portion of the vena cava superior, contained within the pericardium.—4. Same vein without the pericardium.—5. Vena azygos.—6. Trunk of the internal mammary vein of the right side.—7. Right subclavian vein.—8. Internal jugular.—9. Thyroid vein.—10. Common trunk of the supra-scapular and posterior scapular veins.—11. Facial vein.—12. Anastomosis with the ophthalmic vein.—13. Frontal vein.—14. Occipital vein.—15. Superficial temporal vein.—16. Axillary vein.—17. Cephalic vein.

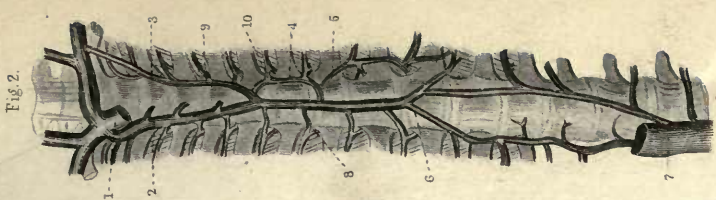
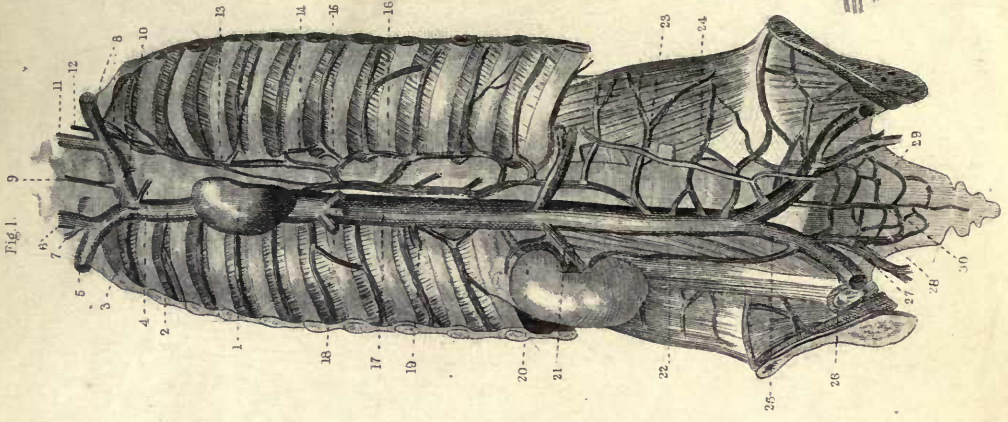
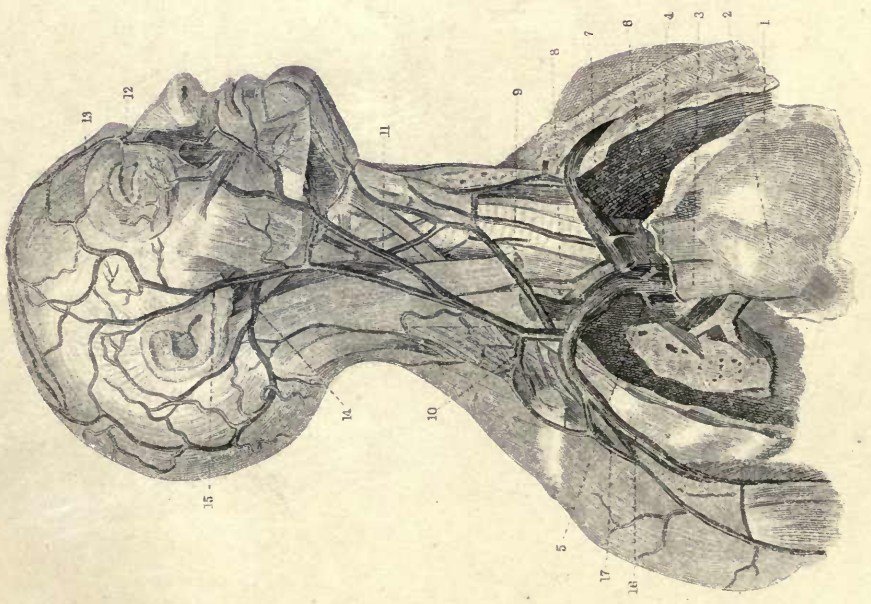
ANGEOLOGY, Pl. 17.


Fig. 1. *—1. Right auricle of the heart.—2. Vena cava superior.—3. Internal mammary vein of the right side.—4. Mediastinal vein.—5. Right subclavian vein.—6. Internal jugular.—7. External jugular.—8. Left subclavian vein.—9. Middle thyroid vein.—10. Left internal mammary vein.—11. Left internal jugular.—12. External jugular.—13. Great left superior intercostal vein.—14 and 15. Branches of anastomoses between two intercostal veins.—16. Semi-azygos vein.—17. Vena cava inferior.—18. Hepatic veins.—19. Common trunk of the spermatic veins.—20. Capsular vein.—21. Renal vein.—22. Branch of communication between a branch of the renal vein and the primitive iliac vein.—23 and 24. Lumbar veins.—25. Primitive iliac vein.—26. External iliac vein.—27. Internal iliac, or hypogastric vein.—28 and 29. Lateral sacral veins.—30. Middle sacral vein.

Fig. 2.—1. Superior vena cava.—2. Vena azygos.—3. Great superior intercostal vein of the left side.—4 and 5. Branches which supply the place of the vena semi-azygos.—6. Terminating branches of the vena azygos.—7. Vena cava abdominalis.—8, 9, and 10. Intercostal veins, opening, the first into the vena azygos, the second into the great intercostal vein of the left side, and the third into the vein which supplies the place of the vena azygos.

Fig. 3. A uterus, intended to show the sinuses of the uterus.

*See diagrammatic cut in Plate No. 77.

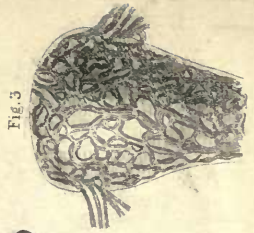






Fig. 1. A DIAGRAM OF THE VENOUS SINUSES OF THE DURA MATER, AS SEEN ON A VERTICAL SECTION THROUGH THE CRANIUM.

1. Superior longitudinal sinus.—2. Inferior longitudinal sinus.—3. Straight sinus, connecting (1) and (2) and receiving the venæ Galeni (11).—4. Torcular Herophili, where four sinuses meet.—5, 5. Lateral sinus, pursuing a curved irregular course.—6. Superior petrosal sinus, joining the lateral (5) with the cavernous sinus (8) and the jugular vein (9).—8. Cavernous sinus.—9. Inferior petrosal sinus, joining the cavernous sinus (8) and the jugular vein (9).—10. Venæ Galeni.—(5 and 7).—10. Occipital sinus.—11. Venæ Galeni.—12. Vein passing from the nasal cavity to the superior longitudinal sinus.—13. Foramen cœcum.

Fig. 2. A DIAGRAM OF THE VENOUS SINUSES OF THE DURA MATER, AS SEEN ON A HORIZONTAL SECTION THROUGH THE CRANIUM.

A. Anterior fossa of skull.—B. Middle fossa.—C. Posterior fossa.—F. S. Frontal sinus.—1. Torcular Herophili.—2, 2. Lateral sinuses.—3, 3. Occipital sinuses, enclosing the foramen magnum.—4, 4. Superior petrosal sinuses.—5, 5. Inferior petrosal sinuses.—6. Transverse sinus.—7, 7. Cavernous sinuses.—8. Circular sinus.—9. Opening of internal jugular vein of either side.—10. Ophthalmic vein, communicating with the cavernous sinus.—11, 11. A branch between the occipital (3) and inferior petrosal sinuses (5).—12, 12. Veins passing through the posterior condyloid foramina to the lateral sinuses.

FIG. 1.

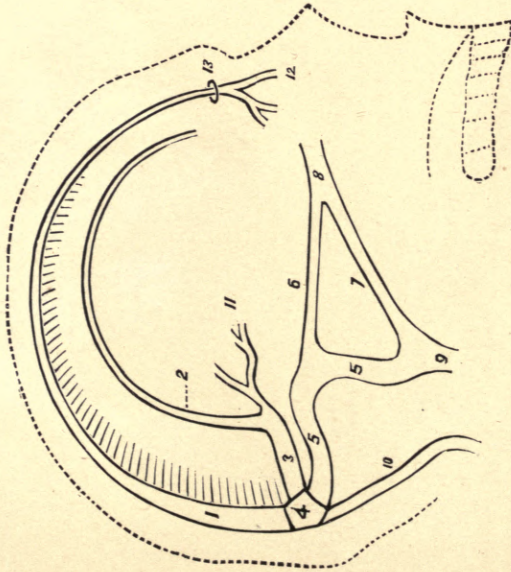
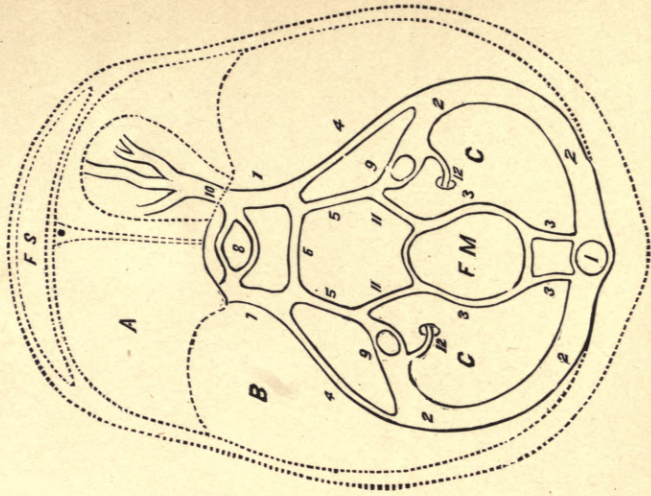



FIG. 2.





ANGIOLOGY, Pl. 19.

Fig. 1. A DIAGRAM OF THE AZYGOS VEINS AND THE LARGE VEINS OF THE THORAX AND ABDOMEN (after Wilson).

1. Superior vena cava.—3. Left innominate vein.—3. Right innominate vein.—4. Right subclavian vein.—5. Right internal jugular vein.—6. Right external jugular vein.—7. Right anterior jugular vein.—8. Inferior vena cava.—9. External iliac vein.—10. Internal iliac vein.—11. Common iliac vein (of the two sides).—12. Lumbar veins.—13. Spermatic vein.—14. Renal vein.—15. Right vena azygos, arising from the lumbar veins.—16. Hepatic veins, opening into the vena cava.—17. Intercostal veins, opening into the right vena azygos.—18. Left vena azygos.—19. A point of origin of the vena azygos from the left renal vein.—20. The left vena azygos, crossing to empty into the right vena azygos.—21. The superior intercostal vein of the left side, communicating with the left vena azygos and opening into the left innominate vein.

Fig. 2. A DIAGRAM OF THE PORTAL VEIN AND ITS TRIBUTARIES (after Wilson).

1. The inferior mesenteric vein; it is traced by means of dotted lines behind the pancreas (2) to terminate in the splenic vein (3).—4. The spleen.—5. Gastric veins, opening into the splenic vein.—6. The superior mesenteric vein.—7. The descending portion of the duodenum.—8. Its transverse portion, which is crossed by the superior mesenteric vein and by a part of the trunk of the superior mesenteric artery.—9. The portal vein.—10. The hepatic artery.—11. The ductus communis choledochus.—12. The divisions of the duct and vessels at the transverse fissure of the liver.—13. The cystic duct leading to the gall-bladder.

Fig. 3. A DIAGRAM OF THE THORACIC DUCT, SHOWING ITS COURSE, RELATIONS, AND TERMINATION (after Wilson).

1. The arch of the aorta.—2. The thoracic aorta.—3. The abdominal aorta; showing its principal branches divided near their origin.—4. The arteria innominata, dividing into the right carotid and right subclavian arteries.—5. The left carotid.—6. The left subclavian.—7. The superior cava, formed by the union of 8, the two vena innominata; and these by the junction, 9, of the internal jugular and subclavian vein at each side.—10. The greater vena azygos.—11. The termination of the lesser in the greater vena azygos.—12. The receptaculum chyli; several lymphatic trunks are seen opening into it.—13. The thoracic duct, dividing opposite the middle of the dorsal vertebrae into two branches which soon reunite; the course of the duct behind the arch of the aorta and left subclavian artery is shown by a dotted line.—14. The duct making its turn at the root of the neck and receiving several lymphatic trunks previously to terminating in the posterior aspect of the junction of the internal jugular and subclavian vein.—15. The termination of the ductus lymphaticus dexter.

FIG. 1.

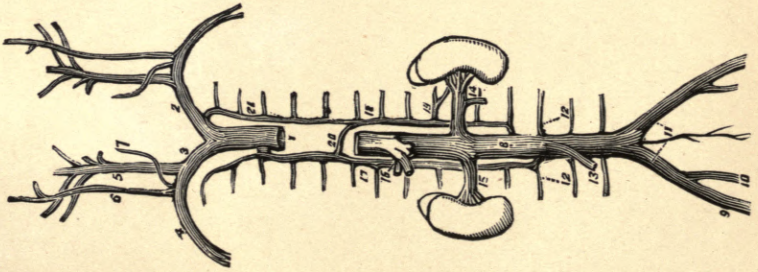


FIG. 2.

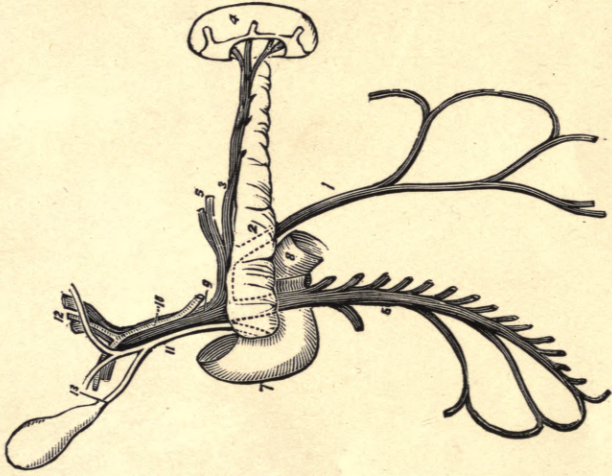
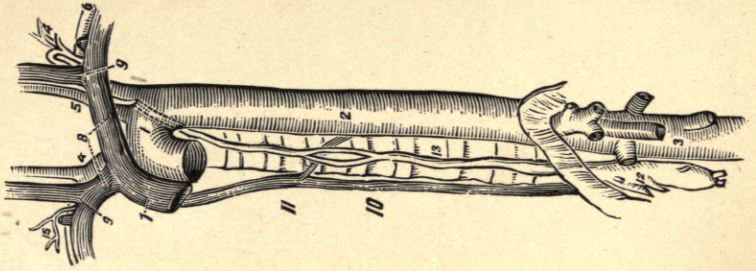


FIG. 3.



VENA PORTÆ.*

1. Liver.—2. Gall-bladder, continuous with the cystic and hepatic ducts, and the ductus communis choledochus.—3. Hepatic artery.—4. Vena cava inferior.—4, 4. Pancreas divided at the point of union of its head with the body.—5, 5. The two lower portions of the duodenum.—6, 6, 6. Convolutions of the small intestines.—7. Cæcum and ascending colon.—8. Descending colon, sigmoid flexure, and commencement of the rectum.—9. Spleen.—10. Stomach, turned over.—11, 11. Veins of the small intestine.—12. Right colic vein.—13. Great mesenteric vein.—14, 14. Splenic vein.—15. Inferior mesenteric, opening into the splenic vein.—16. Inferior gastric vein.—17. Superior gastric vein, opening into, 18. The trunk of the vena portæ.—19. Sinus of the vena portæ.—20. Remains of the umbilical vein.—21. Remains of the ductus venosus, the vessel which in the fetus forms a direct communication between the umbilical vein and the vena cava inferior.

* See diagrammatic cut in Plate No. 77.

Fig. 1. FŒTAL CIRCULATION.

1. Fœtal surface of the placenta, where the ramifications of the umbilical arteries and vein are seen, covered by the envelopes of the fetus.—2. Chorion.—3. Amnion.—4. Umbilical cord.—5. Separation of the vessels of the cord, on entering the abdomen at the umbilicus, into the two arteries and vein.—6. Umbilical vein.—7. Anastomosis of the umbilical vein with the sinus of the vena portæ.—8. Trunk of the vena portæ.—9. Ductus venosus.—10. Anastomosis of the ductus venosus with the vena cava inferior.—11. Vena cava inferior above the diaphragm.—12. Right auricle of the heart.—13. Right ventricle.—14. Ascending portion of the aorta.—15. Vena cava superior.—16. Pulmonary artery.—17. Branch of the pulmonary artery, divided.—18. Ductus arteriosus.—19. Descending aorta.—20. Abdominal portion of the aorta.—21, 21. Primitive iliac arteries.—22, 22. Umbilical arteries, which form in the fetus a continuation of the internal iliaes.

Fig. 2. HEART AND PRINCIPAL BLOOD-VESSELS.

Right auricle opened.

1. Vena cava inferior.—2. Eustachian valve.—3. Foramen of Botal, or foramen ovale, which forms a communication in the fetus between the two auricles.—4. Vena cava superior.—5. Ventricles.—6. Pulmonary artery.—7. Ductus arteriosus.—8. Aorta.

Fig. 3. THYMUS GLAND.

Fig. 1.

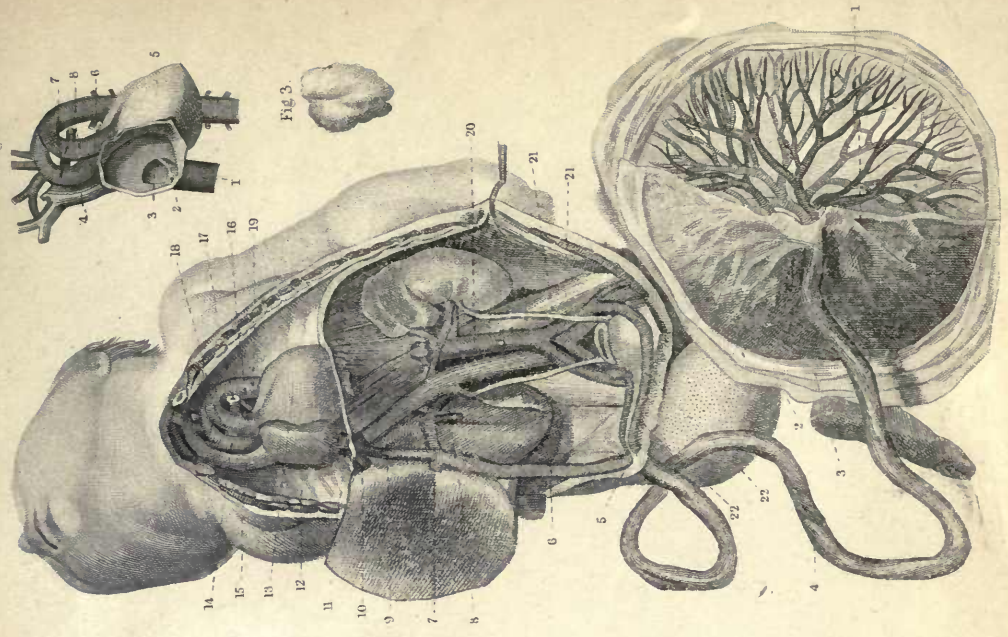


Fig. 2.

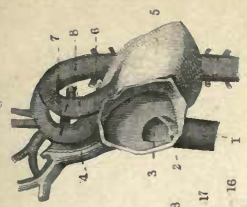


Fig. 3.

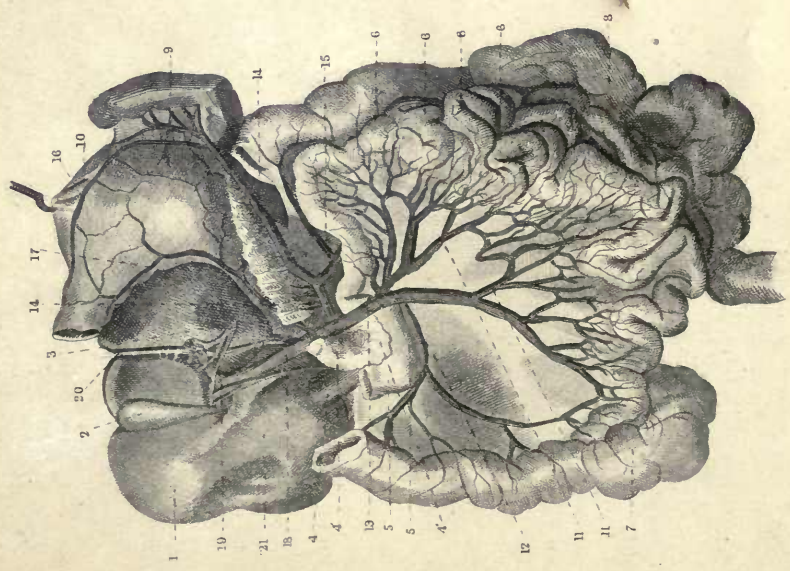




Fig. 1. THE POSTERIOR SUPERFICIAL SPINAL VEINS.

1. A posterior costo-transverse ligament.—2. An external intercostal muscle.—3. A dorsal vein, anastomosing with those which are above and below, and with those of the opposite side, to form a net-work, which extends the entire length of the vertebral column.

Fig. 2. THE ANTERIOR INTERNAL SPINAL VEINS.

This is a view of the posterior surface of the body of the vertebræ. The posterior half of the vertebral canal is removed.

1, 1, 1, 1, 1, 1. Anterior longitudinal sinuses.—2, 2, 2, 2, 2. Anterior transverse sinuses.—3, 3, 3. External veins, communicating with the internal veins of the vertebral canal.

Fig. 3. POSTERIOR INTERNAL SPINAL VEINS.

The anterior half of the vertebral canal is removed.

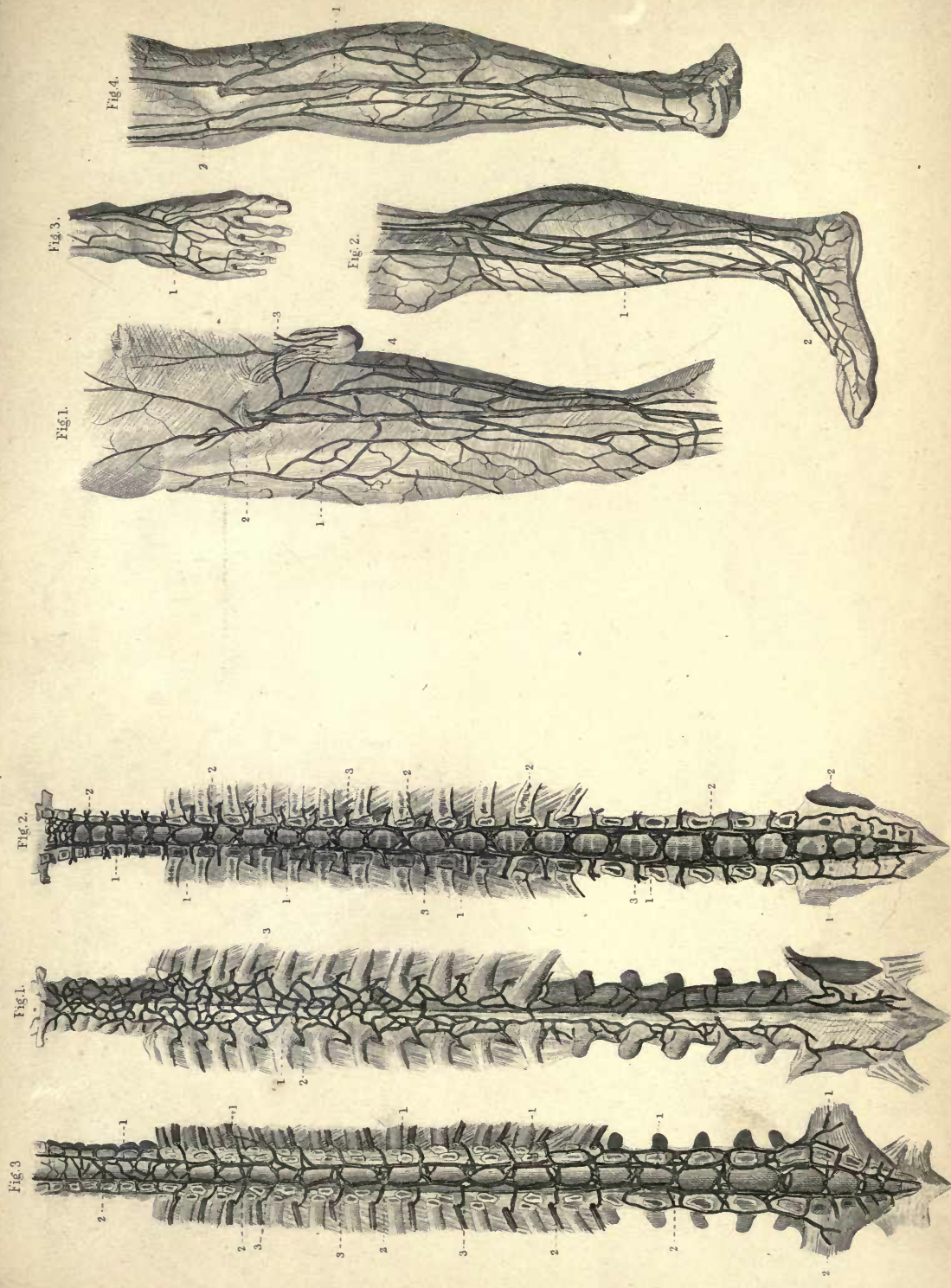
1, 1, 1, 1, 1, 1. Posterior longitudinal sinuses.—2, 2, 2, 2, 2. Posterior transverse sinuses.—3, 3, 3. Intercostal veins, communicating with the internal veins of the vertebral canal.


Fig. 1.—1. Internal saphenous vein.—2. Superficial epigastric vein.—3. Dorsal vein of the penis.—4. Large branch of the saphenous vein.

Fig. 2.—1. Internal saphenous vein, on the internal side of the leg.—2. Internal saphenous vein, on the dorsum of the foot.

Fig. 3. Venous arch resulting from the anastomosis of the two saphenæ.

Fig. 4.—1. External saphenous vein.—2. Internal saphenous.





ANGEOLOGY, Pl. 24.

Fig. 1. SINUSES OF THE FALX CEREBRI.

1. Superior longitudinal sinus.—2. Inferior longitudinal sinus.—3. Straight sinus.—4. Vena Galeni.—5. Torcular Herophili.

Fig. 2. SINUSES AT THE BASE OF THE CRANIUM.

1. Opening of the superior longitudinal sinus into the torcular Herophili.—2. Horizontal portion of the lateral sinus.—3. Oblique portion.—4. Sinus of the internal jugular vein, where the inferior petrosal sinus opens into it.—5. Superior petrosal sinus.—6. Cavernous sinus.—7. Transverse sinus.—8. Coronary sinus.

Fig. 3. TORCULAR HEROPHILI OPENED FROM BEHIND.

1. Superior longitudinal sinus.—2. Orifice of the straight sinus.—3, 3. Orifices of the occipital sinuses.—4, 4. Lateral sinuses.

Fig. 4. Parietal bone where the external table has been removed to show the long sinuses, or venous canals.

Figs. 5 and 6. Os brachii and ulna, sawn for the same purpose.

Fig. 7. SINUS OF THE VERTEBRÆ.

Body of the vertebra is sawn transversely.

1, 1, 1, 1. Longitudinal sinuses laid open.—2. Anterior transverse sinus, into which a sinus of the body of the vertebra opens.—3. Posterior transverse sinus.—4, 4. Lateral transverse sinuses.—5, 5. External veins communicating with the vertebral sinuses.

ANGEOLOGY, Pl. 25.

THE POSTERIOR DEEP LYMPHATIC GANGLIA, AND VESSELS OF THE LOWER EXTREMITY.

Fig. 1.—1. Posterior tibial vein.—2. Peroneal vein.—3. Popliteal vein.—4, 4. Posterior tibial lymphatic vessels.—5. Peroneal lymphatic vessel.—6, 6, 6. Popliteal lymphatic ganglia and vessels.

Fig. 2. The superficial muscles on the posterior part of the thigh and hip are removed.

1, 1. Popliteal lymphatic ganglia and vessels.—2, 2. Deep lymphatic vessels.—3. Sciatic lymphatic ganglia and vessels.—4. Gluteal lymphatic ganglia and vessels.

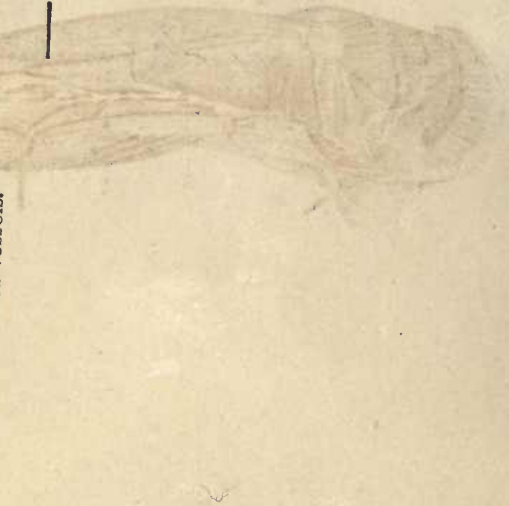


Fig. 4.

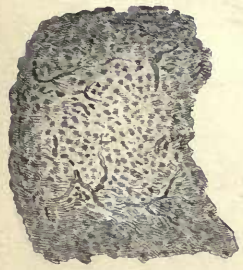


Fig. 5.

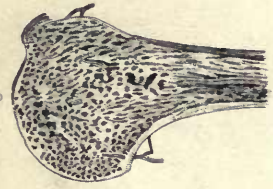


Fig. 1.

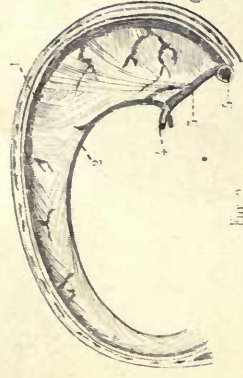


Fig. 7.

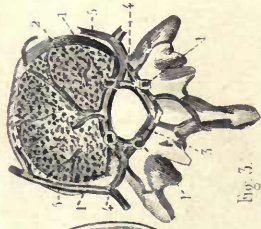


Fig. 2.

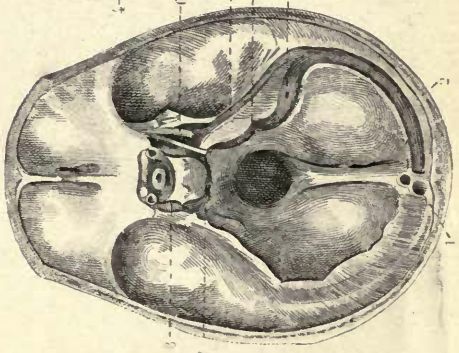


Fig. 3.

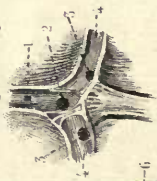

Fig. 6.

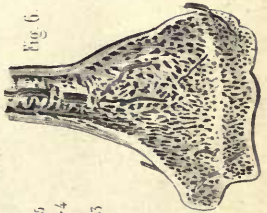


Fig. 2.

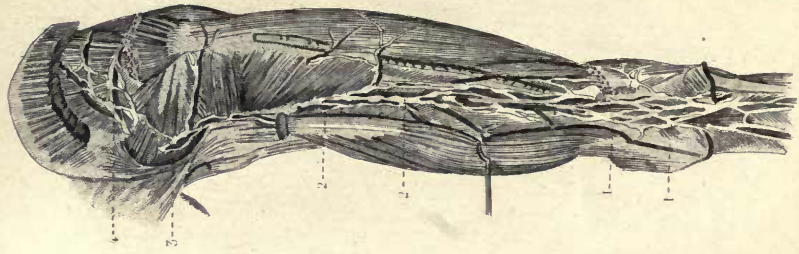
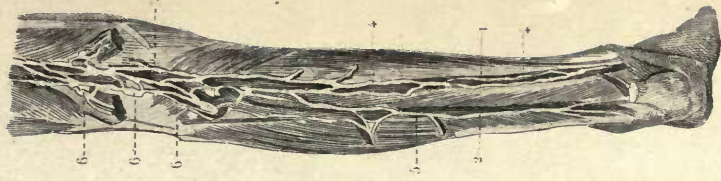



Fig. 1.







ANGEOLOGY, PL. 26.

THE ANTERIOR DEEP LYMPHATIC GLANDS, AND VESSELS OF THE LOWER EXTREMITY

Fig. 1.—1. Anterior tibial vein.—2. Deep lymphatic vessels.—3. Anterior tibial ganglion.—4. Superficial lymphatic vessels of the thigh.

Fig. 2.—1. Femoral vein.—2. Vena profunda femoris.—3. External iliac vein.—4. Internal iliac, or hypogastric vein.—5. Vena cava inferior, or abdominal vena cava.—6, 6. Deep lymphatic vessels of the thigh.—7. Deep inguinal ganglia.—8. External iliac lymphatic ganglia and vessels.—9. Internal iliac lymphatic ganglia and vessels.—10. Lumbar lymphatic ganglia and vessels.



ANGEOLOGY, PL. 27.

Fig. 1. LYMPHATIC VESSELS OF THE FOOT.

A great many take their origin on the dorsal surface, and accompany the internal saphena vein.

Fig. 2. SUPERFICIAL LYMPHATIC VESSELS OF THE LOWER EXTREMITY, AND LOWER HALF OF THE ABDOMINAL WALLS.

1. Superficial lymphatic vessels of the lower extremity, which accompany the internal saphena vein.—2. Inguinal lymphatic glands.—3. Lymphatic vessels of the lower half of the abdominal walls.—4. Lymphatic vessels of the scrotum and penis.

Fig. 3. SUPERFICIAL LYMPHATIC VESSELS OF THE POSTERIOR PART OF THE LEG.

They accompany the external saphena vein in great numbers.

Fig. 4. SUPERFICIAL LYMPHATIC VESSELS OF THE UPPER PART OF THE THIGH, HIP, AND LOINS.

Fig. 2

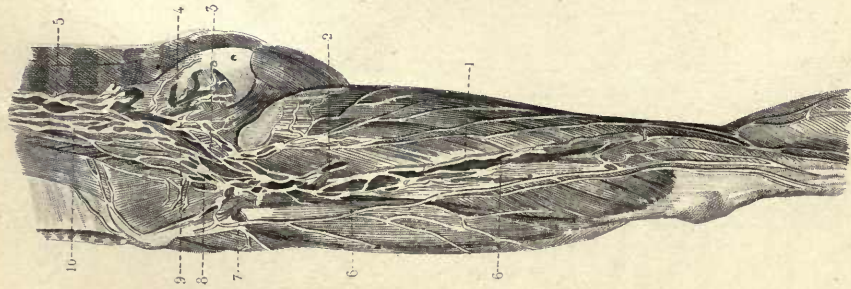


Fig. 1

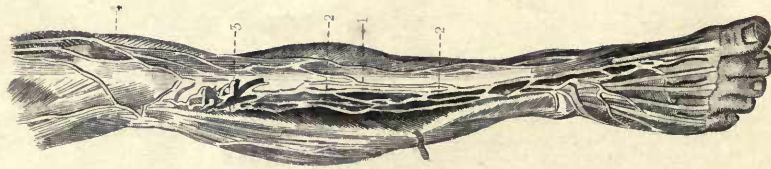


Fig. 4

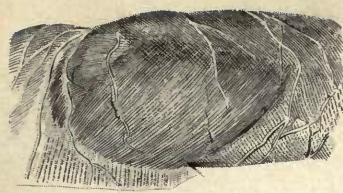
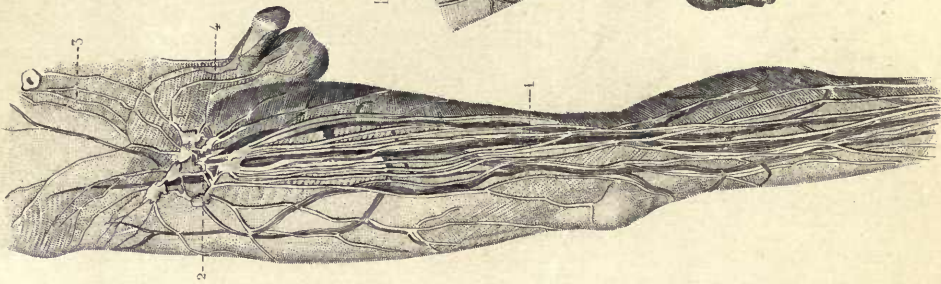



Fig. 1.

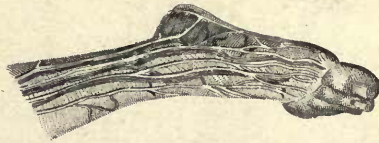

Fig. 2





ANGEOLOGY, PL. 28.

LYMPHATIC GANGLIA AND VESSELS OF THE ABDOMINAL VISCERA.

- 1, 1. Lymphatic vessels of the small intestines, called the lacteal or chyloferous vessels.—2, 2. Mesenteric ganglia.—3, 3. Lymphatic vessels of the large intestines.—4, 4. Mesocolic ganglia.—5. Common lacteal vessel opening into the thoracic duct.—6. A lymphatic vessel of the spleen.—7. A lymphatic vessel of the pancreas.—8, 8. Lymphatic vessels of the inferior surface of the liver.



ANGEOLOGY, PL. 29.

FIG. 1. SUPERFICIAL LYMPHATIC VESSELS OF THE UPPER EXTREMITY.

1. One of the superficial veins of the fore-arm.—2, 2. Superficial lymphatic vessels of the fore-arm and arm.—3. Lymphatic ganglia of the axilla.

FIG. 2. DEEP LYMPHATIC VESSELS AND GANGLIA OF THE UPPER EXTREMITY.

- 1, 1, 1. Deep veins of the fore-arm.—2. Lymphatic vessels which accompany them.—3. Lymphatic ganglia at the bend of the arm.—4, 4. Brachial veins.—5, 5. Lymphatic vessels which accompany them.—6. One of the ganglia situated in the course of these vessels.—7. Axillary ganglia.



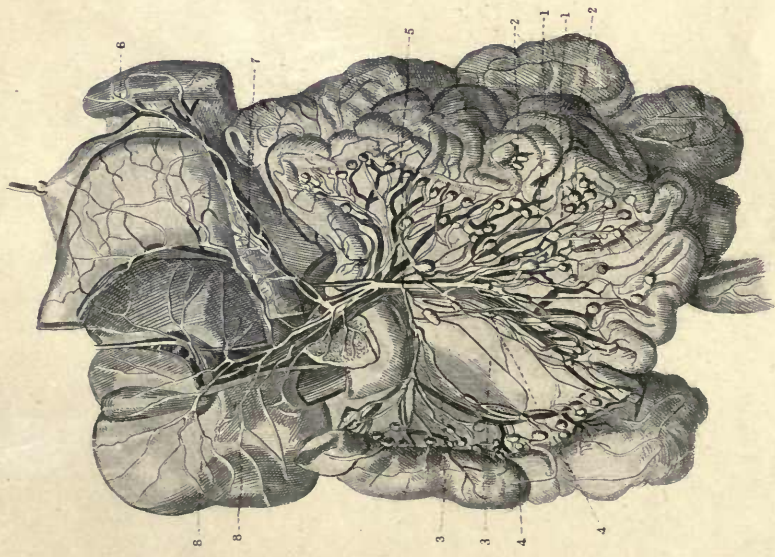


Fig. 1.

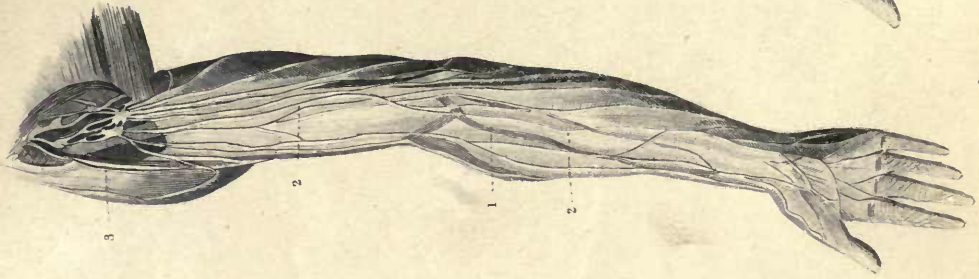
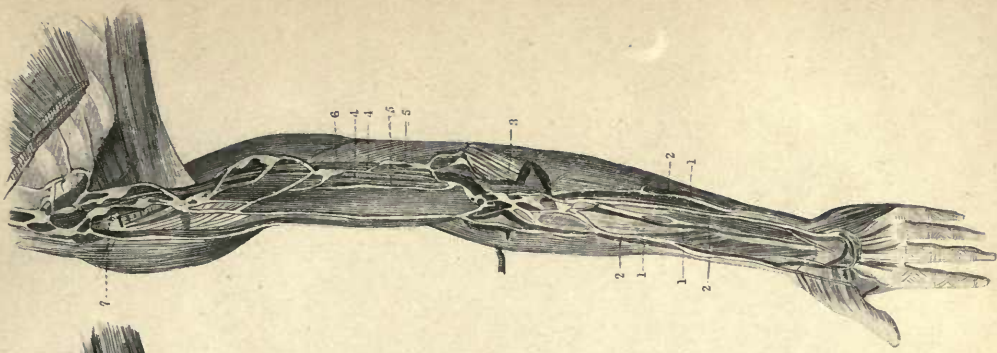


Fig. 2.



ANGEIOLOGY, PL. 30.

THORACIC DUCT,* &c.

1. Vena cava superior.—2. Vena azygos.—3. Thoracic duct.—4. Part of the hypogastric plexus, composed of vessels and ganglia.—5. External iliac plexus.—6. Lumbar plexus.—7. Commencement of the thoracic duct, generally called the receptaculum chyli, or the reservoir of Pecquet.—8. Common centre of the lacteals, opening into the thoracic duct.—9, 9. Intercostal lymphatic vessels.—10, 10. Deep lymphatic vessels of the lungs.—11. Thoracic duct, opening into the left subclavian vein.—12. Great lymphatic vein, opening into the right subclavian vein.

* See diagrammatic cut in Plate No. 77.

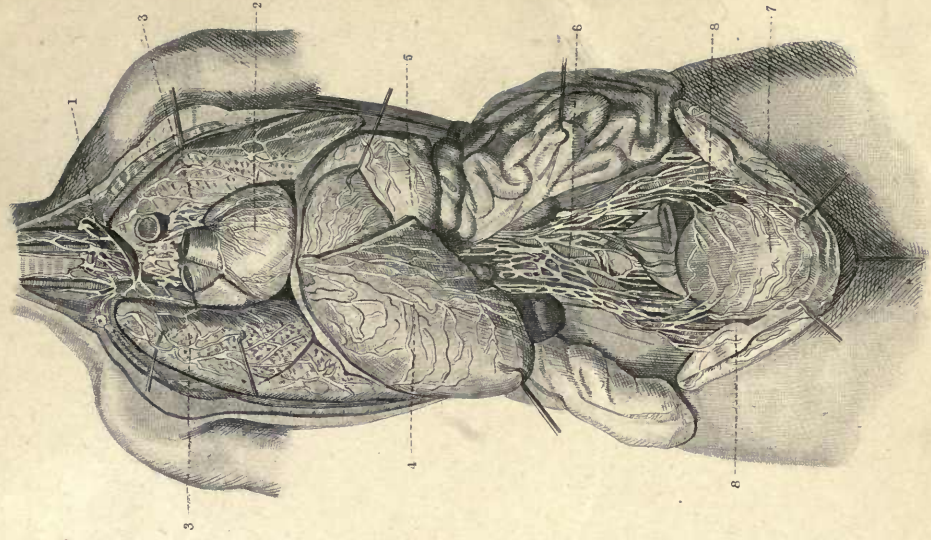
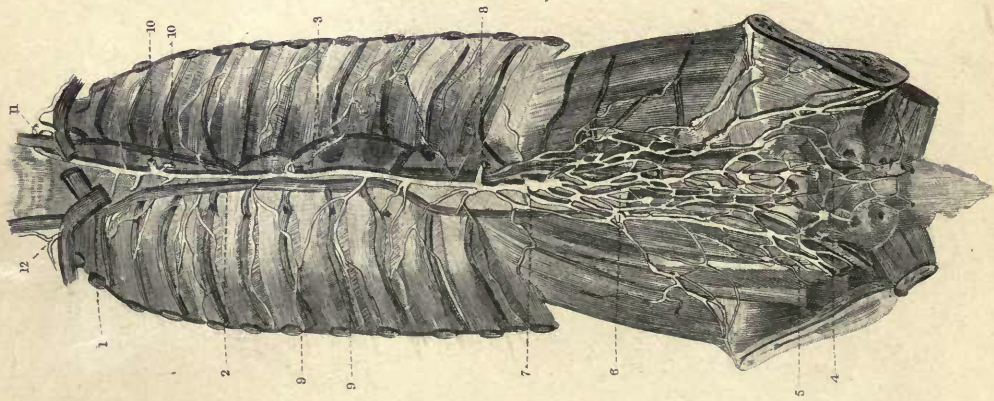



ANGEIOLOGY, PL. 31.

LYMPHATIC VESSELS OF THE THORACIC AND ABDOMINAL VISCERA.

1. Lymphatic ganglia and vessels of the lower part of the trachea.—2. Heart and its lymphatic vessels.—3, 3. Lungs and the superficial lymphatic vessels.—4. Liver and lymphatic vessels of its upper surface.—5. Stomach and lymphatic vessels of its upper surface.—6. Lumbar lymphatic ganglia and vessels.—7. Uterus and its lymphatic vessels.—8, 8. Ovaries, broad ligaments, and their lymphatic vessels.







ANGEOLOGY, PL. 32.

LYMPHATIC VESSELS AND GANGLIA OF THE AXILLA,
HEAD, AND NECK.

1. Primitive carotid artery.—2. Internal jugular vein.—3. External jugular vein.—4. Axillary artery.—5. Axillary vein.—6. One of the lymphatic vessels of the thoracic parietes.—7. Lymphatic ganglia and vessels of the axilla.—8, 8, 8. Superficial lymphatic vessels of the cranium.—9, 9, 9. Superficial lymphatic vessels of the face.—10. Parotid ganglia.—11. Submaxillary ganglia.—12, 12. Lymphatic ganglia of the neck.

NEUROLOGY, PL. 1.

Fig. 1. CORPUS CALLOSUM.

The cerebrum is cut horizontally, on a level with the upper surface of the corpus callosum on the left side, a little below it on the right.

1. The white or medullary substance is separated from the corpus callosum and turned back.—2. Centrum ovale of Vieussens, formed by the upper surface of the corpus callosum, and by the mass of white substance in each hemisphere.—3. Corpus callosum.—4. Raphé of the corpus callosum, or longitudinal tracts.

Fig. 2. FORNIX, &c.

The corpus callosum is removed.

1. Reflected portion of the corpus callosum.—2. Lamina of the septum lucidum, divided, forming the fifth ventricle.—3. Fornix.—3'. Foramen of Monro, by which the choroid plexus of the lateral ventricles becomes continuous with that of the pia mater lining the third ventricle.—4. Choroid plexus.—5. Posterior extremity of the corpus callosum.—6. Digital cavity.—7. Hippocampus minor.—8. Corpus striatum.—9. Tania semicircularis.—10. Thalamus nervi optici.

Fig. 1.

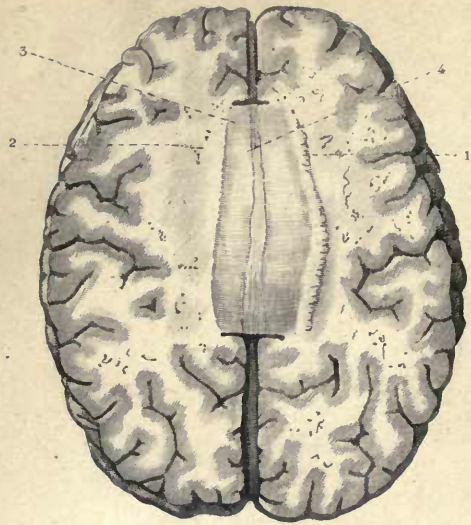
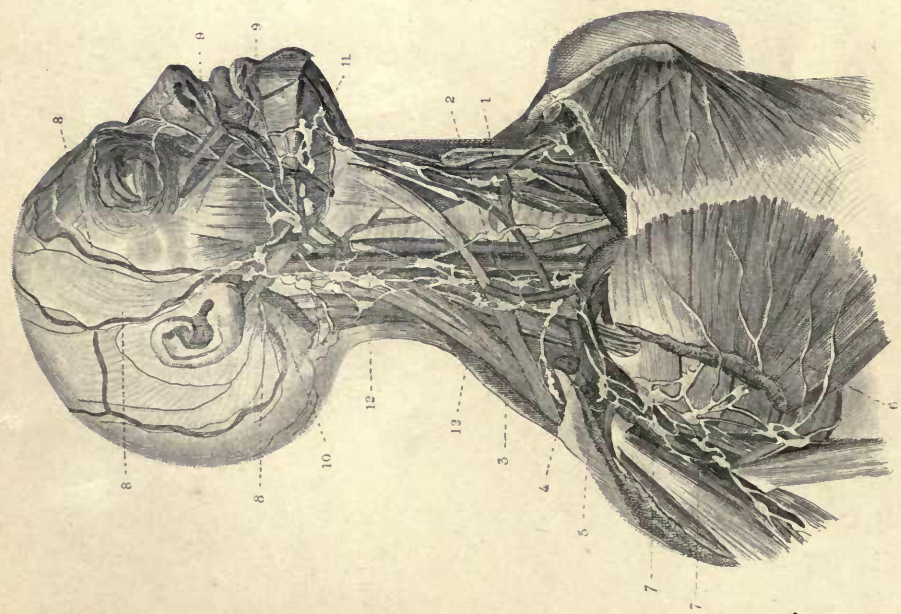
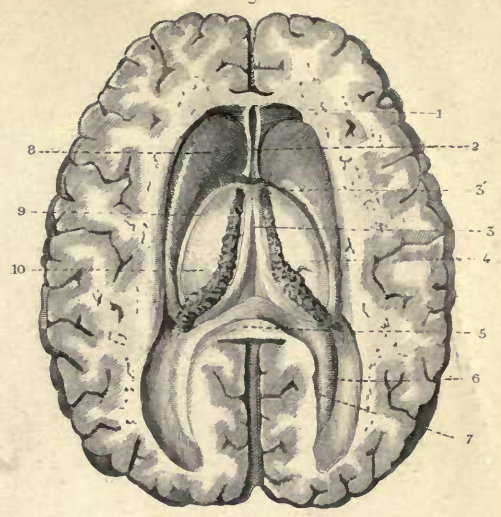


Fig. 2.



NEUROLOGY, PL. 2.

Fig. 1. BRAIN (upper surface).

1. Great fissure of the brain.—2. Right hemisphere.—3. A simple convolution.*—4. A compound convolution.—5. A simple anfractuosity.†—6. A compound anfractuosity.

Fig. 2. CEREBRUM, CEREBELLUM, NODUS CEREBRI, AND MEDULLA OBLONGATA.

1. Commencement of the longitudinal fissure.—2. Anterior lobe.—3. Fissure of Sylvius.—4. Middle lobe.—5. Commissure of the optic nerves.—6. Tuberculum cinereum and infundibulum.—7. Corpora mamillaria.—8. Crura cerebri, called the anterior prolongation of the nodus cerebri.—9. Pons Varolii.—10. Cerebellum.—11. Termination of the lobules of the superior surface.—12. Lobulus nervi pneumogastrici.—13. Lower vermiform process.—14. Corpus pyramidale.—15. Corpus olivare.—16. Corpus restiforme.—17. Olfactory nerve.—18. Optic nerve.—19. Third pair of nerves, or motores oculorum.—20. Fourth pair of nerves, or pathetici.—21. Fifth pair, or trigemini.—22. Sixth pair, or abducentes.—23. Seventh pair, composed of the facial and auditory nerve, the seventh and eighth of modern anatomists.—23'. Glosso-pharyngeal and pneumo-gastric nerves.—24. Spinal accessory.—25. Hypoglossal nerve.

* A convolution is often called a "gyrus."
 † Often called a "sulcus."

NEUROLOGY, PL. 3.

Fig. 1. DURA MATER.

The cranium opened by a vertical and a horizontal section.*

1. Falx cerebri.—2. Superior longitudinal sinus.—3. Inferior longitudinal sinus.—4. Straight sinus.—5. Confluence of the sinuses, the torcular Herophili.—6. Tentorium cerebelli.—7. Right side of the small circumference of the tentorium cerebelli.—8. Left side of the same circumference.—9. Termination of this circumference at the anterior clinoid process.—10. Termination of the great circumference at the posterior clinoid process.

Fig. 2. DURA MATER.

The tentorium cerebelli is removed on the right side.

1. Falx cerebri.—2. Superior longitudinal sinus, opened.—3. Torcular Herophili.—4. Left side of the tentorium cerebelli.—5. Falx cerebelli.

* See diagrammatic cuts on Plate No. 76.



Fig 1

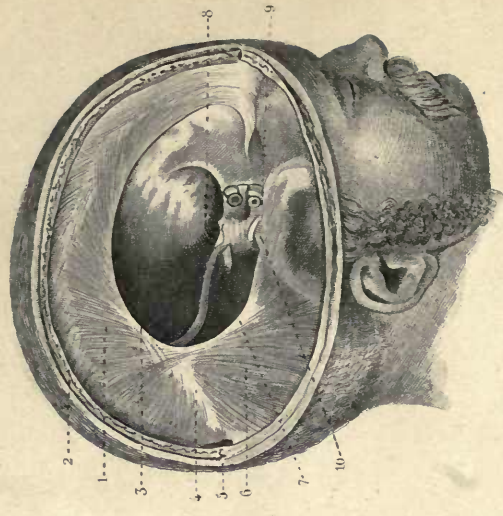


Fig 2

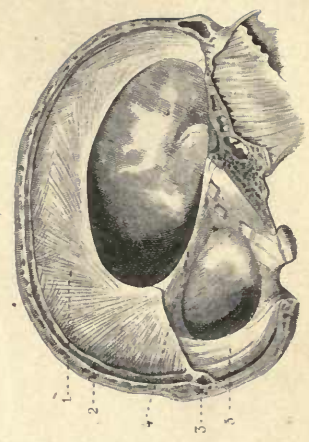


Fig 1

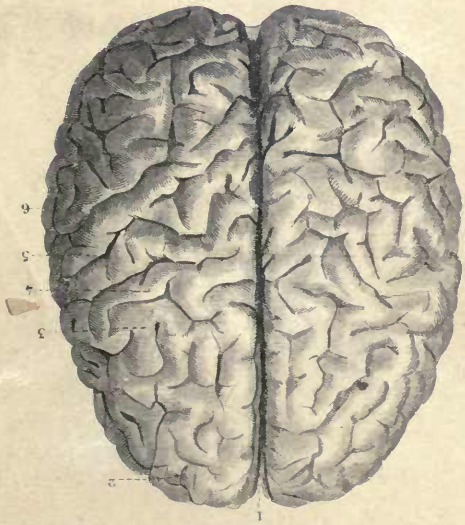
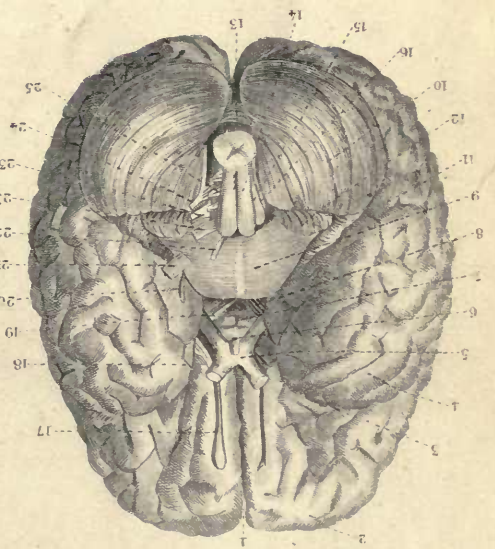



Fig 2





NEUROLOGY, Pl. 4.

Fig. 1. THIRD AND FIFTH VENTRICLES. UPPER PORTION OF THE LATERAL VENTRICLES. UPPER SURFACE OF THE CEREBELLUM.

1. The two laminae of the septum lucidum, which enclose a space, the fifth ventricle, or ventricle of Cuvier.—2. The pedicles of the anterior pillar of the fornix, divided and turned over.—3. Anterior commissure.—4. Commissura mollis.—5. Third ventricle.—6. Posterior commissure.—7. Pineal gland and its pedicles.—8. Tubercula quadrigemina.—9. Corpus striatum.—10. Lamina cornea of the tænia semicircularis.—11. Tænia semicircularis.—12. Thalamus nervi optici.—13. Upper surface of the cerebellum.—14. Superior vermiform process.

Fig. 2. VERTICAL SECTION OF THE BRAIN IN THE MEDIAN LINE.

1. Corpus callosum.—2. Peduncle of the corpus callosum.—3. Great convolution of the cerebrum, overlapping the corpus callosum, and forming what is sometimes called the labium corporis callosi.—4. Septum lucidum.—5. Anterior commissure.—6. Fornix.—7. Foramen of Monro.—8. Commissura mollis.—9. Thalamus nervi optici.—10. Pineal gland, and its anterior and posterior prolongations.—11. Tubercula quadrigemina.—12. A deep anfractuosus, which separates the posterior lobe from the middle.—13. Valve of Vieussens.—14. Ligamenta lamellosa.—15. Arbor vitæ.—16. Fourth ventricle.—17. Lamina at the base of the fourth ventricle.—18. Posterior cord of the spinal marrow.—19. Antero-posterior fibres of the anterior pyramids.—20. Nodus cerebri.—21. Cerebral prolongation of the nodus cerebri.—22. Aqueduct of Sylvius.—23. Mammillary eminence.—24. Tuber cinereum.—25. Pituitary body and infundibulum.—26. Commissure of the optic nerves.—27. Lamina which closes the third ventricle in front.

* The *calcarine fissure*.

† Called also the pons Varolii.

NEUROLOGY, Pl. 5.

Fig. 1. BRAIN STUDIED FROM BELOW UPWARD.

The middle lobes of the cerebrum are removed.

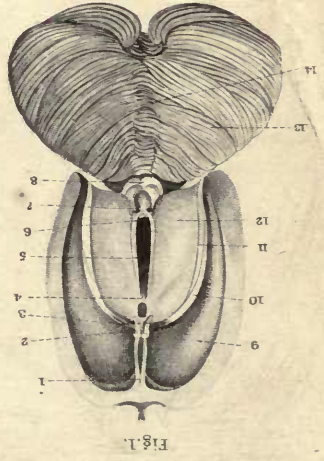
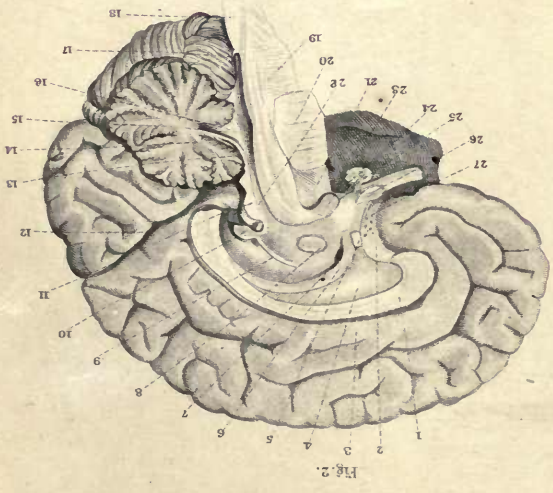
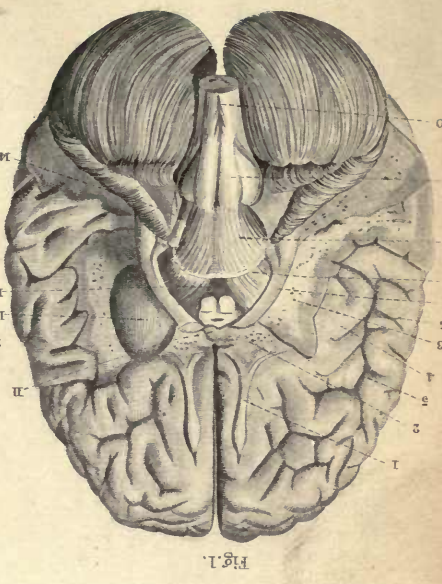
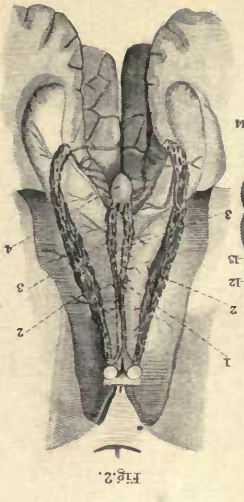
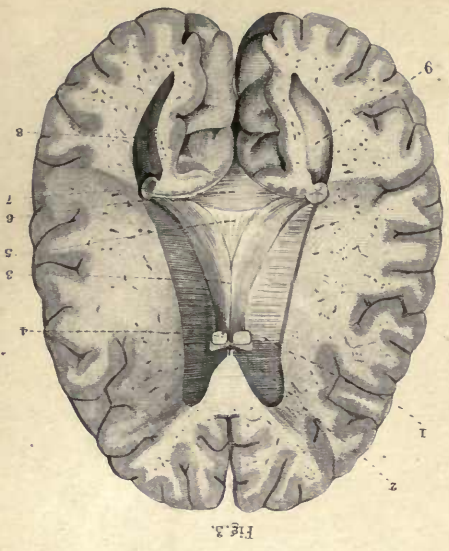
1. Olfactory nerve.—2. Anterior perforated substance.—3. White substance lying in contact with the lower part of the corpus striatum; below this is found the group of convolutions which correspond to the cornu ammonis and pes accessorius.—4. Group of convolutions which correspond to the lower portion of the corpus striatum.—5, 5. Great anfractuosus which terminates them.—6. Optic nerve.—7. Crus cerebri.—8. Fasciculus traversing the nodus cerebri, and becoming continuous with the crus cerebri.—9. Corpus pyramidale.—10. Crossing of these bodies.—11. Tuber cinereum, continuous above with the commissure of the optic nerves.—12. Lower portion of the corpus striatum.—13. Posterior perforated substance.—14. Origin of the fifth pair of nerves.

Fig. 2. VELUM INTERPOSITUM AND CHOROID PLEXUS.

1. Velum interpositum.—2, 2. Choroid plexus of the lateral ventricles.—3, 3. Choroid plexus of the inferior surface of the velum interpositum.—4. Pineal gland.

Fig. 3. CORPUS CALLOSUM.—FORNIX.

1. Corpus callosum.—2. Anterior commissure.—3. Fornix.—4. One of the divisions of the anterior pillar.—5. Lyræ.—6. Posterior extremity of the corpus callosum.—7. Cornu ammonis, cut.—8. Digital cavity.—9. Hippocampus minor.






Fig. 1. TRANSVERSE SECTION OF THE CEREBRUM IN FRONT OF THE ANTERIOR COMMISSURE.

The anterior lobes are removed.

1. Commissure of the optic nerves.—2. Lamina which closes the third ventricle in front.—3. Anterior commissure, traced into the substance of the corpus striatum.—4. Anterior part of the fornix.—5. Remains of the septum lucidum.—6. Corpus callosum.—7. Space between the upper surface of the corpus callosum and the reflected portion of the hemispheres.—8. Choroid plexus.—9. Upper portion, and, 10. Lower portion of the corpus striatum, separated by the inner capsule.—11. Continuity of the crus cerebri with the white substance of the corresponding hemisphere of the cerebrum.—12. Fissure of Sylvius.

Fig. 2. TRANSVERSE SECTION OF THE CEREBRUM ON A LINE WITH THE COMMISSURA MOLLIS.

The posterior part of the brain is removed.

1. Pituitary body.—2. Infundibulum.—3. Mammillary eminences.—4. Third ventricle.—5. Commissura mollis.—6. Fifth ventricle.—7. Corpus callosum.—8. Lateral portion of the fornix.—9. Choroid plexus.—10. Thalamus nervi optici.—11. Upper portion, and, 12. Lower portion of the corpus striatum.—13. Section of the crus cerebri and optic nerve.—14. Group comprehending the corpus fimbriatum, the cornu ammonis, and the fascia dentata.

Fig. 3. TRANSVERSE SECTION OF THE CEREBRUM BEFORE THE ANTERIOR COMMISSURE.

The posterior part of the brain is removed.

1. Reflected portion of the corpus callosum.—2. Fifth ventricle.—3. Corpus callosum.—4. Continuity of the corpus callosum with the crus cerebri, which divides the gray substance of the corpus striatum into two portions.—5. White central portion of the hemisphere and its prolongations.

Fig. 4. VERTICAL SECTION OF THE RIGHT LOBE OF THE CEREBELLUM, TO SHOW THE ARBOR VITÆ.

1. White central spot, or trunk of the arbor vitæ.—2. Corpus rhomboideum.—3, 3. Branches and ramifications of the arbor vitæ.

Fig. 1. CEREBELLUM.

The lobules of its upper surface are removed.

1. Communication between the third and fourth ventricle.—2. Process of the inferior tuberculum quadrigeminum.—3. Tubercula quadrigemina.—4. Processus cerebelli ad testes.—5. Commissure of the valve of Vieussens.—6. Fourth pair of nerves.—7. Valve of Vieussens.—8. Lingveta lamina, which covers it in part.—9. Central white substance of the cerebellum.—10. Lobe of the circumference.

Fig. 2. CEREBELLUM.

The central white substance is removed as far as the corpus rhomboideum, and the ventricle is laid open.

1. Processus cerebelli ad testes: the fibres of the two processes are seen to form a commissure beneath the tubercula quadrigemina.—2. Valve of Vieussens divided, and its two laminae displayed.—3. Free extremity of the lower vermiform process in the fourth ventricle.—4. Lobule of the medulla oblongata.—5. Corpus rhomboideum.—6. Choroid plexus of the fourth ventricle.—7. Interior of this ventricle.

Fig. 3. VIEW OF THE VENTRICLES.

The parts are separated.

1. Fifth ventricle.—2. Anterior pillar of the fornix, divided into two pedicles: the fissure which these pedicles leave between them is called the valve.—3. Anterior commissure.—4. Infundibulum.—5. Third ventricle.—6. Aqueduct of Sylvius, or, as it is frequently named, the *iter a tertio ad quartum ventriculum*.—7. Fourth ventricle.—8. Calamus scriptorius.

Fig. 4. ANTERIOR WALL OF THE FOURTH VENTRICLE.

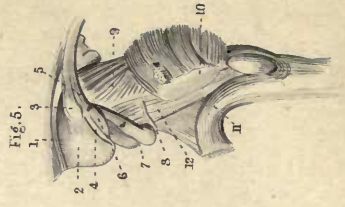
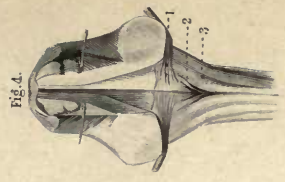
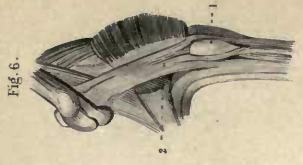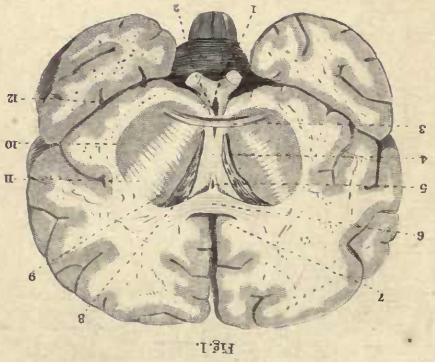
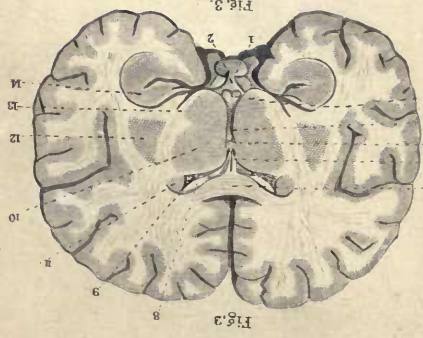
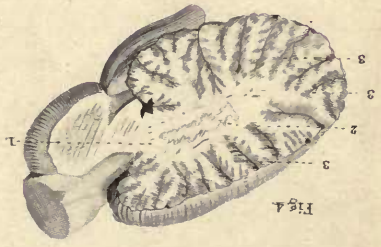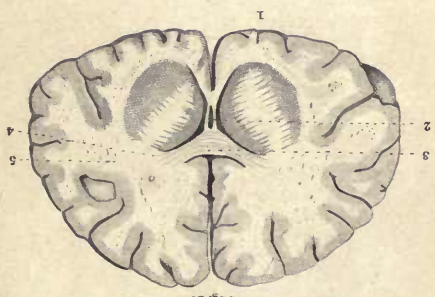
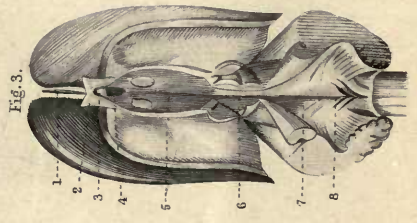
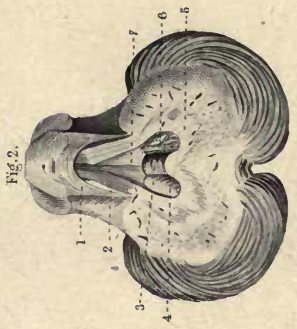
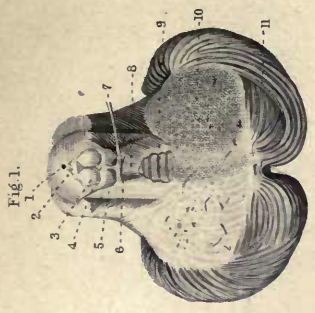
1. Roots of the auditory nerve.—2. Lamina cornea of the fourth ventricle.—3. Mammillary projection which bounds this ventricle.


Fig. 5. POSTERIOR PART OF THE THALAMUS NERVI OPTICI, AND THE CORPUS CALLOSUM VIEWED IN PROFILE.

1. Tenia semicircularis.—2. Posterior extremity of the thalamus nervi optici.—3. Corpus geniculatum externum.—4. Small white cord arising from the thalamus.—5. Corpus geniculatum internum.—6. Tubercle situated in the neighbourhood of the corpora geniculata.—7. Tubercula quadrigemina.—8. Fourth pair of nerves.—9. Crus cerebri.—10. Crus cerebelli, cut.—11. Corpus restiforme.—12. Lateral bundle of the isthmus.

Fig. 6. The fibres of the pons Varolii are cut to show the continuity of the lateral fasciculus of the pons Varolii with the fibres of the spinal marrow.

1. Corpus Olfvare.—2. Lateral fasciculus of the pons Varolii.





NEUROLOGY, Pl. 8.

Fig. 1. ANTERIOR SURFACE OF THE NODUS CEREBRI AND SPINAL MARROW.—DURA MATER, LIGAMENTUM DENTICULATUM, &c.

1. Dura mater.—2. Ligamentum denticulatum.—3, 3. Tooth-like processes.—4. One of the spinal nerves.—5. Hypo-glossal nerve.—6. Eighth pair of the old anatomists: glosso-pharyngeal, pneumo-gastric, and spinal accessory.—7. Seventh pair: facial and auditory.—8. Fifth pair.—9. Sixth pair.—10. Third pair.—11. Bundle of lower spinal nerves, forming the cauda equina.—12. Lumbar, or lower enlargement of the spinal marrow.—13. Middle, or cervical enlargement.—14. Upper, or occipital enlargement.—15. Anterior median groove.—16. Antero-lateral groove.—17. Corpus olivare.—18. Corpus pyramidale.—19. Nodus cerebri.—20. Crura cerebri.

Fig. 2. SPINAL MARROW ON A LARGER SCALE.

1. Dura mater.—2. Ligamentum denticulatum.—3. Anterior root of a spinal nerve, divided.—4. Anterior root.—5. Posterior root and ganglion.—6. Anterior groove.—7. Antero-lateral groove.

Fig. 3. POSTERIOR SURFACE OF THE SPINAL MARROW, &c.

1. Posterior furrow.—2. Calamus scriptorius.—3. Posterior column of the spinal marrow.—4. Division of the posterior column by a groove.—5. Mammillary enlargements of the posterior column.—6. Corpus restiforme.

Fig. 4. STRUCTURE OF THE MEDULLA OBLONGATA.

1. Anterior pillar of the spinal marrow, divided into two portions, which surround the corpus olivare, and which reunite beyond it.—2. Lateral column, divided into two portions, one of which passes behind the corpus olivare, the other passes behind the anterior column to interlace with a similar portion of the opposite side.—3. Interticement.—4. Posterior fibres coming to the corpus olivare from the anterior and lateral pillars.—5, 5. Corpora pyramidalia, resulting from the crossing of fibres, and from fibres from the anterior pillars.—6, 6. Fasciculi formed by the union of the anterior and posterior columns of the spinal marrow, continuous with, 7, 7. The crura cerebri.

Fig. 5. VERTICAL SECTION OF THE CORPORA OLIVARIA.

1. Outer layer of the corpus olivare.—2. Corpus dentatum.—3. Central nucleus.

Fig. 6. VERTICAL SECTION OF THE NODUS CEREBRI AND MEDULLA OBLONGATA.

1. Longitudinal fibres, separated from each other in the substance of the nodus cerebri.—2. White cord, which seems to proceed from the corpus olivare.—3. Black substance of the crus cerebri.

Fig. 7, 8, 9. SECTIONS OF THE SPINAL MARROW BELOW THE MEDULLA OBLONGATA.

Fig. 10. SECTION ON A LEVEL WITH THE DECUSSATION.

Fig. 11. SECTION OF THE MIDDLE PART OF THE MEDULLA OBLONGATA.

Fig. 12. SECTION AT THE UNION OF NODUS CEREBRI AND MEDULLA OBLONGATA.

NEUROLOGY, Pl. 9.

1. Corpus callosum, turned aside.—2. White line, situated at the union of the corpus callosum with the radiating fibres of the crura cerebri, on the outside of the corpora striata.—3, 3. Lamina of the septum lucidum, enclosing a fissure called the fifth ventricle.—4. Anterior commissure.—5. Pedicles of the fornix, cut.—6. Commissura mollis.—7. Third ventricle.—8. Pineal gland, turned aside to bring into view, 9. Its proper commissure.—10. The posterior commissure of the brain.—11. Tubercula quadrigemina, eminences named the nates and testes.—12. Prolongation of the superior tuberculum quadrigeminum, cut, passing beneath the white external layer of the thalamus nervi optici. The upper portion of the thalamus nervi optici is removed.—13. Tubercle, from which arise the fibres subjacent to the above-named prolongation.—14. White external lamina of the thalamus nervi optici.—15. Anterior pedicle of the pineal gland.—16. Tænia semicircularis.—17. Corpus striatum, the upper part of which is cut off and removed.—18. White fibres of the crus cerebri, traversing the corpus striatum.

Fig. 2. INFERIOR AND POSTERIOR PORTIONS OF THE LATERAL VENTRICLES.

1. Cornu ammonis, or pes Hippocampi.—2. Its eminence.—3. Corpus fimbriatum.—4. Hippocampus minor and digital cavity.

Fig. 3.—1. Corpus fimbriatum, turned outward.—2. Fascia dentata.

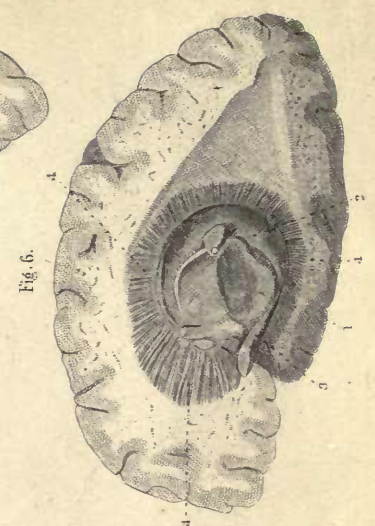
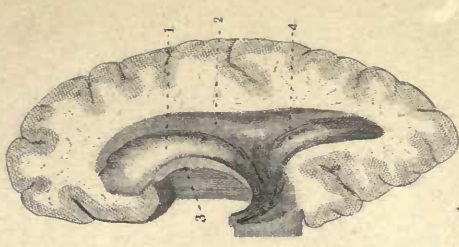
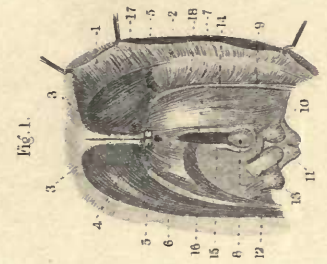


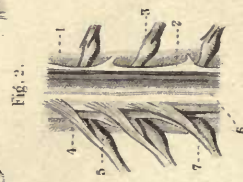
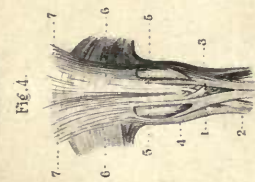

Fig. 4. NODUS CEREBRI AND MEDULLA OBLONGATA.

1. Nodus cerebri.—2, 2. Crura cerebri.—3, 3. Crura cerebelli.—4. Fifth pair of nerves.—5. Fibres of the nodus cerebri, passing in various directions.—6. Corpus pyramidale.—7. Corpus olivare.—8. Processus arciformes.

Fig. 5. NODUS CEREBRI, THE SUPERFICIAL FIBRES OF WHICH ARE REMOVED.

The deep white fibres are seen intimately blended with the gray substance, and forming a sort of raphé.

Fig. 6.—1. Crus cerebri, divided, and passing beneath the thalamus nervi optici.—2. Posterior part of the thalamus nervi optici, continuous with, 3. The optic nerve.—4, 4. Radiating crown of Keil. The upper part of the corpus striatum is removed.






Fig. 1. A DIAGRAM TO SHOW THE COURSE OF THE LARGE AND SMALL PETROSAL AND VIDIAN NERVES.

A. Otic ganglion.—B. Meckel's ganglion.—C. Anterior surface of the petrous portion of the temporal bone.—D. The apex of the petrous portion, where the internal carotid artery enters the cavity of the cranium.—E. The base of the petrous portion, where the external auditory canal enters it, and to which the pinna is attached.—F. The superior border of the petrous portion, which separates the middle and posterior fossae of the interior of the cranium.

1. The FACIAL NERVE entering the *internal auditory canal* on the posterior surface of the petrous portion of the temporal bone—as shown by the line being dotted.
 —2. The nerve following the curve of the *aqueduct of Fallopius* within the temporal bone.—3. The nerve escaping from the base of the skull, and the temporal bone as well, by means of the *stylo-mastoid foramen*.—4. The LARGE PETROSAL NERVE, arising from the facial nerve within the aqueduct of Fallopius, escaping into the cavity of the cranium by means of the *hiatus Fallopii* (at 4), then leaving the cranial cavity by the *foramen basis cranii* (foramen lacerum medium) (at 6), then entering the *Vidian canal* (9), in company with a filament from the carotid plexus (8), to form the *Vidian nerve* (10), and, finally, terminating in Meckel's ganglion (B).—5. The SMALL PETROSAL NERVE, arising from the facial nerve in the aqueduct of Fallopius, then entering the cavity of the cranium through the *foramen for the small petrosal nerve* (at 5), then leaving the cranial cavity by the *foramen ovale* (7), and going to the otic ganglion (A).—6. The foramen lacerum medium.—7. The foramen ovale.—8. The carotid filament, which helps to form the Vidian nerve (10).—9. The Vidian canal.—10. The Vidian nerve, formed by the large petrosal nerve and a filament from the carotid plexus.

Fig. 2. A DIAGRAM TO SHOW THE GENERAL COURSE OF THE MOTOR AND SENSORY NERVE-FIBRES WITHIN THE CEREBRUM, CRUS, AND PONS VAROLII (after Seguin).

P. Parietal lobe of cerebrum.—F. Frontal lobe of cerebrum.—M. Motor fibres.—T. Temporo-sphenoidal lobe of cerebrum.—O. Occipital lobe of cerebrum.—S. Sensory fibres (dotted).—C. Q. Corpora quadrigemina.—O. T. Optic thalamus.—N. L.—Nucleus lenticularis (a part of the corpus striatum).—N. C. Nucleus caudatus (the part of the corpus striatum seen on the floor of the lateral ventricle of the brain).—1. The sensory

portion of the medulla, pons Varolii, and crus cerebri (the fibres of the tegumentum cruris).—2. The motor portion of the same (the fibres of the basis cruris).

This drawing shows the general distribution of the sensory fibres to the occipital and temporo-sphenoidal, and of the motor fibres to the parietal and frontal lobes. It also illustrates the general relation of both the motor and sensory fibres of the cerebrum to the basal ganglia (optic thalamus and corpora striata) and to the corpora quadrigemina.

Fig. 3. A DIAGRAM TO SHOW THE RELATION OF THE OPTIC NERVE TO THE OPHTHALMIC ARTERY IN THE OPTIC FORAMEN.

N. Optic nerve.—O. Ophthalmic artery.

Fig. 4. A DIAGRAM TO SHOW THE DECUSSATION OF MOTOR NERVE-FIBRES IN THE MEDULLA OBLONGATA (after Seguin).

P. V. Pons Varolii.—M. O. Medulla oblongata.—O. Olivary body.—A. P. Anterior pyramid of the medulla oblongata.—S. C. Spinal cord.—D. The point of decussation of the motor fibres of the medulla oblongata.

In this diagram, the fact is shown that some of the fibres of the anterior pyramid, occasionally, do not decussate, but pass directly down the spinal cord. These fibres comprise the so-called "direct bundle." The fibres which do decussate are called, in contradistinction to the direct bundle, the "crossed bundle." The relative proportion of the size of these two bundles (crossed and direct) vary very much in different individuals. The experiments of Fiechsig have demonstrated that, while the direct bundle may possibly be absent, it may sometimes exceed in size the crossed bundle. This variation is important as tending to explain the occurrence of those rare cases of hemiplegia upon the same side as the exciting lesion within the cerebrum.

Fig. 5. A DIAGRAM ILLUSTRATING THE GENERAL COURSE OF THE MOTOR AND SENSORY FIBRES OF THE SPINAL CORD (after Brown-Séquard).

M. Motor fibres.—S. Sensory fibres.—D. Point of decussation of the motor fibres in the medulla oblongata. This diagram shows that the motor fibres decussate only in the medulla oblongata, while the sensory fibres decussate at their point of attachment to the spinal cord. The ganglion on the sensory fibres is also shown.

Fig. 6. A DIAGRAM TO SHOW THE RELATION OF THE OPTIC NERVE TO BLOOD-VESSELS WITHIN THE ORBIT.

The nerve is seen to be surrounded by the ciliary arteries. In the center of the nerve is seen the ciliary centralis retinæ.

FIG. 1.

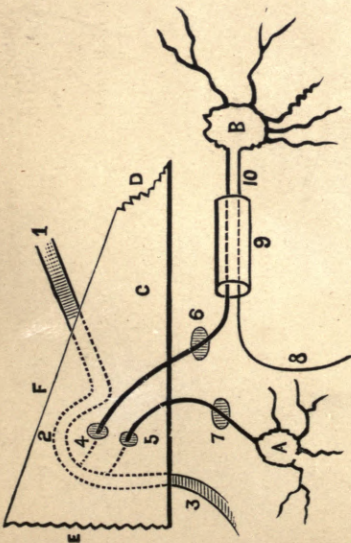


FIG. 3.

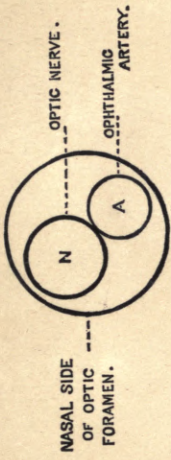


FIG. 5.

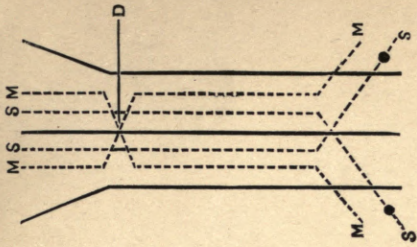


FIG. 4.

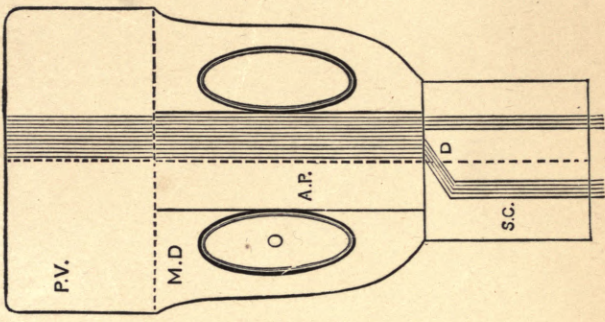


FIG. 2.

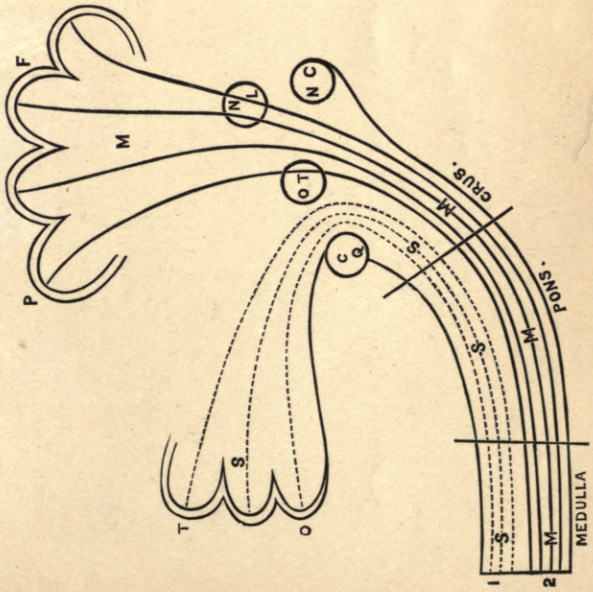
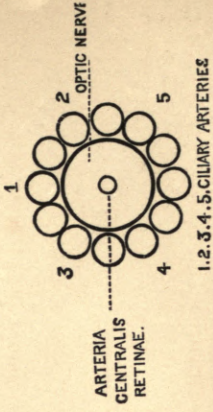


FIG. 6.



NEUROLOGY, PL. 11.

Fig. 1. The internal part of the thalamus nervi optici is scraped off and removed.

1. A fasciculus of increase from the medulla oblongata, to become blended in the thalamus nervi optici.—2. Crus cerebri.—3. Mammillary eminence, by pursuing a curved direction, becoming continuous with the thalamus nervi optici.—4. Pedicle of the anterior pillar of the fornix, continuous with the mammillary eminence.—5. Anterior commissure.—6. Corpus callosum.—7. Septum lucidum, divided.—8. Corpus striatum.—9. Tænia semicircularis.—10. Upper part of the thalamus nervi optici.—11. Pineal gland and its two prolongations.—12. Tubercular quadrigemina.—13. Valve of Vieussens.—14. Fourth ventricle.

Fig. 2. LATERAL VENTRICLES OF THE CEREBRUM.

1. Upper portion of a lateral ventricle.—2. Posterior portion, or digital cavity.—3. Hippocampus minor.—4. Lower portion.—5. Cornu ammonis.—6. Plexus choroides.—7. Corpus fimbriatum.

Fig. 3. LOWER SURFACE OF THE CEREBELLUM.

1. Upper vermiform process.—2. Lower vermiform process.—3. Lobule of the medulla oblongata, or amygdala.—4. Lobule of the pneumo-gastric nerve.—5, 5. Other lobules.—6, 6. Lobules of the circumference.

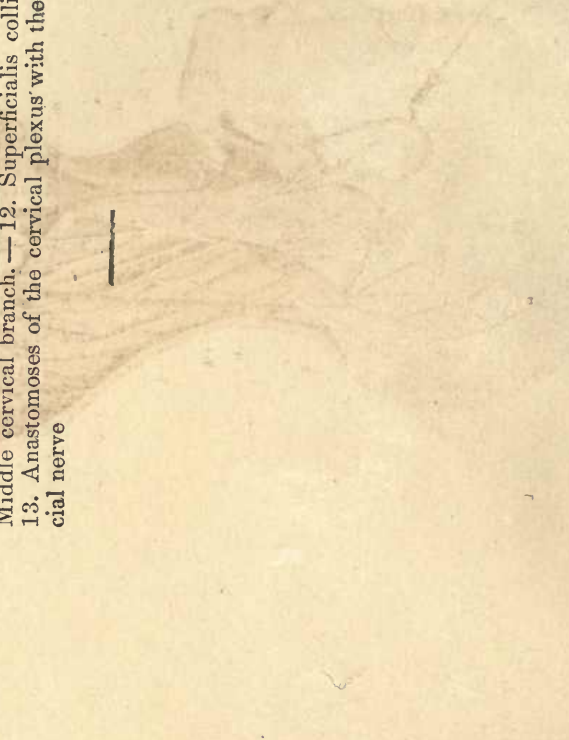
Fig. 4. MEDULLA OBLONGATA TURNED UPWARD.

1, 1. Auditory nerves.—2, 2. Lobules of the pneumo-gastric nerves.—3. Lower vermiform process.—4, 4. Valves of Tharin.

NEUROLOGY, PL. 12.

CERVICAL PLEXUS, superficial portion.

1. Temporal branch of the fifth pair.—2. Posterior branch of the second cervical nerve.—3. Inferior branch of the facial nerve.—4. Auricular branch of the cervical plexus.—5. Great mastoid branch.—6. Small mastoid branch.—7. Other posterior recurrent branches.—8. Spinal accessory nerve.—9. Supra-acromial branch.—10. Supra-clavicular branch.—11. Middle cervical branch.—12. Superficialis colli.—13. Anastomoses of the cervical plexus with the facial nerve



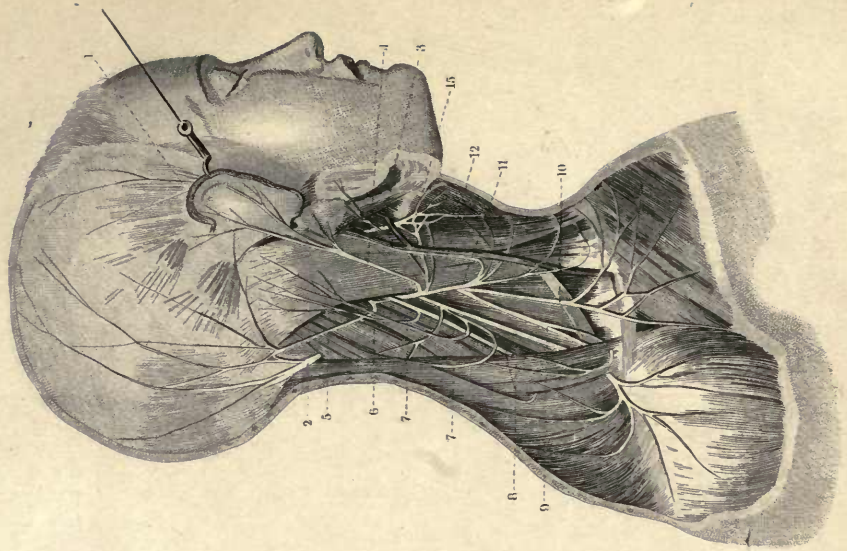


Fig. 3.



Fig. 2.

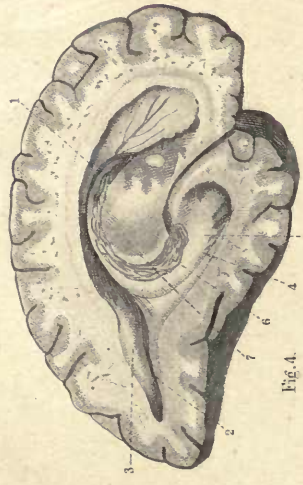


Fig. 4.

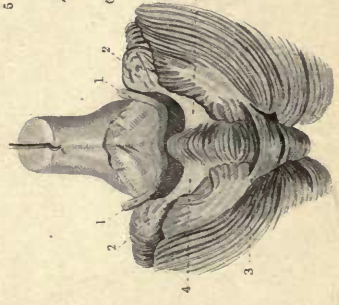
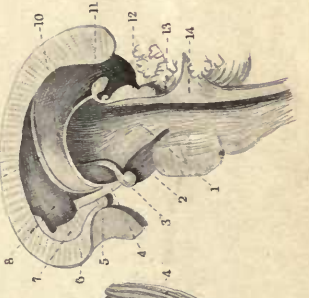


Fig. 1.



NEUROLOGY, Pl. 13.

DEEP PORTION OF THE CERVICAL PLEXUS, AND THE BRACHIAL PLEXUS.

The thorax is laid open on the right side.

1. Facial nerve.—2. Pneumo-gastric nerve.—3. In-ternal carotid artery.—4. Spinal accessory nerve.—5. Anastomoses of the spinal accessory nerve with the cervical plexus.—6. Hypo-glossal nerve, dividing into the hypo-glossal nerve proper and the descen-dens duodecimi.—7. Anterior branch of the first cervical nerve, anastomosing with the hypo-glossal nerve and with the pneumo-gastric.—8. Descending cervical branch of the cervical plexus, anastomosing with the corresponding branch of the hypo-glossal.—9. Phrenic nerve.—10, 10. Deep cervical branches of the cervical plexus.—11. Brachial plexus.—12. Branch to the subclavius muscle, sending a filament to the phrenic nerve.—13. Anterior thoracic branch- es.—14. Lateral thoracic branch, or the branch of the serratus magnus.—15, 16, and 17. Subscapular branches going to the subscapularis, latissimus dorsi, and teres major muscles.—18. Axillary artery, sur- rounded by a sort of sheath formed by branches go- ing to the arm.—19. Brachial branches.

NEUROLOGY, Pl. 14.

Fig. 1. FACIAL NERVE AFTER IT HAS EMERGED FROM THE AQUEDUCT OF FALLOPIUS, &c.

1. Posterior branch of the second cervical nerve.—2. Mastoid branches of the cervical plexus.—3. Trunk of the cervical plexus, giving origin to one of the mastoid branches of the cervical plexus, to the auricular, and middle cervical branch.—4. Malar filament of the orbital branch of the superior maxillary nerve.—5. Intra-orbital nerves.—6. Frontal branch of the fifth pair.—7. Twig from the lachrymal branch.—8. Buc- cal branch of the inferior maxillary nerve.—9. Superficial tem- poral branch of the same nerve.—10. Mental branch of the dental nerve.—11. Hypo-glossal nerve.—12. Trunk of the fa- cial nerve, giving off the posterior auricular twig, a twig to the posterior belly of the digastric muscle, and the stylo-hyoid twig, and then dividing into temporal, orbital, nasal, buccal, inferior maxillary, and cervical twigs.

Fig. 2. FACIAL NERVE IN THE AQUEDUCT OF FALLOPIUS MECKEL'S GANGLION, OTIC GANGLION, GANGLION OF ANDERSH, &c., &c.

1. Fifth pair.—2. Spheno-palatine, or Meckel's ganglion.—3. Vidian branch of this ganglion, and its division into a cran- ial filament, which inosculates with the facial nerve, and into a carotid filament, which inosculates with the sympathetic on the walls of the internal carotid artery.—4. Lingual branch of the fifth pair, receiving the inosculating twig given off from the facial when lodged in the aqueduct of Fallopius, and called the chorda tympani.—5. Otic ganglion and its twig, by means of which it communicates with Jacobson's nerve and with the facial.—6. Facial nerve, and the twig which it receives from the auditory nerve.—7. Twig of communication with the facial.—8. Origin of the chorda tympani.—9. Inosculation with the glosso-pharyngeal.—10. Inosculation with the pneu- mo-gastric.—11. Glosso-pharyngeal nerve, and its slight en- largement, known by the name of the ganglion of Andersh, from which the nerve of Jacobson ascends into the tympanum.—12. Ascending branches of the superior cervical ganglion, inosculating with and constituting the carotid plexus, from which proceed a filament which inosculates with the Vidian nerve, and another filament which inosculates with Jacobson's nerve.

Fig. 3. AUDITORY NERVE.

- The lamina of bone which conceals the labyrinth is removed
1. Facial nerve, and its inosculation with the cranial fila- ment of the Vidian.—2. Chorda tympani, between the incus and the handle of the malleus.—3. Auditory nerve.—4. Branch to the cochlea.—5. Branch to the vestibule and semicircular canals.

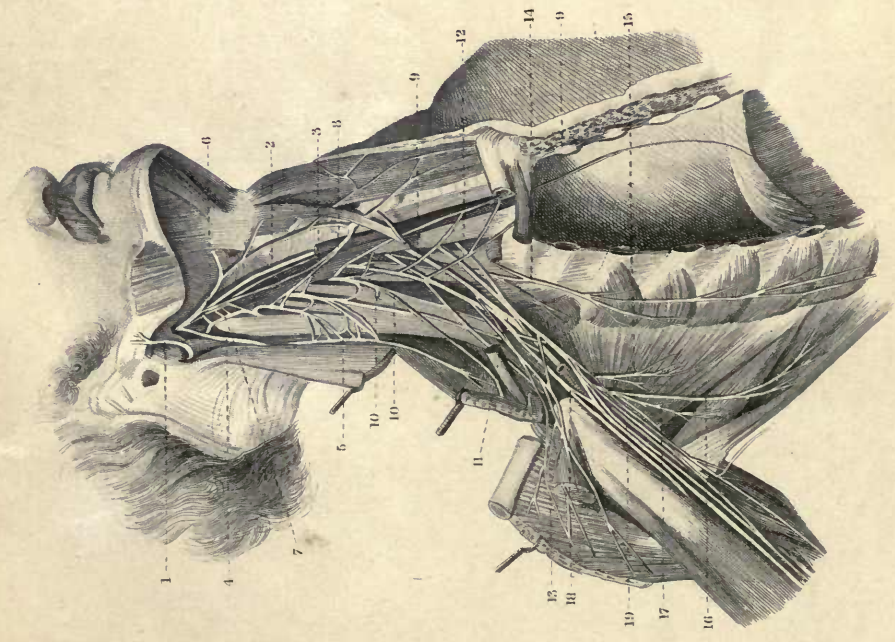


Fig. 1.

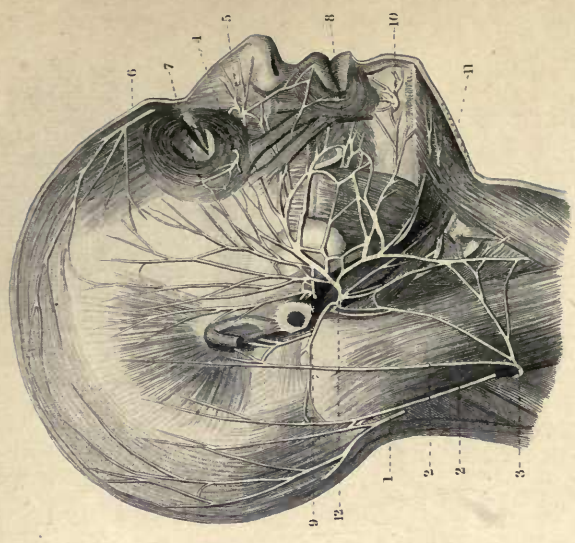


Fig. 3.

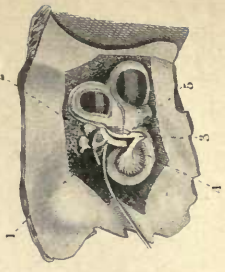
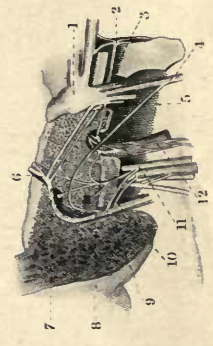


Fig. 2.





NEUROLOGY, PL. 15.

DEEP NERVES OF THE UPPER EXTREMITY.

The flexor carpi radialis, palmaris longus, and flexor digitorum sublimis are cut through.

Fig. 1.—1. Brachial artery.—2. Radial artery.—3. Ulnar artery.—4. Musculo-cutaneous nerve.—5. Median nerve.—6. Branch to the deep muscles on the anterior surface of the fore-arm, or the interosseous nerve.—7. Cutaneous palmar branch.—8. Division of the median nerve into two branches, which in their turn subdivide.—9. Ulnar nerve.—10. Division of the palmar branch of the ulnar nerve into, 11. Superficial palmar branch, and into, 12. Deep palmar branch.—13. Radial nerve, and its subdivision into, 14. Anterior branch, and into, 15. Posterior branch.

Fig. 2. RADIAL NERVE.

The triceps extensor cubiti and the superficial muscles on the dorsal surface of the fore-arm are divided.

1. Radial nerve.—2. Posterior branch of the radial nerve, dividing into superficial and deep branches.

NEUROLOGY, PL. 16.

Fig. 1. SUPERFICIAL NERVES OF THE UPPER EXTREMITY.

1. Basilic vein.—2. Cephalic vein.—3. Cutaneous branch of the radial nerve.—4. Superficial portion of the musculo-cutaneous nerve.—5, 5. Divisions of this nerve.—6. Internal cutaneous nerve.—7. External branch of the same nerve.—8. Internal branch.—9. Accessory branch of the internal cutaneous nerve.—10. Cutaneous branch of the median nerve.—11. One of the collateral branches of the median nerve.

Fig. 2.—1, 1. Cutaneous filaments of the circumflex nerve.—2, 2. Cutaneous branches of the radial.—3, 3. Branches of the internal cutaneous nerve.—4, 4. Branches of the external cutaneous nerve.—5. Inosculation of this nerve with the radial.—6. Dorsal branch of the ulnar nerve, dividing into two collateral branches, one for the ulnar border of the little finger, the other for the last two interosseous spaces.—7. Anterior branch of the radial nerve, having reached the dorsal surface, dividing into two branches, one for the external border of the thumb, the other for the first two interosseous spaces.—8. Inosculation between the radial and ulnar nerves.—9. Division of one of the collateral branches into two digital twigs.

Fig. 2.

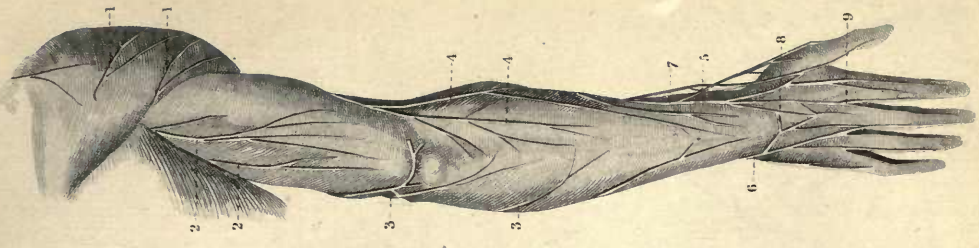


Fig. 1.

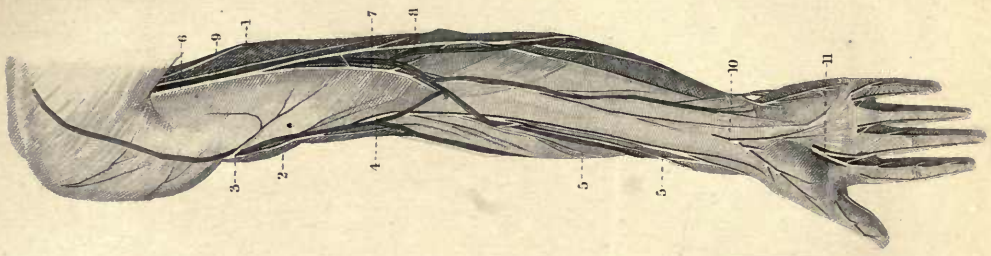


Fig. 2.

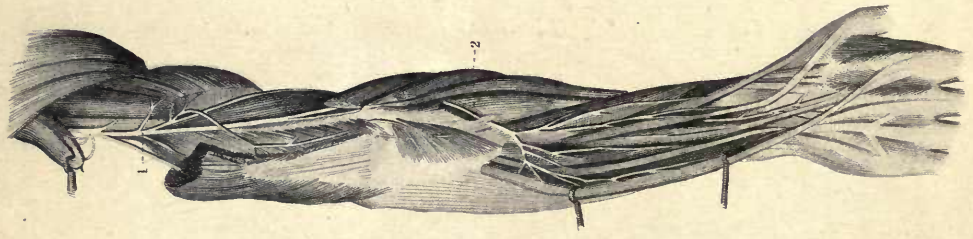
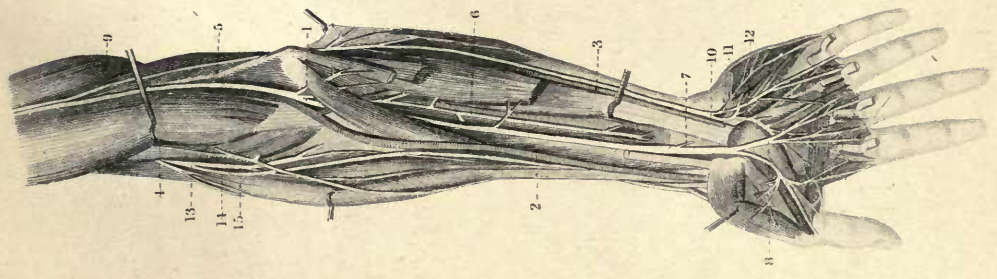


Fig. 1.





NEUROLOGY, Pl. 17.

INTERCOSTAL NERVES. The pectoralis major and minor muscles are removed. The obliquus externus and rectus abdominis are divided, and removed in some places.

1. Axillary vein: the artery is removed.—2. Portion of the brachial plexus and two thoracic branches.—3. Brachial twig of the first intercostal nerve.—4. Brachial twig of the second intercostal nerve.—5. Inosculation between two branches.—6. Division of an intercostal branch into, 7. A superficial branch, and, 8. A deep branch.—9. Gluteal branch of the twelfth intercostal nerve.—10. Termination of the ilio-scrotal branch of the lumbar plexus.—11. Inguino-cutaneous branch.—12. Twig of the genito-crural branch.—13, 13. Portions of the deep nerves after they have become superficial.

NEUROLOGY, Pl. 18.

Fig. 1. THE GLUTEUS MAXIMUS IS DIVIDED AT ITS LOWER PORTION.

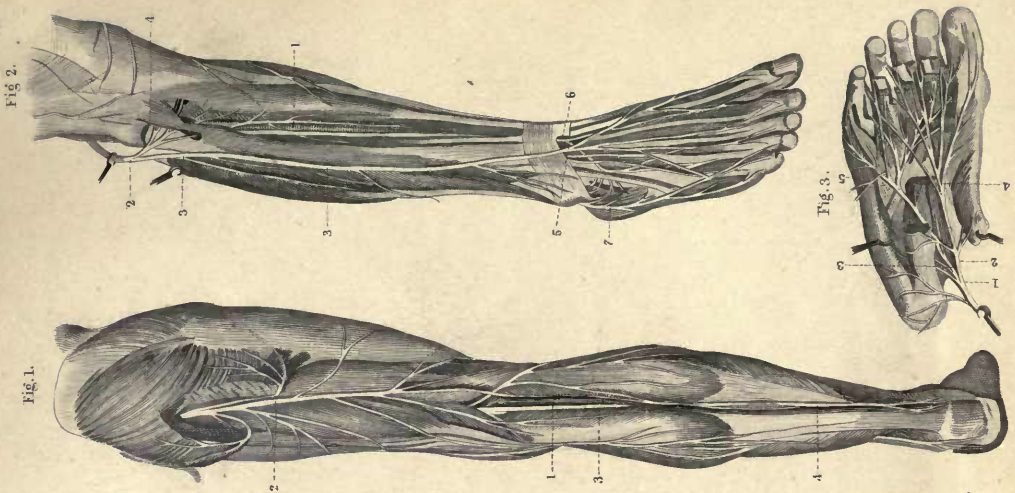
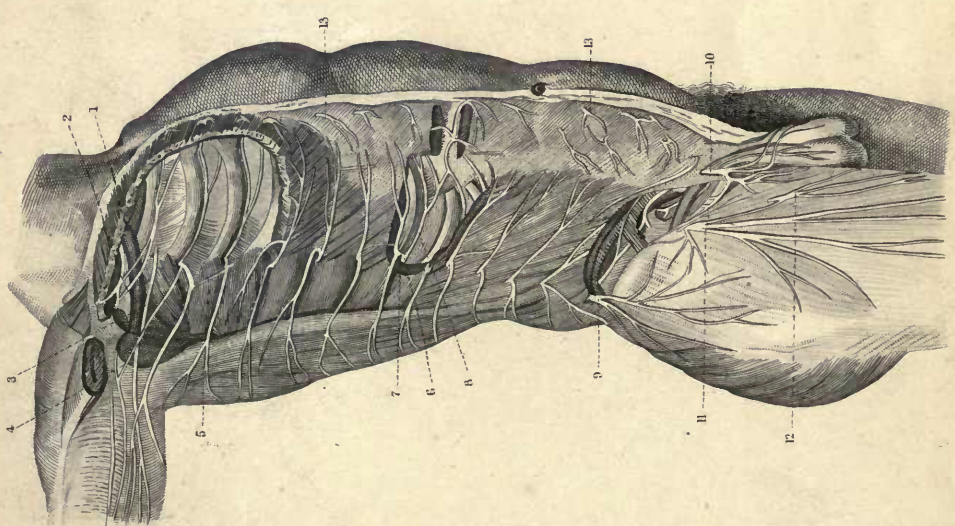
1. External saphenous vein.—2. Posterior cutaneous branch.—3. External saphenous nerve.—4. Inosculation of the external saphenous nerve with a twig of the external popliteal trunk.


Fig. 2.—1. Anterior tibial artery.—2. External popliteal nerve, and its division into, 3, 3. Musculo-cutaneous branch, and into, 4. Anterior tibial nerve.—5. Division of the musculo-cutaneous branch into two superficial dorsal branches of the foot, one for the inner border of the great toe, the other for the two middle interosseous spaces.—6. Division of the anterior tibial nerve into two deep dorsal branches.—7. Termination of the external saphenous nerve.

Fig. 3. PLANTAR NERVES.

The adductor pollicis and flexor brevis digitorum muscles are divided.

1. Posterior tibial nerve, and its division into, 2. Internal plantar nerve, and into, 3. External plantar nerve.—4. Division of the internal plantar nerve into four collateral branches.—5. Division of the external plantar nerve into a superficial and into a deep branch.





NEUROLOGY, PL. 19.

Fig. 1. LUMBAR PLEXUS.

1. Twelfth intercostal nerve.—2. Lumbar portion of the great sympathetic.—3. Sacral plexus.—4. Lumbar plexus.—5. Ilio-scrotal branch.—6. Inguino-cutaneous branch.—7. Genito-crural branch.—8. Anterior crural nerve.—9. Obturator nerve.—10. Lumbo-sacral nerve.

Fig. 2. ANTERIOR CRURAL NERVE AND ITS BRANCHES.

1. Femoral vein.—2. Femoral artery.—3. Anterior crural nerve.—4. Musculo-cutaneous branch.—5. Branch to the sheath of the vessels.—6. Internal saphenous vein.—7, 7. Saphenous nerve.—8. Inner division of the musculo-cutaneous branch of the external popliteal trunk.—9. Branch of internal saphenous nerve.

NEUROLOGY, PL. 20.

NERVES SITUATED ON THE POSTERIOR PART OF THE TRUNK.

Portions of the trapezius, splenius, complexus, trachelo-mastoideus, latissimus dorsi, and gluteus maximus muscles, &c., &c., are removed.

1, 1, 1. Posterior twigs of the superficial branches of the intercostal nerves.—2. Posterior branch of the first cervical nerve, or sub-occipital.—3. Posterior branch of the second cervical nerve.—4. Inosculation of this branch with the great mastoid branch.—5, 5. Posterior branches of two cervical nerves.—6. Intercostal branch.—7. External twig of a dorsal branch.—8. Internal twig of a dorsal branch.—9. Posterior branch of a lumbar nerve.—10. Posterior branch of a sacral nerve.

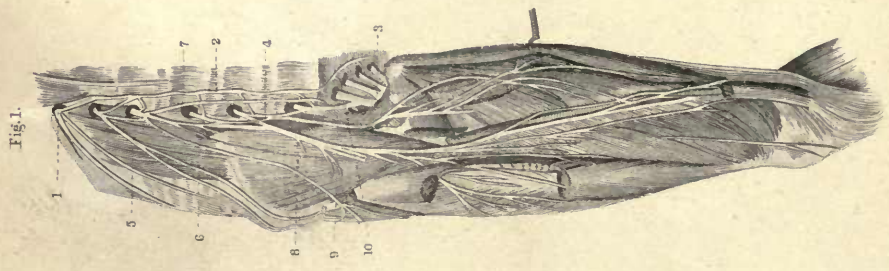
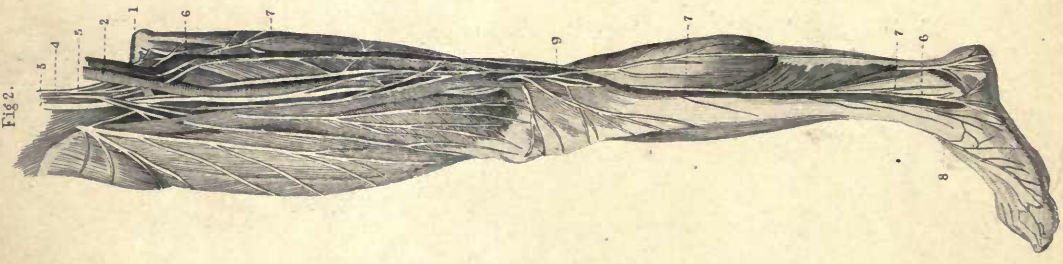
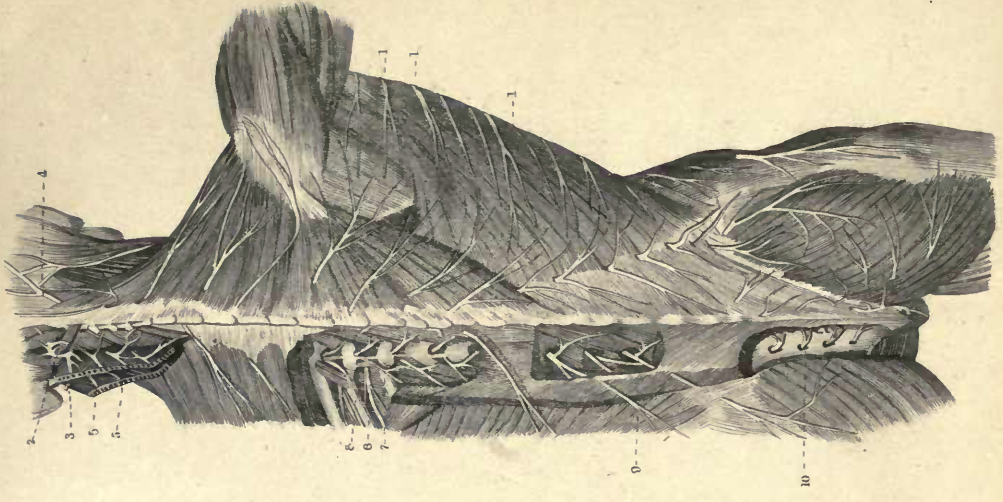



Fig. 2.

Fig. 1.



NEUROLOGY, PL. 21.

Fig. 1. SACRAL PLEXUS.

The pelvis and vertebral column are divided at the median line. The pelvic viscera are divided and drawn down.

1. Branch of the anterior crural nerve.—2. Obturator nerve.—3. One of the sacral ganglia inosculating with one of the sacral nerves.—4. Lumbo-sacral nerve.—5. Sacral plexus, and, 6. Its numerous branches.—7. Pudic nerve.—8. Upper branch of the pudic nerve.—9. Lower branch.

Fig. 2. SCIATIC NERVE.

The gluteus maximus and medius, the biceps, gastrocnemii, and soleus are divided, and in part turned aside.

1. Upper gluteal nerve.—2. Inferior gluteal nerve.—3. Sciatic twig.—4. Cutaneous nerve.—5. Pudic nerve.—6. Sciatic nerve.—7. External popliteal nerve.—8. Internal popliteal nerve.

Fig. 3. The soleus muscle is removed.

1. External saphenous nerve, divided.—2. Posterior tibial nerve.

NEUROLOGY, PL. 22.

Fig. 1. PASSAGE OF THE CRANIAL NERVES THROUGH THE FORAMINA AT THE BASE OF THE CRANIUM.

1. Tentorium cerebelli.—2. Nervous twig of the tentorium cerebelli.—3. Internal carotid artery.—4. Pituitary body and infundibulum.—5. Bulb of the olfactory nerve.—6. Optic nerve, or second pair.—7. The third pair, or motores oculorum.—8. Pathetici, or fourth pair.—9. Trifacial, or fifth pair.—10. Abducentes, or sixth pair.—11. Facial nerve, or portio dura of the seventh pair.—12. Auditory nerve, or portio mollis of the seventh pair.—13. Glosso-pharyngeal nerve, or first division of the eighth pair.—14. Nervus vagus, or pneumo-gastric, or second division of the eighth pair.—15. Spinal accessory, or nervus accessorius of Willis, or third division of the eighth pair.*—16. Hypo-glossal, or ninth pair.—17. Vertebral artery.—18. Occipital foramen, or foramen magnum.

Fig. 2. NERVES OF THE EYE.

The roof of the orbit is removed.

1. Outer wall of the orbit.—2. Crista galli.—3. Foramina of the cribriform plate of the ethmoid bone.—4. Optic nerve.—5. Internal carotid artery.—6. Third pair of nerves.—7. Upper branch of this nerve.—8. Inferior branch of the same nerve.—9. Lenticular ganglion, which receives, from behind, two roots, and which gives off, before, the ciliary nerves.—10. Ciliary nerves, which are seen on the choroid, the upper portion of the sclerotic being removed.—11. The fifth pair of nerves.—12. Ophthalmic branch.—13. Nasal branch of the ophthalmic.—14. Two ciliary nerves, coming from the nasal branch.—15. Division of the nasal branch.—16, 16. Sixth pair of nerves; the external rectus is drawn in a direction outward by a hook.

Fig. 3. THIRD AND SIXTH PAIR OF NERVES.

The eye is reflected forward.

1. Third pair of nerves.—2. Upper branch of this nerve, receiving an inosculating twig from the sixth pair.—3. Inferior branch of the same nerve, and its division into three branches.—4. Twig of the inferior branch going to the inferior oblique muscle of the eye.—5. Sixth pair of nerves.

* As modern anatomists, with much propriety, consider the seventh pair of Willis as constituting two pairs, and the eighth of the same anatomist as forming three pairs, the cerebral nerves are now described as constituting twelve instead of nine pairs. The portio dura the seventh, the portio mollis the eighth, the glosso-pharyngeal the ninth, the pneumo-gastric the tenth, the spinal accessory the eleventh, and the hypo-glossal the twelfth.

Fig. 2.

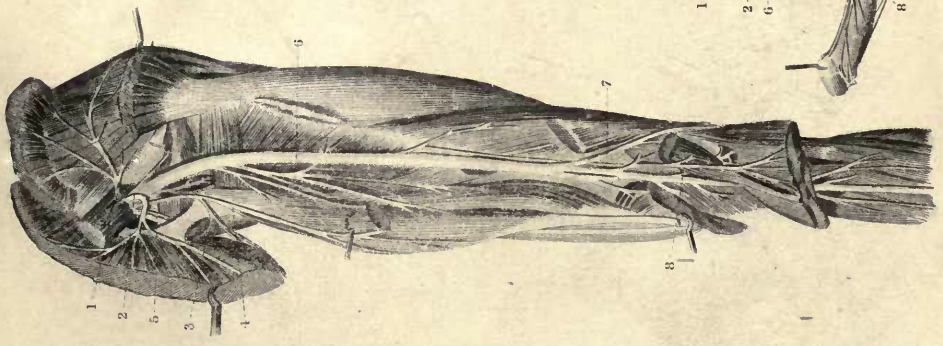


Fig. 3.



Fig. 1.

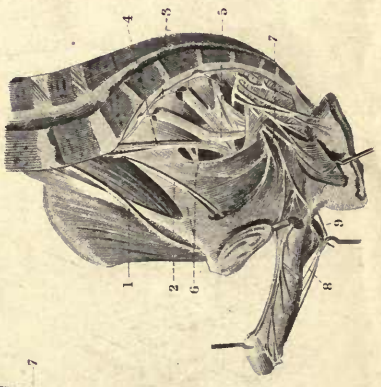


Fig. 1.

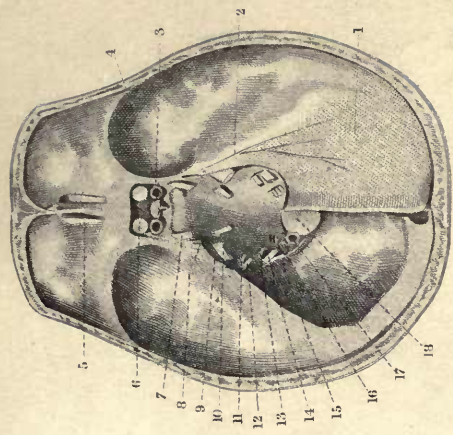


Fig. 2.

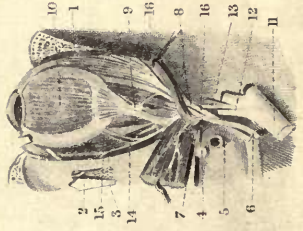
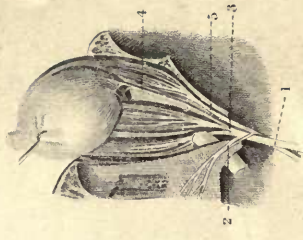


Fig. 3.



NEUROLOGY, Pl. 23.

Fig. 1. OPHTHALMIC BRANCH OF THE FIFTH PAIR.

1. Skin of the forehead, turned down.—2. Optic nerve.—3. Third pair of nerves.—4. Fourth pair, or pathetic.—5. Ophthalmic branch.—6. Lachrymal twig.—7. Inosculation of the fourth pair with the lachrymal branch.—8. Frontal nerve.—9. Nasal nerve.—10. Internal filament of the nasal nerve.

Fig. 2. SUPERIOR MAXILLARY BRANCH OF THE FIFTH PAIR, &c., &c.

1. Lachrymal twig of the ophthalmic branch.—2. Orbital twig of the superior maxillary branch.—3. Ganglion of Meckel, or sphenopalatine ganglion, receiving, from above, two filaments from the maxillary nerve; giving off, below, the palatine nerves; behind, the Vidian, or pterygoid.—4. Cranial filament of the Vidian nerve.—5. Carotid filament of the same nerve.—6. Posterior dental branches.—7. Twig to supply the gums.—8. Anterior dental twig.—9. Inosculation of the dental nerves and the net-work which results.—10. Division of the superior maxillary branch into the infra-orbital nerves.—11. External branches of the inferior maxillary branch of the fifth pair.—12. Superficial temporal nerve.—13. Inferior dental nerve, cut.—14. Lingual nerve, and its inosculation with the corda tympani.—15. Sub-maxillary ganglion.—16. Glossopharyngeal nerve.—17. Spinal accessory nerve.—18. Pneumogastric nerve.—19. Hypo-glossal nerve.—20. Internal carotid artery.

Fig. 3. INFERIOR MAXILLARY BRANCH OF THE FIFTH PAIR.

1. Inferior branch in the foramen ovale.—2. Temporal nerve.—3. Branch passing to the external pterygoid muscle.—4. Buccal nerve.—5. Masseteric nerve.—6. Superficial temporal nerve, and its inosculations with the facial nerve.—7. Dental nerve.—8. Mental branch.—9. Lingual nerve, and its inosculation with the chorda tympani.—10. Internal pterygoid nerve.

NEUROLOGY, Pl. 24.

Fig. 1. BRACHIAL PLEXUS.

1 and 2. Fifth and sixth cervical nerves (anterior branches)—3. Cord resulting from their inosculation, and dividing into, 4. Musculo-cutaneous, or external cutaneous nerve, and into, 5. Median twig.—6. Eighth cervical, and, 7. First dorsal nerve.—8. Cord resulting from their inosculation, dividing into, 9. Median twig; into, 10. Ulnar nerve, and sometimes into, 11. Internal cutaneous nerve.—12. Accessory nerve of the internal cutaneous.—13. Median nerve.—14. Seventh cervical nerve, lying between the other divisions of the brachial plexus, and assisting in its formation.—15. Lateral thoracic branch.—16. Radial nerve.

Fig. 2.—1. Trapezius muscle, turned over.—2. Rhomboideus.—3. Spinal accessory nerve.—4, 4. Deep cervical branches of the cervical plexus and of the brachial plexus.—5. Supra-scapular nerve.—6. Circumflex nerve.

Fig. 3.—1, 1. Palmar digital nerves of a finger.—2, 2. Nervous arches formed by the inosculation of two digital nerves.

Fig. 4.—1, 1. Dorsal digital nerves of a finger.—2, 2. Dorsal branches furnished by the palmar nerves.

Fig. 5.—1. Palmar nerve.—2. Dorsal branch of a palmar nerve.—3. Dorsal nerve, inosculating with the dorsal branch of the palmar nerve.—4. Ungual twig of the palmar nerve.

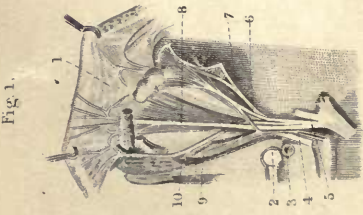


Fig. 3.

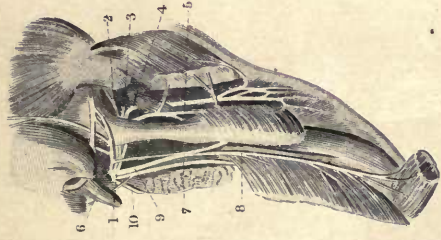


Fig. 2.

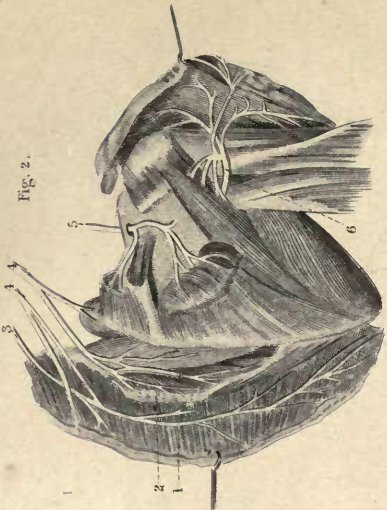
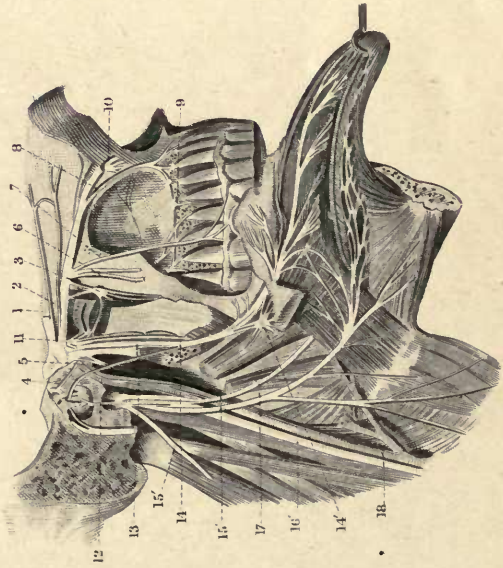


Fig. 2.

Fig. 1.



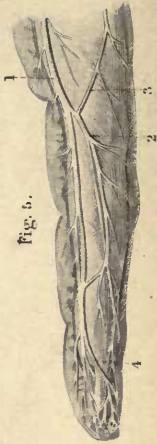Fig. 4.




Fig. 3.



Fig. 5.





OLFACTORY NERVE. TRIGEMINUS, INFERIOR MAXILLARY BRANCH.
LARYNGEAL NERVES.

Fig. 1. OLFACTORY NERVE, NASO-PALATINE NERVE, &c.

1. Divisions of this nerve on the septum of the nasal fossæ.
- 2. Internal filament of the nasal branch of the ophthalmic.
- 3. Naso-palatine nerve.—4. Other branch of the septum.

Fig. 2. INFERIOR MAXILLARY NERVE VIEWED FROM WITHOUT.

The zygomatic arch is removed.

1. Masseteric branch.—2. Buccal branch.—3. Divisions of this branch on the external surface of the buccinator muscle.
- 3'. Branch to the external pterygoid muscle.—4. Deep temporal branches.—5. Superficial temporal branch, anastomosing with the facial nerve.—6. Facial nerve.—7. Inferior dental branch.

Fig. 3. JENTIGULAR GANGLION. FIFTH PAIR OF NERVES VIEWED FROM WITHIN. OTIC GANGLION.

1. External divisions of the olfactory nerve.—2. Fifth pair of nerves, its ganglion, and its division into three branches.—3. External filament of the nasal branch of the ophthalmic.—4. Spheno-palatine ganglion, or the ganglion of Meckel.—5, 5, 5. Nasal ramifications of the spheno-palatine and palatine nerves.—6. Palatine nerves.—7. Lingual branch of the fifth, and its innosulation with the chorda tympani.—8. Inferior dental nerve and its innosulating filament.—9. Superficial temporal branch.—10. Pterygoid branch of the inferior maxillary nerve.—11. Otic ganglion.—12. Filament from this ganglion, which goes to the Eustachian tube, and to the mucous membrane of the nasal fossæ.—13. Petrosal branch, innosulating with the Vidian.—14. Filament of the internal muscle of the malleus.—15. Filament distributed to the coats of the internal maxillary artery, and which innosulates with the superficial temporal nerve.—16. Facial nerve.—17. Chorda tympani, passing between the handle of the malleus and the lower branch of the incus.

Fig. 4.—1. Superior laryngeal nerve.—2. Inferior laryngeal nerve, or recurrent.—3. Innosulation of the two laryngeal nerves.

GREAT SYMPATHETIC, INFERIOR PORTION.—THORACIC, LUMBAR, AND SACRAL GANGLIA, SOLAR PLEXUS, &c.

- 1, 1, 1. Three thoracic ganglia and their innosulations with the intercostal nerve.—2, 2. Aortic branches.—3, 3. Branches of the pulmonary plexus, belonging to the right pneumo-gastric nerve, cut.—4. Great splanchnic nerve.—5. Small splanchnic nerve.—6, 6. Solar plexus.—7. Semilunar ganglion of the right side.—8. Pneumo-gastric nerve of the right side.—9. Pneumo-gastric of the left side, giving numerous branches to the anterior surface of the stomach.—10. Supra-renal plexus.—11. Renal plexus.—12. Nerves distributed to a portion of intestine.—13. Aortic plexus.—14. Spermatic plexus.—15, 15. Two lumbar ganglia; their innosulations with the lumbar nerves and with the aortic plexus shown.—16, 16. Two sacral ganglia: these sacral ganglia innosculate with each other, and with filaments of the sacral nerves, from which innosulation plexuses arise, which accompany the arteries of the pelvis.—17. Sacral plexus.

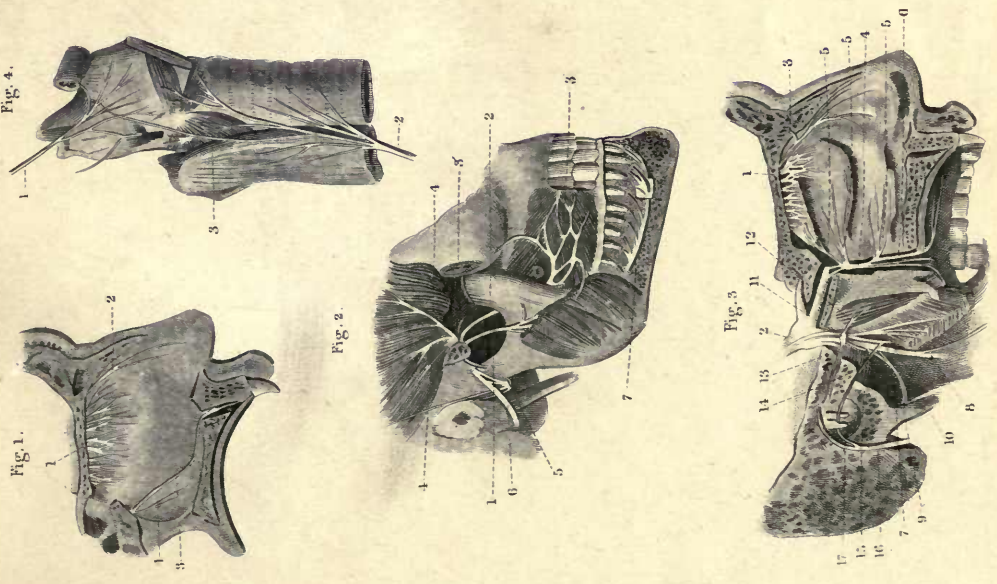
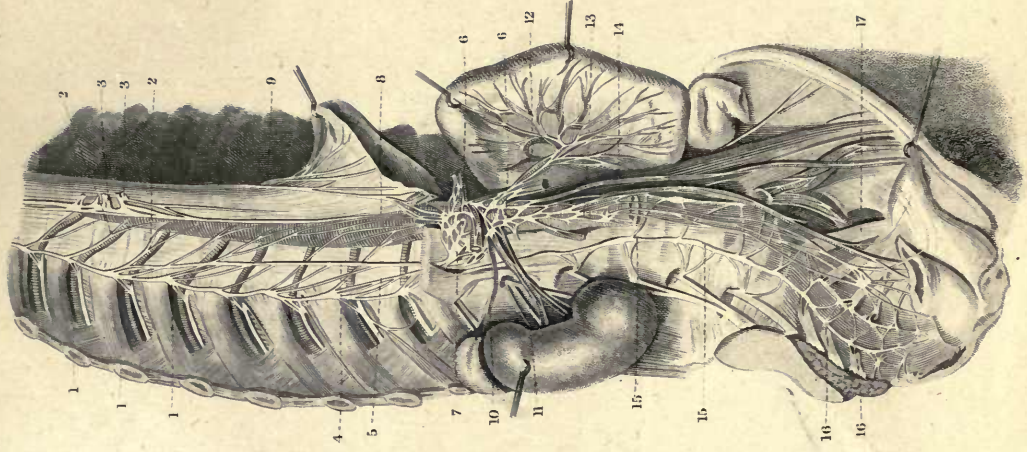


Fig. 1. A DIAGRAM TO SHOW THE METHOD OF DISTRIBUTION OF THE FIBRES OF EACH OPTIC TRACT.

A. Outer fibres of each tract, going to outer or temporal half of the corresponding retina.—B. Inner fibres of each tract, decussating and going to the nasal side of the opposite retina.—E. Optic nerve, in front of the chiasm.—C'-C'. The optic chiasm.—D. Retina, showing the two lateral halves supplied from two sources.—D'-E'. Spot, where pressure would produce blindness of the temporal half of corresponding eye and nasal half of opposite eye.—A.-B.' Region, where pressure would produce blindness of both halves of one retina, since both the decussating and direct fibres would be impaired.—B'. or C. Spots, where pressure would produce blindness of the nasal half only of each retina.—C'. C'. Spots, where pressure would produce blindness of the temporal half only of the retina of the same side; or, if both be pressed upon, blindness in the outer half of both retinae.—B'. C'. C. C'. Region, which, if destroyed, would cause total blindness.

Fig. 2. A DIAGRAM TO SHOW THE LIMITS OF COLOR PERCEPTION BY THE RETINA.

In this diagram, the results of the researches of the German investigators have been so clearly defined by Dr. Hirschberg, as to simplify the examination of the retina, and enable any deviation from its normal condition to be perceived and recorded.

—————stands for the limit of vision for white objects.
 - - - - - " " " " " " " " " " " "
 - - " " " " " " " " " " " "
 " " " " " " " " " " " "

P. for the papilla of the retina.
 The letters on the color lines indicate the color which each represents.

The center of the diagram, from which the lines diverge, corresponds to the "macula lutea," the center of the "yellow spot of Sömmering"; while the numbers on the lines are placed at equal degrees from the center, to enable the oculist to designate the exact situation of special points of interest pertaining to any ophthalmoscopic examination.

FIG. I.

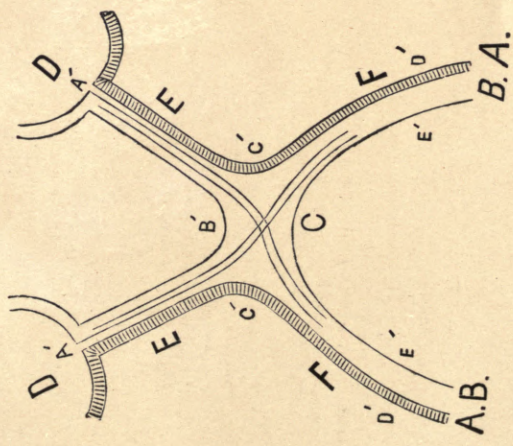


FIG. 2.

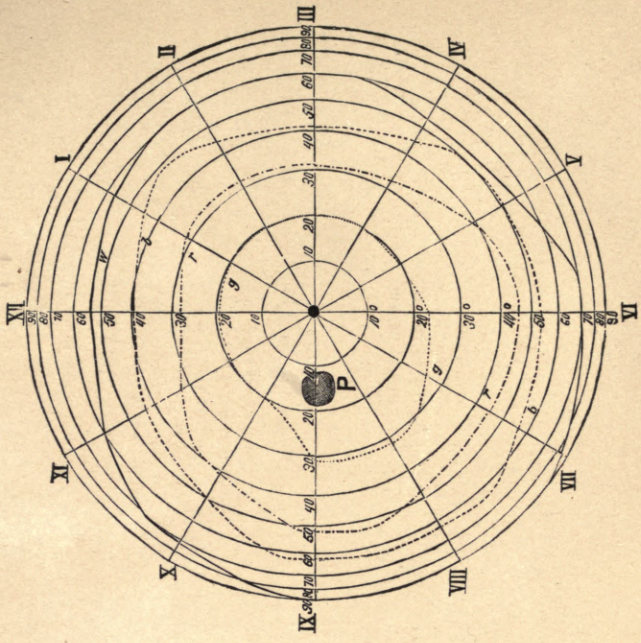


Fig. 1. A DIAGRAM OF THE COURSE OF THE FIBRES OF THE OPTIC NERVE IN THE RETINA (after Weber).

P. The papilla, where the optic nerve enters.—M. The macula lutea.

Fig. 2. A DIAGRAM SHOWING THE AXES OF ROTATION OF THE EYEBALL (after Fick).

The black lines indicate the direction of the power applied by each of the six ocular muscles. The dotted lines indicate the axis of rotation of the eyeball. The axis of rotation for the rectus externus and rectus internus muscles, being perpendicular to the page, cannot be shown in the diagram.

A TABLE SHOWING THE ACTION OF THE OCULAR MUSCLES.

Straight movements.	To elevate the eye	Rectus superior.
		Obliquus inferior.
To depress the eye.....	To abduct toward the nasal side.....	Rectus inferior.
		Obliquus superior.
To abduct toward the malar side.....	To elevate and adduct the eye.....	Rectus internus.
		Rectus externus.
To depress and adduct the eye.....	To elevate and abduct the eye.....	Rectus superior.
		Rectus internus.
Oblique movements.	To depress and abduct the eye.....	Obliquus inferior.
		Rectus inferior.
To depress and abduct the eye.....	To depress and abduct the eye.....	Obliquus superior.
		Rectus superior.
To depress and abduct the eye.....	To depress and abduct the eye.....	Rectus externus.
		Obliquus inferior.
To depress and abduct the eye.....	To depress and abduct the eye.....	Rectus inferior.
		Rectus externus.
To depress and abduct the eye.....	To depress and abduct the eye.....	Obliquus superior.
		Rectus superior.

Fig. 3. A DIAGRAM OF THE COURSE AND DISTRIBUTION OF THE FIFTH CRANIAL OR TRIGEMINUS NERVES.

1. The crus cerebri.—2. The sensory root of the nerve.—3. The motor root of the nerve.—4. The Gasserian ganglion, upon the motor root only.—5. The ophthalmic nerve, passing through the sphenoidal fissure.—6. The superior maxillary nerve, passing through the foramen rotundum to enter the sphenomaxillary fossa.—7. The inferior maxillary nerve, passing through the foramen ovale in company with the motor root, which soon joins it.—8. A filament sent backward to the tentorium cerebelli.—9. The frontal nerve.—10. The lachrymal nerve.—11. The nasal nerve.—12. The supra-orbital nerve, passing through the foramen of the same name.—13. The supra-trochlear nerve.—14. The long ciliary nerves to the iris.—15. The lenticular or ciliary ganglion.—16. The temporo-malar nerve, showing its division into the temporal branch and the malar branch.—17. The sphenopalatine nerves, going to Meckel's ganglion.—18. The posterior dental nerves, given off just before the sup. maxillary nerve enters the infra-orbital canal after passing through the sphenomaxillary fossa.—19. The anterior dental nerves, given off in the antrum.—20. The nasopalatine nerve, escaping at the anterior palatine foramen.—21. The anterior palatine nerves, after escaping from the posterior palatine foramen.—22. The deep temporal nerve.—23. The masseteric branch.—24. The buccal branch, which often also supplies the external pterygoid muscle.—25. The pterygoid branch, going chiefly to the internal pterygoid muscle.—26. The posterior palatine nerves, after escaping from the posterior palatine foramen, going to the muscles of the soft palate.—27. The articular nerve, going to the muscles and thus embracing the middle meningeal artery.—28. The gustatory or lingual nerve, distributed to the anterior two-thirds of the tongue.—29. The inferior dental nerve, passing through the inferior dental canal, beneath the teeth of the lower jaw.—30. The mylo-hyoid nerve, a branch of the inferior dental nerve.—31. The chorda tympani nerve, joining the gustatory nerve, and, possibly, bringing to it the perception of taste.—32. The middle meningeal artery.—33. The fibres going to the carotid and cavernous plexus, of the sympathetic system.—34. The Vidian nerve, going from Meckel's ganglion to the Vidian canal.

GANGLIA OF THE FIFTH NERVE.

L. The lenticular ganglion, sending fibres to iris and ciliary muscle.—C. The Gasserian ganglion.—O. The otic ganglion, lying on the inferior maxillary nerve below the foramen ovale.—S. The submaxillary ganglion, connected with the gustatory and chorda tympani nerves.

Fig. 4. A DIAGRAM TO SHOW THE NERVE DISTRIBUTION TO THE INTEGUMENT OF THE HEAD AND FACE.

1. Region supplied by the supra-orbital branch of the 5th nerve.—2. Region supplied by the supra-trochlear branch of the 5th nerve.—3. Region supplied by the infra-trochlear branch of the 5th nerve.—4. Region supplied by the buccal branch of the 5th nerve.—5. Region supplied by the mental branch of the 5th nerve.—6. Region supplied by the superficial cervical from the cer. plexus.—7. Region supplied by the supra-auricular from the cer. plexus.—8. Region supplied by the temporo-malar, a branch of the 5th nerve.—9. Region supplied by the lachrymal, a branch of the 5th nerve.—10. Region supplied by the auriculo-temporal, a branch of the 5th nerve.—11. Region supplied by the great occipital (a spinal nerve).—12. Region supplied by the small occipital from the cer. plexus.—13. Region supplied by the supra-clavicular nerve from the cervical plexus.—14. Region supplied by the supra-clavicular

FIG. 1.

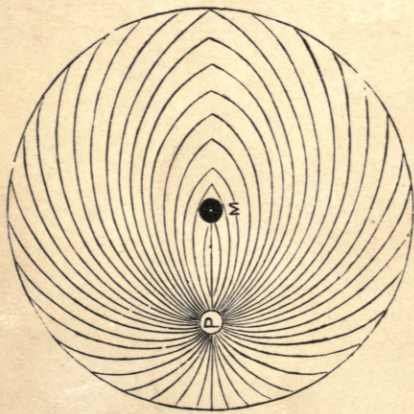


FIG. 3.

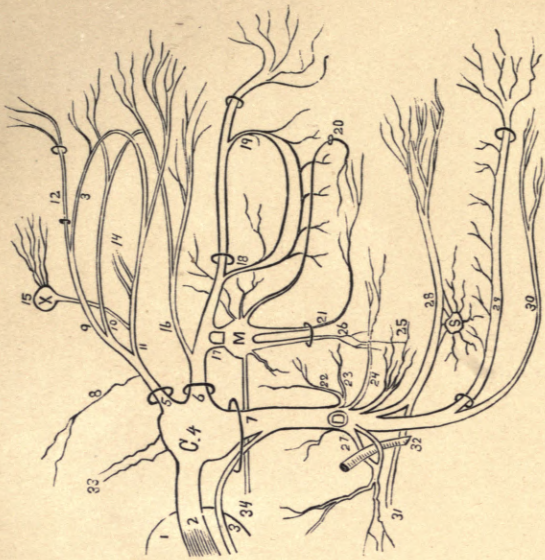


FIG. 2.

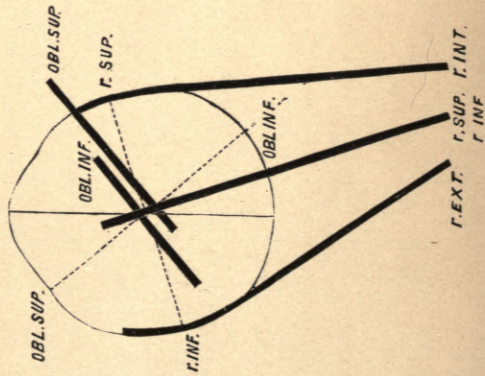
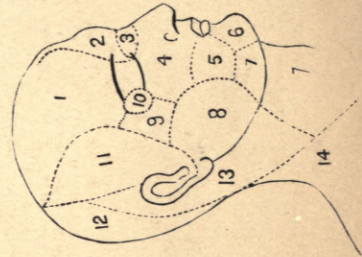


FIG. 4.






Fig. 1. A DIAGRAM OF THE COURSE AND DISTRIBUTION OF THE FACIAL OR SEVENTH CRANIAL NERVE.

1. Main trunk of nerve in internal auditory canal.—
2. Branches of communication with auditory nerve.—
3. Orifice of aqueduct of Fallopius.—4. Large petrosal nerve.—5. Small petrosal nerve.—6. External petrosal nerve.—7. Filaments to the laxator tympani muscle.—
8. Chorda tympani nerve.—9. Stylo-mastoid foramen.—10. Posterior auricular nerve.—11. Filament supplying the stylo-hyoid and digastric muscles.—12. The temporo-facial division of the nerve.—13. The temporal branches.—14. The malar branches.—15. The infra-orbital branches.—16. The buccal branches.—17. The supra-maxillary branches.—18. The infra-maxillary branches.—19. The CERVICO-FACIAL division.—20. "Intumescentia gangliiformis"—the seat of origin of the petrosal nerves.

Fig. 2. A DIAGRAM OF THE SPIRAL CANAL OF THE COCHLEA (as shown on a *transverse section*).

- S. V. The scala tympani.—S. M. The scala media.—S. T. The scala vestibuli.—1. Membrane of Reissner.
2. "Organ of Corti," covered by the "Membrana tectoria," or "Membrane of Corti."—3. Membrana basilaris.—4. Ligamentum spiralis, extending the whole length of the spiral canal of the cochlea.—5. Upper layer of the lamina spiralis ossæ.—6. Lower layer of the lamina spiralis ossæ.—7. A nerve filament escaping from the central canal of the modiolus, and going to the organ of Corti.—8. A ganglion attached to the nerve filament called the "ganglion spirale."

Fig. 3. A DIAGRAM TO SHOW THE RELATIONS BETWEEN THE FACIAL NERVE AND SOME OF THE PORTIONS OF THE FIFTH CRANIAL NERVE.

- A. Gasserian ganglion.—B. Ophthalmic nerve.—C. Superior maxillary nerve.—D. Inferior maxillary nerve (sensory portion).—E. Inferior maxillary nerve (motor portion).—M. Meckel's ganglion.—1. Facial nerve entering the aqueduct of Fallopius.—2. Intumescentia gangliiformis (an enlargement on the nerve).—3. Facial nerve, following the curve of the aqueduct of Fallopius.—4. Facial nerve, escaping from the stylo-mastoid foramen.—5. Large petrosal branch, joining carotid filament (11) to form the Vidian nerve, and entering the Vidian canal.—6. Small petrosal branch, going to "Otic ganglion" (10).—7. Chorda tympani nerve, escaping from the "canal of Huguier" after winding over the upper border of drum membrane of ear (9).—8. Gustatory nerve, joining with the chorda tympani nerve.—9. External drum membrane of the ear.—10. Otic ganglion.—11. Filament from carotid plexus to form the Vidian nerve.

FIG. 1.

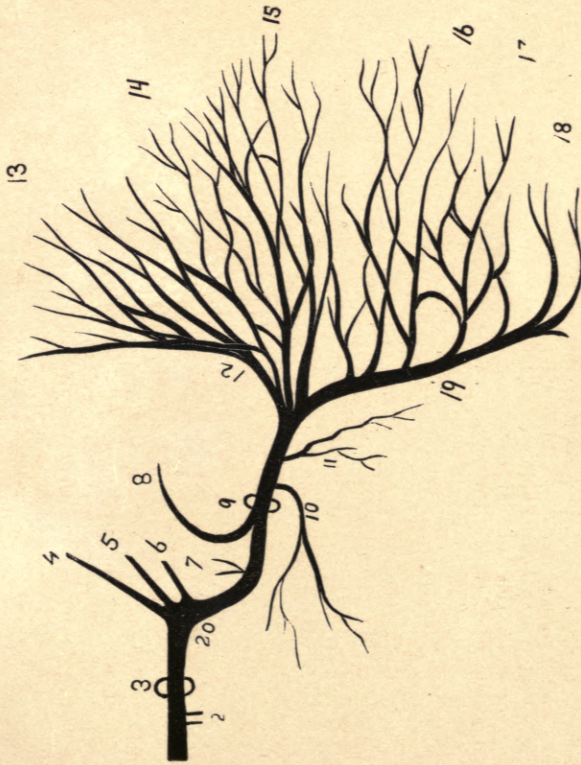


FIG. 2.

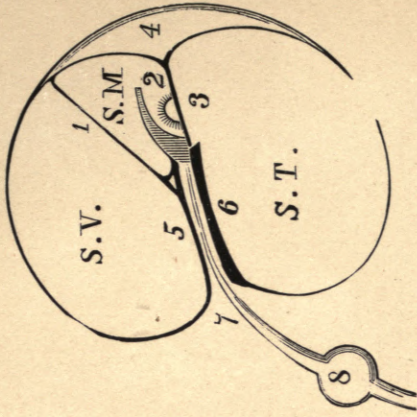


FIG. 3.

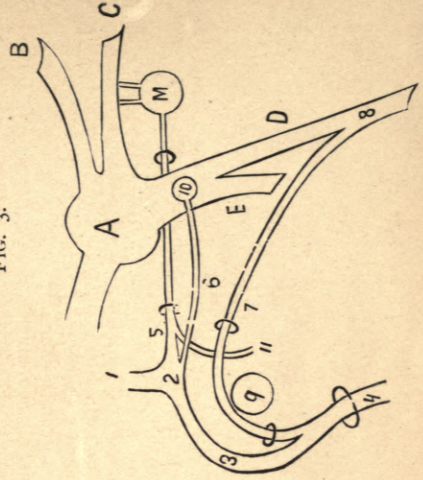


Fig. 1. A DIAGRAM TO ILLUSTRATE THE MECHANISM OF HEARING.

A. The auditory canal (the arrow showing the waves of sound entering.)—B. The cavity of the middle ear, or "tympanum."—C. The utricle, communicating with the semicircular canals.—D. The sacculæ, communicating with the scala vestibuli of the cavity of the cochlea.—E. The Eustachian tube, allowing of the entrance of air into the middle ear from the pharynx.—1. The membrana tympani, which first receives the vibrations of the waves of sound.—2. The chain of bones, which transmit these vibrations to the membrane covering the fenestra ovalis (annular ligament of the stapes.)—3. The membrane, covering the fenestra ovalis.—4. The foramen rotundum, where the waves of sound return to the cavity of the middle ear and are lost (membrana tympani secondaria).—5. The ampullæ of the semicircular canals.—6. The semicircular canals.—7. The "scala vestibuli" of the cochlea.—8. The cupola, at the apex of the cochlea where the scala vestibuli and the scala tympani of the cochlea join each other.—9. The "scala tympani," leading downward from the cupola of the cochlea to the foramen rotundum.—10. Internal auditory canal, where the auditory nerve enters.

Fig. 2. A DIAGRAM OF THE COURSE AND DISTRIBUTION OF THE EIGHTH CRANIAL OR AUDITORY NERVE.

1. Auditory nerve entering the meatus auditorius internus.—2. Communicating filaments to the facial nerve given off in the internal auditory canal.—3. Filaments, given off to supply the cochlea.—4. Filaments given off to supply the posterior semicircular canal.—5. Filaments given off to supply the sacculæ.—6. Filaments given off to supply the utricle.—7. Filaments given off to supply the external semicircular canal.—8. Filaments given off to supply the ampullæ of the superior semicircular canal.

Fig. 3. A DIAGRAM TO SHOW THE COURSE AND DISTRIBUTION OF THE NINTH CRANIAL OR GLOSSO-PHARYNGEAL NERVE.

1. Filaments of origin—extending into the medulla oblongata.—2. The jugular foramen, through which the nerve escapes from the cranium.—3. The jugular ganglion, developed upon the nerve in the jugular foramen.—4. The "ganglion of Andersch" or the "petrosus ganglion."—5. The auricular branch, deriving a filament also from the pneumogastric nerve.—6. A communicating branch to the pneumogastric nerve.—7. A communicating branch to the sympathetic nerve.—8. The tympanic branch or "Jacobson's Nerve," distributed to the middle ear.—9. A communicating branch to the carotid plexus of the sympathetic.—10. The tonsillar branches, distributed to the tonsil.—11. A portion of the pharyngeal plexus, formed also by the pneumogastric nerve.—12. The lingual branches, distributed to the mucous membrane and the papillæ of the base and sides of the tongue.

FIG. 1.

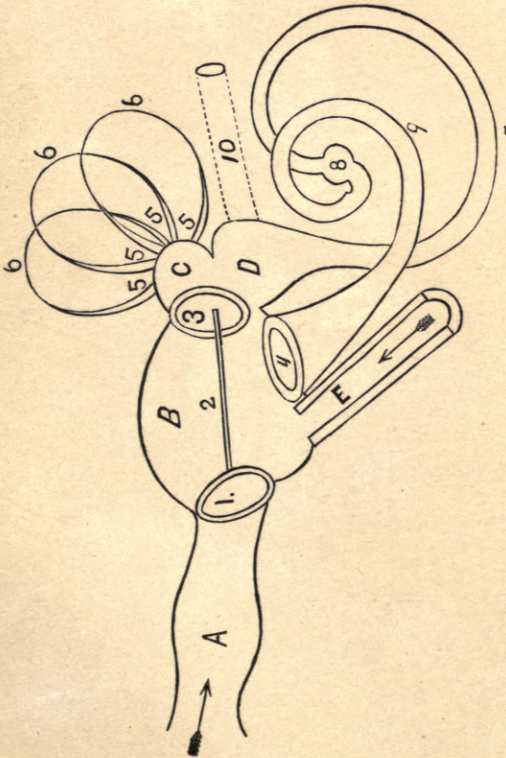


FIG. 2.

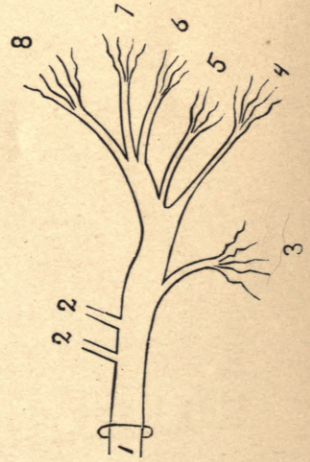


FIG. 3.

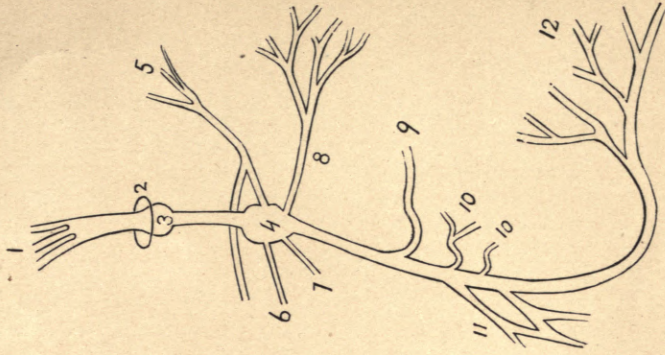


Fig. 1. A DIAGRAM SHOWING THE BRANCHES OF DISTRIBUTION AND OF COMMUNICATION OF THE TENTH CRANIAL OR PNEUMOGASTRIC NERVE.

CERVICAL PORTION OF NERVE.

1. The filaments of origin of the pneumogastric nerve.
- 2. The spinal accessory nerve, escaping from the medulla oblongata below the pneumogastric nerve.—3. The upper communicating filament between the pneumogastric and the spinal accessory nerves (often absent).
- 4. The "ganglion of the root," situated in the jugular foramen.—5. The jugular foramen, showing the transmission of three nerves.—6. The communicating filament between the pneumogastric and the glosso-pharyngeal nerves.—The glosso-pharyngeal nerve, from its point of origin to its escape from the cavity of the cranium.—8. The "ganglion of the trunk" of the pneumogastric nerve.—9. The lower filament of communication between the pneumogastric and spinal accessory nerves, which probably controls the muscles of the larynx concerned in *phonation* and *respiration*.—10. The communicating filament from the arcade, formed by the first and second cervical nerves.—11. The communicating filament from the facial nerve, which helps to form the auricular branch of the pneumogastric, or "Arnold's nerve."—12. The three sets of filaments which join the pneumogastric nerve to the superior cervical ganglion of the sympathetic system.—13. The auricular branch of the pneumogastric, or "Arnold's nerve," partly formed by the facial filament (11).—14. The branches to the "pharyngeal plexus," formed also, in part, by the glosso-pharyngeal.—15. The superior laryngeal nerve, supplying the mucous lining of the larynx and the cricothyroid muscle.—16. The "depressor nerve of the heart," formed by two roots, one from the pneumogastric, and the other from the superior laryngeal nerve.—17. The inferior or recurrent laryngeal nerve, winding around an artery (19), and then returning to the larynx to supply the muscles of phonation.—18. The cervical cardiac nerves (sometimes three in number) going to the cardiac plexus.—19. The subclavian artery (if on the right side), and the arch of the aorta (if on the body).

Fig. 2. THORACIC AND ABDOMINAL PORTION OF THE NERVE.

20. The thoracic cardiac nerves, assisting to form the cardiac plexus.—21. The filaments of communication between the pneumogastric nerve and the thoracic ganglia of the sympathetic system.—22. The branches given off by the pneumogastric nerve to assist in forming the posterior pulmonary plexus.—23. The branches given off to assist in forming the anterior pulmonary plexus.—24. The branches which form the œsophageal plexus, and which assist in the performance of the third period of the act of deglutition.—25. The gastric branches, supplying the coats of the stomach.—26. The hepatic branches, accompanying the portal system of veins.—27.—The intestinal branches, controlling, to a large extent, the peristaltic action of that canal.—28. Branches which can be traced to the kidneys, the spleen, and the suprarenal capsules.

FIG. 1.

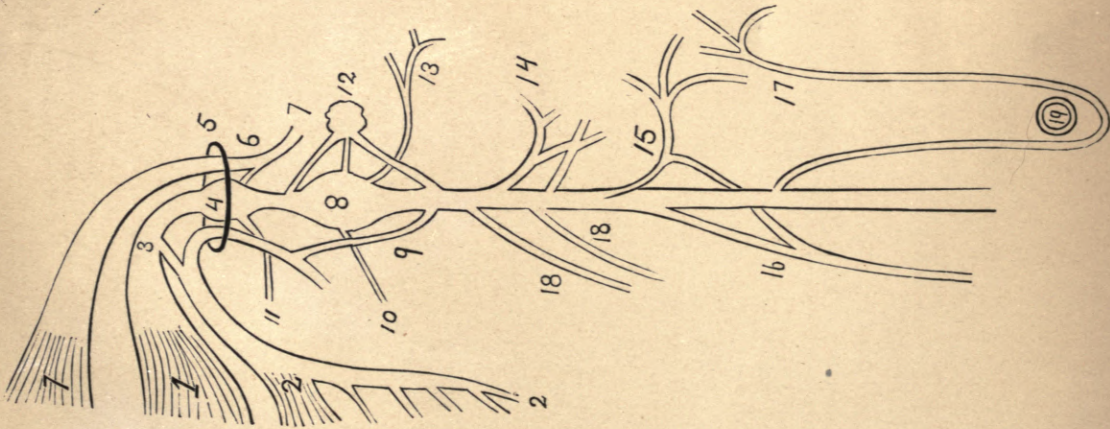


FIG. 2.

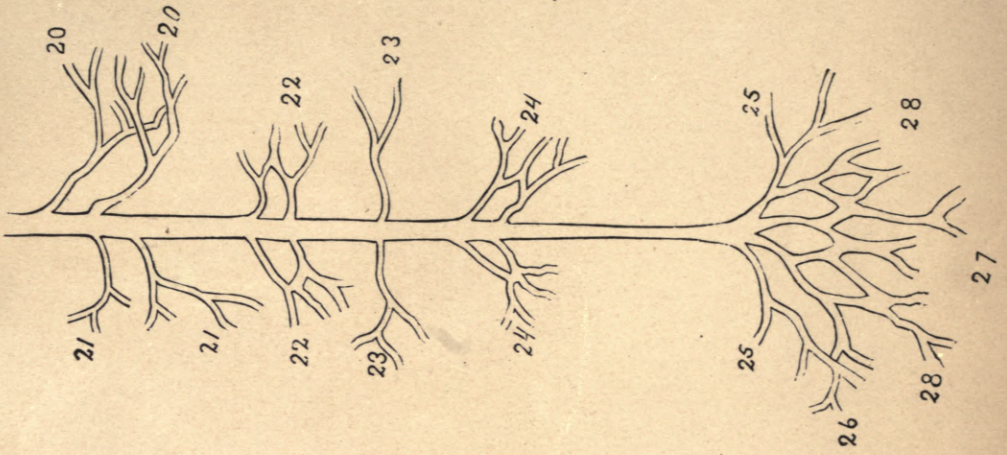


Fig. 1. A DIAGRAM TO SHOW THE COURSE AND DISTRIBUTION OF THE ELEVENTH CRANIAL OR SPINAL ACCESSORY NERVE.

1. The accessory portion of the nerve arising from the medulla oblongata.—2. The spinal portion of the nerve arising from the spinal cord (cervical region).—3. A filament arising from the 1st and 2d cervical nerves and joining the spinal portion of the spinal accessory nerve, before passing through the foramen magnum.—4. The foramen magnum, showing the spinal portion of the nerve entering the cranium.—5. The jugular foramen, showing the spinal and accessory portions of the nerve communicating as they pass through it.—6. The large filament going to the pneumogastric nerve to supply the muscles of the larynx, and a small filament returning to the trunk of the spinal-accessory nerve from the pneumogastric nerve.—7, 8, 9. Filaments of communication between the spinal-accessory nerve and the 3d, 4th, and 5th cervical nerves.—10. Muscular branches to the sterno-cleido-mastoid muscle.—11. Muscular branches to the trapezius muscle.—12. Communicating filaments from the cervical plexus of nerves,

Fig. 2. A DIAGRAM TO SHOW THE COURSE AND DISTRIBUTION OF THE TWELFTH CRANIAL OR HYPOGLOSSAL NERVE.

1. Trunk of hypoglossal nerve, escaping from the medulla oblongata.—2. Anterior condyloid foramen.—3. Filaments of communication to the pneumogastric nerve.—4. Filaments of communication to the superior cervical ganglion of the sympathetic system.—5. Filaments of communication to the 1st and 2d spinal nerves of the cervical region.—6. The descendens noni nerve, forming a loop with the communicans noni nerve (19), and giving off muscular branches from the loop.—7. Muscular filaments to the thyro-hyoid muscle.—8. Muscular filament to the genio-hyoid muscle.—9. Muscular filament to the genio-hyo-glossus muscle.—10. Muscular filament to the hyo-glossus muscle.—11. Muscular filament to the stylo-glossus muscle.—12. The occipital artery, around which the hypoglossal nerve winds before reaching the tongue.—13. A branch of the communicans noni nerve, derived from the 2d cervical nerve.—14. A branch of the communicans noni nerve, derived from the 3d cervical nerve.—15. A muscular branch to the omo-hyoid muscle (anterior belly).—16. A muscular branch to the sterno-hyoid muscle.—17. A muscular branch to the sterno-thyroid muscle.—18. A muscular branch to the omo-hyoid muscle (posterior belly).—19. The communicans noni nerve, joining the descendens noni nerve to form a loop.

FIG. 1.

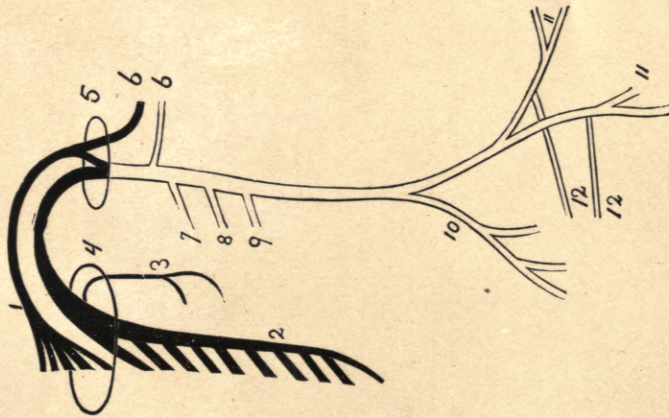


FIG. 2.

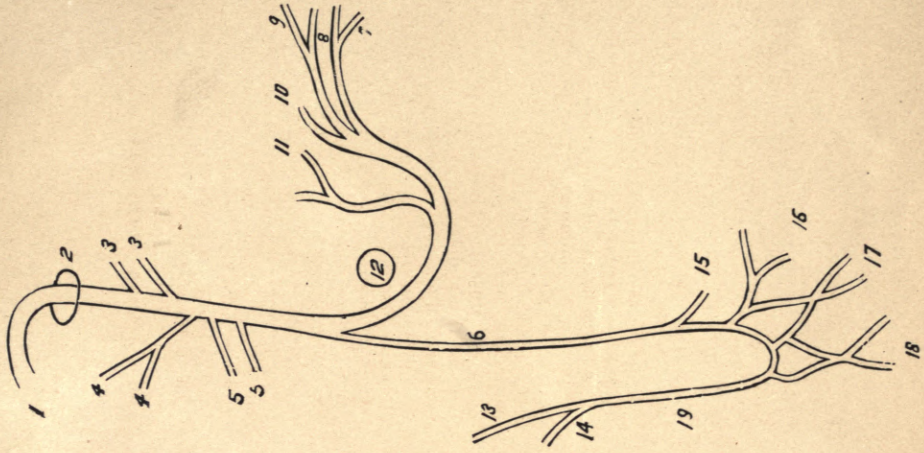


Fig. 1. GREAT SYMPATHETIC, SUPERIOR PORTION.—CARDIAC NERVES AND PLEXUS.

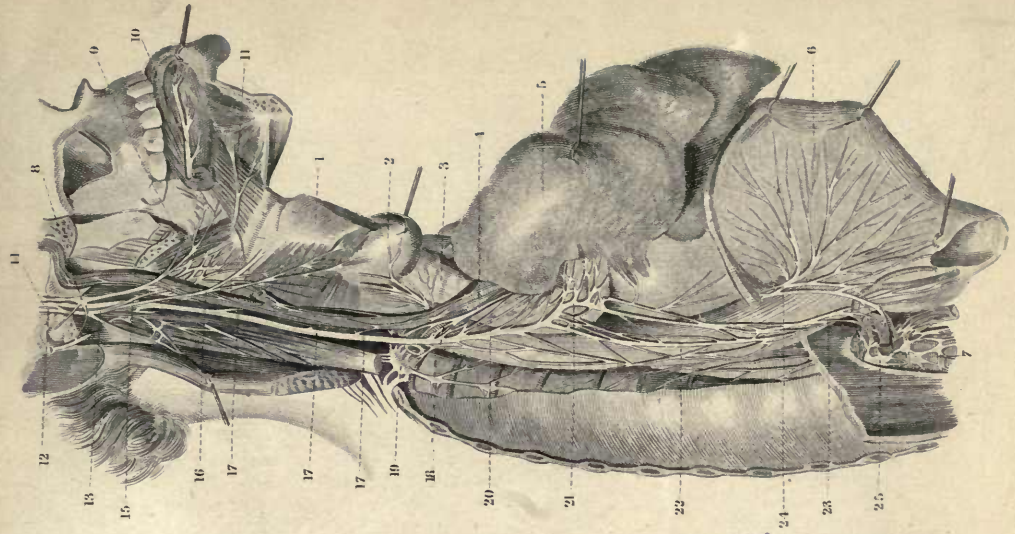
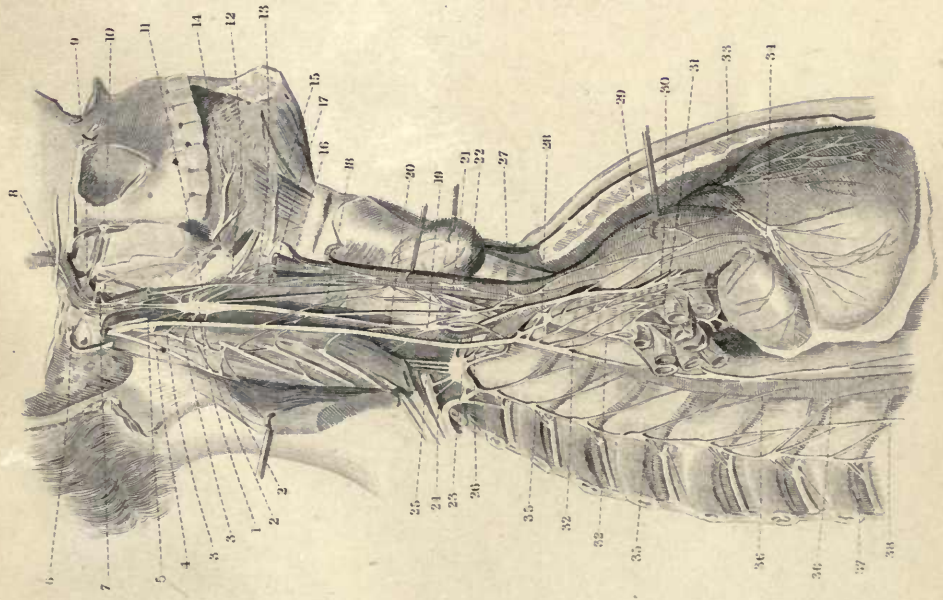
The pericardium is laid open.

1. Superior cervical ganglion.—2. Twigs of this ganglion, which innoscule with the spinal accessory.—3. Innosculation with two of the cervical nerves.—4. Innosculation with the pneumo-gastric nerve.—5. Upper branches of the superior cervical ganglion.—6. Innosculation with Jacobson's nerve.—7. Innosculation with the otic ganglion.—8. Innosculation with the sixth pair of nerves.—9. Innosculation with the Vidian nerve.—10. Spheno palatine ganglion, or the ganglion of Meckel, giving off the Vidian nerve posteriorly; superiorly, two branches, which innoscule with the superior maxillary nerve, and inferiorly, two inferior branches (palatine nerves).—11. Pharyngeal and carotid branches.—12. Glossopharyngeal nerve.—13. Pharyngeal plexus.—14. Lingual nerve of the fifth pair.—15. Hypo-glossal nerve.—16. Carotid branches.—17. Superior cardiac nerve.—18. One of the cardiac branches of the pneumo-gastric nerve.—19. Middle cervical ganglion.—20. Superior branches of this ganglion: one is continuous with the superior cervical ganglion, two others innoscule with the cervical nerves.—21. Middle cardiac nerve, re-enforced by a very thick twig, arising from the twig of communication between these two ganglia.—22. Innosculation of this nerve with the inferior laryngeal of the pneumo-gastric.—23. Inferior cervical ganglion.—24. Innosculation with the nerves of the brachial plexus.—25. Branches which enter the canal of the vertebral artery.—26. Branches which innoscule with the middle cervical ganglion, some passing before, others behind the subclavian artery.—27. Inferior cardiac nerve.—28. Innosculation of the pneumo-gastric with the cardiac nerves.—29. Cardiac nerves in front of the aorta.—30. Cardiac nerves between the aorta and pulmonary artery.—31. Cardiac nerves branches of the pneumo-gastric, and their innosculations with the cardiac nerves.—33. Anterior cardiac plexus.—34. Posterior cardiac plexus.—35, 35. Two thoracic ganglia.—36. Aortic branches of two ganglia.—37. Innosculation of a thoracic ganglion with one of the intercostal nerves.—38. Great splanchnic nerve.

EIGHTH PAIR OF NERVES OF WILLIS, WHICH INCLUDES THE GLOSSO-PHARYNGEAL, PNEUMO-GASTRIC, AND SPINAL ACCESSORY, OR THE NINTH, TENTH, AND ELEVENTH PAIRS OF THE MODERN ARRANGEMENT.

The chest is opened, the stomach and the right lung are drawn: forward, the internal jugular vein is removed, and the foramen lacerum jugulare is opened from without.

1. Larynx.—2. Thyroid body.—3. Trachea.—4. Arteria in nuchata, dividing into the right subclavian, which is cut, and into the right primitive carotid, which divides into external and internal carotid.—5. Right lung.—6. Stomach.—7. Solar plexus.—8. Glosso-pharyngeal nerve, ganglion of Andersh, Jacobson's nerve, and the innosculating twig with the facial nerve.—9. Various other filaments of the glosso-pharyngeal and lingual filaments.—10. Lingual branch of the fifth pair.—11. Hypoglossal nerve.—12. Spinal accessory nerve.—13. Division of this nerve into a muscular branch, and the nervus accessorius ad par vagum.—14. Nervus vagus, or pneumo-gastric nerve.—15. Pharyngeal twig, uniting with the filaments of the glosso-pharyngeal and great sympathetic to form the pharyngeal plexus.—16. Superior laryngeal twig, divided into external and internal laryngeal.—17, 17. Cardiac branches.—18. Origin of the inferior laryngeal, or recurrent nerve: it passes behind the right subclavian artery, on the right side, and on the left behind the arch of the aorta, and reappears at the lower part of the neck.—19. Lower cervical ganglion of the sympathetic nerve, with its numerous branches.—20. Tracheal twigs of the pneumo-gastric.—21. Pulmonary and great sympathetic.—22. CEsophageal branches.—23. Pneumo-gastric of the right side, terminating in the solar plexus.—24. Pneumo-gastric of the left side, expanding into numerous branches on the anterior surface of the stomach, and giving off some branches to the solar plexus.—25. Solar plexus.



TABLE

INDICATING THE ORDER IN WHICH THE FIGURES SHOULD BE CONSULTED AND THE ORGANS DISSECTED.

Pl. 1. Fig. 1, 2, 3, 4.	Pl. 24. Fig. 1, 3, 2.
Pl. 4. Fig. 1.	Pl. 23. Fig. 1, 2, 3, 4.
Pl. 3. Fig. 1, 2, 5, 6, 3, 4.	Pl. 26.
Pl. 2. Fig. 2, 3, 8, 7, 4, 5, 6.	Pl. 28. Fig. 4.
Pl. 2. Fig. 1, 2, 3.	Pl. 29. Fig. 1.
Pl. 6. Fig. 1, 2, 3, 4, 5, 6, 7, 8, 9, 10, 11.	Pl. 27.
Pl. 7. Fig. 1, 2, 3, 4, 8, 7, 5, 6.	Pl. 28. Fig. 2, 3.
Pl. 6. Fig. 12.	Pl. 29. Fig. 2.
Pl. 5. Fig. 5, 1, 2, 3, 4, 6, 7, 8.	Pl. 28. Fig. 1.
Pl. 8. Fig. 1, 5, 3, 4, 6, 2, 7.	Pl. 30.
Pl. 11. Fig. 1, 2, 3, 4, 5, 6.	Pl. 33.
Pl. 10. Fig. 1, 2, 3, 4, 5, 6, 7, 8, 9, 10, 11, 12, 13, 14.	Pl. 32. Fig. 1, 2, 3.
Pl. 9. Fig. 1, 2, 3, 6, 7, 8, 9, 4, 5, 10, 11.	Pl. 31. Fig. 1, 2, 3, 4.
Pl. 12. Fig. 1, 2, 3, 4, 8, 6, 7, 5, 9, 10.	Pl. 34. Fig. 1, 2, 3.
Pl. 14. Fig. 1, 2, 3.	Pl. 37. Fig. 1, 2, 3, 4.
Pl. 17. Fig. 2, 3, 4, 6, 5.	Pl. 36. Fig. 1, 2, 3.
Pl. 14. Fig. 4, 5.	Pl. 35. Fig. 1, 2.
Pl. 17. Fig. 1.	Pl. 38. Fig. 1, 2, 3.
Pl. 14. Fig. 6.	Pl. 41. Fig. 1, 2, 3, 4.
Pl. 16. Fig. 1, 2, 3, 4, 5.	Pl. 40. Fig. 6, 1, 2, 3, 4, 5.
Pl. 15. Fig. 1, 2, 3, 4.	Pl. 45. Fig. 1, 2.
Pl. 18. Fig. 1, 2, 3, 4, 5, 6, 7, 8.	Pl. 39. Fig. 1, 2, 5, 6.
Pl. 21. Fig. 1, 2, 3, 4, 5, 6, 7, 8.	Pl. 42. Fig. 1, 2, 3, 4, 5, 6, 7.
Pl. 20. Fig. 1, 2, 3, 4, 5, 6, 7.	Pl. 45. Fig. 3, 4, 5.
Pl. 19. Fig. 1, 2, 3, 4, 5, 6, 7.	Pl. 39. Fig. 3, 4.
Pl. 22. Fig. 1, 2.	Pl. 44. Fig. 2, 3, 4, 5, 6, 7.
Pl. 25. No. 3. 1. 2. 4.	Pl. 43. Fig. 1, 2, 3, 4, 5, 6, 7, 8.
	Pl. 46. Fig. 1, 2, 3, 4, 5, 6, 7.
	Pl. 49. Fig. 1, 2, 3, 4, 5, 6, 7, 8, 9, 13.
	Pl. 48. Fig. 1, 2.
	Pl. 47. Fig. 1, 2, 3, 4, 5, 7, 6, 8.
	Pl. 44. Fig. 1.
	Pl. 50. Fig. 3, 4.
	Pl. 53. Fig. 1, 2, 3, 4.
	Pl. 50. Fig. 1, 2.
	Pl. 52.
	Pl. 51. Fig. 1, 2.
	Pl. 54. Fig. 1, 2, 3.

TABLE.

Pl. 57.	Fig. 1, 2, 3, 4, 5, 6
Pl. 56.	
Pl. 55.	Fig. 1, 2, 3, 4.
Pl. 58.	Fig. 1, 2, 3, 4, 5, 6.
Pl. 61.	
Pl. 60.	Fig. 1, 2, 3, 4, 5
Pl. 59.	Fig. 1, 2, 3, 4.
Pl. 63.	Fig. 1, 2.
Pl. 72.	Fig. 1, 2.
Pl. 66.	
Pl. 65.	
Pl. 64.	
Pl. 68.	
Pl. 71.	Fig. 1, 2, 3
Pl. 70.	Fig. 1, 2.
Pl. 69.	Fig. 1, 2, 3.
Pl. 72.	Fig. 3.
Pl. 74.	
Pl. 73.	Fig. 1, 3, 2.
Pl. 78.	
Pl. 75.	Fig. 1, 2, 3.
Pl. 81.	Fig. 1, 2, 3, 4.
Pl. 80.	Fig. 1, 2, 3.
Pl. 79.	Fig. 1, 2, 3.
Pl. 82.	Fig. 1, 2, 3, 4, 5, 6.
Pl. 88.	Fig. 1, 2, 3, 4.
Pl. 84.	Fig. 1, 2.
Pl. 83.	Fig. 1, 2.
Pl. 86.	
Pl. 89.	
Pl. 88.	
Pl. 87.	Fig. 1, 2.
Pl. 90.	
Pl. 93.	Fig. 1, 2.
Pl. 92.	Fig. 1.
Pl. 91.	Fig. 1, 2.
Pl. 94.	Fig. 1.
Pl. 97.	Fig. 1, 2, 3, 4.

TABLE

Pl. 96.	Fig. 1, 6, 2, 3.
Pl. 92.	Fig. 2
Pl. 96.	Fig. 4, 5.
Pl. 95.	Fig. 1, 2, 3.
Pl. 101.	Fig. 1, 2.
Pl. 99.	Fig. 1.
Pl. 97.	Fig. 5, 6
Pl. 94.	Fig. 2.
Pl. 101.	Fig. 3, 4.
Pl. 99.	Fig. 2, 3, 4.
Pl. 98.	Fig. 1, 2, 3, 4, 5, 6, 7, 8, 9, 10, 11.
Pl. 102.	
Pl. 103.	
Pl. 114.	Fig. 1, 2
Pl. 106.	Fig. 1, 2.
Pl. 105.	Fig. 1, 2.
Pl. 114.	Fig. 3, 4, 5.
Pl. 107.	
Pl. 109.	Fig. 1, 2
Pl. 111.	Fig. 1.
Pl. 108.	Fig. 1.
Pl. 111.	Fig. 2.
Pl. 108.	Fig. 2.
Pl. 111.	Fig. 3.
Pl. 108.	Fig. 3.
Pl. 110.	
Pl. 112.	Fig. 1.
Pl. 113.	Fig. 1.
Pl. 112.	Fig. 2, 3.
Pl. 104.	Fig. 1.
Pl. 113.	Fig. 2, 3.
Pl. 115.	Fig. 2, 3, 1.
Pl. 104.	Fig. 2, 3.
Pl. 124.	
Pl. 123.	
Pl. 116.	

THE ESSENTIALS OF ANATOMY.

PREPARED AS A TEXT-BOOK FOR STUDENTS AND A WORK OF REFERENCE FOR THE
GENERAL PRACTITIONER.

By WILLIAM DARLING, M.D., F.R.C.S., Professor of Anatomy, and A. L. RANNEY, A.M., M.D., Adjunct Professor of Anatomy in the Medical Department of the University of the City of New York.

OCTAVO, CLOTH EXTRA, \$4.00.

The work will be especially valuable to many members of the profession and for use as a text-book, as it is based on the lectures of Prof. DARLING, whose method of instruction is characterized by great originality and by an attractive system which has been well recognized.

The main divisions of the work are as follows:

PART I.—**GENERAL INTRODUCTION TO ANATOMY**, with definitions of the terms used and their application.

PART II.—**OSTEOLOGY**. Giving a description of each bone and tables of the important points pertaining to each.

PART III.—**MYOLOGY**. Including the origin and insertion of muscles, with their physiological action, nerve supply, and surgical importance, classified both separately and in groups.

PART IV.—**ANGIOLOGY**. Describing the origin, distribution, and surgical relations of the various vessels of the body.

PART V.—**NEUROLOGY**. A tabulated arrangement of the nerves of the human body, and the chief points in the gross anatomy of the cerebro-spinal axis.

PART VI.—**SPLANCHNOLOGY**. Comprising a description of the various organs of the body in such a form as to assist the memory of students and to aid easy reference.

PART VII.—**ANATOMY OF THE PERINEUM OF THE MALE AND FEMALE**, with reference to the surgical importance of each.

EXTRACTS FROM THE OPINIONS OF PRACTICAL INSTRUCTORS.

I have examined "Essentials of Anatomy," by Drs. Darling and Ranney, and am so well pleased with it that I shall speak approvingly of it and add it to the lists of books recommended to students. The skill of a veteran teacher is displayed in arranging facts for ready access, and a profligality of words has not rendered it difficult to find what one wishes when wanted. It is a capital book for ready reference while seeking information for practical use. A convenient book to have ready at hand.—Yours respectfully, C. L. FORD, Professor of Anatomy, University of Michigan and Long Island College Hospital, Brooklyn, N. Y.

Used as the authors designed—as the complement of present standard text-books—it will prove exceedingly valuable, both to students who need to be told what is important and what not, and to practitioners who desire a work to which they can easily and quickly refer. I shall recommend it to our students.—Yours very truly, J. F. BALDWIN, Professor of Anatomy, Columbus Medical College, Columbus, Ohio.

I have carefully examined Prof. Darling's "Essentials of Anatomy," which you so kindly sent to me, and it gives me pleasure to say that I regard it as a valuable addition to anatomical text-books. I find it accurate, systematically arranged and eminently practical. As a book of reference it will be found very valuable to the busy practitioner.—Most sincerely yours, S. H. WEEKS, Professor of Anatomy, Medical School of Maine.

I regard the work as one of great value, especially to the student. It is superior to any work yet published on Anatomy, in its classifications and tabulations, by which it offers great aid to memory, which is a very desirable feature in all works upon Anatomy.—Yours truly, L. W. BINGHAM, Demonstrator of Anatomy in the University of Vermont, Burlington, Vt.

G. P. PUTNAM'S SONS, PUBLISHERS, NEW YORK.

J.R. 11/6/43

412576

Ranney, Ambrose Loomis (ed.)
Anatomical plates...

MA
R

NAME OF BORROWER.

DATE.

University of Toronto
Library

DO NOT
REMOVE
THE
CARD
FROM
THIS
POCKET



