

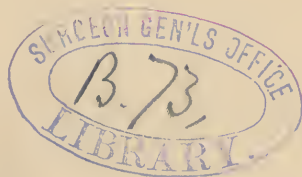
GOODELL. (W.)

A Case of
Vaginal Ovariectomy

BY
WILLIAM GOODELL, A. M., M. D.
PHILADELPHIA



REPRINT FROM VOLUME II
Gynecological Transactions
1878



TRANSACTIONS
OF
The American Gynecological Society.

VOL. I., FOR THE YEAR 1876.

400 pages. Many illustrations.

The Annual Address by the President, Dr. Fordyce Barker, of New York, and the following papers:—

- I. Etiology of Uterine Flexures, with the proper mode of treatment indicated. By Thomas Addis Emmet, New York.
- II. Cicatrices of the Cervix Uteri and Vagina. By Alexander J. C. Skene, M. D., New York.
- III. Extirpation of the Functionally Active Ovaries for the Remedy of otherwise Incurable Diseases. By Robert Battey, Rome, Ga.
- IV. On Central Rupture of the Perineum. By J. Matthews Duncan, M. D., Edinburgh, Scotland.
- V. Viburnum Prunifolium (Black Haw); its Uses in the Treatment of the Diseases of Women. By Edward W. Jenks, M. D., Detroit, Mich.
- VI. An Illustration of Xenomenia. By Theophilus Parvin, M. D., Indianapolis, Indiana.
- VII. Relations of Pregnancy to General Pathology. By Robert Barnes, M. D., London, Eng.
- VIII. The Spontaneous and Artificial Destruction and Expulsion of Fibrous Tumors of the Uterus. By W. H. Byford, Chicago, Ill.
- IX. Case of Abdominal Pregnancy, treated by Laparotomy. By T. Gaillard Thomas, M. D., New York.
- X. Pneumatic Self-Replacement in Dislocations of the Gravid and Non-gravid Uterus. By Henry F. Campbell, M. D., Augusta, Ga.
- XI. Hydrate of Chloral in Obstetrical Practice. By W. L. Richardson, M. D., Boston, Mass.
- XII. Labor Complicated with Uterine Fibroids and Placenta Previa. By James R. Chadwick, M. D., Boston, Mass.
- XIII. Latent Gonorrhœa, with Regard to its Influence on Fertility in Women. By Emil Noeggerath, M. D., New York.
- XIV. Death from Urinemia in Certain Cases of Malignant Diseases of the Uterus. By Alfred Wiltshire, M. D., London, England.
- XV. Clinical Memoir on some of the Genital Lesions of Childbirth. By William Goodell, M. D., Philadelphia, Pa.
- XVI. Hermaphroditism. By Lawson Tait, F. R. C. S., Birmingham, England.
- XVII. Cases of Cystic Tumors of the Abdomen and Pelvis. By George H. Bixby, M. D., Boston, Mass.
- XVIII. Case of Solid Uterus Bipartitus; both ovaries removed for the relief of epileptic seizures ascribed to ovarian irritation. By E. Randolph Peaslee, M. D., New York.
- XIX. The Origin and History of Calculi found in the Bladder after the Cure of Vesico-Vaginal Fistula by Operation. By Henry F. Campbell, Augusta, Ga.
- XX. Rare Forms of Umbilical Hernia in the Fetus. By James R. Chadwick, M. D., Boston, Mass.
- XXI. In Memoriam Gustav Simon. By Paul F. Mundé, M. D., New York.

Price of Volume I., \$5.00.

As contributions to advanced gynecology they exceed in value anything which we have ever before seen collected in any one volume.—*N. Y. Medical Record.*

This volume of Transactions is certainly superior to any book of the kind that has been issued by the American Press.—*St. Louis Clinical Record.*

Now we have the first of, we hope, a long row of volumes which will bear comparison with the Transactions of European Societies. Indeed, these must look to their laurels in this noble emulation.—*Edinburg Medical Journal.*

This volume is one of the best collections of gynecological papers that has been published this year.—*Annales de Gynécologie.*

VOLUME II.

650 pages, 12 chromo-lithographs and many other illustrations.

Contains the following papers, with the discussions to which they gave rise:—

- I. Annual Address, on Medical Gynecology. By the President, Dr. Fordyce Barker, of New York.
 - II. The Functions of the Anal Sphincters, so called. With two wood-cuts. By Dr. James R. Chadwick, of Boston, Mass.
 - III. Excision of the Cervix Uteri; its Indications and Methods. With one wood-cut. By Dr. John Byrne, of Brooklyn, N. Y.
 - IV. Report on the Corpus Luteum. With twelve chromo-lithographic plates. By Dr. John C. Dalton, of New York.
 - V. The Pathology and Treatment of Puerperal Eclampsia. By Professor Otto Spiegelberg, of Breslau, Prussia.
 - VI. Dilatation of the Cervix Uteri for the Arrest of Uterine Hemorrhage. By Dr. George H. Lyman, of Boston.
 - VII. The Principles of Gynecological Surgery applied to Obstetric Operations. By Dr. A. J. C. Skene, of Brooklyn, N. Y.
 - VIII. On the Necessity of Caution in the Employment of Chloroform during Labor. By Dr. William T. Lusk, of New York.
 - IX. The Present Status of the Intra-Uterine Stem in the Treatment of Flexions of the Uterus. By Dr. Ely Van de Warker, of Syracuse, N. Y.
 - X. Supplement to the report of a case of Xenomenia made at the first Annual Meeting in 1876. By Dr. Theophilus Parvin, Indianapolis, Ind.
 - XI. A Case of Vaginal Ovariectomy. By Dr. William Goodell, of Philadelphia, Penn.
 - XII. Is there a Proper Field for Battey's Operation? By Dr. Robert Battey, of Rome, Ga.
 - XIII. Subsulphate of Iron as an Antiseptic in the Surgery of the Pelvis. By Dr. H. P. C. Wilson, of Baltimore, Md.
 - XIV. Tetanus after Ovariectomy. By Dr. Theophilus Parvin, of Indianapolis, Ind.
 - XV. Sarcoma of the Ovaries. By Dr. Washington L. Atlee, of Philadelphia, Penn.
 - XVI. The Value of Electrolysis in the Treatment of Ovarian Tumors, as seen in the Light of Recent Experience. By Dr. Paul F. Mundé, of New York.
 - XVII. Congenital Absence and Accidental Atresia of the Vagina; Mode of Operation to Establish the Canal, and to Evacuate retained Menstrual Blood. With three wood-cuts. By Dr. Thomas Addis Emmet, of New York.
 - XVIII. Case of Sarcoma of the Kidney in a negro child. With Heliotype. By Dr. W. H. Geddings, Aiken, S. C.
 - XIX. The Hystero-Neuroses. By Dr. George J. Engelmann, of St. Louis, Mo.
 - XX. Cases illustrating Important Points connected with Ovariectomy. By Dr. Gilman Kimball, of Lowell, Mass.
 - XXI. The Radical Treatment of Dysmenorrhœa and Sterility by Rapid Dilatation of the Canal of the Neck of the Uterus. With one wood-cut. By Dr. Ellwood Wilson, of Philadelphia, Penn.
 - XXII. Dr. Uvedale West's Views of Rotation, as illustrated by the Contrast between the Mechanism of Simple Occipito-Posterior Positions and those of the Bregmato-Cotyloid Variety. By Dr. John P. Reynolds, of Boston, Mass.
 - XXIII. Vascular Tumors of the Female Urethra; with the Description of an Instrument devised to Facilitate their Removal. By Dr. A. Reeves Jackson, of Chicago, Ill.
 - XXIV. Lying-in Hospitals; especially those in New York. By Dr. Henry J. Garrigues, of Brooklyn, N. Y.
 - XXV. The Simpler Varieties of Perineal Laceration; their Consequences and Treatment. By Dr. Thaddeus A. Reamy, of Cincinnati, Ohio.
 - XXVI. The Cyclical Theory of Menstruation. By Dr. John Goodman, of Louisville, Ky.
 - XXVII. In Memoriam Charles E. Buckingham. With a Heliotype Portrait. By Dr. George H. Lyman, of Boston, Mass.
- Index of Obstetric and Gynecological Literature of all Countries, from July 1, 1876, to January 1, 1877.

The price of Volume II. is \$6.50. The 2 volumes will be sent by mail or express, post-paid, for \$10.00. Address,

HOUGHTON, OSGOOD & CO., BOSTON.

A CASE OF VAGINAL OVARIOTOMY.

BY WILLIAM GOODELL, A. M., M. D.,

Philadelphia, Penn.



SINCE the question of the removal of ovarian cysts *per vaginam* is still *sub judice*, I need no apology for offering the following history of a case in point.

Mary D., an unmarried woman aged twenty-two years, was perfectly well until about two years ago, when she took a long journey by rail, and, through modesty, allowed her bladder to become over-distended. From that day she began to have uterine and vesical troubles, which steadily increased in severity. The latter finally became so exacting that she had to give up a situation as child's nurse, and to depend for support on the charity of some benevolent ladies. On the 15th of last February she was brought to my office by my friend Dr. W. S. Stewart, who is the medical consultant of the home where she was lodging. He told me that she had great difficulty in getting a movement of the bowels, and was worn out by a very frequent and very urgent desire to empty the bladder. The act of voiding her urine was of itself a painful and a difficult one; yet it would be repeated sometimes every hour at night, and every half hour when she was on her feet — as, for instance, in ironing. During her last two catamenial periods she was unable to pass her water, and had to call in Dr. Stewart to draw it off. She was pale and haggard from her sufferings, and very querulous.

I found the cervix uteri hugging the symphysis pubis a little to the left, and behind it a dense and immovable tumor which shelved down into Douglas's pouch. The fundus of the womb lay above the pubes on the right side,

but it was so immovable, and projected so far forward, that I at first mistook it for an outgrowth of a uterine fibroid. The sound, however, rectified this mistake, and gave a measurement of *plus* four inches. The girl, being very nervous, kept her abdominal muscles so tense that no information could be gained from supra-pubic palpation. But, after repeated examinations, an obscure sense of fluctuation was elicited *per vaginam*.

Being admitted into the Hospital of the University of Pennsylvania, she was, on February 21st, etherized and brought before the class. Nothing more was gained from this examination than that the tumor could not be dislodged from the pelvic cavity, and that by supra-pubic palpation it could be outlined behind the highly situated fundus of the womb. Feeling now very sure that it contained fluid, I aspirated it, *per vaginam*, and withdrew one large tumblerful and a half of an odorless and a straw-colored fluid. The tumor now so wholly collapsed that not a trace of it could be felt from above or from below. The womb regained its proper position, became movable, and shrank back to a measurement of *minus* three inches. My diagnosis leaned to a unilocular ovarian cyst with firm uterine and pelvic adhesions, but, to put matters beyond doubt, I submitted a specimen of the fluid to my friend, Professor James Tyson, from whom, in matters of this kind, there is in Philadelphia no appeal. The following is his report:—

“A grumous, yellow fluid, neutral in reaction, with a specific gravity of 1113, highly albuminous, and depositing copiously a sediment made up largely of crystalline particles, which proved on microscopic examination to be cholesterol plates. In addition were numerous granule cells, and large numbers of the so called ‘ovarian cell;’ also numerous bacteria. The above are the usual characters of ovarian fluid, and it is believed to be ovarian.”

After this operation my patient lost all her tormenting pressure-symptoms. She could now hold her water, and pass it without distress. For three days she felt well.

Then she began to complain, first, of a supra-pubic pain, and afterwards of her old troubles. I found the cyst rapidly refilling. By March 3d its upper surface could be easily felt reaching very nearly up to the navel, and on that day I withdrew by the aspirator very nearly a quart of a turbid fluid containing broken-down blood and giving off a slight odor of sulphureted hydrogen. Again the tumor collapsed wholly beyond recognition. This operation relieved her bladder troubles, but it was followed by marked symptoms of blood poisoning, such as fever, creeping chills, complete loss of appetite, constant nausea, pallor alternating with hectic flushes, sweating, a pulse always over 100, and a body heat ranging from 99.5° to 101.5° . There were also stabs of pain in the right pelvic region, but no tympanites. Her urine had now to be drawn off. The cyst began rapidly to fill, and its removal was clearly indicated, but she was timid, and her friends, whom she wished to consult, lived in a neighboring State. At my visit on the evening of Tuesday, March 13, I found her pulse over 120, her temperature up to 102.5° , her skin and conjunctivæ with an icteric tint, and her lips studded with a crop of vesicles. She was incessantly vomiting and fortunately so frightened that I wrung from her the permission to remove the cyst.

On the next day, at noon, I proceeded to operate, with the aid of Drs. C. T. Hunter, W. S. Stewart, B. F. Baer, H. R. Wharton, G. S. Hull, and T. Lancaster. My patient was put in the lithotomy position — the one which I prefer to any other in the operation for vesico-vaginal fistulæ and in many vaginal operations — and another careful examination made. The fundus of the womb lay now to the left and well above the symphysis. The cervix, like a mere nipple, pouted out from the tumor somewhat low down in the vagina, and to the right of its median line. The sound gave a measurement of five inches. By forcing my finger high up between the tumor and the pubes, I found that the supra-vaginal portion of the cervix was small,

round, and stem-like. It gave precisely the same feeling as in prolapse of the womb with hypertrophic elongation of the supra-vaginal portion of its cervix.

Finding it impossible to push up the cyst into the abdominal cavity, I determined to attempt its removal *per vaginam*, and, if frustrated, to stitch the lips of an opening made in it to the edges of the vaginal incision. Accordingly, two duck-bill specula being introduced, the space between them was divided by two strokes of Küchenmeister's scissors. As soon as Douglas's pouch was opened there gushed out unexpectedly several ounces of very fetid pus. Numerous adhesions now presented themselves. All within reach of two fingers were broken, and the cyst was then caught by a volsella forceps, and emptied by aspiration. The fluid first drawn off, about two quarts in amount, consisted of a dirty, grumous pus, and the gas pumped out of the receiving bottle was so abominably offensive as fairly to turn my stomach. The trocar-needle then entered another cyst which gave about an ounce of clear, syrupy fluid. A spray of chloralum was kept playing upon the parts. I washed my hands in a stronger solution, and proceeded to draw down the cyst, and break up other adhesions, which successively came within reach. What with these adhesions, and with the small working space which the vagina of a virgin affords, every step of the cyst's withdrawal was attended with much difficulty. But this was finally attained by the repeated introduction of two volsella forceps, the one over the other, Dr. Hunter and I making alternate traction. The cyst was found to be without a pedicle, and closely attached to the womb, which now presented itself at the opening, but no coil of intestines was felt during the operation. I at first thought of attempting the enucleation of the cyst, but was afraid that from retraction of the parts involved some bleeding vessel might get beyond reach. So the left broad ligament was transfixed by a long-handled perineum-needle carrying two double ligatures, and each half tied. But, in order to get a button of tissue sufficiently

large to prevent the ligature from slipping off, a portion of the cyst had to be cut off, leaving a circular opening in it as large as a silver half dollar. Free drainage from the pelvic abscess was secured by bringing all the ligatures out of the wound.

The cyst contained a few smaller ones, and, in addition, several calcareous plates. Decomposition had been limited to the mother-cyst, for the contents of the small ones were clear, glairy, and sweet.

My patient lay for several days in rather a critical condition, her only encouraging symptom being unmitigated crossness. No peritonitis kindled up, but septic symptoms still held on, and with them a copious and very offensive discharge from the vagina. She had no control over her bladder, and threw up all her food and medicine. Rectal suppositories of quinia were therefore resorted to, and enemata of beef-essence and whiskey. As mere vaginal injections did not sweeten her person, and as her body-heat and pulse kept up, I began, on the sixth day, to wash out Douglas's pouch twice daily with a solution of two drachms of the liquor sodæ chlorinatæ to a pint of water. This was thrown into the peritoneal cavity through a flexible male catheter. Every irrigation brought away a very grumous and offensive matter. The first one gave her much relief and lowered her pulse and temperature. From that day she began to mend. These irrigations were kept up for ten successive days. They then began to give her a good deal of pain in the wound and were accordingly discontinued.

Her convalescence was steady, but by no means speedy. Some time elapsed before her appetite came back, and then, from a hysterical dysphagia, she could not swallow solid food. Either from the seton-like action of the ligatures or from the walls of the abscess, a free and an offensive discharge kept on. It was not until April 1st that she was able to sit up in bed, and not until two weeks after that she could be helped into a chair. The ligatures, how-

ever, still held on ; and she was up and about while they were hanging out of the vagina. Their presence annoyed her very much and she grew morbid about them. On April 26, she worked herself up to a pitch of desperation, and, giving the ligatures a violent tug, tore them off. A momentary pang of pain was followed by the escape of about four ounces of blood. I saw her shortly afterwards and at once put her to bed. Pelvic soreness lasted for several hours, but nothing worse came of this reckless act. She fared better than she deserved, and two weeks later was well enough to go home.

As far as I can discover, my case makes the sixth on record of the removal of an ovarian cyst *per vaginam*. All of them took place in this country. The pioneer in this new mode of performing ovariectomy, was our distinguished associate, Dr. T. Gaillard Thomas,¹ who met with his case in 1870. The cyst "was equal in size to a large orange, . . . and could readily be pushed out of the pelvic cavity." It contained from six to eight ounces of bile-like fluid, was without adhesions, and, after being emptied, "passed without difficulty into the vagina." It had a pedicle which was transfixed by a needle armed with a double ligature, and tied on each side. Dr. Thomas then cut off the cyst, together with the free ends of the ligature, close to the knot, and returned the pedicle into the abdominal cavity. One suture sufficed to close up the vaginal wound. The operation proved an easy one, lasting but thirty-five minutes. Owing to gross imprudence on the part of the woman, her convalescence was delayed by an attack of parametritis.

The second case is reported by Dr. R. Davis, of Wilkesbarre, Pa.² From the size of the cyst and from the extent

¹ *Diseases of Women*, 1874, p. 733.

² *Transactions of the Medical Society of Pennsylvania*, 1874, vol. x., Part I., p. 221.

of the adhesions, it deserves more than a mere passing notice. On May 29, 1872, Dr. Davis was called to see Mrs. J. T., a multipara, aged 29, and found her abdomen distended by two tumors of very nearly equal size. One of them proved to be the womb advanced to about the seventh month of pregnancy; the other, an ovarian cyst extending upward several inches above the navel, and so low down as to fill up the pelvic cavity. On August 7th labor set in with the os uteri almost beyond reach. Unsuccessful efforts having been made to lift the tumor out of the pelvis, the cyst was tapped *per vaginam*. It collapsed, the womb descended, and a still-child, presenting by the breech, was born without difficulty. The woman made a rapid recovery.

Summoned again on September 15, to see his patient, Dr. Davis found the tumor had regained its original size and site. It now bulged down so low in the vagina as to be within easy reach, and presented a surface capable of a large incision. The previous use of the trocar had shown that the cyst was unilocular, and probably without adhesions. For these reasons it was decided to attempt its removal *per vaginam*. The operation, which was performed three days later, is described as follows:—

“The patient, having been placed upon the table and etherized, was secured in the position for lithotomy. Two Sims’s specula were now introduced into the vagina, and held by assistants; one making traction anteriorly, the other posteriorly. In this manner the posterior wall of the vagina, covering the tumor, was brought nicely into view. The vagina was now caught with a tenaculum, drawn well down, and incised through the fornix, to the extent of about four inches. After the hemorrhage, which persisted for some time, had ceased, the remaining dissection was made, the peritoneum being divided upon a bent grooved director. The shining cyst-wall was thus exposed. To my dismay, pretty firm pelvic adhesions were found to exist, and I confess to having had many misgivings at this point, as

to the success of my undertaking. I proceeded, however, to sever the adhesions with my finger as far as that could be done ; but they extended beyond the reach of the finger. The specula were now removed, and with the whole hand introduced into the vagina and through the wound, all the adhesions were broken up, first in the pelvis, then in the abdominal cavity between the peritoneum and the tumor anteriorly, and between the tumor and omentum ; the hand being carried for that purpose to a point two inches above the umbilicus. The specula were now reinserted ; the cyst was secured by a tenaculum and tapped with a curved trocar and canula. As the fluid all escaped, I had the great satisfaction of seeing the cyst, almost without traction, come down into the vagina and into my hand. The pedicle, which was long, was secured by a double ligature ; the stump was returned into the peritoneal cavity, and one end of each ligature was left uncut and brought out at the lower portion of the incision. The cul-de-sac of Douglas was carefully sponged out, and two stitches in the upper portion of the incision completed the operation ; the lower portion being left open for drainage. The patient rallied well. Indeed, the patient suffered less from shock in this case than in any other case of ovariectomy I ever witnessed. At no time, after the first evening, did the pulse rise above a hundred. She recovered without a bad symptom, and in four weeks after the operation she called on me at my office perfectly well. One point in the history of the case, after the operation, deserves mention as bearing upon the question of vaginal drainage in ovariectomy. For four days after the operation there was an abundant watery, dark-colored, and very fetid discharge *per vaginam*, sufficient to saturate completely three or four times a day a folded sheet placed under her. The question arises, had this discharge had no outlet, would it not have produced either peritonitis or septicemia, or both ? The tumor was composed of a single cyst of the right ovary, and weighed, with its contents, about nine pounds."

The third case is described by Dr. J. T. Gilmore of Mobile.¹ The cyst was movable and not larger than a small orange. It had a pedicle one inch and a half in length, which was ligated and the cyst cut off. The vaginal opening was closed by three silver sutures, one of them being so passed through the pedicle as to keep the knot outside of the peritoneal cavity. Dr. Gilmore remarks that he "found the whole procedure extremely simple and easy. The whole operation was executed without a change of posture (Sims's position), and consumed only about ten minutes." The body-heat never went above 100, and all medical attendance was discontinued after the twenty-fifth day.

The fourth case in the order of time occurred in the practice of another of our associates, Dr. Robert Battey.² The tumor turned out to be a pedunculated dermoid cyst of the left ovary, as large as a small orange. It contained a ball of hair, and a bone-plate half an inch in length and a quarter of an inch in thickness. A ligature was thrown around the pedicle, and the ends were brought out. A loop of intestines and the right ovary followed the tumor through the incision. They were returned; no bad symptoms occurred, and the woman soon recovered.

Dr. Clifton E. Wing reports the fifth case.³ Defecation was impeded by a small, elastic, and immovable tumor in Douglas's pouch. On February 10, 1876, an aspirator-needle withdrew two drachms of dark, bloody fluid, diagnosed to be the result of "an old hemorrhagic effusion." No bad results followed this operation. On March 30 the hollow needle was again plunged in, and several ounces of the same kind of fluid were pumped out. All the ordinary symptoms of a mild septicemia followed this aspiration, and she began to lose strength and appetite. On April 19 an exploring needle passed in *per vaginam* per-

¹ *New Orleans Medical and Surgical Journal*, November, 1873, p. 341.

² *Atlanta Medical and Surgical Journal*, 1874, p. 146.

³ *Boston Medical and Surgical Journal*, November 2, 1876, p. 516.

mitted the escape of a few drops of an "exceedingly offensive matter." It was now plain that the fluid, "whether it came from an old hœmatocele, or from a hemorrhagic ovarian cyst," ought to be removed at once. After opening Douglas's pouch, the tumor was found to be an ovarian cyst as large as an orange. It was bound down by loose adhesions, which easily gave way before the finger. Its bulk being reduced by twisting, it was brought out into the vagina. It had no pedicle proper, but was readily enucleated by one finger. Some bleeding took place. The broad ligament slipped back into the abdominal cavity, and a coil of small intestines appeared at the opening. It was, therefore, closed by three silk sutures. These sufficed to prevent hernia, but left room enough to introduce a catheter. Fetid fluid in the cul-de-sac gave rise to septic symptoms, but, after a daily irrigation through a double catheter, all these vanished and the patient made a good recovery.

Since this meeting has been in session our distinguished ovariologist, Dr. Washington L. Atlee, has kindly furnished me with the following notes of a hitherto unpublished case of vaginal ovariectomy. They show that his operation antedates all others, and I gladly embody them in my paper.

"February 7, 1857, in consultation with Dr. William Corson I visited Mrs. H. S., of Swedes Forge, Montgomery County, Pa. She was forty-seven years old, and had not passed the climacteric period of life. Her abdomen had been considerably enlarged, but was then smaller in consequence of vaginal discharges, which had occurred two or three weeks before I saw her. The fluid which escaped resembled gum arabic water, and had a somewhat offensive odor.

"Notwithstanding she was a woman of spare habit, she had rapidly lost weight. The hypogastric region was enlarged and occupied by a tumor of less resistance than a fibroid, feeling more like a dense multilocular tumor. It was painful to pressure and scarcely movable. The pelvis was wholly occupied by a large, and not very tense cyst,

covered by the anterior wall of the vagina. On separating the vulva the mass could be seen. The cul-de-sac of the vagina was high up above the brim of the pelvis, and the vaginal canal could be traced going up back of the tumor. I passed my hand into the vagina, but the os uteri was entirely beyond reach. This examination gave considerable pain, and the hand came away stained with blood. The bladder was elevated into the left inguinal region, as ascertained by the sound. This accounted for an occasional difficulty in making water.

“ Here there was a tumor occupying the hypogastric and pelvic regions, situated anterior to the uterus, forcing this organ and the bladder into the abdominal cavity, and stretching the front wall of the vagina over it. The case, however, was so unique that I could not make out a clear diagnosis. It was decided, however, to open the pelvic cyst through the wall of the vagina. This was done, and a considerable quantity of purulent-like fluid was removed. As the patient was suffering very much, further proceedings were postponed.

“ March 13, 1857, I visited her with Dr. Corson again. He had, in the mean time, enlarged the original incision. The hypogastric tumor had diminished in size, and the soreness had also decreased. The discharge had continued. The tumor in the pelvis had become more dense. It was found to be adherent to the parts around it, but most of the adhesions were easily broken up with the finger, while several bands had to be severed by the probe-pointed bistoury. I thus succeeded in detaching the lower portion of the tumor as far as the finger could reach. To accomplish this I had to enlarge the incision in the vaginal coat. As the case was a novel one, and the ground untrodden, it was thought best to suspend for the present further attempts, with the hope that nature itself might throw off the tumor. Should that not be the case, it was determined to bring down the mass by force, break up the adhesions, and enucleate the whole of it from its bed, and remove it.

“ March 25, 1857, we saw the patient again. Her health and strength had improved, but very little change had occurred in the tumor. Before proceeding to the final operation I made another careful examination. By means of a catheter in the bladder, and a finger in the rectum, I satisfied myself that neither of these organs complicated the case.

“ The abdomen being well supported by Dr. Corson, I passed my fingers over the anterior portion of the detached tumor until the point of adhesions was reached, and then with the other hand introduced the crotchet-shaped hook, and firmly planted it in that portion of the mass. By means of the hook I was able to drag down the tumor, and, at the same time, by the fingers, to detach the adhesions, as these were brought within reach. In this way I finally succeeded in enucleating the entire front portion of the tumor, and rolling it entirely out of the vagina. There still remained a large part of the tumor adherent posteriorly, and as the delivered mass interfered with the further progress of the operation, the latter was excised. The remainder of the tumor was equally adherent, and was managed in the same way, and the whole of it was finally removed.

“ On examining the pelvis afterwards, the shreddy bed of the tumor alone remained. The small uterus could scarcely be recognized among the loose tissue, and still occupied an elevated position. Very little hemorrhage occurred, and although no anesthetic was used, the suffering was not intense. The tumor was very much mutilated by the efforts at removal, and proved to be much larger than had been suspected before the operation. It was ovarian and multilocular. September 30, 1858, Dr. Corson called to see me, and reported that Mrs. S. was entirely restored to health, and that menstruation was more regular than ever before. April 4, 1875, I incidentally met the patient in Philadelphia at her son's residence. She was the picture of health, and had never been sick since the operation.”

As bearing on the subject, I cannot refrain from referring

to a very curious and perhaps unique case of the successful removal of an ovarian cyst *per rectum*. It happened in the practice of Mr. A. W. Stocks, surgeon to the Salford Royal Hospital,¹ who reports it as follows :—

“E. J., aged 45, slightly built, married, had three children; she was last confined about twenty-two years ago. She menstruated regularly up to two years ago, irregularly till eight months ago, and not at all since. About eleven years back, a tumor about the size of a walnut appeared at the anus when getting out of bed, becoming larger on exertion. It was accompanied by faintness and uneasiness, especially when sitting down. She was always costive, and could neither micturate nor defecate unless she replaced the tumor manually. She had lately experienced difficulty in coition. The lump had increased in size during the last ten months, and had come down always while at work, producing a good deal of pain in the hypogastrium, more particularly when she was in the upright position. She felt best when lying down. The prolapse was large, being about the size of a small cocoa-nut.”

“*March* 15, 1872. When she was placed upon the operating-table, and under the influence of chloroform, for the purpose of having the simple prolapsus ani, as it was supposed to be, relieved by operation, defecation took place, the contents of the bowel being expelled in such a peculiar manner as to lead to the further and more precise examination of the tumor. It was then discovered that the orifice of the bowel, instead of being at the most dependent part, was on the posterior aspect, and about half way between the edge of the anus and the lowest part of the prolapse. On introducing the finger into the rectum, a large mass was found to occupy the anterior fold of the prolapsed bowel, of globular shape, and capable of being encircled easily at its base. *Per vaginam*, the cervix uteri was found tilted forward and to the right side. The uterine sound could only be passed three quarters of an inch, and a fin-

¹ *British Medical Journal*, October 16, 1875, p. 487.

ger passed into the rectum could be easily approximated to the one in the vagina over the tumor, clearly showing an absence of continuity between the uterus above and the mass below. Moreover, on rubbing the tips of the fingers together, a hardened cord could be felt slipping between them. The conclusion, therefore, at once arrived at, was that this cord was the Fallopian tube, and that the tumor was a small ovarian cyst, which had fallen through Douglas's pouch, become entangled with the prolapsed rectum, and protruded through the anus, dragging the uterus itself out of its normal position. It was evident that to give permanent relief it was necessary that this tumor should be removed. Accordingly, an incision was made in the anterior aspect of the prolapse parallel to the axis of the bowel, and, after breaking down some slight adhesions posteriorly, a small ovarian cyst was easily turned out. The pedicle was divided, after being secured by a strong hempen ligature, the end of which was left hanging out of the wound, and the wound was drawn together by an interrupted suture. There was considerable hemorrhage, and the flaccid bowel was left outside the anus.

"*April 23.* The protruded portion of the bowel was about the size of a walnut. Defecation was fairly under her control, and she could draw the prolapse back without manual assistance. The tumor was a unilocular ovarian cyst, and contained about five and one half ounces of brown, slightly viscid fluid. The ovary and fimbriated Fallopian tube were attached to it."

REMARKS. — Dr. Wing's case and my own show that the removal of the fluid of ovarian cysts, by the aspirator, is by no means wholly without danger. Notwithstanding the small size of the hollow needle employed, and the precautions taken to avoid the introduction of air, this simple operation was followed in both cases by putrefactive changes within the cyst, and in my own case, beside, by an extramural lodgment of pus. Two other examples of this kind, both fatal, are furnished by Dr. P. F. Mundé in his unriv-

aled "Report on the Progress of Gynecology during the year 1875."¹ In one, septicemia was induced merely by the puncture of the cyst with the fine nozzle of a hypodermic syringe, and by the withdrawal of a few minims of fluid. In the other, one of a polycyst occurring in the practice of the reporter, peritonitis and septicemia were set up after the use of a fine aspirator-needle. In a private note, dated April 26th, Dr. Mundé kindly gives me the history of a fifth case which lately occurred in the practice of one of his friends. A single aspiration was followed by inflammation of the cyst, and by the generation of gas in its cavity. The woman died with symptoms of rupture of the cyst. No autopsy was allowed. Such unfortunate accidents should warn one never to tap a polycyst, unless, as Dr. Peaslee holds, one is ready to perform ovariectomy within twenty-four hours.

The success attending both Dr. Wing's and my own case show also that Keith and Wells are undoubtedly right in recommending the removal of an ovarian cyst, even after grave symptoms of peritonitis or of septicemia have set in.

It also confirms the estimate put by Peaslee on the cleansing out of the peritoneal cavity by irrigation. The profession of my own city have hitherto had too great a respect for this serous membrane,—a respect greatly enhanced by the unfortunate experience of one of my colleagues. In a case of extra-uterine (ventral) fetation at term, he had safely delivered the woman by means of a vaginal incision. For several days his patient did so well as to give every promise of a speedy recovery. But the discharges becoming offensive, a weak solution of the potassium permanganate was thrown up the vagina. Intense pain was at once complained of, general peritonitis set in, and the woman, a few hours later, died in a state of collapse. The knowledge of this fact gave me some misgivings; nor were they allayed by the ominous shake of my colleague's

¹ *American Journal of Obstetrics*, April, 1876, p. 146.

head. But the result far exceeded my expectations. Every injection brought away putrid matter, and from the very first one my patient began to mend. Nor need the fear that air may be carried into the peritoneal cavity deter one from resorting to these injections. Pure air must surely be less hurtful than the fetid gas generated by putrefactive changes. And so I found it in my case, for the syringe was an imperfect one, and bubbles of air passed freely into the abdominal cavity. Besides, the recent experiments of Frédéricq¹ prove that unfiltered air can with impunity be projected for hours upon the peritoneum of such warm-blooded animals as guinea-pigs and rabbits.

Another lesson taught by my own case and that of Dr. Davis, is the great need for drainage in some cases of ovariectomy. In Dr. Davis' case there came away for four days after the operation, "an abundant, watery, dark-colored, and very offensive discharge, *per vaginam*, sufficient to saturate completely three or four times a day a folded sheet placed under her." And he pertinently asks: "Had this discharge had no outlet, would it not have produced either peritonitis or septicemia or both?" My case did not yield so great a discharge, but what came away was abundant enough to soil several napkins daily, and putrid enough to poison the air of a large ward. Schröder, however, may be right in the opinion,² that when infection is guarded against, the exudations do not decompose, and consequently do not give rise to septic phenomena. There is plenty of elbow-room here for investigators.

In the treatment of the pedicle, after vaginal ovariectomy, the ordinary clamp is, of course, out of question; there is no room for it. A special one for this purpose might be constructed, but its utility would be questionable. I should be loath to trust to anything short of the ligature. Enucleation, or even the use of the hot or the cold wire, might

¹ *London Medical Record*, February 15, 1877, from *Annales et Bulletin de la Société de Médecine de Gand*, November, 1876.

² *New York Medical Record*, September 25, 1875.

be followed by hemorrhage, and after the broad ligament springs back out of view, the bleeding point could not be secured, unless the pediclé were a long one. Had there not been in my case a lodgment of pus in Douglas' pouch, I should have used the gut-ligature, and, after cutting it off close to the knot, have closed up the vaginal opening.

The scope of vaginal ovariectomy must necessarily be limited. Its performance is beset with too many difficulties to make it a rival of the ordinary operation. But there are certain conditions, in which I am sure that it can be resorted to with greater advantage. When, for instance, a small polycyst lodges in Douglas' pouch, or a large unadherent monocyst bulges down into the pelvic cavity. True, adhesions cannot always be foreseen; but if the removal of the cyst through the vaginal incision prove impracticable, and the operator be driven to gastrotomy, then nothing more will have been done than the preliminary establishment of a probably needful drainage opening.

Thus far there have been reported no fatal cases from this mode of removing an ovarian cyst. And, indeed, it stands to reason that the risk should be lessened; for fewer important structures are aggrieved, the chance of infection is not so great, and good drainage must, *per force*, be established by the very site of the incision. Such being the case, we shall, in future, I think, feel more warranted in extirpating an ovarian cyst while it is small and not liable to contract adhesions than to wait, as is usually done, for the woman to brood over it, and to suffer from it for months. I am now watching with great interest the left ovary of a young single lady. It is now as large as a hen's egg, and lies so loosely moored in Douglas' pouch, as to make its removal a matter of no difficulty. I am yet uncertain whether its size depends upon mere congestion or upon cystic degeneration. At my last examination I fancied that fluctuation was present. Should this turn out to be so, and

should the gland grow, I would unhesitatingly urge its removal, *per vaginam*, while it is yet small and movable, and before it attains such a size, or it contracts such adhesions as would compel the supra-pubic incision.

