

A Parks/Lucas

COUNTY OF LOS ANGELES										CASE REPORT				DEPARTMENT OF CORONER				
1	APPARENT MODE ACCIDENT										CASE NO 2020-00802							
	SPECIAL CIRCUMSTANCES										CRYPT 23							
LAST FIRST MIDDLE DOE, JOHN										AWA		#						
ADDRESS										CITY		STATE		ZIP				
SEX	RACE APPEARS	DOB	AGE	HGT	WGHT	EYES	HAR	TEETH	PACHL NAR	IG VIEW	CONDITION							
MALE	Caucasian				122 lb	UNKNOWN	GRAY			No	POOR CONDITION							
MARK TYPE										MARK LOCATION		MARK DESCRIPTION						
NEX										ADDRESS		CITY		STATE		ZIP		
PLEASE SEE CASE NOTES																		
RELATIONSHIP					PHONE					NOTIFIED BY					DATE		TIME	
SIN					DL ID					STATE					PENDING BY			
IDENTIFIED																		
LAX		MARK #		CS #		FBI #		MILITARY #		POB								
IDENTIFIED BY NAME (PRINT)										RELATIONSHIP		PHONE		DATE		TIME		
PLACE OF DEATH / PLACE FOUND										ADDRESS OR LOCATION		CITY		STATE		ZIP		
MOUNTAIN SIDE										4232 LA VIRGENES RD.		CALABASAS		CA		91303		
PLACE OF INJURY			AT WORK		DATE		TIME		LOCATION OR ADDRESS		STATE		ZIP					
MOUNTAIN SIDE			No		1/26/2020				4232 LA VIRGENES RD., CALABASAS, CA		CA		91303					
DOD		TIME		FOUND OR PROVIDED BY														
1/26/2020		10:10		LACFD SMITH														
OTHER AGENCY INV OFFICER										PHONE		REPORT NO.		NOTIFIED BY		NO		
TRANSPORTED BY										TO		DATE		TIME				
OTHER										LOS ANGELES FSC		1/27/2020		17:55				
FINGERPRINTS		Yes		CLOTHING		Yes		FA RPT		No		MORTUARY						
MED. EX.		No		INVEST PHOTO #		0		SEAL TYPE				HCSP RPT				No		
PHYS. EX.		No		EVIDENCE LOG		No		PROPERTY?		No		HCSP CHART				No		
SUGGESTION		No		GSR NO				RPT. NO.				PF NO.						
SYNOPSIS										<p>THE DECEDENT WAS ONE OF NINE INDIVIDUALS INVOLVED IN A HELICOPTER CRASH ON 01/26/2019. ON 01/26/2019 A SIKORSKY S-76B THAT THE DECEDENT WAS RIDING IN CRASHED INTO MOUNTAINOUS TERRAIN IN THE CITY OF CALABASAS. WEATHER CONDITIONS AT THE TIME OF THE COLLISION WERE REPORTED TO BE FOGGY. THE HELICOPTER APPEARS TO HAVE CRASHED INTO A MOUNTAIN BEFORE MAKING A SMALL SKIP AND COMING TO REST NEAR A HIKING TRAIL. THE TAIL OF THE HELICOPTER WAS LOCATED SOUTH OF THE MAIN BODY OF THE HELICOPTER. VARIOUS AIRCRAFT PARTS WERE STREWN FOR APPROXIMATELY 100 YARDS NORTH OF THE APPARENT MAIN POINT OF IMPACT. THE DECEDENT WAS OBSERVED LYING ON THE VEGETATION COVERED GROUND NORTHWEST OF THE MAIN WRECKAGE.</p>								
KRISTINA MCGUIRE					DATE					REVIEWED BY		DATE						
547544					<i>K. McGuire</i>					1/27/2020		<i>[Signature]</i>						
					INVESTIGATOR					TIME		TIME						
					23:53							1/28/20						
												0010						
FORM #3 NARRATIVE TO FOLLOW? <input type="checkbox"/>																		

COUNTY OF LOS ANGELES										CASE REPORT				DEPARTMENT OF CORONER	
1	APPARENT MODE ACCIDENT										CASE NO 2020-00802				
	SPECIAL CIRCUMSTANCES Media Interest, Multiple Deaths										CRYPT 23				
LAST FIRST MIDDLE ALTOBELLI, JOHN										AWA		#			
ADDRESS 174 LESSAY										CITY NEWPORT BEACH		STATE CA		ZIP 92657	
SEX	RACE APPEARS	DOB	AGE	HGT	WGHT	EYES	HAR	TEETH	PACHL NAR	IG VIEW	CONDITION				
										No	POOR CONDITION				

2 of 4

CASE REPORT

COUNTY OF LOS ANGELES		CASE REPORT		DEPARTMENT OF CORONER	
1	APPARENT MODE	ACCIDENT			CARE NO
	SPECIAL CIRCUMSTANCES	Media Interest, Multiple Deaths			2020-00802
LAST FIRST MIDDLE		AFA		#	
ALTOBELLI, JOHN					
ADDRESS		CITY		STATE	ZIP
174 LESSAY		NEWPORT BEACH		CA	92657
SEX	RACE	DOB	AGE	HGT	WGT
MALE	CAUCASIAN	5/8/1963	56	5'11"	122 lbs
HAIR	EYES	HAIR	TEETH	SCALP W/HAIR	NO VIEW
GRAY	UNKNOW	GRAY			No
MARK TYPE		MARK LOCATION		MARK DESCRIPTION	
RELATIONSHIP		PHONE		NOTIFIED BY	
				INV. K. MCGUIRE	
SSN		DL ID		STATE	
				FENCING BY	
METHOD		FINGERPRINTS FROM DOJ		DATE	
				1/27/2020	
LAP		MARK #		DOB	
DEFICED BY NAME (PRINT)		RELATIONSHIP		PHONE	
DOJ FINGERPRINTS				DATE	
				1/27/2020	
PLACE OF DEATH/PLACE FOUND		ADDRESS OR LOCATION		CITY	
MOUNTAIN SIDE		232 LAS VIRGENES RD.		CALABASAS	
				ZIP	
				91303	
PLACE OF INJURY		AT WORK		DATE	
MOUNTAIN INSIDE		No		1/26/2020	
		TIME		LOCATION OR ADDRESS	
				4232 LAS VIRGENES RD., CALABASAS, CA	
ZIP		91303			
DOD		TIME		FOUND OR PRONOUNCED BY	
1/26/2020		16:10		LACFD SMITH	
OTHER AGENCY INV. OFFICER		PHONE		REPORT NO.	
TRANSPORTED BY		TO		DATE	
OTHER		LOS ANGELES FSC		1/27/2020	
				TIME	
				17:55	
FINGERPRINTS		CLOTHING		PART	
Yes		Yes		No	
MID. EV.		INVEST. PHOTO #		HOSP RPT	
No		0		No	
PHYS. EV.		EVIDENCE LOG		HOSP CHART	
No		No		No	
SUICIDE NOTE		OSR NO		RCPT NO.	
No				FF NO.	
<p>SYNOPSIS THE DECEDENT WAS ONE OF NINE INDIVIDUALS INVOLVED IN A HELICOPTER CRASH ON 01/26/2019. ON 01/26/2019 A SIKORSKY S-76B THAT THE DECEDENT WAS RIDING IN CRASHED INTO MOUNTAINOUS TERRAIN IN THE CITY OF CALABASAS. WEATHER CONDITIONS AT THE TIME OF THE COLLISION WERE REPORTED TO BE FOGGY. THE HELICOPTER APPEARS TO HAVE CRASHED INTO A MOUNTAIN BEFORE MAKING A SMALL SKIP AND COMING TO REST NEAR A HIKING TRAIL. THE TAIL OF THE HELICOPTER WAS LOCATED SOUTH OF THE MAIN BODY OF THE HELICOPTER. VARIOUS AIRCRAFT PARTS WERE STREWN FOR APPROXIMATELY 100 YARDS NORTH OF THE APPARENT MAIN POINT OF IMPACT. THE DECEDENT WAS OBSERVED LYING ON THE VEGETATION COVERED GROUND NORTHWEST OF THE MAIN WRECKAGE.</p>					
KRISTINA MCGUIRE 547544 <i>K. Maser</i> INVESTIGATOR		DATE 1/27/2020 TIME 23:53		REVIEWED BY LARRY DIETZ <i>Larry</i> DATE 1/28/2020 TIME 00:18	

FORM #3 NARRATIVE TO FOLLOW?



3 of 4



County of Los Angeles, Department of Coroner
Investigator's Narrative



Case Number: 2020-00802

Decedent: ALTOBELLI, JOHN

Information Sources:

1. Aircraft Accident Investigation Report, National Transportation Safety Board, Washington D.C. 20594.
2. On scene investigation.

Investigation:

Initial reports indicate that on 01/26/2020 at approximately 0945 hours multiple witnesses called 911 reporting that a helicopter had crashed into the foothills of the Santa Monica mountains above Las Virgenes Road in the City of Calabasas. Deputies from the Los Angeles County Sheriff's Department and personnel from the Los Angeles County Fire Department responded to the scene. Upon arrival to the scene nine decedents were located and pronounced dead at 1010 hours by Los Angeles County Fire Department personnel.

On 01/26/2020 at 1338 hours Officer Rodriguez from the Los Angeles County Sheriff's Department-Homicide Bureau called to report this multi-decedent helicopter crash fatality to Investigator Jeffrey Guilmette at the Los Angeles County Department of the Medical Examiner-Coroner. I was assigned this Special Operations Response Team (SORT) field case at 1400 hours by Acting Supervisor Anthony Lopez. I arrived on scene at approximately 1620 hours and cleared the scene at approximately 1930 hours. On 01/26/2020 the following SORT team members responded to the scene for a coordinated search and decedent removal:

M. Lee #605743, L. Cervantes #639654, P. Ngayan #531611, B. Kim #602036, E. Napoles #465129, M. Gutierrez #479704, R. Estrada #486093, R. Gonzalez #503064, J. Fallot #644073.

On 01/27/2020 at approximately 0630 hours I returned to the scene and cleared the scene at approximately 1600 hours. On 01/27/2020 the following SORT Team Members returned to the scene for a continued coordinated search and decedent removal:

M. Lee #605743, L. Cervantes #639654, P. Ngayan #531611, B. Kim #602036, E. Napoles #465129, M. Gutierrez #479704, R. Estrada #486093, R. Gonzalez #503064, J. Fallot #644073, F. Fernandez #486349, M. Molina #421452.

Forensic Attendant P. Ngayan transported all decedents to the Forensic Science Center.

Also present at the scene were Chief B. Elias, Captain E. Tauscher and Dr. J. Lucas.

Location:

Place of Injury/Death: Mountainside, 4232 Las Virgenes Road, Calabasas, CA 91303.

Informant/Witness Statements:

A review of a report issued by the National Transportation Safety Board revealed the following information:

On 01/26/2020 at 0945 hours a Sikorsky S-76B helicopter, N72EX, collided with hilly terrain near the city of Calabasas. The helicopter held 8 passengers and a pilot who were all killed on impact. The Sikorsky was in an 8-passenger seat configuration with two pilot stations up front and eight passengers in the rear, separated by a bulkhead with sliding acrylic windows. Passenger seating was 2 four-occupant divans, one facing forward and the other rearward. A main impact crater measuring 24 feet by 15 feet in diameter was observed with the main wreckage noted to be about 127 feet along a 347° true bearing from the impact crater. The helicopter was destroyed by impact forces and fire with the entire fuselage/cabin and both engines subjected to a post-crash fire.



Informant/Witness Statements:

A review of a report issued by the National Transportation Safety Board revealed the following information:

4 of 4

On 01/26/2020 at 0945 hours a Sikorsky S-76B helicopter, N72EX, collided with hilly terrain near Calabasas. The helicopter held 8 passengers and a pilot who were all killed on impact. The Sikorsky was in an 8-passenger seat configuration with two pilot stations up front and eight passengers in the rear, separated by a bulkhead with sliding acrylic windows. Passenger seating was 2 four-occupant divans, one facing forward and the other rearward. A main impact crater measuring 24 feet by 15 feet in diameter was observed with the main wreckage noted to be about 127 feet along a 347° true bearing from the impact crater. The helicopter was destroyed by impact forces and fire with the entire fuselage/cabin and both engines subjected to a post-crash fire.



**County of Los Angeles, Department of Coroner
Investigator's Narrative**



Case Number: 2020-00802

Decedent: ALTOBELLI, JOHN

Scene Description:

The scene is mountainous, vegetation covered terrain located east of 4232 Las Virgenes Road in the City of Calabasas. Due to the size of the scene a stake was placed at a central point located just north of what appears to be the main fuselage. The GPS coordinates of the stake were 34°8'14" N and 118°41'33" W. What appeared to be an initial point of impact designated by a disturbance to the soil and vegetation and various helicopter parts, personal property and human remains were located approximately 120 feet south of the designated central stake. The helicopter wreckage, personal property and human remains were spread in a cone shape across the area starting at the initial point of impact and spreading toward the north stopping at the north side of a ravine. A designated hiking path was located surrounding the scene.

Evidence:

No evidence was collected for this case.

Body Examination:

The decedent is an adult Caucasian male observed lying on a vegetation covered slope northwest of the main wreckage. He was wearing a black sweater and underwear. He has gray hair, an unknown eye color and natural teeth. Upon external examination I observed significant trauma was noted to his head, left arm and lower body.

Identification:

On 01/27/2020 at 1844 hours the decedent was positively identified as John Edward Altobelli (DOB: 05/08/1963) via Department of Justice fingerprints.

Next of Kin Notification:

I provided telephonic notification of the decedent's death to [REDACTED], [REDACTED] decedent.

Tissue Donation:

Not addressed.

Autopsy Notification:

No exam request was noted.

KRISTINA MCGUIRE
#547544

SUPERVISOR

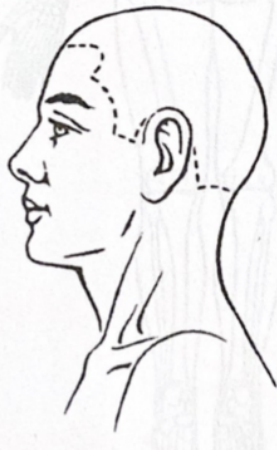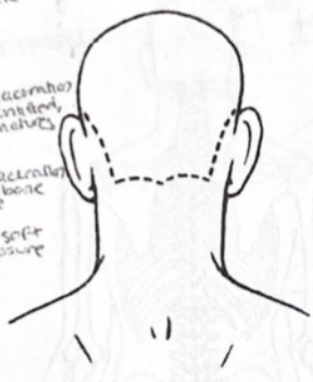
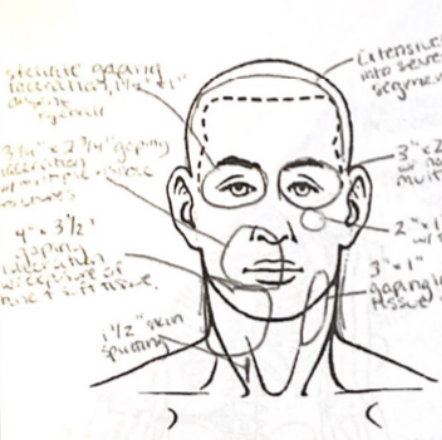
02/13/2020
Date of Report

22

Anti-fracture of mandible, portions of the maxilla w/ teeth are identified

2020-00802
DOE, JOHN
ACCIDENT

23



Date 1-28-2020

[Signature] M.D.
Deputy Medical Examiner

27

2020-00802
DOE, JOHN
ACCIDENT

23

COUNTY OF LOS ANGELES

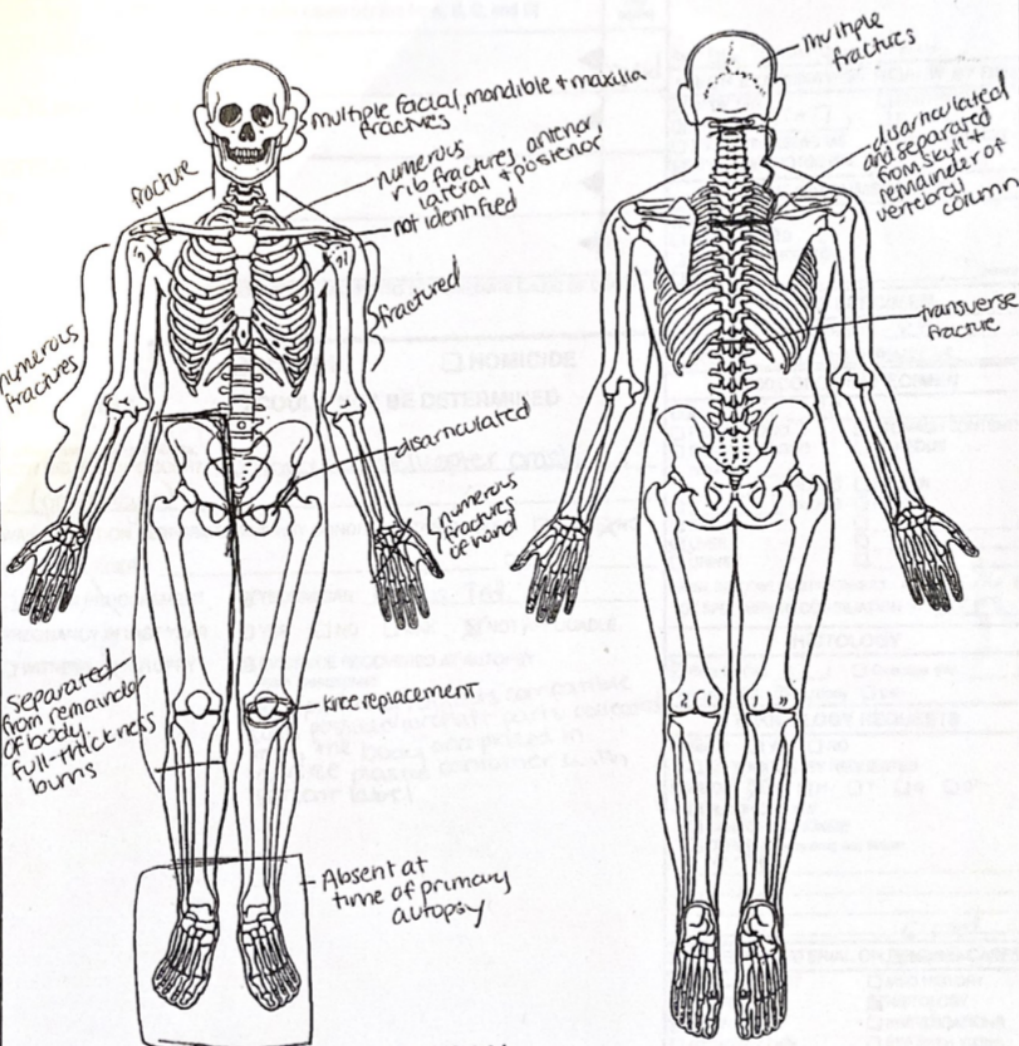
DEPARTMENT OF MEDICAL EXAMINER - CORONER

27

2020-00802

DOE JOHN
ACCIDENT

23



Review of photograph subsequent to primary autopsy reveals the right foot with attached distal tibia and fibula. The left foot is not visually recognizable.
RP4-23-20

1-28-2020

AUTOPSY CLASS: A B C Examination Only D

FAMILY OBJECTION TO AUTOPSY

RESIDENT *Robert Palko*

DME

- MICROBIOLOGY
- RADIOLOGY CONS.
- CONSULT ON:
- BRAIN SUBMITTED
- NEURO CONSULT
- CRIMINALISTICS
- GSR
- SEXUAL ASSAULT
- OTHER
- EYE PATH. CONS.
- DME TO CUT

WHITE - File Copy

CANARY - Forensic Lab

PINK - Certification

GOLDENROD - DME

(Rev. 9/13)

4 of 6

COUNTY OF LOS ANGELES

AUTOPSY CHECK SHEET

DEPARTMENT OF CORONER

16

2020-00802

DOE, JOHN
ACCIDENT

23

EXTERNAL EXAM

Sex M
Race Caucasian
Age
Height
Weight 22 lbs
Hair Brown
Eyes absent
Sclera absent
Teeth partially present + in good repair
Mouth
Tongue
Nose
Chest
Breasts
Abdomen
Scar
Genitals
Edema
Skin
Decubitus

Not identified

HEART WL

Pericardium RV
Hypertrophy Septum
Dilation LV
Muscle Septum
Valves

Coronaries

AORTA transected distal to L subclavian a.

VESSELS

LUNGS WL

R Not identified

L
Adhesions
Fluid
Atelectasis
Oedema
Congestion
Consolidation
Bronchi
Nodes

PHARYNX

TRACHEA transected

THYROID present

THYMUS invol

LARYNX multiple fractures

HYOID

ABDOMINAL WALL FAT

PERITONEUM

Fluid
Adhesions
LIVER WL portions of liver
Capsule 400g
Lobules
Fibros
G B
Calculus
Bile ducts

SPLEEN WL Not identified

Color
Consistency
Capsule
Malpignment

PANCREAS present

ADRENALS Not identified

KIDNEYS WL

R portions of kidney(s) 50g

L

Capsule

Cortex

Vessels

Pelvis

Ureters

BLADDER

GENITALIA Not identified

Prostate

Testes

Uterus

Tubes

Ovaries

OESOPHAGUS

STOMACH

Contents scant brown-tan contents

DUOD. & SM. INT. tan-yellow contents OTHER PROCEDURES

APPENDIX present

LARGE INT. brown-green stool

ABDOM. NODES

SKELETON

Spine

Marrow

Rib Cage

Long bones

Pelvis

SCALP

CALVARIUM

BRAIN WL Not identified

Dura

Fluid

Ventricles

Vessels

Middle ears

Other

PITUITARY

SPINAL CORD

TOXICOLOGY SPECIMENS

Liver

SECTIONS FOR

HISTOPATHOLOGY

#1 liver

MICROBIOLOGY

DIAGRAMS #20, 27, 22

X-RAYS CT

OTHER PROCEDURES

GROSS IMPRESSIONS

Date

1-28-2020

Time

0930-1300

Deputy Medical Examiner

Robert Palko



Department of Medical Examiner-Coroner, County of Los Angeles

FORENSIC SCIENCE LABORATORIES

1104 North Mission Road, Los Angeles, CA 90033

Laboratory Analysis Summary Report



Lucas, Jonathan M.D.

Deputy Medical Examiner
1104 North Mission Road
Los Angeles, CA 90033

Pending Tox

LARYNX
HYOID
ABDOMINAL WALL FAT

multiple fractures

Date 1-28-2020	Time 0930-1300	Deputy Medical Examiner <i>Robert Parker</i>
-------------------	-------------------	---

Form #16.doc

76A878-(REV. 3/05)

5 of 6



Department of Medical Examiner-Coroner, County of Los Angeles

FORENSIC SCIENCE LABORATORIES

1104 North Mission Road, Los Angeles, CA 90033

Laboratory Analysis Summary Report



Lucas, Jonathan M.D.

Deputy Medical Examiner
1104 North Mission Road
Los Angeles, CA 90033

Pending Tox

Coroner Case Number: 2020-00802 Decedent: ALTOBELLI, JOHN

<u>SPECIMEN</u>	<u>SERVICE</u>	<u>DRUG</u>	<u>RESULT</u>	<u>ANALYST</u>
-----------------	----------------	-------------	---------------	----------------

Alcohol Quantitation/Confirmation

Liver

Alcohol-GC/FID-MS	Ethanol	SNS	-----
-------------------	---------	-----	-------

Drug Screen

Liver

ELISA-Immunoassay	Benzodiazepines	PP	J. Posada
ELISA-Immunoassay	Cocaine and Metabolites	ND	J. Posada
ELISA-Immunoassay	Fentanyl	ND	J. Posada
ELISA-Immunoassay	Marijuana: 11-nor-Delta-9-Carboxy-THC	ND	J. Posada
ELISA-Immunoassay	Methamphetamine & MDMA	ND	J. Posada
ELISA-Immunoassay	Opiates: Codeine & Morphine	ND	J. Posada
ELISA-Immunoassay	Opiates: Hydrocodone & Hydromorphone	ND	J. Posada
ELISA-Immunoassay	Phencyclidine	ND	J. Posada

Drug Screen/Confirmation

Liver

Bases-GC/NPD &/or MS	Basic Drugs	ND	R. Cabrera
Benzos (Free)-LC/MS	Benzodiazepines	ND	B. Helmer

Print Date: *RP* Thursday, March 5, 2020

ANAB ISO/IEC 17025:2005 Forensic Science Testing Laboratories Page 1 of 2

RP 4-30-20

Coroner Case Number: 2020-00802 Decedent: ALTOBELLI, JOHN

<u>SPECIMEN</u>	<u>SERVICE</u>	<u>DRUG</u>	<u>RESULT</u>	<u>ANALYST</u>
-----------------	----------------	-------------	---------------	----------------

NOTE: AKA John Doe.

Legend:

ND	Not Detected	SNS	Specimen Not Suitable
----	--------------	-----	-----------------------

6 of 6

RP 4-30-20

Coroner Case Number: 2020-00802 Decedent: ALTOBELLI, JOHN

<u>SPECIMEN</u>	<u>SERVICE</u>	<u>DRUG</u>	<u>RESULT</u>	<u>ANALYST</u>
-----------------	----------------	-------------	---------------	----------------

NOTE: AKA John Doe.

Legend:

g	Grams	ND	Not Detected	SNS	Specimen Not Suitable
g ^w	Gram Percent	ng/g	Nanograms per Gram	TNP	Test Not Performed
Inc.	Inconclusive	ng/mL	Nanograms per Milliliter	ug	Micrograms
mg	Milligrams	PP	Presumptive Positive	ug/g	Micrograms per Gram
		QNS	Quantity Not Sufficient	ug/mL	Micrograms per Milliliter

The alcohol analysis was performed in accordance to California Code of Regulations "Title 17" compliance by a qualified analyst in the Forensic Toxicology Laboratory, Forensic Laboratories Division, County of Los Angeles Department of Medical Examiner - Coroner.

Enzyme-linked immunosorbent assay (ELISA) provides only a preliminary analytical result that is contingent upon a confirmatory test. A "presumptive positive" (PP) signifies a detection of a drug class and must be confirmed by additional testing for true identification and/or quantitation of specific drug(s) present in the specimen.

Per the Department's Evidence Retention Policy, the blood specimen(s) will be retained for one year (minimum) and all other specimens six months (minimum) from Autopsy.

Final Review By:
Sarah Buxton de Quintana
Supervising Criminalist I

Date: 3/5/20

The above results relate only to the items sampled and tested and have been technically and administratively reviewed and are the opinions and conclusions of the analyst noted. The final review has been certified by the noted Toxicologist to ensure that all standard operating procedures were followed as set by the Forensic Toxicology Laboratory, Forensic Sciences Laboratory Division, County of Los Angeles Department of Medical Examiner-Coroner.

12**AUTOPSY REPORT**No. 2020-00802
ALTOBELLI, JOHN

I performed an autopsy on the body of →

at _____
the DEPARTMENT OF MEDICAL EXAMINER-CORONER

Los Angeles, California

on January 28, 2020 at 0930 hours
(Date) (Time)

From the anatomic findings and pertinent history I ascribe the death to:

(A) BLUNT TRAUMA

DUE TO OR AS A CONSEQUENCE OF

(B)

DUE TO OR AS A CONSEQUENCE OF

(C)

DUE TO OR AS A CONSEQUENCE OF

(D)

OTHER CONDITIONS CONTRIBUTING BUT NOT RELATED TO THE IMMEDIATE CAUSE OF DEATH

MANNER OF DEATH

ACCIDENT

HOW INJURY OCCURRED

COMMERCIAL HELICOPTER CRASH (PASSENGER)

Anatomic Summary:

- I. Extensive blunt force injuries of head, torso, and extremities with:
 - A. Comminuted fractures of skull, facial bones, vertebral column, extremities
 - B. Evisceration of brain and wide exposure of abdominal cavity and lower extremities
 - C. Lacerations of major organs and vascular structures
- II. Status post total knee replacement of the left knee
- III. Please also see related Medical Examiner cases, 2020-00795, 2020-00796, 2020-00797, 2020-00798, 2020-00799, 2020-00800, 2020-00801, and 2020-00803

12**AUTOPSY REPORT**No. 2020-00802
ALTOBELLI, JOHN

Page 2

CIRCUMSTANCES:

Please see Investigator's Report.

DATE OF INJURY: January 26, 2020

DATE OF DEATH: January 26, 2020

IDENTIFYING FEATURES:

The body is identified by coroner tags, 2020-00802, John Doe, which is subsequently identified by fingerprints as John Altobelli.

There is a total knee replacement of the left knee joint which

AUTOPSY REPORTNo. 2020-00802
ALTOBELLI, JOHN**12**Page 2**CIRCUMSTANCES:**

Please see Investigator's Report.

DATE OF INJURY: January 26, 2020**DATE OF DEATH:** January 26, 2020**IDENTIFYING FEATURES:**

The body is identified by coroner tags, 2020-00802, John Doe, which is subsequently identified by fingerprints as John Altobelli. There is a total knee replacement of the left knee joint which contains the following serial number on the tibial base plate: "5520B6001|No.6|AGX4TB." There is extensive fragmentation of the skin, soft tissue, and bony structures of the torso, pelvis, and lower extremities. No scars or tattoos are identified. A silver metallic ring is identified on the ring finger of the left hand with an inner inscription of "14K". It is removed during the autopsy and booked into property.

DESCRIPTION OF TRAUMATIC INJURIES:

Please refer to forms #20, #22, and #27 for visual approximations of the injuries described below. The order in which the injuries are described is not intended to imply the order in which the injuries occurred.

DESCRIPTION OF BLUNT FORCE TRAUMATIC INJURIES:**Blunt force trauma, head and neck:****External:**

1. Right eye and face: 1 1/4 inches by 1 inch stellate gaping laceration with exposure of the underlying soft tissue and loss of the eye
2. Right cheek, mouth, and nose: 3 1/4 inch by 2 3/4 inch gaping laceration with exposure of the underlying soft tissue and bony structures
3. Right inferior face and neck: 4 inch by 3 1/2 inch gaping laceration with exposure of the underlying soft tissue and bony structures
4. Left eye and face: 3 inch by 2 1/4 inch gaping laceration with exposure of the underlying soft tissue and bony structures
5. Left cheek: 2 inch by 1 3/4 inch gaping laceration with exposure of the underlying soft tissue and bony structures

AUTOPSY REPORTNo. 2020-00802
ALTOBELLI, JOHN**12**Page 3

6. Lower left face and left neck: 3 inch by 1 inch gaping laceration with exposure of the underlying soft tissue and bony structures

6. Left cheek: 2 inch by 1 3/4 inch gaping laceration with exposure of the underlying soft tissue and bony structures

COUNTY OF LOS ANGELES

12

AUTOPSY REPORT

DEPARTMENT OF MEDICAL EXAMINER-CORONER

No. 2020-00802
ALTOBELLI, JOHN

Page 3

6. Lower left face and left neck: 3 inch by 1 inch gaping laceration with exposure of the underlying soft tissue and bony structures
7. Avulsion of the mid-scalp region extending from the right upper arm/chest, behind the right ear, across the top of the scalp, behind the left ear, and down the anterior left chest and left arm

Internal:

1. Multiple comminuted fractures of the facial bones, maxilla, and mandible
2. Multiple comminuted skull fractures with lacerations of the dura mater and evisceration of the brain which is not identified
3. Multiple fractures of the hyoid bone with associated hemorrhage in the investing fascia
4. Transection of the cervical vertebral column

Blunt force trauma, torso:

External:

1. Right chest, medial to the right nipple: red, dried abrasion
2. Central chest: 2 1/2 inch by 2 1/4 inch abrasion
3. Left chest: extending from the central chest abrasion noted above, lateral to the left nipple and upwards is a red abrasion with an overall measurement of 5 inches by 1 1/2 inches, within which, is a distinct linear, vertical, abrasion of the left upper chest measuring 1/8 inch in width
4. Right abdomen: there are two distinct red, dried abrasions, extending from the upper abdomen to the middle of the abdomen
5. Right lower abdomen: 1 3/4 inch in length by 1/2 inch in width horizontal linear abrasion
6. Right lower abdomen, lateral and inferior to the umbilicus: 2 inch by 2 1/2 inch abrasion
7. Lateral right hip: 1 1/4 inch by 1/2 inch abrasion
8. Left lower abdomen: two vertical linear abrasions ranging in width from 1/8 inch to 3/16 inch, with clearing between the abrasions
9. Left abdomen: 2 1/2 inch by 2 1/2 inch gaping laceration with exposure of the underlying soft tissue and evisceration of the intestine
10. Left mid-abdomen: red, dried abrasion

COUNTY OF LOS ANGELES

12

AUTOPSY REPORT

DEPARTMENT OF MEDICAL EXAMINER-CORONER

No. 2020-00802
ALTOBELLI, JOHN

Page 4

11. Mid-to-lower back: multiple irregularly-shaped abrasions measuring 1 1/4 inch by 1 inch and 2 1/4 inch by 3 inches, along with a curvilinear abrasion spanning 9 inches in length with a width ranging from 1/16 inch to 1/2 inch.

AUTOPSY REPORT

No. 2020-00802
ALTOBELLI, JOHN

12

11. Mid-to-lower back: multiple irregularly-shaped abrasions measuring 1 1/4 inch by 1 inch and 2 1/4 inch by 3 inches, along with a curvilinear abrasion spanning 9 inches in length with a width ranging from 1/16 inch to 1/2 inch.

Internal:

1. There is extensive tissue disruption and hemorrhage with loss of anatomic structures
2. Transection of the aorta distal to the left subclavian artery
3. Transection of the trachea
4. Multiple comminuted anterior, lateral, and posterior rib fractures
5. Transection of the upper cervical and lower thoracic vertebral column
6. Fractures of the sternum
7. Multiple contusions of the small intestine and mesentery
8. Evisceration of visceral organs with unidentified heart, lungs, gallbladder, spleen, adrenal glands, bladder, prostate, and testicles

Blunt force trauma, upper extremities:

External:

1. Lateral right shoulder: 2 1/2 inch linear abrasion with surrounding red-purple contusion
2. Posterior right upper arm: 7 inch by 5 inch gaping laceration with exposure of the underlying soft tissue and bony structures
3. Anterior right forearm: 8 inch by 5 inch gaping laceration extending from the elbow to the wrist with associated surrounding red-purple contusion and exposure of the underlying soft tissue
4. Right thenar eminence: 3 inch by 3/4 inch gaping laceration with surrounding red-purple contusion
5. Red-purple contusions of the right upper arm, forearm, and hand ranging from 1/2 inch to 8 inches
6. Red-purple contusions of the left upper arm, forearm, and hand ranging from 3 inches to 12 inches.
7. Anterior left upper arm: 2 1/4 inch by 1/4 inch abrasion
8. Posterior left upper arm: 5 inch by 4 1/4 inch gaping laceration with exposure of the underlying soft tissue

AUTOPSY REPORT

No. 2020-00802
ALTOBELLI, JOHN

12

9. Left upper arm and forearm: 10 inch by 4 inch gaping laceration with associated surrounding contusion and exposure of the underlying soft tissue
10. Left middle finger avulsion

Internal:

ranging from 3 inches to 12 inches.

7. Anterior left upper arm: 2 1/4 inch by 1/4 inch abrasion
8. Posterior left upper arm: 5 inch by 4 1/4 inch gaping laceration with exposure of the underlying soft tissue

AUTOPSY REPORT

No. 2020-00802
ALTOBELLI, JOHN

12

Page 5

9. Left upper arm and forearm: 10 inch by 4 inch gaping laceration with associated surrounding contusion and exposure of the underlying soft tissue
10. Left middle finger avulsion

Internal:

1. Proximal and distal dislocations of the right and left clavicles
2. Fracture of the right clavicle
3. Fractures of the right and left scapulae
4. Fractures of the proximal and distal aspects of the right humerus
5. Dislocation of the left clavicle
6. Fracture of the proximal aspect of the right ulna
7. Fractures of the proximal and distal aspects of the right radius
8. Fracture of the upper aspect of the left humerus
9. Multiple fractures of the left hand

Blunt force trauma, lower extremities:

External:

1. Extreme fragmentation of bony and soft tissues
2. There are full-thickness burns of the separated right pelvis and attached portion of the right lower extremity with a strong odor of fuel

Internal:

1. Left hip disarticulation
2. Vertical fracture of the anterior pelvis with complete separation of the right pelvis
3. Mid-shaft transverse fractures of the bilateral tibia and fibula
4. The left foot is not identified

CLOTHING:

The decedent's clothing has been removed prior to autopsy, and the clothing is examined separately. The clothing includes a black long-sleeved shirt with "Dri-Fit" on the neck label and "XL". There is a silver Nike swoosh on the anterior aspect of the shirt. There is a separate black, long-sleeve shirt with a partial zipper on the central neck/chest and "COAST BASEBALL" inscription on the left chest with an American flag graphic. There is also an

AUTOPSY REPORT

No. 2020-00802
ALTOBELLI, JOHN

12

Page 6

inscription of the apparent lateral right upper arm with "How big is your Chihuahua?" and "Cerveza" below it. There is an "Under Armour" label on the inside of the neck. Portions of navy or black boxer underwear are present with no identifiable label. A right,

The deceased's clothing has been removed prior to autopsy, and the clothing is examined separately. The clothing includes a black long-sleeved shirt with "Dri-Fit" on the neck label and "XL". There is a silver Nike swoosh on the anterior aspect of the shirt. There is a separate black, long-sleeve shirt with a partial zipper on the central neck/chest and "COAST BASEBALL" inscription on the left chest with an American flag graphic. There is also an

6 of 11

COUNTY OF LOS ANGELES

DEPARTMENT OF MEDICAL EXAMINER-CORONER

12

AUTOPSY REPORT

No. 2020-00802
ALTOBELLI, JOHN

Page 6

inscription of the apparent lateral right upper arm with "How big is your Chihuahua?" and "Cerveza" below it. There is an "Under Armour" label on the inside of the neck. Portions of navy or black boxer underwear are present with no identifiable label. A right gray shoe with the Nike swoosh and gray-black sock are present. The articles of clothing have multiple defects with attached fragments of tissue and vegetation matter. There is also a strong odor of fuel on all the clothing.

EVIDENCE OF THERAPEUTIC INTERVENTION:

At the time of autopsy, there is no evidence of recent medical therapeutic intervention.

Note: The following observations are limited to findings other than the injuries as described above.

EXTERNAL EXAMINATION:

The body is that of an unembalmed, refrigerated, fragmented, adult male who appears the reported age of 56 years. The body weighs 122 pounds. There are extensive blunt force injuries involving the entire body with extensive tissue disruption of the head, torso, and extremities. There is evisceration, deep exposure of body cavities, and numerous comminuted fractures with separation of bone fragments. There is abundant vegetation present on and in the body including twigs, grass, and possible aircraft parts. Rigor mortis is absent. Livor mortis is unable to be assessed.

The scalp hair is brown, straight and approximately 1 3/4 inches in maximum straightened length. There does not appear to be any temporal or vertex balding. Mustache and beard are present in the shape of a goatee, which is composed of brown-gray, 1/16 inch hair with the remainder of the beard and mustache close-shaven. The eyes are not identified. There are no apparent earlobe piercings. The fingernails are short and well-kempt ranging from 9/16 inch in length (thumb) to 3/8 inch in length (pinky) without any overhang. There is no foam in the nares or oral cavity. Portions of the mandible and maxilla are present and contain teeth in good repair.

The genitalia are those of an adult male.

COUNTY OF LOS ANGELES

DEPARTMENT OF MEDICAL EXAMINER-CORONER

12

AUTOPSY REPORT

No. 2020-00802
ALTOBELLI, JOHN

Page 7

INTERNAL EXAMINATION:

(pink), without any overhang. There is no tooth in the mandibular oral cavity. Portions of the mandible and maxilla are present and contain teeth in good repair.

The genitalia are those of an adult male.

CITY OF LOS ANGELES

DEPARTMENT OF MEDICAL EXAMINER-CORONER

12

AUTOPSY REPORT

No. 2020-00802
ALTOBELLI, JOHN

Page 7

INTERNAL EXAMINATION:

There is extensive tissue destruction with loss of normal anatomic structure. The neck organs including tongue, proximal trachea, aortic arch and portion of the descending aorta, pharynx and larynx are identified. The esophagus, stomach, pancreas, small intestine, portions of the large intestine including the appendix are identified. Portions of the liver and kidney(s) are identified. The following organs are not visually identified at the time of autopsy: eyes, brain, heart, lungs, gallbladder, spleen, adrenal glands, urinary bladder, prostate gland, and testicles.

NECK:

The neck organs are removed en bloc with the tongue. There is no edema of the larynx. The larynx is intact and without fractures or soot deposition. The superior aspect of the trachea is present and there is no soot deposition. The tongue when sectioned shows no trauma.

SYSTEMIC AND ORGAN REVIEW:

MUSCULOSKELETAL SYSTEM:

No abnormalities of the uninjured bony framework or muscles are identified.

CARDIOVASCULAR SYSTEM (PLEASE SEE DESCRIPTION OF INJURIES SECTION):

A segment of thoracic aorta is present and transected distal to the left subclavian artery. A portion of the arch is identified; however the ascending aorta and heart are not visually identified.

GASTROINTESTINAL SYSTEM (PLEASE SEE DESCRIPTION OF INJURIES SECTION):

The esophagus is intact throughout and is without ulcers or varices. The stomach contains scant brown-tan partially digested liquid contents without identifiable food particles. The mucosa is unremarkable. There are tan-yellow contents within the small intestine and brown-green stool within the identified large intestine. Aside from the contusions of the small intestine, the small intestine and colon are unremarkable. The appendix is present and unremarkable. The pancreas occupies

76A798P-Rev 8/9/13

CITY OF LOS ANGELES

DEPARTMENT OF MEDICAL EXAMINER-CORONER

12

AUTOPSY REPORT

No. 2020-00802
ALTOBELLI, JOHN

Page 8

a normal position ~~without~~ and without fibrosis, pancreatitis, or necrosis.

COUNTY OF LOS ANGELES

DEPARTMENT OF MEDICAL EXAMINER-CORONER

AUTOPSY REPORT

No. 2020-00802
ALTOBELLI, JOHN

12

Page 8

a normal position and is brown-tan, lobulated and without fibrosis, pancreatitis, or necrosis.

HEPATOBIILIARY SYSTEM (PLEASE SEE DESCRIPTION OF INJURIES SECTION):

The identified portions of liver are extensively fragmented and weigh 400 grams. They are red-brown in appearance. The cut surface is smooth and is without cirrhosis. The gallbladder is not identified.

URINARY SYSTEM (PLEASE SEE DESCRIPTION OF INJURIES SECTION):

Portions of identified kidney(s) weigh 50 grams in combined weight. They are brown-red and glistening in appearance.

HEMOLYMPHATIC SYSTEM:

The bone is not remarkable. The bone marrow of the rib is unremarkable.

ENDOCRINE SYSTEM:

The thyroid is unremarkable. The parathyroid glands are not identified. The thymus is not identified.

SPECIAL SENSES:

The middle and inner ear are not dissected.

SPINAL CORD:

A portion of spinal cord is identified free-floating within the thorax.

EVIDENCE COLLECTION:

Multiple foreign objects compatible with possible aircraft parts are collected from the body and placed in an oversize plastic container with a case label.

RETAINED TISSUE:

Representative sections from various organs are preserved in one storage jar.

HISTOLOGIC KEY:

1. Liver

COUNTY OF LOS ANGELES

DEPARTMENT OF MEDICAL EXAMINER-CORONER

AUTOPSY REPORT

No. 2020-00802
ALTOBELLI, JOHN

12

Page 9

TOXICOLOGY:

Left upper arm muscle is submitted to the lab as a typing specimen. Liver is collected and submitted to the lab for a comprehensive toxicology screen.

1. Liver

COUNTY OF LOS ANGELES

DEPARTMENT OF MEDICAL EXAMINER-CORONER

AUTOPSY REPORT

No. 2020-00802
ALTOBELLI, JOHN

12

Page 9

TOXICOLOGY:

Left upper arm muscle is submitted to the lab as a typing specimen. Liver is collected and submitted to the lab for a comprehensive toxicology screen.

SPECIAL PROCEDURES:

None

PHOTOGRAPHY:

Photographs have been taken prior to the course of the autopsy. Photographs are also taken during the course of the autopsy.

RADIOLOGY:

Seventeen postmortem x-rays and a postmortem computed tomography (CT) scan are obtained and reveal medical hardware consistent with a knee replacement and a radio-dense circular object within the hand bones. There are multiple fractures and disarticulation of bony structures.

WITNESSES:

There were no witnesses.

DIAGRAMS USED:

Diagram forms #20, #22 and #27 were used during the performance of the autopsy. Medical Examiner diagrams are not intended to be facsimiles nor are they drawn to scale.

MICROSCOPIC REPORT:

Liver: histologic section of the liver shows fragmentation of the tissue with scattered translucent to green foreign material that is refractile under polarized light. There is necrosis of some hepatocytes in some of these areas. There are a few areas that show intrasinusoidal inflammatory infiltrates, composed of lymphocytes and neutrophils. There is no significant steatosis, fibrosis or inflammatory infiltrates in the preserved areas. There is no hemorrhage within the submitted tissue. Scattered portal tracts are identified and are without inflammatory infiltrates. During processing there was folding of the tissue which partially obscures some of the submitted tissue.

Microscopic diagnosis: Liver with refractile foreign material and no significant natural disease

COUNTY OF LOS ANGELES

DEPARTMENT OF MEDICAL EXAMINER-CORONER

AUTOPSY REPORT

No. 2020-00802
ALTOBELLI, JOHN

12

COUNTY OF LOS ANGELES

DEPARTMENT OF MEDICAL EXAMINER-CORONER

20

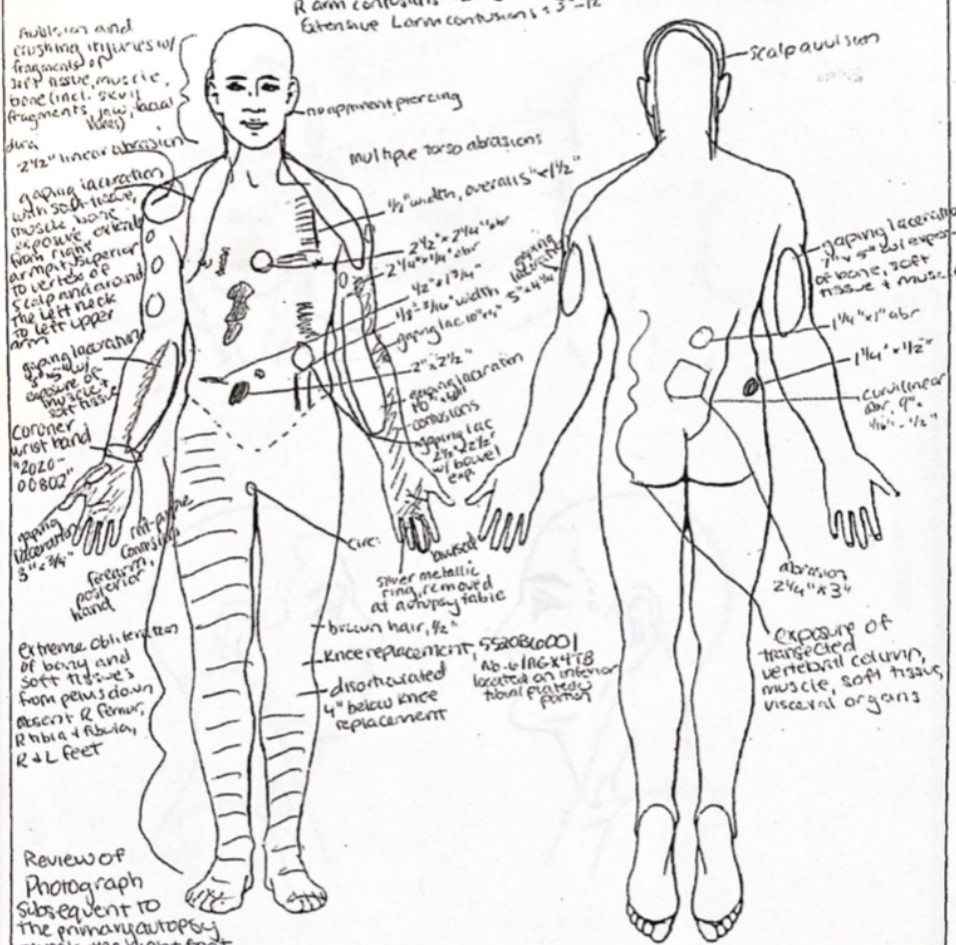
Multiple deforming injuries of the head, torso, upper extremities, back and lower extremities

Black hair, straight, 1 3/4" max length
Short brown-gray mustache and beard
Amberant vegetative debris including twigs, grass
Short, empty fingernails 9/16" thumb, 3/8" pinky
Numerous fractures R humerus, R radius, R ulna
L humerus, L hand
R arm contusions: 1/2" - 6"
Extensive L arm contusions: 3" - 12"

2020-00802

COE, JOHN
ACCIDENT

23



Date 4-28-2020

[Signature]
Deputy Medical Examiner

M.D.

(Rev. 9/13)