




MEDICAL SCHOOL  
LIBRARY



Gift of

Panama-Pacific Intern'l  
Exposition Company.





Digitized by the Internet Archive  
in 2007 with funding from  
Microsoft Corporation

ANATOMY AND PHYSIOLOGY

FOR NURSES

---

BUNDY



TEXT-BOOK  
OF  
ANATOMY AND PHYSIOLOGY  
FOR NURSES

BY  
ELIZABETH R. BUNDY, M. D.

MEMBER OF THE MEDICAL STAFF OF THE WOMAN'S HOSPITAL OF PHILADELPHIA; GYNECOLOGIST  
NEW JERSEY TRAINING SCHOOL, VINELAND; FORMERLY ADJUNCT PROFESSOR OF  
ANATOMY, AND DEMONSTRATOR OF ANATOMY IN THE WOMAN'S MEDICAL  
COLLEGE OF PENNSYLVANIA; FORMERLY SUPERINTENDENT  
OF CONNECTICUT TRAINING SCHOOL FOR NURSES  
NEW HAVEN, ETC.

SECOND EDITION  
REVISED AND ENLARGED

WITH A GLOSSARY AND 215 ILLUSTRATIONS  
42 OF WHICH ARE PRINTED IN COLORS

PHILADELPHIA  
P. BLAKISTON'S SON & CO.  
1012 WALNUT STREET

1913

M

UNIV OF CALIF

LIBRARY

COPYRIGHT, 1906, BY P. BLAKISTON'S SON & CO.  
PRINTED, 1906.

REPRINTED, 1907, 1909, 1910, 1911.

SECOND EDITION.

COPYRIGHT, 1912, BY P. BLAKISTON'S SON & CO.

PRINTED, 1912.

REPRINTED WITH CORRECTIONS, 1913.

REPRINTED SEPTEMBER, 1913.



QM26  
B94  
1913

## PREFACE TO THE SECOND EDITION.

---

In making this revision of the Anatomy for Nurses, the opportunity has been embraced for extending the scope of the book to include more definitely the subject of Physiology, in recognition of the demand that a further knowledge of that branch be included in the equipment of the well-trained nurse.

To present under one cover, with the necessary brevity and still with sufficient clearness, these two important branches of study (each of which should have a volume by itself) is not a simple task, but it has been undertaken with the hope that the combined Anatomy and Physiology for Nurses will meet the need created by the advanced requirements of the present time.

It has seemed better to refer the student to the glossary for the meanings of unfamiliar words than to interrupt the text by too frequent definitions, therefore the glossary is enlarged and its definitions are made more descriptive.

The order of subjects is necessarily changed as new material has been added. The number of chapters is increased, and certain topics, such as Foods and Digestion, Development, Repair and Functions of Bones, the Lymphatic System, and the Nervous System have been elaborated, and the whole so arranged that by the association of *structure* and *function* in the various parts of the body, a better comprehension of both may be attained.

The index has been carefully revised, with suitable additions in accordance with the text.

An extensive correspondence with Hospital and Training School Superintendents has elicited several suggestions which are here gratefully acknowledged, with sincere appreciation of the many kind expressions accompanying them, concerning the usefulness of the Anatomy as heretofore printed.

This edition is offered with the hope that it will merit a continuation of the favor accorded to its predecessor.

ELIZABETH R. BUNDY.



## PREFACE AND DEDICATION TO FIRST EDITION.

---

The pupil-nurse in a training-school has very few hours at command for the study of text-books, but it is hoped that she may find in this "Anatomy for Nurses" an aid to the acquirement of that knowledge of the human body which is essential to the full understanding of her important duties.

In preparing a book of this kind, the inevitable difficulty of selection, when dealing with a subject of such magnitude, is at once manifest. What appears from one point of view to be of minor interest, is from another paramount in importance; while in truth, no detail is of itself insignificant.

The author trusts that in the present work such matters as are not available for immediate use in the hospital ward may still be of value, to meet the growing need of the graduate-nurse as she finds herself developing with the practice of her profession. It was, in part, to meet this frequently expressed need that the work was undertaken.

The old plan of systematic anatomy is followed, but the usual order of subjects is not strictly observed. For example, the description of the blood-vessels is deferred until the student shall have become familiar with many of the organs from which a large number of vessels derive their names.

The chapter entitled "Foods and Digestion" is introduced in response to a request.

Concerning the use of anatomic terms, indications point to the general adoption of the nomenclature accepted by the German Anatomical Society at the meeting of 1895, in Basle, Switzerland. The B. N. A., as it is called, will soon be in use among the younger physicians at least; therefore, many of the terms belonging to it are here introduced, and several tables are given which include names not found in the text.

The author gratefully acknowledges her indebtedness to Dr. Marie L. Bauer for valuable aid in the preparation of the book,

and to Drs. Frances C. Van Gasken and J. William McConnell for assistance in the reading of proofs and for helpful suggestions.

The original illustrations, most of which are printed in colors, are drawn by Chas. F. Bauer.

To the members of the nursing profession, with cherished recollections of labors and responsibilities shared, this Text-book of Anatomy is dedicated.

ELIZABETH R. BUNDY.

# CONTENTS.

## INTRODUCTORY.

PAGE.

Plan of study; anatomic terms; muscle, nerve, and connective tissues; epithelial tissues; serous and mucous membranes; processes included in <i>metabolism</i> of the body . . . . .	I
--	---

## CHAPTER I.

### BONE TISSUE AND BONE CLASSIFICATION. ARTICULATIONS.

Chemical composition of bone; structure of osseous tissue; marrow; medullary and nutrient canals; shapes and surfaces; periosteum; ossification; divisions of the skeleton; joint movements; <i>remarks</i> . . . . .	8
---	---

## CHAPTER II.

### BONES AND ARTICULATIONS OF THE SKULL.

Bones of the cranium; sutures and fontanelles; bones of the face; the mandibular joint; the skull as a whole; four larger fossæ of the skull; the teeth; dentition; care of the teeth; <i>clinical and obstetric notes</i> . . . . .	16
--	----

## CHAPTER III.

### BONES AND ARTICULATIONS OF THE SPINAL COLUMN AND TRUNK

The vertebræ; <i>ligamenta flava</i> ; <i>ligamentum nuchæ</i> ; movements of spinal column; spinal curves; bones and articulations of the thorax; the pelvic girdle; <i>sacro-sciatic ligaments</i> ; dorsal and ventral, or neural and visceral cavities; <i>clinical and obstetric notes</i> . . . . .	35
---	----

## CHAPTER IV.

### BONES AND ARTICULATIONS OF THE EXTREMITIES.

Bones of the upper extremity; pronation and supination; bones of the lower extremity; patella; <i>Y-ligament</i> , <i>crucial ligaments</i> ; arches of the foot; comparison of extremities; articular nerves; <i>clinical and surgical notes</i> ; <i>special notes</i> . . . . .	50
--	----

## CHAPTER V.

### COMPLETION, REPAIR AND PHYSIOLOGY OF BONES.

Completion of long bones; the skeleton at different ages; bones in infancy; greenstick fracture; rachitis; spina bifida; process of repair; functions of bone tissues; <i>surgical and special notes</i> . . . . .	70
--	----

## CHAPTER VI.

## THE CONNECTIVE TISSUE FRAMEWORK AND SKELETAL MUSCLE SYSTEM.

Fascia, deep and superficial; *inguinal ligament*; bursæ; structure of muscles; tendon and aponeurosis; origin and insertion; muscles of expression, of neck and thorax; abdominal muscles and linea alba; sheath of rectus, semilunar and transverse lines. Diaphragm; *surgical and clinical notes; special points* . . . 75

## CHAPTER VII.

## MUSCLES OF THE EXTREMITIES.

Structure and action of muscles of upper extremity; axillary space; pronators and supinators; vaginal synovial membranes; *annular ligaments*; palmar fascia; muscles of lower extremity; popliteal space; *annular ligaments*; Physiology of muscle tissue; muscle tissue a source of heat and electricity; tetanus; cramp; fatigue; *clinical notes; special points*; classification by actions . 94

## CHAPTER VIII.

## THE ORGANS OF DIGESTION.

Alimentary tract or canal; glands of digestive apparatus; enzymes; saliva, *alkaline*; the stomach; gastric juice, *acid*; the intestine; intestinal fluids, *alkaline*; villi; ileo-colic valve; cecum and appendix; rectum and anal sphincters; peristalsis; liver and gall bladder; bile; the porta; *notes, clinical and surgical* . 120

## CHAPTER IX.

## FOODS AND DIGESTION.

Four classes of foods in dietary; air as food; food combination; reasons for cooking food; Digestion, mechanical and chemical; mastication, insalivation; gastric digestion (*acid*), *chyme*; intestinal digestion *chyle*; peristalsis; absorption; *clinical notes* . . . . . 141

## CHAPTER X.

## THE BLOOD AND CIRCULATORY ORGANS.

Blood-corpuscles or cells. Erythrocytes and leucocytes; amoeboid movements, diapedesis; plasma (*alkaline*); normal saline solution; coagulation; arteries, capillaries; veins; the heart; chambers and valves of heart; endocardium; systole and diastole; the pulse; pericardium; course of blood through the heart; *surgical and clinical notes; important notes* . . . . . 152

## CHAPTER XI.

## THE CIRCULATION AND PHYSIOLOGY OF THE BLOOD.

Pulmonary vessels; aorta and branches; arteries of the head, of the upper extremity; palmar arches; thoracic, abdominal and pelvic arteries; arteries of the lower extremity; veins, deep and superficial; jugular veins; azygos veins; superior vena cava; inferior vena cava; portal circulation; fetal circulation; Physiology of blood; phagocytes; opsonic index; collateral circulation; *clinical and surgical notes* . . . . . 167

## CHAPTER XII.

**THE LYMPHATIC SYSTEM.**

	PAGE.
Lymph spaces, capillaries and vessels; lymph, origin; lymph glands or nodes; edema, effusion; thoracic duct; right lymphatic duct; principal nodes; the lymph stream; metastasis; summary of functions; <i>clinical notes</i> . . . . .	194

## CHAPTER XIII.

**THE RESPIRATORY ORGANS AND RESPIRATION.**

The respiratory tract; the nose, nares and choanae; the larynx; trachea, bronchi and bronchial tubes; ciliated epithelium; air cells; the lungs; the pleura; respiratory movements; respiration and heat production; modifications of breathing; <i>clinical notes</i> . . . . .	202
--	-----

## CHAPTER XIV.

**THE KIDNEYS. THE SKIN. ELIMINATION.**

Structure of the kidney; the ureter; composition of urine; suppression of urine; retention of urine; structure of the skin; elasticity; glands; hair and nails; composition of perspiration; regulation of body temperature; <i>clinical notes</i> . . . . .	211
--	-----

## CHAPTER XV.

**MAMMARY GLANDS. DUCTLESS GLANDS. GENERAL METABOLISM.**

Structure of mammary gland; milk; colostrum; mammary abscess; ductless glands and internal secretion; the spleen, structure and blood supply; leukemia; the pancreas, structure and blood supply; adrenals, adrenalin; thyroid body; cretinism; thymus body an infantile structure; secretion and secreting organs; excretion and excreting organs; animal heat, variations and regulation of temperature; <i>clinical and practical notes</i> . . . . .	219
--	-----

## CHAPTER XVI.

**THE NERVE SYSTEM.**

Two divisions of the nerve system; the neuron, cell body and nerve fiber; cerebro-spinal division; gray and white nerve tissues; nerve centers; spinal cord and membranes; structure of spinal nerves; <i>surgical and clinical notes</i> . . . . .	229
---	-----

## CHAPTER XVII.

**THE SPINAL NERVES.**

Anterior and posterior divisions; the cauda equina; cervical plexus, phrenic nerve; brachial plexus, radial, ulnar and median nerves; lumbar plexus, femoral nerve; sacral plexus, sciatic nerve; Physiology of spinal cord and spinal nerves; reflex action; co-ordination; electrical stimulus; <i>points of interest</i> . . . . .	235
---	-----

## CHAPTER XVIII.

## THE BRAIN AND CRANIAL NERVES.

	PAGE.
Structure of brain, cortex and fibers; fissures; ganglia; internal capsule; cerebellum; medulla oblongata; pons; crura; ventricles of brain; membranes of brain; cranial nerves; Physiology of brain and cranial nerves; cerebral localization, <i>surgical and clinical notes</i> . . . . .	249

## CHAPTER XIX.

## THE SYMPATHETIC DIVISION OF THE NERVE SYSTEM.

Vertebral ganglia; cardiac and splanchnic nerves; cardiac and celiac (solar) plexuses; semilunar ganglia; functions of sympathetic nerves; vasomotor and reflex, presiding over visceral action; Physiology of nerve system as a whole; <i>important notes</i> . . . . .	262
--	-----

## CHAPTER XX.

## THE SPECIAL SENSES AND THE VOICE.

General and special sensation; the sense of smell, olfactory region; the sense of touch, touch corpuscles; the sense of taste, taste buds; the sense of hearing, external ear and auditory canal; middle ear or tympanum and auditory tube; internal ear or labyrinth; the sense of sight; structure of eyeball; lacrimal gland; the voice; organs of the voice; organs of speech; vocal glands; <i>clinical notes</i> . . . . .	270
--	-----

## CHAPTER XXI.

## THE PELVIC ORGANS.

The rectum; bladder; urethra; urethral caruncle; the prostate gland; the uterus; uterine or Fallopian tubes; the ovaries, ovulation; corpus luteum; menstruation; the menopause; the vagina and infra-vaginal portion of cervix uteri; the pudendum; the perineum; the testes and spermatic cord; <i>clinical and surgical notes</i> . . . . .	283
--	-----

## CHAPTER XXII.

## A BRIEF STUDY OF IMPORTANT REGIONS.

The head; the neck; thorax and thoracic viscera; abdomen, abdominal viscera and peritoneum; the ischio-rectal fossa; the axillary space; the ante-cubital space; Scarpa's triangle or the femoral trigone; Hunter's canal or the adductor canal; the popliteal space; the inguinal rings and inguinal canal; the femoral rings and femoral canal; hernia; the extremities compared; review notes; points for compression of larger arteries of the body . . . . .	292
---	-----

## CHAPTER XXIII.

## REFERENCE TABLES.

The systemic arteries; names of systemic arteries and veins according to the B. N. A. . . . .	311
Glossary . . . . .	321
Index . . . . .	331



# ANATOMY AND PHYSIOLOGY FOR NURSES.

---

## INTRODUCTORY.

**Anatomy** deals with the *structure* of the body in its different parts; **physiology** teaches the uses or *functions* of those parts.

### PLAN OF STUDY.

We shall study first the framework of the body—the **bones** which give support to all other structures, with the **joints** by which they are held together, either loosely or firmly; and the **muscles** by which they are moved and still further connected.

Afterward will be presented the organs or **viscera** (which are enclosed in the two general cavities formed by the bones and muscles) with their *nerve supply*, and the system of *vessels* by which the entire body receives its nutriment. We shall see that all these parts are wrapped in delicate **connective tissue**, and held in place by bands and sheaths of the same substance. The muscles are stretched upon the bones, the firm layers and partitions of **deep fascia** bind them in place, the wrapping of **superficial fascia** keeps them warm and flexible, and the **skin** or **integument** makes an elastic and sufficient covering for the whole.

The study of the **nerves** by which these structures receive their stimulus, and the action and interaction of the various parts, will follow.

The organs of the **special senses** receive attention, and the last section is devoted to a review of the several regions of the body which, it is hoped, will prove interesting and profitable.

### ANATOMIC USE OF TERMS.

The **anatomic position** is that with the face toward the observer and the palms turned forward, and the terms *anterior*, *posterior*,

*right, left, etc.*, are to be understood with this position in mind. Thus, the *anterior surface* of the hand is always the *palm*; and, if we speak of any part as situated to the right we mean that it is nearer to the right side of the *body which we are studying* (which for convenience we will call the "subject"), but it has no relation whatever to the right side of the student. Of course the words *superior* and *inferior* are easily understood, but the use of the words *medial* and *lateral* (formerly internal and external) requires special mention. Imagine a line drawn through the middle of the head and trunk and striking the floor between the feet, thus dividing the body into right and left halves. This is called the *median line*. Any part or surface of one-half of the body is said to be *medial* to another part if it is nearer the median line while in the anatomic position, or *lateral* to another part if it is farther from the median line.

All of these terms once applied to a part of the body belong to it always. For example, the little finger is always *medial* to the others and the great toe is likewise medial, because these relations are established once for all while the subject is in the anatomic position. Likewise, the palm is the *anterior* surface of the hand even if it be temporarily turned backward.

The words *exterior* and *interior* are applied to the parts of the body which are on the surface or within, respectively.

*Proximal*, means nearer to the head; *distal*, farther from the head. Thus we may speak of the proximal end of the finger, or the distal end of a toe, or the proximal end and distal end of an arm or a leg.

## TISSUES AND MEMBRANES OF THE BODY.

The simplest form of living matter is *protoplasm*. A *living cell* may be nothing more than a definite quantity of protoplasm (called *cytoplasm* or *bioplasm*) or it may be more complex, having a *nucleus*, when it is said to be nucleated, and it may have a *nucleolus* within the nucleus. A nucleated cell is capable of forming new cells by the division of its substance, the division always *beginning in the nucleus*.

Sometimes the cell is enveloped by a thin membrane called the *cell wall*.

**Tissue.**—Any collection of cells held together by intercellular substance is a **tissue**. The various tissues of the body are composed of cells (and intercellular substance) which are developed in special ways; for example:

**Muscle tissue** is composed largely of cells which are highly developed in the power to contract.

**Nerve tissue**, of cells which are particularly sensitive to special kinds of stimulus.

**Connective tissue** is the fibrous soft framework of the entire body—the connecting structure by means of which all of its parts are held together. (Fig. 1.)



FIG. 1.—CONNECTIVE-TISSUE BUNDLES OF VARIOUS THICKNESSES OF THE INTERMUSCULAR CONNECTIVE TISSUE OF MAN.  $\times 240$ .—(Stöhr.)

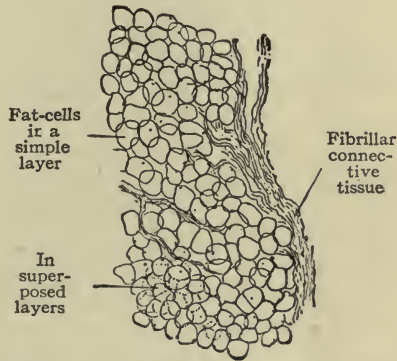


FIG. 2.—ADIPOSE TISSUE.—(Stöhr.)

Under this heading are included the following varieties:

*Fibrous tissue*, a form of connective tissue containing slender white fibers, closely packed together.

*Areolar tissue*, containing the same kind of fiber cells loosely woven into a network (often called cellular tissue).

*Adipose tissue*, a variety of areolar tissue with cells containing fat. (Fig. 2.)

*Elastic tissue*, a form of connective tissue containing many elastic fibers, pale yellow in color. (Fig. 3.)

*Osseous tissue*, composed largely of cells having the power to utilize mineral substances of the blood in the formation

of bone. (The *intercellular* substance is filled with mineral matter.) (Figs. 6 and 7.)

*Cartilage*, a form of connective tissue with firm white elastic substance (*intercellular* substance) between its cells.

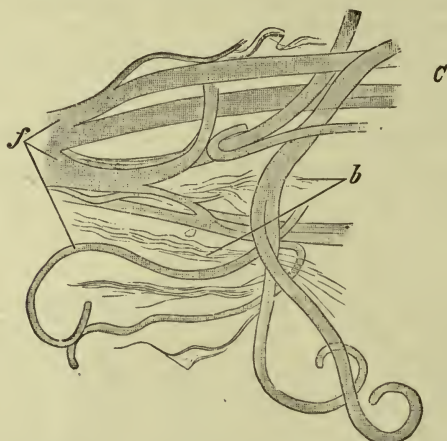


FIG. 3.—ELASTIC FIBERS.  $\times 560$ . Very thick elastic fibers *f*, from ligamentum nuchæ of ox; *b*, connective-tissue bundles.—(Stöhr.)

Many cartilages are covered with a thin membrane called *perichondrium*, similar to the periosteum of bones (see page 10).

The principal varieties are:

*Hyaline cartilage* which has few cells and much intercellular substance. (Fig. 4.)

*White fibro-cartilage* which contains many white fibers, giving to it additional strength.

*Yellow or elastic fibro-cartilage* which contains elastic fibers giving additional elasticity.

**Note.**—Most bones are formed in cartilage. (See Ossification page 11.)

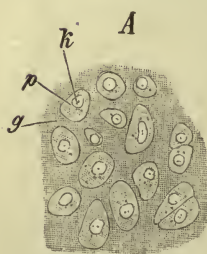


FIG. 4.—HYALINE CARTILAGE.

**Epithelial tissue** forms the surface layers of the body both within and without. It is composed of layers of cells resting upon a base of the simplest possible substance, which holds the cells together and which bears vessels and nerves for their use. The *form* of epithelial cells varies with their location and use or function. (Fig. 5.)

The *epithelium of the exterior* of the body is formed by flattened cells, arranged in few or many layers according to the degree of

friction or pressure to which the skin of the part may be exposed. The covering thus formed varies therefore in thickness, from that of the delicate covering of the lips to the tough sole of the foot.

The *epithelium of interior surfaces* is quite different. Its cells may be flattened; spherical, cuboid or columnar in shape and it is always moist.

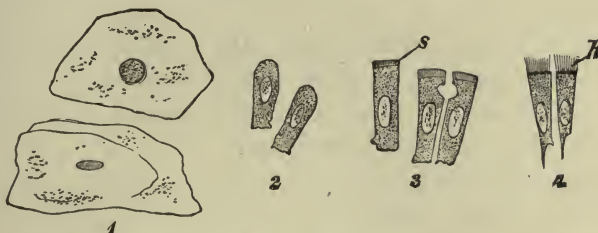


FIG. 5.—EPITHELIAL CELLS OF RABBIT, ISOLATED.  $\times 560$ . 1. Squamous cells (mucous membrane of mouth). 2. Columnar cells (corneal epithelium). 3. Columnar cells with cuticular border *s*, (intestinal epithelium). 4. Ciliated cells; *h*, cilia (bronchial epithelium).—(Stöhr.)

In the lining of the air passages the epithelial cells are *ciliated*, that is, they bear tiny hair-like projections of their substance called *cilia*, which are in constant waving motion, always in the same direction, sometimes slow, sometimes rapid.

In the *digestive* organs the *epithelial layer* plays an important part in the formation of digestive fluids, and also in the absorption of digested food.

In the lining of *closed cavities* it assists in the formation of the fluids which they contain (example, the *pleura*).

Included under this heading are:

*Gland tissue*, where a layer of cells has the power to form a special substance from the blood. (*Adenoid tissue* resembles gland tissue.)

*Mucous membranes*, which line all interior surfaces to which air has access. Their special cells produce a clear thick fluid called *mucus* which keeps the surfaces moist.

*Serous membranes*, which line the closed cavities of the body. They are themselves closed sacs containing a clear thin fluid called *serum* which prevents the surfaces from rubbing together.

*Synovial membranes*, which line the interior of movable joints; they contain a thick fluid called *synovia* which like serum prevents friction.

The epithelial lining of the heart and blood-vessels, serous membranes, and lymph vessels, is called *endothelium*.

**Clinical notes.**—Mucous membranes are well supplied with blood-vessels and bleed freely when wounded, as seen in operations upon the nose and throat.

An accumulation of serum in the large serous membrane of the abdomen causes the condition called *ascites* (a variety of dropsy).

The processes of **secretion** and **excretion** are carried on through epithelial cells.

**Secretion** is the process of separating substances from the blood (generally in fluid form). Such substances if useful to the body are called *secretions*; if they are waste matters to be thrown off or eliminated, they are called **excretions**.

*Secreting organs*—mucous and serous membranes, all glands.

*Excreting organs*—lungs, kidneys, liver, cutaneous glands.

To summarize the functions of epithelial tissues—they are *protective, secretory, excretory, absorptive*.

An **organic substance** is a substance formed by living cells, whether they are single or arranged together in organs. Organic substances disappear in burning.

An **organ** is any part of the body designed for a special function or use; it may be composed of several kinds of tissue. An organ in the interior of the body (internal organ) is called a **viscus** (pleural, *viscera*). Examples, *heart, lungs*.

A **system** is composed of a number of organs of similar structure. Examples, the *muscular system*, the *nervous system*.

An **apparatus** is composed of a number of organs of like or different structures, so arranged and associated that their action together will serve a special purpose. Example, the *digestive apparatus*.

**Metabolism.**—This term is used to express in one word the related processes of *building up* and *breaking down* which are constantly going on in all living cells.

The cell appropriates materials and combines them to perfect itself; in the exercise of its function it uses up some portion of its substance and so must be again built up, to be again pulled apart—in endless repetition.

Cell action in some tissues results principally in liberating *heat* and in *body movement*, as in muscles. In others it forms new compounds for other cells to use—for example, the liver cells form *glycogen*; the gastric glands secrete

*gastric juice*, etc. Again, certain cells combine waste matters to get them into shape for other organs to excrete, for example, the formation of *urea* in the liver. In this way food materials are used for different purposes and worked over in different tissues until waste alone remains.

These examples (and many more which might be given) illustrate the *metabolism* which is constantly taking place in the body.

## CHAPTER I.

### BONE TISSUE AND BONE CLASSIFICATION, ARTICULATIONS.

**Bone tissue** is conspicuously a hard tissue. This hardness is due to the mineral or *inorganic* substances which it contains. They are mostly *phosphate* and *carbonate of lime* and form two-thirds of the weight of an adult bone. The remaining one-third is composed of *organic* or animal substances, consisting of *vessels*, *marrow*, *bone corpuscles*, and *gelatinous matter*.

The *mineral* portion alone may be seen in a bone which has been burned, thus destroying the organic substances. This leaves the bone still hard, but very brittle and easily crushed. The pale grayish color of a burned bone is noticeable, the result of the loss of all the marrow and blood which it contained before, and which gave it a pinkish tinge.

The *organic* portion of a bone may be shown by immersing it in dilute hydrochloric acid for a few days. The mineral salts will be thus dissolved out, leaving the flexible and elastic organic portion which still retains the shape of the bone. A long bone after the lime salts are removed in this way, is said to be *decalcified*, and may be bent and twisted, or even tied in a knot.

By these experiments it is seen that the mineral matter gives hardness to a bone, while the animal matter gives flexibility and elasticity. The proportions of the two kinds of substance vary at different ages. The bones of a child are soft because they have not enough mineral matter to make them hard, while the bones of




FIG. 6.—VERTICAL SECTION OF A LONG BONE.—(Testut.)



an aged person are brittle, because they no longer contain sufficient animal matter to keep them elastic.

The hardest part of any bone is at its surface; it is white in color like ivory, and is called *compact* bone tissue. The deeper part is porous, and is therefore called *spongy* tissue (also named *cancellous* tissue, because its appearance suggests lattice work). (See Fig. 6.)

*Compact* tissue is most abundant on the shafts of the long bones, which by their situation in the extremities are exposed to external violence, and therefore need especial strength for resistance. Since it is important that the bones be slender as well as strong, these two results are gained by packing the bone tissue as closely as possible.

*Cancellous* tissue is more abundant in the parts of bones where extent of surface is desirable. For example, the enlarged extremities of long bones are composed of cancellous tissue covered with a thin

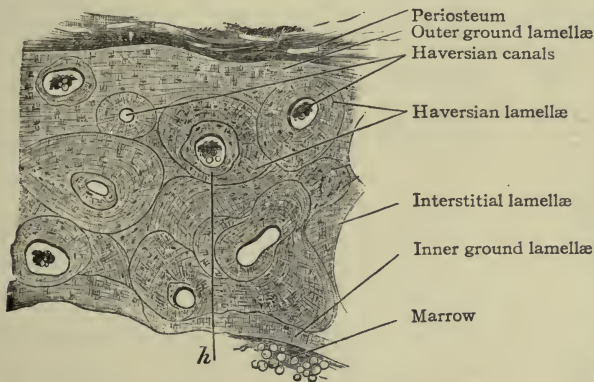


FIG. 7.—FROM A CROSS-SECTION OF A METACARP OF MAN.  $\times 50$ . The Haversian canals contain a little marrow (fat-cells).—(Stöhr.)

compact layer; thus they can give attachment to many tendons and ligaments, while the spongy character of the bone prevents increase in weight.

The *marrow* of bones is contained in the spaces of cancellous tissue, where it is thin and red, and in little canals running through the bone substance. Under the microscope may be seen small channels in the compact tissue called *Haversian canals*, which contain minute vessels and a little marrow. A large canal called the *medullary canal* runs in the shaft of each long bone, containing firm yellow marrow and larger vessels.

*Articular surface* of bone is that portion which enters into the formation of a movable joint. It consists of a very compact tissue called the *articular layer* or *articular lamella*.

#### SURFACE MARKINGS OF BONE.

Any inequality of the surface of a bone, whether it be an elevation or depression, or an opening, is called a "marking." The most prominent elevations often occur where the muscles are attached to the periosteum (owing partly to the calcification of these attachments); and the greatest enlargements of bones are at their extremities, where they form important joints.

A *process* is a decided projection; the larger processes are called *tuberosities*, small ones, *tubercles*.

A *spine* is usually a long or a sharp projection.

A *crest* is a prominent border; it may be rather broad.

A *condyle* is a rounded articular eminence.

A *fossa* is a depression or concavity.

A *foramen* is a hole through a bone.

#### PERIOSTEUM.

There is no such thing as bare bone in the normal state; all bones are closely covered more or less completely with a strong fibrous membrane called **periosteum**. This membrane is essential to the life of the bone, because many blood-vessels which nourish it lie in the periosteum until they become divided into minute branches which then enter the bone tissue.

The articular surface of bone is the only portion which is not covered with periosteum.

A bruise of sufficient violence will so injure the periosteum that it no longer serves for the purpose of nutrition, and that area of bone immediately underneath the injured membrane dies from want of food, and becomes "dead bone" (the process is called *necrosis*). The sensation imparted by a probe which touches dead bone is that of roughness, and is distinctly different from the feeling of sound bone with its smooth covering of periosteum. A similar membrane called *endosteum* lines the canal in the shaft of long bones. It bears the "nutrient" artery which, in the cavity

of the shaft, divides into two branches running in the endosteum toward the two extremities.

The deep layers of the periosteum contain bone-forming cells. (See OSSIFICATION.)

#### CLASSIFICATION OF BONES ACCORDING TO SHAPE.

According to differences of shape and arrangement of their tissue, bones are classified as *long*, *short*, *flat*, and *irregular*. A long bone has always a *shaft* of *compact* tissue, and two enlarged *extremities* of *cancellous* tissue with a thin compact covering. The shaft is hollow, containing yellow marrow, this cavity being called the *medullary canal*.

A *short* bone has neither shaft nor extremity; it is composed of *cancellous* tissue with a thin compact covering.

A *flat* bone is arranged in layers, two of *compact* tissue with one of *spongy* or *cancellous* tissue between them.

An *irregular* bone conforms to no special definition.

REMARKS.—In no part of anatomy is it more important that the student should learn the structures from the actual specimens than in the division called *osteology*. The *bones* are to be studied, *not the book*. It is supposed that with the bone in the hand the student will use the book as a *key*, by means of which she will become acquainted with the names of its parts and their uses. The habit of studying the *human body itself* rather than the description of it, cannot be too soon nor too firmly established.

#### OSSIFICATION.

**Ossification** is the formation of bone from cartilage or membrane by the deposit of mineral substances, mostly salts of lime. *Flat* bones develop in membrane; others in cartilage.

The deposit of mineral matter begins in small spots, forming *centers of ossification* which gradually increase in size until the entire bone is completed. *Long* bones have always three centers at first—one for the shaft, and one for each extremity—others appear-



FIG. 8.—RIGHT FEMUR, ANTERIOR, SHOWING EXTREMITIES OR EPIPHYSES, AND SHAFT OR DIAPHYSIS.—(MORRIS.)

ing later, at different dates. (The extremities are named *epiphyses*, the shaft being the *diaphysis*) (see Fig. 8). The principal parts of a bone are ossified separately, uniting with each other after all are developed. **Ossification** begins before birth in all bones except the coccyx, those of the carpus, and four in the tarsus; but many bones remain in two or more pieces during childhood and youth.

The *periosteum* of bone has an inner layer in which, also, the process of ossification goes on. Consequently, when it becomes necessary to remove a portion of bone, if it can be done without taking the periosteum away the bone will re-form. This has occurred many times, particularly in the case of the mandible.

**The nutrition of bone.**—Bones have a free blood supply from a network of small arteries in the periosteum. One special artery, larger than the others, enters the *nutrient canal* which leads to the interior of the shaft (this vessel is called the *nutrient artery*).

## THE HUMAN SKELETON.

The skeleton of the body comprises 200 bones, as follows:

In the cranium.....	8
In the face.....	14
In the spinal column.....	24
In the pelvis.....	4
In the upper extremities.....	64
In the lower extremities.....	60
Ribs.....	24
Os hyoides.....	1
Sternum.....	1

---

200

These are joined together or *articulated* to form the hard, strong framework of the body—the *natural skeleton*.

In addition to these, there are four bones in each ear called *ossicles*, or “little bones.”

According to their location in the body they are classified as follows: Bones of the *Head and Neck, Trunk, Extremities*.

The bones of the **head** form the **skull**, which supports the face and the organs of special sense, and securely encloses the brain within its cavity. The bones of the **neck** connect the head with the trunk, and support the tongue and various other structures.

The bones of the **trunk** assist to form a cavity, divisible into three portions—the *thorax*, the *abdomen*, and the *pelvis*.

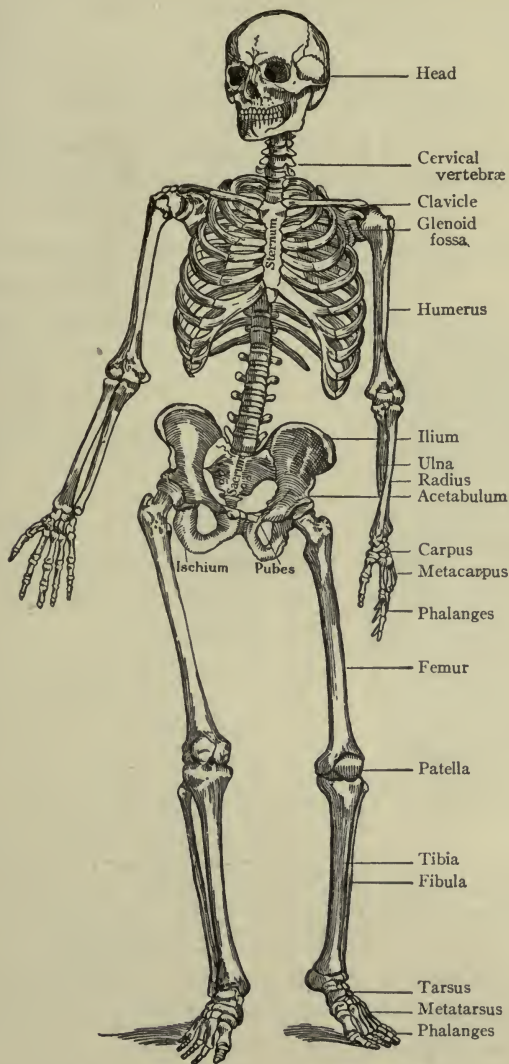


FIG. 9.—BONY SKELETON.—(Gould's Illustrated Dictionary.)

The bones of the four **extremities** contribute the solidity and strength which are necessary for their uses in various positions of the body.

## ARTICULATIONS (ARTHROSES).

**Articulations** are formed when two or more bones are connected together, or when bone and cartilage are joined. They may be immovable, or movable.

## IMMOVABLE JOINTS (SYNARTHROSES).

In these the bones are held together firmly by fibrous tissue, sometimes by a thin layer of cartilage which becomes calcified in later life.

The best examples of *immovable* joints are found in the *skull*, where the flat bones are joined at their edges, forming *sutures*. (See page 16, Fig. 11.)

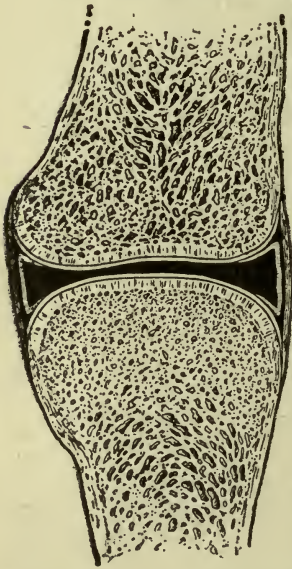


FIG. 10.—ILLUSTRATION SHOWING ESSENTIAL STRUCTURES IN A MOVABLE JOINT (Diagrammatic.)

The surfaces of bone which are to be connected together (articular surfaces) are made of a specially hard compact tissue called *articular bone*. It is smoother than other portions of the bone and easily recognized by the eye. It has no periosteum, but is covered by firm white hyaline cartilage—the *articular cartilage*.

To hold the bones together, bands or cords of white fibrous tissue are provided, strong and flexible, but not elastic. They are called *ligaments*. The ligaments pass from one bone to the other on every side of the joint, like a capsule, completely enclosing it, and the capsule thus formed is lined by *synovial membrane*, so named because

## MOVABLE JOINTS (DIARTHROSES).

In these the bones are not closely joined, but are loosely connected by *ligaments* which allow freedom of movement between the surfaces. They are best studied in the extremities, where all varieties of movable joints are found.

The **essential structures** in a movable joint are four in number: *Articular bone*, *articular cartilage*, *ligaments*, *synovial membrane with synovia*.

The surfaces of bone which are to be connected together (articular surfaces) are made of a specially hard compact tissue called *articular bone*. It is smoother

it secretes a fluid called *synovia* (the lubricating fluid or "joint-oil") which resembles in appearance the white of egg and prevents friction.

The synovial membrane not only lines the capsule but is attached to the margins of the articular cartilages.

Seven varieties of movement are allowed by these joints. They are:

Flexion, or bending.

Extension, or straightening.

Rotation, or rolling.

Circumduction, a free sweeping movement in a circle.

Abduction, or moving away from a middle line.

Adduction, or moving toward a middle line,

Gliding (which explains itself).

Movable joints are classified according to the movements of individual joints, or by peculiarities of structure. The most important are the following:

Class.	Motions.	Example.
Hinge (ginglymus).....	Flexion and extension. . . .	<i>Elbow, Knee.</i>
Ball and socket (Enarthrosis).....	In all directions. . . . .	<i>Shoulder, Hip.</i>
Pivot (Trochoides).....	Rotation within a ring. . . .	<i>Head of Radius.</i>
	Rotation of ring around a pivot. . . . .	<i>Atlas and axis.</i>
Arthrodia.....	Gliding.....	<i>Carpal joints.</i>

There are other joints in which motion is so slight that they are not classed as movable, nor do they possess a cavity containing synovia. They have been well described by the term *yielding*. In these the bones are usually connected by fibro-cartilage discs. Examples are found in the joints of the pelvis (page 46) and in the spinal column (page 38).

## CHAPTER II.

### BONES AND ARTICULATIONS OF THE SKULL.

The skull includes the cranium and face.

#### BONES OF THE CRANIUM, 8.

Frontal..... 1	Parietal..... 2
Occipital..... 1	Ethmoid..... 1
Temporal..... 2	Sphenoid..... 1

**Frontal bone** (*os frontale*).—In the anterior part of the skull, shaped like a cockle-shell, and consisting of the *frontal part*, or forehead, the two *orbital parts*, and the *nasal part*. The frontal

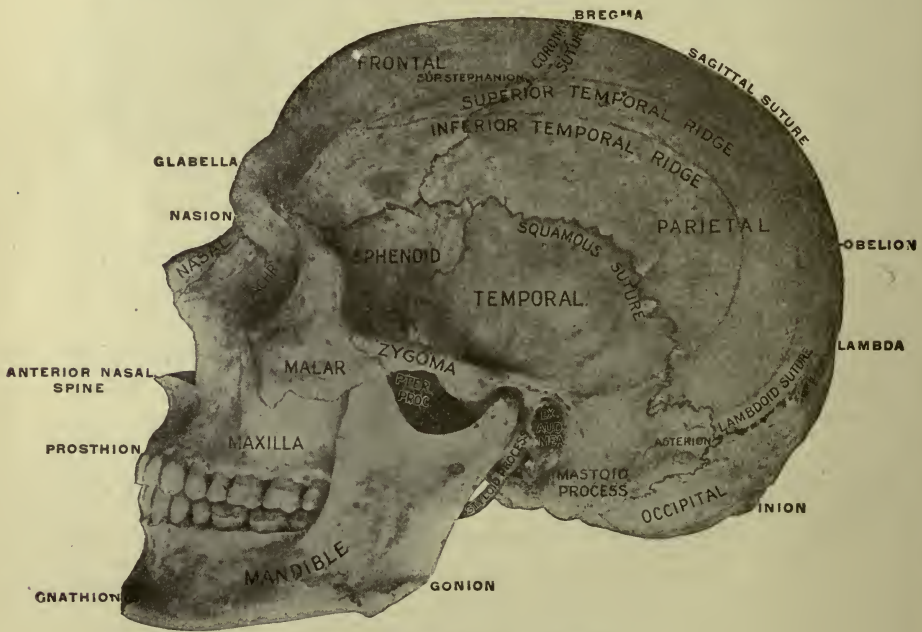

FIG. II.—THE SKULL.—(Gerrish.)

part (*squama frontalis*) is flat in structure, and unites above with the parietal bones. This part is bounded below by a prominent border forming the two *supraorbital margins*. At the medial



third of each margin is a *supraorbital notch* (sometimes foramen) for the supraorbital nerve, artery, and vein. Just above the margins are the *superciliary arches*, which bear the eyebrows and mark the position of spaces in the frontal bone called the *frontal sinuses*. These sinuses begin to develop at the age of seven years and grow larger as time advances. They communicate with the nose, and contain air. The smooth space between the eyebrows is the *glabella*.

The **nasal part** is just below the glabella.

The **orbital parts** (or plates) of the frontal bone are so called because they are in the roof of the orbits, or eye-sockets; the space between these parts is occupied by the ethmoid bone and is called the *ethmoid notch*. Just underneath the lateral part of the superior margin of the orbit is a small fossa (the *lacrimal fossa*), containing the *lacrimal gland*, where the tears are formed.

At birth the frontal bone is in halves—right and left—which become united in early life.

**Occipital bone** (*os occipitale*).—At the back of the skull and consisting of two portions: *squamous* (scale-shaped) and *basal* (Figs. 11 and 20).

The **squamous portion** (*squama occipitalis*) is flat in structure, triangular in shape, and joined to the parietal bones. The most prominent point on the back of the skull is on this portion, and is called the *occipital protuberance* or *inion*.

The **basal portion** bends forward, extending far enough toward the front to form the roof of the throat. This portion presents a large opening called the *foramen magnum* (or great foramen), which transmits the spinal cord. At the sides of the foramen magnum are two smooth prominences, called the *occipital condyles*, which rest upon the first bone of the spinal column, whereby the nodding movement of the head is permitted.

The inner surface of this bone has broad grooves for the *transverse sinuses* (lateral sinuses); also one for the *sagittal sinus* (superior longitudinal sinus).

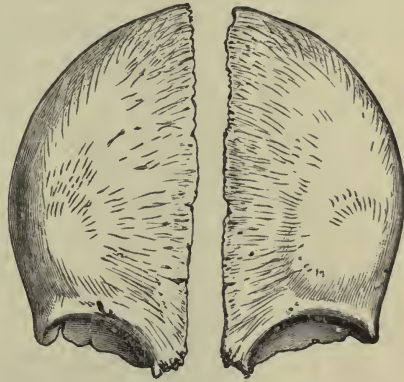


FIG. 12.—FRONTAL BONE, SHOWING THAT IT ORIGINATES IN HALVES.—(MORRIS.)

**Temporal bones** (*ossa temporales*).—Right and left; situated at the sides and base of the skull. (See Figs. 11 and 13.)

Each **temporal bone** consists of four portions—the *squamous*, the *mastoid*, the *petrous*, and the *tympanic*.

The **squamous portion** (*squama temporalis*) is flat, and presents the *zygomatic process* in the form of a ridge running forward in front of the ear to the cheek. Below the beginning of this process is the canal leading into the ear and called the *external auditory meatus*; just in front of that is the *mandibular fossa*, where the lower jaw-bone, or *mandible*, is joined to the temporal bone (Fig. 11).

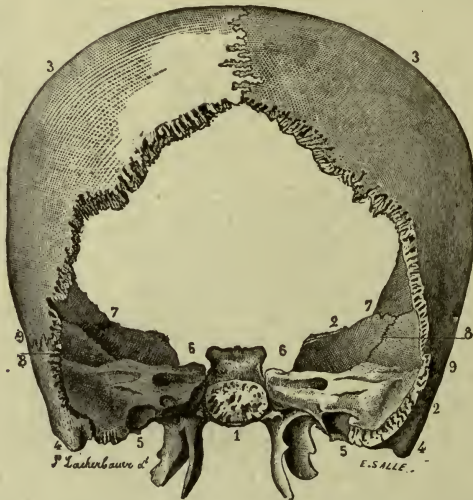


FIG. 13.—PARIETAL, TEMPORAL, AND SPHENOID BONES;  
POSTERIOR ASPECT.

1, Body of sphenoid bone; 2, 2, greater wing and squamous portion of sphenoid bone; 3, 3, parietal bones; 4, 4, mastoid process of temporal bones.—(Gould's Dictionary.)

The occipital bone occupies the space included between these bones.

The **mastoid portion** forms the prominence behind the ear and terminates in the *mastoid process*, which contains a number of small cavities, the *mastoid cells*. They all communicate with the middle ear, and mastoid disease may therefore follow an infection of the middle ear.

The inner surface of this portion shows the *sigmoid groove* for the *transverse sinus*.

The **petrous portion** is exceedingly hard, like stone, hence its name. A slender point of bone, called the *styloid process*, is seen

on its lower surface, and the carotid artery, on its way to the brain, passes through the *carotid canal*, which is in this portion.

The petrous bone contains the greater part of the ear, and the internal auditory canal for the auditory nerve, or nerve of hearing, is on its posterior surface (seen within the skull).

The **tympanic portion** forms the greater part of the external auditory meatus, or canal.

**Parietal bones** (*ossa parietales*).—Right and left, situated at the top and sides of the head, and so named because they form the sides or *walls* of the skull. They are flat in structure, and nearly square in shape, and the *four borders* are called *sagittal*, *squamous*, *frontal*, and *occipital* (Figs. 11 and 13).

At the extremities of the borders are the angles—the *frontal* and *occipital* angles above, and the *sphenoid* and *mastoid* angles below. The most prominent point on the side of the skull is near the center of the parietal bone and is called the *parietal eminence*.

On the inner surface of this bone well-marked *grooves* are seen for the middle meningeal artery, and *depressions* for the convolutions of the brain.

**Ethmoid bone** (*os ethmoidale*).—Situated between the orbits and, therefore, in the upper part of the nose. (For illustration see pages 29, 30.)

It consists principally of two lateral portions formed of spongy bone, and containing the *ethmoid cells* or *sinuses*. These portions are called **ethmoid labyrinths**. They are in the *walls of the nasal cavity*, and the cells open into it, therefore they contain air. The labyrinths are attached to the borders of the **horizontal plate**, situated in the roof of the nose and perforated for the passage of the nerves of smell.

The upper part of the *nasal septum*, which divides the nasal cavity into two parts, is formed by the vertical plate of the ethmoid, which hangs from the horizontal plate, and is, therefore, between the two labyrinths (Fig. 25).

Two of the *turbinated bones* (superior and middle) are seen projecting from the medial surface of the labyrinths (Fig. 24). (For description of inferior turbinated see page 22.)

**Sphenoid bone** (*os sphenoidale*).—Immediately behind the ethmoid, to which it is joined. Its shape resembles a bat with

the wings spread (Figs. 11 and 13). It consist of a *body*, *wings*, and two *pterygoid processes*. The **body** is joined to the ethmoid in front, and to the occipital behind. It is hollow, and its two cavities (called the *sphenoid sinuses*) communicate with the nose. The **wings**, two pairs—*greater and lesser*—extend outward from the body at about the level of the orbits. The *optic foramen*, for the optic nerve, is in the lesser wing.

The **processes** extend downward from the body, completing the back part of the sides of the nose.

**Note.**—The lateral extremities of the *greater wings* may be seen at the sides of the skull, between the frontal and temporal bones; the sphenoid is thus wedged in behind the face, between it and the other cranial bones. (The name *sphenoid* signifies *wedge-like*.)

### ARTICULATIONS OF THE CRANIUM.

The joints of the cranium are called **sutures**. Most of them are formed by the *interlocking* of irregular edges of the bones held firmly together by fibrous tissue between them. Sometimes the edges resemble saw-teeth in form, and then the suture is *dentated* or *serrated*. Sometimes the edges are smooth and overlap each other, and sometimes one fits between two others; but they are always immovable. (For illustration, see Fig. 11.)

The sutures which are most important for the nurse to recognize are those formed with three borders of the parietal bones. The two *sagittal* (or superior) borders, uniting with each other, form the **sagittal** suture; the *frontal* borders, uniting with the frontal bone, form the **coronal** suture, while the *occipital* borders, uniting with the occipital bone, form the **lambdoid suture**.

### BONES OF THE FACE, 14.

Nasal.....	2	Palate.....	2
Lacrimal.....	2	Inferior turbinated....	2
Zygomatic.....	2	Vomer.....	1
Superior maxillary... 2		Inferior maxillary, or	
united, form the <i>maxilla</i> .		<i>mandible</i> .....	1

**Nasal bones** (*os nasale*, sing.).—Right and left. (Fig. 11.) They are flat in structure and form the bridge of the nose, being joined to each other in the median line of the face and to the frontal bone above.

**Lacrimal bones** (*os lacrimale*, sing.).—Right and left; small and thin, situated in the walls of the orbits, just under the extremity of the supraorbital margin (Figs. 11 and 23). In this bone is the beginning of the canal in which the *lacrimal duct* runs conveying the tears into the nose, thus preventing them from overflowing the eyelids and running down the cheek.

**Zygomatic bones** (*os zygomaticum*, sing.).—Forming the prominences of the cheek (Fig. 11). They are especially noticeable in certain races, as the Chinese, for example, who have high “cheek bones.”

**Maxilla** (or upper jaw-bone).—Situated in the front of the face, and composed of the two superior maxillary bones joined

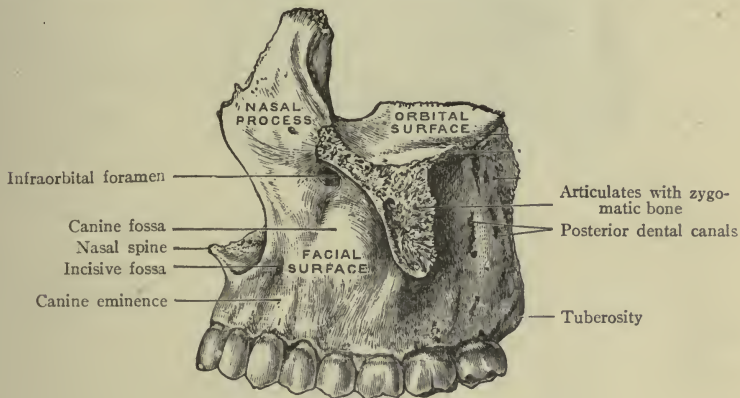


FIG. 14.—THE MAXILLA.—(Morris.)

together below the nostrils. It supports the cheeks, helps to form the nose and also the floor of the orbits. It consists of a body and several processes.

The **body** is hollow, the space being called the *maxillary sinus* or *antrum of Highmore* which opens into the side of the nasal cavity. In the lower border of the body the teeth are imbedded, the sockets of the large teeth being in the floor of the antrum, which explains how a diseased tooth may lead to antrum trouble.

The foramen on the surface of the body just below the orbit is called the *infraorbital foramen*. It is on a line with the supraorbital foramen of the frontal bone already mentioned.

**Processes.**—The **frontal process** extends upward along the side of the nasal bone to join the frontal. The **palate process**

is in the roof of the mouth, the bony part of the roof being called the *hard palate*. The **alveolar process** (or alveolus) is the thick border of bone in which the upper teeth are fixed. This process is very spongy and is sometimes broken in extracting a tooth. The **zygomatic process** joins the zygomatic bone to form the prominence of the cheek.

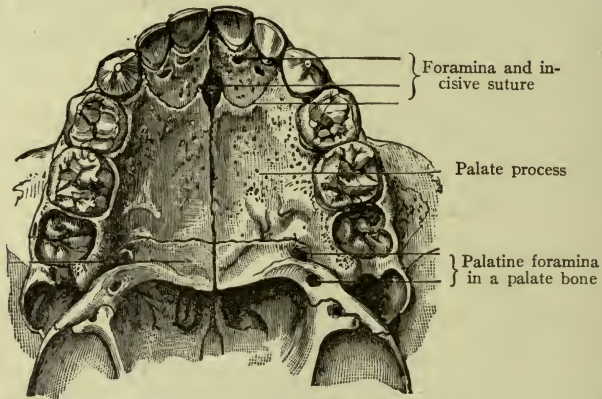


FIG. 15.—THE HARD PALATE, OR ROOF OF THE MOUTH.—(MORRIS.)

**Palate bones** (*os palatinum*, sing.).—Right and left; shaped like the capital letter L, and placed behind the maxilla. The **upright portion** is in the side of the nose at the back; the **horizontal portion** lies in the floor of the nose, being at the same time in the roof of the mouth, and thus completing the *hard palate* (Figs. 20 and 24).

**Inferior turbinated bones** (*concha nasalis inferior*, sing.).—Right and left; situated in the right and left walls of the nasal cavity below the superior and middle turbinated bones which belong to the ethmoid (Fig. 24). Each is composed of a thin plate of spongy tissue, having one edge rolled under like a shell (*concha*); they extend from front to back on the lateral wall of the cavity.

**Clinical note.**—*Hypertrophy* (or overgrowth) of the inferior turbinated bone is a frequent cause of obstruction to proper breathing.

**Vomer.**—A thin bone resembling a plowshare in shape, joined above with the *vertical plate* of the ethmoid, and below with the *maxilla*, thus forming the lower part of the *septum of the nose*. It

is this part of the septum which is sometimes bent to one side, or "deflected," and it often presents a "spur" on one of its surfaces. (The vertical plate of the ethmoid and the vomer together form the *bony septum* Fig. 25.)

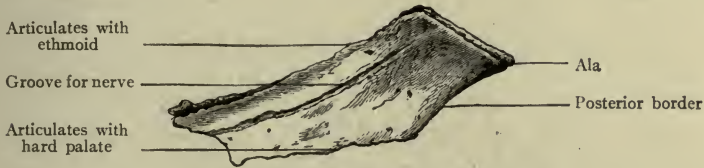


FIG. 16.—THE VOMER.—(Morris.)

**Mandible** (inferior maxillary, or lower jaw-bone, *mandibula*).—The only movable bone in the skull. It consists of a body having on either side a ramus (or branch) which is attached by ligaments to the temporal bone.

The **body** is the lower portion, shaped much like a horseshoe, with a thickened border (the *alveolus*) which bears the lower teeth.

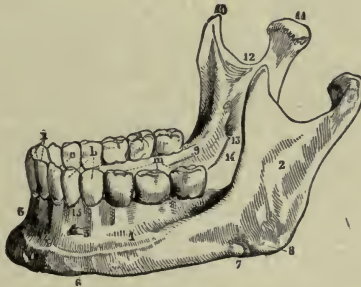


FIG. 17.—THE MANDIBLE.

1, Body of bone; 2, ramus; 3, symphysis; 4, incisive fossa; 5, mental foramen; 6, depression for passage of facial artery; 7, angle of jaw; 8, coronoid process; 9, condyle; 10, sigmoid notch; 11, alveolar border; a, incisors; b, bicuspid; c, canines; m, molars.—(Gould's Dictionary.)

On each side is an opening called the *mental foramen*, which is in a line with the infraorbital and supraorbital foramina, already mentioned.

Each of these three openings transmits an important nerve, artery, and vein, bearing the same name as the foramen. See Surgical note, p. 258.

The **ramus** extends upward from the body, and ends in two *processes*, one of which is the *condyle*; it is this condyle which articulates with the temporal bone to form the temporo-maxillary joint.

**Clinical note.**—Dislocation of this joint easily occurs if the mouth is opened too widely.

The *angle* of the jaw or mandible, is the posterior extremity of the lower border. The prominence of the angle differs in different people and at different ages.

## ARTICULATIONS OF THE FACE.

The bones of the face are all irregular, and many of them are very frail. They are fixed by *sutures* with one exception—that of the mandible which moves freely. (For description of a movable joint, see page 14.)

### THE MANDIBULAR JOINT.

The mandibular joint is a *hinge-joint*, and the only movable joint in the skull. The action may be felt in front of the ear.

The bony surfaces are the *condyle* of the mandible and the *mandibular fossa* of the temporal bone. They are covered with

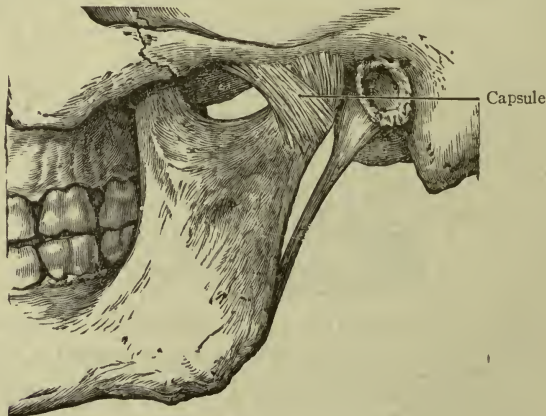


FIG. 18.—MANDIBULAR JOINT.—(After Morris.)

cartilage and connected by *ligaments forming a capsule*, which is sufficiently loose to allow the condyle to glide freely in the fossa, back and forth or sidewise, as in opening and closing the mouth and masticating the food.

**Surgical notes.**—If the mouth be suddenly opened very widely, as in hearty laughing, dislocation easily results—that is, the condyles glide too far forward and slip in front of the fossa,



making it impossible to close the mouth. To correct this condition (or "reduce the dislocation") press the jaw forcibly *downward* and *backward* with the thumbs placed upon the *molar teeth*. (First wrap the thumbs with a napkin to protect them, as the mouth will close suddenly.)

### POINTS OF INTEREST IN CONNECTION WITH THE SKULL AS A WHOLE.

#### THE CRANIUM.

The cranium is a firm, strong case for the brain, composed largely of flat bones, the layers of these flat bones being called the *tables of the skull*. The innermost table is very brittle and may be fractured by a blow which does not break the outer one, and owing to this brittleness it is called the *vitreous*, or *glassy layer*.

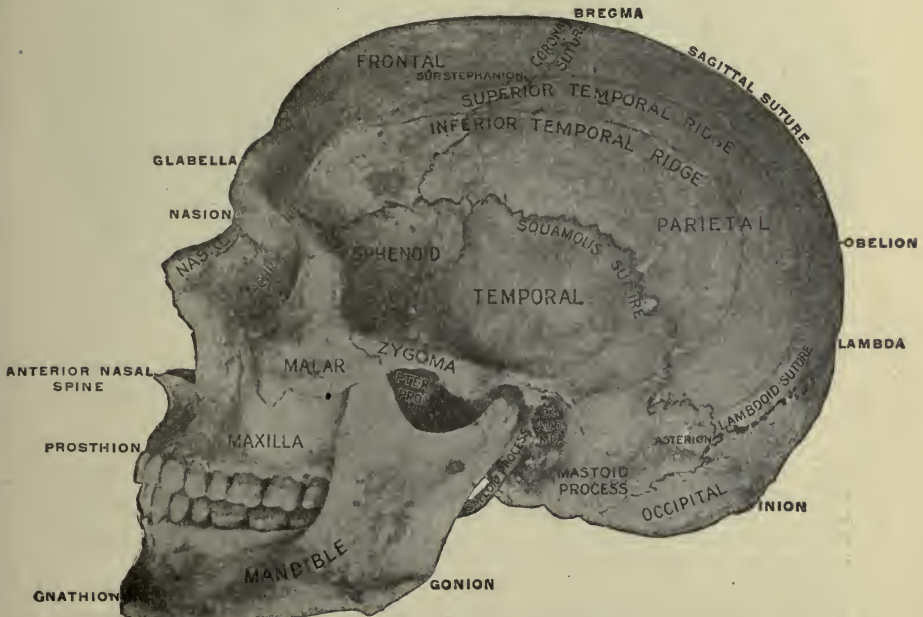

FIG. 19.—THE VERTEX AND SIDE OF THE SKULL.—(Gerrish.)

Observing the illustrations, or better, with the skull in the hand, the student may trace the **frontal**, two **parietal**, and **occipital** bones forming the *vault of the skull*, or the *vertex*; and at the sides the *squamous* and *mastoid portions* of the **temporal** bones and the tip of the *great wing of the sphenoid*.

Turning the skull upside down, observe the base. In the median line at the back is the basal part of the **occipital** bone, with the *foramen magnum* and the *condyles* on either side of it. In front of that are the *body* and *processes of the sphenoid*, and the roof of the mouth (or *hard palate*) bounded by the upper teeth. Tracing forward from the lateral part of the occipital bone is the

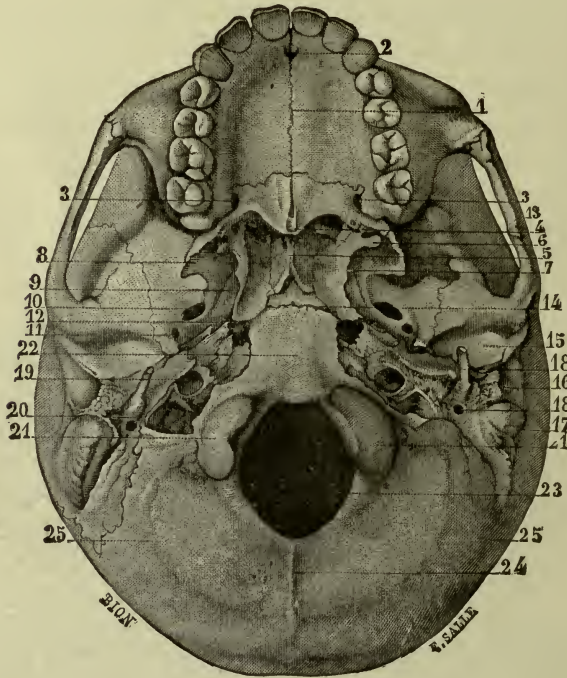


FIG. 20.—BASE OF SKULL.

1, 2, 3, Foramina and sutures in hard palate; 4, post-nasal spine; 5, nasal septum; 6, 7, 8, 9, 10, 11, 12, pterygoid processes, and markings on sphenoid bone; 13, zygomatic arch; 14, spheno-occipital suture; 15, 16, 17, 18, 19, 20, markings on temporal bone; 21, 21, condyles of occipital bone; 22, basal portion of occipital bone; 23, foramen magnum; 24, 25, crest and lines of occipital bone.—(Gould's Dictionary.)

*petrous portion* of the **temporal**, with its sharp *styloid process* and round opening of the *carotid canal*; and in front of the *temporal* is the *great wing of the sphenoid*. The **ethmoid** may be seen through the *posterior nares* where the **turbinated bones** (better, *shell-bones*) are all visible.

Numerous openings or *foramina* pierce the base of the skull, for vessels and nerves. The *jugular foramen* is just back of the

*carotid canal*; through it the jugular vein leaves the skull to pass downward in the neck. The interior surfaces of all cranial bones show depressions for the convolutions of the brain.

### THE FACE.

(See Figs. 19, 23.)

Beginning with the forehead, note the two *frontal eminences*, and below these the *superciliary arches* with the *glabella* between them. Still lower, the *supraorbital arches*, with the *nasal notch* between them, to which the nasal bones are attached. Observe the *lacrimal canal* at the medial side of the orbit leading to the nasal

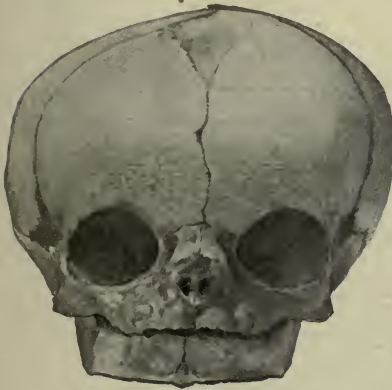


FIG. 21.—SKULL OF NEW-BORN CHILD, SHOWING FRONTAL FONTANELLE. —(Edgar.)

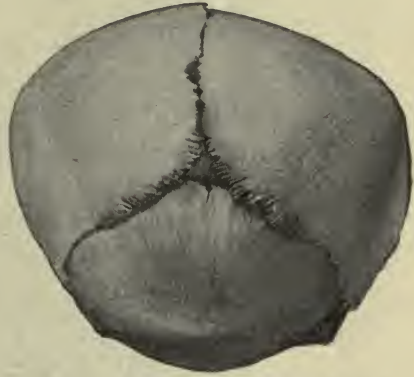

FIG. 22.—OCCIPITAL FONTANELLE. Both cuts show moulding of the head. —(Edgar.)

cavity. Below the orbit, locate the *infraorbital foramen* on the surface of the *maxilla* and the *mental foramen* on the body of the *mandible*.

Remember that these three foramina transmit three very sensitive *nerves*, as follows: The *supraorbital nerve* for the forehead, the *infraorbital nerve* for the cheek, and the *mental nerve* for the lower lip and chin. (Blood-vessels bearing the same names accompany these nerves.)

The prominences at the sides of the cheeks are made by the *zygomatic bones*. The openings of the nasal cavity are the *anterior nares*, within which may be seen the *septum*, and the *middle* and *inferior turbinated bones* (shell bones).

## THE SKULL AT BIRTH.

The bones are only partially developed, a considerable space between them being occupied by membrane (in some places, cartilage), and the frontal bone is in two pieces.

**Fontanelles.**—The *parietal* and *frontal* bones are incomplete at the angles where their sutures meet, leaving a diamond-shaped space above the forehead where there is only membrane, and which is called the *anterior* or *frontal fontanelle*. The *parietal* and *occipital* bones are also lacking where their sutures meet, leaving a triangular soft spot called the *posterior* or *occipital fontanelle*, which is much smaller. These fontanelles are closed as the bones develop; the *occipital* in a few months, the *frontal* before the end of the second year.

**Obstetric note.**—Owing to the fact that the bones are not firmly jointed, they can be made to overlap and thus adapt the shape of the child's head to the passage which it must traverse during birth. This is called the *moulding of the head* (Figs. 21 and 22).

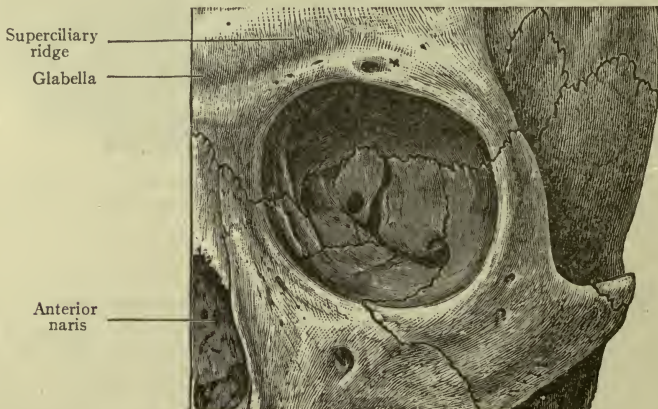


FIG. 23.—THE ORBIT.—(After Morris.)

## FOSSÆ OF THE SKULL.

The four large fossæ of the exterior of the skull are the temporal, infratemporal, orbital, and nasal.

The **temporal fossa** (*fossa temporalis*).—The thinnest part of the skull (Fig. 19). It is bounded by the temporal ridge and the zygomatic arch, occupied by the *temporal muscle*, and covered

by a strong membrane, called the *temporal fascia*, through which the motion of the muscle may be felt.

**Infratemporal** (or zygomatic) *fossa*.—At the side of the skull below the temporal fossa, from which it is separated by the zygomatic arch (Fig. 19). It is covered by the ramus of the mandible, and occupied by two of the *muscles of mastication*, and also by a number of important arteries, veins, and nerves.

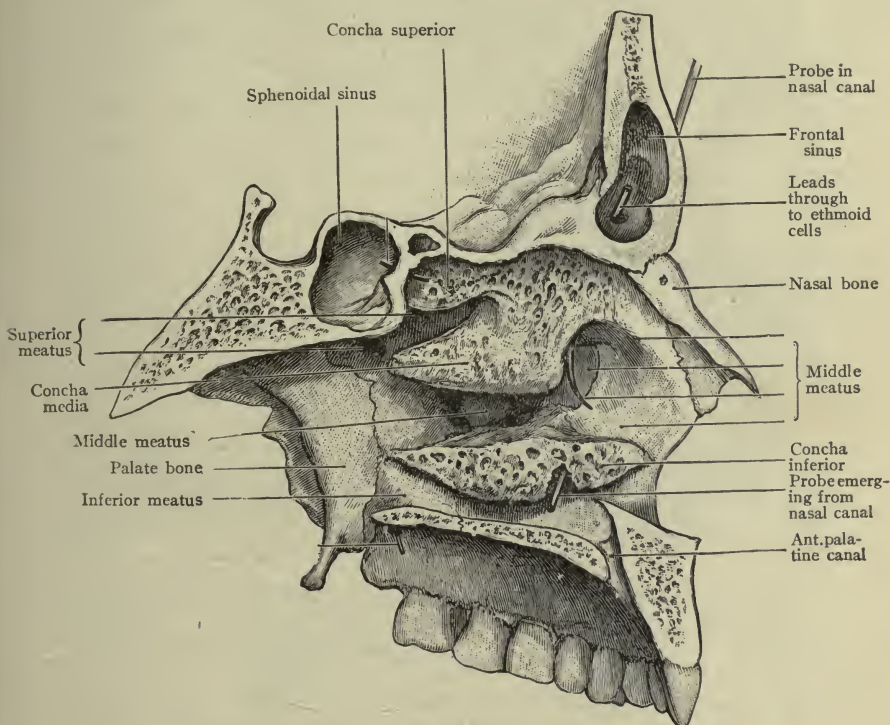


FIG. 24.—LATERAL WALL OF NASAL FOSSA OR CAVITY.—(Morris.)

**Orbital fossa** (or orbit).—Containing the eye. It is shaped like a pyramid, the apex being at the back of the fossa. The large opening on the face is bounded by the *margins* of the orbit, having the frontal bone above, the maxilla below, and the zygomatic bone on the lateral side.

The orbital plate of the frontal bone is in the *roof* of the orbit, and the orbital plate of the maxilla in the *floor*. The lacrimal and ethmoid bones are in the *medial wall*, the sphenoid and zygomatic bones in the *lateral wall*.

The *lacrimal canal* begins in the lacrimal bone and runs down into the nose. The *optic foramen*, for the optic nerve, is at the apex of the fossa.

**Nasal fossa.**—*Roof* formed by nasal and ethmoid bones; *floor* by maxillary and palate bones; *lateral wall* by nasal, ethmoid, maxillary, and palate bones; *septum* by ethmoid and vomer (Fig. 24).

The openings on the face, or *anterior nares*, are bounded by the maxillary and nasal bones, and separated by the vomer. The *posterior nares* are bounded by the sphenoid and palate bones, separated by the vomer, and open into the throat. *Turbinated bones* are seen on the lateral walls of the fossæ.

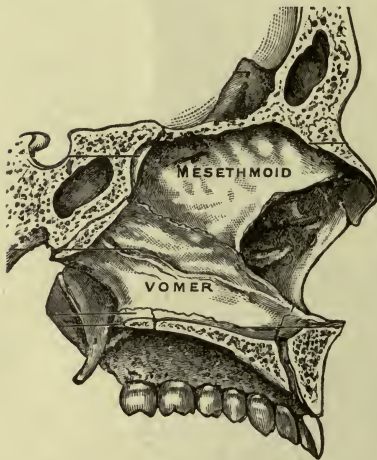


FIG. 25.—THE BONY SEPTUM.  
Body of sphenoid immediately behind it.  
—(Morris.)

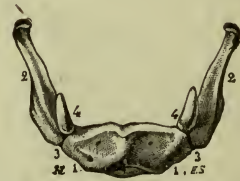

FIG. 26.—HYOID BONE, ANTERIOR ASPECT.

1, 1, Anterior or convex surface of body; 2, 2, greater cornua; 3, 3, junction of greater cornua with body; 4, 4, lesser cornua.—(Gould's Dictionary.)

Each nasal fossa communicates with four sinuses: the *sphenoid*, *ethmoid*, *frontal*, and *maxillary*. The sphenoid sinus opens into the *upper* and back part; the ethmoid, frontal, and maxillary (or *antrum of Highmore*) open at the *side*, lower down. The lacrimal canal also opens at the side near the floor.

The nasal fossæ are lined with mucous membrane (the *Schneiderian* membrane) which is continued into all of the sinuses and the pharynx.

**Clinical note.**—Inflammation of this membrane may extend into any of the sinuses, causing *sinusitis*. If this occurs in the frontal region, a dull pain is felt over the eyes; if in the ethmoid region, a pain at the side of the nose and a change in the sound of the voice

(*nasal tone*) are noted. The inflammation frequently extends into the *antrum of Highmore*.

The *sense of smell* resides in the upper part of the nose, the olfactory nerves coming down through the sieve-like plate of the ethmoid bone in the roof of the fossa.

### BONES OF THE NECK.

Hyoid, (*os hyoides*); seven cervical vertebræ.

**The hyoid bone, or os hyoides.**—Shaped like the letter **U**, situated in front of neck, about on a level with the chin, and suspended by ligaments and muscles from the styloid process of the temporal bone. The hyoid is not articulated to any other bone. It consists of a *body* and four *cornua* (or *horns*), and is designed to give attachment to the muscles of the tongue, and to others which connect it to the mandible above and sternum and clavicle below.

**Seven cervical vertebræ.**—The **seven cervical vertebræ** and their articulations will be described with the spinal column.

### THE TEETH.

A tooth is composed of dentine or tooth-bone, and consists briefly of a crown, a neck, and a root.

The **crown** is the exposed portion and is covered with hard white *enamel*. The **root** (connected with the crown by the **neck**)




FIG. 27.—A MOLAR TOOTH IN SECTION AND A CANINE TOOTH.—(Morris.)

is concealed in the socket of the jaw and is covered with *cement*. The shape of the tooth varies from that of the flat incisor or cutting tooth, to the broad one for crushing and grinding.

The **incisors** are the front teeth, four in number in each jaw. They are used for biting and cutting the food.

The **cuspid** (pointed) or *canine* teeth are situated next to the incisors; they also bite.

The **bicuspid**s (two-pointed) or pre-molars, and the **molars** are for purposes of mastication.

The shapes of all are shown in the illustrations.

The teeth are hollow and contain *tooth-pulp*. This consists of a delicate meshwork of vessels and nerves entering at the point of the root.

The *upper* teeth are imbedded in the alveolus of the maxilla, or upper jaw; the *lower* teeth in the alveolus of the mandible, or lower jaw.

### Dentition : the Eruption of the Teeth.

The teeth make their appearance in two sets, called temporary and permanent.

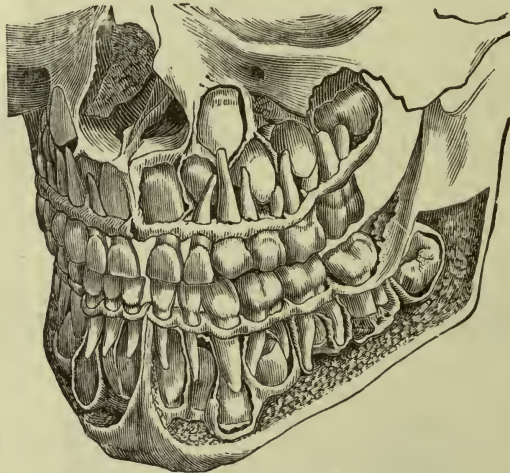


FIG. 28.—THE TEMPORARY TEETH.

The rudiments of the permanent teeth are seen enclosed in the bones.—(Gorgas.)

The **temporary teeth** are twenty in number; their eruption or “cutting” usually begins at about the seventh month and proceeds in following order:

Two lower central incisors .....	at 7 months.
Two upper central incisors .....	at 8 to 10 months.
Two upper lateral incisors .....	at 9 to 12 months.
Two lower lateral incisors .....	at 12 to 15 months.
Four first molars, 1 right, 1 left in each jaw .....	at 12 to 15 months.
Four canines, 1 right, 1 left in each jaw .....	at 16 to 22 months.
Four second molars, 1 right, 1 left in each jaw ..	at 24 to 30 months.

**Twenty teeth in the temporary set at two and one-half years of age.**



Thus, at one year of age the average child will have six teeth; at two years, sixteen; and the full number before it is three years old. Many exceptions occur, for example: the dentition of artificially fed children may be delayed; and it is oftenest late in children affected by rachitis or "rickets."

The upper canines are known in the nursery as "eye-teeth"; the lower canines as "stomach teeth."

**Clinical points.**—"Teething" or "cutting" of the temporary set occurs while the digestive tract is still in process of development and very easily disturbed; therefore special care should be

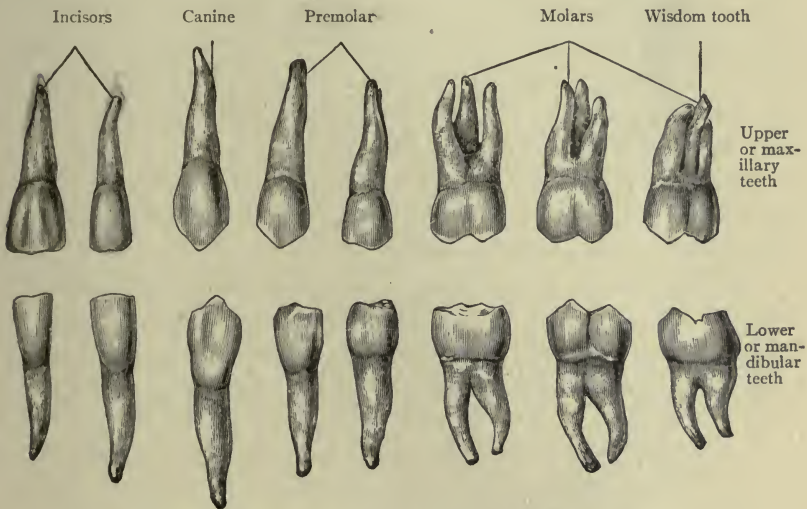


FIG. 29.—THE TEETH OF AN ADULT.—(Morris' Anatomy.)

given to the child's diet both as to quality and quantity. Likewise, the always delicate nervous system is at this time most easily irritated and excitement and fatigue should be avoided. These two points are equally important.

Meanwhile the permanent teeth are forming (Fig. 29). They gradually push toward the surface, cutting off the blood supply to the temporary teeth which become loose and fall out.

The **permanent teeth** are thirty-two in number. At the age of six years the first permanent molar ("six-year molar") should appear; the others follow in order somewhat like the following:

Four first molars, 1 right, 1 left, in each jaw . . . . .at 6 years.  
Eight incisors, 2 central, 2 lateral, in each jaw . . .at 7 to 8 years.  
Eight bicuspids, 2 right, 2 left, in each jaw . . . . .at 8 to 10 years.  
Four canines, 1 right, 1 left, in each jaw . . . . .at 12 to 14 years.  
Four second molars, 1 right, 1 left, in each jaw . . .at 12 to 15 years.  
Four third molars, 1 right, 1 left, in each jaw . . . .at 17 to 25 years.  
(The third molars are called "wisdom teeth.")

**Thirty-two teeth in permanent set at twenty-five years of age.**

**Clinical notes.**—*Caries*, or *decay* of teeth, is due to bacterial action. This is favored by accumulation of particles of food, the warmth and moisture of the mouth furnishing perfect conditions for the development of bacteria. Careful cleansing with brush or dental floss, or both, will prevent this and thus aid in preserving the teeth. Care is important in the use of brush or floss or toothpick, not only that the removal of injurious particles may be well done but in order to avoid wounding the mucous membrane which covers the gums, thus exposing them to bacterial irritation.

*Recession of the Gums.*—Any irritation (as by bacteria) of the gums may be followed by their recession, which exposes the dentine where it is not protected by enamel.

Sudden changes of temperature, as from hot to cold liquids, is injurious to the enamel. Acids as ordinarily taken in food, have no special action upon the teeth but sweets may do harm by their fermentation in a mouth where teeth are not kept clean.

## CHAPTER III.

### BONES AND ARTICULATIONS OF THE SPINAL COLUMN AND TRUNK.

The bones of the spinal column are twenty-six in number. They are *irregular* and are arranged as follows, from above downward:

24 separate vertebræ	}	7 cervical in the neck. 12 thoracic in the back. 5 lumbar in the loins.
1 sacrum.....	}	in the pelvis.
1 coccyx.....		

A **vertebra** consists of a *body* and an *arch*, joined together to form a ring of bone with a space enclosed called the *vertebral foramen*, which is occupied by the spinal cord. The **bodies** are composed of spongy bone, placed one above the other and held together by discs of fibrocartilage between them. In this way the solid and flexible portion of the spine is constructed.

The **arch** consists of two *roots* next to the body, and two *laminae* which meet at the back. There are seven *processes* on the arch of each vertebra,—four *articular* (two to form joints with the bone above, two for the bone below); two *transverse* (projecting from the sides), and one *spinous* which projects backward. The row of spinous processes is felt by passing the finger down the back in the median line; that of the seventh vertebra is easily seen, and this bone is called the *vertebra prominens*.

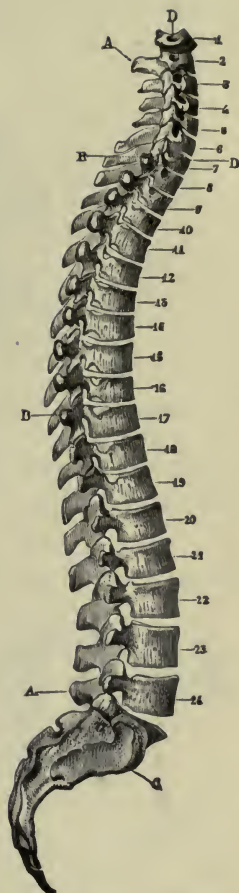


FIG. 30.—VERTEBRAL COLUMN, LATERAL ASPECT.  
1-7, Cervical vertebræ; 8-10, dorsal vertebræ; 20-24, lumbar vertebræ; A, A, spinous processes; B, B, articular facets of transverse processes of first ten dorsal vertebræ; C, auricular surface of sacrum; D, D, foramina in transverse processes of cervical vertebræ.—(Gould's Illus. Dictionary.)

## POINTS OF SPECIAL INTEREST.

The **cervical** vertebræ present a foramen at the base of the transverse process, the *transverse foramen*, through which an artery runs to the brain, entering the skull through the foramen magnum. (There are no transverse foramina in the dorsal or lumbar regions.) Their *spinous processes* are cleft or bifid.

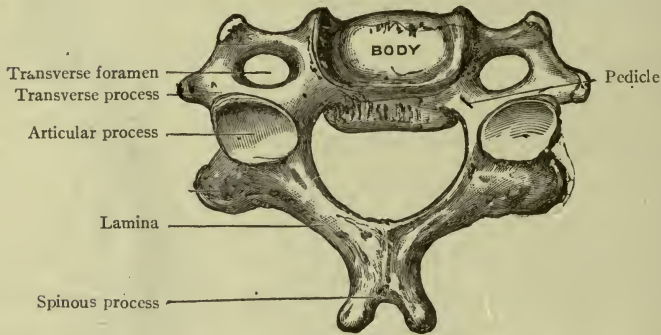


FIG. 31.—CERVICAL VERTEBRA, SHOWING BIFID SPINOUS PROCESS.—(MORRIS)

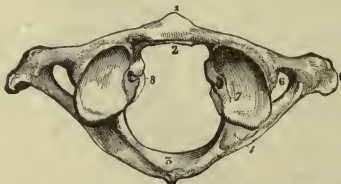


FIG. 32.—ATLAS, SUPERIOR SURFACE.

1, Tubercle of anterior arch; 2, articular facet for odontoid process of axis; 3, posterior arch and posterior tubercle; 4, groove for vertebral artery and first cervical nerve; 5, transverse process; 6, transverse foramen; 7, superior articular process; 8, tubercle for attachment of transverse ligament.—(Gould's Dictionary.)

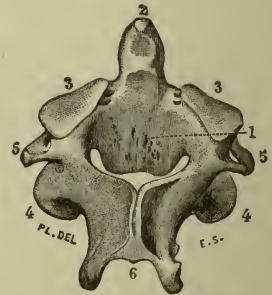


FIG. 33.—AXIS, POSTEROSUPERIOR VIEW.

1, Posterior surface of body; 2, odontoid process; 3, 3, superior articular processes; 4, 4, inferior articular processes; 5, 5, transverse processes; 6, spinous process.—(Gould's Dictionary.)

The first is called the *atlas*. It is a mere ring but has the usual number of processes (Fig. 32). The *atlas* is so named because it bears the weight of the skull (as Atlas, the fabled giant, bore the globe upon his shoulders).

The second is the *axis*. A strong process projects upward from its body forming a pivot for the ring-like atlas to revolve around. The pivot is called the *tooth* (or odontoid process) and is held in its place in the front part of the ring of

the atlas (Fig. 32) by a strong ligament, which prevents it from pressing upon the spinal cord.

The **thoracic** vertebræ are peculiar, in that their bodies present marks for the head of ribs; also, they have long transverse and spinous processes.

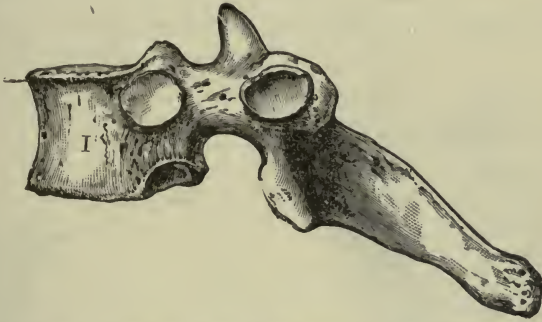

FIG. 34.—A THORACIC VERTEBRA, SHOWING MARKS FOR HEAD OF RIB.—(Morris.)

The **lumbar** vertebræ are the largest and strongest in the column, the bodies being conspicuously thicker than in the other regions, especially in the case of the fifth.

There are various other modifications of bones in the three regions—cervical, dorsal, and lumbar—which need not be mentioned here.

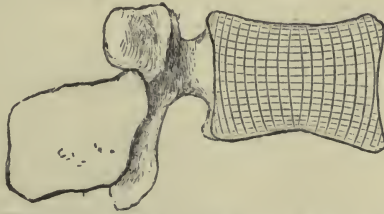


FIG. 35.—A LUMBAR VERTEBRA IN SECTION TO SHOW THE PRESSURE CURVES.—(Morris.)

**Sacrum.**—An *irregular* bone formed by the consolidation of five incomplete vertebræ, and joined to the last lumbar. Its general shape is that of a curved wedge; it is placed with the base upward, and the *concavity forward*, forming the “*hollow of the sacrum.*” A canal extends from the base to the apex, called the *sacral canal*, which is a continuation of the spinal (or neural) canal.

There are two sets of short canals, running *from front to back* through the sacrum. Seen from the front they present the *an-*

*terior sacral foramina*; seen from the back, the *posterior sacral foramina* (for the passage of nerves). The *angle* formed by the sacrum and the fifth lumbar vertebra projects sharply forward and is called the *promontory*.

**Coccyx.**—The terminal bone of the spinal column, and formed of four very rudimentary vertebræ. The *base* is joined to the sacrum; the *apex* is directed downward and forward.

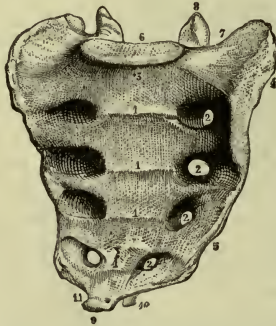


FIG. 36.—SACRUM, ANTERIOR ASPECT.

1, 1, 1, Bodies of sacral vertebræ with transverse lines of union; 2, 2, 2, 2, anterior sacral foramina; 3, base; 4, auricular surface of lateral aspect; 5, its inferior portion; 6, articular surface of base; 7, notch for formation of last lumbar intervertebral foramen, 8, superior articular process of first sacral vertebra; 9, apex of sacrum; 10, cornu; 11, notch for transmission of fifth sacral nerve.—(Gould's Illustrated Dictionary.)

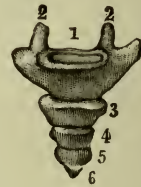

FIG. 37.—COCCYX, ANTERIOR ASPECT.

1, Base; 2, 2, cornua; 3, second coccygeal vertebra; 4, third coccygeal vertebra; 5, fourth coccygeal vertebra; 6, fifth coccygeal vertebra.—(Gould's Illustrated Dictionary.)

## THE ARTICULATIONS OF THE SPINAL COLUMN.

The *bodies* of the vertebræ are connected by discs of *fibrocartilage* which are placed between them. They serve not only to connect the vertebræ but to give flexibility to the column, so that it may bend in any direction, and they also make it elastic. The *bodies* are further connected by fibrous bands on their anterior and posterior surfaces. (Slightly movable or *yielding* joints.)

The *arches* are connected by broad thin ligaments between the laminae, thus completing the spinal or neural canal, which contains the spinal cord. (These ligaments are an exception to the rule, in that they are *elastic*; they are called the *ligamenta flava*.) The *articular processes* are covered with cartilage and enclosed by *capsules* which are lined with synovial membrane, forming true movable joints. These are gliding joints. (*Arthrodia*.)

The only independent movements of the head are provided for by the arrangement of the *atlas* and *axis*. The cup-like articular processes of the atlas receive the condyles of the occipital bone to allow the *nodding* motion of the head. The occipital bone is held to the atlas by ligaments, and *rotation of the atlas* around the tooth of the axis turns the *head also, from side to side*.

The **ligamentum nuchæ** is a name given to a thick elastic band (not a true ligament) which stretches from the occipital protuberance to the seventh spinous process. It helps to sustain the weight of the head while bending forward, and is particularly well developed in the larger grazing animals.

From the seventh cervical down to the sacrum a *supraspinous* ligament is stretched, attached to all the spinous processes.

The *movements* of the spinal column are **flexion, extension, lateral flexion, and rotation**. Motion is freest in the cervical region, and most restricted in the dorsal.

**Clinical note.**—The limited motion between neighboring bones becomes a wide range in the column as a whole and may be increased by frequent and judicious exercises.

### THE SPINE AND THE SPINAL CURVES.

The length of the **spine** is about 27 inches. The solid portion is a flexible and elastic *column* which bears the weight of the head and its delicate organs without giving them the full force of the jar caused by walking, running, etc. The flexibility of the column allows the whole body to move with freedom and grace, while the strength of the spine makes it suitable for the attachment of the extremities. The *arches*, connected by their ligaments, enclose the **spinal** or **neural canal**, which extends

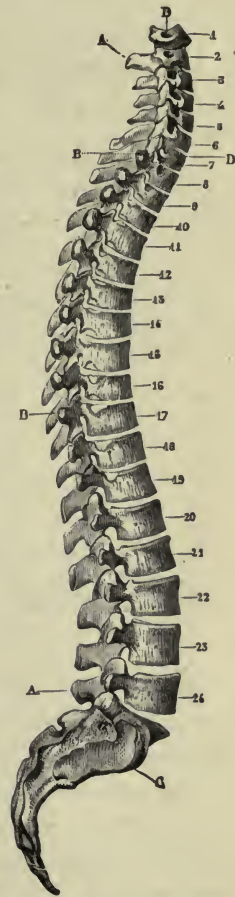


FIG. 38.—SPINE AND SPINAL CURVES.

through the sacrum to the base of the coccyx. Since the spinal canal contains the spinal cord there must be places of exit for the spinal nerves; these are found in the *intervertebral foramina* between the roots of the arches.

The spine has *four curves*: cervical, thoracic, lumbar, and sacral.

The **cervical** and **lumbar** curves are *concave posteriorly*, as is seen to a slight degree in the back of the neck, and more plainly in the so-called "small of the back"; while the **thoracic** and **sacral** curves are *concave anteriorly*, to accommodate the organs in the thorax and pelvis.

These curves are caused by variations in the thickness of the bodies and cartilage discs. For example, the *thoracic bodies* are slightly thicker at the back, while the *lumbar bodies* are thicker in front.

A *lateral curve* usually exists in the upper thoracic region, but this may be called *accidental*, as it is explained by the excessive use of one or the other arm.

## THE TRUNK.

INCLUDES THE THORAX, ABDOMEN AND PELVIS.

### BONES OF THE THORAX.

Sternum.....	1
Ribs (costæ).....	24
Thoracic vertebræ.....	12

**Sternum** or breast-bone.—Placed in the front of the thorax. It is about 6 inches long, flat in shape and structure, and its two surfaces are called *anterior* and *posterior*. It has three divisions, the *manubrium*, the *body*, and the *xiphoid appendix* (Fig. 39).

The upper border of the sternum is notched—the *sternal* (or *jugular*) *notch*; the lateral borders give attachment from above downward to the clavicle and the cartilages of the first seven ribs. The *xiphoid appendix* is the lowest portion of the bone and gives attachment to some of the muscles of the abdomen. It remains cartilaginous until middle life.

**Ribs** (costæ).—Twelve in each side of the thorax, forming a series of movable elastic arches. They consist of a bony portion



(the *costal bone*) and a flexible portion (the *costal cartilage*). They are flat in structure, curved in shape.

The posterior or vertebral extremity is the *head*, next to the head is the *neck*, and the remaining bony portion is the *shaft*. The inner surface of the shaft is marked by a *groove* at its lower border (the *costal groove*) in which the intercostal nerves and vessels run, being thus protected from external injury.

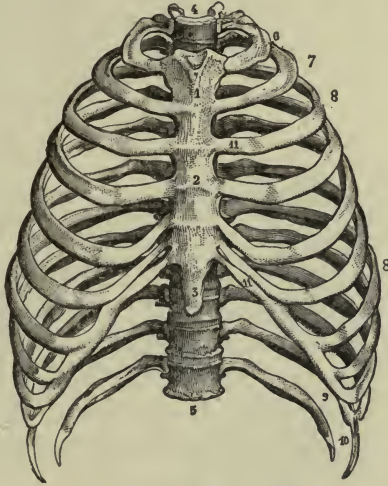
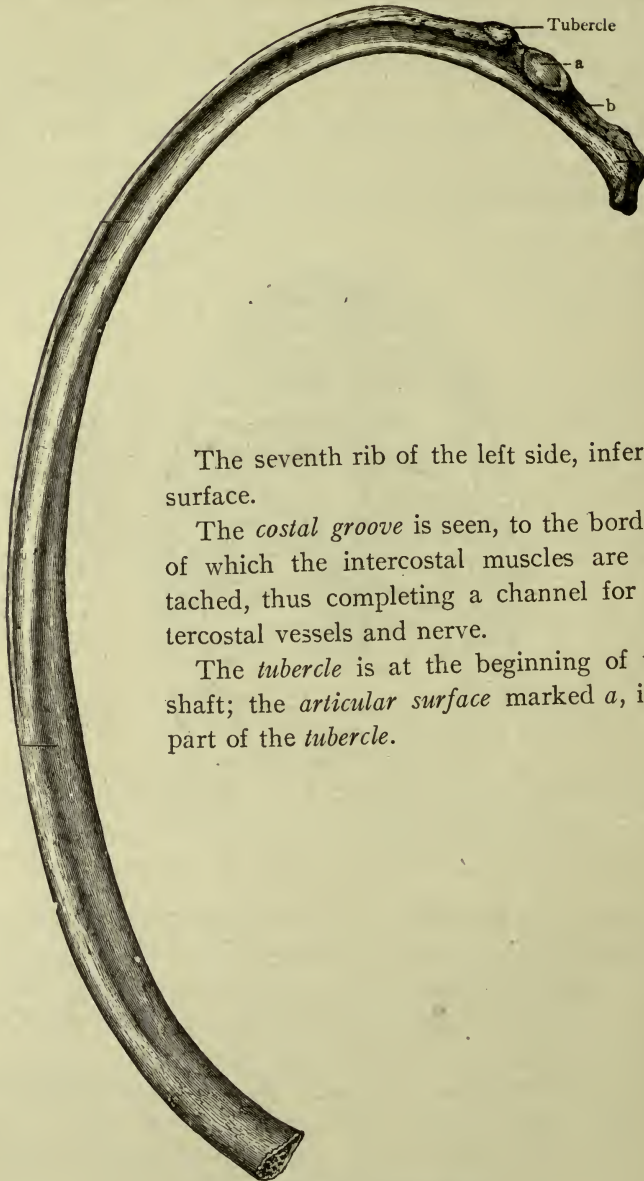


FIG. 39.—THE THORAX.

1, 2, Manubrium and body of sternum; 3, xiphoid appendix; 4, circumference of apex of thorax; 5, circumference of base; 6, first rib; 7, second rib; 8, 8, third, fourth, fifth, sixth, and seventh ribs; 9, eighth, ninth and tenth ribs, 10, eleventh and twelfth ribs; 11, 11, costal cartilages,—(Gould's Dictionary.)

The first seven are called "*true ribs*," being connected in front with the sternum by their cartilages. The remaining five are "*false ribs*"; the *eighth*, *ninth* and *tenth* are connected in front, each to the one above; the *eleventh* and *twelfth*, are not connected with anything in front, and are called "*floating ribs*."

**Thoracic vertebræ.**—Twelve in number; described with the bones of the spinal column.



The seventh rib of the left side, inferior surface.

The *costal groove* is seen, to the borders of which the intercostal muscles are attached, thus completing a channel for intercostal vessels and nerve.

The *tubercle* is at the beginning of the shaft; the *articular surface* marked *a*, is a part of the *tubercle*.

FIG. 40.—THE SEVENTH RIB.  
a, articular surface for transverse process; b, neck.—(Morris.)

## ARTICULATIONS OF THE THORAX.

**Sternum.**—The three pieces (*manubrium*, *body*, and *xiphoid appendix*) are connected together by *fibro-cartilages* and *anterior* and *posterior ligaments*. After middle life they become united in one bone.

**Ribs (costæ).**—The costal cartilages are connected in front to the sternum, or to each other, as already mentioned. The *heads* articulate with the bodies of two thoracic vertebræ. (Exceptions: the *first*, *eleventh*, and *twelfth* are each connected to one body.) Where the neck of the rib joins the shaft (marked by a tubercle) it rests against the tip of the *transverse process* of a vertebra behind

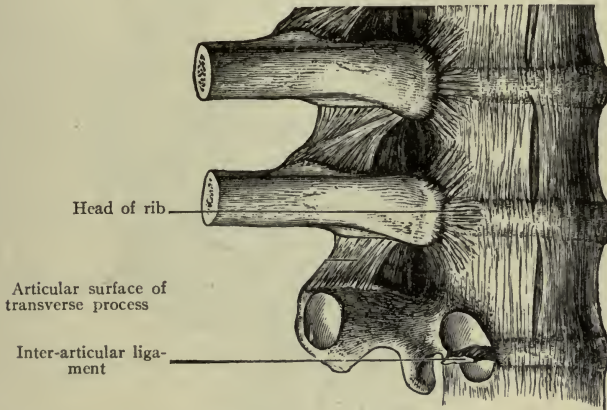


FIG. 41.—HEADS OF RIBS ARTICULATING WITH TWO VERTEBRÆ.—(After Morris.)

it, which thus forms a brace for it. All of these joints are enclosed by *capsules* and lined with *synovial membrane*, providing for the movements of the ribs in breathing, talking, etc. (Figs. 39, 41).

**Vertebræ.**—Their joints have been described.

By the articulation of the ribs with the spine at the back and sternum in the front, the **bony thorax** is completed. It is shaped like a cone, flattened before and behind, and shortest in front (the sternum reaching only as low as the ninth dorsal vertebra). The intervals between the ribs are called the *intercostal spaces*.

The elasticity of the ribs and cartilages and their gliding joints, give a yielding character to the thoracic walls to accommodate the movements of the lungs within.

## BONES OF THE ABDOMEN.

The five lumbar vertebræ, already described.

## BONES OF THE PELVIC GIRDLE.

The bones are.....	{	Hip bones.....	2
		Sacrum.....	1
		Coccyx.....	1

**Hip-bone** (*os coxæ*).—Consisting of three parts which are entirely separate in the child. They are the *os ilium*, the *os ischii*, and the *os pubis*; they unite in forming a cup-shaped cavity called the *acetabulum*, seen on the lateral surface of the bone. The acetabulum is the socket of the hip-joint (Fig. 42).

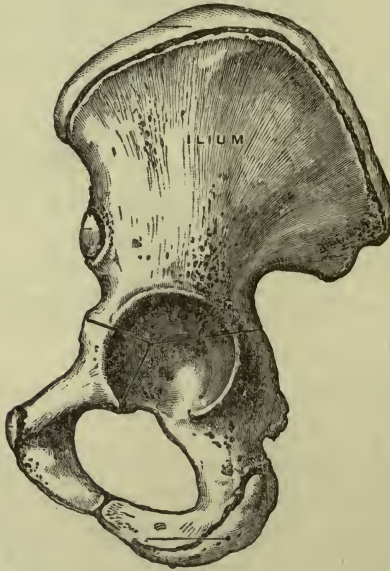

FIG. 42.—HIP-BONE, EXTERIOR.—(Morris.)

The *os ilium* is the highest part of the hip-bone and has a broad expanded portion called the *wing* (or *ala*). The medial surface of the wing is the *iliac fossa*, which is filled with the *iliac muscle*; the lateral surface is crossed by three *curved lines* (called the *posterior gluteal*, the *anterior gluteal*, and the *inferior gluteal lines*).

The *superior border* is called the *crest*. It can be easily felt, and the anterior extremity is known as the *anterior superior iliac spine*, more often called the *spine of the ilium*.

The **os pubis** is the anterior division of the hip-bone. It has a *body* and two branches, or *rami*. The *body* joins the ilium, the *superior ramus* has a short projection called the *spine of the pubes*, and the *inferior ramus* extends downward and backward to join the ischium, thus forming the upper part of the *pubic arch*. The two pubic bones join each other in the median line, forming the *pubic symphysis* (*symphysis pubis*).

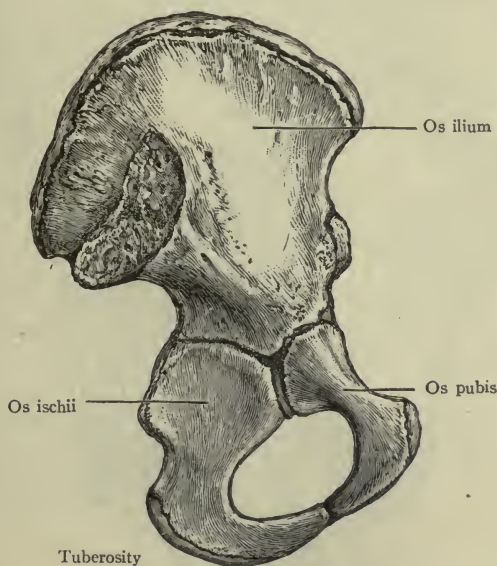


FIG. 43.—HIP-BONE, INTERIOR, BEFORE UNION OF PARTS.—(Morris.)

The **os ischii** (or the ischium), the lowest part of the hip-bone,—has a sharp *spine* projecting backward, a *tuberosity* upon which the trunk rests in the sitting position, and a *ramus* which joins the pubic ramus to complete the *pubic arch*.

The ilium, ischium, and pubes united form the *hip-bone* (*os coxæ*). Two large notches are seen on the posterior border of the completed bone, separated by the *spine of the ischium* and called the *sciatic notches*. The upper one is the *greater* and the lower one is the *lesser* sciatic notch. In front of the acetabulum is the

*obturator foramen*, the largest foramen in the skeleton. It is almost entirely closed by the *obturator membrane*, which is composed of white fibrous tissue.

### THE ARTICULATIONS OF THE PELVIS.

The two hip-bones unite with each other in front at the *pubic symphysis*, but the sacrum is between them in the back, having the coccyx attached to its apex, and thus the *pelvic girdle* is formed, usually called the **pelvis** (or *basin*). These joints have no cavity, and are only slightly movable, or *yielding*. There is a distinct disc of fibro-cartilage at the pubic symphysis.

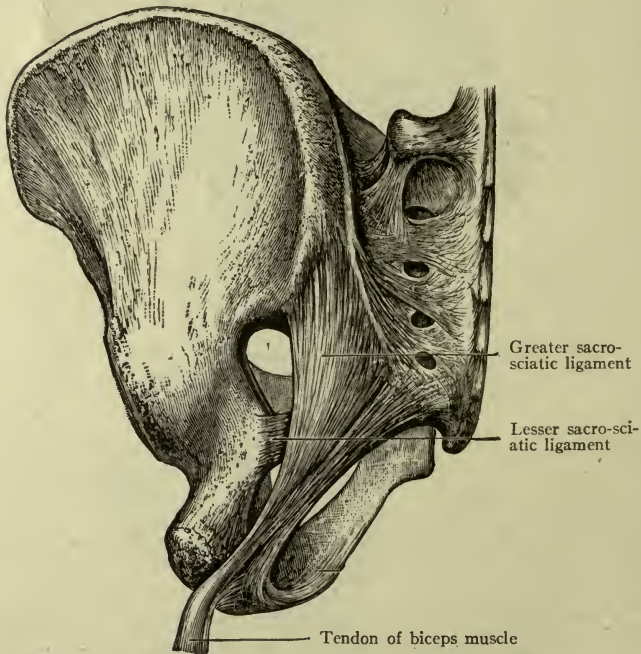


FIG. 44.—GREATER AND LESSER SACRO-SCIATIC LIGAMENTS AND FORAMINA.—(Morris.)

**Obstetric note.**—The pubic symphysis and the sacro-iliac symphysis probably soften slightly during pregnancy. The sacro-coccygeal joint has limited motion until middle life advances, when it may become fixed.

**Sacro-sciatic ligaments** (Fig. 44).—Two strong bands are stretched between the sacrum and the ischium. They have no connection with any joints but are called the *greater* and the *lesser sacro-sciatic ligaments*. The *greater*

(ligamentum sacro-tuberosum) extends from the borders of the sacrum and coccyx to the *tuberosity* of the ischium; the *lesser* (ligamentum sacro-spinosum) is placed immediately in front of it, extending from the sacrum and coccyx to the *spine* of the ischium. Thus are formed two foramina with the lesser ligament between them, the one above being called the **greater sciatic foramen**, and the one below the *lesser sciatic foramen*. (The sciatic nerves pass through the greater foramen.)

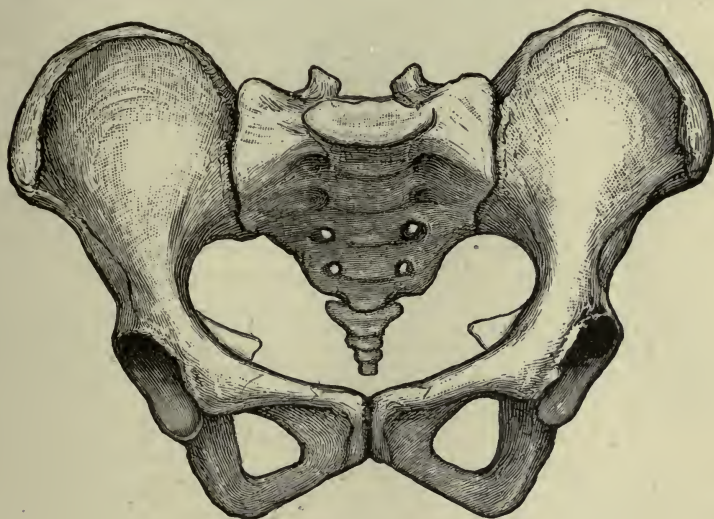


FIG. 45.—THE PELVIS.—(Morris.)

*Poupart's ligament*, or the *inguinal ligament*, may be felt like a tight cord stretched between the spine of the ilium and the spine of the pubis—"from spine to spine."

### The Pelvis or Pelvic-Girdle.

**False pelvis.**—The *upper* part, between the wings of the *ilia*. It is broad and shallow.

**True pelvis.**—The lower part, bounded by the *pubes* in front, the *ischia* at the sides, and the *sacrum* and *coccyx* at the back. It is deeper and narrower.

The *female* pelvis has lighter bones, a wider pubic arch, and greater capacity than the male pelvis; the sacrum is less curved and the sacral promontory less projecting.

The limiting line or boundary between the *false* and the *true pelvis* is a curved line called the *brim*, and the space included

is the *inlet*; the lower opening is the *outlet*. The inlet and the outlet are also known as the *superior* and *inferior straits*. The measurements or *diameters* of these straits in the female pelvis are as follows:

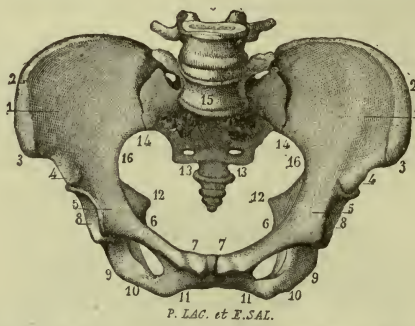


FIG. 46.—THE PELVIS. INLET, OR SUPERIOR STRAIT.—(Gould's Dictionary.)

1, Iliac fossa; 2, crest of ilium; 3, anterior-superior spine of ilium; 4, anterior-inferior spine of ilium; 5, ilio-pectineal joint; 6, 7, body and symphysis of pubes; 8, acetabulum; 9, tuber of ischium; 10, 11, pubic arch; 12, spines of ischia; 13, coccyx; 14, sacro-iliac joint; 15, is placed just above the promontory.

#### INLET (Edgar's Obstetrics).

Antero-posterior.....	11 cm.
(Symphysis to promontory.)	
Oblique.....	12½ cm.
(Ilio-pectineal joint to sacro-iliac joint.)	
Transverse.....	13½ cm.
(Widest part of brim.)	

#### OUTLET.

Antero-posterior.....	9½-12 cm.
(Symphysis to tip of coccyx.)	
Transverse.....	11 cm.
(Between tuberosities.)	

### THE DORSAL AND VENTRAL CAVITIES OF THE BODY.

By articulation of the bones of the head and trunk a framework is formed for two cavities, within which are situated the internal organs or viscera. (These delicate and important parts must be provided with surrounding structures which insure both their safety and efficiency.)

The cavities are called **dorsal** and **ventral**, or *neural* and *visceral*. Briefly speaking, they may be described as situated



posteriorly and anteriorly to the solid part of the spinal column or bodies of the vertebræ.

The *spinal canal* is a part of the **dorsal** or **neural cavity** which extends into the interior of the skull, the bones of the cranium being modified vertebræ, and the cavity within them representing the uppermost part of the neural canal.

The dorsal or neural cavity contains the brain and spinal cord, well protected within firm, unyielding walls.

The *mouth, neck, thorax, abdomen* and *pelvis* inclose the **ventral** or **visceral cavity**, which is in front of the spinal column. The bony walls are very incomplete, especially in the abdomen. They are finished out by *muscles*; this arrangement allows the walls to be flexible and yielding in character, thus securing to the organs contained, that freedom of movement which is necessary to their perfect action. The *diaphragm* (page 91) divides the ventral cavity into two portions, upper and lower; the *pelvic floor* (page 103) completes the boundary below.

The ventral cavity contains the organs of respiration, circulation, digestion and reproduction; also the kidneys and bladder, which are organs of elimination.

Having studied the bones of the dorsal and ventral cavities or those of the head and trunk, we will proceed in Chapter IV to those of the extremities.

## CHAPTER IV.

### BONES AND ARTICULATIONS OF THE EXTREMITIES.

#### BONES OF THE UPPER EXTREMITY.

The upper extremity, as the artist sees it, begins with the arm. The *anatomist* includes the shoulder as a part of the extremity. The bones are therefore as follows:

In the <b>shoulder</b> .....	clavicula	}	..... 2
	scapula	}	
In the <b>arm</b> .....	humerus	}	..... 1
In the <b>forearm</b> .....	radius	}	..... 2
	ulna	}	
In the <b>wrist or carpus</b> <sup>1</sup>	scaphoid	} 1st row... }	..... 8
	semilunar		
	cuneiform		
	pisiform		
	trapezium	} 2d row... }	
trapezoid			
os magnum			
unciform			
In the <b>hand</b> .....	palm or metacarpus (metacarpal bones)	}	5
	fingers or digits (phalanges)	}	..... 14

32

<sup>1</sup> The names of carpal bones are given as follows in Spalteholz's Hand Atlas:

1st row—os naviculare manus.	2nd row—os multangulum majus.
os lunatum.	os multangulum minus.
os triquetrum.	os capitatum.
os pisiforme.	os hamatum.

**Note.**—The end of a bone which is nearest to the trunk is called the *proximal* extremity; the other end is the *distal* extremity. The same terms are applied to surfaces.

#### THE SHOULDER OR SHOULDER-GIRDLE.

**Scapula**, or shoulder-blade (Fig. 47).—Placed at the upper part of the chest, behind the ribs (from the second to the eighth). It is flat and irregular in structure, and triangular in shape.

The margins are called the *superior*, the *vertebral*, and the *axillary*; the angles, *lateral*, *medial*, and *inferior*. The inferior angle and vertebral border or margin usually project a little backward, sometimes very notably, making the so-called "*winged scapula*."

The anterior surface (costal surface) is called the *subscapular fossa*, and is filled with the subscapular muscle. The posterior or dorsal surface is crossed by a rough ridge called the *spine of the scapula* which terminates in an important process, the *acromion*, overhanging the shoulder-joint.

Below and in front of the acromion is the *coracoid process*.

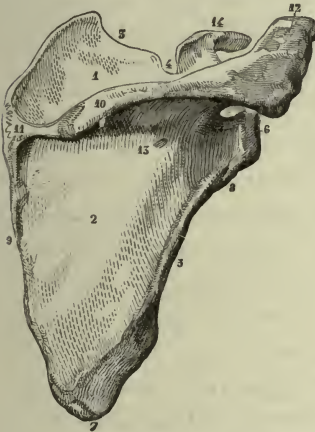

FIG. 47.—SCAPULA, POSTEROEXTERNAL ASPECT.

1, Supraspinous fossa; 2, infraspinous fossa; 3, superior or coracoid border; 4, coracoid or suprascapular notch; 5, axillary or lateral border; 6, anterior angle and glenoid cavity; 7, inferior angle; 8, rough impression for long head of triceps; 9, medial or spinal or vertebral border; 10, spine; 11, smooth surface over which trapezius muscle glides; 12, acromion; 13, base of spine; 14, coracoid process.—(Gould's Dictionary.)



FIG. 48.—CLAVICLE, INFERIOR ASPECT.

1, Longitudinal depression for insertion of subclavius muscle; 2, rough impression for attachment of costoclavicular ligament; 3, 3, for attachment of coraco-clavicular ligaments; 4, 4, posterior border; 5, 5, anterior border; 6, facet for articulation with sternum; 7, facet for articulation with acromion.—(Gould's Dictionary.)

The lateral angle presents a shallow depression called the *glenoid cavity*. This cavity forms the socket of the shoulder-joint.

**Clavicula** (or collar-bone, Fig. 48.)—Long in shape, but having no medullary canal. It is curved like an italic letter *f* and placed horizontally across the front of the upper ribs. The inner extremity articulates with the sternum and is therefore called the *sternal extremity*. The outer extremity articulates with the acromion process of the scapula, and is called the *acromial extremity*.

**Clinical note.**—The weight and curves are increased by exercise, and both bones are usually more developed in men than in women.

The clavícula is easily broken, especially in children, being frequently the seat of "green-stick" fracture.

The clavícula and scapula together form the **shoulder-girdle**, which is open at the back, but closed in front by the sternum placed between the two claviculæ.




FIG. 49.—LEFT HUMERUS, ANTERIOR ASPECT.

1, Shaft of body; 2, head; 3, anatomic neck; 4, greater tubercle; 5, lesser tubercle; 6, 7, 8, 9, markings for muscles; 10, orifice for nutrient artery; 11, capitulum; 12, trochlea; 13, 14, lateral and medial epicondyles; 15, 16, lateral and medial borders; 17, coronoid fossa.—(Gould's Dict.)

### THE ARM OR BRACHIUM.

**Humerus.**—Long in structure and shape, having a *shaft* with a *medullary canal* and *two extremities* (Fig. 49).

The **upper extremity** (proximal extremity) includes the **head, neck and tubercles**.

The *head* articulates with the glenoid cavity of the scapula to form the shoulder-joint; the short, thick, *anatomic neck* joins the head to the shaft; and just below the neck are the *greater* and *lesser tubercles* for the attachment of muscles to rotate the arm. The **lower extremity** curves slightly forward and presents two projections at the sides called the *medial* and *lateral epicondyles*; the medial is the longer and consequently it is more frequently broken off. Between the epicondyles are the articular surfaces for the elbow-joint, the *trochlea* for the ulna and the *capitulum* for the radius.

The **shaft** has three borders and three surfaces (like all long bones).

The *anterior* and *medial* borders run from the greater and lesser tubercles. In the upper part they are called the *crests of the tubercles* and the groove for the long tendon of the biceps muscle is between them (formerly called bicipital groove).

The broad, shallow groove containing the radial nerve winds across the posterior surface.

**Note.**—The slender portion of the shaft just below the tubercles is called the *surgical neck*, because it is so often fractured.

### FOREARM, OR ANTEBRACHIUM (FIG. 50).

**Ulna.**—A long bone in structure and form, situated in the medial side of the forearm (the ulnar side). The **upper extremity** presents

two strongly marked processes,—the *olecranon*, projecting upward from the back and curving forward, and the *coronoid*, projecting forward from the front and curving upward. Thus these processes curve toward each other, and the cavity between them is the *semilunar notch*. It receives the trochlea of the humerus to form the elbow-joint. On the lateral side of the coronoid process is the *radial notch*, where the head of the radius lies.

The **lower extremity** is the **head** of the ulna, which lies in the ulnar notch of the radius. There is a well-marked projection on this head called the *styloid process*.

The posterior border of the shaft is subcutaneous and may be traced down from the point of the elbow. The space between the radius and the ulna is called the *interosseous space*, and is occupied by an interosseous membrane.

**Radius.**—A long bone in structure and in form, situated on the lateral side of the forearm (the radial side).

The **upper** (or proximal) **extremity** is the **head**, which is depressed at the top to fit the *capitulum* of the humerus. Below the head is the *neck*, and below that, in front, is the **tuberosity of the radius** for the attachment of the biceps muscle of the arm. The **lower** (or distal) **extremity** of the radius is broad and thick, and is the largest bone in the formation of the wrist-joint.

On its lateral border is the *styloid process*. Running across the upper half of its anterior surface is the *oblique line*, which is a part of the anterior border.

**Special notes.**—The *head of the humerus* is *proximal* and articulates with the glenoid cavity of the scapula. The *head of the radius* is *proximal* and articulates with the humerus. The *head of the ulna* is *distal*.

The *upper end* of the *ulna* is its largest part, and an important bone in the *elbow-joint*. The *lower end* of the *radius* is the largest part, and important in the *wrist-joint*. Observe that in the long bones of the *upper extremity* the *nutrient foramina* are in the shafts and are directed *toward the elbow-joint*. They transmit nutrient arteries to nourish the bones.

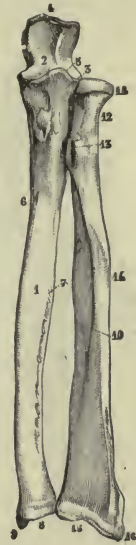


FIG. 50.—LEFT ULNA AND RADIUS, ANTERIOR SURFACES.—(Gould.)

1, Shaft or body of ulna; 2, semilunar notch; 3, radial notch occupied by radial head; 4, olecranon; 5, coronoid process; 6, orifice for nutrient artery; 7, interosseous borders with interosseous space between; 8, head of ulna; 9, styloid process of ulna; 10, shaft or body of radius; 11, 12, head and neck of radius; 13, tuberosity of radius; 14, marking for muscle; 15, 16, lower extremity and styloid process.

## CARPUS.

The carpal bones (*ossa carpi*) are eight in number, and are typical *short* bones. They are arranged in two slightly curved rows—the first and second—with the convexity of the curves turned upward toward the radius, the first row articulating with it.

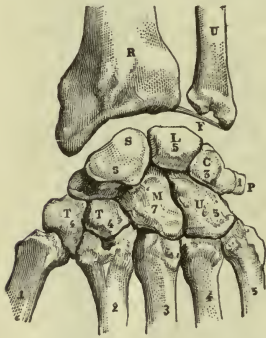


FIG. 51.—BONES OF CARPUS, DORSAL SURFACE.—(Gould's Dictionary.)

## FIRST ROW.

**Navicular** (*os naviculare*).—On the radial side of the wrist, named from its *shape* which resembles a boat, and marked by a *tubercle*.

**Semilunar** (*os lunatum*).—Well named from its *half-moon shape*.

**Cuneiform** (*os triquetrum*).—Very slightly resembling a *wedge*.

**Pisiform** (*os pisiforme*).—Resembling the half of a *split pea*, and placed in front of the cuneiform.

## SECOND ROW.

**Trapezium** (*os multangulum majus*).—On the radial side, marked by a *ridge*.

**Trapezoid** (*os multangulum minus*).—The smallest of the carpal bones.

**Os magnum** (*os capitatum*).—The largest, having *head, neck, and body*.

**Unciform** (*os hamatum*).—Named for its *unciform* or *hook-shaped process*.

When the carpus is seen from the front, four prominent points are to be noted, namely—the *tubercle of the navicular* and *ridge of the trapezium*, on the radial side; the *pisiform* bone and *hook of the unciform* on the ulnar side. These mark the boundaries of a deep groove where the long tendons of the fingers glide.

## THE METACARPUS OR PALM (FIG. 52).

The five metacarpal bones (*ossa metacarpalia*) are long in shape but have no medullary canal. Each has a *base*, a *shaft*, and a *head*, the *head being distal*. The bases are articulated with the

second row of the carpus, and the heads with the first row of the phalanges. The *first* corresponds to the thumb; the *second* to the index finger; the *third* to the middle finger, the *fourth* to the ring finger, and the *fifth* to the little finger.

The spaces between them are *interosseous spaces* and are occupied by interosseous muscles.

**Note.**—The *third* metacarpal bone (of the middle finger) is the longest, and its *head* is the most prominent when the hand is clenched, as in making a “fist.”

### PHALANGES.

These are the bones of the fingers and thumb (*digits*). A finger has three, *first*, *second* and *third*; the thumb has two, *first* and *second*. They are long in shape, but without a medullary canal. Each has a *base*, a *shaft*, and a *head*, the *head* being *distal*. The first row of phalanges includes those which are next to the metacarpal bones. The terminal phalanges (those of the third row) have each a horse-shoe-shaped border on the anterior surface for the support of the sensitive finger tip; because these bones bear the nails, they are called the *ungual phalanges*.<sup>1</sup>

**Résumé.**—With the limb in the **anatomic position**, observe the *groove* for the biceps muscles on the front of the humerus, beginning between the greater and lesser tubercles. In the forearm, note that the *ulna* is the bone of the *elbow-joint*, while the *radius* makes the *wrist-joint*; that their shafts are parallel and the palm is turned forward, and the carpus curved to help in forming the hollow of the hand (or the “cup of Diogenes”), and that the thumb is on the radial side, and free.

<sup>1</sup> This description of the metacarpal bones and phalanges follows that of standard text-books. It would seem, however, more in accordance with the facts to consider the palm as composed of *four metacarpal* bones—one for each finger—and to give to the thumb *three phalanges*, since the bone commonly called the first metacarpal (or the metacarpal of the thumb) resembles those of the first row of the phalanges in both form and development.

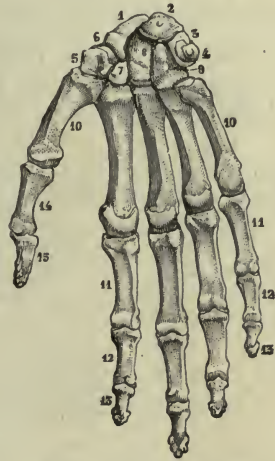


FIG. 52.—RIGHT HAND, PALMAR OR VOLAR SURFACE.

1-9, Carpus, and grooves for tendons; 10-10, metacarpus; 11, 11, phalanges; 12, 12, 2d phalanges; 13, 13, 3d phalanges; 14, 15, 1st and 2d phalanges of thumb.—(Gould's Dictionary.)

## ARTICULATIONS OF THE UPPER EXTREMITY.

**Sterno-clavicular**, a gliding joint (*arthrodia*).—This is the one joint by which the upper extremity articulates with the trunk.

Articular surfaces; on the upper angle of the *manubrium* and the sternal end of the *clavicula*. *Anterior* and *posterior ligaments* connect the bones, forming a *capsule*. (The joint is divided by a disc of fibro-cartilage into two cavities and there are *two synovial membranes*.)

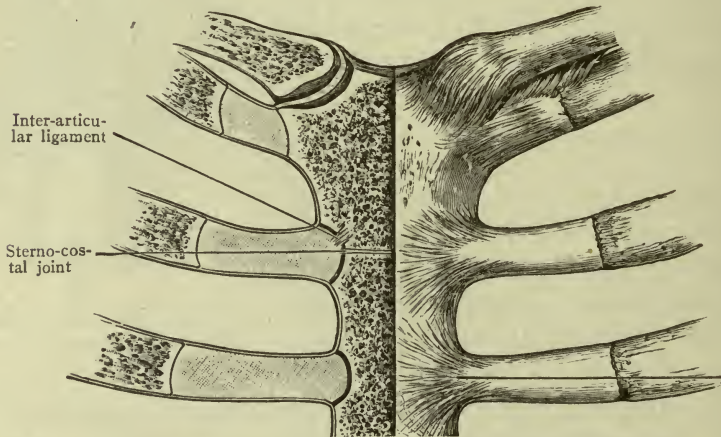


FIG. 53.—STERNO-CLAVICULAR JOINT,—(Morris.)

The inter-articular cartilage is shown in the joint of the right side; capsules shown on the left side.

**Motions.**—*Gliding*, by which the shoulder moves upward, downward, backward and forward.

**Ligaments not connected with the joint but useful in preventing dislocation:**—The *costo-clavicular*, holding the clavicle to the first rib, and the *conoid* and *trapezoid* connecting it with the coracoid process of the scapula.

**Acromio-clavicular.**—A small gliding joint between the *acromion process of the scapula* and the *acromial end of the clavicle*. It is enclosed by a *capsule*.

**Shoulder-joint.**—A ball-and-socket joint (*enthrosis*). Articular surfaces: the *head of the humerus* and the *glenoid fossa of the scapula*. The fossa is deepened by a rim of fibro-cartilage called the *glenoid margin*. The *capsule* is attached to the scapula around the margin of the glenoid fossa, and to the humerus around the anatomic neck. It is so loose that the head of the humerus will



fall an inch away from the glenoid fossa by its own weight if the surrounding muscles be removed; it contains a *synovial membrane* which covers the glenoid margin and folds like a sheath around the long tendon of the biceps muscle (Fig. 54).

**Motions.**—In every possible direction, as *flexion, extension, abduction, adduction, rotation, and circumduction*, with greater freedom than any other joint of the body, because the socket is so shallow and the capsule is so loose.

**Elbow-joint.**—A hinge-joint (*ginglymus*) (Fig. 55).

Articular surfaces: the *trochlea of the humerus* in the *semilunar notch of the ulna*, and the *capitulum of the humerus* in the depressed *head of the radius*.

The ligaments—*anterior, posterior, medial, and lateral*—together compose a large *capsule*. (They are attached to the humerus above the olecranon fossa at the back, and above the coronoid and radial fossæ in front.) The *synovial membrane* is extensive.

**Motions.**—The elbow-joint proper is capable of *flexion and extension only*, like all hinge-joints.

The radius and ulna are connected together at their extremities, making rolling joints (see p. 15); their shafts give attachment to an *interosseous membrane* of white fibrous tissue which almost fills the space between the bones.

**Wrist-joint.**—Between the forearm and the carpus, having a variety of gliding motions, but used principally as a hinge-joint. Articular surfaces: Above—the *lower end of the radius* and the *triangular cartilage* (or articular disc); below—the *first row of carpal bones* (not including the pisiform). The ligaments—*anterior, posterior, medial, and lateral*—enclose the joint like a capsule.

**Motions.**—*Flexion, extension*, and slight lateral bending (or from side to side) making *abduction and adduction*. (If the hand is bent far backward or over-extended, this is *dorsal flexion*.)

**Surgical note.**—The *anterior* ligament of the wrist-joint is

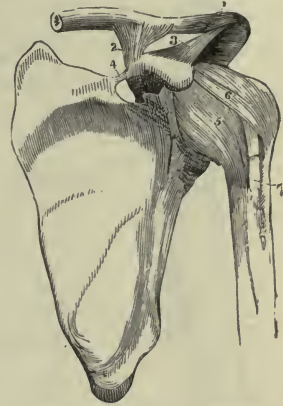


FIG. 54.—LEFT ACROMIO-CLAVICULAR AND SHOULDER-JOINTS.

1, Acromio-clavicular joint; 2, 3, conoid and trapezoid ligaments; 4, transverse ligament, across suprascapular notch; 5, 6, capsule; 7, groove for biceps tendon.—(Potter's Anatomy.)

remarkably strong and seldom torn; the lower end of the radius breaks instead, under sudden great force, as in Colles' fracture.

**Carpal.**—Eight bones arranged in two rows, bound firmly together by short ligaments. *Motions*—*Gliding* only.

**Metacarpal.**—Five bones, articulated by their *bases* to the *carpus*, and by their *heads* to the digits. Head of first, belonging to thumb, is free; heads of others connected together by a transverse band. *Motions*—*Slight gliding*, except in case of the thumb, which may be flexed or bent upon the palm; extended or straightened; abducted from hand; adducted toward hand.

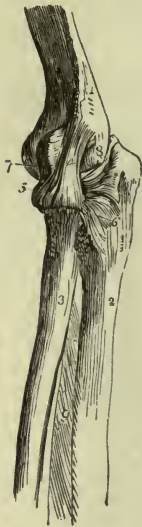

FIG. 55.—LEFT ELBOW-JOINT, LATERAL ASPECT.

1, Humerus; 2, 3, ulna and radius; 4, lateral ligament; 5, orbicular or ring ligament; 6, lateral portion of capsule; 7, anterior portion of capsule; 8, lateral epicondyle. — (Potter's Anatomy.)

**Surgical note.**—In the normal hand, a dislocation of the thumb is most difficult of reduction, because the metacarpal head and the base of the first phalanx are interlocked in such a manner as to form what is called a joint by *reciprocal reception*, or “saddle joint.”

**Phalangeal.**—Three bones in each finger, two in the thumb. *Anterior*, *posterior*, and *lateral* ligaments. *Motions*.—*Flexion* and *extension*.

**Note.**—In the completed hand, the fingers and the thumb can be moved from side to side, independently; that is, they can be *spread apart* (*abduction*) and *drawn together* (*adduction*) (p. 102).

#### SUPINATION AND PRONATION.

These are terms applied to certain movements of the extremities. They are best seen in the forearm where they change the position of the hand.

The *head of the radius* rests in the radial notch of the ulna, held there by a circular band called the *ring ligament* (orbicular), and it can be *rolled* forward or backward, within the ring (a form of pivot joint). Of course, the shaft moves at the same time, the lower end turning forward or backward around the head of the ulna, and the

wrist and hand must accompany it. When the radius and the ulna are placed in the anatomic position, their *shafts are parallel* and the hand lies upon its back; this is **supination**. If the radius *rolls forward*, the shafts become *crossed*, and the hand lies upon its face; this is **pronation**.

**Surgical notes.**—Supination and pronation are very important movements. If they are prevented the hand loses much of its usefulness, therefore fractures of the shafts would not be set in the position of pronation, lest adhesions should form between the *crossed shafts*, preventing supination.

BONES OF THE LOWER EXTREMITY.

In the Thigh.....	Femur.....	.....	1	
In the Leg.....	{ Tibia..... Fibula..... }	.....	2	
In the Tarsus <sup>1</sup> .....	{ Talus..... Calcaneus..... Cuboid..... Navicular bone.. 1st cuneiform... 2d cuneiform... 3d cuneiform... }	1st row... }	..... 7	
				2d row... }
Metatarsus—5 metatarsal bones.....				5
Toes and Digits—14 phalanges.....				14
Patella—1 sesamoid bone.....			1	

30

<sup>1</sup>As given by Spalteholtz—

Talus	} 1st row	Os cuboideum	} 2d row.
Calcaneus		Os naviculare pedis	
(os calcis)	Os cuneiforme I		
	Os cuneiforme II		
	Os cuneiforme III		

THE THIGH.

**Femur.**—The largest bone in the body.

Its **upper extremity** presents a nearly spherical *head* joined by a *neck* to the *shaft*, and resting in the acetabulum. At the junction of the neck and shaft are the two trochanters,—the *trochanter major* on the lateral side, and the *trochanter minor* on the medial and posterior side. The **lower extremity** presents two

*condyles* projecting downward, the *medial* and the *lateral*. The medial is slightly longer and the lateral slightly broader of the two; and the deep notch between them is called the *intercondyloid notch* or *fossa*. There is a projection from the side of each condyle called the *medial* and the *lateral epicondyle*.



FIG. 56.—THE FEMUR, LEFT POSTERIOR ASPECT.

1, 1, Linea aspera; 2, 2, 3, divisions of linea aspera; 4, 4, divisions of linea aspera; 5, 6, head, and mark for ligamentum teres; 7, neck; 8, 9, trochanter major; 10, trochanter minor; 11, 12, lateral and medial condyles; 13, intercondyloid notch; 14, 15, lateral and medial epicondyles.—(Gould's Dictionary.)

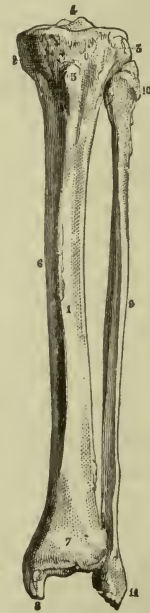


FIG. 57.—LEFT TIBIA AND FIBULA, ANTERIOR ASPECT.

1, Shaft or body of tibia; 2, 3, medial and lateral condyles; 4, spine or intercondyloid eminence; 5, tubercle of tibia; 6, crest or shin; 7, 8, lower extremity, and medial malleolus; 9, shaft or body of fibula; 10, upper extremity or head of fibula; 11, lower extremity and lateral malleolus.—(Gould's Dictionary.)

The **shaft** has a prominent posterior border called the *linea aspera*. This divides lower down into two lines running to the condyles and enclosing a smooth triangular space called the *popliteal space*, or *plane of the femur*. The other borders are not plainly seen.

## THE LEG (FIG. 57).

**Tibia.**—A long bone in the medial side of the leg. Its **upper extremity** is the *head*, which is composed of two *condyles*, medial and lateral, having shallow depressions on the top to bear the condyles of the femur. Between these depressions is the *intercondyloid eminence*, or *spine of the tibia*. The *tuberosity of the tibia* is a large elevation in front, just below the head. The **lower extremity** has a projection downward from its medial surface called the *medial malleolus*, which helps to form the ankle-joint.

The **shaft** has a prominent anterior border called the *crest* or *shin*, which is plainly felt under the skin. This border and the medial surface are both called *subcutaneous* because no muscles cover them.

**Fibula.**—A long bone, in the lateral side of the leg, slender and easily broken. Its **upper extremity** is the *head*, which has a short *styloid process* pointing upward. The lower extremity is the *lateral malleolus*, which helps to form the ankle-joint.

**Note.**—The space between the tibia and fibula is called the *interosseous space*, and is occupied by *interosseous membrane*.

The lower extremities of these two bones form the prominences at the side of the ankle known as the *ankle-bones*; they are the medial and the lateral *malleoli*, which, being subcutaneous, are especially exposed to blows.

**Special notes.**—Observe that the *heads* of all three bones are *proximal*; that the fibula does not form any part of the knee-joint; that the *nutrient foramina* all run *from the knee*.

## THE TARSUS (FIG. 58).

There are seven *tarsal bones* arranged in two irregular rows to form the arches of the foot, or *instep*.

## FIRST ROW.

**Talus** (astragalus).—On the tibial side. Has a *head*, a *neck*, and a *body*; the *body* is received between the two malleoli to form the *ankle-joint*, and the *head* is turned forward toward the toes. It rests upon the calcaneus.

**Calcaneus** (os calcis) or bone of the heel.—The largest tarsal bone. It is under the talus (astragalus), and bears the weight of the entire body in the erect position. The *tuberosity of the calcaneus* projects backward beyond the ankle, and gives attachment to the largest tendon in the body, the tendon of Achilles (*tendo Achillis*).

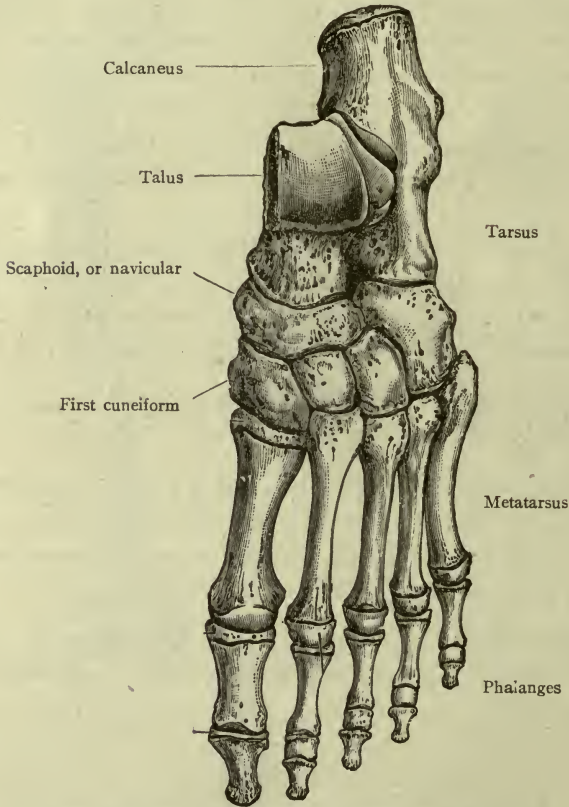


FIG. 58.—BONES OF LEFT FOOT.—(Morris.)

#### SECOND ROW.

**Navicular** (os naviculare).—On the tibial side, in front of the talus, articulating with its head.

**Cuneiform bones** (or wedge-shaped bones).—In front of the navicular. They are three in number, **first**, **second**, and **third**.

**Cuboid** (os cuboideum).—It lies in front of the calcaneus.

## THE METATARSUS.

The five metatarsal bones in the foot resemble the metacarpal bones of the hand in their general characteristics, with some special developments; the *interosseous spaces* between them are occupied by interosseous muscles.

## PHALANGES.

Fourteen in number, as in the hand, and arranged in a similar manner—two for the great toe, and three for each of the other toes.

**Note.**—The great toe is in the *medial* border of the foot.

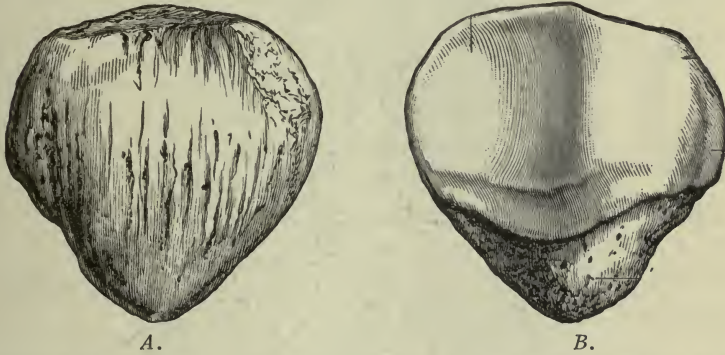


FIG. 59.—LEFT PATELLA. A, ANTERIOR SURFACE, B, POSTERIOR SURFACE.—(MORRIS.)

## PATELLA.

The **patella** is the largest sesamoid bone. It is triangular in shape, placed in front of the knee-joint, and held to the tuberosity of the tibia by a strong band about three inches long—the so-called *ligament of the patella*. Its location while the body is erect is in front of the condyles of the femur, but in the sitting position it is in front of the *lower ends* of the condyles, and in kneeling it is beneath them.

## ARTICULATIONS OF THE LOWER EXTREMITY.

**Hip-joint** (ball-and-socket joint (*Enarthrosis*), Fig. 60).—Articular surfaces: *head of the femur*, and the *acetabulum* deepened by the glenoid rim of the acetabulum (a rim of fibro-cartilage). The bones are directly connected by the *ligamentum teres* (or round ligament) within the joint, which is attached by one extremity near

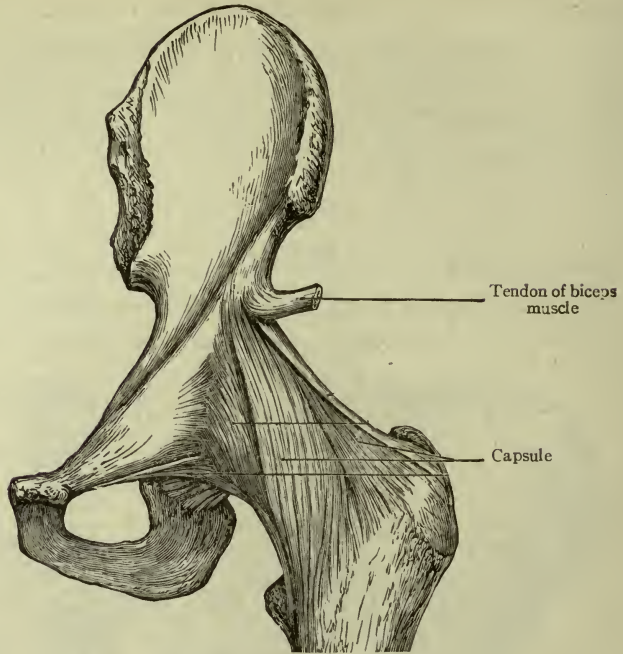


FIG. 60.—HIP-JOINT.—(Morris.)

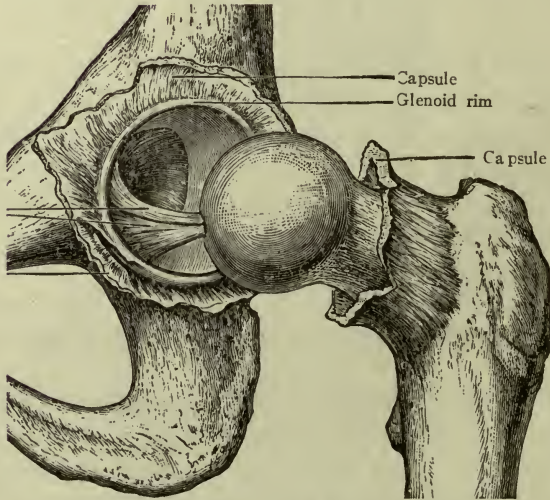


FIG. 61.—LIGAMENTUM TERES.—(Morris.)



the middle of the head, and by the other to the bottom of the acetabulum (Fig. 61).

A **capsule** encloses the joint (Fig. 60). It is strengthened by special bands of fibers extending to surrounding bones,—one, the *ilio-femoral* from the ilium to the great trochanter, resembles an inverted letter **Y**, and was formerly called the *Y-ligament*; also the ligament of Bigelow. The synovial membrane not only lines the capsule but invests the ligamentum teres.

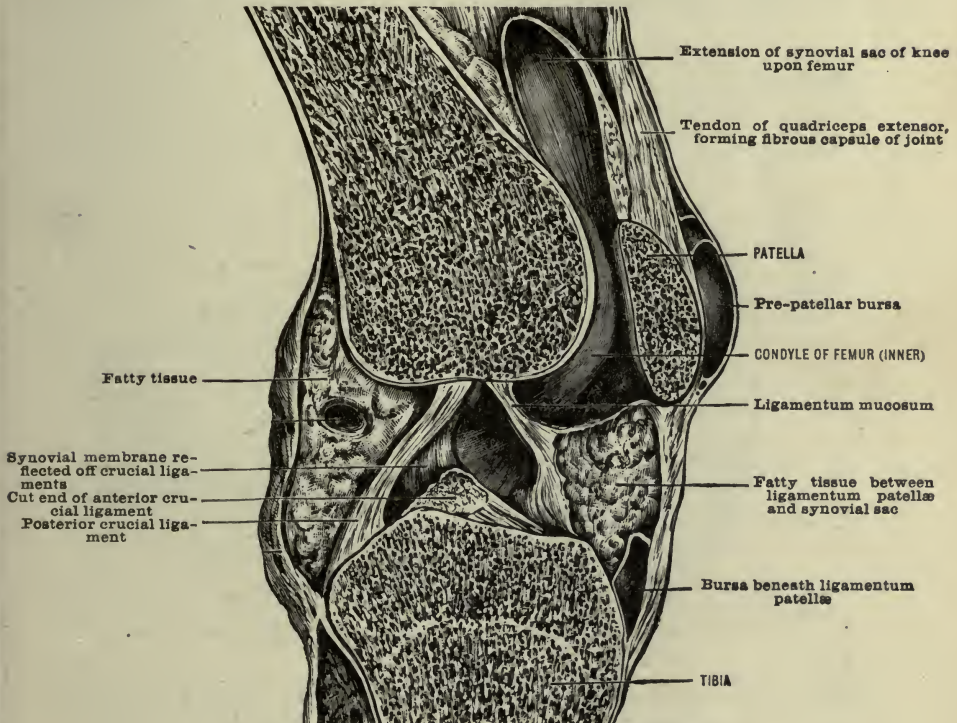


FIG. 62.—INTERIOR OF KNEE-JOINT.—(Morris.)

**Motions.**—Free motion in every direction, like that of the shoulder.

**Knee-joint** (hinge or *ginglymus* joint) (Fig. 62).—Articular surfaces: the *condyles of the femur*, the *head of the tibia*, and the posterior surface of the *patella*. The two surfaces on the top of the tibia are shallow, but their depth is increased by *semilunar fibro-cartilages* attached around the borders, thus forming shallow cups for the condyles.

The femur and tibia are directly connected by two ligaments within the joint, which cross each other and are therefore called the *crucial ligaments*. (One passes from the front of the spine to the lateral condyle, the other passes from behind the spine to the medial condyle.) The patella lies in front of the condyles, being imbedded in a thick tendinous band about three inches long which continues to the tuberosity of the tibia. This band is really the tendon of insertion for some thigh muscles, and is improperly called the *ligament of the patella*. It serves as the *anterior liga-*

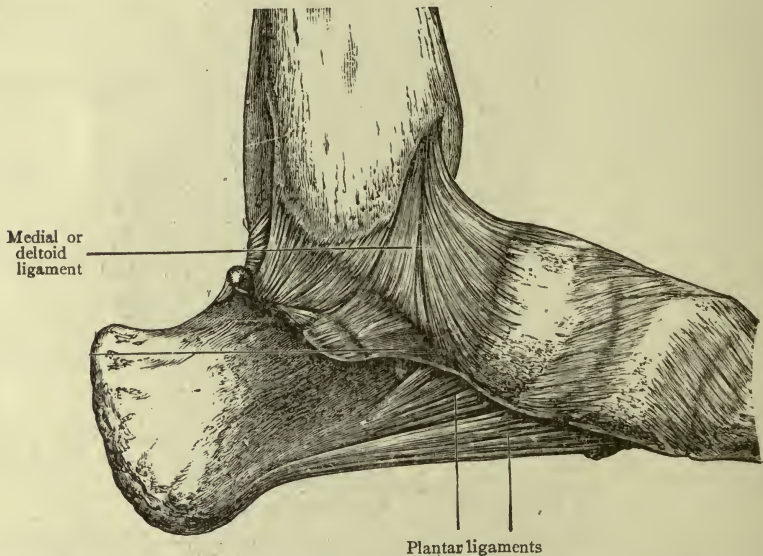


FIG. 63.—LIGAMENTS OF THE ANKLE-JOINT AND PLANTAR REGION.—(Morris.)

*ment* of the joint but is at the same time the quadriceps extensor tendon, sometimes called the patellar tendon. There are distinct *medial* and *lateral* ligaments, and some strong oblique bands at the back; and all are connected by a **capsule** which encloses the joint cavity.

The synovial membrane is very extensive (Fig. 62); it covers the crucial ligaments and semilunar cartilages.

**Motions.**—*Flexion, extension, and very limited rotation* of the leg.

**Note.**—The patella cannot be drawn upward under any circumstances. When the knee is flexed, it lies against the lower ends of the condyles, and in

kneeling the condyles rest upon it. The elasticity of the great muscles to which the patellar tendon belongs, allows very free motion and at the same time keeps the patella always in place close to the condyles.

**Bursæ.**—There are several small cavities called *bursæ*, the use of which is to prevent friction in the tissue outside the knee-joint. They usually communicate with the joint. The largest one is, however, subcutaneous, being in front of the patella between it and the skin. (Fig. 62 and page 77.)

**Surgical note.**—This *prepatellar bursa* is subject to frequent pressure and easily becomes inflamed and enlarged, making the so-called “housemaid’s knee.”

**Ankle-joint.** (hinge-joint).—Articular surfaces on the medial and lateral *malleoli* and the body of the *talus*. They are connected by *anterior*, *posterior*, *medial*, and *lateral* ligaments.

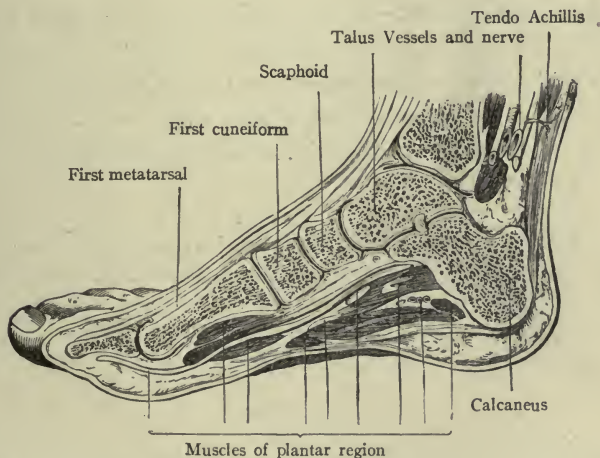


FIG. 64.—MEDIAL BORDER OF RIGHT FOOT, SHOWING BONES IN POSITION.—(Morris.)

The medial is often called the *deltoid* ligament, from its shape  $\Delta$  like the Greek letter delta, and the lateral ligament is in three distinct bands, the *anterior*, *middle*, and *posterior*.

**Motions.**—*Flexion*, *extension*, and slight *abduction* and *adduction*; also lifting the medial border, or *eversion*, and lifting the lateral border, or *inversion*.

**Notes.**—The *transverse ligament* is a special band behind the talus, connecting the two malleoli, to prevent backward dislocation of foot in jumping, running, etc.

There is no motion of the lower extremity which corresponds to supination

in the upper, the whole extremity being in the permanently pronated position, which brings the great toe toward the median line of the body, or on the *medial* border of the foot. (The thumb is on the *lateral* border of the hand.)

**Tarsal.**—An *interosseous* ligament connects the talus to the calcaneus; it is the strongest one in the body. Short fibrous bands connect the various tarsal bones to each other to complete the instep, and there is one *elastic* ligament upon which the *head of the talus* rests. It assists to prevent excessive jarring as the foot strikes the ground. (This is the only ligament containing elastic tissue in the extremities.)

**Metatarsal.**—Like the metacarpal, except that the heads are *all* joined together by a transverse band; the great toe is not free.

**Phalangeal.**—Like those of the hand.

**Arches of the foot.**—The principal arch is from the heel to the ball of the foot; a second one, the transverse, is equally important. The arteries and nerves in the sole of the foot are protected from pressure by these arches, which are preserved not only by the ligaments and the shape of the bones, but by the tendons of certain muscles.

**Practical points.**—In *walking* the weight is transmitted principally through the talus, the navicular, and three cuneiform bones to the three medial toes, giving the “springy” step to the well-arched foot. In *standing*, it falls more upon the calcaneus, and is distributed through the cuboid to the two lateral toes as well.

### RÉSUMÉ.

Comparing the joints in the upper and lower extremities, note that both the shoulder and hip are ball-and-socket joints; that the elbow and knee are hinge-joints, as are also the wrist and ankle; but whereas in the wrist *extension is limited*, in the ankle it is so free as to bend the top of the foot almost against the leg, becoming *dorsal flexion*, and is actually called *flexion of the ankle-joint*, the term extension being used to signify the act of straightening the foot in a line with the leg.

The back of the hand and the top of the foot are both called the *dorsum*; the face of the hand is the palm or *volar* surface, and the sole of the foot is the *plantar* surface. The *thumb* is free; the *great toe* is bound with the others.

The following table of articular nerves is inserted in this place for convenient reference, when, in the care of painful joint affections, the nurse may be interested to know the names of the particular nerves involved.

#### NERVE SUPPLY TO THE PRINCIPAL JOINTS.

Temporo-mandibular.	Fifth cranial or trifacial.
Shoulder.	Suprascapular, subscapular, axillary.
Elbow.	Musculo-cutaneous (principally).
Wrist and hand.	Ulnar, median, deep branch of radial.
Joints of spinal column.	Spinal nerves.
Hip.	Femoral, obturators, sciatic.
Knee.	Femoral, obturator, tibial, peroneal.
Ankle and foot.	Deep branch of peroneal, two plantar nerves.

## CHAPTER V.

### COMPLETION, REPAIR AND FUNCTIONS OF BONES.

#### NOTES CONCERNING THE COMPLETION OF LONG BONES.

In the *humerus*, *radius*, and *ulna*, the nutrient canals lead *toward the elbow* and the bones are completed here at an earlier date than at the wrist or shoulder. In the *femur*, *tibia*, and *fibula*, the nutrient canals lead *away from the knee*; and the bones are completed first at the hip and the ankle.

**Surgical notes.**—The time of *union of the extremities and shafts* of long bones is important from a surgical viewpoint. Thus, in the ends of bones at the *elbow-joint* the extremities join the shafts at about the *seventeenth or eighteenth year*; therefore, injuries near the elbow-joint before this age may cause a separation of the parts, called an epiphyseal fracture. The *upper end* of the *humerus* and *lower ends* of the *radius* and *ulna* unite with their shafts at about the twentieth year; therefore, in the case of an injury of the shoulder or wrist before this age the same possibility is borne in mind.

In the lower extremity certain differences are noted, since the *nutrient arteries* run differently. The bones are completed first at the *upper end of the thigh*, at about nineteen, and at the *lower end of the leg* at about eighteen or twenty years, while the knee is completed last, at between twenty and twenty-five.

It is important for the nurse to understand something of the nature of the baby's skeleton. The general condition at certain periods of life is also of interest.

#### BRIEF SURVEY OF THE SKELETON AT DIFFERENT AGES.

##### At birth :

- Head.....*Skull*-bones have unossified borders and angles, therefore, the membrane is soft at the fontanelles; the base of the skull is largely in cartilage, and the bones are slightly movable.  
*Face*-bones small and very incomplete.
- Spinal column.....*Bodies* of vertebrae partially ossified, with much cartilage between them.  
*Arches*, each in two separate pieces or halves.
- Pelvic-girdle.....*Hip*-bones (*ossa coxæ*) in two pieces, well separated by cartilage.  
*Sacrum* partially ossified.  
*Coccyx* not at all ossified.
- Ribs.....Shafts only are bony.

- Sternum.....Presents a number of small centers, imbedded in cartilage.
- Upper extremity.....*Shoulder-girdle* ossified at acromial end of clavicle and in body of scapula; other parts are cartilage.  
*Long bones*—Shafts partially ossified.  
*Carpus*—all bones entirely cartilaginous.
- Lower extremity.....*Long bones*—Shafts partially ossified; at the knee the ends of the femur and the tibia have begun to ossify.  
*Tarsus*—three bones (talus, calcaneus, and cuboideum) have begun to ossify.  
 The *metacarpal*, *metatarsal* and *phalangeal* bones have thin lines of osseous tissue before birth.

**At age of 20 years :**

- Head }  
 Hands } .....All completed.  
 Feet }
- Long bones.....All completed except tibia and fibula whose upper ends are not yet united with the shafts.
- Ribs }  
 Sternum } .....Are in two pieces each.
- Shoulder-girdle.....Clavicle, sternal end still separate. Scapula soft at borders and processes.
- Pelvic-girdle.....Hip-bones (*ossa coxæ*) completed. Sacrum and coccyx still in two or more pieces.
- Spinal column.....All parts ossified.

**At age of 25 years :...** The skeleton is practically completed. The bones are strong, and the proper proportions of animal and mineral matter are preserved during adult life.  
 The coccyx may unite with the sacrum in middle life, thus modifying one of the diameters of the pelvic outlet.

**In old age :.....** There is no more growth. The supply of animal matter decreases, and the bones become brittle so that they may be easily broken.

POINTS OF PRACTICAL INTEREST CONCERNING THE BONES IN INFANCY.

*First*, the baby's bones are soft, and are still largely composed of cartilage. *Second*, since the process of ossification is going on continually, the proper shape of the cartilage should be preserved in order that the shape of the future bone may be normal. In infancy the **skull** bones are movable as well as soft, and the shape of the baby's head may be altered by pressure. Witness the Flat-head Indians, who bind a board across the top of the infant's skull.

The **spine** and the vertebral extremities of the ribs are composed largely of cartilage; it is therefore evident that not only should a baby's back be supported, but the child should rest in a horizontal position, the spine being so soft that it cannot easily be held upright, even if the little muscles were strong enough to do this without fatigue.

The **pelvis and hip**.—During the first year or two both the *sacrum* and the *coccyx* are still in separate pieces, while the centers in the three portions of the *hip-bones* are well separated by cartilage, leaving the acetabulum unossified; the head of the femur is also soft. Consequently, a thought only is needed to explain why the clothing about a baby's hips should leave them free from pressure.

**Note**.—An advantage is derived from the softness of the skeleton during childhood, as the many jarrings and tumbles incident to the child's experience are far less injurious to the jelly-like frame than they would be to a harder one.

**Green-stick fracture**.—Up to the age of four years the bones are sufficiently soft to *bend* rather than break, as an older bone would do under similar circumstances. Usually some of the fibers do break, but not the whole bone; this is called a *green-stick* fracture, because the bone behaves like a bough of green wood when forcibly bent.

**Rachitis or rickets**.—In this disease ossification is delayed, and the bones are more soft and yielding than usual until completely ossified. The extremities grow larger and the shafts are often bent. When the mineral salts are finally deposited the bone is permanently misshapen.

**Spina bifida**.—In the formation of the vertebræ, the completion of the *arches and spinous processes* occurs latest in the lower lumbar and upper sacral region. Sometimes it is not perfect, and the spinal canal is then left open. This condition is known as *spina bifida* and the membranes and fluid of the spinal cord protrude, forming a tumor upon the child's back. *Spina bifida* occurs rarely in other regions.

#### REPAIR OF BONE.

When a bone is broken nature repairs it in her own way.

First, more blood flows to the part; then a certain amount of animal matter like cartilage, appears about the fracture, forming



a *callus*. This is soon hardened by deposit of mineral matter and the callus becomes bone, but the mark of fracture and repair will always remain. The callus will form and unite the ends of bone even if they are not well matched, but in this case deformity will result.

**Surgical note.**—"Setting" a fractured bone consists in placing the ends in proper position, or "apposition." This, nature cannot do, because the muscles above and below are pulling them out of place, therefore the skill of the surgeon is required for its accomplishment.

**Practical point.**—The nursing care of a fracture is directed to the end of keeping the bone *supported in position*, and as far as may be, perfectly quiet until the callus is hardened, so that the least possible deformity will remain. To accomplish this the nurse must not only have a knowledge of anatomy, but must exercise skill and judgment to an unusual degree.

## PHYSIOLOGY OF BONE AND THE SKELETON.

At first thought it would appear that not much could be said concerning the physiology of bone tissue, which is a finished product, the changes which it undergoes being directed solely to its own preservation. The ability of bone to repair injuries by utilizing material from the blood is, however, a physiological process; and the membranes which cover bony surfaces (periosteum outside, endosteum within medullary canals) have a well-defined function in the formation of bone tissues, already referred to. One of the most important functions of the body, namely:—providing an *origin* for *cells* (or corpuscles) *of the blood*, belongs to the marrow of bones. Cancellous bone contains in its spaces thin red marrow (the "red bone marrow" of clinic use) in which red cells have their origin, while the medullary canals of long bones contain a firmer fatty marrow where many of the white cells of the blood have their beginning.

Taking a broad view, we find many points of interest in the bones and the skeleton which they comprise, some of which have already been touched upon. It is their *mechanical* physiology which is conspicuous and of great importance—they afford attachment to muscles; they enclose cavities; they sustain pressure.

Their usefulness is due to their physical characteristics—for instance, the *hardness* of bones enables the framework which they compose to support the soft parts of the body, and in certain localities enables them to protect internal organs. An important example is the *neural canal* with its contents—the brain and spinal cord.

Again, it is this same quality of hardness which enables the skeleton to bear direct pressure and the body weight. Osseous tissue in certain bones—notably the femur and the *os coxæ*—is especially arranged in *lines of pressure* for this purpose; namely, that superimposed weight may be borne with the least strain upon the bone.

The relation between the *shapes* of bones and the arrangement of their two tissues has a direct bearing upon their usefulness and the convenience with which it is exercised.

Examples are seen in the long bones—their (comparatively) large *extremities* enter into the formation of joints; they also give attachment to many muscles which move the joints. Here, extent of surface is needed and cancellous bone is used with but a thin covering of compact, thus securing the necessary surface without undue weight. Their *shafts* give attachment to fewer muscles, but their position in the extremity exposes them to violence (applied transversely) and calls for endurance of strain. Hence, for these two reasons—first, that extent of surface is unnecessary; and second, that strength and endurance are demanded—the compact tissue is appropriate. It also secures a convenient slenderness of bone where the bulk of muscle tissue is greatest.

By far the greatest variety of functions is seen in the *articulated skeleton*, whereby the movements necessary to the well-being of the individual are made possible by the character of the *joints*.

The movements of the trunk are limited, but sufficient for the needs of the organs which it contains; while those of the extremities are many and free. They may resist external force; they may themselves overcome opposing forces. They may be used as weapons of offense or defense. Facilities for transporting the body from place to place, or *locomotion*, are provided by the articulated bones of the lower extremities; and the power of the upper extremities to perform a thousand necessary acts would not exist without a similar framework. These points have been mentioned already, and will be dwelt upon later in connection with the study of the muscular system.

## CHAPTER VI.

### THE CONNECTIVE TISSUE FRAMEWORK AND THE SKELETAL MUSCLE SYSTEM.

#### THE FASCIÆ OF THE BODY AND MUSCLES OF THE HEAD AND TRUNK.

Although present in every part of the body, the *connective tissue* is so conspicuously associated with the muscle system that a few facts of interest concerning this universal tissue are here reviewed, before commencing the study of the muscles.

For muscles it is a veritable framework, as will be seen. In *fibrous* form it is conspicuous on their surfaces as sheaths, or as separating one from another; and in tendons. As delicate *areolar* tissue it invades them, bearing tiny vessels and nerves and forming *tissue-spaces*.

This it does in all organs—wrapping them, supporting their cells, and invading them to convey vessels and nerves. It fills in spaces between organs, and accompanies large vessels to and from them. It connects organs to each other; and everywhere it forms a network of *tissue-spaces* containing nutritive fluid obtained from the blood-vessels for the cells of the body.

If one could imagine that everything in the human body except connective tissue could be destroyed, the remaining portion would bear the same relation to the body that had been, as a skeleton leaf bears to a fresh green one.

#### THE FASCIÆ OF THE BODY.

The word *fascia* is applied to the connective tissue which surrounds various organs or lines cavities. *Fascia* is found in every part of the body, and we shall study here two varieties, which are associated with the muscles and skin. They are called the *deep* and the *superficial fascia*.

The **deep fascia**.—This is a firm layer of connective tissue with but small spaces between its fibers, therefore it is dense and

tough. It is white and smooth, and seldom contains any fat. The *deep fascia* covers the muscles and binds them down, and also separates them into groups, thus forming *intermuscular septa*. (Many muscle fibers arise from intermuscular septa.) (Fig. 65.)

**Special points.**—The **inguinal ligament** (Fig. 74) is a band of the deep fascia between the spine of the ilium and the tubercle of the pubes. It feels like a cord from one bone to the other. The **fascia lata** (*broad fascia*) is the deep

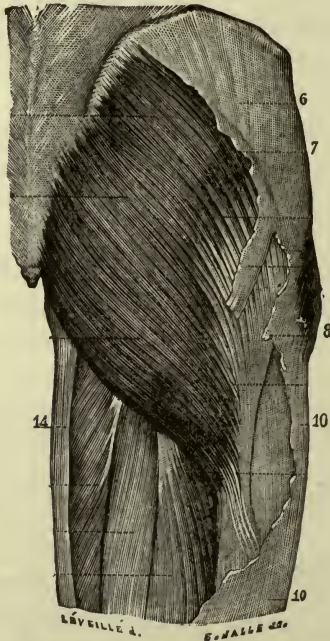


FIG. 65.—DEEP FASCIA OF THIGH (Partial). 6, 7, 8, 10, 14, indicate portions of fascia lata.—(Gould's Dictionary.)

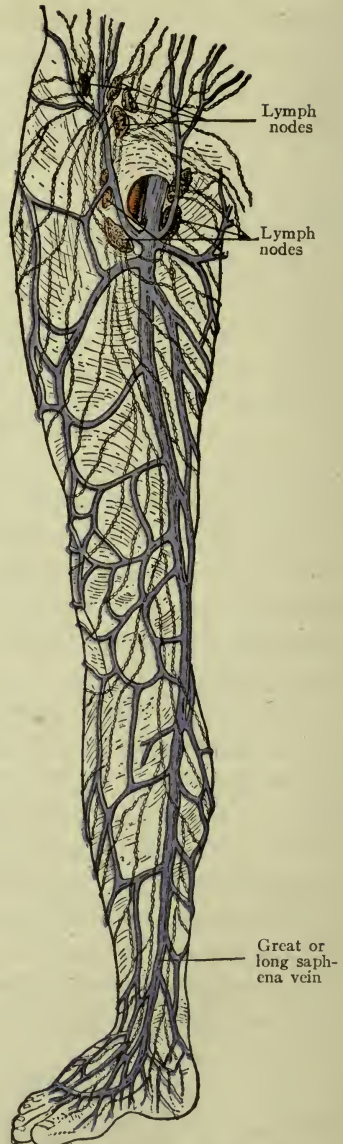


FIG. 66.—SHOWING OVAL FOSSA. The superficial fascia has been dissected away, leaving cutaneous veins lying upon deep fascia.

fascia of the thigh; it is thicker and stronger than any other fascia of the body. It is attached to the hip-bones above and the leg-bones below. A portion which is especially tense and strong may be felt on the lateral side of

the thigh, above the tuberosity of the femur, like a tight band attached to the tibia; it is called the *ilio-tibial band*. See page 105, *tensor fascia lata*.

The **oval fossa** or *saphenous opening* in the fascia lata is an inch and a half below the medial portion of the *inguinal ligament*. It allows the long saphena vein to pass through to the femoral vein (Fig. 66).

The **lumbar fascia** is not a part of the general deep fascia of the body, but belongs to the transversus muscle described on p. 90. It is attached behind to the *lumbar vertebræ*, above to the *last two ribs*, and below to the *crest of the ilium*.

The **superficial fascia** covers the *deep fascia*. It lies immediately beneath the skin in its whole extent and consists of loose-meshed connective tissue, arranged somewhat in layers, and containing the subcutaneous fat. It also imbeds the superficial or cutaneous arteries, veins, and nerves between its layers. In places where the fascia is thin, as on the back of the hand, the veins are easily seen. This fascia is closely connected with the skin, and they glide together over the deeper structures.

A **bursa** is a sac in the fascia which contains smooth fluid resembling synovia. *Bursæ* are found where much pressure or friction occurs between different structures. They act like water-cushions, thus saving the tissues from bruising or rubbing. The largest subcutaneous bursa is in the superficial fascia in front of the patella. It is called the *prepatellar bursa* (Fig. 62).

**Surgical note.**—When the prepatellar bursa becomes inflamed and enlarged, it forms “housemaid’s knee.”

Sometimes bursæ are placed underneath tendons or between muscles, and these deep ones may communicate with joints. There is a large one between the gluteus maximus and the tuberosity of the ischium, and another between the same muscle and the great trochanter.

**Note.**—The *transversalis* and *pelvic fasciæ* are described on pages 93 and 103.

### MUSCLES, THEIR IMPORTANCE.

The growth of bone and fashioning of joints has but prepared the way for more important ends to be accomplished.

The head and trunk protect and support the vital organs, but the food and the air upon which their life depends come only through

the aid of those constant workers, the **muscles**. All motion of any sort in the body, whether conscious or unconscious, is due to their action. If the motion is voluntary it is due to muscles which are controlled by the will, or *voluntary* muscles. Muscles which cannot be controlled by the will are *involuntary*; they are found in the internal organs of the body, or the viscera, and in the coats of the vessels.

All other muscles are *voluntary*, and since they are attached to bones they are called *skeletal* muscles.

**Note.**—The general appearance of muscle tissue may be learned from specimens obtained in markets, and almost all of the various shapes may be studied in the domestic fowl.

#### STRUCTURE OF MUSCLES.

Muscles consist chiefly of collections of red fibers, each fiber composed of little bundles of *muscle-cells*. All of these are wrapped in connective tissue, bound together and enclosed in a sheath.

Examining a muscle with care, we can strip off the sheath of connective tissue (*epi-mysium*), and we shall find that it sends layers down into the muscle to form septa or partitions (*peri-mysium*) enclosing the bundles (or *fasciculi*) of which the muscle is made up.

With the aid of the microscope the *fiber cells* which compose the bundles are revealed, surrounded by still more delicate connective tissue (*endo-mysium*).

Also, under the microscope the fiber cells of voluntary muscle tissue appear striped, consequently voluntary muscle is said to be striped or *striated*. Involuntary fiber cells are plain—involuntary muscle is unstriped or *non-striated*. This sort of muscle is found in internal organs, whose work must go on continually without our conscious supervision.

*Exception.*—The heart: which acts whether we will or not, although its muscle is *striated*.

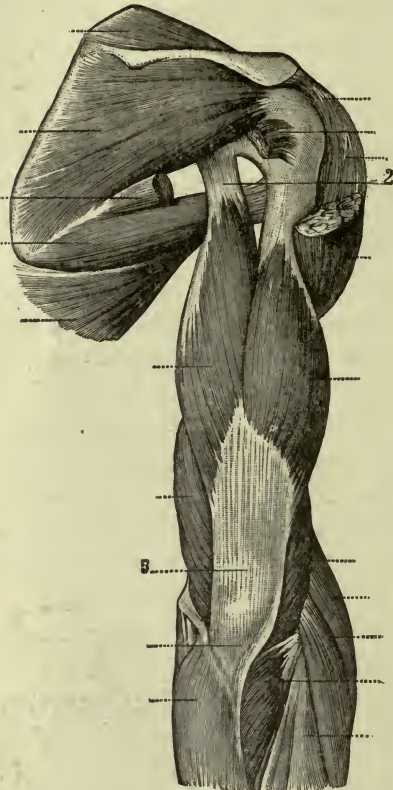


FIG. 67.—SHOWING EXTREMITIES OF MUSCLES. 2, Tendon. 5, Aponeurosis.—(Holden.)

In most cases the connective tissue is prolonged beyond the muscle into a white cord or band called a *tendon*, if the muscle is long and thick; or into a broad thin layer called an *aponeurosis* if the muscle is flat; and by these tendons and aponeuroses the muscles are attached to bones and other organs. Sometimes the red fibers are attached directly to the parts which they move, but in by far the greater number the tendons are conspicuous (Fig. 67).

Muscles are described as consisting of a *body* and two *extremities*; the *body* or belly being the red contracting part which swells in action, while *tendons* (which are possessed by most of the muscles) are simply strong white fibrous bands having no power to contract and no elasticity. This is equally true of the aponeuroses.

The attachments of the *extremities* are spoken of as the origin and the insertion. The extremity which is *stationary* while the other end moves, is the *origin*; the end which *moves with* the organ attached to it, is the *insertion*. The *insertion is always pulled toward the origin* when the muscle contracts.

#### THE MUSCLES OF THE TRUNK.<sup>1</sup>

**Intercostal muscles.**—In two sets, the *internal* and the *external*, which occupy the intercostal spaces. The fibers run obliquely from rib to rib, the *internal* fibers running *upward and forward*, the *external* fibers running *downward and forward*.

**Action.**—They move the ribs up and down in breathing and the various acts associated with it.

<sup>1</sup> Many skeletal muscles have their origin partly from the deep fascia covering them. The bony origins only are given here, as a rule.

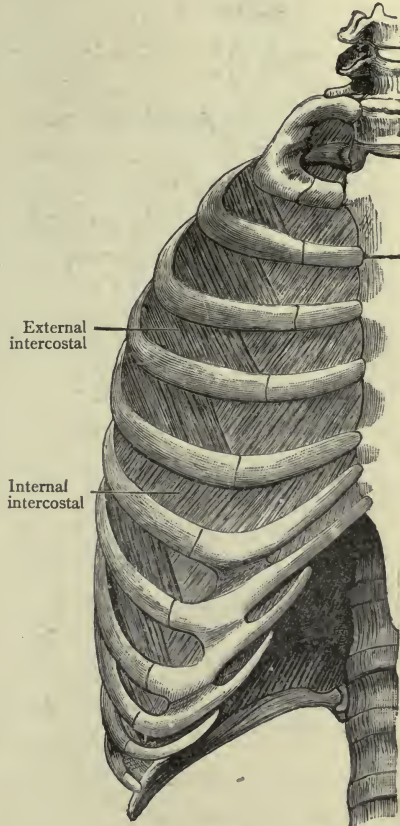


FIG. 68.—INTERCOSTAL MUSCLES.—(Morris.)

## PRINCIPAL MUSCLES OF THE BACK.

In the skeleton a broad groove exists on either side of the spinous processes, which is filled in its whole extent with many vertical muscles of different lengths, the use of which is to hold the spine in the erect position; also they assist to move it in various directions.

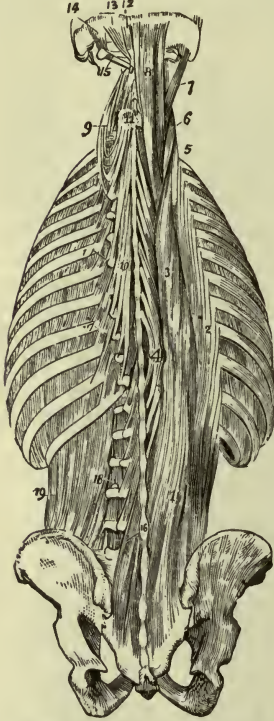


FIG. 69.—THE FIGURES REFER TO THE SPINAL GROUP AND THE QUADRATUS LUMBORUM.—(Potter's Anatomy.)

The **erector spinæ** is the name given to this large group, which is bound down in its place by a thin layer of fibrous tissue called the *vertebral aponeurosis*. This muscle group extends from the skull to the lower part of the sacrum (Fig. 69).

The action is most easily seen in the lumbar and dorsal regions, where it is not deeply covered with other muscles.

*Nerves.*—*Posterior spinal.*

The **latissimus dorsi** (broadest of the back, Fig. 70).—This muscle covers most of the erector spinæ and a great portion of the back of the trunk.

**Origin.**—The spinous processes, from the sixth thoracic down to the end of the column.

Also the crest of the *ilium* and a few fibers from the inferior angle of the scapula.

**Insertion.**—The crest of the lesser tubercle of the humerus.

**Action.**—Principally to pull the arm backward and keep the scapula or shoulder-blade close to the chest; brought prominently into use in rowing a boat or when the body is suspended by the hands and an effort is made to draw it up.

*Nerves.*—*Posterior spinal and long subscapular.*

## MUSCLES OF THE BACK OF THE NECK.

These muscles move the head and neck. Only the most important are here described.

The **splenius**.—This muscle is in two portions, the splenius of the head (capitis) and the splenius of the neck (cervicis) (Fig. 69).



**Origin.**—The spinous processes of the last cervical and first six thoracic vertebræ. **Insertion.**—Partly upon occipital and mastoid bones (*splenius capitis*) and partly upon the transverse processes of the upper vertebræ (*splenius cervicis*).

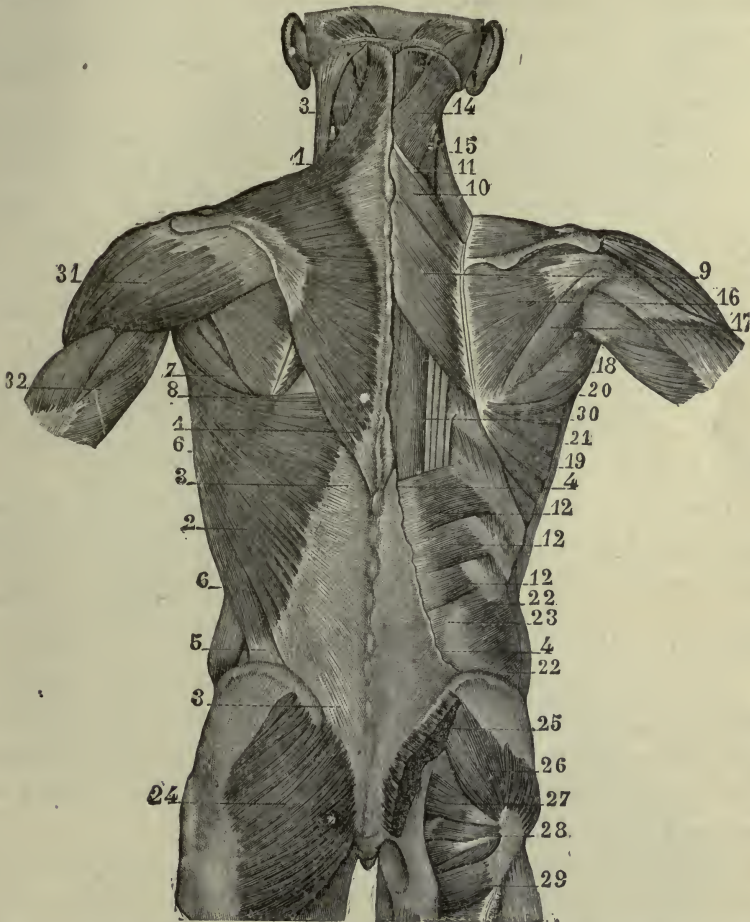


FIG. 70.—SUPERFICIAL AND MIDDLE MUSCULAR LAYERS OF THE POSTERIOR ASPECT OF THE TRUNK.—Holden.)

1, Trapezius; 2, latissimus dorsi; 3, aponeurosis; 4, 5, 6, 8, 19, 20, different portions of latissimus dorsi; 9-12, deep muscles; 13, sterno-mastoid; 14, splenius; 15, elevator of scapula; 16, infraspinatus; 17, teres minor; 7, 18, teres major; 21, portion of anterior serratus; 22, 23, abdominal muscles; 24, 25, gluteus maximus; 26-30, deep muscles; 31, deltoid; 32, triceps.

**Action.**—The muscle of one side alone will rotate the head, twisting the neck. The muscles of both sides acting together simply pull the head backward or extend it and the neck.

**Nerves.**—*Posterior cervical.*

The **trapezius** covers the other muscles of the back of the neck, and also the upper portion of the latissimus dorsi. It is one of the largest muscles in the body (Fig. 70). The two muscles, right and left together make a large diamond-shaped sheet.

**Origin.**—The occipital bone, the ligamentum nuchæ, and the spinous processes of the thoracic vertebræ. **Insertion.**—The spine of the scapula and lateral third of the clavícula.

**Action.**—With the *shoulders stationary* the trapezius acts upon the head to pull it backward or sideways. With the *head stationary* it can elevate the shoulder-girdle and the whole upper extremity with it. Both muscles together can draw the shoulders back. If the hands grasp a bar above the head these muscles will assist to draw the body up. The largest two of the “climbing muscles” are the latissimus dorsi and the trapezius.

*Nerves.*—Cervical, and spinal accessory.

**Note.**—Observe in the illustration its *tendinous* area, which remains flat during action of the muscle.

**Clinical Note.**—Spasmodic action of the trapezius is often the cause of wry-neck, or *torticollis*, and this may be increased by spasm of the splenius.

#### MUSCLES OF HEAD, AND FRONT AND SIDE OF THE NECK (Fig. 71).

The *muscles of expression* are those of the scalp and face. They are closely connected with the under surface of the skin, or with each other; they have no deep fascia over them, and therefore their slightest contraction is shown on the face, thus varying the movements and lines of expression.

**Epicranial muscle.**—On the forehead and the top and back of the head—a broad thin muscle made up of two distinct parts with an *aponeurosis* between them. The posterior part is the *occipitalis*, taking **origin** from the curved line of the occipital bone and ending in the aponeurosis on the top of the head. The anterior part is the *frontalis*, having **origin** in the aponeurosis, and passing down over the forehead to the **insertion** in the tissues of the eyebrows.

**Action.**—Principally to lift the eyebrows, producing the transverse wrinkles across the forehead which express surprise. The skin is closely connected with this double muscle in its whole length,

so that contraction causes movement of the scalp. (Some people can move the scalp backward and forward by contracting the two portions alternately).

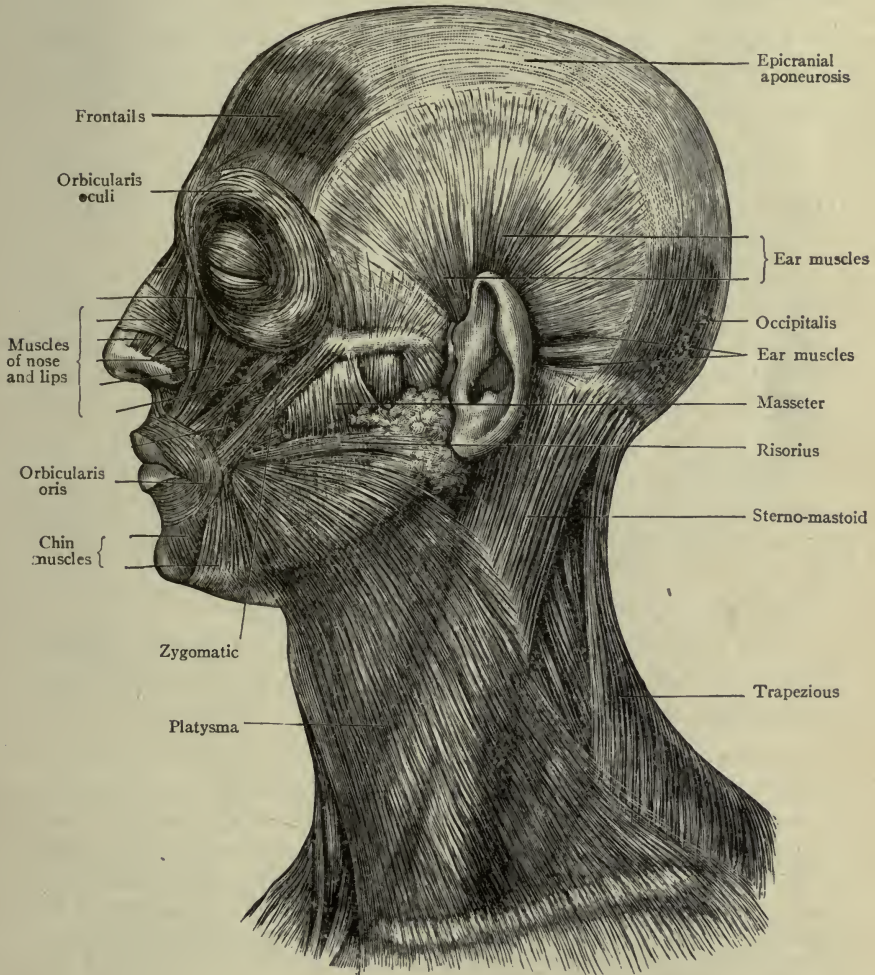


FIG. 71.—MUSCLES OF THE HEAD AND NECK.—(MORRIS.)

The aponeurosis extends in a thin layer at the side over the temporal region, giving origin to certain small muscles which move the ear. The scalp and ear usually move together.

*Nerve.*—Seventh cranial (or facial).

**Orbicularis oculi.**—The ring-like muscle of the eyelid. It is attached to the medial border of the orbit. Some of its fibers are in the lid—the *palpebral* portion—while others surround the lids like a broad flat ribbon, forming the circular or *orbital* portion, and bearing the eyebrows (Fig. 71).

**Action.**—When the palpebral fibers contract the lids cover the eyeballs lightly; when the circular fibers contract the lids are pressed against the ball.

*Nerve.*—*Seventh cranial.*

**Levator palpebræ** (elevator of the eyelid).—Within the orbit.

**Origin.**—At the apex of the orbit. **Insertion.**—In the upper lid.

**Action.**—It lifts the lid and opens the eye.

*Nerve.*—*Seventh cranial.*

**Corrugator.**—The muscle which wrinkles the eyebrow. **Origin.**—The frontal bone. **Insertion.**—The under surface of eyebrow.

**Action.**—It draws the brows downward and inward toward each other; it is the *frowning* muscle.

*Nerve.*—*Seventh cranial.*

**Orbicularis oris** (ring muscle of the mouth).—Surrounds the opening of the mouth, constituting the larger portion of the lips. The fibers have only one bony attachment—below the septum of the nose.

**Action.**—It closes the mouth.

The lips themselves are moved in various ways by muscles above and below them—the *elevators* and *depressors* of the lips (all supplied by the *seventh cranial nerve*).

**Special points.**—Most of the changes in the expression of the face are caused by the action of the *ring muscles* and of those which are attached to them. For example, the *lifting of the eyelids* by the frontalis expresses *surprise*. The *wrinkling of the brows* by the corrugators speaks *disapproval* or *bewilderment*. The risorius, or *laughing* muscle, draws the *corners of the mouth* outward. The *sneering* muscle lifts the *nostril, and lip* together. *Pleasure* is expressed by the lifting of the angles of the *lips upward and outward*, while grief depresses them. (There are but three of the depressors, or *grieving* muscles, on each side, and six for the manifestation of happier feelings.)

#### MUSCLES OF MASTICATION, FIVE IN NUMBER

The **temporal** muscle.—Occupying the entire temporal fossa.

**Origin.**—The floor of the fossa, and the temporal fascia covering it. **Insertion.**—The coronoid process of the mandible.

**Action.**—It closes the mouth and draws the mandible or lower jaw-bone backward.

*Nerve.*—*Fifth cranial (or tri-facial).*

The **masseter**.—At the side of the face (Fig. 73). **Origin.**—The zygomatic arch. **Insertion.**—The lateral surface of the ramus of the mandible.

**Action.**—It closes the mouth and moves the jaw forward slightly.

*Nerve.*—*Fifth cranial.*

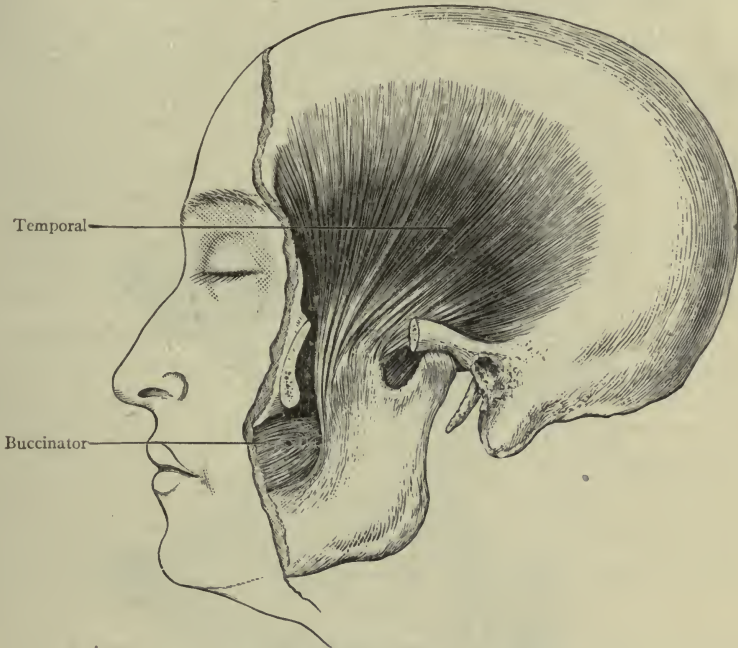


FIG. 72.—THE TEMPORAL MUSCLE.—(MORRIS.)

The **internal pterygoid**.—In the infra-temporal fossa covered by the ramus of the mandible on which it is inserted.

**Action.**—It closes the mouth and moves the jaw forward and sideways.

**External pterygoid.**—Also in the infra-temporal fossa and inserted on the mandible.

**Action.**—It moves the jaw forward and sideways.

*Nerve.*—*Fifth cranial.*

**Buccinator.**—**Origin**, from both the maxilla and the mandible on the alveolar borders. The fibers approach each other, interlacing and running forward, and some of them join the lip muscles, constituting the **insertion** (Fig. 72).

**Action.**—It helps to close the mouth, and keeps the food between the teeth during the act of mastication.

**Nerves.**—*Fifth and seventh cranial.*

By the action of the first four muscles the food is divided and crushed, and also ground; the external pterygoid is especially a grinding muscle. The function or use of these four would be somewhat limited without the aid of the buccinator.

### MUSCLES IN THE FRONT OF THE NECK.

The **ribbon muscles**, thin and flat, connecting the larynx and hyoid bone above, with the sternum, rib, and clavicle below.

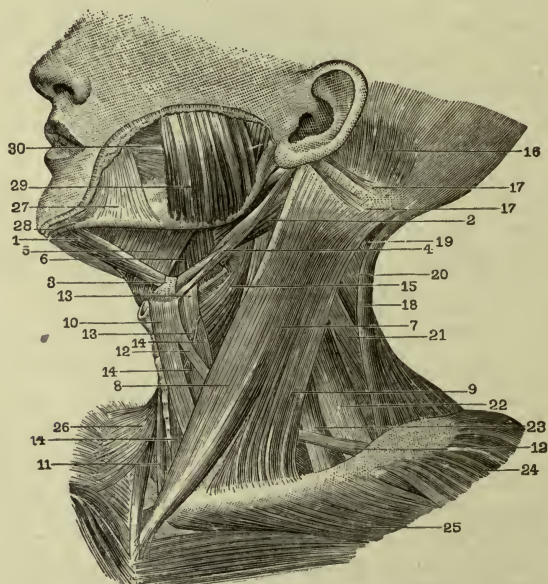


FIG. 73.—MUSCLES IN FRONT OF THE NECK.

1, 2, 3, Digastric muscle; 4, stylo-hyoid; 5, mylo-hyoid; 6, hyo-glossus; 7, 8, 9, sterno-mastoid; 10, 11, 12, 13, 14, ribbon muscles; 15, pharynx; 16, occipitalis; 17, ear muscles; 18, trapezius; 19, 20, splenius; 21, levator scapulae; 22, 23, scalene; 24, deltoid; 25, pectoralis major; 26, right platysma; 27, 28, lip muscles; 29, masseter; 30, buccinator.—(From Holden.)

They are the **sterno-hyoid**, the **sterno-thyroid**, and the **omo-hyoid** (a *double-bellied* muscle, with an intervening tendon, the inferior belly being attached to the upper border of the scapula, the superior belly to the hyoid bone, while the *tendon* between them glides through a loop of fascia attached to the clavicle).

**Action** of the three muscles.—They draw the hyoid bone and the larynx downward, and steady them.

*Nerves.*—*Ninth cranial, or hypoglossal.*

The **digastric** is another *double-bellied* muscle (Fig. 73).

The posterior belly is attached to the mastoid process (medial surface); the anterior belly to the under surface of the mandible close to the symphysis. The *intervening tendon* glides through a loop of fascia connected with the hyoid bone.

**Action.**—It draws the mandible downward, and opens the mouth. It is assisted by some other short muscles connecting the mandible to the hyoid bone.

*Nerves.*—*Seventh cranial and fifth cranial.*

The **mylo-hyoid** (Fig. 73) is a flat muscle which forms the floor of the mouth, being attached by one border to the inner surface of the body of the mandible, and by the other to the hyoid bone, which, it will be remembered, is on a level with the mandible.

**Action.**—It can draw the hyoid bone forward in the act of swallowing, thus keeping the larynx out of the way of the food.

*Nerves.*—*Seventh cranial (and cervical).*

The **platysma**.—As the muscles of the back and side of the neck are covered by the trapezius, so those of the front and side are covered by the *platysma*, which is a broad thin sheet of muscular fibers attached above to the mandible and the fascia of the side of the face, and below to the deep fascia on the front of the shoulder (Fig. 71). Like the face muscles, it is not covered by deep fascia, and since it moves the skin, it is like them a *muscle of expression*. It draws the angle of the mouth downward, and strong contractions of the muscle assist in causing an appearance as of one in a "great rage." The action of this muscle in grazing animals is displayed when used to shake off insects which alight upon the skin of the neck.

The **sterno-cleido-mastoid** (Figs. 71, 73) is the most conspicuous muscle in the side of the neck. **Origin.**—By two divisions, one on the sternum (sternal, or medial origin), the other on the clavicle (clavicular, or lateral origin). **Insertion.**—The mastoid process and upper curved line of the occipital bone.

**Action.**—Principally to pull the mastoid process toward the sternum and clavicle. If the *right* muscle contracts the right mastoid process comes downward and forward and the *chin turns upward to the left*. If the *left* muscle contracts the left mastoid is pulled downward and forward and the *chin goes upward to the right*. Both muscles together simply bend the head forward, or flex it.

*Nerves.*—*Spinal accessory (and cervical).*

**Clinical note.**—The sterno-mastoid is another muscle which is sometimes the seat of spasmodic contractions, causing wry-neck, or *torticollis*.

**Levator scapulæ.**—The elevator of the scapula is an important muscle in the side of the neck. **Origin.**—The upper three or four transverse processes. **Insertion.**—The medial angle of the scapula.

**Nerves.**—*Cervical*.

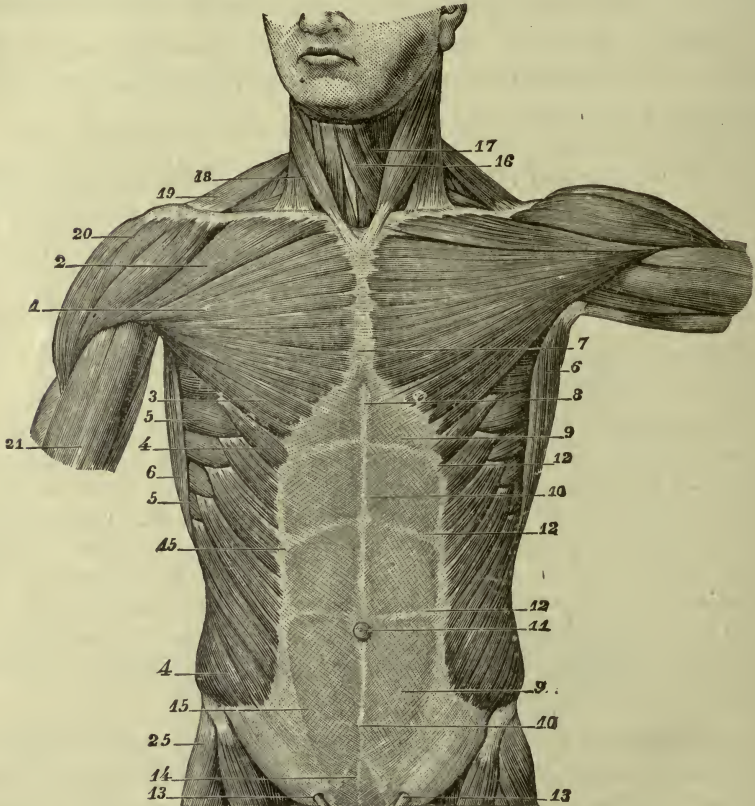


FIG. 74.—ANTERIOR SURFACE OF THE ABDOMINAL WALL.

1, 2, 3, 7, Pectoralis major; 4, external oblique; 5, serratus anterior; 6, latissimus dorsi; 8, xiphoid appendix; 9, 9, 15, aponeurosis of ext. oblique; 10, 14, linea alba; 11, umbilicus; 12, transverse lines of aponeurosis; 13, 13, subcutaneous abdominal ring; 16, 17, 18, 19, refer to muscles of neck; 20, deltoid.—(Gould's Dictionary.) Lower border of aponeurosis is *inguinal ligament*.

## THE ABDOMINAL WALL.

The abdominal wall has no bones except the lumbar vertebræ, being mostly muscular and aponeurotic. Each lateral half is composed of one vertical muscle in front, next to the median line;



another in the back, next to the spinal column; and three well-developed layers having fibers of different directions, at the sides.

**Rectus abdominis** (Fig. 75).—This is the vertical muscle in front. **Origin.**—The body of the pubes. **Insertion.**—The ensiform appendix and the cartilages of the fifth, sixth, and seventh ribs. It is therefore narrow below and broad above, and its outer border is *curved* from the seventh rib down to the pubes. This is indicated in the fascia over the muscle by a distinct line called the *linea semilunaris* (*semilunar line*).

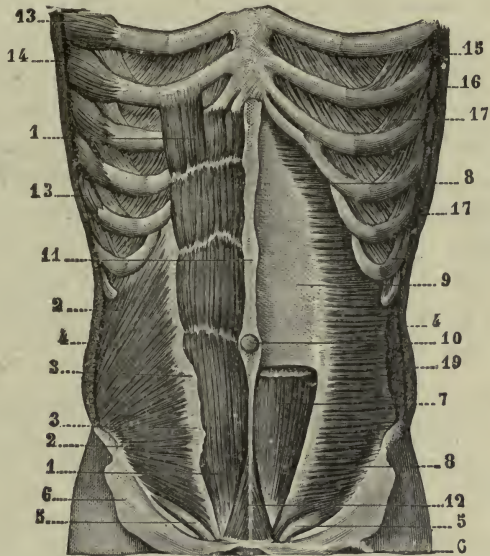


FIG. 75.—INTERNAL OBLIQUE AND TRANSVERSE MUSCLES.

1, Rectus abdominis; 2, 2, 3, 3, internal oblique and cut edge of its aponeurosis; 4, 4, cut edge external oblique; 5, 5, spermatic cords; 6, aponeurosis ext. oblique turned down; 7, rectus, upper part removed; 8, 8, 9, transversus muscle; 10, umbilicus; 11, 12, linea alba; 13, serratus anterior; 14, 15, cut edge latissimus dorsi; 17, 17, external intercostal; 19, cut edge external oblique.—(Gould's Dictionary.)

**Action.**—It compresses the abdominal organs.

**Nerves.**—*Lower thoracic.*

**Quadratus lumborum.**—This is the vertical muscle at the back (Fig. 69). **Origin.**—The crest of the ilium. **Insertion.**—The lowest rib and transverse processes of the lumbar vertebræ. It occupies the space at the back of the trunk between the thorax and pelvis, being covered by the erector spinæ and latissimus dorsi.

**Action.**—It draws the rib down and the spine to one side—*lateral flexion of the trunk.*

*Nerves.*—*Lower thoracic.*

The three layers at the side and front consist of the **obliquus externus** or *external oblique*; the **obliquus internus**, or *internal oblique*; and the **transversus** muscles. They occupy the space between the eight lower ribs above, and the ilium and pubes below. Being broad and flat they do not possess tendons of the usual kind, but many of their muscle fibers terminate in layers of white fibrous tissue called *aponeuroses*, which continue to the median line, there blending with the layers from the opposite side. This produces a firm interlacing of white fibers called the **linea alba** or *white line*, stretched between the ensiform appendix above and the body of the pubes below. It is a very strong and important line, through which, a little below the middle, the umbilical cord passes in the fetus. This point in the linea alba is indicated by the **umbilicus**, or navel.

The **external oblique** (Fig. 74) is the outermost of the three layers. **Origin.**—The lower eight ribs. Direction of fibers, downward and forward. **Insertion.**—Some fibers on the crest of the ilium; others in an aponeurosis which passes to the linea alba.

*Nerves.*—*Lower thoracic.*

**Special point.**—The lower border of the aponeurosis of this muscle between the spine of the ilium and the spine of the pubes is firm and unyielding, easily felt, and important to be recognized; it is called the **inguinal ligament** (or *Poupart's ligament*).

The **internal oblique** (Fig. 75) lies underneath the external oblique. **Origin.**—The lumbar fascia, crest of the ilium, and lateral half of the inguinal ligament. Direction of fibers, upward and forward. **Insertion.**—Some fibers on the lower four ribs, others in the linea alba, and the lowest ones on the crest of the pubes.

*Nerves.*—*Lower thoracic and ilio-inguinal.*

The **transversus** (Fig. 75) is the innermost of the three layers. **Origin.**—The lower six ribs, the lumbar fascia, crest of the ilium, and lateral half of the inguinal ligament. Direction of fibers, transversely across the side of the abdomen, toward the front. **Insertion.**—In the linea alba, and the crest of the pubes. On the pubes it is blended with that part of the internal oblique which is attached to the same bone, making the *conjoined tendon*.

*Nerve.*—*Lower thoracic.*

**Action, of the three broad muscles.**—They compress the abdominal viscera and expel the contents of those which are hollow.

The *fibers from the inguinal ligament*, of both internal oblique and transversus muscles, arch downward to the pubes.

#### SHEATH OF THE RECTUS ABDOMINIS (FIGS. 74, 75).

In the lower fourth of the *linea semilunaris*, the entire thickness is continued forward as one layer in front of the muscles. In the upper three-fourths the *linea semilunaris* divides into two layers which meet again in the *linea alba*; thus a compartment is formed to be occupied by the rectus muscle.

This is called the *sheath of the rectus*, with its anterior and posterior layers, the anterior layer being thickest and strongest in the lower part where the greatest strain would be brought upon it.

**Lineæ transversæ** (transverse lines).—At three different levels above the umbilicus the anterior layer of the sheath is held down to the rectus muscle by fibers forming three *transverse lines*.

**Note.**—The location of all these markings—the semilunar line, the white line, and the three transverse—may be seen on the surface of the body during the action of the muscles; and in a piece of statuary representing the trunk they should be plainly indicated (Fig. 74).

#### ROOF OF THE ABDOMEN.

The *roof* of the abdomen is the *diaphragm*; it has no floor of its own, the pelvic floor serving for both cavities (page 103).

**The diaphragm.**—This is a broad, thin, *dome-shaped muscle* separating the abdominal and thoracic cavities. The central portion is aponeurotic, serving for the *insertion* of the remaining or muscular portion.

**Origin.**—a. By two vertical bundles at the sides of the lumbar vertebræ. These vertical portions are the *crura* of the diaphragm. Their fibers turn forward, crossing and interlacing before they end

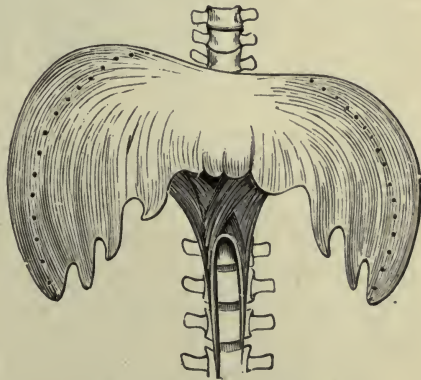


FIG. 76.—THE DIAPHRAGM.  
Dotted lines indicate descent in contraction.  
—(Holden.)

in the central tendon. b. From arches of lumbar fascia and the lower boundary of the thorax (seventh to twelfth ribs and xiphoid appendix).

**Insertion.**—In a flat central tendon, shaped like a clover leaf, near the center of the dome. The *lateral portion arches higher than the central*, forming a *cupola* on each side.

**Action.**—When the **diaphragm** contracts it becomes flattened, pressing upon the abdominal organs; when it relaxes, it springs back to its dome-shape, as high as the fourth or fifth rib, pushing gently against the lungs.

*Nerve.*—*Phrenic.*

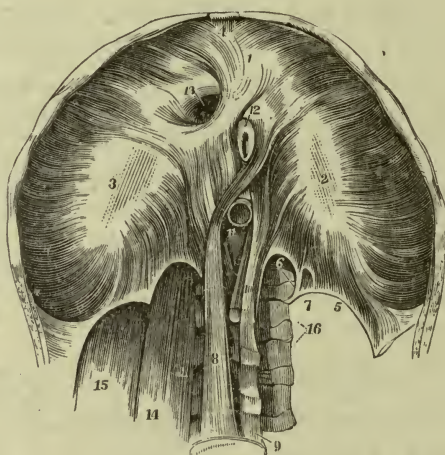


FIG. 77.—THE DIAPHRAGM, INFERIOR SURFACE.

1, 2, 3, Tendinous leaflets; 4, muscle fibers; 5, 6, 7, tendinous arches; 8, 10, fibers arising from vertebræ; 11, aorta—a large artery; 12, esophagus, leading to stomach; 13, opening for vena cava.—(Potter's Compend of Anatomy.)

**Special points.**—This muscle forms the floor of the thorax, and at the same time the roof of the abdomen (convex floor, concave roof). There are three openings in it at the back part for the passage of a large artery and vein,—the aorta and vena cava, and the esophagus.

With the muscles thus far described the walls of the cavities of the trunk—dorsal and ventral—are completed (see page 48).

#### INTERIOR ABDOMINAL MUSCLES.

The **psoas major** and **iliacus**.—These are two muscles within the abdomen (on the posterior wall) which pass out over the brim of the pelvis into the thigh.

**Psoas major.** **Origin.**—The sides of the lumbar vertebræ.  
**Insertion.**—Trochanter minor of the femur.

**Iliacus.** **Origin.**—The iliac fossa. **Insertion.**—With the psoas on the trochanter minor of the femur.

**Action.**—They act together as one muscle, the **ilio-psoas**, to flex the thigh, at the same time rotating it, so that the *foot turns outward*.

*Nerves.*—Lumbar and femoral.

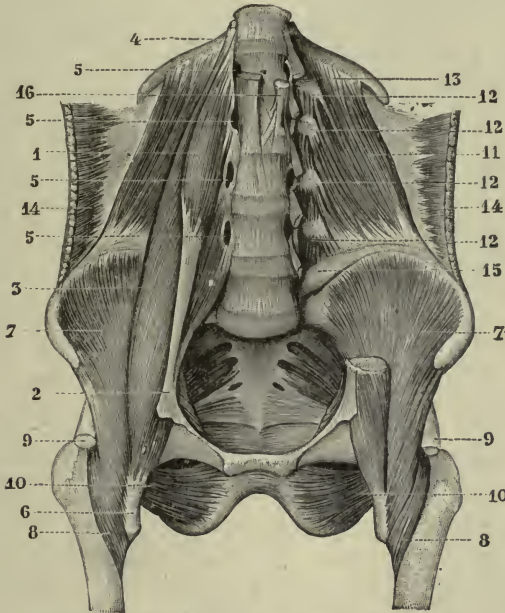


FIG. 78.—ABDOMINAL MUSCLES, INTERIOR.

1-5, Psoas minor and major; 6, attachment of psoas major to trochanter minor, 7, 7, 8, 8, iliacus; 9, 9, cut tendon rectus femoris; 10, 10, obturator externus; 11-13 quadratus lumborum; 14, 14, transversus.—(Gould's Dictionary.)

**Surgical note.**—Disease of the lumbar vertebræ resulting in pus forms *psoas abscess*. The pus often follows the muscle fibers downward and appears below the inguinal ligament.

(The *psoas minor* is a small muscle in front of the major.)

The **transversalis fascia** is a layer of loose connective tissue which completely lines the abdomen; it is continuous with the iliac fascia on the iliacus muscle and with the pelvic fascia below.

## CHAPTER VII.

### MUSCLES OF THE EXTREMITIES.

The muscles of the extremities are frequently named for their use, and they may all be grouped according to their action; as *flexors*, to bend the joints over which they pass, and *extensors* to straighten them; *pronators* and *supinators*; *abductors* and *adductors*; and *rotators*, inward or outward. Their origins are not only from bones, but from fascia, and the fibrous septa between them. This is true of most muscles to some extent, but particularly so in the extremities.

The bony attachments only are given here.

### MUSCLES OF THE UPPER EXTREMITY.

#### SHOULDER MUSCLES.

**Supraspinatus.**—On the dorsal surface of the scapula. **Origin.**—The *supraspinous* fossa, the tendon passing over the head of the humerus to the **insertion** on the top of the greater tubercle.

**Action.**—It lifts the arm away from body (abduction).

**Infraspinatus.**—Also on the dorsal surface of the scapula. **Origin.**—The *infraspinous* fossa. **Insertion.**—The greater tubercle of the humerus (below the supraspinatus).

**Action.**—It rotates humerus outward (the *palm turns forward*).

*Nerve, both muscles.*—*Suprascapular.*

**Teres minor.** **Origin.**—The axillary border of the scapula. **Insertion.**—The greater tubercle, just below the infraspinatus.

**Action.**—It rotates humerus outward (*palm turns forward*).

*Nerve.*—*Axillary.*

**Teres major.** **Origin.**—Near the inferior angle of the scapula (on axillary border). **Insertion.**—The shaft of the humerus (crest of lesser tubercle), joining the tendon of the latissimus dorsi and acting with it (Fig. 79).

**Action.**—It draws the arm backward, and rotates it inward (the palm turns backward).

*Nerve.*—*Subscapular (lower).*

**Subscapularis** (Fig. 81). **Origin.**—The subscapular fossa.  
**Insertion.**—The lesser tubercle of the humerus.

**Action.**—It holds head of humerus in place and rotates it inward (the palm turns *backward*).

The **deltoid** (Fig. 80).—Is triangular in shape and forms a sort of cap over the shoulder-joint. **Origin.**—The spine and acromion of the scapula, and the lateral portion of the clavicle. **Insertion.**—The lateral surface of the humerus at the middle of the shaft, on the *deltoid tuberosity*.

**Action.**—Principally to elevate the humerus to a horizontal position (acting with the supraspinatus, an *abductor* of the arm).

*Nerve.*—*Axillary*.

The **serratus anterior** (Figs. 70, 80).—A large flat and important muscle which lies between the scapula and the thorax. **Origin.**—By separate slips from eight ribs, on the front and side of the thorax. **Insertion.**—The *vertebral border* of the scapula. It lies close to the side of the thorax, covering a considerable portion of the ribs and intercostal muscles.

**Three actions.**—It holds the scapula firmly in place and pulls it forward, thus pushing the arm ahead. If the shoulders are held firmly it can elevate the ribs, assisting inspiration. It sustains the weight of the body when resting upon hands and knees, as in *creeping*.

*Nerve.*—*Long thoracic or external respiratory*.

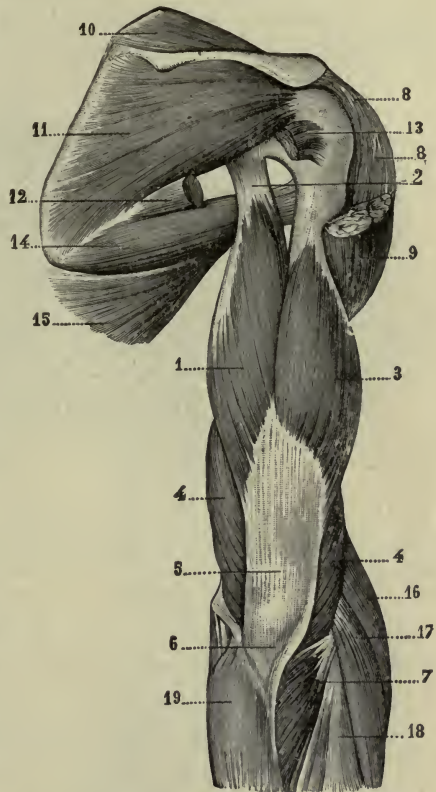


FIG. 79.—MUSCLES OF THE SHOULDER.

1, 2, 3, 4, 5, Triceps; 6, attachment to olecranon; 7, anconeus; 8, 8, 9, deltoid (portion removed); 10, supraspinatus; 11, infraspinatus; 12, 13, two extremities of teres minor (intervening portion removed); 14, teres major; 15, latissimus dorsi; 16, 17, 18, 19, muscles of forearm.—(Gould's Dictionary.)

## BREAST MUSCLES.

**Pectoralis major.** **Origin.**—*Clavicular portion*, on the sternal end of the clavicle; *sternal portion*, on the surface of the sternum and on six upper ribs. **Insertion.**—By a broad strong tendon on the shaft of the humerus, on the crest of the greater tubercle. Figs. 74, 80.

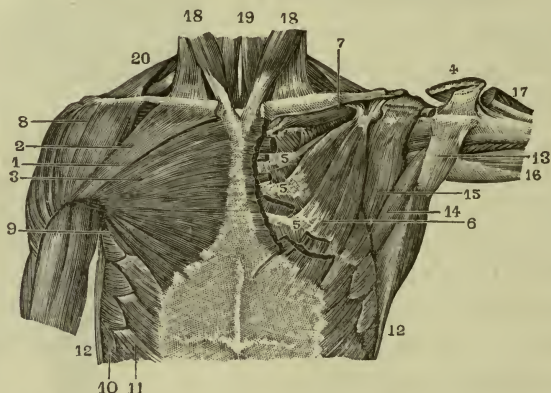


FIG. 80.—MUSCLES OF ANTERIOR ASPECT OF THORAX.

1-5, Pectoralis major; 6, 9, pectoralis minor; 7, subclavius; 8, deltoid; 10, anterior portion of anterior serratus; 11, external oblique; 12, 13, latissimus dorsi; 14, teres major. —(Gould's Dictionary.)

**Action.**—It draws the arm to the front of the thorax, opposing the latissimus dorsi; thus it also is a "rowing" muscle.

The **pectoralis minor** is entirely covered by the major.

**Origin.**—Three upper ribs. **Insertion.**—The coracoid process of the scapula. **Action.**—It pulls the shoulder downward. It may pull ribs upward in labored breathing or forced inspiration.

*Nerves of both muscles.*—*Anterior thoracic.*

**Note.**—When the whole body is drawn upward by the hands, as when hanging from a trapeze, the two *pectorals*, the *trapezius* and the *latissimus* are acting together.

The **subclavius** is a small muscle lying in the subclavian groove between the clavicle and first rib. It may elevate the ribs or depress the clavicle.

## ARM MUSCLES.

## Anterior.

**Biceps brachii** (a two-headed muscle). **Origin.**—The scapula: the *long head* above the glenoid fossa, and the *short head* on the



coracoid process. **Insertion.**—By one tendon on the tuberosity of the radius (Fig. 81).

**Action.**—It flexes the forearm on the arm.

*Nerve.*—*Musculo-cutaneous.*

**Note.**—If the *biceps brachii* begins to contract while the hand is pronated, the first effect would be to pull the radial tuberosity around and place the hand in the *supinated position*, then flexion would follow; in other words, the biceps may act as both a *supinator and flexor*.

The **coraco-brachialis.**—A smaller muscle, close to the biceps. **Origin.**—The tip of the coracoid process. **Insertion.**—The shaft of humerus, medial side, opposite the deltoid.

**Action.**—It lifts the humerus forward.

*Nerve.*—*Musculo-cutaneous.*

The **brachialis.**—Is underneath the biceps. **Origin.**—The anterior surface of the humerus. **Insertion.**—The tubercle of the ulna, just below the coronoid process.

**Action.**—With the biceps it flexes the forearm.

**Note.**—This is a broad muscle and covers the front of the elbow-joint.

*Nerve.*—*Musculo-cutaneous* and *radial.*

## ARM MUSCLES (FIG. 79).

### Posterior.

The **triceps brachii** (a three-headed muscle). **Origin.**—The *long head*, on the scapula, just below the glenoid fossa; the *medial* and *lateral* heads on the posterior surface of the humerus, separated by the groove for the radial nerve. **Insertion.**—The (top of the) olecranon process of the ulna.

**Action.**—It extends the forearm (opposing the biceps).

*Nerve.*—*Radial.*

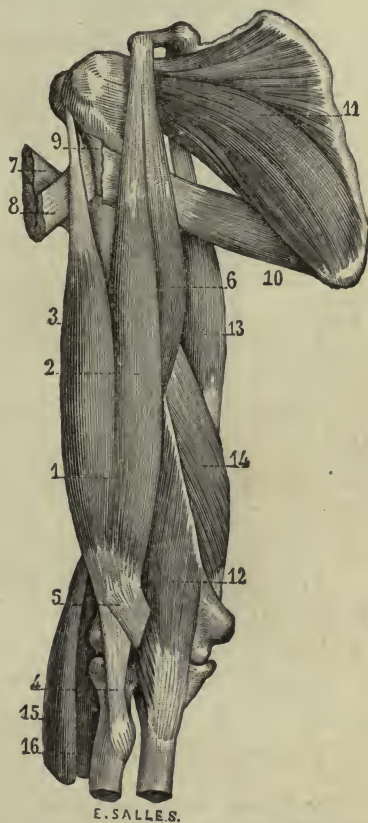

FIG. 81.—MUSCLES OF THE ARM.

1, 2, 3, 5, Biceps and bicipital fascia; 4, attachment of biceps to tuberosity of radius; 6, coracobrachialis; 7, 8, insertion of pectoralis major; 9, latissimus dorsi (insertion); 10, teres major; 11, subscapularis; 12, brachialis; 13, 14, two heads of triceps.—(Holden.)

**Note.**—The back of the triceps is covered at its lower portion by a fibrous layer (aponeurosis) which receives many of the muscular fibers. In action, the *three heads swell* while this fibrous layer remains flat.

## MUSCLES OF THE FOREARM.

### Anterior.

The **superficial flexors**.—The medial epicondyle of the humerus gives origin to a group of superficial muscles which flex the wrist and fingers (Fig. 82).

**Flexor carpi radialis**, or *radial flexor* of the wrist. **Origin.**—The medial epicondyle. **Insertion.**—The base of the second metacarpal bone (that of the index-finger).

*Nerve.*—Median.

**Flexor carpi ulnaris**, or *ulnar flexor of the wrist*. **Origin.**—The medial epicondyle and dorsal border of the ulna. **Insertion.**—The base of the fifth metacarpal bone.

**Action of the two.**—To flex the wrist.

*Nerve.*—Ulnar.

**Flexor digitorum sublimis**, or *superficial flexor of the fingers*. **Origin.**—The medial epicondyle, the upper extremity of the ulna, and the shaft of the radius (the three long bones). **Insertion.**—By four tendons, one for each finger, on the second row of the phalanges.

**Action.**—It flexes the second joints of the fingers, but not the finger-tips.

*Nerve.*—Med'an.

**Deep flexors.**—The shafts of the bones give origin to the deep flexors of the fingers and thumb, which act upon the third row of the phalanges.

**Flexor digitorum profundus**, or *deep flexor of the fingers*.—Is underneath the superficial flexor. **Origin.**—The shaft of the ulna. **Insertion.**—By four tendons, on the third or last row of phalanges.

**Action.**—It flexes the finger-tips.

**Note.**—Since the tendons of the superficial flexor stop at the second phalanges, while those of the deep flexor pass to the *third* phalanges, there is a fissure in each superficial tendon just before it ends, through which the deep tendon passes forward to the bone of the finger-tip (Fig. 82).

*Nerves.*—Median and ulnar.

**Flexor pollicis longus**, or *long flexor of the thumb*.—**Origin.**—The shaft of the radius (under flexor sublimis). **Insertion.**—The last phalanx of the thumb.

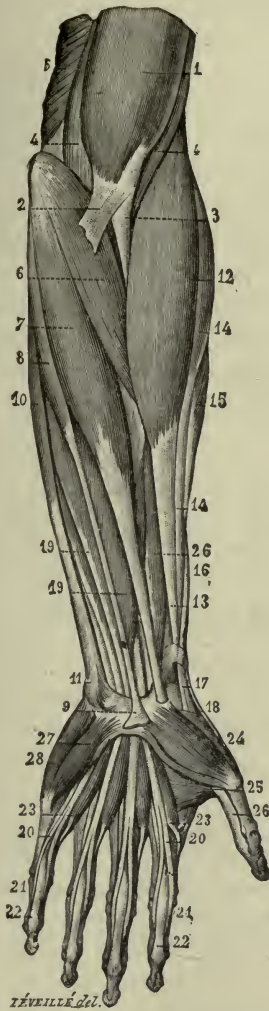


FIG. 82.—MUSCLES OF THE FOREARM.

1, 2, 4, 4, Muscles of arm; 3, tendon of insertion of biceps; 6, round pronator; 7, radial flexor of wrist; 8, 9, palmaris longus; 10, 11, ulnar flexor of wrist; 12, 13, brachio-radialis; 14-18, muscles and tendons belonging to posterior of forearm; 19, 19, superficial flexor of fingers; 20, 20, 21, 21, tendons of the same, showing fissure; 22, 22, tendons of deep flexor coming through fissure to reach the third row of phalanges.—(Holden.)

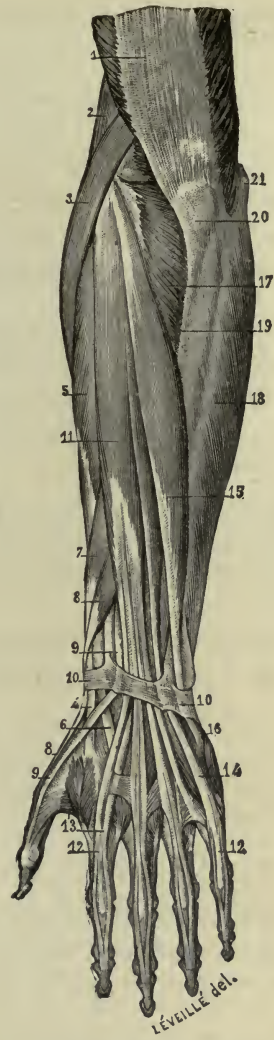


FIG. 83.—MUSCLES OF THE FOREARM, DORSAL ASPECT.

1, Aponeurosis of triceps; 2, upper end of brachio-radialis; 3, 4, long radial extensor of wrist; 5, 6, short radial extensor of wrist; 7, 8, 8, 9, 9, extensors of thumb; 10, 10, annular ligaments; 11, 12, 12, common extensors of fingers; 13, 14, special extensors for index and little fingers; 15, 16, ulnar extensor of wrist; 18, ulnar flexor of wrist; 19, posterior border of ulna; 20, olecranon process of ulna; 21, medial epicondyle.—(Holden.)

**Action.**—It flexes the tip of the thumb.

*Nerve.*—*Ulnar.*

**Note.**—These tendons for the fingers and thumb lie in the deep groove on the front of the carpus. Friction between them is prevented by sheaths of synovial membrane.—*vaginal synovial membranes.*

#### THE TWO PRONATORS, THE ROUND AND THE SQUARE.

**Pronator teres**, or *round pronator* (Fig. 82).

**Origin.**—The medial epicondyle, and a small slip from the ulna (coronoid process). It passes across to the lateral side of the radius, to the **insertion** at the middle of the shaft.

*Nerve.*—*Median.*

**Pronator quadratus**, or *square pronator*.

**Origin.**—The shaft of the ulna. **Insertion.**—The shaft of the radius. It lies just above the wrist and underneath the long muscles (close to the bones).

*Nerve.*—*Ulnar.*

**Action** of the two pronators.—They rotate the radius so as to turn the *palm downward* (or *backward*).

One slender muscle, which is superficial to all, is the **palmaris longus**. It arises on the medial epicondyle and is attached below to the palmar fascia to keep it tense—a *tensor* of the palmar fascia.

*Nerve.*—*Median.*

**Note.**—It is understood that the muscles arising from the epicondyle have a common tendon of origin.

**Practical point.**—Observe, by experimenting, that flexion and moderate pronation are naturally performed together, and are associated in the majority of the motions which are required of the upper extremity.

#### MUSCLES OF THE FOREARM (FIG. 83).

##### Posterior.

The lateral epicondyle of the humerus and the ridges above it give origin to the muscles which extend the wrist and fingers.

**Extensor carpi radialis longus**, or *long radial extensor of the wrist*. **Origin.**—Lateral border and epicondyle of humerus.

**Insertion.**—The base of the *second* metacarpal bone.

*Nerve.*—*Radial.*

**Extensor carpi radialis brevis**, or *short radial extensor*. **Origin**.—The lateral epicondyle. **Insertion**.—The base of the *third* metacarpal bone.

*Nerve*.—Deep branch of radial.

**Extensor carpi ulnaris**, or *ulnar extensor of the wrist*.—**Origin**.—The lateral epicondyle and dorsal border of the ulna. **Insertion**.—The base of the *fifth* metacarpal bone.

**Action** of the three.—They extend the wrist.

*Nerve*.—Deep branch of radial.

**Extensor digitorum communis**, or *common extensor of the fingers*. **Origin**.—The lateral epicondyle. **Insertion**.—By four tendons, on the second and third rows of phalanges, in such a way that it can extend the bones of either row separately or both at the same time.

The little finger has a special extensor for its tip (*extensor minimi digiti*). The index finger also has a special extensor (*extensor indicis*), and the thumb has three—two for its phalanges, and one for its metacarpal bone. By forcibly extending the thumb these three tendons are brought into view; the one for the tip of the thumb being at a little distance from the other two; thus they bound a little hollow which has been called the “anatomic snuff box.”

*Nerves of all*.—Deep branch of radial.

#### THE TWO SUPINATORS.

The **supinator**. **Origin**.—The lateral epicondyle and upper end of the shaft of the ulna. It winds around the head and neck of the radius to the **insertion** on upper part of the shaft. This is the chief supinator; it is entirely covered by other muscles.

**Action**.—It rotates the radius and turns the *dorsum of the hand downward or backward*.

*Nerve*.—Deep branch of radial.

The **brachio-radialis** (Fig. 82). **Origin**.—The lateral border of the humerus. **Insertion**.—The styloid process of the radius.

**Action**.—It assists in both flexion and *supination* of the forearm. (This muscle was formerly called the long supinator.)

*Nerve*.—Radial.

#### ANNULAR LIGAMENTS.

These are special bands of deep fascia holding in place those tendons which pass the wrist-joint. They include the tendons in

canals through which they glide freely. Friction is prevented by synovial sheaths within the canals. The fascia which binds down the *extensor* tendons is the *dorsal ligament* of the wrist; that which confines the *flexor* tendons is the *transverse ligament* of the wrist.

### MUSCLES OF THE PALM (FIG. 82).

There is a group of muscles in the palm of the hand which move the *thumb* in various directions (flexion, abduction, adduction, and so on). They form the elevation called the *thenar eminence*, or the "ball of the thumb." A similar group for the little finger forms the *hypotheneal eminence*.

They arise mostly on carpal bones and deep fascia and are inserted on first phalanges. In the hollow of the hand between these two eminences lie the long tendons, already described, on their way to the fingers; also some small muscles between them and beneath them.

The *interosseous muscles* fill the interosseous spaces. The action of the dorsal group is to spread the fingers apart (*abduction*) while that of the palmar group is to bring them together (*adduction*).

**Note.**—A line drawn from the middle of the wrist to the tip of the middle finger is called the *median line of the hand*. To *abduct* the fingers and thumb is to draw them away from this line,—in other words, *from* the middle finger. To *adduct* them is to draw them *toward* the middle finger.

*Nerves.*—To the *hypotheneal muscles*.—*Ulnar*. To *thenar muscles*.—*Median and ulnar*.

The muscles in the palm are covered by particularly dense, deep fascia called the **palmar fascia**, or palmar aponeurosis.

### MUSCLES OF THE LOWER EXTREMITY.

#### The Pelvis—Interior.

**False pelvis.**—The *iliacus* is the only muscle in the false pelvis; it is already described with the *psoas major*, page 93.

**True pelvis.**—The *piriformis*. **Origin.**—The front of the sacrum; it passes out through the great sciatic notch to the **insertion** on the top of the great trochanter.

**Action.**—External rotation of the femur.

*Nerve.*—From *sacral plexus*.

**Obturator internus** (also within the true pelvis, Fig. 87).

**Origin.**—The surface of obturator membrane, and a portion

of bone around it; it passes out through the small sciatic notch to the **insertion** on the great trochanter.

**Action.**—External rotation of the femur.

*Nerve.*—From sacral plexus.

The *floor of the pelvis* consists of two flat muscles on either side, the **levator ani** and the **coccygeus**.

Their **origin** is on the interior of the pelvic wall,—that is, on the pubic bone and the spine of the ischium, and a line of fascia

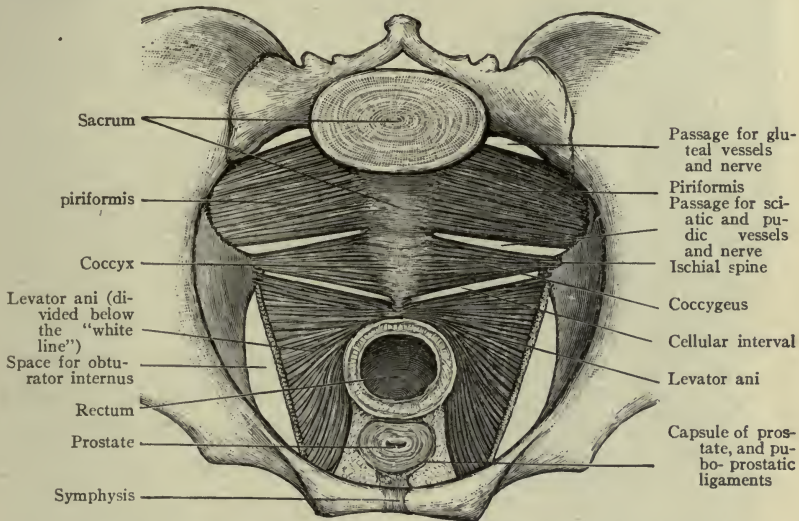


FIG. 84.—INTERIOR AND FLOOR OF THE TRUE PELVIS.—(Morris.)

between these two points. **Insertion.**—The muscles meet each other in the median line, being also attached to certain pelvic organs (bladder and rectum in the male; bladder, rectum, and vagina in the female) and to the coccyx. Their **action** supports the pelvic organs, especially the rectum, and lifts them in various motions of the body, as in respiration.

*Nerve.*—From sacral nerves.

**Special notes.**—These two muscles form a *concave floor* like an inverted dome, which is the *pelvic diaphragm*. When this dome contracts it rises.

There are two openings in the pelvic floor for the bladder and rectum, and a third opening in the female pelvis for the vagina.

The **pelvic fascia** is a continuation of the transversalis fascia which lines the abdomen and of the iliac fascia which covers the

iliacus muscle. It covers the obturator muscle and its fascia and the muscles of the floor, and forms ligaments for the pelvic viscera.

### THE PELVIS—EXTERIOR.

**Three gluteal muscles.**—From the three gluteal lines of the os coxæ and the spaces above them, arise three gluteal muscles.

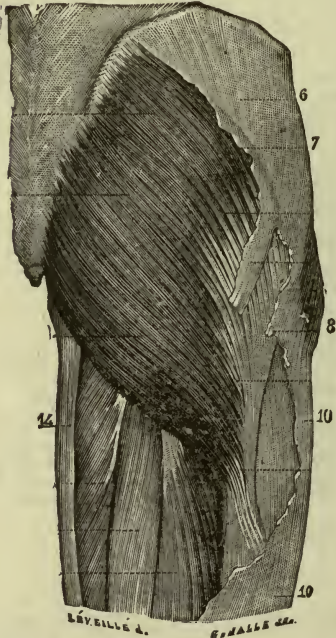


FIG. 85.—THE GLUTEAL REGION.

1, 2, 3, 4, 5, 5, Gluteus maximus; 6, 7, 8, 10, fascia lata; 9, lower end of tensor fasciæ latæ; 11, upper portion of biceps femoris; 12, upper portion of semitendinosus; 13, upper portion of semimembranosus; 14, gracilis. —(Gould's Dictionary.)

**Insertion.**—The fossa of great trochanter. **Action.**—External rotation of femur. (Fig. 78.)

*Nerve.*—Obturator.

**Practical point.**—Observe the number of muscles for *external* rotation and note that the usual position of the foot is with the *toes turned out*.

**Gluteus minimus. Origin.**—The inferior line and space above it. **Insertion.**—The front of great trochanter.

**Action.**—It abducts the thigh and rotates the femur slightly inward (so that the foot turns in).

**Gluteus medius. Origin.**—The anterior or middle line and space above it up to the crest. **Insertion.**—The outer surface of great trochanter.

**Action.**—Abduction of the femur and some rotation outward.

*Nerve of both.*—*Superior gluteal.*

**Gluteus maximus. Origin.**—The posterior line and space behind it to the crest (also from the back of sacrum). **Insertion.**—The back of great trochanter and the shaft below it, also the deep fascia, or *fascia lata*.

**Action.**—External rotation of femur; it is also a powerful extensor of the hip-joint when one rises from the sitting position, or in mounting steps. It also abducts the thigh.

*Nerve.*—*Inferior gluteal.*

**Obturator externus. Origin.**—The obturator membrane and bone around

it. **Action.**—External rotation



## MUSCLES OF THE THIGH.

## Anterior.

On the front and the sides of the femur are the muscles which extend the leg—four in number—which blend at their insertion, therefore constituting a four-headed muscle, the *quadriceps femoris*. They are the *rectus femoris*, the *vastus lateralis*, *vastus medialis* and the *vastus intermedius*.

**Rectus femoris. Origin.**—The anterior inferior spine of the ilium, and the upper border of the acetabulum. **The three vasti. Origin.**—On the linea aspera and the three surfaces of the femur. **Insertion of the four.**—By one tendon passing in front of the knee-joint to the tubercle of the tibia. (It encloses the patella and has been improperly called the ligamentum patellæ.)

**Action.**—They extend the leg as in walking, or with great force in kicking; these muscles also keep the patella in place during various positions of the knee.

*Nerve.*—Femoral.

The *sartorius*.—The longest muscle in the body; it passes across the front of the quadriceps. **Origin.**—The anterior superior spine of the ilium. **Insertion.**—The inner surface of the tibia, just below the head.

**Action.**—Since it passes across to the medial side of the thigh, and behind the medial epicondyle, it flexes the leg and at the same time lifts it in such a way that when both legs are acted upon together, they are *flexed and crossed*, hence the name, signifying “tailor” muscle.

*Nerve.*—Femoral.

The *tensor fasciæ latæ*.—Is attached to the anterior part of the crest of the ilium between two layers of the fascia lata; it makes tense the outer portion

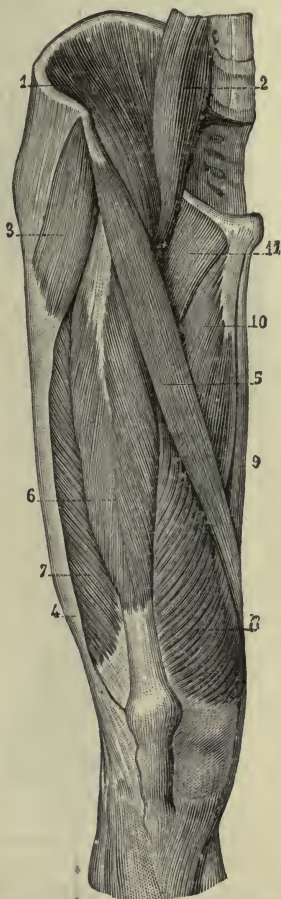


FIG. 86.—MUSCLES OF THE THIGH.

1, 2, Iliacus and psoas; 3, 4, tensor fasciæ latæ; 5, sartorius; 6, rectus femoris; 7, vastus lateralis; 8, vastus medialis; 9, gracilis; 10, adductor longus; 11, pectineus.—(Holden.)

of the fascia which is connected with the tibia, or the *ilio-tibial band*. (This is felt like a strong cord above the lateral epicondyles.) It also rotates the thigh inward (Fig. 86).

*Nerve.*—*Superior gluteal.*

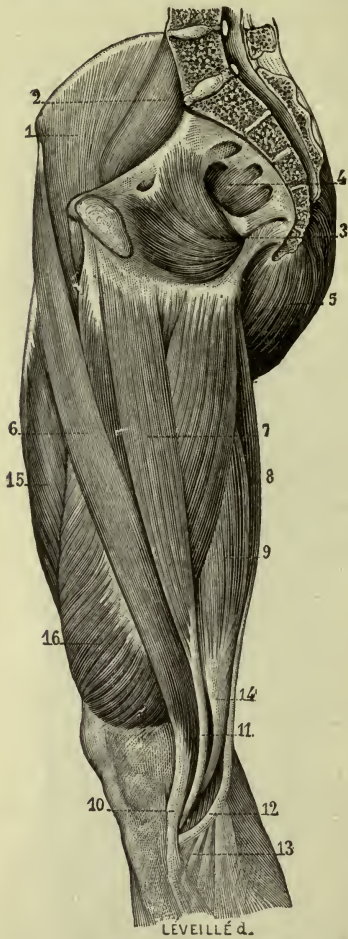


FIG. 87.—MEDIAL ASPECT OF THE THIGH AND PELVIS.

1, 2, 3, 4, Iliacus, psoas, obturator, piriformis; 5, gluteus maximus; 6, sartorius; 7, gracilis; 8, semitendinosus; 9, semimembranosus; 10, 11, 12, tendons of sartorius, gracilis, and semitendinosus; 14, tendon of semimembranosus.—(Gould's Dictionary.)

others, behind the medial epicondyle, making the borders of a deep space—the *popliteal space*, or ham. They are called “ham-string” tendons.

## MUSCLES OF THE THIGH.

### Posterior.

The muscles are three in number—the biceps femoris, semitendinosus, and semimembranosus (Figs. 87, 88).

The **biceps femoris**. **Origin.**—*Long head* on the tuber of the ischium, *short head* the linea aspera (lateral lip). **Insertion.**—The head of the fibula.

The **semitendinosus** and the **semimembranosus** also arise on the tuber of the ischium, and are **inserted** on the tibia, medial surface and back of head. (Their names indicate their shape, one being tendinous in half its length, and the other aponeurotic, or membranous.)

**Action.**—These three muscles act together to flex the knee.

*Nerve to the three.*—*Sciatic.*

**Notes.**—They also assist the gluteus maximus to *extend the thigh*, as in rising from a chair. The biceps tendon may be felt behind the lateral epicondyle; the two

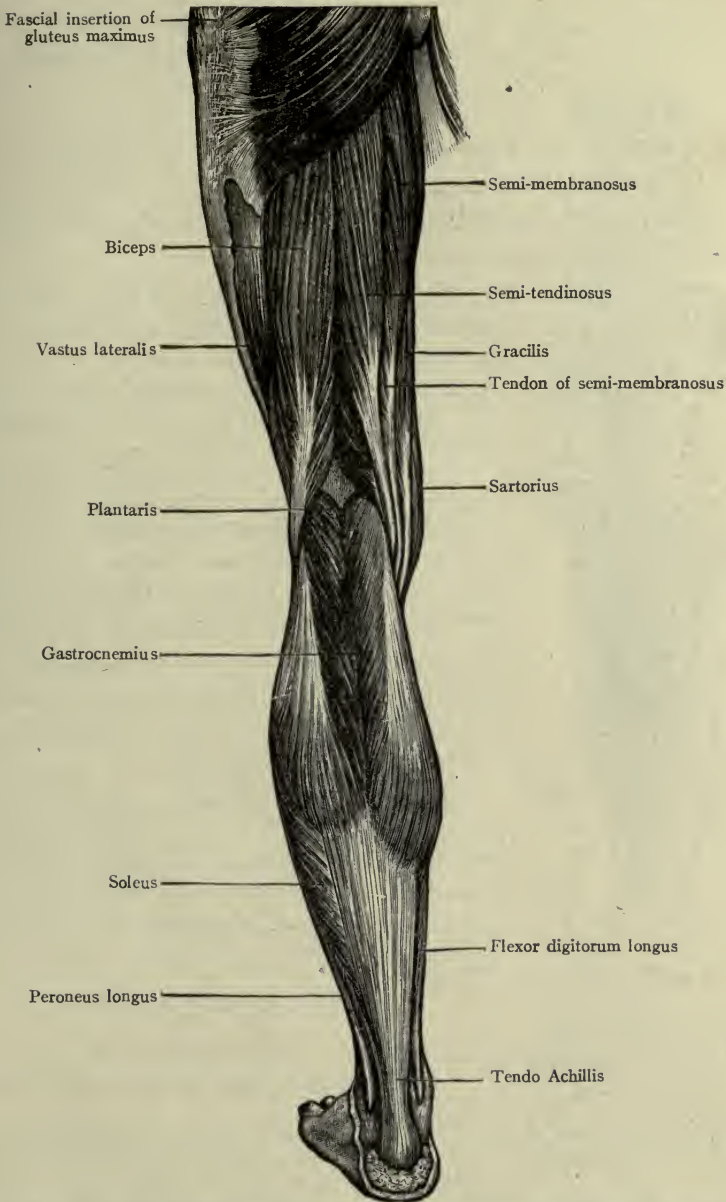


FIG. 88.—POSTERIOR OF THIGH AND LEG AND HAMSTRING TENDONS (Morris).

Hamstring tendons.....	{ Lateral side, biceps femoris. { semitendinosus. { semimembranosus. { sartorius. { gracilis.

The **popliteus** is a flat muscle behind the knee-joint, forming part of the *floor of the popliteal space*.

The most important muscles in the medial side of the thigh are the four adductors (FIG. 89).

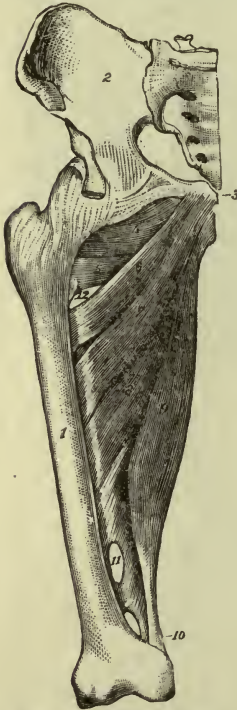


FIG. 89.—ADDUCTORS.  
1, 2, 3, Femur, ilium, pubes; 4, external obturator muscle; 5, 6, 7, 8, 9, 10, adductor muscles; 11, 12, openings for vessels passing to back part of thigh.—(Gould's Dictionary).

The **adductor longus**. **Origin**.—From the superior ramus of the pubes. **Insertion**.—The middle of the linea aspera.

The **adductor brevis**. **Origin**.—Upper part of the pubic arch. **Insertion**.—The linea aspera behind and above the longus.

The **adductor minimus**. **Origin**.—The lower part of the pubic arch. **Insertion**.—The linea aspera, behind the brevis (upper part).

The **adductor magnus**. **Origin**.—Pubic arch and tuber of the ischium. **Insertion**.—Linea aspera (behind the others), and medial epicondyle.

**Action of the four**.—They all adduct the femur (rotating it outward) and draw the thighs together as in horseback riding.

*Nerve to the four*.—Obturator.

**Note**.—The *magnus* makes a broad sheet of muscle between the quadriceps which extends the knee, and the muscles on the back which flex it. *The longest and strongest fibers of the magnus rotate the femur inward*. They run between the tuber of the ischium and the medial epicondyle.

## MUSCLES OF THE LEG.

### Anterior.

These muscles flex the ankle and extend the toes.<sup>1</sup>

The muscles in the front of the leg are *between the tibia and the fibula*; the medial surface of the tibia, having no muscles upon it, is called *subcutaneous*.

The **tibialis anterior**. **Origin**.—The shaft and head of the tibia (lateral surface) and the interosseous membrane.

<sup>1</sup> **Note**.—This movement of the toes is *dorsal flexion*.

**Insertion.**—The first cuneiform and first metatarsal bones.

*Nerve.*—*Deep peroneal.*

The **peroneus tertius**. **Origin.**—The shaft of the fibula (lower part). **Insertion.**—The fifth metatarsal bone.

**Action** of the two.—To flex the ankle. The tibialis acting alone lifts the *medial* border of the foot; the peroneus lifts the *lateral* border.

*Nerve.*—*Deep peroneal.*

The **extensor hallucis longus**, or *long extensor* of the *great toe*. **Origin.**—The shaft of the fibula and the interosseous membrane.

**Insertion.**—The last phalanx of the great toe.

**Action.**—To extend the great toe.

*Nerve.*—*Deep peroneal.*

The **extensor digitorum longus**, or *long extensor* of the *toes*. **Origin.**—The shaft of the fibula and interosseous membrane (a few fibers from head of tibia). **Insertion.**—By four tendons on the second and third phalanges of the *four lateral* toes, like the similar extensor of the fingers.

**Action.**—To extend the toes.

*Nerve.*—*Deep peroneal.*

**Note.**—These two muscles, since they pass *in front* of the ankle-joint, *flex* it.

On the dorsum of the foot the **extensor digitorum brevis** has four slender tendons for the *four medial* toes.

*Nerve.*—*Deep peroneal.*

## MUSCLES OF THE LEG.

### Posterior.

These muscles extend the ankle and flex the toes; they all pass *behind* the *medial malleolus*. They are covered by the calf muscles.

The **tibialis posterior**. **Origin.**—Shaft of both tibia and fibula and the interosseous membrane. **Insertion.**—Navicular and first cuneiform bones.

**Action.**—Extension of the ankle.

*Nerve.*—*Tibial.*

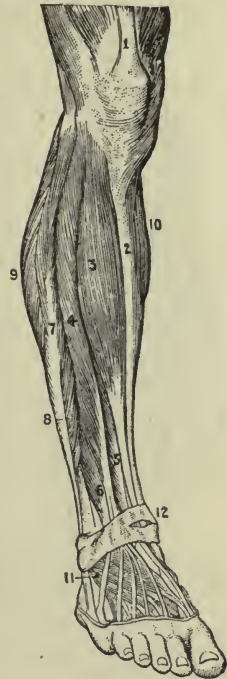


FIG. 90.—MUSCLES OF THE LEG, ANTERIOR.

1, Rectus femoris; 2, tibia; 3, tibialis anterior; 4, long extensor of toes; 5, long extensor of great toe; 6, peroneus tertius; 7, 8, peroneus longus, p. brevis; 9, 10, lateral and medial heads, gastrocnemius; 11, short extensor of toes; 12, annular ligament (Gould's Dictionary)

The **long flexor of the great toe**, or *flexor hallucis longus*. **Origin**.—Shaft of fibula. **Insertion**.—Last phalanx of the great toe (Fig. 91).

*Nerve*.—*Tibial*.

**Long flexor of the toes**, or *flexor digitorum longus*. **Origin**.—Shaft of fibula. **Insertion**.—By four tendons on the last phalanges of the *four lateral toes* (Fig. 91).

**Action** of these two muscles.—Flexion of the tips of the toes.

*Nerve*.—*Tibial*.

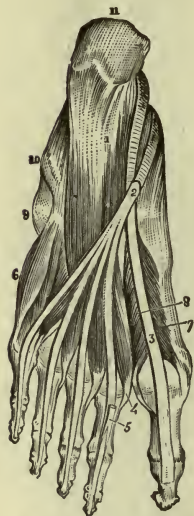


FIG. 91.—MUSCLES OF THE PLANTAR REGION, MIDDLE LAYER.

1, Accessory muscle; 2, *long flexor of toes* dividing into four tendons; 3, tendon of *long flexor of great toe*; 4, 5, 6, 7, 8, plantar muscles; 9, projection of fifth metatarsal bone; 10, sheath of tendon of peroneus longus; 11, calcaneus (Gould's Dictionary).

#### LEG—LATERAL SIDE (FIG. 92).

**Peroneus longus**. **Origin**.—Shaft of fibula. **Insertion**.—In the sole of the foot, first metatarsal bone. The tendon passes *behind the lateral malleolus* and crosses in the sole to the medial border of the foot.

**Peroneus brevis**. **Origin**.—Shaft of fibula. **Insertion**.—Base of fifth metatarsal bone. The tendon passes *behind the lateral malleolus*.

**Action** of these two muscles.—They extend the ankle and lift the lateral border of the foot.

*Nerve to both*.—*Superficial peroneal*.

**Note**.—As the tibialis anterior and peroneus tertius flex the foot, so the tibialis posterior and peroneus brevis extend it.

**Orthopedic note**.—The *P. longus* makes a chord for the transverse arch of the foot, being the most important muscle to preserve that arch from being flattened.

#### CALF MUSCLES (FIGS. 88, 92).

##### Triceps suræ, and plantaris.

The **gastrocnemius**. **Origin**.—By two heads just above the condyles of the femur. **Insertion**.—On the calcaneus.

**Note**.—The two heads form the *lower* boundaries of the popliteal space.

The **soleus** is covered by the gastrocnemius. **Origin**.—Medial border of the tibia and lateral border of the fibula. **Insertion**.—The os calcis, with the above muscle.

**Action** of the two.—They join to form one muscle, the **triceps**

**suræ** (or triceps of the calf), which has the strongest tendon in the body, the *tendo calcaneus* (*tendon of Achilles*) by which they are attached to the os calcis, and, therefore, they lift the heel. If the muscles of both legs act at the same time, the whole body is lifted on the toes.

*Nerve to both.*—Tibial.

The **plantaris**. **Origin.**—With the outer head of the gastrocnemius. **Insertion.**—With the *tendo calcaneus*.

**Note.**—The belly is short and small; the tendon is the longest in the body.

The **calf muscles** constitute a group of great power, as by them one lifts oneself to stand upon the toes.

The sole of the foot, or **plantar region**, resembles the palm of the hand in having special groups of muscles for the great and little toes, with the long flexor tendons lying between them, and a dense *fascia* covering them. This is called the **plantar fascia**.

The nerves are *medial and lateral plantar*.

#### ANNULAR LIGAMENTS.

The tendons which pass from the leg to the foot are kept in place by special ligaments, anterior and lateral, and surrounded by synovial sheaths as in the wrists.

**POINTS.**—*Eversion* of the foot, or lifting the medial border, is done by the tibialis anterior.

*Inversion.*—Or lifting the lateral border, by the peroneus tertius, and peroneus longus.

*Adduction.*—By deep posterior muscles of the leg.

*Abduction.*—By external muscles of the leg.

Observe certain similarities and differences in the extremities. Extension of the *elbow* is accomplished by the three-headed muscle,

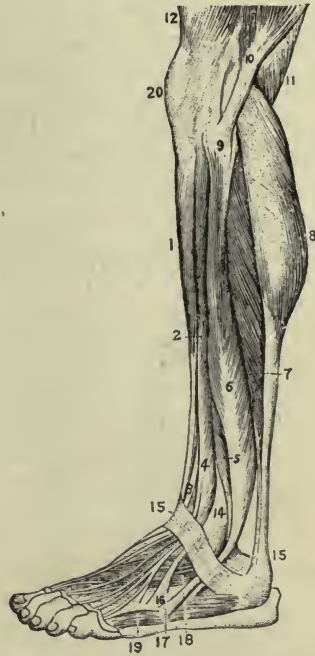

FIG. 92.—LATERAL ASPECT AND CALF OF LEG.

1, 2, 3, 4, Lateral view, muscles passing in front of ankle; 5, 6, peroneus brevis and p. longus (behind ankle); 7, 8, soleus and gastrocnemius; 9, head of fibula; 10, biceps femoris; 11, semimembranosus; 13, *tendo Achillis*; 15, annular ligament; 16, 17, insertions of peroneus tertius and brevis; 18, short extensor of toes; 19, plantar muscle; 20, patella (Gould's Dictionary).

the triceps. Extension of the *knee* requires a powerful four-headed muscle, the quadriceps.

The great toe is on the *medial* border of the foot, the thumb is on the *lateral* border of the hand. This is so because the terms medial and lateral are applied to the *pronated* position of the lower extremity and the *supinated* position of the upper extremity.

In the upper extremity the joints are all flexed in one direction, as though the limb might be rolled up. In the lower extremity they flex and extend alternately, as though the limb were folded back and forth.

### STRUCTURE AND PHYSIOLOGY OF MUSCLES.

A completed muscle is a complicated structure. It consists of:

First, the essential muscle substance in the muscle cells.

Second, connective tissue wrappings and partitions.

Third, tendons and aponeuroses.

Fourth, blood and lymph vessels.

Fifth, muscle nerves.

The *connective tissue* supports all of the other structures and protects the muscle, preserving its shape and stability.

The *tendons* and *aponeuroses* provide a means whereby the attachment to other organs is kept within a small space.

Example: The *biceps of the arm* contains many fibers, but the slender tendons of this muscle occupy only small areas upon the surface of the bones. The *aponeurosis* of that very powerful muscle, the *quadriceps femoris*, receives the insertion of the muscle fibers, and by this means only a narrow surface is required for insertion upon the bone. But for arrangements like these, the skeleton would of necessity be inconveniently large.

The *blood-vessels* bring the nutritive fluid which, in the tissue-spaces, bathes each little fiber, and is gathered up by the *lymph vessels*.

The *nerves* bring to each fiber its natural stimulus to action.

The work of muscle tissue is done in the *fiber cell*. This when stimulated, contracts, bringing the two ends of the fiber nearer to each other, and naturally the fiber swells as it shortens. So with the myriad of fibers in a muscle; when they contract, the *muscle* swells and shortens (Fig. 93 illustrates the changes produced). This results in *motion*, which appears as the organs attached are moved.



All skeletal muscles are so attached as to be tense, that is, they are just a little stretched, so that it is easier for them to act than not. (A cut across a muscle releases it from tension and leaves a gaping wound.)

The actions of muscles are regulated by their attachments, and the function is often expressed in the name. If muscles or their tendons pass in front of a joint, for instance, causing flexion, they are frequently called *flexors*; or if they pass behind such joints, they may be called *extensors*; and so with other muscles and joints. Examples: Flexors of the wrist, extensors of the fingers, etc. Many other examples will occur to the student, as *abductors*, *adductors*, *pronators*, etc.

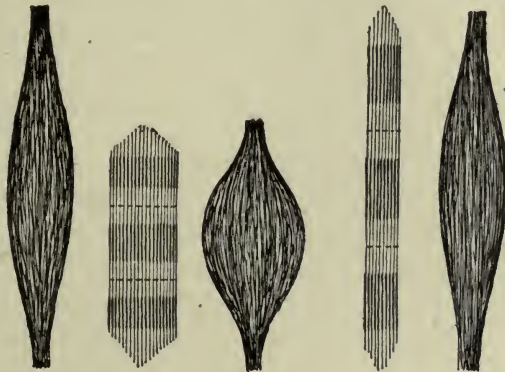


FIG. 93.—SHOWING CHANGE OF SHAPE IN CONTRACTION (Brubaker).

As the *location* determines the function of a muscle, so it often suggests the name, as the *pectoralis* major and minor, the *intercostals*, etc. Sometimes the *shape* is named, as the *orbicularis* of the mouth or of the eyelids (orbicular muscles, or *sphincters*, surround and control openings). *Shape and location* may together suggest a name sometimes, as the *latissimus dorsi*, the *rectus abdominis* (broadest-of the back and straight of the abdomen)<sup>1</sup> and others, expressing or implying the function of the muscle.

One of the most useful and interesting muscles in the body is the *diaphragm*. Although a voluntary muscle in structure, it is associated with visceral action. (For general description see page 91.)

The special interest attending this muscle arises from its location

<sup>1</sup> The full Latin name includes the word *musculus* (*muscle*); for the sake of brevity it is omitted.

as well as its structure. Situated between the great cavities of the trunk it acts upon the organs belonging to both. In contraction, it encroaches upon the cavity of the abdomen pressing upon abdominal organs, and thus aids in expelling the contents of abdominal and pelvic viscera. In this act (expulsion from abdomen or pelvis) it is fixed in contraction (holding the breath) so that other muscles can act efficiently. Examples: *defecation, parturition*. Ceasing to contract it rises to its inactive or dome-shape; and as this is accompanied by slight abdominal pressure upward, the effect upon the thorax is to shorten it, causing gentle pressure upon the lungs.

In *contraction*, therefore, it compresses the abdomen and enlarges the thorax; in *relaxation*, it enlarges the abdomen and compresses the thorax. This alternate enlargement and compression of the thorax explains its most important function—that of a breathing muscle, or *muscle of inspiration*.

**Special points.**—The lateral portions of the diaphragm are the most movable portions, being mostly muscular. Here the lungs rest upon the falling and rising floor, themselves alternately expanding and contracting. The heart lies upon the least movable portion—consequently the diaphragm supports the heart but does not press against it unless pushed up from below.

Similar functions pertain to another muscle constituting the floor of the pelvis (the *levator ani and coccygeus* taken together), which rises and falls with the displacement and functioning of abdominal organs. With the combined contraction of these two, and relaxation of the diaphragm, the whole body of abdominal and pelvic organs moves upward, and *vice versa*.

Passing to the consideration of more complicated movements, we find that all functions of the body depend in the beginning upon muscle action.

For respiration we must have the muscles of the thorax; for swallowing or deglutition, the muscles of the tongue and throat; for speaking, those of the tongue and face: The heart itself is a collection of muscles influencing the entire body, since without circulation of blood all processes of life must cease.

The arms and hands become organs of *prehension* when by use of their numerous muscles they reach out to gather things in; the lower limbs are organs of *locomotion*, only because their muscles enable them to bear and transport the body from place to place. Even the

ability to stand still is due to a balanced tension of muscles, which keeps the joints quiet.

Finally, various *emotions* may be expressed by muscle-action without a spoken word, both by changes of the face (referred to, p. 82) and gestures of the body. Compare the erect posture of the person ready and alert, with the drooping figure of despondency or the lax one of indolence. Read the meaning of the firm, quick footstep, and contrast it with the uncertain and halting one. Note how the hand may welcome, or repel. Even the eye would be far less expressive were the iris immovable. Indeed, we might well see a literal meaning in the old adage—"Actions speak louder than words." Thus muscle action means much more than simple movement, and it all depends ultimately upon the specially developed attribute of the muscle cell—*contractility*.

#### MUSCLE TISSUE, A SOURCE OF HEAT AND ELECTRICITY.

Thus far we have considered only one result of muscle action; namely, the production of *motion*. Muscle tissue is built up of food derived from the blood—contraction means a using up of its substance, and the formation of waste products. These chemical processes are going on continually, and all chemical action is accompanied by the production of *heat*. A muscle in action is therefore a machine for producing *body heat*, and since the muscular system comprises so large a portion of the human body (weighing nearly three times as much as the bones), it is one of the chief sources of heat; for the double reason that it includes a great deal of tissue, and that it is more constantly at work than any other tissue in the body.

We all know that the body temperature rises during muscular exercise; as the vessels dilate, bringing oxygen for chemical action, heat is rapidly evolved and waste is swept away. (Blood- and lymph vessels carry both food and waste.)

In addition to other results of muscle activity, a slight current of electricity is produced, appreciable only by certain experiments.

#### MODIFICATIONS OF MUSCLE ACTION.

**Clinical notes.**—*Tetanus* is a condition of the muscles in which the contractions are so rapid that the action appears to be continuous; the stimuli come so rapidly that the fibers cannot relax.

It may be due to various causes: to drugs, as strychnine; to bacterial poisoning through invasion of wounds, or to disordered conditions of the nerve system. It may be voluntary in character. When one deliberately stiffens the body or any portion of it the rigidity thus occurring is tetanic.

*Cramp* is sudden involuntary contraction of muscle-fiber, spasmodic in character and so violent as to be exceedingly painful.

*Convulsive movements* or *convulsions* (*spasms*) are due to involuntary and forcible action of several muscles or groups of muscles.

The movements vary with the number of muscles involved.

*Fatigue* of muscle tissue follows prolonged use, evidenced by sensations of pain in the muscles themselves, probably due to an accumulation of waste matters when the muscle is not quite equal to the demands made upon it.

LARGE MUSCLES CLASSIFIED ACCORDING TO THEIR MOST FREQUENT ACTION.

REGION.	ACTION.	MUSCLES.
TRUNK.....	To enclose cavities and aid in respiration.....	Intercostals. Quadratus lumborum. Obliquus externus. Obliquus internus. Transversus.
	To separate cavities and aid in respiration.....	Diaphragm.
	Floor of trunk and aiding above muscles.....	Levator ani. Coccygeus.
HEAD.....	To move spine and trunk.....	Abdominal group. Erector spinæ. Ilio-psyas.
	To extend head.....	Erector spinæ. Trapezius.
	To flex head.....	Sterno-mastoids. Trapezius.
	To rotate head.....	Sterno-mastoid.
SHOULDER.....	To lift shoulder.....	Trapezius.
	To pull shoulder backward.....	Trapezius.
ARM.....	To pull shoulder forward.....	Anterior serratus.
	To pull arm forward.....	Pectorals.
	To pull arm backward.....	Latissimus dorsi.
	To abduct (lift) arm.....	Deltoid.
	To adduct (pull downward).....	Pectorals. Latissimus dorsi.
	To rotate arm ( <i>supination</i> ).....	Infraspinatus. Teres minor. Subscapularis. Teres major.
	To rotate arm ( <i>pronation</i> ).....	

## LARGE MUSCLES CLASSIFIED ACCORDING TO THEIR MOST FREQUENT ACTION.—(Continued.)

REGION.	ACTION.	MUSCLES.
FOREARM.....	To flex forearm.....	Biceps brachii. Brachialis. Brachio-radialis.
	To extend forearm.....	Triceps.
	To rotate ( <i>supination</i> ).....	Supinator. Biceps brachii. Brachio radialis.
WRIST.....	To rotate ( <i>pronation</i> ).....	Pronator teres. Pronator quadratus.
	To flex wrist.....	Flexor carpi radialis. Flexor carpi ulnaris.
HAND.....	To extend wrist.....	Extensor carpi radialis, (long and short). Extensor carpi ulnaris.
	To flex fingers.....	Flexor digitorum (sublim.). Flexor digitorum (pro- fund.).
THIGH.....	To extend fingers.....	Extensor digitorum (com.).
	To flex thumb.....	Thenar group.
	To extend thumb.....	Three extensors of thumb.
THIGH.....	To flex thigh.....	Ilio-psoas.
	To extend thigh..... (also to extend trunk)	Gluteus Maximus. Biceps femoris. Semitendinosus. Semimembranosus.
	To rotate (outward).....	Glutei-med. and min. Sartorius.
LEG.....	To rotate (inward).....	Four adductors. Two obturators. Gluteus min.
	To abduct.....	Tensor fasciæ latæ. Adductor magnus (long fibers of).
	To adduct.....	Three glutei. Four adductors.
LEG.....	To flex leg.....	Biceps femoris. Semitendinosus. Semimembranosus. Sartorius.
	To extend leg.....	Quadriceps femoris, (rectus and three vasti.)
	Rotation (outward).....	Sartorius.
ANKLE.....	Rotation (inward).....	Biceps.
	To flex ankle.....	Tibialis ant. Peroneus tertius.
FOOT.....	To extend ankle.....	Tibialis post. Peronei (long and short).
	To flex toes.....	Flexor digitorum (longus). Flexor pollicis (longus).
FOOT.....	To extend toes.....	Extensor digitorum (longus). Extensor hallucis (longus).

## SPINAL NERVE SUPPLY TO PRINCIPAL MUSCLE GROUPS.

REGION.	MUSCLES.	NERVE.
SIDE OF NECK.....	Three scalmi muscles. Elevator of angle of scapula.....	Cervical branches of bra- chial plexus.
THORAX AND SHOUL- DER.....	Intercostal..... Diaphragm..... Sacro-spinalis (erector spinæ)... Latissimus dorsi..... Supra- and infraspinatus..... Subscapularis. Teres major..... Teres minor..... Deltoid..... Pectoralis major and minor.....	Intercostal. Intercostal and phrenic. Spinal. Long subscapular. Suprascapular.  Subscapular. Axillary. Axillary and ant. thoracic. Ant. thoracic.
ARM, ANTERIOR.....	Biceps. Coraco-brachialis..... Brachialis.....	Musculo-cutaneous. Musculo-cutaneous and radial.
ARM, POSTERIOR.....	Triceps.	
FOREARM, POSTERIOR...	Supinators and extensors of wrist. Extensors of fingers.....	Radial (musculo-spiral). Deep branch of radial.
FOREARM, ANTERIOR...	Pronators and superficial flexors.. Flexor carpi ulnaris and deep flexors..... (The deep flexor of fingers has also a branch from median.)	Median.  Ulnar.
HAND.....	Thenar eminence (muscles of thumb)..... Hypothenar eminence (muscles of little finger)..... Interossei.....	Ulnar and median.  Ulnar. Ulnar.
ABDOMEN AND PELVIS.	Rectus and pyramidalis. Quadratus lumborum. External and internal oblique. Transversus. Psoas and iliacus..... Levator ani. Perineal muscles..... Piriformis..... Gluteus maximus..... Gluteus medius and minimus. Tensor fasciæ latæ..... Obturator, external and internal.	Lumbar plexus.    Pudic. Sacral plexus. Inferior gluteal. Superior gluteal.
THIGH.....	Three adductors. Gracilis.....	Obturator.
THIGH, ANTERIOR....	Quadriceps. rectus. two vasti. crureus.....	Femoral (anterior crural).
THIGH, POSTERIOR....	Biceps. Semitendinosus. Semimembranosus.....	Sciatic.

SPINAL NERVE SUPPLY TO PRINCIPAL MUSCLE GROUPS.—(Continued.)

REGION.	MUSCLES.	NERVE.
LEG, ANTERIOR.....	Anterior muscles (extensors).....	Deep peroneal (anterior tibial).
LEG, LATERAL.....	Peroneus longus and brevis.....	Superficial peroneal (musculo-cutaneous).
LEG, POSTERIOR.....	Calf muscles.	Tibial nerve.
FOOT.....	Deep muscles (flexors).....	Deep and superficial peroneal.
	Dorsum.....	Deep and superficial peroneal.
	Plantar region.....	Medial and lateral plantar.

## CHAPTER VIII.

### THE ORGANS OF DIGESTION.

#### MOUTH, PHARYNX, ESOPHAGUS, STOMACH, AND INTESTINES.

These, with the glands which secrete the digestive fluids, constitute the **digestive apparatus**.

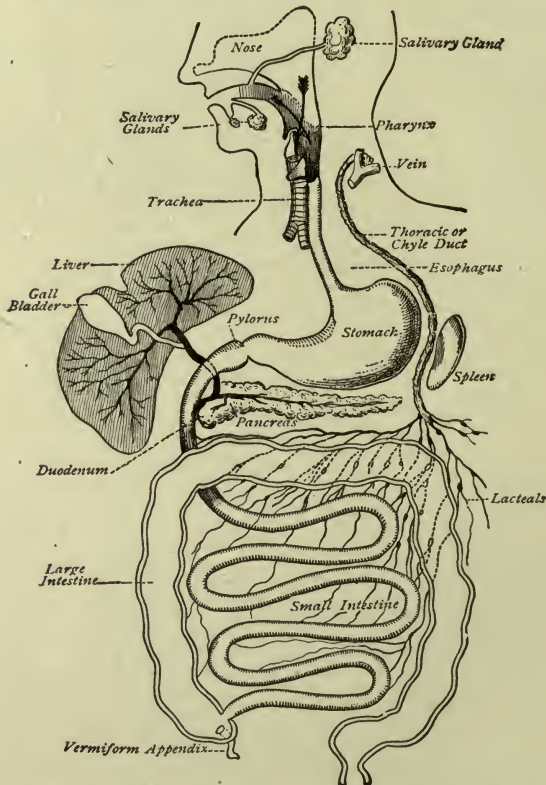


FIG. 94.—GENERAL SCHEME OF THE DIGESTIVE TRACT, WITH THE CHIEF GLANDS OPENING INTO IT; TOGETHER WITH THE LACTEALS ARISING FROM THE INTESTINE AND JOINING THE THORACIC DUCT (Landois).

The **alimentary tract** or canal is a series of channels included within the organs named, constituting a long tube of mucous mem-



brane through which the food passes. The glands which secrete the *digestive fluids* open into this tract.

The digestive fluid of the mouth is *saliva*.

The digestive fluid of the stomach is *gastric juice*.

The digestive fluids of the intestines are *intestinal juice*, and *pancreatic juice* (assisted by *bile*).

Each of these fluids contains one or more of the peculiar substances called *enzymes*.

An *enzyme* is a *ferment* which by its presence causes certain changes in other substances.

The enzymes of the digestive fluids cause the chemical changes in food which are necessary for its digestion.

The glands are	{	Salivary, opening into the mouth.
		Peptic, " " stomach.
		Intestinal, " " intestines.
		Pancreas, " " small intestine.
		Liver, " " small intestine.

The tongue, teeth and glands are **appendages** of the alimentary canal.

## THE MOUTH.

The **mouth**, or oral cavity, is enclosed partly by muscles and partly by bones. The muscles are the *lip muscles* in front, the *buccinator* at the sides, and the *mylo-hyoid* in the floor. The bones are the *maxilla* and the *palate*-bones above, and the *mandible* below.

The *roof* of the mouth is called the **palate**; the bony portion is the *hard palate*, and the muscular portion attached to it is the *soft palate* or the *velum palati* (veil of the palate). In the middle of the soft palate is the *uvula*, which is a small projection downward. All of these bones and muscles are in pairs, right and left.

**Surgical note.**—If, owing to lack of development they are not joined in the middle line, *cleft palate* results. The cleft may be partial or complete, and the divided upper lip is called *harelip*.

The oral cavity is lined with mucous membrane which is always moist in health. The part of the cavity between the lips and the teeth is the *vestibule*.

The mouth contains the teeth and the tongue.

The teeth are already described.

The **tongue** lies in the floor of the mouth with its base curved downward at the back and attached to the hyoid bone. It is com-

posed of muscles, and covered with mucous membrane which forms a special fold underneath the tip of the tongue connecting it with the floor; this fold is called the *frenum linguae*. When the frenum is short we say the tongue is "tied."

A little clip with the scissors is often sufficient to free it, but this is done with care as an artery runs forward very near the frenum.

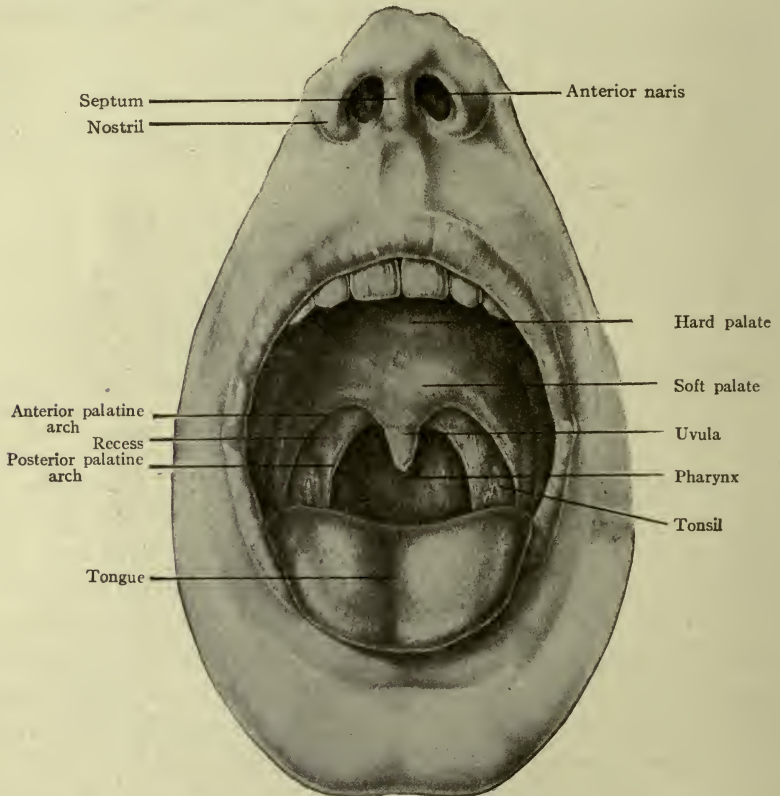


FIG. 95.—THE ORAL CAVITY (Deaver).

The *dorsum*, or superior surface of the tongue, is covered with small projections called *papillæ*, of three sizes,—the *vallate*, the largest, forming a V-shaped row at the back; the *fungiform*, next in size, scattered over the surface but most numerous at the tip and sides, and bright red in color; and the *filiform*, the smallest, covering the anterior two-thirds of the dorsum and borders (Fig. 96).

The **tongue** aids in mastication and swallowing, or deglutition. It is also an important organ of speech and the principal organ of *taste*.

**Note.**—The perception of bitter substances is plainer in the *posterior* portion, while sweet, sour, and salty substances are more quickly recognized in the *anterior* part and at the borders.

Some elevations of mucous membrane on either side of the base of the tongue form the *lingual tonsils*. (These are seen only with the aid of the laryngoscope.)

The mouth opens at the back into the pharynx, through the passage called the *isthmus of the fauces*. This passage is bounded by two *folds* on each side running downward from the soft palate and

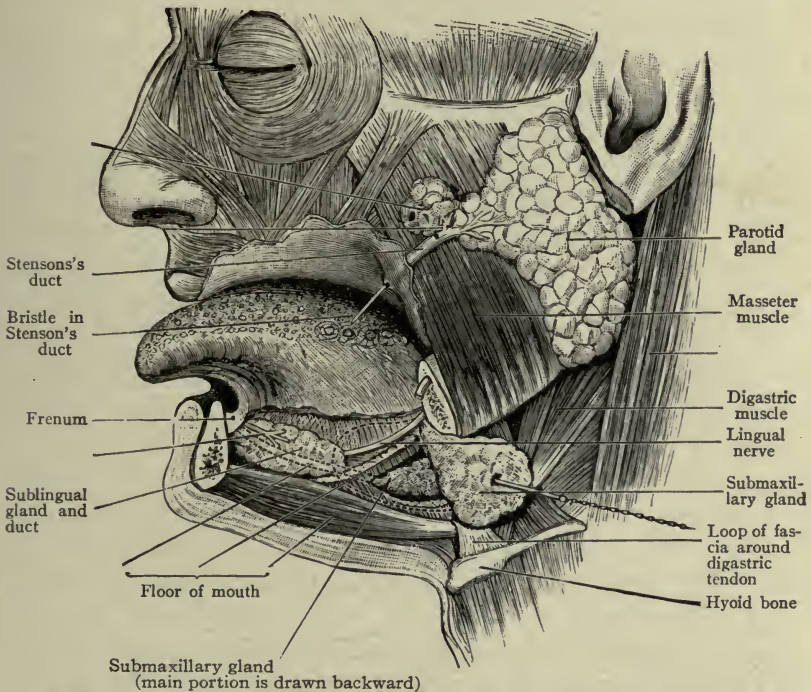


FIG. 96.—SALIVARY GLANDS AND PAPILLÆ OF TONGUE (Morris).

called the *palatine arches*, or *pillars of the fauces*. Between the anterior and posterior arch of either side is the **palatine tonsil**, a gland-like body the use of which is not clearly understood<sup>1</sup> (Fig. 95).

It presents small openings upon its surface leading into recesses or crypts which are surrounded by the *follicles of the tonsils*.

**Clinical note.**—**Follicular tonsillitis** is an inflammation of the mucous membrane and follicles in the crypts.

<sup>1</sup> The student may see all of these structures by examining her own mouth with the aid of a hand-mirror and a good light.

**Salivary glands.**—The digestive fluid of the mouth is called *saliva*. It is secreted by the *salivary glands*, three in number on each side—the parotid, submaxillary, and sublingual.

The **parotid** gland is situated in front of and below the ear, and has a duct about two inches long (*Stenson's duct*) which runs forward to open into the mouth opposite the second molar tooth of the upper jaw, piercing the buccinator muscle. It secretes an abundant watery fluid.

The surface line of Stenson's duct is drawn from the lobe of the ear to the middle of the upper lip.

The **submaxillary** gland lies under the angle of the jaw, opening into the floor of the mouth close to the frenum, by *Wharton's duct*. It secretes a thicker fluid than the parotid gland.

The **sublingual** gland lies in the (anterior) floor of the mouth and opens under the tongue near the frenum, by several small ducts. This also secretes a thicker fluid.

The fluid which is constantly present in the mouth and commonly called *saliva*, is a mixture of the secretion of the salivary glands and the mucous glands of the mouth.

The *reaction of the saliva is alkaline*. The enzyme or ferment of saliva is *ptyalin*.

### THE PHARYNX.

The **pharynx**, or throat, receives the food from the mouth. It occupies a space in front of the spinal column from the base of the skull to the fifth cervical vertebra, its *roof* being formed by the *body of the sphenoid* bone, joined to the *occipital*. The walls of the pharynx consist of three pairs of muscles called the *constrictors*—upper, middle, and lower, strengthened by a fibrous layer and lined with mucous membrane.

The illustration shows that the constrictors are flat muscles attached at the sides to the structures in front of the pharynx. Thus, from above downward, their **origin** is on the pterygoid process, a special ligament, the mandible, side of the tongue, hyoid bone, thyroid and cricoid cartilages. The fibers all join a fibrous line, or raphe, at the back, which is suspended from the base of the occipital bone. This is their **insertion**.

By due contraction of these muscles the food is grasped and pressed downward into the esophagus. They are composed of *striated* or voluntary muscle fibers.

The upper part of the pharynx is behind the nose and is called the *nasal part*, or *naso-pharynx*. The middle part is behind the mouth and is called the *oral part*, or *oro-pharynx*. (It is this part which we see when looking directly into the throat.) The lower part is behind the larynx and is called the *laryngeal part*, or the *laryngo-pharynx*.

The *openings of the pharynx* are seven in number: the two *choanæ* (posterior nares) communicating with the nose; the two

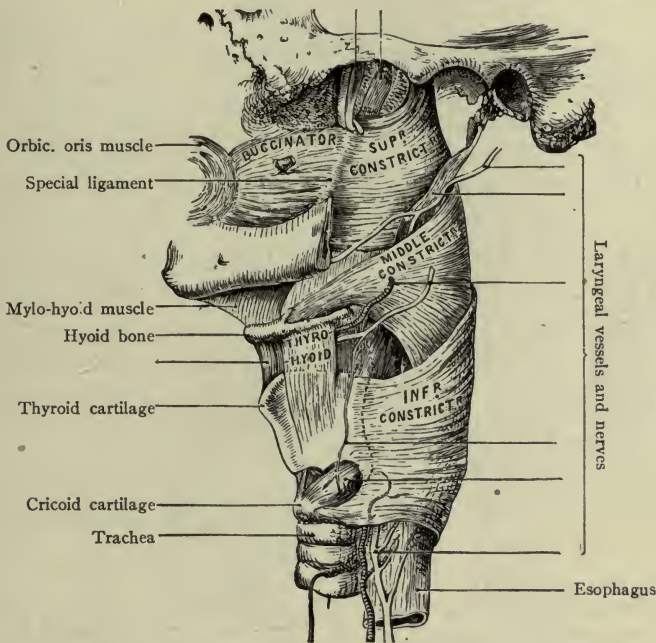


FIG. 97.—THE PHARYNX (Holden).

*auditory (Eustachian) tubes* communicating with the ears, and the *isthmus of the fauces*, communicating with the mouth. Below, it communicates with the larynx (the opening being guarded by the epiglottis), and opens into the esophagus.

The food passes through the oro-pharynx and laryngo-pharynx, the naso-pharynx being an air-passage.

In the roof of the pharynx is a small mass of lymphoid tissue called the *pharyngeal tonsil*.

## THE ESOPHAGUS.

The **esophagus** (Figs. 97, 98) begins at the lower end of the pharynx and extends downward in the neck in front of the spinal column, to pass into the thorax. It finally comes forward in front

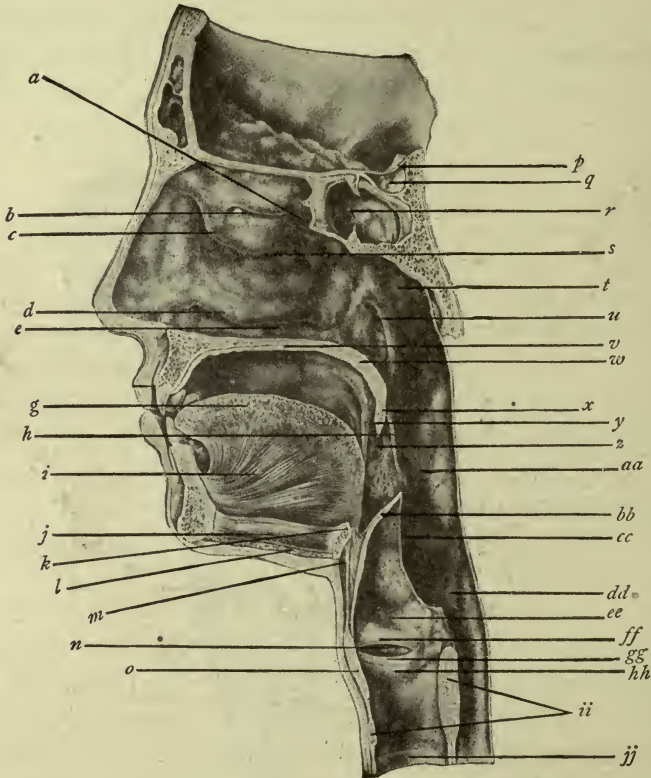


FIG. 98.—SHOWING SITUATION OF PHARYNX BEHIND NOSE, MOUTH, AND LARYNX (from Deaver's "Surgical Anatomy").

*b, a, c, s, d, e*, Turbinal bones and meatuses of the nose; *g, i*, tongue; *h*, posterior palatine arch; *y*, anterior palatine arch; *k*, hyoid bone; *j*, mylo-hyoid muscle (floor of mouth); *m*, thyro-hyoid membrane; *n*, ventricle of larynx; *p, q, r*, sphenoid bone and sphenoidal sinus; *v*, hard palate; *w*, soft palate; *x*, uvula; *z*, tonsil; *t*, naso-pharynx; *u*, orifice of auditory tube; *aa*, oro-pharynx; *dd*, laryngo-pharynx; *bb*, epiglottis; *ee*, upper portion of larynx; *gg*, vocal bands; *ff*, false vocal bands; *hh*, lower part of larynx; *ii*, cricoid cartilage; *jj*, trachea.

of the aorta, passes through the diaphragm, and terminates in the stomach. It is a tube about nine inches long, having two layers of muscles (circular within, longitudinal without) and lined with mucous membrane. By contraction of the different muscles from above downward the food is passed along to the stomach.

The esophagus lies at first immediately behind the trachea. The upper part is composed of *striated*, or *voluntary* muscle like that of the pharynx; in the lower part the muscle is *non-striated*, or *involuntary*, like the stomach.

At the termination in the stomach, the circular fibers are most numerous, forming the *cardiac sphincter* which prevents the return of stomach contents.

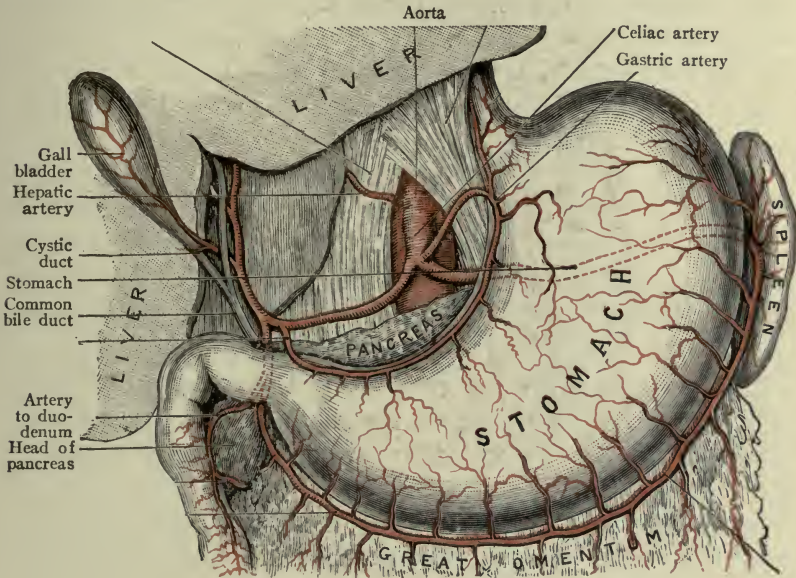


FIG. 99.—THE STOMACH AND SPLEEN (Morris).

The remaining organs of digestion are contained in the abdominal cavity, which is lined with a serous sac or membrane called *peritoneum* (see p. 299). These organs are developed from an original straight tube behind the peritoneum. Therefore, as they grow, they press forward against it and get a covering which is called their *serous layer*. Their muscular coats are all *involuntary* or *unstriped* muscle.

#### THE STOMACH.

The **stomach** (gaster, Fig. 99) is in the epigastric region of the abdomen just below the diaphragm. Shape and size: like a curved flask, ten to twelve inches long and six to eight wide at the larger end,

which is turned toward the left side. Average capacity: five pints in distension; two pints when moderately filled.

The *stomach* has two surfaces, two borders, two extremities and two orifices.

The *surfaces* are the *anterior*—looking slightly upward; and the *posterior*—looking slightly downward.

The *borders* are usually called *curvatures*; the upper border is the *lesser curvature* (about five inches in length); the lower border is the *greater curvature* (about twenty inches in length).

The left extremity is the expanded portion called the *fundus* of the stomach (also the *greater cul-de-sac*), and the *cardiac end* (from its nearness to the heart).

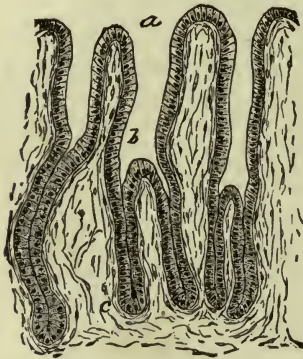


FIG. 100.—SECTION OF PYLORIC GLANDS FROM HUMAN STOMACH.

a. Mouth of gland leading into long, wide duct (b), into which open the terminal divisions. c. Connective tissue of the mucosa (after Piersol).

The right extremity is called the *pyloric extremity*. It is just below the liver.

The orifices are at the extremities. At the left is the *esophageal orifice* guarded by the sphincter of the cardia; at the right is the *pyloric orifice*, guarded by the sphincter of the pylorus or “gate-keeper.”

The *coats* or *tunics* of the stomach are four in number—*mucous*, *submucous*, *muscular*, and *serous*.

The *mucous layer*, or *mucosa*, is the innermost layer. It is pink in color but becomes bright red when food is present, from the increased blood-supply necessary for digestion. It lies in *folds*, or *rugæ*, running from one extremity to the other—the *longitudinal folds*. This layer contains the gastric glands which secrete the gastric juice and pour it through their ducts into the stomach.

The gastric glands are tubular in form, microscopic in size, and very numerous (their number is estimated at 5,000,000). They differ markedly in the two portions of the stomach. The *cardiac* glands secrete the digestive ferments, *pepsin* and *rennin*, while the pyloric glands secrete mucus also (Fig. 100).

The *reaction of the gastric juice* is *acid* (owing to hydrochloric acid).



The *submucosa* is a network of connective tissue next to the mucous coat. It bears fine vessels, nerves and lymphatics, and connects the mucous and muscular tunics together loosely, so that when the stomach is distended the *longitudinal folds* simply disappear, without injury to the mucous membrane.

The *muscular coat* (or *tunic*) comprises three layers of non-striated muscle: internal, middle and external. The internal layer consists of oblique fibers (it is a thin layer and is mostly confined to the cardiac portion). The middle layer is a complete layer of circular fibers. They are most numerous at the extremities of the stomach, where they form two ring-shaped bundles. One is the *sphincter of the cardia*, surrounding the lower end of the esophagus and the cardiac orifice of the stomach; the other is the *sphincter of the pylorus*, which is a strong ring-muscle diminishing the size of the pyloric orifice so that it is the narrowest portion of the alimentary tract (a half-inch, or 3 mm.). The external layer consists of longitudinal fibers (fibers running lengthwise) which are continued from the similar layer of the esophagus, and pass on to those of the intestine.

The *serous coat* (or *tunic*) is a portion of the great serous membrane of the abdomen, called the *peritoneum* (page 299). The two surfaces of the stomach are covered by different layers of peritoneum which will be described elsewhere (page 137).

The position of the stomach is oblique, the pyloric end being on a lower level than the cardiac. It is also the movable end.

The location of the stomach is mostly in the epigastric region (Fig. 106). It is below the portion of the diaphragm which supports the heart; behind it are the largest artery and vein in the body—the aorta and the inferior vena cava. The pyloric end extends under the liver in the right hypochondrium, while the cardiac end is in the left hypochondrium, in contact with the spleen.

**Clinical notes.**—When the stomach is empty it tends to a vertical position; when filled, it swings upward and forward to become again oblique. If much distended, as with gas, it embarrasses the action of the heart by pressure.

The infant's stomach is nearly or quite vertical and easily overflows; its capacity at birth is one ounce, reaching two ounces at about the end of a fortnight.

## THE INTESTINE.

The **intestine** or bowel, begins at the pyloric orifice of the stomach and continues to the end of the alimentary tract. It is from twenty-five to thirty feet in length (Fig. 101).

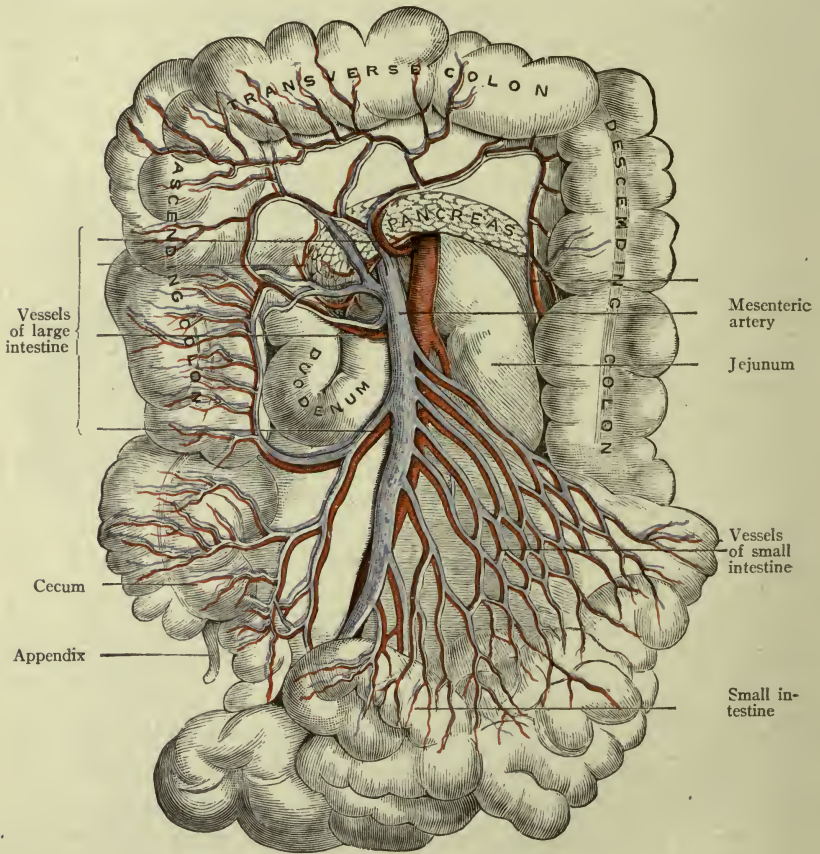


FIG. 101.—THE INTESTINES (Morris).

Large intestine thrown upward, small intestine drawn to left.

Like the stomach, it is composed of four coats or tunics—*mucous*, *submucous*, *muscular* and *serous*.

The *mucous coat* is the *glandular coat*; that is, the glands which secrete *intestinal juice* are imbedded in the *mucous coat*, and their ducts open on its surface.

In addition, small gland-like bodies of lymphoid structure are scattered throughout this coat. They have no ducts. They are probably lymph nodules—the so-called *solitary glands*.

The *submucous coat* bears the fine vessels and nerves which supply the mucous coat. It connects the mucous and muscular coats together.

The *muscular coat* comprises two layers (like the esophagus), an inner layer of circular fibers, an outer one of longitudinal fibers.

The intestine is divided into the following parts:

Small intestine	{	Duodenum	Large intestine	{	Cecum	{	Ascending
		Jejunum			Colon		Transverse
		Ileum			Rectum		Descending

### The Small Intestine.

The **small intestine** is about twenty feet in length, and about two inches wide in its upper (widest) part. It extends from the stomach to the colon, beginning with the pyloric sphincter in the right hypochondrium and ending with the ileo-colic sphincter in the right iliac region.

The *mucous coat* of the small intestine forms *circular folds* (old name, *valvulae conniventes*) which are *permanent*, that is, they never disappear however widely the bowel may be distended. They serve to increase the area of mucous membrane for purposes of digestion and absorption (Fig. 103).

The secreting *glands* which are found in every part of the small intestine are called the *intestinal glands* (or *intestinal follicles*, or *glands of Lieberkühn*). They are tubular in shape, and secrete the greater portion of the *intestinal juice*. The *ferment* of the glands of Lieberkühn is not known. The *reaction of the secretion is alkaline*.

The entire *mucous coat* is covered with tiny projections hair-like in size (from 1/2 to 1 mm. long) called *villi*, which give it a velvety appearance (Fig. 102).

In the midst of each villus is a minute *lymph-capillary*, surrounded by a fine network of blood-vessels and lymph-spaces, the whole covered by a layer of the special epithelium of the intestine.

The villi are *absorbing* structures or **absorbents**. (They may be demonstrated in a good light by laying a piece of intestinal wall in a shallow tray of clear water; the water will float their free extremities.)

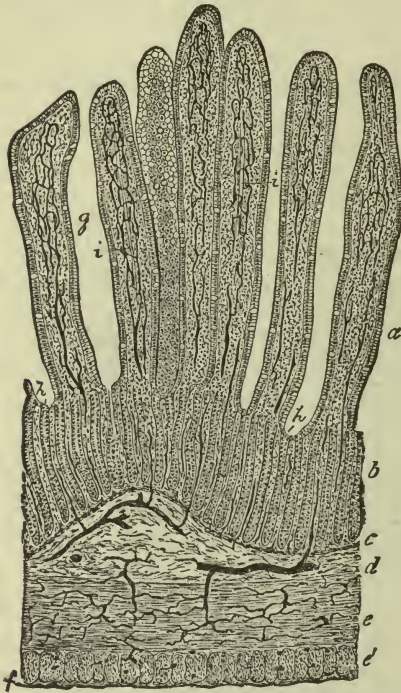

FIG. 102.—SECTION OF INJECTED SMALL INTESTINE OF CAT.

*a, b.* Mucosa *g.* Villi. *i.* Their absorbent vessels. *h.* Simple follicles. *c.* Muscularis mucosæ. *j.* Submucosa. *g. é.* Circular and longitudinal layers of muscle. *f.* Fibrous coat. All the dark lines represent blood-vessels filled with the injection mass (Piersol).

The *muscular coat* is in two layers—circular within, longitudinal without—pretty evenly distributed.

The *serous coat* covers all except a portion of the first division (see *duodenum*).

The **duodenum** is the first division of the small intestine

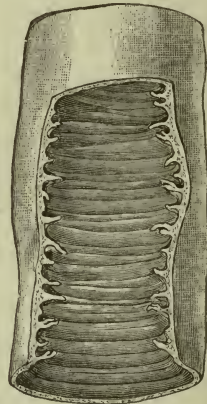


FIG. 103.—CIRCULAR FOLD OR VALVULÆ CONNIVENTES (MORRIS).

(Fig. 104). (It is about ten inches long, begins at the pyloric end of the stomach, curves upward and backward to make a horse-shoe bend to the right and downward, and then continues across to the left side of the spinal column thus making a *superior, descending and inferior* part.)

The *circular folds* of the *mucous coat* begin in the lower portion and are unusually large.

There are special glands in the duodenum not found elsewhere, called *duodenal glands* or *Brunner's glands*; they furnish a portion of the intestinal juice.

**Note.**—The inferior part of the duodenum is behind the peritoneum, *this part has no serous coat.*

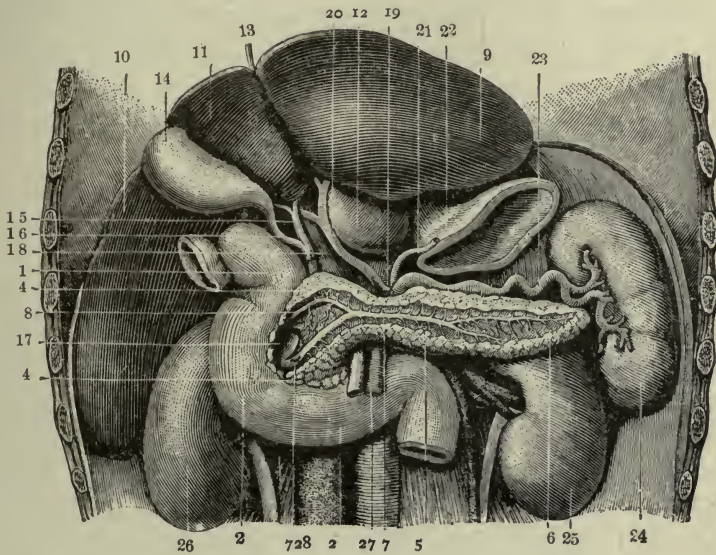


FIG. 104.—LIVER, PANCREAS, DUODENUM, SPLEEN AND KIDNEYS. 1, 2, 3. Duodenum. 4, 4, 5, 6, 7, 7, 8. Pancreas and pancreatic ducts. 9, 10, 11, 12, 13. Liver. 14. Gall bladder. 15. Hepatic duct. 16. Cystic duct. 17. Common duct. 18. Portal vein. 19. Branch from the celiac axis. 20. Hepatic artery. 21. Coronary artery of the stomach. 22. Cardiac portion of the stomach. 23. Splenic artery. 24. Spleen. 25. Left kidney. 26. Right kidney. Section of pancreas to show ducts. Liver turned upwards and stomach removed to show duodenum.

The **jejunum** is the second division of the small intestine—so named because it is found empty. It possesses all of the characteristic structures: *villi*, *circular folds*, *intestinal* and *solitary glands*. It lies in the umbilical and the two lumbar regions.

The **Ileum** is the third division of the small intestine—so named because of its frequent twisting. There is no definite separation between the end of the jejunum and the beginning of the ileum.

The *villi*, *circular folds*, *intestinal glands* and *solitary glands* are all found in the ileum. The circular folds diminish in size as the necessity for their presence grows less in the lower portion, but the *solitary glands* increase in size and number. They are grouped into

various oblong patches, toward the lower end of the ileum, the Peyer's patches or *agminated glands*. (The largest patches may measure three inches in length.)

The *reaction of the intestinal fluids* is *alkaline*.

**Clinical note.**—The *solitary glands* (more especially the *Peyer's patches*), become inflamed and ulcerated in typhoid fever.

The **ileum** ends in the right iliac region by opening into the large intestine. This orifice is doubly guarded; first, by two folds of mucous membrane strengthened by fibrous tissue, called the *ileo-cecal valve*; second, by a circular muscle called the *ileo-colic sphincter*; this is the more important of the two.

### The Large Intestine.

The **large intestine** is about five feet long and two and one-half inches wide in the widest part. It begins where the small intestine ends (in the *right iliac* region), ascends through the *right lumbar*, crosses the abdomen in front of the small intestine, descends to the *left iliac* region, and thence down through the pelvis, ending in front of the coccyx. (See Regions of the Abdomen, p. 296.)

The *mucous coat* is smooth and rather pale. No folds are present, and no villi, but the *solitary* and *tubular glands* are numerous.

The circular fibers of the *muscular* coat are evenly distributed, but the *longitudinal* fibers of the cecum and colon are arranged in three bands, placed at even distances apart. These bands are shorter than the tube itself, therefore they gather it into puffs which give the bowel a sacculated appearance. By this, the large bowel may be recognized at once, even should it be really small in actual size in some portion of its extent.

The *serous coat* covers the greater part of the large intestine; the exceptions will be noted later.

The **four divisions of the large intestine** are the cecum, the colon, the sigmoid loop, and the rectum (Figs. 101, 105).

The **cecum**, or first division, is a short pouch hanging below the level of the *ileocolic valve* and presenting the opening of the *appendix vermiformis* or appendix ceci. The *three longitudinal bands* of the muscular coat meet at the base of the **appendix**, which is a small tube three or four inches long, attached to the posterior side of

the cecum. It often turns upward, quite as often downward, and may lie transversely. It has all four coats, with intestinal and solitary glands, but is of no use.

**Clinical note.**—Owing to its small size any substance which enters the appendix is apt to be retained, and if it is of an injurious character it will cause *appendicitis*. This disease is more often caused by the action of harmful bacteria than the celebrated cherry-stone. Small intestinal worms have been found within the appendix.

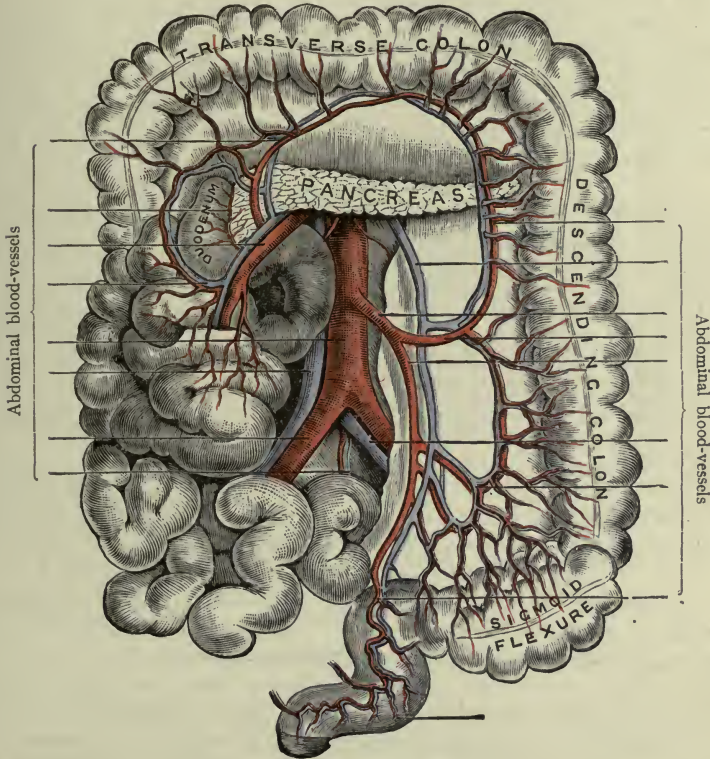


FIG. 105.—THE LARGE INTESTINE.

The small intestine and its vessels are drawn to the right to show the sigmoid colon and the rectum. The transverse colon is thrown upward (Morris).

The *ilio-cecal valve* consists of two folds of mucous membrane with muscle fibers between the layers. They are placed at the end of the ilium where it opens into the colon, and project toward each other, leaving only a slit-like passage.

The **colon** begins at the ilio-cecal valve. The first part, or

*ascending colon*, passes upward in the right lumbar region. After making a bend under the liver—the *right colic flexure* (or hepatic flexure), it becomes the *transverse colon*, which hangs in a loop across the abdomen in front of the small intestine. Another bend occurs under the spleen, the *left colic flexure* (or splenic flexure); thence the *descending colon* passes downward in the left lumbar region to the left iliac fossa. Here it makes an S-shaped or *sigmoid* bend and becomes the so-called *sigmoid colon*. It then enters the pelvis to become the *rectum*.

**Surgical note.**—The *ascending colon* lies so close to the posterior abdominal wall that there is *no peritoneum behind it*, and the *descending colon* also is bare in a narrow strip at the back, consequently the surgeon may take advantage of this condition to open the colon without wounding the peritoneum, in the operation called *lumbo-colotomy*.

The **rectum** is about five to seven inches long, very distensible, and so called because it has no convolutions, but simply follows the curve of the pelvic wall, lying in front of the sacrum and coccyx. In the last inch or inch and a half it bends backward (*perineal flexure*) to pass the tip of the coccyx. This is the *anal canal*, and it ends at the opening called the *anus* (Fig. 105).

The portion above the anal canal is the widest part—the *rectal pouch*.

The *muscular membrane* of the rectum is red, and usually presents two or three special  *folds* about two or three inches above the anus, called the *rectal folds*, or Houston's valves.

The largest, a permanent fold, is on the right side about two and one-half inches above the anus and called the *third sphincter*. Two smaller ones, not permanent, are on the left side, above and below the former.

The *muscular coat* has the two layers, circular and longitudinal. The *peritoneal coat* covers the front and sides of the upper part only.

The *reaction* of the fluids in the *large intestine* is **alkaline**.

**Sphincters of the anus.**—The circular fibers around the *anal canal* form the *internal sphincter*.

The *external sphincter* is a flat circular muscle just under the skin around the anus. The function of the sphincters is to guard and control the anus.

**Clinical note.**—The point of a syringe should be passed in an *upward* and *forward* direction through the anal canal, and then turned backward.



## RÉSUMÉ.

The alimentary tract begins with the mouth and ends with the large intestine, passing through the head, neck, thorax, and pelvis. It is practically a long tube of mucous membrane surrounded by layers of muscle and held to them by connective tissue. The *mucous membrane* contains glands which secrete the digestive fluids. The *muscle layers* pass the food along, that it may be acted upon in all portions of the tract; and wherever free motion accompanies the digestion of the food, a *serous layer* is added outside of all to prevent friction.

The digestive fluid of the stomach is *acid*; in all other parts it is *alkaline*.

**Peristalsis** is the name given to the peculiar motion of the stomach and intestine during the passage of their contents. The circular fibers compress the food and at the same time the longitudinal fibers shorten the tube. This action goes on from above downward, causing a sort of worm-like movement which is described as *peristalsis*, or *peristaltic movement*.

The **mesentery** is the fold of peritoneum which holds the *jejunum* and *ileum* in place. This fold leaves the posterior abdominal wall at a line inclining downward to the right, about five or six inches long; but it includes twenty feet of intestine, and therefore it is like a very full ruffle twenty feet in length with a band of six inches. The vessels and nerves of the intestine lie between the layers of the mesenteric fold.

Any fold of peritoneum which connects a portion of intestine to the wall of the trunk is a mesentery. The *meso-colon* connects the colon with the abdominal wall; the *meso-rectum* connects the rectum with the pelvic wall; the large *mesentery* holds the ilium and jejunum to the posterior abdominal wall.

An omentum is a fold of peritoneum connected with the stomach. The *greater omentum* hangs from the greater curvature; the *lesser omentum* connects the lesser curvature with the liver (being called the *gastrohepatic* omentum); and the gastrosplenic omentum connects the stomach and spleen. Two layers of peritoneum pass from the under surface of the liver to the lesser curvature of the stomach, forming the *lesser omentum*. They then separate to enclose the surfaces of the stomach, making its serous coat. They come together again at the greater curvature and hang down in the shape of a large serous sac with double walls, the *greater omentum*, which hangs in front of the small intestine.

**Note.**—The transverse meso-colon usually becomes adherent to the greater omentum (Fig. 106).

## THE PANCREAS.

The **pancreas** (Figs. 104, 105) is a gland situated behind and below the stomach. It is about seven inches long and somewhat

resembles a hammer in shape, the *head* being turned to the right and lying within the curve of the duodenum, the *body* crossing to the left, and the *tail* reaching the spleen. It secretes an abundant

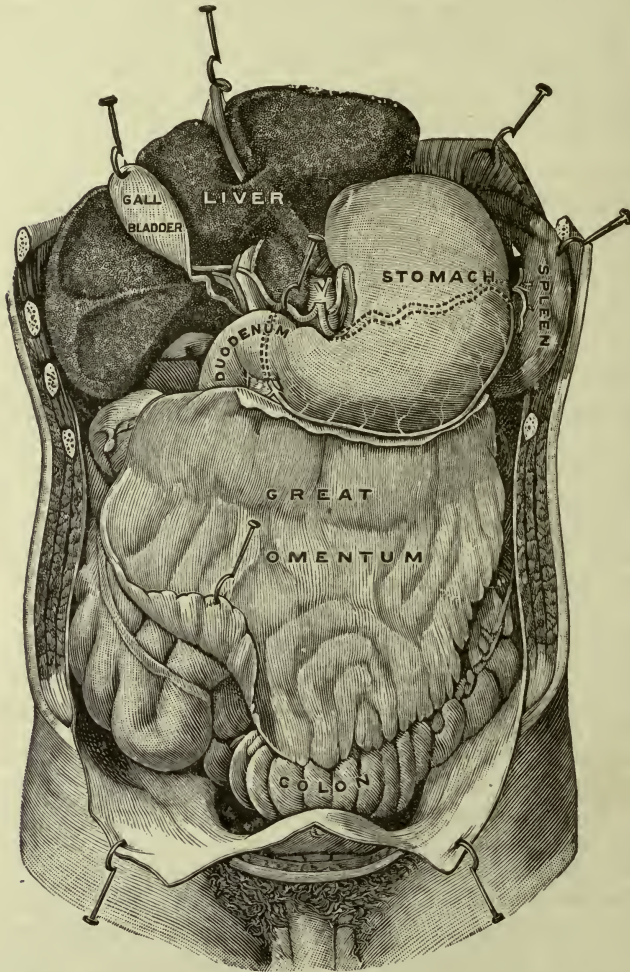


FIG. 106.—THE ABDOMINAL ORGANS (Gerrish, after Testut).

The liver is turned upward to show the inferior surface with the gall-bladder. The vessels entering and leaving the porta are also seen, the lesser omentum having been removed.

*alkaline pancreatic fluid*, conveyed by the *pancreatic duct* to the duodenum. The duct opens (with the common bile duct) into the duodenum about four inches from the pylorus.

The three pancreatic ferments are *amyllopsin*, *trypsin* and *steapsin* (for *starch*, *proteid* and *fat*) (see page 147).

### THE LIVER.

The **liver** (Fig. 106) is the largest abdominal organ, and the largest gland in the body. Its normal weight is between three and four pounds (1300 to 1700 grams). It is underneath the diaphragm, in the right upper portion of the abdomen, the thin left lobe extending across the epigastric region above the stomach. Its general shape is that of a wedge, much thicker at the right side than the left, and with the thin edge turned forward. The upper surface is convex, and marked off by a ligament into two lobes, right and left. The lower surface is divided by five fissures into five lobes. The largest fissure is the *transverse*, the **porta** (or *gate*) for the passage of vessels,<sup>1</sup> nerves and ducts.

The liver secretes a yellow *alkaline* fluid called **bile** which is conveyed through the porta two by ducts, the *right hepatic* and *left hepatic*; these unite to form one, the **hepatic duct** proper, which is soon joined by the cystic duct from the gall-bladder.

The **gall-bladder** occupies a fissure on the inferior surface of the liver. It is a pear-shaped sac three or four inches long, of fibrous tissue and muscle fibers lined with mucous membrane and partially covered with peritoneum. It contains a variable quantity of bile (or "gall") in reserve. The only opening of the gall-bladder is for the *cystic duct*, which joins the hepatic to form the **common bile-duct**, or *ductus communis choledochus*. This opens into the duodenum with the pancreatic duct (Fig. 104, 106).

**Note.**—The production of bile is continuous; its flow into the intestine is intermittent. It appears in the duodenum only during the process of digestion; in the interval it is stored in the gall-bladder.

The substance of the interior of the liver is composed of secreting cells called *hepatic cells*, grouped in *lobules*, with a multitude of blood-vessels, lymphatics and nerves, supported by connective tissue.

An *hepatic lobule* measures only about a millimeter ( $\frac{1}{25}$  of an inch) in width. Between its cells there is a fine network of hepatic and portal blood-vessels, and lymph spaces; also *bile passages*. The blood-vessels empty into hepatic veins; the lymph spaces form lymph vessels, and the bile passages lead to small *bile ducts* which unite and reunite to form the *hepatic ducts*.

<sup>1</sup> *Lymph vessels* and *hepatic artery*. Hepatic veins take a different route.

Vessels passing through the <i>porta</i> (or transverse fissure) of the liver:	{	Entering	{	Hepatic artery. Portal vein
		Leaving	{	Two hepatic ducts. Lymphatics.

All of the hepatic *veins* leave the liver at the back, opening at once into a larger vein running to the heart (the inferior vena cava). The great quantity of venous blood which the liver contains gives to it its dark color.

Five *ligaments* of the liver hold it in place attaching it to the diaphragm and abdominal wall—the *round*, the *broad*, the *coronary*, and *two lateral*.

The *round ligament* is a cord (the remains of the umbilical vein) inclosed in the *broad*, which, with the *lateral* and *coronary*, is of peritoneum. It is the broad ligament which connects the superior surface of the liver with the diaphragm and is therefore called the *suspensory ligament*. It also marks off the right from the left lobe on that surface.

## CHAPTER IX.

### FOODS AND DIGESTION.

#### FOODS.

The human body is a machine constantly in motion; therefore, its cells continually use up their force, and continually need renewing. The material for this renewal is supplied by the food which we eat, and as the various parts of the body are composed of quite different tissues, so the food is of a mixed character.

The composition of the tissues requires that for their growth and repair *four classes of food principles* must be included in the dietary.

1. Proteids.
2. Carbohydrates (sugars and starches).
3. Fats.
4. Mineral salts.

In the body:—

1. *Proteids* are found in all tissues of the body, most abundantly in the *blood*, as serum albumin, fibrinogen, hemoglobin; in the *lymph*, as serum albumin; in the *muscles*, as myosinogen; in the *milk*, as caseinogen.

2. *Carbohydrates* (or sugars and starches) are found principally in the *blood*, as dextrose; in the *liver* and *muscles*, as glycogen; in the *milk*, as lactose. (Glycogen is an animal starch formed within the body, the others are sugars. Dextrose and grape sugar are the same.)

3. *Fats* are found in *subcutaneous fasciæ* and around organs, as adipose tissue; in *milk*, as emulsion; in *blood cells*, *nerves*, *lymph*, as lecithin;<sup>1</sup> in *bones*, as marrow.

4. *Mineral salts* are found in all tissues and fluids of the body, in *fluids* especially, as water; in *bones and teeth* especially, as lime salts; in *muscle*, *nerves and blood*, as potassium salts; in *all tissues*, as sodium; in *red blood cells*, as iron.

The blood must draw from all four classes of *food principles* for its composition, since it bears to all parts of the body their food. "The blood is the life."

<sup>1</sup> Probably derived from nerve tissue in the body

In the dietary:

**Proteids** must be supplied to all tissues. They are the *tissue builders*. They may be obtained from *meats*, as myosin and albumin; *eggs*, as albumin from white, vitelline from yolk; *grains*, as gluten; *vegetables*, as vegetable albumin (peas, beans, corn, etc.).

**Starches and sugars** are utilized by liver and muscles and are probably the principal sources of muscle energy. They and their compounds are easily oxidized, that is, combined with oxygen. They are obtained from *fruits*, as sugar (dextrose); from *milk*, as lactose; from *cereals*, *peas*, *beans* and *potatoes*, as starch; from *sugar cane*, *beets*, etc., as cane sugar or saccharose.

**Fats** are needed for the marrow of bones, as protective coverings, and to fill in spaces between organs. Also to preserve body heat as well as to produce it.

They are obtained from animal foods, from milk, from grains, corn, oats, etc., and formed in the body from sugars.

**Mineral salts** are needed everywhere, although in small quantities, as a rule.

*Water* is the most important, being indispensable to life. It constitutes nearly three-fourths of the body weight and is universally present, even in the hardest tissues (*e.g.*, enamel of teeth). Its most important uses are:

1. To hold in solution the nutritive principles and make it possible that the tissues may absorb them.
2. To sweep away the waste products to organs which can excrete them.

It is obtained from all foods, but must be added in bulk (Small quantities are formed within the body.)

*Sodium chloride* stands next in importance. In an unexplained way it is necessary to the normal activities of the tissues. It must be added to other foods.

*Phosphate of calcium* is needed by bones and teeth, forming a large proportion of their weight. It is the most abundant mineral salt (next to water). It is obtained from *vegetables*, *grains* and *proteid foods*.

*Iron* is a necessary constituent of red blood cells, in hemoglobin. It is obtained from *meats* and other *animal foods* and some vegetables.

*Atmospheric Air as Food*.—Sugars, starches and fats consist of carbon, hydrogen and oxygen (CHO). The proteids add nitrogen

(CHNO) and a little sulphur (CHNOS). (The formulæ are omitted, the symbols being sufficient for our purpose.) These elements are all furnished in suitable quantities by the food as described, except oxygen. This is obtained in great measure from the air we breathe, which consists of nitrogen and oxygen.

This atmospheric nitrogen does not form combinations with other elements; it is thought to serve only as a diluent for oxygen.

The *oxygen* is the important element. It passes from the lungs into the blood and is carried by the red cells to the tissues at large. (This is further described in Chapter XIII.)

With the exception of *oxygen*, (which is introduced into the system through the lungs), food enters the system through the alimentary tract, being here prepared for the uses for which it is designed, by the process of digestion.

Different articles of food should be combined in such way as to secure proper adjustment of food principles to body needs.

For example: with *meats*, *vegetables* should be served rather than milk or eggs.

Avoid a number of starchy vegetables in the same meal. For example: to *potatoes*, or *rice*, or *hominy*, add *green vegetables*, as *string-beans*, *spinach*; *celery*, etc.

There is good reason for adding *butter* to *bread* and *oil* to *salad*, as neither flour nor green things contain fat.

*Milk* is well combined with *starchy food*, having within itself both proteids and fat. *Eggs* can take the place of meat to a large extent; they may be combined with milk.

The *shell* or *husk* of *grain* contains certain mineral salts which are about our only source of silica for the hair and teeth; therefore—give whole grains to growing children.

*Whole-wheat* flour, and *ripe beans* or *peas*, contain proteid in a vegetable form; ripe corn (*cornmeal*) contains more fat than other cereals, and protein as well.

All vegetables contain a varying amount of fiber which is indigestible, but which is beneficial, since it serves to prevent the concentration of waste matters in too small bulk for the action of the large intestine. Three reasons for *cooking* food are as follows:—

*Cooked starch* is more easily digested than raw, for the following reasons: The change of starch into sugar requires that it should first be *hydrated*, that is, water must be added to it. It exists in granules

and each granule of starch has a covering of cellulose which is practically indigestible. In the process of cooking, the boiling water penetrates to the granule, uniting with it and causing it to free itself from the envelope. At once it can be acted upon by *ptyalin* if in the mouth, or *amylopsin* if in the small intestine. With raw starch, hydration goes on slowly or not at all. Imperfectly cooked starch is unwholesome for the same reason.

*Vegetables* also should be thoroughly cooked both on account of the starch which they contain, and the fibrous material, which needs partial disintegration by heat.

*Meats* are more easily digested if cooked long enough to soften their connective tissue fibers. By heat these are converted into a gelatinous substance which can be disposed of by pepsin and trypsin.

**Clinical note.**—The “*scraped beef sandwich*” so often ordered for patients, contains the substance of the *muscle cell* alone, which has been scraped away from the connective tissue fiber; it is easily digestible because it may at once be converted into peptone without the necessity for first digesting the tougher covering.

## DIGESTION.

**Digestion** is the process of so changing the food that its nutritive parts may be absorbed into the system.

The organs described in Chapter VIII are so connected and arranged that they receive and act in consecutive order upon the food, causing a series of changes which result in separating *nutriment* from waste and preparing it for absorption, expelling the waste from the system.

The **process of digestion** begins in the *mouth* and continues throughout the small intestine. The food is first divided into small pieces by means of the teeth. This is *mastication*. At the same time it is mixed with saliva; this is *hydration* and *insalivation*.

By the act of swallowing, the softened mass is passed into the pharynx and down through the esophagus to the stomach. This is *deglutition*. (The soft palate prevents it from going upward to the nose, and the epiglottis prevents it from entering the larynx.)

The *stomach* now takes charge. The mass is compressed and moved about by the layers of the muscular coat until it is thoroughly saturated with gastric juice, and becomes a pale yellowish fluid called *chyme*. As fast as this is accomplished, the *pylorus*, or gate-



keeper, allows it to go through into the *duodenum*, where it meets the intestinal and pancreatic juices, and bile.

Continuing through the *small intestine* it loses in increasing measure its fluid and nutritious portions, and in the *large intestine* it is still further reduced to waste alone, which is expelled from the body.

The food is subjected to two sorts of processes in each division of the alimentary tract; the first is *mechanical*, the second *chemical*.

The first occurrence which follows the introduction of food, is an increased flow of blood to the part and activity of the secreting cells as the food arrives, beginning with the secretion of saliva. In fact, the cells may begin to work beforehand, being stimulated by the thought of food.

In the **mouth** the mechanical process includes *mastication* and *insalivation*. By the teeth the food is divided, then crushed and ground; at the same time it is softened by saliva. The *parotid* saliva does most of this, being the most abundant; it is poured into the mouth just outside the upper second molar and thus it mixes at once with the mass as it is crushed and ground. *Submaxillary* and *sublingual* saliva contain much more mucin, and lubricate as well as soften the food.

The *chemical* process consists in the conversion of *starch* into *sugar*. This is accomplished by **ptyalin**, a ferment (or *enzyme*) in the saliva. Starch is not soluble, therefore, not absorbable. Sugar is both. Not all the starch taken at one time is digested in the mouth for the reason that it leaves the mouth too soon. (If it is retained in the mouth for some time, especially if mastication be continued, the presence of the sugar thus formed will be evident to the taste.)

*Ptyalin* cannot act in acid fluids: *The saliva is alkaline.*

Being masticated and insalivated the food is passed through the pharynx and esophagus into the stomach. The tongue presses against the hard palate, thus giving the bolus (as the prepared mass is called) an impulse toward the isthmus of the fauces; as it passes through this space the upper pharyngeal constrictor muscle grasps it and passes it on—then the middle and the lower constrictors in turn—and it enters the esophagus. (Meanwhile the soft palate has prevented it from going upward and the epiglottis from entering the larynx.)

Through the cardiac sphincter of the esophagus it enters the

**stomach.** Here the *mechanical* process consists in the action of the muscle coats, which move the food about that it may be still more softened and thoroughly mixed with gastric juice. The contractions of the muscles of the stomach go on in a wave-like manner toward the pylorus. They alternately constrict and relax the walls of the cavity.

The *chemical* process in the stomach consists in the conversion of proteid substances into **peptones** by the action of hydrochloric acid and pepsin. *Gastric juice* contains two ferments or enzymes, *pepsin* and *rennin*. **Pepsin** attacks the *proteids* after they have been acidified (it cannot work in alkaline fluids).

In the digestion of *meats*, the *acid* softens the connective tissue fibers (which are already partially gelatinized by cooking) and thus prepares them for the action of the pepsin. *Eggs* are digested in the same manner but more easily, having so little connective tissue.

*Milk* is first acted upon by **rennin** which sets free the *albumin* contained and brings out the *casein* from the caseinogen, in the form of a soft coagulum or *curd*. *Pepsin* then transforms both into *peptone*.

*Clinical note.*—The curdled milk which a healthy baby regurgitates is a normal substance; the rennin has acted and it only needs the pepsin to complete its digestion.

*Vegetables* are digested in the stomach only so far as the protein which they contain is concerned; *sugar* and *starch* not at all.

*Fats* are freed from their connective tissue envelopes and float as little globules; they are not themselves digested here.

**Note.**—The *mineral salts* do not require digestion. They are already dissolved in the water for the purpose of entering into combinations in the tissues.

When any portion of the stomach contents is sufficiently prepared by gastric digestion, the pyloric sphincter relaxes and the rather thick yellowish fluid called **chyme** passes through it into the duodenum and thence into the jejunum and ileum.

Here the *mechanical* process is a continuation of the *peristaltic movement* of the stomach. The circular fibers, by frequent constrictions of the tube, divide the mass and force it along, at the same time preventing a too rapid passage. The longitudinal fibers assist, by a series of wave-like contractions.

The *chemical* process consists in the further digestion of pro-

teids, sugars and starch; also the digestion of fats. Therefore the intestinal fluid contains several ferments, being a mixture of *pancreatic juice*, *intestinal juice* and *bile*.

The *intestinal juice* completes the digestion of *sugar* (and possibly of starch); its ferment is *invertin*.

The *pancreatic juice* acts promptly upon *starch* by the ferment *amyllopsin*, changing it to sugar. It converts *protein* into *peptones* by the ferment *trypsin*, and it digests *fats* by means of the ferment *steapsin*, which emulsifies them into a white fluid called **chyle**.

The *bile* which is poured into the duodenum with the pancreatic fluid is an aid to digestion in ways not perfectly understood. The intestinal ferments all act in alkaline fluids, and bile is alkaline. Experiments and observation have proved that the presence of bile in the intestine is necessary to nutrition; without it a person may eat large quantities of food and still lose weight daily. It is believed that it assists the absorption of fats and it pretty certainly delays putrefactive changes in the intestines. It may also stimulate peristalsis.

**Clinical notes.**—The reason for abstaining from ice-water during digestion is that the various ferments cannot do their work in a temperature much less than 100° F. (If people *will* eat ice-cream after dinner they should at least take it slowly, that the whole process of digestion be not too long delayed by the necessity of waiting for the temperature to rise again to 100°.)

The activity of the salivary glands of the infant does not begin under three or four months. The feeding of starchy foods should be delayed in accordance with this fact.

The passage of food through the intestine is normally slow, and thus it is fully exposed to the surfaces of the circular folds of the mucous membrane. By the absorption of digested food the intestinal contents are diminished in quantity and changed in character, containing less water and approaching a firmer consistency. After passing through the *ileo-colic sphincter* into the large intestine there is little but waste remaining, undigested food forming the major portion. This collection of waste, liquids, coloring matter and undigested food is called **feces**. The *coloring matter* is derived partly from bile, partly from food (it may be modified by drugs; for example, iron and bismuth giving a black color to the feces). (The *odor* is due to sulphuretted hydrogen and to skatol—it also is

modified by food.) The *consistency* depends upon the amounts of water and mucus, approaching a liquid form when the intestinal contents are hurried through the tube before absorption can take place.

*Defecation* is the act of expelling the feces. The bowel muscles contract and the sphincter relaxes; the abdominal muscles assist by compressing the organs from above. The dietary which contains the largest proportion of waste material will leave the greatest quantity of feces and lead to more frequent defecation than one which is made up of digestible substances only. The peristaltic action of the bowel is made more effective by the presence of a reasonable amount of matter to be acted upon.

*Diarrhea* is the passing of frequent loose or watery stools. It occurs when the contents of the small intestine are hurried along too rapidly by some irritating substance which causes excessive peristalsis and a leakage of the watery portion of the blood.

*Constipation* is caused by a too concentrated diet and slow peristalsis. Since bile is a natural stimulant to the muscles of the bowel, constipation is often associated with a torpid liver; it is also caused by lack of fluids in the bowel. Therefore this is one reason why water is an important food.

#### ABSORPTION OF FOOD.

Accompanying the digestion of food the absorption of nutritive principles takes place.

It is not proven that food is absorbed from the stomach; as fast as it is digested there, it is discharged as **chyme** into the small intestine. After it is acted upon by intestinal fluids it is ready to be absorbed. The *villi* (page 131) are the absorbents which perform this function in the intestine. The *epithelial cells* with which they are covered take up and transmit the new substances (formed by digestion) into *lymph spaces* within the villus, from which they go either into the *blood-vessels* or *lymph capillaries* (page 149) which it contains.

*Water and mineral salts* (dissolved in the water).—These must pass into the *blood capillaries*, thence into *intestinal veins*, and through them to the *portal vein* (page 188). By this they are taken to the *liver*.

*Sugars, dextrose and levulose* (which result from the digestion of carbohydrates). These pass by the same route, namely, blood capillaries and veins to the *liver*.

*Peptones* also find their way in the same manner to the portal blood and the *liver*.

Thus it appears that all *proteins, sugars, water and salts* pass through the *liver*. There, water and salts are used for various combinations; sugars are converted into glycogen to a great extent and stored for future use; and proteids furnish tissue food and materials for bile.

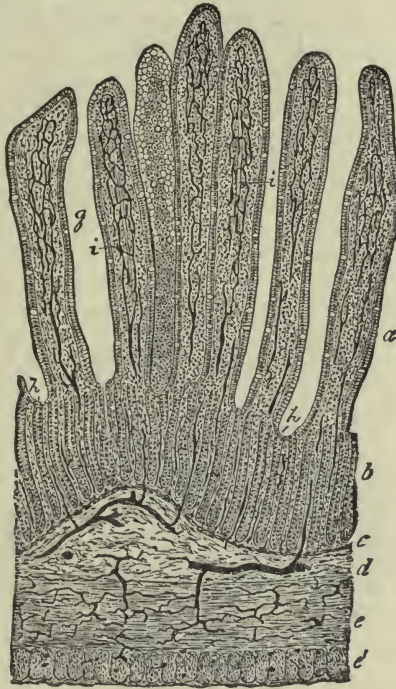

FIG. 107.—SECTION OF INJECTED SMALL INTESTINE OF CAT. *a, b.* Mucosa. *g.* Villi. *i.* Their absorbent vessels. *h.* Simple follicles. *c.* Muscularis mucosæ. *j.* Submucosa. *g, e.* Circular and longitudinal layers of muscle. *f.* Fibrous coat. All the dark lines represent blood-vessels filled with the injection mass (Piersol).

**Glycogen.**—This product of the action of liver cells upon carbohydrates is stored in the liver. When needed it is returned to the blood (as sugar again) and distributed to the tissues, notably to the muscles. Being readily oxidized it favors the rapid changes in muscles which result in motion. Therefore, it follows that sugar and starch are sources of muscle energy.

**Urea.**—This is another substance which appears as a result of the activity of the liver cell. It represents the final form of waste derived from the metabolism of proteid substances. It is a very poisonous waste and is eliminated from the blood by the kidneys.

Having yielded materials for these functions, the remaining food substances are carried away from the liver by *hepatic veins* and finally

into the general circulation, to be distributed to the tissues of the body.

There remain the *fats*: These, being transferred by the epithelial cells to the lymph-spaces, take the other route, in the form of an emulsion known as *chyle*. They pass into the *lymph capillaries* of the intestine (so-called *lacteals*), which open into the *lymph vessels* in the submucous coat. - By these vessels the chyle finally reaches the *thoracic duct* and is carried into the general circulation to be distributed to the tissues of the body (Fig. 108).

Another view is held concerning the digestion and absorption of fats—that the results of digestion are soaps and glycerin, which are easily absorbed. However they may be absorbed by the epithelium, they are in the form of an emulsion in the lacteals.

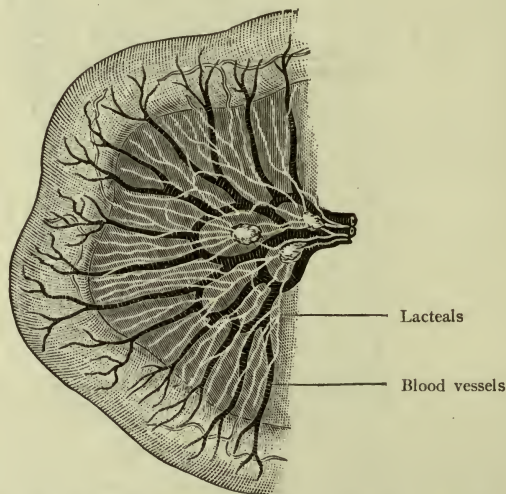


FIG. 108.—LOOP OF SMALL INTESTINE WITH LACTEALS (Morris).

*In the tissues.*—The solution of nutritive substances, having been carried by the blood-vessels to the minutest channels in the body, passes into the tissue spaces as **lymph**, which bathes the cells themselves so that they may receive the material necessary for their action and upbuilding.

Different tissues appropriate their different foods, and each gives back the products of its own activities as tissue wastes, which in turn enter the blood to be carried to tissues which can make another use of them, or to organs which can dispose of them as excretions.

**Digestion.**—Is the process of so *changing the food* that it may be absorbed.

**Absorption.**—Is the process of taking up certain substances and conveying them to the blood.

**Circulation.**—Is the process of carrying the blood and other substances to every part of the body.

**Assimilation.**—Is the process which goes on in the tissue cells whereby they make use of the food which is conveyed to them.

We have now to study the organs which distribute the products of digestion, and the composition of the food-bearing fluids—*blood* and *lymph*. *Assimilation* is nature's own secret, not yet revealed to the mind of man.

## CHAPTER X.

### THE BLOOD AND THE CIRCULATORY SYSTEM.

#### THE BLOOD.

The blood is the most important fluid in the body. It not only carries food to every part, but bears waste matters to those organs which can dispose of them in the form of excretions. It consists of a clear yellowish fluid called *plasma* and small round cells (invisible to the naked eye) called **corpuscles** (little bodies), which float in the plasma.

The corpuscles are of two sorts, red and white.

It is convenient to follow the usage common in clinical work and speak of them as *red* and *white cells*. A third, smaller, colorless cell exists in blood, named a *blood plate*.

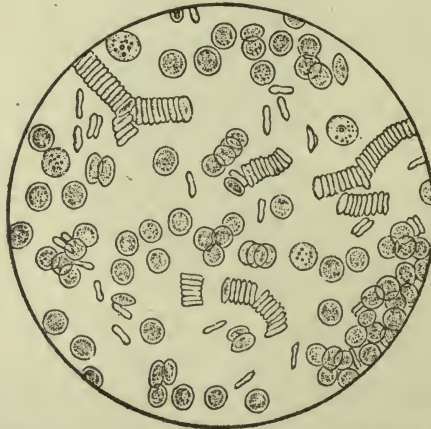


FIG. 109.—CORPUSCLES OF BLOOD, AS SEEN UNDER THE MICROSCOPE.

Four white ones are shown. The red ones have a tendency to form rows (Funke and Brubaker).

The temperature of the blood is about  $100^{\circ}$  F.

The *reaction* is *alkaline*.

The **red cells** (*erythrocytes*) are non-nucleated, flexible and elastic. They are very numerous, numbering 4,000,000 to 4,500,000 in a cubic centimeter. They measure about  $\frac{1}{2500}$  of an inch in



diameter, and their shape has been usually described as that of a flattened sphere (Fig. 109).

**Note.**—The illustration presents the appearance under the microscope of blood which has been removed for a time from the vessels and cooled. Careful studies under other conditions, indicate that the living cells are slightly *bell-shaped*.

The *red cells* are composed largely of *hemoglobin*. This itself is amber colored, but when a great number of cells are together as in a drop of blood, it gives the red hue to the fluid.

*Hemoglobin* is a proteid substance whose most important property is its power to combine with oxygen and to give it up. It contains a minute quantity of iron in combination (*hematin*) which is necessary to life processes.

The *origin of the red cells* is in the *red marrow* of cancellous bone.

The *white cells* or *leucocytes* are of different sizes (the largest being about  $\frac{1}{2000}$  of an inch in diameter). They move more slowly in the plasma and are far less numerous, numbering only about 7500 in a centimeter.

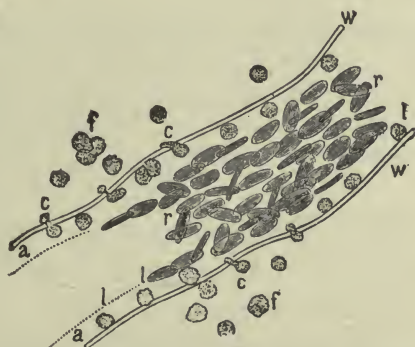


FIG. 110—WHITE CORPUSCLES PENETRATING CAPILLARY WALLS (Landois and Stirling).

They are nucleated, flexible and elastic. Their shape is spherical (often irregular), and they consist of a transparent material containing one or several nuclei and many fine granules (of proteid substances).

The white cells frequently change their shapes by means of *ameboid movements*, that is, like the *ameba*, they thrust out portions of their substance and draw them back. They can send out little

prolongations and draw floating particles to themselves, or they can wrap themselves around foreign substances.

They possess also the power of slipping (squeezing) through the walls of capillary vessels. This is called *diapedesis* (Fig. 110).

Of the five distinct varieties of leucocytes the percentage of *polymorphonuclear cells* (*nuclei of many shapes*) is the largest.

The polymorphonuclear cells (oftenest called *polynuclear*) and the lymphocytes are called *phagocytes*, because they destroy bacteria by absorbing and digesting them. This process is called *phagocytosis* (to be referred to later on).

The *origin of the white cells* is from two sources; the *lymphocytes* originate in lymph glands and other lymphoid tissues; the *polynuclear* leucocytes and others are developed from cells in the marrow of long bones.

The **plasma** is a thin watery *saline* fluid in which the corpuscles float. It contains both nutritive and waste matters in solution, and also certain elements from which fibrin is derived. The *fibrin* is essential to the production of a *blood-clot*, without which hemorrhage would never cease of its own accord.

The substances dissolved in the watery portion of the plasma are:

<i>Nutritive</i> (derived from food).....	{	Proteids . . .	{	Serum-albumin Fibrinogen Paraglobulin
		Sugars Fats		
<i>Waste products</i> (derived from tissue changes).	{	Extractives	{	Urea Uric acid, etc.
<i>Mineral salts.</i> Chiefly salts of	{	Sodium Potassium Calcium		

The *serum-albumin* is the great tissue builder. The *fibrinogen* is the fibrin maker (paraglobulin may assist in this; its use is not fully known).

*Sugars* and *fats* are tissue foods.

*Mineral salts* preserve the necessary alkalinity of the blood and assist in the formation of certain tissues (as bone). Sodium chloride (common salt) is the most abundant (and to this is due the *salinity* of the blood).<sup>1</sup>

<sup>1</sup> A "normal saline solution" contains salt in the proportion found in blood.

## Coagulation of Blood.

Blood which is exposed to the air at the usual temperature is seen to separate into distinct portions—a red, jelly-like mass and a transparent straw-colored layer which is thinner. The dark mass is the *coagulum*, consisting of fibrin with corpuscles entangled in it. The straw-colored layer above it is *serum*, which is plasma bereft of its fibrin and corpuscles (Fig. III). This same process may occur at the mouth of a blood-vessel which has been cut or ruptured, if the stream be not too forcible, and it is nature's way of stopping the flow.

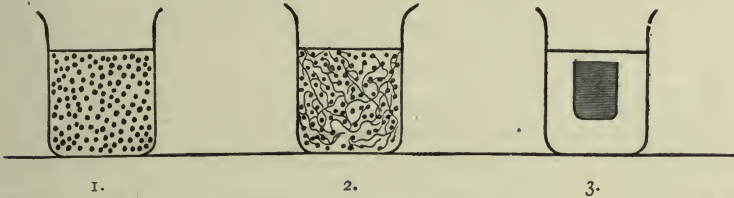


FIG. III.—DIAGRAM TO ILLUSTRATE THE PROCESS OF COAGULATION. 1. Fresh blood, plasma, and corpuscles. 2. Coagulating blood (birth of fibrin). 3. Coagulated blood (clot and serum) (Waller).

A clot of fibrin may be formed within a blood-vessel if the interior surface is rough and the stream slow; this does not occur in health.

The formation of fibrin from fibrinogen is a process confined to the plasma; the corpuscles remain unchanged and are simply incidental constituents of the coagulum or clot. Fibrin itself is colorless, as may be seen when it is whipped out from fresh blood by twigs or rods.

The coagulation time of blood is of some importance, as it varies in health or disease; for example, it is delayed in certain inflammatory conditions.

## DIAGRAM OF CHANGE FROM FLUID TO COAGULATED BLOOD.

Fluid blood	{	<i>Corpuscles</i> , they unite with <i>Plasma</i> , consists of	}	to form <i>Coagulum</i>	}	Coagulated blood
		<div style="display: inline-block; vertical-align: middle;"> <i>Fibrin</i>  <i>Serum</i> remains <i>Serum</i> </div>				

*Opsonins and the opsonic index.*—It is believed that the phagocytic action of white cells is regulated by the presence in the blood of chemical substances (still undescribed) called *opsonins*, by which invading bacteria are prepared for absorption and digestion by the phagocytes. The measure of the power thus residing in the blood

is expressed as the *opsonic index*. The opsonic index is high or low, according to the number of bacteria which the cells may be able to dispose of.

There is some reason for thinking that a special opsonin exists for each kind of bacterium.

## THE CIRCULATORY SYSTEM.

This system includes the heart and blood-vessels or arteries, capillaries and veins. They are the organs which contain the blood.

The heart is a pump. The arteries are elastic tubes which receive the blood directly from the heart. The capillaries are small vessels into which the arteries lead, and the veins carry the blood from the capillaries back to the heart.

**Arteries.**—Vessels which convey the blood *away from* the heart. They are flexible tubes whose walls consist of three layers or coats—*external*, *middle*, and *internal* (or *tunica adventitia*, *tunica media*, and *tunica intima*). The *external* coat is composed of fibrous tissue to which the strength and toughness of the vessel is due; the *middle* is composed of elastic tissue and *unstriped* muscle fibers, giving to arteries their yielding and contractile character; the *internal* is thin and smooth and is a continuation of the lining of the heart. (It is sometimes called the serous coat.) Arteries of medium size have most *muscle* tissue, while the larger ones have most *elastic* tissue. It is owing to their elasticity that arteries remain open when they are empty or cut across.

**Note.**—The *internal* coat is the only one which is continuous throughout the entire circulatory system.

**Surgical note.**—When a ligature is tied tightly around an artery the *middle* coat may be felt to break down under the cord, while the external one remains whole, owing to its toughness.

The arteries give off branches which divide and subdivide until the smallest ones can be seen only with the microscope—they are called *arterioles*. The arterioles lead to the vessels which are smallest of all—the *capillaries*.

**Capillaries.**—Vessels which receive blood from the arteries and carry it to the veins. They exist in nearly every part of the body, except cartilages, hair, nails, cuticle, and the cornea of the eye. Their walls have only the *internal* coat, a single layer of cells—*endothelium*. It is through these thin walls that the work of exchange

is performed between the blood and the various tissues of the body, nutritive material being taken from the blood and certain waste substances being returned to it. To provide vessels for this exchange is the *function* of the capillaries.

Their average diameter is  $\frac{1}{2500}$  of an inch—just enough to permit the easy passage of the corpuscles.

**Veins.**—The vessels which gather the blood from the capillaries and carry it *to the heart*; they are formed by the uniting of capillaries.

They are at first very small (called *venules* or *venous radicles*) but constantly grow larger by uniting with each other, although they often branch and reunite.

*Veins*, like arteries, have three coats, but their middle coat is neither so elastic nor so muscular, so that they are softer, and when empty or cut, they collapse. The inner coat of the veins presents, at intervals, semilunar folds, making pockets called *valves*, which allow the blood to flow *toward* the heart, but prevent it from setting backward freely. (If the veins are very well filled the location of the valves may be recognized by an appearance of *puffing out* at those points where they exist.) (Fig. 112.)

Blood-vessels possess nerves<sup>1</sup> which, by controlling the *muscular coats*, regulate the amount of blood flowing through them at a given time to the structures which they supply. (An organ at work needs more blood than an organ at rest.)

They also possess tiny blood-vessels in their walls, the *vasa vasorum*.

All blood-vessels have *sheaths* of connective tissue. In the case of the larger ones these are quite strong and sometimes inclose a vein, an artery, and a nerve together.

### THE HEART.

The **heart** is a hollow muscular organ through which the blood passes, placed behind the sternum and just above the central tendon of the diaphragm.

**Note.**—The muscle tissue of the heart is called the *myocardium*.

<sup>1</sup> Vaso-motor nerves.

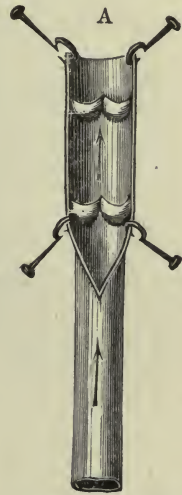


FIG. 112.—A VEIN LAID OPEN TO SHOW VALVES.

It is shaped like a cone, about five inches long and three and one-half inches wide, with the *base* turned upward toward the right shoulder and the *apex* pointing downward toward the left side. It is composed of several layers of muscle fibers which are peculiar, being *involuntary and at the same time striped*.

The *cavity* of the heart is divided by a *septum* into right and left portions, and as it lies in the body the right heart is nearly in front of the left. Each side consists of two chambers, an *auricle* (atrium) and a *ventricle* (ventriculum) (Fig. 114).

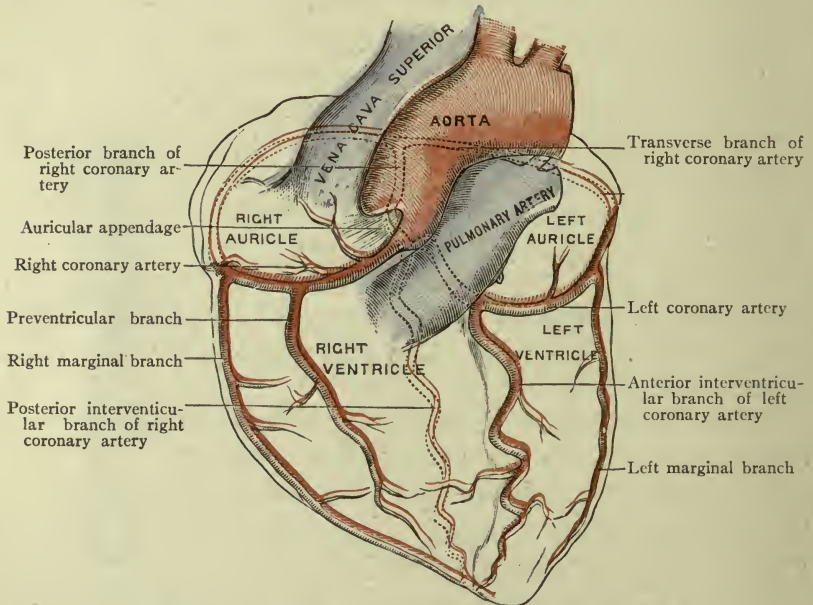


FIG. 113.—ANTERIOR SURFACE OF HEART (Morris).  
The coronary arteries supply the substance of the heart.

The **auricles** receive blood and pass it into the ventricles. Their walls are thin and flabby. The **right auricle**, or atrium, presents two large openings for the entrance of veins, and one for communication with the right ventricle. The veins are the *superior vena cava* from the head and upper extremities; the *inferior vena cava* from the trunk and lower extremities. It also has a transverse fold on the posterior wall called the *Eustachian valve* or valve of the inferior vena cava, and a round depression on the septum between the two auricles (atria), called the *oval fossa* (*fossa ovalis*). The **left**

**auricle** presents two large openings and several small ones for veins, and communicates with the left ventricle.

The **ventricles** expel blood from the heart. They include the apex of the heart and their walls are thick and strong, the left one being the thicker and larger of the two. Certain muscle fibers in

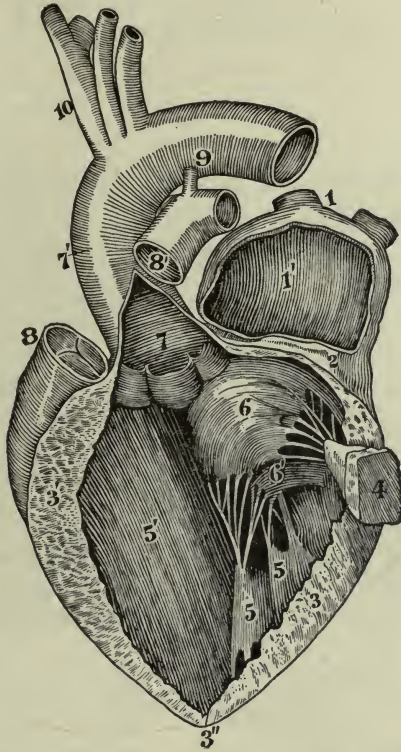


FIG. 114.—INTERIOR OF LEFT HEART. (Observe the difference in thickness of the walls in auricle and ventricle.) (Allen Thomson in Brubaker.)

1, L. atrium or auricle; 2, division between it and ventricle; 3, wall of left ventricle; 4, a band of muscle fibers severed; 5, other muscle bands; 6, a leaflet of mitral valve, with tendinous cords; 7, aorta (a large artery) laid open to show semilunar valves; 8, pulmonary artery (semilunar valves closed); 9, arch of aorta.

the ventricles pass downward to wind around the apex of the heart and then turn upward; others are transverse, still others oblique; the arrangement causing the heart to harden in contraction, with a twisting motion from right to left and a forcible pressure against the chest wall. This is felt in the fifth interspace, at the left of the sternum and is called the *cardiac impulse*.

The *muscle band of His* is a name given to a bundle of muscle fibers which connects the auricles and ventricles; the contraction impulse is believed to travel from auricle to ventricle by these fibers.

The interior of the ventricles is marked with a number of ridges or bands of muscle fibers (the *trabeculæ carneæ*), and certain of these are attached by *tendinous cords* to the valves of the heart. Each ventricle opens into a large artery, which conveys the blood away—the *pulmonary artery* from the right ventricle, the *aorta* from the left.

**Note.**—In the new nomenclature the name "*atrium*," or *forechamber*, is given to the main part of the auricle, and the word auricle applies to the *auricular appendage alone*; the opening from auricle to ventricle is called *ostium venosum*.

**Endocardium.**—The lining of the heart. It is thin and firm, resembling serous membrane in appearance, and is continuous with the lining of the arteries and veins, thus making a perfectly smooth surface throughout, for the current of blood.

#### THE VALVES OF THE HEART.

The **valves** of the heart are formed by folds of endocardium strengthened by fibrous tissue and placed at certain orifices of the

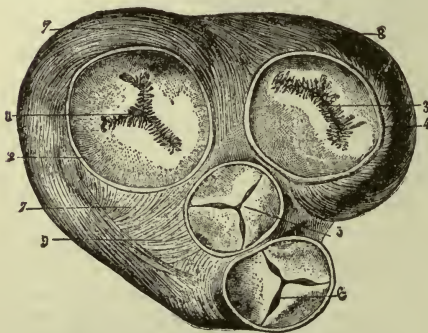


FIG. 115.—VALVES OF THE HEART.

1. Right auriculo-ventricular orifice, closed by the tricuspid valve. 2. Fibrinous ring. 3. Left auriculo-ventricular orifice, closed by the mitral valve. 4. Fibrous ring. 5. Aortic orifice and valves. 6. Pulmonic orifice and valves. 7, 8, 9. Muscular fibers (auricles removed) (Bonamy and Beau.)

different chambers—two in the right heart and two in the left. The opening between the *right* auricle and ventricle (right ostium venosum) is guarded by the *tricuspid valve*, which is composed of three leaflets. It allows the blood to flow down into the ventricle but prevents it from flowing back. The opening between the *left* auricle and ventricle (left ostium venosum) is guarded by the *bicuspid* (or *mitral*) valve, composed of

two leaflets, allowing the blood to flow down into the ventricle but not to return. (Both the tricuspid and mitral valves are connected



to certain muscle bands of the ventricles by *tendinous cords* which control the motion of the leaflets, preventing them from flying upward too far when the ventricles contract.) (Fig. 114.)

The opening from the *right* ventricle into the artery which leaves it (*pulmonary artery*), is guarded by three semilunar valves, which are half-moon shaped pockets called the *pulmonary valves*. Likewise the opening from the *left* ventricle into its artery (*aorta*) is guarded by three semilunar valves called the *aortic valves* (Fig. 115).

The semilunar valves allow the blood to flow in one direction only—that is, *away* from the heart.

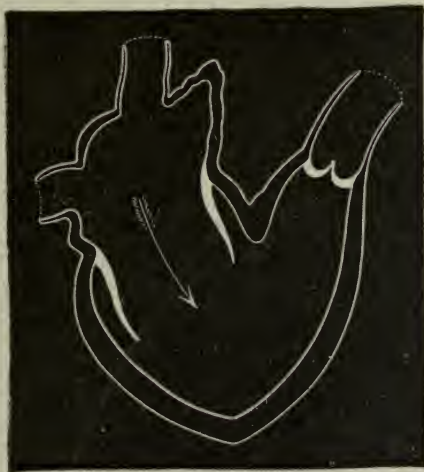

FIG. 116. (DIAGRAM.)

The right auricle receiving blood and passing it through tricuspid valve into right ventricle, which is dilated (*semilunar valves closed*) (Dalton in Brubaker).

#### FUNCTIONS OF THE CHAMBERS OF THE HEART.

The auricles, having received blood from the veins opening into them (the right—blood from entire body; left—from lungs alone) gently contract together to send it down into the ventricles; quickly the ventricles contract, forcibly and together, expelling blood into the two large arteries—the *pulmonary* carrying it to the lungs, the *aorta* to all parts of the body. This process is the *systole of the heart*; it occupies about eight-tenths of a second, perhaps a trifle more. Then comes the resting-time when the heart is dilating and filling again, called the *diastole of the heart*.

During the systole of the auricles, the tricuspid and mitral valves are open and the semilunar valves are closed. During systole of the ventricles the tricuspid and mitral valves close, and the semilunar valves are open (Figs. 116, 117).

The thickness of the ventricle wall is explained by the need for sending blood to a distance, the greater thickness of the left being made necessary by the far greater work required of it.

The systole of the ventricles corresponds to the "heart-beat." It occurs at perfectly regular intervals in health, the rate being from

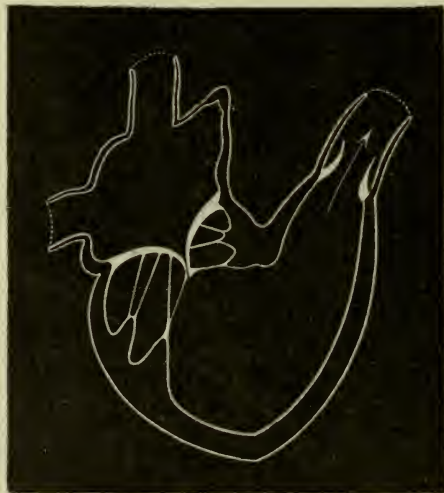

FIG. 117.

The right ventricle filled, contracts and expels blood through semilunar valves (*tricuspid valve closed*) (Dalton in Brubaker).

sixty to seventy per minute in men, and from seventy to eighty in women. The heart's action is more rapid in the upright position than in sitting or lying, and is increased by any exercise, however gentle. Excitement or emotion will quicken it at once, and it is always faster in children, being about one hundred and forty in the newly born and reaching an average rate of ninety to one hundred at the age of three years; ninety in youth, seventy in adults, and eighty in old age.

**The Pulse.**—The effect of the heart-beat upon the current of the blood may be felt in the arteries, which are distended for an instant by the blood forced into them as the ventricles contract.

This gives the effect of a *beating in the arteries*, which is called the *pulse*. The pulse-rate corresponds with the heart-beat; therefore, the rate and force of the heart's action are judged by means of the pulse.

### The Heart Sounds.

The action of the heart causes certain *sounds*, named the *first* and *second*. The first accompanies the sudden closure of the *tricuspid and mitral* valves, as the ventricles contract. It is the *systolic*

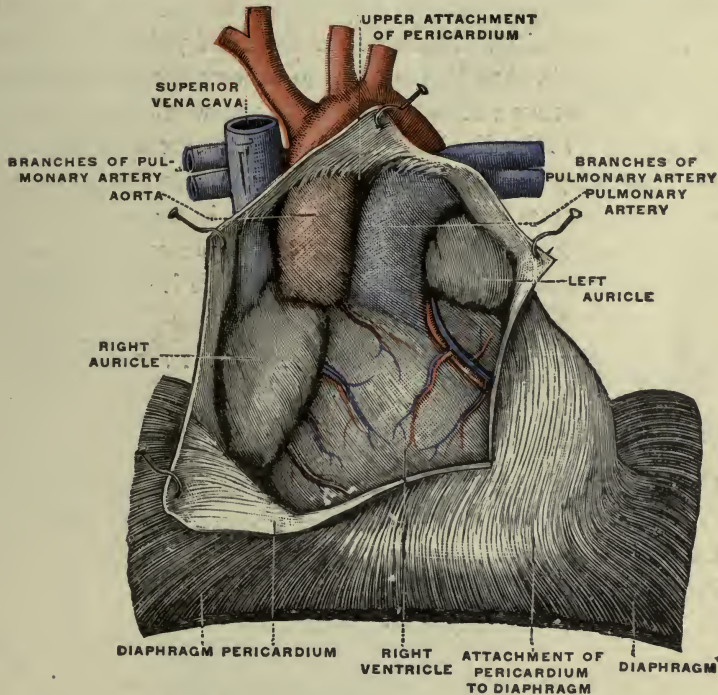


FIG. 118.—The heart *in situ*. The pericardium has been cut open in front, and reflected (Testut).

sound—caused by the systole of the ventricles. The second accompanies the sudden closure of the *semilunar* valves. It is the *diastolic* sound, occurring with the diastole of the ventricles.

The first or *systolic sound* is the louder and larger, being due to the contracting of muscle fibers as well as to closure of valves. The second, *diastolic sound* is short and sharp, due to valve closure only. The two sounds are compared to the spoken words—*lubb dupp*.

When the blood is forced into the elastic arteries by a contraction or beating of the heart it stretches them. When the contraction is ended, the wall of the artery recoils and there is a setting back of the blood for an instant toward the heart, but it is stopped by the closing *semilunar valves*, which thus make the *second sound*.

**Clinical note.**—If the valves of the heart are rough, the sounds are changed by a “murmur.” If they cannot close perfectly, a portion of the blood will flow backward instead of going forward, and this is *regurgitation*. This, also, changes the sound of a valve and causes a murmur.

The **pericardium** (Fig. 118).—A loose serous sac enclosing the heart. The layer which closely covers the heart, or the visceral layer, is the *epicardium*. It covers the aorta and pulmonary arteries for about one inch, then leaves them to become the *parietal layer* or lining of the fibrous sac which encloses the whole, and which is closely attached to the diaphragm below and the great vessels above. A small quantity of pericardial fluid prevents friction between the surfaces, as the smoothly covered heart beats in the smoothly lined cavity; this increases in inflammation of the pericardium, or *pericarditis*, and it is sometimes necessary to remove it by tapping.

#### REVIEW.—PRINCIPAL POINTS OF INTEREST IN THE HEART.

##### RIGHT AURICLE.

- Openings of two large veins bringing blood from the body.
- Opening of coronary sinus bringing blood from the heart itself.
- Oval fossa and annulus ovalis.
- Eustachian valve (or valve of inferior vena cava).
- R. Ostium venosum with tricuspid valve.

##### RIGHT VENTRICLE.

- R. Ostium venosum and tricuspid valve.
- Opening for pulmonary artery, and pulmonary valves.
- Trabeculæ carneæ (fleshy bands), and the tendinous cords connecting them with tricuspid valve.

##### Left Auricle.

- Openings of three or four pulmonary veins.
- L. Ostium venosum with bicuspid (or mitral) valve.

## LEFT VENTRICLE.

L. Ostium venosum and bicuspid valve.

Opening for aorta and aortic valves.

Trabeculæ carneæ and the tendinous cords connecting them with the bicuspid valve.

## THE COURSE OF THE BLOOD THROUGH THE HEART.

**Résumé.**—The blood enters the right auricle, passes down into the right ventricle, and out through the pulmonary artery to the lungs; it returns by the pulmonary veins to the left auricle, passes down

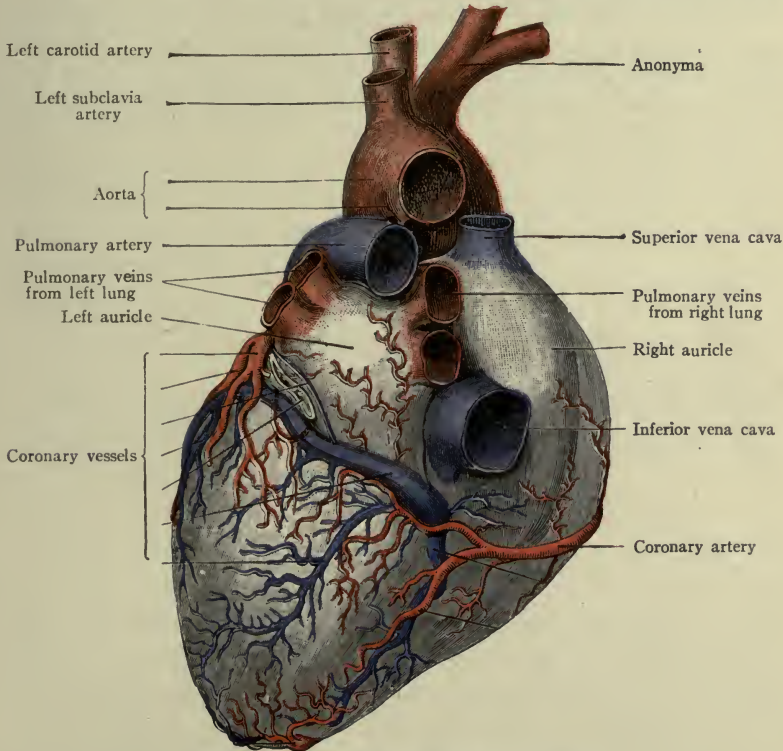


FIG. 119.—POSTERIOR SURFACE OF HEART.  
Pulmonary veins bringing pure blood to left auricle (Morris' Anatomy).

into the left ventricle, and out through the aorta to every part of the body, from which it is returned by two large veins to the right auricle again.

The course from the *right ventricle* through the lungs and back to the *left auricle* is called the **pulmonary circulation** (Fig. 119).

The course from the *left ventricle* through the entire body or "system" and back to the *right auricle* is called the **systemic circulation** (Fig. 120).

**Important notes.**—Pure blood is carried from the heart through the systemic arteries to all tissues in the body to nourish them. This blood is called *arterial* blood; it is bright red in color. The terms *pure blood* and *arterial blood* are used to signify one and the same thing.

Impure blood from the tissues of the body is returned to the heart by the systemic veins. It is called venous blood; it is purple-red or blue in color and contains waste matters. The terms *impure blood* and *venous blood* are used to signify one and the same thing.

The *venous* blood from the body is poured into the *right side of the heart*, from which the pulmonary artery conveys it to the lungs. Consequently the pulmonary artery is unlike others, because it carries venous blood *from* the heart; and the pulmonary veins are peculiar because they carry arterial blood *to* the heart.

## CHAPTER XI.

### THE CIRCULATION AND FUNCTIONS OF BLOOD.

#### THE PULMONARY CIRCULATION.

This is the circulation of the blood through the lungs, that it may become aerated or purified.

The **pulmonary artery** leaves the right ventricle, carrying impure blood, and soon divides into two branches, the *right* and *left* (one for each lung), which break up into a capillary network around the air cells. From this network veins arise which, by uniting, form two from each lung, making the *four pulmonary veins* carrying purified blood to the left side of the heart. They enter the left atrium.

#### THE SYSTEMIC CIRCULATION.

This is the circulation of the blood through the entire body or "system," that it may nourish the tissues and organs (Fig. 120).

##### Arteries of the Systemic Circulation.<sup>1</sup>

The **aorta**, having received the pure blood from the lungs, leaves the left ventricle, arches over the root of the left lung to the left side of the fourth thoracic vertebra, then (gradually coming to the front of the spinal column) passes down through the diaphragm, and ends by dividing at the fourth lumbar vertebra, (a little below the level of the umbilicus). Thus it consists of three portions: the arch, the thoracic aorta, and the abdominal aorta (Fig. 121).

**The arch of the aorta extends from the heart to the body (lower border) of the fourth thoracic vertebra.** It reaches almost as high as the sternal (or jugular) notch.

It may be felt in thin persons by pressing the finger tip down behind the bone.

<sup>1</sup> The names of all of the arteries are given in tabular form on page 312. Only the principal ones are here described.

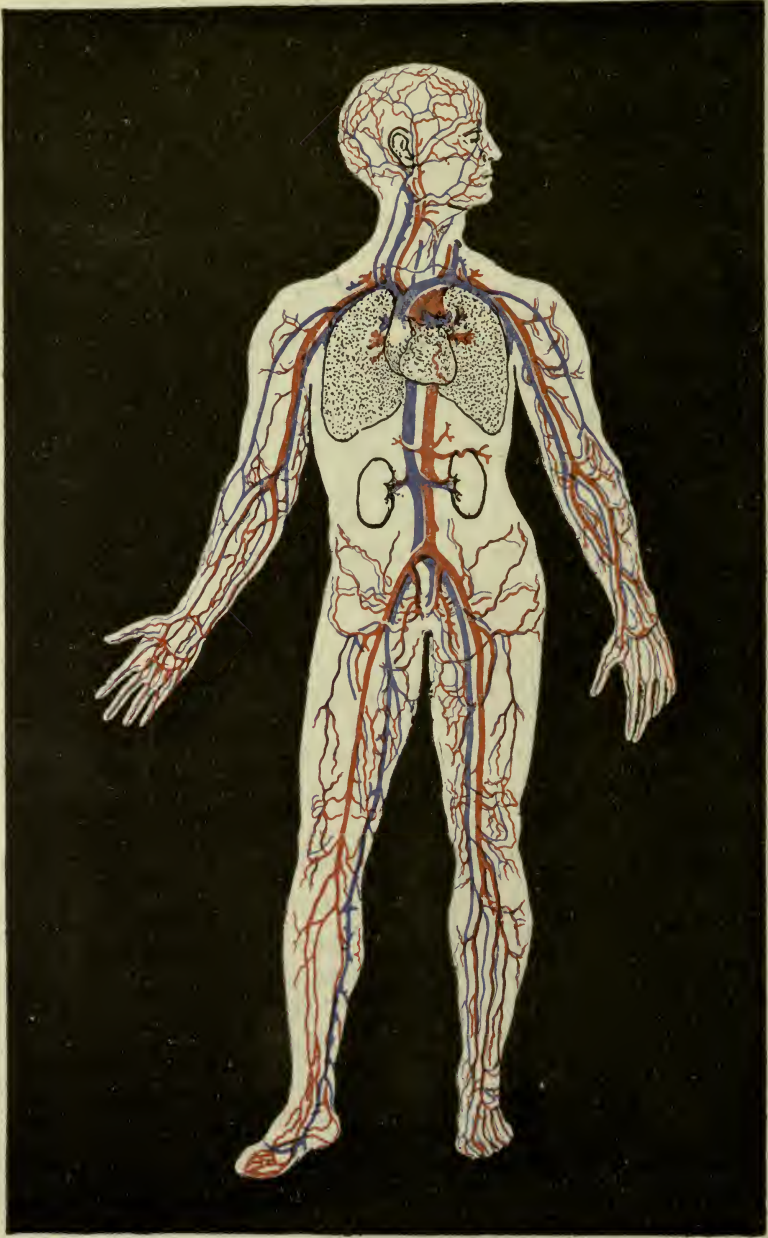


FIG. 120.—SCHEME OF SYSTEMIC CIRCULATION.  
Arteries colored red; veins blue.



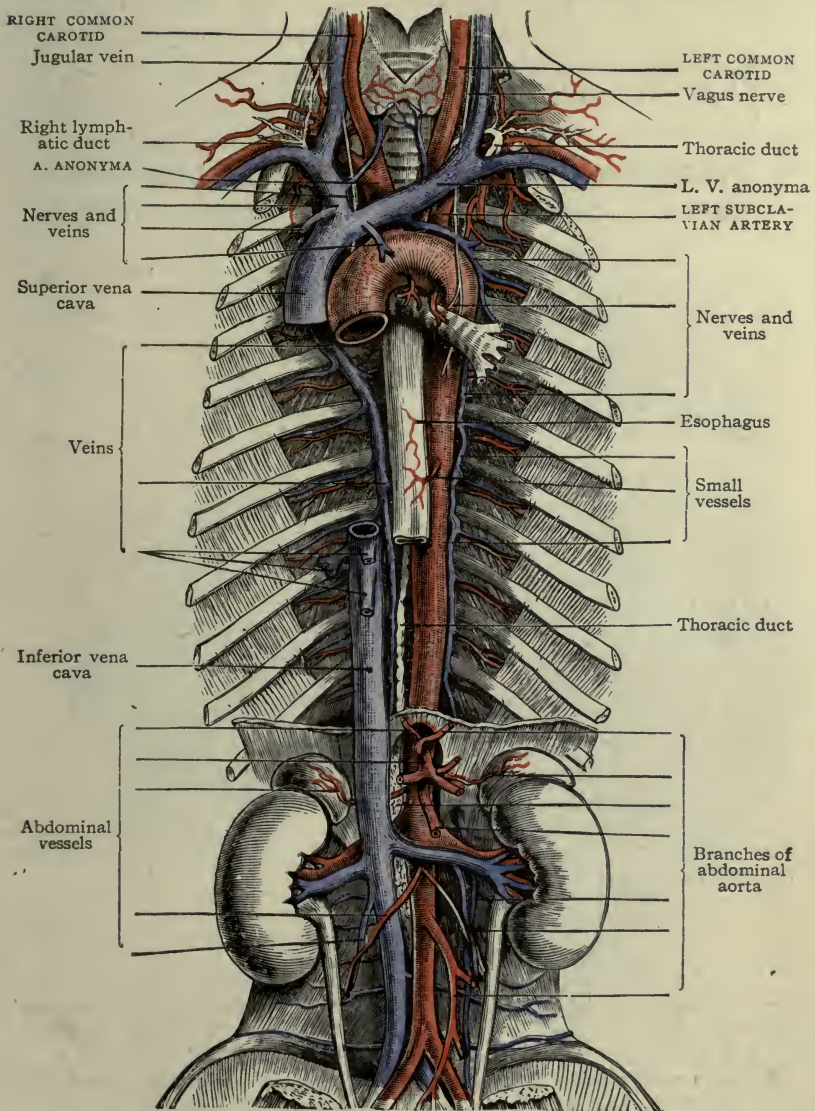


FIG. 121.—THE AORTA, SHOWING THE THREE PORTIONS (Morris).

*Branches of the arch in their order:*

- Two coronary (right and left) . . . . .to heart muscle (Fig. 113).
- One anonyma, 1½ inches long . . . . .
  - Right subclavian to right upper extremity.
  - Right common carotid to right head and neck.
- One left common carotid . . . . .to left head and neck.
- One left subclavian . . . . .to left upper extremity.

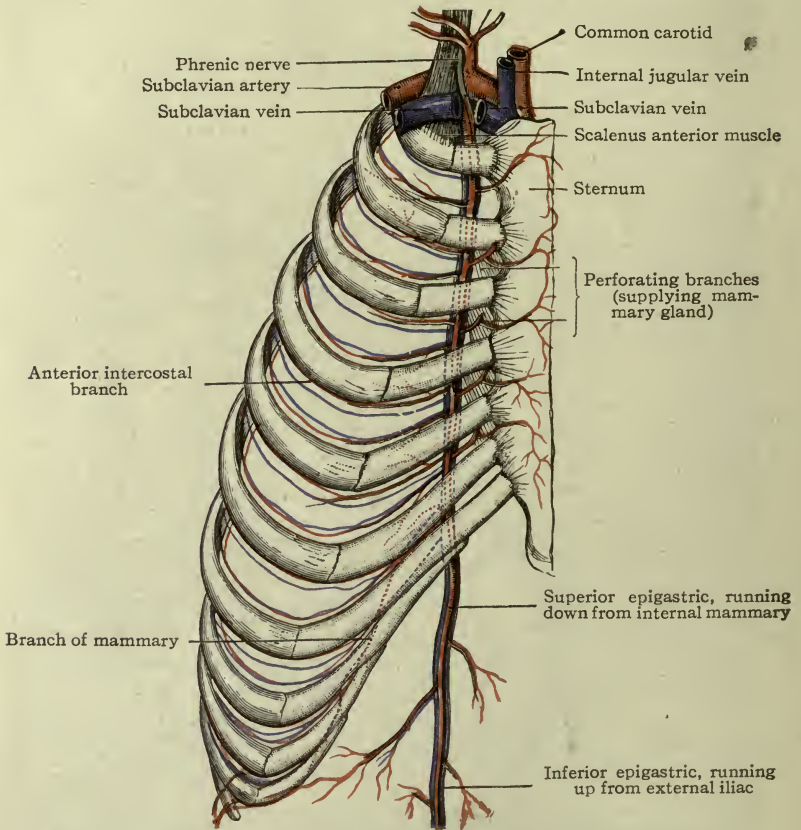


FIG. 122.—SHOWING SUBCLAVIAN ARTERY AND TWO OF ITS BRANCHES (Thyroid axis and internal mammary) (Morris).

THE PRINCIPAL ARTERIES OF THE UPPER EXTREMITY.

The **subclavian artery** (Fig. 122) passes out over the first rib and under the clavicle (therefore *subclavian*) to the axilla, or armpit. The brachial plexus lies above it in the neck, and the

subclavian vein is in front of it. The right subclavian is a branch of the anonyma. Both subclavians end at the lower border of the first rib.

*Branches.*—The *vertebral* branch runs upward through transverse processes of the vertebræ to the brain.

The *internal mammary* branch runs downward inside the chest behind the ribs (giving some arteries to the mammary gland), into the abdominal muscle.

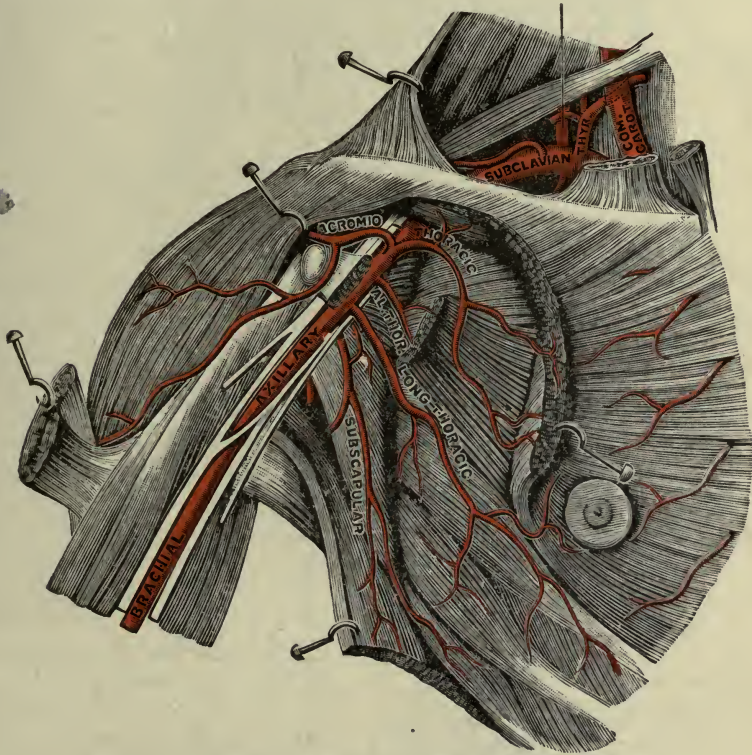


FIG. 123.—SUBCLAVIAN AND AXILLARY ARTERIES (Testut).

The *thyroid axis* is a short trunk; it gives a branch to the thyroid gland and others to the neck and shoulder.

An *axis* (artery) is a short vessel dividing at once into two or three.

The **axillary artery** is a continuation of the subclavian. It begins, therefore, where the subclavian ends—in the apex of the axilla, at the lower border of the first rib—and continues through the axillary space<sup>1</sup> (Fig. 123).

<sup>1</sup> Axillary space, p. 300.

*Branches (thoracic, subscapular, circumflex.)*—To all structures around the axilla. One, the *lateral thoracic*, gives arteries to the mammary gland.

The **brachial artery** begins where the axillary ends, at the lower border of the axilla, or armpit, and extends downward in

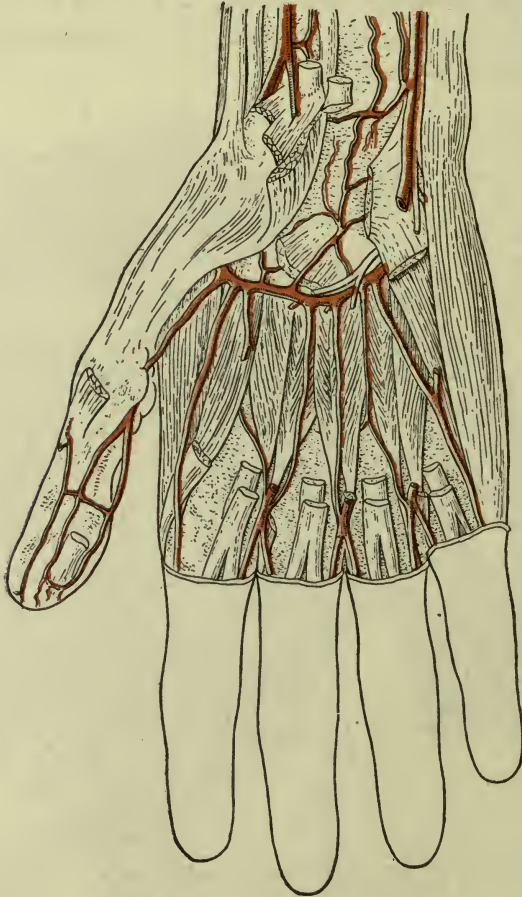


FIG. 124.—DEEP PALMER ARCH.

Made by continuation of the radial artery. This is covered by the muscles of the thenar and hypothenar eminences.

front of the arm (with the biceps muscle) to the bend of the elbow, where it divides into the radial and the ulnar arteries. Its branches supply the muscles of the humerus and the bone itself. (The *median nerve* lies next to this artery under the border of the biceps muscle.) (Figs. 123, 125.)

The **radial** and the **ulnar** arteries pass downward in the radial and ulnar sides of the fore-arm to the hands. The **radial** supplies the muscles in front of the radius, and winds to the back of the wrist to find its way to the *palm* by passing forward between the first two metacarpal bones. It forms the **deep palmar arch**, which crosses the palm *under* the long tendons (Fig. 124).

The **ulnar** supplies the muscles in front of the ulna, and forms the **superficial palmar arch**, which crosses over the long tendons in the palm (Fig. 125).

**Note.**—The superficial arch crosses the palm opposite the level of the web of the thumb when put “on the stretch.” The deep arch crosses about a finger-width nearer the wrist.

The *digital* arteries run in the sides of the fingers; they are branches of the superficial arch.

**Clinical note.**—The pulsation of the radial artery is easily felt above the wrist in front, next to the tendon of the radial flexor of the wrist.

**Surgical note.**—A direct communication exists between the deep and superficial arches, consequently severe hemorrhage easily occurs in the palm, since blood will flow from radial and ulnar arteries at one and the same time, and it is sometimes necessary to ligate both.

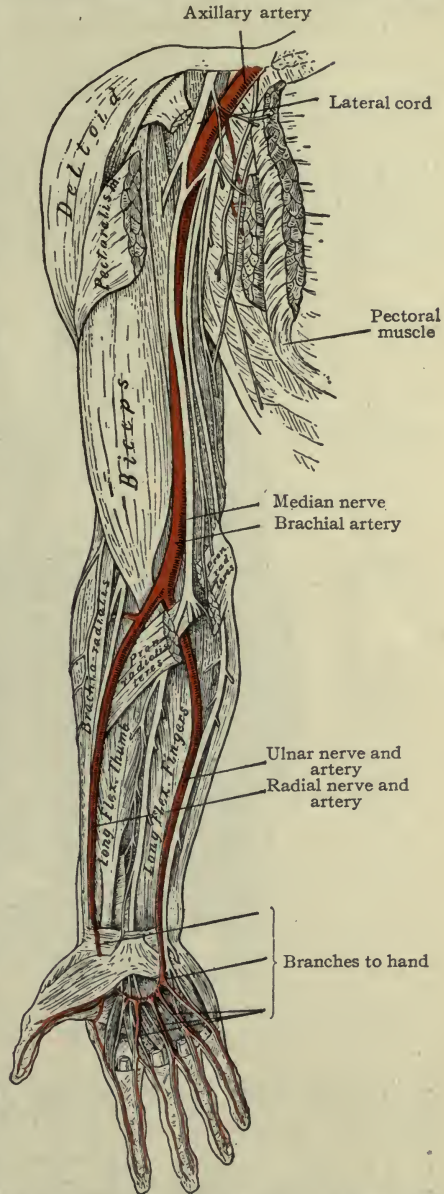


FIG. 125.—AXILLARY, BRACHIAL, RADIAL AND ULNAR ARTERIES. SUPERFICIAL ARCHES.

## PRINCIPAL ARTERIES OF THE HEAD AND NECK.

The **common carotid arteries**.—The *right* is a branch of the *anonyma*; the *left* is directly from the arch of the aorta. They proceed upward on either side of the trachea, with the internal jugular vein on the lateral side and the vagus nerve behind them. They carry the blood supply of the head and neck (Fig. 121).

The common carotid divides at the upper border of the thyroid cartilage into internal carotid for the interior of the head, and external carotid for the exterior of the head and the neck.

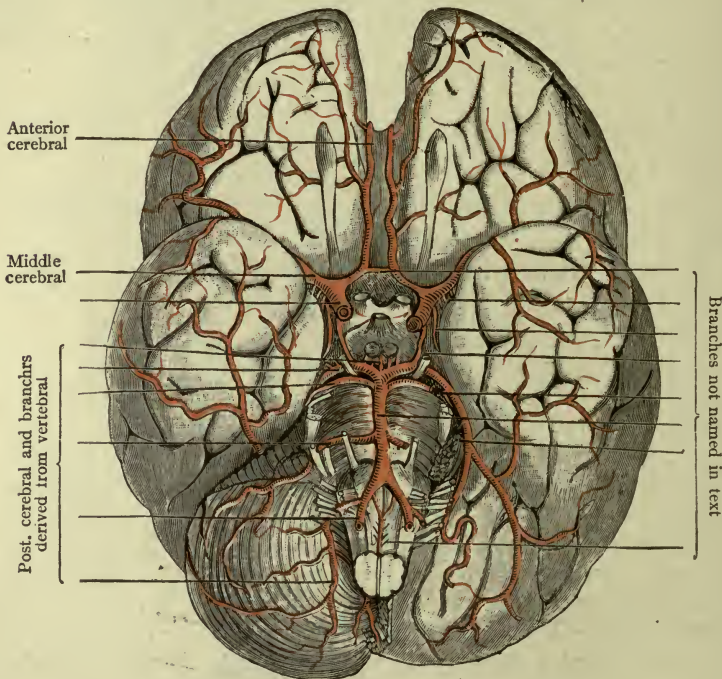


FIG. 126.—ARTERIES OF THE BRAIN (MORRIS).

Cerebral arteries pass from the base of the brain to all parts of the surface.

The **internal carotid** is deep in the neck; it runs up to the head and through the carotid canal into the cranial cavity.

Principal branches.—*Ophthalmic*, to eye and appendages, nose, and forehead. (The *supraorbital* artery is a branch of the ophthalmic.)

*Middle cerebral* to the brain, *anterior cerebral* to the brain (Fig. 126).

**Note.**—The internal carotid makes four sharp turns after entering the carotid canal in the petrous bone, and by this means the force of the current in this large vessel is modified before it reaches the delicate tissues of the brain. The internal jugular vein and vagus nerve accompany it in the neck.

The **external carotid** artery supplies the face, and front of the neck and scalp (Fig. 127).

Principal branches.—*Superior thyroid*, to the thyroid gland and larynx. *Lingual*, to the tongue and tonsil. *Facial* (or *external maxillary*) to the face, soft palate and tonsil. *Occipital*, to the back of the head and neck.

**Clinical notes.**—The external maxillary (facial) artery runs toward the bridge of the nose. It sends two labial arteries to the borders of the lips; and the one in the upper lip supplies a branch to the septum of the nose, therefore, compression of the upper lip will sometimes stop “nose-bleed.”

The *lingual* artery ends at the tip of the tongue, in a branch (ranine) which might be severed in cutting too freely for “tongue-tie.”

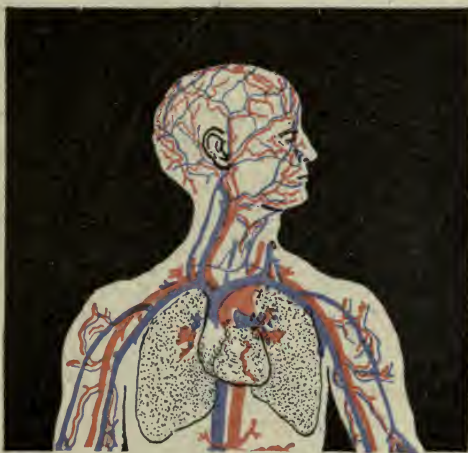

FIG. 127.—FACIAL, TEMPORAL AND OCCIPITAL ARTERIES.

Having given off its branches, the external carotid passes into the substance of the parotid gland and divides into the temporal and internal maxillary.

The **temporal** passes through the parotid gland and across the zygoma to the side of the head, supplying *temporal branches* to the scalp. The **internal maxillary** runs between the muscles of mastication in the infratemporal fossa to the deep parts of the face,

including the nose and pharynx. The dental arteries are all derived from this vessel.

**Collateral Circulation.**—An important descending branch of the occipital artery runs down under the deep muscles of the neck to unite with one derived from a branch of the subclavian, thus making a short route between the subclavian and the external carotid; the blood can flow in this indirect way to the head if the external carotid be ligated.

#### PRINCIPAL ARTERIES OF THE TRUNK.

**The thoracic aorta extends from the fourth dorsal vertebra to the diaphragm (Fig. 129).**

**Branches.**—*Intercostal*, 11 pairs, to the intercostal spaces; *bronchial* to lung tissues;<sup>1</sup> *pericardial* to pericardium; *esophageal* to esophagus, and *mediastinal* to glands and tissues between the lungs (the mediastinal space).

**Note.**—These *aortic intercostal* arteries run rather more than half way to the front, in grooves under the borders of the ribs, accompanied by intercostal nerves and veins.

**The abdominal aorta extends from the opening in the diaphragm to the body (lower border) of the fourth lumbar vertebra—a little above the level of the umbilicus (Fig. 128).**

**Branches.**—*Phrenic* to the diaphragm and *lumbar* (4 pairs) to the abdominal wall, *sacral* to sacrum and rectum.

**Branches to viscera:** The *celiac* artery, dividing into *gastric*, for the stomach; *hepatic*, for the liver;<sup>2</sup> *splenic* (or *lienal*), for the spleen.

*Superior mesenteric*, to the small intestine and these parts of the large intestine, namely—cecum, ascending and transverse colon.

*Inferior mesenteric*, to the remainder of the large intestine, namely—descending and sigmoid colon, rectum.

Two *renal* arteries, to the kidneys.

*Adrenal* arteries, to the adrenal bodies.

The *ovarian* arteries, to the ovaries, or the *spermatic* arteries to the testes.

<sup>1</sup> Bronchial arteries have very little to do with respiration; they are the *nutrient* arteries of the lungs.

<sup>2</sup> The hepatic circulation is a double one: Both venous and arterial blood enter the liver. The *portal vein* (with products of digestion for the liver to work over) and the *hepatic artery* (with the oxygen with which this work is to be done) enter together through the portal fissure. (The venous blood of both leaves the liver by *hepatic veins*, page 189.)



The *ovarian* artery runs downward into the pelvis and passes between the layers of the broad ligament to the ovary, freely supplying it and the Fallopian tubes. It ends by anastomosing with the uterine artery (Figs. 128, 132).

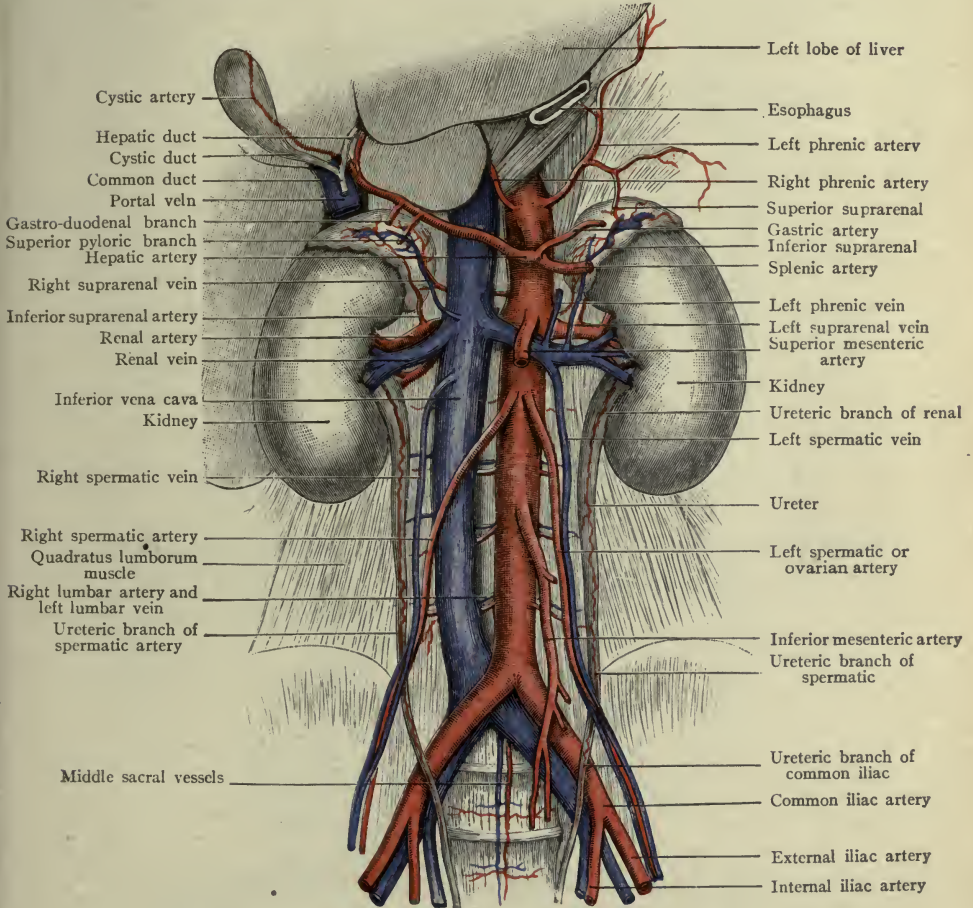


FIG. 128.—BRANCHES OF THE ABDOMINAL AORTA (Morris).

Note that the *right* common iliac is longer than the *left*.

The *spermatic* artery runs downward and along the brim of the pelvis to pass out through the inguinal canal with the spermatic cord; it continues downward in the scrotum to supply the testes (Fig. 128).

**Special notes.**—The *superior mesenteric* lies between the layers of the mesentery. The *inferior mesenteric* lies partly in the left meso-colon; it terminates as the *superior hemorrhoidal* in the upper part of the rectum.

The *gastric* artery follows the lesser curve of the stomach, and is frequently called the *coronary* artery. The *hepatic* and *splenic* both send large branches to the greater curve of the stomach, and also to the pancreas and duodenum, before reaching the liver and spleen.

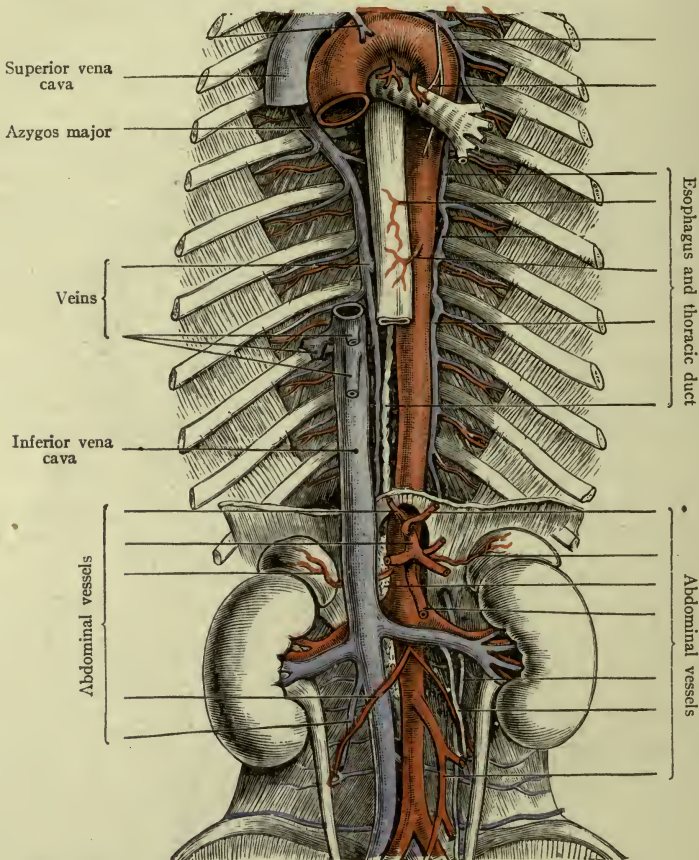


FIG. 129.—COURSE OF THORACIC AND ABDOMINAL AORTA (Morris)

The *abdominal aorta* divides (bifurcates) at the lower border of the *fourth lumbar vertebra* into the *right common iliac* and the *left common iliac* (Fig. 128).

The two **common iliac** arteries diverge and when they reach the sides (right and left) of the lumbo-sacral joint, each divides into *hypogastric* (or *internal iliac*) and *external iliac* (see Fig. 128).

The **hypogastric artery** passes into the pelvis and gives off branches which supply the parts within and without the pelvic wall, including the perineum, and all of the pelvic viscera *except the ovaries*.

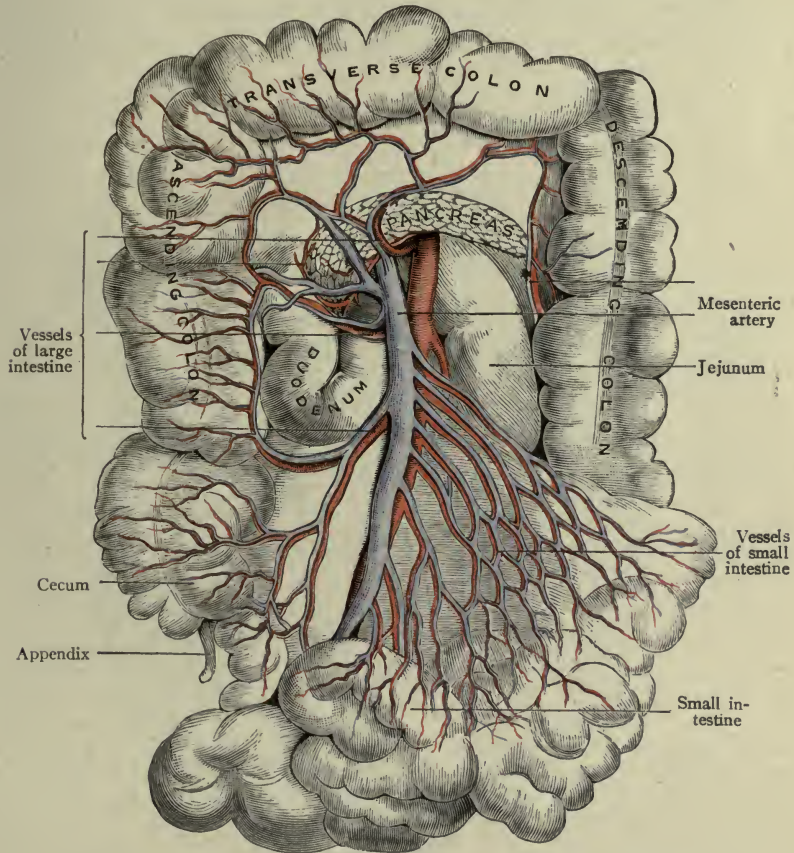


FIG. 130.—SUPERIOR MESENTERIC ARTERY AND VEIN (Morris).  
Supplying the whole of the small intestine, and about one-half of the large intestine.

*Visceral branches.*—*Middle hemorrhoidal*, to the rectum.<sup>1</sup>

*Vesical* (two) to the bladder.

*Uterine* to the uterus.

*Vaginal* (several) to the vagina.

<sup>1</sup> The blood-vessels of the rectum are called hemorrhoidal; those of the bladder, vesical.

The *uterine* artery (Fig. 132) passes between the layers of the broad ligament to the *cervix of the uterus*, then runs upward along the side of the *body*, supplying it freely with blood, and anastomosing with the ovarian artery.

The arteries of the organs in the lower part of the pelvis are numerous. There are: three (or four) *vaginal* arteries, three (or more) *vesical* arteries, three *hemorrhoidal* arteries, all derived from

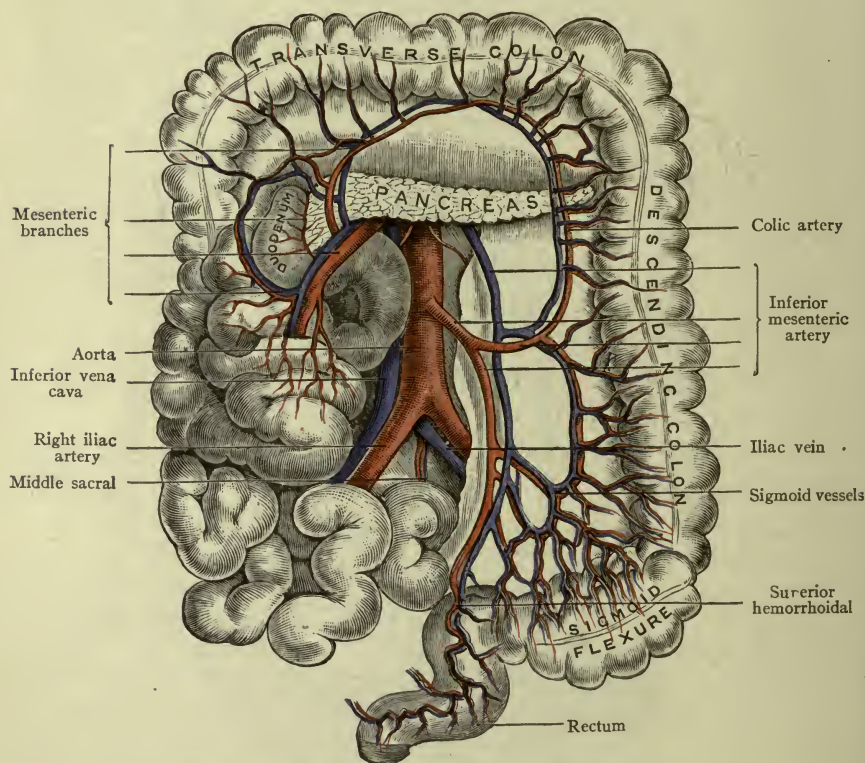


FIG. 131.—INFERIOR MESENTERIC ARTERY (Morris).  
Supplying a portion of large intestine only, ending as hemorrhoidal.

the hypogastric or its branches, except the *superior hemorrhoidal* which is the *terminal portion of the inferior mesenteric*.

There are also two *perineal* arteries.

These all anastomose freely with each other and with other arteries, so that a wound in this region is followed by an abundant flow of blood from more than one vessel.

**Note.**—The hypogastric arteries in the fetus are large. After giving off their branches they turn upward to the umbilicus where they leave the body of the child, and become the two *umbilical arteries* twining around the umbilical vein in the umbilical cord. After birth, these portions of the vessels no longer transmit blood but dwindle to fibrous cords lying close to the anterior abdominal wall.

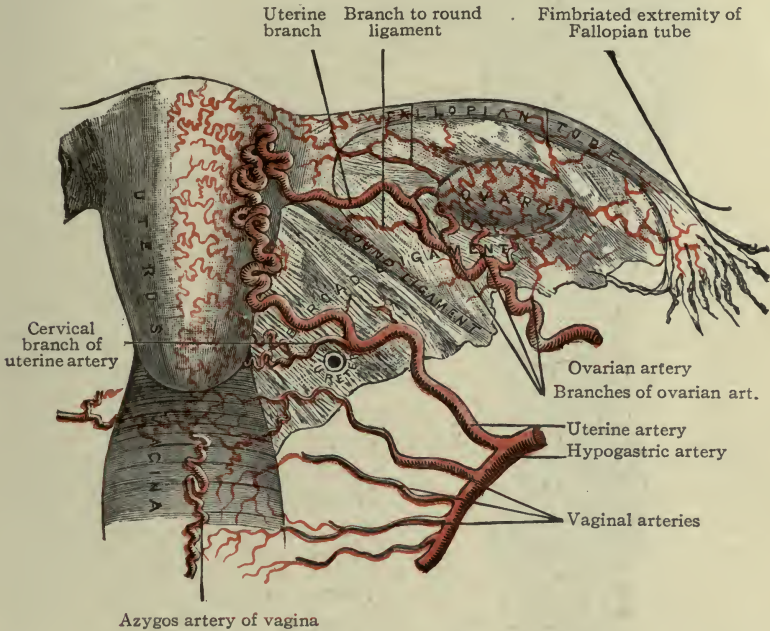


FIG. 132.—UTERINE AND OVARIAN ARTERIES.

(Uterine, a branch of hypogastric; ovarian, a branch of aorta. Note the location of the ureter (Morris).

### PRINCIPAL ARTERIES OF THE LOWER EXTREMITY.

The **external iliac** distributes its branches almost entirely to the lower extremity. It is about four inches long and follows the brim of the pelvis to the inguinal ligament where it becomes *femoral*.

**Collateral circulation.**—The *inferior epigastric* branch of the external iliac anastomoses with the *superior epigastric* branch of the internal mammary, in the substance of the rectus muscle, thus making an indirect route from the arch of the aorta to the iliac vessels if the abdominal aorta or iliac artery be ligated.

The **femoral artery** (Fig. 133) is a continuation of the external iliac, passing through the *femoral trigone* and the adductor canal to the popliteal space,<sup>1</sup> where it becomes the *popliteal artery*. Its branches supply the skin and fascia of the abdomen and external genital organs, and all structures of the front and sides of the thigh. The largest branch is called the *deep femoral*, which lies close to the medial side of the femur and gives three *perforating* branches to pass through the adductor magnus muscle and supply the back of the thigh.

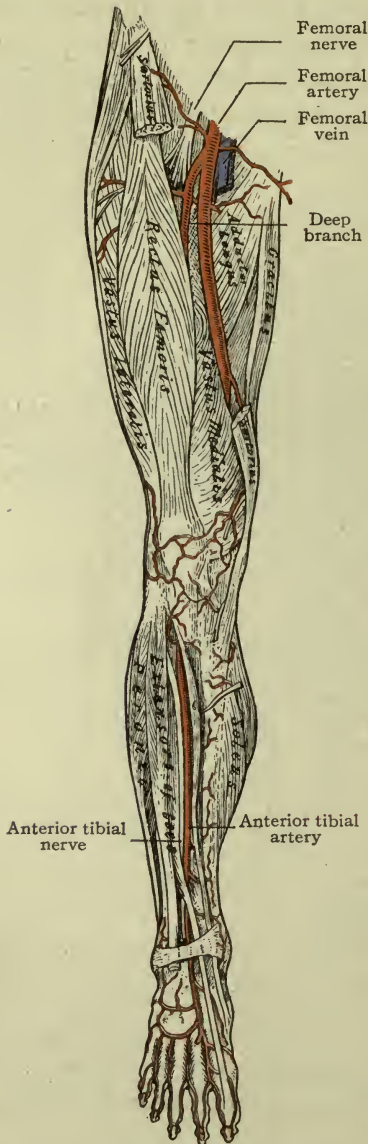

FIG. 133.—THE FEMORAL ARTERY.

(the dorsum of the foot), ending between the first and second toes.

<sup>1</sup> See p. 303, Popliteal Space.

**Note.**—The femoral vein is on the medial side of the femoral artery until it reaches the popliteal space.

The **popliteal artery** is a continuation of the femoral, beginning at the end of the adductor canal (the opening in the adductor magnus) and running through the popliteal space. Its branches supply the boundaries and floor of the space and the knee-joint; it divides into *anterior* and *posterior tibial* arteries (Fig. 134).

The **anterior tibial** (Fig. 143) comes forward between the tibia and fibula, supplying the front of the leg; it then becomes the *dorsalis pedis* (upon the

The anterior tibial passes in front of the ankle-joint, with the long tendons of the toe muscles.

The **posterior tibial** (Fig. 134) supplies the back of the leg and sole of the foot.. It lies between the calf muscles and the deep muscles, and runs behind the medial malleolus, dividing then into medial and lateral plantar arteries for the medial and lateral portions of the sole, or plantar region.

### The Veins.

All veins<sup>1</sup> run toward the heart.

Beginning as very small vessels formed by the union of *capillaries*, they unite and reunite until they make two sets of larger vessels called the *deep* and *superficial veins*.

The **deep veins** accompany arteries, being enclosed in the same sheath with them, and receiving veins corresponding to the branches of these arteries. Arteries of medium size usually have two companion veins (or *venæ comites*); large ones have but one, and it sometimes bears a name differing from that of the artery. (Example—internal *carotid* artery, internal *jugular* vein.)

The **superficial veins** do not usually accompany arteries. They lie in the superficial fascia, gathering blood from skin and fascia, and many of them are called *cutaneous*. Very frequently the deep and superficial veins communicate, through short connecting branches.

<sup>1</sup> The names of all of the veins are given in tabular form on page 378. Only the principal ones are here described.

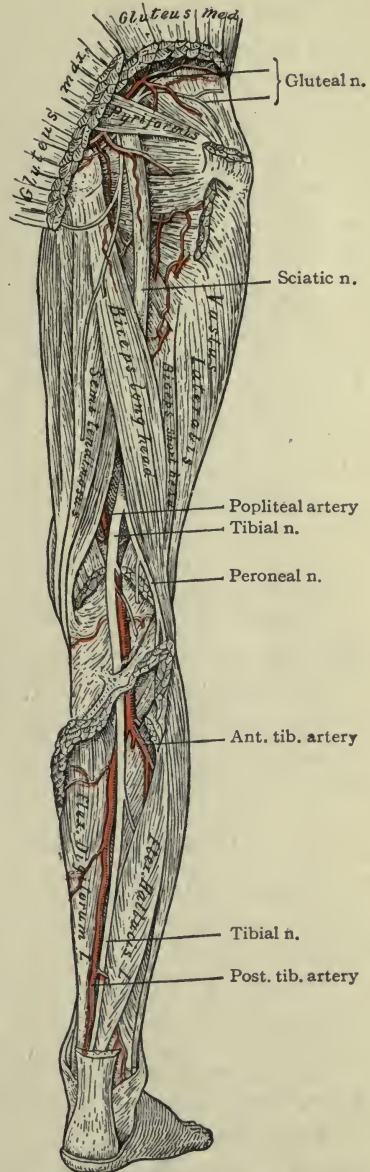


FIG. 134.—THE POPLITEAL ARTERY.

connecting branches.

PRINCIPAL VEINS OF THE HEAD AND NECK (FIGS. 127, 139).

**Deep.**—From the deep face and cranial cavity; they empty into the internal jugular vein (Figs. 121, 127).

The **internal jugular** is a continuation of the *transverse sinus*, (a venous channel inside the skull, which ends at the jugular foramen). This vein lies on the lateral side of the internal carotid artery in the upper part of the neck, and further down at the side of the common carotid artery, with the vagus nerve between and behind them. It ends by uniting with the subclavian vein.

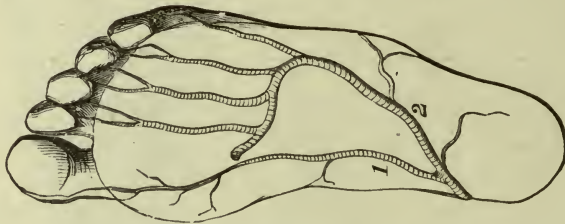


FIG. 135.—DEEP ARTERIES IN SOLE OF FOOT.  
1, Internal plantar; 2, external plantar (Holden).

**Superficial.**—From the scalp, ear, and face, bearing the names of the arteries (usually); they empty into the **external jugular vein** which opens into the subclavian.

There are many veins in the spongy bone between the compact layers of cranial bones, and these communicate by *emissary veins* with the sinuses and also with the scalp veins.

PRINCIPAL VEINS OF THE UPPER EXTREMITY.

**Deep.**—From the hand and wrist; they form *ulnar* and *radial* veins (running with arteries of the same name) which unite to form *brachial* veins.

The *brachial* veins in turn unite to form the *axillary*, and the axillary becomes *subclavian*.

The external jugular vein empties into the subclavian at about the middle of the clavicle. It is easily seen through the platysma muscle.

**Superficial.**—From fore arm; groups of veins, both anterior and posterior, form two, called the *basilic* and *cephalic*, which empty into the *axillary* vein.

A *median* vein in front of the elbow connects the basilic and the cephalic, Fig. 136.



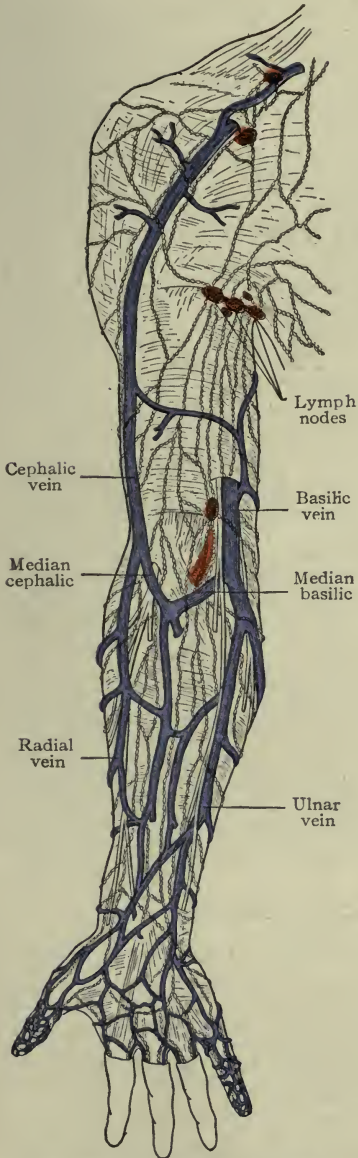


FIG. 136.—SUPERFICIAL VEINS, UPPER EXTREMITY.

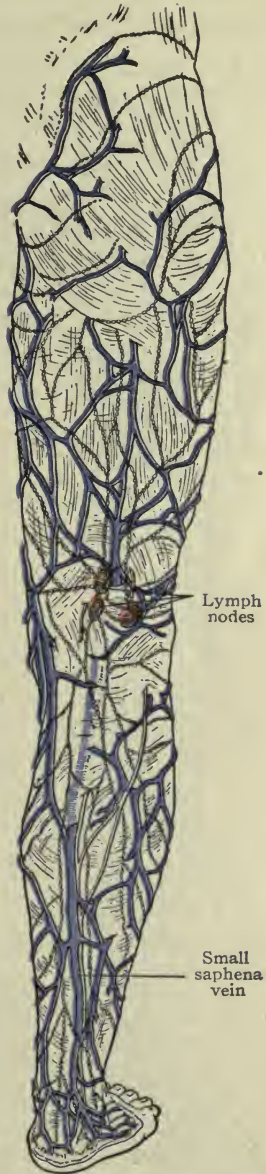


FIG. 137.—SUPERFICIAL VEINS, LOWER EXTREMITY.

The *subclavian*, having gathered blood from the entire upper extremity, unites with the *internal jugular* to form the *innominate vein*; the *anonyma veins* (*right and left*) unite to form the **superior vena cava**.

The *left anonyma vein* is the longer of the two, since it must cross to the right side to join the right vein.

### The Superior Vena Cava.

The superior vena cava is formed by the union of the two *anonyma veins*. It lies on the right side of the arch of the aorta, and opens into the right atrium of the heart (Fig. 121).

### VEINS OF THE THORAX.

Blood from all of the *intercostal veins* (except in the first space) finally reaches the *great azygos vein*, which opens into the **superior vena cava** (Fig. 129).

The blood of the heart itself is returned directly to the right atrium by a *coronary vein* called the *coronary sinus*. All other thoracic organs return their blood to *azygos veins* and these to **superior vena cava**.

### SUMMARY.

The venous blood from all structures above the diaphragm (except the heart) is returned *through the superior vena cava* to the right heart (right atrium) (p. 165).

### PRINCIPAL VEINS OF THE LOWER EXTREMITY.

**Deep.**—From the dorsum of the foot the veins form the *anterior tibial veins*; from the sole of the foot, the *posterior tibial*.

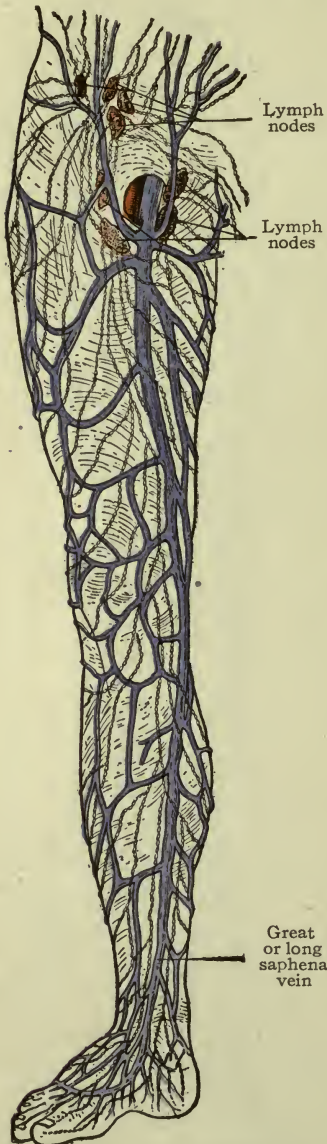


FIG. 138.—SUPERFICIAL VEINS, ANTERIOR.

The tibial veins unite to form the *popliteal*, which continues as the *femoral*, and these two veins receive others corresponding in name to the branches of the arteries which they accompany.

**Superficial.**—From the lateral part of the foot and leg, by the *small saphena* vein, to the *popliteal* (Fig. 137).

From the dorsum and medial part of the foot and leg by the *great saphena* vein to the *femoral*, passing through the oval fossa in the fascia lata, below the inguinal ligament (Fig. 138). The *femoral* vein becomes *external iliac*.

#### VEINS OF THE PELVIS AND ABDOMEN.

The veins of the pelvic organs are large and numerous.

In the vaginal walls and around the lower end of the vagina, also in the rectum especially, they form close networks or *plexuses* which when wounded bleed profusely. The veins of the anal canal are prone to become congested and assume a varicose condition constituting *hemorrhoids*.

The *pelvic* veins empty into the hypogastric, and the hypogastric and external iliac veins unite to form the *common iliac*.

The right and left common iliac veins unite to form the **inferior vena cava** (Fig. 139).

#### The Inferior Vena Cava.

This is formed by the union of the two common iliac veins at the right side of the bifurcation of the abdominal aorta (at the level of the lower border of the fourth lumbar vertebra). It runs upward through the abdomen, on the right side of the aorta, close to the spinal column, to pass through the diaphragm and enter the pericardium and right atrium of the heart.

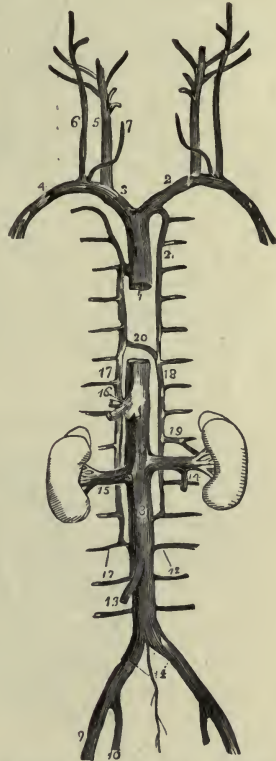


FIG. 139.—SHOWING FORMATION OF THE LARGE VEINS.

1, Superior vena cava, 2, 3, innominate veins; 4, right subclavian; 5, 6, int. and ext. jugular veins; 8, inferior vena cava; 14, common iliac veins. (Remaining references not given.) (Holden.)

From the abdominal *walls* the *phrenic* and *lumbar* veins open into the *inferior vena cava*.

From abdominal *viscera* the *renal* and *adrenal* veins open into the *inferior vena cava*.

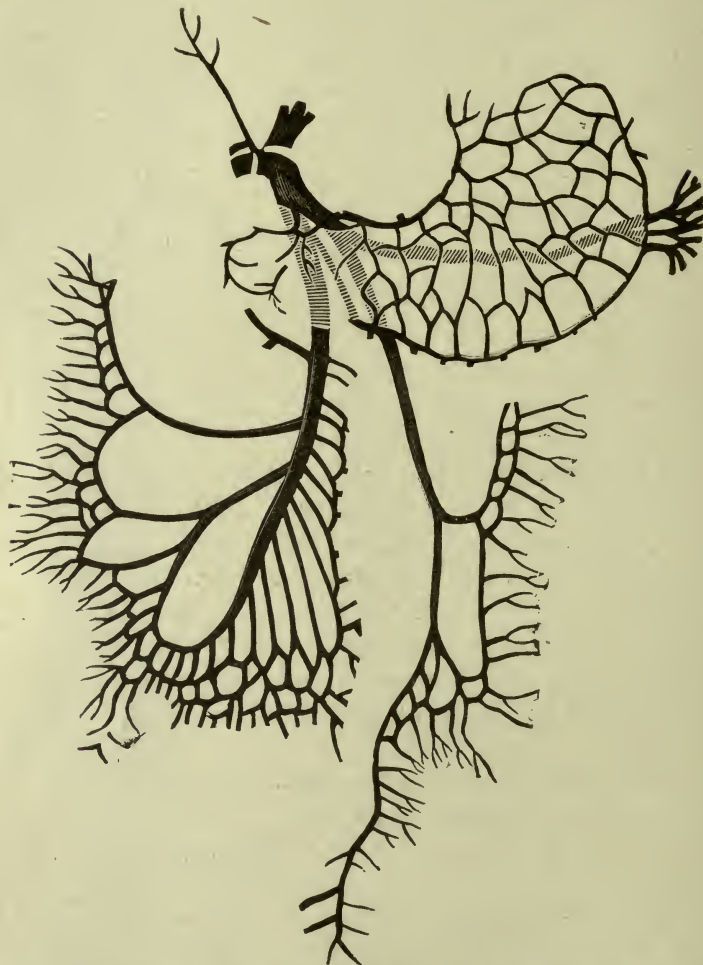


FIG. 140.—SCHEME OF FORMATION OF PORTAL VEIN, BY VEINS FROM SPLEEN, STOMACH AND INTESTINES.

The *right ovarian* and *right spermatic* veins open into the *inferior vena cava*; the *left ovarian* and *left spermatic* veins open into the *left renal vein* which carries their blood to the inferior vena cava.

The *splenic* (or *lienal*), *gastric*, and *mesenteric* veins form the

**portal vein**, which is four inches long and enters the liver at the transverse fissure or porta (Figs. 106, 140).

### THE PORTAL CIRCULATION.

This is the circulation of venous blood through the liver. The **portal vein** bears the products of digestion from stomach and intestines; entering the liver it divides into branches which form an extensive net-work in its substance.

Having been distributed through these fine capillaries, the blood leaves the liver by the *hepatic veins*, which open directly into the *inferior vena cava*.

### SUMMARY.

The venous blood from all structures (practically) below the diaphragm, is returned through the **Inferior Vena Cava** to the heart (right atrium).

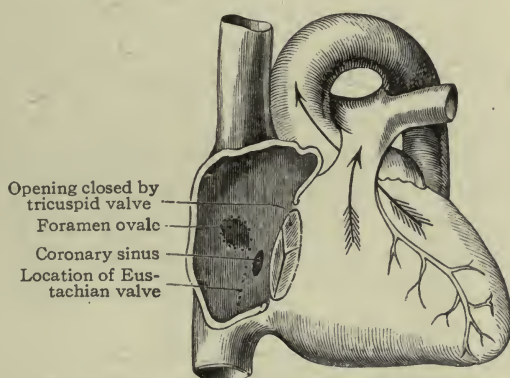


FIG. 141.—INFANT'S HEART.  
Showing interior of right atrium (Holden).

### THE FETAL CIRCULATION.

The fetus is nourished by blood brought from the uterine (placental) arteries of the mother, through a special vessel called the **umbilical vein**. After circulating in the body of the child it is returned to the placenta by two special vessels called the **umbilical arteries**. (Fig. 142.)

During intrauterine life the lungs do not contain air, therefore,

the interchange of oxygen and carbon dioxid in the blood must be accomplished elsewhere. This also is brought about by means of the placental vessels.

The plan of fetal circulation requires still other special provision, namely:

The **foramen ovale**.—An opening in the septum between the two atria (Fig. 141).

The **Eustachian valve**.—A fold of endocardium in the R. atrium, (so placed as to direct the blood from the inferior vena cava through the foramen ovale).

The **ductus arteriosus**.—A short trunk ( $1/2$  inch long) which connects the pulmonary artery with the arch of the aorta.

The course of the blood is as follows: *Arterial blood* is brought through the *umbilical vein* which enters the body at the umbilicus, runs upward under the liver giving branches to that organ; and terminates (as the ductus venosus) by opening into the inferior vena cava, just below the diaphragm. It flows at once into the *right atrium* of the heart, where it is guided by the Eustachian valve through the *foramen ovale* into the left atrium; from there it passes into the left ventriculum and through the aorta, to be distributed.

The greater portion of this current goes to the head and upper extremities, from which it returns to the right atrium again and passes down into the right ventriculum; thence into the pulmonary artery, but not to the lungs (except a very small portion); it is delivered instead by the *ductus arteriosus* to the aorta, at a point where the arch begins to descend, and joins the small current already there, to supply the trunk and lower extremities.

The greater portion of this blood leaves the fetus before it reaches the lower extremities, by way of the *two umbilical arteries*, and returns to the placenta for re-oxygenation; while that which goes to the lower extremities is later emptied into the inferior vena cava to be again mixed with blood from the umbilical vein on its way to the fetal heart.

**Notes.**—The liver is the only organ to receive blood just as it comes from the mother; the baby's liver is very large. The head and upper extremities are next supplied, although with a slight admixture of venous blood (which came through the inferior vena cava); they are well developed. The pelvis and lower extremities receive but a small supply of venous with a slight admixture of arterial blood; they are not so well developed.

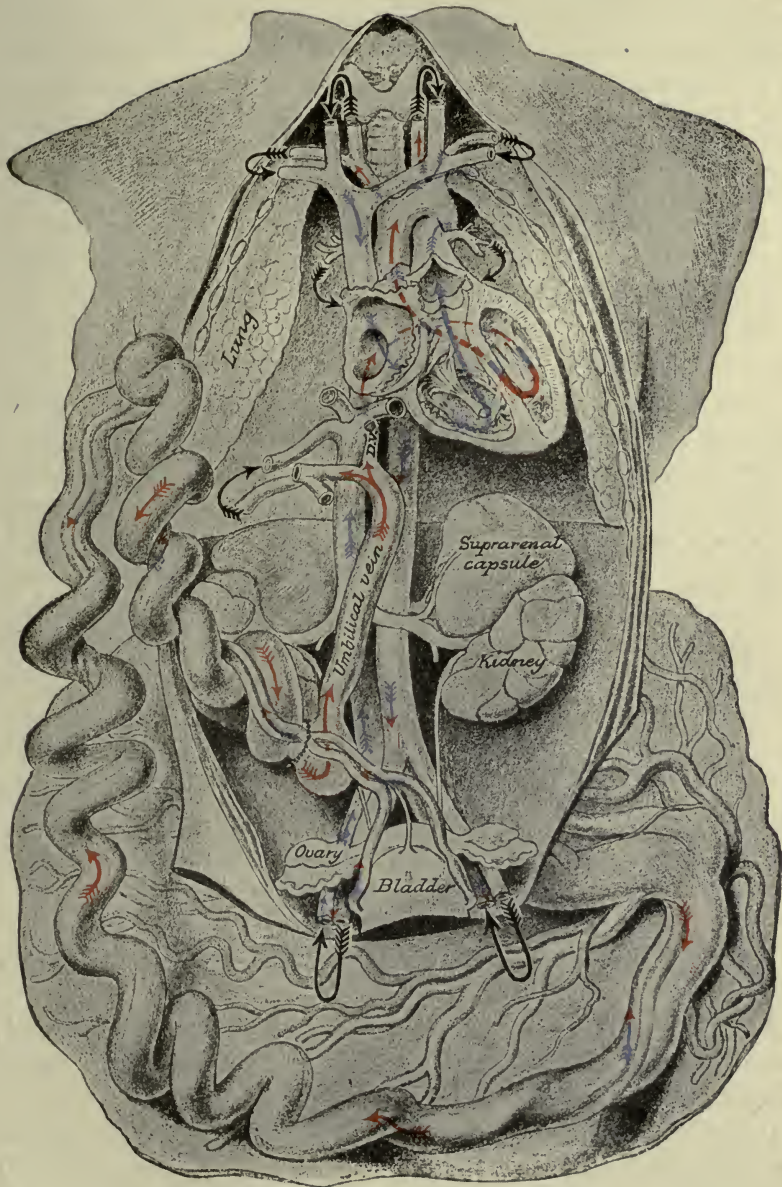


FIG. 142.—THE FETAL CIRCULATION (MORRIS).

**The placenta.**—The *placenta* is formed in a portion of the lining membrane of the uterus, by an intricate arrangement of the uterine vessels of the mother with the umbilical vessels of the fetus. It is here that the umbilical arteries coming from the fetus, end; and the umbilical vein going to the fetus, arises. Here also the interchange of gases and of waste and nutritive matter between fetal and maternal blood, is carried on.

The **umbilical cord** connects the placenta and the fetus. It comprises the two arteries and the one vein, protected by a gelatinous substance or “Wharton’s jelly,” in which they are embedded.

### PHYSIOLOGY OF THE BLOOD.

We have learned that the nutritious portions of the food are, after digestion, poured into the blood and circulated throughout the body; also that cell action results in waste which is returned to the blood. Again, that tissue changes are chemical in their nature and chemical action is accompanied by heat; this is imparted to the blood, which can in turn convey heat to other parts.

Here then, are three important functions of the blood:

1. To *convey food* (including oxygen from the lungs) *to* the tissues.<sup>1</sup>
2. To *convey waste* (including carbon dioxide) *from* the tissues.
3. To *equalize* the *body temperature*. Add to these:
4. To *provide water* for dissolving waste substances to be removed from the body by skin, kidneys and intestine.
5. To be a medium for *transporting internal secretions* (page 220).
6. To furnish its own remedy for hemorrhage by bearing the factors of *coagulation*.

(The blood is the source of water supply as well as food supply for the body.)

The special functions of the *blood cells* have been outlined, namely: The *oxygen-bearing* property of red cells and the *phagocytic power* of the white.

Any irritation of the tissues is promptly followed by an increase in the blood and lymph supply of the part, and (if long continued) crowding of cells in the capillaries. The *leucocytes* put forth little prolongations of their substance which penetrate the vessel wall,

<sup>1</sup> It must not be forgotten that *oxygen* makes tissue changes possible—hence the importance of the blood as an *oxygen carrier*.



and gradually the cells themselves work their way through. This causes a hardened or *indurated* condition which will soon disappear if not excessive, but with severe irritation the process goes on to inflammation (the cells crowding each other to death) and pus results.

In case of *bacterial invasion*, the leucocytes surround and absorb the offending organisms, thus protecting the body from the effects of their toxins. This they are doing continually because we are constantly taking bacteria of various sorts into our systems. So long as the number is not too great the *phagocytes* can take care of them, it is only when there are too many, that they cannot be overcome. It is due to the character of the *capillary walls*, that the blood cells can migrate into the tissues (diapedesis).

Consisting as it does of a single layer of endothelial cells, the capillary wall also renders possible the *interchange* of *fluids* between the blood-vessels and the tissues. This interchange is accomplished by the physical process of *osmosis*, which may be defined as the diffusion of two liquids or solutions through an intervening membrane.

*Simple diffusion* is the mixing of two liquids when poured together, to form a uniform solution.

*Filtration* is the passing of a liquid through a membrane or other substance for the purpose of removing some portion altogether.

It is probable that all three processes go on in the tissues.

## CHAPTER XII.

### THE LYMPHATIC SYSTEM.

The **lymphatic system** comprises an extensive arrangement of *lymph vessels* or *lymphatics*, and *lymph nodes* or *glands*—both deep and superficial (Fig 143).

This system pervades the entire body for the circulation of **lymph**—a nutritive fluid derived from the blood. It is by this means that foods which have been absorbed from the digestive organs and poured into the blood, are separated out for the use of the tissues and conveyed to them.

**Lymph spaces.**—Between the cells and collections of cells of every tissue, except cuticle, hair and nails, are found minute *tissue spaces* or *lymph spaces*, communicating freely with each other. There are also spaces around the smallest blood-vessels and nerves (called respectively *perivascular* and *perineural* spaces). These all communicate with the beginnings of *lymph-capillaries* (just how, is disputed).

**Lymph capillaries.**—These resemble blood capillaries in that they have but a single coat (of endothelium). They permeate the tissues in every direction, forming a close network, from which lymph vessels or lymphatics originate by the uniting of small channels to form larger ones (as veins originate).

**Lymph vessels.**—Are delicate and transparent, but have three flexible coats. (One elastic, two fibro-muscular.) They are provided with *valves*, formed by folds of the lining at very short intervals, which give the appearance of beading to the vessels. This arrangement allows the lymph to flow toward the heart but prevents it from moving in the other direction.

The lymph vessels of the intestines have been called *lacteals* because of their milky appearance during the process of digestion the whitish color being due to the presence of fat globules transmitted by the lymph capillaries of the villi. This fat-bearing lymph is called *chyle*.

Within the tissues of the body the lymph vessels are too small to be seen by the naked eye, but they unite again and again, to form larger ones (although still very small) which in some places may be seen entering or leaving glands, until finally two remain—the *right lymphatic duct* and the *thoracic duct*, which have a diameter of 3 or 4 mm.

**Lymph** is a transparent watery *saline* fluid with lymph corpuscles floating therein. It contains *nutritive substances* for the tissues and *waste matters* derived from them.

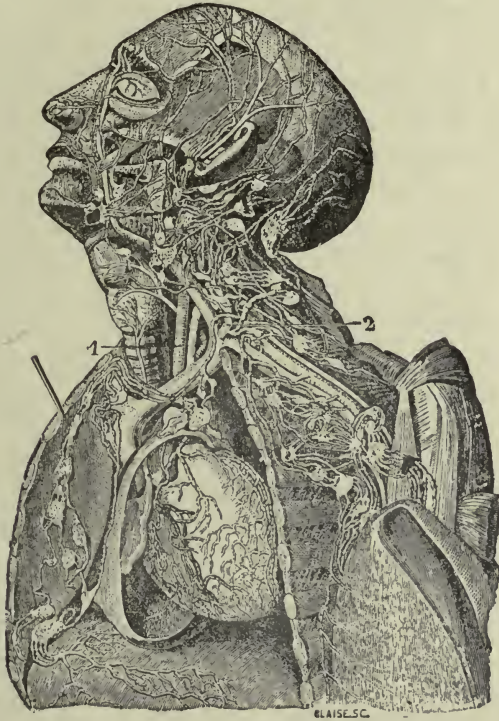


FIG. 143.—LYMPHATIC VESSELS AND NODES.

1 and 2 are portions of the THORACIC DUCT (Holden).

The description of plasma applies very well to lymph, always keeping in mind that lymph is more watery and carries *lymph cells* while plasma bears blood cells; also it will coagulate, but slowly and not so firmly, with a pale clot because of the absence of red cells.

The *origin of lymph* is primarily from the blood. The walls of the blood-capillaries allow a transudation of thin plasma or serum

into the *tissue spaces*, and this is the source of *nutritive principles*. *Waste matters* are added as the result of the activities of the tissues themselves; they represent the "*tissue waste*." This fluid, conveyed by lymph-capillaries to lymph-vessels is carried to lymph glands, where it gathers the lymph corpuscles which float in it.

**Lymph glands** or *lymph nodes* are small round or oval bodies of a reddish color, varying in size from that of a pin head to a small bean, and intersecting the lymph vessels in certain regions of the body. They are numerous in the *neck*, *axilla* and *groin*, also in the *thorax* and *abdomen*.

A *lymph gland* is invested with a thin but firm capsule (fibromuscular) which sends septa or partitions into the interior, to support the gland substance in small compartments. The *gland substance* lies loosely in this capsule and in the compartments, leaving spaces for the passage of lymph around the different portions and around the whole. It contains great numbers of young *corpuscles*, which are added to the lymph stream as it washes through the gland, and appear later as the *lymphocytes of the blood*.

**Lymph** is brought to the glands by *afferent* lymph vessels, usually several for each gland. After flowing through the various spaces in and around the gland substance, it leaves by *efferent* vessels, which unite to carry the stream on its way toward the large veins.

A specimen taken from an *efferent* vessel and examined under the microscope will show a greater number of lymphocytes than one taken from an *afferent* vessel.

**Clinical notes.—Edema** is an accumulation of lymph in the tissue spaces. We have seen that an interchange between the blood and lymph capillaries is continually going on, the blood providing lymph, the tissues receiving it, abstracting nutriment and adding waste; returning it to the blood, but in less quantity than was received; the excess which remains in their spaces being carried by lymph vessels to the venous blood.

Should this balance of interchange be disturbed, the effect is evident at once. A too abundant supply, or an obstruction to the outflow, would overwhelm the tissues with fluid, causing *edema*.

**Clinical Notes.**—Inflammation of serous membranes, if severe, results in the accumulation of lymph or serum in their cavities—this is an *effusion*.

Inflammation in the tissues themselves causes an excess of lymph accompanying the increased flow of blood. The accumu-

lation of lymph with leucocytes and red cells from the blood, causes *induration*.

The largest lymph vessel is called the **thoracic duct** (Fig. 121). It is about 18 inches long, having an average diameter of a small goose-quill. It begins at the second lumbar vertebra, in a little pouch called the *receptacle of the chyle* (or *receptaculum chyli*) and runs up behind the aorta, through the diaphragm. It then continues upward through the thorax to the level of the seventh cervical vertebra, where it arches to the left to open into the subclavian vein, at the junction with the left internal jugular. Thus the *lymph and chyle* join the current of venous blood on its way to the heart for circulation and distribution.

The **right lymphatic duct** is a short vessel, a half inch in length, which opens into the right subclavian vein at the junction with the right internal jugular. Through this channel *lymph* alone joins the venous blood on its way to the heart.

**Note.**—The cavities of *serous membranes*, as peritoneum, pleura, pericardium and others, belong to the system of lymph-spaces, but of a special kind. They are surrounded by capillaries which communicate with them by tiny openings in the membrane, called *stomata*.

## SITUATION OF THE PRINCIPAL GROUPS OF GLANDS OR NODES.

### BELOW THE DIAPHRAGM.

**Lower extremity.**—*Popliteal*, in the popliteal space, *inguinal* (important) at the oval fossa and along the inguinal ligament (Fig. 145).

**Pelvis:** *External* and *internal iliac*, with the external and internal iliac vessels.

**Abdomen:** *Mesenteric*, between the layers of the mesentery (about 150); *lumbar*, in front of the aorta and vena cava. These are numerous.

### ABOVE THE DIAPHRAGM.

**Upper extremity.**—*Epitrochlear*, above the internal epicondyle; *axillary*, under the axillary walls, and *clavicular*, along the subclavian vessels (Fig. 146).

The axillary glands are *superficial*, under the borders of the muscle boundaries; and *deep* around the axillary vessels. These are very important.

**Head:** *Occipital*, below the occiput; *auricular*, behind the ear; *parotid*, upon the parotid gland; *submaxillary*, under the angle of the jaw.

**Neck:** *Superficial cervical*, near the *external jugular vein*; *deep cervical*, with the large vessels (carotid arteries and *internal jugular vein*.) (Important.)

**Thorax:** *Mediastinal*, with the vessels in the mediastinum;<sup>1</sup> *bronchial*, with bronchial tubes and vessels—these are numerous.

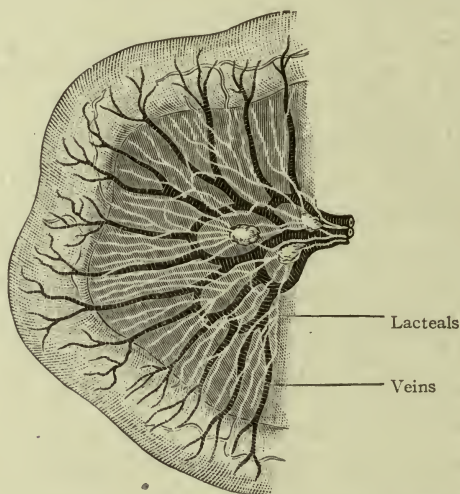


FIG. 144.—LACTEALS AND MESENTERIC GLANDS (Morris).

## DIRECTION OF THE LYMPH STREAM.

### BELOW THE DIAPHRAGM.

From the lower extremity up through *popliteal*, *saphenous*, and *inguinal* glands to the *external iliac*, and thence to the *lumbar* glands.

From the **buttock** and **anterior parts of the genital organs** to the *inguinal*, *external iliac*, and thence to the *lumbar* glands.

In the **deeper parts of the genital organs** to the *internal iliac*, and thence to the *lumbar* glands.

From the **pelvic organs** or **viscera** to the *internal iliac*, and thence to *lumbar* glands.

The **ovaries**, **tubes**, and **fundus of the uterus** send their lymph *directly to the lumbar glands*, instead of first through the internal iliac.

From the **abdomen**, lymph from the **abdominal walls** flows to *lumbar* glands (sometimes indirectly), also from the **kidneys** and **adrenals** to the *lumbar* glands.

<sup>1</sup> See page 297, The mediastinum.

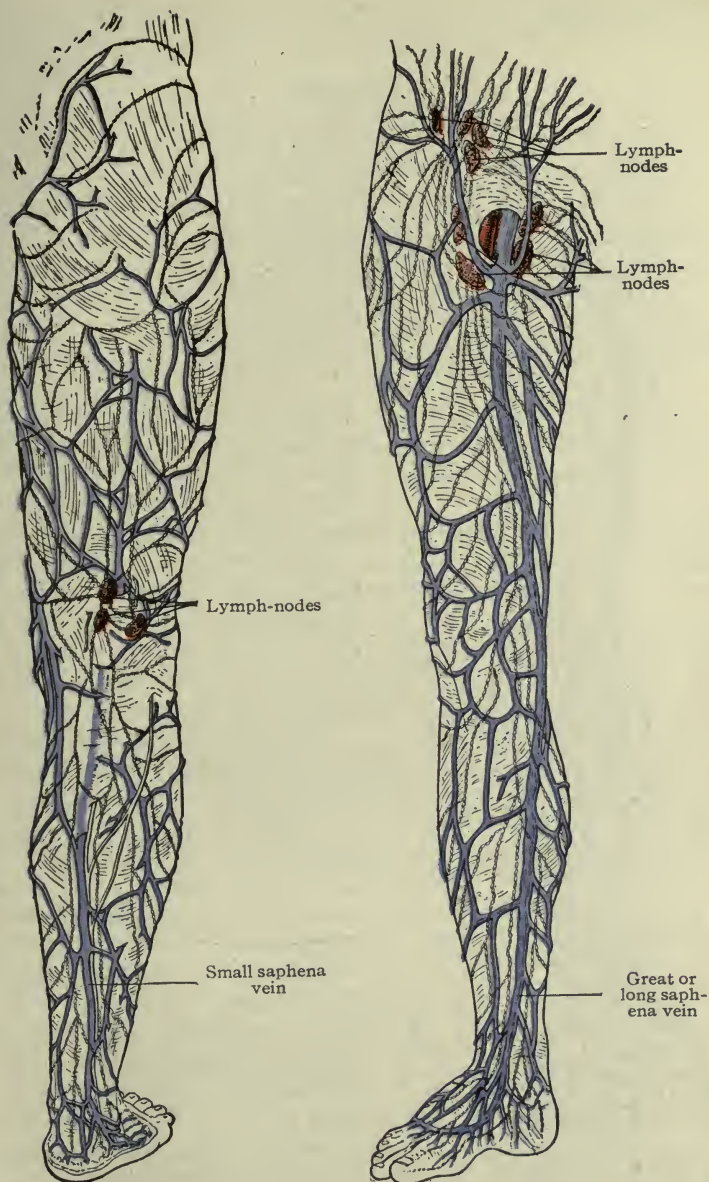


FIG. 145.—THE LYMPHATICS AND LYMPH-NODES OF THE LOWER EXTREMITY.

From **intestines** through *mesenteric* glands to the **thoracic duct**; from all remaining abdominal organs to the *thoracic duct* (except upper surface of the liver).

All lymph which flows through **lumbar** glands runs to the **thoracic duct**, and through it to the *left subclavian vein*.

**Note.**—The lymphatics in the mesentery, coming from the *small intestine*, convey not only lymph but chyle also, which is light in color and gives to them a milky appearance, therefore their name, *lacteals* (Fig. 144).

#### ABOVE THE DIAPHRAGM, LEFT SIDE.

From the **left upper extremity** through *axillary* and *subclavian* glands to the *deep cervical* glands, thence to *thoracic duct*.

From **left head and neck**, superficial: face and scalp, to *occipital*, *submaxillary*, *superficial cervical*, and then *deep cervical* glands. Deep: face, throat and neck, to *deep cervical* glands and thence to *thoracic duct*.

From the **left thorax**, walls and viscera (including left half of heart), to *thoracic duct*.

#### ABOVE THE DIAPHRAGM, RIGHT SIDE.

From the **right upper extremity** through *axillary*, *subclavian*, and *deep cervical* glands, to the *right lymphatic duct* (Fig. 121).

From the **right head and neck** through *occipital*, *submaxillary*, *superficial* and *deep cervical*, to *right lymphatic duct*.

From the **right thorax**, walls and viscera (including right half of heart), to *right lymphatic duct*.

**Lymphatics of the mammary gland.**—Most of these empty into *superficial* and *deep axillary* glands; a few pass through the chest

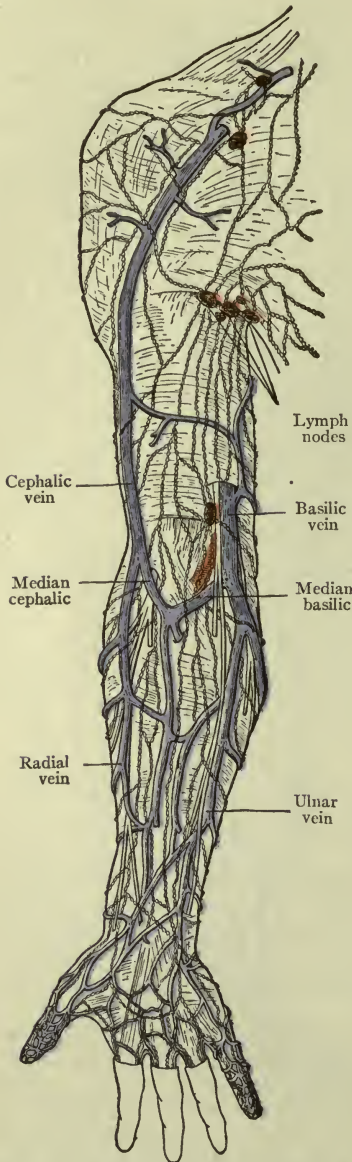


FIG. 146.—LYMPHATICS AND NODES OF UPPER EXTREMITY.



wall to *mediastinal* glands, and those of the nipple and areola of the two sides communicate with each other.

#### SUMMARY.

The **right lymphatic duct** gathers lymph from the right upper extremity, right head, neck, thorax and thoracic viscera, and the upper surface of the liver.

The **thoracic duct** gathers lymph from all other parts of the body—that is, the *left side* above the diaphragm, and *all* parts *below* the diaphragm, except the upper surface of the liver. The two ducts empty into the two subclavian veins, and thus the lymph joins the blood current.

**Clinical notes.**—Certain conditions of disease in an organ or tissue are followed by enlargement of the nearest glands which receive lymph from that part. If the disease be not arrested, the glands next in order will suffer, and the next, and the next.

Disease of the mammary gland will cause swelling, first, of the superficial glands under the border of the pectoral muscle, and later of the deep axillary and clavicular glands. *Mediastinal glands* are sometimes affected when the upper portion of the gland is diseased.

Disease of the tonsils will affect the submaxillary and cervical glands.

Disease of the pharynx, the cervical glands.

Disease of the larynx will affect the cervical glands, and may affect the mediastinal and bronchial glands.

Disease of the upper extremity will cause swelling of the axillary glands.

Disease of the lower extremity will affect the saphenous group and the inguinal.

Disease of the external genital organs and lower end of vagina will affect the inguinal glands along the inguinal ligament.

Disease of the neck of the womb (cervix uteri) will affect *iliac* glands, while disease of the body of the womb (fundus uteri), or of ovaries or tubes, will affect *lumbar* glands.

The transmission of the causes of disease from one organ to another by the lymphatics is called **metastasis**, it is often seen to follow a malignant growth.

#### THE FUNCTIONS OF THE LYMPH SYSTEM.

By the *lymph spaces*, to transmit nutritive fluid from the blood to the tissues, and waste matters from the tissues to the blood.

By *lymph capillaries and vessels*, to convey lymph to the blood in the large veins.

By *lymph nodes* or *glands*, to give origin to *lymphocytes*, and to filter out and retain poisonous or injurious substances from the lymph stream.

## CHAPTER XIII.

### THE RESPIRATORY ORGANS AND RESPIRATION.

**Respiration** is breathing.

*Inspiration* is the act of drawing air into the lungs; *expiration* is the act of expelling it. An inspiration and an expiration together constitute a **respiration**.<sup>1</sup>

The **respiratory organs** are the nose, pharynx, larynx, trachea, bronchial tubes, and lungs, with the thorax and its muscles, including the diaphragm; and the pulmonary blood-vessels. These organs constitute the **respiratory apparatus** and they include the **respiratory tract**, which is a series of channels or air-passages at the termination of which the air comes into contact with the *respiratory epithelium*.

**The nose.**—The part that is supported by the nasal bones is the bridge of the nose. The *nostrils* are the expanded portion; they contain no bones, but small plates of cartilage instead, which are moved by little muscles, therefore, they may be expanded or contracted.

The cavity of the nose is divided into the right and left nasal cavities by a partition called the *septum*, the anterior portion of the septum being formed by the triangular cartilage of the nose, and the remaining portion by bones—the vomer and the vertical plate of the ethmoid. The openings upon the face are the *nares* (anterior nares) and those at the back (looking into the nasopharynx) are the *choanæ* (posterior nares) (Figs. 95 and 147).

On the lateral wall of each nasal cavity are the three *turbinated bones* or *shells* (conchæ), and three spaces or passages directly underneath them, named as follows: the *superior meatus* (or passage) beneath the superior concha (or shell); the *middle meatus* beneath the middle concha; and the *inferior meatus* beneath the inferior concha.

<sup>1</sup>By *air* is meant the atmospheric air by which we are surrounded. It consists principally of the two gases, *oxygen* and *nitrogen*, one hundred parts by weight of air, containing a little more than twenty of oxygen (20.81) and a little less than eighty of nitrogen (79.19). It is the oxygen which is the essential part of inspired air.

The nasal cavities and all of the sinuses which communicate with them are lined with mucous membrane, which prevents the drying effect of the air upon the passages, tends to arrest foreign particles, and moderates the temperature of the air on its way to the lungs.

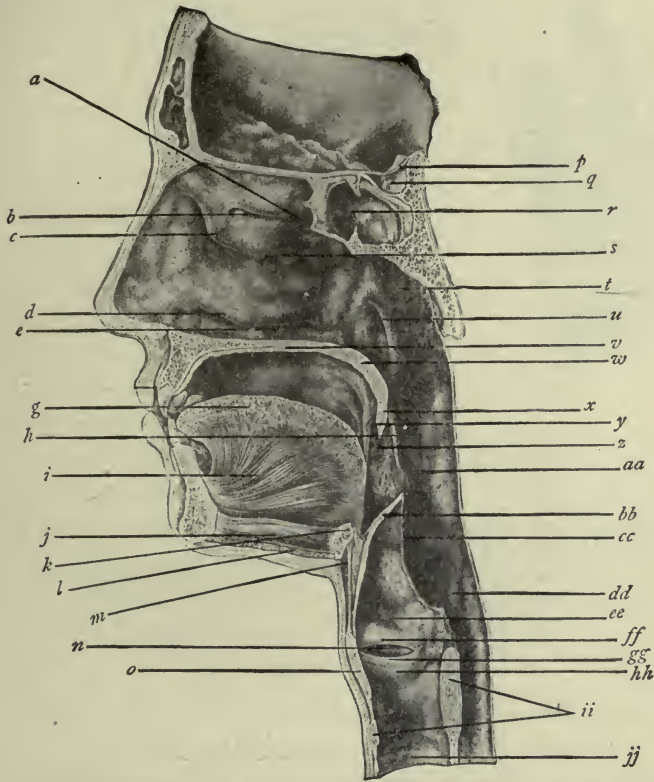


FIG. 147.—NASAL CAVITY AND NASO-PHARYNX (From Deaver's Surgical Anatomy).

*b*, Superior turbinal; *a*, superior meatus; *c*, middle turbinal; *s*, middle meatus; *d*, inferior turbinal; *e*, inferior meatus; *g*, *i*, *j*, tongue; *k*, hyoid bone; *p*, *q*, *r*, sphenoid bone and sphenoidal sinus; *t*, naso-pharynx; *v*, hard palate (floor of nose).

The remaining references are explained in another chapter (p. 126).

### THE PHARYNX.

The **pharynx** is the space behind the nose, mouth, and larynx. Its use is to transmit air from the nose, and food from the mouth. As an air-passage it is included with the respiratory organs. (The air passes from the nose through the pharynx to the larynx.)

## THE LARYNX.

The **larynx** is situated below the hyoid bone, in front of the pharynx, and projects slightly forward in the neck. It is constructed of fibro-cartilages connected with each other by ligaments and lined by mucous membrane. The largest fibro-cartilage is the *thyroid*, which forms the *prominence of the larynx* known as "Adam's apple." Below the thyroid is the *cricoid* cartilage, shaped like a seal ring, and placed with the broad part at the back, where two small pyramid-shaped cartilages rest upon it; they are the *arytenoids*. These are all connected by *gliding joints*. (Other cartilages, very minute, are not mentioned.)

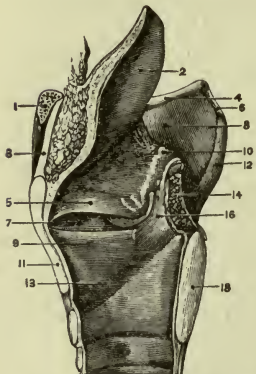


FIG. 148.—INTERIOR OF LARYNX (LEFT SIDE REMOVED).

2, Epiglottis; 5, so-called "false vocal cord"; 9, vocal band; 13, thyroid cartilage; 14, arytenoid cartilage. The other figures refer to parts not mentioned in the text.

The *epiglottis* is a leaf-shaped flexible cartilage extending upward from the thyroid in front, and resting against the base of the tongue. During swallowing this is bent backward over the entrance of the larynx by the action of small muscles, to allow the food to pass over it into the esophagus.

(For the Larynx, the Organ of the Voice, see page 281.)

## THE TRACHEA.

The **trachea** is a flexible tube about one inch in diameter and four and one-half-inches long, extending downward from the larynx to the level of the fourth thoracic vertebra. It is fibrous and elastic, and stiffened with rings of cartilage which are incomplete at the back; unstriped muscle fibers take their place, constituting the *tracheal muscle*.

The tracheal muscle by the action of its fibers, varies the size of the trachea and makes the tube soft where the esophagus lies next to it.

The *trachea* divides into two branches called *bronchi*. The *right bronchus* is one inch long; the left is two inches long. (It passes under the arch of the aorta.)

The **bronchi** divide into branches called *bronchial tubes* which subdivide again and again until the smallest tubes, called *bronchioles*,

are formed. These lead to the spaces called *alveoli*, and the air cells clustered about them.

The bronchi and larger bronchial tubes are like the trachea in structure, consisting of fibrous and elastic tissue with incomplete rings of cartilage. In the smaller tubes the rings become irregular plates or discs, and in the bronchioles the cartilage is absent altogether. The walls are here very thin and contain circular muscle fibers (non-striated), the *bronchial muscle*.

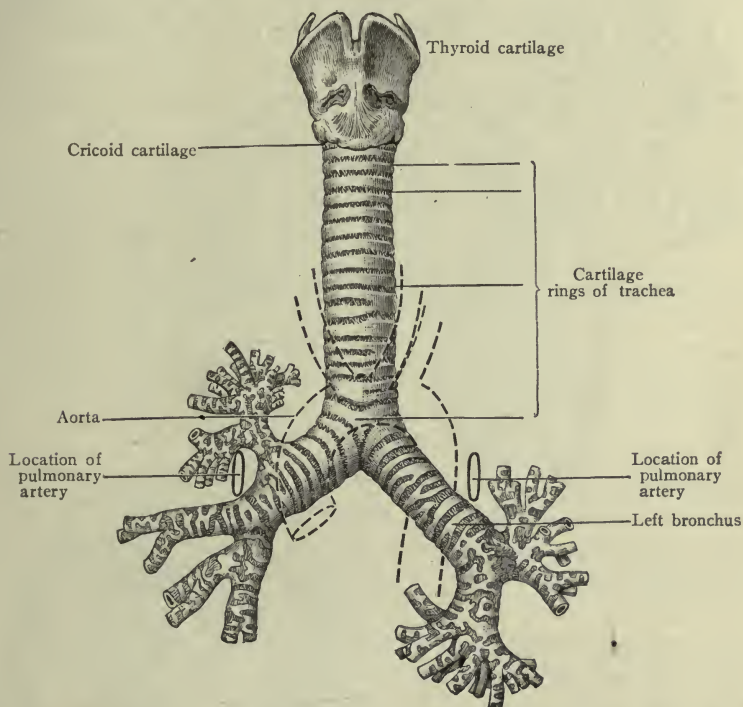


FIG. 149.—LARYNX, TRACHEA, AND BRONCHI (Morris, modified from Bourger).

The entire tract from the trachea down to the air cells is lined with mucous membrane, bearing *ciliated epithelium* as far as the smallest tubes.

The *cilia* of the air passages are fine hair-like projections from the surface; they have a waving motion.

### THE LUNGS.

The **lungs** are two in number, *right and left*, situated in the right and left sides of the thorax, occupying the space enclosed by the ribs (not that portion between the sternum and the spinal

column). They resemble a flattened cone in shape, the *apex* extending one inch above the clavicle, the *base* resting upon the diaphragm. The *right lung* is broader and shorter than the other, but it has *three lobes, upper, middle, and lower*. The *left lung* has *two lobes*.

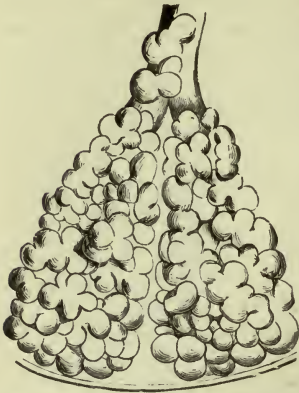

FIG. 150.—CLUSTERS OF AIR-CELLS (Holden, from Kölliker).

**Note.**—The left lung is narrower than the right and does not cover the apex of the heart, otherwise it would be exposed to the motion of the “heart beat.”

The **lung substance** consists of branches of the bronchi and their divisions down to the bronchioles, and the spaces terminating in *air-cells*. These structures are surrounded by blood-vessels, nerves, and lymphatics, grouped together in *lobules*, supported by fine fibro-elastic connective tissue and wrapped in *pleura*.

Each bronchiole terminates in a lobule (Fig. 150).

The **root of the lung** is composed of the large bronchial tubes, blood-vessels, and nerves (see illustration (Fig. 151)).

The bronchial tubes are the primary divisions of the bronchi; the blood-vessels are—first, the *bronchial arteries* for the nutrition of the lung substance; second, the *pulmonary arteries* which form a fine network of capillaries around the air-cells, third, the bronchial and pulmonary *veins*.

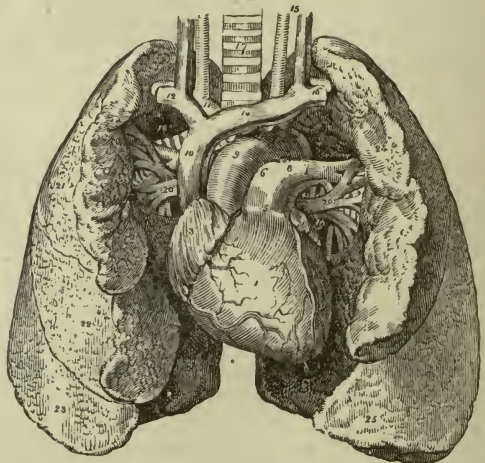


FIG. 151.—THE LUNGS WITH HEART BETWEEN THEM.

#### THE PLEURA.

Each lung is covered (except at the root) by a thin transparent sac of serous membrane called the *pleura*. One side of this sac is

closely applied to the lung, forming the *pulmonary pleura*; the other side fits as closely to the ribs, forming the *costal pleura*. Within the sac is a small quantity of serous fluid (secreted by the endothelium of the pleura), which prevents friction when the ribs move and the lungs expand or contract.

Although the *bony thorax* is bounded above by the first rib, the *thoracic cavity* extends an inch above the rib on each side, bounded by an expansion of the costal pleura and lodging the *apex of the lung*.

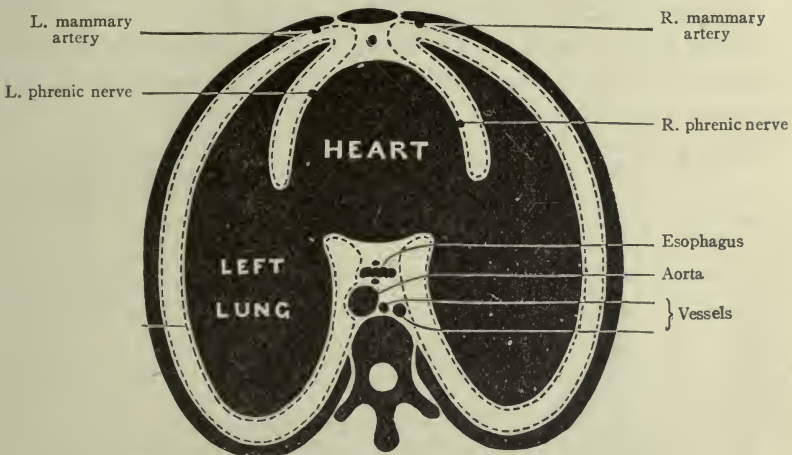


FIG. 152.—THE PLEURAL SACS.

The dotted lines indicate the pleural sacs, with space between the layers (Holden).

**Clinical note.**—If the pleura becomes inflamed the quantity of fluid diminishes and the surfaces rub together, causing acute pain and a fine crackling sound as of friction. This condition is *pleurisy* (or pleuritis).

**Résumé.**—In respiration, or the act of breathing, the *inspired air* enters the nasal chambers, passes through the naso-pharynx, oropharynx, larynx, trachea, bronchi, bronchial tubes, and bronchioles, to the aveoli and air-cells or *air vesicles*.

## THE PHYSIOLOGY OF THE RESPIRATORY PROCESS.

The **function of the respiratory apparatus** is first, to accomplish an interchange in the lungs, between the *oxygen* of the air and *carbon dioxide* of the blood, in other words—to bring nutriment to the blood and to remove waste from it.

We have seen how the blood returns from the digestive organs laden with food which is to be distributed throughout the body, and that these products of digestion are made over in the tissues by a process of *oxidation*. The source of the *oxygen* for this process, is the air we breathe. It passes through the air vesicles and the capillary walls into the blood, thence into the lymph spaces and tissue cells, the *tissue products* returning (through the spaces and the vessel walls) to the blood.

Thus, the gas called *carbon dioxide* (resulting from tissue action) is brought by the blood to the lungs; passing through the capillary walls and the air vesicles, it is exhaled in the breath and thus removed from the body. Consequently, *respiration* is a process not only of nutrition but of *elimination* as well.

This interchange is accomplished in part by the physical process of *diffusion of gases*. (The epithelium of the air vesicles may have a special function to this end, and is called respiratory epithelium.)

By *inspiration* we take air, with its oxygen, into the lungs; by *expiration* we expel it with carbon dioxide, small quantities of ammonia and organic waste matter, and moisture.

This important process is made possible by the movements of the thorax as follows:

**In inspiration.**—The external intercostal muscles elevate the ribs and spread them apart, increasing the width of the chest;<sup>1</sup> the diaphragm contracts, pulling down its central tendon and thus increasing the depth of the chest; the lungs expand and receive the in-drawn air.

**In expiration.**—The ribs fall easily back into place, assisted by internal intercostals and abdominal muscles; the diaphragm relaxes, returning to its dome shape, and the air is pressed out.

These acts are performed, in health, with regularity, that is, rhythmically. The number of respirations in a moment varies from about 40 in the newly born to 18 in the adult. Normal respiration is slowest when one is lying down or when sleeping. The rate is increased during physical exercise or by emotion, and in visceral inflammations, as pneumonia, pleurisy, peritonitis, etc., also in fevers generally.

<sup>1</sup> The Pectoralis Major and some others assist in deep breathing or *forced inspiration*.



Average respiratory rate at different ages:

At one year .....	30
“ six years .....	25
“ twelve years .....	20

Soon after this age, the normal proportion between the number of respirations and the pulse rate, is as one to four.

The normal *respiratory sound* has been well compared to the rustling of leaves when the gentlest of breezes is blowing through them.

The tissues which are most active require most oxygen. Consequently we can create a demand and obtain a supply by voluntary *muscle exercise* in good air, thus feeding the blood and through it the whole body, with this most important element of food.

**Respiration contributory to body heat** by providing oxygen for **tissue change**.

Of all organs the muscles are most constantly at work; they can dispose of more oxygen than any other part of the body. By rapid oxidation they generate more heat, but only so long as the *respiratory organs* keep pace with the demand for rapid breathing.

It is natural to breathe more rapidly as well as more deeply on a cold day, because a low temperature of the surrounding air stimulates (reflexly) the various activities of the body to meet the call for warmth, and the respiratory process must be among the first to respond.

**Summary.**—*Respiration* is a *nutritive* process, an *eliminative* process and a contributing *source of body heat*.

#### SPECIAL MODIFICATIONS OF RESPIRATORY MOVEMENTS.

*Rapid* breathing is called *hyperpnea*.

Temporary *cessation* of breathing is called *apnea*.

*Labored* breathing, is *dyspnea*.

*Dyspnea* follows any interference with the interchange of gases in the lungs. It may be caused by diminishing the entrance of oxygen, or by increasing the  $\text{CO}_2$ . It is usually due to imperfect circulation in the pulmonary vessels.

*Asphyxia* is the condition resulting from a complete cutting off of oxygen or an excessive increase of carbon dioxide. It may be sudden or gradual, but if unrelieved, ends only in death.

The change of color noted in the face of one suffering from dyspnea and still more from asphyxia, is due to the accumulation of carbon dioxide in the blood.

The importance of fresh air in sufficient quantity cannot be over-estimated. One thousand cubic feet of space for each adult, (equal to a room 10 feet in height, length and breadth) renewed about three times hourly, is not too much.

## CHAPTER XIV.

### THE KIDNEYS. THE SKIN. ELIMINATION.

The **kidneys** (renes) are organs of excretion; that is, they separate certain waste matters from the blood, in a definite form for removal from the body.

They are situated for the most part in the posterior lumbar region, just in front of the quadratus lumborum muscles, extending from

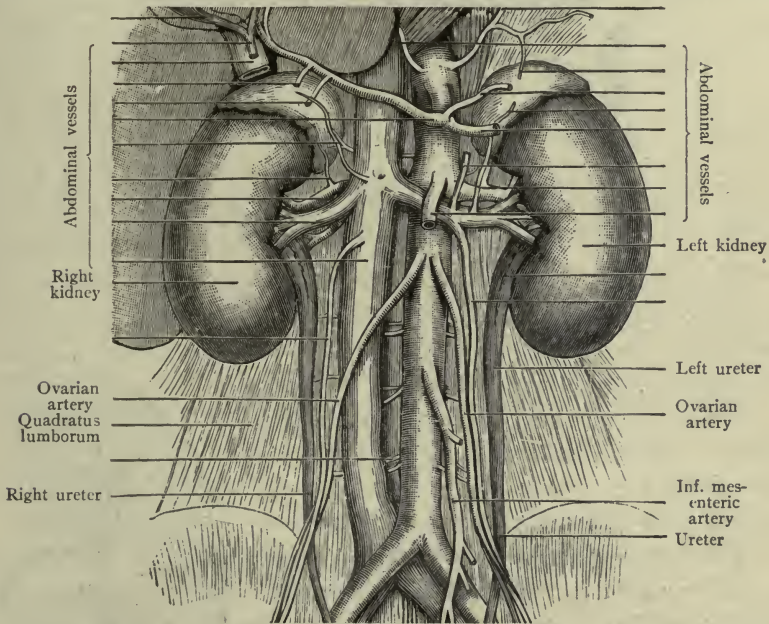


FIG. 153.—THE KIDNEYS (Morris).

about the tenth rib to within two or three inches from the crest of the ilium. They are shaped like a bean, about four or five inches long and one and one-half inches wide, with the concave border, or *hilus*, turned toward the spinal column; and they are imbedded in fat *behind* the peritoneum.

The **kidney** is hollow, the cavity within being called the *sinus*. It is covered by a fibrous capsule which also lines the sinus.

**Structure.**—A kidney is a mass of minute tubes, the *uriniferous tubules*. At the beginning of each is a bulb-like enlargement,

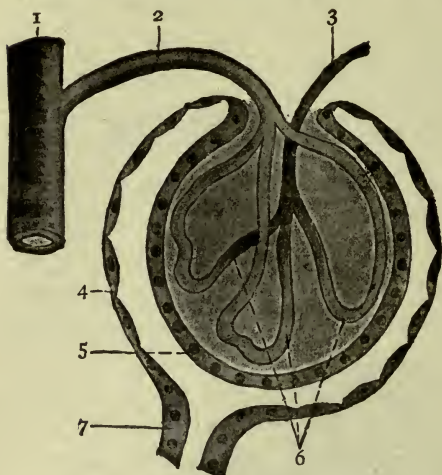


FIG. 154.—SCHEME OF THE RENAL OR MALPIGHIAN CORPUSCLE.

1. Interlobular artery. 2. Afferent vessel.  
3. Efferent vessel. 4. Outer wall. 5. Inner wall.  
6. Glomerulus. 7. Neck of tubule (Stöhr).

indented to form a deep hollow (Bowman's capsule, Fig. 154) which encloses a tuft of renal blood-vessels. The capsule and vessels together constitute a *Malpighian* or *renal corpuscle*. As the tubule leaves the bulb it twists and turns many times and is called the *convoluted tubule*. It has a network of blood-vessels around it. The convoluted tube finally becomes *straight*, and at last several straight ones unite to form a *collecting tube* which opens into the sinus.

Malpighian corpuscles and *convoluted* tubes occupy most of the portion of the kidney near the surface, forming the *cortex* (or *cortical portion*). The *straight* or collecting tubes are grouped together into *pyramids*, pointing toward the interior and forming the *medullary portion*. The apex of each pyramid projects into the sinus, presenting the openings of several collecting tubes (Fig. 155).

The cells which line this system of tubes do the work of *excreting the urine* from substances in the blood, thus relieving it of poisonous elements which would surely cause death if allowed to remain.

The urine is conducted from the kidney to the bladder through the *ureter*, a slender musculo-fibrous duct about twelve inches long, the upper end of which is enlarged and called the *pelvis of the kidney*. (It occupies the sinus.) It has a thin layer of muscle fibers and is lined with mucous membrane. The two ureters

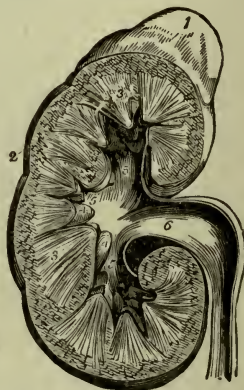


FIG. 155.—SECTION OF KIDNEY (POTTER).

extend into the true pelvis to the base of the bladder, where they terminate about one inch apart. (The course of the ureter is further described on page 283 with the description of the bladder.)

**Clinical notes.**—The amount of urine excreted by a person varies greatly, but in health *averages* 48 ounces or 3 pints daily; it is directly affected by the quantity of fluid which the person drinks and the amount of perspiration formed.

*Renal colic* is caused by the attempt to pass a small stone, or calculus, through the ureter.

## PHYSIOLOGY OF THE KIDNEYS.

This is to remove waste matters from the blood in the form of an excretion called *urine*. **Urine** is a watery fluid of amber color, somewhat heavier than water (1010–1020), with a characteristic odor, and having the temperature of the body at the time of voiding. Its *reaction* is normally *acid*.

The *coloring* matter is derived from bile pigments; it is deep or pale, as the urine contains less or more water. The *weight* is due to the salts contained, both organic and inorganic (or mineral) and this also is modified by the amount of water. Both *water and salts* vary markedly with the dietary of the individual.

**Clinical notes.**—The color and odor may both be modified by drugs or by articles of food. (For example, turpentine causes the odor of violets, while that imparted by asparagus is well known.) Urine containing blood cells is smoky in appearance; and every nurse knows what methylene blue will do.

The most important substance to be excreted in the urine is **urea**. This represents the absolutely useless material remaining from proteid foods. It is prepared for excretion in the liver. It is the substance which if allowed to accumulate in the system becomes a deadly poison, causing death by *uremia*.

*Uric acid* is proteid waste in another form and smaller quantity. *Phosphates* of sodium, potassium and calcium are present normally, also other mineral salts, sodium chloride (common salt) being the most abundant.

*Water* is necessary for the solution of all these solids (they would be solid without water). This varies in quantity in many systemic conditions. Increased activity of the lungs and skin, for example, removes water from the blood and leaves the urine more dense. Fevers are always accompanied by a *decrease* in the quantity. It

may be *increased* by nervous excitement; nervous urine is pale and thin, since it is the water which is increased.

*Suppression of urine* means inability of the kidney to act.

The process of excretion in the kidney is one of *filtration* and *secretion*. The kidney has a large blood supply through the renal artery, which enters at the hilum and divides at once into several branches. The capillaries from these arteries are very numerous. They enter first the capsule of the Malpighian body (*afferent vessels*) and form a cluster or tuft there, from which the *water* and *salts* are filtered out and pass into the tubule. They then leave the capsule (*efferent vessels*) and twist themselves about the convoluted tubules, whose epithelial cells select the organic substances—*urea*, *uric acid* and others. These are washed down by the watery solution coming from the capsule, to the apices of the pyramids and there discharged into the pelvis of the kidney, as *urine*.

The ureter conducts the urine from the kidney to the urinary bladder, where in due time it is expelled through the urethra. The act of expelling the urine is *micturition* (clinically we often speak of it as *urination*). The bladder walls contract, the sphincter of the urethra relaxes, and the urine escapes.

If the bladder is not able to expel its contents we say the patient has *retention* of urine. This inability may be so complete that the bladder becomes entirely filled and the sphincter can no longer act; the urine dribbles away and the condition is one of "retention with overflow" from inability of the bladder to contract.

## THE SKIN.

The **skin**, or integument, is the elastic and protective covering of the body. It consists of two layers, a deep one called the *corium*, and a superficial one called the *epidermis*.

The *corium* or "true skin" (*cutis vera*) is a vascular, elastic and sensitive layer, red and soft; resting upon a loose subcutaneous tissue. Its deep portion is well supplied with vessels and nerves (*tactile cells*) supported by a *fibrous and elastic* network (reticular layer) which contains *non-striated muscle* fibers and fat. In this layer are the blood-vessels, nerves and lymphatics.

Tiny projections called *papillæ* rise from this network portion, each papilla containing a special nerve-ending called a *touch corpuscle*. They are arranged in rows forming ridges which are circular on the front of the finger tips. It is a remarkable fact that

no two fingers or toes are alike in this respect, hence the *thumb- or finger-mark* is a means of identification.

The papillæ constitute a "papillary layer." There are still other nerve endings in the corium for different sensations.

The *epidermis* (or cuticle) completely covers the *corium*. It consists of layers of cells of varying character and thickness. The deeper cells are soft and nucleated, but near the surface they become flat and dry, until finally they are mere tiny scales.

The *epidermis* has no vessels and scarcely any nerves, consequently it is not sensitive and does not bleed.

The deep layers of the *epidermis* contain the coloring matter or *pigment* of the skin, which comes away with a blister. The pigment varies in different people and races. Exposure to heat and sun deepens it.

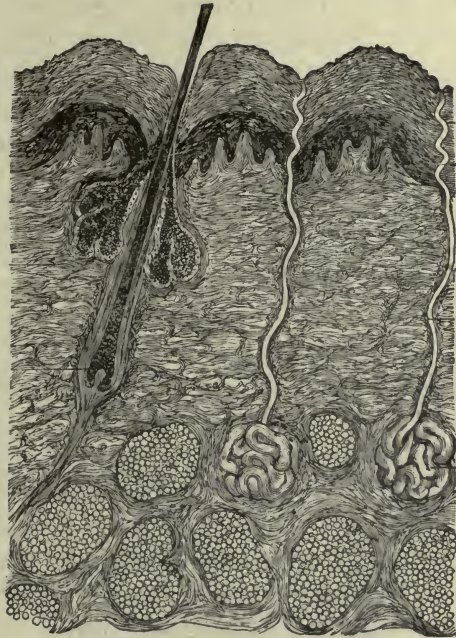


FIG. 156.

Showing the layers of the skin (greatly magnified), with the sweat glands and oil glands, and a hair in its follicle (Brubaker).

— demonstrated in the dressing of a blister, when it is incised to allow the escape of serum which has accumulated between it and the corium or true skin.

The surface of the *epidermis* is continually wearing away and new layers of epithelial cells are exposed, to become dry and scaly, and to be shed in their turn. It varies in thickness according to the degree of friction, or pressure, or exposure which it encounters. Witness the palms of the hands, and the soles of the feet.

The *elasticity* of the skin is demonstrated when a cut is made through the corium. The edges retract and some effort is required to bring them together again. The elasticity is due not only to the

elastic fibers in the deep layer of the corium, but to the muscle fibers, small though they be.

The **glands of the skin** are in the corium; their ducts pass through the epidermis to open upon the surface. They are of two kinds—the *sebaceous glands* and the *sweat glands (sudoriferous glands)*.

The **sebaceous glands** are found in the skin of all parts of the body except the palms and soles. They are most numerous upon the face. They produce an oily substance called *sebum* which renders the skin soft and pliable. Their ducts open into the depressions (follicles) for the roots of hairs, consequently they preserve the softness and glossiness of the hair.

Ear wax, or *cerumen*, is secreted by specialized glands in the auditory canal.

**Note.**—The vernix caseosa which is found upon the skin of the new-born child is an accumulation of sebaceous matter which has served to protect the skin from the effect of long submersion in the amniotic fluid.

The **sweat glands (sudoriferous glands)** are found in the skin of the entire body. Each gland consists of a coiled tube embedded in the corium, with a duct opening upon the surface; these ducts open upon the ridges made by the rows of papillæ. With an ordinary magnifying glass the droplets of sweat may be seen.

The *sweat* or *perspiration* is a thin watery fluid (highly acid, but saline to the taste), containing a number of substances in solution, derived from the vessels in the network of the corium. The most important are *salt, phosphates, urea* and *carbon dioxide*.

It is estimated that the 2,000,000 or more glands secrete nearly a liter of perspiration daily, in health. The process goes on continually; when the rate of excretion is moderate and uniform we are not aware of it, because the moisture is removed in various ways as soon as formed—this is *insensible perspiration*. When the removal does not keep pace with the production, the accumulation on the skin becomes *sensible perspiration*.

The **appendages of the skin** are the *glands* already described, the *nails* and the *hairs*.

The **nails** belong to the cuticle (being modifications of its epithelium). They give protection to, and add power and ease in using the digits. They lie upon a bed of corium called the *matrix*, from which they grow; if the matrix be destroyed the nail is lost and no new one will grow in its place. The *root* of the nail is embedded



in a fold of skin; the white semicircle at the root is called the *lunula* (little moon).

The **hairs** also belong to the cuticle. They are distributed over the greater part of the surface of the body, being conspicuous on the scalp.

A hair consists of a *root* and a shaft. The *root* rests upon a minute *papilla* in the bottom of a depression or *hair follicle*. The nerves and blood-vessels do not run beyond the papilla.

The *shaft* extends outward from the root, and contains the *pigment* which decides the color of the hair.

The hairs lie obliquely on the skin but may be made to stand erect by the contraction of a tiny muscle bundle placed at the root of each one. These are the *erectors of the hairs*. It is their action which gives the appearance called "goose-flesh." The softness and the gloss of hair are due to the oil which is poured into the follicles by the oil glands.

**Note.**—The fine hair on the skin of the new-born child is called *lanugo*. It begins to grow at about the fifth month of intra-uterine life, and wears away soon after birth.

The hairs which border the eyelids are called *cilia*.

## PHYSIOLOGY OF THE SKIN.

The skin has a triple function. It is the *protective* covering of the body; an organ of *excretion* and an organ of the *special sense of touch*.

As a *protective* it is mechanical only; the insensitive layers receiving first the impressions of external forces—heat, cold, blows, etc., diminish their effects on deeper and sensitive ones.

As an organ of touch it is referred to on page 271.

Its most important function is that of secreting perspiration. *Perspiration* is a clear watery fluid consisting of a solution of certain waste products of metabolism (tissue waste), in other words, *water and solids*. It is *acid* in reaction; *saline* to taste. The quantity excreted by a healthy active person in twenty-four hours, has been estimated as one quart.

Although the amount of *solids* in the perspiration is small, it is enough to embarrass the system if retained, and to relieve it if the kidneys are disabled. *Urea* is one of the substances contained in perspiration, and in diseased conditions of the kidneys the *skin* is able to excrete an increased quantity of urea.

The removal of tissue waste is, however, not the only important use of perspiration. By bringing water to the surface of the skin, it is a most efficient agent for *regulating the temperature* of the body. Muscle exercise, for example, which increases heat production, is accompanied by increased activity of the sweat glands, and the consequent *evaporation of water* carries off the excess of heat generated in the muscles. Again, high temperature of the surrounding atmosphere causes dilatation of the cutaneous vessels, and more perspiration and consequent *evaporation*. Conversely, a cold atmosphere stimulates the cutaneous vessels to contract, and stops the production of sensible perspiration.

**Clinical note.**—From these facts one may understand why it is so important to conserve the surface temperature of a patient with nephritis, or with diminution of urine from any cause, by the use of blankets and warm clothing; and to increase it oftentimes by the use of hot baths, packs, etc.

In health the *quantity* of perspiration is modified by the *dietary*, particularly by the amount of liquid taken, and the kind of liquid; also by the character of clothing, the season of the year, etc.

It may be noted that the activities of the skin and kidneys alternate with *change of season*; in summer when the skin is active the urine is scanty. In winter, when the skin is inactive the urine is free.

In *fevers*, cutaneous vessels are dilated, but the nerve stimulus to cell action is dulled; the effect of baths upon the skin is to abstract heat, improve the tone of cutaneous structures, and favor the action of the glands.

In renal diseases, *activity of the skin* is to be promoted; in fevers, activity of the kidneys is encouraged as well as of the skin.

**Summary.**—The skin is *protective, excretory*, an organ of *special sense* and of *heat regulation*.

## CHAPTER XV.

### MAMMARY GLANDS. DUCTLESS GLANDS. GENERAL METABOLISM.

#### THE MAMMARY GLANDS.

The **mammary glands** are placed between two layers of *superficial fascia* in front of the thorax, occupying a space between the third and sixth ribs, inclusive. They are covered by a layer of adipose tissue and lie between two layers of superficial fascia. They

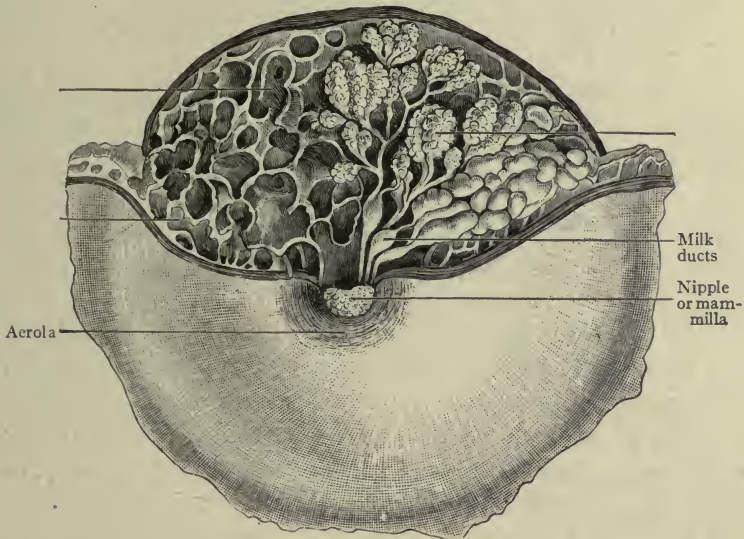


FIG. 157.

Showing enlarged milk ducts during lactation (Morris).

consist of little tubes, lined with milk-secreting cells and grouped in small lobules, held together by connective tissue imbedded in adipose. The lobules unite to form lobes, 18 or 20, each with its own duct, consequently 18 or 20 *milk ducts* approach the *nipple* and open at its summit. The nipple is surrounded by a ring of darker modified skin called the *areola*.

The function of the mammary gland is the secretion of milk. This is a true secretion; the cells of the tubules forming a new sub-

stance from materials brought by the blood, which, although not utilized in the body where it is formed, is not only useful but capable of sustaining life.

**Milk** is a bluish-white fluid consisting of clear plasma (*milk plasma*) holding nutritive substances in solution and floating myriads of oil globules, to which it owes its white color. It is a natural emulsion. The variety of nutritive substances contained is sufficient for the development of the body of the infant.

The special *protein* of milk is *caseinogen*, from which *casein* is derived in the process of digestion (see p. 146). (Artificial coagulation of milk separates the casein and fat from the plasma, the *curd* from the *whey*.)

The *sugar* of milk is *lactose*.

The *salts* are the various salts found in foods and body tissues.

During pregnancy the areola acquires a deeper color, which is permanent. (A secondary areola may form.)

At this time the blood supply of the gland increases, the glands become large, and changes occur in the lining of the tubules, which result in the secretion of milk. This is perfected soon after the end of pregnancy.

The first fluid which is drawn from the breast is called *colostrum*; it contains an excess of sugar and inorganic salts, and a substance which acts as a laxative for the infant.

The secretion of milk is influenced by the diet of the mother and may be modified in both quantity and quality by food selection. A still greater effect is produced by the condition of the nervous system; it is well known that fright or anger, or intense emotion, affect the milk so as to make it injurious to the infant. Fatigue, worry, loss of sleep etc., are all to be avoided by the nursing mother.

**Surgical note.**—*Mammary abscess* is caused by infection through a break or fissure in the skin of the nipple, the pus forming between the lobules of the gland. *Post-mammary abscess* is in the fascia behind the gland.

## THE DUCTLESS GLANDS.

These are the organs which resemble glands but have no ducts. They are supplied with sympathetic nerves, and possess many lymphatics and blood-vessels; the secretions which they produce are carried in these vessels. The most important ductless glands are the *spleen*, *adrenal bodies* and *pancreas* in the abdomen; *thyroid*, *parathyroid*, and *thymus* bodies in the neck.

## THE SPLEEN.

The **spleen** (or **lien**) is situated at the left of the stomach, directly beneath the diaphragm by which it is entirely covered. It is oval in shape, convex on the lateral surface and concave on the medial, where a depression called the *hilus* is seen for the passage of vessels and nerves (Fig. 104. p. 133).

The fibromuscular capsule which forms the surface of the spleen sends numerous septa into the interior, and within the spaces of the network thus formed the *splenic pulp* is contained. This consists of *blood* which has escaped from the open terminals of numberless capillaries, of *lymphoid cells* and *broken down red cells*, *coloring matter* and particles of *waste*.

Small collections of lymphoid cells around the capillaries may be seen upon section of the organ; they are the *Malpighian bodies of the spleen*; their function is obscure.

The *splenic artery* is the largest branch of the celiac axis and the consequent large blood supply gives a *dark red color* to the spleen. The peritoneal covering completely surrounds it, except to allow vessels and nerves to pass through the hilus.

The function of the spleen is not well understood, as both animals and human beings have been known to live in health after its removal, but from its structure and the results of examinations of blood from both the splenic artery and splenic vein, it is thought that white cells are there added to the blood, and worn-out red cells are destroyed.

**Clinical notes.**—The elasticity of the capsule allows frequent variations in size, which in health are normal; it is always larger during digestion and smaller in fasting. In certain diseased conditions it is much increased in size, as in malaria; and notably in *leukemia*, which is characterized by an enormous increase in the number of white cells in the blood, as well as in the size of the organ itself.

## THE PANCREAS.

In addition to the digestive ferments of the pancreas it would seem that it produces another substance, which either disposes of sugar in the blood, or is associated with the glycogenic function of the liver, or both. This is supposed to be the special function<sup>1</sup> of

<sup>1</sup> Now disputed.

groups of cells called "islands of Langerhans" which are embedded in the substance of the pancreas. They resemble glands but have no ducts; they are surrounded by a network of capillaries and their *internal secretion* is probably transmitted by these vessels.

The blood supply to the pancreas is very free, being derived from the *hepatic*, *splenic* and *superior mesenteric* arteries. This indicates the importance of the gland (Figs. 104, 105).

#### THE ADRENAL BODIES.

The **adrenals** (*suprarenal capsules*), are two small gland-like bodies resting on the upper extremities of the kidneys, hence their name. They are triangular in shape, yellowish in color, and have many blood-vessels and nerves. They are important organs, as it is found that when they are removed death follows soon, but their use is not yet fully understood. It has, however, been determined that their *internal secretions*, *adrenalin*, *epinephrin*, stimulate the muscles of the heart and arteries, thus increasing blood pressure. In the disease called "bronzing of the skin," or Addison's disease, these bodies are found to be changed.

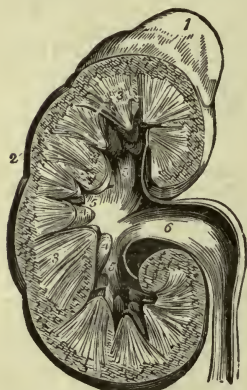


FIG. 158.—THE ADRENAL BODY IS SEEN RESTING UPON THE KIDNEY.

#### THE THYROID BODY.

The **thyroid body** is situated in the anterior part of the neck. It has two *lateral lobes* lying close to the trachea and connected by a middle portion called the *isthmus*. These lobes are about one and one-fourth inches wide, and extend about two inches upward along the sides of the larynx.

The substance of the thyroid body is made up of closed sacs containing a thick semifluid substance (*colloid substance*). They are surrounded by many capillaries; the *thyroid arteries* being four in number, the blood supply is very free.

The *function of the thyroid body* is important but not well explained. It is observed that the development of both mind and body is arrested if the thyroid be absent, or if it does not itself develop in childhood; this condition is known as *cretinism*.

*Degeneration* or complete removal, in adult life, is followed by

excessive growth (but imperfect development) of connective tissue and skin elements, or *myxedema*.

From these and other clinical observations it is evident that the *internal secretion* of this body exercises an important influence upon nutrition. It also stimulates cardiac action, and restrains a tendency to obesity.

Simple enlargement of the thyroid body constitutes *goiter*, which is said to be frequent in certain countries where the drinking water contains much lime.

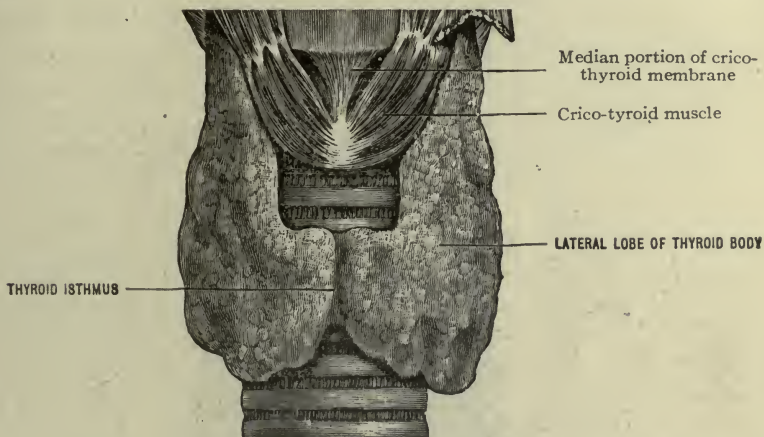


FIG. 159.—THYROID BODY (Morris).

#### THE PARATHYROID BODIES.

The **parathyroid bodies** are small bodies situated above and laterally to the thyroid, two on each side. They have an abundant blood supply. Their function is not explained but it is now known that their removal is followed by convulsive affections, tremor, etc., suggesting the presence of an irritant which did not exist before. Consequently it may be that their *internal secretion* is capable of destroying or perhaps preventing the formation of certain toxic substances.

Both parathyroid and thyroid bodies contain iodine in combination within some other substance.

#### THE THYMUS BODY (Fig. 160).

The **thymus body** is an organ of fetal and infantile life, situated below the thyroid, being mostly in the thorax and reaching down to

the pericardium. It is two and one-half inches long at the age of two years, but dwindles slowly from that time on, leaving only some shreds of tissue at the age of fourteen.

### THE PITUITARY BODY (Fig. 179).

The **pituitary body** (*hypophysis cerebri*) is now included among ductless glands. It rests in the sella turcica of the sphenoid bone. By investigation it has been learned only that *degeneration* of this

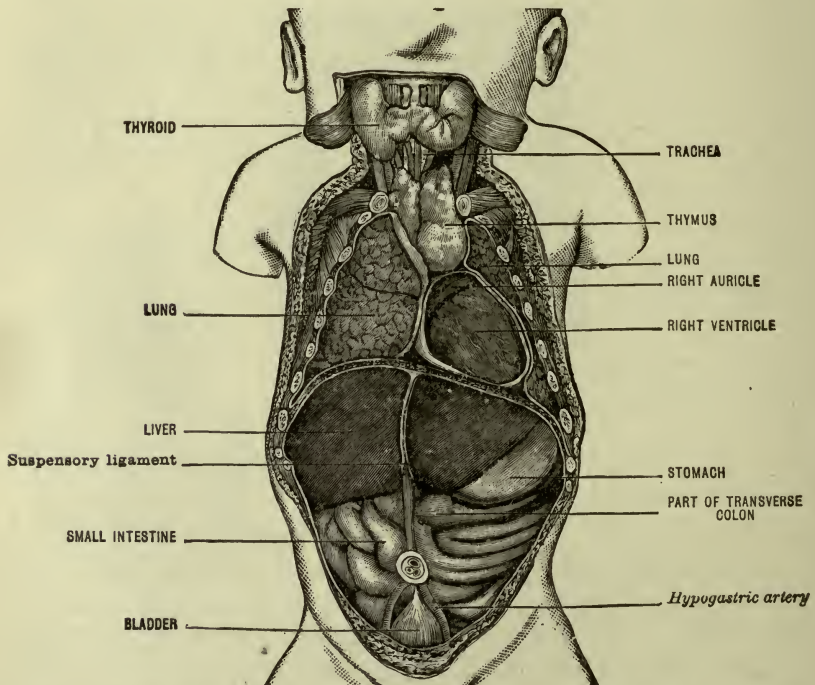


FIG. 160.—VISCERA AT BIRTH. NOTE THE THYMUS BODY, THE SIZE OF THE LIVER AND THE LOCATION OF THE BLADDER AND THE HYPOGASTRIC ARTERIES (MORRIS after Rudinger).

body accompanies the disease called *acromegaly*, which is characterized by an overgrowth or hypertrophy of the bones of the face and extremities.

Certain conclusions have been founded upon this association, presupposing that it produces an *internal secretion* which regulates the growth of bones.

It probably has some effect upon the force of cardiac action.



## SECRETION, ELIMINATION, HEAT PRODUCTION.

We have now studied the various organs which form **secretions**, or substances which may either be devoted to a special use in the body, or expelled as of no further use. These latter are known as *excretions*.

Following, is an enumeration by way of review, of the principal organs whose secretions are used in the body:

First.—The *epithelial cells* of all *surface membranes and cavities* should be included:

Those of *mucous* membranes, secreting mucus.

Those of *serous* membranes, secreting serum (as in the pleural, pericardial and peritoneal cavities, and the subdural and subarachnoid spaces of brain and spinal cord).

Those of *synovial* membranes, secreting synovia.

The secreting *cells of glands* come next.

The *salivary, gastric and intestinal* glands secrete *saliva, gastric and intestinal juices*.

The *liver* secretes *bile* (and forms glycogen).

The *mammary glands* secrete milk.

The *lacrimal glands* secrete tears.

The *sebaceous glands* secrete sebum.

Of the secretions of so-called *ductless glands*.

That of the *pancreas* favors glycogen-processes in the liver.

That of the *adrenal bodies* increases blood pressure.

That of the *thyroid body* influences tissue metabolism, increases cardiac action, and diminishes obesity.

That of the *parathyroids* prevents or destroys toxins in the blood.

That of the *pituitary body* (or *hypophysis*) restrains growth of osseous tissue.

The *spleen and lymph glands* supply white cells.. } to blood.

The *marrow of bones* supplies red cells..... } to blood.

The *ovaries* produce ova.

The *testes* produce spermatozoa.

Thus, the secretions of the organs named, serve various purposes, aiding or influencing nutrition or assisting in the formation of other substances.

**Excretions.**—These are the substances which must be eliminated from the body.

All tissue action uses up some material, leaving a varying remnant of waste matter which cannot be utilized—like the ashes from a fire. These wastes appear either dissolved in water as *urine* and *perspiration*, or in the form of gas or vapor.

Tissue waste may be reduced ultimately to comparatively few substances, the most important being *urea*, *carbon dioxide*, various *salts* and *water*. Urea is most abundant in *urine*,  $\text{CO}_2$  in *exhaled air*, and all of these in small quantity in *perspiration*.

Therefore, the **organs of elimination** are:

The *kidneys*, which excrete urine.

The *skin*, which excretes perspiration.

The *lungs*, which exhale carbon dioxide, organic matters, ammonia and water.

## ANIMAL HEAT.

The cell activities described in the preceding pages, in other words—the processes of *metabolism*, all generate *heat*. This is an important matter, as an internal temperature of about  $100^\circ$  F. is necessary to the normal activity of the body tissues. This, the tissues themselves can accomplish with proper materials in the form of food, and oxygen for the chemical work, the latter being supplied in the air we breathe.

A slight rise of temperature normally accompanies digestion, especially if hot foods be taken. The kind of food which is eaten has a direct effect upon the production of heat; proteid substances yield more than starchy foods, while fats yield more than proteids and starches together.

As the body is continually generating heat so it is continually losing it in various ways—to the surrounding atmosphere by radiation, to clothing by conduction, by evaporation from the lungs and the skin, etc., etc.

In cold weather heat production is desired. This can be accomplished by selecting heat-generating foods, by taking hot foods and by muscle exercise; the heat thus generated can be conserved by clothing the body in materials which prevent radiation and conduction, as wool or silk. In hot weather heat production is to be

avoided and heat dissipation is sought; this is facilitated by the selection of starchy and proteid foods, taking cool drinks and wearing lighter garments, as cotton or linen.

For health and comfort it is necessary that a proper relation be maintained between *heat production* and *heat dissipation*. For this, the body possesses its own *self-regulating* mechanisms; for example, muscle exercise produces heat, but the associated activity of the sweat glands so favors heat escape, that the injurious effect of excessive body heat is prevented. Again, the viscera concerned in digestion (notably the liver) generate much heat; by the blood it is carried to the cooler extremities.

A high temperature of the surrounding atmosphere so affects the nerve centers, that the respiratory function is stimulated and evaporation from the lungs increased, at the same time activity of the skin is very marked and evaporation of perspiration follows.

These natural processes of mutual accommodation result in preserving a necessary uniform temperature of the body, which makes it independent, within reasonable limits, of external surroundings. The *normal temperature*,  $98.4^{\circ}$  F., is maintained so long as heat production and heat escape are properly adjusted to each other. *Elevation of temperature* is caused when production is too rapid or dissipation is too slow. *Very high* temperature indicates *excessive metabolism* and *impaired dissipation*. (Another result of excessive metabolism is seen in the *wasting* of the body in fevers, as typhoid fever.)

*Subnormal* temperature indicates diminished tissue change or metabolism, suggesting impairment of vitality. (A temperature of  $77^{\circ}$  F. is followed by death, as cell activity cannot go on in a temperature so low.)

**Range of normal temperature.**—The normal adult temperature is  $98.4^{\circ}$  F. in the axilla, in the mouth slightly higher. It is a degree higher in the rectum.

During early life when metabolism is active it is slightly higher than in later years. In old age it is often a degree higher than in middle life.

A difference of a degree is noted, in health, between the temperature of early morning and evening, for example, at 5 A. M. and 5 P. M.

## Average range of body temperature for different ages:

In infancy.....	99—99.5
At puberty.....	99
In adult life:	
Axillary.....	98.4
Oral.....	98.8
Rectal.....	99.2

**Practical Conclusions and Clinical Notes.**

The temperature of a patient should be taken before a meal, or after digestion, not during it.

In cold weather hot foods containing fats are appropriate for the generation of heat; in hot weather starchy foods and cool drinks are in order.

Alcohol causes a temporary sense of warmth by quickening the circulation, but this is followed by dilation of the surface capillaries and a consequent radiation of heat. The use of alcohol before exposure to a low temperature should be avoided, unless some very reliable measure is taken for preventing surface radiation.

Muscle exercise is accompanied by dilation of surface vessels and escape of heat; this continues for some time after the exercise has ceased, therefore, care should be taken to guard against too great loss of heat and a consequent "cold" due to chilling of the surface, especially when exposed to a draft of air.

The fact that the body loses heat rapidly by conduction, should warn the nurse against putting cold garments on a delicate patient, and especially against placing a patient in a cold bed. Remember that the body of the patient must furnish the heat to warm the bed and this makes an unnecessary demand upon vitality already impaired by illness.

CHAPTER XVI.  
THE NERVE SYSTEM.

NERVE TISSUES AND THE SPINAL CORD.

The foundation cells of which nerve tissues are composed are microscopic in size and called neurons. A *neuron* consists of a nucleated *cell body*, an *axon*, and *terminal divisions*.

The *cell body* has short branches called *dendrites*, one of which (sometimes two) grows longer to form the *axon* or *axis cylinder* which becomes a *nerve fiber*.

**Note.**—The term *nerve cell* is often used to signify the cell body of a neuron.

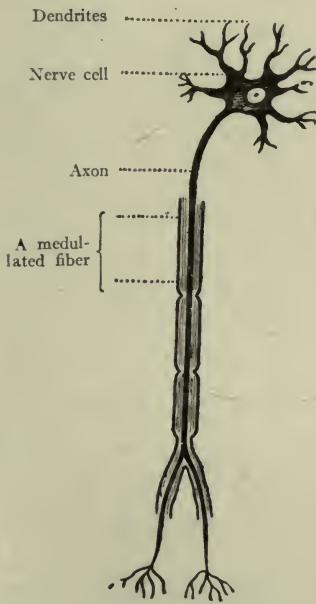


FIG. 161.

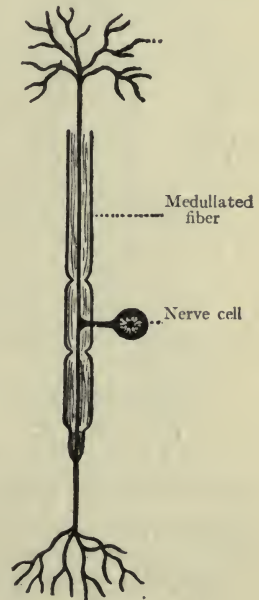


FIG. 162.

FIGS. 161, 162.—NERVE CELLS (Brubaker).

When the axon is invested with a sheath, the *medulla*, it is a *medullated nerve fiber*, and such are found in voluntary muscles and all sensitive parts of the body. Axons without sheaths are known

as *non-medullated nerve fibers*, and such are found in involuntary muscles and in the walls of internal organs.

Structures composing a medullated nerve fiber:

1. The **axon** or *axis-cylinder*.
2. **Medulla** or *myelin* (white substance of Schwann).
3. **Neurilemma**, a transparent membrane inclosing the myelin (sometimes absent).

Structures composing a non-medullated nerve fiber:

1. The **axon** or *axis-cylinder*.
2. **Neurilemma** (sometimes absent).

*Medullated nerves* are found in voluntary muscles, skin, mucous and serous membranes, joints and special sense organs.

*Non-medullated nerves* are found in glands, vessels, hollow viscera, and muscle fibers at roots of hairs.

The axons or nerve fibers terminate in fine branches, which connect them either with various organs or with the dendrites of other cell bodies, as the case may be.

For want of more accurate language, we say that impulses are *transmitted through fibers* either to or from cell bodies. If *to* the body, the fiber and cell constitute an *afferent neuron* (afferent, bearing toward); if *from* the cell body the neuron is *efferent* (efferent, bearing away).

**Important to remember.**—*The cell body is necessary to the life of the fiber.*

## THE TWO DIVISIONS OF THE NERVE SYSTEM— CEREBRO-SPINAL, SYMPATHETIC.<sup>1</sup>

### THE CEREBRO-SPINAL DIVISION OF THE NERVE SYSTEM.

The brain and spinal cord with their nerves constitute the **cerebro-spinal system**, and since the brain and cord contain the largest and most important centers, this is often called the **central nerve system** (Fig. 163).

**Nerve tissues in the cerebro-spinal system** appear to the eye as of two kinds, *gray* and *white*. The gray tissue, commonly called "gray matter," is composed of cell bodies and their branches. The so-called "white matter" is composed of *medullated fibers* belonging to the cells.

<sup>1</sup> For description of the Sympathetic Division see page 262.

<sup>1</sup> For description of the Brain and Cranial Nerves see page 249.

A **nerve** (of the cerebro-spinal system) consists of many fibers bound together; it resembles in appearance a white cord and may be so small as to be distinguished with difficulty, or as large as a child's finger—like the great sciatic nerve.

A *nerve* is constructed after the same plan as that of a muscle. A connective tissue sheath (*epi-neurium*) sends partitions (*peri-neurium*) between bundles of fibers, and a delicate membrane (*endo-neurium*) surrounds each fiber.

Nerves divide into branches which may interlace with others or join them in a common sheath, but no fiber ever *unites* with another. Each one continues throughout the length of the nerve of which it forms a part.

**Nerve centers** are the gray cell bodies to which nerves belong, and which are *necessary to the life of the fibers*.

This term is commonly used to signify a collection of cells whose fibers form nerves having a special function, or which preside over a group of movements. (A definite collection of gray cells is also called a *ganglion*.) *Motor nerves* transmit motor impulses *from centers to muscles*, while *sensory nerves* transmit impressions from the various parts of the body *to the centers* which receive them. (We commonly speak of motor nerves as running *down*, and sensory nerves as running *up*, referring them to the spinal cord or brain.)

#### THE SPINAL CORD.

The **spinal cord** lies within the spinal canal in the spinal column, being continuous with the brain. It is a round white structure about seventeen inches long, extending from the atlas to the second lumbar vertebra, where it ends in a slender *terminal filament* which continues to the end of the canal. The thickness is about half an inch, being greater in the lower cervical and lower dorsal regions, making the *cervical and lumbar enlargements* where nerves are

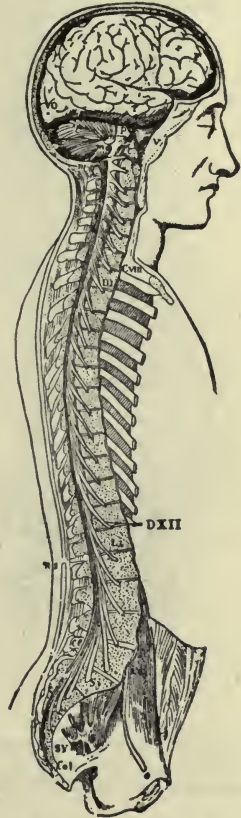


FIG. 163.—THE BRAIN AND SPINAL CORD (Quain, after Bourguery).

given off for the extremities. It presents a median fissure in front and another at the back, marking off its right and left *halves*. Other fissures divide each half into anterior, lateral, and posterior *columns* or tracts.

A transverse section will show that the interior of the cord is grayish in color instead of white, and this portion is largely made up of the gray cell-bodies and their branches, arranged in masses which are continuous throughout the length of the cord.

The section will also show that the area occupied by the gray portion, roughly resembles two crescents (one in either side), connected together across the middle. The extremities of the crescents are called the *anterior* and *posterior horns*.

A canal runs through the center of the gray portion called the *central canal*, which may be traced throughout the length of the cord, but is easily seen only in the upper part.

The white portion consists of the *bundles* or *tracts* of the cord. There is a general division into three in each half—the *anterior*, *lateral*, and *posterior tracts*. The fibers in the anterior and a portion of the lateral tracts are connected with the cells of the *anterior horn*. They conduct *motor impulses*. The fibers in the posterior and a portion of the lateral tracts are connected with the *posterior horn*, and conduct *sensory impressions*.

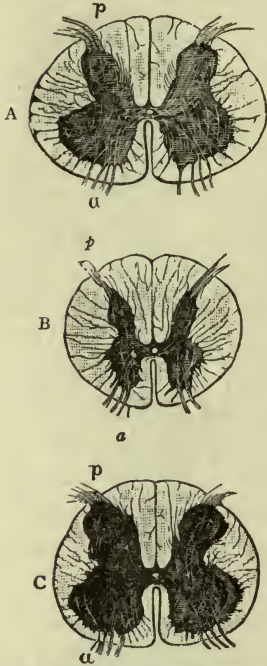


FIG. 164.—THREE SECTIONS OF SPINAL CORD.

A, Cervical region; B, thoracic region; C, lumbar region; p, posterior horn; a anterior horn (Holden).

#### MEMBRANES OF THE SPINAL CORD.

The *pia mater*.—A delicate membrane which bears the blood-vessels and is very closely applied to the surface of the cord (the *vascular* membrane of the cord).

The *arachnoid* (web-like).—Outside of the *pia mater*. A *serous* membrane containing fluid to make a water-cushion for the cord.



The **dura mater**.—A strong white *fibrous* membrane, tubular in shape, in which the cord is loosely suspended. It is attached above to the margin of the foramen magnum.

The space between the dura and the arachnoid is the *subdural* space; that between the arachnoid and pia is the *subarachnoid* space; they contain *cerebro-spinal fluid*. The subarachnoid space is largest in the lower portion. (The fluid in this space mixes with that of the central canal through a small opening in the pia, at the base of the brain.)

The membranes are also called the *meninges*, and their blood-vessels are the *meningeal vessels*. *Spinal meningitis* is inflammation of the meninges of the cord.

**Surgical note.**—The operation of *lumbar puncture* is for the purpose of opening the dura and arachnoid and drawing off a certain quantity of cerebro-spinal fluid.

#### SPINAL NERVES.

A spinal nerve is a collection of motor and sensory fibers connected with the spinal cord by two roots—an *anterior root* running from the motor cells and tracts and a *posterior root* running to the sensory tracts and cells.

The two roots become imbedded in one sheath at the intervertebral foramen which transmits the nerve from the spinal canal.

**Note.**—The “ganglion of the root” is a small ganglion on the *posterior* root where the true root fibers arise.

The ganglion contains the *cell-bodies* of fibers in the posterior roots: they are necessary to the life of these roots. Two axons arise from each ganglion cell; one becomes part of a spinal nerve and ends in a sensitive part of the body (skin, mucous membrane, muscle tissue and lining of joints); the other forms a fiber of the *posterior root* of the same spinal nerve, and enters the cord to become associated with cells of both posterior and anterior horns. (The fibers of the anterior roots arise in the cells of the anterior horns.)

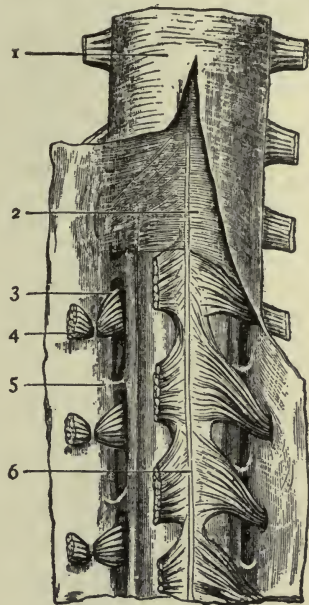


FIG. 165.—MEMBRANES OF SPINAL CORD.

1, Dura mater; 2, arachnoid; 3, post. root of nerve; 4, ant. root of nerve, divided; 5, pia mater; 6, linea splendens (Morris, after Ellis).

**Clinical note.**—Since the spinal nerves contain both motor and sensory fibers, they are called *mixed nerves*; and since the antero-lateral divisions of the cord are motor tracts, and the postero-lateral divisions are sensory tracts, we can understand how injury in one region will cause *paralysis of motion*, and injury in the other will cause *paralysis of sensation*; while injury of a *mixed nerve* will cause loss of both motion and sensation in the parts to which the nerve belongs.

## CHAPTER XVII.

### THE SPINAL NERVES.

There are *thirty-one pairs* of spinal nerves. They leave the spinal canal at the intervertebral foramina in the different regions and are named accordingly.

Cervical . . . . .	8
Thoracic . . . . .	12
Lumbar . . . . .	5
Sacral . . . . .	5
Coccygeal . . . . .	1

The first cervical, emerging above the atlas, is called the *suboccipital*.

The **cauda equina**.—The spinal cord, being 17 inches long, reaches only to the *second lumbar vertebra*, therefore the nerves emerging through the foramina *below this level* must have lain in the canal for some distance before leaving it, especially those which appear in the lowest or pelvic region. If the canal be opened at the back and the cord lifted out, these long nerves are seen hanging from it in a crowd, suggesting the appearance of a horse's tail, the "*cauda equina*," which therefore is composed of the *lumbar, sacral, and coccygeal* nerves while they are still in the neural canal. The *terminal filament* extends downward in their midst.

All spinal nerves divide at once into *posterior* and *anterior divisions*, both divisions containing motor and sensory fibers (Fig. 168).

The *posterior divisions* send nerves to posterior regions of neck and trunk; the *anterior divisions* (communicate with the sympathetic system, and then) send nerves to anterior and lateral regions of the neck and trunk, and to the upper

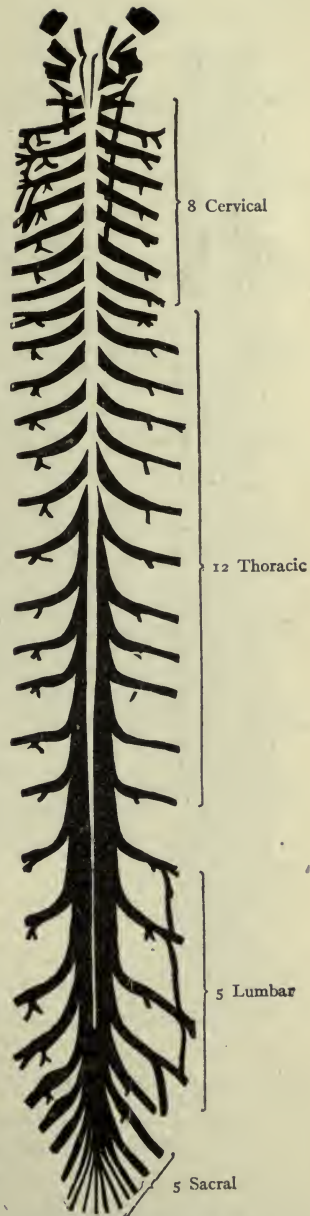


FIG. 166.—DIAGRAM OF SPINAL NERVES.

and lower extremities.<sup>1</sup> In all regions except the thoracic, the anterior divisions interlace with each other to form *plexuses* before giving off nerves.

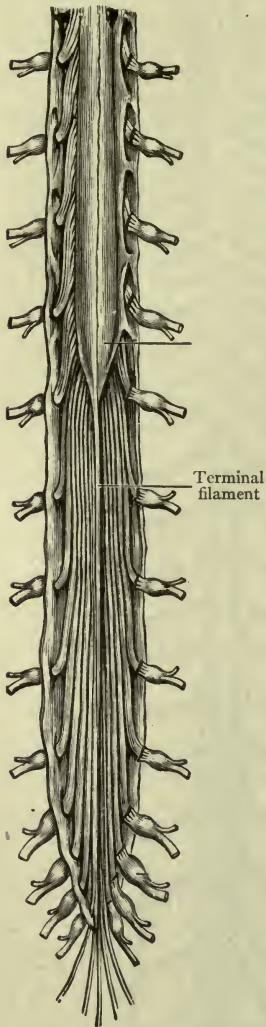


FIG. 167.—CAUDA EQUINA  
(Morris).

The most important plexuses are:  
The *cervical plexus* (formed by the upper four *cervical* nerves).

The *brachial plexus* (formed by the lower four *cervical* and *first thoracic* nerves).

The *lumbar plexus* (formed by the upper three and part of the fourth *lumbar* nerves).

The *sacral plexus* (formed by the *lower lumbar*, and upper three and most of fourth *sacral* nerves).

The larger nerves only are described in the text. Résumés are added for reference.

For nerves supplying the joints see page 69.

### CERVICAL NERVES.

*Posterior divisions.*—These send branches to the back of the head as well as muscles and skin of the neck. *Largest posterior branch.*—The *great occipital* (from second *cervical*), to supply the scalp.

*Anterior divisions.*—The upper four form the *cervical plexus*. The lower four enter the *brachial plexus*.

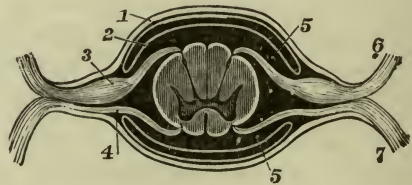


FIG. 168.—SHOWING DIVISION OF NERVE.

1, Dura mater; 2, arachnoid; 3, ganglion of post. root; 4, ant. root; 5, space containing spinal fluid; 6, post. division of nerve (Holden).

The *cervical plexus*.—Most of the branches of this plexus supply muscles of the neck (front and side). One exception is the

<sup>1</sup> The communicating branches to sympathetic ganglia are of great importance, serving to connect the cerebro-spinal and sympathetic division into one great nerve system.

*great auricular* (*auricularis magnus*) which supplies the external ear. Another is the—

**Most important nerve of this plexus, the phrenic.**—It passes downward through the thorax (between the lung and heart) to supply the *diaphragm* (Fig. 169). Its importance is due to the fact that the diaphragm is one of the principal breathing muscles,

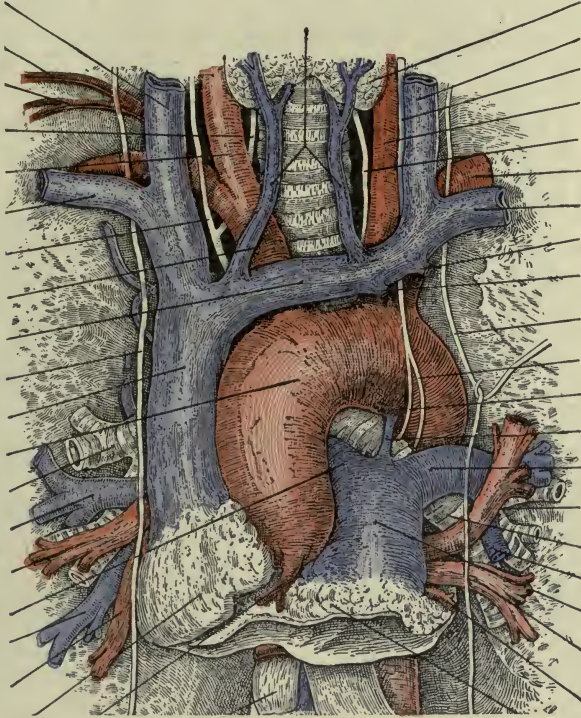


FIG. 169.—THE PHRENIC NERVES, RIGHT AND LEFT, RUN DOWNWARD ON EITHER SIDE OF THE GREAT VESSELS AND THE HEART (After Morris).

and the nerve has for that reason been called the “*internal respiratory nerve* of Bell.” (Sir Charles Bell was a famous anatomist in former times.)

**The brachial plexus.**—This plexus is so named because most of its branches supply muscles of the upper extremity (including the shoulder) and those connected with it.

First important branch, given off in the neck—the *long thoracic*. It passes downward along the side of the thorax to supply the *anterior*

*serratus* muscle (p. 95). This muscle is used in forced respiration and the nerve has been called therefore the "*external respiratory nerve*."

The greater part of the brachial plexus is situated in the *axilla*; most of its branches are given off there

Branches:	<i>Suprascapular</i> , to	$\left\{ \begin{array}{l} \text{supraspinatus} \\ \text{infraspinatus} \end{array} \right.$
Three large cords:	<i>Lateral, medial, posterior</i> .	
<i>Branches of the cords:</i>		
From lateral cord:	<i>Thoracic</i> , to pectoral muscles. <i>Musculo-cutaneous</i> , to biceps and brachialis (and their integument). <i>Upper root of median nerve</i> .	
From medial cord:	<i>Lower root of median nerve</i> . <i>Thoracic</i> , to pectoral muscles. <i>Cutaneous</i> , to integument of forearm. <i>Ulnar</i> , to ulnar muscles.	
From posterior cord:	<i>Subscapular</i> to	$\left\{ \begin{array}{l} \text{subscapularis, teres major,} \\ \text{latissimus dorsi (the } \textit{long} \\ \text{subscapular).} \end{array} \right.$
	<i>Axillary</i> , to deltoid and teres minor. <i>Radial</i> , to posterior of forearm and hand.	

The three *large nerves* derived from the brachial plexus are:

The **ulnar** from the medial cord.

The **median** from the medial and lateral cords.

The **radial** from the posterior cord.

The **ulnar nerve** runs downward in the medial side of the arm, passes behind the medial epicondyle into the forearm, and ends in the palm (Fig 170).

In the forearm it supplies: Flexor carpi ulnaris.

Flexor digitorum (*profundus*).

In the hand it supplies: Interossei.

Little finger muscles.

Thumb muscles (one and a half).

The **median nerve** runs downward in the arm, close under the border of the biceps muscle. It then passes in front of the elbow joint into the forearm, and continues between the layers of flexor muscles to the palm.

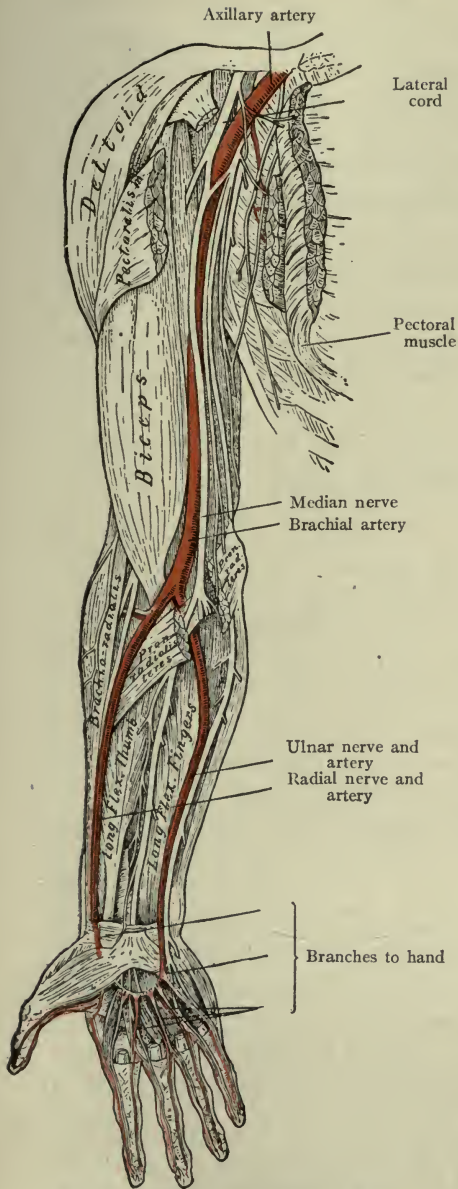


FIG. 170.—BRACHIAL PLEXUS AND ANTERIOR NERVES.

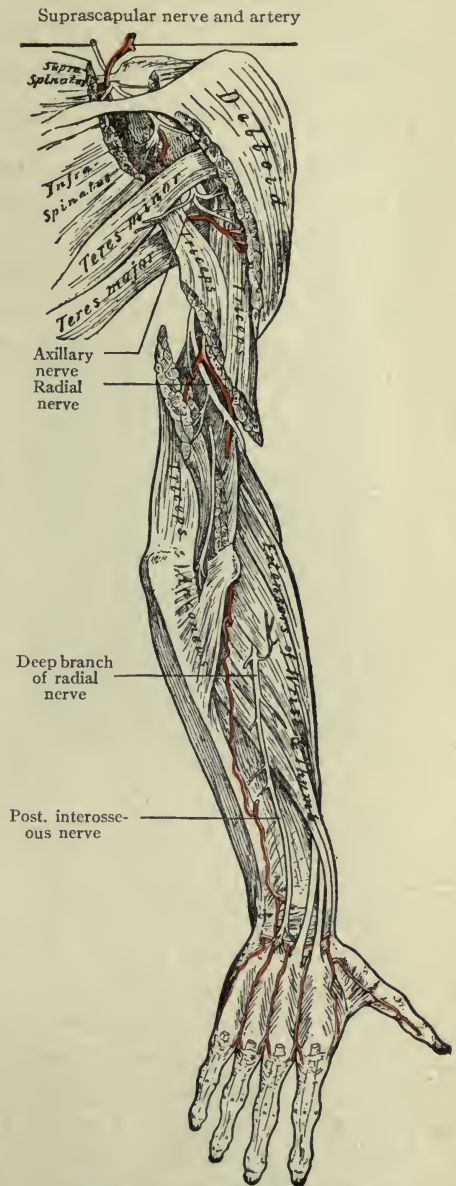


FIG. 171.—THE RADIAL NERVE.

In the forearm it supplies: Flexor carpi radialis.  
 Flexor digitorum (sublimis).  
 Flexor digitorum profundus (partially).  
 Supinator.

In the hand it supplies: Thumb muscles (except one and a half).

The **radial** nerve passes to the back of the arm, winding across the humerus in the radial groove, under the triceps muscle (Fig. 171).

Just above the elbow it divides into two branches, the *deep* and *superficial branches* of the radial nerve.

The *superficial branch* is a cutaneous nerve. It runs downward in the radial side of the forearm to supply integument of the hand and fingers posteriorly.

The *deep branch* passes to the back of the forearm, lying under cover of extensor muscles, all of which it supplies.

Branches of the radial nerve:

In the arm: .....To the triceps.  
 To brachio-radialis.  
 To brachialis (partially).

Branches of the deep branch of the radial nerve:

In the forearm: .....To the extensor carpi radialis (long and short).  
 To the extensor digitorum (comunis).  
 To the extensor of index finger.  
 To the extensor of little finger.  
 To the extensors of the thumb.

**Résumé.**—The general distribution of the muscle nerves arising from the brachial plexus, is to deep muscles of the neck and the external respiratory muscle (anterior serratus); to shoulder and axillary muscles; arm, forearm and hand.

The three long muscular nerves derived from the brachial plexus are the **ulnar** nerve from the medial cord, running down *behind the medial epicondyle* into the forearm and hand (supplying ulnar muscles, little finger muscles and the interossei, and a part of the thumb group); the **median** nerve from the medial and lateral cords, running down along the medial border of the biceps muscle into the forearm, to end in the palm (supplying the biceps and brachial muscle, all of the flexors of the forearm except on the ulnar side,



and most of the thumb muscles); the **radial** nerve from the posterior cord, running in its groove to the front of the lateral epicondyle, and dividing into the *deep and superficial branches of the radial nerve*. By the radial and its deep branch all of the posterior muscles of the arm and forearm are supplied.

**Nerves of the skin of the hand.**—*Front* of the thumb, index, middle, and one-half of the ring finger, the *median* nerve. *Back* of thumb, index, middle, and one-half of ring finger, the *superficial branch of the radial* nerve. Both *front and back* of little finger and one-half of ring finger, the *ulnar* nerve.

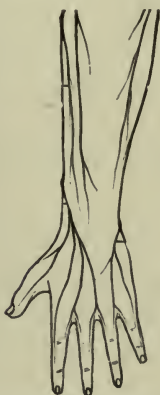

FIG. 172.—DORSAL SURFACE OF LEFT HAND (Morris).

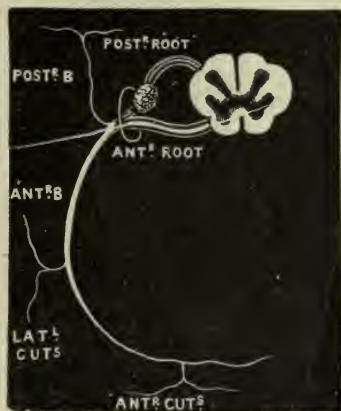


FIG. 173.—AN INTERCOSTAL NERVE (Holden).

**Points of interest.**—The **ulnar** nerve in the arm is with the inferior profunda artery and passes behind the medial epicondyle; it may be easily felt in the groove behind the epicondyle, where pressure causes a sensation of pain and tingling as far as the little finger. In the forearm it is on the ulnar side of the ulnar artery and they pass in front of the wrist.

The **median** nerve, in the arm, is with the biceps muscle and brachial artery, and they pass in front of the elbow; in the forearm, it lies between the deep and superficial muscles and passes with their tendons in front of the wrist.

The **radial** nerve lies in the groove for the radial nerve between two heads of the triceps muscle, with the superior profunda artery, and comes to the front of the elbow.

The *superficial branch* of the radial nerve in the front of the forearm is on the radial side of the radial artery; it winds around behind the wrist-joint.

The *deep branch of the radial nerve* is in the back of the forearm with the dorsal interosseous artery; they do not extend below the wrist.

**Note.**—For the distribution of nerves to the principal joints, see page 69.

## THORACIC NERVES (FIG. 173).

There are twelve pairs of thoracic nerves:

*Posterior divisions.*—These send branches to muscles and skin of the back.

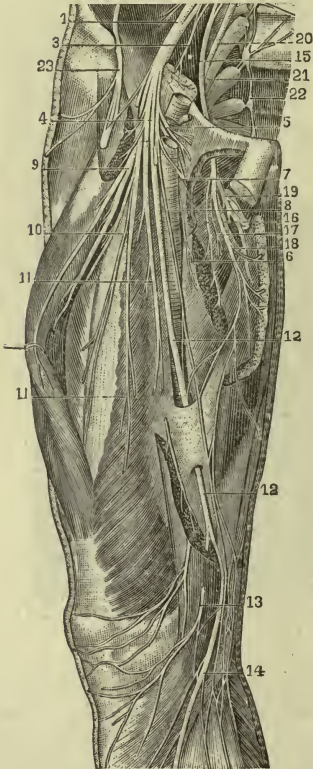


FIG. 174.—THE FEMORAL NERVE.

1, Femoral nerve; 2, 3, small nerves from lumbar plexus; 4, 5, 6, 7, 8, 9, 10, 11, 11, branches of femoral nerve; 12, 12, 13, 14, long saphenous nerve and its branches; 15, obturator nerve; 16, 17, 18, 19, branches of obturator nerve; 20, 21, lumbo-sacral cord; 23, external cutaneous nerve (Gould's Dictionary).

Branches: the principal are:

*Ilio-hypogastric*, cutaneous to hypogastrium, and over the ilium (dorsum).

*Inguinal*, to internal oblique and transversus muscles.

*Genito-femoral*, to round ligament of uterus, cremaster muscles of spermatic cord.

*Anterior divisions.*—These form the **intercostal** nerves; the first assists in the formation of the brachial plexus. All run in the grooves under the borders of the ribs, supplying intercostal muscles and the upper portion of the abdominal muscles, also the skin over the muscles. They accompany intercostal arteries.

## LUMBAR NERVES

There are five pairs of Lumbar Nerves.

*Posterior divisions.*—These send branches to muscles of the back; and skin of the back, hip, and sacral region.

*Anterior divisions.*—The *upper three* and a portion of the *fourth* form the *lumbar plexus*. The remainder of the fourth and the whole of the fifth form the *lumbo-sacral cord* (Fig. 174).

**The lumbar plexus.**—This plexus lies within the abdomen, in the substance of the psoas muscle. Its branches supply abdominal walls, and front and sides of the thigh (also integument of both regions). They are all given off in the abdomen.

*Obturator*, to the external obturator and the four adductors.

*Femoral*, to the quadriceps muscle (rectus and three vasti).

The **femoral nerve** (*anterior crural*) is the largest branch of the lumbar plexus. It passes from the abdomen, under the inguinal ligament, into the thigh (on the lateral side of the femoral artery), and breaks up at once into branches—cutaneous and muscular, for the four large divisions of the *quadriceps extensor* muscle and the integument which covers them.

The *long saphenous* branch of the femoral nerve is the longest nerve in the body, running nearly the whole length of the extremity; it supplies integument only, on the medial side of the leg and foot.

The lumbo-sacral cord passes into the pelvis to unite with sacral nerves and to form the sacral plexus.

## SACRAL NERVES.

*Posterior divisions*.—These send branches to muscles and skin of the back of the pelvis.

*Anterior divisions*.—The upper three, and greater part of the fourth, join the sacral plexus.

The **sacral plexus**.—The branches of this plexus supply the muscles within and around the pelvis, the posterior part of the thigh, and the entire leg and sole of the foot.

Branches: (All leave the pelvis through the great sciatic foramen.)

*Gluteal*, two (*superior* and *inferior*) to glutei muscles.

*Pudic*, to the levator ani, rectum (sphincter ani), perineum, and external genital organs.

*Small sciatic*, to posterior thigh and external genital organs. This is a *cutaneous* nerve.

*Great sciatic*, to posterior thigh, and entire leg and foot (except medial border) *muscles and skin*.

The **great sciatic nerve** is the largest nerve in the body. It leaves the pelvis by way of the great sciatic notch and runs downward between posterior thigh muscles to the popliteal space, where it divides into *tibial* and *common peroneal* nerves (Fig. 175).

The only portion of the great sciatic nerve which is not covered by muscles, lies in the deep groove between the great trochanter of the femur and the tuberosity of the ischium.

Branches: To the Biceps,  
Semitendinosus,  
Semimembranosus.

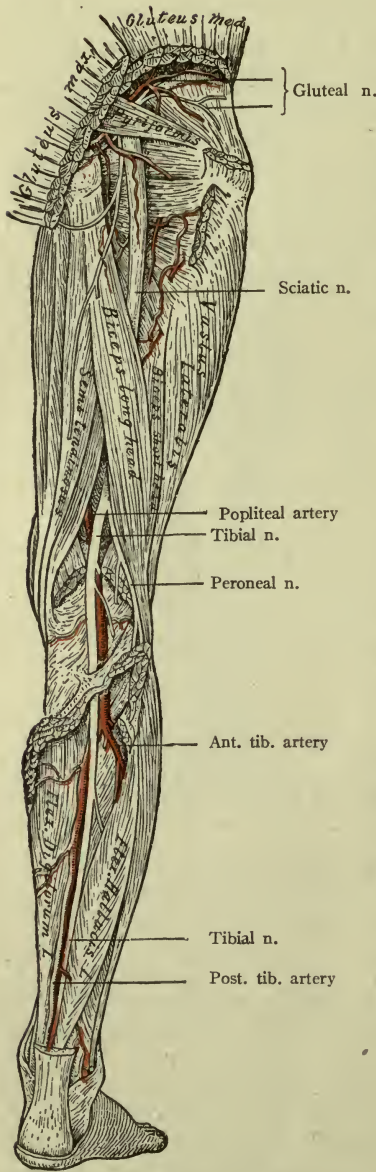


FIG. 175.—THE SCIATIC NERVE.

The division of the great sciatic nerve occurs in the upper part of the popliteal space. The tibial nerve (*internal popliteal*) runs down through the popliteal space (with the popliteal artery and vein) to the leg. It then descends under cover of the calf muscles to the ankle; below the medial malleolus it divides into *medial* and *lateral plantar* nerves.

Branches:

In the leg.—To the Tibialis posticus.  
Flexor digitorum (longus).  
Flexor hallucis.

In the foot.—By *medial plantar*, to great toe muscles and interossei.

By *lateral plantar*, to muscles of little toe.

The tendons of the first three (tibialis and two long flexors of toes) pass *behind* the *lateral malleolus*. They *extend* the foot.

The **common peroneal nerve** (*external popliteal*) winds round the neck of the fibula to the front of the leg, and divides into the *deep peroneal* and *superficial peroneal* nerves.

The *deep peroneal* (formerly *anterior tibial*) descends to the ankle, and ends on the dorsum of the foot between the first and second toes.

Branches:

In the leg.—To the Tibialis anticus.  
Extensor hallucis.  
Extensor digitorum (longus).  
Peroneus tertius.

In the foot.—Extensor digitorum (brevis).

The tendons of the muscles in the leg—(tibialis, two long extensors of toes, and one peroneus) pass *in front of the ankle-joint*. They *flex* the foot.

The *superficial peroneal (musculo-cutaneous)* runs downward in the substance of the peroneal muscles to the foot.

Branches:

*Muscular*.—To the Peroneus longus, peroneus brevis.

*Cutaneous*.—To dorsum of foot.

Their tendons pass *behind the lateral malleolus*. They *extend* the foot.

**Points of interest**.—The superior gluteal nerve, with the superior gluteal artery; the sciatic nerve, with the sciatic artery; and the pudic nerve, with the pudic artery, all pass *out* from the pelvis through the *great sciatic foramen*; the pudic nerve and artery return through the small sciatic foramen.

The *obturator* nerve and the obturator artery pass through the obturator foramen.

The *femoral nerve* is on the lateral side of the femoral artery, under the inguinal ligament.

### THE COCCYGEAL PLEXUS.

The remaining sacral nerves and the coccygeal nerve communicate in a small plexus, which is important in that it sends branches to the *viscera of the pelvis*.

### Summary.

The spinal nerves are distributed to all skeletal muscles and integument except those of the front of the head, face, and chin. Through sympathetic connections they also supply secreting cells of glands and walls of viscera.

### FUNCTIONS OR PHYSIOLOGY OF THE SPINAL CORD AND SPINAL NERVES.

The spinal cord is so intimately connected with the brain by conducting fibers in the tracts, that it is impossible to explain all of its functions without referring to the brain, but certain ones may be exercised *independently*, and a few of these will be considered briefly in this connection.

The spinal cord a *center for reflex action*. This is one of the most important of its functions and the simplest form of nerve and muscle action. (Acts which may be performed without thinking of them are reflex.)

We have already seen that the cord comprises an interior portion of gray nerve tissue surrounded by white; *cell bodies* and their branches forming the *central gray* portions and *white fibers* forming the *columns* or *tracts*.

In each lateral half of the cord the cell tissue is grouped in crescents. Fibers in the posterior tracts transmit *sensory* impulses from various parts of the body *to cells* in the *posterior horns* of the crescents. Fibers in the anterior tracts transmit *motor* impulses *from cells* in the *anterior horns* to various parts of the body (their axons arise in cells of the anterior horns) (Fig. 176).

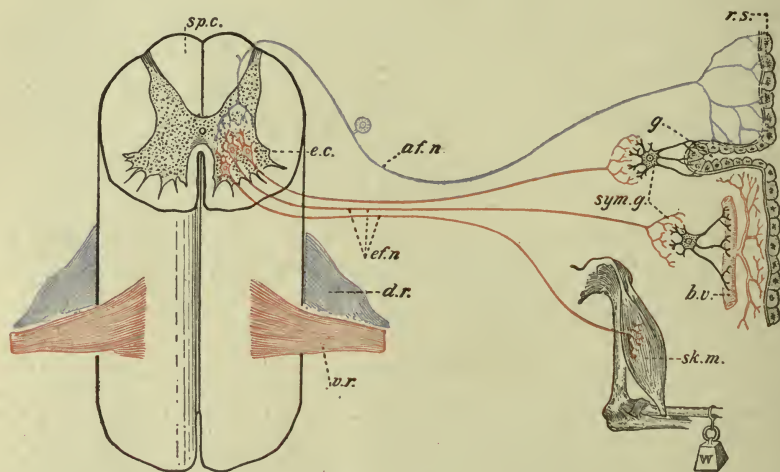


FIG. 176. DIAGRAM SHOWING THE STRUCTURES INVOLVED IN THE PRODUCTION OF REFLEX ACTIONS (G. Bachman). *r.s.* Receptive surface; *af.n.* afferent nerve; *e.c.* emissive or motor cells in the anterior horn of the gray matter of the spinal cord, *sp.c.*; *ef.n.* efferent nerves distributed to responsive organs, *e.g.*, directly to skeletal muscles, *sk.m.*, and indirectly through the intermediation of sympathetic ganglia, *sym. g.*, to blood vessels, *b.v.*, and to glands, *g.* The nerves distributed to viscera are not represented.

Here we have the apparatus for **reflex muscle action**.—A sensory or *afferent* nerve receives an impression, and transmits a series of impulses to the spinal cord. These are received by a cell which in its turn is stimulated, and liberates energy to be conducted by a motor or *efferent* nerve to a muscle, and the muscle contracts. This act is comparatively simple.

Most muscle activities, however, are complex, requiring the combined action of several organs; in these cases many motor cells and nerves must be stimulated, and this is accomplished by means of

additional neurons within the cord, whose fibers *associate* the activities of different regions. For instance, an unsuspected blow upon the hand is followed instantly by a drawing back of the hand and arm; most of the muscles of the upper extremity will have been called into action; in other words, many motor cells (in the lower cervical region of the cord) have been stimulated to a sudden liberation of energy, showing the effect of *one* stimulus when conducted by connecting fibers to many cells.

*Walking* was in the beginning a voluntary act, but *education of the centers* has made them independent and it has become reflex. So with piano-playing, and many others.

**Tendon reflex.**—A familiar example is the “knee jerk” or *patellar reflex*. This may be elicited by striking the patellar tendon when partly stretched. The impression thus produced, quickly reaches the motor cells which innervate the quadriceps muscle, and the leg is slightly extended. (There are several tendon reflexes.)

**Skin reflex.**—Irritation of the sole of the foot causes the plantar muscles to contract (a *plantar reflex*). Scratching the skin of the side of the abdomen causes contraction of abdominal muscles (*abdominal reflex*). There are other skin reflexes.

The spinal cord also contains centers for controlling the tone of vessel walls or *vascular tone*. Also for stimulating the action of *secreting glands*, and for *muscle action of viscera*. These functions are exercised through the sympathetic ganglia with which it is widely connected.

Finally, it contains centers which influence (or control) certain *processes of nutrition*—*trophic centers*.

It appears at once that the spinal cord is able, from the wide distribution of its nerves, to provide for most of the activities of the body.

Taken as a whole it may be regarded as a great *common center of sensation and motion*; and because of many connecting fibers running upward, downward, and transversely, it can combine and to some extent regulate, the functions of many different parts so that systematic *groups of movement*, or series of movements, may be executed by organs more or less distant in the body.

In other words, the spinal cord can to some extent *coordinate* the functions of the spinal nerves and skeletal muscles.

To repeat the functions of the **spinal cord**, they are to preside over:

1. Reflex action.
2. Muscle tone.
3. Vessel tone.
4. The action of secreting glands.
5. Nutrition (trophic action).

These may all be exercised independently by cells in the anterior horns and their nerve connections. (Other functions will be mentioned in connection with those of the brain.)

The *function of the spinal nerves* is to connect all parts of the body (except face, chin and anterior part of head) with the spinal cord, for the purpose of conducting sensory and motor impulses to and from the cord.

In referring to motor nerves we have thus far mentioned their natural stimulus only, that is,—the impulse generated by a motor cell. The *electric current* applied to a motor nerve in any part of its course will excite its activity, showing in muscle contraction, etc. This is an *artificial stimulus*, and the most powerful one known.

(The special functions of individual nerves have already been considered in foregoing pages.)



## CHAPTER XVIII.

### THE BRAIN AND CRANIAL NERVES.

The **cerebro-spinal** or **central** nerve system comprises the Brain and Spinal Cord with their nerves. The spinal cord and its nerves are already described in Chapters XVI and XVII.

The **brain**<sup>1</sup> is ovoid in shape, composed of gray cells and white fibers, situated within the cranial cavity and continuous through the foramen magnum with the spinal cord.

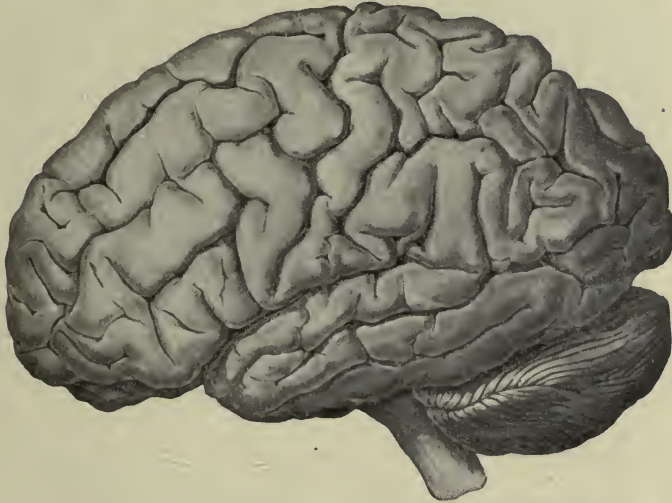

FIG. 177.—THE EXTERNAL SURFACE OF THE BRAIN (Deaver).

The surface consists of *gray cells* and their branches and is called the *cortex* of the brain, while the interior is *white*, with several ganglia (collections of "gray matter") imbedded within it.

The surface or cortex of a well-developed brain is marked by many fissures, separating curved ridges called *convolutions* (or *gyres*), the number and depth of which correspond with the degree

<sup>1</sup> A review of pages 229 and 230 is recommended before studying the description the brain.

of development, the brain of a new-born child being comparatively smooth.

The white portion is composed of white fibers (the medullated axons of the cell bodies). They run in many directions. Some connect the different main divisions of the brain; others run from one part of the cortex to another; others still, in great number, connect the brain and spinal cord (Fig. 178). Taken together, they make up the mass of the brain itself.

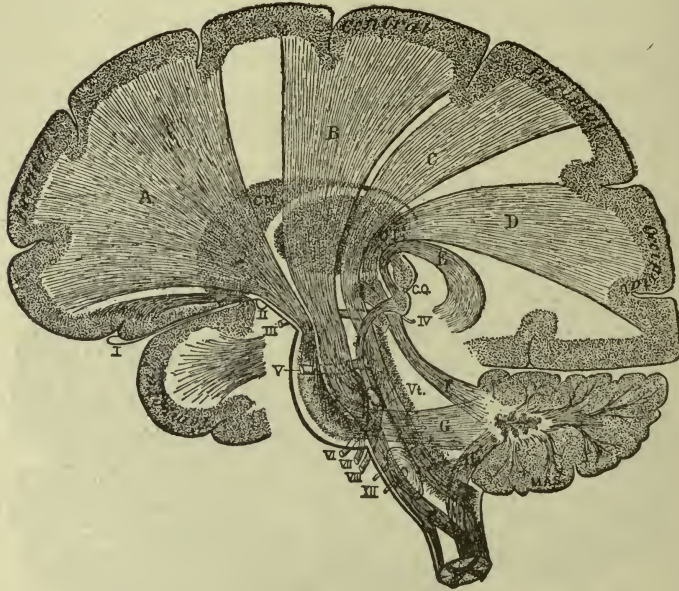

FIG. 178.

The letters mark the white fibers. They connect the cortex with other parts, also different parts of cortex together. Many fibers are seen to pass through the basal ganglia. The Roman numerals indicate nerves (Brubaker, after Starr).

The *white fibers* (Fig. 178) connect the *cortex* with the spinal cord; some connect different parts of the brain together. Taken together they compose the bulk of the brain, as already stated.

The brain has four principal parts, the cerebrum, cerebellum, medulla oblongata, and pons Varolii.

The **cerebrum** is the largest division and occupies nearly the whole cranial vault. It is divided into two *hemispheres*, right and left, by a *longitudinal fissure*. At the bottom of this fissure white fibers are seen to pass from one side to the other, thus forming a

transverse commissure, connecting the hemispheres, and called the *corpus callosum* (Fig. 179). Each hemisphere is marked off by specially deep fissures, into *lobes*, the principal ones being the *frontal*, *parietal*, *occipital*, and *temporal*. The principal fissures between the lobes are: the fissure of *Rolando* between the frontal and parietal; the *parieto-occipital*, between the parietal and occipital; and the *fissure of Sylvius*, between the temporal lobe below and the frontal and parietal above it.

*Important note.*—The fissure of Rolando is often called the *central fissure*, and the *convolutions* in front of and behind it, are called the *central convolutions* (anterior and posterior).

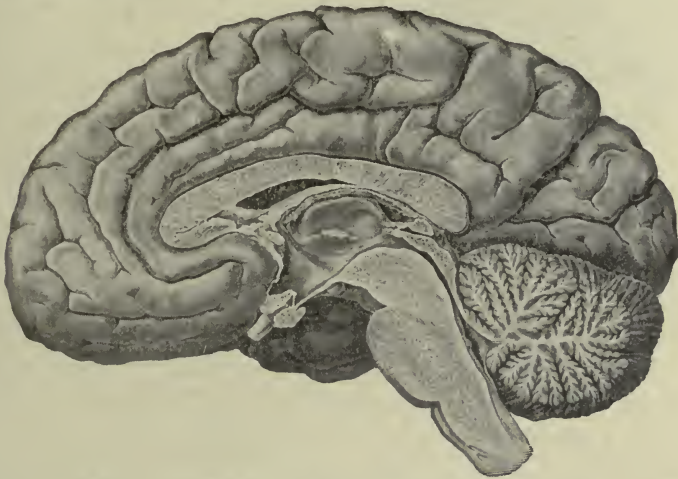

FIG. 179.—MEDIAN SURFACE OF A HEMISPHERE, SHOWING THIRD AND FOURTH VENTRICLES; ALSO THE CORPUS CALLOSUM DIVIDED, AND THE STRUCTURE OF THE CEREBELLUM WITH THE PONS IN FRONT OF IT. THE PITUITARY BODY IS SUSPENDED FROM THE FLOOR OF THE THIRD VENTRICLE (Deaver).

Within the white substance of the hemispheres are the largest ganglia in the brain, and since they are situated near the base, they are called *basal ganglia*. They are the *optic thalamus*, the *lentiform nucleus*, and the *caudate nucleus* (Fig. 181). The white matter between the optic thalamus and the other two, constitutes the *internal capsule*. Here are the fibers which connect centers in the cortex with those in the spinal cord; hence the great importance of the internal capsule.

The hemispheres are not solid, but each encloses a cavity called the *lateral ventricle*, shaped like the italic letter *f* with a projecting arm (laterally and downward). The extremities of the

ventricle are called *horns*; the *anterior horn* being in the frontal lobe, the *posterior horn* in the occipital, and the *lateral* or *descending horn* in the temporal lobe. The great ganglia of the brain are in the floor of the lateral ventricles (hence called *basal ganglia*).

The lateral ventricles are named like the hemispheres—*right* and *left*.

There are certain other basal ganglia which are important, although smaller in size.

The **cerebellum**, or little brain, also consists of *white* matter covered with *gray*. It has two hemispheres (situated in the cerebellar fossæ of the occipital bone) which are not definitely separated like the hemispheres of the cerebrum, but are connected by a median portion called the *vermis*, or worm. The convolutions are but slightly curved and are called ridges, and the furrows (or sulci) are very deep; a section shows that they are so arranged as to resemble the branches of the tree called *arbor vitæ* (Fig. 179).

The **medulla oblongata**, although situated within the cranium (in front of the foramen magnum), is the upper enlarged portion of the spinal cord and, like it, is *white externally* and *gray within*.

Its *anterior columns* are called the *pyramids* (or *pyramidal tracts*), and consist of motor fibers passing downward from the brain. Most of the fibers of each pyramid cross to the opposite side, appearing to interlace in the median fissure (the *decussation of the pyramids*), going to form the *crossed pyramidal tracts*; the others pass downward first (as the *direct pyramidal tract*) and cross, a few at a time, at lower levels in the cord. Thus it is that motor fibers coming from one side of the brain pass to the other side of the cord, and this is the explanation of paralysis of one side of the body, following injuries of the other side of the brain.

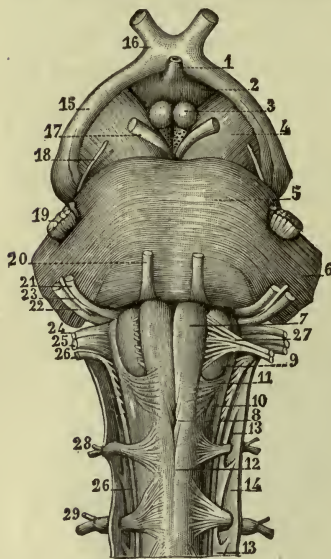


FIG. 180.—PONS AND MEDULLA, ANTERIOR SURFACE.

1, 2, 3, Structures belonging to cerebrum; 4, crura of cerebrum; 5, pons Varolii; 9, 10, 11, 13, 14, lateral surface and membranes of medulla; 7, pyramid; 8, decussation of pyramids; 12, anterior median fissure; 13-27, cranial nerves; 28, 29, 1st and 2d spinal nerves (Holden).

The *posterior columns* of the medulla contain sensory fibers going upward to the brain, while the *lateral tracts* contain both motor and sensory fibers (like the cord). Most of the sensory fibers also cross at different levels.

The medulla contains centers for the most important nerves of the body—respiratory: cardiac, vaso-motor, *et al.*

The **pons Varolii**, or bridge of Varolius, is situated in front of the medulla, below the cerebrum and cerebellum, and so named because fibers run through it from all three of the other parts of the brain, as though it were a bridge between them. It, also, is white externally and gray within, and is not unlike the cord, although in a still more modified form than the medulla.

Two large nerve bundles are seen diverging from the anterior border of the pons, the *crura of the cerebrum* (often called *peduncles*). They contain all of the motor and sensory fibers of the cerebrum which pass through the pons, to or from the cord. The fibers to and from the cerebellum form *peduncles of the cerebellum* smaller in size.

### THE FIVE VENTRICLES OF THE BRAIN (Fig. 181).

The five ventricles are different portions of one cavity, which is continuous with the central canal of the spinal cord. The two **lateral** ventricles have been mentioned. The **third** ventricle is between them, and the **fourth** ventricle is behind the third, being in the medulla and pons; some of the most important nuclei or centers of the body are imbedded in the floor of the fourth ventricle.

Each lateral ventricle communicates with the third through an opening called the *foramen of Munro*; the third communicates with the fourth through the *aqueduct of the cerebrum* (aqueduct of Sylvius), a slender canal in the crura and pons; and the fourth ends in the *central canal of the cord*. These spaces are therefore continuous, and they contain *cerebro-spinal fluid*.

The so-called **fifth** ventricle is not a portion of the general cavity—not a true ventricle. It is a narrow space in front of the third, having no opening whatever.

**Clinical note.**—*Hydrocephalus* is caused by an accumulation of fluid in the ventricles, enlarging them and pressing upon the brain substance, and consequently upon the bones of the skull. It is very likely to occur in children who have rickets, or “rickets.”

A similarity in structure and arrangement of parts is plainly evident in the brain and spinal cord. Recall the cord—a collection of nerve fibers,

the greater number running up or down, but with many passing from one side to the other; a central canal surrounded by collections of "gray matter"; two lateral halves connected by transverse commissural fibers.

These parts may all be traced in the brain. The *central canal* extends through the medulla and pons into the cerebrum, expanding into a general

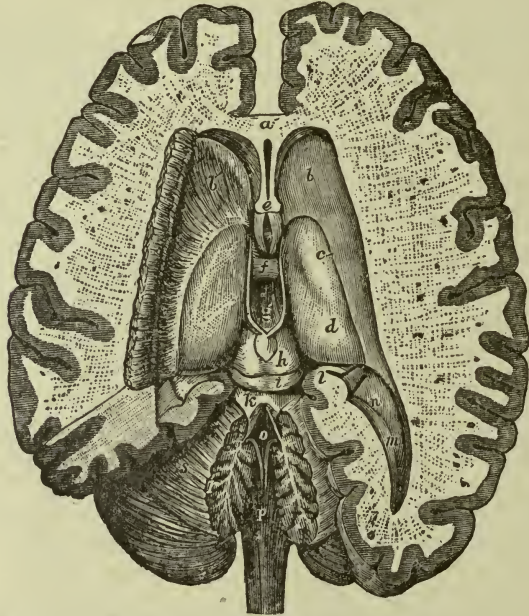


FIG. 181.—THE VENTRICLES, SHOWING BASAL GANGLIA IN THE FLOOR OF THE LATERAL VENTRICLES (Hirschfeld and Leveillé).

*a*, Anterior portion of corpus callosum; *b*, caudate nucleus; *c*, location of lentiform nucleus; *d*, optic thalamus; *h*, *i*, quadrigeminal bodies; *g*, **third ventricle**; *o*, **fourth ventricle**; *p*, medulla. The fifth ventricle is in front of *e*.

ventricular cavity. *Gray matter* (ganglia) lies close to this canal, even projecting into it. The *white fibers* are here, but they diverge on every side, and many take new directions; also the halves of the brain are connected by *transverse* (commissural) fibers (the corpus callosum). The brain has one part not found in the cord (and a most important part), viz., a covering of "gray matter," or *cortex*.

### THE MEMBRANES OF THE BRAIN.

These are three in number, the pia mater, arachnoid, and dura mater, like those of the cord, and continuous with them.

The **pia mater** fits closely to the brain, following all convolutions and uneven surfaces; it is necessary to the life of the brain, as

periosteum is to bone, and for the same reason—it bears the blood-vessels which nourish it.

The **arachnoid** lies close to the pia but stretches across the furrows, leaving *subarachnoid spaces* for cerebro-spinal fluid as in the spinal cord. The largest spaces are at the base of the brain where the greatest irregularities of surface are found.

The **dura**, firm, white and tough, covers the others loosely and lines the entire skull, taking the place of periosteum. It has a number of *meningeal arteries* branching in its substance, for its own nourishment and the nourishment of the skull bones (since it is their internal periosteum). It sends layers between the large divisions of the brain—one between the hemispheres of the cerebrum is called the *falx cerebri*, and one stretched over the cerebellum is called the *tentorium cerebelli*. They support the weight of portions of the brain in different positions of the head.

The dura also presents several large veins called *sinuses* which collect the blood from the brain. The largest are the *sagittal (longitudinal)* running from front to back in the median line, and the two *transverse sinuses (lateral) right and left* which end in the *internal jugular vein* at the jugular foramen.

**Surgical note.**—The transverse or lateral sinus lies partly in a deep groove on the *mastoid bone (sigmoid groove)* and this adds to the gravity of operations in the mastoid region.

**Clinical note.**—Inflammation of the membranes is *meningitis*. When affecting the dura it is *pachymeningitis*; when it is of the pia and arachnoid, it is *leptomeningitis*.

## THE CRANIAL NERVES.

There are 12 pairs of cranial nerves. They are seen at the base of the brain and leave the skull through various foramina in the cranial bones. Some are nerves of motion, some of sensation and some are mixed (Fig. 182). They are named as follows:

- |                                      |                                      |
|--------------------------------------|--------------------------------------|
| 1. Olfactory.                        | 7. Facial.                           |
| 2. Optic.                            | 8. Acoustic or <i>auditory</i> .     |
| 3. Oculo-motor.                      | 9. Glosso-pharyngeal.                |
| 4. Troclear, or <i>pulley</i> nerve. | 10. Vagus, or <i>pneumogastric</i> . |
| 5. Trifacial, or <i>trigemimus</i> . | 11. Spinal accessory.                |
| 6. Abducens.                         | 12. Hypoglossal.                     |

The first, or **olfactory** (Fig. 182), is the nerve of smell. Being sensory it is traced toward the brain.

Minute nerves from the upper part of the nasal mucous membrane (*olfactory region*), pass up through the sieve-like plate of the ethmoid bone and enter the *olfactory bulb*; from the bulb proceeding in a soft band of fibers called the *olfactory tract*, to the brain, most of them finally reaching the *temporal lobe*, where they end in the center for the sense of smell, or *olfactory center*.

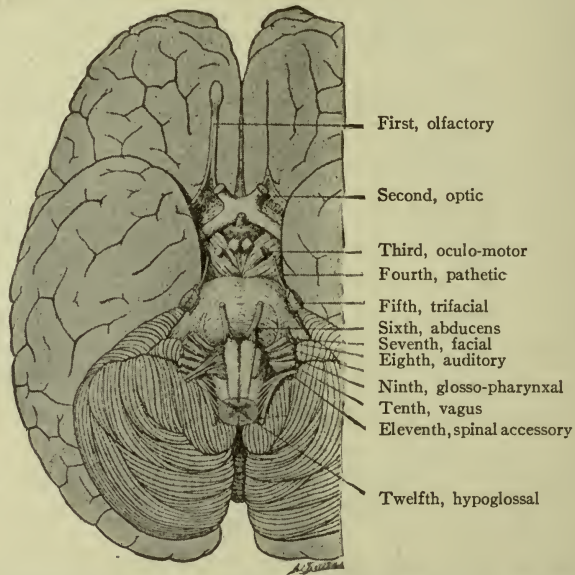


FIG. 182.—BASE OF BRAIN AND CRANIAL NERVES, SHOWING RELATION OF THE PONS, MEDULLA, AND CEREBRUM (Monat and Doyen; Brubaker).

The second, or **optic** (Fig. 183), is the nerve of vision. It begins in the retina.

The retinal fibers are gathered to form the nerve, which passes through the optic foramen into the cranial cavity. The two optic nerves meet above the body of the sphenoid bone, and most of the fibers cross each other there, forming the *optic commissure* (or *chiasm*), and then proceed to the *occipital lobes*, where they end in the *visual centers*. (Fig. 180, 16, *optic chiasm*.)

The third, or **oculo-motor** (Fig. 183), is the mover of the eyes. It proceeds from the base of the brain and enters the orbit, to supply four of the muscles of the eyeball, and also the elevator of the upper lid. (Eye muscles thus supplied: *Superior*, *inferior*, and *internal recti*, and *inferior oblique*.)



By the action of the first three the eye is turned upward, downward and outward; the inferior oblique turns it upward and outward.

The third nerve supplies also the *circular fibers of the iris* which contract the pupil of the eye, and the *accommodation muscle*—by which the eye is focused for viewing objects at different distances.

The fourth, or **trochlear** nerve, is so called because it supplies the muscle which rolls the eye downward and outward (the superior oblique muscle; the tendon passes through a loop and bends around like the rope on a pulley or trochlea).

The fifth, or **trifacial** (trigeminal), is the great *sensory* nerve of the face, nose and throat.

Some *motor* fibers for muscles of mastication accompany the sensory fibers and thus there are said to be *two roots*; *sensory* and *motor*.

The sensory root has a large ganglion, *semilunar* (or *Gasserian*) *ganglion*, and in front of this it is in three divisions, called the *ophthalmic*, *maxillary*, and *mandibular* nerves. The *ophthalmic* nerve lies in the orbit; it is the nerve of sensation of the structures contained therein; also of the eyelids and side of the nose. The *maxillary* nerve appears at the infraorbital foramen. It is the nerve of sensation for the upper teeth and the cheek and temple. The *mandibular* nerve is

in the infratemporal fossa, and is the nerve of sensation for the lower teeth and structures of the lower jaw. The *motor root* joins this branch to supply the muscles of mastication.

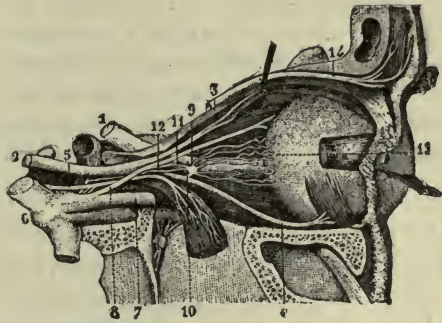


FIG. 183.—NERVES OF THE ORBIT.

1, Optic nerve; 2, Oculo-motor (3d); 5, abducens (6th). Other figures mark various branches. 10, Ciliary ganglion (Sappey).

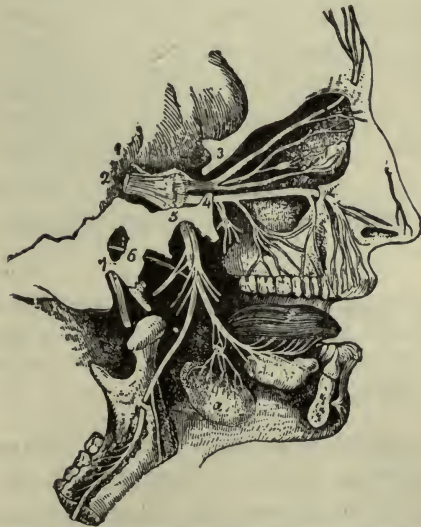


FIG. 184.—THE DISTRIBUTION OF THE THREE DIVISIONS OF THE FIFTH NERVE (Leidy).

The nerve of the sense of taste, called the *lingual* (or *gustatory*), accompanies the mandibular nerve from the anterior two-thirds of the tongue.

**Surgical notes.**—Facial neuralgia is sometimes so severe and intractable that the semilunar ganglion is removed by the surgeon. This interferes with sensation of the face, but not with motion.

Three sensitive points on the face where three sensory branches of the tri-facial pass through foramina: the supraorbital foramen, for the supraorbital branch of the ophthalmic; the infraorbital foramen for the infraorbital branch of the maxillary; the mental foramen for the mental branch of the mandibular. Section of these nerves is sometimes done for facial neuralgia.

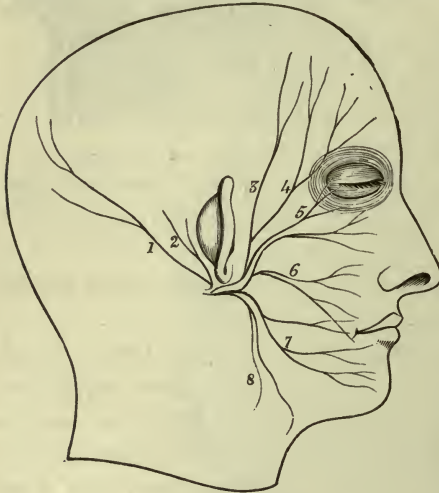


FIG. 185.

The figures mark the branches of the seventh or facial nerve (Holden).

The sixth, or **abducens**, is a motor nerve, supplying the external rectus muscle, which turns the eye outward, or abducts it.

The seventh, or **facial** (Fig. 185), is a motor nerve. It passes through the channel in the petrous bone called the *facial* or *Fallopian canal*, (which brings it close to the middle ear). Emerging from the skull it passes forward

through the parotid gland, and divides into many branches supplying all the muscles of expression.

**Clinical note.**—If this nerve is paralyzed, the side of the face supplied by the injured nerve droops and is useless, and the eye fails to close. The face will be drawn toward the *un*-injured side by the opposite nerve; this is plainly seen if the patient smiles, or attempts to whistle.

The eighth, or **auditory** (acoustic), is a sensory nerve. It has two portions—the *cochlear*, or proper nerve of hearing, and the *vestibular*, or nerve of equilibration. Both pass from the internal ear through the internal auditory canal to the *medulla*. (See page 275, Nerves of the Internal Ear.)

The ninth, or **glosso-pharyngeal**, is a mixed nerve. The motor fibers pass from the medulla through the jugular foramen and supply the muscles of the tongue and pharynx, as its name suggests.



## FUNCTIONS OR PHYSIOLOGY OF THE BRAIN AND CRANIAL NERVES.

The **cerebrum** presides over all conscious acts, and recognizes all sensations. The anterior portion of the frontal lobes is said to be the region of mental activity or the seat of the intellect.

**Cerebral Localizations.**—Connections between *cortical areas* and certain parts of the body have been noted, and their control over those parts has been demonstrated (Figs. 186, 187). Among them are the centers for *face* muscles and for the *upper extremity*, in

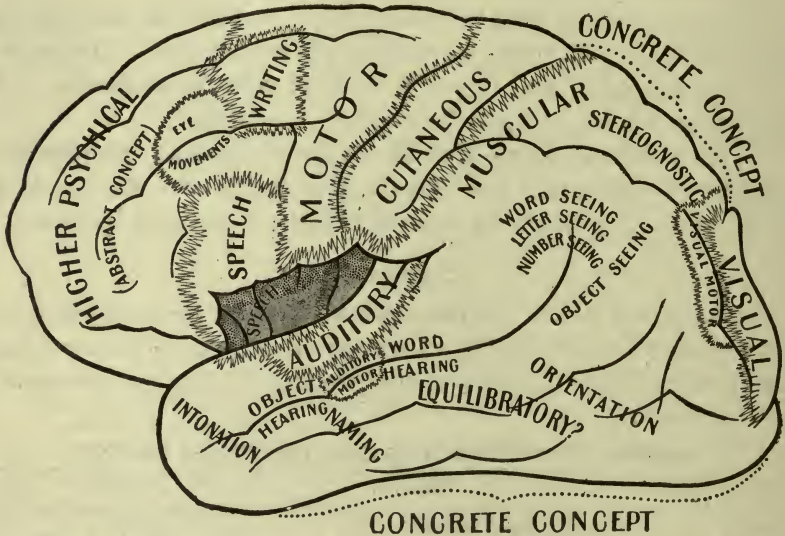


FIG. 186.—THE AREAS AND CENTERS OF THE LATERAL ASPECT OF THE HUMAN HEMICEREBRUM (C. K. Mills).

the *anterior central convolution*; the centers for *speech* muscles in the *lower convolutions* of the *frontal lobe*. (Broca's convolution is the third left frontal.) Likewise the centers for the special senses are fairly well known—as for *vision* and memory in the *occipital lobe*; for *taste* in *temporal*; for *touch* in the *parietal*; and for *hearing* and *smell* in the *temporal* and *frontal*.

The function of the **cerebellum** is to associate or coordinate the actions of muscle-groups for the accurate performance of special movements. This is most conspicuously shown in maintaining the *equilibrium of the body*, whether standing or walking. Injury to the cerebellum results therefore in vertigo and dizziness, in loss of

the power to keep one's balance, and of the ability to walk without staggering.

The **medulla oblongata** contains many important governing centers. Among them, are those for the organs of circulation and respiration; these are situated near each other and constitute the "vital knot." Consequently this part of the nerve system presides over processes of the body which are necessary to life itself, and when one remembers that the motor and sensory fibers which

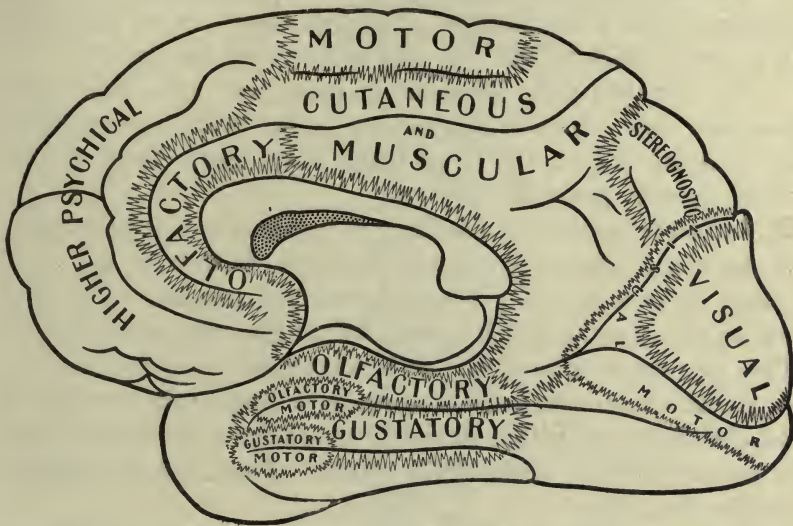


FIG. 187.—THE AREAS AND CENTERS OF THE MESIAL ASPECT OF THE HUMAN HEMICEREBRUM (C. K. Mills).

connect the brain and cord all pass through the medulla, it is easy to understand that injury here produces far-reaching results.

The **pons varolii** is associated with the medulla in its cranial nerve connections; most of its fibers are conducting paths between the other parts in the cranial cavity.

The **function** of the **cranial nerves** is to connect parts of the head and face, also certain muscles of the neck, with the brain. Through the *vagus* (or pneumogastric) nerve—the heart, lungs and digestive organs possess cranial connections.

## CHAPTER XIX.

### THE SYMPATHETIC DIVISION OF THE NERVE SYSTEM.

We have thus far considered those nerve actions which are associated with consciousness. Although some may be performed in a purely reflex manner, all may be exercised voluntarily.

The Sympathetic Division is concerned with *involuntary* processes only. Nerve stimulus between the central nerve system and internal organs, and to all involuntary muscle fibers, is conveyed through *sympathetic nerves*.

The nerve tissues of this division are mostly *gray*, a large majority of the fibers being non-medullated. This division of the nerve system consists of many *ganglia* connected together with nerve trunks, and of *nerves* which connect the ganglia with various organs. They also communicate freely with the cerebro-spinal division.

About twenty-two pairs of *sympathetic ganglia* are arranged in two chains situated within the body, at the sides of the vertebræ, and connected below in front of the coccyx. These are the *vertebral ganglia* (Fig. 188).

(Others are situated in the head and the cavities of the body—thoracic, abdominal and pelvic; these are intimately connected with the viscera contained therein.)

The *vertebral ganglia* are named according to their location. They are *cervical*, *thoracic*, *lumbar*, *sacral* and *coccygeal*. They all receive communicating branches from spinal nerves.

The branches or *nerves* from these various ganglia interlace in close networks forming plexuses, which follow the course of *arteries*, supplying their walls and the *viscera* to which they run. They also supply the cells of glands.

Special branches from *cervical* ganglia accompany arteries to the head, larynx, pharynx, thyroid body, and heart.

Special branches from *thoracic* ganglia accompany arteries to lungs and esophagus in the thorax; stomach, liver, spleen, and other viscera in the abdomen. (The branches passing through the

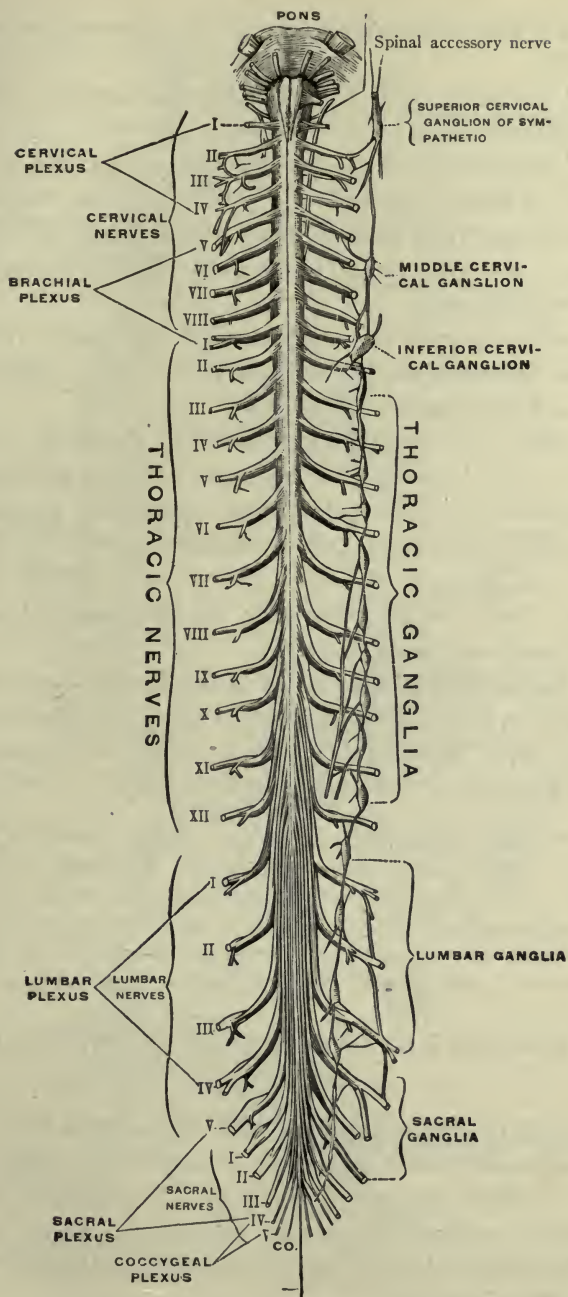


FIG. 188.—LEFT SYMPATHETIC GANGLIA SHOWING COMMUNICATIONS WITH SPINAL NERVES (Testut).

diaphragm to abdominal viscera are called *splanchnic nerves*—three on each side.)

Special branches from *lumbar* ganglia accompany arteries to kidneys and pelvic organs.

Special branches (or nerves) from the *sacral* ganglia accompany arteries to the pelvic organs.

The most important *plexuses* are the cardiac and the pulmonary in the thorax, the celiac (solar) in the abdomen, and the hypo-gastric in the pelvis (Fig. 189).

The **cardiac plexus** lies underneath and behind the arch of the aorta. Its branches supply the *heart* and *lungs*, following the coronary and pulmonary arteries.

The **celiac (or solar) plexus** is in the abdomen, in front of the aorta, at the beginning of the celiac artery. It contains two large ganglia—the right and left *celiac (semilunar) ganglia*. This plexus controls the vessels and muscular coats of the abdominal viscera; it has been called the *abdominal brain*. Thus it may be understood how a severe blow over the plexus would produce a very widespread and serious result.

The **hypo-gastric plexus** is in front of the fifth lumbar vertebra and divides to form the right and left pelvic plexuses, which are distributed to all of the pelvic viscera (along with branches from the sacral ganglia and lumbar-spinal nerves).

**Notes.**—Cardiac nerves from the cervical ganglia descend to the thorax, entering the *cardiac plexuses* and supplying the heart and lungs. Certain branches from the thoracic ganglia form *splanchnic nerves* which descend to the abdomen, entering the *celiac plexus* and *celiac ganglia*, and supplying digestive organs. Certain nerves from the lumbar ganglia descend to the *hypo-gastric plexus* to enter the *pelvic plexuses*, supplying pelvic organs.

## FUNCTIONS OR PHYSIOLOGY OF THE SYMPATHETIC NERVES.

The work of organs supplied with sympathetic nerves is performed *involuntarily* and *unconsciously* save in its results. *Visceral muscles, secreting cells, vessel walls*, are all under the immediate domain of the sympathetic ganglia and nerves, whose motor and sensory fibers are parts of the great nerve system of the body, through communicating branches.

Certain facts indicate a communication between the *brain* and sympathetic nerves, for instance: the thought of food causes a flow



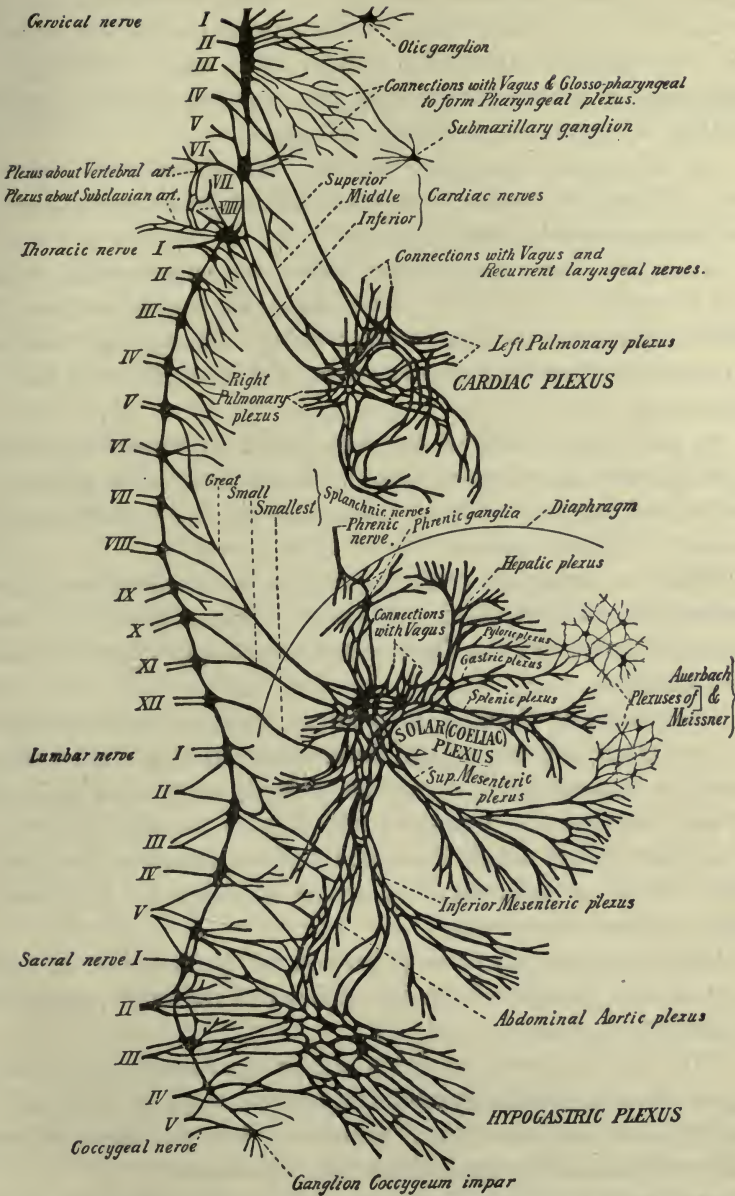


FIG. 189.—PRINCIPAL GANGLIA AND PLEXUSES OF THE SYMPATHETIC SYSTEM (MORRIS).

of saliva (*salivary cells* are stimulated—think of a lemon). Fright or anxiety may inhibit or prevent the secretion of saliva; or interfere with digestion through a similar effect upon other digestive fluids; and it is well known that the *secretion of milk* is greatly modified by mental or emotional influences.

So with general *vaso-motor* action. We all know the blanched face of fright or mental shock; the flush of joyous excitement; or the blush of embarrassment.

Again the effect of *vaso-motor* action may be seen when intense cold is applied to the skin. The cutaneous vessels contract, the blood is driven out, the skin becomes white. The opposite condition is caused by heat—the vessels dilate, the blood flows in and the skin is red.

By alternate action of the two kinds of vaso-motor nerves (*vaso-dilators* and *vaso-constrictors*), the blood-supply is adapted to special and varying needs of different parts of the body, and the balance of pressure preserved in all of their vessels.

When an organ has work to perform its vessels *dilate* and the necessary blood is supplied. When the work is finished the vessels return to their usual size (their vessel-tone being restored by vaso-constrictors).

The process of *digestion*, for example, requires that there should be much blood in many organs; the same is true of general *muscular exercise*. Consequently, to exercise violently after a full meal is a mistake, because the muscles would deprive the digestive organs of the extra blood which they need, and an attack of indigestion might follow; at best, digestion would be delayed. It would be better to delay the exercise.

Many examples might be given and will probably occur to the mind of the student, of the interactions of different parts of the sympathetic system.

These are the processes which must go on more or less continuously. Some may be suspended temporarily, as gland secretions, or digestion, or the formation of excretions, but they never entirely cease without causing the death of the individual.

### Summary.

The *sympathetic* nerves supply *all involuntary muscles*, the coats of blood-vessels and the cells of secreting glands. They are

the nerves of *unconscious* life, as the *cerebro-spinal* nerves are the nerves of voluntary and conscious life.

## SUMMARY OF THE FUNCTIONS OF THE NERVE SYSTEM AS A WHOLE.

We have now concluded the study (briefly) of the entire nerve system, and we have seen how intimately its various parts are connected. Only through a knowledge of these connections can the functions of the system be understood.

*Different parts* of the **spinal cord** are associated one with another by conduction fibers, and the cord is connected with the *brain* above by many more, running upward or downward through the *medulla* and *pons*. (On the inferior surface of the brain we see these fibers as *crura* or penduncles, disappearing in the substance of the cerebrum and cerebellum; they are finally connected with the gray cells of the cortex.)

In the *spinal cord and its nerves* we find the apparatus for reflex action which appears in so many phases—as muscle contraction, muscle-tone, vessel tone, etc. The *spinal cord*, then, is a great *reflex center*, a *conducting pathway*, and an organ of *coordination* of skeletal muscles.

Included in the **medulla** are centers for still more important reflexes: the *respiratory center*; the *cardio-vascular center* or center for heart-action and vessel-tone combined; the *heat regulating center*; *deglutition center*, and others. Certain of these may be modified by the will; for example, the respiratory act—we may take a long full breath or a short and shallow one; breathe rapidly or slowly, at will. Deglutition is still nearer to the realm of voluntary movements—only when food reaches the esophagus, is the act of deglutition purely reflex. (Here is the first appearance of unstriated muscle in the digestive tract.)

Going higher we find the **cerebellum** presiding over the *coordination* of conscious and voluntary movements, through its connection with the cortex of the cerebrum on one hand, and the pons, medulla and cord on the other. Also upon the cerebellum depends the maintenance of *body equilibrium*. For this it is necessary that the *semicircular canals* of the internal ear should be normal and in perfect connection with the cerebellum. Other sensory connections

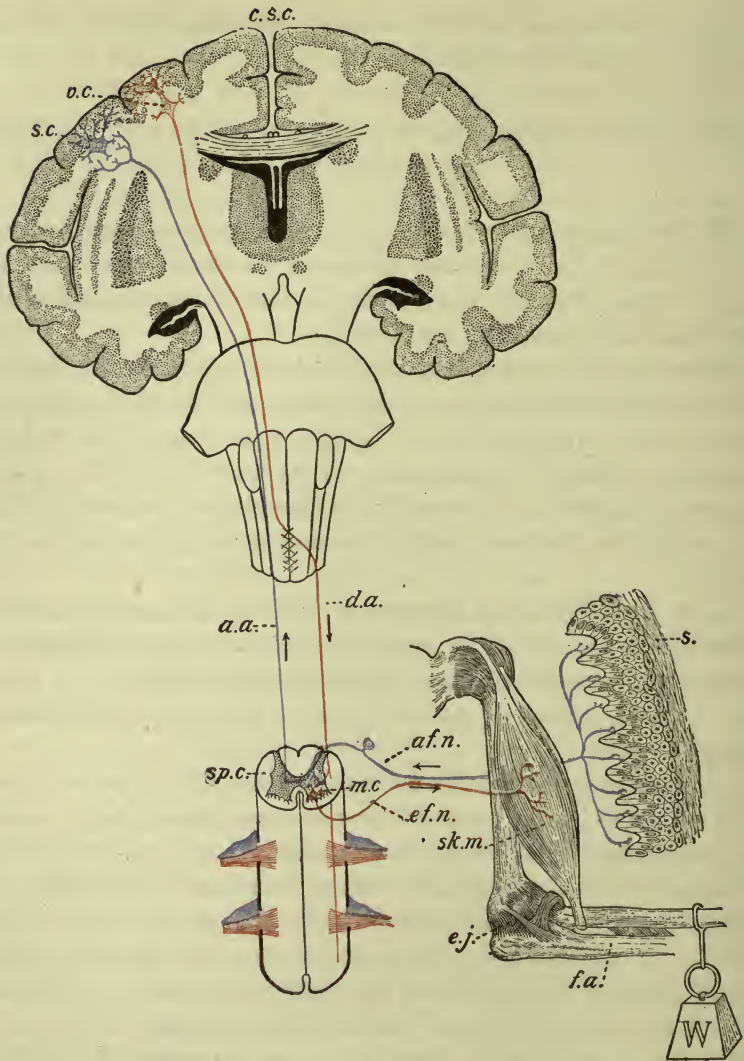


FIG. 190.—DIAGRAM SHOWING THE RELATION OF SKELETAL, MUSCLE AND NERVE TISSUES (G. Bachman). *f.a.* Bones of the forearm representing the skeletal tissue; *e.j.* the elbow joint, the fulcrum of the lever formed by the bones of the forearm; *W*, a weight acting in a downward direction and representing the passive force of gravity; *sk.m.* a skeletal muscle acting in an upward direction and the source of the active power to be applied to the lever; *sp.c.* transection of the spinal cord showing the relation of the white and the gray matter; *m.c.* a motor cell in the anterior horn of the gray matter; *ef.n.* an efferent nerve-fiber connecting the motor cell from which it arises with the skeletal muscle and contained in the ventral roots of the spinal nerves; *af.n.* an afferent nerve-fiber arising from the ganglion cell along its course and connecting the skin, *s.*, on the one hand with the spinal cord on the other hand and contained in the dorsal roots of the nerves; *c.s.c.* coronal section of the cerebrum showing the relation of the gray to the white matter; *v.c.* a volitional or motor cell; *d.a.* a descending axon

also contribute to the exercise of this function; for example, to walk unaided without vision is possible, but not in a straight line; or, to walk with feet benumbed is difficult, more so to stand motionless; showing that the cerebellum is stimulated to the coordination by which equilibrium is maintained, by more than one sort of stimulus, probably by many.

Going still higher, we find in the **cerebrum** the perfecting of the plan for bringing the whole sentient and moving organism into the domain of consciousness and the will. This is by means of the connections of the *cerebrum* through the *pons*, *medulla*, and *cord* and their *nerves*, with every part of the body *from which afferent* impulses and *to which efferent* impulses may be transmitted (Fig. 190).

Concerning the reception and originating of ideas, the exercise of thinking—in other words, intellectual processes—we know nothing, except that these activities certainly depend for their normal manifestation upon a normal cerebrum. A well-developed cerebrum has good convolutions and deep furrows. These indicate mental power, being of more importance than the mere size of the brain. The brain of the infant possesses all of the interior parts, as ganglia, etc., but the cortex is almost smooth. With the growth of the child and quickening of the mind, the convolutions and furrows appear and develop.

The **sympathetic division** of the nerve system is the medium of communication (through *communicating branches*) of nerve impulses between the cerebro-spinal system and the organs concerned in involuntary processes (notably those connected with *nutrition* and *growth*) through control of *secreting cells* and *vessel-tone*.

---

or nerve-fiber connecting the volitional cell from which it arises with the motor cell in the spinal cord; *s.c.* a sensor cell; *a.a.* an ascending axon or nerve-fiber connecting a receptive cell from which it arises (not shown in the diagram) with the sensor cell in the gray matter of the cerebrum. The nerve-fibers which pass outward from the spinal cord to the glands, blood-vessels, and the muscle walls of the viscera, have for the sake of simplicity been omitted from the diagram.

## CHAPTER XX.

### THE SPECIAL SENSES AND THE VOICE.

In studying the structure and functions of the nerve system, we learn that sensory stimuli are received in every part of the body by *afferent nerves*, and conducted to sensory cells in the spinal cord; there, they either evoke a muscle response of reflex character, or are transmitted by connecting tracts to the brain, where the result is *sensation* of some sort: as for example, of *temperature*—whether of the surrounding air, or of bodies which we touch; or of other conditions—whether *hard* or *soft*, *wet* or *dry*, *rough* or *smooth*, etc., etc. These are common and *definite sensations* and by them we gain knowledge of the world about us.<sup>1</sup>

Others there are, which are definable in general terms only, and are not definitely located, although plainly felt. For instance, we are *hungry*, or *thirsty* or *tired*; after pain we have a *sense of relief*, etc., the route for stimulus and response in these matters is through visceral and vaso-motor nerves and their spinal and cerebral connections, and by them we gain acquaintance with our individual selves.

Still other mechanisms are adapted to a more definite class of sensations, by which we learn still more extensively to know the world in which we live; these are called the *organs of the special senses*.

The special senses are: **smell, touch, taste, hearing and sight.** The organs concerned are the *nose*, the *skin*, the *tongue*, the *ear* and the *eye*.

It is understood that all consciousness of sensation is based upon the final reception of sensory impressions by the brain. So far as a "sense" may be said to reside anywhere, it resides in the *brain*, for without it there are no senses as we know them.

<sup>1</sup> We do not now refer to cranial nerves in which the arrangement is similar but more intricate.

The **nose** is the organ of the **sense of smell**. In the nasal chambers is a layer of special cells—*olfactory cells*—supported by a basement membrane, forming the *Schneiderian membrane* (or pituitary membrane). The upper part only of the nose is the *olfactory region*. Here the sensory nerves arise which proceed through the foramina in the roof of the nose (the cribriform plate) to the brain.

In quiet respiration most of the air passes in and out through the lower parts of the nasal chambers, diffusing gradually into the upper parts. Although most odors are readily perceived as soon as one comes into the atmosphere containing them, a slight odor is better appreciated by means of an effort to draw the air through the *olfactory region*, in other words, a sniff. The odorous particles are thus brought into contact with the *olfactory cells*, and the impressions made upon them are transmitted by the delicate *olfactory nerves* through the cribriform plate to the *olfactory bulbs* and thence by the *olfactory tracts* to the *olfactory center* in the *temporal lobe of the brain*.

The sense of smell is valued for the pleasurable sensations which it affords, as an adjunct to the sense of taste, and as a sentinel to warn us of danger when in the vicinity of irritating or poisonous gases, etc. The degree of development of this sense in lower animals is remarkable; they readily "scent danger."

## THE SENSE OF TOUCH.

The **skin** and the **mucous membrane of the mouth** constitute the organ of the special **sense of touch** (all mucous membranes are sensitive to temperature and pain, but only that of the mouth is sensitive to touch).

The special nerve endings are situated in the deeper layers and the papillæ (general description page 214). And upon their number and nearness to the surface, depends the acuteness of this sense. (An area covered by thick layers of epidermis is not so sensitive as one where it is thin; and *vice versa*.)

There are several forms of nerve endings: *tactile cells*, for common sensations, found throughout the skin in the deeper layers and the papillæ; *touch corpuscles*, also in the papillæ and especially numerous in the palm and finger tips, where sensation is particularly acute;

other forms in muscles and tendons; others still, for the perception of heat and cold, etc., etc.

The sense of touch includes many varieties of impressions by means of which we may judge of surroundings, and gain the necessary knowledge concerning the external world whereby we can adjust ourselves to its conditions.

Simple *contact* evokes no sensation without a certain degree of pressure; *touch* and *pressure* are therefore closely related; with increased pressure comes the impression of *weight*. If pressure is sufficiently increased, *pain* will be felt, which is due to the disturbance of nerves more deeply situated.

Again, a touch imparts also a sensation of *place*, the place where it occurs; therefore the sense of touch includes the *place sense*.

### THE SENSE OF TASTE.

The **tongue** is spoken of as the **organ of taste**, since it bears the *taste buds*. (For general description of the tongue see page 121.) The sense of taste may be regarded as a specialization of the sense of touch and the two mechanisms somewhat resemble each other.

The nerve endings which are developed for this purpose are scattered over the surface of the tongue, and in (certain of) the papillæ, in the palate and palatine arches (possibly sometimes in the pharynx). They are found in small oval bodies called *taste buds*, which are in direct connection with the *gustatory nerves*.

In order to excite the nerves of taste, substances must be either already *in solution* or *soluble* by the saliva; a perfectly dry substance may be felt by the tongue and its temperature, etc.; will be appreciated, but it cannot be tasted. Although all flavors may be recognized in all parts of the tongue, some are more keenly appreciated in one portion than another; for example: the *bitter* flavors are more plainly tasted in the *posterior* region, while perception of *sweets* is more marked in the *anterior* parts. The *borders* seem to apprehend *acids* more quickly than the dorsum.

Touch, temperature, and smell are all associated with taste. If a substance is too hot the sense of taste is overcome by the sense of pain. Many people who have been deprived of the sense of smell (by disease or injury) assert that they no longer possess the sense of taste, or that, if present, it is greatly impaired.



## THE SENSE OF HEARING.

The organ of the sense of hearing is the **ear**. It has three divisions: external, middle, and internal (Fig. 191).

The **external ear** is that part which is on the outside of the skull. The expanded portion, mostly of cartilage covered with skin, is the *auricle*; the deepest depression is the *concha*, and the opening at the bottom of the concha leads to the *external auditory canal* (or meatus).

This *auditory canal* is one and one-quarter inches in length, formed partly by the cartilage of the auricle and partly by the temporal bone. It curves slightly *upward*, and then *downward* and *forward*. It is lined with skin which bears stiff hairs in the outer portion, and contains the glands which secrete "ear wax" (*ceruminous glands*).

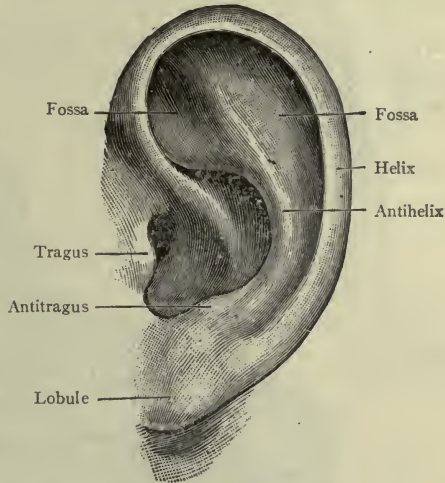


FIG. 191.—THE EXTERNAL EAR (Morris).

It is important to remember the length and direction of this canal.

The membrane at the end of the canal is called the *membrana tympani*, or membrane of the drum. It is a fibrous membrane covered with very sensitive skin on the outer surface, and mucous membrane within (Fig. 192).

The **middle ear** is the *tympanum*, or *drum*. It consists of a small cavity in the petrous bone, on the inner side of the membrane of the drum. Its height is barely half an inch, and the other measurements are smaller still. It contains the *little bones* and forms the beginning of the *auditory tube*.

The *auditory* (or *Eustachian*) *tube* begins in the wall of the middle ear and ends as a roll of cartilage opening into the pharynx.

The **tympanum** is really an air chamber, since it communicates with the throat by the *auditory* (or *Eustachian*) *tube*, and both tube and tympanum are lined with a continuation of the same mucous membrane. An opening at the back of the tympanum leads into

the *mastoid antrum*, and through this, inflammation of the middle ear frequently extends to the mastoid cavities.

**Note.**—The mucous membrane of the pharynx is continued through the auditory tube into the tympanum, and through that into the mastoid cells.

Two openings lead from the tympanum to the internal ear—the oval (or *vestibular*) window and the round (or *cochlear*) window.

The round window is closed by a membrane called the *secondary membrane* of the tympanum. The oval window is closed by a fibrous layer and the base of the stirrup bone (p. 275).

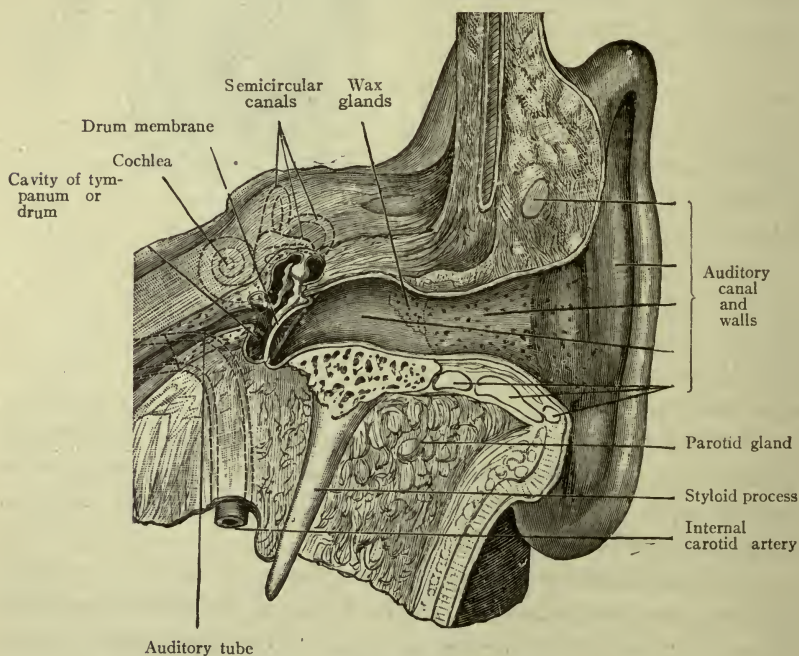


FIG. 192.—THE EAR (Morris).

The **internal ear** is still more deeply situated in the petrous bone. It is extremely complicated, consisting of semicircular canals, vestibule, and cochlea, and well named the *labyrinth*. There are three *semicircular canals* placed at right angles to each other; the *cochlea* resembles a snail-shell in form, and both communicate with the *vestibule* which is between them.

The *cochlea* communicates with the tympanum by the *round* or *cochlear window*, and the *vestibule* communicates with the tympanum by the *oval* or *vestibular window*.

The *internal ear* or *labyrinth*, contains a clear fluid called *perilymph*. Lying in the perilymph is a *membranous labyrinth* containing *endolymph*. The membranous labyrinth is of the same shape, having all the different parts as the bony labyrinth.

**Ossicles.**—A chain of three ossicles (or little bones) is suspended across the tympanum—the *malleus*, *incus*, and *stapes*. The malleus (or *hammer*) is attached by the handle to the membrane of the drum, the incus (or *anvil*) comes next, and then the stapes (or *stirrup*) with its base fitting the oval window of the middle ear. Any vibration of the membrane of the tympanum is at once transmitted by this chain of bones across the tympanum, and through the oval window to the nerves of the internal ear (Fig. 193).

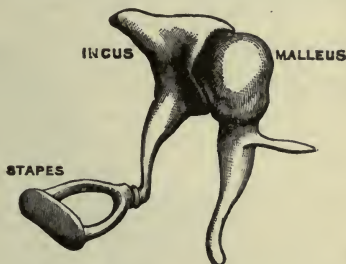


FIG. 193.—BONES OF THE EAR (Morris).

#### NERVES OF THE INTERNAL EAR.

The **cochlear division** of the **auditory nerve** is the true nerve of hearing. Its terminal filaments are within the cochlea; they receive impressions transmitted by the vibrating chain of bones in the tympanum, through the oval window, and conduct them to the brain. The **vestibular division** of the auditory nerve is distributed in the vestibule and semicircular canals; it is not concerned in hearing, but is necessary to the power of preserving equilibrium in standing, walking, etc. A person in whom this nerve has been destroyed cannot walk steadily, and is not subject to sea-sickness.

**Summary.**—The *function* of the *external ear* is to gather and direct the sound waves to the membrane of the tympanum. In the *middle ear* (or *tympanum*) the vibrations of the membrane are transmitted by the chain of ossicles to the oval window, and through the perilymph of the *internal ear* to auditory nerves within the cochlea. The impressions thus made are conducted to the brain and we hear.

The vestibular branch of the auditory nerve is not stimulated in this manner, but by certain changes in the position of the body, sometimes of the head alone.

## THE SENSE OF SIGHT.

**The eye** is the organ of sight. It is situated in the orbital fossa. It is a sphere or globe having for its surface three layers called the *coats* or *tunics of the eye*—namely the *sclera* and *cornea* (fibrous), the *choroid* and *iris* (vascular), and the *retina* (nervous). They contain three transparent structures—the *aqueous humor*, *crystalline lens* and *vitreous body*.

The **sclera** is the “white of the eye.” It is dense and tough, protecting the more delicate structures within. One-sixth of the surface of the ball in front is occupied by the **cornea** instead of the

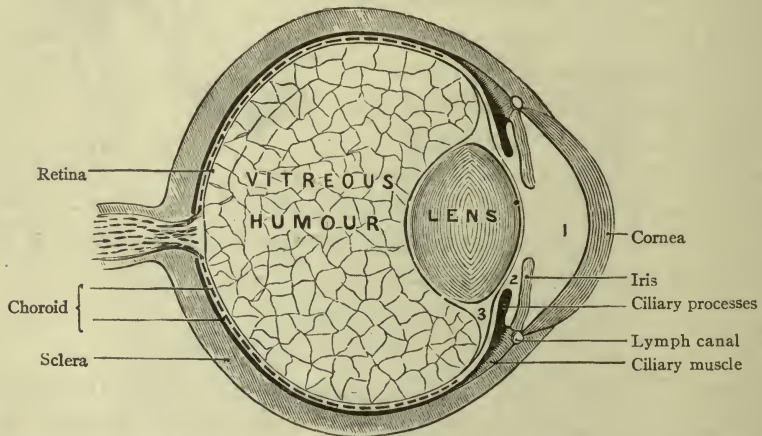


FIG. 194.—A SECTION OF THE EYE (Holden).  
1, Anterior chamber; 2, posterior chamber. The aqueous humor occupies the two chambers.

sclera, and this also is dense and tough, but *transparent* for the admission of light. It contains no blood-vessels, but many tiny lymph-spaces. It is the most prominent part of the eyeball, and its convexity may be seen by looking across an eye from the side. The junction of the cornea with the sclera resembles the fitting of a watch-crystal in its case.

The portion of the sclera which is visible when the eyelids are separated, and also the cornea, are both covered by a thin membrane called the *conjunctiva*; it is a modified mucous membrane, bearing blood-vessels which can be easily seen, especially if a little dilated.

The **choroid**.—The middle coat, next to the sclerotic, is neither dense nor tough, but is made up of fine tissue fibers bearing a very

delicate and close network of blood-vessels. It is the *vascular coat* of the eye, and lines the sclera only, *not* the cornea. Many *pigment cells* are contained in the choroid coat, giving to it a deep brown color so that it makes a dark chamber of the eye (Fig. 195).

The *iris*.—There is no choroid behind the cornea. Its place is supplied by the *iris*, which resembles a circular curtain attached by its edge to the choroid, and having a round aperture in the center called the *pupil* or the “star of the eye.” The iris contains a network

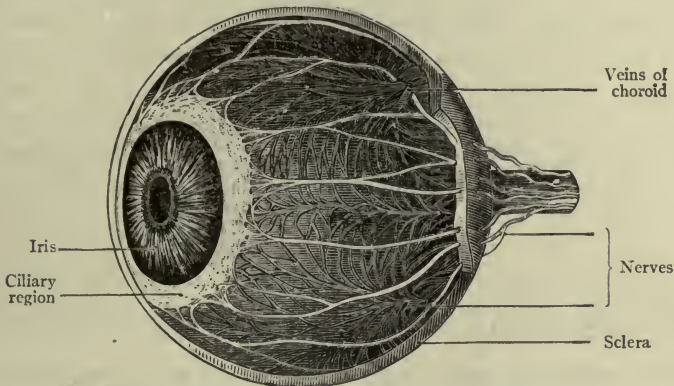


FIG. 195.—THE CHOROID AND IRIS (Holden).

of fine vessels and pigment cells, varying in color according to the amount of pigment. (Blue eyes have least, black eyes most.) It has muscular fibers arranged in two sets—*circular*, or ring fibers, and so-called *radiating*, or straight fibers. The circular fibers surround the pupil. Thus, when they contract, as in a bright light, they diminish its size. The straight fibers run from the outer border of the iris toward the pupil, and therefore when they contract they act upon the margin to enlarge the opening. Briefly, the pupil is *contracted* by the circular fibers, and *dilated* by the straight or radiating fibers, thus regulating the amount of light admitted within the eye.

The *retina* is the innermost coat, of many layers, within the choroid. This is a very delicate structure in which are the beginnings of the optic nerve fibers. It is the coat which is essential to vision—no retina, no vision. The outermost layer of the retina is the one which contains the rods and cones, or the *visual cells*. Like the sclera and choroid, the retina is incomplete in front.

From the cells in the retina delicate fibers are prolonged and gathered together to make the **optic nerve**, which pierces the choroid

and the sclerotic, passes through the optic foramen of the orbit, and thence back to the brain. The *optic disc* is the spot where the optic nerve leaves the retina; it is situated a little to the nasal side of the center of the retina (Fig. 196).

The *macula lutea* is a spot in the center of the retina opposite the mid-point of the normal pupil. In the center of this spot is a depression called the *fovea centralis* which is the center of vision; only the cone-shaped visual cells are here present.

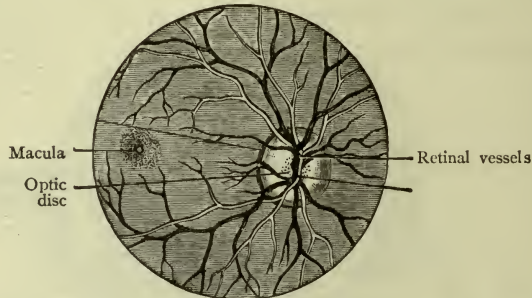


FIG. 196.—THE RETINA AS SEEN WITH THE AID OF THE OPHTHALMOSCOPE (Morris).

The **vitreous body** is glass-like, as its name signifies, both in appearance and transparency. It consists of a jelly-like substance contained in a *hyaloid membrane* within the three coats. It transmits and directs the rays of light to the retina; also it aids in preserving the shape of the eyeball (Fig. 194).

The **crystalline lens** is situated immediately in front of the vitreous body, in a shallow depression like a cup on the anterior surface, and held there by delicate fibers which act as a *suspensory ligament*. It is a *double convex lens* with a *capsule*, both perfectly transparent so that light may pass through, and it is able to *converge the rays* of light so that they will fall correctly upon the retina. The lens is behind the iris, the margin of the pupil resting lightly upon it.

The *ciliary muscle* is in the interior of the eyeball, around the junction of the choroid and iris, thus lying a little farther forward than the border of the lens. Its action modifies the shape of the lens, by which arrangement the eye is able to accommodate itself to the different distances of surrounding objects. This is the process of *accommodation*. To "paralyze the accommodation" is to make the ciliary muscle powerless, so that the eye cannot try to see near objects, as it always does unconsciously, in its normal condition. Atropin will do this.

**Clinical notes.**—Inflammation of the iris, or *iritis*, may cause adhesions to the lens unless the margin of the pupil be drawn away. This is the reason for

the use of atropin, which weakens the circular fibers while it stimulates the straight ones, or, in other words, dilates the pupil.

*Cataract* is a thickening of the lens which makes it opaque and gives it a milky appearance. The remedy is excision or removal of the lens, after which a convex lens of glass in front of the eye gives a good degree of vision. A cataract is *in* an eye, not *over* it, and must be taken *out*, not *off*.

**Aqueous humor and chambers of the eye.**—The space between the cornea and the lens is partially divided by the iris into two portions—the *anterior* and *posterior chambers* of the eye. They contain a thin clear fluid, called the *aqueous humor*, which floats the iris and aids in preserving the shape of the cornea (Fig. 194).

**Note.**—The rays of light which fall upon the retina must first pass through the *media* (or structures which direct their course) in the following order: the *cornea*, *aqueous humor*, *crystalline lens*, and *vitreous body*. Should any one of these lose its transparency, vision would be impaired or perhaps lost.

The *capsule of Tenon* is a fibrous capsule outside the eyeball, loosely investing it and its muscles. It is disposed like a serous membrane—having two layers, one of which lines the orbit and the other is loosely applied to the eyeball.

#### APPENDAGES OF THE EYE.

The **eyebrows**, resting upon the superciliary ridges, or elevations caused by the frontal sinuses (p. 17).

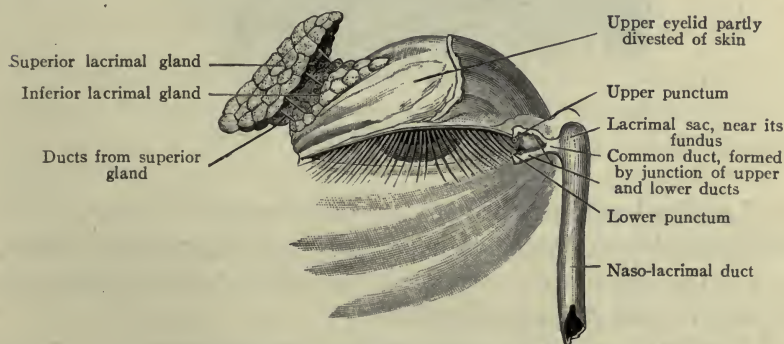


FIG. 197.—LACRIMAL APPARATUS (Morris).

The **eyelids** (or palpebræ), attached to the margin of the orbits and necessary for the protection of the eye. They have five layers, —*skin*, smooth and thin; *fascia*—thin and delicate; *muscle*—the palpebral portion of the orbicular muscle; *fibrous*—containing a stiff

plate of connective tissue, the *tarsal plate*; and *mucous*—the layer which lines the lid (Conjunctiva).

The *tarsal glands* are in the tarsal plates; their oily secretion prevents the lids from adhering to each other. (They are called *Meibomian glands*.)

The angles formed by the extremities of the eyelids are the *medial* and the *lateral angles* (inner and outer canthi). At the *medial angle*, each lid presents a small elevation, the *lacrimal papilla*, with a minute opening (*punctum*) where the tears enter a small canal which leads to the *lacrimal sac*; from the lacrimal sac they flow through the *nasal duct* to the *nasal cavity*.

The **eyelashes**, or *cilia*, are kept soft and flexible by an oily substance secreted by their own oil glands in the margin of the lid.

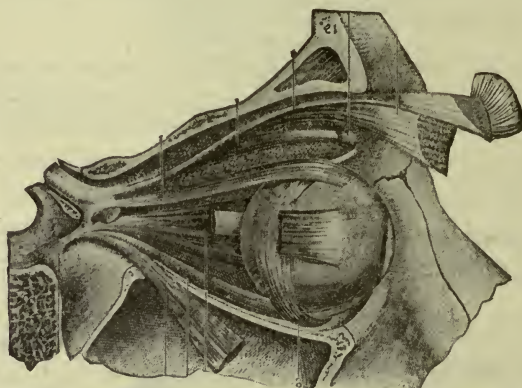


FIG. 108.—THE MUSCLES OF THE EYEBALL (Holden).  
A small section of the upper eyelid is shown.

**Lacrimal gland.**—The gland which secretes the tears. It is situated in the lacrimal fossa of the frontal bone, beneath the lateral end of the orbital arch, and has several ducts for the discharge of the tears under the upper eyelid.

**Conjunctiva.**—This is the sensitive mucous membrane which is attached to the margins of the eyelids to line the lids and cover the eye. The tears flow across it and keep it bathed, preventing the injurious effect of dust and other foreign substances. They are then conducted by the little lacrimal canals and nasal duct to the nose.



**Clinical Note.**—The conjunctiva is supplied with blood-vessels most of which are invisible except when they become congested. In active inflammation or *conjunctivitis* they are so enlarged as to give the membrane a bright red color.

The lids are closed by the action of the *orbicularis* (the palpebral fibers) (p. 84). They are opened by the *levator palpebræ*, which lifts the upper lid, uncovering the eye, while the orbicularis relaxes.

**Motions of the eyeball.**—The eyeball is moved by six slender muscles which have their origin at the apex of the orbit, and their insertion upon the sclera at a little distance from the cornea.

The *superior rectus* rolls the ball upward.

The *inferior rectus* rolls the ball downward.

The *internal rectus* rolls the ball inward.

The *external rectus* rolls the ball outward.

The *superior oblique* rolls the ball downward and outward.

The *inferior oblique* rolls the ball upward and outward.

**Clinical note.**—If these muscles are well balanced the pupil is directed straight forward while they are at rest, but if they are of quite unequal strength the eye will be turned habitually in some special direction. This condition is called *squint* or *strabismus*, or “cross-eye.” It oftenest happens with either the internal or external rectus.

## THE VOICE.

The **voice**, by which we establish most frequent communication with the outside world, is a special endowment for the expression of ideas awakened by consciousness of the senses. It is therefore not inappropriately considered in this connection.

The **larynx** is the **organ of the voice**. (The larynx, lips, tongue and teeth are the *organs of speech*.) A brief description of the larynx is given on page 204.

The structures which are specially concerned in the production of the voice, in addition to the cartilages there described, are the **vocal bands** (also known as *vocal cords*, and *true vocal cords*). These are stretched across the larynx from front to back, being attached to the thyroid cartilage anteriorly and the cricoid posteriorly, and dividing the cavity into upper and lower portions (Fig. 148).

They are composed of *fibrous* and *muscle tissue* covered with mucous membrane. The space between them is the *glottis*.

Small muscles, belonging altogether to the larynx, control the *position* and *tension of the vocal bands* by their action on the cartilages to which the bands are attached, thus producing the different tones of the voice as the breath passes between them. Tense bands and a narrow glottis are necessary for a high note. Lax bands and a wide glottis are the conditions for a low note.

Above them are two membranous folds, one on either side, formerly called *false vocal cords*.

**Note.**—It has been generally taught that the voice is caused by vibrations of the vocal bands, but accurate observations by Miss Alice Groff, of Philadelphia, and other investigators, have proved that this is not the case, the voice-sounds being like those of a horn rather than a stringed instrument.

With the aid of *lips*, *tongue*, and *teeth*, the voice sounds are so modified that *speech* becomes possible, and with it the expression of ideas, and communication between individuals.

## CHAPTER XXI.

### THE PELVIC ORGANS.

#### IN THE MALE PELVIS.

The rectum.  
The urinary bladder.  
The prostate gland.

#### IN THE FEMALE PELVIS.

The rectum.  
The urinary bladder.  
The uterus.  
The ovaries, and uterine tubes.  
The vagina.

The **Rectum** is already described (page 136).

The **Bladder** is the receptacle and reservoir for the urine and is situated in the pelvis just behind the pubic bones. It is a *non-striated* muscular sac, lined with mucous membrane which lies in irregular folds when the sac is empty, but becomes smooth when it is filled. It has an incomplete serous covering above and posteriorly.

The upper portion of the bladder is the *vertex*; the lower part is the *base*. There are three openings in the bladder wall, two for the entrance of urine and one for expelling it.

The urine enters through the two *ureters* (p. 213) or ducts of the kidney, which, having reached the pelvis, proceed below the broad ligaments, to run forward and enter the base of the bladder, there discharging the urine.

The opening for the escape of the urine is called the *internal orifice*. It leads into a canal called the *urethra* which ends at the *external orifice* (or *meatus*), and through it the urine is expelled from the body. The internal orifice is guarded by circular muscle fibers forming a *sphincter*—the *sphincter vesicæ* (sphincter of the bladder). The openings of the *ureters* are about one inch from the *internal orifice*, and the same distance apart, thus these three openings mark the corners of a triangle at the base of the bladder, called the *trigone*.

The **urethra** is a fibro-muscular canal lined with mucous membrane. It begins at the internal orifice of the bladder, ends at the

external orifice or *meatus urinarius*, and conducts the urine from the body.

The *female urethra* is about one and one-half inches long and  $\frac{1}{4}$  inch wide, but is very distensible. It curves slightly downward toward the external meatus.

**Clinical note.**—The catheter should pass a little upward after entering the urethra (Fig. 199).

A **urethral caruncle** is an exceedingly painful little tumor projecting from the urethral mucous membrane. It is a collection of sensitive blood-vessels and nerves.

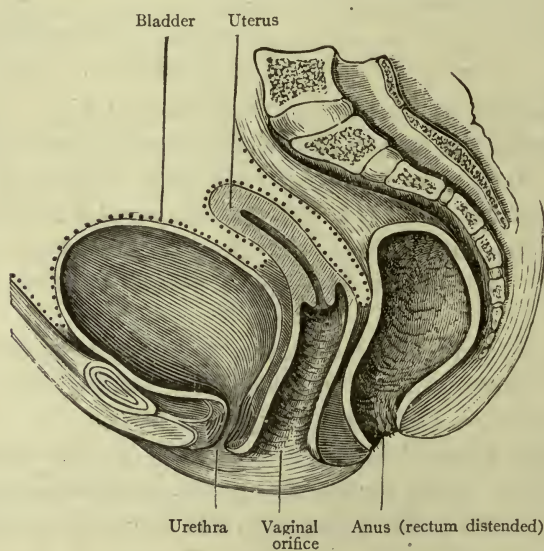


FIG. 199.—PELVIC ORGANS, FEMALE PELVIS (Holden).  
Dotted lines indicate peritoneum.

The **prostate gland** is situated at the base of the *male bladder*, immediately in front of the rectum and surrounding the first portion of the urethra.

**Clinical Note.**—When empty, the bladder lies entirely in the pelvis, but if it contains more than eight ounces it begins to rise into the abdomen. It has been known to extend as high as the umbilicus.

**Surgical note.**—The peritoneum covers the vertex and a portion of the *posterior surface only*; therefore, the bladder may be entered in front through an incision just above the symphysis pubis without wounding the peritoneum.

## THE UTERUS AND APPENDAGES.

These constitute the *internal generative organs*.

The appendages are the *uterine* (or *Fallopian*) *tubes* and the *ovaries* (Fig. 200).

## THE UTERUS.

The **uterus**, or *womb*, is situated between the bladder and the upper part of the rectum. It is a hollow organ shaped somewhat

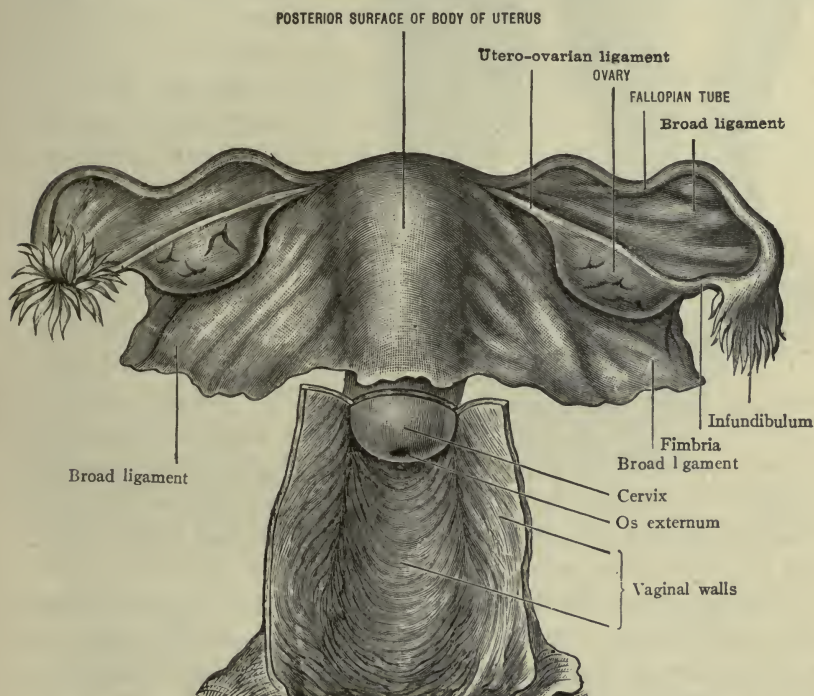


FIG. 200.—UTERUS AND APPENDAGES, POSTERIOR (MORRIS).

like a pear, about two and one-half or three inches long, and one and one-half inches wide at the larger end, which is called the *fundus* and is placed uppermost.

The uterus is composed of non-striated muscles arranged in three layers, and lined with mucous membrane bearing ciliated epithelium. Its walls are about three-eighths of an inch thick. It consists of two portions, the *body* and the *neck* or *cervix*, the *body* being a little longer of the two.

The **body** is flattened, but is more convex at the back than in front, while the **cervix** is round.

The *cavity* of the uterus corresponds to the general shape of the organ, being triangular in the body and round in the cervix. At the upper angles of the body are the openings which lead into the Fallopian tubes. Between the body and the cervix is the *internal os*,

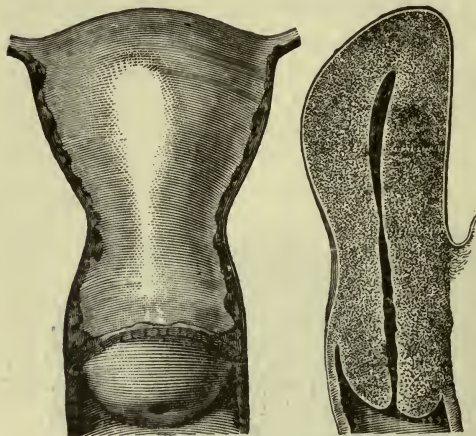


FIG. 201.—THE UTERUS.

Showing cavity and attachment of vagina (Morris).

the opening at the lower extremity of the cervix being called the *external os*, which is bordered by the *anterior and posterior lips*. The uterus is covered with peritoneum, except in front of the cervix.

When the uterus receives an impregnated ovum its *function* is exercised in protecting and nourishing the growing embryo until it becomes a fully developed fetus.

The mucous membrane thickens to form a bed for the embryo, and becomes a part of the *placenta* or "afterbirth." The muscle fibers grow in size and number and the weight increases from the original ounce and a half to one or more pounds.

The function of the uterus is concluded with the expulsion of the fetus and placenta. It then contracts rapidly, and the process of *involution* softens and discharges the remains of tissue which it no longer needed.

**Clinical note.**—*Subinvolution* is incomplete involution.

**Position.**—The *fundus of the uterus* is normally inclined somewhat forward, while the *os externum* looks downward and backward. If the fundus turns too far forward this is *anteversion*; if it inclines backward, *retroversion*.

A *bend* may exist where the neck joins the body. This is *flexion*. When the body is bent forward, this is *anteflexion*; when backward, *retroflexion*.

#### THE UTERINE TUBES (FALLOPIAN TUBES).

The **uterine tubes (Fallopian tubes)** two in number (Fig. 200), extend outward from the upper angles of the uterus; they have a

fibro-muscular structure and are lined with mucous membrane. Each tube is about four inches long. At the beginning it is only large enough to allow the passage of a small bristle, but it becomes larger toward the end, expanding into a trumpet-shaped extremity called the *infundibulum*, which is fringed or *fimbriated*, and which is connected with the ovary below by a slender band (or *fimbria*).

The function of the *uterine* (or *Fallopian*) *tube* is to convey the ovum from the ovary to the cavity of the uterus.

### THE OVARIES.

The ovaries, two in number, lie on either side of the body of the uterus, each one being connected to it by a short cord called the *ovarian ligament*. An **ovary** is about three-quarters of an inch long, a half-inch wide, and shaped like an almond (Figs. 200, 202).

The ovaries are covered with peritoneum (except at the border where vessels enter and leave).

**Structure of the ovary.**—A collection of connective-tissue fibers enclosing many vessels and nerves, and a multitude of little *ovisacs* (egg sacs) called **Graafian follicles**. These follicles are at first microscopic in size, but when developed they may be seen by the naked eye. Each one contains an **ovum**, or egg.

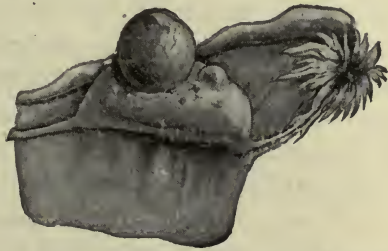

FIG. 202.—OVARY WITH MATURE GRAAFIAN FOLLICLE ABOUT READY TO BURST (Ribomont-Dessaigues-Lewis).

**Ovulation.**—As the follicle with its ovum grows in size it approaches the surface of the ovary, and when it is mature the sac ruptures and the ovum escapes, to be taken by the *uterine* (or *Fallopian*) *tube* to the uterus, from which it is discharged through the vagina, usually with a quantity of blood.

The function of the ovary (*ovulation*) begins with *puberty*, which is the maturing of the pelvic organs and mammary glands. It is usually established at about fourteen years of age (earlier in warm climates, later in cold). From that time the development of at least one ovum occurs in about every twenty-eight days.

**Menstruation** is the periodical discharge of blood from the uterus. The mucous membrane thickens and sheds its superficial

cells, which are renewed after the flow ceases. This probably accompanies ovulation. When an *impregnated* ovum reaches the uterus menstruation is suspended.

The *cessation* of menstruation is the *menopause* or *climacteric*. It occurs at about forty-five years of age (and may be as late as fifty or over). It is followed by gradual atrophy of the generative organs.

*Corpus luteum* is the name given to a yellow substance which forms in the ruptured Graafian follicle. It ordinarily shrinks and disappears within a month. The *corpus luteum* left by an impregnated ovum, however, grows larger and remains present until the end of pregnancy.

### THE VAGINA.

The **Vagina** is the muscular canal extending from the uterus to the surface of the body, where it terminates at the *vaginal orifice* (Figs. 199, 200).

It is situated between the base of the bladder in front and the lower portion of the rectum behind, from which organs it is separated by *connective tissue septa* (*vesico-vaginal*, and *recto-vaginal* septa). It curves slightly forward, and is four inches long in its posterior wall and about two and three-quarter inches in the anterior. It has two layers of muscles, strengthened by fibrous tissue and lined by mucous membrane which lies in transverse folds. The *columns of the vagina* are two median ridges, one on the anterior and one on the posterior wall, extending throughout their length.

The vagina is attached to the cervix of the uterus at a little distance *above* the external os (about half an inch in front and three-quarters of an inch at the back); therefore the examining finger may feel the cervix projecting into the canal. This is the *infra-vaginal portion of the cervix* (Fig. 199, 200).

**Note.**—The urethra lies close to the anterior vaginal wall, feeling like a thick cord in the septum between the two canals (the *urethro-vaginal septum*).

### LIGAMENTS OF THE UTERUS.

The uterus is sustained in the pelvis by folds of peritoneum which connect it to the pelvic walls and to the bladder and rectum. The principal ones are the *broad ligaments*.



The *broad ligaments* are folds of peritoneum extending laterally from the sides of the uterus, like wings, to the sides of the pelvic cavity. Each fold encloses the uterine tube, ovary, and round ligament of its own side.

The *round ligaments* are two muscular and fibrous cords, which extend from the angle of the uterus lateral-ward and forward through the inguinal canal, to be attached to the tissues upon the pubic bone. They aid in preserving the normal position of the uterus with the fundus forward.

#### THE EXTERNAL GENERATIVE ORGANS.

The **pudendum muliebre** (*vulva*).—The name given to the parts situated in front of the pubic arch of the female pelvis. They are:

The **mons veneris**, a cushion of adipose and fibrous tissue in front of the body of the pubic bone.

The **labia majora**.—Two folds of skin containing adipose and loose connective tissue, continuous in front with the mons, and joined together posteriorly by a fold of skin called the *posterior commissure*, about an inch in front of the anus. (The depression in front of this commissure is the *fossa navicularis*.)

The space between the labia majora is the *pudendal cleft*.

The **labia minora**.—Two folds situated between the labia majora, about one-half as long, and joined *anteriorly* in the *hood of the clitoris*. Between them is the space called the *vestibule*. (They sometimes unite posteriorly in a thin fold called the frenulum.)

The **clitoris**.—A small body, somewhat less than an inch in length, nearly covered by the *hood*. It contains many vessels and nerves. The extremity is called the *glans* of the clitoris; the hood is normally free from the glans and if adhesions form they should be separated, since they are a source of nervous irritation.

The **vestibule**.—A triangular space below the clitoris, and between the labia minora. In the middle of the vestibule is the orifice of the urethra, or *external meatus*.

Below the vestibule is the orifice of the vagina, or *vaginal orifice*, partially closed by a circular fold of mucous membrane called the *hymen*.

The ragged edges left by rupture of the hymen are called *caruncula myrtiformes*. An *imperforate hymen* is one which extends entirely across the vaginal orifice, closing it altogether. A little way, laterally, from the middle of the hymen are the openings of the ducts of the glands of Bartholin, one on either side.

The **peritoneum of the pelvis** (Fig. 199) is a portion of the general peritoneum. It lines the pelvic walls, covers the rectum (except the lowest part) and other pelvic organs, and the floor.

In the male pelvis it dips between the rectum and bladder forming the *recto-vesical pouch*.

In the female pelvis it forms a *utero-vesical* pouch in front of the uterus, and a *utero-rectal* pouch behind it. It also extends over the tubes, ovaries, and round

ligaments at the sides, thus making the folds called the *broad ligaments*, which connect the uterus with the sides of the pelvic cavity.

The *utero-rectal* pouch is the *pouch of Douglas* (or Douglas's cul-de-sac). It is the lowest part of the peritoneal cavity, extending down *an inch or more behind the vagina*.

**Note.**—The *pelvis of the infant* is undeveloped and the pelvic organs lie partly in the abdomen. As growth advances they are finally contained in the pelvis, at about the fourteenth year.

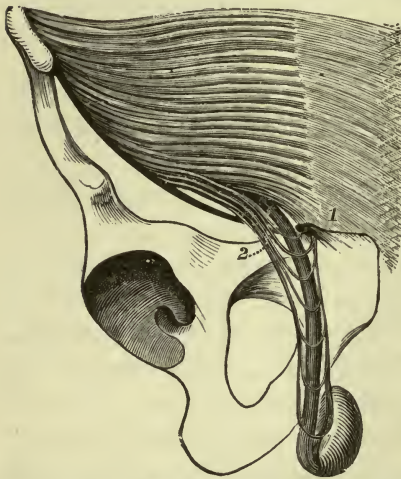


FIG. 203.—SHOWING TESTIS AND DUCTUS DEFERENS SUSPENDED BY SPERMATIC CORD (Holden).

**Perineum.**—The name **perineum** properly signifies the parts bounded by the out-

let of the pelvis, but we generally apply it to the portion in front of the rectum.

In the *female perineum*, the part between the lower ends of the vagina and rectum is the *perineal body*. This is a triangular body composed of connective tissue and adipose, the *base of the triangle* being covered by skin and measuring about one inch, between the vulva and the anus. It contains several muscles, some of which are connected with the sphincter ani.

The perineum is distensible, and stretches to a remarkable extent during labor.

From the *male perineum* a pouch of skin and fascia is suspended, called the *scrotum*. The fascia contains scattered muscle fibers and is called the *dartos*.

The scrotum contains the **testes** which are two in number, the right and the left. They consist essentially of minute tubes in which the *seminal fluid* is secreted, and which open into larger ones leading to the *duct of the testis*, or the *ductus deferens*.

The *ductus deferens* passes upward from the testis through the subcutaneous ring and the inguinal canal, then down into the pelvis and beneath the bladder, where it runs forward to enter the urethra.

The **spermatic cord**.—The testis is suspended in the scrotum by the *spermatic cord*, which reaches from the abdominal inguinal ring to the bottom of the scrotum, and contains the *cremaster muscle*. Contraction of the *cremaster* muscle lifts the testis and draws it upward in the scrotum (Fig. 203).

*Descent of the Testis*.—During fetal life the testis is situated in the abdominal cavity, just below the kidney, but it slowly descends to pass through the inguinal canal, reaching the subcutaneous ring at about the eighth month, and at birth it should be in the scrotum. It may descend more slowly, or may be arrested at any point, but usually finds its place in time.

In the scrotum it is surrounded by a double sheath of the peritoneum (*tunica vaginalis*) which accompanied it, and which became shut off from the great peritoneal sac as the subcutaneous ring closed around it.

In caring for the male infant it is important to note the condition of the *foreskin* (or *prepuce*). This is a fold of skin which covers the *glans penis*. It should be sufficiently loose to be easily drawn back, or *retracted*, in order that careful cleansing of the parts may prevent accumulations of sebaceous material, or *smegma*. If this is not done, irritation is caused by retained substances, and also by adhesions which are apt to form.

*Circumcision* is cutting off the foreskin (literally—*cutting around*).

## CHAPTER XXII.

### A BRIEF STUDY OF IMPORTANT REGIONS.

#### THE HEAD AND NECK.

The **scalp**.—Observe the larger *arteries*—the *supraorbital* in front, the *temporal* and *posterior auricular* at the sides, and *occipital* at the back—that their general course is upward toward the vertex, and therefore a bandage may be so adjusted around the head as to cut off the blood supply to a great extent.

The *nerves* have similar names and take a similar course.

The tense *temporal fascia* covers the temporal muscle above the zygoma.

#### THE FACE.

The main artery, *external maxillary* (or *facial*), runs obliquely upward toward the side of the nose; its course is tortuous, so that the play of the facial muscles will not interfere with the passage of the blood current. The *facial vein* is lateral to the artery and not very close to it. *Pulsation of the artery* may be felt where it crosses the lower border of the mandible, about one inch in front of the angle.

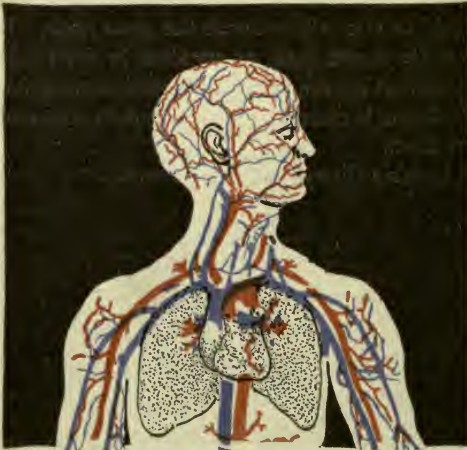

FIG. 204.—SUPERFICIAL VESSELS OF HEAD.

The *external carotid* artery bifurcates in the substance of the *parotid gland* in front of the ear, forming the *temporal* and *internal maxillary* arteries. The *pulsation of the temporal* is felt as it crosses the zygoma, and both here and

over the *external maxillary* on the border of the mandible, the character of the heart's action may be appreciated while the patient is under the influence of ether.

The *motor nerves* (*facial nerve*) come through the parotid gland and radiate on the side of the face, transversely toward the nose, upward toward the eye and forehead, and downward toward the neck.

*Sensory nerves*, branches of the *trifacial* (*trigeminus*), appear at the three foramina mentioned elsewhere—*supraorbital*, *infraorbital* and *mental*—the three particularly sensitive spots in the front of the face.

**Practical note.**—The *tongue* muscles and the floor of the mouth (*mylo-hyoid muscle*) are both connected with the mandible. Therefore, if the jaw be held forward and upward, it will control the position of the tongue when the muscles are relaxed, as under ether. Hence, the necessity for this precaution to prevent the tongue from falling back into the throat.

## THE NECK.

The *skin* of the back of the neck is very tough and the *fascia* very dense. These facts account for the pain of inflammation here, due to the consequent pressure upon the rather numerous nerves, as in carbuncle.

The spine of the *seventh cervical vertebra* is always easily felt. This is the *vertebra prominens*.

The two *sterno-cleido-mastoid* muscles are conspicuous at the side of the neck, situated near each other at their origin, and diverging above. The *thyroid cartilage* of the *larynx* projects in front—the so-called Adam's apple. The *external jugular vein* runs from behind the ear downward, toward the middle of the clavicle, and is covered by the *platysma* muscle. It is sometimes selected for the operation of "bleeding," or *phlebotomy*, and the incision to expose the vein is made *across* the muscle fibers, because by their retraction the vessel is well uncovered (Fig. 71, p. 83).

The *sternomastoid* and *trapezius* are the muscles affected in the commonest form of wry-neck or *torticollis*, which is usually due to spasm of the muscles.

## THE TRIANGLES OF THE NECK (FIG. 205).

These are spaces between certain muscles, as follows: In front of the sterno-mastoid is an *anterior triangle* divided by the superior belly of the omo-hyoid into two, called the **carotid** and **muscular triangles**; behind the sterno-mastoid is a *posterior triangle* divided by the inferior belly of the omo-hyoid into two, called the **occipital** and **subclavian triangles**.

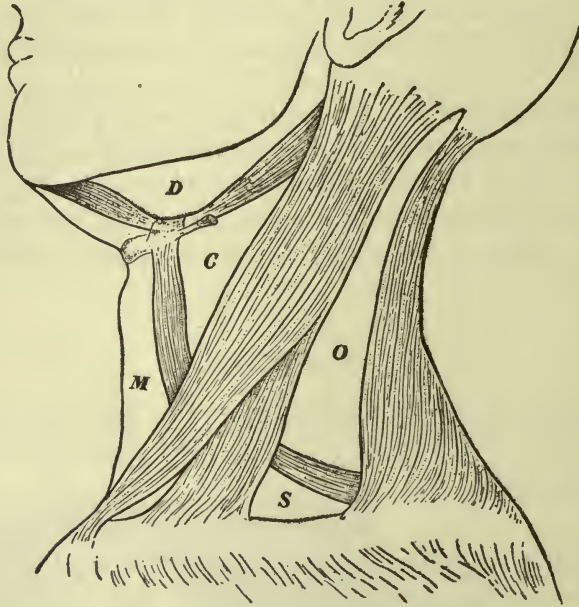


FIG. 205.—TRIANGLES OF THE NECK.

C, Carotid triangle; M, muscular triangle; O, occipital triangle; S, subclavian triangle; D, digastric triangle.

In the **muscular triangle** is the *common carotid artery*, with the *internal jugular vein* on the lateral side of it, and the vagus nerve behind them both.

In the **carotid triangle** the same structures are found, but here the artery divides, forming the *external* and *internal carotid* arteries at about the level of the upper border of the thyroid cartilage, or Adam's apple.

**Surgical note.**—The carotid is called the *triangle of election* because, since the vessels are near the surface, the surgeon would naturally choose, or *elect*, this place for the operation of ligation. In the **muscular triangle** the vessels

are more deeply placed and covered by the lower portion of the sterno-mastoid. Ligation of the artery would be done here only under necessity, so it is called the *triangle of necessity*.

**Occipital triangle.**—The *occipital artery* and nerve run through this triangle.

**Subclavian triangle.**—Most important structures are *subclavian artery* and *vein*, *brachial plexus*, and *phrenic nerve*.

**Clinical note.**—Pressure in this triangle, close to the clavicle, will be felt by the nerves of the brachial plexus. Pressure downward and backward close to the sterno-mastoid will compress the subclavian artery against the first rib. Its pulsation is plainly felt.

**Submaxillary triangle.**—This is a small space marked off from the carotid by the digastric muscle. It contains the *submaxillary gland* and *external maxillary artery*.

#### THE THORAX AND THORACIC VISCERA.

The **bony thorax** is narrow above and broad below, but the proportions are reversed in the completed human body by the presence of the large muscles which connect the upper extremity to the thorax.

Observe the *transverse ridge* on the *sternum*, marking the junction of the first and second pieces (the manubrium and the body). The second rib joins the sternum at this ridge (FIG. 206).

The boundaries of the **completed thorax** are the spinal column at the back, the sternum in front, and the ribs at the sides, with the intercostal muscles in the intercostal spaces and the diaphragm in the floor. It is covered behind by the muscles of the back, while the anterior serratus is on the side and the pectoral muscles are in front. The shoulder-blades are placed behind the thorax.

The *intercostal* arteries and nerves are protected from injury by their position under the borders of the ribs. A stab-wound would have to be directed upward to reach them.

All muscles which are attached to the ribs are *muscles of respiration*, the intercostals having considerable power, but the diaphragm being most important. When it contracts it is depressed, increasing the depth of the thoracic cavity, while the other muscles broaden the cavity by lifting the ribs, and thus room is made for expansion of the lungs in *inspiration*. As the ribs fall and the diaphragm ceases to contract, it rises, returning to its dome shape,

and thus the air is pressed from the lungs in *expiration*. These two acts complete a *respiration*, or an act of breathing, which occurs normally about eighteen times in a minute. If respiration is very difficult other muscles are called into play, as in asthma, when the struggle for breath is so great that "forced inspiration" is necessary.

The erector spinae muscles are always on duty, to steady the spine in order that the ribs may have a point of departure.

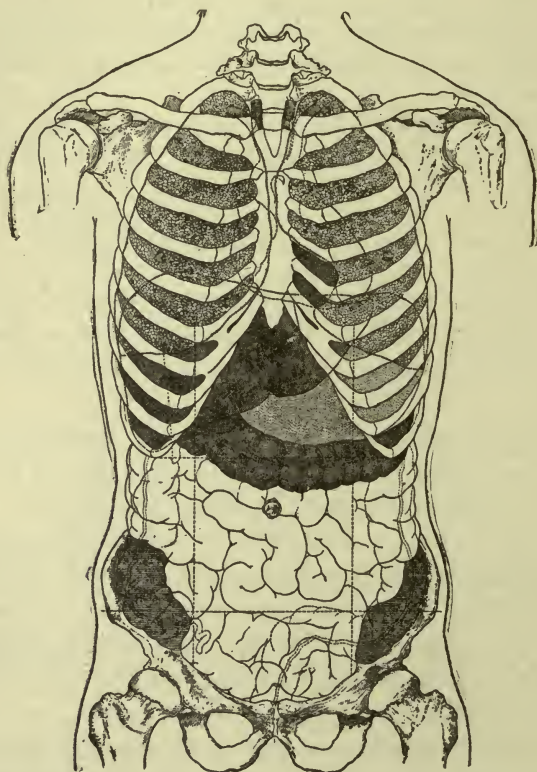


FIG. 206.—THORACIC AND ABDOMINAL VISCERA, ANTERIOR.

The *cardiac impulse* is felt (sometimes it may be seen) between the fifth and sixth ribs, half way between the sternum and the nipple line.

The *mammary gland* covers the front part of the spaces from the third to the fifth ribs. It lies between layers of the superficial fascia in front of the pectoralis major muscle.

The *superior opening* transmits the *trachea*, *esophagus*, and



important *vessels* and *nerves*. The floor (or *diaphragm*) has three openings—one for the passage of the *aorta* and *thoracic duct*, one for the *inferior vena cava*, and one for the *esophagus* and *vagus nerves*.

The **thoracic viscera** are the *esophagus*, *trachea* and *bronchi*, *lungs*, and *heart*. The *esophagus* lies close to the spinal column, and the *trachea* is in front of the esophagus, dividing into the large bronchi, whose branches are the bronchial tubes. The *heart* and large vessels are in the anterior and middle part of the thoracic cavity (Fig. 206).

The *heart* is wrapped in the *pericardium*, and each *lung* is wrapped in a *pleural sac* which is placed between the lung and the chest wall. An incision through that part of the wall which is bounded by the ribs would pierce the *costal pleura* and open the *pleural cavity*. A wound of the lung would injure the *pulmonary pleura* (Fig. 152).

The large nerves in the thoracic cavity are the *vagi*, lying close to the esophagus, the *sympathetic*, whose branches form cardiac and pulmonary plexus, and the two *phrenic* nerves, right and left, running down on either side of the pericardium to the diaphragm.

The **mediastinum** is the space between the lungs. In it all of the thoracic viscera except the lungs are situated.

#### THE ABDOMEN, ABDOMINAL VISCERA, AND PERITONEUM.

The boundaries of the completed **abdomen** are the *spinal column* and *quadratus lumborum muscles* at the back, the *hip-bones* below, the *rectus muscles* in front, and the *broad flat muscles* at the side. The *diaphragm* is its roof. The *transversalis fascia* lines the cavity, and the *peritoneum* is within the fascia, held to it by areolar tissue called *subperitoneal* or *subserous* tissue.

On the anterior surface of the abdomen observe the outline made by the lower ribs, between the thorax and abdomen, the two sides meeting in the *subcostal angle* just below the sternum. The *scrobiculus cordis*, or pit of the stomach, is a slight depression at the very point of the subcostal angle, caused by a weak spot in the attachment of the abdominal muscles. If the abdomen is distended, the depression disappears. The *linea alba* is between the two rectus muscles, and the semilunar lines (or *lineæ semilunares*) are at the sides of the recti. The *transverse lines* (*lineæ transversæ*) may be seen when the recti contract.

The *subcutaneous inguinal ring* is just above the tubercle of the pubic bone; the *abdominal inguinal ring* is a half inch above the middle of the *inguinal ligament*. The *conjoined tendon* is behind the subcutaneous ring.

The abdominal muscles and skin are supplied by the *lower intercostal* and *first lumbar nerves*.

The **regions of the abdomen** are outlined in the following manner: Imagine a horizontal plane passing through the abdomen at the level of the tenth costal cartilage, and another at the level of the anterior superior spine of the ilium. These would divide

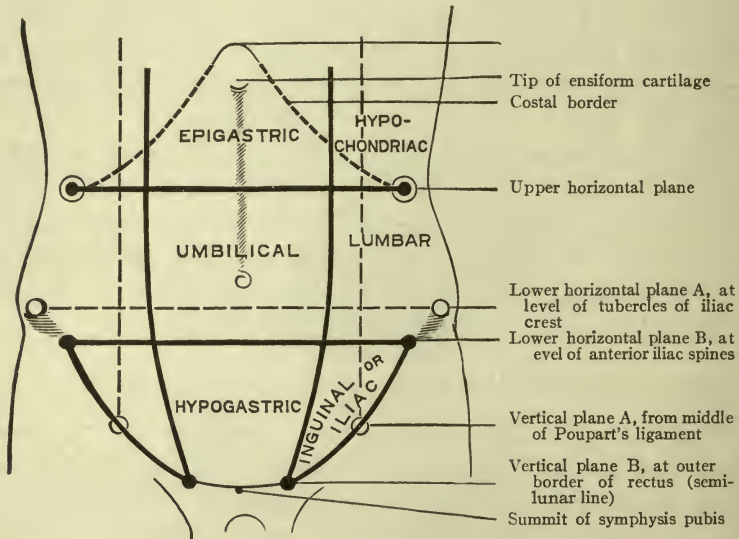


FIG. 207.—DIAGRAM OF THE ABDOMINAL REGIONS (MORRIS).

it into three portions—upper, middle, and lower. Then imagine two vertical planes passing through the middle point of the inguinal ligament on either side, and dividing each of these three portions into three *regions*, making *nine* in all.

The middle region is called the *umbilical*, having the umbilicus on the anterior surface. Above that is the *epigastric*, and below it is the *hypogastric*. At the sides of the epigastric region are the *right* and *left hypochondriac*. At the sides of the umbilical region are the *right* and *left lumbar*; and at the sides of the hypogastric region are the *right* and *left iliac*, or *inguinal*.

The **abdominal viscera** are the *stomach, intestines, liver, spleen, pancreas, kidneys, and adrenal bodies*. The *great vessels* are at the back. The *sympathetic ganglia* are at the sides of the vertebræ, with the celiac and other *plexuses* situated on the large vessels.

The *kidneys* are behind all of the other viscera, and the *ureters* run down close to the posterior wall of the abdomen on their way to the bladder.

The *receptaculum chyli*, or beginning of the *thoracic duct*, is in front of the second lumbar vertebra. The *inferior vena cava* lies on the right side of the aorta.

The principal organ in the *epigastric* region is the *stomach*; in the *right hypochondriac*, the *liver*; in the *left hypochondriac*, the *spleen*. The *umbilical* region is occupied mostly by *small intestines*. The right and left *kidneys* are in the two *lumbar* regions, with the *ascending colon* in front of the right, and the *descending colon* in front of the left kidney. The *cecum* and *appendix* are in the *right inguinal* region; the *bladder*, in the *hypogastric*.

Each region contains portions of several viscera in addition to those named. Scarcely any organ save the spleen and cecum can be said to belong to but one region.

The **peritoneum** is a closed sac of serous membrane like a water-bag, which is placed between the abdominal wall and abdominal viscera. It is practically in front of the viscera, and tucked in around them at the sides. One side of the sac is closely applied to the abdominal wall, and is called the *parietal peritoneum*, while the other side is fitted to the viscera, and called the *visceral peritoneum*. Normal peritoneum is perfectly transparent, and the viscera are plainly seen through the visceral layer. The *peritoneal cavity* contains a little serous fluid and nothing else.

An incision in the abdominal wall, including the *parietal peritoneum*, opens the peritoneal cavity. An incision into one of the organs involves the *visceral peritoneum*, with these exceptions:

The posterior surface of the liver.

The posterior surface of the ascending colon. The kidneys.

The transverse portion of the duodenum. The front of the bladder behind the symphysis. *These parts have no serous layer.*

The lowest portion of the peritoneal cavity is in the pelvis, extending down about three and a half inches in front of the rectum.

In the female this is called the *recto-uterine fossa*, or *pouch of Douglas*. In the male it is the *recto-vesical fossa*.

The folds of the peritoneum which are connected with the stomach are called *omenta* (p. 137).

The folds which connect the intestines to the abdominal wall are called *mesenteries* (p. 137).

The folds which connect other organs to the abdominal or pelvic walls are called *ligaments*. Those for the bladder are called *vesical ligaments*.

The *ligaments of the liver* are the *broad*, the *round*, the *coronary*, and the two *lateral* ligaments, which connect it to the diaphragm and the anterior abdominal wall.

Sometimes certain little pockets, or fossæ, exist in the peritoneum, behind the different portions of intestine. If a loop or knuckle of bowel slips into one of these fossæ it may press its way through it and pass behind the peritoneal sac. This is a *retro-peritoneal hernia*.

#### THE ISCHIO-RECTAL FOSSA.

This is a space between the ischium and the rectum. It is filled with loose connective tissue and adipose, and a few vessels and nerves are therein contained. The skin of the buttock forms the floor of the fossa; the lower part of the rectum is the medial wall; the fascia of the obturator muscle forms the lateral wall.

**Surgical note.**—If infection occur in this region, a very large abscess might result, the pus burrowing freely in the loose tissues. Ischio-rectal abscess is often caused by internal fistula.

#### THE AXILLARY SPACE.

The *axilla* is the armpit. Its shape is that of a *pyramid*, with the *apex* under the shoulder-girdle at the level of the first rib, the *base* of the pyramid being the *floor of the space* and composed of the skin and fascia crossing from the thorax to the arm. The *walls* of the space are formed by muscles—the *serratus* (principally) on the medial wall, covering the ribs; the long tendon of the *biceps* in its groove on the lateral wall; the *pectoral* muscles in the anterior wall, and the *subscapularis*, *latissimus dorsi* and *teres major* in the posterior wall.

The importance of this space is due to the large vessels and

nerve, and the lymph nodes, which are found in it. The vessels are the *axillary artery* and *vein*; the nerves are the *brachial plexus* and branches. A chain of *superficial lymph nodes* lies under the border of the *pectoralis major*, and a collection of deep ones is grouped around the large vessels; there are also a few near the posterior wall.

### THE ANTE-CUBITAL SPACE.

A triangular space in front of the elbow-joint.

Boundaries.—The *brachio-radialis*, *pronator teres*, and an imaginary *line* connecting the two *epicondyles*.

Important structures.—*Biceps tendon*, *brachial artery* and *veins*, *median nerve*. The artery is between the tendon and the nerve,

lying on the *brachialis* muscle. *Tendon* on *lateral* side of *artery*—Tendon, A-rtery, N-erve. The artery divides here.

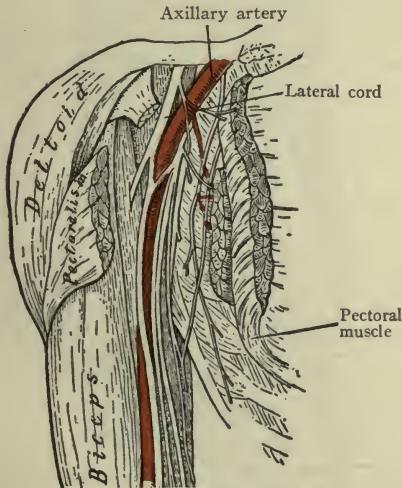


FIG. 208.—AXILLARY SPACE.  
Axilla laid open by division of anterior wall.

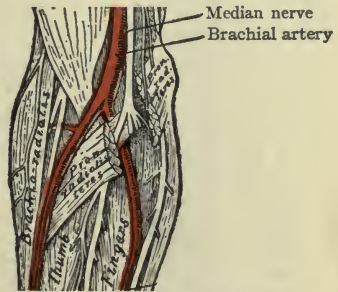


FIG. 209.—ANTE-CUBITAL SPACE.  
Pronator muscle divided to show ulnar artery.

### SCARPA'S TRIANGLE (TRIGONUM FEMORALE).

This triangle is on the front of the thigh. The *base* is formed by the *inguinal ligament*, the *lateral border* by the upper half of the *sartorius*, the *medial border* by the *adductor longus*, and the *apex* by the crossing of these two muscles on the medial side of the thigh at about the middle.

The most important structures in the triangle are the *femoral artery* and *vein* lying side by side, in a line from the middle of the

base to the apex. The femoral nerve and branches are to the lateral side of the artery.

Order of structures as they pass under the inguinal ligament: V-*ein*, A-*rtery*, N-*erve*, the vein being medialward.

### HUNTER'S CANAL (ADDUCTOR CANAL).

This is a passage from the front of the thigh around the medial side to the posterior, beginning at the apex of *Scarpa's triangle* and ending in the *popliteal space* by an *opening in the adductor magnus* muscle. The *femoral artery* passes through this canal, with the femoral vein on the medial side of the artery. The long saphenous nerve is sometimes within the canal and sometimes outside it.

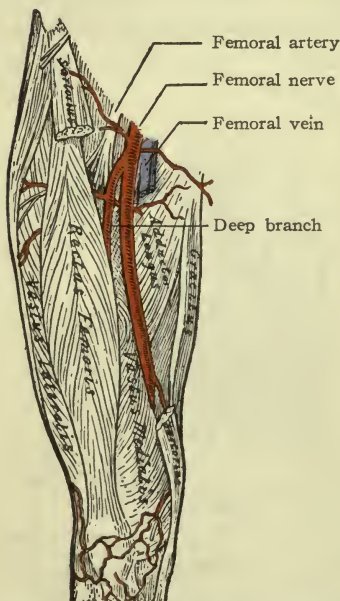


FIG. 210.—STRUCTURES IN SCARPA'S TRIANGLE; PORTION OF SARTORIUS REMOVED.

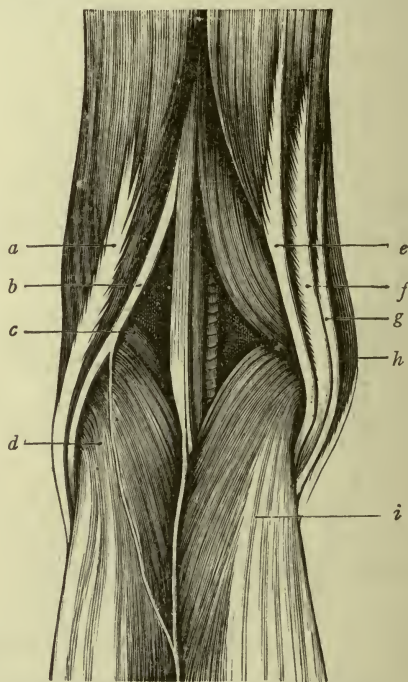


FIG. 211.—POPLITEAL SPACE (Holden).  
*a*, Biceps; *b*, peroneal nerve; *c*, plantaris;  
*d*, lateral head of gastrocnemius; *e*, semi-  
 tendinosus; *f*, semimembranosus; *g*, gracilis;  
*h*, sartorius; *i*, medial head of gastrocnemius.

### THE POPLITEAL SPACE.

This is a deep diamond-shaped space behind the knee-joint. Its *floor* is formed, from above downward, by the *popliteal surface* of

the *femur*, the *posterior ligament* of the joint, and the *popliteus muscle*. The boundaries of the upper half of the space are made by the *biceps* tendon on the lateral side, and the *semitendinosus* and *semimembranosus* on the medial side. The boundaries of the lower half are the *lateral* and *medial heads* of the *gastrocnemius*. These muscles are all very prominent, making the space deep. The *popliteal space* owes its importance to the large vessels and nerves which it contains—the *popliteal artery*, the *popliteal vein*, and *tibial* and *common peroneal nerves*. They are all deeply situated, the artery being the deepest, and are imbedded in adipose tissue and covered with strong fascia, being thus well protected.

#### THE INGUINAL RINGS AND INGUINAL CANAL.

There is an opening in the aponeurosis of the *external oblique muscle* just above the pubic bone, which is called the **subcutaneous inguinal ring**, being under the skin in the inguinal region.

There is an opening in the *transversalis fascia*, half an inch above the mid-point of the inguinal ligament. This is called the **abdominal inguinal ring**, opening into the abdominal cavity in the inguinal region. The passage from one ring to the other is the **inguinal canal**.

The *internal oblique* and *transversus* muscles form the *conjoined tendon* immediately behind the *subcutaneous ring*, and their lower muscle fibers arch over the canal, forming its upper boundary.

#### THE FEMORAL RING AND FEMORAL CANAL.

The **femoral ring** (*annulus femorale*) is a weak place in the pelvic wall, under the inguinal ligament, where the femoral vessels do not occupy the whole of the space in their sheath. It is on the medial side of the vein, bounded medially by *Gimbernat's ligament* (which is at the medial extremity of the inguinal ligament) and closed by transversalis fascia only, which at this spot is called the *crural septum* (*septum crurale*).

The **femoral canal** extends downward from this ring about three-quarters of an inch in the sheath of the femoral vessels.

#### HERNIA.

**Hernia** is defined as a tumor formed by the protrusion of contents of a cavity through its wall. This may occur at any weak place

in the wall, but is most frequent in the region of the *inguinal* or *femoral canals*.

If any structure slips accidentally through the inguinal canal it forms an **inguinal hernia**, which most commonly contains a loop of bowel. To replace the bowel or other structure is to *reduce the hernia*. If the loop cannot be replaced, the hernia is *irreducible*; and should it become so distended as to interfere with the circulation, it will be *strangulated*.

In *direct inguinal hernia* the contents of the tumor have passed directly through the *conjoined tendon* and *subcutaneous ring*. In *indirect inguinal hernia* the contents of the tumor have passed through the whole length of the inguinal canal—that is, first the *abdominal ring*, then the *canal*, then the *subcutaneous ring*.

**Umbilical hernia** occurs at the umbilicus; **ventral hernia** at any other part of the abdominal wall, *except* one or both rings.

**Diaphragmatic hernia** occurs at a weak or defective point in the diaphragm where an abdominal structure may press its way into the thorax.

In **femoral hernia** the bowel or other organ passes through the *femoral ring* into the *femoral canal* and pushes its way through the *femoral sheath* at the *oval fossa*, or saphenous opening.

#### THE EXTREMITIES COMPARED.

Both *extremities* are servants of the head and trunk. The *lower*, being fashioned for bearing weight and also for walking or running, are organs of locomotion, transporting the body from place to place as necessity or convenience may dictate; while the *upper* are organs of prehension, since they can reach forth and secure various things which are required for the use of the body.

*Flexion* of the *arm* is accomplished by a two-headed muscle—the *biceps*; flexion of the *thigh* by a double muscle, the *ilio-psoas*. *Extension* of the *elbow* is accomplished by a three-headed muscle, the *triceps*; extension of the *knee* requires a powerful four-headed muscle, the *quadriceps*.

We have learned to apply the terms *medial* and *lateral* to the body while in the *anatomical position*, in which the *forearm* is *supinated*; therefore the *thumb* is said to be on the *lateral* border of the hand, but the leg cannot be supinated, and the *great toe* lies on the *medial* border of the foot.



Observe that the *toes* of civilized man are freely *flexed* and *extended*, but have no other independent motions. They are slightly affected by the action of plantar muscles, but the foot has lost the suppleness it might have had without wearing shoes. The *fingers*, however, can all be moved sideways; the *median line* of the *hand* is a line drawn to the tip of the middle finger, and the digits are said to be abducted or adducted, according as their motion is from or toward this line.

The freedom and mobility of the *thumb* add very greatly to the usefulness of the hand in grasping, carrying, etc. If the finger tips approach each other, the hand falls into a gently curved position forming a cup, the "cup of Diogenes." If the hand be closed forcibly with the thumb holding the fingers against the palm, it becomes a solid irregular mass, the "fist," and so an ever-available weapon of offense or defense.

The shoulder (and whole upper extremity) is *pulled forward* by the action of the *anterior serratus* on the shoulder blade, and if this motion is accompanied by a sudden forcible extension of the arm and forearm, that is "striking out from the shoulder."

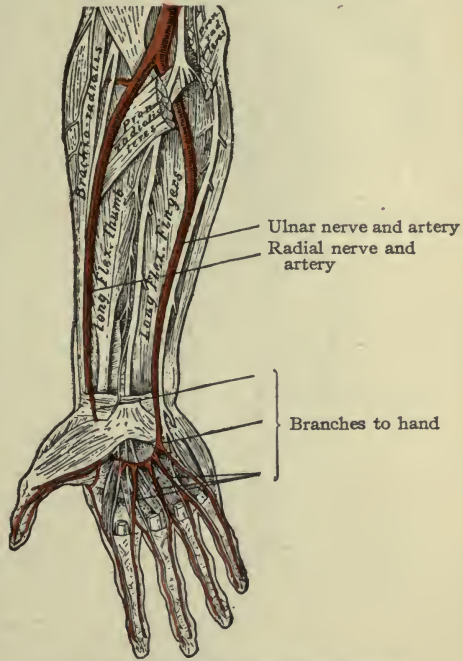


FIG. 212.—THE FOREARM, ANTERIOR.

#### REVIEW NOTES CONCERNING THE EXTREMITIES.

The upper extremity—From the shoulder down, the anterior surface is the *flexor* surface, and the posterior is the *extensor* surface of the extremity.

**Arm. Anterior.**—The *biceps* muscle, with the *median* nerve and *brachial* vessels on its medial border. **Posterior.**—*Triceps* muscle, with *radial* nerve in the groove between the two humeral heads.

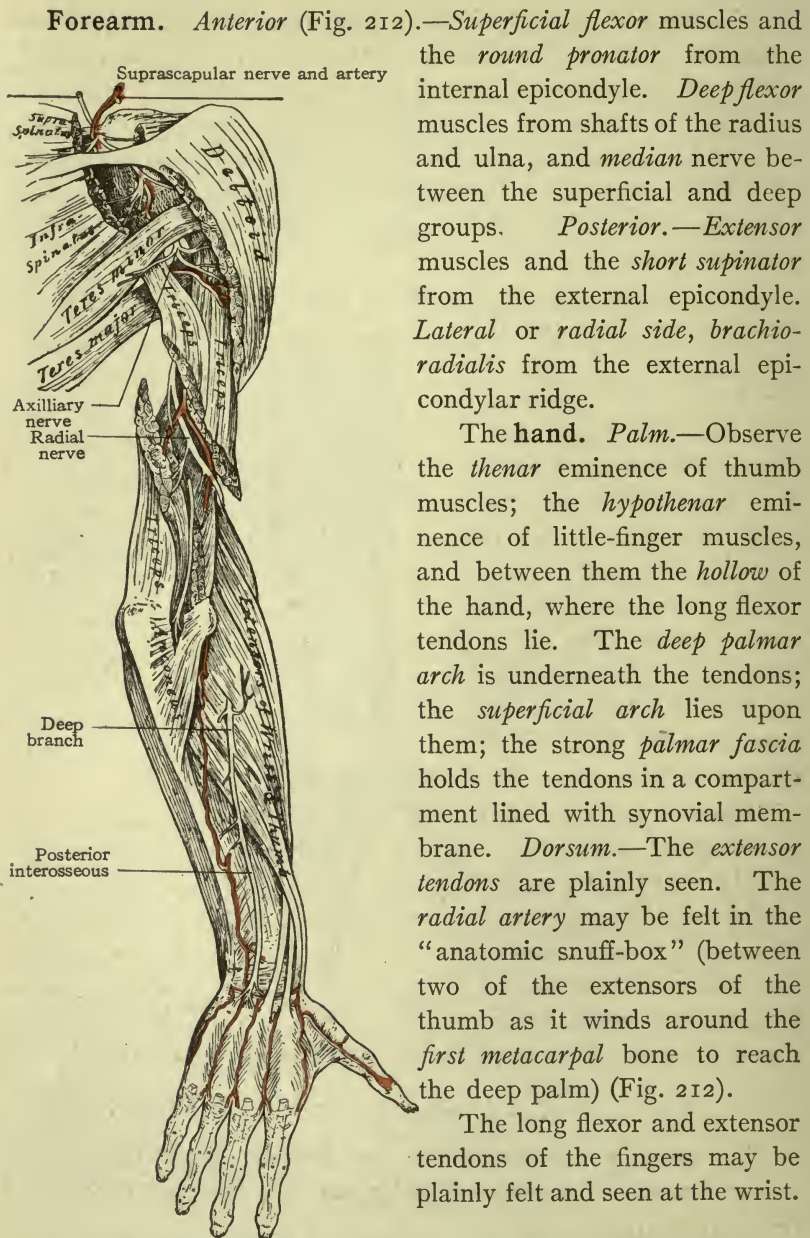


FIG. 213.—THE ARM AND FOREARM, POSTERIOR.

The lower extremity.—The *inguinal ligament* stretches from the spine of the *ilium* to the *tubercle of the pubes*.

The *femoral artery*, *femoral vein*, and *femoral nerve* pass under the ligament, the artery lying on the *psoas muscle*. Their order from the medial side outward is V-*ein*, A-*rtery*, N-*erve*.

From the hip down, the *anterior surface* is alternately *flexor* and *extensor* . . . . .

{ Flexor for hip.  
 { Extensor for knee.  
 { Flexor for ankle.  
 { Extensor for toes.

The *posterior surface* is exactly the reverse . . . . .

{ Extensor for hip.  
 { Flexor for knee.  
 { Extensor for ankle.  
 { Flexor for toes.

**Thigh.**—*Anterior and sides* of the femur are covered by the *quadriceps muscle*, which extends the knee. The *sartorius muscle* crosses from the anterior spine of the ilium to the middle of the medial side of the thigh and down to the tibia, and when it contracts it makes a *depression* rather than an elevation, because it binds the soft tissue under it. *Posterior.*—The *biceps*, *semimembranosus* and *semitendinosus* muscles flex the knee; they are *hamstring* muscles, making the upper boundaries of the *popliteal space*. The *medial* side of the thigh is occupied by the *adductor* muscles, with the *obturator nerve* and vessels.

**Leg.** *Anterior.*—The medial surface of the tibia is called *subcutaneous* because it is not covered by muscles; the *long saphenous nerve* and *vein* extend the whole length of this surface.

The *anterior tibial muscles* occupy the neighboring surfaces of the tibia and fibula, and their tendons all pass in front of the ankle-joint to *flex* it (dorsal flexion). The *lateral side* of the leg is occupied by the *peroneus longus* and *brevis* whose tendons pass *behind* the lateral malleolus to *extend* the foot. They are accompanied by the superficial peroneal nerve which supplies them (ant. tibial nerve).

The long tendons for the toes are plainly visible on the *dorsum* or top of the foot, and also those of the short flexor, which has four tendons belonging to the four medial toes.

*Posterior.*—The *calf muscles*, which lift the heel, completely cover the deep muscles whose tendons pass into the sole of the foot *behind* the medial malleolus to *extend* the foot.

The deep, or *posterior tibial muscles*, lie between tibia and fibula bound down by the *deep transverse fascia* of the leg.

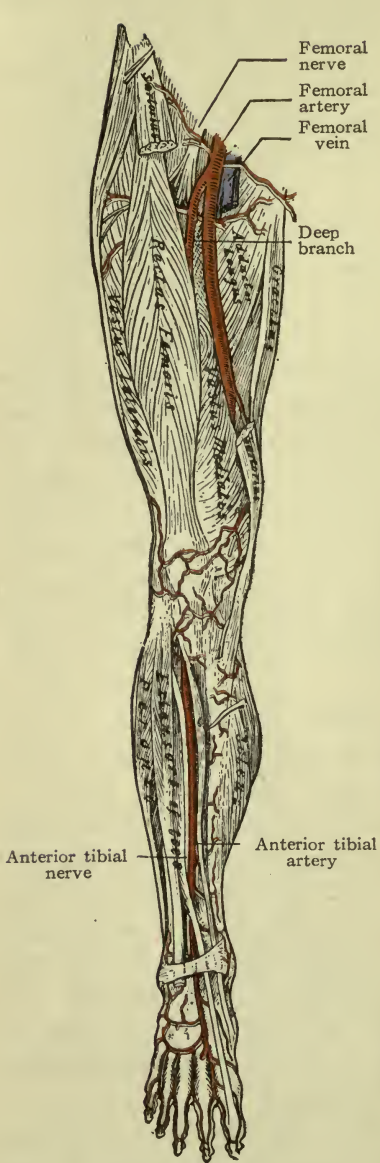


FIG. 214.—THE FEMORAL ARTERY.

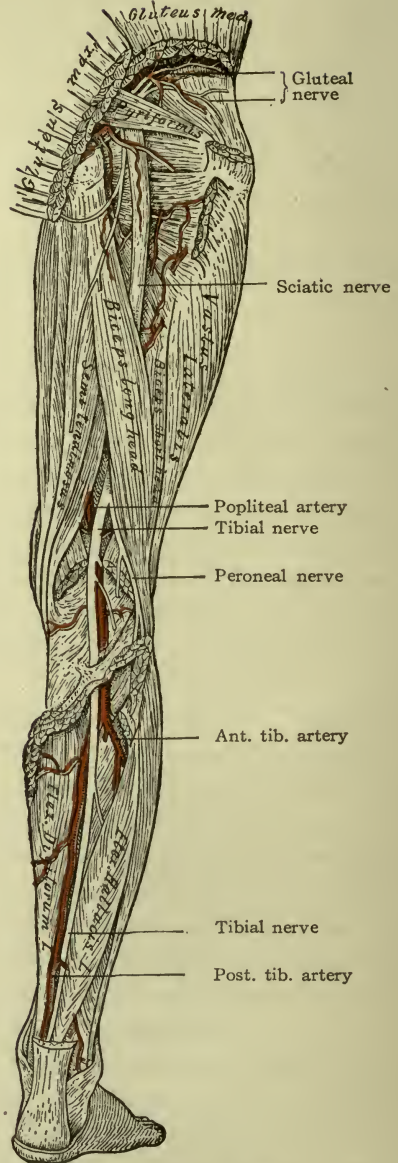


FIG. 215.—THE SCIATIC NERVE

The large nerves for the lower extremity are the **femoral** and the **sciatic**.

The **femoral** comes under the inguinal ligament into Scarpa's triangle and immediately breaks up into branches which supply the structures of the thigh, the *long saphenous* nerve being the only branch to go below the knee. It runs all the way to the medial border of the foot.

The **sciatic** comes through the great sciatic notch, descending between the great trochanter and the tuber of the ischium into the back of the thigh, to divide into the *tibial* and the *common peroneal* nerves. The *tibial nerve* continues under the calf muscles and into the plantar region. The *peroneal nerve* winds around the head of the tibia to the front of the leg, sending the *deep peroneal* branch to the anterior muscles, and dorsum of the foot.

#### LOCATION OF LARGE VESSELS AND NERVES IN THE EXTREMITIES.

The vessels and nerves are so placed as to be in the least possible danger from pressure or blows. For example, the *axillary* vessels and *brachial plexus* are deep in the axilla; the *brachial* vessels and *median* and *ulnar nerves* are on the less exposed side of the arm, and they pass *in front of* the elbow-joint where the motion of the joint will not interfere with them. So in the forearm, the *radial* and *ulnar* arteries and nerves are protected by muscles. At the wrist they also pass into the hand on the *flexor surface*.

The large nerve which passes behind the humerus, the *radial nerve*, is covered by the thick triceps muscle and winds to the *front* of the bone to pass the elbow-joint on its way to the forearm.

The *femoral* vessels and nerves are in the fold or *flexure* of the groin, and they wind around the femur to reach the *flexor surface* of the knee. Both *anterior* and *posterior tibial* arteries are well protected by muscles—the *posterior tibial* especially—which is under the *calf muscles* and the *transverse fascia* of the leg. As it passes the ankle-joint it lies under strong ligaments on the *medial side* of the joint, where it would not be put on the stretch during any natural motion of the foot nor exposed to blows. Again, the large arteries of the hand are in the *palm*, while those of the foot are in the *sole*.

## POINTS FOR COMPRESSION OF LARGER ARTERIES.

The **temporal**, on the zygoma.

The **external** maxillary, on the lower border of the mandible.

The **subclavian** on the first rib, behind the clavicle (downward and backward).

The **axillary**, on the humerus, in the lower part of the axilla.

The **brachial**, on the humerus, under medial border of the biceps muscle.

The **radial** and **ulnar**, on the bones of same name, in the lower part.

The **femoral**, against the ramus of the pubic bone, just below the inguinal ligament.

**Note.**—The subclavian artery is crossed by the *scalenus anticus* muscle which divides it into first, second, and third portions. The axillary artery is crossed by the *pectoralis minor muscle*, which divides it into first, second, and third portions. The common carotid artery is crossed by the *omo-hyoid muscle*; the portion below the muscle is in the *muscular* triangle of the neck; the portion above is in the *carotid* triangle.

CHAPTER XXIII.  
REFERENCE TABLES.

# THE SYSTEMIC ARTERIES.

## BRANCHES AND DISTRIBUTION, AND COLLATERAL CIRCULATION.

### NAMES OF LARGER ARTERIES.

<p><b>AORTA, ARCH</b> . . . . . INNOMINATE</p> <p>LEFT COMMON CAROTID . . . . .</p> <p>LEFT SUBCLAVIAN . . . . .</p> <p>SUPERIOR THYROID . . . . .</p> <p>LINGUAL . . . . .</p> <p>FACIAL OR EXT. MAXILLARY . . . . .</p> <p>ASCENDING PHARYNGEAL . . . . .</p> <p>POST. AURICULAR . . . . .</p> <p>OCCIPITAL . . . . .</p> <p>EXTERNAL CAROTID divides . . . . .</p> <p>INTERNAL CAROTID . . . . .</p> <p>MIDDLE CEREBRAL . . . . .</p> <p>ANTERIOR CEREBRAL . . . . .</p> <p>POSTERIOR COMMUNICATING . . . . .</p> <p>CHOROID . . . . .</p> <p>VERTEBRAL . . . . .</p> <p>INTERNAL MAMMARY . . . . .</p> <p>THYROID AXIS . . . . .</p> <p>SUPERIOR INTERCOSTAL . . . . .</p> <p>ACROMIAL THORACIC . . . . .</p> <p>LATERAL THORACIC . . . . .</p> <p>SUBSCAPULAR . . . . .</p> <p>ANTERIOR CIRCUMFLEX . . . . .</p> <p>POSTERIOR CIRCUMFLEX . . . . .</p>	<p>RIGHT SUBCLAVIAN</p> <p>RIGHT COMMON CAROTID . . . . .</p> <p>LEFT COMMON CAROTID . . . . .</p> <p>LEFT SUBCLAVIAN . . . . .</p> <p>SUPERIOR THYROID . . . . .</p> <p>LINGUAL . . . . .</p> <p>FACIAL OR EXT. MAXILLARY . . . . .</p> <p>ASCENDING PHARYNGEAL . . . . .</p> <p>POST. AURICULAR . . . . .</p> <p>OCCIPITAL . . . . .</p> <p>EXTERNAL CAROTID divides . . . . .</p> <p>INTERNAL CAROTID . . . . .</p> <p>MIDDLE CEREBRAL . . . . .</p> <p>ANTERIOR CEREBRAL . . . . .</p> <p>POSTERIOR COMMUNICATING . . . . .</p> <p>CHOROID . . . . .</p> <p>VERTEBRAL . . . . .</p> <p>INTERNAL MAMMARY . . . . .</p> <p>THYROID AXIS . . . . .</p> <p>SUPERIOR INTERCOSTAL . . . . .</p> <p>ACROMIAL THORACIC . . . . .</p> <p>LATERAL THORACIC . . . . .</p> <p>SUBSCAPULAR . . . . .</p> <p>ANTERIOR CIRCUMFLEX . . . . .</p> <p>POSTERIOR CIRCUMFLEX . . . . .</p>	<p>Right upper extremity.</p> <p>{ R. ext. carotid to right side neck and head—exterior.</p> <p>{ R. int. carotid to right side neck and head—interior.</p> <p>{ L. int. carotid to left side neck and head—interior.</p> <p>{ L. ext. carotid to left side neck and head—exterior.</p> <p>to left upper extremity.</p> <p>to thyroid gland.</p> <p>to tongue, larynx and tonsil.</p> <p>to face and tonsil.</p> <p>to throat and tonsil.</p> <p>to ear and scalp.</p> <p>to scalp and deep parts of neck; . . . . . one branch to neck—</p> <p>{ Anterior temporal—to scalp and side of face.</p> <p>{ Posterior temporal—to scalp.</p> <p>ear, pharynx, <i>dura mater</i> (<i>infraorbital</i> is a branch of)</p> <p>to eye and eye muscles, lacrimal gland and eyelids, forehead and nose, (the <i>Supraorbital</i> is a branch of)</p> <p>to parietal and temporal parts of brain . . . . .</p> <p>to parietal and frontal parts of brain . . . . .</p> <p>connects right and left <i>ant. cerebrals</i> . . . . .</p> <p>connects middle cerebrals with <i>post. cerebrals</i> (from basilar) . . . . .</p> <p>to lateral ventricle and large ganglia.</p> <p>up through transverse processes and foramen magnum; supplies neck, spinal cord, <i>brain</i>. The two vertebrals unite to form the basilar . . . . . { R. POST. CEREBRAL { L. POST. CEREBRAL</p> <p>down in chest, supplies intercostals, <i>mammary gland</i>, diaphragm, and rectus abdominis.</p> <p>Inferior thyroid to thyroid gland.</p> <p>{ Transverse artery of neck to neck and shoulder.</p> <p>{ Suprascapular to shoulder. . . . .</p> <p>to thoracic wall.</p> <p>to shoulder and pectoral muscles . . . . .</p> <p>thoracic wall, <i>mammary gland</i>.</p> <p>to shoulder muscles and latissimus dorsi . . . . .</p> <p>to front of shoulder-joint.</p> <p>to back of shoulder-joint and deltoid muscle.</p>	<p>ANASTOMOSIS BETWEEN EXT. CAROTID AND SUBCLAVIAN.</p> <p>CIRCLE OF WILLIS.</p> <p>ANASTOMOSING CIRCLE AROUND SHOULDER-JOINT.</p>
---	--	--	--



BRACHIAL . . . . .	SUP. PROFUNDA . . . . .	in spiral groove, triceps muscle	
	INFERIOR PROFUNDA . . . . .	downward, inner side of arm	
	NUTRIENT . . . . .	to humerus (about the middle)	
	ANASTOMOSING . . . . .	down toward elbow	
	RECURRENT . . . . .	to elbow-joint	} in forearm.
	MUSCULAR . . . . .	to neighboring muscles	
	ANTERIOR CARPAL . . . . .	to wrist	
	SUPERFICIAL VOLAR . . . . .	to ball of thumb	} in hand.
	METACARPAL AND INTEROSSEI . . . . .	to back of hand and fingers	
	POSTERIOR CARPAL . . . . .	to wrist	
	PRINCEPS POLLICIS . . . . .	to thumb	
	RADIALIS INDICIS . . . . .	to index finger	
	DEEP PALMAR ARCH . . . . .	supplies the palm of the hand.	
	TWO RECURRENT . . . . .	upward to elbow-joint.	
ULNAR . . . . .	{ anterior interosseous, in front of interosseous membrane, gives nutri-		
	{ ent arteries		
	{ posterior interosseous, behind interosseous membrane, } to both bones.		
	{ to muscles of forearm.		
MUSCULAR . . . . .	CARPAL, ANTERIOR AND POSTE-		
	RIOR . . . . .	to wrist.	
	SUPERFICIAL PALMAR ARCH . . . . .	gives <i>digital</i> branches to fingers.	
AORTA, THORACIC . . . . .	INTERCOSTAL, 10 OF 11 PAIRS . . . . .	to muscles in intercostal spaces, and upper abdomen.	
	BRONCHIAL . . . . .	to lungs.	
	PERICARDIAL . . . . .	to pericardium.	
	ESOPHAGEAL . . . . .	to œsophagus.	
	MEDIASTINAL . . . . .	to mediastinal structures.	
	PHRENIC . . . . .	to diaphragm.	
	LUMBAR, 4 PAIRS . . . . .	to abdominal muscles	} THESE SUPPLY ABDOMINAL AND PELVIC WALLS.
	MIDDLE SACRAL . . . . .	to front of sacrum	
	SUPRARENAL . . . . .	to suprarenal (or adrenal) bodies.	
	RENAL . . . . .	to kidneys	
	SPERMATIC . . . . .	to testes, or OVARIAN to ovaries	
	CELIAC . . . . .	{ Gastric—to stomach	
		{ Hepatic—to liver; also branches to stomach and pancreas	
		{ Splenic—to spleen; also branches to stomach and pancreas	
		{ Ileo-colic—to cecum and appendix	
		{ Right colic—to ascending colon	
		{ Middle colic—to transverse colon	
		{ Left colic—to descending colon	
		{ Sigmoid (several) to sigmoid colon	
		{ Superior hemorrhoidal—to rectum	
		{ Right internal iliac.	
		{ Right external iliac.	
		{ Left internal iliac.	
		{ Left external iliac.	
			} THESE SUPPLY ABDOMINAL VISCERA, RECTUM, AND OVARIES OR TESTES.
	SUPERIOR MESENTERIC . . . . .		
	INFERIOR MESENTERIC . . . . .		
	ABDOMINAL AORTA divides . . . . .	{ RIGHT COMMON ILIAC . . . . .	
		{ LEFT COMMON ILIAC . . . . .	



# NAMES OF ARTERIES ACCORDING TO THE B. N. A.

## NAMES OF LARGER ARTERIES.

**ARCUS AORTAE** . . . . . A. ANONYMA . . . . .  
BRANCHES AND DISTRIBUTION, AND COLLATERAL CIRCULATION.  
 { A. subclavia dextra . . . . .  
 { A. carotis communis, dextra . . . . .  
 { A. carotis interna dextra.  
 { A. carotis interna sinistra.  
 { A. carotis externa sinistra.
 { A. carotis externa sinistra.
 . . . . .

**A. CAROTIS INTERNA** . . . . .  
 A. CAROTIS COMMUNIS SINISTRA . . . . .  
 A. SUBCLAVIA SINISTRA . . . . .  
 A. THYREOIDEA SUPERIOR . . . . .  
 A. LINGUALIS . . . . .  
 A. MAXILLARIS EXTERNA . . . . .  
 A. PHARYNGEA ASCENDENS . . . . .  
 A. AURICULARIS POSTERIOR . . . . .  
 A. OCCIPITALIS . . . . .

The A. carotis externa divides . . . . .  
 { A. TEMPORALIS SUPERFICIALIS { Ramus frontalis,  
 { A. MAXILLARIS INTERNA { Ramus parietalis,  
 { A. infra-orbitalis, a branch of

**A. CAROTIS INTERNA** . . . . .  
 A. CEREBRI MEDIA . . . . .  
 A. CEREBRI ANTERIOR . . . . .  
 A. COMMUNICANS POSTERIOR . . . . .  
 A. CHOROIDEA . . . . .  
 A. VERTEBRALIS . . . . .  
 A. MAMMARIA . . . . .

**A. SUBCLAVIA** . . . . .  
 TRUNCUS THYREOCERVICALIS . . . . .  
 TRUNCUS COSTO CERVICALIS . . . . .  
 A. THORACALIS SUPREMA . . . . .  
 A. THORACO ACROMIALIS . . . . .  
 A. THORACALIS LATERALIS . . . . .  
 A. SUBSCAPULARIS . . . . .  
 A. CIRCUMFLEXA HUMERI ANTERIOR . . . . .  
 A. CIRCUMFLEXA HUMERI POSTERIOR . . . . .  
 A. PROFUNDA BRACHII . . . . .  
 A. COLLATERALIS ULNARIS SUPERIOR . . . . .  
 A. COLLATERALIS ULNARIS INFERIOR . . . . .  
 A. NUTRICIA HUMERI . . . . .  
 A. RECURRENS RADIALIS . . . . .  
 RAMI MUSCULARES . . . . .  
 RAMUS CARPEUS VOLARIS . . . . .  
 RAMUS VOLARIS SUPERFICIALIS . . . . .  
 A. CARPEUS DORSALIS . . . . .  
 A. METACARPEA DORSALIS . . . . .  
 A. RECURRENTES ULNARES . . . . .

**A. AXILLARIS** . . . . .  
 A. BRACHIALIS . . . . .  
 A. RADIALIS . . . . .  
 A. ULNARIS . . . . .

**A. CEREBRI ANTERIOR** . . . . .  
 A. CEREBRI POSTERIOR . . . . .  
 A. CEREBRI MEDIA . . . . .  
 A. CEREBRI INFERIOR . . . . .  
 A. CEREBRI SUPERFICIALIS . . . . .  
 A. CEREBRI PROFUNDA . . . . .  
 A. CEREBRI MEDIA . . . . .  
 A. CEREBRI INFERIOR . . . . .  
 A. CEREBRI SUPERFICIALIS . . . . .  
 A. CEREBRI PROFUNDA . . . . .

**A. VERTEBRALIS** . . . . .  
 A. VERTEBRALIS ANTERIOR . . . . .  
 A. VERTEBRALIS POSTERIOR . . . . .  
 A. VERTEBRALIS MEDIA . . . . .  
 A. VERTEBRALIS INFERIOR . . . . .  
 A. VERTEBRALIS SUPERFICIALIS . . . . .  
 A. VERTEBRALIS PROFUNDA . . . . .

**A. MAMMARIA** . . . . .  
 A. MAMMARIA INTERNA . . . . .  
 A. MAMMARIA EXTERNA . . . . .  
 A. MAMMARIA MEDIA . . . . .  
 A. MAMMARIA SUPERFICIALIS . . . . .  
 A. MAMMARIA PROFUNDA . . . . .

**A. THYREOIDEA SUPERIOR** . . . . .  
 A. THYREOIDEA INFERIOR . . . . .  
 A. THYREOIDEA MEDIA . . . . .  
 A. THYREOIDEA PROFUNDA . . . . .

**A. LINGUALIS** . . . . .  
 A. LINGUALIS ANTERIOR . . . . .  
 A. LINGUALIS POSTERIOR . . . . .

**A. MAXILLARIS EXTERNA** . . . . .  
 A. MAXILLARIS INTERNA . . . . .  
 A. MAXILLARIS MEDIA . . . . .  
 A. MAXILLARIS PROFUNDA . . . . .

**A. PHARYNGEA ASCENDENS** . . . . .  
 A. PHARYNGEA MEDIA . . . . .  
 A. PHARYNGEA PROFUNDA . . . . .

**A. AURICULARIS POSTERIOR** . . . . .  
 A. AURICULARIS ANTERIOR . . . . .

**A. OCCIPITALIS** . . . . .  
 A. OCCIPITALIS ANTERIOR . . . . .  
 A. OCCIPITALIS POSTERIOR . . . . .

**A. CEREBRI MEDIA** . . . . .  
 A. CEREBRI ANTERIOR . . . . .  
 A. CEREBRI POSTERIOR . . . . .  
 A. CEREBRI MEDIA . . . . .  
 A. CEREBRI INFERIOR . . . . .  
 A. CEREBRI SUPERFICIALIS . . . . .  
 A. CEREBRI PROFUNDA . . . . .

**A. CEREBRI ANTERIOR** . . . . .  
 A. CEREBRI POSTERIOR . . . . .  
 A. CEREBRI MEDIA . . . . .  
 A. CEREBRI INFERIOR . . . . .  
 A. CEREBRI SUPERFICIALIS . . . . .  
 A. CEREBRI PROFUNDA . . . . .

**A. CEREBRI POSTERIOR** . . . . .  
 A. CEREBRI ANTERIOR . . . . .  
 A. CEREBRI MEDIA . . . . .  
 A. CEREBRI INFERIOR . . . . .  
 A. CEREBRI SUPERFICIALIS . . . . .  
 A. CEREBRI PROFUNDA . . . . .

**A. CEREBRI MEDIA** . . . . .  
 A. CEREBRI ANTERIOR . . . . .  
 A. CEREBRI POSTERIOR . . . . .  
 A. CEREBRI MEDIA . . . . .  
 A. CEREBRI INFERIOR . . . . .  
 A. CEREBRI SUPERFICIALIS . . . . .  
 A. CEREBRI PROFUNDA . . . . .

**A. CEREBRI INFERIOR** . . . . .  
 A. CEREBRI ANTERIOR . . . . .  
 A. CEREBRI POSTERIOR . . . . .  
 A. CEREBRI MEDIA . . . . .  
 A. CEREBRI INFERIOR . . . . .  
 A. CEREBRI SUPERFICIALIS . . . . .  
 A. CEREBRI PROFUNDA . . . . .

**A. CEREBRI SUPERFICIALIS** . . . . .  
 A. CEREBRI ANTERIOR . . . . .  
 A. CEREBRI POSTERIOR . . . . .  
 A. CEREBRI MEDIA . . . . .  
 A. CEREBRI INFERIOR . . . . .  
 A. CEREBRI SUPERFICIALIS . . . . .  
 A. CEREBRI PROFUNDA . . . . .

**A. CEREBRI PROFUNDA** . . . . .  
 A. CEREBRI ANTERIOR . . . . .  
 A. CEREBRI POSTERIOR . . . . .  
 A. CEREBRI MEDIA . . . . .  
 A. CEREBRI INFERIOR . . . . .  
 A. CEREBRI SUPERFICIALIS . . . . .  
 A. CEREBRI PROFUNDA . . . . .

**A. CEREBRI MEDIA** . . . . .  
 A. CEREBRI ANTERIOR . . . . .  
 A. CEREBRI POSTERIOR . . . . .  
 A. CEREBRI MEDIA . . . . .  
 A. CEREBRI INFERIOR . . . . .  
 A. CEREBRI SUPERFICIALIS . . . . .  
 A. CEREBRI PROFUNDA . . . . .

**A. CEREBRI ANTERIOR** . . . . .  
 A. CEREBRI POSTERIOR . . . . .  
 A. CEREBRI MEDIA . . . . .  
 A. CEREBRI INFERIOR . . . . .  
 A. CEREBRI SUPERFICIALIS . . . . .  
 A. CEREBRI PROFUNDA . . . . .

**A. CEREBRI POSTERIOR** . . . . .  
 A. CEREBRI ANTERIOR . . . . .  
 A. CEREBRI MEDIA . . . . .  
 A. CEREBRI INFERIOR . . . . .  
 A. CEREBRI SUPERFICIALIS . . . . .  
 A. CEREBRI PROFUNDA . . . . .

**A. CEREBRI MEDIA** . . . . .  
 A. CEREBRI ANTERIOR . . . . .  
 A. CEREBRI POSTERIOR . . . . .  
 A. CEREBRI MEDIA . . . . .  
 A. CEREBRI INFERIOR . . . . .  
 A. CEREBRI SUPERFICIALIS . . . . .  
 A. CEREBRI PROFUNDA . . . . .

**A. CEREBRI INFERIOR** . . . . .  
 A. CEREBRI ANTERIOR . . . . .  
 A. CEREBRI POSTERIOR . . . . .  
 A. CEREBRI MEDIA . . . . .  
 A. CEREBRI INFERIOR . . . . .  
 A. CEREBRI SUPERFICIALIS . . . . .  
 A. CEREBRI PROFUNDA . . . . .

**A. CEREBRI SUPERFICIALIS** . . . . .  
 A. CEREBRI ANTERIOR . . . . .  
 A. CEREBRI POSTERIOR . . . . .  
 A. CEREBRI MEDIA . . . . .  
 A. CEREBRI INFERIOR . . . . .  
 A. CEREBRI SUPERFICIALIS . . . . .  
 A. CEREBRI PROFUNDA . . . . .

**A. CEREBRI PROFUNDA** . . . . .  
 A. CEREBRI ANTERIOR . . . . .  
 A. CEREBRI POSTERIOR . . . . .  
 A. CEREBRI MEDIA . . . . .  
 A. CEREBRI INFERIOR . . . . .  
 A. CEREBRI SUPERFICIALIS . . . . .  
 A. CEREBRI PROFUNDA . . . . .

CONNECTION BETWEEN A.  
 CAROTIS EXTERNA AND  
 A. SUBCLAVIA.

CIRCLE  
 AROUND  
 THE  
 ELBOW-  
 JOINT.

NAMES OF ARTERIES ACCORDING TO THE B. N. A.—(Continued).

NAMES OF LARGER ARTERIES.

- A. ULNARIS . . . . . A. INTEROSSEA COMMUNIS . . . . .  
 RAMI MUSCULARES { A. interossea volaris.  
 RAMUS CARPEUS VOLARIS { A. interossea dorsalis.  
 RAMUS CARPEUS DORSALIS

BRANCHES AND DISTRIBUTION, AND COLLATERAL CIRCULATION.

*Arcus volaris superficialis* gives AA. digitales (to fingers).

- AORTA THORACALIS** . . . AA. INTERCOSTALES  
 AA. BRONCHIALES  
 RAMI PERICARDIACI  
 AA. OESOPHAGICALES  
 RAMI MEDIASTINALES

- AORTA ABDOMINALIS** . . . . . } These supply abdominal and pelvic walls  
 A. PHRENICA INFERIOR . . . . .  
 AA. LUMBALES . . . . .  
 A. SACRALIS MEDIA . . . . .  
 AA. SUPRARENALES . . . . .  
 AA. RENALES . . . . .  
 AA. SPERMATICAE INTERNAE . . . . .  
 A. COELIACA . . . . .

- { A. gastrica sinistra . . . . .  
 A. hepatica . . . . .  
 A. lienalis . . . . .  
 A. ileocolica . . . . .  
 A. colica dextra . . . . .  
 A. colica media . . . . .  
 A. colica sinistra . . . . .  
 AA. sigmoidae . . . . .  
 A. hemorrhoidalis superior . . . . .

These supply abdominal viscera, rectum, and ovaries or testes.

- A. ILLIACA COMMUNIS DEXTRA  
 A. ILLIACA COMMUNIS SINISTRA (A. iliaca communis divides . . . . . { A. hypogastrica.  
 . . . . . { A. iliaca externa.)

CIRCLE AROUND HIP-JOINT,  
"CRUCIAL ANASTOMOSIS."

- A. HYOGASTRICA . . . . .
- A. ILIO-LUMBALIS . . . . .
- A. GLUTAEA SUPERIOR . . . . .
- A. GLUTAEA INFERIOR . . . . .
- A. OBTURATORIA . . . . .
- A. PUDENDA INTERNA . . . . .
- A. VESICALIS INFERIOR . . . . .
- A. UTERINA . . . . .
- A. HEMORRHOIDALIS MEDIA . . . . .
- A. SACRALIS LATERALIS . . . . .
- A. EPIGASTRICA INFERIOR . . . . .
- A. CIRCUMFLEXA PROFUNDA ILIUM . . . . .
- A. FEMORALIS . . . . .
- A. EPIGASTRICA SUPERFICIALIS . . . . .
- A. CIRCUMFLEXA ILIUM SUPERFICIALIS . . . . .
- AA. PUDENDAE EXTERNAE . . . . .
- A. PROFUNDA FEMORIS . . . . .
- A. circumflexa femoris lateralis . . . . .
- A. circumflexa femoris medialis . . . . .
- A. perforans prima . . . . .
- A. perforans secunda . . . . .
- A. perforans tertia . . . . .

- RAMI MUSCULARES . . . . .
- A. GENU SUPREMA . . . . .
- AA. SURALES . . . . .
- A. GENU SUPERIOR MEDIALIS . . . . .
- A. GENU INFERIOR MEDIALIS . . . . .
- A. GENU SUPERIOR LATERALIS . . . . .
- A. GENU INFERIOR LATERALIS . . . . .
- A. GENU MEDIA . . . . .
- AA. RECURRENTES . . . . .
- AA. MUSCULARES . . . . .
- AA. MALLEOLARES . . . . .
- A. DORSALIS PEDIS . . . . .
- AA. larscae . . . . .
- A. arcuata . . . . .
- A. metatarsca dorsalis . . . . .
- Ramus plantaris profundus (to join arcus plantaris) . . . . .

CIRCLE AROUND KNEE-JOINT.

- A. POPLITEA . . . . .
- (A. poplitea divides . . . . .)
- { A. tibialis anterior . . . . .
- { A. tibialis posterior . . . . .
- A. TIBIALIS ANTERIOR . . . . .
- AA. RECURRENTES . . . . .
- AA. MUSCULARES . . . . .
- AA. MALLEOLARES . . . . .
- A. DORSALIS PEDIS . . . . .
- AA. larscae . . . . .
- A. arcuata . . . . .
- A. metatarsca dorsalis . . . . .
- Ramus plantaris profundus (to join arcus plantaris) . . . . .
- A. TIBIALIS POSTERIOR . . . . .
- AA. MUSCULARES . . . . .
- A. NUTRICIA TIBIAE . . . . .
- A. MALLEOLARIS . . . . .
- RAMI CALCANEI MEDIALES . . . . .
- A. tibialis posterior divides . . . . .
- { A. plantaris medialis . . . . .
- { A. plantaris lateralis . . . . .
- forms arcus plantaris . . . . .

CIRCLE AROUND ANKLE-JOINT.

- A. tibialis posterior divides . . . . .
- { A. plantaris medialis . . . . .
- { A. plantaris lateralis . . . . .
- forms arcus plantaris . . . . .

VENA CAVA SUPERIOR.

THE SYSTEMIC VEINS—B. N. A.

RIGHT UPPER EXTREMITY  
(current flows upward).

*Deep* veins.

vv. ulnares }  
vv. radiales }

*Superficial* veins. v. basilica empties into . . . . .  
v. cephalica empties into . . . . .

R. HEAD AND NECK

(current flows downward). *Superficial* veins. v. jugularis externa empties into . . . . .  
*Deep* veins from face, throat and neck and brain to . . . . .

L. UPPER EXTREMITY . . . . . Veins in a similar manner form the . . . . .

L. HEAD AND NECK . . . . . Veins in a similar manner form the . . . . .

NOTE.—V. anonyma sinistra crosses in front of branches of aorta (arch) to join v. anonyma dextra.

THORAX

(current toward heart). vv. intercostales empty into }  
vv. bronchiales empty into }  
vv. mediastinales empty into }  
vv. pericardiaci empty into }  
vv. esophageales empty into }  
vv. cardiaci empty into vena cordis magna and sinus coronarius cordis which opens into atrium dexter.

v. azygos }  
v. hemiazygos }  
v. hemiazygos accessoria }  
v. azygos collects from the other two and  
opens into VENA CAVA SUPERIOR.

R. LOWER EXTREMITY  
(current upward) . . . . .

*Deep* vv. plantares—sole of foot—vv. tibiales posteriores }  
vv. dorsales—top of foot—vv. tibiales anteriores }  
v. poplitea = v. femoralis = v. iliaca externa dextra.

*Superficial*, posterior of leg to saphena parva empties . . . . .  
medial of leg and thigh to saphena magna empties . . . . .

R. PELVIS . . . . . Deep walls and viscera . . . . .

vv. uterinae  
vv. vesicales  
vv. pudendae  
vv. gluteae inferiores  
vv. obturatoriae . . . . .

. . . . . v. hypogastrica dextra.

L. LOWER EXTREMITY . . . . . Veins in similar manner form the . . . . .

. . . . . v. iliaca externa sinistra.

L. PELVIS . . . . . Veins in similar manner form the . . . . .

. . . . . v. hypogastrica sinistra.

VENA CAVA INFERIOR.

V. ILIACA COMMUNIS DEXTRA (2 inches). V. ILIACA COMMUNIS SINISTRA (2 inches).

ABDOMEN.	Viscera. . . . .	} VENA PORTAE to Liver—vv. hepaticae } PORTAL CIRCULATION. } to VENA CAVA INFERIOR	
	v. gastrica . . . . .		"
	v. hepatica . . . . .		"
	v. pancreatica . . . . .		"
	v. mesenterica superior . . . . .		"
	v. mesenterica inferior . . . . .		"
	vv. adrenales to . . . . .		"
	vv. renales to . . . . .		"
	vv. ovaricae . . . . .		"
	or		
	vv. spermaticae to . . . . .	"	
	vv. phrenicae to . . . . .	"	
	vv. lumbales to . . . . .	"	
	v. epigastrica superficialis to v. iliaca externa to v. iliaca communis to	"	
	v. epigastrica superior to v. mammae interna to v. anomyia to	"	
	Walls. . . . .	VENA CAVA SUPERIOR	

ATRIUM  
OF  
RIGHT  
HEART.

SUMMARY.

Venous blood from parts *above the diaphragm* is conveyed to VENA CAVA SUPERIOR.  
Venous blood from parts *below the diaphragm* is conveyed to VENA CAVA INFERIOR.

NOTE.—The vena cava inferior is on the right side of the aorta abdominalis, and runs up through an opening in the diaphragm to the heart.





- Abdomen.** From a word meaning *to conceal*. The abdomen contains or *conceals* the abdominal organs.
- Abduction.** From a Latin word meaning *to lead from*. The *abducens* muscle leads, or turns, the eye from the median line.
- Acetabulum.** A small vessel or cup for vinegar. The name given to the round depression or cavity of the hip bone or *os coxae*, for the head of the femur.
- Acid.** Sour. Acids redden blue litmus paper.
- Accommodation.** The adjusting or focussing of the eye for vision at different distances.
- Acromegaly.** A disease characterized by over-growth of the face and extremities.
- Acromion.** From Greek words meaning *summit* and *shoulder*. The process of bone at the highest point of the shoulder.
- Adduction.** Leading toward.
- Adenoid.** Resembling a gland or *aden*. A gland-like growth in the naso-pharynx.
- Adipose.** Fatty, Fat.
- Afferent.** Bearing toward. Afferent vessels enter organs.
- Ala.** A wing. (Plural, *alae*.)
- Alimentary.** Pertaining to food or *aliment*, as the *alimentary tract*, which contains the food until it is digested.
- Alkaline.** Opposite of *acid*. An alkali turns red litmus paper blue.
- Alveolus.** The border of the jaw bone, named for the cavities which contain the teeth. (*Alveolus*, a little hollow.)
- Ameba.** A one-celled, jelly-like living being, which constantly changes its form.
- Ameboid movements.** Movements which cause a change of form, like those of the *ameba*.
- Amylopsin.** The starch-digesting ferment of pancreatic fluid.
- Anastomosis.** The opening of one vessel into another. Literally—*to bring to a mouth*.
- Ancon.** The elbow. *Anconeus*, a muscle of the elbow-joint.
- Annulus.** A little ring. (*Annulus ovalis*, the oval little ring of the heart.)
- Anonyma.** Without a name.
- Antebrachium.** The forearm. From *ante*, before, and *brachium*, the arm.
- Antecubital.** Applied to the space in front of the elbow. From *ante*, before, and *cubit*; the forearm.
- Antrum.** A cave. The hollow in the maxilla is called the *Antrum of Highmore*.
- Aorta.** The largest artery in the body.
- Apnea.** Suspension of breathing.
- Aponeurosis.** A layer of strong white fibrous tissue (meaning from a tendon).
- Aqueous.** Watery, from *aqua*, water.
- Arachnoid.** Like a spider's web, for fineness. One of the membranes of the brain and spinal cord.
- Areolar.** Having little spaces.
- Artery.** A vessel carrying blood away from the heart.
- Arthrosis.** A joint or *articulation*.
- Arytenoid.** Shaped like the mouth of a pitcher.
- Assimilation.** The taking up of nutriment by the body tissues, in such a manner that it becomes a part of them.
- Atlas.** A fabled giant who bore the globe upon his shoulders. The first cervical vertebra, upon which the skull rests.
- Atrium.** A hall, a chamber of the heart where blood enters.
- Atrophy.** Wasting. From a Greek word signifying *want of nourishment*.
- Auricular.** Shaped like, or belonging to, an ear or *auricle*.
- Axis.** The second cervical vertebra. Named because of the pivot around which the atlas revolves (like a wheel around an axis).
- Axone.** An axis. The essential part of a nerve fiber.

- Azygos.** Without a yoke. The name of certain vessels which are not in pairs.
- Biceps.** Having two heads, as the *biceps* femoris; *biceps* brachii.
- Bicuspid.** Having two points or cusps. A *bicuspid* tooth.
- Bone corpuscle.** A formation cell of bone tissue.
- Brachialis.** Belonging to the arm, or *brachium*.
- Bronchus.** An air tube. (Plural, *bronchi*.) The smallest air tubes are called *bronchioles*.
- Buccinator.** From a word meaning *trumpet*. The blowing or trumpeting muscle.
- Bursa.** Literally, a purse. The *bursæ* are small sacs containing fluid and found in the fascia under skin, or muscles, or tendons.
- Calcaneus.** The heel bone. The *tendo calcaneus*, or tendo Achillis, is attached to the *calcaneus*.
- Calculus.** A stone-like body formed in some fluid of the body. *Renal calculus*, in the kidney; *biliary c.*, in the gall-bladder, etc.
- Callus.** A thickened portion of the skin. The material thrown out (*provisional callus*) for the repair of fractured bone, to become the *permanent callus* when the bone is completely ossified.
- Cancellous.** Resembling lattice work. A *cancellous* or spongy bone.
- Canine.** Resembling a dog. *Canine teeth*, like a dog's teeth.
- Canthus.** The angle at the meeting of upper and lower eyelid; plural *canthi*.
- Capillary.** Resembling a hair in size. (*Capillus*, a hair.)
- Capitulum, or capitulum.** A little head, an eminence on the lower extremity of the humerus.
- Capsule.** A structure which encloses an organ or part. (The *capsule* of a joint.)
- Carbo-hydrate.** A substance composed of carbon and water; sugars and starches.
- Cardiac.** Belonging to the heart or *cardia*.
- Caries.** Decay of bone. *Carious*, decaying.
- Carotid.** The name of the large arteries of the neck, once thought to cause sleep. From a Greek word meaning to *produce sleep*.
- Caruncle.** A small soft projecting tumor. *Urethral caruncle*, a minute tumor of the urethral mucous membrane, made up mostly of nerves and vessels.
- Casein.** The proteid or cheesy part of milk.
- Cauda equina.** A horse-tail. The name given to the bundle of spinal nerves in the lower portion of the spinal canal.
- Cecum.** Blind. The blind pouch at beginning of the large intestine.
- Celiac (cœliac).** Pertaining to the *celia* or belly.
- Center.** In the nerve system, a *center* is a collection of gray cells. The *central nerve system* comprises the brain and spinal cord, which contain the large nerve *centers*. *Central convolutions* contain a majority of motor centers.
- Cerumen.** The wax of the ear. (*Cera*, wax.)
- Cervix.** Neck. *Cervical*, belonging to or resembling a neck.
- Choana.** A funnel. The *choanæ* are the posterior openings from the nose into the pharynx.
- Choroid.** Like the *chorion*, which is a fetal membrane bearing blood-vessels.
- Cicatrix.** A scar. It is formed of fibrous connective tissue.
- Cilia.** Eyelashes. *Ciliated*, having tiny hair-like projections, as *ciliated epithelium*.
- Ciliary.** The *ciliary region* of the eye presents radiating lines, caused by folds of the tissues composing it (*ciliary processes*).
- Circumduction.** Leading around. This is the motion made when a part is moved around in a circle, one end being stationary. The extremities, the digits and the head, may be circumducted.
- Circumflex.** To bend around. *Circumflex* arteries wind around the arm or thigh.
- Circumvallate.** Walled around. The circumvallate papillæ at the base of the tongue are encircled by a ridge.
- Clavicle.** The *clavicula*, which resembles a very ancient key.
- Climacteric.** Literally, *the round of a ladder*. Any time of life when the system is believed to undergo marked and permanent changes; usually applied to the time of the cessation of menstruation.
- Coagulation.** From *coagulare*, to curdle. The clotting of blood. *Coagulum*, a blood clot.
- Coccyx.** A cuckoo's beak. The bone at the end of the spinal column, named from its shape.
- Cochlea.** A conch-shell. A cavity of the internal ear resembling a snail-shell in form.
- Collateral.** From words meaning *side* and *together*. *Collateral circulation* is secured by the union of branches of two vessels, whereby the main current of fluid may be carried by this side route if necessary.

- Commissure.** A placing together. A commissure connects two parts of an organ, as the *commissures* of the brain.
- Communis.** Common. Applied to a muscle whose tendons are common to several organs.
- Concha.** A shell.
- Condyle.** A knuckle. A rounded eminence of bone.
- Conoid.** Shaped like a cone.
- Convolut.** Twisted.
- Co-ordinate.** From words meaning *together*, and *to order or regulate*. *Co-ordination* is the systematic acting together of several parts.
- Coracoid.** Like a crow's beak. The *coracoid* process of the scapula.
- Corium.** Leather. The deep portion of the skin from which leather is made.
- Cornea.** Horny. The tough transparent membrane in the anterior of the eyeball.
- Cornua.** Plural of *cornu*, a horn.
- Coronal or coronoid.** Pertaining to, or resembling a crown.
- Coronary.** The *coronary* arteries encircle the base of the heart.
- Corpus callosum.** The transverse commissure of the cerebral hemispheres.
- Corpuscle.** A little body. A blood cell. *Malpighian corpuscle*, a structure in the kidney. *Lymph corpuscle*, a cell formed in a lymph gland.
- Corpus luteum.** Yellow body. The substance formed in a ruptured Graafian follicle of the ovary.
- Cortex.** Bark. The superficial layer, as the *cortex* of the brain.
- Costal.** Relating to a rib or *costa*.
- Coxæ.** Plural of *coxa*, the hip; *os coxæ*, the bone of the hip.
- Cranium.** The part of the skull which contains the brain.
- Crest.** A ridge of bone, either on a surface or at the border.
- Cretinism.** The condition of a *cretin* or undeveloped person, both mentally and physically.
- Cribriform.** Resembling a sieve.
- Cricoid.** Like a ring. The *cricoid cartilage* of the larynx is shaped like a seal ring.
- Crucial.** Like a cross. The *crucial ligaments* cross each other.
- Crural.** Belonging to or like the lower extremity, from *crus*, a leg; as the *crural nerve*, the *crura* (or legs) of the diaphragm.
- Cystic.** Relating to a *cyst*, or a sac containing fluid (*cystic duct*). A *cystic ovary* has cysts developed from its substance.
- Deglutition.** The act of swallowing.
- Deltoid.** Shaped like the Greek letter *delta*,  $\Delta$ .
- Dental.** From *dens*, a tooth, belonging to a tooth.
- Dentated.** Having points which resemble teeth.
- Dentition.** The eruption or "cutting" of the teeth.
- Diapedesis.** A *jumping through*. The passing of blood cells through the walls of capillaries.
- Diaphragm.** A wall across a space. The muscle which separates the cavity of the thorax from that of the abdomen.
- Diaphysis.** The greater part of the shaft of a bone.
- Diarthrosis.** A movable joint.
- Diastole.** A Greek word meaning *a drawing apart*. The dilation of the chambers of the heart.
- Digit.** A finger or toe.
- Distal.** Farthest from the head or trunk.
- Dorsal.** Belonging to the *dorsum*, or back.
- Duodenum.** Meaning twelve. The duodenum is twelve finger-widths long.
- Dura mater.** *Hard mother*. The fibrous outer membrane of the brain and spinal cord.
- Edema.** Swelling caused by effusion of serous fluid into areolar tissues.
- Efferent.** Bearing from. Efferent vessels leave organs.
- Effusion.** An abnormal pouring out (or secreting) and collection of fluid in the body.
- Eliminate.** From words meaning *without the threshold*. To excrete substances which are useless.
- Embryo.** The ovum and structures belonging to it constitute the *embryo*, until the fourth month of intrauterine life.
- Endo-.** Within. *Endocardium*, within the heart. *Endothelium*, the epithelium of the interior of circulatory organs.

- Endomysium.** The sheath of a muscle-fiber.
- Endosteum.** The lining of medullary canals in long bones.
- Ensiform.** Sword-shaped. The appendix of the sternum.
- Enteric.** Pertaining to the *enteron* or intestine, as *enteric* or *typhoid fever*.
- Enzyme.** Any ferment in a digestive fluid.
- Epi.** Upon, as *epi-condyle*, *epidermis*, *epiglottis*.
- Epimysium.** The connective tissue muscle sheath.
- Epiphysis.** A part of a bone which is formed independently, and joined later, to complete the whole bone.
- Epithelial.** Pertaining to epithelium.
- Epithelium.** The uppermost or superficial layer of cells of a body surface.
- Erythrocyte.** A red cell of the blood. A red corpuscle.
- Esophagus.** From a Greek word meaning *to carry food*. The *esophagus* transmits food from pharynx to stomach.
- Ethmoid.** Sieve-like. The *ethmoid bone* has many openings on its surface.
- Excretion.** A waste substance to be removed from the body. The process of removing waste from the tissues.
- Extension.** Stretching out or extending. (Bending backward as over-extension.)
- Eversion.** Turning outward. To *evert* an eyelid is to fold it back so as to expose the interior surface.
- Falx.** A sickle.
- Falciform.** Sickle-shaped.
- Fascia.** A band; plural, *fascia*. The tissue which binds organs or parts of organs together.
- Fauces.** From the Latin word *fauces*, the throat. *Isthmus* of, the space bounded by the soft-palate, tonsils and tongue. *Pillars* of, folds connecting the soft palate, with the tongue and pharynx. (The tonsil is between the pillars of either side.)
- Femoral.** Belonging to the *femur* or thigh bone.
- Fetus.** After the fourth month, the embryo becomes the *fetus*.
- Fibrin.** A proteid substance of the blood which causes coagulation.
- Filiform.** Thread-like in shape, slender; as *filiform papillae* of the tongue.
- Fimbria.** A fringe; *fimbriated*, having a fringe-like appearance.
- Fissure.** A cleft or groove, as a *fissure* of the brain surface.
- Fistula.** A pipe. A tube-like passage caused by disease.
- Flava.** Plural of *flavus*, yellow. Applied to elastic ligaments, which contain yellow elastic tissue.
- Flexion.** Bending. *Flexure*, a bend.
- Follicle.** A very small sac (or bag) containing a secretion.
- Fontanelle.** A little spring. A membranous spot in the infant's skull; the name suggested by the rising and falling caused by the child's respirations.
- Foramen.** A hole. Plural, *foramina*.
- Fossa.** A depression or concavity.
- Fourchette.** A little fork.
- Fovea.** A small pit. The *fovea centralis* is a tiny depression in the macula lutea of the retina.
- Frenum.** A curb or bridle. The *frenum linguae* is the fold of mucous membrane attaching the tongue to the floor of the mouth.
- Fundus.** The base.
- Fungiform.** Shaped like a fungus or mushroom.
- Fusiform.** Spindle-shaped.
- Ganglion.** A knot. (Plural, *ganglia*.) A collection of nerve cells.
- Gaster.** The stomach, *Gastric*, belonging to the stomach or *gaster*.
- Gastrocnemius.** The belly of the leg. The prominent muscle of the calf of the leg.
- Genioglossus.** Belonging to the chin and tongue.
- Genu.** A knee.
- Glabella.** A little smooth space. The smooth space between the eyebrows.
- Gladiolus.** A little sword. The body of the sternum.
- Gland.** A collection of cells which can form a secretion or an excretion.
- Glans.** The head of the clitoris or penis.
- Glenoid.** Having the form of a shallow cavity. Belonging to a cavity.
- Glossopharyngeal.** Belonging to the tongue and pharynx.
- Glottis.** The upper opening of the larynx. *Epiglottis*, the leaf-shaped cartilage upon the upper border of the larynx.

- Glucose.** Grape sugar. Dextrose.
- Gluteus.** Belonging to the *gluteus* or buttock.
- Glycogen.** A white substance formed principally in the liver. Sometimes called *animal starch*.
- Gustatory.** Associated with the sense of taste.
- Gyre.** From *gyrus*, a circle. A convolution, (referring to the convolutions of the brain).
- Haversian.** Name applied to the tiny canals in bone tissue, from the English anatomist Havers.
- Hepatic.** Belonging to the liver or *hepar*.
- Hemoglobin.** The oxygen-carrying substance of red blood cells, to which their color is due.
- Hemorrhoidal.** From a word meaning *flowing with blood*. Pertaining to a *hemorrhoid* or pile.
- Hilum.** Literally, a *little thing*. Applied to the depression where vessels enter and leave an organ.
- Hormones.** Chemical substances (character unknown), formed (probably) in ductless glands, and conveyed by the blood to other organs, to influence their activity.
- Hyaline.** Resembling glass. *Hyaloid* has a similar meaning.
- Hydration.** Saturating with water.
- Hydrocephalus.** A collection of fluid either within the ventricles or outside of the brain.
- Hyoid.** U-shaped, as the *hyoid bone*.
- Hypertrophy.** Over-growth. Derived from two Greek words meaning *too much nourishment*.
- Hypochondrium.** Under the cartilage. The *hypochondriac region* is under the cartilages of ribs. (*Hypo-* under.)
- Hypogastric.** Under the stomach.
- Hypoglossal.** Under the tongue.
- Hypothenar.** Under the palm or sole. The eminence on the medial side of the palm or the sole.
- Ileum.** A roll or twist; the portion of small intestine which appears rolled or convoluted.
- Ilium.** The upper portion of the hip-bone or *os coxae*.
- Incisor.** A cutting instrument. The front teeth are *incisors*.
- Index.** Indicator. The first finger named from its common use.
- Infra.** Beneath.
- Infundibulum.** A funnel-shaped space or part.
- Inguinal.** Belonging to or near to the thigh or *inguen*.
- Inlet.** The superior opening or *brim* or *strait* of the pelvis.
- Innominatum.** Unnamed.
- Inorganic.** A term applied to certain substances, mostly mineral, found in all organs but not produced by them.
- Instep.** The bend of the foot, dorsal aspect.
- Inter.** Between, as *intercostal*, between ribs; *intercellular*, between cells, etc.
- Inversion.** A turning in, as *inversion* of the eyelashes; *inversion* of the foot.
- Invertin.** The ferment of intestinal juice.
- Involution.** The changing back to a former condition of an organ which has fulfilled a function, as the *involution of the uterus* after parturition.
- Iris.** A circle or halo of colors. The colored circle behind the cornea of the eye.
- Ischium.** The lowest part of the hip-bone or *os coxae*.
- Jejunum.** Empty. The third portion of the small intestine, usually found empty.
- Jugular.** Belonging to the neck or *jugulum*.
- Kidney or ren** (plural, *renes*). An important organ of elimination or excretion in which the urine is formed.
- Labium.** A lip. (Plural, *labia*.)
- Lacrimal.** Having to do with tears or *lacrymæ*, as the *lacrimal glands*.
- Lacteal.** Like milk (from *lac*, milk). The *lacteals* are lymph vessels which carry the milky-looking chyle.
- Lactose.** Milk sugar.
- Lambdoid.** Resembling the Greek letter lambda  $\lambda$ .
- Lamella.** A little plate, or thin layer.
- Lamina.** A plate or layer.

- Larynx.** The part of the air-passage extending from the base of the tongue to the trachea.
- Latissimus.** Broadest. *Latissimus dorsi*, broadest of the back.
- Lens.** A glass or crystal curved and shaped to change the direction of (or refract) rays of light.
- Lentiform.** Shaped like a lens.
- Leptomeningitis.** Inflammation of the thin membranes of the brain—the arachnoid and pia mater.
- Leucocyte.** A white cell of the blood or lymph. *Leucocytosis*, an increase in the number of leucocytes.
- Levator.** A lifter. *Levator palpebræ*, lifter of the eyelid.
- Linea.** A line.
- Linea alba.** A white line.
- Linea aspera.** A rough line.
- Lingual.** Belonging to the tongue or *lingua*.
- Lobule.** A little lobe.
- Lumbar.** Belonging to the loin or *lumbus*.
- Macula.** A spot. *Macula lutea*, yellow spot.
- Major.** Greater or larger.
- Malar.** Belonging to the cheek or *mala*.
- Malleolus.** A little hammer. The two *malleoli* are the lower extremities of tibia and fibula.
- Mammary.** Pertaining to the breast or *mamma*.
- Mandible.** Derived from *mandere*, to chew. The lower jaw-bone.
- Manubrium.** A handle. The first part of the sternum.
- Masseter.** A chewer. One of the muscles of mastication or *chewing*.
- Mastitis.** Inflammation of the breast.
- Mastoid.** Shaped like a breast.
- Maxilla.** The jaw-bone. Applied to the upper jaw-bone.
- Meatus.** A passage.
- Medial.** Toward the middle line.
- Median.** Middle, as the median line of the body.
- Mediastinum.** From Latin words meaning *to stand in the midst*. The space in the middle of the thorax.
- Medulla.** Marrow.
- Medullary.** Pertaining to, or like, marrow. The *medullary canals* contain marrow.
- Meninges.** Membranes. Membranes of the brain and spinal cord.
- Mental.** From the Latin word *mens*, the mind.
- Mental.** From the Latin word *mentum*, the chin.
- Mesentery.** From two Greek words, meaning *middle* and *bowel*. (The mesentery connects the bowel with the posterior abdominal wall.)
- Metastasis.** From a Greek word meaning *to transpose*.
- Minimus.** Least or smallest. *Minimi digiti*, of the smallest digit.
- Minor.** Lesser.
- Mitral.** Resembling a miter in outline.
- Molar.** Like a mill-stone or *mola*. The *molar* teeth grind the food.
- Mucous.** Containing or resembling *mucus*.
- Mucus.** A thick clear fluid secreted by the cells of mucous membranes.
- Naris.** The nostril. (Plural, *nares*.)
- Navicular.** Boat-shaped, as the *navicular* bone.
- Necrosis.** The death of a portion of tissue, while still surrounded by living structures.
- Neural.** Pertaining to nerves. The *neural axis* is the spinal cord. The *neural canal* is the spinal canal. The *neural cavity* contains the brain and spinal cord.
- Neuron.** A single nerve cell with its branches.
- Nucha.** The nape of the neck.
- Nucleolus.** A smaller nucleus within the nucleus of a cell.
- Nucleus.** A small round body near the center of a cell. The most important part of a nucleated cell.
- Nutrient.** Nourishing.
- Nutrition.** The process of nourishing the cells of living tissues.
- Olecranon.** The large process at the upper end of the ulna. The head of the elbow.
- Occipital.** Belonging to the back of the head, or the occiput.
- Odontoid.** Resembling a tooth in shape.

- Omentum.** A fold of peritoneum connected with the stomach.
- Omos.** The shoulder. Omo-hyoid, belonging to shoulder and hyoid bone, as the *omo-hyoid* muscle.
- Ophthalmic.** Belonging to the eye or *ophthalmos*.
- Ora serrata.** The serrated or toothed margin of the retina.
- Orbicular.** Ring-shaped. A ligament which resembles a little circle.
- Organ.** A structure designed for a particular function or use. *Organic substances* are formed in, or by, organs.
- Os.** A bone. (Plural, *ossa*.)
- Os.** A mouth. (Plural, *ora*.)
- Osseous.** Bony.
- Ossification.** The formation of bone.
- Osteology.** The science which treats of bones.
- Ostium venosum.** A venous door. The door or opening from an atrium to a ventricle in the heart, for the passage of venous blood.
- Outlet.** The inferior opening or strait, of the pelvis.
- Ovum.** An egg. (Plural, *ova*.)
- Palpebra.** An eyelid. *Palpebral fissure*, the fissure between the eyelids.
- Pancreas.** From words meaning *all* and *flesh*. Pancreatic fluid digests all foods.
- Papilla.** A Latin word meaning a *nipple*. A soft conic eminence.
- Parietal.** Resembling a wall (*paries*).
- Parotid.** Near the ear. The *parotid gland* is around the external ear.
- Parturition.** The act of bringing forth, or giving birth to, young.
- Patella.** A little pan. The sesamoid bone in front of the knee-joint; the "knee pan."
- Pectoral.** Connected with the breast, as *pectoral muscles*.
- Pedicle.** A little foot.
- Pelvis.** A basin. The cavity in the lowest part of the trunk.
- Pericardium.** Around the heart.
- Perichondrium.** Around cartilage.
- Perimysium.** The connective tissue around small bundles of muscle fibers.
- Perineal.** Pertaining to the *perineum*, that region of the body in front of the anus.
- Periosteum.** Around bone.
- Peristalsis.** From two Greek words, meaning *around* and *constriction*. The intestinal movements which propel the food.
- Peritoneum.** From two Greek words, meaning *around* and *stretch*. The serous membrane around abdominal organs.
- Peroneal.** Relating to the fibula or *perone*. *Peroneal* nerves supply muscles on the fibula.
- Petrous.** Hard, like a rock.
- Phagocyte.** White blood-cells having the power to take micro-organisms into their substance and to digest them.
- Phalanges.** Plural of *phalanx*, a body of troops drawn up closely together. The fingers and toes.
- Pharynx.** That part of the food passage which connects the mouth and esophagus. The upper part is the *naso-pharynx*, an air passage.
- Phlebotomy.** Cutting a vein. The operation of bleeding or venesection.
- Pia mater.** Tender mother. The delicate membrane which bears the blood-vessels of brain and cord.
- Pigment.** Coloring matter.
- Plantar.** Belonging to the sole of the foot or *planta*.
- Plasma.** *Something moulded*. The name given to the fluid portion of the blood, from which tissues are formed.
- Platysma.** Broad. Platysma muscle.
- Pleura.** A side. The name of the serous membrane which lines the thorax and covers the lungs.
- Plexus.** An arrangement of vessels and nerves which appear to be woven together.
- Pneumogastric.** Belonging to the lungs and stomach.
- Pollicis.** Genitive form of *pollex*, the thumb.
- Polymorphonuclear.** Having nuclei of various shapes.
- Poples.** The ham; a space behind the knee (popliteal space).
- Popliteal.** Belonging to the *poples* or back of the knee.
- Porta.** A gate. The portal vein enters the *porta* or gate of the liver.
- Prehension.** Taking hold of.

- Pre-molar.** Applied to the teeth which stand immediately in front of the molars.
- Process.** In anatomy, a projection.
- Pronation.** Literally, bending forward. The position of the hand when the thumb is toward the body. The act of turning the hand face downward, or in the *prone* position.
- Prostate.** From Greek words meaning *stand before*. The prostate gland is in front of the neck of the bladder.
- Protoplasm.** A simple gelatinous cell substance. **Bioplasm.** (Plural, *bioplasms*.)
- Protuberance.** A knob-like projection.
- Proximal.** Near the head or trunk.
- Psychical.** Pertaining to the mind.
- Pterygoid.** Wing-shaped.
- Pubes.** The anterior portion of the *os coxae*.
- Pulmonary.** Pertaining to the lung or *pulmo*.
- Quadriceps.** Four headed.
- Rachitis.** From two words meaning *spinal column* and *inflammation*. A disease in which the bones are deficient in lime salts.
- Radius.** A rod or spoke. The lateral bone of the forearm.
- Ramus.** A branch, as the *ramus* of the mandible.
- Raphé.** A seam. The union of two parts in a line, like a seam.
- Reaction.** Response to a stimulus or test. The iris reacts to the stimulus of light. Urine reacts to the litmus test.
- Reflex action.** The simplest form of nerve response.
- Receptaculum chyli.** Receptacle of the chyle, the beginning of the thoracic duct.
- Recession.** Withdrawal, as the margin of the gums from the teeth.
- Rectus.** Straight, as *rectus muscles*. *Rectum* has the same meaning.
- Recurrent.** Running back. *Recurrent arteries* turn back.
- Renal.** Pertaining to the *ren* or kidney.
- Retina.** A net. The complicated nerve coat of the eye.
- Rugæ.** Folds. (Plural of *rugæ*.) Wrinkles.
- Saccharose.** Cane sugar.
- Sacral.** Relating to the *sacrum*, or bone which protects the pelvic organs which were held sacred by the ancients.
- Sagittal.** Like an arrow—straight. The straight suture of the skull.
- Saline.** Salty.
- Saliva.** The mixed secretions of glands of the mouth and salivary glands.
- Saphenous.** Manifest or plainly seen. The large superficial vein on the medial side of the lower extremity and the longest vein in the body.
- Sartorius.** From the Latin *sartor*, tailor. The "tailor muscle."
- Sciatic.** *Ischiatic*. Pertaining to the ischium.
- Sclerotic.** Hard. The *sclerotic* is the tough fibrous coat of the eye; the *sclera*.
- Scrobiculus cordis.** Literally, pit of the heart. The little depression at the end of the sternum. The "pit of the stomach."
- Sebaceous.** Applied to the glands which produce the oil or *sebum* of the skin.
- Secretion.** A substance either nourishing or useful, formed by glandular cells.
- Septum.** A partition. (Plural, *septa*.)
- Serous.** Of the nature of *serum*, a thin watery fluid derived from the blood.
- Serrated.** Having teeth like the border of a saw.
- Serum.** A watery fluid separated from blood.
- Sesamoid.** Resembling a grain in form. Applied to small nodules of bone sometimes found in tendons.
- Shaft.** The main portion of a long bone.
- Sigmoid.** Curved like the letter S. As the *sigmoid* (or transverse) sinus; the *sigmoid* colon.
- Sinus.** A curve, or a hollow. A bone sinus contains air. An abnormal passage opening on the surface of the body is sometimes called a sinus.
- Soluble.** That which can be dissolved or made into a *solution*.
- Sphenoid.** Wedge-shaped.
- Sphincter.** A muscle which closes an orifice.
- Splanchnic.** Pertaining to the viscera or internal organs.
- Squamous.** Shaped like a scale.
- Steapsin.** The pancreatic ferment which digests fats.
- Sternum.** Breast bone.



- Striated.** Striped
- Styloid.** Pointed, like the *stylus*, which was used in ancient times for writing.
- Sub.** Under.
- Subcutaneous.** Under the skin.
- Submucous.** Under mucous membrane.
- Subserous.** Under serous membrane.
- Sudoriferous.** Bearing sweat, as sudoriferous glands. (*Sudoriparous* has the same meaning.)
- Super.** Above.
- Superciliary.** Above the eyelashes.
- Supercilium.** The eyebrow, or prominence above the eyelashes.
- Supination.** The attitude of one lying on the back. The position of the hand when the little finger is next to the body, or when lying upon the back.
- Supra.** Above.
- Sural.** Belonging to the calf or *sura*, as the *sural* muscles.
- Surgical neck.** The constriction below the head of a long bone at the narrowest portion of the shaft. The *anatomic neck* is the constriction (however slight) immediately next to the head, between it and the shaft. The *surgical neck* of the humerus and the *anatomic neck* of the femur are best examples.
- Suture.** A seam. (Latin, *sutura*). The joints of the cranium are *sutures*.
- Symphysis.** A growing together, as the *symphysis* of the mandible.
- Synarthrosis.** An immovable joint.
- Synovia.** A fluid resembling the white of an egg, found in joint cavities and vaginal synovial membranes.
- Systole.** A Greek word meaning *contraction*. The contraction of the chambers of the heart.
- Talus.** The ankle bone upon which the tibia rests.
- Tendo Achillis.** The tendon of Achilles. The tendon of calf muscles attached to the *calcaneus* or heel bone by which Achilles was held when his mother submerged him in the river Styx, to render him invulnerable. Only the heel remained un-wetted.
- Tentorium.** A tent. The tentorium cerebelli (of the cerebellum) covers the cerebellum.
- Teres.** Round. (*Ligamentum teres*—round ligament.)
- Testes, or Testicles.** The glandular bodies which secrete semen.
- Thalamus.** A Greek word meaning a *bed*. The optic thalamus is in the base or bed of the brain.
- Thenar.** Relating to the palm or sole. *Hypothenar*—under the palm or sole—applied to the eminences on the side corresponding to the little finger or toe.
- Thorax.** The chest. The portion of the trunk which contains the heart and lungs.
- Thyroid or thyreoid.** Shield shaped.
- Torticollis.** Twisted neck, wry neck.
- Trabeculæ.** *Little beams*. (Plural of *trabecula*.) The cross bands of connective tissue which support soft structures—as in the spleen.
- Trapezium.** A four sided symmetrical figure. *Trapezoid*, resembling a trapezium, but not symmetrical. *Trapezius*, applied to a muscle of the back.
- Triceps.** Three headed.
- Trigone.** A space or surface having three angles or corners.
- Trochanter.** From a word signifying a *wheel*. (The muscles which are attached to the trochanters roll the femurs.)
- Trochlea.** A pulley. A trochlear surface is a grooved convexity, as the *trochlea* of the humerus.
- Trypsin.** The ferment of the pancreas which digests proteids.
- Tuber.** A swelling or bump.
- Tubercle.** A small projection like a swelling.
- Tuberosity.** A large projection on a bone.
- Tumor.** A swelling of soft tissues.
- Turbinated.** Rolled, like a scroll.
- Tympany.** The condition caused by inflation of intestines with gas, so that they sound hollow upon percussion, like a *tympanum* or drum.
- Ulna.** A cubit; the elbow. The longer bone in the medial side of the forearm.
- Umbilicus.** From a Latin word, *umbo*, the name of the elevated or depressed point in the middle of an oval shield.

- Ungual.** Belonging to the nail or *unguis*.
- Urea.** A substance representing the chief nitrogenous product of tissue waste.
- Ureter.** The duct of the kidney, which conveys urine to the bladder.
- Urethra.** The passage through which urine is expelled from the bladder.
- Uvula.** From *uva*, a grape, or cluster of grapes (which hangs down from the branch where it grows).
- Vaginal.** Like a sheath.
- Vallate.** Situated in a cavity which is surrounded by a ridge.
- Valvulæ conniventes.** Little valve-like folds. Seen on the mucous coat of the small intestine.
- Vascular.** Having many blood-vessels.
- Vaso-motor.** Literally, *vessel-mover*. Applied to the nerves which dilate blood-vessels or contract them.
- Velum.** Veil. *Velum palati*, the veil, or soft hanging portion of the palate or roof of the mouth.
- Vena cava.** A large hollow vein.
- Venesection.** Cutting a vein. "Bleeding" or phlebotomy.
- Ventral.** Toward the front of the body, as the *ventral cavity*.
- Ventricle.** Literally, a *little belly*. From the Latin *venter*. A cavity in the brain, or in the heart.
- Vermiform.** Worm-shaped.
- Vertebra.** From a Latin word meaning *to turn*. Certain movements of the vertebræ turn the body from side to side.
- Vertex.** The crown of the head.
- Vestibule.** A cavity of the internal ear through which stimulating impulses are transmitted to auditory and vestibular nerves.
- Villus.** A hair (pl. *villi*). The villi of the intestine are hair-like in shape and belong to the mucous coat.
- Viscus.** An internal organ of the head or trunk. (Plural, *viscera*.)
- Vitreous.** Glassy. The *vitreous humor* resembles glass in appearance. The *vitreous layers* of the skull are brittle like glass.
- Volar.** Belonging to the palm or *vola*.
- Xyphoid.** Sword-shaped. The third piece of the sternum is the *xyphoid* or ensiform appendix.
- Zygoma.** A yoke. The arch of bone at the side of the face formed by zygomatic processes of frontal and maxillary bones.

## INDEX.

- Abdomen. abdominal organs, 297  
regions of, 298  
Abdominal brain (Solar Plexus) 264  
Abdominal wall, 88  
Absorption, 148, 151  
Accommodation, 278  
Acromegaly, 224  
Adipose tissue, 3  
Adrenal bodies, 222  
Air, or atmosphere, 143, 202  
Alimentary canal, 120  
Ameboid movements, 153  
Anatomic position and use of terms, 1  
Animal heat, 226  
Antibrachium or forearm, 52  
Antrum of Highmore, 21  
Aorta, 167 169  
Apnea, 209  
Aponeurosis, description of, 79  
Apophysis, 12  
Apparatus, 6  
Appendix ceci (vermiformis), 134  
Aqueeduct of Sylvius (of cerebrum), 253  
Aqueous humor, 279  
Arachnoid of brain, 255  
of cord, 232  
Arbor vitæ, 252, (illus. 251)  
Arches of foot, 68  
of hand, 172, 173  
of vertebræ, 35  
Areolar tissue, 3  
Arm, bone of, 52  
muscles of, 96  
Arterioles and arteries, 156  
Articular surface, 10  
Articulations or joints, 14  
of cranium, 20  
of face, 24  
of lower extremity, 63  
of pelvis, 46  
of spinal column, 38  
of thorax, 43  
of upper extremity, 56  
Ascites, 6  
Asphyxia, 209  
Assimilation, 151  
Atlas, 36  
Auditory tube (Eustachian), 125, 273  
Auricle of heart, 158  
Axillary space, 300  
Axis (artery), 171  
(bone), 36  
Axon, 229  
Bifurcation of aorta, 178  
Bile, 139, 147  
Bladder, 283  
Bioplasm, 2  
Blood, 152  
Bone, articular, 14  
markings, 10  
repair of, 72  
tissue, 8  
Bones, completion of, 70  
in infancy, 71  
of abdomen, 44  
of cranium, 16  
of ear, 275  
of face, 20  
of lower extremity, 59  
of neck, 31  
of pelvis, 44  
of spinal column, 35  
of thorax, 40  
of upper extremity, 50  
shapes of, 11  
Brain, 249  
fissures of, 251, 252  
hemispheres of, 250  
lobes of, 251  
Breast (mammary gland), 219  
muscles of, 96  
Bronchi, 204  
Bronchial muscle, 205  
Bursa (pleural, *bursæ*), 67, 77  
Callus, 72  
Canal, adductor, 302  
anal, 136  
auditory, 273  
carotid, 19  
central (of cord), 232  
femoral, 303  
Haversian, 9  
Hunter's (or adductor), 302  
inguinal, 303  
internal auditory, 19, 273  
medullary, 9  
nasal (or lacrimal), 30  
neural, 39  
nutrient, 70  
semicircular, 274  
spinal (neural or dorsal), 49  
Cancellous or spongy tissue, 9  
Capillaries, 156  
Capitulum (capitellum), 52  
Capsule, Bowman's, 212  
internal, 251  
of joints, 14  
of lens, 278  
of Tenon, 279  
Cardiac impulse, 196

- Cartilage, 4  
   articular, 14  
   costal, 41  
   fibro-, semilunar, 65  
     sterno-clavic., 56  
   triangular, 57  
 Cauda equina, 235  
 Cavities of body, 48  
   dorsal or neural, 49  
   ventral or visceral, 49  
 Cecum, 134  
 Cell, description, 2  
 Cell body (nerve), 229  
 Centers, brain (illus.), 260, 261  
   nerve, 231  
   of ossification, 11  
 Central fissure, 251  
 Cerebellum, 252  
 Cerebral localization, 260  
 Cerebro-spinal fluid, 233  
   system, 230  
 Cerebrum, 250  
 Cervical nerves, 236  
 Cervix uteri, 285, 286  
 Chambers of eye, 279  
 Choroid coat of eye, 276  
 Chyle, 147  
 Chyme, 144  
 Cilia, of air passages, 205  
   of eyelids, 217  
 Ciliary muscle, 278  
 Circulation, (def.), 151  
   collateral, 176, 181  
   fetal, 189  
   portal, 189  
   pulmonary, 167  
   systemic, 167, 168  
 Circumcision, 291  
 Clitoris, 289  
 Coagulation of blood, 155  
 Coccyx, 38  
 Cochlea, 274  
 Colon, 135  
 Colostrum, 220  
 Compact bone tissue, 9  
 Compression of arteries, 310  
 Condyle (def.), 10  
 Condyles, occipital, 17  
   of femur, 60  
   of mandible, 23  
   of tibia, 61  
 Conjoined tendon, 90, 298  
 Conjunctiva, 276  
 Connective tissue, 75  
 Corium of skin (cutis vera), 214  
 Cornea, 276  
 Corpus callosum, 251  
 Corpuscle of blood, 152, 153  
   of kidney (Malpighian), 212  
   of skin (touch), 214  
   of spleen, 221  
 Corpus leutum, 288  
 Cortex of brain, 249  
 Cranium, 16, 25  
 Crest (def.), 10  
 Crura of cerebrum, 253, 267  
   of diaphragm, 91  
 Crystalline lens, 278  
 Cutis vera (skin), 214  
 Dartos, 290  
 Defecation, 148  
 Deglutition, 144  
 Dendrite, 229  
 Dentition (eruption of teeth), 32  
 Diameters of pelvis, 48  
 Diapedesis, 154  
 Diaphragm, 91, 113  
   of pelvis, 103  
 Diaphysis, 12  
 Diastole of heart, 161  
 Digestion, 144, 151  
 Digestive fluids, 121  
 Dorsal cavity, 48  
 Duct, common bile, 139  
   cystic, 139  
   hepatic, 139  
   lacrimal, 279, 280  
   pancreatic, 138  
   right lymphatic, 197  
   Stenson's, 124  
   thoracic, 197  
   Wharton's, 124  
 Ductus arteriosus, 190  
   communis choledochus (or *common bile duct*), 139  
   deferens (vas def.), 291  
 Duodenum, 132  
 Dura mater, brain, 255  
   cord, 233  
 Dyspnea, 209  
 Ear, 273  
 Edema, 196  
 Elastic tissue, 3  
 Elimination, organs of, 226  
 Endocardium, 160  
 Endosteum, 10  
 Endothelium, 6, 156  
 Enzyme (def.), 121  
 Epicardium, 164  
 Epicondyle of femur, 60  
   of humerus, 52  
 Epidermis, 214  
 Epigottis, 204  
 Epiphysis, 12  
 Epithelium, 4  
   ciliated, 5, 205  
   respiratory, 208  
 Erythrocyte (red cell), 152  
 Esophagus, 126  
 Ethmoid notch, 17  
 Eustachian tube (auditory), 125, 273  
 Excreting organs, 6, 226  
 Excretion, 226  
 Expiration, act of, 208

- External genital organs, 289  
 Extremities compared, 304  
 Eye, 276  
 Eyebrows, 279  
 Eyelids, 279  
 Face, bones of, 26, 27  
   muscles of, 84  
   vessels and nerves, 292  
 Fallopian or uterine tubes, 286  
 Falx cerebri, 255  
 Fascia of body, deep, 75  
   iliac, 103  
   lata, 76  
   lumbar, 77  
   palmar, 102  
   pelvic, 103  
   plantar, 111  
   superficial, 77  
   temporal, 84-292  
   transversalis, 93  
   transverse of leg, 307  
 Feces, 147  
 Fibrin, 155  
 Fibrous tissue, 3  
 Fissure of Rolando (central), 251  
   of Sylvius, 251  
   transverse of liver (porta), 139  
 Floor of mouth, 121  
   of pelvis, 103  
   of thorax, 91  
 Fontanelles, 28  
 Foods, 141  
 Foramen (def.), 10  
   infraorbital, 21  
   intervertebral, 40  
   jugular, 26  
   magnum, 17  
   mental, 23  
   Munro, 253  
   obturator or thyroid, 46  
   optic, 30  
   ovale, 190  
   sciatic, 47  
   supraorbital, 17  
   transverse, 36  
   vertebral, 36  
 Forearm, bones of, 52  
   muscles of, 98  
 Foreskin (prepuce), 291  
 Fossa (def.), 10  
   glenoid, 51  
   intercondyloid, 60  
   ischio-rectal, 300  
   lacrimal, 17  
   navicularis, 289  
   ovale (heart), 158  
   (thigh), 77  
   subscapular, 51  
 Fosse of skull, 28  
 Frenum linguæ (bridle of tongue), 122  
 Gall bladder, 139  
 Ganglia, basal, 251  
   semilunar, 264  
   sympathetic (autonomic), 263-5  
 Ganglion, 231  
   Gasserian, 257  
   root of spinal nerve, 233  
 Gastric juice, 128  
 Glabella, 17  
 Gland (definition), 5  
   of Bartholin, 290  
   ceruminous, 273  
   ductless, 220  
   intestinal, 131, 133, 134  
   Peyer's, 134  
   lacrimal, 280  
   lymph, 196  
   mammary, 219  
   Meibomian (tarsal), 280  
   prostate, 284  
   salivary, 124  
   sebaceous, 216  
   sudoriferous, 216  
   tissue, 5  
 Glossary, 321  
 Glottis, 282  
 Graafian follicle, 287  
 Greenstick fracture, 72  
 Glycogen, 149  
 Hair, 217  
 Hamstring tendons, 108  
 Heart, 157  
   diastole of, 161  
   function of chambers, 161  
   muscle, 158  
   sounds, 163  
   systole of, 161  
   tendinous cords of, 160  
 Hearing, 273-5  
 Heat (body), 226  
 Hemoglobin, 153  
 Hemorrhoidal arteries, 180  
 Hernia, 304  
   retro-peritoneal, 300  
 Hip-bone (os coxæ), 44  
 Housemaid's knee, 67, 77  
 Hymen, 289  
 Hypophysis cerebri, 224  
 Hyperpnea, 209  
 Pleum, 133  
 Plium (os), 44  
 Inguinal rings, 298, 303  
 Inorganic substances of bone, 8  
 Insertion of muscles, 79  
 Inspiration, act of, 268  
 Instep (arches of foot), 68  
 Intercellular substance, 3  
 Intermuscular septa, 79  
 Interosseous spaces, 53, 55, 61, 63  
 Internal secretions, 220  
 Intestine, 130  
   large, 134

- Intestine, small, 131  
Iris, 277
- Joint or articulation, 14  
  immovable, 14  
  motions of, 15  
  movable, 14  
  yielding, 15  
Jugular notch, 40  
  veins, 184
- Kidneys, 211
- Labia majora, 289  
  minora, 289
- Labyrinth (ear), 274
- Lacteals, 150
- Lanugo, 217
- Large vessels and nerves, 309
- Larynx, 204
- Leucocytes, 153
- Leukemia, 221
- Ligament, annular, 101, 111  
  of Bigelow (Y), ileo-femoral, 65  
  broad, 289-90  
  crucial, 66  
  deltoid, 67  
  dorsal of wrist, 102  
  elastic, 38, 68  
  Gimbernat's, 303  
  inguinal (Poupart), 47, 76, 90, 298  
  of liver, 140  
  orbicular, 58  
  of patella, 105  
  sacro-sciatic, 46  
  structure of, 14  
  suspensory of lens, 278  
  transverse of ankle, 67
- Ligaments of uterus, 288
- Ligamentum nuchæ, 39  
  teres, 63, 64
- Linea alba, 90  
  aspera, 60  
  semilunaris, 89
- Lineæ transversæ, 91
- Liver, 139
- Lumbo-sacral cord, 242
- Lungs, 205
- Lymph, 150, 195  
  capillaries, 194  
  corpuscles, 196  
  nodes (lymphatic glands), 196  
  origin of, 195  
  spaces, 194  
  vessels, 194
- Lymphatic ducts, 197  
  system, 194
- Lymphocytes, 196
- Malleolus, lateral, 61  
  medial, 61
- Manubrium, 40
- Marrow, 9
- Mastication, 145
- Meatus, external auditory, 273  
  of nose, 202  
  of urethra, 283
- Median line, 2
- Mediastinum, 297
- Medulla (of brain), 252  
  of bone (marrow), 111  
  fatty sheath of nerve fiber, 229
- Medullary canal, 11
- Medullated fibers, 229, 230
- Membranes of body, 5  
  of brain, 254  
  of spinal cord, 232
- Menopause (climacteric), 288
- Menstruation, 287
- Mesentery, 137, 300
- Metabolism, 6
- Metacarpus, 54
- Metatarsus, 63
- Metastasis, 201
- Micturition, 214
- Milk, 220
- Mons veneris, 289
- Motions of eyeball, 281
- Mouth (oral cavity), 121
- Movable joint, description of, 14
- Mucous membrane, 5
- Muscles, action of, 113, 116  
  of abdomen, 89  
  of back, 80  
  of breast, 96  
  of face, 84  
  of head and neck, 82  
  of lower extremity, 102  
  of mastication, 84  
  of pelvis, 102, 104  
  of upper extremity, 94  
  ribbon, 86  
  structure of, 79, 112  
  tension of, 113
- Muscle band of His, 160  
  tissue, 78
- Myocardium, 157
- Nails, 216
- Nares, 204
- Nasopharynx, 125
- Necrosis (of bone), 10
- Nerve centers, 231  
  cylinder, 229  
  supply to joints, 69  
  to muscle groups, 118, 259  
  tissue, 230
- Nerves, cervical, 236  
  coccygeal, 245  
  cranial, 255  
  lumbar, 242  
  motor, 231  
  sacral, 243  
  sensory, 231  
  spinal, 233, 235  
  thoracic, 242

- Neural cavity, 49  
 Neurilemma, 230  
 Neuron, 229  
 Nose, 202  
 Notes, blood, 153  
   blood-vessels, 156, 157, 160, 173, 175,  
     176, 181, 182, 190  
   bones, 20, 50, 52, 55, 61, 63, 66, 67, 72  
   digestive organs, 123, 133, 137, 139,  
     146  
   lymph system, 197, 200  
   muscles, 77, 78, 82, 91, 96, 97, 98,  
     100, 102, 106, 108, 109, 110, 111  
   nerve system, 229, 233, 264, 274  
   pelvic organs, 288, 290  
   respiratory organs, 206  
   skin, 216, 217  
   special senses, 279, 282  
 Notes clinical, blood-vessels, 164, 173, 175  
   bones, 22, 24, 39, 33, 34, 39, 51  
   digestive organs, 123, 129, 134,  
     135, 136, 144, 146, 147  
   kidney, 213 (two)  
   lymph system, 196 (two), 201  
   muscles, 82, 88, 115, 116  
   nerve system, 253, 255, 258  
   pelvic organs, 284, 286,  
     regional, 295  
   respiratory, 207  
   skin, 215, 218  
   special senses, 278, 281 (two)  
   spleen, 221  
 Notes obstetric, 28, 46  
 Notes practical and special, blood-vessels,  
   166, 178  
   bones, 53, 61, 68, 73  
   muscles, 76, 84, 90, 92, 100, 103,  
     104, 110, 114  
   nerve system, 230, 241, 245, 251  
   regional, 293, 310  
 Notes surgical, bones, 24, 59, 67, 70, 72,  
   73  
   muscles, 77  
   abscess, 93, 220  
 Nucleus and nucleolus, 2  
   caudate, 251  
   lentiform, 251  
 Nutrient artery, 10  
  
 Obturator membrane, 46  
 Olfactory region, 271  
 Omentum, 137, 300  
 Opsonic index, 155  
 Optic commissure (chiasm), 256  
   disc, 278  
   nerve, 256, 277  
   thalamus, 251  
 Orbit, 29  
 Organ and organic substance, 6, 8  
 Origin of blood cells, 73  
   of muscles, 79  
 Os coxæ or hip bone, 44  
 Osmosis, 193  
  
 Osseous tissue, 3, 8  
 Ossicles, 275  
 Ossification, 11  
 Ostium venosum, 160  
 Ovary and ovum, 287  
 Ovulation, 287  
  
 Palate, hard, 22  
   soft, 121  
 Palatine arches, 123  
 Palm, or metacarpus, 54  
 Pancreas, 137, 221  
 Papilla, hair, 217  
   of skin, 214  
   tongue, 122  
 Parathyroids, 223  
 Patella, 63  
 Peduncles of brain, 253  
 Pelvic floor, 103  
   girdle, 47  
   organs, 283  
 Pelvis, 47  
 Pepsin, 128, 146  
 Peptones, 146  
 Pericardium, 164  
 Perichondrium, 4  
 Perineal arteries, 180  
 Perineum, 290  
 Perineurium, 231  
 Periosteum, 10  
 Peristalsis, 137  
 Peritoneum, 299  
 Perivascular spaces, 194  
 Perspiration, 216  
 Peyer's patches, 134  
 Phagocytes, 154  
 Phalanges, 55  
 Pharynx, 124, 203  
 Physiology of blood, 192  
   of bone, 73  
   of brain, 260  
   of cord, 245  
   of digestive organs, 144  
   of kidneys, 213  
   of lymph system, 201  
   of muscle, 112  
   of nerves, 231, 248  
   of nerve system, 267  
   of ovary, 287  
   of respiratory organs, 207  
   of skin, 217  
   of sympathetic nerves, 264  
   of uterus, 286  
 Pia mater of brain, 254  
   of cord, 232  
 Pillars of fauces, 123  
 Pituitary body (hypophysis), 224  
 Placenta, 192  
 Plasma, 154  
 Pleura, 206  
 Plexus, cardiac, 264  
   celiac, 264  
   cervical, 236

- Plexus, brachial, 237  
   hypogastric, 264  
   lumbar, 242  
   pulmonary, 264  
   sacral, 243  
 Pons varolii, 253  
 Popliteal plane, 60  
   space, 106, 107  
 Porta of liver, 139  
 Portal vein, 189  
 Pouch of Douglas, 290  
 Process (def.), 10  
   acromion, 51  
   alveolar, 22  
   articular, 35  
   coracoid, 51  
   coronoid, 53  
   frontal, 21  
   mastoid, 18  
   odontoid, 36  
   olecranon, 53  
   palate, 21  
   pterygoid, 20  
   spinous, 35  
   styloid, 18, 26  
     of fibula, 61  
     of radius, 53  
     of ulna, 53  
   transverse, 35  
   unciform, 54  
   zygomatic, 18, 22  
 Promontory, 38  
 Pronation, 58, 59  
 Protoplasm, 2  
 Ptyalin, 145  
 Pubic arch, 45  
   symphysis, 46  
 Pudendum, 289  
 Pulse, 162  
 Pylorus, 128  
 Pyramids and tracts (medulla), 252  
   decussation of, 252  
 Rachitis, 72  
 Receptaculum chyli, 107  
 Rectum, 136  
 Reference tables, 311  
 Reflex action, 246  
 Reflex, abdominal, 247  
   patellar, 247  
   plantar, 247  
   skin, 247  
 Rennin, 128, 146  
 Respiration, 202  
   air in, 207  
   rate of, 209  
 Résumé, alimentary tract, 137  
   course of blood in heart, 165  
   lower extremity, 68  
   upper extremity, 55  
 Retina, 256, 277  
 Ribs, 40  
 Sacrum, 37  
 Saddle joint, 58  
 Saliva, 124  
 Sartorius or "tailor muscle," 105  
 Scalp, 202  
 Scarpa's triangle, 301  
 Schneiderian membrane, 30  
 Sciatic nerves, 243  
 Sciatic notches, 45  
 Sclera, 276  
 Scrobiculus cordis, 297  
 Scrotum, 290  
 Secreting organs, 6, 225  
 Secretions, 6, 225  
 Semilunar notch, 53  
 Sensory impressions, 232  
 Septum, 30  
 Serous membrane, 5  
 Sheath of rectus, 91  
 Shoulder girdle, 50  
 Sigmoid groove, 18, 255  
 Sight, 276  
 Sinus, ethmoid, 19  
   frontal, 17  
   of kidney, 211  
   maxillary, 21  
   sphenoid, 20  
   transverse (lateral), 184  
 Sinusitis, 30  
 Skeleton, 12, 13  
 Skin, 274  
 Skull, as a whole, 25  
   at birth, 28  
   at different ages, 70, 71  
   bones of, 6  
   completion of, 71  
   points of interest, 25  
 Smell, 271  
 Special senses, 270  
 Speech, 282  
 Spermatic cord, 291  
 Sphincter, anal, 136  
   cardiac, 127  
   ileo-colic, 134  
   pupillary, 277  
   pyloric, 128  
   vesical, 283  
 Spina bifida, 72  
 Spinal canal, 39  
   column, 39  
   cord, 231  
 Spine (def.), 10  
   intercondyloid, 60  
   of ilium, 45  
   of ischium, 45  
   of pubes, 45  
   of scapula, 51  
 Splanchnic nerves, 264  
 Spleen, *lien*, 221  
 Spongy or cancellous tissue, 9  
 Sternum, 43  
 Stomach (gaster), 127  
 Straits of pelvis, 48



- Supination, 58, 59  
 Summary, cerebro-spinal nerves, 259  
   \* functions of cranial nerves, 261  
     of skin, 218  
     of spinal cord, 248  
   nerve system, 267  
   respiration, 209  
   return of lymph, 201  
   return of venous blood, 189  
   spinal nerves, 245, 248  
 Superciliary arch, 17  
 Supraorbital margin, 16  
   notch (or foramen), 17  
 Surgical neck of humerus, 52  
 Sutures, 20  
 Sympathetic (autonomic) nerves, 262  
 Symphysis pubis, 45  
   sacro-iliac, 46  
 Synovial membrane, 5  
 System (def.), 6
- Tactile cells, 271  
 Tables of skull, 25  
 Tarsus, 61  
 Taste, 272  
 Teeth, 31  
   eruption of, *dentition*, 32  
 Temperature of body, 227  
 Tendinous cords, 160  
 Tendon of Achilles or *tendo calcaneus*,  
   107, 111  
 Tendons 79  
 Tentorium cerebelli, 255  
 Terminal filament, 231, 235  
 Testes, 291  
 Thenar eminences, 102  
 Thorax, bones of, 40, 43  
 Thymus body, 223  
 Thyroid (*thyreoid*) body, 222  
 Tissues, 3  
 Tissue spaces, 194  
 Tongue, 121  
 Tonsil, 123  
   lingual, 123  
   palatine, 123  
   pharyngeal, 125  
 Touch, 271  
 Trachea, 204  
 Triangles of neck, 294  
 Trigone, bladder, 283  
   femoral, 301  
 Trochanters, 59  
 Trochlea, 52  
 Trophic centers, 247  
 Trunk, 13, 40  
 Tuber ischii (tuberosity), 45  
 Tubercles of humerus, 52  
 Tuberosity of calcaneus, 62  
 Tympanum, 273
- Umbilical artery, 181  
   cord, 192  
   vein, 189, 192  
 Urea, 149, 213  
 Ureter, 212, 283  
 Urethra, 284  
 Urethral caruncle, 283  
 Urination (micturition), 214  
 Urine, 213  
 Uterine tubes (Fallopian), 286  
 Uterus, 285  
 Uvula, 121
- Vagina, 288  
 Vaginal synovial membranes, 100  
 Valve, Eustachian, of heart, 158, 190  
 Valve, Houston's, 136  
   ileo-cecal, 134  
 Valves of heart, 160  
   of veins, 157  
 Vasa vasorum, 157  
 Vaso motor nerves, 266  
 Veins, structure, 157  
 Velum palati, 121  
 Vena cava inferior, 187  
   superior, 186  
 Ventral cavity, 48  
 Ventricles of brain, 253  
   of heart, 159  
 Vermis (of cerebellum), 252  
 Vertebrae, 35, 36, 37  
 Vertebral aponeurosis, 80  
 Vertex of skull, 25  
 Vestibule (ear), 274  
   (pudendum), 289  
 Villi, 131, 148  
 Vitreous body, 278  
   layer (cranial bones), 25  
 Viscera, abdominal, 299  
   thoracic, 297  
 Visceral cavity, 49  
 "Vital knot" (nœud vital), 261  
 Vocal bands and voice, 281  
 Vola, *palm*, 68
- Wharton's jelly, 192  
 Xyphoid appendix, 40  
 Y-ligament, 65  
 Zygoma, 18



get water  
around  
the hole





UNIVERSITY OF CALIFORNIA  
MEDICAL CENTER LIBRARY

**THIS BOOK IS DUE ON THE LAST DATE  
STAMPED BELOW**

Books not returned on time are subject to a fine of 50c per volume after the third day overdue, increasing to \$1.00 per volume after the sixth day. Books not in demand may be renewed if application is made before expiration of loan period.

JAN 30 1942

OCT 25 1943

FEB 6 1948

DEC 28 1950

NOV 2 - 1951

QM26	Bundy, E.R.	8514
B94	Text-book of anatomy and	
1913	physiology for nurses. 2d	
	ed., rev. and enl.	
<i>Luede</i>	SEP 28 1942	SEP 28 1942
<i>Paul Sweet</i>	JAN 30 1942	FEB 5 1942
<i>Payne</i>	OCT 25 1942	OCT 21 1943
<i>Bowen</i>	FEB 6 1945	JAN 30 1944
<i>Galloway</i>	DEC 28 1950	DEC 18 1950
<i>Moussan</i>	NOV 2 - 1950	OCT 26 1951

8514-

