



THE
ABNER WELLBORN CALHOUN
MEDICAL LIBRARY
1923



CLASS R

BOOK _____

PRESENTED BY


Capt. Lee Walker





ELEMENTS OF ANATOMY.

VOL II.



Wadley

ELEMENTS OF ANA

BY

JONES QUAIN, M.D.

Fifth Edition.

EDITED BY

RICHARD QUAIN, F.R.

AND

WILLIAM SHARPEY, M.D.

PROFESSORS OF ANATOMY AND PHYSIOLOGY
IN UNIVERSITY COLLEGE, LONDON.

IN TWO VOLUMES.

ILLUSTRATED WITH NUMEROUS ENGRAVINGS OF

VOL. II.

Gift
Capt. Lee Walker
1944

LONDON :
Printed by S. & J. BENTLEY, WILSON, and FLEY,
Bangor House, Shoe Lane.

CONTENTS OF THE SECOND VOLUME.

	PAGE		PAGE
NERVOUS SYSTEM	667	SPINAL NERVES IN GENERAL—	
CEREBRO-SPINAL AXIS	667	<i>continued.</i>	
Weight of different parts	668	The Lumbar Plexus	854
Spinal Cord	673	Branches of	855
Encephalon	680	of Sacral and Coccygeal	
Medulla Oblongata	682	Nerves	865
Pons Varolii	688	The Sacral Plexus	866
Cerebrum	690	Branches of	867
Cerebellum	720	SYMPATHETIC NERVE IN GE-	
Internal structure of Cere-		NERAL	879
bro-spinal Axis	726	The Gangliated Cords of	
Connexions of Cranial		Sympathetic Nerve	881
Nerves	745	Cervical portion of	<i>ib.</i>
Membranes of Brain and		Thoracic portion of	887
Spinal Cord	751	Lumbar portion of	889
Development of Brain and		Sacral portion of	890
Spinal Cord	758	The Prevertebral part of	
CRANIAL NERVES IN GENERAL.	767	Sympathetic Nerve	891
Olfactory	768	The Cardiac Plexus	<i>ib.</i>
Optic	769	The Epigastric or solar	
Third Pair	<i>ib.</i>	Plexus	893
Fourth Pair	771	The Diaphragmatic Plexus	894
Fifth Pair	772	The Supra-renal Plexus	895
A. Ophthalmic Nerve	774	The Renal Plexus	<i>ib.</i>
B. Upper Maxillary Nerve	779	The Spermatic Plexus	<i>ib.</i>
C. Lower Maxillary Nerve	786	The Cæliac Plexus, and	
Sixth Pair	794	its Divisions	<i>ib.</i>
Seventh Pair	<i>ib.</i>	The Superior Mesenteric	
A. Facial Nerve	<i>ib.</i>	Plexus	897
B. Auditory Nerve	800	The Aortic Plexus	<i>ib.</i>
Eighth Pair	<i>ib.</i>	The Inferior Mesenteric	
A. Glosso-pharyngeal	801	Plexus	898
B. Pneumo-gastric	805	The Hypogastric Plexus	<i>ib.</i>
C. Spinal Accessory	812	The Inferior Hypogastric	
Ninth Pair	813	Plexus	899
SPINAL NERVES IN GENERAL.	817	The Hæmorrhoidal Nerves	<i>ib.</i>
The Posterior divisions of		The Vesical Plexus	<i>ib.</i>
Spinal Nerves	820	The Prostatic Plexus	900
of Cervical Nerves	<i>ib.</i>	The Nerves of the Ovary	901
of Dorsal Nerves	823	The Vaginal Plexus	<i>ib.</i>
of Lumbar Nerves	824	The Nerves of the Uterus	<i>ib.</i>
of Sacral Nerves	825	ORGANS OF THE SENSES	903
of Coccygeal Nerves	826	THE EYE	<i>ib.</i>
The Anterior Divisions of		The Appendages of the Eye	<i>ib.</i>
Spinal Nerves	<i>ib.</i>	The Globe of the Eye	909
of first four Cervical Nerves	827	THE EAR	925
The Cervical Plexus	828	The external Ear	<i>ib.</i>
of last four Cervical Nerves	833	The Middle Ear or Tym-	
The Brachial Plexus	833	panum	931
Branches of	834	The Internal Ear, or Laby-	
of Dorsal Nerves	848	rinth	942
of Lumbar Nerves	853	THE NOSE	955
		Nasal Fossæ	959

	PAGE		PAGE
ORGANS OF DIGESTION	965	ORGANS OF RESPIRATION—	
The Mouth	966	<i>continued.</i>	
The Teeth	967	The Larynx	1158
The Tongue	998	The Thyroid Gland	1178
The Palate	1003	The Thymus Gland	1182
The Tonsils	1006	THE URINARY ORGANS	1187
The Salivary Glands	1007	The Kidneys	1187
The Pharynx	1012	The Suprarenal Capsules	1198
The Œsophagus	1013	The Ureters	1201
The Abdomen	1016	The Urinary Bladder	1203
The Stomach	1020	The Urethra	1212
The small Intestine	1029	ORGANS OF GENERA-	
The Duodenum	1038	TION	1214
The Jejunum and Ileum	1040	OF THE MALE	<i>ib.</i>
The large Intestine	1041	The Prostate Gland	<i>ib.</i>
The Cæcum	1044	The Penis	1217
The Colon	1047	The Urethra	1225
The Rectum	1048	The Muscles of the Penis	
The Anus and its Muscles	1051	and Urethra	1229
Development of the Ali-		The Testis and Spermatic	
mentary Canal	1055	Cord	1233
The Liver	1057	The Coverings of	<i>ib.</i>
The excretory Apparatus of,	1073	The Testes	1240
Development and foetal		The Vas Deferens	1246
peculiarities of,	1076	The Vesiculæ Seminales	
The Pancreas	1080	and Ejaculatory Ducts	1248
The Spleen	1084	OF THE FEMALE	1252
The Peritonæum	1090	The Vulva	<i>ib.</i>
Parts situated in each region		The Vagina	1257
of the Abdomen	1096	The Uterus	1259
ORGANS OF CIRCULATION	1098	The Ovaries and Fallopian	
The Thorax	1098	Tubes	1266
The Pericardium	1100	DEVELOPMENT OF THE GENITO-	
The Heart	1101	URINARY ORGANS	1270
Development of the Heart		THE MAMMARY GLANDS	1280
and great Blood-vessels	1125	SURGICAL ANATOMY	1284
Peculiarities of the Foetal		The Parts concerned in In-	
Heart and Circulation	1128	guinal Herniæ	1285
ORGANS OF RESPIRATION	1134	Inguinal Herniæ	1294
The Trachea and Bronchi	<i>ib.</i>	The Parts concerned in	
The Pleuræ	1139	Femoral Hernia	1303
The Lungs	1141	Femoral Hernia	1309
Development of the Lungs		The Perinæum and Ischio-	
and Trachea	1156	Rectal Region	1313
INDEX		Lateral operation of Li-	
		thotomy	1321
			1325

NERVOUS SYSTEM.

CEREBRO-SPINAL AXIS.

THE *nervous system* consists of two parts—a central part, which includes the brain and spinal cord, and is named the cerebro-spinal axis, and a peripheral part, which comprises all the nerves in the body. The anatomy of the nerves, which again are subdivided into a cerebro-spinal and a sympathetic system, will be subsequently treated of, whilst the present section will be devoted to a description of the central portion of the nervous system.

Nervous system ;
central and peripheral.

The *cerebro-spinal axis* is contained partly within the cavity of the cranium, and partly within the vertebral canal ; it is symmetrical in its form and structure throughout, consisting of a right and a left half, which correspond in every particular, and are joined together along the middle line by fibres of nervous substance, which pass across the longitudinal fissures existing between them. These connecting fibres form the commissures of the brain and spinal cord.

Cerebro-spinal centre is symmetrical,

Enclosed within the skull and the vertebral canal, the cerebro-spinal axis is protected by the bony walls of those two cavities ; but it is also surrounded by three membranes, which afford it additional protection and support, and are subservient to its nutrition. These envelopes, which will be described hereafter, are, a dense fibrous membrane named the *dura mater*, a serous membrane called the *arachnoid*, and a highly vascular membrane named the *pia mater*.

and enclosed within skull and vertebral canal ;

The cerebro-spinal axis is divided by anatomists into the encephalon (ἐν, κεφαλή, the head), the enlarged upper part contained within the cranium, and the *spinal cord*, contained within the spinal canal. The encephalon is again divided into the *cerebrum*, or *brain proper* ; the *cerebellum*, little brain, or *after-brain* ; the *tuber annulare*, or pons Varolii, and the *medulla oblongata*. It should be remarked, that the term *brain*, in a general sense, is commonly applied to the entire encephalon, but that it also has a limited application to the cerebrum only.

consists of spinal cord and encephalon, which is again divided.

WEIGHT OF THE ENCEPHALON.

The chief sources of information on this subject are the tables published by Dr. Sims,* Dr. Clendinning,† Tiedemann,‡ and Dr. John Reid.§ The following table is deduced from their observations. The weights given by Tiedemann have been converted into ounces averdupois, the weight employed by the three British observers. All instances of fractional parts of ounces are classed with the next highest integral number, so that the term 50 oz., for example, includes all cases of brains weighing more than 49 oz., but not exceeding 50. From the tables of Dr. Sims and Dr. Clendinning those cases have been rejected in which cerebral disease is said to have existed.

TABLE I.

MALES, aged 21 years and upwards.						FEMALES, aged 21 years and upwards.							
Weight in oz. averdupois.	Number of brains at each weight observed by				Total number at each weight.	Classification into three groups, to show the prevailing weight.	Weight in oz. averdupois.	Number of brains at each weight observed by				Total number at each weight.	Classification into three groups, to show the prevailing weight.
	Clendinning.	Sims.	Tiedemann.	Reid.				Clendinning.	Sims.	Tiedemann.	Reid.		
34	—	—	—	1	1	62 cases. { from 34oz. to 45oz. } Difference 11.	31	—	—	—	1	32 cases. { from 31oz. to 40oz. } Difference 9.	
37	—	2	—	—	2								
38	1	—	—	—	1								
39	—	3	—	—	3								
40	—	2	—	—	4								
41	—	3	—	—	5								
42	2	4	2	—	8								
43	—	6	2	—	11								
44	1	6	2	—	12								
45	6	8	—	—	15								
46	2	10	—	—	20	170 cases. { from 46oz. to 53oz. } Difference 7.							
47	2	6	—	—	10								
48	4	8	2	—	11								
49	3	2	2	—	12								
50	4	4	5	—	13								
51	3	3	2	—	19								
52	—	5	4	—	6								
53	4	2	4	—	10								
54	3	2	1	—	11								
55	—	—	2	—	4								
56	—	—	1	—	6								
57	—	—	—	—	2								
58	—	1	4	—	2								
59	—	1	2	—	3								
60	—	—	—	—	1								
61	—	—	2	—	1								
62	—	—	1	—	1								
63	—	—	—	—	1								
65	—	—	1	—	1								
Tot. 35+78+39+126=278						Tot. 30+72+12+77=191							

* Sims ; Medico-Chirurg. Trans., vol. xix., pp. 353-7.

† Clendinning ; Medico-Chirurg. Trans., vol. xxi., pp. 59-68.

‡ Tiedemann ; Das Hirn des Negers, Heidelberg, 1837, pp. 6, 7.

§ Reid ; London and Edinburgh Monthly Journal of Medical Science, April, 1843, p. 298, &c.

According to this table, the maximum weight of the adult male brain, in a series of 278 cases, was 65 oz., and the minimum weight 34 oz. In a series of 191 cases, the maximum weight in the adult female was 56 oz., and the minimum 31 oz.; the difference between the extreme weights in the male subject being no less than 31 oz., and in the female 25 oz. The weight of the adult male brain appears, therefore, to be subject to a wider range of variety than that of the female. By grouping the cases together in the manner indicated by brackets, it is found that in a very large proportion, the weight of the male brain ranges between 46 oz. and 53 oz., and that of the female brain between 41 oz. and 47 oz. The *prevailing* weights of the adult male and female brain may therefore be said to range between those terms; and by taking the mean, an *average* weight is deduced of 49½ oz. for the male, and of 44 oz. for the female brain,—results which correspond closely with the statements generally received.

in male ;
in female ;

average
weight
in each
sex.

Although many female brains exceed in weight particular male brains, the general fact is sufficiently shewn, that the adult male encephalon is heavier than that of the female,—the average difference being from 5 to 6 oz. This general superiority in absolute weight of the male over the female brain, is shewn by Table II. to exist at every period of life. In new-born infants the brain was found by Tiedemann to weigh 14¼ oz. to 15¾ oz. in the male, and 10 oz. to 13¼ oz. in the female.*

Male
brain is
heavier
at all
periods.

Anatomists have differed considerably in their statements as to the period at which the brain attains its full size, and also as to the effect of old age in diminishing the weight of this organ. Sømmerring concluded that the brain reached its full size as early as the third year; the Wenzels and Sir W. Hamilton fixed the period about the seventh, and Tiedemann between the seventh and eighth. Gall and Spurzheim were of opinion that the brain continued to grow until the fortieth year. The tables of Dr. Sims shew a gradual increase in the weight of the brain up to the twentieth year, and a further irregular increase, until the maximum is reached between forty and fifty years, after which there is a decrease. From the following Table (II.), founded on the observations of Sims, Tiedemann, and Reid, it appears that in general the weight of the brain increases rapidly up to the seventh year, then more slowly to between sixteen and twenty, and again more slowly to between thirty-one and forty, at which time it reaches its maximum point. Beyond that period, there appears a slow but progressive diminution in weight of about 1 oz. during each subsequent decennial period; thus confirming the opinion, that the brain diminishes in advanced life. It will also be seen from the table that the general results are the same in both sexes.

Brain
reaches its
maximum
weight

about 31
to 40 years,
then di-
minishes.

* This fact is not without interest in practical midwifery, for it has been shewn that by far the larger number of difficult labours occur in the birth of male children. Professor Simpson—London and Edinburgh Monthly Journal of Medical Science, 1845.

TABLE II.

Weight in oz.	Birth.	1 to 4	4 to 7.	7 to 10.	10 to 15.	16-20.	21-30.	31-40.	41-50.	51-60.	61-70.	71-80.	81 to 90.	Weight in oz.
10	1													10
12	1													12
14	2													14
16	1													16
18	1													18
20	1													20
22	1													22
24	1													24
26	1													26
28	1													28
30	1													30
32	1													32
34	2													34
36	2													36
38	1													38
40	2													40
42	2													42
44	1													44
46	1													46
48	1													48
50	1													50
52	1													52
54	1													54
56	1													56
58	1													58
60	1													60
62	1													62
64	1													64
66	1													66

* This Table contains the weight of 580 brains of both sexes, 325 male and 255 female, arranged according to age. The horizontal lines mark the weight in oz. (averdupois), each line or interspace indicating a difference of two ounces. The vertical columns show the ages from birth up to 90 years, the width of each column being proportionate to the period which it includes. The figures in these columns show the number of brains at each weight.

The curved lines, drawn, as nearly as may be, through the average weight in each column, present to the eye the different variations in weight through the whole period. The accented figures and the dark line refer to the female brains. The dotted line drawn between two of the columns of male brains is intended to show that the extreme deviation of the thin line at that place is regarded as an irregularity, depending probably on the small number of male brains collected at that age.

All other circumstances being alike, the size of the brain appears to bear a general relation to the mental power of the individual,—although instances occur in which this rule is not applicable. The brain of Cuvier weighed upwards of 64 oz.,* and that of the late Dr. Abercrombie about 63 oz. averdupois.† On the other hand, the brain in idiots is remarkably small. In three idiots, whose ages were sixteen, forty, and fifty years, Tiedemann found the weight of their respective brains to be $19\frac{3}{4}$ oz., $25\frac{3}{4}$ oz., and $22\frac{1}{2}$ oz.; and Dr. Sims records the case of a female idiot twelve years old, whose brain weighed 27 oz.

Size of brain in proportion to intellect.

The weight of the human brain being taken at about 3 lbs. (48 oz.), it is found to be absolutely heavier than the brain of all the lower animals except the elephant and whale. In the elephant, the brain, according to Perrault, Moulins, and Sir A. Cooper, weighs between 8 and 10 lbs.; whilst that of the whale was found by Rudolphi, in a specimen 75 feet long, to weigh upwards of 5 lbs.‡

Human brain as compared with animals.

The *relative weight of the encephalon to the body* is liable to great variation; nevertheless, the facts to be gathered from the tables of Clendinning, Tiedemann, and Reid, furnish this interesting general result:—In a series of 81 males, the average proportion between the weight of the brain and that of the body, at the ages of twenty years and upwards, was found to be as 1 to 36·5; and in a series of 82 females, to be as 1 to 36·46. In these cases, the deaths were the result of more or less prolonged disease; but in 6 previously healthy males, who died suddenly from disease or accident, the average proportion was 1 to 40·8.

Weight of brain to weight of body,

in health;

The proportionate weight of the brain and body is greater at birth than at any other period of life, being, according to Tiedemann, about 1 to 5·85 in the male, and about 1 to 6·5 in the female. From the tables already referred to, it further appears that the proportion diminishes gradually up to the tenth year, being then about 1 to 14. From the tenth to the twentieth year, the relative increase of the body is most striking, the ratio of the two being at the end of that period about 1 to 30. After the twentieth year, the general average of 1 to 36·5 prevails, with a further trifling decrease in advanced life.

at different periods of life;

Viewed in relation to the weight of his body, the brain of man may be stated generally to be heavier than the brains of the lower animals; but there are some exceptions to the rule, as in the case of certain species of small birds, in the smaller apes, in monkeys, and in some small rodent animals.

as compared with animals.

In some of the examples in the following table,§ the brain is heavier, and in others lighter relatively to the body than it is in man.

* Emille Rousseau—*Maladie et autopsie de M. G. Cuvier*. *Lancette Française*. Mai 26, 1832. The precise weight given by M. Rousseau is 3 livres, 11 ounces, $4\frac{1}{2}$ gros (old French weight). This being reduced to kilogrammes and thence converted into oz. averdupois, gives 64 oz. and nearly one-third.

† Cormack's *Journal*, December, 1844. Dupuytren's brain is stated by Tiedemann (op. cit. p. 9,) to have weighed 58 oz. Apothecary's wt. = $63\frac{1}{2}$ oz. averdupois. But in the Report of the Autopsy published in the *Lancette Française*, Feb. 1835, the weight is given as 2 livres 14 ounces (old French wt. = only to 50 oz. Averdupois.

‡ In Tiedemann, op. cit. p. 15.

§ Selected from Cuvier's *Leçons, &c.*, 2d edition, par F. G. Cuvier & Laurillard, 1845. Paris.

Blue-headed Tit	1 to 12	Porpoise . . .	1 to 93
Canary . . .	1 to 14	Rabbit . . .	1 to 140
Goldfinch . . .	1 to 24	Cat . . .	1 to 156
Linnet . . .	1 to 24	Dog . . .	1 to 305
Monkey (small) . . .	1 to 22	Horse . . .	1 to 400
Field-mouse . . .	1 to 31	Elephant . . .	1 to 500
Gibbon . . .	1 to 48	Sheep . . .	1 to 350
Rat . . .	1 to 76	Ox . . .	1 to 860*

Weight of brain to body in the four classes of vertebrata. M. Leuret† has found, from extensive observation, that the proportionate weight of the brain to the body, in the four classes of vertebrate animals, may be represented by the following numbers :

In Fishes, as	1 to 5668	In Birds,	1 to 212
Reptiles,	1 to 1321	Mammalia,	1 to 186

WEIGHTS OF THE SEVERAL PARTS OF THE ENCEPHALON.

As the result of observations made in reference to this subject, on the brains of 53 males and 34 females, between the ages of twenty-five and fifty-five, Dr. J. Reid has given the following table :—

Weight of cerebrum, cerebellum, pons, and medulla oblongata.	Average weight of	Males.		Females.		Difference.	
		oz.	drs.	oz.	drs.	oz.	drs.
	cerebrum	43	15 $\frac{3}{4}$	38	12	5	3 $\frac{3}{4}$
	“ cerebellum	5	4	4	12 $\frac{1}{4}$	0	7 $\frac{3}{4}$
	“ pons and medulla oblongata	} 15 $\frac{3}{4}$		1	0 $\frac{1}{4}$	0	$\frac{1}{2}$
	“ entire encephalon	50	3 $\frac{1}{2}$	44	8 $\frac{1}{2}$	5	11

From this it appears that the proportionate weight of the cerebellum to that of the cerebrum, is, in the male, as 1 to 8 $\frac{1}{4}$, and in the female as 1 to 8 $\frac{1}{4}$.

Ratio between cerebr. and cerebell. In the new-born infant the ratio is strikingly different to what it is in the adult, being, according to Chaussier, from 1 to 13 to 1 to 26; by Cruveilhier it was found to be 1 to 20.

In most mammalia, the cerebellum is found to be heavier in proportion to the cerebrum, than it is in the human subject; in other words, the cerebrum is larger in proportion to the cerebellum in man.

Ratio of cerebr. to cerebral nerves. Semmerring‡ pointed out the fact that the brain is larger in proportion to the nerves connected with it in man than in the lower animals. With the view of shewing the size of the brain in proportion to the rest of the nervous

* We are indebted to Professor Owen for the following information concerning the relative weight of the brain and body in the Chimpanzee (*Simia Troglodytes*).

Weight of brain, in a half-grown male 9 $\frac{3}{4}$ oz.

Weight of body, in a nearly adult female, 61lbs. = 976 oz.

Proportion between the two weights 1 to 100.

† Anat. Comp. du Syst. Nerv., &c. Paris, 1839. Tom. i., p. 423.

‡ De basi encephali, Gœttingæ. 1778.

system in different cases, a comparison has been made of the width of the cerebrum with that of the medulla oblongata. From this it appears, that the proportionate diameter of the brain to that of the medulla oblongata is greater in man than in any animal, except the dolphin, in which creature it must be remembered that the cerebral lobes exhibit a disproportionate lateral development. The width of the cerebrum in man, as compared with that of the medulla oblongata at its base or broadest part, is about 7 to 1.

In the ourang it is	6 to 1	Width of cerebr. to width of medulla oblong. in man ;
In certain monkeys . . .	5 and 4 to 1	
In the dog	11 to 6	
In the cat	11 to 4	
In the rabbit	8 to 3	
In the ox	13 to 5	
In the horse	21 to 8	
In the falcon	34 to 13	
In the sparrow	18 to 7	
In the dolphin	13 to 1*	in animals.

WEIGHT OF THE SPINAL CORD.

Divested of its membranes and nerves, the spinal cord in the human subject weighs from 1 oz. to $1\frac{3}{4}$ oz., and therefore its proportion to the encephalon is about 1 to 33. Meckel gives it as 1 to 40.

The disproportion between the brain and the spinal cord becomes less and less in descending the scale of the vertebrata, until at length, in the cold-blooded animals, the spinal cord becomes heavier than the brain. Thus, in the mouse, the weight of the brain, in proportion to that of the spinal cord, is as 4 to 1 ; in the pigeon, as $3\frac{1}{3}$ to 1 ; in the newt, only as $\frac{5}{8}$ to 1 ; and in the lamprey, as $\frac{1}{7}$ to 1.

In comparison with the size of the body, the spinal cord in man may be stated in general terms to be much smaller than it is in animals. In regard to the cold-blooded animals, to birds, and to small mammalia, this has been actually demonstrated, but not in reference to the larger mammalia.

THE SPINAL CORD.

The *spinal cord*, or *spinal marrow* (medulla spinalis), is that part of the cerebro-spinal axis which is situated within the vertebral canal. It extends from the margin of the foramen magnum of the occipital bone, to about the lower part of the body of the first lumbar vertebra. It forms the continuation of the medulla oblongata above, and ends below in a slender filament, which is prolonged to the termination of the sacral canal.

The spinal cord does not occupy, either by its length or thickness, the entire space within that canal. On the contrary, does not fill the canal ;

* Cuvier's Leçons : ut suprâ.

invested closely by a proper membrane (the pia mater), the cord is enclosed within a sheath, both longer and larger than itself, which is formed by the dura mater, and which is itself separated from the walls of the canal by numerous vascular plexuses, and much loose cellular tissue. The interval between the investing membrane and the sheath of the cord, is lined by a serous membrane (the arachnoid), and is filled by a fluid called the cerebro-spinal fluid. Within this space the cord is suspended or supported by proper ligaments, which serve to fix it at different points to its sheath. The anterior and posterior roots of the several pairs of spinal nerves pass across the space from the surface of the cord, towards the corresponding intervertebral foramina. Since the cord terminates at the upper part of the lumbar region, it occupies only the two upper thirds of the spinal canal, and the elongated roots of the lumbar and sacral nerves, which descend nearly vertically from the cord to reach the lumbar intervertebral and the sacral foramina, form a lash of nervous cords named the *cauda equina*, which occupies the remaining and lower third of the spinal canal.

has a space
around it,
and a
sheath ;

a space
below it,
containing

cauda
equina.

Position
of lower
end varies ;

Although the cord usually ends near the lower border of the body of the first lumbar vertebra, it sometimes terminates a little above or below that point, as opposite to the last dorsal or to the second lumbar vertebra. The position of the lower end of the cord also varies according to the state of curvature of the vertebral column, in the flexion forwards of which, as in the stooping posture, the end of the cord is slightly raised.—In the fœtus, at an early period, the length of the cord corresponds with that of the vertebral canal ; but after the third month, the canal and the roots of the lumbar and sacral nerves begin to grow more rapidly in proportion so that at birth the lower end of the cord reaches only to the third lumbar vertebra.

reaches
bottom of
spinal canal
in fœtus.

Its length,
form, and

enlarge-
ments,
cervical,
lumbar ;

The length of the spinal cord is from fifteen to eighteen inches ; and it varies in diameter in different situations. Its general form is cylindrical, but it is somewhat flattened before and behind. It is not of uniform size or shape throughout, but presents two enlargements—an upper, or cervical, and a lower, or lumbar. The cervical enlargement is of greater size and extent than the lower. It reaches from the third cervical to the first dorsal vertebra ; its greatest diameter is from side to side. The lower or lumbar enlargement is situated about opposite the

last dorsal vertebra ; its greatest diameter is from before backwards, and by Foville* it is said to be chiefly due to an increase in bulk of the anterior region of the cord.—Below this enlargement, the cord tapers into a conical point. Sometimes it forms one or two bulbs or swellings towards its lower end. The cervical and lumbar enlargements have an evident relation to the size of the nerves which supply the upper and lower limbs, and which are connected with those regions of the cord,—in accordance with the general fact observed in the animal kingdom, that near the origin of large nerves, the nervous substance is accumulated in larger proportion. On its commencement in the embryo, the spinal cord is destitute of these enlargements, which, in their first appearance and subsequent progress, correspond with the growth of the limbs.

is pointed at lower end ;

sometimes swellings there.

The long free and slender filament in which the cord terminates, descends in the middle line amongst the nerves composing the cauda equina, and, becoming blended with the lower end of the sheath opposite to the first or second sacral vertebra, passes on to be fixed to the lower end of the sacral canal, or to the base of the coccyx. It is named the *central ligament* of the spinal cord ; it is of a fibrous structure, and contains no nervous substance, except for a short distance at its upper end ; it is, therefore, not a nerve, although it was at one time so considered, and was named *nervus impar*. It appears to be a prolongation of the pia mater or innermost membrane, which, being attached at its lower end to the dura mater and vertebral canal, keeps pace with the latter in its growth, whilst the cord relatively shortens. It consists of fibrous tissue with a few fine elastic filaments intermixed ; and it must assist in supporting the cord, and in maintaining its position during the movements of the trunk. A small vein has been sometimes seen upon it.

Termination of cord.

Central ligament is not a nerve,

but a prolongation of membranes.

When removed from the vertebral canal, and divested of its membranes, the spinal cord is seen to be marked by longitudinal *fissures*. Of these, two run along the middle line, one in front and the other behind, and are named the *anterior* and *posterior median fissures*, fig. 160, *a* and *p*. By means of these, which penetrate only a certain distance into its substance, the

Median fissures of cord

* *Traité compl. de l'Anat., &c. du Syst. Nerv. Cerebro-Spinal.* Paris, 1844. Part I., p. 138.

divides
it into
halves.

cord is divided into two lateral and symmetrical halves, which, however, are connected in their whole length by a cross portion of nervous substance called the *commissure*.

Anterior
fissure.

The *anterior median fissure*, *a a'*, is more distinct than the posterior, and penetrates about one-third of the thickness of the cord, but its depth increases towards the lower end. It contains a fold or lamelli-form process of the pia mater, and also many bloodvessels, which are thus conducted to the centre of the cord. At the bottom of this fissure is seen the connecting portion of white substance named the *anterior white commissure*.

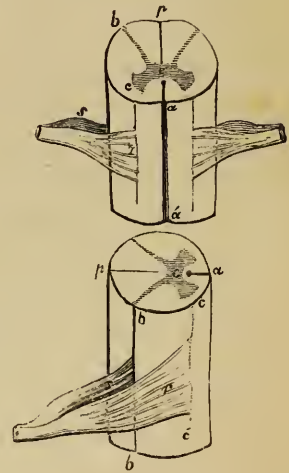
Posterior
fissure.

The *posterior median fissure*, *p p*, is less marked in the greater part of its extent than the anterior, but becomes more evident towards the upper part of the cord. Numerous bloodvessels, accompanied by slender filamentous processes derived from the inner membrane pass into this fissure. Lastly, the bottom of the fissure is separated from the central grey matter of the cord only by a very thin layer of white substance, which has been named the *posterior white commissure*; but some maintain that the fissure actually reaches the grey matter.

Lateral
fissures
opposite
roots of
nerves.

Besides these two *median* fissures, two *lateral* furrows or fissures have been described on each side of the cord, corresponding with the lines of attachment of the spinal nerves. The anterior and posterior roots of these nerves, as will be hereafter specially described, are attached to the cord in four rows, of which two are seen in front, fig. 160, *r*, at a little distance on either side of the anterior median fissure, and two behind, *s*, near the posterior median fissure. Now, along the line of attachment of the posterior roots, there is in each half of the

Fig. 160.*



* Plans in outline, shewing the front Δ , and the sides, \square , of the spinal cord with the fissures upon it; also sections of the grey and white matter, and the roots of the spinal nerves. *a, a*, Anterior. *p p*, Posterior fissure. *b*, Posterior, and *c*, Anterior horn of grey matter. *e*, Grey commissure. *a e c*, Anterior white column. *c e b*, Lateral columns. *a e b*, antero-lateral column. *b e p*, Posterior columns. *r*, Anterior, and *s*, Posterior roots of a spinal nerve.

the cord a fissure leading down to the grey matter, which there comes to the surface. This is the *posterior lateral fissure*, *b*, by which the corresponding half of the cord is divided into an anterior and a posterior column.

Posterior lateral fissure is evident.

By some anatomists, an *anterior lateral fissure* has been described as existing along the line of attachment of the anterior roots, *B, c c'*; but, in reality, there is no fissure to be seen on the surface at this part, although the white substance of the cord is divided by a prolongation of the grey matter, *A. c*, from within, which, however, does not reach the surface. Thus, each lateral half of the cord is divided by the posterior lateral fissure into a *posterior*, *p e b*, and an *antero-lateral* column, *a e b*; and although we cannot trace an anterior lateral fissure, this antero-lateral portion of the cord may, for the convenience of description, be considered as subdivided into an *anterior* and a *lateral column* by the internal grey matter.

Anterior lateral is not so.

Columns of antero-lateral cord.

On the posterior surface of the cord, (throughout *its whole length*, according to Foville, but much more evidently in the upper part,) there are two slightly-marked longitudinal furrows situated one on each side, close to the posterior median fissure, and marking off, at least in the cervical region, a slender tract, named the *posterior median* column. Between the roots of the spinal nerves, on each side, the cord is convex, and sometimes has a longitudinal mark upon it, corresponding with the line of attachment of the ligamentum denticulatum.

Posterior median.

Foville* states that in a new-born child, there is a narrow accessory bundle of white matter, running along the surface of the lateral column, separated from it by a streak of greyish substance. According to the same authority, this narrow tract enlarges above, and may be traced upwards along the side of the medulla oblongata into the cerebellum.

Structure of the spinal cord.—The spinal cord consists of white and grey nervous substance. The white matter is situated externally, whilst the grey matter is disposed in the interior, in a peculiar manner, to be now described. On a transverse section, figs. 160, 161, it presents two crescent-shaped masses of similar form, placed one in each lateral half of the cord with their convexities towards one another, and joined across the middle by a transverse portion of grey matter. Each of these

Structure of cord.

Central grey matter forms two crescents, joined back to back.

* Op. cit. p. 285.

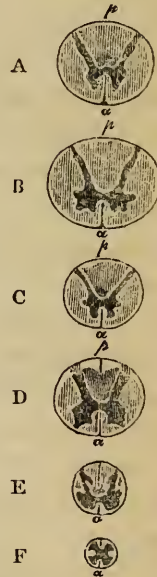
grey crescents has an anterior and a posterior cornu or horn. Of these, the posterior is long and narrow, and reaches the surface at the posterior lateral fissure. The anterior horn is shorter and thicker than the posterior; it extends towards the line of attachment of the anterior roots of the nerves, but it does not reach the surface of the cord. The transverse median portion of grey matter which connects the two crescents is named the *grey commissure* of the cord, *e*. In front of it, there is a tolerably thick layer of white substance, separating it from the bottom of the anterior median fissure, *a*; this is named the *anterior white commissure*. In like manner there is another white layer behind the grey matter, named the *posterior white commissure*, but this is very thin and indistinct, so that its existence has been denied by anatomists of good authority.

At its junction with the white substance, the grey matter presents a somewhat jagged or indented outline, especially in the anterior horn of each crescent.

At the tip of the posterior horn, which is somewhat enlarged, the grey matter has a peculiar semi-transparent aspect, whence it was named by Rolando, *substantia cinerea gelatinosa*.

The white substance forms by far the larger portion (it is said nearly seven-eighths) of the cord. Owing to the peculiar arrangement of the grey matter, the white substance in each semi-cylindrical half of the cord is divided into two principal columns, which have been already noticed in describing its surface; viz., a posterior and an antero-lateral column. The posterior column, fig. 160, *p e b*, is situated between the posterior median fissure and the posterior lateral fissure with the corresponding cornu of grey matter: it is wedge shaped, the point of the wedge being

Fig. 161.*



Grey com-
missure.

White
commiss-
ure;
anterior
and
posterior.

Subst.
gelatinosa.

White
substance
is more
abundant
than grey.

Its co-
lumns,
posterior,

* Shews sections of the cord at various heights, exhibiting the internal grey matter, and in some cases the anterior and posterior median fissures (Arnold). A. Section between 2nd and 3rd cervical nerve. B. Below the 6th cervical. C. Below the 10th dorsal. D. Below the 3rd lumbar. E. Below 2nd sacral. F. Below 5th sacral nerve. *a a a a*, Anterior surface. *p*, Posterior surface of cord.

directed forwards towards the centre. The remaining portion of white substance constitutes the antero-lateral column *a e b*, which is bounded behind by the posterior cornu of grey matter *b*, and on the inner side by the anterior median fissure *a*. It is partially subdivided by the anterior grey cornu *c*, into a lateral, *c e b*, and an anterior column, *a e c*, the latter being joined to the corresponding column of the other half of the cord by means of the white commissure.

antero-lateral,

subdivided into anterior, and lateral.

According to this view there are three principal columns in each half of the cord, viz., an anterior, a lateral, and a posterior column, in addition to the slender tract adjoining the posterior median fissure already described, which is generally reckoned as part of the posterior column.

Posterior median column.

The white substance of the cord has been described as if disposed in thin wedge-shaped and longitudinal laminae, placed in a radiating manner, with their inner edges in contact with the grey matter. Such a regular arrangement of lamellae does not exist, but the white substance is collected into compressed longitudinal bundles, between which small blood vessels run transversely into the substance of the cord, supported for a certain distance by delicate processes of membrane derived from the pia mater.

White substance not laminated, but in bundles.

There is an appearance of transverse decussating bundles in the anterior commissure, but this is to be attributed to the frequent interruption of the white substance by foramina for the transmission of small blood vessels.

Transverse fibres.

The arrangement of the white and grey substances, though agreeing generally with the description just given, is somewhat modified at different parts of the cord, as may be seen in sections made at different heights. Thus, the horns of the grey crescents are long and slender in the cervical portion, fig. 161, A, B., short and more slender in the dorsal, C, and short but much wider in the lumbar region, D, E; so that the grey matter appears, in a series of sections, to be, relatively to the white, more abundant in the lumbar region of the cord, E, less so in the cervical region, A, B, and least so in the dorsal, C, D. The quantity of white matter is greatest in the neck. Towards the lower end of the cord F, the double crescentic appearance gradually ceases, and the grey matter is collected into a central mass, which is indented at the sides. At its extreme point, according to Remak and Valentin, it consists of grey matter only.

Arrangement of grey and white matter varies

at different heights.

Canal in spinal cord in animals, and in human fœtus ;

but is closed afterwards, except at upper end ;

though this is a disputed point.

In fishes, reptiles, and birds, during the whole period of life, a canal exists along the centre of the spinal cord. It is found also in the fœtus of mammiferous animals, and even in the young of that class. In the human fœtus, as shewn by Tiedemann, there also exists, until after the sixth month, a central canal formed by the closing in of an open groove previously existing. In the adult human subject, the upper portion of this canal can be traced from the point of the calamus scriptorius in the floor of the fourth ventricle, for about half an inch or more down the centre of the cord, where it ends in a cul-de-sac. Much controversy, however, has prevailed in regard to the extent to which this canal exists in the adult, and many writers have maintained that it is to be found through the whole length of the cord, situated between the grey and white commissures.

The attention of anatomists has recently been directed to this point by the microscopic observations of Drs. Stilling and Wallach,* who maintain that the canal may be traced in the adult low down in the cord, appearing on a section as a small round foramen in the centre of the grey matter. We must confess that, on careful examination, we have only now and then been able to discover an aperture, which has much the appearance of a divided blood vessel.

The minute or microscopic structure of the cord, including the arrangement of the roots of the nerves within it, will be considered afterwards.

THE ENCEPHALON.

Encephalon and its parts.

We have now to describe the four principal parts into which the encephalon is divided, viz., the cerebrum, the cerebellum, the pons Varolii and the medulla oblongata. But their general position within the skull, and their relations to each other, require first to be understood.

Cerebrum is largest part ;

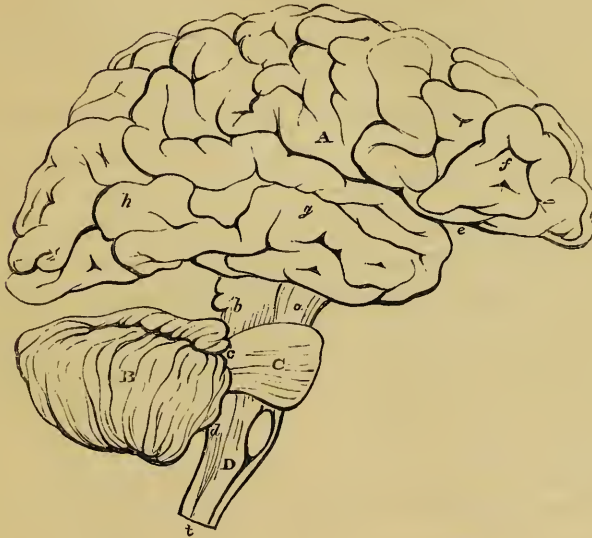The *cerebrum*, fig. 162, A, which constitutes the highest and by far the largest part of the human encephalon,† occupies the upper and larger portion of the cranial cavity. A line drawn

* *Über die Textur des Rückenmarks.* Leipzig, 1842.

† See pp. 668, 672, for the weight of these parts.

from a little above the orbit to the auditory meatus, met by another from the occipital protuberance to the same point, will its position

Fig. 162.*



nearly indicate on the living head, the inferior limit of the cere- in skull ;
brum. In front, it rests in the anterior fossa of the base of the skull ; behind this, in the middle fossa ; and still further back, it overlies the cerebellum, beyond which it projects posteriorly, resting on the tentorium, a horizontal partition formed by the dura mater between the cerebrum and the cerebellum. In all this extent, as well as above and at the sides, the cerebrum is free and unattached, but from the middle of its under surface there proceeds a comparatively narrow and constricted portion, part of which, *a*, forming the crura cerebri or peduncles of the brain, its pedun-
descends into the pons Varolii below, and, through it, is contin- cles.
ued into the medulla oblongata ; whilst another part, *b*, passes down to join the cerebellum.

The *cerebellum*, *B*, is placed beneath the hinder part of the Cerebel-
lum.

* A plan in outline, showing, in a lateral view, the parts of the encephalon separated somewhat from each other. *A*. Cerebrum. *f, g, h*. Its anterior, middle, and posterior lobes. *e*. Fissure of Sylvius. *B*. Cerebellum. *c*. Pons Varolii. *D*. Medulla oblongata. *a*. Peduncles of cerebrum. *b*. Superior ; *c*. Middle ; and *d*. Inferior peduncles of cerebellum. The parts marked *a, b, c, c*, form the isthmus encephali.

cerebrum, by which it is completely overlapped, the tentorium separating one from the other. It is lodged in the inferior occipital fossæ, and is attached to the rest of the encephalon, at its fore part, by means of connecting portions named *crura*: of these, two, *b*, ascend to the cerebrum, two, *d*, pass downwards to the medulla oblongata, *D*, and two, *c*, horizontally forwards, so as to embrace the peduncles of the brain, in front of which they unite to form the transverse eminence of the *pons Varolii*.

Pons Va-
rolii.

The *pons*, *c*, itself rests upon the upper part of the basilar process, in front; it receives the cerebral peduncles above, and the middle *crura* of the cerebellum behind and at the sides; whilst the medulla oblongata is connected with it below.

Medulla
oblongata.

Lastly, the *medulla oblongata*, *D*, descending obliquely backwards from the lower border of the pons, is placed beneath the middle of the cerebellum, and rests on the basilar groove, until it reaches the foramen magnum, where it is continuous with the spinal cord, *t*.

Cavities or
ventricles
of Brain.

Situated in the interior of the brain, surrounded by nervous substance and lined by a delicate membrane, are certain serous cavities, called *ventricles*. These, which are five in number, will be described with the parts of the encephalon in which they occur.

We shall now proceed to describe those parts in the following order: the medulla oblongata, the pons Varolii, the cerebrum, and the cerebellum.

THE MEDULLA OBLONGATA.

Medulla
oblongata :

The *medulla oblongata*, fig. 165, *v*, is that part of the encephalon which is immediately connected with the upper end of the spinal cord. It is bounded above by the lower border of the pons Varolii, whilst it is continuous below with the spinal cord, opposite the foramen magnum. By some, its inferior limit is, with reason, fixed rather lower down, on a level with the upper border of the atlas, at a point which corresponds with the lower extremity of the anterior pyramids, to be presently described.*

its limits ;

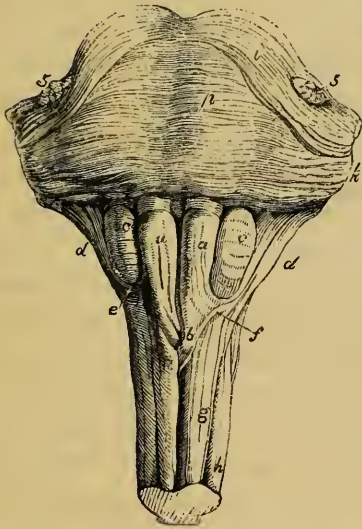
sometimes
differently
defined ;

* The term *medulla oblongata*, as employed by Willis, by Vieussens, and by those who directly followed them, included the *crura cerebri* and pons Varolii, as well as that part between the pons and the foramen magnum, to which, by Haller first, and by most subsequent writers, this term has been restricted.

The medulla oblongata inclines obliquely downwards and backwards, fig. 166, towards the foramen magnum. Its anterior surface rests in the basilar groove, whilst its posterior surface is received into the fossa, named the vallecula, between the hemispheres of the cerebellum, and there forms the floor of the fourth ventricle. To its sides, several large nerves are attached, fig. 165.

It is of a pyramidal form, fig. 163, having its broad extremity turned upwards, from

Fig. 163.*



form ; its position ;
 from which it tapers to its point of connection with the spinal cord : it is expanded laterally at its upper part. Its length from the pons to the lower extremity of the pyramids is about an inch and a quarter ; its greatest breadth is about three quarters of an inch ; and its thickness, from before backwards, about half an inch. dimensions.

The pia mater having been removed, the medulla oblongata is seen to be marked longitudinally by an anterior and a posterior fissure, which are continuous with those of the spinal cord. Of these, the *anterior*, between *a a*, terminates immediately below the pons *p*, in a cul-de-sac, called the foramen cœcum, by Vicq-d'Azyr. It is penetrated by a fold of the pia mater. Its fissures ; anterior ;

The *posterior* fissure, fig. 164, is deep but narrow ; it is continued upwards into the floor of the fourth ventricle, *v v'*, where it becomes a superficial furrow, and is gradually lost. posterior.

By means of these two fissures, the medulla oblongata is

* An anterior view of the medulla oblongata. *a a*. Anterior pyramids. *b*. Their decussation across the middle line. *c c*. The olivary bodies. *d d*. Restiform bodies. *e*. Arciform fibres. *f*. Fibres shewn by Solly to pass from anterior column of cord to cerebellum. *g*. Anterior column. *h*. Lateral column. *p*. Pons Varolii. *i*. Its upper fibres. 5, 5. Roots of fifth nerves.

Columns of cord are here differently arranged.

partially divided like the cord, into two lateral and symmetrical halves. But here the resemblance ceases; for on each side of the median line an entirely new arrangement prevails; the lateral fissures disappear, and the surface of each half of the medulla presents four eminences or columns, which, on commencing at the anterior fissure and proceeding backwards each way to the posterior fissure, are met with in the following order: the anterior pyramids, the olivary bodies, the restiform bodies, and the posterior pyramids.

Anterior pyramids ; shape ; pass through Pons Varolii to brain; form the sides of anterior fissure.

The *anterior pyramids*, fig. 163, *aa*, so called from their position and shape, are two bundles of white substance, placed on either side of the anterior fissure, which are narrower at the lower end, and become broader and more prominent as they ascend towards the pons Varolii. At their upper end they are constricted, and thus enter the substance of the pons, *p*, through which their fibres may be traced into the peduncles of the brain. The outer border of each pyramid is marked off from the olivary body, *c*, by a slight depression. By their inner borders the pyramids form the sides of the anterior fissure. Over a space, commencing about eight or ten lines below the pons and extending to the lower end of the medulla, a portion of each pyramid, arranged in several bundles, passes downwards across the fissure to the opposite side. This *decussation of the pyramids*, *b*, as it is called, is partial, for it affects only the innermost fibres and consists of from three to five intersecting bundles from either side. When traced from below, it is found that the whole, or a great part of these fibres come forwards from the deep portion of the lateral columns of the cord (as appears first to have been pointed out by Rosenthal),* and advance to the surface, between the diverging anterior columns, *gg*, which are thus thrown aside.

Opposite pyramids decussate, by fibres coming principally or entirely from behind.

Only inner fibres decussate.

The outer portion of each pyramid does not decussate; it consists of fibres, derived from the anterior column of the cord: these all ascend and are joined by the decussating por-

* Ein Beytrag zur Enecephalotomie, 1815.

† The decussation of the anterior pyramids was noticed about the beginning of the last century by Mistichelli. Though doubted by Morgagni, Haller, Vieq-d'Azyr, and many others, it is a well-established fact, and has been supposed to afford some explanation of the cross effect of certain injuries and diseases of the brain.

tion from the opposite side. Together they form a prismatic bundle or column of white fibres, which extends deeply into the substance of the medulla, and is triangular in a cross section, (see fig. 173, b.)

The anterior pyramids contain no grey matter.

The *olivary bodies* (olivæ, seu corpora olivaria), fig. 163, c c, are two prominent oval masses placed to the outer side of the pyramids, and sunk to a considerable depth in the substance of the medulla oblongata, appearing on its surface like two smooth oval eminences. They are placed parallel to the outer border of the pyramids, and therefore incline outwards towards their upper end. They do not reach the pons Varolii above, being separated from it by a deep depression; nor do they extend so far in a downward direction as the pyramids, than which they are considerably shorter.

No grey matter.

Olivary bodies;

project on front of medulla;

The olivary bodies consist externally of white substance, of which the fibres chiefly run longitudinally; and internally of a grey nucleus, named *corpus dentatum* or *ciliare*.

white externally; grey nucleus within, named corpus dentatum;

On making a section, whether horizontal or vertical, this grey matter which is of a light yellowish colour, appears in form of a zig-zag line, circumscribing a whitish substance within, and interrupted towards the centre of the medulla, (see fig. 173, 174, c). The grey matter or nucleus of the olivary body therefore is arranged in the form of a pouch or capsule, which is open at its upper and inner part and has its sides corrugated or plicated, so as to give the indented appearance to a section, from which its name has been derived. This pouch is, moreover, surrounded with white matter externally, and through its open part white fibres pass into or issue from its interior, and connect it with other parts of the brain. The external fibres of the anterior columns of the cord, which are here thrown outwards, as already mentioned, are continued upwards, on the surface of the medulla oblongata, and then pass partly on the outside and partly beneath the olivary bodies—being joined in their further progress by the fibres issuing from the olivary nucleus. To these fibres on each side, the term olivary fasciculus has been applied.

Why so named.

Grey matter interrupted on inner side.

White fibres form olivary fasciculus.

The *restiform bodies* (corpora restiformia). Behind and to the outer side of the olivary body, are two lateral rounded eminences or columns, called from their rope-like appearance, the *restiform bodies*, fig. 163, d d. These are directly conti-

Restiform bodies,

at sides and
back of
medulla,

form infe-
rior pe-
duncles of
cerebellum ;

White
fibres of
restiform
body,

from each
column of
cord.

Fibres
shewn by
Solly.

Grey mat-
ter.

nuous with the posterior, and with part of the antero-lateral columns of the cord; they diverge slightly as they ascend, and thus occasion the great width of the medulla at its upper part. Each of them passes into the corresponding hemisphere of the cerebellum, and constitutes its inferior peduncle.

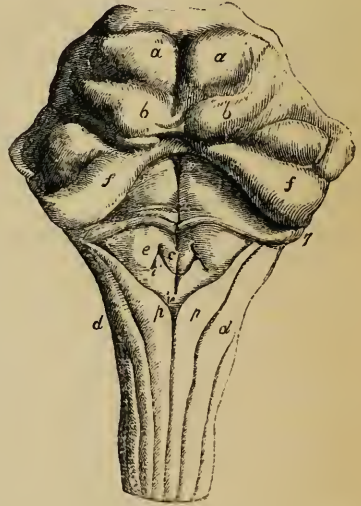
The restiform bodies are well seen, on a posterior view fig. 164, *dd*. First, they are in contact with the small tracts of the medulla, named the posterior pyramids, *p*.; but higher up they become free and prominent, and assist in forming the lateral boundaries of the fourth ventricle.

By far the larger portion of the external white substance of the restiform body consists of longitudinal fibres, which include all those belonging to the posterior column of the cord, except the fasciculi graciles, *p*, some derived from the lateral column, and also a small band from the anterior column. This last-named band, fig. 163, *f*, runs obliquely below the olivary body and connects the anterior column with the cerebellum, as was first shewn by Mr. Solly.†

The part of the posterior column of the cord which belongs to the restiform body of the medulla, is named the fasciculus cuneatus by the German anatomists: below *d*, on the right side.

There is a considerable portion of grey matter in the interior of the restiform body. This is for the most part much dif-

Fig. 164.*



* Posterior view of the medulla oblongata, and back of the pons Varolii. The peduncles of the cerebellum are cut short. *dd*. Restiform bodies, (fasciculi cuneati,) passing up to become inferior peduncles of cerebellum. *pp*. Posterior pyramids. *vv*. Posterior fissure, or calamus scriptorius, extending along the floor of the fourth ventricle. *aa*. Testes. *bb*. Nates. *ff*. Superior peduncles of cerebellum. *c*. Eminence connected with hypoglossal nerve. *e*. With glosso-pharyngeal nerve. *i*. With vagus nerve. *v*. With spinal accessory nerve. 7, 7, Roots of auditory nerves.

† Phil. Trans. for May, 1836.

fused ; but one large mass, fig. 173, *d*, continuous below with the substantia gelatinosa, or grey matter forming the posterior cornu of the cord, is thrown out towards the side of the medulla, and generally appearing as a longitudinal streak at the surface, forms the grey tubercle of Rolando (tuberculo cinereo).

Grey tubercle of Rolando.

The *posterior pyramids* (fasciculi graciles), *pp*, fig. 164, of the medulla oblongata, are the smallest of the four columns into which it is divided. They are situated in contact with each other, one on either side of the posterior median fissure. They consist entirely of white fibres, and are continuous with the posterior slender tracts already described as existing on the posterior median aspect of the cord. On reaching the lower part of the medulla, the posterior pyramids become somewhat swelled out, and then, diverging from one another, they become closely applied to the restiform bodies, and have been considered to be blended with them, and therefore to contribute to form the inferior peduncles of the cerebellum. But, according to Burdach and Arnold, these small columns ascend to the cerebrum.

Posterior pyramids, or fasc. graciles, are very slender ;

their connections.

The triangular portion of the back of the medulla, which is bounded on each side by the diverging posterior pyramids below, and by the restiform bodies higher up, constitutes the floor of the fourth ventricle, that part of it, namely, which is called the *calamus scriptorius*, *v'*. Upon it, the grey matter of the centre of the medulla oblongata is, as it were, opened out to view. It is marked by a median furrow *v v'*, and at its lower end is a tubular recess, or cul-de-sac, passing down the centre of the medulla for a few lines. This, which has been sometimes named the *ventricle of Arantius*, is all that remains in adults of the central canal of the spinal cord already spoken of.

Floor of fourth ventricle.

Calamus scriptorius.

Ventricle of Arantius.

In the upper part of the floor of the ventricle are two longitudinal eminences, one on each side of the middle furrow. These are formed by two bundles of white fibres, mixed with much grey matter, the *fasciculi teretes* of some authors, *les faisceaux innominés* of Cruveilhier. They seem to be derived from part of the lateral columns of the cord ; Cruveilhier believes, however, that they arise from the grey matter at the lower end of the medulla oblongata.

Fascic. teretes.

The mode in which the columns of the spinal cord are re-arranged so as to form those of the medulla oblongata, has been

incidentally alluded to in the foregoing description; but the subject will be hereafter resumed in considering the internal structure.

Transverse
white
fibres of
medulla
oblongata.
Arciform
fibres.

Santorini, and subsequently Rolando, described a set of superficial white fibres on the fore part and sides of the medulla oblongata, crossing over it below the olivary bodies. From their direction they were named *fibræ vel processus arciformes*, fig. 163, e. They belong to a system of white fibres which pass transversely or horizontally, and consequently across the direction of the longitudinal columns already described. Part of them run from behind forwards in the median plane, forming a sort of septum between the lateral halves of the cord, and have been named *septal* fibres, fig. 174, i. It is probable that the arciform fibres are a continuation of these central fibres in front; and there is also reason to suppose that they form the transverse medullary white striæ, in the floor of the fourth ventricle, which are connected with the origin of the auditory nerves, fig. 164, 77, and which will hereafter be described.

Septal
fibres.

Transverse
fibres are
more or less
apparent
on surface.

Sometimes the greater part of the pyramidal and olivary bodies is covered by a thin stratum of these transverse fibres, which appear to issue from the anterior median fissure; but, most commonly, these superficial fibres appear only at the lower extremity of the olive, as the arciform fibres already mentioned. These differences are, most probably, owing not to the presence of the fibres at one time, and their absence at another, but to the circumstance of their running sometimes superficially, and at other times deeply in their transverse course.

THE PONS VAROLII, OR TUBER ANNULARE.

Pons
Varolii;

its position;

named
meso-ce-
phalon, and
nodus
cerebri.

Its upper

The *pons Varolii*, or *annular protuberance* (tuber annulare), fig. 163, p, fig. 165, o, is a comparatively small portion of the encephalon, which occupies a central position on its under surface, above and in front of the medulla oblongata, below and behind the crura cerebri, and between the middle crura of the cerebellum, with all which parts it is connected. From its position and connections it has been named *mésocéphalon* (Chaussier) and *nodus encephali* (Rau, Sæmmerring).

The under surface of the pons Varolii is of course seen in the base of the brain, fig. 165, o, whilst its upper surface, or

the back, continuous with that of the medulla oblongata, forms part of the floor of the fourth ventricle, fig. 164. surface or back.

The under surface forms a white transverse quadrangular eminence, fig. 163, *p.*, fig. 165, *o.*, projecting in relief beyond the level of the medulla oblongata and crura cerebri, which, as we shall see, are connected with each other through its substance. It is this part, in particular, which is named the *annular protuberance*, because it embraces, as in a ring, the longitudinal portions of the nervous axis,— and also the *pons*, because, when viewed from below, it seems to cross over those parts like a bridge. Its under surface
forms annular protuberance or pons proper ;

It rests on the upper part of the basilar groove. It is marked with transverse bands and striæ, which indicate the course of its superficial fibres. Along the middle line it presents a shallow longitudinal groove, which is wider in front than behind, and is prolonged over the anterior and posterior borders of the pons. The basilar artery runs along this groove, in the floor of which are perforations for the transmission of small branches of that vessel. is striated across ;
and grooved vertically.

The anterior and posterior borders of the pons are well defined. The anterior is more extended than the posterior, and its outline is more convex from side to side. Its borders defined ;

The crura cerebri, fig. 165, *d, t.*, appear to emerge from beneath it. At the sides, the limits of the pons Varolii are quite arbitrary, for it merely becomes narrower owing to its being gathered, as it were, into a compressed bundle on each side *l.* These two bundles pass obliquely outwards and backwards into the cerebellum, and form its middle peduncles. at sides forms middle crura of cerebellum.

The substance of the pons Varolii consists of transverse and longitudinal white fibres interspersed with a quantity of diffused grey matter. The transverse fibres, with a few exceptions to be particularized hereafter, enter the cerebellum under the name of the middle crura or peduncles, and form a commissural system for its two hemispheres. The longitudinal fibres are those which ascend from the medulla oblongata into the crura cerebri, augmented, it would seem, by others which arise within the pons from the grey matter scattered through it. The arrangement of both these sets of fibres in the interior of the pons will be referred to hereafter ; but we may notice now the layer of transverse fibres, fig. 163, which are next the surface. Structure : consists of longitudinal and transv. fibres with grey matter.

Superficial
transverse
fibres.

The fibres composing this layer do not all run parallel to each other. The middle fibres pass directly across, the lower set ascend slightly, whilst the upper fibres, which are the most curved, descend obliquely to reach the crura cerebelli on each side. There is always one superficial band, *i*, of the superior fibres, which crosses obliquely downwards over the middle and lower fibres, to gain the anterior surface of the corresponding crus.

THE CEREBRUM.

Cerebrum ;

The *cerebrum* or brain proper, fig. 162, A, as already mentioned, is the highest, and by far the largest portion of the encephalon. It is of an ovoid shape, but is irregularly flattened on its under side. It is placed in the cranium with its small end forwards, its greatest width being opposite to the parietal eminences.

is divided
into two
hemi-
spheres ;

The cerebrum consists of two lateral halves, or *hemispheres*, as they are called, which, though connected by a median portion of nervous substance, are separated in a great part of their extent by a fissure, named the great longitudinal fissure, which is seen on the upper surface of the brain and partly also upon its base, fig. 165, *a x b*.

surface
covered
with con-
volutions,
and sulci ;
is grey
externally.

The cerebral hemispheres are not plain and uniform upon the surface, but are moulded into numerous smooth and tortuous eminences, named *convolutions* or gyri, which are marked off from each other by deep furrows, called sulci, or *anfractuosities*. These convolutions are coloured externally; for the surface of the cerebral hemispheres, unlike the parts hitherto described, is composed of grey matter.

Longitudi-
nal fissure,

Upper surface of the cerebrum.—The *great longitudinal fissure*, seen upon the upper surface of the brain, extends from before backwards throughout its whole length in the median plane, and thus separates the cerebrum, as already stated, into a right and left hemisphere. On opening this fissure, it is seen, both before and behind, to pass quite through to the base of the cerebrum; but in the middle it is interrupted by a transverse portion of white substance, named the *corpus callosum*, fig. 166, *a b*, which connects the two hemispheres together. In the natural state, this fissure is occupied by a vertical process of the dura mater—the falx cerebri,—which dips down

between
hemi-
spheres.

between the two hemispheres, not quite reaching to the corpus callosum.

Each cerebral hemisphere has an outer or convex surface, which is in contact with the vault of the cranium, an inner or flat surface, of a crescent-shape, which forms one side of the longitudinal fissure ; and an irregular under surface, which rests on the base of the skull, and on the tentorium cerebelli.

Under surface of cerebrum.—The under surface of each hemisphere, fig. 165, is marked off into three parts, called *lobes*, which are named according to their position, anterior, middle, and posterior, *A B C*, also *f g h*, fig. 162. The division between the anterior and middle lobes, which is very distinct, is indicated by a deep cleft, named the Sylvian fissure, *s s'*. There is no such evident demarcation between the middle and posterior lobes ; but anatomists have considered, as the posterior lobe, that part of the hemisphere which lies over the cerebellum.* The under surface of the anterior lobe is triangular and excavated to adapt it to the roof of the orbit on which it rests. The middle lobe, fig. 162, *g*, is rounded and prominent, and occupies the middle fossa of the skull—the edge of the lesser wing of the sphenoid bone corresponding with the Sylvian fissure. The posterior lobe, *h*, is smooth and slightly concave on its under surface, where it rests on the arch of the tentorium.

The Sylvian fissure, fig. 162, *e*, 165, *s s'*, which separates the anterior and middle lobes, passes at first upwards and backwards in the outer part of the hemisphere, and divides into two branches. At the entrance of the fissure is seen a bundle of white substance passing from the anterior to the middle lobe, named *fasciculus unciformis* (Reil).

On opening the fissure out, there is exposed to view a triangular prominent portion of the cerebral mass, named the *island of Reil* (*insula*). It is marked by small and short convolutions, which are sometimes called *gyri operi*, because in the natural state of the parts they are covered by the sides of the fissure.

Under surface or base ;
divided into lobes :

anterior,

middle,

and posterior lobes.

Sylvian fissure :

Fascic. unciformis.

Island of Reil, or gyri operi.

* It is right to remark that some anatomical writers admit only *two* lobes, reckoning the middle and posterior lobes as a single one, under the name of the posterior lobe.

It has already been stated that the entire surface of the cerebral hemispheres is marked by *convolutions* and sulci, some of which, it must not be forgotten, are concealed from view in the great fissures. These convolutions do not exactly resemble each other in all brains, nor are they symmetrical on the two sides of the same brain, although there is a certain correspondence in their general direction.

Convolutions ;

their form ;

structure ;

depth ;

subdivided into smaller ones

Nature of convolutions.

Arrangement, complex.

Each convolution may be described as presenting a summit or rounded free border, two sides, and a base, by which it is connected with the general cerebral mass. The outer portion of the convolutions (including, of course, the sides and bottom of the sulci) consists of a layer of grey matter, which is here called the *cortical substance* or *layer*: they are covered closely throughout by the pia mater, a vascular membrane, which sends processes down to the bottom of the sulci between them. These sulci are generally about an inch deep; but in this respect there is much variety in different brains, and in different parts of the same brain; in other words, the depth of the convolutions varies considerably: those upon the outer convex surface of the hemisphere are the deepest. In general, the depth of a convolution exceeds its width; and its width, near the summit, is greater than through its base.

The free border of a large convolution, or the side of an unusually deep one, is sometimes grooved longitudinally, or marked with shallow notches, so as to be partially divided into smaller or subordinate gyri. All the convolutions are continuous with each other, if not upon the surface, at least within the anfractuositities; for, if one appears to end abruptly, it will be found on examination to sink between and then run into others, across the bottom of the intervening sulci.

Since the external grey or cortical substance is continuous over the whole surface of the cerebral hemispheres, being found alike within the sulci and upon the gyri, a far greater extent of grey matter is obtained with a given size of the organ than could have been the case, had the hemispheres been plain and destitute of convolutions.

The general arrangement of the convolutions has been made the subject of study by various anatomists in earlier and recent times, but much yet remains to be elucidated. An attempt to describe individual gyri would be quite useless, owing to

their irregularity in different cases, and their want of symmetry in the same brain. Nevertheless, there are some sufficiently constant in presence, and characteristic in situation and form, to admit of being specially described.

It has also been shown that certain of the cerebral convolutions precede others in their appearance in the series of mammiferous animals; for in the lowest mammalia, and in all inferior classes of vertebrata, the cerebrum is not convoluted on the surface.

Their first appearance in animals.

Among the earliest convolutions to appear are those of the island of Reil, which are concealed in the Sylvian fissure. As seen in the human brain, they radiate from the summit to the base of the triangular eminence formed by the island, and are separated by shallow sulci.

Convolution of island of Reil.

Surrounding the convolutions of the island (gyri operati), and forming the lips of the Sylvian fissure, is a very large convolution, named *convolution of the Sylvian fissure*. This is also early in its appearance in animals: in them it is, at first, simple in form, and completely surrounds the fissure, forming a curve, open in front and below. In the human brain, fig. 165, *ff*, it is tortuous and much folded, so as to form many subordinate gyri, corresponding with the front, upper, and under border of the fissure. The commencement of this convolution, *f*, in front of the fissure, forms the outer part of the triangular orbital surface of the anterior lobe. From its outer border proceed numerous secondary gyri, which extend in various directions on the convex surface of the hemisphere, fig. 162; and its inner border receives, in a similar manner, the radiating convolutions of the island of Reil.

Convolution of Sylvian fissure.

Perhaps the most distinct and symmetrical convolution in the whole brain is that named the *internal convolution, convolution of the corpus callosum, gyrus fornicatus*. Commencing (fig. 166, *h*), on the under surface of the brain, immediately before the part named the anterior perforated space, it ascends a short distance in front of the anterior recurved extremity of the corpus callosum, *a*, and then runs backwards, *h'*, immediately above that body, as far as its posterior extremity: there it turns downwards and forwards, *h''*, embracing the cerebral peduncle, fig. 165, *t*, to reach the entrance of the Sylvian fissure, *h'*. This long convolution, therefore, describes a sort of ring open or interrupted

Gyrus fornicatus;

embraces
corp. callos.;

forms the
border of
grey mat-
ter ;

is covered
by reticu-
lated white
substance ;

forms the
crest of
Rolando.

Marginal
convolution
of the long.
fiss. ;

its course
along the
border of
fissure ;

its termina-
tion at point
of middle
lobe.

Supra-
orbital con-
volutions.

opposite the Sylvian fissure, and embracing the corpus callosum above, and the cerebral peduncle below. It thus occupies the entire margin of the convoluted surface of the hemisphere, and, as was pointed out by Foville, forms a sort of rim or border to the grey matter, whence it is named by him *convolution d'ourlet*. The surface of this convolution, especially towards its termination below, is covered by a very thin cribriform layer of white substance, which, with the grey matter beneath, gives the surface a mottled aspect. This has been called the *reticulated white substance*. The gyrus fornicatus is variously grooved in different brains, and from its upper border are given off secondary gyri, which extend in different directions upon the inner or flat surface of the hemisphere, fig. 166. From the appearance of the convolution and its offsets in this situation, the name *processo cristato* was applied to it by Rolando.

Another large convolution may be traced, according to Foville, more or less indented or interrupted, however, in its course, along the line of junction between the convex and flat surfaces of the hemisphere,—in other words, along the corresponding lip of the great longitudinal fissure. This, which might be called the *marginal convolution of the longitudinal fissure*, commences on the under surface of the brain (figs. 165, 166, *x*), in common with the gyrus fornicatus, and passing forwards, forms the inner border of the triangular orbital surface of the anterior lobe, and is here cleft as it were into two by a deep sulcus, into which the olfactory nerve 1, is received. Turning next over the front and upper surface of the cerebrum, it may generally be traced for some distance along the margin of the longitudinal fissure *x' x''*, but soon becomes marked by deep sulci ; and thus interrupted, may be followed round the posterior extremity *y*, and afterwards along the under surface of the hemisphere forwards as far as the point of the middle lobe, running parallel for some space with the under portion of the gyrus fornicatus.

The convolutions on the under surface of the anterior lobe have been usually mentioned separately by anatomists. The outer border, fig. 165, of this triangular surface is formed by the commencement of the convolution of the Sylvian fissure *f* ; the inner border, *x*, by the marginal convolution of the

longitudinal fissure, in the sulcus on which the olfactory nerve is lodged. The intermediate excavated part is occupied by other convolutions, less regular in their direction. At the apex of the triangle behind, the two borders are connected by a short and but slightly elevated convolution, *s*, which bounds the anterior perforated space in front.

It remains only to notice those gyri which occupy the outer or convex surface of the hemisphere, between the marginal convolution of the longitudinal fissure and that of the Sylvian fissure. The general direction of these, see fig. 162, *f h g*, which are the largest, the most complicated, and the least symmetrical of all the convolutions of the human brain, is not longitudinal, like those previously described, but transverse or somewhat oblique. It has been remarked by Foville that they frequently become branched like the letter *Y*, as they proceed upwards and backwards towards the longitudinal fissure.

Convolutions on outer surface of cerebrum:

large, complex, and unsymmetrical.

M. Foville considers that the convolutions may be arranged into four principal groups or orders, founded in a great measure on their relative connections with the anterior perforated space, which, in his estimation, is a part of the highest importance.

Foville's four orders of convolutions.

The *first* order issues from the perforated space, and consists of two portions. One, large and vertical, is the gyrus fornicatus, minus its ascending secondary gyri; the other, short and horizontal, is the slightly-elevated ridge which bounds the perforated space, in front and on the outer side.

First includes gyrus fornicatus and another.

The *second* order, also consisting of two portions, commences from the horizontal portion of the first order, on the limits of the perforated space. One part corresponds with the marginal convolution of the longitudinal fissure, as already described, except that part of it on the orbital surface of the anterior lobe, which lies to the outer side of the olfactory sulcus; the other part is the convolution of the Sylvian fissure.

Second includes convolutions of longitudinal and Sylvian fissures.

The *third* order consists of two sets, of which one occupies the inner surface of the hemisphere, and connects the gyrus fornicatus in its whole length with the marginal convolution of the longitudinal fissure; the other set lies in the Sylvian fissure, forms the island of Reil, and connects the short horizontal portion of the first order with the convolution surrounding that fissure.

Third are internal convolutions and those of island of Reil.

The convolutions of the *fourth* order, the largest, deepest, and least symmetrical of all, are quite detached from the perforated space, and have no relation to the first order of convolutions. They connect the two convolutions of the second order together, viz., the marginal convolution of the median fissure and that of the Sylvian fissure, and occupy the outer or convex surface of the cerebral hemisphere.

Fourth, occupy outer surface of brain.

M. Leuret has arrived at some interesting conclusions in reference to the

Leuret's

views ;
founded on
anatomy of
convolu-
tions in
mammalia ;
at first
none ;

cerebral convolutions in mammalia, which class of animals are arranged by him, in connection with this point, into as many as fourteen groups.

In the lowest group—represented by the bat, mole, rat, &c.—the cerebral hemispheres, as in birds, are quite plain and smooth, though divided by a Sylvian fissure. In the second group—including the rabbit, beaver, and porcupine—that fissure is more strongly marked ; but there are only a few slight depressions on the surface of the hemispheres, indicating the future sulci between the convolutions.

earliest ap-
pearance.

In the third group—formed by the fox, wolf, and dog—the simplest form of true convolutions is first met with ; and they are named by M. Leuret, *fundamental convolutions*. In the brain of the fox, taken as a typical example, they are six in number : they are all simple in outline, distinct from each other, and form a series of longitudinal curved lines on the surface of the hemisphere, running from before backwards.

Funda-
mental con-
volutions
run length-
wise ;
external,

Four of them, named *external*, are placed on the convex surface of the hemisphere. Of these, one forms the curved lip or border of the Sylvian fissure, and surrounds the island of Reil ; the other three, also curved in this direction, are placed parallel with the first, and one above another,—the fourth, or *superior* convolution, being placed on the margin of the longitudinal fissure. The fifth convolution (*anterior*) forms the under and fore part of the anterior lobe, and is named the supra orbital convolution. The sixth (*internal*) is placed above the corpus callosum, and corresponds with the gyrus fornicatus.

anterior,
and
internal.

Modified
in number,
complex-
ity, and

In the succeeding groups, up to the thirteenth, various changes take place in the condition and mode of connection of these fundamental convolutions, which cannot be detailed here. Thus, in all cases excepting in the feline tribe, they are reduced in number to five, or four—the reduction affecting the external convolutions. In some cases they are bifurcated at certain points, or marked by divisions or depressions, or they are undulated in their course. Lastly, they are very commonly united, at more or less frequent intervals, by short *supplementary* convolutions.

union
by suppl-
ementary
ones.

Higher in
the scale ;
additional
system of
transverse
gyri.

In the brain of the elephant (which stands in the thirteenth group) M. Leuret recognises another additional set of convolutions, which have a more decidedly transverse direction than the short supplementary convolutions above alluded to. These new convolutions (*superior transverse*), forming two rows and separated by a groove, occupy the upper and outer part of the hemisphere, and cross or interrupt, as it were, the fundamental longitudinal convolutions.

In the last group (that of the monkeys) these *superior* transverse convolutions, forming two distinct rows, separated by an intermediate groove, are still more evident.

Fundamen-
tal.

In the human cerebrum, M. Leuret, by help of a comparison between the brain of the foetus and the adult, has represented three external fundamental convolutions, which are tortuous, and frequently communicate with each other. Besides these, there is the internal convolution (gyrus fornicatus) and supraorbital convolution (?).

Between the anterior and posterior portions of the three external convolutions, are interposed, on the upper surface of the brain, two sets of *transverse* convolutions, divided by a distinct sulcus, which runs outwards and forwards from the longitudinal fissure, so that the right and left grooves form a V-shaped line, open in front. This fissure, also noticed in the brains of the elephant and monkey, is stated by Leuret to be very constant, and is named by him the fissure of Rolando.*

transverse convolutions in human brain.

Fissure of Rolando.

From the preceding account of the cerebral convolutions, it would appear that those situated upon the outer or convex surface of the hemisphere—the fourth order of M. Foville, and the superior transverse convolutions of M. Leuret—attain their highest development in man, and are indeed particularly characteristic of the human brain. To this peculiarity, however, must be added, the elongation of the cerebrum backwards by the increased development of the posterior lobe, and the greater complexity of the vertical convolutions in the median fissure, and of those of the island of Reil.

General inference concerning the convolutions most characteristic of man.

Base of the cerebrum, fig. 165.—When the brain is turned with its base uppermost, and the parts of which it is composed are allowed to fall asunder by their own weight, two large bundles, *d, t*, consisting of white substance externally, are seen to emerge together from the fore part of the pons Varolii, *o*, and, separating from each other as they proceed forwards and outwards, to enter the inner and under part of the right and left cerebral hemispheres. These white bundles, which are marked on the surface with longitudinal striæ, are the *peduncles* (*crura*) of the cerebrum. Just before entering the corresponding hemisphere, each is crossed by a flattened white cord, named the *optic tract*, *u u*, which, adhering by its upper border to the peduncle, is directed forwards and inwards, and meets in front with its fellow of the opposite side to form the optic commissure, *c*, from the fore part of which the optic nerves *2, 2*, proceed.

Base of cerebrum.

Cerebral peduncles or crura.

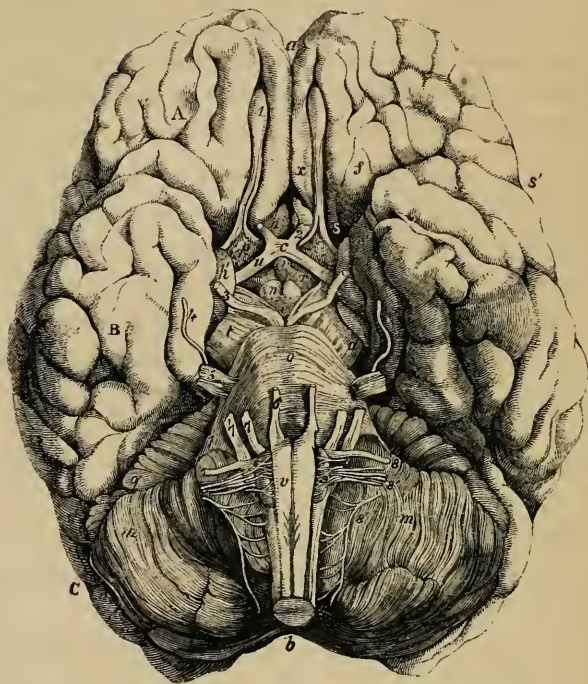
Optic tract.

Limited behind by these diverging peduncles, and in front by the converging optic tracts, is a lozenge-shaped interval,

Interpeduncular

* In the Hunterian Lectures for 1842, Professor Owen gave the results of his observations on the comparative anatomy of the convolutions. He had previously, in 1833, called attention to this study as a means of determining "the amount and locality of the convolutions of the human brain which are analogous to those of the lower animals." On the anatomy of the Cheetah; Zoological Trans. vol. i.

Fig. 165.*



space,
and its
contained
parts.

called the *interpeduncular space*, in which, are found the following parts:—the posterior perforated space, the corpora albicantia, the tuber cinereum, infundibulum, and pituitary body.

* Shews the under surface or base of the encephalon freed from its membranes—A. anterior, B. middle, and C. posterior lobe of cerebrum.—*a*. The fore part of the great longitudinal fissure. *b*. Notch between hemispheres of cerebellum. *c*. Optic commissure. *d*. Left peduncle of cerebrum. *e*. Posterior perforated space. *e* to *i*. Interpeduncular space. *f f'*. Convolution of Sylvian fissure. *h*. Termination of gyrus fornicatus behind the Sylvian fissure. *i*. Infundibulum. *l*. Right middle crus or peduncle of cerebellum. *m m*. Hemispheres of cerebellum. *n*. Corpora albicantia. *o*. Pons Varolii, continuous at each side with middle crura of cerebellum. *p*. Anterior perforated space. *q'*. Horizontal fissure of cerebellum. *r*. Tuber cinereum. *s s'*. Sylvian fissure. *t*. Left peduncle or crus of cerebrum. *u u*. Optic tracts. *v*. Medulla oblongata. *x*. Marginal convolution of the longitudinal fissure.—1 to 9 indicate the several pairs of cerebral nerves, numbered according to the usual notation, viz. 1. Olfactory nerve. 2. Optic. 3. Motor nerve of eye. 4. Pathetic. 5. Trifacial. 6. Abducent nerve of eye. 7. Auditory, and 7'. Facial. 8. Glosso-pharyngeal, 8'. Vagus, and 8''. Spinal accessory nerve.

Immediately in front of the pons is the *posterior perforated space* (*locus perforatus posterior*), *e*, a deep fossa situated between the peduncles, the bottom of which is composed of greyish matter, connecting the diverging crura together, and named pons Tarini. It is perforated by numerous small openings for the passage of bloodvessels; and some horizontal white striæ usually pass out of the grey matter and turn round the peduncles immediately above the pons.

Posterior perforated space.

Vessels enter here.

In front of this fossa are two round white eminences, each about the size of a pea, placed one on either side, surrounded by grey matter, and connected together across the middle line. These white bodies (*corpora albicantia*—corp. mammillaria), *n*, are formed, as will hereafter be seen, by the anterior extremities of the fornix, a part situated in the interior of the brain: hence they have also been named *bulbs of the fornix*. In the fœtus they are at first blended together, and become separated about the beginning of the seventh month. In most vertebrate animals there is but one white eminence, or corpus albicans, in this position.

Corpora albicantia, or

bulbs of fornix.

The interval between the corpora albicantia and the optic tracts is occupied by a soft and slightly prominent mass of grey substance, the *tuber cinereum* (Sæmmerring), *r*, which is connected with the surrounding parts of the cerebrum, and shuts in the third or middle ventricle below, forming part of what is termed the floor of that cavity. From the middle of the tuber cinereum is prolonged a conical process of a reddish colour, directed downwards and forwards, and about two lines in length, named the *infundibulum*, *i*, also fig. 166, *i*, to the summit of which is attached the *pituitary body*, *p*. This grey prolongation, from the tuber cinereum, is hollow at its base, and for a short distance downwards, and its cavity communicates above with the third ventricle—whence its name *infundibulum* (funnel).

Tuber cinereum.

Infundibulum.

The *pituitary body*, fig. 166, *p*, formerly called pituitary gland, from its being erroneously supposed to discharge *pituita* into the nostrils, is a small reddish grey mass, of a somewhat flattened oval shape, being widest in the transverse direction. In the natural position of the brain it occupies the sella turcica of the sphenoid bone. It consists of two lobes, of which the anterior is larger, and concave behind, where it embraces the

Pituitary body;

occupies the sella turcica;

consists of two lobes.

smaller posterior lobe. Its weight is from five to ten grains. In the adult it is solid, and its general structure is firm.

The anterior lobe consists of two kinds of matter, one hard and grey, the other, situated within, softer and of a yellowish white colour. The posterior lobe is darker and redder than the anterior. Both are very vascular; but they have no ducts, nor, indeed, any other glandular character.

In the fœtus, the pituitary body is proportionally large, and contains a cavity which communicates, through that of the infundibulum, with the third ventricle.

The tuber cinereum, as already mentioned, is bounded before by the *optic commissure*, which, together with the optic tracts, will be fully noticed under the description of the optic nerve.

Still confining our attention to the parts in the middle line of the base of the brain, we observe in front of the optic commissure, the anterior portion of the great longitudinal fissure, which reaches down between the hemispheres in this situation. At a short distance in front of the commissure, this fissure is crossed by a white transverse mass, which is the anterior recurved extremity of the corpus callosum. On gently turning back the optic commissure, a thin connecting layer of grey substance, the *lamina cinerea*, fig. 166, behind *h*, is seen proceeding backwards from the corpus callosum to the commissure, to become continuous (supposing the parts in their natural position) above the commissure with the grey matter of the tuber cinereum. This thin grey layer, which is also connected at the sides with the grey substance of the anterior perforated space to be presently described, forms part of the anterior boundary of the third ventricle: it is very generally torn in removing the brain from the skull; and in that case, an aperture is made into the fore part of the third ventricle.

In front of the optic tract, and near the entrance of the Sylvian fissure, there is situated a greyish quadrangular space on each side, named the *anterior perforated space* (*locus perforatus anticus*) fig. 165, *pp*.

Each anterior perforated space is bounded in front by the convolutions of the anterior cerebral lobe, on which are seen the roots of the olfactory nerve 1; behind, by the optic tract; on the outer side, by the middle lobe, and the commencement of the Sylvian fissure; and on the other side, by the

Optic com-
missure.

Fore part
longit. fis-
sure.

Lamina
cinerea;

is often
torn.

Anterior
perforated
space:
boundaries;

median fissure and the lamina cinerea. It is placed immediately beneath the corpus striatum, a large mass of grey matter in the interior of the brain, to be hereafter noticed. The grey surface of each perforated space is crossed by a broad white band, which may be traced from the middle of the under surface of the corpus callosum in front, backwards and outwards along the side of the lamina cinerea towards the entrance of the Sylvian fissure. These bands on the two sides are named the *peduncles of the corpus callosum*. The anterior perforated space, especially that part of it next the Sylvian fissure, is pierced with a multitude of small holes for the passage of bloodvessels, most of which are destined for the corpus striatum.

lies beneath
corpus
striatum.

Peduncles
of the corp.
callosum.

When the entire encephalon is viewed from below (as in fig. 165), the back part of the under surface of the cerebrum is concealed by the cerebellum, *m*, and the pons Varolii, *o*. If, however, these parts be removed, it will be seen that the two hemispheres of the cerebrum are separated behind as they are in front, by the descent of the great longitudinal fissure between them, and that this fissure is arrested by a cross mass of white substance, forming the posterior end of the corpus callosum. This posterior part of the great longitudinal fissure is longer than the anterior portion.

Hind part
of longitud.
fissure.

INTERNAL PARTS OF THE CEREBRUM.

Having completed the survey of the parts seen externally upon the cerebrum, we proceed to examine its internal anatomy. This will be more readily understood in detail, if some general idea be previously obtained of it.

The hemispheres, it will be remembered, are connected together in the middle by the corpus callosum, and it is obvious that the structures filling up the interpeduncular space, serve also as connecting media. Between the corpus callosum above and the peduncles below, the two hemispheres are partially separated from each other, so as to leave an interval, the general ventricular space, across which some slighter connecting portions of nervous substance pass from one hemisphere to another.

General
idea of
cerebrum ;
its hemi-
spheres and
their
modes of
connection ;
and the
ventricular
space.

Again, as seen on a transverse vertical section of the cerebrum, fig. 177, the peduncles *b*, *g*, diverge as they ascend towards the hemispheres, and pass on each side through two large masses of

grey matter, sometimes called ganglia of the brain,—at first through the thalamus opticus, *l*, and afterwards through a much larger mass named corpus striatum, *k*. These two masses of grey matter project somewhat, as smooth convex eminences, on the upper and inner surface of the diverging fibres of the peduncles. Immediately above the thalami and corpora striata, the hemispheres are connected together across the median plane by the corpus callosum, *q*; and it is between the under surface of the latter, *s*, and the upper surface of the eminences mentioned and the interpeduncular structures, that the general ventricular space is situated in the interior of the cerebrum. The upper part of this space is again divided by a median vertical partition, so as to form the two lateral ventricles: below this, it forms a single cavity named the third or middle ventricle, which communicates with both the lateral ventricles above, and, below, with the ventricle of the cerebellum or fourth ventricle. The median vertical partition, which separates the lateral ventricles from each other, consists at one part (septum lucidum) of two layers, between which is contained the fifth and remaining ventricle of the brain.

Ventricular space ;
how divided into five cavities or ventricles.

Use of sections.

The anatomy of these parts is conveniently studied by removing successive portions of the hemispheres by horizontal sections, beginning from above.

First section of hemispheres from above. White and grey matter exposed.

The first horizontal section, to be made about half an inch above the corpus collosum, displays the internal white matter of each hemisphere, speckled with red spots where its bloodvessels have been divided, and surrounded on all sides by the grey matter which is seen to follow accurately the convoluted surface, and to be of nearly equal thickness at all points. This white central mass in each hemisphere was named by Vicq-d'Azyr the *lesser oval centre* (centrum ovale minus). On separating the remaining portions of the two hemispheres from each other, it is seen that they overlap the corpus callosum for some distance at each side. These projecting margins of the hemispheres, which are, in fact, part of the gyrus fornicatus, on each side, have been named *labia cerebri*, and the spaces covered in by them, the *ventricles of the corpus callosum*,—though these parts do not seem to need any special designation.

Borders of hemispheres overhang corp. callos.

Next section.

The hemispheres being in the next place sliced off down to the level of the corpus callosum, the white substance of that part

is seen to be continuous with the internal medullary matter of both hemispheres: and the large white medullary mass thus displayed, surrounded by the border of cortical substance, constitutes what is generally described as the *centrum ovale* of Vieussens.

Centrum ovale of Vieussens.

It may here be stated generally, that the grey matter of some of the convolutions in the posterior part of the brain, consists, as seen on a section, of an external darker and an internal light layer, fig. 167, *r*. This appearance is usually well marked on the inner or flat surface of the posterior lobe. Some authors (Baillarger, Remak, and Foville) describe several alternate white and grey layers in the cortical substance of many of the convolutions.

External or cortical substance, arranged in several layers.

The *corpus callosum* (seen in section, fig. 166, *a, b,*) which is now supposed to be completely exposed above, also named the beam of the brain (*trabs cerebri*) and *great commissure*, is the cross portion of white substance which lies between the hemispheres at the bottom of the longitudinal fissure. It is three inches and upwards in length, and extends further forwards than backwards, reaching to about an inch and a half of the anterior, and not quite two inches and a half of the posterior extremity of the cerebrum. It is about eight or ten lines in width behind, and somewhat narrower in front. Its thickness, which can only be seen on a vertical section, fig. 166, is greater at the ends than in the middle, and is greatest behind, where it amounts to three lines. In form it is somewhat arched from before backwards. Its upper surface, (partly seen at fig. 167, *d,*) is deeply marked by transverse fasciculi, which indicate the cross direction of the greater number of its fibres. Along the middle line is seen a line or mark, called the *raphe* or seam, which is bounded laterally by two white tracts, placed close to each other, named *striæ longitudinales*, or *nerves of Lancisi*. On each side, near the margin of the gyrus fornicatus, are seen other longitudinal lines (*striæ longitud. laterales*) which are occasioned by a few scanty white fibres having that direction. The arteries of the corpus callosum run along its upper surface, and the edge of the falx cerebri approaches closely to it behind, though not in front.

Corpus callosum:

great commissure of cerebrum; its dimensions;

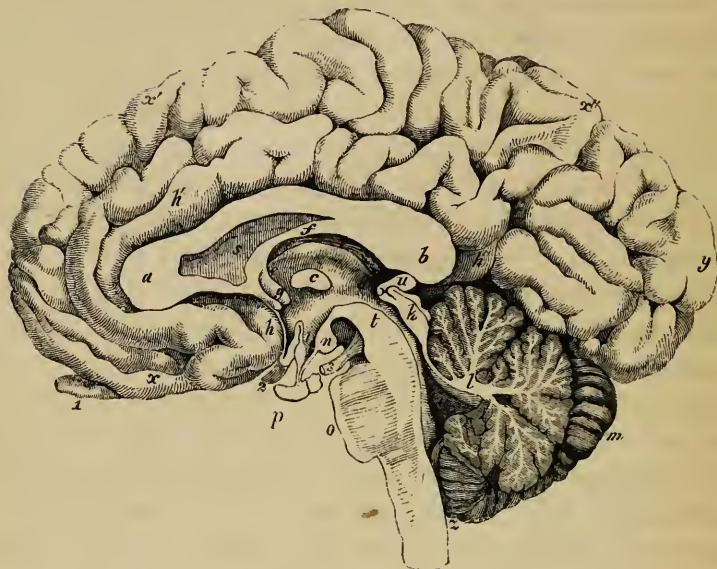
consists of cross fibres:

the raphe, striæ longitudinales, and striæ long. laterales.

At the two sides, the corpus callosum is connected with the white substance of the hemispheres by an extension of its fibres into them.

Corp. call. is continued laterally into hemispheres;

Fig. 166.*



its anterior
border or
genu ;
its beak ;

In front it is reflected downwards and backwards, between the anterior lobes, towards the base of the brain, forming a bend named the knee (genu) *a*. The inferior or reflected portion, which is named the beak (rostrum), becomes gradually narrower as it descends (behind *h*). It is attached at each side to the anterior cerebral lobe, and is connected at its point by means of the lamina cinerea with the optic commissure. It also gives off the two bands of white substance, already noticed as the *pedun-*

its pedun-
cles.

* A vertical section in the median plane, of the cerebrum, cerebellum, pons, and medulla oblongata—the parts being all represented in their natural position. (After Sæmmering.) *a*. Anterior, and *b*. Posterior extremity of corpus callosum, which is seen in section. *d, c, e*. Third ventricle. *c*. Soft commissure. *d, e*. Thalamus opticus, forming side of third ventricle. *f*. Fornix, united behind to corpus callosum. *b, g*. Anterior pillars of fornix. Between *g* and *h*, anterior commissure. Behind *h*, lamina cinerea. *h h' h''*. Convolution of corpus callosum or gyrus fornicatus. *i*. Infundibulum. *k*. Corpora quadrigemina, seen in section. *k* to *l*. Valve of Vieussens. *l*. Section of cerebellum, shewing white and grey matter—appearance named arbor vitæ. *m*. Notch of cerebellum. *n*. Corpus albicans of right side. *o*. Pons Varolii (section). *p*. Pituitary body. *r*. Choroid plexus. *s*. Septum lucidum. *t*. Cerebral peduncle of right side in section. *u*. Pineal gland. *v*. Cavity of fourth ventricle. *d* to *v*. Iter a tertio ad quartum ventriculum, or aqueduct of Sylvius. *x x' x''*. Marginal convolution of the longitudinal fissure. *y*. Posterior lobe of cerebrum. *z*. Opening leading into fourth ventricle. 1. Olfactory nerve. 2. Optic nerve divided through optic commissure. 3. Third nerve, or motor oculi.

cles of the corpus callosum, which, diverging from one another, run backwards across the anterior perforated space on each side to the entrance of the Sylvian fissure.

Behind, the corpus callosum terminates in a free thickened border (*bourrelet*), the under surface of which is also free for a little distance forwards. Posterior extremity is thick.

The under surface of the corpus callosum is connected behind with the fornix, *f*, a structure to be presently described, and in the rest of its length with the septum lucidum, *s*, the vertical partition between the lateral ventricles. Connections below to other parts;

Although it presents a few longitudinal white fibres on its surface, the corpus callosum consists almost entirely of fibres having a transverse course towards each side, and spreading in all directions into the substance of the two hemispheres. Only the median portion of these fibres between the hemispheres is seen without dissection. As the transverse fibres from the anterior and posterior lobes of the cerebrum are necessarily aggregated in large numbers near the corresponding ends of the corpus callosum, its relative thickness at those points, in comparison with the rest of its extent, is accounted for; and since the posterior lobe reaches further beyond the corpus callosum than the anterior, the greater thickness behind is also explained. its structure;

By dividing the fibres of the corpus callosum in a longitudinal direction at a short distance on each side of the middle line, and about midway between the two ends of the hemispheres, an opening is made into the right and left *lateral ventricles* of the brain. These ventricles form part of the general ventricular space within the cerebrum; they are serous cavities, and are lined by a delicate epitheliated membrane, which is provided with cilia. In the natural state, their walls are moistened internally with a serous fluid, which sometimes exists in considerable quantity, even in a healthy brain. why thicker at the ends.

Henlé states that the lining membrane of the ventricles consists of epithelium only, which lies immediately on the nervous matter. We have once observed an appearance unfavourable to this view. In the instance in question, the membrane over the surface of the corpora striata and adjacent parts was raised into small vesicular elevations by a clear fluid,—an appearance which was most probably due to a plexus of lymphatic vessels distended with lymph. Lateral ventricles; how exposed;

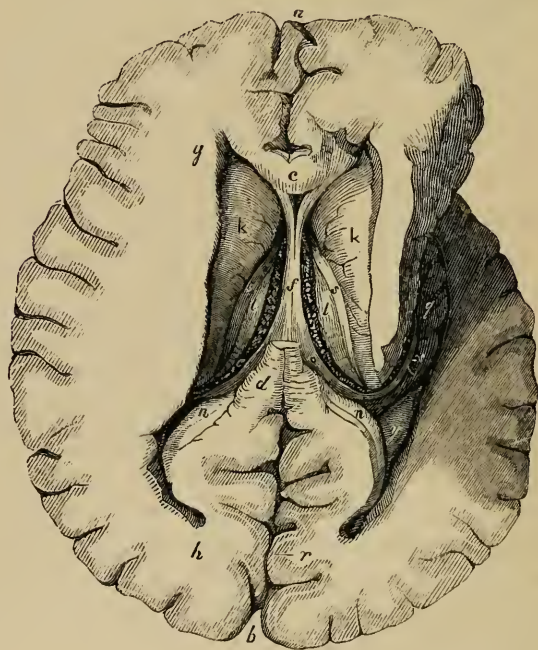The part of the lateral ventricles which is laid open by the are lined by serous membrane, ciliated; contain fluid.

The body,
and three
horns or
cornua.

Ventriculi
tricornes ;
directions
of cornua ;

steps already indicated, is named the *centre* or *body* ; from this point each ventricle is extended in three directions, forming so many prolongations named *horns* (cornua), which may be displayed by carefully slitting up and removing the white medullary substance of the hemisphere which covers them in. From the direction taken by these cornua, they are named the anterior, posterior, and middle or descending cornua ; and the lateral ventricles themselves are named *ventriculi tricornes*. The *anterior cornu*, fig. 167, *g*, passes forwards and outwards in the substance of the anterior lobe ; the *posterior cornu*, *h*, backwards, outwards, and inwards in the posterior lobe ; and

Fig. 167.*



* Section of cerebrum, displaying the lateral ventricles.—On the right side the descending cornu is laid open. *a, b*. Parts of great longitudinal fissure. *c*. Section of front of corpus callosum. *d*. Part of posterior end of the same. *f*. The body of the fornix. *e*. The left choroid plexus. *g*. Anterior cornu, *h*, posterior, and *g*, descending cornu of the lateral ventricle. *k k*. Corpora striata. *l l*. Optic thalami. *n n*. Right and left hippocampus minor. *o*. Posterior pillar of fornix, becoming continued as the corpus fimbriatum. *q*. Cornu ammonis, or Pes hippocampi. *r*. Shows alternate grey and white layers in cortical substance. *s s*. Right and left tania semicircularis. *v*. Corpus fimbriatum. *y*. Eminentia collateralis.

the *descending cornu*, *q*, which traverses the middle lobe, passes at first backwards, outwards, and downwards, and then changing its course, runs forwards and inwards nearly to the point of the middle lobe. The posterior cornu, also named the *digital cavity*, is very variable in extent, even in the two sides of the same brain. digital cavity.

The parts forming the boundaries of the lateral ventricles, and those seen within them, may be first enumerated, and will afterwards be described in detail.

The *body* of this ventricle is covered in by the corpus callosum, which is therefore said to form its roof. On the inner side in the median plane is a vertical partition, the *septum lucidum*, fig. 166, *s*, which descends between the two lateral ventricles, from the under side of the corpus callosum, to the fornix. The *fornix*, *f*, itself, attached to the lower edge of the septum, is partly seen in the floor of this part of the ventricle. Appearing from below the outer margin of the fornix is seen a red vascular fringe, the *choroid plexus*, *e*, next to that a portion of the upper surface of the *thalamus opticus*, *l*. Beyond the thalamus is the *corpus striatum*, *k*, and between the two last-named parts, is a narrow tape-like band, *tania semicircularis*, *r*. On the outer side of the corpus striatum we arrive again at the under surface of the corpus callosum. Parts contained in body of ventricle.

The anterior cornu is also covered in by the corpus callosum; it turns round the anterior free extremity of the corpus striatum, descending as it proceeds, and is bounded behind by that body, and in front by the reflected part of the corpus callosum. Parts anterior cornu.

The middle or descending cornu turns round the back part of the optic thalamus which appears in its cavity, and forms its anterior boundary. It is covered in by the thalamus, and by the medullary substance of the middle lobe. The principal object seen upon its floor is a long curved eminence, which follows the direction of the cornu towards its anterior extremity, and is notched, or indented on its surface; this is the *hippocampus major*, *q*. Along the inner edge of this eminence is seen a narrow white band, named *corpus fimbriatum*, *v*, which is prolonged from the fornix; to the inner side of that is a part of the choroid plexus, *e*, and next to that the back of the optic thalamus. Parts in middle cornu.

The posterior cornu seems, as it were, scooped out of the Parts in

posterior
cornu.

substance of the posterior lobe. The choroid plexus does not enter it. On its floor is seen a longitudinal ridge, named *hippocampus minor*, or *ergot, n*; and at the junction of the posterior with the descending cornu, between the hippocampus major and minor, is a smooth eminence, which varies much in size, named *eminentia collateralis, y*.

Septum
lucidum ;
separates
lateral ven-
tricles ;

The *septum lucidum*, is a thin translucent partition, (fig. 166, s,) placed between the two lateral ventricles. It extends vertically between the corpus callosum above, and the anterior part of the fornix below ; and as the latter sinks down in front away from the corpus callosum, the septum is somewhat triangular in form, being deep before and narrow behind. The septum lucidum is attached above, in front, and for a certain space below, to the corpus callosum, fitting in, as it were, into its anterior reflected portion. Below and further back it is attached to the fornix.

is double,

and con-
tains fifth
ventricle,

This vertical septum is double, being composed of two perfectly distinct laminæ, having an interval between them, which contains fluid, and is lined by an epitheliated membrane. This is the *fifth ventricle, ventricle of the septum*, or *Sylvian ventricle*. It may be laid open by cutting through the corpus callosum, and detaching it for a certain distance from the upper border of the septum, (as in fig. 167.) In the human embryo, and also in some animals, the cavity of this ventricle communicates with that of the third ventricle in front and below ; but in the adult human brain it forms a separate and insulated cavity. Tarin described a small fissure in it between the pillars of the fornix ; but this is unusual. In disease it is often distended with fluid.

which is a
distinct
cavity.

Structure
of septum
lucidum.

Each of the laminæ of the septum which form the sides of the fifth ventricle, consists of an internal layer of white substance and an external layer of grey matter.

Fornix ;

its shape
and posi-
tion ;

consists of
two parts ;

The *fornix* is a white longitudinal band, extending along the lower edge of the septum lucidum, and attached behind to the under surface of the corpus callosum. It appears in the floor of both lateral ventricles, fig. 167, *f, o*, and dips downwards at each extremity, fig. 166, *f*, but rises in the middle so as to form a sort of vault or arch (fornix), which is free on its under surface. It may be described as consisting of two lateral halves, which are separated from each other in front and behind, but between

those points are joined together in the median plane. The two parts in front form the anterior pillars of the fornix; the middle conjoined part is named the body; and the hind parts, which are again separated from each other, form the posterior pillars.

The *body* of the fornix, fig. 167, *f*, is triangular in shape, being broad and flattened behind, where it is connected with the under surface of the corpus callosum, and narrower in front as it dips down to leave that body,—the space between them being filled up by the septum lucidum. Its lateral edges are in contact with the choroid plexuses, and its under surface rests upon a membrane, which connects those two plexuses together (velum interpositum).

its body is triangular.

The *anterior crura* or *pillars* of the fornix, figs. 169, 170, *f*, consisting entirely of white fibres, descend slightly apart from each other through a quantity of grey matter on the sides of the third ventricle, fig. 179, *t'*, as far as the corpora albicantia, *n*, where they turn up and enter the substance of the corresponding optic thalamus, *. The external or white portion of each of the corpora albicantia is composed of the fibres of the corresponding pillar of the fornix, which there forms a twisted loop. These pillars might therefore be described as commencing in the substance of the thalami, descending into the corpora albicantia, in which they are twisted in the manner described, then rising up through the grey matter on the sides of the third ventricle, becoming free above, and at length joining together to form the body of the fornix. They are connected with the peduncles of the pineal gland, and with the tænia semicircularis, as will be afterwards described.

Anterior pillars of fornix; descend to corpora albicantia, and then turn up into thalamus.

Immediately behind the anterior pillars of the fornix, a small opening is seen on either side. The two openings pass downwards and backwards towards the middle line, and meeting below, lead into the upper part of the third ventricle. The passage thus formed is the *foramen of Monro*. It is single below, where it communicates with the third ventricle, but divides above, somewhat like the letter Y, into two branches, one to each lateral ventricle. In this way it will be seen that all three ventricles communicate with each other at this point.

Foramen of Monro; is behind pillars of fornix;

is single below and double above.

The two flat bands into which the fornix divides behind are its *posterior pillars* or *crura*, fig. 167, *o*. Adhering at first

Posterior pillars of fornix,

in
descending
cornu.

to the under surface of the corpus callosum, they pass backwards diverging from each other; and then leaving the corpus callosum, turn suddenly downwards into the descending cornu of the corresponding lateral ventricle, where we shall presently follow them. On dividing the fornix across in front, and turning it back with the corpus callosum, so as to expose the under surface, a triangular portion of the latter, fig. 169, *e*, is seen between the diverging posterior crura of the fornix, marked with lines, some of which are transverse, but others longitudinal or oblique. To this part the term *lyra* has been applied.*

Hippo-
campus
minor.

In the posterior cornu of the lateral ventricle, we have to examine the *hippocampus minor*, 167, *n*, also called the *ergot* or *calcar avis*, from its resemblance to a cock's spur. It is a white eminence pointed at its posterior extremity, forming a relief along the inner side of the cornu: beneath the white surface it consists of grey matter, which is part of the cortical substance of the hemispheres, corresponding with the bottom of a sulcus seen on the inner surface of the posterior lobe.

Hippo-
campus
major.

The *hippocampus major* (pes hippocampi; or cornu ammonis, from its resemblance to a ram's horn) is a large white eminence, *q*, already mentioned as lying along the floor of the descending cornu of the lateral ventricle. Behind the pes, and between it and the hippocampus minor, is another white eminence known as the *eminentia collateralis*, *pes accessorius*, *y*, which has a similar relation to a convolution as the lesser hippocampus, and is often as large as, or larger than that elevation. The hippocampus major becomes enlarged, towards its anterior and lower extremity, and is indented or notched on its edge, so as to present some resemblance to the paw of an animal, whence, no doubt, its name of pes hippocampi.

Eminent.
collateralis.

Hippo-
campus,
indented or
notched.

The external white substance of the hippocampus major is partly derived from the posterior pillar of the fornix, which, as

* The varying direction of these lines has been represented by Vicq-d'Azyr, who attributes them to the impression of the vessels of the subjacent velum interpositum. The term *corpus psalloides* given by the early anatomists to the fornix, in consequence of its resemblance to an arch (*ψαλλιδιοειδής*—Galen; from *ψαλις* or *ψαλλις*, fornix, an arch), was erroneously interpreted by Winslow and others, who supposed that it meant something which had the appearance of a harp or similar stringed instrument, and that it was intended specially to designate the part marked with the linear impressions described, which accordingly was named *lyra* and *psalterium*.

already stated, enters the descending cornu of the lateral ventricle. The remaining part of that pillar forms a white band, like a tape, which is attached along the inner border of the great hippocampus and forms the *tænia hippocampi*, or *corpus fimbriatum*, *v*. It reaches down to the end of the pes, but its further connections are not well known.

Posterior pillar of fornix is prolonged as corpus fimbriatum.

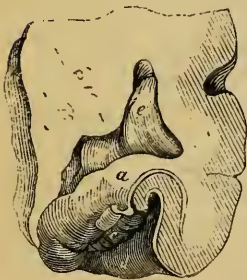
Along the inner border of the corpus fimbriatum, (which is a continuation of the posterior pillar of the fornix,) and between it and the thalamus is the prolongation of the choroid plexus, *e*, occupying in this situation a part of the transverse fissure to be presently described. On separating the corpus fimbriatum from the plexus, and raising the edge of the former, we discover a grey indented ridge, which runs parallel with it, but which, strictly speaking, is situated outside the cavity of the cornu. This is the *fascia dentata*, fig. 168, *c*.

Fascia dentata.

The structure of the pes hippocampi is best examined by making a cross section through it. It will then be seen that its

Structure of the hippocampus major.

Fig. 168.



surface is composed of white substance, fig. 168, *a*, which is continuous with that of the corpus fimbriatum. Within, it contains a stratum of grey matter, *b*, doubled on itself, and continued from the cortical substance on the adjacent convolution of the middle lobe (part of the gyrus fornicatus). This grey layer accompanied by the thin coating of white matter, *d*, already described in this situation as the reticulated white substance

Internal grey matter is curled up.

(see p. 694), is first bent inwards, and then curls outwards upon itself, so as to terminate by a free indented edge, which appears at the surface as the fascia dentata, *c*.

From what has preceded it will have been understood that the fornix is applied in nearly its whole length to the optic thalamus of each side—the body of the fornix, fig. 157, *f*, resting on the upper surface of the thalamus, *l*, and each posterior pillar being applied to the posterior surface of that body

Great transverse fissure of cerebrum ; how formed ;

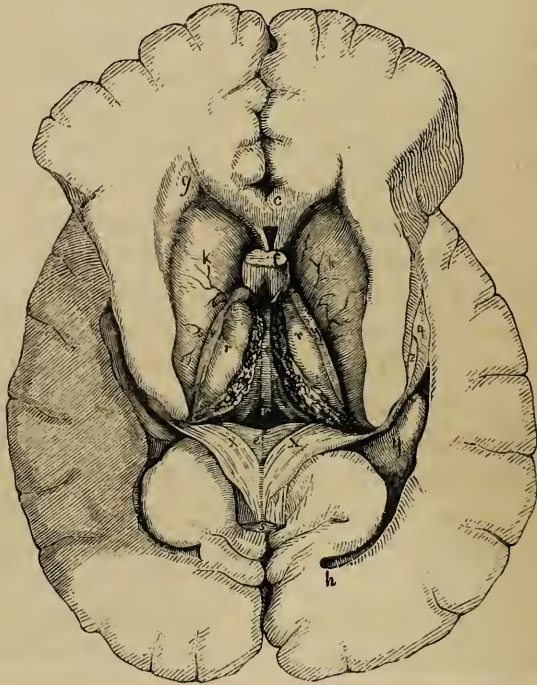
* Section of the hippocampus major, to show the arrangement of its grey and white substance. *a*. White layer on its surface. *b*. Grey substance which becomes rolled up. *d*. White reticulated substance, on the surface of gyrus fornicatus. *c*. Fascia dentata. *e*. Cavity of lateral ventricle.

gives pas-
sage to pia
mater ;

is closed by
ventricular
membrane.

in the descending cornu. On separating these two parts it will be seen that a fissure exists between them. This is named the *transverse fissure of the cerebrum*. Through it the pia mater, from the exterior of the brain, passes into the ventricles to form the choroid plexuses. This fissure runs downwards and forwards into each descending cornu ; it therefore extends from the point of the descending cornu of one side to that of the other, reaching as far forwards as the foramen of Monro, its extent corresponding exactly with that of the choroid plexuses. It is closed on the inner side by the lining membrane of the lateral ventricle, which is said to pass from the fornix to the thalamus over the choroid plexus.

Fig. 169.*



* A section of the cerebral hemispheres, showing both lateral ventricles, after the fornix has been divided and turned back, to expose the velum interpositum. *c*. The anterior portion of corpus callosum, cut across. *e*. The lyra, or under surface of back of corpus callosum. *f*. Anterior pillars of fornix cut across. N.B. These are represented of too great size. *g*. Anterior, *h*, posterior cornu of lateral ventricle. *kk*. Corpora striata. *q*. Pes hippocampi. *rr*. Thalami optici. *ss*. Tænia semicircularis. *tt*. Choroid plexuses. *v*. velum interpositum. *xx*. Posterior pillars of fornix. *y*. Eminentia collateralis.

On raising up the fornix, it will be seen that it rests on a vascular membrane which is interposed between it and the parts beneath. This is named the *velum interpositum* or *tela choroidea*, fig. 169, *v*. It connects the choroid plexuses of the two sides together, and like them is a prolongation of the pia mater. This last-named membrane passes from the outer surface of the brain underneath the corpus callosum and fornix, and above the corpora quadrigemina, the pineal gland and the thalami, through the transverse fissure into the lateral ventricle. The membranous prolongation thus formed, is of a triangular shape: the middle part of it is covered by the fornix and constitutes the velum interpositum, whilst the remainder projects at each side of the fornix into the lateral ventricles, and forms by its free borders the right and left choroid plexuses.

Velum interpositum, or tela choroidea; connects the choroid plexuses.

The *choroid plexuses*, fig. 167, &c., *e e*, appear like two red knotted fringes, reaching from the foramen of Monro to the point of each descending cornu. They are represented as being covered by a reflection of the lining membrane of the ventricle, which in this way is considered to keep the choroid plexuses outside the serous cavity of the ventricle, just as the intestines are excluded from the cavity of the peritoneum; but in admitting this view, it must be remembered that the epithelium changes its character where it covers the plexuses.

Choroid plexuses

At the foramen of Monro, where the middle and lateral ventricles communicate, their lining membrane is continuous, and here the two choroid plexuses are connected with one another.

are joined together at foramen of Monro.

On raising the velum interpositum, two slight vascular fringes are seen running along its under surface, and diverging from each other behind. They form the *choroid plexuses* of the third ventricle.

Choroid plexus of third ventricle.

The choroid plexuses consist of a highly vascular villous membrane. The villi with which they are covered are again divided upon their surfaces and at their borders into smaller processes, along which fine vessels are seen to run. They are covered by a single layer of thick epithelium composed of large roundish corpuscles, in each of which is seen, besides a distinct nucleus, a small bright yellow spot. The arteries of the velum interpositum and choroid plexuses enter from behind beneath the corpus callosum, and also at the point of the descending cornu: after ramifying in the plexuses, they send branches beneath the ventricular

Structure; covered with a peculiar epithelium;

their arteries,

and veins. lining membrane to enter the substance of the brain. Veins issuing from the cerebral substance are seen on the surface of the ventricles, and for the most part join the veins of the choroid plexuses. The greater number of these terminate in two principal vessels named the veins of Galen, which run backwards on the velum interpositum, and passing out beneath the corpus callosum pour their blood into the straight sinus, having generally first united into a single trunk.

The velum having next been removed, the optic thalami are brought fully into view, and the cavity of the third ventricle, situated between them. In front and to the outer side of the thalami, as already stated, are the *corpora striata*. These last are two large ovoid masses of grey matter, fig. 167, &c., *k k*, the greater part of which is embedded in the middle of the white substance of the hemisphere of the brain, whilst a part projects into the fore part of the body and the anterior cornu of the lateral ventricle. This *intraventricular portion* of the corpus striatum, *k k*, fig. 169, 170, is of a pyriform shape, its larger end being turned forwards, and its narrow end being directed outwards and backwards, so that the optic thalami of the two sides are received between the diverging corpora striata. The surface of the corpus striatum is composed of grey matter; it is covered by the lining membrane of the ventricle and is crossed by veins of considerable size. At some depth from the surface white fibres may be seen on cutting into it, which are prolonged from the corresponding cerebral peduncle and give it the streaked appearance from which it has received its name.

The *extra-ventricular* portion of the corpora striata will be afterwards described.

Along the inner border of each corpus striatum, and in a depression between it and the optic thalamus, is seen a narrow whitish semitransparent band, named *tænia semicircularis*, fig. 167, &c., *s s*, which continues backwards into the descending cornu of the ventricle, where its connexions cannot be assigned with precision. In front it reaches the corresponding anterior pillar of the fornix, and descends in connexion with that cord of white substance. It is more transparent and firm on the surface, especially at its fore part: and this superficial stratum has been named *stria cornea*. The *tænia* consists of longitudinal white fibres, the deepest of which running

Corpora
striata;

partly
bedded in
hemi-
sphere;

partly seen
in ventri-
cles.

Surface is
grey.

Tænia
semicircu-
laris.

Stria
cornea.

between the corpus striatum and the thalamus, were named by Viessens *centrum geminum semicirculare*. Beneath it are one or two large veins, which receive those upon the surface of the corpus striatum and end in the veins of the choroid plexuses.

The *thalami optici*, figs. 167 to 170, *ll*, (posterior ganglia of the brain) are of an oval shape, and rest on the corresponding cerebral crura, which they in a manner embrace. On the outer side each thalamus is bounded by the corpus striatum and *tænia semicircularis*, and is then continuous with the medullary substance of the hemisphere. Its upper surface is free and prominent and is partly seen in the lateral ventricle, *k*, and partly covered by the fornix. The posterior surface, which is also free, projects into the descending cornu of the lateral ventricle. The inner sides of the two thalami are turned towards each other, and form the lateral boundaries of the third ventricle, across which, however, they are connected by a grey mass of nervous substance, named the soft commissure. Near the fore part of each thalamus is a small elevation on its upper surface, named its *anterior tubercle*, fig. 170, *. The optic thalami are white on the surface, and consist of several layers of white fibres intermixed with grey matter.

Thalami
optici;

in part are
free and
seen in
ventricles.

Anterior
tubercle of
optic. thal.

The *third ventricle*, fig. 170, *z* to *s*, is a narrow longitudinal fissure or cleft placed between the optic thalami, which bound it on its two sides. It is covered above by the *velum interpositum* and the fornix. Beneath, its floor is formed by the following parts, which have been already described, as seen on the base of the cerebrum, viz., commencing from behind, the posterior perforated space, the *corpora albicantia*, the *tuber cinereum* and *infundibulum*, and the *lamina cinerea*, which also serves to close it in front, as high as the anterior commissure. Passing across the cavity of the third ventricle are seen three commissures, named from their position, anterior, middle, and posterior.

The third
ventricle ;
its bounda-
ries.
its roof ;
floor ;
parts form-
ing it ;

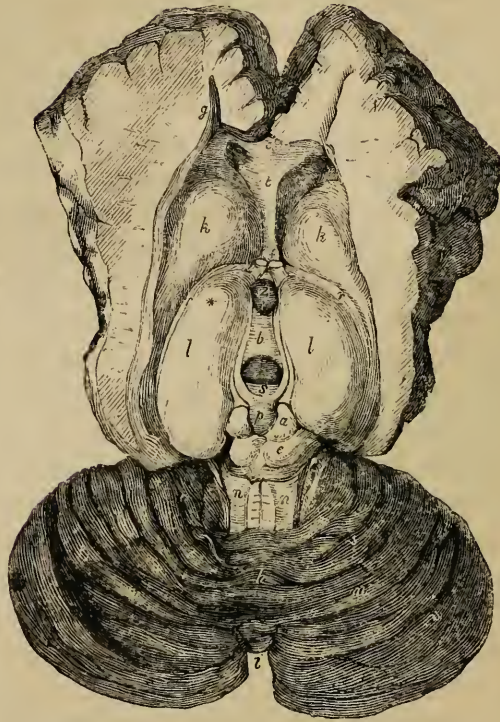
its commis-
sures.

The *middle* or *soft commissure*, *b*, (*com. mollis*,) is composed almost entirely of grey matter, and connects the two thalami. It is sometimes, though very rarely, wanting; but it is more frequently torn across in examining the brain.

Middle or
soft commis-
sure.

The *anterior* commissure, in front of *z*, is a round bundle of white fibres, placed immediately in front of the anterior pillars of the fornix, and crosses between the *corpora striata*. It

Fig. 170.*



marks the anterior boundary of the ventricle; its fibres extend laterally through the corpora striata, a long distance into the substance of the cerebral hemispheres.

and poste-
rior.

The *posterior commissure*, *s*, also white, is placed across the back part of the ventricle, immediately before and below the pineal gland. It is smaller than the anterior commissure, and has the form of a flattened band. It passes into the thalami on each side, but does not extend so far into the substance of the brain as the anterior commissure.

* Section of the cerebrum, displaying the surfaces of the corpora striata, and optic thalami, the cavity of the third ventricle, and the upper surface of the cerebellum.—*a e*. Corpora quadrigemina,—*a testis*, *e nates*. *b*. Soft commissure. *c*. Corpus callosum. *f*. Anterior pillars of fornix. *g*. Anterior cornu of lateral ventricle. *h k*. Corpora striata. *l l*. Optic thalami. * Anterior tubercle of the left thalamus. *z* to *s*. Third ventricle. In front of *z*, anterior commissure. *b*. Soft commissure. *s*. Posterior commissure. *p*. Pineal gland, with its peduncles. *n n*. Processus a cerebello ad testes. *m m*. Hemispheres of the cerebellum. *h*. Superior vermiform process. *i*. Notch behind cerebellum.

The following apertures lead from or into the third ventricle :
 Above and before is the foramen of *Monro*, by which the third communicates with the two lateral ventricles.

Apertures
of third
ventricle.

Behind, is an opening leading into the *iter a tertio ad quartum ventriculum*, or *aqueduct of Sylvius*, fig. 166, *d, v*, which passing down below the posterior commissure, and the corpora quadrigemina, conducts into the fourth ventricle.

Aqueduct
of Sylvius.

In the floor of the third ventricle is a deep pit, corresponding with the infundibulum, and generally named *iter ad infundibulum*, but there is no outlet at this part.

Iter ad in-
fundibu-
lum ; not
an outlet.

The lining membrane of the lateral ventricles is continued down through the foramen of *Monro*, and lines the third ventricle, whence it extends along the Sylvian aqueduct into the fourth ventricle. *Bichat* conceived that this membrane was continuous with the arachnoid membrane on the exterior of the brain, and he therefore named it the internal arachnoid. He supposed that the external arachnoid membrane entered the third ventricle in the form of a tubular process, which passed beneath the posterior end of the corpus callosum and fornix, above the pineal gland and through the velum interpositum, and thus opened into the upper and back part of the third ventricle. The existence of this canal, named the *canal of Bichat*, is doubtful. It is certainly not constant.

Foramen of
Monro.

Lining
membr.
of ventricle.

So-called
canal of
Bichat.

Pineal gland and *corpora quadrigemina*.—Behind the third ventricle, and in front of the cerebellum, are certain eminences, which may be reached from the surface of the brain. These are the corpora quadrigemina, and above them is the pineal gland.

The *pineal gland*, fig. 166, *u*, fig. 170, *p*, (conarium,) so named from its shape (pinus, conus, the fruit of the fir,) is a small reddish body, which is placed beneath the back part of the corpus callosum, and rests upon the anterior pair of the corpora quadrigemina. It is very firmly attached to the under surface of the velum interpositum, so that it is liable to be torn away from the brain in removing that membrane. It is about three lines in length, and its broad part or base is turned forwards, and is connected with the rest of the cerebrum by white substance. This white substance is principally collected into two small rounded bundles, named *peduncles* of the pineal gland, which pass forwards upon the optic thalami, to which they are attached along the upper limit of the third ventricle, and may be traced

Pineal
gland ;

its pedun-
cles ;

inferior
peduncles.

Structure :
is hollow ;
contains
fluid and
gritty
matter,
acervulus
cerebri.

Corpora
quadrige-
mina,
are two
pairs.

Anterior
pair larger
and darker.

Connexions
with
cerebellum
below.

Connexions
at sides.

Brachia.

in that direction as far as the anterior pillars of the fornix, in conjunction with which they descend, fig. 170. These peduncles are connected with each other behind. The base of the pineal gland is also connected by a transverse lamella of white substance with the back of the posterior commissure. Some anatomists have described two *inferior peduncles*, which descend upon the inner surface of the thalami.

The pineal gland is very vascular. It is hollowed out into two or more cells, which, sometimes at least, open anteriorly into the ventricle, and almost always contain, besides a viscid fluid, a quantity of gritty matter, named *acervulus cerebri*. This consists of microscopic round particles, aggregated into small compound masses, which are again collected into larger groups. It is composed of earthy salts combined with animal matter ; viz. phosphate and carbonate of lime, with a little phosphate of magnesia and ammonia (Stromeyer). It is found at all ages, frequently in young children, and sometimes even in the fœtus. It cannot, therefore, be regarded as the product of disease. This sabulous matter is frequently found on the outside of the pineal body, or even deposited upon its peduncles.

The *corpora* or *tubercula quadrigemina* are four rounded eminences, fig. 170, *a e*, separated by a crucial depression, placed two on each side of the middle line, one before another. They are connected with the back of the optic thalami, and with the cerebral peduncles at either side ; and they are placed above the passage leading from the third to the fourth ventricle.

The upper or anterior tubercles, fig. 164, *aa*, are somewhat larger and darker in colour than the posterior, *bb*. In the adult, both pairs are solid and are composed of white substance outside, containing grey matter within.

They receive bands of white fibres from below, the chief of which are derived from a fasciculus named the fillet. A white cord also passes up on each side from the cerebellum to the corpora quadrigemina, and is continued onwards to the thalami : these two white cords are the *processus a cerebello ad testes*, or superior peduncles of the cerebellum, fig. 164, *f*, fig. 170, *nn*.

At each side, the corpora quadrigemina send off two white tracts, which pass to the thalami and to the commencements of the optic nerves. These tracts are prominent on the surface, and are sometimes named *brachia*.

In the human brain these quadrigeminal bodies are small in comparison with their size in the series of animals. In ruminant, soliped, and rodent animals, the anterior tubercles are much larger than the posterior, as may be seen in the sheep, horse, and rabbit; and hence have been applied the names *nates* to the anterior and *testes* to the posterior tubercles. In the brains of carnivora, the posterior tubercles are rather the larger.

In man are small.
Form in animals.

In the fœtus this part of the brain appears very early, and then forms a large proportion of the cerebral mass. The eminences are at first single on each side and hollow. They are constant in the brains of all vertebrate animals, but in fishes, reptiles, and birds, they are only two in number and hollow: in marsupialia and monotremata, they are also two in number, but are solid.

In fœtus, appear early.
are hollow, and single on each side.

To the outer side of the corpora quadrigemina and on the under and back part of each optic thalamus, are found two small oblong and flattened eminences, connected with the posterior extremity of the optic tract. These optic tracts, which we have already seen on the base of the cerebrum, attached to and embracing the under side of the corresponding peduncles, may be traced back to the thalami. Each tract becomes flattened and broader as it approaches the thalamus, and makes a bend as it turns round the peduncle to reach the back part of that body. Near this bend, which is named the *knee* (genu), are placed the two small eminences just spoken of. They are two little masses of grey matter about the size and shape of coffee beans, placed one on the outer and one on the inner side of the genu of the optic tract, and hence are named respectively *corpus geniculatum, externum* and *internum*. They send fibres into the optic tract and also into the thalamus of the same side.

Corpora geniculata.

Course of optic tract:

its genu; has two small eminences near it,

corpora geniculata.

Origin of optic tracts.

The fibres of these tracts are therefore derived from three sources, viz., the thalamus, the tubercula quadrigemina, and the corpora geniculata.

Processus a cerebello ad testes.

Extending downwards and somewhat outwards from the corpora quadrigemina to the fore part of the cerebellum, and connecting the latter with the cerebrum are two large white cords, the *processus a cerebello ad testes*, fig. 170, *n n*, already alluded to. Between them is stretched a thin semi-transparent layer of nervous matter, which lies over the passage from the third to the fourth ventricle, and, lower down, covers in a part of the

Valve of Vieussens.

Its attach- fourth ventricle itself. This is the *valve* of Vieussens, between
ments; *nn* (velum medullare anterius). It is narrow above, where it is
connected with the quadrigeminal bodies, and broader below,
where it is continuous with the median portion of the cerebellum.

pillars; From its attachment at the sides to the *processus ad testes*,
and these latter have been described as the *pillars* of the valve.
structure.

The upper portion of the valve is composed of medullary sub-
stance, but a few transverse ridges of grey matter extend upon
its lower half, as if they were prolonged from the grey lamellæ
of the cerebellum with which it is there continuous. From be-
tween the posterior quadrigeminal tubercles a slight median ridge,
named *frænulum*, descends a little way upon the velum; and on
each side of this the commencing transverse fibres of the fourth
pair or pathetic nerves may be seen.

The frænulum of the valve.

The valve of Vieussens is overlapped and concealed by the
adjacent folia of the cerebellum, which must be drawn back in
order to bring it into view.

THE CEREBELLUM.

The cerebellum, consists of body and peduncles.

The *cerebellum*, *little brain*, or *after brain* consists of a *body*
and three pairs of *crura* or *peduncles*, by which it is connected
with the rest of the encephalon. They are named superior,
middle, and inferior peduncles, and have all been incidentally
mentioned.

Superior peduncles;

The *superior peduncles*, connect the cerebellum with the ce-
rebrum (*crura ad cerebrum*). They are the parts already de-
scribed under the name of the *processus ad testes*.

inferior;

The *inferior peduncles* (*processus a cerebello ad medullam*;
crura ad medullam) pass downwards to the back part of the me-
dulla oblongata, and correspond with the restiform bodies.

and middle;

The *middle peduncles* (*crura ad pontem*) pass from the mid-
dle of the cerebellum around the outer side of the *crura* of the
cerebrum, and meet in front in the pons Varolii, constituting its
transverse fibres. They connect the two halves of the cerebellum
together below.

are com- posed of white fibres.

All these peduncles consist of white fibres only; and they
pass into the interior of the cerebellum at its fore part. Their
connections within that organ will be afterwards described.

Body of cerebellum; colour;

The *body* of the cerebellum being covered with cortical sub-

stance is of a grey colour externally, but is rather darker on the surface than the cerebrum. Its greatest diameter is transverse ; it is about three and a half or four inches wide, about two or two and a half from before backwards, and about two inches deep in the thickest part, but is much thinner all round its outer border.

dimensions.

It consists of two lateral *hemispheres* joined together by a median portion called the *worm*, or vermiform process, which in birds and in some animals still lower in the scale is the only part existing.

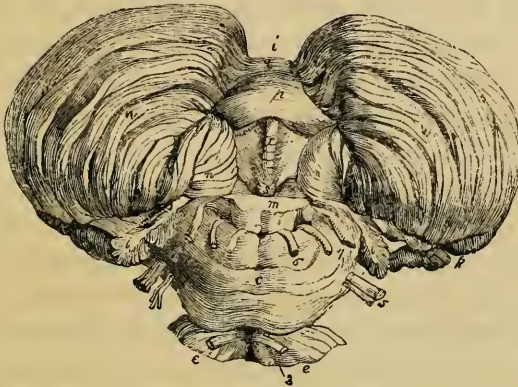
Consists of two hemispheres and a median portion.

The hemispheres are separated behind by a deep *notch*, figs. 170, 171, *i*, so that the outline of the two, as seen from above, resembles a very wide-shaped heart as drawn on playing cards, the notch being directed backwards. On the upper surface, the median portion or superior vermiform process, fig. 170, *h*, though slightly elevated, is scarcely marked off from the hemispheres, so that the general surface of the organ, which is here inclined on either side, is uninterrupted. Below, the hemispheres are convex and are separated by a deep fossa, named the *valley*, fig.

Hemispheres separated behind by notch ;

below by vallicula.

Fig. 171.*



* An under view of the cerebellum, seen from behind,—the medulla oblongata, *m*, having been cut off a short way below the pons. (Reil.) *c*. Pons Varolii. *d*. Middle crus of cerebellum. *ee*. Crura cerebri. *i*. Notch on posterior border. *k*. Commencement of horizontal fissure. *l*. Flocculus or subpeduncular lobe. *m*. Medulla oblongata cut through. *q* to *s*. The inferior vermiform process, lying in the vallicula. *p*. Pyramid. *r*. Uvula. *nn*. Amygdalæ. *s*. Nodule or laminated tubercle. *x*. Posterior velum, partly seen. *w*. Right and left hemispheres of cerebellum. 3 to 7. Nerves. 33. Motores oculorum. 5. Trigeminal. 6. Abducent nerve. 7. Facial and auditory nerves.

171, *i* to *s* (vallecula), which is continuous with the notch behind. Into this hollow the medulla oblongata, *m*, is received in front, and the falx cerebelli behind. The under surface of the median portion of the cerebellum appears in this depression, and is sometimes named the inferior vermiform process.

The folia of cerebellum.

The body of the cerebellum at the surface and for some depth consists of numerous nearly parallel laminæ or folia, which are composed of grey and white matter, and might be compared with the gyri of the cerebrum, but are smaller and not convoluted. These are separated by sulci of different depths.

Horizontal fissure.

One principal fissure or sulcus, named the *great horizontal fissure*, divides the cerebellum into an upper and a lower portion. It begins in front at the entrance of the middle crura, and passes horizontally backwards around the outer border of the hemispheres. From this primary fissure numerous others proceed on both the upper and under surface, forming parallel curves, having their concavities turned forwards and separating the folia from each other. All these furrows do not go entirely round the hemisphere, for they often coalesce with one another; and some of the smaller furrows have even an oblique course between the others. Moreover, on opening the larger fissures many of the folia are seen to lie concealed within them, and do not reach the surface of the cerebellum.

Other smaller fissures.

Lobes of cerebellum,

Certain fissures, which are deeper than the rest and constant in their position, have been described as separating the cerebellum into lobes, which are thus named:—

on upper surface;

The *central lobe*, fig. 170, *v*, situated on the upper surface, consists of about eight folia, immediately adjoining the anterior concave border. The *superior and anterior lobe*, *m*, and the *superior and posterior lobe*, *u*, are placed between the central lobe and the great horizontal fissure. On the under surface, fig. 171, *w*, are seen successively the *inferior posterior lobe*, the *slender lobe*, the *biventral lobe*, the *amygdalæ*, *n n*, and the *sub-peduncular lobe* or *flocculus*. This last-named lobule,

on under surface.

Flocculus or subpedunc. lobe.

l l, lobule of the pneumo-gastric nerve (Vicq-d'Azyr), *sub-peduncular lobe* (Gordon), or *flocculus*, projects behind and below the middle peduncle of the cerebellum. It is connected by a slender pedicle of white fibres to the rest of the hemisphere; but its exposed surface is grey, and is subdivided into a few small laminæ.

Within the vallecule, or on its borders, the following parts are seen. Lobes in or near vallecule.

Commencing from behind, a conical and laminated projection, named the *pyramid*, is first met with, *p*. In front of that is another smaller projection, called the *uvula*, *r*, which is placed between the two rounded lobes at the sides of the vallecule, named the *amygdalæ*, *nn*: these terms being suggested by a comparison with the parts so named in the throat. Between the uvula and amygdalæ on each side, but concealed from view, is extended a ridge of grey matter indented on the surface, and named the *furrowed band*. Still further forward is the anterior pointed termination of the inferior vermiform process, named the *nodule*, *s*, which projects into the fourth ventricle, and has been named the *laminated tubercle* (Malacarne). On each side of the nodule is a thin white lamella of a semilunar form, which is attached by its posterior convex border, and is free and concave in front. The outer ends of these lamellæ are attached to the flocculi, and the inner ends to the nodule, and to each other in front of that projection. The two lamellæ together constitute the *posterior medullary velum*, *x*, (velum medul. post.), which has been compared with the valve of Vieussens, —the one being attached to the superior extremity and the other to the inferior extremity of the middle or vermiform portion of the cerebellum. This posterior velum is covered in and concealed by the amygdalæ, and cannot be properly seen until those lobules have been turned aside. Amygdalæ. The furrowed band. Nodule. Posterior velum.

The Fourth Ventricle.—The space left between the medulla oblongata in front and the cerebellum behind, is named the fourth ventricle, or *ventricle of the cerebellum*, fig. 166, *v*. The fourth ventricle.

The cavity of this ventricle is contracted above and below, and is widest across its middle part. The anterior extremity of the inferior vermiform process projects into it from behind, and higher up it is covered by the Vieussenian valve. It is bounded laterally by the superior peduncles, and lower down it is shut in at the sides by the reflection of its lining membrane from the medulla to the cerebellum. The upper end of the ventricle is continuous with the Sylvian aqueduct or passage (*iter*) leading up to the third ventricle. Its cavity and boundaries.

The anterior boundary or *floor* of the fourth ventricle, fig. 164, *v* 7 *v*' 7, is formed by the back of the medulla oblongata Its floor;

lozenge
shaped.
Parts seen
in it.

and pons Varolii. It is shaped like a lozenge, truncated at its upper part. Below, it is bounded by the diverging posterior pyramids and restiform bodies surmounted along their margin by a band of nervous substance called the *ligula*. In the middle of the floor is seen the longitudinal median fissure, *v v'*, which is gradually obliterated towards the upper part of the ventricle, and forms at its lower end, where it meets the converging borders of the posterior pyramids the point of the *calamus scriptorius*, *v'*. Near this is the small orifice already described as leading into the remnant of the canal in the spinal cord.

Calamus
scriptorius.

Fasciculi
teretes.

Along the sides of the median fissure, in the upper part of the ventricle, are placed two rounded longitudinal eminences, greyish below, but appearing white higher up, fig. 164. These are the *fasciculi teretes*, fig. 177, *a*, (*faisceaux innominés*,—Cruveilhier,) which pass up from the medulla along the back of the pons and enter the cerebrum.

Grey
matter on
floor,
arranged
into
eminences.

Towards the lower part of the ventricle, the central grey matter of the medulla is opened out on the surface, being covered only by a thin translucent layer, and forms several small angular elevations, fig. 164, *e, c, i, v'*, which, as we shall hereafter see, have been recently shown to be connected with the origin of the eighth, ninth, and probably the fifth pairs of nerves. The grey matter in the floor of the fourth ventricle has been named *fasciolæ cinereæ*. Upon it, several transverse white lines or striæ are usually observed, passing across from the median fissure, around the sides of the restiform bodies. Some of these white striæ form part of the roots of the auditory nerves, γ, γ , a few run slantingly upwards and outwards on the floor of the ventricle, whilst others again embrace the corresponding half of the medulla oblongata. These transverse lines are sometimes wanting, in which case the white fibres on which they depend probably exist at some depth beneath the surface.

Forms
fasciolæ
cinereæ.
Is crossed
by white
striæ.

The lining
membrane;
communi-
cations with
third ven-
tricle,

The *lining membrane* of the ventricle is continuous with that of the other ventricles through the aqueduct of Sylvius, in which situation it is marked by delicate rugæ, oblique or longitudinal in direction. At the sides it is reflected from the medulla to the cerebellum, as already stated, and extends for a considerable distance outwards between the flocculus and the seventh and eighth nerves. At the lower end of the ventricle, this cavity communicates with the subarachnoid space. This communica-

with sub-
arachnoid
space.

tion, as stated by Magendie, may be generally shewn independently of laceration. Bichat described the lower end of the fourth ventricle as being closed by the lining membrane, a condition which may perhaps sometimes exist.

Projecting into the fourth ventricle at each side, and passing from the point of the inferior vermiform process outwards and upwards to the outer border of the restiform bodies, are two small vascular processes, which have been named the *choroid plexuses* of the fourth ventricle.

Has small choroid plexuses.

Section of the cerebellum.—Sections of this part, in any or in all directions, show that the surface of the hemispheres and vermis, even at the bottom of the smallest furrows, is composed of a continuous layer of grey matter; and that the white medullary substance is accumulated in the centre, but sends off numerous thin and flat processes, which pass into the middle of each grey lamina. Owing to this arrangement, sections of the cerebellum present a beautifully foliated or arborescent appearance, which however is most perfectly seen on a vertical section made in the median plane, where the relative quantity of the central white matter is small. The appearance in question has been named *arbor vitæ*, fig. 166, *l*.

Cerebellum: grey outside

and

white within.

Arbor vitæ.

In the lateral hemispheres where the peduncles enter, the white matter is more abundant; and if a section be made through either hemisphere half way between its centre and the middle of the vermiform process, it will display a nucleus of grey matter, which is named the *corpus dentatum* of the cerebellum, fig. 172, *b*. This presents the appearance of a waved line of yellowish brown matter, surrounded by white substance and containing whitish matter within. This line is interrupted at its upper and inner part. In whatever direction the section is carried through the corpus dentatum, this waved line is seen, so that the dentate body may be described as consisting of a plicated pouch or capsule of grey substance open at one part and inclosing white matter in its interior, like the corpus dentatum of the olivary body. White fibres may be traced out from it to the superior peduncles of the cerebellum and to the valve of Vieussens.

Corpus dentatum of cerebellum

is an open sac of grey matter.

INTERNAL STRUCTURE OF THE CEREBRO-SPINAL AXIS.

The brain and spinal cord consist of *grey* and *white* nervous matter; the former being also called the *cineritious*, or where it lies upon the surface the *cortical* substance, and the latter being also named *medullary*. The microscopic structure of these two components of the nervous centres is given in the part devoted to the general anatomy.

White substance of brain and cord, fibrous and laminated.

Of the white or medullary substance, it may here be stated that it consists of microscopic fibres arranged into laminae and bundles, between which intervening vessels ramify. The existence, course, and arrangement of these fibrous plates and bundles, which are rendered much more evident by hardening the brain in alcohol, are found to be constant in all cases; but our knowledge of their apparently complicated connections with each other and with the grey matter, is at present imperfect and fragmentary; for which reason, the subject can only be briefly treated of consistently with the limits and purposes of the present work. For more detailed information the reader is referred to the special treatises enumerated below.*

INTERNAL STRUCTURE OF THE SPINAL CORD.

Spinal cord; The general arrangement of the white and grey substances in the spinal cord may be here briefly recapitulated.

its white column

The white matter in each half of the cord, is divided by the fissures or by the grey matter within into three columns, fig. 160, an anterior *a e c*, lateral *c e b*, and posterior *b e p*. The anterior and lateral columns are continuous with each other at the surface, there being no antero-lateral fissure, and form in fact but a single column—the antero-lateral column *a e b*. The posterior columns include also the two small tracts placed one on

* Vieq-d'Azyr.—Traité de l'Anat. et Physiol., 1786; Reil.—Various Memoirs in his Archiv für die Physiologie; Rolando—Sopra la vera struttura del Cervello, 1828; Mayo—Engravings of Structure of Brain and Spinal Cord, 1827; Solly—The Human Brain, &c., 1836; Cruveilhier,—Anatomie Descriptive, 1835; Arnold—Bemerkungen über den Bau des Hirns, &c., 1838—and Icones Anatomicae. Fase. I.; Foville—Traité de l'Anat., &c. du Système Nerveux Cerebro-Spinal, avec planches, 1844; Förg—Vom innern Baue des Gehirns, 1844.

each side of the posterior median fissure, sometimes named the slender fasciculi (see p. 677). The substance of all these columns is penetrated at intervals by bloodvessels, which are supported on fine membranous processes, and in this way it is broken up into separate compressed bundles or into lamellæ having a radiated arrangement. The white matter of the two halves of the cord is continuous before and behind the central grey substance by means of the anterior and posterior white commissures. Lastly, it may be mentioned that the white substance of the cord consists of tubular nervous fibres, having for the most part a longitudinal course.

are made up of irregular lamellæ ;
its two white commissures ;

The *grey matter*, as seen on a section, forms two crescent-shaped masses, turned back to back and joined across the median plane by the grey commissure, figs. 160, 161. The small posterior cornu or horn of each crescent reaches the surface at the posterior lateral fissure. The anterior horn is larger and does not quite reach the surface of the cord. The grey matter of the posterior horn, *substantia gelatinosa*, has a peculiar microscopic structure, for it contains no ganglionic corpuscles ; such bodies, however, are found in the anterior cornu, the grey matter of which was named by Rolando *substantia spongiosa*.

grey matter ;
shape ;

its minute structure.

Origin of the spinal nerves.—The anterior and posterior roots of the spinal nerves are attached along the sides of the cord, opposite to the corresponding cornua of the grey matter, fig. 160, —the posterior roots, *s*, in a perfectly straight line, and the anterior roots, *r*, scattered somewhat irregularly upon the surface. It may be right here to remark that the anterior roots contain the motor, and the posterior roots the sensory filaments in each nerve.

Roots of the nerves, apparent origin.

Anterior and posterior.

As to the *deep* connexions of these roots, it has long been supposed that part at least of their fibres entered into or passed out of the grey matter. In regard to the posterior roots, this is easily demonstrated, for the white fibres pass at once into the tip of the posterior horn of grey matter, in the posterior lateral fissure. The anterior roots have been said to reach the anterior grey cornu, by passing through the superficial stratum of white substance over it ; but actual demonstration of the fact is yet wanted.

Deep connexions with grey matter

Both the anterior and posterior roots are undoubtedly connected with the white matter of the cord ; but there is consider-

with white columns.

able difference of opinion as to the precise manner in which this connexion takes place.

Precise connexions of roots with grey and white matter.

According to one view (Grainger*), both roots are in part connected to the grey matter, and in part to the lateral column only of the white substance. Now, in regard to the anterior roots, from the scattered manner in which they arise, it is plain that they cannot well be limited as to their place of origin in the manner alleged, but that some of their filaments are connected with the anterior column. As to the posterior roots, they are mostly attached to the lateral column, but in some parts of the cord, they undoubtedly are connected also with the posterior column. This indeed corresponds with Bellingeri's opinion, who believes that each root (both anterior and posterior) has three deep connexions, one with the grey matter and one with each of the adjacent white columns; but, as already stated, the anterior roots have not yet been satisfactorily traced into the grey substance.

Course within the cord.

Are they continued up the cord?

The course of the white fibres of the nerves within the cord is not yet clearly made out. Those which enter the grey matter are believed by some (Grainger) to terminate there; whilst it has been generally supposed that those which are connected with the white substance ascend continuously up the cord to reach the brain. Others again believe (with Valentin) that the fibres which enter the grey matter are prolonged for some way upwards among its ganglionic corpuscles, and then pass into the white column, with which they at length become continuous.

Stilling's views.

That roots of each nerve are interlaced, and do not ascend in the cord;

The recently published views of Drs. Stilling and Wallach are totally different from those above mentioned. According to these observers, the roots of the nerves have no direct connexion with the white matter, and none of them run upwards in the cord. On the contrary, the fibres of all four roots enter the grey matter, and run horizontally through, in such a manner as to be completely interlaced or intermixed within it. Thus, to follow one of the posterior roots, it is said that, having entered the corresponding grey cornu, its fibres are disposed in three ways;—some, keeping on the same side of the cord, pass forwards through the anterior cornu and form part of the anterior root of that side; whilst others, crossing through the grey commissure into the opposite half of the cord, run through its two grey cornua and assist in forming its anterior and posterior roots. The fibres of

* On the Spinal Cord. 1837.

all four roots have a similar arrangement, so that some fibres of each root are continuous with some of the other three.

It is to be observed, however, that the method of investigation pursued by Stilling and Wallack, viz., that of examining thin transverse sections of the cord by means of a low power of the microscope, is not well adapted to determine the connexion and course of the nervous fibres. Moreover, it has been shown, by subsequent observations made on the spinal cord of the frog*, for the purpose of testing the accuracy of Stilling's views, that the roots of the nerves pass at least a short distance upwards, and that, at any rate, some of their white fibres are continuous with the longitudinal fibres of the cord.

are unsatisfactory and opposed to other facts.

It must be remembered, however, that there is no direct anatomical evidence to prove, that the fibres are continued all the way up to the brain.

No proof of fibres reaching cerebrum.

INTERNAL STRUCTURE OF THE MEDULLA OBLONGATA.

The white and grey constituents of the spinal cord, when they have reached the medulla oblongata become increased in size, and are altered in their arrangement, in the manner now to be described. The three white columns of the cord are disposed as follows.

White and grey matter increased. Arrangement of columns of cord. Posterior columns go to cerebel,

1. The *posterior column*, figs. 176, 177, *e*, consisting of the fasciculus cuneatus and the slender fasciculus which higher up is named posterior pyramid, forms the restiform body. This, being joined by some fibres from the lateral column, and, as indicated by Solly, by a few from the anterior column, enters the cerebellum as its inferior peduncle, fig. 172, *n*,—the part called the posterior pyramid, *p*, fig. 177, excepted, which according to careful inquirers † passes up with the fasciculi teretes to the cerebrum.

excepting post. pyramid.

2. The *lateral column* ascends towards the base of the olivary body, and is disposed of in three ways; some of its fibres from the surface and deep part join the restiform body and go to the cerebellum; a larger number, fig. 175, *x*, come forwards between the anterior columns, and crossing the median plane, form the chief part of the opposite anterior pyramid, *b*; the remaining

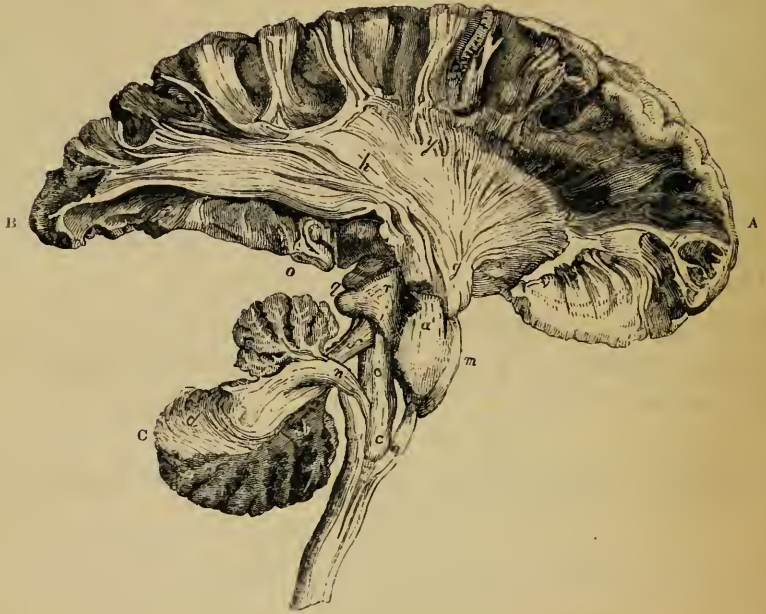Lateral column; goes part to cerebel.,

part to cerebrum, through

* Budge—Müller's Archiv: 1844, p. 160.

† Burdach—Bau und Leben des Gehirns, 1819; Arnold,—Foville,—Förg—Operibus citatis.

Fig. 172.*



anterior
pyramids,
or fasc.
teretes.

Anterior
columns,

a small part
to cerebell.

remainder
to cere-
brum;

fibres pass up to the cerebrum, as the fasciculi teretes, (fig. 172, behind *c'*; faisceaux innominés), appearing on the back of the pons Varolii, in the upper part of the floor of the fourth ventricle, fig. 177, *a*.

3. The *anterior columns*, having reached the apex of the anterior pyramids, are thrust aside from their median position by the decussating fibres derived from the lateral columns, and are then distributed in three divisions. One, very small, ascends obliquely backwards beneath the olive, and joins the restiform body (Solly). Another division passes directly up, its fibres embracing the olivary nucleus, fig. 172, *c*, above which they are again collected together, and joined by other fibres arising from the

* General view of the connexion of columns of medulla oblongata with cerebellum and cerebrum (Mayo). A. Anterior lobe. B. Posterior lobe of cerebrum. c. Cerebellum. a. Anterior pyramid. a'. Continuation of same in pons. c. Olivary body. c'. Olivary fasciculus. Behind c'. Fasciculi teretes. d. White laminae of cerebellum. f. Superior peduncles of cerebellum—proecessus ad testes. g. Anterior portion of peduncle—fibres of crust. h. Radiating peduncular fibres of cerebrum. hyy. Part of corona radiata. h'. Central fibres of convolutions. i. Fillet. l. Back of thalamus. m. Pons Varolii. o. Section of pes hippocampi. r. Tegmentum. yy. Indicates white fibres escaping from corpus striatum.

corpus dentatum, so as to form the olivary fasciculus, *c'*; this ascends through the pons and at the side of the cerebral peduncle under the name of the fillet, fig. 176, *c, i, h*, and reaches the corpora quadrigemina by *i*, and the cerebral hemispheres by *h*. The remaining division of the anterior column ascends into the anterior pyramid, *a*, fig. 172, forming its outer part. The anterior pyramids therefore are composed of fibres from the lateral and anterior columns, and are continued up through the pons into the peduncles of the cerebrum.

through
fillet.

or anter.
pyramids.

It is to be remembered, however, that the separation between these different tracts of white fibres cannot be clearly followed out through the whole structure of the medulla oblongata; for, at a certain depth from the surface, they are found to be more or less blended with one another.

Limits of
columns of
medulla not
well de-
fined.

Grey matter of the medulla oblongata.—In ascending into the medulla oblongata, the grey matter becomes more abundant, and gets blended with all the white fasciculi, excepting the anterior pyramids, fig. 173, *b b*, which are composed entirely of white substance. The posterior horns increase in size, and are directed more to the side, where they appear at the surface in the form of a narrow grey stripe, which was called by Rolando, *tuberculo cinereo, d*. A distinct mass of grey substance, forming the *corpus dentatum, c c*, exists within the olivary body.

Grey mat-
ter of med.
appears at
side as grey
tubercle,
and is
blended
with white;

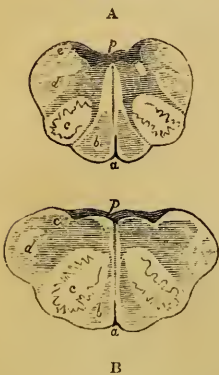
forms cor-
pus denta-
tum, or
olivary
nucleus; is
exposed at
back of me-
dulla.

The grey commissure of the cord, as it is continued upwards, becomes exposed at the back of the medulla, *p p*, in the floor of the fourth ventricle, owing to the divergence of the posterior white fasciculi; and it eventually disappears as a distinct median structure, being mixed with the white fibres of the fasciculi teretes.

According to the observations of Stilling, some part of the grey matter at the back of the medulla, forms special deposits

Grey nuclei
for 8th and
9th nerves.

Fig. 173.*



* Sections of the medulla oblongata—natural size—(Arnold). A. About middle of medulla. B. Higher up. *a*. Anterior fissure. *b*. Anterior pyramid. *c*. Olivary body and corpus dentatum. *d*. Grey tubercle. *p*. Posterior fissure in floor of fourth ventricle, where grey matter is accumulated.

Position of
these in
medulla ;

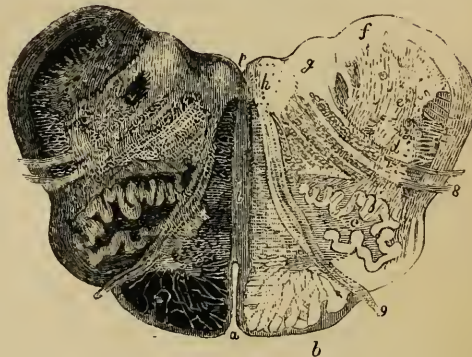
in floor of
4th ventri-
cle.

1st for
spinal
accessory.

2d, for
hypoglos-
sal.

or nuclei, connected with the roots of the spinal accessory, vagus, glosso-pharyngeal and hypoglossal nerves. Of these nuclei, the first or lowest is concealed in the substance of the medulla ; whilst those which are situated higher up gradually appear as small triangular eminences in the floor of the fourth ventricle, near the point of the calamus scriptorius.—See fig. 164, in which *v'* shows the position of the nucleus for the spinal accessory, *i* that for the vagus, *e* that for the glosso-pharyngeal, and *c* that for the hypoglossal nerve. The *first nucleus* is that for the spinal accessory nerve. It reaches some way down in the cord, and then appears, on a transverse section, like a lateral process extending from the grey crescent between its anterior and posterior horns, and from it the slender and straggling roots of the nerve run outwards to the surface ; as it extends upwards it approaches the middle and back part of the medulla oblongata, *v'*. In front of this nucleus, and close to the centre of the medulla, is another, the *second*, fig. 174, *h*, commencing higher up and connected with the hypoglossal nerve, the roots of which coming forwards between the anterior

Fig 174.*



* Section of the medulla oblongata, magnified two diameters, reduced from Stilling's plate. In this figure, which is viewed by transmitted light, Stilling regards the lighter parts as composed of grey matter. But on viewing a similar section by direct light, it appears to us that the roots of the nerves, the transverse curved lines, and the antero-posterior septum are really composed of white substance. *a*. Anterior, and *p*, posterior fissure. *b*. Pyramid. *c*. Olivary body, and its corpus dentatum. *d*. Grey tubercle in lateral fasciculus. *f*. Nucleus for glosso-pharyngeal nerve. *g*. Nucleus for vagus. *h*. That for hypoglossal nerve. *i*. The antero-posterior septum. *8*. Roots of vagus nerve. *9*. Roots of hypoglossal nerve.

pyramid and the olivary body, appear at the surface in the depression between those parts. Continuing to ascend, these two nuclei reach the back of the medulla, and then make their appearance in the floor of the fourth ventricle. Higher up, the nucleus for the spinal accessory nerve is succeeded by a *third* in the same line, *g*, which is connected with the nervus vagus, and is also placed to the outer side of that for the hypoglossus, *h*. Further out, a *fourth* nucleus, *f*, begins to be observed, belonging to the glosso-pharyngeal nerve. The last change in the arrangement of these small grey masses consists in the gradual narrowing of the nucleus of the par vagum, and the approximation of those for the hypoglossal and glosso-pharyngeal nerves, which were previously separated by it.

3d, for
vagus.

4th, for
glosso-
pharyng.

Langenbeck and Förg maintain that the part regarded by Stilling as the nucleus for the glosso-pharyngeal nerve is really the place of origin of the greater root of the fifth or trigeminal nerve.

Nucleus for
5th nerve.

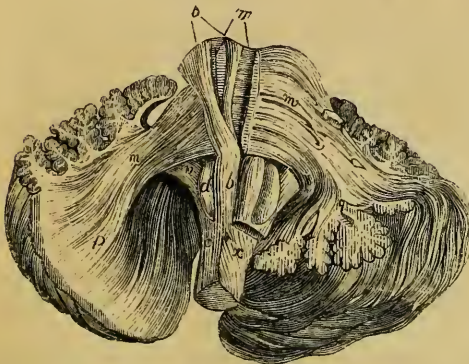
The *horizontal white fibres* which form the antero-posterior septum, fig. 174, *i*, in the medulla oblongata, will be described along with a similar set of fibres existing in the pons.

INTERNAL STRUCTURE OF THE PONS VAROLII.

The pons Varolii consists of transverse white fibres, and of the longitudinal fibres prolonged through them from the medulla, intermixed with much grey matter.

Fibres of
pons and
grey matter.

Fig. 175.*



On dissecting it from the front, a superficial white layer, figs. 175, 176, *m*, also fig. 163, *p*, *i*, is met with, which extends on either side into the middle crus of the cerebellum. Behind this are seen the prolonged fibres of the anterior pyramids, *b*, which, as they

Superficial
layer, trans-
verse ;

next, longi-
tudinal ;

* Fibres of medulla oblongata and pons, arranged in alternate layers.—(Anold). *b*. Anterior pyramid. *b'*. Prolongation of same through pons

ascend through the pons, are widely separated into smaller bundles, intersected by other transverse white fibres, *m'*, which, like those upon the surface, are continued into the cerebellum. Amongst these two decussating sets of fibres is a large quantity of grey matter.

then other
transverse;

lastly,
other lon-
gitudinal.

The arrangement just described extends to a considerable depth in the pons, but is succeeded by a third layer, which consists entirely of longitudinal fibres. This comprehends the olivary fasciculus, fig. 176, *c, i, h*, and the fasciuli teretes, *t*, which, as we have frequently mentioned, run up on each side and in the floor of the fourth ventricle, intermixed with much grey substance.

Septal fibres
of medulla
oblongata,

Septum of the medulla oblongata and pons.—Besides the white fibres already described, there exist in the medulla oblongata and pons others which extend from behind forwards, fig. 174, *i*, in the median plane. In the medulla, fig. 166, these appear above the decussation of the pyramids. Some issuing from the anterior fissure and turning round the sides of the medulla, form the arciform fibres and those, (sometimes named *fibræ transversæ*,) which occasionally cover the anterior pyramids and olivary bodies: others, appearing at the surface, in the floor of the fourth ventricle, give rise to the transverse white striæ generally seen in that situation. These parts have been already described (p. 688).

and of Pons.

A median septum, of the same kind, obviously exists throughout the whole height of the pons, in its back part, but becomes indistinct in approaching the front or basilar surface, except towards its upper and lower edge, where the superficial fibres of the pons are manifestly continuous in the median line with these septal fibres; and bundles of white fibres, belonging to the same system, encircle the crura cerebri at their emergence from the upper border of the pons.

According to Foville, a few of the fibres from each of the three principal longitudinal elements of the medulla turn forwards and become continuous

c. Olivary bundle. *d.* Olive. *m.* Superficial transverse fibres of pons. *m'*. Deeper transverse fibres. *m''*. Prolonged as middle peduncle of cerebellum. *p, q.* Their continuation into laminæ or folia of same. *n.* Inferior peduncle. *x.* Decussating portion of left lateral column, crossing over to right anterior pyramid.

with the transverse fibres of the pons ; and, in like manner, one or more small bundles from each of the *crura cerebri* take a similar transverse course.*

INTERNAL STRUCTURE OF THE CEREBELLUM.

The cerebellum consists of an internal white medullary mass, containing on each side the *corpus dentatum* ; of an external grey or cortical layer, covering the leaves or *folia* ; and of three pairs of white peduncles.

Structure of cerebellum.

The *folia* consist of white matter covered externally with grey. The structure of each of them appears to be this :—from the central white mass of the cerebellum, thin plates, composed of white fibres, pass up in the centre of the *folia*, and divide into subordinate white laminae, corresponding with the subdivisions of the *folia*. Many of these *central white laminae* can be traced continuously from the peduncles of the cerebellum. Upon these central plates are laid other *collateral lamellae*, which are not connected with the fibres proceeding from the middle of the cerebellum, but merely pass from one folium to another. Superficial to these white fibres is the grey cortical substance.

Structure of folia.

Central white plates.

Collateral fibres.

This *grey matter* is not uniform throughout its whole thickness, but is composed of two or more layers differing in colour and other characters ;—resembling, in this respect, the cortical substance of the posterior convolutions of the cerebrum.

Grey matter consists of several layers.

The *white fibres*, composing the peduncles of the cerebellum are thus arranged in its interior.

Peduncles of cerebellum ;

The *middle peduncles*, fig. 175, *m*, which are the most superficial, pass from the pons *Varolii*, with the transverse fibres of which they are directly continuous, and enter the lateral parts, *m, p*, of the cerebellum. They may be traced into the *folia* of those parts, *q*, and form a large share of each hemisphere.

middle ;

The middle peduncles being removed, the *inferior peduncles* (*restiform bodies*) come into view, figs. 172, 175, 176, *n*. They pass upwards into the middle part of the cerebellum, in the *folia* of which they are distributed, especially to those of the upper surface.

inferior ;

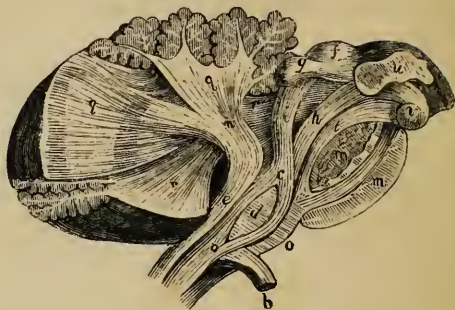
The *superior peduncles*, figs. 172, *f*, 176, *r*, which are

superior.

* Foville, op. cit., Pl. II., figs. 2 and 3. Pl. III., figs. 5 and 6.

placed nearest to the middle line, are principally connected with the folia of the inferior vermiform process; but a considerable number of them pass into or issue from the grey capsule of the corpus dentatum, which has been already described.

Fig. 176.*



INTERNAL STRUCTURE OF THE CEREBRUM.

Fibres of
cerebrum ;
form three
principal
systems :
ascending,

transverse,
and col-
lateral.

Ascending
peduncular
fibres.
Main body,

The fibres of the cerebrum, though exceedingly complicated in their arrangement, and forming many different collections, may be referred to three principal systems, according to the general course which they take, viz.—1. *Ascending or peduncular fibres*, which pass up from the medulla oblongata to the hemispheres, and constitute the two crura or peduncles of the cerebrum. They increase in number as they ascend through the pons, and still further in passing through the optic thalami, and striated bodies, beyond which they spread in all directions into the hemispheres. These were named by Gall the *diverging* fibres. 2. *Transverse or commissural* fibres which connect the two hemispheres together. These are the converging fibres of Gall. 3. *Longitudinal or collateral* fibres, which, keeping on the same side of the middle line, connect more or less distant parts of the same hemisphere together.

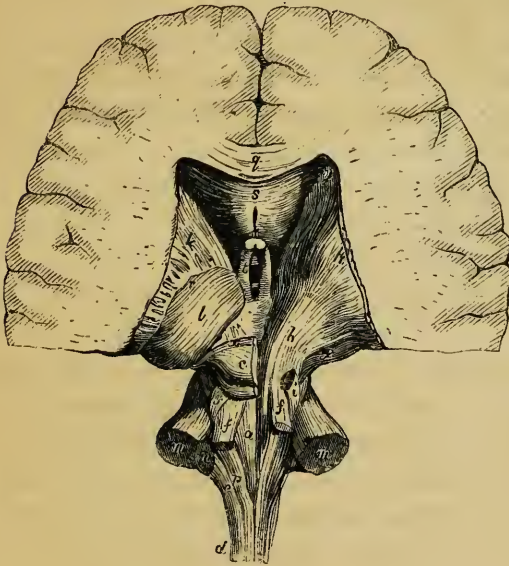
1. The *peduncular* fibres consist of a main body and of certain accessory bundles of fibres.

a. The *main body* on each side is derived from the anterior

* Arrangement of columns of medulla ; and of superior and inferior peduncles of cerebellum.—(Arnold). *a.* Part of anterior column, which ascends to the olive. *b.* Decussating portion of lateral column. *c.* Olivary fasciculus. *d.* Olive. *e.* Restiform body. *f, g.* Corpora quadrigemina. *c, h, i.* Fillet. *h.* Part which goes to cerebral peduncle. *i.* Part going to corpora quadrigemina. *m m'.* Transverse fibres of pons, cut through. *n.* Inferior peduncle of cerebellum. *o.* septal fibres of medulla oblongata. *q q.* Fibres of inferior peduncle continued into cerebellum. *r r.* Superior peduncle. *u.* Thalamus. *v.* Corpus albicans.

pyramid, fig. 172, *a*, from the prolongation of the lateral column (one of the fasciculi teretes, fig. 177, *a*,) and from the posterior

Fig. 177.*



pyramid, *p*. After it has passed through the pons and become increased in amount, it is separated into two parts in the crus cerebri by a layer of dark cineritious matter, named *locus niger*. The lower or superficial part, which is derived from the pyramid, consists almost entirely of white fibres, collected into coarse

separated into two parts by grey deposit, or locus niger.

White fibres form crust and

fasciculi, and is named the *crust* or *basis*, fig. 172, *g*, or the *fasciculated portion* of the peduncle (Foville). The upper part, composed principally of the fasciculus teres and posterior pyramid, is named the *tegmentum*, *b*; it is softer and finer in texture, and is mixed with much grey matter.

tegmentum.

Still increasing in number within the peduncle, these two sets of fibres continue to ascend, fig. 172, *g*, and pass above the optic tracts through the thalamus, fig. 177, *b l*, and corpus striatum, *k h*. Receiving fresh accessions of fibres there, they are continued on into the medullary substance of the corresponding

Course through thalami and corp. striata;

* Back view of peduncular fibres of cerebrum, attached to hemispheres.—(Arnold). *a*. Fasciculus teres of left side. *b*. Fibres of tegmentum ascending through thalamus. *c*. Left corpora quadrigemina. *e*. Restiform body. *f f*. Superior peduncles of cerebellum—processus ad testes. *g*. Fibres of crust. *i i*. Fillet of both sides. *k k'*. Corpora striata:—on the right side, the grey matter stripped off to show radiating fibres of fibrous cone. *l*. Left thalamus. *m m*. Sections of middle peduncles of cerebellum. *n*. Section of left inferior peduncle. *p*. Left posterior pyramid. *q*. Corpus callosum. *s*. Under surface of same—below *s*, cavity of fifth ventricle. *t*. Left anterior pillar of fornix. *y y*. Decussation of radiating fibres, with those of corpus callosum.

hemisphere, fig. 172, *h y*. The anterior fibres, or those of the crust, *g*, pass principally, if not entirely, through the corpus striatum. The posterior fibres, or those of the integumentum, *r*, run, some through the thalamus, *l*, but the greater part at least through the corpus striatum also.

intersect in those bodies, and also with fibres of corp. call.

As they pass through these large grey masses or ganglia, the two sets of fibres intersect or cross each other, and on emerging beyond the grey matter, fig. 177, *y*, they again decussate with the commissural fibres or transverse fibres, *s*, of the corpus callosum, *q*. After that, they spread into the hemisphere in every direction, and reach the cortical substance of the convolutions.

Reach convolutions.

Accessory fibres to peduncles. Process. ad testes.

The accessory fibres of the peduncular system are as follows:—

b. The superior peduncles of the cerebellum, (processus ad testes), figs. 172, 177, *f*, which are continued up beneath the corpora quadrigemina, *q*, *c*, and form part of the tegmentum.

The fillet.

c. The bundle of fibres on each side, named the *fillet*, *lemniscus*, *schleife*, *i*.—This, which is originally derived from the anterior column of the cord, forms the olivary fasciculus, fig. 176, *c*, of the medulla oblongata, as previously described. Reinforced by fibres from the corpus dentatum of the olivary body, *d*, it ascends through the back part of the pons, still increasing in size. Appearing at the side of the cerebral peduncle, above the upper border of the pons, fig. 177, *i i*, it divides into two portions, of which one, fig. 176, *i*, crosses over the superior peduncle of the cerebellum to the corpora quadrigemina, meeting its fellow of the opposite side; whilst the other, *h*, is continued upwards with the fibres of the tegmentum.

Fibres from corp. quadrigemina,

d. Other accessory fibres to the peduncles take their rise in the grey matter of the corpora quadrigemina, *g*, *f*, (the *brachia*), and proceed on to the thalami, *u*.

and corp. geniculata.

e. Lastly, another set, having a similar destination, are derived from the corpora geniculata.

Corpus striatum, divided into two portions by peduncular fibres,

Corpus striatum and *corona radiata*. The principal mass of each corpus striatum is concealed in the substance of the cerebral hemisphere, whilst a part of it, fig. 177, *k k*, appears in the lateral ventricle. The ascending white fibres of the corresponding peduncle, spreading out in a radiating manner, pass

up through and between these two parts of the corpus striatum and divide the grey matter into an extra- and an intra-ventricular portion.

The assemblage of these radiating fibres, fig. 172, *g* to *y y*, might be compared to a fan, bent into the form of an incomplete hollow cone, having its concave surface turned downwards and outwards; hence the names *corona radiata* (Stabkranz) applied to them by Reil, and *fibrous cone*, by Mayo. On cutting through the corpus striatum across the direction of these fibres, the section of the fibrous cone appears as a broad white band, extending from the anterior to the posterior extremity of that grey mass, and separating it into its outer and inner portions already mentioned. On dissecting the corpus striatum from the ventricle, and removing its intraventricular grey substance, we meet, at some depth from the surface, with these white fibres, which being intermixed with the grey matter, give to the body its streaked appearance. The extraventricular portion, which lies somewhat lower than the inner portion, is situated between the radiating peduncular fibres, and the island of Reil, and may be exposed by dissecting the hemisphere from the Sylvian fissure. In this dissection, the convolutions of the island are first removed; beneath the white matter of those gyri, a thin layer of grey substance is met with, which has been named the *claustrum* (Burdach): deeper than this, white matter again appears,—forming, however, but a very thin layer,—on removing which the extraventricular portion of the corpus striatum is exposed. In this dissection the striated body is also seen to be continuous below with the anterior perforated space, where the grey matter reaches the surface of the brain; whilst around its upper margin, now completely exposed, appears a zone of white radiating fibres, which is the continuation of the corona radiata, after its passage through the grey matter. On next scraping away the latter, the fibrous cone is entirely displayed from its outer side. In doing this, the fibres of the anterior commissure, of which we shall presently make mention, also come into view.

which here form the corona radiata.

Dissection of corpus striatum from Sylvian fissure.

Is covered by grey layer or claustrum.

Is immediately over anterior perforated space.

Lastly, it may be mentioned, that if the brain be cut through in a plane perpendicular to the surface of the island, the section of the grey layer, named the claustrum, appears as a narrow dark line situated between the island and the corpus striatum.

Transverse fibres of cerebrum.

Those of corpus callosum,

form the tapetum.

Anterior commissure, reaches a long way in brain ;

Posterior commissure, only a short distance.

Collateral fibres of cerebr.

2. The *transverse, commissural* or connecting fibres of the cerebrum include the following sets :—

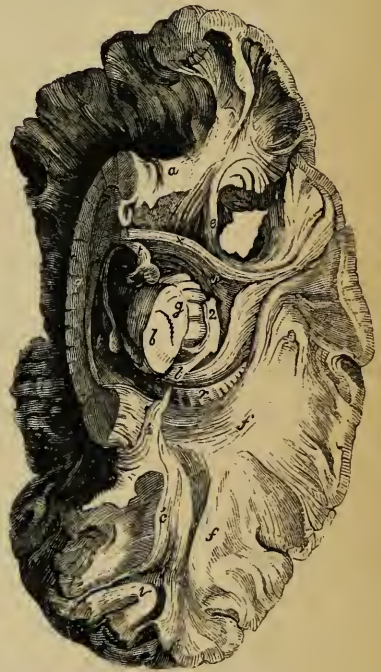
a. The cross fibres of the corpus callosum, fig. 177, *q.*—These are more numerous at each end of the corpus callosum than in the middle, and form the thickest mass behind. Passing laterally into the substance of the hemispheres, some are directed upwards, whilst others spread outwards on the roof of the lateral ventricles, forming there what is named the *tapetum*, *s.* Having next intersected the peduncular radiating fibres at *yy*, they then spread out into the hemispheres, reaching the grey matter of the convolutions.

b. The *anterior commissure*, fig. 178, *x.*—This is a round bundle of white fibres, seen in the fore part of the third ventricle, from which it passes laterally into the corpora striata, and bending backwards, extends a long way in the hemispheres, reaching into the middle lobe on each side.

c. The *posterior commissure*, also situated in the third ventricle, runs through the optic thalami, and is soon lost in the substance of the hemispheres in that situation.

3. The third system of fibres in the cerebrum, the

Fig. 178.*



* Under surface of left hemisphere dissected.—(After Mayo.) *a.* Anterior, and *a'*, posterior part of fillet of corpus callosum. *b, g.* Section of cerebral peduncle. *b.* Tegmentum. *g.* Crust, separated by locus niger. *c'*. Fibres reaching from back of corpus callosum to posterior lobe. *e.* Fasciculus uncinatus, connecting anterior and middle lobes, across the Sylvian fissure. *ff.* Transverse fibres from corpus callosum. *l.* Back of thalamus. *m.* Corpus albicans. *q.* Corpus callosum. *r.* Radiating fibres of hemisphere. *t.* Anterior pillar of fornix. *v.* Collateral fibres of convolutions. *x.* Anterior commissure. *2.* Part of optic tract.

longitudinal or *collateral*, may be comprehended under the following heads.

a. The *fornix*, fig. 179, *tt'*.—This forms a longitudinal bundle on each side, which, as already mentioned, might be described as commencing in the thalamus, *, near its anterior tubercle. It then descends to the corpus albicans, *n*, of its own side, turns round in that eminence, and ascending to form the anterior pillar, *t*, may thence be traced backwards in conjunction with that of the opposite side, until it separates posteriorly, where it spreads out in part upon the pes hippocampi in the descending cornu of the lateral ventricle, and is prolonged as the corpus fimbriatum nearly to the point of the middle lobe.

Those of fornix extend from thalamus

to point of middle lobe.

b, c. The white fibres constituting the *tænia semicircularis*, fig. 167, *s*, and those of the peduncles of the pineal gland, fig. 170, *p*, may perhaps be regarded as accessories to the fornix. They both join its anterior pillars in front. Behind, the *tænia* is lost on the back of the thalamus in the descending cornu; and the pineal peduncles end in the pineal gland, so that they are regarded by some as forming a transverse commissure.

Fibres of tænia, and pineal peduncles.

Foville traces the *tænia* from part of the posterior pyramids, as will be presently noticed.

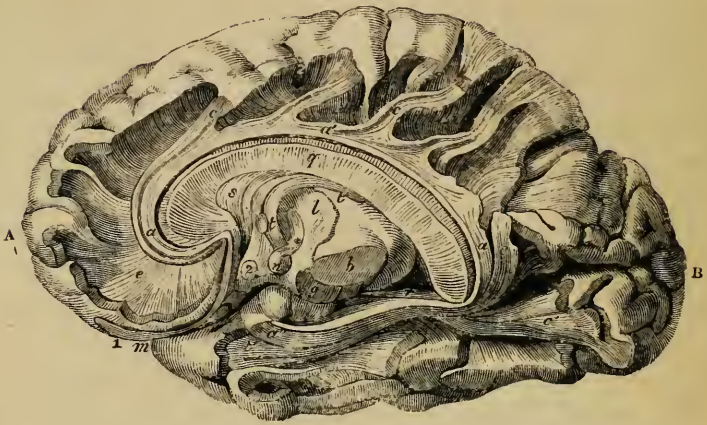
d. The *striæ longitudinales*, upon the upper surface of the corpus callosum, also belong to this system. They are distinguished into the middle and lateral longitudinal striæ. In front, they are connected with the peduncles of the corpus callosum, and through them with the anterior perforated space. Their posterior connections are uncertain; according to Foville, they join the posterior pillars of the fornix.

Longitudinal fibres of corpus callosum.

e. *Fibres of the gyrus fornicatus; fillet of the corpus callosum* (Mayo). These fibres constitute the white substance of the gyrus fornicatus, and take a longitudinal course, fig. 179, *a a' a''*, immediately above the transverse fibres of the corpus callosum, *q*. In front, *a*, they bend downwards within the gyrus to which they belong, and are connected with the anterior perforated space, being joined by certain longitudinal fibres, which run along the under surface of the corpus callosum near the middle line, passing near and upon the upper edge of the septum lucidum. Behind, *a c*, they turn round the back of the corpus callosum and descend to the point of the middle lobe, *a''*, where,

Fibres of gyrus fornicatus; their great extent;

Fig. 179.*



send offsets
into convo-
lutions of
inner
surface.

Fasciculus
uncinatus in
Sylvian
fissure ;

connects
anterior and
middle
lobes.

Collateral
fibres of
convolu-
tions.

according to Foville, they again reach the perforated space. Offsets, *c c c*, from these fibres pass upwards and backwards into the secondary convolutions in the longitudinal fissure derived from the gyrus fornicatus.

f. Fasciculus uncinatus.—Under this name is described a white bundle, fig. 178, *e*, seen on the lateral aspect of the hemisphere, passing across the bottom of the Sylvian fissure, and connecting the anterior with the middle and posterior lobes. The fibres of this bundle expand at each extremity, and the superficial portion of them curve or hook sharply between the contiguous parts of the anterior and middle lobes,—whence it has received its name.

g. The convolutions of the cerebrum are connected with each other by white fibres, which lie immediately beneath the cortical substance. Some of them, fig. 178, *v*, pass across the bottom of a sulcus between adjacent convolutions ; whilst others, which are long and run deeper, connect convolutions situated at a greater distance from one another.

* Dissection of fibres of gyrus fornicatus, and of fornix. (From Foville, slightly altered.) A. Anterior, B. Posterior lobe. *a a' a''*. Fibres of gyrus fornicatus. *c*. Of its accessory gyri. *b*. Tegmentum ; and *g*. crust—the two separated by locus niger. *l*. The thalamus. *n*. Corpus albicans. *q*. Corpus callosum. *r*. Radiating fibres of hemisphere. *s*. Septum lucidum. *t*. fornix. *t'*. Anterior pillar. * Commencement in thalamus. 1. Olfactory nerve. 2. Optic commissure.

The central part of the white substance of each convolution is formed by fibres having a different origin ; some, fig. 172, *h'*, being derived from the radiating peduncular fibres, and, according to most anatomists, others from the transverse fibres of the corpus callosum.

Central fibres of convolutions.

The researches of Foville have led him to differ considerably from other anatomists, as to the course of the fibres of the cerebrum, as will be seen from the following statement of his views :—

Foville's views of fibres of cerebrum.

1. The *crust*, or *fasciculated portion* of each cerebral peduncle, derived from the anterior pyramid, forms by itself the peduncular fibrous cone, and is thence continued on into the radiating fibres of the cerebrum, which are destined only for the convolutions on the convex surface of the hemisphere, including the outer half of the marginal convolution of the longitudinal fissure, and the inner half of the convolution of the Sylvian fissure.

Fibres of crust form radiating set ; go only to part of convolutions.

2. The fibres of the *tegmentum*, having entered the thalamus, pass on in two ways—no part of them, be it observed, joining the radiating peduncular fibres.

Fibres of tegmentum surround the radiating set. None go direct to convolutions.

a. One set pass upwards through the thalamus and corpus striatum, above which they then turn inwards, and, joining with those of the opposite side, form the transverse fibres of the corpus callosum. The corpus callosum is therefore regarded as a commissure of the cerebral peduncles only—none of its cross fibres spreading into the convolutions, as is generally believed.

Part surround thalami, corp. striata and ventricles, and form corpus callosum ; others reach anterior perf. space.

b. The second set of fibres of the tegmentum, corresponding with the fasciculi teretes and part of the posterior pyramids, run forwards near the middle line, along the under side of the third ventricle and corpus striatum, through the grey matter in front of the pons, to the anterior perforated space. The remaining part of the posterior pyramid, forms the *tænia semicircularis*, which, passing down in front of the anterior pillar of the fornix, also reaches the perforated space. From this space more fibres are reflected upwards on the sides of the corpus striatum to join the corpus callosum.

Connected with these are longitudinal arched fibres :

3. As dependencies of the posterior peduncular fibres, and connected with them at the borders of the anterior perforated space, are :—

a. Several sets of longitudinal arched fibres, which embrace, in a series of rings, the radiating peduncular system. These are—the deep fibres of the *tænia semicircularis*—a somewhat similar band beneath the outer part of the corpus striatum—the half of the fornix with the corpus fimbriatum—the longitudinal fibres placed on the upper and under surface of the corpus callosum, and those of the septum lucidum ; and, lastly, two remarkable systems of longitudinal fibres—one constituting the entire white substance of the gyrus fornicatus (from end to end), also, of its accessory convolutions, and of the inner half of the marginal convolution of the longitudinal fissure ; and the other, forming the white substance of the convolutions of the island of Reil, and the adjoining half of the convolution of the Sylvian fissure. None of the parts just named receive fibres from the radiating peduncular set.

one arch forms white substance of several convolutions.

Also other fibres lining ventricles, and covering convolutions.

b. In connection with this system is a thin stratum of white fibres, found upon the internal surface of the ventricles, and prolonged through the transverse fissure into the reticulated white substance covering the lower end of the gyrus fornicatus; whence, according to Foville, it extends, as an exceedingly thin layer of medullary matter, all over the cortical substance of the hemisphere.

Anterior commissure.

c. The anterior commissure does not reach the convolutions, but radiates upon the outer sides of the corpora striata and thalami.

Grey matter of encephalon;

Grey matter of the encephalon. Considering the imputed physiological importance of the grey nervous substance, it may be well to mention connectedly the different positions in which it is found in the several parts of the encephalon.

its position on surface;

By far the larger amount is situated upon the convoluted surface of the cerebrum and the laminated surface of the cerebellum, forming in each case the external cortical layer of cineritious matter.

at base of brain;

In the middle part of the base of the brain it is seen to be accumulated along the under side of the third ventricle in a layer of varying thickness extending from a little above the optic commissure to the back part of the interpeduncular space, forming the lamina cinerea, the tuber cinereum, and the grey matter in the posterior perforated space, the infundibulum and pituitary body being continuous with it below. Towards each side, in front, the lamina cinerea is connected with the grey matter of the anterior perforated space, whence a continuity of the cineritious substance may be traced forwards into the olfactory nerve, as far as its obtuse extremity, the olfactory lobe. Moreover, this median stratum of grey matter seen on the floor of the third ventricle is prolonged upwards on the sides of the thalami, passes across as the soft commissure, partly surrounds the anterior pillar of the fornix, (having entered below into the interior of the corpus albicans,) and is extended higher up on the sides of the septum lucidum. In the crura cerebri, the grey matter is collected into a dark mass, the locus niger, and is also diffused among the fasciculi of the tegmentum; below this it is continuous with that of the pons and medulla oblongata, and through them with that of the spinal cord, as has already been sufficiently described.

in interior of brain;

in peduncles of brain;

in pons, medulla, and spinal cord.

In the centre of each of the corpora quadrigemina, grey matter is also found, and it occurs in the pineal gland, and in the cor-

pora geniculata. These last bodies appear to be appendages of the large masses of grey matter situated in the interior of the cerebrum, named the optic thalami; which again are succeeded by the still larger collections of this substance, and indeed the largest situated within the brain, viz., the corpora striata. The grey matter of each corpus striatum is continuous below with that of the anterior perforated space; and on its outer side, is the thin layer of grey matter named the claustrum, the connexions of which are not well understood.

In corp. quadrigem and geniculata; in thalami and corp. striata.

In the centre of each hemisphere of the cerebellum is the corpus dentatum.

In cerebellum;

CONNEXIONS OF THE CRANIAL NERVES WITH THE ENCEPHALON.

The *cranial* nerves arise from the under part of the brain and issue through the foramina in the base of the skull. They are usually reckoned as forming *nine* pairs (see fig. 165, where they are numbered ¹ to ⁹). The several designations of these nerves as well as their course within the cranium will be subsequently described. It is here proposed to give an account of their connexions with the encephalon, or what is usually called their root or *origin*.

Cranial nerves are nine pairs.

The roots of the nerves may be traced for some depth into the substance of the encephalon, a circumstance which has led to the distinction of the *deep* or *real* origin, and the *superficial* or *apparent* origin, by which latter is understood the place at which the nerve appears attached to the surface of the encephalon. The superficial origin of these nerves is quite obvious, but their deeper connection is, in most cases, a matter of much uncertainty. For this reason the apparent origin is described before the deep origin, which is less perfectly known.

Origins are deep or superficial.

1. The first or *olfactory* nerve, figs. 165, 166, ¹, small in man in comparison with animals, lies on the under surface of the anterior lobe to the outer side of the longitudinal median fissure, lodged in a sulcus between two straight convolutions. Unlike other nerves, it consists of a large proportion of grey matter mixed with white fibres, and, indeed, is rather to be considered a prolongation of the anterior lobe. It enlarges into a *bulb*, *olfactory bulb*, in front, which also contains much grey matter,

First pair, or olfactory nerves

are prolongations of cerebrum. Olfactory bulb.

and from this part small soft nerves descend through the cribriform plate of the skull into the nose. On turning back the bulb, it is seen that the nerve behind that part is three-sided, its upper edge lying in the groove or sulcus above mentioned. When traced backwards, it is found to be spread out and attached behind to the under surface of the anterior lobe by means of *three* portions or *roots*, named external, middle, and internal, which pass in different directions.

Nerve has
three roots:

external or
long;

The *external* or *long* root consists of a band of medullary fibres, which passes, in the form of a white streak, outwards and backwards along the anterior margin of the perforated space, towards the posterior border of the Sylvian fissure, where it may be followed into the substance of the cerebrum. Its further connexions are doubtful, but it has been stated that its fibres have been traced to the following parts, viz., the convolutions of the island of Reil, the anterior commissure, and the superficial layer of the optic thalamus (Valentin).

middle or
grey;

The *middle* or *grey* root is of a pyramidal shape, and consists of grey matter on the surface, which is prolonged from the adjacent part of the anterior lobe and perforated space. Within it there are white fibres, which have been traced to the corpus striatum.

internal or
short.

The *internal root* (*short* root, Scarpa), which cannot always be demonstrated, is composed of white fibres which may be traced from the inner and posterior part of the anterior lobe, where they are said by Foville to be connected with the longitudinal fibres of the gyrus fornicatus.

Second pair,
or optic
nerves.

2. The *second* pair of nerves, or the *optic* nerves, ², of the two sides meet each other at the optic commissure (chiasma), *c*, where they partially decussate. From this point they may be traced backwards around the crura cerebri under the name of the optic tracts.

Origin from
brain by
optic tracts.

Each *optic tract*, *u*, arises from the optic thalamus, the corpora quadrigemina, and the corpora geniculata. As it leaves the under part of the thalamus, it makes a sudden bend forwards and then runs obliquely across the under surface of the cerebral peduncle, fig. 180, ², in form of a flattened band, which is attached by its anterior edge to the peduncle; after this, becoming cylindrical, it adheres to the tuber cinereum, from which

and, as was first pointed out by Vicq-d'Azyr,* from the lamina cinerea it is said to receive an accession of fibres, and thus reaches the optic commissure.

In the *commissure* the nerves of the two sides undergo a partial decussation. The outer fibres of each tract continue on to the eye of the same side; the inner fibres cross over to the opposite side; and fibres have been described as running from one optic tract to another along the posterior part of the commissure, and others between the two optic nerves in its anterior part (Mayo).

Structure of optic commissure.

In front of the commissure, the nerves enter the foramen opticum, receiving a sheath from the dura mater and acquiring greater firmness.

The fibres of origin of the optic tract from the thalamus are derived partly from the superficial stratum, and partly from the interior of that body. According to Foville, this tract is also connected with the tænia semicircularis, and with the termination of the gyrus fornicatus; and he states further, that where the optic tract turns round the back of the thalamus and the cerebral peduncle it receives other delicate fibres, which descend from the grey matter of those parts.—(Op. cit. p. 514.)

3. The *third pair* of nerves, ³, (motores oculorum,) have their *apparent* or superficial origin from the inner surface of the crura cerebri in the interpeduncular space, immediately before the pons, fig. 180, ³. Each nerve consists of a number of funiculi which arise in an oblique line from the surface.

Third pair, or motor nerves of eye:

As to their *deep* connexions,—the fibres of origin are found to diverge in the substance of the crus, some being traced to the locus niger, others running downwards in the pons amongst its longitudinal fibres, and others, again, turning upwards to be connected with the corpora quadrigemina and Vieussenian valve.

their deep origin.

4. The *fourth pair*, *pathetic* or *trochlear* nerves, figs. 165, 180, ⁴, the smallest of those which are derived from the brain, are seen at the outer side of the crura cerebri immediately before the pons. Each nerve may be traced backwards round the peduncle to below the corpora quadrigemina, where it arises from the upper part of the valve of Vieussens, fig. 170. The roots of the nerves of opposite sides are connected together

The fourth pair, or pathetic nerves, are very small.

Deep origin.

* Op. cit. p. 72, pl. xxi.

across the middle line, in the form of a white band or commissure in the substance of the velum.

Fifth pair, or trigeminal nerves.
Superficial origin.

5. The *fifth* pair of nerves, *par* trigeminum, *trifacial* nerves. The superficial origin of these nerves, figs. 165, 180, 5, is from the side of the pons Varolii, where the latter is connected with the middle crus cerebelli, considerably nearer to the upper than to the lower border of the pons.

Arises by two roots: the smaller or motor; the larger or sensory.

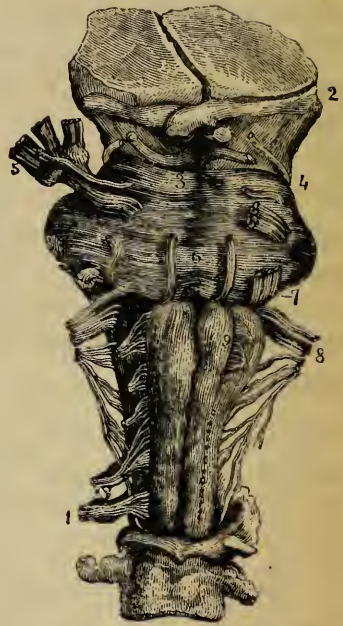The fifth nerve consists of a larger or sensory, and a smaller or motor root, fig. 180. The smaller root is at first concealed by the larger, and is placed a little higher up, there

being often two or three cross fibres of the pons between them. On separating the two roots, the lesser one is seen to consist of a very few funiculi. In the *larger* root the funiculi are numerous, amounting sometimes to nearly a hundred. This root acquires its neurilemma sooner at the circumference than in the centre, so that the outward cords are longer than those within, and when the bunch of funiculi is pulled away, a small conical eminence of white substance remains behind.

The deep connexion, of large root,

Deep origin. The *greater* root runs beneath the transverse fibres of the pons towards the lateral part of the medulla oblongata behind the olivary body. Several anatomists trace it into the floor of the fourth ventricle, between the fasciculi teretes and the restiform bodies. By some it is considered to be continuous with the fasciculi teretes and lateral columns of the

Fig. 180.*



* Front view of crura cerebri, pons, medulla oblongata, and part of spinal cord (Bell). The origins of some of the cranial nerves are shown. 2. Optic nerve. 3. Motor oculi. 4. Pathetic nerve. 5. Fifth, or trifacial nerve. 6. Abducent nerve. 7. Auditory and facial nerves—seventh pair. 8. Eighth pair, including glosso-pharyngeal, vagus, and spinal accessory nerves. 9. Hypoglossal nerve. 1. A spinal nerve.

cord, whilst others connect it with the grey mass which is regarded by Stilling as the nucleus of the glosso-pharyngeal nerve.

The *motor* root was supposed by Bell to descend to the pyramidal body, and Retzius believes that he has confirmed that opinion by dissection; but the deep connection of this root is not known with certainty.

of small root.

According to Foville, some of the fibres of the sensory root of the fifth nerve are connected with transverse fibres in the pons, whilst others spread out on the surface of the middle peduncle of the cerebellum, and enter that part of the encephalon beneath the folia.—(Op. cit. p. 506.)

6. The *sixth* nerve (*abducens*), *motor oculi externus*, figs. 165, 180, ⁶, takes its apparent origin from between the pyramidal body and the pons Varolii by means of a large and a smaller bundle. It really arises from the pyramid, and to a small extent from the pons also.

Sixth pair, or abducent nerves.

7. The *seventh* pair of nerves, ⁷, ^{7'}, appear on each side at the posterior margin of the pons, opposite its junction with the middle peduncles of the cerebellum, and therefore in a line with the place of attachment of the fifth nerve. The seventh nerve is divided into two perfectly distinct portions, which, in fact, are two different nerves: the one, named the *portio dura*, is the muscular nerve of the face; the other, or *portio mollis*, is the nerve of hearing.

Seventh pair,

consists of two distinct nerves:

The *portio dura* or *facial* nerve, ⁷, placed a little nearer to the middle line than the *portio mollis*, may be traced to the medulla oblongata between the restiform and olivary fasciculi, with both of which it is said to be connected. Some of its fibres are derived from the pons.

portio dura, or facial nerve;

Connected with the *portio dura*, and intermediate between it and the *portio mollis*, is a smaller white funiculus, first described by Wrisberg (*portio inter duram et mollem*). The roots of this accessory portion are connected deeply with the lateral column of the cord.

The *portio mollis*, figs. 165, 180, ^{7'}, or auditory nerve, rises from the floor of the fourth ventricle, at the back of the medulla oblongata, in which situation, as already described, numerous white striæ are seen, which form the commencement of the nerve, fig. 164. These roots are connected with the grey matter, and

and portio mollis, or auditory nerve.

some appear to come out of the median fissure. The nerve then turns round the restiform body, and becomes applied to the lower border of the pons, receiving accessions from the former of those parts, and according to some authorities from the latter also.

Foville says that the roots of the portio mollis are also connected by a thin layer on the under surface of the middle peduncle with the cortical substance of the cerebellum; also, with the small lobule named the flocculus; and with the grey matter at the borders of the calamus scriptorius.

Eighth pair of nerves, consists of three portions, viz. :

8. The *eighth* pair, figs. 165, 180, ⁸ ^{8'} ^{8''}, of cranial nerves consists of a series of funiculi which arise along a lateral line from the medulla oblongata, and cervical part of the spinal cord.

glosso-pharyngeal, vagus, and spinal accessory.

The uppermost bundle is the *glosso-pharyngeal* nerve, ⁸; next to this, and lower down, is the *par vagum* or *pneumo-gastric* nerve, ^{8'}, consisting of a larger number of white cords. The roots of both these nerves are attached superficially to the fore part of the restiform body. Still lower, is the *spinal accessory* nerve, ^{8''}, which comes up from the side of the spinal cord, enters the skull by the foramen magnum, and is associated with the vagus nerve, as it passes out through the foramen lacerum.

Apparent origin of spinal accessory.

The accessory nerve arises within the spinal canal from the lateral column of the cord, near the posterior lateral fissure, by a series of slender roots, which commence about as low down as the sixth cervical nerve. The nerve passes upwards between the posterior roots of the cervical nerves and the ligamentum denticulatum,—its several funiculi of origin successively joining it as it ascends. On entering the skull, it receives funiculi from the side of the medulla oblongata.

Deep connections of eighth nerve.

These three portions of the eighth pair are connected *deeply* with grey nuclei within the cord and medulla oblongata, as already fully described (see p. 732).

Ninth or hypoglossal nerve;

9. The *ninth* nerve, figs. 165, 180, ⁹, (hypoglossal,) arises, in a line continuous with that of the anterior roots of the spinal nerves, by scattered funiculi from the furrow between the olivary body and the anterior pyramid.

its deep connexion.

Its roots are traced by Stilling to one of the grey nuclei already described in the medulla oblongata.

THE MEMBRANES OF THE BRAIN AND SPINAL CORD.

As already stated, the cerebro-spinal axis is protected by three *membranes*, named also *meninges* (μῆνιγγες). They are:—

1. An external fibrous membrane, named the *dura mater*, which closely lines the interior of the skull, and forms a loose sheath in the spinal canal; 2. An internal cellulo-vascular tunic, the *pia mater*, which accurately covers the brain and spinal cord; and 3. An intermediate serous sac, the *arachnoid* membrane, which, by its parietal and visceral layers, covers the internal surface of the *dura mater* on the one hand, and is reflected over the *pia mater* on the other.

Membranes
of brain
and cord ;
three in
number.
Names.

THE DURA MATER.

The *dura mater*, a very strong dense inelastic fibrous tunic, of considerable thickness, is closely lined on its inner surface by the outer portion of the *arachnoid*, and with it, therefore, forms a *fibro-serous* membrane, which is free, smooth, and epitheliated on its inner surface, where it is turned towards the brain and cord, but which, by its outer surface, is connected in a different manner in the cranium, and in the spinal canal.

Dura mater
—with
arachnoid,
is a fibro-
serous tunic.

The outer surface of the *cranial* portion adheres to the inner surface of the bones, and forms their internal periosteum. The connexion between the two, in a great measure, depends on bloodvessels and small fibrous processes, which pass from one to the other; and the *dura mater*, when detached and allowed to float in water, presents a flocculent appearance on its outer surface, in consequence of the torn parts projecting from it.

In the
cranium,
forms
internal
periosteum ;

The adhesion between the membrane and the bone is more intimate opposite the sutures, and also generally at the base of the skull, which is uneven, and perforated by numerous foramina, through which the *dura mater* is prolonged to the outer surface, being there continuous with the pericranium. The fibrous tissue of the *dura mater* becomes blended with the cellular sheaths of the nerves, at the foramina which give issue to them.

adheres
closely to
bones.

Sheath for
cranial
nerves.

In leaving the skull, the *dura mater* is intimately attached to the margin of the foramen magnum; but within the vertebral canal it forms a loose sheath around the cord, (*theca*.)

In the
spine,

is a loose sheath.

and is not adherent to the bones, which have an independent periosteum. Towards the lower end of the canal a few fibrous slips proceed from the outer surface of the dura mater to be fixed to the vertebræ. The space intervening between the canal and the dura mater is occupied by loose fat, by watery cellular tissue, and by a plexus of spinal veins.

Sheaths for spinal nerves.

Opposite each intervertebral foramen the dura mater presents two openings, placed side by side, which give passage to the two roots of the corresponding spinal nerve. It is continued as a tubular prolongation on the nerve, and is lost upon its sheath. Besides this, it is connected with the circumference of the foramen by cellular tissue.

Consists of two layers :

The fibrous tissue of the dura mater, especially within the skull, is divisible into two distinct layers, and at various places these layers separate from each other and leave intervening channels, called *sinuses*. These sinuses, which have been elsewhere described, are canals for venous blood, and are lined with a continuation of the internal membrane of the veins.

forms sinuses,

and three processes or partitions.

The dura mater also sends inwards into the cavity of the skull three strong membranous *processes*, or *partitions*, which are regarded as duplicatures of its inner layer. Of these, one descends vertically in the median plane, and is received into the longitudinal fissure between the two hemispheres of the cerebrum. This is the *falx cerebri*. The second is an arched or vaulted partition, stretched across the back part of the skull, between the cerebrum and the cerebellum: it is named the *tentorium cerebelli*. Below this, another vertical partition, named *falx cerebelli*, of small extent, passes down between the hemispheres of the cerebellum.

Their names.

Falx cerebri, divides hemispheres.

The *falx cerebri* is narrow in front, where it is fixed to the crista galli, and broader behind, where it is attached to the middle of the upper surface of the tentorium, along which line of attachment the straight sinus is situated. Along its upper convex border, which is attached above to the middle line of the inner surface of the cranium, runs the superior longitudinal sinus. Its under edge is free, and reaches to within a short distance of the corpus callosum, approaching nearer to it behind. This border contains the inferior longitudinal sinus.

Tentorium,

The *tentorium*, or *tent*, is elevated in the middle, and de-

clines downwards in all directions towards its circumference, in correspondence with the upper surface of the cerebellum. Its inner border is free and concave, and leaves in front of it an oval opening, through which the isthmus encephali descends. It is attached behind and at the sides by its convex border to the horizontal part of the crucial ridges of the occipital bone, and there encloses the lateral sinuses. Further forward it is connected with the upper edge of the petrous portion of the temporal bone—the superior petrosal sinus running along this line of attachment. At the point of the pars petrosa, the external and internal borders meet, and may be said to intersect each other—the former being then continued inwards to the posterior, and the latter forwards to the anterior clinoid process.

covers
cerebellum.

Its attach-
ment in
front.

The *falx cerebelli* (falx minor) descends from the middle of the posterior border of the tentorium with which it is connected, along the vertical ridge named the internal occipital crest towards the foramen magnum, bifurcating there into two smaller folds. Its attachment to the bony ridge marks the course of the posterior occipital sinus, or sinuses.

Falx
cerebelli.

Structure. The dura mater consists of white fibrous tissue, arranged in bands and laminae, crossing each other. It is traversed by numerous bloodvessels which are destined for the bones. Minute nervous filaments, derived from the fourth and fifth cranial nerves, and, according to some anatomists, from the sympathetic, are described as entering the dura mater.

Dura mater
is fibrous
and carries
blood-
vessels.
Its nerves.

Glandula Pacchioni. Upon the external surface of the dura mater, in the vicinity of the longitudinal sinus, are seen numerous small fleshy-looking elevations, generally collected into clusters, named glands of Pacchioni. The inner surface of the calvarium is marked by little pits, which receive these eminences. Similar excrescences are seen on the internal surface of the dura mater, and also upon the pia mater on each side of the longitudinal sinus: moreover, some project into that sinus itself.

Glands of
Pacchioni ;

form and
position ;

It seems probable that these small bodies are originally developed from the pia mater, and extend themselves through the dura mater to the external surface, causing a partial absorption or separation of the fibres of that membrane. In like manner, those seen in the longitudinal sinus seem to have perforated the dura mater, carrying before them a covering of the venous lining

probable
mode of
growth ;

structure ; membrane. They consist, according to Valentin, of exudation corpuscles, and, in an older or more advanced condition, are composed of fibres. The cerebral layer of the arachnoid in the neighbourhood of these growths is usually thickened and opaque, and often adheres to the parietal portion.

not found in early age ; These bodies are not found at birth ; and according to the brothers Wenzel, exist in very small number, if at all, under the third year. Beyond the seventh year they are usually found, and they increase in number greatly as life advances ; in some cases, however, they are altogether wanting. In animals there appears to be no corresponding structure.

Similar bodies are often found attached to the choroid plexuses of the fourth ventricle.

are perhaps results of disease. From all the circumstances of their history, these so-called glands of Pacchioni have been regarded by many as the result of a chronic action, producing an unnatural deposit in this situation. They are certainly not glandular in their nature.

THE PIA MATER.

Pia mater covers nervous centres. The *pia mater* is a delicate cellulo-vascular membrane, richly supplied with vessels, which immediately invests the brain and spinal cord.

On cerebrum ; is closely applied. Upon the hemispheres of the brain, it is applied to the entire cortical surface of the convolutions, and dips into all the sulci. From its internal surface a multitude of small vessels enter the grey matter and extend for some distance perpendicularly into the substance of the brain. This inner surface of the cerebral pia mater is on this account very flocculent, and is named *to mentum cerebri*. On the cerebellum a similar arrangement exists, but the membrane is finer and the vessels from its inner surface are not so long. The pia mater is also prolonged into the ventricles and there forms the *velum interpositum* and choroid plexuses.

To mentum cerebri ; on cerebell. ; in ventricles.

Cellulo-vascular structure ; *Structure.* It consists of interlaced bundles of cellular tissue, conveying great numbers of bloodvessels ; and, indeed, its peculiar office, both on the brain and spinal cord seems to be that of providing a nidus or matrix for the support of the bloodvessels, as these are subdivided before they enter the nervous substance. According to Folmann and Arnold it contains numerous lymphatic vessels.

contains lymphatics.

On the *spinal* cord the pia mater has a very different structure from that which it presents on the encephalon, so that it has even been described by some as a different membrane under the name *neurilemma of the cord*. It is thicker, firmer, less vascular, and more adherent to the subjacent nervous matter: its greater strength is owing to its containing fibrous tissue, which is arranged in longitudinal shining bundles. A process of this membrane dips down into the anterior fissure of the cord, and serves to conduct bloodvessels into that part. At the roots of the nerves, both in the spine and in the cranium, the pia mater becomes continuous with their neurilemma.

On the spinal cord;

is thicker ;

is prolonged on nerves ;

Towards the upper part of the cord, the pia mater presents a greyish mottled appearance, which is owing to pigment particles deposited within its tissue.

is sometimes stained with pigment.

THE ARACHNOID MEMBRANE.

The *arachnoid* is a very fine delicate serous membrane, which, like other membranes of that class, forms a shut sac and consists of two portions, viz., a visceral (or cerebral) and a parietal layer.

Arachnoid, a shut serous sac.

The *parietal* layer, as already said, adheres to the dura mater of the brain and spinal cord,—the adhesion of one membrane to the other being most intimate.

Parietal portion.

The *visceral* portion passes over the various eminences and depressions on the cerebrum and cerebellum, without dipping into the sulci and smaller fissures; nor is it uniformly and closely adherent to the pia mater. The interval left between these two membranes is named generally the subarachnoid space.

Visceral portion, in cranium.

This *subarachnoid space* is wider and more evident in some positions than in others. Thus,—in the longitudinal fissure, the arachnoid does not descend to the bottom, but passes across, immediately below the edge of the falx, at a little distance above the corpus callosum. In the interval thus left, the arteries of the corpus callosum run backwards along that body. At the base of the brain and in the *spinal canal* there is a wide interval between the arachnoid and the pia mater. In the former situation, this subarachnoid space extends over the pons and the interpeduncular space as far forwards as the optic nerves: around the cord, this space is also of considerable extent.

Subarachnoid space ; in longitudinal fissure,

at base of brain, and in spine :

A certain quantity of *fluid* is contained within the proper sac

contains fluid ;

communicates with fourth ventricle.

Subarachnoid space divided by a septum behind.

Nerves and vessels covered by arachnoid.

Structure.

Cerebro-spinal fluid: quantity; composition;

of the arachnoid; but it has been shown by Magendie that the chief part of the cerebro-spinal fluid is lodged under the arachnoid, in the subarachnoid space, which usually communicates by an opening at the point of the fourth ventricle with the general ventricular cavity, as elsewhere stated. (Fig. 166, z.)

Magendie also pointed out the existence of a sort of septum dividing the spinal subarachnoid space at the back of the cord. This is a thin membranous partition, which passes in the median plane from the pia mater covering the posterior median fissure of the cord to the opposite part of the loose portion of the arachnoid membrane. It is incomplete and cribriform; and consists of bundles of white fibres interlaced more or less with one another. Fibrous bands of the same texture pass across the subarachnoid space in various situations both within the spinal canal and at the base of the brain, stretching thus from the arachnoid to the pia mater.*

As the cerebral and spinal nerves proceed to their foramina of exit from the cranium and vertebral canal, they are loosely surrounded by tubular sheaths of the arachnoid membrane, which extend along each nerve from the visceral to the parietal layer.

Structure. When examined under the microscope, the arachnoid is found to consist of bundles of fibres like those of fibrous tissue, interlaced with one another. A simple layer of scaly epithelium can be demonstrated on various parts of its free surface, and probably exists all over.

Cerebro-spinal fluid.—This is a very limpid serous fluid, which occupies the subarachnoid space. When collected immediately after death, its quantity was found by Magendie in the human subject to vary from two drachms to two ounces. It is slightly alkaline, and consists, according to an analysis by Lassaigne, of 98·5 parts of water, the remaining 1·5 per cent.

* I was at one time disposed to think that the subarachnoid space was lined throughout by a delicate serous membrane, and that the septum above described consisted of a duplication of this membrane, extending from the loose arachnoid to the cord, as the mesentery passes to the intestine. I was led to entertain this idea, on considering that the space in question contains fluid; that the loose portion of the arachnoid is separable, in many parts, into two layers; and that a thin membrane can be raised from the surface of the ligamentum denticulatum and the roots of the nerves, as they pass across the space. I have since found, however, that this view will not stand the test of microscopic scrutiny; for the internal layer has not the defined surface of a serous membrane, but is composed of openly-reticulated bundles of filaments, like cellular tissue. W. S.

being solid matter, animal and saline. In experiments made on the dog, it was found by Magendie to be reproduced in thirty-six hours, after it had been drawn off by puncturing the membranes at the lower part of the cord.

Its chief use is probably mechanical, there being obvious advantages in the delicate structures placed within the cranium and spine being surrounded by a fluid medium. As just now stated, it is rapidly secreted, and perhaps it is also as readily absorbed; and thus, being easily susceptible of changes in its quantity, it may, in this way, admit of variations in the amount of blood circulating in the vessels of the brain and spinal cord, although the cranio-vertebral cavity in which they are lodged does not vary in its capacity.

Ligamentum denticulatum. This is a narrow fibrous band which runs along each side of the spinal cord in the subarachnoid space, between the anterior and posterior roots of the nerves, commencing above at the foramen magnum and reaching down to the lower pointed end of the cord. By its inner edge this band is connected with the pia mater of the cord. Its outer margin is widely scolloped or serrated, and the points of its serratures or denticulations are attached, in the intervals between the nerves, to the inner surface of the dura mater, being covered at their insertion by the arachnoid membrane. The first or highest denticulation is fixed opposite the margin of the foramen magnum, between the occipital artery and the hypoglossal nerve; and the others follow in order, alternating with the successive pairs of spinal nerves. In all, there are about twenty-two of these points of insertion. At the lower end, the ligamentum denticulatum is continued into the terminal filament of the spinal cord, which thus connects it to the dura mater at the lower end of the sheath, and might therefore, although much longer, be compared with its lateral denticulations.

Structure. It consists of white fibrous tissue, mixed with many exceedingly fine elastic fibres, seen on applying acetic acid. It is obviously continuous on the one hand with the fibrous tissue of the pia mater, and with that of the dura mater on the other.

The use of the ligamentum denticulatum is obviously to support the cord and its nerves.

The pia mater of the cord presents a conspicuous fibrous band, running down in front over the anterior median fissure. This was named by Haller, *linea splendens*.

easily re-produced;

uses.

Ligament. denticulat.:

outer border scolloped;

extent of its denticulations;

number—twenty-two.

Consists of fibrous, with elastic tissue.

Linea splendens.

BLOODVESSELS OF THE BRAIN AND SPINAL CORD.

Arteries of brain and cord ; their general position.

The arteries of the brain and in part those of the spinal cord are derived from the internal carotid and vertebral arteries. These vessels having passed across the arachnoid cavity get into the subarachnoid space and then divide and subdivide into branches, which, in their further course to the nervous centres, are supported by the pia mater, and, it may be remarked, are more deeply placed in the various fissures and sulci than the small veins, which do not accompany the arteries, but pursue a different course and are seen upon the surface of the pia mater.

Veins ; their general position.

Moreover, it is also to be observed, that whilst the main branches of the arteries are situated at the base of the brain, the principal veins tend towards the upper surface of the hemispheres) where they enter the superior and inferior longitudinal sinuses : the veins of Galen, however, coming from the lateral ventricles and choroid plexuses, run backwards to the straight sinus.

DEVELOPMENT OF THE BRAIN AND SPINAL CORD.

Vertebral column and nervous centres are first formed in embryo.

The cerebro-spinal axis, with the cranio-vertebral cavity surrounding it, is the part of the embryo which first begins to be formed. It commences in the external or serous layer of that portion of the ovum which has been named the blastoderma or germinal membrane, in form of a groove dilated at one extremity, and bounded by two ridges named the dorsal plates (laminæ dorsales). See fig: 181, and description of that figure.

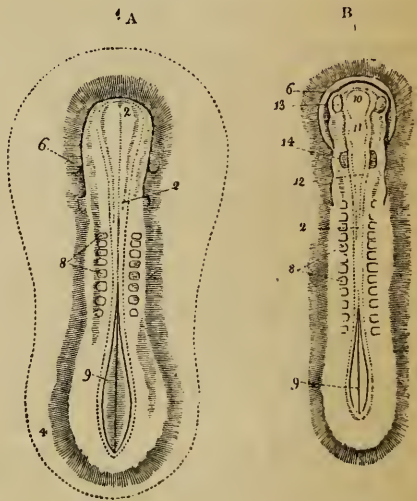
Primitive groove.

Dorsal plates.

Commencement of vertebræ.

On each side of the groove, near its middle, the small quadrangular rudiments of the vertebræ,

Fig. 181.*



* Shews the early condition of the nervous centres in the embryo of the fowl—(Reichert). A. The sides of the groove have united in a great extent,

fig. 181, ⁸, begin to appear in the substance of the dorsal plates ; while a thin portion of each dorsal plate next the groove is destined to form, along with its fellow of the opposite side, the rudiments of the cerebro-spinal axis.

In the progress of development, the dorsal plates unite over the groove, at first in the middle and then at the extremities, and thus convert it into a canal, in which the commencing brain and spinal cord may soon be discovered. The enlarged or cephalic end, A, ², of this *cranio-vertebral* canal, as it might be named, is dilated into three vesicles, B, ¹⁰, ¹¹, ¹², which afterwards form the cranial cavity, and in which the encephalon is developed ; whilst the remaining part of the canal (the vertebral part) ultimately contains the spinal cord.

Formation of cranio-vertebral canal ;

The matter of which the cerebro-spinal axis is at first composed soon separates, according to Baër, into an external layer, which forms its membranous envelopes, and an internal tubular portion, which afterwards becomes the proper nervous substance.

of membranes ; and of nervous centres.

DEVELOPMENT OF THE SPINAL CORD.

The *spinal cord*, formed, as already stated, by the union of two lamellæ derived from the inner surface of the dorsal plates, is at first a groove open in its whole length on the dorsal aspect ; but the edges of this groove soon meet, so as to form a medullary tube. At the ninth week Tiedemann* has seen the borders of this groove still apart ; at the twelfth they were in close contact, so as to form a sort of tube, but they could be easily separated from one another. The perfect closing of this groove is delayed towards the lower end of the cord, which is slightly enlarged, and presents a longitudinal median slit, analogous to the rhomboidal sinus in birds.—Fig. 181, ⁹.

Spinal cord ; first a groove, then a tube.

The central cavity of the medullary tube formed by the closure of the groove is gradually narrowed by the thickening of the two halves of the cord and by the deposition of grey matter, and at last is obliterated in the human species throughout its entire length, except for about half an inch below the fourth ventricle. In many animals, however, it is persistent throughout life.

Central cavity is at length closed.

Grey matter.

The *anterior fissure* of the cord is developed very early, and contains even at first a process of the pia mater.

Anterior fissure of cord.

The *cervical* and *lumbar enlargements* opposite the attachments of the brachial and crural nerves, appear at the end of the third month : in these

Enlargements of cord.

and converted it into a canal ; the dilated cephalic extremity is seen at 2 ; from 2 to 9 is the groove partly closed ; 9 is the open part at the lower end, which remains afterwards as the rhomboidal sinus. 8. Rudiments of the vertebræ.—B. The groove is closed except at 9—the rhomboidal sinus. 8. Plates of vertebræ. 10. Anterior or first vesicle ; 11, second or middle ; and 12, third or posterior vesicle.

* To save the repetition of references, it may be stated here, that the description of the successive changes of development in the spinal cord and brain, and the periods at which they occur, are taken from Tiedemann's account. *Anatomie und Bildungs-geschichte des Gehirns*. Nürnberg, 1816.

Relative
length of
cord and
canal.

Cauda
equina.

situations the central canal, at that time not filled up, is somewhat larger than elsewhere.

At first the cord occupies the whole length of the vertebral canal, so that there is no cauda equina. At the beginning of the fourth month, the vertebræ having grown faster than the cord, the latter seems as it were to have retired up into the canal, and the *cauda equina* is commenced. At the ninth month, the lower end of the cord is opposite the third lumbar vertebra.

DEVELOPMENT OF THE ENCEPHALON.

Primitive
cephalic
vesicles ;
three in
number.
First
vesicle.

The three cephalic dilatations of the primitive cranio-vertebral cavity, fig. 181, B, ¹⁰, ¹¹, ¹², contain *three* hollow *vesicles* of nervous matter, which are the rudiments of the future encephalon.

The anterior or *first vesicle* soon becomes divided into an anterior and a posterior portion. The anterior portion forms the principal mass of the hemispheres, fig. 182, A ⁶, with the corpora striata, 7; whilst the posterior portion, 5, is developed into the thalami and third ventricle.

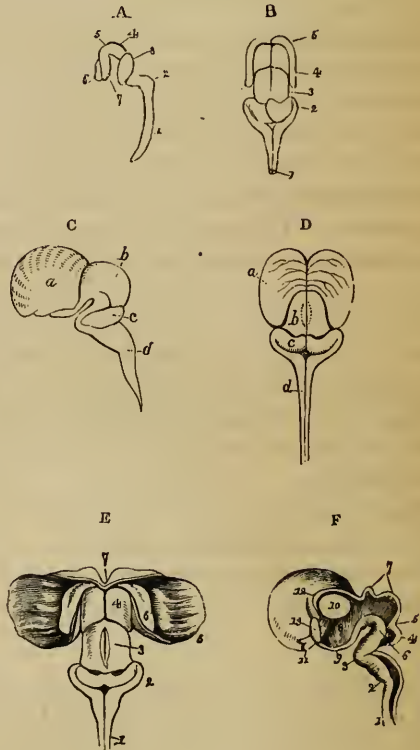
Second.

The *second* or middle vesicle, 4, forms the corpora quadrigemina above, and the crura cerebri below, —its cavity remaining as the Sylvian aqueduct.

Third.

The *third* or posterior vesicle, 3 to 2, continues incomplete above for some time, as far as nervous substance is concerned. At length its anterior portion, 3, is closed over and forms the cerebellum above, whilst on its under surface the

Fig. 182.*



* These figures shew the early form of the brain and spinal cord in the human embryo (Tiedemann).—A. At the seventh week, viewed from the side. 1. Spinal cord. 2 to 3 is the third vesicle; 4, the middle vesicle; 5, 6, 7, the first or anterior vesicle. 2, is on the hind part of medulla, or the

pons Varolii appears. The posterior portion, on the other hand, ², continues open on its dorsal aspect, and forms the medulla oblongata and fourth ventricle.

These three vesicles, at first arranged in a straight line one before the other, soon alter their position, in correspondence with the curving downwards of the cephalic end of the embryo. Thus at the seventh week, as figured by Tiedemann, there is an angular bend forwards between the hindmost vesicle and the rudimentary spinal cord, ¹,—the projecting angle (backwards) being named the cervical tuberosity, ². Another bend, but in the opposite direction, exists between that part of the third vesicle which forms the medulla oblongata, and that which gives rise to the cerebellum, ³. Lastly, a third angle is produced by a bend forwards and downwards in the region of the middle vesicle, ⁴, from which the corpora quadrigemina are developed, and which forms, at this period, the highest part of the encephalon; whilst the anterior or first vesicle, ⁵, ⁶, ⁷, is bent nearly at a right angle downwards.

Arrange-
ment of
vesicles is
soon angu-
lar.

Position of
first
vesicle.

At a later period of development, this first vesicle, which, as stated above, represents the cerebral hemispheres, increases greatly in size upwards and backwards, and gradually covers first the thalami, then the corpora quadrigemina, and lastly the cerebellum.

On laying open the rudimentary encephalon, two tracts of nervous matter are seen to be prolonged upwards from the spinal cord upon the floor of the cephalic vesicles: these tracts, which are doubtless connected with the anterior and lateral parts of the cord, are the rudiments of the *crura cerebri* and corresponding columns of the medulla oblongata.

Rudiments
of *crura*
cerebri.

cervical tuberosity. 3. The cerebellum. 4. Corpora quadrigemina. 5. Optic thalami. 6. Cerebral hemisphere. 7. Corpus striatum.—B. At the ninth week, seen from behind. 1. Spinal cord, and medulla oblongata, open behind. 2. Cerebellum. 3. Corpora quadrigemina. 4. Thalami, still uncovered. 5. Right and left hemispheres, now very thin.—C, D. At the twelfth week, side and back views. *a*. Cerebrum. *b*. Corpora quadrigemina. *c*. Cerebellum. *d*. Medulla oblongata. N.B. The thalami at this period are covered by the cerebral hemispheres.—E, F. At the twelfth week: in E, which is seen from behind, the hemispheres are reflected outwards. 1. Cord and medulla oblongata. 2. Cerebellum. 3. Corpora quadrigemina. 4. Thalami, which are here uncovered by the reflection of the hemispheres. 5, 6. The right corpus striatum, embedded in the hemisphere. 7. The point of commencement of corpus callosum. F. Is a vertical median section, shewing the cavity from the cord up to the third ventricle. 1, 2. Spinal cord and medulla, still hollow. 3. Bend at which pons Varolii is to be formed. 4. Cerebellum. 5. Lamina (superior peduncles) leading up to corp. quadrigemina. 6. Crura cerebri. 7. Corpora quadrigemina. 8. Third ventricle. 9. Infundibulum. 10. Thalamus, now solid. 11. Optic nerves. 12. Cleft leading into lateral ventricle. 13. Commencing corpus callosum.

FURTHER DEVELOPMENT OF THE PRIMARY VESICLES.

Third vesicle.

Formation of medulla oblong. and fourth ventricle.

Restiform bodies.

Anterior pyramids.

Olivary bundles and tubercle.

Fasc. ciner. and striæ.

Formation of cerebellum.

Corpus dentatum.

Lobes, folia, hemispheres, and other divisions.

Peduncles.

Formation of pons.

The *third vesicle*. The posterior portion of this vesicle, corresponding with the *medulla oblongata*, is never closed above by nervous matter. The open part of the medullary tube constitutes the floor of the *fourth ventricle*, which communicates below with the canal of the spinal cord, and eventually forms the *calamus scriptorius*.

The three elements of the *medulla oblongata* begin to be distinguished about the third month; first, the *restiform* bodies which are connected with the commencing *cerebellum*, and afterwards the anterior pyramids and olives. The *anterior pyramids* become prominent on the surface and distinctly defined in the fifth month; and by this time also their decussation is evident. The *olivary fasciculi* are early distinguishable, but the proper *olivary body*, or tubercle, does not appear till about the sixth month. The *fasciæ cineræ* of the fourth ventricle can be seen at the fourth or fifth month, but the *white striæ* not until after birth.

The anterior part of the third vesicle is soon closed above by nervous substance, and forms the commencing *cerebellum*, A, ³. This part exists, B, ²; about the end of the second month, as a delicate medullary lamina, forming an arch behind the *corpora quadrigemina* across the widely-open primitive medullary tube.

According to Bischoff, the *cerebellum* does not commence by two lateral plates which grow up and meet each other in the middle line; but a continuous deposit of nervous substance takes place across this part of the medullary tube, and closes it in at once. This layer of nervous matter, which is soon connected with the *corpora restiformia*, or inferior peduncles, increases gradually up to the fourth month (see C, D, C, also E, ²), at which time there may be seen on its under surface the commencing *corpus dentatum*: in the fifth month, a division into five lobes has taken place; at the sixth, these lobes send out *folia*, which are at first simple, but afterwards become subdivided. Moreover, the *hemispheres* of the *cerebellum* are now relatively larger than its median portion, or *worm*. In the seventh month the organ is more complete, and the *flocculus* and *posterior velum*, with the other parts of the inferior vermiform process, are now distinguishable, except the *amygdalæ*, which are later in their appearance.

Of the *peduncles* of the *cerebellum*, the *inferior* pair (*corp. restiformia*) are the first seen—viz., about the third month; the *middle* peduncles are perceptible in the fourth month; and at the fifth, the *superior* peduncles and the *Vicussenian valve*, F ⁵. The *pons Varolii* is formed, as it were, by the fibres from the hemispheres of the *cerebellum*, embracing the pyramidal and olivary fasciculi of the *medulla oblongata*. According to Baer, the bend which takes place at this part of the *encephalon*—just over ⁷, A, also at ³ F—thrusts down a mass of nervous substance before any fibres can be seen; and in this substance transverse fibres, continuous with those of the *cerebellum*, are afterwards developed. From its relation to the

cerebellar hemispheres the pons keeps pace with them in its growth ; and, in conformity with this, its transverse fibres are few, or entirely wanting in those animals in which there is a corresponding deficiency or absence of the lateral parts of the cerebellum.

The *second or middle vesicle*. The *corpora quadrigemina*—A, ⁴, B and E, ³; c and D, *b*—are formed in the upper part of the middle cephalic vesicle, A, ⁴; the hollow in the interior of which, shown in D, communicates with those of the first and third vesicles. The *corpora quadrigemina*, in the early condition of the human embryo, are of great proportionate volume, in harmony with what is seen in the lower vertebrata, but subsequently they do not grow so fast as the anterior parts of the encephalon, and are therefore soon reached by the cerebral hemispheres, which at the sixth month cover them in completely. Moreover, they become gradually solid, by the deposition of matter within them ; and as, in the mean time, the *cerebral peduncles*, D, ⁶, are growing rapidly in size in the floor of this second cephalic vesicle, the cavity in its interior is quickly filled up, with the exception of the narrow passage named the *Sylvian aqueduct*. The fillet is distinguishable in the fourth month. The *corpora quadrigemina* of the two sides are not marked off from each other by a vertical median groove until about the sixth month ; and the transverse depression separating the anterior and posterior pairs is first seen about the seventh month of intra-uterine life.

Second vesicle.

Formation of corpora quadrigemina.

Cerebral peduncles, and Sylvian aqueduct.

The *first or anterior vesicle*, A, ⁵, ⁶, ⁷. This vesicle, as already stated, is divided into two portions—viz., a posterior, which is developed into the optic thalami and third ventricle, and an anterior, which forms the principal mass of the cerebral hemispheres, including the *corpora striata*.

First vesicle.

Posterior portion.

a. The two *optic thalami*—A, ⁵ B and c, ⁴—consist, therefore, at first of a single hollow sac of nervous matter, the cavity of which communicates in front with the interior of the commencing cerebral hemispheres, and behind with that of the middle cephalic vesicle (*corpora quadrigemina*). Soon, however, by means of a deposit taking place in their interior, behind, below, and at the sides, the thalami become solid, F, ¹⁰, and at the same time a cleft or fissure appears between them above, and penetrates down to the internal cavity which continues open at the back part opposite the entrance of the *Sylvian aqueduct*. This cleft, or fissure, is the *third ventricle*. Behind, the two thalami continue united by the *posterior commissure*, which is distinguishable about the end of the third month, and also by the *peduncles of the pineal gland*. The *soft commissure* could not be detected by Tiedemann until the ninth month ; but its apparent absence at earlier dates may perhaps be attributed to the effects of laceration.

Formation of optic thalami.

Third ventricle.

Posterior commissure

Soft commissure.

At an early period the *optic tracts* may be recognised as hollow prolongations from the outer part of the wall of the then vesicular thalami. At the fourth month these tracts are distinctly formed.

Optic tracts.

The *pineal gland*, according to Baer, is developed from the back part of the thalami, where those bodies continue joined together ; but it is suggested by Bischoff that its development may be rather connected with the pia

Pineal gland.

mater. It was not seen by Tiedemann until the fourth month: subsequently, its growth is very slow; and it at first contains no gritty deposit, which, however, was found by Sœmmerring at birth.

Tuber cinereum.

The *tuber cinereum* may be recognised on the under surface of the first vesicle before the third month, according to Valentin, who thinks that its development is connected with that of the corpora albicantia.

Infundibulum.

The *infundibulum*, E, ⁹, appears at a very early period, extending from the lower part of the anterior cephalic vesicle into a depression in the base of the rudimentary cranium. It is thought by Baer to be the anterior extremity of the primitive medullary tube.

Pituitary body.

Rathké asserts, on the ground of observations recently made, that the first condition of the *pituitary body* is that of a small sac or pouch derived from the mucous membrane of the pharynx, which is prolonged upwards into the base of the cranium, in the form of a cul de sac, and reaches the point of the infundibulum. This sac is afterwards shut off from the pharyngeal cavity, and the closed vesicle thus formed becomes attached to the infundibulum, and constitutes the pituitary body. Reichert, on the other hand, regards this body as the remains of the anterior extremity of the corda dorsalis. Tiedemann describes it as a large soft mass at the end of the third month.

Anterior part of first vesicle.
Corpora striata.

b. The *corpora striata*, which, with the rest of the cerebral hemispheres, are evolved from the anterior portion of the first cephalic vesicle, at ⁷, A, appear as two dark masses rising up from the floor of that part of the vesicle, one on each side. Unlike the thalami, the corpora striata, E, ⁶, are always concealed, being included from the first in the vesicular cerebral hemispheres, into the cavity of which they soon project from the outer side and from below.

Cerebral hemispheres.

The right and left *cerebral hemispheres*, which at first are proportionately small, appear as two little hollow vesicles, A, ⁶, which bud out, one on each side, from the fore part of the anterior primary cephalic vesicle; and as these go on growing laterally, a longitudinal median depression is soon formed between them, B, ⁵. Continuing to remain hollow, but yet enlarging, and having their walls increased in thickness, the hemispheres form, during the fourth month (Tiedemann), two smooth shell-like lamellæ, c and d, a, which include the cavities afterwards named the *lateral ventricles*, and the parts contained within them. Following out the subsequent changes affecting the exterior of the cerebral hemispheres, it is found that about the fourth month the first traces of some of the *convolutions* appear, the intermediate *sulci* commencing only as very slight depressions on the hitherto smooth surface. Though the hemispheres continue to grow quickly upwards and backwards, the convolutions become distinct by comparatively slow degrees at first; but towards the seventh and eighth months they are developed with great rapidity, and at the beginning of the last month of intra-uterine life appear to be completely formed.

Lateral ventricles.

Convulsions and sulci.

The *Sylvian fissure*, which afterwards separates the anterior from the middle lobe of each hemisphere, begins as a very slight depression between them about the fourth month.

From the earliest period the hemispheres, E, ⁵, conceal the corpora striata, ⁶; by the end of the third month they have extended so far backwards as to have covered the thalami, E, ⁴, F, ¹⁰; at the fourth, they reach the corpora quadrigemina; at the sixth, they cover those bodies and great part of the cerebellum, beyond which they project backwards by the end of the seventh month.

Progressive growth of hemispheres backwards.

Between and within the hemispheres other changes take place. At first there is no corpus callosum, and no fornix; nor is there any separation of the common internal cavity into two lateral cavities or ventricles.

Changes within hemispheres.

According to Tiedemann, the *corpus callosum*, which certainly commences in front, is first seen about the end of the third month, as a narrow vertical band or commissure—E, ⁷, F, ¹³—extending across between the fore part of the two hemispheres. Subsequently it becomes horizontal, and grows backwards together with the hemispheres, until it completely covers the optic thalami. Tiedemann considers that it results from the junction across the median plane of the radiating fibres of the hemispheres. In the same way, he supposes that the *anterior commissure*, which is seen during the third month, is formed by the union of other peduncular fibres, which have passed through the corpora striata.

Corpus callosum.

Anterior commissure.

Bischoff, however, is of opinion that the corpus callosum has its origin in the part of the anterior primitive vesicle, situated between the rudimentary hemispheres, where these continue united together in front, at the bottom of the median longitudinal depression which is formed between them. From this point, he describes it as extending backwards over the thalami.

The *fornix*, like the corpus callosum, appears to be formed in conjunction with the hemispheres. According to Bischoff, its anterior pillars begin near the same point as the commencing corpus callosum, but of course behind it: whilst the body and posterior pillars are formed upon the internal and posterior borders of the growing hemispheres. The fornix certainly commences in front, like the corpus callosum. Burdach says its anterior pillars are seen about the same time as the rudiments of this latter body (second month); but Tiedemann and Valentin place the period at the end of the third month,—the *corpora albicantia* having appeared a little earlier, at first as a single mass. The posterior pillars are not seen until the fourth or fifth month. Their free border forms the *corpus fimbriatum* on each side, and their enlarged extremity appears then to constitute the commencing *pes hippocampi*, the indentations upon which, however, are not evident until the ninth month. The *hippocampus minor* appears at the end of the fourth month, as a folding inwards of the hemisphere into the ventricular cavity.

Fornix.

Corpora albicantia.

Corp. fimbriatum.

Pes major and pes minor.

In the course of development, the fore part of the fornix separates from the under surface of the corpus callosum, leaving two thin vertical lamellæ, which form the *septum lucidum*, and the intermediate fifth ventricle. At first, this ventricle communicates with the cavity of the third ventricle below, but it is afterwards completely occluded by the union of the two lamellæ. The septum and fifth ventricle are recognised only about the fifth month.

Septum lucidum, and fifth ventricle.

Formation
of lateral
ventricles ;

In the first instance, the vesicular cerebral hemispheres enclose a common cavity ; but as the median longitudinal depression is formed between them, as the corpus callosum and fornix are developed from before backwards, and as the septum lucidum descends from one to the other in the median plane, this single cavity is divided into *the two *lateral ventricles*, which after a time communicate with each other, and with the third ventricle, by a narrow slit, F, ¹² ; and, finally, only by the foramen of Monro. The form of each ventricular cavity depends upon that of the several parts which project into it. Thus its *anterior cornu* is produced around the anterior extremity of the corpus striatum, and its *descending cornu* behind the thalamus and below the striated body. The *posterior cornu* is later in its appearance, and is developed in the substance of the posterior lobe, as that extends itself backwards. The lateral ventricles, or rather the parts of which their walls are composed, do not acquire their characteristic forms until the eighth or ninth month.

their
cornua.

GREY AND WHITE SUBSTANCE OF THE NERVOUS CENTRES.

Distinction
of grey and
white mat-
ter.

The distinction between the grey and white substances is not at first to be made out ; but there is no evidence to show that one precedes the other in its formation. Valentin states that he has distinguished the one from the other at the third month : less from the difference in their colour than from their microscopic characters.

MEMBRANES OF THE ENCEPHALON.

Formation
of mem-
branes.

It is remarked by Bischoff, that the membranes of the brain are everywhere formed by the separation of the outer layer of the primitive cephalic mass ; and thus, that the *pia mater* does not send inwards processes into the fissures or sulci, or into the ventricular cavities ; but that every part of this vascular membrane, including the *choroid plexuses* and *velum interpositum*, is formed in its proper position upon the nervous matter.

Pia mater.

Dura mater.

The pia mater and dura mater have both been detected about the seventh or eighth week, at which period the tentorium cerebelli existed. At the third month, the falx cerebri, with the longitudinal and lateral sinuses, could be made out ; and the choroid plexuses of both the lateral and fourth ventricles were distinguishable. No trace of arachnoid, however, could be seen until the fifth month.

Arachnoid.

CRANIAL NERVES

ALL nerves issuing from the cerebro-spinal centre which are transmitted through apertures in the base of the skull, are included in the class of *cranial nerves*. Definition.

These nerves are named numerically, according to the relative position of the apertures for their transmission through the cranium; and they are likewise distinguished by other names, taken chiefly from the organs or parts to which they are distributed (*e. g.* facial, glosso-pharyngeal), or from the functions to which they minister (olfactory, optic, &c.) Nomenclature of nerves.

The number of the cranial nerves is differently stated by anatomists. The difference is mainly owing to the circumstance, that under one system the nerves which enter the internal auditory meatus, and those which pass through the jugular foramen, are in each case considered a single pair (seventh and eighth) divisible into parts; while under another system each of the nerves is numbered separately. The classifications exemplifying the two modes of numbering—those of Willis and Sæmmerring—are subjoined:— Difference as to numbers recognised.

WILLIS.		SÆMMERRING.	
First pair of nerves,	Olfactory nerves.		
Second	„ Optic.	}	The first six names are the same as those of Willis.
Third	„ Oculo-motor.		
Fourth	„ Pathetic.		
Fifth	„ { Trifacial or trigeminal.		
Sixth	„ Abducent-ocular.		
Seventh	{ nervus durus, Facial. n. mollis, Auditory.		
Eighth	{ n. vagus,* Pneumo-gastric.	Eighth „ Auditory.	
	{ n. accessorius, { Spinal accessory.	Ninth „ { Glosso-pharyngeal.	
Ninth	„ { Lingual or hypoglossal.	Tenth „ Pneumogastric.	
Tenth	„ Suboccipital.	Eleventh „ { Spinal accessory.	
		Twelfth „ { Lingual or hypoglossal.	

* Willis described the glosso-pharyngeal nerve as a branch of the vagus.

The arrangement of Sæmmerring is the preferable one, as being the simplest and most natural; for each of the parts included in the seventh and eighth pairs of Willis is really a distinct nerve. But as the plan of Willis is in general use, it will most conveniently be followed here: with the exception, however, that the tenth pair (suboccipital) of that anatomist will be ranged with the spinal nerves. The cranial nerves will therefore be regarded as consisting of nine pairs.

Arranged
like spinal
nerves.

It may be mentioned that some anatomists, looking to the resemblance between the bones of the skull and the vertebræ of the spinal column, have endeavoured to show an analogy between the nerves also. Accordingly, cranial nerves which possess ganglia, and others devoid of ganglia, have been grouped together, so as to form compound nerves, named cranio-vertebral; and thus regarded, they have been looked upon as analogous to spinal or (according to the language of this system) spino-vertebral nerves. The arrangement suggested by Professor Müller will illustrate this mode of viewing the cranial nerves:—

1. The first cranio-vertebral nerve is composed of the fifth, third, fourth, sixth (and facial?) nerves.
2. In the second cranio-vertebral nerve are included the pneumo-gastric, glosso-pharyngeal, and spinal accessory nerves.
3. The hypoglossal is the third cranio-vertebral nerve.

OLFACTORY NERVE.

The olfactory or first cranial nerve (*nervus olfactorius, par primum*), the special nerve of the sense of smelling, is distributed exclusively to the nasal fossæ. The course of this nerve within the cranium has been already described (*ante*, page 745). It remains to add an account of the branches as they are distributed in the interior of the nose.

Branches
from olfac-
tory bulb,

and their
coverings.

From the under surface of the olfactory bulb, fig. 188, ¹, numerous branches proceed through the holes in the cribriform plate of the ethmoid bone, each being invested by tubular prolongations of the membranes of the brain. These tubes of membrane vary in the extent to which they are continued on the branches. Thus the offsets of the dura mater sheathe the filaments, and join the periosteum lining the nose; those of the pia mater become blended with the neurilemma of the nerves; and those of the arachnoid re-ascend to the serous lining of the skull.

The branches are arranged in three sets. The inner set, lodged for a while in grooves on the surface of the bone, ramify in the pituitary membrane of the septum; the outer set, fig. 188, extend to the upper two spongy bones, and the plane surface of bone in front of these; and the middle set, which are very short, are confined to the roof of the nose. The distribution of the olfactory nerves is confined to the nasal fossæ; none of the branches reach the lower spongy bones.—(See Anatomy of the Nose.)

Distribu-
tion of fila-
ments in
nasal fossa.

OPTIC NERVE.

The optic or second cranial nerve (*nervus opticus, par secundum*), a nerve of special sense, belongs exclusively to the eye. The connexion of this nerve with the nervous centre, and the optic tract with the commissure of the nerves of opposite sides, have been described at a former part of this work (page 746).

From the commissure at the base of the brain, each nerve diverges from its fellow, becomes round and firm, and is incased in a neurilemma. In the orbit, which it enters by the optic foramen, it is invested with a sheath of the dura mater, and surrounded by the recti muscles; and finally, after piercing successively the sclerotic and choroid coats at the back of the eyeball, it expands into the retina.—(See the Anatomy of the Eye.)

Course in
orbit.

Ends in
retina.

THIRD PAIR OF NERVES.

This nerve, the common motor nerve of the eyeball, (*nerv. motorius oculi, par tertium*) fig. 184, ⁴, gives branches to five of the seven muscles of the orbit.

Like the other motor nerves, the third is round, firm, and white; it is invested from the first by a sheath of pia mater, and afterwards by a tube of the arachnoid membrane.

In its course to the orbit, this nerve is contained in the external fibrous boundary of the cavernous sinus with other nerves; and on entering the canal appropriated to it in the dura mater, the serous covering of the arachnoid is reflected from it.*

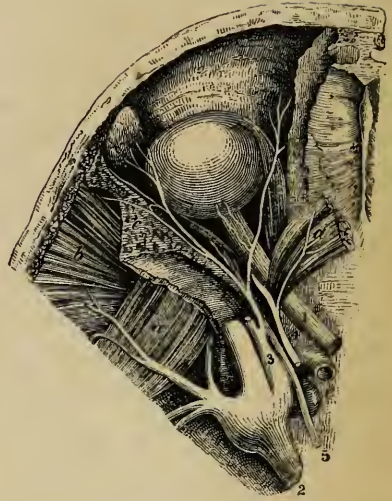
Course at
base of
skull,

* For an account of the relative position of the orbital nerves before they enter the orbit, see the statement placed after the description of this (the third) nerve.

Divides
into two
parts.

After receiving one or two delicate filaments from the cavernous plexus of the sympathetic, the third nerve divides near the orbit into two parts, which are continued into that cavity between the heads of the external rectus muscle.

Fig. 184*



Upper por-
tion.

Branches.—The *upper*, the smaller *division*, fig. 184, is directed inwards over the optic nerve to the rectus superior muscle of the eye, and the elevator of the eyelid, to both which muscles it furnishes offsets.

Lower
portion.

The *lower* and larger *division* of the nerve, fig. 187, separates into three branches; of which one reaches the inner rectus; another the lower rectus; and the third, the longest of the three, runs onward between the lower and the outer rectus, and terminates below the ball of the eye in the inferior oblique muscle. The last-mentioned branch is connected with the lower part of the lenticular ganglion by a short thick cord, and gives two filaments to the lower rectus muscle.

How nerves
enter
muscles.

The several branches of the third nerve enter the muscles to which they are distributed, on that surface of the muscle, in each case, which looks towards the eyeball.

Position of certain nerves at the cavernous sinus, and as they enter the orbit.—As several nerves are placed close together at the cavernous sinus, and as they enter the orbit through the same foramen, a statement will now, once for all, be made respecting the position they bear one to the other, in order to save the repetition which otherwise would be necessary when each of the nerves in question is under consideration.

* The deep nerves of the orbit seen from above by removing the bone and dividing the elevator of the upper eyelid and the upper rectus muscle. (From Arnold.) *a.* Internal pterygoid muscle. *b.* Temporal muscle. *c.* Cut surface of bone. *d.* Elevator of the eyelid and upper rectus muscle. *e.* Carotid artery 1. Optic nerve. 2. Fifth nerve. 3. Ophthalmic nerve. 4. Third nerve. 5. Sixth nerve.

At the cavernous sinus.—In the dura mater which bounds the cavernous sinus on the outer side, the third and fourth nerves and the ophthalmic division of the fifth are placed, as regards one another, in their numerical order, both from above downwards and from without inwards. The sixth nerve is close to the carotid artery—not in the wall of sinus. Near the sphenoidal fissure, through which they enter the orbit, the relative position of the nerves is changed, and their number is augmented, the sixth nerve being here close to the rest, and both the third and ophthalmic nerves being divided—the former into two, the latter into three parts.

Order of
nerves at
cavern.
sinus ;

In the sphenoidal fissure.—The fourth, and the frontal and lachrymal branches of the fifth, which are here higher than the rest, lie on the same level, the first-named being the nearest to the inner side ; and these nerves enter the orbit above the muscles, fig. 185. In entering the same cavity, the remaining nerves pass between the heads of the outer rectus muscle: the upper division of the third being highest, the nasal branch of the fifth next, the lower division of the third beneath these, and the sixth below all.

in entering
orbit.

FOURTH PAIR OF NERVES.

The fourth (pathetic nerve, *nervus trochlearis*, n. patheticus, par quartum), fig. 185, *, is the smallest of the cranial nerves, and is distributed only to the upper oblique muscle of the orbit.*

From the remoteness of its place of origin, (see p. 747,) this nerve has a longer extent in the skull than any other cranial nerve. It has the same general course as the third in the wall of the cavernous sinus, and through the sphenoidal fissure. Before reaching the sinus it is on a level with the margin of the tentorium cerebelli, by the side of the pons Varolii ; and it enters an aperture in the free border of the tentorium, outside that for the third nerve, and near the posterior clinoid process. Continuing onwards through the outer wall of the cavernous sinus, the fourth nerve enters the orbit by the sphenoidal fis-

Length in
skull.

Course.

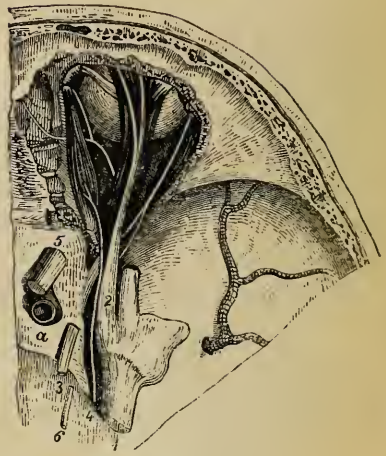
* This nerve receives its name from entering the dura mater in the base of the skull, next to the third.

Fig. 185.*

sure, and above the muscles. Its position with reference to other nerves in this part of its course has been already referred to (*ante*, page 771).

Connex-
ions.

While in its fibrous canal in the outer wall of the sinus, the fourth nerve is joined by filaments of the sympathetic, and not unfrequently is blended with the ophthalmic division of the fifth. Bidder states that some offsets are here given from it to the dura mater.†



Distribu-
tion.

In the orbit, fig. 185, 4, the fourth nerve inclines inwards above the muscles, and finally enters the orbital surface of the upper oblique muscle.

FIFTH PAIR OF NERVES.

Various
functions of
this nerve.

The fifth, or trifacial nerve (*nerv. trigeminus*, *nerf trifacial*, *par quintum*), fig. 186, the largest cranial nerve, is somewhat analogous to the spinal nerves. It is a nerve of special sense (taste), and it imparts common sensibility (the sense of touch) to the face and the fore part of the head, as well as to the eye, the nose, the ear, and the mouth. This nerve, moreover, supplies motor filaments to the muscles of mastication.

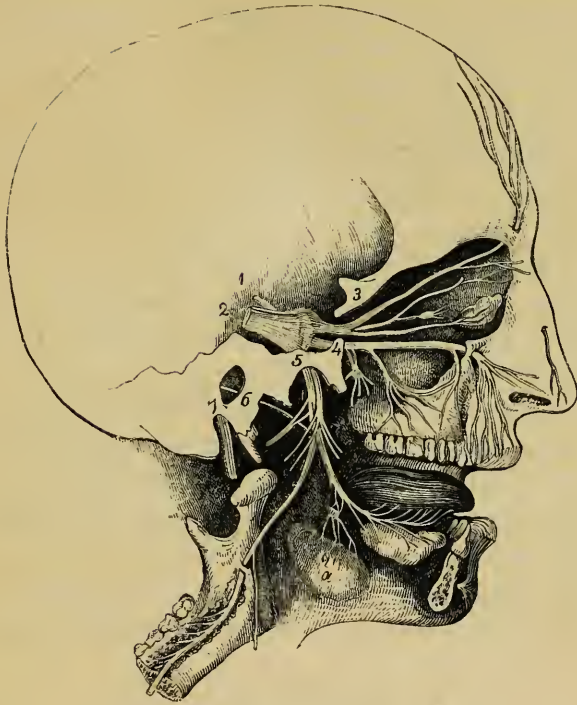
Course of
the roots
in the skull.

The roots of the fifth nerve after emerging from the surface of the encephalon (*ante*, p. 748), are directed forwards, side by side, to the middle fossa of the skull, through an aperture in the dura mater, on the summit of the petrous part of the temporal bone. Here the larger root alters in appearance: its

* The nerves in the orbit above the muscles, brought into view by removing the roof of the orbit and the periosteum (Arnold). 1. Fifth nerve. 2. Ophthalmic branch of same nerve. 3. Third nerve. 4. Fourth nerve. 5. Optic nerve. 6. Sixth nerve. a. Internal carotid artery.

† Three or more small filaments are described as extending in the tentorium as far as the lateral sinus, and one is figured as joining the sympathetic on the carotid artery.—*Neurologische Beobachtungen*, Von. Dr. F. H. Bidder Dorpat. 1836.

Fig. 186.*



fibres diverge a little, and enter a semilunar body, the Gasserian ganglion; whilst the smaller root passes beneath the ganglion, without being united in any way to it, and joins outside the skull the lowest of the three divisions of the nerve which issue from the ganglion.

The *ganglion of the fifth nerve* or *Gasserian ganglion* (ganglion semilunare seu Gasserianum) occupies a depression on the upper part of the petrous portion of the temporal bone, near its point, and is crescentic in form, the convexity being turned forwards. On its inner side the ganglion is joined by filaments from the carotid plexus of the sympathetic nerve, and, according to some anatomists, it furnishes from its back part filaments to the dura mater.

Gasserian
ganglion.

* A plan of the branches of the fifth nerve, modified from a sketch by Sir C. Bell. *a.* Submaxillary gland, with the submaxillary ganglion above it. 1. Small root of the fifth nerve, which joins the lower maxillary division. 2. Larger root, with the Gasserian ganglion. 3. Ophthalmic nerve. 4. Upper maxillary nerve. 5. Lower maxillary nerve. 6. Chorda tympani. 7. Facial nerve.

Divisions of fifth nerve ; outline of their arrangement.

Two, sensory.

One, compound nerve.

How far analogous to a spinal nerve.

From the fore part, or convex border of the Gasserian ganglion, proceed three large branches. The highest (first or ophthalmic division) enters the orbit; the second, the upper maxillary nerve, is continued forwards to the face, below the orbit; and the third, the lower maxillary nerve, is distributed chiefly to the ear, the tongue, the lower teeth, and the muscles of mastication. The first two divisions of the nerve proceeding wholly from the ganglion, confer sensibility on the structures in which they ramify; but the last, in addition to that function, gives motor branches to the muscles referred to, the additional fibres being derived from the smaller root which is joined with this part of the nerve. The third division is therefore a compound nerve, for in it are combined motor and sensory fibres. This part of the fifth cranial nerve is therefore analogous to a spinal nerve; but with the difference, that while all the offsets of a spinal nerve are believed to partake of both motor and sensory fibres only a portion of the lower maxillary nerve is so compounded, the motor root being joined, as already stated, with but a part of the fibres emanating from the ganglion.

A. OPTHALMIC NERVE.

Course in skull.

Connexion with sympathetic.

The ophthalmic nerve, or first division of the fifth nerve, (*ramus quinti paris primus vel ophthalmicus*,) fig. 186, ³, is the smallest of the three offsets from the Gasserian ganglion. It is a flat fasciculus, about an inch in length, and is directed upwards to the sphenoidal fissure, where it ends in branches which continue onwards through the orbit. In the skull this division of the fifth nerve is contained in the process of the dura mater bounding externally the cavernous sinus, and it is here joined by filaments from the cavernous plexus of the sympathetic: according to Arnold, it gives recurrent branches to the tentorium cerebelli.† The fourth nerve frequently communicates by a considerable branch with this nerve.

* There is as much difference of statement among modern as among ancient authorities respecting nerves to the dura mater. Bidder delineates branches furnished to this membrane from the fourth nerve. Arnold represents the nerves as coming from the ophthalmic division of the fifth. Purkinje supposes them to be derived from filaments of the sympathetic nerve that run along the meningeal arteries; and Valentin states that they emanate from the sympathetic on the carotid artery. Mr. Swan says that the sixth nerve "sends several filaments to the dura mater behind the Gasserian ganglion."

Near the orbit the ophthalmic nerve furnishes from its inner side the nasal branch, and then divides into the frontal and lachrymal branches. These offsets are transmitted separately through the sphenoidal fissure, and are continued through the orbit (after supplying a few filaments to the eye) to the lachrymal gland, to the nose, the eyelids, and the muscles and integument of the forehead. Branches.

1. Lachrymal Branch.

The lachrymal branch, fig. 185, at its origin is external to the frontal, and is contained in a separate tube of dura mater. In the orbit it courses along the outer part, above the muscles, to the outer angle of the cavity. When near the lachrymal gland, the nerve has a connecting filament with the orbital branch of the upper maxillary nerve, and when lying in close apposition with the gland, it gives many filaments to this and to the conjunctiva. Finally, the lachrymal nerve penetrates the palpebral ligament, and ends in the upper eye-lid, the terminal ramifications being joined by the facial nerve.* Position in the orbit.
Branches.
Communications.

2. Frontal Branch.

The frontal branch, fig. 185,², the largest offset of the ophthalmic, is, like the preceding nerve, above the muscles in the orbit, and occupies the middle of the cavity, being between the elevator of the upper eyelid and the periosteum. About midway between the base and summit of the orbit, the nerve divides into branches (supratrochlear and supraorbital), which, after emerging at the fore part of the orbit, supply the muscles and integument of the forehead and the upper eyelid. Position in the orbit.
Division.

a. The internal or *supratrochlear branch*, fig. 185, is prolonged to the point at which the pulley of the upper oblique muscle is fixed to the orbit. Here it gives downwards a filament of connexion to the infratrochlear branch of the nasal nerve, and issues from the cavity between the orbicular muscle of the lids and the bone. In this last position filaments are distributed to the upper eyelid. The nerve next pierces the orbicularis palpebrarum and Supra-trochlear branch.

In consequence of the junction which occurs between the ophthalmic division of the fifth and the fourth nerve, the lachrymal branch sometimes appears to be derived from both.—Mr. Swan considers this the usual condition of the lachrymal nerve.—*A Demonstration of the Nerves of the Human Body*, page 36. London, 1834.

occipito-frontalis muscles, furnishing offsets to these muscles and the corrugator supercilii, and after ascending on the forehead, ramifies in the integument.

Supra-orbital branch: *b.* The external or *supraorbital branch*, fig. 186, passes through the notch of the same name to the forehead, and ends in muscular, cutaneous, and pericranial branches; while in the notch this nerve distributes filaments (palpebral) to the upper eyelid.

palpebral; muscular; cutaneous; and pericranial offsets. The *muscular branches* referred to, supply the corrugator of the eyebrow, the occipito-frontalis, and the orbicular muscle of the eyelids, and join the facial nerve in the last muscle. The *cutaneous nerves*, among which two (outer and inner) may be noticed as the principal branches, are placed at first beneath the occipito-frontalis. The outer one, the larger, perforates the tendinous expansion of the muscle, and ramifies in the scalp as far back as the lambdoidal suture. The inner branch reaches the surface sooner than the preceding nerve, and ends in the integument over the parietal bone. The *pericranial branches* arise from the cutaneous nerves beneath the muscle, and end in the pericranium covering the frontal and parietal bones.

3. Nasal Branch.

The nasal branch (r. oculo-nasalis) fig. 186, which is more deeply placed than either of the other branches of the ophthalmic nerve, occupies a place successively in the cavities of the orbit, the cranium, and the nose. In its circuitous course this nerve has many and varied connexions.

Origin, and course in orbit.

Separating from the first division of the fifth nerve in the wall of the cavernous sinus, the nasal nerve enters the orbit between the heads of the outer rectus. Within the orbit it inclines inwards over the optic nerve, beneath the elevator of the upper eyelid and the upper rectus muscle, to the inner wall of the cavity. In this oblique course across the orbit it furnishes a single filament to the lenticular ganglion, and two or three (ciliary) directly to the eyeball; and at the inner side of the cavity it gives off a considerable branch (infrotrochlear), which leaves the orbit at its fore part. After furnishing these offsets, the nasal nerve enters the anterior of the two foramina in the inner wall of the orbit, and passing above the ethmoidal cells, appears for a short space in the cranium. Within the skull, the nerve lies in a groove on the edge of the cribriform plate of the ethmoid bone, by which it is conducted to a special aperture at the side of the crista galli. By that opening it is transmitted to the roof of the nasal fossa, where it ends in two branches, one of which

Course in base of the skull;

(external nasal) reaches the integument of the side of the nose, and the other (internal nasal) ramifies in the pituitary membrane. The branches, which have been indicated as furnished by the nasal nerve, will now be referred to in detail.

reaches the nose.

a. The *branch to the lenticular ganglion* (*radix longa ganglii ciliaris*), fig. 186, very slender, and about half an inch long, arises generally between the heads of the rectus. This small branch is sometimes joined by a filament from the cavernous plexus of the sympathetic or from the upper division of the third nerve; it lies on the outer side of the optic nerve, and enters the upper and back part of the lenticular ganglion, constituting its long root.

Branches in orbit : one to lenticular gangl.

b. The *long ciliary nerves*, fig. 187, two or three in number, are situated on the inner side of the optic nerve; they join one or more of the nerves from the lenticular ganglion, (short ciliary,) and after perforating the sclerotic coat of the eye, are continued between it and the choroid to the ciliary ligament and the iris.

Long ciliary : end in iris.

c. The *infratrochlear branch* fig. 186, runs forwards along the inner side of the orbit below the upper oblique muscle, and receives near the pulley of that muscle a filament of connection from the supratrochlear nerve. The branch is then continued below the pulley (whence its name) to the inner angle of the eye, and ends in filaments which supply the orbicular muscles of the lids, the caruncula, and the lachrymal sac, as well as the integument of the eyelids and side of the nose.

Infra-trochlear.

In the cavity of the nose the nasal nerve ends by dividing into the following branches;—

Branches to nose.

d. The *branch to the nasal septum* (*ramus septi*) extends to the lower part of the partition between the nasal fossæ, supplying the pituitary membrane near the fore part of the septum.

Branch to septum.

e. The *external branch* (*r. externus seu lateralis*), fig. 188², descends in a groove on the inner surface of the nasal bone; and after leaving the nasal cavity between that bone and the lateral cartilage of the nose, fig. 186, it is directed downwards to the tip of the nose, beneath the compressor nasi muscle. While within the nasal fossa, this branch gives two or three filaments to the fore part of its outer wall, which extend as far as the lower spongy bone. The cutaneous part joins the facial nerve.

Cutaneous branch.

Summary.—The first division of the fifth nerve is altogether sensory in function. It furnishes branches to the ball of the eye and the lachrymal gland; to the mucous membrane of the nose and eyelids; to the integument of the nose and the fore part of the head; and to the muscles above the upper half of the circumference of the orbit. Some of the cutaneous fila-

Summary.

ments join offsets of the facial nerve, and the nerve itself communicates with the sympathetic.

OPHTHALMIC GANGLION.

Ganglia connected with the divisions of fifth nerve.

There are four small ganglionic masses connected with the divisions of the fifth nerve: the ophthalmic ganglion with the first division, Meckel's ganglion with the second, and the otic and submaxillary ganglia with the third division of the nerve. These several bodies receive sensory nerves from the fifth, motor nerves from other sources; and twigs from the sympathetic; and the nerves thus joining the ganglia are named their roots.

Ophthalmic gang.

The *ophthalmic* or *lenticular* ganglion (gang. ophthalmicum, semilunare, vel ciliare) fig. 187,

Fig. 187.*

Its nature.

serves as a centre for the supply of nerves—motor, sensory, and sympathetic—to the eyeball.

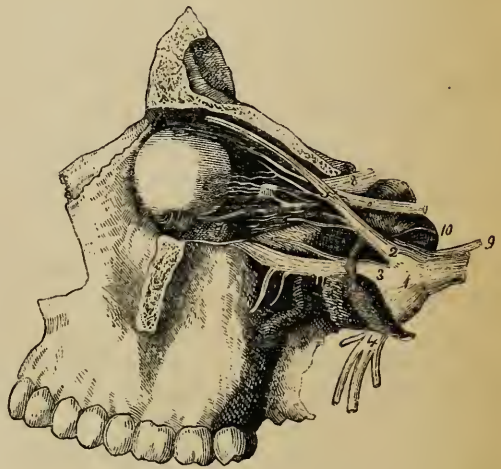
Position.

It is a small reddish body, situate at the back of the orbit, between the outer rectus muscle and the optic nerve, and generally in contact with the ophthalmic artery. Rounded, or

Form.

Roots and branches.

somewhat quadrangular in shape, it is joined behind by offsets from the fifth, the third, and the sympathetic nerves; and from its fore part proceed ciliary nerves to the eyeball.—From the quantity of fat surrounding the ganglion, it is not always easy to detect it.



* A representation of some of the nerves of the orbit, especially to show the lenticular ganglion (Arnold). 1. Ganglion of the fifth. 2. Ophthalmic nerve. 3. Upper maxillary. 4. Lower maxillary. 5. Nasal branch, giving the *long* root to the lenticular ganglion. 6. Third nerve. 7. Inferior oblique branch of the third connected with the ganglion by the *short* root. 8. Optic nerve. 9. Sixth nerve. 10. Sympathetic on the carotid artery.

Union of the ganglion with nerves : its roots. The border of the ganglion directed backwards receives three nerves. One of these, the *long root*, fig. 187, from the nasal branch of the ophthalmic trunk, joins the upper part (upper angle) of this border. Another branch, the *short root*, fig. 187, thicker and much shorter than the preceding, and sometimes divided into parts, is derived from the branch of the third nerve supplied to the lower oblique muscle, and is connected with the lower part (lower angle) of the ganglion. The *third small nerve*, fig. 187, emanates from the cavernous plexus of the sympathetic, and reaches the ganglion with the long upper root; or these two nerves may be inseparably conjoined before reaching the ganglion.*

Branches of the ganglion. From the fore part of the ganglion arise ten or twelve delicate filaments—the *short ciliary nerves*, fig. 187. These nerves are disposed in two fasciuli, arising from the upper and lower angles of the ganglion, and they run forwards, one set above, the other below the optic nerve, the latter being the more numerous. They are accompanied by filaments from the nasal nerve (long ciliary), with which some are joined. Having entered the eyeball by apertures in the back part of the sclerotic coat, the nerves are lodged in grooves on its inner surface; and at the ciliary ligament, which they pierce, (some few appearing to be lost in its substance,) they turn inwards and ramify in the iris.

B. UPPER MAXILLARY NERVE.

The upper maxillary nerve, or second division of the fifth cranial nerve (ramus quinti paris secundus, v. maxillaris superior), fig. 186,⁴ is intermediate in size and situation between the ophthalmic and lower maxillary nerves.

This nerve, named from its connection with the upper maxilla, has an almost horizontal direction, in great part through that bone, to the face. It commences at the middle of the Gasserian ganglion, presenting at its origin the appearance of a flattened band, and speedily leaves the skull by the foramen rotundum of the sphenoid bone, having previously become round and firm. After escaping from the cavity of the skull the nerve crosses the sphenomaxillary fossa, and enters the canal in the floor of the orbit (in the orbital plate of the upper maxilla), by which it is conducted to the face. As soon as it emerges from the infraorbital foramen, the upper maxillary nerve terminates beneath the elevator of the upper lip in branches

* Other roots have been assigned to the ganglion. See a paper by Valentini in Müller's Archiv for 1840.

which spread out to the side of the nose, the eyelid, and the upper lip.

Branches :
outline of.

Branches.—In the speno-maxillary fossa a branch ascends from the upper maxillary nerve to the orbit, and one or two descend to join Meckel's ganglion, and to be distributed to the nose and mouth. Whilst the nerve is in contact with the upper maxilla, it furnishes dental branches—one on the tuberosity of the bone, the other at its fore part. To these must be added the terminal branches already indicated.

1. Orbital Branch.

Orbital br.
divides into

The orbital or temporo-malar branch, a small cutaneous nerve, enters the orbit by the speno-maxillary fissure, and divides into two branches (temporal and malar), which are distributed, as their names imply, to the temple and the prominent part of the cheek.

a temporal
branch,

a. The *temporal branch* is contained in an osseous groove or canal in the outer wall of the orbit, and leaves this cavity by a foramen in the malar bone. When about to traverse the bone, it is joined by a communicating filament, (in some cases, two filaments,) from the lachrymal nerve. The nerve is then inclined upwards in the temporal fossa between the bone and the temporal muscle, perforates the temporal aponeurosis an inch above the zygoma, and ends in cutaneous filaments over the temple. The cutaneous ramifications are united with the facial nerve, and sometimes with the superficial temporal nerve of the third division of the fifth.

and a
malar
branch.

b. The *malar branch* (r. subcutaneus malæ), lies at first in the loose fat in the lower angle of the orbit, and is continued to the face through a foramen in the malar bone, where it is frequently divided into two filaments. In the prominence of the cheek this nerve communicates with the facial nerve.

2. Spheno-palatine Branches.

Spheno-pal.
brs. con-
nected w.
Meckel's
gang.

The spheno-palatine branches, fig. 186, two in number, descending from the trunk of the nerve in the speno-maxillary fossa, arc connected with the ganglionic body (Meckel's ganglion), which is placed in that fossa, and are distributed to the nose and palate. These branches will be described with the ganglion referred to.—See p. 782.

3. Posterior Dental Branches.

Poster.
dental :
two brs.

The posterior dental branches, fig. 186, two in number, are directed outwards over the tuberosity of the maxillary bone.

a. One of the branches enters a canal in the bone by which it is conducted to the teeth, and gives forwards a communicating filament to the anterior dental nerve. It ends in filaments to the molar teeth and the lining membrane of the cavity in the upper maxillary bone, and near the teeth joins a second time with the anterior dental nerve. Posterior of the two ;

b. The *anterior* of the two branches, lying on the surface of the bone, is distributed to the gums of the upper jaw and to the buccinator muscle. anterior.

4. Anterior Dental Branch.

The anterior dental branch, leaving the trunk of the nerve at a varying distance from its exit at the infraorbital foramen, enters a special canal in front of the antrum of Highmore. In this canal it receives the filament from the posterior dental nerve, and divides into two branches, which furnish offsets for the front teeth. Anter. dental.
two brs.

a. One branch, the *inner* one, supplies the incisor and canine teeth. Filaments from this nerve enter the lower meatus of the nose, and end in the membrane covering the lower spongy bone. Inner branch.

b. The *outer* branch gives filaments to the bicuspid teeth, and is connected with the posterior dental nerve. Outer.

5. Infraorbital Branches.

The infraorbital branches fig. 186, which are large and numerous, spring from the end of the upper maxillary nerve beneath the elevator muscle of the upper lip, and are divisible into palpebral, nasal, and labial sets.

a. The *palpebral branch* (there may be two branches) turns upwards to the lower eyelid in a groove or canal in the bone, and supplies the orbicular muscle; it ends in filaments which are distributed to the lid in its entire breadth. At the outer angle of the eyelids this nerve is connected with the facial nerve. Branch to eyelid ;

b. The *nasal branches* are directed inwards to the muscles and integument of the side of the nose, and they communicate with the cutaneous branch of the nasal nerve furnished by the first division of the fifth nerve. to side of the nose ;

c. The *labial branches*, the largest of the terminal branches of the upper maxillary nerve, three or four in number, are continued downwards beneath the proper elevator of the upper lip. Branching out as they descend, these nerves are distributed to the integument, the mucous membrane of the mouth, the labial glands, and the muscles of the upper lip. to the upper lip.

Connexion
w. facial
nerve.

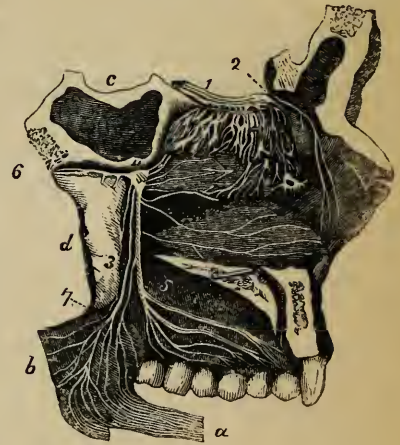
Near the orbit the infraorbital branches of the upper maxillary nerve are joined by branches of the facial nerve, the union between the two being named *infraorbital plexus*.

SPHENO-PALATINE GANGLION.

Situation.

The spheno-palatine ganglion, commonly named Meckel's ganglion, fig. 188, has its seat on the spheno-palatine branches of the upper maxillary nerve, and is deeply placed in a hollow (spheno-maxillary fossa) between the pterygoid process of the sphenoid bone and the upper maxilla, and close to the spheno-palatine foramen. It is of a greyish colour, triangular in form or heart-shaped, and convex on the outer surface.

Fig. 188.*



Form.

The grey or ganglionic substance is not mixed with all the fibres of the spheno-palatine branches of the upper maxillary nerve, but is placed

Ganglionic
structure
only partial.

at the back part, at the point of junction of the sympathetic or deep branch of the vidian, so that the spheno-palatine nerves proceeding to the nose and palate pass to their destination without being involved in the ganglionic mass.

Branches.

Considering the ganglion as a centre from which offsets proceed, there are branches from it directed upwards to the orbit, some downwards to the palate, others inwards to the nose, and one or two pass backwards to (or, perhaps better, received from) the sympathetic and facial nerves.

* A view of the olfactory nerve, and of Meckel's ganglion seen from the inner side. (From Scarpa). *a*. Elevator muscle of the soft palate thrown down. *b*. Part of the soft palate. *c*. Body of the sphenoid bone. *d*. Internal pterygoid plate. 1. Bulb of the olfactory nerve, giving branches over the upper two spongy bones. 2. Nasal branch of the ophthalmic nerve. 3. Smaller palatine nerve. 4. Meckel's ganglion. 5. Larger palatine nerve, dividing in the roof of the mouth. 6. Vidian nerve. 7. External palatine nerve.

1. Ascending Branches.

The ascending branches, very small, and three or more in number, enter the orbit by the spheno-maxillary fissure, and supply the periosteum.*

Ascending series.

2. Descending Branches.

The descending branches, continued chiefly from the sphenopalatine branches of the upper maxillary nerve, (*ante*, page 780), are the palatine nerves (large, small, and external). They are distributed to the tonsil; to the soft palate—its glandular and muscular substance, and mucous membrane; to the gums and glands of the hard palate; and to the mucous membrane of the nose.

Descending series consists of palatine nerves.

a. The *larger* or *anterior palatine* nerve, fig. 188, ⁵, descends in the largest palatine canal, and divides in the roof of the mouth into branches, which are received into grooves in the hard palate, and extend forward nearly to the incisor teeth. In the mouth it supplies the gums, glandular structure, and mucous membrane of the hard palate, and joins in front with the naso-palatine nerve. When entering its canal, this palatine nerve gives a nasal branch which ramifies on the middle and lower spongy bones; and a little before leaving the canal, another branch is supplied to the membrane covering the lower spongy bone: these are *inferior nasal branches*. Opposite the lower spongy bone springs a small branch, which is continued to the soft palate in a separate canal behind the trunk of the nerve.

Larger palatine nerve;

its inferior nasal branches.

b. The *smaller* or *posterior palatine* branch, fig. 188, ³, arising near the preceding nerve, enters, together with a small artery, the smaller palatine canal, and by this it is conducted to the soft palate, the tonsil, and the uvula. According to Meckel, it supplies the levator palati muscle.

Smaller palatine nerve.

c. The *external palatine* nerve, fig. 188, ⁷, the smallest of the series, courses between the upper maxilla and the external pterygoid muscle, and enters the external palatine canal between the maxillary bone and pterygoid process of the palate bone. At its exit from the canal it gives inwards a branch to the uvula, and outwards another to the tonsil and palate. Occasionally, this nerve is altogether wanting.

External palatine nerve:

sometimes wanting.

* Bock describes a branch ascending from the ganglion to the sixth nerve; Tiedemann, one to the lower angle of the ophthalmic ganglion. The filaments described by Hirzel as ascending to the optic nerve, most probably join the ciliary nerves which surround that (the optic) nerve.

3. Internal Branches.

Internal
brs.

The internal branches furnished from the ganglion consist of the naso-palatine, and the upper and anterior nasal, which ramify in the lining membrane of the nose.

Upper an-
terior nasal
nerves.

a. The *upper anterior nasal*, fig. 188, are very small branches, and enter the back part of the nasal fossa by the sphenopalatine foramen. Some few are prolonged to the posterior and upper part of the septum, and the remainder ramify in the membrane covering the upper two spongy bones, and in that lining the posterior ethmoid cells.

Naso-pala-
tine nerve ;on nasal
septum ;descends to
mouth.The two
united.

b. The *naso-palatine nerve* (nervus naso-palatinus,* nerve of Cotunnius) (see woodcut in the description of the nose), long and slender, leaves the inner side of the ganglion with the preceding branches, and after crossing the roof of the nasal fossa is directed forwards on the lower part of the septum nasi, between the periosteum and the pituitary membrane, towards the anterior palatine foramen. It descends to the roof of the mouth by a separate canal† which opens below in the centre of the anterior palatine foramen, the nerve of the right side being behind its fellow, and in a distinct canal (Scarpa). In the mouth the two naso-palatine nerves are connected one with the other, and they end in several filaments; these are distributed to the papilla behind the incisor teeth, and communicate with the great palatine nerve. In its course along the septum, small filaments are furnished from the naso-palatine nerve to the pituitary membrane.‡

4. Posterior Branches.

Poster. brs.

The offsets directed backwards from the sphenopalatine ganglion are the vidian and pharyngeal nerves.

Vidian
nerve.

a. The *vidian nerve* (nerv. vidianus v. pterygoideus), fig. 188, ⁶, is so named from the canal of the sphenoid bone in which it is contained. Supposing this nerve to proceed backwards, as is customary in anatomical works, it arises from the back of the ganglion, which seems to be

* This nerve was so named by Scarpa, in an Essay (with Engravings) on the nerves of the nose, published in 1785. (*Annotiones Anatomica*, lib. ii.) Scarpa mentions, that when his essay was prepared for the press, an engraving, containing a representation of this nerve, which Cotunnius had caused to be made twenty-three years before, was shown him by Girardi. The engraving had not, and has never been published.—It is stated by John Hunter that he dissected the nerve as early as 1754, and repeatedly used the preparation of it in his anatomical lectures. Hunter adds that, in 1782, he showed his drawings and engravings of the nerves of the nose to Scarpa, who was then in London.—See "*Observations on certain parts of the Animal Economy*:" London, 1786.

† See Osteology, p. 63.

‡ Scarpa denies the existence of branches on the septum. Consult also Wrisberg, "*De nervis arterias venasque comitantibus*." (*Comment.*, t. i., p. 374.)

prolonged into it, courses backwards through the vidian canal, and after emerging from this divides into two branches; one of these, the superficial petrosal, joins the facial nerve, while the other, the carotid branch, communicates with the sympathetic.* Whilst the vidian nerve is in its canal, it gives inwards to the nose some small branches, the *upper posterior nasal*, which supply the membrane of the back part of the roof of the nose and septum, as well as the membrane covering the end of the Eustachian tube.

in osseous canal.

Upper posterior nasal offsets.

The separate course of the branches resulting from the division of the vidian nerve will now be described.

Branches of vidian.

The *superficial petrosal branch*, fig. 190, ², enters the cranium through the cartilaginous substance filling the foramen lacerum anterius at the base of the skull. Lying then on the outer side of the carotid artery and beneath the Gasserian ganglion, the nerve is directed backwards in a groove on the petrous portion of the temporal bone to the hiatus Fallopii; and it is finally continued through the hiatus Fallopii to the aqueduct of the same name, where it joins the gangliform enlargement of the facial nerve.

Superficial petrosal enters skull and joins facial nerve.

The *carotid or sympathetic portion* of the vidian nerve, shorter than the other, is of a reddish colour and softer texture. Like the preceding branch, it is surrounded by the cartilaginous substance filling the aperture (foramen lacerum anterius) at the point of the petrous portion of the temporal bone; and it is inclined backwards, also on the outer side of the carotid artery, to end in the filaments of the sympathetic surrounding that vessel.

Carotid branch.

—In accordance with the view taken of the ganglia connected with the fifth nerve, (p. 778,) the parts of the Vidian nerve, above described as directed backwards from the sphenopalatine ganglion, should be considered as beginning from the facial nerve and the carotid plexus, and coursing forwards (either separately or after being united) to join the ganglion and constitute two of its roots, the third being derived from the sphenopalatine nerves.

Vidian differently viewed.

b. The *pharyngeal nerve* is inconsiderable in size, and instead of emanating directly from the ganglion, may be derived altogether from the vidian. This branch, when a separate nerve, springs from the back of the ganglion, enters the pterygo-palatine canal with an artery, and is lost in the lining membrane of the part of the pharynx behind the Eustachian tube.

Pharyngeal nerve.

Summary. The upper maxillary nerve, with Meckel's ganglion, supplies the integument of the side of the head, and the muscles and integument of the lower eyelid, the side of the nose, and the upper lip. The following parts likewise receive their nerves from the same source, viz., the upper teeth, the lining membrane of the nose and upper

Summary.

Parts supplied by upper maxillary nerve.

* The vidian nerve is here described as it was by Meckel, as a single cord, dividing into parts. Some anatomists consider the petrosal and carotid branches as quite distinct one from the other in their whole length, and connected only by being contained in the same fibrous tube.

part of the pharynx, of the antrum of Highmore, and of the posterior ethmoid cells; the soft palate, tonsil, and uvula; and the glandular and mucous structures of the roof of the mouth.

Its connexions with other nerves.

But few communications take place with other nerves. In the face the upper maxillary nerve joins freely with the facial nerve; it is, moreover, through the medium of Meckel's ganglion, connected with the facial nerve by the superficial petrosal branch of the vidian, and with the sympathetic by the carotid branch of the same nerve.

C. LOWER MAXILLARY NERVE.

Outline of nerve.

The lower maxillary nerve, fig. 186, ⁵, is the third and largest branch of the fifth nerve. It furnishes branches to the tongue (the gustatory nerve), to the external ear, to the lower teeth, and to the muscles, the mucous membrane and integuments about the lower maxillary bone.

Two roots.

This nerve is made up of two portions, which are unequal in size, the larger being derived from the Gasserian ganglion, and the smaller being the slender motor root of the fifth nerve. These two parts leave the skull by the oval foramen in the sphenoid bone, and unite immediately after their exit. A few lines beneath the base of the skull, and under the external pterygoid muscle, the lower maxillary nerve separates into two primary divisions, one of which is higher and smaller than the other. From these divisions the branches to various parts emanate as follows:—

Division into two portions.

Smaller portion.

The *small*, or *upper division*, receives nearly all the fibrils of the smaller (motor) root of the fifth nerve, and terminates in offsets to the temporal, masseter, buccinator, and pterygoid muscles. A few of the filaments of the motor root are applied to the larger division of the nerve, and are conveyed to other muscles, viz., the mylo-hyoid, the tensor of the membrane of the tympanum, and the circumflexus palati. The branches will now be considered individually.

Its branches are given to muscles.

1. Deep Temporal Branches.

Deep templ., two brs.

The deep temporal branches are two in number, one being placed near the back part, the other near the front of the

temporal fossa, and beneath the temporal muscle to which both are distributed.

a. The *posterior branch* (r. temporalis profundus posterior) is of small size, and is sometimes conjoined with the masseteric branch. It courses upwards in a groove in the bone above the external pterygoid muscle. The posterior branch.

b. The *anterior branch* (r. temporalis profundus anterior) is placed like the preceding between the bone and the pterygoid muscle, and is then reflected over the crest of the sphenoid bone to the fore part of the temporal fossa. It is frequently joined with the buccal nerve, and sometimes with the other deep temporal branch. Anterior branch.

2. Masseteric Branch.

This branch is directed outwards also above the external pterygoid muscle, and has an almost horizontal course in front of the articulation of the lower maxillary bone, and through the sigmoid notch of the maxilla, to the inner surface of the masseter muscle. It ramifies in the muscle nearly to its lower end. When the nerve passes by the articulation of the lower jaw, it gives one or more filaments to that joint, and occasionally it furnishes a branch to the temporal muscle. Masseteric br.

reaches inner side of muscle.

3. Buccal Branch.

The buccal branch (r. buccinatorius, v. buccinatorio-labialis), pierces the substance of the external pterygoid muscle, and courses forwards to the face under cover of the ramus of the lower maxillary bone, or through the fibres of the temporal muscle. On the buccinator muscle, its fibres separate into *two branches*, which will be presently noticed. Buccal br.

on outer side of muscle.

From the buccal nerve, while passing through the pterygoid muscle, is given a branch (pterygoid) to that muscle; and when it has passed beyond the same muscle, two or three ascending offsets are furnished to the temporal muscle. Under the ramus of the maxilla it gives filaments to the upper part of the buccinator; these perforate the fibres of the muscle, and end in the buccal glands and the mucous membrane lining the inner surface of the muscle. Offsets from buccal br.

a. The *upper branch* of the two into which the buccal nerve divides communicates with the facial nerve in a plexus around the facial vein, and supplies the integument and the upper part of the buccinator muscle. Its upper division;

b. The *lower branch*, directed to the angle of the mouth, forms, like the upper one, a plexus around the facial vein, and is distributed to the in- lower one.

tugment, to the buccinator muscle and the mucous membrane lining it, as well as (according to Meckel) to the muscles of the angle of the mouth.*

4. Pterygoid Branches.

The pterygoid branches are two in number: one for each of the pterygoid muscles.

Branch to
external
pterygoid ;

a. The *external pterygoid branch* is most frequently derived from the buccal nerve. It may be a separate offset from the smaller portion of the lower maxillary nerve.

to internal
pterygoid.

The *nerve* of the *internal pterygoid* muscle, fig. 189, at its origin is closely connected with the otic ganglion, and enters the inner or deep surface of the muscle.

Larger
division of
lower
maxillary.

The *lower* and *larger division* of the lower maxillary nerve divides into three parts, viz. the auriculo-temporal, gustatory, and lower dental. The auriculo-temporal soon leaves the short common trunk, and the other two nerves separate one from the other afterwards, at a variable distance below the base of the skull.

Its divi-
sions.

1. AURICULO-TEMPORAL NERVE.

The auriculo-temporal nerve (*nerv. temporalis superficialis*), fig. 186, as the name implies, is distributed to the ear and the temple.

Course
behind con-
dyle of jaw.

The nerve often commences by two roots, between which may be placed the middle meningeal artery. It is directed at first backwards, beneath the external pterygoid muscle, to the inner side of the articulation of the jaw; and then changing its course, turns upwards between the ear and the joint, where it is covered by the parotid gland. Lastly, emerging from beneath the parotid, it divides into two temporal branches.

Branches.

Branches.—Besides the terminal branches just referred to, the auriculo-temporal nerve furnishes branches to the ear, the temporo-maxillary joint, and the parotid gland, as well as communicating filaments to other nerves. These will now be severally noticed.

Lower
auricular.

a. The *auricular branches* are two in number. One of these, the *lower* of the two, arising behind the articulation of the jaw, distributes branches to the ear below the external meatus; and other filaments, turning round the internal maxillary artery, join the sympathetic nerve.

* "De quinto pare nervorum cerebri," in Ludwig.—"Scriptores Neurologici." t. i.

The *upper auricular branch*, leaving the nerve in front of the ear, enters the integument covering the tragus and the pinna above the external auditory meatus. Both auricular nerves are confined to the outer surface of the ear.—See *Nerves of the External Ear*.

Upper auricular.

b. Branches communicating with the facial nerve, and the otic ganglion. The branches which join the facial nerve, commonly two in number, pass forward around the carotid artery. The filaments to the otic ganglion arise near the beginning of the auriculo-temporal nerve.

Branches to facial nerve and otic ganglion.

c. Branches to the meatus auditorius and temporo-maxillary articulation. The nerves to the meatus, two in number, spring from the point of connexion of the facial and auriculo-temporal nerves, and enter the interior of the auditory meatus between its osseous and cartilaginous parts. One or two filaments sometimes perforate the cartilage and are lost on the convex surface of the meatus. The nerve to the articulation comes from the preceding branches, or directly from the auriculo-temporal nerve.

Branches to meatus and articulation.

d. The parotid branches are given from the nerve while it is covered by the gland.

Parotid branches.

e. Temporal Branches.—One of these, the smaller and *posterior* of the two, supplies the anterior muscle of the auricle, and distributes filaments to the upper part of the pinna and the integument above it. The *anterior* temporal branch extends with the superficial temporal artery to the top of the head, and ends in the integument.* It is often united with the temporal branch of the upper maxillary nerve.

Temporal : posterior,

anterior.

2. GUSTATORY NERVE.

The gustatory nerve, or lingual branch of the fifth, fig. 186, has an oblique direction inwards, under cover of the lower maxillary bone, to the tongue.

Deep position beneath jaw.

This nerve is deeply placed in the whole of its course, and has the following connections with surrounding parts. At first it is beneath the external pterygoid muscle with the dental nerve, lying to the inner side of that nerve, and is sometimes united to it by a cord which crosses over the internal maxillary artery. In the same place the gustatory nerve is joined at a small angle by the chorda tympani. Next, it is placed between the internal pterygoid muscle † and the lower maxilla; and it is then inclined obliquely inwards to the side of the tongue, over the upper constrictor of the pharynx, (where this muscle is at-

Union with chorda tympani.

Course to tongue

* Meekel mentions a communication between this branch and the occipital nerve.

† It has been observed by Meekel to give filaments to this muscle (op. cit.)

tached to the maxillary bone) and above the deep portion of the submaxillary gland. Lastly, the nerve is continued along the side of the tongue to its apex, lying below the sublingual gland and in contact with the mucous membrane of the mouth.

Branches ; The *branches*, which are few, leave the nerve by the side of the tongue. Some supply the mucous membrane of the mouth and the contiguous salivary glands; some enter the tongue and its papillæ; and others connect the gustatory nerve with the hypoglossal nerve and the submaxillary ganglion.

to submax. gang. ; a. The branches to the submaxillary ganglion are two or three in number. See *Submaxillary Ganglion*.

to join ninth nerve ; b. Those which are connected with offsets from the hypoglossal nerve form a plexus at the inner border of the hyoglossus muscle.

to mucous membrane ; c. The branches distributed to the mucous membrane of the mouth are given from the nerve by the side of the tongue, and supply the gums also.

to sub-lingual gland ; d. Some delicate filaments are likewise distributed to the substance of the sublingual gland.

to tongue. The lingual or terminal branches perforate the muscular structure of the tongue, and divide into filaments, which are continued almost vertically upwards to the conical and fungiform papillæ. Near the tip of the tongue the branches of the gustatory and hypoglossal nerves are united.

3. INFERIOR DENTAL NERVE.

The inferior dental nerve (*maxillaris inferior*, Meckel), fig. 186, is the largest of the three branches of the lower maxillary nerve.

Course. It courses forwards through the lower maxillary bone, and terminates on the face.

Connexions. Before the nerve enters the canal in the lower maxilla, it has the same relative position as the gustatory nerve, near which it lies,—that is to say, it is first beneath the external pterygoid muscle, and then between the internal pterygoid and the ramus of the lower maxilla, but separated from the muscle by the internal lateral ligament of the articulation. Being then received into the canal appropriated to it and the dental artery in the bone just named, the nerve is conducted forwards beneath the teeth, to which it gives filaments, as far as the foramen (mental) in the side of the bone. Here it bifurcates: one part, the in-

In maxillary bone.

Division.

incisor branch, is continued onwards within the bone to the middle line; the other (labial branch) escapes by the foramen to the face. Branches.

In addition to the branches already indicated, the dental nerve, when about to enter the foramen on the inner surface of the ramus of the jaw, gives off a slender offset, the mylo-hyoid branch.

a. The *mylo-hyoid branch* is lodged in a groove on the inner surface of the ramus of the maxillary bone, in which it is confined by fibrous membrane, and is distributed to the lower or cutaneous surface of the mylo-hyoid muscle and to the anterior belly of the digastric muscle. Occasionally one or two filaments of this nerve enter the submaxillary gland. Branch to mylo-hyoid muscle: supplies digastric.

b. The *dental branches* supplied to the molar and bicuspid teeth correspond to the number of the fangs of those teeth. Each branch enters the hole in a fang, and terminates in the pulp of the tooth. Dental nerves.

c. The *incisor branch* has the same direction as the trunk of the nerve; it extends to the middle line from the point of origin of the labial branch, and supplies nerves to the canine and incisor teeth. Incisor branch.

d. The *labial (mental?) branch* emerging from the bone by the foramen on its outer surface, divides beneath the depressor of the angle of the mouth into two parts:— Labial branch

One of these, the outer division, supplies the depressor anguli oris and orbicularis oris muscles, and the integument. It communicates with the facial nerve. joins facial nerve,

The inner division, the larger of the two, ascends to the lower lip beneath the quadratus menti muscle, to which it gives filaments: the greater number of the branches end on the inner and outer surfaces of the lip. These (inner) branches assist but slightly in forming the plexus of union with the facial nerve. and ends in lower lip.

Summary.—The lower maxillary, or third division of the fifth, is partly a compound nerve. It furnishes a nerve of special sense to the tongue (the gustatory nerve). Cutaneous filaments ramify on the side of the head, and the external ear, in the auditory passage, the lower lip and the lower part of the face. Branches are furnished to the mucous membrane of the mouth, the lower teeth and gums, the salivary glands, and the articulation of the lower jaw. Lower maxillary partly compound nerve.
A nerve of taste.
Branches to skin and mucous membrane.

This nerve supplies the muscles of mastication (viz., the masseter, temporal, and two pterygoid), also the buccinator, the mylo-hyoid, the circumflexus palati, and the tensor of the tympanum; and the smaller or motor part of the fifth nerve being distributed among the branches furnished to these mus- Brs. to muscles without and with other nerves.

cles, each is a compound nerve. The muscles of the lower lip and angle of the mouth likewise receive offsets from the lower maxillary nerve; but these muscles are also furnished with branches from the facial nerve.

Communi-
cations with
other
nerves.

The gustatory nerve communicates with the facial nerve through the chorda tympani, and with the hypo-glossal nerve both on the hyo-glossus muscle and in the substance of the tongue. The auriculo-temporal nerve is connected with the same nerve in the substance of the parotid gland. Lastly, the inferior dental joins the facial nerve, forming a large plexus in which the nerves are freely united one with the other.

Two ganglia
connected
with infer.
maxillary
nerve.

Ganglia connected with the inferior maxillary nerve.—Two small ganglia (otic and submaxillary), having the general characters and arrangement ascribed to these bodies (*ante*, page 778), are connected with the lower maxillary nerve: one with the trunk of the nerve, the other with its lingual branch (the gustatory nerve).

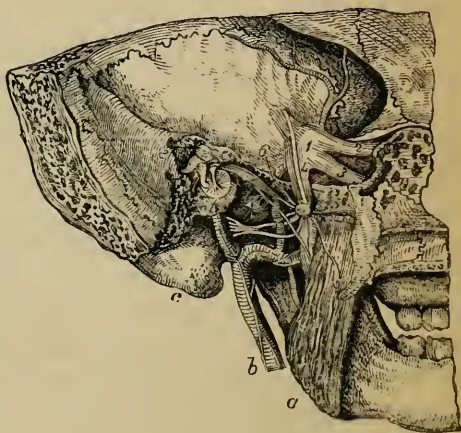
Otic Ganglion.

Otic
ganglion.

The otic ganglion (gang. oticum v. auriculare,—Arnold), fig. 189, of a reddish grey colour, is situate on the deep surface of the lower maxillary nerve, nearly at the point of junction of the motor fasciculus with that nerve, and around the origin of the internal pterygoid branch. Its outer side is thus in contact with the lower maxillary nerve; its inner surface is close to the cartilaginous part of the Eustachian tube and the circumflexus palati muscle; and behind it is the middle meningeal artery.

Situation
and con-
nexions.

Fig. 189.*



* The otic ganglion seen from the inner side. (From Arnold.) *a*. Internal pterygoid muscle. *b*. Carotid artery with the sympathetic. *c*. Mastoid process. *d*. Membrane of tympanum. *e*. Bones of tympanum 1. Gasserian ganglion. 2. First division of fifth. 3. Second division. 4. Third division. 5. Branch to tensor palati. 6. Small superficial petrosal nerve. 7. Chorda tympani. The nerve of the internal pterygoid muscle is seen on the muscle.

The nervous filaments attached to this ganglion are divisible into those by which it is connected with nerves, and those given from it to certain muscles. Branches.

Connexion with nerves—roots. The ganglion is connected with the lower maxillary nerve, especially with the branch furnished to the internal pterygoid muscle and with the auriculo-temporal nerve, and is believed thus to obtain motor and sensory fibrils or roots; it is brought into connexion with the sympathetic by a filament from the plexus on the middle meningeal artery. This ganglion has likewise communication with the glosso-pharyngeal and facial nerves by means of the small petrosal nerve prolonged to it from the tympanic plexus. Roots from fifth and sympath. nerves.
Connex. w. glosso-pharyng. and facial.

Branches. Two small nerves are distributed to muscles—one to the tensor of the membrane of the tympanum, the other to the circumflexus palati. The latter leaves the fore part of the ganglion; the former is directed backwards outside the Eustachian tube to the osseous canal containing the muscle for which it is destined. (See the figure.) Branches to tensors of tympanum and palate.

Submaxillary Ganglion.

The submaxillary ganglion (ganglion maxillare,—Meckel), fig. 186, is placed above the deep portion of the submaxillary gland, and is connected by filaments with the gustatory nerve. It is about the size of the ophthalmic ganglion. By the upper part or base it receives branches from nerves (roots), whilst from the lower part proceed the offsets which are distributed from the ganglion. Sub-maxillary ganglion. Position. Size.

Connexion with nerves—roots. A few filaments are derived from the gustatory nerve, and of these one or two are connected with both the fore and back part of the ganglion. The ganglion, it is believed, also receives, at its back part, a branch from the facial nerve; this is the chorda tympani, prolonged to the ganglion by the side of the gustatory nerve. The connexion with the sympathetic takes place by means of an offset from the filaments on the facial artery. Roots from fifth, facial, and sympath. nerves.

Branches. Some nerves, five or six in number, radiate to the substance of the submaxillary gland. Others from the fore part of the ganglion, longer and larger than the preceding, end in the mucous membrane of the mouth, and in Wharton's duct.* Branches to submax. gland and mucous memb.

A difference may be noticed between the structures to which the ganglia above described furnish offsets. The otic ganglion supplies muscles exclusively, while the submaxillary ganglion gives no muscular offsets. Contrast between the two ganglia.

* According to Meckel ("De quinto pare," &c.), a branch occasionally descends in front of the hyoglossus muscle, and after joining with one from the hypoglossal nerve, ends in the genio-hyoglossus muscle.

SIXTH PAIR OF NERVES.

The sixth cranial nerve (nerv. abducens, par sextum), fig. 184,⁵, is distributed exclusively to the outer rectus muscle in the orbit, and from the action assigned to that muscle, it is sometimes named the “abducent nerve” of the eyeball.

Course
within
the skull;

From the point of origin (before pointed out page 749), the nerve courses forwards at the base of the skull, through the cavernous sinus and the sphenoidal fissure to the orbit. It enters the sinus by an opening in the dura mater behind the body of the sphenoid bone, but is separated from the blood by the thin lining membrane. In the sinus this nerve lies on the outer side of the carotid artery, and here receives one or two filaments of communication from the sympathetic. In entering the orbit (between the heads of the external rectus muscle) it is above the ophthalmic vein. The nerve is distributed to the outer rectus by two or three filaments, which pierce the ocular surface of the muscle.*

ends in
external
rectus.

SEVENTH PAIR OF NERVES.

In the seventh cranial nerve of Willis are combined two nerves having a distinct origin, distribution, and function. One of these (facial) is the motor nerve of the face; the other (auditory) is the special nerve of the sense of hearing. Both enter the internal auditory meatus in the temporal bone, but they are soon separated one from the other.

Seventh
comprises
two nerves.

A. FACIAL NERVE.

The place of origin of the facial nerve (nerv. durus paris septimi,—Willis; seventh cranial nerve,—Sæmmerring) has been mentioned in connexion with the account given of the nervous centre (*ante*, p. 749). Its course being tortuous and its branches numerous, it will be convenient to divide the description of this nerve into two parts: the first part comprising the portion which intervenes between the origin of the nerve and its entrance into the parotid gland; the second extending to the termination of the nerve.

Facial
nerve.

* The sixth nerve, according to Boek (“*Beschreibung des Fuenften Nerven-paares*”—1817), is joined in the orbit by a filament from Meekel’s ganglion.

THE NERVE FROM ITS ORIGIN TO THE PAROTID GLAND.

From its place of origin, the facial nerve is inclined outwards with the auditory nerve to the internal auditory meatus. The facial lies in a groove on the auditory nerve, and the two are united in the auditory meatus by one or two nervous filaments. At the bottom of the meatus the facial nerve enters the aqueduct of Fallopius, and follows the windings of that canal to the surface of the skull. The course through the temporal bone is first almost horizontal outwards, between the cochlea and vestibule, to the inner wall of the tympanum, and it is then turned suddenly backwards above the fenestra ovalis towards the pyramid. Where it bends, the nerve presents a reddish gangliform enlargement (*intumescentia ganglioformis*), which marks the junction of several nerves. Opposite the pyramid it is arched downwards behind the tympanum to the stylo-mastoid foramen, by which it leaves the osseous canal.

Enters auditory aperture ;

and aqueduct of Fallopius,

to reach the surface.

Within the temporal bone the facial is connected with several other nerves by separate branches ; and immediately after issuing through the stylo-mastoid foramen, it gives off three small branches,—viz., the posterior auricular, digastric, and stylo-hyoid nerves.*

Branches.

1. Connexions with other Nerves.

a. Filaments to the auditory nerve. In the meatus auditorius one or two minute filaments pass between the facial and the trunk of the auditory nerve.

With auditory.

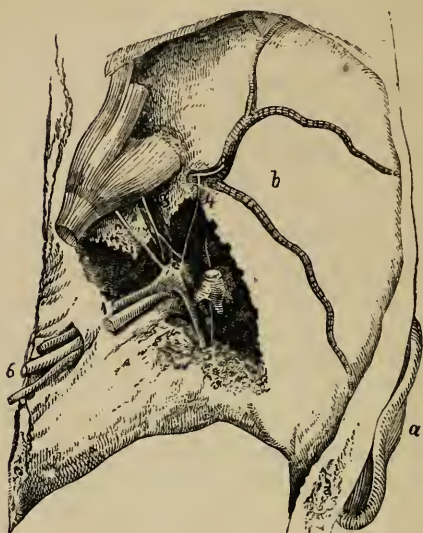b. Nerves connected with the gangliform enlargement. About two lines from the beginning of the aqueduct of Fallopius, where the facial nerve swells into a gangliform enlargement, it is joined by the large superficial petrosal branch, fig. 190, ², from the vidian nerve. To the same enlargement of the facial nerve are likewise united a filament from the small superficial petrosal nerve, fig. 190, ³, derived from the tympanic nerve,† and

With vidian, tympanic,

* Some anatomists describe a branch to the stapedius muscle. But the existence of a muscle, and therefore of the nerve, is doubtful.

† There is a difference in opinion concerning this branch, arising from its smallness and the difficulty of determining from what nerve it is primarily derived. According to one opinion, the small superficial petrosal nerve is the continuation to the otic ganglion of the tympanic nerve (Jacobson's), and is united by a filament to the enlargement of the facial. According to another manner of viewing the nerve, it begins in the swelling on the facial, connects the facial with the otic ganglion, and receives only a filament of union from Jacobson's nerve.

Fig. 190.*



lastly, the external superficial petrosal nerve, fig. 190, ⁴, which is furnished by the sympathetic accompanying the middle meningeal artery.†

and sym-
path.
nerves;
with pn.
gastric.

c. Filaments from the auricular branch of the pneumo-gastric. Near the exit of the facial nerve from the aqueduct of Fallopius it is joined by one or more of these filaments.

2. Chorda Tympani.

Chorda
tympani.

The nerve thus named leaves the trunk of the facial nerve below the level of the pyramid,‡ and crosses the tympanum to join the gustatory nerve, along which it is believed to be conducted to the submaxillary ganglion. After

* This drawing represents the middle fossa of the base of the skull with the petrous part of the temporal bone cut through so as to expose the nerves joining the facial: (from Bidder).—*a.* External ear. *b.* Middle fossa of the skull with the middle meningeal artery branching on it. 1. Facial nerve by the side of the auditory. 2. Large superficial petrosal nerve. 3. Small superficial petrosal nerve lying over the tensor tympani muscle. 4. The external superficial petrosal nerve. 5. Chorda tympani. 6. Eighth nerve.

† This nerve, named and described by Bidder, enters a canal on the upper surface of the petrous portion of the temporal bone, external to the small superficial petrosal, and commonly joins the facial beyond the swelling.

‡ Other views are taken of the origin of this nerve. Thus it is said to arise from the gangliform enlargement of the facial, and to accompany this nerve to the foramen by which it enters the tympanum; or, that it is only a prolongation from the large superficial petrosal (Vidian), which courses along the facial nerve without joining it, and becomes the chorda tympani.

passing through a short canal behind the tympanum, it enters that cavity by an aperture below the level of the pyramid, and close to the ring of bone containing the membrane of the tympanum ; and being invested by the mucous lining of the cavity, it is directed forwards across the membrana tympani and the handle of the malleus to a foramen at the inner side of the Glasserian fissure. After emerging from the tympanum through the opening referred to, the nerve lies beneath the external pterygoid muscle, and is inclined obliquely forwards to the gustatory nerve, which it meets at an acute angle. Lastly, coursing along the gustatory nerve, with which it is connected by one or more filaments, the chorda tympani ends in the submaxillary ganglion,—or, according to some anatomists, joins inseparably with that nerve.

Enters tympanum,

crosses and leaves it.

Joins gustatory nerve, and ends in sub-max. ganglion.

3. Posterior Auricular Branch.

This branch, fig. 191, ², arises close to the stylo-mastoid foramen : it turns backwards below the external auditory meatus, and is joined by the auricular branch of the pneumo-gastric. Arrived in front of the mastoid process, it divides into an auricular and an occipital portion ; in this situation, either the nerve or one of its branches is further connected with the great auricular nerve of the cervical plexus.

Post. Auric.

The *auricular division* supplies fasciculi to the retrahent muscle of the ear, and ends in the integument on the posterior aspect of the auricle.

Auricular part.

The *occipital branch* is directed backwards beneath the small occipital nerve (from the cervical plexus) to the posterior part of the occipito-frontalis muscle ; it lies close to the bone, and, besides supplying the muscle, gives upwards filaments to the integument.

Occipital part.

4. Digastric and Stylo-hyoid Branches.

The *digastric branch* arises in common with that for the stylo-hyoid muscle, and is split into many filaments, which enter the digastric muscle : one of these, after perforating the digastric, joins the glosso-pharyngeal nerve near the base of the skull.

Digastric branch.

The *stylo-hyoid branch*, long and slender, is directed inwards from the digastric branch to the muscle from which it is named. This nerve is connected with the carotid plexus of the sympathetic nerve.

Stylo-hyoid branch.

THE FACIAL NERVE FROM THE STYLO-MASTOID FORAMEN TO ITS END.

In this part of its course the facial nerve is continued forwards through the substance of the parotid gland, and divides in the gland, behind the ramus of the lower maxilla, into two primary branches, from which numerous offsets spread out over the side of the head, the face, and the upper part of the neck. The two primary divisions of the nerve are named temporo-facial

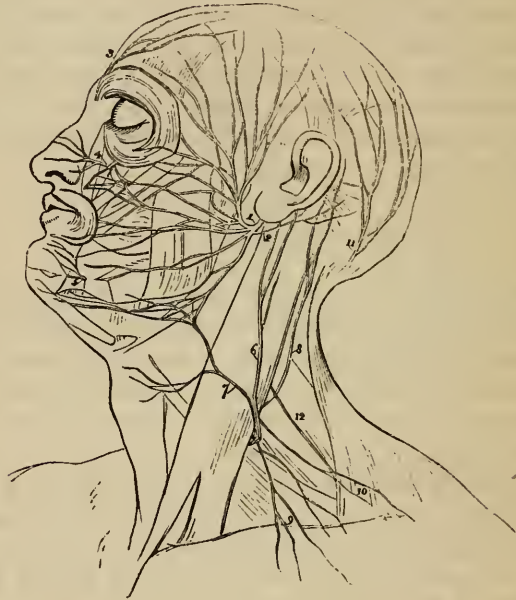
Facial nerve in parotid.

Its division.

Pes anserinus.

and cervico-facial: they are at first flattened and subdivided. This part of the nerve, with its divisions, is known as the "pes anserinus." *

Fig. 191.†



Temporo-facial division.

Branches.

Connexion with fifth nerve.

The **TEMPORO-FACIAL DIVISION**, the larger of the two, takes the direction of the trunk of the facial nerve through the parotid gland. Its ramifications and connexions with other nerves form a network over the side of the face, extending as high as the temple, and as low as the mouth. These branches are arranged into temporal, malar, and infra-orbital sets.

Near its commencement this division of the facial is connected with the auriculo-temporal nerve (of the fifth) by one or two filaments which turn round the external carotid artery; and it gives some filaments to the tragus of the outer ear.

* The designation appears to have originated in a comparison made by Winslow.

† Plan of the facial nerve and the superficial branches of the cervical plexus. 1. Facial nerve. 2. Posterior auricular branch. 3. Supraorbital nerve. 4. Infraorbital. 5. Lower maxillary labial branch. 6. Great auricular nerve. 7. Superficial cervical nerve. 8. Small occipital. 9 and 10. Clavicular and supraacromial branches. 11. Great occipital. 12. Spinal accessory nerve.

a. The *temporal branches* ascend over the zygoma to the side of the head. Some end in the anterior muscle of the auricle, and the integument of the temple, and communicate with the temporal branch of the upper maxillary nerve near the ear, as well as with (according to Meekel) the auriculo-temporal branch of the lower maxillary nerve. Other branches enter the occipito-frontalis, and the orbicular muscle of the eyelids, and join offsets from the supraorbital branch of the ophthalmic nerve.

Temporal branches.

b. The *malar branches* cross the malar bone to the outer angle of the orbit, and supply the orbicular muscle and the corrugator of the eyebrow. Some filaments are distributed to both the upper and the lower eyelid: those in the upper eyelid join filaments from the lachrymal and supra-orbital nerves; and those in the lower lid are connected with filaments from the upper maxillary nerve. Filaments from this series communicate with the malar branch (r. subcutaneus malæ) of the upper maxillary nerve.

Malar branches.

c. The *infraorbital branches*, of larger size than the other branches, are almost horizontal in direction, and are distributed between the orbit and mouth. They supply the buccinator and orbicularis oris muscles, the elevators of the upper lip and angle of the mouth, and likewise the integument. Numerous communications take place with the fifth nerve. Beneath the elevator of the upper lip these nerves are united in a plexus with the branches of the upper maxillary nerve; on the side of the nose they communicate with the nasal, and at the inner angle of the orbit with the infratrochlear nerve. The lower branches of this set are connected with the cervico-facial division.

Infra-orbital branches.

The **CERVICO-FACIAL DIVISION** of the facial nerve is directed obliquely through the parotid towards the angle of the lower jaw, and gives branches to the face, below those of the preceding division, and to the upper part of the neck. The branches are named buccal, supramaxillary, and inframaxillary. In the gland this division of the facial nerve is joined by filaments of the great auricular nerve of the cervical plexus, and offsets from it enter the substance of the gland.

Cervico-facial division.

Branches.

a. The *buccal branches* communicate with the temporo-facial division, cross the masseter muscle, and join on the buccinator muscle with filaments of the buccal branch of the lower maxillary nerve.

Buccal branches.

b. The *supramaxillary branch*, fig. 191, sometimes double, gives an offset over the side of the maxilla to the angle of the mouth, and is then directed inwards, beneath the depressor of the angle of the mouth, to the muscles and integument between the lip and chin: it joins with the labial branch of the lower dental nerve.

Supra-maxillary branch.

c. The *inframaxillary branches* (r. subcutanei colli), fig. 191, perforate the deep cervical fascia, and, placed beneath the platysma muscle, form arches across the side of the neck as low as the hyoid bone. Some branches join

Infra-maxillary branches.

the superficial cervical nerve beneath the platysma, others enter that muscle, and a few perforate it to end in the integument.

Summary.

Supplies
muscles
and
integument;

and joins
other
nerves.

Summary. The facial nerve is the motor nerve of the face. It is distributed to the muscles of the ear and of the scalp; to those of the mouth, nose, and eyelids; and to the cutaneous muscle of the neck (platysma). It likewise supplies branches to the integument of the ear, of the side and back of the head, as well as to that of the face, and the upper part of the neck.

This nerve is connected freely with the three divisions of the fifth nerve, and with the submaxillary and spheno-palatine ganglia; with the glosso-pharyngeal and pneumo-gastric nerves; with the auditory, the sympathetic, and the spinal nerves.

B. AUDITORY NERVE.

The auditory nerve (*nervus mollis paris septimi*,—Willis, eighth cranial nerve of Sæmmering) is the special nerve of the sense of hearing, and is distributed exclusively to the internal ear.

Enters
meatus
auditor. ;
connected
with facial
nerve.

Division.

As the auditory nerve is inclined outwards from its connexion with the medulla oblongata to gain the internal auditory meatus, it is in contact with the facial nerve, but a small arterial branch destined for the internal ear partially separates them. Within the meatus the two nerves are connected one to the other by one or two small filaments. Finally the auditory nerve bifurcates in the meatus: one of the parts is the nerve of the cochlea; the other enters the vestibule of the internal ear. The distribution of these branches will be described with the ear.

EIGHTH PAIR OF NERVES.

Eighth con-
sists of
three
nerves.

The eighth cranial nerve is composed of three distinct nerves—the glosso-pharyngeal, pneumo-gastric, and spinal-accessory. Besides issuing from the skull by the same foramen, these nerves have but little in common. Two of them, the glosso-pharyngeal and pneumo-gastric, are attached to the medulla oblongata in the same line, (*ante p. 448,*) and resemble one another somewhat in their distribution, for both are distributed to the beginning of the alimentary canal. But the other,

the spinal accessory, takes its origin from the spinal cord, (p. 750,) and is distributed exclusively to muscles.

A. GLOSSO-PHARYNGEAL NERVE.

The glosso-pharyngeal nerve (one division of the eighth pair, ninth cranial nerve of Sæmmering), fig. 194, ¹, is destined, as the name implies, for the tongue and pharynx.

This small nerve is directed outwards from its place of origin over the flocculus to the foramen lacerum jugulare, through which it leaves the skull with the pneumo-gastric and spinal accessory nerves, but in a separate tube of dura mater.* In passing through the foramen, where it is placed somewhat in front of the other nerves, this nerve is contained in a groove, or in a canal in the lower border of the petrous portion of the temporal bone, and presents, successively, two ganglionic enlargements, —the jugular ganglion, and the petrous ganglion.

Exit from skull by lacerated opening.

Ganglia.

In the neck the glosso-pharyngeal nerve is very deeply placed at its commencement, but less so towards its termination. After leaving the skull, it soon appears between the internal carotid artery and the jugular vein; and in its course to the tongue and pharynx is at first directed downwards over the carotid artery and beneath the styloid process and the muscles connected with the process, to the lower border of the stylo-pharyngeus muscle. Here, changing its direction, the nerve curves inwards to the tongue, forming an arch on the side of the neck. In this last part of its course, it is placed on the stylo-pharyngeus and the middle constrictor muscle of the pharynx, above the upper laryngeal nerve; and near the tongue it is beneath the hyo-glossus muscle, where it ends in offsets distributed to the pharynx, the tonsil, and the tongue.

Course outside skull;

to tongue and pharynx.

Position to surrounding parts.

The *jugular ganglion*† (gang. superius vel jugulare), fig. 194, ⁴,

Jugular ganglion.

* The jugular foramen has two projecting points of bone for the attachment of separate portions of the dura mater. Thus the foramen is divided into three parts: one in front for the lower petrosal sinus, one behind for the lateral sinus, and a central one for the three nerves.

† This ganglion was known to Ehrenritter, but it has been particularly described by Müller.—See “*Medicinische Zeitung herausgegeben von dem Verein für Heilkunde in Preussen.*” Berlin, 1833; and Müller’s “*Archiv. f. Anat. u. Physiol.*” 1834 and 1837.

the smaller of the two ganglia of the glosso-pharyngeal nerve, is situate at the upper part of the osseous groove in which the nerve is laid during its passage through the jugular foramen. Its length is from half a line to a line, and the breadth from half to three-fourths of a line. It is placed on the outer side of the trunk of the nerve, and involves only some of the fibres,—a small fasciculus passing by the ganglion, and joining the nerve below it.

Petrous
ganglion ;

The *petrous ganglion* (ganglion inferius vel petrosum,—Andersch), fig. 194, ⁵, is contained in a hollow in the lower border of the petrous part of the temporal bone, (receptaculum ganglioli petrosi), and measures about three lines in length. This ganglion includes all the filaments of the nerve, and resembles the gangliform enlargement of the facial nerve. From it arise the small branches by which the glosso-pharyngeal is connected with other nerves at the base of the skull: these are the tympanic nerve, and branches to join the pneumo-gastric and sympathetic.

Gives
branches.

Branches
of the nerve.

The *branches* of the glosso-pharyngeal nerve are divisible into two series: in the first will be ranged those derived from the petrous ganglion, and serving chiefly to connect this nerve with others; and the second will comprise the nerves distributed from it in the neck.

CONNECTING BRANCHES, AND TYMPANIC BRANCH.

Branches to
pn. gastric
and sym-
path. ;

1. From the petrous ganglion spring three small filaments:—One passes to the auricular branch of the pneumo-gastric, one to the upper ganglion of the sympathetic, or *vice versá*, and a third to the ganglion of the root of the pneumo-gastric. The last is not very constant.

to facial
nerve.

2. The *branch* to or from the *facial nerve* perforates the digastric muscle; it is connected with the trunk of the glosso-pharyngeal below the petrous ganglion.*

Tympanic
nerve :

3. The *tympanic branch* (nerve of Jacobson; r. tympanicus), fig. 192, ⁴, arises from the petrous ganglion, and is conducted to the tympanum by a special canal† in the petrous part of the temporal bone. On the inner wall of the

* There is sometimes another branch to the trunk of the pneumo-gastric.

† The orifice of this canal is in the ridge of bone between the jugular fossa and the carotid foramen; and the canal is directed upwards to the inner wall of the tympanum. From it three channels branch off: one bends down to the carotid canal; a second ascends to the hiatus Fallopii; and the third reaches the upper part of the petrous portion of the temporal bone, external to the hiatus Fallopii.

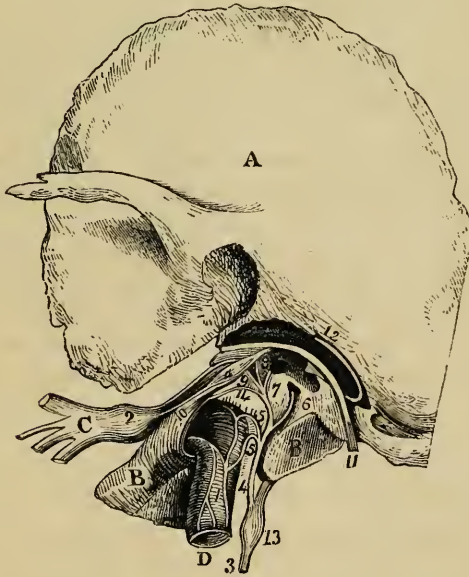
tympanum fig. 192, the nerve joins with an offset, ⁵, from the sympathetic in a plexus (tympanic), and distributes filaments to the membrane lining the tympanum and the Eustachian tube, as well as one, ⁶, to the fenestra rotunda, and another, ⁷, to the fenestra ovalis.

Tympanic plexus;

From the tympanic nerve are given three *connecting branches*, by which it communicates with other nerves; these occupy the channels continued from the osseous canal, through which the nerve enters the tympanum. One branch enters the carotid canal and joins with the sympathetic on the carotid artery.* A second, fig. 192, ⁸, is united to the large superficial petrosal nerve, as this lies in the hiatus Fallopii. And the third, fig. 192, ⁹, is di-

its branches to tympanum; to join sympath. and large petrosal nerve;

Fig. 192.†



rected upwards, beneath the canal for the tensor tympani muscle, towards the surface of the petrous portion of the temporal bone, where it becomes

* Or this filament may be said to spring from the carotid plexus, and join Jacobson's nerve in the tympanic plexus.

† A drawing of the tympanic nerve from Breschet's work on the ear. A. Squamous part of temporal bone. B. Petrous portion of same. C. Lower maxillary nerve. D. Internal carotid artery. a. Tensor tympani muscle. 1. Carotid plexus. 2. Otic ganglion. 3. Glosso-pharyngeal nerve. 4. Tympanic nerve. 5. Branches to carotid plexus. 6. Branch to fenestra rotunda. 7. Branch to fenestra ovalis. 8. Branch to join the large superficial petrosal nerve. 9. Small superficial petrosal nerve. 10. Nerve to tensor tympani muscle. 11. Facial nerve. 12. Chorda tympani. 13. Petrosal ganglion of glosso-pharyngeal. 14. Branch to the membrane lining the Eustachian tube.

to otic gang. and facial nerve. the *small superficial petrosal nerve*,* and under this name is continued to the exterior of the skull through a small aperture in the sphenoid and temporal bones, to end in the otic ganglion. As this petrosal nerve passes by the gangliform enlargement of the facial, it has a connecting filament with that enlargement.†

BRANCHES DISTRIBUTED IN THE NECK.

- Carotid branches. 1. The *carotid branches* course along the internal carotid artery, and unite with the pharyngeal branch of the pneumo-gastric and with branches of the sympathetic.
- Pharyngeal branches and plexus. 2. The *pharyngeal branches*, three or four in number, unite opposite the middle constrictor of the pharynx with branches of the pneumo-gastric and sympathetic to form the *pharyngeal plexus*. Nerves to the mucous membrane of the pharynx perforate the muscles, and extend upwards to the base of the tongue and the epiglottis, and downwards nearly to the hyoid bone.
- Muscular branches. 3. The *muscular branches* are given to the stylo-pharyngeus and constrictor muscles.‡
- Tonsillitic branches. 4. *Tonsillitic branches*. When the glosso-pharyngeal nerve is near the tonsil, some branches are distributed on this body in a kind of plexus (*circulus tonsillaris*). From these nerves, offsets are sent to the soft palate and the isthmus of the fauces, where they join the palatine nerves.
- Lingual branches. 5. *Lingual branches*. The glosso-pharyngeal nerve divides into two parts at the border of the tongue. One turns to the upper surface of the tongue, supplying the mucous membrane at its base; the other perforates the muscular structure, and ends in the mucous membrane as far forwards as the *papillæ circumvallatæ*, and filaments enter those *papillæ*.
- Summary. *Summary*.—The glosso-pharyngeal distributes branches to the mucous membrane of the tongue and pharynx. The muscles supplied by it are some of those of the pharynx and base of the tongue. It is connected with the following nerves, viz.:—the lower maxillary division of the fifth, the facial, the pneumo-gastric (the trunk and branches of this nerve), and the sympathetic.

* Bidder always found the small superficial petrosal nerve in an osseous canal—never on the surface of the bone. This observer states, too, that the nerve passes from the skull through the sphenoid bone and the petrous portion of the temporal.—“*Neurologische Beobachtungen*.”

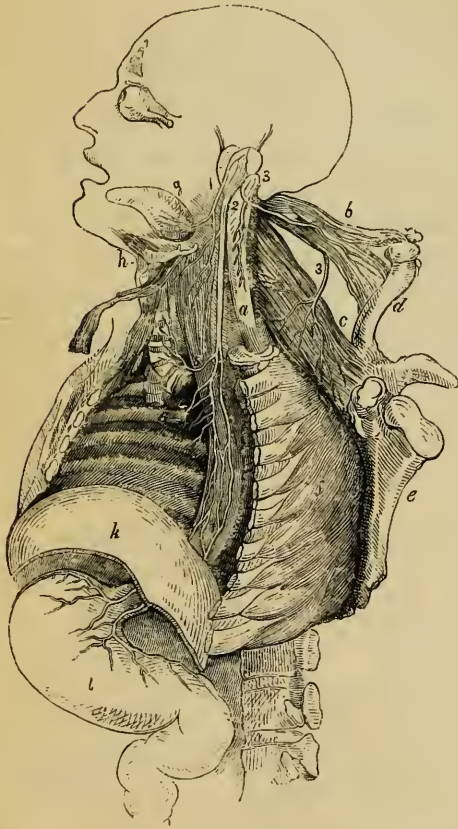
† Jacobson described an anterior or internal branch given from the tympanic nerve to the sphenopalatine ganglion.

‡ An additional muscular nerve to the digastric and stylo-hyoid muscles is noticed by Cruveilhier.—*Anat. Descrip.* t. iv. It is probable that this nerve is but the connecting branch between the facial and glosso-pharyngeal nerves.

B. PNEUMO-GASTRIC NERVE.

The pneumo-gastric nerve (nervus vagus, par vagum, sympatheticus medius, a division of the eighth pair of Willis, tenth cranial nerve, — Sœmmerring),

Fig. 193.*



Pn.-gastric ;
longest cranial nerve.
It extends through the neck and the cavity of the chest to the upper part of the abdomen ; and it supplies nerves to the organs of voice and respiration, to the alimentary canal as far as the stomach, and to the heart.

THE NERVE, FROM ITS ORIGIN TO THE THORAX. — The filaments by which this nerve arises from the medulla oblongata are collected together, so as to give rise to a flat fasciculus, which is directed

Course in cranium.

Exit from skull.

over the flocculus to the foramen lacerum in the base of the skull.

In passing through the opening at the base of the skull the pneumo-gastric nerve is contained in the same sheath of dura mater, and surrounded by the same tube of arachnoid membrane as the spinal accessory nerve ; but it is separated from the end

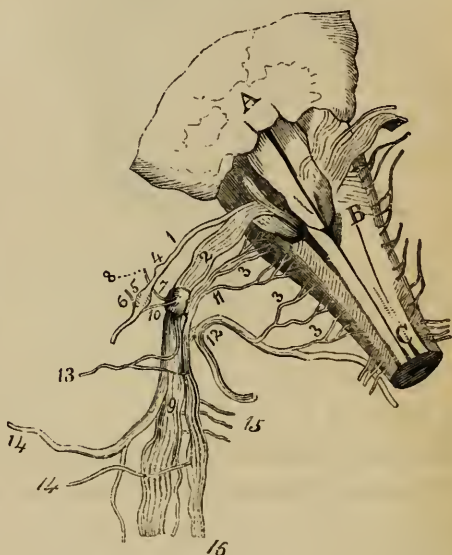
* A plan, representing the distribution of the divisions of the eighth pair of cranial nerves (altered from Bell). *a.* Spinal cord. *b.* Sterno-mastoid muscle. *c.* Trapezius. *d.* Clavicle. *e.* Scapula. *f.* Side of the chest. *g.* Tongue. *h.* Larynx. *k.* Diaphragm. *l.* Stomach. 1. Glosso-pharyngeal nerve. 2. Pncumo-gastric. 3. Spinal accessory nerve. 4. Upper laryngeal branch of vagus. 5. Lower laryngeal or recurrent branch. 6. Pulmonary branches. 7. Some nerves of œsophageal plexus.

of the lateral sinus by a process of fibrous membrane, or of bone, and from the glosso-pharyngeal nerve by a process of membrane. In the foramen the filaments of the nerve become aggregated together; and it here presents a ganglionic enlargement, distinguished as the ganglion of the root of the pneumogastric.

Course and
connexions
in the neck.

After its passage through the foramen, the vagus nerve is joined by the accessory part of the spinal accessory nerve, and a second ganglion is formed upon it (the ganglion of the trunk of the nerve). Several communications are at the same time established with the surrounding nerves. In its course along the neck the nerve has a straight direction, and a fixed position with respect to the cervical vessels; for, enclosed in the sheath of those vessels, it is between the internal carotid artery and the internal jugular vein as far as the thyroid cartilage, and afterwards between the same vein and the common carotid artery. When entering the thorax, the nerve of the right side crosses over the subclavian artery at right angles, and gives the recurrent branch to the larynx round that vessel; but on the left side it is parallel with the subclavian artery, and the recurrent laryngeal branch arises in the chest opposite the arch of the aorta.

Fig. 194.*



Upper gan-
glion of

The *upper ganglion*,

* Diagram from Bendz of the ganglia and communications of the divisions of the eighth pair. A. Cerebellum. B. Medulla oblongata. c. Spinal cord. 1. Root of glosso-pharyngeal nerve. 2. Roots of vagus. 3. Roots of spinal accessory. 4. Jugular ganglion. 5. Petrous ganglion. 6. Tympanic branch. 7. Ganglion of the root of vagus. 8. Auricular branch. 9. Ganglion of the trunk of vagus. 10. Branch from the last to the petrous ganglion. 11. Inner portion of spinal accessory. 12. Outer portion of the same. 13. Pharyngeal branch of vagus. 14. Upper laryngeal branch.

or ganglion of the root of the pneumo-gastric nerve* (gang. superius v. radiceis nervi vagi) fig. 194, 7, is situate in the foramen lacerum. It is of a greyish colour, and resembles the ganglion on the posterior root of a spinal nerve. This body is nearly circular, and about two lines in diameter; it has connecting filaments with other nerves—viz., with the facial, the petrous ganglion of the glosso-pharyngeal, the spinal accessory, and the sympathetic.

pneumo-gastric : is in foramen.

Connexions with nerves.

The *lower ganglion*, or ganglion of the trunk of the pneumo-gastric nerve†) (ganglion inferius v. trunci nervi vagi) fig. 194, 9, is about half an inch below the preceding. Occupying the trunk of the nerve outside the skull, it is of a cylindrical form and reddish colour, and measures about ten lines in length and two in breadth. The ganglion does not include all the fibres of the nerve; the fasciculus, which is sent from the spinal accessory to join the vagus, is the part not involved in the ganglionic substance. It communicates with the spinal accessory, the hypoglossal, the spinal, and sympathetic nerves.

Lower ganglion :

placed in neck.

Does not involve all the nerve.

THE PNEUMO-GASTRIC NERVES IN THE THORAX.—In the chest the pneumo-gastric nerves supply branches to the lungs and heart, and are then continued through the cavity along the œsophagus to the stomach. As there is some difference between the nerves of opposite sides in this part of their course, a separate notice of each becomes necessary.

Nerves of opposite sides differ in chest. 1

The *right* pneumo-gastric nerve is inclined by the side of the trachea to the back of the root of the lung, where it spreads out in a plexus (posterior pulmonary). From the lower part of the plexus two large cords, the continuation of the nerve, are directed to the œsophagus, on which they subdivide, and, with similar branches of the nerve of the left side, form the œsophageal plexus. Near the lower part of the œsophagus

Nerve of right side :

15. Branches to the sympathetic. 16. Fasciculus of spinal accessory prolonged with vagus.

* These ganglia have been described particularly by Bendz.—See "*Tractatus de Connexu inter Nervum Vagum et Accessorium Willisii.*" Hen. Car. Bang Bendz. Hauniæ, 1836.—Either the one or the other ganglion had been previously noticed by the greater number of anatomists.

† This ganglion was named *superior laryngeal* by Sir Astley Cooper, from the supposition that it was the special ganglion of the superior laryngeal nerve, and that it bestowed sensory powers on that nerve.—See a paper in "*Guy's Hospital Reports*," No. 5. Oct. 1837. London.

these branches are collected on each side into a single cord ; and this cord on the left side is placed on the fore part of the œsophagus, while it is behind that tube on the right side. In this manner the trunks of both nerves are continued into the abdomen.

is behind
œsophagus.

Left nerve :

The nerve of the *left side*, which is placed nearer to the fore part of the thorax than its fellow, at first lies between the left carotid and subclavian arteries, and behind the left innominate vein. Next it crosses over the arch of the aorta (round which turns the recurrent laryngeal branch), and then reaches the back part of the root of the lung. Lastly, the nerve rests on the front of the œsophagus, as before stated.

crosses arch
of aorta ;

is before
œsophagus.

Both nerves
in abdomen.

IN THE ABDOMEN:—Both pneumo-gastric nerves enter the abdomen with the œsophagus, and are distributed to the surfaces of the stomach, the left nerve spreading on the fore part, and the right on the posterior aspect of that organ. Offsets are also given to plexuses of the sympathetic: from the right nerve one to the cœliac plexus, and from the left another to the left hepatic plexus.

BRANCHES OF THE PNEUMO-GASTRIC NERVE.

Some of the branches serve to connect the pneumo-gastric with other nerves, and other branches are distributed to the muscular substance or the mucous lining of the organs which the nerve supplies. The principal connecting branches of this nerve are derived from the ganglia. In the different stages of its course, branches are supplied to various organs as follows:—In the jugular foramen, a branch is given to the ear; in the neck, branches are successively furnished to the pharynx, the larynx, and the heart; and in the thorax additional branches are distributed to the heart, and others to the lungs and the œsophagus. The terminal branches in the abdomen have been already indicated.

Branches :
arrange-
ment and
outline of.

CONNECTING BRANCHES AND AURICULAR BRANCH.

1. *Connexions between the upper ganglion of the vagus nerve and the spinal accessory, glosso-pharyngeal, and sympathetic nerves.*—The connection with the spinal accessory is effected by one or two filaments. The filament to the petrous ganglion of the glosso-pharyngeal is directed transversely; it is not always present. The communication with the sympathetic is

Connecting
branches
with upper
ganglion.

established by means of the ascending offset of the upper cervical ganglion.

2. The *auricular branch* connects the pneumo-gastric with the facial nerve in the petrous substance of the temporal bone, and is then continued to the pinna of the ear. Arising from the ganglion of the root, this branch is joined by a filament from the glosso-pharyngeal nerve; it then turns backwards along the outer boundary of the jugular foramen to an opening near the styloid process. Next, it traverses the substance of the temporal bone, crossing the aqueduct of Fallopius, about two lines from its lower end, and, reaching the surface between the mastoid process and the external auditory meatus, is distributed to the integument of the back of the ear. In the bone the auricular branch is connected with the facial nerve (which it crosses), and on the surface it joins with an offset of the posterior auricular branch of the same nerve.

Auricular branch.

Crosses jugular foramen and passes through the bone.

Supplies pinna and is connected with facial.

3. *Connections of the second ganglion of the vagus with the spinal accessory, hypo-glossal, sympathetic, and spinal nerves.*—Independently of its connection with the inner division of the spinal accessory, which becomes part of the pneumo-gastric nerve, this ganglion is connected by filaments with the trunk of the hypo-glossal, with the upper cervical ganglion of the sympathetic, and with the loop formed between the first two cervical nerves.

Connecting branches of second ganglion.

BRANCHES FOR THE PHARYNX, LARYNX, AND HEART.

1. Pharyngeal Branch.

The pharyngeal branch, fig. 194, ¹³, arises from the upper part of the ganglion of the trunk of the nerve. In its progress inwards to the pharynx this nerve crosses, in one case over, in another under the internal carotid artery; and it divides into branches, which, conjointly with others derived from the glosso-pharyngeal, the superior laryngeal, and the sympathetic nerves, form a plexus (*pharyngeal*) behind the middle constrictor of the pharynx. From the plexus, branches are given to the muscular structure and the mucous membrane of the pharynx. As the pharyngeal nerve crosses the carotid artery, some filaments join those which the glosso-pharyngeal distributes on the same vessel.—There is sometimes a second pharyngeal branch.

Pharyngeal nerve.

Joins pharyngeal plexus.

2. Superior Laryngeal Branch.

This nerve, fig. 194, ¹⁴, springs from the middle of the ganglion of the trunk of the pneumo-gastric nerve. It is directed inwards to the larynx beneath the internal carotid artery, and divides beneath that vessel into two branches, dis-

Superior laryngeal :

division. tinguished as external and internal laryngeal, both ramifying in the structures of the larynx.

External branch. The *external laryngeal* branch, the smaller of the two divisions, at the side of the pharynx gives backwards filaments to the pharyngeal plexus and to the lower constrictor muscle; and it is finally prolonged beneath the muscles on the side of the larynx to the crico-thyroid muscle* and the thyroid body in which it ends. In the neck this branch joins the upper cardiac nerve of the sympathetic.

Internal branch. The *internal* division of the laryngeal nerve is continued to the interval between the hyoid bone and the thyroid cartilage, where it perforates the thyro-hyoid membrane with the laryngeal branch of the thyroid artery, and sends an offset to join the recurrent branch, after distributing several filaments to the mucous membrane.†

The latter ends in mucous membrane of larynx *a. Branches to the mucous membrane.*—Some twigs of the internal laryngeal nerve enter the mucous membrane of the pharynx, and communicate with filaments to the same part from the recurrent nerve; others are directed upwards in the arytaeno-epiglottidean fold of mucous membrane to the base of the tongue, the epiglottis, and epiglottidean gland; and others are reflected downwards in the lining membrane of the larynx, extending to the chorda vocalis: these last are placed on the inner side of the laryngeal pouch.

and joins recurrent. *b. The communicating branch* to the recurrent laryngeal nerve is very slender, and lies beneath the lateral part of the thyroid cartilage, under which the junction between the two nerves takes place.

3. Recurrent Laryngeal Branch.

Inferior laryngeal branch. The recurrent or inferior laryngeal branch of the vagus nerve, fig. 193, ⁵, as the name expresses, has a reflex course to the larynx, but the point of departure from the vagus nerve and the connexions are not the same on both sides of the body.

Right and left differ in origin. The nerve on the *right side* arises at the top of the thorax, winds round the subclavian artery, and crosses beneath the common carotid and lower thyroid artery in its course to the

* Bendz describes branches to the muscles fixed to the oblique line on the thyroid cartilage—viz., to the constrictor, sterno-thyroid, and thyro-hyoid muscles.

† A branch to the arytaenoid muscle is sometimes described. It is difficult to say whether the nerve supplies that muscle, but it appears to do so. A branch enters the muscle, some filaments seem to end in it, and others proceed through it to the mucous membrane.

trachea. On the *left side* the recurrent nerve is bent round the arch of the aorta at the point where the obliterated ductus arteriosus is connected with the arch, and is thence inclined upwards to the trachea.

Each nerve in its course to the larynx is placed between the trachea and œsophagus, supplying branches to both tubes; and, whilst making the turn round its vessel, each gives nerves to the deep cardiac plexus. At the lower part of the cricoid cartilage the recurrent nerve distributes muscular branches, a few offsets to the mucous membrane, and a single communicating filament.

Course of both nerves.

a. The *branches* to the *mucous membrane* of the pharynx, few in number, unite in their ramifications with branches from the upper laryngeal nerve.

Branches to mucous memb.,

b. The *muscular branches* supply all the proper muscles of the larynx, except the cryeo-thyroid muscle, which is supplied from the upper laryngeal nerve.

to muscles,

c. The *communicating filament* joins the long branch of the upper laryngeal nerve beneath the side of the thyroid cartilage.

and to join upper laryng.

4. Cardiac Branches.

The cervical cardiac branches arise both at the upper and the lower part of the neck. The *upper branches* are small, and join the cardiac nerves of the sympathetic. The *lower*, a single branch, arises as the pneumo-gastric nerve is about to enter the chest. On the right side this branch lies by the side of the innominate artery, and joins one of the cardiac nerves destined for the deep cardiac plexus; it gives some filaments to the coats of the aorta. The branch of the left pneumo-gastric crosses the arch of the aorta, and ends in the superficial cardiac plexus.

Upper and lower cardiac branches.

BRANCHES IN THE CHEST AND ABDOMEN.

1. Cardiac Branches.

The thoracic cardiac branches of the right side leave the trunk of the pneumo-gastric, as this nerve lies by the side of the trachea: they pass inwards on the air-tube, and end in the deep cardiac plexus. The corresponding branches of the left side come from the left recurrent laryngeal nerve.

Thoracic cardiac brs.

2. Pulmonary Branches.

Two sets of pulmonary branches are distributed from the pneumo-gastric nerve to the lung; and they reach the root of the lung, one on its fore part, the other on its posterior aspect. The *anterior* pulmonary nerves, two or three in number, are of small size. They join with filaments of the sympathetic

Pul. nerves two sets.

Anterior branches

and
plexus.

continued on the pulmonary artery, and with these nerves constitute the *anterior pulmonary plexus*. Behind the root of the lung the pneumo-gastric becomes flattened, and gives several branches (of much larger size than the anterior branches), which, with filaments derived from the third and fourth thoracic ganglia of the sympathetic, form the *posterior pulmonary plexus*. Offsets from the last-named plexus extend along the ramifications of the air-tube through the substance of the lung.

Posterior
branches
and plexus.

3. Œsophageal Branches.

Œsopha-
geal hrs.
and plexus.

The œsophagus within the thorax receives branches from the pneumo-gastric nerves, both above and below the pulmonary branches. The latter are the larger, and are derived from the *œsophageal plexus* (plexus gulæ). This plexus is formed by connecting cords between the nerves of the right and left sides, while they lie in contact with the œsophagus.

4. Gastric Branches.

Left
nerves are
on front
of stomach;

The branches distributed to the stomach (*gastric nerves*) are the terminal branches of both pneumo-gastric nerves. The nerve of the left side, on arriving, guided by the œsophagus, opposite the cardiac orifice of the stomach, divides into many branches: some of these extend over the fore part of the stomach; others lie along its small curvature, and unite with branches of the right nerve and the sympathetic; and filaments are continued between the layers of the small omentum to the left hepatic plexus. The right pneumo-gastric nerve distributes branches to the posterior surface and the cardiac end of the stomach; and a part of this nerve is continued from the stomach to the left side of the cœliac plexus of the sympathetic.

right are
behind it.

Summary.

Supplies
pharynx,
œsoph. and
stomach;
larynx, tra-
chea, lungs,
and heart.
Connexion
with other
nerves.

Summary.—The pneumo-gastric nerves supply branches to the upper part of the alimentary canal, viz., the pharynx, œsophagus, and stomach; and to the respiratory organs, namely, the larynx, trachea, and lungs. These nerves give branches likewise to the heart and great vessels by means of their communication with the cardiac plexus. Each pneumo-gastric nerve is connected with the following cranial nerves—the spinal accessory, glosso-pharyngeal, facial, and hypoglossal; also, with some spinal nerves; and with the sympathetic in the neck, the thorax, and abdomen.

C. SPINAL ACCESSORY NERVE.

Spin. acces.

The spinal nerve accessory to the vagus nerve, or, as it is shortly named, the spinal accessory nerve (*nervus spinalis ad par vagum accessorius*, eleventh cranial nerve of Sæm-merring), fig. 194, gives a fasciculus to join the trunk of the

pneumo-gastric, and supplies branches to the sterno-mastoid and trapezius muscles.

The place of origin of this nerve from the spinal cord and its course in the spinal canal to the cranium, where it is associated with the other parts of the eighth pair, have been already described, *ante* p. 448. From the side of the medulla oblongata it is directed outwards to the foramen lacerum posterius, and is transmitted through that opening in the same sheath of dura mater as the pneumo-gastric nerve. In the foramen this nerve is connected with the ganglion of the root of the pneumo-gastric by one or more short filaments. After escaping from the cranium, it is concealed by the internal jugular vein, and immediately divides into two parts, one of which (the internal part) joins the vagus nerve, the other (the external one) supplies the sterno-mastoid and trapezius muscles.

Passes from spinal canal into skull, leaves latter by foramen lacer. post.

Division into two parts.

The *internal or accessory division*, the smaller of the two, gets at once into contact with the vagus nerve, close to the base of the skull, and blends with that nerve beyond its second ganglion.*

Internal division, joins vagus.

The *external division* of the spinal accessory nerve is directed backwards, and after crossing the internal jugular vein, in one case over, in another under the vein, perforates the sterno-mastoid muscle, at the same time supplying it with branches, and communicating in its substance with branches of the cervical plexus. Crossing, in the next place, the neck behind the sterno-mastoid, the nerve passes beneath the trapezius muscle. Here it forms a kind of plexus with branches of the third and fourth cervical nerves, and distributes offsets to the trapezius, which extend nearly to the lower edge of the muscle. Besides the communications between the spinal accessory and the spinal nerves already mentioned, another communication is formed with branches of the cervical nerves in the interval between the two muscles to which the nerve is distributed.

External division. Course to sterno-mastoid ;

and under trapezius, supplies both.

Connexion with spinal nerves.

NINTH PAIR OF CRANIAL NERVES.

The hypoglossal, or ninth cranial nerve (nerv. hypoglossus,

Ninth nerve.

* It is stated by Bendz that a filament is given from the spinal accessory to the pharyngeal nerve above the place of junction with the vagus, and that fibrils of the same nerve have been traced into each of the muscular offsets of the pneumo-gastric nerve.

par nonum,—Willis, twelfth cranial nerve,—Sœmmerring), fig. 195, is the motor nerve of the tongue.

Cranial part
of nerve.

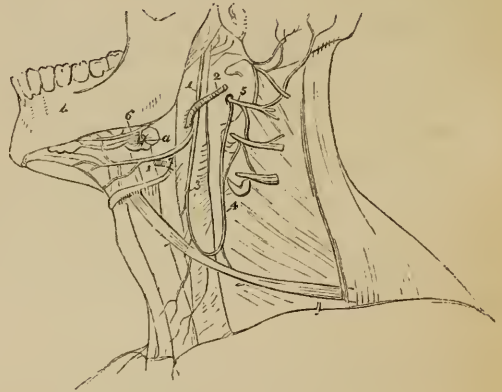The filaments by which this nerve arises from the medulla oblongata are collected into two bundles, which converge to the anterior condyloid foramen of the occipital bone. Each bundle of filaments perforates the dura mater separately opposite the foramen, and the two are joined after they have passed through it.

Course from
base of skull
at first
downward ;

After leaving the cranium, this nerve descends almost vertically to the lower border of the digastric muscle, and, changing its course, is thence directed forwards above the hyoid bone, and between the muscles in this situation to the under part of the tongue.

then for-
wards.

Fig. 195.*



Connexions.

As it descends from the base of the skull, the hypoglossal nerve lies at first very deeply with the vagus nerve, to which it is connected ; but it gradually approaches nearer to the surface, passing between the internal carotid artery and the jugular vein. Where it curves forward towards the tongue, the nerve turns round the occipital artery, and then crosses the external carotid below the tendon of the digastric muscle. It next sinks under the mylo-hyoid muscle, lying between it and the hyo-glossus, and at the inner border of the latter is connected with the gustatory nerve. Finally, it is continued in the fibres of the genio-hyoglossus muscle beneath the tongue to its point, and distributes branches upwards to the muscular substance.

Turns
round occi-
pital artery.

Branches.

The principal *branches* of this nerve are distributed to muscles on the fore-part of the neck and to the tongue ; a few

* Diagram of the trunk of the hypoglossal nerve. 1. Trunk of the nerve. 3. Descending cervical branch. 4, 5. Two nerves from the second and third cervical nerves to form the arch with the descendens noni.

serve to connect it with some of the neighbouring nerves. The several branches are disposed in the following manner:—

CONNEXION WITH OTHER NERVES.

1. *Connexion with the pneumo-gastric.*—Close to the skull the hypoglossal nerve is connected with the second ganglion of the pneumo-gastric by separate filaments, or both nerves are united so as to form but one mass.

2. *With the sympathetic and first two spinal nerves.*—Opposite the first cervical vertebra the nerve communicates with the upper cervical ganglion of the sympathetic, and with the loop connecting the first two spinal nerves in front of the atlas.

MUSCULAR BRANCHES.

1. Descending Branch of the Ninth Nerve.

This branch (*r. descendens noni*), fig. 195, leaves the ninth nerve where this turns round the occipital artery, or, it may be, higher up.* It is directed across the sheath of the carotid vessels, from the outer to the inner side, and joins about the middle of the neck in a loop with one or two branches of the cervical plexus. The convexity of this loop is turned downwards; and the connexion between the nerves is effected by means of two or more interlacing filaments, which inclose an irregularly-shaped space. From this interlacement of the nerves, filaments are continued backwards to the posterior belly of the omo-hyoid, whilst others are directed forwards to the anterior belly of the same muscle, and to the sterno-hyoid and sterno-thyroid muscles. It occasionally happens that a filament is continued to the chest, where it joins the cardiac and phrenic nerves.

Descendens noni is over sheath of cervical vessels,

connexion with cervical nerves.

Supplies muscles below hyoid bone.

Varies in position.

It is not uncommon to find the descending branch of the ninth nerve in the sheath with the large cervical vessels, and in such cases it may be placed either over or under the vein.

2. Branches to the Tongue and Neighbouring Muscles.

Branches are distributed to the following muscles, viz., the thyro-hyoid, stylo-glossus, hyo-glossus, genio-hyoid, and genio-hyo-glossus. These branches separate from the nerve where it is contiguous to the several muscles; that for the thyro-hyoid muscle near the end of the hyoid bone before the nerve passes beneath the mylo-hyoid muscle. Lastly, the hypoglossal nerve, when arrived close to the middle of the tongue with the ranine artery, gives off several long slender branches, which pass upwards into the substance of the organ. Some of the branches join with offsets from the gustatory nerve.

Nerves to muscles of tongue and those attached to hyoid bone.

Lingual branches.

Summary.—The hypoglossal nerve supplies all the muscles

Summary.

* This nerve may be derived altogether from the pneumo-gastric, or from both the pneumo-gastric and hypoglossal nerves.

connected with the os hyoides, including those of the tongue, with the exception of the digastric, the mylo-hyoid and the middle constrictor of the pharynx. The sterno-thyroid muscle likewise receives its nerve from the same source.

It is connected with the following nerves, viz. pneumo-gastric, gustatory, some spinal nerves, and the sympathetic.

THE SPINAL NERVES.

THE spinal nerves are characterised by their origin from the spinal cord and their direct transmission outward from the spinal canal in the intervals between the vertebræ. Taken together these nerves consist of thirty-one pairs; and, like the vertebræ between which they issue from the spinal canal, they are arranged into groups named cervical, dorsal, lumbar, sacral, and coccygeal. In these groups the nerves are equal in number to the vertebræ composing the division of the column with which they are associated, but with these exceptions, namely, that eight cervical nerves are recognized, and there is usually but a single coccygeal nerve.*

Each spinal nerve springs from the spinal cord by two roots which approach one another, and, with few exceptions, join in the corresponding intervertebral foramen into a single cord; and each cord so constructed separates immediately into two divisions, one of which is destined for parts in front of the spine, the other for parts behind it.

The nerves which do not emerge from the spinal canal through intervertebral foramina, and on account of which a reservation has been made above, are the first and second cervical, the last sacral, and the coccygeal nerve. The two cervical nerves issue from the canal over the laminae of the vertebræ,—the first over the atlas, the second over the axis; and the other two take their course outwards through the end of the sacral canal.

The connexions of the roots of the spinal nerves with the spinal cord, and the manner in which they are disposed with reference to its investing membranes, have been treated of already (*ante*, p. 676, 750, 754). It remains to notice the

* Among seven cases which appear to have been examined with great care, Professor Schlemm ("Observat. Neurologiæ," Berolini, 1834) found two coccygeal nerves on each side in one instance, and on one side in another case. In all the rest there was but a single coccygeal nerve on each side. The occurrence of two coccygeal nerves is, therefore, an exception to the usual arrangement.

characters by which each of the two roots is distinguished, and the peculiarities they present in different sets of nerves.

THE ROOTS OF THE SPINAL NERVES.

Posterior roots ; distinctive characters. Size. Ganglia ;

The *posterior roots* of the nerves are distinguished from the anterior roots by their greater size, as well as by the greater thickness of the fibrils of which they are composed. But these roots are chiefly characterised by the presence of ganglia. At some distance from the spinal cord the fibrils of the posterior root of an individual nerve are aggregated into two bundles ; and these swell, so to say, into the ganglionic enlargement.

Size and shape of ganglia.

Ganglia of the spinal nerves.—The spinal nerves are each furnished with a ganglion ; but the first cervical or suboccipital nerve is in some cases without one. The ganglia are proportioned in size to the nerves on which they are formed. They are oval in shape, and many are partially divided or notched at the inner side, the two parts involving the bundles into which the fibrils of the posterior roots have just been said to be arranged.

Their position.

The ganglia are placed in the intervertebral foramina, immediately beyond the point at which the roots perforate the dura mater lining the spinal canal. From this statement those on a few nerves are to be excepted. Thus, the first and second cervical nerves, which leave the spinal canal over the laminæ of the vertebræ, have their ganglia opposite that part. The ganglion of the coccygeal nerve is placed within the canal in the sac of dura mater, and at a variable distance from the origin of the nerve ; and the ganglion of the last sacral nerve, in some cases, occupies a similar position.

Exceptions.

Anterior roots.

The *anterior roots* of the spinal nerves are, as will be inferred from what has been already stated, the smaller of the two, and are devoid of ganglionic enlargement.

Roots differ in classes of nerves.

The roots of the different groups of spinal nerves vary considerably in size, and some variation is likewise observable in the relative thickness of the fibrils of which they are composed.

The size in cervical nerves.

Size.—The roots of the upper *cervical nerves* are much smaller than those of the lower nerves, the first being much the smallest. The posterior roots of these nerves exceed the anterior in size more than in the other classes of the spinal

nerves, and they are likewise composed of fibrils which are considerably larger than those of the anterior roots.

The roots of the *dorsal nerves*, exception being made of the first, (which resembles the lowest cervical nerves and is associated with them in its distribution,) are of small size, and vary but slightly, or not at all, from the second to the last. The fibrils of both roots are thinly strewed over the cord, and are slender, those of the posterior exceeding in thickness those of the anterior root in only a small degree.

Dorsal
nerves:
their size.

The roots of the lower *lumbar*, and of the upper *sacral nerves*, are the largest of all the spinal nerves; those of the lowest sacral and the coccygeal nerve are, on the other hand, the slenderest of all. All these nerves are crowded together on the lower end of the cord. As regards the relative size of the roots of the same nerves: the anterior are the smaller, but the disproportion between the two is not so great as in the cervical nerves.

Lumbar
and sacral:
size.

Length and direction of the nerves in the spinal canal.—The place at which the roots of the upper cervical nerves are connected with the spinal cord being nearly opposite the foramina by which they leave the canal, these roots are in consequence very short. But the distance between the two points referred to is gradually augmented from nerve to nerve downwards, so that the place of origin of the lower cervical nerves is the breadth of at least one vertebra, and that of the lower dorsal nerves about the breadth of two vertebræ above the foramina, by which they respectively emerge from the canal. Moreover, as the spinal cord extends no further than the first lumbar vertebra, the length of the roots of the lumbar, sacral, and coccygeal nerves increases rapidly from nerve to nerve, and in each case may be estimated by the distance of the foramen of exit from that point. Owing to their length and the appearance they present in connexion with the spinal cord, the aggregate of the roots of the nerves last referred to have been named the “*cauda equina*.”*

Length of
roots: of
upper
cervical;

of lower
cervical and
dorsal;

of lumbar,
sacral, and
coccygeal.

Cauda
equina.

* This designation originated with a comparison made by Laurentius, who, it may be added, regarded the nervous cords which occupy the lower part of the spinal canal as a portion of the spinal cord. His words are these:—

“*Medulla autem è caluarizæ rotu’do et amplo foramine prodiens, primum*

Direction
of roots.

The direction the roots take within the canal requires brief notice. The first cervical nerve is directed horizontally outwards. The roots of the lower cervical and the dorsal nerves at first descend over the spinal cord, held in connexion with it by the arachnoid till they are arrived opposite the several intervertebral foramina, where they are directed horizontally outwards. The nerves of the cauda equina are vertical in direction.

The two roots of each of the spinal nerves unite immediately beyond the ganglion on the posterior one, and the trunk thus formed separates immediately, as already mentioned, into two divisions, anterior and posterior. To these we shall now turn attention, beginning with the latter.

Certain characters common to the posterior divisions of all the spinal nerves will first be noticed. Afterwards the arrangement peculiar to each group of nerves (cervical, dorsal, &c.) will be separately considered.

POSTERIOR DIVISIONS OF THE SPINAL NERVES.

Poster.
divis. of
nerves
smaller
than anter.
Each divi-
des into
two brs.

The posterior divisions of the spinal nerves are, with few exceptions, smaller than those given to the fore part of the body. Springing from the trunk, which results from the union of the roots of the nerves in the intervertebral foramina, they turn backwards, and soon divide each into two parts or branches, distinguished as *external* and *internal*; and these are distributed to the muscles and the integument behind the spine. Exceptions to this general statement respecting the division of the nerves will be found in the arrangement of the first cervical and the lower sacral nerves; the peculiarities which they present will be shewn in the special description of those nerves.

POSTERIOR DIVISIONS OF THE CERVICAL NERVES.

Cervical
nerves.

These nerves, except the first two, are directed backwards beneath the posterior intertransverse muscle, and divide behind that muscle into the external and internal branches.

amplissima et crassissima, sensim attenuatur, id est, medullarem substantiam amittit, non corpoream molem quam eandem ubique servat; tandem cum ad dorsi fines pervenit, tota in funiculos et filamenta caudam fere equinam referentia absumitur."—And. Laurentius, "Hist. Humani Corporis." Lib. x. Cap. xii. Parisiis, 1600.

The *external branches* give only muscular offsets, and are distributed to the slender muscles prolonged to the neck from the erector spinæ, namely, the cervicalis descendens and the transversalis colli with the trachelo-mastoid. That of the second nerve is the largest of the series of external branches, and is often united to the corresponding branch of the third; it supplies the complexus muscle, which covers it, and ends in the splenius and trachelo-mastoid muscles. The first cervical nerve has no offset, similar to the external branch of each of the other cervical nerves.

Extern. brs.

First has none.

The *internal branches*, which are larger than those above described, are differently disposed at the upper and the lower parts of the neck. Excluding those of the first and second nerves, which require separate notice, they are directed inwards to the spinous processes of the vertebræ; but the branches derived from the third, fourth, and fifth nerves take that course over the semispinalis, and beneath the complexus muscle, and having reached the spines of the vertebræ, are continued outwards to the integument; while, on the other hand, the branches from the lowest three cervical nerves are placed beneath the semi-spinalis muscle, and end in the muscular structure without furnishing (except occasionally the sixth) any offset to the skin. The last three nerves are the smallest of the series.

Internal brs.

position to muscs. diff's. at upper and lower part of neck.

The muscles supplied by the internal branches just described are the complexus, semispinalis colli, the interspinales, and the multifidus spinæ.

Muscular offsets.

The *cutaneous branches*, referred to as furnished by the internal branches of some of the cervical nerves, reach the surface by the side of the spinous processes, after passing through the fibres of the complexus (or at the inner side of that muscle), and through the splenius and trapezius muscles; and then turning transversely outwards are distributed in the integument over the trapezius muscle.

Cutaneous nerves.

The first three cervical nerves deviate more or less from the arrangement now described, and require to be noticed individually.

PECULIARITIES IN THE POSTERIOR DIVISIONS OF CERTAIN CERVICAL NERVES.

1. Suboccipital Nerve.

Sub-occip.
nerve.
Position in
the neck.

The posterior division, which is the larger of the two divisions of the suboccipital nerve, emerges over the arch of the atlas, between it and the vertebral artery, to the space bounded by the larger rectus and the two oblique muscles; and after a very short course, divides into branches for the surrounding muscles. One branch descends to the lower oblique muscle, and gives a filament, which passes through the fibres of that muscle, or over it, to join the second cervical nerve; another ascends over the larger rectus muscle, supplying it and the smaller rectus; a third enters the upper oblique muscle;* and a fourth sinks into the complexus, where that muscle covers the nerve and its branches.

Branches
to muscles.

Occasional
cutaneous
branch.

A *cutaneous branch* is occasionally given to the back of the head from the suboccipital nerve; it accompanies the occipital artery, and is connected beneath the integument with the great and small occipital nerves.†

2. Second Cervical Nerve.

Second
cervical.
Connexion
in neck.

The posterior division of the second cervical nerve is much the largest of the series. When the nerve has passed through the ligament between the arches of the vertebræ, it lies below the inferior oblique muscle, (which it supplies with one or two filaments,) and receives a communicating branch from the first nerve. The nerve then separates into its external and internal branches; the former of which has been noticed with the corresponding branches from the cervical nerves.

Division.

Great occi.
nerve.

The *internal branch* of this nerve, from its size and destination named the *great occipital nerve*, is directed upwards on the lower oblique muscle, and is transmitted to the surface through the complexus and trapezius, near their cranial attachments.

* Asch states that this branch supplies the rectus capitis lateralis muscle. "De Primo Pare Nervorum Medullæ Spinalis," § xxxiii. in Ludwig "Scriptores Neurologici," vol. i.

† This nerve has occasionally been found in the dissecting room of University College. It was first recognised by James Harrison, M.D. (Session 1839-40), and subsequently traced more fully by Mr. E. Hearne.

As soon as the nerve is free from the muscles, it is joined by an offset of the cutaneous part of the third cervical nerve; and ascending with the occipital artery, it divides into branches, which radiate over the occipital part of the occipito-frontalis muscle, some appearing to enter the muscle, and others joining the smaller occipital nerve.

An *auricular branch* is sometimes supplied to the back of the ear by the great occipital nerve, and *muscular branches* are furnished to the complexus. Whilst it is beneath the complexus, the nerve in some cases is joined by an offset from the third cervical nerve.

Auricular and muscul. branches.

3. Third Cervical Nerve.

The posterior division of the *third cervical nerve* differs from the nerves below it, chiefly in this respect—viz., that in addition to a cutaneous branch to the neck, it furnishes another to the skin over the occiput, which is hence named its occipital branch.

Third cervl. gives cutaneous br. to occiput.

This *occipital branch* separates from the cervical cutaneous branch beneath the trapezius, perforates that muscle, and ramifies in the integument on the lower part of the occiput, lying at the inner side of the great occipital nerve. It is connected with that nerve.

Between the posterior divisions of the first three cervical nerves a connexion is in some cases established beneath the complexus by means of communicating branches; and this communication between the nerves M. Cruveilhier has designated as “the posterior cervical plexus.” The arrangement referred to can, however, scarcely be said in any case to constitute a plexus, inasmuch as the connecting cords are single, and do not furnish offsets, and, moreover, the connexion between the nerves is often altogether wanting.

Nerves sometimes connected by loops.

POSTERIOR DIVISIONS OF THE DORSAL NERVES.

Like the posterior divisions of the other spinal nerves, these are smaller than the anterior divisions (intercostal) from the same nerves, and divide between the transverse processes of the vertebræ into internal and external branches.

Dorsal nerves.

The *internal branches* of the upper six nerves appear in the

Internal

branches ; interval between the multifidus spinæ and the semispinalis
of upper dorsi: they supply those muscles, and become cutaneous by
six, the side of the spinous processes of the vertebræ. The same
of lower branches of the lower six dorsal nerves are placed between the
six. multifidus spinæ and longissimus dorsi, and end in the former
muscle without giving branches to the integument.

External The *external branches* increase in size from above down-
branches. wards, and the lower five or six give cutaneous offsets. These
external branches are directed through or beneath the longis-
simus dorsi to the cellular space between this muscle and the
sacro-lumbalis; and they supply both those muscles, together
with the small muscles by which they are continued upwards to
the neck, and the levatores costarum.

Cutaneous The *cutaneous branches* of the dorsal nerves vary in their
nerves ; position, according as they are derived from the internal or the
of the external branches above described. Those from the internal
upper six ; branches of the upper six nerves perforate the rhomboid and
trapezius muscles close to the spines of the vertebræ, and are
of the directed outwards in the integument; the branch from the
lower six. second nerve reaches as far as the scapula. Gangliform enlarge-
ments will often be found on these nerves. The cutaneous
nerves given from the external branches emanate from the lower
five or six dorsal nerves, and are transmitted to the integument
through the lower serratus muscle and the fleshy part of the
latissimus dorsi, in a line with the angle of the ribs.

It will be observed, that where cutaneous nerves are supplied
by the internal branches, there are none from the external branches
of the same nerves,* and *vice versâ*; and that the branches
which give cutaneous offsets are larger than those that end in
muscles without reaching the skin.

POSTERIOR DIVISIONS OF THE LUMBAR NERVES.

The branches given backwards from the lumbar nerves re-
semble those of the lower dorsal nerves in their position between
the transverse processes, and their division into internal and

* Valentin states that there are cutaneous nerves from all the external
and internal branches; "Scemmerring V. Bau," &c. While this state-
ment is dissented from, it should be remarked that the cutaneous nerves
are not always limited to the number mentioned in the text.

external branches between the multifidus spinæ and erector spinæ muscles.

The *external branches* enter the erector spinæ, and give filaments to the intertransverse muscles. From the upper three, cutaneous nerves are supplied; and from the last, a fasciculus descends to the corresponding branch of the first sacral nerve.—The *cutaneous nerves* given from the external branches of the first three lumbar nerves, pierce the fleshy part of the sacro-lumbalis, and the aponeurosis of the latissimus dorsi; they cross the crest of the ilium near the edge of the erector spinæ, and terminate in the integument of the gluteal region. One or more of the filaments may be traced as far as the great trochanter of the femur.

External
branches:

their
cutaneous
offsets.

The *internal branches* wind backwards in grooves close to the articular processes of the vertebræ, and sink into the multifidus spinæ muscle.

Internal
branches.

POSTERIOR DIVISIONS OF THE SACRAL NERVES.

These nerves issue from the sacrum through the foramina on its posterior aspect. The first three are covered at their exit from the bone by the multifidus spinæ muscle, and they bifurcate like the posterior divisions of the other spinal nerves; but the remaining two, which are below that muscle, have a peculiar arrangement, and require separate examination.

First three;

last two.

The *internal branches of the first three* sacral nerves are small, and are lost in the multifidus spinæ muscle.

Internal
branches:

The *external branches* of the same nerves are united with one another, and with the last lumbar and fourth sacral nerves, so as to form a series of anastomotic loops on the upper part of the sacrum. These branches are then directed outwards to the cutaneous or posterior surface of the great sacro-sciatic ligament, where, covered by the gluteus maximus muscle, they form a second series of loops, and end in cutaneous nerves.*

and external
brs. of first
three.

The *cutaneous nerves* derived from the second series of loops last referred to, pierce the great gluteus muscle in the direction of a line from the posterior spine of the ilium to the tip of the

Cutaneous
nerves.

* In six dissections made by Mr. Ellis, the arrangement of these nerves mentioned in the text was the most frequent. The variations to which it is liable are these:—the first nerve may not take part in the second series of loops, and the fourth may be associated with them.

coccyx. They are commonly three in number,—one is near the innominate bone, another opposite the extremity of the sacrum, and the third about midway between the other two. All are directed outwards over the great gluteal muscle.

Peculiar
arrange-
ment of
last two.

The *last two sacral nerves* placed, as already stated, below the multifidus spinæ muscle, are smaller than those above them, and are not divided into branches like those nerves. They are connected one with the other by a loop on the back of the sacrum, and the lowest is joined in a similar manner with the coccygeal nerve: one or two small filaments from these sacral nerves are distributed behind the coccyx.

POSTERIOR DIVISION OF THE COCCYGEAL NERVE.

This division of the coccygeal nerve is very small, and separates from the anterior division of the nerve in the sacral canal. It is joined by a communicating filament from the last sacral nerve, and ends in the fibrous structure about the posterior surface of the coccyx.

ANTERIOR DIVISIONS OF THE SPINAL NERVES.

The anterior divisions of the spinal nerves are distributed to the parts of the body situated in front of the vertebral column, including the limbs. They are, for the most part, considerably larger than the posterior divisions of the nerves, and the greater size is attributable to the greater mass of muscular and other structures which they are destined to supply. These nerves spring from the trunk resulting from the union of the two roots of the spinal nerves in the intervertebral foramina, and are thence directed forwards to their destination. The first two cervical nerves deviate from this arrangement; and the sacral and coccygeal nerves have, in some degree, a peculiar disposition. The peculiarities in each of these cases will be noticed in the special description of the nerves.

Size.

Origin.

Exceptions

Connected
with sym-
pathetic;
form plexus,
except dor-
sal nerves.

The anterior branch of each spinal nerve is connected by slender filaments with the sympathetic. Lastly, the cervical, lumbar and sacral nerves form plexuses of various forms; but the dorsal nerves remain separate one from the other.

ANTERIOR DIVISIONS OF THE FIRST FOUR CERVICAL NERVES.

The four upper cervical nerves form the cervical plexus by their anterior divisions. These appear at the side of the neck, between the scalenus medicus and rectus anticus major muscles; and each divides into two parts, one of which communicates with the nerve above, and the other with the nerve below. Each of these nerves is connected by a communicating filament with the first cervical ganglion, or with the cord connecting that ganglion with the second. Before the description of the plexus resulting from the intercommunication of these nerves is entered on, some peculiarities in the disposition of the first two cervical nerves must be noticed.

The nerves form plexus ;

are connected with sympath.

PECULIARITIES IN THE FIRST AND SECOND NERVES.

1. Suboccipital Nerve.

The anterior division of the first nerve runs forwards in a groove on the atlas, and bends downwards in front of the transverse process of that vertebra to join the second nerve. In this course forwards it lies beneath the vertebral artery, and at the inner side of the rectus lateralis muscle, to which it gives a branch.* As it crosses the foramen in the transverse process of the atlas, the nerve is joined by a filament from the sympathetic; and from the arch (*loop of the atlas*) it makes in front of that process, branches are supplied to the two anterior recti muscles. Short filaments connect this part of the nerve with the pneumo-gastric, the hypoglossal, and the sympathetic nerves.

Suboccipl.

Course to join second nerve.

Branches.

2. Second Cervical Nerve.

The anterior division of the second cervical nerve, beginning between the arches of the first two vertebræ, is directed forwards between their transverse processes, being placed outside the vertebral artery, and beneath the intertransverse and other muscles fixed to those processes. In front of the intertransverse muscles the nerve divides into an ascending part, which joins the first cervical nerve, and a descending part to the third.

Second nerve. Course forwards.

Joins nerves above and below.

* Valentin notices filaments distributed to the articulation of the occipital bone with the atlas, and to the mastoid process of the temporal bone.

CERVICAL PLEXUS.

Position. The cervical plexus is formed by the first four cervical nerves, and distributes branches to some of the muscles of the neck, and to a portion of the integument of the head and of the neck. It is placed opposite the first four vertebræ, beneath the sterno-mastoid muscle, and rests against the middle scalenus muscle and the elevator of the angle of the scapula. The disposition of the nerves in the plexus is easily recognized. Each nerve, except the first, branches into an ascending and a descending part: and these are united in anastomotic loops with the contiguous nerves. From the union of the second and third nerves, superficial branches are supplied to the head and neck; and from the junction of the third with the fourth, arise the cutaneous nerves of the shoulder and chest. Muscular and communicating offsets spring from the same nerves.

Arrangement of nerves in plexus. The *branches* of the plexus will be separated into two sets or classes—a superficial and deep one: the former consisting of those which ramify over the cervical fascia, supplying the integument and some also the platysma; the latter comprising branches which are distributed for the most part to the muscles. Again, each of these sets admits of being subdivided into two series, according to the direction the nerves take. Thus, the superficial nerves will be subdivided into an ascending and descending series;—the deep nerves into an internal and external series.

SUPERFICIAL BRANCHES (ASCENDING SERIES).

1. Superficial Cervical Nerve.

Division into This nerve, fig. 191, ⁷, ramifies in front of the sterno-mastoid muscle. It takes origin from the second and third cervical nerves, turns forward over the sterno-mastoid about its middle, and, after perforating the cervical fascia, divides beneath the platysma myoides into two branches, which are distributed to the anterior and lateral part of the neck.—This nerve may be represented by two or more cords, the branches into which it divides when a single nerve being distinct one from the other from their commencement in the plexus.*

* Valentini describes three superficial cervical nerves, which he names superior, middle, and inferior. "Sæmmerring v. Bau," &c.

The *upper branch* gives an ascending offset with the external jugular vein, and communicates freely with the facial nerve, (cervico-facial division); it is then transmitted through the platysma to the surface, supplies that muscle, and ramifies in the integument of the upper half of the neck on its fore part, filaments reaching as far as the lower maxilla. The *lower branch* likewise pierces the platysma, and is distributed below the preceding branch, its filaments extending as low as the sternum.

upper
branch ;lower
branch.

While the superficial cervical nerve ramifies over the platysma myoides, the facial nerve is beneath the muscle.—According to Valentin many anastomotic arches are formed on the side of the neck between those two nerves, as well as between the branches of the former, one with the other.

2. Great Auricular Nerve.

This nerve (n. auricularis magnus) (fig. 191, ⁶,) winds round the outer border of the sterno-mastoid, and is directed obliquely upwards beneath the platysma-myoides, between the muscle and the fascia of the neck, to the lobe of the ear. Here the nerve gives a few small offsets to the face, and ends in auricular and mastoid branches.

Branches.

The *auricular branches* are directed to the back of the external ear, on which they ramify, and are connected with the branches derived from the facial and pneumo-gastric nerves. One of these branches reaches the outer surface of the ear by a fissure between the anti-helix and the concha. A few filaments are supplied to the outer part of the lobule likewise.

Auricular
branch.

The *mastoid branch* is united to the posterior auricular branch of the facial nerve, and ascends over the mastoid process to the integument behind the ear.

Mastoid
branch.

The branches of the great auricular nerve which extend to the integuments of the face pass over the parotid gland. Some slender filaments penetrate deeply through the substance of the gland, and communicate with the facial nerve.

Facial
branches.

3. Small Occipital Nerve.

The smaller occipital nerve (n. occipitalis minor) (fig. 191, ⁸,) varies in size, and is sometimes double. It springs from the second cervical nerve, and is directed almost vertically to the head, along the posterior border of the sterno-mastoid muscle. Having perforated the deep fascia near the cranium, the small occipital nerve is continued upwards between the ear and the great occipital nerve, and ends in cutaneous filaments which extend higher than the ear, and communicate with offsets from the larger occipital nerve, as well as with the posterior

Course.

distributed
to the head

auricular branch of the facial. It appears to supply the occipito-frontalis muscle.*

Auricular branch.

From the small occipital nerve near the ear is given an *auricular branch* (ram. auricularis superior posterior), which is distributed to the upper part of the ear on its posterior aspect, and to the elevator muscle of the auricle. This auricular branch is an offset from the great occipital nerve, when the small occipital has less than its usual size.

SUPERFICIAL BRANCHES OF THE CERVICAL PLEXUS

(DESCENDING SERIES).

Supraclavicular Nerves.

Number.

The descending series of the superficial nerves, fig. 191, are thus named. There are two of these nerves, or, in some cases, a greater number. They arise from the third and fourth cervical nerves, and descend in the interval between the sterno-

Position in neck.

mastoid and the trapezius muscles. As they approach the clavicle, the nerves are augmented to three or more in number, and are recognized as internal, middle, and posterior.

Termination.

Inner branch.

The *inner* (sternal) branch, which is much smaller than the rest, ramifies over the inner half of the clavicle, and terminates near the sternum.

Middle.

The *middle branch*, lying opposite the interval between the pectoral and deltoid muscles, distributes some offsets over the fore part of the deltoid, and others over the pectoral muscle. The latter join the small cutaneous offsets of the intercostal nerves.

Posterior.

The *posterior branch* (acromial) is directed outwards over the acromion and the clavicular attachment of the trapezius muscle, and ends in the integument of the upper and back part of the shoulder.

DEEP BRANCHES OF THE PLEXUS: INNER SERIES.

1. Connecting Branches.

Connexion w. vagus, hypoglossal, and sympathetic.

The cervical plexus is connected near the base of the skull with the trunks of the pneumo-gastric, hypoglossal, and sympathetic nerves, by means of filaments intervening between these nerves and the loop formed by the first two cervical nerves in front of the atlas. (See p. 827.)

* According to Valentin (op. cit.) the small occipital nerve gives branches to the occipito-frontalis muscle, and reaches the upper part of the head. The same anatomist further states that connexions take place between the occipital and auricular nerves, some being placed over, and some beneath the occipito-frontalis muscle.

2. Muscular Branches.

a. Branches are supplied to the anterior recti muscles ; they proceed from the cervical nerves close to the vertebræ, including the loop between the first two of these nerves (*ante*, page 827). Branches to recti ;

b. Other branches, two in number, are connected with the descending branch of the hypoglossal nerve (*r. descendens noni*), forming, with that nerve, a small plexus from which the muscles below the *os hyoides* are supplied (see *ante*, page 815). One of the branches is derived from the second cervical nerve, and the other from the third. Both branches cross inwards either over or, it may be, under the internal jugular vein, (the position varying in different cases,) and unite with the branch of the hypoglossal. The junction between these nerves takes place usually in front of the sheath of the large bloodvessels ; but in some cases it is within the sheath. The position, in either case, is determined by that of the branch from the hypoglossal nerve.* To descendens noni, and muscles below os hyoides.

3. Phrenic Nerve.

The diaphragmatic or phrenic nerve, the special nerve of the diaphragm, courses through the thorax to its destination. Phrenic nerve.

It commences by two roots from the third and fourth cervical nerves, and receives usually another fasciculus from another of these nerves (the fifth). As it descends in the neck, the nerve is inclined inwards over the anterior scalenus muscle ; and near the chest, it is joined by a filament of the sympathetic, sometimes also by another filament derived from the fifth and sixth cervical nerves. Course in the neck.

As it enters the thorax each phrenic nerve is placed between the subclavian artery and vein, and crosses over the internal mammary artery near its root. Through that cavity each takes nearly a straight direction, in front of the root of the lung on its own side, and along the side of the pericardium,—between this and the mediastinal part of the pleura. Near the diaphragm it divides into branches, which separately penetrate the fibres of that muscle, and then diverging one from the other, are distributed on its under surface. Course in the chest.

The two phrenic nerves differ in their connexions at the upper part of the thorax, and somewhat in their length likewise. Termination in diaphragm.

* M. Cruveilhier describes an interchange of fibres at the place of connexion ; so that a filament of the spinal nerve is directed upwards along the branch of the hypoglossal, and *vice versâ*.

Difference in connexions,

on right
side ;

on left side.

Latter is
the longer
of the two.

The *right nerve* is placed more deeply than the left, and is at first directed along the outer side of the right innominate vein, and the descending vena cava. The *nerve of the left side* is a little the longer of the two, in consequence of the oblique position of the pericardium round which it winds, and also because of the diaphragm being lower on this than on the opposite side. This nerve crosses in front of the arch of the aorta, and the pulmonary artery.

Branches.

Besides the terminal branches supplied to the diaphragm, each phrenic nerve gives filaments to the pericardium, and receives sometimes an offset from the union of the *descendens noni* with the spinal nerves.*

Union with
sympathe-
tic.

One or two filaments of the nerve of the right side join in a small ganglion with diaphragmatic branches of the solar plexus; and from the ganglion offsets are given to the supra-renal capsule, the left hepatic plexus, and the lower vena cava. On the left side there is a junction between the same two nerves near the openings in the diaphragm for the œsophagus and the aorta, but without the appearance of a ganglion.

DEEP BRANCHES OF THE PLEXUS: EXTERNAL SERIES.

Deep
branches.

These nerves are distributed to muscles on the side of the neck, and some are connected freely with the spinal accessory nerve.

Muscular branches.

For sterno-
mastoid.

The *sterno-mastoid* receives a branch from the second cervical nerve. Two other branches proceed from the third nerve to the *levator anguli scapulae*; and from the cervical nerves, as they leave the spinal canal, branches are given to the middle scalenus muscle. Further the *trapezius* has branches prolonged to it, and thus, like the sterno-mastoid, this muscle receives nerves both from the spinal accessory and the cervical plexus.

Lev. ang.
scapulae.
Middle
scalenus.
Trapezius.

Connexion with the spinal accessory nerve. This nerve is connected with the branches of the cervical plexus furnished to the sterno-mastoid,—in the substance of the muscle; also with the branches distributed to the trapezius,—the connexion between the nerves being beneath this muscle, and having the appearance of a plexus; and with another offset of the cervical plexus in the interval between the two muscles.

Summary.

Summary of the cervical plexus.—From the cervical plexus are distributed cutaneous nerves to the back of the head, part of

* Mr. Swan notices this union as occurring only on the left side.—Valentin mentions other filaments supplied by the phrenic nerve to the remains of the thymus gland, the phrenic vessels, and the anterior pulmonary plexus.

the ear and face, and to the anterior half of the neck. The muscles supplied from the plexus are the sterno-mastoid, the anterior recti, the levator anguli scapulæ, the trapezius, the scalenus posticus, and the diaphragm. By means of its branches the plexus communicates with the pneumo-gastric, spinal accessory, hypoglossal, and sympathetic nerves.

ANTERIOR DIVISIONS OF THE LOWER FOUR CERVICAL NERVES.

The anterior divisions of the four lower cervical nerves appear between the scaleni muscles, and go to form the brachial plexus. They are much larger than the corresponding divisions of the upper cervical nerves, and the manner in which they join to form the plexus is different. Each of these nerves is connected by a filament with the sympathetic,—the part of that nerve in the immediate neighbourhood of each, *i. e.* with one of the two lower cervical ganglia, or the plexus on the vertebral artery.

Go to form brachial plexus.
Connexion w. sympath.

BRACHIAL PLEXUS.

This large plexus, from which the nerves of the upper limb are supplied, is formed by the union of the anterior divisions of the four lower cervical and the first dorsal nerves; and it further receives a fasciculus from the last of the nerves (fourth), which go to form the cervical plexus. The plexus reaches from the lower part of the neck to the axillary space, where it terminates opposite the coracoid process of the scapula in large offsets for the supply of the limb. From the interval between the anterior and middle scaleni muscles, the nerves descend beneath the clavicle, lying at first on the outer side of the large artery (subclavian and axillary), and afterwards in more close connexion with the vessel. In the neck they have little of a plexiform arrangement, but they enter into various connexions in the axilla, and to the aggregate of all the term brachial plexus is applied.

Nerves which form plexus.
Its extent.

The manner in which the nerves are disposed in the plexus is liable to some variation, but the following may be regarded as the arrangement most frequently met with. The fifth and sixth cervical are joined at the outer border of the scalenus, and then receive the seventh nerve,—the three nerves

Arrange-ment of nerves in plexus.

giving rise to one great cord ; the eighth cervical and the first dorsal nerves are united in another cord whilst they are between the scaleni muscles : the two cords thus formed lie side by side, and at the outer side of the axillary vessels. Lastly, a third cord is produced opposite the clavicle, or a little lower than this, by the union of a fasciculus from each of the other two. The three cords of which the plexus now consists, are placed as follows :—one on the outer side of the axillary artery, one on its inner side, and one behind that vessel. The largenervous cords which constitute the plexus at its lower end are continued into the branches which supply the arm.

Branches,
divided into
two sets.

Branches.—The branches furnished by the foregoing nerves are numerous, and may be conveniently divided into two classes—viz., those that arise above the clavicle, and those that take origin below the bone.

A. BRANCHES ABOVE THE CLAVICLE.

The branches which arise from the nerves before their union into a plexus, end in the muscles of the shoulder and the side of the chest, with the exception of the communicating fasciculus to join the phrenic nerve.

Br. joins
phrenic.

Branch *to join the Phrenic Nerve.* This small branch is an offset from the fifth cervical nerve ; it joins the phrenic nerve on the anterior scalenus muscle.

Br. for sca-
leni and
long. colli ;

Branches for *the Scaleni and Longus Colli Muscles.* These nerves spring in an irregular manner from the lower cervical nerves close to their place of emergence from the vertebral foramina.

For rhombd.

The branch for *the rhomboid muscle* arises from the fifth nerve, and is directed backwards to the base of the scapula through the fibres of the middle scalenus, and beneath the levator anguli scapulæ. It is distributed to the under surface of the rhomboid muscle, and gives sometimes a branch to the levator scapulæ.

For
subclavius.

The nerve of *the subclavius muscle*, of small size, begins in the cord which results from the union of the fifth and sixth cervical nerves. It is directed over the outer part of the subclavian artery to the under surface of the subclavius muscle. This little nerve is commonly connected with the phrenic nerve in the neck or in the chest, by means of a slender filament.

Posterior Thoracic Nerve.

Posterior
thoracic

The posterior thoracic nerve (external respiratory of Bell) is distributed exclusively to the large serratus muscle. Formed in the substance of the middle scalenus muscle by two roots, one from the fifth and one from the sixth nerve, it reaches the surface of that muscle, lower than the nerve of the rhomboid muscle, and is often connected with that nerve. After emerging from

is the nerve

the scalenus muscle, the posterior thoracic nerve descends behind the brachial plexus on the outer surface of the serratus magnus, and extends nearly to the lower border of this muscle, supplying it with several branches (fig. 200). of the serratus magnus.

Suprascapular Nerve.

The suprascapular nerve arises from the first cord of the plexus, and bends beneath the trapezius to the dorsal surface of the scapula, where it is placed between the muscles and the bone. Entering the supraspinous fossa of the scapula, through the notch in its upper border, (beneath the ligament which crosses the notch,) the suprascapular nerve supplies two branches to the supraspinatus, one being near the upper, the other one near the lower part of the muscle; and it is then transmitted in front of the spine of the scapula to the infraspinous fossa, where it ends in the infraspinatus muscle. Supra. scap.
is nerve of supra-spinatus and infra-spinatus.

In the upper fossa of the scapula, a slender *articular filament* is given to the shoulder-joint, and in the lower fossa other offsets enter the same joint and the bone (scapula). Gives filmt. to shoulder-joint.

B. BRANCHES GIVEN FROM THE BRACHIAL PLEXUS BELOW THE CLAVICLE.

These, the remaining offsets of the brachial plexus, supply muscles on the fore-part of the chest, some of the muscles and integument of the shoulder, and the remainder of the upper limb.

Origin of nerves from the plexus. The several nerves now to be described are derived from the three great cords of the plexus in this order: Origin of branches fr. plexus.

From the outer cord,—the external of the two anterior thoracic nerves, the outer head of the median, and the musculo-cutaneous.

From the inner cord,—the inner of the two anterior thoracic, the internal cutaneous and ulnar, the nerve of Wrisberg, and the inner head of the median.

From the posterior cord,—the subscapular nerves, the musculo-spiral, and the circumflex.

The nerves traced to the spinal nerves. If the fasciuli, of which the principal nerves are composed, be followed through the plexus, they may be traced to the spinal nerves named for each in the subjoined table. The higher numbers refer to the cervical nerves, the unit to the dorsal nerve:— Origin of branches fr. spinal nerves.

Subscapular from	5.6.7.8.	External cutaneous from	5.6.7.
Circumflex	{ 5.6.7. or 5.6.7.8.1.	Ulnar nerve	{ 5.6.7.8.1. or 7.8.1. or 8.1.
Internal cutaneous	8.1.	Median nerve	{ 5.6.7.8.1. or 5.6.7.8.
Smaller internal cutaneous	8.1.	Musculo-spiral	6.7.8.

Some difference will be found between the statements of anatomists who have investigated the point—for instance, Scarpa (“*Annotationes Anatom.*”) and Kronenberg, (“*Plex. nervor. Structura et Virtutes*”)—with respect to the nerves to which the branches are assigned. Such difference is, doubtless, owing to the variation which actually exists in different cases.

Anterior Thoracic Nerves.

Anter. thor. Two in number. The anterior thoracic nerves, two in number, supply the pectoral muscles. They are distinguished as external and internal.

External. *a.* The *external*, or more superficial branch, crosses inwards over the axillary artery, and terminates in the great pectoral muscle.

Internal. *b.* The *internal*, or deeper branch, comes forwards between the axillary artery and vein to the small pectoral muscle, and is joined by a branch from the preceding. This nerve presents a plexiform division beneath the small pectoral muscle, and supplies branches to it and to the larger pectoral muscle.—The two preceding nerves are connected by a filament which forms a loop over the artery at its inner side.

They form loop on artery.

Subscapular Nerves.

Three subscapular nrvs. These nerves are three in number. They are distinguished as upper, lower, and long subscapular, and are destined for the subscapularis, teres major, and latissimus dorsi muscles.

Upper : *a.* The *upper* nerve, the smallest of the subscapular nerves, penetrates the upper part of the subscapular muscle. Lower : *b.* The *lower* nerve gives a branch to the same muscle at its axillary border, and ends in the teres major muscle. There is sometimes a distinct nerve for the last-named muscle. *c.* The *long subscapular* nerve, the largest of the three, runs along the lower border of the subscapular muscle to the latissimus dorsi, to which it is distributed.

Long subscapular.

Circumflex Nerve.

Circumflex nerve. The circumflex or axillary nerve (fig. 197) gives both muscular and cutaneous nerves to the shoulder. At first this nerve is placed behind the axillary artery, but at the lower border of the subscapular muscle it is inclined backwards, and separates into an upper and a lower division.

Divides into two parts.

Upper br. The *upper division* winds round the neck of the humerus, extending to the

anterior border of the deltoid muscle, which covers it. Branches are distributed to that muscle; and one or two *cutaneous filaments*, after penetrating the muscular fibres, are bent downwards, and supply the integument over the lower part of the muscle.

distribd. to deltoid and to skin.

The *lower division* of the circumflex nerve supplies, near its commencement, branches to the teres minor and to the back part of the deltoid, the nerve given to the former muscle presenting a gangliform enlargement. It is then directed forwards on the cutaneous surface of the deltoid, below its middle, and after perforating the deep fascia, ramifies in the integument over the lower two-thirds of the muscle (fig. 198,²), one branch extending to the integument over the long head of the triceps muscle.

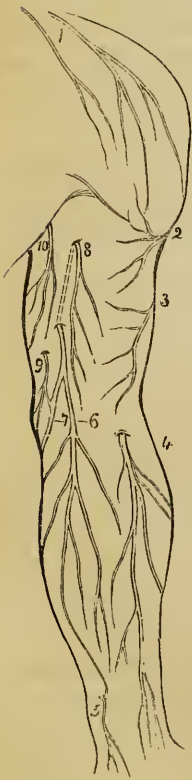
Lower br. supplies deltoid; teres minor; and skin.

An *articular filament* for the shoulder-joint arises from the circumflex nerve near its commencement. It continues with the trunk of the nerve to the lower border of the scapula, and enters the capsular ligament below the subscapular muscle.

Branch to shoulder-joint.

Internal Cutaneous Nerve.

Fig. 196.*



At its origin from the brachial plexus, this nerve is placed on the inner side of the axillary artery. As it descends, it approaches the surface, and becomes cutaneous about the middle of the arm. After perforating the fascia—or in some cases, before it has penetrated that membrane—the internal cutaneous nerve is divided into two parts; one (the outer part) being destined for the anterior, the other for the posterior surface of the fore-arm.

Int. cutan. nerve.

Cutaneous at middle of arm.

Division into two.

The *external branch*, fig. 196,⁶, crosses, at the bend of the elbow, over (in some cases behind) the median basilic vein. Below the elbow-joint, this branch is placed in front of the fore-arm—towards its inner side, with the cutaneous veins, and distributes filaments as far as the wrist; one of these is, in some instances, joined with a cutaneous branch of the ulnar nerve (fig. 196,⁵).

Part to front of fore-arm.

The *internal branch* of the nerve,⁷, inclines obliquely downwards, at the inner side of the basilic vein, and winding to the back of the fore-arm, over the prominence of the internal condyle of the humerus, extends somewhat below the middle of the fore-arm, fig. 198,⁷. Above the elbow this branch is connected with the smaller internal cutaneous nerve, (nerve of Wrisberg,)

Part to back of fore-arm.

* Plan of the cutaneous nerves on the front of the arm.—1. Supraclavicular nerves. 2. Branches of the circumflex nerve. 3. External cutaneous branch.

and afterwards communicates with the outer division of the internal cutaneous.*

Cutaneous
offset in
upper arm.

Near the axilla the internal cutaneous gives an offset (fig. 196,⁸) through the fascia to the integument of the arm. This small branch lies a little to the outer side of the nerve from which it springs, and reaches to, or nearly to, the elbow, distributing filaments outwards to the integument over the biceps muscle. The same branch is often connected with the intercosto-humeral nerve.

Summary.

Summary.—The internal cutaneous nerve gives filaments to the inner and fore part of the arm, and to the inner part of the fore arm, on the anterior and the posterior surface. Its offsets are connected with the smaller internal cutaneous nerve, and with the ulnar nerve.

Small Internal Cutaneous Nerve.

Nerve of
Wrisberg.

The smaller internal cutaneous nerve (nerv. cutaneus internus minor vel ulnaris Wrisbergii,—Klint,† (fig. 196,⁹) assists the larger internal cutaneous nerve in supplying the inner side of the arm.

Varies in
place of
origin fr.
plexus.

This nerve commonly arises from the inner cord of the brachial plexus in connexion with the larger internal cutaneous and the ulnar nerves; but it is sometimes derived from the posterior cord of the plexus with the musculo-spiral and circumflex nerves. In the axilla, the nerve of Wrisberg is concealed at first by the axillary vein, but it soon appears on the inner side of that vessel, and communicates with the intercosto-humeral nerve. It is then placed along the inner side of the brachial vessels to about the middle of the arm, where it pierces the fascia, and is continued immediately beneath the integument to the interval between the internal condyle of the humerus and the olecranon, fig. 198,⁶.

Position.

Perforates
fascia.

neous (upper branch) of the musculo-spiral nerve. 4. Musculo-cutaneous. 5. Branch of ulnar nerve. 6. Internal cutaneous: external branch. 7. Inner branch of that nerve. 8. Offset to the upper-arm from same. 9. Nerve of Wrisberg. 10. Intercosto-humeral nerve.

* Mr. Swan describes a connexion near the wrist between this branch and the dorsal branch of the ulnar nerve.

† This nerve appears to have been first made known by Wrisberg in his lectures; and the first published account of it is contained in an Essay by one

Branches. In the lower third of the arm, branches of this little nerve are directed almost horizontally to the integument on its posterior aspect; and the nerve ends at the elbow, by dividing into several filaments, some of which are directed forwards over the inner condyle of the humerus, while others are prolonged downwards behind the olecranon.

Branches.

Connexion with intercosto-humeral nerve. The connexion between the nerve of Wrisberg and the intercosto-humeral nerve presents much variety in different cases:—in some, there are two or more inter-communications, forming a kind of plexus on the posterior boundary of the axillary space; in others, the intercosto-humeral nerve is of larger size than usual, and takes the place of the nerve of Wrisberg, only receiving in the axilla a small filament from the brachial plexus, and this small communicating filament represents in such cases the nerve of Wrisberg.

Connexion w. intercosto-humeral.

Summary. The nerve of Wrisberg is the cutaneous nerve of the lower half of the upper arm on its inner and posterior aspect. It supplies the skin below the cutaneous branch of the musculo-spiral nerve.

Summary.

Musculo-cutaneous Nerve.

The musculo-cutaneous or external cutaneous nerve (fig. 197, ⁵)^{cu} supplies branches to the muscles of the arm, and to the integument of the forearm. It is deeply placed between the muscles as far as the elbow, and below this point is immediately under the integument.

Musculo-cutaneous outline of Nerve.

Muscular part. Arising from the brachial plexus opposite the small pectoral muscle, this nerve perforates the coraco-brachialis muscle;* and passing obliquely across the arm between the biceps and brachialis anticus muscles reaches the outer side of the limb a little above the elbow. Here it perforates the fascia and commences its subcutaneous course on the forearm, which will presently be described.

Course and connexions of muscular part.

Branches. As it descends through the arm, the nerve distributes branches to the muscles as follows:—Before it reaches the coraco-brachialis, one branch is given to that muscle and to the short head of the biceps; and other filaments are furnished to the coraco-brachialis, while the nerve lies within its fibres. Lower down, where the nerve is placed between the biceps and brachialis anticus, branches are supplied to both those muscles. Lastly, the humerus and the elbow-joint receive small filaments from the same source.

Muscular branches.

of his pupils; see Klint, "De Nervis Brachii," in Ludwig "Script. Nevrol. min." tom. iii.

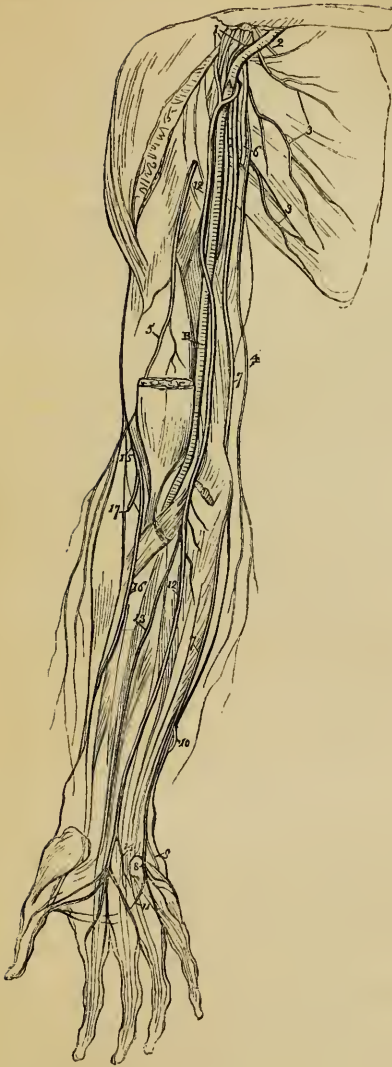- Cutaneous part ; position. The CUTANEOUS PART of the musculo-cutaneous nerve, fig. 196,⁴, approaching the integument at the outer side of the biceps muscle, and nearly opposite the elbow-joint, crosses behind the median-cephalic vein, and inclining outwards, divides into two branches which supply the integument on the outer side of the forearm, one on its anterior, the other on its posterior aspect.
- Two branches.
- Anter. br. The *anterior branch* descends near the radial border of the forearm. It is placed in front of the radial artery near the wrist, and distributes some filaments over the ball of the thumb. Piercing then the fascia, it accompanies the artery to the back part of the carpus. This branch is connected at the wrist with an offset of the radial nerve.
- w. radial artery.
- Poster. br. The *posterior branch* of the external cutaneous nerve is directed outwards to the back of the forearm, and ramifies in the integument of its lower third, extending as far as the wrist, fig. 198,¹⁰. It communicates with a branch of the radial nerve, and with the external cutaneous branch of the musculo-spiral nerve.
- Position.
- Variation in course of nerve. *Some peculiarities* of the nerve. In some cases, it does not perforate the coraco-brachialis muscle. It is from time to time found to be an offset of the median nerve ; and in this case, the coraco-brachialis muscle receives a separate branch from the brachial plexus.
- Summary. *Summary.*—The musculo-cutaneous nerve supplies three muscles in front of the humerus, and the integument on the outer side of the forearm. Communications are established between it and the radial and the external cutaneous branch of the musculo-spiral.

ULNAR NERVE.

- Outline of Nerve. The ulnar nerve, (fig. 197,⁷) supplies both muscular and cutaneous branches to the fore-arm and the hand. In its whole course it lies along the inner (ulnar) side of the limb
- Position in the arm. At its commencement the ulnar nerve lies at the inner side of the axillary artery, and retains the same position with respect to the brachial vessels nearly to the middle of the arm. From this point it gradually inclines inwards, through the internal

* The nerve is sometimes named "perforans Casserii," the first term of this designation having reference to the mode in which the nerve is connected with the coraco-brachialis muscle. As regards the association of the name of Casserius with the musculo-cutaneous nerve, it should be mentioned that this anatomist named the muscle "perforatus," but he does not appear to have distinguished the nerve in the manner which seems to be implied. See "Julii Casserii Placentini Tab. Anatom.:" (D. Bucetius explicat. addidit), Tab. 19 and 20. Francforti, 1632.

Fig. 197.*



intermuscular septum, to the interval between the olecranon and the inner condyle of the humerus, and reaches the forearm between the two heads of the flexor carpi ulnaris. From the axilla to the place at which it sinks beneath the muscle last named, the nerve is covered only by the fascia, and may be felt through the integument, a little above the elbow.

IN THE FOREARM : The ulnar nerve extending in a straight course to the outer side of the pisiform bone of the carpus, is concealed by the flexor carpi ulnaris, as far as the middle of this part of the limb ; and thence onwards, it lies at the outer side of the same muscle, covered only by the integument and fascia. In the whole course from the elbow to the carpus, it rests against the deep flexor of the fingers ; and the ulnar artery,

Position in the forearm.

Connexion w. ulnar artery.

which is separated from the nerve by a considerable interval at the elbow, is in contact with it (on the outer side) in the lower half of the forearm.

* A plan of the nerves of the arm. A. Axillary artery. B. Brachial artery. Nerves : 2. Suprascapular. 3. Subscapular. 4. Internal cutaneous. 5. Musculo-cutaneous. 6. Circumflex. 7. Ulnar. 8. Superficial branch of the same on to the hand. 12. Median. 13. Anterior interosseous. 15. Musculo-spiral. 16. Radial. 17. Posterior interosseous.

No br.
in arm.

Branches.—In its course along the upper arm the ulnar nerve gives off no branch. The offsets derived from it at the elbow and in the forearm, are as follows:—

Articular
br.

1. *Articular nerves.* These consist of some small filaments supplied to the elbow-joint, as the nerve passes close behind the joint.

Suppls. two
muscles of
forearm.

2. *Muscular branches.* One branch enters the upper part of the flexor carpi ulnaris, and another supplies the two inner divisions (the inner half) of the deep flexor of the fingers.

Cutans. br.
in forearm.

3. *Cutaneous branches.* These are two small nerves that arise about the middle of the forearm, by a common trunk. One pierces the fascia, and turning downwards, joins a branch of the internal cutaneous nerve, fig. 196,⁵. This branch is often absent. The second, a *palmar branch*, lies on the ulnar artery, which it accompanies to the hand. This little nerve gives filaments around the vessel, and ramifies in the integument of the hand, joining in some cases with other cutaneous offsets of the ulnar or median nerve.

Dorsal
branch
supplies
fingers,

4. *Dorsal branch of the hand.* This large offset, leaving the trunk of the ulnar nerve about two inches above the wrist, winds backwards beneath the flexor carpi ulnaris, and divides into branches, one of which ramifies on the inner side of the little finger, and another divides to supply the contiguous sides of that finger and the ring finger. On the back of the metacarpus, this nerve joins with an offset of the radial nerve, and from the union of the two, filaments are distributed to the opposed sides of the ring finger and the middle finger. The several posterior digital nerves now described are united with offsets directed backwards from the anterior digital nerves furnished by the median and ulnar.

and joins
radial nve.
Connexion
w. anterior
digital
nerves.

Articular nerves. Besides the foregoing branches the ulnar nerve supplies some filaments to the wrist-joint.

Palmar part
of nerve.

PALMAR PART OF ULNAR NERVE.—On the annular ligament, or somewhat beyond it, the nerve separates into two parts, one of which is superficial, and the other is deeply placed in the hand.

Superficial
part: its
branches.

a. The superficial division accompanying the ulnar artery, supplies digital nerves at the inner side of the hand, and gives likewise a branch to the palmaris brevis muscle, and offsets to the integument.*

Digital
nerves for
little finger
and one
side of ring
finger.

Digital nerves. One of these belongs to the ulnar side of the little finger. The other is connected in the palm of the hand with a digital branch of the median nerve, and at the cleft between the little and ring fingers, gives an offset to the opposed sides of each. The disposition of the digital branches on the fingers is the same as that of the median nerve, to be presently described.

* These may be found to communicate with the palmar nerves given from the median or ulnar.

b. The *deep palmar division* of the ulnar nerve follows the course of the deep palmar arch of vessels, beneath the long flexor tendons, and in contact with the interosseous muscles. Deep palmar nerve.

Branches.—At its commencement, branches leave the deep palmar nerve to supply the small muscles of the little finger. As it lies across the metacarpal bones, it distributes two branches to each interosseous space—one for the palmar, the other for the dorsal interosseous muscle; and the branches of the second and third palmar interossei supply filaments to the innermost two lumbricales muscles. Opposite the space between the thumb and the index-finger, the nerve ends in branches to the adductor pollicis, and the inner part of the flexor brevis pollicis. Branches to muscles of little finger, to interossei, to lumbricales, and some muscles of thumb.

Summary.—The ulnar nerve gives cutaneous filaments to the lower part of the forearm (to a small extent), and to the hand on its palmar and dorsal aspects. It supplies the following muscles, viz.:—the ulnar flexor of the carpus, the deep flexor of the fingers (its inner half), the short muscles of the little finger, with the palmaris brevis, the inner part of the short muscles of the thumb, and the interosseous muscles of the hand, with the two internal lumbricales. Lastly, it contributes to the supply of the elbow and the wrist joints. Summary. Cutaneous, muscular and articular brs.

MEDIAN NERVE.

This nerve, fig. 197, is placed along the middle of the limb (whence its name), and it occupies a position intermediate between the ulnar and the musculo-spiral (with the radial) nerves. Beginning by two roots (one from the outer, the other from the inner cord of the brachial plexus), which unite before the axillary artery or on its outer side, the nerve is in contact with that artery and its continuation, the brachial artery, nearly to the elbow. In this position (near the elbow-joint) it is placed at the inner side of the vessel, having crossed obliquely over it. Median nerve. Position. Connexions.

IN THE FOREARM:—The median nerve, after passing between the two heads of the pronator teres, is placed between the superficial and the deep flexor muscles of the fingers, until it arrives at the lower end of the forearm. Here it is for a short space covered only by the integument and the fascia, and it lies between the radial flexor of the carpus, and the superficial flexor of the fingers. Finally, the nerve leaves the forearm beneath the anterior annular ligament of the carpus. Position in forearm.

Branches.—The median nerve usually gives no offset in the Branches.

upper-arm. In the forearm it distributes branches to the muscles in its immediate neighbourhood, and a single cutaneous filament. These are disposed as follows :

- To muscles of the forearm.
1. *Muscular branches.* All the muscles on the front of the forearm (pronators and flexors), except the flexor carpi ulnaris and part of the deep flexor of the fingers, are supplied from the median nerve, and the several branches separate from the nerve near the elbow-joint. The branch furnished to the pronator teres often arises above the joint.
- Anter. inteross. is very long ; placed btw. deepest muscles, and supplies them.
2. *Anterior interosseous nerve.* This is the longest branch of the median nerve, and it supplies the deeper muscles of the forearm. Commencing at the upper part of the forearm, beneath the superficial flexor of the fingers, the interosseous nerve courses downward with the anterior interosseous artery on the interosseous membrane, and between the long flexor of the thumb and the deep flexor of the fingers, to the pronator quadratus muscle, in which it ends. Offsets are distributed to the two muscles between which the nerve lies in its progress downwards.
- Cutans. palmar br.
3. *Cutaneous palmar branch.* This small nerve pierces the fascia of the forearm close to the annular ligament, and after crossing over that ligament, ends in the integument of the palm about its middle. It is connected with the cutaneous palmar branch of the ulnar nerve, and distributes some filaments over the ball of the thumb. The filaments last referred to communicate with offsets of the radial or the external cutaneous nerve.

Position of nerve on hand.

Separates into two primary parts.

THE MEDIAN NERVE IN THE HAND.—After passing from beneath the annular ligament of the carpus, the median nerve is covered by the palmar fascia with the integument, and rests against the tendons of the flexor muscles. Somewhat enlarged, and slightly reddish in colour, it here separates into two parts of nearly equal size. One of these (the external one) supplies some of the short muscles of the thumb, and gives digital branches to the thumb and the index finger ; and the second division supplies the middle finger, and in part the index and ring fingers. The branches thus indicated are distributed as follows :—

- Supplies part of muscles of thumb.
1. *Branch to muscles of the thumb.* This short nerve subdivides for the abductor, the opponens, and the outer head of the flexor brevis pollicis muscle.—The remainder of the small mass of muscles of the thenar eminence (the part placed at the inner side of the long flexor tendon) is supplied by the ulnar nerve.
- Digital nerves.
2. *Digital nerves.* The digital nerves are five in number, and belong to the thumb, and the fingers as far as the outer side of the ring finger. As they approach the cleft between the fingers, these nerves are close to the integument in the intervals between the processes of the palmar fascia : the

three external remain undivided, but the fourth and fifth bifurcate and supply each the contiguous sides of two fingers.

The *first* and *second* nerves lie along the sides of the thumb, and the former (the outer one) is connected with the radial nerve over the ball of the thumb. First and second.

The *third*, destined for the radial side of the index finger, gives a muscular branch to the first or most external lumbricalis muscle. Third.

The *fourth* supplies the second lumbricalis, and divides into branches for the opposed sides of the index and middle fingers. Fourth.

The *fifth*, the most internal of the digital nerves, is connected with the ulnar nerve, and splits to furnish a branch each to the ring and middle fingers. Fifth.

Each digital nerve divides at the end of the finger into two branches, one of which supplies the pulp on the fore part of the finger; the other ramifies beneath the nail. Branches pass from each nerve forwards and backwards to the integument of the finger: and one larger than the rest inclines backwards by the side of the first phalanx of the finger, and after joining the dorsal digital nerve, ends in the integument over the last phalanx. Arrange-
ment of
digital
nerves.

Summary.—The median nerve gives cutaneous branches to the palm, and to several fingers. It supplies the pronator muscles, the flexors of the carpus, and the long flexors of the fingers (except the ulnar flexor of the carpus, and part of the deep flexor of the fingers), and likewise the outer half of the short muscles of the thumb, and two lumbricales. Median
nerve dis-
tributed to
pronator
and flexor
muscles and
to skin of
hand.

Some similarity will be observed between the course and distribution of the median and ulnar nerves. Neither gives any offset in the arm. Together they supply all the muscles in front of the forearm and the hand, and together they supply the skin of the palmar surface of the hand, and impart tactile power to all the fingers. Parallel
between
median and
ulnar nervs.

MUSCULO-SPIRAL NERVE.

The musculo-spiral nerve, the largest offset of the brachial plexus, fig. 197, occupies chiefly the back part of the limb, and supplies nerves to the extensor muscles, as well as, to some extent, to the skin likewise. Size of nrv.

At its commencement, this nerve is placed behind the axillary vessels. In its progress downwards it winds in a spiral manner (whence the distinctive name) from the inner to the outer side Positior.
and
connexions.

of the limb behind the humerus, between it and the triceps muscle. On the outer side of the arm the nerve descends in the interval between the supinator longus and brachialis anti-cus muscles, to the outer condyle of the humerus, where it ends by dividing into the radial and posterior interosseous nerves.

Fig. 198.*

Divides
near bend
of elbow.

Branches in
upper-arm.

The branches given from the musculo-spiral nerve in its course through the upper-arm, are found on the inner side of the humerus, behind that bone, and on its outer side.

a.—*Internal branches.*—These consist of muscular and cutaneous branches :—

Brs. for
triceps
muscle.

1. *Muscular branches* for the inner and middle heads of the triceps. That for the inner division of the muscle is long and slender ; it lies by the side of the ulnar nerve, and reaches as far as the lower third of the upper arm.

Internal
cutaneous.

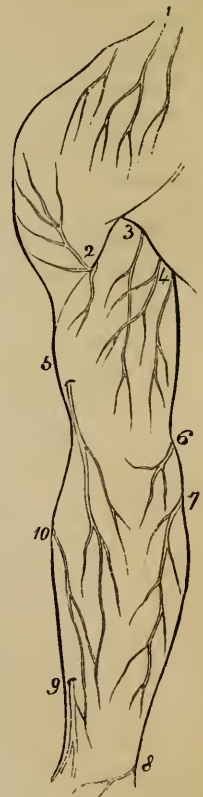2. The *internal cutaneous* branch of the musculo-spiral nerve, fig. 198, ³, commonly unites in origin with the preceding. It winds backwards beneath the intercosto-humeral nerve, and after supplying offsets to the skin, ends about two inches from the olecranon ; in some bodies it extends as far as the olecranon. This nerve is accompanied by a small cutaneous artery.

Brs. for
triceps and
anconeus.

b. *Posterior branches.*—Whilst the musculo-spiral nerve is between the triceps muscle and the humerus, it gives off a large fasciculus, which subdivides into muscular branches.—These *muscular branches* supply the outer head of the triceps muscle and the anconeus. The *branch* of the *anconeus* is remarkable for its length, being, at the same time, slender ; it descends in the substance of the triceps, to the interval between the outer condyle of the humerus and the olecranon, to terminate in the muscle for which it is destined.

Brs. for
two muscles
of forearm.

c. *External branches.* This series comprises branches to muscles and long cutaneous branches.—1. *The Muscular branches*, supply the supinator longus, extensor carpi radialis longior, (the extensor carpi radialis brevior



* Plan of the cutaneous nerves of the back of the arm and forearm. 1. Supra-acromial branches of the cervical plexus. 2. Cutaneous branches of the circumflex nerve. 3. Internal cutaneous of the musculo-spiral. 4. Intercosto-humeral branches. 5. External cutaneous (inferior) of the musculo-spiral. 6. Ending of the nerve of Wrisberg. 7. Part of the internal cutaneous for the back of the forearm. 8. Offset from the dorsal branch of the ulnar nerve. 9. Radial nerve. 10. Branch of the musculo-cutaneous for the back of the forearm.

receiving its nerve from the posterior interosseous,) and in most cases the brachialis anticus.

2. *External cutaneous branches.* These are two in number, and are disposed as follows :—

The *upper branch*, the smaller of the two, fig.196, ³, is directed downwards to the fore part of the elbow, along the cephalic vein, and distributes filaments to the lower half of the upper-arm, on its anterior aspect. The *lower branch* extends as far as the wrist, fig. 198, ⁵, distributing offsets to the lower half of the arm, and to the forearm, on their posterior aspect. It appears beneath the integument at the outer side of the arm, about its middle, and passes to the forearm over the outer side of the bend of the elbow. About the middle of the forearm it turns from the outer to the posterior aspect of the limb, and is connected near the wrist with a branch of the external cutaneous nerve.

Two extern. cutaneous. brs.

Lower br., reaches wrist.

Of the two nerves which result from the division of the musculo-spiral, one, the radial, is altogether a cutaneous nerve, and the other (posterior interosseous) is the muscular nerve of the back of the forearm.

Primary divisions of musculo-spiral.

A. RADIAL NERVE.

The radial nerve, after separating from the musculo-spiral, is placed in front of the forearm, close to its outer side, and afterwards turning backwards, is distributed to the integument of the back of the hand. At first it is concealed by the long supinator muscle, and lies a little to the outer side of the radial artery. This position beneath the supinator is retained to about three inches from the lower end of the radius, where the nerve turns outwards beneath the tendon of that muscle, and becomes subcutaneous. Now it separates into two branches, which ramify in the integument over the dorsal aspect of the thumb and the next two fingers, in the following manner :

Radial a cutaneous nerve.

Position, change in,

Division.

Branches. One branch, the *external* one, extends to the radial side of the thumb, and is joined by a branch of the external cutaneous nerve. It distributes filaments over the ball of the thumb.

External branch.

The *internal division* of the radial nerve communicates with a branch of the external cutaneous nerve on the back of the forearm, and on the hand joins in an arch with the dorsal branch of the ulnar nerve. It then divides into digital nerves for the outer fingers.—*Dorsal digital nerves.* One of these ramifies on the ulnar side of the thumb, and the second on the radial side of the index finger. The third divides between the opposed sides of the index and middle fingers ; and the fourth between the middle and ring fingers. This last branch is connected with a branch of the ulnar nerve. On the sides of the fingers the posterior digital nerves now described join offsets sent backwards from the palmar digital nerves.

Internal branch.

Digital nerves.

B. POSTERIOR INTEROSSEOUS NERVE.

Poster.
inteross.
a muscular
nerve.

This nerve, the larger of the two divisions of the musculo-spiral nerve, winds to the back of the forearm through the fibres of the supinator brevis muscle, and is prolonged between the deep and superficial layers of the extensor muscles to the interosseus membrane, which it approaches about the middle of the forearm.

Course.

Much diminished in size by the separation of numerous branches for the muscles, the nerve at the lower part of the forearm lies beneath the extensor of the last phalanx of the thumb and the tendons of the common extensor of the fingers, and terminates on the back of the carpus in a gangliform enlargement. From this body filaments are given to the ligaments and articulations on which it rests.

Termination
on
carpus.

Supplies
extensor
muscles and
supinator
brevis.

The *branches* of the interosseous nerve enter the surrounding muscles, viz. : the extensor carpi radialis brevis and supinator brevis, the superficial layer of extensor muscles, except the anconeus, and the deep layer of the same muscles ;—that is to say, the nerve supplies the supinators and the extensors of the carpus and of the fingers, with the exception of the supinator longus and the extensor carpi radialis longior.

Summary.
Nerve supplies
extor.
and supinr.
muscles of
limb.

Summary of the musculo-spiral nerve.—The trunk of the nerve supplies the extensor muscles of the elbow-joint, and gives a filament to one of the flexors of the same joint (brachialis anticus), but this muscle receives its principal nerves from another source. Before dividing, the nerve likewise gives offsets to two muscles of the forearm (the long supinator, and the long radial extensor of the carpus). The posterior interosseous division distributes nerves to the remaining muscles on the outer and back part of the forearm (the short supinator and the extensors).

Cutaneous
branches.

Cutaneous nerves are distributed, from the trunk of the nerve and its radial division, to the lower part of the upper arm, to the fore-arm, and to the hand—on the posterior and outer aspect of each.

ANTERIOR DIVISIONS OF THE DORSAL NERVES—

INTERCOSTAL NERVES.

Intercostal
nerves.

These nerves, fig. 200, which from their position with respect to the ribs are named *intercostal*, are twelve in number, and

are distributed to the walls of the thorax and abdomen. The connecting cords with the sympathetic nerve are placed in the intercostal spaces, close to the vertebræ.

Connexion
w. sympath.

The intercostal nerves pass separately to their destination, without forming any plexus by the connexion or interlacement of their fibres, and in this respect they differ from the other spinal nerves. From the intervertebral foramina they are directed transversely across the trunk, and nearly parallel one to the other. The upper nerves, with the exception of the first, are confined to the parietes of the thorax, while the lower nerves are continued from the intercostal spaces to the muscles and integument of the abdomen. This difference in distribution constitutes the ground of the division of the intercostal nerves into two sets, between which the nerves are divided equally.

Do not
form plexus.

Course.

Division
into two
sets.

THE UPPER INTERCOSTAL NERVES.

In their course to the fore part of the chest, these nerves accompany the intercostal bloodvessels. After a short space they pass between the strata of the intercostal muscles, and, about midway between the vertebræ and the sternum, give off the lateral cutaneous branches. The nerves are now continued forwards, amid the fibres of the internal intercostal muscles as far as the costal cartilages, where they come into contact with the pleura. In approaching the sternum, they cross the internal mammary artery and the fibres of the triangularis sterni muscle. Finally these nerves pierce the internal intercostal muscle and the greater pectoral, and end in the integument, under the name of the anterior cutaneous nerves of the thorax.

Upper six
(first ex-
cepted).
Course and
connexions
in intercost.
spaces.

Become
subcutane-
ous at
sternum.

Branches.—Besides the cutaneous nerves (two sets) already indicated, many branches are distributed from the intercostal nerves to the neighbouring muscles. The several offsets require separate notice.

Branches.

a. The *lateral cutaneous nerves of the thorax*, fig. 199, pierce the external intercostal and serratus magnus muscles in the same line, a little behind the level of the great pectoral muscle. Each of these nerves, except that from the second intercostal, (the first intercostal nerve has already been excluded from the general account of these nerves,) divides into two branches, which reach the integument at the same time, or at a short distance one from the other, and take opposite directions, one forward, the other backward, and hence are named anterior and posterior.

Lateral
cutaneous.

Division
into two
branches.

Anter. brs. The *anterior branches*, ², are continued forwards to where the cutaneous nerves, reflected outwards from the fore part of the thorax, end. Several of these branches reach the mammary gland and the nipple; and from the lower nerves offsets are supplied to the digitations of the external oblique muscle of the abdomen.

Poster. brs. The *posterior branches*, ³, turn backwards to the integument over the scapula and the latissimus dorsi muscle. That derived from the second intercostal nerve is the largest of these branches, and ends in the skin of the arm; it will be presently noticed under the name "intercosto-humeral nerve." The branch from the third nerve ramifies in the axillary space, and a few filaments likewise reach the arm.

Anter. cutaneous nerves.

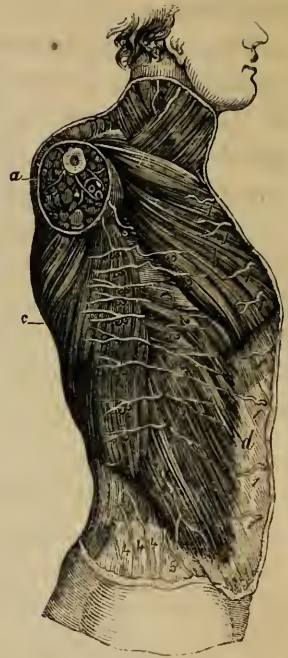Branches to mammary gland.

Muscular.

b. The *anterior cutaneous nerves of the thorax*, ¹, (reflected nerves,—A. Cooper,) which are the terminal twigs of the intercostal nerves, are reflected outwards in the integument over the great pectoral muscle. The branch from the second nerve is connected with the supraclavicular and the lateral cutaneous nerves; those from the third and fourth nerves are distributed to the mammary gland.

c. *Muscular branches*.—Numerous filaments, which are usually slender and of various lengths, are supplied to the intercostal muscles, and the triangulus sterni. At the anterior part of the chest, some of these branches cross the cartilages of the ribs, passing from one intercostal space to another.

Fig. 199.*



PECULIARITIES OF CERTAIN DORSAL NERVES.

1. First Dorsal Nerve.

First dorsal joins brachial plexus. No lateral

The anterior division of this nerve enters almost wholly into the brachial plexus. Usually it does not supply a lateral cutaneous branch; but when that ordinarily given from the

* Plan of the cutaneous nerves of the chest and abdomen (altered from a plate of M. Bourguery). *a.* Section of the arm. *b.* Pectoral muscle. *c.* Latissimus dorsi. *d.* External oblique. *e.* Serratus magnus. 1, 1, 1. Anterior cutaneous nerves of the chest and belly. 2, 2, 2. Anterior branches of the lateral cutaneous nerves of the chest and belly. 3, 3, 3. Posterior branches of the same. 4, 4, 4. Cutaneous branches from the posterior divisions of the lumbar nerves. 5. Ilio-hypogastric. 6. Small occipital nerve.

second dorsal nerve (intercosto-humeral nerve) is wanting, a branch from the first takes its place. Before emerging from the thorax to join the brachial plexus, this nerve gives off a small *intercostal branch*, which courses along the first intercostal space, in the manner of the other intercostal nerves. From this branch is derived the first of the anterior cutaneous nerves of the thorax. The cutaneous nerve, however, is wanting in some cases.

cutaneous br.
Gives a small intercostal nerve.
Anter. cutaneous.

2. Second Intercostal Nerve.

The second intercostal nerve differs from the rest, chiefly in the size of its lateral cutaneous branch. This branch is the largest of the series of lateral cutaneous nerves. It commonly wants the anterior division, and the posterior one is distributed to the skin of the arm, under the name intercosto-humeral nerve.

Second. nrv.
Peculiarity in size of lateral cutan. br.

The *intercosto-humeral* nerve, proceeding from the source just indicated, crosses the axillary space to reach the arm, and is connected in the axilla with an offset of the nerve of Wrisberg. Now penetrating the fascia, it becomes subcutaneous, and ramifies in the integument of the upper half of the arm, on its inner and posterior aspect, fig. 198, 4: a few filaments reach the integument over the scapula. The branches of this nerve cross over the internal cutaneous offset of the musculo-spiral nerve, and a communication is established between the two.—The size of the intercosto-humeral nerve (and the same may be said of the extent to which it supplies the integument) is in the inverse proportion to the size of the other cutaneous nerves of the upper arm, especially the nerve of Wrisberg (see *ante*, page 839).

Intercosto-humeral.
Connexion w. nerve of Wrisberg. Course in arm.

THE LOWER INTERCOSTAL NERVES.

The lower intercostal nerves, with the exception of the last, pass through the intercostal spaces, (fig. 200;) and in this part of their course they have the same arrangement as the nerves of the upper series. From the anterior ends of the intercostal spaces, they are continued, between the internal oblique and the transverse muscle of the abdomen, to the outer edge of the rectus. Perforating its sheath, they then enter the substance of this muscle, and terminate in small cutaneous branches (anterior cutaneous).

Nerves at first betw. ribs like upp. nerves; then continued betw. abdominal muscles.

These nerves supply the intercostal and abdominal muscles, and they are connected one with another between the muscles of the abdomen. About the middle of their course, offsets (lateral cutaneous nerves of the abdomen) are transmitted to the integument as from the upper intercostal nerves.

Branches.

Lateral cutaneous nerves.

a.—The *lateral cutaneous nerves of the abdomen*, fig. 199, pass to the integument through the external intercostal, and external oblique muscles, in a line with the corresponding nerves on the thorax, and divide in the same manner into anterior and posterior branches.

their anterior; and

The *anterior branches* are the larger, and are directed inwards in the superficial fascia, with small cutaneous arteries, nearly to the edge of the rectus muscle.

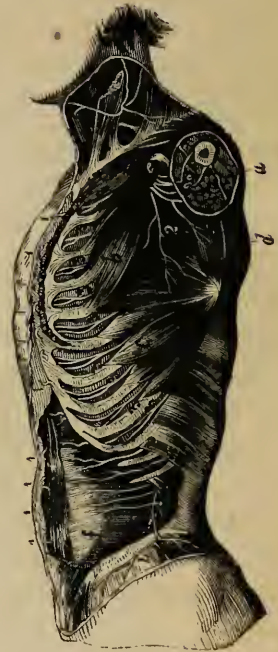posterior branches.

The *posterior branches* bend backwards over the latissimus dorsi muscle, and extend towards the cutaneous nerves of the back.

Anterior cutaneous nerves.

b.—The *anterior cutaneous nerves*† of the abdomen become subcutaneous near the linea alba, with small perforating arteries. Their number and position is very uncertain. They are directed outwards towards the lateral cutaneous nerves, fig. 199.

Fig. 200.*



Last dorsal is below the last rib.

Last Dorsal Nerve.

The anterior division of this nerve is below the last rib, and is contained altogether in the abdominal wall. The nerve has the general course and distribution of the others, between the internal oblique and transversalis, but before taking its place between those muscles, it crosses the upper part of the quadratus lumborum, and pierces the aponeurosis of the transverse muscle (lumbar fascia.) This nerve is connected by offsets with the nerve above, and occasionally with the ilio-hypogastric branch

* Plan of the intercostal nerves, (altered from Bougery.) *a.* Cut surface of the arm. *b.* Pectoralis minor muscle. *c.* Serratus magnus muscle. *d.* Subscapular muscle. *f.* Transverse muscle of the abdomen. 1, 1, 1, 1. Anterior cutaneous nerves of the thorax and abdomen. 2. Posterior thoracic nerve. 3, 3, 3. Intercostal nerves. 4. Lateral cutaneous branch of the last dorsal nerve.

† A second set of anterior cutaneous branches is described by Professor Cruveilhier as existing at the outer edge of the rectus muscle.

of the lumbar plexus. Near the spine it sometimes communicates with the first lumbar nerve by means of a small cord (dorsi-lumbar) in the substance of the quadratus lumborum.

The *lateral cutaneous branch* of the last dorsal nerve (fig. 200, 4,) becomes subcutaneous by passing through both oblique muscles: it is then directed downwards over the crest of the ilium to the integument covering the fore part of the gluteal region and the upper and outer part of the thigh, some filaments reaching as far as the great trochanter of the femur.

Lateral cutaneous br. over gluteal region.

ANTERIOR DIVISIONS OF THE LUMBAR NERVES.

The anterior divisions of the lumbar nerves increase in size from the first to the fifth, and all, except the fifth, besides giving off branches outwards, are connected together by anastomotic loops, so as to form the lumbar plexus. On leaving the intervertebral foramina, these nerves are connected by filaments with the sympathetic nerve, and the filaments are longer than those connected with other spinal nerves, in consequence of the position of the lumbar sympathetic ganglia,—on the fore part of the bodies of the vertebræ. In the same situation small twigs are furnished to the psoas and quadratus lumborum muscles.

Lumb. nvs. Four go to form lumbar plexus.

Connexion w. sympath.

Twigs to psoas and quad. lumb.

The anterior division of the fifth lumbar nerve, as just stated, does not enter into the lumbar plexus. Having received a vertical branch from the nerve next above it, it descends to join the anterior division of the first sacral nerve, and thus forms part of the sacral plexus. The cord resulting from the union of a part of the fourth with the fifth nerve, is named the *lumbo-sacral* nerve.

The fifth, with part of fourth, joins the sacral plexus.

Lumbo-sacral cord.

Superior Gluteal Nerve.

Before joining the first sacral nerve, the lumbo-sacral cord gives off from behind the superior gluteal nerve, which leaves the pelvis through the large sacro-sciatic foramen, above the pyriformis muscle, and divides, like the gluteal artery, into two branches, which are distributed chiefly to the smaller gluteal muscles.

Superior gluteal

The *upper* branch runs together with the gluteal artery, along the origin of the gluteus minimus, and is lost in it, and in the gluteus medius. The *lower* branch crosses over the middle of the gluteus minimus, between it and the gluteus medius, and having supplied filaments to both these muscles, is continued forwards, and terminates in the tensor muscle of the fascia lata.

supplies glut. med. glut. minim. and tensor fasc. lat.

LUMBAR PLEXUS.

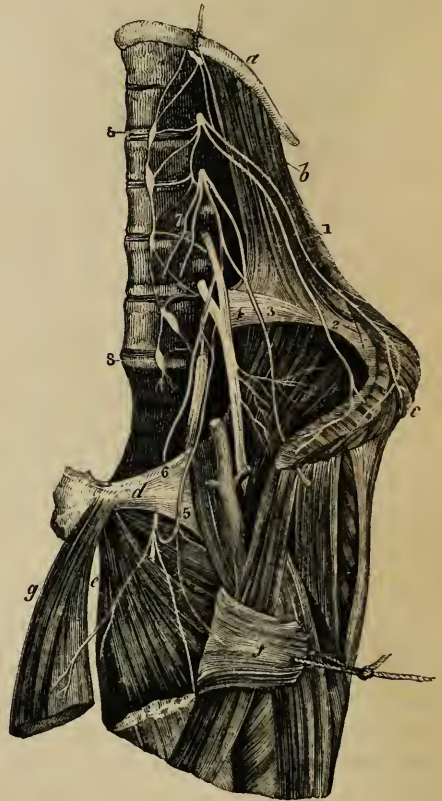
Lumbar
plexus.

The lumbar plexus is formed by the connexion of the anterior divisions of the four upper lumbar nerves. It is placed in the substance of the psoas muscle, in front of the transverse processes of the corresponding vertebræ. Above, the plexus is narrow, and is sometimes connected with the last dorsal nerve by a small filament named dorsi-lumbar; below it is wider, and is joined to the sacral plexus by means of the lumbo-sacral nerve.

Construc-
tion of
plexus and
origin of
branches.

The arrangement of the nerves constituting the plexus, and the mode of origin of its several branches, may be thus stated:—The first nerve gives off the ilio-hypogastric and ilio-inguinal nerves, and sends downwards a communicating branch to the second nerve. The second furnishes the genito-crural and external cutaneous nerves, and gives a connecting branch to the third nerve. From the third nerve, besides the descending branch to the fourth, two branches proceed: one of which, the larger, forms part of the anterior crural nerve; the other, a part of the obturator nerve. The fourth nerve sends two branches, which serve to complete the obturator and anterior crural nerves, and a connecting branch to the fifth nerve. The fifth, with the connecting branch just mentioned, is the lumbo-sacral nerve already described.

Fig. 201.*



* The lumbar plexus and its branches (slightly altered from Schmidt).
a. Last rib. *b.* Quadratus lumborum muscle. *c.* Oblique and transverse muscles, cut near the crest of the ilium. *d.* Os pubis. *e.* Adductor brevis muscle. *f.* Pectineus. *g.* Adductor longus. 1. Ilio-hypogastric branch. 2. Ilio-inguinal. 3. External cutaneous branch. 4. Anterior crural nerve.

The *branches* of this plexus form two sets, which are distributed, one to the lower part of the wall of the abdomen, the other to the fore part and inner side of the lower limb. Among the former set are the ilio-hypogastric and ilio-inguinal nerves, and part of the genito-crural; and to the latter belong the remaining part of the genito-crural nerve, the external cutaneous, the obturator, and the anterior crural nerves.

Branches supply abd. wall (lower part) and lower limb.

Ilio-hypogastric and Ilio-inguinal Nerves.

The two upper branches from the lumbar plexus, viz.—the ilio-hypogastric and ilio-inguinal (superior and middle musculocutaneous,—Bichat), are both derived from the first lumbar nerve, and are destined to supply nearly similar parts. They become subcutaneous by passing between and then through the broad muscles of the abdomen, and end in the integument of the groin and scrotum (or labia pudendi), as well as in that covering the gluteal muscles. In the relative size of these two nerves, a principle of compensation is observed to exist,—the extent of distribution of the one being inversely to the extent of the other.

Abdominal branches.

The two upper ones have a similar course.

A. The *ilio-hypogastric* nerve, fig. 201, ¹, passes from within the cavity of the abdomen to its walls, in which it is placed at first between the muscles, and ends beneath the skin. Emerging from the upper part of the psoas muscle at its outer border, it runs obliquely over the quadratus lumborum to the crest of the ilium; and there perforating the transverse muscle of the abdomen, gets between that muscle and the internal oblique, and divides into an iliac and a hypogastric branch.

Ilio-hypogastric nerve,

its course.

a. The *iliac branch* pierces the attachment of both oblique muscles, immediately above the upper border of the ilium, and is lost in the integument over the gluteal muscles,—behind the part supplied by the lateral cutaneous branch of the last dorsal nerve.

Iliac branch.

b. The *hypogastric* or *abdominal* branch, continues on between the transverse and internal oblique muscles, and is connected with the ilio-inguinal nerve near the crest of the ilium. It then perforates in succession both the oblique muscles, passing through the external oblique near the pubes,

Hypogastric or abdominal br.

5. Accessory obturator. 6. Obturator nerve. 7. Genito-crural nerve divided into two at its origin from the plexus. 8. Gangliated cord of the sympathetic nerve.

and not far from the middle line. Having become subcutaneous, this branch is distributed to the skin over the hypogastric region, fig. 203, ¹.

Difference
in size.

The size of the iliac branch of this nerve varies according to that of the lateral cutaneous branch of the twelfth dorsal. The hypogastric branch is not unfrequently joined with the last dorsal nerve between the muscles, and near the crest of the ilium.

Ilio-inguinal
nerve.

B. The *ilio-inguinal nerve*, fig. 201, ², (inferior musculo-cutaneous,—Bichat), smaller than the preceding, with which it has a common origin from the first lumbar nerve, supplies the integument of the groin. It descends obliquely outwards over the quadratus lumborum, and then over the iliacus muscle. In this part of its course, the nerve is placed lower down than the ilio-hypogastric; and having perforated the transverse muscle, further forward than that nerve, communicates with it between the abdominal muscles, near the anterior end of the crest of the ilium. Passing through the fleshy part of the internal oblique muscle, and afterwards through the external abdominal ring, the ilio-inguinal nerve becomes subcutaneous, fig. 203, ², and is distributed to the skin upon the groin, as well as to that upon the scrotum in the male, or the labium pudendi in the female. In its progress this nerve furnishes branches to the internal oblique muscle.

Crosses qua-
dratus lum-
borum and
iliacus.

Perforates
the three
abdominal
muscles.

Ends in
skin.

Muscular
branches.

Varies in
origin and
size.

The ilio-inguinal nerve occasionally arises from the loop connecting the first and second lumbar nerves. It is sometimes small, and ends near the crest of the ilium by joining the ilio-hypogastric nerve, which in that case gives off an inguinal branch, having a similar course and distribution to the ilio-inguinal nerve, the place of which it supplies.

Genito-crural Nerve.

Genito-cru-
ral nerve.

The genito-crural nerve (Bichat), fig. 201, ⁷, as its name implies, belongs partly to the external genital organs and partly to the thigh. It is derived chiefly from the second lumbar nerve, but also receives a few fibres from the connecting cord between that nerve and the first. The nerve descends obliquely through and afterwards on the fore part of the psoas muscle towards Poupart's ligament, dividing at a variable height into an internal or genital, and an external or crural branch.*

In front of
psoas.

Two brs.

Its genital
branch:

a. The *genital branch* lies upon or near the external iliac artery, and sends

* This nerve often bifurcates close to its origin from the plexus, in which case its two branches perforate the psoas muscle in different places. Schmidt describes them as separate nerves, naming the genital branch, external spermatic, and the crural branch, lumbo-inguinal.

filaments on that vessel ; then perforating the transversalis fascia, it passes through the inguinal canal with the spermatic cord, upon which it communicates with the inferior pudendal nerve, and is then lost upon the cremaster muscle. In the female it accompanies the round ligament of the uterus, and is distributed to the labium pudendi.

b. The *crural branch* descends upon the psoas muscle beneath Poupart's ligament into the thigh. Immediately below that ligament, and at the outer side of the femoral artery, it pierces the fascia lata, fig. 203, 7 ; and, having become subcutaneous, supplies the skin on the upper part of the thigh, and communicates with the middle cutaneous branch of the anterior crural nerve. Whilst passing beneath Poupart's ligament, some filaments are prolonged from this nerve on to the femoral artery.*

External Cutaneous Nerve.

This nerve, fig. 201, 3, descends through the lower part of the abdomen, and ends in the integument upon the outer side of the thigh.

Commencing from the loop formed between the second and third lumbar nerves, it reaches the surface of the psoas muscle about the middle of its outer border. Thence it is directed across the iliacus muscle to the notch beneath the anterior superior spine of the ilium, where it escapes from the abdomen. Whilst passing beneath Poupart's ligament to enter the thigh, it divides into two branches of nearly equal size :—

a. One, the *posterior branch*, perforates the fascia lata, and subdivides into two or three others, which turn backwards and supply the skin upon the outer surface of the limb, from the upper border of the ilium nearly to the middle of the thigh ; the highest among the branches are crossed by the cutaneous branches from the last dorsal nerve.

b. The second, or *anterior branch* of the external cutaneous nerve, is at first contained in a sheath or canal formed in the substance of the fascia lata ; but, about four inches below Poupart's ligament, it enters the subcutaneous cellular tissue, and descends beneath the skin along the outer part of the front of the thigh, giving off branches in its course, and ending near the knee. The principal offsets are those springing from its outer side.

The two branches of the external cutaneous nerve communicate one with the other at the upper part of the thigh ; and, in some cases, the anterior branch reaches quite down to the knee, and communicates there with the long saphenous nerve.

* It is stated by Schmidt, that when the crural branch of the genito-crural nerve is large, and commences high up near the plexus, he has observed it to give off a muscular branch, which was distributed to the lower border of the internal oblique and transversalis muscles.

OBTURATOR NERVE.

- Obturator nerve. The obturator nerve (internal crural), fig. 201,⁶ is distributed to the adductor muscles of the thigh, and to the hip and knee-joints.
- Origin from plexus. This nerve arises from the lumbar plexus by two cords or roots, one proceeding from the third and the other from the fourth lumbar nerve. Having emerged from the inner border of the psoas muscle, opposite to the brim of the pelvis, it runs along the side of the pelvic cavity, above the obturator vessels, as far as the opening in the upper part of the thyroid foramen, through which it escapes from the pelvis into the thigh. Here it immediately divides into an anterior and a posterior branch, which are separated one from the other by the short adductor muscle.
- Placed at inner side of psoas; in thyroid foramen. Divides into two parts. The *anterior division*, placed in front of the adductor brevis and behind the pectineus and adductor longus muscles, gives some muscular offsets; and then inclines downwards to the middle of the thigh, at its inner side, where,—at the lower border of the adductor longus and still beneath the fascia—it communicates by an offset with the internal cutaneous branch of the anterior crural nerve, and with a branch of the long saphenous nerve, forming a sort of plexus. This branch of the nerve then turns outwards upon the femoral artery, and surrounds that vessel with small filaments.
- Anterior division: supplies muscles, and forms an interlacement, or plexus under fasc.
- Branches of anter. division. *Branches.*—Near the thyroid membrane, the anterior division of the obturator nerve gives off an articular branch to the hip-joint. Beneath the pectineus muscle, it receives a communicating branch from the accessory nerve to the obturator, when that nerve exists; and in the same situation supplies branches to the gracilis and adductor longus muscles, and occasionally also others to the adductor brevis and pectineus.
- Unusual cutaneous branch; reaches inside of leg; takes place of internal cutaneous. *Occasional cutaneous nerve.*—In some instances the communicating offset above described is larger than usual, and is prolonged downwards as a cutaneous nerve to the thigh and leg. When thus enlarged the branch referred to, after escaping below the border of the long adductor muscle, descends along the posterior border of the sartorius to the inner side of the knee. Here it perforates the fascia, communicates with the long saphenous nerve, and extends down the inner side of the limb, supplying the skin as low as the middle of the leg.
- Its poster. division. When this cutaneous branch of the obturator nerve is present, the internal cutaneous branch of the anterior crural nerve is small, the size of the two nerves bearing an inverse proportion one to the other.
- The *posterior or deep division* of the obturator nerve having

passed through some fibres of the external obturator muscle, crosses behind the short adductor to the fore part of the adductor magnus, where it divides into many branches, all of which enter the muscles, excepting one which is prolonged downwards to the knee-joint.

is behind short adductor.

Branches.—The *muscular* branches supply the external obturator and the great adductor muscle, with also the short adductor, when that muscle receives no offset from the anterior division of the nerve.

Branches for muscles.

The *articular* branch (for the knee) rests at first on the adductor magnus, but perforates the lower fibres of that muscle, and thus reaches the upper part of the popliteal space. Supported by the popliteal artery, and sending filaments around that vessel, the nerve then descends to the back of the knee-joint, and enters the articulation through the posterior ligament.*

Branch for knee-joint.

Accessory Obturator Nerve.

The accessory obturator nerve (*nervus ad obturatorem accessorius*, *inconstantans*—Schmidt), a small and inconstant nerve,† communicates with the obturator nerve in the thigh, and is distributed to the hip-joint, fig. 201, 5.

Accessory obturator. is inconst.

Arising from the obturator nerve near its upper end, or from the third and fourth lumbar nerves, this accessory nerve descends beneath the fascia along the inner border of the psoas muscle, as far as the body of the pubes, beyond which it gets behind the pectineus muscle, and ends by dividing into several branches. Of these one joins the anterior branch of the obturator nerve; another penetrates the pectineus on its under surface; whilst a third enters the hip-joint with the articular artery.

Origin.

supplies hip-joint.

This nerve is sometimes small, and ends in filaments which lie upon and perforate the fibrous capsule of the hip-joint. When it is altogether wanting, the hip-joint receives branches from the obturator nerve itself.

When absent, obtur. takes its place.

Summary.—The obturator nerve and its accessory give branches to the hip and knee joints, also to the adductor muscles of the thigh, and, in some cases, to the pectineus. Occasionally a cutaneous branch descends to the inner side of the thigh, and to the inner and upper part of the leg.

Summary.

ANTERIOR CRURAL NERVE.

This nerve, fig. 201, 4, supplies the muscles which extend the leg, and sends cutaneous branches to the fore part of the thigh and the inner side of the leg.

Anterior crur. nerve,

It is the largest branch of the lumbar plexus, and is derived in part from the second, but principally from the third and fourth lumbar nerves. Situated at first, like the other branches

is largest of all lumbar nerves.

* See a paper by Dr. A. Thomson, London Med. and Surg. Journal, No. xcv.
 † Schmidt states that he found this nerve 'four or five times in nine or ten bodies.'—'Commentar. de Nervis lumbalibus,' § xl.

Origin from
plexus.

of this plexus, among the fibres of the psoas, it emerges from the outer border of that muscle near its lower part, and is then lodged between the psoas and iliacus muscles, in which position it descends beneath Poupart's ligament into the thigh.

On the
thigh,

On the thigh, fig. 202, the anterior crural nerve is placed deeply between the psoas and iliacus muscles, about half an inch to the outer side of the femoral artery, and soon becoming flattened out, divides into two parts, of which one is anterior and furnishes cutaneous branches, while the other (the posterior, or deep part), is distributed to muscles. In some cases, it is found to divide into four instead of two parts.

divides into
two sets of
branches.

Its branches
in the abdn.

Branches.—The branches given from the anterior crural nerve *within the abdomen* are few and of small size. Some supply the iliacus muscle, and one ramifies over the femoral artery.

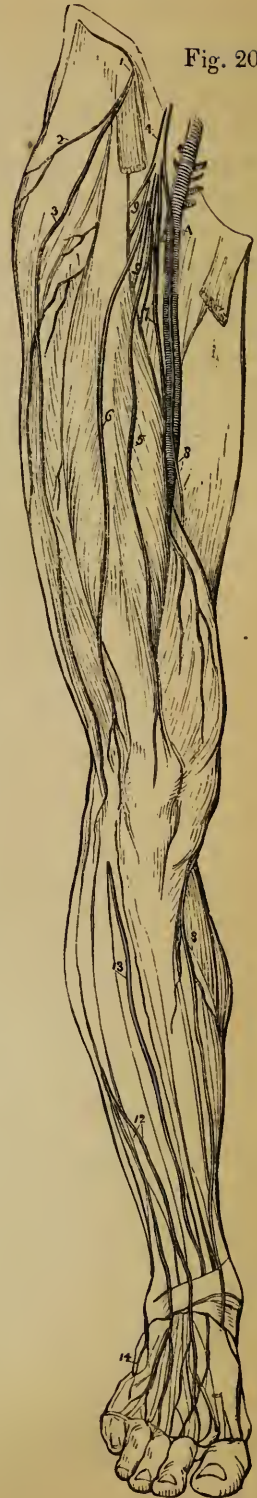For iliacus
muscle.

The *iliacus* receives three or four small branches, which are directed outwards from the nerve to the fore part of the muscle.

On femoral
artery.

The *nerve of the femoral artery* (nerv. arteriæ crurali proprius, — Schmidt,) divides into numerous filaments upon the upper part of that vessel.—This small branch varies somewhat in its origin. It sometimes arises lower down than usual in the thigh; it may,

Fig. 202.*



* Plan of nerves given from the lumbar plexus to the lower limb. 1. External cutaneous nerve. 2, 3, Branches of the same. 4. Anterior crural nerve. 5, 6, Middle cutaneous. 7. Internal cutaneous (anterior portion). 8. Long saphenous nerve. 9, 10. Muscular branches. 12. Cutaneous branch of the musculo-cutaneous nerve of the leg. 13. Anterior tibial.

on the other hand, be found to take origin above the ordinary position, and in this case it proceeds from the middle cutaneous nerve when that branch springs from or near the lumbar plexus. In either case, its ultimate distribution is the same as that already described.

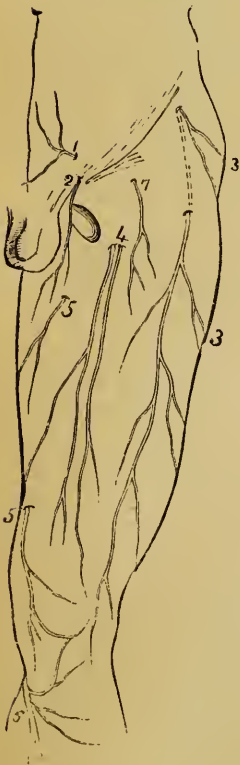
From the principal or terminal divisions of the nerve the remaining branches take their rise as follows:—

A. From the ANTERIOR DIVISION, cutaneous branches are given to the fore part of the thigh, and to the inner side of the leg. They are the middle and internal cutaneous nerves and the long saphenous nerve. One of the muscles (the sartorius) receives its nerves from this series.

Cutaneous branches of nerve.

Middle Cutaneous Nerve.

Fig. 203.



The middle cutaneous nerve, fig. 203, pierces the fascia lata about three inches below Poupart's ligament, and soon divides into two branches, ⁴, which descend side by side beneath the integument on the forepart of the thigh to the inner side and front of the patella. These two branches give off on each side numerous offsets to the skin. After the nerve has become subcutaneous, it communicates with the crural branch of the genito-crural nerve, and also with the succeeding nerve, the internal cutaneous.

Middle cutan. nerve.

This nerve sometimes arises from the anterior crural, high up within the abdomen.

Varies in origin.

Internal Cutaneous Nerve.

The internal cutaneous nerve, fig. 203, ⁵, gives branches to the skin on the inner side of the thigh, and the upper part of the leg; but the extent to which it reaches depends upon the presence of the 'occasional cutaneous' branch of the obturator nerve.

Internal cutans. nerve;

This nerve lying beneath the fascia lata, descends obliquely over the upper part of the femoral artery.

its course.

* Plan of the cutaneous nerves on the front of the thigh. 1. Iliohypogastric branch. 2. Ilio-inguinal branch. 3, 3. Branches of external cutaneous nerve. 4. Branches of middle cutaneous nerve. 5, 5. Internal

Division. It divides either in front of that vessel, or at its inner side, into two branches, (one anterior, the other internal,) which pierce the fascia separately. These two branches sometimes arise as distinct offsets from the anterior division of the anterior crural nerve.

Small branches with saphs. vein in thigh.

Branches of the internal cutaneous nerve. Previously to dividing into its two ultimate branches, this nerve gives off two or three cutaneous twigs, which accompany the upper part of the long saphenous vein. The highest of these perforates the fascia near the saphenous opening, and reaches down to the middle of the thigh. The others appear beneath the skin lower down by the side of the vein: one, larger than the rest, passes through the fascia about the middle of the thigh, and extends to the knee.—In some instances, these small offsets spring directly from the anterior crural nerve, and they often communicate with each other.

Terminal branches. Anterior;

The two terminal branches of the nerve are disposed as follows:—

a. The anterior branch, ⁵, descending in a straight line to the knee, perforates the fascia lata in the lower part of the thigh, and afterwards runs down near the intermuscular septum, giving off filaments on each side to the skin. Finally, it is directed over the patella to the outer side of the knee, communicating, as it crosses above the joint, with a branch of the long saphenous nerve. Very often, however, it receives only a small filament from the saphenous nerve, and then takes the place of the branch usually given by the latter to the integument over the patella.

varies in position. Occasional offsets.

This branch of the internal cutaneous nerve sometimes lies above the fascia in its whole length. It occasionally gives off a cutaneous filament, which accompanies the long saphenous vein, and in some cases it communicates with the branch to be next described.

The inner branch.

b. The inner branch of the internal cutaneous nerve descends along the posterior border of the sartorius muscle to the inner side of the knee, fig. 205, ¹, where it perforates the fascia lata, and communicates by a small branch with the long saphenous nerve, which here descends in front of it. Having given off some cutaneous filaments to the lower part of the thigh on its inner side, the nerve is then continued downwards to be distributed to the skin upon the inner side of the leg.

Its cutans. branch to leg,

Whilst beneath the fascia, this branch of the internal cutaneous nerve joins in an interlacement, on the inner side of the thigh, with branches of the obturator and saphenous nerves.—Where the communicating branch of the obturator nerve, just referred to, is of large size, and is continued to the skin of the leg, the internal cutaneous nerve does not reach beyond the interlacement of nerves in which it has been stated to take part; occasionally, however, a few filaments are found to reach as far as the knee.

forms an interlacement with other nerves.

Cutans. br. sometimes wanting.

cutaneous: the lower number refers to the anterior division of this nerve. 6. Long saphenous nerve, when become subcutaneous. 7. Crural branch of the genito-crural nerve.

Long Saphenous Nerve.

The long or internal saphenous nerve, fig. 202, ⁸, which supplies in part the skin upon the thigh and leg, is the largest of the cutaneous branches of the anterior crural nerve. In some cases it arises in connexion with one of the deep or muscular branches.

Long saphenous nerve.

This nerve is deeply placed as far as the knee, and, in the rest of its course, is subcutaneous. In the thigh it accompanies the femoral vessels, lying at first somewhat to their outer side, but lower down approaching close to them, and passing beneath the same aponeurosis. When the vessels pass through the opening in the adductor muscle into the popliteal space, the long saphenous nerve separates from them, and is continued downwards beneath the sartorius muscle to the inner side of the knee; where, having first given off as it lies upon the inner condyle of the femur a branch which is distributed over the front of the patella, it becomes subcutaneous by piercing the fascia between the tendons of the sartorius and gracilis muscles.

Course in the thigh.

Position at the knee;

Having become subcutaneous, the nerve then accompanies the long saphenous vein along the inner side of the leg down to the foot, fig. 206, ¹. The position it bears with regard to the vein is liable to variation. It may be described as descending behind the inner border of the tibia, and, about the lower third of the leg, dividing into two branches. One of these follows the margin of the tibia, and terminates near the inner ankle; whilst the other and larger branch accompanies the vein in front of the ankle, and ends in the integument on the inner side of the foot. Some filaments are found to enter the tarsal ligaments.

in the leg.

Branches.—*a.* About the middle of the thigh, the long saphenous nerve gives off a *communicating branch* to join in the interlacement already noticed as formed beneath the fascia lata by this nerve and branches of the obturator and internal cutaneous nerves. After it has left the aponeurotic covering of the femoral vessels, the long saphenous nerve has, in some cases, a further connexion with one or other of the nerves just referred to.

Interlacement with other nvs.

b. The branch given to the *integument in front of the patella* perforates the sartorius muscle and the fascia lata; and, having received a communicating offset from the internal cutaneous nerve, divides into many filaments, which spread out upon the fore-part of the knee. Some of these descend, and are connected with other branches of the long saphenous nerve below the knee; others turn outwards, and, by uniting with branches of the middle and external cutaneous nerves, form a plexus (plexus patellæ).

Branch to skin in front of patella.

Plexus patellæ.

Br. small,
and place
taken by int.
cutaneous.
Long saph.
connect. w.
nvs. in leg.

—In some bodies, the last-described branch is very small, and ends by joining the internal cutaneous nerve, which, in that case, supplies its place on the front of the knee-joint.

Besides the communications already mentioned, the long saphenous nerve is connected in the leg with the cutaneous branch, derived either from the internal cutaneous or obturator nerve.

Deep brs.
of anterior
crur. nerve;

B. The DEEP SERIES of the branches of the anterior crural nerve supply the muscles situated on the fore part of the thigh, and also one of those on the inner side, viz., the pectineus. They may be thus described.

Muscular Branches.

Branch
for pectins;

The branch to the *pectineus* muscle (which sometimes forms one of the anterior series) crosses inwards behind the femoral vessels, and enters the muscle on its anterior aspect.

to sartorius,
three or
four;

The *sartorius* muscle receives three or four branches, which arise in common with the cutaneous nerves, and mostly reach the upper part of the muscle.

for rectus.

The *rectus* muscle receives a distinct branch on its under surface.

That of vastus
externus
gives an articular
br. to knee.

The nerve for the *vastus externus*, of considerable size, descends with the branches of the external circumflex artery, towards the lower part of the muscle. It gives off a long slender *articular* filament, which reaches the knee, and penetrates the fibrous capsule of the joint.

Branch for
crureus and
internal
vastus;

Another large branch divides into two sets, which enter the *vastus internus* and the *crureus* about the middle of those muscles. The nerve of the vastus internus (sometimes inaptly named the short saphenous nerve), before penetrating the muscular fascioli, gives a small offset to the knee-joint. This *articular* nerve passes along the internal intermuscular septum, with a branch of the anastomotic artery, as far as the inner side of the joint, where it perforates the capsular ligament, and is directed outwards on the synovial membrane beneath the ligamentum patellæ.

gives an
articular
nerve to
knee.

Summary.

Summary.—The anterior crural nerve is distributed to the skin upon the fore-part and inner side of the thigh, commencing below the terminations of the ilio-inguinal and genito-crural nerves. It also furnishes a cutaneous nerve to the inner side of the leg and foot.

Cutaneous
branches.

Muscular
branches.

All the muscles on the front and outer side of the thigh, receive their nerves from the anterior crural, and one of the muscles on the inner side of the limb (the pectineus) is also in part supplied by this nerve.—The tensor muscle of the fascia lata is supplied from a different source, viz., the superior gluteal nerve.

Lastly, two branches are given from the same nerve to the knee-joint. Articular branches.

ANTERIOR DIVISIONS OF THE SACRAL AND COCCYGEAL NERVES.

Sacral nerves.—The anterior divisions of the first four of these nerves emerge through the anterior sacral foramina, and the fifth escapes with the coccygeal nerve from the sacral canal at its end. Number of nerves.
Exit from sacral canal;

The first two of the sacral nerves are of large and about equal size, the others diminish rapidly, and the fifth is exceedingly slender. Like the corresponding divisions of all the other spinal nerves, the anterior divisions of the sacral nerves communicate with the sympathetic nerve; and the communicating cord is very short, the ganglia of the latter being close to the inner margin of the foramina of the sacrum. their size;

The first four nerves (the fourth in part) contribute to form the sacral plexus. The fifth has no share in the plexus,—it ends in the perinæum. The fourth and fifth nerves have therefore some peculiarities in the manner of their distribution; and, as the description will occupy but a short space, these two nerves will be noticed first, before the details of the other nerves and the numerous branches to which they give rise are followed out. outline of their arrangement.

The Fourth Sacral Nerve.

Only one part of the anterior division of this nerve joins the sacral plexus; the remainder, which is nearly half the nerve, supplies branches to the viscera and muscles of the pelvis, and sends downwards a connecting filament along the side of the coccyx to the fifth nerve. Fourth nerve joins plexus, and gives brs. besides.

The *visceral branches* of the fourth sacral nerve are directed forwards to the lower part of the bladder, and communicate freely with branches from the sympathetic nerve. Numerous offsets are distributed to the neighbouring viscera, according to the sex; they will be described with the pelvic portion of the sympathetic nerve.—The foregoing branches are, in some instances, furnished by the third sacral nerve instead of the fourth. Visceral branches.

Of the *muscular branches*, one enters the *levator ani*, piercing that muscle on its pelvic surface; another, in some cases, penetrates the *coccygeus*, whilst a third supplies the *external sphincter* muscle of the rectum. The last Muscular branches.

branch, after passing either through the coccygeus, or between it and the levator ani, reaches the perinæum, and is distributed likewise to the integuments between the anus and the coccyx.

The Fifth Sacral Nerve.

Fifth nerve; The anterior division of this, the lowest sacral nerve, runs forwards through the coccygeus muscle opposite the junction of the sacrum and the first coccygeal vertebra;* it then descends upon the coccygeus nearly to the tip of the coccyx, where it turns backwards through the fibres of that muscle and the gluteus maximus, and ends in the integument upon the posterior and lateral aspect of the bone.

ends in skin.

Other branches and connexions with nerves. As soon as this nerve appears in front of the bone (in the pelvis), it is joined by the descending filament from the fourth nerve, and lower down by the small anterior division of the coccygeal nerve. It supplies small filaments to the coccygeus muscle.

The Coccygeal Nerve.

Anter. div. of coccygeal nerve joins last sacral. The anterior division of the coccygeal, or, as it is sometimes named, the sixth sacral nerve, is a very small filament. It escapes from the spinal canal at its end, pierces the sacro-sciatic ligament and the coccygeus muscle, and upon the side of the coccyx is joined with the fifth sacral nerve, partaking in the distribution of that nerve.

THE SACRAL PLEXUS.

Sacral plex.; The lumbo-sacral cord, (formed as before described by the junction of the fifth and part of the fourth lumbar nerves), the anterior divisions of the first three sacral nerves and part of the fourth, unite to form this plexus. The construction of the plexus differs from that of any other of the plexus formed by the spinal nerves. This is formed by the junction of the several constituent nerves into one broad flat cord. To the place of union the nerves proceed in different directions, the upper ones being very oblique, while the lower are nearly horizontal in their course; and, as a consequence of this difference in direction, they diminish in length from the first to the last. The sacral plexus thus constructed, rests on the anterior surface of the pyriform muscle, opposite the side of the sacrum. It is broadest at the upper part, where the nerves join, and narrow at

nerves wh. form it.

Peculiar construction of plexus;

its connexions;

* The nerve occasionally passes through a foramen (fifth sacral) formed between the sacrum and the coccyx.—See *ante*, p. 17.

the lower end, where it escapes through the great sacro-sciatic foramen, and is continued into or ends in the great sciatic nerve. ends in gt. sciatic nve.

Branches.—The sacral plexus supplies the larger part of the nerves of the lower limb, and furnishes some small offsets to structures connected with the pelvis. The branches are the following :—Small offsets to muscles within the pelvis (internal obturator and pyriformis) ; and to other muscles on the back of the pelvis (gemelli and quadratus femoris) ; the pudic nerve ; the small sciatic nerve ; and the great sciatic nerve. Outline of branches.

Small Muscular Branches.

The small nerves supplied to muscles situated within the pelvis, and to others on its outer side, will be placed together under this head.

To the *pyriformis muscle*, one or more branches are given, either from the plexus or from the upper sacral nerves before they reach the plexus. Nerves of pyriformis in pelvis.

The *nerve of the internal obturator muscle* arises from the upper part of the plexus—from the part, therefore, which is formed by the connexion of the lumbo-sacral and the first sacral nerves. It turns behind the spine of the ischium with the pudic vessels, and is then directed forwards through the small sacro-sciatic foramen to reach the inner surface of the obturator muscle. Nerve of obt. intern.; turns round spine of ischium.

The *superior gemellus* receives a small branch, which arises near the pudic nerve, from the lower part of the plexus. Upper gemellus.

The little nerve which supplies the *lower gemellus* and *quadratus femoris* muscles springs from the lower part of the plexus. Concealed at first by the great sciatic nerve, it passes beneath the gemelli and the tendon of the internal obturator, —between those muscles and the capsule of the hip-joint,—and reaches the deep (anterior) surface of the quadratus. It furnishes a nerve to the lower gemellus, as well as a small articular filament to the back part of the hip-joint. Lower gemellus and quad. fem.: one nerve for both; is close to capsule of hip-joint, and gives it a filament.

In some cases the nerve last described proceeds from the upper end of the sciatic nerve instead of the plexus ; but it is usually derived from the latter source in the manner already mentioned. Variation in place of origin.

Pudic Nerve.

This nerve, fig. 204, supplies the lower end of the rectum, the perineum, and in part the external genital organs. Arising from Pudic nve.; outline of.

Origin and course. the lower part of the sacral plexus, the pudic nerve turns behind the spine of the ischium, and then passes through the small sacro-sciatic foramen, where it usually gives off an inferior hæmorrhoidal branch. It is next directed upwards and forwards along the outer part of the ischio-rectal fossa with the pudic vessels, and divides into two terminal branches; one of these is the perineal nerve, the other ends on the dorsum of the penis.

Division into two parts.

Perinl. nr.; *a.* The *perineal nerve*, the lower and much the larger of the two divisions of the pudic nerve, lies below the pudic artery, and is chiefly expended in branches to the integument (superficial perineal). It likewise supplies offsets to several muscles and slender filaments to the corpus spongiosum urethræ; some of these latter, before penetrating the erectile tissue, run a considerable distance over its surface.

gives filaments to corp. spong. urethræ.

Branches of perinl. nrve. The cutaneous and muscular offsets of the perineal nerve are distributed as follows:—

Two superfl. perineal.

Poster. br.

connexn. with other brs. in perinm.

Anter. br.

with perinl. artery.

The *superficial perineal* branches are two in number, and are distinguishable as posterior and anterior. The *posterior* one, which first separates from the perineal nerve, reaches the back part of the ischio-rectal fossa, and from thence turns forwards in company with the anterior branch to reach the scrotum. Whilst in the fossa, it gives filaments inwards to the sphincter ani and to the skin in front of the anus. It communicates with the anterior branch to be next noticed, as well as with the inferior pudendal branch of the small sciatic nerve and the inferior hæmorrhoidal nerve.—The *anterior* branch descends to the fore part of the ischio-rectal fossa; and, after passing forwards with the superficial perineal artery, ramifies in the skin on the fore part of the scrotum and on the surface of the penis. This branch sends small twigs to the levator ani muscle also.

In the female, both the superficial perineal branches terminate in the external labium pudendi.

Musclr. brs. of perineal nerve.

The *muscular branches* given off from the perineal division of the pudic nerve generally arise by a single trunk, which is directed inwards under cover of the transversalis perinei muscle, and divides into several offsets; these are distributed among the muscles of the perineum,—viz., the transversalis perinei, erector penis, accelerator urinæ, and compressor urethræ.

Dorsal nrve. of penis;

b. The *dorsal nerve of the penis*, the upper division of the pudic nerve, continues in the course of the pudic artery between the layers of the deep perineal fascia, and afterwards through the suspensory ligament of the penis. It thus reaches the dorsum of the penis, along which it passes as far as the glans, where it divides into filaments for the supply of that

gives brs. to glans penis, to

part. On the penis, this nerve is joined by branches of the sympathetic system, and it distributes offsets to the integument on the upper surface and sides of the organ, including the prepuce. One large branch penetrates the corpus cavernosum penis.

integument, and corp. cavernos.

In the female, this division of the pudic nerve is much smaller than in the male. It takes a similar course, and ends upon the clitoris.

Is smaller in female.

The *inferior hæmorrhoidal* nerve arises from the pudic nerve at the back of the pelvis, or directly from the sacral plexus. It is transmitted through the small sacro-sciatic foramen, and then descends towards the lower end of the rectum. Some of the branches of this nerve end in the external sphincter and the adjacent skin of the anus; others reach the skin in front of that part, and communicate with the inferior pudendal branch of the small sciatic nerve and with the superficial perineal nerve.

Inferior hæmorrh. nerve, var. in origin.

Small Sciatic Nerve.

The small sciatic nerve (*nervus ischiadicus minor*) is chiefly a cutaneous nerve, supplying the integument over the posterior aspect of the thigh and (to a small extent) the leg; it also furnishes branches to one muscle—the *gluteus maximus*.

Small sciatic nerve;

This nerve is formed by the union of two or more nervous cords, derived from the lower part of the sacral plexus. Leaving the pelvis through the great sacro-sciatic foramen below the pyriform muscle, it descends beneath (before) the *gluteus maximus*, and at the lower border of that muscle comes into contact with the *fascia lata*, under which it continues its course downwards along the back of the limb. The nerve perforates the *fascia* a little below the knee, fig. 205, ³, and, thus become subcutaneous, accompanies the short saphenous vein beyond the middle of the leg. Its terminal cutaneous branches communicate with the short saphenous nerve.

mode of origin;

course undr. *gluteus* and *fascia* along back of limb.

Ends below midd. of leg.

The branches of the small sciatic nerve are as follows:—

Branches.

The *inferior gluteal* branches.—These are given off under the *gluteus maximus*, and supply the lower part of that muscle.—A distinct gluteal branch commonly proceeds from the sacral plexus to the upper part of the muscle.

Infer. glutl. to *gluteus maximus*; other nerve for same.

The principal *cutaneous branches* of the nerve escape from beneath the

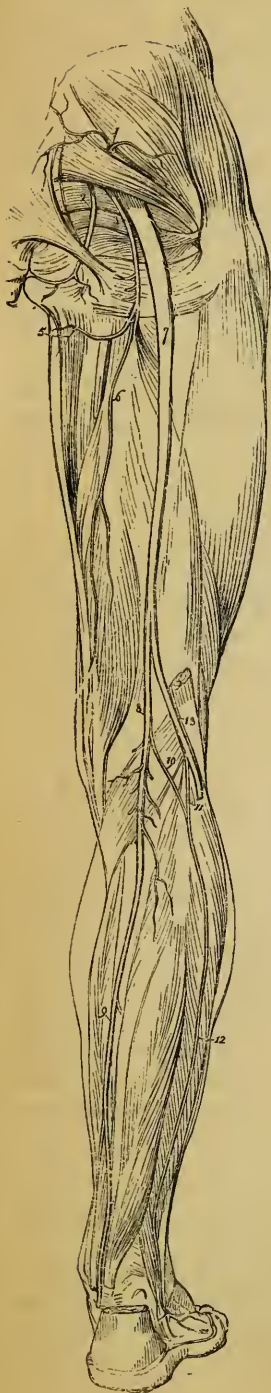Cutans. brs;

- form two sets. lower border of the gluteus maximus ; they form an external and an internal set.
- Intern. set ; The *internal* branches are mostly distributed to the skin of the inner side of the thigh at its upper part. One, however, which is much longer than the rest, the *inferior pudendal* branch, turns forwards below the tuberosity of the ischium to reach the perineum. Having pierced the fascia lata, on the outer side of the ramus of that bone, the cutaneous filaments of this branch extend forward to the front and outer part of the scrotum, and communicate with the superficial perineal nerve.
- Inf.pudend. nerve ; In the female, the inferior pudendal branch is distributed to the external labium pudendi.
- distribution in female.
- Extern. set. The *external* cutaneous branches, two or three in number, turn upwards in a retrograde course to the skin over the outer part of the great gluteal muscle. In some instances one takes a different course, descending and ramifying in the integuments over the outer side of the thigh nearly to the middle.
- Other cutaneous brs. lower down. Whilst descending beneath the fascia of the thigh, the small sciatic nerve sends off some other small cutaneous filaments. One of these, arising somewhat above the knee-joint, perforates the fascia, and is prolonged over the popliteal region to the upper part of the leg.

GREAT SCIATIC NERVE.

- Grt. sciatic nerve ; the largest in body ; The great sciatic nerve (*nervus ischiadicus*), fig. 204, 7, the largest nerve in the body, distributes offsets to the back of the thigh, and supplies the leg and the foot with their nerves.
- is continuation of sacral plexus. This large nerve is the continuation of the lower end of the sacral plexus, as that escapes from the pelvis through the sacro-sciatic foramen, below the pyriformis muscle. Placed deeply at the back of the limb, the nerve reaches down below the middle of the thigh, where it divides into two large branches, named the internal popliteal and external popliteal nerves. The bifurcation of the large nerve may take place, however, at any point intermediate between the sacral plexus and the lower part of the thigh ; and, occasionally, it is found to occur even within the pelvis, a portion of the pyriformis muscle being interposed between the two great parts into which the nerve divides.
- Place of division var. At first the great sciatic nerve lies in the hollow between the great trochanter of the femur and the tuberosity of the ischium, together with the small sciatic nerve and the sciatic artery, (a branch of this artery running in the substance of the nerve.) It is here covered by the gluteus maximus, and rests on the external rotator muscles of the thigh. Lower down it is in contact, in front, with the adductor magnus, and is covered
- Connexions.

Fig. 204.*



(behind) by the long head of the biceps muscle.

Branches—In its course downwards, the great sciatic nerve supplies offsets to some contiguous parts, viz., to the hip-joint, and to the muscles at the back of the thigh.

The *articular branches* are derived from the upper end of the nerve, and enter the capsular ligament of the hip-joint, on its posterior aspect. They sometimes arise from the sacral plexus.

The *muscular branches* are given off beneath the biceps muscle; they supply the flexors of the leg, viz., the biceps, semitendinosus, and semimembranosus. A branch is likewise given to the adductor magnus.

The two large branches into which the great sciatic nerve divides are distributed to the limb from the knee downwards, one (the internal popliteal) supplying the back of the leg and the sole of the foot; while the other (external popliteal) supplies the fore part of the leg and the dorsum of the foot.

INTERNAL POPLITEAL NERVE.

The internal popliteal nerve, † fig.

* Plan of the great and small sciatic nerves. 1. Superior gluteal nerve. 2. Pudic nerve. 3. Small sciatic nerve. 4. Inferior pudendal branch. 5. Continuation of the small sciatic in the thigh. 6. Great sciatic nerve. 7. Internal popliteal nerve. 8. Posterior tibial nerve. 9. Short saphenous nerve. 10, 12. Peroneal communicating branch. 11. External popliteal or peroneal nerve.

† The inner division of the sciatic nerve, from its commencement to its partition at the foot, is generally described in anatomical works without any separation into parts; and the name applied by different writers to this long cord, as might be expected, varies considerably, e. g. "eruralis internus," or "popliteus internus,"—Winslow: "tibialis posterior,"—Haller: "sciatique poplitée interne,"—Sabatier: "tibicus,"

the larger
division;

at first, away
fr. vessels;

afterwards
close to
them.

Branches of
intern. popl.
nerve.

204, ⁸, the larger of the two divisions, following the same direction as the parent trunk, continues along the back part of the thigh and through the middle of the popliteal space. It lies at first at a considerable distance from the popliteal artery (at its outer side and nearer to the surface); but, from the knee-joint downwards, is close to the vessel, and crosses over it to the inner side. The nerve is covered at first by the biceps muscle, and afterwards has the same connexions with neighbouring parts as the popliteal blood vessels.

Branches.—The internal popliteal nerve supplies branches to the knee-joint, to the muscles of the calf of the leg, as well as to the skin on the posterior aspect of the leg, and on the dorsum of the foot at its outer margin. They are disposed as follows:—

Articular Nerves.

Three to
knee-joint.

The articular branches are generally three in number: two of these accompany the upper and lower articular arteries of the inner side of the knee-joint, the third follows the middle or azygos artery. These nerves pierce the ligamentous tissue of the joint.—The upper one is wanting in some cases.

Muscular Branches.

The muscular branches of the internal popliteal nerve arise behind the knee-joint, while the nerve is between the heads of the gastrocnemius muscle:—

Brs. for
gastrocn.,
plantaris,
soleus, and

popliteus
muscles.

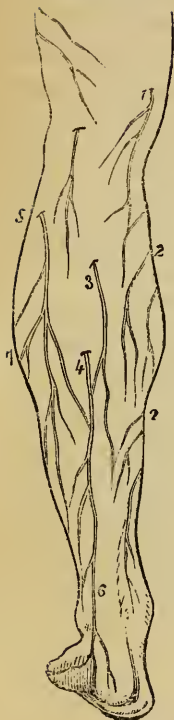
A single branch, which soon bifurcates, supplies the two parts of the *gastrocnemius*. The small nerve of the *plantaris* muscle is derived from the branch just described, or from the main trunk (internal popliteal). The *soleus* receives a branch of considerable size, which enters the muscle on its posterior aspect after descending to it in front of the gastrocnemius. Lying deeper than the preceding branches, and arising somewhat below the joint, is the nerve of the *popliteus* muscle. It descends along the outer side of the popliteal vessels; and, after turning beneath the lower border of the muscle, enters its deep or anterior surface.

—Jordens: “tibialis vel tibieus,”—Fischer, &c. One or other of the foregoing names, or some modification of them, is used by more modern writers.

As the terms “popliteal” and “tibial,” which are the bases of this varied nomenclature, are adapted respectively to only a particular portion of the entire nerve, it is probably best to divide it into parts, and to apply to each part the appropriate designation. This arrangement has the advantage of a nearer correspondence with the manner of dividing the bloodvessels.

Short or External Saphenous Nerve.

Fig. 205.†



The cutaneous branch of the internal popliteal nerve (ramus communicans nervi tibici, — Jordens *; communicans tibialis, — auctor. var.) may be named as above, because of its following very nearly the course of the short saphenous vein. It descends along the leg beneath the fascia, resting on the gastrocnemius (at first between the heads of the muscle) to about midway between the knee and the foot. Here it perforates the fascia, (fig. 205, 4,) and is usually joined by a branch from the external popliteal nerve (communicans peronei). After receiving this communicating branch, the short saphenous nerve descends beneath the integument near the outer side of the tendo-achillis in company with the short saphenous vein, and turns forward beneath the outer malleolus to end in the skin at the side of the foot and on the little toe. On the dorsum of the foot this nerve communicates with the musculo-cutaneous nerve.

Short saph. nerve ;

at first is under fasc.

Joined by communic. peronei ;

with short saph. vein ; ends on side of foot.

In some cases, the short saphenous nerve supplies the outer side of the fourth toe, as well as the little toe. The union between the saphenous nerve and the offset of the external popliteal nerve occurs in some cases higher than usual, occasionally even at or close to the popliteal space. It sometimes happens that the communication between the nerves is altogether wanting.

Connexion between the hrs. varies in position ; it may be altogether wanting.

* This nerve, and the offset of the external popliteal nerve which joins it, appear to have been first named from the fact of their connexion one with the other by Jordens ("Descriptio Nervi Ischiadici," Erlangæ, 1788). This manner of designating the branches in question was followed very generally by Anatomical writers until late years, and it has been adopted by most neurologists, — *e. g.*, Fischer ("Descript. Anatom. Nerv. lumbalium, sacralium et extremitatum inferiorum," Lipsiæ, 1791); Bock ("Abbildungen der Rückenmarksnerven," &c., Leipzig, 1827).

Boyer and Bichat, in their general treatises on Anatomy, have named the offset of the internal popliteal nerve "external saphenous;" and it is not uncommon to find, in modern books, this name and the older nomenclature mixed up in the following manner:—The two branches, before their junction, are named "communicating" branches of the tibial and peroneal nerves respectively; and the nerve resulting from their union is the external saphenous nerve. M. Cruveilhier, again, treats of the two branches as "tibial saphenous" and "peroneal saphenous."

† Plan of the cutaneous nerves on the posterior aspect of the leg. 1. Inner division of the internal cutaneous nerve. 2, 2. Branches of the long saphenous. 3. Small sciatic become cutaneous; the offset above it in a direct line is a branch of the same nerve. 4, 6. Short saphenous nerve. 5. Peroneal communicating nerve.

POSTERIOR TIBIAL NERVE.

Post. tibl. ;
with post.
tibl. art. ;

From the lower margin of the popliteus muscle, where it assumes this designation, the nerve continues with the posterior tibial artery, lying for a short space at the inner side and afterwards at the outer side of the vessel, as far as the interval between the inner malleolus and the heel; and here it divides into the two plantar nerves (internal and external). The posterior tibial nerve, like the vessels, is covered at first by the muscles of the calf of the leg, afterwards only by the integument and fascia, and it rests against the deep-seated muscles.

divides into
two plantar
nerves.

Branches of
post. tibl.
are given

Branches.—The deep muscles on the back of the leg and integument of the sole of the foot receive branches, which leave the posterior tibial nerve in its course along the leg.

to deep
muscles of
leg ;

a. The *muscular branches* emanate from the upper part of the nerve, either separately or by a single common trunk; and one is distributed to each of the following muscles, viz., the tibialis posticus, the long flexor of the toes, and the long flexor of the great toe. The branch which supplies the last-named muscle runs along the peroneal artery before penetrating the muscle.

and one to
skin on sole
of foot.

b. The *plantar cutaneous* branch, furnished from the posterior tibial nerve, perforates the internal annular ligament, and ramifies in the integument at the inner side of the sole of the foot and beneath the heel.

Internal Plantar Nerve.

Int. plantar
is larger
than exter.

supls. three
inner toes ;
and fourth
partly.

The internal plantar, the larger of the two nerves furnished to the sole of the foot, accompanies the internal or smaller plantar artery, and supplies the nerves to both sides of the three inner toes, and to one side of the fourth. From the point at which it separates from the posterior tibial nerve, it is directed forwards under cover of the abductor of the great toe, and divides, opposite the posterior end of the metatarsus at the interval between the muscle just named and the short flexor of the toes, into four digital branches, and at the same time communicates with the external plantar nerve.

Brs. given
to muscles
and skin.

Branches.—As the internal plantar nerve courses forwards, small offsets are supplied to the abductor pollicis and flexor brevis digitorum; and some small branches perforate the plantar fascia to ramify in the integument of the sole of the foot.

Digital brs ;

The *digital branches*, which are named numerically from within outwards, (the innermost being first, and so on,) pass from under cover of the plantar fascia behind the clefts between the toes. The first or innermost branch continues single, but

outline of.

the other three bifurcate to supply the adjacent sides of two toes. These branches require separate notice.

The *first* digital branch is that destined for the inner side of the great toe; it becomes subcutaneous farther back than the others, and sends off a branch to the short flexor muscle of this toe.

First, to inner side of great toe.

The *second* branch, having reached the interval between the first and second metatarsal bones, furnishes a small offset to the first lumbricalis muscle, and bifurcates some way behind the cleft between the great toe and the second to supply their contiguous sides.

Second, to grt. toe and second.

The *third* digital branch corresponds with the second intercrosseous space, gives a slender filament to the second lumbricalis muscle, and divides in a manner similar to the second branch into two offsets for the sides of the second and third toes.

Third ends on second and third toes.

The *fourth* digital branch crosses to the third space, and is distributed to the adjacent sides of the third and fourth toes. It receives a communicating branch from the external plantar nerve.

Fourth, on third and fourth toes.

Along the sides of the toes, cutaneous and articular filaments are given from these digital nerves; and, opposite the unguis phalanx, each gives a dorsal branch to the parts beneath the nail, and then runs on to the pulp of the toe, where it is distributed like the nerves of the fingers.

Offsets to joints, under nails, and to ends of toes.

External Plantar Nerve.

The external plantar nerve completes the supply of digital nerves to the toes, furnishing therefore branches to the little toe and half the fourth; and gives a deep branch of considerable size, which is distributed to several of the short muscles in the sole of the foot.

External plantar completes digital brs. and supplies muscs.

This nerve runs obliquely forwards towards the outer side of the foot with the external plantar artery, between the flexor brevis digitorum and the flexor accessorius, as far as the interval between the former of these muscles and the abductor of the little toe. Here it divides into a superficial and a deep branch, having previously furnished offsets to the flexor accessorius and the abductor digiti minimi.

Accompanies extern. plantar artery; divides into two parts.

a. The *superficial division* separates into two digital branches, which have the same general arrangement as the digital branches of the internal plantar nerve. They are distributed thus:—

Two digital nerves.

Digital branches.—One of the digital branches continues undivided, and runs along the outer side of the little toe. It is smaller than the other, and pierces the plantar fascia further back. The short flexor muscle of the little

One to outer side of little toe:

toe and the two interosseous muscles of the fourth metatarsal space receive branches from this nerve.

other
divides
between
same toe
and fourth.
Deep br.
of external
plantar.

The larger digital branch communicates with an offset from the internal plantar nerve, and bifurcates behind the cleft between the fourth and fifth toes to supply one side of each.

b. The *deep* or *muscular* branch of the external plantar nerve dips into the sole of the foot with the external plantar artery under cover of the tendons of the flexor muscles and the adductor pollicis, and terminates in numerous branches for the following muscles:—all the interossei (dorsal and plantar) except one or both of those in the fourth space, the two outer lumbricales, the adductor pollicis and the transversalis pedis.

THE EXTERNAL POPLITEAL OR PERONEAL NERVE.

External
popl. nerve.

Course
along biceps
muscle;
round upper
end of fib.

This nerve,* fig. 204, descends obliquely along the outer side of the popliteal space, lying close to the biceps muscle. Continuing downwards over the outer part of the gastrocnemius muscle (between it and the biceps) to the fibula below its head, the nerve turns round that bone, passing between it and the peroneus longus muscle, and then divides into the anterior tibial and the musculo-cutaneous nerves.

Branches :

Some articular and cutaneous branches are derived from the external popliteal nerve before it divides.

Articular Nerves.

External
articular,

The articular branches, two in number, are conducted to the outer side of the capsular ligament of the knee-joint by the upper and lower articular arteries of that side.—They sometimes arise together, and the upper one occasionally springs from the great sciatic nerve before its bifurcation.

Recurrent
articular.

From the place of division of the external popliteal nerve, a *recurrent articular* nerve ascends through the tibialis anticus muscle with the recurrent artery to reach the fore part of the knee-joint.

Cutaneous Nerves.

Communi-
cans peron.

The cutaneous branches, two or three in number, supply the skin on the back part and outer side of the leg. The largest of these is the *peroneal communicating branch*, (r. *communicans peronei*, — Jordens ; *communicans fibularis*) (fig. 205, ⁵) which joins about the middle of the back of the leg with the short saphenous nerve as already mentioned in the description of that nerve. In some instances, however, it continues a separate branch and reaches down to the heel.

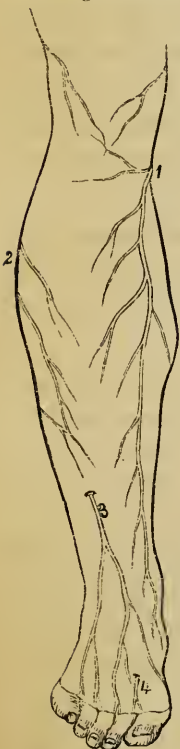* “Small sciatic ramus or sciaticus externus,”—Winslow : “tibialis anterior, exterior,”—Haller : “sciatique poplitée externe,”—Sabatier : “peroneus,”—Jordens : “peroneus seu popliteus externus,”—Fischer.

Another cutaneous branch extends along the outer side of the leg to the middle or lower part, sending offsets both backwards and forwards, fig. 206, 2. Other cutaneous br.

MUSCULO-CUTANEOUS NERVE.

The musculo-cutaneous (peroneal) nerve is the principal cutaneous nerve of the dorsum of the foot, and also supplies the muscles on the outer part of the leg. It descends between the peronei muscles and the long extensor of the toes, and reaches the surface by perforating the fascia in the lower part of the leg on its anterior aspect. As soon as the nerve becomes subcutaneous, fig. 206, 3, or even before, it divides into two branches, distinguished as external and internal. When the division occurs while the nerve is in contact with the muscles, the two branches may be found to perforate the fascia at different heights. Musculo-Cutans. nrv.
Course among muscles ; becomes subcutans.

Fig. 206.*



Whilst between the muscles, the musculo-cutaneous nerve gives its muscular branches to the peroneus longus and peroneus brevis ; and, before its final division, some cutaneous offsets are distributed to the lower part of the leg. Musc. brs.
small cuts. branches.

The *internal* division of the musculo-cutaneous nerve, fig. 206, passing forwards along the dorsum of the foot, furnishes a branch to the inner side of the great toe, and other branches to the contiguous sides of the second and third toes. It also gives offsets, which extend over the inner ankle and the corresponding side of the foot. This nerve communicates with the long saphenous nerve on the inner side of the foot, and with the anterior tibial nerve between the great toe and the second toe. Int. div. gives digl. branches ;
connected w. long saph. and ant. tibl. nerves.

The *external* division, larger than the internal, one, courses over the foot towards the fourth toe, which, together with the contiguous borders of the third and fifth toes, it supplies with branches. Cutaneous nerves, derived from this branch, spread over the outer ankle and the outer side of the foot, where it is connected with the short saphenous nerve. Ext. div. supplies outer toes ;
joins ext. saph. nerve.

The dorsal digital nerves are continued on to the last phalanges of the toes.

The number of toes supplied by each of the two divisions of the musculo-cutaneous nerve is liable to vary ; together, they commonly supply Number of digl. nerves

* Plan of the cutaneous nerves on the forepart of the leg, and the dorsum of the foot. 1. Long saphenous, become subcutaneous. 2. Branches of the external popliteal. 3. Musculo-cutaneous. 4. Anterior tibial.

supplied by all the toes on their dorsal aspect, excepting the outer side of the little toe, each varies. which receives a branch from the short saphenous nerve, and the adjacent sides of the great toe and the second toe, to which the anterior tibial nerve sends a branch.

ANTERIOR TIBIAL NERVE.

Ant. tibl. The anterior tibial (interosseous nerve), like the preceding deeper than form. nerve, and supplies chiefly mscl. nerve, extends through the leg to the foot, and supplies muscular and cutaneous branches; but this nerve is more deeply placed, and is distributed chiefly to muscles, while the largest part of the musculo-cutaneous nerve is given to the integument.

Course, Commencing between the fibula and the peroneus longus, the anterior tibial nerve inclines obliquely beneath the long extensor of the toes to the fore part of the interosseous membrane, on which structure it comes into contact with the anterior tibial vessels, fig. 202; and with those vessels (having the same connexions with neighbouring parts) it descends to the front of the ankle-joint, where it divides into an external and an internal branch. The nerve first reaches the outer side of the anterior tibial artery, above the middle of the leg; and, after crossing in front of that vessel once or oftener, lies to its outer side at the bend of the ankle.

to reach anter. tibl. vessels; and with the vessels.

Offsets to muscles.

In its course along the leg, the anterior tibial nerve gives slender filaments to the muscles between which it is placed, namely, the tibialis anticus, the long extensor of the toes, and the proper extensor of the great toe.

Ext. br. : for short extensor and tarsal joints.

The more *external* of the two branches which result from the division of the anterior tibial nerve, turns outwards over the tarsus beneath the short extensor of the toes; and, having become enlarged (like the posterior interosseous nerve on the wrist) terminates in branches which supply the short extensor muscle, and likewise the articulations of the foot.

Int. branch, with dorsal art. of foot: ends betw. great toe and second.

The *internal branch*, continuing onwards in the direction of the anterior tibial nerve, accompanies the dorsal artery of the foot to the first interosseous space, and ends in two branches, fig. 206, †, which supply the integument on the neighbouring sides of the great toe and the second toe on their dorsal aspect. It communicates with the internal division of the musculo-cutaneous nerve.

Summary.—The great sciatic nerve with its divisions supplies the integument of the leg, with the exception of a part which derives nerves from the small sciatic and the anterior crural nerve. It likewise supplies the muscles on the back of the thigh, and those of the leg and foot. The several joints of the lower limb receive filaments from the same nerve.

THE SYMPATHETIC NERVE.

The sympathetic system of nerves (*nervus intercostalis* ; *nerfs de la vie organique*—Bichât).—The viscera generally are supplied with nerves from this system, but some organs likewise receive offsets from the cerebro-spinal system, as the lungs, the heart, and the upper and lower ends of the alimentary canal. The characters by which the sympathetic nerve is distinguished having been already pointed out, it is only necessary to say in this place that it is reddish or grey in colour, and that it is softer in texture than the cerebro-spinal nerves.

Symphath. nerve ; supplies viscera. Some viscera receive other nerves also.

In this system three parts may be distinguished, as follows :—

Divisions.

a. The part which first requires notice is to be regarded as the centre of the sympathetic. It consists of two gangliated cords, —or of a series of ganglia placed longitudinally, and connected by intervening cords,—situate along the fore part of the vertebral column, at the sides, for the most part, of the bodies of the vertebræ, and extending from the base of the skull to the coccyx. The two cords lie parallel one to the other as far as the sacrum, on which bone they gradually converge, till they both terminate in a single ganglion on the coccyx. This long cord is considered divisible into parts corresponding with the divisions of the vertebral column ; and thus, cervical, dorsal, lumbar, and sacral portions are recognised.

Gangliated cords ;

before verteb. column in whole length.

Parts of cord.

The ganglia are equal in number to the vertebræ on which they lie, except in the neck, where there are but three. These bodies are conveniently regarded as so many centres, receiving nerves, and distributing offsets to the viscera. They are severally connected with the spinal nerves in their neighbourhood by means of short cords ; and each connecting cord consists of a white and a grey portion, the former proceeding from the spinal nerve to the ganglion, while the latter takes the opposite course—from the ganglion to the spinal nerve. At its upper end the gangliated cord likewise communicates with certain cranial nerves.—The cords intervening between the

Ganglia.

Connected with spinal nerves ;

connecting cords contain white and grey parts.

ganglia, like those connecting the ganglia with the spinal nerves, are compounded of a grey and a white part, the latter being continuous with the portions of spinal nerves already traced to the ganglia.

Branches from ganglia on arteries and to viscera.

From the ganglia, or their intervening cords, offsets are given for the supply of the viscera; and these offsets follow the course of the arteries to the organs for which they are destined. Branches are likewise sent to join the large prevertebral plexuses to be presently noticed. The offsets from the ganglia partake of both kinds of nerves (the proper sympathetic and the spinal systems), the nerves or roots, which join the ganglia from the spinal system, being continued onwards with others which originate in the ganglia. From this circumstance, and the facts above mentioned respecting the constitution of the gangliated cord, it follows that the so-named sympathetic nerve is composed of two forms of nerve-fibre: one of which is peculiar, and originates in the ganglia of the sympathetic system, while the other is borrowed from the cerebro-spinal nerve.*

Prevertebral plexuses:

b. The second division of the sympathetic comprises three large aggregations of nerves, or nerves and ganglia situated in front of the spine (prevertebral plexuses), and occupying respectively the thorax, the abdomen, and the pelvis. They are single or unsymmetrical, and are named respectively the cardiac, the solar, and the hypogastric plexus. These plexuses each receive branches from both the gangliated cords above noticed, and they constitute centres from which the viscera are supplied with nerves.

receive branches from gangliated cords, and give branches to viscera.

Cephalic ganglia.

c. In the third series will be ranged certain small ganglia which are dispersed through the cranium at irregular intervals. These are connected more or less directly with the upper part of the gangliated cords, and more immediately with the fifth pair of cranial nerves. They furnish branches for the most part to the organs of sense; and they are known as the ophthalmic, the sphenopalatine, otic, and submaxillary ganglia.

The ganglia last referred to having been before fully described in connexion with the fifth pair of cranial nerves, it remains to enter here into the details of the first two divisions of the sympathetic system.

* For an account of the microscopical appearance of the sympathetic nerve, see the General Anatomy of Nerve.

A. THE GANGLIATED CORDS.

I. THE CERVICAL PART.

In the neck each gangliated cord is deeply placed beneath the sheath of the great cervical blood-vessels, and is in contact with the muscles which immediately cover the fore part of the vertebral column. It comprises but three ganglia, which are distinguished by their relative position, being placed respectively at the upper and lower end and the middle of the neck. The ganglia require to be separately described.

Cervical part has but three ganglia.

THE UPPER CERVICAL GANGLION.

This is the largest of the ganglia of the gangliated cord. It is usually fusiform in shape: but there is a good deal of variety in this respect in different cases, the ganglion being occasionally broader than usual (in various degrees), and from time to time constricted at intervals.* It has the reddish-grey colour characteristic of the ganglia of the sympathetic system; and it is placed on the larger rectus muscle, opposite the second and third cervical vertebræ, and beneath the internal carotid artery.

First cervical is largest ganglion of cord.

It is opposite 2nd and 3rd verteb. and under carotid artery.

Connexion with spinal nerves.—At its outer side the superior cervical ganglion is connected with the first four spinal nerves, and the connecting cords have the arrangement before pointed out in the general description (page 879).

Connected with four spinal nerves;

Connexion with cranial nerves.—Small branches connect the ganglion or its cranial cord, with the second ganglion of the pneumo-gastric, and with the ninth cranial nerve, near the base of the skull. And in this place may likewise be noticed another branch, which is directed upwards from the cord issuing from the upper part of the ganglion, and divides at the base of the skull into two filaments. One of these ends in the second (petrosal) ganglion of the glosso-pharyngeal nerve; while the other, entering the jugular foramen, joins the ganglion of the root of the pneumo-gastric.

with ninth, and with ganglia of vagus and glosso-phar. nerves.

* The occurrence of constrictions has given rise to the opinion that the ganglion may result from the coalescence of several ganglia; and in this way it has been sought to account for its greater size, and for the diminished number of the cervical ganglia.

BRANCHES OF THE GANGLION.

Pharyngeal Nerves and Pharyngeal Plexus.

Pharyngeal nerves join others to form plexus behind mid. constrictor.

These nerves arise from the upper part of the ganglion, and are directed obliquely inwards to the side of the pharynx. Opposite the middle constrictor muscle they unite with branches of the pneumo-gastric and glosso-pharyngeal nerves; and by their union with those nerves the *pharyngeal plexus* is constructed. Branches emanating from the plexus are distributed to the muscles and mucous membrane of the pharynx.

Upper Cardiac Nerve.

Cardiac nerves: one from each cervl. ganglion.

They vary on opposite sides;

and in different cases.

Mode of termination is constant.

First cardiac nerve;

is behind carotid sheath.

Ends in deep cardiac plexus.

A few preliminary remarks on the cardiac nerves are here necessary. The cervical ganglia of the sympathetic furnish each a cardiac branch, named, like the ganglion from which it arises, Upper, Middle and Lower; but the branches are not altogether disposed in the same way on the opposite sides of the body, and we shall therefore have to notice the two sides separately.

The cardiac nerves are continued singly, or in connexion, to the large prevertebral plexus (cardiac plexus) of the thorax. In this, as in other parts of the sympathetic system, considerable variety occurs as to the disposition of the branches in different cases; and where one branch happens to be of smaller size than common, another will be found to possess an increased size, as if to compensate for the defect. But the arrangement of the branches at their termination in the organs to which they are distributed appears to be always the same.

The *upper cardiac nerve* (*r. cardiacus superficialis*) of the *right side* is constructed from two or more branches of the ganglion, with, in some instances, an offset from the cord connecting the first two ganglia. In its course in the neck the nerve lies behind the carotid sheath, in contact with the longus colli muscle; and it is placed over the lower thyroid artery and the recurrent laryngeal nerve. Entering the thorax, it passes, in some cases before, in others behind the subclavian artery, and is directed along the innominate artery to the back part of the arch of the aorta, where it ends in the deep cardiac plexus, a few small filaments continuing also to the front of the great vessel. Some branches are distributed to the thyroid body; they accompany the inferior thyroid artery.

In its course downwards the cardiac nerve is repeatedly connected with other branches of the sympathetic, and with the pneumo-gastric nerve. Thus, about the middle of the neck it is joined by some filaments from the external laryngeal nerve; and, rather lower down, by one or more filaments from the trunk of the pneumo-gastric nerve; lastly, on entering the chest, it joins with the recurrent laryngeal.—Instead of passing to the thorax in the manner above described, the nerve may be found to join the cardiac branch furnished from one of the other cervical ganglia.*

Is connected with laryngeal nerves.

The superficial cardiac nerve of the *left side* has, while in the neck, the same course and connexions as that of the right side. But within the chest it follows the left carotid artery to the arch of the aorta, and ends in some instances in the superficial cardiac plexus, while in others it joins the deep plexus; and accordingly it passes either in front of the arch of the aorta or behind it.

On left side,

ends in the superficial card. plexus.

Vascular Branches.

The nerves which ramify on the arteries (*nervi molles*) spring from the front of the ganglion, and reach the trunk of the carotid artery, which they entwine. An offset is continued on each branch of the external carotid, and forms a slender plexus upon it. These nerves or plexuses have the same designation as the arteries they surround. From the plexus on the facial artery is derived the filament which joins the submaxillary ganglion; and, from that on the middle meningeal artery, offsets have been described as extending to the otic ganglion, as well as to the gangliform enlargement of the facial nerve (*ante*, page 795 and *fig.* 190). Lastly, a communication is established between the plexus on the carotid artery and the digastric branch of the facial nerve.

Nervi molles accompany brs. of ext. carotid;

join submax. and otic gangl.

and facial nerve.

Small ganglia are occasionally found on some of the foregoing vascular plexuses, close to the origin of the vessels with which they are associated. Those which have been described are an inter-carotid one (placed in the angle of the bifurcation of

Ganglia on nerv. molles.

* Scarpa describes this as the common disposition of the superficial cardiac nerve, but M. Cruveilhier (*Anat. Descript.*, t. iv.) states that he has not in any case found the cardiac nerves exactly to correspond with the figures of the "*Tabulæ Neurologicæ.*"

the common carotid artery), and lingual, temporal, and pharyngeal ganglia.

The foregoing branches will be found to correspond in a great measure with the branches of other ganglia; but we now proceed to examine an offset which is peculiar to the first cervical ganglion.

Ascending or Cranial Branch.

Cranl. prolongation fr. first cervl. gangln.

on intern. carotid.

Its two parts.

External part forms carotid plexus.

Intern. part forms cavern. plexus.

Branches on cerebral and ophthalm. arteries.

The ascending offset of the first cervical ganglion is soft in texture and of a reddish tint, seeming to be in some degree a prolongation of the ganglion itself. In its course to the skull, it is concealed by the internal carotid artery, with which it enters the carotid canal in the temporal bone; and it is then divided into two parts, which are placed one on the outer side, the other on the inner side of the vessel.

The *external part*, or division, distributes filaments to the internal carotid artery, and, after communicating by means of other filaments with the internal division of the cord, forms the *carotid plexus*.

The *inner division*, rather the smaller of the two, also supplies filaments to the carotid artery, and goes to form what is named the *cavernous plexus*. The several parts of these divisions of the cranial cord are prolonged on the trunk of the internal carotid, and extend to the cerebral and ophthalmic arteries, around which they form secondary plexuses.* One plexus enters the eye-ball with the central artery of the retina.

Carotid Plexus.

Carotid plexus; its position.

The carotid plexus, situate, as before mentioned, on the outer side of the internal carotid artery at its second bend (reckoning from below), or between the second and third bends, joins the fifth and sixth nerves, and gives many filaments to the vessels on which it lies. †

Branches join sixth nerve;

Branches. 1. The connexion with the *sixth nerve* is established by means of one or two filaments of considerable size, which are applied to that nerve where it lies by the side of the internal carotid artery.

* It was said by Ribes (Mem. de la Société Méd. d'Emulation, tom. viii. p. 606,) that the cranial prolongations of the sympathetic nerve from both sides were joined one with the other on the anterior communicating artery, — a small ganglion or a plexus being formed at the point of juncture. This connexion has not been satisfactorily made out by other observers.

† Valentin describes nerves furnished to the dura mater from this plexus.

2. The filaments connected with the *Gasserian ganglion* of the fifth nerve proceed in one case from the carotid plexus, in another from the cavernous. and gangl. of fifth.
3. The filament which constitutes the deep branch or part of the *vidian nerve* is directed forwards to the pterygoid canal, through the cartilaginous substance closing the foramen lacerum anterius in the base of the skull. A branch forms deep part of vidian.
- In that canal it becomes associated with the deep branch of the vidian, and is continued forward to the sphenopalatine ganglion. (See ante, page 784.)

Cavernous Plexus.

The cavernous plexus, named from its position in the sinus of the same name, is placed below and rather to the inner side of the highest turn of the internal carotid artery. Besides giving branches on the artery, it communicates with the third, the fourth, and fifth cranial nerves which enter the orbit.*

Cavernous plexus.

Position.

- Branches.*—1. The filament which joins the *third nerve* comes into connexion with it close to the point of division of that nerve. Brs. join the third,
2. The branch to the *fourth nerve*, which may be derived from either the cavernous or carotid plexus, joins the nerve where it lies in the wall of the cavernous sinus. fourth, and ophthal. div. of fifth cerebral nerve.
3. The filaments connected with the *ophthalmic division* of the *fifth nerve* are supplied to its inner surface. One of them is continued forward to the lenticular ganglion, either in connexion with, or distinct from the nasal nerve (ante, 779).

MIDDLE CERVICAL GANGLION.

The middle ganglion (ganglion thyroideum), which is much the smallest of the cervical ganglia, is placed on or near the inferior thyroid artery. It is usually connected in the ordinary way with the fifth and the sixth spinal nerves, but the communication with those nerves is not constant.

Second cervical gangl. very small, is connected with infer. thyrd. arty.

BRANCHES DERIVED FROM THE GANGLION.

Thyroid branches.—From the inner side of the ganglion some nerves proceed along the inferior thyroid artery to the thyroid body, where they join the recurrent laryngeal and the external laryngeal nerves. Whilst on the artery, these branches communicate with the upper cardiac nerve.

Branches for thyroid body.

Middle Cardiac Nerve.

The middle cardiac nerve (*nervus cardiacus profundus*)

Middle card. nerve

* A second communication between the sympathetic and the sixth nerve, taking place below the bend of the carotid, has been described by some anatomists.

in neck is behind sheath of vessels; in chest is on trachea; ends in deep cardc. plex. Is connected with first cardc. nerve and with recurrent laryngeal.

v. magnus) is prolonged to the chest beneath the sheath of the common carotid artery, and in front of the subclavian artery, or, it may be, behind this vessel. In the chest it lies on the trachea, where it is joined by filaments of the recurrent laryngeal nerve, and it ends in the right side of the deep cardiac plexus. While in the neck, the nerve communicates with the upper cardiac nerve and the recurrent branch of the pneumo-gastric.—When the middle cervical ganglion is small, the middle cardiac nerve may be found to be an offset of the inter-ganglionic cord.

The foregoing account of the nerve has reference to the right side of the body: on the *left side*, the middle cardiac nerve enters the chest between the left carotid and subclavian arteries, and joins the left side of the deep cardiac plexus.

LOWER CERVICAL GANGLION.

Third cervl. gangln.

behind vert. artery;

connected w. last two cervl. nerves and indirectly with others.

The lower or third cervical ganglion is irregular in shape, usually somewhat round or semilunar, and is frequently united in part to the first thoracic ganglion. Placed in a hollow between the transverse process of the last cervical vertebra and the neck of the first rib, it is concealed by the vertebral artery.

Connexion with spinal nerves.—This ganglion is connected directly by short communicating cords, in the manner of other ganglia, with the last two cervical nerves. Moreover, branches which pass from the ganglion along the vertebral artery (see page 887), supplying twigs to this vessel, are also connected with other cervical nerves, and thus additional communications are established between the two systems.

BRANCHES OF THE LOWER CERVICAL GANGLION.

Lower Cardiac Nerve.

Third cardc. nerve:

ends in deep cardc. plex.

Connex. w. midd. cardc. and w. brs. of recurrent laryngeal.

The lower cardiac nerve, issuing from the third cervical ganglion or from the first thoracic, and inclining inwards behind the subclavian artery, terminates, like the other cardiac nerves, in the cardiac plexus behind the arch of the aorta. It communicates with the middle cardiac and recurrent laryngeal nerves behind the subclavian artery. On the *left side*, the lower cardiac often becomes blended with the middle cardiac nerve, and the cord resulting from their union terminates in the deep cardiac plexus.

Branches on the vertebral artery; vertebral plexus.—From the lowest cervical and the first dorsal ganglia a few slender branches ascend along the vertebral artery in its osseous canal, forming a plexus round the vessel by their intercommunications, and supplying it with offsets.* This plexus is connected with the cervical spinal nerves as far upwards as the fourth.

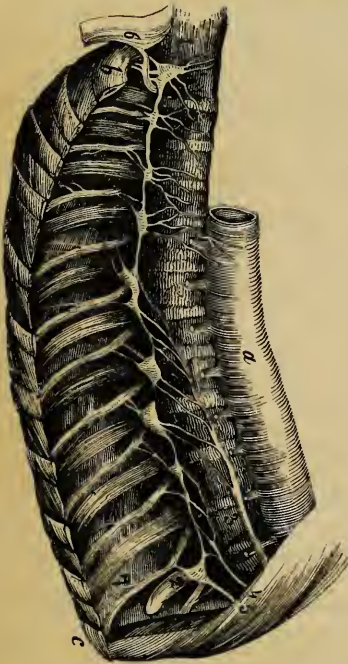Plexus on vertebral artery; connected with spinal nerves.

A couple of branches pass from the lower cervical ganglion to the first dorsal ganglion in front of the subclavian artery, forming loops round the vessel (*ansæ Vieussenii*), and supplying it with small offsets.

Loops on subclavian artery.

2. THORACIC PART OF THE GANGLIATED CORD.

Fig. 207.†



In the thorax the knotted cord is placed on each side of the spinal column, over the line of the heads of the ribs; and it is uninterruptedly continuous with the same part in the neck and in the abdomen. It is covered by the pleura.

Gangliated cord in chest behind pleura.

Opposite the head of each rib the cord presents for the most part a greyish enlargement or ganglion, so that there are commonly twelve of these; but, from the occasional coalescence of two masses, the number is uncertain. The first ganglion is much larger than the rest, and is of an elongated form. It is often blended with the lower cervical ganglion. The rest are small, and are not inaptly described as hordeiform.

Twelve ganglia:

Connexion with the spinal nerves.—The branches of con-

each has two

* Little gangliiform enlargements have been described as existing on the plexus, but they do not possess the vesicles which belong to true ganglia (Valentin). The existence of the enlargements in question is doubted by M. Cruveilhier.

† A representation of the ganglia of the sympathetic in the chest; (the ganglia are represented larger than natural.) The wood-cut is taken from part of a plate in Mr. Swan's work.—a. Aorta. b. First rib. c. Eleventh rib. 1. First thoracic ganglion. 2. Last thoracic ganglion. 3. Large splanchnic ganglion.

connecting
cords with
spinal nerve.

nexion between the spinal nerves and the ganglia of the sympathetic, fig. 207, are usually two in number for each ganglion.

BRANCHES OF THE GANGLIA.

Branches of
first six,
small, end
on aorta and
bones.

The branches furnished by the *first six ganglia*, fig. 207, are much smaller than those of the lower six, and are distributed in a great measure to the thoracic aorta, the vertebræ, and ligaments. One or two branches enter the posterior pulmonary plexus.*

Brs. from
lower six
give three
splanchnic
nerves to
abdomen.

The branches furnished by the *lower six ganglia* unite into cords, which pass from the thorax to the abdomen, and join plexuses in the latter cavity. The cords referred to are three in number on each side, are named "splanchnic," and are distinguished as the great, the small, and the smallest splanchnic nerve.† They occur in the thorax in the order in which they are here mentioned, the largest being at the same time highest, and the smallest lower than the rest.

The Great Splanchnic Nerve.

Great
splanchnic
nrve. formed
fr. several
thoracic
ganglia,

This nerve or cord, fig. 207,³ appears at first sight to be formed by roots supplied by the thoracic ganglia from the sixth or seventh to the tenth inclusive; but, by examination after immersion in acetic or diluted nitric acid, small filaments may be traced upwards as far as the third ganglion, or even, according to Mr. Beck, as far as the first.‡

Gradually augmented by the successive addition of the several roots, the cord descends obliquely inwards over the bodies of

nic nerve. 4. Small splanchnic nerve. 5. Smallest splanchnic nerve. 6. Part of the brachial plexus.

* Mr. Swan represents branches of the second, third, and fourth ganglia as united in a *plexus* (which he names thoracic) on the bodies of the vertebræ. Offsets from the plexus are mentioned by this anatomist as entering the pulmonary and cardiac plexuses, while some are continued beneath the œsophagus to the corresponding plexus on the opposite side.

† Wrisberg noticed a fourth splanchnic nerve, which he found but eight times, though he sought it in many bodies. He proposed to call it the highest splanchnic nerve (*nervus splanchnicus supremus*). It is described as formed by offsets from the cardiac nerves, and from the lower cervical, as well as some of the upper thoracic ganglia. Consult the "Observ. Anatom. de Nerv. Viscerum particula prima," p. 25, sect. iij. "De nervo sympathico maximo."

‡ See a paper entitled "On the Nerves of the Uterus, by J. S. Beck, Esq." in the Philosophical Transactions, Part 2, for 1846.

the dorsal vertebræ; and, after perforating the crus of the diaphragm, (the point at which it passes through the muscle varying in different cases,) terminates in the semilunar ganglion, frequently also sending some filaments to the renal plexus and the supra-renal body.

perforates diaphragm,
ends in semilunar ganglion.

The splanchnic nerve is remarkable from its white colour and firmness, which are owing to the preponderance of the spinal nerve-fibre in its composition.

In the chest the great splanchnic nerve is not unfrequently divided into parts, and forms a little plexus with the small splanchnic nerve. Occasionally too a small ganglion (ganglion splanchnicum) is formed on it over the last dorsal vertebra, or the last but one; and when it presents a plexiform arrangement, several small ganglia have been observed on its divisions.

Small Splanchnic Nerve.

The small or second splanchnic nerve, fig. 207,⁴ springs from the tenth and eleventh ganglia, and from the cord between those ganglia. It continues with the preceding nerve through the diaphragm, and ends in the cœliac plexus. In the chest this nerve often communicates with the large splanchnic nerve; and in some instances it furnishes filaments to the renal plexus, especially if the lowest splanchnic nerve is very small or wanting.

Second splanchnic nerve from eleventh and twelfth ganglia; ends in cœliac plexus.

Smallest, or Third Splanchnic Nerve.

This nerve (nerv. renalis posterior—Walter), fig. 207,⁵ arises from the last thoracic ganglion, and communicates sometimes with the nerve last described. After piercing the diaphragm, it ends in the renal plexus, and in the lowest part of the cœliac plexus.

Third splanchnic nerve from last ganglion; ends in renal plexus.

3. LUMBAR PART OF THE GANGLIATED CORD.

In the lumbar region the two gangliated cords, continuing from the thoracic series of ganglia behind the diaphragm, approach one to the other more nearly than in the thorax. They are placed before the bodies of the vertebræ, each lying along the inner margin of the psoas muscle; and that of the right side is partly covered by the vena cava.

Gangliated cords on lumb. vertebræ closer one to the other.

The ganglia are small, and hordeiform in shape. They are

Four ganglia.

commonly four in number, but occasionally their number is diminished, and then their size is proportionably enlarged.

Cords connecting w. spinl. nrvs. are long ; they pass betw. psoas, and verteb.

Connexion with spinal nerves.—In consequence of the greater distance at which the lumbar ganglia are separated from the intervertebral foramina of the spine, the cords connecting them with the spinal lumbar nerves are longer than in other parts of the sympathetic system. There are generally two connecting cords for each ganglion, but the number is not so uniform as it is in the chest; nor are those belonging to any one ganglion connected with the same spinal nerve in all cases.

The connecting cords accompany the lumbar arteries, and, as they cross the bodies of the vertebræ, are covered by the fibrous bands from which the larger psoas muscle partly takes its origin.

Branches of the Lumbar Ganglia.

Branches go to aortic and hypogastric plexuses.

The branches of these ganglia are uncertain in their number. Some join a plexus on the aorta; others descending go to form the hypogastric plexus. Several filaments are distributed to the vertebræ, and to the ligaments connecting those bones.

4. SACRAL PART OF THE GANGLIATED CORD.

Gangliated cords on sacrum converge and are connected on coccyx.

Over the sacrum the gangliated cord of the sympathetic nerve is much diminished in size, and gives but few branches to the viscera. Its position on the front of the sacrum is along the inner side of the anterior sacral foramina; and, like the two series of those foramina, the two cords approach one another in their progress downwards. The upper end of each is connected with the last lumbar ganglion, sometimes by a double inter-ganglionic cord; at the opposite end, the lowest sacral ganglion is connected with that of the other side by means of a single median ganglion. This ganglion (*ganglion impar*) is placed on the forepart of the coccyx. The sacral ganglia are usually five in number; but the want of constancy both in size and number is more marked in these than in the thoracic or lumbar ganglia.

Ganglion impar.

Five sacral ganglia.

Cords connecting w. spinl. nrvs. very short.

Connexion with spinal nerves.—From the proximity of the sacral ganglia to the spinal nerves at their emergence from the bone, the communicating branches are very short: they are two in number for each ganglion, and are in some cases con-

nected with two different sacral nerves. The coccygeal nerve communicates with the last sacral or the coccygeal ganglion.

Branches of the Sacral Ganglia.

The branches are much smaller in size than those from the ganglia in other parts of the cord. They are for the most part expended on the front of the sacrum, and they join the corresponding branches from the opposite side. Some filaments from one or two of the first ganglia enter the hypogastric plexus, while others go to form a plexus on the middle sacral artery. From the lower end of the sympathetic (i. e. the loop connecting the two cords, and on which the coccygeal ganglion is formed), filaments are given to the coccyx and the ligaments about it.

Branches are small.

Twigs to hypogastric plexus, and on middle sacral artery.

B. PREVERTEBRAL PART OF THE SYMPATHETIC NERVE.

This portion of the sympathetic system, it has been already stated, consists of certain unsymmetrical plexuses placed before the spine, and serving as centres from which nerves are furnished to the viscera. Those recognised are the cardiac, solar, and hypogastric plexuses. They are composed of assemblages of nerves, or nerves and ganglia. Each receives nerves from the gangliated cord of both sides; and these nerves, as will presently appear in the special description of the plexuses, take origin from the ganglia at a distance above the plexus.

Prevert. plexuses in chest, abdomen and pelvis.

Each receives nrvs. fr. gangl. cords, and gives brs. to viscera.

From the plexuses are furnished branches or secondary plexuses for the supply of the viscera. These offsets accompany the arteries in their course to the viscera for which they are respectively destined.

1. CARDIAC PLEXUS.

The prevertebral plexus of the thorax is thus named. To it several branches (cardiac), given from the cervical ganglia of the sympathetic, and from the vagus nerve, converge as to a common centre; and from it proceed the nerves which supply the heart, as well as some offsets which assist in supplying the lungs.

Cardc. plex. formed by branches of sympath. and vagus nerves.

The large cardiac plexus of nerves lies above the base of the heart upon the two great arteries which issue from it (aorta, and pulmonary artery). In the general network formed by

these nerves there are reckoned two subdivisions, which are partially separated one from the other, and are distinguished as the superficial, and the deep or great cardiac plexus. The branches pass from these to the heart, in two bundles, which accompany the nutritious arteries of the organ, and from this circumstance are called coronary plexuses.

Superficial Cardiac Plexus.

Superficial plexus in curve of aorta receives a cardiac nerve fr. sympath. and from vagus, both of left side.

(Gangl. of Wrisberg.)

The superficial cardiac plexus lies in the concavity of the arch of the aorta, in front of the right branch of the pulmonary artery. In it terminates the superficial or first cardiac nerve of the left side, either wholly or in part, with the lower cardiac branch of the left pneumo-gastric nerve (in some cases, also, that of the right side); and it is joined by a prolongation forward from the deep cardiac plexus. A small ganglion (*ganglion of Wrisberg*) is frequently found at the point of union of the nerves. The plexus ends in the anterior coronary plexus, and it furnishes laterally filaments along the pulmonary artery to the anterior pulmonary plexus of the left side.

Anter. coronary plexus, formed from superficial cardc. plex. with an addition from deep plexus.

The anterior coronary plexus, a prolongation in greatest part from the superficial cardiac plexus above described, is at first continued forward between the aorta and the pulmonary artery, and is thence conducted by the right or anterior coronary artery to the heart. Where the anterior coronary artery appears between the large vessels, the coronary plexus receives an accession from the deep cardiac plexus.

Deep Cardiac Plexus.

Deep cardc. plexus, is behind arch of aorta;

receives all cardc. nerves of sympath. and vagus, except one fr. each of these on left side.

The deep cardiac plexus (*plexus magnus profundus—Scarpa*) is much larger than the superficial one, and is placed behind the arch of the aorta, between it and the end of the trachea, and above the division of the pulmonary artery.

This plexus receives all the cardiac branches of the cervical ganglia of the sympathetic nerve, except the first one (superficial cardiac nerve) of the left side. It likewise receives the cardiac nerves furnished by the vagus and by the recurrent laryngeal branch of that nerve, with the exception of the lower cardiac nerve of the left side.

Branches end mostly in posterior

The nerves issuing from the great cardiac plexus end in greatest part in the posterior coronary plexus. But some join

the anterior coronary plexus; and a few filaments are added to the pulmonary plexuses. coronary plexus.

There is some difference as to the course pursued by the nerves issuing from the plexus on the right and left side. The branches descending from the *right side* of the plexus pass, some in front of the right pulmonary artery, others behind the vessel. The former, which is much the more numerous set, after sending some filaments to the anterior pulmonary plexus, are directed along the trunk of the pulmonary artery, and become part of the anterior coronary plexus; while the nerves stated to be behind the right pulmonary artery are distributed to the right auricle of the heart, and a few filaments are continued into the posterior coronary plexus.

On the *left side*, a few branches pass forward by the ductus arteriosus to join the superficial cardiac plexus; but the great body of the nerves of this side end in the posterior coronary plexus, after giving branches to the left auricle of the heart, and to the anterior pulmonary plexus.

The posterior coronary plexus is derived chiefly from the left side of the deep cardiac plexus, but is joined by nerves from the right portion of that plexus. It surrounds the branches of the coronary artery at the back of the heart, and supplies mostly the muscular substance of the ventricles. Posterior coronary plex. fr. deep cardiac plexus.

The nerves constituting the coronary plexuses accompany, as already stated, the branches of the arteries, and, after subdividing minutely, enter the muscular substance of the heart. Nervous filaments are said to ramify under the lining membrane of the heart, but they are not as easily distinguished in man as in some animals, the sheep, for example. (Valentin.) Ganglia of small size have been found by Remak* on the branches of the cardiac nerves in several mammifers, both on the surface of the heart and in the muscular substance, where they were observed to be very numerous; but Valentin failed to detect such ganglia in the human heart. Nerves of coronary plexus follow arteries and supply muscular structure; some under endocardium.

2. EPIGASTRIC OR SOLAR PLEXUS.

The epigastric plexus, which is the largest of the prevertebral plexuses, is placed at the upper part of the abdomen, behind the stomach, and in front of the aorta and the pillars of the diaphragm. Surrounding the origin of the cœliac axis and the upper mesenteric artery, it occupies the interval between the supra-renal bodies, and extends downwards as far as the pancreas. The plexus consists of nervous cords, and several ganglia of various size connected together by nervous cords. The large splanchnic nerves of both sides, and some branches of the pneumo-gastric, terminate in it. The offsets or branches sent Solar plex. close to cœliac and super. mesent. arteries; consists of ganglia and connecting cords; receives splanchnic

* Müller's Archiv. 1844.

nerves and branches of vagus. from it are very numerous, and they accompany the arteries to the principal viscera of the abdomen, constituting so many secondary plexuses on the vessels.

Ganglia.

Ganglia.—The solar plexus contains, as already mentioned, several ganglia; and by the presence of these bodies, and their size, it is distinguished from the other prevertebral plexuses. Two of the ganglia (one for each side), which differ from the rest by their greater size, require separate notice. Named *semilunar*, though they have often little of the form the name implies, they occupy the upper and outer part of the plexus on each side, and are placed close to the supra-renal bodies, by the side of the cœliac and the superior mesenteric arteries. At the upper end, which is expanded, each ganglion receives the great splanchnic nerve, and from it, branches radiate in different directions.

Semilunar is principal one;

gt. splanchnic nerve ends in it.

Branches of solar plex. accompanyg. the branches of aorta.

Offsets from the plexus.—These have the same plexiform arrangement as the large plexus from which they are derived. Each secondary plexus, as it accompanies a branch of the aorta, surrounds the vessel with a kind of membranous sheath, and is named from the vessel by which it is supported. Accordingly, diaphragmatic, cœliac, renal, mesenteric, and other plexuses are recognised.

Diaphragmatic plexuses.

Diaphragmic. nerves follow artrs.

and sink into diaphragm.

Ganglion on right side where phrenic nerve connected with this plexus.

Twigs to hepat. plex. on left side.

The nerves (inferior diaphragmatic) composing each of these plexuses are derived from the upper part of the semilunar ganglion, and are larger on the right than on the left side. Accompanying the arteries along the lower surface of the diaphragm, the nerves sink into the substance of the muscle. They furnish some filaments to the supra-renal body, and join with the spinal phrenic nerves.

At the right side, on the under surface of the diaphragm, and near the supra-renal body, there is a small ganglion (*gang. diaphragmaticum*), which marks the junction between the phrenic nerves of the spinal and the sympathetic systems. From this small ganglion filaments are distributed to the vena cava, the supra-renal body, and the hepatic plexus. On the left side the ganglion is wanting, but some filaments are prolonged to the hepatic plexus.

Supra-renal plexus.

The supra-renal nerves issue from the outer part of the semi-lunar ganglion and from the solar plexus, a few filaments being added from the diaphragmatic nerve. They are short, but numerous in comparison with the size of the body which they supply; and they enter the upper and inner parts of the supra-renal capsule. These nerves are continuous below with the renal plexus. The plexus is joined by branches from one of the splanchnic nerves, and presents a ganglion (*gangl. splanchnico-supra-renalē*) where it is connected with those branches. The plexus and ganglion are smaller on the left than on the right side.

Supra-renal plexus;

supplies supra-renal body; receives twigs from a splanchnic nerve; a ganglion at place of union.

Renal Plexus.

The nerves forming the renal plexus, which are about fifteen or twenty in number, emanate for the most part, like the preceding nerves, from the outer part of the semilunar ganglion; but some are added from the solar plexus and the aortic plexus. Moreover, filaments of the smallest splanchnic nerve, and occasionally from the other splanchnic nerves, terminate in the renal plexus. As they follow onwards the renal artery, ganglia of different sizes are formed on these nerves. Lastly, dividing with the divisions of the vessel, the nerves follow the vessels into the substance of the kidney. On the right side some filaments are furnished to the vena cava, behind which the plexus passes with the renal artery, and others go to form the spermatic plexus.

Renal plex.;

joined by third splanchnic nerve.

Twigs for vena cava.

Spermatic Plexus.

This small plexus commences in the renal plexus, but receives in its progress with the spermatic artery an accession from the aortic plexus. Continuing downwards to the testis, the spermatic nerves are connected with others, which accompany the vas deferens and its artery from the pelvis.

Spermatic plexus,

joined by nerves on vas deferens.

In the female, the plexus, like the artery, is distributed to the ovary and the uterus.

Ovarian plexus.

Cœliac Plexus, and its subdivisions.

The cœliac plexus is of large size, and is derived from the fore part of the great epigastric plexus. It surrounds the cœliac

Cœliac divides into three plexus.

axis in a kind of membranous sheath, and subdivides, as the artery, into coronary, hepatic, and splenic plexuses. The plexus receives offsets from one or more of the splanchnic nerves, and on the left side a branch from the pneumo-gastric nerve is continued into it (Swan).

Coronary of stomach,
joins pyloric and vagus nerves.

a. The *coronary plexus* is placed with its artery along the small curvature of the stomach, and unites with the nerves which accompany the pyloric artery, as well as with branches of the pneumo-gastric nerves. The nerves of this plexus enter the coats of the stomach, after lying a short distance beneath the peritoneum.

Hepatic

b. The *hepatic plexus*, the largest of the three divisions of the cœliac plexus, ascends with the hepatic vessels and the bile-duct, and, entering the substance of the liver, ramifies on the branches of the vena portæ and the hepatic artery. Offsets from the left pneumo-gastric and from the diaphragmatic nerves join the hepatic nerves at the left side of the hepatic vessels.

is joined by twigs of left vagus ;

gives secondary plexs.:

pyloric to stomach ;

From this plexus are furnished filaments to the right suprarenal plexus, as well as other secondary plexuses which follow branches of the hepatic artery. Thus there is with the pyloric artery a *pyloric plexus*, which gives branches on the small curvature of the stomach, and is connected with the pneumo-gastric nerves, as well as with the plexus on the coronary artery.

gastro-epipl. and gastro-duodenal supplying stomach, duodenum, and pancreas ;

and cystic for gall-bladder.

Again, a *gastro-epiploic* and a *gastro-duodenal plexus* are furnished from the hepatic plexus. The former surrounds the right gastro-epiploic artery, and communicates with the nerves from the splenic plexus, which lie on the left gastro-epiploic vessel ; while the gastro-duodenal plexus supplies the duodenum and the pancreas, and joins the mesenteric plexus. The plexuses just noticed supply filaments to the stomach, chiefly at its pyloric end. Near the liver the *cystic plexus* is derived from the same source as the nerves last described, and is conveyed to the gall-bladder by the cystic artery.

Splenic plexus, besides spleen,

furnishes stomach and pancreas w. nerves.

c. The *splenic plexus* is continued on the splenic artery and its divisions into the substance of the spleen. This plexus is reinforced at its beginning by branches from the left semilunar ganglion, and by a filament from the right vagus nerve. It furnishes the *left gastro-epiploic* and *pancreatic* plexuses, which course along the branches of the splenic artery bearing the same appellation, and, like the vessels, are distributed to the stomach and pancreas.

Superior Mesenteric Plexus.

The plexus accompanying the superior mesenteric artery, whiter in colour and firmer than either of the preceding offsets of the solar plexus, envelopes the artery in a membraniform tube, and receives a prolongation from the junction of the right pneumo-gastric nerve with the cœliac plexus. About the root of the artery, ganglionic masses (gangl. meseraica) occur in connexion with the nerves of this plexus.

Super. me-
sent. plex.

Ganglia.

The offsets of the plexus are in name and number the same as the vessels; and, in the same manner as the vessels, they supply the greater part of the small intestines, viz. the jejunum and ileum, as well as the ascending and the transverse colon. The pancreas also receives nerves from the superior mesenteric plexus. The nerves are distributed as follows:—

Nerves to
same parts
of intest. as
the arteries
they accom-
pany.

Closely encircling the superior mesenteric artery, the plexus enters with that vessel between the layers of the mesentery, and furnishes secondary plexuses around the branches of the artery: viz. *intestinal* nerves to the small intestine, and plexuses for the supply of the large intestine, named severally *ileo-colic*, *right colic*, and *middle colic*. In their progress to the intestine some nerves quit the arteries which first supported them, and are directed forwards in the intervals between the vessels. As they proceed, they divide, and unite with lateral branches, like the arteries, but without the same regularity; and they enter the intestine where the mesentery is connected with it. The highest of the foregoing nerves, those on the jejunum, communicate with the gastro-duodenal plexus; and those distributed to the transverse colon (middle colic nerves) join with the left colic nerves furnished from the inferior mesenteric plexus.

Connexions
between the
nerves.

The Aortic Plexus.

The aortic or inter-mesenteric plexus is placed along the abdominal aorta, and occupies the interval between the origin of the superior and inferior mesenteric arteries. This plexus may be considered a prolongation of the solar plexus, which supplies nerves to accompany some of the lower branches of the aorta. Above, it consists, for the most part, of two lateral portions, (connected with the semilunar ganglia and renal plexuses,) which are extended on the sides of the aorta, but with communi-

Aortic plex.

at sides and
in front of
aorta;

cating branches over that vessel. It is joined, moreover, by branches of some of the lumbar ganglia.

besides giving other plex., supplies vena cava with nerves.

The aortic plexus furnishes the inferior mesenteric plexus and part of the spermatic, gives some filaments to the lower vena cava, and ends in the hypogastric plexus.

Inferior Mesenteric Plexus.

Infer. mesent. plex.

supplies same parts as infer. mesent. art.

The inferior mesenteric plexus is derived principally from the left lateral part of the aortic plexus, and closely surrounds with a network the inferior mesenteric artery. It distributes nerves to the left or descending part and the sigmoid flexure of the colon, and assists in supplying the rectum. The nerves of this plexus, like those of the superior mesenteric plexus, are firm in texture, and whitish in colour.

As it proceeds along the artery, the inferior mesenteric plexus divides into the following secondary plexuses, viz. *left colic*, *sigmoid*, and *superior hæmorrhoidal*, which surround respectively the branches of the artery. In their progress to the intestine, the nerves of these plexuses subdivide, and join, like the branches of the superior mesenteric nerves: the highest branches (those on the left colic artery) are connected with the last branches (middle colic) of the superior mesenteric plexus, while others in the pelvis unite with offsets from the inferior hypogastric plexus of the left side.

3. HYPOGASTRIC PLEXUS.

Hypogastric plexus

placed betw. common iliac arters.; formed by branches fr. aortic plex. to which branches fr. lumb. gangl. are joined.

No ganglia in this plex.

The hypogastric plexus (plexus hypogastricus superior, seu uterinus communis—Tiedemann; plex. hypogastr. medius seu impar—Müller; inferior aortic plexus), the prevertebral assemblage of nerves destined for the supply of the viscera of the pelvis, lies invested in dense cellular membrane, in the interval between the two common iliac arteries. The nerves from which it is formed, about twelve in number on each side, descend from the aortic plexus, receiving filaments from the lumbar ganglia, and, after crossing the common iliac artery, form an interlacement with as many nerves from the opposite side. The plexus contains no ganglia. At the lower end it divides into two parts, which are directed forward, one to each side of the pelvic viscera.

Inferior Hypogastric Plexuses.

Inferior hypogastric plexus (plexus gangliosus inferior; hypogastricus lateralis inferior—Tiedemann; plexus hypogastricus inferior—Müller; pelvic plexus—Beck). Each of the two prolongations of the hypogastric plexus is continued forward by the side of the rectum, its branches entering into repeated communications as they descend, and forming at the points of connexion small knots, which contain a little ganglionic matter. After descending some way, they become united with branches of the spinal nerves, as well as with a few offsets of the sacral ganglia, and the union of all constitutes the inferior hypogastric plexus. The spinal branches, which enter into the plexus, are furnished from the third and fourth sacral nerves (in greatest number by the former of these); a couple of filaments being likewise added from the second sacral nerve. Small ganglia are formed at the place of union of the nerves, as well as elsewhere in the plexus (plexus gangliosus—Tiedemann).

Infer. hypogast. plex.:

one at each side of pelvic viscera.

Formed by branches fr. hypogastric plexus, and from sacral nerves.

Spinal nerves wh. join plexus.

Ganglia.

From the plexus so constituted numerous nerves are distributed to the pelvic viscera. They correspond with the branches of the internal iliac artery, and of course vary with the sex; thus, besides hæmorrhoidal and vesical nerves, which are common to both sexes, there are nerves special to each, namely, those destined, in the male, for the prostate, vesicula seminalis, and vas deferens; in the female, for the vagina, uterus, ovary, and Fallopian tube.

Branches of plex. follow arteries to all the pelvic viscera.

The nerves distributed to the urinary bladder and the vagina contain a larger proportion of spinal nerves than those furnished to the other pelvic viscera.—The offsets of the inferior hypogastric plexus will now be noticed separately.

Vesical and vaginal nerves in large proportion fr. spinl. nrves.

Inferior Hæmorrhoidal Nerves.

These slender nerves pass away from the back part of the inferior hypogastric plexus. They join with the nerves (superior hæmorrhoidal) which descend from the abdomen with the inferior mesenteric artery, and penetrate the coats of the rectum.

Infer. hæmorrhoidal joined to super. hæmorrhoidal.

Vesical Plexus.

The nerves of the urinary bladder are very numerous. They are directed from the anterior part of the inferior hypo-

Vesical nerves numerous.

gastric plexus to the side and lower part of the bladder. At first, these nerves accompany the vesical blood-vessels, but afterwards they leave the vessels, and subdivide into minute fibrils, before perforating the muscular coat of the organ. From the vesical plexus, nerves, or what may be considered secondary plexuses, are given in the male to the vas deferens and the vesicula seminalis.

Nerves peculiar to male.

Nerves w. vas deferens and vesicula seminalis.

a. The nerves of the vas deferens ramify around that tube, and communicate in the spermatic cord with the nerves of the spermatic plexus. *b.* Those furnished to the vesicula seminalis form an interlacement on the vesicula, and some branches penetrate its substance. Other filaments from the prostatic nerves reach the same structure.

Prostatic Plexus.

Prostatic nerves

This plexus is continued from the lower part of the inferior hypogastric plexus. The nerves are of considerable size, and pass onwards between the prostate and the levator ani. Some are furnished to the gland (from which they are named), and to the vesicula seminalis; and the plexus is then continued forward to supply the erectile substance of the penis, where the nerves are named "cavernous."

furnish cavernous nerves.

Cavernous nerves (of the penis).* — These are very slender, and difficult to dissect. Continuing from the prostatic plexus, at the fore part of the prostate gland, they pass onwards beneath the arch of the pubes, and through the muscular structure connected with the membranous part of the urethra, to the dorsum of the penis. At the anterior margin of the levator ani muscle some short filaments from the pudic nerve join the cavernous nerves. After distributing twigs to the prostate at its fore part, these nerves divide into branches for the erectile substance of the penis, as follows :

Cavernous nerves penetrate the outer covering of corp. cavernosum.

a. *Small cavernous nerves* (nervi cavernosi minores—Müller), which perforate the fibrous covering of the corpus cavernosum near the root of the penis, and end in the erectile substance.

b. The *large cavernous nerve* (n. cavernosus major), which extends forward on the dorsum of the penis, and dividing, gives filaments that penetrate the

* These nerves have been made the subject of a monograph by Professor Müller; it is entitled "Ueber die Organischen Nerven der erectilen männlichen Geschlechtsorgane," &c. Berlin, 1836.

corpus cavernosum, passing with or near the cavernous artery (art. profunda penis). As it continues onwards, this nerve joins with the dorsal branch of the pudic nerve, about the middle of the penis, and is distributed to the corpus cavernosum. Branches from the foregoing nerves reach the corpus spongiosum urethræ.

The remaining nerves are peculiar to the female.

Nerves peculiar to female.

Nerves of the Ovary.

The ovary is supplied chiefly from the plexus prolonged on the ovarian artery from the abdomen; but it receives another offset from the uterine nerves.

Ovary receives a nerve, besides those w. its arty.

Vaginal Plexus.

The nerves furnished to the vagina leave the lower part of the inferior hypogastric plexus—that part with which the spinal nerves are more particularly combined. They are distributed to the vagina without previously entering into a plexiform arrangement; and they end in the erectile tissue, on its lower and anterior part.

Vaginal nerves.

Nerves of the Uterus.

These nerves are given from the upper part of the inferior hypogastric plexus—more immediately from the lateral fasciculus prolonged to this plexus from the hypogastric plexus, above the point of connexion with the sacral nerves. Separating from the plexus opposite the neck of the uterus, they are directed upwards with the blood-vessels along the side of this organ, between the layers of its broad ligament. The larger part of the nerves soon leave the vessels, and after dividing repeatedly, (but without communicating one with the other, and without forming any gangliform enlargements,) sink into the substance of the uterus, penetrating, for the most part, its neck and the lower part of its body. One branch, continuing directly from the common hypogastric plexus, reaches the body of the uterus above the rest; and a nerve from the same source ascends to the Fallopian tube. Some very slender filaments are differently disposed from the preceding nerves: these form a plexus round the arteries, and terminate on or with those vessels. On the last-mentioned plexiform vascular branches minute ganglia are

Uterine nerves

ascend with vessels at side of uterus.

Some leave the vessels;

(Nerve of Fallopian tube.)

others continue with the vessels.

formed at intervals. Lastly, the fundus of the uterus often receives a branch from the ovarian nerve.* (See Mr. Beck's paper, especially the plate marked 12.)

Uterine nerves do not increase during pregnancy.

The *nerves of the gravid uterus*.—The recent dissections of Mr. Beck (if, as they seem to be, accurate) prove that the nerves do not alter in their thickness during pregnancy, at least that no alteration occurs before they enter the tissue of the uterus; while that organ itself, and the vessels which supply it, undergo a remarkable augmentation in size.

Difference of opinion on this subject.

It is doubtless owing to the great difficulty of dissecting the uterine nerves, mixed up as they are with arterics, veins, and lymphatics, together with laminated cellular membrane, and, as a result of this difficulty, to the want of adequate dissections, that anatomists have come to opposite conclusions respecting the state of the nerves in the circumstances indicated in the last paragraph: some, as William Hunter, Professor Tiedemann, and Dr. Lee, stating that the nerves are enlarged in the gravid uterus; while others, including John Hunter, maintained the opposite opinion. With respect to the researches of Mr. Beck referred to in the text: the representations of the gravid uterus and of the unimpregnated uterus of a person who had borne children, which are contained in his paper, show the nervous fibrils to be of the same size in both cases; and the author (it is stated in a note, page 222,) has ascertained by another dissection, that no difference in thickness is perceptible between the nerves of the virgin uterus and those just alluded to.

* From the preceding statement it may be inferred that the uterus does not receive any considerable supply of nerves. It is necessary, however, to mention, that Dr. Robert Lee has described and given representations of a large additional system of uterine nerves not previously noticed by any anatomist, at least not noticed as nervous structures; and the observations of this enquirer, if correct, would prove that the uterus is supplied with nerves in great abundance,—that it is in fact to a considerable extent covered with a stratum of nervous plexuses and ganglia.

The Editor has not embodied the statements peculiar to Dr. Lee with the account of the uterine nerves contained in this work, in consequence of having come to the conclusion, from his own examination of the subject, that Dr. Lee has been mistaken with respect to the nature of the structure he has been the first to describe as nerve—namely, the layer of fibres lying immediately under the peritoneum in the form of “a great web,” and extending over a large part of the uterus.—For the details of the researches here adverted to, see “The Anatomy of the Nerves of the Uterus,” by Robt. Lee, M.D. F.R.S., London, Baillièrè, 1841; and two papers by the same author in the “Philosophical Transactions” for 1842.

ORGANS OF THE SENSES.

THE EYE.

BESIDES the several structures which compose the globe of the eye, and constitute it an optical instrument, there are certain external accessory parts which protect that organ, and are intimately connected with the proper performance of its functions. These are known as the "appendages of the eye," (they have been named likewise *tutamina oculi*); and they include the eye-brows, the eye-lids, the organs for secreting the sebaceous matter, and the tears, together with the canals by which the latter fluid is conveyed to the nose. The orbits in which the eyes are lodged have been already described (ante, page 87.)

Appendages
of the eye.

A. APPENDAGES OF THE EYE.

1. THE EYE-BROWS.

The eye-brows (*supercilia*) are arched ridges, surmounting on each side the upper border of the orbit, and forming a boundary between the forehead and the upper eye-lid. They consist of thick integument, studded with stiff, obliquely set hairs, under which lies some fat, with part of the *orbicularis palpebrarum* and the *corrugator supercilii* muscles. By the last-named muscle and the *occipito-frontalis* the brows are moved in opposite directions, to influence the admission of light to the eye, and in the expression of different passions.

Eyebrows;

acted on by
muscles.

2. THE EYE-LIDS.

The eye-lids (*palpebræ*) are two thin moveable folds placed in front of each eye, and calculated to conceal it, or leave it exposed, as occasion may require. The upper lid is larger and

Eye-lids.

The upper one is the larger, and light is admitted by the elevation of this lid.

Canthi and fissura palpebræ.

On extent of latter depends apparent size of eyeball.

Edges of lids thick and straight.

Papilla near inner angle.

Skin of lids thin.

Cellular membrane devoid of fat.

The upper lid has a peculiar muscle.

Tarsal cartilages; upper one, the larger, is broad at middle.

more moveable than the lower, and has a muscle (levator palpebræ superioris) exclusively intended for its elevation. Descending below the middle of the eye, the upper lid covers the transparent part of the organ; and the eye is opened, or rather the lids are separated, by the elevation of the upper one under the influence of the muscle referred to. The eye-lids are joined at the outer and inner angles (*canthi*) of the eye; the interval between the canthi (*fissura palpebrarum*) varies in length in different persons, and, according to its extent, (the size of the globe being nearly the same,) gives the appearance of a larger or a smaller eye. At the outer angle, which is more acute than the inner, the lids are in close contact with the eye-ball; but, at the inner canthus, the caruncula lachrymalis intervenes. The free margins of the lids are straight, so that they leave between them, when approximated, merely a transverse chink. The greater part of the edge is flattened, but towards the inner canthus it is rounded off for a short space; and, where the two differently formed parts join, there exists on each lid a slight conical elevation (*papilla lachrymalis*), the apex of which is pierced by the aperture (*punctum*) of the corresponding lachrymal duct.

Structure of the lids.—The skin covering the eye-lids is thin and delicate; and at the line of the eye-lashes, altered in its character, joins the conjunctival mucous membrane which lines the inner surface of the lids and is reflected over the front of the eye-ball. Beneath the skin, and in the fold formed between it and the conjunctiva, the following structures are successively met with, viz.:—a layer of fine cellular tissue, without fat; the fibres of the orbicular muscle; a thin fibrous membrane, attached round the margin of the orbit to the periorbitum; the tarsal cartilages, to which also this fibrous membrane is connected; and finally the Meibomian glands. In the upper eye-lid there is (in addition to these parts, which are common to both lids,) an expansion from the tendon of the levator palpebræ, already noticed: it lies close against the conjunctiva. The structures now enumerated require separate examination.

The *tarsal cartilages* (*tarsi*) are two thin plates of fibro-cartilage, placed one in each lid, and serving to give shape and firmness to these parts. The upper cartilage, the larger, is half oval in form, being broader near the centre and narrow-

ing towards the angles of the lids ; the lower is thinner, smaller, and more nearly of a uniform breadth throughout. The free or ciliary edge of the cartilages, which is straight, is thicker than any other part. The margin towards the orbit is thin, and connected to the periosteum by means of a layer of fibrous membrane, which is stronger near the outer canthus than elsewhere, and has been there named the *external tarsal ligament*. The thin edge of the upper cartilage likewise receives the tendon of the levator palpebræ muscle. Near the inner canthus the cartilages end in fibrous slips, which are closely attached to the tendo palpebrarum (see page 246).

They are thick at edge of lids. Connected with periosteum by tarsal ligament.

Meibomian glands (glandulæ Meibomii), fig. 208.—On the

Meibomian glands :

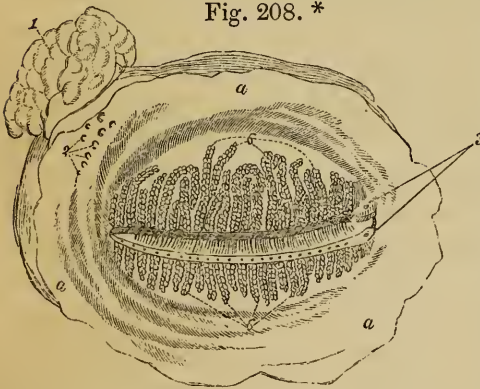


Fig. 208.*

ocular surface of each lid are seen from thirty to forty parallel vertical lines of yellow granules, lying immediately under the conjunctival mucous membrane. They are sebaceous follicles, embedded in grooves at the back of the tarsal cartilages, and opening on the free margin of the lids by

in grooves of cartilages ; open at edges of lids.

minute orifices, generally as many in number as the lines of follicles themselves. These glands consist of nearly straight excretory tubes, each of which is closed at the end, and has numerous small, sessile, cæcal appendages growing from its sides. The tubes are lined by mucous membrane, on the surface of which is a layer of scaly or pavement epithelium cells.

Consist of tubes with cæcal dilatations.

The *eye-lashes* (cilia) are short curved hairs, arranged in two or more rows along the margin of the lids, just at the line of union between the skin and conjunctival mucous membrane. The lashes of the upper lid, more numerous and longer than the lower, have the convexity of their curve directed down-

Cilia.

* Fig. 208. Meibomian glands seen from the inner or ocular surface of the eye-lids, with the lachrymal gland—the right side.—a. Palpebral conjunctiva. 1. Lachrymal gland. 2. Openings of lachrymal ducts. 3. Lachrymal puncta. 6. Meibomian glands.

wards and forwards; whilst those of the lower lid are arched in the opposite direction. Near the inner canthus these hairs are weaker and more scattered. A few slender hairs grow likewise from the caruncula lachrymalis.

Lachrymal caruncula formed of follicles.

Plica semilunaris.

Caruncula lachrymalis, fig. 209,⁵.—This is a small red conical body, occupying the inner angle of the eye-lids; it consists of a group of follicles, covered by mucous membrane. The membrane on the outer side of the caruncle is formed into a semilunar fold (*plica semilunaris*), fig. 209,⁴, the concavity of which looks towards the cornea. The follicles secrete a peculiar fluid for lubricating the mucous surface; and the semilunar fold of membrane is considered as the rudiment of the third eye-lid (*membrana nictitans*) found in some animals.

3. THE LACHRYMAL APPARATUS.

The assemblage of parts which constitute the lachrymal apparatus are the following, viz.:—the gland by which the tears are secreted at the outer side of the orbit; the two canals into which the fluid is received near the inner canthi; and the sac with the duct continued from it, through which the tears pass to the interior of the nose.

Lachrymal gland under outer angle of orbit.

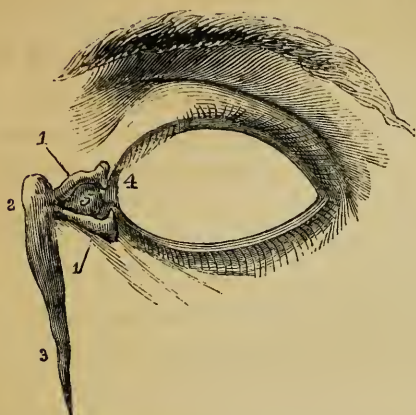Ducts of gland, eight or ten in number.

The *lachrymal gland*, fig. 208,¹, is an oblong body, about the size of a small almond, placed in the upper and outer part of the orbit, and immediately behind its anterior margin. The upper surface of the gland, convex, is lodged in a depression in the orbital plate of the frontal bone, to the periosteum of which it adheres by fibrous bands; the lower surface is adapted to the convexity of the eye-ball, and is in contact with the upper and the outer recti muscles. The fore part of the gland, separated from the body of the organ by a slight depression, and sometimes described as a second lobe, is closely adherent to the back of the upper eye-lid, and is covered, on the ocular surface, only by a reflexion of the conjunctiva. The lachrymal ducts, usually eight or ten in number, are very small, and emerge from the thinner portion of the gland. After running obliquely under the mucous membrane, and separating at the same time one from the other, they open by separate orifices, fig. 208,², a little above the outer canthus.

Lachrymal canals.—On the margin of each lid, near the

inner angle, and in front of the fold of membrane called plica

Fig. 209.*



of membrane called plica semilunaris, is a small elevation (papilla lachrymalis), already described. Each papilla is perforated by a small aperture (*punctum lachrymale*), fig. 208,³; and at these apertures commence two small canals (*canaliculi*), fig. 209,^{1,1}, which convey the tears from the eye to the lachrymal sac. The upper canal is rather the smaller and longer of the

Lachrymal canals begin with puncta.

Each forms an angle near commencement.

two: it first ascends from the punctum; then makes a sudden bend, and is directed inwards and downwards to join the lachrymal sac. The lower canal descends from the corresponding punctum; and soon changing its direction, as the upper one, takes a nearly horizontal course inwards. Both canals are dilated where they are bent. In some cases they unite near the end to form a short common trunk: more commonly they open separately, but close together, into the sac.

They open together in the sac.

The *lachrymal sac* and *nasal duct* together constitute the passage by which the tears are conveyed from the lachrymal canals to the cavity of the nose. The lachrymal sac, fig. 209,³, the upper dilated portion of the passage, is situate at the side of the nose, near the inner canthus of the eye, and lies embedded in a deep groove in the unguis and upper maxillary bones. It is of an oval form; the upper end closed and rounded, and the lower end gradually narrowing into the nasal duct; on the outer side, and a little in front, it receives the lachrymal canals. The sac is composed of fibrous membrane, adhering closely to the bones above mentioned, and strengthened by fibrous processes sent from the *tendo palpebrarum*, which crosses a little above its middle. The inner surface is covered by a reddish mucous membrane, which

Lachr. sac.

in groove of supermaxillary and unguis bones.

Crossed by tendon of orbicular. palpebr. and receives an expansion from it.

* Fig. 209. Sketch of the apparatus for conveying the tears to the nose on the left side.—1. Canaliculi. 2. Lacrimal sac. 3. Nasal duct. 4. Plica semilunaris. 5. Caruncula.

is continuous, through the canaliculi, with the conjunctiva, and through the nasal duct with the mucous membrane of the nose. The sac is covered by the tendo palpebrarum, and by some of the inner fibres of the orbicular muscle of the lids.

Nasal duct ends in lower meatus of nose :

The nasal duct (ductus ad nasum), about six or seven lines in length, extends through the upper maxillary bone to the fore part of the lower meatus of the nose, the osseous canal being completed by the unguis and lower turbinate bones. A tube of fibrous membrane, continuous with the lachrymal sac, adheres to the parietes of this canal, and is lined by mucous membrane, which, at the opening into the nose, is often arranged in the form of an imperfect valve. The nasal duct is rather narrower in the middle than at either end ; its direction is not quite vertical, but inclines slightly outwards and backwards.

is directed down, with inclination backwards and outwards.

4. THE CONJUNCTIVA.

Conjunctiva lines lids, covers sclerotic and cornea. These parts have different characters.

The conjunctiva is a mucous membrane which lines the ocular surface of the eye-lids, and is reflected over the fore part of the sclerotic, and the anterior surface of the cornea. Over each of these several parts it presents peculiar and distinctive characters.

Palpebral part.

a. The *palpebral portion* of the conjunctiva is opaque and red, is thicker and more vascular than any other part of the membrane, and has on its free surface numerous fine papillæ, freely supplied with nerves and covered with epithelium. At the margins of the lids the palpebral conjunctiva enters the ducts of the Meibomian glands ; through the puncta lachrymalia it passes into the canaliculi, and is continuous with the lining membrane of the lachrymal sac ; and it is prolonged into the orifices of the ducts of the lachrymal gland. At the inner canthus it is folded to form the *plica semilunaris*, and covers the *caruncula lachrymalis*.

Sclerotic part.

b. The *sclerotic portion* of the conjunctiva, changing its character at the line of reflection from the eye-lids, becomes thinner, and loses its papillary structure. It is also transparent and nearly colourless, although generally marked by a few scattered branches of blood-vessels. The vessels of the sclerotic portion are arranged in two layers, which are supplied from different sources, but anastomose freely, particularly round the margin of the cornea. Of these the superficial net-work is derived from the palpebral and lachrymal arteries ; and the deep layer, from the muscular and anterior ciliary branches of the ophthalmic artery.

Corneal part.

c. The *corneal conjunctiva* is still thinner than the sclerotic portion of the membrane, and is more transparent and adherent. Vessels are said to have

been recently demonstrated* in this part of the conjunctiva in the healthy eye, their arrangement being as follows :—The vessels form by close anastomoses a circle around the border of the cornea ; and, from the angles of union between them, minute offsets pass towards the centre of the cornea, while others arising in the same place insinuate themselves between the cornea and sclerotic, and become connected with the vessels of the choroid.

B. THE GLOBE OF THE EYE.

The globe or ball of the eye is placed in the fore part of the orbital cavity, fixed principally by its connection with the optic nerve behind, and the muscles with the eye-lids in front, but capable of changing its position within certain limits. The recti and obliqui muscles closely surround the greater part of the eye-ball ; the lids, with the plica semilunaris, and caruncle, are in contact with it in front ; and behind it is supported by a quantity of loose fat. The form of the eye-ball is irregularly spheroidal ; and, when viewed in profile, is found to be composed of segments of two spheres, of which the anterior is the smaller and more prominent : hence the diameter taken from before backwards exceeds the transverse diameter by about a line. The segment of the larger sphere corresponds to the sclerotic coat, and the portion of the smaller sphere to the cornea.

Globe of eye supported by optic nerve, muscles, and lids ;

embedded on loose fat ;

consists of parts of two spheres.

Except when certain muscles are in action, the axes of the eyes are nearly parallel ; the optic nerves on the contrary diverge considerably from one another, and consequently each nerve enters the corresponding eye a little to the inner or nasal side of the axis of the globe.

Axes of eyes are parallel.

The eye-ball is composed of several investing membranes, concentrically arranged, and of certain fluid and solid parts contained within them. The membranes, neither of which forms a complete coat to the eye, are the conjunctiva, sclerotic, cornea, choroid, iris, retina, membrane of the aqueous humour, capsule of the lens, and hyaloid membrane. The parts enclosed are the aqueous and vitreous humours, and the crystalline lens.

Constituents of eye-ball.

* By Professor Gaddi, from the injection of the body of a child two years old. "Bullet. delle Scienze mediche," 1844. Cited in Mr. Paget's "Report on the Progress of Human Anatomy and Physiology," 1844-45, part 2, in Brit. and Foreign Med. Review.

1. THE SCLEROTIC.

Sclerotic maintains form of eye.

Covers four-fifths of globe.

Muscles fixed to it. Inner surface: *membrana fusca*.

Is thickest behind.

Continuous with sheath of optic nerve.

Lamina *cribrosa*.

The sclerotic (*cornea opaca*), one of the most complete of the tunics of the eye, and that on which the maintenance of the form of the organ chiefly depends, is a strong, opaque, unyielding, fibrous structure, composed of bundles of strong white fibres, which interlace with one another in all directions. The membrane covers about four-fifths of the eye-ball, leaving a large opening in front, which is occupied by the transparent cornea, and a smaller aperture behind for the entrance of the optic nerve. The outer surface is white and smooth, except where the tendons of the recti and obliqui muscles are inserted into it. The inner surface is of a light brown colour, and rough from the presence of a delicate cellular tissue (*membrana fusca*), through which branches of the ciliary vessels and nerves cross obliquely. The sclerotic is thickest at the back part of the eye, and thinnest in front: the opening for the optic nerve is somewhat smaller at the inner than on the outer surface of the sclerotic. The fibrous sheath of the nerve continued from the dura mater blends with the sclerotic round the margin of the aperture; and the internal covering (*neurilemma*) sends numerous membranous processes which cross the nerve in various directions. In consequence of this latter arrangement, when the nerve is cut off close to the eye-ball, the point of its attachment is marked by a circular group of pores (*lamina cribrosa*), in which lies the soft nervous matter, readily removed by maceration.*

2. THE CORNEA.

Cornea: transparent part of outer covering.

Mode of connexion with sclerotic.

The cornea (*cornea pellucida*), fig. 215,³ is a transparent structure, occupying the aperture left in the fore part of the sclerotic, and forming about one-fifth of the surface of the globe of the eye. It is closely united with the anterior margin of the sclerotic, and the disposition of the two at the place of union varies; in one case the cornea is overlapped by the sclerotic.

* A different explanation has been given of these appearances. Some anatomists describe the nerve as passing through a series of holes in the sclerotic itself; and the part of this membrane so perforated is known as the *lamina cribrosa*.

rotic, while in another it appears to be received into a groove in that membrane. The circumference of the cornea is not quite circular in form, the transverse being rather longer than the vertical diameter. The anterior surface is more convex than the sclerotic, and consequently projects beyond it: the actual degree of convexity, however, varies in different persons, and at different periods of life. It is covered by the conjunctiva, already described, fig. 215. The posterior surface of the cornea is concave, assists in bounding the anterior chamber of the eye, and is lined by a very thin and closely adherent film of membrane,* fig. 215,¹¹ which can be traced no further than the margin of the iris.

Projects beyond line of sclerotic.

Is covered by conjunctiva.

The cornea is thicker than any part of the sclerotic membrane; and is for the most part composed of soft and indistinct fibres arranged in several concentric strata. Between the layers is a fine cellular tissue which tears more readily than the substance of the cornea itself, and contains a small quantity of albuminous fluid (*liquor corneæ*). When macerated in water, or steeped in acid, the cornea becomes opaque, with the exception of a layer on the posterior surface, the *elastic cornea*,† which retains its transparency perfectly, and appears to undergo no change. This layer, when separated from the rest of the cornea, curls up, presents a peculiarly bright and glistening appearance, and breaks with a semi-vitreous fracture. It is covered on the surface next the aqueous humour by the thin membrane already noticed.

3. THE CHOROID.

The *choroid tunic* (*tunica vasculosa*) is a dark vascular membrane, lying between the sclerotic and the retina. Pierced behind by the optic nerve, it extends from this point to the ciliary ligament and to the fore part of the hyaloid membrane, where it is thrown into folds round the margin of the crystalline lens. The outer surface, nearly black in colour, is loosely connected with the sclerotic by a layer of cellular tissue, already described, in which are contained the ciliary nerves and the long ciliary arteries and veins; but these, being destined for the supply of the iris, form no part of the choroid. The

Choroid: a vascular and dark-coloured membrane.

Nerves and vessels between it and sclerotic.

* The thin membrane here alluded to is by some considered as the proper membrane of the aqueous humour, and by others as a layer of epithelium covering that membrane.

† This structure has been named by Dr. Jacob the "elastic cornea." By many writers it is considered as a thickened portion of the membrane of the aqueous humour ("capsula aquea cartilaginosa").

Extends fr. end of optic nerve to ciliary procs. Is continuous with these.

Consists of vessels connected together and covered w. pigment.

Veins : their trunks.

Peculiar arrangement. (Vasa vorticosa.)

Arteries :

short ciliary.

Arrangement different fr. veins.

Pigment : most abundant at inner side of choroid. Membrane and cells of pigment.

inner surface of the choroid is soft and villous, highly vascular, and of a deep brown or black colour. In front it is attached to the membrane of the vitreous humour by means of the ciliary processes ; elsewhere it is but loosely connected with the outer surface of the retina—the part named Jacob's membrane.

The choroid is composed of minute ramifications of arteries and veins, united by cellular membrane, and covered, particularly on the inner surface, by a dark brown pigment.

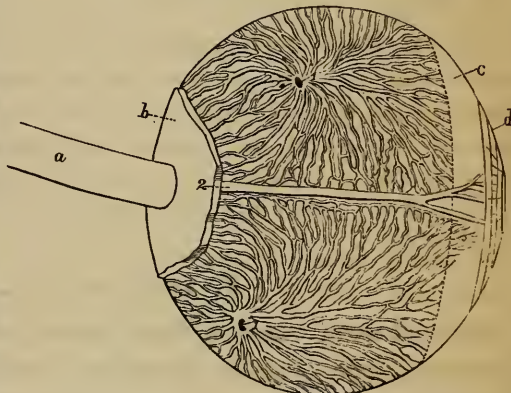
a. The *veins of the choroid*, fig. 210, constitute an outer layer, partially separable from the arterial network, and easily recognised by the direction of the larger vessels. These converge to four nearly equi-distant trunks, fig. 210, ¹, which pass through the sclerotic about half-way between the margin of the cornea and the entrance of the optic nerve, and pour their contents into the ophthalmic vein. From their whirl-like arrangement they are known as *vasa vorticosa*.

b. The *arteries of the choroid* are furnished by the short ciliary branches of the ophthalmic, fig. 212, ¹, which pierce the sclerotic close to the optic nerve, and divide into branches arranged parallel to the axis of the eye-ball. Communicating freely, they form a net-work (*tunica Ruyschiana*) on the inner or concave surface of the venous layer just described,

from which they may be distinguished by their smaller size, their more parallel arrangement, and their closer and finer communications. The ultimate distribution of both arteries and veins is at the inner villous surface of the choroid, the great vascularity of which may be shewn by injecting either set of vessels.

c. The *pigment* (*pigmentum nigrum v. fuscum*), of a deep brown, almost black colour, tinges the outer surface of the choroid, as before said ; but is much more abundant on the inner surface of that tunic, where it forms a continuous layer, which increases in thickness as it approaches the fore part of the eye. It is covered by, and contained in, a membrane of peculiar structure (*membrane of the pigment*) ; and is composed of flat, hexagonal

Fig. 210.*



* An enlarged view of the veins of the choroid. (From Arnold.)—1. Trunks of the *venæ vorticosaë* where they pierce the sclerotica. 2. Ciliary nerve accompanied by the *vena ciliaris longa*. *a.* Optic nerve. *b.* Back part of the sclerotica. *c.* *Ligamentum ciliare*. *d.* Iris.

cells, about the 1000th of an inch in diameter, each cell presenting the appearance of a central transparent point (*nucleus*), surrounded by a black margin. In albinos the colouring matter is deficient; but a central nucleus is still visible.

Albinos want colouring matter.

4. THE ANNULUS ALBIDUS. (CILIARY LIGAMENT.)

Annulus albidus (annulus cellulosus—Zinn; ligamentum ciliare — Winslow), fig. 212, 215. — This is a flat, circular, narrow band of greyish-white substance, lying under the fore part of the sclerotic, close behind the junction of that tunic with the cornea, and serving to connect together several structures in its vicinity. In a transverse section, this band presents a wedge-like form. The thicker margin, directed forwards, assists in bounding the cavity of the aqueous humour, and gives attachment to the circumference of the iris; the posterior or thinner margin of the band is continuous with the fore part of the choroid, though it differs obviously from that membrane in being destitute of pigment, and much less freely supplied with vessels. The greater part of the outer surface of the annulus albidus is only loosely connected to the sclerotic by cellular membrane; but, just behind the margin of the cornea, a firmer union is effected by means of a narrow ring of tough white fibres, to which the term *ciliary ligament* is sometimes more particularly applied. (Krause.) In this situation, and between the annulus, the cornea, and the sclerotic, is inclosed a small circular canal, named the *canal of Fontana*, or sinus circularis iridis, fig. 215. The inner portion of the annulus, less distinctly fibrous, is connected with the ciliary processes, and is traversed by numerous branches of the ciliary nerves, which divide and communicate with each other in its substance before entering the iris.

Ann. albidus:

behind junction of sclerot. and cornea.

Connected in front w. iris, behind with choroid.

One part closely joined to sclerot. by tough fibres (*ciliary ligament*).

Canal of Fontana.

Nerves pass through inner portion of annulus albidus.

5. CILIARY PROCESSES. (CORPUS CILIARE.)

Whilst the outer cellular layer of the choroid appears to blend with the thin portion of the annulus cellulosus, the vascular elements of the tunic, with the pigment in large quantity, extend inwards behind the iris and in front of the vitreous humour. Approaching the margin of the crystalline lens, this prolongation of membrane is thrown into about 60 or 70 radiated folds (*ciliary processes*), the aggregate of which is

Ciliary processes: continued fr. choroid.

Consist of 60 or 70 folds, covrd. w. pigment.

These alternately long and short.

Each consists of a plain and a prominent part.

Ora serrata.

Blood-vessels.

Iris :

hangs in aqueous humour.

Fixed to annulus albidus in front of ciliary processes.

Pupil not quite in centre.

called the *corpus ciliare*, fig. 211, ¹. alternately long and short, are highly vascular, and of a deep brown or black colour. Each ciliary process is broad and flattened behind (*pars non plicata*), fig. 211; but is narrower and more prominent in front (*pars plicata*), fig. 211, where it projects into the posterior chamber, and digitates with somewhat similar radiated folds (*zonula Zinnii*) attached to the fore part of the membrane

of the vitreous humour. A sinuous or dentated line (*ora serrata*) marks the commencement of the flat portion of the *corpus ciliare* from the anterior end of the choroid membrane.

The *blood-vessels of the ciliary processes* are very numerous, and are derived from the fore part of the choroid membrane. At the *ora serrata* several small arterial branches enter each ciliary process, at first running parallel to each other and communicating sparingly. As they enter the prominent folded portion (*pars plicata*), these vessels become tortuous, subdivide minutely, and inosculate frequently by cross branches. Finally they form short arches or loops, and turn backwards to pour their contents into the radicles of the veins.

On the free border of the fold, one artery, larger than the rest, extends the whole length of each ciliary process, and communicates with a long venous trunk which runs a similar course on the attached surface.

The folds or processes,
Fig. 211.*



6. THE IRIS.

The *iris*, fig. 211, is a thin, flat, membranous septum, perforated near the centre by a circular aperture (the *pupil*). Hanging vertically in the aqueous humour, it divides unequally the space between the cornea and the crystalline lens. The outer or larger border of the iris is attached to the annulus albidus, immediately behind the margin of the cornea, and in front of the ciliary processes; the inner edge corresponds to the aperture of the pupil, and moves freely in the aqueous humour. The *pupil*, the circular aperture already referred to, is situate a little to the inner or nasal

* View of the ciliary processes and iris from behind (enlarged).—
1. Ciliary processes. 2. Iris. 3. Pupil.

side of the centre of the iris, and varies in size according to the state of contraction or dilatation of the fibres of which that structure is composed.

On the anterior surface the iris is marked by radiating lines, and is differently coloured in different persons; the tinge being usually somewhat deeper round the pupil than elsewhere. Closely examined, it presents, about midway between its borders, numerous small irregular elevations, from which little ridges or bands converge towards the centre of the pupil. The posterior surface of the iris itself is colourless, but is hidden by a quantity of black pigment contained under a thin transparent membrane (*uvea*), similar in structure to that already described in the choroid, except that the cells composing it are not quite so accurately formed and regularly arranged. This surface is also marked by lines extending between the pupillary and the ciliary margins, which correspond to radiating bands: they are seen more distinctly after the removal of the uvea.

Colour various, deeper at edge.

Covered behind with pigment, in form of membrane (*uvea*).

Structure.—The iris contains radiating and circular fibres, which, though in man presenting no transverse markings, are now generally admitted to be muscular in their nature. The radiating fibres are most distinct near the larger margin; they arise, in front of the circular fibres, from the corneal edge of the annulus albidus, and are covered at this point by a reflexion of the fine membrane that lines the concave surface of the cornea. They converge towards the pupil, interlacing freely with one another; and finally, much reduced in size, are lost amongst the stronger circular fibres. The circular fibres are situate more at the back of the iris, and produce, by their contraction, the many transverse folds seen on that surface. They are most numerous close around the pupil (*sphincter pupillæ*), and are least distinct midway between this and the ciliary margin.

Muscular in structure.

Radiating fibres.

Circular fibres.

Arteries of the iris.—The proper vessels for the supply of the iris are the long ciliary and anterior ciliary arteries.

Arteries.

a. The *long ciliary arteries*, fig. 212, ², two in number, and derived from the ophthalmic, pierce the sclerotic a little before, and on either side of, the optic nerve. Having gained the interval between the sclerotic and choroid coats, they extend horizontally forwards through the cellular tissue (*memb. fusca*) to the annulus albidus. In this course they nearly

Long ciliary.

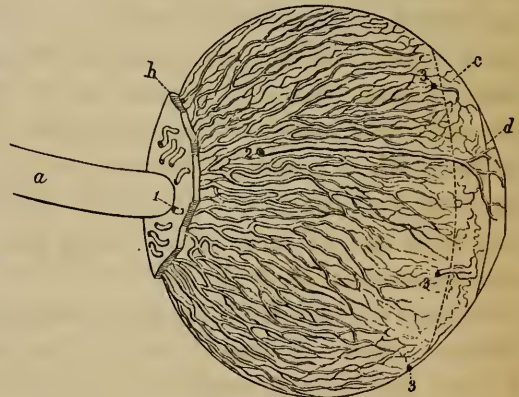
correspond in direction to the axis of the eye-ball, the outer vessel being, however, a little above, and the inner one a little below the level of that line. A short space behind the fixed margin of the iris each vessel divides into an upper and a lower branch, and these anastomosing with the corresponding vessels of the opposite side of the eye, form a vascular ring (*circulus major iridis*). From this circle smaller branches arise, by transverse offsets from one to another, freely communicating by transverse offsets from one to another, form a second circle of anastomosis (*circulus minor*).

Anterior
ciliary.

b. The *anterior ciliary arteries*, fig. 212,³, several in number, but smaller than the vessels just described, are supplied from the muscular and lachrymal branches of the ophthalmic artery, and pierce the sclerotic about a line behind the margin of the cornea; finally, they divide into branches which join the *circulus major*.

c. Besides these special arteries, numerous minute vessels enter the iris from the ciliary processes, which are highly vascular in their structure.

Fig. 212.*



Veins.

(Canal of
Fontana.)

Nerves:

Ciliary.

The *veins of the iris* follow closely the arrangement of the arteries just described. The canal of Fontana appears to communicate with this system of vessels.

The *nerves* for the supply of the iris are named ciliary: they are numerous and large; and, before entering the iris, divide in the substance of the annulus albidus.

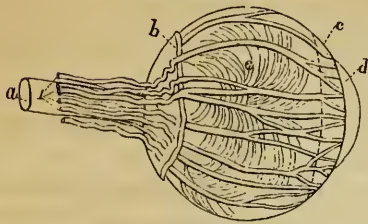
About 20;
fr. lenticular
gangl. and
nasal nerve;
pass betw.
sclerot. and
choroid.

The *ciliary nerves*, fig. 187, about twenty in number, and derived from the lenticular ganglion and the nasal branch of the ophthalmic division of the fifth nerve, pierce the sclerotic near the entrance of the optic nerve, fig. 213,¹, and immediately come in contact with the choroid. They are somewhat flattened in form, are partially embedded in grooves on the inner surface of the sclerotic, and communicate with each other occasionally before entering the annulus albidus. When the sclerotic is carefully stripped from the subjacent structures, these nerves are seen lying on the surface of the choroid. Within the substance of the annulus albi-

* An enlarged view of the arteries of the iris. (From Arnold.)—*a.* Optic nerve. *b.* Sclerotic. *c.* Ciliary ligament. *d.* Iris. 1. Posterior ciliary arteries perforating the sclerotic. 2. Long (external) ciliary artery. 3. Anterior (short) ciliary arteries. (The figure is larger than natural.)

dus the ciliary nerves subdivide

Fig. 213.*



minutely, a few being lost in the substance of that band, but the greater number passing on to the iris. On account of its connexion with the nerves, Scœmmerring considered the annulus albidus a ganglionic structure, naming it *circulus gangliiformis*.

Subdivide in annulus albidus, before entering iris.

Pupillary Membrane (membrana pupillaris).—In foetal life

Pupillary membr. closes pupil in fetus.

Is transparent and vascular.

a delicate transparent membrane thus named closes the pupil, and therefore completely separates the anterior from the posterior chamber of the aqueous humour. The pupillary membrane contains minute vessels, continuous with those of the iris and of the capsule of the crystalline lens; they are arranged in loops, which converge towards each other, but do not quite meet at the centre of the pupil. At about the seventh or eighth month of foetal life these vessels gradually disappear; and, in proportion as the vascularity diminishes, the membrane itself is absorbed from near the centre towards the circumference. At the period of birth, often a few shreds, sometimes a larger portion, and occasionally the whole membrane, is found persistent.

Period of disappearance.

7. THE RETINA.

The *retina* (tunica nervea) is a delicate, almost pulpy membrane, continuous with the optic nerve, and thence extending within the choroid nearly to the margin of the crystalline lens. In the living subject it is transparent; but, when slightly decomposed, or when moistened with alcohol or nitric acid, it becomes opaque, and assumes a greyish-white colour.

Retina continuous w. optic nerve; reaches as far nearly as lens.

Is transparent.

The retina is in contact by its outer surface with the choroid, and by its inner surface with the hyaloid membrane; but, as far forwards as the posterior margin of the ciliary processes, its connexion with these two structures is very slight, and easily torn through. At the dentated border (*ora serrata*) of the ciliary processes the retina is somewhat thickened, and seems

Betw. choroid and hyaloid membranes;

apparently ends at ciliary pro-

* Ciliary nerves on the outer surface of the choroid. (From Arnold.)—*a.* Optic nerve. *b.* Back part of the sclerotic. *c.* Ciliary ligament. *d.* Iris. *e.* Outer surface of the choroid. 1. Ciliary nerves perforating the back of the sclerotic. (The nerves are made too large in the figure.)

cesses, but enters in an altered form under these.

to end in a defined margin. Modern observers, however, (e. g. Valentin and Bidder,) find that it is continued over the inner surface of the ciliary processes; though, from its tenuity, and close adherence to these processes and to the hyaloid membrane, it is with difficulty displayed.*

Central spot (limbus luteus.)

The concave inner surface of the retina presents at the back of the eye several objects of interest. Directly in a line with the axis of the eye-ball is a circular yellow spot (*limbus luteus*), about a line or a line and a half in diameter, and marked in the centre by what appears like a minute hole†—the *foramen centrale* of Sœmmerring. Nearly two lines to the inner or nasal side of the yellow spot is a flattened circular papilla (*colliculus*), corresponding with the situation in which the optic nerve pierces the choroid coat. Between these two points extends a small projection or fold of the retina (*plica centralis retinae*).

Colliculus of optic nerve to inner side of centre.

Plica centralis between.

Structure.—Three very different structures are distinguishable in the retina; an outer membrane (the membrane of Jacob), an inner vascular net-work, and an intermediate stratum of nervous substance.

Jacob's membrane.

a. The *membrane of Jacob* ‡ may be raised from the outer surface of the retina by injecting air, or even introducing mercury, beneath it when the eye is under water.

Consists of minute columns.

By microscopical observation, this part of the retina has been found to consist of small columns or rods placed at right angles with the surface of the membrane, like the pile of velvet, fig. 214, A. The bodies referred to are of two kinds, one being smaller and more numerous than the other. The small rods are solid and six-sided prisms, narrowed to a point at the end next the choroid, *d*; and they are grouped round the larger bodies. These, which are named by Hannover "twin cones" (*coni gemini*), are shorter than the preceding, and are cleft at the outer end into two short blunt points.

Smaller rods.

"Twin cones."

Viewed on the outer surface, fig. 214, B, this structure has the appearance of a mosaic pavement. The ends of the little cones are received into small sheaths on the pigment-cells of the choroid; each polygonal pigment-cell

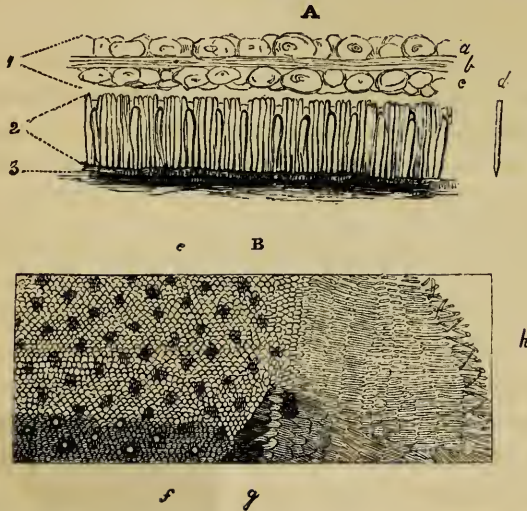
* This is seen better in the fœtal, than in the adult eye. It is still undecided whether all, or, if not, which, of the component parts of the retina are thus prolonged.

† The appearance of an aperture seems to be produced by the absence at this point of the medullary substance of the retina, the vascular layer being alone continued over it.

‡ So named after Dr. Jacob, who described it in the *Phil. Trans.*, 1819.

corresponding to six or eight of the twin cones, with the more numerous simple rods which surround them, fig. 214, A.

Fig. 214.*



b. Medullary layer.—The essential element of the retina, and that on which depends its capability of receiving the impressions of light, is an expansion of nervous matter derived from the optic nerve. Diverging from the opening in the choroid, the tubular fibres of the optic nerve radiate towards the anterior end of the retina, the fibres becoming more slender, and the spaces between them increasing in width as they advance to the fore part of the eye; and they are covered on the inner and outer surface with a layer of nerve-cells, fig. 214, A.

Fibres radiate fr. optic nerve;

are placed betw. nerve-cells.

Termination of fibrs. not fully ascertained.

As regards the mode of termination of the nerve-fibres, anatomists are not agreed. They have been said to form loops where they end at the anterior margin of the retina (Valentin); but Hannover states that his observations render it probable that they terminate by free extremities. While the manner of their termination is not determined with certainty, no doubt is

* Fig. A. An enlarged plan of the retina, in section.—1. The nervous structure, viz. the nerve-fibres (*b*) between nerve-cells (*a, c*). 2. Jacob's membrane. 3. Inner surface of choroid. *d*. One of small pointed bodies of Jacob's membrane.

Fig. B. The outer surface of Jacob's membrane. (From Hannover's *Recherches Microscopiques*, &c. 1844.)—Opposite *e*, the twin cones are obscurely seen, not being in focus, while, at the lower part of the figure, near *f*, the same bodies are clearly discernible. Towards the right side of the figure, where the objects are disturbed, the twin cones project like papillæ at *g*, the small rods being in a great measure lost at this place. And these (small bodies) are seen to become horizontal towards the extremity of the object, *h*, where some are in disorder.

entertained as to the place at which it occurs. It is agreed, at least as regards the eye of the lower animals, that none of the fibres end at the bottom of the eye, all reaching the fore part of the organ, as before mentioned.

Vessels of retina.

c. The *vascular layer* (lamina vasculosa retinæ) consists of a fine net-work of arteries and veins, held together by cellular membrane. It supports the nervous substance of the retina, which may readily be washed from its outer surface after short maceration in water. The *arteries* entering into the formation of this layer are principally derived from the arteria centralis retinæ, a branch of the ophthalmic, which, conducted through the substance of the optic nerve, enters the retina at the centre of the optic papilla and immediately gives off several diverging branches. The posterior ciliary arteries likewise send minute twigs to assist in forming the vascular layer of the retina. The *veins* are considerably larger and more tortuous than the arteries, but follow much the same course and distribution.

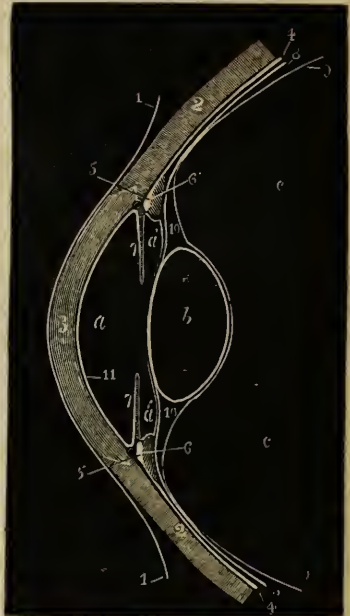
8. THE AQUEOUS HUMOUR.

Aqueous humour

The *aqueous humour* (humor aqueus) is a colourless, transparent, watery fluid, containing a minute quantity of albumen and chloride of sodium in solution, which occupies the interval between the cornea in front, and the crystalline lens and folded ends of the ciliary processes behind. The space thus bounded is partially divided by the iris into two compartments of unequal size (*anterior and posterior chambers*), of which that in front of the iris (the anterior chamber) is the larger. In the fœtus, the separation between the two is completed by the *membrana pupillaris*.

occupies anterior and posterior chambers of eye; which are separated by iris.

Fig. 215.*



Membr. of aqs. humur.

The *membrane of the aqueous humour*.—It has been supposed that the

* Plan of the structures in the fore part of the eye, seen in section.—1. Conjunctiva. 2. Sclerotic. 3. Cornea. 4. Choroid. 5. Annulus albidus: before this is seen the canal of Fontana. 6. Ciliary processes. 7. Iris. 8. Retina. 9. Hyaloid membrane. 10. Canal of Petit (made too large). 11. Membrane of the aqueous humour (too thick). a. Aqueous humour: anterior chamber and (a) posterior chamber. b. Crystalline lens. c. Vitreous humour.

aqueous humour is secreted from the surface of a serous membrane, known under this name, lining the walls of this cavity. A thin membrane has already been described as covering the back of the cornea, and thence prolonged, over the edge of the ciliary ligament, to the outer margin of the iris, beyond which it has not been traced. Another fine membrane exists over the posterior surface of the iris and the projecting ends of the ciliary processes; but, as yet, no corresponding structure has been demonstrated either over the capsule of the crystalline lens, or over the fore part of the iris.

9. THE VITREOUS HUMOUR.

The *vitreous humour* occupies about the two posterior thirds of the cavity of the eye, and consists of a clear, thin fluid (*humor vitreus*), inclosed in a fine, transparent membrane (*membrana hyaloidea*). This membrane not only forms a general investment for the whole bulk of fluid, but sends numerous delicate cellular processes inwards to inclose and support the humour in the form of a semi-solid gelatinous body, called the vitreous body. The *vitreous body* (*corpus vitreum*) is irregularly spheroidal in form, and presents at its fore part a cup-shaped depression, which lodges the posterior or larger segment of the crystalline lens. On the surface of the corpus vitreum, immediately around this depression, are a number of closely set black lines, so arranged as to form a circle of rays round the margin of the lens. When first exposed, by separating the vitreous body from the ciliary processes, these lines appear of unequal thickness, from the presence of a quantity of adhering pigment; but, when the colouring matter is removed by careful washing, regular projections or folds of membrane are brought into view (*processus ciliares hyaloidea*), the aggregate of which is called the *zone of Zinn*, or *zonula ciliaris*. Their inner ends do not quite touch the lens, a narrow interval (*zonula lucida*) being left where the hyaloid membrane assists in bounding the posterior chamber of the eye. In their mode of arrangement, these folds resemble the ciliary processes, in the intervals of which they are received, and to which they are attached by cellular tissue. They differ from the ciliary processes, however, in being rather longer and much less prominent.

Vitreous humour: occupies two-thirds of eye; inclosed in hyaloid membrane.

On fore part depression for lens, and around this is zone of Zinn.

This (last) formed of ciliary processes of hyaloid.

The hyaloid membrane, for about a line outside the depression for the crystalline lens, consists of two layers, fig. 215, ¹⁰. One

Canal of Petit:

is external
to lens ;

slightly
sacculated.

Connexion
with retina
at fore part.

Hyaloid
canal for
capsular
artery (in
fœtus).

Arrangem.
of membr.
upon vitrs.
humour.

of these, immediately inclosing the vitreous humour, passes behind the posterior division of the capsule of the lens ; whilst the other, adhering to the ciliary processes, appears to end in the anterior part of the capsule close to the margin. The space left between the two layers of membrane forms round the circumference of the lens a circular passage, the canal of Petit (*canal godronné*),¹⁰ the interior of which is crossed at regular intervals by imperfect membranous septa. When the space is filled with air injected through the outer membrane, an appearance as of a string of beads is produced ; the situation of the bands above mentioned is then marked by a series of constrictions, between which the walls of the canal are forced to project.

Behind the ora serrata of the corpus ciliare, the outer surface of the hyaloid membrane is in contact, but is very slightly connected, with the concave surface of the retina ; but, in front of the serrated line, it has been seen that the two structures are inseparably united. Opposite the optic papilla is a small aperture in the vitreous body ; through which, in the fœtal eye, a minute branch of the central artery of the retina enters. The vessel extends through the middle of the vitreous humour to the back of the crystalline lens ; and in this course it is lodged in a tubular process of the hyaloid membrane, called the *hyaloid canal*.

No vessels or nerves have been traced in the membrane of the vitreous humour.

Hannover* has lately investigated the arrangement of the vitreous body and its membrane. After long maceration in chromic acid, he finds it crossed by about 180 delicate membranous septa, disposed somewhat like the segments of the pulp of an orange, with the angles of the inclosed spaces directed towards the axis of the eye-ball. The sectors do not however meet at this line, but leave a cylindrical portion of the vitreous body of a homogeneous texture, extended between the optic nerve and the centre of the posterior surface of the lens. This is larger in the fœtal than in the adult eye ; and through it passes the central artery. The fluid inclosed in the areolæ of the vitreous body becomes slightly gelatinous after this maceration.

* Müller's Archiv., 1845.

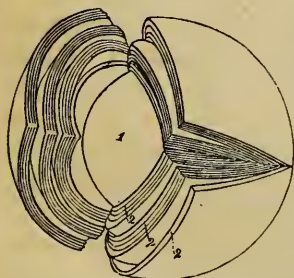
10. THE CRYSTALLINE LENS.

The *crystalline lens*, fig. 215, *b*, is a colourless, transparent, solid body, having the form of a doubly convex lens, situate directly in the axis of vision, and interposed between the aqueous and vitreous humours. Its anterior surface projects within a very short distance of the back of the iris, and assists in bounding the posterior chamber of the eye. The posterior surface, more convex than the anterior, is received into a depression on the fore part of the vitreous body. The circumference is circular, rounded at the margin, and corresponds with the circular canal (canal of Petit) already described in the hyaloid membrane.

The crystalline lens is inclosed in a transparent *capsule*, the characters of which differ much on its fore and back part. That portion of the capsule which covers the anterior surface of the lens is thick, and of a peculiar, firm, semi-cartilaginous structure, retaining its transparency and brilliancy (like the layer already described at the back of the cornea) when macerated in water, or even after being immersed in alcohol or dilute nitric acid. The posterior division of the capsule, on the contrary, is thin and membranous, adheres closely to the hyaloid membrane, and is whitened by the action of spirit. The circumference of the capsule is connected with the inner folded ends of the ciliary processes.

The proper substance of the lens adheres but slightly to the inner surface of the capsule; a small quantity of fluid occasionally intervening, which is called the *liquor Morgagni*. In a fresh lens the outer portion is soft and gelatinous. Beneath this is a firmer layer; and in the centre is the hardest part, or *nucleus*. After immersion in alcohol, nitric acid, or boiling water, these several parts assume a uniform density, and are then seen to be made up of essentially

Fig. 216.*



The lens :
opposite pupil;
is doubly convex ;
close to iris;
received into hollow in vitrs. humr.

Capsule is thicker in front of lens than behind it.

Connected at circumf. with ciliary processes.

Liquor Morgagni.

Lens becomes denser towards middle ;

* A crystalline lens hardened in alcohol, split into three segments, each of which is again separated into layers, leaving a central nucleus. (From Arnold.)—1. Nucleus. 2, 2, 2. External layers.

consists of concentric layers, wh. split into segments.

Each layer made up of fibres.

Capsular artery in fœtus runs thro' hyaloid canal.

Lens at different periods of life.

the same structures. When so treated, the lens may be separated into concentric lamellæ, all of which split in the same way into segments, the apices meeting at two opposite points in the circumference, fig. 216, ². These layers are further composed of microscopic fibres arranged side by side, and adhering together by regularly dentated margins. The crystalline lens of the adult seems to be devoid of blood-vessels; but in the fœtus numerous vessels exist in the capsule, which readily admit of injection.

The *capsular artery* in the fœtus leaves the *arteria centralis retinæ* at the centre of the optic papilla, and crossing through the substance of the *corpus vitreum*, as already described, enters the posterior portion of the capsule of the lens, where it divides into radiating branches. These form a fine net-work, turn round the margin of the lens, and extend forward to become continuous with the vessels in the pupillary membrane and the iris. The vessels are contained in the *capsulo-pupillary membrane*, which connects in the fœtus the pupillary edge of the iris with the margin of the capsule of the lens.* This vessel is found only in the fœtal eye.

Changes in the lens by age.—In form, colour, degree of transparency, and density, the lens presents marked differences at different periods of life.

In the *fœtus*, the lens is nearly spherical: it has a slightly reddish colour, not perfectly transparent, and is softer and more readily broken down than at a more advanced age.

In the *adult*, the anterior surface of the lens becomes less convex than the posterior; and the substance of the lens is firmer, colourless, and transparent.

In *old age*, it is flattened on both surfaces; it assumes a yellowish or amber tinge, and is apt to lose its transparency as it gradually increases in toughness and specific gravity.

* Some authors (Albinus, Ziun, &c.) state that they have traced vessels from the capsule entering the substance of the lens itself.

THE EAR.

THE organ of hearing is divisible into three parts: the external ear, the tympanum or middle ear, and the labyrinth or internal ear; and of these the first two are to be considered as accessories or appendages to the third, which is the sentient portion of the organ.

Ear divided into three parts.

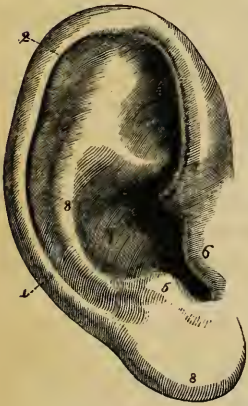
A. THE EXTERNAL EAR.

Included in this term are the pinna,—the part of the outer ear which projects from the side of the head,—and the meatus or passage which leads thence to the tympanum, and is closed at its inner extremity by the membrane interposed between it and the middle ear (*membrana tympani*).

External ear consists of pinna and meatus.

1. THE PINNA.

Fig. 217.*



The *pinna*, or auricle, fig. 217, situate behind the articulation of the lower jaw, and in front of the mastoid process of the temporal bone, is flattened and ovoid, folded at the margins, and irregularly concave towards the opening of the meatus auditorius, round which it is attached. The fixed portion of the pinna is in front of, and a little below its centre; and the free and expanded part extends from this point backwards and outwards, forming an angle with the opposed surface of the cranium.

Pinna presents elevations and depressions

Though the general form of the auricle is concave, (to fit it for collecting and concentrating the undulations of sound,) the outer surface is marked by several winding ridges and hollows, to which distinct names have been given. The largest and deepest concavity, a little below the centre of the organ, is called the *concha*, fig. 217, ⁷; it surrounds the entrance to the

Concha, the deepest hollow, is continued into

* A view of the outer surface of the pinna.—1. Helix. 2. Fossa of the helix. 3. Antihelix. 4. Fossa of the antihelix. 5. Antitragus. 6. Tragus. 7. Concha. 8. Lobule.

external meatus. The elevations: external auditory meatus, and is unequally divided at its upper part by a ridge, which is the beginning of the helix. In front of the concha, and projecting backwards over the meatus auditorius, is a conical prominence, the *tragus*, ⁶, frequently covered with hairs. Behind this, and separated from it by a deep notch (*incisura intertragica*), is another smaller elevation, the *antitragus*, ⁵, which is directed upwards and forwards, and also assists in bounding the concha. Beneath the *antitragus*; and forming the lower end of the auricle, is a thick rounded piece called the *lobule*, ⁸, which is devoid of the firmness and elasticity that characterise the rest of the pinna. The thinner and larger portion of the pinna is bounded by a prominent and incurved margin, the *helix*, ¹, which springing above and rather within the *tragus*, from the hollow of the concha, surrounds the upper and posterior margin of the auricle, and gradually loses itself in the back part of the lobule. Within the helix is another curved ridge, the *antihelix*, ³, which may be said to begin below, at the *antitragus*. From this point it sweeps round the hollow of the concha, (forming the posterior boundary of that concavity,) and divides ultimately into two secondary ridges which diverge as they ascend to the helix.

antitragus;

lobule;

helix;

antihelix.

The fossæ: *Fossæ of the pinna.*—Between the helix and the single portion of the antihelix is a narrow, curved groove, the *fossa of the helix* (*fossa innominata, scaphoidea*) ¹²; and between the bifurcations of the upper part of the antihelix is a somewhat triangular depression, the *fossa of the antihelix*, (*fossa triangularis vel ovalis*) ⁴.—The largest of the fossæ, the concha, has been already described.

that of helix;

of antihelix; concha.

The inner or posterior surface of the pinna looks towards the side of the head, and presents several irregularities, the reverse of those just mentioned as on the outer side. The largest prominences correspond to the concha and fossa of the helix; and the principal depression is in the situation of the antihelix.

Structure of the pinna.—The pinna is composed of a thin plate of cartilage covered with skin; but at certain parts the cartilage is deficient, and its place is supplied by fibrous membrane, cellular tissue, and fat. The pinna has also several ligaments and small muscles, which assist in preserving its position and form.

a. The *skin of the pinna* is thin, closely adherent to the cartilage, and supplied with sebaceous follicles, which are most abundant in the hollow of the concha.

b. The *cartilage* presents all the inequalities of surface already described as apparent in the upper part of the pinna; and on this structure, in fact, the irregularities are formed. But the cartilage does not extend into the lobule, which is made up of fat and tough cellular membrane attached to the edge of the cartilage and inclosed in a fold of the skin. Between the tragus and beginning of the helix the cartilage is again deficient, the deep notch there left being bridged over in the natural state by dense fibrous membrane. Behind the antitragus, and between it and the end of the helix, is a smaller notch, which gives to the posterior margin of the auricle a tail-like end, directed towards the lobule. At the fore part of the pinna, opposite the first bend of the helix, is a small conical projection of the cartilage, called the *process of the helix*, to which the anterior ligament is attached. Behind this process is a short vertical slit in the helix; and on the surface of the tragus is a similar but somewhat longer fissure. The substance of the cartilage is naturally brittle, but is much strengthened by a firm fibrous perichondrium.

Cartilage of pinna

does not extend to lobule.

Deficiencies in cartilage.

c. Of the *ligaments of the pinna*, the most important are two which assist in attaching it to the side of the head. The *anterior* ligament, broad and strong, extends from the process of the helix to the root of the zygoma. The *posterior* ligament fixes the back of the auricle (opposite the concha) to the outer surface of the mastoid process of the temporal bone. A few fibres attach the tragus also to the root of the zygoma.

Ligaments anter. and poster. fix pinna.

The proper ligaments of the pinna are so placed as to cross over the fissures and intervals left in the cartilage: thus a strong band of fibrous tissue stretches from the tragus to the beginning of the helix, crossing over the meatus, and completing the boundaries of the concha. Another layer of fibres exists on the inner or cranial surface of the pinna, which assists in maintaining the regular arched form of the auricle.

Others bind parts of cartilage together.

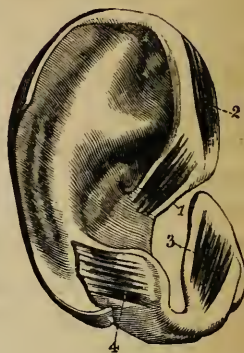
d. Of the *muscles of the pinna*, those which are attached by one end to the side of the head, and move the pinna as a whole, have been already described (p. 244): there remain to be examined several smaller muscles, composed of thin layers of pale

Muscles: some extend from a neighbouring part to

pinna, and act on it. Others reach from one portion of it to another.

fibres, which extend from one part of the pinna to another. These are the proper muscles of the organ; and, if sufficiently strong, would act in modifying the form of that part of the external ear. Five small muscles are generally enumerated in each ear, though some writers have increased this number.

Fig. 218.*



Small musc. of helix ;

1. The *smaller muscle of the helix* (m. minor helicis), ¹, is a small bundle of oblique fibres, lying over, and firmly attached to that portion of the helix which springs from the bottom of the concha.

larger muscle of same ;

2. The *greater muscle of the helix* (m. major helicis), ², lies vertically along the anterior margin of the pinna. By its lower end it is attached to the process of the helix; and above, its fibres terminate opposite the point at which the ridge of the helix turns backwards.

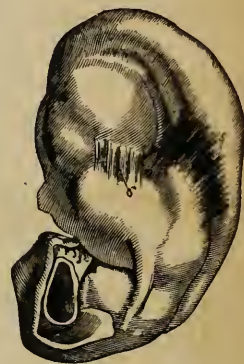muscle of tragus ;

3. The *muscle of the tragus* (m. tragicus), ³, is a flat bundle of short fibres covering the outer surface of the tragus: its direction is nearly vertical.

of antitragus ;

4. The *muscle of the antitragus* (m. antitragicus), ⁴, is placed obliquely over the antitragus and behind the lower part of the antihelix. It is fixed at one end of the antitragus, from which point its fibres converge slightly to be inserted into the tail-like extremity of the helix, above and behind the lobule.

Fig. 219.†



transverse and

5. The *transverse muscle* (m. transversus auriculæ), ⁵, lies on the inner or cranial surface of the pinna, and consists of radiating fibres which extend from the back of the concha to the prominence which corresponds with the groove of the helix. The name *obliquus auris* (Tod), ⁶, has been applied to a few fibres stretching from the back of the concha to the convexity directly above it; but these appear rather to form a part of the transverse muscle.

oblique muscles.

The pinna is supplied with vessels and nerves from several different sources, and these (particularly the vessels) communicate freely on its surface.

* A view of the muscles on the outer surface of the pinna.—1. The smaller muscle of the helix. 2. The larger muscle of the helix. 3. Tragicus. 4. Antitragicus.

† A view of the muscles on the inner surface of the pinna.—5. The transverse muscle of the auricle. 6. The oblique muscle.

e. Arteries of the Pinna.—The *posterior auricular* artery (p. 482), a branch from the external carotid, is distributed chiefly on the posterior or inner surface, but sends small branches round and through the cartilage to ramify on the outer surface of the pinna. Besides this artery, the auricle receives others [*anterior auricular*] from the temporal (p. 483) in front, and a small artery from the occipital behind (p. 481).

Arteries:
posterior
auricular;

anterior
auricular.

f. The veins correspond much in their course with that of the arteries. They join the temporal vein, and return their blood therefore through the external jugular.

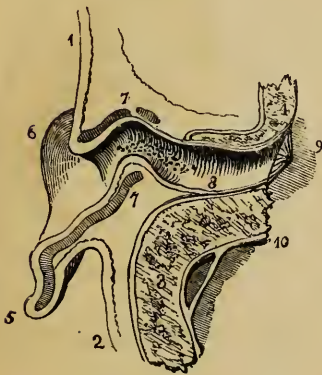Veins.

g. Nerves of the Pinna.—The *great auricular* nerve (p. 829), a branch from the cervical plexus, supplies the greater part of the back of the auricle, and sends small filaments with the posterior auricular artery to the outer surface of the lobule and part of the ear above it. The *posterior auricular* nerve, derived from the facial (p. 797), after communicating with the *auricular branch of the pneumo-gastric*, ramifies on the back of the ear and supplies the retrahent muscle. The upper muscles of the auricle receive their supply from the *temporal branches of the same nerve*. The *auriculo-temporal* nerve (p. 788), a branch of the third division of the fifth nerve, gives filaments chiefly to the outer and anterior surface of the pinna.

Nerves are
derived fr.
cervical
plexus,
pneumo-
gast. and
fifth pair.

2. THE EXTERNAL AUDITORY CANAL.

Fig. 220.*



The external auditory canal (meatus auditorius externus), fig. 220, extends from the bottom of the concha to the membrane of the tympanum, and serves to convey to the middle chamber of the ear the vibration of sound collected by the auricle. The canal is rather more than an inch in length, and its course inwards is slightly tortuous. Beginning

External
meatus ends
at membr.
of tympan.

Is curved;

at the concha, it inclines at first upwards and forwards, then makes a little turn backwards, and finally dips downwards and forwards to its termination. The caliber of the passage is smallest about the middle; the

* Horizontal section of the external meatus seen from above. (After Sæmmering.)—1. Skin of the face in front of the ear. 2. Skin of the head behind the ear. 3. Mastoid process. 4. Osseous part of the external auditory meatus. 5. Hinder part of the pinna, cut through. 6. Lobule. 7. Cartilage of auricle seen in section. 8. External auditory meatus. 9. Membrana tympani. 10. Dura mater.

outer opening is larger in the vertical diameter, but the tympanic end of the tube is slightly oval in the opposite direction. Owing chiefly to the oblique direction of the membrana tympani, the floor of the meatus is longer than its roof.

The meatus is composed of a partly cartilaginous, partly osseous tube, lined by a prolongation of the skin of the pinna.

is formed of
cartilage
and bone.

Cartilaginous
part.

a. The *cartilaginous* part of the meatus forms somewhat less than half the length of the passage. It is continued from the cartilage of the pinna, and is firmly attached to the rough and prominent margin of the external auditory aperture in the temporal bone. The substance of the cartilaginous tube is continuous with that of the auricle only by a narrow slip; the two parts of the cartilage being nearly separated by two or three deep fissures (*fissures of Santorini*), which are directed across the axis of the canal. There is a large deficiency of the cartilage also at the upper part of the meatus, the space being filled up by dense fibrous membrane.

Osseous
part of
meatus.

b. The *osseous portion* of the meatus, which is a little longer and rather narrower than the cartilaginous part, extends through the substance of the temporal bone, from the external auditory foramen to the membrane which forms the outer wall of the tympanum (*membrana tympani*). At the inner end of the canal is a shallow groove, which extends round the sides and floor of the meatus, but is deficient above; into this the margin of the membrane referred to is inserted.

Skin lines
meatus and
covers mem-
brane of
tympanum.

c. The *skin* of the meatus is continuous with that covering the pinna, but is very thin, and becomes gradually thinner towards the bottom of the passage. It is firmly adherent to the sides of both the cartilaginous and the osseous parts of the canal; and, at the bottom of this, the epidermis is stretched over the surface of the *membrana tympani*, forming the outer layer of that structure. After maceration in water, or when decomposition is advanced, the cutaneous lining of the passage may be separated and drawn out entire, and then it appears as a small tube closed at one end somewhat like the finger of a glove. The skin is covered with fine hairs, and contains many little oval bodies of a brownish-yellow colour, which are glands for secreting the cerumen or ear-wax (*glandula ceruminosa*). These glands are most abundant about the middle of the canal, where their numerous openings may be seen to perforate the skin.

Wax
glands.

d. Vessels and nerves.—The external auditory meatus is supplied with arteries from the posterior auricular, internal maxillary, and temporal arteries; and with nerves chiefly from the temporo-auricular branch of the fifth nerve.

B. THE MIDDLE EAR OR TYMPANUM.

The tympanum, or drum, the middle chamber of the ear, is a narrow irregular cavity in the substance of the temporal bone, placed between the inner end of the external auditory canal and the labyrinth. It receives the atmospheric air from the pharynx through the Eustachian tube, and contains a chain of small bones, by means of which the vibrations, communicated at the bottom of the external meatus to the membrana tympani, are conveyed across the cavity to the internal ear,—the sentient part of the organ. The tympanum contains likewise minute muscles and ligaments which belong to the bones referred to, as well as some nerves which end within this cavity, or only pass through it to other parts. The cavity opens, or is continued, into cells (mastoid) of the temporal bone, and through it the atmospheric air reaches those cells. — The boundaries, foramina, and canals of the tympanum will be first described, and then the parts contained in the cavity will come under examination.

Tympanum: is in temporal bone, betw. membrana tympani and the internal ear; receives air from post. nares; and contains small bones with muscles and nerves.

I. THE CAVITY OF THE TYMPANUM.

This space is very narrow from without inwards, but measures from before backwards and from above downwards nearly half an inch. For the sake of greater precision in describing the several parts seen on the surfaces of bone which bound the tympanum, it is usual to consider the cavity as presenting a roof, and a floor, an outer and an inner wall, an anterior and a posterior boundary.

Boundaries of tympanum.

The *roof* of the tympanum is formed by a thin plate of bone, which may be easily broken through, so as to obtain a view of the tympanic cavity from above; and is situate in the upper part of the petrous part of the temporal bone near the angle of union with the squamous portion. The *floor* is very narrow, the outer and inner boundaries meeting at an acute angle.

Roof.

Floor.

The *outer wall* is formed by a thin semitransparent membrane (membrana tympani), which closes the inner end of the external auditory meatus, and, to a small extent, by bone.

Outer wall.

The *membrana tympani*, fig. 221, A B, is nearly circular, and is slightly concave on the outer surface. It is inserted into the groove already noticed at the end of the meatus externus, and

Membr. of tympanum.

this is fixed obliquely in groove of bone.

Malleus is fixed to it.

Membrane concave on outer surf.

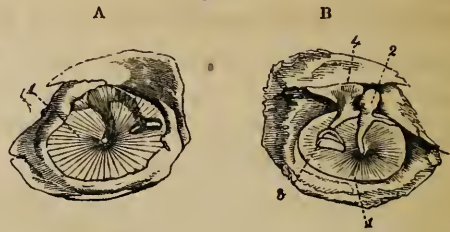
It consists of a peculiar structure, with a layer borrowed fr. skin, and another fr. mucous membrane.

Fissure of Glaser; and hole for chorda tympani.

On inner wall of tympanum are seen :

so obliquely that the membrane inclines towards the anterior and lower part of the canal at an angle of about 45° . The handle of one of the small bones of the tympanum, the malleus, descends between the middle and inner layers of the membrana tympani to a little below its centre, and is firmly fixed to it; and, as the direction of the process of the bone is slightly inwards, the outer surface of the membrane is thereby rendered concave.

Fig. 221.*



Structure of the Membrane.—Though very thin, the membrana tympani is composed of three distinct structures: a prolongation of the cuticle of the external meatus forms the outer layer; the mucous membrane lining the cavity of the tympanum furnishes an inner layer; and between those two is the proper substance of the membrane, made up of fine, closely arranged fibres. The greater number of the fibres radiate from near the centre to the circumference; but within these are circular fibres, which are more scattered and indistinct, except close to the margin of the membrane, where they form a dense, almost ligamentous ring. Concerning the precise nature of the fibres of the membrana tympani, anatomists are not agreed.†

Immediately in front of the ring of bone into which the membrana tympani is inserted, a small fissure (*fissura Glasseri*) opens into the glenoid cavity of the temporal bone. It lodges a little muscle or ligament, which is inserted into the long process of the malleus. To the inner side of this fissure is the opening of a small canal,‡ through which the chorda tympani nerve escapes from the cavity of the tympanum and the skull.

The *inner wall* of the tympanum, fig. 222, which is formed by the outer surface of the internal ear, is very uneven, presenting several elevations and foramina. Near its upper part is

* Membrana tympani from the outer (A) and from the inner (B) sides. —1. Membrana tympani. 2. Malleus. 3. Stapes. 4. Incus.

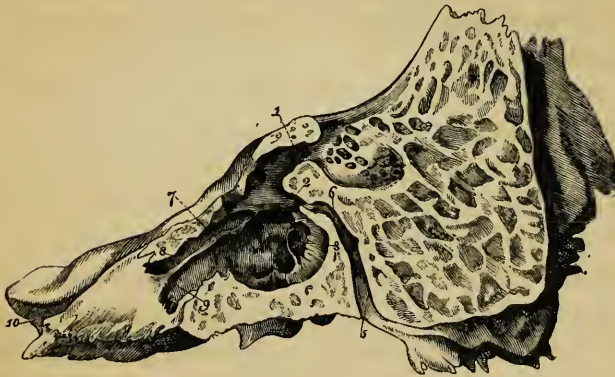
† Sir E. Home (Philosoph. Trans. vol. xc. p. 1, and cxiii. p. 23) and Meckel have attempted to establish the fact of its muscularity; but this conclusion has not met with the concurrence of other observers.

‡ It is named, by Cruveilhier, the canal of Huguier. See his Anat. Descript., Paris, 1834, tom. iii. p. 506.

an ovoid, or nearly kidney-shaped opening (*fenestra ovalis*), fig. 222, ², and fig. 226, which leads into the cavity of the vestibule. This opening, the long diameter of which is trans-

fenest.oval,
which is
nearly kid-
ney-shaped;

Fig. 222.*



verse, with a slight inclination downwards in front, is occupied in the recent state by the base of the stapes, and the annular ligament connected with that process of bone. Above the fenestra ovalis, and between it and the roof of the tympanum, is a transverse ridge, which corresponds to part of a bony canal (*aqueduct of Fallopius*), containing the portio dura of the seventh nerve: below it is a larger and more rounded elevation, which is caused by the projection outwards of the first turn of the cochlea. This projection is called the *promontory*, or *tuber cochleæ*,⁴; it is marked by several grooves, in which lie the nerves of the tympanic plexus (see note, p. 802).

the ridge of
aqueduct of
Fallopius;

and pro-
muntory,
w. grooves
for tympc.
nerves.

The grooves on the promontory extend between two very small foramina, situate, the one at the upper, and the other at the lower part of the promontory; and these foramina open into two small canals. The upper canal (*canalis tympanicus*, Arnold) extends through the petrous portion of the temporal bone, to its upper surface, and ends close to the hiatus Fallopii. The lower canal leads downwards and inwards, also through the substance of the bone, to the base of the skull, and opens between the outer orifice of the carotid canal and the foramen lacerum jugulare.

* A view of the inner wall of the tympanum, from Gordon (Engravings of the Skeleton, 1818).—1. Openings of mastoid cells. 2. Fenestra ovalis. 3. Fenestra rotunda. 4. Promontory. 5. Aqueduct of Fallopius. 6. Junction of the canal for the chorda tympani with the aqueduct. 7. Processus cochleariformis. 8. Canal of the tensor tympani. 9. Eustachian tube. 10. Orifice of the carotid canal.

Also fenest. rotund., wh. is rather triangular than round ;

closed by membrane.

At back part tympan. opens into mastd. cells.

Pyramid is behind fenest. oval.

In front of tympanum, process cochleariform. separates canal of tensor tympani muscle, fr. opening of Eustach. tube.

This tube leads to up. part of pharynx.

It is directed forward and inwards.

Below and behind the promontory, and somewhat hidden by it, is a roundish or, more correctly, a triangular aperture* (named *fenestra rotunda*),³ which lies within a funnel-shaped depression. In the dried bone, the fenestra rotunda opens into the scala tympani of the cochlea; but, in the recent state, it is closed by a thin membrane,—*the secondary membrane of the tympanum* (Scarpa).

The *posterior wall* of the tympanum presents at its upper part a larger, and several smaller openings, fig. 222,¹ which lead into irregular cavities (*mastoid cells*) in the substance of the mastoid process of the temporal bone. These cells communicate freely with one another, and are lined by mucous membrane continuous with that which lines the tympanum. Behind the fenestra ovalis, and directed forwards, is a small conical eminence, called the *pyramid*, or eminentia papillaris, fig. 223,¹². Its apex is pierced by a foramen, from which emerges the tendon of the stapedius muscle. From this foramen may be traced a minute canal, which turns downwards in the posterior wall of the tympanum, and joins obliquely the descending part of the aqueduct of Fallopius.†

The *anterior end* of the tympanum gradually narrows at its lower part towards the apertures of two parallel canals, which are partially separated from each other by a lamina of bone (*processus cochleariformis*), fig. 222,⁷. The upper and smaller canal, about half an inch long, lodges the tensor tympani muscle, fig. 225,⁷; its tympanic orifice is situate directly in front of the fenestra ovalis, and is surrounded by the expanded and everted end of the cochleariform process. The lower and larger of the two canals forms the osseous portion of the Eustachian tube.

The *Eustachian tube* (*tuba vel ductus Eustachii*) is a canal, formed partly of bone, partly of cartilage and membrane, which leads from the cavity of the tympanum to the upper part of the pharynx. From the tympanum it is directed forwards and inwards, with a little inclination downwards; and its entire

* Haller described it as a canal having two openings, rather than a mere foramen. (*Elementa Physiologiæ*, lib. xv. § 26. See also Scarpa, "De structura fenestræ rotundæ, et de tympano secundario anatomicæ observationes." Mutinæ, 1772.)

† Described by Huguier in Cruveilhier, (*Anat. Descript.* tom. iii. p. 501.)

length is from an inch and a half to two inches. The *osseous* division of the Eustachian tube, fig. 222,⁹ begins in the lower and fore part of the tympanum, below the cochleariform process, and gradually contracting in diameter as it extends forwards, ends in a jagged opening at the anterior margin of the petrous portion of the temporal bone, close to the angle of junction with the squamous portion. The *anterior* part of the tube, fig. 223,⁵ is formed of a triangular piece of cartilage, the edges of which are slightly curled round towards each other, leaving an interval at the outer side, in which the canal is completed by dense fibrous membrane. Narrow behind, the tube gradually expands till it becomes wide and trumpet-shaped in front; and the anterior part is compressed from side to side, and is fixed to the inner plate of the pterygoid process of the sphenoid bone. The anterior opening is oval in form, and is placed obliquely at the side and upper part of the pharynx, into which its prominent margin projects behind the lower meatus of the nose, and above the level of the hard palate. Through this aperture the mucous membrane of the pharynx enters, and is continuous with that which lines the cavity of the tympanum.

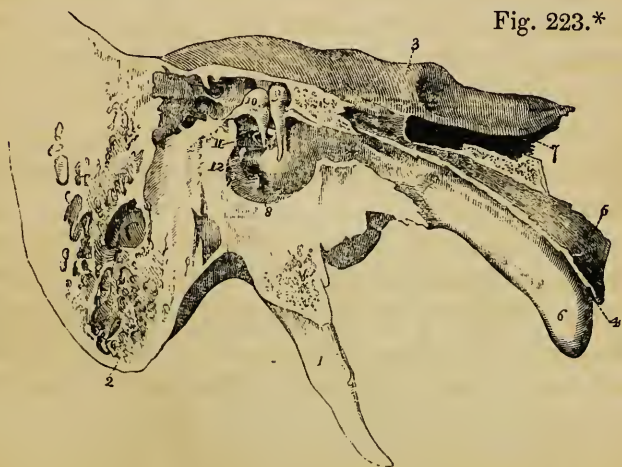
Bony near tympan., it is formed of cartilage and membr. towards anterior end.

Very narrow behind, it is expanded and trumpet-shaped in front.

2. SMALL BONES OF THE EAR.

Three small bones (ossicula auditûs) are contained in the

Small bones of ear.



upper part of the tympanum, fig. 223: of these, the outermost

* A view of the inner wall of the tympanum and Eustachian tube in the

One connected w. membr. tympan.; another with fenest. oval.; the third between these.

(malleus) is attached to the membrana tympani, fig. 221; the innermost (stapes) is fixed in the fenestra ovalis; and the third (incus), placed between the other two, is connected to both by minute joints, fig. 224, D. The first two are placed in nearly a vertical direction, the last is horizontal. The result is a species of angular and jointed connecting rod between the outer and inner walls of the tympanic cavity, which serves to communicate vibrations from the membrana tympani to the fluid contained in the vestibule of the internal ear.

MALLEUS.

Malleus :

head,

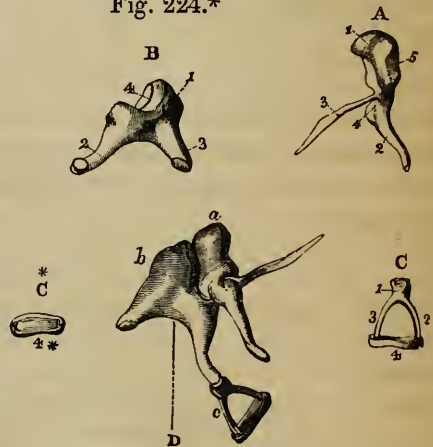
articular surface,

handle,

a. The *malleus* has been named from a fancied resemblance in form to a hammer. It consists of a central thicker portion, with processes of different lengths. At the upper end of the bone is a rounded *head* (*capitulum*), fig. 224, A, 1, which is lodged in the upper part of the tympanum, above the membrana tympani, fig. 221, B; and presents internally and posteriorly an irregularly oval plane surface, 224, A, 5, covered with cartilage, for articulation with the incus. Below the head is a constricted part or *neck* (*cervix*); and beneath this another slight enlargement of the bone, to which the processes are attached. The *handle* (*manubrium*) of the malleus, A, 2, is a tapering and slightly twisted process, which is compressed from before

backwards to near its point, where it is flattened in the opposite direction. The handle of the malleus is directed nearly vertically, with a slight inclina-

Fig. 224.*



recent state, with the small bones in their natural position. (Arnold.)—1. Styloid process of the temporal bone. 2. Mastoid process. 3. Fore part of the pars petrosa. 4. Pharyngeal portion of the Eustachian tube. 5. Its cartilaginous part. 6. Its mucous surface. 7. Carotid canal. 8. Fenestra rotunda. 9. Malleus. 10. Incus. 11. Stapes. 12. Pyramid and stapedius. The suspensory ligament of the malleus, and the upper and posterior ligaments of the incus, are also seen.

* The bones of the tympanum enlarged. (Arnold.)—A. Malleus. 1. Head. 2. Handle. 3. Long process. 4. Short process. 5. Articular surface. B. Incus. 1. Body. 2. Long process. 3. Short process. 4. Articular surface for the head of the malleus. C. Stapes. 1. Head. 2. Posterior crus. 3. Anterior crus. 4. Base. c.* Base of stapes. D. The three bones in their natural position with regard to each other.

tion forwards and inwards, and is received between the middle and inner layers of the membrana tympani, to which it is closely attached. At the fore part and near the base of this process is a small elevation, to which the tensor tympani muscle is attached, fig. 225. The *long process* (processus gracilis), fig. 224, A,³, is a very slender spine of bone, often broken off in removal from the tympanum, which projects at nearly a right angle from the neck of the malleus, and extends thence obliquely downwards and forwards to the Glasserian fissure. Its end is flattened and expanded, and is connected generally by ligamentous fibres and sometimes by bony matter to the sides of the fissure. The *short process* (processus brevis vel obtusus), A,⁴, is a low conical eminence springing from beneath the cervix, and projecting outwards towards the upper part of the membrana tympani. It is in contact with the middle layer of that membrane, and is not, therefore, so completely invested, as the greater part of the malleus, by the mucous lining of the tympanum.

INCUS.

b. The *incus*, fig. 224, B, has been compared to an anvil in form (hence its name); but it perhaps resembles more a bicuspid tooth with the fangs widely separated. It presents a body and two processes. The *body* of the incus,¹ is somewhat square, and is situate in the upper and back part of the tympanum, above the margin of the membrana tympani. It presents a deeply concave articular surface,⁴ which is directed upwards, forwards, and a little outwards, and receives the head of the malleus. The surfaces of the little ball-and-socket joint thus formed are tipped with articular cartilage and covered by a synovial membrane. The *shorter* of the two processes (*crus breve*) of the incus,³ projects nearly horizontally backwards from the upper part of the body of the bone. The end is rough, and is often connected by ligamentous fibres with the posterior wall of the tympanum near the entrance of the mastoid cells. The *long process* (*crus longum*),² tapers rather more gradually, and is slightly bent as it descends nearly vertically behind the handle of the malleus. On the inner surface of its point is a rounded tubercle, tipped with cartilage (*processus lenticularis*): this tubercle, which articulates with the head of the stapes, has been described as a separate bone, under the name of *os orbiculare seu lenticulare*.

STAPES.

The *stapes*, the third and innermost bone of the ear, fig. 224, c, is in shape remarkably like a stirrup (whence its name), and is composed of a head, a base, and two crura. The *head*,¹ is directed outwards towards the membrana tympani, and has on its end a slight depression, covered with cartilage, which articulates with the lenticular process of the incus. The *base*,⁴ is placed horizontally in the fenestra ovalis, to the margin of which it is fixed by ligamentous fibres. The form of the base is irregularly oval, the upper margin being curved, while the lower one is nearly straight. The crura of the stapes diverge from a constricted part (*neck*) of the bone, imme-

diately behind the head, and are attached to the outer surface of the base near its extremities. The anterior crus is the shorter and straighter of the two. The crura, with the base of the stapes, inclose a small triangular space, which in the recent state is occupied by a thin membrane, stretched across. A shallow groove runs round the opposed surfaces of the bone, and into this the membrane is received.

3. LIGAMENTS AND MUSCLES OF THE TYMPANUM.

Connexion
betw. bones.

The small bones above described are connected with each other, and attached to the walls of the tympanum by ligamentous fibres, in such a manner as to admit of a certain degree of movement at each of the points at which two bones come into contact. By this means apparently the vibrations of the membrana tympani are transmitted to the internal ear without that sudden shock which would be inevitable were the bony communication rigid and unyielding.

Joints are
formed
betw. them.

With regard to the connexion between the several bones of the tympanum, it has already been said that the head of the malleus is received into a cup-shaped depression in the body of the incus, and that the lenticular process of the incus articulates with the head of the stapes. The surfaces of bone entering into the formation of these small joints are tipped with cartilage, covered by synovial membrane, and surrounded by short ligamentous fibres in the form of capsular ligaments.

Mucous
membr. sur-
rounds the
bones.

Muscles and
ligaments ;

The attachment of the bones of the ear to the walls of the tympanum is effected partly by the reflexions of the mucous membrane lining that cavity, but chiefly by ligaments and muscles. Owing to the minuteness of these structures, and their being covered by vascular mucous membrane, it is difficult to recognise with certainty their exact nature; and hence much difference of opinion exists amongst authors as to the number of the muscles of the tympanum. Sæmmerring* describes four; Tod† increases the number to nine; but the general tendency of modern anatomical investigations is to throw doubts on the muscular nature of two or three of those even mentioned by Sæmmerring.

* Sæmmerring, S. T. *Icones Organi Auditûs Humani*.

† Tod, D. *The Anatomy and Physiology of the Organ of Hearing, &c.* Lond. 1832.

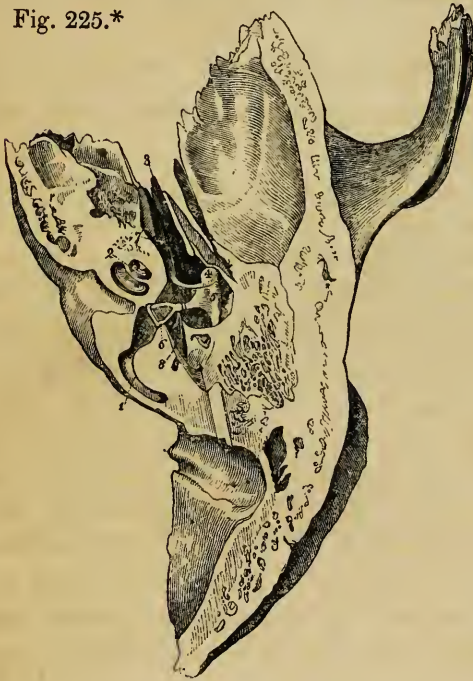The greater number of these structures (muscular and ligamentous) are attached to the malleus.

most are connected w. malleus.

Tensor tympani, fig. 225, ⁷ (*musculus internus mallei*).—This is the only muscle of the tympanum concerning the nature of which there is no dispute.

Tensor tympani

Fig. 225.*



It consists of a long, tapering, fleshy part, and a slender tendon. The muscular fibres arise from the cartilaginous end of the Eustachian tube and the adjoining surface of the sphenoid bone, and from the sides of a small canal, already described, above and parallel to the osseous portion of the Eustachian tube. In this canal the muscle is conducted nearly horizontally backwards to the fore part of the cavity of the tympanum. Immediately in front of the fenestra ovalis the tendon of the muscle bends at nearly a right angle over the processus cochleariformis, and passes thence outwards to be inserted into the fore part

is above Eustachian tube ;

turns from inner side of tymp. outwards to malleus.

of the handle of the malleus, near its root and below the processus gracilis.

The *laxator tympani major* of Sæmmerring is by many anatomists believed to be fibrous tissue covered by mucous membrane, and supplied with vessels which give it somewhat the appearance of muscular structure. Under the idea that it is simply fibrous, this has been named the *anterior ligament of the malleus*. Arising from the spinous process of the sphenoid bone, and slightly from the cartilaginous part of the Eustachian tube, it is directed backwards and inwards, passes through the Glasserian fissure, and is inserted into the neck of the malleus, just above the root of the processus gracilis.

Laxr. tymp.

The *laxator tympani minor* of Sæmmerring (*posterior ligament of the malleus*—Lincke) is made up of reddish fibres, which are fixed at one end to the upper and back part of the external auditory meatus, pass forwards

Laxr. tymp. minor.

* A view of the contents of the tympanum seen from above, after cutting away the roof of the cavity and part of the pars petrosa of the temporal bone.—1. Inner semicircular canal opened. 2. Cochlea exposed. 3. Eustachian tube. 4. Caput mallei. 5. Incus. 6. Stapes. 7. Tensor tympani. 8. Stapedius.

and inwards between the middle and inner layers of the membrana tympani, and are inserted into the outer border of the handle of the malleus, and the short process near it.

The *suspensory ligament of the malleus** (ligamentum teres vel superius) consists of a little round bundle of fibres, which descend perpendicularly from the roof of the tympanum to the head of the malleus. It is about two lines in length.

No muscles
attached to
incus.

The incus has no muscles attached to it. This bone is kept in position chiefly by its attachments, already noticed, with the malleus and stapes.

Ligament of
that bone.

It is likewise suspended by a small ligament (the *posterior ligament of the incus*, fig. 223), which extends from near the point of the short crus directly backwards towards the posterior wall of the tympanum, where it is attached to the side of the pyramid, near the entrance to the mastoid cells. Arnold moreover describes an upper ligament of the incus, fig. 223, which attaches the upper part of the incus (near its articulation with the malleus) to the roof of the tympanum. Its direction is parallel with, and close behind the suspensory ligament of the malleus.

The stapes is provided with a little muscle which acts on the outer end or head, and a ligament which fixes the base in such a manner as to permit a limited degree of motion of the whole bone.

Stapedius
in pyramid.

The *stapedius muscle*, fig. 225, ⁶, is lodged in the hollow of the pyramid, from the sides of which its fibres arise. The tendon pierces the aperture at the apex of that little elevation, and passing forwards, is inserted into the neck of the stapes, close behind the articulation of that bone with the lenticular process of the incus. The muscularity of the stapedius has been questioned by some anatomists. Sæmmerring figures a branch of the portio dura supplying it. A very slender spine of bone has been found occasionally in the tendon of the stapedius in man; and a similar piece of bone, though of a rounder shape, exists constantly in the horse, the ox, and other animals.

Annular
ligt. con-
nects stapes
w. fenest.
ovalis.

The *annular ligament of the stapes* (ligamentum orbiculare vel annulare bascos stapedis) connects the base of the bone to the margins of the foramen (fenestra ovalis), in which it is lodged. The fibres of the ligament are covered on the outer side by the mucous lining of the tympanum, and on the inner side by the membrane of the vestibule.

4. THE LINING MEMBRANE OF THE TYMPANUM.

Mucous
membr. con-
tinued from

The tympanum is lined throughout by a thin, vascular, fibro-mucous membrane, which is continuous with the mucous

* Seen in fig. 223, over number 9.

membrane of the pharynx through the Eustachian tube, and is further prolonged from the tympanum backwards into the mastoid cells. It adheres closely to the walls of the cavity, forms the inner layer of the membrana tympani, assists in covering over the fenestra rotunda, and gives a more or less complete investment to the bones and muscles of the tympanum, and to the nerves which cross that cavity. The mucous membrane which lines the cartilaginous part of the Eustachian tube resembles much the membrane of the pharynx, with which it is immediately continuous. It is thick, villous, and highly vascular, covered with vibratile cilia, and provided with many simple mucous glands which pour out a thick secretion. In the osseous part of the Eustachian tube, however, this membrane gradually changes its character; and in the tympanum and mastoid cells it is paler, thinner, and less vascular, presents no traces of mucous follicles or cilia, and secretes a less viscid, yellowish fluid.

Eustachian tube and into mastoid cells; covers small bones.

Differs from membr. in pharynx.

5. VESSELS AND NERVES OF THE TYMPANUM.

The arteries of the tympanum, though very small, are numerous, and are derived from several branches of the external and internal carotid.

Arteries

The fore part of the cavity is supplied chiefly by the *tympanic branch of the internal maxillary* (see p. 485), which enters by the fissure of Glasser. The back part of the cavity, including the mastoid cells, receives its arteries from the *stylo-mastoid branch of the posterior auricular artery* (see p. 482), which is conducted to the tympanum by the aqueduct of Fallopius. These two arteries also form a vascular circle round the margin of the membrana tympani. The smaller anastomosing arteries of the tympanum are, the *petrosal branch* of the middle meningeal, which enters through the hiatus Fallopii; the *Vidian branch* of the descending palatine, through the Vidian canal; branches through the bone from the *internal carotid* artery, furnished from that vessel whilst in the carotid canal; and occasionally a twig along the Eustachian tube from the *ascending pharyngeal* artery.

fr. internal maxillary;
post. auric.

internal carotid.

The *veins* of the tympanum pour their contents through the middle meningeal and pharyngeal veins, and through a plexus near the articulation of the lower jaw, into the internal jugular vein.

Veins.

Nerves.—The tympanum contains several nerves; for, besides

Nerves.

those which supply the parts of the middle ear, there are several which merely serve to connect nerves of different origin.

The lining membrane of the tympanum is supplied by filaments from the plexus (tympanic plexus), which occupy several small and shallow grooves described as being on the inner wall of the cavity, and particularly on the surface of the promontory (see page 802).

Tympanic
plexus.

The *tympanic plexus* is formed by the communications between, 1st, the tympanic branch (*nerve of Jacobson*) from the petrous ganglion of the glossopharyngeal; 2nd, a *filament from the carotid plexus* of the sympathetic; 3rd, a branch which joins the *great superficial petrosal nerve*, from the Vidian; 4th and lastly, the *small superficial petrosal nerve*, from the otic ganglion.

These nerves having been already described with the trunks from which they are severally derived, it is only necessary to indicate them here as they are seen in the tympanum. The nerve of Jacobson, fig. 192, ⁴, enters the tympanum by a small foramen near its floor, which forms the upper end of a short canal in the petrous portion of the temporal bone, beginning at the base of the skull between the carotid foramen and the jugular fossa. The nerve from the carotid plexus, ⁵, is above and in front of this, and passes through the bone directly from the carotid canal. The branch to the great superficial petrosal nerve, ⁸, is lodged in a canal which opens on the inner wall of the tympanum in front of the fenestra ovalis. The small superficial petrosal nerve, ⁹, also enters at the fore part of the cavity beneath the canal for the tensor tympani.

Nerve of
tensor tym-
pani from
otic gangl.

Chorda
tymph.

The tensor tympani muscle receives its nerve from the otic ganglion, fig. 192, ¹⁰; and the stapedius is figured by Sæmmerring as supplied by a filament from the facial nerve. The chorda tympani is not destined for the supply of any part of the middle ear; it is invested in a tubular reflexion of the lining membrane of the tympanum, and its course across the cavity has been described (see page 796).

C. THE INTERNAL EAR, OR LABYRINTH.

Intern. ear.

This, which is the essential or sensory part of the organ of hearing, is contained in the petrous portion of the temporal bone. It is made up of two very different structures, known respectively as the osseous and the membranous labyrinth.

Osseous
labyrinth
lodged in

1. The *osseous labyrinth* is lodged in the cancellated structure of the temporal bone, and presents, when separated

from this, the appearance shewn in the enlarged figure (226). It is incompletely divided into three parts, named respectively the vestibule, the semicircular canals, and the cochlea. They are lined throughout by a thin serous membrane, which secretes a clear fluid (perilymph).

petrous part of temp. bone.

2. The *membranous labyrinth* is contained within the bony labyrinth, and, being smaller than it, a space intervenes between the two, which is occupied with the perilymph just referred to. This structure supports numerous minute ramifications of the auditory nerve, and incloses a liquid secretion (endolymph). The parts thus briefly noticed will now be described in detail.

Membrs. labyrinth within preceding, and smaller than it.

Supports nervous structures.

I. THE OSSEOUS LABYRINTH.

a. The *vestibule*, fig. 226, ¹, forms a sort of central chamber of the labyrinth, which communicates in front with the cochlea,

Vestibule communicates with other two parts, also w. tympan. and intern. meatus.

Fig. 226.†



behind with the semicircular canals, on the outer side with the cavity of the tympanum, and on the inner side with the meatus auditorius internus. The vestibule is irregularly ovoidal in shape, and is slightly flattened or compressed from without inwards. The outer wall, which separates it from the cavity of the tympanum, presents the fenestra ovalis, ², already noticed, which is closed, in the recent state, by the base of the stapes and its annular ligament. Near the upper part of the inner

Fovea hemi-ellipt.

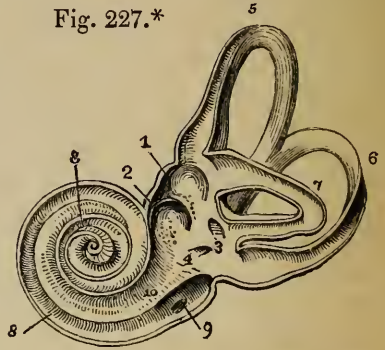
wall is an ovoid depression called the *fovea hemi-elliptica*, fig. 227, ¹ (sinus ovatus—Sæmmering); and beneath this is another rounder pit, the *fovea hemispherica*, ² (sinus rotundus—

Fovea hemispher.

† An enlarged view of the labyrinth from the outer side. (After Sæmmering.)—1. Vestibule. 2. Fenestra ovalis. 3. Superior semicircular canal. 4. External semicircular canal. 5. Posterior semicircular canal. 6. First turn of the cochlea. 7. Second turn. 8. Apex of cochlea. 9. Fenestra rotunda. * Ampullæ of semicircular canals.—The smaller figure represents the osseous labyrinth of its natural size.

Crista. Sœmmerring). Between the two hollows extends a transverse ridge, which is named the *crista vestibuli*, or eminentia pyramidalis. Both the ridge and the hemispherical fossa are pierced with many small holes, which serve to transmit branches of the auditory nerve from the internal auditory meatus. Behind the fovea hemispherica is the small oblique opening of a canal, ⁴ (the *aqueduct of the vestibule*), which extends to the posterior surface of the petrous portion of the temporal bone; it transmits a small vein in a tubular prolongation of membrane. At the back part of the vestibule are five round apertures, leading into the semicircular canals; and at the lower and fore part of the cavity is a larger opening, that communicates with the scala vestibuli of the cochlea (*apertura scalæ vestibuli*).

Fig. 227.*



Three semicircular canals:

five openings into vestib.

Ampulla at one end of each.

Superior vertical rises to upper surf. of petrous part of temp. bone.

b. The *semicircular canals*, fig. 226, ^{3, 4, 5}, are three bony tubes, situate above and behind the vestibule, into which they open by five apertures, already noticed. Each tube is bent so as to form the greater part of a circle; and each presents, at one end, a slightly dilated part, called the *ampulla*. In other respects, namely, in position with regard to the vestibule, in direction, and in length, the canals differ from one another. The *superior* semicircular canal, fig. 226, ³, is *vertical* in direction; and, rising above any other part of the labyrinth, forms a smooth round projection on the upper surface of the petrous portion of the temporal bone. The anterior or dilated end of the canal opens by a distinct orifice into the upper part of the vestibule; whilst the opposite extremity joins the corresponding non-dilated end of the posterior vertical semicircular canal, and enters by a common aperture with it into the back part of the

* Section of the labyrinth (from Sœmmerring), showing the inner surface of the cavity.—1. Fovea hemi-elliptica. 2. Fovea hemispherica. 3. Common opening of the superior and posterior semicircular canals. 4. Opening of aqueduct of the vestibule. 5. The superior; 6. the posterior; and 7. the external semicircular canals. 8. Spiral canal of the cochlea (scala tympani). 9. Aqueduct of the cochlea. 10. Lamina spiralis.

vestibule. The *posterior* semicircular canal, fig. 226,⁵ also *vertical* in direction, is the longest of the three tubes. The ampulla of this canal is attached to the lower and back part of the vestibule; and the cylindrical crus joins the common trunk above described. The *external* semicircular canal, fig. 226,⁴ is placed *horizontally*, and opens by two distinct orifices into the upper and back part of the vestibule. This canal is shorter than either of the other two.

Post. vertical, the longest, is joined w. preceding.
External or horizontal, the shortest, is in angle betw. other two.

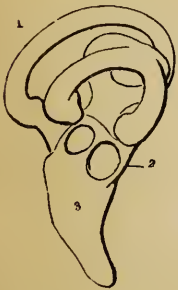c. The *cochlea*, fig. 226,^{6, 7, 8} is the third and most anterior division of the internal ear. When the dense bony substance, in which it lies embedded, is picked away, the cochlea presents the form of a blunt cone, the base of which is turned towards the internal auditory meatus, whilst the apex is directed outwards, with an inclination forwards and downwards. The surface of the cone is marked by a spiral groove, which gives to this part of the labyrinth somewhat the appearance of a spiral shell—whence its name.

Cochlea: is conical; base towards internal meatus.

A general idea of the plan on which this more complex portion of the labyrinth is constructed, may be obtained by first supposing it to be a gradually tapering bony tube of a certain length, which is divided into two compartments by a partition (partly bone and partly membrane), the two compartments being distinct, except at the end, where they communicate

Plan of cochlea. A straight tube partially divided into two parts.

Fig. 228.*



one with the other in consequence of the deficiency of the partition. Such is the simplest idea of this division of the internal ear, and it actually exists in this form in the ear of birds. See fig. 228,³.

The names given to certain parts may be indicated here. The partition is called the lamina spiralis, and the reason for the term "spiral" will presently appear; the two half-tubes, which are termed *scalæ*, are distinguished by the addition of the names of the cavities (tympa-num and vestibule) into or towards which they open respectively; the place at which the half-tubes join is the *helicotrema*; and the end of the tube covering

this over is the *cupola*.

In order to convert the straight tube now noticed into the spiral one named *cochlea*, it must be supposed to be coiled on itself so as to intercept a conical space—the first turn making much the widest sweep, fig. 226; and this space is occupied by the spongy substance of the temporal bone. The added bony matter, which supports the coils of the tube, together with the inner surface of the tube itself, constitutes what is called the *modiolus*.

The tube coiled so as to become spiral.

* Osseous labyrinth of the barn owl (*Strix flammea*). (From Breschet.)—
1. Semicircular canals. 2. Vestibule. 3. Cochlea.

Canal of cochlea makes two turns and half: first turn widest.

Cupola is end of canal.

Modiolus:

thick in first turn of cochlea; expands at end:


formed of inner surf. of spiral tube and some cancellated bony matter.

Canals for nerves and vessels.

Spiral lamina is an incomplete partition in spiral canal of cochlea;

The *spiral canal of the cochlea* (*canalis spiralis cochleæ*), fig. 229, ^{3, 4}, is about an inch and a half long, and about the tenth of an inch in diameter at the broadest part, which is turned towards the cavity of the vestibule. From this point the canal makes two turns and a half round the central pillar, (from left to right in the right ear, and in the opposite direction in the left ear,) and ends by an arched and closed extremity called the *cupola*, which forms the apex of the whole cochlea. The first coil, being composed of the largest portion of the tube, nearly hides the second turn from view; and, bulging somewhat into the tympanum, forms the round elevation on the inner wall of that cavity called the promontory.

Fig. 229.*



The *modiolus* (*columella cochleæ*), fig. 229, ¹, forms the central pillar or axis round which turn the spiral canal and the spiral lamina. It is much thicker within the first turn of the cochlea than at any other part; rapidly diminishes in size through the second coil; and again slightly expands within the last half-turn or cupola, fig. 229. The outer surface of the modiolus is dense, being, in fact, composed of the walls of the spiral canal; but the centre is soft and spongy, and is pierced by many small canals for the passage of the auditory nerve from the inner meatus to the lamina spiralis, fig. 230. One of these canals, larger than the rest (*canalis centralis modioli*), runs from the base through the centre of the modiolus to the apex, where it expands slightly, and forms what has been named the *infundibulum*.

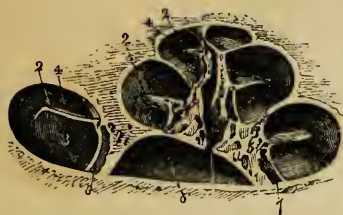The *spiral lamina* (*lamina spiralis*), fig. 230, is, in the dried state, a thin, flat, osseous plate, growing from and winding round the modiolus, and projecting into the spiral canal, so as partially to divide it into two *scalæ*. In this state the separation of the *scalæ* is incomplete; firstly, because the osseous lamina is deficient at the apex of the cochlea, where it forms a

* Diagram showing the form and structure of the dry cochlea (laid open.)—1. Modiolus. 2. Lamina spiralis. 3. Scala tympani. 4. Scala vestibuli.

sort of open hook-like termination (*hamulus*); and, secondly, because its free margin does not, at any part, reach much further

forms hamulus at end;

Fig. 230.*



than about two-thirds of the distance between the modiolus and the outer wall of the spiral canal. This free edge of the osseous lamina gives attachment in the recent state to a membranous septum (membranous zone), which is continued outwards to

be inserted into the circumference of the spiral canal. Within the attached portion of the osseous lamina, and therefore winding close round the modiolus, is a small canal, named by Rosenthal the *canalis spiralis modioli*.

and contains a canal where joined to modiolum.

The osseous lamina is thin and dense near its free margin; but near the modiolus it is composed of two denser outer plates, inclosing a more open and spongy structure, in which run numerous small canals, continuous, but running at right angles with the canals in the centre of the modiolus. In these are lodged filaments of the auditory nerve.

The *scalæ* are the two passages into which the general canal of the cochlea is divided by the lamina just described. One of these, the *scala tympani*, fig. 230, ³, communicates with the cavity of the tympanum by the fenestra rotunda, which, in the recent state, is closed by the secondary membrana tympani, and with the scala vestibuli by an opening (*helicotrema*) left at the apex of the cochlea, in consequence of the deficiency of the lamina spiralis in the last half-turn of the canal. In the wider part of the tympanic scala, and close to the fenestra rotunda, is the orifice of a small canal, fig. 227, ⁹ (*aqueductus cochleæ*), which extends downwards and inwards through the substance of the petrous part of the temporal bone to near the jugular fossa, and transmits a small vein. The surface of the spiral lamina which looks towards this scala is marked with numerous transverse striæ.

Divisions of cochlea.

Scala tympani.

Both scalæ join at helicotrema.

Aqueduct of cochlea.

The *scala vestibuli*, fig. 230, ⁴, (rather narrower than the scala

Scala vestibuli.

* Section of the cochlea. (From Arnold.)—1. Foramen centrale modioli. 2. Lamina spiralis ossea. 3. Scala tympani. 4. Scala vestibuli. 5. Cellular substance of the modiolus.

tympani in the first turn of the cochlea,) opens freely into the cavity of the vestibule, and communicates, as already described, with the scala tympani at the apex of the modiolus. The transverse grooves on the surface of the lamina which is directed towards the scala are less marked than those in the scala tympani.

Osseous labyrinth is lined by thin membrane, which secretes perilymph.

d. The lining Membrane of the osseous Labyrinth.—This is a thin fibro-serous membrane, which closely adheres to the whole inner surface of the several parts of the labyrinthic cavity just described. From the vestibule it is prolonged directly into the semicircular canals, the scala vestibuli of the cochlea, and the aqueductus vestibuli; and through the opening of the helicotrema it is further continued into the scala tympani and aqueductus cochleæ. It has, however, no communication with the lining membrane of the tympanum, being, like that membrane, stretched across the openings of the round and oval fenestræ. The outer surface of the lining membrane of the labyrinth is rough, and adheres closely, like periosteum, to the bone: the inner surface is pale and smooth, is covered with epithelium like that of the arachnoid, and secretes a thin, slightly albuminous or serous fluid. This secretion, first described by Cotunnus, and hence known to anatomists as the *liquor Cotunnii*, has been called by Blainville the *perilymph*. It separates the membranous from the osseous labyrinth in the vestibule and semicircular canals, occupies alone the cavities of the scalæ in the cochlea, and is continued into the aqueducts as far as the membrane lining these passages remains pervious.*

2. THE MEMBRANOUS LABYRINTH.

Membranous labyrinth:

supports nervous structure.

Within the osseous labyrinth, and separated from its lining membrane by the perilymph, is a membranous structure, which serves to support the ultimate ramifications of the auditory nerve. In the vestibule and semicircular canals this membrane has the form of a rather complex sac, and incloses a fluid called the endolymph: in the cochlea the analogous structure merely

* According to Breschet and Huschke, the lining membrane of the labyrinth is, in fetal life, continuous with the dura mater and arachnoid of the skull; and the aqueducts in the adult mark the points of communication, nearly obliterated by the development of the bone and the gradual closing in of the osseous labyrinth.

completes the lamina spiralis, and is covered by the membrane which lines the general cavity of the osseous labyrinth.

a. The part of the *membranous labyrinth* contained in the *vestibule* (*membranous vestibule*) consists of two rounded portions, which, though closely connected together, appear to be distinct sacs. The larger of the two, the *common sinus* (*sinus communis vel utriculus*), fig. 231,⁵ is of an oblong form, and slightly flattened from without inwards. It is lodged in the upper and back part of the osseous vestibule, and fills the depression called the fovea hemi-elliptica. Opposite the crista vestibuli several small branches of the auditory nerve enter from the foramina in the bone; and here the walls of the common sinus are thicker and more opaque than elsewhere. The cavity of the common sinus communicates with that of the membranous semicircular canals by five orifices, and contains, besides endolymph, a small mass of calcareous matter. The smaller vestibular bag, named the *sacculæ*, fig. 231,⁶ is more nearly spherical than the common sinus, but, like it, is somewhat flattened. The sacculæ is situated in the lower and fore part of the cavity of the osseous vestibule, close to the opening from the scala vestibuli of the cochlea, and is received into the hollow of the fovea hemispherica, from the bottom of which many branches of nerve enter. The sacculus appears to have a cavity distinct from that of the utricule, but is filled with the same thin and clear fluid (endolymph), and contains a similar cretaceous body.

b. The *membranous semicircular canals*, fig. 231, are about one-third the diameter of the osseous tubes in which they are lodged; but in number, direction, and general form they so closely resemble the bony canals, that a separate description is thus far unnecessary. The membranous canals, which are hollow, open into the sinus communis by four single orifices, and one which is common to two canals. They are filled with the same fluid (endolymph). The ampullæ are thicker and less translucent than the rest of these tubes, and nearly fill their bony cases. That part of each ampulla which faces the concavity of the corresponding osseous semicircular canal is free, rounded and prominent externally, and smooth on the inner surface; whilst the opposite portion is flattened, receives branches of nerves and blood-vessels,

Membranous vestibule consists of two parts.

Common sinus is lodged in fovea hemi-elliptica;

receives nerves;

and is continuous w. semicirc. canals.

Sacculæ :

lodged in fovea hemispherica.

Both sacs filled with endolymph.

Membranous semicircular canals much smaller than bony canals :

open into com. sinus of vestib.

Ampullæ receive the nerves; and they present a septum wh. partly divides the interior into two.

and, when opened, presents on its inner surface a transverse projection (*septum transversum*), which partially divides the cavity into two.

The structure of the walls of the common sinus, sacculus, and membranous semicircular canals presents many points of resemblance. The membrane of which they are formed is generally thin and semitransparent; but it is thicker and more opaque where nerves and vessels enter. On the outer surface is a layer of minutely ramified blood-vessels and loose cellular tissue, which sometimes contains irregular deposits of pigment-cells. Next to this vascular net-work, branches of the auditory nerve are distributed in the form of a distinct layer, within which is fine cellular tissue, with, according to Huschke, a film of closely set nucleated epithelium-cells. It is doubtful how far the nervous layer extends into the undilated portion of the semicircular canals.

Membrane is thickest where nerves and vessels ramify on it.

Endolymph fills membranous labyrinth of vestibule and semicircular canals.

Otolithes in common sinus and sacculæ: their characters.

The *endolymph* (*aqua labyrinthi membranacei*, vel humor vitreus auris) is a thin, limpid fluid, contained in the sacculus, common sinus, and semicircular canals, and is immediately in contact with the layer of epithelium-cells lining these cavities. The endolymph contains little but water, and resembles closely the perilymph already described.

The *otolithes* (otoconies—Breschet) are two small rounded bodies, contained, the one in the common sinus, and the other in the sacculus, and composed of particles of carbonate and phosphate of lime agglutinated together by mucus and animal matter. Huschke describes the calcareous particles as distinctly crystalline, whilst Mr. Wharton Jones distinguishes them as oval and somewhat pointed granules. These bodies are slightly attached to the walls of the membranous labyrinth opposite the points of entrance of the nerves into the common sinus and sacculus, but otherwise they float freely in the endolymph.

Membrane in cochlea differs widely fr. preceding;

is flat, and completes septum between scalæ, forming most of septum towards apex of cochlea.

c. The *membranous structure of the cochlea* is very different in its constitution from the rest of the membranous labyrinth, to which it is analogous only in affording a surface on which the auditory nerve divides, in order to be exposed to the undulations of the fluid of the internal ear. The cochlea is entirely filled with perilymph; and the nervo-membranous structure which constitutes its sentient portion is flat, and arranged in a spiral form, so as to assist, with the osseous lamina, in separating the two scalæ. The *lamina spiralis membranacea* stretches across from the free margin of the osseous lamina to the outer circumference of the spiral canal. In the first turn of the cochlea it forms about one-third of the breadth of the septum between the scalæ; but towards the apex of the cochlea the proportion between the two parts of the lamina is gradually

reversed, until, near the helicotrema, the membranous parts of the lamina are left unsupported by any plate of bone.

In the first and second turn of the cochlea the membranous spiral lamina contains, close around the margin of the osseous plate, some cartilaginous tissue, together with particles of bone. This has given occasion to Breschet to distinguish the *zonula cartilaginea* and the *zonula membranacea*; the former ending, like the osseous lamina, in a hook-like turn (*hamulus cartilagineus*); and the latter expanding at its termination, as just described, and forming the most transparent and delicate part of the septum. Within the membranous lamina spiralis is a flattened expansion of the cochlear branch of the auditory nerve, covered on the upper surface by the membrane lining the scala vestibuli, and on the lower surface by the membrane of the scala tympani, fig. 232. Between the nervous filaments, which will be presently described, are numerous scattered opaque and osseous granules.

3. VESSELS OF THE LABYRINTH.

a. Arteries.—The *internal auditory artery*, a branch from the basilar, enters, together with the auditory and facial nerves, the internal meatus of the ear, and at the bottom of that shallow canal divides into vestibular and cochlear branches. The *vestibular* branches are distributed to the common sinus, sacculus, and semicircular canals, with the branches of nerve which they accompany through the bony foramina. The *cochlear* branches, fig. 232, twelve or fourteen in number, traverse the many small canals in the modiolus and bony lamina spiralis, and are distributed in the form of a fine net-work on the membrane lining the two scalæ. Of the two, the membrane of the scala vestibuli is said to be the more vascular. Besides the foregoing, which is the chief artery of the internal ear, the *stylo-mastoid* branch of the posterior auricular (see p. 482), and occasionally the occipital artery (Jones), send twigs to the vestibule and posterior semicircular canal.

Arteries of
intern. ear.
Internal
auditory.

Stylo-mas-
toid.

b. Veins.—The veins of the *cochlea* principally converge towards a small spiral sinus which is contained between the layers of the membranous lamina spiralis, close to its peripheral attachment. The veins of the *vestibule* and semicircular canals accompany the arterial branches, and, joining the circular sinus of the cochlea at the base of the modiolus, pour their contents into the superior petrosal sinus.

Veins.

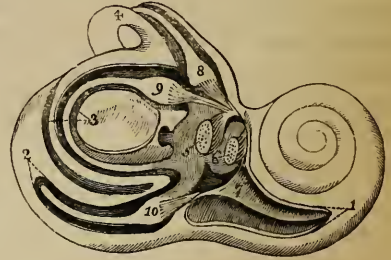
4. THE AUDITORY NERVE.

Auditory
nerve

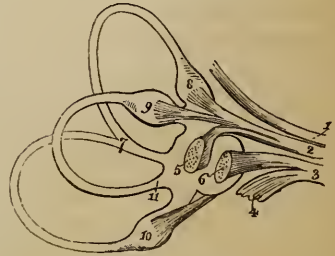
divides in
internal
meatus into
fibrils,
which pass
through
foramina at
end of
meatus.

The special nerve of the sense of hearing (*portio mollis paris septimi, nervus auditorius*) is the only nerve distributed to the labyrinth, or internal ear. Its course from the brain to the end of the internal auditory meatus, and its connexion with the facial nerve whilst in that canal, have been described. (See p. 800.) At the bottom of the meatus the auditory nerve comes in contact with a perforated plate of bone, which assists in bounding the cavities of the vestibule and cochlea; and through the perforations in this bone the filaments of the nerve, minutely divided, pass to their destination in the internal ear. Before entering the foramina, the auditory nerve divides into an anterior and a posterior branch (*cochlear and vestibular nerves*); but there is some difference of opinion amongst anatomists as to the usual precise distribution of these two primary branches. Having traversed the shell of bone, and entered the cavity of the osseous labyrinth, the filaments are grouped into fasciculi, which correspond in number with the several parts of the membranous labyrinth to which

Fig. 231.* A



B



* Fig. 231. A. Membranous labyrinth displayed in situ by cutting away part of the osseous labyrinth. (After Breschet.)—1. Spiral canal of the cochlea. 2. Posterior vertical semicircular canal opened to show the membranous canal within. 3. External or horizontal semicircular canal; the whole of the membranous canal seen. 4. Superior vertical semicircular canal. 5. Common sinus. 6. Saccule. 7. Lamina spiralis. 8. Membranous ampulla of anterior semicircular canal. 9. Ampulla of the external, and, 10, ampulla of posterior canal.

B. Membranous labyrinth detached. (Breschet.)—1. Portio dura of seventh nerve. 2. Anterior portion of the portio mollis, giving branches to the anterior and the external ampullæ and to the utricule. 3. Posterior portion of auditory nerve, giving branches to saccule and cochlea. 4. Nerve to cochlea. 5. Common sinus. 6. Saccule. 7. Common end of the superior vertical and posterior vertical semicircular canals. 8, 9, and 10 as in fig. A. 11. Undilated end of external or horizontal canal.

they are given. There are six of these fasciculi,—the common sinus, the sacculus, the three ampullæ of the semicircular canals, and the cochlea, receiving one each.

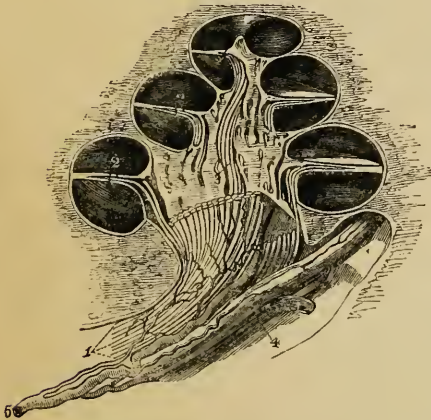
Primary Division of the Nerve.—The nerves for the supply of the *common sinus*, and of the *superior* and the *external semicircular canals*, pass through a cluster of foramina in the upper and back part of the perforated plate of bone at the bottom of the meatus, close behind the aperture of the aqueductus Fallopii, and enter the cavity of the vestibule along the ridge (*crista vestibuli*), between the hemi-elliptical and hemispherical depressions. The filaments then unite into a common trunk, fig. 231, B, ², which afterwards sends one branch to the common sinus, a second to the ampulla of the external, and a third to the ampulla of the superior semicircular canal. The fibrils for the *sacculus* enter the vestibule by a smaller group of foramina, which are situated below those just described, and open at the bottom of the fovea hemispherica. The nerve of the *posterior semicircular canal* is a long slender branch which traverses a small passage in the bone behind the foramina for the nerve of the sacculus. It enters the flattened side of the ampulla.

Nerves of vestibule and semicirc. canals.

The nerve of the *cochlea*, fig. 231, B, ⁴, and fig. 232, is shorter, flatter, and broader than any of the other nerves of the internal ear, and perforates the

Nerves of cochlea perforate modiolus, and turn outwards between plates of lamina spiralis.

Fig. 232.*



bone by a number of foramina at the bottom of the internal meatus, below the opening of the Fallopian aqueduct. These foramina are arranged in a shallow spiral groove (*tractus spiralis foraminulentus*), which corresponds with the coils of the canal of the cochlea; and they lead into little bony canals, which follow first the direction of the axis of the cochlea, through the modiolus, and then pass at right angles to the axis, between the plates of the bony lamina spiralis. In the centre

of the spiral groove above noticed is a larger foramen, which leads to the *canalis centralis modiolus*. Through the central foramen and straight canal the filaments for the last half-turn of the lamina spiralis and canal of the

* Fig. 232. Section of the cochlea (from Arnold), showing the mode of distribution of some of the nerves and the artery of the internal ear.—1. Auditory nerve. 2. Nerves in the lamina spiralis. 3. Central nerve of the cochlea. 4. Nerve of the vestibule. 5. Internal auditory artery.

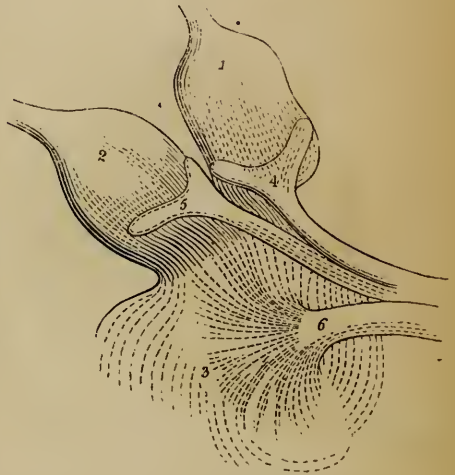cochlea are conducted, fig. 232,³ whilst the first two turns are supplied by filaments,² which occupy the smaller foramina and bent canals.

—The greater number of anatomists (including Sæmmerring, Arnold, Cruveilhier) describe the cochlear nerve as the anterior division of the portio mollis. According to Breschet,* however, the auditory nerve is divided into two branches, one of which (*nerf auditif antérieur*) supplies the common sinus and ampullæ of the anterior and the external semicircular canals, whilst the other (*nerf auditif postérieur*) sends off the cochlear nerve, and the nerves of the sacculus and posterior semicircular canal.

Ultimate Distribution of the Branches of the auditory Nerve.—In the membranous vestibule and semicircular canals, the nervous filaments, deprived of the thicker sheath which covered them whilst in the auditory meatus, are invested in a thin prolongation of the membranous labyrinth itself (Breschet), this being always thicker at the points at which the nerves enter. The nerves of the *common sinus* and *sacculæ* terminate nearly in the same manner. They perforate the membrane somewhat obliquely, and forming a slight projection on the inner surface of the sacs, divide at once into a fine pulpy net-work analogous to the retina of the eye. The net-work is composed of radiating lines of nervous globules deprived of their neurilemma and supported on a fine vascular membrane; it is in close contact with the otolithes, and is separated from the endolymph only by a layer of epithelium-cells.

The nerves of the *semicircular canals* enter the flattened or least prominent side of the ampullæ, where they each form a forked swelling, fig. 233, which corresponds with the transverse septum already described in the interior of the dilatation. From the forked swelling a pulpy nervous layer, deprived of neurilemma, extends into the transverse septum and over the inner surface of the walls of the ampulla; but it is yet undetermined how far the nerve extends into the undilated portion of the semicircular canals.

Fig. 233.†



Manner in
wh. nerves
end :

in common
sinus and
sacculæ,
they project
inwards,
and are con-
nected with
otolithes ;

in semicirc.
canals they
are forked,
and project
inwards
upon septa
of ampullæ ;

* Recherches anatomiques et physiologiques sur l'Organe de l'Ouïe, &c. Paris, 1836.

† Fig. 233. The ampullæ of the superior and external semicircular canals and part of the common sinus, showing the arrangement of the nerves. (From Steifensand.)—1. Ampulla of superior, and, 2, ampulla of external semicircular canals. 3. Common sinus. 4 and 5. Fork-like swellings of the nerves to the ampullæ. 6. Radiating end of the nerve to the common sinus.

The nerve of the *cochlea*, as it passes through the modiolus and osseous lamina spiralis, divides into minute cylindrical branches, which, on entering the middle or cartilaginous zone become very indistinct, and are mixed up with granules and particles of osseous matter. The precise mode of their ultimate distribution is still uncertain. By Searpa they were said to form brushes, and by Sæmmerring a feather-like arrangement, of filaments. By Treviranus they were thought to end in papillæ; and according to Breschet they become flattened, anastomose together, and terminate in loops which are surrounded by irregularly scattered granules.

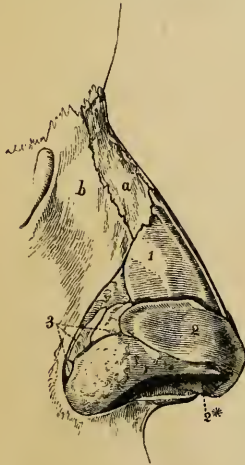
in cochlea they are disposed on membrs. lamina spiralis.

THE NOSE.

THE nose is the special organ of the sense of smell; but it has other functions to fulfil,—for, communicating freely with the cavities of the mouth and lungs, it is concerned in respiration, voice, and taste; and, by means of muscles on its exterior, which are closely connected with the muscles of the face, it assists in the expression of the different passions and feelings of the mind.

The nose ministers to other functions than that of smell.

Fig. 234.†



This organ consists of, first, the anterior prominent part, composed of bone and cartilage, with muscles which slightly move the latter, and two orifices (*anterior nares*) opening downwards; and, secondly, of the two nasal fossæ, in which the olfactory nerves are expanded. The narrow cavities last mentioned are separated one from the other by a partition (*septum narium*) formed of bone and cartilage:

The anter. projecting part.

The nasal fossæ, with the openings fr. these.

they communicate at the outer side with hollows in the neigh-

† Fig. 234. View of the bones and cartilages of the outer nose, from the right side. (Arnold.)—a. Nasal bone. b. Nasal process of upper maxillary bone. 1. Right upper lateral cartilage. 2. Lower lateral cartilage, its outer part. 2*. Inner part of the same. 3. Sesamoid cartilages.

bouring bones (ethmoid, sphenoid, frontal, and superior maxillary); and they open backwards into the pharynx through the posterior nares. The parts here indicated in connexion will now be noticed in detail.

1. BONES OF THE NOSE.

Bones of nose.

The outer projecting part of the nose is supported in part by the nasal bones, and the nasal processes of the superior maxillary bones, forming the bridge of the nose. The large triangular opening left between those bones has been described (at p. 83), and the bones which inclose the cavity of the nose have also been described (ante, p. 89).

2. CARTILAGES OF THE NOSE.

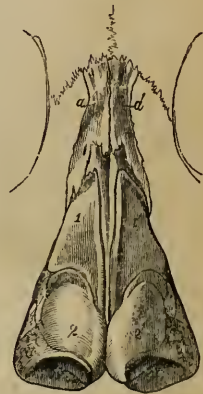Cartilages occupy space left in dried skull, and complete septum.

These are the chief support of the outer part of the organ. They occupy the triangular opening seen in front of the nasal cavity in the dried skull, and assist in forming the septum between the nasal fossæ. There are two larger, and three smaller cartilages on each side, and one central piece or cartilage of the septum.

Upper latl. cartilage continues from nasal bone; is trianglr.

The *upper lateral cartilages* (cartilagine laterales nasi), fig. 234,¹ and 235,¹ are situate in the upper part of the projecting portion of the nose, immediately below the free margin of the nasal bones. Each cartilage is flattened and triangular in shape, and presents one surface outwards, and the other inwards towards the nasal cavity. The anterior margin, thicker than the posterior one, does not quite meet the lateral cartilage of the opposite side, but is closely united with the edge of the cartilage of the septum; the lower margin is connected by fibrous membrane with the lower lateral cartilage; and the posterior edge is inserted into the ascending

Fig. 235.*



* Fig. 235. Bones and cartilages of the nose, seen from the front. (Arnold.)—a. Nasal bones. 1. Upper lateral cartilages. 2. Lower lateral cartilages.

process of the upper maxilla, and the free margin of the nasal bone.

The *lower lateral cartilages* (*cartilagine alarum nasi*),

Fig. 236.†

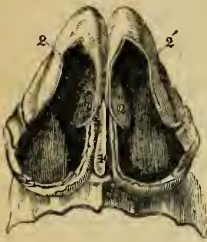


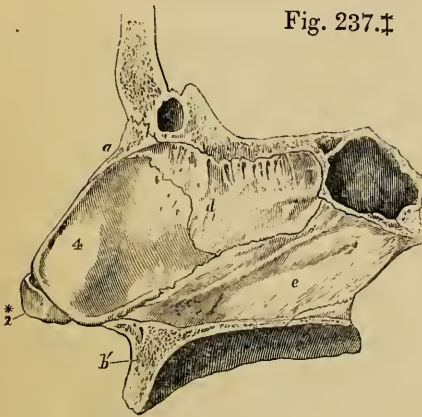
fig. 234, and 236,², are thinner than the preceding, below which they are placed, and are chiefly characterised by the curve which they form. Each cartilage consists of an elongated plate, so bent upon itself as to pass at each side of the orifice of the nose, and, by this arrangement, serving to keep it open. One portion supports and gives form

Lower lateral
is curved,
part being
at each side
of nostril.

to the upper part of the ala; and the other projects backwards, and bounds the nostril on the inner side. The *outer portion* is somewhat oval and flattened, or irregularly convex externally. Behind, it is attached to the margin of the ascending process of the upper maxilla, by tough fibrous membrane, in which are two or three cartilaginous nodules (*cartilag. minores vel sesamoideæ*); above, it is fixed,

Sesamoid
cartilages.

Fig. 237.‡



also by fibrous membrane, to the upper lateral cartilage, and to the lower and fore part of the cartilage of the septum; towards the middle line it leaves a deep groove, at the bottom of which it adheres to the opposite cartilage. The *inner portion* of the lower lateral cartilage, ^{2*}, forms a small part of the columna nasi, where it projects be-

low the anterior angle of the cartilage of the septum. This

† Fig. 236. View of the cartilages of the nose, looking into the nostrils from below. (From Arnold.)—2. Outer part of the lower lateral cartilages. 2*. Inner part of the same. 4. Lower edge of the cartilages of the septum.

‡ Fig. 237. Osseous and cartilaginous septum of the nose, seen from the left side. (After Arnold.)—a. Nasal bone. b. Superior maxillary bone. c. Sphenoidal sinus. d. Central or perpendicular plate of the ethmoid bone. e. Vomer. 2*. Inner part of the (right) lower lateral cartilage of the nose. 4. Cartilage of the septum.

part of the cartilage of the ala is thicker than the rest of the structure, curls outwards, and ends in a free rounded margin, which projects outwards towards the nostril, fig. 236,^{2*}. The lower and most prominent portion of the ala of the nose, like the lobule of the ear, is formed of cellular tissue, unsupported by cartilage, and covered with skin.

Cartilage of septum connected with bones, nasal, ethmoid, and vomer.

The *cartilage of the septum* (cartilago septi narium), fig. 236,⁴, and 237,⁴, has a somewhat triangular outline, and is thicker at the edges than near the centre. It is placed nearly vertically in the middle line of the nose, and completes, at the fore part, the separation between the nasal fossæ. The anterior margin of the cartilage, thickest above, is firmly attached to the back of the nasal bones near their line of junction,^a; and below this it lies between, and is united with, the fore part of the upper lateral, and the inner portions of the lower lateral cartilages. The posterior margin is fixed to the lower and fore part of the central plate of the ethmoid bone,^{d 1}; and the lower margin is received into a groove in the upper or anterior edge of the vomer. †

3. THE MUSCLES OF THE NOSE.

Muscles of nose.

These are described with the muscles of the face, with which they are associated in position, attachments, and function. They are the pyramidalis nasi, the levator labii superioris alæque nasi, the compressor naris, the depressor alæ nasi, and the levatores proprii alæ nasi, (anterior et posterior). (See ante, p. 249.)

4. THE SKIN.

Skin : characters of.

Over the upper part and sides of the nose, the skin is thin and loosely connected with the bones and cartilages on which it lies. Over the lower lateral cartilages, it gradually becomes firmer and more adherent; and in the free part of the alæ, where it has no extra support, it is thick and solid. It is here closely adherent to the muscles, and incloses small, separate, hard granules of fat. At the free margin of the ala the skin is folded on itself, and incloses, with the inner part of

† M. Cruveilhier describes a thin band of this cartilage "prolongement caudal" which extends backwards and upwards in the groove of the vomer, to be attached to the rostrum of the sphenoid bone. (Anatomie Descriptive, 1834, vol. iii. p. 429.)

the lower lateral cartilage, and lower part of the septum nasi, an oval aperture on each side (*naris, apertura nasi externa*), which leads into the corresponding nasal fossæ. The skin of the nose is studded, particularly in the grooves of the alæ, with numerous small openings, which lead to sebaceous follicles. Within the margin of the nostrils, there are several short, stiff, and slightly curved hairs (*vibrissæ*), which grow from the inner surface of the alæ and septum nasi, up to the point at which the skin is continuous with the mucous membrane lining the cavity of the nose.

Vibrissæ.

NASAL FOSSÆ.

The nasal fossæ, and the various openings into them, with the posterior nares, have been described as they exist in the skeleton (see ante, p. 89), and that description is also generally applicable to the nose in a recent state; but there are certain differences in the form and dimension of parts, which, as they depend on the arrangement of the lining membrane, will be noticed after the general account to be given of that membrane.

Nasal fossæ.

5. PITUITARY OR SCHNEIDERIAN MEMBRANE.

The cavities of the nose are lined by a mucous membrane of peculiar structure, which, like the membrane that lines the cavity of the tympanum, is almost inseparably united with the perosteum and perichondrium, over which it lies. It belongs, therefore, to the class of fibro-mucous membranes; and it is highly vascular. Named the pituitary membrane, it is continuous with the skin, through the anterior openings of the nose; with the mucous membrane of the pharynx, through the posterior apertures of the nasal fossæ; with the conjunctiva, through the nasal duct and lachrymal canaliculi; and with the lining membrane of the several sinuses which communicate with the nasal fossæ. The pituitary membrane, however, varies much in thickness, vascularity, and general appearance in these different parts. It is thickest and most vascular over the turbinate bones (particularly the inferior), from the most dependent parts of which it forms, in front and behind, projections, which increase the surface, and make the turbinate bones appear, in the recent state, longer and more prominent than they are in the skeleton. On the

Pituitary membrane

is fibro-mucous and vascular.

Continuous with other mucous membranes.

Is not uniform in thickness and vascularity.

septum narium, the pituitary membrane is still very thick and spongy; but in the intervals between the turbinate bones, and over the floor of the nasal fossæ, it is considerably thinner.

Lining
membrane
of sinuses is
thin.

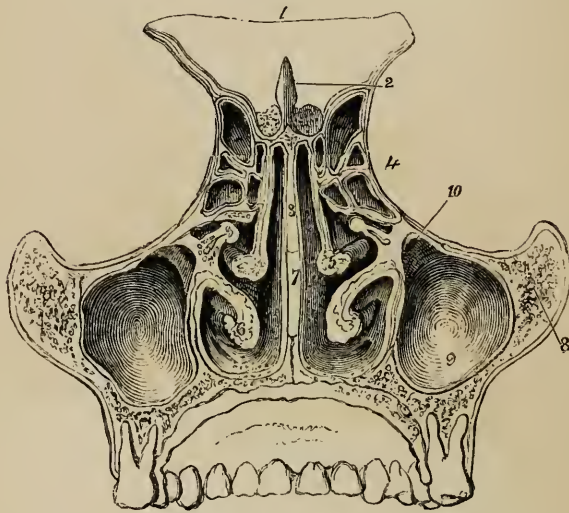
The mucous lining membrane of the antrum of Highmore, of the frontal sinuses, and of the ethmoidal and sphenoidal cells, contrasts strongly with that which occupies the nasal fossæ, being very thin and pale, and wearing the appearance more of a serous than of a mucous membrane.

Epithe-
lium.

The lining membrane of the nose is defended by a layer of epithelium, which, in the fore part of the cavity, is laminated; but which in the rest of the nasal fossæ, and in the cavities which communicate with them, is covered with vibratile cilia. This membrane likewise contains a nearly continuous layer of mucous glands, the orifices of which are apparent on the surface, fig. 239. The glands are most numerous about the middle and fore part of the nasal fossæ, and are largest at the back of the septum, near the

Mucous
glands.

Fig. 238.*



floor of the nasal cavity. They are much smaller and less numerous in the membrane lining the several cavities, already mentioned, which communicate

* A view from behind of a transverse and vertical section of the nasal fossæ in the recent state, shewing the partition between them, the spongy bones on their outer side, the meatuses, and the cells or sinuses which communicate with these cavities.—1. Sphenoid bone. 2. Crista galli. 3. Central plate of ethmoid. 4. Ethmoid cells. 5. Middle spongy bone. 6. Lower spongy bone. 7. Vomer. 8. Malar bone. 9. Antrum of Highmore. 10. Opening from same into middle meatus.

with the nasal fossæ.—The vessels and nerves which ramify in the pituitary membrane will be presently described.

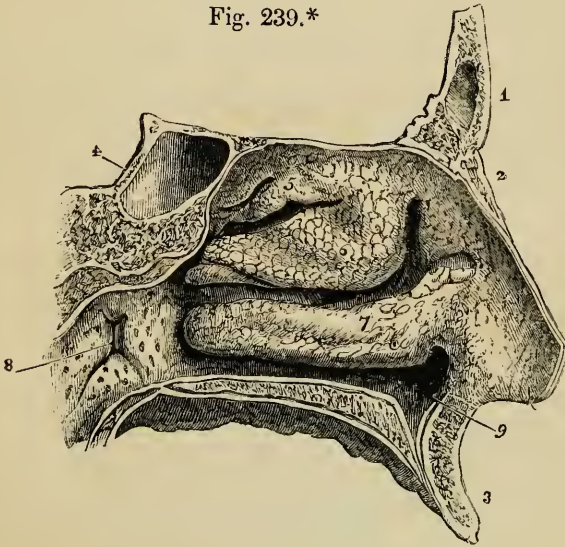
The effect of the pituitary membrane on the form and dimensions of the nasal fossæ, before mentioned, as causing the difference which exists between those cavities in the skeleton and in the recent state, will now be further adverted to.

Pituitary membrane changes dimensions of fossæ,

First : owing to the thickness of the membrane in question, (which not only lines the walls of the fossæ, but covers the spongy bones on both sides,) the nasal cavity is much narrower in the recent state. (See fig. 238.) Secondly, in consequence of the prolongations of membrane, already alluded to, on the free margins of the turbinate bones, these bones, and more particularly the lower pair, appear in the recent state to be both more prominent and longer in the direction from before backwards, than in the dried skull. Thirdly, by the arrangement of the mucous membrane round the orifices which open into the nasal fossæ, some of the foramina in the bones are narrowed or completely closed.

and of the openings fr. sinuses.

Fig. 239.*



In the *upper meatus*, the small orifices which lead into the posterior ethmoidal cells, and through them into the sphenoidal sinuses, are merely lined by a prolongation of the thin mucous membrane which continues into these

Openings fr. poster. ethmoidal

* The outer wall of the left nasal fossa covered with the pituitary membrane.—1. Frontal bone. 2. Nasal bone. 3. Superior maxillary. 4. Sphenoid. 5. The upper spongy bone. 6. Middle spongy bone. 7. Lower spongy bone.—The three meatuses of the nose are seen below the three last-named bones.—8. The opening of the Eustachian tube.

cells and sphenoidal sinuses. Spheno-pal. foramen.

cavities ; but the spheno-palatine foramen (of the dried bones) is covered over by the Schneiderian membrane, so that no such opening exists in the recent nasal fossæ.

Openings fr. anter. ethmoid. cells, frontl. sinus and antrum.

In the *middle meatus*, the aperture of the infundibulum, nearly hidden by an over-hanging fold of membrane, leads directly into the anterior ethmoidal cells, and through them into the frontal sinus. Below and behind this, the passage into the antrum of Highmore is surrounded by a circular fold of the pituitary membrane, (sometimes prominent and even slightly valvular,) which leaves a nearly circular aperture much smaller than the foramen in the bony meatus.

Nasal duct.

In the *lower meatus*, the inferior orifice of the nasal duct is defended by two nearly vertical folds of membrane, between which is a narrow slit ; and the folds are often adapted so accurately together as to prevent even air from passing back from the cavity of the nose to the nasal sac. The anterior palatine foramina, (described at p. 63,) are in the recent state generally closed by the Schneiderian membrane. Sometimes, however, a narrow funnel-shaped tube of mucous membrane descends for a little distance into the canals, but is closed before it reaches the roof of the palate.* Lastly, the apertures in the cribriform plate of the ethmoid bone are likewise covered over by membrane.

Anter. pal. foramina.

6. THE BLOOD-VESSELS OF THE NOSE.

The nose receives numerous branches from the facial, internal maxillary, and ophthalmic arteries, which anastomose very freely with each other. Its veins join the facial and ophthalmic trunks.

Arteries of nose on outer side and in cavities.

Arteries.—On the outer surface of the nose, the *alæ* and *columna nasi* are supplied by the coronary artery of the upper lip and the lateral nasal,—both branches of the facial artery (see p. 479). The sides and upper part of the nose receive branches from the lateral nasal (just mentioned), the nasal branch of the ophthalmic artery, which emerges above the *tendo tarsi* (p. 494), and from the infra-orbital artery. The ethmoidal cells, frontal sinuses, and roof of the nasal cavity receive their blood from the anterior and posterior ethmoidal branches of the ophthalmic artery (p. 494). The vascular membrane over the spongy bones and meatus of the nose derives its chief supply from the spheno-palatine branches of the internal maxillary artery (p. 488) ; and the alveolar artery, from the same trunk, sends twigs into the antrum of Highmore. The chief artery of the septum springs also from the spheno-palatine, and anastomoses in the anterior palatine canal with the terminal

* Vesalius, Stenson, and Santorini believed that the tube of membrane, above alluded to, opens generally into the roof of the mouth by a little aperture close behind the interval between the central incisor teeth. Haller, Scarpa, and, more recently, Jacobson, find that in man it is usually closed, and often difficult of detection. (See Cuvier's Report on a Paper by Jacobson. "Annales du Muséum d'Hist. Naturelle ;" Paris, 1811 ; vol. xviii. p. 412.)

branch of the descending palatine artery (p. 487), which runs from the soft palate into the nose.

Veins.—From the outer surface of the nose the blood is returned principally by radicles of the facial vein. Within the cavity of the organ, the veins, which are very much larger than the arteries, form a plexus between the mucous and fibrous layers of the pituitary membrane, particularly over the spongy bones and the septum. Some of the largest of these vessels make their exit through the spheno-palatine foramen, and, by means of the alveolar branch, join the facial vein. Others, from the roof of the nasal fossæ, ethmoidal cells and frontal sinuses (ethmoidal veins), enter the orbit, and join the ophthalmic vein. The veins of the nose communicate freely with the veins within the cavity of the skull through the foramina in the cribriform plate of the ethmoid bone.

Veins of nose.

7. THE NERVES OF THE NOSE.

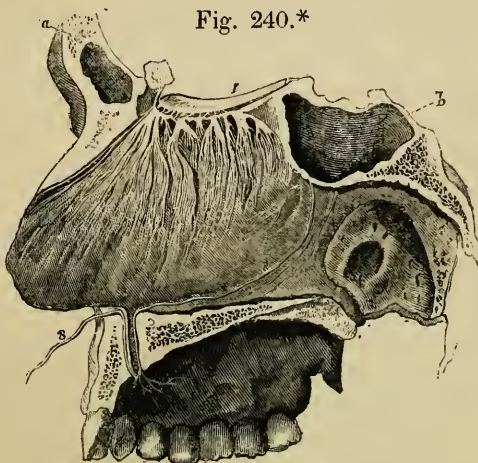
The nerves of the nose, like the vessels, are numerous ; the largest and most important being that which endows it with the power of receiving the impressions of smell.

Several nerves.

OLFACTORY NERVE.

The origin of this nerve, the passage of its branches through the cribriform plate of the ethmoid bone, and the arrange-

Olfactory.



ment of these branches after they enter, and begin to divide in, the cavity of the nose, have been already described (ante,

* The nerves of the septum narium on the left side. (From Scarpa.)—*a.* Frontal bone. *b.* Sphenoid. 1. The bulb of the olfactory nerve. 8. Nasopalatine nerve.

pp. 745 and 768). The general distribution of the outer and inner set of branches is nearly similar. At first, lodged in grooves on the surface of the bone, the nerves enter obliquely the substance of the Schneiderian membrane, so as to get between the mucous and fibrous layers. Here they soon divide into brush-like and flattened tufts of filaments, which, spreading out laterally, and communicating freely with similar branches on either side, form a fine and close network, with long and narrow intervals between the points of junction. Whilst thus dividing, the nerves are enveloped in sheaths of dura mater, prolonged from the foramina in the ethmoid bone, which makes them much firmer than where they are connected with the olfactory bulb.

The nerves of the septum, fig. 240, are rather larger than those of the outer wall of the nasal fossæ; as they descend, they become very indistinct, and are not visible on the lower fourth of the septum. The nerves of the outer wall, fig. 188, are divided into two groups;—the posterior branches are distributed over the surface of the upper spongy bone, and the anterior branches descend over the middle spongy bone, but are then too small to be traced even round the free margin of this bone. No branch of the olfactory nerve has been found in the mucous membrane, over the lower spongy bones or the middle and lower meatus.

Branches in the substance of pituitary membrane.

The nerves ramify only in nasal fossæ, and do not reach the lower part of these.

Other nerves from portio dura, fifth pair, and Meckel's ganglion.

The smaller nerves of the nose have been already fully described, and will, therefore, here be merely enumerated and referred to. On the outer surface of the nose are distributed branches of the facial and infra-orbital nerves (p. 781), the infra-trochlear nerve, and a twig of the nasal branch of the ophthalmic (p. 777). To the upper and anterior part of the septum and outer wall of the nasal fossæ are given other branches of the nasal division of the ophthalmic nerve. To the upper and back part of the septum, and to the upper spongy bones, are distributed nerves derived from the vidian nerve (p. 785), and from the spheno-palatine ganglion (p. 784). The middle of the septum receives the naso-palatine nerve (fig. 240), as it courses to the anterior palatine foramen. The middle and lower spongy bones are supplied by offsets from the larger palatine branch of the spheno-palatine ganglion (fig. 188); and lastly, the lower meatus and the lower spongy bone are further furnished with little twigs from the anterior dental nerve, a branch of the upper maxillary (p. 781).

ORGANS OF DIGESTION.

THE *digestive apparatus* includes that portion of the organs of assimilation within which the food is received and partially converted into chyle, and from which, after the chyle has been absorbed, the residue, or excrement is expelled. It consists of a main or primary part named the *alimentary canal*, and of certain *accessory organs*.

Digestive organs consist of

The alimentary canal is a long membranous tube, commencing at the mouth and terminating at the anus, composed of certain tunics or coats, and lined by a continuous mucous membrane from one end to the other. Its average length is about thirty feet, being about five or six times the length of the body. The upper part of it is placed beneath the base of the skull, the succeeding portion is situated within the thorax, and the remainder is contained within the cavity of the abdomen. In these several situations, its form, dimensions, and connexions, its structure and its functions, are so modified, that certain natural subdivisions of it, bearing different names, have been recognised by all anatomists.

the alimentary canal,

It may be considered as composed of two parts; one situated above the diaphragm, and the other below that muscular partition, and therefore within the abdomen. The first division consists of the organs of mastication, insalivation, and deglutition; and comprises the *mouth*, the *pharynx*, and the *œsophagus* or gullet. The second division consists of the organs of digestion properly so called, and of those of defæcation; viz. the *stomach*, the *small intestine*, and the *great intestine*.

composed of several parts,

The accessory parts are, chiefly glandular organs, which pour their secretions into it at different points. They consist of the *salivary glands* (named the *parotid*, *submaxillary*, and *sublingual*;) the *liver* and *pancreas*. Besides these large glandular organs, a multitude of small glands, compound, follicular or tubular, are collected together at certain points, or scattered over

and of accessory organs.

large portions of the inner surface of the alimentary canal: these will be described with the mucous membrane of each part. The remaining accessory organs are the *teeth*, the *jaws*, the *tongue*, and the *spleen*.

THE MOUTH.

- The mouth. The *mouth* (fig. 258) is the space included between the lips and the throat or fauces. It is bounded in front by the lips *dd*, at each side by the cheeks, below by the tongue *b*, and above by the hard and soft palate, *a* and *c*; whilst behind it communicates with the pharynx at 3, through an opening called the *fauces* (isthmus faucium). The cavity of the mouth, with its contained parts, (excepting, of course, the teeth) is lined throughout by a mucous membrane, which is of a pink rosy hue during life, but pale-grey after death, and which presents peculiarities of surface and structure to be noticed hereafter.
- Fauces, or isthmus faucium. The lips: The *lips*, which bound the anterior aperture or *rima* of the mouth, are composed of an external layer of skin, and of an internal layer of mucous membrane; between which are found, besides muscles, vessels and nerves, already fully described in other parts of this work, some cellular tissue, fat, and numerous small glands. The principal muscle is the orbicularis oris; but several others are inserted into this one at various points, and enter more or less into the formation of the lips. The free border of the lips is protected by a dry umucous membrane, which becomes continuous with the skin, is covered with numerous minute papillæ, and is highly sensitive. On the inner surface of each lip, the mucous membrane forms a fold in the middle line, connecting the lip with the gums of the corresponding jaw. These are the *fræna* or *frænula* of the lips: that of the upper lip is much the larger of the two.
- their papillæ, fræna, and glands. Numerous small glands, called *labial glands*, are found beneath the mucous membrane of the lips, around the opening of the mouth. They are situated between the mucous membrane and the orbicularis oris muscle. They are compound glands of a rounded form, the largest of them not exceeding the size of a split pea; and they open into the mouth by distinct orifices.
- The cheeks: The *cheeks*, like the lips, consist of a cutaneous, a muscular, and a mucous layer, besides fat, cellular tissue, glands, vessels,

and nerves. The principal muscle of the cheek is the buccinator, but the two zygomatici, the masseter, the orbicularis palpebrarum, and the platysma in part enter into its formation. There is a remarkable accumulation of fat between the masseter and buccinator muscles. Between the last-named muscle and the mucous membrane are the *buccal* glands, similar to the labial glands, but smaller. Two or three glands, larger than the rest, found between the masseter and buccinator muscles, and opening by separate ducts near the last molar tooth, are called the *molar* glands.

their
muscles,

and glands,
buccal and
molar.

The duct of the parotid gland also opens upon the inner surface of the cheek, opposite to the second upper molar tooth.

Immediately behind the lips and cheek, are the *dental arches*, consisting of the teeth, gums, and maxillæ. The jaw-bones, the articulation and movements of the lower maxilla, and the muscles used in mastication are elsewhere described. The *gums* (gingivæ), which scarcely require a notice, are composed of a dense fibrous tissue, connected very closely with the periosteum of the alveolar processes, and covered by a red and not very sensitive mucous membrane, which is smooth in its general surface, but immediately around the teeth is beset with fine papillæ.

Dental
arches.

Gums.

THE TEETH.

In the human subject, as in mammalia generally, two sets of teeth make their appearance in the course of life, of which the first constitutes the *temporary*, *deciduous*, or *milk* teeth, whilst the second is named the *permanent* set. The temporary teeth are twenty in number, ten in each jaw, and the permanent set consists of thirty-two, sixteen above and sixteen below. Deficiencies in the number of the teeth sometimes occur, but much more frequently the number is increased by one or more supernumerary teeth. These are usually small, and provided with only a single fang; and, though generally distinct, they are sometimes attached to other teeth: they occur more frequently near the front than the hinder teeth, and are more often met with in the upper than in the lower jaw.

Human
teeth: two
sets.

Their num-
ber.

Super-
numerary
teeth.

General Characters of the Teeth.—Though the teeth are distinguished by peculiarities of external configuration into several classes, they have all certain characters in common. Thus,

General
characters.

The parts of a tooth.

each tooth is described as consisting of three portions, viz. one which projects above the gums and is named the body or *crown*,—another which is lodged in the alveolus or socket, and constitutes the root or *fang*,—and a third, intermediate between the other two, and from being more or less constricted named the cervix or *neck*. The size and form of each of these parts vary in the different kinds of teeth.

How fixed in jaw.

The roots of all the teeth are implanted into the alveoli of the jaws, and are accurately fitted to them, by a peculiar mode of union, called gomphosis, (*γομφος*, a nail). Each alveolus is lined by the periosteum, which is also reflected on to the contained fang, and invests it as high as the cervix. This dental periosteum, sometimes named the periodontal membrane, is blended with the dense and slightly sensitive tissue of the gums, which closely surrounds the neck of the tooth. The roots of all the teeth taper from the cervix to the point, and this form, together with the accurate adjustment to the alveolus, has the effect of distributing the pressure during use, over the whole socket, and of preventing its undue action on the apex of the fang through which the blood-vessels and nerves enter.

Periodontal membrane.

Names of teeth of each set.

The thirty-two permanent teeth consist of four incisors, two canines, four bicuspid, and six molars, in each jaw. The twenty temporary teeth are four incisors, two canines, and four molars, above and below. There are no bicuspid among the temporary teeth, but the eight deciduous molars are succeeded by the eight bicuspid of the permanent set. The relative position and arrangement of the different kinds of teeth in the jaws may be shewn by the following scheme, which also exhibits the relation between the two sets in these respects :

Comparison of them.

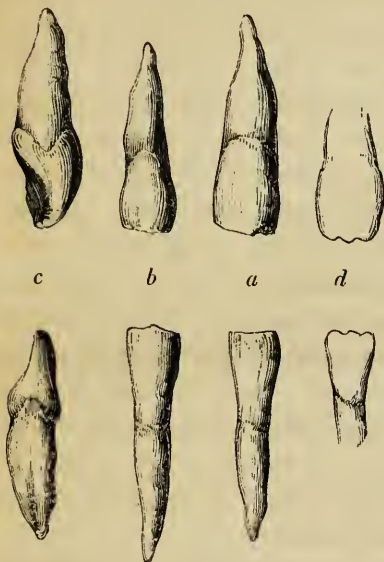
		<small>MO. CA. IN. CA. MO.</small>	
Temporary teeth.....	{	Upper	2 1 4 1 2 = 10
	}	Lower	2 1 4 1 2 = 10
<hr style="width: 50%; margin: 0 auto;"/>			
		<small>MO. BI. CA. IN. CA. BI. MO.</small>	
Permanent teeth.....	{	Upper	3 2 1 4 1 2 3 = 16
	}	Lower	3 2 1 4 1 2 3 = 16

Special characters.
Incisors: eight.
Crowns;

Special Characters of the Permanent Teeth.—The *incisors*, (fig. 241, a, b,) eight in number, are the four front teeth in each jaw, and are so named from being adapted for cutting or dividing the soft substances used as food. Their *crowns* are chisel-

shaped, and have a sharp horizontal cutting edge, which, by continued use, is bevelled off behind in the upper teeth, but, in the lower teeth, is worn down in front. Before being sub-

Fig 241.*



jected to wear, the horizontal edge of the incisor teeth is serrated or marked by three small prominent points, (*d*.) The anterior surface of the crown is slightly convex, and the posterior concave, (*c*). The *fang* is long, single, conical, and compressed at the sides, where it sometimes though rarely presents a slight longitudinal furrow.

fangs ;

The lower incisor teeth are placed vertically in the jaw, but the upper teeth are directed obliquely forwards. The upper incisors are, on the whole, larger than the lower

differences among them.

ones. In the upper jaw the central incisors are larger than the lateral, whilst the reverse is the case in the lower jaw, the central incisors being there the smaller, and being, moreover, the smallest of all the incisor teeth.

The *canine* teeth (*canini*, *cuspidati*), four in number, (fig. 242,) are placed one on each side, above and below, immediately next to the lateral incisors. They are larger and stronger than the incisor teeth. The *crown* is thick and conical, convex in front and hollowed behind, (*b*,) and may be compared to that of a large incisor tooth the angles of which have been filed away, so as to leave a single central point or *cuspidate*, (*a*,) whence the name *cuspidate* applied to these teeth. The point always becomes worn down by use. The *fang* of the canine teeth is single, conical, and compressed at the sides ;

Canine : four.

Crown ;

fang :

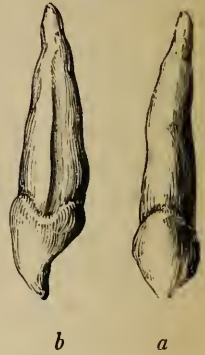
* Incisor teeth of the right side of the upper and lower jaws.—*a*. The middle incisors, upper and lower, seen in front. *b*. The lateral incisors, ditto. *c*. The middle incisors seen on the side, to shew the chisel shape of the crown. The fang of the lower tooth is marked by a slight groove. *d* shews the indented edge of the incisors before they are subjected to wear.

it is longer than the fangs of any of the other teeth, and is so large as to cause a corresponding prominence of the alveolar arch: on the sides (*b*) it is marked by a groove, an indication, as it were, of the cleft or division which appears in the teeth next following.

differences
among
them.

The upper canines, popularly called the *eye-teeth*, are larger than the lower, and in consequence of this, as well as of the greater width of the upper range of incisors, they are thrown a little farther outwards than the lower canine teeth. In the dog-tribe, and in the carnivora generally, these teeth acquire a great size, and are fitted for seizing and killing prey, and for gnawing and tearing it when used as food.

Fig. 242.*



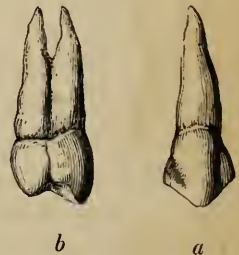
Bicuspid:
eight.

The *bicuspid*s (*bicuspidati*), (fig. 243,) also called the small, false, or premolars, are four in each jaw; they are shorter and smaller than the canines, next to which they come, two on each side. The *crown* is compressed

Fig. 243.†

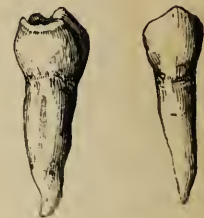
Crown ;

before and behind, its long diameter being across the jaw; it is convex, not only on its outer or labial surface, (*a*), like the preceding teeth, but on its inner surface also, which rises vertically from the gum, (*b*;) its free surface, which is therefore broader than that of an incisor or canine tooth, is surmounted by two pointed tubercles or cusps, of which the external one is larger and higher than the other. The



fang:

fang is also flattened and is deeply grooved in all cases, shewing a tendency to become double. The apex of the fang is generally bifid, and in the second upper bicuspid, the root is



* Canine tooth of the upper jaw, or eye-tooth.—*a*. Seen in front. *b*. Lateral view; shewing the long fang, grooved on the side.

† Bicuspid tooth of the upper and the lower jaw.—*a*. Front view. *b*. Lateral view, shewing the two cusps of the crown and the groove on the side of the fang, which has become cleft in the upper tooth.

often cleft for a considerable distance, (b.) The upper bicuspids are larger and more characteristic in form than the lower ones. Sometimes the first lower bicuspid has only one tubercle distinctly marked, *i. e.* the external, and in that case approaches in figure to a canine tooth.

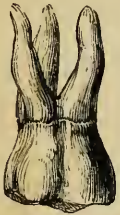differences among them.

The *molar* teeth, (fig. 244,) true or large molars, or multicuspid teeth, are twelve in number, and are arranged behind the bicuspid teeth, three on each side, above and below. They are distinguished by the large size of the crown, and by the great width of its grinding surface. The first molar is the largest, whilst the third is the smallest, in each range, so that in point of size a gradation is observed in these teeth. The last molar in each range, owing to its late appearance through the gums, is called the *wisdom-tooth*, *dens sapientiae*. The *crowns* of the molar teeth are low and cuboid in their general form. Their outer and inner surfaces are convex, whilst they are rather flattened before and behind. The grinding surface is nearly square in the lower teeth, and rhomboidal, in the upper, the corners being rounded off: it is not smooth, but is provided with four or five trihedral tubercles or cusps (whence the name of multicuspidati), separated from each other by a crucial depression. The upper molars have four cusps situated at the angles of the masticating surface, (see figure:) of these the internal and anterior cusp is the largest, and is frequently connected with the posterior external cusp by a low oblique ridge. In the upper wisdom teeth, the two internal tubercles are blended together. The crowns of the lower molars, which are larger than those above, have five cusps, (see figure,) the additional one being placed between the two posterior cusps, and rather to the outer side: this is especially evident in the lower wisdom teeth, in which the crown is smaller and rounder than in the others. The *fangs* of

Molars : twelve.

Dens sapientiae.
Crowns :

Fig. 244.*



of upper, four cusps ;

of lower, five cusps.

Fangs :

* First molar tooth of the upper and the lower jaw. The crown of the upper molar has four cusps, and its root three fangs. The crown of the lower has five cusps, and its root two fangs.

of upper,
three ;

all the molar teeth are multiple. In the two anterior molars of the upper jaw, they are three in number, viz., two placed externally, which are short, divergent, and turned towards the antrum of the superior maxilla; and a third or internal fang, which is larger and longer, and is directed towards the palate. This third fang is often slightly grooved, especially when the two internal cusps are very distinct, and sometimes it is divided into two. The two anterior molars of the lower jaw have each two fangs, one anterior, the other posterior, which are broad, compressed and grooved on the faces that are turned towards each other: they have an inclination or curve backwards in the jaw, and are either slightly divergent or are nearly in contact with each other; sometimes one or both of them is divided into two smaller fangs. In the wisdom-teeth of both jaws the fangs are generally connate or collected into a single irregular conical mass, which sometimes shews traces of a subdivision into two fangs in the lower teeth, and into three in the upper teeth: these connate fangs are either directed backwards in the substance of the jaw, or are curved or bent irregularly.

of lower,
two ;

of wisdom
teeth,
connate.

The bicuspid and the molar teeth, from the breadth of their crowns, are fitted for bruising, crushing, and grinding the food in mastication.

Dental arch
entire in
man :
upper arch
larger.

The entire set of teeth in each jaw form an even curve or arch, which is not broken by any intervals, as is the case in the dental apparatus of many animals, even in the *Quadrupana*. The upper dental arch is rather larger than the lower one, so that the teeth of the upper jaw slightly overhang the lower set. This is owing principally to the fact that the lower teeth are placed either vertically, as in front, or are set so as to look somewhat inwards, as is seen behind and at the sides, whilst the corresponding teeth of the upper jaw have an inclination forwards in front and outwards behind. The crowns of the whole series of teeth in man are remarkably even in height, in which, however, they diminish very slightly from the incisors backwards to the wisdom-teeth. In consequence of the large proportionate size of the upper central incisors, the other teeth of the upper jaw are thrown somewhat backwards, so that in closure of the jaws they come into contact partly with their corresponding lower teeth and partly with the lower teeth next following. Since, however, the upper dental

Crowns
even.

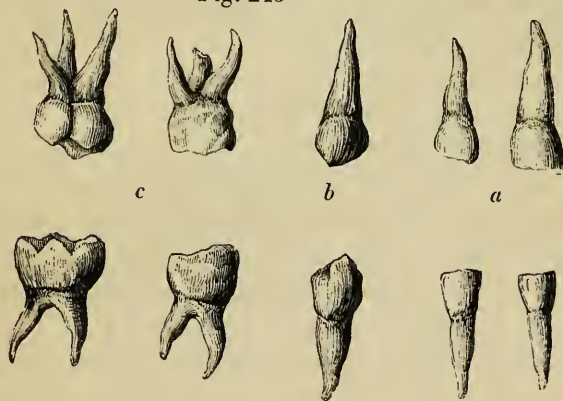
Each upper
tooth
touches two
lower.

arch is rather larger, and the crowns of the molars, especially the wisdom-teeth, above, are smaller than those below, the dental ranges terminate behind at the same point in both jaws.

The *Milk Teeth*, (fig. 245.) The forms of the different kinds of the temporary teeth resemble those of the permanent set; but they are all smaller. The temporary molar teeth (c) present some

Milk teeth resemble permanent.

Fig. 245*



peculiarities. The hinder one of the two is always the larger; it is the largest of all the milk teeth, and is larger even than the second permanent bicuspid, by which it is afterwards succeeded. The *crown* of the first upper milk molar has only three cusps, two external and one internal; that of the second has four distinct cusps. The first lower temporary molar has four cusps, and the second five, of which in the latter case three are external. The *fangs* of the temporary molars resemble those of the permanent set, but they are smaller, and are more divergent from the neck of the tooth.

Peculiarities of milk molars.

Structure.—On making a section of a tooth, the hard substance of which it is composed is found to be hollow in the centre, (fig. 246.) The form of the cavity bears a general resemblance to that of the tooth itself; it occupies the interior of the crown, is widest opposite to the neck, and extends like a fine canal down each fang, at the point of which it opens by a small orifice. In the crown of the incisor teeth the cavity is pro-

Structure.

Central cavity,

* Milk teeth of the right side of the upper and lower jaws.—a. The incisors. b. The canines. c. The molar teeth; the upper having three fangs, and the lower only two.

longed into two fine linear canals, which proceed one to each corner of the crown ; in the bicuspid and molar teeth it advances a short distance into each cusp.

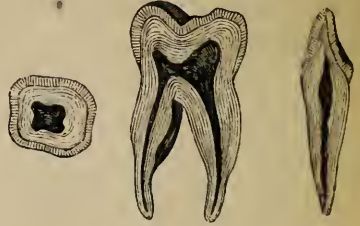In the case of a root formed by the blending of two or more fangs, as occurs occasionally in the wisdom-teeth, each division has a separate canal prolonged down to its apex. The central cavity of a tooth is called the *pulp-cavity*, because it is occupied and accurately filled by a

called
pulp cavity.

Dental
pulp.

soft, highly vascular, and sensitive substance, called the *dental pulp*. This pulp consists of cellular filaments, amongst which numerous nuclei are rendered visible by the action of acetic acid. It is well supplied with vessels and nerves, which are derived from the internal maxillary artery and the fifth pair, and which enter the cavity through the small aperture at the point of each fang : according to Valentin and Hannover, the terminations of the nervous fibres are looped.

Fig. 246.*



Solid part
of tooth
consists of
three sub-
stances.

The solid portion of the tooth is composed of three distinct substances, viz., the proper dental substance, *ivory* or *dentine*, (fig. 247, ¹), the *enamel* (⁴), and the *cement* or *crusta petrosa* (³). The dentine constitutes by far the larger part of the hard substance of a tooth ; the enamel is found only upon the exposed part or crown ; and the cement covers with a thin layer the surface of the implanted portion or fang.

Dentine,
ivory, or
tooth sub-
stance is
the chief
part.

A. The *ivory, tooth substance, or dentine*, (¹, Owen,) forming the principal mass or foundation of the body and root of a tooth, gives to both of these parts their general form, and immediately encloses the central cavity (²). It resembles very compact bone in its general aspect and chemical relations, but is not identical with it in structure, or in the exact proportions of its earthy and animal constituents.

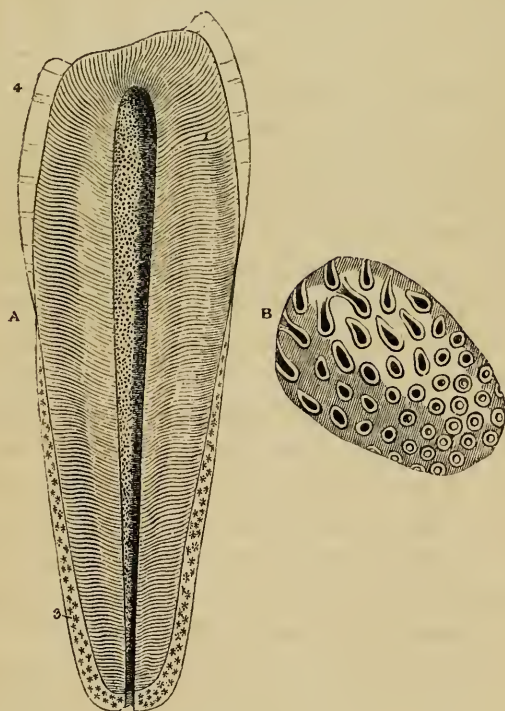
Its chemical
composition.

According to the analyses of Berzelius and Bibra, the dentine of human teeth consists of 28 parts of animal, and 72 of earthy

* Longitudinal section of an incisor and a molar tooth, with a transverse section of the latter. These shew the pulp cavity, with its extension into the fangs ; also the relative position and extent of the dentine or ivory, with its covering of enamel on the crown.

matter. The former we have found to be resolvable into gelatin by boiling, as is generally believed, although Bibra describes it as similar to chondrin, mixed with a little fat. The latter is composed of phosphate of lime with traces of fluoride of calcium, the proportion being, according to Bibra, 66·7 pr. ct., carbonate of lime, 3·3, phosphate of magnesia and other salts, 1·8. Berzelius found 5·3 parts of carbonate of lime.

Fig. 247.*



Though appearing to the naked eye to have a compact structure, the dentine, when examined under the microscope, is seen

* After Retzius.—A. Magnified representation, or rather diagram, of a bicuspid tooth divided longitudinally. 1. The ivory or dentine, shewing the direction and primary curves of the dental tubuli. 2. The pulp cavity, shewing the orifices of the tubuli. 3. The crusta petrosa or cement covering the fang as high as the border of the enamel at the neck. The stars indicate that it contains lacunæ like those of bone. 4. The enamel resting on the dentine. B. Section of the dentine made across the tubuli, highly magnified. The cavity or lumen of the tubes, their walls, and the inter-tubular substance are seen. On the left hand, the tubuli are cut obliquely.

Is composed of tubes and an inter-tubular substance. The tubuli: to consist of an immense number of very fine tubes, having distinct parietes, and passing very close to each other, through a hard intermediate substance, named the intertubular tissue. These tubes, called *dental tubuli*, were long since discovered and described by Leeuwenhoek, but his observations were disregarded until the tubular structure was again brought to light through the modern researches of Purkinjé and Retzius, by whom, and by others, it has now been very minutely examined and described. The tubules of the dentine open at their inner end into the pulp-cavity, appearing as minute orifices on its sides, (2.) From thence they pass in a radiated manner through every part of the ivory towards its periphery. In the upper portion of the crown they have a vertical direction; but towards the sides, and in the neck and root, they become gradually oblique, then horizontal, and are finally even inclined downwards towards the point of the fang. The course of the tubules is not straight, but each describes, in passing from the central to the peripheral part of the dentine, two or three gentle curves (*primary* curvatures, Owen), and is besides bent throughout its whole length into numerous fine undulations, which follow closely upon one another; these are the *secondary* curvatures. In adjacent tubules both kinds of curvatures so far correspond that the tubes themselves are nearly parallel, being only slightly divergent from each other; and as they divide several times dichotomously, and at first without being much diminished in size, they continue to occupy the substance of the dentine with nearly equidistant tubes, and thus produce, when seen in fine sections of the tooth made parallel to their course, a striated appearance, as if the dentine were made up of fine parallel fibres. The concurrence of many of these parallel curvatures of the dental tubuli produces, by the manner in which they reflect the light, an appearance of concentric lines in the dentine, see figs. 246, 247, which may be well seen with a low magnifying power. The average diameter of each tubule near its inner and larger end is $\frac{1}{4500}$ of an inch, and the distance between adjacent tubules is about two or three times their width. (Retzius.) From their sides numerous immeasurably fine branches are given off, which penetrate the hard intertubular substance, where they either anastomose or terminate abruptly, or, according to some, end in very minute

cells. These lateral ramuscles are said to be more abundant in the fang. Near the periphery of the ivory they are very numerous, and, together with the main tubules themselves, which there, by rapid division and subdivision also become very fine, terminate by joining together in loops, or end in little dilatations, from which other ramuli are given off, or in minute cells. They are also occasionally seen to pass on into the cement which covers the fang, and to communicate with the small ramified canals of the characteristic lacunæ found in that osseous layer. The minute cells belonging to the intertubular substance of the human tooth are very few in number and small, and hence not conspicuous, but they are larger and more numerous in the tooth of the horse. They are most distinct in the outer layer of the dentine, which is immediately beneath the enamel or cement, and is named the *granular* layer by Purkinjé. The surface of the dentine where it is in contact with the enamel is marked by undulating grooves and ridges, and also by numerous minute hexagonal depressions, to which the microscopic fibres of the enamel are accurately adapted.

The dental tubules, when highly magnified, appear like dark lines against transmitted light, but are white when seen upon a black ground. This is owing either to their containing an opaque granular calcareous deposit, as some suppose, or merely to a certain degree of opacity of their parietes. Their tubular character is proved by the fact that ink, and other fluids, together with minute bubbles of air, have been seen to pass along them. Their walls are comparatively thick, and are readily distinguishable from the intertubular substance, as may be seen in a transverse section, similar to that figured by Retzius, fig. 247, B. In the temporary, and sometimes even in the permanent teeth, the tubules are constricted at short intervals, so as to present a moniliform character. (Nasmyth, Owen, Tomes.)

The *intertubular substance* is translucent, and finely granular (Tomes); it contains the greater part of the earthy substance of the dentine. The animal basis which remains after this has been removed by an acid, is described by Henlé as separable into bundles of pale flattened granular fibres running in a direction parallel with the tubes, and by Nasmyth as consisting of brick-shaped cells, built up, as it were, around the tubules, which, we may remark, are by this observer regarded as solid

their ramus-
culi, and

termina-
tions.

Cells of
dentine ;

very incon-
spicuous in
human
tooth.

Granular
layer of
dentine.

Ridges and
pits on
surface.

Nature of
tubuli ;

their cavi-
ties and
parietes.

Inter-tubu-
lar sub-
stance ;
its earthy
and its ani-
mal matter ;
its structure
doubtful :

in cachalot
is divisible
into laminæ,
like those
of bone.

The enamel
is hardest
part of
tooth.

Its chemical
composition:

nearly all
earthy
matter ;

consists
of fibres or
prisms ;

their course ;

curvatures.

Fissures in
enamel ;

fibres. Neither of these statements, however, is easily reconcilable with what we have observed in the softened teeth of the cachalot or sperm whale ; for in these the animal substance can be readily torn into fine lamellæ, disposed parallelly with the internal surface of the pulp cavity, and therefore across the direction of the tubules. In these lamellæ the sections of the tubules appear as round or oval apertures, the lamellæ having the same relation to the tubules as those of true bone to the canaliculi (p. cxlii.)

B. The *enamel* (fig. 247, ⁴) is that hard white covering which encrusts and protects the exposed portion or crown of a tooth. It is the hardest of all the dental tissues, but it becomes worn down by protracted use. It is thickest on the grinding surface and cutting edges of the teeth, and becomes gradually thinner towards the neck, where it ceases. Its extent and thickness are readily seen on charring the tooth, by which the dentine becomes blackened, whilst the enamel, owing to the very small quantity of animal matter in its composition, remains white. According to Bibra, it contains of earthy constituents 96·5 per cent., viz., phosphate of lime with traces of fluoride of calcium 89·8, carbonate of lime 4·4, phosphate of magnesia and other salts 1·3 ; and has only 3·5 per cent. of animal matter. Berzelius, however, gives the proportion of carbonate of lime as 8, and of animal matter as only 2 per cent.

The enamel (fig. 248, ⁴) is made up entirely of very hard and dense microscopic fibres or prisms, composed almost wholly of earthy matter, arranged closely together, side by side, and set by one extremity upon the subjacent surface (⁶) of the dentine (¹.) On the summit of the coronal portion of the tooth, these enamel fibres are directed vertically, but on the sides they are nearly horizontal. As seen on a section they are disposed in gently waving lines, parallel with each other, but not so regular as the curvatures of the tubuli of the dentine, with which they have no agreement. The concurrence of these parallel curvatures produces, as in the case of the dentine, an appearance of concentric lines (⁵) in the enamel, which may be seen with a lens of low power. Minute fissures not unfrequently exist in the deep part of the enamel, which run between clusters of the fibres down to the surface of the dentine ; and other much larger and evident fissures are often

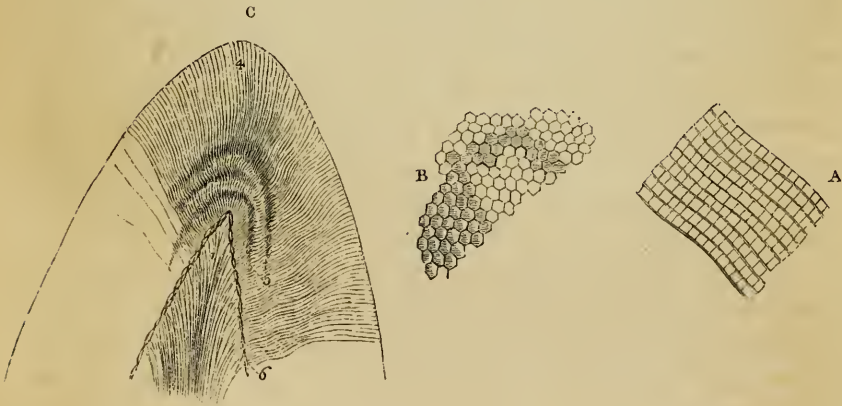
observed leading down from the depressions or crevices between the cusps of the molar and premolar teeth. The surface of the enamel, especially in the milk teeth, is marked by concentric ridges, which may be distinguished with a common magnifying glass, and which are probably occasioned by the ridges and furrows already described upon the coronal portion of the dentine.

surface
marked
with ridges.

The enamel fibres are described by Retzius as being solid hexagonal prisms, but by others they are said rather to be four-

Enamel
fibres, hex-
agonal ;

Fig. 248.*



sided. Their diameter varies slightly, and is ordinarily about $\frac{1}{500}$ of an inch. They are marked at small intervals by dark transverse lines, (fig. 248, A.) According to Mr. Tomes, the fibre is not in all cases solid, but has an extremely minute cavity in part or the whole of its length, which is best seen in newly developed enamel, but is also visible in adult teeth. Their inner ends are implanted, as it were, into the minute hexagonal depressions found on the surface of the dentine, ⁶, whilst the outer ends, somewhat larger in diameter, are free, and present,

their size,
striae, and
interior.

* After Retzius.—c. Portion of the crown of a growing incisor tooth, divided longitudinally and magnified, to shew the structure of the enamel. 1. The dentine, with its tubes. 4. The enamel, consisting of waved fibres. 5. Parallel curvatures of its fibres, giving rise to the appearance under a lower power of concentric lines parallel to the surface. 6. Pitted surface of the dentine on which the enamel fibres rest. B. Portion of the surface of the enamel, shewing the hexagonal ends of its fibres. A. Lateral view of enamel fibres, to shew their curves and the transverse structure upon them. A and B magnified 350 diameters.

when examined with a high magnifying power, a tessellated appearance, (B.)

Enamel
nearly
all dissolved
in acids ;

growing
enamel thus
broken up
into prisma-
tic cells.

On submitting the enamel to the action of dilute acids, it is almost entirely dissolved, and leaves scarcely any discernible traces of animal matter. Near the deep surface this is rather more abundant, according to the observations of Retzius, who conceived that it there aided in fixing the enamel fibres. By the aid of an acid, the enamel of newly formed or still growing teeth, may be broken up, and its structural elements more easily distinguished. The prisms are then found to have interposed between them a delicate membranous structure, representing, in fact, the walls of cells which have coalesced and formed moulds for the deposition of the calcareous matter. As this latter accumulates the membranous structure becomes almost or entirely obliterated, and the now earthy prisms are inseparably consolidated. The transverse striæ are considered by Retzius and others as the indication of the pre-existing walls of coalesced cells.

Cement, or
crusta
petrosa :
is a layer
of bone.

Coronal
cement, a
very thin
layer ;

accumulates
in old age ;

its struc-
ture, cells,
and canali-
culi ;

c. The third substance which enters into the formation of the teeth is the *crusta petrosa* or *cement*, (fig. 247, 3.) This is a layer of true bone, slightly modified in structure, which invests that part of the dentine which is not protected by the enamel. It covers the whole fang, towards the lower end of which it becomes gradually thicker, and is especially developed at the apex, and along the grooves of the compound fangs. Besides this it has been traced by Purkinjé, Nasmyth, and Owen, as a very thin layer, which, however, soon gets worn off, over the enamel upon the crown ; and in the compound teeth of many herbivorous animals, the existence of this coronal cement is evident enough. As life advances the cement is generally found to become thicker, especially near the apex of the fang, where it sometimes blocks up the orifice leading into the pulp-cavity.

The *crusta petrosa* contains cells and canaliculi resembling those of bone ; they are placed lengthwise around the fang, and give off minute radiated ramifications, which are often found to proceed from one side only of a cell, towards the *periodontal* surface (Tomcs). These cells have not been seen in the coronal cement of human teeth, but only in that of the implanted portion : in the deeper layers of the cement the fine canaliculi

sometimes anastomose with some of the terminal tubules of the subjacent dentine. Where the cement is very thick it may contain vascular canals, analogous to the Haversian canals of bone. On the deciduous teeth the cement is thinner and contains fewer cells. In chemical composition it resembles bone, and contains 30 per cent of animal matter. The cement is, according to some, extremely sensitive at the neck of the tooth, if it be exposed by retraction of the gum. By its connection with the surrounding membranous structures it contributes to fix the tooth in the socket. It is the seat of the bony growths or exostoses sometimes found upon the teeth.

its vascular
canals ;

its use.

D. It has been long observed that, after the age of twenty years or later, the central cavity of a tooth becomes gradually diminished in size, by the deposit of a hard substance on the inner surface of the dentine, whilst the pulp slowly shrinks or disappears. This additional substance, once considered to be an extension of the cement into the interior of the tooth, has been shewn to have a distinct structure, in part resembling dentine, and in part bone. It is the *horny substance* of Blumenbach, and is named *osteodentine* (Owen), and *secondary dentine* (Tomes). It is traversed by canals, which contain blood-vessels, and are surrounded by concentric lamellæ, like the Haversian canals of bone. From these canals, numerous tubules radiate in all directions, but have no calciferous cells connected with them ; moreover, the tubules are larger than those of bone, resembling, in this respect, and also in their mode of ramification, the tubes of the dentine. This newly added structure may or may not coalesce with the previously formed dentine ; it appears to be produced by a slow conversion of the dental pulp.

Pulp cavity
is filled up,
as life ad-
vances, by

osteoden-
tine ;

intermediate
in character
between
bone and
teeth.

DEVELOPMENT OF THE TEETH.

The development of the teeth includes a description of their origin and growth, as distinct organs,—of their order of eruption in two sets,—and also an account of the formation of their component tissues, the dentine, enamel, and cement.

Develop-
ment of
teeth

The recent observations of Arnold and Goodsir, made independently of each other, have given precision to our knowledge concerning the origin and mode of growth of the teeth, and

from mu-
cous mem-
brane.

Changes in
jaws.

Formation
of loculi ;

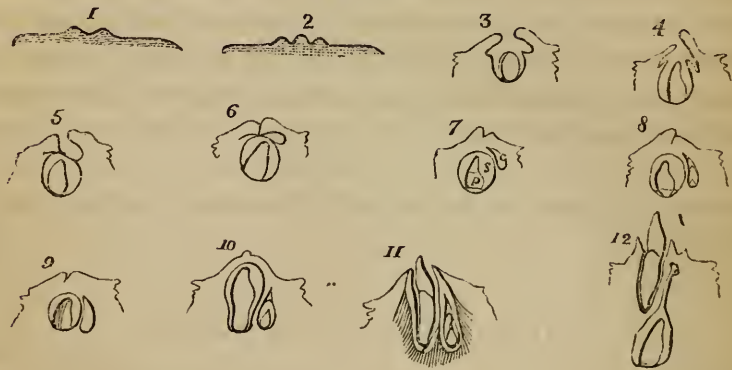
afterwards
the alveoli.

Changes in
mucous
membrane.

have fully established the fact, that the teeth are developed from the mucous membrane covering the edges of the maxillary arches. The changes which take place in the bones of the jaws relate only to the formation of the sockets for the teeth. In the earliest condition these bones present no appearance of alveoli, but, concurrently with certain changes in the mucous membrane, to be immediately described, a wide groove is developed along the edge of the jaw, which gradually becomes deeper, and is at length divided across by thin bony partitions, so as to form a series of four-sided cells. These bony septa are not distinctly formed until nearly the fifth month of fetal life. By the subsequent growth of the bone, these cavities or loculi are gradually closed round, but always continue open at the edge of the jaw. By the end of the sixth month they are distinctly formed, but continue afterwards, (see figs. 30, c, and 35, pages 65 and 74,) in proportion to the growth of the teeth, to increase in size and depth, by the addition of new matter, which widens and deepens the jaw.

The first stages in the development of the teeth, as observed by Arnold and Goodsir, consist of certain changes in the mucous membrane covering the borders of the maxillæ. (Consult fig. 249,

Fig. 249.*



* From Goodsir.—A series of diagrams, representing imaginary sections made across the edge of the lower jaw of the fetus at different periods, in order to shew the successive stages in the development of the sac of a temporary incisor tooth, and of the succeeding permanent tooth, from the mucous membrane of the jaw.—1. The dental groove is formed in the mucous membrane. 2. The groove widens, and has a papilla at the bottom: this is the papillary stage. 3, 4, and 5 represent the follicular stage; the lips of the groove enlarge, and form a sunken follicle, in which the papilla, now enlarged

and its description.) About the sixth week of embryonic life, a depression or groove, having the form of a horse-shoe, appears along the edge of the jaw, in the mucous membrane of the gum; this is the *primitive dental groove* (Goodsir). From the floor of this groove (supposed to be represented in a transverse section, in fig. 249, 1) a series of ten papillæ, as at 2, arise in succession in each jaw, and constitute the germs or rudimentary pulps of the milk teeth. The order in which these papillæ appear is very regular. The earliest is that for the first milk molar tooth; it is seen at the seventh week, as soon as the dental groove is formed; at the eighth week that for the canine tooth appears; the two incisor papillæ follow next, at about the ninth week, the central one before the lateral; lastly, the second molar papilla is visible at the tenth week, at which period this, the *papillary stage* (2) of the rudiments of the teeth is completed. The papillæ in the upper jaw appear a little earlier than those in the lower jaw.—In the next place, the margins of the dental groove become thickened and prominent, especially the inner one; and membranous septa pass across between the papillæ from one margin to the other, so as to convert the bottom of the groove into a series of follicles, each containing one of the papillæ. These changes constitute the *follicular stage* (3); they take place in the same order as that in which the papillæ appeared, and are completed about the fourteenth week, (fig. 249, 4, and fig. 250.) During the early part of this period the papillæ grow rapidly, they begin to show peculiarities of form, and project from the mouths of

Dental groove.

Formation of milk teeth.

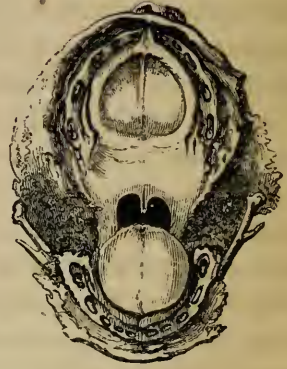Papillary stage.

Follicular stage.

and beginning to acquire the form of the future tooth-pulp, is hid. Membranous opercula, or laminae, are formed from the sides of the follicle, and, as seen in 5, meet over, leaving a lunated depression behind. The diagram, 5, supposing the opercula to be gently opened out, may be taken to represent a cross section through an incisor follicle, as indicated by the dotted line *a b*, fig. 253. 6. The lips of the groove also meet, except the lunated depression, *c*. 7. The opercula and lips of the groove cohere; the follicle becomes a closed sac (*s*); the papilla is the tooth-pulp (*p*), and has the shape of the crown of the future tooth; and the lunated depression becomes a cavity of reserve (*c*) for the development of the succeedaneous permanent tooth: the saccular stage is now complete. The remaining figures, 8 to 12, shew the commencement of the cap of dentine on the pulp, the subsequent steps in the formation of the milk tooth, and its eruption through the gum (11); also the gradual changes in the cavity of reserve, the appearance of its laminae and papilla, its closure to form the sac of the permanent tooth, its descent into the jaw, behind and below the milk-tooth, and the long pedicle (12) formed by its upper obliterated portion.

the follicles. Soon, however, the follicles become deeper, so as to hide the papillæ, (fig. 250,) which now assume a shape corresponding with that of the crowns of the future teeth. Small laminae, or opercula of membrane, (fig. 249, 4 and 5,) are then developed from the sides of each follicle, their number and position being regulated, it is said, by the form of the cutting edges and tubercles of the intended teeth: the incisor follicles (fig. 253, ³, ⁴) having two laminae (o), one external and one internal; the canine (³), three, of which two are internal,

Fig. 250.*



Saccular stage.

and the molars (¹, ⁵) four or five each.—The lips of the dental groove, as well as the opercula, now begin (fig. 249, 6) to cohere over the follicles from behind forwards, the posterior lip being very much thickened; the groove itself is thus gradually obliterated (7), the follicles are converted into closed sacs (s), and the *saccular stage* of the milk teeth is thus completed about the end of the fifteenth week. Certain lunated depressions (5, 6, c, also fig. 253, c), which are formed one behind each of the milk follicles about the fourteenth week, escape the general adhesion of the lips of the groove. From these depressions, as will be afterwards described, the sacs of the ten anterior permanent teeth are subsequently developed.

Cavities of reserve.

Dental sacs,

The *dental sacs* (fig. 249, 7 s), thus formed by the closure of the follicles, continue to enlarge, as well as their contained papillæ (p). The walls of the sacs, which soon begin to thicken, consist of an outer fibro-cellular membrane, and an internal highly vascular layer, lined by epithelium; their blood-vessels are derived partly from the dental arteries which course along the base of the sacs, and partly from those of the gums.

and dental pulps; their structure; vessels and nerves.

The papillæ, now the dental pulps, adhere by a wide base to the bottom of the sacs, and, having acquired a perfect resemblance to the crowns of the future teeth, the formation of the

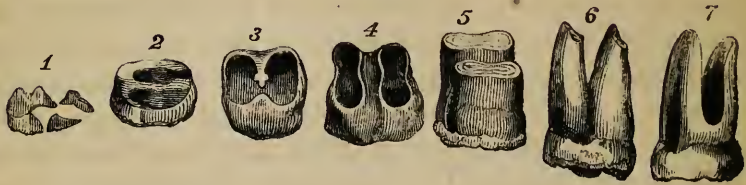
* An enlarged view of the upper jaw and palate of a fœtus at about the fourteenth week, shewing the follicular stage of the development of the milk teeth. The ten follicles, each containing a papilla, are distinctly seen.

hard substance commences in them. This process begins very early, and by the end of the fourth month of fœtal life, thin shells or caps of dentine are found on all the pulps of the milk teeth, and a little later on that of the first permanent molar. The mode in which it proceeds, taking a canine tooth as an example, may be stated as follows: a thin osseous shell or cap of dentine appears on the point of the pulp; this increases in extent by a growth around its edges, and in thickness by a similar formation in its interior, the latter taking place at the expense of the substance of the pulp itself, which accordingly decreases in proportion. This growth of the tooth continues until the crown is completed of its proper width, and then the pulp undergoes a constriction at its base to form the cervix of the tooth. From that time the pulp elongates and continues to become narrower, so as to construct the fang, (10, 11.) During the whole period, another process has been going on, by which the outer surface of the crown is covered with the enamel. This substance is formed from a thickened portion of the parietes of the sac, which is accurately adapted to the surface of the dental pulp, or to its cap of dentine, and was called by Hunter the *outer* pulp. Sooner or later, after the completion of the crown, this part of the tooth appears through the gum, (11,) whilst the growth of dentine to complete the fang is continued at the surface of the elongating pulp, which gradually becomes encroached upon by successive formations of hard substance, until only a small cavity is left in the centre of the tooth, containing nothing but the reduced pulp, supplied by a slender thread of vessels and nerves, which enter by a little aperture left at the point of the fang after the dentine is completed. In the case of teeth, having complex crowns and more than a single fang, the process is somewhat modified. On the surface of the dental pulp of such a tooth, as many separate little shells of dental substance are formed as there are eminences or points, (fig. 251, ¹;) these soon coalesce, (²;) and the formation of the tooth proceeds as before as far as the cervix. The pulp then becomes divided into two or more portions, corresponding with the future fangs, and the ossification advances in each as it does in a single fang. A horizontal projection or bridge of dentine (3, 4) shoots across the base of the pulp, between the commencing fangs, so that if the tooth be

Formation
of dentine.Growth of
the crown
of the fang.Formation
of enamel.Eruption of
tooth.Completion
of fang.Formation
of com-
pound
crowns and
fangs.

removed at this stage and examined on its under surface, its shell presents as many apertures as there are separate fangs. In all

Fig. 251.*



teeth, the pulp originally adheres by its entire base to the bottom of the sac, but when more than one fang is to be developed, the pulp is, as it were, separated from the sac in certain parts, so that it comes to adhere at two or three insulated points only, whilst the dentine continues to be formed along the intermediate and surrounding free surface of the pulp.

Formation
of dentine

is not by
secretion,

but by ossi-
fication.

Intimate
structure of

Formation of the hard tissues of the teeth.—*a. The Dentine.*—It was at one time supposed that this substance was formed by a process of ossification similar to what takes place in the cartilages of true bones; but this opinion subsequently gave way to another, which prevailed until lately, and attributed the formation of the tooth to a process of secretion from the surface of the pulp. The older notion has since been revived by Schwann, in applying his doctrine of the development of tissues from cells, to the observations previously made by Purkinjé and Raschkow. By these last-named inquirers, the dentine was described as being formed in continuous layers from without inwards, the pulp supplying the material: Schwann expressed his opinion, that it was in reality the *ossified pulp*. This doctrine has received general support from subsequent observers, and it may be regarded as established; but the precise changes which accompany the conversion of the pulp into dentine, are not yet satisfactorily determined.

Previously to the commencement of ossification, the primitive pulp is found to consist of microscopic nucleated cells, (pulp-

* Shews the mode of formation of a molar tooth with two fangs. (Blake.)
—1. Distinct caps of dentine, which afterwards unite. 2, 3. A bridge of dentine is beginning to stretch across the base of the tooth-pulp, and is completed in 4. Henceforth the pulp is double, and each part forms its own fang.

granules, Purkinjé), more or less rounded in form, and embedded in a clear matrix containing a few very fine molecules, thinly disseminated in it. It contains no cellular fibres, but is highly vascular. The capillary vessels are most abundant at the points where ossification is to commence, but do not reach the surface. At the exterior of the pulp, the rounded cells become elongated, and arranged perpendicularly to the surface, so as to form a tolerably regular layer, resembling a columnar epithelium. Besides this, the entire pulp is covered by a fine pellucid homogeneous membrane, named the *preformative membrane*, (Purkinjé, Raschkow.)

pulp before ossification;

its cells elongate; arranged closely at surface;

the preformative membrane. Deposition of earthy matter;

occurs in successive portions of pulp.

Changes in preformative membrane.

In the process of ossification, as described by Schwann, the elongated cells, at the surface of the pulp, together with the intercellular matrix, become gradually solidified by impregnation with earthy matter, and are thus converted into dentine. Similar changes of elongation, apposition, and solidification by earthy deposit, occur in successive layers of cells, which go on being developed in the pulp. The *preformative membrane* is either obliterated, or according to Purkinjé, Retzius, and Raschkow, is the part first to undergo ossification, which then proceeds to affect the tissue of the pulp immediately beneath it. The granular layer (Purkinjé) found upon the surface of the dentine next to the enamel, and in which the microscopic cells are chiefly found, is conjectured to result from the ossification of this membrane; and the enamel fibres are supposed to be implanted in the minute hexagonal depressions formed on its outer surface. This preformative membrane was noticed by Mr. T. Bell, who thought, however, in accordance with the views then generally entertained, that the dentine was deposited on its outer surface. On gently separating the newly formed cap of dentine from the formative pulp, in the growing teeth of the human subject or of animals, and examining it under the microscope, the elongated cells of the pulp are found adhering in numbers to the inner surface of the newly formed dentine. The hard substance undoubtedly increases at the expense of the pulp, and different observers have described the mode in which the pulp-cells, their nuclei and the intercellular matrix, are converted into the tubuli and intertubular substance of the dentine; but from our own observations we have not been able to confirm these descriptions, and we are dis-

Pulp-cells adhere to newly formed dentine;

mode of
conversion
doubtful.

posed to regard the precise nature of the conversion of the soft tissue into the dentine as still a matter for investigation.

Schwann's
views.

Schwann at first conceived that the tubuli were prolongations of the cells, and that the intertubular substance was formed by the calcification of the matrix, but he abandoned this idea after comparative researches in animals.

Henlé's.

Henle thought that the cells, in becoming impregnated with earthy matter, formed the bundles of fibres of which the dentine is supposed by him to consist ; whilst the nuclei became elongated into the hollow tubes.

Owen's.

Owen believes that the nuclei of the elongated cells, having themselves become lengthened, divide both longitudinally and transversely to develop secondary cells which continue included within the primary cells. These secondary cells then elongate and together with their nuclei join end to end. Calcification proceeds in all parts, except in the nuclei of the secondary cells which remain as the cavities or lumina of the tubes ; the walls of the secondary cells are supposed to form the parietes of the tubes, and the material between the secondary cells together with the walls of the primary cells to be converted into the intertubular substance. The bifurcation of the tubuli is said to result from the junction of two secondary cells with a single one in a deeper layer of the pulp ; and the constricted or moniliform appearance of the tubuli already mentioned as having been seen by some observers in growing or even in mature teeth, is thought to depend on an imperfect coalescence of the nuclei. In the teeth of young animals, Mr. Tomes states that he has noticed the division of the cells and their subsequent coalescence to form the tubes, but he has failed to recognise the existence of primary cells including secondary ones. We must confess, that, after a careful examination of the human teeth, we have been unable to discover any of the above described changes, except the enlargement of the more superficial cells of the pulp and their elongation in the immediate vicinity of the dentine.

Formation
of enamel
from the

b. The Enamel.—This substance is formed by a peculiar organ developed in the outer wall of the sac, at the same time that the dentine is being produced by the pulp. Its formation commences very early. The membranous wall of the sac, soon after its opercula have united together, becomes thickened and pulpy, and at length applies itself in the form of a soft mass accurately adapted to the surface of the primitive dental pulp, or at a later period to the cap of dentine. This thickened part of the sac is the *outer pulp* of Hunter, which, as he stated, is the formative organ of the enamel (*organon adamantinæ*. Purkinjé). The structure of this enamel pulp is very remarkable ; it is described by Todd and Bowman as consisting of an open web of distinct fibres, holding within their reticulations a clear fluid, and having a bright spot at their place

outer pulp
or enamel
pulp,

which has a
remarkable
structure :

of junction. The same structure was previously described by Purkinjé and Raschkow, as formed by radiating cells, like the actinenchyma of vegetable tissues. The surface of this structure, turned towards the inside of the dental sac, is covered with a fine transparent simple membrane, upon which rests a thick stratum of nucleated cells, which compose the *enamel membrane* (*membrana adamantina*, Purkinjé), a structure analogous to epithelium. From the vascular part of the enamel pulp, villous processes, containing blood-vessels, project into the enamel membrane, at the part corresponding with the grinding surface of the tooth. At first, the layer of cells composing the enamel membrane is in contact with the dental pulp. When, however, the shell of dentine begins to be formed, a succession of those nucleated cells, uniting in rows, arrange themselves vertically to its surface, become elongated and prismatic, and being impregnated with earthy matter, form the solid prismatic fibres of the enamel, which coalesce firmly together. Whilst the enamel is being formed, it is soft and chalky, and can easily be separated into its component cells. Afterwards the membranous portion of it is nearly all obliterated, and the nuclei entirely disappear, or according to Tomes, elongate into a very fine central canal in each fibre. No enamel is formed except on the crown of the tooth; either because the enamel pulp adheres to the cervix, or because the character of the membrane of the sac changes at that point.

on its surface is the enamel membrane, which is epithelial.

Its cells become enamel prisms.

c. *The Cement*.—This osseous layer appears to be formed, simultaneously with the dentine of the fang, by the periodontal membrane, from the margin of the enamel downwards. As to the origin of the coronal cement, it is supposed by some that the enamel membrane itself, after its proper function has ceased, is converted into that substance, and by others that it pours out a material which subsequently becomes ossified.

The cement, formed by periodontal membrane.

Eruption of the temporary teeth.—At the time of birth (fig. 252) the crowns of the anterior milk teeth, still enclosed in their sacs, are completed within the jaw, and their fangs begin to be formed. Their appearance through the gums follows a regular order, but the period at which each pair of teeth is cut varies within certain limits. The eruption commences at the age of seven months, and is completed about the

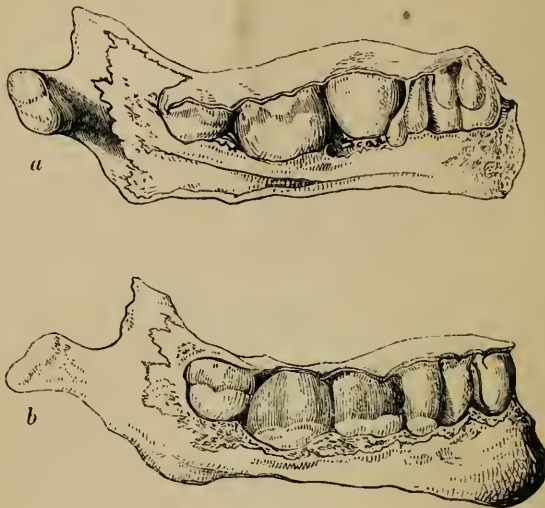
Cutting of milk teeth

begins at seven months old;

complete at
second year.

end of the second year. It begins with the central incisors of the lower jaw, which are immediately followed by those of the

Fig. 252.*



Its order.

upper jaw ; and, as a general rule, each of the lower range of teeth rises through the gum before the corresponding tooth of the upper set. The following scheme indicates in months, the order and time of eruption of the milk teeth.

MOLARS.	CANINES.	INCISORS.	CANINES.	MOLARS.
24—12	18	9 7 7 9	18	12—24

Gums
become
rounded
and dark
purple ;

Before the teeth protrude through the gum, this undergoes some peculiar changes : its edge at first becomes dense and sharp, but as the tooth approaches it, the sharp edge disappears, the gum becomes rounded or tumid, and is of a purplish hue ; the summit of the tooth is seen like a white spot or line through the vascular gum, and soon after rises through it. As the crown of the tooth advances to its ultimate position, the elongated fang becomes surrounded by a bony socket or al-

* *a* Left, and *b* right, half of the lower jaw of a child at birth, with part of the bone taken away to shew the tooth-sacs as they lie underneath the gum. The lower figure shews the saes of the milk-teeth and first permanent molar, exposed by removing the bone from the outside ; the upper figure shews the same from the inside, with the saes of the permanent incisors and canine lying behind those of the corresponding milk-teeth.

veolus. Before the eruption, the mucous membrane is studded with a number of small white bodies, which were described by Serres, as glands, (*dental glands*), and were supposed by him to secrete the tartar of the teeth. Meckel thought they were small abscesses, because no aperture could be detected in them. As examined in a fœtus of six months, we have found them to be little round pearl-like bodies situated in the chorion of the mucous membrane, and having no aperture. They are small spherical capsules of various sizes, lined with a thick stratum of epithelium, the inner cells of which are flattened or scaly, like those lining the cheek, and are so numerous as almost to fill up the cavity.

Are studded with dental glands,

which have no orifice.

Development of the permanent teeth.—The preceding description of the structure of the dental sacs and pulps, and of the mode of formation of the several parts of a tooth, applies to the permanent, as well as to the milk teeth.

Formation of permanent teeth :

The origin and progressive development of the sacs of the permanent teeth, have still to be considered. There are six more permanent teeth in each jaw than there are milk teeth, (see p. 968,) and it is found that the sacs of the ten anterior permanent teeth, which succeed the ten milk teeth, have a different mode of origin from the six additional or superadded teeth, which are formed further back in the jaw.

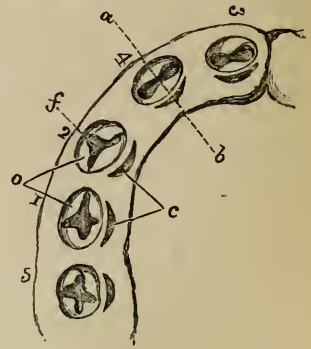
The sacs and pulps of the ten *anterior permanent* teeth have their foundation laid before birth, behind those of the milk set ; and as they are found, after a time, attached to the sacs of the temporary teeth, (figs. 252, 256,) it was conceived that they sprouted or shot out from these latter. This has been disproved by the observations of Goodsir, who has shewn that the sacs of the ten anterior permanent teeth are developed from the dental groove, independently of the milk sacs. Recurring to the follicular stage of the temporary teeth, which is completed about the fourteenth week (see pp. 983-4), it will be remembered that behind each milk follicle there is formed a small lunated recess, (fig. 249, 5^c, 6 ; and fig. 253,^c.) similar in form to an impression made by the nail. As already stated, the mucous membrane lining these recesses escapes the general adhesion of the lips and sides of the dental groove, so that when the latter closes they are converted into so many cavities, which are called by Mr. Goodsir, "*cavities of reserve*," (fig. 249, 7^c.)

the ten anterior,

formed in cavities of reserve

They are ten in number in each jaw, and are formed successively from before backwards. They ultimately form the sacs for the incisor, canine, and bicuspid permanent teeth. These cavities soon elongate and recede into the substance of the gum behind the milk follicles, above and behind in the upper jaw, below and behind in the lower, (8 to 12.) In the mean time, a papilla appears in the bottom of each, (that for the central incisor appearing first, at about the sixth month), and one or more folds, (8, 10), or opercula, as in the case of the temporary teeth, are developed from the sides of the cavity, and by their subsequent union, divide it into two portions, the lower portion containing the papilla, and now forming the dental sac and pulp of the permanent tooth; and the upper and narrower portion being gradually obliterated in the same manner as the primitive groove was closed over the milk-sacs, (10, 11.) When these changes have taken place, the permanent sac adheres to the back of that for the temporary tooth. Both of them continue then to grow rapidly, and after a time it is found that the bony socket not only forms a cell (fig. 254, *b'*) for the reception of the milk sac (*b*), but also a small posterior recess or niche (*a'*), for the permanent sac (*a*), with which the recess keeps pace in its growth. Confining our description now, for convenience, to the lower jaw only, it is found that at length

Fig. 253.*



behind the milk teeth;

these change into dental sacs.

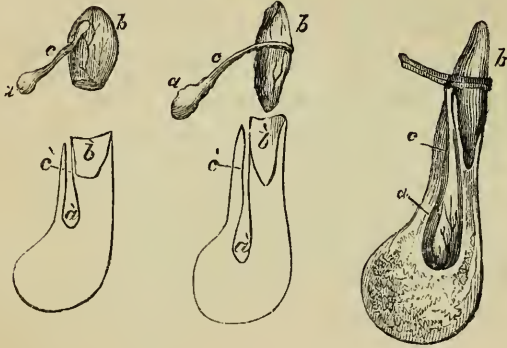
Changes in bone also.

Permanent tooth sac recedes in jaw;

* Diagram of the left half of the lower jaw at about the fourteenth week, slightly altered from Goodsir. It is considerably magnified, to shew the follicles of the milk teeth opened out, their opercula, and the position of the lunated recesses behind them, from which the sacs of the five anterior permanent teeth are developed.—1 to 5. Milk-teeth follicles, numbered in their order of appearance and formation. 1. First molar. 2. Canine. 3. Central incisor. 4. Lateral ditto. 5. Second molar. *a, b*. A dotted line to indicate the direction in which the cross sections, represented in fig. 249, are supposed to be made: such a section carried through the follicle for the second incisor would correspond best with diagram 5 in that cut, supposing the opercula and the lips of the follicles were not opened out. *f*. The cavity of the follicle, the papilla being hid. *o, o*. The opercula. *c*. Lunated depressions, which resist the subsequent adhesion of the mucous membrane, and become the cavities of reserve for the permanent teeth.

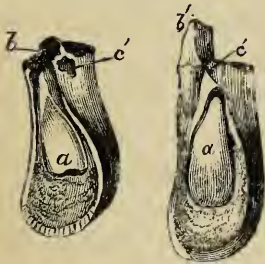
the permanent sac so far recedes in the bone as to be lodged in a special osseous cavity at some distance below and behind the milk tooth, the two being completely separated from

Fig. 254.*



each other by a bony partition (figs. 254, 255, 256). In descending into the jaw, the permanent sac (fig. 254, *a, a, a*)

Fig. 255.+



acquires at first a pear-shape, and is then connected with the gum by a solid membranous pedicle, *c*. The recess in the jaw has a similar form; it presents a cell, *a*, *a*, for containing the sac itself, which is drawn out into a long canal, *c*, *c*, opening on the edge of the jaw, by an aperture seen behind the cor-

is pear-shaped or pediculated;

is lodged in a proper cell in the bone;

responding milk tooth (fig. 255, *c'*). This canal lodges the above-mentioned membranous pedicle. The permanent tooth (*a*), which is developed from its dental pulp and enamel pulp, in the manner already described, is separated from the socket and root of

* After Blake, with additions in outline.—These figures are intended to shew the relation between the sac of the milk tooth and that of the corresponding permanent tooth, together with the relation of both to the substance of the lower jaw. In all cases *a* is the sac of the permanent tooth, *c* its pedicle, *b* that of the milk tooth, or the milk tooth itself. *a'*, *b'*, and *c'* in the diagrams below indicate the two recesses, with the intermediate canal, in which the parts *a*, *b*, and *c* are lodged in the jaw.

+ After Blake.—Position of a milk and a permanent tooth in the lower jaw.—*a*. Permanent tooth. *b*. Milk tooth, or its socket. *c*. Orifice of a canal in the bone, which transmits the pedicle of a permanent tooth sac.

bone is absorbed, and fang of milk tooth.

the milk tooth by a bony partition, against which, as well as against the root of the milk tooth, *b*, just above it, it presses in its rise through the gum, so that these parts are in a greater or less extent absorbed. When this has proceeded far enough, the milk tooth becomes loosened, falls out or is removed, and the permanent tooth then takes its place. The milk teeth and the permanent teeth are said by Serres to be supplied by two different arteries, the obliteration of the one going to the temporary teeth, being regarded by him as the cause of their destruction, but of this there is no sufficient proof.

Six posterior permanent teeth, arise in posterior cavities of reserve,

The six *posterior* (or "*superadded*") *permanent* teeth, that is, the three permanent molars on each side, do not come in the place of other teeth. They arise from successive extensions of the dental groove carried backwards in the jaw, posterior to the milk teeth, and named "*posterior cavities of reserve.*"

formed in mucous membrane.

During the general adhesion of the dental groove occurring at the fifteenth week, the part posterior to the last temporary molar follicle continues unobliterated, and thus forms a cavity of reserve, in the fundus of which a papilla ultimately appears, and forms the rudiment of the first permanent molar tooth: this takes place very early, viz. at the sixteenth week. The bottom part of this cavity is next converted by adhesion into a sac, which encloses the papilla, whilst its upper portion elongates backwards so as to form another cavity of reserve, in which, at the seventh month after birth the papilla for the second molar tooth appears. After a long interval, during which the sac of the first permanent molar, and its contained tooth, has acquired great size, (fig. 256,) and that of the second molar has also advanced considerably in development, the same changes once more occur, and give rise to the sac and papilla of the wisdom tooth, the rudiments of which are visible at the sixth year. The subsequent development of the permanent molar teeth takes place from these sacs just like that of the other teeth.

First permanent molar.

Second.

Last.

Period of calcification.

Calcification begins first in the anterior permanent molar teeth. Its order and periods are thus stated for the upper jaw, the lower being a little earlier. First molar, five or six months; central incisor, soon after; lateral incisor and canine, eight or nine months; two bicuspids, two years and over; second molar,

five or six years; third molar, or wisdom tooth, about twelve years.

Eruption of the permanent teeth.—The time at which this occurs in regard to each pair of teeth in the lower jaw is exhibited in the subjoined tables, given on the authority of Dr. Blake and Mr. Cartwright. The corresponding teeth of the upper jaw appear somewhat later.

Cutting of permanent teeth.

BLAKE.		YEARS.	CARTWRIGHT.		YEARS.	Periods.
Molar, first	6½	Molar, first,	}	5 to 7	
Incisors, central	7	Incisors, central inferior			
„ lateral	8	„ „ superior..		6 — 8	
Bicuspsids, anterior	9	„ lateral		7 — 9	
„ posterior	10	Bicuspsids, anterior		8 — 10	
Canines	11 to 12	Canines		9 — 12	
Molars, second	12 to 13	Bicuspsids, posterior		10 — 12	
„ third (or wisdom)	17 to 25	Molars, second		12 — 14	
			„ third (wisdom)		17 — 25	

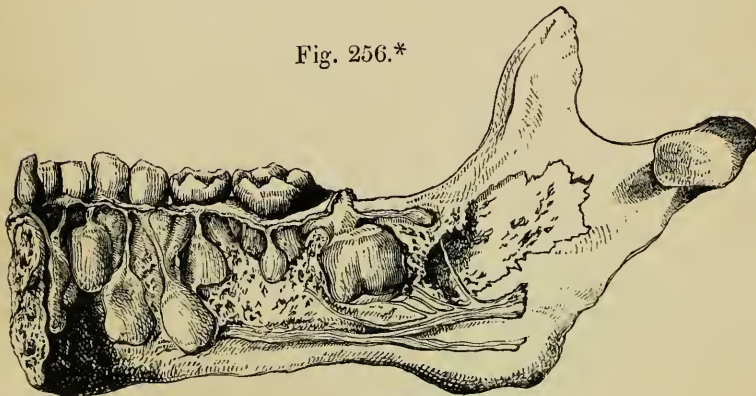
It is just before the shedding of the temporary incisors, *i. e.* about the fifth year, that there is the greatest number of teeth in the jaws. At that period there are all the milk teeth, and all the permanent set except the wisdom teeth, making forty-eight.

Most teeth in jaws at fifteenth year.

During the growth of the teeth the jaw increases in depth and length, and undergoes certain changes in form. In the child it is shallow, (fig. 35,) but it becomes much deeper in the

Changes in jaw :

Fig. 256.*



* Part of lower maxilla of a child, containing all the milk teeth of the right side, and the incisors of the left. Sacs and pedicles of the permanent teeth (except the wisdom tooth), exposed by removing part of the bone on the inside. The alveolar canal also laid open to shew the course of the nerve. The large sac near the ramus of the jaw is that of the first permanent molar; and above and behind it, is seen the commencing rudiment of the second molar.

in their
arches ;
in length.

adult, (fig. 34.) In the young subject the alveolar arch describes almost the segment of a circle ; but in the adult the curve is semi-elliptical. The increase which takes place in the length of the jaw arises from a growth behind the position of the milk teeth, so as to provide room for the three additional teeth on each side, belonging to the permanent set. At certain periods in the growth of the jaws there is not sufficient room in the alveolar arch for the growing sacs of the permanent molars ; and hence those parts are found at certain stages of their development to be enclosed in the base of the coronoid process of the lower jaw, (fig. 256,) and in the maxillary tuberosity in the upper jaw, but afterwards successively assume their ultimate position as the bone increases in length. The space taken up by the ten anterior permanent teeth exactly corresponds with that which had been occupied by the ten milk teeth ; the difference in width between the incisors of the two sets being compensated for by the smallness of the bicuspids in comparison with the milk molars to which they succeed. Lastly, the angle formed by the ramus and body of the lower jaw differs at different ages ; thus it is obtuse in the infant ; approaches nearer to a right angle in the adult ; and again becomes somewhat obtuse in old age, (figs. 34, 35.)

Ten milk
teeth are
replaced by
ten anterior
permanent
teeth.

Angle of
lower jaw
changes.

Vessels of
tooth-pulp.

Relation of the blood-vessels to the tooth.—There is no evidence that the blood-vessels send branches into the hard substance. The red stain sometimes observed in the teeth, after death by asphyxia, and the red spots otherwise found in the dentine are due to the imbibition of blood effused on the surface of the pulp. The dentine formed in young animals fed upon madder is tinged with that colouring matter, but this does not appear to take place when the growth of the tooth is completed. Nevertheless the tubules of the dentine may serve to convey through its substance nutrient fluid poured out by the blood-vessels of the pulp. The teeth are sometimes stained yellow in jaundice.

Comparison
of teeth and
bone.

Analogy between teeth and bone.—By the older anatomists the teeth were considered to be identical with bone, and were described as parts of the skeleton. Subsequently to this they were compared to the cuticular tissues, but the revelations of the microscope have tended to reestablish the former opinion.

The enamel is the only part which has no analogy with bone. The

crusta petrosa is in all respects similar to bone ; and, in regard to the dentine, numerous points of resemblance have been clearly established. Their chemical constituents are the same in nature, although they differ somewhat in their proportions but the bones themselves vary in this respect at different ages, and even in different parts of the same skeleton.

The tubuli of the dentine and the canaliculi of bone though differing materially in size are suggestive one of the other : the former open on the interior of the pulp cavity, and the latter on the walls of the Haversian canals ; they both branch out and anastomose by their finest twigs ; and both communicate with minute cells or lacunæ, situate in the surrounding hard substance, which, though very inconspicuous and rare in the human tooth, are large and very evident in the teeth of animals. It happens, moreover, that in the bones of osseous fishes these lacunæ are very few in number.

Dentine is very like bone.

The pulp cavity of a tooth with its vascular contents, and the Haversian canals of bone with their nutrient vessels, may be justly compared together. If we imagine a section of a group of coalesced teeth, the pulp cavities with their surrounding tubuli would represent a series of Haversian canals with their canaliculi ; and in the teeth of the lower animals, as already mentioned, these tubuli are even connected with numerous lacunæ. The inner portion of the tooth of the walrus presents a structure analogous to what is here imagined, inasmuch as the pulp cavity is divided into branches which resemble Haversian canals, and have radiating tubuli proceeding from them. A similar structure is seen in the osteo-dentine or secondary dentine formed within the human teeth, which thus, it may be remarked, agrees both in nature and position with the core of the walrus tooth. It is stated by Mr. Tomes that in one or two specimens he has seen vascular canals traversing the dentine of the fang of the human tooth, proceeding from the pulp cavity outwards. The mode of growth of teeth and bone is evidently not so different as was formerly supposed, but until the stages of this process in both are better understood, it would be premature to attempt any minute comparison between them in this respect.

Pulp cavity like canal of Havers.

It has been offered as an objection to the assumed analogy, that the teeth, unlike bones, are in part at least uncovered by soft tissues ; but true bony structures are sometimes similarly situated, as in the cutaneous plates of the sturgeon or armadillo, and the antlers of the deer.

Vibrios of the mouth.—It may be mentioned here, that in the white sordes surrounding the necks of the teeth, Leeuwenhoek discovered by the microscope numerous minute animalcules of the *Vibrio* kind which exhibit very active movements, and which are probably produced in such portions of vegetable and animal matters used as food, as happen to adhere between the margin of the gums and the teeth.

Vibrios of mouth.

More recently Buhlmann has observed fine transparent fibres on the surface of the teeth, especially where tartar had been allowed to gather on them. These fibres were slightly elastic, but consisted of some sort of inorganic substance, probably of a siliceous nature, for they resisted the action of the strongest acids and alkalis.

Fibres of tartar.

THE TONGUE.

The tongue: The *tongue* is the proper organ of taste, and owing to its position in the floor of the mouth, and to its great mobility, it assists in mastication and deglutition, and also in articulation.

its form ; In its general form, the tongue is adapted to the interval between the two halves of the lower jaw : thus it is wider, and at the same time thicker, at its *base* or *root*, which is turned backwards, and narrower and thinner at its *apex* or *tip*, which is directed forwards against the inner surface of the lower incisor teeth. The base and the posterior part of the under surface of the tongue are attached ; but the fore part of its under surface, the sides or borders, the upper surface and the tip, are free.

its attachments, by muscle, The *attachments* of the tongue are partly muscular, or fibro-cellular, and in part consist of reflections of the mucous membrane of the mouth. Thus, it is connected to the soft palate by the palato-glossus muscle, to the styloid process by the stylo-glossus, to the hyoid or *lingual bone* by the hyoglossus and some fibro-cellular tissue, and, lastly, to the inferior maxilla by the genio-hyo-glossus (fig. 258).

by folds of membrane ; By means of the mucous membrane, the tongue is connected behind with the epiglottis ; three folds, named the glosso-epiglottic folds or *frænula*, of which the middle one is the larger, pass backwards from the one to the other, (figs. 258, 259.) On each side of these, the tongue is connected with the pharynx, and farther outwards with the soft palate, by the two arches or pillars of the fauces (*r, i*). Lastly, from the under surface of the tongue, at the sides and also in front, the mucous membrane is reflected over the sublingual gland to the inner surface of the gums of the lower jaw ; and it forms in the middle line, in front, a median fold called the *frænum linguæ*.

its frænum.

Under surface is smooth.

Ducts open beneath it.

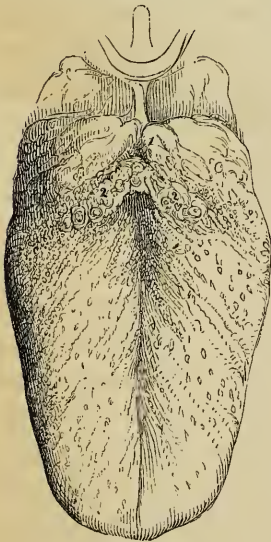
The *free surface* of the tongue.—The free portion of the under surface of the tongue is covered by a thin and smooth mucous membrane. In front, beneath the tip of the organ, it is marked by a median line continuous with the *frænum linguæ*. Near this line, on each side, the ranine vein may be distinctly seen through the mucous membrane, and close to it lies the artery of the same name. The ducts of the right and left submaxillary glands also end in the floor of the mouth,

one on each side of the frænum; and further back, in the groove between the sides of the tongue and the lower jaw, are found the orifices of the several ducts belonging to the sublingual glands.

The rounded *borders* of the tongue become gradually thinner in approaching the apex of the organ. The mucous membrane, in passing over them from below, gradually acquires the papillary character of that on the upper surface.

The *upper surface* or *dorsum* of the tongue (fig. 257) is convex in its general outline, and is marked along the middle in its whole length by a slight furrow called the *raphé*, which indicates its bilateral symmetry. About half an inch from the base of the tongue, the raphé often terminates in a depression (¹), closed at the bottom, which is called the *foramen cæcum* (*Morgagni*), and in which several mucous *glands* and follicles open.

Fig. 257.*



Borders have papillæ.

Upper surface, or dorsum:

its raphé.

Foramen cæcum.

Lingual papillæ,

of three kinds.

Pap. circumvallatæ.

The upper surface of the tongue is covered all over with numerous projections or eminences named *papillæ*. They are found also upon the tip and free borders, where however they gradually become smaller, and disappear towards its under surface. These papillæ are distinguished into three orders, varying both in size and form.

The *large papillæ* (*papillæ maximæ, vallatæ, vel circumvallatæ*), eight to fifteen in number, (²) are found on the back part of the tongue, arranged in two rows, which run obliquely backwards and inwards, and meet towards the foramen cæcum, like the arms of the letter V. They are situated in cuplike cavities or depressions of the mucous membrane, and are shaped like an inverted cone, of which the apex is attached to the bottom of the cavity, and the broad flattened base appears on the surface. They are therefore surrounded, as it were, by a circular furrow or trench, around which again is an annular elevation of the

* Shews the upper surface of the tongue.—1. Foramen cæcum, (*Morgagni*.) 2, 2. *Papillæ vallatæ*. The fungi-form papillæ are also indicated.

mucous membrane, covered with the smaller papillæ. The exposed surface of the papillæ vallatæ is beset with numerous smaller papillæ or filaments; and in some of them there is found a central depression into which mucous follicles open.

Pap. capitatæ.

The *middle-sized* papillæ (papillæ mediæ, capitatæ, vel fungiformes), more numerous than the last, are little rounded eminences scattered over the middle and fore part of the dorsum of the tongue; but they are found in greater numbers and closer together near and upon the apex. They are easily distinguished by their more intensely red colour. They are narrow at their point of attachment, but are gradually enlarged towards their free extremities, which are blunt and rounded, and are covered with smaller filamentous appendages or papillæ.

Pap. conicæ and filiformes.

The *smallest papillæ* (papillæ minimæ), which include the *papillæ conicæ* and *filiformes*, are the most numerous of all. They are minute, conical, tapering, or cylindrical processes, which are densely packed over the greater part of the dorsum of the tongue, towards the base of which they gradually disappear. They are arranged in lines, which correspond at first with the oblique direction of the two ridges of the papillæ vallatæ, but gradually become transverse towards the tip of the tongue. At the sides they are longer and more filiform, and arranged in parallel rows, perpendicular to the border of the tongue. The filiform papillæ are paler and provided with a thicker epithelium than the other kinds; and they are also covered with small and rather stiff secondary papillæ. Interspersed between these three kinds of papillæ, and also at the back part of the tongue behind the papillæ vallatæ, there are found numerous minute projecting filaments, concealed by the epithelium, and scarcely visible until that be removed (Todd and Bowman).

Other filaments.

Structure of papillæ.

These different kinds of papillæ are highly vascular and sensitive prolongations of the mucous coat of the tongue. When injected, they seem to consist almost entirely of capillary vessels: the papillæ vallatæ containing many vascular loops, whilst the smallest papillæ are penetrated by only a single loop. Nerves proceed in abundance to those parts of the tongue which are covered with papillæ, into which the nerve-tubes penetrate. The epithelium covering the papillary surface is of considerable thickness, and belongs to the squamous kind: over

Epithelium of tongue.

the filiform papillæ it is denser than elsewhere, and presents an imbricated arrangement; on some, it forms a lash or pencil of fine fibres; and, on others, it approaches closely in character and structure to hairs. The papillæ are undoubtedly the parts chiefly concerned in the special sense of taste; but they also possess, in a very acute degree, common tactile sensibility; and the filiform papillæ, armed with their denser epithelial covering, serve a mechanical use, in the action of the tongue upon the food.

Uses of
papillæ.

The mucous membrane of the tongue is provided with numerous follicles and glands. The follicles, simple and compound, are scattered over the surface; but the rounded conglomerate glands, called *lingual glands*, are collected about the posterior part of the dorsum of the tongue, near the papillæ vallatæ and foramen cæcum, into which the ducts of several of these glands open. Other small glands are found also beneath the mucous membrane of the borders of the tongue. There is, in particular, a small group of these glands on the under surface of the tongue near the apex. They are there aggregated into a little oblong mass, out of which several ducts proceed and open separately on the mucous membrane. This little gland, or group of glands, was pointed out by Blandin, and has been more lately described and figured by Nuhn.

Follicles
and glands,

beneath
the tip.

The substance of the tongue is chiefly composed of muscular fibres, running in different but determinate directions;—hence the variety and regularity of its movements, and its numerous changes of form. Many of the contractile fibres of the tongue belong to muscles which enter at its base and under surface, and attach it to other parts: these, which have been already enumerated, are called the *extrinsic muscles* of the tongue, and have been elsewhere described (pp. 271—4, and 289). Other bands of fibres constitute the *intrinsic* or proper muscles, and are arranged in two principal longitudinal layers, with a large intervening mass of transverse fibres.

Muscles of
tongue,

extrinsic
and
intrinsic.

The first, *superior*, or *superficial* longitudinal layer, named *lingualis superficialis*, is placed on the upper surface of the tongue, immediately beneath the mucous membrane, and is traceable from the apex of the organ backwards to the hyoid bone. The individual fibres do not run the whole of this distance, but are attached at intervals to the submucous and glan-

Lingualis
superficialis.

dular tissues. The entire layer becomes thinner towards the base of the tongue, near which it is overlapped at the sides by a thin plane of oblique or nearly transverse fibres derived from the palato-glossus and hyo-glossus muscles.

Lingualis
proprius,

vel inferior.

The *inferior* or *deep* longitudinal layer* of muscular fibres, placed at the under surface of the tongue, is the *lingualis* muscle, properly so called, of Douglas, Albinus, and other anatomists, and is sometimes described as the *lingualis inferior*. It consists of a rounded muscular band, extending along the under surface of the tongue from base to apex, and lying outside the genio-hyo-glossus, between that muscle and the hyo-glossus. . Posteriorly, some of its fibres are lost in the substance of the tongue, and others reach the hyoid bone. In front, having first been joined, at the anterior border of the hyo-glossus muscle, by fibres from the stylo-glossus, it is prolonged beneath the border of the tongue as far as its point.

Lingualis
transversus.

The *transverse* muscular fibres of the tongue (*lingualis transversus*) form together with the intermixed fat a considerable part of its substance. They are found in the interval between the upper and lower longitudinal muscles, and they intersect extensively with the other muscular fibres. Passing across each way from the median plane of the tongue, they reach its dorsum and borders; and they are considered by some anatomists to take a distinct origin from a median fibrous partition to be presently described. In proceeding outward from the middle line, these transverse fibres have also an inclination upwards, so that they form a series of curves, having the concavity turned upwards. Other transverse fibres, according to Theile, arise from the hyoid bone, between the attachment of the two genio-hyo-glossi muscles, and run outwards and upwards on each side to reach the border of the tongue. All these fibres intersect, by bundles, the ascending fasciculi of the genio-hyo-glossus and hyo-glossus muscles.

Vertical
fibres in
tongue,

not a dis-
tinct sys-
tem.

Special vertical fibres have also been described by Gerdy and Cruveilhier as existing in the tongue. Fibres having a vertical direction may undoubtedly be seen on making perpendicular sections of this organ in man; but it is the opinion of Theile, that those seen in a longitudinal vertical section belong to the ascending fasciculi of the genio-hyo-glossus, or hyo-glossus, and the additional vertical fibres which appear in a similar

section made transversely belong to the oblique bundles of the transverse system of fibres.

These intrinsic muscles of the tongue serve principally to alter its form, retracting or elongating it in various directions. The superficial longitudinal fibres can also curve the tip of the tongue upwards, and the lower set can curve it downwards. Between the several layers and bundles of muscular fibres, there is always found a considerable quantity of a soft fatty tissue, and also a very fine cellular web.

Actions of muscles.

Fat of tongue.

In the median line, towards the base of the tongue and in the midst of the muscular substance, there is a vertical layer of fibrous tissue, which forms a partial septum between the two halves of the organ. This is connected behind with the hyoid bone; and in front, it is lost between the muscles. It is well known, that, in animals of the dog tribe, a fusiform fibro-cartilage is found in the middle of the tongue near its under surface; and Blandin has described a thin fibro-cartilaginous lamina in the human tongue as forming a part of the vertical median septum, but, according to Krause, in most instances there is no trace of such a structure. The last writer further states, that, when it does exist, it is about three or four lines in height and length; its borders are irregular; its two sides serve as points of insertion to muscular fibres; and it is often imperfect, or pierced with small holes.

Septum of tongue

represents fibro-cartilage in dog.

The arteries of the tongue are derived from the lingualis, with some small branches from the facial and ascending pharyngeal. The veins for the most part correspond.

Vessels of tongue.

The nerves of the tongue (exclusive of branches from the sympathetic nerves) are three: viz. the lingual or *gustatory* branch of the *fifth* pair, which supplies the papillæ and mucous membrane of the fore part and sides of the tongue; the lingual branch of the *glosso-pharyngeal*, which sends filaments to the mucous membrane at the base of the tongue, and especially to the papillæ vallatæ; and, lastly, the *hypo-glossal* nerve, which is distributed to the muscles.

Nerves from those sources.

THE PALATE.

The roof of the mouth is formed by the palate, which consists of two portions; the fore part being named the hard palate, and the back-part, the soft palate.

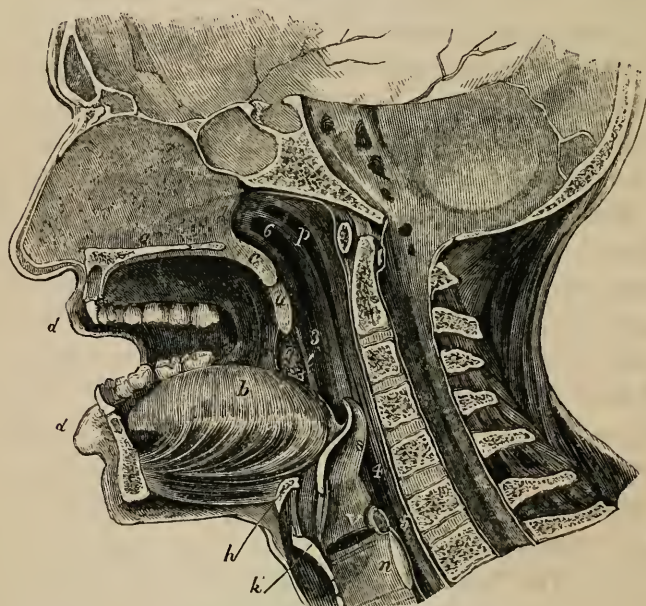
The palate.

Hard
palate;
its bones,

and mucous
membrane.

The osseous framework of the *hard* palate, *a*, fig. 258, the general form and component pieces of which have been described at p. 83, is covered by the periosteum, and by the lining membrane of the mouth, which adhere intimately together. The mucous membrane, which is continuous with that of the gums, is thick, dense, rather pale, and much corrugated, especially in front and at the sides; but is smoother, thinner,

Fig. 258.*



Palatal
glands.

and of a deeper colour behind. Along the middle line is a ridge or raphé, ending in front in a small eminence, which corresponds with the lower opening of the anterior palatine canal, and receives the terminal filaments of the naso-palatine and anterior palatine nerves. The membrane of the hard palate is provided with many muciparous glands, which form a conti-

* Median section of the nose, mouth, pharynx, and larynx.—*a*. Septum of the nose; below it, is the section of the hard palate. *b*. The tongue. *c*. Section of velum pendulum palati. *d, d*. Lips. *u*. Uvula. *r*. Anterior arch or pillar of fauces. *i*. Posterior arch. *t*. Tonsil. *p*. Pharynx. *h*. Hyoid bone. *k*. Thyroid cartilage. *n*. Cricoid cartilage. *s*. Epiglottis. *v*. Glottis. *1*. Posterior opening of nares. *3*. Isthmus faucium. *4*. Superior opening of larynx. *5*. Passage into œsophagus. *6*. Mouth of right Eustachian tube.

nuous layer between the membrane and the bone, and it is covered with a squamous epithelium.

The *soft* palate (velum pendulum palati: *c*) is formed of mucous membrane inclosing muscular fibres and numerous glands. It constitutes an incomplete and moveable partition between the mouth and the pharynx. It is attached to the posterior border of the hard palate, the membranous portion of which is thus continued obliquely downwards and backwards. At the sides, the soft palate is also connected with the lining membrane of the mouth and pharynx. Its lower border is free, and has depending from its middle a red conical process called the *uvula*, *u*. From the base of the uvula, on each side, the free margin of the velum forms two arched folds, which pass outwards and then downwards, one behind the other. These are the *anterior and posterior arches of the palate*. The anterior arches, *r*, run downwards and forwards to the sides of the tongue near its base; whilst the posterior arches, *i*, which approach more closely together, and may therefore be easily seen behind the anterior arches on looking into the throat, run downwards and backwards to the sides of the pharynx. Between the anterior and posterior palatine arch of each side, there is therefore a triangular recess, and in this the corresponding tonsil or amygdala, *t*, is placed. The interval between the palatine arches of the two sides, bounded above by the free margin of the soft palate, and below by the tongue, is the passage leading from the mouth into the pharynx, named the *isthmus faucium*, (before ³;) and the arches are called the *pillars* of the fauces.

The anterior or under surface of the velum, which is visible in the mouth, is concave. The mucous membrane, continuous with that of the hard palate, is thinner and darker than it, and is covered with a scaly epithelium. It is marked by a slight median ridge or raphé, which descends towards the uvula, and indicates the original separation of the velum into two lateral halves.

The posterior surface of the soft palate, slightly convex or arched, is continuous above with the floor of the posterior nares. It is slightly elevated along the middle line, opposite to the uvula. The greater portion of its mucous membrane, as well as that of the free margin of the velum, is covered with a

Soft palate;

uvula;

arches of
palate;fauces —
the isthmus
and pillars.Under sur-
face of
velum.Upper
surface.

Epithelium ciliated. squamous epithelium ; but quite at its upper portion, near the orifice of the Eustachian tube, ⁶, the epithelium is columnar and ciliated.

Palatine glands. On both surfaces of the velum are found numerous small glands, called the *palatine* glands. They particularly abound on the upper surface, where they form quite a glandular layer ; they are also very abundant in the uvula.

Muscles of palate. *Muscles.*—Between the two layers of mucous membrane of which the velum is composed, are situated the muscles of the soft palate. They consist of five muscles on each side ;—two superior, viz. the levator palati and the circumflexus or tensor palati ; two inferior, viz. the palato-glossus and the palato-pharyngeus,—of which the former is enclosed in the anterior palatine arch, and the latter in the posterior arch ; and lastly, one median, which descends into the uvula, and with the muscle of the opposite side forms the azygos uvulæ. The description of these muscles, and of their action, will be found at pp. 287-9.

THE TONSILS.

Tonsils : The *tonsils* (tonsillæ, amygdalæ) are two prominent bodies, which occupy the recesses formed, one on each side of the fauces, *t*, between the anterior and posterior palatine arches.

their size ; They are usually about six lines in length, and four in width and thickness ; but they vary much in size in different individuals.

connexions ; The outer side of the tonsil is connected with the inner surface of the superior constrictor of the pharynx, and approaches very near to the internal carotid artery. Considered in relation to the surface of the neck, the tonsil corresponds to the angle of the lower jaw, where it may be felt beneath the skin when it is enlarged. Its inner surface, projecting into the fauces between the openings ; palatine arches, presents from twelve to fifteen orifices, which give it a perforated appearance. These orifices lead into recesses in the substance of the tonsil, from which other and smaller orifices structure ; conduct still deeper into numerous compound crypts or follicles, the whole being lined with continuations of the buccal mucous membrane. The tonsils therefore consist of groups of compound muciparous crypts. They yield a mucous fluid, which lubricates vessels the fauces. The tonsils receive a very large supply of blood from

many sources, viz. from the tonsillar and palatine branches of the facial artery, and from the descending palatine, the ascending pharyngeal and the dorsalis linguæ. Its *veins* are numerous, and enter the tonsillar plexus on its outer side. Its nerves come from the glossopharyngeal nerve, and from the fifth pair.

vessels and
nerves.

THE SALIVARY GLANDS.

The saliva, which is poured into the mouth, and there mixed with the food during mastication, is secreted by three pairs of glands, named, from their respective situations, the *parotid*, *submaxillary*, and *sublingual* glands. Agreeing in their general physical characters and minute structure, they differ in their size, form, and position.

Salivary
glands:
three pairs.

The Parotid Gland.

The *parotid gland*, (*παρα*, and *ους, ωτος*,) so called from being placed near the ear, is the largest of the three salivary glands. It lies on the side of the face, in front of the ear, and beneath the skin; but it extends deeply into the space behind the ramus of the lower jaw. Its weight varies from five to eight drachms.

Parotid
gland: its
situation,
weight, and
connexions.

Its outer surface is rounded and lobulated, and is covered by the skin and fascia, and partially by the platysma muscle. It is bounded above by the zygoma, below by a line drawn backwards from the lower border of the jaw to the sterno-mastoid muscle, and behind by the external meatus of the ear, the mastoid process, and sterno-mastoid muscle. Its anterior border, which is in contact with the ramus of the lower jaw, is less distinctly defined, and advances forwards to a variable extent on the masseter muscle. It is from this anterior border of the gland that the excretory duct passes off; and there is sometimes found in connexion with the duct, and lying upon the masseter muscle, a small process or a separated portion of the gland, which is called *glandula socia* (*socia parotidis*). On trying to raise the parotid gland from its position, it is found to extend far inwards, between the mastoid process and the ramus of the jaw, towards the base of the skull, and to be intimately connected with several deep-seated parts. Thus, above, it reaches into and occupies the posterior part of the glenoid cavity; behind and below, it touches the digastric

The
glandula
socia.

Deep con-
nexions.

muscle, and rests on the styloid process and styloid muscles; and, in front, under cover of the ramus of the jaw, it advances a certain distance between the external and internal pterygoid muscles.

Connexions
with vessels
and nerves.

The internal carotid artery and internal jugular vein are close to the inner or deep surface of the gland. The external carotid artery, accompanied by the temporal and internal maxillary veins, passes through the parotid gland, and in that situation gives origin to the anterior auricular, transverse facial, temporal, and internal maxillary arteries. The gland is also traversed by the facial nerve, which divides within its substance, and by branches of the great auricular nerve.

The parotid
duct :

The *parotid duct*, named also the *Stenonian duct*, appears at the anterior border of the gland, about one finger's breadth below the zygoma, and runs forwards over the masseter muscle, accompanied by the socia parotidis, when that accessory portion of the gland exists, and receiving its ducts. At the anterior border of the masseter, the duct turns inwards through the fat of the cheek and pierces the buccinator muscle; and then, after running for a short distance obliquely forwards beneath the mucous membrane, opens upon the inner surface of the cheek, by a small orifice opposite the crown of the second molar tooth of the upper jaw. Its direction across the face may be indicated by a line drawn from the lower margin of the concha of the ear to midway between the red margin of the lip and the ala of the nose. The length of the Stenonian duct is about two inches and a half, and its thickness about one line and a half. Where it perforates the buccinator, its canal is as large as a crow-quill, but its orifice, which is the smallest part of it, will only admit a very fine probe. The duct is surrounded by cellular tissue, and, besides this, consists of an external, dense, and thick fibrous coat, in which contractile fibres are described, and of an internal mucous tunic, which is continuous with that of the mouth, but which is covered, from the orifice of the duct as far as to the smallest branches, with a columnar epithelium.

its course,

direction,

length,

diameter,

and
structure.

Structure of
parotid :

The parotid gland belongs to the class of compound cellular glands, and consists of numerous flattened lobes, held together by the ducts and vessels, and by a dense cellular web, which is continuous with the fascia upon its outer surface; but the gland has no special or proper coat. The lobes are again

divided into lobules, each of which consists of the branched terminations of the duct, and of vessels, nerves, and fine cellular tissue. The ducts terminate in closed vesicular extremities, about $\frac{1}{1200}$ th of an inch or more in diameter, and having capillary vessels ramifying upon them.

The vessels of the parotid gland enter and leave it at all points. The arteries are derived directly from the external carotid, and from those of its branches which pass through or near the gland. The veins correspond. The absorbents join the deep and superficial set in the neck; and there are often one or more lymphatic glands embedded in the substance of the parotid. The nerves come from the sympathetic (carotid plexus), and also, it is said, from the facial and the superficial temporal and great auricular nerves.

its vessels
and

nerves.

The Submaxillary Gland.

The *submaxillary gland*, the next in size to the parotid gland, is of a rounded form, and weighs about 2 or $2\frac{1}{2}$ drachms. It is situated immediately below the base and the inner surface of the inferior maxilla, and above the digastric muscle. In this position it is covered in by the skin and the platysma myoides, and its inner surface rests on the mylo-hyoid, hyo-glossus, and stylo-glossus muscles; above, it corresponds with a depression on the inner surface of the jaw-bone; and it is separated behind from the parotid gland, merely by the stylo-maxillary membrane. The facial artery, just before it mounts over the jaw-bone, lies in a groove upon the back part and upper border of the gland.

Submaxillary gland:

situation
and

connexions.

The *duct* of the submaxillary gland, named the *Whartonian duct*, which is about two inches in length, passes off from the gland, together with a thin process of the glandular substance, around the posterior border of the mylo-hyoid muscle, and then runs forwards and inwards above that muscle, between it and the hyo-glossus and genio-hyo-glossus, and beneath the sublingual gland, to reach the side of the frænum linguæ. Here it terminates, close to the duct of the opposite side, by a narrow orifice, which opens at the summit of a small caruncle seen beneath the tongue. The structure of this gland is like that of the parotid; but its lobes are larger, its surrounding

The duct:

its point of
termina-
tion;

Structure of gland ; cellular web is finer, and its attachments are not so firm. Moreover, its duct has much thinner coats than the parotid duct.

vessels and nerves. Its blood-vessels are branches of the facial and lingual arteries and veins. The nerves include those derived from the small submaxillary ganglion, as well as branches from the myloid division of the inferior dental nerve, and the sympathetic.

The Sublingual Gland.

Sublingual gland : weight, situation, and connexions ; The *sublingual gland*, the smallest of the salivary glands, is of a narrow oblong shape, and weighs scarcely one drachm. It is situated along the floor of the mouth, where it forms a ridge between the tongue and the gums of the lower jaw, covered only by the mucous membrane. It reaches from the frænum linguæ, in front, where it is in contact with the gland of the opposite side, obliquely backwards and outwards for rather more than $1\frac{1}{2}$ inch. On its inner side it rests on the genio-hyo-glossus ; beneath, it is supported by the mylo-hyoid muscle, which is interposed between it and the submaxillary gland ; but it is here in close contact with the Whartonian duct, with the accompanying deep portion of the last-named gland, and also with the lingual nerve.

structure. Ducts are numerous : The lobules of the sublingual gland are not so closely united together as those of the other salivary glands, and the ducts from many of them open separately into the mouth, along the ridge which indicates the position of the gland. These ducts, named *ductus Riviniani*, are from eight to twenty in number. Some of them open into the duct of Wharton. One, longer than the rest, (which is occasionally derived in part also from the submaxillary gland,) runs along the Whartonian duct, and opens either with it or very near it ; this has been named the duct of Bartholine.

Vessels, &c. The sublingual and submental arteries and veins supply this small gland. The nerves are numerous, and are derived from the lingual branch of the fifth pair.

Saliva : *Saliva*.—The saliva secreted by these glands is a clear limpid fluid, containing a few microscopic granular corpuscles. Its specific gravity is 1.006 to 1.008, and it has only about 1 to $1\frac{1}{2}$ parts of solid matter in 100. It is always alkaline during the act of mastication ; but afterwards becomes acid, and remains so

until the next time of taking food. Its chief ingredients, besides water and mucus, are a peculiar animal extractive substance, named salivine, with some alkaline and earthy salts. It is remarkable, besides, for containing a minute proportion of sulphocyanide of potassium.

contains
sulphocya-
nogen.

Development.—In mammalia, according to Müller and Weber, the salivary glands, as shewn in the case of the parotid gland in the embryo of the sheep, (fig. 259,) first appear in the form of a simple canal with bud-like processes lying in a blastema, and communicating with the cavity of the mouth. This canal becomes more and more ramified to form the ducts, whilst the

Develop-
ment.

Fig. 259.*

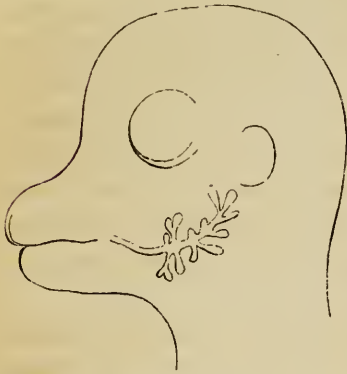
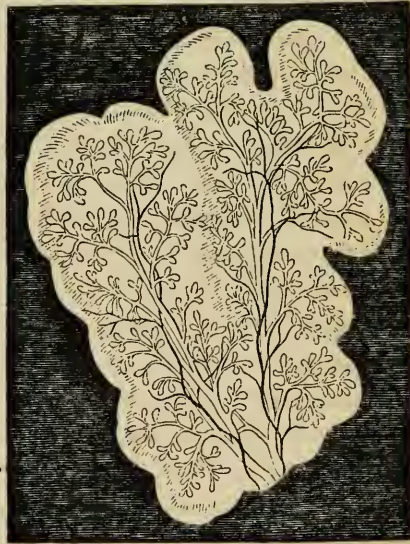

Fig. 260.†



blastema soon acquires a lobulated form, (fig. 260,) corresponding with that of the future gland, and at last wholly disappears, leaving the branched ducts, with their blood-vessels and connecting tissues. The submaxillary is said to be the first formed; then the sublingual and the parotid.

* Early appearance of the parotid gland in the embryo of the sheep.—(Müller).

† Lobules of the parotid gland, in the sheep's embryo, in a more advanced condition.—(Müller).

THE PHARYNX.

- Pharynx : The pharynx (fig. 258, p. 5) is that part of the alimentary canal which intervenes between the cavity of the mouth and the œsophagus. It is situated behind the nose, mouth, and situation ; larynx, in front of the vertebral column, and between the great vessels of the neck ; reaching from beneath the basilar process of the occipital bone down to the level of the cricoid cartilage, opposite the fifth cervical vertebra, where it ends in the œsophagus.
- form ; It forms an oblong sac, open at the lower end, and imperfect in front, where it presents apertures leading into the nose, mouth, and larynx, but closed in other directions, viz. above, behind, and at the sides. The walls of this sac consist of a fascia or layer of fibrous tissue, dense at its upper part, but lax and weak below, surrounded by muscles, and lined by a mucous membrane. Its upper end forms a *cul-de-sac* beneath a cul-de-sac above ; the basilar process, to which and also to the petrous portion of the teinporal bone it is attached by a tendinous expansion, which descends some distance on its posterior and lateral surfaces.
- connexions ; Behind, it is loosely connected by cellular tissue to the prævertebral fascia covering the bodies of the cervical vertebræ and the muscles which rest upon them. At the side it has similar connections, by loose cellular tissue, with the styloid process and its muscles, and with the large vessels and nerves of the neck. In front, the walls of the pharynx are attached in succession to the sides of the posterior nares, the mouth, and the larynx. Thus, commencing above by a tendinous structure only, at the petrous portion of the temporal bone and the Eustachian tube, its walls are connected by means of muscle and fibrous membrane, first, with the internal pterygoid plate, then with the pterygo-maxillary ligament, and next with the mylo-hyoid ridge of the lower jaw : below this, again, they are attached to the sides of the tongue, to the hyoid bone, and stylo-hyoid ligament ; and lastly, to the thyroid and cricoid cartilages.
- length and width. The pharynx is about four inches and a half in length, and is somewhat wider across than it is deep from before backwards. Its width above is moderate ; its widest part is opposite the cornua of the hyoid bone, and below this it rapidly contracts

towards its termination, opposite the cricoid cartilage, which is the narrowest part.

The velum pendulum palati projects backwards into the pharynx, and during the passage of the food is applied to its posterior wall. Seven openings lead into the cavity of the pharynx; viz. above the velum the two posterior openings of the nares ⁽¹⁾, and at the sides the apertures of the Eustachian tubes ⁽⁶⁾; below the velum there is first the passage leading from the mouth ⁽³⁾, then the superior opening of the larynx ⁽⁴⁾, and, lastly, the passage into the œsophagus ⁽⁵⁾.

Openings
into
pharynx
are seven.

Structure.—The *muscles* of the pharynx are the superior, middle, and inferior constrictors, the stylo-pharyngeus, and the palato-pharyngeus (see pp. 282, 289). At the upper end of the pharynx, its structure is strengthened by a firm dense fascia, already referred to, named the pharyngeal aponeurosis, which is attached above to the basilar process, and, at the sides, to the petrous portion of the temporal bones. It diminishes in thickness as it descends.

Its muscles;
fascia;

The *mucous* membrane lining the inner surface of the pharynx is continuous at the several apertures with that of the adjacent cavities. It varies somewhat in its character in different parts. Its upper portion is thick where it adheres to the periosteum of the basilar process, but is much thinner near the entrance of the Eustachian tube and the posterior nares: in this situation numerous *glands* are found collected in a layer beneath the mucous membrane. In the part opposite the fauces, the mucous membrane exactly resembles that of the mouth, and is provided with glands. Lower down it becomes paler, and at the back of the larynx it forms several longitudinal folds or plicæ. According to Henlé, the epithelium upon the upper portion of the pharynx, as low down as a horizontal line level with the floor of the nares, is columnar and ciliated; but, below that point, is squamous and destitute of cilia.

mucous
membrane;
glands,
and
epithelium.

THE ŒSOPHAGUS.

The *œsophagus* or gullet is a membranous tube leading from the pharynx to the stomach, and forming the passage through which the food descends into the latter organ. It commences at the cricoid cartilage, (fig. 258, ⁵.) opposite the

Œsophagus.
Its extent;

fifth cervical vertebra, and, descending along the front of the spine, passes through the diaphragm opposite the ninth dorsal vertebra, and then ends by opening into the cardiac orifice of the stomach, (fig. 262, ².)

The length of the œsophagus is about nine inches. The diameter of its passage is less than that of any other division of the alimentary canal, its smallest part being at the commencement behind the cricoid cartilage; it is also constricted in passing through the diaphragm, but, below that, gradually widens into the stomach. The œsophagus is nearly straight in its direction, having only two or three slight curvatures. Of these, one corresponds with the antero-posterior flexure of the vertebral column in the neck and thorax. It also has two slight lateral bendings, for though at its commencement it is placed upon the median line, yet, towards the root of the neck, it inclines to the left side; from thence to the fifth dorsal vertebra it gradually resumes its position towards the middle line, and, finally, it deviates again to the left, at the same time coming forward towards the œsophageal opening of the diaphragm.

The œsophagus is for the most part applied to the anterior surface of the spine, being connected with it and with the longus colli muscle by loose cellular tissue: the thoracic duct ascends obliquely from right to left, between it and the bodies of the upper dorsal vertebræ, and towards its lower extremity it is placed in front of the aorta. In the *neck*, the œsophagus lies immediately behind the trachea; on each side of it is the common carotid artery, and also a part of the thyroid body, but, as it inclines to the left side, it is in more immediate connection with the left carotid; the recurrent laryngeal nerves ascend between the œsophagus and trachea. In the *thorax*, the gullet is covered in front by the lower part of the trachea, by the commencement of the left bronchus, and by the back of the pericardium. The aorta, except near the diaphragm, where the œsophagus is in front of the vessel, lies rather to the left, and the vena azygos to the right; the pneumogastric nerves descend in close contact with its sides, and form a plexus around it, the left nerve coming down gradually in front, and the right nerve retiring behind it. Lastly, the œsophagus, which is here placed in the interval between the two pleuræ, receives a partial covering on each side from those membranes.

length, and width.

Is not quite straight.

Its connexions

in the neck;

in the thorax.

The walls of the œsophagus are composed of three coats; viz. an external or muscular, a middle or cellular, and an internal or mucous coat.

Structure.
Three coats.

The *muscular* coat consists of two layers of fibres, disposed in different planes, and taking opposite directions; these are an *external* longitudinal layer, and an *internal* circular layer. This twofold arrangement of the muscular fibres of the alimentary canal prevails throughout its whole length; but the two layers are here much thicker, more uniformly disposed, and more evident than elsewhere, except quite at the lower end of the rectum. The external or *longitudinal* fibres are disposed at the commencement of the tube in three fasciculi, seen one in front, and one on each side of the œsophagus. The lateral bundles are blended above with the inferior constrictor of the pharynx; the anterior fasciculus arises from the back of the cricoid cartilage at the prominent ridge, between the crico-arytenoid muscles, and then spreads out obliquely on each side of the gullet as it descends, and soon blends with the lateral bundles to form a continuous layer around the tube. The internal or *circular* fibres are continuous above with those of the inferior constrictor of the pharynx. The rings or circles which they form around the tube have a transverse direction at the upper and lower part of the œsophagus, but in the intervening space are somewhat oblique. At the lower end of the œsophagus, both layers of fibres become continuous with those of the stomach.

Muscular coat consists of

external longitudinal,

and internal circular fibres.

The muscular coat of the upper end of the œsophagus is red, and consists of the striped muscular fibres; but lower down it becomes paler, and is principally composed of the plain muscular fibres. A few striped fibres, however, are found mixed with the others, and have been traced throughout its whole length, and even, it is said, upon the cardiac end of the stomach. (Ficinus.)

Muscular fibres are striped above,

and plain below.

The *cellular* coat is placed between the muscular and mucous coats, and connects them together but very loosely.

Cellular coat.

The *mucous membrane* is of firm texture, and is paler in colour than that of the pharynx or stomach. From its loose connections its outer surface is freely moveable on the muscular tunic; and when the latter is contracted and the œsophagus is shut, as happens when it is not giving passage to

Mucous coat :

food, the sides of the tube are in mutual contact. In this state, the mucous membrane is thrown into longitudinal folds, which disappear on distension of the canal.

Minute papillæ are seen upon this mucous membrane, placed at some distance from each other; and the whole is covered with a thick squamous epithelium, which can be traced as far as the cardiac orifice of the stomach, where it suddenly changes its character, as will be hereafter noticed.

The gullet is provided with many small compound glands, named *œsophageal glands*, which are especially numerous at the lower end of the tube.

THE ABDOMINAL PORTION OF THE DIGESTIVE ORGANS.

That part of the digestive canal which is found beneath the diaphragm, and consists of the stomach and intestines, is situated within the cavity of the *abdomen*, the extent, boundaries, and regions of which may here be briefly explained.

THE ABDOMEN.

The abdomen (*abdere*, to conceal) is the largest cavity in the body, and is lined by an extensive and complicated serous membrane, named the peritonæum.

Including the cavity of the pelvis, which in fact constitutes its lower part, it extends from the diaphragm above, to the levatores ani muscles below; and from the transversales muscles in front, to the spine, the quadrati lumborum, and iliaci muscles behind. All of these structures, excepting the diaphragm and spine, are lined with a fibrous layer or *fascia*, which is differently named according to the parts to which it is attached. Through these several structures, which taken together constitute the walls of the abdomen, several apertures exist for the transmission of vessels or other organs into and out of the cavity. Thus, superiorly, there are three principal apertures in the diaphragm, for the passage of the aorta, the vena cava, and the œsophagus. In front, there is the umbilicus, which is pervious during foetal life, and then transmits the umbilical vessels. Lower down, there is an opening on each side for the femoral vessels, and a second on each side for the spermatic cord in the male, and the round ligament of the uterus in the female. In the pelvic portion of this great cavity

its papillæ are small, and its epithelium is thick.

Its glands.

The abdomen :

its limits,

or walls ; its openings,

above,

in front,

and below.

there is an opening for the termination or outlet of the intestinal canal, and another for that of the genito-urinary passages. To these may be added several smaller openings for blood-vessels and nerves.

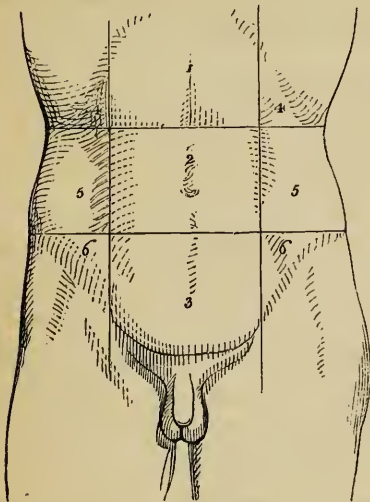
The cavity, as above defined, contains the greater part of the digestive organs, the urinary organs, and the internal organs of generation. It is subdivided into two parts: an upper and larger part, *the abdomen*, properly so called; and a lower part, named the *pelvic cavity*. The limits between the abdominal and pelvic portions of the cavity are marked by the brim of the pelvis.

Its contents, and divisions.

For the purpose of enabling precise reference to be made to the situation and condition of the contained organs, the

The abdomen proper is marked off into regions.

Fig. 261.*



abdomen proper has been artificially subdivided into certain regions, the boundaries of which are indicated by lines drawn upon the surface of the body. Thus, two transverse lines drawn round the body divide it into three zones; viz. an upper, a middle, and a lower. One of these transverse lines, commencing at the most prominent point of the costal cartilages at one side, is drawn across to the corresponding point on the opposite side, and thence round the back to the place

at which it began. The other line, proceeding from the crest of the ilium at one side, extends to that of the other, and so round the body, as in the former instance. These zones are further subdivided into three parts by means of two perpendicular lines, drawn from the cartilage of the eighth rib, at each side, down to the centre of Poupart's ligament.

* Surface of the abdomen, with lines drawn upon it, marking off its artificial subdivision into regions. 1. Epigastric region. 2. Umbilical. 3. Hypogastric or pubic. 4, 4. Right and left hypochondriac. 5, 5. The two lumbar; and 6, 6. The right and left iliac regions.

Names of
those
regions

The upper zone is thus marked off into the right and left *hypochondriac* ($\upsilon\pi\omicron$, under; $\chi\omicron\nu\delta\rho\omicron\varsigma$, the cartilage) *regions* (fig. 261, ⁴ ⁴), and the *epigastric* ($\epsilon\pi\iota$, upon; $\gamma\alpha\sigma\tau\rho\eta$, the stomach) *region* (¹), which is sometimes called *scrobiculus cordis*. The middle zone is divided into the *umbilical* region in the centre (²), and the right and left *lumbar* regions (⁵ ⁵); and the inferior zone into the *hypogastric* or *pubic* region (³), in the centre, and the *iliac* region at each side (⁶ ⁶).

Fig. 262.*

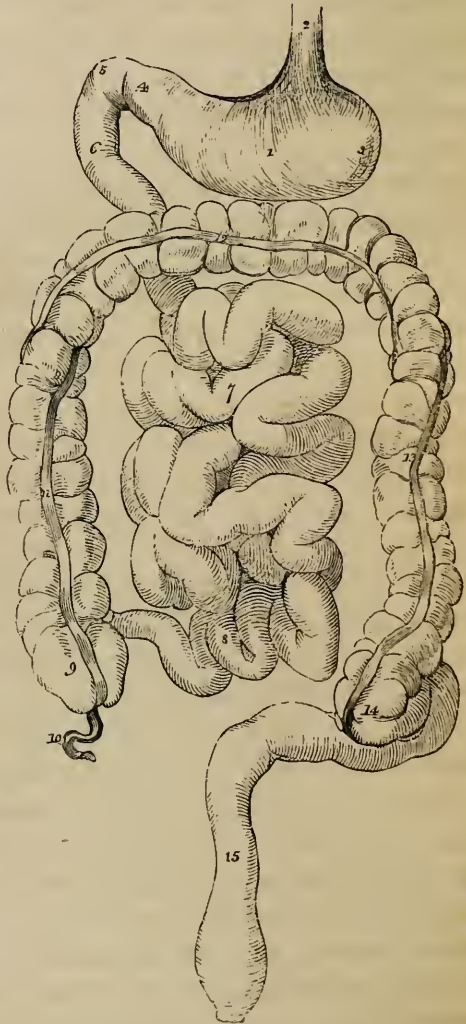
Abdominal
portion of
digestive
canal

Now the subdiaphragmatic or abdominal portion of the alimentary canal, and its several accessory viscera, occupy nearly the whole of the cavity of the abdomen—the urinary organs, and some part of the organs of generation taking up but a very limited space within it.

consists of
stomach,
small intestine,
and large
intestine.

This part of the digestive tube is subdivided into the stomach, (fig. 262, ¹) the small intestine and the great intestine (⁶–¹⁵) distinctions which are founded on evident differences of form and structure. The

small intestine is further distinguished by anatomists into three



* Diagram of the stomach and intestines, to shew their course.—1. Stomach. 2. Oesophagus. 3. Left, and 4. right end of stomach. 5, 6. Duodenum. 7. Convolutions of jejunum. 8. Those of ileum. 9. Caecum. 10. Vermiform appendix. 11. Ascending. 12. Transverse; and 13. Descending colon. 14. Commencement of sigmoid flexure. 15. Rectum.

parts, named the *duodenum* (6), the *jejunum* (7), and the *ileum* (8). The large intestine, also, is distinguished into the *cæcum* (9), the *colon* (11-14), and the *rectum* (15). Moreover, the colon itself is named, in its different parts, the *ascending* (11), *transverse* (12), and *descending* (13) colon; and, at its lower part, presents a remarkable bend, called the *sigmoid flexure* (14).

On opening the abdomen, from the front, these several parts, and also the viscera appended to them, are seen to be more or less covered by the general lining membrane of the cavity, named the peritonæum; and are found to be attached to its posterior and upper walls, by means of folds or duplicatures of that membrane, which include the blood-vessels, nerves, and lymphatics belonging to each organ.

Arrangement of the peritonæum.

A general idea of the position and arrangement of the abdominal viscera may be obtained by referring them to the transverse colon. This portion of the large intestine crosses through the abdomen from right to left, immediately behind the anterior wall, a little above the umbilicus. Together with the peritonæal fold, called the transverse mesocolon, by which it is attached behind, the transverse colon divides the abdominal cavity into two parts, one being above and the other below it.

Position of the viscera of abdomen.

The transverse colon:

Above it, are found the liver, with its excretory apparatus, which occupies the right hypochondrium, a part of the epigastrium, and extends a short way into the left hypochondrium; the stomach, which lies in the epigastric and left hypochondriac regions; the spleen, which is closely applied to the left end of the stomach; and, lastly, the commencement of the duodenum, which is continuous with the right end of the stomach.

parts above it;

Below the transverse colon, and covered by a process of the peritonæum, containing fat, and called the great omentum, are found the convolutions of the jejunum and ileum, attached by the mesentery. These convolutions occupy the umbilical and hypogastric regions, and are surrounded by the large intestine, which occupies the iliac and lumbar regions on each side, and crosses the upper part of the umbilical region, as already mentioned. On lifting up the transverse colon, with its mesocolon, the termination of the duodenum is seen passing under it; and, placed across the spine, at the root of the mesocolon, and above the last portion of the duodenum, is found the pancreas. The rectum, or lower part of the large intestine, passes down into the pelvic cavity.

parts below it.

Parts seen
after
removal of
digestive
organs.

On removing the digestive organs from the abdomen, the kidneys, supra-renal capsules, and ureters, the great blood-vessels, lymphatics and nerves, are found lying quite at the back of that cavity. The bladder when full, and the uterus in its gravid state, project upwards into the abdomen, and displace the small intestine.

THE STOMACH.

The sto-
mach :

The stomach (fig. 262, ¹: γαστήρ) is that dilated portion of the alimentary canal which intervenes between the œsophagus and the duodenum, and within which the food is retained to be acted on by the gastric juice, and to be converted into chyme.

its position,

This organ is seated in the left hypochondriac and the epigastric regions, and in a part also of the right hypochondrium. It is placed across behind the anterior wall of the abdomen, beneath the liver and diaphragm, and above the transverse colon.

shape,

The stomach, when distended, has the shape of an irregular cone having a rounded base and being curved upon itself. The left extremity (³) is the larger, and is named the *great* or *splenic* end of the stomach. The *right* or *small* end (⁴) is also named the *pyloric* extremity. Of its two orifices, the one by which food enters from the œsophagus is named the *cardiac* orifice (fig. 263, *o*), the other, by which the stomach communicates with the duodenum, and which is placed on a little lower level, and more forwards, is the *pyloric* orifice (*q*).

and orifices.

Its extre-
mities

The œsophagus terminates in the stomach two or three inches from the great extremity, which projects beyond that tube to the left, and is named the *great cul-de-sac* or *fundus* (*c*).

and borders.

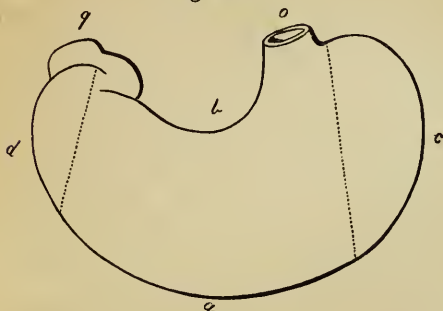
Between the cardiac and the pyloric orifices, the outline of the stomach is curved along its upper and lower borders. The upper border, about three inches in length, is concave, and is named the *lesser curvature* (*b*); while the lower border, which is much longer, and, except towards the pylorus, convex, forms the *greater curvature* (*a*). These two borders or curvatures constitute the limits between the *anterior* and the *posterior* surfaces of the organ.

Towards the pylorus (*q*), the small end of the stomach describes a double bend, opposite to the first turn of which is a

prominence or bulging, sometimes named the *small cul-de-sac* or *antrum pylori* (*d*).

Dimensions.—These vary greatly according to the state of Size.

Fig. 263.*



distension of the organ. When moderately filled, its length is about ten or twelve inches; and its diameter, at the widest part, from four inches to four inches and a half. According to Clendinning, it weighs, when freed from other parts, about four

ounces and a half in the male, and somewhat less in the female.

Connections.—The stomach is in contact with many surrounding parts, to several of which it is attached in different ways. Connex-ions.

Its anterior and posterior surfaces are free, smooth, and covered with peritonæum. The anterior surface, which is directed slightly upwards as well as forwards, is in contact above with the diaphragm and the under surface of the liver, and lower down with the abdominal parietes opposite to the epigastric region, which is hence named the *pit* of the *stomach*. The posterior surface is turned downwards and backwards, and rests upon the transverse meso-colon, and further back, upon the pancreas and great vessels of the abdomen. Covered in front and behind by peritonæum.

At its cardiac orifice it is continuous with the œsophagus, and is, therefore, fixed to the œsophageal opening in the diaphragm, being also connected with that muscle by a reflection of the peritonæum, sometimes named the *gastro-phrenic ligament*. This is, therefore, the most fixed part of the stomach, and is placed higher, and at the same time further back, than any other part of the organ. The pyloric extremity, situated lower down, nearer to the surface, and having greater freedom of motion, is continuous with the duodenum. It is covered by the concave surface of the liver, and, in some cases, touches the Attached by the œsophagus, the gastro-phrenic ligament, and the duodenum;

* Diagram outline of stomach.—*a*. Great curvature. *b*. Lesser curvature. *c*. Left end, great cul-de-sac or fundus. *d*. Small cul-de-sac or antrum pylori. *e*. Œsophageal orifice or cardia. *g*. Duodnal orifice or pylorus.

neck of the gall-bladder. The lesser curvature, which is turned upwards and backwards, is connected by means of a fold of the peritonæum, named the lesser or *gastro-hepatic omentum*, with the under surface of the liver. From the greater curvature of the stomach proceeds another double layer of peritonæum, loaded with fat, which is called the great or *gastro-colic omentum*. The duplicature of peritonæum, forming the gastro-hepatic omentum, having reached the lesser curvature of the stomach, separates into its two layers, of which one passes over the anterior surface, and the other upon the posterior surface of the organ, as far to its greater curvature: here they again become applied to one another, and, leaving the stomach, pass down in front of the small intestine, and form the great omentum, which, again turning upwards, becomes attached to the transverse colon. The blood-vessels and lymphatics of the stomach pass within these duplicatures of the peritonæum, and reach the organ along its two curvatures. Lastly, the great cul-de-sac is in contact partly with the diaphragm, but chiefly with the concave surface of the spleen, with which it is connected by means of a fold of peritonæum, named the *gastro-splenic omentum*, and by its contained vessels.

also by the
gastro-
hepatic,

gastro-colic,

and gastro-
splenic
omenta.

Position of
stomach
liable to
variation.

When the stomach is distended, its position and direction are changed. The œsophageal end being fixed to the back part of the diaphragm cannot alter much, but the duodenal extremity has more liberty of motion. The lesser curvature is, also, tolerably well fixed to the liver by the small omentum, while the great curvature is the most moveable part: accordingly, when the stomach is distended, this curvature is elevated and at the same time carried forwards, whilst the anterior surface is turned upwards and the posterior surface downwards.

Structure :
consists of
four coats.

Structure.—The walls of the stomach consist of four distinct coats, held together by fine cellular tissue. They are named, in order from within outwards, the serous, muscular, cellular, and mucous coats. By some the cellular coat is not reckoned as a separate tunic. Taking all the coats together, the walls of the stomach are thinner than those of the œsophagus, but rather thicker than those of the intestines generally. They are thickest at the pyloric end, and thinnest in the great cul-de-sac.

Serous coat
is external,

The *external* or *serous* coat, derived from the peritonæum, is a thin, smooth, transparent, and elastic membrane, which covers

the entire viscus, excepting along its two curvatures, from which, as already mentioned, it is reflected so as to form the small and great omenta. Along the place of this reflection, between the borders of the stomach and the two layers of the peritonæum, is a three-sided space, occupied by loose cellular tissue, and containing the larger blood-vessels and lymphatics of the organ, which, in this way, reach and run along the two curvatures. The existence of this space, and the loose nature of the attachment of the peritonæal tunic in its neighbourhood, must facilitate the alternate distension and collapse of the stomach. In other situations, the serous coat adheres firmly to the muscular coat.

and is part of peritonæum ;

is wanting along the borders.

The second, or *muscular*, coat is composed of three sets of fibres, named, from their direction, the longitudinal, the circular and the oblique fibres, which form three layers.

Muscular coat :

The first, or outermost layer consists of the *longitudinal* fibres, which are, in fact, a continuation of those of the œsophagus. They spread out in a radiating manner from the cardiac orifice, for which reason they are sometimes called the *stellate* fibres, and are found in greatest abundance along the curvatures, especially on the lesser one. On the anterior and posterior surfaces they are very thinly scattered, or are not to be found at all. Towards the pylorus they are arranged more closely together and form a thicker uniform layer, which becomes continuous with the longitudinal fibres of the duodenum.

consists of external longitudinal,

The second set are the *circular* fibres, which form a complete layer over the whole extent of the stomach. They commence by small and thinly scattered rings at the left extremity of the great cul-de-sac, describe larger and larger circles as they surround the body of the stomach, and towards the pyloric end again form smaller rings and at the same time become much thicker and stronger than at any other point. At the pylorus itself, they are gathered into an annular bundle, which projects inwards into the cavity and forms, together with a covering of mucous membrane, the pyloric sphincter.

middle or circular,

The innermost muscular layer is incomplete, and consists of the *oblique* fibres. These oblique fibres are continuous with the circular fibres of the gullet ; they embrace the cardiac orifice on the left, where they form a considerable stratum, and from that point descend obliquely upon the anterior and posterior surfaces of the stomach, where they spread out from one

and internal or oblique fibres.

another and gradually disappear. They are best seen from the inside of the stomach, after removing the mucous membrane.

The fibres are involuntary.

The muscular fibres are of a pale reddish colour. They belong to the class of plain fibres, but amongst them, however, Ficinus and Valentin have found some connected with the longitudinal layer which are indistinctly striated.

Cellular or fibrous coat; also called sub-mucous, nervous,

The *cellular*, or fibrous coat of the stomach is a tolerably distinct layer placed between the muscular and mucous coats, and connected with both. It has also been named from its position the *submucous* coat, and from its white colour, the *nervous* tunic; but it consists essentially of a dense filamentous areolar tissue. It serves to support the mucous coat, and also forms a layer in which the blood-vessels ramify before they enter that membrane: hence it is sometimes called the *vascular* coat. This is not the only cellular layer in the walls of the stomach, for one may be demonstrated between the muscular and serous coats, serving to connect them together, but it is very fine and is not described as a separate tunic.

or vascular coat.

Mucous coat: its colour varies during health.

The internal, or *mucous*, coat is a smooth, soft, rather thick and pulpy membrane, which has generally a palish pink hue owing to the blood in its capillary vessels, but which, after it has been well washed, is of a greyish white or pale straw colour. In some cases, however, it presents this pale aspect without any previous washing. In infancy the vascular redness is more marked, the surface having then a rosy hue, but it becomes paler in childhood, and in aged persons is often of an ash-grey colour. During digestion its vessels become congested, and when examined in that condition it is always much darker than usual.

Post-mortem changes, and other alterations of interest.

After death a few hours will often suffice to change its colour to a dirty brown tint, mottled and streaked in some cases with dull red lines, corresponding with the course of the veins. This alteration is owing to the exudation of the colouring matter of the blood, and is especially met with in old subjects, in whom the mucous membrane is always thin. In acute inflammation, or after the introduction of irritating substances or of strong acrid poisons, it becomes of a bright red, either all over or in spots, patches or streaks of variable sizes. Corrosive poisons, the gastric juice, and sometimes regurgitating bile, may stain it variously, black, brown, yellow, or green; and the effect of chronic inflammation is to leave the membrane of a slate-grey colour.

Independently of all these modifying circumstances connected with the

stomach itself, as was pointed out by Dr. Yelloly and others, the colour of the gastric mucous surface is liable to be influenced by causes of a more general nature. Thus, it has been found that in cases of obstructed venous circulation, as when death occurs from hanging or from drowning, and also in certain diseases of the heart, the internal surface of the stomach is reddened to a greater or less extent; but the amount of vascularity may vary from circumstances which are not well understood, and may be found greatly increased in cases in which none of those already named exist.

The gastric mucous membrane is thickest in the pyloric portion of the stomach, and thinnest in the great cul-de-sac. It always becomes thinner in old age. Its thickness.

The outer or *adherent* surface of the mucous membrane is connected with the muscular coat so loosely as to be moveable upon it. In consequence of this, and of the great extent and want of elasticity of the mucous membrane as compared with the other coats, the internal surface of the stomach, when that organ is in a contracted state, is thrown into numerous convoluted ridges, *rugæ*, which are produced by the puckering of the mucous, accompanied by the cellular coat, and are entirely obliterated by distension of the stomach. These folds of the mucous coat are most evident along the great curvature, and have a general longitudinal direction. Rugæ, or folds.

On examining the gastric mucous membrane closely with the aid of a simple lens, it is seen to be marked throughout, but more plainly towards the pyloric extremity, with little depressions or cells named *alveoli*, (fig. 264,) which have a polygonal figure, and vary from about $\frac{1}{200}$ th to $\frac{1}{100}$ th of an inch across, being larger and more oblong near the pylorus. The alveoli, or cells.

Fig. 264.*

E



Towards the pyloric region of the stomach, where the mucous membrane is thicker than elsewhere, the margins of these alveoli are elevated into pointed processes, which may be compared to rudimentary *villi*, the perfect Fringes, or rudimentary villi.

forms of those appendages existing only in the small intestine, and making their appearance in the duodenum, immediately beyond the pylorus.

* View of the cells of the mucous membrane of the human stomach, magnified thirty-two diameters. After Dr. Sprott Boyd. The hexagonal cells with their intermediate elevated margins, and the mouths of the tubuli at the bottom of each, are shewn.

The tubuli
of the
stomach :

their size,

form,

and struc-
ture.

Mucous

At the bottom of the alveoli or pits above described, and also in the intervals between them, are seen small round apertures, which are the mouths of minute tubes, placed perpendicularly to the surface, closed at their attached or deep extremity which rests on the submucous cellular tissue, and opening at the other on the inner surface of the stomach. On making a vertical section of the membrane, and submitting it to the microscope, it is seen to consist almost entirely of these small *tubuli*, arranged close to, and parallel with each other, (fig. 265.) Their diameter varies from $\frac{1}{500}$ th to $\frac{1}{360}$ th of an inch, and their length from $\frac{1}{60}$ th to $\frac{1}{20}$ th of an inch. At the cardiac end of the stomach, where the membrane is thinnest, they are shorter and are simply tubular; but, in approaching the pyloric portion, they gradually become longer and assume a more complicated form, for though quite straight near their orifices, they are convoluted or irregularly sacculated towards their deep or closed extremity. These characters are most perfect near the pylorus. Sometimes two or more of these compound tubuli unite, and open by a single orifice. They exist at all parts of the stomach, even where the alveoli are indistinct or absent; they contain a colourless fluid, with granular matter, and appear to be the secreting organs of the gastric juice. They are formed of a simple homogeneous membrane, lined by a columnar epithelium, (fig. 266), which becomes spheroidal towards their closed extremity.

In some cases, much more evidently than

Fig. 265.*

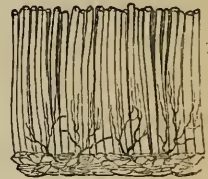
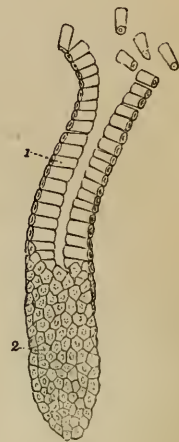


Fig. 266.†



* Section of the mucous membrane of the stomach of the Pig, made perpendicular to the surface, showing the tubuli: the blood-vessels in the submucous cellular tissue are injected. Magnified about twenty diameters. (Boyd.)

† One of the tubuli from the stomach of the Pig. It is cut obliquely, and shows the columnar epithelium with which it is lined; at the lower part the outer or attached ends of the columnar particles are seen, with their contained nucleus. After Wasmann.

in others, the surface of the mucous membrane in the pyloric portion of the stomach, and also along the adjacent part of the great curvature, presents to the naked eye numerous rounded and whitish eminences, surrounded by slight circular furrows. Cruveilhier suggests that the term granular or glandular might be applied to stomachs having this appearance. The eminences in question have been carefully examined by Bischoff, who states that they have no peculiar structure, and are merely thicker portions of the mucous membrane. But although a finely mamillated or convoluted appearance (somewhat like the surface of the brain represented in miniature) of the mucous membrane of the stomach may be caused by simple elevations which are not glandular, this membrane is nevertheless provided with lenticular follicles, which when unusually prominent give rise to an appearance similar to that above described. These follicles are marked with a depression in the centre, and are found in greater or less numbers all over the stomach, but are most numerous towards the pylorus. They are best seen in the stomachs of infants and children. Around the cardiac orifice they assume the character of multilocular crypts.

membrane is studded with small eminences,

of which some are glandular.

The mucous membrane of the stomach is covered with an epithelium, so thin, however, that its existence was long doubted by anatomists, who conceived that the epithelial layer ceased at the festooned border of the œsophageal mucous membrane. A distinct epithelium exists all over the stomach, covering the margins and floors of the alveoli, and lining the tubuli also (fig. 266). It for the most part belongs to the columnar variety, alternating in some parts with the squamous, which is composed of very minute polygonal scales.

Its epithelium.

Vessels and nerves.—The stomach is a highly vascular organ. Its *arterial* branches, derived from all three divisions of the cœliac axis, reach the stomach between the folds of the peritonæum, and form, by anastomosing together, two principal arterial arches, which are placed along its two curvatures. That situated along the lesser curvature is formed by the union of the coronary artery and the pyloric branch of the hepatic artery; while the one found at the great curvature is formed by the junction of the right gastro-epiploic branch from the hepatic artery, and the left gastro-epiploic from the splenic. Besides these, the great cul-de-sac receives the vasa brevia, which are branches

Arteries of stomach are branches of cœliac axis.

of the splenic artery. After ramifying between the several coats and supplying them with blood, and especially after dividing into very small vessels on the submucous cellular tunic, the ultimate arterial branches enter the mucous membrane, and ramifying freely, pass to its surface between the tubuli, and end in a capillary network upon the hexagonal borders of the alveoli.

The veins, The *veins*, corresponding with the arteries, return the residual blood into the splenic and superior mesenteric veins, and also directly into the vena portæ.

lymphatics, The *absorbents* are very numerous; they form a deep and a superficial set, and pass through lymphatic glands found along the two curvatures of the stomach.

and nerves. The *nerves*, which are large, consist of the terminal branches of the two pneumo-gastric nerves, belonging to the cerebro-spinal system, and of offsets from the sympathetic system, derived from the solar plexus. The left pneumo-gastric nerve descends on the front, and the right upon the back of the stomach.

The pylorus; The *Pylorus*.—While there is no special apparatus at the cardiac orifice of the stomach for closing the passage from the œsophagus, the opening at the pyloric end, leading from the stomach into the duodenum, is provided with a sphincter muscle. On looking into the pyloric end of the stomach, the mucous membrane is seen projecting in the form of a circular fold, called the *pylorus*, leaving a correspondingly narrow opening. Within this fold are circular muscular fibres, belonging to the general system of circular fibres of the alimentary canal, which are here accumulated in the form of a strong band, whilst the longitudinal muscular fibres and the peritonæal coat pass over the pyloric fold to the duodenum, and do not enter into its formation. Externally the pylorus may be easily felt, like a thickened ring, at the right end of the stomach. Internally its opening is usually circular, and less than half an inch across, so that it is the narrowest part of the whole alimentary canal. Occasionally the orifice is oval, and it is often placed a little to one side. Sometimes the circular rim is imperfect, and there are found instead two crescentic folds, placed one above and the other below the passage (Huschke); and, lastly, there is occasionally but one such crescentic fold.

its position, and structure.

Its opening;

presents certain varieties.

THE SMALL INTESTINE.

The remaining part of the alimentary tube, extending from the stomach to the anus, constitutes the *intestines*, or the intestinal canal. It is divided into two portions, one named the small intestine, in which the bile and the pancreatic juice are added to the digestive mass, and the fluid chyle is formed and fitted for absorption by the lacteal vessels; and the other called the large intestine, through which the residual and excrementitious matter is conveyed out of the body.

The intestines divided into small and large.

The *small intestine* (*intestinum tenue*; fig. 262, ^{6, 7, 8}) reaches from the pylorus to the ileo-colic valve, at which it opens into the large intestine. It consists of a long tube, having a convoluted course, measuring on an average about twenty feet in the healthy adult, and becoming gradually, though slightly, narrower from its upper to its lower end. Its numerous convolutions occupy the middle regions of the abdomen, and are surrounded by the large intestine. They are connected with the back of the abdominal cavity, and are held in their position by a covering and fold of the peritonæum, named the mesentery, and by numerous blood-vessels and nerves.

Small intestine, twenty feet long, and convoluted;

The small intestine is arbitrarily divided into three portions, which have different names; the first eight or ten inches immediately succeeding to the stomach, and comprehending the widest and most fixed part of the tube, being called the *duodenum* (⁶), the upper two-fifths of the remainder being named the *jejunum* (⁷), and the lower three-fifths the *ileum* (⁸). There are no distinct lines of demarcation between these three parts, but there are certain peculiarities of connection and certain differences of internal structure to be observed in comparing the upper and lower ends of the entire tube, which will be pointed out after it has been described as a whole.

divided into duodenum, jejunum, and ileum.

Structure.—The walls of the small intestine are composed of four coats, resembling those of the stomach in their nature and relative position, and named accordingly the serous, muscular, cellular, and mucous coats.

Its structure: consists of four coats.

The external or *serous* coat is a thin transparent tunic, smooth on its outer surface, and attached firmly at its inner side by means of cellular tissue to the succeeding or muscular coat. Derived from the peritonæum, this serous coat almost entirely

Serous coat

is peri-
toneal ;

surrounds the intestinal tube, leaving only a narrow interval along one border of the intestine, where it is reflected from it and becomes continuous with the two layers of the peritonæal duplicature named the mesentery. The line at which this reflection takes place is named the *attached* or *mesenteric border* of the intestine. The opposite border and sides of the tube, which are covered by the peritonæum, are quite free and moveable upon the adjacent parts.

covers all
but attach-
ed border,
and forms
mesentery.

The
mesentery ;
its uses ;

The mesentery itself, which is some inches broad, is connected at its posterior margin with the back of the abdomen, so that it serves to support the intestine, and at the same time leaves it capable of a considerable degree of movement. The blood-vessels, lacteals, and nerves are also conveyed along the mesentery, and reach the intestine at its attached border, where for a small space the serous coat is wanting.

is wanting
at duode-
num.

The upper part of the small intestine, named the duodenum, is but partially covered by the peritonæum, which there forms no mesentery.

Muscular
coat :

consists of
longitudinal
and circular
fibres ;

The *muscular* coat consists of two layers of fibres ; an outer longitudinal, and an inner or circular set. The *longitudinal* fibres are but very thinly scattered, and are most obvious along the free border of the intestine. The *circular* layer is much thicker and more distinct ; its fibres are placed closely together, and run in a circular direction around the bowel, but it does not appear that they individually form perfect rings.

of the
plain kind.

Vermicular
or peristal-
tic move-
ments.

This muscular tunic becomes gradually thinner towards the lower part of the small intestine. It is pale in colour, and is composed of plain muscular fibres. The progressive contraction of these fibres, commencing in any part of the intestine, and advancing in a downward direction, produces the peculiar *vermicular*, or *peristaltic* movement, by which the digestive mass is forced onwards through the canal. In this movement the circular fibres are mainly concerned ; but the longitudinal fibres also aid in it ; and those found along the free border of the intestine will evidently straighten or unfold, as it were, its successive convolutions.

Cellular
coat :

The *cellular* coat of the small intestine is a tolerably distinct and whitish layer, of a loose texture, which is connected more firmly with the mucous than with the muscular coat, between which two it is placed. By turning a portion of the intestine

inside out, and then blowing forcibly into the cavity, the cellular tunic may be inflated, the air being driven into its areolar tissue, through the part at which the peritonæal investment is wanting. This cellular, or, as it is by some named, sub-mucous coat, supports the mucous membrane, and forms a sort of layer in which the vessels divide and subdivide into smaller branches preparatory to entering the mucous tissue. It consists of filamentous cellular tissue, mixed with fine elastic fibres.

affords a nidus for the vessels.

The internal or *mucous* coat is characterised by presenting all over its inner surface a finely flocculent, or shaggy appearance, like the pile upon velvet, owing to its being covered with multitudes of minute processes, named *villi*; hence it is also named the *villous* coat. It is one of the most vascular membranes in the whole body, and it is naturally of a reddish colour in the upper part of the small intestine, but becomes paler, and at the same time thinner towards the lower end. It presents for consideration, 1. the epithelium; 2. the large *folds* called *valvulæ conniventes*; 3. the *villi*; 4. the *glands*; and 5. the vessels.

Mucous coat:

is covered with villi, and is highly vascular.

1. *Epithelium*.—Every part of the surface is covered by a thin, transparent *epithelium*, of the columnar or cylindrical kind. The prismatic particles of this covering are represented in fig. 268.

Its epithelium is columnar.

2. *Valvulæ Conniventes*.—The folds and wrinkles found upon the inner surface of the œsophagus and stomach may be completely obliterated by full distension of those parts of the alimentary canal. In the lining membrane of the small intestine, however, there exist, beside such effaceable folds, other permanent ones, which cannot be obliterated, even when the tube is forcibly distended. These permanent folds are the *valvulæ conniventes*, or valves of Kerkring. They are crescentic projections of the mucous membrane, placed transversely to the course of the bowel, each of them reaching only about one-half or two-thirds of the distance around the interior of the tube, and following closely upon one another along the intestine.

Its valves, or valvulæ conniventes:

The largest of these valves are about two inches long and one-third of an inch wide at the middle or broadest part; but the greater number are under these dimensions. Large and small valves are often found to alternate with each other. Some of them are bifurcated at one end, and others terminate

their size, shape, and structure.

abruptly, appearing as if suddenly cut off. Each valve consists of a fold of the mucous membrane, that is, of two layers placed back to back, united together by cellular tissue. They contain no muscular fibres, and are therefore not contractile. Being extensions of the mucous membrane, they serve to increase the absorbent surface to which the food is exposed, and at the same time they contribute to delay its passage along the intestine.

Valves
begin a
short dis-
tance below
pylorus,

continue to
middle of
ileum, and
then cease.

The villi :

their forms,

length, and
width,

numbers,

and struc-
ture.

There are no valvulæ conniventes quite at the commencement of the duodenum; about an inch or somewhat more below the pylorus they begin to appear; beyond the point at which the bile and pancreatic juice are poured into the duodenum they are very large, regularly crescentic in form, and placed near to each other; they continue thus through the rest of the duodenum and along the upper half of the jejunum; below that point they begin to get smaller and further apart; and finally, towards the middle of the ileum, having gradually become more and more irregular and indistinct, sometimes even acquiring a longitudinal direction, they altogether disappear.

3. *Villi*.—The *villi*, peculiar to the small intestine, which give to its internal surface the velvety or villous appearance already spoken of, are small, elongated, and highly vascular processes, which are found situated closely together over every part of the mucous membrane, upon the valvulæ conniventes, as well as between them. (See fig. 269.) They are best displayed by putting a piece of intestine, well cleansed from its mucus, under water, and examining it with a simple lens. The prevalent form of the villi is that of minute, flattened, triangular processes; others are conical or cylindrical, or even clubbed at the free extremity. Two or even three villi are occasionally seen connected together at their base.

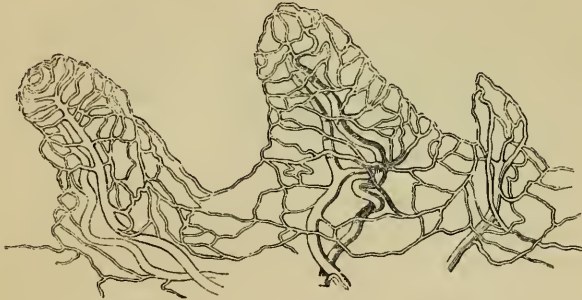Their *length* varies from $\frac{1}{4}$ th to $\frac{1}{3}$ d of a line, or even more; and the broad flattened kinds are about $\frac{1}{6}$ th or $\frac{1}{8}$ th of a line wide, and $\frac{1}{20}$ th or $\frac{1}{24}$ th of a line thick. They are largest and most numerous in the duodenum and jejunum, and become gradually shorter, smaller, and fewer in number in the ileum. In the upper part of the small intestine Krause has estimated their number at from 50 to 90 in a square line; and in the lower part at from 40 to 70 in the same space: he calculates their total number to be at least four millions.

The *structure* of these villi is complicated: each consists of a

prolongation of the simple membrane, which forms the surface of the proper mucous layer, covered by epithelium and inclosing blood-vessels and lacteal vessels, with a greater or less number of small granular corpuscles and fat globules, of various sizes :

They are extensions of mucous coat.

Fig. 267.*



nerves have not yet been demonstrated in the villi, though they probably are not wanting. Each villus receives one or more small *arterial* twigs, which divide, and form upon its surface, beneath the epithelium and limiting membrane, a fine capillary network, from which the blood is returned for the most part by a single *vein*. The villi also contain *absorbent* vessels, which at the base of each villus pass into the general network of the lacteals of the mucous membrane. Their mode of origin within the villi is not yet determined with certainty. By most old observers, as Lieberkuehn, Hunter, Cruikshank, and Hewson, the lacteals were supposed to commence at the free surface of the villi by one or more *open* mouths ; but all the modifications of this opinion are now given up, and the best authorities agree in believing that they form a *closed* system of vessels. This view, indeed, had been advocated by Mascagni, Albert Meckel, and Rudolphi, who considered that they commenced by a *network*. Henlé states that he has found only a single lacteal vessel, with a free, distended, but closed extremity in each cylindrical villus, and two such vessels not anastomosing together in the broader villi. Krause has figured the main lacteal of a villus as beginning by several branches, some having free and closed extremities, and others joining in a network ; but it is questionable

Their blood-vessels and lacteals :

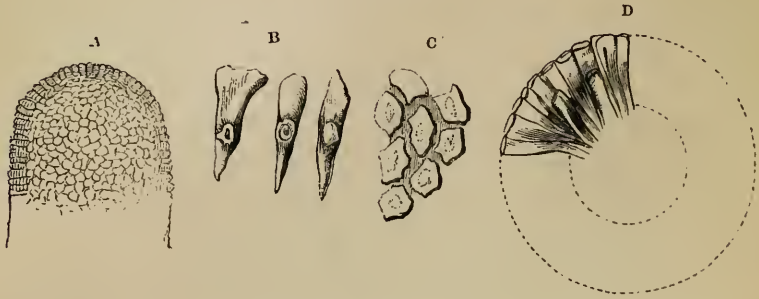
the latter form a closed system of vessels.

* Magnified view of the blood-vessels of the intestinal villi, showing an artery and vein, and a superficial capillary network. After a preparation injected by Lieberkuehn.

Their
epithelium.

whether this appearance may not be owing to reticular vessels imperfectly filled. The epithelium (fig. 268) forms a thin, transparent, but very distinct layer upon the surface of the villi. (A.)

Fig. 268.*



It resembles the epithelial covering of the rest of the mucous membrane, and consists of elongated, prismatic, columnar particles (B C), arranged compactly together, and perpendicularly to the surface (D).

Intestinal
glands.

4. *Glands*.—The glandular structures found in the mucous coat of the small intestine are the crypts or follicles of Lieberkuehn, the solitary glands, the patches of Peyer's glands, and Brunner's glands, the last being peculiar to the duodenum.

Crypts of
Lieber-
kuehn ;
are small
tubes ;

The *crypts* of Lieberkuehn, the smallest of these glandular structures, are found in every part of the small intestine, between the villi and surrounding the larger glands. They consist of minute tubes, closed at their attached extremity, and placed more or less perpendicularly to the surface, upon which they open by little orifices. (See fig. 269, 270.) They appear to be analogous to the tubuli of the stomach, but they are invariably simple in form, and are placed further apart from each other. Similar tubules are found in the large intestine also. The crypts of Lieberkuehn vary in length from the $\frac{1}{50}$ th to the $\frac{1}{20}$ th of a line, and their diameter is about $\frac{1}{50}$ th of a line. The walls of the tubes are thin, and lined with a columnar epithelium: their contents are fluid and trans-

their size

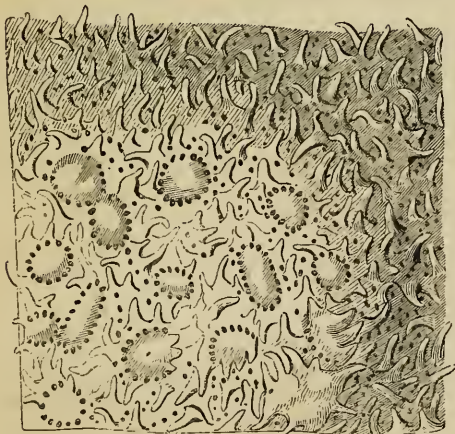
* Epithelium of small intestine, magnified (Henlé).—A. Ideal representation of the surface of a villus, showing the ends of the epithelium particles. B. Columnar particles of epithelium from the jejunum. C. Columns of intestinal epithelium viewed from their free extremities. D. The same, as seen in a cross section of an intestinal villus.

parent, with granules interspersed. These crypts are sometimes filled with a whitish substance, which most probably consists chiefly of desquamated epithelium and mucus.

The *agminated glands*, or *glands of Peyer*, (who discovered and described them in 1677,) are found in groups or patches, having an oblong figure, and varying from half an inch to two or even four inches in length, and being about half an inch or rather more wide. These patches are placed lengthways in the intestine at that part of the tube most distant from the mesentery; and hence, to obtain a view of them, the bowel should be opened along its attached border.

The patches of Peyer's glands (see fig. 269 and its description) consist of groups of small, round, flattened vesicles or capsules, usually filled with a whitish semi-fluid matter, and

Fig. 269.*



situated beneath the mucous membrane, the surface of which is depressed into little shallow pits, at or rather under the bottom of which the capsules are placed. The intermediate surface of the membrane is beset with villi and Lieberkuehn's crypts: the villi are also sometimes found even over the capsules, and the crypts are collected in circles around the capsules, but do not communicate with them. In some subjects these small capsules are found almost empty, and then they are difficult of detection. They are usually entirely closed; but it has been supposed that they open from time to time to dis-

Peyer's glands are in oblong patches on free border of the bowel;

consist of groups of capsules,

which are usually closed, but may open occasionally.

* Enlarged view of a part of a patch of Peyer's glands. (Boehm.) It shows the different forms of the individual vesicles, the zone of foramina belonging to Lieberkuehn's follicles around each, the mouths of other of those follicles and numerous villi situated between the vesicles, not upon them, and, lastly, the surrounding darker part of the mucous membrane beset merely with villi and follicles.

charge their contents into the intestine, for Krause has observed that in the pig they are occasionally open, and a similar observation has since been made by Dr. Allen Thomson, not only in the pig, but in the human intestine also.

Coats of intestine beneath are adherent and vascular.

Opposite to the patches of Peyer's glands, the mucous and cellular coats of the intestine adhere more closely together than elsewhere, so that in those situations it is impossible to inflate the cellular coat. The corresponding parts of the intestine are also exceedingly vascular; and the lymphatic vessels form plexuses, which correspond in figure with the patches and may be very readily injected.

Patches are twenty to thirty.


In all, there are from twenty to thirty of these oblong patches. They are larger and placed at shorter distances from each other, in the lower part of the ileum; but in the upper portion of that intestine and in the lower end of the jejunum, the patches occur less and less frequently, become smaller, and are of a nearly circular form.

Still smaller irregularly shaped clusters of these capsules are found scattered throughout the intestine, and may be regarded as transitions to the next form of glands, named *solitary*, which differ from the agminated glands only in the circumstance of being separate.

The solitary glands are like single capsules of Peyer's.

The *solitary glands* (*glandulæ solitariæ*) are soft, white, rounded, and slightly prominent bodies, about the size of a millet-seed, which are found scattered over the mucous membrane in every part of the small intestine. They are found on the mesenteric as well as on the free border, between and upon the *valvulæ conniventes*, and are rather more numerous in the lower portion of the bowel. These small glands have no orifice, but consist of closed vesicles or capsules (fig. 270.), exactly resembling those forming the clusters of Peyer's glands, having rather thick but easily destructible walls, and usually containing in their interior an opaque, whitish fluid, which abounds in fine granules. The free surface of the capsules, which is slightly

Fig. 270.*



* Solitary gland of the small intestine, magnified. (Boehm.)—The surface is beset with villi: the mouths of numerous crypts of Lieberkuehn are also seen.

elevated when they are full, is beset with the intestinal villi; and, placed around them very irregularly, are seen the open mouths of the crypts of Lieberkuehn.

The nature of the solitary and agminated glands is, after all, very obscure, and their use not understood. From the observations of Krause and Thomson, it is to be presumed that their thick and granular contents are poured from time to time into the intestinal canal.

Brunner's glands are small rounded compound glands, first pointed out by Brunner, which exist in the duodenum, where they are most numerous at the upper end; according to Huschke, they are also found quite at the commencement of the jejunum. They are embedded in the cellular tunic, and may be exposed by dissecting off the muscular coat from the outside of the intestine. They are true compound glands, consisting of minute lobules, and containing branched ducts, which open upon the inner surface of the intestine. Their secretion has not been examined, but it is probably of importance in the digestive process.

Brunner's glands found only in the duodenum.

5. *Blood-vessels and absorbents*.—The branches of the mesenteric artery, having reached the attached border of the intestine, pass round its sides, dividing into numerous ramifications and frequently anastomosing at its free border. Most of the larger branches run immediately beneath the serous tunic; many pierce the muscular coat, supplying it with vessels as they pass, and having entered the submucous cellular layer, ramify in it, so as to form a close network, from which still smaller vessels pass on into the mucous coat, and terminate in the capillary network of the folds, villi, and glands of that membrane, which is the most vascular of all the intestinal tissues. The fine capillaries of the muscular coat are arranged in two layers of oblong meshes, which accompany and correspond in direction with the longitudinal and circular muscular fibres. The *veins* accompany the arteries.

Blood-vessels of small intestine:

arrangement within the coats.

The *absorbents* are also very numerous, and consist of a superficial and a deep set, which commence by a network on the mucous and serous surfaces of the bowel. The superficial network forms longitudinal meshes arranged like the fibres of the external muscular layer; while the deep set, in which the lacteals of the villi terminate, form a network with meshes arranged trans-

Absorbents are superficial or lymphatic, and deep or lacteal;

end in mesenteric glands. versely like the circular muscular fibres. The two sets unite freely together, and at the attached border of the intestine end in numerous larger vessels, which pass off between the layers of the mesentery, and enter the mesenteric glands.

THE DUODENUM.

The duodenum : The *duodenum* (fig. 281, *d*) extends from the pylorus (*p*) to the place where the superior mesenteric vessels (the artery is marked *n*,) coming forwards beneath the lower border of the pancreas, cross vertically over the intestinal tube to reach the root of the mesentery.

its length referred to in its name; This is the shortest and widest part of the small intestine. It measures only 8 or 10 inches, or nearly about the breadth of *twelve* fingers; hence its name.

its diameter; curved course. Its diameter varies between an inch and a half, and an inch and three quarters.* The course of the duodenum is also peculiar, for it describes a single large curve somewhat resembling a horse-shoe, the convexity of which is turned towards the right, whilst the concavity is in the opposite direction, and embraces the head of the pancreas.

Its peculiarities as to position, peritonæum and structure. It is also placed more deeply, and held more fixedly in its position than the rest of the small intestine. It has no mesentery, and is covered only partially by the peritonæum. Its muscular coat is thicker; and its mucous membrane is the seat of the compound glands of Brunner. Lastly, the common bile-duct and the pancreatic duct open into this part of the intestinal canal.

Course and connections of its ascending, Three portions of the duodenum, differing from each other in their course and connections, are separately described by anatomists; viz. the ascending, descending and transverse portions.

The first, or *ascending* portion, which is about two inches long, commences at the pylorus, and passing upwards, backwards, and to the right side, reaches as far as beneath the neck of the gall-bladder, where the intestine bends suddenly downwards. This first portion of the duodenum is for the most part free, and entirely surrounded by the peritonæum. Above, and

* These and other measurements relating to the intestinal canal are given on the authority of Huschke.

in front of it, are the liver and gall-bladder, and it is commonly found stained by the exudation of bile from the latter a few hours after death. Behind it, is the hepatic duct, with the blood-vessels passing up to the liver.

The second, or *descending* portion, commencing at the bend below the neck of the gall-bladder, passes vertically downwards in front of the right kidney as low as the second or third lumbar vertebra, where the bowel turns across to the left to form the transverse portion. This part of the duodenum is the least perfectly invested by the peritonæum, which covers only its anterior surface,—the posterior surface being connected to the right kidney and the vertebral column, by cellular tissue. In front is the transverse colon and mesocolon, the upper layer of which is continuous with the peritonæal covering of the duodenum. To the left is the head of the pancreas, which adapts itself to the shape of the intestine on that side. The common bile-duct descends behind the left border of this part of the duodenum, and together with the pancreatic duct, which accompanies it for a short distance, perforates the coats of the intestine obliquely at the lower part of its left or concave border. In the interior of this part of the intestine, the *valvulæ conniventes* begin to appear; and an eminence or papilla found about four inches below the pylorus, on the inner and back part of the intestine, marks the situation of the common orifice of the biliary and pancreatic ducts.

The third, or *transverse* portion, somewhat the longest and narrowest, crosses obliquely from right to left, in front of the second lumbar vertebra, ascending a little so as to end in the jejunum at the left side of that bone. It is placed immediately behind the root of the transverse mesocolon, the two layers of which passing, the one upwards, and the other down, afford it a covering in front. Behind, it is attached by cellular tissue to the vertebral column, the pillars of the diaphragm, the vena cava, and the aorta. Along its upper border it is connected by vessels and cellular tissue with the pancreas. The superior mesenteric vessels pass from beneath the pancreas over the intestine at the point where it terminates in the jejunum.

Vessels and nerves.—The vessels which supply the duodenum are derived from the superior pancreatico-duodenal and pyloric branches of the hepatic artery, and from the inferior pancreatico-

duodenal branch of the superior mesenteric artery. Its veins open into the gastro-duodenal and superior mesenteric vein. Offsets from the solar plexus, directed along the arteries, supply it with nerves.

THE JEJUNUM AND ILEUM.

The jejunum succeeds to duodenum, and is followed by the ileum.

No distinct limit between jejunum and ileum.

Differences of character are gradual.

Vessels and nerves.

The *jejunum*, so called from its being generally found empty after death, follows the duodenum, and includes the upper two-fifths of the remainder of the small intestine; while the succeeding three-fifths constitute the *ileum*, so named from its numerous coils or convolutions. Both the jejunum and the ileum are attached and supported by the mesentery. The convolutions of the jejunum are situated in part of the umbilical and left iliac regions of the abdomen; while the ileum occupies part of the umbilical and right iliac regions, together with the hypogastric, and even descends into the pelvis, from which its lower end, supported by the mesentery, which is here very short, ascends obliquely to the right and somewhat backwards, over the corresponding psoas muscle, and ends in the right iliac fossa, by opening into the inner side of the commencement of the large intestine. There is no defined limit between the jejunum and the ileum, but the character of the intestine gradually changes from its upper to its lower end, so that a comparison of portions of the two intestines, remote from each other, presents certain well-marked differences. Thus, the jejunum is wider, and its coats are thicker; it is more vascular, and therefore it has a deeper colour; its valvulæ conniventes are long, wide, and numerous; and the patches of Peyer's glands are smaller, less frequent, and mostly confined to its lower part. The ileum, on the other hand, is narrower; its coats are thinner and paler; the valvulæ conniventes are small, and gradually cease towards its lower end; lastly, the groups of Peyer's glands, are larger and more numerous. The diameter of the jejunum varies from one inch and a half to one inch; that of the ileum from one inch and a quarter to less than an inch. A given length of the jejunum accordingly weighs more than the same of the ileum.

Vessels and nerves.—The jejunum and ileum receive their numerous vessels from the superior mesenteric artery and vein. Their nerves descend along the arterial branches from the solar plexus.

THE LARGE INTESTINE.

The *large intestine*, (intestinum crassum : fig. 262,^{9 to 15}.) The large intestine :
 which extends from the termination of the ileum to the anus, is distinguished from the small intestine, by its direction, its size, and its sacculated form. It differs also in the thickness and structure of its muscular and mucous coats.

It commences in the right iliac fossa, and ascends through its course,
 the lumbar region into the right hypochondrium; then, turning suddenly to the left, it passes across the front of the abdomen, opposite to the confines of the epigastric and umbilical regions, into the left hypochondrium; again altering its direction, it bends downwards and descends through the left lumbar to the left iliac region, where it makes a double turn upon itself; finally, it dips into the pelvis, and following the front of the sacrum and coccyx, terminates at the anus. In this course, the large intestine describes the greater part of a circle, which occupies the several regions already mentioned, reaches as high as the liver and stomach, and surrounds the convolutions of the small intestine.

The large intestine is divided by anatomists into the cæcum and subdivisions ;
 (including the vermiform appendix), the colon, and the rectum; and the colon is again subdivided, according to its direction, into four parts, called the ascending, transverse, and descending colon, and the sigmoid flexure.

The large intestine is held in its position, in some places by its mode of attachment,
 peritonæal folds resembling the mesentery; and, in others, by a partial covering of peritonæum, and where this is deficient, by cellular tissue, which connects it to the back of the abdominal and pelvic cavities. On the whole it is more fixed, and therefore less liable to displacement, than the small intestine.

The length of the large intestine is usually about five or six length,
 feet; being about one-fifth of the whole length of the intestinal canal. Its diameter, which greatly exceeds that of the small intestine, varies at different points from two inches and a half to about one inch and a half. It diminishes gradually, from its commencement at the cæcum, to its termination at the anus; excepting that there is a well-marked dilatation of the rectum just above its lower end.

In outward form, the greater part of the large intestine differs form,

remarkably from the small intestine; for, instead of representing an even cylindrical tube, its surface is thrown into numerous sacculi, marked off from each other by intervening constrictions, and arranged in three longitudinal rows, separated by three flat bands of longitudinal muscular fibres. This sacculated structure is not found in the rectum.

and
structure.

Structure.—The walls of the large intestine consist of four coats, resembling those of the small intestine, namely, the serous, muscular, cellular, and mucous.

Serous coat:

The *external* or *serous* coat, derived from the peritonæum, forms a complete investment only to certain portions of the intestine; in other parts the serous covering is incomplete; and at the lower end of the tube it is entirely wanting. Along the colon, and upper part of the rectum, the peritonæal coat is developed into numerous little pouches, filled with adipose tissue. These fatty processes are named *appendices epiploicæ*.

forms
appendices
epiploicæ.

Muscular
coat:
the
longitudinal
fibres form
three bands,

The *muscular* coat, like that of every part of the intestinal canal, consists of external longitudinal and internal circular fibres. The *longitudinal* fibres, though found in a certain amount all around the intestine, are, in the cæcum and colon, principally collected into three remarkable flat longitudinal bands. These bands, sometimes called the ligaments of the colon, are about half an inch wide, and half a line thick; they commence upon the bottom of the cæcum, at the attachment of the vermiform appendix, and may be traced along the whole length of the colon as far as the commencement of the rectum, where they spread out, so as to surround that part of the intestinal tube with a continuous layer of longitudinal muscular fibres. One of these bands, named the *posterior*, is placed along the attached border of the intestine; another corresponds with its *anterior* border, and, in the transverse colon, is situated at the attachment of the great omentum; whilst the third band (*lateral*) is found along the free side of the intestine, that is, on the inner border of the ascending and descending colon, and on the under border of the transverse colon. It is along the course of this third band that the *appendices epiploicæ* are most of them attached. Measured from end to end, these three bands are shorter than the membranous part of the tube, so that in the intervals between the bands this is puckered or thrown into the sacculi already mentioned. Accordingly, if the longitudinal bands be stripped

which are
shorter than
the other
parts of the
tube, and
throw it
into sacculi.

off, the sacculi are obliterated, and the intestine is lengthened. The transverse constrictions, seen outwardly between the sacculi, appear on the inside of the intestine as sharp ridges separating the cells, and are composed of all its coats.

The *circular* muscular fibres form but a thin layer over the general surface of the cæcum and colon, but are accumulated in larger numbers between the sacculi. In the rectum, especially towards its lower part, the circular fibres form a very thick and powerful muscular layer.

The circular fibres.

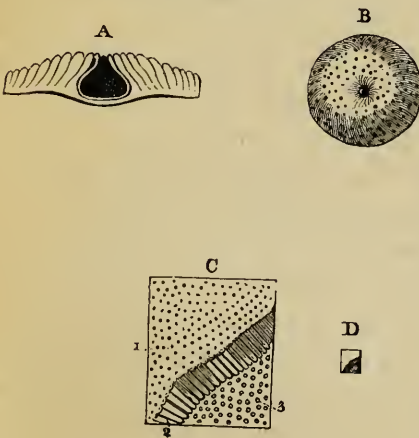
The *cellular* or submucous coat requires no special notice.

Cellular coat.

The *mucous* membrane is on the whole pale, but is much redder and darker in the rectum than elsewhere. It differs from the lining membrane of the small intestine in having no folds, like the *valvulæ conniventes*, and also in being quite smooth and destitute of villi. Viewed with a lens, its surface is seen to

Mucous coat has no valves ;

Fig. 271.*



be marked all over by the orifices of numerous tubuli (fig. 271, c, d.) resembling those of the stomach and the crypts of the small intestine. These follicles are arranged perpendicularly to the surface of the membrane ; they are longer and more numerous, and are placed more closely together and at more regular intervals than those of the small intestine. Their orifices are circular, and they

its tubes

give the mucous membrane a cribriform aspect.

Besides these, there are scattered over the surface of the whole large intestine numerous rounded, whitish, glandular bodies, about $\frac{1}{3}$ or $\frac{1}{2}$ a line in diameter, and therefore much larger than

and its glandular crypts.

* Tubuli and follicles of the large intestine, magnified. (Boehm.)—
 A. Section of a solitary follicle. B. Opening of the same on the surface of the mucous membrane. C. Tubuli, of which the mucous membrane principally consists. D. Natural size of same piece of membrane. 1. Their orifices seen on the surface. 2. Side view of the tubuli themselves. 3. Surface of the submucous or cellular coat, showing small pits corresponding with the closed ends of the tubuli.

the tubuli. These are follicular recesses or crypts (A, B), very simple in structure. Their orifice is narrowed, but it leads into a dilated cavity, having thin walls, closely surrounded by the small perpendicular tubuli. They are most abundant in the cæcum and in its vermiform appendix.

Epithelium. The epithelium, which covers the general surface of the mucous membrane, and lines the tubuli and follicles, is of the columnar kind.

THE CÆCUM.

The cæcum is a blind pouch:

The cæcum (262,⁹) is that part of the large intestine which is situated below the entrance of the ileum; it is named *cæcum*, or the blind gut (*caput cæcum coli*), because it forms a cul-de-sac, or short rounded pouch extending downwards from the commencement of the colon, with which it is continuous above, without any line of demarcation. Its length is about $2\frac{1}{2}$ inches, and its diameter nearly the same: it is the widest part of the large intestine.

its situation, and connections in right iliac fossa.

The cæcum is situated in the right iliac fossa, immediately behind the anterior wall of the abdomen. It is covered by the peritonæum in front, below and at the sides; but behind it is usually destitute of peritonæal covering, and is attached by cellular tissue to the fascia covering the right iliacus muscle. In this case the cæcum is comparatively fixed; but in other cases the peritonæum surrounds it almost entirely, and forms a duplicature behind it, called the *meso-cæcum*.

The meso-cæcum.

Proceeding from the inner and back part of the cæcum, at its lower end, is a narrow, round, and tapering portion of the intestine, named the *appendix cæci*, or, from its resemblance to a worm, *appendix vermiformis* (¹⁰). This process (fig. 272, *p*) is usually about the width of a large quill or rather more, and varies from three to six inches in length, differing much in its dimensions in different cases. Its general direction is upwards and inwards behind the cæcum, and after describing a few slight turns, it ends in a blunt point. It is retained in its position by a small fold of peritonæum, which forms a mesentery for it. This cæcal appendix is hollow down to its extremity; and its cavity communicates with that of the cæcum by a small orifice, sometimes guarded by a fold of mucous membrane. Its coats are the same as those of the cæcum, and quite as thick. The longi-

The vermiform appendix:

its size, form, and

structure.

tudinal muscular fibres, which are continuous with those of the three bands described upon the cæcum and colon, form a uniform layer around the appendix. Its mucous membrane resembles that of the cæcum, but it is abundantly provided with the solitary follicular glands.

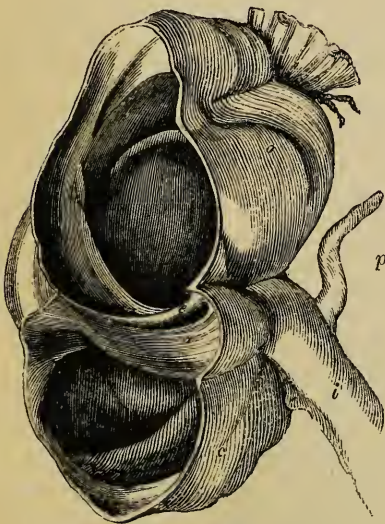
In the early embryo there is at first no cæcum. This part of the bowel gradually grows out from the rest, and in the first instance forms a tube of uniform calibre. In this state no appendix is seen; but subsequently the lower part of the tube, relatively speaking, ceases to grow, and becomes the vermiform appendix, whilst the upper portion continues to be developed with the rest of the intestine. A distinct appendix exists in the ourang-outang and in the wombat, but, as far as is known, in no other animal.

Mode of growth of cæcum, and its appendix.

Ileo-cæcal, or *ileo-colic valve*.—The lower part of the small intestine (fig. 272, *i*), ascending from left to right, and from before backwards, enters the commencement of the large intestine, with a considerable degree of obliquity, about two inches and a half from the bottom of the cæcum (*c*), and opposite the

Ileo-colic valve:

Fig. 272.*



junction of the latter with the colon (*o*), above. The opening leading from the ileum into the large intestine is guarded by a valve, composed of two segments, or folds (*e*, *a*). This is the *ileo-cæcal*, or *ileo-colic valve*: it is also called the valve of Bauhin and the valve of Tulpus, though Fallopius had described it before either of those anatomists.

its position;

The entrance between the two segments of the valve, which is best displayed by laying open the commencement of the large intestine,

consists of two segments;

* Shows the junction of the small and large intestines, and, the cæcum and colon being laid open, displays the ileo-cæcal valve. *a*. The lower segment. *e*. The upper segment of the valve. *c*. The cæcum. *o*. The ascending colon. *i*. The end of the ileum. *p*. The appendix. From Santorini, slightly altered.

the aperture ;

the fræna of the valve.

along the right side, after it has been distended and dried, is a narrow elongated aperture, of a somewhat elliptical form, and having a nearly transverse or horizontal direction. The anterior end of this aperture, which is turned slightly to the left, is rounded, but the posterior end is narrow and pointed. It is bounded above and below by two prominent semilunar folds, which project inwards towards the cæcum and colon. The lower fold (*a*) is the larger of the two ; the upper (*e*) is placed more horizontally. At each end of the aperture these folds coalesce, and are then prolonged as a single ridge for a short distance round the cavity of the intestine, forming the *fræna* or *retinacula* of the valve. The convex attached border of the upper fold corresponds with the line of connection between the upper surface of the ileum and the colon, and that of the lower fold with the junction of the under surface of the ileum and the cæcum. Their free concave margins are turned towards the large intestine, having a slight inclination upwards, and are brought into apposition when the cæcum is distended, so as completely to close the aperture and mechanically prevent any reflux into the ileum.

Structure of segments : consist of mucous coat and circular fibres only.

Each segment of the valve consists of two layers of mucous membrane, continuous with each other along the free margin, and including between them, besides the submucous cellular tissue, a number of muscular fibres, continued from the circular fibres of the ileum and from those of the large intestine also. The longitudinal muscular fibres and the peritonæal coat take no part in the formation of the valve, but are extended uninterruptedly from one intestine to the other. If, indeed, the serous tunic, and the longitudinal muscular fibres be divided, the ileum may be drawn out, with the aid of a little cautious dissection, from the side of the large intestine, and the folds of valve will be completely effaced,—the small intestine seeming then to open into the large, by a funnel-shaped orifice like that leading from the œsophagus into the stomach.

Two surfaces of valves differ in character.

The mucous membrane covering the surface of each valvular segment which is turned towards the ileum, is derived from the lining membrane of that intestine, and is provided with its characteristic villi ; while the other surface, turned towards the large intestine, is smooth and destitute of villi, and is more regularly marked with the orifices of the small tubuli. These

differences are apparent quite up to the free margin of the valve, where the two kinds of mucous membrane become continuous.

THE COLON.

The *right* or *ascending* colon (fig. 262,¹¹) situated in the right lumbar and hypochondriac regions, commencing at the cæcum opposite to the ileo-colic valve, ascends vertically to the under surface of the liver, near the gall-bladder, where it advances forwards and then turns abruptly to the left, forming what is named the *hepatic flexure* of the colon. The ascending colon is smaller than the cæcum, but larger than the transverse colon. It is overlaid in front by some convolutions of the ileum, and is bound down firmly by the peritonæum, which passes over its anterior surface and its sides, and generally leaves its posterior surface to be connected by cellular tissue with the fascia covering the quadratus lumborum muscle, and with the front of the right kidney. In some cases, however, the peritonæum passes nearly round it, and forms a distinct though very short right meso-colon.

The colon :
its ascend-
ing or right
portion.

The *transverse colon* (¹²) passes across from the right hypochondrium, through the upper part of the umbilical region, into the left hypochondrium. Sometimes it is found as low as the umbilicus or even lower. At each extremity it is situated deeply towards the back part of the abdominal cavity, but in the middle advances forwards, and lies close to the anterior wall of the abdomen. Hence it describes an arch, the concavity of which is turned towards the vertebral column; and it has accordingly been named the *arch* of the colon.

Transverse
colon :

forms the
arch of the
colon;

Above, the transverse colon is in contact with the under surface of the liver, the gall-bladder, the great curvature of the stomach, and the lower end of the spleen. Below it, are the convolutions of the small intestine, the third portion of the duodenum being behind it. By its posterior border it is attached to the mesocolon, a very large and wide duplicature of the peritonæum, which serves to connect this part of the large intestine to the back of the abdominal cavity, at the same time allowing it more freedom of movement than the other parts. The two layers of the mesocolon, having separated to enclose the transverse colon and form its peritonæal coat, meet again

its connec-
tions;

its meso-
colon.

along its anterior border and become continuous with the great omentum, which therefore lies upon the intestine, and is connected with it. The lower border of the stomach also frequently rests upon the transverse colon.

The left or descending colon.

The *left* or *descending* colon (¹³) is continuous with the left extremity of the transverse colon by a sudden bend, named the *splenic flexure*. It then descends almost perpendicularly through the left hypochondriac and lumbar regions to the left iliac fossa, where it ends in the sigmoid flexure. The peritonæum affords a covering to it only in front and at the sides, whilst behind, it is connected by cellular tissue to the left crus of the diaphragm, the quadratus lumborum and the left kidney. It is usually concealed behind some convolutions of the jejunum.

The sigmoid flexure :

The *sigmoid flexure* of the colon (¹⁴), situated in the left iliac fossa, consists of a double bending of the intestine upon itself in the form of the letter S, immediately before it becomes continuous with the rectum at the margin of the pelvis opposite to the left sacro-iliac symphysis. It is covered all round by the peritonæum, which, however, is reflected from it behind to form a distinct meso-colon. By this the intestine is attached to the iliac fossa, but it is very moveable. It is placed immediately behind the abdominal parietes, or is concealed only by a few turns of the small intestine. The sigmoid flexure is the narrowest part of the colon.

its meso-colon.

Vessels and nerves.

Vessels and Nerves.—The cæcum, and the ascending and transverse colon, receive their vessels from the right side of the superior mesenteric artery ; and the descending colon and sigmoid flexure from the inferior mesenteric. The veins end in those which accompany the arteries just named. The nerves are offsets from the superior and inferior mesenteric plexuses. Lastly, the absorbents enter the lymphatic glands placed along the blood-vessels.

THE RECTUM.

The rectum, or lower part of intestine :

The lowest portion of the large intestine, named the *rectum*, (fig. 262, ¹⁵, and fig. 311, *bbh*.) extends from the sigmoid flexure of the colon to the anus, and is situated entirely within the true pelvis, at its back part.

its situation

Commencing opposite to the left sacro-iliac junction, (fig. 311,

b,) it is directed at first obliquely downwards, and from left to right, to gain the middle line of the sacrum. It then changes its direction, and curves forward in front of the lower part of the sacrum and the coccyx, and behind the bladder, vesiculæ seminales, and prostate in the male, (*b'*,) and at the back of the cervix uteri and vagina in the female. Opposite to the prostate, (*p*,) it forms another turn, and inclines downwards and backwards (*h*) to reach the anus. The *intestinum rectum*, therefore, is not actually straight. Seen from the front, the upper part of the rectum presents a lateral inclination from the left to the median line of the pelvis; and when viewed from the side, (as in fig. 311,) it offers two curves, one corresponding with the hollow front of the sacrum and coccyx, and the other at the lower end of the bowel, forming a shorter turn in the opposite direction.

and course:

it is not straight, as its name would imply:

its curves,

Unlike the rest of the large intestine, the rectum is not sacculated, but is smooth and cylindrical; and it has no separate longitudinal bands upon it. It is about six or eight inches in length; and is rather narrower than the sigmoid flexure at its upper end, but becomes dilated into a large ampulla or reservoir, immediately above the anus.

form, and

The upper part of the rectum is in contact in front with the back of the bladder, (or uterus in the female,) unless some convolutions of the small intestine happen to descend into the interval between them. This part is surrounded by peritonæum, (*r*,) which attaches it behind to the sacrum by a duplicature named the *meso-rectum*. Lower down, the peritonæum covers the intestine in front and at the sides, and then its anterior surface only; still lower, it quits the intestine altogether, and is reflected forwards to ascend upon the back of the bladder (*a*) in the male, and of the upper part of the vagina and the uterus in the female. In passing from the rectum to the bladder, the peritonæum forms a cul-de-sac, (*r'*,) which extends between the intestine and the bladder to within a short distance of the prostate, and is bounded on the sides by two lunated folds of the serous membrane.

connections with bladder, &c.;

with peritonæum.

Below the point where the peritonæum ceases to cover it, the rectum (at *b'*) is connected to surrounding parts by cellular tissue, which is mostly loaded with fat. In this way it is attached behind to the front of the sacrum and the coccyx, and at the

Connections at lower part:

sides to the coccygei and levatores ani muscles. In front, it is in immediate connection with a triangular portion of the base of the bladder; on each side of this, with the vesiculæ seminales (*v*); and further forwards, with the under surface of the prostate, (*p*.) Beyond the prostate, where the rectum turns downwards to reach the anus, it becomes invested by the fibres of the internal sphincter, and embraced by the levatores ani muscles, which form a support for it. Lastly, at its termination it is surrounded by the external or proper sphincter ani muscle, (*h*.) In the female, this lower portion of the rectum is firmly connected with the back of the vagina.

with the
sphincter
ani muscles.

Structure.

Structure.—The rectum differs in some respects from the rest of the large intestine, viz. in regard to its muscular and mucous coats.

Muscular
coat.

The muscular coat is much thicker: the external or longitudinal fibres form a uniform layer around it and cease near the lower end of the intestine; the internal or circular fibres, on the contrary, become more numerous in that situation, where they form what is named the internal sphincter muscle. The longitudinal fibres are paler than the circular fibres, but both layers become darker and redder towards the termination of the bowel. The bands composing the internal sphincter muscle are found to contain striped muscular fibres.

Mucous
coat:

The mucous membrane of the rectum is thicker, redder, and more vascular than that of the colon; and it moves freely upon the muscular coats—in that respect resembling the lining membrane of the œsophagus. It presents numerous folds of different sizes, and running in various directions, nearly all of which are effaced by the distension of the bowel. Near the anus these folds are principally longitudinal, and seem to depend on the contraction of the sphincter muscles outside the loosely connected mucous membrane. The larger of these folds were named by Morgagni the *columns* of the rectum (*columnæ recti*). Higher up in the intestine, the chief folds are transverse or oblique. Three prominent folds, larger than the rest, being half an inch or more in width, and having an oblique direction in the interior of the rectum, have been pointed out specially by Mr. Houston.* One of these projects backwards from the upper and fore part of the rectum, opposite the prostate gland;

its folds;

of which
some are
named the
columns;
others are
oblique.

* Dublin Hospital Reports, Vol. v.

another is placed higher up, at the side of the bowel; and the third still higher. From the position and projection of these folds, they may more or less impede the introduction of instruments.

Vessels and Nerves.—The *arteries* of the rectum spring from three sources, viz. the superior hæmorrhoidal branches from the inferior mesenteric; the middle hæmorrhoidal branches from the internal iliac directly or indirectly; and, lastly, the external or inferior hæmorrhoidal branch from the pudic artery. The *veins* are very numerous, and form a complex interlacement, the hæmorrhoidal plexus, around the lower end of the bowel above the anus. They end partly in the internal iliac vein by branches which accompany the middle hæmorrhoidal artery, and partly in the inferior mesenteric vein. Hence, the blood from the rectum is returned in part into the vena cava, and in part into the portal system. The *lymphatics* enter some glands placed in the hollow of the sacrum, or those of the lumbar series. The *nerves* are also very numerous, and are derived from both the cerebro-spinal and the sympathetic systems. The former consist of branches derived from the sacral plexus; and the latter, of off-sets from the inferior mesenteric and hypogastric plexuses.

Vessels :
arteries;

veins,
end in vena
cava and
vena portæ.

Lympha-
tics.
Nerves are
mixed—
spinal and
sympa-
thetic.

THE ANUS AND ITS MUSCLES.

The *anus*, or lower opening of the alimentary canal, is a dilatable orifice, surrounded internally by the mucous membrane, and externally by the skin, which two structures here become continuous with and pass into each other. The skin around the borders of the anus, which is thrown into wrinkles or folds during the closed state of the orifice, is covered with numerous sensitive papillæ, and is provided with hairs and sebaceous follicles.

The anus.

The lower end of the rectum and the margin of the anus are, moreover, embraced by certain muscles, which serve to support the bowel, and to close its anal orifice. These muscles, proceeding from within outwards, are, the internal sphincter, the levatores ani (with which we may associate the coccygei), and, lastly, the external sphincter ani.

Its muscles:

The *internal sphincter* muscle (sphincter ani internus) is a muscular ring or rather belt, surrounding the lower part of the rectum, an inch above the anus, and extending over about half an inch of the intestine. It is two lines thick, and is paler than

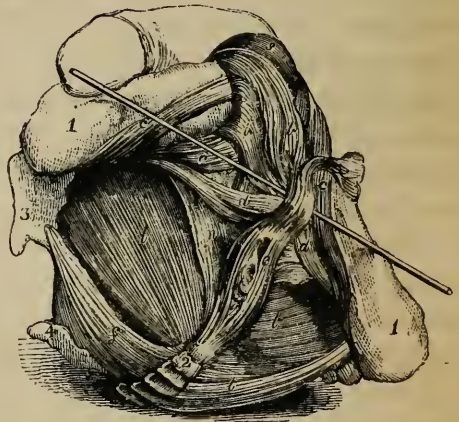
internal
sphincter;

the external sphincter. Its fibres are continuous above with the circular muscular fibres of the rectum, and, indeed, it consists merely of those fibres more numerous developed than elsewhere, and prolonged down further than the external longitudinal fibres. Opposite to the internal sphincter, the mucous membrane of the rectum is elevated into a ring.

external
sphincter ;

The *external sphincter* (figs. 273, *e*; 311, *h*; 340, *e*; sphincter ani externus) is a flat oval muscle, placed immediately beneath the skin surrounding the margin of the anus. It is elliptical in form, being about an inch wide opposite to the anus, and becoming narrow at its posterior and anterior extremities, which are between three and four inches apart, and are fixed, one to the coccyx, and the other to the middle point of the perinæum.

Fig. 273.*



Posteriorly, it is attached to the tip and back of the coccyx, (fig. 273, *e*;) by means of a narrow bundle of tendinous fibres; whilst, anteriorly, in front of the anus, about midway between that orifice and the bulb of the urethra (in the male), it becomes blended, (near the probe in fig. 273,) through the medium of a common fibrous structure, with the transverse muscles of the perinæum, (*d*;) and with the muscles embracing the urethral bulb, (*b, b*.) In the female, the anterior extremity of the external sphincter unites with the constrictor vulvæ and the transversi perinæi muscles. The intermediate and wider portion of the sphincter is disposed like other orbicular muscles, and is composed of fleshy bundles, which embrace the intestine and

* Muscles of the perinæal region. (Santorini.)—1. Ramus of ischium. —2. Coccyx. 3. Ischial spine and tuberosity. 4. Side of sacrum. *b, b*. Bulbo-cavernosus, or accelerator urinæ. *c, c*. Ischio-cavernosus, or erector penis. *d, d*. Transversi perinæi. *e*. External sphincter ani. *f*. Coccygeus. *l, l*. Levatores ani. *n*. Layer of fascia covering levator ani. *s*. Spongy part of the urethra. The probe is placed beneath the central fibrous structure of the perinæum.

intersect each other, or unite in a commissure before and behind it.

The lower or external surface of this muscle is covered only by the skin; the upper or internal surface is in contact with the paler fibres constituting the internal sphincter, and also with some cellular tissue which separates it, though imperfectly, from the lowest fibres of the levatores ani muscles.

The action of the external and internal sphincters is sufficiently obvious.

The *levatores ani* muscles, (figs. 273; 341, 11,) one right and the other left, are two broad and thin muscular layers, which take origin from the inner surface of the sides of the true pelvis, and, passing obliquely downwards and inwards, meet across the outlet of that cavity, so as together to form a thin, funnel-shaped muscle, which embraces the parts descending through it, and constitutes, as it were, a moveable floor to the pelvic cavity.

Levator ani;

forms a muscular floor to pelvis.

The *origin* of each levator muscle is most extensive; and, in order to explain it clearly, it is necessary to advert for an instant to the arrangement of the fasciæ of the pelvis, with which it is intimately connected. The pelvic fascia, in descending from the brim of the pelvis, covers the upper part of the internal obturator muscle, and may be traced as a single fibrous layer, as far as to a white line or band which stretches from near the symphysis pubis to the spine of the ischium. Along this line, the fascia may be said to split into two layers: one, named the obturator fascia, which continues downwards over the remainder of the internal obturator muscle; and the other, called the recto-vesical fascia, which passes inwards and downwards towards the side of the rectum, bladder, and prostate in the male, and of the rectum and vagina in the female.

Origin is very extensive:

Now the levator ani is situated between the obturator and recto-vesical fasciæ, in close contact, however, with the under surface of the last-named fascia, immediately beneath which it forms a broad and thin muscular stratum. The greater part of the muscle arises above, from along the angle of divergence of the obturator and recto-vesical fasciæ, that is, from the under surface of the white band above mentioned as stretching from near the symphysis pubis to the spine of the ischium. Besides this long line of origin from the fasciæ, the levator ani arises behind from the spine of the ischium, (3,) and, in front, from the

from pelvic fascia,

ischium,

and pubes, posterior surface of the body and ramus of the pubes, near to the symphysis and close above the pubic arch (fig. 317, 3.)

Course and
insertion of
fibres,

From this extensive origin the fibres of the levator proceed downwards and inwards towards the middle line of the floor of the pelvis. Its hindmost fasciculi are inserted upon the side of the lower end of the coccyx; the bundles next in order, anteriorly, interlace or unite in a median raphé with the corresponding muscle, in the interval between the coccyx and the margin of the anus; the middle and larger portion of the muscle is prolonged upon the lower part of the rectum, where it is connected with the fibres of the internal, but more particularly of the external sphincter; and, lastly, the anterior muscular bundles pass between the rectum and the genito-urinary passages, and, descending (in the male) upon the side of the prostate, unite beneath the neck of the bladder, the prostate, and the neighbouring part of the urethra, with corresponding fibres from the muscle of the opposite side, and blend also with those of the external sphincter and deep transverse perinæal muscles.

to coccyx,
to borders
of anus,

in front of
anus,

beneath
genito-
urinary
passages.

Anterior
portion
beneath
prostate,

forms leva-
tor pros-
tatae.

Connec-
tions.

The anterior portion of the levator ani, which arises from the ramus of the pubes, close to the symphysis and above the pubic arch, and also from the adjacent fasciæ, is sometimes separated at its origin by cellular tissue from the rest of the muscle. From this circumstance, and from its connection with the prostate gland, it was described by Santorini, and since by Albinus and Sæmerring, as a distinct muscle, under the name of the *levator prostatae*. In the female, the anterior fibres of the levator ani descend upon the sides of the vagina, and are intimately connected with it.

The upper or pelvic surface of the levator ani is in contact with the recto-vesical fascia, and with part of the pelvic viscera. Its under or perinæal surface appears at the side of the external sphincter, in the ischio-rectal fossa, (fig. 341, *l*.) where it is covered by a thin layer of membrane (*n*) derived from the deep perinæal fascia, and also by a large quantity of fat, (fig. 340, *v*.) The posterior border of the muscle is continuous with the coccygeus. Its anterior border does not reach the middle line in front, but leaves between it and the corresponding border of the opposite muscle an interval beneath the pubic arch, through which the genito-urinary passages have their exit from the pelvis.

The levatores ani support and elevate the lower end of the rectum, and also the bladder and prostate. They flex and at the same time fix the coccyx. Uses.

The *coccygeus* muscle (fig. 273, *f*) is placed deeply on each side, at the back part of the outlet of the pelvis, and assists in closing that cavity, behind and below, by stretching across from the spine of the ischium to the sides of the sacrum and coccyx. This muscle is connected to, or even continuous with, the posterior part of the levator ani. It is composed of fleshy and tendinous fibres, forming a thin, flat, and triangular plane, which arises by its apex from the spine of the ischium (3) and the lesser sciatic ligament, and is attached along its base to the border of the coccyx (2) and the lower part of the sacrum, (4.) Its internal or pelvic surface assists in supporting the rectum; its external or under surface rests on the front of the sacro-sciatic ligaments, and on the glutæus maximus muscle. Coccygei : situation ; origin ; attachment,

The coccygei muscles merely aid in flexing and fixing the coccyx. and use.

DEVELOPMENT OF THE ALIMENTARY CANAL.

In the ovum of the bird, the mucous layer of the germinal membrane, which lies next to the yolk, soon comes to be distinguished into a central and a peripheral part. From the central part the alimentary canal is afterwards formed, whilst the circumference extends so as to enclose the yolk and form the yolk sac or vitelline sac, which after a time is drawn through the umbilicus into the abdomen of the chick. Development of alimentary canal.

In mammalia and man, the origin of the alimentary canal is precisely similar. It commences in the mucous layer of the blastoderm in form of a groove, which is soon changed into a tube at each end, but is left open in the middle upon the ventral aspect, and communicates by means of a tube, named the omphalo-enteric canal or vitelline duct, with the vitelline sac. This duct is soon obliterated, and the vitelline sac becomes the umbilical vesicle, which is henceforth connected with the embryo only by a slender elongated pedicle containing the omphalo-mesenteric vessels, and is finally atrophied. In man.

The *alimentary canal* itself is at first a straight tube closed at each end, and placed along the front of the vertebral column, to which it is closely attached above and below, (supposing the embryo to be placed in an erect position,) whilst in the middle of its course it is connected by a median membranous fold, or rudimental *mesentery*. Soon, however, it advances from the spine, and forms a simple bend in the middle of the body, with a straight portion at its upper and lower end. The middle or apex of the bend advances to Is at first straight; then forms a bend.

umbilicus, where it is connected with the umbilical vesicle by the pedicle, and also by the omphalo-mesenteric vessels, which pass out there to the vesicle.

A dilatation for the stomach :

By the early appearance of a slight dilatation, which forms the future stomach, the primitive simple tube is divided into an upper and a lower portion.

changes in part above the dilatation ;

a. From the upper portion, besides the œsophagus, which is formed by a gradual elongation of the part, there are ultimately developed the mouth, tongue, and salivary glands, the pharynx, larynx, trachea, and lungs. At first the upper end is closed ; at length a wide aperture appears, which is not the mouth, properly so called, but an opening upon which the mouth and lips are subsequently developed as superadded parts, commencing after the eighth or ninth week.

in the dilatation,

b. The dilated portion of the tube which forms the stomach turns over on its right side, so that the border, which is connected to the vertebral column by the membranous fold (or true mesogastrium) comes to be turned to the left,—the position of the tube being still vertical, like the stomach of some animals. By degrees it becomes more dilated, chiefly on what is now the left border but subsequently the great curvature, and assumes first an oblique and finally a transverse position, carrying with it the mesogastrium, from which the great omentum is afterwards produced. The pylorus is seen at the third month, but is very slightly marked. Immediately below the stomach, the duodenum is formed ; and upon this part of the canal commence the rudiments of the liver, pancreas, and spleen, the two former having protrusions of the mucous membrane growing into their blastemic mass.

and in the part below it.

c. In the meantime the part below the stomach becomes the intestinal canal ; that portion of it which is suspended by a mesentery forming (besides the duodenum) the jejunum, the ileum, the cœcum, and the colon, whilst the lower and attached part constitutes the rectum. The place of distinction between the small and the large intestine, which is soon indicated by the protrusion of the cœcum, is at a point just below the apex or middle of the simple bend already mentioned. As the *small* intestine grows, the part below the duodenum forms a coil which at first lies in the commencing umbilical cord, but retires again into the abdomen about the tenth week ; afterwards it continues to elongate, and its convolutions become more and more numerous. The diverticula sometimes found projecting from the small intestine are supposed to be developed from a persistent portion of the vitelline duct, which continues to grow with the rest of the bowel. The *large* intestine is at first less in calibre than the small. The development of the cœcum and its appendix has already been described. (p. 1045.) It appears as a protrusion a little below the apex of the bend in the primitive intestinal tube, and, as well as the commencing colon, is at first lodged in the umbilicus with the coil of small intestine. The appendix is at first of equal width. The ileo-cœcal valve appears at the commencement of the third month. When the coils of intestine and cœcum have retired from the umbilicus into the abdomen, the colon is at first to the left of the

Small intestine.

Large intestine.

convolutions of the small intestine, but then, together with the meso-colon, crosses over its upper part at the junction of the duodenum and jejunum. The cœcum and transverse colon are then found just below the liver; finally, the cœcum descends to the right iliac fossa. At the fourth or fifth month the parts are in the same position as in the adult.

The lower straight and attached portion of the tube eventually forms the rectum. The anal orifice does not exist at first, but appears a week or so later than the oral opening.

Coats of the intestine.—At a very early period the walls of the intestinal tube appear to consist of two layers, both of which are originally composed of nucleated cells. The outer one is more transparent than the other, and is supposed by Bischoff to be metamorphosed into the muscular and cellular coats, whilst the inner layer forms the mucous membrane. The serous coat is said to be developed afterwards upon the surface of the intestine, and, at the same time, upon that of all the other abdominal organs, and on the walls of the abdomen. The mucous membrane is at first very thick, and is soon provided with a conspicuous layer of epithelium, which after a time accumulates in considerable quantities in the intestinal canal. At first, villous processes or folds of various lengths are formed throughout the whole canal. After a time they disappear in the stomach and large intestine, but remain persistent in the intermediate portions of the tube. According to Meckel, they are formed from larger folds, which become serrated at the edge and divided into villi.

Formation of coats of intestine : muscular, serous and mucous.

In the meantime, the mucous coat is completed by the development of the gastric tubules, the follicles of Lieberkuehn, and the solitary and agminated glands.

THE LIVER.

The liver (*hepar, jecur*, fig. 142, ¹) is the large gland which secretes the bile. It is very constant in the animal series, being found in all vertebrate, and, in a more or less developed condition, in most invertebrate tribes.

The liver :

In the human subject it is situated in the upper part of the abdominal cavity, occupying the right hypochondriac region, and extending across the epigastric region into a part of the left hypochondrium. It is placed immediately beneath the diaphragm, above the stomach, duodenum, and colon, behind the cartilages of the ribs, and in front of the vena cava, aorta, and crura of the diaphragm, which latter parts are interposed between the gland and the vertebral column.

its situation ;

The liver is a solid organ, of a dull reddish brown colour, with frequently a dark purplish tinge along the margin. It has an upper smooth and convex surface, and an under surface (fig. 142) which is uneven and concave : the circumference, or

general characters, and form.

border, at which these two surfaces meet, is thick and rounded behind and to the right, that is, at the posterior border and right extremity of the liver; but it becomes gradually thinner towards the left and in front, where it forms the left extremity and the sharp anterior margin.

Dimensions:
the largest
gland in the
body;

The liver is the largest gland in the body, and by far the most bulky of the abdominal viscera. It measures about ten or twelve inches transversely from right to left, between six and seven inches from its posterior to its anterior border, and about three inches from above downwards at its thickest part, which is towards the right and posterior portion of the gland. The average bulk of the liver, according to Krause, is eighty-eight cubic inches. Its ordinary weight in the adult is stated to be between three and four pounds, or more nearly from fifty to sixty ounces avoirdupois.

its weight;

According to the facts recorded by Dr. John Reid,* it weighed, in 43 cases out of 82, between 48 and 58 ounces in the adult male; and in 17 cases out of 36, its weight in the adult female ranged between 40 and 50 ounces. It is generally estimated to be equal to about 1-36th of the weight of the whole body; but in the fœtus, and in early life, its proportionate weight is greater.

its specific
gravity.

The specific gravity of the liver, according to Krause and others, is between 1·05 and 1·06: in fatty degeneration this is reduced to 1·03, or even less.

Its surfaces:
upper
surface is
convex, and

The form, position, and connections of the surfaces and borders of the Liver.—The *upper convex surface*, free, smooth, and covered by peritonæum, is accurately adapted to the vault of the diaphragm above, and is covered, to a small extent in front, by the abdominal parietes. The line of attachment of a fold of peritonæum, named the broad ligament of the liver, marks off this surface unequally into a right and a left portion. The right portion is much larger and more convex than the left, and reaches higher beneath the ribs, corresponding thus with the elevated position of the diaphragm on that side. By means of the diaphragm, the liver is separated from the concave base of the right lung, the thin margin of which descends so as to intervene between the surface of the body and the solid mass of the liver—a fact well known to the auscultator.

covered by
diaphragm;

* Lond. and Edin. Monthly Journal of Med. Science, April, 1843.

The convex surface of the liver is protected, on the right, by the six or seven lower ribs, and in front by the cartilages of the same and by the ensiform cartilage—the diaphragm, of course, being interposed. Being suspended by ligaments to the diaphragm above, and supported below, in common with the rest of the viscera, by the abdominal muscles, the situation of the liver is modified by the position of the body, and also by the movements of respiration: thus, in the upright or sitting posture, the liver reaches below the margin of the thorax; but in the recumbent position, the gland ascends an inch or an inch and a half higher up, and is entirely covered by the ribs, except a small portion opposite the substernal notch. Again, during a deep inspiration, the liver descends below the ribs, and in expiration retires behind them. In females the liver is often permanently forced downwards below the costal cartilages, owing to the use of tight stays: sometimes it reaches nearly as low as the crest of the ilium; and, in many cases, its convex surface is indented from the pressure of the ribs upon it.

is protected
by the
lower ribs.

Position of
the liver
changes.

The *under* or *concave* surface of the liver, (fig. 274,) which is directed downwards and backwards, is uneven. Besides several depressions found at its points of contact with other organs, as the stomach, colon, and kidneys, it presents certain divisions or lobes, and several fissures, to be presently described. The greater part of this surface is free and covered by the peritonæum; but this is not the case where the large vessels enter the gland, nor where it is attached by cellular tissue to adjacent parts. It is separated into two unequal parts, one right⁽¹⁾ and the other left⁽²⁾, by a longitudinal or antero-posterior fissure, (3, 4.) The part to the left of this fissure is supported on the pyloric extremity and anterior surface of the stomach, on which it moves freely. (See fig. 281, in which the liver is represented as turned upwards, with the stomach.) When the stomach is quite empty, the left part of this surface of the liver may overlap the cardiac end of that viscus. To the right of the longitudinal fissure the liver rests and moves freely upon the first part of the duodenum, and upon the hepatic flexure of the colon, at the juncture of the ascending and transverse portions of that intestine. Further back it is in contact with the fore part of the right kidney and supra-renal capsule, for which it presents one or two corresponding depressions. The gall-

Under
surface is
concave and
uneven;

is divided
into lobes.

Its
connexions
below.

bladder is also attached to this right portion of the under surface of the liver by peritonæum, loose cellular tissue, and vessels.

The *anterior border* of the liver, a thin, free, and sharp margin, is the most moveable part of the gland. Opposite the longitudinal fissure (3) and the line of attachment of the broad ligament this anterior border presents a notch, which separates the right and left lobes of the liver, and lodges the round ligament. To the right of this notch there is often another slight one opposite the fundus of the gall-bladder, (10.)

The *posterior border* of the liver, which is directed backwards and upwards, is thick and rounded on the right side, but becomes gradually thinner towards the left. It is the most fixed part of the organ, and is firmly attached by cellular tissue to the diaphragm, the peritonæum being here reflected away from the liver on to the diaphragm, so as to form the *coronary ligament*. This border of the liver is curved opposite to the projection of the vertebral column, and has a deep groove for the reception of the ascending vena cava.

Of the two *extremities* of the liver, the *right* is placed lower down, and is thick and obtuse; whilst the *left* is the thinnest part of the gland, and ascends to a higher level, reaching across to the cardiac end of the stomach. Both extremities are attached to the diaphragm by peritonæal folds, named the lateral ligaments.

Besides being attached to large blood-vessels, and supported by the parts beneath and by the abdominal muscles, the liver is suspended by its ligaments, which are five in number.

The Ligaments.—These are five in number, and, with one exception (the ligamentum teres), are formed merely by folds of the peritonæum. 1. The *broad, falciform, or suspensory ligament* is a wide thin membrane, composed of two layers of peritonæum, closely united together. By one of its margins it is connected with the under surface of the diaphragm, and with the posterior surface of the sheath of the right rectus muscle of the abdomen, as low as the umbilicus; and by another it is attached along the convex surface of the liver, from its posterior border to the notch in its anterior border. The remaining margin of the ligament is free, and contains between its layers the round ligament. 2. The *round ligament (ligamentum teres)* is a dense fibrous cord, which ascends from the umbilicus, within the

Anterior border is sharp;

posterior border is rounded.

Right extremity is thick, and left thin.

Ligaments of liver are five.

Broad, falciform, or suspensory;

round ligament;

lower edge of the broad ligament, towards the notch in the anterior border of the liver, and there enters the longitudinal fissure on the under surface. It is the remains of the umbilical vein of the fœtus. 3. The *coronary* ligament is formed by the reflection of the peritonæum from the diaphragm to the posterior border of the liver. In this situation there is a broad triangular portion of the gland, which is attached by firm cellular tissue to the diaphragm, and the surrounding reflection of the peritonæal membrane constitutes the coronary ligament. 4 and 5. Both on the right and the left end of the liver the peritonæum also forms a triangular reflection, extending to the adjacent part of the diaphragm: these are the *right* and *left lateral* or *triangular* ligaments, of which the left is longer and more distinct than the other.

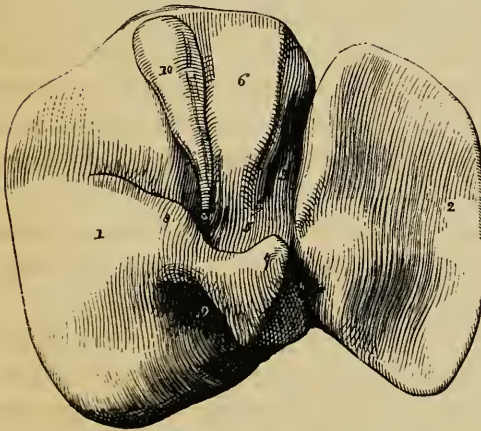
coronary
ligament;

right and
left lateral
ligaments.

The Lobes.—The lobes of the liver, like the ligaments, are five in number; and,

Lobes are
also five.

Fig. 274.*



indeed, anatomists have endeavoured to trace the number five in respect also of the fissures and vessels of the gland. The *lobes* are named the right and the left, the lobe of Spigelius, the caudate or tailed lobe, and the square lobe. 1, 2. The *right* and *left* lobes (fig. 274, 1, 2,) are separated from each other on the under surface by the longitudinal fissure

Right and
left lobes;

(3, 4), and in front by the interlobular notch: on the convex surface of the liver there is no other indication of a separa-

* View of the under surface of the liver, the anterior border being turned upwards.—1. Right lobe. 2. Left lobe. 3, 4. Longitudinal fissure. 3. Umbilical fissure. 4. Fissure or fossa of the ductus venosus. 5. Transverse or portal fissure. 6. Lobulus quadratus. 7. Lobulus Spigelii. 8. Lobulus caudatus. 9. Fissure or fossa of the vena cava. 10. Gall-bladder, which lies in the fossa cystis felleæ.

tion between them than the line of attachment of the broad ligament. The right lobe is of a long square form; it is much larger and thicker than the left, which is nearly triangular in outline, and constitutes only about one-fifth or one-sixth of the entire gland. 3, 4, 5. The other three lobes are small, and might be said to form a part of the right lobe, on the under surface of which they are situated. The *Spigelian* lobe (⁷, lobulus Spigelii) projects in the form of a pyramidal mass from the middle of the back part of the liver, and is bounded by three large fissures (^{5, 9, 4}), to be immediately described, which lodge the vena portæ, the vena cava, and the remains of the ductus venosus. The *caudate* or *tailed* lobe (⁸) is a sort of ridge which extends from the base of the Spigelian lobe to the under surface of the right lobe. This, in the natural position of the parts, passes forwards above the foramen of Winslow, the Spigelian lobe itself being situated behind the small omentum, and projecting into the omental sac. The *square* lobe (⁶, lobulus anonymus, lobulus quadratus) is that part which is situated between the gall-bladder (¹⁰) and the great longitudinal fissure, and in front of the fissure for the portal vein.

Spigelian
lobe;

caudate
lobe;

square lobe.

Fissures or
fossæ are
five.

Transverse,
or portal
fissure;

longitudi-
nal fissure,
consisting
of umbilical
fissure

The Fissures.—Of the five *fissures* or *fossæ* of the liver, which are seen on its under surface only, all are not of equal significance. 1. The *transverse* fissure, or *portal* fissure, (⁵) is the most important, because it is here that the great vessels and nerves enter, and the hepatic duct passes out. It is situated across the middle of the right lobe, somewhat nearer to its posterior than its anterior border, occupying its inner half only, and meeting nearly at right angles with the longitudinal fissure. It is bounded in front by the square lobe (⁶), and behind by the Spigelian lobe (⁷) and the caudate lobe (⁸). These boundaries were compared to the *pillars* of a *gate*, the fissure itself being likened to a gateway, *porta*; and hence the large vein to which it gives admission was named *vena portæ*, or *vena portarum*. Besides this vessel, the hepatic artery and nerves and the hepatic duct and principal lymphatics enter or pass out at the transverse fissure, which has therefore been termed the *hilus* of the liver. 2, 3. The *longitudinal* fissure, which separates the right and left lobes of the liver from each other, is divided into two parts by its meeting with the transverse fissure. The anterior part, named the

umbilical fissure (³), contains the umbilical vein in the fœtus, and the remains of that vein in the adult, which then constitutes the round ligament. It is situated between the square lobe and the left lobe of the liver, the substance of which often forms a bridge across the fissure, so as to convert it partially or completely into a canal. The posterior part (⁴) is named the *fissure* of the *ductus venosus* (*fossa ductus venosi*); it continues the umbilical fissure backwards between the lobe of Spigelius and the left lobe; and it lodges the ductus venosus in the fœtus, and in the adult a slender cord or ligament into which that vein is converted. 4. The *fissure* or *fossa* of the *vena cava* (⁹) is situated at the back part of the liver, between the Spigelian lobe on the left and the right lobe on the right, separated from the transverse fissure by the caudate lobe. It is continued upwards in an oblique direction on to the posterior border of the liver, and may almost be said to join behind the Spigelian lobe with the fissure for the ductus venosus. It is at the bottom of this fossa that the blood leaves the liver by the hepatic veins, which end here in the vena cava. The substance of the liver in some cases unites around the vena cava, and encloses that vessel in a canal. 5. The last remaining fissure, or, rather, *fossa*, (*fossa cystis felleæ*,) is that for the lodgment of the gall-bladder (¹⁰): it is sometimes continued into a slight notch on the anterior margin of the liver.

and fissure
of ductus
venosus ;

fissure for
vena cava ;

fossa for
gall-bladder.

Besides these, there are two shallow impressions on the under surface of the right lobe: one in front (*impressio colica*), corresponding with the hepatic flexure of the colon; and one behind (*impressio renalis*), corresponding with the right kidney.

Two im-
pressions,
named colic
and renal.

Vessels and Ducts.—1, 2. The two vessels by which the liver is supplied with blood are the hepatic artery and the vena portæ. The *hepatic artery*, (fig. 142, *d*,) a branch of the cœliac axis, is intermediate in size between the other two branches of that trunk, being larger than the coronary artery of the stomach, but not so large as the splenic artery. It is, therefore, a small vessel in comparison with the size of the organ to which it is distributed. It enters the transverse fissure, and there divides into a right and left branch, for the two principal lobes of the liver. Sometimes there is an hepatic branch, derived from the coronary artery of the stomach or from the superior mesenteric. The coats of the liver also receive small vessels from other

Vessels are
also of five
kinds.

Hepatic
artery ;

sources, as from the branches of the phrenic, internal mammary, and epigastric arteries.

By far the greater part of the blood which passes through the liver,—and this is its chief peculiarity as a gland,—is conveyed to it by a large vein, the *vena portæ*, (fig. 158, *a*.) This vein is formed by the union of nearly all the veins of the chylipoietic viscera, viz. those from the stomach and intestines, the pancreas and spleen, omentum and mesentery, and those from the gall-bladder also. It enters the *porta*, or transverse fissure, where, like the hepatic artery, it divides into two principal branches.

3. The *bile duct* or *hepatic duct* is, also, formed by the union of a right and left branch, which issue from the bottom of the transverse fissure, and soon unite at a very obtuse angle. (Figs. 158 and 281.)

The three vessels above mentioned ascend to the liver between the layers of the gastro-hepatic omentum, above the foramen of Winslow, and thus reach the transverse fissure together. Their relative position is as follows:—The bile-duct is to the right, the hepatic artery to the left, and the large portal vein is behind and between the other two. They are accompanied by numerous lymphatic vessels and nerves, and are surrounded by a cellular tissue named the capsule of Glisson. The branches of these three vessels accompany one another in their course through the liver nearly to their termination; and in this course are surrounded by a common investment (Glisson's capsule), which is prolonged into the interior of the organ.

4. The *hepatic veins*, which convey the blood out from the liver, pursue an entirely different and independent course through its substance, and pass out at its posterior border, where, at the bottom of the fossa already described, they end by two principal branches, besides other smaller ones, in the *vena cava*.

5. The last order of vessels belonging to the liver are the *lymphatics*. They are large and numerous, and form a deep and a superficial set. The deep lymphatics accompany the vessels in the portal canals, to be presently described, and emerge at the transverse fissure. The superficial set form a network on the upper and under surfaces of the organ, and com-

vena portæ ;

hepatic duct.

These three sets of vessels enter portal fissure, and

run together in liver, surrounded by Glisson's capsule.

Hepatic veins.

Lymphatics.

municate freely with each other and also with the deep set. (See p. 659.)

Nerves.—The *nerves* of the liver are derived partly from the celiac plexus, and partly from the pneumogastric nerves, especially from the left pneumogastric. They enter the liver supported by the hepatic artery and its branches; along with which they may be traced a considerable way in the portal canals, but their ultimate distribution is not known.

The nerves:
from sym-
pathetic
and
parvagum.

Structure of the Liver.

Coats.—The liver has two coverings, viz. a serous coat and a proper cellular coat. The *serous* coat, smooth, moist, shining, and transparent, is derived from the peritonæum, and covers every part of the free surface of the gland; but it is deficient at the part of the liver round which the suspensory, coronary, and two lateral ligaments are reflected to the diaphragm, and also at the bottom of the several fissures or fossæ, especially those for the vena portæ, vena cava, and gall-bladder. It adheres closely to the proper or cellular coat.

The coats
of liver are
two :
serous or
peritonæal,
which is
incomplete ;

The *cellular* or *fibrous* coat, as it is also called, invests the whole gland. Opposite to the parts covered by the serous coat it is thin and difficult to demonstrate; but where the peritonæal coat is absent, as at the posterior border of the liver, and in the portal fissure, it is denser and more evident. Its inner surface is attached to the hepatic glandular substance, being there continuous with the delicate cellular tissue between the lobules of which the gland is composed. At the transverse fissure it becomes continuous with the capsule of Glisson.

cellular or
fibrous,
which is
complete,
and is
continuous
with
Glisson's
capsule.

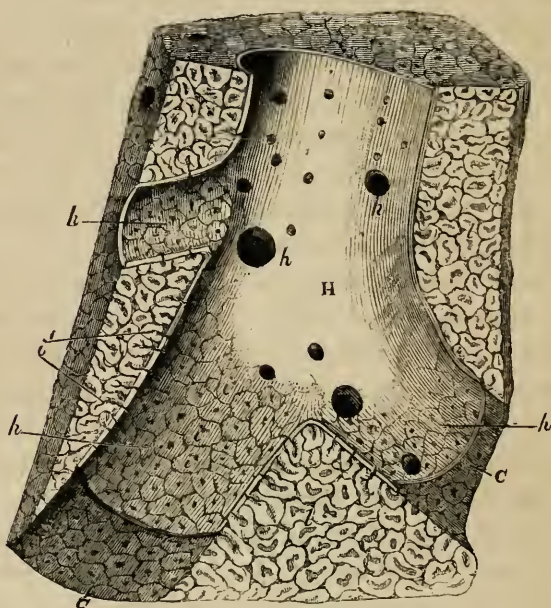
The *proper substance* of the liver, which has a reddish brown colour and a mottled aspect, is compact, but not very firm. It is easily cut or lacerated, and is not unfrequently ruptured during life from accidents, in which other parts of the body have escaped injury. When the substance of the liver is torn, the broken surface is not smooth but minutely granular, and this is owing to the fact of its being composed of a multitude of small masses called *lobules*, (fig. 275, l.) These lobules vary from half a line to nearly a line in diameter; they are closely-packed polyhedral bodies, about the size of a pin's head, which are held together by fine cellular tissue, and by the blood-

Substance
of liver is
firm,
granular,
and com-
posed of
small
lobules,

united by
interlobular
tissue.

vessels and ducts. This interlobular tissue is continuous with the fibrous coat on the exterior of the liver, and also with the capsule of Glisson within the portal canals. Such, at least, are the views entertained by Mr. Kiernan.* Some anatomists of authority, as Weber and Krukenberg, while they admit the existence of fissures between the lobules to give passage to the vessels, deny that the lobules are completely insulated, believing that they coalesce at different points. After a second investigation of this point, Müller still adheres to the opinion of Mr. Kiernan.† On the surface of the liver the lobules are triangular,

Fig. 275.‡



and more or less flattened on their exposed surface; but deeper within the substance of the gland, they have usually four or five

* Philosoph. Transactions, 1833, vol. ii.

† Archiv. 1843.

‡ Section of an hepatic vein and surrounding substance of the liver. (Kiernan.)—H. Hepatic venous trunk, against which the sides of the lobules (*l*) are applied. *h, h, h*. Sublobular hepatic veins, on which the bases of the lobules rest, and through the coats of which they are seen as polygonal figures. *i*. Mouth of the intralobular veins, opening into the sublobular veins. *i'*. Intralobular veins shewn passing up the centre of some divided lobules. *l, l*. Cut surface of the liver. *c, c*. Walls of the hepatic venous canal, formed by the polygonal bases of the lobules.

sides. They are all compactly arranged around the sides of certain branches (*h, h*) of the hepatic veins (H), each lobule resting by a smooth surface, or *base*, upon the vein, and being connected with it by a small venous trunk (*i*), which arises in the centre of the lobule (*i'*), and passes out from the middle of its base to end in the larger subjacent vessel. The small veins proceeding from the centre of the lobules are named the *intra-lobular* veins (*i'*) and those on which the lobules rest, the *sublobular* veins (*h, h*). If one of these sublobular veins be opened, the bases of the lobules (*i*) may be seen through the coats of the vein, which are here very thin, forming a tessellated appearance, each little polygonal space representing the base of a lobule, and having in its centre a small spot, which is the mouth of the intralobular vein. When divided in the direction of a sublobular vein, the attached lobules present a foliated appearance, as at *i'*, for that part of their surface which is not in contact with the vein is itself slightly lobulated or developed into blunt processes. Cut in a transverse direction, they present a polyhedral form. (Fig. 276.)

The lobules are arranged around hepatic veins, and each contains a small vein of that system.

The *hepatic* veins, which may now be traced, commence in the centre of each lobule by the union of its capillary vessels into a single independent intralobular vein. (Fig. 277, *h*.) These minute intralobular veins (fig. 275, *i'*) open at once into the sides of the subjacent sublobular veins, (*h, h, h*.) The sublobular veins are of various sizes, and anastomose together. Uniting into larger and larger vessels, they end at length in another kind of hepatic venous trunks, (H,) which receive no intralobular veins. Lastly, these venous trunks, converging towards the posterior border of the liver, and receiving in their course other small sublobular veins, terminate in the vena cava, at the bottom of the fossa already described. In this course the hepatic veins and their successive ramifications are unaccompanied by any other vessel. Their coats are extremely thin; the sublobular branches adhere immediately to the lobules, and even the larger trunks have but a very slight cellular investment, which connects them to the substance of the liver. Hence the divided ends of these veins are seen upon a section of the liver as simple open orifices, surrounded closely by the solid substance of the gland, (*c, c*.)

Course of the hepatic veins :

intra-lobular, sublobular, and hepatic venous trunks.

Run along through the liver; surrounded by lobules, and remain open when cut across.

2. The vena portæ and hepatic artery, which, together with

Vena portæ

and hepatic artery :

lie, with ducts, in the portal canals ;

surrounded by cellular sheath, or Glisson's capsule.

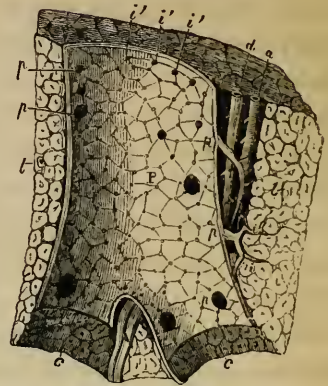
Course of portal veins : vaginal, interlobular, and lobular branches,

end in lobular plexuses.

the biliary ducts, enter the liver at the transverse fissure, have a totally different course, arrangement, and distribution from those of the hepatic vein. Within the liver the branches of these three vessels lie together in certain canals, called *portal canals*, which are tubular passages formed in the substance of the gland, commencing at the transverse fissure, and branching upwards from that part in all directions. Each portal canal (even the smallest) contains, as shewn in a longitudinal section, (fig. 276,) one principal branch of the vena portæ (P), of the hepatic artery (a), and of the biliary duct, (d); the whole being invested by the continuation, along the canals, of the cellular sheath named Glisson's capsule. This arrangement of the parts is rendered evident by making a cross section of a portal canal, when the large orifice of the portal vein, accompanied by the biliary duct (of much smaller size) and a branch of the hepatic artery, which is the smallest of the three, are seen, surrounded by a web of cellular tissue, which separates them from the substance of the liver.

The *portal veins*, (P,) as they lie in the portal canals, give off lateral branches, named *vaginal veins* (pp), which ramify and form a plexus in Glisson's capsule, and then send off smaller branches, called *interlobular veins*, (ii, upon the substance of the gland to the right,) which enter between the lobules, (fig. 277, pp,) and, after ramifying freely, and, according to Kiernan, anastomosing, penetrate the surface of the lobules themselves, and end in a capillary network within them, (b.) From this network the intralobular (hepatic) vein of each lobule (h) takes its origin. In the smaller portal canals the vaginal veins and plex-

Fig 276.*



* Section of a portal canal and portal vein lying in it, in company with the hepatic artery and duct. (Kiernan).—P. Branch of vena portæ, situated in c, c, a portal canal, formed amongst the lobules of the liver (l, l.) pp, p. Vaginal branches of portal vein, giving off smaller ones, (i, i,) named interlobular veins. i', i'. Orifices of several interlobular veins seen at the top of the figure, arising at once from the large vein. a. Hepatic artery. d. Hepatic duct.

uses are less evident, for many of the interlobular veins (as at *i', i'*, fig. 276) arise at once from the principal branch (*p*) of the vena portæ. In the smaller canals, too, the capsule of Glisson is very thin, as if its office were no longer needed; for (like the periosteum and pia mater) it seems principally to be required as a tissue in which the vessels may divide into smaller branches before they enter the structure which they have to supply.

The *hepatic artery* (*a*) also gives off its *vaginal* and *interlobular* branches. These are distributed to the coats of the various vessels, (especially to the ducts, which become very red in a successful injection,) to the capsule of Glisson, the interlobular cellular tissue, and the proper coat of the liver, (*rami vasculares*, *rami capsulares*). There are but few of its branches between the lobules, and still fewer have been found within their margin. Kiernan believes that the branches of the hepatic artery terminate in a system of capillary vessels, from which the blood is collected and conveyed into the portal veins, by means of small venous radicles, which may be considered as intra-hepatic tributary branches of the vena portæ, analogous to the superior mesenteric, the splenic, the cystic, and other extra-hepatic branches or roots of that great vein. The blood from the hepatic artery, therefore, reaches the hepatic veins only indirectly through the intervention of the vena portæ.

This opinion, which was also that of Ferrein,† and is now supported by Theile,‡ is opposed to the view that the hepatic artery and vena portæ communicate, by means of a common capillary system, with the hepatic veins,—an opinion still maintained by several anatomists of authority.

The branches of the *hepatic ducts* (*d*) have been traced emerging from the surface of the lobules (*d*, fig. 277), and forming between them an interlobular plexus of ducts. Branches from this plexus enter the portal canals as *vaginal* branches, and there unite into larger and larger ducts, which do not anastomose. There is always one principal duct in each portal canal.

Structure of the Lobules.—From what has preceded, the arrangement of the blood-vessels within each lobule will be readily understood. The ultimate branches of the vena portæ

Course of hepatic artery: vaginal and interlobular branches; vascular and capsular branches.

Mode of termination, to form branches of vena portæ.

Differences of opinion.

Course of hepatic ducts.

Structure of lobules: arrange-

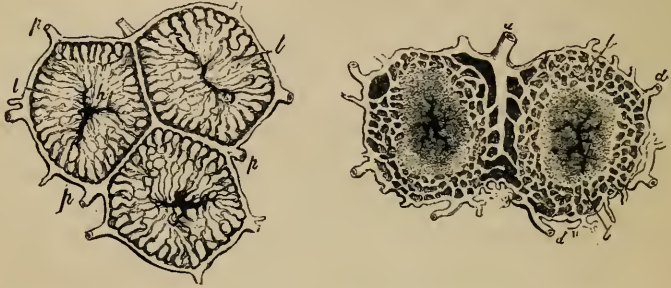† Ferrein, *Mém. de l'Acad. des Sciences*, 1733.

‡ Theile, *Hand-Wörterbuch der Physiologie*, (Wagner's,) p. 342.

ment of
minute
blood-
vessels
or capillary
plexuses
of each
lobule.

(fig. 277, *p, p,*) having ramified upon the surface of a lobule, enter it at all points, and form a plexus within it (*b*), composed of radiating and transverse connecting vessels. These having become reduced by division and subdivision to a capillary size,

Fig. 277.*



form a network from which arise the commencing radicles of the intralobular hepatic vein in the centre, (*h*.) As already stated, opinions are still divided as to the relation of the capillaries of the hepatic artery to the capillary network within the lobules. From the ultimate distribution of the branches of the vena portæ, it is evident that the blood of that vessel is largely concerned in the secretion of the bile. The hepatic artery, on the other hand, is essentially the nutrient vessel of the constituent parts of the gland, and its blood either previously enters the portal system as suggested by Kiernan, and thus as portal blood assists in the secretion of the bile, or, as supposed by others, it reaches the capillary system of the lobules in the condition of arterial blood.

Mottled
aspect of
liver, owing
to arrange-
ment of
blood-
vessels.

The distribution of the portal and hepatic veins within the lobules, as just described, has suggested an explanation of the mottled aspect of the liver, an appearance which has led to the erroneous idea of there being two substances in each lobule, one darker than the other. The colour of the hepatic substance is pale yellow, and would be uniform throughout, were it not varied according to the quantity of blood contained in its different vessels. Thus,

* Two diagrams shewing the arrangement of the blood-vessels and of the ducts within and between the lobules. (Kiernan.)—*p, p*. Interlobular branches of portal vein. *b, b*. Intralobular venous plexus, connecting the portal veins (*p, p*) with the intralobular vein (*h*) in the centre, which is the commencing branch of the hepatic vein. In the second figure, *d, d* are two branches of the hepatic duct, which is supposed to commence in a plexus situated towards the circumference of the lobule marked *b, b*, called by Kiernan the biliary plexus. Within this is seen the central part of the lobule, containing branches of the intralobular (hepatic) vein.

if the system of hepatic veins be congested, the centre of each lobule is dark, and its margin pale: this is the common case after death, and is named by Mr. Kiernan *passive* congestion. In what is considered an *active* state of hepatic congestion, the dark colour extends to the portal system, across the interlobular fissures, leaving intermediate spaces, which remain as irregular pale spots: this state occurs especially in diseases of the heart. When, on the other hand, the portal system is congested, which is rare, and occurs generally in children, the margins of the lobules are dark, and their centres pale.

The interstices between the blood-vessels in each lobule are occupied by the commencement of the biliary ducts, and they also contain a peculiar substance (the *hepatic substance*), composed of numerous microscopic nucleated corpuscles. These corpuscles present specific characters; they are evidently concerned in the secretion of the bile, and are named the *hepatic cells* or *corpuscles*.

Spaces between vascular network contain the ducts and the hepatic corpuscles.

Ducts.—According to Mr. Kiernan the biliary ducts (fig. 277, *d*) commence within the lobules by numerous ramifications, which form a closed network or plexus (*b, b*), occupying principally the outer portion of each lobule. The anastomosis of the ducts was doubted by Müller, who, having observed that in the lower animals, and also in the embryo of birds, the biliary ducts terminate in tufts of tubes, having free and blind extremities, thought it probable that a similar structure existed in the human liver. Since the discovery of the hepatic cells, both of these views have undergone considerable modification in the opinion of anatomists. Thus, it is conceived by Krukenberg and Theile that the interstices between the network of capillary blood-vessels in the lobules represent the reticular ducts of Kiernan; and, further, that these interstices or ducts are lined, and in a manner filled by the secreting nucleated hepatic cells. It has been questioned whether these intervascular spaces are bounded by a proper limiting or constituent membrane, or whether the nucleated cells lie in immediate contact with the coats of the capillaries; but the former opinion is on the whole the more probable. It has been further noticed, first by Dujardin and Berger, and afterwards by Henlé, Müller, and others, that the nucleated cells lie in linear series between the vessels, and for the most part present a similar radiated arrangement from the centre towards the margin of the lobules. E. H. Weber conceived that a single file or row of these

Commencement of the ducts.

Different views upon this.

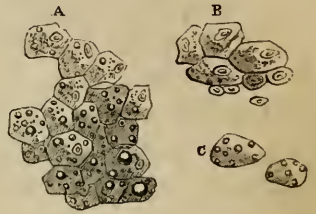
Radiated arrangement of the cells.

cells was contained in each of the finest ducts, or rather formed the tubular cavity of such a duct by successively opening into each other. Henlé conceives that the commencing ducts are mere interstitial channels in a mass of cells filled with bile, and that these nascent and imperfect ducts pass into others, which have a distinct bounding membrane and lining epithelium. He supposes that the bile either exudes from the cells into the intercellular channels, or escapes into these channels by the destruction or solution of the adjoining cells, which give place to others successively undergoing the same process. Other anatomists, again, as Theile, suppose that ducts do not exist at all as such within the lobules, but commence upon their outer surface; and that the secreted bile either finds its way into them by oozing through and between the nucleated cells, or is introduced into them by rupture and subsequent intercommunication of the cells, which is said to take place in succession along the rows of cells which radiate from the centre to the margin of a lobule.

Hepatic cells or corpuscles are polyhedral and nucleated; are coloured :

The Hepatic cells.—These are nucleated cells of a spheroidal, compressed, or polyhedral form, (fig. 278, A,) having a mean diameter of from $\frac{1}{1080}$ th to $\frac{1}{840}$ th of an inch; according to Henlé they are some of them only $\frac{1}{1716}$ th of an inch in diameter. They present some colour even when highly magnified, being of a faint yellowish hue. They usually include a very clear bright nucleus of a rounded form, within which again one or two nucleoli may be seen. The cells also contain very fine granular or vesicular molecules.

Fig. 278.*



their contents and

In many cases, too, the cells of the human liver and of that of quadrupeds have larger and smaller semi-transparent fat-globules in their interior. Their nucleus is frequently quite indistinguishable; and sometimes, on the other hand, cells are observed which are provided with two separate nuclei. As already stated, they lie in rows or streaks amongst the vessels, radiating from the centre of the lobules towards their circumference.

radiated arrangement.

* Hepatic cells. (Dr. Baly.)—A. From healthy human liver. B. From a case of supposed cirrhosis. C. From the sheep's liver.

Aberrant biliary ducts.—In the duplicature of the peritonæum forming the left lateral ligament of the liver, and also in the two fibrous bands which sometimes convert the fossa for the vena cava and the fissure of the umbilical vein into canals, there have been found biliary ducts of tolerable size which are not surrounded with lobules. These aberrant ducts, as they might be called, are described by Ferrein and by Kiernan: they anastomose together in form of a network, and are accompanied by branches of the vena portæ, hepatic artery, and hepatic vein.

THE BILE.

The bile, as it flows from the liver, is a thin greenish yellow fluid; but that which remains in the gall-bladder becomes darker, more viscid, andropy. It contains as adventitious particles mucus and epithelium corpuscles. The specific gravity of the bile is from 1.026 to 1.030. It has a sweetish bitter taste, and an alkaline reaction. It is a saponaceous compound, containing the following ingredients:—water, mucus, colouring matters (composed, according to Berzelius, of a yellow substance named cholepyrrhine, a brown substance named bilifulvine, and a green matter or biliverdine), fatty acids, viz. the margaric and oleic, combined with soda, free fat, cholesterine, salts, and, lastly, the most important ingredient of the bile, namely, choleic or bilic acid, a resinous or fatty acid, which is also in a state of combination with soda. This choleic acid consists principally of carbon and hydrogen, but it also contains nitrogen; it is very easily decomposed, and gives rise to ammoniacal and other compounds.

The bile: its chemical constituents are numerous.

THE EXCRETORY APPARATUS OF THE LIVER.

The excretory apparatus of the liver consists of the hepatic duct, the cystic duct, the gall-bladder, and the common bile-duct, or ductus communis choledochus.

The excretory ducts and the gall-bladder.

The *hepatic duct*, (fig. 281,) commencing at the transverse fissure of the liver, descends to the right, within the gastro-hepatic omentum, in front of the vena portæ, and to the right of the hepatic artery. Its diameter is about two lines, and its length nearly two inches. At its lower end it meets with the cystic duct, coming down from the gall-bladder; and the two ducts uniting together at an acute angle, form the ductus communis choledochus (*f*).

The hepatic duct: its course out of the liver.

The *gall-bladder* (*g*) is a pear-shaped membranous sac, about three or four inches long, rather more than an inch across at its widest part, and capable of containing about eight or ten fluid-drachms. It is lodged obliquely in a fossa on the under

The gall-bladder: its shape, size, and position;

its fundus and neck. surface of the right lobe of the liver, so that its large end or *fundus*, which projects beyond the anterior border of the gland, is directed downwards, forwards, and to the right, whilst its body and narrow end or *neck* are inclined in an opposite direction, viz. upwards, backwards, and to the left.

Its connexions.

The *upper surface* of the gall-bladder is attached to the liver by cellular tissue and vessels, along the fossa formed between the square lobe and the remainder of the right lobe. Its *under surface* is free and covered by the peritonæum, which is here reflected from the liver, so as to include and support the gall-bladder from below. Sometimes, however, the peritonæum completely surrounds the gall-bladder, which is then suspended by a kind of mesentery at a little distance from the under surface of the liver. The *fundus* of the gall-bladder, which is free, projecting, and always covered with peritonæum, touches the abdominal parietes immediately beneath the margin of the thorax, opposite the tip of the tenth costal cartilage. Below, it rests on the commencement of the transverse colon; and, further back, the gall-bladder is in contact with the duodenum, and sometimes with the pyloric extremity of the stomach. In consequence of these relations with the hollow viscera and with the surface, gall-stones occasionally make their way from the gall-bladder into the intestines, or even externally, by a process of adhesion and ulcerative absorption. The *neck* of the gall-bladder, which is gradually narrowed, forms two curves upon itself like an S, and then, having become much constricted, and changing its general direction altogether, bends downwards and terminates in the cystic duct.

Position of the fundus

and of the neck.

Structure :

Structure.—Besides the peritonæal investment, the gall-bladder has two distinct tunics, viz. a cellular and a mucous coat.

has a cellular and probably contractile coat,

The *cellular* coat is strong, and consists of bands of dense shining white fibres, which interlace in all directions. These fibres resemble those of cellular tissue; and, as a matter of inference only, they are supposed to possess contractility. In recently killed quadrupeds the gall-bladder contracts on the application of a stimulus; and in the larger species, such as the ox, muscular fibres of the plain variety have been found in this coat. It forms the framework of the organ, and supports the larger blood-vessels and lymphatics.

The *mucous* coat, which is generally strongly tinged of a yellowish brown colour with bile, is elevated upon its inner surface into innumerable ridges, which, uniting together into meshes, leave between them depressions of different sizes and of various polygonal forms. This structure gives to the interior of the gall-bladder an areolar aspect, which is similar to what is seen on a smaller scale in the *vesiculæ seminales*. These areolar intervals become smaller towards the fundus and neck of the gall-bladder; and at the bottom of the larger ones, other minute depressions, rendered visible by a lens, apparently lead into numerous mucous recesses or follicles. The whole of the mucous membrane is covered by columnar epithelium, and it secretes an abundance of viscid mucus.

and a mucous coat:

this last is areolar on its inner aspect.

At the points where the neck of the gall-bladder curves on itself, there are strong folds or projections of its mucous and cellular coats into the interior.

At neck of gall-bladder folds exist.

The gall-bladder is supplied with blood by the *cystic* branch of the right division of the hepatic artery, along which vessel it also receives nerves from the *cæliæ* plexus. The cystic veins empty themselves into the *vena portæ*. The lymphatics join those of the liver.

Vessels, nerves, and lymphatics.

The gall-bladder is a receptacle or reservoir for such bile as is not immediately required in digestion. The bile contained within it becomes darker and inspissated, receiving some addition of mucus, and becoming more ropy and viscid, but beyond this it undergoes no further change.

Uses of gall-bladder.

The *cystic duct* is about an inch or rather more in length. It runs downward and to the left, thus forming an angle with the direction of the gall-bladder, and unites with the hepatic duct to form the *ductus communis*. In its interior, the mucous membrane is elevated in a singular manner into a series of crescentic folds, which are arranged in an oblique direction, and succeed closely to each other, so as to present very much the appearance of a continuous spiral valve. When distended, the outer surface of the duct appears to be indented in the situation of these folds, and dilated or swollen in the intervals, so as to present an irregularly sacculated or twisted appearance.

The cystic duct:

has spiral folds in its interior.

The *common bile duct*, (fig. 281, *f*: *ductus communis choledochus*.) the largest of the three ducts, being from two to three lines in width, and nearly three inches in length, conveys

The common bile duct:

is formed by
cystic and
hepatic
ducts ;

its course ;

perforates
the coats of
duodenum
obliquely,
and ends
with
pancreatic
duct.

Structure
of bile
ducts :

their
glands ;

of several
kinds.

Develop-
ment of
gall-
bladder.

the bile both from the liver and the gall-bladder into the duodenum. It continues downwards and backwards in the course of the hepatic duct, between the layers of the gastro-hepatic omentum, in front of the vena portæ, and to the right of the hepatic artery. Having reached the descending portion of the duodenum, it continues downwards on the inner and posterior aspect of that part of the intestine, covered by or included in the head of the pancreas, and, for a short distance, in contact with the right side of the pancreatic duct. Together with that duct, it then perforates the muscular wall of the intestine, and after running obliquely for three-quarters of an inch between its several coats, and forming an elevation beneath the mucous membrane, it becomes somewhat constricted, and opens by a common orifice with the pancreatic duct on the inner surface of the duodenum, at the junction of the second and third portions of that intestine, and rather more than three inches below the pylorus.

Structure.—The structure of all the bile ducts is alike. Their cellular coat is strong and distensible. The mucous membrane is provided with numerous glands, the openings of which are scattered irregularly in the larger ducts, but in the small subdivisions of the hepatic duct are arranged in two longitudinal rows, one at each side of the vessel.

The mouths of these glands have been long known, and were supposed to be merely the openings of mucous follicles ; but the structure of the glands of the biliary ducts has been recently found by Theile to be more complicated. According to his observations, which we have been able to confirm, some of them are ramified tubes, which occasionally anastomose together, and often present lateral saccular dilatations similar to the Meibomian glands. Others, again, which are more solid and clustered together, are little cellular glands opening into the bile duct by a single orifice. Sometimes these cellular glands are attached to the tubular glands, and open into them.

Development.—According to some the gall-bladder is developed as a branch or diverticulum from the bile duct outside the liver ; but Meckel says it arises in a deep notch in the substance of the gland. It is at first tubular, and then has a rounded form. The alveoli in its interior appear about the sixth month. At the seventh month it first contains bile. In the fœtus its direction is more horizontal than in the adult.

Varieties in the excretory apparatus of the liver.—The gall-bladder is occasionally wanting; in which case the hepatic duct is much dilated within the liver, or in some part of its course. Sometimes the gall-bladder is irregular in form, or is constricted across its middle, or, but much more rarely, it is partially divided in a longitudinal direction. Direct communications by means of small ducts, (named hepato-cystic,) passing from the liver to the gall-bladder, exist regularly in various animals; and they are sometimes found, as an unusual formation, in the human subject.

Varieties in gall-bladder and bile ducts.

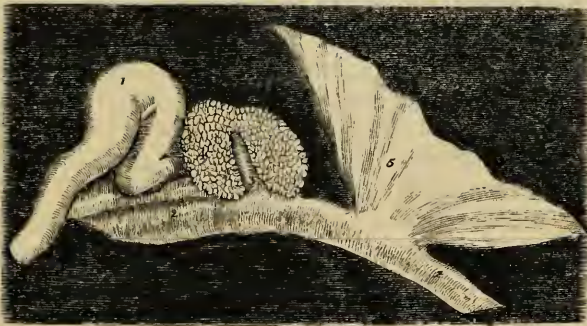
The right and left divisions of the hepatic duct sometimes continue separate for some distance within the gastro-hepatic omentum. Lastly, the common bile duct not unfrequently opens into the duodenum, apart from the pancreatic duct.

DEVELOPMENT AND FETAL PECULIARITIES OF THE LIVER.

The liver begins to be formed at a very early period of foetal life. Its development has been traced in the bird, (fig. 279,) from a conical protrusion

Development of liver:

Fig. 279.*



of the intestinal canal⁽³⁾, surrounded by a soft mass or blastema⁽⁴⁾, in which, by a subsequent process of growth, the ducts are formed. In the mammalian embryo (the dog) it has been found by Bischoff to commence by a double mass of blastema attached to the outer wall of the intestinal tube immediately beneath the dilatation for the stomach, and having a conical protrusion of the internal membrane passing into each division of the mass. In a very early condition, ramified lines or commencing ducts may be seen as in other glands; but this appearance is not afterwards visible, owing to the thickness and colour of the gland, and also in consequence of the development of nucleated cells.

at first a soft mass, with a protrusion of intestinal mucous membrane in it.

Size.—In the human foetus, at the third or fourth week, the liver is said to

Its size in

* Early condition of the liver in the chick at the fifth day of incubation. (Müller.)—1. The heart, as a simple curved tube. 2. The intestinal tube. 3. Conical protrusion of the coat of the commencing intestine, on which the blastema of the liver is formed. 4. The rudimentary liver. 5. Portion of the mucous layer of the germinal membrane.

fœtus :
at first very
large.

constitute one half the weight of the whole body. This proportion, however, gradually decreases as development advances, until at the full period the relative weight of the fœtal liver to that of the body is as 1 to 18.

Lobes are
equal.

In the early fœtus the right and left lobes of the liver are of equal, or nearly equal, size ; and just before birth the difference between them is not great, the relative weight of the left lobe to the right being nearly as 1 to 1.6.

Position is
more sym-
metrical.

Position.—In consequence of the greater equality as to size between the two lobes, the position of the fœtal liver in the abdomen is more symmetrical, as regards the middle line of the body. In the very early fœtus it occupies nearly the whole of the abdominal cavity ; and at the full period it still descends an inch and a half below the margin of the thorax, overlaps the spleen on the left side, and reaches nearly down to the crest of the ilium on the right.

Its form is
rounder,
and its
colour
darker.

Form, Colour, &c.—The fœtal liver is thicker from above downwards, and has therefore a rounder form than in the adult. It is generally of a darker hue. Its consistence and specific gravity are both less than in the adult.

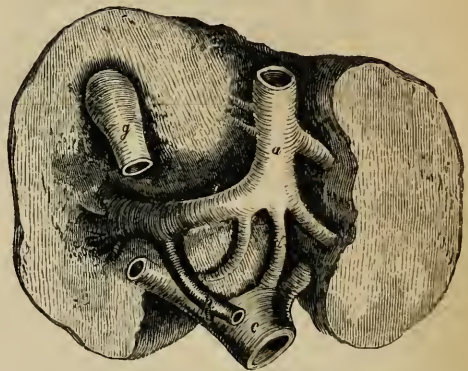
Its blood-
vessels are
peculiar.

Blood-Vessels.—Lastly, the blood-vessels of the fœtal liver present most important peculiarities, with which, indeed, all those previously mentioned are more or less connected.

Course of
umbilical
vein.

Up to the moment of birth most of the blood returned from the placenta by the umbilical vein passes through the liver of the fœtus before it reaches the heart. At this period the umbilical vein runs from the umbilicus along the free margin of the suspensory ligament towards the anterior border and under surface of the liver, beneath which it is lodged (fig. 280, a) in the umbilical fissure, and proceeds as far as the transverse fissure. Here it divides into two branches : one of these (d), the smaller of the two, continues onward in the same direction, and joins the vena cava (e) ; this is the *ductus venosus*, which occupies the posterior part of the longitudinal fissure, and gives to it the name of the fossa of the ductus venosus. The other and larger

Fig. 280.*



Ductus
venosus.

* Under surface of the fœtal liver, with its great blood-vessels, at the full period. The rounded outline of the organ, and the comparatively small difference of size between its two lobes, are seen. a. The umbilical vein, lying in the umbilical fissure, and turning to the right side at the transverse fissure (o), to join the vena porta (p) : the branch marked d, named the ductus venosus, continues straight on to join the vena cava inferior (c). A few branches of the umbilical vein enter the substance of the liver at once. g. The gall-bladder. (After an enlarged model.)

branch (the trunk of the umbilical vein) turns to the right along the transverse or portal fissure^(o), and ends in the vena portæ^(p), which in the fœtus is comparatively of small dimensions. Moreover, the umbilical vein, as it lies in the umbilical fissure, and before it joins the vena portæ, gives off some lateral branches, which enter the left lobe of the liver. It also sends a few branches to the square lobe and to the lobe of Spigelius.

The blood of the umbilical vein therefore reaches the ascending vena cava in three different ways. Some passes directly into it by the ductus venosus; another, and the principal portion, passes first through the portal veins, and then through the hepatic veins; whilst a third portion enters the liver directly, and is also returned to the cava by the hepatic veins.

Blood of umbilical vein.

Changes after birth.—Immediately after birth, at the cessation of the current hitherto passing through the umbilical vein, and at the commencement of an increased circulation through the lungs, the supply of blood to the liver is diminished perhaps two-thirds. The umbilical vein and ductus venosus become empty and contracted, and, soon after, they begin to be obliterated, and are ultimately converted into the fibrous cords already described—that one which represents the umbilical vein, constituting the round ligament of the liver. At the end of six days the ductus venosus has been found to be closed; but it sometimes continues open for several weeks.

Changes after birth :

contraction of umbilical vein and ductus venosus ;

Concurrently with, and doubtless in some measure dependent on, the sudden diminution in the quantity of blood supplied to the liver after birth, this organ appears at first to become absolutely lighter; and, according to some data, this decrease of weight is not recovered from until the conclusion of the first year. After that period, the liver, though it increases in size, grows more slowly than the body, so that its relative weight in regard to the body, which was 1 to 18 just before birth, becomes gradually less and less. At about five or six years of age it has reached the proportion maintained during the rest of life, viz. 1 to 36.

changes in bulk ;

The relative weight of the left lobe to that of the right (which, as above stated, is about 1 to 1.6 immediately before birth) undergoes a diminution afterwards. Thus, at a month old, it has been found to be as 1 to 3, and in after life the proportion is generally 1 to 4 or 5.

changes in the size of lobes.

Varieties.—The liver is not subject to great or frequent deviation from its ordinary characters. Sometimes it retains the thick rounded form which it presents in the fœtus; and it has occasionally been found without any division into lobes. On the contrary, Sæmmerring has recorded a case in which the adult liver was divided into twelve lobes; and similar cases of multiple liver (resembling that of some animals) have been now and then observed by others. A detached portion, forming a sort of *accessory* liver, is occasionally found appended to the left extremity of the gland by a fold of peritonæum containing blood-vessels.

Varieties in liver.

THE PANCREAS.

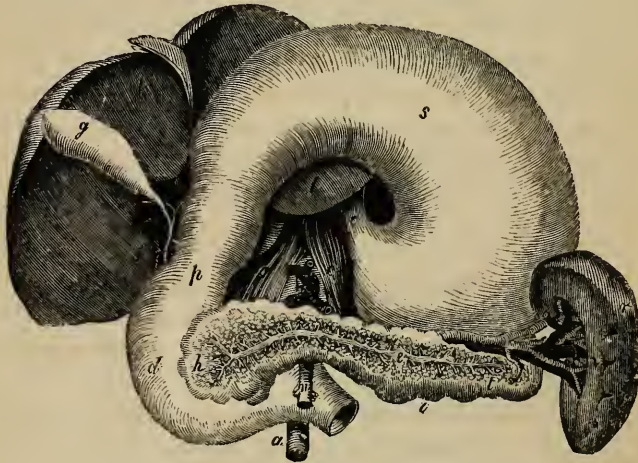
The
pancreas :
is placed at
back of
abdomen.

The *pancreas* (fig. 281, *h, t*: *πας κρεας*, *all flesh*) is a long, narrow, flattened gland, larger at one end than the other, which lies deeply in the cavity of the abdomen, immediately behind the stomach, and opposite the first lumbar vertebra. Its larger end, which is turned to the right, is embraced by the curvature of the duodenum, whilst its left or narrow extremity reaches to a somewhat higher level, and is in contact with the spleen. It extends, therefore, across the epigastric into both hypochondriac regions.

Its form

In its general form the pancreas bears some resemblance to a hammer, or, what is a better comparison, to a dog's tongue. Its

Fig. 281.*



broad end is named the *head* (*h*), the narrow extremity the *tail* (*t*), and the intermediate portion, which is compressed in front and behind, the *body* of the gland (*i*).

* In this figure, which is altered from Tiedemann, the liver and stomach are turned up, to shew the duodenum, the pancreas, and the spleen. *l*. The under surface of the liver. *g*. Gall-bladder. *f*. The common bile duct, formed by the union of a duct from the gall-bladder, called the cystic duct, and of the hepatic duct coming from the liver. *o*. The cardiac end of the stomach, where the oesophagus enters. *s*. Under surface of the stomach. *p*. Pyloric end of stomach. *d*. Duodenum. *h*. Head of pancreas; *t*, tail; and *i*, body of that gland. The substance of the pancreas is removed in front, to shew the pancreatic duct (*e*) and its branches. *r*. The spleen. *v*. The hilus, at which the blood-vessels enter. *c*. Crura of diaphragm. *n*. Superior mesenteric artery. *a*. Aorta.

The right or large end of the pancreas is bent from above downwards, and accurately fills the curvature of the duodenum. The lower extremity of this curved portion passes to the left, behind the superior mesenteric vessels, forming the posterior wall of the canal in which they are enclosed. This part of the gland is sometimes marked off from the rest, and is then named the *lesser pancreas*.

and direction.

The lesser pancreas.

The pancreas varies considerably, in different cases, in its size and weight. It is usually from 6 to 8 inches long, about $1\frac{1}{2}$ inch in average breadth, and from half an inch to an inch in thickness, being thicker at its head and along its upper border than elsewhere. The weight of the gland, according to Krause and Clendinning, is usually from $2\frac{1}{4}$ oz. to $3\frac{1}{2}$ oz.; but Meckel has noted it as high as 6 oz., and Sæmmering as low as $1\frac{1}{2}$ oz.

Size and weight.

The principal attachment of the pancreas is to the duodenum (*d*), with which it is connected by numerous blood-vessels and cellular tissue, but more particularly by its own excretory duct or ducts. It is also retained in its position by its connexion with several large blood-vessels, and by a layer of the peritonæum. Thus, its anterior surface, concealed by the lower border of the stomach, which moves freely over the gland, is covered by that part of the peritonæum which forms the ascending layer of the transverse mesocolon along the root of which the gland may be said to lie. Behind, the pancreas is attached by cellular tissue to the vena cava, the aorta, the superior mesenteric artery (*n*) and vein, the commencement of the vena portæ, and the pillars of the diaphragm, all of which parts, besides many lymphatic vessels and glands, are interposed between it and the upper lumbar vertebra. To the left of the vertebral column, the pancreas is attached behind in a similar way to the left supra-renal capsule and kidney and to the renal vessels. Of the large vessels situated behind the pancreas, the superior mesenteric artery and vein are embraced by the substance of the gland, so as sometimes to be enclosed in a complete canal, through which they pass downwards and forwards, and then appear beneath the lower border of the pancreas, between it and the termination of the duodenum. The cæliac axis is above the pancreas; and lying in a groove along the upper border of the gland are found the splenic artery and vein, the vein pursuing a straight, and the artery a tortuous course, (figs. 143, 158.) Both

Connexions

with peritonæum,

with other viscera,

with large blood-vessels,

of these vessels supply numerous branches to the body and tail of the pancreas, the narrow extremity of which is thus suspended or attached to the inner border of the spleen. The head of the pancreas, embraced by the inner curved border of the duodenum, is attached more particularly to the descending and transverse portions of that intestine, beyond which it projects somewhat both in front and behind. The ductus communis choledochus passes down behind the head of the pancreas, and is generally received into a sort of groove or canal in its substance.

and with
the duo-
denum.

Structure :

its lobes
and
lobules ;

has no
special coat ;

resembles
salivary
glands.

The
pancreatic
duct :

its course

and mode
of origin ;

runs near
common
bile duct ;

Structure.—The pancreas belongs to the class of compound conglomerate glands. In its general characters, and also in its intimate structure, it closely resembles the salivary glands, but it is somewhat looser and softer in its texture. It consists of numerous lobes and lobules, of various sizes, held together by cellular tissue, blood-vessels, and ducts. The cellular tissue penetrates between the larger and smaller lobules, and connects them more or less firmly together into groups and into a whole ; it also serves to attach the entire gland to adjacent parts, but it forms no consistent investment or capsule around it. The lobules, aggregated into masses, are rounded or slightly flattened at the sides, so as to be moulded or adjusted compactly to each other ; their substance is of a reddish cream-colour, and the arrangement of the commencing ducts and vessels is similar to that in the lobules of the parotid gland, which has been already described (p. 1009).

The principal excretory duct, called the *pancreatic duct*, (fig. 281, *e*,) or the *canal of Wirsung*, (by whom it was discovered in the human subject in 1642,) runs through the entire length of the gland, from left to right, buried completely in its substance, and placed rather nearer its lower than its upper border. Commencing by the union of the small ducts derived from the groups of lobules composing the tail of the pancreas, and receiving in succession at various angles, and from all sides, the ducts from the body of the gland, the canal of Wirsung increases in size as it advances towards the head of the pancreas, where, amongst other large branches, it is usually joined by one derived from that portion of the gland called the lesser pancreas. Curving slightly downwards, the pancreatic duct then comes into contact with the left side of the ductus communis choledochus, which it accompanies to the back part of the descending portion

of the duodenum. Here the two ducts, placed side by side, pass very obliquely through the muscular and cellular coats of the intestine, and terminate, as already described, (p. 1076,) on its internal mucous surface, by a common orifice, situated at the junction of the descending and horizontal portions of the duodenum, between three and four inches below the pylorus. It sometimes occurs that the pancreatic duct and the common bile duct open separately into the duodenum. The pancreatic duct, with its branches, is readily distinguished from the glandular substance, from the very white appearance of its thin fibrous walls. Its widest part, near the duodenum, is from 1 line to $1\frac{1}{2}$ line in diameter, or nearly the size of an ordinary quill; but it may be easily distended beyond that size. It is lined by a remarkably thin and smooth mucous membrane, which near the termination of the duct occasionally presents a few scattered follicles.

perforates coats of duodenum;

ends within it.

Size of duct, and

structure.

Sometimes the pancreatic duct is double up to its point of entrance into the duodenum; and a still further deviation from the ordinary condition is not unfrequently observed, in which there is a *supplementary* duct, derived from the lesser pancreas or some part of the head of the gland, opening into the duodenum by a distinct orifice, at a distance of even one inch or more from the termination of the principal duct. Like the salivary glands, the pancreas receives its blood-vessels at all points. Its arteries are derived chiefly from the pancreatico-duodenal branch of the hepatic artery, and from the splenic artery; but it also receives branches from the root of the superior mesenteric. Its blood is returned by the splenic and superior mesenteric veins. Its lymphatics terminate in the lumbar vessels and glands. The nerves of the pancreas are derived from the solar plexus.

Duct is sometimes double.

Blood-vessels of pancreas, from numerous sources:

its nerves.

Development.—In its origin and development, the pancreas altogether resembles the salivary glands. It appears a little earlier than these glands, in the form of a small bud from the left side of the intestinal tube, close to the commencing spleen.

Development.

Secretion.—The fluid secreted by the pancreas, called the *pancreatic juice*, flows into the duodenum through the common orifice of the two ducts, probably accompanied by some bile, and, then being mixed with the chyme, assists in the further changes of the latter. Owing to the striking resemblances in structure between the pancreas and the salivary glands, the former was named by the German anatomists the abdominal salivary gland; but

Pancreatic juice:

somewhat like saliva,
but differs from it.

recent analyses have shewn some important differences in the constitution of their respective secretions. Like the saliva, the pancreatic juice is a clear colourless fluid, which has diffused in it a few microscopic corpuscles; it presents sometimes an acid and sometimes an alkaline reaction, and it contains mucus, chloride of sodium, phosphate and sulphate of soda, and phosphate and carbonate of lime. It differs from saliva, in having a larger proportion of solid constituents, in containing albumen and caseine, and in being quite free from sulphocyanogen.

THE SPLEEN.

The spleen: The spleen (fig. 281, *r*: lien, $\sigma\pi\lambda\eta\nu$) is a soft, highly vascular, and easily distensible organ, of a dark bluish or purplish grey colour. It is situated in the left hypochondrium, at the cardiac end of the stomach (fig. 142, ⁶), between that viscus and the diaphragm, and is protected by the cartilages of the ribs. Though extraordinarily rich in blood-vessels, the spleen has no excretory duct; it is therefore associated by anatomists with the thyroid body and supra-renal capsules, as one of the class of blood-glands or vascular glands.

its situa-
tion ;

it has no
duct ;

is a blood-
gland.

Form is
irregular.

The shape of the spleen is irregular and somewhat variable: it forms a compressed oval mass, placed nearly vertically in the body, and having two faces, one external convex and free, which is turned to the left, the other internal and concave, which is directed to the right, and is applied to the cardiac end or great cul-de-sac of the stomach. The borders or circumference resulting from the junction of these two faces may, for the purposes of description, be conveniently considered as forming an anterior and a posterior border, and an upper and lower end.

Its con-
nexions :

the hilus,

at which
vessels and
nerves en-
ter :

The external free convex face of the spleen, smooth and covered by the peritonæum, is in contact with the under surface of the left side of the diaphragm, and corresponds with the ninth, tenth, and eleventh ribs. The internal concave face is irregular, and is divided into two unequal portions or surfaces, one anterior and larger, the other posterior and smaller, which meet at a longitudinal or vertical fissure, named the *hilus* or fissure of the spleen (*v*). Along the bottom of this fissure are large openings or depressions, which transmit blood-vessels, with lymphatics and nerves, to and from the interior of the organ. In some cases there is no distinct fissure, but merely a row of openings for the vessels; and in others the situation of the hilus is occupied by a longitudinal ridge, interrupted by the

vascular orifices. Two layers of peritonæum, reflected from the spleen, at the borders of the hilus, on to the great cul-de-sac of the stomach, and containing between them the splenic vessels and nerves and the vasa brevia, constitute the *gastro-splenic omentum* (ligamentum gastro-lienale), which thus serves to attach the spleen to the cardiac end of the stomach. In front of the gastro-splenic omentum, the concave face of the spleen is smooth, invested with peritonæum, and is closely applied to the stomach; the posterior portion of that face, situated behind the ligament and hilus, is in contact with the left pillar of the diaphragm and the corresponding supra-renal capsule. The tail of the pancreas touches the lower end of the inner surface of the spleen.

is supported by the gastro-splenic omentum

The anterior margin of the spleen, which is free, and curved so as to be applied to the stomach, is thin, and often slightly notched, especially towards its lower part. The posterior border and upper end are thick or rounded, and rest against the left kidney and the diaphragm. To the former the spleen adheres by loose cellular tissue; and to the latter it is attached by a reflection of the peritonæum, named the *suspensory ligament* (ligamentum phrenico-lienale). The lower end is pointed, and is in contact with the left end of the arch of the colon, or with the transverse mesocolon.

and by its suspensory ligament.

As the spleen is attached by the gastro-splenic omentum to the stomach, and by the suspensory ligament to the diaphragm, its position in the abdomen is necessarily changed by the movements of those parts. Thus, during expiration and inspiration, it rises and falls with the diaphragm,—not, however, descending below the margins of the ribs, when of its ordinary size.

It moves in expiration and inspiration.

The spleen varies in magnitude more than any other organ in the body; and this not only in different subjects, but in the same individual, under different conditions—sometimes appearing shrunk, and at others being much distended. On this account it is difficult or impossible to state what are its ordinary weight and dimensions: in the adult it is generally about 5 or $5\frac{1}{2}$ inches from the upper to the lower end, 3 or 4 inches from the anterior to the posterior border, and 1 or $1\frac{1}{2}$ inch from its external to its internal surface; and its usual volume, according to Krause, is from $9\frac{3}{4}$ to 15 cubic inches.

Its size

In the greater number of a series of cases examined by Dr. John

and weight

both vary
much.

Reid, its weight ranged from 5 to 7 oz. in the male, and was somewhat less in the female; but even when perfectly free from disease, it may fluctuate between 4 and 10 oz. After the age of forty the average weight gradually diminishes. The specific gravity of this organ, according to Haller, Sœmmerring, and Krause, is about 1·060 to 1·000. In intermittent and in other fevers the spleen is much distended and enlarged, reaching below the ribs, and weighing as much as 18 or 20 lbs. In enlargement and solidification of this organ, it has been known to weigh upwards of 40 lbs.; and it has been found reduced by atrophy to two drachms.

Structure :
of two coats
and a dark
substance.

Structure.—The spleen has two membranous investments,—a serous coat derived from the peritonæum, and a special albugineous fibro-elastic tunic. The substance of the organ, which is very soft and easily lacerated, is of a dark reddish-brown colour, but acquires a bright red hue on exposure to the air. Sometimes, however, the substance of the spleen is paler, and has a greyish aspect. It also varies in density, being occasionally rather solid though friable. The substance of the organ consists of a reticular frame-work of white elastic bands, of an immense proportion of blood-vessels, the larger of which run in elastic canals, and of a peculiar intervening pulpy substance, besides lymphatic vessels and nerves. As previously mentioned, it has no system of ducts.

External
serous coat

The *external* serous or peritonæal coat is thin, smooth, and firmly adherent to the elastic tunic beneath, but it may be detached by careful dissection, commencing at the borders of the hilus. It forms only a partial covering for the spleen, for though it closely invests the free surface of this organ, it is wanting opposite the hilus and at the posterior border, where the peritonæum is reflected from the spleen on to the stomach and diaphragm.

forms only
a partial
covering.

Internal
coat is
elastic ;

The *internal*, elastic, or proper tunic is much thicker and stronger than the serous coat, unlike which it covers the entire surface of the organ. It is whitish in colour, and is composed of interlaced bundles of cellular tissue mixed with a fine elastic tissue. In addition to these there are found, especially in the bullock's spleen, pale soft fibres, apparently plain or unstriped muscular fibres, resembling those of the middle coat of arteries.*

contains
also soft
fibres, like
plain mus-
cular fibres.

* The statement in the text is founded on what I had observed more

This elastic tunic cannot be raised from the spleen, because numerous bands or prolongations pass from its internal surface into the substance of the organ. Along the hilus this coat is reflected into the interior of the spleen, in the form of elastic sheaths or canals, which surround or include the large blood-vessels and nerves, and their principal branches. Stretching across in all directions between these sheaths, and traversing the intermediate substance of the spleen, are multitudes of small elastic bands, named *trabeculæ* (diminutive of *trabs*, a beam): many of these bands, moreover, are attached to the internal surface of the proper tunic of the spleen, which they exactly resemble in structure, and of which they form the inward prolongations just spoken of. The proper coat, the sheaths of the vessels, and the trabeculæ being all of a highly elastic nature, constitute a distensible framework, which contains in its interstices or areolæ the vessels and the red pulpy substance of the spleen. It is owing to this structure, endowed perhaps with vital contractility as well as mere elasticity, that the organ is capable of such great and sudden alterations of size. The arrangement of the elastic sheaths and trabeculæ may be easily displayed by pressing and washing out the intervening substance.

sends off sheaths for vessels, and also trabeculæ.

The splenic artery and vein, alike remarkable for their great proportionate size, having entered the spleen by six or more branches, ramify in its interior, enclosed within the elastic

The blood-vessels are very large.

than two years ago, and have since been in the habit of mentioning in my lectures. The observation, however, was not followed up. Since the above was in type, I have received from Professor Kölliker a paper (from the "Mittheilungen der Zürcher naturforschenden Gesellschaft," for June 1847) containing the results of investigations made by him into the structure of the spleen in many different animals, from which, without being aware of my observation, he arrives at the conclusion that the spleen is a "muscular organ." The muscular fibres are of the plain variety, and mixed with elastic or nuclear fibres. In some animals, as the pig, dog, and cat, they exist in the allugineous or proper coat, the sheaths of the vessels and the trabeculæ; in the rabbit they are wanting in the coat, and in the ox, according to Kölliker, they are found only in the small-sized and microscopic trabeculæ, the rest of the trabecular structure and proper coat consisting merely of elastic and cellular tissue. He finds that the muscular tissue of the spleen is, for the most part, made up of short flat pale fibres from $\frac{1}{600}$ to $\frac{1}{240}$ inch long, bearing oblong nuclei. As to the human spleen, he could discover muscular structure neither in the proper coat, nor in the larger trabeculæ; but the fine microscopic trabeculæ appeared to be made up of elongated cells, with round nuclei, which he is disposed to regard as elements constituting a muscular tissue. He could obtain no unequivocal evidence of contraction on irritating the spleen in recently killed animals.—W. S.

The
arteries.

sheaths already described. The smaller branches of the arteries run along the trabeculæ, and terminate in the proper substance of the spleen in small tufts or pencils of capillary vessels. The

The veins.

veins, which greatly exceed the arteries in size, anastomose frequently together, so as to form a close venous plexus, placed in the intervals between the trabeculæ, and supported by them. It is stated by Krause that the veins form numerous lateral dilations or diverticula, which communicate with the general plexus, and the walls of which are formed principally by the lining membrane of the veins. Each large vein also receives in its course many small branches, the orifices of which give a dotted appearance to the interior of the vein. From the facility with which fluid injections pass from the arteries into the veins, the communication between the two sets of vessels must be very free; but the mode in which it takes place is not yet determined.

The splenic
substance
lies be-
tween the
trabeculæ
and the
vessels :
microscopic
characters.

The *proper substance* of the spleen is a soft pulpy mass, of a dark reddish brown colour, which, when squeezed out from between the trabeculæ, resembles grumous blood, and, like that fluid, acquires a brighter hue on exposure to the air. This pulpy substance lies altogether outside the veins, between the branches of the venous plexus. As shewn by the microscope, it consists chiefly of numerous rounded granular bodies, which have a reddish colour, and are about the size of the blood corpuscles. Their cohesion is very slight, and the terminal tufts of the arterial system of vessels spread out amongst them. In examining the substance of the spleen, elongated caudate corpuscles are seen in rather large numbers.

The white
spots of
spleen, are
some of
them the
ends of
trabeculæ,

On closely inspecting the surface of a section of the spleen, a number of white spots of variable size are always seen. For the most part these are evidently the ends of divided trabeculæ or blood-vessels; but in the ox, pig, sheep, and some other animals, and also, too, in the human subject, there are found distinct white vesicular bodies attached to the trabeculæ which support the small arteries, and embedded in groups of six or eight together in the dark red substance of the spleen. These little vesicles or capsules, formerly known as the Malpighian *corpuscles of the spleen*, were discovered in the pig by Malpighi, who thought they were situated within the veins. They are rounded capsules, varying in diameter from $\frac{1}{25}$ th to $\frac{1}{60}$ th of an inch, and consisting of two coats, the external apparently

others are
small
vesicles or
capsules ;

continuous with the trabecular tissue supporting the arteries. They are filled with a soft, white, semi-fluid matter, which contains microscopic globules, resembling, except in colour, those composing the red pulp of the spleen. It may be remarked, that both these kinds of globules are very like the chyle corpuscles.

These capsules are attached in groups to the smaller vascular sheaths or trabeculæ, by the minute branches of a small artery, which is itself supported by the elastic sheath or band. In some of the lower animals they are sessile, but in the human spleen they are pedunculated. The arterial capillaries do not penetrate them, but appear to form around them a sort of vascular coat or envelope. It has been conjectured by some that these vesicular bodies are dilatations of the lymphatics of the spleen, but their true nature and connexions are not yet ascertained.

Arrangement of the capsules.

Their blood-vessels.

The lymphatic vessels of the spleen are very abundant, and form a superficial and deep set. The superficial set appear as a network beneath the serous coat, receive occasional branches from the substance of the spleen, and run towards the hilus. The deep lymphatics accompany the blood-vessels, and emerge with them at the hilus, whence, communicating with the superficial set, they proceed along the gastro-splenic omentum to the neighbouring lymphatic glands. The mode in which the lymphatics commence in the spleen is unknown.

The lymphatics are numerous.

Mode of origin unknown.
Nerves.

The splenic nerves derived from the solar plexus surround and accompany the splenic artery and its branches. They have been traced by Remak deeply into the interior of the organ.

Development.—The spleen appears in the fœtus, about the seventh or eighth week, on the left side of the dilated part of the alimentary tube, or stomach, and close to the rudiment of the pancreas. By the tenth week it forms a distinct lobulated body placed at the great end of the stomach. After birth it increases rapidly in size; and in comparison with the weight of the body, it is as heavy a few weeks after birth as in the adult. This organ is peculiar to vertebrate animals.

Development.

Small detached roundish nodules are occasionally found in the neighbourhood of the spleen, similar to it in substance. These are commonly named *accessory* or *supplementary* spleens (*splenculi*; *lienculi*). One or two is the most common number, but four, seven, and even twenty-three have been met with in one subject. They are small rounded masses, varying from the size of a pea to that of a walnut. They are usually situated near the lower

Occasional varieties.

Splenculi or supplementary spleens.

end of the spleen, either in the gastro-splenic omentum, or in the great omentum. These separate splenculi in the human subject bring to mind the multiple condition of the spleen in some animals, and also the notching, often deep, of the anterior margin of this organ in man.

Function of
the spleen
unknown.

Uses.—The function of the spleen is unknown. Besides any mechanical office it may perform, as a diverticulum for the blood, it is thought by many to be concerned in the formation of that fluid. It has been imagined to be an appendage of the lymphatic system; and it has also been supposed to assist in preparing blood for the secretion of the bile. But it would be useless to recount all the various hypotheses which have been at different times entertained respecting its offices.*

THE PERITONÆUM.

The peri-
tonæum or
lining mem-
brane of the
abdomen;
is not quite
closed in
the female;

The common cavity of the abdomen and pelvis is lined by a serous membrane, named the *peritonæum* (*περιστεῖνω*), which is reflected over the contained viscera. It is the most extensive and complicated of all the serous membranes, and like them it forms a shut sac, on the outside of which are placed the viscera which it covers. In the female, however, it is not completely closed, for the two Fallopian tubes at their free extremity open into the cavity of the peritonæum. The internal surface of the peritonæal membrane is free, smooth, and moist, and is covered by a thin squamous epithelium, (fig. 20', p. xciv.) Its external or attached surface adheres partly to the inner walls of the abdomen and pelvis, and partly to the outer surface of the viscera situated within them. The former part, named the *parietal* portion, is connected loosely with the fasciæ lining the abdomen and pelvis, but more firmly along the middle line of the body in front, as well as to the under surface of the diaphragm. This connexion takes place by means of a cellular layer, distinct from the abdominal fasciæ, and named the *sub-peritonæal* or *retro-peritonæal* membrane. The *visceral* portion, which is thinner than the other, forms a more or less perfect investment to the

its parietal

and visceral
portions;

* Kölliker is led to infer from his observations that the blood corpuscles suffer destruction, or at least decomposition, in the spleen. He supposes that they decrease in size, group together in round clumps, which acquire nuclei and envelopes, so as to constitute cells filled with altered blood corpuscles; that the substance of the contained blood corpuscles is then resolved into pigment granules, of a golden yellow, brown or black colour, and that the cells may thus remain or become blanched into colourless cells very much resembling the pale corpuscles of the blood. He is uncertain how they are finally disposed of.—(See his paper already quoted.)

abdominal and pelvic viscera. Some of these organs, as the liver, spleen, stomach, and small intestine, (except the duodenum,) the transverse colon, sigmoid flexure, upper end of the rectum, and the uterus and ovaries, are almost entirely surrounded by peritonæum. Others receive only a partial covering from it, as the two lower portions of the duodenum, the cæcum, the ascending and descending colon, the middle portion of the rectum, and the upper part of the vagina and bladder. Over a few parts, the peritonæum passes without forming any distinct coat for them, as the pancreas, supra-renal capsules, and kidneys. Lastly, the lower end of the rectum, the base and neck of the bladder, the prostate in the male and the lower part of the vagina in the female, have no peritonæal investment.

mode in which it covers the viscera.

Folds.—Besides covering the viscera, the peritonæum forms numerous duplicatures, which not only serve as means of attachment and support to the various organs, but also enclose the vessels and nerves of each part, as they pass to and from the back part of the abdomen. Some of these folds, constituting the *mesenteries*, connect certain portions of the intestinal canal with the posterior wall of the abdomen: they are, the mesentery properly so called for the jejunum and ileum, the meso-cæcum, transverse and sigmoid meso-colon, and the meso-rectum. Other duplicatures, which are called *omenta*, proceed from one viscus to another: they are distinguished as the great omentum, the small omentum, and the gastro-splenic omentum. Lastly, certain reflections of the peritonæum from the walls of the abdomen or pelvis to viscera which are not portions of the intestinal canal, are named *ligaments*: these include the ligaments of the liver, spleen, uterus, and bladder, and are elsewhere described with the organs to which they are respectively attached.

Folds of the peritonæum are

mesenteries,

omenta,

or ligaments.

Omenta.—The *great omentum*, *gastro-colic omentum*, or *great epiploon* (*επιπλω*; fig. 142, 7), is a broad process of peritonæum which depends from the lower border of the stomach and the transverse colon, and below that point lies free, in front of the convolutions of the small intestine, reaching nearly as low down as the pelvis. On the left the great epiploon is continuous with the gastro-splenic omentum: to the right it reaches only to the duodenum. At its upper border, which is concave, and attached to the great curvature of the stomach, it consists

Great omentum covers the convolutions of small intestine;

of two coherent layers of serous membrane, descending, one from the front, the other from the back of the stomach (fig. 282, s). These two layers (*e*), applied one to the other, descend to the lower convex limit of the omentum, which hangs freely in the abdomen, and there turning upwards (*f*), ascend to be attached along the transverse colon (*c*), becoming continuous with its peritonæal coat; hence the name, gastro-colic omentum. In its lower free portion, that is, below the colon, it therefore comprehends in its thickness four layers of peritonæum, two ascending and two descending. This may be demonstrated in young subjects: in the adult the two double layers become inseparably united. The compound structure thus formed is very thin, and is sometimes perforated with holes like lace. It always contains some adipose tissue, and in fat subjects it is much loaded. Large vessels descending from the gastro-epiploic arteries supply it with blood.

its lower part contains four layers.

Small omentum, passes from stomach to liver.

Behind its right border is the foramen of Winslow.

The sac of the omentum.

The *small* or *gastro-hepatic omentum*, the *small epiploon*, is a duplicature of the peritonæum, which extends from the lesser curvature of the stomach to the transverse fissure and to the fossa of the ductus venosus, on the under surface of the liver (at *n*), and encloses the hepatic vessels and ducts. At the left border of this omentum its two layers pass on to the end of the œsophagus; but at the right border they become continuous with each other, so as to form a free rounded margin, and enclose the vena portæ, the hepatic artery, and the biliary duct. Behind this free margin with its contained vessels, in front of the ascending vena cava, and immediately below the Spigelian lobe of the liver, is an opening or short canal, named the *foramen of Winslow* (in which the probe marked *d*, in fig. 282 is placed). This canal leads down behind the stomach into a space named the *sac of the omentum* (which is shaded dark in the diagram). This space, which may be shewn by holding the parts asunder, is therefore placed behind the small omentum and below the liver: it extends downwards between the posterior surface of the stomach and the upper or ascending layer of the transverse meso-colon. In young subjects, by forcing air into the foramen of Winslow, the continuance of this sac is further shewn between the two descending and the two ascending lamellæ of the great omentum, down to the lower border of that process of the peritonæum. Its smooth lining membrane is continuous

with the rest of the peritonæum at the foramen of Winslow, which is therefore not a perforation in the peritonæum.

The *gastro-splenic omentum* (or *ligament*) is another duplicature which passes from the cul-de-sac of the stomach to the borders of the hilus of the spleen. It contains the splenic vessels and the vasa brevia. At its right or lower margin it is continuous with the great omentum.

The gastro-splenic omentum.

Mesenteries.—The *mesentery* proper is that large and important duplicature of the peritonæum which is attached by its posterior border to the front of the vertebral column, and is connected along its anterior border with the convolutions of the jejunum and ileum. Its attachment to the vertebral column, named the root of the mesentery, is not more than six inches long, and extends in an oblique line from the left side of the second lumbar vertebra to the right sacro-iliac symphysis. At its upper end this border of the mesentery receives the superior mesenteric vessels, and is continuous with the under surface of the transverse meso-colon; at the lower end it gradually spreads into the peritonæum of the ascending colon. The anterior border of the mesentery, to which the intestine is attached, is of much greater length.

The mesentery proper.

Supports small intestine.

At its widest part the mesentery is about four inches from its vertebral to its intestinal border. Between the two layers of serous membrane of which it consists are placed, besides some fat, numerous branches of the superior mesenteric artery and vein, together with nerves, lacteal vessels, and the mesenteric glands (see p. 651). In front, the two layers open out, as it were, to embrace the intestinal tube, and become continuous along its free border, thus forming its peritonæal covering.

Contains blood-vessels and nerves and absorbents.

Meso-cæcum.—In some cases the cæcum is suspended at a short distance from the right iliac fossa, by a distinct duplicature of the peritonæum, which is termed the meso-cæcum; but, more commonly, the peritonæum merely binds down this part of the large intestine, and forms a distinct but small mesentery for the vermiform appendix only.

Meso-cæcum.

Meso-colon.—The ascending and descending portions of the colon are bound down by the peritonæum, which usually passes only over the front and sides of the intestine, but sometimes forms a narrow duplicature behind them, named ascending or

Meso-colon.

descending meso-colon. The transverse part of the colon, however, is always supported by a very broad duplicature, named the *transverse meso-colon*. This is, in fact, formed by the continuation backwards of the two ascending layers of the great omentum, which, after reaching the front of the transverse colon, separate so as to enclose that intestine, and, meeting again behind it, are continued backwards (as the transverse meso-colon) to the spine. Here its two layers diverge, one continuing upwards over the pancreas, and the other downwards over the transverse portion of the duodenum, both these organs thus obtaining a partial peritonæal covering. The peritonæum forms rather a broad duplicature behind the freely suspended sigmoid flexure of the colon.

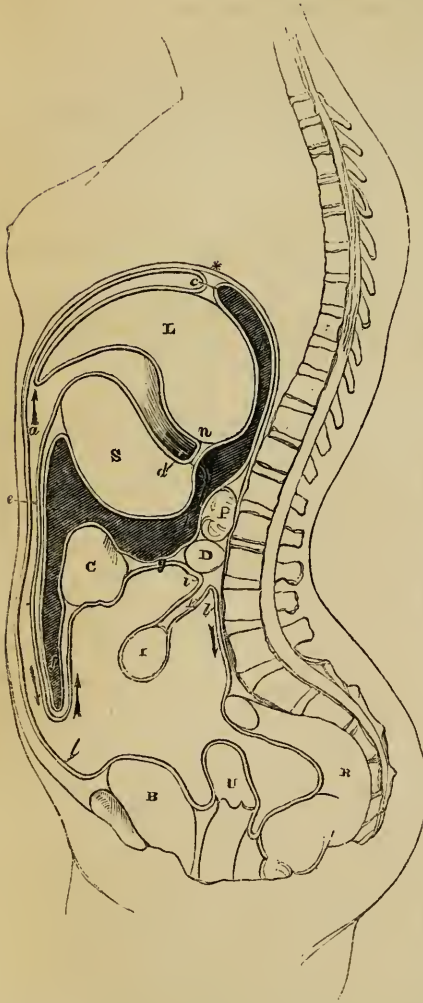
Meso-
rectum. The *Meso-rectum* is a narrow duplicature which connects the upper part of the rectum with the sacrum.

Mode of
tracing the
continuity
of the peri-
tonæum.

The way in which the peritonæum is reflected from the walls of the abdomen and from one organ to another, and the mode in which its numerous duplicatures are formed, may now be traced eonsecutively. Commencing at the small omentum (fig. 282, *n*) as a starting-point, that structure will be found to consist of two layers of the serous membrane. Of these we shall first follow the upper or anterior, and then the lower or posterior layer. 1. The *upper* layer may be traced to the small curvature of the stomach (*s*), and then over the anterior surface of that organ as far as the great curvature; from this it reaches down, forming the *outermost* layer of the great omentum (*e*), at the lower border of which it becomes reflected upwards, and ascends to the transverse colon (*c*); having invested the under surface of this part of the large intestine, it passes backwards, forming the under layer of the transverse meso-colon (*g*), and reaches the back of the abdominal cavity beneath the transverse part of the duodenum (*d*). Below this point it is continued on either side to the right and left colon, and thus on to the anterior wall of the abdomen, whilst in the middle it is prolonged forwards (*i*) from the spine to the small intestine (*l*), after investing which, it returns to the front of the spine, and thus completes the mesentery (*k*), which, as elsewhere mentioned, consists of two contiguous layers. From the root of the mesentery it descends in front of the spine (*l*), and partially invests the rectum (*r*), the uterus (*v*), and the bladder (*b*), forming folds at the points of reflection from one organ to another, as is elsewhere more particularly described. From the summit of the bladder it is prolonged to the anterior wall of the abdomen (*l*), and then continues to ascend as high as the costal cartilages (*a*), where it comes into contact with the diaphragm (*), and lines the under surface of that muscle. From the diaphragm, the layer of peritonæum we are now tracing is reflected upon the liver, at *c*, forming its lateral and the upper layer of its coronary ligaments: it reaches the liver,

too, as the suspensory or broad ligament, a nearly median duplicature passing off from the right rectus muscle and diaphragm; it next invests the upper and then the under surface of the liver (L), as far as the transverse fissure,

Fig. 282.*



where it is reflected down upon the hepatic vessels, forming the upper or anterior layer of the small omentum (*n*), from which we began to trace its reflections. 2. The *under* or posterior layer of the small omentum may be traced to the small curvature of the stomach, and thence along the posterior surface of this organ as far as its great curvature; from this point the membrane reaches down, forming the innermost layer of the great omentum (*f*), at the lower border of which it is reflected up to the transverse colon (*c*); after investing the upper surface of this part of the large intestine, it is reflected back towards the spine, forming the upper layer of the transverse meso-colon (*g*); it is thence prolonged (*h*) in front of the pancreas (*p*) and the crura of the diaphragm: from the under surface of the diaphragm it is reflected on to the liver at *c*, and helps to form the under layer of its coronary ligament: having invested the under surface of the liver as far as the transverse fissure, it is there reflected downwards, and forms the under or posterior layer of the small omentum (*n*), from which we commenced

the description, and the right border of which, being free, forms the an-

* Diagram to facilitate the tracing of the duplicatures formed by the peritonæum in lining the abdomen and covering the several viscera. The asterisk is immediately above the diaphragm. L. The liver. S. The stomach. P. Pancreas. D. Duodenum. C. Colon. I. Ileum. R. Rectum. U. Uterus. B. Bladder. The shaded part of the diagram represents the sac of the great omentum. The dark curved probe, *d*, is placed in the foramen of Winslow, leading down behind the lesser omentum into the sac of the omentum. The italic letters are referred to in the text.

terior margin of the foramen of Winslow (through which the probe (*d*) is placed). In ascending along the back of the abdominal cavity to the liver, this posterior layer passes to the right over the vena cava, and there bounds the foramen of Winslow behind, and still further to the right becomes continuous with the general peritonæal membrane.

The peritonæum may, of course, also be traced continuously from any other point of its surface.

Its vessels
and nerves.

Vessels and Nerves.—The vessels and nerves of the peritonæum are derived from many sources. Its internal surface is moistened with a thin fluid. It serves to attach or suspend the viscera, to support their vessels and nerves, and, where that is required, to facilitate their movements on each other.

PARTS SITUATED IN EACH REGION OF THE ABDOMEN.

Position of
abdominal
viscera.

Subjoined is an enumeration of the organs situated in the different regions of the abdomen.

Epigastric region	}	The middle part of the stomach, with its pyloric extremity, the left lobe of the liver, the hepatic vessels, and lobulus Spigelii, the pancreas, the cæliacæ axis, the semilunar ganglia, part of the vena cava, also of the aorta, vena azygos and thoracic duct, as they lie between the crura of the diaphragm.
Hypochondriac, right	}	The right lobe of the liver, with the gall-bladder, part of the duodenum, the hepatic flexure of the colon, the right supra-renal capsule, and part of the corresponding kidney.
Hypochondriac, left	}	The large end of the stomach with the spleen and narrow extremity of the pancreas, the splenic flexure of the colon, the left supra-renal capsule, and upper part of the left kidney. Sometimes also a part of the left lobe of the liver.
Umbilical	}	Part of the omentum and mesentery, the transverse part of the colon, transverse part of the duodenum, with some convolutions of the jejunum and ileum.
Lumbar, right	}	Ascending colon, lower half of the kidney, and part of the jejunum.

Lumbar, left.	{	Corresponding parts at the opposite side.
Hypogastric	{	The convolutions of the ileum, the bladder in children, and, if distended, in adults also; the uterus when in the gravid state.
Iliac, right	{	The cæcum, ileo-cæcal valve, the ureter, and spermatic vessels.
Iliac, left	{	Sigmoid flexure of the colon, the ureter, and spermatic vessels.

ORGANS OF CIRCULATION.

Thoracic
viscera.

THE heart or central organ of the circulation, the membranous sac or pericardium in which it is enclosed, as well as the lungs, the pleuræ, and several other parts, are lodged in the chest or thorax, which will be first briefly described.

THE THORAX.

The thorax :

The thorax resembles a truncated cone, somewhat flattened before and behind, so that its greatest width is transverse. Its narrow truncated apex is above, and its broader base below.

its walls ;

The walls of the thorax are formed in front by the sternum and the costal cartilages, together with the muscles attached to those parts ; at the sides by the ribs and intercostal muscles, and behind by the ribs and the dorsal portion of the vertebral column.

its upper
opening ;

The upper opening of the thorax is bounded at each side by the first rib, in front by the top of the sternum, and behind by the first dorsal vertebra : the diameter of this aperture from side to side is longer than from before backwards ; its plane slants backwards and upwards ; and through it pass many parts : viz., commencing from the front, the sterno-hyoid and sterno-thyroid muscles, the trachea, œsophagus, and thoracic duct, and the longi colli muscles ; on each side are the great arteries and veins of the head, neck, and upper limbs, together with the pneumogastric, sympathetic, and phrenic nerves. The summit of each lung, together with the upper end of its containing sac or pleura, also mounts a short distance through this aperture of the thorax, above the level of the first rib.

its lower
opening or
base.

The lower opening or base of the thorax is bounded in front by the ensiform cartilage, behind by the last dorsal and first lumbar vertebræ, and at the sides by the last six ribs ; its plane is also oblique in its direction, but, contrary to that of the upper opening, it is inclined backwards and downwards, so that the

cavity of the thorax reaches lower down, and is of greater vertical extent behind than in front. The diaphragm, which is attached to and closes the base of the thorax, forms a convex floor, which is alternately elevated and depressed in the acts of expiration and inspiration. On the right side the diaphragm rises higher than on the left, so that the thoracic cavity is not so deep on that side of the chest.

In the natural condition, the thorax is divided into two lateral cavities or chambers, which contain the right and left lungs. Each of these compartments is lined throughout by a serous membrane, named the pleura, which forms a distinct shut sac, and, besides investing the lung, is reflected, near the middle line, from the front to the back of the thorax. The partition formed by the two pleuræ, named generally the *mediastinum*, extends from the summit to the base of the cavity, and from the sternum back to the spine, inclining somewhat to the left side below: between its two layers, which are separated a considerable distance from each other, are lodged the heart and the great blood-vessels, enclosed in the sac of the pericardium, and, besides this, several other parts. The two layers of the mediastinum separate from one another in approaching the sternum in front and the vertebræ behind, and the intervals between them in these situations are called respectively the cavities of the *anterior and posterior mediastinum*. Between the layers of the anterior mediastinum are found the triangulares sterni muscles, and the remains of the thymus gland; and in the cavity of the posterior mediastinum, behind the pericardium, are situated the trachea, the œsophagus, the thoracic duct, the descending aorta, the vena azygos, and the pneumogastric and splanchnic nerves, with lymphatics and cellular tissue.

The heart, great vessels, and pericardium are seated behind the sternum and the costal cartilages, occupying a region of about four inches in width, extending from the second intercostal space on the right side to the fifth space on the left, and reaching further on the left than on the right of the middle line. The principal part of the remainder of the thoracic cavity is occupied by the lungs.

On striking the walls of the chest, the difference between the sounds emitted by the spongy lung and by the compact mass of the heart, enables us to determine by the ear the relative situation of those organs during life;

The two pleuræ.

The mediastinum:

parts situated therein.

Position of heart, and great vessels.

Percussion and auscultation.

and the height to which the liver ascends beneath the ribs may be ascertained in a similar manner. In cases of thoracic disease, percussion, in addition to auscultation, is also an invaluable means of diagnosis; and, in order to give precision to the employment of both methods, the healthy physical signs have been minutely described over many different regions of the chest, which are artificially distinguished by writers on these subjects.*

THE PERICARDIUM.

The pericardium is a conical sac :

The *pericardium* ($\pi\epsilon\rho\iota$, and $\kappa\eta\rho$, *the heart*) is a membranous sac, which encloses the heart and the commencement of the large vessels connected with that organ.

It is of a conical shape, its base being attached below to the upper surface of the diaphragm, whilst the apex surrounds the great vessels springing from the base of the heart, as high as their first subdivisions. The heart itself, being attached only at its base, which is placed upwards, is thus suspended freely in the pericardiac cavity.

its position and connexions.

The pericardium is situated behind the sternum and the cartilages of the fourth, fifth, sixth, and seventh ribs of the left side. The lower part of the front of the sac is connected, by means of cellular tissue, with the sternum, but higher up it recedes from that bone, and is covered by the remains of the thymus gland. Behind, it is in contact with the bronchi, œsophagus, and descending aorta. On the sides it is covered by the reflected layers of the right and left pleuræ, which separate it from the lungs. Below, it rests on and is attached to the central aponeurosis or cordiform tendon of the diaphragm, and extends further to the left side, encroaching on the muscular portion on that side.

Structure.

The pericardium is a fibro-serous structure, composed of two membranous layers, one external and fibrous, the other internal and serous. The *fibrous* layer enters into the formation of the free portion or sac of the pericardium, but is not reflected on to the heart. It is a dense, thick, and unyielding membrane, consisting of fibres which interlace in every direction. At the base of the pericardium these fibres are blended with those of the central aponeurosis of the diaphragm; and above, where the

The fibrous layer.

* See the different works on auscultation, also a paper by Mr. Sibson, "On the Changes induced in the Situation, &c. of Organs in Health and Disease," *Transact. Prov. Med. and Surg. Association*, 1844.

pericardium embraces the large blood-vessels, the fibrous layer is continued on to them in the form of tubular prolongations, which become gradually lost upon their external coats. The superior vena cava, the four pulmonary veins, the aorta, and the right and left divisions of the pulmonary artery, in all eight vessels, receive prolongations of this kind.

The internal or *serous* layer is of much greater extent than the fibrous membrane, for, representing a shut sac, part of which is inverted or thrust into itself, it not only lines the inner surface of the fibrous layer, and the part of the diaphragm to which that layer is attached, but is also reflected upon the commencement of the great vessels and surface of the heart. It has, therefore, a visceral and a parietal portion. The latter of these adheres firmly by its outer surface to the fibrous membrane, and becomes continuous with the visceral portion, upon the arch of the aorta and other great vessels, about two or two and a half inches from the base of the heart. In passing round the aorta and pulmonary artery, it encloses both those vessels in a single sheath. It is reflected also upon the superior cava, and on the four pulmonary veins, and forms a deep cul-de-sac between the entrance of the last-named vessels into the left auricle. The inferior cava receives but a very scanty covering of this coat, inasmuch as that vessel enters the right auricle almost immediately after passing through the diaphragm.

The serous layer.

The inner surface of the serous layer, which is free and smooth, is moistened with a small quantity of a thin fluid, which facilitates the movements of the heart within its enclosing sac. The use of the pericardium is evidently to suspend the heart in its place, to insulate it from other parts, and to facilitate its movements.

The fluid of pericardium.

Cases of congenital absence of the pericardium have sometimes been met with; the heart, in these cases, lies with the left lung in the cavity of the left pleura, and receives its serous covering from that membranc.

Absence of pericardium.

THE HEART.

The heart lies between the lungs, enclosed in the sac of the pericardium, and connected with the large veins and arteries of the lungs and body (see fig. 283).

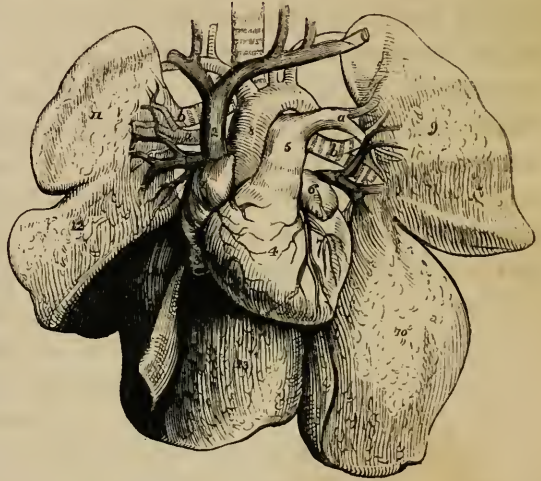
The heart :

its form is conical ;

Its general form is that of a blunt cone, flattened on its under surface. The broader end or base by which it is attached, is directed upwards, backwards, and to the right, against a part of the vertebral column extending from about the fourth to the eighth dorsal vertebra. The apex is turned downwards, forwards, and to the left, and corresponds in the dead body with the cartilage of the sixth rib, but in the living subject strikes against the walls of the chest, in the space between the cartilages

is oblique position ;

Fig. 283.*



is liable to vary.

of the fifth and sixth ribs, a little below the left mamilla. The heart, therefore, has an oblique position in the chest ; and, besides this, it projects further into the left than into the right half of the thoracic cavity, passing about an inch or an inch and a half beyond the middle line in the one direction, and upwards of three inches in the other. Its position is affected more or less by that of the body, and it comes more extensively into contact with the anterior walls of the chest when the body is in the prone posture or lying on the left side. In inspiration, also, when the diaphragm sinks and the lungs expand its apex is withdrawn from the thoracic parietes.

Its connections,

At its base the heart is attached to the great blood-vessels, and is also connected with them by the serous layer of the peri-

* A shaded diagram, representing the heart and great vessels, injected and in connection with the lungs : the pericardium is removed.—1. Right auricle. 2. Vena cava superior. 3. Vena cava inferior. 4. Right ventricle. 5. Pulmonary artery, dividing into two branches, *a a*, one for the right, the other for the left lung. 6. Point of the left auricle. 7. Part of left ventricle. 8. Aorta. 9, 10. Two lobes of the left lung. 11, 12, 13. Three lobes of the right lung. *a, a*. Right and left pulmonary arteries. *b, b*. Right and left bronchi. *v, v*. Right and left pulmonary veins. The relative position of these three vessels is seen to differ on the two sides.

cardium, which passes from one to the other. In other directions it is free, and moveable in the sac of the pericardium. The anterior surface is convex in its general form; it is turned upwards as well as forwards, and is directed towards the sternum and costal cartilages, from which, however, it is partly separated by the lungs, these advancing over it especially during inspiration, in which condition only about two square inches are left uncovered. The posterior, which is also the under surface, is flattened, and rests on the diaphragm. Of the two borders or margins formed by the meeting of the anterior and posterior surfaces, the right or lower border, called *margo acutus*, is comparatively thin, and is longer than the upper or left border, which is more rounded, and is named *margo obtusus*.

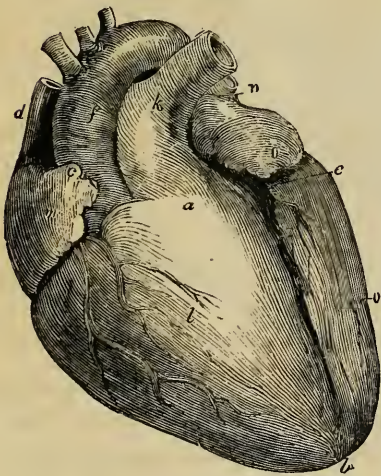
surfaces,

and
borders.

The heart is a hollow muscular organ, divided by a longitudinal septum into a right and left half, each of which is again subdivided by a transverse constriction into two compartments, communicating with each other, and named an *auricle* and a *ventricle*. These subdivisions are indicated even on the surface of the organ: thus, a deep transverse groove (fig. 285, *d, e*: the *auriculo-ventricular furrow*), interrupted in front (fig. 284) by the root of the pulmonary artery, *a*, divides the heart into the auricular and the ventricular portion. The auricular portion

Cavities of
the heart,
are four;
viz. two
auricular,
right and
left;

Fig. 284.*



(*m n*), situated above and behind the transverse furrow, is comparatively thin and flaccid in its structure, and is immediately

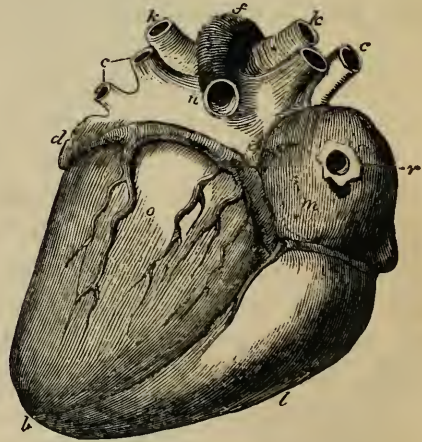
* Front or upper surface of the heart and great vessels injected and placed obliquely, but its apex is not tilted forward as in the body. *a*. Conus arteriosus or infundibulum of right ventricle. *b*. Notch at apex of heart. *c*. Auricular appendage of right auricle. *d*. Vena cava superior. *e, b*. Anterior longitudinal furrow, marking the division between the ventricles. *f*. The aorta. *k*. Pulmonary artery. *l*. Right ventricle, of which the chief part is seen in front. *m*. Right auricle. *n*. Left auricle, seen only to a small extent, with its appendage projecting forward. There is another letter *o*, on the left ventricle.

connected with the great veins; it is divided by an internal septum into two distinct cavities, named the right (*m*) and left (*n*) *auricles*, from the circumstance that each is provided with an appendage resembling an ear (*auricula*).

Below and before the transverse groove is the ventricular portion (*l o*), which is conical, and flattened on its posterior or under surface, has very thick walls, and is connected with the great arterial trunks. It is marked off into a *right* (*l*) and a *left* (*o*) *ventricle* by two longitudinal furrows, (sulci longitudinales,) situated one (fig. 284, *e, b*) on the anterior, the other (fig. 285, *e, b*) on the posterior surface of the heart, and extending from the base of the ventricular portion towards the apex, a little to the right of which they meet and form a slight notch (*b*).

The anterior longitudinal furrow is nearer to the left border, whilst the posterior furrow approaches nearer to the right border of the heart, so that the right ventricle (*l*) forms more of the anterior, and the left (*o*) more of the posterior surface of this organ, (see figs. 284, 285.) Since, also, the two longitudinal furrows meet a little to the right of the apex, it follows that the left ventricle is somewhat the longer of the two and forms the point of the heart. Lying within the transverse and longitudinal furrows are found the proper

Fig. 285.*



and two
ventricular,
right and
left.

Its furrows.

Apex is
formed by
left ven-
tricle.

* Back or under surface of the same heart. *b*. Apex of heart, slightly notched. *c, c*. Pulmonary veins, two on each side. *d*. Auricula of left auricle. *e*. Point of entrance of coronary vein into the back of right auricle, *m*. *d, e*. indicate part of the transverse or auriculo-ventricular furrow, occupied by the large coronary vein. *f*. The aorta. *k k*. Right and left division of the pulmonary artery. *l*. Right ventricle, only the smaller part seen. *m*. The right, and *n*. the left auricle: the division or furrow between them is distinctly seen. *o*. The left ventricle, of which the greater part is seen behind. *r*. Orifice of the vena cava inferior, constricted by the ligature used to keep in the injection.

nutrient vessels of the heart, named the coronary or cardiac arteries and veins.

Considered in respect of function, the heart is also a double organ, composed of two functionally distinct parts, each consisting of an auricle and a ventricle. The right portion receives into its auricle, from the two venæ cavæ and other small veins, the dark venous blood returning from the various parts of the body, and, by means of its ventricle, propels it through the pulmonary artery into the lungs. The red blood returning from the lungs by the pulmonary veins, reaches the left part of the heart at its auricle, and is forced onwards by the left ventricle, through the aorta, into the body. In this order, pursuing the course of the blood, the four cavities of the heart may conveniently be described.

Heart is a double organ ;

its right and left halves.

1. The *right auricle* (*m*) forms the right anterior and lower part of the base of the heart, and is in contact below with the diaphragm. It presents two parts, which, though not marked off by any precise line of division, yet differ in size and form. One of these, large, somewhat quadrangular, and composed of very thin walls, occupies the interval between the two venæ cavæ, so as to receive directly the blood which they convey ; hence it is named *sinus venosus*, and also *atrium*. The other part forms a small conical pouch (fig. 284, *c*), which projects forwards and to the left, between the right ventricle (*l*) and the aorta (*f*), like an appendage to the general cavity : it is sometimes named “auricular appendage,” but more frequently *auricula*, or the “proper auricle,” from its resemblance in shape to a dog’s ear. It is triangular in form, compressed, and slightly dentated at its border. Its walls are thicker and more muscular than those of the sinus venosus.

Right auricle :

its sinus or atrium ;

and its auricula or appendix.

The external surface of the auricle, unattached in the greater part of its extent, is prolonged upwards, forwards, and to the left side into its auricular appendage ; below it is connected with the right ventricle, and internally and posteriorly with the left auricle. Into its upper and posterior corner opens the vena cava superior (*d*), and into the lower and posterior part the inferior vena cava (fig. 285, *r*).

Its connexions.

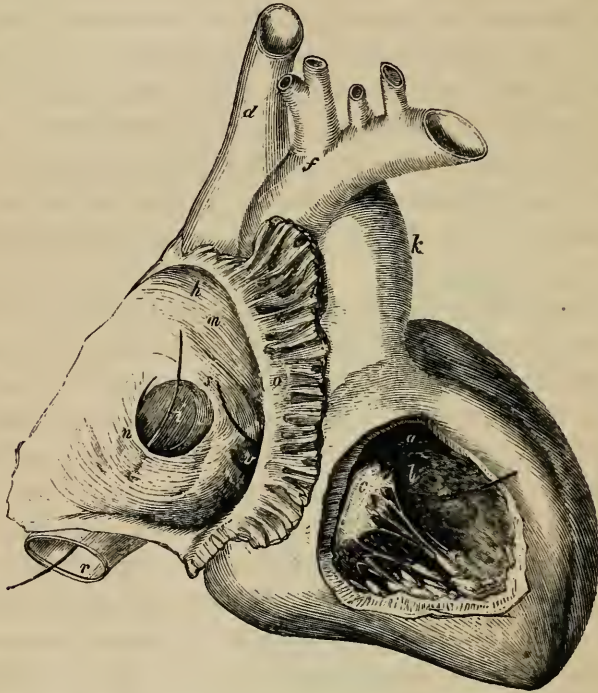
To examine its interior, an incision may be made from the conflux of the venæ cavæ horizontally across its anterior wall, and from the middle of this cut another may be carried upwards

Its interior ;

into the superior cava. On laying open the cavity of the auricle, (fig. 286, *m*.) it is seen to be lined throughout by a very thin, smooth, transparent, shining membrane, similar to the lin-

is partly
smooth,

Fig. 286.*



ing membrane of the veins, with which it is continuous. The inner surface of the sinus venosus is for the most part even, but the interior of the auricular appendage, and of the adjoining

* Heart placed with its anterior surface upwards, and its apex turned to the right hand of the spectator. The right auricle and right ventricle are both opened. Parts in right auricle:—*b*. Entrance of vena cava superior, which is itself marked, *d*. Inferior cava, marked *r*, has a probe passed through it into the auricle. *m*. The smooth part of the auricle. *o*. Musculi pectinati, seen in the auricular appendix which is cut open. *n*. Eustachian valve placed over the mouth of the inferior cava. *i*. Fossa ovalis, or vestige of the foramen ovale. *s*. Annulus ovalis. The probe leading from *s* into the right ventricle passes through the auriculo-ventricular opening. *v*. Mouth of the coronary vein. Parts in the right ventricle, in which the other end of the probe, from *s*, appears:—*a*. Cavity of conus arteriosus, leading to the pulmonary artery, *k*. *l*. Convex septum between the ventricles. *c*. Anterior segment of the tricuspid valve connected by slender cords, the chordæ tendineæ, to the musculi papillares, *e*. *f*. The aorta.

anterior wall of the sinus, is marked by several prominent muscular fasciculi, running transversely, and named *musculi pectinati* (*o*). The opening (*h*) of the superior cava (*d*) into the auricle is directed downwards and forwards, whilst that of the inferior cava (*r*), which is considerably larger than the other, is turned upwards and inwards (*i*). At the angle of union of these two veins there exists in the hearts of certain quadrupeds a prominence of the inner surface, which was named by Lower a tubercle, (*tubercle of Lower*.) In the human heart this elevation is so little marked as scarcely to deserve the name assigned to it. The left and posterior side of the auricle is formed by the *septum auricularum*, a partition which separates it from the left auricle. At the lower part of this septum, and just above the orifice of the inferior vena cava, is situated an oval depression (*i*), named *fossa ovalis*, which is the vestige of the foramen ovale (figs. 296-7, *o*) of the fœtal heart, (*vestigium foraminis ovalis*), and indicates the original place of communication between the two auricles. It is bounded above and at the sides by a prominent ridge or border (*s*), which is deficient below, and is called *annulus ovalis*—*isthmus Vieussenii*. Between the highest part of the floor of the depression and the corresponding portion of the annulus there sometimes exists a small slit, which leads upwards beneath the annulus into the left auricle, forming thus an oblique and valved aperture between the two cavities. At the line of union between the anterior margin of the inferior cava and the auricle is situated a thin crescentic membranous fold (*n*), called the *Eustachian valve*, which crosses over the mouth of the vein. One border of this valve is convex, and is continuous with the wall of the auricle and the anterior margin of the venous orifice. The other, which is free and concave, ends in two pointed extremities or cornua; of these, the left cornu is attached to the left or anterior border of the annulus ovalis, whilst the right extremity is lost on the wall of the auricle between the two cavæ. The Eustachian valve consists of a duplicature of the lining membrane of the auricle, containing occasionally a few muscular fasciculi. In the fœtus, this valve (fig. 296, *e*) is proportionably large, and serves to direct the blood of the inferior cava towards the foramen ovale; whilst in after life it may tend somewhat to prevent the reflux of the blood into the inferior cava. In the adult it is compara-

and partly marked by musculi pectinati. Openings of venæ cavæ.

Tubercle of Lower.

Septum of auricles.

Fossa ovalis.

Annulus ovalis.

Valve of Eustachius:

its structure;

is large in the fœtus,

but afterwards changes.

Valve of Thebesius.

Foramina Thebesii.

Opening leading to right ventricle.

Right ventricle :

is pyramidal ; is prolonged into conus arteriosus.

Its interior ; its walls.

The ventricular septum.

Cross section of cavity.

tively small, but varies greatly in size in different cases. It is often cribriform or perforated by numerous foramina, and sometimes it is reduced to a few slender filaments, or is even altogether wanting. To the left of this valve, between it and the opening into the ventricle, to be presently noticed, is situated the orifice of the large coronary vein (*v*), protected by a semicircular valve, which is sometimes double, and which, though figured by Eustachius, is often named the *valve of Thebesius*. Besides this opening, numerous small foramina may be observed in different parts of the auricle, which are called *foramina Thebesii*. Some of them are little recesses closed at the bottom ; whilst others are the mouths of minute veins, (*venæ minimæ cordis*.) Lastly, in the floor of the auricle, and situated in front and to the left of the inferior cava, is a large opening, (indicated by the probe drawn from near *s*,) leading into the right ventricle, named the *right auriculo-ventricular* opening. It is of an oval form, and at least an inch in diameter, admitting three fingers easily : its margin is surrounded by a whitish tendinous ring to which is attached the base of the tricuspid valve, to be presently described with the right ventricle.

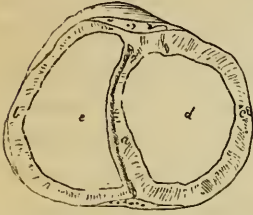
2. The *right* or *anterior* ventricle (figs. 284, 285, *l*,) occupies the right border of the heart, the larger part of its anterior surface, and the smaller part of its posterior surface, reaching from the right auricle to the apex. Its form is somewhat pyramidal ; and the upper and anterior part of its base, which is turned upwards, forms a conical prolongation, named *infundibulum*, or *conus arteriosus*, (fig. 284, *a*,) from which the pulmonary artery (*k*) arises.

To examine the interior of this ventricle, it is best to reflect upwards a V-shaped flap, made in its anterior wall, (fig. 286.) In doing this, it will be found that its muscular parietes are much thicker than those of the auricle, and, moreover, that they are thickest at the base of the ventricle, becoming gradually thinner towards its point. The left wall formed by the *septum ventriculorum* (*l*), is convex and bulges into the ventricular cavity, so that a cross section of this has a crescentic figure, (see diagram, fig. 287.) The interior of the ventricle is lined with a thin membrane, continuous with that of the auricle on the one hand, and with that of the pulmonary artery on the other. The inner surface is covered with a number

of irregular rounded muscular bands, named *columnæ carneæ*, which form quite a network in some parts of the ventricle, and may be classified into three kinds. The *first* kind merely form

Columnæ carneæ ;
are of three kinds.

Fig. 287.*



attached by their under side as well as by the two extremities ; the second are adherent by their two ends only, and are free in the rest of their extent ; whilst the third kind form three or four bundles, named *musculi papillares*, (fig. 286, e,) which are directed from the apex towards the base of the ventricle, and end

Musculi papillares.

in small tendinous cords, *chordæ tendineæ*, through which they are connected with the segments of the tricuspid valve (c). These *columnæ carneæ* disappear in the conus arteriosus, where the surface is smooth and even (a).

Chordæ tendineæ.

There are two openings in the right ventricle, viz. the auriculo-ventricular orifice, leading from the right auricle, and the arterial orifice, conducting to the pulmonary artery. The *auriculo-ventricular* opening, (through which, in fig. 286, the probe is passed,) already seen from the auricle, is situated in the base of the ventricle ; it is oval in form, and is guarded by a large valve, named, from its tripartite figure, the *tricuspid valve* (valvulæ triglochines). The *arterial* orifice, which is circular in form, is situated, as already mentioned, at the summit of the conus arteriosus (a) ; it is placed in front and to the left of the auricular opening, and is also higher up. Its orifice is guarded by three small membranous folds, called the *sigmoid* or *semilunar* valves. Between these two openings the muscular substance of the heart forms a prominent rounded ridge, which projects into the ventricle, and seems to mark off its cavity into two compartments,—one immediately following the auricular opening, the other adjacent to the arterial orifice and forming the funnel-shaped portion or conus arteriosus previously mentioned.

Its openings are two, viz. from right auricle,

and into pulmonary artery.

Both guarded with valves.

The *tricuspid* valve, (fig. 286, c) consists of three pointed flaps or segments of a triangular, or rather trapezoidal shape,

Tricuspid valve ; its three segments;

* Diagram of a section across the ventricles, the upper portion being represented as if seen from below, to show the form of the two cavities.— a. Interventricular septum. b. Section of wall of right, and c. that of left ventricle. e. Crescent-shaped cavity of right, d. oval cavity of left ventricle.

formed by a doubling of the lining membrane of the auricle and ventricle, containing within it numerous tendinous fibres. At their bases these segments are continuous with one another, so as to form an annular membrane, and are thus attached to the tendinous ring around the margin of the auricular opening: in the rest of their extent they lie in the cavity of the ventricle, having the chordæ tendineæ attached to their free margin and outer surface. One of the segments is turned towards the septum of the ventricles; another is placed more to the right, against the anterior and right wall of the cavity; whilst the third and largest division of the valve, lying more on the left, is interposed, as it were, between the auricular and arterial openings, and has its ventricular surface directed forwards and upwards. The chordæ tendineæ, already referred to, arising chiefly from the muscoli papillares, but some also from the wall and especially the septum of the ventricle, proceed to be inserted into the margins of the valvular segments, and also into their ventricular surface, i. e. the one turned towards the ventricle. The cords arising from one papillary muscle or group of muscles run up in the angular interval between two adjacent segments of the valve, and, diverging from each other, are attached to both.

The structure of the tricuspid valve, and also that of the corresponding valve in the left ventricle, named the mitral valve, and especially the mode of attachment of the chordæ tendineæ, have been carefully studied by Kürschner.* He finds, that, between the three principal segments of this valve, there are, though not constantly, as many smaller intermediate lobes. The middle part of each segment is thicker than the rest, whilst the marginal part is thinner, more transparent, and jagged at the edges. He further states that the papillary muscles of the ventricle are arranged into three groups. The chordæ tendineæ from each group are connected some with the two adjacent principal segments, between which they run, and some with the smaller intermediate lobe. Three kinds of cords belong to each segment: *a*, the first set, generally two to four in number, and proceeding from two different muscular groups, or from one group and the wall of the ventricle, run to the base or attached

their position and connexions to chordæ tendineæ.

Structure of the valve;

its smaller lobes;

the tendinous cords are of three kinds.

* Wagner's Handwörterbuch, art. "Herzthätigkeit."

margin of the segment, and are there connected also with the tendinous ring around the auriculo-ventricular opening; *b*, the second set, four to six in number, and smaller than the first, proceed also from two adjacent papillary muscular groups, and are attached to the back or ventricular surface of each segment at intervals along two or more lines extending from the points of attachment of the tendons of the first order at the base of the valve to near its free extremity; *c*, the third set, which are still more numerous and much finer, branch off from the preceding ones, and are attached to the back and edge of the thinner marginal portion of the valves. Their points of attachment lie in straight lines proceeding from the insertions of the tendons of the second order to the margin of the valve. Lastly, it may be remarked, that Kürschner has confirmed the observation of Senac, that muscular fibres may be found passing down into the segments of the tricuspid valve from the parietes of the right auricle.

Muscular
fibres in
the valve.

During the contraction of the ventricle, the tricuspid valve is applied over the opening leading from the auricle, and prevents the blood from rushing back into that cavity. Being retained by the chordæ tendineæ, the expanded flaps of the valve resist the pressure of the blood, which would otherwise force them back through the auricular orifice; the papillary muscles, contracting as the cavity of the ventricle itself is shortened during its systole, are supposed thus to prevent the valves from yielding too much towards the auricle, which might have been the case had the chordæ tendineæ been longer, and fixed directly into the wall of the ventricle.

Action of
the valve.

The *semilunar* valves,* placed at the mouth of the pulmonary artery, consist of three semicircular folds, each of which is attached by its convex border to the side of the artery where it joins with the ventricle, whilst its straight border is free, is directed towards the area of the vessel, and presents in its middle a small fibro-cartilaginous knot, called *nodulus*, or *corpus Arantii*, (fig. 289, *c*.) These valves consist of a duplication of the lining membrane with enclosed tendinous structure.

The semi-
lunar or sig-
moid valves;
are three.

Corpora
Arantii.

* The form and structure of these valves is precisely similar to those at the commencement of the aorta, though they are not so thick and strong. The letters of reference introduced into the following description apply to the aortic valves, fig. 289.

Structure of
the valves :

their action.

Part of the latter runs along and strengthens the free margin of the valve, and is there attached to the nodule. Other tendinous fibres, again, may be described as spreading out from the nodule, and extending to the attached border of the valve, occupying its whole extent, except two narrow lunated portions (*e*), one on each side of the nodule and adjoining the free margin of the valve. These parts, which are named *lunulae*, are therefore thinner than the rest. During the contraction of the ventricle the valves lie against the sides of the pulmonary artery, and allow the blood to flow on ; but during the ventricular diastole, when the column of fluid in the pulmonary artery is checked, and is partially thrown back by the elasticity of the coats of that vessel, the sigmoid valves spread out across the arterial orifice, and completely close it. When the valves are thus closed, the three nodules meet in the centre of the vessel, and the thin lunated parts are closely applied by their opposed surfaces to each other, and are held together as well as exempted from strain, by the opposite and equal pressure of the blood on either side, so that, the greater the pressure, the more accurate must be the closure. The force of the reflux is sustained by the stouter and more tendinous part of the valve.*

Origin of
pulmonary
artery ;
its sinuses.

Beyond the sigmoid valves the commencement of the pulmonary artery presents three slight dilatations or recesses in its wall, one being placed behind each valve. These are the sinuses of Valsalva, which, however are much more marked at the root of the aorta.

The left
auricle ;

its sinus ;

3. The *left auricle* occupies the left and posterior part of the base of the heart. Like the right auricle, it consists of a larger portion, named the atrium or sinus venosus, and of an auricular appendix. The *sinus* of the auricle is to a great extent concealed by the pulmonary artery and the aorta, which cover it in front, the appendix alone being visible without detaching those vessels or inverting the position of the heart (fig. 284, *o*). When distended, the atrium (fig. 285, *n*) is four-sided, or rather cuboid in form. In front it rests against the aorta and pulmonary artery (fig. 284, *f, k*) ; behind, on each side, it receives two pulmonary veins (fig. 285, *c c*), those of the left lung entering very close together. On the right it is in contact with the

* On this subject, see A. Retzius in Müller's Archiv, 1843, p. 14.

other auricle (*m*), and from its upper and left side projects the *auricular appendage* (*d*), which is narrower, longer, and more curved than that of the right auricle; the margins of the appendix are also more deeply indented, and its point, which advances forwards, and towards the right side, rests upon the root of the pulmonary artery. its auricula,

The interior of the appendix presents *musculi pectinati* similar to those in the right side of the heart, but the cavity of the sinus venosus generally (fig. 288, *a*) is smooth; besides which, its walls are thicker than those of the right auricle, and its lining membrane is less transparent. Posteriorly are the openings of the pulmonary veins (*c c*), two on each side, which are entirely without valves. The two veins of either or both sides may unite into one before entering the auricle, whilst in other cases there is found an additional opening on one side. On the septum between the auricles, a slight lunated mark or depression (*e*) may be observed, which is the vestige of the foramen ovale, as it appears upon the left side. The depression is limited below by a slight crescentic ridge, the concavity of which is turned upwards. This ridge is in fact the now adherent border of a membranous valve, which is applied in the fœtus to the left side of the then open foramen ovale; when the adhesion of this valve occurs lower down than usual, a small pouch is left, reaching a variable distance from the depression; and, as formerly mentioned, when the adhesion is imperfect, a narrow passage permanently exists between the two auricles, through which, however, unless when unusually direct and open, the blood can scarcely be supposed to pass. Lastly, in the lower and fore part of this auricle is situated the left *auriculo-ventricular* opening, (indicated by the probe passed from *e*.) to the margin of which is attached the mitral valve of the left ventricle. It is of an oval form, and is rather smaller than the corresponding opening between the right auricle and ventricle. its interior.

4. The *left* or posterior *ventricle* occupies the left border of the heart, but, owing to the obliquity of the septum between the ventricles, only about a third of its extent appears on the anterior surface of the organ, the rest being seen behind, (figs. 284, 285, *o*.) It is longer than the right ventricle, and it reaches lower down at the apex of the heart. The cross section of its cavity is oval (fig. 287, *d*), not crescentic, for the septum Openings of the pulmonary veins.

The septum; trace of foramen ovale.

Opening into left ventricle.

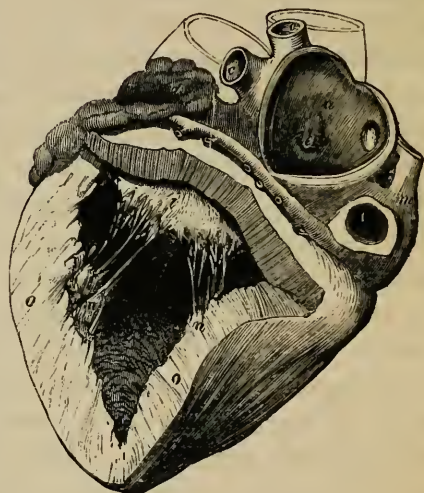
The left ventricle: its position and form;

its interior; on this side is concave. To expose its interior, two incisions may be made through its walls, parallel with the anterior and posterior longitudinal furrows of the heart, and uniting near the apex. On raising up the flap so formed, the great thickness of the walls of this ventricle (fig. 288, *o o*), as compared with the right, is conspicuously seen, the proportion between them in this respect being as 3 to 1. The walls are thickest towards the widest part of the ventricle, about one-third of its length from the base: from this point they become thinner towards the auricular opening; but they are still thinner towards the apex, which is the weakest part. The lining membrane of this ventricle, which is continuous with that of the left au-

great thick-
ness of its
walls;

its lining
membrane.

Fig. 288.*



ricle and the aorta, is usually less transparent than that of the right ventricle, especially after a certain age. In the interior of the cavity are found *columnæ carneæ*, *musculi papillares*, with *chordæ tendineæ*, and two orifices guarded with valves. The *columnæ carneæ*, like those of the right side, are of three different kinds; they are, on the whole, smaller, but are more numerous and more densely reticulated, and are directed for the most part from the base to the point of the heart. Their inter-sections are very numerous near the apex of the cavity, and also along its posterior wall, but the upper part of the anterior wall

* Heart seen from behind, and having the left auricle and ventricle opened. Parts in left auricle:—*a*. Smooth wall of auricular septum. *c, c, c*. Openings of the four pulmonary veins. *d*. Left auricular appendage. *e*. Slight depression in the septum, corresponding to the fossa ovalis on the right side. A probe is seen which passes down into the ventricle through the auriculo-ventricular orifice. Parts in left ventricle:—*i*. Posterior segment of the mitral valve, behind which is the probe passed from the left auricle. *n, n*. The two groups of *musculi papillares*. *o*. Section of the thick walls of this ventricle, which may be compared with that of the walls of the right ventricle, fig. 286. *r*. Entrance of inferior cava.

is comparatively smooth. Two large fleshy eminences (*nn*), *musculi papillares*, larger than those of the right ventricle, formed of lesser bundles, one from the anterior, the other from the posterior surface, pass upwards and terminate each in a blunted extremity, from which numerous *chordæ tendineæ* branch off to be inserted into the edges of a large valve (*i*), which protects the opening leading from the left auricle. This opening (*left auriculo-ventricular*, through which the probe descends) is placed at the left and posterior part of the base of the ventricle, behind and to the left of another orifice (*aortic*) which leads into the aorta. It is surrounded by a tendinous margin, to which the valve above alluded to is attached. This valve resembles in structure the tricuspid valve of the right ventricle, but it is much thicker and stronger in all its parts, and, moreover, it consists of only two pointed divisions or segments, continuous at their attached bases, whence it is named the *bicuspid* or *mitral* valve. The larger of the two segments is suspended in front of the other, between the auricular and the aortic orifices. There are usually two smaller lobes at the angles of junction of the two principal segments, more apparent than those of the tricuspid valve. The *chordæ tendineæ* are attached in the same way

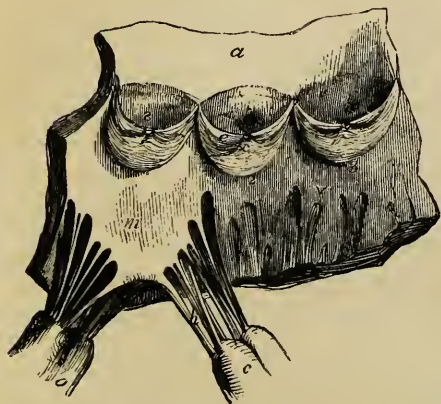
Musculi
papillares.

Chordæ
tendineæ.

Opening
from the
auricle.

Bicuspid or
mitral
valve.

Fig. 289.*



as to the tricuspid valve, but they are altogether stronger, and perhaps less numerous. A few muscular fibres also occur in this valve. (Kürschner.) The arterial or *aortic* orifice is a smaller circular opening, placed in front and to the right of the auriculo-ventricular opening, and very close to it, being separated from it only by the attach-

Opening
into the
aorta.

ment of the anterior segment of the mitral valve. It leads

* Part of the left ventricle, and commencement of the aorta laid open to show the sigmoid valves.—*a*. Portion of the aorta. *v*. Muscular wall of left ventricle. 1, 2, 3. Semilunar or sigmoid valves. *c*. Corpus arantii in one of them. *e*. Thin lunated marginal portion or lunula. *s, t, t*. Sinuses of Valsalva. *t, t*. Mouths of the two coronary arteries of the heart. *m*. An-

The semi-lunar valves.

Corpora Arantii.

Sinuses of Valsalva.

to the aorta, and is guarded by three valvular semilunar folds, resembling in form and structure those found at the root of the pulmonary artery, and called, like them, *sigmoid* or *semilunar* valves. These aortic semilunar valves (fig. 289, 1, 2, 3) are, however, thicker and stronger than those of the right side of the heart, the lunulæ (*e*) are more strongly marked off, and the central nodules, or *corpora Arantii* (*c*), are larger. Their structure and mode of connexion with the artery will be presently described. Behind each valve, the wall of the aorta (*a*) is dilated into three almost hemispherical pouches (*s, t, t*), named the sinuses of Valsalva, from two of which (*tt*) the two nutrient arteries of the heart arise. These sinuses are much more marked than those at the root of the pulmonary artery. (See also p. 456, and fig. 135.)

STRUCTURE OF THE HEART.

Component tissues of the heart.

The heart consists chiefly of muscular tissue which is attached to certain fibrous structures, and is covered externally by a serous coat, while the cavities are lined by a proper membrane. Its walls are also supplied with blood-vessels, absorbents, and nerves, and contain more or less fat, with some cellular tissue.

Pericardium. Endocardium, differs on two sides of heart.

The external serous membrane is the visceral or reflected portion of the pericardium. The internal covering, or *endocardium*, is a thin transparent membrane, differing somewhat on the two sides of the heart. On the left side of the heart it is continuous with the lining membrane of the pulmonary veins and aorta, and is usually found more opaque than on the right side, where it is prolonged into the veins of the body and into the pulmonary artery. Like the corresponding membrane of the arteries, it appears to be more liable to disease in the left cavities of the heart.

According to Theile, the endocardium is very thin on the musculi pectinati of the auricles and on the columnæ carneæ of the ventricles. It is

terior segment of the mitral valve, the fibrous structure of which is continuous above with the aortic tendinous zone, opposite the attached margin of the sigmoid valve, marked 1. Opposite the valves, 2 and 3, the tendinous zone receives below the muscular substance of the ventricle *v*. *h*. Larger chordæ tendineæ. *oo*. Musculi papillares.

thicker, however, on the smooth walls of the auricular and ventricular cavities, and on the muscoli papillares, especially near their tips. It is, on the whole, thicker in the auricles than in the ventricles, and attains its greatest thickness in the left auricle. In both auricles the endocardium may be separated into two layers; one superficial or internal and thin, the other deeper, thicker, and composed of elastic fibres and cellular tissue: this deep layer is not prolonged with the inner one upon the valves and into the ventricles. Purkinje and Raeschel* found elastic fibres beneath the endocardium, in both auricles, and in the corpora Arantii, but not in the ventricles.

Its structure.

The *fibrous* structure of the heart consists of the firm rings which surround the auriculo-ventricular and great arterial orifices, of the fibrous tissue already mentioned as entering into the formation of the different valves, and also of the chordæ tendinæ. All of these fibrous structures are more strongly developed on the left side of the heart. The auriculo-ventricular rings serve as points of attachment to the muscular substance of the auricles and ventricles, and also to the base of the tricuspid and mitral valves and to some of their tendinous cords. The left auriculo-ventricular ring is firmly blended, at the fore part of its right margin, with the fibrous structure surrounding the aortic orifice; and behind the aortic opening, between it and the two auriculo-ventricular openings, there is found a fibro-cartilaginous mass, which is connected with the several fibrous rings, and to which the muscular substance also is attached. In some large animals, as in the ox and elephant, there is a small piece of bone in this situation.

Fibrous parts in the heart.

The auriculo-ventricular rings;

fibro-cartilage;

bone.

Around the pulmonary and aortic orifices are found tendinous rings to which the commencement of the large vessel is fixed.† Each of these rings is formed by a fibrous band or zone, one edge of which is even, and gives attachment to the muscular fasciculi of the ventricle, whilst the other is scolloped into three deep semi-lunar notches, and is firmly fixed to the middle coat of the large artery. The semicircular margins of the notches just mentioned are much thicker and stronger than the rest of the tissue, and from the small depth of the tendinous zone the notches descend nearly through to its ventricular edge, almost

The arterial rings; their structure and mode of connexion with the

* De Arteriarum et Venarum Structura. Breslan, 1836.

† The mode in which the two great arteries are attached has been carefully examined, described, and figured by Dr. John Reid. Cyclop. Anat. and Physiology, art. Heart, p. 587.

muscular
substance;

with the
commence-
ment of the
artery,

and with
the sigmoid
valves.

reaching the muscular substance, which, indeed, is attached to the middle of the stout tendinous semi-circular margins. The middle coat of the artery presents a festooned border, divided into three convex semicircular segments, which are received into and attached to the corresponding notches of the tendinous ring. In this part of the artery its middle coat is thinner, and the sides of the vessel are slightly dilated to form the sinuses of Valsalva. It is further to be observed, that the fibres of the middle coat have here a peculiar arrangement; for, instead of being all annular, they appear to diverge from the projecting points of the tendinous ring, and spread out upwards and laterally upon the walls of the vessel. In the same situation the external or cellular coat of the artery is also thin, but the connexion of the vessel to the heart is strengthened by the serous layer of the pericardium without and by the endocardium within. Moreover, the convex or attached borders of the semilunar valves are also connected with the inner surface of the upper notched border of the arterial fibrous ring; that is to say, a semilunar fold of the lining membrane is projected inwards along the margin of each semilunar notch to form the valve, and the tendinous structure contained within it is continuous with that of the ring. Lastly, it must be remarked, that, on the left side of the heart, the tendinous zone of the aortic orifice, whilst it gives attachment to the aorta and the semilunar valves above, is continuous below, in the posterior part of its circumference, not with the muscular substance of the left ventricle, but with a part of the anterior segment of the mitral valve. (Fig. 289.)

MUSCULAR FIBRES OF THE HEART.

Muscular
fibres of
the heart,

are involun-
tary but
striped.

The muscular substance of which the walls of the heart are principally composed consists of bands of fibres, arranged in an intricate manner, and connected together by a very fine filamentous cellular tissue, so small in quantity that its existence has been denied. The muscular fibres belong to the involuntary class, but are of a deep red colour, and are marked with transverse striæ.

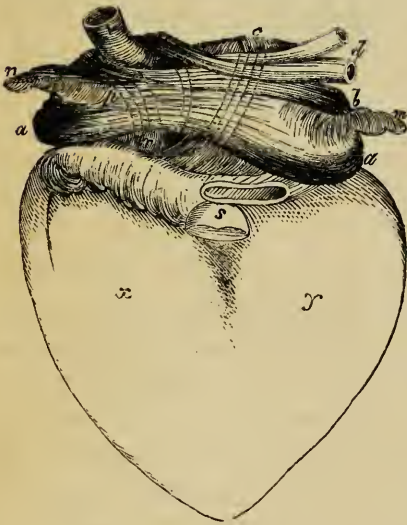
The fibres of the auricles are independent of those of the ventricles, the two sets being connected together only by the

intervention of the fibrous rings around the auriculo-ventricular orifices; so that when these rings are destroyed by boiling a heart for some hours, the auricles may be easily separated from the ventricles.

Fibres of the auricles.—These consist of a superficial set, common to both cavities, and of deeper fibres proper to each.

1. The *superficial* common or *transverse* fibres (fig. 290, *a a b*; 291, *a h*) run transversely over both sinuses, near the base of which, especially on the anterior surface, they are most distinctly marked. They form only a thin and incomplete

Fig. 290.*



layer: those near the surface are longer than those which lie deeper; some of them pass into the interauricular septum (fig. 291, *e*). The deeper fibres, which are *proper* to each auricle, consist of two sets, viz. the looped and the annular fibres.

2. The *looped* fibres (fig. 290, *c c*, *p r*; 291, *c c*) pass over the auricle and are attached by both extremities to the corresponding auriculo-ventricular rings. 3. The *annular* fibres encircle the auricular appendages (fig. 290, *n m*) from

Fibres of auricles :
superficial or transverse ;

deeper fibres,

looped,

and annular.

end to end, some longitudinal fibres running within them. These annular fibres also surround the entrances of the venæ cavæ and coronary vein on the right (fig. 290, 291, *v v*), and of the pulmonary veins (*d d*) on the left side of the heart,—the muscular fibres extending for some distance from the auricle upon the veins, especially upon the superior vena cava and the pulmonary veins.

* Anterior view of the auricles, shewing the arrangement of their muscular fasciculi. (Gerdy).—*a, a, b*. The superficial or transverse fibres, forming an incomplete layer, more numerous near the base of the auricles, *a a*; and opening to embrace the veins, *v, d*, and the auricular appendices, *m n*. *c c*. Deeper layer, or looped fibres of left auricle. *p, r*. Looped fibres of right auricle. *n*. Right, and *m*. left auricular appendix, surrounded by the annular fibres. *v*. Vena cava superior. *d*. Pulmonary veins. *s*. Arterial orifices for pulmonary artery and aorta. *x*. Right, and *y*, left ventricle.

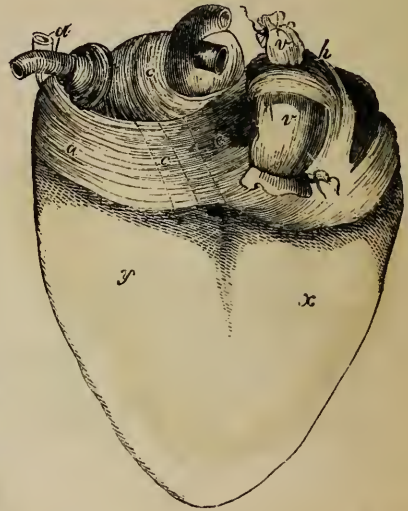Fibres of
ventricles.

Fibres of the ventricles.—The muscular fibres of the ventricles have a much more intricate arrangement, which has in a great measure baffled all the attempts yet made to unravel it. We shall here confine ourselves to a very brief statement of what is most generally received.

Fig. 291.*

General
arrange-
ment.

In the first place, it may be observed, that, as in the case of the auricular fibres, some of the ventricular muscular bands are common to both ventricles, whilst others, which are principally found at or near the base of the heart, belong exclusively to one ventricle. It further appears that most of the fibres are connected by both ends to the auriculo-ventricular fibrous



rings, either directly or by means of the chordæ tendinæ: some of them, however, are inserted into the fibrous zones around the arterial openings. The length of these ventricular fibres accordingly varies in different bundles. As to direction, a few of them only have a longitudinal course; the greater number run obliquely or spirally across the ventricles, and even form twisted loops towards the point of the heart, whilst the deeper fibres become more and more transverse, and at length assume almost a circular direction.

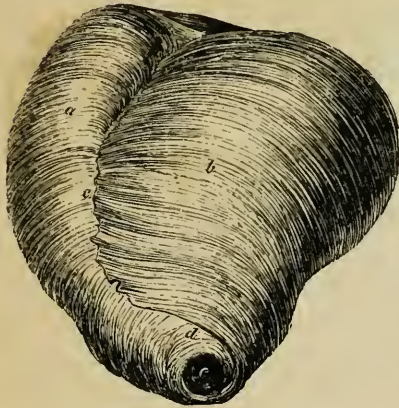
Spiral or
twisted
fibres

Twisted or spiral fibres.—These are disposed in a succession of layers of various thickness. The *superficial* fibres on the fore part of the ventricles (fig. 292, *a, b*) run in an oblique direction from above downwards, and from right to left, whilst those seen on the back of the heart, where, however, they be-

* Posterior view of auricles, shewing the muscular fasciculi. (Gerdy.)—*a.* Superficial or transverse fibres passing to the septum auricularum at *e.* *c.* Looped fibres of left auricle. *d.* The two left pulmonary veins: the two right veins are seen, but are not marked. *h.* Looped fibres of right auricle. *v, v.* Venæ cavæ superior and inferior, entering right auricle. *x.* Right, and *y,* left ventricle.

come more vertical, incline from left to right. Hence the entire arrangement of these outer fibres is spiral, as may be best seen at and near the point of the heart. These superficial fibres are longer than those which are seated next beneath them;

Fig. 292.*



and it is found, that, on reaching the apex of the heart, they coil round, and dipping in beneath the border of the next deeper and shorter set, (as at *d*,) pass into the interior of the ventricles, and then ascending, spread out upon the inner surface of those cavities.

turn in at the point of the heart;

As they are about to penetrate at the apex of the heart, they are arranged in a whorl, called the *vortex* (as represented in the figure at *e*). In this situation the coiling fibres

form the vortex,

in a boiled heart may be unravelled so as to lay open the point of the left ventricle without tearing a single fibre. The cavity of the right ventricle is afterwards reached in the same way. (Reid.) Those fibres which lie immediately beneath the superficial set have a similar arrangement; that is, they turn round the lower border of those which are still deeper, and so on, forming shorter and shorter loops; the more superficial including, as it were, the deeper loops. Having reached the interior of the ventricles, they pass up to form the walls, the septum, and the muscoli papillares of those cavities, and are ultimately fixed to the auriculo-ventricular tendinous rings, either at once or through the intervention of the larger chordæ tendineæ. In consequence of the preceding arrangement, some anatomists have represented the fibres of the ventricles as consisting of a middle layer, incomplete at the apex, and of an

and then reach the interior of the ventricles.

* Superficial muscular fibres of ventricles, shown from the front in a heart, after boiling and removal of the serous coat. (Reid.)—*a*. Oblique fibres of the right ventricle. *b*. Left ventricle. *c*. Anterior longitudinal furrow, into which most of the fibres appear to penetrate, though a few pass across. *d*. The superficial fibres turning round to reach the interior of the ventricles, and forming the vortex, *e*.

external and internal layer, which are continuous with each other at the apex, through the aperture there left in the middle layer. According to Dr. John Reid, to whose description reference has already been made, even the intermediate fibres (or the middle layer) have a similar arrangement to those which cover them, that is, the more superficial turn in beneath the still shorter and deeper bands.

Some of this spiral set of fibres pass in or out at the inter-ventricular furrows before and behind, and then turn round one or the other ventricle; but others pass over the furrows and embrace both cavities. Comparatively few fibres pass across the anterior longitudinal furrow (*c*). Part of the fibres which join in forming the vortex, (*d e*), appear to come out of the anterior fissure (*c*). On tracing these back into the fissure, they are seen to be dovetailed, as it were, with fibres from the right ventricle, which may be traced into the same fissure, and then they take an almost longitudinal direction in the septum, contributing especially to form its right part, and extending as far as its base. (Reid.)

Circular fibres; nearer to the base of ventricles,

Circular fibres.—Near the base of each ventricle there are found nearly circular fibres, which dip into the anterior or posterior longitudinal furrows, or pass across to the opposite side, and then entering the substance of the ventricle, turn up towards the tendinous rings at the base. More of these fibres cross over the posterior than the anterior furrow; when these latter are removed, the two ventricles may, with very little force, be separated from each other.

and very deep.

The deepest fibres of all are also circular, or nearly so. Towards the base of the ventricles they form imbricated bands, both ends of which turn upwards to reach the tendinous rings. Some of these embrace both ventricles, but the innermost only one.

Arteries, veins, and nerves of the heart.

Vessels and nerves.—The substance of the heart receives its blood through the two coronary *arteries* (see p. 463). All its *veins* terminate in the right auricle; besides the great cardiac or coronary vein, (seen in fig. 285,) and another principal branch there are two smaller orders of veins (see p. 649). The *cardiac* nerves given off by the cardiac plexuses appear rather small in comparison with the bulk of the organ; they are derived partly from the spinal and partly from the sympathetic

system, (see p. 891.) Besides the large ganglia in the cardiac plexuses at the base of the heart, the nerves present minute ganglia at different points along their course in its substance: these have been figured and described by Remak.* (See p. 893.)

WEIGHT AND DIMENSIONS OF THE HEART.

The size and weight of the heart, the thickness of its walls, the capacity of its several cavities, and the width of its great orifices, have been made the subject of extensive observation, more especially with the view to determine some standard dimensions with which to compare the deviations occurring in disease.

Size of the heart

Size.—It was stated by Laennec, as the result of his experience, that the heart in its natural condition is about equal in size to the closed hand of the individual. This, however, is but an imperfect kind of comparison. It is usually said to be about five inches long, about three and a half in its greatest width, and two and a half in its extreme thickness from the anterior to the posterior surface; but linear measurements of a flaccid organ like the heart are not of much value.

Weight.—The average weight of the heart in the adult can be more satisfactorily determined than its size, although, besides the differences resulting from sex, it ranges between rather wide limits depending on the general weight of the body.

Its mean weight has been stated differently at 10 oz. (Meckel), 7 or 8 oz. (Cruveilhier), 8½ oz. (Bouillaud), and 9 to 10 oz. (Lobstein). From the tables of Dr. Clendinning, who examined its weight in nearly 400 cases, the average is found to be 9½ oz. in the male, and 8¼ in the female. Dr. John Reid observes, that in an athletic male it would be expected to be 10 oz., but in a moderately sized individual about 8 oz. More recently the last-named observer has published tables† which appear to shew that all the preceding estimates are rather too low; for in eighty-nine adult males, between twenty-five and fifty-five years of age, (who died of diseases not of the heart,) the *average* weight was full 11 oz., and in fifty-three females under similar circumstances the average was full 9 oz.,—giving a difference, therefore, of 2 oz. between the sexes.‡ Moreover, the mean weight of the heart in twelve previously healthy adult males, who perished by accidents, was found by Dr. Reid to be as high as 12¼ oz. The *prevalent* weights, as deduced from the tables of Drs. Reid and Peacock, are from 10 to 12 oz. in the male, and from 8 to 10 oz. in the female.

its weight; different estimates;

average of recent observations.

The prevalent weight.

The weight of the heart maintains some general proportion to that of the body. According to Tiedemann this is about 1 to 160; by Clendinning it was found to be 1 to 158 in males, and 1 to 149 in females; and by Reid to

Proportion to weight of body.

* Froriep's Notizen, 1838, p. 137; and Müller's Archiv., 1844, p. 463, taf. xii.

† Lond. and Edin. Monthly Journal of Med. Science, April 1843, p. 323.

‡ These results are confirmed by the tables since published by Dr. T. B. Peacock, in the same journal, in 1846.

be 1 to 169 in a series of thirty-seven males, and 1 to 176 in twelve females ; but in the healthy males dying suddenly the ratio was as 1 to 173.

Weight increases with age.

It was shewn by Clendinning* that the heart continued to increase in weight up to an advanced period of life, but at a comparatively slower rate subsequently to the age of twenty-nine years. We subjoin his results, as well as some derived from Reid's observations. It would seem from both tables that the progressive increase in weight is more marked in men than in women.

CLENDINNING.				REID.			
Age in years.	Weight in oz.		Age in years.	Weight in oz. and drms.			
	Males.	Females.		Males.	Females.		
15 to 29	8½	8¼	16 to 20	8.10	6.13		
30 — 50	9½	8¾	20 — 30	10. 4	8.		
50 — 60	10¼	8	30 — 40	10. 8	9. 3		
60 — +	10½	8	40 — 50	11. 7	9. 8		
			50 — 60	11.10	9.14		
			60 — 70	12. 6	9. 5		
			70 — +	9. 6	12. 6		

Entirely in accordance with these observations upon the increase of the heart's weight according to the age, it has been found by M. Bizot† that this organ continues to enlarge in all its dimensions as life advances, viz. in length, breadth, and thickness of its walls. The greatest increase was detected in the substance of the left ventricle and the ventricular septum.

Thickness of walls of auricles, and of ventricles.

Thickness of the walls.—Of the two auricles the left is rather the thicker, and the left ventricle is very much more so than the right. The ordinary thickness of the right auricle is stated by Bouillaud to be 1 line, and of the left, 1½ line.

The walls of the left ventricle, as compared with those of the right, have been said to have a proportionate thickness of 2 to 1 by Laennee and Andral, 3 to 1 by Cruveilhier, and 4 or even 5 to 1, by Sæmmerring. In infancy and old age the ratio, according to Andral, is as 3 or 4 to 1. The measurements made by M. Bizot on this point are very precise. In the adult he found the proportion between the two ventricles to be about 2½ to 1.

The walls of the right ventricle he found to be thickest at the base, from whence they gradually become thinner towards the apex, where they are thinnest. In the left ventricle, on the contrary, the walls are thickest in the middle, thinner at the base, and thinnest at the apex. The annexed table indicates the mean thickness of the ventricular walls in lines, from the age of sixteen years upwards, in males and females :—

		Right Ventricle.	Left Ventricle.	Ventricular Septum.
Male Heart.	Base	1 ¹¹ / ₁₂₂	4 ⁶⁵ / ₁₂₂	—
	Middle	1 ⁵⁰ / ₁₂₂	5 ¹⁹ / ₁₂₂	5½
	Apex	1 ⁴ / ₁₂₂	3 ⁹⁵ / ₁₂₂	—
Female Heart.	Base	1 ⁸⁰ / ₁₂₀	4 ³ / ₈	—
	Middle	1 ³⁵ / ₁₂₀	4 ⁵ / ₈	5
	Apex	0 ¹¹² / ₁₂₀	3 ¹³ / ₃₀	—

* *Medic. Chir. Transact.*, 1838.

† *Mém. de la Soc. Medic. d'Observation de Paris*, tom. i. p. 262. 1836.

Capacity of the auricles and ventricles.—To determine with precision the absolute and relative capacities of the four cavities of the heart, as they exist during life, is impossible; and their capacity is so much influenced by their different states of distension, and also by the different degrees of contraction of their muscular walls at the moment of death, that no constant numerical relation in this respect can be looked for between them. Hence the most opposite statements prevail, especially with regard to the size of the ventricular cavities.

Capacity of the four cavities of the heart.

The capacity of the left ventricle, from which the other cavities can at any rate differ but little, has been calculated by different anatomists at $1\frac{1}{2}$ fluid ounces and 4 oz.; it probably does not exceed 2 oz., which is the quantity usually stated.

The auricles are generally admitted to be a trifle less than the ventricles. The right auricle is also said to be a little larger than the left, in the proportion of 5 to 4. (Cruveilhier.) With regard to the two ventricles, it is asserted by some that the right is really larger than the left; by others (Lower, Sabatier, Andral) that the two have an equal capacity; whilst Cruveilhier, who judges from the effect of injections, has found the left to be the larger of the two. In the ordinary modes of death, the right ventricle is always found more capacious than the left, and this is probably owing to its being distended with blood, in consequence of the cessation of the circulation through the lungs. The left ventricle, on the other hand, is found nearly empty. There are reasons for believing, however, that during life any difference between the two cavities is very trifling, if it exist at all.

Their relative capacity.

Size of the ventricular openings.—The right auriculo-ventricular opening, and the orifice of the pulmonary artery, are both found to be somewhat larger after death than the corresponding openings on the left side of the heart. Their circumference given in inches is thus stated by Bouillaud.*

Size of the openings in the two ventricles.

		Max.	Med.	Min.
Auriculo-ventricular orifices	{ Right	4	$3\frac{10}{12}$	$3\frac{9}{12}$
	{ Left	$3\frac{10}{12}$	$3\frac{6}{12}$	$3\frac{3}{12}$
Arterial orifices	{ Right (Pulmonary)	$2\frac{10}{12}$	$2\frac{7}{12}$	$2\frac{6}{12}$
	{ Left (Aortic)	$2\frac{8}{12}$	$2\frac{5}{12}$	$2\frac{4}{12}$

DEVELOPMENT OF THE HEART AND GREAT BLOOD-VESSELS.

The Heart.—The heart first appears as an elongated sac or dilated tube lying at the fore part of the embryo, and having two veins connected with it behind, and a large arterial trunk proceeding from it in front. Very soon this tube, which has contractile walls, becomes curved or bent upon itself like a horse-shoe, and projects on the ventral aspect of the body (fig. 279, 1).

The heart; is at first a tube, which bends, and divides into three parts.

As this bending increases the venous end approaches the arterial, and at the same time, the tube, which goes on growing, becomes divided by two slight constrictions into three compartments, opening successively into each other (fig. 293). The first next to the veins (1) is the *auricular* portion 2), the one following is the *ventricular* (3), and the last, from which

* *Traité des Malad. du Cœur*, tom i. p. 52. Paris, 1835.

Bulbus arteriosus, and the five vascular arches.

certain arteries proceed, is named the *arterial bulb* (bulbus arteriosus, †). (See also fig. 294, A, B., with the description.) From the arterial bulb five vessels arise on each side, and, turning round the pharyngeal cavity, meet in front of the vertebræ, and join into a single vessel, which is the future

Fig. 293.*


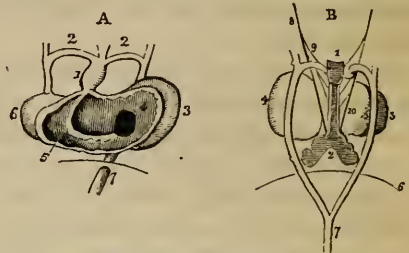


Fig. 294.†



thoracic aorta. These vascular arches make their appearance in succession from before backwards, and never all co-exist, for those which first appear become obliterated before the last or posterior ones are formed. This rudimentary condition of the heart and great vessels is, to a certain degree, analogous to the heart and branchial vessels of fishes.

In the meantime, the auricular portion has become placed behind the ventricular compartment, and relatively to that cavity considerably enlarged. Moreover, two little pouches appear upon it, one at each side, which form the future auricular appendages. The walls of the ventricular portion are already thicker than the rest.

Progress of these.

The next series of changes consists in the gradual subdivision of the single auricle, ventricle, and arterial bulb, each respectively into two, to form the right and left auricles, the right and left ventricles, and the pulmonary artery and aorta.

Septum of ventricles.

This subdivision commences first in the single *ventricular* portion of the heart (fig. 294, †). A small notch appears externally to the right of the apex, which goes on increasing in depth for some weeks, and then is again gradually

* Heart of the chick at the forty-fifth and sixty-fifth hours of incubation, forming a curved tube, seen to be constricted at intervals into three compartments. (Dr. A. Thomson.)—1. Venous trunks entering the auricular end of the heart. 2. Auricular portion. 3. Ventricular portion. 4. Bulbus arteriosus.

† Heart of human embryo about the fifth week. (Baer.)—A. Heart seen on the ventral aspect, and laid open. 1. Bulbus arteriosus. 2. Arterial arch on each side uniting behind to the aorta. 3. Auricular portion of heart. 4. Opening leading from the single auricular, 3, to the single ventricular cavity, 6. 5. Septum of the ventricles commencing on the floor of the cavity. 6. Ventricular portion of heart. 7. Vena cava inferior, passing through the diaphragm. B. Back view of the same heart, with the rudimentary respiratory organs. 1. Larynx and trachea. 2. Lungs. 3. Ventricular, and 4. auricular part of the heart. 6. Diaphragm. 7. Descending aorta formed by the union of a right and left aortic arch. 8, 9, 10. Trunk and branches of pneumo-gastric nerves.

obliterated. In the meantime, about the fourth week, a septum (³) begins to arise up internally from the right side of the apex and anterior wall of the cavity, and proceeds in the direction of the base, where the arterial bulb (¹) leads off; and about the eighth week this interventricular septum is complete. Traces of the subdivision of the *auricular* portion commence early in the form of a slight constriction on the outer surface, which marks off the future auricles, the left being at first the smaller of the two; but the auricular septum is not begun until after that of the ventricles is finished. About the ninth week it appears growing from above and behind downwards and forwards, and at length comes to meet and coalesce below with the rising edge of the interventricular septum. The interauricular septum, however, remains incomplete, and leaves an opening in the middle which forms the *foramen ovale* (figs. 296-7, *o*). The further steps in the separation of the auricles are connected with the changes which take place at the entrance of the great veins. The two large vessels terminating in the auricular extremity of the heart now correspond with the superior and the inferior vena cava, (fig. 296, *s, c,*) and open into it at some distance apart. At first, after the interauricular septum is partly formed above, the inferior cava opens into the left auricle, which is the smaller of the two, and for some time there is no valve to the foramen ovale. About the twelfth week, that valve rises up on the left side of the entrance of the vein, which thus comes to open into the right auricle; whilst at the same time the separation of the two auricles is also rendered more complete by the gradual advance of the valve (*v*) over the foramen ovale, but the passage nevertheless continues open until after birth.

Septum of auricles.

Foramen ovale,

and its valve.

Another valvular fold is developed on the right and anterior border of the orifice of the inferior cava, between it and the superior cava; this is the Eustachian valve (*e*). It appears to continue the opening of the inferior cava (*c*) towards the foramen ovale, (in the direction of the probe marked *b,*) and directs the blood of the vein through that passage.

Eustachian valve.

The left auricle has at first no connexion with the pulmonary veins, nor has it yet been ascertained how this is afterwards established.

As the interventricular septum is approaching the base of the heart, that is, about the seventh or eighth week, the arterial bulb becomes also divided by an internal partition, meeting from opposite sides, into two vessels, which are slightly turned on each other, and are so adjusted as to become connected one with each ventricle: these vessels afterwards constitute the commencement of the pulmonary artery and of the aorta. A furrow subsequently begins on the outside, and completes the separation into two vessels.

Formation of the commencement of the aorta and pulmonary artery,

The great vessels.—Whilst the arterial bulb (diagram, 295,¹) is thus converted into the commencement of the pulmonary artery and aorta, the five vascular arches already described as arising from it undergo metamorphosis; but embryologists are not agreed as to the precise way in which this takes place.

It is generally admitted, however, that the fourth arch on the left side (³), (counting from before,) which receives blood from the aortic division of the bulb is persistent and continuing to enlarge, eventually becomes the arch of

and of the rest of those vessels,

the aorta. The fourth arch on the right side, as well as all the more anterior arches on both sides, are obliterated in a greater or less extent, but certain portions of them remaining pervious and connected with the aortic arch (3) are supposed to form the commencement of the great vessels rising from it (4,5). The fifth pair of arches (2,2') are, according to Baer, connected with the pulmonary division of the bulb, and sending ramifications into the lungs, form the right and left branches of the pulmonary artery: the further or distal portion (2') of the right arch is understood to be obliterated, whilst the corresponding part of the left side (2) is continued into the aorta as the *ductus arteriosus*.

from
the five
primitive
vascular
arches.

Rathke's
views.

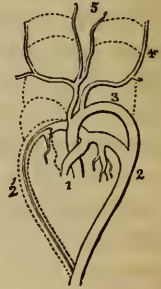
Rathke's statement is somewhat different.† According to him, the fifth arch of the right side is wholly obliterated. The right division of the arterial bulb is dilated at its commencement into the conus arteriosus of the right ventricle, and by its other end is continued into the fifth arch of the left side, and forms the commencement of the pulmonary artery. From this arch, near its commencement, a branch proceeds to the lungs, dividing into two, and forming along with the right division of the arterial bulb the pulmonary artery and its two primary divisions. That part of this arch which is beyond the origin of the vessel sent to the lungs is continued into the aorta, and forms the *ductus arteriosus*, a passage which continues open until after birth.

The valves
and
muscular
substance.

Valves.—The development of the auriculo-ventricular and sigmoid valves has not been satisfactorily traced in the heart of mammalia.

Muscular substance.—Originally the heart is composed of a mass of nucleated cells, similar in character to those which primarily constitute the other organs of the body. Muscular tissue is subsequently formed in it; but its motion commences and proceeds for some time, whilst it is yet composed of cells and before any fibres appear.

Fig. 295.*



PECULIARITIES OF THE FŒTAL HEART AND GREAT VESSELS.—FŒTAL CIRCULATION.

The heart
of fœtus
is at first
vertical.

Position.—The fœtal heart, even after all its parts are formed, continues to be placed vertically in the thorax until about the fourth month, when the apex begins to turn towards the left side, so as to give it an oblique position.

Size.—As compared with the body the heart is very much larger in the

* Illustrates Baer's view of the transformation of the arterial bulb and vascular arches in mammiferous animals.—1. Two tubes resulting from the division of the arterial bulb. 3. Fourth arch of left side remaining as arch of the aorta. 4, 5. Great vessels arising from it. 2, 2'. Fifth pair of arches sending branches into the lungs and forming the right and left divisions of the pulmonary artery. 2'. Further portion of the right arch obliterated. 2. Corresponding part of left arch joining the aorta and forming the ductus arteriosus.

† Müller's Archiv. 1843, p. 276.

early fœtus than at later periods or subsequently to birth. At one time, indeed, it occupies nearly the whole thoracic cavity. At the second month its weight to that of the body is said by Meekel to be 1 to 50; but the ratio becomes gradually reduced to 1 to 120 at birth. In the adult the average is about 1 to 160.

Its
proportion
to body.

For a long period the auricular portion is larger than the ventricular, and the right auricle is more capacious than the left; but towards birth these peculiarities disappear, and the ventricular portion becomes the larger part of the heart. As to the ventricles themselves, the right is at first the smaller; afterwards it becomes the larger of the two, and at birth their proportion is about equal. In the right ventricle the infundibulum is at first less marked than afterwards.

Relative
size of
its parts.

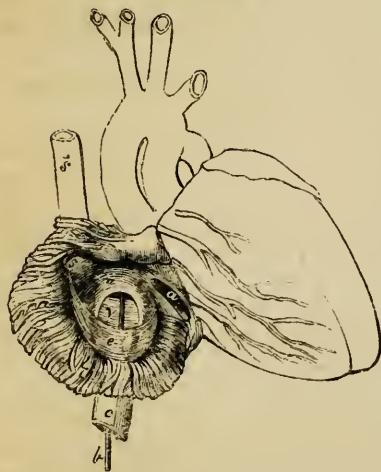
Structure.—For a time the walls of the ventricles are, comparatively speaking, very thick, and the thickness of both is about the same. In approaching the full period, however, the left begins to be the thicker of the two. But the two chief differences in the internal economy of the fœtal heart are the communication which exists between the two auricles by the foramen ovale, and the large size of the Eustachian valve.

Peculiarities
in
structure.

The large oval orifice named the *foramen ovale* (figs. 296, 297, *o*) is placed at the lower and back part of the auricular septum, and is said to

The foramen
ovale;

Fig. 296.*



attain its greatest size at the sixth month. The valve (*v*) by which it is more or less covered, and the mode in which it is eventually obliterated after birth, have been already alluded to (p. 1127). Being developed from the posterior border of the entrance of the inferior cava, the valve turns off that orifice from the left into the right auricle. At the same time, it rises up on the left side (see fig. 297) of the rim of the foramen ovale, which becomes continuous with it at the sides, but (as indicated by the probe in both figures) remains open above the free margin of the valve, which is concave and turned

its closure
by a valve.

upwards. At length the valve passes beyond the upper part of the foramen altogether; and even then, owing to its position on the left side of the opening,

* Front view of heart of fœtus at four months, the right auricle being laid open. (Kilian.)—*s*. Vena cava superior. *s*. Mouth of the same vein. *c*. Vena cava inferior. *b*. A probe passed along that vein into the right auricle, behind the Eustachian valve, *e*, and on the right aspect of the valve, *v*, of the foramen ovale, and through that opening, *o*, into the left auricle. *a*. The right auriculo-ventricular opening.

it admits the passage of blood from the right to the left auricle, but not in the reverse direction. This valve consists of a duplicature of the lining membrane, containing a few muscular fasciculi and some dense cellular tissue.

The
Eustachian
valve.

The formation, connexions, and structure of the *Eustachian valve*, which is very large in the fœtus (fig. 296, *e*), have been already described (pp. 1107, 1127).

The pulmonary artery of the fœtus, (fig. 298, *p*,) in passing from the

Fig. 297.*

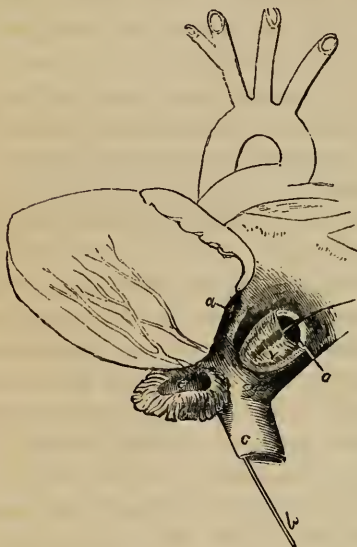
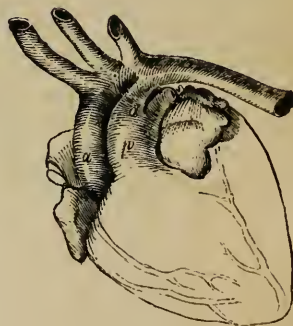

Fig. 298.†



Ductus
arteriosus.

right ventricle, first gives off the branch to the right lung, and then appears to divide into its left branch and the short but wide tube named the *ductus arteriosus* (*d*). This vessel, which is nearly as wide as the pulmonary artery itself, is the size of a goose-quill at the time of birth, and about half an inch long. It conducts the chief part of the blood of the right ventricle into the aorta (*a*), which it joins obliquely at the termination of the arch, a little below the origin of the left subclavian artery.

Umbilical
or
hypogastric
arteries.

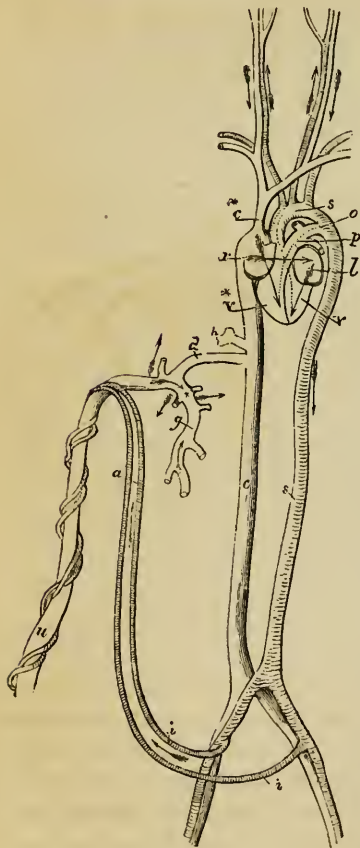
Besides the usual branches of the descending aorta intended to supply the abdominal viscera and the lower limbs, two large vessels, named hypogastric or *umbilical arteries*, (see diagram, fig. 299, *i, i*,) arise from the com-

* Back view of heart of same fœtus at four months, with the left auricle opened. (Kilian).—*c*. Inferior cava, through which the probe is passed, the upper end reaching into the left auricle through the foramen ovale, *o*, and on the right aspect of the valve, *v*, which is seen to be applied and partly affixed to the left margin of the opening or foramen, *o*. *e*. Left auricular appendix laid open. *a*. Left auriculo-ventricular orifice.

† Heart of an infant five days old. Front view. (Kilian).—*a*. Aorta. *p*. Pulmonary artery. *d*. Ductus arteriosus, joining the termination of the aortic arch, just beyond the origin of the left subclavian artery.

mon iliaes, and passing out of the abdomen, proceed along the umbilical cord, coiling round the umbilical vein (*u*), to reach the placenta. The commencement of each of these vessels afterwards forms the trunk of the corresponding internal iliac artery (see p. 571), and, from their size, they might

Fig. 299.*



even be regarded in the fœtus as the continuations of the common iliac arteries into which the aorta divides. From the placenta the blood is returned by the umbilical vein (*u*), which, after entering the abdomen, communicates by one branch (fig. 280, *o*) with the portal vein of the liver, and sends another, named the *ductus venosus* (*d*), to join the vena cava inferior (*c*), as more fully described in the account of the vessels of the liver, (p. 1078.)

Ductus
venosus.

Course of the blood in the fœtus.—The right auricle, at which it is convenient to commence, receives its blood from the two venæ cavæ. The blood brought by the superior cava (fig. 299, *c**) is simply the venous blood returned from the head and upper half of the body; whilst, on the other hand, the inferior cava, (*c*), which is considerably larger than the superior, conveys not only the blood from the lower half of the body, but also that which is sent back from the placenta through the umbilical vein (*u*). This latter stream of blood reaches the vena cava inferior, partly by the ductus venosus direct (*d*), and partly by the hepatic veins (*h*) after circulating through the liver in connexion with the blood of the vena portæ (*g*).

Circulation
in the
fœtus.

Now, the blood of the superior cava (*c**), descending over the Eustachian valve, and mixed with a small portion of that from the inferior cava, passes

Course of
blood of
superior
cava,

* A diagram to shew the course of the blood in the fœtus.—*s*, *s*. The aortic arch and descending aorta. *i*, *i*. Hypogastric or umbilical arteries, afterwards forming the trunk of the internal iliaes, arising from the common iliaes. *a*. The same arteries ascending to the umbilicus. *u*. Umbilical vein. *d*. Ductus venosus, a branch of the umbilical vein which goes direct to the inferior cava, *c*. * The branch of the umbilical vein which joins the vena portæ. *g*. Vena portæ which returns the blood from the digestive organs. *h*. Hepatic veins which return the mixed portal and placental blood after its circulation through the liver. *c*. Inferior cava. *c**. Superior

on into the right ventricle (*v**), and is thence propelled into the trunk of the pulmonary artery (*p*). A small part of it is then distributed through the branches of that vessel to the lungs, and returns by the pulmonary veins to the left auricle; but by far the larger part passes through the ductus arteriosus (*o*) into the aorta (*s*), below the place of origin of the arteries of the head and upper limbs, and mixed probably with a small quantity of the blood flowing along the aorta from the left ventricle, descends partly to supply the lower half of the body and the viscera, but principally to be conveyed along the umbilical arteries (*i, i'*) to the placenta. From all these parts it is returned by the vena cava inferior, the vena portæ, and the umbilical vein; and, as already noticed, reaches the right auricle through the trunk of the inferior cava.

and of
inferior
cava.

The blood of the inferior cava (*c*) is partly distributed with that of the superior cava as already described, but the larger portion, directed, as is supposed, by the Eustachian valve through the foramen ovale, flows from the right (*r*) into the left auricle (*l*), and thence, together with the comparatively small quantity of blood returned from the lungs by the pulmonary veins, passes into the left ventricle (*v*), from whence it is sent into the arch of the aorta (*s*), to be distributed almost entirely to the head and upper limbs. A certain portion of it, however, probably flows on into the descending aorta and joins the large stream of blood from the ductus arteriosus. From the upper half of the body the blood is returned by the branches of the superior cava to the right auricle, from which its course has been already traced.

Mixture of
these two
streams.

Sabatier was of opinion that no mixture of the two streams of blood from the two venæ cavæ took place in the right auricle, but that all the blood of the inferior cava went into the left auricle and ventricle, whilst that of the superior cava reached the right ventricle. He thought, however, that the two kinds of blood were intermixed at the junction of the ductus arteriosus with the aorta. The entire separation of the two streams of blood of the venæ cavæ, as supposed by Sabatier, is not generally admitted in the mature fœtus; but there is reason to believe that it does take place in earlier stages. In fact, the inferior cava, as already mentioned, at first opens into the left auricle, and must therefore convey its blood immediately into that cavity. As the fœtus approaches maturity, more and more of the blood of the inferior cava joins the stream from the superior cava; and, indeed, the course of the blood, and the relative position of the veins,

cava. *r*. Right auricle. *v**. Right ventricle. *l*. Left auricle, and *v*. Left ventricle. *p*. Pulmonary artery. *o*. Ductus arteriosus. *s*. Arch of the aorta. The arrows indicate the course of the blood along the several blood-vessels. The blood of the superior cava, *c**, mostly descends through the right auricle, *r*, as shewn by one arrow, into the right ventricle, *v**. That of the inferior cava, *c*, ascends through the right auricle, *r*, passes, as shewn by another arrow, into the left auricle, *l*, and thence into the left ventricle, *v*. The course of the blood from the right ventricle into the pulmonary artery, *p*, and ductus arteriosus, *o*, and from the left ventricle into the aorta, *s*, is shewn by two dotted lines.

as well as other original peculiarities of the foetal heart, become gradually altered, to prepare the way as it were for the more important changes which take place at birth.

From the preceding account of the course of the blood in the foetus, it will be seen, that, whilst the renovated blood from the placenta is principally conveyed to the upper or cephalic half of the fetus, the lower half of the body is chiefly supplied with the blood which has already circulated through the head and upper limbs, exhibiting in this a certain analogy with the mode of circulation in the turtle and various other reptiles. The larger portion of this latter stream of blood, however, is again sent out of the body to be changed in the placenta. This duty is principally performed by the right ventricle, which after birth is charged with an office somewhat analogous, in having to propel the blood through the lungs. But the passage of the placental blood is longer than that of the pulmonary, and the right ventricle of the foetus, although probably aided by the left in the placental circulation, also takes at least a large share in the ordinary circulation through the lower half of the body; and hence, perhaps, the reason why the right differs less in thickness from the left ventricle in the foetus than in the adult.

Changes after birth.—The immediate changes which take place at birth consist of the sudden cutting off of the placental circulation and the simultaneous commencement of an increased flow of blood through the lungs, which then perform their office as respiratory organs. The foramen ovale, the ductus arteriosus, and the other circulatory passages peculiar to the foetus are gradually closed, and the right and left cavities of the heart henceforth cease to communicate directly with each other. According to Bernt, the ductus arteriosus begins to contract immediately after several inspirations have taken place: in three or four days he sometimes found it closed; on the eighth day it was obliterated in one half the cases examined, and on the tenth day in all. The foramen ovale appears to continue open a little longer, and it sometimes remains so throughout life, as already described (p. 1113). The umbilical arteries, the umbilical vein and the ductus venosus shrink and begin to be obliterated from the second to the fourth day after birth, and are generally completely closed by the fourth or fifth day.

Placental blood is chiefly sent to upper half of foetus.

Changes in circulation at birth.

Closure of ductus arteriosus, foramen ovale, and blood-vessels peculiar to foetus.

ORGANS OF RESPIRATION.

THE organs of respiration consist of the thorax (already described), the *lungs* and the windpipe. The *larynx*, which is affixed to the upper end of the air tube, and opens above into the pharynx, will be separately described afterwards.

THE TRACHEA AND BRONCHI.

The *trachea* or *windpipe*, (*τραχεία ασπρηγία*, *arteria aspera*,) the common air-passage of both lungs, is an open tube which commences at the larynx above, and divides below into two smaller tubes, named the right and the left bronchus, there being one for each lung.

The trachea is placed in the middle line of the body, being situated partly in the neck and partly in the thorax, and extends from the lower border of the cricoid cartilage of the larynx on a level with the fifth cervical vertebra, to opposite the third dorsal vertebra in the thorax, where it is crossed in front by the arch of the aorta, and at or immediately below that point bifurcates into the two bronchi. It usually measures from four inches to four inches and a half in length, and from three quarters of an inch to one inch in width; but its length and width are liable to continual variation, according to the position of the larynx and the direction of the neck; moreover it usually widens a little at its lower end, and its diameter is always greater in the male than in the female. In form the trachea resembles a cylinder, rounded in front and at the sides, but flattened behind. Its rounded portion is firm and resistant, owing to that part of its walls containing a series of horizontal cartilaginous rings, which, however, are deficient behind, so that the posterior flattened portion is entirely membranous.

The trachea is nearly everywhere invested by a loose cellular tissue, and is very moveable on the surrounding parts. Both in the neck and in the thorax, it rests behind against the œsophagus, which intervenes between it and the vertebral

column, and towards its lower part projects somewhat to its left side. The recurrent nerves ascend to the larynx between these two tubes.

In the neck, the trachea is situated between the great vessels, its sides being close to the common carotid arteries; at its upper end it is embraced by the lateral lobes of the thyroid body, the middle part or isthmus of which crosses over it just below the larynx. It is also covered in front by the sterno-thyroid and sterno-hyoid muscles, and in the small interval between the muscles of the two sides by the deep cervical fascia. The inferior thyroid veins and the *arteria thyroidea ima* (of Neubauer), when that vessel exists, also lie upon its anterior surface; whilst at the root of the neck, in the episternal notch, the innominate artery and the left carotid pass obliquely over it as they ascend to gain its sides.

Its con-
nexions
in the neck,

In the thorax, the trachea is covered by the first piece of the sternum, together with the sterno-thyroid and sterno-hyoid muscles; lower down, by the left innominate vein, then by the commencement of the innominate artery and left carotid, which pass round to its sides, next by the arch of the aorta and the deep cardiac plexus of nerves, and quite at its bifurcation, by the place of subdivision of the pulmonary artery. Placed between the two pleuræ, the trachea is contained in the posterior mediastinum, and has on its right side the pleura and pneumo-gastric nerve, and on the left, the left carotid artery, the pneumo-gastric and its recurrent branch, together with some cardiac nerves.

and in the
thorax.

The two *bronchi*, (fig. 283, *b, b*), named from their relative position *right* and *left*, commence at the bifurcation of the trachea behind the arch of the aorta, and proceed laterally, one towards the root or place of attachment of each lung, where they are found on a plane posterior to the pulmonary arteries and veins. They differ from each other in length, width, direction, and connexion with other parts. The *right* bronchus, wider but shorter than the left, measuring about an inch in length, passes outwards almost horizontally into the root of the right lung on a level with the fourth dorsal vertebra: it is embraced above by the *venaazygos*, which hooks forwards over it, to end in the *vena cava superior*; the right pulmonary artery lies at first below it and then in front of it. The *left*

The bron-
chi, or two
divisions of
windpipe.

Right one
is short and
wide;

left is nar-

lower and longer.

bronchus, smaller in diameter, but longer than the right, being nearly two inches in length, inclines obliquely downwards and outwards beneath the arch of the aorta to reach the root of the left lung, which it enters on a level with the fifth dorsal vertebra, that is, about an inch lower than the right bronchus. The left bronchus crosses in front of the œsophagus and descending aorta; the arch of the aorta turns backwards and to the left over it, and the left pulmonary artery lies first above it and then on its anterior surface. The remaining connexions of each bronchus, as it lies within the root of the corresponding lung, and the mode in which it subdivides there into bronchia, will be presently described.

They resemble trachea.

In form the bronchi exactly resemble the trachea on a smaller scale; they are rounded and firm in front and at the sides, where they are provided with imperfect cartilaginous rings, and they are flattened and membranous behind.

Structure of the Trachea.

Component parts of the trachea.

The trachea is composed of a series of thin horizontal cartilages, resembling in form imperfect rings, which are connected together by a continuous membranous tube, consisting chiefly of a fibrous layer lined in its interior by the mucous membrane belonging to the air passages. The walls of the trachea also contain muscular fibres, elastic tissue, and glands, besides vessels, nerves, and cellular tissue.

Cartilaginous rings; their number, form, dimensions,

The *cartilages* and *fibrous membrane*.—The cartilages are from sixteen to twenty in number. Each has the form of a ring or hoop imperfect behind, so as to represent rather more than two thirds of a circle, and resembling, when removed from the connecting fibrous membrane, the letter C. Their depth from above downwards is from one line and a half to two lines, and their thickness half a line. The outer surface of each is flat, but the inner surface is rounded or convex from above downwards: this is best seen upon a vertical section, which is thicker in the middle and thinner at the upper and lower edge. They are held together by a strong fibrous membrane which connects the edges of the adjacent cartilages. This membrane is elastic and extensible in a certain degree, and not only occupies the intervals between the cartilages, but is prolonged over

and mode of connexion;

their outer and inner surfaces, so that they are, as it were, embedded in it. The layer covering the outer side of the rings is stronger than that within them, and from this circumstance, together with the roundness of their inner surfaces, they may be felt more prominently on the interior than the exterior of the trachea.

The cartilages terminate abruptly behind, (fig. 305, *r.*) At the back of the trachea, where they are altogether wanting, the fibrous membrane (*l*) is continued across between their ends, but it is here looser in its texture.

are wanting behind.

The first or highest cartilage, which is connected by the fibrous membrane with the lower margin of the cricoid cartilage, is broader than the rest, and is often divided at one end. Sometimes it coalesces in a greater or less extent with the cricoid or with the succeeding cartilage. The lowest cartilage, which is placed at the bifurcation of the trachea into the bronchi, is also peculiar in shape: thus, in the middle it is very deep and thick, owing to its lower border being prolonged downwards, and at the same time bent backwards so as to form a curved projection between the two bronchi; whilst, on each side, it is produced into a short semicircular or imperfect ring, which embraces the commencement of the corresponding bronchus. The cartilage next above this one is slightly widened in the middle line. Of the other cartilages, it is found, that sometimes the extremities of two adjacent ones are united together, and that not unfrequently a cartilage is divided at the end into two short branches, the opposite end of the next one being likewise bifurcated so as to maintain the parallelism of the entire series. The use of these cartilaginous hoops is to keep the trachea open, a condition essential for the maintenance of the respiratory function.

Peculiarities in some of them.

Muscular fibres.—Between the fibrous and the mucous membrane at the posterior flattened part of the trachea, there is found a continuous pale reddish layer, consisting of transverse muscular fibres (fig. 305, *n.*) which pass across, not only between the posterior extremities of the cartilages, but opposite the intervals between the rings also. Those which are placed opposite the cartilages are attached to the ends of the rings, and encroach also for a short distance upon the adjacent part of their inner surface.

Transverse muscular fibres found behind trachea;

These fibres belong to the involuntary class of muscular

are involuntary.

fibres, and are destitute of striæ. They are best seen by taking away the fibrous membrane and the small glands of the trachea from behind. They can approximate the ends of the cartilages so as to render the walls of the trachea tense, and at the same time diminish its area.

Elastic fibres.—Situated immediately beneath the tracheal mucous membrane, and adhering intimately to it, are numerous longitudinal fibres of yellow elastic tissue. They are found all round the tube, internal to the cartilages and the muscular layer, but are much more abundant along the posterior membranous part, where they are principally collected into distinct longitudinal bundles, which produce visible elevations or flutings of the mucous membrane. These bundles are particularly strong and numerous opposite the bifurcation of the trachea. The elastic longitudinal fibres serve to restore the windpipe to its ordinary length after it has been stretched in its movements.

The *glands.*—The trachea is provided with very numerous mucous glands, the constant secretion from which serves to lubricate its internal surface. The largest of these glands are small roundish lenticular bodies, situated at the back part of the tube, lying close upon the outer surface of the fibrous layer, or occupying little recesses formed between its meshes (fig. 305): these are compound glands; their excretory ducts pass forwards between the muscular fibres and open on the mucous membrane, where multitudes of minute orifices are perceptible. Other similar but smaller glands are found upon and within the fibrous membrane between the cartilaginous rings. Lastly, there appear to be still smaller glands lying close beneath the mucous coat.

The *mucous membrane.*—This, which is continuous above with that of the larynx, and below with that of the bronchi and their ramifications, is smooth and of a pale pinkish white colour in health, though when congested or inflamed, it becomes intensely purple or crimson. It is covered with a ciliated columnar epithelium, the vibratile movements of which, as is best seen at the back of the trachea, tend to drive the mucous secretion upwards towards the larynx.

Vessels and nerves.—The arteries of the trachea are principally derived from the inferior thyroid; the veins enter the adjacent plexuses of the thyroid veins. The nerves come from

Yellow elastic fibres; are longitudinal; seen inside trachea.

Tracheal glands; found behind,

and on sides of trachea.

Mucous lining, is pale, and ciliated.

Vessels and nerves.

the trunk and recurrent branches of the pneumo-gastric, and from the sympathetic system.

Structure of the bronchi.

The general structure of the bronchi corresponds with that of the trachea in every particular. Their *cartilaginous* rings, which resemble those of the trachea in being imperfect behind, are, however, shorter and narrower. The number of rings in the right bronchus varies from six to eight, whilst in the left, the number is from nine to twelve.

Component parts of bronchi ; their rings.

The bronchi are supplied by the bronchial arteries and veins, and the nerves are from the same source as those of the trachea.

THE LUNGS AND PLEURÆ.

The *lungs* (*pulmones*) are double organs situated in the lateral parts of the thorax, one right and the other left, on each side of the heart and large vessels, from which they are separated by the pericardium, and by the two layers of the pleura which form the median partition or mediastinum already described (p. 1099). They occupy by far the larger part of the cavity of the chest, and during life are so accurately adapted to its varying dimensions, that they are always in contact with the internal surface of its walls. Each lung is attached at a comparatively small part of its inner or median surface by a part named the *root*, and by a thin membranous fold which is continued downwards from it. In other directions the lung is free, and its surface is closely covered by a serous membrane, proper to itself and to the corresponding side of the thorax, and named accordingly, the right or left *pleura*.

The lungs, two in number ; their situation ;

and mode of attachment.

THE PLEURÆ.

The *pleuræ* are two independent serous membranes forming two shut sacs, quite distinct from each other, which line the right and left sides of the thoracic cavity, form by their approximation in the middle line the mediastinal partition, and are reflected each upon the root and over the entire free surface of the corresponding lung.—There is, therefore, a right and a left pleural sac.

The pleuræ are two shut serous sacs.

Each pleura consists of a *visceral* and a *parietal* portion, the former being named *pleura pulmonalis*, because it covers the

Pleura pulmonalis,

and costalis. lung; and the latter, where it lines the ribs and intercostal spaces, being called *pleura costalis*. The parietal portion also includes that part which covers the upper convex surface of the diaphragm, and the median layer which enters into the formation of the mediastinum and is reflected on the sides of the pericardium.

Anterior
mediasti-
num.

Owing to the oblique position of the heart downwards and towards the left, that portion of the mediastinum which extends between the pericardium and the back of the sternum, named the *anterior mediastinum*, has also an oblique direction, so that its lower end is found a little to the left side of that bone. Somewhat higher than the middle of the sternum, and at a little distance behind its second piece, the two layers of the anterior mediastinum, that is, the *two pleuræ*, touch each other over a small space, their contiguous surfaces being closely connected together by cellular tissue. Above and below this point, and also immediately behind the bone, there is an interval between the layers, which also inclines downwards and to the left, and contains certain parts already noticed. Proceeding backwards from the anterior mediastinum the two pleuræ cover the sides of the pericardium as far as the root of the lung, and behind that part pass on to reach the sides of the vertebral column, thus forming the *posterior mediastinum*, which, with its important contents, has been previously described.

Posterior
mediasti-
num.

Ligamen-
tum latum
pulmonis.

At the root of each lung, which is enclosed by its own pleura, the visceral and parietal portions of this membrane are continuous with each other; and commencing immediately at the lower border of the root, there is found a triangular fold or duplicature of the serous membrane, extending vertically between the inner surface of the lung and the posterior mediastinum, and reaching down to the diaphragm, to which it is attached by its point: this fold, which serves to attach the lower part of the lung, is named *ligamentum latum pulmonis*.

Upper cul-
de-sac of the
pleura lies
in the neck.

The upper part of each pleura, which receives the apex of the corresponding lung, projects in the form of a cul-de-sac through the superior aperture of the thorax into the neck, reaching an inch, or even an inch and a half above the margin of the first rib, and passing up between the lower end of the scaleni muscles,—a small slip of which arising from the transverse process of the last cervical vertebra, is described by

Mr. Sibson* as expanding into a dome-like aponeurosis or fascia, which covers or strengthens the pleural cul-de-sac, and is attached to the whole of the inner edge of the first rib. The right pleura is generally stated to reach higher in the neck than the left, but in twenty observations recorded by Mr. Hutchinson,† the right lung was higher in ten cases, and the left in eight, whilst in two the height was equal on the two sides. Owing to the height of the diaphragm on the right side (corresponding with the convexity of the liver), the right pleural sac is shorter than the left; it is at the same time wider.

Height to which it reaches.

Structure.—The pleura possesses the usual characters of serous membrane. The costal part of the membrane is the thickest, and may be easily raised from the ribs and intercostal spaces. On the pericardium and diaphragm the pleura is thinner and more firmly adherent, but it is thinnest and least easily detached upon the surface of the lungs.

Structure of pleuræ.

THE LUNGS.

Form.—Each lung is of a conical shape, having its base turned downwards, and its inner side much flattened. The *base* is broad, concave, and of a semilunar form, and rests upon the arch of the diaphragm. It is bounded all round by a thin margin, which is received in the interval between the ribs and the costal attachment of the diaphragm; and it reaches much lower down behind, and at the outer side than in front and towards the middle line. The *apex* forms a blunted point and as already mentioned, reaches into the root of the neck, above the margin of the first rib, where it is separated from the first portion of the subclavian artery by the pleural membrane.

Form of the lungs is conical.
The base;

apex;

The *outer surface* of the lung, which moves upon the thoracic parietes, is smooth, convex, and of great extent, corresponding with the arches of the ribs and costal cartilages. It is of greater depth behind than in front. The *posterior* border is obtuse or rounded, and is received into the deep groove formed by the ribs at the side of the vertebral column; measured from above downwards, it is the deepest part of the lung. The *anterior* border is thin and overlaps the pericardium, forming a sharp margin, which touches the sides of the anterior media-

outer surface;

hinder border;

the anterior border;

* Op. citat.

† Op. citat. postea.

stinum, and, opposite the middle of the sternum, is separated during inspiration from the corresponding margin of the opposite lung only by the two thin and adherent layers of the mediastinal septum. The *inner surface* of the lung, which is flattened or concave, is turned towards the mediastinum, and is adapted to the convex pericardium. Upon this surface, somewhat above the middle of the lung, and considerably nearer to the posterior than the anterior border, is the part called the *root*, where the bronchi and great vessels enter and pass out. Each lung is traversed by a long and deep fissure, which is directed from behind and above, downwards and forwards. It commences upon the posterior border of the lung, about three inches from the apex, and extends obliquely downwards to the anterior margin, penetrating nearly through to the root of the organ. The portion of lung, or *upper lobe*, (fig. 283, ⁹ and ¹¹), as it is called, which is situated above this fissure, is smaller than the one below it, and is shaped like a cone with an oblique base, whilst the *lower* and larger lobe (¹⁰ and ¹³) is more or less quadrilateral. In the right lung only there is a second and shorter fissure, which runs forwards and upwards from the principal fissure to the anterior margin, thus marking off a third small portion, or *middle lobe* (¹²), which appears like an angular piece separated from the anterior and lower part of the upper lobe. The left lung, which has no such middle lobe, presents a deep notch in its anterior border, into which the apex of the heart (enclosed in the pericardium) is received. Besides these differences, the right lung is shorter, but at the same time wider than the left, the perpendicular measurement of the former being less, owing to the diaphragm rising higher on the right side to accommodate the liver, whilst the breadth of the left lung is narrowed, owing to the heart and pericardium encroaching on the left half of the thorax. On the whole, however, as is seen on comparisons of weight, the right is the larger of the two lungs.

Weight, dimensions, and capacity.—The lungs vary much in size and weight according to the quantity of blood, mucus, or serous fluid, they may happen to contain, which is greatly influenced by the circumstances immediately preceding death, as well as by other causes. The weight of both lungs together, as generally stated, ranges from thirty to forty-eight ounces,

inner surface,

and root.

The fissures,

and lobes.

An additional lobe in right lung.

Differences between the two lungs.

Dimensions of lungs vary.

General weight of each lung.

the more prevalent weights being found between thirty-six and forty-two ounces. The proportion borne by the right lung to the left is about twenty-two ounces to twenty, supposing the weight of both to be forty-two ounces. The lungs are not only absolutely heavier in the male than in the female, but appear to be heavier in proportion to the weight of the body. The general ratio between the weight of the lungs and body, in the adult, fluctuates, according to the estimate of Krause, between one to thirty-five and one to fifty.

Heavier in male.

The following tables, deduced from Dr. Reid's and Mr. Hutchinson's observations, shew the average weights of the right and left lungs, and of both lungs together, and also the relative weight of the lungs to the body in a certain number of adults, of both sexes.

AVERAGE OF TWENTY-NINE MALES AND TWENTY-ONE FEMALES.—(REID.)		
	MALE.	FEMALE.
Right lung.....	24 oz.	17 oz.
Left lung	21 oz.	15 oz.
	45 oz.	32 oz.

Weight of each lung in both sexes ;

AVERAGE OF TWENTY-FIVE MALES AND THIRTEEN FEMALES.—(REID AND HUTCHINSON.)		
	MALE.	FEMALE.
Proportionate weight of the } lungs to the body..... }	1 to 37	1 to 43.

as compared with body.

The *size* and *cubical* dimensions of the lungs are influenced so much by their state of inflation, and are therefore so variable, that no useful application can be made of the measurements sometimes given. The quantity of *air* which they contain under different conditions has been investigated by many inquirers, whose statements on this point, however, are exceedingly various. The volume of air contained in the lungs after a forced expiration has been estimated by Goodwyn at 109 cubic inches. After an ordinary expiration it would seem that at least 60 cubic inches more are retained in the chest, giving a total of 170 cubic inches in that condition of the lungs. The amount of air drawn in and expelled in ordinary breathing, has been very differently estimated by different observers; it is most probably from 16 to 20 cubic inches. The recent extensive and important researches of Mr. Hutchinson on this subject, have led him to the conclusion that, on an average, men of a mean height, between five and six feet, can, after a complete inspiration, expel from the chest, by a forced expiration, 225 cubic inches of air at a temperature of 60°. This quantity is called by Mr. Hutchinson the *vital capacity* of the lungs. If to it be added the average quantity found by Goodwyn to be retained in the lungs after complete expiration, viz. 109 cubic inches, the result will yield 335 cubic inches of air at 60°, as the average total capacity of the respiratory organs for air in an adult male of ordinary height.

Size of lungs varies.

Quantity of air employed in different states of lung.

Mr. Hutchinson's observations.

The *vital capacity* (or difference between extreme expiration and extreme inspiration) is found by Hutchinson to bear a singularly uniform relation to the *height* of the individual, increasing eight cubic inches for every additional inch of stature above five feet. Its relations with the *weight* of the body are not thus regularly progressive, for it appears to increase about one cubic inch for each additional pound between the weights of 105 pounds and 155 pounds, or $7\frac{1}{2}$ stone and 11 stone, and to *decrease* at a similar rate between the weights of 11 and 14 stone, or 155 and 200 pounds. From the age of 15 to 35 years the vital capacity continues to advance with the growth and activity of the frame, but between the ages of 35 and 65 it diminishes at the rate of upwards of one cubic inch per annum. This differential or *vital capacity* is by no means in proportion to the *size of the thorax*, whether that be estimated by the circumference of the chest, or by the sectional area of its base, or by its absolute capacity, as ascertained by measuring its cubical contents after death. It is found rather, that the vital capacity is strictly commensurate with the *extent of the thoracic movements*, and with the *integrity of the lungs* themselves; so that in phthisis, for example, it becomes reduced by 10 to 70 per cent, according to the stage of the disease. Changing from the erect to the sitting posture is accompanied by a diminution of the vital capacity, which in one case fell from 260 cubic inches to 255 cubic inches, and on lying down it was further diminished to 230 cubic inches in the supine, and 220 cubic inches in the prone position of the body. Lastly, it is lowered by from 12 to 20 cubic inches, by the presence of a full meal in the stomach.*

The lung-substance floats in water.

Its specific gravity;

crepitates when squeezed;

Texture and consistence.—The substance of the lung is of a light porous spongy structure, and, when healthy, is buoyant in water; but in the fœtus, before respiration has taken place, and also in cases of congestion or consolidation from disease, the entire lungs, or portions of them, will sink in that fluid. The specific gravity of a healthy lung, as found after death, varies from 345 to 746, water being 1000. When the lung is fully distended its specific gravity is 126, whilst that of the pulmonary substance, entirely deprived of air, is 1056. (Krause.) When squeezed, the lungs impart to the finger a crepitant sensation, which is accompanied by a peculiar noise, both effects being owing to the air contained in the tissue. On cutting into the lung, the same crepitation is heard, and there exudes from the cut surface a reddish frothy fluid, which is partly mucus from the air-tubes and air-cells, and partly a

* See Mr. Hutchinson's Papers (Journal of Statistical Society, Aug. 1844, and Medico-Chirg. Transactions, vol. xxix. 1846,) for further details, for a description of the mode of measuring the vital capacity, and of the application of this measurement as a test of the health.

serous exudation, tinged with blood and rendered frothy by the admixed air. This fluid escapes in largest quantity from the posterior portion of the lung.

The pulmonary tissue is endowed with great elasticity, in consequence of which, the lungs collapse to about one-third of their bulk, when the thorax is opened and the resistance offered by the walls of that cavity to the atmospheric pressure on their outer surface is in this way removed. Owing to this elasticity also, the lungs, when artificially inflated out of the body, resume their previous volume if the air be again allowed to escape.

is highly elastic.

Colour.—In infancy the lungs are of a pale rose-pink colour, which might be compared to blood-froth; but as life advances they become darker, and are mottled or variegated with spots, patches, and streaks of dark slate-colour, which sometimes increase to such a degree as to render the surface uniformly black. The dark colouring matter to which this is owing is deposited mostly near the surface of the lung; it is not found so abundantly in the deeper substance. It exists sometimes in the air-cells, and on the coats of the larger vessels. Its quantity increases with age, and is said to be less abundant in females than in men. In persons who follow the occupation of colliers, the lungs are often intensely charged with black matter. The black colouring substance of the lung is unlike the black pigment of the choroid coat of the eye or of the Negro's skin, for it is not destroyed by the action of chlorine. It seems to be a carbonaceous mixture, consisting of carbon and some animal matter. A black substance of precisely the same nature is found in the bronchial glands.

Their colour is mottled red and slate-colour or black.

The colouring substance; seems to be carbonaceous;

Opinions differ as to the source of this carbonaceous deposit; some have contended that it is introduced into the lungs from without, by the inhalation of minute particles of carbon floating in the air: the very dark colour of the lungs of colliers has been supposed to favour this view, but it is by no means established. On the contrary, it is supposed by many that its existence is in some way connected with the chemical changes incidental to the respiratory process,—that, for example, it may consist of carbon eliminated from the blood, not as carbonic acid, but in the form of a solid deposit within the pulmonary tissue.

its source.

STRUCTURE OF THE LUNGS.

Structure of lungs.
External coat.

Subserous tissue.

The lungs are composed of an external or serous coat, a subserous cellular layer, and of the pulmonary substance. Beneath the serous covering, which has been already noticed, is a thin layer of *subserous* cellular membrane mixed with much elastic tissue. It is continuous with the cellular tissue in the interior of the lung, and has been described as a distinct coat under the name of the second or inner layer of the pleura. In the lungs of the lion, seal, and leopard, this subserous layer forms a very strong membrane, composed principally of elastic tissue.

Substance of lung consists of little lobules;

compressed and held together by

The *substance* of the lung is composed of numerous small lobules which are attached to the ramifications of the air-tubes, and are held together by those tubes, by the blood-vessels, and by an interlobular cellular tissue. These lobules are of various sizes, the smallest uniting into larger ones; they are polyhedral, or bounded by flattened sides, and are thus compactly fitted to each other and to the larger air-tubes and vessels of the lungs. On the surface of the organ they are pyramidal, with a lozenge-shaped base turned outwards, from half a line to a line in diameter: in the interior of the lung they have many sides, and are of various shapes. Though mutually adherent, they are quite distinct one from the other, and may be readily separated by dissection in the lungs of young animals, and in those of the human fœtus.

interlobular cellular tissue.

The *interlobular cellular tissue* which invests these lobules and connects them together, and is continuous with the subpleural cellular membrane, is very fine. It is generally moistened with serosity, is traversed by numerous lymphatic vessels, and contains no fat. In one form of disease of the lung, named interlobular emphysema, this intermediate tissue becomes inflated with air, which has escaped by rupture from the interior of the lobules. By forcing air beneath the serous coat of the lung, this condition may be imitated after death; and in either case the lozenge-shaped bases of the larger lobules may be seen on the surface of the organ bounded by elevated lines formed by the inflated interlobular tissue.

Each lobule is a lung in miniature;

These small pulmonary lobules may be regarded as lungs in miniature, the same elements entering into their composition as

form the lung itself. The structure of a single lobule represents in fact that of the entire organ, each lobule, besides its investment of cellular membrane, being made up of the following constituents: the *air tubes* and their *terminating cells*, the *pulmonary* and *bronchial* blood-vessels, with lymphatics, nerves, and interstitial cellular tissue. The different vessels and nerves just enumerated enter the lung by its root. Up to that point the air-tubes, or right and left bronchi, have already been traced, and the bronchial arteries and veins, the lymphatics and the pulmonary plexuses of nerves have also been elsewhere described (see pages 550, 629, 663). It remains to follow the pulmonary vessels up to the same point.

its compo-
nent parts.

PULMONARY ARTERY AND VEINS.

The *pulmonary artery*, (fig. 283,⁵) is a short wide vessel, which carries the dark blood from the right side of the heart to the lungs. It arises from the infundibulum or conus arteriosus of the right ventricle, and passes for the space of nearly two inches upwards, and at the same time backwards and to the left side, to reach the concavity of the aortic arch, where it bifurcates into its right and left branches, *a, a*. The mode of attachment of the pulmonary artery to the base of the ventricle has already been fully noticed. At each side of its commencement is the corresponding coronary artery springing from the aorta, and in contact with its sides are the two auricular appendages. It is at first in front of the aorta, and conceals the origin of that vessel; but higher up, where it lies in front of the left auricle, it crosses to the left side of the ascending aorta, and is finally placed beneath the transverse part of the arch. The pulmonary artery and the aorta are connected together by the serous layer of the pericardium, which for the space of about two inches forms a single tube around both vessels. Rather to the left of its point of bifurcation it is connected to the under side of the aortic arch by means of a short fibrous cord, which passes obliquely upwards, backwards, and to the left. This is the remains of a large vessel peculiar to the fœtus, named the ductus arteriosus, which has been previously described.

Pulmonary
artery;

its origin,
course, and
connexions.

The *two branches* of the *pulmonary artery*.—The *right branch*, longer and somewhat larger than the left, runs almost transversely outwards behind the ascending aorta and the

Its right
and left
branches.

superior vena cava into the root of the right lung. The *left branch*, shorter than the right, passes horizontally in front of the descending aorta and left bronchus into the root of the left lung.

Pulmonary veins are four in number ;

their course.

Pulmonary Veins.—The *pulmonary veins*, (fig. 283, *v, v,*) which convey the red blood back from the lungs to the left side of the heart, ultimately converge into *four* short venous trunks, which are found two on each side in the root of the corresponding lung. The two veins of the *right* side, which are longer than those of the left, pass below the right pulmonary artery, and behind the superior vena cava, the right auricle, and the aorta, to enter the left auricle. The two *left* pulmonary veins reach the same cavity after a shorter course, passing in front of the descending aorta.

Root of the Lung.

Root of the lung, how formed ;

The root of each lung is composed of the bronchus and the large blood-vessels, together with the nerves, lymphatic vessels and glands, all of which parts are closely connected together by cellular tissue, and are enclosed in a sheath formed by the reflection of the pleura.

its connexions on the two sides.

The root of the right lung lies behind the superior vena cava and part of the right auricle, and below the azygos vein, which arches over it to enter the superior cava. That of the left lung passes below the arch of the aorta, and in front of the descending aorta. The phrenic nerve descends in front of the root of each lung, and the pneumogastric nerve behind, whilst the ligamentum latum pulmonis is continued from the lower border. The bronchus, together with the bronchial arteries and veins, the lymphatics and lymphatic glands, are placed on a plane posterior to the great blood-vessels ; the pulmonary artery lies more forward than the bronchus, and to a great extent conceals it, whilst the pulmonary veins are still further in advance. The pulmonary plexuses of nerves lie on the anterior and posterior aspect of the root beneath the pleura, the posterior being the larger of the two.

The order of position of the great air-tube and pulmonary vessels from above downwards differs on the two sides (see fig. 283) ; for whilst on the right side the bronchus is highest and the pulmonary artery next, on the left, the air-tube, in

getting beneath the arch of the aorta, has to pass below the level of the left pulmonary artery, which is the highest vessel. On both sides the pulmonary veins are the lowest of the three.

Before entering the substance of the lung, the bronchus divides into two branches, an upper and a lower, one being intended for each corresponding lobe. The lower branch is the larger of the two, and on the right side gives off a third small branch which enters the middle lobe of that lung. The subsequent ramifications of the bronchi through the lungs have been distinguished by the name of *bronchia*.*

Entrance of
bronchus
into the
lung ;

The pulmonary artery also divides, before penetrating the lung to which it belongs, into two branches, of which the lower is the larger and supplies the lower lobe. The upper of these two branches, gives the branch to the middle lobe. A similar arrangement prevails in regard to the right pulmonary veins, the upper one of which is formed by branches proceeding from the superior and middle lobes of the right lung.

of artery ;

and of veins.

Arrangement and Structure of Parts within the Lung.

The Air-tubes.—The principal subdivisions of the bronchi, go on dividing and subdividing in succession into smaller and smaller tubes, named generally the *bronchia* or the *bronchial* tubes, which diverge through the lung in all directions, and never anastomose. The prevailing form of division is dichotomous ; but sometimes three branches arise together, and often lateral branches are given off at intervals from the sides of a main trunk. The larger branches diverge at rather acute angles, but the more remote and smaller ramifications spring more and more obtusely. After a certain stage of subdivision, each bronchial tube is reduced to a very small calibre, and, forming what has been termed a *lobular bronchial tube*, enters a distinct pulmonary *lobule*, within which it undergoes still further division, and at last ends in the small cellular recesses named the *air cells* or *pulmonary cells*. It follows, therefore, that a multitude of air-cells, supported and invested by cellular tissue and opening into the finest branches of a lobular bronchial tube, constitute together with vessels and nerves

Interior of
lung.

Air-tubes,
or bronchia ;

divide and
subdivide,
and

end in air-
cells.

Structure of
each lobule.

* "Eos ramos veteres *bronchia*, *syringes* et *aortas* dixerunt." Haller, Elem. Phys.

a *pulmonary lobule*,—that several of these combined together form a larger lobule,—and that a large number of these again are aggregated together to form a *lobe*.

Bronchia
are circular.

Cartilages
are lami-
nated and
scattered
about ;

are not
found in
the fine
tubes.

Fibrous,

mucous,

elastic,

and muscu-
lar elements
of bronchia.

Air-cells
are the ends
of air-tubes.

Within the lungs the air-tubes are not flattened behind like the bronchi and trachea without, but form completely circular tubes. Hence, although they contain the same elements as the larger air-passages, reduced gradually to a state of tenuity, they possess certain peculiarities of structure. Thus, the *cartilages* no longer appear as imperfect rings running only upon the front and lateral surfaces of the air-tube, but are scattered over all sides of the tube in the form of irregularly-shaped plates of various sizes, adapted as it were to each other. These cartilaginous laminae are most marked at the points of division of the bronchia, where they form a sharp concave ridge projecting inwards into the tube. They may be traced, becoming however rarer and rarer, and of course greatly reduced in size, as far as those divisions of the bronchia, which are only one-fourth of a line in diameter, beyond which the tubes are entirely membranous. The use of these cartilages is evidently to keep the air-tubes open ; and the reason why they are not found in the finest branches is probably because these can never be completely emptied of air. The *fibrous* coat extends to the very smallest tubes, becoming thinner by degrees and degenerating into cellular tissue. The *mucous membrane*, which extends throughout the whole system of air-passages, and is continuous with that lining the air-cells, is also thinner than in the trachea and bronchus, but it retains its ciliated columnar epithelium. The yellow longitudinal bundles of *elastic* fibres are very distinct in both the large and small bronchia, and may be followed as far as the tube can be laid open. The *muscular* fibres, which in the trachea and bronchi are confined to the back part of the tube, here surround it with a continuous layer of annular fibres, lying outside the irregular cartilaginous plates ; they are found, however, beyond where the cartilages exist, and appear as irregular annular fasciculi even in the smallest tubes : they are pale and unstriped, and have all the characters of the involuntary muscular fibres.

The Air-cells, or Pulmonary cells.—These cells, in which the finest ramifications of each lobular bronchial tube ultimately terminate, are in the natural state always filled with air. They

are readily seen on the surface and upon a section of a lung which has been inflated with air and dried; also upon portions of fœtal or adult lung injected with mercury. In the lungs of some animals, as of the lion, cat, and dog, they are very large, and are distinctly visible on the surface of the organ. In the adult human lung they vary from $\frac{1}{200}$ to $\frac{1}{70}$ th of an inch in diameter; they are larger on the surface than in the interior, and largest towards the thin edges of the organ: they are also said to be very large at the apex of the lung. Their dimensions go on increasing from birth to old age, and they are larger in men than in women. In vesicular emphysema, and in asthmatic persons, they are unnaturally and sometimes enormously increased in size.

Air-cells readily seen.

Their size, which varies.

Very different opinions as to the mode of communication of the air-cells with each other and their connection with the bronchial tubes have been entertained. All anatomists are now agreed that the cells of one lobule, isolated by its investing membrane, do not communicate with those of another. Some, however, maintain that the cells within each lobule communicate freely by lateral anastomoses, or even so as to form a labyrinth of short canals, enclosed by the proper membrane of the lobule and opening into its bronchial tube. By others again, it is held that the air-cells do not communicate directly, but are the terminations of the air-tubes, which ramify like a tree without anastomosing, and have been supposed to end either in bunches of blind dilated extremities (Willis), or in very short hemispherical pullulations, which are scarcely if at all dilated (Reisseissen).

Cells of each lobule separate;

opinions regarding them differ.

From recent observations on the lungs of man and mammalia,* it would appear that, on tracing one of the smaller bronchial tubes, suppose for example one entering a separate lobule, the small air-tube divides and subdivides from four to nine times, according to the size of the lobule; its branches, which diverge at more and more obtuse angles, at first diminish at each subdivision, but afterwards continue stationary in size, being about $\frac{1}{50}$ th to $\frac{1}{30}$ th of an inch in diameter. Moreover, they gradually lose their cylindrical form, and appear more like

Air-tubes, subdivision of,

* See Rainey, Med. chir. Transact, vol. xxviii, 1845. Rossignol, Recherches sur la Structure intime du Poumon, &c., Bruxelles, 1846.

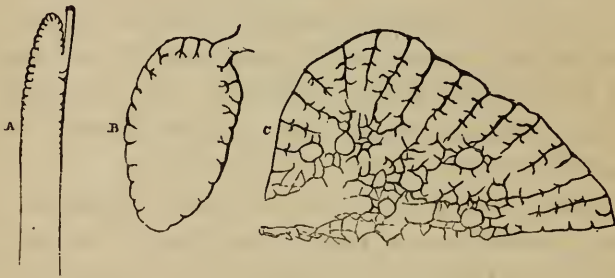and connection with the air-cells.

Shape of the cells ;

mode of communication with each other.

irregular passages through the substance of the lung, which are beset, at first sparingly, but afterwards closely and on all sides, with numerous little recesses or dilatations, and ultimately terminate near the surface of the lobule in a group of similar recesses. These small recesses or loculi, whether seated along the course or at the extremity of an air-passage, are in fact the *air-cells*. They give the loculated character to a section of the lung, as seen when magnified by a moderate power, which reveals a honeycomb structure, traversed by the comparatively large air-passages. The cells themselves appear like polyhedral alveolar cavities, separated from each other by thin and rather shallow intervening septa, and of course opening into the air-passages. They do not open into one another by anastomosis or lateral communication, but freely communicate through the medium of the common air-passage to which they belong. The ultimate arrangement of the finest air-passages and air-cells in the lungs of mammalia would seem, therefore, closely to resemble, though on a smaller scale, the reticulated structure of the tortoise's lung, in which large open passages lead in all directions to clusters of wide alveoli, separated from each other by intervening septa of various depths.

Fig. 300.*



Structure of smallest bronchial tubes and air-cells.

At the point where the small bronchial tubes lose their cylindrical character, and become covered on all sides with the cells, their structural elements also undergo a change. The

* Three diagrams, to shew the progressive advance in the cellular structure of the lungs of reptiles.—A. The upper portion of the lung of a serpent: the summit has cellular walls, the lower part forms merely a membranous sac. B. Lung of the frog, in which the cellular structure extends over the whole internal surface of the lung, but is more marked at the upper part. C. Lung of the turtle: the cells here have extended so as to occupy nearly the whole thickness of the lung.

muscular fibres disappear, the longitudinal elastic bundles are broken up into an interlacement of areolar and *elastic tissue*, which surrounds the tubes and forms the basis of their walls. The *mucous* membrane becomes less opaque, and ceases to be provided with a ciliated epithelium. On the contrary, it is exceedingly delicate, consisting merely of a thin transparent membrane, covered by a stratum of squamous epithelium. A similar membrane lines the air-cells, and by a doubling inwards of itself, forms the intervening septa. The walls of the cells, their orifices, and the margins of the septa, are supported and strengthened by scattered and coiled elastic fibres. The arrangement of the capillary vessels will be noticed immediately.

The pulmonary vessels.—These vessels, which are very large, and convey the blood sent through the lung for aeration, have the following arrangement within that organ :—

The branches of the *pulmonary* artery accompany the bronchial tubes, but they subdivide more frequently, and are much smaller, especially in their remote ramifications. They do not anastomose in their course, and at length terminate upon the walls of the air-cells in a fine and dense *capillary net-work*, from which the radicles of the *pulmonary veins* arise. The smaller branches of these veins, especially near the surface of the lung, frequently do not accompany the bronchia and arterial branches (Dr. T. Addison, Bourger), but are found to run alone for a short distance through the substance of the organ, and then to join some deeper vein which does run by the side of a bronchial tube, uniting together, and also forming, according to Rossignol, frequent lateral communications. The veins coalesce into large branches, which at length accompany the arteries, and thus proceed to the root of the lung. In their course through the lung, the artery is usually found above and in front of a bronchial tube, and the vein below.

The pulmonary vessels are peculiar, inasmuch as the artery conveys dark blood, whilst the veins carry red blood. The pulmonary veins, unlike the other veins of the body, are not more capacious than their corresponding arteries ; indeed, according to Winslow, Santorini, Haller, and others, they are somewhat less so. These veins have no valves. Lastly, it may be remarked, that whilst the arteries of different lobules are independent, their veins freely anastomose together.

Pulmonary vessels

within the lung.

Pulmonary arteries and veins.

Peculiarities of these.

Pulmonary
capillaries.

The *capillary* net-work of the pulmonary vessels is spread beneath the thin transparent mucous membrane of both the terminal and lateral air-cells, and is found wherever the finest air-tubes have lost their cylindrical character, and become beset with cells. Around the bottom of each cell there is an arterial circle, which communicates freely with similar neighbouring circles, the capillary system of ten or twelve cells being thus connected together, as may be seen upon the surface of the lung. From these circular vessels, which vary in diameter from $\frac{1}{270}$ to $\frac{1}{84}$ inch, the capillary net-work arises, covering the bottom of each cell, ascending also between the duplicature of mucous membrane in the intercellular septa, and surrounding the openings of the cells. According to Mr. Rainey, the capillary net-work, where it rises into the intercellular partitions, forms a double layer in the lungs of reptiles, but is single in the lungs of man and mammalia.

Their dis-
tribution

and size.

The capillaries themselves are very fine, the smallest measuring, in injected specimens, from $\frac{1}{2540}$ to $\frac{1}{3000}$ th inch; the network is so close that the meshes are scarcely wider than the vessels themselves. The coats of the capillaries are also exceedingly thin, and thus more readily allow of the free exhalation and absorption of which the pulmonary cells are the seat. Keil and Hales estimated the entire extent of the inner surface of the air tubes and pulmonary cells at more than 21,000 square inches; but no great reliance can be placed on such calculations.

Bronchial
vessels in
the lung.

The bronchial vessels.—The bronchial *arteries* and *veins*, which are much smaller than the pulmonary vessels, carry blood for the nutrition of the lung, and are doubtless also the principal source of the mucous secretion found in the interior of the air-tubes, and of the thin albuminous fluid which moistens the pleura pulmonalis.

Bronchial
arteries.

The *bronchial arteries*, from one to three in number for each lung, arise from the aorta, or from an intercostal artery, and follow the divisions of the air-tubes through the lung. They are ultimately distributed in three ways: many of their branches ramify in the bronchial lymphatic glands, the coats of the large blood-vessels, and on the walls of the large and small air-tubes, as far as these retain their cylindrical form and their opaque ciliated mucous membrane; others form plexuses in the inter-

lobular cellular tissue ; and lastly, branches spread out upon the surface of the lung beneath the pleura.

The *superficial* set, or subpleural *arteries*, form plexuses and a capillary network, which may be distinguished from those of the pulmonary vessels of the superficial air-cells by their tortuous course and open arrangement, and also by their being outside the investing membrane of the lobules, and by ultimately ending in the branches of the *superficial* set of *bronchial veins*. Of the deeper seated *arteries*, those which supply the bronchial lymphatic glands, and those which penetrate a certain distance upon the air-tubes and large vessels, end in corresponding *deep bronchial* veins ; the interlobular arterial plexuses send venous radicles, which end either in the superficial or the deep set of bronchial veins, and serve to connect them together ; lastly, the capillary net-work of the innermost branches of the bronchial arteries, which is found upon the finest cylindrical air-tubes, communicates with the system of pulmonary vessels, so that its blood returns by the pulmonary veins. The exact nature of this last-named communication is difficult to determine, inasmuch as experiments by injection, especially of so delicate a capillary system as that of the lung, are liable either to be defective or to be rendered inaccurate by rupture and extravasation. According to Ruysch, Haller, Soemmerring, and Reisseissen, the terminations of the deep bronchial arteries anastomose with those of the pulmonary arteries, or, at any rate, the capillary networks of the two sets of vessels anastomose. Rossignol denies even the latter mode of communication, because he could not succeed in injecting from the pulmonary artery the vessels of the cylindrical air-tubes, which are destitute of air-cells : he believes that the only communication between the bronchial and pulmonary vessels is by means of some minute bronchial venous radicles which end in the pulmonary veins.

It was found by Rossignol, first, that injections by the bronchial arteries returned by both the pulmonary and bronchial veins, but not by the pulmonary artery ; secondly, that injections by the pulmonary arteries returned entirely by the pulmonary veins, but not by the bronchial arteries ; and thirdly, that by injecting the pulmonary veins, it was easy to fill all the other vessels, viz. : the pulmonary artery and the bronchial arteries and veins.

The *bronchial veins*, therefore, have not quite so large a distribution in the lung as the bronchial arteries. The superficial

Superficial set,

deeper set end in different ways.

Bronchial veins.

and deep veins unite at the root of the lung, and on the right side open into the vena azygos, on the left usually into the superior intercostal vein.

The absorbent vessels.—The lungs are well supplied with lymphatic vessels and glands. The lymphatics consist of a *superficial* and a *deep* set. The former constitute a network on the surface of the lung, and being joined by the interlobular lymphatics of the deep set, which traverse the interlobular cellular tissue, run towards the root of the lung. Here, together with the deep absorbents, they pass through the bronchial lymphatic glands found in that situation. These glands, which are numerous and of considerable size, lie, some within the lung around the largest bronchia, and some near the bifurcation of the trachea and around the bronchi. They have a great tendency to induration, and usually contain much of the peculiar carbonaceous colouring matter already mentioned as existing in the lung, and which is also found in abundance along the course of the lymphatic vessels.

Nerves.—The lungs are supplied by nerves from the anterior and posterior pulmonary plexuses (pp. 811, 893). These are formed chiefly by branches from the pneumogastric nerves, joined by others from the sympathetic system. The fine nervous cords enter at the root of the lung, and follow the air-tubes. Their final distribution requires further examination. According to Remak, whitish filaments (from the par vagum) follow the bronchia as far nearly as the surface of the lung. Greyish filaments proceeding from the sympathetic, and having very minute ganglia upon them in their course, have also been traced by the last mentioned anatomist to the bronchia and pleura.

DEVELOPMENT OF THE LUNGS AND TRACHEA.

The lungs first appear as two little protrusions upon the front of the œsophageal portion of the alimentary canal, completely hid by the rudimentary heart and liver. These primitive protrusions or tubercles are visible, in the chick on the third day of incubation (see fig. 301 for their appearance on the fourth day). According to Baër and others, they are, from the first, *hollow*, their internal cavities communicating with the œsophagus and being lined by a prolongation of its inner layer. At a later period they are connected with the œsophagus by means of a long pedicle, which ultimately forms the trachea, whilst the bronchia and air-cells are developed by the successive ramifica-

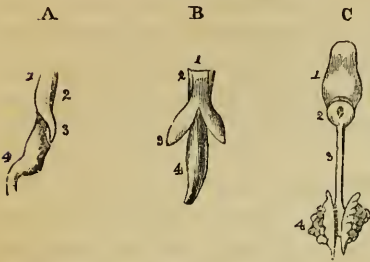
Lymphatic
vessels

and glands.

Nerves.

tion of the internal cavity to form cæcal tubes, after the manner of the ducts of glands. Reichert and Bischoff, on the other hand, are of opinion that the rudiments of the lungs are at first *solid*, and are produced by a thickening or

Fig. 301.*



protrusion of the outer layers only of the oesophageal tube. The inner layer never enters them, but they soon become connected with the commencing trachea, which appears like a white streak along the whole length of the oesophagus. The rudimentary lungs, which are at first smooth and undivided, consist of two masses of blastema composed of nucleated cells. In their substance, the bronchi soon begin to form as solid white tracts,

which join the trachea, and the future cavity in their interior first appears as a deeper coloured line. The ultimate bronchial ramifications, and probably the air-cells too, are formed by the successive budding out and subsequent excavation of the earlier developed bronchial tubes.

As to the *trachea* itself, its precise mode of origin and formation is undetermined. Baër regards it as a tubular prolongation from the oesophagus, but this is doubtful, and others believe it to be formed upon the oesophagus, and afterwards to open into that canal. According to Fleischmann, the rings of the trachea are seen at the fourth week in the human embryo, formed of lateral halves which afterwards unite. Rathké and Valentin state, on the contrary, that they arise by simple strips of cartilage. They appear to increase in number during development. The vibratile cilia have been seen very early.

For a long time the lungs are very small, and occupy only a little space at the back part of the chest. In an embryo 16 lines in length, their proportionate weight to the body was found by Meckel to be 1 to 25; in another, 29 lines long, it was 1 to 27; at 4 inches in length 1 to 41, and at the full period 1 to 70. Huschke found that the lungs of still-born *male* children were heavier in proportion to the weight of the body than those of female children; the ratio being, amongst females, 1 to 76, and in males 1 to 55.

Changes after birth.—No organ undergoes such rapid and remarkable changes after birth, as those which, in consequence of the commencement of respiration, affect the lungs in almost every respect, viz., in size, position,

* Illustrates the development of the respiratory organs.—(Rathke.)—
A. Oesophagus of a chick, on the fourth day of incubation, with the rudimentary lung of the left side, seen laterally. 1. The front, and 2. The back of the oesophagus. 3. Rudimentary lung protruding from that tube. 4. Stomach. B. The same seen in front, so as to shew both lungs. C. Tongue and respiratory organs of embryo of the horse. 1. Tongue. 2. Larynx. 3. Trachea. 4. Lungs seen from behind.

form, consistence, texture, colour and weight. An accurate knowledge of these changes furnishes the only means of distinguishing between a still-born child and one that has respired.*

Position, size, and form.—In a fœtus at the full period or in a still-born child, the lungs, comparatively small, lie packed at the back of the thorax, and do not entirely cover the sides of the pericardium; subsequently to respiration, they expand and completely cover the pleural portions of that sac, and are also in contact with every part of the thoracic parietes, which is covered with the pleural membrane. At the same time, their previously thin sharp margins become more obtuse, and their whole form is less compressed.

Consistence, texture, and colour.—The introduction of air, and of an increased quantity of blood into the compact, heavy, granular, yellowish-pink, gland-like substance of the fœtal lungs, which ensues immediately upon birth, converts their tissue into a loose, light, rose pink, spongy structure, which, as already mentioned, floats in water. The changes thus simultaneously produced in their consistence, colour, and texture, occur first at their anterior borders, and proceed backwards through the lungs: they, moreover, appear in the right lung a little in advance of the left.

Weight.—The *absolute weight* of the lungs, having gradually increased from the earliest period of development to birth, undergoes at that time from the blood then poured into them, a very marked addition, amounting to more than one-third of their previous weight: for example, the lungs before birth weigh about one and a half ounce, but, after complete expansion by respiration, they weigh as much as two and a half ounces. The *relative weight* of the lungs to the body, which, at the termination of intra-uterine life is about 1 to 70, becomes, after respiration, on an average about 1 to 35 or 40, a proportion which is not materially altered through life. Their *specific gravity* is at the same time changed from 1·056 to about ·342.

Changes in the trachea after birth.—In the fœtus the trachea is flattened before and behind, its anterior surface being even somewhat depressed; the ends of the cartilages touch; and the sides of the tube, which now contains only mucus, are applied to one another. The effect of respiration is at first to render the trachea open, but still flattened in front; afterwards it becomes convex.

THE LARYNX, OR ORGAN OF VOICE.

The upper part of the air passage is modified in its structure to form the *organ of voice*. This organ, named the *larynx*, is

Larynx is organ of voice.

* It must be remembered that these changes may present themselves, in different cases, in every possible degree of variety, owing to the amount of respiration which has taken place, in either or both lungs. For particular details on these points, and also for an explanation of certain sources of fallacy, see the proper treatises on medical jurisprudence.

placed at the upper and fore-part of the neck, where it forms a considerable prominence in the middle line. It lies between the large vessels of the neck, and below the tongue and os hyoides, to which bone it is suspended. It is covered in front by the cervical fascia along the middle line, and on each side by the sterno-hyoid, sterno-thyroid, and thyro-hyoid muscles, by the upper end of the thyroid body, and by a small part of the inferior constrictor of the pharynx. Behind, it is covered by the pharyngeal mucous membrane, and forms the anterior boundary of the lower part of the pharynx, into which cavity it opens above, whilst below it leads into the windpipe.

Situation and connection.

The larynx is cylindrical at the lower part, where it joins the trachea, but it widens above, becomes flattened behind and at the sides, and presents a blunted vertical ridge in front.

Form.

The larynx consists of a framework of cartilages, articulated together and connected by proper ligaments, two of which, named the *true vocal* cords, are immediately concerned in the production of the voice. It also possesses muscles, which move the cartilages one upon another, a mucous membrane lining its internal surface, numerous mucous glands, and lastly, blood-vessels, lymphatics and nerves, besides cellular tissue and fat.

Component parts.

Cartilages of the Larynx.

The cartilages of the larynx consist of three single and symmetrical pieces, named respectively the *thyroid cartilage*, the *cricoid cartilage*, and the *cartilage of the epiglottis*, and of six others, which occur in pairs, namely, the two *arytenoid cartilages*, the *cornicula laryngis*, and the *cuneiform cartilages*. In all there are nine distinct pieces, the two cornicula and two cuneiform cartilages being very small. Of these, only the thyroid and cricoid cartilages are seen on the front and sides of the larynx (see fig. 304); the arytenoid cartilages, surmounted by the cornicula laryngis, together with the back of the cricoid cartilage, on which they rest, form the posterior wall of the larynx, whilst the epiglottis is situated in front, and the cuneiform cartilages on each side of the upper opening.

Cartilages of larynx;

in all nine;

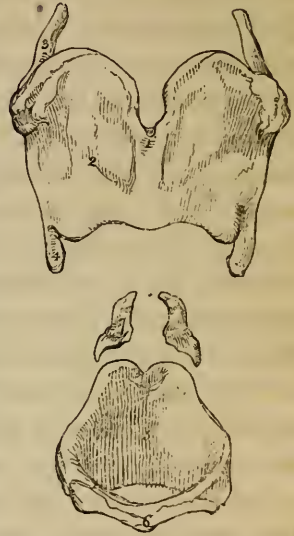
their situation.

The *thyroid* cartilage (cartilago thyreoidea, v. scutiformis; θυρεός, a shield, and εἶδος,) is the largest of the pieces composing the larynx. It is formed by two flat lamellæ, united in front, at an acute angle along the middle line, where they form a

Thyroid cartilage; the largest;

its form. vertical projection (fig. 302), which becomes gradually effaced, as it is traced from above downwards. The two lamellæ, diverging one from the other backwards, embrace the cricoid cartilage, and terminate posteriorly by two thick projecting vertical borders, separated widely from each other; hence, the thyroid cartilage is altogether wanting behind. The angular projection on the anterior surface in the median line is subcutaneous, and is much more prominent in the male than in the female, being named in the former the *pomum Adami*. The *lateral halves* (2), or lamellæ, named the *alæ*, are somewhat quadrilateral in form, and are perfectly symmetrical. The *external* flattened surface of each ala is marked by an indistinct *oblique line*, which, commencing at a tubercle situated at the back part of the upper border of the cartilage, passes downwards and forwards, so as to mark off the anterior three-fourths of the surface from the remaining posterior portion. This line gives attachment below to the sterno-thyroid, and above to the thyro-hyoid muscle, whilst the small smooth surface behind it gives origin to part of the inferior constrictor of the pharynx, and affords attachment, by means of cellular tissue, to the thyroid body. On their *internal* or *posterior* surfaces, the two alæ are smooth, and slightly concave, and by their union in front, form a retreating angle within corresponding with the ridge on the anterior aspect of the cartilage. The greater portion of the internal surface of the thyroid cartilage is connected to other parts, but the upper and posterior portion of each ala is lined loosely by the mucous membrane of the pharynx only, and forms the outer boundary of a lateral groove seen on each side at the back of the larynx. The

Fig. 302.*



Pomum
Adami.

The alæ;

their outer
surface;

inner sur-
face;

* Cartilages of the larynx separated and seen in front.—1 to 4. Thyroid cartilage. 1. Vertical ridge, or Pomum Adami. 2. Right ala. 3. Superior, and 4, inferior cornu of the right side. 5, 6. Cricoid cartilage. 7. Right arytenoid cartilage.

upper border of the thyroid cartilage is slightly concave at the sides, and deeply notched in the middle line, above the *pomum Adami* (1). This border is connected, in its whole extent, to the os-hyoides by a strong membrane, named the thyro-hyoid. The lower border, which is shorter than the upper, is scolloped out into three shallow concavities, a wider one in the middle and a smaller one at each side, separated from the first by an intervening tubercle. This border is connected with the cricoid cartilage, in the median line by the crico-thyroid membrane, and on each side by the crico-thyroid muscle. The *posterior* borders of the thyroid cartilage, which are rather thick and rounded, have a vertical direction, and are prolonged upwards and downwards, into two processes, named cornua, which form respectively the posterior limits of the shallow lateral notches seen on the upper and lower margins of the cartilage. The stylo-pharyngeus and palato-pharyngeus muscles of each side are attached to these posterior borders. Of the four *cornua*, all of which bend inwards, the two *superior*, or *great* cornua (3), pass backwards, upwards, and inwards, and terminate each by a blunt extremity, which is connected, by means of the lateral thyro-hyoid ligament, to the tip of the corresponding great cornu of the os hyoides. The *inferior*, or *smaller*, cornua (4), which are somewhat thicker but shorter, are directed forwards and inwards, and present each, on the inner aspect of the tip, a smooth surface, for articulation with a prominence on the side of the cricoid cartilage.

and . poste-
rior borders.

The cornua :
superior ;

inferior.

The cricoid cartilage, so named from its being shaped like a ring, (*κρηκος*, a ring ; *ειδος*,) is thicker in substance and stronger than the thyroid cartilage ; it forms the inferior, and a considerable portion of the back part of the larynx, and is the only one of the cartilages which completely surrounds this organ. It is deeper behind (5), where the thyroid cartilage is deficient, measuring in the male about an inch from above downwards, but is much narrower in front (6), where its vertical measurement is only two lines and a half. The cricoid cartilage is circular *below*, but *higher* up it is somewhat compressed laterally, so that the passage through it is elliptical, its antero-posterior diameter being longer than the transverse. The *external* surface is convex and smooth in front and at the sides, where it affords attachment to the crico-thyroid muscles, and

Cricoid car-
tilage is like
a ring ;

but is thick-
er behind ;

its posterior
surface.

behind these to the inferior constrictor muscle on each side. The surface posteriorly is three or four times deeper and somewhat broader. It presents in the middle line a slight vertical ridge, to which some of the longitudinal fibres of the œsophagus are attached. On each side of this ridge is a broad depression for the posterior crico-arytenoid muscle, and externally and anteriorly to that a small rounded and slightly raised surface for articulation on either side with the inferior cornu of the thyroid cartilage. The *internal* surface of the cricoid cartilage is smooth, and is lined by the laryngeal mucous membrane. The lower border is rounded and horizontal, and is connected by a membrane to the first ring of the trachea. The upper border which, owing to the greater depth of the cartilage behind, is inclined obliquely upwards and backwards, is connected, in front, to the thyroid cartilage by the crico-thyroid membrane. On each side it gives attachment to the lateral part of the crico-thyroid membrane, and to the lateral crico-arytenoid muscle. Posteriorly this border of the cartilage presents a slight notch in the middle line, where it gives origin to some of the fibres of the arytenoid muscle. On the sides of this notch, and consequently on the highest part of the cartilage, are two convex oval articular facettes, directed upwards and outwards, to which the arytenoid cartilages are articulated.

Two aryte-
noid carti-
lages ;
placed on
cricoid ;

The *arytenoid cartilages*, (cartilaginee arytenoideæ, v. pyramidales, fig. 302, 7; ἀρύταινα, a kind of ewer, εἶδος,) are two in number, and are perfectly symmetrical in form. They may be compared to two three-sided pyramids recurved at the summit, measuring from five to six lines in height, resting by their bases on the posterior and highest part of the cricoid cartilage, and approaching near to one another towards the median line. Each measures upwards of three lines in width, and more than a line from before backwards. Of its three faces, the *posterior* is broad, triangular, and excavated from above downwards, so that the summit of the cartilage is curved backwards. This concave smooth surface lodges part of the arytenoid muscle. The *anterior* surface, convex in its general outline, and somewhat rough, gives attachment to the thyro-arytenoid muscle, and, by a small tubercle, to the corresponding superior or false vocal cord. The *internal* surface, which is the narrowest of the three, and somewhat flattened, is parallel

with and very near to that of the opposite cartilage, being covered by the laryngeal mucous membrane. The anterior and posterior borders, which limit the internal face, ascend nearly in the same vertical plane, whilst the external border, which separates the anterior from the posterior surface, is directed obliquely upwards and inwards.

their surfaces,

The *base* of each arytenoid cartilage is slightly hollowed, having towards its inner part a smooth surface for articulation with the cricoid cartilage. Two of its angles are remarkably prominent, viz. ; one *external*, short, and rounded, which projects backwards and outwards, and into which the posterior and the lateral crico-arytenoid muscles are inserted ; the other *anterior*, which is more pointed, and forms a horizontal projection forwards, to which the corresponding true vocal cord is attached.

and base.

Vocal cords are fixed to them.

The *apex* of each arytenoid cartilage curves backwards and a little inwards, and terminates in a rounded point, which is surmounted by a small cartilaginous appendage named *corniculum laryngis*, to be next described.

The *cornicula laryngis*, or *cartilages of Santorini*, (*capitula Santorini*,) are two small yellowish cartilaginous nodules of a somewhat triangular or conical shape, which are articulated with the summits of the arytenoid cartilages, and serve as it were to prolong them backwards and inwards. They are sometimes united to the arytenoid cartilages.

Two cartilages of Santorini.

The *cuneiform cartilages*, or *cartilages of Wrisberg*, are two very small soft yellowish cartilaginous bodies, placed one on each side of the larynx in the fold of mucous membrane, which extends from the summit of the arytenoid cartilage to the epiglottis. They have a conical form, their base or broader part being directed upwards. They occasion small conical elevations of the mucous membrane within the larynx, a little in advance of the cartilages of Santorini, with which, however, they are not directly connected.

Two cuneiform cartilages.

The *epiglottis*, (*επιγλωττις* ; fig. 305, *e*.) is a single median part formed by a thin lamella of yellow cartilage, shaped somewhat like a cordate leaf, and covered by mucous membrane. It is placed in front of the superior opening of the larynx projecting upwards immediately behind the base of the tongue. In the ordinary condition its direction is vertical, the free

The epiglottis ;

placed in front of glottis,

which it covers.

Its cartilage;

its anterior surface,

and posterior.

Laryngeal cartilages; not all of same structure.

Ligaments of the larynx;

extremity curving forward towards the tongue, but during the act of swallowing it is carried downwards and backwards over the entrance into the larynx, which it covers and protects.

The cartilage of the epiglottis is broad and somewhat rounded at its upper free margin, but inferiorly becomes pointed, and is prolonged by means of a long, narrow, fibrous band (the thyro-epiglottic ligament) to the deep angular depression between the alæ of the thyroid cartilage, to which it is attached, behind and below the median notch. Its *lateral* borders, which are convex, are only partly free, being in part concealed within the folds of mucous membrane, which pass back on each side to the arytenoid cartilages. The *anterior* or *lingual* surface is free only in the upper part of its extent, where it is covered by mucous membrane. Lower down, the membrane is reflected from it forwards to the base of the tongue, forming one median fold and two lateral folds or frænula, sometimes called the glosso-epiglottidean ligaments. The adherent portion of this surface is also connected with the posterior surface of the os hyoides by means of a median elastic tissue named the hyo-epiglottic ligament, and is moreover in contact with some glands and fatty tissue. The posterior or *laryngeal* surface of the epiglottis, which is free in the whole of its extent, is convex from above downwards, but concave from side to side. It is closely covered by the mucous membrane, on removing which, the yellow cartilaginous lamella of which the epiglottis consists is seen to be pierced by numerous little pits and perforations, in which are lodged small glands which open on the surface of the mucous membrane.

Structure of the cartilages of the larynx.—The epiglottis, together with the cornicula laryngis and cuneiform cartilages, are composed of what is called yellow or spongy cartilage, which has little tendency to ossify. The structure of all the other cartilages of the larynx resembles that of the costal cartilages, like which, they are very prone to ossification as life advances (see p. cxxviii).

Ligaments of the larynx.—The ligaments of the larynx are *extrinsic*, or those which connect it with contiguous parts, as the os hyoides and the trachea, and *intrinsic*, by means of which its several cartilaginous pieces are connected one to the other.

Extrinsic ligaments.—The larynx is connected with the os hyoides by a broad membrane and by two round lateral ligaments. The *thyro-hyoid membrane*, or *middle thyro-hyoid ligament*, is a broad, fibrous, and somewhat elastic membrane, which passes up from the whole length of the superior border of the thyroid cartilage to the os hyoides, being attached not to the inferior margin of that bone, but along the highest part of its internal or posterior surface. Owing to this arrangement, the top of the larynx, when drawn upwards, is permitted to slip within the circumference of the hyoid bone, between which and the upper part of the thyroid cartilage, there is occasionally found a small synovial bursa. The thyro-hyoid membrane is thick and sub-cutaneous towards the middle line, but on each side becomes thin and loose, and is covered by the thyro-hyoid muscles. Behind it is the epiglottis with the mucous membrane of the base of the tongue, separated however by much adipose tissue and some glands. It is perforated by the superior laryngeal artery and nerve of each side.

extrinsic ;
thyro-hyoid
membrane
or ligament.

At the posterior limits of the thyro-hyoid membrane are found the right and left *lateral thyro-hyoid ligaments*, rounded yellowish cords, which pass up from the superior cornua of the thyroid cartilage, to the rounded extremities of the great cornua of the hyoid bone. These lateral thyro-hyoid ligaments are distinctly elastic, and frequently enclose a small oblong cartilaginous nodule, which has been named *cartilago triticea*: sometimes this nodule is bony.

Lateral thyro-hyoid ligaments.

Cartilago triticea.

The membrane which connects the lower border of the larynx (cricoid cartilage) to the first ring of the trachea, forms the commencement of that tube.

Intrinsic ligaments.—The thyroid and cricoid cartilages are connected together in front and at each side. In the former direction, a strong triangular yellowish ligament, consisting chiefly of elastic tissue, is attached to the contiguous borders of these two cartilages. It is named the *crico-thyroid membrane*, and sometimes the *pyramidal* or *conoid* ligament (fig. 304, c.). Its base is turned downwards, and is fixed to the upper margin of the cricoid cartilage. Its anterior surface is convex and is covered at the sides by the crico-thyroid muscles, and crossed horizontally by a small anastomotic arterial arch, formed by the junction of the crico-thyroid branches of the right and left supe-

Intrinsic ligaments.

Crico-thyroid membrane.

rior thyroid arteries. The posterior surface of this membrane is covered only by the mucous membrane of the larynx.

Lateral crico-thyroid ligaments.

On tracing the crico-thyroid membrane backwards, its lateral portions, which are fixed on each side to the inner lip of the upper border of the cricoid cartilage, become much thinner and are found to be continuous upwards with the lower margin of the inferior or true vocal cords, becoming blended with them firmly in front. These lateral portions of the crico-thyroid membrane, described by Cruveilhier as the *lateral crico-thyroid ligaments*, are lined by the mucous membrane of the larynx, and correspond externally with the lateral crico-arytenoid and adjoining thyro-arytenoid muscles.

Crico-thyroid articulations.

On the *sides*, the inferior cornua of the thyroid cartilage are connected by two small but distinct articulations, having each a ligamentous capsule and a synovial membrane, with the sides of the cricoid cartilage. The prominent oval articular surfaces of the cricoid cartilage are directed upwards and outwards, whilst those of the thyroid cartilage, which are slightly concave, look in the opposite direction. The capsular fibres form a stout band behind this small joint, which possesses but little motion.

Crico-arytenoid articulations.

The *crico-arytenoid* articulations are looser than the crico-thyroid just described. They are surrounded by a series of thin capsular fibres, which, together with a loose synovial membrane, serve to connect the convex elliptical articular surfaces on the upper border of the cricoid cartilage with the concave articular depressions seen on the bases of the arytenoid cartilages. There is, moreover, a strong *posterior crico-arytenoid* ligament on each side, (fig 306, 13, 13,) arising from the cricoid, and inserted into the inner and back part of the base of the arytenoid cartilage.

Posterior crico-arytenoid ligaments.

The summits of the arytenoid cartilages and the cornicula laryngis have usually a fibrous and synovial capsule to connect them, but it is frequently indistinct.

Hyo-epiglottic and thyro-epiglottic ligaments.

Two yellow elastic bands belonging to the epiglottis, named the *hyo-epiglottic* and *thyro-epiglottic* ligaments, which connect the epiglottis in the middle line with the hyoid bone and the thyroid cartilage, have already been incidentally noticed. The *aryteno-epiglottidean* ligaments and the *superior thyro-arytenoid* ligaments or false vocal cords, both of which are

little more than folds of mucous membrane, and also the *inferior thyro-arytenoid* ligaments or true vocal cords, will be most conveniently described with the interior of the larynx.

Interior of the larynx.—The *superior aperture* of the larynx (see fig. 305), by which it communicates with the pharynx, is a triangular opening, wide in front and narrow behind, the lateral margins of which slope obliquely downwards and backwards. It is bounded in front by the epiglottis (*e*), behind by the summits of the arytenoid cartilages (*a*) and cornicula laryngis with the crescentic border of mucous membrane crossing the median space between them, and on the sides by two folds of mucous membrane, named the *aryteno-epiglottidean folds*, which, enclosing a few ligamentous and muscular fibres, pass forwards from the tips of the arytenoid cartilages and cornicula to the lateral margins of the epiglottis.

Parts seen inside the larynx are the superior aperture of larynx.

The aryteno-epiglottic folds.

On looking down through the superior opening of the larynx, the air-passage below this part is seen to become gradually contracted, especially in its transverse diameter, so as to assume the form of a long narrow fissure running from before backwards. This narrow part of the larynx is called the *glottis*. It is situated on a level with the lower part of the arytenoid cartilages. Below it, at the upper border of the cricoid cartilage, the interior of the larynx assumes an elliptical form, and lower down still it becomes circular. The glottis is bounded laterally by four strongly marked folds of the mucous membrane, stretched from before backwards, two on each side, and named the *vocal cords*. The *superior* vocal cords are much thinner and weaker than the inferior, and are arched or semi-lunar in form; the *inferior* or *true* vocal cords are thick, strong, and straight. Between the right and left inferior vocal cord is the narrow opening of the glottis, named the *rima glottidis*, and sometimes the *glottis vera*, or *true glottis* (fig. 306, ¹). Bounded above by the superior and below by the inferior vocal cord of each side, are two deep oval depressions, seen of course, one on each side of the glottis, and named the *sinuses*, or *ventricles* of the larynx (fig. 303, *v*); and lastly, leading upwards from the anterior part of these depressions, and on the outer side of the superior vocal cord, are two small culs-de-sac, named the *laryngeal pouches* (*s*). Each of these parts, which are covered with the mucous membrane, requires a separate description.

The glottis.

The vocal cords ; two superior and two inferior.

The rima glottidis, the ventricles, and the laryngeal pouches.

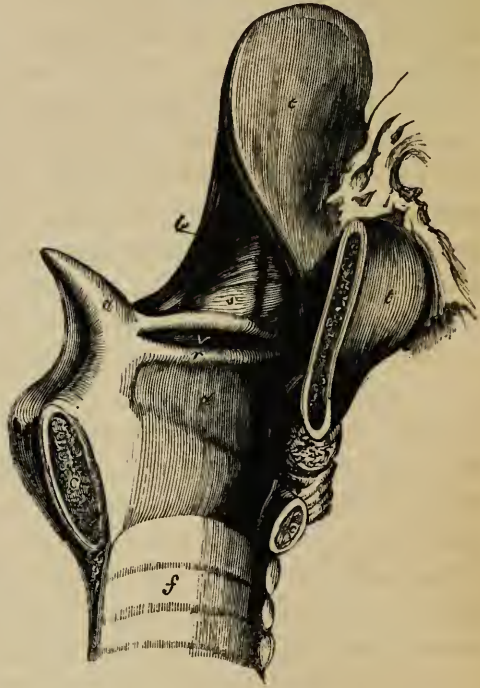
Superior
vocal cords.

The *superior vocal cords*, also called the *false* vocal cords, because they are not concerned in the production of the voice, are two folds of mucous membrane, containing a few slight fibrous fasciculi, named the *superior thyro-arytenoid ligaments*.

Superior
thyro-ary-
tenoid liga-
ments.

These ligaments (above *v*, fig. 303) are fixed in front to the depression between the alæ of the thyroid cartilage, somewhat above its middle, close to the attachment of the epiglottis; whilst behind they are connected to the tubercles on the rough anterior surface of the arytenoid cartilages (*a*). Above, they are continuous with the scattered fibrous bundles contained in the aryteno-epiglottidean folds. Below, enclosed in the mucous membrane, each forms a free crescentic margin, which bounds the corresponding ventricle of the larynx, the aperture of which is seen on looking down into the laryngeal cavity, because the superior vocal cords are separated farther from each other than the inferior cords.

Fig. 303.*



The inferior
or true vo-
cal cords ;
or inferior
thyro-ary-
tenoid liga-
ments.

The *inferior* or *true vocal cords* (fig. 303, *r* ; 306, ³, ³), for it is by their vibration that the voice is produced, are two bands of elastic tissue, named the *inferior thyro-arytenoid ligaments*, which are attached in front to about the middle of the depression

* View of the interior of the left half of the larynx, to show the ventricle and laryngeal pouch. (After Hilton ; Guy's Hosp. Reports, No. 5.)
a. Left arytenoid cartilage. *c, c*. Sections of the cricoid cartilage. *t*. Thyroid cartilage. *e*. Epiglottis. *v*. Left ventricle of the larynx. *r*. Left inferior or true vocal cord. *s*. Laryngeal pouch. *b*. Aryteno-epiglottidean muscle, or compressor sacculi laryngis. *f*. Inside of trachea, which has been added to this figure.

between the alæ of the thyroid cartilage below the superior cords, and are inserted behind to the elongated anterior processes of the base of the arytenoid cartilages. These bands consist of closely arranged parallel fibres. They are continuous below with the thin lateral portions of the crico-thyroid membrane; on their outer side they are in contact with and connected to the fibres of the thyro-arytenoid muscles; in other directions they are free, and are covered by the mucous membrane, which is here so thin and closely adherent as to shew the white colour of these ligaments through it. Their upper and free edges, which are sharp and straight, form the lower boundaries of the ventricles, and are the parts thrown into vibration during the production of the voice. Their inner surfaces are flattened, and look towards each other.

The *rima glottidis* (fig. 306, ¹), an elongated fissure, formed between the inferior or true vocal cords, and, posteriorly, between the bases of the arytenoid cartilages, is, when slightly open, of a lancet-shape, the pointed extremity being turned forwards; when further opened it is triangular, becoming widened behind; and in its fully dilated condition it has the figure of an elongated lozenge, with its posterior angle truncated. This aperture is the narrowest part of the interior of the larynx; in the adult male it is about eleven lines, or nearly an inch in its antero-posterior measurement, and about four lines across at its widest part, which may be dilated to nearly half an inch. In the female its dimensions are less, its antero-posterior diameter being about eight lines, and its transverse diameter about two. The vocal ligaments, which are shorter than the glottis, measure about seven lines in the male and five in the female.

The rima
glottidis.

The *ventricles*, or *sinuses* of the larynx (fig. 303, *v*), formed between the superior and inferior vocal cords on each side, are two oblong cavities, narrower at their orifice than in their interior. The upper margin of each is crescentic, and the lower straight; the outer surface is covered by the upper fibres of the corresponding thyro-arytenoid muscle.

The ventri-
cles or si-
nuses of the
larynx.

The small culs-de-sac, named the *laryngeal pouches* (*s*), lead from the anterior part of the ventricle upwards, for the space of half an inch, between the superior vocal cords on the inner side, and the thyroid cartilage on the outer side, reaching as high as to the upper border of that cartilage at the sides of the epiglottis.

The laryn-
geal
pouches.

their compressor muscles.

Each of these supplementary cavities is conical in shape, and curved slightly backwards, so as to have been compared in form to a Phrygian cap. Its opening into the corresponding ventricle is narrow, and is generally limited by two folds of the lining mucous membrane. Numerous small glands, sixty or seventy in number, open into its interior, and it is surrounded by a quantity of fat. Externally to the fat, this little pouch receives a fibrous investment, which is continuous below with the superior vocal cord. Over its laryngeal side and upper end, is a thin layer of muscular fibres (compressor sacculi laryngis, arytaeno-epiglottideus inferior; Hilton) connected above with those found in the arytaeno-epiglottidean folds (*b*). The upper fibres of the thyro-arytenoid muscles pass over the outer side of the pouch, some few being attached to its lower part. Lastly, the laryngeal pouch is supplied abundantly with nerves, derived from the superior laryngeal.

Muscles of the Larynx.

Muscles of the larynx extrinsic, and intrinsic.

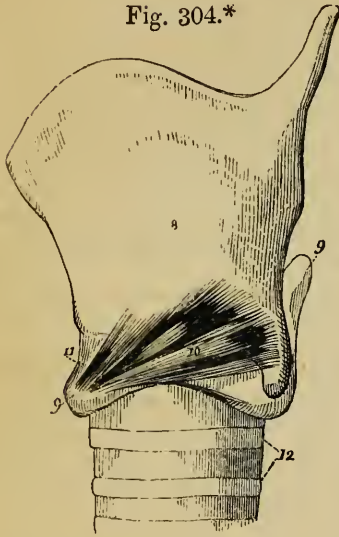
Besides certain extrinsic muscles already described, viz.: the sterno-hyoid, omo-hyoid, sterno-thyroid, and thyro-hyoid muscles, together with the muscles of the supra-hyoid region, and the middle and inferior constrictors of the pharynx, all of which act more or less upon the entire larynx, there are certain *intrinsic muscles* which move the different cartilages upon one another. These intrinsic muscles are the *crico-thyroid*, the *posterior crico-arytenoid*, the *lateral crico-arytenoid*, the *thyro-arytenoid*, and the *arytenoid*, together with certain slender muscular fasciculi connected with the epiglottis. All these muscles, except the arytenoid, which crosses the middle line, exist in pairs.

Two crico-thyroid muscles.

The *crico-thyroid muscle* (crico-thyroideus, fig. 304, ¹⁰) is a short thick triangular muscle, seen on the front of the larynx, situated on the fore-part and side of the cricoid cartilage. It *arises* by a broad origin from the cricoid cartilage, reaching from the median line backwards upon the lateral surface, and its fibres, passing obliquely upwards and outwards and diverging slightly, are *inserted* into the lower border of the thyroid cartilage, from the tubercle on each side of the median notch to the lesser cornu, and also into the anterior border of the latter process. The fibres of insertion reach from half a line to

a line upon the inner surface of the thyroid cartilage. The lower portion of the muscle, which is nearly horizontal in direction, and is inserted into the lesser cornu, is usually distinct from the rest. Some of the superficial fibres are almost always continuous with the inferior constrictor of the pharynx.

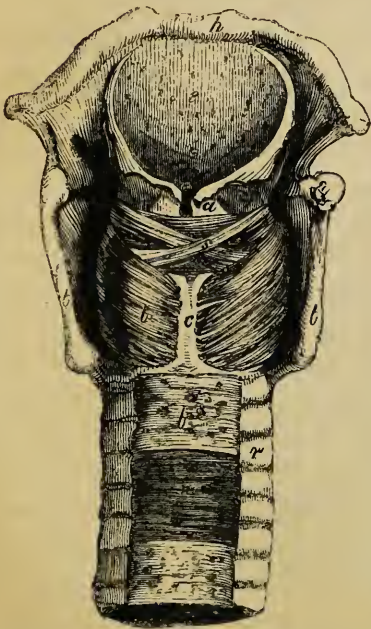
Fig. 304.*



The inner borders of the muscles of the two sides are separated from each other in the middle line by a triangular interval, broader above than below, and occupied by the crico-thyroid membrane. The crico-thyroid muscle is covered by the sterno-thyroid, and it covers the fore-part of the lateral crico-arytenoid and thyro-arytenoid muscles: its lower border is in contact with or covered by the thyroid body, and its upper border adjoins the inferior constrictor of the pharynx.

cles: its lower border is in contact with or covered by the thyroid body, and its upper border adjoins the inferior constrictor of the pharynx.

Fig. 305.†



The *posterior crico-arytenoid muscle* (crico-arytænoideus posticus, fig. 305, *b*), is found

Two posterior crico-arytenoid muscles.

* Side view of the thyroid and cricoid cartilages, with part of the trachea; after Willis. 8. Thyroid cartilage. 9, 9. Cricoid cartilage. 10. Cricothyroid muscle. 11. Cricothyroid membrane or ligament. 12. Upper rings of trachea.

† Posterior view of larynx, and part of trachea, dissected to shew the muscles.— *a*. Right arytenoid cartilage. *t, t*. Posterior margins of thyroid cartilage. *c*. Back of cricoid cartilage. *h*. Os hyoideus. *e*. Epiglottis. *b*. Left posterior crico-arytenoid muscle. *s*. Arytenoid muscle. *l*. Fibrous membrane at back of trachea, with the glands lying in it. *n*. Muscular fibres of the trachea.

ular fibres of the trachea. *r*. Cartilaginous rings of trachea.

at the back of the larynx beneath the mucous membrane in that situation. It arises from the broad depression seen on the corresponding half of the posterior surface of the cricoid cartilage. From this broad origin its fibres converge upwards and outwards towards the base of the arytenoid cartilage. The upper fibres are short and almost horizontal; the middle are the longest and run obliquely; whilst the lower or anterior fibres are nearly vertical. The muscle is *inserted* (fig. 306, ⁴), by a narrow slip, partly fleshy and partly tendinous, into the external process, or posterior and outer surface of the base of the arytenoid cartilage, behind the attachment of the lateral crico-arytenoid muscle. This muscle is situated between the pharyngeal mucous membrane and the cricoid cartilage.

Two lateral crico-arytenoid muscles.

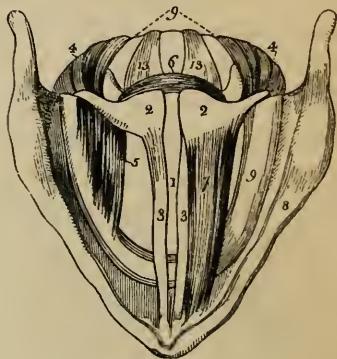
The *lateral crico-arytenoid muscle* (crico-arytænoideus lateralis, fig. 306, ⁵).—To obtain a proper view of this muscle and the thyro-arytenoid, which will be next described, it is necessary to remove the corresponding ala of the thyroid cartilage, by which they are in a great measure hidden.

The *lateral crico-arytenoid* is smaller than the posterior, and is of an oblong form. It *arises* from the upper border of the side of the cricoid cartilage, its origin extending as far back as the articular surface for the arytenoid cartilage. Its fibres passing obliquely backwards and upwards, the anterior or upper ones being the longest, are *attached* to the external

process or outer side of the base of the arytenoid cartilage and to the adjacent part of its anterior surface, in front of the insertion of the posterior crico-arytenoid muscle.

This muscle lies in the interval between the ala of the thy-

Fig. 306.*



* A diagram, slightly altered from Willis, shewing a bird's eye view of the interior of larynx.—1. Opening of the glottis. 2, 2. Arytenoid cartilages. 3, 3. Vocal cords. 4, 4. Posterior crico-arytenoid muscles. 5. Right lateral crico-arytenoid muscle; that of the left side is removed. 6. Arytenoid muscle. 7. Thyro-arytenoid muscle of the left side; that of the right side is removed. 8. Upper border of the thyroid cartilage. 9, 9. Upper border and back of the cricoid cartilage. 13. Posterior crico-arytenoid ligament.

roid cartilage and the interior of the larynx, being lined within by the mucous membrane of the larynx. Its anterior part is covered by the upper part of the crico-thyroid muscle. The upper border is in close contact and indeed is sometimes blended with the thyro-arytenoid muscle.

The *thyro-arytenoid* (thyro-arytænoideus, fig. 306,⁷) is a broad flat muscle situated above the lateral crico-arytenoid. It is thick below and in front, and becomes thinner upwards and behind. It consists of several muscular fasciculi, which *arise* in front from the internal surface of the thyroid cartilage, from the lower two-thirds of the retreating angle formed by the junction of the two alæ. They extend almost horizontally backwards and outwards to reach the base of the arytenoid cartilage. The *lower portion* of the muscle, which forms a thick fasciculus, receives a few additional fibres from the posterior surface of the crico-thyroid membrane, and is inserted into the anterior projection on the base of the arytenoid cartilage and to the adjacent part of the surface close to the insertion of the lateral crico-arytenoid muscle. The *thinner portion* of the thyro-arytenoid muscle is *inserted* higher up on the anterior surface and outer border of that cartilage. The lower portion of the muscle lies parallel with the rima glottidis, immediately on the outer side of the corresponding true chorda vocalis (³), with which it is intimately connected, and into the outer surface of which some of its fibres are inserted. According to some authorities, however, the cord and muscle can be completely separated. The upper thin portion lies upon the outer side of the corresponding laryngeal pouch and ventricle close beneath the mucous membrane. The entire muscle may be dissected indeed from the interior of the larynx by raising the mucous membrane and vocal cord. Its outer surface is covered by a loose cellular tissue, which separates it from the internal surface of the ala of the thyroid cartilage. Some of the fibres of this muscle pass round the border of the arytenoid cartilage, and become continuous with some of the oblique fibres of the arytenoid muscle, to be presently described.

Two thyro-arytenoid muscles,

consisting each of two portions.

Santorini described three thyro-arytenoid muscles, an *inferior* and *middle*, which are constant, and a *superior*, as sometimes present. The fibres of the superior fasciculus, when present, arise nearer to the notch of the thyroid cartilage, and are attached to the upper part of the arytenoid cartilage.

Santorini described three portions.

This is named by Sæmmering the *small* thyro-arytenoid, whilst the two other portions of the muscle constitute the *great* thyro-arytenoid of that author.

Muscular fibres connected with the epiglottis.—Under the name of *thyro-epiglottideus* and *arytæno-epiglottideus* muscles, some thin scattered fasciculi have been noticed and described by anatomists, as extending on each side from the thyroid and arytenoid cartilages to the corresponding margin of the epiglottis. The *thyro-epiglottidean* fibres arise from the inner surface of the thyroid cartilage close upon the outer side of the origin of the thyro-arytenoid muscle, and ascend to reach the margin of the epiglottis. They constitute the *depressor epiglottidis*. The *arytæno-epiglottidean* fibres (fig. 303, *b*) arise from the corresponding arytenoid cartilage just above the point of attachment of the superior vocal cord, and passing forwards spread out so as to cover the upper end and part of the side of the laryngeal pouch on its laryngeal aspect, and are finally inserted by a broad expanse into the margin of the epiglottis. That part of the muscle which covers the pouch was described by Mr. Hilton as the *arytæno-epiglottideus inferior* or *compressor sacculi laryngis*, and is stated by him to be distinguished by a cellular interval from another fasciculus of fibres situated higher up in the aryteno-epiglottidean folds, which might be named the *arytæno-epiglottideus superior*. Sometimes a few of the fibres of the aryteno-epiglottidean muscle appear to be continuous round the outer border of the arytenoid cartilage with some of the oblique fasciculi of the arytenoid muscle.

The *arytenoid muscle* (*arytænoideus*, fig. 305, *s*), the only single muscle belonging to the larynx, is situated beneath the mucous membrane on the back of this organ, lying upon the posterior concave surfaces of the arytenoid cartilages, and stretching across the interval between them. This muscle, which is short and thick, arises from the whole length of the outer border and posterior surface of one arytenoid cartilage, and is inserted to the corresponding parts of the other cartilage. It consists of three sets of fibres: one transverse, and two oblique. The transverse fibres (*arytænoideus transversus*), the deepest and most numerous, pass straight across, whilst the two sets of oblique fibres (*arytænoideus obliquus*) pass from the base of one cartilage to the apex of the opposite one, crossing each other in

Thyro and
arytæno-
epiglotti-
dean fibres.

Thyro-epi-
glottid. or
depressor
epiglottidis.

Arytæno-
epiglottid.

Compressor
sacculi la-
ryngis.

One aryte-
noid mus-
cle,

consisting
of oblique
and trans-
verse bun-
dles.

the middle line superficially to the transverse set. Some of these oblique fibres become continuous round the side of the arytenoid cartilage with fibres of the thyro-arytenoid and aryteno-epiglottic muscles, as already mentioned.

The lower border of the arytenoid muscle touches the cricoid cartilage, from which a few muscular fibres generally arise; its posterior surface is covered by the pharyngeal mucous membrane, which is prolonged over its upper border and a small part of its anterior surface between the arytenoid cartilages, to be continued into the interior of the larynx.

ACTION OF THE INTRINSIC MUSCLES OF THE LARYNX.

The two *crico-thyroid* muscles (fig. 304,¹⁰) must cause the thyroid and cricoid cartilages to turn on each other at their posterior articulation, whereby they are made to approach in front, whilst the summit of the cricoid behind is carried forwards upon the cricoid, or, *vice versá*, the cricoid backwards from the thyroid; and since the arytenoid cartilages are moved backwards together with the cricoid, in consequence of their connexion to it by the strong posterior crico-arytenoid ligaments, the action of the crico-thyroid muscles will be to elongate and tighten the vocal cords. The *posterior crico-arytenoid* muscles (fig. 306,^{4,4}) cause the arytenoid cartilages to swing upon their base with a rotatory movement outwards and backwards, which is not hindered by the aforesaid ligament, so that their anterior processes, together with the attached vocal cords, part from each other, and the opening of the glottis is thus dilated. The *lateral crico-arytenoid* muscles (⁵) swing the arytenoid cartilages back again in the opposite direction to the last-named muscles, so as to approximate their anterior extremities, and thus contract the opening of the glottis.

Actions of
laryngeal
muscles.

The *thyro-arytenoid* muscles (⁷) also bring the anterior processes of the arytenoid cartilages together, and thus constrict the glottis. According to Mr. Willis, their further and chief action, is to draw forwards the arytenoid cartilages, with the back part of the cricoid cartilage, to which these are affixed, and thus to cause the cricoid cartilage to turn on the inferior cornua of the thyroid, by which means the crico-thyroid interval in front is increased, and the vocal cords are shortened and relaxed; but, according to another opinion, it has been conceived that these muscles tighten the cords by the rotation inwards of the arytenoid cartilages, or by the action of some fibres supposed to be attached to the outer surface of the cords.

The *single arytenoid* muscle (⁶) approximates the arytenoid cartilages, and thus constricts the posterior part of the rima glottidis. The tendency of some of its fibres, but especially the superficial and oblique ones, to rotate the arytenoid cartilages outwards, and thus, by drawing more apart their anterior processes, to widen the opening of the glottis, is counteracted by the lateral crico-arytenoid muscles. The few scattered fibres of the arytenoid

muscle, which, together with those of the *thyro-arytenoid* and *aryteno-epiglottidean* muscles, encircle as it were the upper part of the larynx, must tend to contract its superior aperture. The fasciculi of the thyro-arytænoidci on the outer side, and those of the aryteno-epiglottidei (fig. 303, *b*) upon the summit and inner side, of the laryngeal pouches, will serve to compress these sacs.

Lastly, the *thyro-epiglottidei*, so far as they operate, are depressors of the epiglottis.

Mucous membrane of larynx.

Its continuity and connexions.

The mucous membrane and glands of the larynx.—The *mucous membrane* of the larynx is continuous above with that of the mouth and pharynx, and below with that of the trachea. Reaching the anterior surface and sides of the epiglottis, from the root of the tongue, it forms the three glosso-epiglottidean folds, and is then reflected over the posterior or laryngeal surface of the epiglottis. From the margins of the epiglottis to the summits of the arytenoid cartilages, it forms the aryteno-epiglottidean folds, or lateral boundaries of the superior aperture of the larynx. Lastly, in the notch between the summits of the arytenoid cartilages, it turns over the upper border of the arytenoid muscle. Sinking thus into the larynx (see fig. 303), it turns over the superior vocal cords, lines the ventricles and sacculi laryngis, and is then reflected over the inferior vocal cords (*r*), below which it descends (*d*) upon the lateral and middle portions of the crico-thyroid membrane, and finally lines the entire inner surface of the cricoid cartilage (*c c*).

Its characters :

is very sensitive ;

has a ciliated epithelium.

The laryngeal mucous membrane is thin and of a pale pink colour. In some situations it adheres intimately to the subjacent parts, especially on the epiglottis, and still more in passing over the true vocal cords, on which it is extremely thin and most closely adherent. About the upper part of the larynx, above the glottis, it is extremely sensitive. In or near the aryteno-epiglottidean folds it covers a quantity of loose cellular tissue, which is liable in disease to infiltration, constituting œdema of the glottis. Like the mucous membrane in the rest of the air passages, that of the larynx is covered in the greater part of its extent with a columnar ciliated epithelium, by the vibratory action of which the mucus is urged upwards. The cilia are found higher up in front than on each side and behind, reaching in the former direction as high as the widest portion of the epiglottis, and in other directions, to a line or two above the border of the superior vocal cords : higher than these points the

epithelium loses its cilia, and gradually assumes a squamous form, like that of the pharynx and mouth.

Glands.—The lining membrane of the larynx is provided with numerous *glands*, which secrete an abundant mucus; and the orifices of which may be seen almost everywhere, excepting upon and near the true vocal cords. They abound particularly upon the epiglottis (fig. 305, *e*), in the substance of which are found upwards of fifty little compound glands. Between the anterior surface of the epiglottis, the os-hyoides, and the root of the tongue, is a mass of yellowish fat, erroneously named the epiglottidean gland, in or upon which some real glands may exist. Another collection of glands, named *arytenoid*, is placed within the fold of mucous membrane in front of each arytenoid cartilage, from which a series may be traced forwards, along the corresponding superior vocal cord. The glands of the laryngeal pouches have already been described.

Laryngeal glands are numerous,

upon the epiglottis,

in aryteno-epiglottic folds and in pouches.

Vessels and Nerves of the Larynx.

The *arteries* of the larynx are derived from the superior thyroid (see p. 474), a branch of the external carotid, and from the inferior thyroid (see p. 513), a branch of the subclavian. The *veins* join the superior middle and inferior thyroid veins. The *lymphatics* are numerous and pass through the cervical glands. The *nerves* are supplied from the superior laryngeal and inferior or recurrent laryngeal branches of the pneumogastric nerves, joined by branches of the sympathetic. The superior laryngeal nerves supply the mucous membrane, and also the crico-thyroid muscles, and in part the arytenoid muscle. The inferior laryngeal nerves supply, in part, the arytenoid muscle, and all the other muscles, excepting the crico-thyroid.

Arteries of larynx.

Veins.

Nerves.

The superior and inferior laryngeal nerves of each side communicate with each other in two places, viz., at the back of the larynx, beneath the pharyngeal mucous membrane, and on the side of the larynx, under the ala of the thyroid cartilage. (See p. 809.)

DEVELOPMENT AND GROWTH OF THE LARYNX.

Development.—The rudimentary larynx consists, according to Valentin, of two slight enlargements having a fissure between them, and embracing the entrance from the œsophagus into the trachea. According to Reichert, the rudiments of the arytenoid cartilages are the first to appear. Rathké, how-

Develop-ment of larynx.

ever, states that all the cartilages form at the same time, and are recognisable together as the larynx enlarges, the epiglottis appearing last. In the human embryo, Fleischmann could not detect the cartilages at the seventh week, though the larynx was half a line in length, but at the eighth week there were visible the thyroid and cricoid cartilages, consisting then and afterwards of two lateral halves, which are united together by the sixth month.

Growth of larynx.
Sexual changes at puberty.

Growth. — During childhood the growth of the larynx is very slow. Richerand found that there was scarcely any difference between the dimensions of this organ in a child of three and in one of twelve years of age. Up to the age of puberty the larynx is similar in the male and female, the chief characteristics at that period being the small size and comparative slightness of the organ, and the smooth rounded form of the thyroid cartilage in front. In the female these conditions are permanent, excepting that a slight increase in size takes place. In the male, on the contrary, remarkable changes rapidly occur, and the larynx speedily becomes more prominent and more perceptible at the upper part of the neck. Its cartilages become larger, thicker, and stronger, and the *alæ* of the thyroid cartilage project forward in front so as to form at their union with one another, at an acute angle, the prominent ridge named *pomum Adami*. At the same time the median notch on its upper border is considerably deepened. In consequence of these changes in the thyroid cartilage, the distance between its angle in front and the arytenoid cartilages behind becomes greater, and the chordæ vocales are necessarily lengthened. Hence the dimensions of the glottis, which, at the time of puberty, are increased by about one-third only in the female, are nearly doubled in the male, and the adult male larynx becomes altogether one-third larger than that of the female.

Enlarges in the male.

Hence male glottis is larger.

Ossification of the cartilages.

Towards the middle of life, the cartilages of the larynx first shew a tendency to ossification; this commences first in the thyroid cartilage, then appears in the cricoid, and lastly in the arytenoid cartilages. In the thyroid cartilage the ossification usually begins at the cornua and posterior borders; it then gradually extends along the whole inferior border, and subsequently spreads upwards through the cartilage. The cricoid cartilage first becomes ossified at its upper border upon each side, near the two posterior articular eminences, and the ossification invades the lateral parts of the cartilage before encroaching on it either in front or behind. The arytenoid cartilages become ossified from below upwards.

THE THYROID BODY.

Thyroid body called a gland but has no ducts.

The *thyroid body* is a soft, reddish, and highly vascular organ, situated in the lower part of the neck, embracing the front and sides of the upper part of the trachea, and reaching up to the sides of the larynx. From its general resemblance to the glandular organs, it has been called the thyroid *gland*, but

it possesses no system of excretory ducts. Its function is unknown, but, owing to its local connexion with the principal cartilage of the larynx, it is usually described with that organ, and has received the name *thyroid*. It is of an irregular, semi-lunar form, consisting of two *lateral lobes*, united together towards their lower ends by a transverse portion named the isthmus. Viewed as a whole, the thyroid body is convex on the sides and in front, forming a rounded projection upon the trachea and larynx. It is covered by the sterno-hyoid, sterno-thyroid, and omo-hyoid muscles, and behind them it comes into contact with the sheath of the great vessels of the neck. Its deep surface is concave where it rests against the trachea and larynx. It usually extends so far back as to touch the lower portion of the pharynx, and on the left side the œsophagus also.

Its form
and connec-
tions.

Each *lateral lobe* measures usually two inches or upwards in length, and three-quarters of an inch in its thickest part, which is below its middle. The right lobe is usually a few lines longer and thicker than the left. The general direction of each is, from below, obliquely upwards and backwards, reaching from opposite the sixth ring of the trachea to the posterior border of the thyroid cartilage, of which it covers the inferior cornu and adjoining part of the ala. The upper end of the lobe, which is thinner, and sometimes called the *cornu*, is usually connected to the side of the thyroid and cricoid cartilages by cellular tissue.

Its two
lobes

and cornua.

The *transverse* part, or *isthmus*, which connects the two lateral lobes together a little above their lower ends, measures nearly half an inch in breadth, and from a quarter to three quarters of an inch in depth; it commonly lies across the third and fourth rings of the trachea, but is very inconstant in size and shape, so that the portion of trachea left uncovered by it is subject to corresponding variation. From the upper part of the isthmus, or from the adjacent portion of either lobe, but most frequently the left, a conical portion of the thyroid body, named, from its shape and position, the *pyramid*, or *middle lobe* (*cornu medium*, *columna media*), often proceeds upwards to the middle of the hyoid bone, to which its apex is attached by loose fibrous tissue. Commonly this process lies somewhat to the left; occasionally it is thicker above than below, or is completely detached, or is split into two parts. Sometimes it appears to consist of fibrous tissue only, but often presents a reddish fibrous appear-

Transverse
part, or
isthmus.

The pyra-
mid or mid-
dle lobe.

ance, as if containing muscular fibres. According to Cruveilhier, the muscle described by Sæmmerring, under the name of the *levator glandulæ thyreoidæ* is nothing more than this process of the thyroid body. There can be no doubt, however, that in certain cases true muscular fasciuli, probably part of the thyrohyoid muscle, descend from the hyoid bone to the thyroid gland or its pyramidal process. It sometimes, though rarely, happens that the isthmus is altogether wanting, the lateral lobes being then connected by cellular or fibrous tissue only.

Weight, The *weight* of the thyroid body varies ordinarily from one to two ounces. It is always larger in the female than in the male, and appears in the former to increase periodically about the time of menstruation. The thyroid body, moreover, is subject to much variation of size, and is, occasionally, the seat of enormous hypertrophy, constituting the disease called goitre. The *colour* of the thyroid body is of a dusky brownish red, but sometimes it presents a yellowish hue.

and colour
of the thy-
roid.

Structure.

Its outer
coat.

Structure.—The texture of this organ is firm and granular. It is invested with a thin transparent layer of dense cellular tissue, which connects it with the adjacent parts, surrounds and supports the vessels as they enter it, and imperfectly separates its substance into small masses of irregular form and size. This interstitial cellular tissue is free from fat.

Its vesicles
and their
contents.

When the thyroid body is cut into, a yellow glairy fluid escapes from the divided substance, which is itself found to consist of multitudes of minute closed vesicles, composed of a simple external capsular membrane, and containing a yellow fluid, with corpuscles resembling cell-nuclei and sometimes nucleated cells floating in it. These vesicles are surrounded by capillary vessels, and are held together in groups or imperfect lobules by areolar tissue. They vary in size from $\frac{1}{850}$ th of an inch in diameter to that of a millet-seed, so as to be visible to the naked eye,—differing in size however, in different individuals, more than in the same thyroid body. The *vesicles* are spherical, oblong, or flattened, and are perfectly distinct from each other; the *corpuscles*, according to Simon,* are in the fœtus and young subject disposed in close apposition and in a single layer on the inner side of the vesicles, but detach themselves in

* Physiological Essay on the Thymus Gland, Lond. 1845, p. 78.

the progress of growth. The fluid coagulates by the action of heat or of alcohol, preserving, however, its transparency. According to the recent analyses, the substance of the thyroid body consists principally of albumen with traces of gelatine, stearine, oleine, and extractive matter, besides alkaline and earthy salts and water. The salts are chloride of sodium, a little alkaline sulphate, phosphates of potash, lime, and magnesia, with some oxide of iron.

Chemical composition.

Vessels.—The *arteries* (pp. 474, 512) of the thyroid body are the superior and inferior thyroids of each side, to which is sometimes added a fifth vessel, named the *lowest* thyroid of Neubauer and Erdmann. The arteries are remarkable for their relative size, and for their frequent and large anastomoses; they terminate in a capillary network, upon the outside of the closed vesicles. The *veins*, which are equally large, ultimately form plexuses on the surface, from which a superior, middle, and inferior thyroid vein (see pp. 620, 627) are formed on each side. The superior and middle thyroid veins open into the internal jugular; the inferior veins emanate from a plexus formed in front of the trachea, and open on the right side into the superior cava, and on the left into the brachio-cephalic vein. The *lymphatics* of the thyroid body are extremely numerous and large, and indeed are supposed to be concerned in conveying into the blood the products formed within this organ.

Arteries,

veins,

absorbents, and

Nerves.—The *nerves* are derived from the pneumo-gastric, and from the middle and inferior cervical ganglia of the sympathetic.

nerves.

Development.—According to Mr. Goodsir,* the thyroid body is derived from, or rather is a remnant of, the blasto-dermic or germinal membrane, an origin which he also assigns to the thymus gland and suprarenal capsules. It may be easily recognised, he says, as distinct from the thymus by its more opaque and homogeneous appearance, and by its containing a larger quantity of vascular tissue round its component cells. According to the same observer, the superior and inferior thyroid arteries are derived respectively from the first and second primitive aortic arches. The transverse part is developed subsequently to the two lateral lobes. In the fœtus, and during early infancy, this organ is relatively larger than in after life; its proportion to the weight of the body in the new-born infant being 1 to 243 or 400, whilst at the end of three weeks it becomes only 1 to 1166, and in

Develop-
ment.

* Philosoph. Transact. 1846.

the adult 1 to 1800. (Krausc.) In advanced life the thyroid body becomes indurated, and frequently contains earthy deposit; its vesicles also attain a very large size.

THE THYMUS GLAND.

Thymus gland or body is a temporary organ.

Its characters,

division into lobes,

and its connections with other parts.

The *thymus gland* or *body* (glandula thymus, corpus thymicum,) is a temporary organ which reaches its greatest size at about the end of the second year, after which period it ceases to grow, and is gradually reduced to a mere vestige. When examined in its mature state in an infant under two years of age, it appears as a narrow elongated glandular-looking body, situated partly in the thorax, and partly in the lower part of the neck; lying, below, in the anterior mediastinal space, close behind the sternum, and in front of the great vessels, and reaching upwards upon the trachea in the neck. Its colour is greyish, with a pinkish tinge; its consistence is soft and pulpy, and its surface appears distinctly lobulated. It consists of *two lateral parts*, or *lobes*, which touch each other along the middle line, and are nearly symmetrical in form, though generally unequal in size, sometimes the left, and sometimes the right lobe being the larger of the two. Often an *intermediate lobe* exists between the two lateral ones, and occasionally the whole body forms a single mass. The forms of the smaller lobules also differ on the two sides.

Each lateral lobe is of an elongated triangular form, its base being directed downwards. The *summit*, or upper extremity, usually mounts up into the neck, reaching above the sternum, as high as to the lower border of the thyroid body. The *base* rests on the upper part of the pericardium, to which it is connected by cellular tissue. The *anterior* surface, slightly convex, is covered by the first and the upper part of the second bone of the sternum, reaching, in the infant at birth, as low down as opposite the fourth costal cartilage. It is attached to the sternum by loose cellular tissue, but opposite the upper part of that bone is separated from it by the origins of the sterno-hyoid and sterno-thyroid muscles, which also cover it in the neck. The *posterior* surface, somewhat concave, rests, in the thorax, upon the front of the aortic arch, and the large arteries arising from thence, and also on the left innominate vein, some cellular tissue interposing between it and these parts. In the neck,

it lies upon the front and corresponding side of the trachea, as high as the thyroid body. Its *external border* is in contact with the corresponding layer of the mediastinal pleura, near the internal mammary artery, and higher up (in the neck), with the carotid artery, or its sheath. The *internal border* is in close contact with that of the opposite lateral lobe. The dimensions of the thymus of course vary according to its stage of development. At birth it measures above two inches in length, an inch and a half wide below, and about three or four lines in thickness. Its weight at that period is about half an ounce. Its specific gravity, which is at first about 1.050, diminishes as the gland continues to waste.

Its size,

weight, and specific gravity.

Structure.—The thymus gland is surrounded by a proper investment of thin areolar tissue, which connects it with surrounding parts, and encloses in a common envelope the smaller masses which compose it. This being removed, the substance of the thymus is found to consist of numerous compressed lobules, connected by a more delicate intervening areolar tissue. These lobules vary in size from that of a pin's head to that of a pea. Each lobule, when divided, is seen to contain several membranous *cells* or *vesicles*. According to Sir Astley Cooper,* the cellular recesses of each lobule open into a small pouch at its base, which in turn communicates with a large elongated *central cavity* running through the corresponding lateral lobes of the gland—the vesicles, the pouches, and the central cavity, all containing a white fluid resembling chyle. This cavity, named by Sir A. Cooper the *reservoir of the thymus*, is represented by him as branching out into diverticula, around which the lobules are disposed, and is described as being lined by a vascular membrane, which is prolonged through the diverticula and pouches into the cells. Moreover, the lobules themselves are said to be held together by a strong band, around which they are attached like knots upon a rope, which is itself arranged spirally around the common central cavity. The existence of a continuous central cavity, containing a chylous fluid, is doubted by Henlé, and denied by Berres, Bischoff, and Haugstedt, who think that the vesicles are perfectly closed, and independent of each other. Mr. Goodsir is of opinion that this common cavity results from

Structure. Its investing membrane,

lobules, and vesicles.

The central cavity

or reservoir

is of doubtful character.

* Anatomy of the Thymus Gland. London, 1832.

the mode of preparation, by the distension and separation of contiguous lobules which adhere only slightly together, whilst the entire glandular mass is enveloped in a strong cellular capsule. Meckel, Tiedemann, and Huschke recognize the presence of a cavity, which, according to the latter, is most distinctly seen in well nourished children, in whom it is distended with a white fluid. Mr. Simon, who by his recent investigations has shewn that the primitive form of the thymus gland is a linear tube, from which, as it grows, lateral branched diverticula subsequently bud out, states, that in the mature thymus, this tube becomes obscure; that the central cavity described and figured by Sir A. Cooper is too large, owing to over-distension; but, nevertheless, that all the parts of each lateral lobe of the thymus do depend on a single common cavity, and that even the terminal vesicles communicate with it by means of the numerous diverticula. The central cavity has no outlet, and the thymus gland has no excretory duct.

The thymus has no duct.

The ultimate vesicles and

their contents.

The walls of the ultimate vesicles are formed of simple homogeneous membrane; they are surrounded by a network of fine capillary vessels, and are supported by a delicate cellular tissue, containing some elastic fibres. The *white fluid* found in the vesicles and interior of the thymus is particularly abundant in stout healthy infants, but scanty in opposite conditions. It contains numerous corpuscles, closely resembling the pale blood-corpuscles and those found in the chyle and in the juice of the lymphatic glands. The milky character of the thymic fluid is owing to the presence of these corpuscles, and not of minute molecules as is the case with the chyle. The corpuscles are either flattened circular discs or spherical bodies, varying in diameter from $\frac{1}{2500}$ th to $\frac{1}{3000}$ th of an inch. They contain a nucleus, composed itself of from one to three, or even four, dark clear granules. According to the observations of Mr. Gulliver, the action of re-agents upon the corpuscles of the fluid of the thymus is precisely similar to that upon the corpuscles of the chyle and lymph.

Its corpuscles have some analogies with those of chyle and lymph.

Arteries,

Vessels.—The *arteries* are derived from various sources, viz., from the internal mammary arteries, the inferior and superior thyroid, the subclavian and carotid arteries. They terminate in capillary vessels, which form a vascular envelope around each vesicle.

The *veins* pursue a different course from the arteries, and, for the most part, open into the left innominate vein. veins,

The *lymphatics* are large, but their course has not been well studied. Sir A. Cooper succeeded in injecting them only once in the human subject. According to Simon, they may be traced through the gland, but do not arise from its cavity; they terminate in the thoracic duct, or in the right lymphatic duct. It is probable that they are concerned in conveying into the blood the products formed in the substance of the thymus. absorbents,

The *nerves* are very minute. Haller thought they were partly derived from the phrenic nerves, but, according to Sir A. Cooper, no filaments from these nerves go into the gland, though, as well as a branch from the descendens noni, they reach the investing capsule. Small filaments, derived from the pneumogastric and sympathetic nerves, descend on the thyroid body, to the upper part of the thymus. Sympathetic nerves also reach the gland along its various arteries, especially on the thymic branch of the internal mammary artery. and nerves.

Chemical Composition.—The substance and fluid of the thymus contain nearly eighty per cent. of water. Its solid animal constituents are composed essentially of albumen and fibrin in large quantities, mixed with gelatine and other animal matter. The salts are principally alkaline and earthy phosphates, with chloride of potassium. It contains, therefore, no constituents especially rich in carbon. Chemical composition of thymus.

Development.—According to Mr. Goodsir,* the thymus gland, like the thyroid body, is essentially a highly-developed remnant of the blasto-dermic membrane, the use of which, both originally and as thus modified, he conceives to be to prepare material for nutritive purposes. At first, according to his statement, the thyroid and thymus are not distinguishable from each other, but soon they become separated by the absorption of a part between them. Develop- ment. Goodsir's

The early development of the thymus has been carefully studied by Mr. Simon,† whose researches were chiefly conducted in the embryos of swine and oxen. In embryos, about half an inch in length, it may be seen by the aid of a high power; and in those of one and a half inch, by the aid of a simple lens. When first distinguishable, it consists of a simple tube closed in all directions, lying along the carotid vessels. The contents of this tube are granular, but do not shew regular corpuscles; its walls are delicate and homogeneous. The tube has no connexion with the respiratory mucous and Simon's researches.

* *Loc. cit.* Philos. Trans. 1846.

† *Op. cit.*

membrane, as was supposed by Arnold ; and, so soon as it is discoverable, it is found to be perfectly distinct from the thyroid body. At intervals along the sides of this tube small vesicles bud out, so as to form lateral diverticula, which contain nucleated corpuscles, and which go on subsequently branching out by twos or fours,—the formation of the permanent vesicles being merely the last repetition of this process. In the human foetus, at about the ninth week the thymus consists of two minute elongated parallel parts, lying chiefly on the upper part of the pericardium, and presenting under the microscope a distinct tubulo-vesicular structure ; it then increases rapidly until birth, but not equally, for it grows especially during the seventh, eighth, and ninth months of intra-uterine existence.

Its growth
in the
foetus.

Changes
after birth.

After birth, the thymus, as already stated, continues to grow to near the end of the second year. According to the observations of Haugstedt and Simon upon the weight of this organ in young animals, it appears for a short time after birth to increase not merely absolutely, but even faster than the rest of the system, and during the next period only to keep pace with the increase of the body. After the second year it ceases to grow, and becomes gradually converted by the eighth or twelfth year into a fatty mass. In this condition the corpuscles of the thymus disappear, forming, according to Simon's opinion, the nuclei of cells which become developed into the cells of adipose tissue. At puberty the thymus is reduced to a mere vestige, losing its original structure entirely, and consisting of brownish tissue found in the upper part of the anterior mediastinum. Traces of it, however, have been found at the twentieth or twenty-fifth year, and, as an extreme exception, at the age of thirty.

Does not
grow after
second
year.
Its last
traces.

The thymus gland presents no difference in the two sexes. It exists, according to Simon, in all animals breathing by lungs, and is persistent in those which hibernate, though only as a mass of fat.

Its uses are
not certain-
ly known.

Function.—The functions of the thymus gland are not known. It was supposed by Hewson, on the ground of the identity between the thymic and lymph particles, that this organ is an appendage to the lymphatic system, and that its particles are concerned in the formation of the blood globules. Others have conceived that its office was in some way to prepare a nutritive fluid for the system of the foetus and early infant. Mr. Simon concludes that the thymus is intended to set aside from the blood a reserve of oxidizable material available for respiration, at a period of life when but a scanty supply of respirable matter is derived from the wear of the muscular tissue.

THE URINARY ORGANS.

THE urinary organs consist of the *kidneys*, by which the urine is secreted, and of the *ureters*, *bladder*, and *urethra*, which are concerned in its excretion and evacuation. As locally connected, the *supra-renal* capsules are usually described with these organs, though they have no relation, as far as is known, to the secretion of urine.

Urinary organs are secretory, excretory, and evacuant.

THE KIDNEYS.

The *kidneys* (*renes*, *νεφροί*), two in number, one right and the other left, are deeply seated in the lumbar region, lying one on each side of the vertebral column, at the back part of the abdominal cavity, behind the peritonæum. They are situated on a level with the last dorsal and the two or three upper lumbar vertebræ, the right kidney however being placed a little lower down than the left, probably in consequence of the vicinity of the large right lobe of the liver. They are maintained in this position by their vessels, and also by a quantity of surrounding loose cellular tissue, which usually contains much dense fat. The *size* of the kidneys varies in different cases. Ordinarily, they measure about four inches in length, two inches in breadth, and an inch or rather more in thickness. The left kidney is usually longer and thinner, whilst the right is shorter and wider in proportion.

The kidneys are two;

their situation,

size,

Weight.—The average weight of the kidney is usually stated to be about $4\frac{1}{2}$ ozs. in the male, and somewhat less in the female. According to Dr. Clendinning,* the two kidneys of the male weigh on an average $9\frac{1}{2}$ ozs., and those of the female 9 ozs. The estimate of M. Rayer† is $4\frac{1}{2}$ ozs. for each organ in the male, and $3\frac{3}{4}$ ozs. in the other sex. Dr. J. Reid's ‡ observations (made on sixty-five males and twenty-eight females, between the ages of twenty-five and fifty-five) would indicate a higher *average* weight, viz. rather more than $5\frac{1}{2}$ ozs. in the former, and not quite 5 ozs. in the latter,—the difference

* *Loc. cit.*

† *Traité des Mal. des Reins*. Paris, 1839.

‡ *Loc. cit.*

between the two sexes being therefore upwards of half an ounce. The *prevalent* weights of the kidney, as deduced from the tables of Dr. Reid, are, in the adult male (160 observations) from $4\frac{1}{2}$ ozs. to 6 ozs., and in the adult female (74 observations) from 4 ozs. to $5\frac{1}{2}$ ozs. The tables more recently published by Dr. Peacock give still higher average results as to the weight of these organs.* The two kidneys are seldom of equal weight, the left being almost always heavier than the right. The difference, according to M. Rayer, is equal to about one-sixth of an ounce. The actual average difference was found by Dr. Reid, in ninety-three cases (male and female), to be rather more than one-fourth of an ounce. The *proportionate* weight of the two kidneys to the *body* is about 1 to 240. The specific gravity of the renal substance is, on an average, 1.052.

The two
differ in
weight.

Form of the
kidney
peculiar.

The surface of the kidney is smooth and has a deep red colour. Its *form* is peculiar: it is compressed before and behind, convex on its outer and concave on its inner border, and somewhat enlarged at its upper and lower ends.

Its surfaces,
anterior

The *anterior* surface, more convex than the posterior, is directed somewhat outwards, and is partially covered at its upper end by the peritonæum, which is separated from it lower down by loose cellular tissue. The duodenum and ascending colon, both destitute of peritonæum behind, are in contact with the anterior surface of the right kidney, and the descending colon with that of the left. The front of the right kidney, moreover, touches the under surface of the liver, and that of the left the lower extremity of the spleen. The *posterior* surface, flatter than the anterior, and embedded in cellular tissue, rests partly upon the corresponding pillar of the diaphragm, in front of the eleventh and twelfth ribs, partly on the quadratus lumborum muscle, or rather on the anterior layer of the lumbar fascia, which covers it, and lastly, on the psoas muscle. The *external border*, convex in its general outline, is directed outwards and backwards towards the walls of the abdomen. The *internal border*, concave and deeply excavated towards the middle, is directed a little downwards and forwards. It presents in its middle a longitudinal *fissure* bounded by an anterior and posterior lip, and named the *hilus of the kidney*, at which the vessels; the excretory duct, and the nerves enter or pass out. In this hilus, the renal vein lies in front, the artery and its branches next, and the expanded excretory duct or ureter

and poste-
rior.

Its outer

and inner
border.

The fissure
or hilus.

* *Loc. cit.*

behind and towards the lower part of the hilus. The *upper end* of the kidney, which is larger than the lower, is thick and rounded, and supports the supra-renal capsule, which also descends a little way upon its anterior surface. This end of the kidney reaches, on the left side, to about the upper border of the eleventh rib, and on the right half a rib's breadth lower. It is moreover directed slightly inwards, so that the upper ends of the two kidneys are nearer to each other than the lower ends, which are smaller and somewhat flattened, diverge slightly from the spine, and reach nearly as low as the crest of the ilium. It may here be remarked that, by placing the larger end of a kidney upwards and its flatter surface backwards, or by noticing the relation of the parts in the hilus, it may be determined to which side of the body the organ belongs.

The upper

and lower
end.

Varieties.—The kidneys present varieties in form, position, absolute and relative size, and number. Thus, they are sometimes found longer and narrower, and sometimes shorter and more rounded than usual. Occasionally one kidney is very small, whilst the other is proportionately enlarged. In either of these conditions the position of the kidney, especially as regards its height upon the ribs, must also vary. Independently of any other change, the kidneys may, one or both, be situated low down, even in the pelvis.

Varieties
in form,
size,
position,
and num-
ber

Cases are now and then met with in which but one kidney is present, the single organ being sometimes, though not always, formed by the apparent junction of the two kidneys across the front of the great blood-vessels and vertebral column. The transverse connecting portion usually has its upper border concave, so as to give the organ a form which has suggested the appellation of the *horse-shoe* kidney. Sometimes two united kidneys are situated on one or other side of the vertebral column, in the lumbar region, or, but much more rarely, in the cavity of the pelvis. In other very rare cases, three distinct glandular masses have been found, the supernumerary organ being placed either in front or on one side of the vertebral column, or in the pelvic cavity.

Horse shoe
kidney.

Structure.—Beneath the layer of fatty tissue (*tunica adiposa*) which in the adult usually surrounds the kidney, but is accumulated especially upon its outer and inner borders, is the proper fibrous coat of the organ. This coat forms a thin, smooth, but firm investment, immediately and closely covering the whole kidney. It consists of dense fibro-cellular tissue, and can easily be torn off from the substance of the gland, to which it adheres by minute processes and vessels.

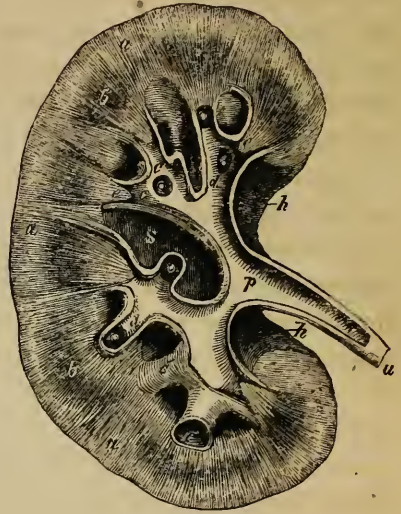
Structure
of kidney.Its outer
coat.

On splitting open the kidney by a longitudinal section, from its outer to its inner border (see fig. 307), the fissure named the

hilus (*h, h*), is found to extend some distance into the interior of the organ, forming a cavity within the solid substance of the gland called the *sinus* of the kidney (*s*). The fibrous coat of the kidney, passing in by the hilus, lines the sides of the sinus, and having reached the bottom of that cavity, surrounds the blood-vessels, giving them sheaths which accompany their principal branches in the substance of the gland, and is reflected upon the divisions of the ureter or excretory duct (*c, c, c*), to be afterwards described. The solid part of the kidney, as is seen

on a section, consists of two substances, differing from one another in aspect, and usually named, from their relative position, the cortical and medullary substances. The *external* or *cortical* substance (*a, a, a*) is situated immediately beneath the fibrous capsule, and forms the superficial part of the organ throughout its whole extent and to the depth of about two lines. The cortical substance moreover sends prolongations inwards towards the sinus (*septula renum*), between which the medullary substance is found. The *internal* or *medullary* substance, on the other hand, does not form a continuous structure, but is collected into a series of conical masses called the *pyramids of Malpighi* (*b, b*), the bases of which are directed towards the surface of the kidney, whilst their apices (*e, e, e*) are turned towards

Fig. 307.*



The hilus leads into the sinus.

The outer or cortical substance.

Septula renum.
Internal or medullary substance.
Pyramids of Malpighi.

* Plan of a longitudinal section of the kidney and upper part of the ureter, through the hilus, copied from an enlarged model.—*a, a, a*. The cortical substance. *b, b*. Broad part of two of the pyramids of Malpighi. *e, e*. Section of the narrow part or apex of two of these pyramids, lying within the divisions of the ureter marked *c, c*. *d, d*. Summits of the pyramids, called papillæ, projecting into and surrounded by the divisions of the ureter. *c, c*. Divisions of the ureter, called the calices or infundibula, laid open. *c*. A calix or infundibulum unopened. *p*. Enlarged upper end of ureter, named the pelvis of the kidney. *s*. Central cavity or sinus of the kidney.

the sinus. There are generally more than twelve pyramids, but their number is not constant, varying from eight to eighteen. The greater part of each pyramid is embedded in the cortical substance, but the summits of these masses, which project into the sinus, are free, and are named the *papillæ* (or *mamillæ*) of the kidney (*d, d*). The cortical portion forms about three-fourths, and the medullary the remaining fourth of the substance of the gland.

The papillæ.

The *cortical* substance is soft and easily lacerated, the torn surface presenting a rough irregular aspect, and having a tolerably uniform red colour. It is sometimes said to be darker than the medullary portion, but this is not the fact, for, though the papillæ or summits of the pyramids are often lighter, their bases are usually darker than the surrounding cortical substance. On closely examining a section of a recent kidney, either with or without the aid of a lens, a number of small round dark red points are seen lying in the cortical substance only, but nowhere reaching quite to the surface of the gland. These are the Malpighian bodies or corpuscles of the kidney, to which we shall presently have again to refer. The *medullary* portion of the kidney, which, as already said, forms the pyramids, is more dense than the cortical, and is distinctly striated, owing to its consisting of minute diverging tubes: hence it is often named the *tubular* substance, but the cortical substance is also tubular.

Structure of the cortical substance.

Malpighian corpuscles.

Structure of the medullary part.

The pyramidal masses found in the adult kidney indicate the original separation of this gland into lobules in the earlier stages of its growth. Each of these primitive lobules is in fact a pyramid, surrounded by a proper investment of cortical substance, and is analogous to one of the lobules of the divided kidneys, seen in many of the lower animals. As the human kidney continues to be developed, the adjacent surfaces of the lobules coalesce and the gland becomes a single mass, and the contiguous parts of the originally separate cortical investments, being blended together, form the partitions between the pyramids already described. Moreover, upon the surface of the kidney even in the adult, after the removal of the fibrous capsule, faintly marked furrows may be traced on the cortical substance, opposite the intervals between the bases of the pyramids, which also indicate the position and course of large veins.

The pyramids,

how formed originally.

Component parts of the kidney.

The entire substance of the kidney, whether cortical or medullary, is composed of the uriniferous or excretory ducts, the bloodvessels, lymphatics, and nerves, connected in some parts by a fine cellular tissue, which, however, exists but in very small quantity, together with an intermediate substance, also very scanty, which has been described as a proper parenchyma.

The ducts :
The ureter ;
its pelvis,

The *ducts*.—The *ureter*, or excretory duct of the gland (*u*), is dilated at its upper end as it approaches the hilus, into a funnel-shaped cavity, compressed before and behind, named the *pelvis* of the kidney (*p*). On entering the sinus, partly concealed by the vessels, the pelvis divides usually into three, or sometimes two, principal tubes, which again subdivide into several smaller tubes named the *calices* or *infundibula* (*c, c, c*). These calices, which vary in number from seven to thirteen, embrace the prominent portions of the pyramids, forming short funnel-shaped tubes, into which the papillæ (*d, d,*) project. Often a single calix surrounds two, sometimes even three papillæ, which are in that case united together ; hence, too, the calices are in general not so numerous as the pyramids and papillæ.

and calices or infundibula :

Structure of these ducts :

their outer and their inner or mucous coat.

Like the rest of the ureter, the calices consist of two coats, viz. a strong external fibro-cellular tunic, which becomes continuous around the bases of the papillæ with that part of the proper coat of the kidney which is continued into the sinus ; and, secondly, a thin internal mucous coat, which is reflected over the summit of each papilla, and is moreover prolonged into a multitude of minute orifices opening on the surface of the papilla, and from which, on pressing the gland, urine may be made to exude.

Orifices upon the papillæ, are those of

These small orifices vary in diameter from $\frac{1}{300}$ th to $\frac{1}{200}$ th of an inch ; they are frequently collected in large numbers at the bottom of a slight depression or *foveola* found near the summit of the papilla.

tubuli uriniferi.

Tubuli uriniferi.—On tracing the minute openings just mentioned, into the substance of the pyramids, they are discovered to be the mouths of small tubes or *ducts*, called the *uriniferous tubes* (tubuli uriniferi), which thus open upon the surface of the several papillæ into the interior of the calices.

Course of the tubuli in the kidney

As these tubuli pass up into the pyramidal substance, they bifurcate again and again at very acute angles, their successive branches running close together in straight and but slightly diverging lines, and continuing thus to divide and subdivide until

they reach the sides and bases of the pyramids, from whence they pass, greatly augmented in number, into the cortical substance. Here, however, they undergo a complete change in their direction, for whereas, in the pyramids the radiating tubes are quite straight, they in the cortical part become at once convoluted in a most intricate manner, and retain this character through the remainder of their course. The *straight* portions of these tubuli were early recognized, and are sometimes named the *ducts of Bellini*, but the existence of tubes in the cortical substance was for a long time unknown; in this situation the tortuous uriniferous ducts are called the *tubes of Ferrein*. Within the pyramids, towards their base, the straight tubes are described as being collected into fasciculi, the tortuous tubuli given off from which into the cortical substance form little indistinct conical masses, reaching to the surface of the kidney, which presents in consequence a minutely lobulated or granular aspect. These aggregations of the uriniferous tubes in separate fasciculi and masses, appear connected in some degree with the arrangement of the intermediate bloodvessels, especially of the veins. They have been named the *pyramids of Ferrein*, a great number of which are included in each of the pyramids of Malpighi and its corresponding cortical substance.

partly straight, forming ducts of Bellini, and partly tortuous, or tubes of Ferrein.

Collected into pyramids of Ferrein.

On a section made across the base of a papilla, Krause has counted the openings of about one hundred of the straight tubes in a square line; and Huschke has enumerated from four to five hundred larger ones with as many of smaller size on the entire section of the base of a single papilla. The uriniferous tubes are largest near their orifices, at a short distance from which, within the papillæ, their diameter varies, according to Huschke, from $\frac{1}{430}$ th to $\frac{1}{240}$ th of an inch. Further on in the pyramid they become smaller, measuring about $\frac{1}{600}$ th of an inch in diameter, and then do not diminish as they continue to bifurcate, but remain nearly of the same uniform average diameter, until they enter the cortical substance, where the convoluted tubuli vary considerably in diameter, and many of them, indeed, (at least when injected,) present great inequalities at intervals along their course, but they maintain commonly the same average width as the straight tubes, namely $\frac{1}{600}$ th of an inch.

Numbers of the tubuli in each papilla;

their size,

at different points;

The uriniferous tubes form a system of canals apart from the bloodvessels, which latter are ramified on their walls in form of a

their independence.

and
structure.

fine capillary network, and at certain parts have a more curious relation to them, to be presently described. The convolution of the tubes provides for a large extent of secreting surface in a small space. Their parietes are formed of a transparent and homogeneous basement membrane, or *membrana propria*, lined by a spheroidal epithelium, which usually occupies about two-thirds of the diameter of the tube. (Fig. 308, A.B.C.)

Their mode
of com-
mencement
in the
kidney,

by saccular
dilatations;

by loops
of various
kinds,

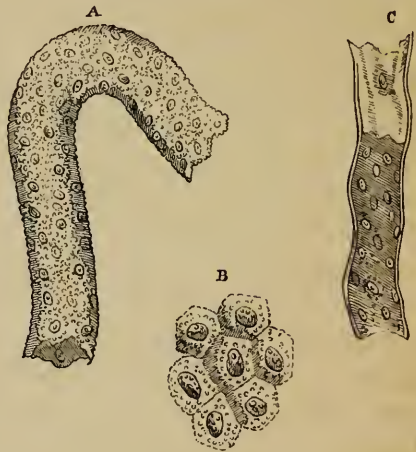and by
free closed
ends.

Bloodves-
sels of
kidney.

Different statements are made by different observers as to the mode in which the convoluted uriniferous tubes terminate or (tracing them in the reverse direction) commence in the cortical substance. According to the description given by Mr. Bowman, each tubulus begins by a little saccular dilatation, which embraces one of the vascular tufts named the Malpighian bodies,—the uriniferous tubes, in fact, being continued from, or rather forming by their dilated commencement, the capsules by which, as noticed by previous observers, these bodies are surrounded. The tortuous tubuli have also been seen forming loops either by the junction of adjacent tubes, or, as stated by Mr. Toynebee,† by the reunion of two branches proceeding from the same tube: in either case, new branches may arise from such loops. Other anatomists again, hold, that, the tubuli also arise by free and simply closed extremities.

Bloodvessels.—The kidneys are highly vascular, and derive their blood from the right and left renal arteries (see p. 561), which are very large in proportion to the size of the organs they supply. Each renal artery divides into four or five branches,

Fig. 308.*



* Portions of the uriniferous tubes magnified (Baly). A. Portion from the cortical substance, lined by its epithelium. B. Epithelial cells, more highly magnified (about 700 times). C. Portion of tube from the medullary substance, at one part deprived of its epithelial lining.

† *Medico-Chir. Transactions.* 1846.

which, passing in at the hilus, between the vein and ureter, may be traced into the sinus of the kidney, where they lie amongst the infundibula, together with which they are usually embedded in a quantity of fat. Penetrating the substance of the organ between the papillæ, the arterial branches enter the cortical substance found in the intervals between the medullary cones, and go on, accompanied by a sheathing of cellular tissue derived from the proper coat and dividing and subdividing, to reach the bases of the pyramids, where they form numerous anastomotic arches. From these arches a multitude of branches are given off, and, after ramifying through the cortical substance, at length end in a system of capillary vessels, which exist through the whole substance of the kidney, and form a network upon the uriniferous tubes. In the medullary portion of the kidney, where the uriniferous tubes are straight, the blood-vessels form oblong meshes parallel with the tubuli. In the cortical substance, the distribution of the small arteries is peculiar, for, before terminating in the common capillary system, they, with probably very few exceptions, enter into the Malpighian bodies, or glomeruli. All the capillaries of the kidney end in venous radicles, which unite to form the renal vein.

Course of the arteries ;

ultimately end in the capillary network.

In the cortical substance, distribution is peculiar.

The Malpighian corpuscles.—These small red bodies, or *glomeruli*, discovered by Malpighi (who, however, did not know their intimate structure), lie embedded in the cortical substance, surrounded loosely by little capsules. They are rounded or slightly oblong in shape, and have an ordinary diameter of $\frac{1}{120}$ th of an inch, but sometimes only of $\frac{1}{200}$ th or $\frac{1}{270}$ th of an inch. When oblong, Krause, has found them to measure $\frac{1}{110}$ th of an inch in length, and $\frac{1}{150}$ th in width.

Malpighian bodies ;

their size ;

These glomeruli were described by Ruysch as consisting of a little coiled artery. They are really, however, little vascular tufts formed, not, as Ruysch supposed, by the convolutions of a single vessel, but by those of two vessels, one afferent (fig. 309, *a*) the other efferent (*e'*), which enter and pass out of the glomerulus (*m*) close to one another. The afferent vessel immediately divides into several branches, which cover the surface of the glomerulus, and end in a finer set of central vessels. From these the efferent vessel arises, and, passing out of the tuft, at length divides into capillaries, which form a plexus around the adjacent tubuli. Mr. Bowman regards the

Each consists of a vascular tuft :

its afferent and efferent vessels.

Bowman's views of

renal circulation.

Connection with the capillary network of the tubes.

The Malpighian bodies lie in capsules,

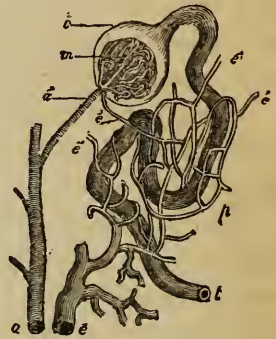
which are continuous with the tubuli uriniferi,

and are terminal or lateral.

efferent vessel as a vein, and consequently as having an arrangement comparable to that of the portal vein, and supports his view by a reference to the peculiar disposition of the vessels in the kidneys of reptiles. Others look on a Malpighian tuft as merely an example of an artery breaking up into a rete mirabile, and then after being reconstructed, continuing beyond as the efferent vessel. All the small arteries of the kidney, it must be borne in mind, do not form glomeruli before ending in the capillary network of the gland, for some of them divide at once into capillaries, without entering these tufts.

Relation of the Malpighian bodies to the uriniferous tubes.—It was thought, by Ruysch, that the single convoluted blood-vessel, supposed by him to form the glomerulus, ultimately became continued on as a straight uriniferous tube; but subsequent researches have shewn that, though the Malpighian bodies have peculiar relations with the commencing tubuli, there is no continuity between the channels of the blood-vessels and those of the secreting ducts. The true relation of the two was discovered by Mr. Bowman, and is essentially this, that the uriniferous tube (*t*), by becoming enlarged, forms a capsule (*c*), into which one of the vascular tufts (*m*) projects, so as to be entirely enclosed within it; and that the two vessels, afferent (*a'*) and efferent (*e'*), which form the tuft, pierce this capsule usually close to each other. Mr. Bowman inferred from his observations that the dilatation was placed at the end or rather commencement of a tube, but it has since been found by Gerlach and others, that it may be formed on one side. Hence it would appear that the capsules in question may be either *lateral* or *terminal*; and for aught that has yet been

Fig. 309.*



* A plan to shew the position of the Malpighian body in its capsule, the continuity of this capsule with the uriniferous tube, and the arrangement of the blood-vessels within and beyond the Malpighian tuft. (Bowman.)—*a*. Branch of an artery. *a'*. Afferent vessel, entering the base of the Malpighian body. *m*. Vascular tuft formed within it. *c*. Capsule of the Malpighian body, continuous with the uriniferous tube, marked *t*. *e'*, *e'*, efferent vessels which enter the plexus, *p*, surrounding the tubule, and finally terminate in the vein, *e*. In this plan a *terminal* capsule is represented.

proved to the contrary, lateral capsules may exist both on tubes which issue from terminal ones, and on tubes which at their commencement are joined with others or form loops.

According to Bowman, the epithelium becomes remarkably thin within the capsule, and, in the frog, is covered with cilia at the neck of the dilated portion. By the same observer, it is further stated, that neither the epithelium nor the basement membrane of the capsule is reflected over the glomerulus, the vessels of which therefore lie, as it were, naked in the capsular cavity. Gerlach, on the other hand, describes the tuft of vessels as covered with a thick layer of nucleated cells, continued from a similar layer lining the capsule.*

Structure of the capsules,
their epithelial lining.

Veins.—Small veins, arising by numerous venous radicles from the capillary network of the kidney, are seen near the surface of the gland, arranged so as to leave between them minute spaces, which appear nearly to correspond with the bases of the so-called pyramids of Ferrein. These vessels, which sometimes have a stellate arrangement (*stellulæ*, Verheyen,) end in larger veins, which again unite into arches around the bases of the pyramids of Malpighi. From thence venous trunks proceed, in company with the arteries, through the cortical envelope between the pyramids, to the sinus of the kidney. Joining together, they escape from the hilus, and ultimately form a single vein, which lies in front of the artery, and ends in the inferior vena cava. (See p. 645.)

Veins of the kidney,
are sometimes stellate.

A number of vessels, both veins and arteries, enter the proper coat of the kidney from the cortical substance, and some supply also the surrounding cellular or adipose tissue.

Vessels of the coats of kidney.

Absorbents.—The lymphatics of the kidney are numerous, consisting of a superficial set, and of deep lymphatics which issue from the hilus with the blood vessels.

Absorbents.

Nerves.—The nerves which have been traced into these organs are small. They come immediately from the renal

Nerves.

* Mr. Toynebee, whose views are different from those above given, conceives that the capsule is not a dilated portion of a uriniferous tube, but is an independent investment, continuous neither with the tube nor with the bloodvessels, but expanded over and enveloping the terminations of both. Further, he believes that the bloodvessels passing into and out of the tuft perforate one end of this proper capsule, whilst the uriniferous tube enters at the opposite point, becomes twisted into a coil in contact with the convoluted blood vessels, and then again emerges from the capsule.

plexus and the lesser splanchnic nerve, and contain filaments derived from both the sympathetic and cerebro-spinal systems.

Inter-
mediate paren-
chyma
composed
of cells.

Intermediate substance.—Bowman has pointed out the existence of a firm granular substance, lying between and uniting the tubes, as well as the vessels, in the medullary part of the kidney; he compares it to a blastema, and states that it is probably composed of cells. Under the name of the *proper parenchyma* of the kidney, Mr. Toynebee has also described a substance, composed of cells, as interposed between and surrounding the tubuli, in the cortical part as well as elsewhere. He further states, that the fine filaments of the nerves within the kidney have appeared to him to be connected with the intertubular or parenchymal cells.*

Development.—The development of the kidneys, and also that of the supra-renal capsules next to be described, will be given with that of the genito-urinary organs generally.

The urine,
its quantity
and

characters.

The Urine.—This is a highly complex fluid, containing in solution *animal compounds* characterised by having a large amount of nitrogen in their composition, and derived, it would seem, from the waste of the tissues; *saline substances*, and *adventitious* matters which have been introduced into the blood. The average quantity secreted daily is about 30 fluid ounces. Its specific gravity varies in health from 1.015 to 1.030, but 1.020 is the average standard. It is acid in its reaction, and contains some mucus and epithelium. One thousand parts of ordinary urine contain 933 pts. of water, and 67 of solid matter. Of the latter, 30 pts. consist of *urea*, the characteristic nitrogenous ingredient of urine; 17 pts. consist of extract with salts soluble in alcohol; 15 pts. are fixed salts, and 1 pt. is uric acid.

SUPRA-RENAL CAPSULES.

The supra-
renal
capsules.

The *supra-renal capsules*, or supra-renal glands, (*glandulæ supra-renales*; *capsulæ supra-renales*, seu *atrabiliaræ*; *renes suc-*

* Mr. Goodsir (Lond. and Edin. Journ. of Med. Science, May, 1842), and more lately Dr. Johnson (Cyclop. of Anat. vol. iv. p. 239) have described a fibro-cellular framework or matrix as pervading every part of the renal substance, and supporting the uriniferous tubes and bloodvessels. We must confess, that although small bundles of fibrous or cellular tissue are met with here and there accompanying vessels in the substance of the kidney, we have not been able to observe any continuous pervading structure of fibro-cellular tissue. The apparently reticular framework which is displayed by washing a thin slice of the kidney has seemed to us to be formed by the basement-membrane of the transversely or obliquely cut tubes, deprived of epithelium and connected by a transparent tissue, which is doubtless made up principally of vessels (although in the uninjected state, these do not definitely appear) and has granular corpuscles irregularly dispersed in it.

centuriati), are two gland-like bodies, situated one on each side of the vertebral column, and, as their name implies, above the kidneys. Each of them is a flattened, triangular body, somewhat resembling a cocked-hat in shape, which surmounts the corresponding kidney. Its *upper* border, convex and thin, is directed inwards and upwards. Its base or concave border, which rests upon the anterior and inner part of the summit of the kidney, to which it is connected by loose cellular tissue, is thick, and almost always deeply grooved. The *posterior* surface rests upon the diaphragm. Its *anterior* surface is covered on the right side by the liver, and on the left by the pancreas and spleen. The inner border of the right supra-renal capsule is in contact with the vena cava inferior, and that of the left with the aorta. The right capsule, like the right kidney, is placed lower down than the left.

The supra-renal capsules vary in *size* in different individuals, and the left is usually somewhat narrower at its base, but is longer from above downwards, and usually larger than the right. They measure from an inch and a quarter to an inch and three-quarters in height, and about an inch and a quarter in width; their thickness is from two to three lines. The *weight* of each supra-renal capsule in the adult is from one to two drachms.

Besides cellular tissue mixed frequently with much fat, the supra-renal capsules have a thin fibrous investment, which also sends numerous processes into their interior, accompanied by many bloodvessels. These processes enter certain furrows, varying in depth and extent, by which the surface of the organ is marked, especially in front and upon its base. Externally, the supra-renal capsules have a yellowish or brownish-yellow colour; but, when divided, they seem to consist of two substances, viz. one *external* or *cortical*, which is of a deep yellow colour, firm and striated, and forms the principal mass of the organ; the other *internal*, which is dark, soft, pulpy, and of a brownish-black hue. Many anatomists describe a cavity within this soft central substance, but some attribute the seeming cavity to accidental laceration of the soft substance, while others look upon it as a venous sinus. The name of atra-biliary capsules, given to these organs, has reference to the dark black colour of their interior.

Cortical
substance is
striated,

and con-
sists of
closed
tube.

Contents
of these
tubes

exhibit
peculiar
minute
granules.

The cen-
tral
portion.

No duct
exists.

Arteries,

veins, and

The *cortical* striated part of the supra-renal capsules has been found, by Mr. Simon, to consist of distinct closed tubes, arranged in columnar masses, perpendicularly to the surface of the organ. These tubes measure, on an average, about $\frac{1}{700}$ th of an inch in diameter. They have no communication with one another, but each consists of a very delicate constituent membrane, which is complete on all sides. The small blood-vessels run parallel to these tubes, frequently anastomose together between them, and surround each tube with a fine capillary network. In the interior of the tubes, are found nucleus-like bodies, mixed with minute yellowish granules, and oily particles with granular matter adhering to them, also nucleated cells containing granular matter and oily molecules. According to Mr. Gulliver's observations, the nucleated corpuscles or cells always exist, in large numbers, in the supra-renal bodies of ruminant animals, but they occur more sparingly in the human subject, and in other animals. They resemble the lymph globules in size, but are often of a reddish colour. The *granules*, or minute *spherules* (Gulliver), form, however, the chief constituents of the substance of the supra-renal gland. Their size is very unequal, varying from $\frac{1}{6000}$ th to $\frac{1}{24000}$ th of an inch, and averaging about $\frac{1}{10000}$ th of an inch. Their great peculiarity consists in their undergoing no change when treated by chemical re-agents, (acids, alkalies, and salts,) excepting after the lapse of a considerable time. The *dark pulpy portion* contained in the *interior* of the supra-renal body seems to be principally composed of a plexus of minute ramified veins, surrounded by the peculiar substance of the organ, and having sometimes amidst them a central venous sinus. Mr. Gulliver has frequently found in the blood of the supra-renal veins numerous minute spherules, which could not be distinguished from those of the glands.

No excretory duct has been found connected with these organs, the office of which is entirely unknown.

Vessels.—The supra-renal bodies receive *arteries* from three sources, viz. from the aorta, the phrenic, and the renal arteries. The distribution of their capillary vessels has already been mentioned.

The *veins*, which pass out from the centre, are usually united into one for each organ. The right vein enters the vena cava

inferior immediately, whilst the left after a longer course, terminates in the left renal vein.

The *lymphatics* are but little known.

lymphatics.

Nerves.—The nerves are exceedingly numerous. They are derived from the solar plexus of the sympathetic, and from the renal plexuses. According to Bergmann, some filaments come from the phrenic and pneumogastric nerves.

Nerves are very numerous.

THE URETERS.

The *ureters* are two nearly cylindrical tubes, one right, the other left, which conduct the urine from the kidneys into the bladder. The upper, dilated, funnel-shaped end of these excretory ducts, called the *pelvis of the kidney*, together with its branches and their ultimate divisions, named the *calices*, have already been described (p. 1192). Towards the lower part of the hilus of the kidney, the so-called pelvis becomes gradually contracted, and, opposite the lower end of the gland, assumes the name of *ureter*, which extends downwards from thence to the posterior and under part or base of the bladder, into which viscus the ureters of both sides open, after passing obliquely through its coats.

The ureters are continuous from kidneys to the bladder,

The ureters measure from sixteen to eighteen inches in length, and their ordinary width is about that of a large quill. They are frequently, however, dilated at intervals, especially near their lower end. The narrowest part of the tube, excepting its orifice, is that contained in the walls of the bladder.

their length, and form,

Each ureter (fig. 310, *u*.) passes, at first, obliquely downwards and inwards, to enter the cavity of the true pelvis, and then curves downwards, forwards, and inwards, to reach the side and base of the bladder (*a*). In its whole course, it lies close behind or beneath the peritonæum (*r*), and is connected to neighbouring parts by loose cellular tissue. Superiorly, it rests upon the psoas muscle, and is crossed, very obliquely, below the middle of the psoas, by the spermatic vessels, which descend in front of it. The right ureter is close to the inferior vena cava. Lower down, the ureter passes over the common iliac, or the external iliac vessels, behind the termination of the ileum on the right side and the sigmoid flexure of the colon on the left. Descending into the pelvis, and, entering the fold of peritonæum, forming the corresponding posterior false ligament of the blad-

course and connection in the male,

der, it gains the lateral part of the base of that viscus, upon which it runs downwards and forwards, below the obliterated hypogastric artery, and crossed upon its inner side, in the male, by the vas deferens (*i*), which passes down between the ureter and the bladder. In the female, the ureters run along the sides of the cervix uteri and upper part of the vagina before reaching the bladder, and hence they are proportionally somewhat longer than in the male.

Having reached the base of the bladder on each side, about two inches apart from one another, the ureters (fig. 311, *u*, *ú*,) enter its coats, and running obliquely through them for nearly an inch, passing at first through the muscular coat, and then between it and the mucous membrane, open at length upon the inner surface by two narrow and oblique slit-like openings, which are situated, in the male, about an inch and a half behind the prostate, and rather more than that distance from each other. This oblique passage of the ureter through the vesical walls, although allowing the urine to flow into the bladder, has the effect of preventing its return up the ureter towards the kidney.

Structure.—The walls of the ureter are pinkish or bluish white in colour. They consist externally of a dense, firm, cellular coat, which in quadrupeds decidedly contracts when artificially irritated, and probably contains pale muscular fibres. According to Huschke, it consists of two layers of longitudinal fibres, with an intermediate one composed of transverse fibres. It becomes continuous above at the calices, with the proper capsule of the kidney.

Internally, the ureter is lined by a thin and smooth *mucous membrane*, which presents a few longitudinal folds when the ureter is laid open. It is prolonged above upon the papillæ, and into the uriniferous tubes, and below becomes continuous with the lining membrane of the bladder. The epithelial particles are of the spheroidal or transitional form.

Vessels.—The ureter is supplied with blood from small branches of the renal, the spermatic, the internal iliac, and the inferior vesical arteries. The veins end in various neighbouring vessels. The *nerves* come from the inferior mesenteric, spermatic, and hypogastric plexuses.

Varieties.— Sometimes there is no funnel-shaped expansion of the

and in the female.

Entrance into the bladder is oblique.

Coats of ureters,—external, which is contractile,

and internal or mucous.

Vessels and nerves.

Occasional varieties.

ureter at its upper end into a pelvis, but the calices unite into two narrow tubes, which afterwards coalesce. Occasionally, the separation of these two tubes continues lower down than usual, and even reaches as low as the bladder, in which case the ureter is *double*. In rare cases, a triple ureter has been met with.

THE URINARY BLADDER.

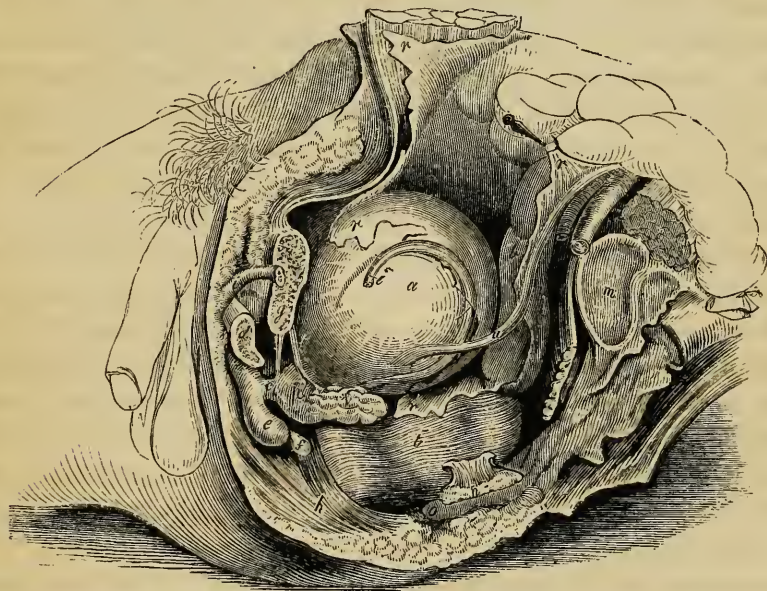
The *urinary bladder* (*vesica urinaria*) is the hollow membranous and muscular viscus which receives the urine poured into it through the ureters, retains it for a longer or shorter period, and finally expels it through the urethra.

The
bladder,

During infancy it is pyriform, and is found in the abdomen, but in the adult (fig. 310, *a*.) it is situated in the pelvic cavity

its situa-
tion,

Fig. 310.*



behind the pubes (*g*), and in front of the rectum (*b*) in the male; but separated from that intestine by the uterus and vagina in the female.

* Lateral view of the viscera of the male pelvis. (Quain's Arteries, Pl. LX.) *a*. Bladder. *b, b'*. Rectum. *c*. Membranous portion of the urethra. *d*. Section of left crus, or corpus cavernosum. *e*. Bulbous extremity of corpus spongiosum or bulb of urethra. *f*. Cowper's gland. *g*. Section of body of pubes. *h*. Sphincter ani muscle. *i*. Part of left vas deferens. *m*. Articular surface of sacrum. *n*. Spine of left ischium sawn off. *o*. Coccyx. *p*. Prostate gland. *r, r*. Peritonæum. *r'*. Cul-de-sac between bladder and rectum. *u*. Left ureter. *v*. Left vesicula seminalis.

size,
shape, &c.,

when
empty,

partly
filled,

or quite
distended.

The body
and cervix
or neck.

The means
of attach-
ment of the
bladder, by
true

The *size* and *shape* of the bladder, its *position* in the abdomino-pelvic cavity, and its *relations* to surrounding parts, vary greatly, according to its state of distension or collapse. When quite empty, the bladder lies deeply in the pelvis, appearing as a triangular sac, flattened before and behind, having its base turned downwards and attached, whilst its apex reaches up behind the symphysis pubis. When slightly distended, it is still contained within the pelvic cavity, and has a rounded form; but when completely filled, it rises above the brim of the pelvis, and becomes ovoidal, or egg-shaped, its larger end, which is also called the *base*, or *inferior fundus*, being directed downwards and backwards towards the rectum in the male and the vagina in the female; and its smaller end or *summit*, or *superior fundus*, pointing towards the lower part of the anterior wall of the abdomen. The long axis of the distended bladder is therefore inclined obliquely upwards and forwards from the base to the summit, in a line directed from the coccyx to some point between the pubes and the umbilicus. In being gradually distended, the bladder curves slightly forwards, so that it becomes more convex behind than in front, and its upper end is by degrees turned more and more towards the front of the abdomen. Lastly, the bladder, when filled, appears slightly compressed from before backwards, so that its diameter in that direction is less than from side to side. Its longest diameter in the male is from base to summit, but in the female, its breadth is greater than its height; and its capacity is said to be, on the whole, larger than in the former sex. The portion of the bladder situated between the base and the summit is often called the *body*.

At the lower part of the anterior surface of this organ, immediately in front of the base, is a narrow funnel-shaped portion, named the *cervix*, or *neck*, which forms the outlet of the bladder, and serves also to attach it below to the urethra. While freely moveable in all other directions upon surrounding parts, the bladder is still further fixed below to the inside of the pelvis, by certain reflections of the recto-vesical fascia, named the *true ligaments* of the bladder. It is supported, moreover, by firm cellular connections with the rectum or vagina, according to the sex, also by the two ureters, the obliterated hypogastric arteries, and the *urachus*, by numerous blood-vessels, and, lastly, by a

partial covering of the peritonæum, which, as it is being reflected to or from this organ in different directions, forms certain folds or duplicatures, named the *false ligaments* of the bladder. All these parts will now be separately described, as well as the relations of the different surfaces of the bladder itself, supposed to be moderately distended. and false ligaments.

The *anterior* surface is entirely destitute of peritonæum, and is placed behind the triangular ligament of the urethra, the subpubic ligament, the symphysis and body of the pubes, and, if the organ be full, the lower part of the anterior wall of the abdomen. It is connected to these parts by loose cellular tissue, and to the back of the pubes by two strong bands of the vesical fascia, named the *anterior* true ligaments. This surface of the bladder may be punctured above the pubes without wounding the peritonæum. In the female, the front of the bladder corresponds, beneath the arch of the pubes, with the part of the vulva between the orifice of the urethra and the clitoris. The front of the bladder.

The *summit* (sometimes named the *superior fundus*) is connected to the anterior abdominal wall by a median cord, named the *urachus*, which is composed of fibro-cellular tissue, mixed near the bladder with some muscular fibres. This cord, which becomes narrower as it ascends, passes upwards from the apex of the bladder behind the linea alba, and in front of the peritonæum, to reach the umbilicus, where it becomes blended with the dense fibrous tissue found in that situation. The urachus is the vestige of a foetal structure, to which we shall have again to advert. Two other rounded cords formed by the obliterated hypogastric arteries, and found one on each side of the urachus, also ascend from the bladder to the umbilicus. In front of these three cords, the summit of the bladder has no peritonæal covering, and when the viscus is filled, touches the abdominal parietes. Behind them, on the other hand, it receives a covering from that serous membrane, and has a few convolutions of the small intestine resting upon it. The summit or superior fundus. The urachus.

The *posterior surface* of the bladder is entirely free, and covered everywhere by the peritonæum (*r*), which is prolonged also for a short distance upon the base of the bladder. In the male, this surface is in contact with the rectum (*b*), and in the female with the uterus, some convolutions of the small intestine Posterior surface of bladder is free.

descending between it and those parts, unless the bladder be very full. Beneath the peritonæum, on each side of the lower portion of this surface, is found a part of the vas deferens (*i*).

Its sides are crossed by certain parts.

The *sides* of the bladder, which, when it is distended, are rounded and prominent, are each of them crossed obliquely by the cord of the obliterated hypogastric artery, which springs posteriorly from the superior vesical artery, and runs forwards and upwards towards the summit of the bladder. Behind and above this cord the side of the bladder is covered by the peritonæum, but below and in front of it the peritonæum does not reach the bladder, which is here connected to the sides of the pelvic cavity by loose cellular tissue, containing fat, and, near its anterior and lower part, by a broad expansion from the vesical fascia. The vas deferens (*i*) crosses over the lower part of this lateral surface, from before, backwards and downwards, and turning over the obliterated hypogastric artery, descends upon the inner side of the ureter (*u*) along the posterior surface to the base of the bladder.

The base or inferior fundus in the male presents

The *base* or *fundus* (bas fond; inferior fundus), is the widest and most depending part of the bladder, and demands special attention. It is directed somewhat backwards as well as downwards, and differs in its relations to other parts according to the sex. In the *male* it rests upon the second portion of the rectum (*b'*), and is covered posteriorly for a short space by the peritonæum, which, however, is soon reflected backwards from it upon the rectum, so as to form the *recto-vesical* pouch or *cul-de-sac* (*r'*). In front of the line of reflection of the serous membrane, the base of the bladder presents a triangular surface, destitute of peritonæum, and separated from the rectum by some dense fibro-cellular tissue only, which adheres to both organs. This triangular surface (fig. 311), is bounded at the sides by the vasa deferentia (*i*) and vesiculæ seminales (*s*), which are here firmly attached to the bladder, as they converge forwards to the prostate gland (*p*); behind, it is limited (at the line *a*) by the reflection of the peritonæum at the cul-de-sac, whilst its apex in front touches the prostate gland. It is in this space, which in the natural state of the parts is by no means so large as it appears after they are disturbed in dissection, that the bladder may be punctured from the rectum without injury to the peritonæum. In the *female*, the base of the

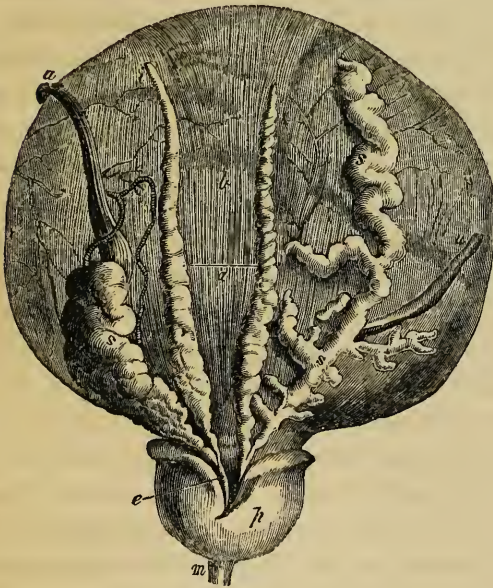
the recto-vesical cul-de-sac,

the vasa deferentia, and vesiculæ seminales.

In the female,

bladder is of less extent, and does not reach so low down in the pelvis as in the male; for it rests against the lower part of the anterior surface of the uterus and the anterior wall of the vagina, both of which organs intervene between it and the rectum. This part of the bladder adheres to the vagina, but the peritonæum forms a pouch between it and the uterus.

Fig. 311.*



The *cervix* or *neck* of the bladder, situated at the lower part of the anterior surface, and immediately in front of the base, is the constricted portion which is directly continuous with the urethra. In the female it is free, being merely surrounded by cellular tissue and blood-vessels, but in the male it becomes encircled by the prostate gland. In the male also, it is nearly horizontal, or even

slightly oblique in an upward direction, owing to the fundus of the bladder being on a somewhat lower level, but in the female its direction is obliquely downwards and forwards, for the cervix is the lowest part of the female bladder, and such is also the case in male infants. The neck of the bladder is supported in front and at the sides by the vesical fascia.

Ligaments of the bladder.—The *true ligaments* of the bladder, four in number, two anterior and two lateral, are all

* Base of the male bladder dissected (Haller). *a'*. Line of reflection of the peritonæum from the base of the bladder. *b*. Part covered by the peritonæum, the longitudinal muscular fibres being seen through the serous coat. *i*. Left vas deferens, ending in *e*, the left ejaculatory duct. *s*. Left vesicula seminalis, also joining the same duct. The right vas deferens, and the right seminal vesicle (which is marked *s, s*, and is unravelled), are also seen. *p*. Under side of prostate gland. *m*. Portion of membranous part of urethra. *u, u*. The ureters, the right one being turned aside.

derived from the vesical portion of the recto-vesical fascia. The *anterior ligaments*, one right, the other left, are two strong whitish bands which pass from the back of the pubes to the front of the neck and lower part of the anterior surface of the bladder. A few of the pale vesical muscular fibres are prolonged into them, and hence they are considered by some as tendons of attachment for the muscular fibres of the bladder. In the male, these anterior ligaments (*pubo-prostatic ligaments*), in passing backwards, first reach the upper surface of the prostate and cover in the anterior fibres of the levatores ani, which spread out on that gland and form the levatores prostatae. Between the two ligaments is a cellular interval, in which are found the dorsal vein of the penis, or of the clitoris. The *lateral ligaments*, much broader and thinner than the anterior, are the lateral portions of the vesical fascia, which proceed inwards to be fixed to the neck and side of the bladder, and (in the male) to the side of the prostate. (See page 445.)

are the two anterior,

or pubo-prostatic,

and the two lateral.

The false ligaments are two posterior,

two lateral,

and one superior.

The inner surface of bladder,

Peritonæal folds or false ligaments.—These are five in number. Two of them, named *posterior false ligaments*, or *recto-vesical folds*, (*plicæ semilunares*; Douglas,) run forward in the male along the sides of the rectum to the posterior and lateral aspect of the bladder, curving upwards when this latter is distended, and bounding the sides of the recto-vesical cul-de-sac of the peritonæum. In the female, these posterior folds pass forward from the sides of the uterus, and are comparatively small. The two *lateral false ligaments* extend from the iliac fossæ to the sides of the bladder; the *superior false ligament* (*ligamentum suspensorium*) formed by the projection of the ascending part of the epigastric arteries and the urachus, into a duplicature of the peritonæum, reaches from the summit of the bladder to the umbilicus.

Internal surface.—On opening the bladder, its internal surface is found to be lined by a smooth membrane, which is so loosely attached to the other coats, that in the flaccid condition of the organ it is nearly everywhere thrown into small wrinkles or folds, which disappear as soon as the bladder is distended. Besides these, the interior of the bladder is often marked by reticular elevations or ridges, corresponding with the fasciculi of the muscular coat.

At the lower and anterior part of the bladder is seen the

orifice leading from its neck into the urethra, around which the mucous membrane is corrugated longitudinally (see fig. 316). Immediately behind the urethral opening, at the anterior part of the fundus, is a small smooth triangular surface, having its apex turned forwards, which, owing to the firmer adhesion of the mucous membrane to the subjacent tissues, never presents any rugæ, even when the bladder is empty. This surface is named the *trigone* (trigone vesical; trigonum vesicæ, Lieutaud); at its posterior angles are the orifices of the two ureters, situated about $1\frac{3}{4}$ inch from each other, and about $1\frac{1}{2}$ inch from the anterior angle, which corresponds with the opening into the urethra. At the last named point is found a slight elevation of the mucous surface, named the *uvula vesicæ* (luette vesicale), which projects from below into the urethral orifice. In the female, the trigone is small, and the uvula indistinct. In the male, this last-named elevation lies a little in advance of the middle lobe of the prostate, and is sometimes prolonged on the floor of the prostatic portion of the urethra. It is formed by a thickening of the submucous tissue. It can scarcely act as a valve to the urethral orifice, but it is sometimes very much enlarged, and then obstructs that passage.

the orifice into the urethra.

The trigone,

and openings of ureters. The uvula vesicæ.

Differences in the female.

The *sides* of the trigone, especially when the muscular coat of the bladder is strong, are bounded by two slight ridges, which pass obliquely backwards and outwards to the orifices of the ureters, and indicate the course of two small bundles of muscular fibres. A prolongation of each of these ridges beyond the openings of the ureters is sometimes seen, caused, it would appear, merely by the lower ends of those canals, as they pass obliquely through the parietes of the bladder. The *posterior* boundary of the trigone is slightly curved, its concavity being directed backwards.

Boundaries of the trigone.

Structure.—The bladder is composed of a *serous*, a *muscular*, and a *mucous* coat, united together by cellular tissue, and supplied with vessels and nerves.

Structure of bladder ;

The *serous* or *peritonæal* coat is a partial covering, investing only the posterior and upper half of the bladder, and reflected from its summit, sides, and under surface, in the manner already described in detail.

its serous coat.

The *muscular* coat.—This consists of bundles of pale unstriped involuntary muscular fibres, which are arranged in two

its muscular coat.

principal but imperfect layers, distinguished, from their position and direction, into the *external* or longitudinal, and the *internal*, transverse or circular.

consists of external longitudinal fibres,

The *external* or *longitudinal* fibres are most distinctly marked on the *anterior* and *posterior* surfaces of the bladder. Commencing in front from the neck of the organ, from the anterior true ligaments, and, in the male, from the adjoining part of the prostate gland, they may be traced upwards along the anterior surface to the summit of the bladder, whence they may be followed down over the posterior surface and base to the under part of the neck of the bladder, where they become attached to the prostate in the male, and to the front of the vagina in the female. Upon the *sides* of the bladder the longitudinal fasciculi run more or less obliquely, and often intersect one another: in the male they reach the sides of the prostate. At the summit a few are continued along the urachus. The longitudinal fibres, taken together, constitute what has been named the *detrusor urinæ* muscle.

of which some form the detrusor muscle,

and of internal circular fibres,

The *internal* or circular fibres are, for the most part, transverse, but, upon the body of the bladder are scattered very thinly and irregularly, having various arrangements in different bladders. Towards the lower part of the organ, they assume a more decidedly circular course, and upon the fundus and trigone form a tolerably regular layer. Close to and around the cervix, immediately behind the prostate in the male, they densely encircle the orifice, and constitute what has been named the *sphincter vesicæ*, which, however, is not distinct from the other circular fibres.

some forming the sphincter muscle.

The ureters have special fibres.

The *muscles of the ureters* are the two muscular bundles, sometimes more clearly seen than at others (and especially in male subjects), which pass obliquely from behind the opening of the urethra, or from the uvula, backwards and outwards to the orifices of the ureters. In the male, these bundles meet behind the prostate, and there end by fibrous tissue in the middle lobe of that gland. They were known to Morgagni, but have more recently been fully described under the name of the "muscles of the ureters" by Sir C. Bell, who supposed that, during the contraction of the bladder, they might maintain the due obliquity of the lower end of the ureters, necessary to prevent reflux of urine into these tubes; others have thought that they

might facilitate the flow of urine into the bladder by stretching the ureters and their orifice downwards.

The muscular coat of the bladder forms so incomplete a covering, that when the organ is much distended, intervals arise in which the walls of the organ are very thin; and should the internal or mucous lining protrude in any spot through the muscular bundles, a sort of hernia is produced, which may go on increasing, so as to form what is called a vesical sacculus, or *appendix vesicæ*, the bladder thus affected being termed *sacculated*. Hypertrophy of the muscular fasciculi, which is liable to occur in stricture of the urethra or other affections impeding the issue of the urine, gives rise to that condition named the *fasciculated* bladder, in which the interior of the organ is marked by strong reticulated ridges or columns.

Muscular tunic is an incomplete layer, occasional protrusions through it.

Fasciculated bladder.

Next to the muscular coat, between it and the mucous membrane, but much more intimately connected with the latter, is a well-marked layer of cellular tissue, frequently named the *cellular*, or *vascular* coat. This submucous cellular layer contains a large quantity of very fine coiled fibres of elastic tissue.

The cellular coat.

The mucous membrane of the bladder is soft, smooth, and of a pale rose-colour. It is continuous above with that of the ureters and kidneys, and below with that lining the urethra. It adheres but loosely to the muscular tissue, except at the trigone, where it is in consequence always smooth. There are no villi upon the vesical mucous membrane, but it is provided with minute follicles, which are most abundant in the vicinity of the neck of the bladder. It is covered with an epithelium, the particles of which are intermediate in form between those of the columnar and squamous varieties. The vesical mucus (according to Mandl) is alkaline, and appears to contain alkaline and earthy phosphates.

The mucous membrane,

its epithelium.

Vessels.—The *superior vesical* arteries are the remaining pervious portions of the hypogastrics; in the adult they appear as branches of the internal iliac. The *inferior* vesical arteries are usually derived from the anterior division of the internal iliac. The uterine arteries also send branches to the bladder in the female. The neck and base of the organ appear to be the most vascular portions. The *veins* form large plexuses around the neck, sides and base of the bladder; they eventually pass

Vesical arteries,

veins,

absorbents,
and nerves.

into the internal iliac veins. The *lymphatics* follow a similar course. The *nerves* are derived partly from the hypogastric plexus of the sympathetic, and partly from the sacral plexus of the cerebro-spinal system. The former are said to be chiefly distributed to the upper part of the bladder, whilst the spinal nerves may be traced to its neck and base.

THE URETHRA.

The
urethra.

The urethra is a membranous tube directed in the median line from behind forwards, beneath the arch of the pubes; by one extremity it is continuous with the neck of the bladder, by the other it opens externally. In the *female*, it serves simply as the excretory passage for the urine; in the *male*, it conducts also the seminal fluid.

In the
female,
its length,

a. The *female urethra*, as compared with that of the other sex, is very short, representing only the commencing part of the male passage. It is only about an inch and a half in length, but is wide and capable of great distension; its ordinary diameter is about three or four lines, but it enlarges towards its vesical orifice. The direction of this canal is downwards and forwards, and it is slightly curved and concave upwards. It lies embedded in the upper or rather the anterior wall of the vagina, from which it cannot be separated; the two passages both perforate the triangular ligament; the upper one, or urethra, is covered by the anterior ligament of the bladder.

and direc-
tion.

The ex-
ternal
orifice
or meatus.

The external orifice, or *meatus urinarius*, opens in the vulva, beneath the symphysis pubis, nearly an inch below and behind the clitoris, between the nymphæ and immediately above the entrance to the vagina. It will be again noticed with the other parts in the vulva. From its orifice, which is the narrowest part of the canal, it passes upwards and backwards between the crura of the clitoris and behind the pubes, gradually enlarging into a funnel-shaped opening as it approaches and joins the neck of the bladder. There is also a dilatation in the floor of the canal, just within the meatus.

Mucous
membrane.

The mucous membrane is whitish, except near the orifice; it is raised into longitudinal plicæ, which are not entirely obliterated by distension, especially one which is particularly marked on the lower or posterior surface of the urethra. Near the bladder the membrane is soft and pulpy, with many tubular

mucous glands. Lower down these increase in size and lie in groups, between the longitudinal folds, and immediately within and around the orifice, the lips of which are elevated, are several larger and wider crypts.

The mucous glands.

The lining membrane is covered with a scaly epithelium, but higher up near the bladder the particles become spheroidal. The submucous cellular tissue contains elastic fibres. Outside this there is a highly vascular structure, in which are many large veins. Between the anterior and posterior layers of the triangular ligament, the female urethra is embraced by the fibres of the compressor urethræ muscle, which will be hereafter described (p. 1231).

The epithelium,

The *vessels* and *nerves* of the female urethra are very numerous, and are derived from the same sources as those of the vagina.

vessels and nerves.

b. The *male* urethra is much longer, and its anatomy more complex; from its additional function and anatomical connexions, the description of it is most conveniently associated with that of the organs of generation.

The male urethra elsewhere described.

ORGANS OF GENERATION.

THE MALE ORGANS OF GENERATION.

Male
organs.

The male organs of generation consist of the *testes* and their *excretory apparatus*, the *prostate* and *Cowper's glands*, and the *penis*, with the *urethra* or genito-urinary passage.

Taking the organs according to their local connection with parts previously described, rather than in a physiological order, we commence with

THE PROSTATE GLAND.

The prostate
gland;

its situation

and size.

The *prostate gland* (from *προϊστημι*, to stand before; fig. 310, *p*) is a firm glandular body, very much resembling a chestnut in shape and size, which surrounds the neck of the bladder and the commencement of the urethra, and is placed in the pelvic cavity, between and below the pubes and behind the triangular ligament. It has been compared to a truncated cone, compressed from above downwards, having its broader part or base turned backwards and upwards towards the neck of the bladder, and its blunted apex in the opposite direction towards the membranous part of the urethra. It usually measures about an inch and a half across at its widest part, an inch or rather more from its base to its apex, and about three quarters of an inch in depth or thickness. Its ordinary weight is about six drachms.

Its connec-
tions above,

below,

The anterior or upper surface of the prostate is flattened and marked with a slight longitudinal furrow: it is about half an inch or rather more beneath the pubic symphysis, and, as well as the sides of the gland, is connected to the pubic arch by a reflection of the pelvic fascia, forming the *pubo-prostatic ligaments* or *anterior ligaments* of the bladder. The posterior or under surface (fig. 311) is smooth, and is marked by a slight depression, or by two grooves, which meet in front, and corre-

spond with the course of the seminal ducts, as well as mark the limits of the lateral lobes in this situation; it is closely united to the rectum, just before the bowel turns downwards to reach the anus, by means of cellular membrane, which is destitute of fat; so that this surface of the gland and also its posterior border, can be felt by the finger introduced into the intestine.

The sides are convex and prominent, and are slung as it were by the anterior portions of the levatores ani muscles, which pass down, on either side, from the symphysis pubis and anterior ligament of the bladder, and spread out on the sides of the prostate. This part of each levator ani is occasionally separated from the rest of the muscle by cellular tissue; it has been named *levator prostatae* (p. 1054). The base of the gland is of considerable thickness, and is notched in the middle: its apex is turned towards the triangular ligament. As already stated, the prostate encloses part of the neck of the bladder and the commencement of the urethra.

and at
the sides.

Its levator
muscle.

The canal runs nearer to the upper than to the under surface of the gland, so that in general it is about two lines distant from the former and four from the latter; but it frequently differs greatly in this respect. The prostatic portion of the urethra is about an inch and a quarter long, and is dilated in the middle; it contains the verumontanum and the openings of the seminal and prostatic ducts, to be afterwards noticed. The common seminal ducts, which pass forwards from the vesiculæ seminales, also go through the lower part of the prostate, enclosed in a special canal, and open into the urethra. This gland is usually described as consisting of three lobes, two of which placed laterally and separated behind by the posterior notch, are of equal size; the third, or *middle* lobe, is a smaller rounded or triangular mass, intimately connected with the other two, and fitted in between them on the under side, lying beneath the neck of the bladder and the immediately adjacent part of the urethra. This third lobe is exposed by turning down the seminal vesicles and ducts, between which and the cervix vesicæ it is placed. When rather prominent in the bladder, it corresponds to the elevation already described in that organ, and named the uvula vesicæ; and when much enlarged, it projects in such a way as to impede or prevent the evacuation of the urine.

The urethra
passes
through it,

The lobes
are three.

Structure.—The prostate is enclosed in a dense fibrous coat,

The coats

of the
gland ;

which is continuous with the recto-vesical fascia and with the posterior layer of the triangular ligament, and is rather difficult either to tear or cut. Mr. Adams describes the fibrous capsule as divisible into two layers, between which the prostatic plexus of veins is enclosed.* The substance of the gland is spongy and more yielding ; its colour is reddish grey, or sometimes of a brownish hue. It consists of numerous small follicles or terminal vesicles opening into elongated canals, which unite into a smaller number of excretory ducts. These appear as pores or whitish streaks, according to the way in which they are exposed on a section. The epithelium in the vesicular terminations is thin and squamous, whilst in the canals it is columnar. The capillary bloodvessels spread out as usual on the ducts and clusters of vesicles, and their different elements are united by areolar tissue, and supported by processes of the deep layer of the fibrous capsule (Adams). The ducts open by from twelve to twenty or more orifices upon the floor of the urethra, as will presently be noticed together with other parts to be seen in the prostatic portion of that canal.

its ducts
and fol-
licles ;

their open-
ings in the
urethra.

Vessels and
nerves.

Vessels and Nerves. The prostate is supplied by branches of the vesical, hæmorrhoidal, and pudic *arteries*. Its *veins* form a plexus around the sides and base of the gland, which is particularly marked in old subjects. These veins communicate in front with the dorsal vein of the penis, and behind with branches of the internal iliac vein. According to Mr. Adams, the lymphatics, like the veins, are seen ramifying between the two layers of the fibrous capsule. The *nerves* are derived from the hypogastric plexus.

Fluid of the
prostate.

Prostatic fluid. This is mixed with the seminal fluid during emission ; as obtained from the human prostate soon after death, it has a milky aspect, which is ascribed, by Mr. Adams, to the admixture of a large number of epithelial cells, and he thinks it probable that, as discharged during life, it is more transparent. According to the same observer, the prostatic fluid has an acid reaction, and presents, under the microscope, numerous molecules, epithelial particles, both squamous and columnar, and granular nuclei, about $\frac{1}{3300}$ inch in diameter. As age advances, this gland is disposed to become enlarged ; and its ducts often contain small round concretions about the size of a millet seed, which are composed of carbonate of lime and animal matter.

* Cyclop. of Anat., vol. iv., p. 147.

THE PENIS.

The penis, which supports the greater part of the urethra in the male, is composed principally of an erectile tissue, occupying three long and nearly cylindrical compartments, or forming three bodies (*corpora*), as they are termed. Of these, two, named *corpora cavernosa penis*, placed side by side, form the principal part of the organ, whilst the other, situated behind or beneath the two preceding, surrounds the canal of the urethra; it is hence named *corpus cavernosum urethræ* or *corpus spongiosum*.

The penis is attached behind to the front of the pubes, and to the pubic arch, by what is termed the *root*; in front it ends in an enlargement named the *glans*. The intermediate portion or *body* of the penis, owing to the relative position of its three compartments, has three sides, and three rounded borders; its widest side is turned upwards and forwards, and is named the *dorsum*. The entire organ is invested by the common *integument*, which will be immediately noticed. The *glans* penis, which is slightly compressed above and below, presents at its summit a vertical fissure, the external orifice of the urethra; its base, which is wider than the body of the penis, forms a rounded projecting border, named the *corona glandis*, behind which is a constriction named the *cervix*; the posterior boundary of the *glans* thus marked off passes down on each side of the under surface, and ends behind the urethral opening, on the sides of a median fold of skin, named the *frænum*.

The Integuments. The *prepuce* or *foreskin* (*præputium*) is a loose circular fold of skin, which is attached around the penis behind the *cervix*, and covers the *glans*. The integument of the penis, which is continued from that upon the pubes and scrotum, forms a close and simple investment, as far as the neck of the *glans*. At this part it leaves the surface and is doubled up to form the *prepuce*. The inner layer of this fold returns to the penis behind the *cervix*, where it is firmly attached, and becoming thus again adherent, is continued forwards over the *corona* and *glans*, as far as the orifice of the urethra, where it meets with the mucous membrane of the urethra, and behind that orifice forms the *frænum of the prepuce*. Upon the body of the penis the skin is very thin, entirely free from fat, and, excepting at the root, from hairs also, in these respects differing

The penis,

composed
of three
corpora.Its root,
glans,
body,and
dorsum.

The glans;

its corona
and cervix.The prepuce
or fore-
skin :

its frænum.

remarkably from that on the pubes, which is thick, covers a large cushion of fat, and, after puberty, is beset with hairs: the skin of the penis is moreover very moveable and distensible, and is dark in colour. At the free margin of the prepuce the integument changes its character, and approaches to that of a mucous membrane, being red, thin, and moist. Numerous lenticular glands are collected around the cervix of the penis and corona; they are named the *glands of Tyson* (*glandulæ Tysoni, vel odoriferæ*), and secrete a sebaceous matter of a peculiar odour (*smegma præputii*) which appears to contain caseine, and easily runs into decomposition. Upon the glans penis the membrane again changes its character; it ceases to contain glands, but its papillæ are highly developed and extremely sensitive, and it adheres most intimately and immoveably to the spongy tissue of the glans.

The glands
of Tyson.

Beneath the skin, on the body of the penis, the ordinary superficial fascia is very distinct; it is continuous with that of the groin, and also with the dartoid tissue of the scrotum. Near the root of the organ there is a dense band of fibro-elastic tissue, named the *suspensory ligament*, lying amongst the fibres of the superficial fascia; it is triangular in form; one edge is free, another is connected with the fore part of the pubic symphysis, and the third to the dorsum of the penis, with the fibrous structures of which it is blended opposite the divergence of the two corpora cavernosa.

The sus-
pensory
ligament.

The integuments of the penis are supplied with blood by branches of the dorsal artery of the penis and external pudic; the veins join the dorsal and external pudic veins.

THE CORPORA CAVERNOSA.

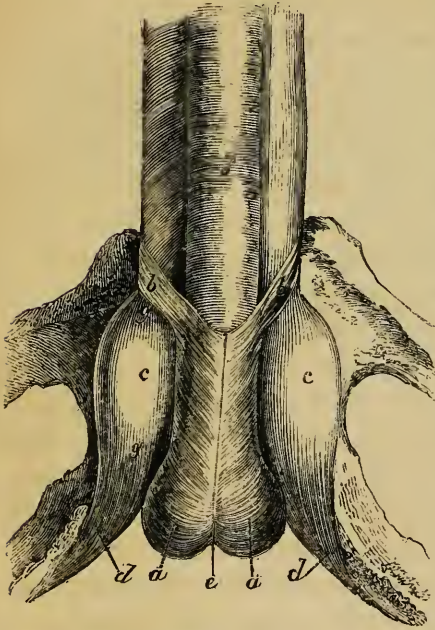
The *corpora cavernosa* form the principal part of the body of the penis, and necessarily determine its form and consistence; and it is owing to the changes which can take place in the erectile tissue within them, that the size and direction of the organ undergo such great alterations. The two corpora cavernosa, which exactly correspond, represent two cylindrical or rather fusiform bodies, placed side by side, flattened on their median aspects, and intimately blended together along the middle line, for the anterior three-fourths of their length, whilst at the back part they separate from each other in form of two tapering processes named *crura* (fig. 312,

The corpora
cavernosa:

their crura

c, c), the whole somewhat resembling the capital letter Y. Commencing behind by a pointed extremity somewhat above the tuberosities of the ischia (*d*), these crura become gradually

Fig. 312.*



enlarged, and are attached, one on each side, to the rami of the ischia and pubes: continuing to ascend, and then advancing from the bones, they approach and speedily become united to each other at the root of the penis. Immediately before their union each of them swells into a slight enlargement (*g to g*), so as to form, what are named by Kobelt, the *bulbs of the corpora cavernosa*, parts which are

and bulbs;

embraced by the erectores penis muscles (*d*), and which attain a much greater proportionate development in some quadrupeds. Beyond this point they are again slightly constricted, and are joined firmly together along the middle line to form the body of the penis, and finally becoming smaller and somewhat pointed again in front, are completely fused together into a single anterior rounded extremity, which is covered by the glans penis and closely connected to its base.

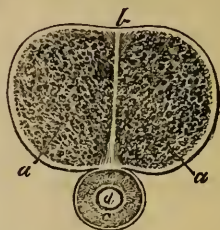
The under surface of the united cavernous bodies presents a deep longitudinal groove, in which is lodged the corpus spongiosum (*f*), containing the greatest part of the canal of the urethra. The upper or anterior surface is also marked with a slight median groove for the dorsal vein of the penis, and near the root is attached to the pubes by the suspensory ligament.

* Part of the ossa pubis and ischia, with the root of the penis attached (Kobelt).—*a, a*. Accelerator urinæ muscle, embracing the bulb of the urethra, which is slightly notched in the middle line, *e*, behind. *b, b*. Anterior slips of the accelerator muscle, which pass round to the dorsum of the penis. *c, c*. Crura of the penis. *d, d*. Erectores penis muscles lying on the crura. *f*. The corpus spongiosum urethræ. *g to g*. Enlargement of the crus, named the bulb of the corpus cavernosum.

their structure and form

Structure. A transverse section (fig. 313) through the penis, besides illustrating the structure of the cavernous bodies, shews their form and connection with the other parts. Above, and at the sides, are seen the section of the two semi-cylindrical cavernous bodies (*a, a*), bounded by a strong fibrous envelope, containing a mass of spongy erectile tissue in their interior, and separated by a vertical fibrous septum in the median plane (*b*). Beneath and between them is the other erectile mass, named the corpus spongiosum (*c*), surrounding the canal of the urethra (*d*).

Fig. 313.*



The median septum is incomplete,

The median septum is thick and complete behind, where the two corpora cavernosa first meet each other; but further forward it becomes thinner, and imperfectly separates their two cavities, for it presents, particularly towards the anterior extremity, numerous clefts or fissures, extending from the dorsal to the urethral edge of the septum, and admitting of a free communication between the erectile tissue of the two sides. From the direction of these slits, the intermediate white portions of the septum are made to resemble in arrangement the teeth of a comb, and hence it is named *septum pectiniforme*.

and named pectiniform.

The dense outer coat.

The external fibrous investment of the cavernous structure is white and dense, from half a line to a line thick, and very strong and elastic. It is composed for the most part of longitudinal bundles of shining white fibres. It is, perhaps, the strongest fibrous tunic in the whole body, but yet it most readily admits of distension up to a certain point. The septum is composed of the same kind of fibres.

The internal areolar structure.

From the interior of the fibrous envelope, and from the sides of the septum, numerous lamellæ, bands and cords composed also of an extensible fibrous tissue, and named *trabeculæ*, pass inwards and run through and across the cavity in all directions, thus sub-dividing it into a multitude of interstices, and giving the entire structure a spongy character. Within these interstices is lodged an intricate plexus of veins, into which the arteries open.

* Section of the corpora cavernosa and corpus spongiosum urethræ. *a, a*. Erectile tissue of corpora cavernosa. *b*. Section of septum pectiniforme. *c*. Corpus spongiosum. *d*. Canal of the urethra.

a. The trabeculæ, whether lamelliform or cord-like, are larger and stronger near the circumference than along the centre of each cavernous body, and they also become gradually thicker towards the crura. The interspaces, on the other hand, are larger in the middle than near the surface, and also become larger towards the fore-part of the penis. The trabeculæ contain the ordinary white fibrous tissue and fine elastic fibres. A pale, reddish tissue has been observed in them by Müller and others, which has been regarded as composed of involuntary muscular fibres; this tissue is much more abundant in the penis of the horse and ass: according to Müller, it resembles muscular substance in yielding no gelatine on boiling, and in its solution in acetic acid being precipitated by the ferrocyanide of potassium.

The
trabeculæ.

b. The veins completely fill the inter-trabecular spaces; their communications are so free and so abundant that on a section the cavernous structure appears a labyrinth of intercommunicating venous areolæ divided by the trabecular tissue. The walls of the veins are very thin, and they are lined by a squamous epithelium. The inter-trabecular veins of the two sides communicate freely through the septum, especially in front; but not directly with those of the corpus spongiosum of the urethra. They return their blood partly by a series of branches which escape between the corpora cavernosa and the corpus spongiosum, and which, accompanied by veins from the latter, mount on the sides of the penis to the vena dorsalis (p. 643), partly by short veins issuing at the upper surface, and immediately joining the dorsal vein, but principally by veins passing out near the root of the penis and joining the prostatic plexus and pudendal veins. According to Kobelt, there are also communications with the cutaneous veins on the abdomen.

The veins
and venous
cells.

c. The arteries of the corpora cavernosa are branches of the pudic artery. The proper cavernous arteries (*profundæ penis*), right and left, supply them chiefly, but the dorsal artery of the penis also sends twigs through the fibrous sheath, along the upper surface, especially in the fore part of the penis (p. 579). Kobelt describes a distinct small branch of the pudic artery which enters the bulbous enlargement of each corpus cavernosum; he, moreover, states that the arteriæ profundæ of the two sides form an anastomotic arch, from which the proper

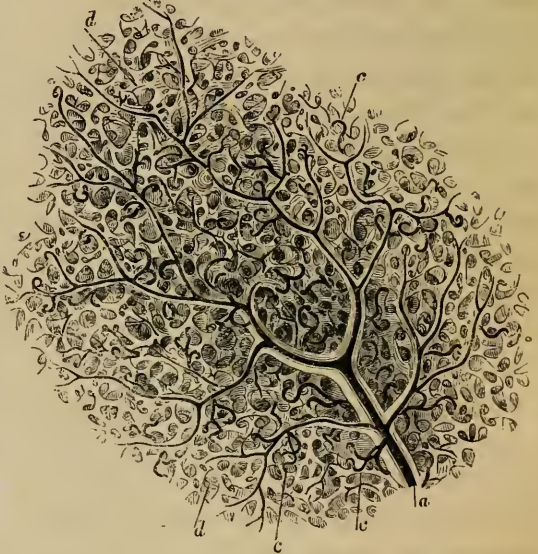
The arteries,

cavernous arteries are given off. Within the cavernous tissue, the numerous branches of the arteries are supported by the trabeculæ, in the middle of which they run (fig. 314, *a*). There is some uncertainty as to their mode of termination, but it is generally assumed

end in capillaries,

that they end in capillaries which open into minute commencing veins, as in other parts. Valentin, however describes the minutest arterial twigs as ending by rather wide funnel-shaped orifices, which open at once into the venous cavities; but this has not been confirmed. Müller has described them as terminating in two

Fig. 314.*



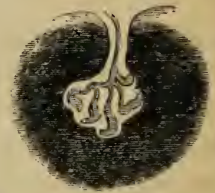which are nutritive,

modes: according to him, some of them, which he considers as the *nutritive* arteries, end in a capillary network, which leads in the usual way to the veins; but others, which were first described by the same observer, terminate in an entirely different and peculiar way. Small ramuscles, he says, consisting of short tendril-like branches (*c*), come off from the sides of the trabecular arteries, and projecting into the vein so

or of a peculiar kind, named helicine.

as to be covered by its lining membrane, end abruptly by dilated extremities (fig. 315). Sometimes they are single, and sometimes in tufts; he has named them the "helicine arteries" (*arteriæ helicinæ*). The existence of these little vessels was

Fig. 315.†



* Portion of the erectile tissue of the corpus cavernosum magnified, to shew the areolar structure and the distribution of the arteries (Müller). *a*. A small artery, supported by the larger trabeculæ, and branching out on all sides. *c*. The tendril-like arterial tufts, or helicine arteries of Müller. *d*. The areolar structure formed by the finer trabeculæ.

† A single tuft or helicine artery projecting into a vein, more highly magnified (Müller).

denied strenuously by Valentin, who thought they were the loose flexuous ends of the vessels of the smallest trabeculæ coiled up by the retraction of the latter after they have been broken or cut across in making a section. They may, however, be seen in the deepest cells, which have not been affected by the knife; and the observations of Krause, Hyrtl, and Erdl appear to confirm the original statement of Müller, as far at least as regards their natural existence. It was supposed by Müller that the dilated ends of these helicine arteries opened into the venous cavities, and Krause also adopts this view; but no opening has been seen in them, and as Müller himself admits, they may be merely arterial diverticula. They are most abundant in the posterior part of the corpora cavernosa and are found in the corresponding part of the corpus spongiosum also; but they have not been seen in the glans penis. They are most distinct in man, but whatever may be their use, they do not appear to be essential to the process of erection.

Different opinions on these vessels.

CORPUS SPONGIOSUM.

The *corpus spongiosum urethræ* commences in front of the triangular ligament of the perinæum, between the diverging crura of the corpora cavernosa, somewhat behind their point of junction, and below the membranous portion of the urethra, by an enlarged and rounded extremity named the *bulb* (figs. 310, *e*; 340, *r*). From thence it extends forwards as a cylindrical, or slightly tapering body, lodged in the groove on the under side of the united cavernous bodies, as far as their blunt anterior extremity, over which it expands so as to form the glans penis already described.

The corpus spongiosum forms both the bulb and the glans.

The posterior bulbous extremity, or *bulb of the urethra* (figs. 310, 312, *e*), varies in size in different subjects. It receives an investment from the triangular ligament, and is embraced by the accelerator urinæ, or bulbo-cavernous muscle (*a, a*). The canal of the urethra (fig. 310, *c*) passes into the bulb behind and above, so that the latter projects below and conceals the membranous portion of that canal. This projecting part of the bulb exhibits, more or less distinctly, a subdivision into two lateral portions or lobes, between which a slight furrow externally and a slender fibrous partition internally extends for a very short distance forwards: in early infancy this is more marked.

The bulbs of the urethra.

It is above and between these two halves that the urethra enters, surrounded by a portion of the spongy tissue, named by Kobelt the *colliculus bulbi*, from which a layer of venous erectile tissue passes back upon the membranous portion of the urethra, and also upon the prostatic part, to the neck of the bladder, lying closely beneath the mucous membrane. From what has preceded, it will be evident that, at first, the urethra is nearer the upper than the lower part of the corpus spongiosum, but it soon gains, and continues to occupy the middle of that body.

The
colliculus
bulbi.

Structure
of spongy
body,
is also
erectile.

Its arteries,

veins,

lymphatics,

Structure.—This is essentially the same as that of the corpora cavernosa, only more delicate. Like the corpora cavernosa, it is distended with blood during erection; but never acquires the same hardness. The outer fibrous tunic is much thinner; the trabeculae of the spongy tissue are finer and more equal in size, and the veins form a nearly uniform plexus between them; in the glans the meshes of this plexus are smallest and most uniform. The helicine arteries are also found in the spongy body, excepting in the part which forms the glans penis. A considerable artery derived from the internal pudic (p. 579), enters the bulb on each side, and supplies the greater part of the spongy body, sending branches as far as the glans penis, which, however, is chiefly supplied by the arteria dorsalis. Besides these, Kobelt describes, as constantly present, another but much smaller branch of the pudic artery, which, he says, enters the bulb on the upper surface, about an inch from its posterior extremity, and runs forwards in the corpus spongiosum to the glans. *Veins* issue from the glans and adjoining part of the spongy body, to end in the vena dorsalis penis; those of the rest of the spongy body for the most part pass out backwards through the bulb, and end in the prostatic and pudic venous plexuses: some emerge from beneath the corpora cavernosa, anastomose with their veins, and end partly in the cutaneous venous system of the penis and scrotum, and partly in the pudic and obturator veins.

The *lymphatics* of the penis form a dense network on the skin of the glans and prepuce, and also underneath the mucous lining of the urethra. They terminate chiefly in the inguinal glands. Deep-seated lymphatics are also described as issuing from the cavernous and spongy bodies and passing under the

arch of the pubes, with the deep veins, to join the lymphatic plexuses in the pelvis.

The *nerves* of the penis are derived from the pudic and from the hypogastric plexus of the sympathetic; they are described at pp. 868 and 900. and nerves.

URETHRA OF THE MALE.

The *male urethra* extends from the neck of the bladder to the extremity of the penis. Its total length has been very differently stated by anatomists, and, indeed, varies much according to the length of the penis, and the condition of that organ. An examination of a great number of cases gave as the greatest length $9\frac{1}{2}$ inches, and the least $7\frac{1}{2}$.^{*} Its diameter varies at different parts of its extent, as will be stated more particularly in detail. The tube itself consists essentially of a continuous mucous membrane, supported by an outer layer of submucous tissue connecting it with the several parts through which it passes. In accordance with the name or character of those parts, three divisions of the urethra are separately described as the *prostatic*, *membranous*, and *spongy* portions. The urethra : its length and width ; both vary.

1. The first, or *prostatic portion*, is the part which passes through the prostate gland. It is from 12 to 15 lines in length, is the widest part of the canal, and is larger in the middle than at either end: at the neck of the bladder its diameter is nearly 4 lines, then it widens a little, so as to be rather more than 4 lines, and in old persons 5 or 6, after which it diminishes like a funnel, until, at its anterior extremity, it is smaller than at its commencement. It passes through the upper part of the prostate, above the middle lobe, so that there is more of the gland below it than above. Though enclosed in the firm glandular substance, it is more dilatable than any other part of the urethra; but at its upper part, immediately at the neck of the bladder, it is, as elsewhere stated, much more resistant. The transverse section of the urethra, as it lies in the prostate, is triangular, the apex being turned downwards. Its three portions. The prostatic portion : its dimensions, connections, and form ; its interior.

The lining membrane of the prostatic portion of the urethra is thrown into longitudinal folds, when no fluid is passing along

* Whately on Strictures.

It contains
the caput
gallinaginis,

the pros-
tatic sinus,

and the
sinus
pocularis.

it; it forms no proper valve at the neck of the bladder, but the elevation named the *uvula vesicæ* is sometimes seen there. Somewhat in advance of this, and along the floor of the passage, projects a narrow median ridge about 8 or 9 lines in length, and $1\frac{1}{2}$ line at its greatest height; this ridge gradually rises into a peak and sinks down again at its anterior or lower end, and is formed by an elevation of the mucous membrane and subjacent tissue. This is the crest of the urethra (*crista urethræ*), more generally called *caput gallinaginis* and *verumontanum*. On each side of this ridge the surface is slightly depressed, so as to form a longitudinal groove, named the *prostatic sinus*, the floor of which is pierced by numerous foramina, the orifices of the prostatic ducts. Through these a viscid fluid oozes on pressure; the ducts of the middle lobe open behind the urethral crest, and some others open before it.

At the fore part of the most elevated portion of the crest, and exactly in the middle line, is a recess usually named the *sinus pocularis*, upon or within the margins of which are placed the slit-like openings of the common seminal, or ejaculatory ducts, one at each side. This median depression was described by Morgagni, who found it distinctly present in twelve out of fifteen cases;* and it has been generally noticed by anatomists and surgical writers since his time, but it has lately attracted renewed attention, as being the probable analogue of the uterus in the other sex. With this view it has been examined by Weber, and named by him *vesica prostatica*:† by Huschke it is more appropriately designated the *utricle* (*utrículus*).‡ It forms a cul-de-sac running upwards or backwards, from three to five lines deep, and usually about one line wide at its entrance and for some distance up, but acquiring a width of at least two lines at its upper end or fundus. The prominent walls of the narrow portion form the urethral crest, and its fundus appears to lie behind and beneath the middle lobe, and between the two lateral lobes of the prostate. Its parietes, which are distinct, and tolerably thick, are composed of fibrous tissue and mucous membrane, and inclose on each side the

* *Adversaria Anat.* iv. animad. 3. p. 6.

† E. H. Weber, *Zusätze zur Lehre vom Baue und Verriehlungen der Geschlechts-Organe*, 1846.

‡ Semmerring's *Anatomic*, vol. v.

ejaculatory duct; numerous small glands open on its inner surface. According to Kobelt and others, the caput gallinaginis contains some well-marked erectile tissue, and it has been supposed that this eminence when distended with blood, may offer an obstacle to the passage of the semen backwards into the bladder.

2. The *membranous* portion of the urethra (fig. 310 c.), comprises the part between the apex of the prostate, and the bulb of the corpus spongiosum. It measures three quarters of an inch or an inch along its upper, but only about half an inch on its lower surface, in consequence of the projection backwards of the bulb beneath it. This is the narrowest division of the urethra. It is placed beneath the pubic arch, the upper concave surface being distant nearly an inch from the bone, leaving an interval, occupied by the dorsal vessels and nerves of the penis, by cellular tissue, and some muscular fibres. Its lower convex surface is turned towards the perinæum, opposite to the point of meeting of the transverse muscles: it is separated by an interval from the last part of the rectum. About a line in front of the prostate, at a distance of nearly an inch below the pubic arch, the membranous part of the urethra passes through the posterior layer of the triangular ligament of the urethra, and is then placed between that and the anterior layer through which it passes some way further forwards, but both of these fibrous membranes are prolonged upon the canal, the one backwards and the other forwards. Between these two layers the urethra is surrounded by a little erectile tissue, by some veins, and also by the fibres of the *compressor urethræ* muscle: beneath it, on each side, are Cowper's glands. This portion of the urethra is more forcibly acted on by muscular structure, in consequence of the surrounding muscular fibres immediately investing its outer surface.

The membranous portion of urethra is narrowest.

3. The *spongy portion* of the urethra, by far the longest and most variable in length and direction, includes the remainder of the canal or that part which is surrounded by the erectile tissue of the corpus spongiosum. Continuing from the membranous part, it ascends at first in front of the symphysis pubis, and then bends downwards and descends to the extremity of the penis. Its length is about six inches; and its form and diameter vary at different parts. Thus the part contained within

The spongy portion of urethra;

includes the bulbous portion,

the bulb, sometimes distinguished as the *bulbous portion*, is somewhat dilated, especially on its floor. The succeeding portion, as far as the glans, is of uniform size, being intermediate in this respect between the bulbous and membranous portions, and averaging three lines or upwards. Seen upon a cross section it appears like a transverse opening. The part situated in the glans has, on the contrary, a vertical direction on a section, and is again considerably dilated, forming what is named the *fossa navicularis*, which is about four or six lines in length, and is most evident in form of a depression on the floor of the urethra.

and the fossa navicularis.

The external orifice of urethra is contracted.

Lastly, at its orifice, which is a vertical fissure about two and a half to three lines in extent, and bounded by two small lips, the urethra is again contracted and reaches its narrowest dimensions. In consequence of its form, and also of the resistant nature of the tissues at its margin, this opening does not admit so large an instrument as even the membranous portion of the canal.

The direction of the urethra, in different conditions.

General direction of Urethra.—Considered as a whole in the flaccid condition of the penis, the urethra describes two curves, so as somewhat to resemble an italic *S*; the prostatic portion runs downwards and forwards,—the membranous portion curves upwards, diverging from the rectum at a considerable angle,—the bulbous portion continues to ascend, and lastly, having bent down again in front of the pubes, the remainder of the spongy portion descends. When the penis is in a state of erection, the urethra describes only a single curve, having its concavity turned upwards. From the details already given, it will further be seen that there are *three* dilatations along the course of the urethra; viz. the prostatic sinus, the bulbous sinus, and the fossa navicularis.

The mucous membrane:

Mucous Membrane.—The lining membrane of the urethra, which forms a part of the genito-urinary mucous membrane, is continuous, on the one hand with that of the bladder, ureters, and kidneys, and on the other with the integument of the glans penis; it is also prolonged, as it were, throughout the whole length of the seminal, prostatic, and other ducts. It is whitish opposite the prostate, but redder further down; in the variable parts of the urethral canal it is thrown into longitudinal folds, which disappear during the state of distension. The seminal and prostatic ducts open into the prostatic portion. In the

its characters and glands.

bulbous portion, near its anterior end, are the two openings of the ducts of *Cowper's glands*.

These little glands themselves (fig. 310, *f*.) are seated further back than the bulb, beneath the fore-part of the membranous portion of the urethra, between the two layers of the triangular ligament, the anterior layer supporting them against the urethra. The arteries of the bulb pass above, and the transverse fibres of the compressor urethræ beneath these glands. They are two small firm rounded bodies, about the size of peas, and of a deep yellow colour. They are compound vesicular or racemose glands, composed of several small lobules held together by a firm investment. The branched ducts, which commence in cellular crypts, unite to form a single excretory duct for each gland, which runs forwards with its fellow for about an inch or an inch and a half beneath the mucous membrane, and the two terminate in the floor of the bulbous part of the urethra by two minute orifices opening obliquely. These glands secrete a viscid fluid, the use of which is not known; their existence is said not to be constant, and they appear to diminish in old age: sometimes there is only one such gland.

Cowper's glands.

Occasionally a third glandular body is found situated in front of and between Cowper's glands; this has been named the *anterior prostate* or *anti-prostatic gland*.

Sometimes a third gland.

The whole lining of the urethra is, moreover, beset with simple mucous glands and follicles, varying much in size. Besides these, there are larger recesses or lacunæ, opening by oblique orifices turned forwards or down the canal. These are most abundant along the floor of the urethra, especially in its bulbous part. One large and conspicuous recess, situated on the upper surface of the fossa navicularis, is named the *lacuna magna*.

The mucous crypts,

and lacuna magna.

MUSCLES OF THE PENIS AND URETHRA.

Erector penis, or *ischio-cavernosus* (figs 273, 339, 340, *c*, *c*; fig. 312, *d*, *d*).—This muscle embraces the unattached surface of the crus penis, and is curved to correspond. It arises behind the extremity of the crus penis from the tuber ischii (on the inner aspect of the bone), and also along the inner and the outer side of the crus, from the corresponding margins of the ramus of the pubes. From these points of origin the fleshy fibres are directed forward to a tendinous expansion,

Erector penis muscle.

which is spread over the lower surface of the crus penis at its fore-part.

This muscle serves to compress the erectile tissue, with which its tendinous fibres are connected, and thus it contributes to produce, or at least maintain, the erection of the penis.*

Accelerator
urinæ
muscle.

Accelerator urinæ—ejaculator seminis, or bulbo-cavernosus (figs. 273, 339, 340, *b, b*; fig. 312, *a, a*).—This is a single muscle, consisting of two symmetrical parts, which together surround a portion of the erectile structure of the penis, the fibres being connected at both ends.

The fleshy fibres of the muscle take origin from the central tendon of the perinæum (by means of which structure the accelerator is connected with the sphincter ani, together with the two transverse muscles), and from the median tendinous raphé (*e*) interposed between the two halves of the muscle. The larger number of the fibres is directed round the bulb and adjoining part of the corpus spongiosum urethræ, and those from opposite sides are joined above that body by a strong aponeurosis. At its fore-part, a portion of the muscle (*b, b*) passes over the sides of the corpus cavernosum, to the dorsum of the penis, to be inserted into a fascia, which covers the dorsal vessels of the organ. The fibres which invest the posterior and most prominent part of the bulb are concealed, more or less, by those contiguous to them; hence they have been described as constituting a deep layer of the muscle. This muscle compresses the the bulb and adjoining part of the corpus spongiosum of the urethra so as to evacuate fluid lodged in the canal, as well as increase the turgescence of the glans during erection.

Transverse
perinæal
muscle.

The *transverse muscle* of the perinæum (figs. 273, 339,

* By Krause the muscles of the two sides have been described as in some cases connected by a thin tendinous expansion, which, according to that anatomist, extends along the outer side of the penis over the dorsal surface of the organ, and at the same time over the vessels lying upon it (Müller's Archiv. 1832), but this connexion between the muscles has been in vain sought for by Theile and Kobelt (Die männlichen und weiblichen Wollust-Organ, 1844). Mr. Houston has also described (Dublin Hosp. Reports, vol. v.), under the name of *compressores venæ dorsalis penis*, two slips of muscle, separated from the erectors penis on each side by an interval, though apparently belonging to them. They are said to arise from the rami of the pubes, above the origin of the erector muscles and crura of the penis, and, ascending forwards, are inserted above the dorsal vein, by joining each other in the middle line. The presence of such muscular slips in the human subject must be very rare.

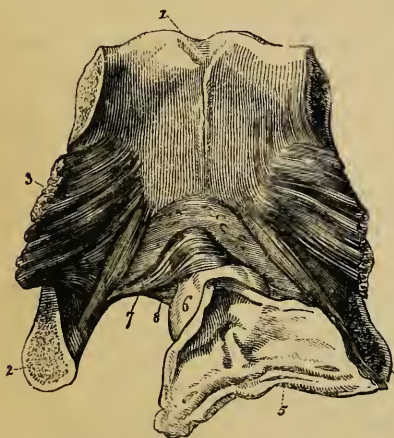
d, d) arises from the inner surface of the ascending ramus of the ischium, and is directed transversely or obliquely forwards and inwards to join with the muscle of the opposite side, as well as with the sphincter ani and accelerator urinæ at the middle of the perinæum; the several muscles being connected by fibrous or dense cellular tissue, which is known as the central tendon of the perinæum. This muscle supports the perinæum, and is accessory to the levator ani. It is said to be sometimes wanting.

Besides the transverse muscle, one or more small slips of muscular fibres are occasionally found on the same plane with it, and connected at one end like that muscle with the bone, while by the other end some slips are joined with the fibres of the accelerator urinæ (or constrictor vaginæ in the female), and others with the external sphincter ani.

Muscular fibres of the urethra.—With the membranous portion or isthmus of the urethra of the male is connected a considerable mass of muscular structure, to which the general term of “compressor of the canal” is applicable; but it consists of parts which will be noticed separately. The whole

Muscles of urethra.

Fig. 316.*



is placed between the layers of the triangular ligament or the deep perinæal fascia, with the arteries of the bulb and Cowper's glands.

Compressor urethrae (new muscles of the membranous part of the urethra, Guthrie; compressor isthmi urethrae; constrictor urethrae membranaceæ, Müller).—This muscle consists of two strata (fig. 316, 7, 8), one of which passes transversely above the ure-

Compressor urethrae.

Transverse fibres.

thra, while the other is beneath the canal. The two layers

* Posterior view of the pubes, with part of the bladder and urethra attached (Santorini).—1. Body. 2. Ramus of the left os pubis. 3. Obturator internus muscle. 4. Urethra. 5. Portion of the fundus and neck of the bladder laid open, shewing the orifices of the ureters, the opening leading into the urethra, and the part called the trigone. 6. The prostate gland. 7. Transverse fibres of the compressor urethrae muscle, passing above the urethra. 8. Similar fibres passing beneath that canal.

are fixed together to the ramus of the pubes on each side by narrow ends; in the middle they are connected respectively with the upper and the lower surface of the urethra, on which they are expanded so as to cover the membranous portion of the canal in its whole length. In some bodies a tendinous raphé, placed over the middle of the urinary canal, separates each stratum into lateral halves; in such cases the fibres may be said to arise from the bone on each side, and to be inserted at the median raphé, where those of opposite sides join. The fibres of the lower part of the muscle cover Cowper's glands.

In the female, the compressor urethræ muscle has a precisely similar arrangement.

Circular
fibres.

Circular fibres, Santorini (stratum internum circulare, Müller).—A series of circular muscular fibres encircles the entire of the membranous part of the urethra, beneath the transverse muscle just described.

Vertical
fibres.

Wilson's muscles (m. pubo-urethrales).—By this name are known two small triangular bundles of muscular fibres, arising each by a tendon, which "is affixed to the back part of the symphysis of the pubes, in the adult about an eighth of an inch above the cartilaginous arch of the pubes, and nearly at the same distance below the attachment of the tendon of the bladder."* The tendons give rise to muscular fibres, which expand as they descend, and are connected on the membranous part of the urethra with the muscular structure above described, one of the muscles being placed at each side of the urethra.

The transverse compressor of the urethra was known to Santorini. One of the representations of it, contained in his posthumous work,† has been copied for the wood-cut. Indistinctly or partially noticed by other anatomists, the muscle was first fully described by Mr. Guthrie‡; and the

* A description of two muscles surrounding the membranous part of the urethra, by James Wilson, in *Medico-Chirurg. Trans.* vol. i. p. 176 (with a plate). London, 1809.

As regards Wilson's muscles:—Professor Müller, after careful examination made in many bodies, satisfied himself that there are no muscular fibres directed downwards from the pubes in the manner assigned to these muscles. Mr. Guthrie arrived at the same conclusion. Still, as Wilson's statement and delineation are very clear, and as in one case I myself saw a few vertical muscular fibres connected with the transverse compressor, it has been thought best to retain the muscles in the text. (R. Q.)

†Septemdecim Tabulæ.

‡ *The Anatomy and Diseases of the Neck of the Bladder, &c.*, 1834.

whole of the muscular structure connected with the membranous part of the urethra was about the same time investigated by Professor Müller; but the results were not published till a later period.*

THE TESTES, AND THEIR EXCRETORY APPARATUS.

The *testicles* or *testes*, the two glandular organs which secrete the seminal fluid, are situated in the scrotum, each being suspended by its spermatic cord. The testes and the

The *spermatic cord*.—The parts which form this cord are the excretory duct of the testicle, named the vas deferens, the spermatic artery and veins, lymphatics, nerves, and connecting cellular tissue. Besides this, both the cord and the testis have several coverings. spermatic cord.

The spermatic cord, thus composed, extends from the internal abdominal ring (p. 441) to the back part of the testicle. Its upper portion lies in the inguinal canal, an oblique passage formed in the lower part of the abdominal walls, and is directed downwards, inwards, and forwards; but, on escaping from that canal at the external abdominal ring, (p. 355,) it descends nearly vertically over the front of the pubes into the scrotum. The construction of the inguinal canal, the connexions of the spermatic cord in passing through it, and the relation of both to inguinal hernia, will be considered in the account of the “inguinal region.”

COVERINGS OF THE TESTIS AND CORD.

Originally, and nearly up to the seventh month of foetal life, the testes, with their ducts and vessels, are situated at the back part of the abdomen, behind the peritonæum. About the last mentioned period each testicle enters the corresponding inguinal canal, and, followed by the spermatic cord, passes into the scrotum. During this change of position, the testis and cord become invested with certain *coverings*, as they are called, derived partly from the serous, muscular, and fibrous layers of the abdominal parietes, and partly from the proper tissues of the scrotum. These coverings, as found in Coverings of the testis, due to its change of position.

* Ueber die organischen Nerven der erectilen männlichen Geschlechts-Organ, &c., 1836.

Their names.

the adult, and as enumerated from without inwards, are, after the *skin*, superficial fascia, and *dartos tissue* of the scrotum, the *intercolumnar fascia*, the *cremaster muscle* and cremasteric fascia, and the *infundibuliform fascia*, which is united to the cord by a layer of loose cellular tissue; lastly, the testicle has a special serous tunic, named the *tunica vaginalis*, which forms a closed sac, and covers the proper *fibrous coat* of the gland.

The scrotum.

The *scrotum*.—The *scrotum* forms a purse-like investment for the testes and part of the spermatic cords. Its condition is liable to certain variations according to the state of the health and other circumstances: thus, it is short and corrugated in robust persons and under the effects of cold, but becomes loose and pendulous in persons of weak constitution, and under the relaxing influence of heat. Its surface is marked off into two lateral halves by a slight median ridge, named the *raphé*, extending forwards to the under side of the penis, and backwards along the perinæum to the margin of the anus.

The skin.

1. The *skin* in this situation is very thin, and is of a darker colour than elsewhere; it is generally thrown into rugæ or folds, which are more or less distinct according to the circumstances already mentioned. It is furnished with sebaceous follicles, the secretion from which has a peculiar odour, and it is covered over with thinly scattered crisp and flattened hairs, the bulbs of which are seen through the skin when the scrotum is extended. The superficial bloodvessels are also readily distinguished through this thin integument.

The dartos.

2. Immediately beneath the skin of the scrotum there is found a thin layer of a peculiar loose reddish tissue, endowed with contractility, and named the *dartos*. This subcutaneous layer is continuous with the *superficial fascia* of the groin, perinæum, and inner side of the thighs, but acquires a different structure, and is perfectly free from fat. This dartoid tissue is more abundant on the fore-part of the scrotum than behind, and, moreover, it forms two distinct sacs, which contain the corresponding testes, and are united together along the middle line so as to establish a median partition between the two glands, named the *septum scroti*, which is adherent below to the deep surface of the *raphé* and reaches upwards to the root of the penis. The *dartos* is very vascular, and consists of a loose areolar tissue containing reddish fasciculi, which have long

The septum scroti.

been recognised as possessing peculiar physiological characters. The microscopical and chemical examination of the dartos did not, however, appear to justify the opinion that it contained muscular tissue, and, accordingly, the slow contractions of the dartos were held to afford an example of non-muscular contractility; but, more recently, distinct muscular fibres, of the plain or unstriped variety, have been recognised in it (see p. clxxiii). Its contractility, as just stated, is slow in its action; it is excited by the application of cold and of mechanical stimuli, but, apparently, not by electricity. By its action the testes are drawn up or sustained, and at the same time the skin of the scrotum is more or less corrugated.

The dartos tissue is contractile :

it contains plain muscular fibres.

The five succeeding layers or coverings are those which are derived from the parietes and lining membranes of the abdomen.

3. The *intercolumnar* or *spermatic* fascia is derived from the tendon of the external oblique muscle of the abdomen. On passing forward through the opening in that tendon, named the external abdominal ring, the spermatic cord receives a thin membranous investment, which is, as it were, continuous with the layer of so-called intercolumnar fibres passing obliquely across the upper border of that opening. This is the *intercolumnar* fascia. It is attached above to the margins of the external ring, and is prolonged downwards upon the cord and testicle. It lies at first beneath the superficial fascia, but lower down beneath the dartos, and it is intimately connected with the layer next in order.

The intercolumnar or spermatic fascia.

4. The succeeding layer is composed of scattered bundles of muscular tissue, connected together into a continuous covering by intermediate cellular membrane. The red muscular portion, which is continuous with the lower border of the internal oblique muscle of the abdomen, constitutes the *cremaster* muscle, or *tunica erythroïdes*, and the entire covering is named the *cremasteric* fascia.

The cremaster fascia,

The *cremaster* muscle, so named because it serves to suspend the testicle (*κρεμάω*, to suspend), commences within the inguinal canal, immediately beneath the lower border of the internal oblique muscle, in the form of two bundles of muscular tissue, which cross obliquely over the front of the spermatic cord; lower down, the muscular fasciculi form a series of

and cremaster muscle :

its loops
upon
the cord.

loops or slings with their concavities turned upwards, which descend upon the front and sides of the cord, and which, becoming in succession longer and longer, ultimately reach as low as the testicle. The scattered bundles of the cremaster muscle would seem to be derived from the internal oblique muscle, and sometimes, perhaps, from the transversalis also. The lowermost fibres of one or both muscles may be supposed to be carried forward by the testicle in its descent into the scrotum. The attachments of the cremaster certainly coincide with this idea of its formation. When carefully examined it is found to consist of an external and an internal portion, the separate bundles of which join to form the loops upon the spermatic cord already spoken of. The external and larger portion arises from the deep surface of Poupart's ligament, or rather from the outer end of the deep crural arch, immediately below the internal oblique muscle, and passing along the spermatic cord, through the external abdominal ring, descends upon it, rather on its outer side, and spreads out into bundles, differing in thickness and length in different subjects. The shorter bundles cross in loops over the cord, while the longest reach down towards the testicle, and are attached, directly or by means of tendinous fibres, to the outer surface of the tunica vaginalis. Most of the bundles then appear to be prolonged upwards on the inner side of the cord, to form the internal and smaller portion of the muscle, which enters the lower end of the inguinal canal, and is inserted by a small tendinous band into the spine and crest of the pubes, close to the insertion of the internal oblique muscle.

Sometimes the loops of the cremaster completely surround the cord, some lying behind it, but the larger number, being, as usual, in front. In these cases it would seem as if the testicles had passed through the fibres of the internal oblique, and not merely beneath them. Occasionally the muscular bundles can be traced only part of the way down the cord, the lower portion of the latter, as well as the testicle, being covered instead by a layer of firm cellular membrane, similar in appearance to that which connects the separate muscular bundles together, and containing some tendinous fibres.

Use of the
cremaster.

The cremaster muscles not only aid in suspending the testes, but can raise them up towards the ring, and, perhaps at the

same time, compress them in a slight degree. They are muscles with striped fibres, and in some persons are completely under voluntary command. Their action is sudden, and altogether distinct from that of the dartos.

In cases of old scrotal hernia, and also in hydrocele, the cremaster becomes very strongly developed. There is, of course, no such muscle in the female; but in that sex, an accidental muscle, analogous to it, may be produced upon an inguinal hernia in its descent beneath the margin of the internal oblique muscle.

5. The *infundibuliform fascia* and *cellular investment* of the cord.—These are continuous above with the *fascia transversalis* and the subperitonæal cellular membrane. Immediately beneath the cremaster muscle and cremasteric fascia, and closely adherent to them, is a thin membranous layer, which loosely surrounds the spermatic cord. It may be traced above, commencing at the internal abdominal ring, in form of a funnel-shaped offset from the transversalis fascia, and is prolonged as a sheath upon the vas deferens and spermatic vessels, as these pass out of the abdomen. It then descends through the inguinal canal and scrotum upon the cord, investing it completely, and being connected below with the posterior part of the testicle and the outer surface of its serous tunic.

The infundibuliform fascia.

On forcing air beneath the infundibuliform fascia, a quantity of loose and delicate cellular tissue is seen to connect its internal or deep surface with the vas deferens and spermatic blood-vessels, and to form lamellæ between them. This areolar tissue is continuous above with the sub-serous cellular tissue found beneath the peritonæum on the anterior wall of the abdomen; below, it is lost upon the back of the testicle. Together with the infundibuliform fascia just described, it forms the *fascia propria* of Sir A. Cooper.

The fascia propria.

Lying amongst this loose cellular tissue, in front of the upper end of the cord, there is often seen a fibro-cellular band, which is connected above with the pouch of peritonæum found opposite the upper end of the inguinal canal, and reaches downwards for a longer or shorter distance along the spermatic cord. Occasionally it may be followed as a fine cord, down to the upper end of the tunica vaginalis; sometimes no trace of it whatever can be detected. It is the vestige of a tubular process of

Remains of the peritonæal process.

the peritonæum, which once connected the tunica vaginalis with the general peritonæal membrane. The testes of the fœtus are placed in the abdomen behind the peritonæum. When they are about to escape from the abdominal cavity, a pouch of the lining membrane extends itself in advance of each testicle along the corresponding inguinal canal towards the scrotum. Into this pouch, or *processus vaginalis peritonæi*, as it is named, the testicle projects from behind, supported by a duplicature of the serous membrane, named the *mesorchium*. Sooner or later after the gland has reached the scrotum the upper part or neck of this pouch becomes obliterated, from the internal abdominal ring near to the upper part of the testicle, leaving no trace but the indistinct fibrous cord already described, whilst the lower part remains as a closed serous sac, into which the testicle depends, and which is henceforth named the tunica vaginalis. Sometimes the tube of peritonæum becomes closed at intervals only, leaving a series of sacculi along the front of the cord; or a long pouch may continue open at the upper end, leading from the abdominal cavity into the inguinal canal. Lastly, in some instances, the peritonæal process remains altogether pervious, and the cavity of the tunica vaginalis is continuous with that of the peritonæum. In such a case of congenital defect, a portion of intestine or omentum may descend from the abdomen into the inguinal canal and scrotum, and constitute what is named a congenital hernia.

The descent
of the testis.

The
processus
peritonæi
and mesor-
chium.

Peritonæal
process is
sometimes
open.

The canal
of Nuck.

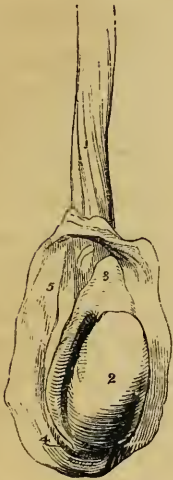Tunica
vaginalis

In the female, an analogous pouch of peritonæum descends in the fœtus, for a short distance along the round ligament of the uterus, and has received the appellation of the *canal of Nuck*. Traces of it may almost always be seen in the adult.

6. The *tunica vaginalis*.—Beneath the parts already described, which form investments common to the cord and testis, is the proper serous covering of the latter, named the *tunica vaginalis*. The mode in which this coat is derived from the peritonæum has just been explained. In its completed condition it forms a shut sac, the opposite walls of which are in contact with each other. Like the serous membranes in general, of which it affords one of the simplest examples, it may be described as consisting of a *visceral* and a *parietal* portion. The former closely invests the greater part of the body of the testis (fig. 317, ²), as well as the epi-

didymis (3, 4), between which parts it recedes in form of a pouch, and lines their contiguous surfaces, and it adheres intimately to the proper fibrous tunic of the gland: hence it is named *tunica vaginalis testis*. Along the posterior border of

Fig. 317.*



the gland, where the vessels and ducts enter or pass out, the serous coat is wanting, being reflected thence so as to become continuous with the *parietal* or scrotal portion,⁽⁵⁾ which completes the sac, and forms a smooth lining membrane to the lower part of the other investments of the testicle, viz. the infundibuliform fascia, the cremaster, and the spermatic fascia, which are there blended together and connected with the external surface of the tunica vaginalis.

The parietal or scrotal portion of the tunica vaginalis is more extensive than that which covers the body of the testis; it reaches upwards, sometimes for a considerable distance, upon the spermatic cord, extending somewhat higher on the inner than on the outer side. It also reaches downwards below the testicle, which, therefore, appears to be suspended at the back of the serous sac, when this latter is distended with fluid.

The internal surface of the tunica vaginalis is free, smooth, epitheliated, and moistened with a small quantity of an albuminous fluid. The epithelium is squamous.

VESSELS AND NERVES OF THE COVERINGS OF THE TESTIS AND CORD.

The *arteries* are derived from several sources. Thus, the two external pudic arteries (p. 590), branches of the femoral, reach the front and sides of the scrotum, supplying the integument and dartos; the superficial perinæal branch of the internal pudic artery (p. 578) is distributed to the back part of the scrotum; and, lastly, more deeply seated than either of these,

* The testicle and part of the spermatic cord, with the tunica vaginalis laid open.—1. Lower part of the spermatic cord. 2. Body of the testicle. 3, 4. The epididymis. 3. Globus major or head. 4. Globus minor or tail. 5. Internal surface of scrotal portion of tunica vaginalis.

of the testis,

of the scrotum.

Arterie of the coverings of the testicle.

The veins, is a branch given from the epigastric artery, named cremasteric (p. 586), because it is chiefly distributed to the cremaster muscle, but it also supplies small branches to the other coverings of the cord, and its ultimate divisions anastomose with those of the other vessels. The *veins*, which, owing to the thinness of the integuments, are apparent on the surface of the scrotum, follow the course of the arteries. The *lymphatics* pass into the inguinal lymphatic glands.

and nerves. The *nerves* also proceed from various sources. Thus, the ilio-inguinal, a branch of the lumbar plexus (p. 855), comes forwards through the external abdominal ring, and supplies the integuments of the scrotum; this nerve is joined also by a filament from the ilio-hypogastric branch of the same plexus: sometimes two separate cutaneous nerves come forward through the external ring. The two superficial perinæal branches of the internal pudic nerve (p. 868) accompany the artery of the same nerve and supply the inferior and lateral parts of the scrotum. The inferior pudendal, a branch of the small sciatic nerve (p. 870) joins with the perinæal nerves, and is distributed to the sides and fore-part of the scrotum. Lastly, a deeper nerve, springing from the lumbar plexus, and named genito-crural (p. 856), comes into contact with the spermatic cord at the internal abdominal ring, passes with it through the inguinal canal, and supplies the fibres of the cremaster, besides sending a few filaments to the other deep coverings of the cord and testicle.

THE TESTES.

The testes: their form and size: The *testes* are suspended in the scrotum at unequal heights, that of the left side being usually lower than the other. They are of an oval form, but are slightly compressed laterally, so that they have two somewhat flattened sides or faces, an upper and a lower end, an anterior and a posterior border. They are from an inch and a half to two inches long, about an inch and a quarter from the anterior to the posterior border, and nearly an inch from side to side. The weight of each varies from three-quarters of an ounce to an ounce, and the left is often a little the larger of the two.

their connections. Both sides of the testicle, the upper and the lower end, and the anterior border, which is rounded, are free, smooth, and

closely invested by the tunica vaginalis. The posterior border, however, which is also called the straight border, is attached to the spermatic cord, and it is here that the vessels and nerves enter or pass out. When the testis is suspended in its usual position, its upper end is directed obliquely forwards and outwards, as well as upwards, whilst the lower, which is rather smaller, has the opposite direction. It follows from this that the posterior or attached border is turned a little upwards, and the outer flattened face slightly backwards.

Along the outer edge of the posterior border of the gland, and resting also on the neighbouring portion of its outer face, is placed a long narrow appendage, named from its position the *epididymis* (ἐπί and δίδυμος, testis.) This body is curved so as to be adapted to the testicle. Its upper extremity, which is enlarged and obtuse, is named the *head* of the epididymis, or *globus major* (³); the lower, which is more pointed, is termed the *tail*, or *globus minor* (⁴); whilst the intervening and narrower portion is named the *body*. The outer convex surface of the epididymis and the thin anterior border are free, and covered by the tunica vaginalis. The inner surface, except at the upper and lower ends, is also free, and invested by the same tunic, which here forms a pouch between the epididymis and the outer face of the testicle, and nearly surrounds the epididymis, except along its posterior border, which is held to the gland by a duplicature of the serous membrane. At its upper and lower extremity the inner surface of the epididymis is attached to the testicle,—the lower end, or globus minor, by fibrous tissue and a reflection of the tunica vaginalis the globus major by the efferent ducts of the testicle also. Lastly, the long posterior border of this appendage is connected with the spermatic cord by numerous blood-vessels, supported by dense cellular tissue.

The epididymis contains a part of the excretory apparatus of the testicle, and is principally composed of the convolutions of a long tortuous canal or efferent duct, which will be presently described.

Upon the head of the epididymis there is very commonly found a small soft pendulous body of a reddish colour, about two or three lines in length. Its presence was first pointed out by Morgagni, but its nature is not known.

Structure of the testis.—Besides the numerous coverings

The epididymis:

its globus major and minor;

its connections.

Structure of the testis.

The tunica
albuginea

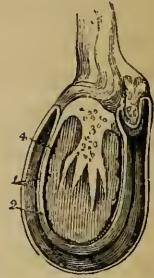forms the
proper coat;

is reflected
in behind to
form the
mediasti-
num testis ;

its processes
through
the gland.

already noticed, the testis is enclosed in a proper coat, named the *tunica albuginea* (fig. 318, ²). This is a dense unyielding fibrous membrane, of a bluish-white colour, and about half a line thick, which immediately invests the soft substance of the testicle, and preserves the form of the gland. It is composed of bundles of fibrous tissue, which interlace in every direction. The outer surface is for the most part covered by the tunica vaginalis, except along the posterior border of the testicle, where the spermatic vessels pass through, and except also at the parts to which the two extremities of the epididymis are attached. From the upper end of the testicle, opposite the globus major, the tunica albuginea is continuous with thin prolongations of fibrous tissue which invest the epididymis, support and hold together the numerous convolutions of its tortuous canal, and are ultimately continued upon the vas deferens.

Fig. 318.*



At the posterior and upper border of the testis, the fibrous tissue of the tunica albuginea is prolonged forwards for a few lines into the substance of the gland, so as to form within it an incomplete vertical septum, known as the *corpus Highmorianum*, and named by Sir A. Cooper *mediastinum testis* (³). Projecting inwards from the back of the testis, it extends from the upper nearly to the lower end of the gland, and it is wider above than below. The firm tissue of which it is composed is traversed by a network of seminal ducts, and by the larger blood-vessels of the gland, which are lodged in channels formed in the fibrous tissue.

From the front and sides of the corpus Highmorianum numerous slender fibrous cords of various lengths are given off in all directions, and are attached by their other ends to the internal surface of the tunica albuginea at different points, so as to assist in maintaining the general shape of the testicle. Other offsets from the mediastinum, consisting of delicate membranous laminæ, meet with similar ones from the tunica albuginea, and enclose the several lobes into which the substance of the testis

* Transverse section of the testis, epididymis, and tunica vaginalis.—1. Tunica vaginalis. 2. Tunica albuginea. 3. Mediastinum testis. 4. Glandular substance.

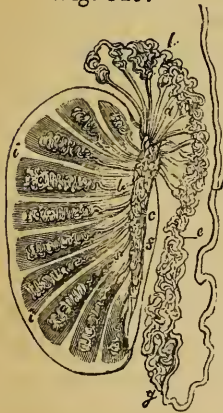
is divided. The whole internal surface of the tunica albuginea is covered by a multitude of fine blood-vessels, which are branches of the spermatic artery and veins, and are held together by a delicate cellular web. Similar delicate ramifications of vessels are seen on the various fibrous offsets of the mediastinum, upon which the blood-vessels are thus supported in the interior of the gland. This vascular net-work, together with its connecting cellular tissue, constitutes the *tunica vasculosa* of Sir A. Cooper.

The vascular layer or tunica vasculosa.

The proper *glandular substance* of the testicle (⁴) is a soft pulpy mass of a reddish-yellow colour, which is divided into numerous small lobes, contained in the separate compartments formed by the fibro-vascular expansions which extend between the corpus Highmorianum and the internal surface of the tunica albuginea (see the illustrative plan, fig. 319).

The glandular substance :

Fig. 319.*



The number of these *lobes* (lobuli testis) has been estimated at 250 by Berres, and upwards of 400 by Krause. Their shape is somewhat conical or pyriform, the larger end of each being turned towards the surface of the testicle, and the smaller one towards the mediastinum. They differ in size according to their position, those which occupy the middle of the gland and reach its anterior border being longer and larger than the rest. The substance of these lobes consists almost entirely of minute convoluted tubes (*a*), named *tubuli seminiferi*, *vascula serpentina*, in the in-

its lobes are numerous.

terior of which the seminal fluid is secreted. Each lobe contains one, two, three, or even more of these convoluted tubules, the coils of which, being but loosely held together, may be more or less successfully unravelled by careful dissection under water. According to Monro, their total number is about 300, and the length of each tubule about sixteen

The tubuli seminiferi :

* A plan of a vertical section of the testicle, to shew the arrangement of the ducts : the length as well as the diameter of the ducts is disregarded.—
a, a. Tubuli seminiferi coiled up in the separate lobes. *b*. Vasa recta.
c. Rete vasculosum testis. *d*. Vasa efferentia ending in the coni vasculosi. *e, g*. Convoluted canal of the epididymis. *h*. Vas deferens.
f. Section of back part of tunica albuginea. *i, z*. Fibrous lamellæ running inwards between the lobes. *s*. Mediastinum testis.

their size,
structure,
and blood-
vessels.

feet; but Lauth estimates their mean number to be 840, and the average length of each to be not more than two feet and a quarter. Their diameter, which is uniform throughout their whole course, is from $\frac{1}{200}$ th to $\frac{1}{150}$ th of an inch. The capillary vessels are distributed in form of a network upon the outer surface of the tubules, supplying them with blood, and constituting, together with fine bundles of cellular tissue in very sparing quantity, a slender bond of union between them; this feeble connection between the tubuli renders necessary their inclosure and support by a dense fibrous capsule. As compared with the ultimate ducts of glands generally, the coats of the tubuli seminiferi are strong, and hence, notwithstanding their comparatively loose aggregation, they may, as well as the system of ducts into which they ultimately unite, be injected with mercury. They are lined with an epithelium, composed of nucleated granular corpuscles. The mode in which they commence, as far as at present known, appears to be twofold, for they have been seen commencing near the surface of the lobes by free closed extremities, but more frequently by anastomotic arches or loops. They also anastomose together occasionally in their course, and the tubuli of adjacent lobes are often found communicating with one another. After an exceedingly tortuous or serpentine course from side to side of the lobe to which they belong, they at length, in approaching the corpus Highmorianum, lose in a great measure the convoluted disposition, becoming at first slightly flexuous and then nearly straight. The separate tubuli of each lobe, and then those of adjoining lobes, unite together into larger tubes, which pass through the fibrous tissue of the mediastinum and amongst the branches of the blood-vessels and form the next order of the seminal ducts.

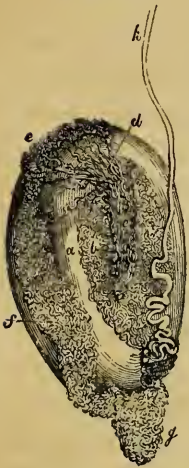The tubuli
recti

and
rete testis.

These, which, from their comparatively straight course, are named *tubuli recti* or *vasa recta* (*b*), are upwards of twenty in number, and are from $\frac{1}{90}$ th to $\frac{1}{70}$ th of an inch in diameter. They pass upwards and backwards through the fibrous tissue as already stated, and end in a close network of tubes, named by Haller the *rete vasculosum testis* (figs. 319, 320, *c*), which lies in the substance of the corpus Highmorianum, along the back part of the testicle, but in front of the primary subdivisions of the spermatic blood-vessels before these enter the gland. The tubes composing the rete have very thin walls.

All the seminal ducts hitherto mentioned, namely the tubuli seminiferi, tubuli recti, and rete testis, are included within the

Fig. 320.*



proper fibrous coat of the testicle, and form in great part the substance of the gland; but the succeeding order of ducts transmit the seminal fluid from the testis to the epididymis, and are named accordingly *vasa efferentia* (d). These are from twelve to fifteen, or sometimes twenty in number; they perforate the tunica albuginea at the upper end of the posterior border of the testicle, opposite to the globus major of the epididymis, of which they may be said to form a part, and in the convoluted canal of which they ultimately terminate. On emerging from the testis, these vasa efferentia are straight, but, becoming more and more convoluted, as they proceed towards the epididymis, they form a

The vasa efferentia,

series of small conical masses, the bases of which are turned in the same direction, and which are named *coni vasculosi* (fig. 319, l. fig. 320, e). The largest of these cones is about eight lines long, and, when unrolled, each is found to consist of a single coiled duct, varying from six to eight inches in length, and the diameter of which gradually decreases from the testis to the epididymis (Huschke). Opposite to the globus major these separate efferent vessels open, at intervals of about three inches, into a single canal or duct, the intervening and subsequent convolutions of which constitute the epididymis itself.

and coni vasculosi.

The *canal of the epididymis* (figs. 319, 320, l, e, g) is disposed in innumerable coils, and extends from the globus major downwards to the globus minor or tail, where, turning upwards, it is continued on as the vas deferens. Its flexuosities are exceedingly numerous, so that when unrolled it is found to be twenty feet and upwards in length. The smallest windings are supported and held together by fine cellular tissue; but, besides this, numerous fibrous partitions are interposed between larger masses

The canal of the epididymis:

* Ducts of the testicle injected with mercury (Haller).—a. Body of the testis. b. Tubuli in the interior of the gland. c. Rete vasculosum testis. d. Vasa efferentia ending in the coni vasculosi. e, f, g. Convoluted canal of the epididymis. h. Vas deferens ascending from the globus minor of the epididymis.

its lobes.

of the coils, which have been named the *lobes* of the epididymis, the general direction of which is across that body. The canal of the epididymis is, at its commencement, about $\frac{1}{70}$ th of an inch in diameter, but it goes on diminishing, till, towards the globus minor, it is about $\frac{1}{90}$ th of an inch, after which it again increases in size, and becomes less tortuous as it approaches the vas deferens. Its coats, which are at first very thin, become thicker as it proceeds.

VAS DEFERENS.

The vas
deferens :its origin
and course,to the
inguinal
canal,and thence
into the
pelvic
cavity,to the
base of
bladder.

The *vas deferens*, or excretory duct of the testis (*h*), is a hard round tube, which forms the continuation upwards of the convoluted canal of the epididymis. It commences at the lower end of that appendage, or the globus minor, and, being at first rather tortuous, but afterwards becoming straight, it ascends upon the inner side of the epididymis, and along the back of the testicle, separated from both, however, by the blood-vessels passing to or from the gland. Continuing, then, to ascend in the spermatic cord, the vas deferens accompanies the spermatic artery, veins, and nerves, as far as the internal abdominal ring. Between the testicle and the external ring its course is vertical; it lies behind the spermatic vessels, and is readily distinguished by its hard cord-like feel. Having passed obliquely upwards and outwards along the inguinal canal, and reached the inner border of the internal abdominal ring, it leaves the spermatic vessels (which extend to the lumbar region), and turns suddenly downwards and inwards into the pelvis, crossing over the external iliac vessels, and turning round the outer or iliac side of the epigastric artery. Running beneath the peritonæum, it reaches the side of the bladder (fig. 310, *i*), on which it curves backwards and downwards to the under surface of that viscus, and then runs forwards to the base of the prostate gland. In its course within the pelvis, the vas deferens gradually approaches nearer to the middle line; it crosses over and to the outer side of the cord of the obliterated hypogastric artery, and to the inner side of the ureter. Beyond this point, where the vas deferens reaches the base of the bladder, it ceases to be covered by the peritonæum, and is found attached to the coats of the bladder, lying between that viscus and the rectum. In this situation (fig. 311, *i*) it runs forwards, and at the same

time inwards, so as gradually to approach its fellow of the opposite side. Upon the base of the bladder, the two vasa deferentia are situated between two membranous receptacles for the semen, named the seminal vesicles (*s, s*); and close to the base of the prostate (*p*), each vas deferens ends by joining with the duct from the corresponding seminal vesicle, which is placed on its outer side, to form one of the two common seminal or ejaculatory ducts (*e*).

It ends
in the
ejaculatory
duct.

The vas deferens, therefore, pursues a long and somewhat complicated course, from its commencement at the lower end of the epididymis to its termination at the base of the prostate, beneath the bladder. It measures nearly two feet in length. In the greater part of its extent it is cylindrical or slightly compressed, and has an average diameter of about one line and a quarter; but towards its termination, beneath the bladder, it becomes enlarged and sacculated, approaching thus in character to the seminal vesicle. Previous to its junction with the duct of that vesicle, it again becomes narrowed to a fine cylindrical canal. The walls of the vas deferens are very dense and strong, measuring one-third of a line in thickness; whilst, on the other hand, the canal is proportionably fine, its area being only from one-fourth to one-half a line across. In the sacculated portion the passage is much wider, and the walls are thinner in proportion.

Its length,
form,
thickness,

Besides an external cellular investment, and an internal lining mucous membrane, the vas deferens is provided with an intermediate tunic, which is thick, dense in structure, somewhat elastic, and of a deep yellowish colour. This coat consists principally of longitudinal fibres, mixed with some circular ones. Huschké describes two longitudinal layers with intermediate circular fibres. These fibres are most probably of a muscular nature. The vasa deferentia of the dog, cat, and rabbit were found by E. Weber to exhibit lively peristaltic contractions when stimulated by means of electricity.

and
structure.

The surface of the mucous membrane is pale; it is thrown into three or four fine longitudinal ridges, and, besides this, in the sacculated portion of the duct, is marked by numerous finer rugæ which enclose irregular polyhedral spaces, resembling in this the lining membrane of the vesiculæ seminales. The epithelium is of the columnar kind.

A vas
aberrans
occasionally
exists.

Vas aberrans.—This name was applied by Haller to a long narrow tube, or diverticulum, discovered by him and since very frequently met with, which leads off from the lower part of the canal of the epididymis, or from the commencement of the vas deferens, and extends upwards in a tortuous manner for two or three inches amongst the vessels of the spermatic cord, where it ends by a closed extremity. Its length, when it is unravelled, ranges from one inch and a half to as much as fourteen inches; and its breadth increases towards its blind extremity. Sometimes this diverticulum is branched, and occasionally there is more than one such aberrant duct. Its structure appears to be similar to that of the vas deferens, but its office is unknown.

THE SEMINAL VESICLES AND EJACULATORY DUCTS.

The seminal
vesicles:
their
structure,
form,

The *seminal vesicles* (vesiculæ seminales; fig. 311, s, s) are two membranous receptacles, situated, one on each side, upon the base of the bladder, between it and the rectum. When distended they form two oblong sacculated bodies, somewhat flattened above but convex below, widened behind and narrow in front. Their length is usually about two inches and a half, and their greatest breadth from four to six lines; but they vary in size in different individuals, and also on opposite sides of the same subject.

and
connections.

Their upper surface is firmly attached to the coats of the bladder, on the under surface of which they extend forwards and inwards from near the terminations of the two ureters to the base of the prostate gland. The posterior obtuse extremities of the two vesiculæ seminales are separated widely from each other, but anteriorly they converge so as to approach the two vasa deferentia, which run forwards to the prostate between them. The small triangular portion of the base of the bladder, which is marked off by the two vesiculæ seminales at the sides, and behind by the line of reflexion of the peritonæum from the rectum to the bladder, rests immediately on that intestine, at least there is nothing interposed but the vasa deferentia. The seminal vesicles themselves are also supported by the sides of the rectum, but they are separated from the bowel by a layer of the recto-vesical fascia, which holds them to the base of the bladder.

The sacculated appearance of the vesiculæ seminales is owing

to their peculiar formation. Each consists of a tube coiled on itself in a complicated manner, and firmly held in that condition by a very dense fibrous tissue. When unrolled (see fig. 311), this tube is found to be from four to six inches long, and about the width of a quill. Its posterior extremity is closed, so that it forms a long cul-de-sac; but there are generally, if not always, several longer or shorter branches or diverticula developed from it, which also end by closed extremities. Its anterior extremity, which forms the fore-part of the vesicula, becomes straight and narrowed, and ends opposite the base of the prostate by uniting on its inner side, at a very acute angle, with the narrow termination of the corresponding vas deferens to form a single canal, which is the common seminal or ejaculatory duct.

They consist of a tube coiled up,

having some diverticula

end in the ejaculatory duct.

Structure of the vesicles.

In structure, the vesiculæ seminales resemble very closely the adjoining sacculated portions of the vasa deferentia. Besides an external fibro-cellular investment, connected with the recto-vesical fascia, they have a proper coat, which is firm, dense and somewhat elastic, and consists of rigid white fibres and of others of a deep yellowish-brown hue. In some animals muscular fibres have been shewn in the coats of the seminal vesicles, and, according to E. H. Weber, they exist in the human subject also. The mucous membrane is pale, or has a dirty brownish-white colour. It is traversed by multitudes of fine rugæ, which form an areolar structure resembling that seen in the gall-bladder, but composed of much finer meshes: this areolar character, as already stated, begins to appear in the lower sacculated part of the vas deferens, and is considered by Weber as constituting a species of glandular structure. The epithelium of the vesiculæ is of the squamous kind; its particles have a granular character.

The seminal vesicles serve as receptacles or reservoirs for the semen, as is easily proved by a microscopic examination of their contents; but, besides this, it is supposed by some that they secrete a peculiar fluid which is incorporated with the semen.

Their use.

The *common seminal ducts*, or *ejaculatory ducts* (fig. 311, *e*.) two in number, are formed on each side by the junction of the narrowed extremities of the corresponding vas deferens and vesicula seminalis, close to the base of the prostate gland. From this point they run forwards and upwards, at the same time ap-

The ejaculatory ducts,

run through
the prostate
and open
into the
urethra.

proaching each other, and then pass side by side through the prostate between its middle and two lateral lobes. After a course of nearly an inch, during which they become gradually narrower, they end in the floor of the prostatic portion of the urethra by two slit-like orifices, placed one on each prominent margin of the longitudinal depression which exists at the anterior part of the verumontanum, named the sinus pocularis, or utriculus virilis. For a short distance the ejaculatory ducts run in the substance of the walls of this sinus. (See p. 1226.)

Their
structure.

The coats of the common seminal duct, as compared with those of the vas deferens and vesicula, are very thin. The strong outer tunic almost entirely disappears after the entrance of the ducts between the lobes of the prostate; and the mucous membrane becomes gradually smoother, and at length passes into that of the urethra.

It is along these ejaculatory ducts that the fluid contained in the seminal vesicles and vas deferens is forced into the urethra.

VESSELS AND NERVES OF THE TESTIS.

The testicle and its excretory apparatus receive blood-vessels and nerves from different sources from those which supply the coverings of those parts.

Arteries of
the testis,
are the
spermatic

The *spermatic artery*, or proper artery of the testicle, (p. 562,) is a slender and remarkably long branch, which arises from the abdominal aorta, and reaching the spermatic cord, descends along it to the gland. In early foetal life its course is much shorter, as the testis is then situated near the part of the aorta from which the artery arises. As the vessel approaches the testicle, it gives off small branches to the epididymis, and then divides into others which perforate the tunica albuginea at the back of the gland, and pass through the corpus Highmorianum; some spread out on the internal surface of the tunica albuginea, whilst others run along between the lobes of the testis, supported by the fibrous processes of the mediastinum. The smallest branches ramify on the delicate membranous septa between the lobes, before supplying the seminiferous tubes.

and
deferent
arteries.

The vas deferens receives from the superior vesical artery a long slender branch, which accompanies the duct, and is hence named the *deferent artery*, or *artery of the vas deferens* (p.

573). It ramifies on the coats of the duct, and reaches as far as the testis, where it anastomoses with the spermatic artery.

The *spermatic veins* (p. 645) commence in the testis and epididymis, pass out at the posterior border of both, and unite into larger vessels, which freely communicate with each other as they ascend along the cord, and form a plexus, named the *pampiniform plexus*. Ultimately two or three veins follow the course of the spermatic artery into the abdomen, where they unite into a single trunk, that of the right side opening into the vena cava, and that of the left into the left renal vein.

Veins,
form a
plexus.

The *lymphatics* (p. 658) accompany the spermatic vessels and terminate in the lumbar lymphatic glands, which lie about the large blood-vessels in front of the vertebral column.

Lymphatics.

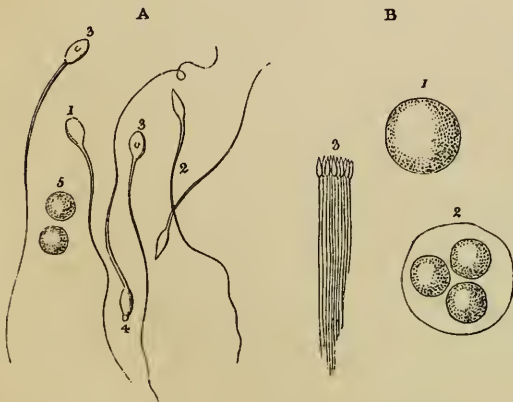
The *nerves* are derived from the sympathetic system. The spermatic plexus (p. 895) is a very delicate set of nervous filaments, which descend upon the spermatic artery from the aortic plexus. Some additional filaments, which are very minute, come from the hypogastric plexus, and accompany the artery of the vas deferens.

Nerves.

The *vesiculæ seminales* receive branches from the inferior vesical and middle hæmorrhoidal arteries. The veins and lymphatics correspond. The nerves belong to the sympathetic system, and come from the hypogastric plexus.

Vessels of
vesiculæ
seminales.

Fig. 321.*



The *semen* is a thick whitish fluid, which consists of a liquor seminis, and of certain solid particles.

The semen
consists of

The *liquor seminis* is colourless, transparent, and of an albuminous nature. It contains floating in it, besides squamous and columnar epithelium cells, oil-like globules and minute granular matter, two principal microscopic

liquor
seminis,

* Spermatozoa from man, and their development. (Wagner.)—A. Spermatozoa from the semen of the vas deferens. 1 to 4. Show their variety

constituents, named the *seminal granules* (Wagner), and the *seminal animalcules*, *spermatozoa* or spermatic filaments.

seminal
granules,
and seminal
animalcules.

The *seminal granules* (fig. 321, 5) are rounded colourless corpuscles, having a granular aspect. They average about $\frac{1}{4000}$ th of an inch in diameter, and may be allied to mucous corpuscles.

The *spermatozoa* (fig. 321. A.) are peculiar particles, endowed with a power of executing a brisk lashing movement. Each consists of a flattened oval part or so-called body, and of a long slender filiform tail. The body is about $\frac{1}{6000}$ th of an inch in width, and the entire spermatozoon is from $\frac{1}{500}$ th to $\frac{1}{400}$ th of an inch in length. The body often contains a spot, and, at its junction with the narrow part or tail, there is frequently a slight projecting fringe or collar. The spermatozoa are developed in the interior of nucleated cells, which become enlarged into transparent vesicular bodies of considerable size (B).

ORGANS OF GENERATION IN THE FEMALE.

Female
organs.

The generative organs in the female consist of the *ovaries*, *uterus*, and *Fallopian tubes*, which are named the *internal*, and the *vagina* and *vulva*, named the *external* organs of generation.

The vulva.

The *vulva*, or *pudendum*, is a general term, which includes all the parts perceptible externally, viz. the mons Veneris, the labia, the hymen or carunculæ, the clitoris, and the nymphæ. The orifice of the urethra also requires to be noticed in connexion with these parts.

Mons
Veneris.
Labia
majora.

The integument on the fore-part of the pubic symphysis is elevated by a quantity of cellular and adipose substance deposited beneath it, and is covered with hair. This part surmounts the labia, and has been called *mons Veneris*. The *labia pudendi* (labia externa v. majora) extend downwards and backwards from the mons, gradually becoming thinner as they descend. They form two rounded folds of integument so placed as to leave an elliptic interval (*rima*) between them, the outer surface of each being continuous with the skin, and covered with scattered hairs, whilst the inner is lined by the commencement of the genito-urinary mucous membrane. Between the skin and mucous membrane there is found, besides fat, vessels, nerves

of character. 5. Seminal granules.—B. Contents of the semen of the testis. 1. Large round corpuscle or cell. 2. A cell containing three roundish granular bodies, from which the spermatozoa are developed. 3. A fasciculus of spermatozoa, as they are seen grouped together in the testis.

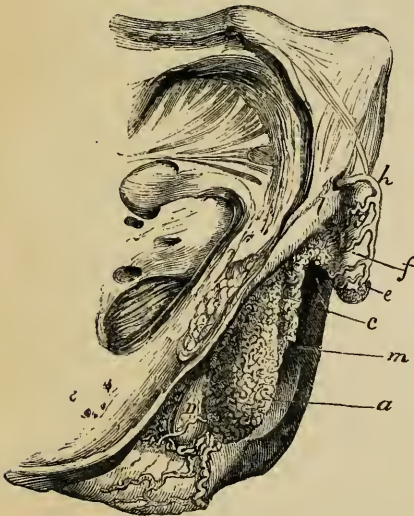and glands, some tissue resembling that of the dartos in the scrotum of the male. The labia majora unite beneath the mons and also in front of the perinæum, the two points of union being called commissures. The posterior or inferior one is about an inch distant from the margin of the anus, the interval between them being named the perinæum. Immediately within the posterior commissure, the labia are connected by a slight transverse fold (*frænulum pudendi*) which has also received the name of *fourchette*, and is commonly torn in the first parturition. The space between it and the commissure has been called *fossa navicularis*.

the posterior commissure, the frænulum or fourchette.

Beneath the anterior commissure, and concealed between the labia, is the *clitoris* (fig. 322 *f.*), a small elongated body analogous in conformation and structure to a diminutive penis, though differing in not being perforated by the canal of the urethra, and also in not having the corpus spongiosum attached along beneath it. It consists of two *corpora cavernosa*, which are attached by *crura* (*l*) to the rami of the ischium and pubes, and are united together by their flattened inner surfaces which form an incomplete pectiniform septum. The body of the clitoris, which is very short and hidden beneath the mucous membrane, is surmounted by a small *glans* (*e*), consisting of spongy erectile tissue. The glans is imperforate, but highly sensitive, and covered with a membranous fold, analogous to the prepuce. There is a small suspensory ligament (fig. 323), like that of the penis; and the two ischio-cavernous muscles, here named *erectores clitoridis* have

The clitoris is like the penis.

Fig. 322.*



erectores clitoridis have

Corpora cavernosa;

Glans;

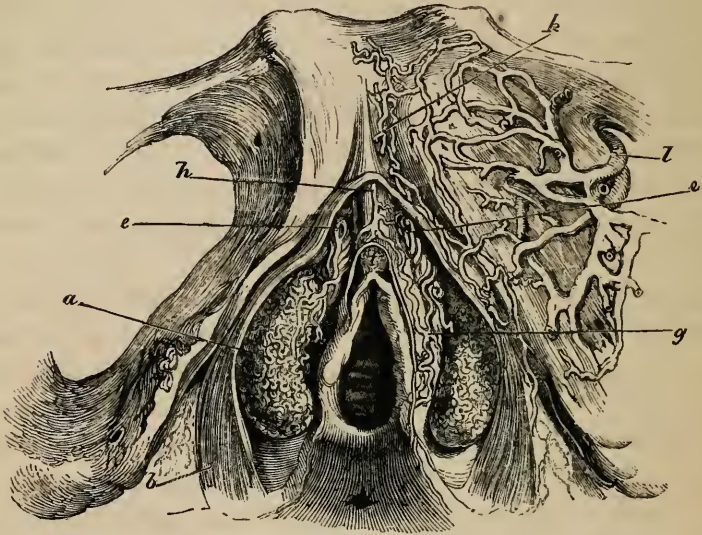
Erector muscles.

beneath the mucous membrane, is surmounted by a small *glans* (*e*), consisting of spongy erectile tissue. The glans is imperforate, but highly sensitive, and covered with a membranous fold, analogous to the prepuce. There is a small suspensory ligament (fig. 323), like that of the penis; and the two ischio-cavernous muscles, here named *erectores clitoridis* have

* Lateral view of the erectile structures of the external organs of generation in the female, the skin and mucous membrane being removed (Kobelt).—*a.* Bulbus vestibuli. *c.* Plexus of veins named pars intermedia. *e.* Glans of the clitoris. *f.* Body of the clitoris. *h.* Dorsal vein. *l.* Right crus of clitoris. *m.* Vulva. *n.* Right gland of Bartholine.

the same connections as in the male, being inserted into the crura of the corpora cavernosa.

Fig. 323.*



From the glans and preputial covering of the clitoris two narrow folds of mucous membrane, in form not unlike a cock's comb, descend obliquely outwards for about an inch and a half, one on each side of the entrance of the vagina. These are the *nymphæ* (labia interna v. minora). Their inner surface is continuous with that of the vagina; the external insensibly passes into that of the labia majora. They contain vessels (fig. 323, *g.*) between the laminæ of tegumentary membrane, but, according to Kobelt, no erectile plexus; indeed they would seem to correspond to the cutaneous covering of the male urethra (supposed to be split open), whilst the erectile structure corresponding to the bulb and spongy body (supposed to be in two halves) lies deeper as will be presently explained.

The
nymphæ.

The ves-
tibule,
and meatus
urinarius.

Between the nymphæ, is the angular interval called the *vestibule*, in which is situated the circular *orifice* of the *urethra*, or *meatus urinarius*, about an inch below the clitoris and just above the entrance to the vagina. The membrane which sur-

* Front view of the erectile structures of the external organs of generation in the female.—*a.* Bulbus vestibuli. *b.* Sphincter vaginae muscle. *c, e.* Venous plexus, or pars intermedia. *f.* Glans of the clitoris. *g.* Connecting veins. *h.* Dorsal vein of the clitoris. *k.* Veins going beneath pubes. *l.* The obturator vein.

rounds this orifice is rather prominent in most instances, so as readily to indicate its situation. The urethra itself has been already described (see p. 1212).

Immediately below the orifice of the urethra is the *entrance* to the *vagina*, which, in the virgin, is usually more or less narrowed by the *hymen*. This is a thin duplicature of the mucous membrane, placed at the lateral and inferior parts of the entrance of the vagina; its form varies very considerably in different persons, but is most frequently semi-lunar, the concave margin being turned obliquely upwards or towards the pubes. Sometimes it is circular and is perforated only by a small round orifice, placed usually a little above the centre; and occasionally it is cribriform, or pierced with several small apertures; and it may completely close the vagina, constituting imperforate hymen. On the other hand, it is often reduced to a mere fringe, or it may be entirely absent. After its rupture, some small rounded elevations remain, called *carunculæ myrtiformes*.

Vaginal opening and hymen.

Carunculæ myrtiformes.

The *mucous membrane* may be traced inwards from the borders of the labia majora, where it is continuous with the skin: it forms a fold over the vascular tissue of the nymphæ, and is then prolonged into the urethra and vagina. It is smooth, reddish in colour, is covered by a scaly epithelium, and is provided with a considerable number of mucous crypts and follicles and with glands which secrete an unctuous and odorous substance. The mucous crypts and follicles are especially distinct on the inner surface of the nymphæ, and near the orifice of the urethra. The sebaceous glands are found beneath the prepuce, and upon the labia majora and outer surface of the nymphæ.

Mucous membrane and follicles.

Sebaceous glands.

The *glands of Bartholine* (fig. 322, n) analogous to Cowper's glands in the male, are two reddish-yellow round or oval bodies, about the size of a large pea or small bean, lodged one on each side of the commencement of the vagina, between it and the *erectores clitoridis* muscles, beneath the superficial perinæal fascia, and in front of the transverse muscles. Their ducts, which are long and single, run forward and open on the inner aspect of the nymphæ, outside the hymen or *carunculæ myrtiformes*.

Glands of Bartholine.

Erectile tissue.—All the parts of the vulva are supplied abundantly with blood-vessels, and in certain situations there are masses composed of venous plexuses, or erectile tissue, which

Erectile tissue of the female organs.

are analogous to those found in the male. The corpora cavernosa and glans clitoridis have already been described. Besides these there are two large leech-shaped masses (figs. 322, 323, *a*) about an inch long, consisting of a network of veins, enclosed in a fibrous membrane, and lying one on each side of the vestibule, a little behind the nymphæ. They are rather pointed at their upper extremities, and rounded below; they are suspended, as it were, to the crura of the clitoris and the rami of the pubes, covered internally by the mucous membrane, and embraced on the outer side by the fibres of the constrictor vaginæ muscle (fig. 323, *b*). These two plexiform masses were known to many of the older anatomists, but have been more recently noticed by Taylor and Guthrie, and particularly described and figured by Kobelt. They are named by the latter *bulbi vestibuli*, (plexûs retiformes, De Graaf; crura clitoridis interna, Swammerdam; corpora cavernosa, Santorini; semi-bulbs, Taylor,) and are considered by that observer to be analogous to the bulb of the urethra in the male, which it will be remembered presents traces of a median division. In front of the bipartite bulb of the vestibule, is a smaller plexus on each side (fig. 322, *c*, fig. 323 *e e*), the vessels of which are directly continuous with those of the bulbus vestibuli behind, and of the glans clitoridis before. This is the *pars intermedia* of Kobelt, and is regarded by him as the analogue of the part of the male corpus spongiosum urethræ which succeeds the bulb: it receives large veins coming direct from the nymphæ.

Bulbus
vestibuli.

Pars inter-
media.

Vessels.

Vessels.—The outermost parts of the vulva are supplied by the superficial pudendal arteries; the deeper parts and all the erectile tissues receive branches from the internal pudic arteries, as in the male. The veins also in a great measure correspond: there is a vena dorsalis clitoridis (*h*), receiving branches from the glans and other parts as in the male; the veins of the bulbus vestibuli pass backwards into the vaginal plexuses, and communicate also with the obturator veins (*l*); above, they communicate with the veins of the pars intermedia, those of the corpora cavernosa and of the glans of the clitoris, and also with the vena dorsalis. The lymphatics accompany the blood-vessels.

and nerves
of the
vulva.

Nerves.—Besides sympathetic branches, which descend along the arteries, especially for the erectile tissues, there are other

nerves proceeding from the lumbar and sacral plexuses; those from the former being the branches of the genito-crural (p. 856), and those from the latter, of the inferior pudendal and internal pudic nerves (p. 867), which last sends comparatively large branches to the clitoris.

THE VAGINA.

The *vagina* is a membranous and dilatable tube, extending from the vulva to the uterus, the neck of which is embraced by it. It rests below and behind on the rectum, supports the bladder and urethra in front, and is enclosed between the levatores ani muscles at the sides. Its direction is oblique from below upwards and backwards, in which course it is also slightly curved, the concavity of the curve being turned upwards and forwards. The axis of the vagina corresponds, therefore, first, with that of the outlet of the pelvis, and higher up with that of the pelvic cavity. In consequence of being thus curved, its length will be found greater if measured along the lower than along the upper wall, being in the latter situation about four inches, while in the former it amounts to five or six. Each end of the vagina is somewhat narrower than the middle part: the lower, which is continuous with the vulva, is the narrowest part, and has its long diameter from before backwards; the middle part is widest from side to side, being flattened from before backwards, so that its anterior and posterior walls are ordinarily in contact with each other; at its upper end it is rounded, and expands to receive the vaginal portion of the neck of the uterus, which is embraced by it at some distance from the os uteri. The vagina reaches higher up on the cervix uteri behind than in front, so that the uterus appears, as it were, to be let into its anterior wall.

On the *inner surface* of the vagina, along the anterior (fig. 325, e) and the posterior walls, a slightly elevated ridge extends from the lower end upwards along the middle line, similar to the raphé in other situations: these ridges are named the *columns* of the vagina, or *columnæ rugarum*. Numerous den- tated transverse ridges, called *rugæ*, will also be observed, particularly in persons who have not borne children, running at right angles from the columns. These columns and rugæ, which are most evident near the entrance of the vagina, and gradually

The
vagina ;
its position,

direction,

and dimen-
sions.

Its inner
surface
marked
with
columns
and rugæ.

become less marked, and disappear towards its upper end, are calculated to facilitate the enlargement of the vagina that occurs during pregnancy and parturition.

Structure
and connec-
tions.

Structure and connexions.—The walls of the vagina are thickest in front, where the urethra is situated, which indeed may be said to be imbedded in the anterior wall of the vaginal passage; in other situations they are thinner. The vagina is firmly connected by cellular tissue to the neck of the bladder, and but loosely to the rectum and levatores ani muscles; at the upper end, for about a fourth part of its length, it receives a covering behind from the peritonæum, which descends in the form of a cul-de-sac thus far between the vagina and the rectum.

The outer
layer.

The external layer of which the vagina is composed is a dense, pale red, highly distensible and vascular cellular tissue, which adheres closely above to the tissue of the cervix uteri. Round the tube a layer of loose erectile tissue is found, which is most marked at the lower part.

The
sphincter
vaginæ
muscle.

At its lower end, the vagina is embraced by muscular fibres, which constitute the *sphincter vaginæ* (fig. 323, *b*). The fibres of this muscle are attached behind to the central point of the perinæum, in common with the sphincter ani and transversus perinæi muscles; they open out to surround the vaginal orifice and vestibule, closely embracing on the outer side the two bulbs of the vestibule, and, again approaching in front, become narrow and are inserted upon the corpora cavernosa of the clitoris, a fasciculus crossing over these and including the vena dorsalis. The two halves of this elliptical muscle appear to be strictly analogous to those of the bulbo-cavernous muscle in the male.

The lining
membrane.

The mucous membrane, besides the columns and rugæ, is provided with numerous muciparous glands and follicles, especially in its upper smoother portion: around the cervix uteri they are very numerous. This membrane, which is continuous with that of the uterus, is covered by a squamous epithelium.

The vessels,

The vagina is largely supplied with vessels and nerves. The arteries are derived from branches of the internal iliac, viz. the vaginal, internal pudic, vesical, and uterine (pp. 572, 576). The veins correspond; but they first surround the vagina with numerous branches, and form at each side a plexus named the *vaginal plexus*. The *nerves* are derived from the hypogastric plexus of

and nerves.

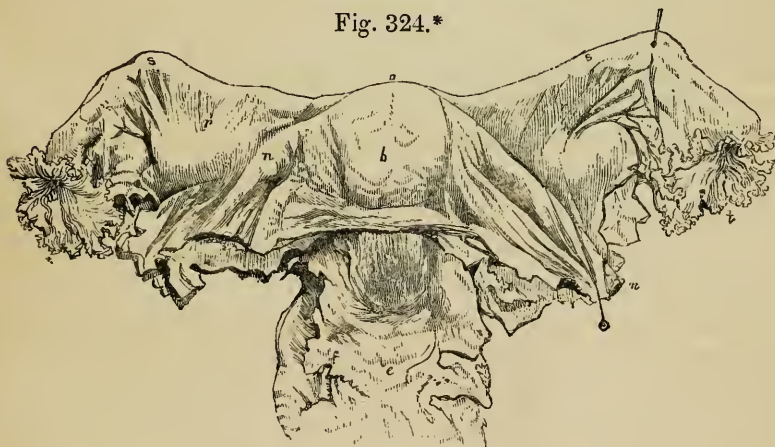
the sympathetic, and from the fourth sacral nerve and pudic nerve of the spinal system; the former are traceable to the erectile tissue (p. 901).

UTERUS.

The *uterus*, *womb*, or *matrix* (fig. 324, *b*), is a hollow organ, having very thick walls, which is intended to receive the ovum, retain and support it during the development of the fœtus, and

The
uterus ;

Fig. 324.*



expel it at the time of parturition. During pregnancy this organ accordingly undergoes a great enlargement in size and capacity, as well as other important changes. It is a pear-shaped body, situated in the cavity of the pelvis, between the bladder and rectum, and projecting into the upper end of the vagina (*e*), with which it is intimately connected. In its ordinary condition the uterus does not reach above the brim of the pelvis. Its upper end is turned upwards and forwards, whilst the lower is in the opposite direction; so that its position corresponds with that of the axis of the inlet of the pelvis, and forms an angle or curve with the axis of the vagina, which corresponds with that of the cavity and outlet. The uterus projects, as it were, upwards into

its shape,

position,

connec-
tions,

* Anterior view of the uterus and appendages.—*a*. Fundus, *b*. body, and *c*. cervix or neck of the uterus. *e*. Front of the upper part of the vagina. *n, n*. Round ligaments of the uterus. *r, r*. Broad ligaments. *s, s*. Fallopian tubes. *t*. Fimbriated extremity. *u*. Ostium abdominale. The position of the ovaries is shewn through the broad ligaments; and also the cut edge of the peritonæum, along the lower border of the broad ligaments and across the uterus.

a fold of the peritonæum, by which it is covered behind and above, and also in front, except for a short distance towards the lower end, where it is connected with the base of the bladder. Its free surface is in contact with the other pelvic viscera, some convolutions of the small intestine usually lying upon and behind it. From its two sides the peritonæum is reflected in the form of a broad duplicature, named the ligamentum latum (*r*), which, together with the parts contained within it, will be presently described.

and dimen-
sions.

The fully developed virgin uterus, for to that condition of the organ the following description applies, is pyriform, but compressed from before backwards, and, therefore, somewhat triangular, the base being turned upwards. Its average dimensions are about three inches in length, two in breadth at its upper and wider part, and nearly an inch in thickness: its weight is from seven to twelve drachms. It is usually described as consisting of the fundus, the body, and the neck.

The
fundus,

body,

The *fundus* (*a*) is the broad upper end which surmounts the body, and extends beyond the points of attachment of the Fallopian tubes. Its border is convex, and it is covered entirely with peritonæum. The succeeding part, or *body* (*b*), gradually narrows as it extends from the fundus to the neck; its two sides or borders are straight; its anterior and posterior surfaces are both somewhat convex, but the latter more so than the former. At the points of union of the sides with the rounded superior border or fundus, are two projecting angles, to which the Fallopian tubes are attached, the round ligaments being inserted a little before, and the ovarian ligaments behind and beneath them; all three of these parts being included in the duplicature of the broad ligaments. The lower, narrower, and more rounded portion of the uterus is named the *neck*, or *cervix uteri* (*c*); it is from four to six lines long; it is continuous above with the body, and, becoming somewhat smaller towards its lower extremity, projects into the upper end of the tube of the vagina, which is attached all round to the substance of the uterus, but extends upwards to a greater distance behind than in front. The projecting portion is sometimes named the *vaginal part* (*pars uteri vaginalis*; fig. 325, *d*). The lower end of the uterus presents a transverse aperture, by which its cavity opens into the vagina; this is named variously *os uteri*, *os uteri*

and neck or
cervix.

The mouth
or os uteri
externum.

externum, and (from some supposed likeness to the mouth of the tench fish) *os tincae*. It is bounded by two thick lips, which are distinguished by their relative position into anterior and posterior, the latter being the thinner and longer of the two. These borders or lips are generally smooth, but, after parturition, frequently become irregular, and are sometimes fissured or cleft.

Owing to the great thickness of its walls (fig. 325, *f*), the *cavity* of the uterus is very small in proportion to the size of the organ. The part corresponding with the body (*b*) is triangular, and flattened from before backwards, so that its anterior and posterior walls touch each other. The base of the triangle is directed upwards, and is curvilinear, the convexity being turned towards the interior of the uterus. This form is owing to the prolongation of the cavity through the substance of the organ towards its two superior angles (*i*), where two minute foramina will be observed, leading into the Fallopian tubes (*s*). At the point where the body is continuous below with the neck, the cavity is slightly constricted, and thus forms what is sometimes named the *internal orifice* (*os uteri internum, isthmus vel ostium uteri*); it is often smaller than the *os externum*, and is a circular opening. That portion of the cavity which corresponds to the *neck* (*c*) resembles a tube slightly flattened before and behind; it is somewhat dilated in the middle, and opens inferiorly into the vagina by the *os tincae*. Its inner surface is marked by two longitudinal ridges or columns, which run, one on the anterior, the other on the posterior wall, and from both of which, rugæ are directed obliquely upwards on each side, so as to present an appearance which has been named *arbor vitæ uterinus*, also *palmae plicatae*.

The cavity,

is triangular
in outline.The os
uteri
internum.The arbor
vitæ
uterinus.

Structure.—The walls of the uterus consist of an external serous layer, an internal mucous membrane, and a proper intermediate tissue. The *peritoneal* layer covers the fundus and body, except at the sides and for about half an inch of the lower part of the body in front, which is attached to the base of the bladder.

Structure.

Serous coat.

The *proper tissue* of the uterus constitutes almost the entire substance of its walls, which are thickest opposite the middle of the body and fundus, and are thinnest at the entrances of the Fallopian tubes. The tissue is very dense; it is composed

Proper tis-
sue.

Muscular
fibres.

of bundles of muscular fibres of the plain variety, interlacing with each other, but disposed in bands and layers, intermixed with much fibro-cellular tissue, a large number of blood-vessels and lymphatics, and a few nerves. The cellular tissue is more abundant near the outer surface. The arrangement of the muscular fibres is best studied in the uterus at the full period of gestation, in which the bands and layers formed by them become augmented in size, and much more distinctly developed. They may be referred to three sets or orders, viz., external, internal, and intermediate. Those of the *external* set are arranged partly in a thin superficial sheet, immediately beneath the peritonæum, and partly in bands and incomplete strata, situated more deeply. A large share of these fibres arch transversely over the fundus and adjoining part of the body of the organ, and converge at either side towards the commencement of the round ligaments, along which they are prolonged to the groin. Others pass off in like manner to the Fallopian tubes, and strong transverse bands from the anterior and posterior surface are extended into the ovarian ligaments. A considerable number of thinly-scattered fibres also pass at each side into the duplicature of the broad ligament, and others are described as running back from the cervix of the uterus into the recto-uterine folds or plicæ semilunares. The fibres of the subperitonæal layer are much mixed with cellular tissue, especially about the middle of the anterior and posterior surfaces of the uterus, in which situation many of the superficial fibres appear to have as it were a median attachment from which they diverge. The fibres on the *inner* surface of the uterus are disposed with comparative regularity in its upper part, being arranged there in numerous concentric rings round the openings of the two Fallopian tubes, the outermost and largest circles of the two series meeting from opposite sides in the middle of the uterus. Towards the cervix the internal fibres run more transversely; elsewhere they take various directions. The *intermediate* fibres, between the external and internal set, pass in bands among the blood-vessels, following no regular course.

The mucous
membrane

The *mucous membrane* which lines the uterus is thin and closely adherent to the subjacent substance, especially in the body of the organ. It is continued from the vagina, and into the Fallopian tubes. Between the rugæ of the cervix, already

described, it is provided with numerous mucous follicles and glands. There are also occasionally found in the same situation certain small transparent vesicular bodies, which, from an erroneous opinion as to their nature, were named the *ovula of Naboth*. They appear to be closed and obstructed mucous follicles, distended with a clear viscous fluid.

and
follicles.

The ovula
of Naboth.

In the body of the uterus the mucous membrane is thin, smooth, soft, and of a reddish-white colour. When seen by aid of a lens, it is found to be marked over with minute dots, which are the orifices of numerous simple tubular glands, somewhat like those of the intestine. Some of these tubular glands are branched, and others are slightly twisted into a coil. These glands can be distinctly seen in the unimpregnated and in the virgin uterus, but they become enlarged and more conspicuous on impregnation. The epithelium is columnar and ciliated as far down as the middle of the cervix, below which point it becomes squamous like that of the vagina and vulva.

The tubular
glands of
the uterus :

its epi-
thelium is
partly
ciliated.

Ligaments of the uterus.—Where the peritonæum is reflected off from the uterus to the rectum behind, and to the bladder in front, it forms, in each position, two semilunar folds, which are sometimes called respectively the *anterior* and the *posterior ligaments* of the uterus. The former are also named the *vesico-uterine*, and the latter, which are more marked, the *recto-uterine folds*, or *plicæ semilunares* of Douglas.

Ligaments
of the
uterus.

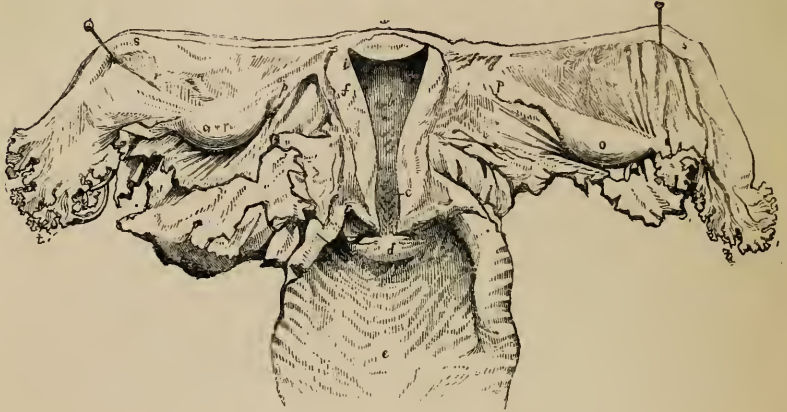
The *broad ligaments* (ligamenta lata, fig. 324, 325, r.) are formed on each side by a fold of the peritonæum, which is directed laterally from the anterior and posterior surfaces of the uterus, to be connected with the sides of the pelvic cavity. The part intervening between the uterus and the pelvis on each side constitutes the ligamentum latum. Between the two layers of the serous membrane are placed, first, the Fallopian tube, which, as will be more particularly described, runs along the upper margin of the broad ligament; secondly, the round ligament, which is in front; thirdly, the ovary and its ligament, which are behind; and, lastly, blood-vessels, lymphatics, and nerves, with some scattered fibres from the superficial muscular layer of the uterus. The *ligament of the ovary* (fig. 325, p) is merely a dense fibro-cellular cord, containing also, according to some authorities, uterine muscular fibres and measuring about an inch and a half in length, which extends from the inner end of the ovary to the

Broad
ligaments.

Ligament
of the
ovary.

upper angle of the uterus, immediately behind and below the point of attachment of the Fallopian tube ; it causes a slight

Fig. 325.*



elevation of the posterior layer of the serous membrane, and, together with the ovary itself, forms the lower limit of a triangular portion of the broad ligament, which has been named the *ala vespertilionis* or bat's wing (*r*).

Alæ ves-
pertilionis.
The round
ligaments.

The *round ligaments* are two cord-like bundles of fibres, about four or five inches in length, attached to the upper angles of the uterus, one on either side (ligamentum rotundum, lig. teres uteri ; fig. 324, *n, n.*), immediately in front of the Fallopian tube. From this point each ligament proceeds upwards, outwards, and forwards, to gain the internal inguinal ring ; and after having passed, like the spermatic cord in the male, through the inguinal canal, reaches the fore-part of the pubic symphysis, where its fibres expand and become united with the substance of the mons Veneris. Besides cellular tissue and vessels, the round ligaments contain plain muscular fibres, like those of the uterus, from which, indeed, they are prolonged. Each ligament

* Posterior view of the uterus and its appendages : the cavity of the uterus being shewn by the removal of its posterior wall ; and the vagina being laid open.—*a*. Fundus, *b*. body, and *c*. cervix of the uterus, laid open. The arbor vitæ is shewn in the cervix. *d*. The os uteri externum, laid open. *e*. The interior of the upper part of the vagina. *f*. Section of the walls of the uterus. *i*. Opening into Fallopian tube. *o*. Ovary. *p*. Ligament of ovary. *r*. Broad ligament. *s*. Fallopian tube. *t*. Fimbriated extremity.

also receives a covering from the peritonæum, which, in the young subject, is prolonged under the form of a tubular process for some distance along the inguinal canal; this, which resembles the vaginiform process of peritonæum originally existing in the same situation in the male, is named the canal of Nuck: it is generally obliterated afterwards, but is sometimes found even in advanced life.

Blood-vessels and nerves.—The *arteries of the uterus* are four in number, viz., the right and left *ovarian* (which correspond to the spermatic of the male) and the two *uterine*. Their origin, as well as the mode in which they reach the uterus and ovaries, has been already described (pp. 562, 573). They are remarkable for their frequent anastomoses, and also for their singularly tortuous course: within the substance of the uterus they seem to be placed in little channels or canals. The *veins* correspond with the arteries: they are very large and form the uterine plexuses, and their thin walls are in immediate contact with the uterine tissue. The course of the lymphatics is described at page 658; they are very large and abundant in the gravid uterus. The *nerves* have been fully described (p. 901). They are derived from the inferior hypogastric plexuses, the spermatic plexuses, and the third and fourth sacral nerves.

The vessels
of the
uterus;

and its
nerves.

The *changes which take place in the uterus* from age, menstruation, and gestation, and the characters presented by this organ after it has once performed the latter function, can only be very generally indicated here.

The uterus
undergoes
changes,

For some time after *menstruation* first commences, the uterus becomes rounder and slightly enlarged at each period, its os externum becomes more rounded, and its lips swollen: subsequently these periodical alterations are not so marked. The organ itself, however, always becomes more turgid with blood, and the mucous membrane appears darker, softened, and thickened.

during
menstrua-
tion.

In *gestation* more extensive alterations ensue, which necessarily affect the size, shape, and position of the organ, the thickness and amount of substance in its walls, the dimensions and form of its cavity, and the character of its cervix and of its os externum and os internum. Its weight increases from about one ounce to one pound and a half or even three pounds. Its colour becomes darker, its tissue less dense, its muscular bundles more evident, and their fibres more characteristic. The round ligaments become enlarged, and their muscular structure more marked; the broad ligaments are encroached upon by the intrusion of the growing uterus between their layers. The mucous membrane and the glands of the body of the uterus become the

and gesta-
tion;

seat of singular changes, which lead to the formation of the decidua membrane; whilst that of the cervix loses its columns and rugæ. The blood-vessels and lymphatics are greatly enlarged, and it is observed that the arteries become exceedingly tortuous, as they ramify upon the organ. The condition of the nerves in the gravid uterus has been already discussed (p. 902).

and
after partu-
rition.

After parturition, the uterus again diminishes, but never regains its original virgin character. Its weight usually remains about two or three ounces in those who have had children; its cavity is larger; the os externum is more rounded, and its margins often puckered or fissured; the arteries continue much more tortuous than they are in the virgin; and its muscular fibres and layers remain more defined.

Changes
from age.

Age.—In the infant the neck of the uterus is larger than the body; and the fundus is not distinguished either by its breadth or its convex outline. These parts afterwards enlarge gradually, until, at puberty, the pyriform figure of the womb is fully established. The arbor vitæ is very distinct, and indeed at first reaches upwards to the highest part of the cavity.

in form,

and tex-
ture.

From the gradual effects of *age* alone, independent of impregnation, the uterus shrinks, and becomes paler in colour, and harder in texture; its triangular form is lost; the body and neck become less distinguishable from each other; the orifices also become less characteristic.

THE OVARIES AND FALLOPIAN TUBES.

The
ovaries,

their size
and connec-
tions.

Their
proper
ligament.

The *ovaries* (fig. 325, *o, o*), the parts analogous to the testicles of the male (*ovaria, testes muliebres*), are two somewhat flattened oval bodies, which are placed one on each side, nearly horizontally, at the back of the broad ligament of the uterus, and are enveloped by its posterior membranous layer. The ovaries are largest in the virgin state; their weight is from three to five scruples, and they usually measure about one inch and a half in length, three-quarters of an inch in width, and nearly half an inch in thickness; but their size is rather variable. Each ovary is free on its two sides, and also along its posterior border, which has a convex outline; but it is attached along its anterior border, which is straighter than the other, and by which alone the vessels and nerves reach it. Its inner end is generally narrow, and is attached to the dense cord already described as the *ligament of the ovary* (*p*), by which it is connected with the uterus. Its outer extremity is more obtuse and rounded, and has attached to it one of the fimbriæ of the Fallopian tube (*s*).

Structure.—The colour of the ovaries is whitish, and their surface is either smooth, or more commonly irregular, and often marked with pits or clefts resembling scars. Beneath the peritonæal coat, which covers it everywhere except along its attached border, the ovary is enclosed in a *proper fibrous coat* (tunica albuginea), of a whitish aspect and of considerable thickness, which adheres firmly to the tissue beneath. When this latter is divided, it is seen to consist of a firm reddish-white vascular structure called the *stroma* (fig. 326, A. 1), in which are lodged

Structure.

The fibrous coat,

and stroma :

Fig. 326.*



a number of small vesicles of various sizes, named the *Graafian vesicles* or *follicles* (vesiculæ Graafianæ). In females who have not had children there are usually from eight to fifteen or twenty of these vesicles in each ovary, varying from the size of a pin's head to that of a pea. As many as thirty, and even fifty have been counted. They are filled with a clear, colourless, albuminous fluid (6), and the larger ones approach the surface of the ovary, on which they may sometimes be distinguished as semi-transparent elevations. These vesicles are not the ova, as was formerly supposed, but each includes, besides its fluid contents, a small round vesicular body, first distinctly pointed out by

The Graafian vesicles.

* A. Graafian vesicle of a Mammal seated in the ovary magnified:—(Baër).—1. Vascular stroma of the ovary. 2. Peritonæal coat of ovary. 3. Outer, and 4. inner tunics of Graafian vesicle. 5. Membrana granulosa of Baër. 6. Fluid in cavity of vesicle. 7. Granular disc of Baër. 8. The ovum.

c. Ovum of the sow, removed from the Graafian vesicle, and lying amongst granular matter. Magnified highly. (Barry).—1. Germinal spot of Wagner. 2. Germinal vesicle of Purkinjé. 3. The yolk. 4. The transparent tunic of ovum. 5. Tunica granulosa (Barry); granular disc (Baër). 6. Adherent granules.

Baër, which is the true *ovum* (8). Sometimes, though rarely, two ova have been found in one vesicle.

The structure of these.

The vesicles of De Graaf have two coats, viz. an external vascular tunic (3) and an internal tunic, named the *ovi-capsule* (4), which is lined with a granular epithelial layer, the *membrana granulosa* (5). At first the ovule appears to be floating near the centre of the vesicle, but, in the mature condition of the latter, it approaches the internal surface of the ovi-capsule, and becomes embedded in a small flattened heap of granular substance (7), which there forms part of the *membrana granulosa*. By rupture of the vesicle the ovum escapes into the Fallopian tube, and is thus conveyed into the womb, while the ruptured vesicle becomes converted into a yellow mass named a *corpus luteum*, which, after persisting for a time, dwindles down into a small fibrous cicatrix.

The ovum ;

The *ovum* itself (fig. 326, A⁸, and B,) is a perfectly spherical body, very constant in size, being about $\frac{1}{120}$ th of an inch in diameter ; it consists of a thick, colourless, and transparent envelope, (*zona pellucida*, Baër ; *membrana pellucida*) (4), which surrounds the substance of the yolk. Within the yolk (3), which is made up of granular matter, is situated a still smaller vesicular body, named the *germinal vesicle* (2), which is about $\frac{1}{720}$ th of an inch in diameter ; and in this again is an opaque spot, having a diameter only of $\frac{1}{3500}$ to $\frac{1}{2500}$ th of an inch, and named the *germinal spot* (*macula germinativa*) (1).

its germinal vesicle, and spot.

The Fallopian tube.

The *Fallopian tubes* (figs. 324, 325, s, s).—These tubes (*tubæ Fallopianæ uterinæ*), which may be considered as ducts of the ovaries, and which serve to convey the ovum from thence into the uterus, are inclosed in the free margin of the broad ligaments. They are between three and four inches in length. Their inner or attached extremity, which proceeds from the upper angle of the uterus, is narrow and cord-like ; but from this point they soon begin to enlarge, and proceeding outwards, one on each side, pursue an undulatory course, and at length, having become gradually wider, they bend backwards and downwards towards the ovary, about an inch beyond which they terminate in an expanded extremity, the margin of which is divided deeply into a number of irregular processes named *fimbriæ*, of which one, somewhat longer than the rest, is attached to the outer end of the corresponding ovary. This wide and fringed

end of the Fallopian tube, or rather *trumpet*, as the term "tuba" literally signifies, is turned forwards, and is named the *fimbriated extremity* (*morsus diaboli, t t*). In the midst of these fimbriæ, which are arranged in a circle, the tube itself opens by a round constricted orifice, *ostium abdominale* (fig. 324, *u*), placed at the bottom of a sort of fissure leading from that fringe which is attached to the ovary. It is by this orifice that an ovum is received at the time of its liberation from the ovary, and is thence conveyed along to the uterine extremity of the tube, which opens into the womb by a very minute orifice, scarcely admitting a fine bristle, and named *ostium uterinum* (fig. 325, *i*). The part of the canal which is near the uterus is also very fine, but it becomes gradually larger to its abdominal orifice, where it is again somewhat contracted.

The fimbriated extremity, the ostium abdominale,

and ostium uterinum.

Beneath the external or peritonæal coat the walls of the tube contain, besides cellular tissue, plain muscular fibres like those of the uterus, arranged in an external longitudinal, and an internal circular layer. The mucous membrane lining the tubes is thrown into longitudinal plicæ, which are broad and numerous in the wider part of the tube; it is continuous, on the one hand, with the lining membrane of the uterus, and at the outer end of the tube with the peritonæum, presenting an example of the direct continuity of a mucous and serous membrane, and making the peritonæal cavity in the female an exception to the ordinary rule of serous cavities, *i.e.* of being perfectly closed. The epithelium in the interior of the Fallopian tube is, like that in the uterus, columnar and ciliated; the inner surface of the fimbriæ is also provided with cilia, and Henlé has even detected ciliated epithelium on their outer or serous surface, but it here soon passes into the scaly epithelium of the peritonæal membrane.

Structure of the tubæ.

Muscular and mucous coats;

the epithelium is ciliated.

Vessels and nerves of the ovaries and Fallopian tubes. The ovaries are supplied by the ovarian *arteries*, analogous to the spermatic in the male (p. 562), which anastomose freely by an internal branch with the termination of the uterine arteries (p. 573). Sometimes this anastomotic branch is so large that the ovary seems to be supplied almost entirely by the uterine artery. It always sends numerous branches to the Fallopian tube. The arteries penetrate the ovary along its attached border, pierce

The ovarian vessels,

the proper coat, and run in flexuous parallel lines through its substance. The *veins* correspond, and the ovarian veins form a plexus near the ovary, named the pampiniform plexus (p. 645). and nerves. The *nerves* are derived from the spermatic or ovarian plexus; and also from one of the uterine nerves, which invariably send an offset to the Fallopian tube (pp. 901, 902).

DEVELOPMENT OF THE GENITO-URINARY ORGANS.

The Urinary Organs.

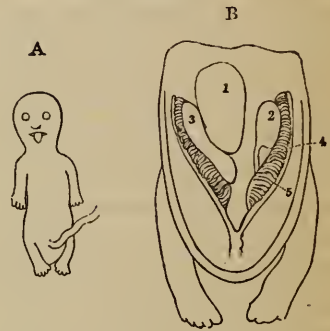
The Wolffian bodies are temporary glands.

In human embryo are small.

Their structure.

The *Wolffian Bodies* and their *Excretory Ducts*.—The development of the genito-urinary organs in reptiles, birds and mammalia, including man, is preceded by the formation of two *temporary* glands, named, after C. F. Wolff, the *Wolffian bodies*. In the embryos of the higher mammalia these organs are proportionally smaller, and disappear earlier than in those of the lower mammalia, birds or reptiles. In the human subject, accordingly, the Wolffian bodies (fig. 327, B, 4) are relatively small, and are found only in very early fetuses. In the mammalian embryo, at a period when the intestinal canal still communicates with the umbilical vesicle, the Wolffian bodies commence in the form of two slight ridges of blastema, placed one on each side of the line of attachment of the intestine to the vertebral column. On reaching their full size, which in man seems to be about the fifth week of embryonic life, they have the appearance of two oblong reddish masses, placed on the sides of the vertebral column and extending from the lower end of the abdomen to the vicinity of the heart. Their structure is decidedly glandular; clear pedunculated vesicles may be early discovered in them, opening into an excretory duct, which runs along the outer side of each organ. These vesicles subsequently become lengthened into transverse and somewhat tortuous cœcal tubes, which open in like manner into the common duct. The Wolffian bodies are highly vascular, their larger blood-vessels run-

Fig. 327.*



* A. Human embryo, eight lines in length. B. Genito-urinary organs of the same magnified (Müller). 1. Supra-renal capsule of right side, which conceals the corresponding kidney. 2. Left kidney and ureter, exposed by removal of the left supra-renal capsule. 3. Right testis or ovary. 4. Wolffian body. 5. Vas deferens or Fallopian tube.

ning between and parallel with the transverse tubules. In the embryo of the coluber natrix, Rathké has observed little vascular tufts, which he compares to the Malpighian corpuscles of the kidneys.

As to the *excretory duct*, Müller is of opinion, that in mammalia, it emanates from the lower end of the Wolffian body, but others agree in stating, that, as in birds, it lies along the outer border of the gland, receiving the tubules in its course. The ducts of the two bodies open into the sac of the allantois, to be presently described.

Their excretory ducts end in allantois.

A whitish secretion has been seen in the ducts of the Wolffian bodies of birds and serpents resembling the urine of those animals, and since, also, the fluid of the allantois has been found to contain uric acid, it is thought that the Wolffian bodies perform the office of kidneys during the early part of foetal life. They are accordingly sometimes named the *primitive* or *primordial kidneys*.

Their secretion is urinous.

As development advances, the Wolffian bodies (1) rapidly become shorter and thicker in proportion; they shrink towards the lower part of the abdominal cavity, and soon become almost entirely wasted. By the end of the second month scarcely any trace of them is visible in the human embryo. They take no part in the formation of the kidneys (2) or suprarenal capsules (1), nor in that of the ovaries or body of the testis (3). Remnants of the tubular structure of these temporary organs are, however, to be found in female embryos, situated in the fold of peritonæum, connecting the ovary with the Fallopian tube (fig. 328, c, 5). Similar appearances of tubuli, with rounded corpuscles intermixed, are met with in the same situation, at later periods of intra-uterine life, and even for some time after birth, constituting what is named the *organ of Rosenmüller*, a structure which J. F. Meckel regarded as an abortive or rudimentary epididymis. Kobelt maintains that a remnant of the Wolffian body persists throughout life, forming in the adult female an appendage to the ovary (*Neben-Eyerstock*) analogous to the epididymis of the male. It is, moreover, supposed by Rathké, that, in the male, the middle tubuli of each Wolffian body, together with its excretory duct, become converted into the epididymis and vas deferens of the corresponding side; and Kobelt has adopted a similar view as to the origin of the epididymis. Lastly, it has been held by Müller, that in mammalia the lower portion of the excretory duct of the Wolffian body persists as part of the corresponding Fallopian tube or vas deferens.

They shrink and nearly disappear.

Remnants of them, in the female, as

organ of Rosenmüller;

and perhaps in the male, also.

The *Kidneys* and *Ureters*.—The *kidneys* commence subsequently to and independently of the Wolffian bodies. They first appear, it is said, about the seventh week, as two small dark oval masses, situated behind the upper part of the Wolffian bodies, which are still large, and completely hide the kidneys. Though at first smooth and oval (fig. 327, B, 2), the kidneys soon assume their characteristic general outline, and about the tenth week are distinctly lobulated (fig. 328, A, 2). The separate lobules, generally about fifteen in number, gradually coalesce in the manner already described (p. 1191.); but at birth, indications of the original lobulated condition of the kidney are still visible on the surface, and the entire organ is

The kidneys; their early form,

more round in its general figure than in the adult. The kidneys are then also situated lower down, than in after life.

their struc-
ture,

The formative blastema of the kidney, as observed by Rathké in the foetal calf, soon contains a series of club-shaped bodies which have their larger ends free and turned outwards, and their smaller ends or pedicles directed inwards towards the future hilus, where they are blended together. As the organ grows these bodies increase in number, and finally, becoming hollow, form the *uriniferous tubes*. At first, short, wide, and dilated at their extremities, the tubuli soon become elongated, narrow, and flexuous, occupying the whole mass of the kidney, which then appears to consist of cortical substance only. At a subsequent period, the tubuli nearest the hilus become straighter, and thus form the medullary substance. The tubuli, as shown by Valentin, are absolutely, as well as relatively, wider in an early condition of the kidney. The Malpighian corpuseles have been seen by Rathké in a sheep's embryo, the kidneys of which measured only two and a half lines in length.

their tubuli,

and cap-
sules.

The ureters,

pelvis and
calices.

The *ureters*, it is stated by Rathké, commence *after* the kidneys, and then become connected with the hilus of each organ, and with the narrow ends of the club-shaped bodies in its interior. At first the growing tubuli do not seem to communicate with the cavity of the ureter; but subsequently, when the wide upper portion of this canal or *pelvis* of the kidney has become divided to form the future *calices*, the pencil-like bundles of the tubuli open into each subdivision of the ureter, and give rise at a later period to the appearance of the *papillæ* and their numerous orifices. The lower ends of the ureters soon come to open into that part of the sac of the allantois, which afterwards becomes converted into the bladder. The researches of Müller Valentin, and Bischoff are in general confirmatory of Rathké's account; Valentin, however, believes that the ureter (which he has seen at the earliest periods), the pelvis of the kidney, and the uriniferous tubules are formed in a general blastema, independently of one another; and that, each part first becoming separately hollowed out, their cavities afterwards communicate with each other. Bischoff states that the ureters appear at the same time as the kidneys, and are formed in continuity with the uriniferous tubules, and moreover that all these parts, which are at first solid, are excavated, not separately but in common, in the further progress of development.

In the advanced foetus and in the new-born infant, the kidneys are relatively larger than in the adult, the weight of both glands compared with that of the body, being, according to Meckel, about one to eighty at birth.

The supra-
renal
bodies.

The Supra-renal Capsules.—Arnold alone has supposed that these organs are formed from a part of the Wolffian bodies severed from the rest. Mr. Goodsir is of opinion that they are remnants of the primitive blastodermic membrane. Other observers attribute to these organs an independent origin. Valentin describes them as originating in a single mass, placed in front of the kidneys, and afterwards becoming divided. Meckel has also seen them partially blended together. Müller has found the supra-renal capsules

in contact, but not united. Bischoff has always seen them separate, and in early conditions closely applied to the upper end of the Wolffian bodies.

In quadrupeds, the supra-renal capsules are at all times smaller than the kidneys; but in the human embryo (figs. 327, 328, A¹) they are for a time larger than those organs, and quite conceal them. At about the tenth or twelfth week, the renal capsules are smaller than the kidneys; at birth the proportion between them is 1 to 3, whilst in the adult it is about 1 to 22. They diminish in aged persons.

The Allantois, Urinary Bladder, and Urachus.—The name of Allantois was originally given to a membranous sac which is appended to the umbilicus of various quadrupeds in the foetal state, and which communicates with the urinary bladder by means of a canal passing through the umbilical aperture and named the urachus. These several parts are formed out of one original saccular process, which passes out from the cloacal termination of the intestine, and which subsequently becomes distinguished into the bladder, the urachus and the allantois strictly so called; and modern embryologists employ the term allantois also to signify the original common representative of the different parts referred to. In this sense an allantois may be said to exist not only in mammalia, but also in birds and reptiles, subject, however, to great differences in its subsequent development and relative importance. Thus in Batrachians it does not extend out of the body at all; in scaly reptiles, on the other hand, as well as in birds and in some quadrupeds, it ultimately surrounds the body of the foetus and spreads itself over the inner surface of the chorion; whilst in other quadrupeds its extra-abdominal portion is of small extent. In man the allantois proper is not only very insignificant in point of size, but also extremely limited in duration, for it vanishes at a very early period in the life of the embryo; and whilst in many animals it serves both as a receptacle for the secretion of the foetal urinary organs, and as a vehicle to conduct the umbilical vessels from the body of the embryo to the chorion to form the placenta (or some equivalent vascular structure), it seems in the human species to serve merely for the latter purpose. The allantoid process communicates below with the intestinal canal, and receives the wide excretory ducts of the Wolffian bodies, the ureters, and the Fallopian tubes or vasa deferentia. By Baer, Rathké, and others, the allantois has been regarded as formed from the intestinal tube, and by Reichert as developed upon the excretory ducts of the Wolffian bodies. Bischoff says that, in the embryos of the rabbit and dog, it commences before the appearance of either the Wolffian bodies or the intestine, as a solid mass projecting forwards from the posterior extremity of the body. This mass soon becomes hollowed into a vesicle, which is covered with blood-vessels, and communicates with the intestine. Continuing rapidly to enlarge, it protrudes between the visceral plates and, when these close together, through the opening of the umbilicus, forming in the rabbit a pear-shaped sac, which conveys blood-vessels (soon recognized as the umbilical vessels) to the chorion to form the foetal part of the placenta.

The allantois in animals,

in man.

Its formation.

In the human embryo, the portion of the allantois situated beyond the

Its metamorphosis into urachus and bladder.

umbilicus disappears entirely at a very early period, and the internal portion, reaching from the umbilicus to the intestine, is first elongated, and then becomes widened below to form the bladder, whilst its upper part shrinks, and is at length completely closed to form the urachus; but, even up to the period of birth, the urachus often remains tubular for a certain distance above the bladder. The account of the metamorphosis of the allantois given recently by Dr. M. Langenbeck is somewhat different. That observer states that the wide part of the allantois originally outside the body of the embryo is not obliterated, but is drawn into the abdominal cavity, its remote portion having previously become constricted to form the future urachus, whilst the part nearest the embryo, together with the narrow portion already within the fœtus, is destined to form the bladder.

The sinus uro-genitalis.

The lower part of the allantois, or rudimentary bladder, receiving as already mentioned the efferent canals of the Wolffian bodies, as well as those of the kidneys and of the ovaries or testes, at first communicates freely with the lower end of the intestinal tube, and when this becomes opened to the exterior, there is formed a sort of cloaca, as in adult birds and reptiles. Soon, however, a separation takes place, and the genito-urinary organs have a distinct passage to the exterior, named the *sinus uro-genitalis*, (fig. 328, B, ⁵) situated in front of the termination of the intestine.

The Organs of Generation.

Generative organs.

The development of the parts concerned in the reproductive function does not begin until after the rudiments of the principal organs of the body have appeared. The internal organs of generation first commence, and for a brief period no sexual difference is perceptible in them. The external organs, which subsequently begin to be formed, are also identical in appearance, in the two sexes, as late as the fourteenth week.

Internal organs. Ovaries and testes.

The *Internal Organs of Generation.* The *Ovaries* and *Testes*.—The rudiments of the *ovaries* or *testes*, for it cannot at first be determined which are ultimately to be produced, appear after the formation of the allantois and Wolffian bodies, but a little sooner than the kidneys. They consist of two small whitish oval masses of blastema (fig. 327, ³), placed on the inner border of the Wolffian bodies. The earliest peculiarities of sex which are distinguishable, occur in the form, position, and structure of these rudiments of the essential reproductive organs. The ovaries, for example, become elongated and flattened, and soon assume first an oblique and then a nearly transverse position (fig. 328, A, ³): the testes, on the other hand, become rounder and thicker, and retain their nearly vertical direction. Moreover, as development advances, the ovaries remain unconnected with the Fallopian tubes, whilst the testes become united with the corresponding excretory canals or vasa deferentia. Lastly, though both ovaries and testicles gradually change their original position, and become situated lower down than at first, the former merely descend to the pelvic cavity, whilst the latter pass through the inguinal canal and enter the scrotum.

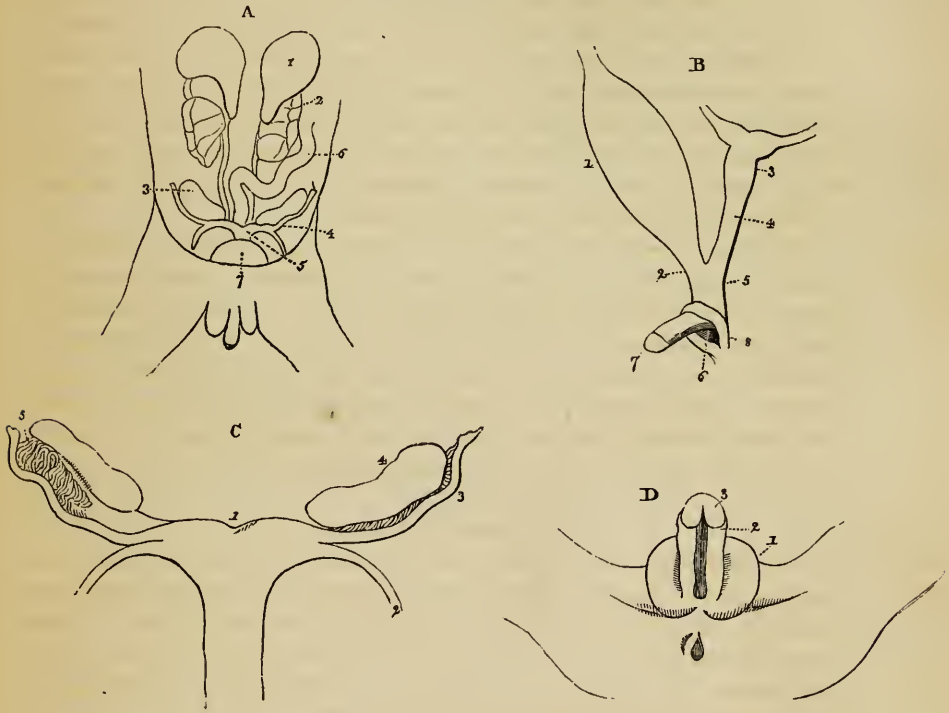
Peculiarities of each.

Their structure.

The changes which take place in the substance of the ovary and testis

have been minutely described by Valentin, who has endeavoured to trace the analogies in the development of each. Bischoff, however, has not succeeded in confirming Valentin's description, and their respective statements

Fig. 328.*



leave the subject yet in doubt. In the human female, according to Bischoff, the Graafian vesicles are not usually visible in the ovarian stroma before birth, but exceptions to this rule occasionally occur. The ovum begins to form in its Graafian vesicle, when this latter is still very small; it soon nearly fills the vesicle, which, however, grows more rapidly afterwards, so as at length to acquire a much greater proportionate size. The develop-

* Genito-urinary organs of a female embryo, measuring three inches and a half in length. (Müller). A. General view. 1. Left supra-renal capsule. 2. Left kidney. 3. Right ovary. 4. Left Fallopian tube. 5. Uterus. 6. Intestine. 7. Bladder. B. Genito-urinary organs viewed from one side and enlarged. 1. Bladder. 2. Urethra. 3. Uterus, bifid. 4. Vagina. 5. Part common to the vagina and urethra, or sinus urethro-genitalis. 6. Common orifice of the urethra and genital organs. 7. Clitoris. C. Internal organs still further magnified. 1. Uterus, bifid, or with the fundus notched. 2. Round ligament. 3. Fallopian tube. 4. Ovaries. 5. Remains of Wolffian bodies. D. External parts, also magnified. 1. Labia majora. 2. Nymphæ, leading down from the under side of the clitoris. 3. Glans clitoridis.

ment of new Graafian vesicles seems to continue as long as the procreative faculty subsists, but beyond the age of puberty it is difficult to detect them in their commencing state.

The Fallo-
pian tubes
and vasa
deferentia ;

their origin
a subject of
difference
of opinion.

The *Tubæ Fallopianæ* and *Vasa deferentia* —The mode of origin of the Fallopian tubes and vasa deferentia has been differently explained by different inquirers. In the female embryo of birds, according to Müller, the oviduct (or Fallopian tube) is formed along the outer border of the Wolffian body, close to but independently of the duct of that gland ; whereas, in the male embryo of the bird, no independent vas deferens could be detected, but the excretory duct of the Wolffian body appeared to become connected by transverse vessels with the corresponding testicle, and to form its vas deferens. In mammalia, on the other hand, in which the excretory duct of the corpus Wolffianum is described by Müller as passing out at its lower end, the Fallopian tube, as well as the vas deferens, is supposed by that observer to be formed out of a distinct canal, which has the appearance of a filament running along the outer border of the Wolffian body, and which ultimately becomes continuous below with a persistent portion of the Wolffian duct. In opposition to this view, Rathké maintained that both the Fallopian tubes and deferent vessels are formed altogether independently of the excretory ducts of the Wolffian bodies, though their rudiments are developed close to those ducts, the situation of which they ultimately come to occupy. Rathké has since been led to adopt a somewhat different opinion : according to this view, which is founded on his researches on the development of the snake, but which he thinks will probably apply also to the higher vertebrata, there is formed along the Wolffian duct in both sexes, a solid filament, which is afterwards converted into a canal open at its upper end. In the female, the duct of the Wolffian body, as well as that body itself, is entirely absorbed, whilst the new canal constitutes the Fallopian tube ; but, in the male, the reverse takes place, the newly formed canal disappearing, and the Wolffian duct becoming the vas deferens, whilst some of the tubuli of the Wolffian body remaining in connection with the duct, probably contribute to form the epididymis. Bischoff, after a careful examination of these parts, declares that the filament formed along the outer border of each Wolffian body, contains not only the excretory duct of that gland, but an efferent sexual canal, which is the rudiment of the Fallopian tube or vas deferens, and that these parts are both formed altogether independently of the Wolffian duct.

Changes
from early
condition.

In the female embryo, the efferent sexual canal (fig. 327, ^a), or future *Fallopian tube*, becomes widened, remains open at its upper end, is comparatively short and free from convolutions, and is only slightly attached to the corresponding ovary (fig. 328, A, c). In the male, on the contrary, the efferent duct, or *vas deferens*, continues of comparatively narrow calibre, connects itself with the testicle, and forms the epididymis, becoming lengthened out and convoluted. Müller also thinks that no part of the Wolffian bodies is converted into the generative organ in either sex. He supposes that the efferent sexual tube or vas deferens becomes connected

with the testicle by means of transverse tubuli which do not belong to the Wolffian body, and that these communicating tubes form the coni vasculosi, whilst the rest of the epididymis is formed by the convolutions of the efferent tube itself. It has already been mentioned that Rathké, and, more recently, Kobelt, are of opinion that the junction of the vas deferens with the testis, is effected by means of some of the transverse tubuli of the corresponding Wolffian body which persist and form the epididymis.

The *descent of the testicles* is a term applied to the passage of the testes from the abdominal cavity into the scrotum. When yet situated at the back of the abdomen, along the inner border of the Wolffian bodies, the testes are covered in front by the peritonæum; and, besides this, soon acquire a proper envelope, which becomes the tunica albuginea. At this period, the blood-vessels and nerves, and, subsequently, the efferent apparatus of the gland or future vas deferens and epididymis, pass to or from the posterior surface of the testis, which is destitute of peritonæal covering. Even before the wasting of the corpora Wolffiana, a slight opaque band or cord lying beneath the peritonæum is seen extending from the lower part of each of these bodies to the inguinal region. When the Wolffian bodies have disappeared, each testis, now increased in size, and connected with its excretory duct, has already moved somewhat lower down in the abdomen of the embryo, and is supported by a suspensory fold or duplicature of the peritonæum, named by Seiler the *mesorchium*. By this time, the opaque cord just mentioned has become much larger, and reaches from the lower end of the epididymis and testis through the inguinal canal to the front of the pubes and to the scrotum, constituting the *gubernaculum testis*, so called because it is supposed to serve as a guide to the testicle in its descent. At the fifth or sixth month of foetal life, the gubernaculum has attained its full development; its upper end, on which the testicle rests, is broader than the lower part, and lies in the peritonæal fold or mesorchium. As the testicle passes from the lumbar region to the iliac fossa, the gubernaculum becomes shorter, and before the gland enters the internal inguinal ring, which takes place in the seventh month, a small pouch of peritonæum appears at that point, and, under the name of the *processus vaginalis peritonæi*, precedes the testicle in its course through the inguinal canal, and enters the scrotum in advance of the gland. By the end of the eighth month the testis is in the scrotum, and a little time before birth, the narrow neck of the peritonæal pouch, by which it previously communicated with the general peritonæal cavity, becomes closed in the manner elsewhere described (p. 1238), and the process of peritonæum, now entirely shut off from the abdominal cavity, remains as an independent serous sac, named the *tunica vaginalis*. It has also been noticed elsewhere, that some of the lowermost fibres of the internal oblique muscle, and even of the transversalis muscle also, appear to be carried down in front of the testicle, to form the *cremaster* muscle.

The office of the gubernaculum is yet imperfectly understood. Hunter, Cooper, Seiler, and others, believed that it contained muscular fibres, which drew the testicle into its new position. Some have supposed that it effected

The descent of the testes.

The mesorchium.

Gubernaculum testis.

Processus vaginalis peritonæi.

Formation of tunica vaginalis.

Structure and office of gubernaculum.

this by a slow and gradual contraction or shortening of its tissue; whilst a third opinion has been, that it merely serves as a guide to the path of the gland. The muscularity of the gubernaculum has been denied by many anatomists, who regard this cord as either cellular or fibrous: it often appears to be partially hollow. According to Mr. Curling, who has recently examined it, it consists of a soft transparent areolar tissue within, and of distinct striped muscular fibres externally. At its lower end, the gubernaculum and these muscular fibres are arranged in three bundles, which are connected respectively with Poupart's ligament, the bottom of the scrotum, and the pubes: some fibres, moreover, are derived from the internal oblique muscle. In the opinion of Mr. Curling, these muscular bundles aid in the descent of the testicle, and afterwards form the cremaster. According to E. H. Weber, the gubernaculum originates in form of a sac filled with fluid and placed in the situation of the inguinal canal. The lower end of this sac is protruded downwards to the bottom of the scrotum: the upper end is extended upwards through the internal abdominal ring, as high as the testicles, passing in the fold of peritonæum by which that organ is suspended, and carrying up along with it some fibres from the internal oblique muscle. Weber conceives that the descent of the testicle is effected by means of an inversion, or as it were an intussusception of the hollow gubernaculum, which inversion commences at the upper orifice of the inguinal canal.* In the female embryo, a small cord corresponding with the commencing gubernaculum in the male, is seen descending to the inguinal region, and ultimately becomes the round ligament of the uterus. It is accompanied by a pouch of peritonæum analogous to the processus vaginalis of the male, and named the canal of Nuck. (See p. 1238.)

Metamorphosis of genito-urinary sinus.

Transformation of the *uro-genital sinus*. Formation of the *female urethra*, *vagina*, and *uterus*, and of the *prostatic portion* of the male *urethra*, the *prostate*, *utricle virilis*, and *vesiculae seminales*.—After the disappearance of the Wolffian bodies, the *sinus uro-genitalis*, formed by the shutting off of the lower part of the allantois from the tube of the intestine, receives, in either sex, only two efferent canals on each side, viz. the ureters, and the Fallopian tubes or the vasa deferentia.

In the female,—

In the *female* embryo, this common genito-urinary passage (fig. 328, B, 5) becomes divided at the bottom into an anterior part, *pars urinaria*, which receives the ureters and ultimately forms the neck of the bladder and the *urethra* (2), and a posterior part, *pars genitalis*, or proper genital passage, which receives the Fallopian tubes and represents the commencing *vagina* (4). The urethra and vagina both open into a still common part or *vestibule* of the genito-urinary passage.

the urethra, vagina, and vestibule;

the uterus.

The Fallopian tubes (fig. c, 3) coalesce at their lower ends so as to form a single median cavity, and thus give rise to the *uterus* (1), or at least to the upper part of that organ, for some observers describe the lower part and cervix as being formed by the upper end of the genital passage, or by a

* Müller's Archiv., 1847, p. 403.

protrusion from it ; the lower part of that passage, according to this view, becoming the vagina. For some time the uterus in the human subject continues to be bifid or two-horned, as in many quadrupeds, but, after the end of the third month, the angle between the orifices of the Fallopian tubes begins to be effaced, and the *fundus* is subsequently completed. Sometimes the bifid uterus continues through life. In the latter months of intra-uterine existence, the cervix uteri is much larger in proportion than the body and fundus, and, with the os uteri, projects into the vagina.

In the *male* embryo, the urinary part of the uro-genital sinus takes the form of a short canal, which represents the *neck of the bladder* with the *prostatic portion of the urethra*. The proper genital passage is formed, according to Rathke, by a conical protrusion of the walls of the common sinus at the place where the deferent ducts open. This observer supposes that the *vesiculæ seminales* begin as two small lateral protrusions from the genital passage at some distance apart from the openings of the vasa deferentia, but that, by the subsequent shortening and eventual median division of the intervening part of the passage, each seminal vesicle comes at length to open into the urethra in conjunction with the deferent duct of its own side. Bischoff believes that the so-called protrusion is due to an increased thickness of the terminations of the vasa deferentia, that the vesiculæ seminales are developed, each from its own vas deferens, and that the thickening of the lower ends of the deferent vessels has some connexion with the formation of the *prostate* gland. The recent researches of E. H. Weber, elsewhere referred to (p. 1226), would seem to shew that the part of the genital passage which in the female is converted into the lower portion of the uterus, remaining, as it were, in a rudimentary condition in the male, constitutes the little pouch, named the *sinus pocularis* or *utricle virilis*, the lips of which, as it were, project into the prostatic portion of the urethra and form the *verumontanum*.

In the male,—the neck of the bladder, urethra,

and prostate.

The utricle virilis, and verumontanum.

The *external Organs* of Generation.—As already stated, these do not begin to be formed until after the internal organs, and, for some time, they have the same form in both sexes.

External organs are at first similar in both sexes.

Up to the fifth week, according to Tiedemann, there is no genito-urinary orifice, and indeed no anus. About the beginning of the sixth week, there is a common opening, for the intestine, the generative and the urinary organs, *i. e.* a sort of *cloacal* aperture. In front of this simple opening, there soon appears a small recurved projecting body, which, as it enlarges, becomes grooved along the whole of its under surface. This is the rudimentary *clitoris* (fig. 328, D, ³) or *penis*, at the summit of which an enlargement is formed which becomes the *glans*. The margins of the groove seen on its under surface are continued backwards on either side of the common aperture, which is now elliptical, and is bounded laterally by two large cutaneous folds. Towards the tenth or eleventh week, a transverse band, the commencing *perinæum*, divides the anal orifice from that of the genito-urinary passage, which latter now appears as a rounded aperture, placed below the root of the rudimentary clitoris or penis, and between the prolonged

Cloaca.

Clitoris or penis.

Perinæum.

margins of the groove beneath that organ. This opening, but not the clitoris or penis, is concealed by the large cutaneous folds already mentioned. In this condition, which continues until the fourteenth week, the parts appear alike in both sexes, and resemble very much the perfect female organs. The rudiments of *Cowper's glands* are, it is said, seen at an early period, near the root of the rudimentary clitoris or penis, on each side of the genito-urinary passage.

Cowper's glands.

Changes in the female,

In the female, the two lateral cutaneous folds enlarge, so as to cover the clitoris and form the *labia majora* (fig. 328, D, 1). The clitoris itself becomes relatively smaller, and the groove on its under surface less and less marked, owing to the opening out and subsequent extension backwards of its margins to form the *nymphæ* (2). The *hymen* begins to appear about the fifth month. Within the nymphæ, the urethral orifice, as already mentioned, becomes distinct from that of the vagina.

and in the male.

In the male, on the contrary, the *penis* continues to enlarge, and the margins of the groove along its under surface gradually unite from the primitive urethral orifice behind, as far forward as the glans, so as to complete the long canal of the male *urethra*. This is accomplished about the fifteenth week. When this union remains incomplete, the condition named *hypospadias* is produced. In the meantime the *prepuce* is formed, and, moreover, the lateral cutaneous folds also unite from behind forwards, along the middle line or *raphé*, and thus complete the *scrotum*, into which the testicles do not descend until the last month of fetal existence.

MAMMARY GLANDS.

The mam-mæ.

The mammary glands (*mammæ*), the organs of lactation in the female, are accessory parts to the reproductive system. They give a name to a large class of animals (*Mammalia*), which are distinguished by their presence. When fully developed in the human female, they form, together with the integuments and a considerable quantity of fat, two rounded eminences (the breasts) placed one at each side on the front of the thorax. These extend from the third to the sixth or seventh rib, and from the side of the sternum to the axilla. A little below the centre of each breast, on a level with the fourth rib, projects a small conical body named the *nipple* (*mamilla*), which points somewhat outwards and upwards. The surface of the nipple is dark, and around it there is a coloured circle or *areola*, within which the skin is also of a darker tinge than elsewhere. In the virgin these parts are of a rosy pink colour, but they are always darker in women who have borne children. Even in the second month of pregnancy the areola begins to enlarge and acquire a darker tinge; these changes go on increasing as gestation advances, and

The nipple and areola.

are considered useful and important signs in judging of suspected pregnancy. After lactation is over, the dark colour subsides, but not entirely. The skin of the nipple is marked with many wrinkles, and is covered with papillæ; besides this, it is perforated at the tip with several foramina, which are the openings of the lactiferous ducts; and near its base, as well as upon the surface of the areola, there are scattered rounded elevations, which are caused by the presence of little glands with branched ducts, four or five of which open on each tubercle. The tissue of the nipple contains a large number of vessels, and its papillæ are highly sensitive; it is capable of a certain degree of erection from mechanical excitement, and this is generally ascribed to turgescence of its vessels, which some regard as forming a species of erectile tissue.

Structure of the nipple.

The base of the mammary gland, which is nearly circular, is flattened, or slightly concave, and has its longest diameter directed upwards and outwards towards the axilla. It rests on the pectoral muscle, and is connected to it by a layer of cellular tissue. The thickest part of the gland is near the centre, opposite the nipple, but the full and even form of the breasts depends chiefly on the presence of a large quantity of fat, which lies beneath the skin, covers the substance of the gland, and penetrates the intervals between its lobes and lobules. This fatty tissue, which is of a bright yellow tinge and rather firm, is divided into lobulated masses by numerous laminæ of fibrous or very dense cellular tissue, which are connected with the skin on the one hand, and on the other with the firm cellular investment of the gland itself, and that is connected behind by similar laminæ with the cellular membrane covering the pectoral muscle: these laminæ serve to support the gland. Beneath the areola and the nipple there is no fat, but merely the firm cellular tissue and vessels surrounding the lactiferous ducts.

The connections of the mamma;

its supporting fascia.

Structure.—The mammary gland consists of a number of distinct glandular masses or lobes, each having a separate excretory duct, held together by a very firm intervening fibrous or cellular tissue, and having some adipose tissue penetrating between them. Each of these divisions of the gland is again subdivided into smaller lobes, and these again into smaller and smaller lobules, which are flattened or depressed, and held together by cellular tissue, blood-vessels, and ducts. The substance

Structure.

Its lobes and lobules,

of the lobules, especially as contrasted with the adjacent fat, is of a pale reddish cream-colour, and is rather firm. It is composed principally of the vesicular commencements of the lactiferous ducts, which appear like clusters of minute rounded cells, having a diameter from ten to thirty times as great as that of the capillary vessels by which they are surrounded. These cells open into the smallest branched ducts, which, uniting together to form larger and larger ones, finally end in the single excretory canal corresponding to one of the chief subdivisions of the gland. The canals proceeding thus from the principal lobes composing the gland, are named the *galactophorous ducts*, and are from fifteen to twenty in number; they converge towards the areola, beneath which they become considerably dilated, especially during lactation, so as to form sacs or sinuses two or even three lines wide, which serve as temporary though small reservoirs for the milk. At the base of the nipple all these ducts, again reduced in size, are assembled together, those in the centre being the largest, and then proceed side by side, surrounded by cellular tissue and vessels, and without communicating with each other, to the summit of the mamilla, where they open by separate orifices, which are seated in little depressions, and are smaller than the ducts to which they respectively belong. According to Pappenheim, the walls of the ducts are composed of cellular tissue, and of longitudinal and transverse elastic filaments. The mucous membrane is continuous with the common integument at the orifices of the ducts; its epithelium is scaly or tessellated, and in the smallest ducts and their ultimate vesicles consists of cells having a diameter very little exceeding that of their nucleus.

Blood-vessels and nerves.—The *arteries* which supply the mammary glands are the long thoracic and some other branches of the axillary artery, the internal mammary, and the subjacent intercostals. The *veins* have the same denomination. Haller described a sort of anastomotic venous circle around the base of the nipple as the *circulus venosus*. The *nerves* are the anterior and middle intercostal cutaneous branches: Müller could not detect any sympathetic nerves accompanying the arteries; but it is probable that they exist.

In the *male*, the mammary gland and all its parts exist, but quite in a rudimentary state, the gland itself measuring only

the ducts
arise in
cells,

and proceed
from the
principal
lobes.

The vessels,

and nerves.

about six or seven lines across, and two lines thick, instead of four inches and a half wide and one and a half thick, as in the female. Occasionally the male mamma, especially in young subjects, enlarges and pours out a thin watery fluid; and, in some rare cases, milk has been secreted.

The male mammary gland.

Varieties.—Two or even three nipples have been found on one gland. An additional mamma is sometimes met with, and even four or five have been observed to co-exist; the superadded glands being most frequently near the ordinary ones, but sometimes at a distant part of the body, as the axilla, thigh, or back.

Varieties in number and position.

SURGICAL ANATOMY.

The surgical anatomy of a large portion of the body has been already discussed in connexion with the principal arteries (p. 470, *et seq.*), but it remains to review certain parts of the walls of the abdomen and pelvis, with reference to surgical operations in which the viscera of those cavities are from time to time concerned.

SURGICAL ANATOMY OF THE PARTS CONCERNED IN
CERTAIN ABDOMINAL HERNIÆ.

The walls of the abdomen, when in a healthy state, unaffected by injury, disease or malformation, retain under all circumstances the viscera within the cavity, except where certain natural openings exist for the passage of blood-vessels; but, at such openings, protrusions of the viscera constituting the disease named "hernia" or "rupture," are liable to occur under the influence of the compression to which the organs are subjected during the production of efforts. For the replacement of the viscus so protruded, an accurate acquaintance with the structure of the part through which the protrusion takes place is required by the surgeon; and, on this account, a separate examination of the seat of each accident as a surgical region becomes necessary.

Where
abdominal
herniæ are
liable to
occur.

Two of the openings by which herniæ escape from the abdomen are situated close together at the groin. One is the canal in the lower part of the broad abdominal muscles, which, in the male, gives passage to the duct and vessels of the testis (spermatic cord), and in the female to the round ligament of the womb. The second opening exists at the inner side of the large femoral blood-vessels.

Hernial protrusions are likewise found to escape at the umbilicus, in the course of the bloodvessels which occupy that opening in the fœtus or in the immediate neighbourhood of the opening, and at the thyroid foramen where the obturator

vessels and nerve pass downwards to the adductor muscles of the thigh. According to the situation they occupy these herniæ are named respectively inguinal, femoral, umbilical, and obturator. They will now be separately noticed; but, inasmuch as the structure of the parts connected with the umbilical and obturator herniæ is by no means intricate, and as, moreover, it is noticed with sufficient detail in text books of practical surgery, it will be unnecessary to refer further to those forms of hernia in this work.

Before details are entered upon, it should be understood that as the various structures which are about to be reviewed in connexion, have been described in former parts of this treatise, with the systems to which they severally belong, we shall here for the most part only refer back to details already given, occasionally however recalling the most important facts, and adding such points as may be material to the object with which the same structures are now brought under consideration.

OF THE PARTS CONCERNED IN INGUINAL HERNIA.

The inguinal hernia, it has been stated above, follows the course of the spermatic cord from the cavity of the abdomen. We shall therefore, before adverting to the hernial protrusions, examine the structure of the abdominal walls in the neighbourhood of the canal in which the cord is placed; and for this purpose it will be supposed that the constituents of those walls are successively laid bare and everted to such extent as would be permitted by two incisions made through them, and reaching, one along the linea alba for the length of three or four inches from the pubes, the other directed from the upper end of the vertical incision outwards to the superior spine of the ilium.

Inguinal hernia.

Dissection.

The *superficial fascia*—for the detailed description of which see p. 438—is connected along the fold of the groin with Poupart's ligament and the upper end of the fascia lata; and, after descending over the spermatic cord into the scrotum, it becomes continuous with the membrane of the same kind which covers the perinæum. Its thickness varies much in different persons, on account of the different quantity of fat contained within its meshes; but in the scrotum the fascia is devoid of fat; as it also is elsewhere towards the internal surface, where its density is at the same time augmented. From the various

Superficial fascia,

varies in thickness.

thickness of this structure on the abdomen and the scrotum, as well as in different persons, it will be inferred that the depth of incision required to divide it in an operation must vary considerably.

Superficial
vessels.

The *superficial vessels* of the groin are encased by the fascia, and are held to separate it into two layers. The vessels which ramify over the inguinal canal and the scrotum are the external pudic and epigastric arteries and veins (pp. 590, 640). The veins, especially the epigastric, are considerably larger than the arteries they accompany [plate 70]. Some of these vessels are wounded in operations performed for the relief of strangulated hernia; but the bleeding from them is small in quantity and rarely requires the application of a ligature or other means to arrest it. The lymphatic glands of the groin (see p. 656) admit of being arranged into two sets. One being placed over Poupart's ligament and parallel with that structure; while the other series is upon the upper part of the thigh at its middle, about the saphenous opening in the fascia lata.

Lymphatic
glands.

Tendon of
external
oblique
muscle.

Separation
of its fibres.

Poupart's
ligament;

is directed
backwards;

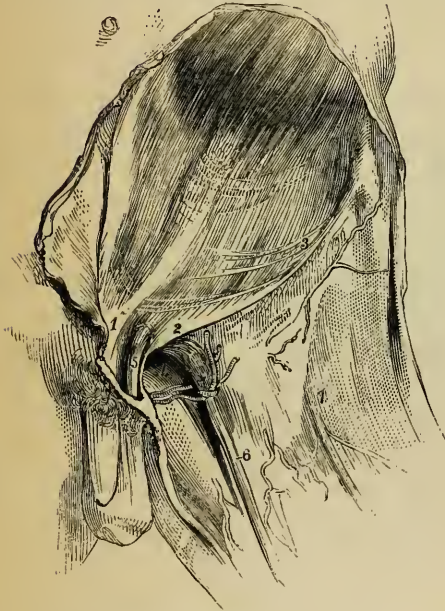
is curved.

When the superficial fascia is removed the aponeurosis of the *external oblique muscle* (see p. 355) is in view, together with, in the male body, the spermatic cord (in the female body the round ligament of the uterus), which emerges from an opening close to the outer side of the spine of the pubes (fig. 329). The lowest fibres of the aponeurosis as they approach the pubes, become separated into two bundles which leave an interval between them for the passage of the cord or ligament just named. One of the bands, the upper one and the smaller of the two, is fixed to the symphysis of the pubes; and the lower band, which forms the lower margin of the aponeurosis, being stretched between the anterior superior spine of the ilium and the pubes is named Poupart's ligament, or the femoral arch. This latter tendinous band has considerable breadth. It is fixed at the inner end to the spine of the pubes, and, for some space outside that process of the bone, to the pectineal ridge. In consequence of the position of the pectineal ridge at the back part of the bone, the ligament is tucked backwards and its upper surface affords space for the attachment of the other broad muscles, at the same time that it supports the spermatic cord. Poupart's ligament does not lie in a straight line between its two fixed points; it curves downwards, and with the curved border the

fascia lata is connected. It is owing to the last mentioned fact that the so named ligament, together with the rest of the aponeurosis of the external oblique

is influenced by the position of the thigh, being relaxed when the limb is bent and the converse. Moreover, the change of the position of the limb exercises a corresponding influence on the state of the other structures connected with Poupart's ligament.

Fig. 329.*



is influenced by the position of the thigh, being relaxed when the limb is bent and the converse. Moreover, the change of the position of the limb exercises a corresponding influence on the state of the other structures connected with Poupart's ligament.

The interval left by the separation of the fibres of the aponeurosis above referred to, is named the *external abdominal ring*, and the two bands by which it is bounded, are

known as its *pillars* or *columns*. The space is triangular in shape, its base being the crista of the pubes, while the apex is at the point of separation of the two columns. The size of the ring varies considerably in different bodies;—in one case its sides will be found closely applied to the spermatic cord: while, in another, on the contrary, the space is so considerable as to be an obvious source of weakness to the abdominal parietes. It is usually smaller in the female than in the male body.

Between the pillars of the abdominal ring is stretched a thin fascia, named, from that circumstance, “intercolumnar;” and a thin diaphanous membrane prolonged from the edges of the opening affords a covering (*fascia spermatica*) to the spermatic cord and the tunica vaginalis testis. The cord passes through the ring over its outer pillar.

Between the pillars of the abdominal ring is stretched a thin fascia, named, from that circumstance, “intercolumnar;” and a thin diaphanous membrane prolonged from the edges of the opening affords a covering (*fascia spermatica*) to the spermatic cord and the tunica vaginalis testis. The cord passes through the ring over its outer pillar.

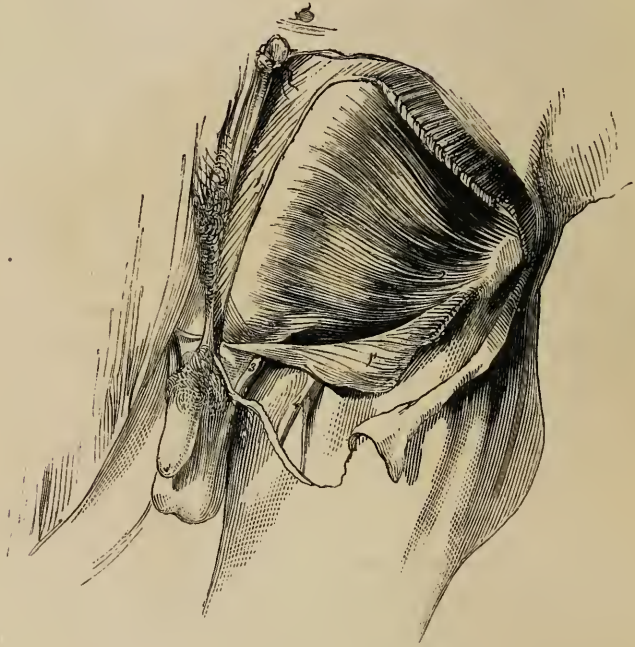
known as its *pillars* or *columns*. The space is triangular in shape, its base being the crista of the pubes, while the apex is at the point of separation of the two columns. The size of the ring varies considerably in different bodies;—in one case its sides will be found closely applied to the spermatic cord: while, in another, on the contrary, the space is so considerable as to be an obvious source of weakness to the abdominal parietes. It is usually smaller in the female than in the male body.

* The aponeurosis of the external oblique muscle and the fascia lata.—
 1. The internal pillar of the abdominal ring. 2. The external pillar of same (Poupart's ligament). 3. Transverse fibres of the aponeurosis. 4. Pubic part of the fascia lata. 5. The spermatic cord. 6. The long saphenous vein. 7. Fascia lata.

Internal
oblique
muscle.

Internal oblique muscle (see p. 356).—After removing the aponeurosis of the external oblique, this muscle is laid bare (fig. 330). The lower fibres are thin and often of a pale colour. Immediately above Poupart's ligament the outer part is mus-

Fig. 330.*



cular, the inner part tendinous. The spermatic cord, when about to escape at the external abdominal ring, passes beneath the fleshy part of the muscle. The fibres in this situation varying considerably in direction from those of the rest of the muscle, pass inwards from Poupart's ligament at first nearly parallel with that structure; and, becoming tendinous, they join with the tendon of the transversalis.

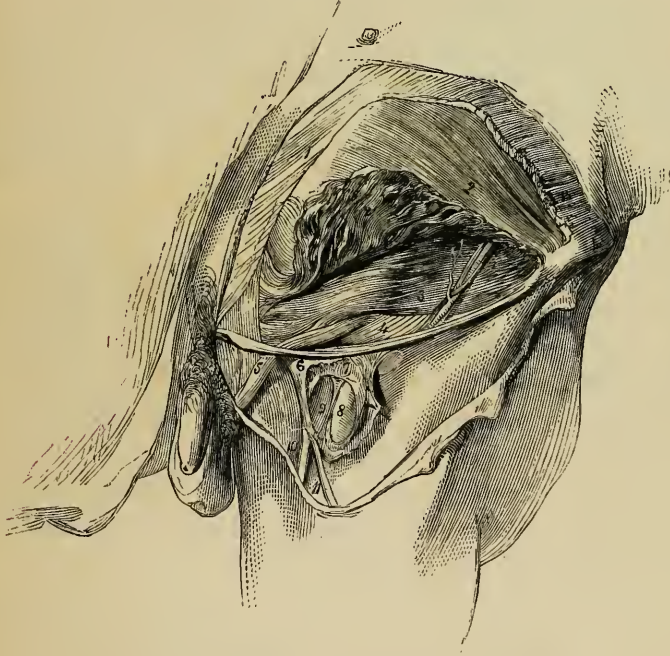Transversa-
lis muscle.

Transversalis muscle.—This muscle (see p. 358) does not, in general, extend down as far as the internal oblique (fig. 331); so that the latter being removed, an interval is observable

* The aponeurosis of the external oblique muscle having been divided and turned down, the internal oblique is brought into view with the spermatic cord, escaping beneath its lower edge.—1. Aponeurosis of the external oblique. 1'. Lower part of same turned down. 2. Internal oblique muscle. 3. Spermatic cord. 4. Saphenous vein.

between the edge of the transversalis and Poupart's ligament, in which the transversalis fascia comes into view; and in which the spermatic cord is seen after having penetrated that fascia. The lower edge of the muscle is commonly close above the

Fig. 331.*



opening for the cord in the subjacent membrane, while the tendon curves to its inner side. So that the margin of the muscle with its tendon has a semicircular direction with respect to the aperture.

* After the removal of the lower part of the external oblique (with the exception of a small slip including Poupart's ligament), the lower portion of the internal oblique was raised, and thereby the transversalis muscle and fascia have been brought into view. The femoral artery and vein are seen to a small extent, the fascia lata having been turned aside and the sheath of the blood-vessels laid open.—1. External oblique muscle. 2. Internal oblique. 2'. Part of same turned up. 3. Transversalis muscle. Upon the last-named muscle is seen a branch of the circumflex iliac artery, with its companion veins; and some ascending tendinous fibres are seen over the conjoined tendon of the two last-named muscles. 4. Transversalis fascia. 5. Spermatic cord covered with the infundibuliform fascia from preceding. 6. Upper angle of the iliac part of fascia lata. 7. The sheath of the femoral vessels. 8. Femoral artery. 9. Femoral vein. 10. Saphenous vein. 11. A vein joining it.

Conjoined tendon of internal oblique and transverse muscles.

The tendinous fibres in which the fleshy part of the two preceding muscles end, are connected together so as to form one layer, which is named the "conjoined tendon of the internal oblique and transverse muscle." This tendon is fixed to the crest of the pubes in front of the rectus muscle, and likewise to the pectineal ridge. It is thus behind the external abdominal ring, and serves to strengthen the wall of the abdomen where it is weakened by the presence of that opening.

Additional tendinous band.

A band of tendinous fibres (fig. 331) directed upwards and inwards over the conjoined tendon in a triangular form gives additional strength to the abdominal wall in the same situation, but the fibres of this structure are often very indistinct.

Cremaster.

Where the spermatic cord is in apposition with the preceding muscle, the cremaster muscle of the testis descends over it. The fibres which compose this muscle are, from their colour, more easily distinguished than the other investments of the cord; and this is especially the case in robust persons or when they are hypertrophied, as sometimes happens in cases of long standing hernia. The outer part of the cremaster is much larger than the portion connected with the pubes; indeed, it sometimes happens that the latter is not to be discerned even with most careful dissection (see p. 1235).

Various conditions of internal oblique and transverse muscles.

When observed in different bodies the lower part of the internal oblique and transverse muscles will be found to present some differences in their physical characters as well as in the manner in which they are disposed with respect to the spermatic cord. Thus:—

a, The transversalis, in some cases, is attached to but a small part of Poupart's ligament, and leaves, therefore, a larger part of the abdominal wall without its support. On the other hand, that muscle may be found to extend so low down as to cover the internal abdominal ring together with the spermatic cord, for a short space. Not infrequently the fleshy fibres of the two muscles are blended together as well as their tendons.

b. Cases occasionally occur in which the spermatic cord, instead of escaping beneath the margin of the internal oblique, is found to pass through the muscle, so that some muscular fibres are below as well as above it. And examples of the transversalis being penetrated by that structure in the same manner are recorded.*

c. In his latest account of the structure of these parts Sir A. Cooper

* Recherches Anatomiques sur les Hernies, &c., par J. Cloquet, pp. 18 and 23, Paris, 1817. Inguinal and Femoral Herniæ, by G. J. Guthrie, plate I, London, 1833.

described the lower edge of the transversalis as curved all round the internal ring and the spermatic cord. "But the lower edge of the transversalis has a very peculiar insertion, which I have hinted at in my work on hernia. It begins to be fixed in Poupart's ligament, almost immediately below the commencement of the internal ring, and it continues to be inserted behind the spermatic cord into Poupart's ligament as far as the attachment of the rectus."* With this disposition of its fibres, the muscle would, in the opinion of the last cited authority, have the effect of a sphincter, in closing the internal ring, and would thus tend to prevent the occurrence of hernia. But the principal object with which the attention of surgeons has been fixed on the muscles in this situation, is in order to account for the active strangulation of hernial protrusions at the internal abdominal ring, and in the inguinal canal.

Fascia transversalis.—This membrane is described as part of the general lining of the abdominal walls at p. 439. Closely connected with the transversalis muscle by means of the cellular membrane interposed between the fleshy fibres of the muscle, it is united below to the posterior edge of Poupart's ligament, there joining with the fascia iliaca; and on the inner side it blends with the conjoined tendon of the internal oblique and transversalis muscles, as well as with the tendon of the rectus. The fascia possesses very different degrees of density in different cases; in some being little more than a loose cellular texture, while in others it is so resistant at the groin,—towards which part it increases in thickness, and especially at the inner side of the internal abdominal ring—that it is calculated to afford material assistance to the muscles in supporting the viscera. By an oval opening in this membrane the spermatic cord (or the round ligament of the womb) begins its course through the abdominal parietes. This opening, named the *internal abdominal ring*, is opposite the middle of Poupart's ligament and usually close above that structure, but occasionally at a distance of three or four lines from it. Its size varies a good deal in different persons, and is considerably greater in the male than the female. From the edge of the ring a thin funnel-shaped elongation (infundibuliform fascia; fascia spermatica interna, Cooper), is continued over the vessels of the spermatic cord.

Fascia transversalis.

Internal abdominal ring: its position.

Covering given to spermatic cord.

Epigastric artery,

Epigastric artery.—The position of this vessel is one of the

* Observations on the Structure and Diseases of the Testis, second edition, p. 36. Ed. by Bransby B. Cooper, F.R.S. London, 1841.

most important points in the anatomy of the inguinal region, from the close connexion which it has with the different forms of inguinal hernia and with the femoral hernia. Accompanied by two veins (in some instances by only one) the vessel ascends under cover of the fascia last described obliquely to the rectus muscle, behind which it then proceeds to its ultimate distribution (see p. 585). In this course the artery runs along the inner side of the internal abdominal ring—close to the edge of the aperture, fig. 333, or at a short interval from it. The vessels of the spermatic cord are therefore near to the epigastric artery; and the vas deferens, in turning from the ring into the pelvis, may be said to hook round it.

at inner
side of
internal
ring.

Inguinal
canal :

its
boundaries.

The Inguinal Canal.—This, the channel by which the spermatic cord passes through the abdominal muscles to the testis, begins at the internal abdominal ring, and ends at the external one. It is oblique in its direction, being parallel with and immediately above the inner half of Poupart's ligament; and it measures two inches in length. In front the canal is bounded by the aponeurosis of the external oblique muscle in its whole length, and at the outer end by the fleshy part of the internal oblique also; behind it, is the fascia transversalis, together with, towards the inner end, the conjoined tendon of the two deeper abdominal muscles. Below, the canal is supported by the broad surface of Poupart's ligament, which separates it from the sheath of the large blood-vessels descending to the thigh and from the femoral canal at the inner side of those vessels.

Spermatic
cord :

direction of
its vessels ;

The spermatic cord, which occupies the inguinal canal, is composed of the arteries, veins, lymphatics, nerves, and excretory duct (vas deferens) of the testis, together with a quantity of loose cellular membrane mixed up with those parts. The direction of the vessels just enumerated requires notice. The artery and vein incline outwards from the lumbar part of the vertebral column to reach the internal abdominal ring, where, after being joined by the vas deferens as it emerges from the pelvis, they change their course, inclining inwards along the inguinal canal; at the end of which they become vertical. There are thus repeated alterations in the direction of the vessels; and while at the beginning and ending all are close to the middle line of the body, they are considerably removed from that point where they come together to emerge from the abdominal cavity.

The coverings given from the constituent parts of the abdominal wall to the spermatic cord and the testis, namely, the cremasteric muscular fibres with the two layers of fascia, between which those fibres are placed (the infundibuliform and spermatic fasciæ), are very thin in their natural state ; but they may be readily distinguished in a surgical operation from the investing superficial fascia, by their comparative density and the absence of fat.

their coverings.

In order to examine the *peritonæum* at the groin it will be best to divide that membrane with the abdominal muscles by two incisions drawn from the umbilicus—one to the ilium, the other to the pubes. The flap thus formed being held somewhat outwards, and kept tense, a favourable view will be obtained of the two fossæ (*inguinal fossæ or pouches*) with the intervening crescentic fold. This fold is formed by the cord remaining from the obliterated umbilical artery, which being shorter than the outer surface of the serous sac, projects it inwards ; and as the length of the cord differs in different cases, so likewise does the size and prominence of the peritonæal fold vary accordingly.

Fossæ of peritonæum :

The lowest part of the outer fossa will be generally found opposite to the entrance into the internal abdominal ring and the femoral ring, while the inner one corresponds with the situation of the external abdominal ring. But the cord representing the umbilical artery, which, it has been stated, causes the projection of the serous membrane into a fold, does not uniformly occupy the same position in all cases. Most frequently it is separated by an interval, from the epigastric artery (fig. 333), while in some cases it is immediately behind that vessel. There is necessarily a corresponding variation in the extent of the external peritonæal fossa. This fact will find its practical application when the internal form of inguinal hernia is under consideration.

their position ;

extent varies.

Between the peritonæum and the fascia lining the abdominal muscles is a connecting layer of cellular structure, named the *subserous cellular membrane*. A considerable quantity of fat is in some cases found in this membrane.

Subserous cellular membrane.

The relative position of some of the parts above referred to may be here conveniently stated, by means of measurements, made by Sir A. Cooper, and adopted after examination by J. Cloquet. But as the distance between given parts varies in

different cases, the following measurements must only be regarded as a general average :—

	MALE.	FEMALE.
From the symphysis of the pubes to the ant. supr. spine of the ilium.....	5½ inches.	... 6 inches.
From the same point to the spine of the pubes...	1⅓ "	... 1⅜ "
" to the inner part of the external abdominal ring.....	0⅞ "	... 1 "
" to the inner edge of the internal abdominal ring	3 "	... 3¼ "
" to the epigastric artery on the inner side of the internal abdominal ring	2¾ "	... 2⅞ "

The conformation of the parts favours the production of hernia.

From the preceding account of the structure of the abdominal wall at the groin, it will be inferred that the defence against the protrusion of the viscera from the cavity is here weaker than at other parts. The external oblique muscle and the fascia transversalis are perforated, while the two intervening muscles are thinner than elsewhere, and more or less defective. To this it must be added that the viscera are impelled towards the same part of the abdomen by the contraction of the diaphragm and the other abdominal muscles, which occurs in the production of efforts to overcome resistance ; and these are the circumstances under which protrusions actually take place.

INGUINAL HERNIÆ.

Inguinal herniæ distinguished as oblique and direct.

The protrusions of the viscera or herniæ, which occur in the course of the inguinal canal, are named 'inguinal.' Of this form of the disease two varieties are recognised : and they are distinguished according to the part of the canal which they first enter into, as well as by the position they bear with respect to the epigastric artery. Thus, when the hernia takes the course of the inguinal canal from its commencement, it is named *oblique*, because of the direction of the canal, or *external*, from the position its neck bears with respect to the epigastric artery. On the other hand, when the protruded part, without following the length of the canal, is forced at once through its termination, *i. e.* through the external abdominal ring, the hernia is named from its course *direct*, or, from its relation to the epigastric artery, *internal*. In these, the two principal varieties of inguinal hernia, there are some modifications which will be adverted to in the special notice of each.

Oblique inguinal hernia.—In the common form of this hernia the protruded viscus carries before it a covering of peritonæum (the *sac* of the hernia), derived from the outer fossa of that serous membrane; and in passing along the inguinal canal to the scrotum, it is successively clothed with the coverings given to the spermatic vessels from the abdominal parietes. The hernia and its sac lie directly in front of the vessels of the spermatic cord, fig. 335 (the intestines and the peritonæum having the same position relatively to those vessels in the abdomen); but when the disease is of long standing the vessels may be found to be separated one from the other, and pressed more or less towards the side or even the fore part of the sac under the influence of the weight of the tumour. The hernia does not extend below the testis even when it attains large size. That it does not is, doubtless, owing to the intimate connexion which the coverings of the cord have with the tunica vaginalis testis.

When the hernia does not extend beyond the inguinal canal, it is distinguished by the name *bubonocèle*; and when it reaches the scrotum, it is commonly named from that circumstance *scrotal hernia*.

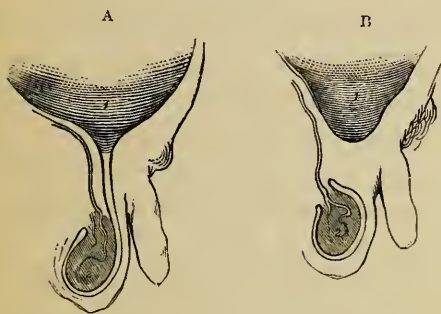
Bubonocèle.
Scrotal
hernia.

There are two other varieties of oblique inguinal hernia, in which the peculiarity depends on the condition of the process of peritonæum that accompanies the testis when this organ is

Congenital
hernia:

moved from the abdomen. In ordinary circumstances the part of the peritonæum, connected immediately with the testis, becomes separated from the general cavity of that serous membrane by the obliteration of the intervening canal, fig. 332 B;

Fig. 332.*



and the hernial protrusion occurring after such obliteration has its peculiarity;

* Plans intended to represent a small part of the peritonæum and the tunica vaginalis testis. In the first, A, the serous investment of the testis is seen to be an elongation from the peritonæum; while in the second, B, the two membranes are shewn distinct one from the other.—1. The peritonæal cavity. 2. The testis.

been completed, carries with it a distinct serous investment—the sac. But if the hernia should be formed before the process of obliteration is begun (fig. 332 A), the protruded part is then received into the cavity of the tunica vaginalis testis, which serves in the place of its sac. In this case the hernia is named *congenital* (hernia tunicæ vaginalis—Cooper). It is thus designated, because the condition necessary for its formation usually exists only about the time of birth; but the same variety of the complaint is occasionally found to be first formed in the adult, obviously in consequence of the tunica vaginalis remaining unclosed,—still continuous with the peritonæum. The congenital hernia, should it reach the scrotum, passes below the testis; and this organ being imbedded in the protruded viscus, a careful examination is necessary, in order to detect its position. This peculiarity serves to distinguish the congenital from the ordinary form of the disease.

may first
form in an
adult;

how dis-
tinguished.

Infantile
hernia:
its nature;

To the second variety of inguinal hernia, in which the distinguishing character depends on the state of the tunica vaginalis testis, the name “infantile” has been applied (Hey). The hernia in this case is covered with a distinct sac, the peculiarity consisting in the circumstance of the rupture with its sac being invested by the upper end of the tunica vaginalis. The relative position of the two serous membranes (the hernial sac and the tunica vaginalis) may be accounted for by supposing the hernia to descend when the process of peritonæum, which accompanies the testis from the abdomen, has been merely closed at the upper end, but not obliterated for any length. As the tunica vaginalis at this period extends upwards to the wall of the abdomen, the hernia, in its descent, soon meets that membrane and becomes invested by it. The exact mode of the investment has not yet been clearly made out by dissection. It may be that the hernia passes behind the upper end of the large serous tunic of the testis which then laps round the sac from before, or that the tunica vaginalis is inverted from above so as to receive the hernia in a depression. But the fact most material for the surgeon is fully ascertained, namely, that during an operation in such a case the hernial sac is met with only after another serous bag (the tunica vaginalis testis) has been divided. The peculiarity here described has been repeatedly found present in the recently formed hernia of grown persons. The term

how dis-
tinguished
in an
operation;

may be
formed on
a grown
person.

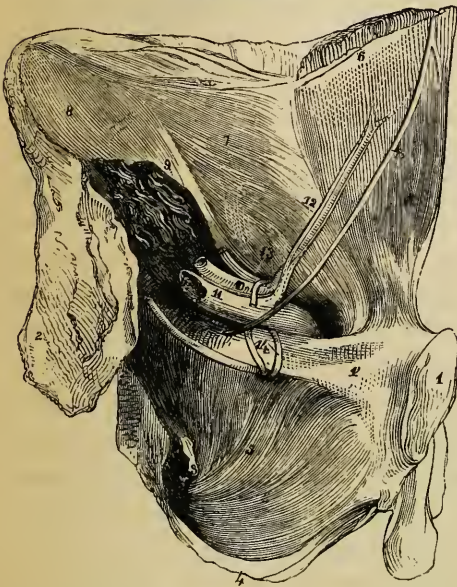
infantile, therefore, like congenital, has reference to the condition of certain parts rather than to the period of life at which the disease is first formed.

In the female, oblique inguinal hernia follows the course of the round ligament of the uterus along the inguinal canal, in the same manner as in the male it follows the spermatic cord. After escaping from the external abdominal ring, the hernia lodges in the labium pudendi. The coverings are the same as those in the male body, with the exception of the cremaster, which does not exist in the female; but it occasionally happens that some fibres of the internal oblique muscle are drawn down over this hernia in loops, so as to have the appearance of a cremaster (Cloquet).

Inguinal hernia of female.

A strictly congenital inguinal hernia may occur in the female, the protruded parts being received into the little diverticulum of the peritonæum (canal of Nuck), which sometimes extends into the inguinal canal with the round ligament. But as this process of the peritonæum, in such circumstances, would probably

Fig 333.*



not differ in any respect from the ordinary sac, there are no means of distinguishing a congenital hernia in the female body.

Direct inguinal hernia (internal: ventro-inguinal). Instead of following the whole course of the inguinal canal, in the manner of the hernia above described, the viscus in this case is protruded from the abdomen to the groin directly through the lower end of the canal, at the external abdominal ring;

Direct inguinal hernia.

and at this point the two forms of hernia, if they coexisted,

* A portion of the wall of the abdomen and of the pelvis is here seen on the posterior aspect, the os innominatum of the left side with the soft parts connected with it having been removed from the rest of the body.—1. Sym-

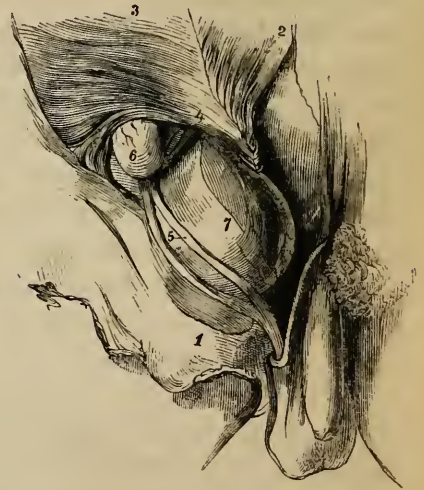
Triangle of
Hesselbach.

would come together. At the part of the abdominal wall through which the direct inguinal hernia finds its way, there is recognised on its posterior aspect a triangular interval, the sides of which are formed by the epigastric artery and the margin of the rectus muscle, the base by Poupart's ligament, (fig. 333). It is commonly named the triangle of Hesselbach.

Fig. 334.*



Fig. 335.†



physis of pubes. 1'. Horizontal branch of same. 2. Irregular surface of the ilium which has been separated from the sacrum. 3. Spine of ischium. 4. Tuberosity of same. 5. Obturator internus. 6. Rectus, covered with an elongation from 7. Fascia transversalis. 8. Fascia iliaca covering iliacus muscle. 9. Psoas magnus cut. 10. Iliac artery. 11. Iliac vein. 12. Epigastric artery and its two accompanying veins. 13. Vessels of spermatic cord, entering the abdominal wall at the internal ring. The ring was in this case of small size. 14. Two obturator veins. 15. The obliterated umbilical artery. This cord, it will be remembered, is not naturally in contact with the abdominal parietes in this situation.

* A direct inguinal hernia on the left side, covered by the conjoined tendon of the internal oblique and transverse muscles.—1. Aponurosis of the external oblique. 2. Internal oblique turned up. 3. Transversalis muscle. 4. Fascia transversalis. 5. Spermatic cord. 6. The hernia. N.B. A small part of the epigastric artery is seen through an opening made in the transversalis fascia.

† A small oblique inguinal hernia, and a direct one, are seen on the right side. A little of the epigastric artery has been laid bare, by dividing the fascia transversalis immediately over it.—1. Tendon of the external oblique. 2. Internal oblique turned up. 3. Transversalis. 4. Its tendon (the epigastric artery is shewn below this number). 5. The spermatic cord (its vessels separated). 6. A bubonocoele. 7. Direct hernia protruded beneath the conjoined tendon of the two deeper muscles, and covered by an elongation from the fascia transversalis.

Through this space the hernia is protruded, carrying before it a sac from the internal fossa of the peritonæum; and it is in general forced onwards directly into the external abdominal ring.

The coverings of this hernia, taking them in the order in which they are successively applied to the protruded viscus, are the following:—The peritonæal sac and the cellular membrane which adheres to it, the fascia transversalis, the tendon common to the internal oblique and transverse muscles (fig. 334), and the intercolumnar (external spermatic) fascia derived from the margin of the external abdominal ring, together with the superficial fascia and the integuments.

The coverings of the hernia.

With respect to one of the structures enumerated, namely, the common tendon of the two deeper muscles, considerable variety exists as to its disposition in different cases. In place of being covered by that tendon, (which my own observations lead me to regard as the most frequent arrangement,) the hernia may be found to pass through an opening in its fibres, or to escape beneath it (fig. 335). Cremasteric muscular fibres are met with (rarely however) upon this hernia.

Disposition of common tendon varies.

The spermatic cord is commonly placed behind the outer part of the direct inguinal hernia, especially at the external abdominal ring (figs. 334-5). It is here that the hernia and the cord in most cases first come together; and their relative position results from the points at which they respectively pass through the ring, the former being upon the crista of the pubes, while the latter drops over the outer pillar of the opening. The hernial sac is not, however, in this case (as the sac of the external form of the disease is) in contact with the vessels of the cord. The investments given from the fascia transversalis to those vessels and to the hernia respectively, are interposed.

Connection with spermatic cord.

But the point at which the internal inguinal hernia passes through the triangular space above described as marked on the posterior aspect of the abdominal wall, is subject to some variation. Instead of pushing directly through the external abdominal ring (the most frequent position), the hernia occasionally enters the inguinal canal nearer to the epigastric artery, and passing through a portion of the canal to reach the external ring, has therefore a certain degree of obliquity. This change in position may coincide with a change of the peritonæal fossa, which furnishes the hernial sac—a change, namely, from the internal fossa

Internal hernia may pass through a part of inguinal canal,

and may be changed from internal fossa of

peritonæum
to external.

to the external one. The alteration of the fossa does not however in all cases coincide with a change in the position of the hernia ; for the cord remaining from the obliteration of the umbilical artery, (which it is that separates the fossæ,) instead of crossing behind the triangle of Hesselbach so as to leave room at either side of it for a hernia to penetrate that space, is, it has been already stated, sometimes directly behind the epigastric artery :—indeed, according to the observations of Cloquet, it is most frequently in this position ;* and when the cord in question is so placed, the hernia, whatever may be its position in the triangle of Hesselbach, can occupy only the internal peritonæal fossa. The inference, however, most important in a practical or surgical point of view, to be drawn from the varying position of the neck of the internal hernia, has reference not to the cord just alluded to, but to the epigastric artery—*i. e.* to the greater or less distance of the neck of the sac from that vessel.

The investments of the internal hernia are likewise liable to be influenced by the position at which it penetrates the abdominal wall. It is in all likelihood when the protrusion occurs outside the ordinary situation, that the hernia escapes beneath the conjoined tendon of the two deeper muscles. It is, moreover, under the same circumstances that hernia is more directly in front of the spermatic cord, and that the cremasteric fibres are among its investments.†

Internal
hernia
rare in the
female.

The internal inguinal hernia is very rarely met with in *the female*. In the single example of the disease that I have had an opportunity of observing, as well as in the cases (a very small number) which I have found recorded in books, the hernia, though not inconsiderable in size, was still covered with the tendon of the external oblique muscle.‡

* Recherches, &c., p. 39, note.

† Mr. Ellis informs me, that in dissecting cases of internal hernia he has repeatedly found fibres of the cremaster spread over it, when the tumor was nearer than usual to the epigastric artery, and only in this event.

‡ See “Treatise on Ruptures,” by Mr. Lawrence, 4th edit. p. 213, and an essay by M. Velpeau in “Annales de Chirurgie Française et étrangère,” tom. i. p. 352.

M. Velpeau, in the essay just referred to, proposes to recognize three varieties of internal hernia, viz., 1. the ordinary form, which passes straight through the external abdominal ring ; 2. an outer oblique variety, which passes through a part of the inguinal canal ; and, 3. an inner oblique one, which, entering the abdominal wall close to the edge of the rectus muscle, is directed outwards in order to reach the opening in the external oblique muscle. The first two forms adverted to by M. Velpeau have been described

Distinctive diagnosis of oblique and direct inguinal hernia.—

The following circumstances, which are brought together from the facts detailed in the preceding pages, or are inferences from those facts, will serve to distinguish the two forms of the disease one from the other. The first named hernia, when recently formed, is elongated and narrow at its upper part, being restrained by the tendon of the external oblique muscle. It is, however, attended with a degree of fulness in the inguinal canal, as well as tenderness, upon pressure being made over the canal. After passing through the external abdominal ring, it is observed to be directly in front of the spermatic cord. The direct hernia, when of small size, is globular; it is protruded more immediately over the pubes; causes no fulness or tenderness in the canal; and the spermatic cord is usually behind its outer side. But the distinction between the two herniæ admits of being made only when the disease is recent and the tumour moderate in size; for when oblique inguinal hernia is of long standing, and has attained considerable size, the obliquity of the inguinal canal no longer remains,—the internal ring being enlarged, and brought inwards opposite the external one,—while at the same time the epigastric artery, borne inwards by the hernia, curves along the inner side of the sac. Under this change, the oblique hernia assumes the appearance of one primarily direct.

Means of distinguishing between oblique and direct herniæ.

The distinction difficult in cases of long standing herniæ.

Operations for the relief of inguinal hernia.—This account of the disposition of the parts connected with the different forms of inguinal hernia, may be concluded by a brief statement of the application of the anatomical facts in practical surgery, either in simply replacing the hernial protrusion, or in the operation required to attain that object when the hernia is otherwise irreducible. In the efforts to effect the replacement of the protruded parts (the taxis), it is to be borne in mind that the abdominal muscles, which in most cases, are the sole obstacle to the attainment of that end, become relaxed, to some extent, by flexing the thigh and inclining the trunk forwards. The direction, too, which the protruded part follows through the

The taxis.

in the text. With respect to the third variety or class sought to be introduced by that surgeon, it should be observed that he seems to have been led to propose it by the observation of a single case—an example of internal hernia in the female.

abdominal walls, ought to influence the direction given to the pressure required in restoring it.

Operation.

When the operation required to set free the constriction which prevents the restoration of the protruded viscus to the abdomen is undertaken, the parts covering the hernia or a portion of it at the upper end, are to be divided, so as to allow the introduction of a knife beneath the "stricture;" and this (the stricture) will be found at the external ring, or, more frequently, at the internal one. To accomplish the object, the tendon of the external oblique is to be laid bare by an incision, beginning somewhat above the upper end of the hernia, and extending downwards below the external ring. If, on examination, the stricture should be ascertained to be at the last-named opening, the division of a few fibres of its circumference will allow a sufficient dilatation for the replacement of the hernia; but if, as generally happens, the seat of the stricture should prove to be higher up,—in the inguinal canal or at the internal ring, the aponeurosis of the external oblique is to be cut through over the canal, and the lower edge of the internal muscles, one of which commonly constitutes the stricture, is then to be divided on a director insinuated beneath them.

The sac not to be opened, if possible.

In the operation indicated in the last paragraph, the sac of the hernia is supposed to be left unopened,—the course which it is best to adopt when the stricture is external to that membrane. Occasionally, however, it happens that the sac itself is the cause of the constriction. When this is the case, or when from some other reason the surgeon is unable, after such an operation as that above noticed, to replace the hernia, it becomes necessary to lay the sac open, in order to divide the constriction at its neck. When the incision required in the last mentioned step of the operation is being made, the epigastric artery is not to be overlooked. From the position that vessel holds, with respect to the oblique and direct forms of hernia respectively, it necessarily follows that an incision outwards through the neck of the sac, in the former variety of the disease, and inwards in the latter, would be free from risk on account of the artery (fig. 335); but, inasmuch as the oblique hernia is liable, in time, to assume the appearance of one primarily direct (see last page), and a want of certainty as to the diagnosis must, on this account, exist in certain cases,—as, moreover, it is advan-

The epigastric artery determines the line of the last incision.

tageous to pursue one course which will be applicable in every case,—the rule generally adopted by surgeons, in all operations for inguinal herniæ, is to carry the incision through the neck of the sac directly upwards from its middle.

OF THE PARTS CONCERNED IN FEMORAL HERNIA.

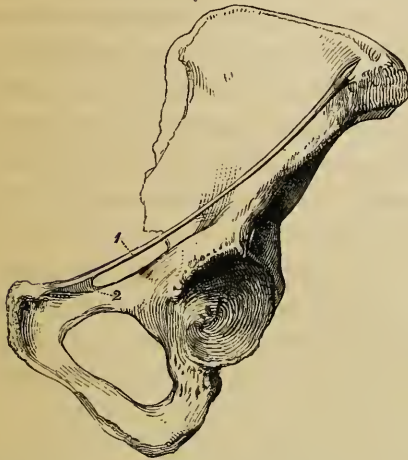The hernia distinguished as ‘femoral’ leaves the abdomen at the groin, under the margin of the broad abdominal muscles, and upon the horizontal branch of the pubes, immediately at the inner side of the large femoral blood-vessels. After passing downwards, for a very short space, about an inch or less, the hernia turns forwards to the forepart of the thigh at the saphenous opening in the fascia lata; and when it has reached this point the swelling may be felt and seen.

Femoral
hernia :
outline of.

The muscles of the abdomen, beneath the edge of which the femoral hernia escapes, are represented by the aponeurotic band of the external oblique muscle, which is commonly known as Poupart’s ligament, but which, in connexion with the femoral hernia, is named the *femoral or crural arch*. Extending from the anterior superior spine of the ilium to the pubes, this band

Femoral
or crural
arch.

Fig. 336.*



widens at its inner end, and, inclining or folding backwards, is fixed to a part of the pectineal line, as well as to the spine of the pubic bone. The small triangular portion attached to the pectineal line (fig. 336) is known as Gimbernat’s ligament (Hey). The outer edge of this part is concave and sharp; with other structures, to be presently described, it forms the inner boundary of the aperture through which the hernia descends.

Gimber-
nat’s liga-
ment.

The breadth and strength of Gimbernat’s ligament

* The innominate bone of the left side with, 1. the femoral or crural arch; 2. Gimbernat’s ligament.

vary in different bodies, and with its breadth varies the size of the opening which receives the hernia.

How the space beneath the arch is occupied.

The space comprised between the femoral arch and the excavated margin of the pelvis is occupied by the conjoined psoas and iliacus, with the anterior crural nerve between those muscles and the external iliac artery and vein at their inner side. Upon these structures the fascia which lines the abdomen is so arranged as to close the cavity against the escape of any part of the viscera, except at the inner side of the blood-vessels. But the arrangement of the parts situated thus deeply (towards the cavity of the abdomen) will be most conveniently entered upon after those nearer to the surface shall have been examined. To this examination we now proceed.

Superficial fascia of the thigh:

The general disposition of the *superficial fascia* met with on removing the common integument from the groin has been described (p. 438). In connexion with the present subject, it will be enough to mention the following facts. The deeper layer of this structure adheres closely to the edge of the saphenous opening, and the careful removal of it is necessary in order adequately to display that aperture. Where it masks the saphenous opening, the deep layer of the superficial fascia supports some lymphatic glands, the efferent vessels of which pass through it; and the small portion of the membrane so perforated is named the *cribriform fascia*. The superficial and the deep fasciæ adhere together along the fold of the groin likewise, and this connexion between the two membranes serves the purpose, at least, of drawing the integument the more evenly into the fold of the groin, when the limb is bent at the hip-joint.

connected with saphenous opening.

Cribriform fascia.

By Scarpa the deep layer of the superficial fascia which covers the abdomen was described as an emanation from the fascia lata, extended upwards over the external oblique muscle.* But different modes of viewing the continuity of such structures depend very much on the manner of conducting the dissection. In the present case, for example, the fascia may be said to proceed from above or from below, according as the parts are dissected from the abdomen downwards or from the thigh upwards. Such difference, however, is no more than a verbal one, the material fact being merely that the two membranes are connected together along the groin.

Fascia lata:

The separation of the *fascia lata* into two parts at the

* A Treatise on Hernia, translated by Wishart, p. 247.

saphenous opening, and the position and connexions of each part, having been described in detail (p. 448), only a few points in the arrangement of this membrane will be noticed in this place. At the lower end of the saphenous opening the iliac division of the fascia is continuous with the pubic by a well defined curved margin immediately above which the saphenous vein ends; above the opening a pointed cornu (falciform process—Burns*) of the same portion of the fascia (fig. 329) extending inwards in connexion with the femoral arch reaches Gimbernat's ligament; and in the interval between the two points now referred to (*i. e.*, from the upper to the lower end of the saphenous opening), the iliac layer of the fascia lata blends with the subjacent sheath of the femoral vessels as well as with the superficial fascia. The pubic part of the fascia covers the pectineus muscle, and is attached to the pectineal ridge of the pubes. Immediately below the femoral arch the iliac and pubic portions lie one before, the other behind the femoral blood-vessels and the sheath of these. They occupy the same position with respect to the femoral hernia.

For an account of the superficial arteries and veins which ramify in the integument in the neighbourhood of the groin, see pp. 590, 640.

The anterior or iliac part of the fascia lata being turned aside the *sheath of the femoral vessels* will be in view, fig. 331. The sheath is divided by septa, so that each vessel is lodged in a separate compartment, and the vein is separated by a thin partition from the artery on one side and from the short canal for the lymphatics on the other side. Along the thigh the sheath is filled by the artery and vein, but behind the femoral arch it is widened at the inner side. Here it is perforated for lymphatic vessels, and on this account is said to be 'cribriform.'† This inner, wider part of the sheath it is that receives the

iliac part ;

pubic part.
Their position with respect to the blood-vessels and to hernia.

Sheath of femoral vessels.

* Edinb. Med. and Surg. Journal, vol. ii. p. 263, and fig. 2.

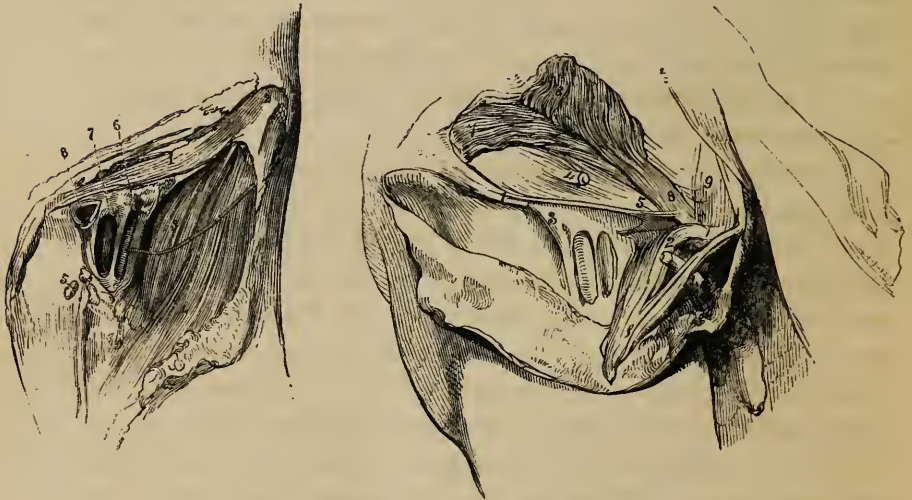In the first edition of Hey's Practical Observations in Surgery, the upper end of this process of the fascia was named the 'femoral ligament;' and since then several anatomists have distinguished the same part as "Hey's ligament." But Mr. Hey dropped the designation in the subsequent editions of the same work, and there seems no good reason for continuing it. Compare the original edition (1803), p. 151, and plate 4, with the third edition (1814), p. 147, and plates 4, 5, and 6.

† The word 'cribriform' being applied to this part as well as to the

femoral hernia (fig. 337); and in connexion with the anatomical description of that disease it is designated the femoral canal. At its upper end the sheath of the vessels is continuous with the lining membrane of the abdomen — with the fascia

Fig. 337.*

Fig. 338.†



transversalis at its fore part (fig. 331, 338), with the fascia iliaca behind.

When the femoral arch is being removed it will be found that a bundle of fibres (fig. 338), springing from its under surface

Deep
femoral
arch.

layer of the superficial fascia stretched across the saphenous opening, the two structures are distinguished in the following manner:—the former is known as the cribriform portion of the sheath of the vessels, while to the latter is assigned the name of cribriform fascia.

* The femoral vessels of the left side, with their sheath laid open, and a small hernia displayed.—1. The lower part of the external oblique muscle. 2. The anterior superior spine of the ilium. 3. Iliacus muscle. 4. Sartorius. 5. Pubic part of the fascia lata. 6. Femoral artery. 7. Femoral vein. 8. A small hernia.

† The groin of the right side dissected so as to display the deep femoral arch.—1. The outer part of the femoral arch. 1'. Part of the tendon of the external oblique muscle, including the femoral arch, and also the inner column of the external inguinal ring, projecting through which is seen a portion of the spermatic cord cut. 2. The femoral arch at its insertion into the spine of the pubes. The fibres outside the numeral are those of Gimbernat's ligament. 3. The outer part of the femoral sheath. 4. The spermatic cord, after having perforated the fascia transversalis. 5. The deep femoral arch—its inner end where it is fixed to the pubes. 6. Internal oblique muscle. 7. Trans-

outside the femoral vessels, extends across the fore part of the femoral sheath, and, widening at its inner end, is fixed to the pecten of the pubes behind Gimbernat's ligament. This tendinous band is known as the *deep femoral arch*. Connected with the same part of the pubes is the conjoined tendon of the internal oblique and transverse muscles (fig. 331). The tendon lies behind the attachment of the deep femoral arch (fig. 338). In many cases the last named structure is not strongly marked; and it may be found to blend with the tendon of the muscles just referred to. Not unfrequently it is altogether wanting.

Attention now being directed to the internal surface of the abdomen (fig. 333):—When the peritonæum has been removed, it will be observed that the fasciæ lining the cavity form for the most part a barrier against the occurrence of hernia; for outside the iliac vessels the fascia iliaca and fascia transversalis are continuous one with the other behind the femoral arch. These fasciæ are, in fact, but parts of the same membrane to which different names are assigned for the convenience of description, just as distinctive names are applied to portions of the same artery. But where the iliac artery and vein occur the arrangement of the fasciæ is different. The vessels rest upon the fascia iliaca; and the membranes, instead of joining at an angle as elsewhere, are continued into their sheath in the manner above described.*

Fasciæ in abdomen.

The opening for the iliac vessels.

The sheath is closely applied to the artery and vein, so that, in the natural or healthy state of the parts there is no space left for the formation of a hernia in the compartments which belong to those vessels; but at the inner side of the blood-vessels will be found a depression which is occupied but partially

versalis. Beneath the lower edge of this muscle is seen the transversalis fascia, which continues into the femoral sheath under the deep femoral arch. 8. Conjoined tendon of the internal oblique and transversalis muscles. 9. A band of tendinous fibres directed upwards behind the external abdominal ring.

* Some anatomists describe the sheath of the vessels as continued down from the membranes in the abdomen, while others regard it as an emanation from the fascia of the thigh, but continuous with the abdominal fasciæ. As this difference in the manner of viewing the structure in question does not alter the facts in any way, it is quite immaterial which of the modes of description is adopted. But it appears to me most natural to regard the sheath as a production of the fascia lata.

with the lymphatics. This is the femoral ring, the orifice of the femoral canal.

Femoral
ring
covered by
membrane.

Femoral ring.—After the removal of the peritonæum, this opening is not at first distinctly discernible, being covered with the laminated cellular membrane (subserous) which intervenes between the peritonæum and the walls of the abdomen. That part of the membrane which covers the ring was found by M. Cloquet to possess in some cases considerable density; and, from being the only barrier in this situation between the abdomen and the top of the thigh, it was named by that observer the *crural septum* (septum crurale). But this structure is usually no more than loose cellular membrane, and it forms but a very slight partition. On clearing it away the ring is displayed, fig. 333. It is a narrow opening, usually of sufficient size to admit the end of the fore finger; the size, however, varies in different cases, and it may be said to increase as the breadth of Gimbernat's ligament diminishes, and the converse. It is larger in the female than in the male body. On three sides the ring is bounded by very unyielding structures. In front are the femoral arches; behind is the horizontal branch of the pubes covered by the pectineus muscle and the pubic layer of the fascia lata; on the outer side lies the external iliac vein, but covered with its sheath; and on the inner side are several layers of fibrous structure connected with the pectineal line of the pubes—namely, Gimbernat's ligament, the deep femoral arch, and the conjoined tendon of the two deeper abdominal muscles with the fascia transversalis (fig. 338). The last mentioned structures—those bounding the ring at the inner side—present respectively a more or less sharp margin towards the opening.

Septum
crurale:
its nature.

Boundaries
of the ring.

Femoral
canal.

Femoral canal.—From the femoral ring, which is its orifice, the canal continues downwards behind the iliac part of the fascia lata, (its falciform process,) in front of the pubic portion of the same membrane, and ends at the saphenous opening. It is about half an inch in length; but in its length the canal varies a little in different cases.

Epigastric
and
obturator
arteries,
and vein.

Blood-vessels.—Besides the femoral vein, the position of which has been already stated, the epigastric artery is closely connected with the ring, lying above its outer side. It not unfrequently happens that the obturator artery descends into the

pelvis at the outer side of the same opening, or immediately behind it; and in some rare cases that vessel turns round the ring to its inner side. Moreover, an obturator vein occasionally has the same course; and small branches of the epigastric artery will be generally found ramifying on the posterior aspect of Gimbernat's ligament. In the male body, the spermatic vessels are separated from the canal only by the femoral arch.

Spermatic
cord.

To the foregoing account of the anatomical arrangement of the parts concerned in femoral hernia, may be added certain measurements, shewing the distances of some of the most important from a given point. They are copied from the work of Sir A. Cooper:—*

	MALE.	FEMALE.
From the Symphysis pubis to the anterior spine of the ilium	5 $\frac{3}{4}$ inches.	... 6 inches.
From same point to the middle of the iliac vein..	2 $\frac{5}{8}$ "	... 2 $\frac{3}{4}$ "
„ to the origin of the Epigastric artery	3 "	... 3 $\frac{1}{4}$ "
„ to the middle of the lunated edge of the fascia lata	3 $\frac{3}{4}$ "	... 2 $\frac{3}{4}$ "
„ to the middle of the femoral ring	2 $\frac{1}{4}$ "	... 2 $\frac{3}{8}$ "

Descent of the hernia.—When a femoral hernia is being formed, the protruded part is at first vertical in its course (fig. 337); but at the lower end of the canal, after the passage of about half an inch, it undergoes a change of direction, bending forward at the saphenous opening; and, as it increases in size, it ascends over the iliac part of the fascia lata and the femoral arch. The hernia thus turns round those structures, passing from behind them to their anterior surface. Within the canal the hernia is very small, being constricted by the unyielding structures which form that passage; but when it has passed beyond the saphenous opening, it enlarges in the loose cellular membrane of the groin; and, as the tumour increases, it extends outwards in the groin towards the spine of the iliac bone. Hence its greatest diameter is transverse.

Direction
of hernia;

it is small
in canal,
but enlarges
beyond it.

Coverings of the hernia.—The sac which is pushed before the protruded viscus, is derived from the external fossa of the peritonæum; except, however, when the cord of the obliterated

The sac.

* On Crural Hernia, p. 5.

Fascia
propria.

umbilical artery is placed outside its ordinary position, in which case the serous membrane furnishes the sac from its internal fossa (see page 1293). After the sac, the hernia carries before it the subserous cellular membrane (septum crurale of Cloquet), which covers the femoral ring, and likewise an elongation from the sheath of the femoral vessels. These two structures combined constitute a single very thin covering, known as the fascia propria of the hernia (Cooper). It sometimes happens that the hernia is protruded through an opening in the sheath, which therefore in that event does not contribute to form the fascia propria.

Diagnosis
between
bubonocele
and femoral
hernia.

Diagnosis.—Passing over the general symptoms of abdominal herniæ and the means of forming the diagnosis between a hernia and several other diseases with which it is liable to be confounded,—subjects which fall within the province of treatises on practical surgery,—I shall limit the observations to be made in this place to the anatomical circumstances which characterise femoral hernia, and serve to distinguish it from the inguinal form of the complaint. When the inguinal hernia descends to the scrotum or to the labium pudendi, and when the femoral hernia extends some distance outwards in the groin, no error in diagnosis is likely to arise. It is only in distinguishing between a bubonocele and a femoral hernia of moderate size that a difficulty occurs. The position of the femoral hernia is, in most cases, characteristic. The tumour is upon the thigh, and a narrowed part, or neck, may be felt sinking into the thigh near its middle. Besides, the femoral arch is usually to be traced above this hernia, while that band is lower than the mass of a tumour lodged in the inguinal canal. At the same time, the latter tumour covers the femoral arch, and cannot, like a femoral hernia when it has turned over that cord, be withdrawn from it. Some assistance will be gained, in a doubtful case, from the greater facility with which the tumour emerging at the saphenous opening admits of being circumscribed, in comparison with the bubonocele, which is bound down by a more resistant structure—the aponeurosis of the external oblique muscle. Other practical applications of the foregoing anatomical observations come now to be considered.

Taxis.

The taxis.—During the efforts of the surgeon to replace the hernia, the thigh is to be flexed upon the abdomen and inclined inwards, with a view to relax the femoral arch; the tumour is,

if necessary, to be withdrawn from over the arch, and the pressure on it is to be directed backwards into the thigh.

The operation.—The replacment of the hernia by the means just adverted to being found impracticable, the operation is undertaken with the view of dividing the femoral canal (or some part of it), thereby widening the space through which the protruding viscus is to be restored to the abdomen, or with the view of relieving strangulation when the restoration of the part is not possible or not desirable. Inasmuch as the manner of conducting the operation chiefly depends on the place at which the constricting structures are to be cut into, it will be convenient in the first instance to determine this point; and with this object we shall inquire into the practicability and safety of making incisions into the femoral canal at different points of its circumference. As the hernia rests upon the pelvis (the pubes), the posterior part of the canal may at once be excluded from consideration; so likewise may its outer side on account of the position of the femoral vein, and the outer part of its anterior boundary also, because of the presence of the epigastric artery in this direction. There remains only the inner boundary with the contiguous part of the anterior one, and through any point of this portion of the ring or canal an incision of the required extent (always a very short one) can be made without danger in nearly all cases. The sources of danger are only occasional; for the urinary bladder when largely distended, and the obturator artery when it turns over the femoral ring—a very unusual course—are the only parts at the inner side of the hernia liable to be injured; while the last named vessel, when it follows the course just referred to, and in the male the spermatic cord, are the structures in peril when the anterior boundary of the canal is cut into towards the inner side of the hernia.

Returning now to the steps of the operation:—After it has been ascertained that the urinary bladder is not distended, the skin is to be divided by a single vertical incision made on the inner part of the tumour, and extending over the crural arch. When the subcutaneous fat (the thickness of which is very various in different persons) is cut through, a small blood-vessel or two are divided, and some lymphatic glands may be met with. The hæmorrhage from the bloodvessels seldom requires any means to restrain it; but the glands, if enlarged,

Operation.

Incision through stricture to be at inner side of hernia.

Blood-vessels cut are small.

Fascia
propria
and sac in
in contact.

retard the operation in some degree. The fascia propria of the hernia, which succeeds to the subcutaneous fat, is distinguished by its membranous appearance and the absence of fat. It is very thin, and caution is required in cutting through it, as the peritonæal sac is immediately beneath : the two membranes are indeed in contact, except in certain cases to be presently noticed. A flat director is now to be insinuated between the hernial sac and the inner side of the femoral canal, space for the instrument being gained by pressing its smooth surface against the neck of the hernia. On the groove of the director so introduced, or under the guidance of the fore-finger of the left hand, if the use of the director should be dispensed with, the probe-pointed bistoury is passed through the canal, and the dense fibrous structure of which it consists is divided, the edge of the knife being turned upwards and inwards, or directly upwards. By the former plan of relieving the stricture, the parts divided are the following, viz., the falciform process of the fascia lata and the structures fixed to the pectineal line of the pubes, namely, Gimbernat's ligament, the inner end of the deep femoral arch, and, it may be, the tendon of the two deep abdominal muscles with the fascia transversalis ; while if the incision be directed upwards, the falciform process of the fascia lata and the two femoral arches are divided. The opening being sufficiently dilated, the protruded part is restored to the abdomen as in the taxis.

Final in-
cision, and
parts
divided.

Sac being
opened.

But it may be found necessary to lay the hernial sac open in order to examine its contents, or in order to relieve the impediment to the return of the hernia, if that should happen to reside in the neck of the sac itself. In this case it will probably be required to add to the vertical incision already made through the integuments and cellular membranes another, directed outwards over the tumour, and parallel with the femoral arch. Such additional incision is readily made, by passing the scalpel beneath the integument and fat, and cutting outwards after the skin has been pierced with the point of the knife. The sac being now opened, the hernia knife is used at the inner side of its neck, while the bowel is guarded with the left hand. During the restoration of the protruded parts, some advantage will be gained if the edges of the divided sac should be held down with a pair or two of forceps in the hands of an assistant.

In the foregoing observations, it has been stated that the fascia propria is in contact with the sac of the hernia, except in certain cases. The exception is afforded by the interposition of fat, and sometimes in considerable quantity. The adipose substance is deposited in the subserous cellular membrane; it has the peculiarity of resembling the fat lodged in the omentum, and it is occasionally studded with small cysts, containing a serous fluid. The hernia will be most readily found in such circumstances behind the inner part of the adventitious substance; which should be turned outwards from the inner side, or cut through.

Fat between fascia propria and sac.

THE PERINÆUM AND ISCHIO-RECTAL REGION.

A connected view of the structures which occupy the outlet of the pelvis becomes necessary, in consequence of the important surgical operations occasionally performed on the genito-urinary organs and the rectum, which are contained in that part. In the examination of these structures, which it is proposed to make in this place, attention will be confined to the male body.

The outlet of the pelvis of the male divided into two parts, viz.

The pelvic bones, as they bound the outlet of the pelvis, are already sufficiently described (p. 150). The anterior portion of the space, which is appropriated to the urethra and the penis, is named the *perinæum*. This part is triangular, the sides being formed by the branches of the ischium and pubes meeting at the symphysis pubis, while a line extended between the two tuberosities of the ischia represents the base of the triangle. In well formed bodies, the three sides of the space are equal in length; but cases occur in which, by the approximation of the ischiadic tuberosities, the base is narrowed; and, we may anticipate the practical application of the anatomical facts so far as to state here, that this circumstance exercises a material influence on the operation of lithotomy, inasmuch as the incisions required in that operation, instead of being oblique in their direction, must, in such circumstances, be made more nearly straight backwards.

the perinæum;

That portion of the outlet of the pelvis which lies behind the perinæum may be named the ischio-rectal region. It contains the end of the rectum; and it is defined by the tuberosities of the ischium, the coccyx, and the great glutæal muscles. We shall now proceed to the detailed examination of the two parts thus mapped out.

ischio-rectal region.

The skin
of the
peri-
næum ;

the raphé.

Superficial
fascia ;

its
influence
when urine
extravas-
ated.

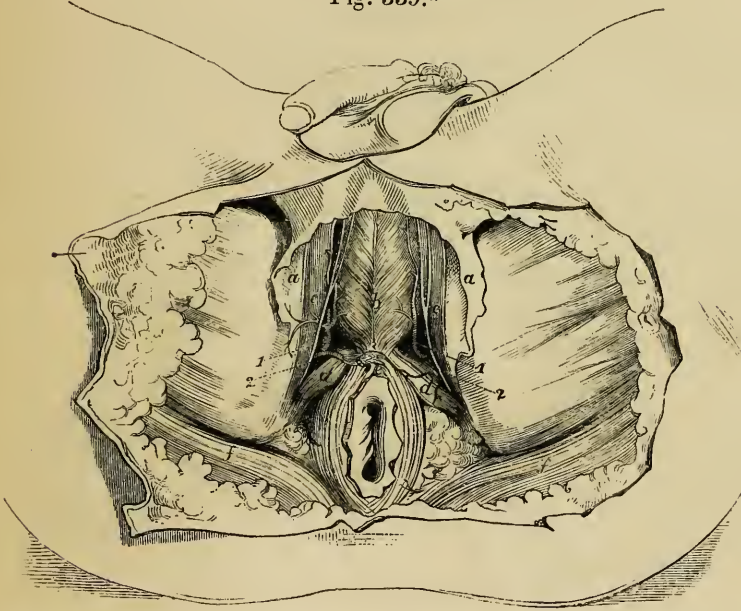
The skin of *the perinæum* continued from the scrotum, and partaking of the characters it has on that part, is dark-coloured, thin, and extensible, loosely connected with the subjacent textures, and in the male body studded with crisp hairs. Around the anus, it is thrown into folds, which are necessary to allow the extension of the orifice of the bowel, during the passage of masses of fæcal matter; and along the middle of the perinæum the median ridge or raphé of the scrotum is continued backwards to the anus. By this mark upon the skin, the large triangle in which is comprised the whole perinæum, is subdivided into two equal parts. To one of these smaller spaces the operations usually performed for gaining access to the urinary bladder are for the most part restricted. The skin of the perinæum is provided with numerous sebaceous follicles.

From the muscles of the perinæum, the skin is separated by cellular membrane and fat, except in the neighbourhood of the anus, where the sphincter of the bowel is immediately in contact with the integument. The deeper part of the fatty cellular membrane,—the *superficial fascia* (see p. 442),—taking on a membranous appearance, has, in a great measure, the same arrangement and characters as the corresponding structure of the groin. With that membrane the perinæal fascia is continuous in front through the scrotum, but at other points it is confined to the perinæum, being fixed laterally to the branches of the ischium and the pubes (fig. 339), while it is continued posteriorly into the deep perinæal fascia, beneath the sphincter ani and in front of the rectum. It is in consequence of these connexions of the superficial fascia of the perinæum, that abscesses do not attain a large size in the perinæum, and that urine effused in consequence of rupture of the urethra does not extend backwards to the rectum or outwards to the thigh, but continues forward, and, if an outlet for its escape should not be afforded by the surgeon, reaches successively the scrotum, the penis, and the groin above Poupart's ligament. In extreme cases the extravasated fluid would spread from the position last mentioned over the anterior part of the abdomen and even to the thorax, its extension downwards to the thigh being restrained by the attachment of the superficial fascia along the fold of the groin.

The *muscles* brought into view by the removal of the superficial fascia are, on each side, the accelerator urinæ, erector penis,

and transversus perinæi, fig. 339. Between these muscles is a depression, in which access may be gained to the membranous part of the urethra, without wounding the erectile tissue of the penis, Muscles of the perinæum.

Fig. 339.*



namely, the corpus spongiosum urethræ with its bulbous enlargement on the one hand, and the crus of the corpus cavernosum on the other, covered respectively by the accelerator urinæ and the erector penis. Along this depression is placed the superficial artery of the perinæum, with the accompanying nerve, and the transverse artery crosses behind it; at the bottom of the depression, after the muscular structure has been turned a little aside, the deep perinæal fascia is met with.

Perinæal artery and nerve.

The last-named membrane, *deep perinæal fascia* (see page 443), fills the space between the rami of the ischium and pubes, and is therefore necessarily triangular in shape (fig. 341). It consists of two laminae of fibrous membrane (fig. 342, *b*), the anterior being much the thicker and more tendinous of the two.

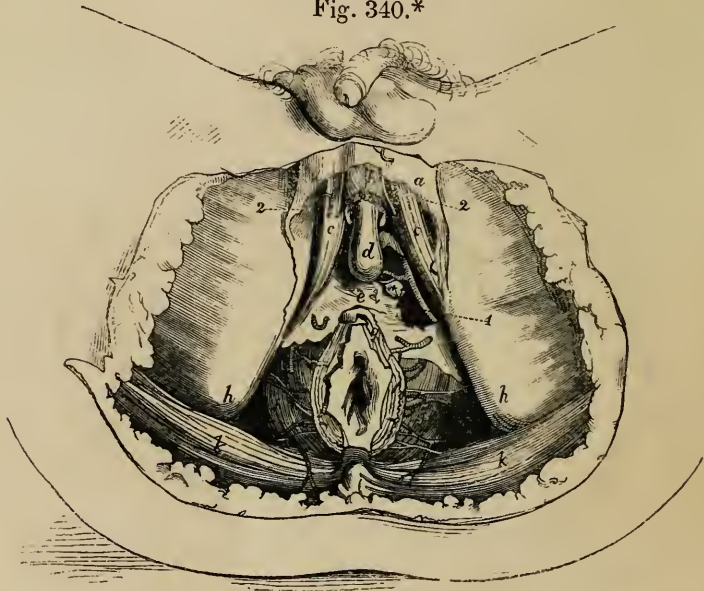
Deep perinæal fascia.

* The perinæum and part of the thighs after the skin and a portion of the superficial fascia had been removed.—*a*. Superficial fascia. *b*. Accelerator urinæ. *c*. Erector penis. *d*. Transversus perinæi. *e*. Upper point of sphincter ani. *f*. The edge of the glutæus maximus.—1. Superficial perinæal artery. 2. Superficial perinæal nerve.

Cowper's glands ; arteries of the bulb ; pudic artery.

The layers are separated by an interval, in which the compressor muscles of the urethra (p. 1231) are lodged together with Cowper's glands and the arteries of the bulb, as well as the pudic arteries and nerves for a short space (fig. 340). Where it is perforated

Fig. 340.*



by the membranous portion of the urethra, the fore part of the deep perinæal fascia is continuous with the fibrous cover of the bulb and corpus spongiosum urethræ, so that the fascia does not present a defined edge to the tube which passes through it. The posterior layer is connected with the capsule of the prostate gland.

Triangular ligament of urethra.

The *anterior* of the two *layers* here and elsewhere in this work (see page 443) noticed as constituting the deep perinæal fascia, is that which alone forms the *triangular ligament of the urethra*. (See especially Camper. *Demonstrationes Anatomico-Pathologicæ*.) It is that layer which, being pierced by the urethra, interferes with the passage of instruments along the canal. Moreover, it is the only part of the structure recognised by most anatomical writers. The slip of membrane described as the *posterior*

* A deeper dissection than that represented in the last figure, the perinæal muscles being removed and also the fat in the ischio-rectal fossa.—*a*. Superficial fascia. *b*. Accelerator urinæ. *c*. Crus penis. *d*. The bulb. *e*. Triangular ligament of urethra. *f*. Levator ani. *g*. Sphincter. *h*. Tuberosity of ischium. *k*. Gluteus maximus. * Cowper's gland of the left side. 1. Pudic artery. 2. Superficial perinæal artery and nerve. The inferior hæmorrhoidal arteries and the artery of the bulb are likewise shewn.

layer of the deep fascia, in accordance with the plan which appears to be now generally received in this country (Colles' "Surgical Anatomy," p. 191; Harrison, "Dublin Dissector," vol. i. p. 312; Guthrie "On the Neck of the Bladder," &c. p. 41), might be regarded as a dependency of the membranes lining the pelvis.

The structure next met with in examining the perinæum, is the levator ani (its forepart) figs. 340, 342, and immediately under that muscle is the prostate. For the anatomical description

Fig. 341.*

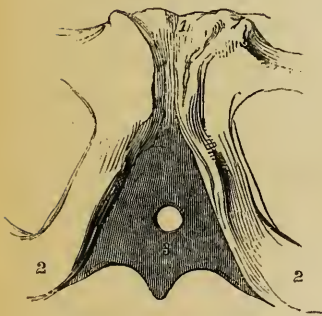
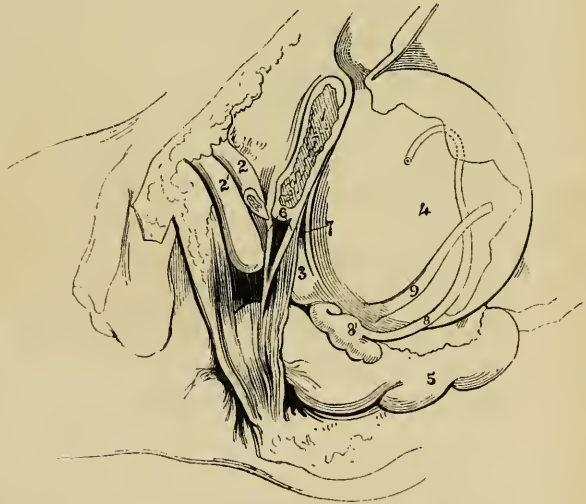


Fig. 342.†



of this gland see page 1214. Here it is only necessary to state, as material to the present object, that placed before the neck of the bladder, around the urethra, behind and below the arch of the pubes, and above the rectum, the prostate is supported by the levator ani and the pelvic fascia,—the latter dropping down from the pubes on its base. It is invested with a fibrous covering, its capsule

* The anterior part of the deep perinæal fascia together with the bones. In consequence of the connexion between the fascia and the fibrous covering of the bulb having been cut, the passage for the urethra appears as a hole. —1. Pubes near the symphysis. 2. Ischium close to its tuberosity. 3. Deep perinæal fascia—its anterior surface.

† The pelvic viscera of the male seen on the left side.—1. The body of the left pubes sawed through. 2. Corpus cavernosum penis. 2'. Corpus spongiosum. 3. Prostate gland, with a portion of the levator ani covering its fore part. 4. Urinary bladder. 5. Intestinum rectum. 6. Deep perinæal fascia—its two layers. 7. Cut edge of the pelvic fascia extending from the pubes to the back part of the prostate. 8. Vas deferens. 8'. Vesicula seminalis. 9. Ureter. The cut edge of the peritonæum is seen jagged over the bladder and the rectum.

and on this account the outer surface does not readily yield to a cutting instrument, while the proper substance of the gland is cut or lacerated with comparative facility. From the increase of its breadth towards the lower surface, it follows that the greatest extent of incision from the urethra, without wholly dividing the gland, would be made in a direction outwards and backwards.

it is felt
through the
rectum.

The examination of the prostate by the surgeon is made through the rectum. It is only through the gut that it can be felt. When the gland is enlarged, as it commonly is in aged persons, the urethra is raised above its natural level and elongated. But the augmentation of size may be partial, affecting one lateral lobe (a rare occurrence) and then the urethra is inclined to one side; or the middle and posterior part or middle lobe may be projected upwards at the orifice of the urethra, so as even to obstruct the escape of urine from the bladder. In this last case the point of the instrument passed along the urethra, must be inclined upwards more than is required in the healthy condition of the parts, in order that it may be made to enter the bladder over the projection referred to. The part of the urethra encircled by the prostate admits of considerable dilatation. For the position of the seminal and other openings into it reference may be made to the description of the canal at page 1225.

Increased
size influ-
ences posi-
tion of
urethra.

Neck of
urinary
bladder.
Pelvic
fascia.

Behind the prostate the neck of the urinary bladder presents itself. Here the bladder is bound to the pubes at its upper part by the pelvic fascia, the bands of which are named its anterior and lateral ligaments. Laterally the fascia reaches the organ in question over the base of the prostate, fig. 342; and an elongation from the same membrane extends from side to side between the bladder and the rectum after investing the vesiculæ seminales and vasa deferentia.

The rec-
tum :

its last part
inclined
backwards,

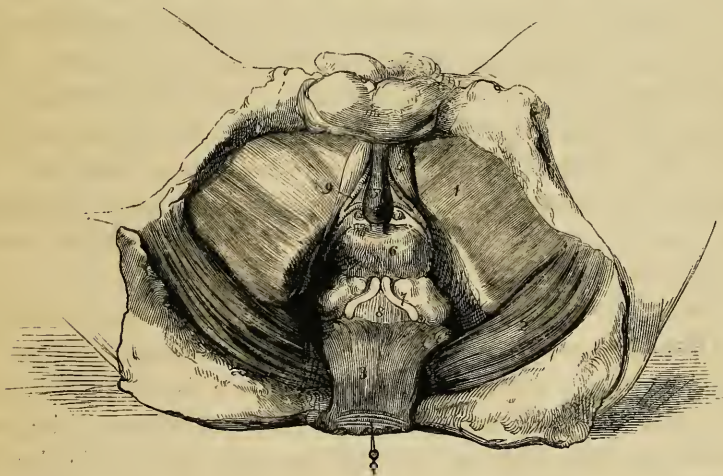
Turning attention in the next place to the *rectum*, which occupies the irregularly-shaped space behind the perinæum, we shall recall a few particulars respecting it. The lowest or third division of the bowel, which measures about an inch and a half in length, is directed obliquely backwards from the fore part of the prostate to the anus (fig. 342); and as at the same time the urethra here inclines forwards with the penis, the space between the two widens towards the surface of the perinæum. Into this space the bulb of the corpus spongiosum drops down, occupying it more or less according as the erectile tissue is more or less

distended. The part of the rectum now under consideration narrows to its end under the influence of the sphincters. It is supported by the levatores ani, which are fixed to its sides, and by the pelvic fascia on the inner surface of those muscles. is narrow.

From this its shortest and narrowest part, the intestine sweeps into the hollow of the sacrum, widening considerably at the same time so as to form a large pouch (fig. 342). This part, which is known as the second division of the rectum, has before it the prostate and the urinary bladder with the seminal vesicles, and above these the recto-vesical pouch of the peritonæum. The rectum and the bladder are in contact one with the other, only in the small triangular space intercepted between the seminal vesicles and the peritonæum (fig. 343); and in this space the

The middle part: its large size; is curved before sacrum.

Fig. 343.*



* Besides the superficial fascia and the perineal muscles, by the removal of which the spongy erectile tissue and the crura penis were uncovered, the anterior layer of the deep perineal fascia was cut away in the preparation for this sketch, and thus the pudic arteries, with their branches for the bulb, and Cowper's glands, have been laid bare. The rectum too having been dissected from its connexions and drawn back, the prostate gland, the seminal vesicles, and part of the urinary bladder have been brought into view.—1. Fascia lata covering the adductor muscles of the thigh. 2. Glutæus maximus. 3. Rectum. 4. Crus penis of left side. 5. Corpus spongiosum urethræ. 6. Prostate. 7. Vesicula seminalis and vas deferens of left side. 8. A small part of urinary bladder. 9. Right dorsal artery, with the artery of the bulb and Cowper's gland resting against the inner layer of the deep perineal fascia. The last-named parts are at considerable depth, but the size within which it was necessary to restrict the drawing, did not admit of the appearance of depth being sufficiently preserved in this representation.

Puncture of bladder through rectum.

bladder may be punctured, in order to evacuate its contents. In performing the operation, the chief guide to the surgeon is the prostate. The instrument is to be passed forward into the bladder behind this gland; but care must be taken to regulate the distance from its margin, so as to avoid wounding on the one hand the vasa deferentia which come into apposition one with the other immediately behind it; and, on the other hand, the peritonæum where this membrane turns from one of the organs to the other. At the same time it is to be remembered, that by the inclination of the trocar to either side, the seminal vesicles would be endangered. The part of the intestine now under observation rests against the conjoined levatores ani, the coccyx, and the sacrum.

Hæmorrhoidal arteries and veins.

The lower end of the rectum receives small arteries on each side from the pudic (fig. 340); but its principal artery (the superior hæmorrhoidal, the continuation of the inferior mesenteric) is placed behind the organ and gives branches to each side. The larger branches do not extend within reach of a forefinger of ordinary length. The veins, like those of the abdomen generally, are without valves. These vessels are very liable to enlarge and become varicose; and this condition is constantly associated with, or even forms, a great part of the disease known as hæmorrhoids.

Ischio-rectal fossa, filled with fat.

Ischio-rectal fossa.—On each side of the rectum between it and the ischium is contained a considerable quantity of fat, the space which it occupies being named the ischio-rectal fossa. This hollow extends backwards from the perinæum to the great glutæal muscle, and is bounded on the inner side by the levator ani as this muscle descends to support the intestine, on the opposite side by the obturator fascia and muscle supported by the ischium. At the outer side and encased in a sheath of the obturator fascia is the pudic artery with the accompanying veins and nerve; and small offsets from these cross the fossa to supply the lower end of the rectum. The pudic artery, it will be observed, is about an inch above the lower surface of the tuber ischii, and at the same time, by its position under that prominence of the bone, it is protected from injury by incisions directed backwards from the perinæum; but in front of this part, in the perinæum, inasmuch as the vessel lies along the inner margin of the branches of the ischium and

Its boundaries.

Pudic artery,

pubes, it is here liable to be wounded when the deeper structures of the perinæum are incised.

The fossa is narrowed as it reaches upwards into the pelvis; such narrowing of the space is the necessary result of the direction of the levator ani, which drops inwards from the fascia on the side of the pelvis, and thus limits the fossa at its upper end.

when liable to be wounded in an operation.

LATERAL OPERATION OF LITHOTOMY.

The intention of the operation, as it is usually performed, is to remove a calculus from the urinary bladder by an opening made through the perinæum and the prostatic part of the urethra. The incisions to attain this end are commonly made on the left half of the perinæum, because this side is most convenient to the right hand of the operator; but, if the surgeon should operate with the left hand, then the opposite (right) side of the perinæum would be most convenient.

Lithotomy,

on left side of perinæum.

The position at which the perinæum is to be incised requires careful consideration. For if the necessary incisions should be made too near the middle line of the body, the bulbous enlargement of the corpus spongiosum urethræ and the rectum are liable to be wounded; and if, on the other hand, the perinæum should be divided towards its outer boundary (the conjoined branches of the pubes and ischium), there is a risk of wounding the pudic artery where that vessel has reached the inner edge of the bone. The incisions are therefore to be made through the area of the small perinæal space in such manner as to avoid both its sides. Again, as to the length to which the several structures are to be incised:—The integument and the subcutaneous cellular membrane must be divided with freedom, because, 1st, the skin does not admit of dilatation during the removal of the foreign body; and 2dly, extensive incisions through the structures near the surface facilitate the egress of urine, which, after the operation, continues for a time to trickle from the bladder. But the prostate and the neck of the bladder, on the contrary, are to be incised in but a small extent. The reasons for this rule may be stated as follows:—By accumulated experience in operations on the living body, it has been found that the structures now under consideration when slightly cut

Circumstances which determine the position of incisions.

First incision to be free.

Deep incisions to be small.

into admit of dilatation, so as to allow the passage of a stone of considerable size, and that no unfavourable consequence follows from the dilatation. Moreover, when these parts are freely divided (cut through), the results of lithotomy are less favourable than in the opposite circumstances. The less favourable results adverted to appear to be due to the greater tendency to infiltration of urine in the cellular membrane of the pelvis; and the occurrence of this calamity probably depends on the fact that when the prostate has been fully cut through, the bladder is at the same time divided beyond the base of the gland, and the urine then is liable to escape behind the pelvic fascia (which it will be remembered is connected with both those organs at their place of junction); whereas if the base of the gland should be left entire the bladder beyond it is likewise uninjured, and the urine passes forward through the external wound.

Steps of
operation.

The steps of the operation by which the foregoing general rules are sought to be carried out are the following:—The grooved staff having been passed into the bladder (and this instrument ought to be of as large size as the urethra will admit), and the body or the patient, as the case may be, having been placed in the usual position—by which position the perinæum is brought fully before the operator with the skin stretched out—the first incision is begun about two inches before the anus, a little to the left of the raphé of the skin, and from this point it is carried obliquely backwards in a line about midway between the tuber ischii and the anus, extending a little way behind the level of the latter. During the incision, the knife is held with its point to the surface, and it is made to pass through some of the subcutaneous cellular membrane as well as the skin. Now, the edge of the knife is applied to the bottom of the wound already formed, in order to extend it somewhat more deeply; and the forefinger of the left hand is passed firmly along for the purpose of separating the parts still further, and pressing the rectum inwards and backwards out of the way. Next, with the same finger passed deeply into the wound from its middle and directed upwards, the position of the staff is ascertained and the structures still covering that instrument are divided with slight touches of the knife,—the finger pressing the while against the point at which the rectum is presumed to

First inci-
sion.

Passage of
the knife
into the
staff;

be. When the knife has been inserted into the groove of the staff (and it reaches that instrument in the membranous part of the urethra) it is pushed onwards through the prostatic portion of the canal with the edge turned to the side of the prostate, outwards, or, better, outwards with an inclination backwards. The knife being now withdrawn, the forefinger of the left hand is passed along the staff into the bladder. With the finger the parts are dilated, and with it, after the staff has been withdrawn, the position of the stone is determined and the forceps is guided into the bladder.

and
through
prostate.

In case the calculus is known to be of more than a moderate size and the knife used is narrow, the opening through the side of the prostate may be enlarged as the knife is withdrawn, or the same end may be attained by increasing the angle which that instrument, while it is being passed onwards, makes with the outer part of the staff. And if the stone should be of large size, it will be best to notch the opposite side of the prostate likewise before the forceps is introduced. The same measure may be resorted to afterwards should much resistance be experienced when the foreign body is being extracted. Lastly, this part of the operation (the extraction of the stone) should be conducted slowly, so as gradually to dilate the parts without lacerating them; and the forceps should be held with its blades one above the other.

Further
division of
prostate in
certain cir-
cumstances.

The Structures divided in the Operation.—In the first incision the integument and the subjacent cellular membrane are divided; afterwards a small part of the accelerator urinæ, and the transversus perinæi with the transverse artery. Then the deep perinæal fascia with the muscular fibres between its layers, the membranous part of the urethra, the prostatic part of the canal, and, to a small extent, the prostate itself are successively incised.

Parts suc-
cessively
cut.

The blood-vessels: their relation to the incisions.—The transverse artery of the perinæum with, it may be, the superficial artery of the perinæum, is the only artery necessarily cut through when the vessels have their accustomed arrangement; for in such circumstances the artery of the bulb is not endangered if the knife be passed into the staff in a direction obliquely upwards, the artery being anterior to the groove of that instrument; neither is there a risk of wounding the pudic artery,

The arteries
divided.

Those
avoided.

unless the incisions through the deep parts (the prostate for instance) should be carried too far outwards.*

Dangers
from
unusual
arrange-
ment of
vessels.

But in some cases the arteries undergo certain deviations from their accustomed arrangement, whereby they are rendered liable to be wounded in the operation. Thus, the artery of the bulb when it arises, as occasionally happens, from the pudic near the tuber ischii, crosses the line of incision made in the operation.† The arterial branches ramifying on the prostate are in some instances enlarged, and become a source of hæmorrhage; ‡ and the veins too on the surface of that gland, when augmented in size, may give rise to troublesome bleeding.§ Lastly, it should be added that the occasional artery (accessory pudic) which takes the place of the pudic when defective, inasmuch as it lies on the posterior edge of the prostate, would be divided if the gland were cut through to its base, and only in this event.||

* For reference to some cases in which the pudic artery was divided in lithotomy, see Mr. Crosse's "Treatise on Urinary Calculus," p. 21. London, 1835.

† "The Anatomy of the Arteries," &c., by R. Quain, p. 442, and plate 64†figs. 1 and 2. A case in which death resulted from division of the artery of the bulb is recorded by Dr. Kerr, in the "Edinb. Med. and Surg. Journal," July, 1847, p. 155.

‡ See an essay, entitled "Remarks on the Sources of Hæmorrhage after Lithotomy," by James Speuce, in the "Edinburgh Monthly Journal of Medical Science," vol. i. p. 166; 1841. And "The Arteries, &c., by R. Quain," p. 445.

§ "The Arteries, &c., by R. Quain," p. 446, and plate 65, fig. 3.

|| Ibid, p. 444, and plate 63. An instance in which fatal consequences resulted from the division of such an artery has been placed on record. See "Case of Lithotomy attended with Hæmorrhage, by J. Shaw, Esq.," in "The London Medical and Physical Journal," vol. lv. p. 3, with a figure. 1826.

INDEX.

- ABDOMEN**, 1016.
 ——— regions of, 1017.
 ——— viscera of, 1019.
 ——— position of, 1096.
 Aberrant duct of testis, 1248.
 ——— ducts of liver, 1073.
 Absorbent glands, *see* Glands Lymphatic.
 ——— system, cclx. *see* Lymphatic system.
 Absorbents, 651. (*See* Lymphatics.)
 Accelerator urinæ, 1230.
 Accessory organs, *see* Particular organs.
 Acervulus cerebri, 718.
 Acetabulum, 146.
 Acini of glands, ccciv.
 Acromion, 110.
 Actions of muscles, *see* Particular muscles.
 Adipose tissue, cviii.
 Air-cells, 1150.
 ——— capillaries of, 1154.
 ——— structure of, 1152.
 ——— tubes, *see* Trachea, Bronchi, and Bronchia.
 Alæ nasi, 957.
 ——— vespertilionis, 1264.
 Albumen, xxv.
 Albuminoid compounds, xxiv.
 ——— principles, chief characters of, xxxii.
 Allantois, 1273.
 Alveoli, 61. 73.
 ——— of mucous membrane, cclxxxii.
 ——— of stomach, 1025.
 Amphiarthrosis, 180.
 Ampulla of labyrinth, 944.
 ——— membranous, 949.
 Amygdalæ, 1006.
 ——— (cerebellum), 722, 723.
 Anastomoses of arteries, cclxii.
 ——— veins, cclxix.
 Anatomy, object of, xvii.
 Anfractuosities, 690.
 Annular protuberance, 688.
 Annulus albidus, 913.
 ——— ovalis, 1107.
 Ansæ Vieussenii, 887.
 Anti-helix, 926.
 Anti-tragus, 926.
 Antrum of Highmore, 64. 91. 962.
 Antrum pylori, 1021.
 Anus, 1051.
 ——— muscles of, 1051-5.
 Aorta, 454.
 ——— abdominal, 552.
 ——— ascending, 458.
 ——— bifurcation of, 566.
 ——— descending, 549. 552.
 ——— development of, 1127.
 ——— thoracic, 549.
 Apertura scalæ vestibuli, 944.
 ——— naris, 959.
 Aponeuroses, cxix. 425.
 ——— particular, *see* Fasciæ.
 ——— abdominal, 355. 357.
 ——— vertebral, 299. 433.
 Apophyses, cxxxiii.
 Appendages, auricular, 1105. 1113.
 ——— of eye, 903.
 Appendices epiploicæ, 1042.
 ——— of auricles of heart, 1105. 1113.
 Appendix vermiformis, 1044.
 ——— vesicæ, 1211.
 Aqueduct of cochlea, 45. 947.
 ——— Fallopius, 43. 933.
 ——— Sylvius, 717. 723.
 ——— vestibule, 44. 944.
 Aqueous humour, 920.
 Arachnoid membrane, 755.
 Arbor vitæ, 725.
 ——— uterinus, 1261.
 Arch of aorta, 456.
 ——— branches of, 460.
 ——— of colon, 1047.
 ——— crural, 1303.
 ——— deep, 441. 1307.
 ——— femoral, 1303.
 ——— deep, 1307.
 ——— palmar, superficial, 540.
 ——— deep, 547.
 ——— plantar, 604. 609.
 ——— pubic, 150.
 ——— zygomatic, 84.
 Arches, palatine, 287. 1005.
 Arciform fibres, 688. 734.
 Areola, 1280.
 Arteriæ helicinæ, 1222.
 ——— receptaculi, 492.
ARTERIES, General Anatomy of, ccxli.
 ——— anastomoses of, ccxlii.

- ARTERIES**, cellular tunic of, ccxlv.
 ——— coat of, external, ccxlv.
 ——— internal, ccxlv.
 ——— middle, ccxlv.
 ——— contractility of, ccxlvii.
 ——— differences of, ccxlv.
 ——— distribution of, ccxli.
 ——— elastic coat of, ccxlv.
 ——— fenestrated membrane of, ccxlv.
 ——— nerves of, ccxlvii.
 ——— physical properties of, ccxliii.
 ——— rete mirabile of, ccxliii.
 ——— sheath of, ccxliii.
 ——— structure of, ccxliii.
 ——— terminations of, ccxlvii.
 ——— tonicity of, ccxlvii.
 ——— tortuosity of, ccxliii.
 ——— vessels of, ccxlv.
 ——— vital properties of, ccxlvii.
ARTERIES OR ARTERY, Descriptive
 Anatomy of, 454.
 ——— acromial, 514. 524.
 ——— alveolar, 487.
 ——— anastomotic, of arm, 534.
 ——— of thigh, 594.
 ——— anastomotica magna, 594.
 ——— angular of face, 479.
 ——— aorta, 454, *see* Aorta.
 ——— articular, knee, inferior, 599.
 ——— superior, 599.
 ——— azygos, 599.
 ——— hip, 575.
 ——— auditory, internal, 951.
 ——— auricular anterior, 483.
 ——— posterior, 482.
 ——— axillary, 521.
 ——— azygos, of knee, 599.
 ——— basilar, 510.
 ——— brachial, 528. 532.
 ——— brachio-cephalic, 464.
 ——— bronchial, 550. 1154.
 ——— buccal, 487.
 ——— of bulb, 579.
 ——— capsular, 561.
 ——— of eye, 924.
 ——— carotid common, 465. 471.
 ——— external, 471.
 ——— branches of, 473.
 ——— internal, 490.
 ——— carpal ulnar anterior, 539.
 ——— posterior, 539.
 ——— radial anterior, 545.
 ——— posterior, 545.
 ——— central of retina, 493. 920. 922.
 ——— cerebellar, anterior, 511.
 ——— inferior, 510.
 ——— superior, 511.
 ——— cerebral, anterior, 495.
 ——— middle, 495.
 ——— posterior, 511.
 ——— cervical ascending, 513.
Artery, cervical princeps, 481.
 ——— profunda, or deep, 520.
 ——— superficial, 515.
 ——— choroid, 495.
 ——— posterior, 511.
 ——— of eye, 912.
 ——— ciliary, 494. 915.
 ——— circumflex, of arm, anterior, 526.
 ——— posterior, 526.
 ——— iliac, 586.
 ——— superficial, 590.
 ——— of thigh, external, 592.
 ——— internal, 592.
 ——— coccygeal, 580.
 ——— cochlear, 951.
 ——— cœliac (axis), 552.
 ——— colic, left, 559.
 ——— middle, 559.
 ——— right, 558.
 ——— comes nervi ischiadici, 580.
 ——— phrenici, 517.
 ——— communicating, of brain,
 anterior, 495.
 posterior, 495. 511.
 ——— of palm, 540.
 ——— coronary, of heart, left, 464.
 right, 463.
 ——— of lips, lower, 479.
 upper, 479.
 ——— of stomach, 554.
 ——— of corpus bulbosum, 579.
 ——— cavernosum, 579.
 ——— cremasteric, 586.
 ——— cystic, 555.
 ——— deferent, 573. 1250.
 ——— dental inferior, 486.
 superior, 487.
 ——— digital, of foot, 605.
 hand, 541.
 ——— dorsal, of carpus, radial, 545.
 ulnar, 539.
 ——— of foot, 607.
 ——— of fore-finger, 546.
 ——— of thumb, 546.
 ——— of tongue, 476.
 ——— of penis, 579.
 ——— of great toe, 608.
 ——— of scapula, 525.
 ——— emulgent, 561.
 ——— epigastric, 585.
 superficial, 590.
 superior, 518.
 ——— ethmoidal, 494.
 ——— facial, 477.
 ——— femoral, 587. 594.
 deep, 590.
 ——— frontal, 494.
 ——— gastric, 556.
 ——— gastro-duodenal, 552.
 ——— epiploic, left, 557.
 right, 555.
 ——— glutæal, 580.

- Artery, hæmorrhoidal, external, 578.
 ————— middle, 573.
 ————— superior, 559.
 ————— helicine, 1222.
 ————— hepatic, 554. 1063. (d). 1067.
 ————— humeral, 528.
 ————— hyoid (lingual), 476.
 ————— (thyroid), 474.
 ————— hypogastric, 570-1.
 ————— iliac, common, 567.
 ————— external, 583.
 ————— internal, 570.
 ————— of fœtus, 571.
 ————— ileo-colic, 558.
 ————— ilio-lumbar, 581.
 ————— infra-orbital, 487.
 ————— infra-spinous, 515.
 ————— innominate, 464.
 ————— intercostal, (aortic,) 551.
 ————— anterior, 518.
 ————— superior, 519.
 ————— interlobular, of liver, 1069.
 ————— inter-osseous; ulnar, 538.
 ————— anterior, 538.
 ————— posterior, 538.
 ————— of foot, 608.
 ————— hand, 545.
 ————— intestini tenuis, 558.
 ————— ischiadic, 580.
 ————— labial, inferior, 479.
 ————— lachrymal, 493.
 ————— laryngeal, 474.
 ————— lingual, 475.
 ————— lumbar, 564.
 ————— malleolar, external, 607.
 ————— internal, 607.
 ————— mammary, external, 524.
 ————— internal, 516.
 ————— masseteric, 487.
 ————— maxillary, external, 477.
 ————— inferior, 486.
 ————— internal, 484.
 ————— superior, 487.
 ————— mediastinal, 518. 551.
 ————— meningeal, anterior, 493.
 ————— middle or great, 485.
 ————— posterior, 481. 509.
 ————— small, 486.
 ————— mesenteric, inferior, 558.
 ————— superior, 557.
 ————— metatarsal, 608.
 ————— middle sacral, 565.
 ————— musculo-phrenic, 518.
 ————— mylo-hyoid, 486.
 ————— nasal, 488.
 ————— lateral, 479.
 ————— of septum, 488.
 ————— nutrient of femur, 593.
 ————— fibula, 602.
 ————— humerus, 533.
 ————— radius, 538.
 ————— tibia, 601.
- Artery, ulna, 538.
 ————— obturator, 574.
 ————— occipital, 480.
 ————— œsophageal, 550.
 ————— ophthalmic, 493.
 ————— ovarian, 562.
 ————— palatine, ascending, 478.
 ————— superior or descending, 487.
 ————— palmar arch, superficial, 540.
 ————— deep, 547.
 ————— palpebral, 494.
 ————— pancreatic, 556.
 ————— pancreatic, great, 556.
 ————— pancreatico-duodenal, 555.
 ————— inferior, 558.
 ————— perforating, of foot, 604-5.
 ————— hand, 548.
 ————— thigh, 593.
 ————— thorax, 518.
 ————— pericardiac, 550.
 ————— perinæal, superficial, 578.
 ————— transverse, 579.
 ————— peroneal, 601.
 ————— anterior, 602.
 ————— posterior, 601.
 ————— pharyngeal, ascending, 489.
 ————— phrenic, 563.
 ————— superior, 517.
 ————— plantar, external, 604.
 ————— internal, 603.
 ————— popliteal, 596.
 ————— princeps cervicalis, 481.
 ————— pollicis, 547.
 ————— profunda, of neck, 520.
 ————— of arm, inferior, 534.
 ————— superior, 533.
 ————— of penis, 579.
 ————— of thigh, 590.
 ————— pterygoid, 487.
 ————— pterygo-palatine, 488.
 ————— pudic, 576.
 ————— accessory, 577.
 ————— in female, 580.
 ————— external, 590.
 ————— pulmonary, 1147. 1153.
 ————— pyloric, 554.
 ————— radial, 541.
 ————— of index finger, 547.
 ————— ranine, 476.
 ————— recurrent inter-osseous posterior, 539.
 ————— radial, 545.
 ————— tibial, 607.
 ————— ulnar, anterior, 537.
 ————— posterior, 537.
 ————— renal, 561.
 ————— sacral, middle, 565.
 ————— lateral, 582.
 ————— scapular, posterior, 515.
 ————— sciatic, 580.
 ————— sigmoid, 559.

- Artery, spermatic, 562. 1250.
 — spheno-palatine, 488.
 — spinal, anterior, 509.
 in neck, 509.
 in thorax, 551.
 in loins, 565.
 median, 510.
 posterior, 509.
 — splenic, 555. 1087.
 — sterno-mastoid, 482.
 — stylo-mastoid, 482.
 — subclavian, 497. 506.
 — sublingual, 476.
 — submental, 478.
 — subscapular, 525.
 — superficial circumflex, iliac,
 590.
 perinæal, 578.
 palmar arch, 540.
 — superficialis volæ, 545.
 — supra-acromial, 514.
 orbital, 493.
 renal, 561.
 scapular, 514.
 spinous, 514.
 sural, 598.
 tarsal, 608.
 temporal, 483.
 anterior, 483.
 deep, 486.
 middle, 483.
 posterior, 484.
 — thoracic acromial, 524.
 alar, 525.
 long, 524.
 superior, 524.
 — thymic, 518.
 — thyroid, inferior, (axis,) 512.
 lowest, 513.
 superior, 474.
 — tibial, anterior, 605.
 posterior, 600.
 — tonsillar, 478.
 — transverse, of face, 483.
 neck, 515.
 perinæum, 579.
 scapula, 514.
 — tympanic, 485.
 — ulnar, 535.
 — umbilical, 571. 1130.
 — uterine, 573.
 — vaginal, 574.
 of liver, 1069.
 of vas deferens, 573. 1250.
 — vasa aberrantia, of arm, 531.
 brevia, 556.
 — vertebral, 507.
 — vesical, inferior, 573.
 superior, 572.
 — vesico-prostatic, 573.
 — vestibular, 951.
 — vidian, 488.
 Arthrodia, 182.
 Articular cartilage, cxxvi.
 Articulations, atlo-axoid, 191.
 acromio-clavicular, 203.
 astragalo-calcaneal, 232.
 scaphoid, 235.
 of axis and atlas, 191.
 calcaneo-cuboid, 233.
 scaphoid, 234.
 carpal, 213.
 carpo-metacarpal, 214.
 costal, 198.
 costo-clavicular, 203.
 cranio-vertebral, 193.
 femoro-tibial, 224.
 foot, 232.
 by gomphosis, 968.
 hand, 213, 214.
 humero-cubital, 206.
 immovable, 180.
 in general, 179.
 of larynx, 1166.
 lower limb, 222.
 mixed, 180.
 movable, 181.
 movements of, 182.
 of pelvis, 217.
 peroneo-tibial, 229.
 pubic, 220.
 radio-cubital, upper, mid-
 dle, and lower, 209, 210.
 carpal, 211.
 of ribs, 198.
 sacro-iliac, 218.
 sacro-vertebral, 217.
 scapulo-humeral, 204.
 sterno-clavicular, 201.
 tarsal, 232-236.
 tarso-metacarpal, 237.
 temporo-maxillary, 195.
 of tympanic bones, 938.
 upper limb, 201.
 of vertebral column, 186.
 Arytenoid cartilages, 1162.
 Aspera arteria, 1134.
 Assimilation, xxxiii.
 Atlas, 10. 24.
 Atrabiliary capsules, 1198.
 Atrium cordis, left, 1112.
 right, 1105.
 Auditory canal, external, 929.
 meatus, external and internal,
 43.
 Auricle of ear, 925.
 muscles of, 244. 927.
 Auricles of heart, *see* Heart.
 Auriculæ, of heart, 1105. 1113.
 Auricular appendices, 1105. 1113.
 Auriculo-ventricular orifices, 1108, 1109.
 1113. 1115.
 size of, 1125.
 rings, 1117.

- Auriculo-ventricular valves, 1109. 1115.
 Axilla, 522.
 Axis, 11. 25.
 — cerebro-spinal, 667. 726. 758.
 — cœliac, 552.
 — thyroid, 512.
 — of nerve fibre, xcii-ii.
 Basement membrane, mucous, cclxxviii.
 — serous, cclxxi.
 — of skin, cclxxxv.
 Basilar bone, 32.
 Basis of cerebral peduncle, 737.
 Bicuspid teeth, 970.
 Bile, 1073.
 Bile-duct, common, 1075.
 — ducts, in general, 1073.
 Bladder, urinary, 1203. 1212.
 — base of, 1204. 1206.
 — in female 1206.
 — coats of, cellular, 1211.
 — mucous, 1211.
 — muscular, 1209.
 — serous, 1209.
 — detrusor, muscle of, 1210.
 — development of, 1273.
 — female, peculiarities of, 1206, 1207.
 — fundus of, inferior, 1204. 1206.
 — superior, 1204, 1205.
 — interior of, 1208.
 — ligaments of, false, 1205. 1208.
 — true, 1205. 1207.
 — neck or cervix, 1204. 1207. 1279.
 — sacculated and fasciculated, 1211.
 — sphincter muscle of, 1210.
 — structure of, 1209.
 — trigone of, 1209.
 — uvula of, 1209.
 — vessels and nerves of, 1211.
 Blastema, xliii.
 — changes in, lx.
 Blood, lxv. lxxxiv.
 — arterial and venous, lxxxiii.
 — chemical composition of, lxxv.
 — coagulation of, lxxii.
 — colouring principles of, lxxx.
 — corpuscles, pale, lxx.
 — red, lxv. xc.
 — course of, ccxxxix.
 — physical properties of, lxv.
 — portal, lxxxiv.
 — table of composition of, lxxxii.
 Bloodvessels, General Anatomy of, ccxxxix.
 — arterial, *see* Arteries, cxcli.
 — capillary, *see* Capillaries, cclii.
 — development of, cclvii.
 — venous, *see* Veins, ccxlix.
 Bone, General Anatomy of, cxxxii.
 — Bone, canaliculi of, cxli.
 — canals of, cxxxvii.
 — cavities of, cxxxiv.
 — chemical composition, cxxxiv.
 — classes of, cxxxiii.
 — compact or cancellated, cxxxvi.
 — diploe of, cxxxvii.
 — eminences of, cxxxiii.
 — formation and growth of, cxlvii.
 — lacunæ or corpuscles, cxl. clviii.
 — lamellæ of, cxxxix.
 — madder, influence of, on, clxi.
 — medulla of, cxliv.
 — processes of, cxxxiii.
 — structure, cxxxvi.
 — vessels of, cxlv.
 BONES, Descriptive Anatomy of, l.
 — astragalus, 168.
 — atlas, 10. 24.
 — axis, 11. 25.
 — calcaneum, or os calcis, 167.
 — carpal, 129. 137.
 — clavicle, 115.
 — coccyx, 17. 28.
 — coronal, 36.
 — costal, 105.
 — cuboid, 169.
 — cuneiform, of carpus, 130.
 — tarsus, three in number, 170.
 — dentate, 11.
 — ethmoid, 55.
 — femur, 155.
 — fibula, 164.
 — frontal, 36.
 — humerus, 117.
 — hyoid, 76.
 — ilium, 141.
 — incus, 937.
 — innominate, 140.
 — ischium, 145.
 — lachrymal, 68.
 — lenticular, 937.
 — lingual, 76.
 — magnum, 132.
 — malar, 66.
 — malleus, 936.
 — maxillary, superior, 61.
 — inferior, 72.
 — metacarpal, 133. 138.
 — metatarsal, 171. 178.
 — nasal, 67.
 — navicular, of carpus, 129.
 — tarsus, 170.
 — number of, 2.
 — occipital, 30.
 — of hand, 129.
 — wrist, 129.
 — fingers, 135. 139.
 — heart, 1117.
 — limb, upper, 109.
 — lower, 155.

- Bones of foot, 167. 175.
 ———— ancle, 167, 176.
 ———— toes, 173. 178.
 ———— skull, 29.
 ———— thorax, 100.
 ———— ear, 935.
 ———— orbicular, 937.
 ———— palate, 68.
 ———— parietal, 35.
 ———— patella, 160.
 ———— pelvic, 149.
 ———— phalangeal, of hand, 135. 139.
 ———— ———— foot, 173. 178.
 ———— pisiform, 130.
 ———— pubic, 143.
 ———— radius, 122.
 ———— ribs, 105.
 ———— ———— true and false, 105.
 ———— ———— peculiarities of some, 107.
 ———— sacrum, 13. 27.
 ———— scaphoid of carpus, 129.
 ———— ———— tarsus, 170.
 ———— scapula, 109.
 ———— semi-lunar, 130.
 ———— sesamoid, in hand, and in
 ———— ———— foot, 174.
 ———— spongy, 49. 58. 71. 91.
 ———— sphenoid, 47.
 ———— stapes, 937.
 ———— sternum, 100.
 ———— tarsal, 167. 176.
 ———— temporal, 40.
 ———— tibia, 160.
 ———— trapezium, 131.
 ———— trapezoid, 132.
 ———— triquetral, 32. 60.
 ———— turbinate, superior, 58.
 ———— ———— inferior, 71.
 ———— tympanic, 45.
 ———— ulna, 125.
 ———— unciform, 132.
 ———— ungual, 68.
 ———— vertebra, dentata, 11.
 ———— ———— prominens, 12.
 ———— vertebrae, 3.
 ———— ———— cervical, 6. 9.
 ———— ———— dorsal, 7. 12.
 ———— ———— lumbar, 8. 13.
 ———— ———— cranial 93.
 ———— ———— Wormian, 32. 60.
 ———— ———— vomer, 71.
- Brain, 667.
 ———— weight of, 668, &c.
 ———— and spinal cord, 667.
 ———— ———— development of,
 ———— ———— 758.
 ———— ———— internal struc-
 ———— ———— ture, 726.
 ———— ———— membranes of,
 ———— ———— 751.
 ———— ———— vessels of, 758.
- Bronchi, right and left, 1135.
- Bronchi, structure of, 1139.
 Bronchia, 1149.
 ———— structure of, 1150.
 ———— subdivisions of, 1151.
 Bronchial tubes, *see* Bronchia.
 ———— vessels, 1154. (*See* Arteries
 ———— and Veins.)
- Bulb of urethra, 1223.
 Bulbs of corpora cavernosa, 1219.
 ———— fornix, 699.
 ———— vestibule, 1256.
- Bulbous portion of urethra, 1228.
 Bulbus arteriosus, 1126.
 Bursæ mucosæ, or synovial, cclxxiv.
 Cæcum, 1044. *See* Intestine, large.
 Calamus scriptorius, 687. 724.
 Calcar avis, 710.
 Calices of kidney, 1192. 1201.
 Canal, alimentary, 965.
 ———— abdominal portion,
 ———— ———— 1018.
 ———— auditory, external, 929.
 ———— of Bichat, 717.
 ———— carotid, 43.
 ———— central of modiolus, 946.
 ———— for chorda tympani nerve, 42.
 ———— ———— 932.
 ———— of cochlea, 946.
 ———— crural, 1308.
 ———— dental, 73.
 ———— of epididymis, 1245.
 ———— femoral, 1308.
 ———— of Fontana, 913.
 ———— godronné, 922.
 ———— of Huguier, 932.
 ———— hyaloid, 922.
 ———— infra-orbital, 63.
 ———— inguinal, 1292.
 ———— lacrymal, 62. 68. 88.
 ———— nasal, 91.
 ———— of Nuck, 1238. 1278.
 ———— palatine, anterior, 63.
 ———— ———— posterior, 62. 69.
 ———— of Petit, 922.
 ———— pterygoid, 52.
 ———— pterygo-palatine, 48. 70.
 ———— spiral, of cochlea, 946.
 ———— ———— modiolus, 947.
 ———— tympanic, 933.
 ———— vertebral, 20.
 ———— vidian, 52.
 ———— of Wirsung, 1082.
- Canaliculi of bone, cxli.
 Canals of Havers, (bone,) cxxxvii.
 ———— lacrymal, 906.
 ———— semicircular, of ear, 944.
- Canine teeth, 969.
 Cancelli of bone, cxxxvii.
 Canthi of eyelids, 904.
 Capillaries, general anatomy of, cclii.
 ———— contractility of, cclvi.
 ———— development of, cclviii.

- Capillaries, network of, ccliii.
 ——— peculiarities of, ccliv.
 ——— structure of, ccliv.
 ——— vital properties of, cclvi.
 ——— of particular organs, *see*
 those organs.
- Capitula laryngis, Santorini, 1163.
- Capsule of lens, 923.
 ——— Glisson, 1068.
- Capsules, supra-renal, 1198.
 ——— development of, 1272.
 ——— synovial, cclxxiii.
- Caput cæcum coli, 1044.
 ——— gallinaginis, 1226.
- Carpus, 129. 137.
 ——— articulations of, 213.
- CARTILAGE, general anatomy of, cxxiv.
- articular, cxxvi.
 ——— costal, cxxviii. 108.
 ——— of epiglottis, cxxviii. 1163.
 ——— formation of, xl.
 ——— fibro-, cxxxi.
 — interarticular, cxxxi.
 — temporary, cli.
 — varieties of, cxxv.
 — yellow, cxxviii.
 — cricoid, 1161.
 — cuneiform, 1163.
 — of ear, 927.
 — ensiform, 102.
- interarticular fibro-carpal,
 213.
 — sacro-coccy-
 gean, 218.
 — interverte-
 bral, 187.
 — pubic, 221.
 — fibro-, lower
 jaw, 197.
 — sterno-clavi-
 cular, 202.
 — acromio-cla-
 vicular, 203.
 — radio-ulnar,
 210.
 — of knee, 227.
- thyroid, 1159.
 ——— xiphoid, 102.
- Cartilages, arytenoid, 1162.
 ——— of bronchi, 1139.
 ——— bronchia, 1150.
 ——— larynx, 1159. 1164.
 ——— ossification of, 1178.
 ——— structure of, 1164.
 ——— nose, 956.
 ——— semilunar of knee, 227.
 ——— sesamoid, of nose, 957.
 ——— tarsal of eyelids, 904.
 ——— of trachea, 1136.
 ——— Santorini, 1163.
 ——— Wrisberg, 1163.
- Cartilago triticea, 1165.
- Caruncula lacrymalis, 906.
- Carunculæ myrtiformes, 1255.
- Casein, xxviii.
- Cauda equina, 674. 819.
- Cavernous plexus, 885.
 ——— sinus, 637.
 — nerves in, 770.
- Cavities of bones, cxxviii.
 ——— of reserve (teeth), 991.
 — posterior, 994.
- Cavity, glenoid, 112.
- Cell-germ, xlii.
 ——— nature of, lii.
- Cells, alterations, substance and con-
 tents of, liv.
- complex, xlix.
 ——— division of into fibres, lvi.
 ——— epidermoid, cclxxxiii.
 ——— formation of, xlv.
 ——— hepatic, xcix. 1072.
 ——— multiplication by sprouting, li.
 ——— of nervous substance, *see* Nerve
 Cells.
- origin and multiplication of, xliii.
 ——— origin of, from nucleus, xlvi.
 ——— origin of, without nuclei, li.
 ——— pigment, liv. cvi. cclxxxiv.
 ——— reduplication of, xlvii.
 ——— secreting, cxcix.
 ——— structure of, xlii.
 ——— transformation of, liii.
 ——— vegetable, xxxviii.
 ——— of bones, *see* Sinuses.
- Cellular tissue, cxiii.
 ——— varieties of, cxiii.
 ——— filaments of, cxv.
 ——— yellow fibres of, cxv.
- Cement of teeth, 980.
 ——— development of, 989.
- Centres of ossification, clxii.
- Centrum geminum semi-circulare, 715.
 ——— ovale, 703.
 — minus, 702.
- Cerebellum, 681. 720.
 ——— crura of, 720.
 ——— fissures of, 722.
 ——— general anatomy of, cciii.
 ——— internal structure of, 735.
 ——— lobes of, 722.
 ——— peduncles of, 720. 735.
 ——— sections of, 725.
 ——— ventricle of, 723.
 ——— weight of, 672.
- Cerebral convolutions, 690. 692.
 ——— classification of,
 695, 696.
 — ventricles, 682. 702.
- Cerebric acid, xxxii.
- Cerebro-spinal axis or centre, 667.
 ——— internal structure of,
 726.
 ——— development of, 758.

- Cerebro-spinal axis, general anatomy of, cxcix.
 ————— fluid, 755-6.
- Cerebrum, 680. 690.
 ————— base, 697.
 ————— convolutions of, 692.
 ————— general anatomy of, cciii.
 ————— crura of, 697.
 ————— fibres, 736.
 ————— ascending or peduncular, 736.
 ————— transverse or commissural, 740.
 ————— longitudinal or collateral, 740.
 ————— Foville's views, 743.
 ————— fissure, transverse, 711.
 ————— longitudinal, 690.
 ————— hemispheres, 690.
 ————— internal parts of, 701.
 ————— internal structure of, 736.
 ————— lobes, 691.
 ————— peduncles of, 697.
 ————— sections of, 702.
 ————— under surface, 691.
 ————— upper surface, 690.
 ————— weight of, 672.
- Cerumen and its glands, 930.
- Cervix uteri, 1260.
 ————— vesicæ, 1207.
- Chambers of eye, 920.
- Cheeks, 966.
- Chemical nature of adipose tissue, xxxi.
 cx.
 ————— bile, 1073.
 ————— blood, lxxv.
 ————— bone, cxxiv.
 ————— cartilage, cxxix.
 ————— cellular tissue, cxvii.
 ————— cuticle, cclxxxiv.
 ————— cutis or corium, cclxxxviii.
 ————— elastic tissue, cxxiv.
 ————— fibro-cartilage, cxxxii.
 ————— fibrous tissue, cxx.
 ————— hairs, ccxciii.
 ————— mucus, cclxxxii.
 ————— muscular tissue, clxxiv.
 ————— nervous substance, clxxxviii.
 ————— pigment, cvii.
 ————— textures, xxiii.
 ————— urine,
- Chiasma or optic commissure, 747.
- Chondrin, xxix.
- Chordæ tendineæ of right ventricle, 1109, 1110.
 ————— of left ventricle, 1115.
 ————— vocales, 11 8.
 ————— Willisii, 636.
- Choroid plexuses, 707. 713.
 ————— of fourth ventricle, 725.
 ————— third ventricle, 713.
 ————— tunic of eye, 911.
- Chyle, lxxxviii.
 ————— corpuscles, lxxxviii.
 ————— plasma of, lxxxviii.
 ————— globules, formation of, xc.
- Chyliferous vessels, 651.
- Ciliary arteries, *see* Arteries.
 ————— body, 913.
 ————— ganglion, 778.
 ————— ligament, 913.
 ————— nerves, long, 777.
 ————— short, 779.
 ————— processes, 913. 921.
 ————— zone, 914. 921.
- Cilia, or eyelashes, 905.
 ————— vibratile, c. cii.
- Ciliary motion, ciii. civ.
- Ciliated epithelium, cxcix.
- Circle of Willis, 495.
- Circulation of blood, ccxl.
- Circulus articuli vasculosus, cclxxxiii.
 ————— iridis, 916.
 ————— tonsillaris, 804.
 ————— venosus of nipple, 1282.
- Clastrum, 739.
- Clitoris, 1253.
 ————— development of, 1279.
 ————— erector muscles of, 1253.
- Coagulation of blood, lxxii.
- Coccyx, 17. 28.
- Cochlea, 945.
 ————— aqueduct of, 45. 947.
 ————— membranous structure of, 950.
 ————— nerves of, 953. 955.
 ————— scalæ of, 947.
 ————— vessels of, 951.
- Colliculus bulbi urethræ, 1224.
 ————— (retina), 918.
- Colon, 1047. *See* Intestine, large.
- Columella cochleæ, 946.
- Columnæ carneæ, left ventricle, 1114.
 ————— right ventricle, 1109.
 ————— rugarum, 1257.
- Commissure optic, 700. 747.
 ————— of cerebrum, anterior, 715.
 ————— 740.
 ————— middle or soft, 715.
 ————— posterior, 716.
 740.
- Commissures of spinal cord, 678.
- Conarium, 717.
- Concha, external ear, 925.
- Condyles of bones, *see* the Bones.
- Conglobate glands, cclxiv.
- Conglomerate glands, ccciv.
- Coni gemini, (retina,) 918.
 ————— vasculosi, 1245.
- Conjoined tendons, 359. 1289.

- Conjunctiva, 908.
 Contractility, vital, xxxiv.
 _____ muscular, clxxvii.
 _____ non-muscular,
 xxxv. clxxxv.
 _____ of arteries, cclxvii.
 _____ capillaries, cclvi.
 _____ skin, ccxcvi.
 _____ veins, ccli.
 Conus arteriosus, 1108.
 Convolutions, cerebral, 690. 692.
 _____ classification of,
 695, 696.
 _____ intestinal, 1040.
 Corium, cclxxxiv. *See* Skin.
 _____ of mucous membrane, cclxxviii.
 Cornea, elastica, 911.
 _____ opaca, 910.
 _____ pellucida, 910.
 Cornicula laryngis, 1163.
 Cornu Ammonis, 710.
 Cornua of ventricles, 706.
 Corona glandis, 1217.
 _____ radiata, 738.
 Corpora, albicantia, 699. 741.
 _____ Arantii, 1111, 1116.
 _____ cavernosa of penis, 1218.
 _____ structure of, 1219.
 _____ helicine arteries of
 1222.
 _____ of clitoris, 1253.
 _____ mammillaria, 699. 741.
 _____ olivaria, 685. 731.
 _____ pyramidalia, 684. 687. 729.
 _____ quadrigemina, 718. ccv.
 _____ restiformia, 685. 729. 735.
 _____ striata, 707. 714. 738. ccv.
 _____ Wolffiana, 1270.
 Corpus callosum, peduncles of, 701.
 _____ 705.
 _____ ventricles of, 702.
 _____ fibres of, 740.
 _____ callosum, 690. 703. 740.
 _____ ciliare, 913.
 _____ dentatum of olivary body, 685,
 731.
 _____ cerebelli, 725.
 _____ fimbriatum, 707. 711.
 _____ geniculatum externum, 719.
 _____ internum, 719.
 _____ Highmorianum, 1242.
 _____ luteum, 1268.
 _____ psaloides, 710.
 _____ spongiosum urethræ, 1223.
 _____ structure of, 1224.
 _____ vitreum, 921.
 Corpuscles of blood, formation of, xc.
 _____ bone, cxl.
 _____ chyle, formation of, lxxxix.
 _____ hepatic, 1072.
 _____ lymph, formation of,
 lxxxix.
 Corpuscles, Malpighian, of kidney, 1191.
 _____ 1195.
 _____ of nervous substance, *see*
 Nerve-cells.
 _____ splenic, 1088.
 _____ of suprarenal bodies, 1200.
 _____ of thymus, 1184.
 _____ of thyroid, 1180.
 Cortical substance of kidney, 1190-1.
 Cotyloid cavity and notch, 147-8.
 _____ ligament, 223.
 Cowper's glands, 1229.
 _____ development of, 1280.
 Cranial nerves, classification of, 767.
 _____ roots of, 745-750.
 _____ first pair (*r*) 745, (*br*)
 768. 963.
 _____ second pair (*r*) 746, (*c*)
 769. 917.
 _____ third pair (*r*) 747, (*c*)
 769, (*br*) 770.
 _____ fourth pair (*r*) 747, (*c*)
 771.
 _____ fifth pair (*r*) 748, (*c*)
 772, (*br*) 774-791.
 _____ its three divisions,
 774.
 _____ sixth pair (*r*) 749, (*c*)
 794.
 _____ seventh pair (*r*) 749 (*c*)
 794, (*br*) 795-800.
 _____ its two portions,
 794.
 _____ eighth, first part (*r*) 733,
 750 (*c*) 801, (*br*) 802.
 _____ second part (*r*)
 733. 750. (*c*)
 805. (*br*) 808.
 _____ third part (*r*) 732,
 750, (*c*) 812,
 (*br*) 813.
 _____ ninth pair, (*r*) 732. 750.
 (*c*) 813. (*br*) 815.
 Cranium. (*See* Skull.)
 _____ size of, to face, 98.
 Crassamentum, lxxv.
 Cremaster muscle, 1235.
 _____ formation of, 1277, 1278.
 Cremasteric fascia, 1235.
 Crest of urethra, 1226.
 Cribriform fascia, 447. 1304.
 _____ lamina of ethmoid bone, 56.
 _____ sclerotic, 910.
 _____ temporal bone, 44.
 Cricoid cartilage, 1161.
 Crista galli, 55.
 _____ ilii, 141.
 _____ pubis, 144.
 _____ urethræ, 1226.
 _____ vestibuli, 944.
 Cruor, lxxvii.
 Crura cerebri, 697. 736.

- Crura cerebelli, 720. 735.
 — of clitoris, 1253.
 — penis, 1218.
 — fornix, 709.
 — diaphragm, 367.
 Crural arch, 1303.
 — deep, 1307.
 — canal, 1308.
 — septum, 1308.
 Crust of cerebral peduncle, 737.
 Crusta petrosa, 980.
 — development, 989.
 Crypt, ccii.
 — multilocular, cciii.
 Crypts, of Lieberkuehn, 1034.
 — large intestine, 1043.
 Crystalline, 923.
 Cul-de-sac, of pleura, 1140.
 — recto-uterine, 1049.
 — recto-vesical, 1049. 1206.
 — of stomach, 1020.
 Cupola, 946.
 Cuspidate teeth, 969.
 Cuticle, cclxxxiii.
 Cutis auserina, ccxcvi.
 — vera, cclxxxiv. (*See Skin.*)
 Cystic duct, 1075.
 Cystis fellea, 1073.
 Cytoblast, xlii.
 Cytoblastema, xliii.
 Dartos, 1234.
 — its fibres, clxxiii.
 Decussation of pyramids, 684.
 Dens sapientiæ, 971.
 Dental arches, 967. 972.
 — glands (Serres), 991.
 — grooves, 983.
 — papillæ, 983.
 — periosteum, 968.
 — pulps, 974. 981. 985.
 — sacs, permanent, 992.
 — temporary, 984.
 — tubuli, 976.
 Denticulate ligaments, 757.
 Dentine, 974
 — development of, 985, 986.
 — secondary, 981.
 Derma, cclxxxiv. (*See Skin.*)
 Descent of testicle, 1238. 1277.
 Development of adipose tissue, cxii.
 — alimentary canal, 1055.
 — anal orifice, 1057. 1280.
 — bladder, 1273.
 — blood corpuscles, xc.
 — bone, cxlvii.—clxii.
 — brain and spinal cord,
 758-9.
 — cartilage, cxxx.
 — cellular tissue, cxviii.
 — clitoris, 1279-80.
 — cremaster muscle, 1277
 1278.
 — Development of epithelium, xc. xcvi.
 — Fallopian tubes, 1276.
 — fibro-cartilage, cxxxii.
 — fibrous tissue, cxxi.
 — generative organs, 1274.
 — external,
 1279.
 — gall-bladder, 1076.
 — great vessels, 1127.
 — grey and white nervous
 substance, 766.
 — heart, 1125.
 — hair, cxccii.
 — hymen, 1280.
 — intestine, large and
 small, 1056.
 — kidneys, 1271.
 — larynx, 1177.
 — liver, 1077.
 — lungs, 1156.
 — lymph and chyle, lxxxix.
 — membranes of encephalon,
 766.
 — mesentery, 1055.
 — muscular tissue, clxxv.
 — neck of male bladder,
 1279.
 — nerves, ccxxxvi.
 — œsophagus, 1056.
 — ovaries, 1274.
 — pancreas, 1083.
 — penis, 1279-80.
 — perinæum, 1279.
 — pigment cells, cviii.
 — prostate, 1279.
 — prostatic part of urethra,
 1279.
 — salivary glands, 1011.
 — scrotum, 1280.
 — spleen, 1089.
 — stomach, 1056.
 — suprarenal capsule,
 1272.
 — teeth, 981.
 — enamel, 988.
 — dentine, 985-6.
 — cement, 989.
 — textures, animal, xlxviii.
 — vegetable, xxxvii.
 — testes, 1274.
 — thymus, 1185.
 — thyroid body, 1181.
 — trachea, 1157.
 — tunica vaginalis, 1238.
 1277.
 — ureters, 1271.
 — urethra of female, 1278
 — urinary organs, 1270.
 — uterus, 1278.
 — vagina, 1278.
 — vasa deferentia, 1276.
 — vulva, 1279.

- Diaphragm, 366.
 — its foramina, 368.
- Diaphysis, cxxxiii.
- Diploe, cxxxvii.
- Diarthrosis, 181.
- DISSECTION of muscles of abdominal
 ————— parietes, 354. 359.
 ————— arm, 314.
 ————— auricular region,
 ————— 244.
 ————— back, 290. 296. 301.
 ————— 307.
 ————— face, 245.
 ————— foot, 411. 413.
 ————— fore-arm, 330.
 ————— gluteal region, 374.
 ————— hand, 346.
 ————— head, 240.
 ————— leg, 396. 402. 406.
 ————— lumbar fascia, 362.
 ————— neck, 265.
 ————— orbit, 262.
 ————— palate, 287.
 ————— pharynx, 282.
 ————— soft palate, 287.
 ————— temporo-maxillary
 ————— region, 256.
 ————— thigh, anterior, 382.
 ————— ————— internal, 389.
 ————— ————— posterior, 393.
- Dissector, directions to the, 240. 419.
- Duct, aberrant, of liver, 1073.
 — of Bartholine, 1010.
 — bile, common, 1075.
 — biliary or hepatic, 1064, (o) 1069,
 — (c) 1073.
 — ————— origins of, 1071.
 — cystic, 1075.
 — ejaculatory, 1249.
 — nasal, 907.
 — pancreatic, 1082.
 — parotid, 1008.
 — Stenonian, 1008.
 — thoracic, 651. 653.
 — ————— right, 651. 654.
- Duct, Whartonian, 1009.
- Ducts of glands, in general, cccvi.
 — Bellini, 1193.
 — galactophorous, 1282.
 — of kidney, 1192.
- Ductus ad nasum, 908.
 — arteriosus, 1128. 1130.
 — ————— closure of, 1133.
 — communis choledochus, 1075.
 — venosus, 1078. 1131.
 — ————— closure of, 1133.
 — ————— fossa of, 1063.
- Ductus Riviniani, 1010.
- Duodenum, 1038, *see* Small Intestine.
- Dura mater, 751.
- Ear, 925.
 — external, 925.
- Ear, external, cartilage of, 927.
 — ————— ligaments of, 927.
 — ————— muscles, extrinsic, 244.
 — ————— ————— intrinsic, 927.
 — ————— internal, or labyrinth, 942. (*See*
 ————— Labyrinth).
 — ————— nerves of, 952. cccxiii.
 — ————— meatus of, external, 43, 929.
 — ————— ————— internal, 43.
 — ————— middle, or tympanum (*see* Tym-
 ————— panum), 931.
 — ————— ossicula of, 935.
- Ejaculatory ducts, 1249.
- Elastic fibres of cellular tissue, cxv.
 — ————— tissue, cxxii.
- Eminences of bones, cxxxiii.
- Eminentia collateralis, 708. 710.
- papillaris (tympanum), 934.
- Enamel-membrane, 989.
- Enamel, of teeth, 978.
 — ————— development of, 988.
 — ————— pulp, 988.
- Enarthrosis, 182.
- Encephalon, blood-vessels of, 759.
 — ————— development of, 759, 760.
 — ————— internal structure of, 729
 — ————— —745.
 — ————— grey matter of, ccii. 744.
 — ————— membranes of, 751.
 — ————— primary divisions of, 680.
 — ————— weight of, 668.
- Endocardium, 1116.
- Endo-lymph, 949, 950.
- Endosmosis, xxii.
- Endosteum, cxliv.
- Epidermis, xcii. cclxxxiii.
- Epididymis, 1241.
 — ————— canal of, 1245.
 — ————— lobes of, 1246.
- Epiglottis, cxxviii. 1163.
- Epiphyses, clx. cxxxiii.
- Epiploon, great, 1091.
 — ————— small, 1092.
- Epithelium, in general, xcii.
 — ————— of air-cells, 1153.
 — ————— arachnoid, 756.
 — ————— arteries, ccxlv.
 — ————— bladder, 1211.
 — ————— bronchi, 1139.
 — ————— bronchia, 1150.
 — ————— capsules of Malpighian
 — ————— bodies, 1197.
 — ————— ciliated, xcix.
 — ————— columnar, xcvi.
 — ————— of conjunctiva, xcvi.
 — ————— cornea, cclxxix.
 — ————— ducts of glands, cccvii.
 — ————— Eustachian tube, 941.
 — ————— Fallopian tube, external,
 — ————— 1269.
 — ————— ————— internal,
 — ————— 1269.

- Epithelium of gall bladder, xcvi. 1075.
 — large intestine, 1044.
 — larynx, 1176.
 — lymphatics, cclxiii.
 — mouth, 1005.
 — mucous membranes, xcii. cclxxviii.
 — nasal fossæ, 960.
 — sinuses, 960.
 — nose, 960.
 — œsophagus, 1013.
 — pericardium, xciv.
 — peritoneum, xciv. 1090.
 — pharynx, 1013.
 — pleura, xciv.
 — prostatic ducts, 1216.
 — scaly or squamous, xciv.
 — of seminiferous tubes, 1244.
 — serous membranes, xciv. cclxxi.
 — small blood-vessels, cclvi.
 — small intestine, xcvi. 1031. 1034.
 — spheroidal, xcix.
 — of stomach, 1027.
 — stratified, xciv.
 — of synovial membranes, cxxvii. cclxxiii.
 — tongue, 1000.
 — trachea, 1138.
 — transitional, xcix.
 — of tubuli uriniferi, 1194. seminiferi, 1244.
 — tunica vaginalis testis, 1239.
 — tympanum, 941.
 — ureters, 1202.
 — urethra, 1213.
 — uriniferous tubes, 1194.
 — uterus, 1263.
 — vagina, 1258.
 — vas deferens, 1247.
 — veins, ccl.
 — velum palati, 1005.
 — ventricles of brain, 705.
 — vesiculæ seminales, 1249.
 — vulva, 1255.
- Epicondyle, 120.
 Epitrochlea, 120.
 Erectile tissue, general characters of, cclvii.
 — of penis, 1220. 1224.
 — vulva, 1255.
- Ergot, 708. 710.
 Eustachian tube, 45. 934.
 Excretion, ccxvii.
 Exosmosis, xxii.
 Extractive matters, xxix.
 Eye, 903.
 — appendages of, 903.
 — ball or globe of, 909.
 — brows, 903.
- Eye, chambers of, 920.
 — coats of, 909.
 — humours of, 909.
 — aqueous, 920.
 — crystalline, 923.
 — vitreous, 921.
 — lashes, 905.
 — lens of, 923.
 — lids, 903.
 — cartilages of, 904.
 — glands of, 905.
 — mucous membrane, conjunctival, 908.
 — membranes, 909.
 — of aqueous humour, 911. 920.
 — capsule of lens, 923.
 — choroid, 911.
 — cornea, 910.
 — hyaloid, 921.
 — iris, 914.
 — Jacob's, 918.
 — pigment, cvi. 912.
 — pupillary, 917.
 — retina, 917.
 — Ruysch's, 912.
 — sclerotic, 910.
 — vitreous humour, 921.
 — muscles of, 261.
 — nerve of (optic), ccxxiii. 746. 769. 917.
 — pigment, cvi. 912.
 — teeth, 970.
- Face, bones of, 61.
 Facial angle, 98.
 Falciform process, 1305.
 Fallopian tubes, 1268.
 — development of, 1276.
 — fimbriæ of, 1268.
 — orifices of, 1269.
- Falx cerebri, 752.
 — cerebelli, 753.
- FASCIA, cxix. 425.
 Fascia abdominal, 355. 357. 360. 438.
 — of biceps of arm, 435.
 — brachial, 434.
 — cervical, deep, 429.
 — superficial, 428.
 — costo-coracoid, 433.
 — cremasteric, 1235.
 — cribriform, 447. 1304.
 — dentata, 711.
 — dorsal, of foot, 452.
 — of fore-arm, 435.
 — of hand, 437.
 — of head and neck, 428.
 — iliac, 441. 1307.
 — infundibuliform, 1237.
 — intercolumnar, 356. 1235. 1287.
 — intercostal, 433.
 — inter-muscular, 426.
 — inter-muscular of arm, 434.
 — thigh, 449.

- Fascia inter-muscular of foot, 453.
 — lata, 382. 447.]
 — muscles of, 383. 449.
 — of leg, 450.
 — of upper limb, 433.
 — of lower limb, 446.
 — lumborum, 362. 442.
 — of mammary gland, 1281.
 — obturator, 445.
 — palmar, 437.
 — parotid, 429.
 — pelvic, 444.
 — perineal, deep, 443. 1315.
 — — superficial, 442. 1314.
 — plantar, 411. 452.
 — prevertebral, 431.
 — propria, femoral, 1310.
 — — inguinal, 1237.
 — recto-vesical, 445.
 — spermatic, 1235. 1287.
 — superficial, 427.
 — — abdominal, 438.
 — — perineal, 442.
 — — of groin, 447. 1285.
 — temporal, 259. 429.
 — of thorax, 432.
 — transversalis, 439. 1291. 1307.
 — vesical, 445.
 Fasciculi graciles, 687. 729.
 — teretes, 687. 724. 729.
 — of muscle, clxv.
 — of nerve, ccix.
 Fasciculus cuneatus, 686. 729.
 — unciformis, 691. 742.
 Fasciolæ cinereæ, 724.
 Fat, cviii.
 — cells, cx.
 — uses of, cxi.
 Fatty matters, xxxi.
 — saponifiable, xxxi.
 — unsaponifiable, xxxii.
 Fauces, 966. 1005.
 Femoral arch, 1303.
 — deep, 1307.
 — canal, 1308.
 — herniæ, *see* Hernia.
 — ring, 1308.
 — sheath, 1305.
 Fenestra ovalis, 933.
 — rotunda, 934.
 Fenestrated membrane, ccxlv.
 — of hair follicle, ccxci.
 Fibræ arciformes, 688. 734.
 — transversæ, 734.
 Fibrin, xxvi.
 Fibro-cartilages, cxxxii.
 Fibro-serous membranes, cclxx.
 Fibrous tissue, cxviii.
 Fibrous cone, 739.
 Filamentous tissue, cxiii.
 Fillet, 738.
 Fillet of corpus callosum, 741.
 Fimbriæ of Fallopiian tube, 1268.
 Fissure of cerebellum, 722.
 — Glaserian, 42. 84. 932.
 — longitudinal of cerebrum, 690.
 — pterygo-maxillary, 85.
 — sphenoidal, 51.
 — spheno-maxillary, 85.
 — Sylvian, 691.
 — transverse of cerebrum, 711.
 — of Santorini, 930.
 Flocculus, 722.
 Fœtus, circulation in, 1131.
 — peculiarities of heart in, 1128.
 — — liver in, 1077.
 — — lungs in, 1157.
 Folds, aryteno-epiglottidean, 1167.
 — recto-uterine, 1263.
 — vesical, 1208.
 — vesico-uterine, 1263.
 Folia cerebelli, 735.
 Follicle, cccii.
 — of hair, cxcx.
 Follicles, sebaceous, cccxiv.
 Foramen, carotid, 44. 82.
 — centrale (retina), 918.
 — cæcum of frontal bone, 38.
 — — tongue, 999.
 — condyloid, 31. 81. 82.
 — dental, inferior, 73.
 — infra-orbital, 62.
 — intervertebral, 6.
 — lacerum, anterior, 82.
 — — posterior, 81.
 — magnum, 31.
 — mastoid, 42.
 — mental, 72.
 — of Monro, 709. 717.
 — obturator, 147.
 — occipital, 31.
 — optic, 50, 51.
 — ovale (bone), 52. 82.
 — — of heart, 1127. 1129.
 — — 1133.
 — — vestige of, 1107.
 — — 1113.
 — palatine anterior, 63. 81. 962.
 — — posterior, 81.
 — parietal, 35.
 — rotundum, 52.
 — sacro-sciatic, great and small,
 — 220.
 — spheno-palatine, 70. 962.
 — spinosum, 52. 82.
 — of Steno, 63.
 — stylo-mastoid, 44. 82.
 — supra-orbital, 37.
 — thyroideum, 147.
 — of Winslow, 1092. 1096.
 Foramina, Thebesii, 650. 1108.
 — dental, superior, 62.
 — of diaphragm, 368.

- Foramina, malar, 66.
 ——— orbital, anterior and posterior,
 58. 88.
- Foreskin, 1217.
- Fornix, 707, 708.
 ——— bulbs of, 699.
 ——— fibres of, 741.
- Fossa of anti-helix, 928.
 ——— canine, 62.
 ——— cystis felleæ, 1063.
 ——— digastric, 42.
 ——— of ductus venosus, 1063.
 ——— glenoid, 42.
 ——— of helix, 928.
 ——— iliac, 141.
 ——— ischio-rectal, 1320.
 ——— infra and supra-spinous, 111.
 ——— jugular, 44.
 ——— myrtiform, 62.
 ——— navicular, 50.
 ——— navicularis, of urethra, 1228.
 ——— ——— vulva, 1253.
 ——— ovalis, heart, 1107.
 ——— pituitary, 48.
 ——— pterygoid, 50.
 ——— spheno-maxillary, 85.
 ——— subscapular, 109.
 ——— temporal, 84.
 ——— trochanteric, 156.
 ——— zygomatic, 85.
- Fossæ, nasal, 89. 959.
 ——— of peritonæum, 1293.
 ——— of skull, internal, 86.
- Fourchette, 1253.
- Fovea hemi-elliptica, 943.
 ——— hemi-spherica, 943.
- Frænulum pudendi, 1253.
- Frænum linguæ, 998.
 ——— of lips, 966.
 ——— præputii, 1217.
- Fringes, synovial, clxxiii.
- Funiculi of nerve, ccix.
- Furcula of sternum, 102.
- Furrow, auriculo-ventricular, 1103.
 ——— inter-ventricular, 1104.
- Furrowed band, 723.
- Galactophorous ducts, 1282.
- Gall-bladder, 1073.
 ——— development of, 1076.
 ——— varieties of, 1077.
- Ganglia, general anatomy of, ccvi.
 ——— of auditory nerve, ccxvi.
 ——— cardiac, 892, 893.
 ——— cephalic, 880.
 ——— hypogastric, 899.
 ——— inferior maxillary nerve, 792.
 ——— lumbar, 890.
 ——— lymphatic, cclxiv.
 ——— mesaraic, 897.
 ——— of nervi molles, 883.
 ——— renal, 895.
 ——— sacral, 890.
- Ganglia, solar, 894.
 ——— semi lunar, 894.
 ——— of spinal nerves, 818.
 ——— sympathetic nerves, ccvi. 879.
 ——— thoracic, 887.
- Gangliated cords, sympathetic, 879.
 ——— cervical part, 881.
 ——— lumbar part, 889.
 ——— sacral part, 890.
 ——— thoracic part, 887.
- Ganglion, azygos, 890.
 ——— cervical, inferior, 886.
 ——— ——— middle, 885.
 ——— ——— superior, 881.
 ——— diaphragmatic, 894.
 ——— on facial nerve, 795.
 ——— of fifth pair, or Gasserian, 773.
 ——— glosso-pharyngeal, 801.
 ——— impar, 890.
 ——— jugular, 801.
 ——— lenticular, 778.
 ——— Meckel's, 782.
 ——— ophthalmic, 778.
 ——— otic, 792.
 ——— petrous, 802.
 ——— pneumo-gastric, 806. 807.
 ——— of portio dura, 795.
 ——— of Ribes, 884.
 ——— semilunar, 894.
 ——— spheno-palatine, 782.
 ——— submaxillary, 793.
 ——— supra-renal, 895.
 ——— thyroid, 885.
- Ganglion-globules, cxcv.
- Ganglionic corpuscles, cxcv.
- Gastro-pulmonary mucous membrane,
 cclxxvi.
- Gelatin, xxix.
- Gelatinous compounds, xxviii. xxxii.
 ——— nerve-fibres, cxciv.
 ——— nature of, ccxxvii.
- Germinal spot, 1268.
 ——— vesicle, 1268.
- Gums, 967.
- Gimbernat's ligament, 1303.
- Ginglymus, 183.
- Glabella, 37.
- GLANDS, secreting, General Anatomy of,
 ccxcvii.
 ——— acini of, ccxiv.
 ——— cellular tissue of, ccv.
 ——— compound, ccxiii.
 ——— conglomerate, ccxiv.
 ——— crypts, ccxii.
 ——— ducts of, ccevi.
 ——— envelope of, ccxvi.
 ——— forms of, ccxii.
 ——— lacunæ, ccxii.
 ——— lobules of, ccxiii.
 ——— lymphatics of, ccv.
 ——— multilocular crypts, ccxiii.
 ——— nerves of, ccv.

- GLANDS parenchyma of, cccvi.
 ——— peculiar, cccv.
 ——— racemose, ccciii.
 ——— reservoirs of, ccxvi.
 ——— simple, ccxii.
 ——— substance of, ccxv.
 ——— tubular compound, ccxvi.
 ——— ——— simple, ccxii.
 ——— vesicles of, ccxiii.
 ——— vesicular, ccxiii.
 ——— vessels of, ccxv.
- GLAND, or Glands, accessory of parotid, 1007.
 ——— anti-prostatic, 1229.
 ——— agminated, ccxv. 1035.
 ——— arytenoid, 1177.
 ——— of Bartholine, 1255.
 ——— Brunner's, 1037. ccxiv.
 ——— buccal, 967.
 ——— ceruminous, ccxii. 930.
 ——— Cowper's, 1229.
 ——— epiglottic, 1177.
 ——— gastric, tubular, 1026.
 ——— ——— follicular, 1027.
 ——— of Havers, cclxxiii.
 ——— labial, 966.
 ——— lacrymal, 906.
 ——— of large intestine, 1043.
 ——— laryngeal, 1177.
 ——— lingual, 1001.
 ——— liver, 1057. *See* Liver.
 ——— mammary, 1280.
 ——— Meibomian, 905.
 ——— molar, 967.
 ——— of mucous membrane, cclxxxi.
 ——— mucilaginous of Havers, cclxxiii.
 ——— œsophageal, 1016.
 ——— of Pacchioni, 753.
 ——— palatine, 1006.
 ——— pancreas, 1080. *See* Pancreas.
 ——— parotid, 1007.
 ——— of Peyer, 1035.
 ——— pineal, 717. ccv.
 ——— pituitary, 699. ccvi.
 ——— pharyngeal, 1013.
 ——— of prepuce, 1218.
 ——— prostate, 1214.
 ——— ——— anterior, 1229.
 ——— salivary, 1007.
 ——— sebaceous, ccxciv.
 ——— of skin, ccxciv.
 ——— ——— small intestine, 1034-7.
 ——— solitary, ccxv. 1036.
 ——— sublingual, 1010.
 ——— submaxillary, 1009.
 ——— sudoriferous, ccxciv.
 ——— thymus, 1182.
 ——— thyroid, 1178.
 ——— tracheal, 1138.
 ——— of Tyson, 1218.
 ——— uterine, 1263.
 ——— of vulva, 1255.
- GLANDS, Lymphatic, General Anatomy of, cclxiv.
 ——— conglobate, cclxiv.
 ——— Descriptive Anatomy, 651.
 ——— axillary, 664.
 ——— bronchial, 663.
 ——— cervical, 666.
 ——— inguinal, 656.
 ——— lumbar, 660.
 ——— mediastinal, 663.
 ——— mesenteric, 652.
 ——— œsophageal, 663.
 ——— popliteal, 656.
 ——— thoracic, 663.
- Glandula socia parotidis, 1007.
 Glandulæ Pacchioni, 753.
 Glans penis, 1217.
 ——— clitoridis, 1253.
 Glenoid cavity, 112.
 ——— fossa, 42.
 ——— ligament, 205.
 Globulin, lxxv. lxxvi.
 Globus major and minor, 1241.
 Glomeruli of kidney, 1195.
 Glottis, 1167.
 ——— rima of, 1169.
 Glycerine, xxxi.
 Gomphosis, 180. 968.
 Graafian vesicles, 1267.
 ——— development of, 1275.
- Granules, elementary, xlv.
 Groin, anatomy of, 1285.
 Growth, lxi.
 Gubernaculum testis, 1277.
 Gullet, 1013.
 Gyri of brain, 690.
 ——— operi, 691.
 Gyrus fornicatus, 693.
 ——— fibres of, 741.
- Hæmatin, lxxv., lxxvi.
 Hæmatosin, lxxv.
 Hairs, cclxxxix.
 ——— attachment of, ccxci.
 ——— chemical nature of, ccxciii.
 ——— development of, ccxcii.
 ——— distribution of, ccxciii.
 ——— follicles, ccxc.
 ——— growth of, ccxcii.
 ——— medulla, ccxc.
 ——— parts of, cclxxxix.
 ——— reproduction of, ccxciii.
 ——— roots of, ccxc.
 ——— stem of, cclxxxix.
 ——— vessels and nerves of, ccxc.-ccxcii.
- Halitus of blood, lxxii.
 Ham, region of the, 597.
 Hamulus of cochlea, 947.
 ——— sphenoid, 50.
 Harmonia, 180.
 Haversian canals, cxxxvii.
 ——— glands, cclxxiii.

- Heart, 1101–1133.
 — apex of, 1102. 1104.
 — atrium of, right, 1105.
 left, 1112.
 — auricles, in general, 1103.
 — auricle of, left, 1112.
 capacity of, 1125.
 development of, 1125.
 fibres of, 1119.
 walls of, 1124.
 — right, 1105.
 capacity of, 1125.
 development of, 1125.
 fibres of, 1119.
 walls of, 1124.
 — auricula or auricular appendix,
 left, 1113.
 auricular appendix,
 right, 1105.
 — bone of, 1117.
 — cavities of, 1103. 1105.
 size of, 1125.
 — cellular tissue of, 1118.
 — chordæ tendinæ of, left ventricle,
 1115.
 right, 1109,
 1110.
 — columnæ carneæ of, left ventricle,
 1114.
 right, 1109.
 — development of, 1125.
 — double, 1105.
 — fibrous rings of, arterial, 1117.
 auriculo ven-
 tricular, 1117.
 — fibrous structures of, 1117. (*See*
 also Valves.)
 — foetal, 1128.
 — foramina of, *see* Foramen and For-
 amina.
 — fossa ovalis of, 1107.
 — furrow, auriculo-ventricular, 1103.
 inter-ventricular, 1104.
 — muscular fibres of, 1118. 1122.
 auricular, 1119.
 ventricular, 1120.
 — muscoli papillares of, left ven-
 tricle, 1115.
 right — 1109.
 pectinati of, left auricle,
 1113.
 right — 1107.
 — nerves of, 893. 1122.
 — office of, ccxxxix.
 — orifices of, aortic, 1115. 1117.
 auriculo-ventricular,
 left, 1113. 1115.
 right, 1108. 1109.
 pulmonary, 1109. 1117.
 size of, 1125.
 — septum, 1103.
 auricular, 1107.
- Heart, septum, ventricular, 1108.
 — serous coat, external, 1116.
 internal, 1116.
 — sinus venosus of, left, 1112.
 right, 1105.
 — structure of, 1116. 1123.
 — sulci of, 1104.
 — valves of, Eustachian, 1107.
 1127. 1130.
 mitral or bicuspid, 1115.
 Thebesian, 1108.
 — , valves of, tricuspid, 1109.
 — valves, auriculo-ventricular, left,
 1115.
 right, 1109.
 — sigmoid or semilunar,
 left, 1116.
 right, 1109. 1111.
 — ventricles, in general, 1104.
 — ventricle of, left, 1113. 1116.
 capacity of, 1125.
 fibres of, 1120.
 walls of, 1114.
 1124.
 right, 1108. 1112.
 capacity of, 1125.
 fibres of, 1120.
 walls of, 1124.
 — vessels of, 1122.
 — vortex of, 1121.
 — weight of, 1123.
- Hearts, lymphatic, cclxviii.
 Helicine arteries, 1222.
 Helicotrema, 947.
 Helix, 926.
 — muscles of, 928.
 — process of, 927.
- Hemispheres, cerebellar, 721.
 — cerebral, 690.
- Herniæ, abdominal, 1284.
 — anatomy of, femoral, 1303.
 inguinal, 1294.
 — congenital, 1295.
 — coverings of, femoral, 1309.
 inguinal, direct, 1299.
 oblique, 1295.
 — direct or internal, 1297.
 in the female, 1300.
 — femoral, 1309.
 diagnosis, 1310.
 fascia propria of, 1310.
 — infantile, 1296.
 — inguinal, direct and oblique,
 1294.
 diagnosis of, 1301.
 — oblique or external, 1294.
 — in the female, 1297.
 — operations for, inguinal, 1301.
 femoral, 1310.
 — sac of, 1295.
 — scrotal, 1295.
- Hiatus Fallopii, 43.

- Hilus of kidney, 1188.
 — liver, 1062.
 — spleen, 1084.
 Hippocampus major, 707. 710.
 — minor, 708. 710.
 Horseshoe-kidney, 1189.
 Humours, of eye, 909. 920. 921. 923.
 Hymen, 1255.
 — development of, 1280.
 Ileo-cæcal, or ileo-colic valve, 1045.
 Ileum, 1040. (*See* Small Intestine.)
 Ilio-pectineal eminence, 142.
 — line, 150.
 Incisor teeth, 968.
 Incisura intertragica, 926.
 Incus, 937.
 Infundibula of kidney, 1192. 1201.
 Infundibulum (brain), 699.
 — (cochlea), 946.
 — (heart), 1108.
 Inguinal canal, 1292.
 — fossæ, of peritonæum, 1293.
 — hernia, (*see* Herniæ).
 — pouches, peritonæal, 1293.
 Interarticular cartilage, cxxxi. 180.
 Intervertebral substance, 187.
 Intestine, large, 1041.
 — cæcum, 1044.
 — coats of, 1042-3.
 — colon, 1047.
 — development of, 1056.
 — divisions of, 1041.
 — follicles of, 1043.
 — glands of, 1043.
 — lymphatics of, 1048-51.
 — mucuous membrane of,
 1043.
 — rectum, 1048.
 — structure of, 1042. 1050.
 — tubuli of, 1043.
 — valve of, 1045.
 — vessels and nerves of,
 1048. 1051.
 Intestine, small, 1029.
 — capillaries of, 1033-38.
 — coats of, 1029-31.
 — convolutions of, 1040.
 — crypts of, 1034.
 — development of, 1056.
 — divisions of, 1029.
 — duodenum, 1038.
 — epithelium of, 1031-34.
 — follicles of, 1034.
 — glands of, 1034.
 — agminated, 1035.
 — Brunner's, 1037.
 — solitary, 1036.
 — tubular, 1034.
 — ileum, 1040.
 — jejunum, 1040.
 — lacteals of, 651. 1033.
 — mesentery of, 1030.
 Intestine, small, mucous membrane of,
 1031.
 — structure of, 1029.
 — tubuli of, 1034.
 — valves of, 1031.
 — vessels and nerves, 1037.
 — villi of, 1032.
 Involuntary muscles, clxxii.
 Iris, 914.
 — nerves of, cxxvii.
 Irritability, muscular, clxxvii.
 — duration after
 death, clxxxiv.
 Ischio-rectal fossa, 1320.
 Island of Reil, 691. 693.
 Isthmus faucium, 966. 1005.
 — Vieussenii, 1107.
 Iter à tertio ad quartum ventriculum, 717.
 — ad infundibulum, 717.
 Ivory of teeth, 974.
 Jacob's membrane, 918.
 Jejunum, 1040. *See* Small Intestine.
 Joint, ankle, 231.
 — elbow, 206.
 — hip, 222.
 — movements of, 184.
 — lower jaw, 195.
 — knee, 224.
 — shoulder, 204.
 — movements of, 184.
 — wrist, 211.
 Joints, in general, 179.
 — movements of, 182.
 — synovial membranes of, cclxxiii.
 Kidneys, 1187. 1198.
 — adipose capsule of, 1189.
 — calices of, 1192. 1201.
 — capillaries of, 1195.
 — coat of, fibrous, 1189.
 — corpuscles of, Malpighian,
 1191. 1195.
 — cortical substance of, 1190,
 1191.
 — development of, 1271.
 — ducts of, 1192.
 — Bellini's, 1193.
 — glomeruli of, 1195.
 — hilus or fissure of, 1188.
 — horseshoe, 1189.
 — infundibula of, 1192.
 — lymphatics of, 1197.
 — medullary substance of, 1190,
 1191.
 — nerves of, 1197.
 — papillæ of, 1191.
 — parenchyma of, 1198.
 — pelvis of, 1192. 1201.
 — primitive or primordial, 1271
 — pyramids of, Ferrein's, 1193.
 — Malpighi's, 1190,
 1191.

- Kidneys, sinus of, 1190.
 ——— structure of, 1189.
 ——— tubuli of, convoluted, 1193.
 ——— Ferrein's, 1193.
 ——— straight, 1193.
 ——— structure of, 1194.
 ——— varieties of, 1189.
 ——— veins of, 1197.
 ——— vessels of, 1194-7.
 ——— distribution of, 1195.
 ——— weight of, 1187.
- Labia pudendi, 1252.
 ——— majora, 1252.
 ——— minora, 1254.
- Labyrinth or internal ear, 942.
 ——— membranous, 943, 948.
 ——— nerves of, 952. ccxxiii.
 ——— osseous, 942, 943.
 ——— its lining membrane, 948.
 ——— vessels of, 951.
- Lacrymal apparatus, 906.
 ——— canals, 906.
 ——— caruncula, 906.
 ——— gland, 906.
 ——— papilla, 904.
 ——— puncta, 904, 907.
 ——— sac, 907.
 ——— muscle of, 248.
- Lacteals, 651. 1033. 1037.
 ——— general anatomy of, cclx.
 ——— cclxii.
- Lactiferous ducts, 1281.
- Lacuna magna, 1229.
- Lacunæ of bone, cxl.
 ——— origin of, clviii.
 ——— mucous, cccii.
- Lamellæ of bone, cxxxix. cxlii.
- Lamina cinerea, 700.
 ——— cribrosa of ethmoid, 56.
 ——— sclerotic, 910.
 ——— temporal bone, 44.
 ——— vasculosa, of retina, 920.
 ——— spiralis, of cochlea, 946.
 ——— membranacea, 950.
- Laminated tubercle, (cerebellum) 723.
- Larynx, 1158.
 ——— articulations of, 1166.
 ——— cartilages of, 1159.
 ——— ossification of, 1178.
 ——— structure of, 1164.
 ——— development of, 1177.
 ——— glands of, 1177.
 ——— interior of, 1167.
 ——— ligaments of, 1164-6.
 ——— mucous membrane of, 1176.
 ——— muscles of, 1170.
 ——— action of, 1175.
 ——— pouches of, 1169.
 ——— ventricles, or sinuses of, 1169.
 ——— vessels and nerves of, 1177.
 ——— vocal cords of, 1168.
- Lemniscus, 738.
- Lens, crystalline, 923.
- Lenticular ganglion, 778.
 ——— bone, 937.
- Lienculi, 1089.
- LIGAMENTS in general, cxix. 181.
- Ligaments, acromio-clavicular, inferior, 203.
 ——— superior, 203.
 ——— alar of axis, 195.
 ——— knee, 229.
 ——— annular of wrist, anterior and posterior, 217, 436.
 ——— of ankle, anterior, 451.
 ——— internal, 451.
 ——— external, 452.
 ——— of radius, 209.
 ——— anterior of fingers, 216.
 ——— carpus, 212.
 ——— elbow, 208.
 ——— arcuate, 367.
 ——— aryteno-epiglottic, 1166.
 ——— astragalo-calcaneal, external, 233.
 ——— interosseous, 233.
 ——— posterior, 233.
 ——— astragalo-scaploid, 235.
 ——— atlo-axoidean, anterior, 193.
 ——— posterior, 193.
 ——— of bladder, anterior, 445, 1208.
 ——— lateral, 446, 1208.
 ——— calcaneo-cuboid, internal, 234.
 ——— inferior, 233, 234.
 ——— superior, 233.
 ——— scaploid, external, 235.
 ——— inferior, 234.
 ——— capsular of hip, 222.
 ——— knee, 226.
 ——— shoulder, 204.
 ——— thumb, 215.
 ——— carpal, dorsal, 213.
 ——— palmar, 213.
 ——— carpo-metacarpal, 214.
 ——— central of spinal cord, 675.
 ——— ciliary, of eye, 913.
 ——— coccygeal, 218.
 ——— common vertebral, anterior, 186.
 ——— posterior, 187.

- Ligaments, conoid, 204.
 _____ of larynx, 1165.
 _____ coracoid, 204.
 _____ coraco-acromial, 204.
 _____ clavicular, 203.
 _____ humeral, 205.
 _____ costo-clavicular, 202.
 _____ coracoid, 433.
 _____ sternal anterior,
 _____ 200.
 _____ posterior, 200.
 _____ transverse, anterior,
 _____ 199.
 _____ middle,
 _____ 199,
 _____ posterior,
 _____ 198.
 _____ vertebral, 198.
 _____ xiphoid, 200.
 _____ cotyloid, 223.
 _____ crico-arytenoid, 1166.
 _____ thyroid, 1165, 1166.
 _____ crucial, 227.
 _____ cruciform, 192.
 _____ deltoid, 231.
 _____ denticulate, 757.
 _____ dorsal, of carpus, 213.
 _____ metacarpus, 214.
 _____ metatarsus, 237.
 _____ tarsus, 236.
 _____ falciform of liver, 1060.
 _____ fibular, anterior, 231.
 _____ middle, 231.
 _____ posterior, 231.
 _____ gastro-lienal, 1085, 1093.
 _____ gastro-phrenic, 1021.
 _____ Gimbernat's, 1303.
 _____ glenoid, 205.
 _____ hyo-epiglottic, 1166.
 _____ ilio-femoral, 223.
 _____ lumbar, 218.
 _____ inter-articular, costal, 198.
 _____ of hip, 223.
 _____ inter-clavicular, 202.
 _____ inter-osseous, astragalo-cal-
 _____ canean, 233.
 _____ carpal, 213.
 _____ metacarpal,
 _____ 214, 215.
 _____ calcaneo-cu-
 _____ boid, 234.
 _____ tarsal, 236.
 _____ metatarsal,
 _____ 238.
 _____ tarso-metatar-
 _____ sal, 237.
 _____ costo-trans-
 _____ verse, 199.
 _____ peroneo-tibial,
 _____ 229.
 _____ inferior,
 _____ 230.
- Ligaments, inter-osseous, radio-ulnar,
 _____ 209.
 _____ inter-spinous, 191.
 _____ inter-transverse, 191.
 _____ inter-vertebral, 187.
 _____ lateral, of carpus, external
 _____ and internal, 212,
 _____ 214.
 _____ elbow, external
 _____ and internal,
 _____ 206.
 _____ knee, external,
 _____ 225.
 _____ internal,
 _____ 224.
 _____ maxilla, external,
 _____ and internal,
 _____ 196.
 _____ ankle, external,
 _____ and internal,
 _____ 231.
 _____ fingers, 216.
 _____ toes, 239.
 _____ of larynx, 1164, 1166.
 _____ of liver, 1060.
 _____ long plantar, 233.
 _____ metacarpal, dorsal, 214,
 _____ 215.
 _____ interosseous,
 _____ 214, 215.
 _____ palmar, 214,
 _____ 215.
 _____ of thumb, 215.
 _____ metatarsal, dorsal, 238.
 _____ plantar, 238.
 _____ mucous, 228.
 _____ of nucha, 293.
 _____ obturator, 222.
 _____ occipito-atloidean anterior
 _____ and posterior, 194.
 _____ axoidean, 195.
 _____ odontoid, 195.
 _____ orbicular, 209.
 _____ ovarian, 1263-6.
 _____ palmar, of carpus, 213.
 _____ fingers, 216.
 _____ of patella, 226, 388.
 _____ peroneo-tibial, superior,
 _____ 229.
 _____ inferior,
 _____ 230.
 _____ of phalanges, fingers,
 _____ 216.
 _____ toes, 239.
 _____ phrenico-lienal, 1085.
 _____ of pinna of ear, 927.
 _____ plantar, long, 233.
 _____ posterior, of carpus, 212.
 _____ elbow, 208.
 _____ knee, 225.
 _____ posticum Winslowii, 225.
 _____ Poupart's, 355, 1286.

- Ligaments, processuum obliquorum, 190.
- pterygo-maxillary, 254.
 - pubic, anterior, 221.
 - posterior, 221.
 - pubo-prostatic, 1208. 1214.
 - pyramidal, of larynx, 1165.
 - radio-carpal, anterior, 212.
 - posterior, 212.
 - rhomboid, 202.
 - round, of radius and ulna, 210.
 - hip, 223.
 - liver, 1060.
 - uterus, 1264. 1278.
 - sacro-coccygeal, anterior and posterior, 218.
 - sacro-iliac, anterior, 219.
 - oblique, 219.
 - posterior, 219.
 - sacro-sciatic, anterior, 219.
 - posterior, 220.
 - sacro-vertebral, 217.
 - stellate, 198.
 - sternal, 201.
 - sterno-clavicular, anterior and posterior, 201. 202.
 - stylo-maxillary, 196. 431.
 - sub-flavus, cxxiii. 190.
 - sub-pubic, 221.
 - supra-spinous, 191.
 - suspensory, of penis, 1218.
 - liver, 1060.
 - tarsal, of eyelid, 905.
 - dorsal, 236.
 - plantar, 236.
 - tarso-metatarsal, 237.
 - teres, of hip joint, 223.
 - radio-ulnar, 210.
 - of thumb, 215.
 - thyro-arytenoid, inferior, and superior, 1168.
 - thyro-epiglottic, 1166.
 - thyro-hyoid, 1165.
 - tibio-tarsal, 232.
 - transverse, costal, external and internal, 199.
 - metacarpal, 215.
 - metatarsal, 239.
 - of acetabulum, 223.
 - atlas, 192.
 - knee, 228.
 - tibio-fibular, 230.
 - of ankle, 230.
 - trapezoid, 204.
 - triangular, 221. 443.
 - of urethra, 1316.
 - of tympanic bones, 938.
 - malleus, 939-40.
 - incus, 940.
 - stapes, 940.
 - of uterus, 1263.
- Ligaments of uterus, broad or falciform, 1263.
- round, 1264.
 - vaginal of hand, 217.
 - vertebral, 186.
 - yellow, of spine, cxxiii. 190.
- Ligamentum latum pulmonis, 1140.
- arcuatum, 367.
 - nuchæ, 293.
- Ligature of the brachial artery, 531.
- carotid, common, 470.
 - iliac, common, 568.
 - external, 584.
 - internal, 571.
 - femoral, 595.
 - sub-clavian, 503.
- Ligula, (fourth ventricle,) 724.
- Limbus luteus, 918.
- Linea alba, 361.
- aspera, 156.
 - splendens, 757.
- Lips, 966.
- Liquor Cotunnii, 948.
- corneæ, 911.
 - Morgagni, 923.
 - sanguinis, lxx. lxxviii.
 - seminis, 1251.
- Lithotomy, 1321.
- Liver, 1057-79.
- aberrant ducts of, 1073.
 - accessory, 1079.
 - capillaries of, 1070.
 - cells or corpuscles of, 1072.
 - coats of, 1065.
 - congestion of, 1070.
 - development of, 1077.
 - ducts of, 1064. cccv.
 - course of, 1069.
 - distribution of, 1071.
 - external to liver, 1073-6.
 - excretory apparatus of, 1073-6.
 - varieties of, 1077.
 - fissures of, 1062.
 - fetal peculiarities of, 1077.
 - fossæ of, 1063.
 - hilus of, 1062.
 - ligaments of, 1060-1.
 - lobes of, 1061.
 - lobules of, 1065.
 - structure of, 1069.
 - lymphatics of, 1064.
 - nerves of, 1065.
 - structure of, 1065.
 - varieties in the, 1079.
 - vessels of, 1063.
 - course, 1067.
 - distribution, 1070.
 - vessels of, distribution in the fetus, 1078.
 - weight of, 1058.
- Lobes of cerebellum, 722.

- Lobes of cerebrum, 691.
 ——— liver, 1061, 1062.
 ——— lung, 1142.
 Lobule of ear, 926.
 Lobules of glands, ccciii.
 ——— particular glands, *see* those
 Glands.
 Lobulus anonymus, 1062.
 ——— caudatus, 1062.
 ——— quadratus, 1062.
 ——— Spigellii, 1062.
 Locus niger, ccv. 737.
 ——— perforatus, anterior, 700.
 ——— posterior, 699.
 Luette vesicale, 1209.
 Lunulæ of nails, cclxxxviii.
 ——— valves of heart, 1112.
 Lungs, 1139–1158.
 ——— air-cells of, 1150, 1152.
 ——— tubes of, 1149, 1150.
 ——— subdivision of, 1151.
 ——— capacity of, 1143.
 ——— capillaries of, 1154.
 ——— cellular tissue of, 1146.
 ——— changes at birth, 1157.
 ——— colour of, 1145.
 ——— development of, 1156.
 ——— fissures of, 1142.
 ——— foetal, 1157.
 ——— form of, 1141.
 ——— gravity, specific, of, 1144.
 ——— lobes of, 1142.
 ——— lobules of, 1146.
 ——— structure of, 1149.
 ——— lymphatics of, 1156.
 ——— nerves of, 1156.
 ——— root of, 1142, 1148.
 ——— size and weight of, 1142.
 ——— structure of, 1146.
 ——— texture of, 1144.
 ——— vessels of, pulmonary, 1147.
 ——— bronchial, 1154.
 Lymph, lxxxv.
 ——— corpuscles, lxxxvi.
 ——— plasma of, lxxxvi.
 ——— duct, right, 651, 654.
 LYMPHATIC SYSTEM, General Anatomy
 of, cclx.
 ——— glands, cclxiv. 651.
 ——— structure of, cclxv.
 ——— uses of, cclxvi.
 ——— hearts, cclxviii.
 ——— outline of, lxxxv.
 ——— vessels, cclx.
 ——— afferent, cclxv.
 ——— coats of, cclxiii.
 ——— development of, cclxix.
 ——— distribution of, cclx.
 ——— efferent, cclxv.
 ——— lacteal, cclxii.
 ——— origin of, cclxi.
 Lymphatic vessels, plexuses of, cclx.
 ——— cclxv.
 ——— structure of, cclxiii.
 ——— termination of, cclxviii.
 ——— valves of, cclxiv.
 ——— vessels and nerves of,
 cclxiii.
 ——— vital properties of,
 cclxiv.
 LYMPHATICS, Descriptive Anatomy of,
 651.
 ——— of the abdomen, 656.
 ——— arm, 664.
 ——— bladder, 657.
 ——— head, 665.
 ——— heart, 662.
 ——— intestines, small, 652.
 ——— 1037.
 ——— kidneys, 658.
 ——— leg, 655.
 ——— limb, lower, 655.
 ——— upper 664.
 ——— liver, 659.
 ——— loins, 660.
 ——— lungs, 661.
 ——— mesentery, 652.
 ——— neck, 666.
 ——— œsophagus, 662.
 ——— pancreas, 659.
 ——— pelvic viscera, 657.
 ——— pelvis, 657.
 ——— penis, 657.
 ——— rectum, 658.
 ——— scrotum, 657.
 ——— spleen, 659.
 ——— stomach, 658.
 ——— testicle, 658.
 ——— thorax, 661.
 ——— thymus gland, 663.
 ——— thyroid gland, 663.
 ——— uterus, 658.
 Lyra, 710.
 Macula germinativa, 1268.
 Malleolus, external, 165.
 ——— internal, 161.
 Malleus, 936.
 Malpighian corpuscles, kidney, 1191.
 ——— 1195,
 ——— spleen, 1088.
 Mammæ, 1280.
 ——— structure, 1281.
 ——— varieties, 1283.
 ——— vessels and nerves, 1282.
 Manubrium, 101.
 Margaric and stearic acids, xxxi.
 Margarin, xxxi.
 Marrow of bone, cxliv.
 Mastoid cells, 931, 934.
 Massa vel moles carnea, 414.
 Matrix, *see* Uterus.
 ——— of nail, cclxxxviii.
 Meatus, auditory, external, 43, 929.

- Meatus, auditory, internal, 43.
 ——— of nose, inferior, 69. 71. 91.
 962.
 middle, 58. 91. 962.
 superior, 58. 91. 961.
 ——— urinarius, female, 1212. 1254.
 male, 1228.
- Mediastinum, anterior, 1099. 1140.
 ——— posterior, 1099. 1140.
 ——— testis, 1242.
- Medulla of bone, cxliv.
 Medulla oblongata, 682.
 ——— back of, 687. 723.
 ——— columns of, 684.
 ——— course of, 729.
 ——— grey matter of, 731.
 cxcix.
 ——— internal structure of,
 729.
 ——— weight of, 672.
 ——— spinalis, 673.
- Medullary substance of kidney, 1190-1.
 Meibomian glands, 905.
- Membrana adamantina, 989.
 ——— fusca, 910.
 ——— nictitans, 906.
 ——— pupillaris, 917.
 ——— sacciformis, 211.
 ——— tympani, 931.
- Membrane of aqueous humour, 911. 920.
 ——— arachnoid, 755.
 ——— capsulo-pupillary, 924.
 ——— choroid, 911.
 ——— costo-coracoid, 433.
 ——— crico-thyroid, 1165, 1166.
 ——— hyaloid, 921.
 ——— Jacob's, 918.
 ——— pituitary, 959.
 ——— thyro-hyoid, 1165.
 ——— Schneiderian, 959.
- Membranes of the brain and spinal cord,
 751.
 ——— development of,
 766.
 ——— mucous, serous, &c., *see*
 Serous membranes, Mucous mem-
 branes, &c.
- Membranous labyrinth, 943. 948.
 ——— portion of urethra, 1227.
- Meninges, 751.
- Mesenteric glands, 652.
 Mesenteries, 1091. 1093.
 Mesentery, 1030. 1093.
 ——— development of, 1055.
- Meso-cæcum, 1044. 1093.
 ——— colon, 1047. 1093.
 ——— rectum, 1049. 1094.
- Mesorchium, 1238. 1277.
 Metacarpus, 133. 138.
 Metatarsus, 171, 178.
 Milk-teeth, 973.
 Modiolus, 946.
- Molar teeth, 971.
 ——— glands, 967.
- Mons veneris, 1252.
 Morsus diaboli, 1269.
 Mouth, 966.
- Mucous membranes, general anatomy
 of, cclxxv.
 ——— alveoli of, cclxxxix.
 ——— attachment of, cclxxxvi.
 ——— basement membrane of,
 cclxxviii.
 ——— corium of, cclxxviii.
 cclxxx.
 ——— divisions of, cclxxv.
 ——— epithelium of, xcii.
 cclxxviii.
 ——— folds and valves of,
 cclxxvii.
 ——— follicles of, cclxxxix.
 ——— gastro-pulmonary,
 cclxxvi.
 ——— genito-urinary, cclxxxvi.
 ——— glands of, compound,
 cclxxxii.
 simple, cclxxxix.
 ——— mammary, cclxxvi.
 ——— nerves of, cclxxxii.
 ——— papillæ of, cclxxx.
 ——— physical properties of,
 cclxxvii.
 ——— regeneration of, cclxxxiii.
 ——— secretion of, cclxxxii.
 ——— structure of, cclxxviii.
 ——— tubuli of, cclxxxix.
 ——— vessels of, cclxxxix.
 ——— villi of, cclxxx.
- Mucus, cclxxxii.
- Multicuspidate teeth, 971.
- Multilocular crypts, ccciii.
- MUSCLES, contraction of, clxxviii.
 ——— origin and insertion of, clxiv.
 clxx.
 ——— penniform, clxv.
 ——— semi-penniform, clxvi.
 ——— sheaths of, clxv.
 ——— structure of, clxiii.
- MUSCLES, Descriptive Anatomy of, 240.
 ——— tables of, 419.
 ——— abdominal, 353.
 ——— abductor digiti minimi, 349.
 ——— ——— pedis, 413.
 ——— ——— indicis, 351.
 ——— ——— oculi (rectus exter-
 nus), 263.
 ——— ——— pollicis, 347.
 ——— ——— pedis, 412.
 ——— accelerator urinæ, 1230.
 ——— accessorii orbicularis oris, 255.
 ——— accessorius (pedis), 414.
 ——— ——— ad sacro-lumbalem,
 303.
 ——— adductor brevis, 391.

- Muscles, adductor digiti minimi, 350.
 _____ longus, 391.
 _____ magnus, 391.
 _____ oculi (rectus inter-
 nus), 263.
 _____ pollicis, 348.
 _____ pedis, 415.
 _____ anconeus, 341.
 _____ anti-tragicus, 928.
 _____ of anus, 1051-5.
 _____ arm, 325.
 _____ arytenoideus, 1174.
 _____ aryteno-epiglottideus, 1174.
 _____ attollens auriculam, 245.
 _____ oculum (rectus of supe-
 rior), 262.
 _____ attrahens aurem (anterior), 245.
 _____ auriculares, superior, posterior,
 et anterior, 245.
 _____ azygos uvulæ, 288.
 _____ of back, 290.
 _____ basio-glossus, 274.
 _____ biceps femoris, 394.
 _____ flexor cubiti, 326.
 _____ biventer cervicis, 307.
 _____ maxillaris, 270.
 _____ brachialis anticus, 327.
 _____ buccinator, 253.
 _____ bulbo-cavernosus, 1230.
 _____ caninus, 251.
 _____ cerato-glossus, 274.
 _____ cervicalis ascendens vel descen-
 dens, 303.
 _____ chondro-glossus, 274.
 _____ ciliaris, 247.
 _____ circumflexus palati, 288.
 _____ coccygeus, 1055.
 _____ complexus, 306.
 _____ minor, 305.
 _____ compressor naris, 249.
 _____ sacculi laryngis, 1174.
 _____ urethræ, 1231.
 _____ venæ dorsalis penis,
 1230.
 _____ constrictor pharyngis, inferior,
 283.
 _____ medius, 284.
 _____ superior, 285.
 _____ isthmi faucium, 289.
 _____ vaginæ, 1258.
 _____ coraco-brachialis, 325.
 _____ hyoideus, 276.
 _____ corrugator supercillii, 247.
 _____ cremaster, 359. 1235.
 _____ crico-arytenoideus lateralis,
 1171.
 _____ posticus, 1171.
 _____ thyroideus, 276. 1170.
 _____ crureus, 387.
 _____ cucullaris, 291.
 _____ deltoideus, 320.
 _____ depressor anguli oris, 252.
- Muscle, depressor epiglottidis, 1174.
 _____ labii inferioris, 253.
 _____ superioris alæque
 nasi, 250.
 _____ oculi (rectus inferior),
 263.
 _____ detrusor urinæ, 1210.
 _____ diaphragma, 366.
 _____ digastricus, 270.
 _____ dilatator naris, anterior, 251.
 _____ posterior, 250.
 _____ of ear, external, 244. 927.
 _____ internal, 939.
 _____ ejaculator seminis, 1230.
 _____ erector clitoridis, 1253.
 _____ penis, 1229.
 _____ spinæ, 301.
 _____ extensor carpi radialis brevis,
 340.
 _____ longior, 339.
 _____ ulnaris, 342.
 _____ coccygis, 310.
 _____ cruris, 385.
 _____ digiti minimi, 342.
 _____ digitorum brevis pedis,
 399.
 _____ communis, 341.
 _____ longus pedis, 398.
 _____ indicis, 345.
 _____ ossis metacarpi pollicis,
 343.
 _____ primi internodii pollicis,
 343.
 _____ pollicis proprius, 397.
 _____ secundi internodii polli-
 cis, 344.
 _____ of eye, 261.
 _____ face, 244.
 _____ flexor accessorius, 414.
 _____ brevis digiti minimi, 349.
 _____ pedis, 416.
 _____ digitorum pedis, 413.
 _____ carpi radialis, 332.
 _____ ulnaris, 333.
 _____ digitorum profundus, 335.
 _____ sublimis, 333.
 _____ longus digitorum pedis,
 408.
 _____ pollicis pedis,
 409.
 _____ pollicis brevis, 347.
 _____ pedis, 415.
 _____ longus, 337.
 _____ of foot, 411.
 _____ forearm, 330.
 _____ gastrocnemius, 403.
 _____ gemellus inferior, 380.
 _____ superior, 380.
 _____ genio-hyo-glossus, 274.
 _____ hyoideus, 273.
 _____ glutæus maximus, 374.
 _____ medius, 376.

Muscle, glutæus minimus, 377.
 ——— gracilis, 390.
 ——— Guthrie's, 1231.
 ——— of hand, 346.
 ——— head, 240.
 ——— hip, 374.
 ——— helicis major, 928.
 ——— ——— minor, 928.
 ——— Houston's, 1230.
 ——— hyo-glossus, 273.
 ——— iliacus, 372.
 ——— indicator, 345.
 ——— infra-costales, 364.
 ——— infra-spinatus, 322.
 ——— inter-costales externi, 364.
 ——— ——— interni, 364.
 ——— inter-ossei manûs dorsales, 350.
 ——— ——— palmares, 352.
 ——— ——— pedis dorsales, 417.
 ——— ——— plantares, 418.
 ——— inter-spinales, 309.
 ——— inter-transversales, 311.
 ——— ischio-cavernosus, 1229.
 ——— of larynx, 1170.
 ——— ——— action of, 1175.
 ——— latissimus dorsi, 293.
 ——— laxator tympani major, 939.
 ——— ——— minor, 939.
 ——— of leg, 396.
 ——— levator anguli oris, 251.
 ——— ——— scapulæ, 297.
 ——— ——— ani, 1053.
 ——— glandulæ thyroideæ, 1180.
 ——— labii inferioris, 253.
 ——— ——— superioris, 251.
 ——— ——— alæque nasi, 249.
 ——— ——— menti, 253.
 ——— oculi, 262.
 ——— palati, 287.
 ——— palpebræ, 248.
 ——— proprius alæ nasi, posterior, 250.
 ——— ——— anterior, 251.
 ——— prostata, 1054. 1215.
 ——— uvulæ, 288.
 ——— levatores costarum, 365.
 ——— lingualis, 1002.
 ——— ——— superficialis, 1001.
 ——— ——— transversus, 1002.
 ——— longissimus dorsi, 304.
 ——— longus colli, 281.
 ——— of lower limb, 370.
 ——— lumbricales manûs, 337.
 ——— ——— pedis, 414.
 ——— mallei externus (laxator tympani, major), 939.
 ——— ——— internus, 939.
 ——— masseter, 257.
 ——— multifidus spinæ, 308.
 ——— mylo-hyoideus, 272.
 ——— myrtiformis, 250.

Muscle, naso-labialis, 256.
 ——— of neck, 265.
 ——— nose, 958.
 ——— obliquus abdominis externus, 355. 1286.
 ——— ——— internus, 356. 1288.
 ——— ——— auris, 928.
 ——— ——— capitis inferior, 311.
 ——— ——— ——— superior, 311.
 ——— ——— oculi inferior, 264.
 ——— ——— ——— superior, 263.
 ——— obturator externus, 381.
 ——— ——— internus, 379.
 ——— occipito-frontalis, 241.
 ——— omo-hyoideus, 276.
 ——— opponens digiti minimi, 350.
 ——— ——— pollicis, 347.
 ——— orbicularis latus, 247.
 ——— ——— oris, 255.
 ——— ——— palpebrarum, 246.
 ——— of palate, 287. 1006.
 ——— palato-glossus, 289.
 ——— ——— pharyngeus, 289.
 ——— palmaris brevis, 349.
 ——— ——— longus, 332.
 ——— pectineus, 390.
 ——— pectoralis major, 315.
 ——— ——— minor, 317.
 ——— of penis, 1229.
 ——— ——— perinæum, 1015-5. 1314.
 ——— peroneus brevis, 401.
 ——— ——— longus, 400.
 ——— ——— tertius, 399.
 ——— of pharynx, 283. 1013.
 ——— plantaris, 405.
 ——— platysma myoides, 267.
 ——— popliteus, 407.
 ——— posterior auris, 245.
 ——— pronator quadratus, 338.
 ——— ——— radii teres, 331.
 ——— psoas magnus, 371.
 ——— ——— parvus, 373.
 ——— pterygoideus externus, 260.
 ——— ——— internus, 259.
 ——— pubo-urethrales, 1232.
 ——— pyramidales abdominis, 360.
 ——— ——— nasi, 249.
 ——— pyriformis, 378.
 ——— quadratus femoris, 381.
 ——— ——— lumborum, 361.
 ——— ——— menti, 253.
 ——— quadriceps cruris, 385.
 ——— rectus abdominis, 359.
 ——— ——— capitis anticus major, 280.
 ——— ——— ——— minor, 281.
 ——— ——— posticus major, 310.
 ——— ——— ——— minor, 31.
 ——— ——— femoris, 386.
 ——— ——— lateralis, 281.
 ——— oculi externus, 263.
 ——— ——— inferior, 263.
 ——— ——— internus, 263.

Muscle, rectus oculi superior, 262.
 — retrahens auriculam, 245.
 — rhomboideus major, 297.
 — ——— minor, 296.
 — risorius, 254.
 — rotatores spinæ, 309.
 — sacro-coccygis, 310.
 — ——— lumbalis, 303.
 — salpingo-pharyngeus, 285.
 — sartorius, 384.
 — Santorini's, 1231.
 — scalenus anticus, 278.
 — ——— medius, 279.
 — ——— posticus, 279.
 — semi-spinalis colli, 308.
 — ——— dorsi, 308.
 — semi-membranosus, 395.
 — semi-tendinosus, 394.
 — serratus magnus, 318.
 — ——— posticus inferior, 298.
 — ——— superior, 298.
 — soleus, 404.
 — sphincter ani externus, 1052.
 — ——— internus, 1051.
 — ——— pupillæ, 915.
 — ——— vaginæ, 1258.
 — ——— vesicæ, 1210.
 — spinalis dorsi, 305.
 — ——— cervicis, 306.
 — splenius capitis, 299.
 — ——— colli, 299.
 — stapedius, 940.
 — sterno-cleido-mastoideus, 268.
 — ——— hyoideus, 275.
 — ——— thyroideus, 276.
 — stylo-glossus, 271.
 — ——— hyoideus, 271.
 — ——— pharyngeus, 271.
 — subclavius, 317.
 — subcerureus, 388.
 — subscapularis, 324.
 — superior auris, 245.
 — supinator radii brevis, 345.
 — ——— longus, 338.
 — supra-spinatus, 321.
 — temporal, 258.
 — tensor fasciæ latæ, 383.
 — ——— palati, 288.
 — ——— tarsi, 248.
 — ——— tympani, 939.
 — ——— vaginæ femoris, 383.
 — teres major, 323.
 — ——— minor, 322.
 — of thigh, 382.
 — thyro-arytænoideus, 1173.
 — ——— epiglottideus, 1174.
 — ——— hyoideus, 276.
 — tibialis anticus, 396.
 — ——— posticus, 410.
 — of tongue, 1001.
 — trachelo-mastoideus, 305.
 — tragicus, 928.

Muscle, transversalis abdominis, 358.
 ———— 1288.
 ———— cervicis, 305.
 ———— nasi, 249.
 — transversus auriculæ, 928.
 ———— pedis, 416.
 ———— perinæi, 1230.
 ———— alter, 1231.
 — trapezius, 291.
 — triangularis oris, 252.
 ———— sterni, 365.
 — triceps extensor cruris, 385.
 ———— cubiti, 328.
 — trochlearis, 263.
 — of tympanum, 939.
 — upper limb, 313.
 — ureters, 1210.
 — urethra, 1229.
 — vastus externus, 386.
 ———— internus, 387.
 — Wilson's, 1232.
 — zygomaticus major, 252.
 ———— minor, 252.

Muscular contractility, xxxv. clxxvii.

— sound, clxxix.

MUSCULAR TISSUE, General Anatomy of,

— chemical nature of, clxxiv.
 — connexion with tendons, clxx.
 — development of, clxxv.
 — elementary particles of, clxvii.
 — fasciculi of, clxv.
 — fibres of, clxvi.
 — filaments of, clxvii.
 — of heart, clxxiii. 1118.
 — involuntary or plain, clxxii.
 — nerves of, clxxi. ccxvi.
 — regeneration of, clxxvi.
 — striæ of, clxix.
 — vessels of, clxx.
 — vital properties of, clxxvii.
 — voluntary, or striped, clxiii.

Musculi papillares, left ventricle, 1115.

— right ventricle, 1109.

— pectinati, left auricle, 1113.

— right auricle, 1107.

Nails, cclxxxviii.

— growth of, cclxxxix.

— matrix of, cclxxxviii.

— reproduction of, cclxxxix.

Nares, anterior, 89. 955. 959.

— posterior, 82. 956. 1013.

— septum of, 90. 958.

Nasal cartilages, 956.

— duct, 907.

Nates (of brain), 719.

NERVES, General Anatomy of, ccix.

— cerebro-spinal, ccix.

- Nerve, cerebro-spinal afferent, ccxxxvi.
 ———— branches of, ccxi.
 ———— communications of, ccxii.
 ———— with sympathetic, ccxxx.
 ———— compound, ccxxv.
 ———— connexion with nervous centre, cxcviii. ccxiv.
 ———— ganglia, ccviii.
 ———— development of, ccxxxvi.
 ———— efferent, ccxxxvi.
 ———— extremities, peripheral, of ccxvi.
 ———— fasciculi of, ccix.
 ———— funiculi of, ccix.
 ———— fibres of, ccxi.
 ———— intracranial portions of, ccxv.
 ———— motor, ccxxxvi.
 ———— nerves of, ccxii.
 ———— neurilema of, ccx.
 ———— organic influence of, ccxxxv.
 ———— origins of, ccxiii.
 ———— ———— apparent, ccxv.
 ———— ———— real or deep, ccxiv.
 ———— peculiarities of, ccxxiv.
 ———— plexuses of, ccxii. (*See* Plexuses of nerves.)
 ———— reflex, ccxxxiv.
 ———— relation of to sympathetic, ccxxxix.
 ———— reunion of, ccxxxviii.
 ———— roots of, ccxiii. ccxxxvi.
 ———— ———— motor, ccxiv.
 ———— ———— sensory, ccxiv.
 ———— sensory, ccxxxvi.
 ———— sheaths of, ccx.
 ———— simple, ccxxxvi.
 ———— structure of, ccix.
 ———— terminations of, ccxvi.
 ———— in ciliary ligament, ccxvii.
 ———— electric organs, ccxxxiii.
 ———— internal ear, ccxxxiii.
 ———— iris, ccxvii.
 ———— muscles, clxxii. ccxvi.
 ———— nose, ccxxii.
 ———— Pacinian bodies, ccxxi.
 ———— retina, ccxxiii.
 ———— skin, frog, ccxvii.
 ———— man, ccxviii.
 ———— tadpole, ccxvii.
 ———— teeth, ccxxii.
 ———— tongue, ccxxii.
 ———— vessels of, ccxi.
- Nerve, cerebro-spinal, vital properties of, ccxxxiv.
 ———— sympathetic, ccxxvi.
 ———— constitution of, ccxxxii.
 ———— differences in, ccxxxvii.
 ———— general character of, ccxxvi.
 ———— relation to cerebro-spinal nerves, ccxxxix.
 ———— relation to roots of spinal nerves, ccxxxii.
 ———— structure of, ccxxvi.
- NERVES, Descriptive Anatomy of, 767.
- Nerv. abducent, (r) 749. (c) 794.
 ———— accessory, spinal, (r) 732. 750. (c) 812. (br) 813.
 ———— accessory to obturator, 859.
 ———— acromial, 830.
 ———— articular, of shoulder joint, 835. 837.
 ———— ———— elbow joint, 842.
 ———— ———— hip joint, 859. 871.
 ———— ———— knee, 859. 864. 872. 876.
 ———— auditory, (r) 749. (c) 794. 800. 952. ccxxxiii.
 ———— auricular, anterior, 788.
 ———— ———— great, 829.
 ———— ———— posterior, 797.
 ———— auricular, of auriculo-temporal, 788.
 ———— ———— par vagum, 809.
 ———— ———— second cervical, 823.
 ———— auriculo-temporal, 788.
 ———— axillary, 836.
 ———— buccal, or buccinator, 787.
 ———— ———— of facial, 799.
 ———— cardiac, inferior, 886.
 ———— ———— middle, or deep, 885.
 ———— ———— pneumogastric, 811.
 ———— ———— superior, or superficial, 882.
 ———— cavernous, of penis, 900.
 ———— cervical, divisions of, anterior, 827. 833.
 ———— ———— posterior, 821.
 ———— ———— superficial, 828.
 ———— cervico-facial, 799.
 ———— chorda tympani, 796.
 ———— ciliary, long, 777. 916.
 ———— ———— short, 779. 916. ccxvii.
 ———— circumflex of arm, 836.
 ———— clavicular, 830.
 ———— coccygeal, divisions of, anterior, 865. 866.
 ———— ———— posterior, 826.
 ———— cochlear, 953. 955.
 ———— communicans tibix, 873.
 ———— ———— peronei, 873. 876.
 ———— of Cotunnus, 784.
 ———— cranial, *see* Cranial Nerves.
 ———— crural, anterior, 859.
 ———— internal, 858.

- Nerve cutaneous, radial, 847.
 — ulnar, 842.
 — abdominal, anterior, 853.
 — lateral, 852, 853.
 — external, of arm, 839.
 — (median), 847.
 — of thigh, 857.
 — internal, of arm, 837.
 — small, 838.
 — (median), 846.
 — of thigh, 861.
 — middle, of thigh, 861.
 — obturator, 858.
 — plantar, 874.
 — thoracic, anterior, 850.
 — lateral, 849.
 — dental, anterior, 781.
 — inferior, 790.
 — posterior, 780.
 — descendens noni, 815.
 — diaphragmatic, 831.
 — digastric, 797.
 — digital, on dorsum of foot, 877, 878.
 — hand, 842, 847.
 — median, 844.
 — plantar, 874, 875.
 — radial, 847.
 — ulnar, 842.
 — dorsal, divisions of, anterior, 848.
 — posterior, 823.
 — of penis, 868.
 — dorsi-lumbar, 853, 854.
 — of dura mater, 772, 774.
 — facial, (*r*) 749. (*c*) 794, (*br*) 795.
 — of femoral artery, 860.
 — frontal, 775.
 — of gall-bladder, 896.
 — gastric, 812, 1028.
 — genito-crural, 856.
 — glosso-pharyngeal, (*r*) 733, 750.
 — (*c*) 801. (*br*) 802.
 — gluteal, inferior, 869.
 — superior, 853.
 — gustatory, 789.
 — hæmorrhoidal inferior, 869, 899.
 — superior, 898.
 — of heart, 893.
 — hepatic, 896.
 — hypo-glossal, (*r*) 732, 750. (*c*) 813.
 — (*br*) 815.
 — ilio-hypogastric, 855.
 — inguinal or ilio-scrotal, 855–856.
 — infra-maxillary, 799.
 — orbital, 781.
 — of facial, 799.
 — trochlear, 777.
 — inguino-cutaneous, 857.
 — intercostal, 848.
 — lower, 851.
 — upper, 849.
 — intercosto-humeral, 851.
 — inter-osseus anterior, 844.
 — inter-osseus posterior, 848.
 — of intestines, 897.
 — ischiadic, great, 870.
 — small, 869.
 — Jacobson's, 802.
 — labial, 781, 791.
 — of labyrinth, 952.
 — lachrymal, 775.
 — of Lancisi, 703.
 — laryngeal, external, 810.
 — inferior, or recurrent, 810.
 — superior, 809.
 — lingual, (*r*) 750. (*c*) 813. (*br*) 815.
 — of fifth, 789.
 — glosso-pharyngeal, 804.
 — lumbar, divisions of, posterior, 825.
 — anterior, 853.
 — lumbo-sacral, 853, 854, 866.
 — malar, subcutaneous, 780.
 — of facial, 799.
 — masseteric, 787.
 — maxillary, inferior, 786–791.
 — superior, 779–785.
 — median, 843.
 — mental, 791.
 — motor of eye, common, (*r*) 747. (*c*)
 — 769. (*br*) 770.
 — external, (*r*) 749. (*c*)
 — 794.
 — musculo-cutaneous, 839.
 — of leg, 877.
 — spiral, 845.
 — mylo-hyoid, 791.
 — nasal, 776. (*br*) 777.
 — of sphenopalatine ganglion,
 — 784.
 — vidian nerve, 785.
 — naso-palatine, 784, 964.
 — obturator, 858.
 — occipital (of facial), 797.
 — great, 822.
 — of third cervical, 823.
 — small, 829.
 — oculo-nasal, 776. (*b*) 777.
 — cesophageal, 812.
 — olfactory, (*r*) 745. (*b*) 768, 963.
 — ccxxii.
 — ophthalmic, (*c*) 774.
 — optic, (*r*) 746. (*c*) 769, 917.
 — ccxxiii.
 — orbital, 780.
 — ovarian, 901.
 — palatine, anterior or larger, 783.
 — external, 783.
 — posterior or smaller, 783.
 — palmar cutaneous, 844.
 — ulnar, deep, 843.
 — superficial, 842.
 — palpebral, 776, 781.
 — pathetic, (*r*) 747. (*c*) 771.
 — perforans Casseri, 840.
 — perineal, 868.

- Nerve, peroneal, 876.
 — petrosal, superficial, large, 785.
 ————— external (sympathetic), 796.
 ————— in the figure, 803.
 ————— small, 804.
 — pharyngeal, 809. 882.
 ————— of glosso-pharyngeal, 804.
 — phrenic, 831.
 — plantar, external, 875.
 ————— internal, 874.
 — pneumo-gastric, (r) 733-750. (c) 805. (br) 808.
 — popliteal, external, 876.
 ————— internal, 871.
 — portio dura, (r) 749. (c) 794. (br) 795.
 ————— mollis, (r) 749. (c) 794. (br) 800. 952.
 — pterygoid, 788.
 — pudental, inferior, 870.
 — pudic, 867.
 — pulmonary, of pneumogastric, 811.
 — radial, 847.
 — recurrent, laryngeal, 810.
 — renal, 894.
 ————— posterior, 889.
 — respiratory, external, 834.
 — sacral, divisions of, anterior, 865.
 ————— posterior, 825.
 — saphenous, long, or internal, 863.
 ————— short, or external, 873.
 — sciatic, great, 870.
 ————— small, 869.
 — spermatic, 895.
 — spheno-palatine, 780. 782.
 — spinal, 817. (See Spinal Nerves.)
 ————— accessory, (r) 732. 750. (c) 812. 813.
 — splanchnic, great, 888.
 ————— small, 889.
 ————— smallest, 889.
 — splenic, 896.
 — stylo-hyoid, 797.
 — sub-cutaneous, of neck, 799.
 ————— malar, 780.
 — sub-occipital, 822. 827.
 — sub-scapular, 836.
 — supra-clavicular, 830.
 — superficial cervical, 828.
 ————— cardiac, 882.
 — supra-maxillary, 799.
 — supra-orbital, 776.
 ————— scapular, 835.
 ————— trochlear, 775.
 — sympathetic, see Sympathetic Nerves.
 — temporal, deep, 786.
 ————— of facial, 799.
 ————— superficial, 788, 789.
- Nerve, temporal, of temporo-malar, 780.
 — temporo-facial, 798.
 ————— malar, 780.
 — thoracic, anterior, 836.
 ————— posterior, 834.
 — thyroid, 885.
 — tibial, anterior, 878.
 ————— posterior, 874.
 — tonsillar, 804. 1007.
 — trifacial, or trigeminal, (r) 748. (c) 772. (br) 774-791.
 — trochlear, (r) 747. (c) 771.
 — tympanic, 802.
 — of tympanum, 941.
 — ulnar, 840.
 ————— of Wrisberg, 838.
 — uterine, 901, 902.
 ————— in gravid state, 902.
 — vaginal, 901.
 — vagus, (r) 733. 750. (c) 805. (br) 808.
 — of vas deferens, 900.
 — vesiculæ seminales, 900.
 — vestibular, 952. 954.
 — vidian, 784.
- Nerve-cells, corpuscles or vesicles, cxcv.
 — development of, cxxxxviii.
 — of encephalon, cciii.-vi.
 ————— ganglia, ccvii.
 ————— spinal cord, cxcix.
 ————— office of, cxxxxiv.
- Nerve-fibres, cxc.
 — afferent, cxxxxiv.
 — axis of, cxcii.
 — of cerebro-spinal nerves, ccxi.
 — development of, cxxxxvi.
 — efferent, cxxxxiv.
 — of encephalon, ccii.-v.
 — of ganglia, ccvii.
 — gelatinous, cxciv.
 ————— nature of, cxxxxvii.
 — office of, cxxxxiv.
 — origin of, in grey matter, cci.
 ————— ganglia, ccviii.
 — of particular nerves, ccxxiv.
 — spinal cord, cc.
 — sympathetic nerves, cxxxxvi.
 — tubular, cxcii.
 — varicose, cxciii.
- Nervi molles, 883.
- NERVOUS SYSTEM, General Anatomy of, clxxxvi.
 ————— cerebro-spinal centre of, cxcix.
 ————— nerves of, ccix.
 ————— divisions or parts of, clxxxvii.
 ————— functions of, clxxxvi.
 ————— ganglia of, ccvi.
 ————— sympathetic portion of, cxxxxvi.

- NERVOUS SYSTEM**, vital properties of, ccxxxiv.
NERVOUS SYSTEM, Descriptive Anatomy of, 667-902.
 ————— cerebro-spinal axis, 667.
 ————— cranial nerves, 767.
 ————— spinal nerves, 817.
 ————— sympathetic nerve, 879.
Nervous Substance, clxxxviii.
 ————— cells or corpuscles of, cxv.
 ————— of cerebro-spinal centre, cxci.
 ————— chemical nature of, clxxxviii.
 ————— of encephalon, grey, cciii. 726.
 ————— white, ccii. 726.
 ————— fibres of, gelatinous, cxci.
 ————— tubular, cxci.
 ————— varicose, cciii.
 ————— of ganglia, ccvii.
 ————— spinal cord, grey, cxci.
 ————— white, cc.
 ————— spinal nerves, ccxi.
 ————— structure of, clxxxix.
 ————— of sympathetic, ccxxvi.
 ————— vesicles of, cxv.
Nervus impar, 677.
Neurilema, ccx.
Neurilema of cord, 755.
Nipple, 1280.
Nodule, cerebellum, 723.
Noduli Arantii, 1111. 1116.
Nodus encephali, 688.
Nose, 955.
 ————— alæ of, 957.
 ————— bones of, 83. 89. 956.
 ————— cartilages of, 956.
 ————— fossæ of, 89. 959.
 ————— mucous membrane of, 959.
 ————— muscles of, 249.
 ————— nerves of, ccxxii. 963.
 ————— septum of, 90. 958.
 ————— skin of, 958.
 ————— vessels of, 962.
Notch, cotyloid, 147.
 ————— sacro-sciatic, great and small, 150.
 ————— sigmoid, 74.
Nuclear fibres, lix.
Nucleolus, xlii.
Nucleus, xlii.
 ————— changes in, lix.
 ————— division of, xlvi.
 ————— origin of, xlv.
Nutrition of textures, lx.
Nutritive secretion, ccxxvii.
Nymphæ, 1254.
Œsophagus, 1013.
 ————— development of, 1056.
Olecranon, 126.
Oleic acid, and **Olein**, xxxi.
Olfactory bulb and nerve, 745. 768. 963. ccxxii.
Olives, or **Olivary bodies**, 685. 731.
Omenta, 1091.
Omentum, gastro-hepatic, 1022. 1092.
 ————— gastro-colic, 1022. 1091.
 ————— gastro-splenic, 1022. 1085. 1093.
 ————— great, 1091.
 ————— small, 1092.
 ————— sac of, 1092.
Opening, saphenous, 448. 1305.
Optic thalami, 707. 715. ccv.
 ————— commissure, 700. 747.
 ————— nerve, (*r*) 746. 769. 917. ccxxiii.
 ————— tract, 697. 746.
Ora serrata, 914. 917.
Orbicular bone, 937.
Orbits, 87.
 ————— muscles of, 261.
 ————— nerves passing into, 771.
 ————— number of bones in, 89.
Organ of Rosenmüller, 1271.
Organon adamantinæ, 988.
Organs of circulation, 1098.
 ————— deglutition, 965.
 ————— digestion, 965.
 ————— proper, 1016.
 ————— generative, female, 1252.
 ————— male, 1214.
 ————— development of, 1274.
 ————— mastication, 965.
 ————— respiration, 1134.
 ————— senses, 903.
 ————— urine, 1187.
 ————— development of, 1270.
 ————— voice, 1158.
Osmazome, xxx.
Os orbiculare seu lenticulare, 937.
 ————— planum, 57.
 ————— tincæ, 1261.
 ————— uteri, externum et internum, 1261.
Ossa triquetra, 32. 60.
 ————— **Wormiana**, 32.
Ossicula auditus, 935.
Ossification, in general, cxlvii.
 ————— of cartilages, ccxxviii. cli.
 ————— centres of, cxlii. *see also* each Bone.
 ————— intra-membranous, cxlviii.
 ————— intra-cartilaginous, cli.
 ————— periods of, cxlii. *see also* each Bone.
 ————— sub-periosteal, cxlix.
Osteo-dentine, 981.
Ostium abdominale, of Fallopiian tube, 1269.
 ————— uterinum, ————— 1269.

- Otic ganglion, 792.
 Otolithes vel otoconia, 950.
 Ovaries, 1266.
 ——— development of, 1274.
 ——— Graafian vesicles of, 1267.
 ——— ligaments of, 1263-6.
 ——— structure of, 1267.
 ——— vessels and nerves, 1269.
 Ovicapsule, 1268.
 Ovula of Naboth, 1263.
 Ovum, 1268.
 ——— development of, 1275.
 Pacinian bodies, ccxix.
 ——— end of nerve-fibre in, ccxxi.
 ——— function of, ccxxii.
 ——— structure of, cxx.
 ——— vessels of, ccxxii.
 Palate, 1003.
 ——— arches of, 287. 1005.
 ——— hard, 81. 1004.
 ——— soft, 287. 1005.
 ——— muscles of, 287. 1006.
 Palpebræ, 903.
 Palpebral cartilages, 904.
 ——— muscles, 246.
 Pampiniform plexus, 645. 1251. 1270.
 Pancreas, 1080.
 ——— development of, 1083.
 ——— duct of, 1082.
 ——— fluid of, 1083.
 ——— lesser, 1081.
 ——— structure of, 1082.
 ——— vessels and nerves of, 1083.
 ——— weight of, 1081.
 Pancreatic duct, 1083.
 ——— juice, 1083.
 Panniculus adiposus, cix. ccxcii.
 Papilla lacrymalis, 904.
 Papillæ, conjunctival, 908.
 ——— cutaneous, cclxxxvi.
 ——— dental, 983.
 ——— mucous, cclxxx.
 ——— conicæ, 1000.
 ——— filiformes, 1000.
 ——— fungiformes, 1000.
 ——— œsophageal, 1016.
 ——— vallatæ, 999.
 ——— of kidney, 1191.
 Par trigeminum, 748. 772.
 ——— vagum, 733. 750. 805. 808.
 Parenchyma of glands, ccxvi.
 ——— of kidney, 1198.
 Parenchymal tissue, cxiii.
 Parotid gland, 1007.
 Pars intermedia of vestibule, 1256.
 Patella, 160.
 Pecten, 144.
 Pectiniform septum, 1220.
 Peculiarities of arteries, *see* each Artery.
 Peduncles of cerebellum, 718. 720. 735.
 ——— cerebrum, 697. 736.
 ——— corpus callosum, 701. 705.
 Peduncles of pineal gland, 717. 741.
 Pelvis, 149.
 ——— articulations of, 217.
 ——— axis of, 152.
 ——— brim and outlet of, 150.
 ——— dimensions of, 154.
 ——— inclination of, 151.
 ——— of kidney, 1192. 1201.
 Penis, 1217. 1225.
 ——— corpus cavernosum, 1218.
 ——— spongiosum, 1223.
 ——— development of, 1279.
 ——— glans of, 1217.
 ——— helicine arteries of, 1222.
 ——— ligament, suspensory of, 1218.
 ——— muscles of, 1229.
 ——— nerves and lymphatics of, 1224.
 ——— vessels of, 1221.
 Penniform muscles, clxv.
 Perforated space, anterior, 700.
 ——— posterior, 699.
 Pericardium, 1100.
 Perichondrium, cxix. cxxx.
 Perilymph, of labyrinth, 948.
 Perinæum, 1313.
 ——— development of, 1279.
 ——— muscles of, 1229. 1314.
 Periodontal membrane, 968.
 Periosteum, cix. cxxxiv. cxliii.
 ——— of teeth, 968.
 Peristaltic action, 1030.
 Peritonæum, 1090-6.
 ——— continuity of, traced, 1094.
 ——— folds of, 1091.
 ——— fossæ or pouches of, 1293.
 ——— ligaments of, 1091.
 ——— mesenteries of, 1093.
 ——— omenta of, 1091.
 ——— structure of, 1090.
 ——— vessels and nerves, 1096.
 Pes anserinus, 798.
 ——— accessorius, 710.
 ——— hippocampi, 710.
 Petrous bone, 42.
 Pia mater, 754.
 ——— of cord, 755.
 Pigment cells, liv. cvi.
 Pigmentum, cclxxxiv.
 ——— of eye, cvi. 912.
 Pillars of fauces, 1005.
 ——— fornix, 709.
 ——— diaphragm, 367.
 Pineal gland, 717.
 Pinna, 925.
 ——— muscles of, 244. 927.
 Pituitary body, 699.
 ——— membrane, 959.
 Phalanges of fingers, 135. 139.
 ——— toes, 173. 178.
 Pharynx, 283. 1012.
 ——— muscles of, 283. 1013.
 ——— action of, 286.

- Plasma of chyle, lxxxviii.
 ——— lymph, lxxxvi.
 ——— blood, lxx.
- Pleura costalis, 1140.
 ——— of mediastinum, 1140.
 ——— pulmonalis, 1139.
- Pleuræ, 1099. 1139.
 ——— structure of, 1141.
- PLEXUSES of Nerves, ccxii.
- aortic, 897.
 ——— inferior, 898.
 ——— brachial, 833.
 ——— branches of, 836.
 ——— cardiac, 891.
 ——— carotid, 884.
 ——— cervical, 828.
 ——— posterior, 823.
 ——— coeliac, 895.
 ——— coronary, anterior, 892.
 ——— posterior, 893.
 ——— of the stomach, 896.
 ——— hepatic, 896.
 ——— hypogastric, 898.
 ——— inferior, 899.
 ——— lumbar, 854.
 ——— branches of, 855.
 ——— mesenteric, inferior, 898.
 ——— superior, 897.
 ——— œsophageal, 812.
 ——— pharyngeal, 804. 809. 882.
 ——— phrenic, 894.
 ——— pulmonary, anterior, 812. 892.
 ——— posterior, 807. 812. 893.
 ——— renal, 895.
 ——— sacral, 866.
 ——— solar, 893.
 ——— spermatic, 895.
 ——— patellar, 863.
 ——— prevertebral, 880.
 ——— cavernous, 885.
 ——— epigastric, 893.
 ——— diaphragmatic, 894.
 ——— supra-renal, 895.
 ——— pancreatic, 896.
 ——— hæmorrhoidal, inferior, 899.
 ——— superior, 898.
 ——— prostatic, 900.
 ——— splenic, 896.
 ——— tonsillar, 804.
 ——— vertebral, 887.
 ——— cardiac, superficial, 892.
 ——— deep, 892.
 ——— gangliosus, 899.
 ——— infraorbital, 782.
 ——— inter-mesenteric, 897.
 ——— ovarian, 901.
 ——— pelvic, 899.
 ——— tympanic, 803. 942.
 ——— vesical, 899.
- PLEXUSES of Lymphatics, cclxi. cclxv.
- PLEXUSES of Veins, ccxlix.
- PLEXUSES, choroid, 707. 713.
 ——— minor, 725.
 ——— ovarian, 645. 1270.
 ——— pampiniform, 645. 1251. 1270.
 ——— pterygoid, 617.
 ——— prostatic, 1216.
 ——— spermatic, 645. 1251.
 ——— uterine, 1265.
- Plica centralis retinæ, 918.
 ——— semi-lunaris, 906.
- Plicæ semi-lunares, 1208. 1263.
- Pomum Adami, 1160.
- Pons Varolii, 682. 688.
 ——— internal structure of, 733.
 ——— weight of, 672.
- Popliteal space, 597.
- Pores of skin, ccxcv.
- Porta or portal fissure, 1062.
- Portal canals, 1068.
 ——— circulation, ccxl.
 ——— vein, 646-9. 1064. (d) 1067.
- Portio dura, nerve, (r) 749. 794. 795.
 ——— mollis, — (r) 749. 794. 800. 952.
- Pouches, laryngeal, 1169.
- Poupart's ligament, 355. 1286.
- Preformative membrane, 987.
- Prepuce, 1217.
- Primitive band or axis of nerve-fibre, cxcii.
- Process, acromion, 110.
 ——— basilar, 32.
 ——— clinoid, 48. 50.
 ——— cochleariform, 45. 934.
 ——— coracoid, 111.
 ——— coronoid, 73.
 ——— hamular, 50.
 ——— of helix, 927.
 ——— mastoid, 42.
 ——— pterygoid, 50.
 ——— sphenoidal, 70.
 ——— styloid, 44.
 ——— vaginal, 44.
 ——— vermiform, 721.
 ——— inferior, 722. 723.
- Processes of bones, cxxxiii.
 ——— ciliary (eye), 913. 921.
- Processus a cerebello ad medullam, 720.
 ——— pontem, 720.
 ——— testes, 718. 719. 720. 738.
- arciformes, 688.
 ——— gracilis (of malleus), 937.
 ——— vaginalis peritonæi, 1238. 1277.
 ——— remains of, 1237.
- Promontory of tympanum, 933.
- Prostate gland, 1214.
 ——— development of, 1279.
 ——— levator muscle of, 1054.
 ——— surgical anatomy of, 1317.
- Prostatic portion of urethra, 1225.

- Prostatic portion, development of, 1279.
 ——— sinus, 1226.
 Protein, xxvi.
 ——— compounds, xxiv.
 Pudendum, 1252.
 Puncta lacrymalia, 904. 907.
 Pupil of eye, 914.
 Pylorus, 1020. 1028.
 Pyramid, in tympanum, 934.
 ——— of cerebellum, 723.
 Pyramids, anterior, 684. 730.
 ——— posterior, 687. 729.
 ——— of kidney, 1190. 1191.
 ——— of Ferrein, 1193.
 ——— Malpighi, 1190. 1191.
 Quadrigeminal bodies, 718.
 Racemose glands, ccciii.
 Raphe of perinæum, 1234. 1280.
 Receptaculum chyli, 653.
 Recto-uterine folds, 1263.
 ——— vesical cul-de-sac, 1206.
 ——— folds, 1208.
 Rectum, 1048. (*See* Intestine, large.)
 ——— structure of, 1050.
 ——— surgical anatomy of, 1318.
 Regeneration of bone, clxiii.
 ——— cartilage, cxxxi.
 ——— cellular tissue, cxviii.
 ——— fibrous tissue, cxxi.
 ——— hair, ccxciii.
 ——— mucous membranes, cclxxxiii.
 ——— muscular tissue, clxxvi.
 ——— nails, cclxxxix.
 ——— nerves, ccxxxviii.
 ——— serous membranes, cclxxii.
 ——— skin, ccxcvi.
 ——— textures, lxiii.
 Renes succenturiati, 1198.
 Reservoirs of glands, ccvii.
 Restiform bodies, 685. 729. 735.
 Rete mirabile, ccxliii.
 ——— mucosum, xcvi. cclxxxiv.
 ——— vasculosum testis, 1244.
 Reticular tissue, cxiii.
 Reticulated white substance, 694.
 Retina, 917.
 Retro-peritonæal membrane, 1090.
 Rigor mortis, clxxxiv.
 Rima glottidis, 1169.
 Ring, abdominal, external, 355. 1287.
 ——— internal, 441. 1291.
 ——— femoral, 1308.
 Roots of nerves, cranial, 745 to 750.
 ——— spinal, 676. 727. 818.
 Rugæ of mucous membrane, cclxxvii.
 Sac lacrymal, 907.
 ——— of omentum, 1092.
 Sacculus vestibuli, 949.
 Sacrum, 13. 27.
 Saliva, 1010.
 Salivary glands, 1007.
 ——— development of, 1011.
 Saphenous nerves, 863. 873.
 ——— opening, 448. 1305.
 ——— veins, 639. 640.
 Sarcolemma, clxvi.
 Sarcous elements, clxvii.
 Satellite veins, ccxlix.
 Scala tympani, 947.
 ——— vestibuli, 947.
 Scalæ of cochlea, 947.
 Scarf-skin, cclxxxiii.
 Schindylesis, 180.
 Schneiderian membrane, 959.
 Sclerotic, 910.
 Scrobiculus cordis, 1018.
 Scrotum, 1234.
 ——— development of, 1280.
 Sebaceous glands, ccxciv.
 Secreting apparatus, ccxcviii.
 ——— cells, ccxcix.
 ——— fringes, cccii.
 ——— glands, ccxcvii.
 ——— membrane, ccc.
 ——— surfaces, cccii.
 ——— increase of, cccii.—ii.
 Secretion, ccxcvii.
 ——— cell-agency in, ccxcix.
 ——— conditions of, ccxcviii.
 ——— nutritive, ccxcvii.
 ——— reservoirs of, ccvii.
 ——— source of, ccxcvii.
 Sella Turcica, 48.
 Semen, 1251.
 Semicircular canals, 944.
 ——— membranous, 949.
 Seminal animalcules, 1252.
 ——— ducts, 1249.
 ——— vesicles, 1248.
 Seminiferous tubes, 1243.
 Semipenniform muscles, clxvi.
 Senses, Organs of, 903 to 964.
 Sensibility, xxxv.
 Septa, intermuscular, 426.
 Septula renum, 1190.
 Septum of auditory ampullæ, 950.
 ——— crurale, 1308.
 ——— of heart, auricular, 1107.
 ——— development of, 1126.
 ——— 1127.
 ——— ventricular, 1108.
 ——— lucidum, 707. 708.
 ——— of medulla oblongata and pons, 734.
 ——— nares, 90. 958.
 ——— nose, cartilaginous, 958.
 ——— osseous, 90.
 ——— pectiniforme, 1220.
 ——— scroti, 1234.
 ——— subarachnoid, 756.
 ——— of tongue, 1003.
 Serous membranes, cclxix.

- Serous membranes, arrangement of, cclxix.
 — fluid of, cclxxi.
 — folds of, cclxix.
 — inflammation of, cclxxii.
 — reparation of, cclxxii.
 — structure of, cclxx.
 — vessels and nerves of, cclxxi.
- Serous vessels, cclvii.
- Serum, lxxv. lxxix.
- Sheath of muscles, clxv.
 — femoral, 1305.
 — of rectus muscle, 360.
- Sheaths of tendons, cclxxv. 124.
- Sigmoid cavity, humerus, 120.
 — ulna, 127.
 — notch, lower jaw, 74.
 — flexure of colon, 1048.
 — valves, pulmonary, 1111.
 — aortic, 1116.
- Sinus, basilar, 638.
 — cavernous, 637.
 — nerves near, 770.
 — circular, 637.
 — of iris, 913.
 — of jugular vein, 619.
 — kidney, 1190.
 — lateral, 636.
 — longitudinal, inferior, 636.
 — superior, 635.
 — occipital, anterior, 638.
 — posterior, 637.
 — petrosal, inferior, 638.
 — superior, 637.
 — of portal vein, 648.
 — pocularis, 1226. 1279.
 — prostatic, 1226.
 — straight, 636.
 — transverse, 638.
 — uro-genitalis, 1274. 1278.
 — venosus, left, 1112.
 — right, 1105.
 — of vestibule, 949.
- Sinuses, aortic, 457. 1116.
 — ethmoidal, 59. 961.
 — frontal, 39. 91. 961.
 — of larynx, 1169.
 — mastoid (cells), 931-4.
 — maxillary, 64. 91.
 — sphenoidal, 48. 91.
 — of Valsalva, aortic, 457. 1116.
 — pulmonary, 1112.
 — (venous) of cranium, 635. 752.
 — confluence of, 635.
- Skeleton, 1.
 — connexions of, 179.
 — human, distinctions of, 94.
- Skin, cclxxxiii.
 — basement membrane of, cclxxxiv.
 — colour of, cvii.
 — corium of, cclxxxiv.
- Skin corium, chemical nature of, cclxxxviii.
 — cuticle, cclxxxiii.
 — chemical nature of, cclxxxiv.
 — cutis vera or corium, cclxxxiv.
 — derma or corium, cclxxxiv.
 — epidermis or cuticle, cclxxxiii.
 — functions of, ccxcvi.
 — furrows of, cclxxxvi.
 — glands, sebaceous, ccxciv.
 — sudoriferous, ccxciv.
 — nails and hairs of, cclxxxviii.
 — nerves of, ccxviii. cclxxxvii.
 — papillæ of, cclxxxvi.
 — pigmentum of, cvi. cclxxxiv.
 — pores of, ccxcv.
 — reproduction of, ccxcvi.
 — rete mucosum of, cclxxxiv.
 — true, cclxxxiv.
 — vessels of, cclxxxvii.
 — vital properties of, ccxcvi.
- Skull, base of, 80.
 — bones of, 29.
 — analogy with vertebræ-92.
 — connexion of, 77.
 — external surface, 80.
 — front of, 83.
 — general conformation of, 79.
 — internal surface, 85.
 — fossæ of, 86.
 — sides of, 84.
- Smegma præputii, 1218.
- Spermatic cord, 1233.
 — coverings of, 1233.
 — fascia, 1235. 1287.
 — vessels, 1250.
- Spermatozoa, 1252.
- Spinal cord, general anatomy of, ccxcix.
 — central canal of, 680.
 — columns of, 677. 726.
 — their course, 729.
 — commissures of, 678.
 — fissures of, 675.
 — internal structure of, 726.
 — ligament of, 675.
 — or marrow, 673.
 — membranes of, 751.
 — sections of, 678.
 — weight of, 673.
- Spinal nerves, 817.
 — divisions of, anterior, 826.
 — posterior, 820.
 — ganglia of, 818.
 — roots of, 676. 727. 818.
 — General Anatomy of, *see* Nerves, general anatomy of.
- Spleen, 1084-90.
 — absorbents of, 1089.
 — accessory, 1089.

- Spleen, capillaries of, 1088.
 — coats of, 1086-7.
 — corpuscles of, 1088.
 — development of, 1089.
 — hilus or fissure of, 1084.
 — ligaments of, 1085.
 — nerves of, 1089.
 — size and weight of, 1085.
 — structure of, 1086.
 — substance of, 1088.
 — trabeculæ of, 1087.
 — vessels of, 1087.
 — uses of, 1090.
- Splenculi, 1089.
- Spongy portion of urethra, 1227.
- Stapes, 937.
- Stearin, xxxi.
- Stellulæ of Verheyen, 1197.
- Stenonian duct, 1008.
- Stomach, 1020.
 — alveoli of, 1025.
 — capillaries of, 1028.
 — coats of, 1022-4.
 — development of, 1056.
 — follicles of, 1027.
 — glands of, 1026.
 — mucous membrane of, 1024.
 — structure of, 1022.
 — tubuli of, 1026.
 — vessels and nerves of, 1027.
 — villi of, 1025.
- Stria cornea, 714.
- Striæ longitudinales, 703. 741.
 — of muscular fibre, clxii.
- Subcutaneous tissue, cxiii.
- Submucous tissue, cxiii.
- Sub-arachnoid space, 755.
 — septum, 756.
- Sub-lingual gland, 1010.
- Sub-maxillary gland, 1009.
- Sub-peduncular lobe, cerebellum, 722.
- Sub-peritonæal membrane, 1090.
- Sudoriferous glands, ccxciv.
- Subserous cellular tissue, cclxxi.
 — tissue, cxiii.
- Substantia cinerea gelatinosa, 678. 727.
 — spongiosa, 727.
- Sulci (brain), 690-692.
 — (heart), 1104.
- Supercilia, 903.
- Superciliary ridges, 37.
- Supplementary organs, *see* those organs.
- Supra-renal capsules, 1198.
 — development of, 1272.
- Surgical anatomy of arteries, brachial, 531.
 — carotid, 470.
 — iliac, common, 568.
 — iliac, external, 584.
- Surgical anatomy of arteries, iliac, internal, 571.
 — epigastric, 1291.
 — femoral, 595.
 — subclavian, 503
 — ischio-rectal fossa, 1313. 1329.
 — hernia, femoral, 1303.
 — inguinal, 1285.
 — perinæum, 1313.
- Sutures, of cranium and face, 77.
- Sweat glands, ccxciv.
- Sylvian aqueduct, 717. 723.
 — fissure, 691.
 — convolution of, 693.
 — ventricle, 708.
- Sympathetic plexuses, 891. *See* Plexuses.
 — nerves, 879.
 — cord of, in neck, 881.
 — loins, 889.
 — pelvis, 890.
 — thorax, 387
 — cranial branches, 884.
 — ganglia of, 879.
 — prevertebral part of, 891.
 — vascular branches of, 883.
 — general anatomy of. *See* Nerve, General Anatomy of.
- Symphysis menti, 72.
 — pubis, 144. 149. 220.
 — sacro-iliac, 218.
- Synarthrosis, 180.
- Synchondrosis, sacro-iliac, 218.
- Synovia, cclxxv.
- Synovial, bursæ, cclxxiv.
 — capsules, cclxxiii.
 — folds or fringes, cclxxiii.
 — membranes, cclxxii.
 — articular, cclxxiii.
 — bursal, cclxxiv.
 — fluid of, cclxxv.
 — structure of, cclxxii.
 — vaginal, cclxxv.
 — sheaths, cclxxv.
- Tanno-gelatin, xxix.
- Tænia semicircularis, 707. 714. 741.
 — hippocampi, 711.
- Tapetum, 740.
- Tarsal ligament, of eyelid, 905.
 — ligaments, foot, 236.
- Tarsi or tarsal cartilages (eyelids), 904.
 — tensor muscle of, 248.
- Tarsus, 167. 176.
- Tartar of teeth, 997.
- Teeth, 967.
 — analogy with bones, 996.

- Teeth, bicuspid, 970.
 — canine, 969.
 — cavity of, 974. 981.
 — cement of, 980. 989.
 — characters of, general, 967.
 ————— special, 968.
 — crusta petrosa of, 980. 989.
 — cuspidate, 969.
 — dentine of, 974.
 — development of, 981.
 — enamel of, 978.
 — eruption of, 985.
 — formation of, 988.
 — growth of, 985.
 — incisor, 968.
 — intertubular substance of, 977.
 — ivory of, 974.
 ————— formation of, 986.
 ————— milk, 973.
 ————— molar, 971.
 ————— multicuspidate, 971.
 ————— nerves of, 974. ccxxii.
 ————— permanent, 968.
 ————— development of, 991.
 ————— eruption of, 995.
 ————— pulps of, 974.
 ————— formation of, 984.
 ————— sacs of, 984, 992.
 ————— structure of, 973.
 ————— supernumerary, 967.
 ————— tartar of, 997.
 ————— temporary, 968. 973.
 ————— development of, 982.
 ————— eruption of, 989.
 ————— shedding of, 995.
 ————— vessels of, 974. 996.
 ————— wisdom, 971.
 Tegmentum, 737.
 Tela choroidea, 713.
 Tendon of Achilles, 405.
 ————— cordiform or central of dia-
 phragm, 368.
 ————— conjoined, 359, 1289.
 ————— (straight) of eyelids, 246. 905.
 Tendons, cxix.
 ————— connection with muscles, clxx.
 Tentorium, 752.
 Testes, 1240-46.
 ————— coni vasculosi of, 1245.
 ————— coverings of, 1233.
 ————— vessels and nerves of,
 1239.
 ————— descent of, 1238. 1277.
 ————— development of, 1274.
 ————— epididymis of, 1241.
 ————— excretory duct of, 1246.
 ————— lobes of, 1243.
 ————— mediastinum of, 1242.
 ————— rete vasculosum of, 1244.
 ————— spermatic cord of, 1233.
 ————— structure of, 1241.
 ————— tubuli of, 1243.
 Testes, tubuli recti of, 1244.
 ————— tunica albuginea of, 1242.
 ————— vaginalis of, 1238.
 ————— vasculosa of, 1243.
 ————— vas aberrans of, 1248.
 ————— deferens of, 1246.
 ————— vasa efferentia of, 1245.
 ————— recta of, 1244.
 ————— vessels and nerves of, 1250.
 ————— (cerebrum, 719).
 Textures in general, xviii.
 ————— chemical composition of, xxiii.
 ————— ultimate, xxiii.
 ————— proximate, xxiii.
 ————— development of, xxxvi,
 vegetable, xxxvii.
 ————— animal, xl.
 ————— elements of, xxi.
 ————— enumeration of, xix.
 ————— nutrition of, lx.
 ————— particular, *see* Tissue, &c.
 ————— permeability of, xxi.
 ————— physical properties of, xxi.
 ————— regeneration of, lxiii.
 ————— systems of, xx.
 ————— vital properties of, xxxiii.
 Thalami optici, 707, 715. ccv.
 Theca vertebralis, 751.
 Thoracic duct, 651. 653.
 Thorax, bones of, 100.
 ————— contents of, 1099.
 ————— general description of, 1098.
 Thymus gland, 1182.
 ————— development of, 1185.
 ————— structure of, 1183.
 ————— vessels and nerves of, 1184-5.
 Thyroid axis, 512.
 ————— body or gland, 1178. 1182.
 ————— development of, 1181.
 ————— levator muscle of, 1180.
 ————— structure of, 1180.
 ————— vessels and nerves of,
 1181.
 ————— cartilage, 1159.
 Tissue adipose, cviii.
 ————— areolar, cxiii.
 ————— cartilaginous, ccxiv.
 ————— cellular, cxiii.
 ————— cuticular, xcii.
 ————— epidemic, xcii.
 ————— epithelial, xcii.
 ————— fibrous, cxviii.
 ————— filamentous, cxiii.
 ————— muscular, clxiii.
 ————— involuntary, clxxii.
 ————— voluntary, clxiii.
 ————— nervous, clxxxix.
 ————— reticular, cxiii.
 Tomentum cerebri, 754.
 Tongue, 998.
 ————— mucous membrane of, 1001.
 ————— muscles of, 1001.

- Tongue, nerves of, 1003. ccxxii.
 ——— papillæ of, 999.
 ——— septum of, 1003.
 ——— vessels of, 1003.
 Tonicity of arteries, ccxlvii.
 ——— muscular, clxxxii.
 Tonsils, 1006.
 Torcular Herophili, 635.
 Trabeculæ of corpus cavernosum, 1220.
 ——— spleen, 1087.
 Trabs cerebri, 703.
 Trachea, 1134.
 ——— cartilages of, 1136.
 ——— development of, 1157.
 ——— glands of, 1138.
 ——— mucous coat of, 1138.
 ——— structure of, 1136.
 ——— vessels and nerves of, 1138.
 Tractus opticus, 697. 746.
 ——— spiralis foraminulentus, 953.
 Tragus, 926.
 ——— muscles of, 928.
 Triangle of Hesselbach, 1298.
 Triangular ligament of urethra, 443.
 1316.
 Trigone of bladder, 1209.
 Trochanters, 156.
 Trochlea, 39. 263.
 Tuba Eustachiana, 45. 934.
 Tubæ Fallopiæ, 1268.
 Tuber annulare, 688.
 ——— cinereum, 699.
 ——— cochleæ, 933.
 ——— ischii, 145.
 Tubercle, grey of Rolando, 31.
 ——— laminated, 723.
 ——— of Lower, 1107.
 Tubercula quadrigemina, 718.
 Tuberculo cinereo, 731.
 Tubular nerve-fibres, cxcii.
 Tubules of nervous substance, cxcii.
 ——— mucous membrane, cclxxxii.
 Tubuli of Ferrein, 1193.
 ——— uriniferi, convoluted, 1193.
 ——— ends of, 1194.
 ——— straight, 1193.
 ——— structure of, 1194.
 ——— of large intestine, 1043.
 ——— recti, 1244.
 ——— seminiferi, 1243.
 ——— of small intestine, 1034.
 ——— stomach, 1026.
 ——— teeth, 976.
 ——— uterus, 1263.
 Tunica, adiposa of kidney, 1189.
 ——— albuginea, 1242.
 ——— of ovary, 1267.
 ——— erythroides, 1235.
 ——— Ruyschiana, 912.
 ——— vaginalis, 1238. 1277.
 ——— vasculosa testis, 1243.
 ——— vasculosa, (eye), 911.
 Tutamina oculi, 903.
 Tympanum, or middle ear, 931.
 ——— bones or ossicula of, 935.
 ——— cavity of, 931.
 ——— ligaments of, 938.
 ——— membrane of, 931.
 ——— lining, 940.
 ——— muscles of, 938.
 ——— scala of, 947.
 ——— secondary membrane of, 934.
 ——— vessels and nerves of, 941.
 Umbilicus, 361.
 Urachus, 1205.
 ——— formation of, 1273.
 Ureters, 1192. 1201.
 ——— development of, 1271.
 ——— muscles of, 1210.
 ——— structure of, 1202.
 ——— varieties of, 1202.
 Urethra, development of, 1278.
 ——— female, 1212.
 ——— compressor muscle of,
 1213, 1232.
 ——— orifice of, 1212. 1254.
 ——— male, 1225.
 ——— bulb of, 1223.
 ——— compressor of, 1231.
 ——— crest of, 1226.
 ——— dilatations of, 1228.
 ——— fossa navicularis of, 1228.
 ——— lacunæ of, 1229.
 ——— mucous membrane of, 1228.
 ——— muscles of, 1229.
 ——— orifice of, 1228.
 ——— portion of, membranous,
 1227.
 ——— bulbous, 1228.
 ——— prostatic, 1225.
 ——— spongy, 1227.
 Urinary, bladder, 1203. (See Bladder.)
 ——— organs, 1187–1213.
 ——— development of, 1270.
 Urine, 1198.
 Uterus, 1259–1266.
 ——— arbor-vitæ of, 1261.
 ——— bifid, 1279.
 ——— cavity of, 1261.
 ——— cellular tissue of, 1262.
 ——— cervix, or neck, 1260.
 ——— changes in, 1265.
 ——— coat of, mucous, 1262.
 ——— serous, 1261.
 ——— development of, 1278.
 ——— fibres of, 1262.
 ——— fundus of, 1260–1279.
 ——— gravid, 1262–5.
 ——— nerves of, 902.
 ——— ligaments of, broad, 1263.
 ——— ovarian, 1264.
 ——— round, 1264–1278.
 ——— nerves of, 901. 1265.
 ——— os or mouth of, external, 1260.

- Uterus os, or mouth of, internal, 1261.
 ———— tincæ of, 1261.
 ———— tissue, proper of, 1261.
 ———— tubular glands of, 1263.
 ———— vessels of, 1265.
 ———— virgin, 1260.
 Utriculus vestibuli, 949.
 ———— virilis, 1226. 1279.
 Uvea, 915.
 Uvula, bladder, 1209.
 ———— cerebellum, 723.
 ———— throat, 1005.
 ———— muscle of, 288.
 Vagina, 1257.
 ———— columns of, 1257.
 ———— development of, 1278.
 ———— sphincter of, 1258.
 Vallecula, 721.
 Valve, of Bauhin, 678.
 ———— cystic duct, 1075.
 ———— Eustachian, 1107. 1127. 1130.
 ———— ileo-cæcal, or ilio-cœlic, 1045.
 ———— mitral, or bicuspid, 1115.
 ———— Thebesian, 1108.
 ———— tricuspid, 1109.
 ———— of Vieussens, 720-723.
 Valves, auriculo-ventricular, left, 1115.
 ———— right, 1109.
 ———— of Kerkring, cclxxvii. 1031.
 ———— lymphatics, cclxiv.
 ———— sigmoid, or semilunar, aortic, 1116.
 ———— pulmo-
 ———— monary, 1109-1111.
 ———— of small intestine, 1031.
 ———— veins, ccli.
 Valvula Thebesii, 649.
 Valvulæ conniventes, cclxxvii. 1031.
 Varicose nerve-fibres, exciii.
 Varieties of vessels or organs, *see* those parts.
 Vas aberrans, 1248.
 ———— deferens, 1246.
 ———— development of, 1276.
 Vasa aberrantia (arteries), brachial, 531.
 ———— afferentia, of lymphatic glands, cclxv.
 ———— brevia, arteries, 556.
 ———— veins, 646.
 ———— chyliifera, 651.
 ———— efferentia, of testis, 1245.
 ———— lymphatic glands, cclxv.
 ———— lactea, 651. cclxii.
 ———— recta, of testis, 1244.
 ———— serosa, cclvii.
 ———— vasorum, cclxvi. ccl.
 ———— vorticiosa, 912.
 Vascula serpentina, 1243.
 VEINS, General Anatomy of, cclxix.
 ———— anastomoses of, cclxix.
 ———— coats of, ccl.
- VEINS, contractility of, ccli.
 ———— distribution of, cclxix.
 ———— plexuses of, cclxix.
 ———— satellite, cclxix.
 ———— structure of, cclxix.
 ———— valves of, ccli.
 ———— vessels and nerves of, ccl.
 ———— vital properties of, ccli.
 VEINS, Descriptive Anatomy of, 612.
 ———— angular, 615.
 ———— articular, of jaw, 617.
 ———— auricular anterior, 617.
 ———— posterior, 617.
 ———— axillary, 624.
 ———— azygos, 628.
 ———— minor, 629.
 ———— basilic, 621.
 ———— basi-vertebral, 632.
 ———— brachial, 623.
 ———— brachio-cephalic, 626.
 ———— bronchial, 629. 1154.
 ———— buccal, 615.
 ———— capsular, 645.
 ———— cardiac, 649.
 ———— cava, inferior, 643.
 ———— superior, 628.
 ———— cerebellar, 634.
 ———— cerebral, 633.
 ———— cephalic, 621.
 ———— of choroid coat, eye, 912.
 ———— comites, brachial, 623.
 ———— femoral, 641.
 ———— inter-osseous, 622.
 ———— popliteal, 641.
 ———— radial, 623.
 ———— tibial, 641.
 ———— ulnar, 622.
 ———— cordis magna, 649.
 ———— media, 649.
 ———— minimæ, 650. 1108.
 ———— parvæ, 650.
 ———— coronary vein, of heart, 649.
 ———— stomach, 647.
 ———— of corpus striatum, 634. 714.
 ———— of cranium, 630. 635-9.
 ———— dental, inferior, 617.
 ———— of diploë, 639.
 ———— dorsal, spinal, 631.
 ———— of penis, 643.
 ———— duodenal, 646.
 ———— emulgent, 645.
 ———— epigastric, superficial, 640.
 ———— ethmoidal, 963.
 ———— facial, 613.
 ———— femoral, 641.
 ———— frontal, 614.
 ———— of Galen, 634.
 ———— gastric, 646.
 ———— gastro-epiploic, 646.
 ———— hepatic, 648. 1064.
 ———— iliac, external, 642.
 ———— internal, 642.

- Veins, iliac, common, 643.
 — innominate, 626.
 — intercostal, anterior, 627.
 — superior, 626.
 — interlobular, 1068. 1070.
 — interosseous, of forearm, 622-3.
 — intra-lobular, 1067. 1070.
 — jugular, anterior, 618.
 — external, 618.
 — internal, 619.
 — laryngeal, 620.
 — lingual, 619.
 — of liver, 1068.
 — lumbar, 644.
 — mammary internal, 627.
 — maxillary internal, 617.
 — median cutaneous, 621.
 — basilic, 621.
 — cephalic, 622.
 — medulli-spinal, 631.
 — meningeal, 617.
 — mesenteric inferior, 646.
 — superior, 647.
 — nasal, 615.
 — occipital, 619.
 — ophthalmic, 638.
 — ovarian, 645.
 — palatine, 616.
 — palpebral inferior, 615.
 — pancreatic, 646.
 — parotid, 617.
 — pharyngeal, 619.
 — phrenic, 645.
 — popliteal, 641.
 — portal, 646-9. 1064. (d.) 1067.
 — posterior scapular, 618.
 — pudic external, 640.
 — pulmonary, 1148. 1153.
 — radial cutaneous, 620.
 — deep, 623.
 — ranine, 616.
 — renal, 645.
 — sacral, middle, 644.
 — salvatella, 621.
 — saphenous, long or internal, 639.
 — short or external, 640.
 — spermatic, 645.
 — spinal, 630-3.
 — great, 632.
 — posterior, 633.
 — splenic, 646. (d.) 1088.
 — subclavian, 624.
 — sub-lobular, 1067.
 — submental, 616.
 — supra-orbital, 614.
 — supra-renal, 645.
 — supra-scapular, 618.
 — temporal, deep, 617.
 — middle, 616.
 — temporo-maxillary, 617.
 — thyroid, superior, 620.
 — middle, 620.
- Veins, thyroid inferior, 627.
 — transverse of face, 617.
 — ulnar-cutaneous anterior, 621.
 — posterior, 621.
 — deep, 622.
 — umbilical, 1061. 1078. 1131.
 — vaginal, 1258.
 — of liver, 1068.
 — vasa brevia, 646.
 — vertebral, 625.
- VEINS, plexuses of, ovarian, 645.
 — pampiniform, 645.
 — 1251.
 — pterygoid, 617.
 — spermatic, 645.
- Velum pendulum palati, 287, 1005.
 — interpositum, 713.
 — medullæ anterior, 720.
 — posterior, 723.
- Vena cava, fossa of, 1063.
 Venæ comites, ccclix.
- Ventricle, of Arantius, 687.
- Ventricles of brain, 682. 702.
 — fifth, 708.
 — fourth, 723.
 — lateral, 705.
 — third, 714.
 — corpus callosum, 702.
 — heart. *See* Heart.
 — larynx, 1169.
- Ventriculi tricornes, 706.
- Vermicular motion, 1030.
- Vermiform process, 721.
 — inferior, 722, 723.
- Vertebra dentata, 11.
 — prominens, 12.
- Vertebrae, 3.
 — cervical, 6. 9.
 — coccygeal, 13.
 — cranial, 92.
 — dorsal, 7. 12.
 — false, 4. 13.
 — general characters of, 4.
 — lumbar, 8. 13.
 — ossification of, 20, 22.
 — peculiarities of, 9.
 — sacral, 13.
 — true, 4.
- Vertebral aponeurosis, 299. 433.
 — column, 3. 18.
 — ligaments of, 186.
 — ossification of, 20, 29.
- Verumontanum, 1226. 1279.
- Vesica prostatica, 1226.
 — fellea, 1073.
 — urinaria, *see* Bladder.
- Vesicles of glands, ccciii.
 — Graafian, 1267. 1275.
 — seminal, 1248. 1279.
- Vesico-uterine folds, 1263.
- Vesiculæ Graafianæ, 1267.
 — seminales, 1248.

- Vesiculæ seminales, development of, 1279.
 ————— vessels and nerves of, 1251.
- Vessels, office of, lxii.
 ————— of different tissues and organs, *see* those parts.
- Vestibule, aqueduct of, 44. 944.
 ————— bulbs of, 1256.
 ————— of ear, 943.
 ————— membranous, 949.
 ————— nerves of, 952, 954.
 ————— sacculæ of, 949.
 ————— scala of, 947.
 ————— sinus of, 949.
 ————— vessels of, 951.
 ————— of vulva, 1254.
- Vestigium foraminis ovalis, 1107. 1113.
- Vibrios of mouth, 997.
- Vibrissæ, 959.
- Vidian canal, 52.
 ————— nerve, 784.
- Villi, cclxxx.
 ————— of small intestine, 1032.
 ————— stomach, 1025.
- Vis nervosa, xxxv. ccxxxv.
- Viscera of abdomen, 1019.
 ————— position of in regions, 1096.
- Viscera of thorax, 1098-9.
- Vital contractility, xxxiv.
 ————— muscular, clxxvii.
 ————— non-muscular, xxxv. clxxxv.
- Vitreous humour, 921.
- Vocal cords, 1168.
- Voluntary muscles, clxiii.
- Vortex, of heart, 1121.
- Vulva, 1252.
 ————— development of, 1279.
 ————— erectile tissue of, 1255.
 ————— mucous membrane of, 1255.
 ————— vessels and nerves of, 1256.
- Wisdom tooth, 971.
- Wolffian bodies, 1270.
- Womb, *see* Uterus.
- Worm (cerebellum), 721.
- Yellow cartilage, cxxviii.
 ————— fibres of cellular tissue, cxv.
 ————— ligaments, cxxiii.
 ————— tissue, cxxii.
- Zomidin, xxx.
- Zonula lucida, 921.
 ————— Zinnii vel ciliaris, 914. 921.
- Zygoma, 41.
- Zygomatic arch, 41. 67.

END.

LONDON :
Printed by S. & J. BENTLEY, WILSON, and FLEY,
Bangor House, Shoe Lane.





