

The muscles of the back are disposed in five layers, one beneath another. The two largest and most superficial are the *trapezius* and the *latissimus dorsi*.

The *trapezius* arises from the middle of the occipital bone, and from the spine as far as the last dorsal vertebra. From this extended line of origin the fibres converge to their insertion in the acromion process and spine of the scapula. The *latissimus dorsi* arises from the last six dorsal vertebrae, and through the medium of the lumbar aponeurosis, from the lumbar and sacral part of the spine and from the crest of the ilium. The fibres pass upwards and converge into a thick, narrow band, which winds around and finally terminates in a flat tendon, which is inserted into the front of the humerus just below its head.

These muscles cover nearly the whole of the back; but as they act upon the bones of the upper extremity, they are often more properly reckoned as belonging to the muscles of that region.

The muscles of the thorax are chiefly concerned with the movements of the ribs during respiration. They are the *intercostals*, *subcostals*, etc.


The chief bulk of the anterior muscular wall of the chest is made up of the *pectoral* muscles, which arise mainly from the front of the sternum. The fibres converging form a thick mass, which is inserted by a tendon of considerable breadth into the upper part of the humerus. As these muscles move the arm, they are, like the superficial muscles of the back, usually reckoned among the muscles of the upper extremity. Covering the pectoral muscles is a superficial fascia (composed of connective tissue) in which are lodged the mammary glands and a variable amount of fat.

The muscular walls of the abdomen are mainly formed by three layers of muscles, the fibres of which run in different directions, those of the superficial and middle layers being oblique, and those of the innermost layer being transverse. In front, these three layers of muscles are replaced by tendinous expansions or aponeuroses, which meet in the middle line, the line of union giving rise to a white cord-like line, the *linea alba*. On each side of this line the fibres of a straight muscle, the *rectus* muscle, extend in a vertical direction between the tendinous



PLATE IV. — MUSCLES OF CHEST AND ABDOMEN. 55, pectoral muscle; 44, serratus magnus; 34, external oblique; 35, rectus abdominis, the external layer of aponeurotic sheath is removed; 38, linea alba; 40, aponeurosis.

UNIVERSITY OF CALIFORNIA
MEDICAL CENTER LIBRARY
SAN FRANCISCO



Gift of
Mrs. Ginelle Lemon



Digitized by the Internet Archive
in 2007 with funding from
Microsoft Corporation

TEXT-BOOK

OF

ANATOMY AND PHYSIOLOGY

FOR NURSES

COMPILED BY

DIANA CLIFFORD KIMBER

GRADUATE OF BELLEVUE TRAINING SCHOOL; ASSISTANT-SUPERINTENDENT NEW YORK CITY
TRAINING SCHOOL, BLACKWELL'S ISLAND, N. Y.; FORMERLY ASSISTANT
SUPERINTENDENT ILLINOIS TRAINING SCHOOL, CHICAGO, ILL.

QM26

K49

1893

New York

THE MACMILLAN COMPANY

LONDON: MACMILLAN & CO., LTD.

1899

[C1893]

All rights reserved

COPYRIGHT, 1893,
BY MACMILLAN AND CO.

Set up and electrotyped September, 1894. Reprinted
November, 1894; February, August, 1895; January, No-
vember, 1896; July, December, 1897; September, 1898;
July, 1899.

Norwood Press
J. S. Cushing & Co. — Berwick & Smith
Norwood Mass. U.S.A.

Affectionately Dedicated

TO MY

FRIEND, SCHOOLMATE, AND SUPERINTENDENT

Louise Barche

GRADUATE OF BELLEVUE TRAINING SCHOOL

AND

SUPERINTENDENT NEW YORK CITY TRAINING SCHOOL

BLACKWELL'S ISLAND, N.Y.

The following illustrations have been copied from Quain's "Anatomy" and Schäfer's "Essentials of Histology," and are used in this work by permission of the authors and publishers of those books, viz. : Figs. 4, 5, 8, 10, 12, 14, 51, 53, 64, 69, 83, 86, 103, 110, 117, 121, 127, 128.

PREFACE.

IN preparing the following pages for publication, it has been my endeavour to keep the fact that I was writing for nurses, constantly in mind. So far as I know, no attempt has yet been made to compile a text-book on anatomy and physiology for the use of nurses, although the subject is more or less universally and systematically taught in our training schools. During several years I have spent much time and trouble in preparing notes on this subject for class-teaching, and it was suggested to me that if these notes could be put into shape, they might prove useful in our schools. The scheme of the book has been practically worked out in class-teaching, and in compiling the notes from standard works on anatomy and physiology, I have sought to abstract that which shall prove valuable and interesting to the nurse, while avoiding those innumerable and minute details indispensable to the medical student.

On first glancing through the following pages, it may be thought that the structural elements of the tissues have been dwelt upon at greater length than is at all necessary, and that the whole subject has been thereby made unnecessarily difficult. In reply to which I can only say that after repeated experiments in teaching, this method has gradually revealed itself to me as the most effectual one for making the subject intelligible, and I have found, after careful instruction in the structure of the tissues, the student most readily understands the functions of the different parts of the body.

It is always well to bear in mind that the primary object of educative methods is to enlarge the mental capacity of the

student, and not to make her swallow a mass of undigested facts. To insist upon accuracy of statement; to enlarge the pupil's vocabulary; to train her to trace from cause to effect in different conditions, — if nothing else is accomplished, this is a great deal, and will make a nurse of distinctly greater value and of higher grade, than one whose mind has not, with all her training, been trained to think.

It seemed best to arrange the book in chapters rather than in lessons, owing to the difficulty of making each subject of an equal length; in the introductory contents, however, a scheme of the subject, arranged in lessons of suitable length, is provided. It is, perhaps, superfluous to suggest that in making use of the text-book for class-teaching, each lesson should be illustrated as far as possible by anatomical charts, skeleton or manikin, and, where obtainable, by specimens from the human subject.

The book has been compiled from the following works: Quain's "Anatomy," edited by E. A. Schäfer, F.R.S., and Prof. G. D. Thane; Gray's "Anatomy," edited by T. Pickering Pick; "Text-book of Physiology," by M. Foster, M.A.; "Physiology and Hygiene," by T. H. Huxley, F.R.S., and D. J. Youmans, M.D.; "Human Physiology," by John C. Dalton, M.D.; "The Human Body," by H. Newell Martin, M.D.; Woods' "Household Practice of Medicine," edited by Fred. A. Castle, M.D.; "The Essentials of Histology," by E. A. Schäfer, F.R.S.; "Practical Normal Histology," by F. M. Prudden, M.D.

I am specially indebted to my friend, Louise Darche, for invaluable assistance. Without her aid, the book would neither have been begun, continued, or finished, and if it meets the requirements of our schools, it will be largely owing to her hearty co-operation and the criticism and advice given by her in every page.

CONTENTS.

ARRANGED IN CHAPTERS AND LESSONS.



CHAPTER I.

	PAGE
(LESSON I.) Introductory — General Outline of the Body ; Different Parts of the Body ; Structural Elements of the Tissues ; The Cell	1

CHAPTER II.

(LESSON II.) Origin of Tissues ; Epithelial Tissues ; Stratified ; Transitional ; Simple	8
--	---

CHAPTER III.

(LESSON III.) Connective Tissues : Connective Tissue Proper ; Adipose or Fat Tissue ; Reticular and Lymphoid Tissue. — (LESSON IV.) Cartilage ; Bone	13
--	----

CHAPTER IV.

(LESSON V.) The Skeleton ; Long and Short Bones. — (LESSON VI.) Flat and Irregular Bones. — (LESSON VII.) General Review of Bones	23
---	----

CHAPTER V.

(LESSON VIII.) The Joints	47
-------------------------------------	----

CHAPTER VI.

(LESSON IX.) Muscular Tissues ; Striated or Striped ; Non-striated or Plain — Attachment of Muscles to Skeleton. — (LESSON X.) Prominent Muscles of the Head and Trunk. — (LESSON XI.) Prominent Muscles of the Limbs	52
---	----

NOTE. — In most training schools in America instruction in class is given from Oct. 1 to June 1, or for thirty-eight consecutive weeks: the lessons in this text-book can be conveniently mastered in the first year's course, taken in the manner indicated in these introductory contents.

LIST OF ILLUSTRATIONS.

FIGURE	PAGE
1. Diagrammatic Longitudinal Section of the Trunk and Head	2
2. Diagram of a Cell	4
3. Consecutive Stages of Cell-Division, with Indirect Division of the Nucleus	6
4. Section of Stratified Epithelium	9
5. Section of the Transitional Epithelium lining the Bladder	10
6. Simple Pavement Epithelium	10
7. Simple Columnar Epithelium	11
8. Glandular Epithelium, with the Cells set round a Simple Saccular Gland	11
9. Ciliated Epithelium from the Human Trachea	11
10. Subcutaneous Areolar Tissue from a Young Rabbit	14
11. Fibrous Tissue from the Longitudinal Section of a Tendon	15
12. A Few Fat Cells from the Margin of a Fat Lobule	17
13. Articular Hyaline Cartilage from the Femur of an Ox	19
14. Transverse Section of Compact Tissue (of Humerus)	21
15. The Skeleton	24
16. The Clavicle	25
17. The Humerus	25
18. The Ulna and Radius	26
19. Bones of the Wrist and Hand	26
20. The Femur	27
21. Bones of the Right Leg	28
22. Bones of the Ankle and Foot	28
23. Occipital Bone	29
24. Parietal Bone	30
25. Frontal Bone	31
26. Nasal Bone	31
27. Lachrymal Bone	31
28. Vomer	32
29. Scapula	32
30. Sternum	33
31. Os Innominatum	34
32. Temporal Bone	35
33. Sphenoid Bone	36
34. Ethmoid Bone	36
35. Malar Bone	37
36. Palate Bone	37

FIGURE	PAGE
37. Inferior Turbinated Bone	37
38. Superior Maxillary Bone	37
39. Inferior Maxillary Bone	38
40. Hyoid Bone	38
41. A Cervical Vertebra	39
42. Side View of Spinal Column, without Sacrum and Coccyx	40
43. The Skull	41
44. The Skull at Birth	42
45. Male Pelvis	43
46. Female Pelvis	43
47. Thorax	44
48. A Toothed or Dentated Suture	47
49. A Mixed Articulation	49
50. A Simple Complete Joint	48
51. Muscular Fibre	52
52. Fragments of Striped Fibres showing a Cleavage in Opposite Directions	53
53. Wave of Contraction passing over a Muscular Fibre of Dytiscus	54
54. Fibre-Cells of Plain Muscular Tissue	55
55. Muscles of Right Eyeball within the Orbit	58
56. Muscles of Eyeball	58
57. Muscles of the Tongue	60
58. Muscles of the Arm	66
59. Muscles in Front of Forearm	67
60. Muscles of the Thigh	68
61. Muscles of the Leg. Superficial View of the Calf	69
62. Red and White Corpuscles of the Blood	75
63. The Heart and Lungs	82
64. Anterior View of Heart, dissected after long Boiling, to show the Superficial Muscular Fibres	83
65. Right Side of Heart	84
66. Left Side of Heart	85
67. Section of Heart at Level of Valves	85
68. Structure of an Artery	88
69. Part of a Vein laid Open	90
70. Portion of Endothelium of Peritoneum	91
71 and 72. The Aorta	95
73. The Carotid, Subclavian, and Axillary Arteries	96
74. Deep Anterior View of the Arteries of the Arm, Forearm, and Hand	97
75. Iliac and Femoral Arteries	100
76. View of Popliteal Artery	101
77. Deep View of the Arteries of the Back of the Leg	102
78. Anterior View of Arteries of the Leg	102
79. Arteries of the Foot	103
80. Sketch of the Principal Venous Trunks	104
81. Superficial Veins of Lower Extremity	105
82. Diagram of Circulation	109
83. Isolated Capillary Network formed by the Junction of Several Hollowed-out Cells, and containing Coloured Blood Corpuscles in a Clear Fluid	118

LIST OF ILLUSTRATIONS.

XV

FIGURE	PAGE
84. A Small Portion of a Lymphatic Plexus	120
85. Lymphatics and Lymphatic Glands of Axilla and Arm	124
86. Diagrammatic Section of Lymphatic Gland	125
87. Vertical Section of a Portion of a Peyer's Patch, with Lacteal Vessels injected	126
88. The Mouth, Nose, and Pharynx, with the Commencement of Gullet and Larynx	130
89. The Larynx as seen by Means of the Laryngoscope	131
90. Front View of Cartilages of Larynx	132
91. Two Alveoli of the Lung	133
92. Anterior View of Lungs and Heart	134
93. Diagram showing the Various Forms of Secreting Structures	143
94. An Intestinal Villus	146
95. The Salivary Glands	155
96. The Mouth, Nose, and Pharynx,* with the Larynx and Commence- ment of Gullet, seen in Section	157
97. Vertical and Longitudinal Section of Stomach and Duodenum	159
98. An Intestinal Villus	160
99. Section through the Lymphoid Tissue of a Solitary Gland	161
100. Cæcum, showing its Appendix, Entrance of Ilium, and Ileo-Cæcal Valve	162
101. Posterior View of Pancreas	163
102. Under Surface of Liver	164
103. Diagrammatic Representation of Two Hepatic Lobules	165
104. Section of Rabbit's Liver, Vessels and Bile Ducts injected	166
105. The Renal Organs viewed from Behind	180
106. Section through the Kidney	182
107. Vascular Supply of Kidney	183
108. Plan of Blood-Vessels connected with the Tubules	184
109. Diagram of the Course of Two Uriniferous Tubules	185
110. Section of Epidermis	189
111. Section of Skin showing Two Papillæ and Deeper Layers of Epidermis	191
112. Piece of Human Hair	192
113. Section of Skin showing the Hairs and Sebaceous Glands	193
114. Coiled End of a Sweat-Gland	194
115. Multi-polar Nerve-Cell	200
116. Nerve-Fibres	201
117. Section of the Internal Saphenous Nerve	202
118. Diagram illustrating the General Arrangement of the Nervous System	203
119. Side View of the Brain and Spinal Cord in Place	204
120. The Base of the Brain	205
121. Transverse Sections of the Spinal Cord at Different Levels	211
122. Base of Brain, Spinal Cord, and Spinal Nerves	212
123. Sections of Spinal Cord and Nerve-Roots	213
124. General View of the Sympathetic System	214
125. Nerve Ending in Muscular Fibre of a Lizard	215
126. Section of Skin, showing Tactile Corpuscle in Papilla	216
127. End-Bulbs from the Human Conjunctiva	217
128. The Upper Surface of the Tongue	220
129. Vertical Longitudinal Section of Nasal Cavity	222

FIGURE	PAGE
130. Semi-diagrammatic Section through the Right Ear	224
131. The Left Eyeball in Horizontal Section from before Back	228
132. Diagrammatic Section of the Human Retina	230
133. Diagram illustrating Rays of Light converging in (A) a Normal Eye, (B) a Myopic Eye, and (C) Hypermetropic Eye	233
134. The Lachrymal Apparatus	235
135. Section of Female Pelvis showing Relative Portion of Viscera	238
136. The Uterus and its Appendages	240
137. Section of an Ovary	242

PLATES.

PLATE	PAGE
I. Forms of Muscles and Tendons	57
II. Muscles of Face, Head, and Neck	59
III. Muscles of Back	61
IV. Muscles of Chest and Abdomen	63
V. The Abdominal Aorta and its Contents	99
VI. Plan of Fœtal Circulation	116
VII. Regions of the Abdomen and their Contents	154

TEXT-BOOK

OF

ANATOMY AND PHYSIOLOGY FOR NURSES.



CHAPTER I.

INTRODUCTORY.—GENERAL OUTLINE OF THE BODY.—DIFFERENT PARTS OF THE BODY.—STRUCTURAL ELEMENTS OF THE TISSUES.—THE CELL.

Introductory.—In looking upon the fully developed human body we are impressed with the complexity of its structure, the perfection of its mechanism, the mysteriousness of its life. To learn to understand something of this structure, this mechanism, this life, is one of our most imperative duties as nurses; for how can we appreciate the significance of abnormal functions, and the seriousness of diseased conditions, unless we are acquainted with the normal functions of the body, and have some knowledge of healthy bodily conditions?

In the following pages we propose to give a description of the structure, of the position, and of the special work or function of each part of the body. We have dwelt specially upon the structure of the different parts, believing that any correct understanding of the bodily functions must be preceded by a certain amount of knowledge concerning the structure of the organs performing these functions.

Before taking up the subject in detail it is well, first of all, to get a general idea of the main divisions, and the position of the different parts, and we shall therefore begin our consideration of the body with an outline of its structure.

General outline of the body.—It is readily seen that the human body is separable into trunk, head, and limbs; the trunk and head are cavities, and contain the internal organs or viscera,

while the limbs are solid or semi-solid, contain no viscera, and are merely appendages of the trunk. The limbs or extremities, upper and lower, are in pairs, and bear a rough resemblance to one another, the shape of the bones, and the disposition of the muscles in the thigh and arm, leg and forearm, ankle and wrist, foot and hand, being very similar.

The trunk and head contain two main cavities, and looking at the body from the outside we should naturally imagine that these two cavities were the cavity of the head and the cavity of the trunk, respectively. If, however, we divide the trunk and head lengthwise into two halves, by cutting them through the middle line from before backwards, we find the trunk and head are divided by the bones of the spine into back and front cavities, and not into upper and lower (*vide* diagram).

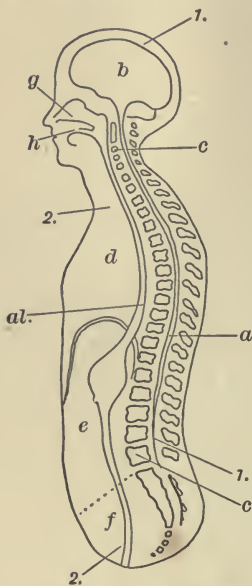


FIG. 1. — DIAGRAMMATIC LONGITUDINAL SECTION OF THE TRUNK AND HEAD. 1, 1, the dorsal cavity; a, the spinal portion; b, the cranial enlargement; c, c, the bodies of the vertebræ forming the partition between the dorsal and ventral cavities; 2, 2, the ventral cavity, subdivided into thoracic cavity (d), abdominal cavity (e), and pelvic cavity (f); g, the nasal cavity; h, the mouth, or buccal cavity. The alimentary canal (al) is represented running through the whole length of the ventral cavity.

The dorsal or back cavity is a complete bony cavity, and is formed by the vertebræ (bones of the spine) and of the bones of the skull. It may be subdivided into the spinal canal, containing the spinal cord, and into the cranial cavity, which is merely an enlargement of the spinal canal, and contains the brain. Connected with the dorsal cavity are the two small orbital cavities containing the organs of sight.

The ventral or front cavity is not a complete bony cavity, part of its walls being formed of muscular and other tissue; it is much larger than the dorsal cavity, and may be subdivided into the thoracic, abdominal, and pelvic cavities. The thoracic cavity, or chest, contains the trachea or windpipe, the lungs, gullet, heart, and the great vessels springing from, and entering into, the heart. The abdominal cavity contains the stomach, liver, gall-bladder, pancreas, spleen, kidneys, small and large

intestines, etc. The pelvic cavity contains the bladder, rectum, and generative organs. Connected with the upper part of the ventral cavity are two small cavities, the buccal cavity, or mouth, containing the tongue, teeth, salivary glands, etc., and the nasal cavity, containing the organ of smell.

Different parts of the body.—In speaking of the different parts of the body, we usually call each part an organ, and we may say that the human body is made up of organs, each organ being adapted to the performance of some special work or function. Thus the lungs are organs specially adapted for performing the function of respiration, the bones are organs adapted for support and locomotion, the kidneys for secreting urine, etc.

Every part or organ, when separated into minute fragments, is found to consist of certain textures or tissues. When the body is thus separated or dissected, and analyzed by the aid of the microscope, we find that the number of distinct tissues is comparatively small, and some of these again, although at first sight apparently distinct, yet have so much in common in their structure and origin one with another, that the number becomes still further reduced, until we can only distinguish four distinct tissues, viz.:—

- | | |
|-------------------------|-----------------------|
| The epithelial tissues. | The muscular tissues. |
| The connective tissues. | The nervous tissues. |

Particles met with in the fluids of the body, such as the little bodies or corpuscles in the blood and lymph, are also reckoned among these elementary tissues.

Some organs are formed of a combination of several of the above tissues; others contain only one or two. Thus the muscles are made up almost entirely of muscular tissue with only a small intermixture of connective tissue, blood-vessels, and nerves; whilst the ligaments or sinews are composed wholly of a variety of connective tissue.

On the other hand, there are certain organs or parts of the body not in themselves distinguished by the preponderance of any tissue. Such are:—

- | | |
|---|---------------------|
| Blood-vessels. | Synovial membranes. |
| Lymphatic vessels. | Mucous membranes. |
| Lymphatic glands and bodies
of like structure. | Secreting glands. |
| Serous membranes. | Integument or skin. |

Thus, though we may say the greater bulk of the body is made up of a combination of four distinct tissues, — the epithelial, connective, muscular, and nervous, — there are parts in which these tissues are so intimately mixed that we cannot distinguish any distinct variety, and we are therefore obliged to class them by themselves.

Structural elements of the tissues. — When any tissue is separated by the aid of the microscope into its simplest parts, such parts are termed the structural elements of the tissue. The simplest structural element of every tissue is a cell or fibre,¹ and however diversified the tissues of the body may appear to be, they all originate as collections of cells. All the varied activities of the body are the result of the activity of the cells which compose it, and it is very desirable, owing also to their being the foundation of all structure (the bricks, as it were, out of which the tissues are built), that we early acquire some definite conception of these tiny elementary bodies.

The cell. — A cell is a minute portion of living substance called protoplasm, which is sometimes enclosed by a cell membrane, and always contains a vesicle which is known as the nucleus.

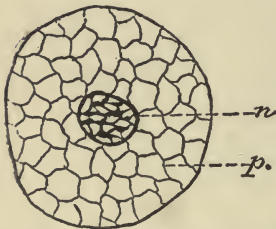


FIG. 2. — DIAGRAM OF A CELL. *n*, nucleus; *p*, protoplasm.

Up to 1865 it was universally believed that protoplasm had no definite parts, or, in other words, was structureless; but, when examined under the highest microscopical power, it appears as an exceedingly fine network of delicate fibres. The width of the meshes varies to some extent; sometimes they are narrow and close, and sometimes wider and more open. The interspaces are filled with a clear soft semi-fluid substance and minute particles or granules of variable size. The microscope can tell us little more than this, though there are good grounds for supposing that there is structure that cannot be directly observed. We have to turn to the chemical nature of protoplasm for light as to the cause of its remarkable properties.

All matter of whatever kind is made up of little particles or atoms, so small that they are perfectly invisible to the human

¹ A fibre is merely a modified cell.

eye even when aided by all the appliances of optical science, and it is only when a number of these atoms unite into one body that they become visible. Every little piece of matter which we can see is built up of thousands, or rather millions, of these atoms. There are many different kinds of atoms. Thus we have carbon, hydrogen, oxygen, and other kinds, each having its own particular weight, and probably its own particular size and shape. They combine by mutual attraction, which in some cases we call cohesion, and in others chemical affinity, according as the atoms are of the same or of different kinds. In this way an endless variety of structures may be built up. These structures may be stable and solid, the myriads of atoms composing them cohering so firmly together that it is almost impossible to separate them; or they may be very unstable, or complex, the particles composing them being of many different kinds and sizes, held together in the loosest fashion, and ready to fall apart at the slightest touch. Again, we may have many structures varying in stability between these two extremes.

Protoplasm is a highly complex structure, and its chemical equilibrium is so unstable that it is ready to break down at the least touch. It is extremely sensitive to any outside stimulus. Slight influences cause it to alter its shape, move, and exhibit other phenomena; these phenomena being mainly due to the inter-action of the chemical affinities of which it is composed.

During the life of a cell its protoplasm is constantly undergoing changes, the chief of which may be enumerated as follows:—

(1) All protoplasm coming in contact with oxygen absorbs it and combines with it. Whenever this combination takes place, a certain amount of the protoplasm is burned or oxidized, and as a result of this oxidation heat and other kinds of energy are produced, and carbonic acid evolved.

(2) All protoplasm is able to take into itself, and eventually convert into its own substance, material that is non-living; this material or food is generally supposed to be a compound chemical substance called *proteid*, which is a combination of nitrogen, carbon, oxygen, and hydrogen. In this way the protoplasm may increase in amount, or in other words the cell may grow; but if the amount of protoplasm does not permanently increase, this is due to the fact that just as much protoplasm is being

broken down by the process of oxidation, and removed from the cell, as is added by the process of assimilation. Chemical changes which involve the building up of living material within the cell have received the general name of *anabolic* changes; those, on the other hand, which involve the breaking down of such material into other and simpler products, are known as *katabolic* changes; while the sum of all the ana- and katabolic changes which are proceeding within the cell are spoken of as the *metabolism* of a cell. These chemical changes are always more marked as the activity of the cell is promoted by warmth, electrical or other stimulation, the action of certain drugs, etc.




FIG. 3.— A TO H, CONSECUTIVE STAGES OF CELL-DIVISION, WITH INDIRECT DIVISION OF THE NUCLEUS. (Diagrammatic.)

(3) The most obvious physical changes which can be seen in living protoplasm, by the aid of the microscope, are those which are termed “amœboid.” This term is derived from the fresh water amœba, which has long been observed to exhibit spontaneous changes of form, accompanied by a flowing of its soft semi-fluid substance. By virtue of this property, the cells can move from one place to another. If one of these cells be observed under a high power

of a microscope, it will be seen gradually to protrude a portion of its protoplasm; this protrusion extends itself, and the main part or body of the cell passes by degrees into the elongated protrusion. By a repetition of this process, the cell may glide slowly away from its original situation and move bodily along the field of the microscope, so that an actual locomotion takes place. When the surface of these free cells comes in contact

with any foreign particle, the protoplasm, by virtue of its amœboid movements, tends to flow round and enwrap the particles, and particles thus enwrapped or incepted may then be conveyed by the cell from one place to another.

The nucleus. — The nucleus of a cell is directly concerned in the reproduction and division of the cells. In dividing, the nucleus passes through a series of remarkable changes, which are too complicated to be studied here. (See Fig. 3.) The result of these changes is that either directly or indirectly the nucleus splits into two, the protoplasm divides and arranges itself around the new nuclei; these daughter cells soon grow to the size of the parent cell, and division of these and consequent multiplication may proceed with great rapidity.

To sum up: The cell assimilates, is continually building itself up, and replenishing its store of energy, is as continually breaking down into simpler products, with a setting free of energy; it grows; it moves; it reproduces itself—in other words, it is alive and is the basis of all life.

CHAPTER II.

ORIGIN OF TISSUES. — EPITHELIAL TISSUES: STRATIFIED, TRANSITIONAL, SIMPLE.

Origin of tissues. — In the first chapter we stated that the body is made up of different parts or organs, each having some special work to do; each part is made up of tissues, of which there are four distinctive kinds; each tissue is made up of structural elements, cells and fibres; and finally, each fibre being a modified cell, the cell is the basis of all the bodily structures.

Thus, in the early embryo, the whole body is an agglomeration of cells. These have all been formed from the ovum or egg-cell, which divides into two cells; these again into two, and so on until numbers of cells are produced. Eventually these cells arrange themselves in the form of a skin or membrane which is composed of three layers. These layers are known respectively as the *epiblast*, or upper layer; the *mesoblast*, or middle layer; the *hypoblast*, or under layer. The epiblast is supposed to give rise to the nervous tissue and most of the epithelial tissue; the mesoblast to the connective and muscular tissues; the hypoblast to the rest of the epithelial tissue. Of these tissues, the epithelial is the simplest, and most nearly allied to the primitive tissue, and will first engage our attention.

Epithelial tissue. — Epithelial tissue is composed entirely of cells united together by cohesive matter. The cells are generally so arranged as to form a skin or membrane, covering the external and internal surfaces of the body. This membrane is seen when the skin is blistered, the thin and nearly transparent membrane raised from the surface being epithelial tissue — in this situation called epidermis, because it lies upon the surface

of the true skin. In other situations, epithelial tissue usually receives the general name of *epithelium*.

Classification.— We may classify the varieties of epithelium according to the shape of the cells which compose them, or according to the arrangement of these cells in layers. Adopting the latter and simpler classification, we distinguish three main varieties: the stratified, consisting of many layers; the transitional, consisting of two or three layers; the simple, consisting of a single layer of cells.

1. **Stratified epithelium.**— The cells composing the different layers of stratified epithelium differ in shape. As a rule, the

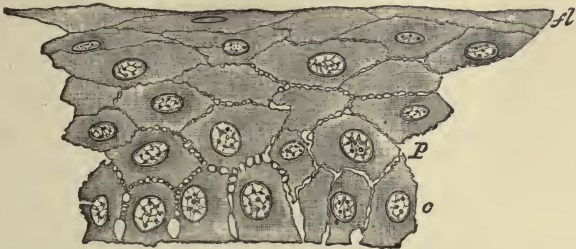


FIG. 4.— SECTION OF STRATIFIED EPITHELIUM. *c*, lowermost columnar cells; *P*, polygonal cells above these; *A*, flattened cells near the surface. Between the cells are seen intercellular channels, bridged over by processes which pass from cell to cell.

cells of the deepest layer are columnar in shape; the next, rounded or many-sided, whilst those nearest the surface are always flattened and scale-like, the protoplasm of the cell being finally converted into a horn-like substance. The deeper soft cells of a stratified epithelium are continually multiplying by cell-division, and as the new cells which are thus produced in the deeper parts increase in size, they compress and push outwards those previously formed. In this way cells which were at first deeply seated are gradually shifted outwards and upwards, growing harder as they approach the surface. The older superficial cells are being continually rubbed off as the new ones continually rise up to supply their places.

Stratified epithelium covers the anterior surface of the eye, lines the mouth, the chief part of the pharynx, the gullet, the vagina, and part of the uterus, but its most extensive distribution is over the surface of the skin, where it forms the epidermis. Wherever a surface is liable to abrasion we find stratified

scaly epithelium, and we may therefore classify it as a protective epithelium.

2. **Transitional epithelium.**—This is a modification of stratified epithelium, consisting only of two or three layers of cells.



FIG. 5.—SECTION OF THE TRANSITIONAL EPITHELIUM LINING THE BLADDER. (Highly magnified.) (E. A. S.) *a*, superficial; *b*, intermediate; *c*, deep layer of cells.

The superficial cells are large and flattened, having on their under surface depressions into which fit the larger ends of the pear-shaped cells which form the next layer. Between the tapering ends of these pear-shaped cells are one or two layers of smaller, many-sided cells, the epithelium being renewed by division of these deeper cells. This kind of transitional epithelium lines the bladder and ureters.

3. **Simple epithelium.**—This is composed of a single layer of cells. The cells forming single layers are of distinctive shape, and have distinctive functions in different parts of the body.

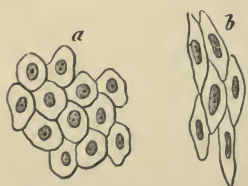


FIG. 6.—SIMPLE PAVEMENT EPITHELIUM. *a*, from a serous membrane; *b*, from a blood-vessel.

The chief varieties are the pavement, columnar, glandular, and ciliated.

In simple **pavement** epithelium the cells form flat, many-sided plates or scales, which fit together like the tiles of a mosaic pavement. It forms very smooth surfaces, and lines the heart, blood-vessels, and lymphatics; the mammary ducts, the serous cavities, etc.

The **columnar** epithelium is a variety of simple epithelium in which the cells have a prismatic shape, and are set upright on the surface which they cover. In profile these cells look somewhat like a close palisade, their edges, however, being often irregular and jagged, especially where free or “wander-cells”

squeeze in between them. Columnar epithelium is found in its most characteristic form lining the mucous membrane of the intestinal canal.

Glandular epithelium is found in the recesses of secreting glands. The cells are of many different shapes, and are usually set round a tubular or saccular cavity, into which the secretion is poured. The protoplasm of these cells is generally filled by



FIG. 7.—SIMPLE COLUMNAR EPITHELIUM. *a*, the cells; *b*, intercellular substance between the lower end of cells.

the materials which the gland secretes.

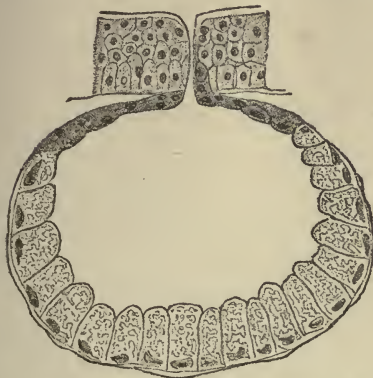

FIG. 8.—GLANDULAR EPITHELIUM, WITH THE CELLS SET ROUND A SIMPLE SACCULAR GLAND. (Highly magnified.) (Flemming.)

In ciliated epithelium the cells, which are generally columnar in shape, bear at their free extremities little hair-like processes which are agitated incessantly with a lashing or vibrating motion. These minute and delicate processes are named *cilia*, and may be regarded as active prolongations of the cell-protoplasm. The manner in which cilia move is best seen when they are not acting very quickly. The motion may be compared to the lash-like

motion of an individual cilium of a short-handled whip, the cilium being rapidly bent in one direction. The motion does not involve the whole of the ciliated surface at the same moment, but is performed by the cilia in regular succession, giving rise to the appearance of a series of waves travelling along the surface like the waves caused by the wind in a field of wheat. When they are in very rapid action, their motion conveys the idea of swiftly running water.

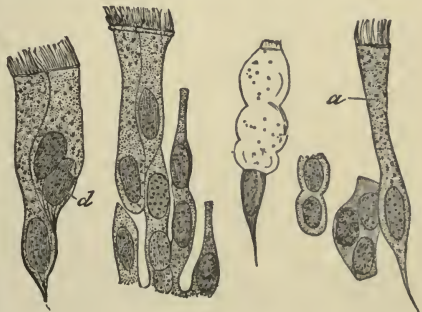

FIG. 9.—CILATED EPITHELIUM FROM THE HUMAN TRACHEA. (Highly magnified.) *a*, large ciliated cell; *d*, cell, with two nuclei.

Cilia have been shown to exist in almost every class of animal, from the highest to the lowest. In man their use is to impel secreted fluids, or other matters, along the surfaces to which they are attached; as, for example, the mucus of the trachea and nasal chambers, which they carry towards the outlet of these passages.

Ciliated epithelium is found in the air passages, the generative organs, ventricles of the brain, and central canal of the spinal cord.

To recapitulate: The most important situations in which a covering or lining of epithelial tissue is found in the body are:—

1. On the surface of the integument, or external skin.
2. On mucous membranes, or internal skin.
3. On the inner surface of serous membranes, and on the inner surface of the heart, blood-vessels, and lymphatics.
4. Lining the ventricles or cavities of the brain, and the central canal of the spinal cord.

Some varieties of epithelium are specially modified to form protective membranes; others to elaborate or make secretions; others, again, to form smooth linings for opposing surfaces; and yet others to keep the surfaces they cover clean, by sweeping outwards material that would otherwise accumulate, and clog important passages.

The hairs, nails, and the enamel of the teeth, are modifications of epithelial tissue.

CHAPTER III.

CONNECTIVE TISSUES: CONNECTIVE TISSUE PROPER, ADIPOSE OR FAT TISSUE, RETICULAR AND LYMPHOID TISSUE, CARTILAGE, BONE.

FOLLOWING the classification of tissues we have adopted, the next group of tissues to be studied is that known as the connective tissue group. This includes :—

- Connective tissue proper.
- Adipose or fat tissue.
- Reticular and lymphoid tissue.
- Cartilage.
- Bone.

These tissues differ considerably in their external characteristics, but are alike in that they all serve to connect and support the other tissues of the body; they tend to pass imperceptibly the one into the other; there are many points of similarity between the cells which occur in them, and we may, therefore, reasonably group them together.

When connective tissue first begins to be formed as a distinctive tissue, the cells which are set apart to form it are round in shape and loosely packed together; later these cells begin to throw out branches and to form a kind of network with open spaces. In these open spaces a semi-fluid substance is deposited which gradually becomes more consistent, and in this substance is developed the particular fibres which are the chief structural characteristics of connective tissue proper.

Our description of epithelial tissue was briefly this: a skin or membrane formed of cells, which cells may be of a variety of shapes, and be arranged in one or more layers. It is distinctly a tissue of cells with very little of what we call intermediate or

intercellular substance lying between the cells. Connective tissue differs from epithelial tissue in having a great deal of intercellular substance between its cells, and according to the manner in which this intercellular substance develops do we get the different varieties of connective tissue.

Connective tissue proper.— There are three modifications of connective tissue proper; viz. the areolar, the fibrous, and the elastic.

Areolar tissue.— If we make a cut through the skin, and proceed to raise it from the parts lying beneath, we observe that it is loosely connected to them by a soft filmy substance of considerable tenacity and elasticity. This is areolar tissue. It is also

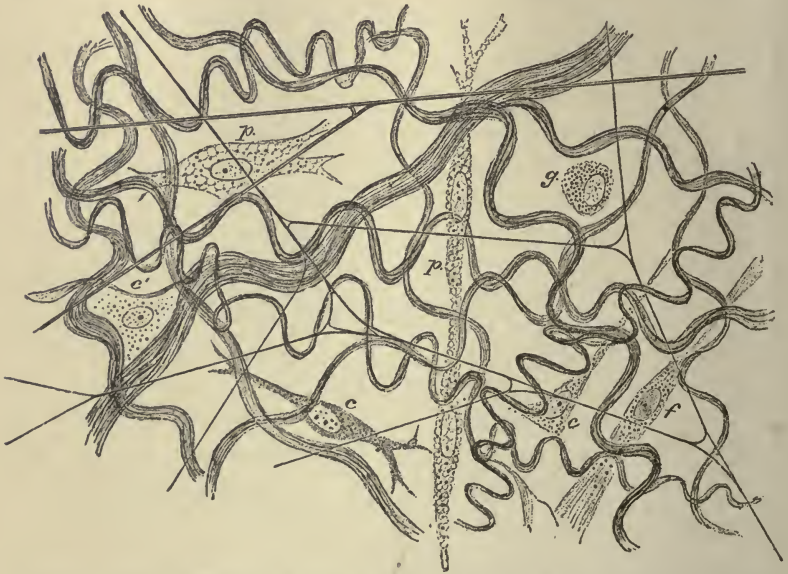


FIG. 10.—SUBCUTANEOUS AREOLAR TISSUE FROM A YOUNG RABBIT. (Highly magnified.) (E. A. S.) The white fibres are in wavy bundles, the elastic fibres form an open network. *p, p*, vacuolated cells; *g*, granular cell; *c, c*, branching lamellar cells; *c'*, a flattened cell, of which only the nucleus and some scattered granules are visible; *f*, fibrillated cell.

found, in like manner, under the serous and mucous membranes,¹ and serves to attach them to the parts which they line or cover. Proceeding further, we find this areolar tissue lying between the muscles, the blood-vessels, and other deep-seated parts; also forming investing sheaths for the muscles, the

¹ These membranes line the internal cavities and surfaces of the body.

nerves, the blood-vessels, and other parts. It both connects and insulates entire organs, and, in addition, performs the same office for the finer parts of which these organs are made up. It is thus one of the most general and most extensively distributed of the tissues. It is, moreover, continuous throughout the body, and from one region it may be traced without interruption into any other, however distant, — a fact not without interest in practical medicine, seeing that in this way air, water, and other fluids, effused into the areolar tissue may spread far from the spot where they were first introduced or deposited.

Seen with the naked eye, areolar tissue appears to be composed of a multitude of fine threads and films crossing irregularly in every imaginable direction, leaving open spaces or *areolæ* between them. Viewed with the microscope, these threads and films are seen to be principally made up of wavy bundles of exquisitely fine, transparent, white fibres, and these bundles intersect in all directions. Mixed with the white fibres are a certain number of elastic fibres, which do not form bundles, and have a straight instead of a wavy outline. The cells of the tissue, of which there are several varieties, lie in the spaces between the bundles of fibres.

On comparing the areolar tissue of different parts, it is observed in some to be more loose and open in texture; in others, more close and dense, according as free movement, or firm connection between parts is to be provided for.

Fibrous tissue. — Fibrous tissue is intimately allied in structure to the areolar tissue, but the bundles of white fibres cohere very closely, and instead of interlacing in every direction run for the most part in only one or two directions, and thus

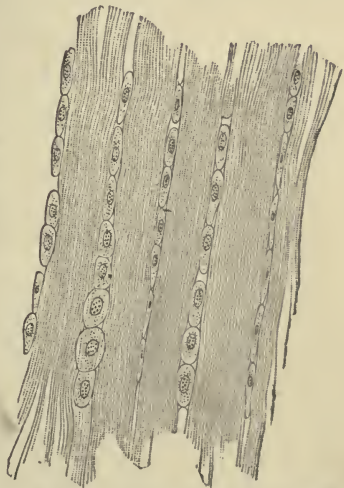

FIG. 11. — FIBROUS TISSUE, FROM THE LONGITUDINAL SECTION OF A TENDON. (After Gegenbauer.)

confer a distinctly fibrous aspect on the parts which they compose. This fibrous tissue is met with in the form of ligaments, connecting the bones together at the joints, and in the form of

sinews or tendons, by means of which the muscles are attached to the bones. It also forms fibrous membranes which invest and protect different parts or organs of the body. Examples of these are seen in the periosteum and perichondrium, which cover the bones and cartilages, and in the dura mater, which lines the skull and protects the brain. Fibrous membranes, called *fasciæ*, are also employed to envelop and bind down the muscles of different regions, of which the great fascia, enclosing the muscles of the thigh and leg, is a well-known example; and, under the name of *aponeuroses*, serve for the attachment of muscles in various parts of the body. It thus appears that fibrous tissue presents itself in the form of strong bands or cords, and of dense sheets or membranes.

Fibrous tissue is white, with a peculiarly shining silvery aspect. It is exceedingly strong and tough, yet perfectly pliant; but it is almost devoid of extensibility. By these qualities it is admirably suited to the purposes for which it is used in the human frame. By its inextensile character, and by its strength, it maintains in apposition the parts which it connects, and we find that the ligaments and tendons do not sensibly yield to extension in the strongest muscular efforts; and though they sometimes snap asunder, it is well known that bones will break more readily than tendons; and the fibrous membranes or aponeuroses are equally strong, tough, and unyielding.

Elastic tissue.—In elastic tissue the wavy white bundles are comparatively few and indistinct, and there is a proportionate development of the elastic fibres. When present in large numbers they give a yellowish colour to the tissue. This form of connective tissue is extensile and elastic in the highest degree, but is not so strong as the fibrous variety, and breaks across the direction of its fibres when forcibly stretched.

It occurs in its most characteristic form in what is called the *ligamenta subflava*, which forms an elastic band between some of the bones of the spine. Elastic tissue is also found in the walls of the air tubes; unites the cartilages of the larynx; and enters largely into the formation of the walls of the blood-vessels, especially of the arteries.

These three varieties of connective tissue agree closely with one another in elementary structure. It is the different arrangement of the cells and fibres, and the relative proportion of

one kind of fibre to the other, that gives them their different characteristics: the interlacing of the wavy bundles of finest fibres, giving us the delicate web-like areolar tissue; the close packing of these bundles, giving us the dense opaque fibrous membranes and bands; and the preponderance of the elastic fibres, furnishing the extensile elastic tissue.

This connective tissue proper, as we have already noted, is used for purely mechanical purposes: forming inextensile bands or pulleys; strong protective membranes; web-like, binding, and supporting material; sheaths of varying degrees of density; elastic bands or membranes; and it also serves to carry the blood-vessels, lymphatics, and nerves to the parts which it connects and covers.

Adipose tissue.—When fat first begins to be formed in the embryo, it is deposited in tiny droplets in some of the cells

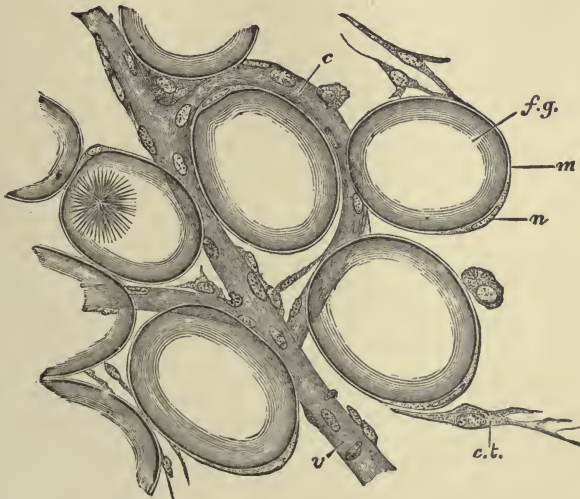


FIG. 12.—A FEW FAT-CELLS FROM THE MARGIN OF A FAT-LOBULE. Very highly magnified. *f.g.* fat-globules distending a fat-cell; *n*, nucleus; *m*, membranous envelope of the fat-cell; *c*, capillary vessel; *v*, veinlet; *c.t.* connective-tissue cell; the fibres of the connective tissue are not shown.

of the areolar connective tissue; these droplets increase in size, and eventually run together so as to form one large drop in each cell. By further deposition of fat the cell becomes swollen out to a size far beyond that which it possessed originally until the protoplasm remains as a delicate envelope sur-

rounding the fat drop. As these cells increase in number they collect into small groups or lobules, which lobules are for the most part lodged in the meshes of the areolar tissue, and are also supported by a fine network of blood-vessels. This fatty tissue exists very generally throughout the body, accompanying the still more widely distributed areolar tissue in most, though not in all, parts in which the latter is found. Still, its distribution is not uniform, and there are some situations in which it is collected more abundantly. It forms a considerable layer underneath the skin, in the subcutaneous areolar tissue; it is collected in large quantity around certain internal parts, especially the kidneys; it is seen filling up the furrows on the surface of the heart; it is deposited beneath the serous membranes, or is collected between their folds; collections of fat are also common around the joints, padding and filling up inequalities; and, lastly, the fat exists in large quantities in the marrow of bones.

Adipose tissue, unless formed in abnormal quantities, confers graceful outlines upon the human frame; it also constitutes an important reserve fund, by storing up fatty materials, derived from the food and brought to it by the blood, in such a form and manner as to be readily reabsorbed into the circulation when needed.

Retiform and lymphoid tissue. — These tissues closely resemble the areolar variety of connective tissue, except that the bundles of fibrils occurring in them are very much finer, and the meshes of the open and fine network are filled with fluid and with lymph cells. The reticular or retiform tissue forms the whole framework of some of the organs of the body, and enters largely into the formation of the mucous membranes. The lymphoid or adenoid tissue composes the greater part of the lymphatic glands, and other allied structures, and is found also in some mucous membranes. These tissues will be more fully described in connection with the organs in which they are found.

Cartilage. — This is the well-known substance called “gristle.” When a very thin section is examined with a microscope, it is seen to consist of nucleated cells disposed in small groups in a mass of intercellular substance. This intercellular substance is sometimes transparent, and to all appearances homogeneous or structureless; sometimes dim and faintly granular, like

ground glass: both these conditions are found in what is called "true" or *hyaline* cartilage, and which is the most typical form of the tissue. There is another variety of cartilage in which the intercellular substance is everywhere pervaded with fibres. When the fibres are of the white variety, it is called *white fibro-cartilage*; when they are elastic fibres, it is called *yellow* or *elastic fibro-cartilage*.

Although cartilage can be readily cut with a sharp knife, it is nevertheless of very firm consistence, but at the same time highly elastic, so that it readily yields to extension or pressure, and immediately recovers its original shape when the constraining force is withdrawn. By reason of these mechanical properties it serves important purposes in the construction of some parts of the body.

Hyaline cartilage occurs principally in two situations; viz. covering the ends of the bones in the joints, where it is known as articular cartilage, and forming the rib cartilages, where it is known as costal cartilage. In both these situations the cartilages are in immediate connection with bone, and may be said to form part of the skeleton. The articular cartilages, in covering the ends or surfaces of bones in the joints, provide these harder parts with a thick, springy coating, which breaks the force of concussion, and gives ease to the motion of the joint. The costal cartilages, in forming a considerable part of the solid framework of the thorax or chest, impart elasticity to its walls. Hyaline cartilage also enters into the formation of the nose, ear, larynx, and windpipe. It strengthens the substance of these parts without making them unduly rigid, maintains their shape, keeps open the passages through them where such exist, and gives attachment to moving muscles and connecting ligaments.

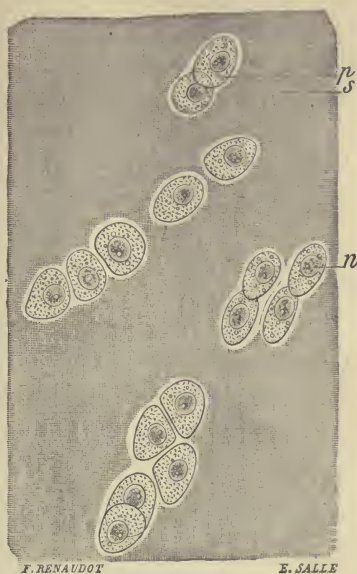


FIG. 13. — ARTICULAR HYALINE CARTILAGE FROM THE FEMUR OF AN Ox. *s*, intercellular substance; *p*, protoplasmic cell; *n*, nucleus. (Ranvier.)

Elastic or yellow fibro-cartilage is tougher and more flexible than hyaline cartilage; it only occurs in parts of the throat and ear.

White fibro-cartilage is found wherever great strength combined with a certain amount of rigidity is required; thus we find it joining bones together, the most familiar instance being the flat round plates or disks of fibro-cartilage connecting the bones of the spine and the pubic bones. White fibro-cartilage very closely resembles white fibrous tissue.

Cartilage is not supplied with nerves, and very rarely with blood-vessels. Being so meagrely supplied with blood the vital processes in cartilage are very slow, and when a portion of it is absorbed in disease or removed by the knife, it is regenerated very slowly. A wound in cartilage is usually at first healed by connective tissue proper, which may or may not become gradually transformed into cartilage. Nearly all cartilages receive their nourishment from the perichondrium which covers them, and which is a moderately vascular fibrous membrane.

Bone. — Bone is a connective tissue in which the intercellular or ground substance is rendered hard by being impregnated with mineral salts.

On sawing up a bone it will be seen that it is in some parts dense and close in texture, appearing like ivory, whilst in others it is open and spongy, and we distinguish two forms of bony tissue, the dense or compact, and the spongy or cancellated. On closer examination, however, it will be seen that the bony matter is everywhere porous, and that the difference between the two varieties of tissue arises from the fact that the compact tissue has fewer spaces and more solid matter between them, and that the cancellated has larger cavities and more slender intervening bony partitions. In all bones the compact tissue, being the stronger, lies on the surface of the bone, and forms an outer shell or crust, whilst the lighter spongy tissue is contained within. The shafts of the long bones are almost entirely made up of the compact substance, except that they are hollowed out to form a central canal — the medullary canal — for the reception of the marrow. Marrow is also found in the spongy portions of the bone in the spaces between the bony partitions.

The hard substance of all bone is arranged in bundles of

bony fibres or *lamellæ*, which in the cancellated texture join and meet together so as to form a structure resembling lattice-work (*cancelli*), and whence this tissue receives its name. In the compact tissue these lamellæ are usually arranged in close rings around canals which carry blood-vessels in a longitudinal direction through the bones. Between the lamellæ are branched cells which lie in cell-spaces or cavities called *lacunæ*, and running out in a wheel-like or radial direction from each lacuna are numerous tiny canals or canaliculi connecting one cell-space or lacuna with another, and forming a system of minute intercommunicating channels.

All bones are covered by a vascular fibrous membrane, the *periosteum*, and, unlike cartilage, the bones are plentifully supplied with blood. If we strip this periosteum from a fresh bone, we see many bleeding points representing the points at which the blood-vessels penetrate the bone. After entering the bone the

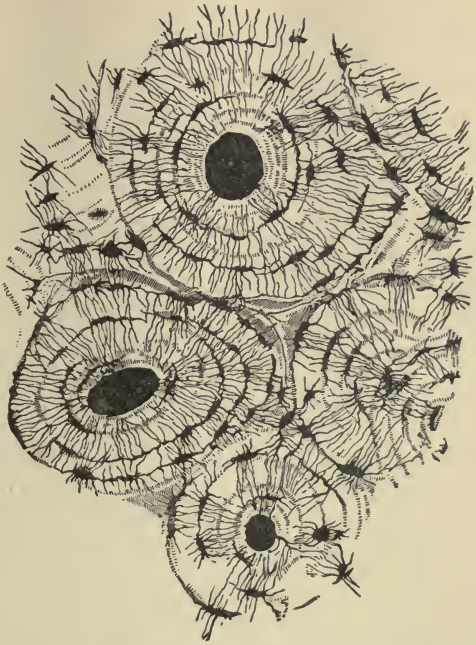

FIG. 14.—TRANSVERSE SECTION OF COMPACT TISSUE (OF HUMERUS). (Magnified about 150 diameters.) (Sharpey.) Three of the Haversian canals are seen, with their concentric rings faintly indicated; also the lacunæ, with the canaliculi extending from them across the direction of the encircling lamellæ, or concentric rings.

blood runs through longitudinal channels which communicate freely with one another, and are called, from the name of their discoverer, Haversian canals. Around these Haversian canals, as we have already stated, the lamellæ are disposed in rings, while the lacunæ containing the bone-cells are also arranged, between the lamellæ, in circles around the canals. As the canaliculi run in a radial direction from the lacunæ, it

follows that the innermost ones must run into the Haversian canals, so that there is a direct communication between the blood in these canals and the cells in the lacunæ. In this way the whole substance of the bone is penetrated by intercommunicating channels, and nutrient matters and mineral salts from the blood in the Haversian canals can find their way to every part.

The mineral or earthy substance which is deposited in bone, and which makes it hard, amounts to about two-thirds of the weight of the bone. It consists chiefly of phosphate of lime, with about a fifth part of carbonate of lime, and a small portion of other salts. The soft or animal matter consists chiefly of blood-vessels and connective tissue, and may be resolved by boiling almost entirely into gelatine: it constitutes about one-third of the weight of the bone. This proportion of animal and earthy constituents is, however, subject to variations. In children the animal matter is apt to predominate, and we find that their bones are more liable to be bent when injured, or only partially broken, as in the typical "green-stick" fracture. Again, in aged people the earthy constituents increase, the animal matter becomes deficient in quality and quantity, and consequently their bones are brittle, and more liable to fracture.

In the re-union of fractured bones new bony tissue is formed between and around the broken ends, connecting them firmly together; and when a portion of bone dies, a growth of new bone very generally takes place to a greater or less extent, and the dead part is thrown off. The periosteum is largely concerned in this process of repair; for if a portion of the periosteum be stripped off, the subjacent bone will be liable to die, while if a large part or the whole of a bone be removed, and the periosteum at the same time left intact, the bone will wholly, or in a great measure, be regenerated.

In the embryo the foundation of the skeleton is laid in cartilage, or in primitive membranous connective tissue, ossification of the bones occurring later. The hardening or ossification of the bones is accomplished by the penetration of blood-vessels and bone-cells, called osteo-blasts, from the periosteum. As they penetrate into the cartilaginous or membranous models, they absorb the cartilage and connective tissue and deposit the true bone tissue at various points until they form the particular bony structure with which we are familiar.

CHAPTER IV.

THE SKELETON.

THE bones are the principal organs of support, and the passive instruments of locomotion. Connected together in the skeleton, they form a framework of hard material, affording attachment to the soft parts, maintaining them in their due position, sheltering such as are of delicate structure, giving stability to the whole fabric, and preserving its shape.

The entire skeleton in the adult consists of two hundred distinct bones. These are :—

The spine, or vertebral column (sacrum and coccyx included)	26
Cranium	8
Face	14
Os hyoides, sternum, and ribs	26
Upper extremities	64
Lower extremities	62
	<hr/>
	200

In this enumeration the *patellæ*, or knee-pans, are included as separate bones, but the smaller *sesamoid* bones, and the small bones of the ear, are not included.

These bones may be divided, according to their shape, into four classes : Long, Short, Flat, and Irregular.

The long and short bones are found in the extremities. The flat and irregular bones are found in the trunk and head, with the exception of the *patellæ*, which are two small flat bones found in the lower extremities, and the *scapulæ*, which are also two flat bones usually reckoned among the bones of the upper extremities.

The bones of the trunk and head are used chiefly to form

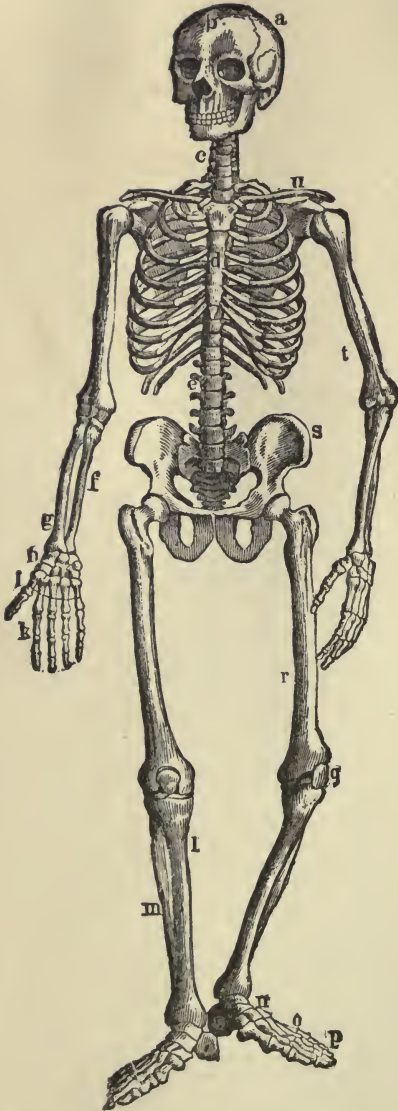


FIG. 15.—THE SKELETON. *a*, parietal bone; *b*, frontal; *c*, cervical vertebræ; *d*, sternum; *e*, lumbar vertebræ; *f*, ulna; *g*, radius; *h*, wrist or carpal bones; *i*, metacarpal bones; *k*, phalanges; *l*, tibia; *m*, fibula; *n*, tarsal bones; *o*, metatarsal; *p*, phalanges; *q*, patella; *r*, femur; *s*, haunch-bone; *t*, humerus; *u*, clavicle.

cavities and to support and protect the organs contained in these cavities. The bones of the extremities enclose no cavities, and are chiefly used in the upper extremity for tact and prehension, and in the lower for support and locomotion; in both situations they form a system of levers. If the surface of any bone is examined, certain eminences and depressions are seen, which are of two kinds: articular and non-articular. Non-articular processes and depressions serve for attachment of ligaments and muscles; the articular are provided for the mutual connection of joints.

Long bones.—A long bone consists of a lengthened cylinder or shaft and two extremities. The shaft is formed mainly of compact tissue, this compact tissue being thickest in the middle; it is hollowed out in the interior to form the medullary canal. The extremities are made up of spongy tissue with only a thin coating of compact substance, and are more or less expanded for greater convenience of mutual connection, and to afford a broad surface for muscular attachment. All long bones are

more or less curved, which confers upon them a certain amount of elasticity, and gives them a more graceful outline.

Long bones of upper extremity: —

Clavicle (collar bone)	2
Humerus (arm)	2
Ulna, 2 } (forearm)	4
Radius, 2 }	
Metacarpus (palm of the hand)	10
Phalanges (fingers)	28
	46

The **clavicle** forms the anterior portion of the shoulder. It articulates by its inner extremity with the sternum, and by its outer extremity with the acromion process¹ of the scapula. In



FIG. 16.—THE CLAVICLE.

the female, the clavicle is generally less curved, smoother, and more slender than in the male. In those persons who perform considerable manual labour, which brings into constant action the muscles connected with this bone, it acquires considerable bulk.

The **humerus** is the longest and largest bone of the upper limb. The upper extremity of the bone consists of a rounded head joined to the shaft by a constricted neck, and of two eminences called the greater and lesser tuberosities. The head articulates with the glenoid cavity of the scapula. The constricted neck above the tuberosities is called the anatomical neck, and that below the tuberosities, the surgical neck, from its being often the seat of fracture. The lower extremity of the



FIG. 17.—THE HUMERUS. *a*, rounded head; *gt*, greater tuberosity; *lt*, lesser tuberosity; *b*, groove for attachment of biceps muscle.

¹ All eminences and projections of bones are termed processes, and these processes were named by the early anatomists, either from their shape or use, or from their fancied resemblance to some well-known object. It is well to look up the meaning of these Greek or Latin words which are used so plentifully in naming all parts of the skeleton; the whole subject will become more interesting, more readily understood, and more easily remembered.

bone is flattened from before backwards into a broad articular surface, which is divided by a slight ridge into two parts, by means of which it articulates with the ulna and radius.

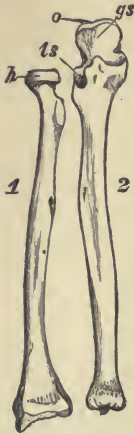


FIG. 18.—THE ULNA AND RADIUS. 1, radius; 2, ulna; o, olecranon process, on the anterior surface of which are seen the large (gs) and the small (ls) cavities, for the reception of the lower end of the humerus and of the head of the radius, respectively; h, head of radius.

Each **metacarpus** is formed by five bones. These metacarpal bones are curved longitudinally, so as to be convex behind, concave in front; they articulate by their bases with the bones of the wrist and with one another, and the heads of the bones articulate with the phalanges.

The **phalanges**, or digits, are the bones of the fingers; they are fourteen in number (in each hand), three for each finger, and two for the thumb. The first row articulates with the metacarpal bones and the second row of phalanges; the second row, with the first and third; and the third, with the second row.

The **ulna** (elbow bone) is placed at the inner side of the forearm, parallel with the radius. Its upper extremity presents for examination two large curved processes and two concave cavities; the larger process forms the head of the elbow, and is called the olecranon process. The lower extremity of the ulna is of small size, and is excluded from the wrist by a piece of fibro-cartilage.

The **radius** is situated on the outer side of the forearm. The upper end is small and rounded with a shallow depression on its upper surface for articulation with the humerus, and a prominent ridge about it, like the head of a nail, by means of which it rotates within the lesser sigmoid cavity of the ulna. The lower end of the radius is large, and forms the chief part of the wrist.

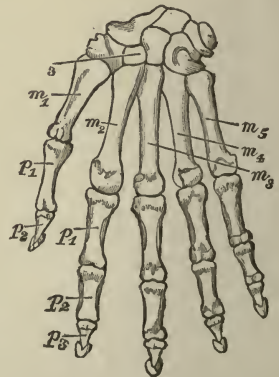


FIG. 19.—BONES OF THE WRIST AND HAND. m^1 to m^5 , metacarpal bones; p^1 , p^2 , p^3 , phalanges; 3, bones of the wrist.

Long bones of the lower extremity: —

Femur (thigh bone)	2
Tibia, 2 } (leg)	4
Fibula, 2 }	
Metatarsus (sole and instep of foot)	10
Phalanges (toes)	28
	44

The bones of the lower extremity correspond to those of the upper extremity, and bear a rough resemblance to them.

The **femur** is the longest, largest, and strongest bone in the skeleton. In the erect position it is not vertical, being separated from its fellow above by a considerable interval, which corresponds to the entire breadth of the pelvis, but inclining gradually downwards and inwards, so as to approach its fellow towards its lower part, for the purpose of bringing the knee-joint near the line of gravity of the body. The degree of inclination varies in different persons, and is greater in the female than the male, on account of the greater breadth of the pelvis. The upper extremity of the femur, like that of the humerus, consists of a rounded head joined to the shaft by a constricted neck, and of two eminences, called the greater and lesser trochanters. The head articulates with the cavity in the os innominatum, called the acetabulum. The lower extremity of the femur is larger than the upper, is flattened from before backwards, and divided into two large eminences or condyles by an intervening notch. It articulates with the tibia and the patella, or knee-pan.



FIG. 20. — THE FEMUR. *b*, rounded head; *gtr*, greater trochanter; *ltr*, lesser trochanter; *n*, neck.

The **tibia** is situated at the front and inner side of the leg, and forms what is popularly known as the shin bone. In the male, its direction is vertical and parallel with the bone of the opposite side; but in the female it has a slight oblique direction outwards, to compensate for the oblique direction of the femur inwards. The upper extremity is large, and expanded into two

lateral eminences with concave surfaces which receive the condyles of the femur. The lower extremity is much smaller than the upper; it is prolonged downwards on its inner side into a strong process, the internal malleolus. It articulates with the fibula and one of the bones of the ankle.

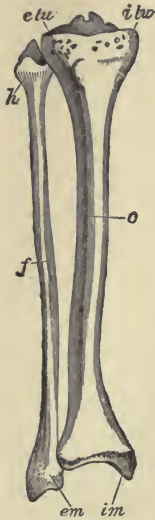


FIG. 21. — BONES OF THE RIGHT LEG. *o*, tibia; *f*, fibula; *etu* and *itu*, lateral eminences for reception of condyles of femur; *h*, head of fibula; *im*, internal malleolus; *em*, external malleolus.

The **fibula** is situated at the outer side of the leg. It is the smaller of the two bones, and, in proportion to its length, the most slender of all the long bones: it is placed nearly parallel with the tibia. The upper extremity consists of an irregular rounded head by means of which it articulates with the tibia. The lower extremity is prolonged downwards into a pointed process, the external malleolus, which lies just beneath the skin. It articulates with the tibia and one of the bones of the ankle.

The **metatarsus** is formed by five bones. These metatarsal bones closely resemble the metacarpal bones of the hand. Each bone articulates with the tarsal bones by one extremity, and by the other with the first row of phalanges.

The **phalanges** of the foot, both in number and general arrangement, resemble those in the hand, there being two in the great toe and three in each of the other toes.

Short bones: —

- Scaphoid.
 - Semilunar.
 - Cuneiform.
 - Pisiform.
 - Trapezium.
 - Trapezoid.
 - Os magnum.
 - Unciform.
- } Bones of the carpus or wrist.

- Os calcis.
 - Astragalus.
 - Cuboid.
 - Scaphoid.
 - Internal cuneiform.
 - Middle cuneiform.
 - External cuneiform.
- } Bones of the tarsus or ankle.

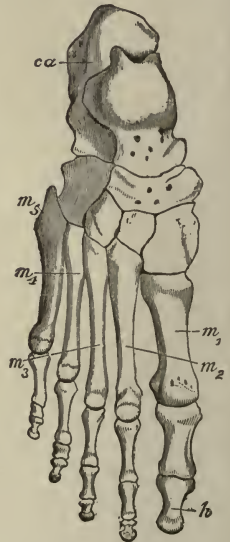


FIG. 22. — BONES OF THE ANKLE AND FOOT. *m*¹ to *m*⁵, metatarsal bones; *h*, phalanges; *ca*, os calcis, or heel bone.

The bones forming the wrists and ankles are small pieces of bone irregularly shaped, and united together by ligaments (*vide* Figs. 19 and 22). Their texture is spongy throughout, excepting at their surface, where there is a thin crust of compact substance: they are closely welded together, and yet, by the arrangement of their ligaments, allow of a certain amount of motion. There are eight carpal or wrist bones and seven tarsal or ankle bones. The carpal bones are arranged in two rows, upper and lower, between the bones of the forearm and metacarpal bones. They are named, from their shape, scaphoid, semilunar, cuneiform, etc. The tarsal bones are larger and more irregularly shaped than the carpal. The largest and strongest of these is the heel bone (*os calcis*), which serves to transmit the weight of the body to the ground, and forms a strong lever for the muscles of the calf of the leg.

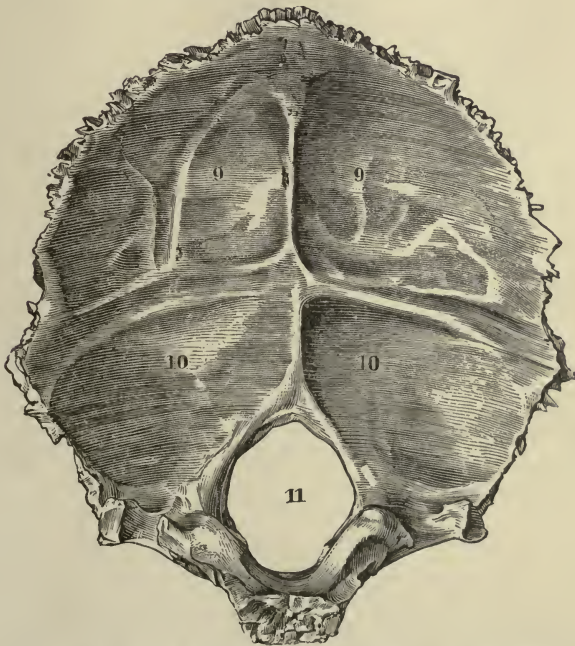


FIG. 23.—OCCIPITAL BONE. Inner surface. 9, 9 and 10, 10, depressions for reception of lobes of brain; 11, foramen magnum.

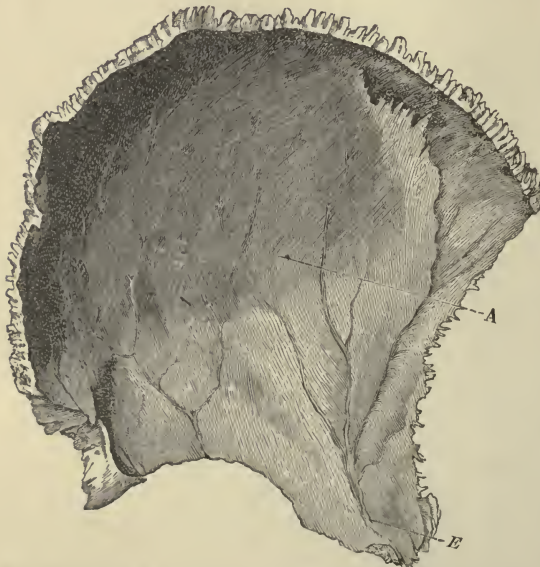Flat bones. — We find the bony tissue expands into broad or elongated flat plates where the principal requirement is either extensive protection or the provision of the broad surfaces for

muscular attachment. The flat bones are composed of two thin layers of compact tissue, inclosing between them a variable quantity of cancellous tissue. In the bones of the skull this outer layer is thick and tough; the inner one thinner, denser, and more brittle. The cancellated tissue lying between the two layers, or "tables of the skull," is called the *diploë*.

Flat bones of the head: —

Occipital	1
Parietal	2
Frontal	<u>1</u>
	4

The **occipital** bone is situated at the back and base of the skull. At birth the bone consists of four parts, which do not unite into a single-bone until about the sixth year. The internal surface is deeply concave, and presents many eminences and



depressions for the reception of parts of the brain. There is a large hole — the *foramen magnum* — in the more interior portion of the bone, for the transmission of the *medulla oblongata*, the enlarged portion of the spinal cord.

The **parietal** bones (*paries*, a wall) form by their union the sides and roof of the skull. The

FIG. 24. — PARIETAL BONE. Inner surface. *A*, parietal depression; *E*, furrow for ramification of arteries.

external surface is convex and smooth; the internal surface is concave, and presents eminences and depressions for lodging the convolutions of the brain and numerous furrows for the ramifications of arteries.

The **frontal** bone resembles a cockle shell in form. It not only forms the forehead, but also enters into the formation of the roof of the orbits, and of the nasal cavity. The arch formed

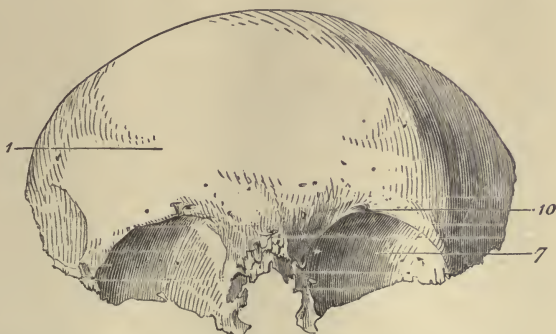


FIG. 25.—FRONTAL BONE. Outer surface. 1, frontal eminence; 7, roof of orbital cavity; 10, orbital arch.

by part of the frontal bone over the eye is sharp and prominent and affords that organ considerable protection from injury. At birth the bone consists of two pieces, which afterwards become united, along the middle line, by a suture which runs from the vertex of the bone to the root of the nose. This suture usually becomes obliterated within a few years after birth, but it occasionally remains throughout life.

Flat bones of the face:—

Nasal	2
Lachrymal	2
Vomer	$\frac{1}{5}$

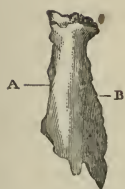


FIG. 26.—NASAL BONE. Outer surface. A, internal border; B, external border.

The two **nasal** bones are two small oblong bones, varying in size and form in different individuals; they are placed side by side at the middle and upper part of the face, forming by their junction “the bridge” of the nose.



FIG. 27.—LACHRYMAL BONE. Outer surface.

The **lachrymal** are the smallest and most fragile bones of the face. They are situated at the front part of the inner wall of the orbit, and

resemble somewhat in form, thinness, and size, a finger-nail.

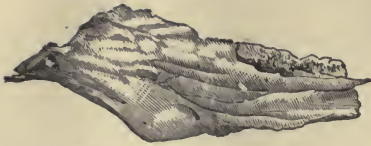


FIG. 28.—VOMER. Side view.

The vomer is a single bone placed at the back part of the nasal cavity, and forms part of the septum of the nose. It is thin, and shaped somewhat like a plough-share, but varies in

different individuals, being frequently bent to one or the other side.

Flat bones of the trunk : —

Scapula, shoulder-blade	2
Os innominatum, haunch-bone	2
Sternum, breast-bone	1
Ribs	24
Patella	2
	31

The scapula, or shoulder-blade, is a large flat bone, triangular in shape, placed between the first and eighth ribs on the back part of the thorax, where it affords considerable protection to the lungs. It is unevenly divided by a very prominent ridge, the spine of the scapula, which terminates in a large triangular projection called, from the Greek, acromion process, or summit of the shoulder. Below the acromion process, and at the head of the shoulder-blade, is a shallow socket, the glenoid cavity, which receives the head of the humerus.

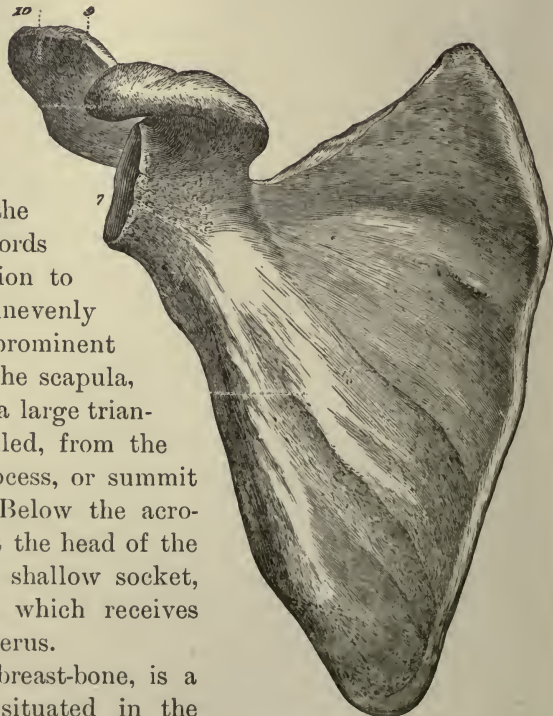


FIG. 29.—SCAPULA. Inner surface. 7, glenoid cavity; 9, end of spine; 10, acromion process.

The sternum, or breast-bone, is a flat narrow bone, situated in the median line in the front of the chest, and consisting, in the adult, of three

portions. It has been likened to an ancient sword. The upper piece, representing the handle, is termed the manubrium or handle; the middle and largest piece, which represents the chief part of the blade, is termed the gladiolus; and the inferior piece, which is likened to the point of the sword, is termed the ensiform appendix. On both sides of the upper and middle pieces are notches for the reception of the sternal ends of the ribs. The ensiform appendix is cartilaginous in structure in early life, but is more or less ossified at the upper part in the adult: it has no ribs attached to it. The sternum is about six inches long, being rather longer in the male than in the female.

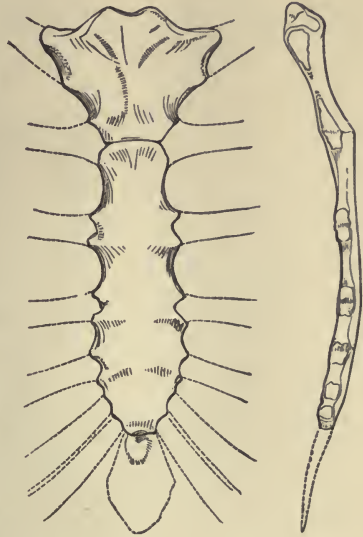


FIG. 30.—STERNUM. Front and side view.

The ribs are elastic arches of bone, forming the chief part of the thoracic walls (*vide* Fig. 47). They are usually twelve in number on each side. They are all connected behind with the vertebræ of the spine, and the first seven pairs are connected with the sternum in front through the intervention of the costal cartilages: these first seven pairs are called from their attachment the vertebro-sternal, or true ribs. The remaining five pairs are termed false ribs; of these, the first three, being attached in front to the costal cartilages, are usually called the vertebro-costal, while the two remaining, being unattached in front, are termed vertebral, or floating ribs. The convexity of each curved rib is turned outwards so as to give roundness to the sides of the chest and increase the size of its cavity; each slopes downwards from its vertebral attachment, so that its sternal end is considerably lower than its dorsal. The spaces left between the ribs are called the intercostal spaces.

The *os innominatum*, or nameless bone, so called from bearing no resemblance to any known object, is a large irregular-shaped bone, which, with its fellow of the opposite side, forms the sides

and front wall of the pelvic cavity. In young subjects it consists of three separate parts, and although in the adult these have become united, it is usual to describe the bone as divisible into three portions,—the ilium, the ischium, and the pubes. The

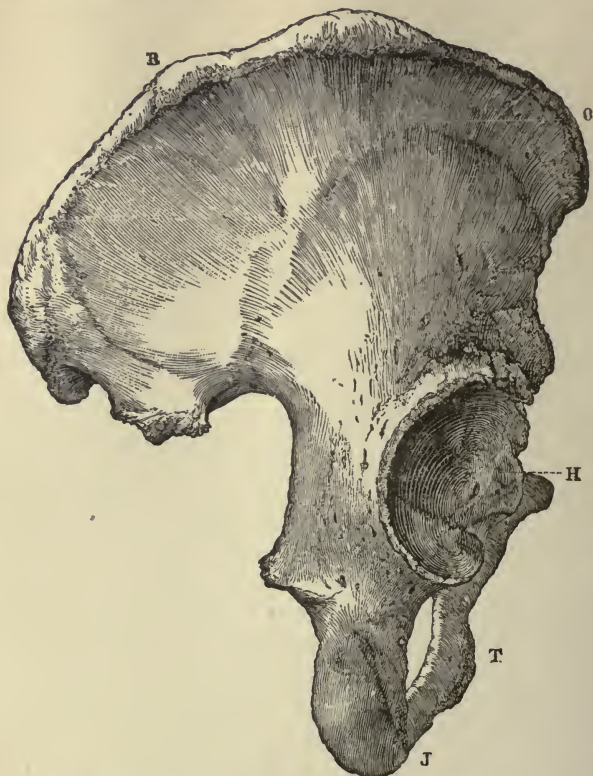


FIG. 31.—Os INNOMINATUM. Outer surface. *R*, *O*, crest of ilium, just below *O* is seen the upper anterior spinous process; *J*, tuberosity of ischium; *T*, part of pubes, between *J* and *T* is seen the thyroid foramen; *H*, acetabulum, below *H* is seen end of pubic bone which, with its fellow of opposite side, forms the symphysis pubis. (For further illustration, *vide* Figs. 45 and 46.)

ilium, so called from its supporting the flank, is the upper broad and expanded portion which forms the prominence of the hip. The ischium is the lower and strongest portion of the bone, while the pubes is that portion which forms the front of the pelvis. Where these three portions of the bone meet and finally ankylose is a deep socket, called the acetabulum, into which the head of the femur fits. Other points of special interest to note in the ossa innominata are (1) the spinous processes formed by

the projections of the crest of the ilium in front, above and below, the two upper or superior spinous processes being in particular well known and convenient landmarks used by surgeons in making anatomical measurements; (2) the largest foramen in the skeleton, known as the door-like or thyroid foramen, situated between the ischium and pubes; and (3) the symphysis pubis, or pubic articulation, which also serves for a convenient landmark in making measurements.

The **patella**, or knee-cap, is a small, flat, triangular bone, placed in front of the knee-joint. It is generally regarded as analogous to the olecranon process of the ulna, which also occasionally exists as a separate piece of bone. The knee-cap serves to protect the front of the knee-joint.

Irregular bones.—The irregular bones are those which, on account of their peculiar shape, cannot be grouped under either of the preceding heads.

Irregular bones of the head :—

Temporal	2
Sphenoid	1
Ethmoid	1
	4

The **temporal** bones are situated at the sides and base of the skull. They are named temporal from the Latin word, *tempus*, time, as it is on the temple the hair first becomes gray and thin, and thus shows the ravages of time. The temporal bones are divided into three parts: the hard, dense portion, called petrous; a thin and expanded scale-like portion, called squamous; and a mastoid portion, which is perforated by numerous holes and contains a number of cells. The internal ear, the essential part of the organ of hearing, is contained in a series of cavities, channelled out of the substance of the petrous portion. Between the squamous and

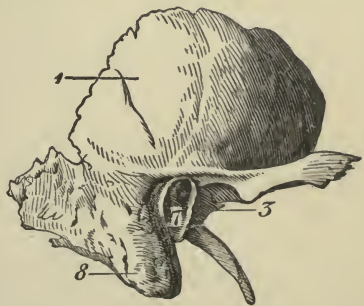


FIG. 32.—TEMPORAL BONE. Outer surface. 1, squamous portion; 7, external opening of auditory canal in petrous portion; 8, mastoid portion; 3, glenoid cavity for reception of condyle of lower jaw.

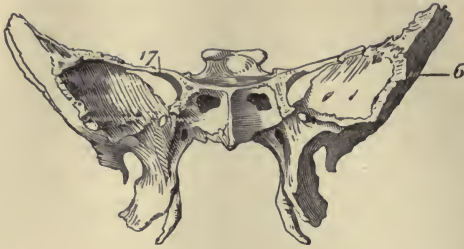

FIG. 33.—SPHENOID BONE. Anterior surface. 6, greater wing; 17, lesser wing.

petrous portions is a socket for the reception of the condyle of the lower jaw.

The sphenoid bone (*sphēn*, a wedge) is situated at the anterior part of the base of the skull, articulating with all the other

cranial bones, which it binds firmly and solidly together. In form it somewhat resembles a bat with extended wings.

The ethmoid bone is an exceedingly light, spongy bone, placed between the two orbits and at the root of the nose, contributing to form a part of each of these cavities. The portion of the bone situated at the back of the nose, and closing the skull cavity in front, is pierced by numerous holes, through which the nerves, conveying the sense of smell, pass. Descending from this perforated plate, on either side of the nasal cavity, are two masses of very thin, spongy, bony tissue.

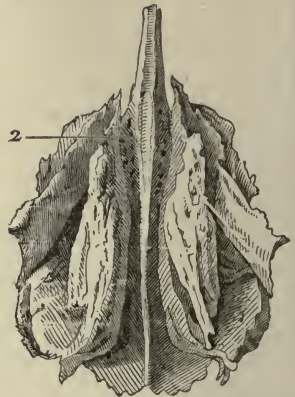


FIG. 34.—ETHMOID BONE. Posterior surface. 2, cribriform, or perforated plate.

The irregular bones of the face : —

Malar	2
Palate	2
Inferior turbinated	2
Superior maxillary	2
Inferior maxillary	$\frac{1}{9}$
	9

The malar or cheek bones form the prominence of the cheek, and part of the outer wall and floor of the orbit.

The palate bones form (1) the back part of the roof of the mouth; (2) part of the floor and outer wall of the nose; and (3) a very small portion of the floor of the orbit.

The inferior turbinated bones are situated on the outer wall of each side of the nostril. Each consists of a layer of thin, spongy bone, curled upon itself like a scroll; hence its name, "turbinated."

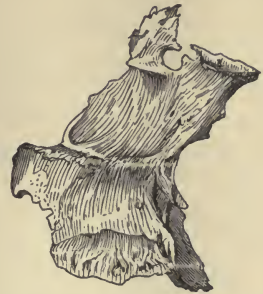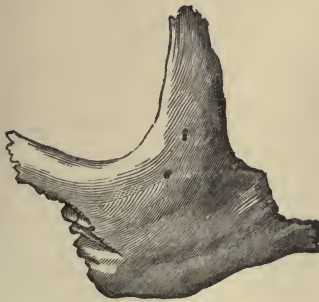


FIG. 35.—MALAR BONE. Outer surface. FIG. 36.—PALATE BONE. Inner surface.

spongy bone, curled upon itself like a scroll; hence its name, "turbinated."

The superior maxillary is one of the most important bones of the face, in a surgical point of view, on account of the number of diseases to which some of its parts are liable. With its fellow of the opposite side, it forms the whole of the upper jaw. Each bone assists in forming part of the floor of the orbit, the floor and outer wall of the nose, and the greater part of the roof of the mouth. That part of the bone which con-




FIG. 37.—INFERIOR TURBINATED BONE. CONVEX SURFACE

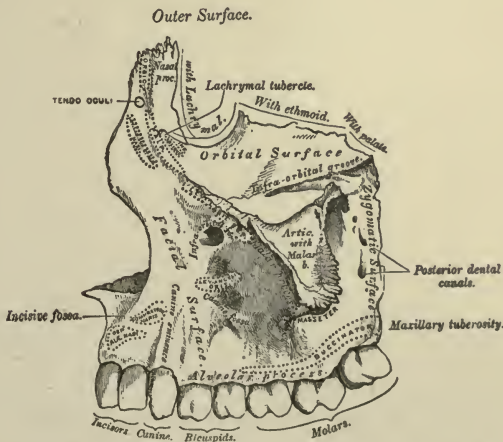


FIG. 38.—SUPERIOR MAXILLARY BONE. Outer surface.

tains the teeth is called the alveolar process, and is excavated into cavities, varying in depth and size according to the size of the teeth they contain. There are eight cavities in each bone: those for the canine teeth are the deepest; those for the molars are widest and subdivided into minor cavities; those for the incisors are single, but deep and narrow.

The inferior maxillary, or lower jaw, is the largest and strongest bone of the face, and serves for the reception of the lower teeth. At birth, it consists of two lateral halves, which join and form one bone during the first or second year. The lower jaw undergoes several changes in shape during life, owing mainly to the first and second dentition, to the loss of teeth in the aged, and the subsequent absorption of that part of the bone which contained them. It articulates, by its condyles, with the sockets in the temporal bones.

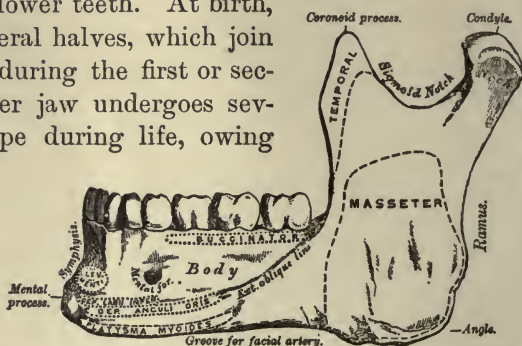


FIG. 39.—INFERIOR MAXILLARY BONE. Outer surface.

The **hyoid, os hyoides**, or tongue bone, is an isolated, U-shaped bone lying in front of the throat, just above “Adam’s apple”; it supports the tongue, and gives attachment to some of its numerous muscles.

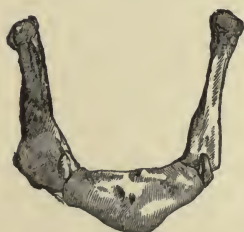

FIG. 40.—HYOID BONE.

The irregular bones of the trunk are comprised in the spine, which is formed of a series of bones called vertebræ. The vertebræ are thirty-three in number, and according to the position they

occupy are named:—

Cervical	7
Dorsal	12
Lumbar	5
Sacral	5
Coccygeal	4

The vertebræ in the upper three portions of the spine are separate throughout the whole of life; but those found in the sacral and coccygeal regions are, in the adult, firmly united, so as to form two bones, five entering into the upper bone or sacrum, and four into the terminal bone of the spine, or coccyx.

Each vertebra consists of two essential parts, an anterior solid portion or body, and a posterior portion or arch. The

bodies of the vertebræ are piled one upon another, forming a solid, strong pillar, for the support of the cranium and trunk, the arches forming a hollow cylinder behind for the protection of the spinal cord. Each arch has seven processes: four articular, two transverse, and one spinous process. The different vertebræ are

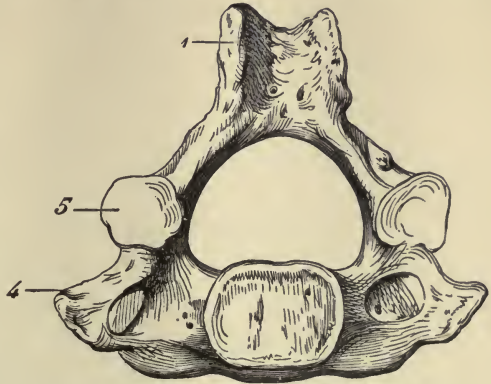


FIG. 41.—A CERVICAL VERTEBRA. Inferior surface. 1, spinous process, slightly bifid; 4, transverse process; 5, articular process, inferior surface. Below the arch, or hollow portion, is seen the solid portion, or body.

connected together by means of the articular processes, and by disks of intervertebral fibro-cartilage placed between the vertebral bodies, while the transverse and spinous processes serve for the attachment of muscles which move the different parts of the spine. In the cervical region of the vertebral column the bodies of the vertebræ are smaller than in the dorsal, but the arches are larger; the spinous processes are short, and are often cleft in two, or bifid. The first and second cervical vertebræ differ considerably from the rest. The first, or atlas, so named from supporting the head, has practically no body, and may be described as a bony ring divided into two sections by a transverse ligament. The dorsal section of this ring contains the spinal cord, and the ventral or front section contains the bony projection which arises from the front of the second cervical vertebra, or axis. This bony projection, or odontoid process, is really the body of the atlas, which in early life separates from its own vertebra and grows on the axis. Around this peg the atlas

rotates when the head is turned from side to side, carrying the

skull, to which it is firmly articulated, with it. The bodies of the dorsal vertebræ are larger and stronger than those of the cervical; they contain depressions for the reception of the vertebral ends of the ribs. The bodies of the lumbar vertebræ are the largest and heaviest in the whole spine. The sacrum, formed by the union of the five sacral vertebræ, is a large triangular bone situated like a wedge between the ossa innominata; it is curved upon itself in such a way as to give increased capacity to the pelvic cavity (*vide* Fig. 46). The coccyx (cuckoo's bill) is usually formed of four small segments of bone, and is the most rudimentary part of the vertebral column.

The vertebral column as a whole.—

The spinal column in a man of average height is about twenty-eight inches long. Viewed from the side it presents four curvatures; one, with the convexity forwards in the cervical region, is followed in the dorsal, by a curve with its concavity towards the chest. In the lumbar region the curve has again its convexity forwards, while in the sacral and coccygeal regions the concavity is turned inwards. These curvatures confer a considerable amount of springiness upon the spinal column which would be lacking were it a straight column: the elasticity is further increased by the disks of fibro-cartilage lying between and connecting the bodies of the vertebræ. These disks or pads

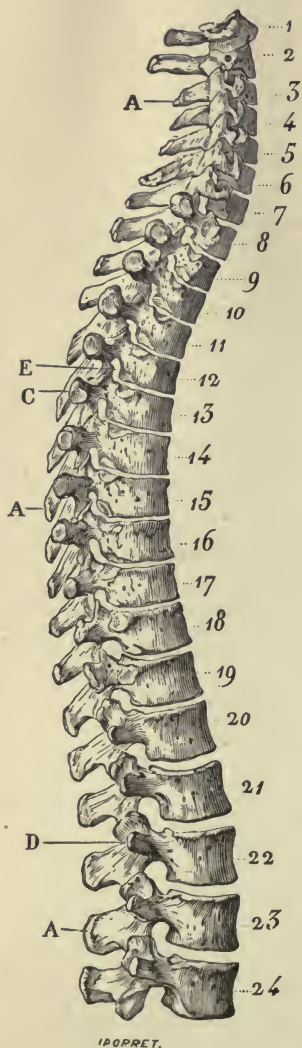


FIG. 42.—SIDE VIEW OF SPINAL COLUMN, WITHOUT SACRUM AND COCCYX. 1 to 7, Cervical vertebræ; 8 to 19, dorsal vertebræ; 20 to 24, lumbar vertebræ; A, A, spinous processes; C, D, transverse processes; E, intervertebral aperture; 1, atlas; 2, axis.

also mitigate the effects of concussion arising from falls or blows, and allow of a certain amount of motion between the vertebræ. The amount of motion permitted is greatest in the cervical region. Between each pair of vertebræ are apertures through which the spinal nerves pass from the spinal cord.

The skull as a whole. — The skull, formed by the union of the cranial and facial bones already described, is divisible into cranium or brain case, and the anterior region or face.

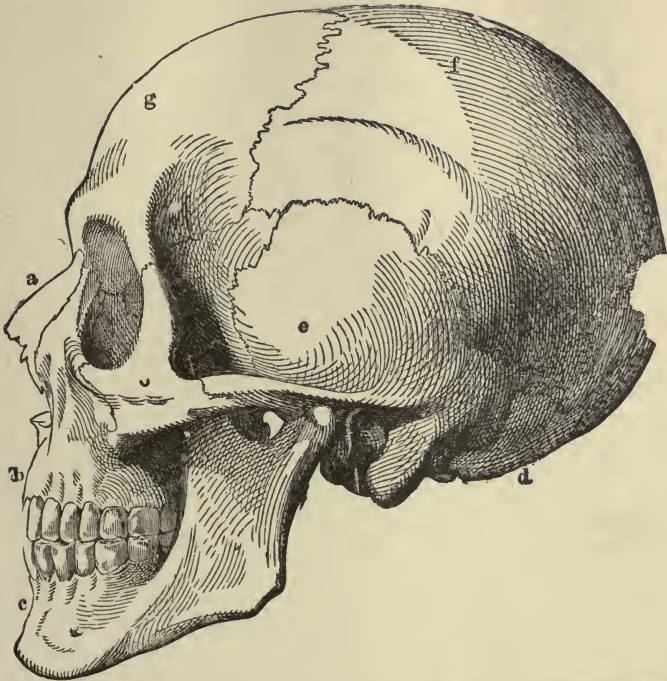


FIG. 43. — THE SKULL. *a*, nasal bone; *b*, superior maxillary; *c*, inferior maxillary; *d*, occipital; *e*, temporal; *f*, parietal; *g*, frontal bone.

The bones of the cranium begin to develop at a very early period of fœtal life, owing to the importance of the organ they have to protect. Before birth the bones at the top and sides of the skull are separated from each other by membranous tissue in which bone is not yet formed. The spaces occupied by this membranous tissue are termed the fontanelles, so named from the pulsations of the brain, which can be seen in some of them,

rising like the water in a fountain. There are six of these fontanelles. The anterior fontanelle is the largest, and is a lozenge-shaped space between the angles of the two parietal

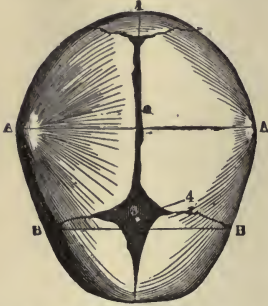


FIG. 44.—THE SKULL AT BIRTH. Superior surface. 1, posterior fontanelle; 2, sagittal suture; 4, anterior fontanelle; A, A, bi-parietal diameter; B, B, bi-temporal diameter.

and two frontal bones. The posterior fontanelle is much smaller in size, and is a triangular space between the occipital and two parietal bones. The other four fontanelles, two on each side of the skull, are placed at the inferior angles of the parietal bones: they are unimportant. The posterior fontanelle is closed by an extension of the ossifying process a few months after birth.

The anterior remains open until the second year, and occasionally persists throughout life. The base of the skull is much thicker and stronger than the walls and roof; it presents a number of openings for the passage of the cranial nerves, blood-vessels, etc.

The diameters of the foetal skull given by King are:—

Occipito-mental (from posterior fontanelle to chin) . .	5½ inches.
Occipito-frontal (centre of frontal bone to occiput) . .	4½ inches.
Bi-parietal (from one parietal prominence to another) . .	3½ inches.

The foetal cranial bones being imperfectly ossified, and their edges separated by membranous intervals, they are readily moulded, and they overlap one another more or less during parturition.

The pelvic cavity.—The pelvis, so called from its resemblance to a basin, is stronger and more massively constructed than either the cranial or the thoracic cavity. It is composed of four bones, the ossa innominata forming sides and front, and the sacrum and coccyx, completing it behind. It is divided by a brim or prominent line, the linea ilio-pectinea, into the false and true pelvis. The false pelvis is all that expanded portion of the pelvis situated above the brim: it forms an incomplete or “false” basin. The true pelvis is all that portion situated below the brim. Its cavity is a little wider in every

direction than the brim itself, while the false pelvis is a great

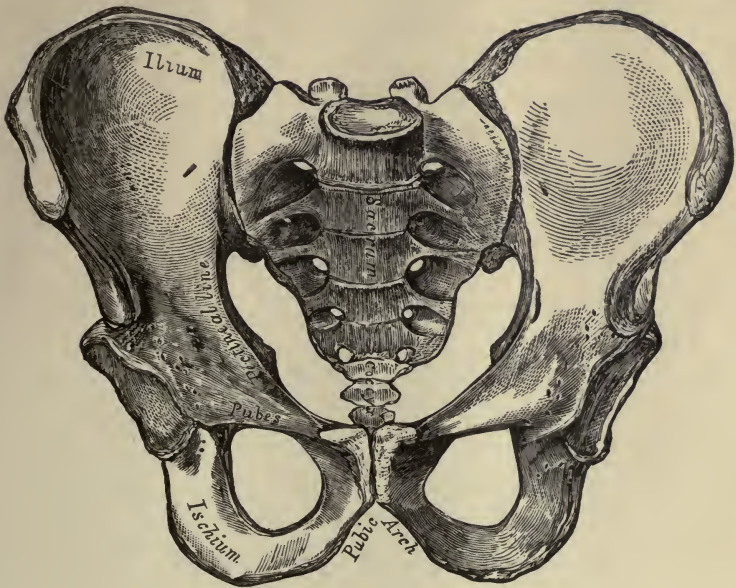


FIG. 45.— MALE PELVIS.

deal wider. The brim is, therefore, a somewhat narrower bony

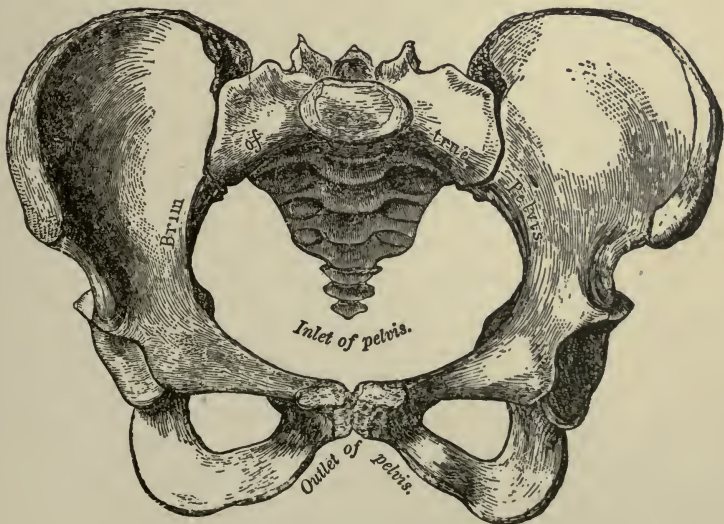


FIG. 46.— FEMALE PELVIS.

ring or aperture between these two; hence it is often termed the "strait." The bony pelvis is a basin without a bottom.

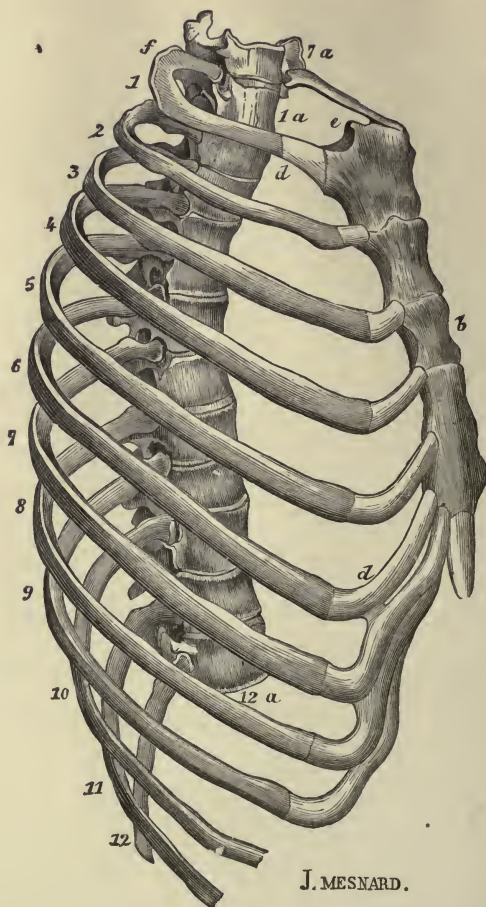


FIG. 47. — THORAX. 1 to 12, ribs; *d, d*, costal cartilages; *e*, upper end of sternum; *b*, middle portion of sternum; *1a*, first dorsal vertebra; *12a*, twelfth dorsal vertebra; *7a*, seventh cervical vertebra; 1 to 7, true ribs; 8 to 12, false ribs; 11, 12, floating ribs.

The opening where the bottom ought to be is the inferior strait or outlet. The female pelvis differs from that of the male in those particulars which render it better adapted to parturition, notably in being altogether wider in every direction, which gives more room for the child to pass; in being altogether shall-

lower, which lessens the distance through which the child has to be propelled; and lastly, in the bones being thinner and smoother.

The diameters of an average female pelvis given by King are: —

Antero-posterior diameter of brim or inlet	4 inches.
Transverse diameter of brim or inlet	4 inches.
Oblique diameter of brim or inlet	4½ to 5 inches.
Antero-posterior of outlet	4½ to 5 inches.
Transverse of outlet	4 inches.
Oblique of outlet	4 inches.

The thoracic cavity.—The thorax or chest is an elongated, conical-shaped cage, formed by the sternum and costal cartilages in front, the twelve ribs on each side, and the bodies of the twelve dorsal vertebræ behind. It contains and protects the principal organs of respiration and circulation.

TABLE OF THE BONES.

HEAD.		
<i>Cranium.</i>	<i>Face.</i>	
Occipital.	Nasal.	
Parietal.	Lachrymal.	
Temporal.	Malar.	
Frontal.	Superior maxillary. /	
Ethmoid.	Inferior maxillary. /	
Sphenoid.	Palate.	
	Inferior turbinated.	
	Vomer. /	
Os hyoides.	} TRUNK.	
Vertebræ {		7 cervical.
		12 dorsal.
		5 lumbar.
		5 sacral, or sacrum.
		4 coccygeal. or coccyx.
Ribs.		
Sternum.		
Ossa innominata.		

Clavicle.	} UPPER EXTREMITY.	Femur.	} LOWER EXTREMITY.		
Humerus.		Tibia.			
Ulna.		Fibula.			
Radius.		Metatarsus.			
Metatarsus.					
Carpus {		Scaphoid.		Tarsus {	Os calcis.
		Semilunar.			Astragalus.
		Cuneiform.			Cuboid.
		Pisiform.			Scaphoid.
		Trapezium.			Internal cuneiform.
		Trapezoid.			Middle cuneiform.
Os magnum.		External cuneiform.			
Unciform.					
Phalanges or digits.				Phalanges or digits.	

CHAPTER V.

JOINTS.

THE various bones of which the skeleton consists are connected together at different parts of their surfaces, and such connections are called joints or articulations.

In all instances some softer substance is placed between the bones, uniting them together, or clothing the opposed surfaces; but the manner in which the several pieces of the skeleton are thus connected varies to a great degree. We distinguish three varieties; viz. those which are (1) immovable, (2) slightly movable, (3) freely movable.

The immovable articulations. — The bones of the cranium and the facial bones (with the exception of the lower jaw) have their adjacent surfaces applied in close contact, with only a thin layer of fibrous tissue or of cartilage placed between their margins. In most of the cranial bones this union occurs by means of toothed edges which fit into one another and form jagged lines of union known as sutures. The suture between the frontal and parietal bones is called the coronal suture; between the parietal and occipital, the lambdoidal; and between the two parietal bones, along the middle line on the top of the crown, the sagittal suture.




FIG. 48. — A TOOTHED, OR DENTATED SUTURE.

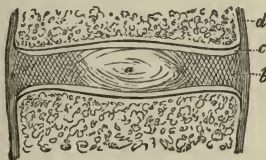


FIG. 49. — A MIXED ARTICULATION. *a, b*, disk of fibro-cartilage; *c*, articular cartilage; *d*, bone.

The slightly movable or mixed articulation. — In this form of articulation the bony surfaces are usually joined together by

broad, flattened disks of fibro-cartilage, as in the articulations between the bodies of the vertebræ. These intervertebral disks being compressible and extensile, the spine can be moved to a limited extent in every direction. In the pelvis the articulation between the two pubic bones (symphysis pubis), and between the sacrum and ilia (sacro-iliac articulation), are also slightly movable. The pubic bones are united by a disk of fibro-cartilage and by ligaments. In the sacro-iliac articulation the sacrum is united more closely to the ilia, the articular surfaces being covered by cartilage and held together by ligaments.

The movable articulations.—This division includes the complete joints,—joints having a secreting membrane placed between their opposing surfaces, which keeps them well lubricated and capable of free movement one upon the other. Each articular end of the bone is covered by cartilage, which provides surfaces

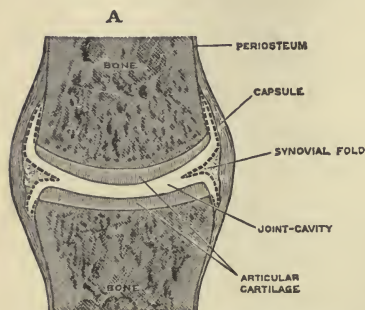


FIG. 50.—A SIMPLE COMPLETE JOINT. The synovial membrane is represented by dotted lines.

of remarkable smoothness, and these surfaces are lubricated by the synovial fluid secreted from the delicate synovial membrane which lines the cavity of the joint. This membrane is continuous with the margin of the articular cartilage, and along with them completely encloses the joint cavity. The bones are united by fibrous connective tissue in the various forms of ligaments, such as membranous

capsules, flat bands, or rounded cords. These ligaments are not always so tight as to maintain the bones in close contact in all positions of the joint, but are rather tightened in some positions and relaxed in others, so that in many cases they are to be looked upon chiefly as controllers of movements, and not as serving solely to hold the bones together. The bones are likewise held together in these joints by atmospheric pressure and by the surrounding muscles.

The varieties of joints in this class have been determined by the kind of motion permitted in each. They are as follows:—

- (1) *Gliding joint.* The articular surfaces are nearly flat,

and admit of only a limited amount of gliding movement, as in most of the articulations of the wrist and ankle, and in the joints between the articular processes of the vertebræ.

(2) *Hinge joint.* The articular surfaces are of such shape as to permit of movement, to and fro, in one plane only, like a door on its hinges. These movements are called flexion and extension, and may be seen in the articulation of the arm with the forearm, in the ankle joint, and in the articulations of the phalanges.

(3) *Ball and socket joint.* In this form of joint a more or less rounded head is received into a cup-like cavity, as the head of the femur into the acetabulum, and the head of the humerus into the glenoid cavity of the scapula. Movement can take place freely in any direction, but the shallower the cup, the greater the extent of motion.

(4) *Pivot joints.* In this form, one bone rotates around another which remains stationary, as in the articulation of the atlas with the axis, and in the articulation of the ulna and radius. In the articulation of the ulna and radius, the ulna remains stationary and the radius rotates freely around its upper end. The hand is joined to the lower end of the radius, and the radius, in rotating, carries the hand with it; thus, the palm of the hand is alternately turned upwards and downwards. When the palm is turned upwards, the attitude is called supination; when downwards, pronation.

The different kinds of movement of which bones thus connected are capable are, — flexion and extension; abduction and adduction; rotation and circumduction.

A limb is flexed, when it is bent; extended, when it is straightened out. It is abducted, when it is drawn away from the middle line; adducted, when it is brought to the middle line. It is rotated, when it is made to turn on its own axis; circumducted, when it is made to describe a conical surface, by rotation around an imaginary axis. No part of the body is capable of perfect rotation, as a wheel, for the simple reason that such motion would necessarily tear asunder all the vessels, nerves, muscles, etc., which unite it with other parts.

As the synovial membranes are intimately connected with the joints, it may be well to give a brief description of them here.

The synovial membranes are composed entirely of connective tissue, with the usual cells and fibres of that tissue. They are distinguished by the nature of their secretion, which is a viscid, glairy fluid, resembling the white of an egg and named synovia. From its nature, it is well adapted for diminishing friction, and thereby facilitating motion.

These membranes are found surrounding and lubricating the cavities of the movable joints in which the opposed surfaces glide on each other; in these situations they are called *articular synovial membranes*. They are found forming sheaths for the tendons of some of the joints, and thus facilitating their motion as they glide in the fibrous sheaths which bind them down against the bones; they are here called *vaginal synovial membranes*, or synovial sheaths. Lastly, they are found in the form of simple sacs, interposed, so as to prevent friction, between two surfaces which move upon each other, and in these situations they take the name of *bursal synovial membranes*, or synovial bursæ. These bursæ may be either deep seated or subcutaneous. The former are, for the most part, placed between a muscle and a bone, or between a tendon and a bone. The subcutaneous bursæ lie immediately under the skin, and occur in various parts of the body, interposed between the skin and some firm prominence beneath it. The large bursa situated over the patella is a well-known example of this class, but similar, though smaller, bursæ are found also over the olecranon, the malleoli, the knuckles, and other prominent parts.

TABLE OF JOINTS.

SYNARTHROSIS, OR IMMOVABLE JOINT.	}	<ol style="list-style-type: none"> 1. <i>Synchondrosis</i>. — A thin layer of cartilage is interposed between the bones to which it adheres closely on each side. 2. <i>Suture</i>. — A thin layer of fibrous tissue is interposed between the bones. Sutures may be dentated, tooth-like; serrated, saw-like; squamous, scale-like; harmonic, smooth; and grooved, for the reception of thin plates of bone.
AMPHIARTHROSIS, OR SLIGHTLY MOVABLE JOINT.	}	<ol style="list-style-type: none"> 1. <i>Symphysis</i>. — The bones are united by a plate or disk of fibro-cartilage of considerable thickness; or by articular cartilages lined by a partial synovial membrane. 2. <i>Syndesmosis</i>. — The bony surfaces are united by an interosseous ligament, as in the lower tibio-fibular articulation.

DIARTHROSIS,
OR
MOVABLE JOINT.

1. *Arthrodia*. — Gliding joint; articulates by plane surfaces which glide upon each other.
2. *Ginglymus*. — Hinge joint; moves backwards and forwards in one plane.
3. *Enarthrosis*. — Ball and socket joint; articulates by a globular head in a cup-like cavity.
4. *Diarthrosis rotatoria*. — Articulates by a pivot process turning within a ring, or by a ring turning round a pivot.

CHAPTER VI.

MUSCULAR TISSUE: STRIATED OR STRIPED; NON-STRIATED OR PLAIN; ATTACHMENT OF MUSCLES TO SKELETON; PROMINENT MUSCLES OF HEAD AND TRUNK; PROMINENT MUSCLES OF LIMBS.

MUSCULAR tissue is the tissue by means of which the active movements of the body are produced. It is a higher kind of tissue than the connective, which, as we have seen, is used chiefly for mechanical purposes. Muscular tissue is irritable, and if we irritate or stimulate it, it will respond. We may irri-




FIG. 51.—MUSCULAR FIBRE. Highly magnified. (E. A. S.) The nuclei are seen on the flat at the surface of the fibre, and in profile at the edges: the sarcolemma is not seen.

tate or stimulate the bones, ligaments, or other connective tissue structures and they will not respond, they will remain immovable; if, however, we stimulate muscular tissue, it will show its response to the stimulation by contracting. This power of the muscle to contract is called muscular contractility. All muscular tissue consists of fibres, and whenever a muscle fibre contracts, it tends to bring its two ends, *with whatever may be attached to them*, together. Influences which irritate or stimulate muscle fibres are spoken of under the general name of stimuli.

Muscle fibres are of two different kinds, and we therefore distinguish two varieties of muscular tissue, the striped or striated, and the plain or non-striated. The striated muscle is nearly always under the control of the will, and is often spoken of as *voluntary*

muscle; the non-striated is usually withdrawn from the control of the will, and is often termed *involuntary* muscle.

Voluntary, striated muscle is composed of long slender fibres measuring on an average about $\frac{1}{500}$ inch in diameter, but having a length of an inch or more. Each fibre consists of three distinct elements: (1) contractile substance, forming the centre and making up most of the bulk of the fibre; (2) nuclei, which lie scattered upon the surface of the contractile substance; (3) the sarcolemma, a thin, structureless tube, which tightly encloses the contractile substance and the nuclei.

If we examine a fresh muscle fibre microscopically, we see that the contractile substance is marked with very fine indistinct longitudinal lines, or striæ; and if we treat the fibre with certain chemical agents,

we find by slightly teasing it with a needle, or some other delicate instrument, that it breaks up along the longitudinal lines into a number of fine fibrils or fibrillæ. Again, if we examine the fibre still further, we find that in addition to the longitudinal striation it is crossed by more distinct narrow dark and light bands or stripes, the relative width of the stripes varying according as the

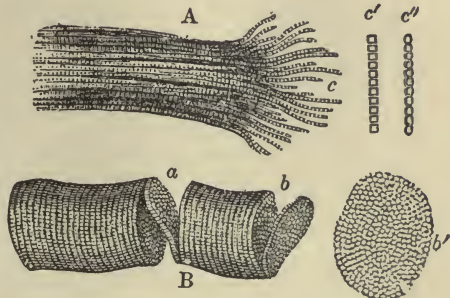


FIG. 52. — FRAGMENTS OF STRIPED FIBRES, SHOWING A CLEAVAGE IN OPPOSITE DIRECTIONS. (Magnified 300 diameters.) *A*, longitudinal cleavage; *c*, fibrillæ separated from one another at the broken end of the fibre; *c' c''*, single fibrils more highly magnified, in *c'* the elementary structures are square, in *c''* round; *B*, transverse cleavage; *a*, *b*, partially detached disks; *b'* detached disk, more highly magnified, showing the sarcous elements.

fibre is seen in a state of contraction or relaxation. So that if now we soak a fibre in an acid solution for twenty-four hours, and then tease it, we find that instead of breaking up *longitudinally* into fibrillæ, it *breaks across* into thin disks. We thus see that by breaking up in these two directions we may conceive of the fibre as being resolvable into a multitude of tiny structures, which elementary structures have been called sarcous elements. It is believed by many observers that these sarcous elements are definite and independent structures, and that they are joined together side by side, and end to end, by a peculiar cementing

substance; this, however, is not proved, and the ultimate structure of muscular fibre is still by no means fully understood. This much, however, is certain, that the contractile substance is a complex chemical structure, and that the molecules of which it is composed readily change their places under the influence of certain stimuli. When a muscle contracts, each section or sarcois element of the fibre broadens and shortens. This broadening and shortening is brought about by the molecules




FIG. 53.—WAVE OF CONTRACTION PASSING OVER A MUSCULAR FIBRE OF *DYTISCUS*. Very highly magnified. *R, R*, portions of the fibre at rest; *C*, contracted part; *I, I*, intermediate condition.

of each section of the fibre changing their places. We shall have a rough image of the movements of the molecules during a muscular contraction if we imagine a company of a hundred soldiers ten ranks deep, with ten men in each rank, rapidly, but by a series of gradations, extending laterally into a double line with fifty men in each line.

The striated muscles are all connected with nerves, and under normal conditions do not contract otherwise than by the agency of the nerves. They are also plentifully supplied with blood-vessels.

The muscular fibres lie closely packed, their ends lapping over on to adjacent fibres, and forming bundles. These bundles are grouped so as to make larger bundles, and in this way the muscles

which are attached to the skeleton are formed.

Involuntary, non-striated muscular tissue is composed of long, somewhat flattened, elongated fibre-cells. Each fibre-cell contains an oval or rod-shaped nucleus, containing one or more

nucleoli. The substance of the fibre-cell is longitudinally striated, but does not exhibit transverse striation. The fibre-cells lie side by side, or lap over one another at the ends, and are joined together by a small amount of cement substance.

This kind of muscular tissue is found arranged around the blood-vessels and most of the hollow viscera. The fibres are variously grouped in different parts of the body; sometimes crowded together in solid bundles, which are arranged in layers and surrounded by connective tissue, as in the intestines; sometimes arranged in narrow interlacing bundles, as in the bladder; sometimes wound in single or double layers around the blood-vessels; and again, running in various directions and associated with bands of connective tissue, they form large compact masses, as in the uterus.

Numerous nerves are supplied to non-striated muscular tissue, and many blood-vessels.

The contraction of this kind of muscular tissue is much slower and lasts longer than the contraction of the striated variety. As a general rule the muscles of the skeleton are thrown into contraction only by nervous impulses reaching them along their nerves; spontaneous contractions, as in a case of "cramps," being rare and abnormal. The plain muscular tissue of the internal organs, however, very often contracts independently of the central nervous system, and under favorable circumstances will continue to do so after the viscera have been removed from the body.

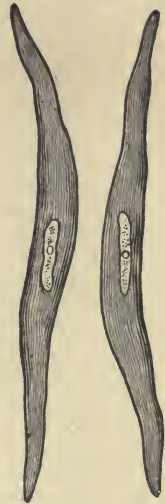


FIG. 54.—FIBRE-CELLS OF PLAIN MUSCULAR TISSUE. Highly magnified.

The great increase in the muscular tissue of the uterus during gestation takes place both by elongation and thickening of the pre-existing fibre-cells, and also, it is thought, by the development of new fibre-cells from small granular cells lying in the tissue. In the shrinking of the uterus after parturition the fibre-cells diminish to their previous size; many of them become filled with fat granules, and eventually many are, doubtless, removed by absorption.

Development of striated muscular tissue.—When the muscular fibres are about to be formed, the cells set apart for this purpose elongate, and their

nuclei multiply, so that each cell is converted into a long, multi-nucleated protoplasmic fibre. At first the substance of the fibre is not striated, but presently it becomes longitudinally striated along one side, and about the same time a delicate membrane, the sarcolemma, may be discovered bounding the fibre; then transverse striation commences, and gradually extends around the fibre, and, finally, the nuclei take up their position under the sarcolemma.

Regeneration of muscular tissue.— It was formerly thought that after removal, by the knife, or by disease, muscular tissue was not regenerated, but that any breach of continuity which might occur in the muscle was filled up by a growth of connective tissue. It would appear, however, that the breach is after a certain lapse of time bridged across by muscular substance, but how the new muscular tissue is formed is not fully understood.

Attachment of muscles to the skeleton.— The muscles are separate organs, each muscle having its own sheath of connective tissue. The connective tissue extends also into the muscle, forming sheaths for the smaller bundles, connecting and binding the fibres and bundles together, and conducting and supporting the blood-vessels and nerves distributed to the muscle fibres.

The muscles vary greatly in shape and size. In the limbs they are of considerable length, forming more or less elongated straps; in the trunk they are broad, flattened, and expanded, forming the walls of the cavities which they enclose.

They are attached to the bones, cartilages, ligaments, and skin in various ways, the most common mode of attachment being by means of tendons. The muscular fibres converge as they approach their tendinous extremities, and gradually blend with the fibres of the tendons, the tendons in their turn inserting their fibres into the bones. Sometimes the muscles end in expanded form in the flat fibrous membranes, called aponeuroses. Again, in some cases, the muscles are connected with the bones, cartilages, and skin, without the intervention of tendons or aponeuroses.

In the description of muscles it is customary to speak of the attachments of their opposite ends under the names of origin and insertion, the first term being usually applied to the more fixed attachment, and the second to the more movable attachment.

The muscular tissue or flesh forms a large proportion of the weight of the whole body. The following has been calculated for a man of one hundred and fifty pounds' weight from the



PLATE I.—FORMS OF MUSCLES AND TENDONS. *A*, adductor of thigh; *B*, biceps of arm; *D*, deltoid; *G*, gastrocnemius; *P'*, pronator of fore-arm; *P''*, pectoral; *R*, rectus abdominis; *R''*, rectus muscle of thigh; *S'*, serratus magnus of thorax; *S''*, semi-membranosus of thigh.

tables of Liebig: skeleton, twenty-eight pounds; muscles, sixty-two pounds; viscera (with skin, fat, blood, etc.), sixty pounds.

The total number of voluntary muscles may be stated at three hundred and eleven. It is not necessary for us to be able to distinguish more than a few of the most prominent. We may conveniently classify these into two groups:—

1. Chief muscles of the head and trunk.
2. Chief muscles of the limbs.

Chief muscles of head, face, neck, and trunk.—The chief muscles of the head are the **occipital** and **frontal** muscles, which, united together by a thin aponeurosis extending over and covering the whole of the upper part of the cranium, are usually known as one muscle, the **occipito-frontalis**. The frontal portion of this muscle is the more powerful; by its contraction the eyebrows are elevated, the skin of the forehead thrown into transverse wrinkles, and the scalp drawn forward.

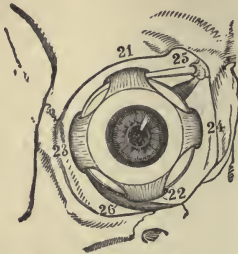


FIG. 55.—MUSCLES OF RIGHT EYEBALL WITHIN THE ORBIT. Seen from the front. 21, superior rectus; 22, inferior rectus; 23, external rectus; 24, internal rectus; 25, superior oblique; 26, inferior oblique.

There are about thirty facial muscles; they are chiefly small, and control the movements of the eye, nose, and mouth.

The six muscles which move the eyeball are the four straight or **recti**, and the two **oblique**, muscles. The four recti have a common origin at the bottom of the orbit; they pass straight forwards to their insertion into the eyeball, one, the superior rectus, in the middle line above; one, the inferior rectus, opposite it below, and one half-way on each side, the external and internal recti. The eyeball is completely imbedded in fat, and these muscles turn it as on a cushion, the superior rectus inclining the axis of the eye upwards,

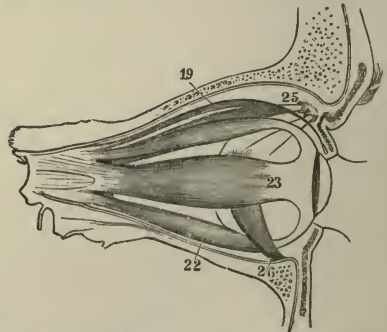


FIG. 56.—MUSCLES OF EYEBALL. Seen from side. 19, elevator muscle of eyelid; 22-26, same as in Fig. 55.

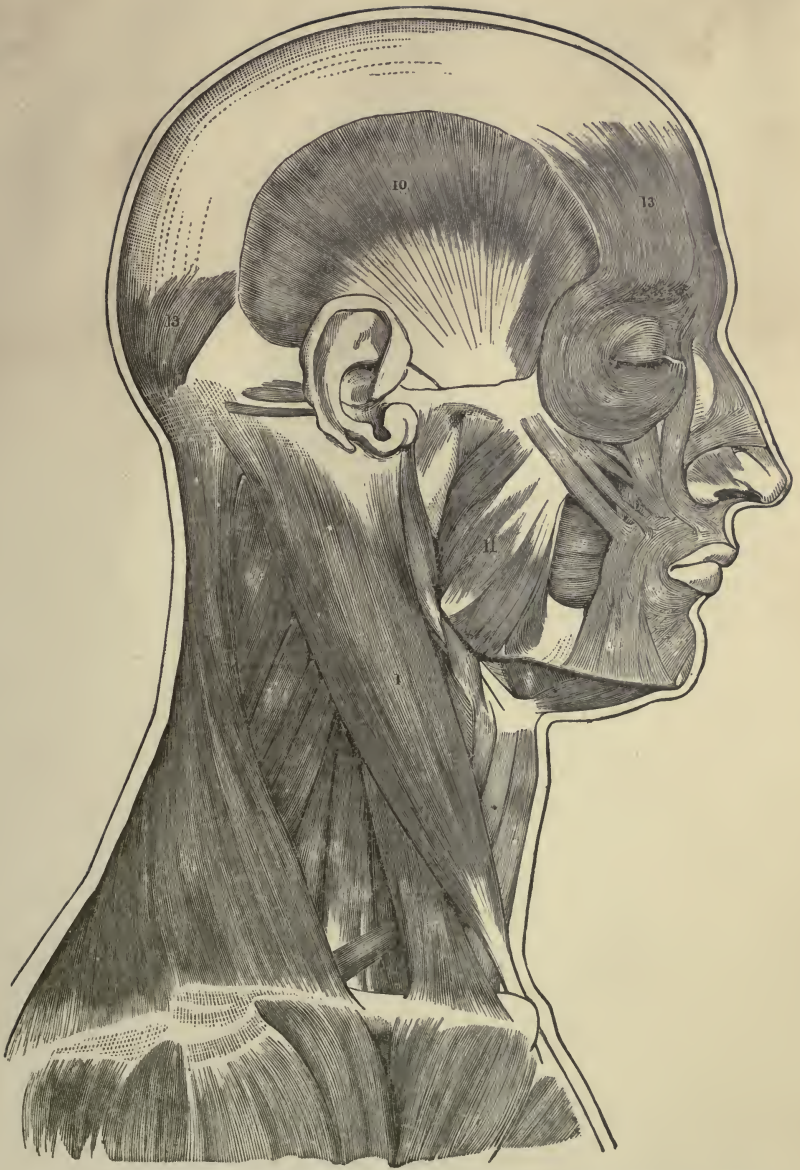


PLATE II. — MUSCLES OF FACE, HEAD, AND NECK. 1, sterno-cleido-mastoid; 10, temporal; 11, masseter; 13, 13, occipito-frontalis.

the inferior downwards, the external outwards, the internal inwards. The two oblique muscles are both attached on the outer side of the ball; their action is somewhat complicated, but their general tendency is to roll the eyeball on its own axis, and pull it a little forward and inward.

The muscles of mastication are the **masseter**, the **temporal**, and the **external and internal pterygoid**. They all have their origin in the immovable bones of the skull, and are all inserted into the movable lower jaw. They generally act in concert, bringing the lower teeth forcibly into contact with the upper; they also move the lower jaw forward upon the upper, and in every direction necessary to the process of grinding the food.

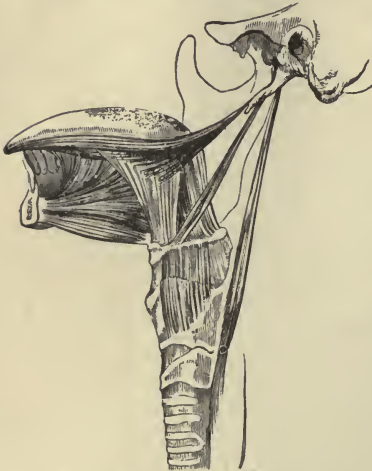

FIG. 57. — MUSCLES OF THE TONGUE.

The chief muscles connecting the tongue and tongue bone to the lower jaw are the **genio-glossus** and **stylo-glossus**. They are interesting to us from the fact that during general anæsthesia they, together with the other muscles, become relaxed, and it is necessary to press the angle of the lower jaw upwards and forwards in order to prevent the tongue from falling backwards and obstructing the larynx.

The most prominent muscle of the neck is the **sterno-cleido-mastoid**. It is named from its origin and insertion, arising from part of the sternum and clavicle, and being inserted into the mastoid portion of the temporal bone. This muscle is easily recognized in thin persons by its forming a cord-like prominence obliquely situated along each side of the neck. It serves as a convenient landmark in locating the great vessels carrying the blood to and from the head. If one of these muscles be either abnormally contracted or paralyzed, we get the deformity called wry neck.

The muscles of the trunk may be arranged in three groups: (1) muscles of the back; (2) muscles of the thorax; (3) muscles of the abdomen.

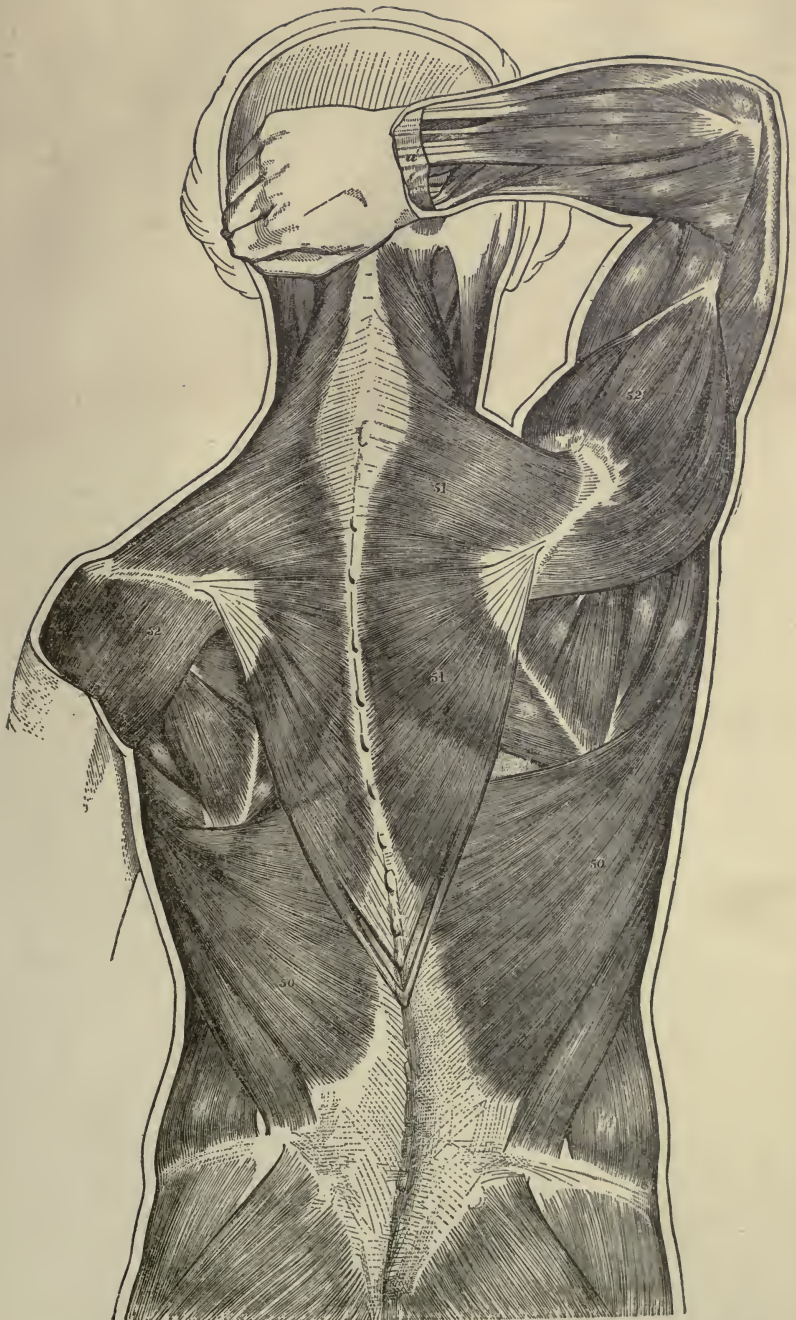


PLATE III.—MUSCLES OF BACK. 50, latissimus dorsi; 51, trapezius; 52, deltoid

The muscles of the back are disposed in five layers, one beneath another. The two largest and most superficial are the **trapezius** and the **latissimus dorsi**.

The **trapezius** arises from the middle of the occipital bone, and from the spine as far as the last dorsal vertebra. From this extended line of origin the fibres converge to their insertion in the acromion process and spine of the scapula. The **latissimus dorsi** arises from the last six dorsal vertebrae, and through the medium of the lumbar aponeurosis, from the lumbar and sacral part of the spine and from the crest of the ilium. The fibres pass upwards and converge into a thick, narrow band, which winds around and finally terminates in a flat tendon, which is inserted into the front of the humerus just below its head.

These muscles cover nearly the whole of the back; but as they act upon the bones of the upper extremity, they are often more properly reckoned as belonging to the muscles of that region.

The muscles of the thorax are chiefly concerned with the movements of the ribs during respiration. They are the **intercostals**, **subcostals**, etc.

The chief bulk of the anterior muscular wall of the chest is made up of the **pectoral** muscles, which arise mainly from the front of the sternum. The fibres converging form a thick mass, which is inserted by a tendon of considerable breadth into the upper part of the humerus. As these muscles move the arm, they are, like the superficial muscles of the back, usually reckoned among the muscles of the upper extremity. Covering the pectoral muscles is a superficial fascia (composed of connective tissue) in which are lodged the mammary glands and a variable amount of fat.

The muscular walls of the abdomen are mainly formed by three layers of muscles, the fibres of which run in different directions, those of the superficial and middle layers being oblique, and those of the innermost layer being transverse. In front, these three layers of muscles are replaced by tendinous expansions or aponeuroses, which meet in the middle line, the line of union giving rise to a white cord-like line, the **linea alba**. On each side of this line the fibres of a straight muscle, the **rectus** muscle, extend in a vertical direction between the tendinous




PLATE IV. — MUSCLES OF CHEST AND ABDOMEN. 55, pectoral muscle; 44, serratus magnus; 34, external oblique; 35, rectus abdominis, the external layer of aponeurotic sheath is removed; 38, linea alba; 40, aponeurosis.

layers. The abdominal muscles are covered and lined by sheets of fasciæ, some of which are very dense and strong, and serve to strengthen weak points in the muscular walls.

The strongest and most superficial of the abdominal muscles is the **external oblique**, the fibres of which, arising from the lower eight ribs, incline downwards and forwards and terminate in the broad aponeurosis, which, meeting its fellow of the opposite side in the linea alba, covers the whole of the front of the abdomen. The lowest fibres of the aponeurosis are gathered together in the shape of a thickened band, which extends from the superior spinous process of the ilium to the pubis, and forms the well-known and important landmark, called from the anatomist who first described it, Poupart's ligament. Just above this ligament, and near the pubic bone, is an oblique opening which transmits the spermatic cord in the male, or the round ligament in the female. This opening, called the external abdominal ring, is often the seat of hernia.

The **internal oblique** muscle lies just beneath the external oblique. Its fibres run upwards and forwards, and end for the most part in a broad aponeurosis. At the outer border of the rectus muscle this aponeurosis divides into two layers, one passing before, the other behind, that muscle: they reunite at its inner border in the linea alba, and thus form a sheath for the rectus.

The **transversalis** muscle lies beneath the internal oblique; the greater part of its fibres have a horizontal direction, and extend forward to a broad aponeurosis in front.

The **rectus** is a long, flat muscle, consisting of vertical fibres situated at the fore part of the abdomen, and enclosed in the fibrous sheath formed by the aponeuroses of the internal oblique. It arises from the pubis, and is inserted into the cartilages of the fifth, sixth, and seventh ribs; it is separated from the muscle of the other side by a narrow interval which is occupied by the linea alba.

The linea alba, or white line, is a tendinous band formed by the union of the aponeuroses of the two oblique and transverse muscles, the tendinous fibres crossing one another from side to side. It extends perpendicularly, in the middle line, from the ensiform portion of the sternum to the pubis. It is a little broader above than below, and a little below the middle it is

widened into a flat circular space, in the centre of which is situated the cicatrix of the umbilicus.

The abdominal muscles perform a threefold action. When the pelvis and thorax are fixed, they compress the abdominal viscera by constricting the cavity of the abdomen, in which action they are much assisted by the descent of the diaphragm. By these means the foetus is expelled from the uterus, the faeces from the rectum, the urine from the bladder, and its contents from the stomach, in vomiting. If the spine is fixed, these muscles raise the diaphragm by pressing on the abdominal viscera, draw down the ribs, compress the lower part of the thorax, and assist in expiration. If the thorax is fixed, and the trunk and arms raised and fixed, they draw the pelvis upwards as a preparatory step to the elevation of the lower limbs in the action of climbing.

The **diaphragm** is a thin musculo-fibrous partition, placed obliquely between the abdominal and thoracic cavities. It is fan-shaped, and consists of muscle fibres arising from the whole of the internal circumference of the thorax, and of an aponeurotic tendon, shaped somewhat like a trefoil leaf, into which the muscle fibres are inserted. (*Vide* Plate V. for illustration of diaphragm.) It has three large openings for the passage of the aorta, the large artery of the body, the inferior vena cava, the largest vein of the body, and the oesophagus or gullet; it has also some smaller openings, of less importance, for the passage of blood-vessels, nerves, etc. The upper or thoracic surface of the diaphragm is highly arched; the heart is supported by the central portion of the arch, the right and left lungs by the lateral portions, the right side of the arch being slightly higher on the right than on the left side. The lower or under surface of the diaphragm is deeply concave, and covers the liver, stomach, pancreas, spleen, and kidneys.

The action of the diaphragm modifies considerably the size of the chest, and the position of the thoracic and abdominal viscera, and it is essentially the great respiratory muscle of the body. The mechanical act of respiration consists of two sets of movements; viz. those of inspiration and of expiration, in which air is successively drawn into the lungs and expelled from them by the alternate increase and diminution of the thoracic cavity. The changes in the capacity of the thorax are

effected by the expansion and contraction of its lateral walls, called *costal* respiration, and by the depression and elevation of the floor of the cavity, through contraction and relaxation

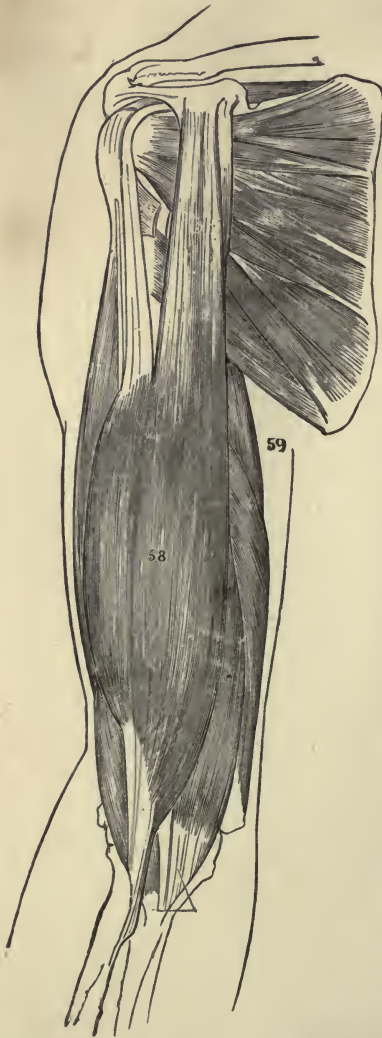

FIG. 58. — MUSCLES OF ARM. 58, biceps;
59, triceps.

of the diaphragm, called *diaphragmatic* or abdominal respiration. These two movements are normally combined in the act of respiration, but in different circumstances one of them may be resorted to more than the other. Abdominal respiration predominates in men and in children, and costal respiration in women. In the act of inspiration the diaphragm contracts, and in contracting flattens out and descends, the abdominal viscera are pressed downwards, and the thorax is expanded vertically. In normal and quiet expiration the diminution of the capacity of the chest is mainly due to the return of the walls of the chest to the condition of rest, in consequence of their own elastic reaction, and of the elasticity and weight of the viscera displaced by inspiration. In more forcible acts of expiration, and in efforts of expulsion from the thoracic and abdominal cavities, all the muscles which tend to depress the ribs, and those which compress the abdominal cavity, concur in powerful

action to empty the lungs, to fix the trunk, and to expel the contents of the abdominal viscera. Thus the diaphragm is an expulsive as well as the chief respiratory muscle of the body.

Muscles of the upper extremity.

—A certain number of muscles situated superficially on the trunk pass to the bones of the shoulder and of the arm, so as to attach the upper limbs to the trunk. Of these, the two superficial muscles we have mentioned as covering the back, the trapezius and latissimus dorsi, and pectoral muscles covering the front of the chest, are the chief. The most prominent muscles found in the upper limbs are:—

- | | |
|----------|-------------|
| Deltoid. | Pronators. |
| Biceps. | Supinators. |
| Triceps. | Flexors. |
| | Extensors. |

The **deltoid** is a coarse triangular muscle covering the top of the shoulder; it extends downwards and is inserted into the middle of the shaft of the humerus. It raises the arm from the side so as to bring it at right angles to the trunk.

The **biceps** is a long fusiform muscle, occupying the whole of the anterior surface of the arm; it is divided above into two portions or heads, from which circumstance it has received its name. It arises by these two heads from the shoulder-joint, and is inserted into the radius. It flexes the forearm on the arm.

The **triceps** is situated on the back of the arm, extending the whole length of the posterior sur-

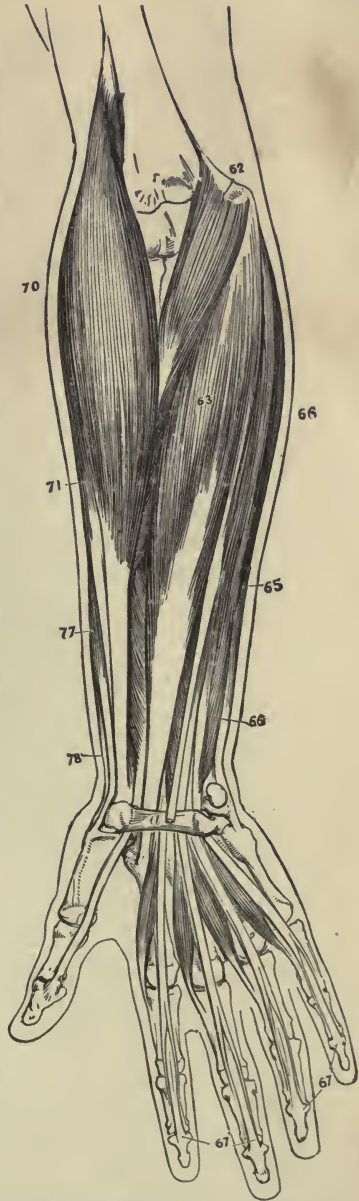


FIG. 59.—MUSCLES IN FRONT OF FOREARM. 62, pronator teres; 63, 65, 66, 67, flexors; 70, supinator longus; 71, 77, 78, extensors; a, annular ligament.

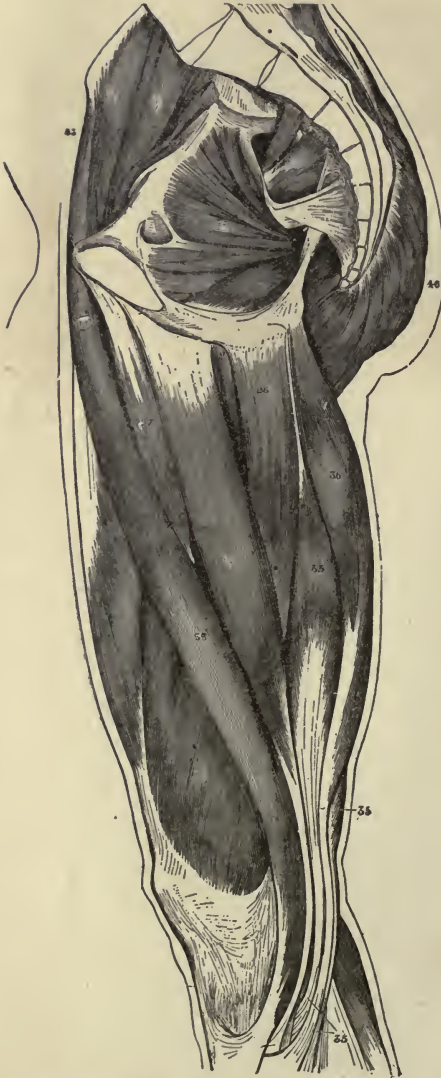

FIG. 60. — MUSCLES OF THE THIGH. 46, gluteus maximus; 36, 35, posterior femoral; 33, sartorius; 27, 26, internal femoral or adductor.

face of the humerus. It is of large size, and divided above into three heads; hence its name. It is inserted into the ulna. It is the great extensor muscle of the forearm, and is the direct antagonist of the biceps.

The muscles covering the forearm are disposed in groups, the **pronators** and **flexors** being placed on the front and inner part of the forearm, and the **supinators** and **extensors** on the outer side and back of the forearm: they antagonize one another. The pronators turn the palm of the hand downwards or prone, the supinators turn it upwards or supine. The flexors and extensors have long tendons, some of which are inserted into the bones of the wrist, and some into the bones of the fingers: they serve to flex and extend the wrist and fingers.

Muscles of the lower extremity. — These include the muscles of hip, thigh, leg, and foot. The most prominent of these are:—

Glutei or gluteal muscles.
Posterior femoral.
Anterior femoral.
Internal femoral.

Tibialis anticus.
Extensors.
Peroneal.
Gastrocnemius.

Soleus.
Flexors.
Tibialis posticus.

If we compare the muscles of the shoulder and arm with those of the hip and leg, we shall see that the anterior muscles of the former correspond roughly with the posterior muscles of the latter, the muscles of the hip and leg, however, being larger and coarser in texture than those of the shoulder and arm.

The **glutei**, or three gluteal muscles, form the chief prominence of the buttocks. They are coarse in texture, and are powerful abductors of the thigh; but the chief action of the largest of these three muscles, the *gluteus maximus*, is to bring the body into the erect posture when the trunk is bent forwards upon the thigh. It also comes into operation in ascending stairs, in leaping, and in rising from the sitting posture.

The **posterior femoral** or hamstring muscles cover the back of the thigh. There are three of these muscles, — the *biceps*, the *semitendinosus*, and the *semimembranosus*. The chief of these is the *biceps*, and is somewhat analogous to the *biceps* covering the front of the arm. The action of the hamstring muscles is to flex the knee and to extend the hip.

The **anterior femoral** muscles are the *quadriceps* and *sartorius*. The *quadriceps* covers the front of the thigh, and is analogous to the *triceps* covering the back of the arm; it is the great extensor of the leg; it also flexes the hip, and antagonizes the action of the hamstring muscles.

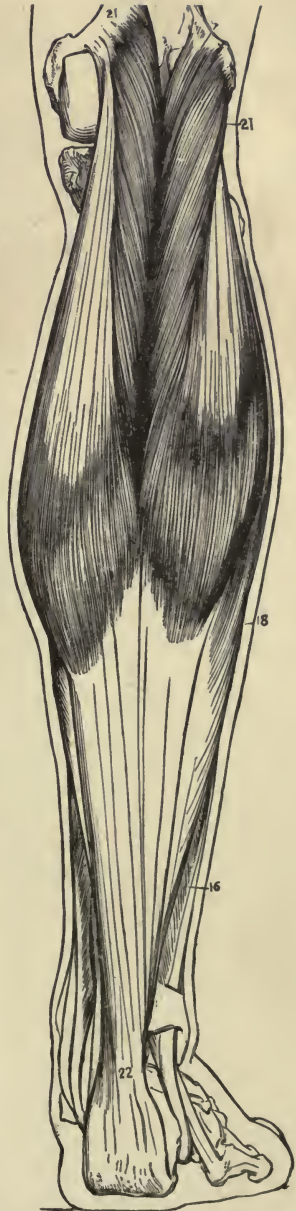


FIG. 61. — MUSCLES OF LEG. SUPERFICIAL VIEW OF THE CALF. 22, tendo Achillis; 21, *gastrocnemius*; 18, *soleus*; 16, *peroneal* muscles.

The sartorius, or tailor's muscle, is a long, ribbon-like muscle, the longest in the body: it crosses the thigh obliquely from its origin in the ilium to its insertion in the tibia. It is supposed to be the muscle principally concerned in producing the posture assumed by the tailor in sitting cross-legged, and hence its name.

The **internal femoral** or adductor muscles occupy the internal portion of the thigh: they are all adductors of the thigh.

The **tibialis anticus**, the **extensors**, and the **peroneal** muscles cover the front and outer side of the leg. The **gastrocnemius** and the **soleus**, the **flexors**, and the **tibialis posticus**, cover the back of the leg. The action of the tibialis anticus and of one of the three peroneal muscles is to flex the ankle, while the action of the tibialis posticus and the other peroneal muscles is to extend the ankle. The flexors and extensors act on the toes.

The **gastrocnemius** and **soleus** form the calf of the leg; they are inserted into a common tendon, the tendo Achillis, which is the thickest and strongest tendon in the body, and is inserted into the os calcis, or heel bone. The muscles of the calf possess considerable power, and are constantly called into use in standing, walking, dancing, and leaping; hence the large size they usually present.

The sole of the foot is protected by a fascia, called the plantar fascia, which is very strong, and the densest of all the fibrous membranes.

Most of the muscles are covered closely by sheets of fibrous connective tissue (*fasciæ*), and this deep layer of tissue forms a nearly continuous covering beneath the superficial or subcutaneous layer of areolar connective tissue, which in a former chapter we saw to be continuous over the whole of the body. Parts of the deep *fasciæ* in the vicinity of the larger joints, as at the wrist and ankle, become blended into tight transverse bands which serve to hold the tendons close to the bones, and receive the name of *annular ligaments*.

TABLE OF CHIEF MUSCLES.

Occipito-frontalis. HEAD.

Temporal.	} <i>Muscles of Mastication.</i>	} FACE.
Masseter.		
Pterygoid.		
Exterior rectus.	} <i>Muscles of the Eye.</i>	
Interior rectus.		
Superior rectus.		
Inferior rectus.		
Superior oblique.		
Inferior oblique.		

Genio-glossus. }
 Stylo-glossus. } TONGUE.

Sterno-cleido-mastoid. NECK.

Intercostals.	} THORAX.
Subcostals.	
Levatores costarum.	
Pectoral major.	
Pectoral minor.	

Diaphragm. BETWEEN THORAX AND ABDOMEN.

Obliquus externus abdominis.	} ABDOMEN.
Obliquus internus abdominis.	
Transversalis abdominis.	
Rectus abdominis.	

Trapezius.	} BACK.
Latissimus dorsi.	

Deltoid. SHOULDER.

Biceps flexor cubiti.	} ARM.
Triceps extensor cubiti.	

Pronators (2).	} FOREARM.
Supinators (2).	
Flexors of the wrist (2).	
Flexors of fingers and thumb (3).	
Extensors of wrist (3).	
Extensors of fingers and thumb (6).	

Glutei {	} HIP.
Maximus.	
Medius.	
Minimus.	

Posterior femoral	{	Biceps flexor cruris.	}	THIGH.
		Semitendinosus.		
		Semimembranosus.		
Anterior femoral	{	Quadriceps extensor cruris.		
		Sartorius.		
Internal femoral	{	Adductor longus.		
		Adductor brevis.		
		Adductor magnus.		

Tibialis anticus.	}	LEG.
Tibialis posticus.		
Peroneal (3).		
Gastrocnemius.		
Soleus.		
Flexors of toes (4).		
Extensors of toes (4).		

CHAPTER VII.

THE VASCULAR SYSTEM: THE BLOOD.

HAVING studied three of the distinctive tissues of the body (the epithelial, connective, and muscular), their structure, position in the body, and the various functions they are especially adapted to perform, we shall next consider the vascular, respiratory, alimentary, and excretory systems, by means of which all the tissues are supplied with the materials necessary for their life and growth, and relieved of all those waste and superfluous matters which are the results of their activity.¹

All the tissues of the body are traversed by minute tubes, called capillary blood-vessels, to which blood is brought by large tubes, called arteries, and from which blood is carried away by other large tubes, called veins. These capillaries form networks, the meshes of which differ in form and size in the different tissues. The meshes of these networks are occupied by the elements (cells or fibres) of the tissues; and filling up such spaces as exist between the capillary walls and the elements of the tissue, is found a colourless fluid, resembling in many respects the fluid portion of the blood, and called lymph. As the blood flows through the capillaries, certain constituents of the blood pass through the capillary wall into the lymph, and certain constituents of the lymph pass through the capillary wall into the blood within the capillary. There is thus an interchange of material between the blood within the capillary and the lymph outside. A similar interchange of material is at the same time going on between the lymph and the tissue itself.

¹ As the nervous tissue is the most highly organized of the tissues, and its functions are very complex and difficult to understand, the consideration of it is deferred until the student has mastered the vascular, respiratory, alimentary, and excretory systems.

Hence, by means of the lymph acting as middleman, a double interchange of material takes place between the blood within the capillary and the tissue outside the capillary. In every tissue, so long as life lasts and the blood flows through the blood-vessels, a fluid is passing from the blood to the tissue, and from the tissue to the blood. The fluid from the blood to the tissue carries to the tissue the material which the tissue needs for building itself up and for doing its work, including the all-important oxygen. The fluid from the tissue to the blood carries into the blood certain of the products of the chemical changes which have been taking place in the tissue — products which may be simply waste, to be cast out of the body as soon as possible, or which may be bodies capable of being made use of by some other tissue. The tissues, by the help of the lymph, *live on the blood*, and the blood may thus be regarded as an internal medium, bearing the same relations to the tissue that the external medium, the world, does to the whole individual. Just as the whole organism lives on the things around it, its air and its food, so the several tissues live on the complex fluid by which they are all bathed, and which is to them their immediate air and food.

The blood. — The most striking external feature of the blood is its well-known colour, which is bright red approaching to scarlet in the arteries, but of a dark-red or purple tint in the veins. It is a somewhat sticky liquid, a little heavier than water, its specific gravity being about 1.055; it has a saltish taste, a slight alkaline reaction, and a temperature of about 100° F.

Seen with the naked eye the blood appears opaque and homogeneous; but when examined with a microscope it is seen to consist of a transparent, colourless fluid, with minute solid particles immersed in it. The colourless fluid is named *plasma* the solid particles *corpuscles*. These corpuscles are of two kinds, the red or coloured, and the white or colourless. In a cubic millimetre¹ of healthy blood there are on an average 5,000,000 red corpuscles, and 10,000 white. The number of white varies much more than that of the red; the proportion of white to the red is usually given at from 1 to 250 up to 1 to 1000.

¹ A millimetre is equal to 0.039, or $\frac{1}{25}$ of an English inch.

Red corpuscles of the blood.—The red corpuscles have a nearly circular outline like a piece of coin, and most of them have a shallow, dimple-like depression on both sides; their shape is, therefore, that of biconcave disks.

The average size is $\frac{1}{3200}$ of an inch in diameter, and about one-fourth that in thickness. When viewed singly by transmitted light the coloured corpuscles do not appear red, but merely of a reddish-yellow tinge, or yellowish-green in venous blood. It is only when the light shines upon a number of corpuscles that a distinct red colour is produced.

When blood is drawn from the vessels, the red disks sink in the plasma: they have a singular tendency to run together, and to cohere by their broad surfaces, so as to form cylindrical columns like piles or rouleaux of coins, and the piles join themselves together in an irregular network. Generally the corpuscles separate on a slight impulse, and may then unite again.

Each red corpuscle is composed of an external colourless envelope with coloured fluid contents.—Quain.

The envelope is a very delicate membrane of a fatty nature, and may be ruptured or dissolved under certain conditions. The colour of the fluid contents is due to a crystallizable substance called hæmoglobin.¹ If water be added to a preparation of blood under the microscope, the water passes into the corpuscle, and the concave sides of the corpuscle become bulged out so that it is rendered globular. By the further action of

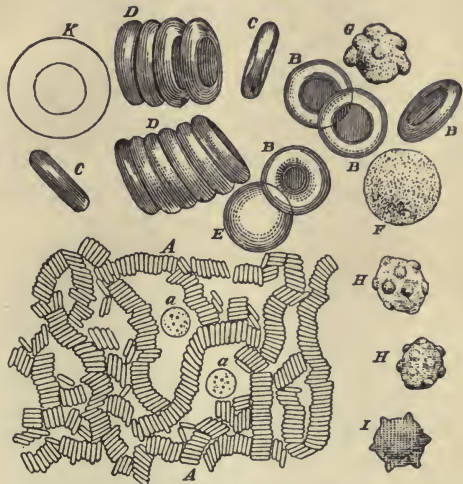


FIG. 62. — RED AND WHITE CORPUSCLES OF THE BLOOD. Magnified. *A*, moderately magnified, the red corpuscles are seen in rouleaux; *a, a*, white corpuscles; *B, C, D*, red corpuscles, highly magnified, seen in different positions; *E*, a red corpuscle swollen into a sphere by imbibition of water; *F, G*, white corpuscles, highly magnified; *K*, white corpuscle treated with acetic acid; *H, I*, red corpuscles wrinkled or crenated.

Each red corpuscle is composed of an external colourless envelope with coloured fluid contents.—Quain.

The envelope is a very delicate membrane of a fatty nature, and may be ruptured or dissolved under certain conditions. The colour of the fluid contents is due to a crystallizable substance called hæmoglobin.¹ If water be added to a preparation of blood under the microscope, the water passes into the corpuscle, and the concave sides of the corpuscle become bulged out so that it is rendered globular. By the further action of

¹ Hæmoglobin is a proteid, and contains, in addition to the usual proteid elements, a certain amount of iron.

water the hæmoglobin is dissolved out of the corpuscle, and the colourless envelope remains as a faint circular outline. On the other hand, the addition of salt to a preparation of blood by absorbing the water causes the corpuscles to shrink, and become wrinkled or crenated. The red corpuscles are practically small flattened bags, or sacs, the form of which may be changed by altering the density of the plasma. They are very soft, flexible, and elastic, so that they readily squeeze through apertures and passages narrower than their own diameters, and immediately resume their proper shape.

Function of the red corpuscles. — The red corpuscles, by virtue of their hæmoglobin, are emphatically oxygen carriers. Exposed to the air in the lungs, the hæmoglobin combines with the oxygen present in the air; this oxygen the hæmoglobin carries to the tissues; these, more greedy of oxygen than itself, rob it of its charge, and the reduced hæmoglobin hurries back to the lungs for a fresh supply. The colour of the blood is dependent upon this combination of the hæmoglobin with oxygen; when the hæmoglobin has its full complement of oxygen, the blood has a bright red hue; when the amount is reduced, it changes to a dark purplish hue. The scarlet blood is usually found in the arteries, and is called arterial; the dark purple in the veins, and is called venous blood.

White corpuscles of the blood. — The white, colourless corpuscles, or leucocytes, are few in number compared with the red, and both on this account, and because of their want of colour, they are not at first easily recognized in a microscopic preparation of blood. Their form is very various, but when the blood is first drawn they are rounded or spheroidal. Measured in this condition they are about $\frac{1}{2500}$ of an inch in diameter. The white corpuscle may be taken as the type of a free animal cell. It is a small piece of protoplasm, containing one or more nuclei, and has no limiting membrane or cell-wall (*vide* Fig. 61 F. G.).

These corpuscles, or cells, possess the power of spontaneous movement, and are capable of changing their form and place. While, when in a state of rest, they assume in general the spheroidal form, we find that when they become active they send out variously shaped processes, some fine and delicate, others broad, and of very irregular shape. We often see, after a process has been thrown out, that it becomes larger and

larger, the cell body becoming correspondingly smaller, until finally the whole cell passes over into the process, thus moving forward. These amœboid movements are always very slow, and are greatly influenced by the temperature, density, and amount of oxygen in the fluid in which the cells lie. By virtue of this locomotive power the white blood cells perform certain evolutions within the blood-vessels; they escape through their walls, and sometimes singly, sometimes in vast numbers, move through the lymph spaces in the surrounding tissues. This is spoken of as the "migration of the white corpuscles." In an "inflamed area" large numbers of white corpuscles are thus drained away from the blood. These migrating corpuscles, or wander cells, may, by following the devious tracks of the lymph, find their way back into the blood; some of them, however, may remain and undergo various changes. Thus in inflamed areas, when suppuration follows inflammation, the white corpuscles which have migrated may become "pus corpuscles."

Again, by virtue of their amœboid movements, the white corpuscles can creep around objects, enveloping them with their own substance, and so putting them inside themselves. As an illustration of this action of the white corpuscle, we may state that, according to some observers in certain diseases in which micro-organisms make their appearance in the blood, the white corpuscles take up these organisms into their substance and probably exert an influence over them, which modifies the course of the disease of which these organisms are the essential cause.

Furthermore, the white corpuscles are not only capable of taking up particles in the blood, but are also capable of giving up modified products to the blood, and it follows that these metabolic changes must necessarily affect the composition of the fluid plasma in which they lie.

The plasma of the blood.—The plasma is a clear, slightly yellowish coloured fluid, consisting for the most part of water, holding in solution or suspension proteid substances, fats, various extractives, and saline matters.

The proteid substances are albumin, para-globulin, and fibrinogen. The albumin and para-globulin occur in about equal quantities; but the fibrinogen, though a most important element in the blood, occurs in very small quantities. The fats are

scanty, except after a meal, or in certain diseased conditions. The extractives, so named because they have to be extracted by special methods from the blood, are very numerous. The most important are perhaps urea, lactic acid, and sugar.

The saline matters are the chlorides and sodium salts, the phosphates and potassium salts being found chiefly in the corpuscles.

Of all these substances, **albumin** probably holds the first place in regard to nutrition, providing, as it does, the greater part of the material necessary for the daily nourishment and renovation of the tissues. In this process, it undergoes a variety of transformations by which it is converted into the structural characteristics of the tissues which it supplies.

Para-globulin is closely allied to albumin in its chemical relations, and no doubt also in its physiological action. Both substances are coagulated by heat, and solidified at a temperature of 160° F.

The **fibrinogen** of the plasma is the substance which produces the fibrin of coagulated blood. It is very difficult to obtain in the fluid condition, owing to the rapidity with which it solidifies when blood is withdrawn from the circulation.

Of the mineral salts, the sodium chloride is the most abundant, constituting nearly 40 per cent of all the saline ingredients. The mineral salts maintain the alkalescence of the blood, a property which is essential to nutrition, and even to the immediate continuance of life, since it enables the plasma to take up the carbonic acid from the tissues and return it to the lungs for elimination.

The clotting of blood.—Blood when drawn from the blood-vessels of a living body is perfectly fluid. In a short time it becomes viscid, and this viscosity increases rapidly until the whole mass of blood becomes a complete jelly. If the blood in this jelly stage be left untouched in a glass vessel, a few drops of an almost colourless fluid soon make their appearance on the surface of the jelly. Increasing in number and running together, the drops after a while form a superficial layer of pale straw-coloured fluid. Later on, similar layers of the same fluid are seen at the sides, and finally at the bottom of the jelly, which, shrunk to a smaller size and of firmer consistency, now forms a clot or crassamentum, floating in a perfectly fluid liquid. The

upper surface of the clot is generally slightly concave. If a portion of the clot be examined under the microscope, it is seen to consist of a network of fine fibrils in the meshes of which are entangled the red and white corpuscles of the blood. The fibrils are composed of the fibrin; and the liquid in which the clot is suspended is blood minus corpuscles and fibrin, and is called serum. The clotting of the blood is entirely dependent upon the fibrin; for if fresh blood, before it has time to clot, be whipped with a bundle of twigs, the fibrin will form on the twigs, and if the whipping of the blood be continued until all the fibrin has been deposited on the twigs, the blood left in the vessel will be found to have lost all power of clotting.

The coagulation of blood is hastened by high temperature, and by contact with any rough surface, or non-living material. On the other hand, a low temperature retards, and the addition of salt in sufficient quantity prevents, coagulation. After death, the blood remains a long time fluid, and it never clots so firmly and completely as when shed. It clots first in the larger vessels, but not until several hours after death in the smaller vessels.

The coagulability of the blood differs in different individuals, and in rare cases is so slight that the most trivial operation involving hemorrhage is attended with great danger.

The quantity of blood contained in the body is a balance struck between the tissues which give to, and those which take away from, the blood. Thus the tissues of the alimentary canal largely add to the blood water and the material derived from food, while the excretory organs largely take away water and the other substances constituting the excretions. From the result of a few observations on executed criminals, it has been concluded that the total quantity of blood in the human body is about $\frac{1}{13}$ of the body weight.

General composition of the blood. — Not only do the *several* tissues take up from the blood and give up to the blood different things at different rates and at different times, but *all* the tissues take up oxygen and give up carbonic acid in varying quantities. From this it follows, on the one hand, that the composition and character of the blood must be forever varying in different parts of the body; and, on the other hand, that the united action of all the tissues must tend to establish and maintain an average uniform composition of the whole mass of blood.

To sum up briefly, the blood is composed of—

PLASMA	{	Proteid substances.
		Fats.
		Extractives.
		Salts.
CORPUSCLES	{	Red
		and
		White.

The plasma is chiefly the carrier of nutriment to the tissues, and of waste matter from the tissues. The red corpuscles are pre-eminently the carriers of oxygen; the white corpuscles may be regarded as scavengers, as important protective elements in many diseases, and possibly as contributors to the construction of new tissue where such has been injured or destroyed.

NOTE. — When we remember that the tissues live on the blood, we recognize the gravity of those diseased conditions in which important elements are being constantly drained away from the blood, as, for example, the albumin in diseases of the kidneys, the red corpuscles in hemorrhage, the water of the blood in cholera, etc. Withdrawal of oxygen, as we all know, causes instant death, and a constant supply of fresh air is a vital necessity of life. Nor is it of less importance that the blood be kept free from those waste matters, — pre-eminently carbonic acid and urea, — which, in accumulating, poison the system, and, if not excreted in sufficient amount, will as surely cause death as the withdrawal from the blood of any of its most vital constituents.

CHAPTER VIII.

THE VASCULAR SYSTEM CONTINUED: HEART; ARTERIES; VEINS; CAPILLARIES.

THE blood, as we have said, is the internal medium on which the tissues live. It is carried through the body by branched tubes named blood-vessels. It is driven along these tubes by the action of the heart, which is a hollow muscular organ placed in the centre of the vascular system. One set of vessels—the arteries—conducts the blood out from the heart and distributes it to the different parts of the body, whilst other vessels—the veins—bring it back to the heart again. The blood from the arteries gets into the veins by passing through a network of fine tubes which connect the two, and which are named, on account of their small size, the capillary (*i.e.* hair-like) vessels.

All the tissues, with the exception of the epithelial tissue, and most of the cartilages, are traversed by these networks of capillary vessels. It is through the thin walls of the capillaries that the interchange of material which is continually going on between the blood and the tissues takes place. It is in the capillaries, then, that the chief work of the blood is done; and the object of the vascular mechanism is to cause the blood to flow through these vessels in the manner best adapted for accomplishing this work.

The use of the arteries is to carry and regulate the supply of blood from the heart to the capillaries; the use of the veins, to carry the blood from the capillaries back to the heart; the use of the heart, to drive the blood in a suitable manner through the arteries into the capillaries, and from the capillaries back along the veins to itself again. We shall see that the structure of these several parts is adapted to these several uses.

The heart.—The heart is a hollow muscular organ, divided

by a longitudinal partition into a right and a left heart, each of which is subdivided by a transverse constriction into two compartments, an upper and a lower, which communicate with each

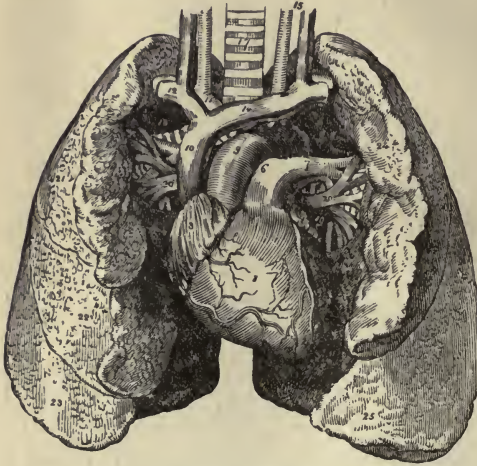


FIG. 63. — THE HEART AND LUNGS. 1, right ventricle; 3, right auricle; 6, 7, pulmonary artery; 9, aorta; 10, superior vena cava; 11, innominate artery; 12, right subclavian vein; 14, innominate vein; 15, left common carotid; 17, trachea; 20, pulmonary veins; 22 to 25, lungs, partially turned back to show veins on left side.

other. Its general form is that of a blunt cone. It is situated in the thorax, between the lungs, and, together with the adjacent parts of the great blood-vessels which carry blood to and from it, is enclosed in a membranous covering, the pericardium. The heart lies nearer to the front than to the back of the chest, and is placed behind the sternum and the costal cartilages, the broader end or base being directed upwards, backwards, and

to the right, while the pointed end or apex points downwards, forwards, and to the left. The impulse of the heart against the wall of the chest is felt in the space between the fifth and sixth ribs, a little below and to the inner side of the left nipple. It has, therefore, a very oblique position in the chest. It is suspended and kept in position by the great vessels at the base, and is also supported by the diaphragm. According to Laennec, the heart in its normal condition is about equal in size to the fist of the individual to whom it belongs.

The main substance of the heart is composed of muscular tissue. Between the muscle fibres is a certain amount of interstitial tissue with numerous blood-vessels and lymphatics, and, in some parts, nerves and ganglia. There is also a considerable amount of fat, chiefly collected at the base of the heart and beneath the pericardium. The muscular tissue of the heart differs from all other involuntary muscular tissue in possessing transverse striæ. The fibres continually branch and unite with

one another so as to form a kind of network or sponge-like substance. The arrangement of the fibres differs in the auricles and the ventricles, and is very intricate; the fibres run transversely, longitudinally, obliquely, and in the apex of the ventricles take a spiral turn or twist. The muscular walls of the auricles are much thinner than those of the ventricles, and the wall of the left ventricle is thicker than that of the right. This difference in bulk is to be accounted for, as we shall see later on, by the greater amount of work the ventricles, as compared with the auricles, have to do. The muscular walls of the heart are abundantly supplied with blood and lymph. The nerves which supply the heart are partly derived from the cerebro-spinal system, and partly from the sympathetic system. Connected with the nerve fibres supplying the heart are groups of nerve cells, or ganglia.

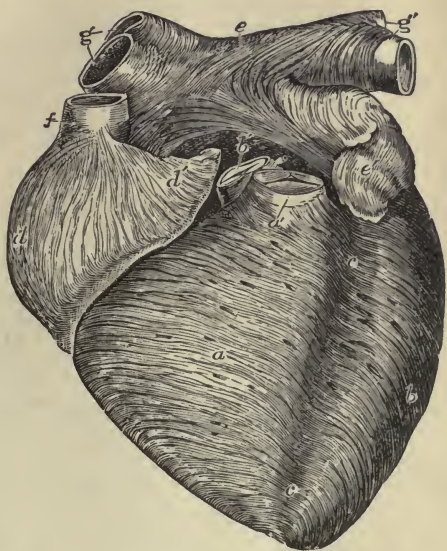


FIG. 64.—ANTERIOR VIEW OF HEART, DISSECTED, AFTER LONG BOILING, TO SHOW THE SUPERFICIAL MUSCULAR FIBRES. (Allen Thomson.) The aorta (*b'*) and pulmonary artery (*a'*) have been cut short close to the semilunar valves. *a*, right ventricle; *b*, left ventricle; *c, c*, groove between ventricles; *d, d'*, right auricle; *e, e'*, left auricle; *f*, superior vena cava; *g', g''*, right and left pulmonary veins. The fibres are seen running in a circular, oblique, transverse, and longitudinal direction.

The heart is covered, as mentioned above, by a membranous covering in the form of a sac. This membranous sac, or pericardium, is one of the serous membranes of the body.¹ It is a sort of double bag; one half of the bag, called the visceral portion (*viscus*, organ), is closely adherent to the heart substance, and also covers the great blood-vessels for about an inch and a half from the base of the heart; the other half, the parietal portion, is continuous with, and reflected over, the visceral portion, so that it loosely envelops both it and the heart.

¹ See note on serous membranes at end of chapter.

The pericardium forms a completely closed sac; its internal surfaces are very smooth and polished, they are lined by epithelium, and secrete a small quantity of serous fluid. As their opposing surfaces, owing to the constant contractions of the heart, are continually sliding one upon the other, they are admirably constructed to protect the heart from any loss of power by friction.

The interior of the heart is lined by a delicate, smooth membrane, called the endocardium. This pavement membrane lines all the cavities of the heart, and is continued into the blood-vessels, forming their innermost coat.

The cavities of the heart. — The heart is divided from the base to the apex, by a fixed partition, into a right and left half.

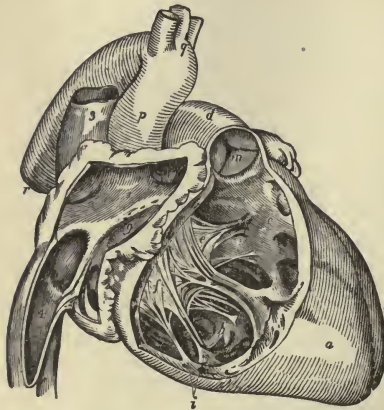


FIG. 65.—RIGHT SIDE OF HEART. 1, cavity of right auricle; 3, vena cava superior; 4, vena cava inferior; 9, entrance of auriculo-ventricular opening; a, right ventricle; b, c, cavity of right ventricle, on the walls of which the columnæ carneæ are seen; d, pulmonary artery; e, f, tricuspid valve; i, columnæ carneæ; m, semi-lunar valve; o, left ventricle; p, ascending aorta; q, arch; r, descending aorta.

The two sides of the heart have no communication with each other: the right side always contains venous, and the left side arterial, blood. Each half is subdivided into two cavities, the upper, called auricle; the lower, ventricle. These cavities communicate with one another by means of constricted openings, the auriculo-ventricular orifices, which are strengthened by fibrous rings, and protected and guarded by valves. The valve guarding the right auriculo-ventricular opening is composed of three triangular flaps, and is hence named tricuspid. The flaps are mainly formed of fibrous tissue covered by endo-

cardium. At their bases they are continuous with one another, and form a ring-shaped membrane around the margin of the auricular opening: their pointed ends are directed downwards, and are attached by cords, the *chordæ tendineæ*, to little muscular pillars provided in the interior of the ventricles for this purpose. The valve guarding the left auricular opening consists of only

two flaps, and is named the bicuspid, or mitral valve. It is attached in the same manner as the tricuspid valve, which it closely resembles in structure, except that it is much stronger and thicker in all its parts.

These valves oppose no obstacle to the passage of the blood from the auricles into the ventricles; but any flow forced backwards gets behind the flaps of the valve (between the flap and the wall of the ventricle) and drives the flaps backwards and upwards, until, meeting at their edges, they unite and form a complete transverse partition between the ventricle and auricle. Being retained by the chordæ tendineæ, the expanded flaps of the valve resist any pressure of the blood which might otherwise force them back to open into the auricle; the muscular pillars, also, to which the chordæ tendineæ are attached, contract and shorten at the same time, and thus help to keep them taut.

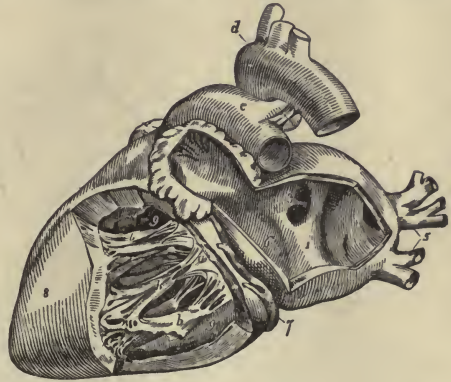


FIG. 66.—LEFT SIDE OF HEART. 1, cavity of left auricle; 3, opening of right pulmonary veins; 5, left pulmonary veins; 6, auriculo-ventricular opening; 8, left ventricle; 9,9, cavity of left ventricle; a, mitral valve, its flaps are attached by the chordæ tendineæ to b, b, the muscular pillars, or columnæ carneæ; d, arch of aorta; e, pulmonary artery.

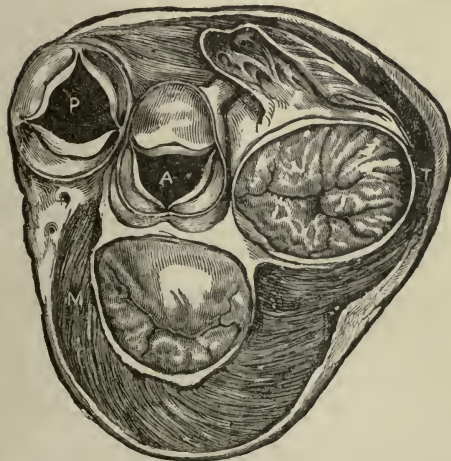


FIG. 67.—SECTION OF HEART AT LEVEL OF VALVES. P, pulmonary artery; A, aorta; M, mitral valve; T, tricuspid valve.

The openings of the veins do not require valves, but both the

Being retained by the chordæ tendineæ, the expanded flaps of the valve resist any pressure of the blood which might otherwise force them back to open into the auricle; the muscular pillars, also, to which the chordæ tendineæ are attached, contract and shorten at the same time, and thus help to keep them taut.

Beside the openings between the auricles and ventricles, each auricle has two or more veins opening into it, and each ventricle has a large artery opening out of it.

arterial openings are provided with a set of valves. These valves, called semilunar valves, consist of three semicircular flaps, each flap being attached by its convex border to the inside of the artery where it joins the ventricle, while its other border projects into the interior of the vessel. The flaps of these valves form a complete barrier, when closed, to the passage of the blood from the arteries into the heart, but offer no resistance to the flow from the heart into the arteries.

The beat of the heart.—So long as life lasts, the muscular tissue of the heart contracts and relaxes unceasingly. We may call the heart a muscular pump, the force of whose strokes is supplied by the contraction of muscular fibres, the strokes being repeated so many times a minute. It is constructed and furnished with valves in such a way that, at each stroke, it drives a certain quantity of blood with a certain force and a certain rapidity from the ventricles into the arteries, receiving, during the stroke, and the interval between that stroke and the next, the same quantity of blood from the veins into the auricles.

The contractions of the heart are rhythmical; that is to say, they occur in a certain order. First, there is a simultaneous contraction of the walls of both auricles; immediately following this, a simultaneous contraction of both ventricles; then comes a pause, or period of rest, after which the auricles and ventricles contract again in the same order as before, and their contractions are followed by the same pause as before. The state of contraction of the heart is called the systole; the state of relaxation and dilatation, its diastole.

If the chest of an animal be opened and artificial respiration kept up, the heart may be watched beating, and a complete beat of the whole heart may be observed to take place as follows:—

The great veins are seen, while full of blood, to contract in the neighbourhood of the heart, the wave of contraction running on towards the auricles, increasing in intensity as it goes. Arrived at the auricles, which are now full of blood, the wave of contraction passes on to them, and they contract suddenly and quickly. During this contraction, the walls of the auricles press towards the auriculo-ventricular orifices, and the blood passes over the tricuspid and mitral valves into the ventricles. The ventricles fill rapidly, and as soon as the auricular systole

is over, they are also seen to contract, their walls becoming very tense and hard; the apex is tilted upwards, and the heart twists somewhat on its own axis. During the ventricular systole, the blood in the ventricles is forced through the semi-lunar valves into the arteries, which are seen to elongate and expand as the blood is pumped into them.

The work of the auricles and ventricles is very unequal. All the auricles have to do is to pump the blood into the ventricles, which at the time are nearly empty cavities with relaxed and flaccid walls. The ventricles, on the contrary, have to pump the blood into tubes which are already full; and if there were no auriculo-ventricular valves, the blood would meet with less resistance in pushing its way backward into the auricles than in pushing open the semilunar valves and forcing its way into the arteries.

Hence the necessity, firstly, of the tricuspid and mitral valves; and, secondly, of the superior thickness and strength of the walls of the ventricles, as compared with those of the auricles; and since the left side of the heart has a larger system of blood-vessels to supply, and more resistance to overcome than the right side, it follows that the left ventricle needs a thicker muscular wall than the right.

The beat of the heart is caused by the rhythmical contractions of its muscular fibres. Whether these contractions are automatic, or dependent upon the ganglia lodged in the cardiac muscular tissue, is uncertain. That the contractions of the heart do not depend upon the general nervous system is certain, for the heart will continue to beat for some little time after its removal from the body. It probably depends upon complex metabolic changes, not yet clearly understood.

The character of the beat, however, is governed and regulated by two sets of nerves. The first set come from the cerebro-spinal centre, and are supplied by the pneumogastric nerves. They are the inhibitory fibres; that is to say, they slow and, with a strong stimulation, will stop for a short time the action of the heart. They weaken the systole, and prolong the diastole. The other set come from the sympathetic nerves, and are accelerating fibres which, upon stimulation, increase not only the rapidity, but the force of the beat. The diastole is shortened, and the systole strengthened.

The sounds of the heart. — If the ear be applied over the heart, certain sounds are heard, which recur with great regularity. The first sound is a comparatively long, booming sound; the second, a short, sharp, sudden one. Between the first and second sounds, the interval of time is very short, too short to be measurable; but, between the second and the succeeding first sounds there is a distinct pause. The first sound is generally supposed to be caused by the contraction of the ventricular walls; the second sound is undoubtedly caused by the sudden closure of the semilunar valves.

These sounds in certain diseases of the heart become changed and obscure, and are replaced by various distinctive and characteristic murmurs.

The arteries. — An artery is usually described as being composed of three coats, — an inner or elastic, a middle or muscular, and an external or areolar.

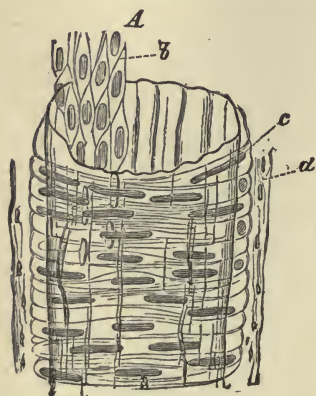


FIG. 68. — STRUCTURE OF AN ARTERY. (Ledig.) *A*, internal coat, with *b*, its inner layer of pavement epithelium; *c*, middle coat, with transverse fibres; *d*, outer coat, with longitudinal fibres.

The *inner* coat of an artery consists of two layers: the inner layer is composed of pavement epithelium, and forms a smooth lining for the tube; the outer layer is a fine network of elastic connective tissue fibres.

The *middle* or muscular coat consists mainly of circularly disposed plain muscular fibres. It has also in most large arteries layers of elastic fibres, which form close felted networks, the fibres running for the most part in an oblique and longitudinal direction.

The *outer* coat is formed of areolar tissue, mixed with which are a good many elastic fibres. The strength of an artery depends largely upon this coat; it is far less easily cut or torn than the other coats, and it serves to resist undue expansion of the vessel. The arteries are also protected by sheaths of connective tissue, which surround and blend with the outer coat.

By virtue of their structure, the arteries are both contractile and elastic. The proportion of the muscular and elastic ele-

ments differs in different arteries; but, as a general rule, the larger arteries are the more elastic, and the smaller the more muscular. The elasticity and contractility of the arteries may be demonstrated by the following example:—

If we tie a piece of a large artery at one end and inject fluid into the other end, the artery swells out to a very great extent, but will return at once to its former size when the fluid is let out. This great elasticity of the arteries adapts them for receiving the additional amount of blood thrown into them at each contraction of the heart. Again, if we stimulate the muscular coat of any of the smaller arteries, the artery will shrink in size, the circularly disposed fibres contracting and narrowing the calibre of the vessel. This contractility is under the control of the nervous system, and as the organs of the body that are at rest do not require so much blood as those that are working actively, the nervous system, the master-regulator of the body's work, is able to diminish or increase the supply of blood to the capillaries in different parts by acting upon this contractile muscular tissue in the arterial walls. The arteries do not collapse when empty; and when an artery is severed, the orifice remains open. The muscular coat, however, contracts somewhat in the neighbourhood of the opening, and the elastic fibres cause the artery to retract a little within its sheath.¹

The walls of the arteries are supplied with both blood-vessels and nerves. The blood-vessels are known as the *vaso-vasorum* vessels and the nerves as the *vaso-motor* nerves.

The veins.—The veins have three coats, and on the whole resemble the arteries in structure. They differ from them, however, in having much thinner walls, and in their walls containing relatively much more white fibrous tissue and much less yellow elastic tissue. They are, therefore, not so elastic or contractile as the arteries, and their walls collapse when empty. Many of the veins, especially those of the limbs, are provided with valves, which are mechanical contrivances adapted to prevent the reflux of the blood. The valves are semilunar folds of the internal coat of the veins; the convex border is attached to the side of the vein, and the free edge points towards the heart.

¹ This property of the severed artery is an important factor in the arrest of hemorrhage.

Should the blood in its onward course towards the heart be, for any reason, driven backwards, the reflux blood, getting between the wall of the vein and the flaps of the valve, will press them inwards until their edges meet in the middle of the channel and close it up. The valves have usually two flaps, sometimes one, and rarely three. The veins, like the arteries, are supplied with both blood-vessels and nerves, the supply, however, being far less abundant.

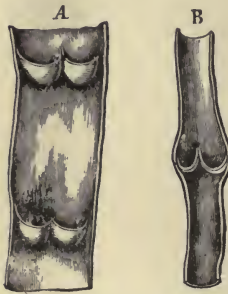


FIG. 69. — *A*, part of a vein, laid open, with two pairs of valves; *B*, longitudinal section of vein, showing valves closed.

The capillaries. — The walls of the capillaries are formed entirely of a layer of simple epithelium composed of flattened cells joined edge to edge by cement substance, and continuous with the layer which lines the arteries and veins. The capillaries communicate freely with one another and form interlacing networks of variable form and size in the different tissues. Their average diameter is so small that only two or three blood-corpuses can pass through them abreast, and in many parts they lie so closely together that a pin's point cannot be inserted between them. They are most abundant, and form the finest networks in those organs where the blood is needed for other purposes than local nutrition, such as, for example, for secretion or absorption. In the glandular organs they supply the substances requisite for secretion; in the intestines they take up the elements of digested food; in the lungs they absorb oxygen and give up carbonic acid; in the kidneys they discharge the waste products collected from other parts; all the time, everywhere through their walls, that interchange is going on which is essential to the renovation, growth, and life of the whole body.

It must be remembered that although the arteries, veins, and capillaries have each the distinctive structure above described, it is at the same time difficult to draw the line between the smaller artery and larger capillary, and between the larger capillary and smallest vein. The veins on leaving the capillary networks only gradually assume their several coats, while the arteries dispense with their coats in the same imperceptible way as they approach the capillaries.

Serous membranes.—Serous membranes are thin and transparent, tolerably strong, extensile, and elastic. They are lined on the inner surface by a simple epithelial layer of flattened cells (endothelium). The surfaces are moistened by a fluid resembling serum, and from which the membranes obtain their name of serous membranes. Here and there between the cells

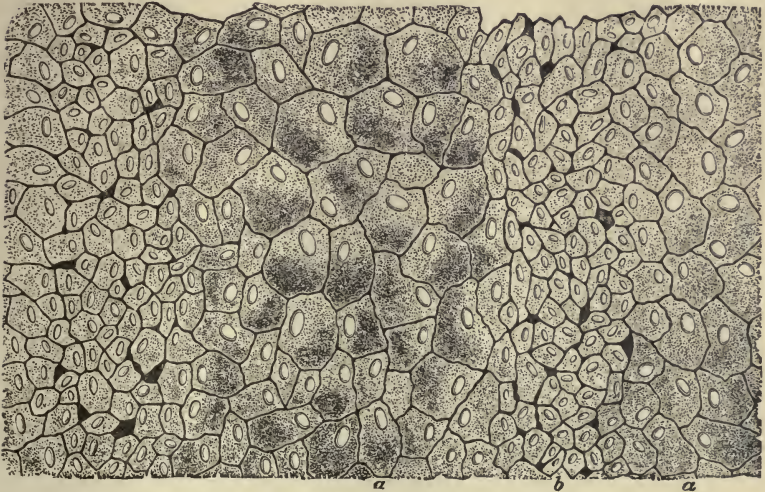


FIG. 70.—PORTION OF ENDOTHELIUM OF PERITONEUM. (Klein.) *a*, larger cells; *b*, smaller ones, with here and there a pseudo-stoma between.

openings are seen, which are of two kinds. The smaller and more numerous are false openings, and are termed pseudo-stomata; the larger or true apertures are termed stomata, and open into subjacent lymphatics. The substance of serous membranes underneath the endothelium is composed of a network of connective tissue containing a variable amount of white and elastic fibres. Where the membrane is thick, this ground substance contains blood-vessels and lymphatics, the lymphatics being exceedingly abundant.

Serous membranes form closed sacs, one part of which is attached to the walls of the cavity which it lines,—the parietal portion,—whilst the other is reflected over the surface of the organ or organs contained in the cavity, and is named the visceral portion of the membrane. In this way the viscera are not contained within the sac, but are really placed outside of it, and some of the organs may receive a complete, while others receive only a partial or scanty investment.

In passing from one part to another the membrane frequently forms folds, some of which are designated by special names, such as the mesentery, meso-colon, and omentum.

The chief serous membranes are the **peritoneum**, the largest of all, lining the cavity of the abdomen; the two **pleuræ**, lining the chest and covering the lungs; the **pericardium**, covering the heart.

The peritoneum in the female is an exception to the rule that serous membranes are perfectly closed sacs, as it has two openings by which the Fallopian tubes communicate with its cavity.

The inner surface of a serous membrane is free, smooth, and polished; the inner surface of one part is applied to the corresponding inner surface of some other part, a very small quantity of fluid only being interposed between the surfaces. The organs situated in a cavity lined by a serous membrane, being themselves also covered by it, can thus glide easily against its walls or upon each other, their motions being rendered smoother by the lubricating fluid.

CHAPTER IX.

THE VASCULAR SYSTEM CONTINUED: ARTERIAL DISTRIBUTION AND VENOUS RETURN.

The arteries.—The arteries, which carry and regulate the supply of blood from the heart to the capillaries, are distributed throughout the body in a systematic manner, and before taking up the circulation we must try to gain a general idea of this system of distribution, in order that we may be able to locate the position of these important vessels. The arteries usually occupy protected situations, that they may be exposed as little as possible to accidental injury. As they proceed in their course they divide into branches, the division taking place in different ways. An artery may at once resolve itself into two or more branches, no one of which greatly exceeds the rest in size; or it may give off several branches in succession, and still maintain its character as a trunk. An artery, after a branch has gone off from it, is smaller than before, but usually continues uniform in diameter until the next secession. A branch of an artery is less in diameter than the trunk from which it springs, but the collective capacity of all the branches into which an artery divides is greater than the parent vessel. Since the area of the arterial system increases as its vessels divide, it is evident that the collective capacity of the smaller vessels and capillaries must be greater than the collective capacity of the trunks from which they arise. As the same rule applies to the veins, it follows that the arterial and venous systems may be represented, as regards capacity, by two blunt cones whose apices are at the heart, and whose bases are united in the capillary system. The effect of this arrangement of the circulatory vessels is to make the blood flow more slowly as it passes through the more widely distributed vessels, and to accelerate

its speed in the larger and less numerous trunks, just as a river flows more rapidly through its narrow and deep channels, and lingers in those that are broad and shallow.

The arteries unite at frequent intervals when they are said to anastomose or inosculate. Such inosculation admits of free communication between the currents of the blood, tend to promote equality of distribution and of pressure, and to obviate the effects of local interruption.

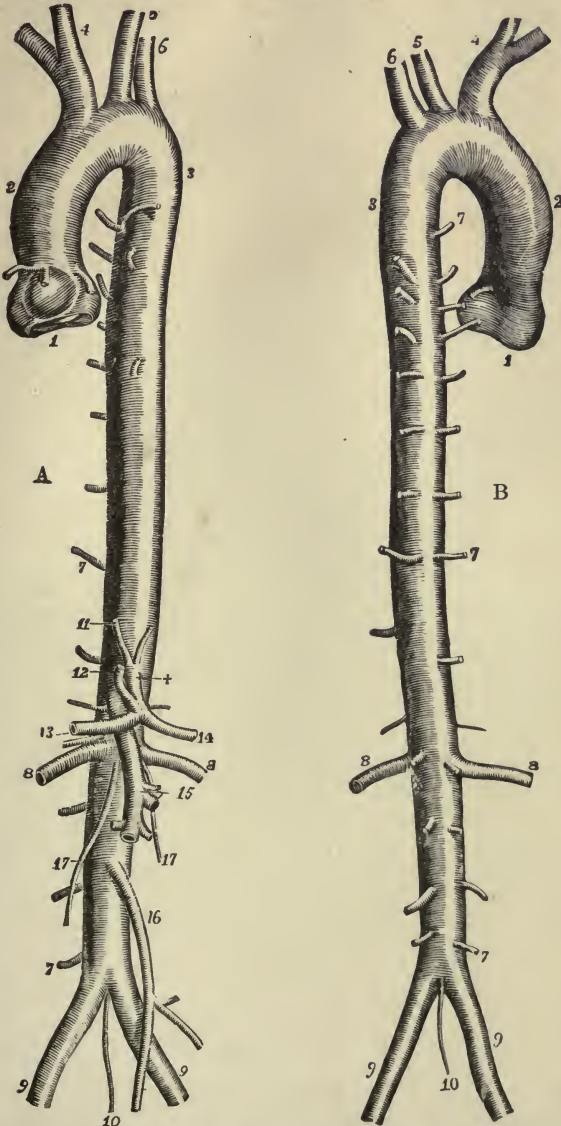
Arteries commonly pursue a tolerably straight course, but in some parts of the body they are tortuous. They often become markedly tortuous in old persons as the walls of the arteries increase in length and size.

In describing the distribution of the arteries we shall first consider the artery arising from the left ventricle of the heart, the **aorta**, and its branches.

The aorta. — The aorta is the main trunk of the arterial system. Springing from the left ventricle of the heart, it arches over the root of the left lung, descends along the vertebral column, and after passing through the diaphragm into the abdominal cavity, ends opposite the fourth lumbar vertebra by dividing into the right and left common iliac arteries. In this course the aorta forms a continuous single trunk, which gradually diminishes in size from its commencement to its termination (from 28 to 17 mm.), and gives off larger or smaller branches at various points. It may be divided into the **ascending aorta**, the short part which is contained in the pericardium; the **arch**, the part extending from the ascending aorta, and forming a well-marked curve in front of the trachea, and around the root of the left lung to the border of the fourth dorsal vertebra; the **descending thoracic aorta**, the comparatively straight part extending to the diaphragm; the **abdominal aorta**, below the diaphragm. The **ascending aorta** gives off two small branches, the **right and left coronary arteries**, which supply the substance of the heart with blood. The **arch** gives off three large trunks, the **innominate**, the **left common carotid**, and the **left subclavian artery**.

The **innominate artery** arises from the right upper surface of the arch, ascends obliquely towards the right, until, arriving on a level with the upper margin of the clavicle, it divides into the **right common carotid** and **right subclavian arteries**. Its usual length is from one to two inches.

The left common carotid arises from the middle of the upper surface of the arch of the aorta, and the left subclavian arises from the left upper surface of the arch.



FIGS. 71, 72. — THE AORTA. *A*, from before; *B*, from behind, with the origin of its principal branches. (R. Quain.) 1, 2, ascending aorta; 2, 3, arch of aorta; 4, innominate artery; 5, left carotid; 6, left subclavian; 7, 7, 7, intercostal and lumbar arteries; 8, 8, renal arteries; 9, 9, common iliac arteries; 10, middle sacral arteries; 11, one of the phrenic arteries; +, cœliac axis; 12, gastric; 13, hepatic; 14, splenic artery; 15, superior mesenteric; 16, inferior mesenteric; 17, 17, spermatic or ovarian arteries.

The common carotid arteries.—As the left common carotid arises from the middle of the upper surface of the arch of the aorta, while the right common carotid arises at the division of the innominate, the left carotid is an inch or two longer than the right. They ascend obliquely on either side of the neck

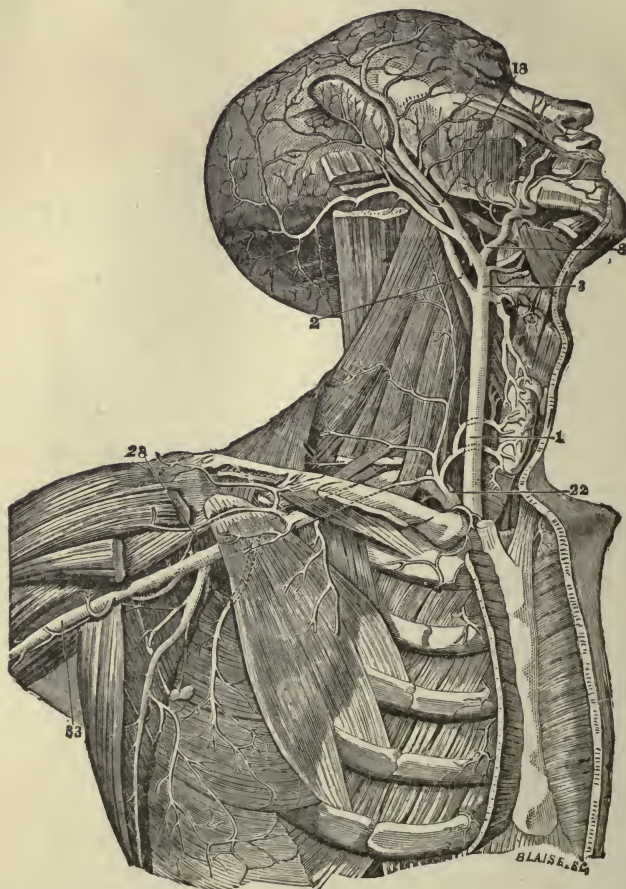


FIG. 73. — THE CAROTID, SUBCLAVIAN, AND AXILLARY ARTERIES. 1, common carotid artery; 2, internal carotid; 3 and 18, external carotid; 8, facial artery; 22, subclavian artery; 28, axillary artery; 33, commencement of brachial artery.

until, on a level with the upper border of the thyroid cartilage, "Adam's apple," they divide into two great branches, of which one, the **external carotid**, is distributed to the superficial parts of the head and face, and the other, the **internal carotid**, to the brain and eye. At the root of the neck the common carotids

are separated from each other by only a narrow interval, corresponding with the width of the trachea; but as they ascend they are separated by a much larger interval, corresponding with the breadth of the larynx and pharynx.

The **external carotid** has eight branches, which are distributed to the throat, tongue, face, and walls of the cranium.

The chief branches of the **internal carotid** are the ophthalmic and cerebral arteries. A remarkable anastomosis exists between the cerebral arteries at the base of the brain. The arteries are joined in such a manner as to form a complete circle, and this anastomosis, known as the "circle of Willis," both equalizes the circulation of the blood in the brain, and also provides, in case of destruction of one of the arteries, for the blood reaching the brain through the other vessels.

The subclavian arteries. — The right subclavian arises at the division of the innominate, and the left subclavian from the arch of the aorta. The subclavian arteries are the first portions of a long trunk which forms the main artery of the upper limb, and which is artificially divided for purposes of description into three parts; viz. the **subclavian, axillary, and brachial** arteries. The subclavian artery passes a short way up the thorax into the neck, and then turns downwards to rest on the first rib. At the outer border of the first rib it ceases to be called

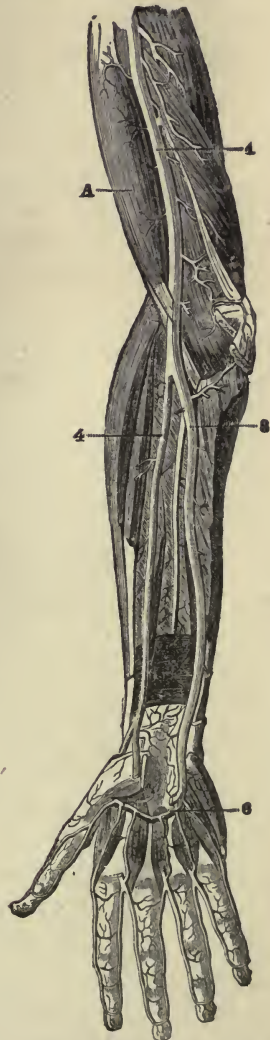

FIG. 74. — DEEP ANTERIOR VIEW OF THE ARTERIES OF THE ARM, FOREARM, AND HAND. A, biceps muscle; 1, brachial artery; 4, radial artery; 6, deep palmar arch; 8, ulnar artery.

subclavian, and is continued as the axillary. It gives off large branches to the back, chest, and neck.

The **axillary** artery passes through the axilla, lying to the inner side of the shoulder joint and upper part of the arm. It gives off branches to chest, shoulder, and arm.

The **brachial** artery extends from the axillary space to just below the bend of the elbow, where it divides into the **ulnar** and **radial** arteries. It may be readily located, lying in the depression along the inner border of the biceps muscle. Pressure made at this point on the artery, from before backwards against the humerus, will control the blood supply to the arm.

The **ulnar** artery, the larger of the two vessels into which the brachial divides, extends along the side of the forearm into the palm of the hand, where it terminates in the **superficial palmar arch**.

The **radial** artery appears, by its direction, to be a continuation of the brachial, although it does not equal the ulnar in size. It extends along the front of the forearm as far as the lower end of the radius, below which it turns round the outer border of the wrist, descends between the bones of the thumb and forefinger, and passes forward into the palm of the hand. It terminates in the **deep palmar arch**. The superficial and deep palmar arches supply the hand with blood.

The **thoracic** aorta extends from the lower border of the fourth dorsal vertebra, on the left side, to the opening in the diaphragm below the last dorsal vertebra, and has a length of from seven to eight inches. The branches, derived from the thoracic aorta, are numerous, but small. They are distributed to the walls of the thorax, and to the viscera contained within it.

The **abdominal** aorta commences about the lower border of the last dorsal vertebra, and terminates below by dividing into the two common iliac arteries. The bifurcation usually takes place about half-way down the body of the fourth lumbar vertebra, which corresponds to a spot on the front of the abdomen, slightly below and to the left of the umbilicus. Its length is about five inches.

The abdominal aorta gives off numerous branches, which may be divided into two sets; viz. those which supply the viscera, and those which are distributed to the walls of the abdomen. The former consists of the **coeliac axis**, the **superior mesenteric**,

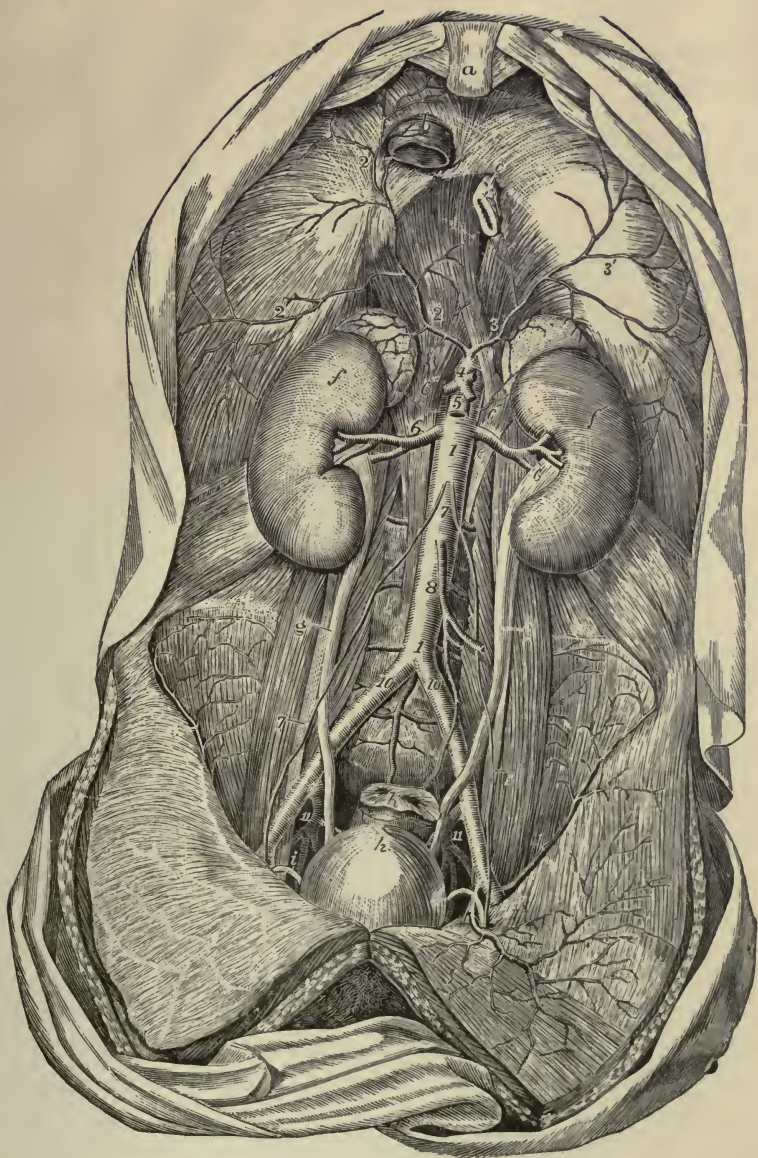


PLATE V. — THE ABDOMINAL AORTA AND ITS PRINCIPAL BRANCHES. (Tiedemann.) *a*, ensiform appendix; *b*, inferior vena cava and *c*, œsophagus, passing through diaphragm; *f, f*, right and left kidneys, with the supra-renal bodies; *g, g*, ureters; *h*, urinary bladder; *k*, rectum, divided near its upper end. 1, 1, abdominal aorta; 2, 2', and 3, 3', right and left inferior phrenic arteries; 4, cœliac axis; 5, superior mesenteric artery; 6, 6, renal arteries; 7, 7, spermatic or ovarian arteries; 8, inferior mesenteric artery; 10, 10, common iliac arteries; 11, placed between external and internal iliac arteries.

the inferior mesenteric, the supra-renal, the renal, and the spermatic or ovarian arteries, while in the latter are included the phrenic, the lumbar, and the middle sacral arteries.

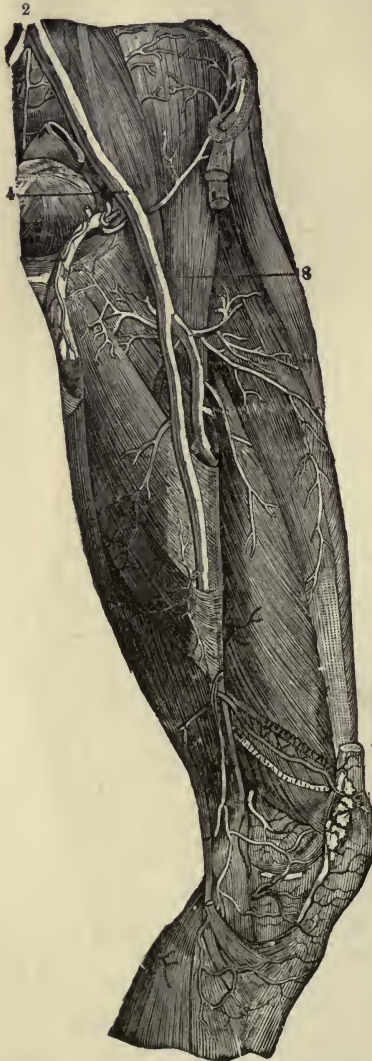

FIG. 75.—ILIAC AND FEMORAL ARTERIES. 2, common iliac artery; 4, external iliac; 8, femoral artery.

The **cœliac** artery, or axis, is a short, wide vessel, usually not more than half an inch in length, which arises from the front of the aorta, close to the opening in the diaphragm. It divides into three branches; viz. the **gastric**, which supplies the stomach; the **hepatic**, which supplies the liver; and the **splenic**, which supplies the spleen, and in part the stomach and pancreas.

The **superior mesenteric** artery arises from the fore part of the aorta, a little below the cœliac axis. It supplies the whole of the small intestine beyond the first portion (the duodenum) close to the stomach, and half of the large intestine.

The **inferior mesenteric** artery arises from the front of the aorta, about an inch and a half above its bifurcation, and supplies the lower half of the large intestine. Continued under the name of the superior hemorrhoidal artery, it also supplies the rectum.

The **renal** arteries are of large size, in proportion to the bulk of the organs which they supply. They arise from the sides of the aorta, about half an inch below the superior mesenteric artery, that of the right side being generally a little lower

down than that of the left. Each is directed outwards, so as to form nearly a right angle with the aorta. Before reaching the kidney, each artery divides into four or five branches.

The **ovarian** arteries, corresponding to the spermatic arteries in the male, arise close together from the front of the aorta, a little below the renal arteries. They supply the ovaries, and, joined to the uterine artery, — a branch of the internal iliac, — also assist in supplying the uterus. During pregnancy the ovarian arteries become considerably enlarged.

The **common iliac** arteries, commencing at the bifurcation of the aorta, pass downwards and outwards for about two inches, and then divide into the **internal** and **external iliac** arteries.

The **internal iliac** artery (hypogastric) supplies branches to the walls and viscera of the pelvis.

The **external iliac** artery forms a large continuous trunk, which extends downwards in the lower limb to just below the knee: it is named in successive parts of its course **external iliac**, **femoral**, and **popliteal**. The external iliac is placed within the abdomen, and extends from the bifurcation of the common iliac to the lower border of Poupart's ligament, where it enters the thigh and is named femoral.

The **femoral** artery lies in the upper three-fourths of the thigh, its limits being marked above by Poupart's ligament, and below by the opening in the great adductor muscle, after passing through which the artery receives the name of popliteal. In the first part of its course the artery lies along the middle of the depression on the inner aspect of the thigh, known as Scarpa's triangle. In this situation the beating of the artery

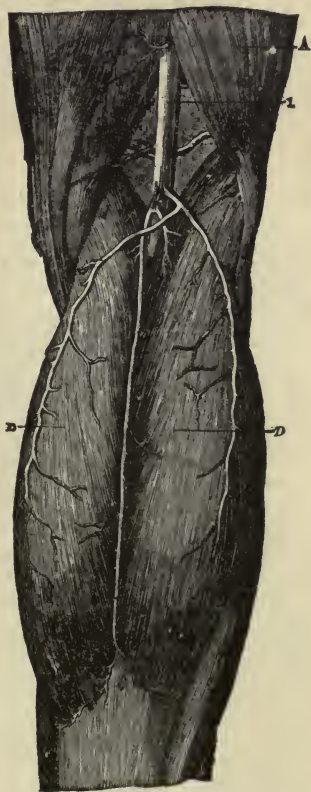

FIG. 76. — VIEW OF POPLITEAL ARTERY. *A*, biceps muscle; *D, D*, gastrocnemius; *I*, popliteal artery.

may be felt, and the circulation through the vessel may be most easily controlled by pressure.

The **popliteal** artery, continuous with the femoral, is placed at the back of the knee; just below the knee joint it divides into the **anterior** and **posterior tibial** arteries.

The **posterior tibial** artery lies along the back of the leg, and extends from the bifurcation of the popliteal to the ankle, where it divides into the **internal** and **external plantar** arteries.

About an inch below the bifurcation of the popliteal, the posterior tibial gives off a large branch, the **peroneal** artery.

The **anterior tibial** artery, the smaller of the two divisions of the popliteal trunk, extends along the front of the leg to the bend of the ankle, whence it is prolonged into the foot under the name of the **dorsal** artery. This unites with the external and internal plantar arteries to form the **plantar arch** which supplies blood to the foot.¹



FIG. 77.—DEEP VIEW OF THE ARTERIES OF THE BACK OF THE LEG. 1, popliteal artery; 6, division of popliteal into anterior and posterior tibial arteries; 8, posterior tibial; 9, peroneal.

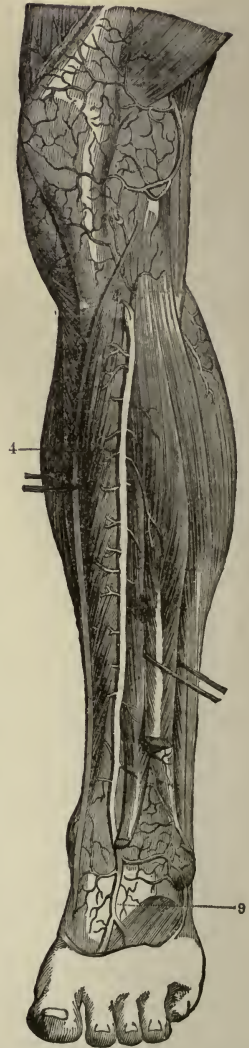


FIG. 78.—ANTERIOR VIEW OF ARTERIES OF THE LEG. 4, anterior tibial artery; 9, dorsal artery.

¹ Outlining the aorta and its branches as an arterial tree will greatly aid the student in mastering the arterial distribution. Also colouring the arteries red in the figures would serve to make their position clearer and more easily remembered.

Venous return. — The arteries begin as large trunks, which gradually become smaller and smaller until they end in the small capillary tubes, while the veins begin as small branches which at first are scarcely distinguishable from the capillaries. These small branches, receiving the blood from the capillaries throughout the body, unite to form larger vessels, and end at last by pouring their contents into the right auricle of the heart through two large trunks, the superior vena cava and the inferior vena cava. The veins, however, which bring back the blood from the stomach, intestines, spleen, and pancreas, do not take the blood directly to the heart, but first join to form a large trunk, — the portal vein, — and carry this blood to the liver. When the portal vein enters the liver, it breaks up into capillaries, which, after branching throughout the liver substance, unite to form the hepatic veins: by them the blood is conveyed into the inferior vena cava. This constitutes what is called the portal circulation, and is the only example in the body of a vein breaking up into capillaries.

The veins consist of a superficial and a deep set, the former running immediately beneath the skin and hence named subcutaneous, the latter usually accompanying the arteries and named *venæ comites*. These two sets of veins have very frequent communications with each other, and the anastomoses of veins are always more numerous than those of arteries.

The **systemic veins** — that is, all the veins of the body with the exception of the pulmonary and portal veins — are naturally divided into two groups.

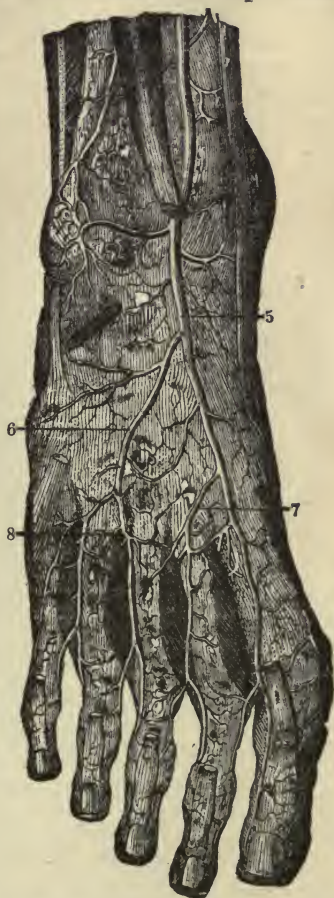

FIG. 79. — ARTERIES OF THE FOOT. 5, anterior tibial artery; 6, 7, 8, branches of dorsal artery.

I. Those from which the blood is carried to the heart by the superior vena cava, viz. the veins of the head and neck and upper limbs, together with those of the spine and a part of the walls of the thorax and abdomen. In this group we may include the veins of the heart, which, however, pass directly into the right auricle without entering the superior vena cava.

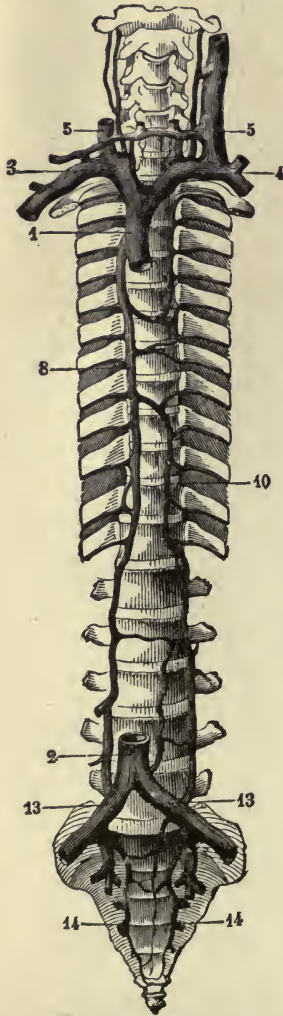


FIG. 80.—SKETCH OF THE PRINCIPAL VENOUS TRUNKS. 1, superior vena cava; 2, inferior vena cava; 3, right subclavian and innominate veins; 4, left subclavian and innominate veins; 5, 5, right and left internal jugular veins; 8, right azygos vein; 10, left azygos vein; 13, 13, common iliac veins; 14, 14, sacral veins.

II. Those from which the blood is carried to the heart by the inferior vena cava; viz. the veins of the lower limbs, the lower part of the trunk, and the abdominal viscera.

1. The blood returning from the head and neck flows on each side into two principal veins, the **external** and **internal jugular**.

The **external jugular** commences near the angle of the jaw by the union of two smaller veins, and descends almost vertically in the neck to its termination in the **subclavian** vein.

The **internal jugular**, receiving the blood from the cranial cavity, descends the neck close to the outer side of the internal and common carotid arteries. It unites at a right angle with the subclavian to form the **innominate** vein.¹

The blood from the upper limbs is returned by a superficial and deep set of veins. The superficial are much larger than the deep, and take a greater

¹ NOTE ON VENOUS CIRCULATION OF THE SKULL.—The blood from the skull is returned from the smaller veins to the internal jugular veins by channels which are not strictly veins, but sinuses. These sinuses are spaces left between the layers of the dura mater, and are lined by a continuation of the lining membrane of the veins.

share in returning the blood, especially from the distal portion of the limb. The deep veins accompany the arteries, and are called by the same names. Both sets are provided with valves, and terminate in the **subclavian vein**.

The blood from the spine, walls of thorax, and abdomen is chiefly returned by the **right and left azygos veins**, which are longitudinal vessels resting against the thoracic portion of the spinal column. They communicate below with the inferior vena cava, and terminate above in the superior vena cava: they thus form a supplementary channel by which blood can be conveyed from the lower part of the body to the heart in case of obstruction in the inferior vena cava.

The **innominate veins**, commencing on each side by the union of the subclavian and internal jugular, behind the inner end of the clavicle, transmit the blood returning from the head and neck, the upper limbs, and a part of the thoracic wall; they end below by uniting to form the **superior vena cava**. Both innominate veins are joined by many side tributaries: they also receive, at the junction of the subclavian and internal jugular, the lymph; on the left side from the thoracic duct, and on the right from the right lymphatic duct.

The **superior or descending vena cava** is formed by the union of the right and left innominate veins. It is about three inches long, and opens into the right auricle, opposite the third rib.

The blood from the lower limbs is also returned by a superficial and deep set of veins. They are more abundantly supplied

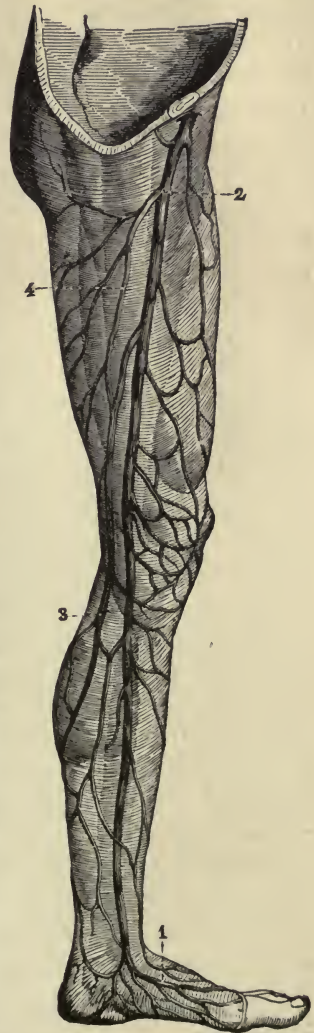

FIG. 81. — SUPERFICIAL VEINS OF LOWER EXTREMITY. — 1, veins of the foot; 2, internal saphenous vein; 3, superficial veins of calf; 4, superficial veins of thigh.

with valves than the veins of the upper limbs. The deep veins accompany the arteries. The two largest superficial veins are the **internal** or **long saphenous**, and the **external** or **short saphenous** vein. The **internal saphenous** extends from the ankle to within an inch and a half of Poupart's ligament. It lies along the inner side of the leg and thigh, and terminates in the femoral vein. The **external saphenous** arises from the sole of the foot, and, passing up the back of the leg, ends in the deep popliteal.

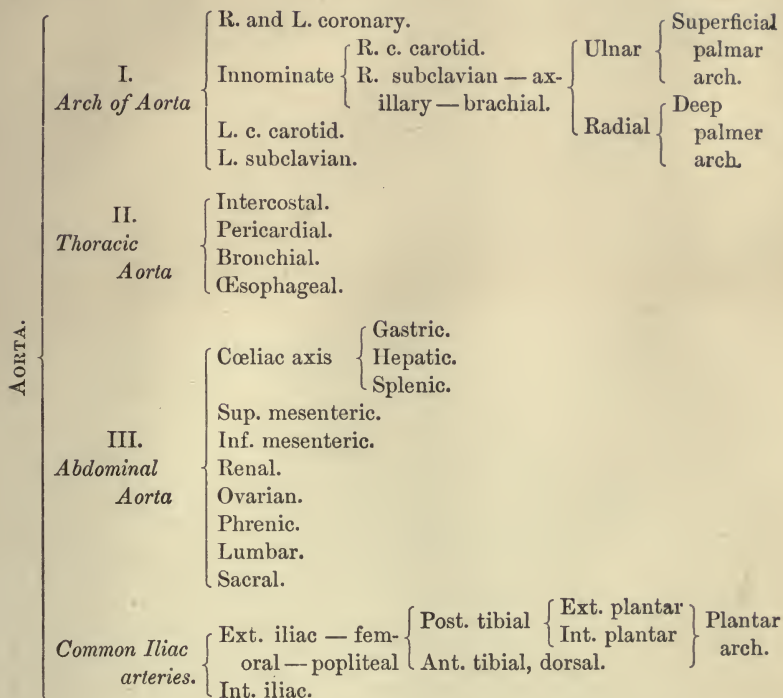
Both deep and superficial veins pour their contents into the **external iliac**. The blood is returned from the pelvis by the **internal iliac** veins, which, uniting with the external iliac, form the two **common iliac** veins. Extending from the base of the sacrum to the fourth lumbar vertebra, the two common iliacs unite to form the **inferior vena cava**.

The **inferior** or **ascending vena cava** returns the blood from the lower limbs, pelvis, and abdomen. It begins at the junction of the two common iliacs, and thence ascends along the right side of the aorta, perforates the diaphragm, and terminates by entering the right auricle of the heart. The inferior vena cava receives many tributaries, the chief of which are the lumbar, ovarian, renal, and hepatic veins.

The pulmonary artery.—The **pulmonary** artery conveys the dark blood from the right side of the heart to the lungs. The main trunk is a short, wide vessel (diameter 30 mm.) which arises from the right ventricle and runs for a distance of two inches backwards and upwards (*vide* fig. 63). Between the fifth and sixth dorsal vertebræ, it divides into two branches,—the right and left pulmonary arteries,—which pass to the right and left lungs.

The pulmonary veins.—The **pulmonary** veins are four short trunks which convey the red blood from the lungs to the left side of the heart, and which are found—two on each side—in the root of the corresponding lung. The pulmonary veins have no valves.

PLAN OF ARTERIAL DISTRIBUTION.



PLAN OF VENOUS RETURN.

The veins from the head, face, and neck unite to form } External (the external jugular terminates in subclavian veins) and internal jugular veins.

The deep-seated and superficial veins from the upper limbs unite to form } Right and left subclavian veins. } The internal jugular unites with the subclavians to form } Right and left innominate } SUP. VENA CAVA.

The deep-seated and superficial veins from the lower limbs unite to form } External iliacs } Right and left common iliacs } INFERIOR VENA CAVA.

The veins from pelvis unite to form } Internal iliacs }

The right and left azygos veins connected with the inferior vena cava below, and superior vena cava above, form a supplementary channel.

The veins from stomach, spleen, pancreas, and intestines unite to form the portal vein, which breaks up into capillaries in the liver, and is returned to the inferior vena cava by the hepatic veins.

CHAPTER X.

THE VASCULAR SYSTEM CONTINUED: THE GENERAL CIRCULATION; THE PULSE AND ARTERIAL PRESSURE; VARIATIONS IN THE CAPILLARY CIRCULATION.

The general circulation of the blood.—At each beat of the heart the contraction of the ventricles drives a certain quantity

of blood, probably amounting to four ounces, with great force into the aorta and pulmonary artery. The aorta delivers this supply of blood from the left ventricle, through its branches, to the capillaries in all parts of the body, except the lungs. In the capillaries, the blood is robbed of oxygen and other constituents necessary for the life and growth of the tissues, is loaded with carbonic acid and other waste matters, and is returned by the superior and inferior venæ cavæ to the right side of the heart. From the right side of the heart, the blood is conveyed by the pulmonary artery to the capillaries in the lungs, where it receives a fresh supply of oxygen and gives up the carbonic acid with which it has become loaded during its circulation through the body. Thus a double circulation is constantly and simultaneously going on, the artery from the left side of

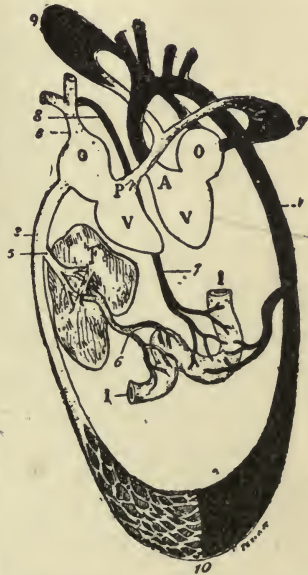

FIG. 82.—DIAGRAM OF CIRCULATION. *A*, aorta; *P*, pulmonary artery; *O, O*, auricles; *V, V*, ventricles; *I, I*, intestines; *F*, liver; 1, descending aorta; 2, inferior vena cava; 3, superior vena cava; 5, hepatic veins; 6, portal vein; 7, 8, thoracic duct; 9, 9, lungs; 10, capillary network between arteries and veins.

the heart sending the pure oxygenated blood to the general system, and the artery from the right side of the heart sending the impure blood to the lungs for purification. The more extensive circulation is usually called the general or systemic circulation, while the lesser circulation is generally known as the pulmonary.

Some features of the arterial circulation. — The flow of blood into the arteries is most distinctly intermittent; sudden, rapid discharges alternating with relatively long intervals during which the arteries receive no blood from the heart. Every time the heart beats just as much blood flows from the veins into the right auricle as escapes from the left ventricle into the aorta, but this inflow is much slower and takes a longer time than the discharge from the ventricles.

The pulse. — When the finger is placed on an artery a sense of resistance is felt, and this resistance seems to be increased at intervals, corresponding to the heart-beat, the artery at each heart-beat being felt to rise up or expand under the finger. This constitutes the pulse; and, in certain arteries which lie near the surface, this pulse may be seen with the eye. When the finger is placed on a vein very little resistance is felt; and, under ordinary circumstances, no pulse can be perceived by the touch or by the eye.

As each expansion of an artery is produced by a contraction of the heart, the pulse, as felt in any superficial artery, is a convenient guide for ascertaining the character of the heart's action. The radial artery at the wrist, owing to its accessible situation, is usually employed for this purpose. Any variation in the frequency, force, or regularity of the heart's action is indicated by a corresponding modification of the pulse at the wrist.

The average frequency of the pulse in man is seventy-two beats per minute. This rate may be increased by muscular action. Even the variation of muscular effort entailed between the standing, sitting, and recumbent positions will make a difference in the frequency of the pulse of from eight to ten beats per minute. Age has a marked influence in the same direction. According to Carpenter, the pulse of the fœtus is about 140, and that of the newly born infant 130. During the first, second, and third years, it gradually falls to 100; by the

fourteenth year to 80; and is reduced to the adult standard by the twenty-first year. At every age, mental excitement may produce a temporary acceleration, varying in degree with the peculiarities of the individual.

As a rule, the rapidity of the heart's action is in inverse ratio to its force. A slow pulse, within physiological limits, is usually a strong one, and a rapid pulse comparatively feeble. The same is true in disturbance of the heart's action in disease; the pulse in fever, or other debilitating affections, becoming weaker as it grows more rapid.

Arterial tension.— When an artery is severed, the flow of blood from the proximal end (that on the heart side) comes in jets corresponding to the heart-beats, though the flow does not cease between the beats. The larger the artery, and the nearer to the heart, the greater the force with which the blood issues, and the more marked the intermittence of the flow.

When a corresponding vein is severed, the flow of blood, which is chiefly from the distal end (that away from the heart), is not intermittent, but continuous; the blood comes out with comparatively little force, and “wells up,” rather than “spurts out.”

The continuous, uninterrupted flow of blood in the veins is caused by the elasticity of the arterial walls. On account of the small size of the capillaries and small arteries the blood meets with a great deal of resistance in passing through them; and, in consequence, the blood cannot get through the capillaries into the veins so rapidly as it is thrown into the arteries by the heart. The whole arterial system, therefore, becomes over-distended with blood, and the greater the resistance, the greater the pressure on, and distension of, the arterial walls. The following illustration will explain how the elasticity of the arteries enables them to deliver the blood in a steady flow to the veins through the capillaries.

If a syringe be fastened to one end of a long piece of elastic tubing, and water be pumped through the tubing, it will flow from the far end in jerks. But if we stuff a piece of sponge into this end of the tubing, or offer in any way resistance to the outflow of the water, the tubing will distend, its elasticity be brought into play, and the water flow from the end not in jerks, but in a stream, which is more and more completely continuous the longer and more elastic the tubing.

Substitute for the syringe the heart, for the sponge the capillaries and small arteries, for the tubing the whole arterial system, and we have exactly the same result in the living body. Through the action of the elastic arterial walls the separate jets from the heart are blended into one continuous stream. The whole force of each contraction of the heart is not at once spent in driving a quantity of blood out of the capillaries; a part only is thus spent, the rest goes to distend the elastic arteries. But during the interval between that beat and the next the distended arteries are narrowing again, by virtue of their elasticity, and so are pressing the blood on in a steady stream into the capillaries with as much force as they were themselves distended by the contraction of the heart.

The degree of tension to which the arterial walls are subjected depends upon the force of the heart-beat, and upon the resistance offered by the smaller arteries, the normal general blood pressure being mainly regulated by the "tone" of the minute arteries.

Variations in the capillary circulation. — Most of the changes in the capillary circulation are likewise dependent upon the condition of the smaller arteries. When under certain nervous influences they contract, the blood supply to the capillaries is greatly lessened; when, on the other hand, they dilate, the blood supply is greatly increased. The phenomena produced by these local variations in the blood supply of certain parts are very familiar to us; the redness of skin produced by an irritating application, the blushing or paling of the face from mental emotion, the increased flow of blood to the mucous membranes during digestion, being all instances of this kind.

But the condition of the capillary walls themselves also exerts an influence upon the capillary circulation. If some transparent tissue, preferably the web of a frog's foot, be watched under the microscope, it will be observed that in the small capillaries the corpuscles are pressed through the channel in single file, each corpuscle as it passes occupying the whole bore of the capillary. In the larger capillaries and smaller arteries and veins the red corpuscles run in the middle of the channel, forming a coloured core, between which and the sides of the vessels is a colourless layer containing no red corpuscles, and called the "peripheral zone." In the peripheral zone are fre-

quently seen white corpuscles, sometimes clinging to the walls of the vessel, sometimes rolling slowly along, and in general moving irregularly, stopping awhile, and then suddenly moving on again.

These are the phenomena of the normal circulation, but a different state of things sets in when the condition of the blood-vessels is altered in inflammation.¹ If an irritant, such as a drop of chloroform, be applied to the portion of transparent tissue under observation, the following changes may be seen to occur: the arteries dilate, the blood flows in greater quantity and with more rapidity, the capillaries become filled with corpuscles, and the veins appear enlarged and full. This condition of distension may pass away, and the blood-vessels return to their normal state, the effect of the irritant having merely produced a temporary redness.

The irritant, however, usually produces a more decided change. The white corpuscles begin to gather in the peripheral zones, and this takes place though the vessels still remain dilated and the stream of blood still continues rapid, though not so rapid as at first. Each white corpuscle exhibits a tendency to stick to the sides of the vessels, and, driven away from the arteries by the stronger arterial current, becomes lodged in the veins. Since white corpuscles are continually arriving on the scene, the inner surface of the veins and capillaries soon become lined with a layer of these cells. Now, though the vessels still remain dilated, the stream of blood begins to slacken, and the white corpuscles lying in contact with the walls of the vessels are seen to thrust themselves through the distended walls into the lymph spaces outside. This migration of the white cells is accomplished by means of their amœboid movements. They thrust elongated processes through the walls, and then, as these processes increase in size, the body of the cell passes through into the enlarged process beyond, the perforation appearing to take place in the cement substance between the pavement epithelial cells forming the walls of the vessels. Through this migration, the lymph spaces around the vessels in the inflamed area become crowded

¹ The following account of the changes occurring in inflammation does not strictly belong to a text-book on physiology, but I have ventured to introduce it, as especially interesting to nurses, out of "Foster's Physiology."

with white corpuscles. At the same time the lymph not only increases in amount, but changes somewhat in its chemical characters; it becomes more distinctly and readily coagulable, and is sometimes spoken of as "exudation fluid." This change of the lymph with the increased quantity, together with the dilated crowded condition of the blood-vessels, gives rise to the swelling which is one of the features of inflammation.

If the inflammation now passes away, the white corpuscles cease to emigrate, cease to stick so steadily to the sides of the vessels, the stream of blood quickens again, the vessels regain their ordinary calibre, and a normal circulation is re-established. But this inflammatory condition, instead of passing off, may go on to a further stage; and, if this is the case, more and more white corpuscles, arrested in their passage, crowd and block the channels, so that, though the vessels remain dilated, the stream becomes slower and slower, until at last it stops altogether, and stagnation or "stasis" sets in. The red corpuscles, in this condition of things, are driven in among the white corpuscles, the vessels are filled and distended with a mingled mass of red and white corpuscles, and it may now be observed that the red corpuscles also begin to find their way through the distended and altered walls of the capillaries into the lymph spaces outside. This is called the *diapedesis* of the red corpuscles.

This stagnation stage of inflammation may be the beginning of further mischief and of death to the inflamed tissue, but it, too, may, like the earlier stages, pass away.

General summary of the circulation.—The perfect circulation of the blood is dependent upon certain factors, the chief of which are: (1) the character of the heart-beat; (2) the contraction and relaxation of the minute arteries; (3) the elasticity and extensibility of the arterial walls; (4) the perfect adjustment of the valves.

The character of the heart-beat is mainly determined by the condition of its muscular substance, and any interference with the nutrition of the heart leading to degeneration of its muscular walls very seriously affects the heart's action.

The contraction and relaxation of the smaller arteries is under the influence of the nervous system, the particular fibres distributed to them being known as the vaso-motor nerves. The widening and narrowing of these arteries not only affects

the local circulation in different parts of the body, but the amount of resistance they oppose to the arterial impulse also influences in some degree the character of the heart-beat.

The elasticity and extensibility of the arteries change with the age of the individual. As we grow older the arterial walls grow stiffer and more rigid, and become less well adapted for the unceasing work they are called upon to perform. The valves also show signs of age as years advance, and even if not injured by disease, do not adjust themselves so perfectly as in early life.

Still, the heart has a marvellous facility for adjusting itself to changed conditions, and the circulation of the blood may go on for years with the integrity of the vascular mechanism greatly impaired.

FŒTAL CIRCULATION. — The peculiarities of the fœtal circulation, leaving details aside, are — the direct communication between the two auricles of the heart through an opening called the foramen ovale; the communication between the pulmonary artery and descending portion of the arch of the aorta by means of a tube called the ductus arteriosus; and the communication between the placenta and the fœtus by means of the umbilical cord.

The arterial blood for the nutrition of the fœtus is carried from the placenta along the umbilical cord by the umbilical vein. Entering the fœtus at the umbilicus the blood passes upwards to the liver and is conveyed into the inferior vena cava in two different ways. The larger quantity first enters the liver, and alone, or in conjunction with the blood from the portal vein, ramifies through the liver before entering the inferior vena cava, by means of the hepatic veins. The smaller quantity of blood passes directly from the umbilical vein into the inferior vena cava, by a tube called the ductus venosus.

In the inferior vena cava the blood from the placenta becomes mixed with the blood returning from the lower extremities of the fœtus. It enters the right auricle and guided by a valve, the Eustachian valve, passes through the foramen ovale into the left auricle. In the left auricle it unites with a small quantity of blood returned from the lungs by the pulmonary veins. From the left auricle the blood passes into the left ventricle, and is distributed by the aorta almost entirely to

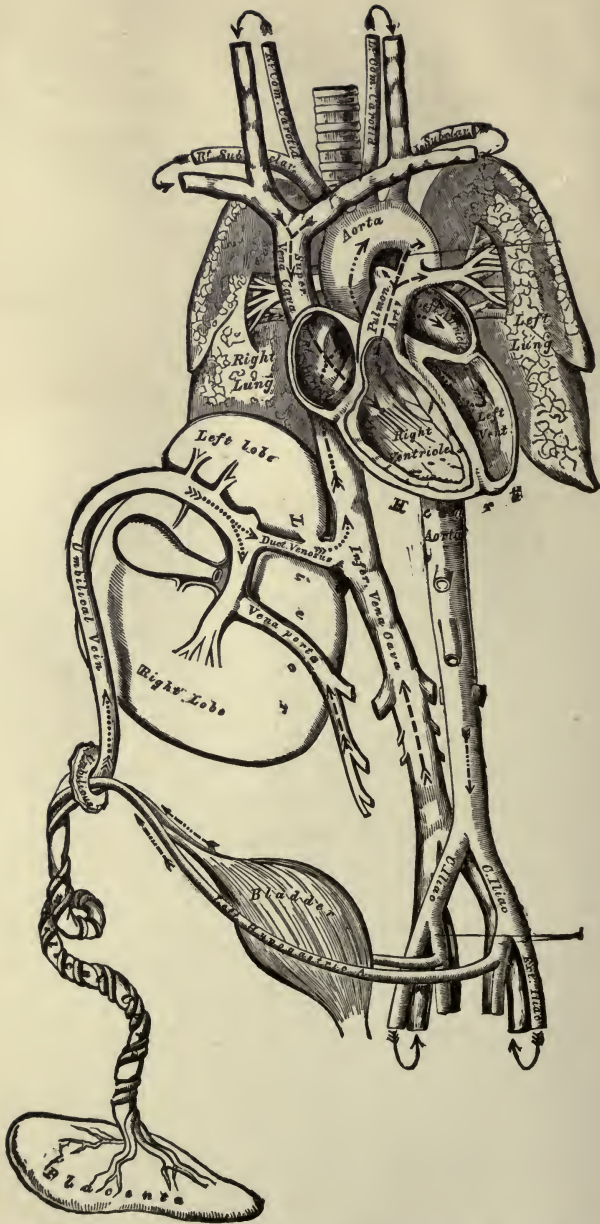


PLATE VI. — PLAN OF FŒTAL CIRCULATION. In this plan, the figured arrows represent the kind of blood, as well as the direction which it takes in the vessels. Thus, arterial blood is figured; venous blood -----; mixed (arterial and venous) ————

the upper extremities. Returned from the upper extremities by the superior vena cava the blood enters the right auricle and, passing over the Eustachian valve, descends into the right ventricle, and from the right ventricle into the pulmonary artery. As the lungs in the fœtus are solid, they require very little blood, and the greater part of the blood passes through the ductus arteriosus into the descending aorta, where, mixing with the blood delivered to the aorta by the left ventricle, it descends to supply the lower extremities of the fœtus, the chief portion of this blood, however, being carried back to the placenta by the two umbilical arteries.

From this description of the foetal circulation, it will be seen : —

1. That the placenta serves the double purpose of a respiratory and nutritive organ, receiving the venous blood from the fœtus, and returning it again charged with oxygen and additional nutritive material.

2. That the greater part of the blood traverses the liver before entering the inferior vena cava; hence the large size of this organ at birth.

3. That the blood from the placenta passes almost directly into the arch of the aorta, and is distributed by its branches to the head and upper extremities; hence the large size and perfect development of those parts at birth.

4. That the blood in the descending aorta is chiefly derived from that which has already circulated in the upper extremities, and, mixed with only a small quantity from the left ventricle, is distributed to the lower extremities; hence the small size and imperfect development of these parts at birth.

Development of blood-vessels and corpuscles. — The blood-vessels and red corpuscles are formed very early in the embryo. They are developed in that portion of the primitive tissue called the mesoblast. The cells which are to form the vessels become extended into processes of varying length, which grow out from the cells in two or more directions. The cells become united with one another, either directly or by the junction of their processes, so that an irregular network is thus formed. Meanwhile the nuclei in the cells multiply, and each nucleus surrounds itself with a small amount of cell protoplasm. The corpuscles thus formed acquire a reddish colour, and the protoplasmic network in which they lie becomes hollowed out into a system of branched canals containing fluid, in which the nucleated coloured corpuscles float. The protoplasmic walls of the vessels gradually change

into the flattened cells which compose the wall of the capillaries, and which form the lining membrane of the arteries and veins. The remaining coats

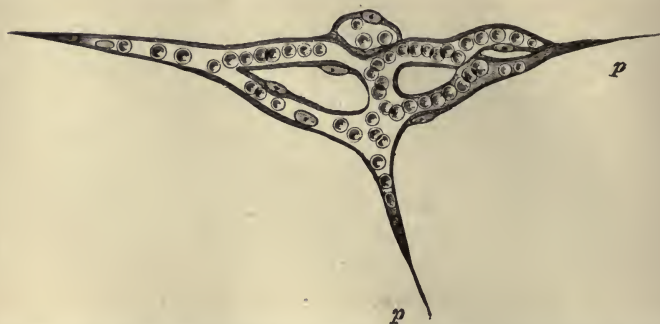

FIG. 83.— ISOLATED CAPILLARY NETWORK FORMED BY THE JUNCTION OF SEVERAL HOLLOWED-OUT CELLS, AND CONTAINING COLOURED BLOOD-CORPUSCLES IN A CLEAR FLUID. *p, p*, pointed cell-processes extending in different directions for union with neighbouring capillaries.

of the larger vessels are developed later from other cells which apply themselves to the exterior of these tubes.

The first white corpuscles do not appear in the vessels so early as the coloured ones. They probably occur in the beginning as free cells and wander in from the outside.

The new vessels which form in the healing of wounds and in the restoration of lost parts are produced by a process which is essentially the same as above described. Blood-corpuscles, however, are not produced within them, and it is still a matter of doubt as to where and how the red corpuscles originate after birth. The white corpuscles are undoubtedly produced to a large extent in the lymphatic glands and other lymphoid structures.

CHAPTER XI.

VASCULAR SYSTEM CONCLUDED: LYMPHATIC VESSELS AND LYMPH. LYMPHATIC GLANDS AND BODIES OF ALLIED STRUCTURE.

The lymphatics.— In addition to the blood-vessels, which form a continuous series of tubes for the passage of the blood, there is another system of vessels in the body, which arise in the different tissues, and pour their contents into the great veins near the heart. The fluid which these vessels contain is absorbed from the tissues, and is called, from its transparent watery appearance, “lymph” (*lymph*, water), while the vessels themselves are known as lymphatics or absorbents.

The absorbents may be divided into two sets: the lacteals, which absorb the milk-like fluid, called chyle, from the intestines and carry it to the thoracic duct; and the lymphatics proper, which take up the lymph from all parts of the body and return it to the blood through the thoracic and right lymphatic ducts. These two sets of vessels, however, are alike in structure, and will be considered together under the general name of lymphatics.

The lymphatics are found in nearly all the tissues that are supplied with blood. The larger trunks usually accompany the deep-seated blood-vessels, and the smaller vessels form networks in all parts of the body where the extensively distributed and penetrative connective tissue is found.

The lymphatics have their origin in the connective tissue. They may be said to begin as irregularly shaped or tubular spaces in the areolæ, and are distinguished from the lymph spaces in the tissue outside by being lined with a single layer of flat, transparent epitheloid cells having a peculiar dentated outline, by means of which they are readily recognized. These

united lymph vessels form very irregular labyrinths, communicate freely with one another, and are altogether wider than the blood capillaries. They form the link between the lymph in

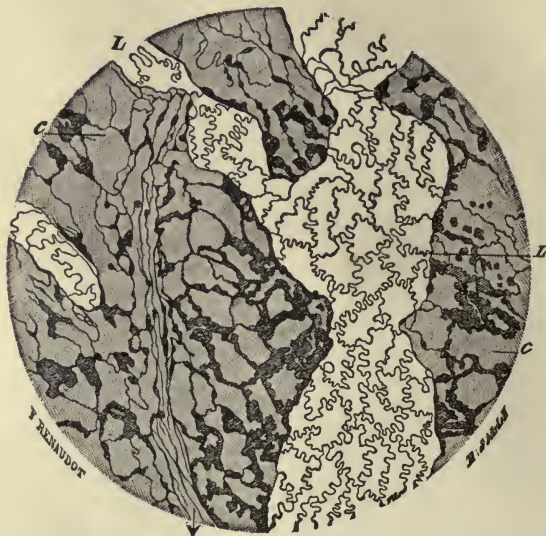


FIG. 84.—A SMALL PORTION OF A LYMPHATIC PLEXUS. Magnified 110 diameters. (Ranvier.) *L*, lymphatic vessel with characteristic epithelium; *C*, cell spaces of the connective tissue abutting here and there against the lymphatics.

the tissues outside of themselves and the regular lymphatic vessels into which they open.¹

In structure, the larger lymphatic vessels closely resemble the veins, except that their walls are somewhat thinner and more transparent, and are more abundantly supplied with valves. The valves are constructed and arranged in the same fashion as those of the veins, but follow one another at such short intervals, that, when distended, they give the vessel a beaded or jointed appearance. They are usually wanting in the smaller networks. The valves allow the passage of material from the smaller lymphatics to the veins, and obstruct the flow of anything in the opposite direction. The lymphatics do not carry to the tissues. Their office is to carry away from the tissues into the veins all the material the tissues do not need.

¹ The serous cavities may be regarded as expanded lymph spaces, as they open by means of their stomata into the lymphatics, and the fluid which moistens their surfaces is really lymph and not serum.

The lymphatics, having attained a certain size, do not unite into larger and larger trunks, but continue of the same diameter until they finally enter two trunks or ducts through which their contents are poured into the veins. The lymphatics from the right arm, and right side of the head, neck, and upper part of the trunk, enter the right lymphatic duct. The vessels from the rest of the body, including the lacteals from the intestines, enter the thoracic duct. As we have stated elsewhere (page 105), these ducts pour their contents into the blood at the junction of the internal jugular and subclavian veins.

The lymph, like the blood in the veins, is returned from the limbs and viscera by a deep and by a superficial set of vessels. In their course from origin to termination most of the lymphatics pass through small masses of tissue, called lymphatic glands, a description of which will be given later on.

The thoracic duct. — The thoracic duct, from fifteen to eighteen inches long in the adult, extends from the second lumbar vertebra to the root of the neck. It lies in front of the bodies of the vertebræ gradually inclining towards the left until, when on a level with the seventh cervical vertebra, it turns outward and arches downwards and forwards to terminate in the angle formed by the junction of the left internal jugular and subclavian veins. The size is usually compared to that of a goose quill. It is dilated below where it receives the lymphatics from the lower limbs and the chyle from the lacteals, the dilatation being known as the *receptaculum chyli*, receptacle of the chyle. The duct is provided with valves, and in other respects closely resembles the larger lymphatics in structure. It is often alternately contracted and enlarged at irregular intervals.

The right lymphatic duct is a short vessel usually from a quarter to half an inch in length. It pours its contents into the blood at the junction of the right internal jugular and subclavian veins.

The lymph. — The lymph is blood minus certain constituents. When examined with the microscope, it is seen to consist of a clear liquid with corpuscles floating in it. The liquid part resembles the plasma of the blood in its composition, except that it contains relatively more water and less solids. It clots when removed from the body, though not so firmly as the

blood. The lymph corpuscles, usually called leucocytes, agree in their characters with the white corpuscles of the blood. They vary in number in different parts, being more numerous in the lymph which has passed through the lymphatic glands than in that which enters these bodies, thus indicating the lymphatic glands as a source of these corpuscles.

The chyle in the lacteals during digestion has a white aspect dependent upon the fatty particles absorbed from the food, and suspended in it like oil globules in milk. After fasting the lacteals contain lymph which differs very little from the lymph found in the ordinary lymphatics.

The lymph, broadly speaking, is blood minus its red corpuscles. The chyle is lymph plus a very large quantity of minutely divided fat.

Movements of the lymph. — The onward progress of the lymph from the tissues to the veins is maintained chiefly by three things. (1) The difference of the pressure upon the lymph in the tissues, and the pressure in the large veins of the neck. As we have already seen in our last chapter the pressure exerted upon the blood in the capillaries is greater than that exerted upon the blood in the veins. This pressure in the smaller blood-vessels is communicated through the blood-plasma to the lymph, and thus, though the lymph is not subjected to the same amount of pressure as the blood in the capillaries, it still stands at a higher pressure than the blood in the veins. We may consider the lymphatics to form a system of vessels leading from a region of higher pressure, viz. the lymph-spaces of the tissues, to a region of lower pressure, viz. the interior of the large veins of the neck. (2) On account of the numerous valves in the lymphatics every pressure upon the tissues in which they lie will, by compressing the vessels, cause an outward flow of their contents. Active muscular exercise and the manipulation of the tissues, as practised in massage, markedly affect the lymph flow. (3) During each inspiration the pressure on the thoracic duct is less than on the lymphatics outside the thorax, and the lymph is accordingly "sucked" into the duct. During the succeeding expiration the pressure on the thoracic duct is increased, and some of its contents, prevented by the valve from escaping below, are pressed out into the veins.

The lymph in the various lymph-spaces of the body varies in

amount from time to time, but under normal circumstances, never exceeds certain limits. Under abnormal conditions, these limits may be exceeded, and the result is known as œdema or dropsy. Similar excessive accumulations may also occur in the larger lymph-spaces, the serous cavities.

The possible causes of œdema are, on the one hand, an obstruction to the flow of lymph from the lymph-spaces, and on the other hand, an excessive transudation, the lymph gathering in the lymph-spaces faster than it can be carried away by a normal flow. œdema is almost always due to the latter cause, viz. excessive transudation.

The inflammatory œdema, due to changes in the walls of the blood-vessels, we have already touched on in speaking of the capillary circulation. In this kind of œdema the transudation is, besides being crowded with migrating corpuscles, more distinctly coagulable than ordinary lymph. Allied to this inflammatory œdema is the "effusion," which appears in the serous cavities when they are inflamed, as in pleurisy and peritonitis.

Functions of the lymph. — The lymph derived from the blood delivers to the elements of the tissues the material each element needs to maintain its functional activity, and returns to the blood the products of this activity, which products may be simple waste, or matters capable of being made use of by some other tissue. There is thus a continual interchange going on between the blood and the lymph. How this interchange is effected may be partially understood by the following illustration.

If a tumbler be completely divided vertically into two compartments by a moist piece of membrane, and a watery solution of common salt be placed in one compartment, and a watery solution of sugar in the other, it will be found after a time that some of the salt has found its way into the solution of sugar, and, *vice versa*, some of the sugar into the salt solution. Such an interchange is said to be due to dialysis or osmosis; and if the process were allowed to go on for some hours, the same proportion of salt and sugar would be found in the solutions on each side of the dividing membrane. So in the living body. The lymph, originally like the blood-plasma (it is blood-plasma forced to transude through the capillaries by the pressure of the blood), becomes altered by the metabolic changes of the tissues

which it bathes, and we have two different fluids, separated by the moist membrane which forms the walls of the blood-vessels, — the lymph in the tissues outside the walls of the capillaries and the blood inside the capillary walls, — and the same conditions may be said to exist as in the salt and sugar solutions just spoken of. And now the same phenomena take place; for though the pressure is higher in the blood-vessels than in the lymph outside, some of the constituents of the lymph pass into the blood by the process of osmosis.

These constituents, which, as we cannot too often emphasize, are products resulting from the activity of the tissues, are carried away by the blood to other tissues, which will either make use of them, or, as in the kidneys, take them up to make excretory fluids, and so remove them from the body.

In consequence of the different wants and wastes of different tissues at different times, both the lymph and blood must vary in composition in different parts of the body. But the loss and gain is so fairly balanced that the average composition is pretty constantly maintained. The blood, on account of the higher pressure, loses more liquid to the lymph than it receives back, but this excess is returned back again to the blood by the lymphatics when they empty their contents into the veins.

Lymphatic glands. — The lymphatic glands are small, solid bodies, placed in the course of the lymphatics and lacteals, through which the contents

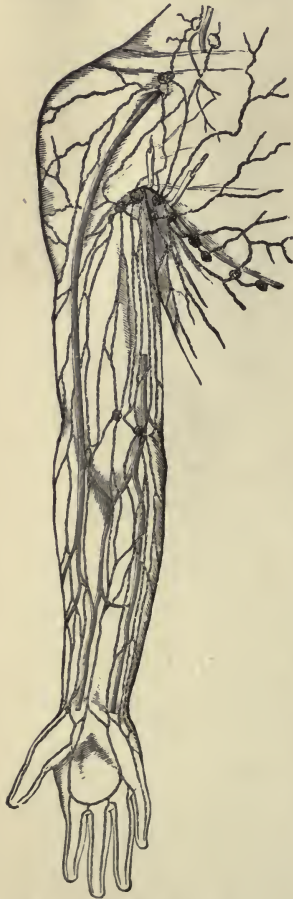

FIG. 85.—LYMPHATICS AND LYMPHATIC GLANDS OF AXILLA AND ARM.

of most of these vessels have to pass in their progress towards the thoracic and right lymphatic ducts. These bodies are collected in numbers alongside of the great muscles of the neck,

and also in the thorax and abdomen, especially in the mesentery, where they are called the mesenteric glands, and alongside of the aorta, vena cava inferior, and the iliac vessels. A few, usually of small size, are found on the external parts of the head, and considerable groups are situated in the axilla, and in the groin, where they receive the name of inguinal glands. Some three or four lie on the popliteal vessels, and usually one is placed a little below the knee, but none farther down. In the arm, they are found as low as the elbow joint.

The size of the lymphatic glands is very various, some being not much larger than a hemp seed, and others as large as an almond, or even larger than this. In shape, they are usually oval.

A lymphatic gland is covered by an envelope, or capsule, of connective and muscular tissue. This capsule sends fibrous

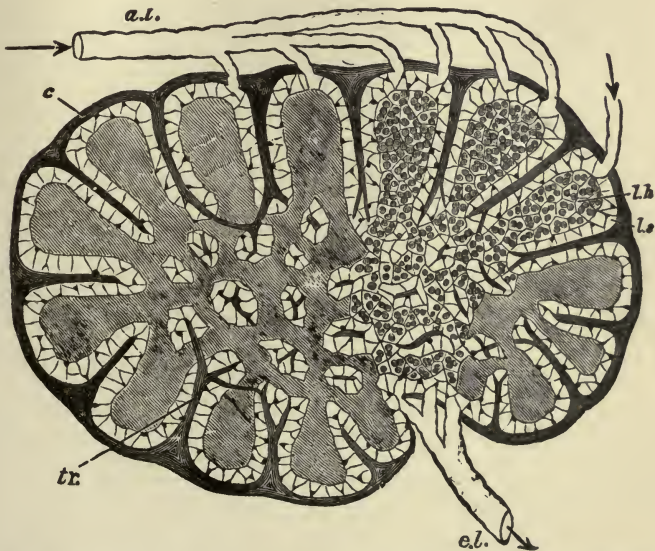


FIG. 86. — DIAGRAMMATIC SECTION OF LYMPHATIC GLAND. (Sharpey.) *a.l.*, afferent lymphatic; *e.l.*, efferent lymphatic; *c.*, capsule, or envelope; *tr.*, trabeculae; *l.s.*, lymph-sinus; *l.h.*, pulpy substance of gland.

bands (*trabeculae*) into the substance of the gland, dividing the exterior portion into more or less regular compartments, and the interior into irregular labyrinths. This framework is occu-

pied by reticular or lymphoid tissue,¹ the fine meshes of which are filled with leucocytes. Between this pulpy substance of the gland and the skeleton framework there is a narrow space (left white in the diagram) which looks as if the pulp had originally filled the framework and then shrunk away slightly on all sides. The spaces thus left form channels for the passage of the lymph, which, entering the more convex surface by afferent vessels, issues, after circulating through the gland, by efferent vessels below. In its passage through the gland the lymph takes up fresh leucocytes, which are continually multiplying by cell division in the glandular substance. The lymphatic glands are plentifully supplied with blood.

Solitary follicles and Peyer's patches. — Closely connected with the lymphatic vessels in the intestines are small, rounded bodies

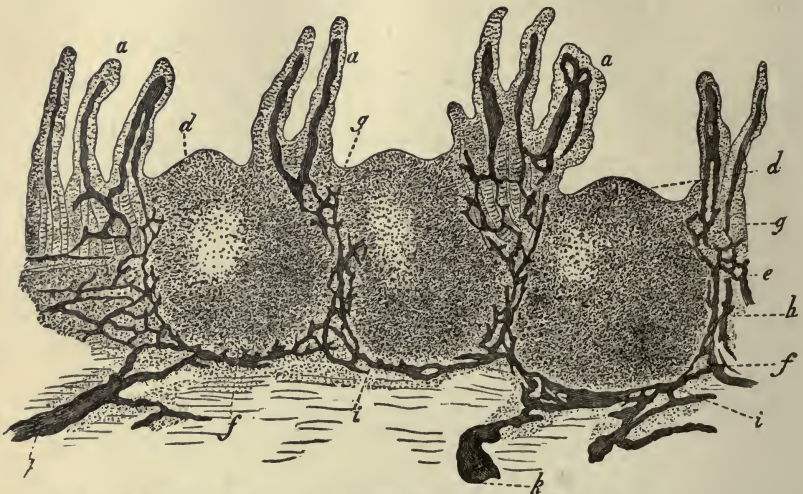


FIG. 87.—VERTICAL SECTION OF A PORTION OF A PEYER'S PATCH, WITH LACTEAL VESSELS INJECTED. *a*, villi, with their lacteals coloured black; *d*, surface of rounded follicle, or solitary gland; *e*, central part; *f*, *g*, *h*, *i*, and *k*, lymph-channels, or lacteal vessels, coloured black.

of the size of a small pin's head, called **solitary glands** or **follicles**. These bodies consist of a rounded mass of fine lymphoid tissue, the meshes of which are crowded with leucocytes. Into this mass of tissue one or more small arteries, enter and form a

¹ Reticular or lymphoid tissue is that variety of connective tissue in which the branched connective tissue cells unite to form delicate networks. The meshes of the network are occupied by fluid in which the leucocytes often, in large numbers, wander to and fro.

capillary network, from which the blood is carried away by one or more small veins. Surrounding the mass are lymph channels which are continuous with the lymphatic vessels in the tissue below.

A **Peyer's patch**, or "agminated gland," as it is often called, is simply a collection of these follicles. A well-formed Peyer's patch consists of fifty or more of these solitary follicles, arranged in a single layer, close under the epithelium of the intestinal mucous membrane, and stretching well down into the tissue beneath. These patches are circular or oval in shape, and from twenty to thirty in number. They are largest and most numerous in the portion of the intestine called the ilium. They increase in size during digestion.

The **tonsils** are two thick masses of lymphoid tissue, placed one on each side of the fauces or throat, into which they project. They are covered by stratified epithelium, and their surfaces are pitted with apertures which lead into recesses or crypts in the substance of the tissue.

The spleen. — The spleen differs in many important particulars from lymphatic glands, but may be conveniently studied in conjunction with them, as it resembles these glands in structure, and is functionally connected with the blood.

Like the lymphatic glands, the spleen is covered by a fibrous and muscular capsule which sends fibrous bands to form a network in the interior of the organ. In the meshes of the fibrous framework lies a soft pulpy substance containing a large amount of blood, and, therefore, of a deep red colour. This soft, red pulp is dotted with whitish specks, which are small masses of lymphoid tissue, and are called the *Malpighian corpuscles of the spleen*.

The blood supplied to the spleen appears to escape from the minute subdivisions of the arteries into the red pulp before entering the exceedingly thin-walled veins by which it is conveyed from the gland. The pulp contains numerous red corpuscles, and many bodies which appear to be red corpuscles in process of decay or destruction, and it is surmised that the red corpuscles are in some way destroyed, and that additional white corpuscles are formed, within the spleen.

The spleen is covered by a portion of the peritoneum, the serous membrane covering the viscera of the abdomen, and

lies upon the left side of the stomach, in the abdominal cavity. It is an elongated, flat body, varying greatly in size at different periods of life. The size is increased during and after digestion, and is always large in well-fed, and small in starved, animals. In certain diseases, and more especially in ague, a temporary enlargement takes place. In prolonged ague, a permanent enlargement of the spleen occurs, and forms the so-called "ague cake."

CHAPTER XII.

THE RESPIRATORY APPARATUS: LARYNX; TRACHEA; LUNGS.
RESPIRATION; EFFECTS OF RESPIRATION UPON THE AIR
WITHIN THE LUNGS, UPON THE AIR OUTSIDE THE BODY,
UPON THE BLOOD; MODIFIED RESPIRATORY MOVEMENTS.

The respiratory apparatus.—Respiration is the main process by means of which the body is supplied with oxygen and relieved of carbonic acid.

A respiratory apparatus consists essentially of a moist and permeable membrane, with blood-vessels containing carbonic acid on one side, and air or fluid containing oxygen on the other. In most aquatic animals, the respiratory organs have the form of gills; in terrestrial or air-breathing animals, the respiratory organs are situated internally under the form of lungs, and are placed in communication with the external air by a tube or windpipe.

In man, the respiratory apparatus may be conveniently divided into the larynx, trachea, and lungs.

The larynx.—The larynx is situated between the base of the tongue and the top of the trachea, in the upper and front part of the neck. Above and behind lies the pharynx, which opens into the œsophagus or gullet, and on either side of it lie the great vessels of the neck.

The larynx is made up of nine pieces of cartilage, united together by ligaments, and moved by numerous muscles. It is lined throughout by mucous membrane,¹ which is continuous above with that lining the pharynx, and below with that lining the trachea. In form, the larynx is narrow and rounded below

¹ Mucous membranes resemble the skin in structure, and may be said to form an internal skin for the cavities of the body which open exteriorly. They always have a basis of connective tissue, are lined with epithelium, and secrete a sticky substance called mucus. For a further description, see page 144.

where it blends with the trachea, but broad above, and shaped somewhat like a triangular box, with flat sides and prominent ridge in front. This prominence, popularly called "Adam's apple," is formed by the union of the two largest pieces of cartilage (the thyroid), of which the larynx is composed.

Across the middle of the larynx is a transverse partition, formed by two folds of the lining mucous membrane, stretching from side to side, but not quite meeting in the middle line. They thus leave in the middle line a chink or slit, running from front to back,

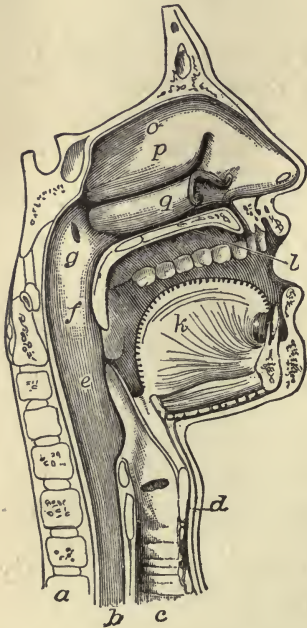


FIG. 88. — THE MOUTH, NOSE, AND PHARYNX, WITH THE COMMENCEMENT OF GULLET AND LARYNX, AS EXPOSED BY A SECTION A LITTLE TO THE LEFT OF THE MEDIAN PLANE OF THE HEAD. *a*, vertebrae; *b*, gullet; *c*, trachea; *d*, larynx; *e*, epiglottis; *f*, soft palate; *g*, opening of Eustachian tube; *h*, tongue; *i*, hard palate; *o, p, q*, inferior turbinate bones of left nasal chamber.

called the glottis or *rima glottidis*. Imbedded in the mucous membranes at the edges of the slit are fibrous and elastic ligaments, which strengthen the edges of the glottis and give them elasticity. These ligamentous bands, covered with the mucous membrane, are firmly attached at either end to the cartilages of the larynx, and are called the vocal cords. The space left between their edges, the glottis, varies in shape and size, according to the action of the muscles upon the laryngeal walls. When the larynx is at rest during quiet breathing, the glottis is V-shaped; during a deep inspiration, it becomes almost round; while, during the production of a high note, the edges of the cords approximate so closely as to leave scarcely any opening at all. The glottis is protected by a leaf-shaped lid of fibro-cartilage, called the epiglottis, which shuts down upon the opening during the passage of food or other matters into the œsophagus.

The vocal cords produce the voice. A blast of air, driven by an expiratory movement out of the lungs, throws the two

elastic cords into vibrations. These impart their vibrations to the column of air above them, and so give rise to the sound which we call the voice.

The larynx is placed in communication with the external air by two channels: the one, supplied by the nasal passages, is always open; the other, furnished by the mouth, can be opened and closed at will.

One advantage of this arrangement is, that when exposed to a very cold temperature, we can close our mouths and breathe through the nasal passages, which, being narrow, thickly lined, and freely supplied with blood-vessels, warm the air before it reaches the lungs.

The trachea.—The trachea or windpipe is a fibrous and muscular tube, the walls of which are strengthened and rendered more rigid by hoops of cartilage embedded in the fibrous tissue. These hoops are C-shaped and incomplete behind, the cartilaginous rings being completed by

bands of plain muscular tissue where the trachea comes in contact with the œsophagus. Like the larynx it is lined by mucous membrane, and has a ciliated epithelium upon its inner surface. The mucous membrane, which also extends into the bronchial tubes, keeps the internal surface of the air passages free from impurities; the sticky mucus entangles particles of dust and other matters breathed in with the air, and the incessant

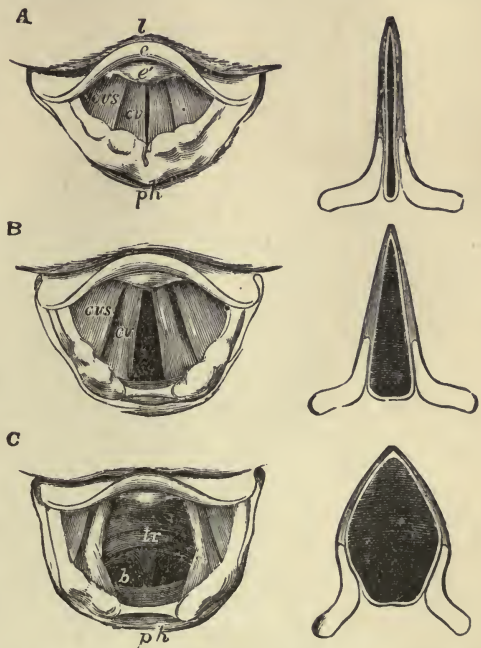


FIG. 89.—THE LARYNX AS SEEN BY MEANS OF THE LARYNGOSCOPE IN DIFFERENT CONDITIONS OF THE GLOTTIS. *A*, while singing a high note; *B*, in quiet breathing; *C*, during a deep inspiration. *l*, base of tongue; *e*, upper free edge of epiglottis; *e'*, cushion of the epiglottis; *ph*, part of anterior wall of pharynx; *cv*, the true vocal cords; *cvs*, the false vocal cords; *tr*, the trachea with its rings; *b*, the two bronchi at their commencement.

movements of the cilia continually sweep this dirt-laden mucus upwards and outwards.

The trachea measures about four and a half inches in length,

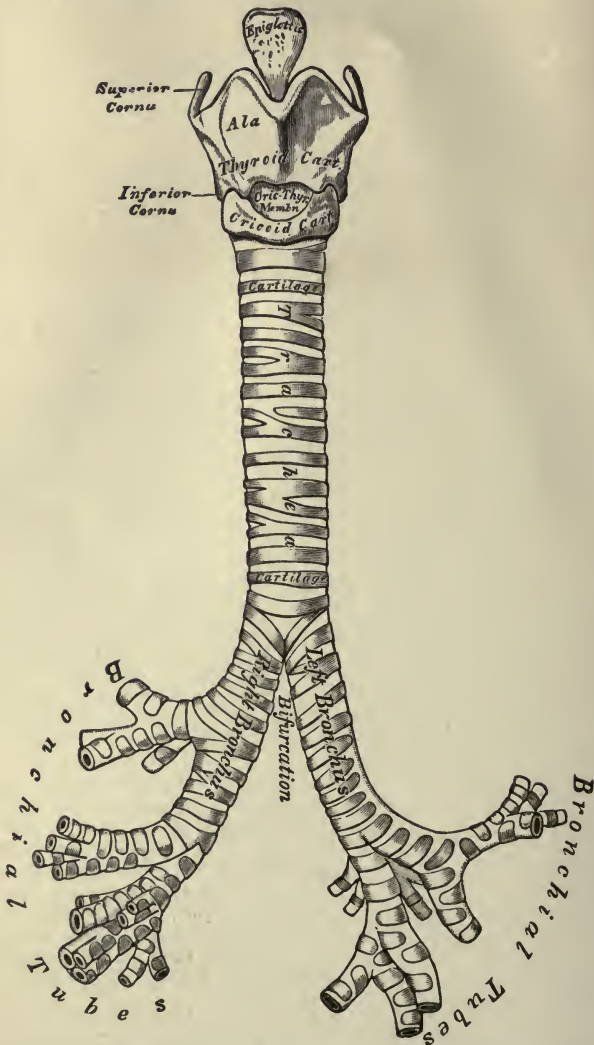


FIG. 90.—FRONT VIEW OF CARTILAGES OF LARYNX. Trachea and bronchi.

and three-quarters of an inch from side to side. It extends down into the thorax from the lower part of the larynx to opposite the third dorsal vertebra, where it divides into two tubes, — the two bronchi, — one for each lung.

The lungs.—The lungs consist of the bronchial tubes and their terminal dilatations, numerous blood-vessels, lymphatics, and nerves, and an abundance of fine, elastic, connective tissue, binding all together.

The two bronchi, into which the trachea divides, enter the right and left lung respectively, and then break up into a great number of smaller branches which are called the bronchial tubes. The two bronchi resemble the trachea in structure; but as the bronchial tubes divide and subdivide, their walls become thinner, the small plates of cartilage drop off, the fibrous tissue disappears, and the finer tubes are composed of only a thin layer of muscular and elastic tissue, lined by mucous membrane. Finally, these finer tubes end in dilated cavities, the walls of which, consisting of a single layer of flattened epitheloid cells, surrounded by a fine, elastic, connective tissue, are exceedingly thin and delicate.

Immediately beneath the layer of flat cells, and lodged in the elastic connective tissue, is a very close network of capillary blood-vessels; and the air reaching the terminal dilatations by the bronchial tubes is separated from the blood in the capillaries by only the thin membranes forming their respective walls.

The terminal dilatations do not end as simple, rounded sacs, like children's air-balloons, but each bronchiole ends in an enlargement having more or less the shape of a funnel, and called an *infundibulum*. Each of these infundibula is subdivided into secondary chambers or cavities, called *alveoli*, the walls of which are honey-combed with "bulgings."¹ In this way the amount of surface exposed to the air and covered by the capillaries is immensely increased.²

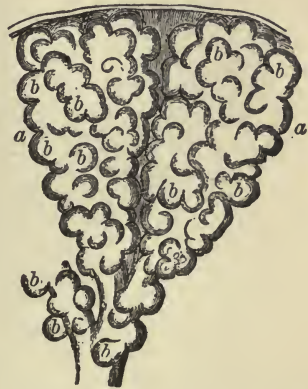

FIG. 91.—TWO ALVEOLI OF THE LUNG. Highly magnified. *b, b*, the air-cells, or bulgings, of the alveoli, *a, a*.

¹ These protrusions may be illustrated by a pea-pod, the walls of which are filled with "bulgings," made by the pressure of the peas.

² The pulmonary alveoli are often spoken of under the general name of air-sacs, and the "bulgings" are known as air-cells.

Broadly speaking, the lungs may be said to consist of a large amount of a film-like elastic membrane, covered by a close network of blood-vessels, which membrane is arranged in the form of irregularly dilated pouches at the end of fine tubes, opening into larger and larger tubes, and finally into the windpipe, which places them in communication with the external air.

By virtue of their structure, the larger bronchial tubes remain permanently open; the smaller tubes, however, are sub-

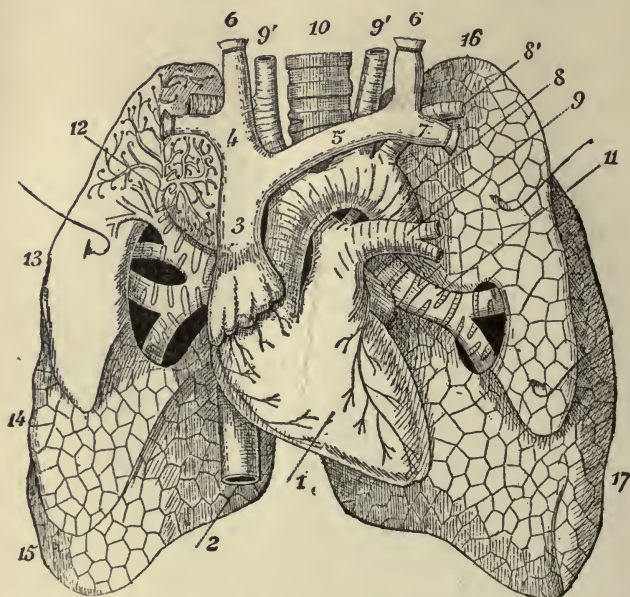


FIG. 92.—ANTERIOR VIEW OF LUNGS AND HEART. 1, heart; 2, inferior vena cava; 3, superior vena cava; 4, right innominate vein; 5, left innominate vein; 6, jugular vein; 7, subclavian vein; 8, arch of aorta; 8', subclavian artery; 9, left pulmonary artery; 9', 9', carotid artery; 10, trachea; 11, left bronchus; 12, ramifications of right bronchus exposed in upper lobe of right lung; 13, 14, middle lobe; 15, lower lobe; 16, upper lobe of left lung; 17, lower lobe of left lung.

ject to collapse when empty; they also may contract under certain nervous influences. The terminal dilatations are eminently elastic and continually expand and contract; they are bathed with lymph, and are always moist.

The two lungs occupy almost all the cavity of the thorax which is not taken up by the heart. The right lung is the larger and heavier; it is broader than the left, owing to the inclination of the heart to the left side; it is also shorter by one

inch, in consequence of the diaphragm rising higher on the right side to accommodate the liver. The right lung is divided by fissures into three lobes. The left lung is smaller, narrower, and longer than the right, and has only two lobes. Each lung is enclosed in a serous sac, the pleura, one layer of which is closely adherent to the walls of the chest and diaphragm; the other closely covers the lung. The base of each lung is attached, by means of the pleura, to the diaphragm, and the apex is attached above the margin of the first rib. The two layers of the pleural sacs, moistened by lymph, are normally in close contact; they move easily upon one another, and prevent the friction that would otherwise occur between the lungs and the walls of the chest with every respiration.

The pressure of the atmospheric air upon the lungs through the air-passages is greater than it can possibly be upon them from the outside through the chest walls, on account of the resistance which the solid chest walls offer to this pressure; and, ordinarily, it is impossible for the lungs to pull away the layer of the pleural sac which adheres to them from the layer which is attached to the chest wall. If, however, the chest wall be punctured, the air from the outside will rush in, distend the pleura, and, squeezing the air out of the air-sacs into the air-passages, cause the lungs to shrivel up and collapse.

Respiration. — The lungs, then, are placed in an air-tight thorax, which they, together with the heart and great blood-vessels, completely fill. By the contraction of certain muscles (see page 65), the cavity of the thorax is enlarged; the lungs are correspondingly distended to fill the enlarged cavity, and, by this distension, the air within the air-sacs becomes expanded and more rarefied than the air outside. Being thus expanded and rarefied, the pressure of the air within the lungs becomes less than that of the air outside, and this difference of pressure causes the air to rush through the trachea into the lungs, until an equilibrium of pressure is established between the air inside the lungs and that outside. This constitutes an inspiration. Upon the relaxation of the inspiratory muscles, the elasticity of the lungs and the chest walls causes the chest to return to its original size, in consequence of which the air within the lungs becomes more contracted and denser than the air outside, the pressure within becomes greater than the pressure without,

and the air rushes out of the trachea until equilibrium be once more established. This constitutes an expiration. An inspiration and an expiration make a respiration.

As in the heart, the auricular systole, the ventricular systole, and then a pause, follow in regular order, — so in the lungs, the inspiration, the expiration, and then a pause succeed one another. Each respiratory act in the adult is ordinarily repeated from fifteen to eighteen times per minute. But this rate varies under different circumstances, one of the most important of which is age. The average rate in the newly born infant has been found to be forty-four per minute, and at the age of five years, twenty-six per minute. It is reduced between the ages of fifteen and twenty to the normal standard.

A condition of rest or activity readily influences the number of respirations per minute. They are always less frequent during sleep, and are markedly increased by severe muscular exercise.

Respiration is an involuntary act. It is possible for a short time to increase or retard the rate of respiration within certain limits by voluntary effort, but this cannot be done continuously. If we intentionally arrest the breathing or diminish its frequency after a short time the nervous impulse becomes too strong to be controlled, and the movements will recommence as usual. If, on the other hand, we purposely accelerate respiration to any great degree, the exertion soon becomes too fatiguing for continuance, and the movements return to their normal standard.

The nervous impulses which cause the contractions of the respiratory muscles arise in the medulla oblongata, travel down the spinal cord, and out along the phrenic and intercostal nerves. If the portion of the medulla oblongata, where these nervous impulses arise, be removed or injured, respiration ceases, and death at once ensues. This part of the medulla is known as the respiratory centre, and is also often called the "vital knot."

The effects of respiration upon the air within the lungs. — At birth the lungs contain no air. The walls of the air-sacs are in close contact, and the walls of the smaller bronchial tubes or bronchioles collapsed and touching one another. The trachea and larger bronchial tubes are open, but contain fluid and not

air. When the chest expands with the first breath taken, the inspired air has to overcome the adhesions existing between the walls of the bronchioles and air-sacs. The force of this first inspiratory effort, spent in opening out and unfolding, as it were, the inner recesses of the lungs, is considerable. In the succeeding expiration, most of the air introduced by the first inspiration remains in the lungs, succeeding breaths unfold the lungs more and more, until finally the air-sacs and bronchioles are all opened up and filled with air. The lungs thus once filled with air are never completely emptied again until after death.

The air remaining in the lungs after expiration is called the old or *stationary* air, into which fresh air is introduced with every inspiration, the fresh or *tidal* air, as it is called, giving up its oxygen to, and taking carbonic acid from, the old or stationary air. Thus the stationary air transacts the business of respiration, receiving, on the one hand, constant supplies of oxygen from the tidal air which it delivers to the blood in the capillaries on the walls of the air-sacs; and, on the other hand, returning, in exchange to the tidal air, the carbonic acid it has received from the blood in these capillaries.

In ordinary respiration the lungs are not distended to their fullest extent, but by more forcible muscular contraction the capacity of the chest can be further enlarged, and a certain additional amount of air will rush into the lungs. This additional amount is often spoken of as *complemental* air. In laboured breathing the contraction of the respiratory muscles not usually brought into play, such as the muscles of the throat and nostrils, becomes very marked.

The entry and exit of the air are accompanied by respiratory sounds or murmurs. These murmurs differ as the air passes through the trachea, the larger bronchial tubes, and the bronchioles. They are variously modified in lung disease, and are then often spoken of under the name of "râles."

The effects of respiration upon the air outside the body.—With every inspiration a well-grown man takes into his lungs about thirty cubic inches of air. The air he takes in differs from the air he gives out mainly in three particulars:—

1. Whatever the temperature of the external air, the expired air is nearly as hot as the blood; namely, of a temperature between 98° and 100° F.

2. However dry the external air may be, the expired air is quite, or nearly, saturated with moisture.

3. The expired air contains about four or five per cent less oxygen, and about four per cent more carbonic acid than the external air, the quantity of nitrogen suffering but little change. Thus:—

	Oxygen.	Nitrogen.	Carbonic Acid.
Inspired air contains . . .	20.81	79.15	0.04
Expired air contains . . .	16.033	79.587	4.38
			(Foster.)

In addition the expired air contains a certain amount of effete matter, of a highly decomposable and impure character. The quantity of water given off in twenty-four hours varies very much, but may be taken on the average to be about nine ounces. The quantity of carbon given off at the same time is pretty nearly estimated by a piece of pure charcoal weighing eight ounces.

If a man breathing fifteen to sixteen times a minute takes in thirty cubic inches of air with each breath, and exhales the same quantity, it follows that in twenty-four hours from three hundred and fifty to four hundred cubic feet of air will have passed through his lungs. And if such a man be shut up in a close room measuring seven feet each way, all the air in the room will have passed through his lungs in twenty-four hours.

Since at every breath the external air loses oxygen and gains carbonic acid and other waste and poisonous matters, it is imperative that some provision be made for constantly renewing the atmospheric surroundings of people in dwelling houses. This is accomplished by ventilation, which consists of a system of mechanical contrivances, by means of which foul air is constantly removed and fresh air as constantly supplied.

The *minimum* amount of air space every individual should have to himself is 800 cubic feet (a room nine feet high, wide, and long contains 729 cubic feet) and this space should be accessible by direct or indirect channels to the outside air.

Effects of respiration upon the blood.—While the air in passing into and out of the lungs is robbed of a portion of its oxygen and loaded with a certain quantity of carbonic acid, the blood as it streams along the pulmonary capillaries is also undergoing important changes. As it leaves the right ventricle it is venous

blood of a dark purple colour; when it enters the left auricle it is arterial blood and of a bright scarlet colour. In passing through the capillaries of the body from the left to the right side of the heart it is again changed from the arterial to the venous condition. The question arises, how is this change of colour effected?

As we have already seen, the blood in the thin-walled, close-set pulmonary capillaries is separated from the air in the air-sacs by only the moist delicate membranes which form their respective walls. By diffusion the oxygen in the air passes through these moist membranes into the venous blood in the pulmonary capillaries, combines with the reduced hæmoglobin which has lost its oxygen in the tissues, and turns it into oxy-hæmoglobin; the purple colour shifts immediately into scarlet, and the red corpuscles hasten onwards to carry this oxy-hæmoglobin to the tissues. Passing from the left ventricle to the capillaries in the tissues the oxy-hæmoglobin gives up some of its oxygen, the colour shifts back again to a purple hue, and the red corpuscles return with this reduced hæmoglobin to the lungs.

The oxygen given up by the blood combines with the elements of the tissues and forms with them unstable chemical compounds which are always breaking down to form more stable compounds, called "oxides." In this process, which is called oxidation, both heat and force are produced and such oxidized products as carbonic acid and urea are evolved.¹ The carbonic acid passes by diffusion into the venous blood, and is carried by it to the right side of the heart and thence to the lungs, a certain quantity, however, escaping from the blood through the kidneys and skin. A small and insignificant amount of oxygen is introduced into the blood through the skin, and, with the food, through the alimentary canal; but, as we have stated in the beginning of this chapter, respiration is the main process by means of which the body is supplied with oxygen and relieved of carbonic acid.

The respiration and circulation are profoundly and intimately

¹ This process of oxidation may be illustrated by the burning of a fire; the oxygen which is in the air combines with the carbon of the wood, heat and light are generated, and oxidized products in the form of carbonic acid and ashes produced.

connected together, any change in the blood immediately affecting the respiration.

It would appear that stimulation of the respiratory centre in the medulla oblongata depends primarily upon the condition of the blood. If the blood is very rich in oxygen the respirations are feeble and shallow; if, on the other hand, the blood is highly venous the respirations are deeper and more frequent, and if the blood remains venous, gradually become forced and laboured until we get the condition called "dyspnœa." Should the blood get more and more venous, the impulses generated in the respiratory centre become more and more vehement. These nervous impulses, instead of confining themselves to the usual nerves distributed to the ordinary respiratory muscles, overflow on to other nerves and put into action other muscles until there is scarcely a muscle in the body that is not affected. The muscles which are thus more and more thrown into action are especially those tending to carry out or to assist expiration; and at last if no relief is afforded the violent respiratory movements give way to general convulsions of the whole body. By the violence of these convulsions the whole nervous system becomes exhausted, the convulsions soon cease, and death is ushered in with a few infrequent and long-drawn breaths.

It has been surmised that the excitability of the respiratory nerve-centre is due to certain chemical substances which act as stimulants. When the blood is rich in oxygen this substance is oxidized or burned, and removed so fast that it is able to exert but little influence on the respiratory nerve-centre; when, however, the blood is poor in oxygen, this substance accumulates and the nerve-centre is powerfully stimulated. Thus when the blood needs oxygen, the respirations are increased to get, if possible, more air into the lungs; if the blood is too rich in oxygen, the respirations become abnormally quiet and shallow.

Modified respiratory movements.— Various emotions may be expressed by means of the respiratory apparatus.

Sighing is a deep and long-drawn inspiration, chiefly through the nose.

Yawning is an inspiration, deeper and longer continued than a sigh, drawn through the widely open mouth, and accompanied by a peculiar depression of the lower jaw.

Hiccough is caused by a sudden, inspiratory contraction of the

diaphragm; the glottis suddenly closes and cuts off the column of air just entering, which, striking upon the closed glottis, gives rise to the characteristic sound.

In *sobbing*, a series of convulsive inspirations follow each other slowly, the glottis is closed, so that little or no air enters the chest.

Coughing consists, in the first place, of a deep and long-drawn inspiration by which the lungs are well filled with air. This is followed by a complete closure of the glottis, and then comes a forcible and sudden expiration, in the midst of which the glottis suddenly opens, and thus a blast of air is driven through the upper respiratory passages.

In *sneezing*, the general movement is the same, except that the opening from the pharynx into the mouth is closed by the contraction of the pillars of the throat and the descent of the soft palate, so that the force of the blast is driven entirely through the nose.

Laughing consists essentially in an inspiration, followed by a whole series of short spasmodic expirations, the glottis being freely open during the whole time, and the vocal cords being thrown into characteristic vibrations.

In *crying*, the respiratory movements are the same as in laughing; the rhythm and the accompanying facial expressions are, however, different, though laughing and crying often become indistinguishable.

CHAPTER XIII.

ALIMENTATION.

SECTION I. Preliminary remarks on secreting glands and mucous membranes.

SECTION II. Food-principles; proteids, fats, carbo-hydrates, water, saline and mineral substances: chemical composition of the body: average composition of milk, bread, and meat. Concluding remarks.

SECTION I. In our last chapter, we described the methods by means of which the blood was supplied with its most vital constituent, oxygen. In the next three chapters, we shall consider how the blood is supplied with those materials through the alimentary canal, which it also constantly requires to maintain the life and growth of the body.

The subject of alimentation, or the process by which the body is nourished, naturally falls into three divisions, viz.:—

- (1) Food.
- (2) Digestion.
- (3) Absorption.

In order, however, to make the subject more intelligible, it will be necessary to make a few preliminary remarks upon the construction of secreting glands and mucous membranes.

Secreting glands.—The secreting glands differ from other glands, such as the lymphatic glands, the tonsils, Peyer's patches, etc., by being always devoted to the function of secretion, and by discharging the secretions they form through little tubes or ducts which open exteriorly. The lymphatic glands and bodies of allied structure are often spoken of as ductless glands, in order to distinguish them from these true secreting glands provided with ducts.

A secretion is a substance elaborated from the blood by cell

action, and poured out upon the external or internal surfaces of the body. An excretion resembles a secretion, except that whereas the secretion is formed to perform some office in the body, the excretion is formed only to be thrown out of the body.

A secretory apparatus consists essentially of a layer of secreting cells placed in close communication with a network of blood-vessels. The simplest form in which a secretory appa-

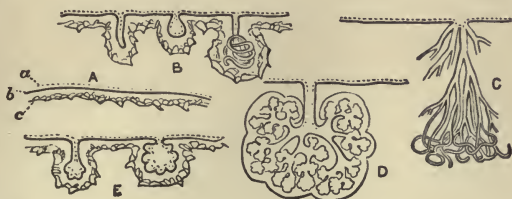


FIG. 93. — DIAGRAM SHOWING THE VARIOUS FORMS OF SECRETING STRUCTURES. *A*, general plan of a secreting membrane; *b*, basement membrane, with cells (*a*) on one side and blood-vessels (*c*) on the other; *B* and *E*, simple tubular, saccular, and coiled tubular glands; *C*, compound tubular gland; *D*, compound saccular, or racemose gland.

ratus occurs is in the shape of a plain, smooth surface, composed of a single layer of epithelial cells, resting usually on a thin membrane, on the under surface of which is spread out a close network of blood-vessels. In order to economize space and to provide a more extensive secreting surface, the membrane is generally increased by dipping down and forming variously shaped depressions or recesses, these depressions or recesses being called the secreting glands.

The secreting glands are of two kinds, simple and compound. The simple glands are generally tubular or saccular cavities, the tube in the tubular variety being sometimes so long that it coils upon itself, as in the sweat glands of the skin; they all open upon the surface by a single duct. In the compound glands, the cavities are subdivided into smaller tubular or saccular cavities, opening by small ducts into the main duct which pours the secretion upon the surface.

However simple or complicated the involuted surface, the secreting process is essentially the same; and in this process the nucleated cells play the most important part. These cells take into their interior those substances from the blood which they require to make the special secretion they are set apart to

form, converting this selected material into chemical compounds, which either act as solvents, as in the digestive juices, or perform some other office in the body. The secretion the cells elaborate escapes from them either by exudation or by the bursting and destruction of the cells themselves. Cells filled with secreting matter may also be detached and carried out entire with the fluid part of the secretion; and, in all cases, new cells speedily take the place of those which have served their office. The glands are provided with lymphatics, and fine nerve fibrils have also been found to terminate in them. That they are under the influence of the nervous system is shown by the fact that impressions made on the nervous system affect the secretions, a familiar instance of which is the flow of saliva into the mouth, caused by the sight, or smell, or even the thought of food.

The position and functions of the several glands will be described later in connection with digestion and elimination.

Mucous membranes.—The mucous membranes, unlike the serous membranes, line passages and cavities which communicate with the exterior. They are all subject to the contact of foreign substances introduced into the body, such as air and food, and also to the contact of secreted matters; hence their surface is coated over and protected by mucus, a thicker and more sticky fluid than the lymph which moistens the serous membranes. The mucous membranes of different parts are continuous, and they may nearly all be reduced to two great divisions; namely, the **gastro-pneumonic** and the **genito-urinary**.

The **gastro-pneumonic** mucous membrane covers the inside of the alimentary canal, the air-passages, and the cavities communicating with them. It commences at the edges of the lips and nostrils, proceeds through mouth and nose to the throat, and thence is continued throughout the entire length of the alimentary canal to the anus. At its origin and termination it is continuous with the external skin. It also extends throughout the windpipe, bronchial tubes, and air-sacs. From the interior of the nose the membrane may be said to be prolonged into the lachrymal passages, and under the name of conjunctival membrane, over the fore part of the eyeball and inside of the eyelids, on the edges of which it again meets with the skin. From the upper part of the pharynx a prolongation

extends, on each side, along the passage to the ear; and offsets in the alimentary canal go to line the salivary, pancreatic, and biliary ducts, and the gall-bladder.

The **genito-urinary** mucous membrane lines the inside of the bladder, and the whole urinary tract from the interior of the kidneys to the meatus urinarius, or orifice of the urethra; it also lines the vagina, uterus, and Fallopian tubes in the female.

The mucous membranes are attached to the parts beneath them by areolar tissue, here named "submucous," and which differs greatly in quantity as well as in consistency in different parts. The connection is in some cases close and firm, as in the cavity of the nose. In other instances, especially in cavities subject to frequent variations in capacity, like the gullet and stomach, it is lax; and when the cavity is narrowed by contraction of its outer coats, the mucous membrane is thrown into folds or *rugæ* which disappear again when the cavity is distended. But in certain parts the mucous membrane forms permanent folds that cannot be effaced, and which project conspicuously into the cavity which it lines. The best marked example of these folds is seen in the small intestine, where they are called *valvulæ conniventes*, and which are doubtless provided for increasing the amount of absorbing surface for the products of digestion. The redness of mucous membranes is due to their abundant supply of blood.

A mucous membrane is composed of a layer of connective tissue called the corium, and by a layer of epithelium which covers the surface. The **epithelium** is the most constant part of a mucous membrane, being continued over certain parts to which the other parts of the membrane cannot be traced, as over the air-sacs in the lungs, and the front of the cornea of the eye. It may be scaly and stratified, as in the throat, columnar, as in the intestine, or ciliated, as in the respiratory tract. The mucus which moistens its surface is either derived from little glands in the mucous membrane, or from the columnar cells which cover the surface. The **corium** of a mucous membrane is composed of either areolar or lymphoid connective tissue. It is usually bounded next to the epithelium by a basement membrane,¹ and next to the submucous tissue by a thin

¹ A basement membrane is formed by a layer of connective tissue cells joined edge to edge.

layer of plain muscular tissue termed the *muscularis mucosæ*: this layer is not always present. The connective tissue layer varies much in structure in different parts; the lymphoid variety is in certain places greatly increased in amount, packed with lymphoid cells, and forms the solitary follicles and Peyer's patches described in Chapter XII.

The small blood-vessels conveying blood to the mucous membranes divide in the sub-mucous tissue, and send smaller branches into the corium, where they form a network of capillaries just under the basement membrane. The lymphatics also form networks in the corium and communicate with larger vessels in the sub-mucous tissue below. The free surface of the mucous membrane is in some parts plain, but in others is beset with little eminences named papillæ and villi.

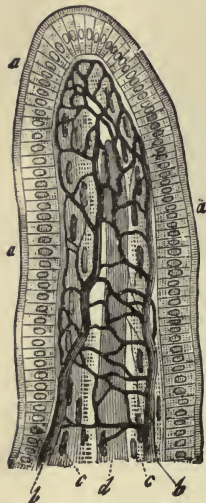


FIG. 94.—AN INTESTINAL VILLUS. *a, a, a*, columnar epithelium; *b, b*, capillary network; *c, c*, longitudinal muscle fibres; *d*, lacteal vessel.

The **papillæ** are best seen on the tongue; they are small processes of the corium, mostly of a conical shape, containing blood-vessels and nerves, and covered with epithelium.

The **villi** are most fully developed on the mucous coat of the small intestine. Being set close together like the pile of velvet, they give a shaggy or villous appearance to the membrane. They are little projections of the mucous membrane, covered with epithelium, and containing blood-vessels and lacteals, and are favourably arranged for absorbing nutritive matters from the intestines.

SECTION II. Food.—Under the term “food” we include all substances, solid or liquid, necessary for nutrition. The question at once arises: What are these substances, and how are they obtained?

If we analyze the food we daily take into our mouths and introduce into the alimentary canal, we find it separable into two divisions; viz. that which is nutritious, and that which is innutritious. The nutritious portion, that which can be digested, absorbed, and made use of by the body, is generally spoken of under the name of **food-stuffs** or **food-principles**: the

innutritious portion, usually by far the smaller of the two divisions, never enters the body at all, properly speaking, but passes through the alimentary canal and is excreted in the form of feces.

Food-stuffs are composed mainly of the elementary chemical substances,—oxygen, carbon, hydrogen, nitrogen,—and may, according to the varying proportions in which these chemical elements combine, form five distinct and different classes of food-stuffs. These are:—

1. Proteids.
2. Fats.
3. Carbo-hydrates.
4. Water.
5. Saline or mineral matters.

Proteids.—Proteids form a large proportion of all living bodies, and are an essential part of all living structures. They contain on an average in every 100 parts about:—

Carbon	53 parts
Hydrogen	7 “
Oxygen	24 “
Nitrogen	16 “

with usually a little sulphur and sometimes a trace of phosphorus and iron. They are the only food-stuffs that contain nitrogen in any appreciable quantity, and are sometimes classed as “nitrogenous” food-stuffs. Proteids occur in the form of *albumin* in the white of egg (egg-albumin), in milk, in blood and lymph (serum-albumin); in the form of *casein* in milk and cheese; of *myosin* and *syntonin* in muscle; of *vitellin* in the yolk of eggs; of *glutin* in flour. Allied to proteids are the *chondrin*, obtained from cartilage, and the *gelatin*, obtained from other varieties of connective tissue, by boiling.

All proteids yield peptones very readily at the temperature of the body under the action of the acid gastric, and alkaline pancreatic juice. These peptones are highly soluble bodies and readily absorbed.

The foods that are most rich in the various forms of proteids are meat, milk, eggs, cheese, all kinds of fish, wheat, beans, and oatmeal.

Fats. — Fats are composed of carbon, hydrogen, and oxygen. They contain on an average in every 100 parts: —

Carbon	76.5 parts
Hydrogen	12 “
Oxygen	11.5 “

The most important fats are *stearin*, *palmatin*, *margarin*, and *olein*, which exist in varying proportions in the fat of animals and vegetable oils, and in milk, butter, lard, etc. The brains of animals and the yolk of eggs contain a complex phosphorized fat, called *lecithin*. Fatty matters are very abundant in olives, sweet almonds, chocolate, castor-oil bean, hemp, and flaxseed. Most of the fatty substances of food are liquefied at the temperature of the body, and are readily oxidized, probably on account of the large amount of carbon which they contain.

Carbo-hydrates. — In the carbo-hydrates there is sufficient oxygen present to saturate all the hydrogen and to form water; hence their name. In the fats, there is not quite so much oxygen as hydrogen; water is, therefore, not formed in them, and in this particular they differ from the carbo-hydrates.

The carbo-hydrates contain in every 100 parts about: —

Carbon	44 parts
Hydrogen	6 “
Oxygen	50 “

The principal carbo-hydrates are *starch* and *sugars*. Starch is found in wheat, Indian corn, oats, and all grains, in potatoes, peas, beans, roots and stems of many plants, and in some fruits. In a pure state, it appears as a white powder, as in arrowroot and cornstarch. Under the influence of dry heat, starch may be converted into a soluble substance, called *dextrine*; and, under the action of certain of the digestive juices, at the temperature of the body, into sugar. Of sugars there are several kinds: *cane sugar* or *sucrose*, obtained chiefly from the sugar cane, beet sugar, and maple sugar; *grape sugar* or *glucose*, found in grapes, peaches, and other fruits (it is also readily manufactured from starch); *milk sugar* or *lactose*, obtained from milk.

Carbo-hydrates are readily oxidized; together with fats, they are often classed as “non-nitrogenous” food-stuffs.

Water is a compound of oxygen and hydrogen, water being

produced whenever two molecules of hydrogen unite with one of oxygen. Next to air, water is the most necessary principle of life. It forms about seventy per cent of the entire bodily weight. It is an essential constituent of all the tissues, as well as forming the chief part of all the fluids of the body. It acts as a solvent upon various ingredients of the food, liquefying them and rendering them capable of absorption. Most of the water of the body is taken into it from without, but it is also formed within the body by the union of hydrogen and oxygen in the tissues.

Mineral salts.—The mineral substances chiefly necessary for nutrition are : —

Chloride	} of soda and potash.
Phosphate	
Sulphate	
Carbonate	

Phosphate	} of lime and magnesia.
Carbonate	

Of these substances, *chloride of soda, sodium chloride* or *common salt*, is the most important mineral ingredient of food. It is contained in nearly everything we eat, but usually not in sufficient quantity to supply all the needs of the body, and we therefore add it as a separate article of diet. It is present in most of the fluids of the body, notably in the blood, the fluidity of which it helps to maintain. The rest of the mineral substances are usually contained in sufficient quantity in an ordinary diet, though occasionally it becomes necessary to supply them independently. Of all the mineral salts, *phosphate of lime* exists in the largest quantity in the body; it enters largely into the composition of the bones, teeth, and cartilages, and gives firmness and solidity to the tissues. It is present in very small quantities in the bodily fluids, with the exception of milk, which contains a notable amount of phosphate of lime, and which is plainly provided for the ossification of the growing bones of infants and young children.

Chemical composition of the body.—Professor Atwater gives the following average composition of the body of man, weighing 148 pounds: —

Oxygen	92.4	} 142.9
Carbon	31.3	
Hydrogen	14.6	
Nitrogen	4.6	
Calcium	2.8	} 5.1
Phosphorus	1.4	
Potassium34	
Sulphur24	
Chlorine12	
Sodium12	
Magnesium04	
Iron02	
Fluorine02	

The human body, from a chemical point of view, may be regarded as a compound of three large classes of chemical substances; viz. proteids, fats, and carbo-hydrates associated with water and mineral salts.

In our first chapter we said that protoplasm was the basis of the life of the body, and from that point of view we may look upon the human body as an assemblage of variously modified protoplasm. But it comes to the same thing, for the chemical composition of protoplasm, so far as it has been possible to analyze it, has been found to agree closely with that of the fully developed organism.

The processes of nutrition that take place in the protoplasmic cell are essentially the same as those which take place in the fully developed body, with this exception, that in the one case it is a very simple, and in the other a very complex, process. In both cases, non-living chemical substances are taken in from without, and converted into material which is endowed with that mysterious property we call life.

To support life, the different food-stuffs must be taken in proper proportion; and, in order that all the tissues and fluids of the body may continue in good condition and perform their functions properly, they must be supplied with all the ingredients necessary to their constitution. A man may be starved to death at last by depriving him of lime phosphate as surely, though not as rapidly, as if he were deprived of albumin or fat. Many a patient in less well-instructed times has been slowly killed by deprivation of water, or by exclusive feeding on beef-teas and jellies.

Average composition of milk, bread, and meat. — The following analyses of the composition of three staple articles of diet — milk, bread, and meat — are taken from Dalton.

Average composition of milk in 100 parts: —

Water	86.4
Proteids	4.3
Sugar	5.2
Fat	3.7
Mineral salts4

Average composition of wheaten bread in 100 parts: —

Starchy matters	56.7
Proteids	7.0
Fatty matters	1.3
Mineral salts	1.0
Water	34.0

Average composition of beef flesh: —

Water	77.5
Proteids	16.0
Fat	5.0
Mineral salts	1.5

Concluding remarks. — The quantity and also the kind of food each individual daily requires depends chiefly upon the nature and the amount of the work he is called upon to perform, and the conditions of the climate in which he lives. Universal experience has taught us that the best sustainers of life are milk and bread and water, with a certain amount of meat and fat. These should form the basis of all our diets, though not to the exclusion of other food-stuffs, for it has also been proved that a mixed diet is always to be preferred to one that consists constantly of the same articles of food.

To determine the relative digestibility of foods is a very difficult matter in view of the individual peculiarities of different people. Strawberries may agree perfectly with ninety-nine people, and with the hundredth, act as a powerful poison. Some persons, as we all know, cannot tolerate milk or eggs, and yet, from a chemical point of view, these foods are eminently suitable articles of diet.

The best diet is that which contains all the articles of food

necessary for the wants of the body in proper proportions, which is agreeable to the individual, and which gives the minimum amount of work to the digestive organs.¹

Food to be of any use to the body must be digested and assimilated. We may partake of an ideal diet and yet remain imperfectly nourished, if our digestive organs are out of order, or our power to absorb and assimilate digested products in any way impaired. In our next chapter we shall describe the alimentary canal, the accessory digestive organs, and the methods by means of which the food is reduced to a condition available for the uses of the body.

¹ For valuable information on the relative value of foods and preparation of the same for the sick, the student is referred to Boland's "Handbook of Invalid Cookery."

CHAPTER XIV.

ALIMENTATION CONTINUED: THE DIGESTIVE APPARATUS; ALIMENTARY CANAL, AND ACCESSORY ORGANS.

THE digestive apparatus consists of the alimentary canal, and the accessory organs, the teeth, salivary glands, pancreas, and liver. By some authorities the spleen is also now included among the digestive organs.¹

Alimentary canal. — The alimentary canal is a musculo-membranous tube extending from the mouth to the anus. It is about six times the length of the body, and the greater part of it is coiled up in the cavity of the abdomen. The diameter of the tube is by no means uniform, being considerably dilated in certain parts of its course. It is composed of three coats from the mouth to where it passes through the diaphragm, and of four coats in the abdominal cavity. These coats are: (1) the mucous; (2) the sub-mucous (described in our last chapter); (3) the muscular; (4) the serous. The muscular coat is composed for the most part of unstriped muscular fibres, the layers of which are disposed in various ways, the most general arrangement being in a longitudinal and circular direction. By the alternate contraction and relaxation of fibres arranged in this fashion (the contractions starting from above), the contents of the tube are propelled from above downwards. The serous coat is derived from the peritoneum, which is the serous membrane lining the walls, and covering the viscera, of the abdomen.

Into the interior of the alimentary canal are poured secretions from the glands in the mucous membrane, with which it is lined, and also secretions from the accessory glands, which lie outside the canal and are connected with its interior by ducts.

The alimentary canal for convenience of description may be divided into: —

¹ Plate VII. shows relative position of digestive organs in abdominal cavity.

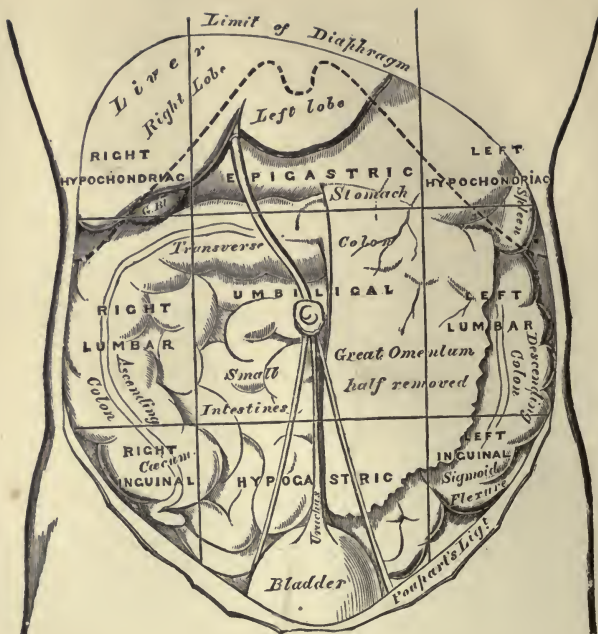

PLATE VII.—REGIONS OF THE ABDOMEN AND THEIR CONTENTS (EDGE OF COSTAL CARTILAGES IN DOTTED OUTLINE).

For convenience of description the abdomen may be artificially divided into nine regions by drawing two circular lines round the body parallel with the cartilages of the ninth ribs, and the highest point of the crests of the ilia; and two vertical lines from the cartilage of the eighth rib on each side to the centre of Poupart's ligament. The viscera contained in these different regions are as follows:—

RIGHT HYPOCHONDIAC.—The right lobe of the liver and the gall-bladder, hepatic flexure of the colon, and part of the right kidney.

EPIGASTRIC REGION.—The middle and pyloric end of the stomach, left lobe of the liver, the pancreas, the duodenum, parts of the kidneys and the suprarenal capsules.

LEFT HYPOCHONDIAC.—The splenic end of the stomach, the spleen and extremity of the pancreas, the splenic flexure of the colon, and part of the left kidney.

RIGHT LUMBAR.—Ascending colon, part of the right kidney, and some convolutions of the small intestines.

UMBILICAL REGION.—The transverse colon, part of the great omentum and mesentery, transverse part of the duodenum, and some convolutions of the jejunum and illum, and part of both kidneys.

LEFT LUMBAR.—Descending colon, part of the omentum, part of the left kidney, and some convolutions of the small intestines.

RIGHT INGUINAL (ILIAC).—The cæcum, appendix cæci.

HYPOGASTRIC REGION.—Convolutions of the small intestines, the bladder in children, and in adults if distended, and the uterus during pregnancy.

LEFT INGUINAL (ILIAC).—Sigmoid flexure of the colon.

Mouth, containing tongue and teeth.

Pharynx.

Œsophagus.

Stomach.

Small intestine	{	Duodenum.
		Jejunum.
		Ilium.
Large intestine	{	Cæcum.
		Colon.
		Rectum.

Mouth or buccal cavity (*vide* Fig. 96). — The mouth is a nearly oval-shaped cavity with a fixed roof and movable floor. It is bounded in front by the lips, on the sides by the cheeks, below by the tongue, and above by the palate. The palate consists of a hard portion in front formed by bone, covered by mucous membrane, and of a soft portion behind containing no bone. The hard palate forms the partition between the mouth and nose; the soft palate arches backwards and hangs like a curtain between the mouth and the pharynx. Hanging from the middle of its lower border is a pointed portion of the soft palate called the uvula; and arching outwards and downwards from the base of the uvula on each side to the roof of the tongue are two curved folds of muscular tissue covered by mucous membrane, called the pillars of the fauces. Just before reaching the tongue, the two pillars, on either side, are separated by a triangular space in which lie the small masses of lymphoid tissue called the tonsils. The fauces is the name given to the aper-

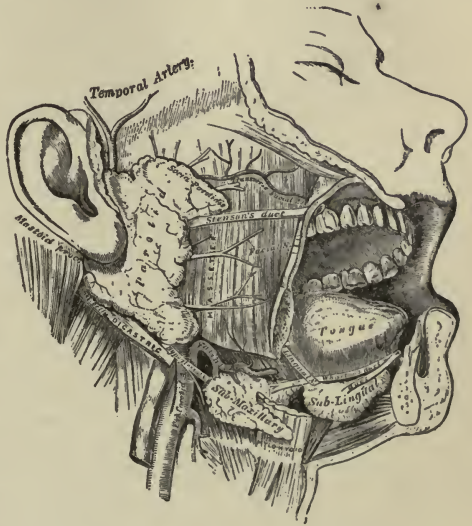


FIG. 95. — THE SALIVARY GLANDS.

ture of the mouth. The uvula is a pointed projection of the soft palate, and the pillars of the fauces are two curved folds of muscular tissue. The tonsils are small masses of lymphoid tissue located in the space between the pillars of the fauces. The fauces is the opening of the mouth into the pharynx.

ture leading from the mouth into the pharynx or throat cavity.

The mucous membrane lining the mouth contains many minute glands which pour their secretion upon its surface, but the chief secretion of the mouth is supplied by the salivary glands, which are three pairs of large compound saccular glands¹ called the parotid, submaxillary, and sublingual, respectively. Each parotid gland is placed just in front of the ear, and its duct passes forwards along the cheek, until it opens into the interior of the mouth opposite the second upper molar.

The submaxillary and sublingual glands are situated below the jaw and under the tongue, the submaxillary being placed further back than the sublingual. Their ducts open in the floor of the mouth beneath the tongue. The secretion of these salivary glands, mixed with that of the small glands of the mouth, is called saliva.

The tongue. — The tongue is a freely movable muscular organ attached by its base to the hyoid bone. Besides being the special seat of the sense of taste, it is a useful aid in mastication and deglutition.²

The teeth. — The semicircular borders of the upper and lower jaw-bones (the alveolar processes) contain thirty-two sockets for the reception of the teeth; extending over the bones and a little way into each socket is a dense insensitive fibrous tissue covered by smooth mucous membrane, the gums.

There are two sets of teeth developed during life: the first or milk teeth, and the second or permanent teeth. The cutting of the milk teeth begins usually at six months and ends with the second year; there are only twenty of these teeth, and they are replaced during childhood by the permanent teeth.³

Each tooth consists of two portions, the crown and the fang: the crown projects into the cavity of the mouth, the fang is embedded in the socket. According to their shape and the use teeth are divided into incisors, canines, bicuspid, and molars.

¹ For description of compound glands see Section I. Chapter XIV.

² A detailed description of the tongue will be found in the chapter on the organs of special sense.

³ The milk teeth are usually cut in the following order, the teeth appearing first in the lower jaw: central incisors, 7th month; lateral incisors, 7th to 10th month; front molars, 12th to 14th month; canine, 14th to 20th month; back molars, 18th to 36th month.

Beginning in the middle line of each jaw and counting from before backwards, there are four incisors, two canines, four bicuspid, and six molars in the upper and in the lower jaw. The incisors have wide sharp edges, and are specially adapted for cutting the food; the canines, or eye teeth, have a sharp pointed edge, are longer than the incisors, and are specially useful for tearing food asunder, or, as in dogs and other carnivora, for holding prey. The bicuspid, or false grinders, are broader, with two points or cusps on each crown: these teeth have only one fang, the fang, however, being more or less completely divided into two. The molars, or true grinders, have broad crowns with small pointed projections, which make them well fitted for crushing and bruising the food: they each have two or three fangs. The twelve molars do not replace the milk teeth, but are gradually added with the extension of the jaws, the last or hindermost molars not appearing until twenty-one years of age: they are often on this account called "wisdom teeth."

The teeth are composed of three bone-like tissues, enamel, dentine, and cement; these substances are all harder than bone, enamel being the hardest tissue found in the body. In the interior of each tooth is a cavity, the pulp-cavity, which is filled with a highly vascular and nervous tissue called the dental pulp. The teeth are developed from epithelium in much the same way as the hairs; for description of which see page 192.

The pharynx.—The pharynx or throat cavity is a musculo-membranous bag, shaped somewhat like a cone, with its broad

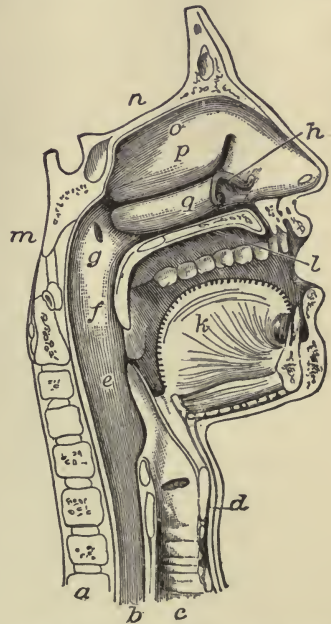


FIG. 96.—THE MOUTH, NOSE AND PHARYNX, WITH THE LARYNX AND COMMENCEMENT OF GULLET, SEEN IN SECTION. *a*, vertebral column; *b*, gullet; *c*, trachea; *d*, larynx; *e*, epiglottis; *f*, soft palate, between *f* and *e* is the opening at back of cavity or fauces; *g*, opening of Eustachian tube; *h*, nasal cavity; *k*, tongue; *l*, hard palate; *m*, sphenoid bone at base of skull; *n*, roof of nasal cavity; *o*, *p*, *q*, placed in nasal cavity.

end turned upwards, and its constricted end downwards to end in the œsophagus. It is about four and a half inches long, and lies behind the nose, mouth, and larynx. Above, it is connected with the base of the skull, and behind, with the cervical vertebræ; in front and on each side are apertures which communicate with the nose, ears, mouth, and larynx.

Of these apertures there are seven: two in front above, leading into the back of the nose, the posterior nares; two, one on either side above, leading into the Eustachian tubes, which communicate with the ears; one midway in front, the fauces; and two below, one opening into the larynx and the other into the œsophagus. The mucous membrane lining the pharynx is well supplied with glands, and at the back of the cavity there is a considerable mass of lymphoid tissue. The muscular tissue in the walls of the pharynx is of the striped variety, and when the act of swallowing is about to be performed the muscles draw the pharyngeal bag upwards and dilate it to receive the food; they then relax, the bag sinks, and other muscles contracting upon the food, it is pressed downwards and onwards into the œsophagus.

The œsophagus or gullet. — The œsophagus is a comparatively straight tube, about nine inches long, extending from the pharynx, behind the trachea, and through the diaphragm, to its termination in the upper or cardiac end of the stomach. The muscular fibres in the walls of the œsophagus are arranged in an external longitudinal and in an internal circular layer. The mucous membrane is disposed in longitudinal folds which disappear upon distension of the tube. The mucous membrane in the mouth, pharynx, and œsophagus is covered for the most part by stratified epithelium.

The stomach. — The stomach is the most dilated portion of the alimentary canal. It is curved upon itself, so that below it presents a long, rounded outline, called the greater curvature, and above a constricted, concave outline, called the lesser curvature.

It is placed transversely in the abdominal cavity, immediately beneath the diaphragm, the larger expanded end lying in contact with the spleen, and the smaller end under the liver. The stomach has necessarily two openings: the one leading into the œsophagus is usually termed the cardiac aperture; the other,

leading into the small intestine, the pyloric. The pyloric aperture is guarded by a kind of valve composed of circular muscular fibres, which form a constricted ring projecting into the pyloric opening. By this arrangement, the food is kept in the stomach until it is ready for intestinal digestion, when the circular fibres relax and allow it to pass.

When moderately distended, the stomach measures about four inches vertically and twelve inches from side to side. It has four coats. The outer serous coat is formed by a fold of the peritoneum. The fold is slung over the stomach, in much the same way as we sling a towel over a clothes-line, and covers it before and behind. The anterior and posterior folds unite at the lower border of the stomach and form an apron-like appendage, the omentum, which covers the whole of the intestines. The omentum often contains a large amount of fat.

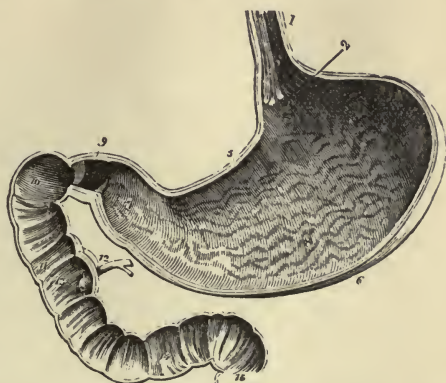


FIG. 97.—VERTICAL AND LONGITUDINAL SECTION OF STOMACH AND DUODENUM. 1, œsophagus, on its internal surface the folds or rugæ of the mucous membrane are shown; 2, cardiac orifice of stomach; 5, lesser curvature; 6, greater curvature; 8, rugæ in interior of stomach; 9, pyloric orifice; 10, 11, 13, interior of duodenum showing valvulæ conniventes; 12, duct conveying the bile and pancreatic juice into duodenum; 15, commencement of jejunum.

The muscular coat of the stomach consists of three layers of unstriated muscular tissue: an outer, formed of longitudinal fibres; a middle, of circular; and an inner, of less well-developed, obliquely disposed fibres. The alternate contraction and relaxation of these fibres causes the food to be carried round and round the stomach, and at the same time, subjects it to considerable pressure.

The mucous membrane is very soft and thick, the thickness being mainly due to the fact that it is densely packed with small tubular glands; it is covered with columnar epithelium, and in its undistended condition is thrown into folds or rugæ. The surface is honeycombed with tiny shallow pits, into which the ducts or mouths of the tubular glands open. The glands are

of two kinds, and secrete mucus, and the special secretion of the stomach, the gastric juice. The stomach is supplied with nerves from the sympathetic system, and also with branches from the pneumogastric nerve, which comes from the cerebro-spinal system.

The small intestine.—The small intestine fills the greater part of the front of the abdominal cavity. It is about twenty feet long, two inches wide at its gastric end, and narrows to nearly one and a quarter inches where it joins the large intestine. The small intestine is divided by anatomists into three portions. The first ten or twelve inches is called the duodenum; the succeeding two-fifths, the jejunum; and the rest, the ilium. The intestines are invested by a fold of the peritoneum in much the same way as the stomach. In this situation, the fold of the peritoneum is called the mesentery, and between its two layers are numerous blood-vessels, lymphatics, and lymphatic glands.

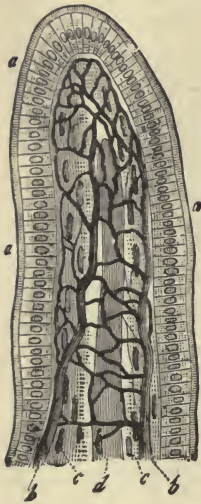


FIG. 98.—AN INTESTINAL VILLUS. *a, a, a*, columnar epithelium; *b, b*, capillary network; *c, c*, lymphoid tissue and muscle fibres; *d*, lacteal vessel.

The muscular coat of the small intestine has only two layers: an outer, thinner and longitudinal; and an inner, thicker and circular.

The mucous coat is highly developed. In the first place it is largely increased by being arranged in permanent folds, the *valvulæ conniventes* (*vide* Fig. 97), which project transversely into the interior of the tube. The onward course of the food is delayed by being caught in the hollows formed by these folds, and thus more thoroughly subjected to the action of the digestive juices: this arrangement also affords a larger surface for absorption. The *valvulæ conniventes* are not found in the beginning of the duodenum, but begin to appear one or two inches from the pylorus; about the middle of the jejunum they begin to decrease in size, and in the lower part of the ilium they almost entirely disappear.

Again, the surface of the mucous membrane is increased by the finger-like projections which are so close set as to give a

shaggy or velvety appearance to the membrane. These projections or villi, as they are termed, extend throughout the whole length of the small intestine, and are especially provided for purposes of absorption. Each villus is a portion of the mucous membrane, and consists of an external layer of columnar cells attached to a basement membrane, and a central mass of lymphoid tissue. In the centre of each villus is the rootlet of a lacteal vessel, while under the basement membrane is a network of capillaries. The blood-vessels and lymphatics of the villi communicate with networks of both vessels in the sub-mucous coat below. Besides these projections formed for absorption,

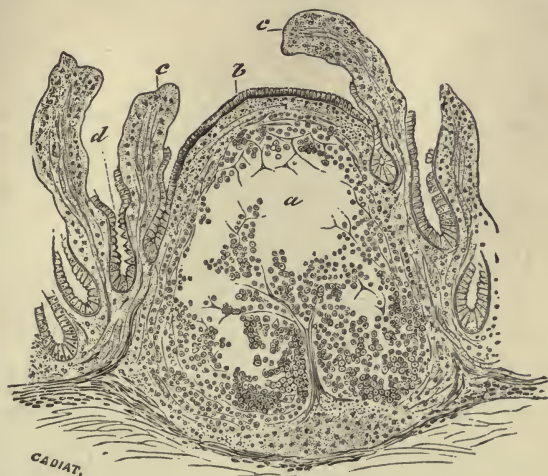

FIG. 99.—SECTION THROUGH THE LYMPHOID TISSUE OF A SOLITARY GLAND. (Cadiat.) *a*, centre of the gland, with the lymphoid tissue fallen away; *b*, epithelium of mucous membrane; *c*, *c*, villi, with epithelium partly broken away; *d*, crypts, or glands, of Lieberkühn.

the mucous membrane is thickly studded with secretory glands; the larger number of these, found all over the surface of the intestine, are called the glands or crypts of Lieberkühn, while a smaller number, found chiefly in the duodenum, are named the duodenal or Brunner's glands. These glands are supposed to secrete the intestinal juice, *succus entericus*.

Again, in the corium of the mucous coat the lymphoid tissue is collected into numerous solitary glands or follicles, and into groups of glands, the Peyer's patches, the functions of which are not yet clearly understood.

The large intestine.—The large intestine is about five feet long, and from two and a half to one and a half inches wide; it extends from the ilium to the anus. It is divided into the cæcum, with the vermiform appendix, the colon, and the rectum.

The *cæcum* (*cæcus*, blind) is a large blind pouch at the commencement of the large intestine. The small intestine opens into the side wall of the large intestine about two and a half inches above its—the large intestine's—commencement, the cæcum forming a cul-de-sac below the opening. Attached to

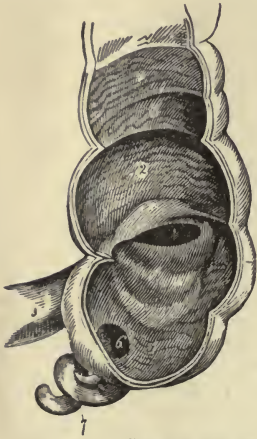


FIG. 100.—CÆCUM, SHOWING ITS APPENDIX, ENTRANCE OF ILIUM, AND ILEO-CÆCAL VALVE. 1, cæcum; 2, commencement of colon; 3, entrance of ilium into the large intestine; 4, ileo-cæcal valve; 6, aperture of vermiform appendix; 7, vermiform appen.

the lower end of the cæcum is a narrow, worm-like tube about the size of a lead-pencil, the vermiform appendix. The cæcum and appendix lie just beneath the front abdominal wall in the right iliac region (*vide* Plate VII.). The opening from the ilium into the large intestine is provided with two large projecting lips of mucous membrane which allow the passage of material into the large intestine, but effectually prevent the passage of material in the opposite direction. These mucous folds form what is known as the ilio-cæcal valve.

The *colon* may be subdivided into the ascending, transverse, and descending colon, and the sigmoid flexure. The ascending portion runs up on the right side of the abdomen until it reaches the liver, then bends abruptly to the left, and is continued straight across the abdomen as the transverse colon until, reaching the left side, it turns abruptly and passes downwards as the descending colon. Reaching the left iliac region on a level with the margin of the crest of the ilium, it makes a curve like the letter S,—hence its name of sigmoid flexure,—and finally ends in the rectum. The *rectum* is from six to eight inches long; it passes obliquely from the left until it reaches the middle of the sacrum, then it follows the curve of the sacrum and coccyx, and finally arches slightly backwards to its termination at the anus. The anal opening is guarded by two circular muscles called, respectively, the internal and external sphincters.

The large intestine has the usual four coats, except near its termination, where the serous is wanting. The muscular coat, along the cæcum and colon, has a peculiar arrangement. The longitudinal fibres are gathered up in three thick bands, and these bands, being shorter than the rest of the tube, the walls are puckered between them. The mucous coat possesses no villi or *valvulæ conniventes*, but is usually thrown into effaceable folds, somewhat like those of the stomach. It contains numerous glands, resembling the crypts of Lieberkühn found in the small intestine.

Accessory organs of digestion. — The accessory organs of digestion are, the teeth and salivary glands (which have already been sufficiently described), the pancreas, and the liver.

The pancreas. — The pancreas is a compound, secreting gland,

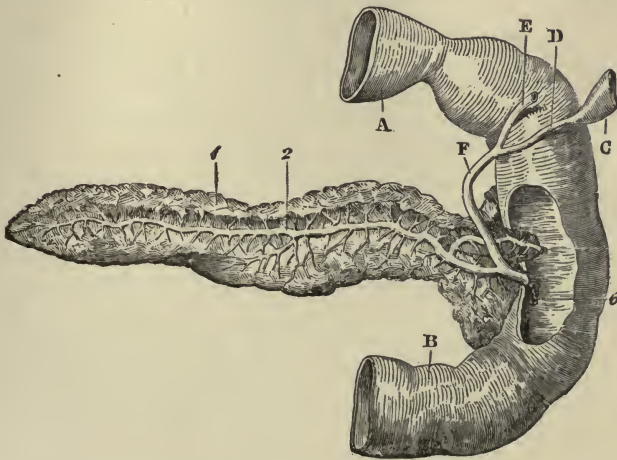


FIG. 101. — POSTERIOR VIEW OF PANCREAS. 1, pancreas; 2, pancreatic duct; 6, opening of common duct, formed by union of pancreatic and choledochus ducts, into duodenum; A, pyloric end of stomach; B, duodenum; C, part of gall-bladder; D, cystic duct; E, hepatic duct; F, choledochus duct.

closely resembling the salivary glands in structure, except that the secreting cavities are saccular in the salivary glands, and more distinctly tubular in the pancreas. The cavities are grouped in lobules, each lobule having its own duct. The lobules are joined together by connective tissue to form lobes, and the lobes, united in the same manner, form the gland. The small ducts open into one main duct, which, running lengthwise through the gland, pierces the coats of the duo-

denum and pours its contents into the interior of the intestine. The secretion formed in the pancreas is called the pancreatic juice.

In shape, the pancreas somewhat resembles a dog's tongue. It is a flat, elongated organ, about six to eight inches in length, one and a half inches in width, and from half an inch to an inch thick. It lies beneath the greater curvature of the stomach and at the back of the abdominal cavity.

The liver.— The liver is the largest gland in the body, weighing ordinarily from fifty to sixty ounces, and measuring ten to

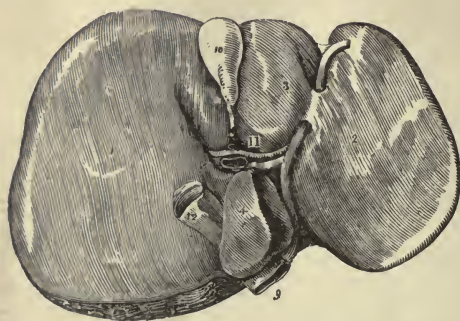

FIG. 102.—UNDER SURFACE OF LIVER. 1, right lobe; 2, left lobe; 3, 4, 5, smaller lobes; 9, 12, inferior vena cava; 10, gall-bladder; 11, transverse fissure, or "gate of liver," containing bile duct, hepatic artery, and portal vein.

twelve inches from side to side, six to seven from above downwards, and three inches from before backwards in its thickest part. It is a dark reddish-brown organ, placed in the upper right and middle portion of the abdomen, and extending somewhat into the left hypochondriac region.

The upper convex surface fits closely into the under surface of the

diaphragm. The under concave surface of the organ fits over the right kidney, the upper portion of the ascending colon, and the pyloric end of the stomach. The liver is unequally divided into two lobes, the right being much larger than the left. It is covered by a layer of peritoneum, and is also suspended and kept in position by ligamentous peritoneal bands.

The liver not only differs in size from the other secreting glands; it also offers other striking peculiarities. First, it receives its supply of blood from two different sources; namely, arterial blood from the hypatic artery, and venous blood from the stomach, spleen, pancreas, and intestines, by means of the portal vein. Secondly, the different parts of the secretory apparatus, the cells, blood-vessels, and ducts, instead of being arranged as elsewhere in distinct tubes or sacs, are closely united and massed together. The secreting cells are collected

into small polyhedral or many-sided masses, called hepatic lobules; the blood-vessels form networks around and in the lobules; while the ducts which carry away the secretion (bile) begin within the lobules in the form of tiny channels, running between the cells.

The whole liver is invested in an envelope or capsule of connective tissue (Glisson's capsule), and the lobules are divided from one another by very delicate partitions of areolar tissue, each lobule being about the size of a pin's head and filled with the special liver cells.

The large portal vein and the small hepatic artery enter the

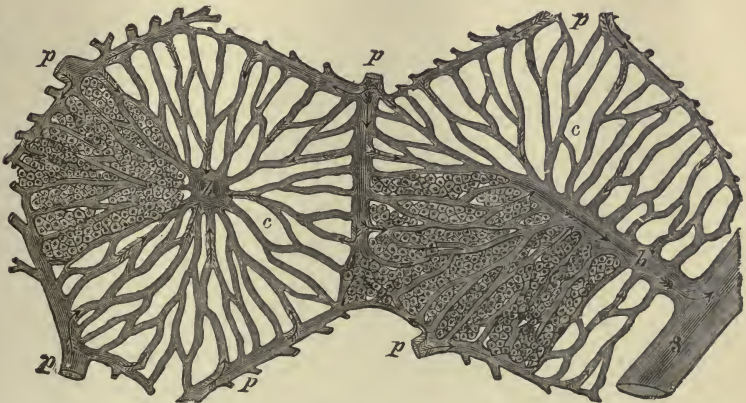


FIG. 103. — DIAGRAMMATIC REPRESENTATION OF TWO HEPATIC LOBULES. The left hand lobule is represented with the intralobular vein cut across; in the right hand one the section takes the course of the intralobular vein. *p*, interlobular branches of the portal vein; *h*, intralobular branches of the hepatic veins; *s*, sublobular vein; *c*, capillaries of the lobules. The arrows indicate the direction of the course of the blood. The liver-cells are only represented in one part of each lobule.

liver together on its under surface at what is called the "gate of the liver," the bile duct passing out at the same place. The branches of these three vessels, enclosed by loose connective tissue, in which are lymphatics and nerves, accompany one another in their course through the organ. The smallest branches penetrate between the lobules, and, surrounding and lying between each lobule, are known as the *interlobular* branches. From the interlobular branches of the portal vein, thus surrounding the circumference of each lobule, run capillary vessels, somewhat like the spokes of a wheel. These capillaries, converging towards the centre, merge into a veinlet, the *intra-*

lobular vein, which, running down the middle of the lobule, empties into a vein at its base. This vein, lying at the base of each lobule, is called the *sublobular* vein, and empties its contents into the hepatic veins, by means of which the blood is conveyed from the back of the liver into the inferior vena cava.




FIG. 104.—LOBULE OF RABBIT'S LIVER, VESSELS AND BILE DUCTS INJECTED. *a*, central or intralobular vein; *b*, *b*, interlobular veins; *c*, interlobular bile duct.

Thus each lobule is a mass of hepatic cells, pierced everywhere with a network of blood capillaries.

The bile ducts commence between the hepatic cells in the form of fine canaliculi lying between the adjacent sides of two cells and forming a close network, the meshes of which correspond in size to the cells. At the circumference of the lobules,

these fine canaliculi pass into the interlobular bile ducts which, running in connection with the blood-vessels, finally empty into the two bile ducts which leave the liver at the opening, spoken of above as the "gate of the liver."

The cells of the liver manufacture bile from the blood, and discharge this into the minute bile canaliculi, whence it passes into the bile ducts to be conveyed into the small intestine. The cells, however, perform another important function, in that they change some of the substances brought to them in the blood from the digestive organs in such a manner as to render these substances suitable for the nutrition of the body; but, at present it will be enough to consider the secretion of bile as the only function of the liver.

The bile is taken from the liver by a right and left duct, which soon unite to form the hepatic duct. The hepatic duct runs downward and to the right for an inch and a half, and then joins at an acute angle the duct from the gall-bladder, termed the cystic duct. The hepatic and cystic ducts together form the common bile duct (*ductus communis choledochus*), which runs downwards for about three inches, and enters the duodenum at the same opening as the pancreatic duct.

The **gall-bladder** (*vide* Fig. 102) is a pear-shaped sac, lodged in a depression on the under surface of the right lobe of the liver. It is lined by columnar epithelium, and its walls are formed of fibrous and muscular tissue. It is held in position by the peritoneum, and serves as a reservoir for the bile. During digestion the bile is poured steadily into the intestine; in the intervals it is stored in the gall-bladder.

To recapitulate: the digestive apparatus may be said to consist of a tube and of important accessory organs placed in close connection and communication with it. For convenience of description, the tube may be divided in sections, each of which is furnished with mechanical and chemical appliances for reducing the food into a soluble condition. First, the mouth cavity, which is provided with muscular cheeks and movable jaw, tongue, teeth, and the chemical solvent, saliva, secreted by the salivary glands; secondly, the two passages, the pharynx and œsophagus, serving to convey the food into the next section, the stomach, which is furnished with muscular walls for crushing and churning the food, and with glands to secrete the acid

digestive solvent, the gastric juice; thirdly, the small intestine, supplied with bile and pancreatic juice, and with a highly specialized mucous membrane adapted to both digestive and absorptive purposes; and lastly, the large intestine, having feeble digestive properties, but serving to absorb all the nutritious portion of the food still remaining, and to pass the residue onwards to be finally thrown out of the body in the form of feces.

CHAPTER XV.

ALIMENTATION CONCLUDED: DIGESTION; CHANGES THE FOOD UNDERGOES IN THE MOUTH, STOMACH, SMALL AND LARGE INTESTINE; SUMMARY OF DIGESTION; ABSORPTION.

Digestion. — Digestion is the process by means of which the food we take into our mouths is transformed into a condition of solution or emulsion suitable for absorption into the blood. This transformation is rapid or gradual according to the nature of the food-stuffs the digestive solvents are called upon to dissolve. We all know practically, for instance, that it takes much longer to digest a piece of beefsteak than a cup of bouillon, and that when we wish to save the digestive powers as much as possible we place a person upon “liquid diet.”

Remembering that the three solid food-stuffs are proteids, fats, and carbohydrates, we will proceed to describe how each of these is transformed into a soluble condition in its course through the alimentary canal.

Changes the food undergoes in the mouth; mastication and deglutition. — When solid food is taken into the mouth it is cut and ground by the teeth, being pushed between them again and again by the muscular contractions of the cheeks and the movements of the tongue until the whole is thoroughly crushed and ground down. During this process of mastication the salivary glands are excited to very active secretion, the saliva is poured in large quantities into the mouth, and mixing with the food moistens it and reduces it to a soft pulpy condition. A certain amount of air caught in the bubbles of the saliva also becomes entangled in the food.

The food thus softened and moistened is collected from every part of the mouth by the movements of the tongue, brought together upon its upper surface, and then pressed backwards

through the fauces into the pharynx. The elevation of the soft palate prevents the entrance of food into the nasal chambers, while the epiglottis bars its entrance into the air passages, and it is guided safely and rapidly through the pharynx into the œsophagus. Here it passes beyond the control of the will; it is grasped by the œsophageal muscles and by a continuous and rapid peristaltic action is carried onwards and downwards into the stomach.

Saliva.—Mixed saliva (spittle) as it appears in the mouth is a glairy, frothy, cloudy fluid, the glairiness or ropiness being due to mucus; micro-organisms are also present in it to some extent, and other foreign matters derived from the food.

Saliva is mainly water containing but little solid matter, its specific gravity varying from 1002 to 1006. It depends for its special action, as a digestive solvent, upon a ferment it contains called ptyalin.¹

The action of saliva upon the food.—The chief function of saliva is to soften and moisten the food and to assist in mastication and deglutition. It has, however, a certain solvent action upon food-stuffs, especially starch. Upon the fats and proteids it has very little effect except to render them softer and better prepared for the action of the other digestive juices.

By the ptyalin-ferment present in saliva, starch, which is an insoluble substance, is changed into grape sugar, a highly soluble and absorbable product. This change is best effected at the temperature of the body, in a slightly alkaline solution, saliva that is distinctly acid hindering or arresting the process. Boiled starch is changed more rapidly and completely than raw, but the food is never retained in the mouth long enough for the saliva to more than begin the transformation of starchy matters. After leaving the mouth, further conversion of starch into sugar is arrested by the acid reaction of the gastric juice, and digestion of this class of food-stuffs is practically suspended until they again come in contact with the alkaline secretions in the upper part of the small intestine.

¹ Ferments are either organized or unorganized bodies; of the former yeast is a well-known example. The fermentative power of yeast which leads to the conversion of sugar into alcohol is dependent upon the life of the yeast-cell. When the yeast-cell dies, fermentation ceases. Ptyalin belongs to the latter class; it is an inorganic substance, not a living organism like yeast.

During the processes of mastication, insalivation, and deglutition, the food is first reduced to a soft pulpy condition; secondly, any starch it may contain begins to be changed into sugar; thirdly, it acquires a more or less alkaline reaction.¹

Changes the food undergoes in the stomach. — The entrance of food into the stomach acts as a stimulant to the whole organ. The blood-vessels dilate, the glands pour out an abundant secretion upon the mucous lining, and the different layers of the muscular coat are excited to a continuous action. Delayed in the stomach by the contraction of the pyloric ring-muscle, the pulpy mass of food is carried round and round, and thoroughly mixed with the gastric juice until it is dissolved into a thick, grayish soup-like liquid, called *chyme*. The chyme thus formed is from time to time ejected through the pylorus, accompanied by morsels of solid, less well-digested matter. This ejection may occur within a few minutes after the entrance of food into the stomach, but does not usually begin until from one to two hours after, and lasts from four to five, at the end of which time the stomach is, after an ordinary meal, completely emptied.

Gastric juice. — Gastric juice, secreted by the small, tubular glands in the mucous lining of the stomach, is a thin, colourless, or pale yellow fluid, of an acid reaction. It contains few solids, and is dependent for its specific action upon a ferment called pepsin, which is only properly active in an acid solution; and we therefore find that free hydrochloric acid in the proportion of 0.2 per cent is always present in normal gastric juice.

Action of gastric juice upon the food. — The gastric juice has no action upon starch, and upon fats it has at most a limited action; that is, if adipose tissue be eaten, it will dissolve the envelopes of the fat-cell and set the fat free, but it has no power to emulsify them. The essential property of gastric juice is the power it has of dissolving proteid matters and of converting them into a substance called peptone. Whatever the proteid may be, whether the albumin of eggs, the gluten of flour in bread, the myosin in flesh, the result is the same, pepsin, in conjunction with an acid at the temperature of the body, transforms them into peptones.

Peptones readily dissolve in water, and pass with ease through animal membranes. They are probably absorbed, as soon as

¹ Weak alkalies stimulate the gastric glands to more abundant secretion.

formed, by the blood-vessels in the walls of the stomach, though some pass in the chyme through the pylorus into the small intestine.

Changes the food undergoes in the small intestine. — The chyme on entering the duodenum, after an ordinary meal, is a mixture of various matters. It contains some undigested proteids; some undigested starch; oils from fats eaten; peptones formed in the stomach, but not yet absorbed; salines and sugar which have also escaped complete absorption in the stomach; all mixed with a good deal of water and the secretions of the alimentary canal. This acid mixture passing into the duodenum excites the secretory action of the pancreas, and stimulates the bile to flow from the gall-bladder; the glands of Lieberkühn and Brunner also become active, and all these secretions being alkaline, the acid chyme is rapidly changed into an alkaline preparation, called *chyle*.

Bile. — Bile, secreted in the lobules of the liver and stored in the gall-bladder until needed, is a fluid of a bright golden red colour, with an alkaline reaction. The chief solid constituents of bile are the bile-salts and the colouring-matters or pigments.

Action of bile on food. — Upon proteids and starch, bile has little or no digestive action. On fats, it has a slight solvent action, and, in conjunction with pancreatic juice, has the power to emulsify them. Bile possesses some antiseptic qualities. Outside the body, its presence hinders putrefactive changes; and when it is prevented from flowing into the alimentary canal, the contents of the intestine undergo changes which do not otherwise take place, and which lead to the appearance of various products, especially of ill-smelling gases. Lastly, the passage of fats through membranes is assisted by wetting the membranes with bile or with a solution of bile-salts. It is known that oil will pass to a certain extent through a filter-paper, kept wet with a solution of bile-salts, whereas it will not pass, or passes with extreme difficulty, through one kept wet with distilled water.

Pancreatic juice. — Healthy pancreatic juice is a clear, somewhat viscid fluid, with a very decided alkaline reaction. It is actively secreted by the pancreas during digestion and flows into the intestine in conjunction with the bile. The Germans call the pancreas the “abdominal salivary gland,” though the

pancreatic juice has a far more extensive action than the saliva.

Among other important constituents the pancreatic juice contains a ferment called trypsin, which, like pepsin, has the power to transform proteids into peptones; trypsin, however, requires an alkaline medium to effect this transformation, while pepsin, as we have already seen, requires the medium to be acid.

Action of pancreatic juice upon food.—On starch pancreatic juice acts with great energy, rapidly converting it into sugar. On proteids it practically exercises the same influence as the gastric juice, for by it proteids are changed into peptones. On fats it has a twofold action: it emulsifies them, and it splits them up into fatty acids and glycerine. If we shake up olive oil with water, the two cannot be got to mix: as soon as the shaking ceases, the oil floats to the top; but if we shake up olive oil with pancreatic juice, the oil remains evenly suspended in it. The reason of this is, that the oil has been minutely divided into tiny droplets, and each droplet surrounded by a delicate envelope supplied from the albumin in the pancreatic juice, so that they cannot fuse together to form the large drops, which would soon float to the top. The pancreatic juice, in thus emulsifying the fats, gives the white colour to the chyle, which is its most striking external characteristic, the innumerable tiny oil-drops reflecting all the light that falls on its surface. Secondly, the fats that are not emulsified are broken up into glycerine and fatty acids. The glycerine is absorbed, and the fatty acids in the presence of an alkali form soaps which are soluble in water and capable of absorption.

Thus pancreatic juice is remarkable for the power it has of acting on all the food-stuffs, — starch, fats, and proteids.

Succus entericus, or intestinal juice.—Succus entericus is a clear, yellowish fluid, having a faintly alkaline reaction and containing a certain quantity of mucus. It is said to have a solvent action upon all the food-stuffs, but at best its powers are slow and feeble, and we have no satisfactory reasons for supposing that the actual digestion of food in the intestine is to any great extent aided by it.

During the passage of the food through the small intestine the remaining proteids, starch, and fats are converted into peptones, sugar, and emulsified fats or soluble soaps, and these

products as they are formed pass either into the lymphatics, or into the blood-vessels in the intestinal walls, so that the contents of the small intestine, by the time they reach the ileo-cæcal valve, are largely deprived of their nutritious constituents. So far as water is concerned, the secretion of water into the small intestine maintains such a relation to the absorption from it that the intestinal contents at the end of the ilium, though otherwise much changed, are about as fluid as in the duodenum.

Changes in the large intestine.— We have no very definite knowledge of the particular changes which take place in the large intestine. The contents become distinctly acid, although the secretions of the intestinal wall are alkaline, and certain acid fermentations must therefore take place in them. These are probably due to the action of micro-organisms; but however this may be, the chief work of the colon is absorption.

By the abstraction of all the soluble constituents, and especially by the withdrawal of water, the liquid contents become, as they approach the rectum, changed into a firm and solid mass of waste matters, ready for ejection from the body, and called *feces*.

The feces.— The feces consist of the undigested and indigestible substances of a meal: among them are the elastic fibres of connective tissue; the cellulose, which is the chief constituent of the envelopes encasing the cells of plants; the indigestible mucin of mucus. These three materials, together with some water, some undigested food-stuffs, and some excretory substances found in the various secretions poured into the alimentary canal, form the bulk of the material expelled from the body.

To sum up the digestive processes:—

The transformation of the food we take into our mouths into products capable of absorption, is mainly a chemical process. The mechanical subdivision, bruising, and crushing of the food, accomplished by the teeth and the muscular contractions of the walls of the alimentary canal, is merely a process of preparation for the solvent action of the digestive juices. Of these juices there are five, each having a special action.

(1) The saliva, containing the digestive ferment ptyalin, transforms starch into sugar.

(2) The gastric juice, containing pepsin (a ferment acting in the presence of an acid), transforms proteids into peptones.

(3) The pancreatic juice, containing trypsin (a ferment acting in the presence of an alkali), transforms proteids into peptones, and, by virtue of other constituents, transforms starch into sugar, and emulsifies fats or turns them into soluble soaps.

(4) Bile, containing bile-salts and other matters, assists the pancreatic juice in saponification and emulsion of fats, promotes absorption of the same, and modifies putrefactive changes in the intestine.

(5) Intestinal juice, containing mucus, transforms all food-stuffs in a feeble fashion, not clearly demonstrated nor understood.

All material that these solvents fail to transform into a soluble and absorbable condition is gradually worked downwards by the peristaltic contractions of the alimentary canal, and finally leaves the body as waste and useless matter.

NOTE. — For the sake of simplicity, we have considered digestion in a broad way as the conversion of practically non-diffusible proteids and starch into more diffusible peptones and highly diffusible sugar, and as the emulsifying of fats. There is reason to believe that some of the sugar may be changed into lactic acid, or even into butyric or other acids, and that some of the proteids are carried beyond the peptone condition. But there is no doubt that the greater part of the proteid is absorbed as peptone, that carbohydrates are mainly absorbed as sugar, and that the greater part of the fat passes into the body as an emulsion.

Absorption. — We have now to consider how the products of digestion find their way out of the alimentary canal into the tissues of the body; for, properly speaking, though the food may be digested and ready for nutritive purposes, it is, until it passes through the walls of the alimentary canal, still practically outside the body.

There are two paths by means of which the products of digestion find their way into the blood: (1) by the capillaries in the walls of the stomach and intestines; and (2) by the lacteals in the walls of the small intestine.

(1) The network of capillary blood-vessels is spread, as we have seen (page 146), immediately beneath the basement membrane of the mucous coat lining the interior of the alimentary canal, and matters in solution pass readily by diffusion or osmosis from the interior of the stomach and intestines into the blood-vessels in their walls. All the blood from the diges-

tive organs is taken by the portal vein to the liver, and the products of digestion are modified by the action of the liver before they are returned to the general circulation by the hepatic veins. The hepatic veins pour their contents into the inferior vena cava, and the blood, enriched with the products of digestion, finally finds its way into the right side of the heart, whence it is taken to the lungs for purification before being sent to all parts of the body.

During the passage of the blood through the liver, the liver-cells not only take from it the material they need to form the bile; they also take from it material to form a starchy substance, called glycogen. This glycogen, stored in the liver-cells, is gradually doled out, as it is needed, to the blood. It is not doled out, however, in the form of glycogen, which closely resembles starch, and is, therefore, insoluble, but in the form of sugar or glucose. Thus the liver is a very complex organ whose cells elaborate bile and glycogen, and by some ferment-body, contained within themselves, convert the glycogen into glucose.

(2) Matters in solution can pass into the blood-vessels, but some other provision is necessary for the absorption of the emulsified fats. We find, accordingly, in the villi, which so closely cover the internal surface of the small intestine, little rootlets or beginnings of lymphatic vessels, which are set apart for the absorption of the fatty products of digestion.

These lymphatic rootlets or lacteals, as they are generally called, occupy the centre of each villus. The emulsified fats pass, probably aided by the bile, into the bodies of the columnar cells on the surface of the villi, and from thence find their way into the interior of the villus, and finally into the beginning of the lacteal.¹ The lacteals carry this fatty matter or chyle to the larger lymphatics in the mesentery, and these empty their contents into the thoracic duct which opens into the great veins on the right side of the neck.

¹ It is supposed that the fat gets into the interior of the lacteals mainly by the action of the leucocytes or lymph corpuscles. First, the fat is taken up by the epithelium cells on the surface of the villus, and, after passing through them, is taken up by the leucocytes; next, the leucocytes migrate, carrying the fat particles by their amœboid movements into the lacteal; and finally, after entering the lacteal, they dissolve or break up and set the fat particles free.

Thus the food in solution finds its way into the right side of the heart after passing through the liver, and the emulsified food after passing through the lymphatics. It is not to be understood that matters in solution do not find their way into the lacteals, nor, on occasion, emulsified fats into the blood-vessels, but, broadly speaking, the food-products find their way into the blood in the manner above described.

Final destination of food-stuffs. — It is impossible to say definitely what becomes of the different food-principles after they have once entered the current of the blood. In general, it may be said that the carbohydrates are used for the production of force, and that the fats are stored in the body and used as fuel. The proteids do all that can be done by the fats and carbohydrates, and, in addition, form the basis of blood, muscles, and all the connective tissues.

Still we cannot say that the carbohydrates perform a certain work in the body and nothing else, or that the proteids and fats do. It is, however, generally understood that the proteids, fats, and carbohydrates each do an individual work of their own better than either of the others can do it. They are also necessary in due proportion to the nutrition of the body and work together as well as in their separate functions.

The body has always a store of material laid by for future use. If this were not the case, a person deprived of food would die immediately, as he does when deprived of oxygen. The great reserve forces of the body are stored in the form of adipose tissue and glycogen. The glycogen is given out during the intervals of eating to supply material for heat and energy; the adipose tissue is not so readily available, but may be called upon during prolonged deprivation from food. For a certain time the heat of the body may be maintained and work done on these substances, although no food except water be taken.

In conclusion we may say the food in the blood supplies the wants of the body in five different ways:—

- “1. It is used to form all the tissues of the body.
- “2. It is used to repair the waste of all the tissues.
- “3. It is stored in the body for future use.
- “4. It is consumed as fuel to maintain the constant temperature which the body must always possess in a state of health.
- “5. It produces muscular and nervous energy.” (Professor Atwater.)

18 c. 27.
Open

CHAPTER XVI.

ELIMINATION; GENERAL DESCRIPTION OF THE URINARY ORGANS; STRUCTURE AND BLOOD-SUPPLY OF KIDNEY; SECRETION OF URINE; COMPOSITION AND GENERAL CHARACTERS OF URINE.

IN the last four chapters we have seen that the blood is constantly supplied by means of the respiratory and digestive mechanisms, with all the chemical substances it requires to maintain the life, growth, and activity of the body. These substances, entering the current of the blood, are carried to all the tissues, and are incessantly combining with the chemical substances of which these tissues are composed. These combinations are not left to chance; each tissue has a special affinity for the chemical substance in the blood which it requires for its own growth and special form of activity; the secretory cell of the liver picks out substances from which it can manufacture bile and glycogen; the muscle fibre assimilates those that will promote the changes upon which depends the power of contractility. We know that the proteid compounds contain the most essential elements for the formation of all kinds of tissue, and that phosphate of lime is a necessary ingredient in the hardening of bone, but we are utterly ignorant of how it comes about that each tissue element is enabled to select the particular material it needs and to reject that which it does not require.

Our bodies are masses of changing atoms, some of which, if we may so express it, are on the "up grade," to construct the various tissues, and some are on the "down grade," to form the waste matters which are the final products of the tissues' activity. These changes, which are incessantly going on while life lasts, are described under the general term of metabolism; the constructive changes being spoken of as anabolic, and the destructive as katabolic, changes. The final products then of

the metabolism of the body will be certain waste matters, and we shall now proceed to describe the mechanism of the organs by means of which these wastes are removed from the body.

Elimination. — In passing through the blood and tissues of the body, the proteids, fats, and carbohydrates are transformed into urea (or some closely allied product), carbonic acid, and water, the nitrogen of the urea being furnished by the proteids alone. Many of the proteids contain sulphur, and also have phosphorus attached to them in some combination, and some of the fats taken as food contain phosphorus; these elements are converted by oxidation into phosphates and sulphates, and are excreted in that form in company with the other salts of the body.

Broadly speaking, then, the waste products are urea, carbonic acid, salts, and water. These leave the body by one or other of three main channels, the lungs, the skin, and the kidneys. Some part, it is true, leaves the body by the bowels, for, as we have seen, the feces contain, besides undigested portions of food, substances which have been secreted into the bowels, and are therefore waste products; but the amount of these is very small and, except in diseased conditions, of no special importance.

The waste matters discharged relatively by the lungs, skin, and kidneys may be stated as follows:—

- | | |
|-----------------|---|
| By the lungs: | The greater part of the carbonic acid.
A considerable quantity of water. |
| By the skin: | A variable but, on the whole, large quantity of water.
A little carbonic acid.
A small quantity of salts. |
| By the kidneys: | All, or nearly all, the urea and allied bodies.
The greater portion of the salts.
A large amount of water.
A very small quantity of carbonic acid. |

We have already studied the mechanism by means of which the lungs rid the blood of carbonic acid and water, and it now remains for us to consider the mechanism of the skin and kidneys. In the present chapter we shall devote ourselves to the consideration of the kidneys, which secrete the urine, and the other urinary organs, the ureters, bladder, and urethra, which collect the urine and conduct it to the outside of the body.

Position and General Description of the Urinary Organs.

The kidneys.—The kidneys are two compound tubular secreting glands placed at the back of the abdominal cavity, one on each side of the lumbar vertebræ. They are bean-shaped, with the concave side turned towards the spine, and the convex side directed outwards. Each kidney is about four inches long, two broad, and one thick, and extends from the eleventh rib to nearly

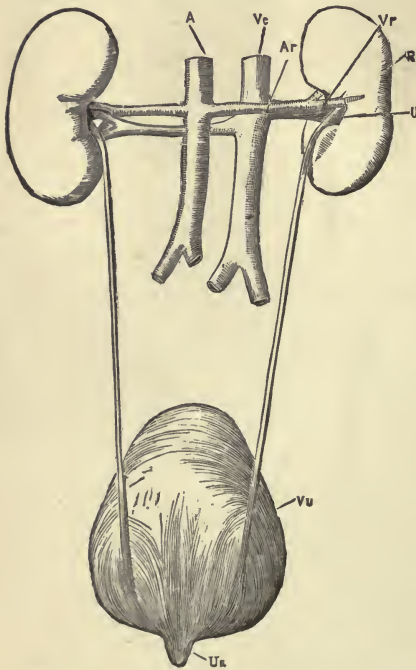


FIG. 105.—THE RENAL ORGANS VIEWED FROM BEHIND. *R*, right kidney; *A*, aorta; *Ar*, right renal artery; *Vc*, inferior vena cava; *Vr*, right renal vein; *U*, right ureter; *Vu*, bladder; *Ua*, urethra.

the crest of the ilium, the right being a little lower than the left in consequence of the large space occupied by the liver. They are covered by a tough envelope of fibrous tissue called the capsule of the kidney, and are usually embedded in a considerable quantity of fat.

The ureters.—The ureters are the excretory ducts of the kidneys. They arise in the middle of the concave side, or *hilus*, of each kidney and proceed obliquely downwards and inwards through the lumbar region of the abdomen into the pelvis, to open obliquely by two constricted orifices into the base of the bladder. Each ureter is of the diameter of a goose

quill, from sixteen to eighteen inches long, and consists of muscular tissue lined by mucous membrane. The muscular coat is arranged in two layers, an outer circular and an inner longitudinal. Outside the muscular coat is a layer of fibrous connective tissue carrying the blood-vessels and nerves with which the tube is supplied.

The bladder.—The bladder is the reservoir of the urine. It

is situated in the pelvic cavity behind the pubes, and is held in position by ligaments. During infancy it is conical in shape and projects above the upper border of the pubes into the hypogastric region. In the adult, when quite empty it is placed deeply in the pelvis; when slightly distended, it has a round form; but when greatly distended, it is ovoid in shape and rises to a considerable height in the abdominal cavity. (*Vide* Plate VII.) When moderately distended, it measures about five inches in length, and three inches across, and the ordinary amount of urine which it contains is about one pint. The bladder consists of plain muscular tissue lined by a strong mucous membrane, and is covered partially by a serous coat derived from the peritoneum. The muscular coat has three layers, the principal fibres of which run longitudinally and circularly, the circular fibres being collected into a layer of some thickness around the constricted portion or neck, where the bladder becomes continuous with the urethra. These circular fibres around the neck form a sphincter muscle which is normally in a state of contraction, only relaxing at intervals, when the accumulation of urine within the bladder renders its expulsion necessary.

The base of the bladder is directed downwards and backwards, and in the female lies in contact with the front wall of the vagina and the lower part of the neck of the uterus. The neck of the bladder is directed obliquely downwards and forwards.

The urethra.—The urethra is a narrow, membranous canal, about an inch and a half in length in the female, and extending from the neck of the bladder to the external orifice or *meatus urinarius*. It is placed beneath the symphysis pubis, and is embedded in the anterior wall of the vagina. Its direction is obliquely downwards and forwards, its course being slightly curved, the concavity directed forwards and upwards. It admits of considerable dilatation, its normal diameter, however, being about a quarter of an inch. It is lined by a mucous coat, which is continuous, externally, with that of the *vulva*, and, internally, with that of the bladder. The external muscular coat is also continuous with that of the bladder, but between the mucous and muscular coats is a layer of thin, spongy tissue, containing a network of large veins.

The structure of the kidney.—The kidney is a secreting gland, constructed upon the general plan of a compound secreting gland, but possessing special features peculiar to itself. If we cut a kidney in two lengthwise, it is seen that the upper end of the ureter expands into a basin-like cavity, into which the solid portion of the kidney projects in conical-shaped masses. This dilated cavity of the ureter is called the pelvis or basin of the kidney, and this pelvis is irregularly subdivided into smaller,

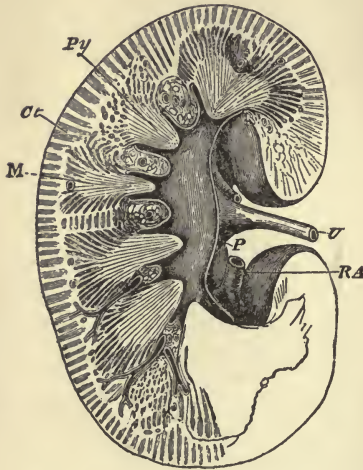


FIG. 106.—SECTION THROUGH THE KIDNEY, SHOWING THE MEDULLARY AND CORTICAL PORTIONS, AND THE BEGINNING OF THE URETER. (Henle.) *Ct*, cortex; *M*, medulla; *Py*, papilla of pyramidal section, projecting into one of the calices of pelvis; *P*, pelvis; *RA*, renal artery; *U*, ureter.

cup-like cavities, called *calices*, which receive the pointed projections of the kidney substance.

The substance of the kidney is readily seen by the naked eye to consist of two distinct parts: an outer, darker, and more solid portion, called the cortex (bark), and an inner, lighter striated portion, called the medulla (marrow), which is not a solid mass, but more or less distinctly divided into pyramidal-shaped sections. The pointed projections or *papillæ* of the pyramids are received by the irregularly disposed cup-like cavities of the pelvis. The bulk of the kidney substance, both in the cortex and medulla,

is composed of little tubes or tubules, closely packed together, having only just so much connective tissue as is sufficient to carry a large supply of blood-vessels and a certain number of lymphatics and nerves. The different appearance of cortex and medulla is due to shape and arrangement of tubules and blood-vessels.

Examined under the microscope, it is seen that the uriniferous tubules begin as little rounded dilatations, called capsules, in the cortex of the kidney. These capsules are joined to the tubules by a constricted neck, and the tubules, after running a very irregular course, open into straight collecting tubes, which pour their contents through openings in the pointed ends or

papillæ of the pyramids into the pelvis of the kidney. (*Vide* Fig. 109.)

The tubules are composed of basement membrane, lined throughout by epithelium cells. The cells vary in the different parts of a tubule, some being more especially adapted to secretory purposes than others.

The blood-supply of the kidney.—For its size, the kidney is abundantly supplied with blood. The renal artery, coming directly from the aorta, divides as it enters the hilus of the kidney into branches, which, slipping around the pelvis, pass inwards between the pyramids. On reaching the boundary line between the cortex and the medulla, the branches divide laterally to form more or less complete arches, (the veins also divide in a similar manner to form venous arches). From the arterial arches, vessels pass upwards through the cortex, giving off at intervals tiny arteries, each of which enters the dilated commencement or capsule of a uriniferous tubule.

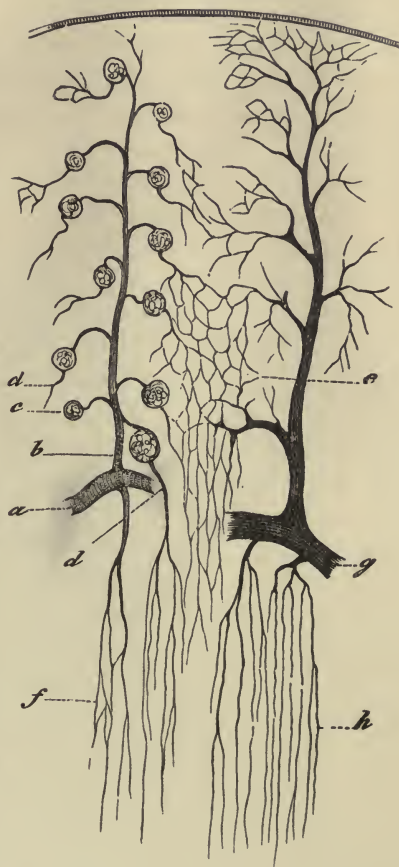


FIG. 107.—VASCULAR SUPPLY OF KIDNEY. (Cadiat.) *a*, part of arterial arch; *b*, arterial branch passing upwards through the cortex; *c*, glomerulus; *d*, efferent vessel; *e*, meshwork of capillaries; *f*, straight arterial vessels of medulla; *g*, venous arch; *h*, straight veins of medulla.

These tiny arteries, entering the capsule, are spoken of as afferent vessels. They push the thin walls of the capsule before them, break up into a knot of capillary vessels, called a *glomerulus*, and finally issue from the capsule as efferent ves-

sels. These efferent vessels do not immediately join to form veins, but break up into a close meshwork of capillaries around the tubules, before they unite to form the larger vessels and pour their contents into the veins forming the venous arches, between the cortex and medulla. In this way the cortex of the kidney is supplied with blood. The medulla also receives its blood-supply mainly from the arterial arches. The blood passes downwards in straight vessels between the uriniferous tubules, to be returned by more or less straight veins to the venous arches, whence it is conveyed by large branches into the renal vein, which leaves the kidney at the hilus and pours its contents into the inferior vena cava.

The renal artery in passing into the kidney is accompanied by a network of nerves, called the renal plexus. They are chiefly vaso-motor nerves, and regulate the contraction and relaxation of the renal blood-vessels.

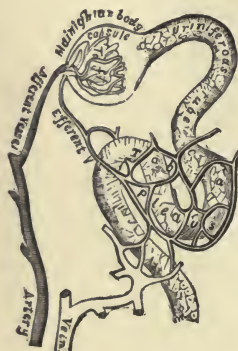


FIG. 108.—PLAN OF THE BLOOD-VESSELS CONNECTED WITH THE TUBULES.

Secretion of urine.—Urine is secreted from the blood in two ways. It is partly removed by a process of transudation or filtration, and partly by the secretory action of the cells lining the uriniferous tubules.

(1) Into the dilated extremity or capsule of each tubule a small artery enters and, pushing the wall of the capsule before it, breaks up into a bunch of looped capillaries. The blood in the loop of capillaries or glomerulus is only separated from the interior of the tubule by the thin walls of the capillaries and the inverted wall of the capsule, which closely covers the glomerulus. The artery entering the capsule is larger than the issuing vein, and, during its passage through the glomerulus, the blood is subjected to considerable pressure. As a result of this, a transudation of the watery constituents of the blood, with some dissolved salts, takes place through the walls of the blood-vessels and of the capsule into the tubule.

(2) After leaving the capsule, the efferent vein breaks up into a meshwork of capillaries, which closely surrounds the tubules, so that the blood is again brought into close communication with the interior of the tubules. The tubules are lined

with secreting cells, and these cells appear to have the power of selecting from the blood the more solid waste matters (especially the urea), which fail to filter through the flat cells forming the wall of the capsule.

Thus the elimination of urine is a double process, being partially accomplished by transudation, and partially by the selective action of the secreting cells lining the tubules.

Excretion of urine.—The uriniferous tubules commence in a dilated extremity, the capsule, and, after a very devious course, terminate in the collecting tubules, which open on the pointed projections or papillæ of the pyramids. The fluid they contain passes into the pelvis of the kidney, whence it is carried along the ureters into the bladder, partly by pressure and gravity, and partly by the peristaltic contractions of the muscular walls of the ureters. In the bladder the urine collects, its return into the ureters being prevented by the oblique entrance of these tubes into the walls of the bladder.

Micturition is normally caused by the accumulation of urine within the bladder. The accumulation stimulates the muscular walls to contract, the resistance of the sphincter at the neck of the bladder is overcome, and the urine is ejected through the urethra. Involuntary micturition may occur as a result of spinal injury, involving the nerve centres which send nerves to the bladder. It may be due to a want of "tone" in the muscular walls, or it may result from some abnormal irritation.

General characters of the urine.—Normal urine may be de-

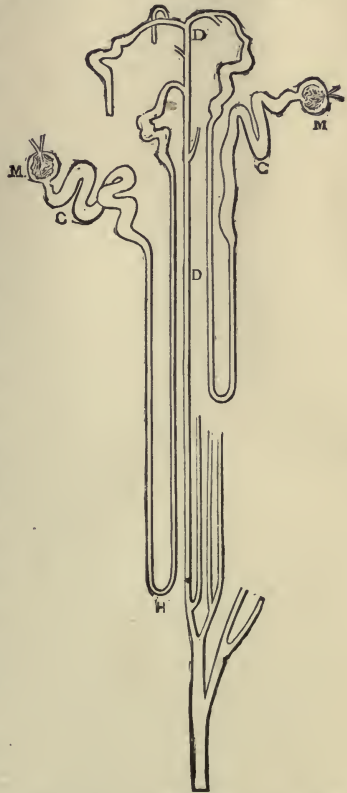


FIG. 109.—DIAGRAM OF THE COURSE OF TWO URINIFEROUS TUBULES. *M*, malpighian capsule, or dilated extremity; *C*, convoluted portion of tube; *H*, loop, consisting of a descending and ascending limb; *D*, collecting tubule.

scribed as a transparent watery fluid, of a pale yellow colour, acid reaction, specific gravity of 1020, and possessing an odour which can only be described as "characteristic" or "urinous." Each one of these characters is liable to some variation within the limits of health as well as in disease.

The *transparency* of urine may be diminished in health by the presence of mucus, derived from the genito-urinary tract, or by the deposit of salts. In disease the urine may become clouded by the presence of pus.

The *colour* of urine depends mainly upon the amount of water it contains; also upon a diminution or increase of colouring matters. In the copious urine of hysteria the colour is very light, while in the diminished flow in fevers it is very high. Abnormal colouring matters are derived from food or medicine, or result from some diseased condition.

The *reaction* of urine should always be tested from a collection of urine passed during twenty-four hours, as it is affected by diet and exercise. The reaction of mixed urine is normally acid.

The *specific gravity* depends upon the amount of solid waste matters present in the urine. In health, it may vary from 1015 to 1025. When the solids are dissolved in a large amount of water, the specific gravity will naturally be lower than when, from a deficiency of water, the urine is more concentrated. It is notably heightened by the presence of sugar in the disease called Diabetes Mellitus.

The composition of urine.—The chief constituents of normal urine are water, urea, uric acid, colouring matters, and salts. Of these constituents, urea is by far the most important, for it is the chief solid waste product of the body. To eliminate urea is the special work of the kidneys, and if for any reason they fail to execute their work, the accumulation of urea in the system leads to termination of life. Urea is the final product of all proteid substances, and consequently a diet rich in proteids will increase the amount of urea in the system. When the kidneys are disabled, it is customary for physicians to lighten their work as far as possible by regulating the diet.

Of the salts, chloride of sodium occurs in the largest quantity; it sometimes disappears temporarily from the urine when, in certain inflammatory diseases, it is needed by the blood.

The chief abnormal constituents that are liable to appear in the urine are albumin, giving rise to a condition called albuminuria, and sugar, giving rise to diabetes. The "casts," which are found in urine in the various forms of Bright's disease, are shed from the tubules in the shape of cylindrical moulds.

The quantity of urine passed in twenty-four hours. — The normal quantity of urine passed in twenty-four hours is from forty to fifty ounces, or about three pints. This will vary in health with the condition of the skin, and the amount of fluid taken into the body. The excretion of water by the kidneys is closely related to that excreted by the skin. When the body is exposed to cold, the blood-vessels in the skin are constricted, and the discharge of water in the form of sweat is checked; at the same time the blood-vessels of the kidneys are dilated, there is a full and rapid stream of blood through the glomeruli, and an increased flow of urine results. On the other hand, when the body is exposed to warmth, the cutaneous vessels are widely dilated, and the skin perspires freely, while the renal vessels being constricted, only a small and slow stream of blood trickles through the glomeruli, and the urine which is secreted is scanty. The effect on secretion, however, is more marked by the amount of fluid absorbed through the alimentary canal; an increased secretion of water always follows an ordinary meal, and when large quantities of water are drunk the amount of urine is correspondingly increased.

The supra-renal capsules. — Lying immediately above each kidney are two small flattened bodies of a yellowish colour. They are usually classified with the ductless glands, as they have no excretory duct. Each organ is invested by a fibrous capsule which sends fibres into the glandular substance; these fibres form a framework for the soft, pulpy substance of the gland, and within the spaces of the framework are groups of cells.

The supra-renal capsules are plentifully supplied with blood-vessels, nerves, and lymphatics, and they contain some striking colouring matters. In disease of these organs, the skin frequently becomes "bronzed," from an increase of pigment or colouring matter. Their special normal functions are unknown.

AMOUNT OF THE SEVERAL URINARY CONSTITUENTS
PASSED IN TWENTY-FOUR HOURS, EXPRESSED IN
GRAMMES AND GRAINS. (MARTIN.)

Urine in 24 hours.	1500 grammes.	23,250 grains.	In 1000 parts.
Water	1428.00	22,134.00	952.00
Solids	72.00	1,116.00	48.00
The solids consist of—			
Urea	33.00	511.50	22.00
Uric acid	0.50	7.75	0.33
Hippuric acid	0.40	6.20	0.27
Kreatinin	1.00	15.50	0.66
Pigments and fats	10.00	155.00	6.66
Sulphuric acid	2.00	31.00	1.33
Phosphoric acid	3.00	46.50	2.00
Chlorine	7.00	108.50	4.70
Ammonia	0.75	12.00	0.50
Potassium	2.50	38.75	1.70
Sodium	11.00	170.50	7.33
Calcium	0.25	3.80	0.16
Magnesium	0.20	3.00	0.13
	71.60	1110.00	47.77

CHAPTER XVII.

ELIMINATION CONCLUDED: THE SKIN. NAILS AND HAIR.
BODILY HEAT: PRODUCTION OF HEAT; LOSS OF HEAT.
DISTRIBUTION OF HEAT; REGULATION OF HEAT.

HAVING described the mechanism by means of which the lungs rid the body of carbonic acid and water, and of how the kidneys relieve it of urea, salts, and water, it now remains for us to explain how the skin plays its part in elimination by yielding up water, and a certain amount of carbonic acid and salts.

The skin. — The skin is not, like the kidneys, set apart to per-

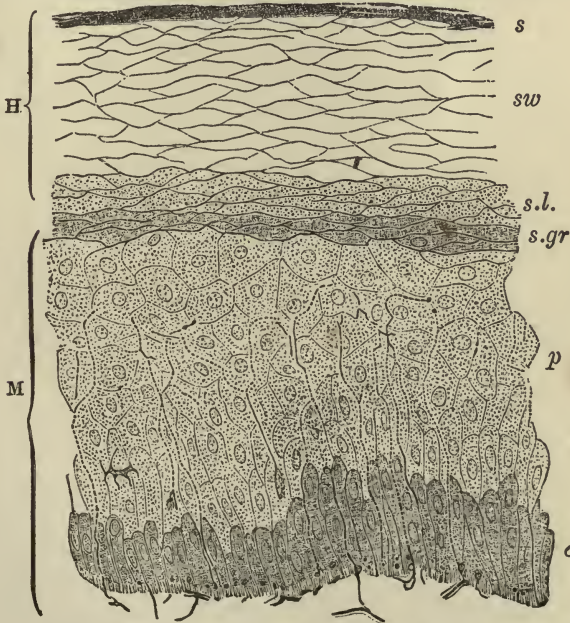


FIG. 110. — SECTION OF EPIDERMIS. (Ranvier). *H*, horny layer, consisting of *s*, superficial horny scales; *sw*, swollen-out horny cells; *s.l.* clear layer; *M*, Malpighian layer, consisting of *s.gr.* granular layer; *p*, many-sided or prickle cells; *c*, columnar cells. Nerve fibrils may be traced passing up between the epithelium cells of the Malpighian layer.

form one special function. It is an important excretory organ, but it is also an absorbing organ; it is likewise the principal seat of the sense of touch, and serves, too, as a protective covering for the deeper tissues lying beneath it.

The skin, like a mucous membrane, consists of two distinct layers; an epithelial covering, and a connective tissue basis. The epithelium is a stratified epithelium and is called the **epidermis**, or **scarf-skin**; the connective tissue layer is called the **derma**, **cutis vera** (**true skin**), or **corium**. The **epidermis** is composed of layers of cells, the deeper of which are soft and protoplasmic, while the superficial layers are hard and horny. Between the two layers is a fairly distinct line of granular-looking cells, the granules in which have been thought to form the horny matter in the superficial cells. In the coloured races the single layer of elongated cells next the corium contains pigment granules.

The growth of the epidermis takes place by the multiplication of the cells in the deeper or Malpighian layer. As these cells multiply by cell-division, they push upwards towards the surface those previously formed. In their upward progress they undergo a chemical transformation, and the soft protoplasmic cells become converted into the flat, horny scales which are constantly being rubbed off the surface of the skin.

The thickness of the epidermis varies in different parts of the body, measuring in some places not more than $\frac{1}{240}$ th of an inch, and in others as much as $\frac{1}{24}$ th of an inch. It is thickest in the palms of the hands and soles of the feet, where the skin is most exposed to abrasion and pressure, but it forms a protective covering over every part of the true skin, upon which it is closely moulded.

No blood-vessels pass into the epidermis; it, however, receives fine nerve-fibrils between the cells of the Malpighian layer.

The **cutis vera** or **true skin** is a highly sensitive and vascular layer of connective tissue. It is, like the mucous membranes, attached to the parts beneath it by a layer of areolar tissue, here named "subcutaneous," which layer, with very few exceptions, contains fat. The connection in some parts is loose and movable, as on the front of the neck; in others, close and firm, as on the palmar surface of the hand and the sole of the foot.

The cutis vera is often described as consisting of two layers, a superficial or papillary layer, and a deeper or reticular layer.

The surface of the superficial or **papillary** layer is increased by protrusions in the form of small conical elevations, called papillæ, and whence this layer derives its name. These papillæ contain for the most part looped blood-vessels, but they also contain the terminations of *medullated* nerve-fibres in the shape of little bodies, called tactile corpuscles.

The papillæ seem chiefly to exist for the purpose of giving the skin its sense of touch, being always well developed where

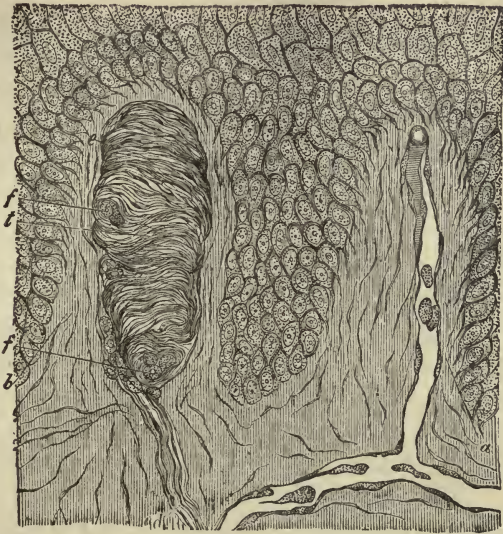

FIG. 111. — SECTION OF SKIN SHOWING TWO PAPILLÆ AND DEEPER LAYERS OF EPIDERMIS. (Biesiadecki.) *a*, vascular papilla, with capillary loop passing from subjacent vessel, *c*; *b*, nerve-papilla, containing tactile corpuscle, *t*; *d*, nerve passing up to tactile body; *f, f*, section of spirally winding nerve-fibres.

the sense of touch is exquisite. The papillæ, containing tactile bodies, are specially large and numerous on the palm of the hand and the tips of the fingers, and on the corresponding parts of the foot, while on the face and back they are small and irregularly scattered.

The **reticular** layer of the corium is a continuation of the papillary layer, there being no real division between them, and is made up of bundles of white fibrous and elastic tissue which gradually blends below with the subcutaneous areolar tissue. It contains networks of blood-vessels, lymphatics, and nerves.

The appendages of the skin are the nails, the hairs, the sebaceous glands, and the sweat-glands. They are all developed as thickenings, or as down-growths, of the Malpighian layer of the epidermis.

The nails.—The nails are composed of clear, horny cells of the epidermis, joined together so as to form a solid, continuous plate. Underneath each nail, the true skin is modified to form what is called the bed or *matrix* of the nail. This bed is very vascular, and is raised up into numerous papillæ. At the hinder part of the bed of the nail the skin forms a deep fold, in which is lodged the root of the nail.



FIG. 112. —PIECE OF HUMAN HAIR. (Highly magnified.) *a*, cuticle; *b*, fibrous substance; *c*, medulla.

The growth of the nail is accomplished by constant multiplication of the soft cells in the Malpighian layer at the root. These cells are transformed into dry, hard scales, which unite into a solid plate, and the nail, constantly receiving additions from below, slides forward over its bed and projects beyond the end of the finger. When a nail is thrown off by suppuration, or torn off by violence, a new one will grow in its place, provided any of the cells of the Malpighian layer are left.

The average rate of growth of the nails is about $\frac{1}{32}$ of an inch per week.

The hairs.—The hairs are growths of the epidermis, developed in little pits, the hair-follicles, which extend downwards into the deeper part of the true skin, or even into the subcutaneous tissue. The hair grows from the bottom of the little pit or follicle, the part which lies within the follicle being known as the root. The substance of the hair is composed of coalesced horny cells, arranged in different layers, and we usually distinguish three parts in the stem or shaft of hairs. An outer layer of delicate, scale-like cells, the *cuticle*; a middle, horny, thick, and coloured portion, formed of elongated cells, the *fibrous substance*; and a central pith formed of angular cells, the *medulla*.

The root of the hair is enlarged at the bottom of the follicle into a bulb or knob, and this bulb is composed of soft-growing

cells, and fits over a vascular papilla which projects into the bottom of the follicle. The hair grows from the bottom of the follicle by multiplication of the soft cells which cover the papilla, these cells becoming elongated to form the fibres of the fibrous portion, and otherwise modified to form the medulla and cuticle. New hairs are produced indefinitely, so long as the papillæ and soft cells remain intact.

The follicles containing the hairs are narrow pits formed by the involutions of the true skin and the epidermis. They slant obliquely upwards, so that the hairs they contain lie down on the surface of the body. Connected with each follicle are small muscles of plain muscular tissue which pass from the surface of the true skin, *on the side to which the hair slopes*, obliquely downwards, to be attached to the bottom of the follicle. When these muscles contract, as they will under the influence of cold

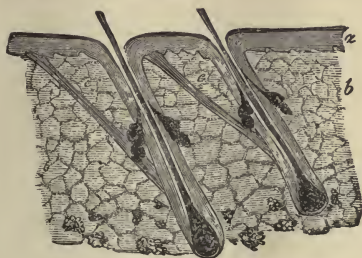


FIG. 113. — SECTION OF THE SKIN SHOWING THE HAIRS AND SEBACEOUS GLANDS. *a*, the epidermis; *b*, corium; *c*, muscles, attached to hair-follicles and to under surface of epidermis.

or terror, the little hairs are pulled up straight, and stand “on end”; the follicle also is dragged upwards so as to cause a prominence on the surface of the skin, whilst the cutis vera, from which the little muscle arises, is correspondingly depressed: in this way the roughened condition of the skin known as “goose-skin” is produced. Hairs grow on an average at the rate of half an inch per month. They are found all over the body, except on the palms of the hands and the soles of the feet, and on the last joints of the fingers and toes.

The sebaceous glands. — The sebaceous glands are small saccular glands, the ducts of which open into the hair-follicles. They are lined with epithelium, and secrete a fatty, oily substance (sebum) which they discharge into the hair-follicles. Several sebaceous glands may open into the same follicle, and their size is not regulated by the length of the hair. Thus, some of the largest are found on the nostrils and other parts of the face, where they often become enlarged with pent-up secretion. The sebum lubricates the hairs and renders them glossy; it also exudes, more or less, over the whole surface of the skin, and

keeps it soft and flexible. An accumulation of this sebaceous matter upon the skin of the foetus furnishes the thick, cheesy, oily substance, called the *vernix caseosa*.

The sudoriferous or sweat-glands.— All over the surface of the skin are minute openings or pores. These pores are the openings through which the sweat-glands pour their secretions upon the surface of the body. The sweat-glands are tubular glands with their blind ends coiled into little balls which are lodged in the true skin or subcutaneous tissue; from the ball the tube is continued as the excretory duct of the gland up through the true skin and epidermis, and finally opens on the surface by a slightly widened orifice. Each tube is lined by a secreting

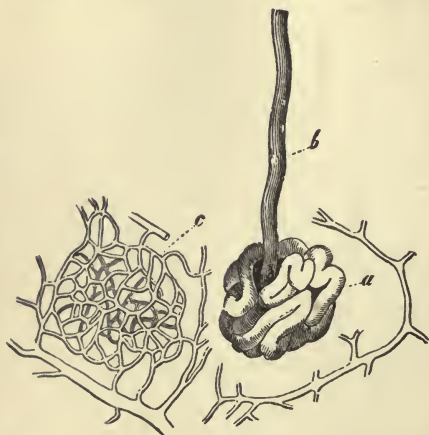

FIG. 114. — COILED END OF A SWEAT-GLAND. *a*, the coiled end; *b*, the duct; *c*, network of capillaries, inside which the sweat-gland lies.

epithelium continuous with the epidermis. The coiled end is closely invested by a meshwork of capillaries, and the blood in the capillaries is only separated from the cavity of the glandular tube by the thin membranes which form their respective walls. The secretory apparatus in the skin is somewhat similar to that which obtains in the kidney; in the

one case the blood-vessels are coiled up within the tube, while in the other the tube is coiled up within the meshwork of blood-vessels.

The sweat-glands are abundant over the whole skin, but they are most numerous on the palm of the hand and on the sole of the foot; in the groin, and especially in the axilla, they are larger than in other parts of the body. At a rough estimate, the whole skin probably possesses from two to two and a half millions of these glands, and their combined secreting power is therefore very great.

Perspiration or sweat.— The sweat is a transparent colourless fluid, of a distinctly salt taste and with a strong, distinctive odour. When the secretion is scanty it has an acid reaction, but when

abundant it is alkaline. The chief normal constituents of sweat are water, salts, fatty acids, and, some authorities state, a slight amount of urea. In various forms of kidney disease urea may be present in considerable quantity, the skin supplementing to a certain extent the deficient work of the renal organs.

Quantity of perspiration. — Under ordinary circumstances, the perspiration that we are continually throwing off evaporates from the surface of the body without our becoming sensible of it. This insensible perspiration, as it is called, usually amounts to about twenty or thirty ounces in the course of twenty-four hours. The amount, however, varies to a great extent — with the condition of the atmosphere; the amount of exercise taken; the quantity of fluid drunk; the action of the kidneys. Variations also occur under the influence of mental emotions, the action of drugs, or are induced by certain diseased conditions. When more sweat is poured upon the surface of the body than can be removed at once by evaporation, it appears on the skin in the form of scattered drops, and we then speak of it as sensible perspiration.

Less important functions of the skin. — Besides being an important excretory organ, the skin is to a slight extent an absorbing organ. In the sound, healthy skin, it is doubtful whether matters in solution can be absorbed through the epidermic covering, but if the horny layers of the epidermis be removed by blistering, matters in solution readily pass into the blood-vessels in the true skin. Oily substances, especially when well rubbed in, are absorbed without removal of the epidermis.

Oxygen in small amount is also taken in through the skin, but this gain to the body is counterbalanced by the carbonic acid which is thrown off.

To sum up: the skin excretes a large amount of water and a small amount of carbonic acid and salts; it absorbs a small amount of oxygen and, under certain conditions, oily substances and watery solutions; it is a protective organ and a tactile organ; it supports two appendages, viz., the hair and nails, and keeps itself flexible, and the hair glossy, by the secretion of sebum.

There is still another function of the skin to be considered before closing this chapter, and that is the part it plays in regulating the temperature of the body.

Bodily heat. — In order that the bodily functions may be properly performed, it is necessary for the body to maintain a certain temperature. Just as plants are killed by the frost, or withered by the heat of the sun, so our tissues die if the bodily temperature falls below, or rises above, a certain limit. Our bodies, however, differ from plants in that they generate and regulate their own temperature, and possess the power of adapting themselves to extremes of external heat and cold, without necessarily suffering any vital injury. But, although the external temperature of the atmosphere may vary considerably without hurting us, the bodily temperature must be kept at an average standard of 98.6° F. (37° C.) if we are to remain in a state of health. Slight variations are compatible with health, the temperature being normally a trifle higher after eating or in the evening of the day, but any variation over a degree above or below 98.6° F. is indicative of danger.

Production of heat. — Heat in the body is produced by the chemical changes that are constantly going on in the tissues. *Wherever metabolic changes are taking place, there heat is set free.* These changes take place more rapidly in some tissues than in others, and in the same tissues at different times. The muscles always manifest a far higher rate of activity than the connective tissues, and consequently the former evolve a larger proportion of the bodily heat than the latter. We might liken the different tissues of the body to so many fireplaces stored with fuel, the fuel in some of the fireplaces being more easily ignited and burning more rapidly than in others. The muscles and the secreting glands, especially the liver, are supposed to be the main sources of heat, as they are the seats of a very active metabolism.

Loss of heat. — The heat thus continually produced is as continually leaving the body by the skin and the lungs, and by the urine and feces. It has been calculated that in every 100 parts about: —

88 per cent is lost by conduction and radiation from the surface of the skin and the evaporation of the perspiration.

9 per cent is lost by warming the expired air and the evaporation of the water of respiration.

3 per cent is lost by warming the urine and feces.

Distribution of heat. — The blood, as we know, permeates all the tissues in a system of tubes or blood-vessels. Wherever oxidation takes place and heat is generated, the temperature of the blood circulating in these tissues is raised. Wherever, on the other hand, the blood-vessels are exposed to evaporation, as in the moist membranes in the lungs, or the more or less moist skin, the temperature of the blood is lowered. The gain and loss of heat balance one another with great nicety, and the blood, circulating rapidly, now through warmer, and again through cooler tubes, is kept at a uniform temperature of about 100° F. In this way the whole body is warmed in somewhat the same way as we warm a house, the warm blood in the blood-vessels heating the tissues, as the hot water in the hot-water pipes heats the rooms in steam-heated dwellings.

Regulation of heat. — We have seen that active changes in the body produce heat. The action of the muscles is a source of heat, the activity of the glands during digestion, the active changes taking place in the tissues during inflammation or suppuration, or the changes caused by some specific micro-organism, and we may say that there are normal and abnormal sources of heat.

Normally, production of heat is balanced by loss of heat, and the chief regulator of this gain and loss is undoubtedly the skin. This is well seen in the case of muscular exercise. Every muscular contraction gives rise to heat, and yet during severe muscular exercise the temperature of the body does not rise, or rises only to a trifling extent. This is accounted for by the fact that when the muscular exertion causes the blood to circulate more quickly than usual, the blood-vessels in the skin dilate, the sweat-glands at the same time are excited to pour out a more abundant secretion, and the heated blood passing in larger quantities through the cutaneous vessels (which are kept well cooled by the evaporation of the perspiration), the general average temperature of the body is maintained.

In pyrexia, or fever, rise of temperature is due to some cause which, while increasing the metabolism of the tissues, at the same time interferes with the process by means of which the body rids itself of superfluous heat. We all know how hot and dry the skin is liable to become in fevers; how we try to restore its function and lower the temperature by baths, sponging, and

packs; how we recognize the first signs of restored function — the moist, warm sweat in the palm of the hand — as a pretty sure sign that the fever is “broken.” If a very high temperature persists for any length of time, the metabolism of the tissues goes on at such a rapid rate that the capital of the body is soon exhausted. Every organ works with feverish activity, the heart and lungs increase their action, the pulse and respiration become more and more hurried, and consequently more and more feeble, until finally, unless relief is obtained, the patient dies of exhaustion.

In exposure to variations of external temperature, the skin is also the chief agent in regulating the heat of the body. Exposure to cold causes the blood-vessels in the skin to contract, the cold acting as a stimulus to the vaso-motor nerves, which control the calibre of the cutaneous blood-vessels. As a result, less blood is sent to the surface to be cooled, and the average blood-temperature is maintained. On the other hand, exposure to warmth causes the cutaneous blood-vessels to dilate, and more blood is sent to the surface to be cooled. Briefly, when the external temperature is high, the cutaneous blood-vessels dilate, and the sweat is also usually poured out upon the surface of the skin; when the external temperature is low, the cutaneous blood-vessels contract, and the skin usually remains dry.

By clothing we can aid the functions of the skin and the maintenance of heat; though, of course, clothes are not in themselves sources of heat. The object of clothing is, in winter, to prevent conduction, radiation, and evaporation of heat from the skin, and, in summer, to promote it. Of the materials used for clothes, linen is a good conductor; calico or muslin not quite so good, while wool, silk, and fur are all bad conductors.

Subnormal temperature. — In some maladies the temperature falls distinctly below the normal. This is no doubt chiefly due to diminished metabolism. In cases of starvation, the fall of temperature is very marked, especially during the last days of life. The diminished activity of the tissues first affects the central nervous system; the patient becomes languid and drowsy, and finally unconscious; the heart beats more and more feebly, the breath comes more and more slowly, and the sleep of unconsciousness passes insensibly into the sleep of death.

CHAPTER XVIII.

NERVOUS TISSUE.—THE CEREBRO-SPINAL SYSTEM: BRAIN AND CRANIAL NERVES; SPINAL CORD AND SPINAL NERVES.—SYMPATHETIC SYSTEM.

Nervous tissue.—Nervous tissue is the most highly organized tissue of the body. It is pre-eminently the “master tissue,” controlling, regulating, and directing all the other tissues. Like muscular tissue, it is irritable and responds to stimuli; but, unlike muscular tissue, it is *not contractile*.

If we stimulate a nerve-fibre, certain molecular changes are started in the fibre, and these changes are transmitted along the fibre without visibly altering its form. We call these changes thus propagated along a fibre, “nervous impulses.” The stimuli that start these nervous impulses are varied and numerous, and may originate from within the body as well as from without. They usually originate from without; as, for example, a ray of light falls on the nervous tissue of the eye, the light stimulates and sets up changes in the nervous tissue which are transmitted along the optic nerve to the brain. These nervous impulses reaching the brain may start other nervous impulses, which, travelling down certain nerves to certain muscles, will cause those muscles to contract, in which case we say a man starts. Again, sound falling on the ear, a drop of water falling on the hand, some change in the air or other surroundings of the body, or some change within the body itself, may so affect the nervous tissue that nervous impulses are started and travel to this point or that, giving rise to movement as they reach muscular tissue, or producing some other effect as they reach other tissues. We may say that nervous tissue generates, transforms, and propagates nervous impulses.

When subjected to the microscope, nervous tissue is seen to

consist of two different structural elements, viz., fibres and cells, both of which are enclosed and supported by a peculiarly arranged connective tissue, and supplied with blood and lymphatic vessels. These fibres and cells are arranged in distinct masses, called "nerve-centres," or in the form of cords, called "nerves." The nervous cords are composed almost entirely of the nerve-fibres, while the nerve-centres contain both fibres



FIG. 115. — MULTI-POLAR NERVE-CELL. (Gerlach.) *a*, axis-cylinder, or nerve-fibre process; *b*, pigment.

and cells. The nerves conduct or propagate nervous impulses, while the nerve-centres generate, transmit, and store them.

Nerve-cells. — Nerve-cells vary much in size and shape; many are large, some being amongst the largest cells met with in the body; others, again, are quite small. The nucleus is generally large, clear, and spherical, with a single large and distinct nucleolus. The cell substance is finely granular, sometimes is indistinctly striated. All nerve-cells have at least one process or branch, — most of them have more; and they are often spoken of, in consequence, as uni-polar, bi-polar, and multi-polar cells. In many nerve-cells

we recognize two distinct kinds of processes: first, those which, soon after leaving the cell, divide and subdivide, until they become exceedingly fine and delicate, and in some cases seem to join equally fine processes from other cells; second, those which do not divide and subdivide, but are prolonged as nerve-fibres.

Nerve-fibres. — These are of two kinds: those having a sheath

of white substance, and called **medullated nerve-fibres**; and those having no white sheath, called **non-medullated nerve-fibres**.

The **medullated nerve-fibres** consist of three parts: (1) the axis-cylinder; (2) the white, or medullary sheath; (3) the neurilemma, or enclosing sheath.

(1) The axis-cylinder is the essential part of every nerve-fibre, and runs as a somewhat indistinct strand in the axis of the fibre, and it is sometimes called the axis-band. It appears to be in every case a direct prolongation of a branch of a nerve-cell, and may therefore be looked upon as a far-extending cell-process. It passes without any break or interruption from the nerve-centres to the periphery; that is to say, it is continuous from end to end, from its origin to its termination.

(2) The medullary sheath surrounding the axis-cylinder is a fatty, semi-solid, white substance, which does not form a complete tube, but at tolerably regular intervals is separated into segments; it is not continuous from end to end like the axis-cylinder, being wanting at the origin and termination of the nerve-fibre. (We may look upon the axis-cylinder as the live or naked wire of the fibre, and the white sheath as the isolating, non-conducting substance.)

(3) The neurilemma or enclosing sheath is a thin structureless tube, which tightly encloses the medullary sheath as the sarcolemma encloses the muscle-fibre.

The **non-medullated fibres** have no medullary sheath and no neurilemma. They frequently branch as the medullated fibres never do except near their termination.

The nerve-fibres are gathered into cords of variable size to form the nerves. These cords are called *funiculi*. Each funiculus has its own sheath of connective tissue. If a nerve is small, it may consist of one funiculus, but in larger nerves several funiculi are united by connective tissue into one large cord

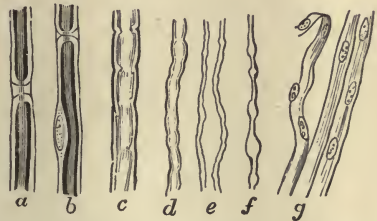


FIG. 116.—NERVE-FIBRES. *a*, nerve-fibre, showing complete interruption of the white substance; *b*, another nerve-fibre with nucleus. In both these nerve-fibres the white substance is stained black with osmic acid, and the axis-cylinder is seen running as an uninterrupted strand through the centre of fibre. *c*, ordinary nerve-fibre unstained; *d*, *e*, smaller nerve-fibre; *f*, varicose nerve-fibre; *g*, non-medullated nerve-fibres.

or nerve, the whole nerve being covered by a dense fibrous sheath of connective tissue.

Besides connecting the funiculi, the connective tissue serves to convey the blood-vessels and lymphatics distributed to the nerve-fibres.

The nerves that conduct nervous impulses towards the nerve-centres are called afferent or sensory nerves, while those that

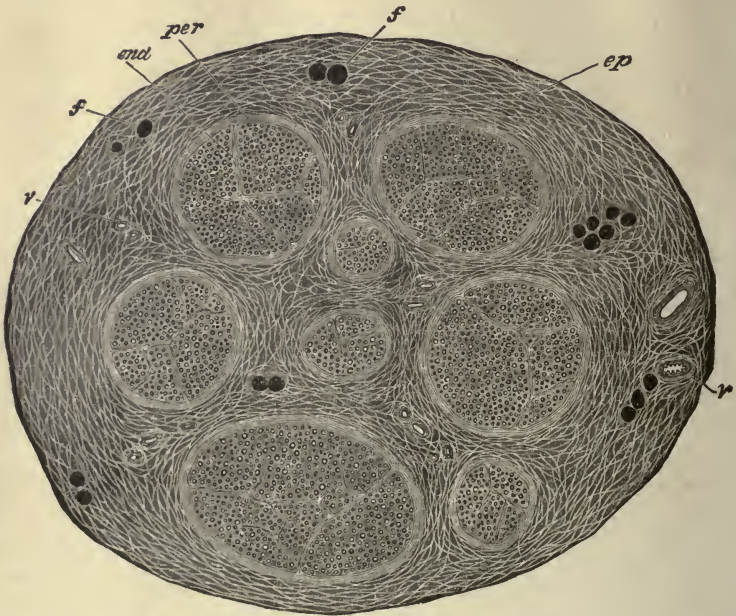


FIG. 117.—SECTION OF THE INTERNAL SAPHENOUS NERVE. Stained in osmic acid and subsequently hardened in alcohol. Drawn as seen under a very low magnifying power. (G. A. S.) *ep*, epineurium, or general sheath of the nerve, consisting of connective tissue separated by cleft-like areolæ, which appear as a network of clear lines, with here and there fat-cells, *f, f*, and blood-vessels, *v.*; *per*, perineurium, or particular sheath of funiculus; *end*, endoneurium, or connective tissue within funiculus, embedded in which are seen the cut ends of the medullated nerve-fibres. The fat-cells and the nerve-fibres are darkly stained by the osmic acid.

transmit nervous impulses from the nerve-centres towards the periphery are termed efferent or motor nerves. Both afferent and efferent fibres may run in the same sheath.

The nervous system.—The great nerve-centre of the body is the cerebro-spinal centre or axis, consisting of the brain and spinal cord. The nerves arising from this centre extend from thence through the body to the muscles, sensible parts, and

other organs, forming the mediums of communication between these distant parts and the great nerve-centre.

Connected with the nerves in various situations are smaller nerve-centres, called ganglia. A series of these ganglia, joined together by nervous bands, form two large chains on either side of the vertebral column, extending from the base of the cranium to the coccyx. These ganglia, with their nerves, are generally called the sympathetic system, and it is usual to speak of the nervous system as consisting of the **cerebro-spinal system** and of the **sympathetic system**.

For convenience of description, we will divide the cerebro-spinal system into —

- (1) Brain and cranial nerves.
- (2) Spinal cord and spinal nerves.

Brain and cranial nerves.

— The brain, the most complex and largest mass of nervous tissue in the body, is contained in the complete bony cavity formed by the bones of the cranium. It is covered by three membranes (also named meninges), — the *dura mater*, *pia mater*, and *arachnoid*.

The *dura mater*, a dense membrane of fibrous connective tissue, lines the bones of the skull, forming their internal periosteum, and covers the brain. It sends numerous prolongations inwards for the support and protection of the different parts of

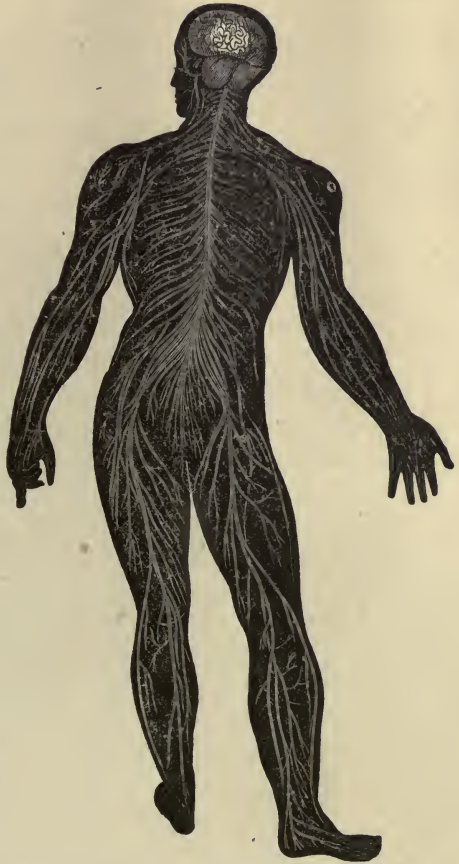

FIG. 118.—DIAGRAM ILLUSTRATING THE GENERAL ARRANGEMENT OF THE CEREBRO-SPINAL SYSTEM.

the brain; it also forms sheaths for the nerves passing out of the skull. It may be called the protective membrane.

The **pia mater** is a delicate membrane of connective tissue, containing an exceedingly abundant network of blood and lymph vessels. It dips down into all the crevices and depressions of the brain, carrying the blood-vessels which go to every part. It may be called the vascular or nutritive membrane.

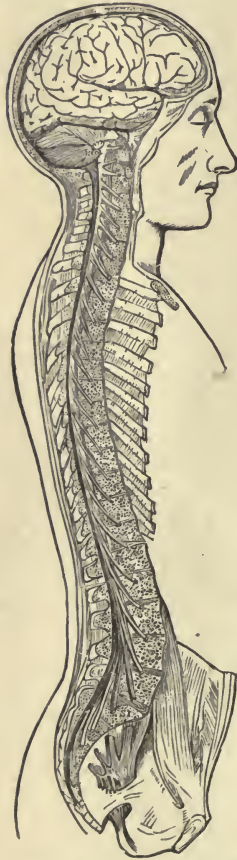

FIG. 119.—SIDE VIEW OF THE BRAIN AND SPINAL CORD IN PLACE. The parts which cover the cerebro-spinal centre are removed.

The **arachnoid** is a delicate membrane which is placed outside the pia mater. It passes over the various eminences and depressions on the surface of the brain, and does not dip down into them like the pia mater. Beneath it, between it and the pia mater, is space (sub-arachnoid space) in which is a certain amount of fluid. The sub-arachnoid space at the base of the brain is of considerable size, and contains a large amount of this clear limpid fluid, called the cerebro-spinal fluid. This fluid probably acts as a sort of protective water-cushion to the delicate nervous structure, and prevents the effects of concussions communicated from without.

The brain is a semi-soft mass of white and gray matter. The white matter consists of very small, medullated nerve-fibres, running in various directions, and supported by a delicate connective tissue framework. The gray matter consists of cells, and fine gray fibres, also supported by connective tissue.

The brain is divided into four principal parts: the cerebrum, the cerebellum, the pons Varolii, and the medulla oblongata.

The **medulla oblongata** is a continuation of the spinal cord, which, on passing into the cranial cavity through the foramen magnum, widens into an oblong-shaped mass. It is directed backwards and downwards, its anterior surface resting on a

groove in the occipital bone, and its posterior surface forming the floor of a cavity between the two halves or hemispheres of the cerebellum. The cavity, called the fourth ventricle, is an expanded continuation of a tiny central canal which runs throughout the whole length of the spinal cord.

The **cerebellum**, or little brain, overhangs the fourth ventricle. It is of a flattened oblong shape, and measures from three and a half inches to four inches transversely, and from two to two and a half inches from before backwards. It is divided in the middle

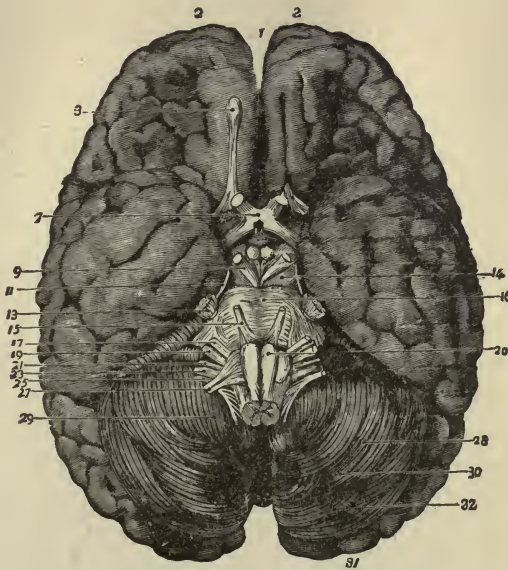


FIG. 120. — THE BASE OF THE BRAIN. 1, longitudinal fissure; 2, 2, anterior lobes of cerebrum; 3, olfactory bulb; 7, optic commissure; 9, 3rd nerve; 11, 4th nerve; 13, 5th nerve; 14, crura cerebri; 15, 6th nerve; 16, pons Varolii; 17, 7th nerve; 19, 8th nerve; 20, medulla oblongata; 21, 9th nerve; 23, 10th nerve; 25, 11th nerve; 27, 12th nerve; 28, 29, 30, 31, 32, cerebellum.

line into two halves or hemispheres by a central depression, each half being subdivided by fissures into smaller portions or lobes. The surface of the cerebellum is traversed by numerous curves or furrows, which vary in depth. In the medulla oblongata, the gray matter is placed in the interior, and the white on the exterior; in the cerebellum, the gray is on the outside, and the white within.

The **pons Varolii**, or bridge of Varolius, lies in front of the medulla oblongata. It consists of alternate layers of transverse

and longitudinal white fibres, intermixed with gray matter. The transverse fibres come mainly from the cerebellum, and serve to join its two halves. The longitudinal fibres come from the medulla oblongata. This bridge is a bond of union between the cerebrum, cerebellum, and medulla oblongata.

The **cerebrum** is by far the largest part of the brain. It is egg-shaped or ovoidal, and fills the whole of the upper portion of the skull. It is almost completely divided by the median fissure into two hemispheres, the two halves, however, being connected in the centre by a broad transverse band of white fibres, called the *corpus callosum*. Each half is subdivided into lobes.

The longitudinal fibres of the medulla oblongata, passing through the pons Varolii, become visible in front of the bridge as two broad, diverging bundles. These two bundles form what are called the *crura cerebri*, or pillars of the brain, and are situated on the under surface of each hemisphere. Between the crura cerebri is a narrow passage (aqueduct of Sylvius) leading from the fourth ventricle into a smaller cavity called the third ventricle. In each side wall of the third ventricle is an opening (foramen of Monro) which leads into two large cavities, the lateral ventricles, and which occupy the centre of each half of the cerebrum. (It will be seen from the above description that the cavities in the centre of the brain are continuous with the central canal in the spinal cord, and also that fibres from the cord pass into the centre of the cerebrum.) Forming the floors of the ventricles, lodged in the crura cerebri, and scattered in their neighbourhood, are irregularly shaped masses of gray matter, intricately connected with one another and with the gray matter in the medulla oblongata. The surface of the cerebral hemispheres is folded, the folds or convolutions being deeper and more numerous in some brains than others: the whole of the convoluted surface is composed of gray matter arranged in several layers of cells and fibres.

The whole brain appears to consist of a number of isolated masses of gray matter—some large, some small—connected together by a multitude of fibres of white matter arranged in perplexing intimacy. But a general arrangement may be recognized. The numerous masses of gray matter in the interior of the brain may be looked upon as forming a more or less contin-

uous column, and as forming the *core* of the central nervous system, while around it are built up the great mass of the cerebrum and the smaller mass of the cerebellum. This central core is connected by various ties with the spinal cord, besides being, as it were, a continuation of the gray matter in the centre of the cord. It is also connected at its upper end, by numberless fibres, to the gray matter on the surface of the cerebrum.

The different masses of gray matter being so closely associated and connected with one another, it will be seen that it becomes a very difficult matter to assign definite functions to definite areas. Of late years, however, a great deal has been accomplished in this direction, and it has become possible to locate the centres that preside over the organs of speech, sight, hearing, etc., and over the movement of muscles in any part of the body. Owing to the crossing or decussation of fibres in the medulla oblongata, injuries to nerve-centres on the right side of the brain will affect the left side of the body, below the decussation.

The average weight of the brain in the male is $49\frac{1}{2}$ oz.; in the female, 44 oz. It appears that the weight of the brain increases rapidly up to the seventh year, more slowly to between sixteen and twenty, and still more slowly to between thirty and forty, when it reaches its maximum. Beyond this age the brain diminishes slowly in weight, about an ounce every ten years. The size of the brain bears a general relation to the capacity of the individual. Cuvier's brain weighed rather more than 64 oz., while the brain of an idiot seldom weighs more than 23 oz. The number and depth of the cerebral convolutions also bear a close relation to intellectual power; babies and idiots have few and shallow folds, while the brains of men of intellect are always markedly convoluted.

The cranial nerves. — The cranial nerves, twelve in number on each side, arise from the base of the brain and medulla oblongata (*vide* Fig. 120), and pass out through openings in the base of the skull. They are named numerically according to the order in which they pass out of the skull. Other names are also given to them derived from the parts to which they are distributed, or from their functions. Taken in their order from before backwards, they are as follows: —

- | | |
|-----------------|-----------------------|
| 1. Olfactory. | 7. Facial. |
| 2. Optic. | 8. Auditory. |
| 3. Motor oculi. | 9. Glosso-pharyngeal. |
| 4. Pathetic. | 10. Pneumo-gastric. |
| 5. Trifacial. | 11. Spinal-accessory. |
| 6. Abducens. | 12. Hypo-glossal. |

The **first** or **olfactory** nerve is the special nerve of the sense of smell. It arises by three roots from the interior of the brain, and sends numerous fibres through the perforated plate of the ethmoid bone, to be distributed to the mucous membrane lining the nasal chamber.

The **second** or **optic** nerve is the special nerve of the sense of sight. It enters the orbit and is distributed to the interior of the eyeball. Before entering the orbit the nerve is connected with its fellow of the opposite side by a band or commissure, and from this union it may be traced back along the optic tract to its deep origin in the central gray matter of the brain.

The **third** or **motor oculi** nerve is the chief mover of the eye; it supplies all the muscles of the eye with the exception of the superior oblique and external rectus. Its origin may be traced back to the gray matter in the medulla oblongata.

The **fourth** or **pathetic** nerve, the smallest of the cranial nerves, supplies the superior oblique muscle of the eye. It arises close to the third nerve.

The **fifth** or **trifacial** nerve is the largest of the cranial nerves. It arises by two roots, — a posterior or sensory, and an anterior or motor. The posterior root is larger than the anterior, and has a ganglion developed on it. The fibres from the two roots coalesce into one trunk, and then subdivide into three large branches: the ophthalmic, the superior maxillary, and the inferior maxillary. The ophthalmic branch is the smallest, and is a sensory nerve. It supplies the eyeball, the lachrymal gland, the mucous lining of the eye and nose, and the skin and muscles of the eyebrow, forehead, and nose. The superior maxillary, the second division of the fifth, is also a sensory nerve and supplies the skin of the temple and cheek, the upper teeth, and the mucous lining of the mouth and pharynx. The inferior maxillary is the largest of the three divisions of the fifth, and is both a sensory and motor nerve. It sends branches to the temple and the external ear; to the teeth and lower jaw; to the

muscles of mastication: it also supplies the tongue with a special nerve (the lingual) of the sense of taste.

The **sixth** or **abducens** nerve supplies the external rectus muscle of the eye.

The **seventh** or **facial** nerve is the motor nerve of all the muscles of expression in the face: it also supplies some muscles of the neck and ear. It arises close to the sixth nerve on the floor of the fourth ventricle.

The **eighth** or **auditory** nerve is the special nerve of the sense of hearing, being distributed exclusively to the internal ear.

The **ninth** or **glosso-pharyngeal** nerve is distributed, as its name indicates, to the tongue and pharynx, being the nerve of sensation to the mucous membrane of the pharynx, of motion to the pharyngeal muscles, and the special nerve of taste to part of the tongue.

The **tenth** or **pneumogastric** nerve has a more extensive distribution than any of the other cranial nerves, passing through the neck and thorax to the upper part of the abdomen. It contains both motor and sensory fibres. It supplies the organs of voice and respiration with motor and sensitive filaments; and the pharynx, œsophagus, stomach, and heart with motor fibres. This nerve is sometimes spoken of as the *par vagus*.

The **eleventh** or **spinal-accessory** nerve consists of two parts: one, the spinal portion, and the other, the accessory portion to the tenth nerve. It is a motor nerve supplying certain muscles of the neck. It differs from the other cranial nerves in arising from the spinal cord, but it leaves the skull by the same aperture as the pneumogastric and glosso-pharyngeal.

The **twelfth** or **hypoglossal** nerve is the motor nerve of the tongue.

All the cranial nerves, with the exception of the two first pairs and the spinal accessory, arise from the gray matter in the medulla oblongata, and any injury to the medulla oblongata is attended with the most serious results, while extensive injury arrests the respiratory processes and causes instant death.

It will be observed that of the twelve pairs of cranial nerves, four, and a part of a fifth, are distributed to the eye; viz. the optic, motor oculi, pathetic, abducens, and the ophthalmic branch of the fifth. The ear has one special nerve, the auditory, and is sparingly supplied with motor and sensitive fibres from other

nerves. The nose has also one special nerve, the olfactory, and is more abundantly supplied than the ear, with motor and sensitive fibres from other nerves. The tongue has two special branch nerves of taste, — the lingual, a branch of the fifth, and the glossal, a branch of the ninth: it has also its own motor nerve, the hypoglossal.

The spinal cord and spinal nerves.—The spinal cord is a column of gray and white soft substance, extending from the top of the spinal canal, where it is continuous with the brain, to about the second lumbar vertebra, where it tapers off into a fine thread. Before its termination it gives off a number of fibres which form a tail-like expansion, called the cauda equina.

Like the brain, the spinal cord is protected and nourished by three membranes. These membranes have the same names and practically exercise the same functions as those enveloping the brain. The dura mater is not attached to the walls of the spinal canal, being separated from them by a certain quantity of areolar and adipose tissue and a network of veins. Therefore, the spinal cord does not fit closely into the spinal canal, as the brain does in the cranial cavity, but is, as it were, suspended within it. It diminishes slightly in size from above downwards, with the exception of presenting two enlargements in the cervical and dorsal regions. It is usually from sixteen to seventeen inches long, and has an average diameter of three-fourths of an inch. The spinal cord is almost completely divided into lateral halves by an anterior and posterior fissure, the anterior fissure dividing it in the middle line in front, and the posterior fissure, in the middle line behind. In consequence of the presence of these fissures, only a narrow bridge of the substance of the cord connects its two halves, and this bridge is traversed throughout its entire length by a minute central canal,—the *canalis centralis*. On making a transverse section of the spinal cord, the gray matter is seen to be arranged in each half in the form of a half-moon or crescent, with one end bigger than the other, and with the concave side turned outwards. The convex sides of the gray matter in each half approach one another, and are joined by the isthmus or bridge which contains the central canal. The tips of each crescent are called its horns or cornua, the front or anterior cornua being thicker and larger than the posterior. The white mat-

ter of the cord is arranged around and between the gray matter, the proportion of gray and white matter varying in different regions of the cord. The white matter, as in the brain, is composed of medullated nerves, and the gray matter of nerve-cells

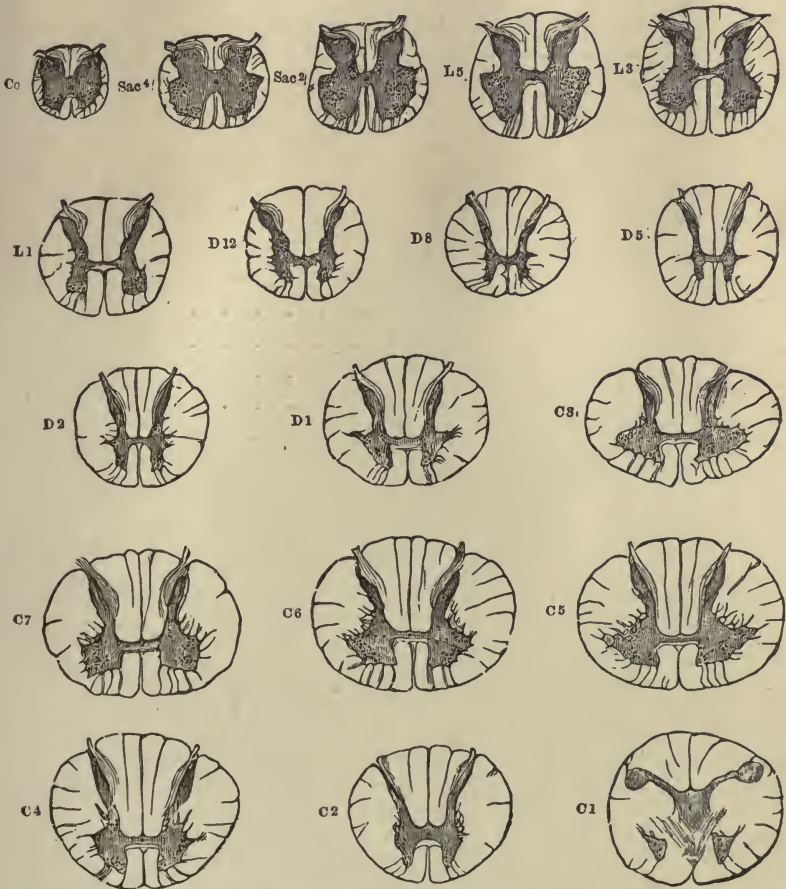


FIG. 121. — TRANSVERSE SECTIONS OF THE SPINAL CORD AT DIFFERENT LEVELS. (Gowers.) (Twice the natural size.) The letters and numbers indicate the position of each section: *Cc*, at level of coccygeal nerve; *Sac*⁴, of 4th sacral; *L*³, at third lumbar, and so on. The gray substance is shaded dark, and the nerve-cells within it are indicated by dots.

and fine gray fibres, all held together and supported by delicate connective tissue. The majority of the nerves run in a longitudinal direction.

There is no real division between the brain and spinal cord,

the brain being built upon the cord, and together they form the great nerve-centre or axis—the cerebro-spinal—which, by means of the cranial and spinal nerves, is placed in connection with all parts of the body. Although the gray matter in the spinal cord is intimately connected with the gray matter in the brain, it has some functions independent of the brain, which will be described in connection with the spinal nerves.

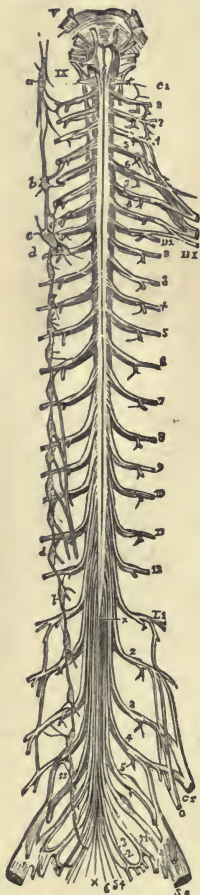


FIG. 122.—BASE OF BRAIN, SPINAL CORD, AND SPINAL NERVES. V, IX, cranial nerves; a, b, c, d, sympathetic ganglia; C¹⁻⁸, spinal cervical nerves; D¹⁻¹², spinal dorsal nerves; L¹⁻⁵, spinal lumbar nerves; S¹⁻⁵, sacral; 6, coccygeal.

The spinal nerves.— There are thirty-one pairs of spinal nerves, arranged in the following groups, and named from the regions through which they pass. They are:—

Cervical	8 pairs
Dorsal	12 “
Lumbar	5 “
Sacral	5 “
Coccygeal	1 pair

The spinal nerves pass out of the spinal canal through the intervertebral foramina, the openings between the vertebræ spoken of in the lesson on the bones of the spine.

Each spinal nerve has two roots, an anterior root and a posterior root. The fibres connected with these two roots are collected into one bundle, and form one nerve just before leaving the canal through the intervertebral openings. Before joining to form a common trunk, the fibres connected with the posterior root present an enlargement, this enlargement being due to a ganglion, or small nerve centre. The fibres of the anterior root *arise from the gray matter* in the anterior cornu, and appear for the most part to be direct prolongations from the nerve-cells there. The fibres of the posterior root, on the other hand, appear to arise in most cases from the cells in the ganglion, and to *grow into the nerve-centres forming the gray matter* in the posterior cornu. The fibres growing from the anterior root are

efferent fibres, and convey nervous impulses from the spinal cord to the periphery. The fibres growing into the posterior root are afferent fibres, and convey nervous impulses from the periphery to the spinal cord. The afferent fibres usually convey sensory impressions, and the efferent motor impulses.

The thirty-one pairs of spinal nerves, containing within the one sheath both afferent and efferent fibres, issue at regular intervals from the spinal canal, and are distributed to all parts of the body, the efferent or motor fibres being distributed to the muscular tissue, and causing contraction of the muscles; the afferent or sensory fibres ending commonly in the skin, and conveying nervous impulses to the nerve-centres which give rise to sensation.

The nervous impulses transmitted by the afferent nerves to the spinal cord are usually forwarded by the cord to the brain, and the nervous impulses sent out along the efferent fibres to

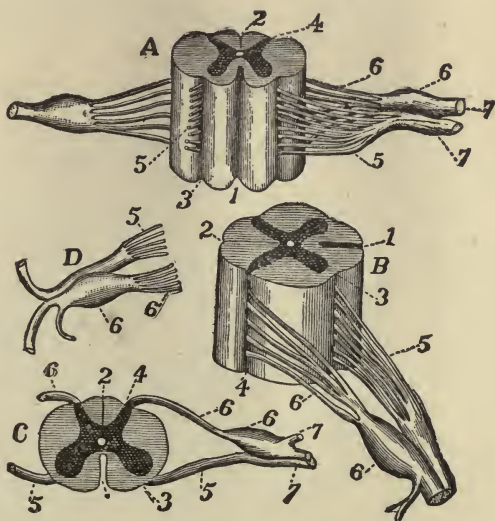


FIG. 123.—SECTIONS OF SPINAL CORD AND NERVE-ROOTS. *A*, anterior view; *B*, side view; *C*, transverse section; *D*, two isolated roots of a spinal nerve. 1, anterior fissure; 2, posterior fissure; 3, groove formed by anterior roots; 4, groove formed by posterior roots; 5, fibres of anterior root; 6, fibres of posterior root; 6, ganglion on posterior root.

the muscles are also commonly transmitted by the spinal cord from the brain. And if the spinal cord be so injured as to practically sever its connection with the brain, it will be found that paralysis and insensibility of the body below the injury will ensue, showing conclusively that, severed from the brain, the ability of the spinal cord to give rise to sensation, or to control muscular contractions, is seriously impaired. Yet the gray matter in the spinal cord has a certain power of its own, for after the cord has been severed from the brain, spasmodic

contraction of muscles can be made to take place. The application of stimuli to the afferent nerve-fibres ending in a portion

of the skin will set up changes in the fibres, which changes will be transmitted by them to the gray matter in the posterior root of the spinal cord. These changes or nervous impulses, instead of being sent up the cord to the seat of sensation in the brain, and thus giving rise to sensation, are transmitted to the gray matter in the anterior root of the cord, and conveyed thence by the efferent fibres to the muscles, which they cause to contract. This power of transforming an afferent into an efferent impulse is termed the reflex power of the spinal cord.

The sympathetic system.—The sympathetic system consists of a double chain of ganglia, placed on each side of the spinal column, and united with each other by longitudinal filaments. The cells in the ganglia are smaller than those in the brain and

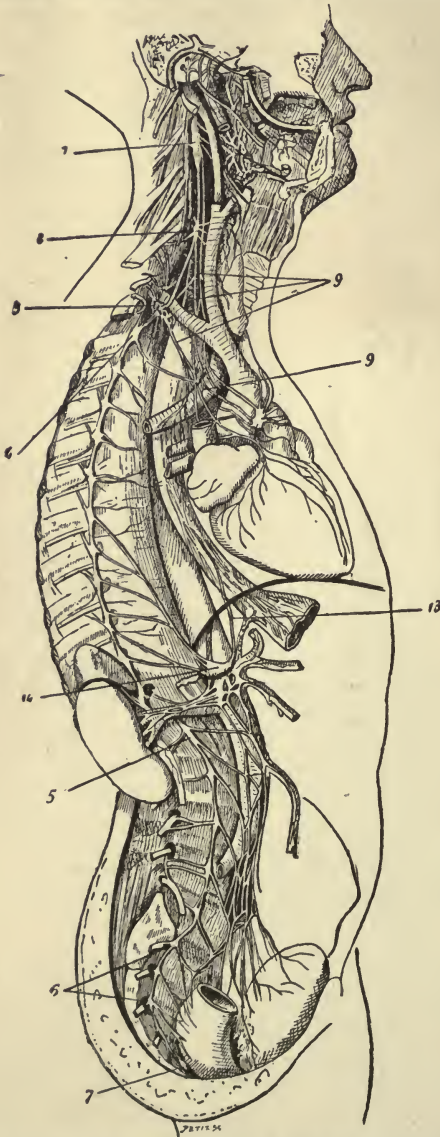


FIG. 124. — GENERAL VIEW OF THE SYMPATHETIC SYSTEM. 1, 2, 3, cervical ganglia; 4, 1st thoracic ganglion; 5, 1st lumbar ganglion; 6, 7, sacral ganglion; 9, 9, cardiac nerves; 13, branch of pneumogastric nerve ending in semi-lunar ganglion; 14, epigastric plexus.

spinal cord, and the fibres that arise from them are mostly of the non-medullated variety.

These ganglia and nerves do not form an independent nervous system, for each ganglion is connected by motor and sensitive fibres with the cerebral system. The sympathetic nerves are distributed to the viscera and blood-vessels, of which the movements are involuntary, and the general sensibility obtuse. They form networks or plexuses upon the heart, about the stomach, and other viscera in the trunk; they also enter the cranium, send branches to the organs of special sense, and, in particular, influence the pupil of the eye. Their most important distribution, however, is in connection with the blood-vessels. They form plexuses around the vessels, especially the arteries, and send fibres to terminate in the involuntary muscular tissue of which the walls of these tubes are largely composed. The nerves thus distributed are called "vaso-motor" nerves.

The unity of the nervous system. — From the foregoing description of the nervous system, it is clear that it forms one continuous whole, through the agency of which all the varied activities of the body are controlled and regulated. We may compare it to a telegraphic system, the central office of which would represent the brain and spinal cord, the more important sub-offices the sympathetic ganglia, and the minor offices the isolated ganglia; while the telegraph wires, directly or indirectly uniting all, would correspond to the nerves. And just as a message started along some outlying wire may be transmitted to a central office, and, according to the information received, will be stopped there, or sent to some other centres to be forwarded by them in one direction, in two directions, or all over the country, — so may a nervous impulse reaching the brain merely excite some change in the brain itself, or be sent out from thence along the nerve-trunks to excite activities in various parts of the body.

Peripheral termination of nerves. — The nerves have their origin

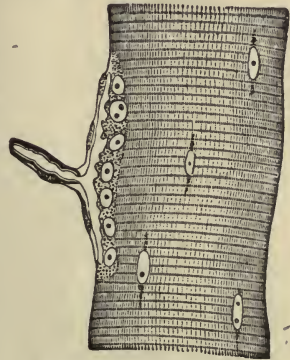


FIG. 125. — NERVE ENDING IN MUSCULAR FIBRE OF A LIZARD. (Kühne.) The end-plate, or motorial ending of the axis-cylinder, is seen sideways.

in the gray matter of the brain, in the spinal cord, and in various ganglia; their termination, or peripheral distribution, is not so easy to determine.

All nerves, medullated or non-medullated alike, in approaching their final distribution, divide; that is, the numerous strands or fibres which go to make up a nerve separate from one another. If we follow a fibre, we find, if it is a medullated one, that the

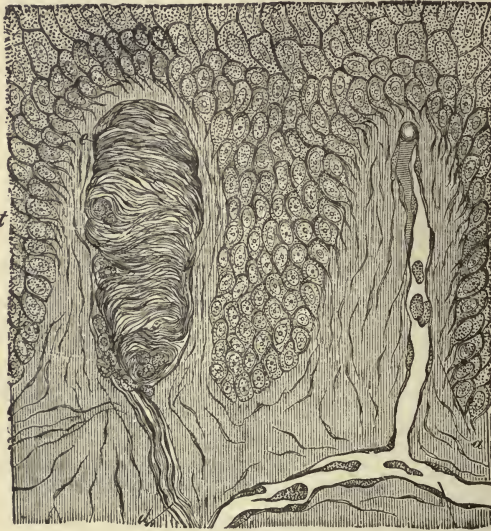

FIG. 126.—SECTION OF SKIN SHOWING TACTILE CORPUSCLE IN PAPILLA. *d*, nerve passing up to tactile corpuscle; *t*, tactile corpuscle.

sheaths enclosing it gradually disappear, and finally the axis cylinder itself splits into its component fibrils. These fibrils may terminate in invisible threads, as between the cells in the Malpighian layer of epidermis, or they may terminate in special end organs, such as the tactile bodies in the papillæ of the skin, the round-end bulbs in the conjunctiva, the motorial ramifications in the muscular fibres, and in other ways too numerous and too complicated for us to attempt to describe.

Degeneration and regeneration of nerves.—The divided ends of a nerve that has been cut across readily reunite by cicatricial tissue,—that is to say, the connective tissue framework unites,—but the cut ends of the fibres themselves do not unite. On the contrary, the peripheral or severed portion of the nerve begins to degenerate, the medullary sheath breaks up into a mass of fatty molecules and is gradually absorbed, and finally the

axis-cylinder also disappears. In regeneration, the new fibres grow afresh from the axis-cylinders of the central end of the severed nerve-trunk, and, penetrating into the peripheral end of the trunk, grow along this as the axis-cylinders of the new nerve, each axis-cylinder becoming after a time

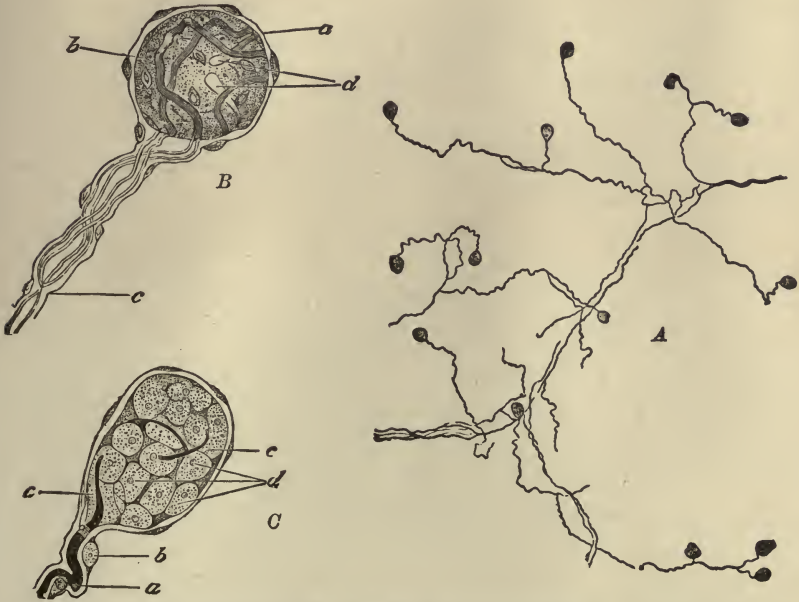


FIG. 127.—END-BULBS FROM THE HUMAN CONJUNCTIVA. (Longworth.) *A*, ramification of nerve-fibres in the mucous membrane, and their termination in end-bulbs, as seen with a lens; *B*, an end-bulb more highly magnified; *a*, nucleated capsule; *b*, core; *c*, entering fibre branching, and its two divisions passing to terminate in the core at *d*; *C*, an end-bulb treated with osmic acid, showing the cells of the core better than *B*.

surrounded with a medullary sheath. Restoration of function in the nerve may not occur for several months, during which time it is presumed the new nerve-fibres are slowly finding their way along the course of those which have been destroyed.

CHAPTER XIX.

THE ORGANS OF SPECIAL SENSE: THE SKIN, THE ORGAN OF THE SENSE OF TOUCH, AND OF HEAT AND COLD; THE TONGUE, THE ORGAN OF THE SENSE OF TASTE; THE NOSE, THE ORGAN OF THE SENSE OF SMELL; THE EAR, THE ORGAN OF THE SENSE OF HEARING; THE EYE, THE ORGAN OF THE SENSE OF SIGHT.

OUR sensations are both varied and numerous, and arise from within and from without. Sensations arising from within ourselves, such as feelings of fatigue, hunger, thirst, restlessness, etc., and to which we can assign no particular place, we usually speak of under the name of *diffuse* or *subjective* sensations. Sensations produced by impressions made on a definite part of the body, and only excited by some particular influence applied to that part of the body, we usually speak of under the name of *special* or *objective* sensations: such are sensations of touch, heat, and cold, of taste and smell, and of sound and light.

Any portion of the body to which a sensation is thus restricted is called a sensory organ, and of these special sensory organs there are five, viz. :—

- The skin, the organ of the sense of touch.
- The tongue, the organ of the sense of taste.
- The nose, the organ of the sense of smell.
- The ear, the organ of the sense of hearing.
- The eye, the organ of the sense of sight.

In order to be conscious of any sensation, it is necessary for the end-organ (that is, the sensory organ which receives impressions) to be placed in communication with the brain, which is the seat of all sensation. If, for instance, the optic nerve, which is the medium of communication between the visual centre in the brain and the end-organ, the eye, be destroyed, the indi-

vidual will be unable to see with that eye. In thinking of the sensory organs, then, we must remember that *they are structures specially modified and adapted to receive certain impressions, which impressions, when conveyed to the brain, give rise to definite sensations.*

The sense of touch. — The sense of touch, as also the sense of heat and cold, is possessed more or less acutely by all parts of the skin, and also by the mucous membrane, or internal skin, lining the nose and mouth. We noted in the lesson on the skin, that the sense of touch is most delicate in those parts where the papillæ of the true skin are most abundant and contain the special nerve-endings called tactile corpuscles, as in the tips of the fingers and toes (*vide* page 191). The feelings of warmth and cold are also caused by exciting sensory nerves distributed to the skin, though they are probably distinct from those which give rise to the sense of touch. The sense of warmth and cold varies also in sensitiveness in different parts of the body, and we involuntarily test the temperature of an iron or of a poultice by holding it to the cheek, and when we are cold we spread the palms of our hands to the fire.

If the nerves of the skin are unduly stimulated by severe pressure, or by exposure to extremes of heat or cold, the sense of touch and of temperature is lost in the sense of pain. This is also the case if the nerves are too freely exposed, as when the epidermis is removed by blistering, or in some other manner, and the skin is left "raw."

The sense of taste. — The special organ of the sense of taste is the tongue, which is a movable muscular organ covered with mucous membrane. The mucous membrane closely resembles the skin in structure, except that the papillæ it contains are more highly developed. The papillæ project as minute prominences and give the tongue its characteristic rough appearance.

Some of the papillæ are simple and resemble those found in the skin; the remainder are compound,¹ and are only found on the surface of the tongue. Of these compound papillæ there are three varieties. The largest, the *circumvallate papillæ*, are about eight or ten in number, and form a V-shaped row near the root of the tongue, with its open angle turned towards the lips.

¹ A compound papilla is one large one bearing several smaller ones on its surface.

The next in size are the *fungiform papillæ*,¹ found principally on the tip and sides of the tongue. The smallest and most numerous are the *filiform papillæ*, found all over the tongue, excepting the root, and bearing on their free surface a form of ciliated epithelium. In some animals the hair-like processes on the fili-

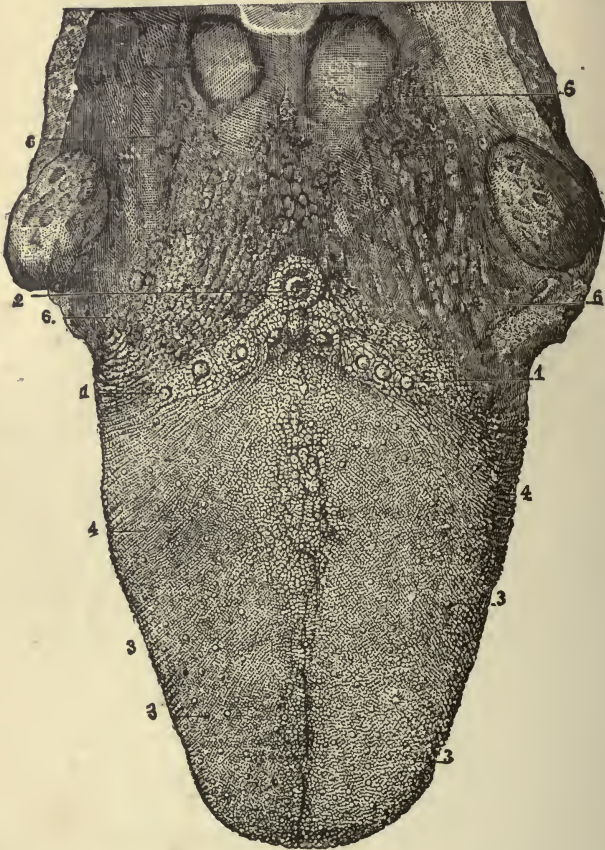


FIG. 128.—THE UPPER SURFACE OF THE TONGUE. 1, 2, circumvallate papillæ; 3, fungiform papillæ; 4, filiform papillæ; 6, mucous glands.

form papillæ are horny in structure, and their tongues are correspondingly roughened, so that they supplement the teeth in the bruising and crushing of food. In man these hair-like pro-

¹ The fungiform papillæ resemble fungi, having an expanded upper portion resting on a short, thick pedicle. The circumvallate papillæ resemble the fungiform, except that they are surrounded by a wall of smaller papillæ.

cesses are exceedingly delicate, and seem to be specially connected with the sense of touch, which on the tip of the tongue is highly developed, and which serves to guide the tongue in its variable and complicated movements.

In the circumvallate, some of the fungiform papillæ, and scattered also over the mucous membrane of the tongue and soft palate, are little clusters of cells lying in cavities of the epithelium, called *taste-buds*. The bases of these cell-clusters, or taste-buds, are supplied with nerve-fibres, and it is surmised that they are more specially connected with the sense of taste than the other portions of the mucous membrane covering the tongue.

The special nerves of the sense of taste distributed to the tongue are the glosso-pharyngeal, or ninth nerve, and the lingual or gustatory, a branch of the fifth nerve. The former supplies the back of the tongue, and section of it destroys taste in that region; the latter is distributed to the front of the tongue, and section of it, similarly, deprives the tip of the tongue of taste.

We often confound taste with smell. Substances which have a strong odor, such as onions, are smelled as we hold them in our mouths; and if our sense of smell is temporarily suspended, as it sometimes is by a bad cold in the head, we may eat garlic and onions and not taste them. Hence the philosophy of holding the nose when we wish to swallow a nauseous dose.

The sense of smell.—The nose is the special organ of the sense of smell. It consists of two parts,—the external feature, the nose, and the internal cavities, the nasal fossæ. The **external nose** is composed of a triangular framework of bone and cartilage, covered by skin and lined by mucous membrane. On its under surface are two oval-shaped openings—the nostrils—separated by a partition. The margins of the nostrils are provided with a number of stiff hairs which arrest the passage of dust and other foreign substances carried in with the inspired air.

The **nasal fossæ** are two irregularly wedge-shaped cavities, separated from one another by a partition or septum, and communicating with the air in front by the anterior nares or nostrils, while behind they open into the back of the pharynx by the two posterior nares. Fourteen bones enter into the formation

of the nasal cavities: the floor is formed by the palate and part of the superior maxillary bones; the roof is chiefly formed by the perforated (cribriform) plate of the ethmoid bone, and by

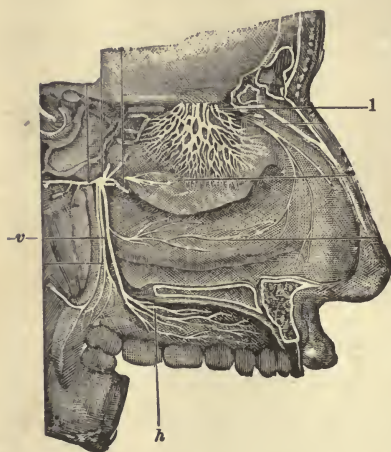


FIG. 129. — VERTICAL LONGITUDINAL SECTION OF NASAL CAVITY. 1, olfactory nerve; v, branch of fifth nerve; h, hard palate.

the two small nasal bones; and in the outer walls we find, in addition to processes from other bones, the three scroll-like turbinated bones. The turbinated bones, which are exceedingly light and spongy, project into the nasal cavities, and divide them into three incomplete passages from before backwards,—the superior, middle, and inferior meatus. The palate and superior maxillary bones separate the nasal and mouth cavities, and the cribriform plate of the ethmoid forms the partition between the cranial and nasal cavities.

The mucous membrane (sometimes called the Schneiderian¹ membrane), which closely covers the nasal passages, is thickest and most vascular over the turbinated bones. In some nasal troubles it becomes much thickened and swollen and occludes the nasal passages to such an extent as to compel us to breathe through the mouth. It contains numerous mucous glands which secrete mucus for the purpose of keeping the membrane moist,—a condition which is essential to perfection of the sense of smell.

The mucous membrane lining the nasal chambers is supplied with nerve-fibres from the first or olfactory nerve, and also with fibres of common sensation from the fifth nerve. The fibres from the olfactory nerves are distributed exclusively to the upper air-passages of the nose, the mucous membrane of which is covered with a specially modified epithelium. These fibres

¹ From Schneider, the first anatomist who showed that the secretions of the nose proceeded from the mucous membrane, and not, as was formerly supposed, from the brain.

come directly from the brain through the cribriform plate, and are essential to the sense of smell. Odorous particles in the air, passing through the lower, wider air-passages, pass by diffusion into the higher, narrower nasal chambers, and, falling on the mucous membrane provided with olfactory nerve-endings, produce sensory impulses which, ascending to the brain, give rise to the sensations of smell.

If we wish to smell anything particularly well, we sniff the air up into the higher nasal chambers, and thus bring the odorous particles more closely into contact with the olfactory nerves.

Each substance we smell causes its own particular sensation, and we are not only able to recognize a multitude of distinct odors, but also to distinguish individual odors in a mixed smell. The sensation takes some time to develop after the contact of the odorous stimulus, and may last a long time. When the stimulus is repeated, the sensation very soon dies out, the sensory terminal organs quickly becoming exhausted. Mental associations cluster more strongly round sensations of smell than round any other impressions we receive from without. A whiff of fresh-mown grass! What associations will it not conjure up for those happy mortals who spent their childish days in country lanes and fields.

The sense of hearing.—The ear is the special organ of the sense of hearing, and is made up of three portions,—the external ear, the middle ear or tympanum, and the internal ear or labyrinth.

The **external ear** consists of an expanded portion, named **pinna** or **auricle**, and the **auditory canal** or **meatus**.

The **auricle** is composed of a thin plate of yellow fibro-cartilage, covered with skin, and joined to the surrounding parts by ligaments and a few muscular fibres. It is very irregular in shape, and appears to be an unnecessary appendage to the organ of hearing, except that the central depression, the **concha**, serves to some extent to collect sound-waves, and to conduct them into the auditory canal.

The **auditory canal** is a tubular passage, about an inch and a quarter in length, leading from the **concha** to the drum-membrane. It is slightly curved upon itself, so as to be higher in the middle than at either end. It is lined by a prolongation of the skin, which in the outer half of the canal is very thick and

not at all sensitive, and in the inner half is thin and highly sensitive. Near the orifice the skin is furnished with a few hairs, and further inwards, with modified sweat-glands, the ceruminous glands, which secrete a yellow, pasty substance, resembling wax.

The **middle ear** or **tympanum** is a small, irregularly flattened cavity, situated in the petrous portion of the temporal bone, and lined with mucous membrane. It is separated from the external auditory canal by the drum membrane (*membrana*

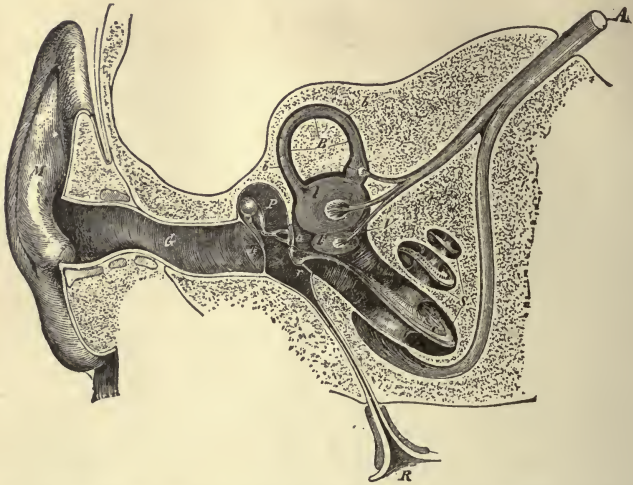


FIG. 130. — SEMI-DIAGRAMMATIC SECTION THROUGH THE RIGHT EAR. *M*, concha; *G*, the external auditory canal; *T*, tympanic, or drum-membrane; *P*, tympanum, or middle ear; *o*, oval window; *r*, round window. Extending from *T* to *o* is seen the chain of the tympanic bones; *R*, Eustachian tube; *V*, *B*, *S*, bony labyrinth; *V*, vestibule; *B*, semicircular canal; *S*, cochlea; *b*, *l*, *v*, membranous labyrinth in semicircular canal and in vestibule. *A*, auditory nerve dividing into branches for vestibule, semicircular canal and cochlea.

tympani), and from the internal ear by a bony wall in which there are two small openings covered with membrane,—the oval window or *fenestra ovalis*, and the round window or *fenestra rotunda*. The cavity of the middle ear is so small that probably five or six drops of water would completely fill it. It communicates below with the pharynx by the small passage called the Eustachian tube, through which air enters the cavity and serves to keep the atmospheric pressure equal on each side of the drum-membrane. The middle ear also communicates above with a number of bony cavities in the mastoid por-

tion of the temporal bone.¹ The cavities, called mastoid cells, are lined with mucous membrane, which is continuous with that covering the cavity of the tympanum.

Stretching across the tympanic cavity is a chain of tiny movable bones, three in number, and named from their shape the *malleus* or hammer, the *incus* or anvil, and the *stapes* or stirrup. The hammer is firmly attached to the drum-membrane, and the stirrup is fastened into the oval window (also covered by membrane) leading into the inner ear. The anvil is placed between the hammer and stirrup, and attached to both by delicate articulations. These little bones are set in motion with every movement of the drum-membrane. Vibrations of the membrane are communicated to the hammer, taken up by the anvil and transmitted to the stirrup, which is driven slightly forward, and sets in motion the membrane covering the oval opening leading into the internal ear.

The **internal ear** or **labyrinth** receives the ultimate terminations of the auditory nerve, and is, therefore, the essential part of the organ of hearing. It consists of (1) a **bony labyrinth**, which is composed of a series of peculiarly shaped cavities, hollowed out of the petrous portion of the temporal bone, and named from their shape the vestibule, the semicircular canals, and cochlea (snail-shell). This bony labyrinth is lined by a serous membrane, which secretes a watery fluid called the perilymph; and lying within the bony labyrinth and perilymph is (2) a **membranous labyrinth**, which is composed of a series of sacs or tubes, fitting more or less closely within the vestibule, semicircular canals, and cochlea. The membranous labyrinth is filled with a watery fluid, called the endo-lymph, and is lined for the most part by specially modified epithelium cells, which are connected with the terminations of the auditory nerve.

We may conceive of the internal ear as a bony cavity, elaborately tunnelled from the expanded entrance or vestibule into semicircular canals above, and into a canal resembling a snail's shell below. In this bony labyrinth is a certain amount of fluid, and a membranous bag, drawn out and expanded at intervals to fit more or less closely within the bony labyrinth. This membranous bag contains fluid, and is lined by a most highly

¹ The mastoid portion of the temporal bone is that rounded mass of bone which one readily distinguishes behind the auricle.

specialized epithelium, some of the cells of which have hair-like processes projecting into the fluid, others have tiny grains of calcareous sand¹ attached to their surfaces, and all of them are connected with the thousands of nerve-fibres into which the auditory nerve divides after entering the internal ear. The construction of the whole ear and its position in the centre of a bone is for the purpose of protecting this delicate and highly organized membrane, by means of which alone sound-impressions can be advantageously conveyed to the brain and give rise to the sensation of hearing.

All bodies which produce sound are in a state of vibration and communicate their vibrations to the air with which they are in contact, and thus the air is thrown into waves, just as a stick waved backwards and forwards in water throws the water into waves.

When air-waves, set in motion by sonorous bodies, enter the external auditory canal, they set the drum-membrane vibrating, stretched membranes taking up vibrations from the air with great readiness. These vibrations are communicated to the chain of tiny bones stretching across the middle ear, and their oscillations cause the membrane leading into the internal ear to be alternately pushed in and drawn out, and vibrations are in this way transmitted to the peri-lymph. Each vibration communicated to the peri-lymph travels as a wave over the vestibule, semicircular canals, and cochlea, and is transmitted through the membranous walls to the endo-lymph. The vibrations of the endo-lymph are communicated to the specially modified cells connected with the endings of the auditory nerve, and nervous impulses are conveyed by the auditory nerve to those parts of the brain, stimulation of which gives rise to the sensation of sound.

The effect produced by a sonorous vibration continues for a short time after the cessation of its cause. Usually the interval between two different impulses is sufficient to allow the first impression to disappear before the second is received, and the ear distinguishes them in succession. But if they follow each other at equal intervals, with a certain rapidity, they produce

¹ In the walls of the vestibule are two small masses, called otoliths, which are composed of grains of calcareous sand. It is not known what special part these otoliths play in the production of sound.

the impression of a continuous sound; and this sound has a higher or lower pitch, according to the rapidity of its vibrations. It has been discovered that sonorous impulses following each other with a rapidity of less than sixteen times per second, are separately distinguishable; but above that frequency they are merged into a continuous sensation. When the sonorous impulses are repeated at irregular intervals, the only characters perceptible in the sound are its intensity and quality. But if they succeed each other at regular intervals, the sound produced has a position in the musical scale as a high or low note. The more frequent the repetitions, the higher the note; but a limit is at last reached, at which the ear fails to perceive the sound, and an excessively high note is therefore inaudible. Sonorous vibrations, perceptible to man as musical notes, range between sixteen per second for the lowest notes, and 38,000 for the highest. (Dalton.)

The sense of sight. — The eye is the special organ of the sense of sight, and consists of the eyeball, or eye proper, and of accessory protective appendages, such as the eyebrows, eyelids, lachrymal glands, etc.

The **eyeball** is contained in a bony cavity, the orbit, which is padded with fat and lined with a membranous capsule, — the capsule of Tenon. This capsule is a serous sac, one layer of which is attached to the posterior portion of the eyeball, while the other lines the orbital cavity: in this way the eyeball is isolated from surrounding structures, and free movement without friction is insured. The orbit is shaped like a four-sided pyramid; the apex, directed backwards and inwards, is pierced by a large opening, — the optic foramen, — through which pass the nerves and blood-vessels distributed to the eyeball. The base of the orbit, directed outwards and forwards, forms a strong bony edge for protecting the eyeball from injury.

The eyeball is spherical in shape, but its transverse diameter is less than the antero-posterior, so that it projects anteriorly, and looks as if a section of a smaller sphere had been engrafted on the front of it.

The eyeball is composed of three coats or tunics, and contains three refracting media or humours. They are as follows: —

- Tunics.** — 1. Sclerotic and cornea.
2. Choroid, iris, and ciliary processes.
3. Retina.

- Refracting media. — 1. Aqueous.
 2. Crystalline lens and capsule.
 3. Vitreous.

The **sclerotic** (derived from a Greek word signifying hard) covers the posterior five-sixths of the eyeball. It is composed of a firm, unyielding, fibrous membrane, thicker behind than in front, and serves to protect the delicate structures contained

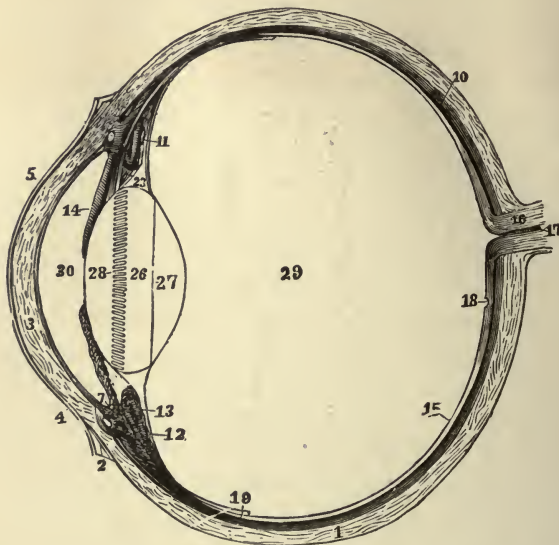


FIG. 131.—THE LEFT EYEBALL IN HORIZONTAL SECTION FROM BEFORE BACK. 1, sclerotic; 2, junction of sclerotic and cornea; 3, cornea; 4, 5, conjunctival membrane; 7, ciliary muscle; 10, choroid; 11, 13, ciliary processes; 14, iris; 15, retina; 16, optic nerve; 17, artery entering retina; 18, fovea centralis; 19, region where sensory part of retina ends; 26, 27, 28, are placed on the lens; 28, suspensory ligament placed around lens; 29, vitreous humour; 30, aqueous humour in anterior chamber.

within it. It is opaque, white and smooth externally, and behind is pierced by the optic nerve. Internally it is stained brown where it comes in contact with the choroid coat. The **cornea** (derived from Latin *cornu*, horn, and therefore also signifying hard) covers the anterior sixth of the eyeball. It is directly continuous with the sclerotic coat, which, however, overlaps it slightly above and below, as a watch-crystal is overlapped by the case into which it is fitted. The cornea, like the

sclerotic, is composed of fibrous tissue, which is both firm and unyielding, but, unlike the sclerotic, it has no colour, and is perfectly transparent: it has been aptly termed the "window of the eye." Both the cornea and the anterior portion of the sclerotic are covered by reflections of the mucous membrane lining the eyelids. This is called the conjunctiva, and, kept well lubricated by the secretions of the eye, gives the eyeball its peculiar shining and glossy aspect. The sclerotic is supplied with very few blood-vessels, and the existence of nerves in it is doubtful; while the cornea has no blood-vessels, but is well supplied with nerves.

The **choroid**, or vascular coat of the eye, is a thin dark-brown membrane lining the inner surface of the sclerotic. It is composed of connective tissue, the cells of which are large and filled with pigment, and it contains a close network of blood-vessels. It extends to within a short distance of the cornea, and then is folded inwards and arranged in radiating folds, like a plaited ruffle, around the lens and just behind the edge of the cornea. The choroid coat, properly speaking, terminates anteriorly in the ciliary processes, arranged, as above stated, in a radiating circle round the lens; but closely connected with the anterior margin of the choroid is the iris.

The **iris** (*iris*, rainbow) is a coloured, fibro-muscular curtain hanging in front of the lens and behind the cornea. It is attached at its circumference to the choroid, with which it is practically continuous, and is also connected to the sclerotic and cornea at the point where they join one another. Except for this attachment at its circumference, it hangs free in the interior of the eyeball. In the middle of the iris is a circular hole—the pupil—through which light is admitted into the eye-chamber. The iris, like the choroid, is composed of connective tissue containing a large number of pigment cells and numerous blood-vessels. It contains in addition two sets of plain muscular fibres. One set forms a flat band round the margin of the pupil, and is called the sphincter or *contractor of the pupil*; the other set consists of radiating fibres converging from the circumference to the centre, and is called the *dilator of the pupil*. The action of these muscle-fibres is affected by light. Under the influence of a bright light the pupil involuntarily contracts so that less light is admitted into

the eye-chamber; in a dim light the pupil involuntarily dilates to admit as much light as possible. The posterior surface of the iris is covered by a thick layer of pigment-cells designed to darken the curtain and prevent the entrance of light. The

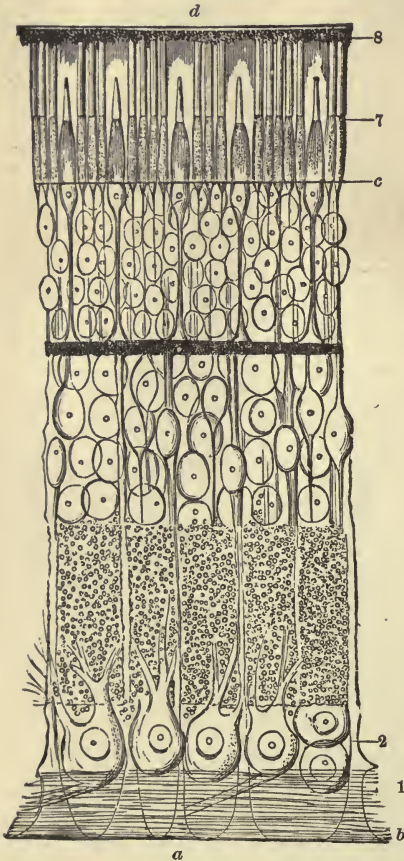


FIG. 132.—DIAGRAMMATIC SECTION OF THE HUMAN RETINA. (M. Schultze.) *a*, inner surface; *b*, internal limiting membrane; 1, layer of nerve-fibres; 2, layer of nerve-cells; *c*, external limiting membrane; 7, layer of rods and cones; 8, pigment cells; *d*, outer surface.

anterior surface of the iris is also covered with pigment cells, and it is chiefly these latter which cause the beautiful colours seen in the iris. The different colours of eyes, however, are mainly due to the amount, and not to the colour, of the pigment deposited.

The retina, the innermost coat of the eyeball, is the most essential part of the organ of sight, since it is the only one directly sensitive to light. The sclerotic is the protective, the choroid the vascular or nutritive, and the retina is the visual or perceptive, layer of the eyeball. It forms a nearly transparent membrane situated between the inner surface of the choroid and the outer surface of the vitreous humour, and extending from the entrance of the optic nerve to the commencement of the ciliary processes, where it terminates by an indented border,

the *ora serrata*. It is composed of eight layers and two limiting membranes, as shown in the accompanying figure (Fig. 132). The most essential of these layers are the first and second,—the layer of nerve-fibres and the layer of nerve-cells,—and the seventh layer,—the layer of the rods and cones. The layer of

nerve-fibres is formed by the expansion of the optic nerve after it has passed through the sclerotic and choroid coats at the back of the eye. At its entrance it forms a slight prominence, and then radiates latterly in every direction in the form of a closely set layer of fine fibrils. The second layer, or layer of nerve-cells, consists for the most part of bipolar¹ cells, processes from which extend into the layer above and below.

The layer of rods and cones is the most remarkable of all the retinal layers; it is composed of elongated nucleated cells, which are supposed by some authorities to be highly specialized epithelium cells: they are directly concerned in producing the sensation of light. Rays of light produce no effect upon the optic nerve without the intervention of the rods and cones. This is proved by the fact that at the entrance of the optic nerve there are no rods and cones, and this spot is quite blind, rays of light falling upon it producing no sensation. There is one point of the retina which is of great importance, and that is the *macula lutea*, or yellow spot. It is situated about $\frac{1}{2}$ of an inch to the outer side of the entrance of the optic nerve. In its centre is a tiny pit (*fovea centralis*) which is the centre of direct vision; that is, it is the part of the retina which is always turned towards the object looked at. From this point the sensitiveness of the retina grows less and less in all directions. In the *fovea centralis* the rods are highly developed, but most of the other layers of the retina are wanting.

Light may be described as consisting of vibrations in the ether which pervades space. These ethereal vibrations enter the eye through the cornea, pass on through the pupil and refracting media, and strike on the retina. Here they excite the rods and cones (cell-bodies specially adapted for receiving stimulation from rays of light), and these pass on their stimulation to the fibres of the optic nerve, which in turn transmit the stimulus to the visual centre in the brain, and the sensation and perception of light is produced.

Behind the layer of rods and cones, and lying on the choroid, is a beautiful mosaic layer of pigment cells containing a purple substance which stains the rods, and is constantly bleached by the action of light and regenerated in the dark.

The refracting media of the eye. — The interior of the eyeball

¹ A bipolar cell is a cell having two processes.

is divided into two chambers by the crystalline lens and iris. The "anterior chamber," the portion in front of the iris, is filled with a colourless, transparent watery fluid, the **aqueous humour**. The "posterior chamber" is filled with a semi-fluid gelatinous substance, the **vitreous humour** or body, so called from its glassy and transparent appearance. Its refractive power, though slightly greater than that of the aqueous humour, does not differ much from that of water. It distends the greater part of the sclerotic, supports the retina, which lies upon its surface, and preserves the spheroidal shape of the eyeball.

The **crystalline lens** is a transparent refractive body, with convex anterior and posterior surfaces, placed directly behind the pupil, where it is retained in position by the counterbalancing pressure of the aqueous humour and vitreous body, and by its own suspensory ligament. It is a fibrous body, composed of long ribband-shaped fibres and enclosed in an elastic capsule. Its refractive power is greater than that of the aqueous or vitreous humour, and it acts by virtue of its double-convex form as a converging lens, bringing parallel or diverging rays to a focus on the posterior surface of the retina. *The function of the crystalline lens is to give perception of form and outline.* If the eye consisted only of a sensitive retina, impressions of light could be received, but the form of objects would not be distinguished. By focussing the rays emanating from an external object, the crystalline lens produces a distinct inverted image of the object on the retina.

The action of the lens, in thus focussing the rays of light at a particular point, may be illustrated in the following manner: If a sheet of white paper be held at a short distance from a candle-flame, in a room with no other light, the whole of the paper will be moderately and uniformly illuminated by the diverging rays. But if a double-convex lens, with suitable curvatures, be interposed between the paper and the light, the outer portions of the paper will become darker, and its central portion brighter, because a portion of the rays are diverted from their original course and bent inward. By varying the distance of the lens from the paper, a point will at last be found where none of the light reaches the external parts of the sheet, but all of it is concentrated upon a single spot; and at this spot will be seen a distinct image of the candle and its flame.

Perception of the figure of external objects therefore depends on the action of the crystalline lens in converging all the rays, emanating from a given point, to a focus on the retina. When the lens of the eye is too convex, and its refractive power excessive, the rays of light converge too soon and cross one another before reaching the retina; consequently, the image produced is not concentrated and distinct, but, dispersed more or less over the surface of the retina, is diffused and dim. On the other hand, if the lens is too flat, the rays do not converge soon enough, and the image is again diffused and indistinct. To remedy a too great convexity of the lens in the short-sighted or myopic eye, concave spectacles are used to disperse the rays; to remedy the flattened lens in the hypermetropic or long-sighted eye, we employ convex glasses to concentrate and focus the rays more quickly.

A normal eye is capable of distinct vision throughout an immense range. We can see the stars millions of miles away, and with the

same eye, though not at the same time, we can see objects within a few inches of us. To be able to see objects millions of miles away and within a short range, the eye has to accommodate or adjust itself to different distances. This accommodation is accomplished mainly by the lens changing its convexity. In accommodation for near objects, the lens becomes more convex and the pupil of the eye likewise contracts. This convexity is brought about by muscular effort,¹ and is always more or less fatiguing. The accommodation for distant objects is a passive condition, the convexity of the lens being unaltered

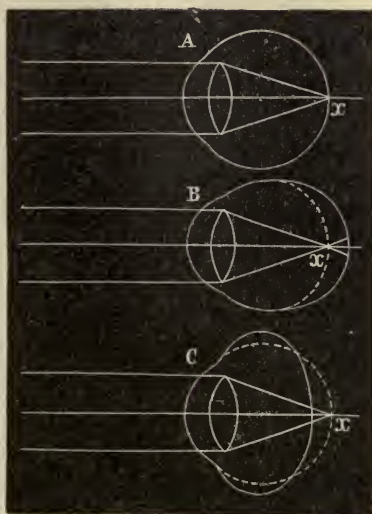


FIG. 133. — DIAGRAM ILLUSTRATING RAYS OF LIGHT CONVERGING IN A NORMAL EYE, (A), A MYOPIC EYE, (B), AND A HYPERMETROPIC EYE (C).

¹ Connected with the lens are tiny muscles, — the ciliary muscles, — contraction of which alters the shape of the lens.

and the pupil of the eye dilated, and it is on this account that the eye rests for an indefinite time upon remote objects without fatigue.

The eyeball is often compared to a photographer's camera. It is essentially a hollow spherical box filled with fluids, having its interior surface blackened by pigment, and containing a system of lenses by means of which images can be formed, and a screen upon which they can be received. In front is a curtain or diaphragm (the iris), with a variable central aperture (the pupil) to regulate the amount of light admitted.

The colour of light is considered to be analogous to the pitch of sound. As the latter is determined by the number of vibrations of the atmosphere which strike the ear in a second, so the former depends on the waves of ether which strike the retina in a second. The lowest note of an ordinary musical scale has, as we have already remarked, sixteen vibrations per second; the highest, 38,000 per second. The number of ether-waves which strike the retina in a second to produce the sensation of red (which lies at the bottom, so to speak, of the colour-scale) is estimated at 474,439,680,000,000. The number required to cause the sensation of violet, which lies at the other extreme of our colour-perception, is estimated at 699,000,000,000,000 !

The muscles which move the eyeball are the four straight or recti and the two oblique. They have been sufficiently described on page 58.

The appendages of the eye are the **eyebrows**, **eyelids** and **lachrymal glands**.

The eyebrows are composed of two arched eminences of thickened skin, connected with three muscles, which by their action control to a limited extent the amount of light admitted into the eye. The eyebrows are furnished with numerous short, thick hairs, lying obliquely on the surface.

The eyelids are two folds, projecting from above and below in front of the eye. They are covered externally by the skin and internally by a mucous membrane, the conjunctiva, which is reflected from them over the globe of the eye. They are composed for the most part of connective tissue, which is dense and fibrous under the conjunctiva, where it is known as the *tarsus*.

Embedded in the tarsus is a row of elongated sebaceous glands

(the Meibomian glands¹), the ducts of which open on the edge of the eyelid. The secretion of these glands is provided to prevent adhesion of the eyelids.

Arranged in a double or triple row at the margin of the lids are the eyelashes; those of the upper lid, more numerous and longer than the lower, curve upwards; those of the lower lid curve downwards, so that they do not interlace in closing the lids. The upper lid is attached to a small muscle which is called the elevator of the upper lid; and arranged as a sphincter around both lids is the *orbicularis palpebrarum* muscle, which closes the eyelids, and is the direct antagonist of the elevator of the upper lid.

The slit between the edges of the lids is called the palpebral fissure. It is the size of this fissure which causes the appearance of large and small eyes, as the size of the lobe itself varies but little. The outer angle of this fissure is called the *external canthus*; the inner angle, the *internal canthus*.

The eyelids are obviously provided for the protection of the eye; movable shades which by their closure exclude light, particles of dust, and other injurious substances.

The lachrymal gland is a compound gland, closely resembling the salivary glands in structure. It secretes the tears, and is lodged in a depression at the outer angle of the orbit. It is about the size and shape of an almond. Its ducts run obliquely beneath the conjunctiva, and open by a series of minute orifices upon the upper surface of the eye.

After passing over the surface of the eyeball, the tears are carried away through minute openings in the inner angle of the eye into

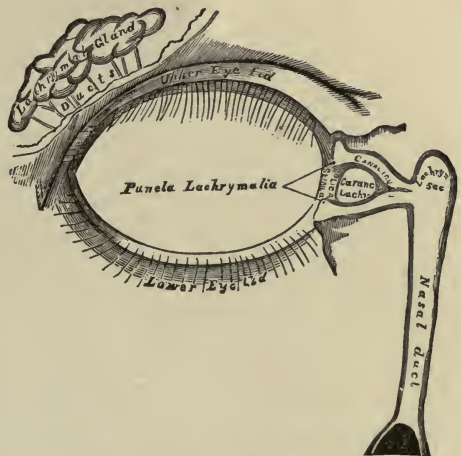


FIG. 134. — THE LACHRYMAL APPARATUS.

¹ By inverting the eyelids, these glands may be seen through the conjunctiva lying in parallel rows.

the lachrymal sac, which is the upper dilated portion of the nasal duct.

The nasal duct is a membranous canal, about three-quarters of an inch in length, which extends from the lachrymal sac to the inferior meatus of the nose, into which it opens by a slightly expanded orifice.

The tears consist of water containing a little salt and albumin. They are ordinarily carried away as fast as formed, but under certain circumstances, as when the conjunctiva is irritated, or when painful emotions arise in the mind, the secretion of the lachrymal gland exceeds the drainage power of the nasal duct, and the fluid, accumulating between the lids, at length overflows, and runs down the cheeks.

CHAPTER XX.

FEMALE GENERATIVE ORGANS.

THE internal female generative organs are vagina, uterus, Fallopian tubes, and ovaries.

The vagina.— The vagina is a distensible and curved musculo-membranous canal, extending from the vulva to the uterus. The posterior wall is about three and a half inches long, while the anterior wall is only three inches. The front or anterior wall is united by connective tissue with the posterior walls of the bladder and urethra, the partition or septum between the bladder and vagina being called the vesico-vaginal, and that between the urethra and vagina, the urethro-vaginal, septum. And, if we divide the posterior wall of the vagina into five sections, we find that the middle *three-fifths* is connected with the rectum, the united walls forming the recto-vaginal septum;¹ the *lower fifth* is separated from the rectum and is joined to the perineum;² while the *upper fifth* extends up behind the neck of the uterus.

The vagina is made up of three coats, an outer, fibrous; middle, muscular; and inner, mucous. The muscular coat increases during pregnancy, and the mucous coat is arranged in transverse folds or rugæ, which allow of dilatation of the canal during labour.

The uterus.— The uterus is a thick-walled, hollow, pear-shaped organ, situated in the middle of the pelvic cavity. Its upper end is a little below the level of the superior strait of the pelvis (*vide* page 43); its lower end projects into the vagina.

¹ Perforations of the vesico-vaginal and recto-vaginal partitions constitute vesico-vaginal and recto-vaginal fistulæ.

² The perineum is a triangular section of tissue, made up of muscles strengthened with fascia, placed between the rectum and vagina, and forming the floor of the pelvis.

The bladder lies in front of it; the rectum, behind; the vagina, below; and the small intestine rests upon it above. Its length is roughly estimated to be about three inches; its greatest width, one and one-half inches; and its thickness, one inch. At the end of pregnancy it attains the length of a foot or more, and measures about eight to ten inches transversely.

The uterus is divided for purposes of description into three

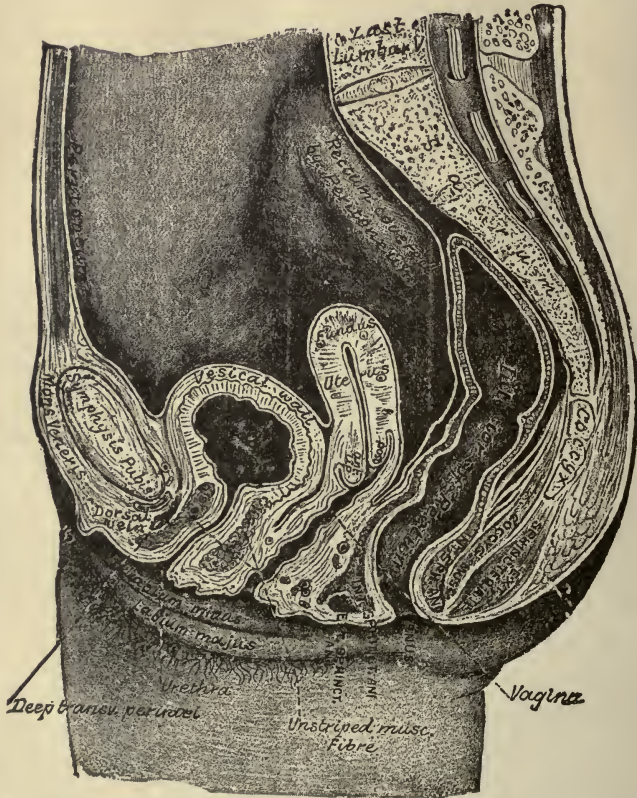


FIG. 135. — SECTION OF FEMALE PELVIS, SHOWING RELATIVE POSITION OF VISCERA.

parts, the fundus, body, and neck. The fundus is the rounded portion projecting above a line drawn transversely through the upper part of the organ. The body is the portion extending from the rounded section, the fundus, to the constricted section, the neck. The neck or cervix extends from the body of the uterus into the vagina.

Owing to the thickness of its walls, the cavity of the uterus

is comparatively small. The cavity is triangular in shape (∇), and has three openings, one at each upper angle, communicating with the Fallopian tubes, and one, the os internum, or internal mouth, opening into the cavity of the cervix below. The cavity of the cervix, which is, of course, continuous with the cavity in the body, is constricted above, where it opens into the body by means of the os internum, and below, where it opens exteriorly by means of the os externum,¹ or external mouth. Between these two openings, the cavity of the cervix is somewhat enlarged.

The walls of the uterus consist mainly of bundles of plain muscular tissue, arranged in layers which run circularly, longitudinally, spirally, and cross and interlace in every direction. A part of the external surface is covered by a portion of the peritoneum in the form of a broad ligament, and the inner surface is lined by a mucous membrane. This mucous membrane is continuous with that lining the vagina and Fallopian tubes. It is highly vascular, provided with numerous mucous glands, and is covered with ciliated epithelium.

The uterus is abundantly supplied with blood-vessels, lymphatics, and nerves. The blood reaches the uterus by means of the uterine arteries from the internal iliacs, and the ovarian arteries from the aorta. Where the neck joins the body of the uterus, the arteries from both sides are united by a branch vessel, called the circumflex artery. If this branch is cut during a surgical operation, or a tear of the neck during parturition extends so far as to sever it, the hemorrhage is very profuse. The arteries are remarkable for their tortuous course and frequent anastomoses. The veins are of large size and correspond in their behaviour to the arteries.

During pregnancy *all* the tissues of the uterus become much enlarged, undergoing what is called a *physiological hypertrophy*. The uterus increases in weight from two or three ounces to two or three pounds. After parturition, it goes back to nearly its former size. The tissues all go through a gradual shrinkage, or what is called a *physiological atrophy*. The enlarged muscles especially undergo fatty degeneration and absorption, called "involution," in contradistinction to "evolution" or develop-

¹ The os externum is bounded by two folds or lips of the mucous membrane, the anterior of which is thick, and the posterior narrow and long.

ment. This process of involution is not accomplished under six weeks, and sometimes requires longer.

The uterus is not firmly attached or adherent to any part of the skeleton. It is, as it were, suspended in the pelvic cavity, and kept in position by ligaments. A full bladder pushes it backward; a distended rectum, forward. It alters its position, by gravity, with change of posture. During gestation it rises into the abdominal cavity.

The uterus has five pairs of ligaments attached to it, the chief of which are the broad and round ligaments. The **broad ligaments** are folds of peritoneum slung over the front and back of the uterus, and extending laterally to the walls of the pelvis. The anterior fold covers the front of the uterus as far as the middle of the cervix, when it turns up and is reflected over

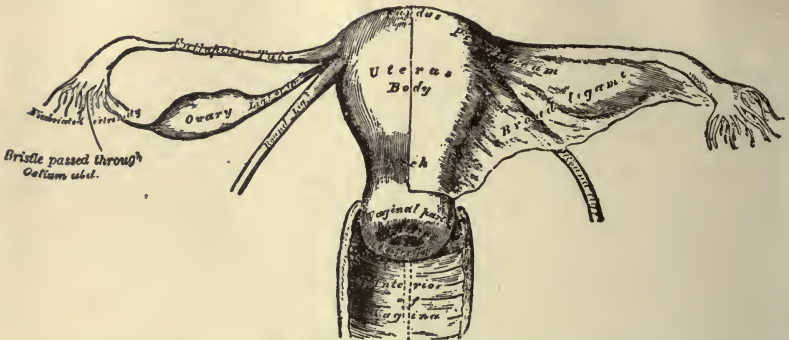


FIG. 136.—THE UTERUS AND ITS APPENDAGES. ANTERIOR VIEW.

the back wall of the bladder. The posterior fold covers the back of the uterus, and extends far enough below to also cover the upper one-fifth of the back wall of the vagina, when it turns up and is reflected over the anterior wall of the rectum. Thus the uterus, with, and between its two broad ligaments, forms a transverse partition in the pelvic cavity, the bladder, vagina, and urethra being in the front compartment, and the rectum in the back compartment. The **round ligaments** are two rounded fibro-muscular cords, situated between the folds of the broad ligament. They are about four and a half inches long, and extend from the upper angle of the uterus forwards and outwards to be inserted into the vulva.

Fallopian tubes.—The Fallopian¹ tubes or oviducts are pro-

¹ Named after Fallopius, an Italian anatomist.

vided for the purpose of conveying the ova from the ovaries into the cavity of the uterus. They are two in number, one on each side, and pass from the upper angles of the uterus in a somewhat tortuous course between the folds and along the upper margin of the broad ligament, towards the sides of the pelvis. Each tube is about four inches in length. Its canal is exceedingly small, and begins at the upper angle of the uterus by a minute opening which will hardly admit of a fine bristle. It continues narrow along the inner half of the tube, and then gradually widens into a trumpet-shaped extremity, which becomes contracted at its termination. The margins of the free trumpet-shaped extremity are frayed out into a number of fringe-like processes, called *fimbriæ* and one of these processes, longer than the rest, is connected with the outer end of the ovary.

The Fallopian tube consists, like the uterus, of three coats: the external or serous coat, derived from the peritoneum; the middle or muscular coat, having a layer of longitudinal and of circular fibres; and the internal or mucous coat, continuous at the inner end with the mucous lining of the uterus, and at the distal end with the serous lining of the abdominal cavity. This is the only instance in the body in which a mucous and serous lining are continuous with one another.

When the ovum is ready for entrance into the Fallopian tube, the fimbriæ of the free end grasp the ovary, the tiny germ-cell is safely conducted into the trumpet-shaped extremity, and is thence carried along by the peristaltic motion of the oviduct into the uterus. This transmission of the cell is also assisted by the ciliated epithelium lining the tube, the motion of the cilia wafting it onwards.

The ovaries.—The ovaries are two small almond-shaped bodies, situated one on each side of the uterus, between the anterior and posterior folds of the broad ligament, and below the Fallopian tubes. Each ovary is attached by its inner end to the uterus by a short ligament—the ligament of the ovary; and by its outer end to the Fallopian tube by one of the fringe-like processes of the fimbriated extremity. The ovaries each measure about one and a half inches in length, three-fourths of an inch wide, and one-third of an inch thick, and weigh from one to two drachms. Their function is to produce, develop,

and mature the ova, and to discharge them when fully formed from the ovary.

The ovaries consist of a framework of connective and muscular tissue, usually called the **stroma** or **bed** of the organ; and of

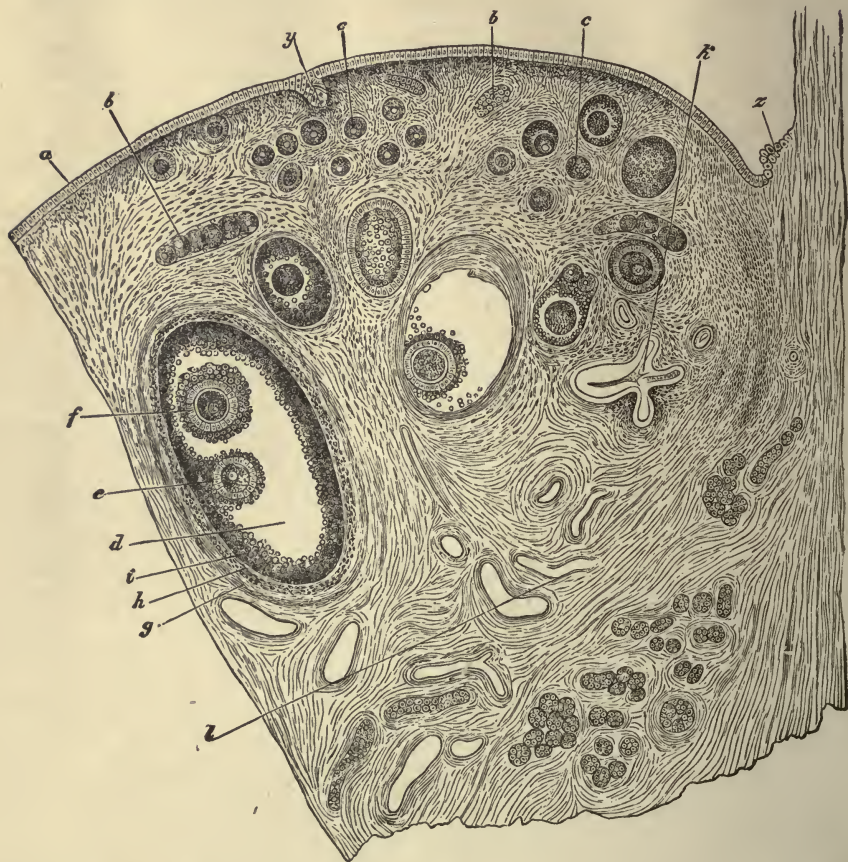


FIG. 137.—SECTION OF AN OVARY. (Waldeyer.) *a*, germ-epithelium; *b*, egg-tubes; *c*, small follicles; *d*, more advanced follicle; *e*, discus proligerus and ovum; *f*, second ovum in same follicle (this occurs but rarely); *g*, outer tunic of the follicle; *h*, inner tunic; *i*, membrana granulosa; *k*, collapsed retrograded follicle; *l*, *l*, blood-vessels; *y*, involuted portion of the germ-epithelium of the surface; *z*, place of the transition from peritoneal to germinal or ovarian epithelium.

numerous vesicles or follicles of different sizes, called the **Graafian** follicles.

The **stroma** contains many blood-vessels and lymphatics. The outer portion is more condensed than the interior, and the whole

is covered by a peculiar layer of columnar epithelium-cells, called germinal epithelium.

The **Graafian follicles** are cavities dotted about in the stroma in large numbers. The smaller ones lie near the surface. The larger are more deeply imbedded, and only approach the surface when they are ready to discharge their contents. The follicles have each their own proper wall or tunic, derived from the connective tissue of the stroma, and each is lined by a layer or layers of granular epithelium-cells, and contains an ovum. The granular layer of cells, closely lining the cavity of the follicle, is termed the *membrana granulosa*, but at one or other side it is heaped up into a mass of cells which projects into the cavity of the follicle and envelops the ovum. This mass of cells which immediately surrounds the ovum is called the *discus proligerus*.

As the follicle matures, fluid collects in the cavity, and, increasing in amount, the follicle gradually becomes larger and more tense. It now approaches the surface and begins to form a protuberance like a small boil upon the outside of the ovary. Finally the wall of the ovary and the wall of the follicle burst at the same point, and the fluid (*liquor folliculi*) containing the ovum, with the loose, irregular mass of cells, the *discus proligerus*, clinging to it, is set free. At the moment of rupture, the ovum is received by the Fallopian tube and afterwards conveyed to the uterus. After the follicle has discharged its contents, it has done its work, and it passes through a series of changes which are more or less persistent, but eventually it is obliterated and disappears. Thus in the very same ovary some of the follicles are mature, or approaching maturity; others are undergoing development; while others are retrograding and disappearing.

The ova are formed from the germ-epithelium on the surface of the ovary, the cells of which become enlarged and dip down into the stroma in the form of little elongated masses. From these groups of cells the Graafian follicles and the ova are produced. The ovum is a highly developed cell about $\frac{1}{125}$ inch in diameter. It has (1) a thick, surrounding envelope or membrane, called the vitelline membrane or *zona pellucida*; (2) within the membrane or cell-wall is the protoplasm of the cell, filled with fatty and albuminous granules, and usually

called the vitellus or yolk; (3) imbedded in the vitellus or yolk is a transparent, sharply outlined nucleus, the germinal vesicle; and (4) in the germinal vesicle is a small dark nucleolus, the germinative spot.

It is impossible for us to trace the growth and development of a fecundated ovum. The subject is too complicated for us to attempt to describe it in a book of this kind, and we shall, therefore, content ourselves with briefly describing the first two or three steps.

Soon after leaving the ovary, the germinal vesicle and germinal spot in a fecundated ovum disappear, and the protoplasm begins to divide inside the vitelline membrane into two halves, in each of which appears a nucleus. The halves divide into quarters, the quarters into eighths, and so the subdivision continues until a great number of minute cells are produced, which soon arrange themselves, close to each other like bricks in a wall, upon the inner surface of the vitelline membrane. The cells thus in close contact with one another form a membrane, called the epiblast. Upon this membrane a second one soon appears, formed in the same way and lining its inner surface. This is called the hypoblast. Subsequently a third membrane, the mesoblast, is developed between the epi- and hypoblast, and from these three membranes all the tissues and complicated structures of the body are evolved.

Upon the arrival of the ovum in the uterus, it is grafted upon the mucous membrane. It usually lodges upon the upper surface of the uterus, between two folds of the mucous lining, which soon grow up all around it, and, as it were, bury the germ in a circular grave. From the thickened mucous membrane lying between the ovum and the uterine wall, the placenta is ultimately formed for the nourishment of the embryo.

The mammary glands. — The mammary gland is a compound gland, formed of branching ducts ending in secretory recesses. The whole organ is divided by connective tissue partitions into a number of lobes, each of which possesses its own excretory duct opening by a separate orifice upon the surface of the nipple, the gland being in fact not a single gland, but several glands bound together. Just before opening on to the nipple, each excretory duct is widened into a flask-shaped enlargement.

The walls of the ducts and of the secreting recesses are formed of a basement membrane lined by epithelium-cells. During lactation the secreting cells become much enlarged, and fatty globules are formed within them. The fatty globules appear to be set free by the breaking down of the inner part of the cell, the protoplasm becoming dissolved also, and forming the proteid substances of the milk. At the beginning of lactation the cells are imperfectly broken up, so that numerous cells containing comparatively large masses of fat (the *colostrum corpuscles*) appear in the secretion.

Human milk has a specific gravity of from 1028 to 1034, and when quite fresh possesses a slightly alkaline reaction. Its average composition in every 100 parts is:—

Proteids	2
Fats	2.75
Sugar	5
Salts	0.25
Water	90
	<hr/>
	100

(Foster.)

GLOSSARY.

- Abdu'cens.** [From the Lat. *ab*, "from," and *duco*, to "lead."] A term applied to the sixth pair of cranial nerves which supply the external recti (*abductor*), muscles of the eye.
- Acetab'ulum.** [From the Lat. *acetum*, "vinegar."] A name given to the cavity in the os innominatum, resembling in shape an old-fashioned *vinegar* vessel.
- Acro'mion.** [From the Gr. *akron*, "summit," and *ōmos*, the "shoulder."] The triangular-shaped process at the *summit* of the scapula.
- Ad'enoid.** [From the Gr. *adēn*, a "gland," and *eidōs*, "form" or "resemblance."] Pertaining to, *resembling a gland*.
- Ad'ipose.** [From the Lat. *adeps*, "fat."] Fatty.
- Af'ferent.** [From the Lat. *ad*, "to," and *fero*, to "bear," to "carry."] *Bearing* or *carrying inwards*, as from the periphery to the centre.
- Ag'minated.** [From the Lat. *agmen*, a "multitude," a "group."] Arranged in clusters, grouped.
- Albu'min.** [From the Lat. *albus*, "white."] Animal albumin is the chief solid ingredient in the *white* of eggs.
- Albuminu'ria.** [A combination of the words "albumin" and "urine."] Presence of *albumin* in the *urine*.
- Aliment'ary.** [From the Lat. *alimentum*, "food."] Pertaining to *aliment* or food.
- Alimenta'tion.** The act of receiving nourishment.
- Alve'olar.** [From the Lat. *alveolus*, a "little hollow."] Pertaining to the alveoli, the *cavities* for the reception of the teeth.
- Amœ'ba.** [From the Gr. *ameibō*, to "change."] A single-celled, protoplasmic organism, which is constantly *changing* its form by protrusions and withdrawals of its substance.
- Amœ'boid.** Like an *amœba*.
- Amphiarthro'sis.** [From the Gr. *amphō*, "both," and *arthron*, a "joint."] A mixed articulation; one which allows slight motion.
- Anabol'ic.** [From the Gr. *anaballō*, to "throw" or "build up."] Pertaining to anabolism, the process by means of which simpler elements are *built up* into more complex.
- Anæsthe'sia.** [From the Gr. *a*, *an*, "without," and *aisthanomai*, to "perceive," to "feel."] A condition of insensibility.

- Anastomo'sis.** [From the Gr. *ana*, "by," "through," and *stoma*, a "mouth."] Communication of branches of vessels with one another.
- Aor'ta.** [Gr. *aortē* from *ærō*, to "raise up."] The great artery that *rises up* from the left ventricle of the heart.
- Aponeuro'sis.** [From the Gr. *apo*, "from," and *neuron*, a "nerve."] A fibrous membranous expansion of a tendon; the nerves and tendons were formerly thought to be identical structures, both appearing as white cords.
- Arach'noid.** [From the Gr. *arachnē*, a "spider," a "spider's web," and *eidōs*, "form" or "resemblance."] *Resembling a web.*
- Are'olar.** [From the Lat. *areola*, a "small space," dim. of *area*.] A term applied to a connective tissue containing *small spaces*.
- Ar'tery.** [From the Gr. *aēr*, "air," and *tērēō*, to "keep."] Literally, an air-keeper (it being formerly believed that the arteries contained air.) A tube which conveys blood from the heart to all parts of the body.
- Arthro'dia.** [From the Gr. *arthron*, a "joint."] A movable joint.
- Artic'ular.** Pertaining to an articulation or joint.
- Asphyx'ia.** [From the Gr. *a*, "without," and *sphysis*, the "pulse."] Literally, *without pulse*. Condition caused by non-oxygenation of the blood.
- At'rophy.** [From the Gr. *a*, "without," and *trophē*, "nourishment."] Wasting of a part from lack of nutrition.
- Aud'itory.** [From the Lat. *audio*, *auditum*, to "hear."] Pertaining to the sense or organ of *hearing*.
- Aur'icle.** [From the dim. of Lat. *auris*, the "ear."] A *little ear*, a term applied to the *ear-shaped* cavities of the heart.
- Auric'ulo-ventric'ular.** Pertaining to the *auricles* and *ventricles* of the heart.
- Az'ygos.** [From the Gr. *a*, "without," and *zygos*, a "yoke."] Without a fellow.
- Bi'ceps.** [From the Lat. *bis*, "twice," and *caput*, the "head."] A term applied to muscles having a double origin or *two heads*.
- Bicus'pid.** [From the Lat. *bis*, "twice," and *cuspis*, the "point of a spear."] Having *two points*.
- Brach'ial.** [From the Lat. *brachium*, the "arm."] Belonging to the *arm*.
- Buc'al.** [From the Lat. *bucca*, the "cheek."] Pertaining to the *cheek*; the mouth cavity formed chiefly by the cheeks.
- Bur'sal.** [From the Gr. *bursa*, a "bag."] Pertaining to *bursæ*, membranous sacs.
- Cæ'cum.** [From the Lat. *cæcus*, "blind."] The *blind gut*.
- Ca'lices, pl. of Ca'lyx.** [From the Gr. *kalyx*, a "cup."] Anatomists have given this name to small *cup-like* membranous canals, which surround the papillæ of the kidney, and open into its pelvis.
- Canalic'ulus, pl. Canalic'uli.** [Dim. of Lat. *canalis*, a "channel."] A *small channel* or vessel.
- Can'cellated.** [From the Lat. *cancelli*, "lattice-work."] A term used to describe the spongy *lattice-work* texture of bone.

- Canthus.** [Gr. *Kanthos*, the "angle of the eye."] The angle formed by the junction of the eyelids, the internal being the greater, the external the lesser, canthus.
- Capillary.** [From the Lat. *capillus*, "hair."] A minutely fine vessel, resembling a *hair* in size.
- Car'bon.** An elementary body, one of the principal elements of organized bodies.
- Carbon'ic Acid, CO₂.** An acid gaseous product.
- Carot'ids.** [Perhaps from the Gr. *karos*, "stupor," because pressing on them produces stupor.] The great arteries conveying blood to the head.
- Ca'sein.** [From the Lat. *caseus*, "cheese."] The albumin of milk; the curd separated from milk by the addition of rennet, constituting the basis of cheese.
- Caud'a Equi'na.** [Lat.] "Horse-tail." A term applied to the termination of the spinal cord, which gives off a large number of nerves which, when unravelled, resemble a *horse's tail*.
- Cell'ulose.** Basis of vegetable fibre.
- Cerebel'lum.** [Dim. of Lat. *cerebrum*, the "brain."] The hinder and lower part of the brain; the *little brain*.
- Cer'ebrum.** [Lat. the "brain."] Chief portion of brain.
- Ceru'minous.** [From the Lat. *cerumen*, "ear-wax."] A term applied to the glands secreting cerumen, *ear-wax*.
- Chon'drin.** [From the Gr. *chondros*, "cartilage."] A kind of gelatin obtained by boiling *cartilage*.
- Chor'dæ Tendin'æ.** [Lat.] Tendinous cords.
- Cho'roid.** [From the Gr. *chorion*, "skin," and *eidōs*, "form" or "resemblance."] A *skin-like* membrane: the second coat of the eye.
- Chyle.** [From the Gr. *kylos*, "juice."] Milky fluid of intestinal digestion.
- Chyme.** [From the Gr. *kymos*, "juice."] Food that has undergone gastric but not intestinal digestion. (Both chyle and chyme signify literally *liquid* or *juice*.)
- Cica'trix.** [Lat. a "scar."] The mark or *scar* left after the healing of a wound.
- Cil'ia.** [Lat. the "eyelashes."] Hair-like processes of certain cells.
- Cil'iary.** Pertaining to the *cilia*.
- Cil'iated.** Provided with *cilia*.
- Circumval'late.** [From the Lat. *circumvallo*, "to surround with a wall."] *Surrounded by a wall*.
- Clav'icle.** [From the dim. of Lat. *clavis*, a "key."] The collar-bone, so named from its shape.
- Coc'cyx.** [Lat. the "cuckoo."] The lower curved bone of the spine, resembling a *cuckoo's bill* in shape.
- Coch'lea.** [Lat. a "snail," a "snail-shell"; hence, anything spiral.] A term applied to a cavity of the internal ear.
- Cœ'liac.** [From the Gr. *koilos*, "hollow."] Pertaining to the abdominal *cavity*.
- Co'lon.** [Gr. *kolon*.] That portion of the large intestine which extends from the cæcum to the rectum.

- Colos'trum.** First milk secreted after labour.
- Colum'næ Car'næ.** [Lat.] "Fleshy columns"; muscular projections in the ventricles of the heart.
- Colum'nar.** Formed in *columns*: having the form of a *column*.
- Com'missure.** [From the Lat. *con*, "together," and *mitto, missum*, to "put."] A joining or uniting together. Something which joins together.
- Con'cha.** [Lat. a "shell."] A term applied to the hollow portion of the external ear.
- Con'dyle.** [From the Gr. *kondylos*, a "knob," or "knuckle."] An articular eminence.
- Conjuncti'va.** [From the Lat. *con*, "together," and *jungo, junctum*, to "join."] A term applied to the delicate mucous membrane which lines both eyelids and covers the external portion of the eyeball.
- Co'rium.** [Lat. the "skin."] The deep layer of the skin; the derma.
- Cor'nea.** [From the Lat. *cornu*, a "horn."] The transparent anterior portion of the eyeball.
- Cor'nal.** [From the Lat. *corona*, a "crown."] Pertaining to the *crown*.
- Cor'onary.** [From the Lat. *corona*, a "crown."] A term applied to vessels, ligaments, and nerves which encircle parts like a *crown*, as the coronary arteries of the heart.
- Cor'pus Callo'sum.** [Lat.] "Callous body," or substance. A name given to the *hard substance* uniting the cerebral hemispheres.
- Cor'puscle.** [From the dim. of Lat. *corpus*, a "body."] A *small body* or particle.
- Cor'tex.** [Lat. "bark."] External layer of kidney: external layer of brain.
- Cos'tal.** [From the Lat. *costa*, a "rib."] Pertaining to the *ribs*.
- Cra'nium.** [Lat.] The skull.
- Crassam'entum.** [From the Lat. *crassus*, "thick."] The *thick deposit* of any fluid, particularly applied to a clot of blood.
- Crena'ted.** [From the Lat. *crena*, a "notch."] *Notched* on the edge.
- Crib'riform.** [From the Lat. *cribrum*, a "sieve," and *forma*, "form."] Perforated *like a sieve*.
- Cru'ra Cer'eбри.** [From the Lat. *crus* (pl. *crura*), a "leg."] *Legs* or pillars of the *cerebrum*.
- Cry'pt.** [From the Gr. *kryptō*, to "hide."] A *secreting cavity*: a follicle or glandular cavity.
- Cu'ticle.** [From the dim. of Lat. *cutis*, the "skin."] A term applied to the upper or epidermal layer of the *skin*.
- Cu'tis Ve'ra.** [Lat.] The true skin; that underneath the epidermal layer.
- Cys'tic.** [From the Gr. *kystis*, the "bladder."] Pertaining to a *cyst*,—a *bladder* or sac.
- Decussa'tion.** [From the Lat. *decusso, decussatum*, to "cross."] The *crossing* or running of one portion athwart another.
- Del'toid.** Having a triangular shape; resembling the Greek letter Δ (*delta*).
- Dex'trin.** A soluble substance obtained from starch.
- Diabe'tes Mel'litus.** [From the Gr. *dia*, "through," *bainō*, "to go," and *meli*, "honey."] Excessive flow of sugar-containing urine.

- Dial'ysis.** [From the Gr. *dialyō*, to "dissolve."] Separation of liquids by membranes.
- Diapede'sis.** [From the Gr. *dia*, "through," and *pēdaō*, to "leap," to "go."] *Passing* of the blood-corpuscles *through* vessel walls without rupture: sweating of blood.
- Di'aphragm.** [From the Gr. *diaphrassō*, to "divide in the middle by a partition."] The *partition* muscle *dividing* the cavity of the chest from that of the abdomen.
- Diarthro'sis.** [From the Gr. *dia*, "through," as implying no impediment, and *arthron*, a "joint."] A freely movable articulation.
- Dias'tole.** [From the Gr. *diastellō*, to "dilate."] The *dilation* of the heart.
- Dip'loë.** [From the Gr. *diploō*, to "double," to "fold."] The osseous tissue between the tables of the skull.
- Dis'cus Prolig'erous,** or germ disk. A term applied to a mass of cell clinging to the ovum when it is set free from the ovary.
- Dis'tal.** [From the Lat. *dis*, "apart," and *sto*, to "stand."] Away from the centre.
- Dor'sal.** [From the Lat. *dorsum*, the "back."] Pertaining to the *back* or posterior part of an organ.
- Duc'tus Arterio'sus.** [Lat.] Arterial duct.
- Duc'tus Ven'o'sus.** [Lat.] Venous duct.
- Duode'num.** [From the Lat. *duodeni*, "twelve each."] First part of small intestines, so called because about *twelve* fingers' breadth in length.
- Du'ra Ma'ter.** [Lat.] The "hard mother," called *dura* because of its great resistance, and *mater* because it was formerly believed to give rise to every membrane of the body. The outer membrane of the brain and spinal cord.
- Dyspne'a.** [From the Gr. *dys*, "difficult," and *pneō*, to "breathe."] *Difficult breathing.*
- Efferent.** [From the Lat. *effero*, to "carry out."] *Bearing* or *carrying outwards*, as from the centre to the periphery.
- Elimina'tion.** [From the Lat. *e*, "out of," and *limen, liminis*, a "threshold."] The act of *expelling* waste matters. Eliminate signifies, literally, to throw out of doors.
- Em'bryo.** The ovum and product of conception up to the fourth month, when it becomes known as the fœtus.
- Enarthro'sis.** [From the Gr. *en*, "in," and *arthron*, a "joint."] An articulation in which the head of one bone is received into the cavity of another, and can be moved in all directions.
- Endocar'dium.** [From the Gr. *endon*, "within," and *kardia*, the "heart."] The lining membrane of the heart.
- En'dolymph.** [From the Gr. *endon*, "within," and Lat. *lympa*, "water."] The fluid in the membranous labyrinth of the ear.
- En'siform.** [From the Lat. *ensis*, a "sword," and *forma*, "form."] Shaped *like a sword.*
- Ep'iblast.** [From the Gr. *epi*, "upon," and *blastos*, a "germ," or "sprout."] The external or upper layer of the *germinal* membrane.

- Epider'mis.** [From the Gr. *epi*, "upon," and *derma*, the "skin."] The outer layer of the *skin*.
- Epiglott'is.** [From the Gr. *epi*, "upon," and *glottis*, the "glottis."] The cartilage at the root of the tongue which forms a lid or cover for the aperture of the larynx.
- Epithe'rial.** [From the Gr. *epi*, "upon," and *thēlē*, the "nipple."] Pertaining to the epithelium, the cuticle covering the *nipple*, or any mucous membrane. The term epithelium is now applied to the tissue composed of cells covering or lining all surfaces of the body.
- Eth'moid.** [From the Gr. *ēthmos*, a "sieve," and *eidōs*, "form," "resemblance."] *Sieve-like*. A bone of the cranium, part of which is pierced by a number of holes.
- Eusta'chian Tube.** A tube extending from behind the soft palate to the drum of the ear, first described by *Eustachius*.
- Fallo'pian.** A term applied to tubes and ligaments first pointed out by the anatomist *Fallopian*.
- Fas'cia, pl. Fas'ciæ.** [Lat.] A bandage, — that which binds; a membranous fibrous covering.
- Fau'ces.** [Lat., pl. of *faux*, *faucis*, the "throat."] The cavity at the back of the mouth from which the larynx and pharynx proceed.
- Fem'oral.** Pertaining to the *femur*.
- Fe'mur.** [Lat.] The thigh.
- Fenes'tra.** [Lat.] A window.
- Fibril'la, pl. Fibril'læ.** [Dim. of Lat. *fibra*, a "fibre."] A *little fibre*.
- Fibrin'ogen.** A proteid in blood plasma, main constituent of fibrin.
- Fib'ula.** [Lat. a "clasp."] The long splinter bone of the leg.
- Fil'iform.** [From the Lat. *filum*, a "thread," and *forma*, "form."] *Thread-like*.
- Fim'briæ.** [Lat. "threads," a "fringe."] A border or *fringe*.
- Fim'briated.** Fringed.
- Fis'sion.** [From the Lat. *findo*, *fissum*, to "cleave."] A *cleaving* or breaking up into two parts.
- Fœ'tus.** The child in utero from the fifth month of pregnancy till birth.
- Fol'licle.** [From the dim. of Lat. *follis*, a "bag."] A *little bag*; a small gland.
- Fontanelle'.** [Fr.] A little fountain. A term applied to the membranous spaces between the cranial bones in the new-born infant, in which the pulsation of the blood in the cranial arteries was imagined to rise and fall like the water in a fountain.
- Fora'men, pl. Foram'ina.** [Lat.] An opening, hole, or aperture.
- Foramen Mag'num.** [Lat.] A large opening.
- Fora'men Ova'le.** [Lat.] An oval opening.
- Fos'sa, pl. Fos'sæ.** [From the Lat. *fodio*, *fossam*, to "dig."] A depression or sinus; literally, a ditch.
- Fo'vea Centra'lis.** [Lat.] Central depression.
- Fun'dus.** [Lat.] The base or bottom of any organ which has an external opening.

- Fun'giform.** [From the Lat. *fungus*, a "mushroom," and *forma*, "form."] Having the *shape* of a *mushroom*.
- Funic'ulus.** [Dim. of Lat. *funis*, a "rope."] A *little cord*, or bundle of aggregated fibres.
- Fu'siform.** [From the Lat. *fusus*, a "spindle," and *forma*, "form."] *Spindle-shaped*.
- Gang'lia**, pl. of **Gang'lion.** [From the Gr. *gagglion*, a "knot."] A *knot-like* arrangement of nervous matter in the course of a nerve.
- Gas'tric.** [From the Gr. *gastēr*, the "stomach."] Pertaining to the *stomach*.
- Gastrocnē'mius.** [From the Gr. *gastēr*, the "belly," and *knēmē*, the "leg."] The *belly-shaped* muscle of the *leg*.
- Genioglos'sus.** [From the Gr. *geneion*, the "chin," and *glōssa*, the "tongue."] A muscle connected with the *chin* and *tongue*.
- Ging'lymus.** [From the Gr. *gigglymos*, a "hinge."] A *hinge-joint*.
- Gladi'olus.** [Dim. of Lat. *gladius*, a "sword."] The middle piece of the sternum.
- Glair'y.** [From the Lat. *clarus*, "clear"; Fr. *clair*.] Like the *clear* white part of an egg.
- Gle'noid.** [From the Gr. *glēnē*, a "cavity," and *eidōs*, "form," "resemblance."] A name given to a shallow *cavity*.
- Glomer'ulus.** [Dim. of Lat. *glomus*, a "clue of thread," or "ball."] A botanical term signifying a small, dense, roundish cluster: a term applied to the *ball-like* tuft of vessels in capsules of the kidneys.
- Glos'so-pharynge'al.** [From the Gr. *glōssa*, the "tongue," and *pharynx*, the "pharynx."] Belonging to the *tongue* and *pharynx*.
- Glot'tis.** [Gr. the "mouthpiece of a flute."] The aperture of the larynx.
- Glute'i**, pl. of **Glute'us.** [From the Greek *gloutoi*, the "buttocks."] The muscles forming the *buttocks*.
- Gly'cogen.** Literally, producing glucose. Animal starch found in liver, which may be changed into glucose.
- Graaf'ian Fol'licles**, or **Ves'icles.** A term applied to the hollow bodies in the ovaries, containing the ova.
- Gramme.** Unit of metric system, 15.43 grains troy.
- Gus'tatory.** [From the Lat. *gusto*, *gustatum*, to "taste."] Belonging to the sense of *taste*.
- Hæmoglo'bin.** [From the Gr. *haima*, "blood," and Lat. *globus*, a "globe," or "globule."] A complex substance which forms the principal part of the *blood-globules*, or red corpuscles of the blood.
- Hæmorrhoi'dal.** [From the Gr. *haima*, "blood," and *rheō*, to "flow."] Pertaining to hæmorrhoids, small tumours of the rectum, which frequently *bleed*.
- Haver'sian Canals.** Canals in the bone, so called from their discoverer, Dr. Clopton Havers.
- Hepat'ic.** [From the Gr. *hēpar*, *hēpatos*, the "liver."] Pertaining to the *liver*.
- Hil'um**, sometimes written **Hil'us.** [Lat.] A small fissure, notch, or depression. A term applied to the concave part of the kidney.

- Homoge'neous.** [From the Gr. *homos*, "the same," and *genos*, "kind."] Of the *same kind* or quality throughout; uniform in nature, — the reverse of heterogeneous.
- Hu'merus.** [Lat. the "shoulder."] The arm-bone which concurs in forming the *shoulder*.
- Hy'aline.** [From the Gr. *hyalos*, "glass."] *Glass-like*, resembling *glass* in transparency.
- Hy'drogen.** An elementary gaseous substance, which in combination with oxygen produces water, H₂O.
- Hy'oid.** [From the Gr. letter *υ*, and *eidos*, "form," "resemblance."] The bone at the root of the tongue, shaped like the Greek letter *υ*.
- Hypermetro'pia.** [From the Gr. *hyper*, "over," "beyond," *metron*, "measure," and *ōps*, the "eye."] Far-sightedness.
- Hyper'trophy.** [From the Gr. *hyper*, "over," and *trophē*, "nourishment."] Excessive growth; thickening or enlargement of any part or organ.
- Hy'poblast.** [From the Gr. *hypo*, "under," and *blastos*, a "sprout" or "germ."] The internal or *under* layer of the *germinal* membrane.
- Hypocho'n'driac.** [From the Gr. *hypo*, "under," and *chondros*, a "cartilage."] A term applied to the region of abdomen *under* the *cartilages* of the false ribs.
- Hypoglos'sal.** [From the Gr. *hypo*, "under," and *glōssa*, the "tongue."] A name given to a nerve which terminates *under* the *tongue*.
- Ile'um.** [From the Gr. *eileō*, to "twist."] The longest *twisting* portion of the small intestine.
- Ile'i'ac.** Pertaining to the ileum.
- Ili'um, pl. Ili'a.** [From the Gr. *eileō*, to "twist."] The upper part of the os innominatum; the haunch-bone; perhaps so called because the crest of the bone turns or *twists* upon itself.
- Infundib'ula.** [Lat. pl. of *infundibulum*, a "funnel."] *Funnel-shaped* canals.
- In'guinal.** [From the Lat. *inguen*, *inguinis*, the "groin."] Pertaining to the *groin*.
- Inos'culate.** [From the Lat. *in*, "into," and *osculum*, a "little mouth."] To unite, to open into each other.
- Insaliva'tion.** The process of mixing the *saliva* with the food in the act of mastication.
- In'sulate.** [From the Lat. *insula*, an "island."] To isolate or separate from surroundings.
- Intercel'lular.** Lying *between cells*.
- Interlob'ular.** That which lies *between* the *lobules* of any organ.
- Inter'stice.** [From the Lat. *inter*, "between," and *sto* or *sisto*, to "stand."] The space which *stands between* things; any space or interval between parts or organs.
- Intersti'tial.** Pertaining to or containing *interstices*.
- Intralob'ular.** That which lies *within* the *lobules* of any organ.
- I'ris.** [Lat. the "rainbow."] The coloured membrane suspended behind the cornea of the eye. It receives its name from the variety of its colours.

- Is'chium.** [From the Gr. *ischuō*, to "support."] The lower portion of the os innominatum; that upon which the body is *supported* in a sitting posture.
- Jeju'num.** [From the Lat. *jejunus*, "fasting," "empty."] The part of the small intestine comprised between the duodenum and ileum. It has been so called because it is almost always found *empty* after death.
- Ju'gular.** [From the Lat. *jugulum*, the "throat."] Pertaining to the *throat*.
- Katabol'ic.** [From the Gr. *kataballō*, to "throw down."] Pertaining to *katabolism*, the process by means of which the more complex elements are rendered more simple and less complex. The opposite of anabolism.
- Lach'rymal.** [From the Lat. *lachryma*, a "tear."] Belonging to the *tears*.
- Lac'tation.** [From the Lat. *lac, lactis*, "milk."] The period of giving *milk*.
- Lac'teal.** A term applied to the lymphatic vessels in the intestines which absorb the *milk-like* fluid, the chyle, from the intestines.
- Lac'tic Acid.** An acid obtained from sour *milk*.
- Lacu'na, pl. Lacu'næ.** [Lat. a "cavity," an "opening."] A little *hollow space*.
- Lambdoi'dal.** [From the Gr. letter Λ (*Lambda*), and *eidos*, "form," "resemblance."] Resembling the Gr. letter Λ .
- Lamel'la, pl. Lamel'læ.** [Lat.] A thin plate or layer.
- Lar'ynx.** The upper part of the air passage, between the trachea and the base of the tongue.
- Latis'simus Dor'si.** [Lat. superlative of *latus*, "broad," "wide," and *dorsum*, the "back."] The *widest* muscle of the *back*.
- Lec'ithin.** [From the Gr. *lekithos*, the "yellow of egg."] A complex, fatty substance found in the brain; in the *yolk of eggs*.
- Leu'cocyte.** [From the Gr. *leukos*, "white," and *kytos*, a "cell."] A term used to denote the *white* or pale corpuscles in the blood and lymph.
- Lig'ament.** [From the Lat. *ligo, ligatum*, to "bind."] Anything that *binds* or unites.
- Lin'ea Alba.** [Lat.] The *white line* formed by the crossing of the aponeurotic fibres in the middle line of the abdomen.
- Lin'ea Ilio-pectine'a.** [Lat.] A line forming the brim of the pelvis, so named from subjacent bone and muscle.
- Lob'ule.** [From the dim. of Lat. *lobus*, a "lobe."] A *small lobe*.
- Lum'bar.** [From the Lat. *lumbus*, the "loin."] Pertaining to the *loins*.
- Lymph.** [From the Lat. *lymphæ*, "water."] A colourless fluid, resembling *water* in appearance.
- Lymphat'ic.** Pertaining to *lymph*; a vessel or tube containing lymph.
- Lymphoid.** [From the Lat. *lymphæ*, "water," and Gr. *eidos*, "form," "resemblance."] Having *resemblance to lymph*.
- Mac'ula Lute'a.** [Lat.] Yellow spot.
- Ma'lar.** [From the Lat. *mala*, the "cheek."] Pertaining to the *cheek*.
- Malle'olus, pl. Malle'oli.** [Dim. of Lat. *malleus*, a "hammer."] A name given to the pointed projections formed by the bones of the leg at the ankle-joint.

- Malpig'hian Bod'ies.** [So called in honour of *Malpighi*, a celebrated Italian anatomist.] A term applied to small bodies or corpuscles found in the kidney and spleen.
- Manu'brium.** [Lat. a "haft," a "handle."] Name given to the upper portion of the breast bone.
- Mar'garin.** One of the three chief constituents of fat.
- Mas'seter.** [From the Gr. *massaomai*, to "chew."] One of the muscles of *mastication*.
- Mas'toid.** [From the Gr. *mastos*, the "breast," and *eidōs*, "form," "resemblance."] Shaped *like the breast*.
- Ma'trix.** [Lat.] The womb. Producing or containing substance.
- Max'illary.** [From the Lat. *maxilla*, a "jaw."] Pertaining to the *maxilla* or *jaws*.
- Mea'tus.** [From the Lat. *meo*, *meatum*, to "pass."] A *passage* or canal.
- Medul'la Oblonga'ta.** [Lat.] The "oblong marrow"; that portion of the brain which lies within the skull, upon the basilar process of the occipital bone.
- Meibo'mian.** A term applied to the small glands between the conjunctiva and tarsal cartilages, discovered by *Meibomius*.
- Mes'entery.** [From the Gr. *mesos*, "middle," and *enteron*, the "intestine."] A duplicature of the peritoneum covering the small *intestine*, which occupies the *middle* or centre of abdominal cavity.
- Mes'oblast.** [From the Gr. *mesos*, "middle," and *blastos*, a "germ" or "sprout."] The *middle* layer of the *germinal* membrane.
- Mesoco'lon.** A duplicature of the peritoneum covering the colon.
- Metab'olism.** [From the Gr. *metabolē*, "change."] The *changes* taking place in cells, whereby they become more complex and contain more force, or less complex and contain less force. The former is constructive metabolism, or anabolism; the latter, destructive metabolism, or katabolism.
- Metacar'pus.** [From the Gr. *meta*, "after," and *karpos*, the "wrist."] The part of the hand comprised between the *wrist* and fingers.
- Metatar'sus.** [From the Gr. *meta*, "after," and *tarsos*, the "instep."] That part of the foot comprised between the *instep* and toes.
- Mi'tral.** Resembling a *mitre*.
- Mo'lar.** [From the Lat. *mola*, a "mill."] A term applied to the teeth which bruise or *grind* the food.
- Molec'ular.** Pertaining to *molecules*.
- Mol'ecule.** [From the dim. of Lat. *moles*, a "mass."] The smallest quantity into which the mass of any substance can physically be divided. A molecule may be chemically separated into two or more atoms.
- Mo'tor Oc'uli.** [Lat.] Mover of the eye.
- Moto'rial.** That which causes movement.
- Mu'cin.** The chief constituent of mucus.
- Mu'cous.** A term applied to those tissues that secrete *mucus*.
- Myocar'dium.** [From the Gr. *mys*, *myos*, a "muscle," and *kardia*, the "heart."] The *muscular* structure of the *heart*.

- Myo'pia.** [From the Gr. *myō*, to "contract," and *ōps*, the "eye."] Near-sightedness.
- My'osin.** Chief proteid substance of muscle.
- Na'ris, pl. Na'rēs.** [Lat.] A nostril.
- Neurilem'ma.** [From the Gr. *neuron*, a "nerve," and *lemma*, a "coat" or "covering."] Nerve-sheath.
- Ni'trogen.** A colourless gas forming nearly four-fifths of the atmosphere: the diluent of the oxygen in the air. Literally, that which *generates nitre*.
- Nucle'olus, pl. Nucle'oli.** [Dim. of Lat. *nucleus*, a "kernel."] A smaller nucleus within the nucleus.
- Nu'cleus, pl. Nu'clei.** [Lat. a "kernel."] A minute vesicle embedded in the cell protoplasm.
- Occipi'tal.** [From the Lat. *occiput*, *occipitis*, the "back of the head."] Pertaining to the *occiput*, the *back part of the head*.
- Odon'toid.** [From the Gr. *odontos*, *odontos*, a "tooth," and *eidōs*, "form," "resemblance."] Tooth-like.
- Œde'ma.** [From the Gr. *oideō*, to "swell."] A *swelling* from effusion of serous fluid into the areolar tissue.
- Œsoph'agus.** [Gr. *oisophagos*, from *oiō*, (fut.) *oisō*, to "carry," and *phagēma*, "food."] The gullet.
- Olec'ranon.** [From the Gr. *ōlenē*, the "elbow," and *kranon*, the "head."] The *head of the elbow*.
- O'lein.** [From the Lat. *oleum*, "oil."] One of the three chief constituents of fat. Oil (*oleum*) signifies literally, juice of the olive (Lat. *olea*).
- Olfac'tory.** [From the Lat. *olfacio*, *olfactum*, to "smell."] Belonging to the sense of *smell*.
- Omen'tum.** [Lat. "entrails."] A duplication of the peritoneum with more or less fat interposed.
- Ophthal'mic.** [From the Gr. *ophthalmos*, the "eye."] Belonging to the *eye*.
- Op'tic.** [From the Gr. *optō*, to "see."] That which relates to *sight*.
- O'ra Serra'ta.** [Lat.] Serrated border.
- Orbicular'is.** [From dim. of Lat. *orbis*, an "orb" or "circle."] Name of the *circular muscles*.
- Or'bita.** [From the Lat. *orbīta*, a "track," "rut of a wheel."] Pertaining to the *orbīta*, the bony cavity in which the eyeball is suspended.
- Ōs, pl. Ō'ra.** [Lat.] A mouth.
- Os, pl. Ossa.** [Lat.] A bone.
- Osmo'sis.** [From the Gr. *ōsmos*, "impulsion."] Diffusion of liquids through membranes.
- Os'sa Innomina'ta, pl. of Os Innomina'tum.** [Lat.] "Unnamed bones." The irregular *bones* of the pelvis, *unnamed* on account of their non-resemblance to any known object.
- Os'teoblasts.** [From the Gr. *osteon*, a "bone," and *blastos*, a "germ" or "sprout."] The *germinal cells* deposited in the development of *bone*.
- O'vum, pl. O'va.** [Lat. an "egg."] The human germ cell.

- Oxida'tion.** The action of oxidizing a body; that is, combining it with oxygen, the result of which combination is an oxide.
- Ox'ygen.** A tasteless, odourless, colourless gas, forming part of the air, water, etc., and supporting life and combustion.
- Pal'mitin.** A solid, crystallizable substance of fat, found in the nervous tissue.
- Pal'pebra,** pl. **Pal'pebræ.** [Lat.] The eyelid.
- Pan'creas.** A compound secreting gland; one of the accessory organs of nutrition. The sweetbread of animals.
- Papil'læ.** [Lat. pl. of *papilla*, a "nipple," a "pimple."] Minute eminences on various surfaces of the body.
- Paraglob'ulin.** A proteid substance of the blood plasma.
- Pari'etal.** [From the Lat. *paries*, *parietis*, a "wall."] Pertaining to a *wall*.
- Parot'id.** [From the Gr. *para*, "near," and *ous*, *ōtos*, the "ear."] The large salivary gland *under the ear*.
- Parturi'tion.** [From the Lat. *parturio*, *parturitum*, to "bring forth."] The act of *bringing forth*, of giving birth to young.
- Par Va'gum.** [Lat.] The "wandering pair." A term sometimes applied to the pneumogastric nerves.
- Patel'la.** [Lat. "a little dish."] A small, *bowl-shaped* bone; the *knee-pan*.
- Pec'toral.** [From the Lat. *pectus*, *pectoris*, the "breast."] Pertaining to the *breast* or chest.
- Ped'icle.** [From the dim. of Lat. *pes*, *pedis*, a "foot."] A stalk.
- Pel'vic.** [From the Lat. *pelvis*, a "basin."] Pertaining to the *pelvis*, the *basin* or bony cavity forming the lower part of the abdomen.
- Pep'sin.** [From the Gr. *peptō*, to "digest."] A ferment principle in gastric juice, having power to convert proteids into peptones.
- Pep'tone.** [From the Gr. *peptō*, to "digest."] A term applied to proteid material *digested* by the action of the digestive juices.
- Pericard'ium.** [From the Gr. *peri*, "about," "around," and *kardia*, the "heart."] The serous membrane *covering the heart*.
- Perichon'drium.** [From the Gr. *peri*, "about," "around," and *chondros*, a "cartilage."] The serous membrane *covering the cartilages*.
- Per'ilymph.** [From the Gr. *peri*, "about," "around," and the Lat. *lympa*, "water."] The *fluid* in the osseous, and *surrounding* the membranous, labyrinth of the ear.
- Perios'teum.** [From the Gr. *peri*, "about," "around," and *osteon*, a "bone."] The membrane *covering the bones*.
- Periph'eral.** [From the Gr. *peri*, "about," "around," and *pherō*, to "bear."] Pertaining to the *periphery* or *circumference*; that which is away from the centre and towards the circumference.
- Peristal'sis.** [From the Gr. *peristellō*, to "surround," to "compress."] Peristaltic action. A term applied to the peculiar movement of the intestines, like that of a worm in its progress, by which they gradually propel their contents.
- Peritone'um.** [From the Gr. *periteinō*, to "stretch around," to "stretch all over."] The serous membrane lining the walls and covering the contents of the abdomen.

- Perone'al.** [From the Gr. *peronē*, the "fibula."] Pertaining to the *fibula*; a term applied to muscles or vessels in relation to the *fibula*.
- Pe'trous.** [From the Gr. *petra*, a "rock."] Having the hardness of *rock*.
- Pey'er's Glands.** The clustered glands in the intestines, so named after the anatomist, *Peyer*, who well described them.
- Phalan'ges.** [Lat. pl. of *phalanx*, a "closely-serried array of soldiers."] A name given to the small bones forming the fingers and toes, because placed alongside one another like a *phalanx*.
- Phar'ynx.** [From the Gr. *pharaō*, to "plough," to "cleave."] The *cleft* or cavity forming the upper part of the gullet.
- Phren'ic.** [From the Gr. *phrēn*, the "diaphragm."] Pertaining to the *diaphragm*.
- Pi'a Ma'ter.** [Lat. *pia* (fem.), "tender," "delicate," and *mater*, "mother."] The most internal of the three membranes of the brain. See *Dura Mater*.
- Pig'ment.** [From the Lat. *pigmentum*, "paint," "colour."] *Colouring matter*.
- Pin'na.** [Lat. a "feather" or "wing."] External cartilaginous flap of the ear.
- Placen'ta.** [Lat. a "thin, flat cake."] A *flat*, circular, vascular *substance* which forms the organ of nutrition for the fœtus in utero.
- Plan'tar.** [From the Lat. *planta*, the "sole of the foot."] Pertaining to the *sole of the foot*.
- Plas'ma.** [From the Gr. *plassō*, "to form."] A tenacious *plastic fluid*, forming the coagulating portion of the blood; that in which the blood-corpuscles float; the liquor sanguinis.
- Pleu'ra.** [Gr. the "side."] A serous membrane divided into two portions, lining the right and left cavities of the chest, and reflected over each lung.
- Plex'us.** [From the Lat. *plecto*, *plexum*, to "knit" or "weave."] A *network* of nerves or veins.
- Pneumogas'tric.** [From the Gr. *pneumōn*, a "lung," and *gastēr*, the "stomach."] Pertaining to the *lungs* and *stomach*.
- Polyhe'dral.** [From the Gr. *polys*, "many," and *hedra*, a "base," a "side."] Many-sided.
- Pons Varo'lii.** [Lat.] "Bridge of Varolius." The white fibres which form a *bridge* connecting the different parts of the brain, first described by *Varolius*.
- Poplite'al.** [From the Lat. *poples*, *poplitis*, the "ham," the "back part of the knee."] The space *behind the knee-joint* is called the *popliteal* space.
- Prismat'ic.** Resembling a *prism*, which, in optics, is a solid, glass, triangular-shaped body.
- Prona'tion.** [From the Lat. *pronus*, "inclined forwards."] The turning of the hand with the palm downwards.
- Prona'tor.** The group of muscles which turn the hand palm downwards.
- Pro'teids.** A general term for the albuminoid constituents of the body.
- Pro'toplasm.** [From the Gr. *prōtos*, "first," and *plassō*, to "form."] A *first-formed* organized substance; primitive organic cell matter.
- Pseudostom'ata.** [From the Gr. *pseudēs*, "false," and *stoma*, *stomatos*, a "mouth."] False openings.

- Pter'ygoid.** [From the Gr. *pteron*, a "wing," and *eidos*, "form," "resemblance."] Wing-like.
- Pty'alín.** [From the Gr. *ptyalon*, "saliva."] A ferment principle in *saliva*, having power to convert starch into sugar.
- Pu'bes, gen. Pu'bis.** [Lat.] The external part of the generative region; the portion of the os innominatum forming the front of the pelvis.
- Pul'monary.** [From the Lat. *pulmo*, pl. *pulmones*, the "lungs."] Relating to the *lungs*.
- Pylor'ic.** Pertaining to the *pylorus*.
- Pylor'us.** [From the Gr. *pylē*, a "gate" or "entrance," and *ouros*, a "guard."] The lower orifice of the stomach, furnished with a circular valve which closes during stomach digestion.
- Pyrex'ia.** [From the Gr. *pyresso*, (fut.) *pyrexo*, to "have a fever."] Elevation of temperature; fever.
- Quad'riceps.** [From the Lat. *quatuor*, "four," and *caput*, the "head."] A term applied to the extensor muscle of the leg, having *four heads* or parts.
- Ra'dius.** [Lat. a "rod," the "spoke of a wheel."] The outer bone of the fore-arm, so called from its shape.
- Râle.** [From the Fr. *râler*, to "rattle in the throat."] A *rattling*, bubbling sound attending the circulation of air in the lungs. Different from the murmur produced in health.
- Rec'tus.** [Lat.] Straight.
- Re'nal.** [From the Lat. *ren*, *renis*, the "kidney."] Pertaining to the *kidneys*.
- Retic'ular.** [From the Lat. *reticulum*, a "small net."] Resembling a *small net*.
- Ret'iform.** [From the Lat. *rete*, a "net," and *forma*, "form."] Having the *form* or structure of a *net*.
- Ret'ina.** [From the Lat. *rete*, a "net."] The most internal membrane of the eye; the expansion of the optic nerve.
- Ri'ma Glot'tidis.** [Lat. *rima*, a "chink" or "cleft."] The *opening* of the *glottis*.
- Ru'gæ.** [Lat. pl. of *ruga*, a "wrinkle."] A term applied to the folds or *wrinkles* in the mucous membrane, especially of the stomach and vagina.
- Sa'crum.** [Lat. neut. of *sacer*, "sacred."] The large triangular bone above the coccyx, so named because it was supposed to protect the organs contained in the pelvis, which were offered in sacrifice and considered *sacred*.
- Sag'ittal.** [From the Lat. *sagitta*, an "arrow."] Arrow-shaped.
- Sal'ivary.** Pertaining to the *saliva*, the fluid secreted by the glands of the mouth.
- Saphe'nous.** [From the Gr. *saphēs*, "manifest."] A name given to the two large superficial veins of the lower limbs.
- Saponifica'tion.** [From the Lat. *sapo*, *saponis*, "soap," and *facio*, to "make."] Conversion into soap.

- Sarcolem'ma.** [From the Gr. *sarx*, *sarkos*, "flesh," and *lemma*, a "covering."] The *covering* of the individual muscle fibrils.
- Sar'cous.** [From the Gr. *sarx*, *sarkos*, "flesh."] *Fleshy*, belonging to *flesh*.
- Sarto'rius.** [From the Lat. *sartor*, a "tailor."] The name of the muscle used in crossing the legs, as a *tailor* does when he sits and sews.
- Scap'ula.** [Lat.] The shoulder-blade.
- Sclerot'ic.** [Lat. *scleroticus*, from Gr. *sklēroō*, to "harden."] *Hard*, tough.
- Seba'ceous.** A term applied to glands secreting *sebum*.
- Se'bum or Se'vum.** [Lat. *sebum*, "suet."] A fatty secretion resembling *suet*, which lubricates the surface of the skin.
- Semilu'nar.** [From the Lat. *semis*, "half," and *luna*, the "moon."] Having the shape of a *half-moon*.
- Se'rous.** Having the nature of *serum*.
- Se'rum.** [Lat.] The watery fluid separated from the blood after coagulation.
- Ses'amoid.** [From the Gr. *sēsamon*, a "seed of the sesamum," and *eidōs*, "form," "resemblance."] *Resembling a grain of sesamum*. A term applied to the small bones situate in the substance of tendons, near certain joints.
- Sig'moid.** [From the Gr. letter Σ, *sigma*, and *eidōs*, "form," "resemblance."] *Curved like the letter S*.
- Sole'us.** [From the Lat. *solea*, a "sandal."] A name given to a muscle shaped like the *sole* of a *shoe*.
- Specific Grav'ity.** The comparative density or gravity of one body considered in relation to another assumed as the standard. In measuring the specific gravity of liquids or solids, water is usually taken as the standard of comparison, being reckoned as a unit.
- Sphe'noid.** [From the Gr. *sphēn*, a "wedge," and *eidōs*, "form," "resemblance."] *Like a wedge*.
- Sphinc'ter.** [From the Gr. *sphiggō*, to "bind tight," to "close."] A circular muscle which contracts the aperture to which it is attached.
- Squa'mous.** [From the Lat. *squama*, a "scale."] *Scale-like*.
- Sta'sis.** [From the Gr. *staō*, to "stop."] Stagnation of the blood current.
- Ste'arin.** One of the three chief constituents of fat.
- Ste'rnum.** [Lat.] The breast-bone.
- Stim'ulus, pl. Stim'uli.** [Lat. a "goad."] Anything that excites to action.
- Sto'ma, pl. Stom'ata.** [From the Gr. *stoma*, *stomatos*, a "mouth."] A *mouth*; a small opening.
- Strat'ified.** [From the Lat. *stratum*, a "layer," and *facio*, to "make."] Formed or composed of *strata* or layers.
- Stri'ated.** [From the Lat. *strio*, *striatum*, to "make furrows."] That which has *striæ*, furrows or lines.
- Stro'ma.** [From the Gr. *strōma*, a "bed."] The foundation or *bed* tissue of an organ.
- Styloglos'sus.** [From the Gr. *stylos*, a "pillar," and *glōssa*, the tongue."] A muscle connected with a *pointed style-like process* of the temporal bone and the *tongue*.
- Subcla'vian.** Under the clavicle.

- Subcuta'neous.** [From the Lat. *sub*, "under," and *cutis*, the "skin."] *Under the skin.*
- Sudoriferous.** [From the Lat. *sudor*, "sweat," and *fero*, to "carry," to "bear."] A term applied to the glands secreting *sweat*.
- Supina'tion.** [From the Lat. *supino*, *supinatum*, to "bend backwards," to "place on the back."] The turning of the hand with the palm upward, the posterior surface of the hand being *supine*.
- Su'pinators.** The muscles which turn the hand with the palm upward.
- Supra're'nal.** [From the Lat. *super*, "over," and *ren*, *renis*, the "kidney."] *Above the kidney.*
- Su'ture.** [From the Lat. *suo*, *sutum*, to "sew together."] That which is *sewn together*, a seam; the seam uniting bones of the skull.
- Sym'physis.** [From the Gr. *syn*, "together," and *phyō*, to "produce," to "grow."] A *union* of bones, usually of symmetrical bones in the median line, as the pubic bones and bones of the jaw.
- Synarthro'sis.** [From the Gr. *syn*, "together," and *arthron*, a "joint."] A form of articulation in which the bones are immovably joined together.
- Synchondro'sis.** [From the Gr. *syn*, "together," and *chondros*, "cartilage."] Union by an intervening growth of cartilage.
- Syndesmo'sis.** [From the Gr. *syn*, "together," and *desmos*, a "ligament."] Union by ligaments.
- Syno'via.** [Supposed to be from the Gr. *syn*, "together," implying union or close resemblance, and *ōon*, an "egg."] A fluid resembling the white of an *egg*.
- Syno'vial.** Pertaining to *synovia*.
- Syn'tonin.** [From the Gr. *synteinō*, to "stretch," to "draw," referring to the peculiar property of muscular fibre.] A name given by Lehmann to a substance obtained from muscular fibre by the action of dilute muriatic acid.
- Sys'tole.** [From the Gr. *systellō*, to "draw together," to "contract."] The *contraction* of the heart.
- Tar'sus.** [From the Gr. *tarsos*, the "instep."] The *instep*: the cartilage of the eyelid.
- Ten'do Achil'lis.** [Lat.] "Tendon of Achilles." The *tendon* attached to the heel, so named because *Achilles* is supposed to have been held by the heel when his mother dipped him in the river Styx to render him invulnerable.
- Thorac'ic.** [From the Gr. *thōrax*, a "breast-plate," the "breast."] Pertaining to the *thorax*.
- Thy'roid.** [From the Gr. *thyreos*, an "oblong shield," and *eidos*, "form," "resemblance."] *Resembling a shield.* A name given to an opening in the ossa innominata: to the piece of cartilage forming the anterior prominence of the larynx: to the gland placed in front of the larynx.
- Tib'ia.** [Lat. a "flute" or "pipe."] The shin-bone, called *tibia*, from its fancied resemblance to a *reed-pipe*.
- Tibia'lis Anti'cus.** [Lat.] The muscle situate at the *anterior* part of the *tibia*.

- Tibia'lis Posti'cus.** [Lat.] The muscle situate at the *posterior* part of the *tibia*.
- Tone.** [Gr. *tonos*, from *teinō*, to "stretch."] The state of *tension* or firmness proper to each organic tissue.
- Trabec'ulæ.** [Lat. pl. of *trabecula*, a "little beam."] A term applied to prolongations of fibrous membranes which form *septa*, or partitions.
- Tra'chea.** [Lat.] The windpipe.
- Transvers'a'lis.** [Lat. from *trans*, "across," and *verto, versum*, to "turn," to "direct."] A term applied to a muscle which runs in a *transverse* direction.
- Trape'zius.** A name given to the two upper superficial muscles of the back, because together they resemble a *trapezium*, or diamond-shaped quadrangle.
- Tri'ceps.** [From the Lat. *tres*, "three," and *caput*, the "head."] A term applied to a muscle having a triple origin, or *three heads*.
- Tri'cuspid.** [From the Lat. *tres*, "three," and *cuspis, cuspidis*, a "point."] Having *three points*.
- Trochan'ter.** [From the Gr. *trochaō*, to "turn," to "revolve."] Name given to two projections on the upper extremities of the femur, which give attachment to the *rotator* muscles of the thigh.
- Tryp'sin.** The ferment principle in pancreatic juice which converts proteid material into peptones.
- Tuberos'ity.** [From the Lat. *tuber, tuberis*, a "swelling."] A *protuberance*.
- Tur'binated.** [Lat. *turbinatus*, from *turbo, turbinis*, a "top."] Formed like a *top*; a name given to the bones in the outer wall of the nasal fossæ.
- Tym'panum.** [From the Gr. *tympanon*, a "drum."] The *drum* or hollow part of the middle ear.
- Ul'na.** [Lat. the "elbow."] The inner bone of the fore-arm, the olecranon process of which forms the elbow.
- Umbil'icus.** [Lat. the "navel."] A round cicatrix or scar in the median line of the abdomen.
- U'rea.** [From the Lat. *urina*, "urine."] Chief solid constituent of *urine*. Nitrogenous product of tissue decomposition.
- Ure'ter.** [From the Gr. *oureō*, to "pass urine."] The tube through which the *urine* is conveyed from the kidney to the bladder.
- Ureth'ra.** [From the Gr. *oureō*, to "pass urine."] The canal through which the *urine* is conveyed from the bladder to the meatus urinarius.
- U'vula.** [Dim. of Lat. *uva*, a "grape."] The small, elongated, fleshy body hanging from the soft palate.
- Vag'inal.** [From the Lat. *vagina*, a "sheath."] *Sheath-like*.
- Val'vulæ Conniven'tes.** [Lat.] A name given to transverse folds of the mucous membrane in the small intestine.
- Vas'a Vaso'rum.** [Lat.] "The vessels of the vessels." The small blood-vessels which supply the walls of the larger blood-vessels with blood.
- Vas'cular.** [From the Lat. *vasculum*, a "little vessel."] Relating to *vessels*; full of vessels.

- Vaso-mo'tor.** [From the Lat. *vas*, a "vessel," and *moveo*, *motum*, to "move."] Causing *motion* to the *vessels*. Vaso-motor nerves cause contraction and relaxation of the blood-vessels.
- Ve'næ Ca'væ**, pl. of **Ve'na Ca'va**. [Lat.] "Hollow veins." A name given to the two great veins of the body which meet at the right auricle of the heart.
- Ve'næ Com'ites**. [Lat.] "Attendant veins." Veins which accompany the arteries.
- Ven'tral**. [From the Lat. *venter*, *ventris*, the "belly."] Belonging to the *belly* cavity.
- Ven'tricle**. [From the dim. of Lat. *venter*, the "belly."] A *small cavity*.
- Ver'miform**. [From the Lat. *vermis*, a "worm," and *forma*, "form."] *Worm-shaped*.
- Ver'nix Caseo'sa**. [Lat.] "Cheesy varnish." The *fatty varnish* found on the new-born infant, which is secreted by the sebaceous glands of the skin.
- Ver'tebræ**, pl. of **Ver'tebra**. [Lat. from *verto*, to "turn."] The bones of the spine.
- Vil'li**. [Lat. pl. of *villus*, "shaggy hair."] The conical projections on the *valvulæ conniventes*, making the mucous membrane look *shaggy*.
- Vis'cera**. [Lat.] The internal organs of the body.
- Vitel'ine**. [From the Lat. *vitellus*, the "yolk of an egg."] A term applied to the *yolk* membrane.
- Vet'lus**. [Lat. from *vita*, "life."] The yolk of an egg.
- Vit'reous**. [From the Lat. *vitrum*, "glass."] *Glass-like*. A name applied to the transparent, jelly-like substance which fills the back part of the eyeball behind the crystalline lens.
- Vo'mer**. [Lat. a "ploughshare."] The thin plate of bone shaped somewhat like a *ploughshare* which separates the nostrils.
- Vul'va**. The external female genitals.
- Zo'na Pellu'cida**. [Lat.] "Pellucid zone." The broad, transparent ring which surrounds the yolk in the centre of the ovum.

INDEX.

- Abdomen, divisions of, 154.
Absorbents, 119.
Absorption, 175.
Adipose tissue, 17.
Adjustment of the eye, how accomplished, 233.
Air-sacs, 133.
Albumin, 78.
Alimentary canal, 153.
Amœboid movement, 77.
Aorta, 94.
 abdominal, 98.
 thoracic, 98.
Aponeuroses, 16.
Appendix vermiform, 162.
Aqueous humour of eye, 232.
Arachnoid membrane, 204.
Areolar tissue, 14.
Arterial tension, 111.
Arteries, of head and neck, 96.
 of lower limb, 101.
 structure of, 88.
 table of, 107.
 of upper limb, 97.
Artery, innominate, 94.
 pulmonary, 106.
Articulation, pubic, 35.
Articulations, freely movable, 48.
 immovable, 47.
 slightly movable, 47.
Auditory nerve, 209, 225.
Auricles of the heart, 84.
- Bile, 172.
Bladder, 180.
Blood, 73.
 circulation of, 109.
 clotting of, 78.
 fibrin of, 79.
 functions of, 73, 80.
- Blood, plasma of, 77.
 red corpuscles of, 76.
 white corpuscles of, 75.
Blood-vessels, 81.
Bodily heat, 196.
Bone, cribriform plate of ethmoid, 36.
 development of, 22.
 ethmoid, 36.
 hyoid, 38.
 structure of, 20.
Bones, 23.
 flat, 29.
 irregular, 35.
 long, 24.
 short, 28.
 table of, 45.
Brain, the, 203.
 different parts of, 204.
 membranes of, 203.
 weight of, 207.
Bread, composition of, 151.
Bronchial tubes, 133.
Bursæ, 50.
- Cæcum, 162.
Canal, alimentary, 153.
 central, of spinal cord, 210.
Canals, Haversian, 22.
Capillaries, 90.
Carbo-hydrates, 148.
Carbonic acid, excretion of, 179.
 proportion of, in air, 138.
Cartilage, 18.
Cavity, buccal, 155.
 dorsal, 2.
 pelvic, 43.
 thoracic, 45.
 ventral, 2.
Cell, the, 4.
Cerebellum, 205.

- Cerebro-spinal system, 203.
 Cerebrum, 206.
 Chordæ tendinæ, 84.
 Choroid coat of eye, 229.
 Chyle, 172.
 Chyme, 171.
 Cilia, 11.
 Circulation, arterial, 110.
 capillary, 112.
 fœtal, 115.
 general, 109.
 portal, 103.
 pulmonary, 109.
 summary of, 114.
 Coccyx, 40.
 Colon, 162.
 Colour, 224.
 Conjunctiva, 144, 229.
 Connective tissue, proper, 14.
 Connective tissues, 13.
 classification of, 13.
 Contractility, muscular, 52, 54.
 Cord, spinal, 210.
 Corpuscles, red, 75.
 tactile, 191, 216.
 white, 76.
 Cranium, 41.
 Crystalline lens, 232.

 Development of blood-vessels and cor-
 puscles, 117.
 of bone, 22.
 of muscular tissue, 55.
 Diaphragm, 65.
 Diastole, 86.
 Diet, 151.
 Digestion, 169, 174.
 Digestive juices, bile, 172.
 gastric, 171.
 intestinal, 173.
 pancreatic, 172.
 saliva, 170.
 Diploë, 30.
 Duct, cystic, 167.
 hepatic, 167.
 nasal, 236.
 pancreatic, 162.
 right lymphatic, 121.
 thoracic, 121.
 Dura mater, 203.

 Ear, the, 223.
 Elastic tissue, 16.
 Elimination, 179.
 Epidermis, 190.
 Epithelial tissue, 8.

 Epithelium, simple, 10.
 simple ciliated, 11.
 simple columnar, 10.
 simple glandular, 11.
 simple pavement, 10.
 stratified, 9.
 transitional, 10.
 Eustachian tube, 158, 224.
 Eye, the, 227.
 Eye-brows, 234.
 Eye-lids, 234.

 Fallopian tubes, 241.
 Fasciæ, 16.
 Fats, 148.
 absorption of, 176.
 digestion of, 172.
 Fibre, non-striated muscular, 54.
 striated muscular, 53.
 Fibrin, 79.
 Fibro-cartilage, 19.
 Fibrous tissue, 15.
 Fontanelle, 42.
 Foramen, thyroïd, 35.
 Food, 146.
 Food-stuffs, classified, 147.

 Gall-bladder, 167.
 Ganglia, 203.
 of spinal nerves, 212.
 of sympathetic system, 214.
 Gastric juice, 171.
 Glands, of Brunner, 161.
 lachrymal, 235.
 of Lieberkühn, 161.
 lymphatic, 124.
 mammary, 244.
 Meibomian, 235.
 salivary, 156.
 sebaceous, 193.
 secreting, 142.
 solitary, 126.
 sweat, 191.
 Glottis, the, 130.
 Glycogen, 176.
 Gullet, the, 158.

 Hæmoglobin, 75.
 Hairs, 192.
 Heart, beat of the, 86.
 cavities of the, 84.
 position of the, 82.
 sounds of the, 88.
 structure of the, 82.
 Heat, distribution of, 197.
 production of, 196.

- Heat, regulation of, 197.
 Humours of the eye, 228, 232.
- Ileo-cæcal valve, 162.
 Impulses, nervous, 199.
 Inflammation, 113.
 Insensible perspiration, 195.
 Intestinal juice, 173.
 Intestine, large, 162.
 small, 160.
 Iris, 229.
- Joints, classification of, 47.
 movements of, 49.
 table of, 50.
 Juice, gastric, 171.
 intestinal, 173.
 pancreatic, 172.
- Kidneys, blood-supply of, 183.
 position of, 180.
 structure of, 182.
- Labyrinth of ear, 225.
 Lachrymal glands, 235.
 Lacteals, 119.
 Larynx, 129.
 Ligamenta subflava, 16.
 Ligaments, 15.
 annular, 70.
 Light, 231.
 Linea alba, 61.
 Liver, position of the, 164.
 secretion of bile by the, 167.
 structure of the, 165.
 Lungs, position of the, 134.
 structure of the, 133.
 Lymph, 73, 121.
 functions of, 123.
 movements of, 122.
 Lymphatic glands, 121.
 Lymphatic vessels, 119.
- Mammary glands, 244.
 Mastication, 169.
 Meat, composition of, 151.
 Medulla oblongata, 204.
 Medullated nerve-fibres, 201.
 Membrane, basement, 145.
 mucous, 144.
 serous, 91.
 synovial, 50.
 Metabolism, 6.
 Milk, composition of, 151.
 Minerals, as food, 149.
 Mouth, the, 155.
- Muscular tissue, 52.
 development of, 55.
 regeneration of, 56.
 Muscles, abdominal, action of, 64.
 attachment of, 56.
 of head and face, 58.
 of neck and trunk, 60.
 of lower extremity, 68.
 table of chief, 71.
 of upper extremity, 67.
- Nails, 192.
 Nares, anterior and posterior, 221.
 Nerve-cells, 200.
 Nerve-fibres, 200.
 Nerves, afferent or sensory, 202.
 cranial, 207.
 degeneration of, 216.
 efferent or motor, 202.
 regeneration of, 216.
 spinal, 212.
 termination of, 216.
 Nervous system, 202, 215.
 Nervous tissue, 199.
 Nitrogenous waste, excretion of, 186.
 Nose, the, 221.
 Nucleus, 7.
- Œdema, 123.
 Œsophagus, 158.
 Organs, 3.
 sensory, 218.
 Osseous tissue, 20.
 Ovary, 241.
 Ovum, description of, 243.
 Oxidation, 139.
 Oxygen, combination of, with hæmo-
 globin, 76, 139.
- Pancreas, 163.
 Pancreatic juice, 172.
 Papillæ, 146, 191, 219.
 Patella, 35.
 Pelvis, 43.
 Pepsin, 171.
 Peptone, 171.
 Pericardium, 83.
 Periosteum, 21.
 Peritoneum, 91.
 Perspiration, 194.
 Peyer's patch, 127.
 Pharynx, 157.
 Pia mater, 204.
 Plasma of the blood, 77.
 Pleura, 91, 135.
 Pons Varolii, 205.

- Pressure, atmospheric, 135.
 Process, 25.
 alveolar, 38.
 external malleolus, 28.
 internal malleolus, 28.
 odontoid, 39.
 olecranon, 26.
 Proteids, 147.
 Protoplasm, 4.
 Ptyalin, 170.
 Pulse, 110.
 Pylorus of stomach, 159, 171.
 Pyramids of kidney, 182.
 Pyrexia, 197.

 Receptacle of the chyle, 121.
 Rectum, 162.
 Regeneration of muscular tissue, 56.
 Respiration, 129, 135.
 abdominal or diaphragmatic, 66.
 costal, 65.
 effect of, upon air outside the body,
 137.
 effect of, upon air within the lungs,
 136.
 effect of, upon the blood, 138.
 Retina, 230.
 Ribs, 33.

 Sacrum, 40.
 Saliva, 170.
 Salivary glands, 156.
 Sebaceous glands, 193.
 Secreting glands, 142.
 Secretion, 142.
 Sensory organs, 218.
 Sight, long and near, 233.
 Skeleton, 23.
 Skin, functions of the, 195.
 structure of the, 188.
 Skull, 41.
 Sound, 226.
 Sphincter muscle of the bladder, 181.
 of rectum, 162.
 Spinal cord, 210.
 Spine, 38, 40.
 Spleen, 127.
 Stomach, the, 158.
 Suprarenal capsules, 187.
 Suture, 47.
 Sweat-glands, 194.
 Symphysis pubis, 35.
 Synovia, 50.
 System, cerebro-spinal, 203.
 nervous, 202.
 sympathetic, 214.
 Systole, 86.

 Teeth, 156.
 Temperature of blood, 74.
 of body, 196.
 Tendons, 16.
 Tension, arterial, 111.
 Thorax, 45.
 Tissue, adipose, 17.
 areolar, 14.
 cartilaginous, 18.
 connective, proper, 14.
 elastic, 16.
 epithelial, 8.
 fibrous, 15.
 muscular, 52.
 nervous, 199.
 osseous, 20.
 Tissues, classification of, 4.
 Tongue, the, 219.
 Tonsils, 127.
 Trachea, 131.
 Tympanum, 224.

 Urea, 186.
 Ureters, 180.
 Urethra, 181.
 Urine, composition of, 186.
 excretion of, 185.
 secretion of, 184.
 Uterus, 238.
 Uvula, 155.

 Vagina, 237.
 Valve, bicuspid or mitral, 85.
 tricuspid, 84.
 Valves in veins, 89.
 semilunar, 86.
 Valvulæ conniventes, 160.
 Vein, portal, 103.
 Veins, of head and neck, 104.
 of lower limb, 105.
 pulmonary, 106.
 right and left azygos, 105.
 structure of, 89.
 systemic, 103.
 table of, 107.
 of upper limb, 104.
 Vena cava, inferior, 106.
 superior, 105.
 Venæ comites, 103.
 Ventricles of the brain, 206.
 of the heart, 84.
 Vertebrae, 39.
 Villi, 146, 161.
 Vocal cords, 130.

 Waste products, 179.
 Water, 148.
 Zona pellucida, 243.

UNIVERSITY OF CALIFORNIA
Medical Center Library

THIS BOOK IS DUE ON THE LAST DATE STAMPED BELOW

Books not returned on time are subject to fines according to the Library Lending Code.

Books not in demand may be renewed if application is made before expiration of loan period.

194882

