

the AFIP LETTER

Visit our Web Site at
<http://www.afip.mil>

Armed Forces Institute of Pathology
Washington, D.C. 20306-6000

Vol. 155, No. 2
APRIL 1997

AFIP Scientists Discover Clues to 1918 Spanish Flu

SCIENTISTS FROM AFIP'S Department of Cellular Pathology, Division of Molecular Pathology, have determined the nature of the virus responsible for the "Spanish flu" outbreak that swept the world in 1918-19, killing at least 21 million people worldwide, including over 43,000 U.S. servicemen. It was the worst infectious disease episode ever. Experts have long theorized that the virus was a dangerous "swine" flu, but it wasn't until the AFIP team performed genetic analysis on preserved tissue samples from victims of the flu that the theory could be confirmed. Their findings now "open the door" to discovering why this particular flu was so deadly (*Science*. 1997;275:1793.)

Flu viruses have been around for centuries, and experts who study them generally agree that they originate in birds and are occasionally transmitted to humans. The result is typically an influenza pandemic.

The viruses also change rapidly, and to combat them, new vaccines must be made each year. In 1918, however, influenza viruses hadn't been discovered and vaccines weren't available.

That spring it was observed that pigs and pig

farmers in Iowa got sick simultaneously. By the fall, a new and deadly flu virus took hold. Victims typically died within a week, their lungs filled with fluid. "No one has ever seen that before or since," says Jeffrey K. Taubenberger, MD, PhD, chief, Division of Molecular Pathology, Department of Cellular Pathology, the lead author of the study. "It was a unique pathology."

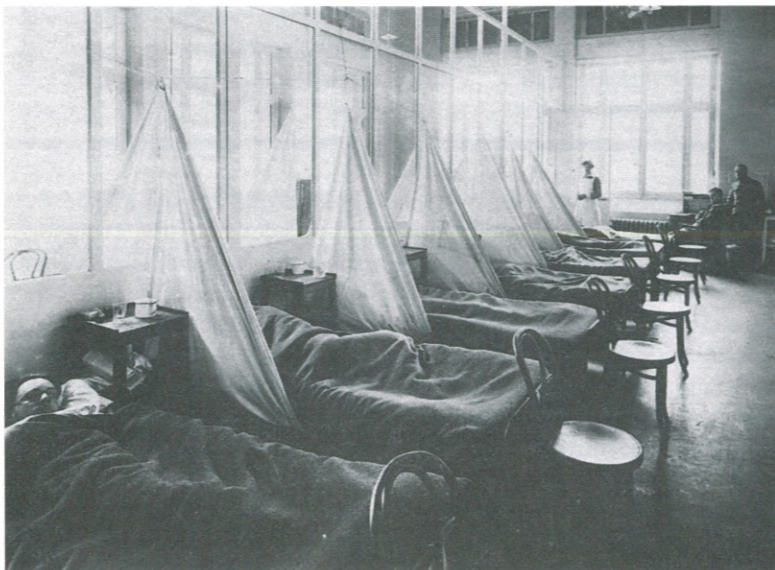Millions died worldwide, including approximately 675,000 Americans. "It killed so many young people that the average life expectancy in the U.S. was reduced by more than 10 years," Taubenberger notes. Among them were thousands of U.S. servicemen mobilized for World War I. Some of the 43,000 who died were autopsied, and their preserved tissue samples were sent to the Army Medical Museum (now the AFIP) for future study.

After the pandemic, came the questions: Why was this flu so devastating? Why did so many die? Theories grew that perhaps the flu had gone directly from birds to pigs, where it mutated into a particularly deadly human virus. By the 1930s, influenza viruses had been discovered, but only an indirect analysis of the serum of 1918 survivors pointed to a "classic swine flu" as the cause.


Over the years, experts have looked at the preserved tissue samples to characterize the virus, but without success. Recent genetic advances, however, led Dr. Taubenberger, molecular biologist Ann Reid, and their colleagues to try again. They began by examining the records of 70 U.S. servicemen who died of the flu. "Since the virus actively replicates for only a few days, we needed tissue samples from a victim who died within 1 week of the onset of symptoms in order to find the

Spanish Flu, continued on page 10

U.S. Army Camp Hospital #45, Aix-les-Bains, France.
Courtesy: National Library of Medicine.



DIRECTOR'S MESSAGE



New Technologies for the 21st Century

Our most recent successes in discovering clues to the 1918 Spanish Flu reflect the scope of AFIP's unique and changing capabilities.

Seventy-nine years and about 2,000,000 accessioned cases came between that day in 1918 when a young soldier's lung tissue was accessioned and the time the "Spanish Flu" viral RNA sequence was published. During that time, archivists meticulously catalogued tissue, preserved it, and filed it so that when the time came it could be retrieved and studied. Tissue can be located in minutes; today a pathologist can interpret that well-preserved and maintained slide as easily as in 1918.

While assuring that our specimens do not change with time, our staff, and the techniques they use, must change. AFIP's Department of Cellular Pathology staff—both the authors of the *Science* paper and others, developed and refined methods for investigating archival tissues using molecular techniques that are second to none. A few years ago, the idea of sequencing RNA from 80-year-old paraffin-embedded blocks would have been considered preposterous. Now these, and similar DNA-based techniques, are used not only in a wide variety of research areas - including breast cancer, soft tissue tumors, hematologic and infectious diseases, but also almost 10,000 times per year in molecular diagnostic assays that are routine at the AFIP.

Creating and maintaining a staff capable of anticipating and meeting the needs of tomorrow is a challenge. AFIP staff includes internationally renowned diagnostic pathologists, microbiologists,

Tumors of the Adrenal Gland and Extra-adrenal Paraganglia

AFIP Atlas of Tumor Pathology, Third Series, Fascicle 19

Ernest E. Lack, MD

Armed Forces Institute of Pathology, Washington, D.C. 1997

ISBN: 1-881041-28-X

During the last two decades there have been major developments in the pathology of the adrenal gland and extra-adrenal paraganglia. Some of the advances in pathology of this endocrine system have come from basic observations of new and evolving entities, unusual associations of endocrine and nonendocrine conditions, as well as the immense contributions of immunologic techniques such as immunohistochemistry and in situ hybridization. In addition to recognition of new entities and better characterization of existing ones, significant advances have been made in normal anatomy of preexisting endocrine structures, thus providing better insight into hyperplastic conditions affecting adrenal cortex, medulla, and extra-adrenal paraganglia, most notably paraganglia in the head and neck region (e.g. carotid body and vagal paraganglia). Sensitive imaging techniques such as computed tomography (CT) scan and magnetic resonance imaging (MRI) have made significant contributions to the better understanding of various disease processes (neoplastic and nonneoplastic) and provide another important dimension to "gross" pathology.

This third series fascicle focuses briefly on normal anatomy as a prelude to in-depth consideration of various tumors and tumorlike lesions. Current insight is

molecular biologists, chemists, computer scientists, and engineers. They carry out basic investigations, using techniques ranging from light microscopy to magnetic resonance microscopy and from histochemical staining to laser Raman spectroscopy and develop new methods, in partnership with "traditional" diagnostic pathologists, that improve both our diagnostic abilities and our understanding of disease pathogenesis.

We are confident that our efforts to preserve the old—both our invaluable

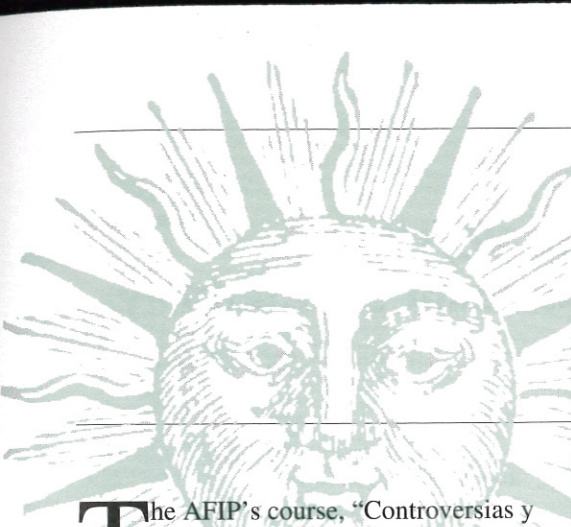
provided for common entities such as the incidentally discovered adrenal mass as well as rare and evolving conditions like primary pigmented nodular adrenocortical disease (PPNAD) and macronodular hyperplasia with marked adrenal enlargement (MHMAE), both considered to be forms of pituitary or ACTH-independent hypercortisolism. Adrenal cortical neoplasms, both benign and malignant, as well as tumors occurring in the pediatric age group are fully covered. Pheochromocytomas are described in detail, including sporadic and familial tumors (also precursor adrenal medullary hyperplasia) as well as unusual examples such as composite pheochromocytoma. There is also in-depth focus on extra-adrenal paragangliomas. A separate section is devoted to neuroblastoma, ganglioneuroblastoma, and related tumors. Throughout the fascicle, emphasis is placed on newer techniques in diagnosis and understanding the biology of these diverse neoplasms. These techniques include cytology, immunohistochemistry, DNA quantitation, cytogenetics, and various molecular probes.

This fascicle is extensively illustrated (over 500 color and over 300 black-and-white photos) and should be a valuable diagnostic resource.

specimen collection and our diagnostic expertise—and develop new technologies and abilities, will enable AFIP to achieve its vision both now and in the 21st century.

Michael J. Dickerson
Col, USAF, MC
The Director

Spanish "Controversies" course set for Santos, Sao Paulo, Brazil, August 20-24



The AFIP's course, "Controversias y Adelantos en Patología Quirúrgica," presented entirely in Spanish, will be held at the Parque Balneario Hotel, Santos, Sao Paulo, Brazil, August 20-24, 1997. Joining AFIP course directors Cesar A. Moran, Maj, USAF, MC; Clara S. Heffess, COL, MC, USA; and Florabel G. Mullick, MD, SES, Director of AFIP's Center for Advanced Pathology, will be Marcello Franco, MD, director of surgical pathology at the University of Sao Paulo and president of the Brazilian Society of Pathologists. Dr. Franco will serve as associate director of the course.

"This course has been offered three previous times—once in Puerto Rico, with 176 attendees; once in Valencia, Spain, with 166 attendees; and most recently in Guadalajara, Mexico, with a record 257 in attendance," says Dr. Mullick. "We anticipate another huge turnout in Santos. The course has clearly demonstrated that Latin American and Spanish pathologists want to strengthen their ties to the AFIP, and we look forward to another successful program in August."

Microscopes will be available at no cost to the participants, who are encouraged to bring their difficult cases for a second opinion from the course faculty. Joining noted experts from the AFIP on the faculty will be representatives from the University of Texas - Southwestern Medical School, Dallas, Texas; Wayne



Tourist Sao Paulo, Brazil. Partial view of Paulista Avenue showing the Art Museum of Sao Paulo.

State University, Detroit, Michigan; Baylor College of Medicine, Houston, Texas; M.D. Anderson Cancer Center, Houston, Texas; University of Granada, Spain; and Mount Sinai Medical Center, Miami, Florida.

New to the 1997 course will be an overview of forensic pathology. Other topics set for discussion include: endocrine pathology, otolaryngic pathology, genitourinary pathology, gynecologic and breast pathology, dermatopathology, pulmonary pathology, soft tissue pathol-

ogy, neuropathology, gastrointestinal pathology, and cytology.

Santos, located in the state of Sao Paulo, is Brazil's largest port city. It is a popular tourist destination in August, with a number of attractive beaches and a pleasant climate.

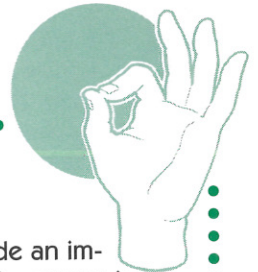
For more information about the course, contact Mr. Carlos Moran at (202) 782-2556, by e-mail at Moran@email.afip.osd.mil, or by FAX at (202) 782-7166.

Customer Satisfaction Surveys mailed to contributors

Ten thousand post cards containing an important customer satisfaction survey will be mailed with consultation reports starting in April and continuing until the supply is exhausted. Contributors are asked to complete the survey and return it postage-paid to AFIP. The survey will provide AFIP with valuable information on how our customers feel about our service. This survey will be compared to ones conducted in 1992 and 1994

to see if our customers feel we have made an improvement in our consultation service. The survey is also available on the AFIP web site (WWW.AFIP.MIL).

For more information, contact Mr. Frank Roberts, Quality Assurance Coordinator, at (202) 782-2695, or by e-mail at ROBERTSF@email.afip.osd.mil.



PROFILES



William Inskeep II, COL, VC, USA appointed Chair, Department of Veterinary Pathology

the Defense veterinary liaison officer with the U.S. Department of Agriculture.

Colonel Inskeep is a graduate of the College of Veterinary Medicine and Biomedical Sciences at Colorado State University, Ft. Collins, Colo., and a diplomate of the American College of Veterinary Pathologists. His military career began with 5 year's service as a Minuteman missile launch control officer, F.E. Warren AFB, Wyo. He served as the installation veterinarian at Yokosuka Navy Base, Japan, and Carlisle Barracks, Pa., with responsibilities for military and privately owned animals, and food safety and quality assurance programs.

Colonel Inskeep completed the 3-year postdoctorate residency in veterinary pathology at the AFIP from 1986 to 1989,

and obtained board certification in 1989. He served as chief, Comparative Pathology Department, at WRAIR from 1989 to 1992, with responsibilities for the necropsy, histopathological, clinical-pathological, and microbiological support. His next assignment was chief, Animal Medicine Office of the Army Surgeon General, from 1992 to 1995, with responsibilities for development and dissemination of policy and doctrine for animal medicine functions in the DoD.

Colonel Inskeep returned to the AFIP in 1995 and became chair, Department of Veterinary Pathology, on December 24, 1996. He and his wife Betty live in Rockville, Md.

WILLIAM INSKEEP II, COL, VC, USA, has been appointed chair, Department of Veterinary Pathology. In his new role, he will be responsible for the department's consultation, education, and research missions; coordinate the laboratory animal medicine program; and serve as registrar of three pathology registries. He will also serve as



William A. Gardner, Jr, MD, elected Chair, Scientific Advisory Board

training at Johns Hopkins and Duke and served on the faculties of the Medical University of South Carolina and Vanderbilt before arriving at the University of South Alabama as chair of the Department of Pathology in 1981.

Dr. Gardner has earned national and international recognition for his research in the area of urologic pathology and has published over 100 articles and book chapters, as well as 6 books in the field. He recently completed a 3-year term as editor-in-chief of the Year Book of Pathology and Clinical Pathology, a worldwide publication for more than 50 years. He currently serves on the editorial board of numerous journals.

He is past president of the Association of Pathology Chairs and immediate past president of the U.S. and Canadian Academy of Pathology. He currently serves as president of the North American Division of the International Academy of Pathology and chairs the Finance

Committee of that division.

He has been the recipient of many awards and honors throughout his career, including being named Outstanding Young Man of America, AOA, and Distinguished Alumnus and Centennial Recognition Awards from the Medical University of South Carolina. In 1996, he was a Fulbright Scholar to Slovakia.

Dr. Gardner has received teaching awards from medical students while at the Medical University of South Carolina, and has been recognized by the University of South Alabama College of Medicine as Distinguished Faculty Member. In the fall of 1994, the university named Dr. Gardner Distinguished Professor of Pathology. In addition to his professorship and chairmanship of the Department of Pathology, he is associate dean for clinical affairs and will assume the position of interim dean and vice president of medical affairs in the spring of 1997.

WILLIAM A. GARDNER, JR, MD, Louise L. Locke professor and chair, Department of Pathology, University of South Alabama, Mobile, Alabama, has been elected chair of AFIP's Scientific Advisory Board. The board, which consists of up to 30 members of the federal and civilian scientific community, provides AFIP departments with sound advice and guidance in support of ongoing programs and new initiatives. Dr. Gardner was appointed to the board in 1996.

A graduate of Wofford College, Dr. Gardner received his master's and medical degrees from the Medical University of South Carolina. He did his graduate

PROFILE



Elson B. Helwig MD, receives Distinguished Pathologist Award

Upon his arrival at the Armed Forces Institute of Pathology in 1946, Dr. Helwig was appointed chair, Department of Skin and Gastrointestinal Pathology, and registrar of the American Registry of Dermal Pathology, serving from 1947 to 1980. He also served as chair, Center for Advanced Pathology, and associate director for consultations from 1955 until 1977.

During this period, Dr. Helwig pioneered the field of dermatopathology as a key founder of the specialty and offered a very popular, thorough, and highly coveted program in dermatopathology known as the Osborne Fellowship. In 1980, he turned to his full-time professional activities as chair, Department of Gastrointestinal Pathology.

During his 44 years at the AFIP, Dr. Helwig has trained many pathologists and dermatopathologists, given hundreds of lectures and seminars nationally and internationally, and authored or coauthored over 200 scientific reports and 7 books. He has served as visiting professor at many universities and holds the rank of clinical professor at the Uniformed Services University of the Health Sciences.

Dr. Helwig has actively served as a member of the editorial boards of several journals and as a member of committees, boards, and panels of national and

international organizations, including the American Academy of Dermatology, American Society of Dermatopathology, American Joint Committee for Cancer Staging and End Results, American Board of Pathology, National Research Council, National Academy of Sciences, International Academy of Pathology, and the World Health Organization.

He has received numerous distinguished honors, awards, and medals, including the Presidential Distinguished Federal Civilian Service Medal; Distinguished Civilian Service Awards from the Department of the Army and Department of Defense; and the first John Shaw Billings Lifetime Achievement Award from the AFIP. One of his most cherished awards was the honorary degree of Doctor of Sciences presented by the Indiana University at the dedication ceremonies for the university's new medical research and library building. This was in recognition of his lifetime of distinguished service to the academic and medical science communities.

ELSON B. HELWIG, MD, received the Distinguished Pathologist Award from the U.S. and Canadian Academy of Pathology at their 86th Annual Meeting in Orlando, Florida, on March 4, 1997. The award was established by the Council of the U.S. and Canadian Academy for recognition of distinguished service in the development of the discipline of pathology, and is presented to an individual who is recognized for making major contributions to pathology over the years.

Born in Pierceton, Indiana, Dr. Helwig attended Purdue University and was a graduate of the Medical School of Indiana University. He began his pathology training in 1933. For the next 9 years, Dr. Helwig served under three giants of pathology: Dr. Howard Karsner of Cleveland, Dr. Shields Warren of Boston, and Dr. Robert Moore of St. Louis.

Dr. Helwig joined the Army in 1942, serving as the chief of pathology branch and executive officer of the 18th Medical General Laboratory, Pacific Ocean Area, and consultant in pathology, Pacific Ocean Area. He remained in the Army Reserves as officer in charge of the medicine and pathology unit, 2901 Research and Development Group, USAR. He retired as a Colonel, Active Reserves, in 1967.

PROFILE

Sarah S. Frankel, MD, named winner of 1997 Castleman Award



SARAH S. FRANKEL, MD, staff pathologist, Division of AIDS and Emerging Infections, Department of Infectious and Parasitic Disease Pathology, received the 1997 Castleman Award from the U.S. and Canadian Academy of Pathology at their 86th Annual Meeting in Orlando, Florida, on March 4, 1997.

Dr. Frankel won the award for her article, "Replication of HIV-1 in Dendritic Cell-Derived Syncytia at the Mucosal Surface of the Adenoid," published in the April 5, 1996 edition of *Science*. The Castleman Award, sponsored by the Massachusetts General Hospital and the U.S. and Canadian Academy of Pathology, is granted for an outstanding paper in the field of human pathology. The awardee must be a pathologist or a pathology resident or fellow who has not yet reached his/her 40th birthday in 1996.

Dr. Frankel's award-winning article

was coauthored by Bruce M. Wenig, MD, Allen P. Burke, MD, Poonan Mannan, MA, Lester D.R. Thompson, MD, Susan L. Abbondanzo, MD, Ann H. Nelson, MD, Melissa Pope, PhD, and Ralph M. Steinman, MD.

The *Science* article reported the finding that human immunodeficiency virus (HIV) appears to continuously replicate in extranodal lymphoid tissues. The researchers discovered HIV actively replicating in the mucous membranes above the lymph glands of the throat in 13 HIV-positive, asymptomatic individuals. These patients (11 of whom did not know they were HIV-positive) had surgery to remove an enlarged tonsil or adenoid.

In a study supported by a research grant from the American Registry of Pathology, Dr. Frankel and her colleagues found that the main site of HIV replication in mucous membranes is dendritic cell-derived syncytia. Discovered in 1973 by coauthor Ralph Steinman, MD, and the late Zanzil Cohn, MD, of the Rockefeller University, dendritic cells are white blood cells with threadlike tentacles that capture bits of protein from infectious agents and present them to T-cell lymphocytes. Scientists believe that studying dendritic cells will be important to designing HIV-1 vaccines.

Dr. Frankel is a graduate of Wellesley College and Rush University Medical College, Chicago. She completed an internship in general surgery and a year of residency training in otorhinolaryngology at the Albert Einstein College of Medicine in New York, and a residency in anatomic pathology at the New York Hospital-Cornell Medical Center in 1990.

Previous assignments included staff positions at The New York Hospital and The Manhattan Eye and Throat Hospital, and as assistant professor of pathology at Cornell University Medical College. In 1991, she moved to Buffalo, New York, where she was on the staff of the Buffalo General Hospital and the Roswell Park Cancer Center. She also served as assistant professor of pathology and ophthalmology at the State University of New York at Buffalo, where she twice received the Siegal Commendation for Excellence in Teaching.

In 1994, Dr. Frankel assumed her present position as staff pathologist at AFIP. She is also a clinical assistant professor of pathology at Georgetown University School of Medicine and serves as a staff scientist in the Division of Retrovirology, Department of Vaccine Development, Walter Reed Army Institute of Research.

REPOSITORY AND RESEARCH SERVICES

FAXes replace case acknowledgement post cards


Due to the success of our initiative to fax case acknowledgement forms to contributors at the time a case is accessioned and the Institute's efforts in decreasing case turnaround times, the Receiving and Accessions Division will no longer be mailing contributors a case acknowledg-

ment post card. The faxing of case acknowledgment forms has substantially improved communications with contributors by quickly providing them the case accession number once assigned, as well as the name and phone number of the department that will be reporting on the case, information not available on the post card. If this change will cause a problem for any of our contributors, we ask that they contact the administrator, Repository and Research Services, at (202)782-2500.

The Receiving and Accessions Division will also no longer routinely

mail x-rays back to contributors, unless they request them at the time of case accessioning. This is the same policy currently in effect for the return of paraffin blocks. This new initiative will not only save postage but will eliminate confusion. The x-rays not immediately requiring return after the case has been finalized will remain on file at the Institute and will be returned upon written/faxed request to our Information Release Office. Anyone having questions concerning this change can contact the above number.

Museum archivist keeps history alive



MICHAEL RHODE HAS BEEN heading the Otis Historical Archives, a division of the AFIP's National Museum of Health and Medicine, for 8 years. Rhode's interest in history led him to seek a job with the Museum while still a student at George Washington University. He returned several years later to head the archives. Joan Redding joined the staff in 1993; she organizes donations so they can be used for research, in addition to her other duties.

"The archives functions both as a repository of information on the Museum and as a collecting division of the Museum," Rhode says. "This means you can find letters from Walter Reed's tenure as curator of the Museum, but also photographs of the Russo-Japanese War donated by Anita McGee, founder of the Army Nurse Corps."

The archives contain a lot of information on the history of the AFIP. "There are of course, the early records when it was still the Museum," he points out. "Then we've got the AFIP historical files that were started in the 1950s. These files have annual reports, building records, and the like. I used them a few years back when a Japanese TV station interviewed us about the building's atomic bomb-proof design."

Rhode answers many questions from the public about the history of medicine. "I'd say we get about three calls or letters a day, sometimes more. People also come in to do research. We ask that they call or write a few weeks in advance, so we can be sure we can help them."

He also occasionally writes exhibits. "I wrote the Civil War medical illustration cases that are on exhibit now. This is actually the fourth version of it that I've written. We have to keep changing the photographs and watercolors, so they won't fade. Hopefully, after it closes, we'll be able to get this exhibit on the Museum's web site, since the artwork won't be displayed again for years," says Rhode.

Does he have a favorite piece? "If I do have one at the moment, it certainly changes over time. I wouldn't pick one of our best-known pieces like 'The Deathbed of Abraham Lincoln' sketch by Museum artist Hermann Faber. I've seen that too many times. I like to find something new. I'm partial to the photographic collections, though," he replied.

Rhode has recently been working on a Civil War medical photography book. "Dr. Blair Rogers, a New York City plastic surgeon, suggested we work on one together years ago. I've written chapters on the Museum and our photographers. Hopefully we'll wrap it up and get it to Duke University for publication this fall. Meanwhile, I've written an introduction to *Photographic Atlas of Civil War Injuries*, a reprint of many of the Museum's photographs.

Redding and Rhode are also working on a *Guide to the Collections*

for the Museum, expected to be published by the American Registry of Pathology. They are hoping to select enough interesting and exciting illustrations to make it attractive to individuals and not just to libraries.

Recently, Rhode has been lecturing on the Museum and its photographic work. "In the past six months, I guess I've spoken four or five times on this. I did a short version for the Washington Society for the History of Medicine in the fall and a longer version for the Smithsonian in February. Fortunately, I can use all the research I did for the book in my talks."

For more information or to use the Otis Archives, contact Rhode at (202) 782-2212, or by e-mail at Rhode@email.afip.osd.mil.

Private Julius Fabry was wounded in August 1864. His leg was amputated at the knee. When his femur became infected, Dr. George Otis, the Museum's second curator, performed the difficult operation of amputating Fabry's leg at the hip. Photographed by Museum staff photographer, E. J. Ward. SP 276.



Portable DNA analysis system delivered to AFIP

By Elizabeth Campos Rajs
Lawrence Livermore Laboratory

A portable DNA analysis system that will allow military specialists to quickly identify human remains in the field, test food and water in remote locations for contamination, and identify pathogenic bacteria on the battlefield was recently delivered to the AFIP by Lawrence Livermore Laboratory.

"Developed by a team of Lab scientists in the Micro Technology Center, the DNA analysis system is revolutionary because of its small size," said M. Allen Northrup, a biomedical engineer and the principal investigator. The hand-held unit operates on 1.5 watts — compared to the laboratory-sized version that consumes 1,000 watts — and the whole system fits in a small suitcase.

"This has wide-ranging applications to the military and society in general," said Victor W. Weedn, LTC(P), MC, USA, Chief Deputy Medical Examiner, Office of the Armed Forces Medical Examiner, and Program Manager, Department of Defense DNA Registry.

Weedn assisted the Defense Advanced Research Project Agency in overseeing this project during the last 3 years.

As a chief deputy in the U.S. government's only medical examiner's office, Weedn has been called around the world to identify human remains. He also was called on to help identify the remains of Czar Nicholas in Russia.

"This is the beginning of a revolution in instrumentation and DNA testing, and Allen Northrup has been at the forefront," Weedn said.

"This is the first time in the world that there's been a product produced for portable DNA testing," he said. "This instrument permits the most rapid, sensitive method of DNA testing available. It permits specific identification of a target molecule as well as quantification of the target molecules, and this instrument could be applied to any DNA testing."

Performing a technique known as

polymerase chain reaction (PCR), the machine makes millions to billions of copies of specific DNA from traces of blood or other cells — whether plant, animal, or germ — at a fraction of the time.

It also performs real-time quantitative detection of the DNA as it is being synthesized, a feature unique to this instrument.


"In experiments in collaboration with Roche Molecular Systems in Alameda and the University of Maryland Medical School, the miniature instrument was used to detect HIV and Hepatitis C virus in human patient samples in less than 20 minutes," Northrup said. "Extremely low viral load levels were detected which has important implications for monitoring therapy of such diseases."

In the past, DNA samples taken in the field had to be sent back to the laboratory for analysis. Now, analysis and identification can take place anywhere in the world in a matter of minutes.

"The portable unit can do it more consistently with more specificity and in a fraction of the time," Weedn said. "I'm thrilled to be a part of this."

For the last 3 years, Northrup's project has been funded by the Department of Defense's Advanced Research Projects Agency's Microelectromechanical Systems Program, under the direction of Ken Gabriel. Turning the unit over to the Army concludes that project, although the team will continue to improve and test the technology with continued DOD funding.

"Without this hardworking critical team, the project wouldn't have been successful. A lot of credit goes to them,"



Rapid DNA testing may become more common thanks to this portable DNA analysis system.

Northrup said.

"The portable DNA analyzer has broad applications," Northrup explained. "It can be used for clinical diagnosis of infectious diseases and cancers, identifying pathogenic bacteria in the environment, and testing agricultural products for diseases. It has potential for broad application for almost all biological analyses and research."

Weedn plans to display one of the machines in the National Museum of Health and Medicine of the AFIP.

"I truly believe in my heart of hearts that this PCR-microchip technology is revolutionary," he said.

AFIP on Global Environmental Collaboration: International Program on Environmental Health and Toxicologic Studies of Arsenosis, Fluorosis, and Thallium Endemic Areas in Southwest Guizhou Province, People's Republic of China

RECENTLY, JOSE A. CENTENO, PhD, a research scientist from the Department of Environmental and Toxicologic Pathology, and four other American scientists were invited to visit Guizhou Province in China to study health problems associated with arsenic, fluoride, and thallium exposures originating from geological materials, particularly high-arsenic coal. The U.S. Task Force was formed as a multidisciplinary, multiagency effort with representatives from the Armed Forces Institute of Pathology, the U.S. Geological Survey, the U.S. Environmental Protection Agency, the University of Arizona, and the Rocky Mountain Poison and Drug Center.

"Health problems associated with high levels of toxic trace elements and metals, including arsenic, fluoride, mercury, and thallium, are known to afflict millions of people in several countries," Centeno points out. "Endemic arsenosis cases have been recently reported in India, Bangladesh, Taiwan, Japan, and Inner Mongolia. In the United States, exposures to arsenic have been reported in several states, including Nevada, Michigan, and Utah."

The influence of geologic materials in human health is an area of fertile scientific and medical research requiring the development of international collaborations in order to understand the distribution, mobilization, and potentially hazardous effects of these materials. Since the early 1950s, more than 3,000 cases of endemic arsenicism induced by burning of high-arsenic coals (As > 1,000 mg/kg) in Southwest Guizhou Province, P.R. China, have been reported. In this region, the coal is locally mined and burned indoors in an open fire without a chimney. The incidence of arsenicism, fluorosis, selenosis, and thallium poisoning cases have been correlated with high levels of these toxic elements and metals found in these coals.

The U.S. delegation was invited by the National Nature Science Foundation of China, the Academy of Sciences, and the



Institute of Geochemistry of China. In collaboration with the Chinese institutions and provincial authorities, Dr. Centeno and his colleagues conducted on-site studies on the extent of the environmental problem and on the assessment of clinical features associated with the presence of arsenic, fluoride, and thallium, and established a dialogue for the development of a memorandum of agreement to conduct medical and toxicologic studies. The environmental health assessment program includes chemical characterization studies, toxicology and clinical treatment, and the collection of clinical and pathological specimens to study the effect(s) of these contaminants in tissue.

"Results from this project could provide useful information to U.S. military medicine by improving our understanding of the human health impact of these contaminants and their distribution, mobility, and behavior in environmental geochemical sites where American troops could be potentially deployed," Centeno says.

The presence of arsenic in these coals in the range of 10 to perhaps 10,000 ppm provides an excellent opportunity to contribute to knowledge of the dose

Members of the U.S. and Chinese Task Forces are (l. to r.): Dr. Jose Centeno (AFIP), medical assistant (China), Dr. Robert Finkelman (USGS), Dr. Judy Mumford (US-EPA), Dr. Dai-xing Zhou (China), Dr. Richard Dart (Rocky Mountain Poison & Drug Center), Prof. Vasken Aposhian (University of Arizona), Dr. Bao-shan Zheng (Institute of Geochemistry, China), and Mr. Chen Chao-gang (geologist).

response of arsenic. This is a major issue being addressed by the Environmental Protection Agency for the upcoming reauthorization of the Clean Water Act, and has particular relevance to the elevated levels of arsenic in drinking water in eastern Michigan, India, and Bangladesh.

Spanish Flu, Continued from page 1

evidence we needed," Taubenberber notes.

Most did not meet the criteria, but a few did, and one case in particular led the team to believe the virus was still replicating when the victim died. Sections from that case revealed focal acute bronchiolitis and alveolitis with individual cell necrosis of bronchiolar epithelial cells, indicative of viral pneumonia.

He was a 21-year-old private who died at Fort Jackson, South Carolina 5 days after being infected. "He was completely healthy with no medical history until he got the flu," Taubenberger says. He and Ann Reid then utilized polymerase chain reaction (PCR) techniques to amplify minute amounts of the victim's genetic material for sequence analysis.

Nine fragments of viral RNA were sequenced from the coding regions of five influenza genes: hemagglutinin, neuraminidase, nucleoprotein, matrix 1, and matrix 2. The sequencing was particularly difficult to accomplish since over the years the viral RNA had broken down into minute pieces only 200 nucleotides long. The technique to isolate RNA from formalin-fixed, paraffin-embedded tissues was developed in the AFIP's Division of Molecular Pathology, and the RNA from this case was extracted by research biologists Amy E. Krafft, PhD, and Karen E. Bijwaard.

Ann Reid devised methods to amplify small fragments of the 1918 viral genes using degenerate PCR primers that would recognize conserved sequences in human, swine, and avian influenza viruses. Once sequences were obtained, she was able to devise PCR primers that more closely matched the sequences from the 1918 flu.

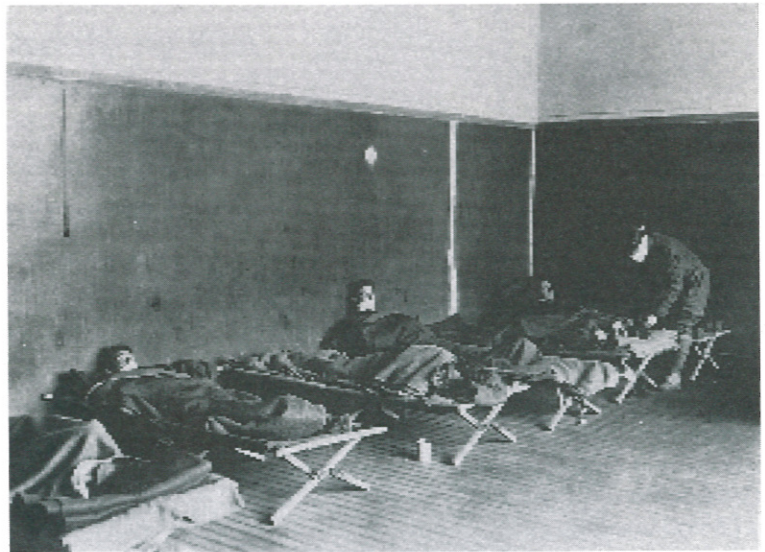"The hemagglutinin gene matches closest to swine influenza viruses, showing the first direct evidence that the virus came into humans from pigs," Taubenberger says. Phylogenetic analyses of the gene fragments from the 1918 virus were performed by research biologist Thomas G. Fanning, PhD, using sophisticated computer software packages that compare differences in related genes.

What does the future hold?

Taubenberger estimates that his team has analyzed about 7% of the virus, but he's confident that continued studies will provide more information about the flu's complete genetic code. "On two other

occasions since 1918, a major flu outbreak has been clearly caused by the appearance of new influenza strains that mutated in pigs—the 1957 Asian flu and the 1969 Hong Kong flu," he points out, "and in 1976 there was an isolated outbreak of a new swine flu virus in humans.

Millions of dollars were spent to vaccinate the population out of fear this could have been as damaging as the 1918 flu. While that particular strain turned out not to be lethal, the 1918 results confirm that 'swine flus' remain a significant public health



U.S. Army field hospital #29, Hollerich, Luxembourg. Courtesy: National Library of Medicine.

threat. Understanding the genetic make-up of this flu may help us combat future epidemics and prevent such a terrible loss of life."

HISTOTECH NOTES

Tri-Service School of Histotechnology

The Tri-Service School of Histotechnology, (Department of Scientific Laboratories), is located on the grounds of Walter Reed Army Medical Center at the Armed Forces Institute of Pathology, Washington, D.C. The school has a staff consisting of a program director, course superintendent, dean of civilian students, two instructors, and eight adjunct faculty members who teach up to 25 students per course. Students are trained in preparing tissue specimens for macroscopic and microscopic examination, postmortem procedures, microtomy, embedding, routine hematoxylin and eosin (H&E) staining and special stains to further pathologic diagnosis.

The school is undergoing major changes to its curriculum to enhance the quality of academia and training of the students to become proficient and qualified histotechnicians. Initially, the Tri-Service School offered two courses on a yearly basis, but the new curriculum will consist of 3 months of academic study and 6 months of actual hands-on training under the supervision of the school's instructors and adjunct faculty members. The school trains military students from the Air Force, Navy, and Army along with civilians either directly out of high school or individuals wishing to change their perspective career fields.

Currently, the school is undergoing approval for accreditation by the National Accrediting Agency for Clinical Laboratory Sciences (NAACLS), which allows students to test for certification through the American Society of Clinical Pathologist (ASCP) to be certified as Histotechnician (HT) ASCP. For additional information about the Tri-Service School of Histotechnology, please forward correspondences to AFIP, Bldg. 54, Rm 2107, 6825 16th Street, NW, Washington, D.C. 20306-6000, call (202) 782-2801, or FAX: (202) 782-7663.

DISCOUNTS . . . (Choose one)

Subscribers:

- 10% Staff discount } I wish to become a new AFIP ATLAS Subscriber
 25% Resident/Fellow discount

Please sign Terms & Conditions. **Credit card number required**

Letter of certification required for Residents/Fellows

- 10% or 25% discount - I am an AFIP ATLAS Subscriber (AAS# _____)

Non-Subscribers:

- 10% discount - I am a FASA member (FASA # _____)
 25% discount - I am a Resident or Fellow - Supply Training Director's name _____

Terms and Conditions: The American Registry of Pathology is authorized to send me the copies ordered of each of the AFIP Atlas of Tumor Pathology fascicles and one copy of each future fascicle, Series III, at a 10% discount (25% for residents) plus shipping and handling for future publications (\$4.00 per book U.S.A., 25% outside continental U.S.A.) The books will immediately be charged to my credit card number and mailed to the address shown below. I understand that I have 14 days in which to return unwanted books to the American Registry of Pathology, with subsequent credit to my account. I also understand that I may withdraw, with written notice, from the "AFIP ATLAS SUBSCRIBERS" program at any time.

Prices subject to change.

Signature _____

Date _____

American Registry of Pathology PUBLICATIONS ORDER FORM

AFIP Atlas of Tumor Pathology

Qty.	Year	Price	Total
Series Three			
.....	Non-Melanocytic Tumors of the Skin (1)	91	\$45.00
.....	Melanocytic Tumors of the Skin (2)	91	45.00
.....	Uterine Corpus & Gest Trophoblastic Dis (3)	92	45.00
.....	Cervix, Vagina, and Vulva (4)	92	45.00
.....	Thyroid Gland (5)	93	58.00
.....	Parathyroid Gland (6)	93	32.00
.....	Mammary Gland (7)	93	59.00
.....	Bones and Joints (8)	93	50.00
.....	Bone Marrow (9)	94	65.00
.....	Central Nervous System (10)	94	60.00
.....	Kidney, Bladder, etc. (11)	94	55.00
.....	Eye and Ocular Adnexa (12)	95	56.00
.....	Lower Respiratory Tract (13)	95	69.00
.....	Lymph Nodes & Spleen (14)	95	69.00
.....	Serosal Membranes (15)	95	45.00
.....	Heart and Great Vessels (16)	96	58.00
.....	Salivary Glands (17)	96	69.00
.....	Esophagus & Stomach (18)	96	69.00
.....	Adrenal Gland & Extra-Adrenal Paraganglia (19)	97	70.00

Payment in U.S. dollars must accompany order

Payment is required in checks drawn on a bank located in the U.S. or Canada, international MasterCard, Visa, American Express, or Eurocard, or an International Postal Money Order made payable to the American Registry of Pathology. Orders shipped insured parcel post. We guarantee delivery, or replacement of damaged goods.

New Subscribers - credit card and phone numbers are required.

Please Choose Method of Payment

- Check or money order payable to American Registry of Pathology enclosed. (U.S. dollars only)
 Charge my MasterCard, Visa, American Express, or Eurocard

--	--	--	--	--	--	--	--	--	--	--	--	--	--	--	--	--	--	--	--

Expiration Date _____

Signature _____

Business Phone _____ FAX # _____
 (required for credit card payment)

Book and CD-ROM sales are not for consignment. We reserve the right to correct any calculation or clerical errors before charging your credit card.

Special Publications			
.....	Human Larynx, Coronal Section Atlas	71	8.00
.....	Billings Microscope Collection	74	25.00
.....	Tropical & Extraordinary Diseases, Vol 1	76	40.00
.....	Tropical & Extraordinary Diseases, Vol 2	76	40.00
.....	Atlas of Kidney Biopsies	80	35.00
.....	Pediatric Autopsy Manual (Reprint 1997)	83	15.00
.....	AFIP Laboratory Methods in Histotechnology	92	35.00
.....	Histopathology Atlas for SIDS	93	40.00
.....	Bone & Joint Tumors of Domestic Animals	94	20.00
.....	Adv Lab Methods in Histology & Pathology	94	45.00
.....	Perinatal Autopsy Protocol	95	10.00
.....	Métodos Histotecnológicos	95	35.00
.....	Pathology of Systemic Lupus Erythematosus	95	35.00

Type or Print clearly. For faster delivery, do not use P.O. boxes.

(Company or personal name) _____

(Address / attention line) _____

(Street) _____

(City, State, ZIP Code and Country) _____

	Total Qty.	(Gross Price) Subtotal	
	_____	_____	
	% of discount from above _____		
	Shipping & Handling	\$4.00 per copy - OR add 6% of subtotal above over five copies if shipped within continental U.S. All other orders add 25% of subtotal	
	Total Cost of BOOK ORDER		

Mail or FAX ENTIRE PAGE to:

NL 4-97

American Registry of Pathology Sales Office
 Armed Forces Institute of Pathology, Room 1077
 Washington, DC 20306-6000

Phone: (202) 782-2666/7 FAX: (202) 782-0941

AFIP Atlas of Tumor Pathology

Electronic Fascicle v.2.0 CD-ROM

CD#	Product Currently Available	Qty	Price	Total
EF301	DERM (fascicles 1 & 2)		\$85.00	
EF302	GYN/Breast (fascicles 3, 4 & 7)		140.00	
EF303	Thyroid/Parathy (fascicles 5 & 6)		85.00	
EF304	Bones & Joints (fascicle 8)		45.00	
EF305	Bone Marrow (fascicle 9)		60.00	
EF306	CNS/Eye (fascicles 10 & 12)		110.00	
EF307	Kidney (fascicle 11)		50.00	
EF308	Lower Respiratory Tract (fascicle 13)		89.00	
SUBTOTAL				

INDIVIDUAL CD-ROM DISCOUNTS AVAILABLE (Multiply subtotal by discount)

Please check applicable discount: (credit card required for subscribers)

- A CD-ROM only Subscriber (staff) 10%
- B CD-ROM only Subscriber (resident/fellow)..... 25%
- C AAS/CD-ROM Subscriber (staff) 15%
- D AAS/CD-ROM Subscriber (resident/fellow) 30%
- E FASA members 10%
- F Residents/fellows 25%
- G None of the above - no discount applies.

Subtract discount here ➔

I am an AFIP Atlas Subscriber (AAS) and wish to add the CD-ROMs to my current subscription.

AAS # _____ (Use discounts C or D)

I am NOT an AFIP Atlas Subscriber but wish to subscribe to CD-ROMs only.

(Use discounts A or B. Residents and fellows must attach letter of certification)

**Sign and Date Terms & Conditions below*

SHIPPING & HANDLING:

Per CD-ROM within continental USA \$4.00

Per CD-ROM outside continental USA \$15.00

Add shipping & handling here ➔

TOTAL CD-ROM ORDER **ALL CD-ROM SALES ARE FINAL**

TOTAL BOOK ORDER (from other side of form)

GRAND TOTAL

Method of Payment: Check Credit Card (see reverse side)

Print your name here _____

Please complete your address on reverse side of form

BS 4-97

New Subscribers please note:

If we receive your application subsequent to the publishing of a new fascicle, it will be shipped automatically.

Terms & Conditions:

The American Registry of Pathology is authorized to send me one copy of each CD-ROM (Electronic Fascicles) as they become available at the applicable discount checked above, plus current shipping and handling charges. The CD-ROMs will immediately be charged to my credit card and mailed to the address indicated on this form. I understand that CD-ROMs are not returnable but will be replaced if found defective within 90 days. I also understand that I may withdraw from the subscription program with written notice. CD-ROM and shipping and handling prices are subject to change.

Signature: _____ Date: _____

Postgraduate Short Courses in Continuing Education

Academic Year 1997

Course Title	Scheduled Dates	Location
7th Anatomic Pathology Update & Review	11-17 May 97	Leavey Conference Center, Georgetown University, Washington, DC
3rd Musculoskeletal Imaging Weekend	17-18 May 97	Loew's Hotel, Annapolis, MD
10th Annual Forensic Anthropology	9-13 June 97	USUHS, Bethesda, MD
6th Annual Descriptive Veterinary Pathology	10-13 June 97	Natcher Center, NIH, Bethesda, MD
12th Annual Diagnostic Exfoliative & Fine Needle Aspiration Cytology	16-20 June 97	AFIP, Washington, DC
Telepathology Workshop	1-3 July 97	USUHS, Bethesda, MD
Descriptive Veterinary Pathology	15-17 July 97	Liverpool, England
Neuropathology Long Course	8 July-26 Sept 97	AFIP, Washington, DC
Genitourinary Radiology	14-18 July 97	AFIP, Washington, DC
Congenital DNA Repair Deficiency in Humans	20-21 July 97	TBA, Poughkeepsie, NY
Musculoskeletal Radiology	21-25 July 97	AFIP, Washington, DC
Neuroradiology	4-8 August 97	AFIP, Washington, DC
44th Annual Pathology of Laboratory Animals	11-14 August 97	Natcher Center, NIH, Bethesda, MD
3rd Annual Current Laboratory Animal Science Seminar	14-15 August 97	Natcher Center, NIH, Bethesda, MD
Ophthalmic Pathology for Ophthalmologists	17-22 August 97	Leavey Conference Center, Georgetown University, Washington, DC
Analytical & Molecular Biological Techniques in Environmental Toxicology & Pathology	18-20 August 97	AFIP, Washington, DC
Controversias y Adelantos en Patología Quirúrgica	20-24 August 97	TBA, Sao Paulo, Brazil
8th Annual Review Gastrointestinal Surgical Pathology & Endoscopic Biopsies of the GI Tract	7-8 September 97	Hyatt Regency, Bethesda, MD
Pediatric Radiology	8-12 September 97	AFIP, Washington, DC
8th Annual Hepatopathology: The Interpretation of Liver Biopsies	9-11 September 97	Hyatt Regency, Bethesda, MD
Pulmonary & Mediastinal Radiology	13-14 September 97	AFIP, Washington, DC
Abdominal & Gastrointestinal Radiology	15-19 September 97	AFIP, Washington, DC
Radiologic Pathologic Correlation	5-9 October 97	George Washington Inn & Conference Ctr., Williamsburg, VA
Metals in Environmental Health & Disease	6-8 October 97	AFIP, Washington, DC
Basic Forensic Pathology	20-24 October 97	DoubleTree Hotel, Rockville, MD
Interpretation of Prostatic Biopsies	1-2 November 97	Holiday Inn, Silver Spring, MD
The Dermatopathology Workshop	7-8 November 97	Ritz-Carlton Pentagon City, Crystal City, VA
Emerging Infections: Clinical & Pathological Update II	8-12 November 97	Emory Conference Center, Atlanta, GA
Update in Surgical Pathology	8-13 December 97	Disney's Contemporary Resort, Orlando, FL

Instructions for Filling Out Application Form

- 1. Accreditation:** The Armed Forces Institute of Pathology is accredited by the Accreditation Council for Continuing Medical Education to sponsor continuing medical education for physicians.
- 2. Course Fee:** Checks for all courses are to be made payable to the American Registry of Pathology (ARP). We can only register an applicant when full payment is received.
- 3. Registration Procedures for International Applicants:**

Civilians:

Mail letter of application to:
 Chief, Program Resources Branch
 E/VCP, Rm 266
 United States Information Agency
 301 4th Street, S. W.
 Washington, D.C. 20547
 FAX: (202) 619-4655

Letter of application should include:

1. Title of course
2. Inclusive dates of course
3. Your present position
4. Your home and office mailing address
5. Your date and place of birth
6. Your country of citizenship
7. Your financial arrangements for stay at this course

(U.S. Government cannot be responsible for any expenses incurred while you are in the U.S.)

With letter of application, attach a copy of course application form, a check drawn on a U.S. bank or international money order, payable to the American Registry of Pathology, in U.S. dollars in the amount required.

Foreign Military:

Request the desired training through your military training channels to the Security Assistance Office of the U.S. Mission in your country.

International Applicants Employed by an Agency of the U.S. Government

Attach to letter of application (see above) a letter certifying employment from your servicing personnel office and mail to:
 International Training Program Manager
 U.S. Army Health Professional Support Agency
 Attn: SGPS-EDI; International Training Officer
 5109 Leesburg Pike
 Falls Church, VA 22041-3258
 FAX: (703) 756-7535

APPLICATION FORM - AFIP COURSES

Course Title & Dates _____
 Name (Last, First, MI) _____
 Mailing Address _____
 City, State, Zip _____
 Phone _____ Specialty _____ Board Status: Certified Eligible
 Citizenship _____ Resident/Fellow Friend of AFIP Membership # _____
 Military/Federal Civilian Employees (Only): Rank/Civilian Grade _____
 Service Agency: _____
 Corps: MC DC NC VC Biomedical/Allied Science
 Payment Enclosed: (Payable in U.S. dollars only) Tuition \$ _____ DoD, VA, and PHS Fee \$ _____
 Method of Payment: Check/Money Order MasterCard Visa
 Card Number _____ Expiration Date _____
 Name as it appears on card _____
 Signature _____

Make All Payments to: AMERICAN REGISTRY OF PATHOLOGY

Mail To: Armed Forces Institute of Pathology
 Education Division
 Washington, D.C. 20306-6000
 Telephone: Office (202) 782-5021/9280
 Toll Free (800) 577-3749 (U.S. only)
 FAX: (202) 782-7164 Internet: CAME@email.afip.osd.mil

Carcinoids of the jejunum and ileum: an immunohistochemical and clinicopathologic study of 167 cases

Allen P. Burke, M.D. Rebecca M. Thomas, M.D. Al M. Elsayed, M.D. Leslie H. Sobin, M.D.

BACKGROUND. Carcinoid tumors of the gastrointestinal tract differ in their clinical and histopathologic features, depending on the site of origin. There are few clinicopathologic studies that specifically describe jejunoileal carcinoid tumors.

METHODS. One hundred sixty-seven ileal and jejunal carcinoids were retrospectively studied with emphasis on clinical, pathologic, immunohistochemical, and prognostic features.

RESULTS. The mean age of patients at the time of presentation was 62 + 12 years (range, 13-93 years). Eight patients had carcinoid syndrome (5%) and 1 had Zollinger-Ellison syndrome. Twenty-six percent of tumors were multiple, and 77% were transmurally invasive; 31% had regional lymph node metastases only, and 32% had liver or mesenteric metastases. Ninety-three percent of tumors had an insular growth pattern. Serotonin was expressed in 86% of tumors (86 of 102), chromogranin in 92%, and neuron specific enolase in 95%. Twenty percent of tumors (10 of 51) expressed prostatic acid phosphatase; 96% were argyrophil, and 98% argentaffin. Of 80 cases with follow-up data (mean follow-up, 52 + 5 months), 21% were dead of disease, 16% were dead of other causes, 19% were alive with disease, and 44% had no evidence of disease at last follow-up. The 5-year KaplanMeier survival estimate for all cases was 58%. By univariate analysis, survival was negatively correlated with distant metastases at the time of surgery ($P = 0.002$), mitotic rate ($P = 0.01$), tumor multiplicity ($P = 0.01$), the presence of carcinoid syndrome ($P = 0.02$), depth of invasion ($P = 0.03$), and female gender ($P = 0.05$); by multivariate analysis, survival was negatively associated with distant metastasis ($P = 0.002$), carcinoid syndrome ($P = 0.01$), and female gender ($P = 0.03$).

CONCLUSIONS. Jejunoileal carcinoid tumors have a relatively high rate of transmural invasion and aggressive clinical behavior. They are usually insular and largely argentaffin, with a high rate of chromogranin and serotonin positivity. These features differentiate jejunoileal carcinoids from other gastrointestinal carcinoids.

Cancer. 1997;79:1086-93.

Detailed RT-ISPCR protocol for preserving morphology and confining PCR products in routinely processed paraffin sections

Yan-gao Man, Zhengping Zhuang, Gary L. Brattbauer, Omar Bagasra and Fattaneh A. Tavassoli

A modified reverse transcription in situ polymerase chain reaction (RT-ISPCR) protocol has been developed for mRNA detection in routinely processed paraffin sections. Compared to previously published methods, this protocol applies several new strategies, including (1) placing tissue sections on regular microscopic slides to reduce the size of the reaction chamber; (2) substituting enzymatic digestion with overnight incubation at 80°C to eliminate "cross-links" induced by formalin fixation; (3) adding anti-AE1/AE3 antibodies to RT solution to create a sponge-like tissue surface to trap and confine newly formed PCR products; (4) reducing the number of high-temperature treatment steps to avoid complete tissue desiccation; and (5) placing sections at 4°C after RT reaction and amplification to facilitate newly formed PCR products to settle down. With these strategies, we have been able to obtain reproducible results in which the morphology of tissue is well preserved, different cell types are readily distinguishable, and the amplified PCR products are easily identifiable. This protocol can also be used for detection of DNA in paraffin sections with stronger signals and better preservation of morphology. The specificity of this method is confirmed by results from different controls and from other approaches, including immunohistochemistry with specific antibodies, in situ hybridization with specific mRNA probes, and tube PCR with the same primers and PCR conditions used for RT-ISPCR. The basic rationale of our approach is discussed.

Cell Vis. 1996;3:389-396.

Inflammatory pseudotumor of lymph nodes: a study of 25 cases with emphasis on morphological heterogeneity

Cesar A. Moran, MD, Saul Suster, MD, and Susan L. Abbondanzo, MD

The clinicopathological and immunohistochemical findings in 25 cases of inflammatory pseudotumor of lymph nodes (115) are

presented. The patients were 13 women and 12 men between 8 and 81 years of age. Clinically, symptoms of prior infection, fatigue, abdominal pain, weight loss, fever of unknown origin, pelvic inflammatory disease, or nausea and night sweats were obtained in 15 patients, whereas six patients presented with asymptomatic lymphadenopathy. In four additional patients, no clinical information was obtained. The involved nodes included cervical, supraclavicular, inguinal, mesenteric, and mediastinal lymph nodes. In two cases, there was synchronous involvement of separate lymph node groups (inguinal and cervical in one case and cervical and mediastinal in another case), whereas in a third patient there was synchronous involvement of the spleen and a paraortic lymph node. Histologically, the lesions were characterized by a fibrosing/inflammatory process that showed marked heterogeneity and striking variation from case to case. Based on their histological features, the lesions could be classified into three different groups: Stage I was characterized by the appearance of single or multiple small foci containing a spindle cell proliferation admixed with a prominent inflammatory background, with complete preservation of the remainder of the nodal architecture; stage II was characterized by more diffuse involvement of the lymph node with a marked inflammatory response admixed with a prominent myofibroblastic proliferation leading to subtotal effacement of the nodal architecture, often with extension of the process beyond the capsule into perinodal fat; and stage III was characterized by almost complete replacement of the lymph node by diffuse sclerosis with scant residual inflammatory elements and total loss of the normal nodal architecture. Immunohistochemical studies in 20 cases showed a striking number of vimentin- and actin-positive myofibroblastic cells with moderate increase in CD20/CD45+ small lymphocytes and polyclonal plasma cells in the stage I lesions, the emergence of numerous CD68+ histiocytes admixed with lymphocytes, plasma cells, and abundant fibrocytic cells in the stage II lesions, and only few remaining scattered CD68+ histiocytes and fibroblasts in the stage III lesions. Our findings suggest that inflammatory pseudotumor of the lymph node represents an evolving, dynamic process that may adopt different morphological appearances depending on its stage of evolution. Recognition of the various stages of this process may be of importance for differential diagnosis with other fibrosing/inflammatory conditions of lymph nodes.

Hum Pathol. 1997;28:332-338.

Armed Forces Institute of Pathology

Washington, D.C. 20306-6000

OFFICIAL BUSINESS

The **AFIP Letter** is published bimonthly by the Armed Forces Institute of Pathology. Its purpose is to furnish timely information on policies, activities, and programs relevant to the military and civilian pathology community. The Secretary of the Army has determined that the publication of this periodical is necessary in the transaction of the public business as required by law of the Department. Use of funds for printing this publication has been approved by DAAG-PAP, letter dated 6 August 1984, in accordance with the provisions of AR 25-30. The views and opinions expressed are not necessarily those of the Department of Defense or the Department of the Army. Comments or proposed material should be addressed to:

The Director

ATTN: AFIP-PA

Armed Forces Institute of Pathology

Washington, D.C. 20306-6000

Telephone (202) 782-2115. DSN 662-2115

FAX: (202) 782-9376 Internet: Kelly@email.afip.osd.mil

Director

Michael J. Dickerson, Col, USAF, MC

Editor

Christopher Kelly, Public Affairs Director

JoAnn P. Mills, Editorial Office

Graphics

Frances W. Card

Photography

Cathy Hemelt

Seth B. Jones

Steve Kruger

Recent Publications by AFIP Staff

1. Burke AP, Thomas RM, Elsayed AM, Sobin LH. Carcinoids of the jejunum and ileum: an immunohistochemical and clinicopathologic study of 167 cases. *Cancer*. 1997;79:1086-1093.
2. Man Y-G, Tavassoli FA. A simple epitope retrieval method without the use of microwave oven or enzyme digestion. *Appl Immunohistochem*. 1996;4:139-141.
3. Man Y-G, Zhuang Z, Bratthauer GL, Bagasra O, Tavassoli FA. Detailed RT-ISPCCR protocol for preserving morphology and confining PCR products in routinely processed paraffin sections. *Cell Vis*. 1996;3:389-396.
4. Moran CA, Suster S, Abbondanzo SL. Inflammatory pseudotumor of lymph nodes: a study of 25 cases with emphasis on morphological heterogeneity. *Hum Pathol*. 1997;28:332-338.
5. Tavassoli FA, Purcell CA, Bratthauer GL, Man Y-G. Androgen receptor expression along with loss of bc1-2, ER, and PR expression in benign and malignant apocrine lesions of the breast: implications for therapy. *The Breast Journal*. 1996;2:261-269.