

HEALTH SCIENCES STANDARD



HX00025054

QM 451

R17
1888



COLUMBIA UNIVERSITY
EDWARD G. JANEWAY
MEMORIAL LIBRARY

To my friend


W. E. G. Janeway

with the regards of the

Author

A. L. R

Aug 16 1888 -



Digitized by the Internet Archive
in 2010 with funding from
Open Knowledge Commons (for the Medical Heritage Library project)

THE
APPLIED ANATOMY OF THE
NERVOUS SYSTEM

*BEING A STUDY OF THIS PORTION OF THE HUMAN BODY FROM A
STANDPOINT OF ITS GENERAL INTEREST AND PRACTICAL
UTILITY IN DIAGNOSIS, DESIGNED FOR USE AS
A TEXT-BOOK AND A WORK OF REFERENCE*

BY

AMBROSE L. RANNEY, A. M., M. D.

Professor of the Anatomy and Physiology of the Nervous System in the
New York Post-Graduate Medical School and Hospital;
Professor of Nervous and Mental Diseases in the Medical Department of the University of Vermont;
Late Adjunct Professor of Anatomy and Lecturer on the Diseases of the Genito-Urinary Organs and
on Minor Surgery in the Medical Department of the University of the City of New York;
Late Surgeon to the Northern and Northwestern Dispensaries;
Resident Fellow of the New York Academy of Medicine;
Member of the Medical Society of the County of New York;
Member of the Neurological Society of New York;
Author of a "Practical Treatise on Surgical Diagnosis," "Practical Medical Anatomy,"
"Electricity in Medicine," "The Essentials of Anatomy," etc.

SECOND EDITION

REWRITTEN, ENLARGED, AND PROFUSELY ILLUSTRATED

"The greatest thing a human soul ever does in this world is to see something, and tell what he saw in a plain way. Hundreds of people can talk for one that can think, but thousands can think for one who can see. To see clearly is poetry, prophecy, and religion all in one"

JOHN RUSKIN

NEW YORK
D. APPLETON AND COMPANY
1888

COPYRIGHT, 1881, 1888,
By D. APPLETON AND COMPANY.

To the Memory of
LAFAYETTE RANNEY, A. M., M. D.,
THIS VOLUME
IS DEDICATED BY HIS SON,
THE AUTHOR.

PREFACE TO THE SECOND EDITION.

THE author has been prompted by the many favorable reviews of the first edition of this work, and by its general adoption as a text-book, to modify its scope and plan, with a view of rendering it more worthy of commendation. It is hoped that its field of usefulness will be materially enhanced by the alterations made.

The changes have been so radical that the present edition may be said to be practically a new work. The section on the brain has been entirely rewritten, in order that the latest discoveries in the anatomy and physiology of that organ should be comprised within its pages. The sections on the cranial nerves and the spinal cord have also been enlarged, and so altered as to make them more comprehensive in their scope. Some cuts of the former edition have been discarded, and better ones selected as substitutes. Many new diagrams have been designed by the author to illustrate the text.

A work upon this field must, of necessity, be to a large extent a discussion of others' views. Originality of treatment of the subject may possibly be claimed for this volume (because diagrammatic illustration forms an important feature in the author's system of teaching); but no work

upon this field can be complete without frequent allusions to, or quotations from, the valuable contributions of the more prominent neuro-anatomists, pathologists, and physiologists.

The new matter incorporated in this edition as well as much of the old edition contains frequent references to the writings of many authors, and it is hoped that their respective views are now correctly and impartially stated at all times. Great care has been exercised in giving full credit to those to whose original work the author owes much of the valuable information here gathered into one volume.

The aim of the author has been to furnish a reliable guide to the student of neurological anatomy and physiology, in which he may find the views of the leading minds in that field accessible, and the main facts which are applicable to diagnosis clearly interpreted. It is still possible that oversights in acknowledgment may have occurred, as is very apt to happen in a work of this kind (since it is but a publication of lectures delivered before classes of students), but, if so, they are unintentional and open to correction.

Much of the new matter of this edition has already appeared in various medical journals, among which may be mentioned the "New York Medical Journal," the "Medical Record," the "Journal of Nervous and Mental Diseases," and the "Archives of Medicine." Some of these lectures have received the unexpected honor of a French and Italian translation.

In the preface to the first edition the author expressed his incentive to the effort, as well as his doubts, as follows:

"The rapid strides, which are being made in the interpretation of the symptoms of nervous diseases, and the in-

roduction of many new terms, which must embarrass the reader of late monographs, unless he be educated to the present standard of knowledge in this field of medicine, seem to the author a reasonable ground for belief, that there is a demand for a volume, which shall fit the practitioner and student to pursue his studies in this special line without embarrassment, if not with increased interest.

“With whatever merits or demerits the volume may possess, I intrust it to the public, conscious that an effort to clear up a field made obscure by visionary theories and endless speculation can not but contain some ground to which exception may be taken. To what extent it will supply the place of a guide in this—the labyrinth of medical science—experience alone must decide.”

Finally, the acknowledgments of the author to the profession (who have decided in his favor by giving the first edition of this work their support in spite of its many imperfections) are now in place. It will be his aim to make subsequent editions, if called for, more complete than the present one.

AMBROSE L. RANNEY.

156 MADISON AVENUE, NEW YORK CITY,
March, 1888.

TABLE OF CONTENTS.

	PAGES
GENERAL INTRODUCTION	1-21
THE NERVOUS SYSTEM CONSIDERED AS A WHOLE.	
ITS COMPONENT PARTS.	
THE GENERAL AXIOMS OF NERVE DISTRIBUTION.	

PART I.

THE BRAIN	21-327
THE CEREBRO-SPINAL AXIS.	
HISTOLOGICAL ELEMENTS OF NERVOUS STRUCTURES.	
VARIETIES OF NERVE CURRENTS:	
Centripetal or sensory.	
Centrifugal or motor.	
FUNCTIONS OF NERVE CELLS AND NERVE FIBERS:	
Isolated conduction of impulses.	
Generation and storage of nerve force.	
Discharge of nerve force.	
Storage of various forms of memories.	
Consciousness and mental processes.	
GRAY MATTER OF BRAIN:	
The cortex cerebri.	
The basal ganglia of cerebrum.	
The cortex cerebelli.	
The tubular gray matter.	
The corpora quadrigemina.	
The gray matter of pons and medulla.	
The various smaller ganglia.	
THE CEREBRUM	27-122
WHITE MATTER OF CEREBRUM:	
The commissural fibers.	
The peduncular fibers.	
The associating fibers.	
The fornix fibers.	
THE PROJECTION SYSTEMS OF MEYNERT AND SPITZKA:	
Reasons for such an arrangement.	

General formation of projection systems.

Cranial nerve tracts.

THE CEREBRAL CORTEX :

Its general construction, color, thickness, etc.

Its connective tissue (neuroglia).

Its layers and their special peculiarities.

Modifications of, in different regions.

The seat of all mental processes and volition.

TOPOGRAPHY OF CEREBRAL CORTEX :

Arrangement of its lobes, lobules, fissures, and sulci.

The classification of its convolutions (Ecker).

FUNCTIONS OF CEREBRAL CORTEX :

The centers of motion.

Motor center of speech (Broca).

Centers of hearing, sight, smell, taste, touch, etc.

Aphasia, as a symptom.

The motor area, and its subdivisions.

Cortical motor paralysis.

Sensory areas of the cortex and their functions.

Occipital lobes.

Parietal lobes (posterior to motor area).

Temporo-sphenoidal lobes.

SYMPTOMS REFERABLE TO CORTICAL LESIONS :

Monoplegia; early rigidity; localized pain; Jacksonian epilepsy; hemianopsia; word-blindness; word-deafness; motor aphasia; paraphasia; mono-anæsthesia; monospasm; abolition of memories of various kinds; hallucinations of vision; vomiting; choked-disk, etc.

SUMMARY OF THE PHYSIOLOGY OF THE CEREBRAL CORTEX :

Its excitable regions.

Its physiological centers.

Views respecting cerebral localization.

Classification of the various monoplegias.

Discrimination between destructive and irritative lesions of the cortex.

The storage of various forms of memories.

Results of widely diffused lesions of the cerebral cortex.

WEIGHT AND GROWTH OF THE BRAIN :

Relative development of component parts.

Rapidity of growth during different periods of life.

INTRA-CEREBRAL LESIONS :

General statements respecting them.

SURGICAL BEARINGS OF CEREBRAL TOPOGRAPHY :

Guides to the more important cortical centers of cerebrum.

Late observations of Horsley respecting the motor centers.

Thane's method of locating Rolando's fissure.

Guides to the fissure of Sylvius.

Indications and contra-indications for trephining.

DIAGNOSTIC SYMPTOMS OF INTRA-CEREBRAL LESIONS: Profound coma; hemiplegia; hemianæsthesia; late post-paralytic rigidity; tremor; hemichorea; athetosis; general convulsions; impairment of special senses; choked-disk, etc.	
THE CORPUS STRIATUM	122-132
NUCLEI OF CORPUS STRIATUM.	
THEIR CLINICAL AND PHYSIOLOGICAL IMPORTANCE.	
FUSION OF THE CAUDATE AND LENTICULAR NUCLEI.	
CELLS OF EACH NUCLEUS.	
LENTICULAR NUCLEUS:	
Its shape, situation, and relations.	
Its fibers.	
Its three members (Glieder).	
CAUDATE NUCLEUS:	
Its shape and relations.	
Its cell groups.	
Its afferent and efferent fibers.	
PROBABLE FUNCTIONS OF THE CORPUS STRIATUM.	
THE OPTIC THALAMUS	132-151
THE GANGLIA ASSOCIATED WITH THE THALAMUS.	
THE SHAPE AND RELATIVE DEVELOPMENT OF THE THALAMUS.	
ITS ANTERIOR AND POSTERIOR TUBERCLES.	
ITS SURFACES AND THEIR RELATIONS TO ADJACENT PARTS.	
THE FIBERS ASSOCIATED WITH THE THALAMUS.	
PROBABLE FUNCTIONS OF THE THALAMUS:	
Ferrier's views; Luys's thalamic centers; Ritti's views respecting hallucinations; the relations of the thalamus to the optic fibers and the main sensory conducting paths, etc.	
THE GRAY LINING OF THE THIRD VENTRICLE:	
Inferior optic ganglion; substantia innominata of Reil; anterior pillar of fornix; bundle of Vicq d'Azyr, etc.	
THE INTERNAL CAPSULE	151-172
RELATIONS OF THE CAPSULE TO THE BASAL GANGLIA OF THE CEREBRUM.	
SUBDIVISIONS OF THE COMPONENT BUNDLES OF THE CAPSULE:	
Caudo-lenticular fibers; facial bundle; general motor tract; general sensory tract; speech tract; optic fibers, etc.	
METHODS OF RESEARCH OF TÜRK, WALLER, FLECHSIG, AND GUDDEN.	
ORIGIN, COURSE, AND TERMINATIONS OF THE MORE IMPORTANT BUNDLES OF THE INTERNAL CAPSULE.	
DIAGNOSTIC SYMPTOMS OF LESIONS OF THE INTERNAL CAPSULE:	
Varieties of lesions encountered; hemiplegia; hemianæsthesia; choked-disk; tremor; athetosis; impairment of special senses; conjugate deviation of the eyes; choreiform movements, etc.	
THE CORPORA QUADRIGEMINA	172-200
THE ANTERIOR AND POSTERIOR PAIR.	
THE BRACHIA AND THEIR RELATIONS.	

FUNCTIONS OF ANTERIOR PAIR.	
RELATIONS OF THESE BODIES TO THE VISUAL SENSE:	
Hemianopsia; probable ganglia of the visual apparatus; intracranial lesions which may affect sight; tests for hemianopsia; varieties of hemianopsia; paralysis, coexisting with hemianopsia; psychical blindness; cortical area of vision; crossed paralysis coexisting with hemianopsia.	
THE CRURA CEREBRI	200-216
THE CRUSTA CRURIS OR MOTOR PORTION.	
THE TEGMENTUM CRURIS OR SENSORY PORTION.	
THE SUBSTANTIA NIGRA.	
THE GANGLIA OF ORIGIN OF THE TEGMENTAL FIBERS.	
THE POSTERIOR LONGITUDINAL FASCICULUS.	
THE LEMNISCUS TRACT.	
THE FORMATIO RETICULARIS.	
FIBERS OF THE SUPERIOR CEREBELLAR PEDUNCLE.	
FIBERS FROM THE POST-OPTIC GANGLION.	
THE GENICULATE BODIES.	
THE RED NUCLEI OF STILLING.	
THE MAMILLARY TUBERCLE.	
THE PINEAL GLAND.	
THE CEREBELLUM	216-243
GENERAL ANATOMY AND RELATIONS OF THE CEREBELLUM.	
CORTEX OF THE CEREBELLUM.	
WHITE SUBSTANCE OF THE CEREBELLUM.	
PROJECTION SYSTEMS OF CEREBELLUM.	
GRAY MASSES INDIRECTLY CONNECTED WITH THE CEREBELLUM:	
Red nuclei of Stilling in the tegmentum.	
Olivary bodies of the medulla.	
Ganglia of the pons Varolii.	
PEDUNCLES OF THE CEREBELLUM:	
Processus ad cerebrum.	
Processus ad pontem.	
Processus ad medullum (restiform body).	
RELATIONS OF CEREBELLUM TO CRANIAL NERVES.	
PROBABLE FUNCTIONS OF THE CEREBELLUM:	
An organ of coördination; relations to visual perceptions; relations to tonic muscular contractions; views of Mitchell, Spencer, Spitzka, and others.	
DIAGNOSTIC SYMPTOMS OF CEREBELLAR LESIONS:	
Cerebellar ataxia; vertigo; titubating gait; staggering; gastric crises; anarthria; occipital pain; nystagmus; amblyopia; choked-disk; amaurosis; rotary movements, etc.	
THE PITUITARY BODY	243, 244
Its general appearance and construction.	
THE MEDULLA OBLONGATA AND PONS VAROLII	244-307
FORM AND FISSURES OF MEDULLA.	
SUBDIVISIONS OF MEDULLA (Krause).	

CHANGES IN GRAY MATTER FROM THAT OF SPINAL CORD, DUE TO FORMATION OF FOURTH VENTRICLE.

THE GRAY MATTER OF THE MEDULLA AND PONS:

- Cranial nerve nuclei.
- Accessory nerve nuclei.
- Superadded gray matter.
- Reticular ganglion (Spitzka).

UPWARD CONTINUATION OF THE ANTERIOR HORNS OF THE SPINAL CORD:

- Nucleus of the pyramid; nuclei of lateral column; hypoglossal nucleus; abducens nucleus; motor-oculi nucleus.

UPWARD CONTINUATION OF THE POSTERIOR HORNS OF THE SPINAL CORD:

- Substantia gelatinosa; reticular ganglion.

UPWARD CONTINUATION OF THE CENTRAL GRAY OF THE SPINAL CORD:

- Posterior spinal accessory nucleus; nuclei of ninth, tenth, and eleventh cranial nerves; lining of fourth ventricle; aqueduct of Sylvius.

ACCESSORY NUCLEI OF THE MEDULLA:

- Inferior facial nucleus; accessory nuclei of the spinal accessory and hypoglossal nerves; the acoustic nuclei.

SUPERADDED GRAY MATTER OF THE MEDULLA AND PONS VARIOLI:

- Triangular nuclei; clavate nuclei; olivary bodies; parolivary bodies; nuclei of the pyramids; middle sensory nucleus of the trigeminus; red nuclei of Stilling; geniculate bodies, etc.

THE WHITE SUBSTANCE OF THE MEDULLA AND PONS:

- General classification of the fibers.

THE PYRAMIDAL TRACTS:

- Their accessory fibers.
- Their course and function.

UPWARD CONTINUATION OF THE ANTERIOR ROOT ZONES OF THE SPINAL CORD:

- Fibers of the formatio reticularis; posterior longitudinal bundles; portion of the fillet or lemniscus tract (?).

THE FILLET OR LEMNISCUS TRACTS:

- Its two bundles—motor (?) and sensory.
- Its relation to motor-oculi nerve.
- Its relations to the triangular and clavate nuclei.
- Its probable function.

THE DIRECT CEREBELLAR TRACTS:

- Association with the vesicular column of Clarke.
- The probable termination of these fibers.
- Probable function of these fibers.

CONTINUATION UPWARD OF BURDACH'S AND GOLL'S COLUMNS:

- The nuclei of these columns; ascending root of fifth nerve; round bundle or the "respiratory bundle" (Krause).

THE SENSORY TRACTS TO THE CEREBRUM :

Researches of Flechsig, Von Monakow, Starr, etc.

Reticular formation.

The fillet tract.

Paths for sensations of pain, touch, and temperature.

Path for the muscular sense.

Relations of these paths to the cerebellum.

The sensory or "pinniform" decussation.

THE SUPERADDED FIBERS OF THE PONS AND MEDULLA :

The fibers of the superior, middle, and inferior cerebellar peduncles.

DIAGNOSTIC SYMPTOMS OF LESIONS OF THE PONS :

Crossed facial paralysis; crossed hemianæsthesia; anarthria; convulsions; conjugate deviation of the eyes; contraction of the pupil; deafness; disturbances of respiration and circulation; unilateral ataxia, etc.

FUNCTIONS OF THE MEDULLA :

A great reflex ganglion; the special physiological centers situated within it; nervous circle of deglutition; nervous mechanism of respiration; nervous mechanism of circulation; vaso-motor center of the medulla, etc.

DIAGNOSTIC SYMPTOMS OF LESIONS OF THE MEDULLA :

Impairment of speech, deglutition, and circulation; diabetes; albuminuria; loss of power of protrusion of tongue; Duchenne's disease; bilateral paralysis of arms and legs; unilateral ataxia; vaso-motor disturbances, etc.

THE VENTRICLES OF THE BRAIN 307-314

Their general situation, shape, formation, and ependyma.

THE CHIEF COMMISSURES OF THE BRAIN 314-316

CORPUS CALLOSUM.

THE FORNIX.

COMMISSURES OF THE THIRD VENTRICLE.

THE MEMBRANES OF THE BRAIN 316-321

THE DURA MATER.

THE ARACHNOID.

THE PIA MATER.

BLOOD-VESSELS OF THE BRAIN 321-327

THE CAROTID SYSTEM AND ITS BRANCHES.

THE VERTEBRAL SYSTEM AND ITS BRANCHES.

PART II.

THE CRANIAL NERVES 329-533

ENUMERATION OF THE NERVES FROM BEFORE BACKWARD.

THE DEEP ORIGIN AND NUCLEI OF THE TWELVE SEPARATE NERVES.

THE OLFACTORY NERVE 341-349

ITS ORIGIN AND CONSTRUCTION.

THE PECULIARITIES OF ITS FILAMENTS.

THE LIMITS OF ITS DISTRIBUTION.	
THE PHYSIOLOGY OF OLFACTION.	
THE ACT OF SNEEZING.	
REFLEX ACTS DEPENDENT UPON THE OLFACTORY NERVE.	
FUNCTIONS OF OLFACTORY NERVE IN ANIMALS.	
RELATIONS OF THE SENSE OF SMELL TO THAT OF TASTE.	
CLINICAL POINTS AFFORDED BY THE OLFACTORY NERVE.	
"Hyperosmia," its tests and causes; "anosmia," its tests and causes.	
THE OPTIC NERVE	349-373
THE OPTIC TRACTS, THEIR ORIGIN AND ATTACHMENTS.	
THE OPTIC CHIASM, ITS CONSTRUCTION AND PHYSIOLOGY.	
DISTRIBUTION OF OPTIC NERVE.	
REFLEX ACTS EXCITED BY OPTIC NERVE.	
DECUSSATION OF OPTIC FIBERS AND ITS PHYSIOLOGY.	
RELATIONS OF THE OPTIC NERVE IN THE ORBIT.	
ANATOMICAL DEFECTS OF VISION AND THEIR CONSEQUENCES.	
"Hyperopia," its tests, causes, and results; "myopia," its tests, causes, and results; "astigmatism," its tests, causes, and results.	
CHANGES OBSERVED IN THE PUPIL.	
Dilatation, its causes and physiology; contraction, its causes and physiology.	
VISUAL SENSATIONS AND THEIR MODIFICATIONS.	
Muscæ volitantes; the "blind spot" of the retina; insensibility of the retina after firm pressure.	
THE PERCEPTION OF COLOR.	
Visual purple and its probable functions; rods and cones of the retina; Young-Helmholtz theory of color vision; limits of different color perceptions; color blindness.	
APPARENT VISION OF OBJECTS NOT REALLY SEEN.	
Its causes.	
EFFECTS OF OPTIC NERVE ON COÖRDINATION.	
Goltz's experiments.	
EFFECTS OF OPTIC NERVE ON THE LACHRYMAL APPARATUS.	
The act of winking the eyelid; effect of closure of eyelid upon the lachrymal canals.	
CLINICAL POINTS AFFORDED BY THE OPTIC NERVE.	
Hemianopsia, temporal, its causes; hemianopsia, nasal, its causes; hemianopsia, bi-nasal, its causes; hemianopsia, bi-temporal, its causes; amaurosis; hyperæsthesia of the optic nerve; amblyopia; atrophy of optic nerve.	
THE MOTOR-OCULI NERVE	373-395
ITS ORIGIN, COURSE, AND DISTRIBUTION.	
THE PHYSIOLOGY OF CONTRACTION OF THE PUPIL.	
PHYSIOLOGICAL REASONS FOR THE DISTRIBUTION OF THE THIRD NERVE.	
MECHANISM OF THE DILATATION OF THE PUPIL.	

MOVEMENTS OF THE EYEBALL.	
DIAGNOSTIC ATTITUDES OF THE HEAD IN OCULAR PARESIS.	
CLINICAL POINTS PERTAINING TO THE THIRD NERVE.	
Megalopsia or macropsia; micropsia; ptosis; motor-oculi paralysis; strabismus. Diseases of the ocular muscles: nystagmus; iritic spasm; contracture; paralysis; tabetic conditions; diplopia; strabismus.	
THE TROCHLEAR OR PATHETIC NERVE	395-397
ITS SUPERFICIAL AND DEEP POINTS OF ORIGIN.	
ITS COURSE AND RELATIONS WITHIN THE CRANIUM.	
ITS POINTS OF CLINICAL INTEREST.	
THE TRIGEMINUS NERVE	397-421
ITS SUPERFICIAL AND DEEP POINTS OF ORIGIN.	
COURSE OF ITS SENSORY AND MOTOR ROOTS WITHIN THE CRANIUM.	
ITS AFFERENT AND EFFERENT FIBERS.	
THE EFFECTS OF SECTION OF THE NERVE.	
On sensation; on mastication; on taste; on hearing; on sight; on smell.	
CLINICAL POINTS PERTAINING TO THE TRIGEMINUS NERVE.	
Neuralgia (tic-douloureux); spasm of the trigeminus; paralysis of its individual branches.	
DIAGNOSTIC VALUE OF THE TRIGEMINUS NERVE.	
Bleaching of the hair; immobility of temporo-maxillary joint; furring of the tongue; ulceration of the cornea; ulceration of the auditory canal; earache; pain in the scalp; conjunctival distribution.	
SURGICAL ANATOMY OF ITS MAIN BRANCHES.	
Section of the supra-orbital nerve; section of the supra-maxillary nerve; section of the inferior-dental nerve.	
THE GANGLIA CONNECTED WITH THE TRIGEMINUS NERVE.	
Ophthalmic, lenticular, or ciliary; sphenopalatine or Meckel's; otic; sub-maxillary.	
THE ABDUCENS NERVE (MOTOR-OCULI EXTERNUS)	421-423
ITS SUPERFICIAL AND DEEP POINTS OF ORIGIN.	
ITS RELATION WITH THE OPHTHALMIC GANGLION.	
ITS CLINICAL RELATIONS.	
THE FACIAL NERVE	423-444
ITS SUPERFICIAL AND DEEP POINTS OF ORIGIN.	
ITS COURSE AND DISTRIBUTION.	
PHYSIOLOGY OF ITS MAIN BRANCHES.	
The petrosal nerves; the chorda tympani nerve; the "pars intermedia" of Wrisberg; the tympanic branch; the facial branches; the muscular branches.	
ITS COMMUNICATIONS WITH OTHER PARTS.	
Branches joining the fifth nerve; branch to the otic ganglion; branch to Meckel's ganglion; sympathetic fibers; its relation to deglutition and speech; its relation to smell; its relation to hearing; its relation to respiration.	

ITS FILAMENTS OF DISTRIBUTION.	
Physiological relation to deglutition; physiological relation to facial expression; physiological relation to mastication.	
CLINICAL POINTS PERTAINING TO THE NERVE.	
Spasm of the facial muscles. Bell's paralysis: intra-cranial variety; auditory variety; rheumatic variety; traumatic variety; syphilitic variety; diphtheritic variety; facial diplegia.	
THE AUDITORY NERVE	444-466
ITS SUPERFICIAL AND DEEP POINTS OF ORIGIN.	
ANATOMICAL STRUCTURE AND PECULIARITIES OF ITS FILAMENTS.	
ITS COURSE AND DISTRIBUTION.	
FUNCTIONS OF ITS VARIOUS BRANCHES.	
THE MECHANISM OF AUDITION.	
External ear, its construction and functions; middle ear, its construction and functions. Internal ear, its construction and functions: the semicircular canals; the vestibule. The cochlea: its scalæ; organ of Corti; membranes and ligaments.	
CLINICAL POINTS PERTAINING TO THE NERVE.	
Auditory vertigo—"Menière's disease"; injuries to the semicircular canals. Neuroses of the auditory nerve: acoustic hyperæsthesia; acoustic anæsthesia.	
THE GLOSSO-PHARYNGEAL NERVE	466-482
ITS SUPERFICIAL AND DEEP POINTS OF ORIGIN.	
ITS GANGLIONIC ENLARGEMENTS.	
ITS COURSE AND RELATIONS.	
ITS EFFERENT OR MOTOR FIBERS.	
ITS AFFERENT OR SENSORY FIBERS.	
ITS FIBERS OF TASTE.	
EFFECTS OF SECTION OF THE NERVE.	
On special sense of taste; on deglutition.	
MECHANISM OF THE ACT OF DEGLUTITION.	
First period; second period; third period; nerves involved; importance of soft palate; the nerve center for the act.	
CLINICAL POINTS PERTAINING TO THE NERVE.	
Glosso-labio-laryngeal paralysis—Duchenne's disease; hypergeusia; ageusia.	
THE PNEUMOGASTRIC NERVE	482-505
ITS SUPERFICIAL AND DEEP POINTS OF ORIGIN.	
ITS INTIMATE AFFILIATION WITH THE GLOSSO-PHARYNGEAL NERVE.	
ITS GANGLIONIC ENLARGEMENTS.	
THE INHERENT FIBERS OF ITS TRUNK.	
ITS BRANCHES OF DISTRIBUTION AND THEIR FUNCTIONS.	
The pharyngeal branches: effects on deglutition; effects on voice. The laryngeal branches: their relation to phonation; their relation to respiration; their relation to spinal accessory nerve. The branches to alimentary canal: their relation to peristaltic action; their relation to secretion. The cardiac branches: depressor nerve of heart's action;	

effects of galvanism. Vaso-motor fibers; effects on blood-vessels. The pulmonary branches: their relation to respiration—acceleratory fibers; inhibitory fibers.	
THE COURSE AND RELATIONS OF THE NERVE ON EACH SIDE OF THE BODY—	
With carotid artery; with jugular vein; with œsophagus; with the lungs; with the abdominal viscera.	
EFFECTS OF SECTION OF THE PNEUMOGASTRIC TRUNK.	
Upon the larynx; upon the lungs; upon the heart. Upon the digestive tract: stomach; liver; intestinal canal.	
CLINICAL POINTS PERTAINING TO THE NERVE.	
Pharyngeal anæsthesia; pharyngeal spasm; pharyngeal paralysis; laryngeal spasm (Kopp's asthma); whooping cough; aneurysmal cough; pulmonary asthma; pulmonary vaso-motor paralysis; angina pectoris; cardiac neuralgia; gastrodynia; boulimia; polydipsia; dyspeptic vomiting; polyphagia.	
THE SPINAL ACCESSORY NERVE	505-518
ITS SUPERFICIAL AND DEEP POINTS OF ORIGIN.	
ITS COURSE AND DISTRIBUTION.	
ITS FILAMENTS OF COMMUNICATION.	
ITS RELATIONS TO THE PRODUCTION OF VOICE.	
THE EFFECTS OF SECTION OF THE NERVE.	
On phonation; on respiration; on deglutition; on the action of the heart; on singing.	
CLINICAL POINTS PERTAINING TO THE NERVE.	
Tonic spasm of sterno-mastoid muscle; tonic spasm of trapezius; clonic spasm of sterno-mastoid and trapezius muscles; salaam convulsion of Newnham; unilateral paralysis of sterno-mastoid and trapezius muscles; bilateral paralysis of sterno-mastoid and trapezius muscles.	
THE HYPOGLOSSAL NERVE (SUB-LINGUAL NERVE)	518-532
ITS SUPERFICIAL AND DEEP POINTS OF ORIGIN.	
ITS COURSE AND DISTRIBUTION.	
THE DESCEDENS NONI BRANCH.	
Functions of the nerve: on deglutition; on articulation.	
CLINICAL POINTS PERTAINING TO THE NERVE.	
Duchenne's disease: abnormalities of speech; abnormalities of voice; impairment of deglutition; facial deformity; lingual tremor. Lingual spasm: lingual paralysis.	
PART III.	
THE SPINAL CORD	533-638
ITS ANATOMICAL CONSTRUCTION, FUNCTIONS, AND CLINICAL BEARINGS.	
ITS CERVICAL AND LUMBAR ENLARGEMENTS.	
ITS FISSURES AND COLUMNS.	

ITS NERVES (THEIR ROOTS AND GENERAL CONSTRUCTION).

ITS MEMBRANES AND THE CEREBRO-SPINAL FLUID.

Their functions and situation.

BLOOD-VESSELS OF THE CORD.

VERTEBRÆ AS GUIDES TO SPINAL SEGMENTS.

HISTOLOGICAL ELEMENTS OF THE CORD.

APPEARANCE OF A TRANSVERSE SECTION OF THE CORD.

Its gray matter; its white matter; its central canal; its commissures. Pathological subdivisions of the cord: columns of Goll; columns of Burdach; columns of Türk; fundamental columns; direct pyramidal columns; anterior root zones; posterior root zones; crossed pyramidal columns; direct cerebellar columns.

FUNCTIONS OF THE SPINAL CORD.

(1) *Organ of conduction.*

Paths of motor impulses; paths of sensory impulses; commissural fibers. Fibers of the spinal cord: motor fibers and their function; sensory fibers and their function; commissural fibers and their function.

(2) *Spinal cord as a nerve center.*

Reflex action of the cord; automatic action of the cord; vaso-motor centers; cilio spinal center; genito-urinary center; tonic action on muscles; center of defecation; center of parturition; center of micturition; center of erection.

(3) *Organ of cöördination of muscular movements.*

CLINICAL POINTS PERTAINING TO THE SPINAL CORD.

The kinesodic system; the æsthesodic system; diseases of its substance.

SYSTEMATIC LESIONS OF ÆSTHESODIC SYSTEM.

(1) *Sclerosis of columns of Goll.*(2) *Sclerosis of columns of Burdach* (locomotor ataxia).

SYSTEMATIC LESIONS OF KINESODIC SYSTEM.

(1) *Sclerosis of columns of Türk.*(2) *Sclerosis of lateral columns* (spasmodic tabes, tetanoid paralysis, spastic spinal paralysis).(3) *Amyotrophic lateral sclerosis of the cord.*(4) *Myelitis of the anterior horns of the gray matter* (atrophic spinal paralysis).(5) *Polio-myelitis.*

Acute variety; infantile spinal paralysis; non-febrile variety; chronic variety.

(6) *Progressive muscular atrophy.*(7) *Central myelitis.*

NON-SYSTEMATIC OR "FOCAL" LESIONS OF THE CORD.

Distinctions between systematic and focal lesions; their physiological effects at different heights.

(1) *Focal lesions of the upper cervical region.*

Symptoms referable to the phrenic nerve; to the respira-

- tory center; to the acceleratory center of the heart; to the pneumogastric nerve.
- (2) *Focal lesions of the cervical enlargement.*
Symptoms referable to cilio-spinal center; to the ulnar nerve; to the acceleratory center of the heart; to the vaso-motor centers.
- (3) *Focal lesions of the mid-dorsal region.*
Symptoms referable to the lower limbs; to the genito-urinary organs; to the reflex excitability of the spinal cord; to the lateral columns of the spinal cord; to the rectum.
- (4) *Focal lesions above the lumbar enlargement.*
Symptoms referable to reflex excitability of the spinal cord; to the genito-urinary organs; to the rectum.
- (5) *Focal lesions of the lumbar enlargement of the spinal cord.*
Symptoms referable to the sciatic nerve; to the rectum.
- (6) *Focal lesions of one lateral half of the spinal cord.*
(a) Spinal hemiplegia—symptoms referable to the intercostal nerves; to the upper extremity; to the lower extremity; to the cilio-spinal center; to the vaso-motor centers.
(b) Hemi-paraplegia—symptoms referable to the trunk; to “trophic” centers; to increased excitability of the spinal cord; to the lower limbs.

PART IV.

THE SPINAL NERVES	639-772
THEIR SUBDIVISIONS AND POINTS OF ESCAPE.	
THE CONSTRUCTION AND RELATIVE SIZE OF THEIR ROOTS.	
THE LENGTH AND INCLINATION OF THEIR ROOTS.	
GENERAL AXIOMS OF NERVE DISTRIBUTION.	
THE UPPER CERVICAL NERVES	648-663
Table of their branches of distribution; the cervical plexus—its situation, formation, superficial branches, deep branches, and communications with other nerves. <i>The communicans noni nerve:</i> its origin and distribution. <i>The phrenic nerve:</i> its origin, course, surgical relations, and physiological function. Clinical points pertaining to the upper cervical nerves: cervico-occipital neuralgia; diaphragmatic neuralgia; clonic diaphragmatic spasm (hiccough); tonic diaphragmatic spasm (diaphragmatic tetanus); and diaphragmatic paralysis.	
THE LOWER CERVICAL NERVES	663-705
Table of their branches of distribution. The brachial plexus: its situation; its formation and abnormalities; its supra-	

clavicular branches; its infra-clavicular branches; its surgical relations; its communications with other nerves. Nerves of the upper extremity; table of the branches of the outer cord of the brachial plexus; table of the branches of the inner cord of the brachial plexus; table of the branches of the posterior cord of the brachial plexus. *The anterior thoracic nerves*: their distribution; their clinical aspects. *The external or musculo-cutaneous nerve*: its course and distribution to muscles; its cutaneous distribution; its relation to the "bent arm" after venesection. Clinical points afforded by it: paralysis and its symptoms; anæsthesia of forearm. *The median nerve*: its origin, course, and distribution; its surgical relations; its cutaneous distribution. Clinical points afforded by it: median paralysis and its symptoms; anæsthesia and its variations. *The internal and lesser internal cutaneous nerves*: their origin, course, and distribution; relations to the intercosto-humeral nerve. *The ulnar nerve*: its origin, course, and distribution; its surgical relations; its cutaneous distribution. Clinical points afforded by it: ulnar paralysis, its causes and symptoms; its relation to the surgery of the elbow-joint. *The sub-scapular nerves*: their origin, course, and distribution; their surgical relations; their cutaneous distribution. Clinical points afforded by them: scapular paralysis. *The circumflex nerve*: its origin, course, and distribution; its surgical relations; its cutaneous and articular branches. Clinical points afforded by it: circumflex paralysis; deltoid atrophy. *The musculo-spiral nerve*: its origin, course, and distribution. Its terminal branches (the radial and interosseous nerves): their distribution to muscles; their cutaneous distribution. Clinical points afforded by it: surgical importance of its peculiar course; its relation to traumatic paralysis; rheumatic affections of the nerve. Lead-paralysis: theories as to its etiology; its symptoms; its differential diagnosis; its duration.

THE DORSAL NERVES

705-722

The thoracic intercostal nerves; the thoracico-abdominal intercostal nerves: their origin, course, and distribution; their relation to the pleura. Clinical points afforded by them: significance and diagnostic value of thoracic pain; significance of pain in the pit of the stomach; significance of pectoral pain; significance and course of pain due to the liver and other viscera. Intercostal neuralgia: its causes; its symptoms; its differential diagnosis. Neuralgia of the mammary gland (mastodynia): its causes and symptoms; its "puncta dolorosa." Paralysis of the dorsal nerves: its relations to kyphosis; its relations to scoliosis. Paralysis of the extensor muscles of the lumbar region: its diagnostic attitude; its differential diagnosis.

	PAGES
THE LUMBAR NERVES	722-743
<p><i>The lumbar plexus</i>: its situation and formation; its chief branches and their general distribution. <i>The ilio-hypogastric nerve</i>: its origin, course, and distribution; neuralgia of the nerve. <i>The ilio-inguinal nerve</i>: its origin, course, and distribution; neuralgia of the nerve; its relation to the peritonæum. <i>The external cutaneous nerve</i>: its origin, course, and distribution; its relation to pains referred to the thigh. <i>The genito-crural nerve</i>: its origin, course, and distribution. Clinical points afforded by it. <i>The anterior crural nerve</i>: its origin, course, and distribution; its physiological functions; its distribution to joints: its cutaneous branches. Clinical points afforded by it: its surgical relations; its relation to pain in the region of the knee. Spasm of the quadriceps extensor muscle. Crural paralysis: its causes and Symptoms. Atrophy of muscles supplied by this nerve. Crural neuralgia: its causes; its "puncta dolorosa"; the "spasmodic contracture of Stromejer." <i>The obturator nerve</i>: its origin, course, and distribution; its distribution to joints; its relation to pain in the vicinity of the knee; its physiological functions. Clinical points afforded by it: obturator neuralgia: obturator paralysis. <i>The accessory obturator nerve</i>: its origin, course, and distribution; its abnormalities.</p>	
THE SACRAL NERVES	743-772
<p>Their anatomical peculiarities. <i>The sacral plexus</i>: its shape and formation; its situation; its branches of distribution. <i>The superior gluteal nerve</i>: its origin, course, and distribution; its physiological function. Clinical points afforded by it: peculiarities of its cutaneous distribution; its surgical relations; gluteal spasm; gluteal paralysis. <i>The muscular branches of the sacral plexus</i>: their distribution; their physiological functions. <i>The small sciatic nerve</i>: its origin, course, and distribution; its physiological functions; relation of its perineal branch to the genital organs. <i>The pudic nerve</i>: its origin, course, and distribution; the inferior hæmorrhoidal nerve; the perineal nerve; the dorsal nerve of the penis. Clinical points afforded by the pudic nerve: its relations to coitus; its relations to micturition; its relations to defecation; neuralgic affection of its branches. <i>The great sciatic nerve</i>: its origin, course, and distribution; its distribution to joints. <i>The external popliteal nerve</i>: its course and branches of distribution. Distribution of nerves to the fascia of the leg. <i>The internal popliteal nerve</i>: its course and branches of distribution. Clinical points afforded by the great sciatic nerve and its branches. Sciatic neuralgia (malum Cotunnii); its causes; modifications of its seat; its characteristic symptoms; its "puncta dolorosa"; its motor</p>	

TABLE OF CONTENTS.

xxiii

PAGES

manifestations; its vaso-motor effects. Spasms of the lower limb: spasmodic contraction of the hip; tonic and clonic spasms of extensor and adductor groups of muscles; spasm of the anterior muscles of the leg. Paralysis of the great sciatic nerve or its branches: sciatic paralysis; peroneal paralysis; tibial paralysis; their sensory manifestations; their trophic disturbances.

INDEX 772-791

LIST OF ILLUSTRATIONS.

FIG.		PAGE
1.	NERVE FIBERS FROM THE HUMAN SUBJECT <i>Kölliker</i>	5
2.	CERVICAL AND THORACIC PORTION OF THE SYMPATHETIC <i>Sappey</i>	6
3.	LUMBAR AND SACRAL PORTIONS OF THE SYMPATHETIC "	8
4.	FIBERS OF REMAK <i>Robin</i>	11
5.	MODE OF TERMINATION OF THE MOTOR NERVES <i>Rouget</i>	12
6.	PLAN IN OUTLINE OF THE BRAIN IN PROFILE <i>Quain</i>	23
7.	A DIAGRAM OF THE CHIEF COMPONENT PARTS OF THE HUMAN BRAIN <i>Ranney</i>	24
8.	A DIAGRAM OF THE GENERAL ARRANGEMENT OF THE FIBERS OF THE CEREBRO-SPINAL SYSTEM <i>Ranney</i> (modified from <i>Landois</i>)	25
9.	DIAGRAM OF THE COMMISSURAL FIBERS OF THE ANTERIOR REGION OF THE BRAIN <i>Luys</i>	27
10.	DIAGRAM OF THE COMMISSURAL FIBERS ON THE LEVEL OF THE CORPUS STRIATUM "	29
11.	DIAGRAM TO ILLUSTRATE THE GENERAL OUTLINE OF THE CORPUS CALLOSUM AND THE FORNIX <i>Allen</i> (modified from)	30
12.	SCHEMATIC REPRESENTATION OF MEYNERT'S THREE PROJECTION SYSTEMS OF NERVE FIBERS <i>Ranney</i>	32
13.	DIAGRAMMATIC REPRESENTATION OF THE FIBERS IN THE CEREBRUM <i>Le Bon</i>	36
14.	DIAGRAM OF THE COURSE OF SENSORY AND MOTOR TRACTS IN THE MESOCEPHALON AND HEMISPHERES <i>Seguin</i>	38
15.	A DIAGRAM OF THE BRAIN IN TRANSVERSE VERTICAL SECTION <i>Dalton</i>	39
16.	STRUCTURE OF THE CONVOLUTIONS <i>Baillarger</i>	44

FIG.		PAGE
17.	CORTICAL CELL OF THE DEEPER ZONES <i>Luyts</i>	46
18.	HALF DIAGRAMMATIC FIGURE OF THE CEREBRAL CORTEX, GIVING A VIEW OF THE ARRANGEMENT OF THE DIFFERENT ZONES OF CELLS, AND THEIR RELATIONS TO ONE ANOTHER, AND TO THE SURROUNDING NEUROGLIA "	49
19.	A TRANSPARENT SECTION FROM A SULCUS OF THE THIRD FRONTAL CONVOLUTION OF THE HUMAN BRAIN <i>Meynert</i>	52
20.	LATERAL VIEW OF THE HUMAN BRAIN, SHOWING ITS LOBES AND FISSURES <i>Ferrier</i>	59
21.	A DIAGRAM OF THE CEREBRUM IN LONGITUDINAL MEDIAN SECTION <i>Dalton</i>	61
22.	A DIAGRAMMATIC FIGURE, SHOWING THE CEREBRAL CONVOLUTIONS "	63
23.	ORBITAL SURFACE OF THE FRONTAL LOBE AND ISLAND OF REIL <i>Turner</i>	64
24.	A DIAGRAM OF THE FIBERS OF A LATERAL HALF OF THE CEREBRUM <i>Reichart</i>	67
25.	SIDE VIEW OF THE BRAIN OF MAN AND THE AREAS OF THE CEREBRAL CONVOLUTIONS <i>Ferrier</i>	79
26.	UPPER VIEW OF THE BRAIN OF MAN AND THE SITUATION OF AREAS OF THE CEREBRAL CONVOLUTIONS "	81
27.	A DIAGRAM ILLUSTRATING THE COURSE OF NERVE IMPULSES IN THE CEREBRUM <i>Dodds</i>	94
28.	SUPERIOR ASPECT OF THE ENCEPHALON <i>Hirschfeld</i>	107
29.	CONVOLUTIONS ON THE INTERNAL ASPECT OF THE CEREBRAL HEMISPHERES <i>Sappey</i>	109
30.	OUTLINE OF SKULL RESTING UPON THE ALVEOLO-CONDYLOID PLANE OF BROCA <i>Seguin</i>	114
31.	ANTERO-POSTERIOR VERTICAL SECTION OF THE RIGHT HEMISPHERE <i>Dalton</i>	123
32.	A DIAGRAM OF THE AFFERENT AND EFFERENT FIBERS OF THE CORPUS STRIATUM <i>Ranney</i>	130
33.	VIEW FROM ABOVE OF THE THIRD VENTRICLE AND A PART OF THE LATERAL VENTRICLES <i>Henle</i>	134
34.	SECTION ACROSS THE OPTIC THALAMUS AND CORPUS STRIATUM IN THE REGION OF THE MIDDLE COMMISSURE <i>Schäfer</i>	136
35.	RIGHT HALF OF THE ENCEPHALIC PEDUNCLE AND CEREBELLUM, AS SEEN FROM THE INSIDE OF A MEDIAN SECTION <i>Reichart</i>	137
36.	A DIAGRAM OF THE NUCLEI OF THE OPTIC THALAMUS AND THE CONVERGING FIBERS ASSOCIATING WITH THEM <i>Luyts</i>	144

FIG.		PAGE
37.	A DIAGRAM OF THE INNER SURFACE OF THE OPTIC THALAMUS, WITH THE TUBULAR GRAY MATTER REMOVED; SHOWING THE THIRD VENTRICLE, AND THE ARRANGEMENT OF NEIGHBORING PARTS	149
	<i>Ranney</i>	
38.	A DIAGRAM OF THE RELATIONS OF THE INTERNAL CAPSULE OF THE CEREBRUM TO ADJACENT STRUCTURES VIEWED FROM ABOVE	152
	“	
39.	A DIAGRAM OF THE SUBDIVISIONS OF THE INTERNAL CAPSULE	154
	“	
40.	A DIAGRAM OF THE AFFERENT AND EFFERENT FIBERS OF THE CORPUS STRIATUM	160
	“	
41.	MILIARY ANEURYSMS	164
	<i>Hammond</i>	
42.	A DIAGRAM OF THE RELATIONS OF THE OPTIC AND OLFACTORY NERVE FIBERS TO SURROUNDING PARTS	185
	<i>Ranney</i>	
43.	A DIAGRAM TO ILLUSTRATE THE LATEST VIEWS IN REFERENCE TO THE COURSE OF THE OPTIC FIBERS	189
	“	
44.	A DIAGRAM OF THE GENERAL COURSE OF FIBERS IN THE “SENSORY” AND “MOTOR TRACTS,” AND THEIR RELATION TO CERTAIN FASCICULI OF THE OPTIC TRACTS	193
	<i>Ranney</i> (modified from <i>Seguin</i>)	
45.	A DIAGRAMMATIC REPRESENTATION OF THE PARTS SEEN IN A HORIZONTAL CROSS-SECTION ON A LEVEL WITH THE SUPERIOR QUADRIGEMINAL BODY	201
	<i>Ranney</i>	
46.	A DIAGRAM OF THE COURSE OF THE FIBERS OF THE CRUSTA CEREBRI (MOTOR) AFTER THEY LEAVE THE PYRAMIDS OF THE MEDULLA	203
	“	
47.	CEREBELLUM AND MEDULLA OBLONGATA	217
	<i>Hirschfeld</i>	
48.	A DIAGRAM OF THE VARIOUS SETS OF FIBERS COMPRISED WITHIN THE CEREBRO-SPINAL SYSTEM	224
	<i>Ranney</i> (modified from <i>Ross</i>)	
49.	A CRUDE DIAGRAM ILLUSTRATING THE THREE PAIRS OF PEDUNCLES OF THE CEREBELLUM	227
	<i>Ranney</i>	
50.	ANTERIOR VIEW OF THE MEDULLA OBLONGATA	245
	<i>Sappey</i>	
51.	ANTERIOR VIEW OF THE MEDULLA AND PONS, DESIGNED TO SHOW SOME OF THE RELATIONS OF SURROUNDING PARTS AND THE APPARENT ORIGIN OF THE CRANIAL NERVES	248
	<i>Ranney</i>	
52.	A DIAGRAM TO SHOW THE MORE IMPORTANT SUBDIVISIONS OF THE SPINAL CORD	250
	<i>Flecksig</i>	
53.	A DIAGRAM OF A SECTION OF THE MEDULLA AT THE MIDDLE OF THE MOTOR DECUSSATION	251
	<i>Ranney</i> (after <i>Quain</i>)	
54.	A DIAGRAM OF A SECTION OF THE MEDULLA AT A SLIGHTLY HIGHER LEVEL THAN IN THE PRECEDING FIGURE	252
	“ “	

FIG.	PAGE
55. TRANSPARENT LATERAL VIEW OF THE MEDULLA, SHOWING THE RELATIVE POSITIONS OF MOST IMPORTANT NUCLEI; RIGHT HALF OF THE MEDULLA, SEEN FROM THE SURFACE OF SECTION; THE PARTS THAT LIE CLOSER TO THIS SURFACE ARE DEEPER SHADED	Erb 254
56. DIAGRAM OF THE CHIEF TRACTS IN THE MEDULLA	" 255
57. A CROSS-SECTION OF THE MEDULLA OBLONGATA ON A LEVEL WITH THE SUPERFICIAL ORIGIN OF THE AUDITORY NERVE	Flechsig 258
58. A TRANSVERSE SECTION THROUGH THE PONS, ON A LEVEL WITH THE ROOTS OF THE SIXTH AND SEVENTH CRANIAL NERVES FROM A NINE MONTHS' EMBRYO	Ranney (modified from Erb and Ross) 260
59. A TRANSVERSE SECTION OF THE MEDULLA (PARTLY SCHEMATIC) MADE THROUGH THE MIDDLE OF THE OLIVARY BODY	Ranney (modified from Spitzka) 262
60. THE PATHS OF THE MOTOR FIBERS OF THE CORD	Ranney (modified from Bramwell) 273
61. A DIAGRAM OF THE TWO SUBDIVISIONS, OR TRACTS, OF THE ANTERIOR ROOT ZONES OF THE SPINAL CORD	Ranney 274
62. A DIAGRAM OF THE RIGHT LATERAL HALF OF A TRANSVERSE SECTION OF THE PONS VAROLII ON A LEVEL WITH THE ORIGIN OF THE FIFTH CRANIAL NERVE	Ranney (modified from Erb) 276
63. A DIAGRAM OF THE COURSE OF CERTAIN SPECIAL NERVE TRACTS WITHIN THE CEREBRUM, CRUS CEREBRI, PONS VAROLII, MEDULLA OBLONGATA, AND SPINAL CORD	Ranney (modified from Flechsig) 280
64. A DIAGRAM OF THE RELATIVE SITUATION AND FUNCTIONAL ASSOCIATION OF THE DIRECT CEREBELLAR COLUMN OF THE SPINAL CORD, AND THE VESICULAR COLUMN OF CLARKE	Ranney 281
65. A DIAGRAM TO ILLUSTRATE THE METHOD OF PRODUCTION OF CROSSED PARALYSIS	Hammond 292
66. VIEW FROM ABOVE OF THE THIRD VENTRICLE AND A PART OF THE LATERAL VENTRICLES	Henle 309
67. A DIAGRAM OF THE INNER SURFACE OF THE OPTIC THALAMUS, WITH THE TUBULAR GRAY MATTER REMOVED, SHOWING THE THIRD VENTRICLE, AND THE ARRANGEMENT OF NEIGHBORING PARTS	Ranney 312
68. THE BASE OF THE SKULL AND CRANIAL NERVES	" 330
69. A DIAGRAM OF THE PROBABLE DECUSSATION OF THE FIBERS OF THE OLFACTORY TRACTS	" 332
70, 71. THE VISUAL TRACTS	Munk 333
72. THE NORMAL VISUAL FIELD	Ross 335

FIG.		PAGE
73.	HORIZONTAL SECTION OF A MONKEY'S BRAIN	337
74.	A DIAGRAM OF THE ORIGIN AND COURSE OF THE FOURTH CRANIAL NERVE	338
75.	SECTION OF THE MEDULLA AT ITS UPPER PART	339
76.	ROOTS OF THE CRANIAL NERVES	342
77.	OLFACTORY GANGLION AND NERVES	343
78.	TERMINAL FILAMENTS OF THE OLFACTORY NERVE	343
79.	INTERNAL BRANCHES OF THE OLFACTORY NERVE	345
80.	OPTIC TRACTS, COMMISSURE, AND NERVES	350
81.	A DIAGRAM OF THE DECUSSATION OF THE OPTIC FIBERS	351
82.	A DIAGRAM OF THE OPTIC FIBERS IN THE RETINA	352
83.	RELATION OF THE OPTIC NERVE AND OPH- THALMIC ARTERY	354
84.	RELATION OF THE OPTIC NERVE TO THE BLOOD-VESSELS, IN THE ORBIT	354
85.	A DIAGRAM OF THE DEFECTIVE DIAMETERS OF THE EYE	356
86.	ANTERIOR VIEW OF THE CRYSTALLINE LENS	362
87.	TWO CUTS OF THE RETINA AND ITS ELE- MENTS	363
88.	A DIAGRAM TO SHOW THE LIMITS OF COLOR VISION	365
89.	LACHRYMAL AND MEIBOMIAN GLANDS	367
90.	LACHRYMAL APPARATUS	368
91.	A DIAGRAM TO SHOW THE EFFECTS OF PRESS- URE ON THE OPTIC NERVE	371
92.	DISTRIBUTION OF THE THIRD CRANIAL NERVE	374
93.	THE CILIARY MUSCLE, LENS, IRIS, AND CORNEA	375
94.	THE CILIARY NERVES AND CHOROID COAT OF EYE	376
95.	THE NERVES OF THE IRIS	377
96.	THE CILIARY NERVES	379
97.	A DIAGRAM SHOWING THE MECHANISM OF THE ACCOMMODATION OF VISION	380
98.	MUSCLES OF THE EYEBALL	382
99.	A DIAGRAM SHOWING THE AXES OF ROTA- TION OF THE EYEBALL	385
100.	TWO DIAGRAMS OF THE ELEMENTS OF THE RETINA	390
101.	DISTRIBUTION OF THE FOURTH CRANIAL NERVE	396
102.	THE OPHTHALMIC DIVISION OF THE FIFTH CRANIAL NERVE	398
103.	A DIAGRAM OF THE DISTRIBUTION OF THE FIFTH CRANIAL NERVE	400

FIG.		PAGE
104.	THE INFERIOR MAXILLARY DIVISION OF THE FIFTH CRANIAL NERVE	401
	<i>Hirschfeld</i>	
105.	THE SUPERIOR MAXILLARY DIVISION OF THE FIFTH CRANIAL NERVE	402
	“	
106.	SUPERFICIAL BRANCHES OF THE FIFTH AND FACIAL NERVES	403
	“	
107.	CUTANEOUS NERVE DISTRIBUTION OF THE HEAD	405
	<i>Flower</i>	
108.	DISTRIBUTION OF THE SIXTH CRANIAL NERVE	422
	<i>Hirschfeld</i>	
109.	THE SUPERFICIAL BRANCHES OF THE FACIAL NERVE	424
	“	
110.	A DIAGRAM OF THE BRANCHES OF THE FACIAL NERVE	425
	<i>Ranney</i>	
111.	EXPRESSION OF THE FACE IN “BELL'S PARALYSIS”	427
	<i>Corfe</i>	
112.	A DIAGRAM OF THE COMMUNICATIONS BETWEEN THE FACIAL AND TRIGEMINUS NERVES	429
	<i>Ranney</i>	
113.	THE CHORDA TYMPANI NERVE	431
	<i>Hirschfeld</i>	
114.	A DIAGRAM OF THE COURSE OF THE VIDIAN AND PETROSAL NERVES	432
	<i>Ranney</i>	
115.	A DIAGRAM OF THE AUDITORY NERVE AND ITS BRANCHES	444
	“	
116.	DISTRIBUTION OF THE COCHLEAR NERVE	445
	<i>Sappey</i>	
117.	GENERAL VIEW OF THE ORGAN OF HEARING	446
	“	
118.	A DIAGRAM TO ILLUSTRATE THE MECHANISM OF HEARING	448
	<i>Ranney</i>	
119.	THE OSSICLES OF THE TYMPANUM	449
	<i>Arnold</i>	
120.	THE BONY LABYRINTH OF A NEW-BORN CHILD	450
	<i>Rüdringer</i>	
121.	A DIAGRAM OF THE LABYRINTH, VESTIBULE, AND SEMICIRCULAR CANALS	451
	“	
122.	A DIAGRAM OF THE COCHLEA ON TRANSVERSE SECTION	452
	<i>Ranney</i>	
123.	A VERTICAL SECTION OF THE “ORGAN OF CORTI”	453
	<i>Waldeyer</i>	
124.	THE TWO PILLARS OF THE “ORGAN OF CORTI”	454
	<i>Sappey</i>	
125.	DISTRIBUTION OF THE COCHLEAR NERVES	455
	“	
126.	MEMBRANA TYMPANI, SEEN FROM WITHIN	458
	<i>Rüdringer</i>	
127.	SECTION OF THE COCHLEA OF THE CAT AND HUMAN FÆTUS	460
	“	
128.	THE GLOSSO-PHARYNGEAL NERVE	468
	<i>Sappey</i>	
129.	A DIAGRAM OF THE GLOSSO-PHARYNGEAL NERVE	468
	<i>Ranney</i>	
130.	THE PAPILLE OF THE TONGUE	469
	<i>Sappey</i>	
131.	A CIRCUMVALLATE PAPILLA	470
	“	
132.	THE FUNGIFORM AND FILIFORM PAPILLÆ	470
	“	
133.	THE TASTE-BUDS	472
	<i>Engelmann</i>	
134.	THE CAVITIES OF THE MOUTH AND PHARYNX	474
	<i>Sappey</i>	

FIG.		PAGE
135.	THE MUSCLES OF THE PHARYNX <i>Sappey</i>	476
136.	ANASTOMOSES OF THE PNEUMOGASTRIC NERVE <i>Hirschfeld</i>	483
137.	A DIAGRAM OF THE CERVICAL PORTION OF THE PNEUMOGASTRIC NERVE <i>Ranney</i>	484
138.	A DIAGRAM OF THE THORACIC AND ABDOMINAL PORTIONS OF THE PNEUMOGASTRIC NERVE "	487
139.	DISTRIBUTION OF THE PNEUMOGASTRIC NERVE <i>Hirschfeld</i>	488
140.	NERVES OF THE LARYNX, POSTERIOR VIEW . <i>Sappey</i>	490
141.	NERVES OF THE LARYNX, LATERAL VIEW . "	490
142.	BRANCHES OF THE PNEUMOGASTRIC NERVE TO THE HEART <i>Bernard</i>	491
143.	THE SPINAL ACCESSORY NERVE <i>Hirschfeld</i>	506
144.	POSTERIOR VIEW OF THE MUSCLES OF THE LARYNX <i>Sappey</i>	507
145.	LATERAL VIEW OF THE MUSCLES OF THE LARYNX "	507
146.	A DIAGRAM OF THE SPINAL ACCESSORY NERVE <i>Ranney</i>	508
147.	THE GLOTTIS, AS SEEN WITH THE LARYNGOSCOPE DURING THE EMISSION OF HIGH-PITCHED SOUNDS <i>Le Bon</i>	509
148.	THE SPINAL ACCESSORY NERVE <i>Sappey</i>	511
149.	DISTRIBUTION OF THE HYPOGLOSSAL NERVE "	519
150.	ANASTOMOTIC LOOP FORMED BY THE DESCENDING BRANCH OF THE HYPOGLOSSAL NERVE AND THE INTERNAL DESCENDING BRANCH OF THE CERVICAL PLEXUS <i>Hirschfeld</i>	520
151.	A DIAGRAM OF THE HYPOGLOSSAL NERVE AND ITS BRANCHES <i>Ranney</i>	521
152.	GLOSSO-LABIO-LARYNGEAL PARALYSIS <i>Hammond</i>	524
153.	GLOSSO-LABIO-LARYNGEAL PARALYSIS "	525
154.	A DIAGRAM OF THE MOTOR POINTS OF THE FACE, SHOWING THE POSITION OF THE ELECTRODES DURING ELECTRIZATION OF SPECIAL MUSCLES AND NERVES <i>Ziemssen</i> (modified from)	528
155.	CERVICAL PORTION OF THE SPINAL CORD <i>Hirschfeld</i>	534
156.	DORSAL PORTION OF THE SPINAL CORD "	534
157.	INFERIOR PORTION OF THE SPINAL CORD AND CAUDA EQUINA "	534
158.	TRANSVERSE SECTION OF THE CERVICAL ENLARGEMENT OF THE SPINAL CORD AT THE ORIGIN OF THE FIFTH PAIR OF NERVES <i>Stilling</i>	536
159.	TRANSVERSE SECTION OF THE SPINAL CORD OF A CHILD SIX MONTHS OLD <i>Gerlach</i>	538
160.	DIAGRAM OF THE ARRANGEMENT OF THE DIFFERENT MEMBRANES AND SPACES AS THEY ARE BELIEVED TO EXIST IN THE SPINAL COLUMN <i>Hilton</i>	540

FIG.		PAGE
161.	A DIAGRAM DESIGNED TO SHOW THE RELATIONS OF THE VERTEBRÆ TO THE SPINAL SEGMENTS, AND OF THE SPINAL NERVES TO THE MOTOR, SENSORY, AND REFLEX FUNCTIONS OF THE SPINAL CORD	Gowers 546
162.	SEMI-DIAGRAMMATIC TRANSVERSE SECTION OF THE GRAY SUBSTANCE OF THE CERVICAL AND LUMBAR ENLARGEMENTS OF THE SPINAL CORD	Erb 553
163.	A PIECE OF THE WHITE SUBSTANCE OF THE SPINAL CORD, AS SEEN ON A TRANSVERSE SECTION	" 554
164.	SECTION OF THE CORD BELOW THE MEDULLA OBLONGATA	Sappey 555
165.	SECTION OF THE CERVICAL ENLARGEMENT OF THE CORD	" 555
166.	SECTION FROM THE DORSAL REGION OF THE CORD	" 556
167.	SECTION OF THE LUMBAR ENLARGEMENT OF THE CORD	" 556
168.	DIAGRAM ILLUSTRATING THE RELATIONS OF THE NERVE-FIBER TRACTS IN THE SPINAL CORD	<i>Ranney</i> (modified from <i>Flechsig</i>) Plate
169.	A DIAGRAM OF THE AREAS OF THE DIRECT AND CROSSED PYRAMIDAL TRACTS IN A SECTION OF THE SPINAL CORD, AND THE FIBERS THAT COMPOSE EACH	<i>Ranney</i> 559
170.	A DIAGRAM ILLUSTRATING THE DEVELOPMENT OF THE DIFFERENT SYSTEMS OF FIBERS IN THE SPINAL CORD	<i>Flechsig</i> 564
171.	DIAGRAM OF A TRANSVERSE SECTION OF SPINAL CORD IN UPPER HALF OF DORSAL REGION	" 565
172.	DIAGRAM OF A SPINAL SEGMENT TO SHOW ITS COMPONENT PARTS	<i>Ranney</i> 567
173.	A DIAGRAM TO ILLUSTRATE THE CIRCLE OF REFLEX ACTION IN A SPINAL SEGMENT	<i>Ranney</i> (modified from <i>Bramwell</i>) 567
174.	A DIAGRAM OF THE PATHS OF MOTOR AND SENSORY CONDUCTION IN THE SPINAL CORD	<i>Ranney</i> (modified from <i>Bramwell</i>) 569
175.	A DIAGRAM OF THE CONNECTIONS OF THE MOTOR AND SENSORY CONDUCTING TRACTS WITH THE SPINAL NERVES	<i>Ranney</i> (modified from <i>Bramwell</i>) 571
176.	A DIAGRAM OF THE VARIOUS PATHS OF SENSORY CONDUCTION IN THE CORD	<i>Ranney</i> 572
177.	MULTIPOLAR NERVE CELL FROM THE ANTERIOR CORNU OF THE SPINAL CORD OF THE OX	<i>Deiters</i> 581

FIG.		PAGE
178.	TRANSVERSE SECTION OF THE GRAY SUBSTANCE OF THE ANTERIOR CORNUA OF THE SPINAL CORD OF THE OX, TREATED WITH NITRATE OF SILVER.	583
	<i>Grandry</i>	
179.	A DIAGRAM OF THE COURSE OF THE FIBERS WHICH COMPOSE THE SPINAL CORD	585
	<i>Ranney</i>	
180.	NERVE CELL FROM THE FERRUGINOUS SUBSTANCE WHICH FORMS THE FLOOR OF THE RHOMBOIDAL SINUS IN MAN	586
	<i>Kölliker</i>	
181.	A DIAGRAM TO SHOW THE DECUSSATION OF MOTOR NERVE FIBERS IN THE MEDULLA OBLONGATA	613
	<i>Flehsig and Seguin</i>	
182.	ATROPHIC SPINAL PARALYSIS WITH CONTRACTURE	619
	<i>Hammond</i>	
183.	PROGRESSIVE MUSCULAR ATROPHY OF THE UPPER EXTREMITY.	621
	"	
184.	PROGRESSIVE MUSCULAR ATROPHY. AGE OF PATIENT, FORTY-FIVE YEARES	622
	<i>Friedreich</i>	
185.	A DIAGRAM SHOWING THE RELATION OF THE SPINOUS PROCESSES OF THE VERTEBRÆ TO THE SPINAL NERVES AND SPINAL CORD	626
	<i>Malgaigne and Seguin</i>	
186.	A DIAGRAM TO SHOW THE COURSE OF THE MOTOR AND SENSORY PATHS IN THE SPINAL CORD.	635
	<i>Brown-Séguard</i>	
187.	A DIAGRAM TO SHOW THE RELATION OF THE SPINOUS PROCESSES OF THE VERTEBRÆ TO SPINAL NERVES	636
	<i>Malgaigne and Seguin</i>	
188.	THE CERVICAL PORTION OF THE SPINAL CORD	642
	<i>Hirschfeld</i>	
189.	THE DORSAL PORTION OF THE SPINAL CORD	642
	"	
190.	THE INFERIOR PORTION OF THE SPINAL CORD AND CAUDA EQUINA	642
	"	
191.	POSTERIOR BRANCH OF THE SECOND CERVICAL NERVE	649
	<i>Arnold</i>	
192.	SUPERFICIAL BRANCHES OF THE CERVICAL PLEXUS	651
	<i>Hirschfeld</i>	
193.	THE NERVE SUPPLY OF THE POSTERIOR PART OF THE HEAD	652
	<i>Hilton</i>	
194.	THE NERVE SUPPLY OF THE POSTERIOR PORTION OF THE HEAD AND NECK	653
	<i>Flower</i>	
195.	A DIAGRAM OF THE BRACHIAL PLEXUS AND ITS BRANCHES	665
	<i>Gray</i>	
196.	ANTERIOR BRANCHES OF THE FOUR LAST CERVICAL AND FIRST DORSAL NERVES	666
	<i>Hirschfeld</i>	
197.	COLLATERAL BRANCHES OF THE BRACHIAL PLEXUS	667
	"	
198.	BRACHIAL PORTION OF THE MUSCULO-CUTANEOUS, MEDIAN, AND ULNAR NERVES	672
	<i>Sappey</i>	
199.	CUTANEOUS NERVES OF THE ANTERIOR SURFACE OF THE FOREARM AND HAND	675
	<i>Hirschfeld</i>	

FIG.		PAGE
200.	CUTANEOUS NERVES OF THE SHOULDER AND POSTERIOR SURFACE OF THE ARM	677
	<i>Sappey</i>	
201.	CUTANEOUS NERVES OF THE POSTERIOR SURFACE OF THE FOREARM AND HAND	678
	"	
202.	BRACHIAL PORTION OF THE MUSCULO-CUTANEOUS, MEDIAN, AND ULNAR NERVES	680
	"	
203.	TERMINAL PORTION OF THE MEDIAN AND ULNAR NERVES	680
	"	
204.	DIAGRAM OF THE REGIONS OF THE CUTANEOUS NERVE DISTRIBUTION ON THE ANTERIOR SURFACE OF THE UPPER EXTREMITY AND TRUNK	682
	<i>Flower</i>	
205.	THE CUTANEOUS NERVES OF THE SHOULDER AND ANTERIOR SURFACE OF THE ARM	685
	<i>Hirschfeld</i>	
206.	THE CUTANEOUS NERVES OF THE ANTERIOR SURFACE OF THE FOREARM AND HAND	685
	"	
207.	BRACHIAL PORTION OF THE MUSCULO-CUTANEOUS, MEDIAN, AND ULNAR NERVES	687
	<i>Sappey</i>	
208.	TERMINAL PORTION OF THE MEDIAN AND ULNAR NERVES	687
	"	
209.	THE CIRCUMFLEX AND SUBSCAPULAR NERVES	693
	"	
210.	THE MUSCULO-SPIRAL NERVE	695
	"	
211.	THE TERMINAL BRANCHES OF THE MUSCULO-SPIRAL NERVE	695
	"	
212.	A DIAGRAM OF THE REGIONS OF CUTANEOUS NERVE DISTRIBUTION ON THE POSTERIOR SURFACE OF THE UPPER EXTREMITY AND TRUNK	697
	<i>Flower</i> (modified from)	
213.	THE MOTOR POINTS ON THE OUTER ASPECT OF THE ARM	701
	<i>Ziemssen</i> " "	
214.	THE MOTOR POINTS ON THE INNER SIDE OF THE ARM	702
	" " "	
215.	THE MOTOR POINTS ON THE EXTENSOR (POSTERIOR) ASPECT OF THE FOREARM	703
	" " "	
216.	THE MOTOR POINTS ON THE FLEXOR (ANTERIOR) ASPECT OF THE FOREARM	704
	" " "	
217.	THE INTERCOSTAL NERVES	707
	<i>Masse</i>	
218.	THE NERVES SITUATED ON THE POSTERIOR PART OF THE TRUNK	709
	"	
219.	A DIAGRAM OF THE REGIONS OF CUTANEOUS NERVE DISTRIBUTION IN THE ANTERIOR SURFACE OF THE UPPER EXTREMITY AND TRUNK	711
	<i>Flower</i> (modified from)	
220.	A DIAGRAM OF THE REGIONS OF CUTANEOUS NERVE DISTRIBUTION ON THE POSTERIOR SURFACE OF THE UPPER EXTREMITY AND TRUNK	715
	" " "	
221.	THE LUMBAR PLEXUS	721
	<i>Hirschfeld</i>	
222.	THE CUTANEOUS NERVES ON THE THIGH	728
	"	

FIG.		PAGE
223.	THE MUSCULAR BRANCHES OF THE ANTERIOR AND INTERNAL PORTIONS OF THE THIGH	731
	<i>Sappey</i>	
224.	A DIAGRAM OF THE CUTANEOUS SUPPLY OF THE ANTERIOR ASPECT OF THE LOWER EXTREMITY	732
	<i>Flower</i> (modified from)	
225.	CUTANEOUS NERVES OF THE ANTERIOR PART OF THE THIGH	735
	<i>Sappey</i>	
226.	DIAGRAM OF THE CUTANEOUS SUPPLY OF THE POSTERIOR ASPECT OF THE LOWER EXTREMITIES	737
	<i>Flower</i> (modified from)	
227.	MUSCULAR BRANCHES OF THE ANTERIOR AND INTERNAL PORTIONS OF THE THIGH	739
	<i>Sappey</i>	
228.	THE SMALL SCIATIC NERVE WITH ITS BRANCHES OF DISTRIBUTION AND TERMINATION	751
	"	
229.	THE GREAT SCIATIC NERVE WITH ITS BRANCHES OF DISTRIBUTION AND TERMINATION	756
	"	
230.	THE EXTERNAL POPLITEAL NERVE	757
	"	
231.	THE INTERNAL POPLITEAL NERVE	759
	"	
232.	THE EXTERNAL SAPHENOUS NERVE AND ITS ACCESSORY, THE COMMUNICANS PERONEI	761
	"	
233.	THE PLANTAR NERVES, THEIR COURSE, ANASTOMOSES, AND DISTRIBUTION	762
	"	
234.	THE DEEP BRANCH OF THE EXTERNAL PLANTAR NERVE	763
	"	
235.	THE MOTOR POINTS ON THE POSTERIOR ASPECT OF THE THIGH	766
	<i>Ziemssen</i> (mod. from)	
236.	THE MOTOR POINTS ON THE ANTERIOR ASPECT OF THE THIGH	768
	" " "	
237.	THE MOTOR POINTS ON THE INNER ASPECT OF THE LEG	770
	" " "	
238.	THE MOTOR POINTS ON THE OUTER ASPECT OF THE LEG	772
	" " "	

GENERAL INTRODUCTION.

*THE NERVOUS SYSTEM CONSIDERED AS A WHOLE, AND
THE AXIOMS OF NERVE DISTRIBUTION.*

GENERAL INTRODUCTION.

GENTLEMEN: The subject of the nervous system, which has been chosen as the theme of my winter's course of lectures, is one which probably comprises more points of practical interest than any other portion of anatomy. I say of practical interest, because there is hardly a field of medicine or of surgery where the nervous system does not help to explain many of the symptoms which might otherwise tend to possibly mislead the practitioner, and where it does not also afford invaluable aid in the diagnosis of obscure affections which might remain unrecognized, without a knowledge of the nerves and of their distribution and function, till the opportunity of relief to the patient has passed.

The distribution of those small nerve-filaments which supply the skin of the body with sensation, and thus allow of the perception of external impressions, such as those of heat, cold, pain, and touch, possesses to-day an importance which is not confined to the researches of the physiologist, but which the advanced physician and surgeon are both keenly alive to grasp in all its practical detail.

In every work now published upon diseases of the nervous system, you will find cuts, which, in less modern treatises, have no analogue. These are designed to show the situation of certain *motor points* on the cutaneous surface of the different anatomical regions of the body, where the electric current can be best applied to accomplish certain desired effects, and also the area of cutaneous distribution of each of the sensory nerves.

The important relationship which exists between the nerves of the skin, the muscles underneath it, and the joints which those muscles move, is affording the enlightened physician a means of tracing the seat of obscure affections, by the use of certain *general rules* governing the nerve-supply of the body, with a degree of accuracy and ease which strikes those not familiar with the method as remarkable.

The investigations of Meynert,¹ Türck,² Charcot,³ Ferrier,⁴ Brown-Séguard,⁵ Clarke,⁶ Flechsig,⁷ Luys,⁸ Broca,⁹ Bouillaud,¹⁰ Andral,¹¹ and a host of others, have awakened the profession to the fact that many of the old ideas of the anatomy and physiology of the brain and the spinal cord were radically wrong. By symptoms referable to certain anatomical regions, the existence of disease in certain corresponding parts of the brain or spinal cord may now be positively localized during life. To what extent this new guide to diagnosis, given us by means of investigations calculated to determine the precise distribution of the nervous system, may be developed in the future, time alone will show. We have, however, ample proof that some positive information of a practical character has been gained, and that a great advance has been made toward accurate knowledge of the anatomy of the nervous centers.

When we consider that every act which distinguishes the animated being from the corpse is dependent upon the influence of the nerves, and that, without these electric wires, the heart would cease to throb, the lungs no longer perform their

¹ "The Brain of Mammals," "Stricker's Histology," New York, 1872.

² A paper originally read before the Academy of Vienna in 1851.

³ "Localizations dans les maladies cérébrales."

⁴ "Functions of the Brain"; "Localization of Cerebral Disease."

⁵ "Lectures on the Physiological Pathology of the Brain," "Lancet," 1876-'77.

⁶ "Researches on the Intimate Structure of the Brain," "Phil. Trans.," London, 1858 and 1868.

⁷ "Die Leitungsbahnen im Gehirn und Rückenmark des Menschen."

⁸ "Functions of the Brain," New York, 1882.

⁹ "Bull. de la Soc. Anat.," 1861.

¹⁰ "Recherches expérimentales sur les fonctions du cerveau." "Jour. de Physiologie," Paris, 1830. "Traité de l'Encéphalite," Paris, 1825.

¹¹ "Clinique Médicale."

function, the eye no longer be capable of vision, the ear no longer perceive sound, and that smell, taste, expression, and movement would cease to exist, we can then understand how much of physiological interest must center around this special study, and how necessary is the thorough understanding of the distribution and function of the individual nerves, if we ever hope to attain a comprehensive grasp of the general plan of our construction.

During the last session, I closed my course of lectures with a description of the general construction of nerves and the anatomy of the human brain. It will assist us, in our study of the distribution and practical utility of the separate nerves of the body, to hastily review the main classifications of nerves and the general plan upon which the nervous system is formed.

The nervous system of the human race consists of the following component parts :

- | | | |
|---|---|--|
| 1st. Cerebro-spinal system. | { | The cerebro-spinal axis.
The motor nerves.
The sensory nerves. |
| 2d. The sympathetic nerve and its vaso-motor connections. | | |
| 3d. Various ganglia, connected with special nerves. | | |

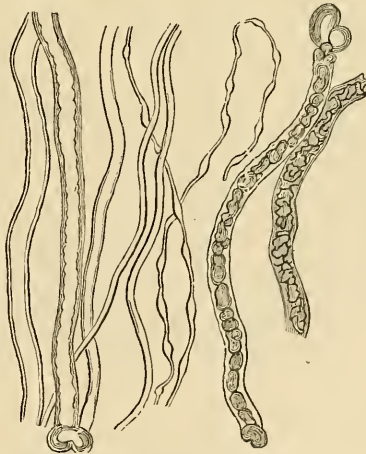


FIG. 1.—Nerve fibers from the human subject ; magnified 350 diameters. (Kölliker.)

Four small fibers, of which two are varicose, one medium-sized fiber with borders of single contour, and four large fibers ; of the latter, two have a double contour and two contain granular matter.

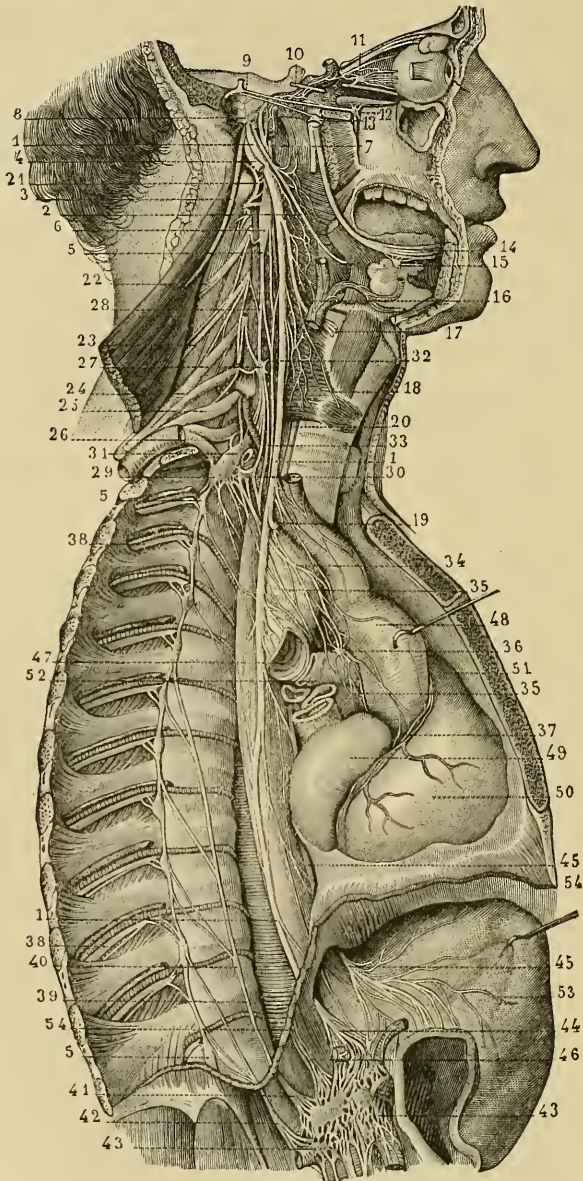


FIG. 2.—Cervical and thoracic portion of the sympathetic. (Sappey.)

- 1, 1, 1, right pneumogastric; 2, glosso-pharyngeal; 3, spinal accessory; 4, divided trunk of the sublingual; 5, 5, 5, chain of ganglia of the sympathetic; 6, superior cervical ganglion; 7, branches from this ganglion to the carotid; 8, nerve of Jacobson; 9, two filaments from the facial, one to the spheno-palatine and the other to the otic ganglion; 10, motor oculi externus; 11, ophthalmic ganglion, receiving a motor filament from the motor oculi communis and a sensory filament from the nasal branch of the

fifth; 12, *spheno-palatine ganglion*; 13, *otic ganglion*; 14, lingual branch of the fifth nerve; 15, *submaxillary ganglion*; 16, 17, superior laryngeal nerve; 18, external laryngeal nerve; 19, 20, recurrent laryngeal nerve; 21, 22, 23, *anterior branches of the upper four cervical nerves, sending filaments to the superior cervical sympathetic ganglion*; 24, *anterior branches of the fifth and sixth cervical nerve sending filaments to the middle cervical ganglion*; 25, 26, *anterior branches of the seventh and eighth cervical and the first dorsal nerves, sending filaments to the inferior cervical ganglion*; 27, *middle cervical ganglion*; 28, *cord connecting the two ganglia*; 29, *inferior cervical ganglion*; 30, 31, *filaments connecting this with the middle ganglion*; 32, *superior cardiac nerve*; 33, *middle cardiac nerve*; 34, *inferior cardiac nerve*; 35, 35, *cardiac plexus*; 36, *ganglion of the cardiac plexus*; 37, *nerve following the right coronary artery*; 38, 38, *intercostal nerves with their two filaments of communication with the thoracic ganglia*; 39, 40, 41, *great splanchnic nerve*; 42, *lesser splanchnic nerve*; 43, 43, *solar plexus*; 44, *left pneumogastric*; 45, *right pneumogastric*; 46, *lower end of the phrenic nerve*; 47, *section of the right bronchus*; 48, *arch of the aorta*; 49, *right auricle*; 50, *right ventricle*; 51, 52, *pulmonary artery*; 53, *right half of the stomach*; 54, *section of the diaphragm*.

The CEREBRO-SPINAL SYSTEM includes, as its first component part, those nerve-centers inclosed within the cavities of the cranium and spinal column, viz., the cerebrum, cerebellum, crus, pons Varolii, medulla oblongata, and spinal cord.

The second component part of the system, viz., the motor nerves, are *efferent nerves*, which carry the impulses of the nerve-centers to the muscles.

The third component part, the sensory nerves, are *afferent nerves*, which carry only sensory impressions from the periphery of the body to the nerve-centers, viz., to the brain or spinal cord.

The cerebro-spinal nerves are usually found in company with the larger blood-vessels. They are protected from injury either by investing muscular layers, or, when near the surface, by the lines of flexion of the joints.

It is worthy of remark that the foramina of exit of the cranial nerves from the base of the skull are less liable to variation than those for the transmission of blood-vessels.

The SYMPATHETIC NERVE¹ comprises a continuous chain of nerve-fibers and ganglionic enlargements, which extends from the head to the coccyx, on both sides of the spinal column, and which is in constant communication along its course with branches of the cerebro-spinal system of nerves. It supplies branches to various ganglia of the thorax and abdomen, and helps to form plexuses of nerves which ramify upon

¹ See Fig. 2 and Fig. 3.

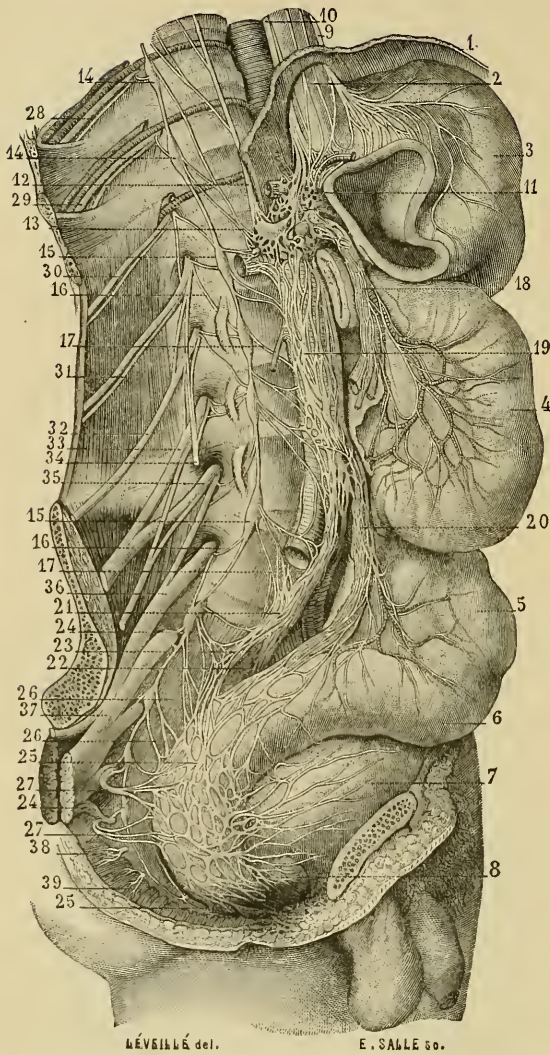


FIG. 3.—*Lumbar and sacral portions of the sympathetic.* (Sappey.)

1, section of the diaphragm; 2, lower end of the cesophagus; 3, left half of the stomach; 4, small intestine; 5, sigmoid flexure of the colon; 6, rectum; 7, bladder; 8, prostate; 9, lower end of the left pneumogastric; 10, lower end of the right pneumogastric; 11, solar plexus; 12, lower end of the great splanchnic nerve; 13, lower end of the lesser splanchnic nerve; 14, 14, last two thoracic ganglia; 15, 15, the four lumbar ganglia; 16, 16, 17, 17, branches from the lumbar ganglia; 18, superior mesenteric plexus; 19, 21, 22, 23, aortic lumbar plexus; 20, inferior mesenteric plexus; 24, 24, sacral portion of the sympathetic; 25, 25, 26, 26, 27, 27, hypogastric plexus; 28, 29, 30, tenth, eleventh, and twelfth dorsal nerves; 31, 32, 33, 34, 35, 36, 37, 38, 39, lumbar and sacral nerves.

the coats of all the principal *blood-vessels*, and which accompany them throughout the length of their course. It is by means of these plexuses upon the blood-vessels that the sympathetic nerve is enabled to control the involuntary muscular fibers within the coats of the blood-vessels, and thus to regulate the *vascular supply* of the various tissues and organs of the body. The nerve-fibers of the sympathetic are therefore often called the “nerves of organic life,” since they regulate the life of tissues by controlling their blood supply; while the cerebro-spinal nerves are contradistinguished as the “nerves of animal life,” since they control those acts which are essential to the life of the individual, such as muscular movement, respiration, etc. The frequent communication between the sympathetic nerves and those of the cerebro-spinal system renders the actions of the two systems in perfect accord, and thus supports the universal *law of harmony* which is so beautifully illustrated in all the works of Nature.

Interspersed along the paths of the motor and sensory nerve-tracts, within the substance of the brain and spinal cord, special centers connected with sympathetic nerve-fibers have been demonstrated—the so-called *vaso-motor centers*.

The exact situation and limits of these centers are still a matter for future investigation. We know, however, that the brain and spinal cord is capable of transforming afferent or sensory impulses into efferent vaso-motor impulses, which create either constriction or dilatation of blood-vessels. Some of the vaso-motor fibers run in the larger nerves of the cerebro-spinal system. As an illustration of this fact, erection of the penis may be artificially produced by stimulation of sensory surfaces, the blood-vessels of that organ becoming dilated to an enormous extent as a result of the sensory impulses transmitted to the spinal cord. Experiments of a similar character made upon the trunks of cerebro-spinal nerves have manifested the effects of stimulation in dilatation of blood-vessels of the limbs.

We know, also, that the brain and spinal cord exercise a so-called “*trophic action*” upon the joints, skeletal muscles,

and other tissues, governing their nutrition and growth, and causing them to respond in the proper way to the demands made upon them by the strains and shocks of daily life.

We are compelled, therefore, to divide the vaso-motor nerves into two classes, the *vaso-dilator* and *vaso-constrictor*. The former allow of vascular dilatation, and excess of blood to the part supplied by the nerve affected or called into action is the result of impulses transmitted by these fibers. The latter have an opposite action, the vessels being diminished in caliber and the blood supply to the part being proportionately decreased. These nerves will be considered in detail later in the course.

The CEREBRO-SPINAL NERVES comprise (1) those which escape from the foramina of the cranium, called the *cranial nerves*; and (2) those which are given off from the spinal cord. The latter escape from the spinal canal by means of foramina between the laminae of the vertebræ, called the "inter-vertebral foramina." These are called *spinal nerves*, in contradistinction to the cranial nerves.

All of the *spinal nerves* arise by *two roots*, thus indicating that they are provided with both motor and sensory filaments. The former constitute the anterior and the latter the posterior root.

The *cranial nerves* are, in some instances, similarly constructed; having two distinct roots. Others have only one. The reason of this anatomical variation is explained by the fact that some of the cranial nerves are destitute of motor fibers, some of sensory fibers, while others are endowed with a special function, such as sight, smell, hearing, and taste.

Motor-nerve fibers differ from sensory-nerve fibers in respect to their method of origin and termination. It may be stated that motor fibers begin and end in masses of protoplasm (nerve-cells or nerve-plates). Sensory nerves appear to arise within the spinal cord from a *net-work of fibers*, whose connections with the sensory cells of the cord are not as yet positively determined. They terminate either in a plexus of nerve-endings, loops, tactile corpuscles, or in some of the

apparatuses connected with the special senses of smell, hearing, or sight.

In the course of lectures which I propose to deliver before you this winter, it is my intention not only to give the anatomical origin, course, and distribution of the various nerves, but also such points of practical value as may be suggested in connection with each; these will aid in remembering the peculiarities which each presents, and possibly guide you often in your practice at the bedside of the sick.

The study of the practical bearing of the distribution of the nerves is to-day assuming an importance in diagnosis which can not be over-estimated; since the physiological phenomena produced by them have a direct influence upon the proper performance of all those functions of the body which may be considered as vital to it.

It is claimed by John Hilton¹ that, if we trace the distribution of the motor nerve filaments from any special nerve trunk to the muscles, we shall find that only those muscles are supplied by each of the individual nerves which are required to render the performance of the *functions*, for which that nerve was designed, complete; and that, if muscles were classified on a basis of their nerve supply, instead of in groups of mere relationship as to locality, a self-evident physiological relation would be shown which would tend greatly to simplify a knowledge of the muscular system in its practical bearings, and to prove a design on the part of the Creator.

Thus, he says, we frequently find muscles close together and still supplied by separate nerves, one of which has possibly to go a long way out of a direct course to reach it, which

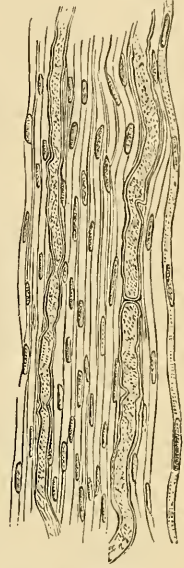


FIG. 4.—Fibers of Remak; magnified 300 diameters. (Robin.)

With the gelatinous fibers are seen two of the ordinary, dark-bordered nerve-fibers.

¹ "Rest and Pain," London. (New York, 1879.)

is contrary to the usual method of Nature, who always employs the simplest means to accomplish her designs; but, if we examine the *action* of these two muscles, we shall find that each one *acts in unison* with the *other muscles supplied by the same nerve*, and that to produce this perfect accord Nature takes what, to a hasty glance, would seem to be a needless step.

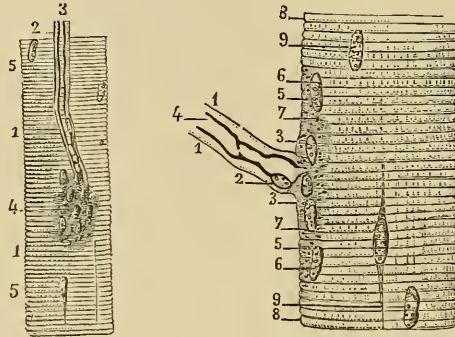


FIG. 5.—Mode of termination of the motor nerves. (Rouget.)

- A, primitive fasciculus of the thyro-hyoid muscle of the human subject and its nerve tube: 1, 1, primitive muscular fasciculus; 2, nerve tube; 3, 3, medullary substance of the tube, which is seen extending to the terminal plate, where it disappears; 4, terminal plate situated beneath the sarcolemma, that is to say, between it and the elementary fibrillæ; 5, 5, sarcolemma.
- B, primitive fasciculus of the intercostal muscle of the lizard, in which a nerve tube terminates: 1, 1, sheath of the nerve tube; 2, nucleus of the sheath; 3, 3, sarcolemma becoming continuous with the sheath; 4, medullary substance of the nerve tube ceasing abruptly at the site of the terminal plate; 5, 5, terminal plate; 6, 6, nuclei of the plate; 7, 7, granular substance which forms the principal element of the terminal plate, and which is continuous with the axis cylinder; 8, 8, undulations of the sarcolemma reproducing those of the fibrillæ; 9, 9, nuclei of the sarcolemma.

He also lays down certain axioms, pertaining to the distribution of nerves and the diagnostic value of pain, which will be often repeated in these lectures, and can not but be most profitable to those who use them as a guide. They are as follows:

“*Superficial pains on both sides of the body, which are symmetrical, imply an origin or cause, the seat of which is central or bilateral; while unilateral pain implies a seat of origin which is one-sided, and, as a rule, exists on the same side of the body as the pain.*”

The bearings of this first axiom will be rendered far more apparent when the regions of the neck and trunk are con-

sidered, since the symptom of *local pain* is of the greatest value in connection with diseases affecting the bones of the spinal column and the spinal cord which they invest; but the same rule may be applied to any of the cranial nerves, with a degree of certainty which seldom admits of error.

Thus Hilton reports a case where a fracture of the base of the skull, involving the orbit, produced amaurosis and tension of that region, with extreme local pain. A grooved probe, passed along the root of the orbit, revealed pus, as was suspected to exist. This was evacuated by the separation of the blades of an ordinary dressing forceps.

As further examples of this axiom, a toothache may accompany an inflamed condition of the temporo-maxillary articulation, or it may create it. Again, opium introduced into the auditory canal will often instantaneously relieve toothache and stiffness of the jaws, by having a narcotic effect upon the peripheral filaments of the same nerves, whose main trunks are distributed to the regions mentioned as relieved.

Severe earache may result directly from the nervous irritation of a diseased tooth, since the filaments of the fifth nerve are distributed to both the ear and the teeth, and thus pain may be felt at a point apparently disconnected from the seat of irritation.

Earache is frequently the result of malignant ulceration of the tongue, since both regions receive a portion of their nervous supply from the fifth cranial nerve.

The second axiom is as follows:

“The same trunks of nerves, whose branches supply the groups of muscles moving a joint, furnish also a distribution of nerves to the skin over the insertions of the same muscles; and the interior of the joint moved by these muscles receives a nerve supply from the same source.”

By this axiom, a physiological harmony is created between these various coöperating structures. Thus any joint, when inflamed, may, by a reflex act through motor branches derived from the same trunk by which it is itself supplied, con-

trol the muscles which move it, and thus insure the rest and quiet necessary to its own repair.

Spots of *local tenderness* in the *cutaneous surface* may, for this reason, likewise be often considered as a guide to a source of irritation of some of the structures supplied by the same nerve, viz., the muscles underneath it, or the joints which are moved by them; and thus even remote affections can be accurately determined, which, were this axiom not used as a guide, might escape recognition till an advanced stage of the disease had been reached.

The distribution of nerves to the under surface of muscles seems to be a rule, as Hilton points out, with comparatively few exceptions. It is stated by Allen that the external oblique muscle of the abdomen and the abductor pollicis are exceptions.

The *shape of muscles* seems to determine the method of nerve-endings, as was first pointed out by Schwalbe. Those muscles whose width exhibits little variation and whose fibers run parallel with one another receive only one nerve, which enters at its middle point. Those muscles that are of a triangular form, and whose fibers converge toward a tendon at its apex, receive the nerve near to the attachment of the tendon. Hilton's axioms of nerve distribution relate to the physiological distribution of nerves to muscles and the adjacent skin.

It is well, however, to quote one other axiom, laid down by the same author, before leaving the subject of the diagnostic value of the cutaneous nerves as indicators of existing disease of other organs, viz.:

“Every fascia of the body has a muscle or muscles attached to it, and every fascia must be considered as one of the points of insertion of the muscles connected to it, in following the previous axiom as to the cutaneous distribution of nerves.”

This guide is especially important in case the rule should be applied to the extremities (arms and legs) where these fasciæ extend over large surfaces, more or less remote from,

and apparently unconnected with, the muscles attached to them; but it is mentioned in this connection, for the special object of calling your attention to those general rules which govern the distribution of the nerves in their entirety, before proceeding to apply them in all their individual bearings.

Without this nervous association between the muscular structures and those composing the joints, there could be no intimation given by the internal parts of their exhaustion or fatigue. Again, through the medium of this same association between the skin and the muscles, great security is given to the joints, by the muscles being made aware of the point of contact of any extraneous force or violence. Their involuntary contraction instinctively makes the tissues surrounding the joints tense and rigid, and this brings about an improved defense for the subjacent joint structures.

From the conclusion of his great work, in which Hilton¹ endeavors to prove that mechanical rest may be used as a cure for most of the surgical disorders, the following sentences are quoted, since they can not be too often repeated:

“I have endeavored to impress upon you the fact *that every pain has its distinct and pregnant signification if we will but carefully search for it.*

“From the pain which follows the intrusion of a particle of dust on to the conjunctiva, and the closure of the eyelid for the security of rest, up to the most formidable diseases which we have to treat, pain the monitor, and rest the cure, are starting-points for contemplation, which should ever be present to the mind of the surgeon.”

In studying the nervous system of man, the special consideration of the brain should first engage our attention, because it is by far the most difficult to thoroughly comprehend. Subsequently each of the twelve nerves of the cranium which arise from the brain-substance should be reviewed, and the more important facts presented by each, which may tend to elucidate its function or explain many direct and reflex

¹ *Op. cit.*

phenomena, should be understood. These are often of great value in the diagnosis of obscure affections.

Later in the course, the anatomy of the spinal cord and the nerves which arise from it should be investigated; noting, in each instance, such points as tend to elucidate the function of the part under consideration, and also such *clinical facts* as can be constantly applied in your daily association with the sick, when difficult questions of diagnosis arise, or when valuable suggestions, as to the methods of treatment employed, seem to be the direct outgrowth of your anatomical study.

It has become rather an established custom with late authors to reverse this order of study, as they commonly direct the attention of their readers first to the construction of the spinal cord, which is much simpler than that of the brain. They then trace the nerve-strands which compose it upward to their connections with the various parts of the brain. It must be acknowledged that this system has some advantages over the one which I shall adopt; but it has also, to my mind, certain disadvantages which have caused me to vary from the more common method of description. In order to avoid any possibility of confusion, however, I shall begin my course with a general description of cerebral and spinal architecture. The diagrams which I shall employ to illustrate this portion of the course will, I trust, prove of great service (Figs. 7, 8, 9, and 10).

Some years since, my friend Prof. E. C. Seguin addressed a class, in beginning a course¹ upon a somewhat similar subject, with words of counsel and earnest pleading for higher professional attainments, which are well worthy of repetition. I therefore quote them to you in the same spirit, trusting that they will kindle in you a renewed vigor and enthusiasm in this special department of science:

“In practice, when we have completed the examination of a patient, several questions are put to us by the patient, by his friends, or by ourselves. These are, in chronological

¹ Delivered before the students of the College of Physicians and Surgeons of New York City, 1878.

order: Is there disease? Where is the disease? What is the disease? What are we to do for the cure of the disease or for the relief of the patient? Will the patient die or recover?

“Of these questions, the one which our client and the world at large consider the most important is the fourth—that relating to treatment and cure. This preference is natural, but highly unscientific; it is a manifestation of that untrained mental action which demands results and scorns methods, which welcomes empirical achievements (provided they be agreeable), and which conduces to the perpetuation of quackery of all kinds. But to the physician who is not a mere prescription writer, who aims at infusing as much science into his practice as possible, and who believes that he is not in the world for the purpose of gratifying his patients at so much per visit, but that he owes himself a debt of training and self-culture, and who has a sincere regard for science—to such a physician the first three questions assume a justly great importance. Pray observe that I do not say paramount importance, but great importance. And the superiority of the humanitarian over the scientific duty becomes less glaring if we bear in mind the truth—and I firmly believe it to be such—that success in treatment now depends, and in the future will still more closely depend, upon the scientific study of the human subject in health and disease. In other words, I would impress you with my own conviction that the best-trained and most scientific physician, if he be not a closet student and theorizer, is the best practitioner.

“We occasionally hear of an over-fine diagnosis, of extreme caution in the treatment of disease, and of the sweeping application of physiological laws to practice by men who are said to be ‘too scientific’; but who can number the errors, nay, the sacrifices of life, which must be laid at the door of the falsely so-called ‘practical men,’ who despise learning and scientific methods? Those of us who see something of the rarer and more formidable kinds of disease fully realize that in medicine, as probably in other applicable sciences,

ignorance leads to rashness and crudity in practice, while ripe knowledge conduces to success, or, at any rate, to caution in prognosis and expectancy in treatment.

“Of the three diagnostic questions — Is there disease? Where is the disease? What is the disease?—the second is the one which forms the key note of these lectures. Where is the lesion producing the disordered actions or symptoms? The method to be followed in arriving at the solution of this question varies somewhat in different departments of medicine. Some lesions can be seen by the trained unaided eye, or felt by the skilled hand; the seat of others can be determined by auscultation and percussion, by the aid of instruments, such as the ophthalmoscope, laryngoscope, speculum, etc. But, in the study of the nervous system, greater difficulties are met with; we are, to a great extent, deprived of these physical aids; we can not appreciate the condition of the brain and spinal cord directly by our special senses, but only by a proper interpretation of the way in which the functions of these parts are performed. In other words, the diagnosis must be made chiefly by reasoning.”

To the words above quoted, I can add nothing, save an earnest endeavor to so place the subject-matter before you as to render it within the grasp of your full comprehension, provided you, in turn, earnestly seek to master it.

THE BRAIN.

ITS ANATOMY, FUNCTIONS, AND CLINICAL ASPECTS.

THE BRAIN.

IN man and the vertebrates, the cerebro-spinal axis may be divided into three separate portions, each perfectly independent of one another, and yet very intimately connected. These are enumerated by Meynert as follows :

1. THE CEREBRUM.

2. THE CEREBELLUM, AND THE APPARATUSES OF CEREBELLAR INNERVATION CONNECTED WITH IT.

3. THE MEDULLARY PORTION OF THE SPINAL CORD, AND ITS EXPANSIONS TO THE DIFFERENT PARTS OF THE ENCEPHALON.

The nervous system of all animals may be subdivided into two distinct histological elements, *nerve-cells* and *nerve-fibers*. The former may be compared to the battery-cells of an electric circuit ; the latter to the wires which conduct the current generated in the batteries.

The nerve-cells are the chief histological elements of the so-called "gray matter" of the brain and spinal cord, and of ganglia found in other parts ; while the white substance of the cerebro-spinal axis may be subdivided by the microscope into distinct fibers, which serve to connect the nerve-cells of some particular region with other nerve-cells or with the muscular apparatus.

Nervous impulses may be divided into two classes : *centripetal* or *sensory*, and *centrifugal* or *motor*.

The former travel from the peripheral portions of the body toward the nerve-centers ; while the latter cause the

muscular apparatus of the body to act, either in direct response to a sensory impression received from without (*reflex movements*), or as the result of volition. Microscopical research enables us to state positively that both of these two forms of nervous impulses are conducted partly through direct tracts of nerve-fibers, and partly by the intercommunication established between nerve-fibers and nerve-cells, and nerve-cells with each other.

We may infer, therefore, that nerve-cells as well as nerve-fibers serve to maintain *isolated conduction* of nerve impulses; and that the former also generate and in some instances record them (cells of memory). We find the morphological expression of the first statement in the fact that the nerve-cells lie with their long axis stretched in the direction of the nerve-fibers with which they are connected; while the second and third propositions are established by physiological research respecting the functions of different regions of the cerebral cortex, as well as by the general arrangement of the cell elements. We are forced, moreover, to accord to the nerve-cell the functional attribute of *sensibility*, as well as the *power of generation and storage of nerve-force, and the discharge of this unknown power in the form of motor impulses*.

There is sufficient ground at present to warrant the belief that all centripetal- and centrifugal-conducting nerve-tracts are prolonged (in spite of apparent dismemberments and reduplications to which the white substance of the cerebro-spinal system is subjected in passing through different collections of gray matter scattered along their course) to the most distant centers of the nervous mechanism, and find a direct and intimate connection with the nerve-cells of the gray substance of the cerebral convolutions.

It seems but rational to assume that the phenomena of *consciousness*, which spring purely from the confluence and union of the various processes of perception, have their seat in the activity of the cerebral lobes; to which all the centripetal or sensory tracts converge and from which all the centrifugal or motor tracts arise.

If we study transparent sections of the brains of small mammals, where the different portions are more clearly defined than in animals of a higher type, and where a low

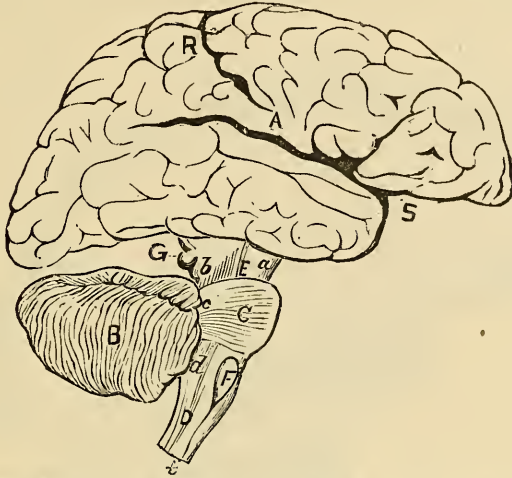


FIG. 6.—Plan in outline of the brain in profile. (Quain.)

The cerebrum is represented in this diagram as separated from the cerebellum more than it naturally should be, in order to show certain important parts. A, the cerebrum; B, the cerebellum; C, the pons Varolii; D, the medulla oblongata; E, the crus cerebri; F, the olivary body; G, the tubercula quadrigemina; S, the fissure of Sylvius; R, the fissure of Rolando; *a*, peduncles of the cerebrum; *b*, superior peduncles of the cerebellum; *c*, middle peduncle of the cerebellum; *d*, inferior peduncles of the cerebellum; *b*, E, *a*, form the isthmus encephali. The convolutions of the cerebrum are not correctly drawn in this cut.

magnifying power reveals the general course of the nerve-fibers as well as the arrangement of the masses of gray matter, we are enabled to grasp some general features of construction which are applicable to the brain of man.

THE GRAY MATTER OF THE BRAIN.

We find, in the first place, that the *nerve-cells* occur in large and distinctly isolated masses, which may be thus enumerated :

1. The gray matter of the exterior of the cerebrum (the *cortex cerebri*) that invests the convolutions. This collection of cells, as an undulating layer folded constantly upon itself, forms a layer, marked by eminences and depressions whose sole object is to obtain an increase of the brain's surface over that of the interior of the cranium.

2. Buried within the substance of each hemisphere of the cerebrum may be found two nodal masses of cells, which rest nearly upon the level of the floor of the cerebrum, and which are named, from their contiguity to this plane, the “*basal ganglia*.”

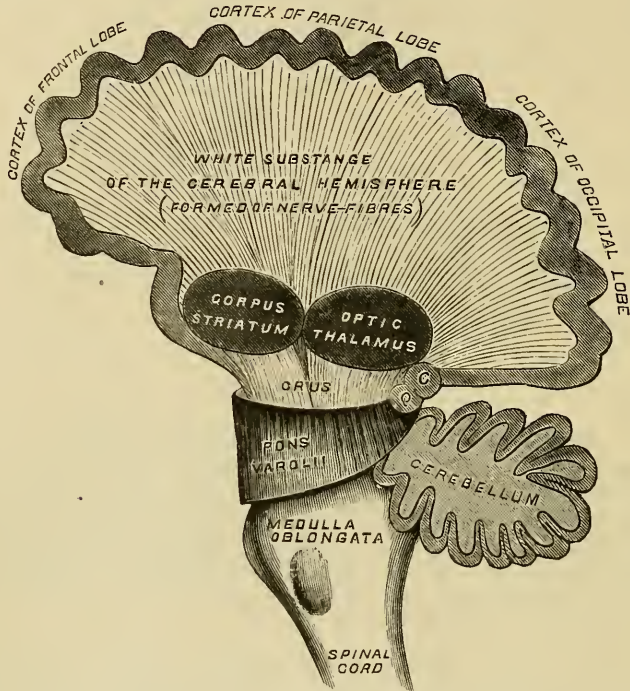

FIG. 7.—A diagram designed by the author to elucidate the chief component parts of the human brain.

The lettering upon the figure will be explained in the text. C. Q., the corpora quadrigemina, or “optic lobes.” The lines within the white substance of the cerebrum or in the “crus” are not intended to convey any impression to the reader of the actual arrangement of the fibers.

Each anterior mass is called the “*corpus striatum*,” from the striated appearance of a section made through its substance.¹

Each posterior mass is called the “*optic thalamus*,” from a supposed association with vision attributed to it by early investigators.

¹ This ganglion has two parts (as shown in Fig. 8)—the *caudate nucleus*, and *lenticular nucleus*. These parts are separated by a bundle of nerve-fibers, the so-called “*internal capsule*” of the cerebrum.

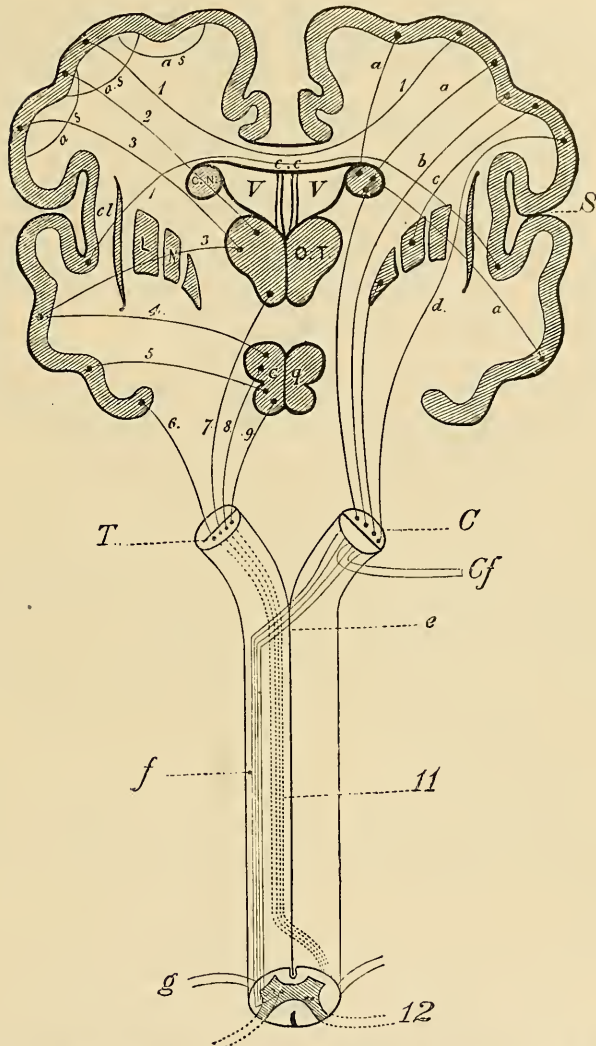


FIG. 8.—A diagram designed by the author to show the general arrangement of the fibers of the cerebro-spinal system. (Modified from Landois.)

The shaded portions represent the collections of gray matter. On the left side of the diagram, the *sensory fibers* of the crus are traced upward from the spinal cord to different portions of the cerebrum; on the right side, the *motor fibers* are similarly represented. Numerals are used in designating the *sensory* and *commissural fibers*; the *motor fibers* are lettered in small type. The cortical layer is shown at the periphery of the cerebral section, with commissural fibers (1) connecting homologous regions of the hemispheres, and associating fibers (*a. s.*) connecting different convolutions of each hemisphere. C. N., *caudate nucleus* of the CORPUS STRIATUM; L. N., *lentiform nucleus* of the same; O. T., OPTIC THALAMUS of each hemisphere, united to its fellow in the median line; *c. q.*, CORPORA QUADRIGEMINA; *c. l.*, CLAUSTRUM, lying to the right of the letters; *c. c.*, CORPUS CALLOSUM, with its commissural fibers; S, FIS-

SURE OF SYLVIVS; *V*, LATERAL VENTRICLE, the fifth ventricle being shown between the two layers of the *septum lucidum*; *C*, the *motor tract* of the CRUS CEREBRI (*basis cruris—crusta*); *T*, the *sensory tract* of the CRUS CEREBRI (*tegmentum cruris*); *Cf*, the *cerebellar fasciculus*, which is turned to the right for perspicuity, but which in reality decussates; *e*, the point of decussation of the motor fibers of the spinal cord; *f*, the course of the *motor fibers* of the spinal cord below the medulla, showing their connection with the cells of the anterior horns of the gray matter, and their continuation into the anterior roots of the spinal nerves (*g*); *a*, fibers which radiate through the caudate nucleus; *b*, fibers of the "*internal capsule*"; *c*, fibers which radiate through the lenticular nucleus; *d*, fibers of the "*external capsule*"; 2, 3, 4, 5, 6, 7, 8, 9, sensory fibers radiating from the tegmentum cruris to the cortex by means of various nodal masses of gray matter; 11, course of the sensory fibers of the spinal cord (shown by dotted lines), intimately connected with the posterior root of the spinal nerve (12), and decussating at or near the point of entrance into the spinal cord. This diagram may be studied in connection with Figs. 7, 9, 10, 11, and 13, with possible benefit to the general reader.

3. The *cerebellum* presents collections of gray matter which occur partly in layers (*cerebellar cortex*) and partly as scattered masses within its substance.

4. The so-called "*tubular gray matter*" (which may be traced as a lining to the inner portions of the *cerebro-spinal axis*¹ from the tuber cinereum to the conus medullaris of the spinal cord) must be recognized as the "permanent expression of the primitive and generic type of brain."

5. Distinct groups of cells are found within the substance of the crus cerebri, the pons Varolii, and the medulla. These will be discussed later.

The diagram (Fig: 8) will make some of these subdivisions of the gray matter of the cerebrum, as well as the fibers which connect them, more apparent than a long verbal description.

It will be seen that the gray matter of the cortex is arranged like a cap to the brain, and embraces the "basal ganglia," the "claustrum," and "corpora quadrigemina"—intermediate portions being left which in the brain itself appear as a white, cheesy mass. These are filled in with lines in the diagram. They indicate the different sets or "systems" of nerve-fibers, as the microscope in the hands of late observers has shown them to exist, and of which this so-called "*white substance*" of the brain is chiefly composed. [A careful study of the text accompanying Figs. 8, 9, and 10

¹ The "cerebro-spinal axis" is a term used to include the brain and the spinal cord collectively.

will enable the reader to grasp the general direction and terminations of the sets of fibers described.]

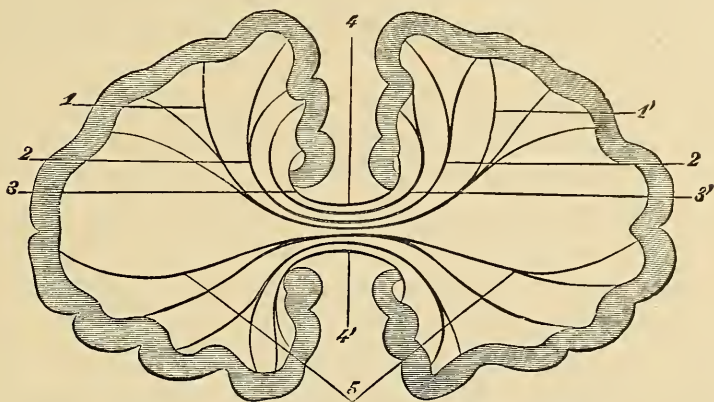


FIG. 9.—Diagram of the commissural fibers of the anterior region of the brain.
(After Luys.)

These form a series of curves one within another, the extremities of each of which plunge into the *homologous regions* of each cerebral lobe, 1, 1', 2, 2', 3 and 3'. They pass through the middle line, and at 4 and 4' give rise to the various appearances which the "corpus callosum" presents. 5, Commissural fibers of the inferior regions. These are curved in an inverse direction as regards the former, the convexity of each set being presented toward that of the other.

THE WHITE MATTER OF THE CEREBRUM.

The FIRST SET OF FIBERS (1 in Fig. 8) will be seen to spring from the cortex, and, after taking a direction which tends to bring them to the level of the superior point of union of the two cerebral hemispheres, to cross over to the side opposite to that from which they arise. After crossing, they can be traced to *homologous regions* of the cortex of the opposite hemisphere. These are commonly called "*commissural fibers.*" They are supposed to be the connecting wires between corresponding portions of the cortex of the cerebral lobes, by the aid of which the *right and left hemispheres* can act in unison with each other when circumstances chance to demand it.

These fibers have a direction which corresponds as a rule to the form of the letter U, and they constitute the transverse fibers of the "*corpus callosum*"—the connecting band of white matter between the hemispheres, seen at the bottom

of the median fissure of the cerebrum when the hemispheres are separated. Commissural fibers can be traced also between the hemispheres (in certain sections of the brain) as an inferior band¹ which lies below the level of the "basal ganglia" (Fig. 10).

There is reason to believe that these connecting fibers (which form nearly if not quite one half of the white substance of the cerebrum) are sufficient, in point of number, to allow of an *anastomosis of the gray matter of the cortex of the two cerebral lobes, cell to cell*. In infinite numbers they seem to spring from every region of the cortex—either directly from the protoplasmic structure of the cell elements, or as delicate fibrils which can be traced no farther than the intercellular structure, where their delicate sheaths become lost. (Luys.)

The SECOND SET OF FIBERS (Fig. 8) to which I would now direct attention are of equal importance from a physiological point of view. Originating from the midst of a plexus of cells in the cortex, they accompany the commissural fibers to the point where the former diverge to the opposite hemisphere, after which a separation takes place. These fibers *do not pass to the opposite hemisphere*, but concentrate themselves, in the region of the superior angle of the ventricle, into bundles placed in close juxtaposition. Some of these fibers are inserted, as a late author expresses it, like "pins in a pin-cushion," into the basal ganglia of the hemisphere from whose periphery they take their origin. Others seem to have no anatomical relationship with the basal ganglia. They are known as the "capsular fibers"; because they constitute a capsule, as it were, for the lenticular nucleus (Fig. 8).

The second set of fibers (if taken collectively) are commonly called "*radiating fibers*," from an analogy between the direction which they take and the rays of light reflected from the surface of a hollow sphere. By some authors they

¹ This may help to explain the fact that the *absence of the corpus callosum* has in exceptional cases been observed to exist without any apparent abnormality in the performance of psychical or motor phenomena during life.

are designated as “*converging fibers*,” because they tend to become focused about the basal ganglia. By others the term “*peduncular fibers*” is employed, because they are destined to pass into the crus cerebri.

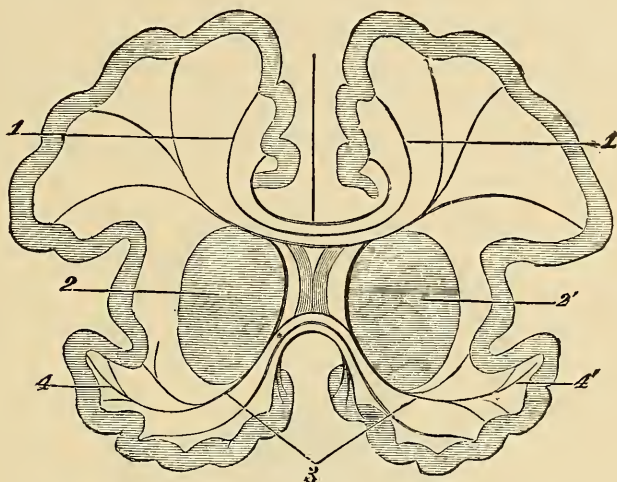


FIG. 10.—Diagram of the commissural fibers on the level of the corpus striatum. (Luys.)

1, 1', groups of transverse fibers, one within another, continuous with those in the previous figure; 2, 2', gray substance of corpus striatum; 3, 3', groups of inferior commissural fibers; 4, 4', these curve into the shape of an 8 to accommodate the corpus striatum, which they help to limit externally.

By directing our attention for a moment to the fact that fibers which are distributed to all portions of the cortex are forced to make their passage from and into the spinal cord through the foramen magnum, in case they are distributed to parts below the head, we shall be led to understand why the peduncular set are properly converging fibers before they become collected into the circumscribed limits necessary for their transmission, through this foramen of the cranium, to reach the spinal cord.

It is important to bear in mind that *this set of fibers has nothing in common with the opposite hemisphere*. The physiological function of the peduncular fibers of the cerebrum consists simply in the transmission of impulses of a centripetal and centrifugal variety to and from the cortex cerebri. It is by means of these nerves that *sensory impressions* received

from without are recorded upon the sensory portions of the cortex, and *motor impulses* are transmitted from the motor regions of the cortex to the muscles of the trunk and extremities. As Meynert aptly puts it, “the sensory nerve-fibers constitute the feelers of the cortical cells, the motor nerves, the tentacles, as it were.”

A THIRD SET OF FIBERS (Figs. 8 and 13) exist within the white substance of the cerebral lobes. They are called “*associating fibers*” (“*fibræ arcuatæ*”—“*collateral fibers*”).

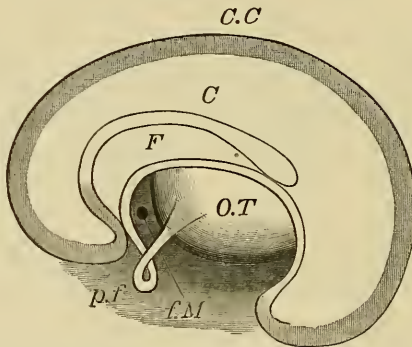


FIG. 11.—A diagram to illustrate the general outline of the corpus callosum and the fornix. (Modified from Allen.)

F, fornix, extending from tip of temporal lobe to the base of the brain, anteriorly. The cavity of the third ventricle lies below its middle third. C., corpus callosum, forming the roof of the lateral ventricles and merging posteriorly with the fornix; C. C., cerebral cortex; f. M., foramen of Monro, joining the lateral ventricle with the third ventricle; p. f., anterior pillar of the fornix, doubling upon itself and returning to the thalamus. All of these parts will be described in detail later in this volume.

These, as was the case with the preceding set, are confined exclusively to the hemisphere in which they are found. They are supposed to be so distributed to the different portions of the cortex of each hemisphere as to act as *commissural fibers for the different cortical centers*. Whether they are always distinct fibers, or simply thread-like anastomoses of the processes arising from the cells of the cortex, is not as yet fully determined. By some authors these fibers are described as dipping downward for some distance into the white substance of the hemispheres and then returning to the cortex, while others describe them as bundles of distinct fibers of varying lengths which invest the inner surface of the cortex.

Finally, attention should be called to a FOURTH SET OF FIBERS that apparently serve to connect the cortex of the temporo-sphenoidal lobes with the optic thalamus by taking an arched direction over that ganglion, and then dipping downward to the base of the brain where they turn upon themselves and pass to the substance of the thalamus. Why these so-called "*fornix fibers*" should take this circuitous route in order to establish communication between the basal ganglia and the temporal cortex is not, as yet, understood. The fornix will be discussed more in detail in subsequent pages. It is shown diagrammatically in Fig. 11.

THE PROJECTION SYSTEMS.—THE CEREBRAL CORTEX of the gray matter covering the convolutions serves as a receptacle for the various impressions of the external world, as portrayed to it by means of the nerves of sensation and the special senses. It has been considered, therefore, by Meynert as analogous to a *projection plane*, the outer world being the projected object; and the nervous system has been subdivided by the same author into three distinct members of a so-called "*projection system*," comprising nerve-fibers and various ganglia interposed along the course of the centripetal and centrifugal nerve-tracts. The views of this author may be stated as follows:

The *first member of the projection system* (Fig. 12) consists of the fibers which are connected with the cortex and which terminate chiefly in the interrupting gray matter of the basal ganglia.

The *second member* of the system comprises those fibers of the crus cerebri, which spring from the basal ganglia and end in the tubular gray substance. These fibers terminate in the tubular gray substance at different levels in order to become functionally associated with different parts of the body. It must be evident, therefore, that the length of these fibers depends entirely upon the portion of the periphery with which they are associated. Most of these fibers are supposed to cross the median line to reach the opposite side of the spinal cord.

The *third member* of the system embraces the nerves which arise from the tubular gray matter; from the point of origin of the third cranial nerves to the termination of the spinal cord.

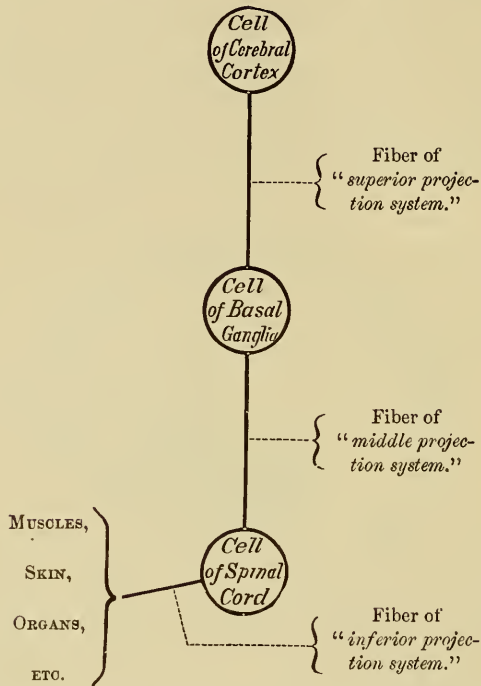
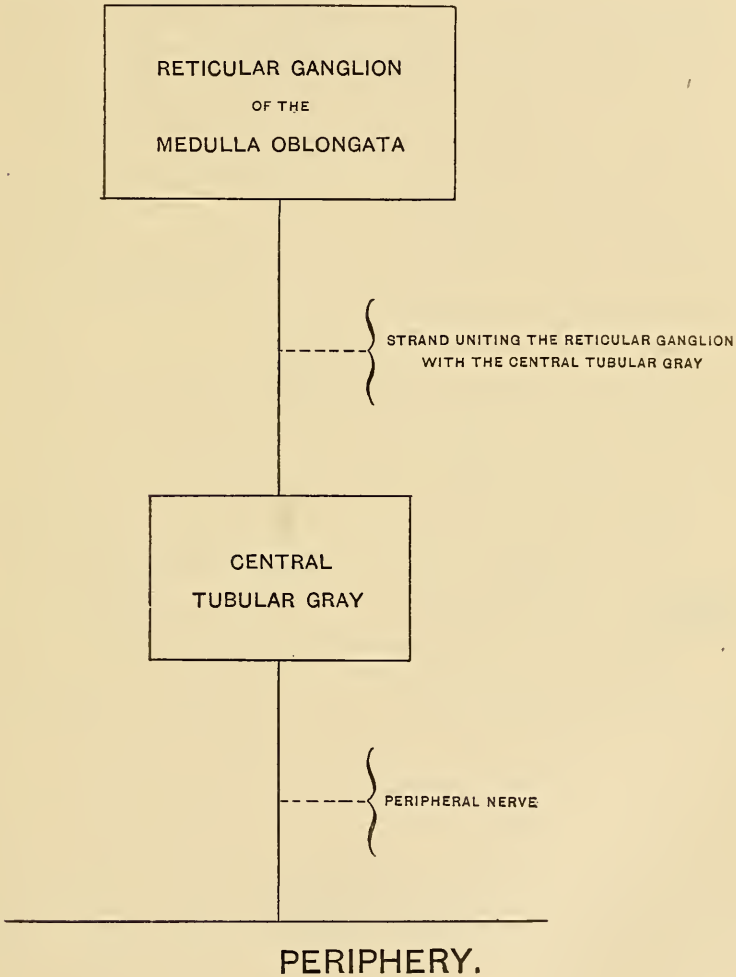


FIG. 12.—A schematic representation of Meynert's three projection systems of nerve-fibers.

Spitzka's classification of the systems of projection tracts and the ganglia associated with them¹ differs from that of Meynert (1) in that he numbers them in accordance with their priority of development, classing the central tubular gray and the spinal nerves as the first projection system; (2) in that he considers the gray masses of the reticular formation of the medulla (the reticular ganglion of this author) as belonging to a special category; (3) in that the cerebellar system is incorporated by this author and excluded from the plan of Meynert; and (4) that the number of the projection systems is increased.

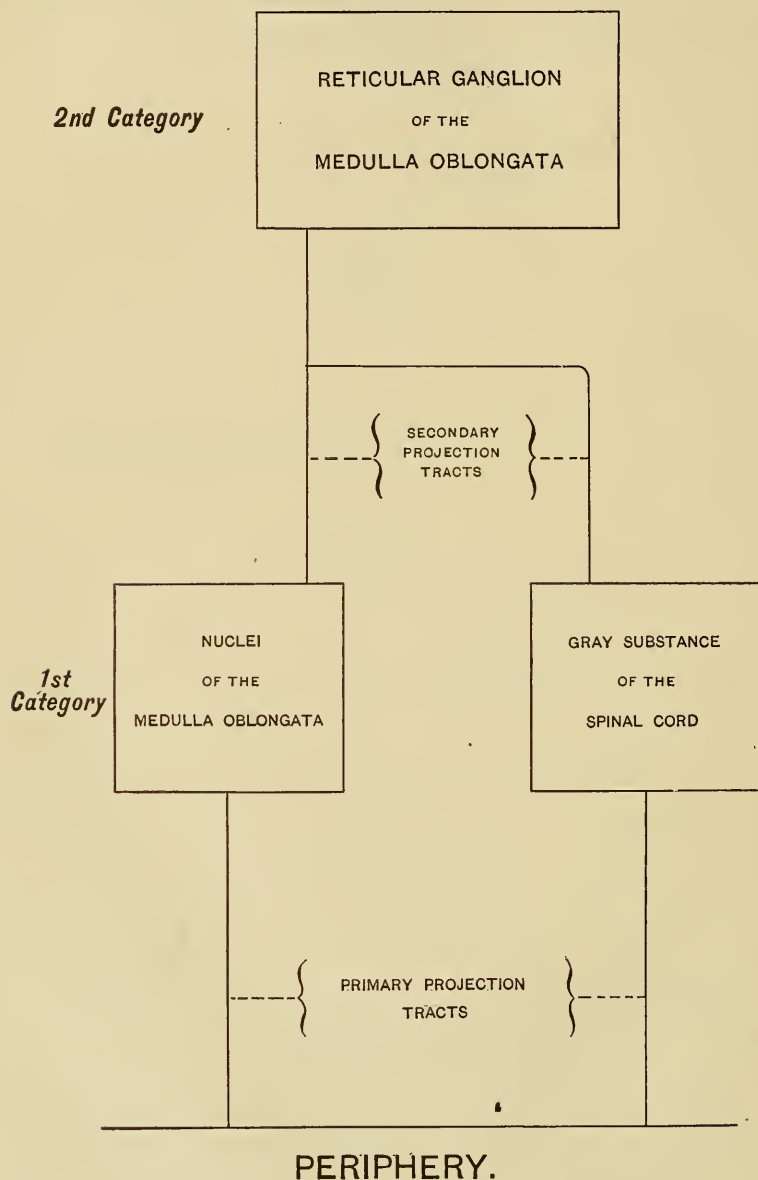
¹ "Jour. of Nervous and Mental Diseases," Oct., 1879.

There is much to be said in favor of the classification of Spitzka, although it is perhaps more difficult of comprehension to the minds of beginners in neuro-anatomy because more complete. The following scheme is employed by that author to interpret his views respecting the incorporation of the reticular ganglion in the projection plan :



Space will not allow of the incorporation of all the excellent diagrams devised by this author to illustrate his views. They can be referred to in the article from which

the above is taken. One other will, however, be introduced to show that author's views respecting the communications between the "reticular ganglion" and the nuclei of the cranial nerve-roots:



The schematic representation of nerve-tracts thus exhibited (if extended cephalad) would include, according to Spitzka, the thalamus as the 4th category, the corpus striatum as the 5th category, and the cortex of the cerebrum as the 6th category. The corpus striatum is placed above the thalamus because certain fibers pass through the latter to reach the former.

It will be perceived that the superior member of the system properly embraces the fibers of the cerebral lobes—the commissural, radiating, and associating systems of fibers (Fig. 8). It is probable, moreover, that the gray matter of the cerebellum (chiefly that of the cerebellar cortex) is intimately connected with the cortex of the cerebrum by still another set of fibers, which constitute a distinct formation, but the ramifications of which can not be so described in this general introduction as to be easily comprehended in all of their anatomical relations.

It may be asked, “Why is there a necessity for the breaking of the nerve-fibers and the introduction of cell-elements in the course of a tract which might be continuous?” “What is the object of so disturbing the simplest form of arrangement?” “What is the function of the nerve-cells so interposed?”

It is not possible, with our present knowledge, to answer all of these inquiries to our complete satisfaction. We have, however, sufficient data for the conclusion, at least, that these interruptions in the course of nerve-fibers are not solely for the purpose of effecting a simple interchange of excitations between different groups of ganglion-cells, placed one above the other, as buckets are passed up and down a ladder from hand to hand (using an illustration borrowed on account of its aptness). There is a morphological significance, not to be overlooked, in these interruptions, which can often be demonstrated. These interposed cells possess the power of *deflecting the current* passing along the nerves to which they are attached, as the switch is used in telegraphy and on railroads. By the use of this simple device, centripetal and centrifugal currents may be allowed to pass without interruption when

necessity demands it; or, again, the direction of the current may be changed, and transmitted (through some other connection which the cell possesses by means of fibers attached to some other of its processes) to a point not situated upon the direct line of the paths of the projection system.

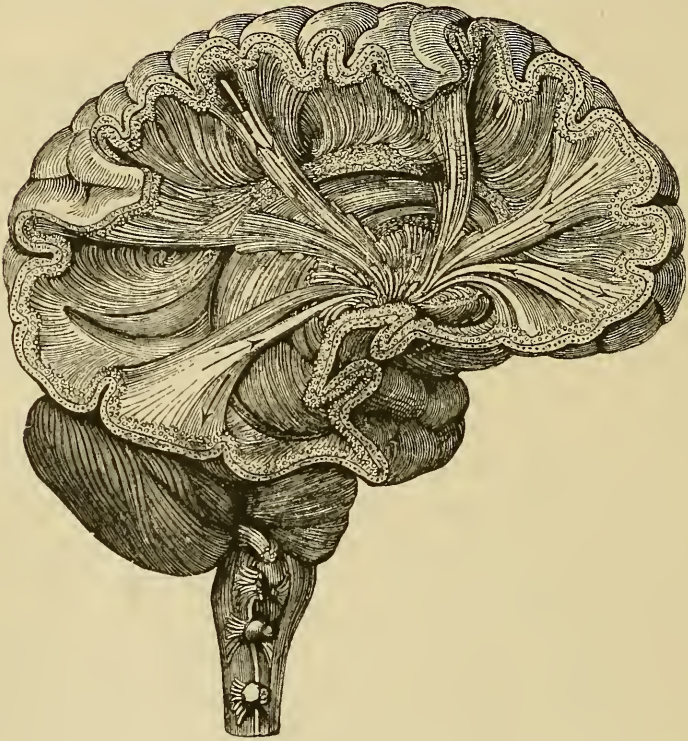


FIG. 13.—*Diagrammatic representation of the fibers in the cerebrum.* (Le Bon.)

We have reason, also, to believe that each nodal mass of gray matter has an automatism of its own, by which it can influence the nerve-fibers in intimate association with it without the intervention of the larger ganglia above, which are in some instances capable of controlling it when necessary.

GENERAL ARRANGEMENT OF THE FIBERS OF THE PROJECTION SYSTEMS.

The systems of nerve-fibers found in the cerebral lobes have already been discussed at some length, but certain additional facts pertaining to the "radiating system" (Fig. 8)

remain untold. Sections of the cerebrum are of aid in mapping out various bundles into which the radiating fibers are grouped. We are enabled to determine with ease a group connected with the "caudate nucleus" and one also with the "lenticular nucleus" of each hemisphere (the two masses of gray matter which together form the "corpus striatum"); again, one connected with the "optic thalamus" and the adjacent "corpus quadrigeminum"; and, finally, a bundle of fibers whose course differs from that of the others—those of the "fornix." The latter appear to connect certain regions of the cortex with the anterior tubercle of the optic thalamus, and a mass of gray matter at the base of the brain, called the "*mammillary tubercle*" or "*corpus candicans*" (Fig. 11).

It is now believed that some of the radiating fibers (those of the internal and external capsule of the cerebrum) are continued directly from the cortex to the crus without the intervention of ganglion-cells.¹ The diagram now introduced (Fig. 14) will aid in following these details.

In the *second member* of the projection system—the "*crus cerebri*"—marked alterations may be observed, in regard to the number, course, and arrangement of the nerve-fibers, from those of the cerebrum.

The actual number of fibers seems to be markedly reduced by passage from the white substance of the cerebral hemispheres through the substance of the basal ganglia. The fibers are, moreover, gathered into two bundles in the crus; whereas, in the cerebrum, they form several bundles before the interruption of these ganglia.

The two bundles of the crus have been named by Meynert the "*basis cruris*" (the "*crusta*") and the "*tegmentum cruris*," from their relative position to each other (Fig. 14). The fibers of the former are connected chiefly with the nuclei of the corpus striatum (as can be seen in the diagram), which constitute its crown, as it were. Those of the latter (the teg-

¹ The latest investigations of Flechsig seem to prove conclusively that this statement is true of the pyramidal tracts. He locates the situation of these fibers in the middle third of the internal capsule, slightly posterior to its knee.

mentum cruris) are connected chiefly with the optic thalamus or the corpus quadrigeminum.

Physiologically, the basis cruris or crusta (Fig. 14) may be regarded as a centrifugal or motor tract, and the tegmentum cruris (Fig. 14) as a centripetal or sensory tract. This statement is not absolutely correct, but it is practically advisable to so regard it.

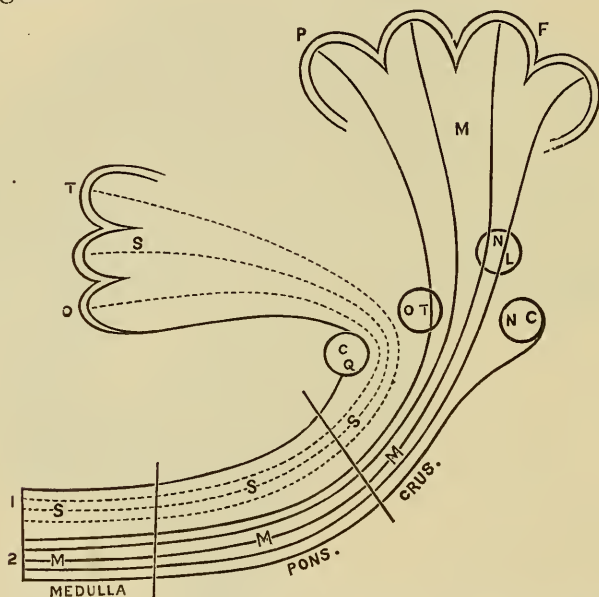


FIG. 14.—Diagram of the course of sensory and motor tracts in the mesocephalon and hemispheres. (Scguin.)

S, sensory tract in posterior region of mesocephalon, extending to O and T, occipital and temporal lobes of hemispheres; M, motor tract in basis cruris, extending to P and F, parietal and (part of) frontal lobes of hemispheres; C. Q., corpus quadrigeminum; O. T., optic thalamus; N. L., nucleus lenticularis; N. C., nucleus caudatus; 1, the fibers forming the "tegmentum cruris" (Meynert); 2, the fibers forming the "basis cruris" (Meynert).

In studying the brains of mammals, these two bundles of fibers and the ganglia connected with them give evidence of an independence of one another which governs the development of each. Where the frontal and parietal lobes are large, we find the "basis cruris" and the two nuclei of the "corpus striatum" (Figs. 8 and 14) highly developed; on the other hand, when these lobes are at their minimum we find the "tegmentum cruris" and its ganglia developed in excess.

There is also physiological evidence to sustain the opinion that the basal ganglia and the two bundles of the crus are capable in themselves of executing, in response to excitation from without, all varieties of movements in an animal deprived of its cerebral lobes (above the level of the basal ganglia) with a nicety and exactness which are astonishing.

The "crus cerebri" suffers a diminution in the fibers of its motor bundle (basis cruris) after its entrance into the substance of the pons Varolii. This is very apparent when the large size of the tract, before its entrance into the pons, is contrasted with the small anterior pyramid of the medulla oblongata, which is its direct continuation after its exit (Fig. 6). The explanation of this fact is as follows: All of the

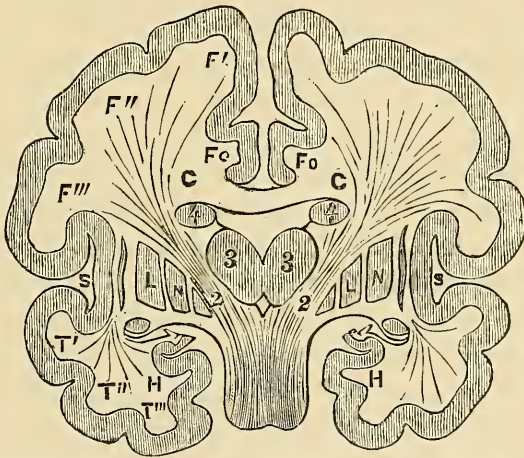


FIG. 15.—A diagram of the brain in transverse vertical section. (Dalton.)

- 1, crus cerebri; 2, internal capsule; 3, optic thalamus; 4, caudate nucleus of corpus striatum; C. C., corpus callosum; L. N., lenticular nucleus of corpus striatum; S, fissure of Sylvius; Fo, gyrus fornicatus; F', first frontal convolution; F'', second frontal convolution; F''', third frontal convolution; T', first temporal convolution; T'', second temporal convolution; T''', third temporal convolution; H, gyrus hippocampi.

peduncular fibers of the cerebrum, which become intermingled with the gray matter of the corpus striatum (the caudate and lenticular nuclei), and which escape from that ganglion as fibers of the basis cruris (Figs. 6 and 14), are not destined to form parts of the projection system.

The ganglion-cells of the pons Varolii exercise, in the case of some special cerebral fibers,¹ the switch-like action previously referred to, and deflect the impulses, which they carry, to the opposite hemisphere of the cerebellum; hence, in the pons, quite a large bundle of distinct fibers appear to leave the direct tract of the basis cruris (Fig. 14) and pass to the cerebellum (through the *processus e cerebello ad pontem*). We have come to learn that a communication between the cerebral cortex and that ganglion is thus established, but its physiological function is not yet ascertained with scientific exactness. This fact, in addition to others which will be brought forward later, leads to the conclusion that the cerebellum is, in some imperfectly understood way, brought into direct relation with the motor tract of the projection system of the cerebrum, and is endowed with some power either of control of or subtle influence over motor impulses.²

If we examine cross-sections of the "pons Varolii" and "crura," we shall perceive that the pons performs for the cerebellum an office analogous to that which the corpus callosum performs for the cerebral hemispheres—the transmission of *commissural fibers* which possibly connect homologous portions of the two lobes, although they seem to become united with the cells of the gray substance of the pons. We may note, furthermore, that these commissural fibers of the pons subdivide the fibers of the basis cruris and tegmentum cruris into smaller bundles or fasciculi. In addition, nodal masses of gray matter may be detected in both the crus and pons.

It is reasonable, therefore, to conclude that the cells of these nodal masses of gray substance establish some form of

¹ These fibers are chiefly grouped during their passage through the lower part of the cerebral hemisphere within the anterior half of the internal capsule. The fibers which arise from the cerebral cortex and apparently terminate in the gray matter of the pons, seem to spring in part from the frontal lobe and in part from the parietal and temporo-sphenoidal lobes. The frontal fibers pass through the anterior half of the internal capsule, and, after their escape from the cerebrum, occupy the *inner one third* of the basis cruris. The fibers from the parietal and temporo-sphenoidal lobes pass through the posterior half of the internal capsule, and occupy (after their escape from the cerebrum) the *outer one third* of the basis cruris.

² This subject will be discussed in connection with the architecture of the cerebellum.

communication between the fibers of the cerebral projection tracts and the commissural fibers of the cerebellum, independent of the fibers of the basis cruris which appear to deflect themselves from the path of the projection system into its substance.

The cerebellum, furthermore, has undoubted association with special fibers of the cerebrum (which are prolonged, subsequently, into the basis and tegmentum cruris) by means of two of its prolongations, viz., the *processus e cerebello ad testes* and the *valve of Vieussens*. The multiplicity of connections which this ganglion has with fibers of the projection system leaves its probable functions a matter of speculation. The theories advanced will merit consideration later in the course.

Finally, the GANGLIA of the brain have intimate relation with certain nerve-tracts which are independent of the projection system proper—viz., the *fibers of special cranial nerves*, which are more or less independent of the tubular gray matter.

The olfactory, optic, and auditory apparatuses must be considered, therefore, as modified types of projection systems, which bear, however, striking analogies to the projection system extending to nerves of spinal origin, although possessing peculiarities of structure essentially their own (Fig. 12). In these modifications of the general arrangement, the middle projection fibers appear, at a first glance, to be wanting, as there is with some cranial nerves, as far as we at present know, no organ which corresponds exactly with the central gray tube of Meynert's projection system. Many observers, however, incline to the view that the peripheral ganglion-cells are analogous to the tubular gray matter. These consider, for example, the fibers of the optic tract as a *middle* system of projection, and the radiating fibers in the retina as the external system of projection.

The *projection tracts of the crus* are prolonged into the medulla oblongata and spinal cord (Fig. 8), where they become more or less intimately associated with the tubular gray matter.

The *third member of the projection system* exhibits an augmentation in the actual number of fibers over those found in the crus; as there can be no doubt that the total number of fibers in the spinal nerves exceed greatly those comprised in the basis and tegmentum cruris. Here, again, we have undisputable evidence that the gray matter of the spinal cord, by means of its cell elements, serves as a means of conduction of nerve impulses, and also as a point of origin for additional nerves, whenever demanded.

The *motor tracts of the basis cruris* become joined to cells in the gray matter of the spinal cord, which are connected with the *anterior or motor roots* of the spinal nerves (see Fig. 8). The *fibers of the tegmentum cruris* unite with similar cells which lie more posteriorly, and are associated with the *posterior or sensory roots* of the cranial and spinal nerves (see Fig. 8). The individual course of the various bundles (that help to form the motor and sensory tracts of the crus cerebri) through the medulla and spinal cord will be described in subsequent pages.

It may be well, however, to state in general terms that each separate nerve-fiber which properly belongs to the projection tracts of the crus finds its course interrupted by the *interpolation of a ganglion-cell* before it reaches the particular spinal nerve, with the action of which it is to become intimately associated. The nerve-cells of the spinal cord help to explain the various phenomena which are comprised under the head of spinal automatism; since, in the beheaded animal, no other source of reflex motor action can be discovered, although its existence has been demonstrated beyond a doubt, both in animals (Pflüger) and even in man (Robin). By the interpolation of nerve-cells in the course of nerve-fibers, sensory impressions may be carried to any one of the three main divisions of gray matter, and there excite a response in the form of a motor impulse, viz., the *tubular gray substance and its expansions*, the *basal ganglia*, or the *cortex of the cerebrum*. These points will be discussed in subsequent pages.

THE CEREBRAL CORTEX.

If a section of the cerebral cortex, in a plane vertical to that of the surface, be pressed between two thin plates of glass and then inspected by transmitted light, it will appear to the naked eye to resolve itself into *secondary zones*, or strata of unequal transparency.

It is this peculiar appearance that has led some anatomists to describe the cortex as consisting of regularly stratified layers of alternating gray and white matter—a statement which is not supported by microscopical research.

The intimate structure of the cortical substance is not the same in all parts of the brain. Many valuable suggestions are afforded by the variations in this respect which special parts present from the type most commonly met with in the convolutions. These will be considered later.

The convolutions of the brain apparently obey some fixed law as regards their development, distribution, and the microscopical characteristics of their cortical layer.

If the most prominent points of the convolutions in any given horizontal or vertical section of the adult brain be united by a curved line, it will be found that the *curve described is continuous* if the brain be in all respects a typical one. In old age, effects of senescence become manifest in the brain, as in the other organs. One of these is a retraction or sinking of certain convolutions, so that a continuous curve no longer unites the tips of all the convolutions over which it is described. In addition, the gray matter of the cortex becomes diminished in thickness in old age; and its color is changed to a yellowish white, on account of a transition of the cell elements into a granulo-fatty state. In certain mental diseases, also, which tend to create a premature dotage, such as alcoholic poisoning, paralytic dementia, melancholic delirium, etc., we are apt to discover an atrophy of the cortical layer.

The *convolutions* of the brain present all varieties of configuration, not only in animals of different species, but even in

the same individual. Even in homologous regions of the brain the convolutions are seldom, if ever, the same in point of outline. Luys suggests that this can be demonstrated by laying a piece of transparent paper over a vertical section of the brain, and tracing upon it the outline of the convolu-

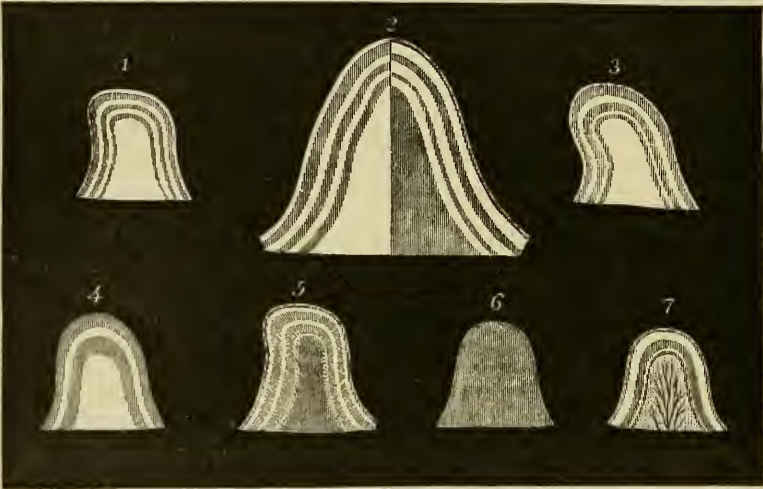


FIG. 16.—Structure of the convolutions. (After Baillarger.)

1, the six alternate gray and white layers in the cortical substance of the convolutions; 2, enlarged section of a convolution—the left half is seen by reflected light—layers arranged as in the preceding figure—in the right half, seen by transmitted light, the medullary layers are rendered dark by their opacity—the layers of gray substance, on the other hand, which are translucent, are represented in white; 3, section of a convolution showing the unequal thickness of the white layers—at first sight only three layers can be distinguished, two gray and an intervening white layer—more attentive examination shows six layers, the superficial and deep white layers being, however, very narrow; 4, section of a convolution showing the three layers of gray matter observed by Vicq d'Azyr in the occipital lobe; 5, tendency to radiation shown by the white fibers in the gray matter of the convolutions; 6, section of a cerebral convolution in a newly-born infant, seen by reflected light—it presents a homogeneous appearance; 7, same section seen by transmitted light—presents the same stratification and tendency to radiation which are observed in the adult.

tions of one side as far as the median line; now double the paper over so as to cover corresponding regions of the opposite side, and no two convolutions will be found to present an absolutely identical contour. The same observer states that, in his extended researches, he has never encountered a brain which was perfectly symmetrical when tested in this way. This statement has a medico-legal value—*asymmetry*

having been thought by some neurologists to be conclusive evidence of existing disease or congenital defect.

The *color of the cortex* differs with age and the race. In the dark-skinned races, especially marked in the negro, it is darker than in the white man; in the babe, it is uniformly grayish, and of a gelatinous consistence; in early childhood, it assumes a somewhat rosy tint; in the adult, its vascularity is apparent; in old age, it assumes a yellowish white color, and loses its vascularity. The gray color of some zones as compared with others is stated by Meynert to be due to the presence of pigment within the cell elements with which the cortex is so abundantly supplied.¹

The *thickness* of the cortical substance varies in different regions of the brain, being thicker in the anterior parts, as a rule, than in the posterior. Its average thickness may be stated to vary from two to three millimetres. Gratiolet has called attention to the curious fact that the thickness of the cerebral cortex is much less in races of small stature than in those of greater average height.

If we make thin sections of the cortex and color them with different reagents (each of which, by its chemical affinity, tends to bring out some special feature in its anatomical construction), and then subject them to the magnifying power of strong objectives, we are enabled to form a clearer conception of the actual construction of the zones of unequal transparency seen by the naked eye (first brought to professional notice by Baillarger) (Fig. 16). By the judicious employment of gradually increasing powers in the microscopic objectives used, the general arrangement of the elements may be first mastered, and, later on, the minute details of each of the component parts may be studied.

In such research we are struck, at first, by the immense numbers of *pyramidal-shaped cells*² which are encountered

¹ We know that the medullary substance of the "island of Reil" and of the "external capsule" is here and there studded thickly with nerve-cells, which, however, *fail to give it a gray appearance* on account of the absence of pigment.

² Meynert pronounces the nerve-cells of the *outer cortical layer* to be distinctly *star-shaped*, but others disagree with him.

within the cortical substance, each of which seems to point toward the surface of the brain; as if attracted toward it, like needles "so magnetized as to always point to the pole."

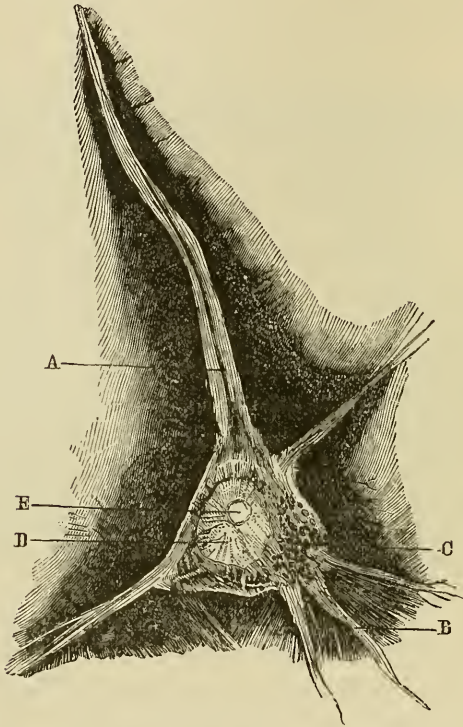


FIG. 17.—Cortical cell of the deeper zones at about eight hundred diameters. (Luys.)

A section of the cell is made through its greater axis, its interior texture being thus laid bare. A represents the superior prolongation radiating from the mass of the nucleus itself; B, lateral and posterior prolongations; C, spongy areolar substance, into which the structure of the cell itself is resolved; D, the nucleus itself seems only to be a thickening of this areolar stroma—it sometimes has a radiated arrangement; E, the bright nucleolus is itself decomposable into secondary filaments.

These are the nerve-cells. They are, furthermore, disposed in *regular strata*, parallel with the surface of the convolutions, and placed successively upon each other. It will be noticed, in the third place, that the *cells grow larger* as you pass from the external strata inward;¹ and that those of each individual layer have some distinctive peculiarities which appear to shed some light upon their function. When we come to

¹ They vary from 10 μ to 40 μ in height.

study the characteristics of the different layers, these points will be discussed. Our attention is drawn, in the fourth place, to the fact that *these cells give off branching processes* which anastomose with each other, thus constituting what may be considered a continuous structure over the whole area of the convolutions. By means of these small, thread-like processes, the cells are probably enabled to communicate vibratory molecular movements from one to the other, while some are the unquestioned means also of communication between the nerve-cells and the nerve-fibers which we have previously discussed. In the fifth place, we encounter an *inter-cellular substance*, which serves to cement the cells and to maintain a fixed position for them, as well as to furnish passage for the vessels of nutrition of the cells. This is the "neuroglia," a connective-tissue formation.

We are now enabled to appreciate the analogy which Malpighi drew between the arrangement of the cells of the cortex and the seeds of the pomegranate, imbedded in the white fibrous tissue which incloses them on all sides.

The *nerve-fibers* probably join the nerve-cells in the region of their bases; the processes given off from the apices of the cells appear to serve as a means of communication between the cells of the different layers of the cortex.

The *nerve-cells*, when examined as individual structures, are found to present a bright nucleus¹ and a nucleolus, and to be destitute of an investing membrane (Luys). In fresh brains, they are of an amber color. When very high powers are used, the protoplasm of the nerve-cells becomes resolved into distinct fibrillæ, which interlace with each other and become agglomerated in the region of the nucleus. The arrangement of these delicate fibrillæ has been compared by one of the most recent investigators (Luys) to the "wickerwork of an osier basket," and the same observer claims that the

¹ In young subjects and in *normal* adult brains, the *nuclei are seldom round or oval*. They are usually *pyramidal* or *spindle-shaped*, running out into sharp ends. Their angles are often seen to project into the cell-processes. Arnold states that the pressure of the protoplasm of the cell tends to make the outline of the nucleus correspond to that of the cell.

nucleus and nucleolus have been resolved by him into distinct secondary filaments which present a radiated appearance. I quote from him as follows: "Imagination is confounded when we penetrate into this world of the infinitely little, where we find the same infinite divisions of matter that so vividly impress us in the study of the sidereal world; and when we thus behold the mysterious details of the organization of an anatomical element, which only reveal themselves when magnified from seven to eight hundred diameters, and think that this same anatomical element repeats itself a thousand-fold throughout the whole thickness of the cerebral cortex, we can not help being seized with admiration; especially when we think that each of these little organs has its anatomy, its individuality, its minute organic sensibility; that it is united with its fellows; that it participates in the common life; and that, above all, it is a silent and indefatigable worker, discreetly elaborating those nervous forces of the psychic activity which are incessantly expended in all directions and in the most varied manners, according to the different calls which are made upon it and set it vibrating."

The *neuroglia*, to which we have referred in a general way as serving as a cement to fix the nerve-cells, allows also of the transmission of blood-vessels into the substance of the cortex. The branches given off from the vessels of the pia mater enter the cortex upon its free surface, and immediately divide into a network of small capillary twigs, which invest the adjacent nerve-cells in an areola extremely rich in blood-vessels. In addition to these two functions, the most superficial layer of the cortex is composed largely of this connective-tissue formation, as will be seen by studying the diagrammatic drawing which I now show you.

This stratum of the cortex has been compared by Luys to the epithelial covering of the mucous and cutaneous surfaces of the body, since he believes that it is designed to protect the nerve-cells from direct contact with the capillaries of the pia mater.

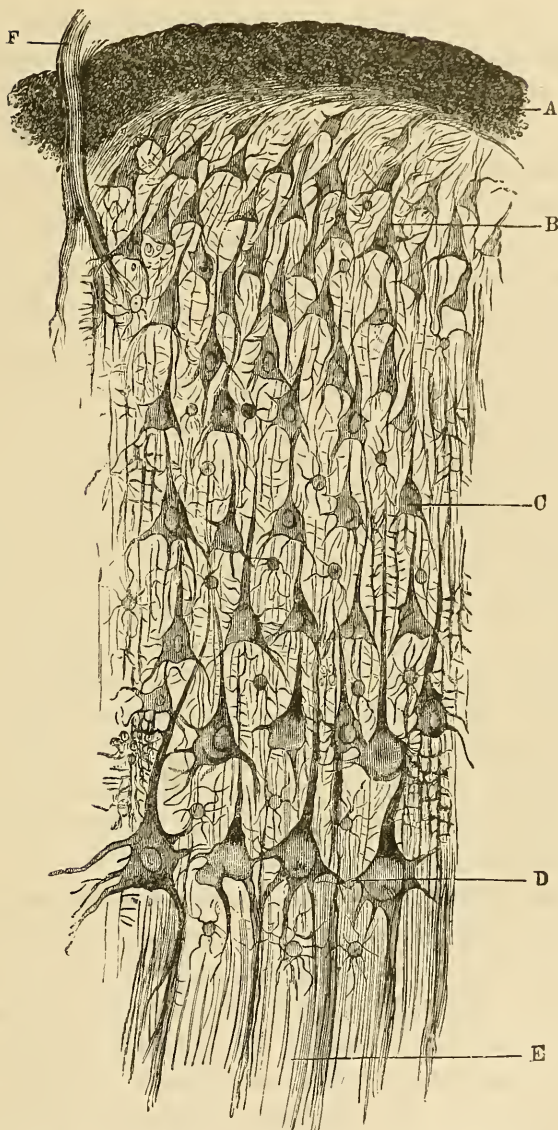


FIG. 18.—Half diagrammatic figure of the cerebral cortex, magnified about two hundred and eighty diameters, giving a view of the entire arrangement of the different zones of cells, and their relations to one another, and to the surrounding neuroglia. (Luys.)

The region A corresponds to the sub-meningeal network of the neuroglia. The region B to the sub-meningeal zones of small cells (region of the *sensorium commune*); the region C is intermediate between the sub-meningeal and the deeper zones of cells which are indicated at D. At E we note the dipping of the fasciculi of white substance into the plexus of cortical cells. F represents a capillary at the moment when it plunges into the tissues of the cortex.

While serving thus as a source of protection and isolation, it probably also filters, as it were, the juices which escape from the meningeal vessels for the nourishment of the nervous elements. This view seems to be supported by a peculiarity in the arrangement of the smaller vessels, which can be traced into the substance of the cortex. They are found to be surrounded for almost their entire circumference by an adventitious sheath, which "invests them like a muff," and prevents the nerve-cells from coming into direct contact with any portion of the vascular system. We are forced, therefore, to believe that the nerve-cells derive their *nutritive elements* only through the mediation of other structures. The external layer of the cortex will subsequently be considered in detail.

We are prepared now to take up the *special types of cortex* which are met with; and to study the hints which are thus afforded respecting the functions of various parts. By the laws of analogy, we are led to infer that parts which have a similarity of construction, and in which the cell-elements are absolutely identical, probably have a similarity of function. If, on the other hand, the function of certain regions has, by physiological experiment, been clearly made out, we are led to study closely the minute structure of those special regions, with the hope of finding other localities where identical formations exist.

The *superficial layer* of the cortex has been described by Virchow as "the neuroglia"; by Kölliker as "connective tissue"; by Deiters as "spongy tissue"; by Rokitansky as "ependyma"; and by Wagner and Henle as "fused ganglion-cell substance." Similar tissue found in the olfactory lobes and Ammon's horn has been named "gelatinous substance" by Clarke, and "molecular substance" by Kupfer. Hence, we must be prepared to meet descriptions of this layer under the above-mentioned headings. This stratum varies perceptibly in thickness in different mammals, and, as Meynert expresses it, seems to be overbalanced and thrown in the shade by the deeper nerve-cell laden strata in the nobler types of brains. We find it relatively thin in the brain of

man and the monkey, thicker in the dog and cat, and thickest (of all the domestic animals) in the calf. The cells found in this layer are chiefly star-shaped (Meynert),¹ have very little protoplasm, and possess many finely divided processes. These are probably non-nervous in function. A few nerve-cells are found, however, which are characterized by an excess of protoplasm (Deiters) and forked processes; and some nerve-fibers may be also detected in this layer (Arndt) in the region of the surface, which interlace in all directions. In the "gyrus uncinatus" this medullary layer is developed to a high degree.

In the majority of the convolutions of the cerebrum the cortex may be subdivided into five strata. The structural differences in the four strata, underlying the one already considered, consist in variations (1) in the relative density of distribution, and (2) in the form of the nerve-cells.

As regards the form, that of the *pyramid* (the only one recognized by Arndt, Luys, Stephany, and others) prevails in the five-strata type of cortex.

In the *second* stratum, the cell elements are of small size and closely packed together; in the *third*, they are of larger size, gradually increasing both in size and distance from each other as you pass inward from the more superficial portion (the type peculiarly indicative of *Ammon's horn*); in the *fourth*, Meynert describes closely packed cells of small size (granule-like formation); in the *fifth*, the same author claims to detect spindle-shaped cells,² which he considers as particularly characteristic of the gray matter of the *claustrum*. The fifth layer of the cerebral cortex is subdivided by Lewis, Clarke, and Baillarger into two layers, thus making six layers. Krause has added a seventh layer, which he describes as being composed of very small cells lying upon the white substance of the centrum ovale. These cells, according to this author, may be pyramidal, stellate, or fusiform.

¹ Deiters recognizes only free *nuclei* in this layer. They measure about 10 μ in diameter, according to this observer.

² The *spindle-shaped cells* are not bipolar. Processes can usually be detected which spring from their sides as well as from their extremities.

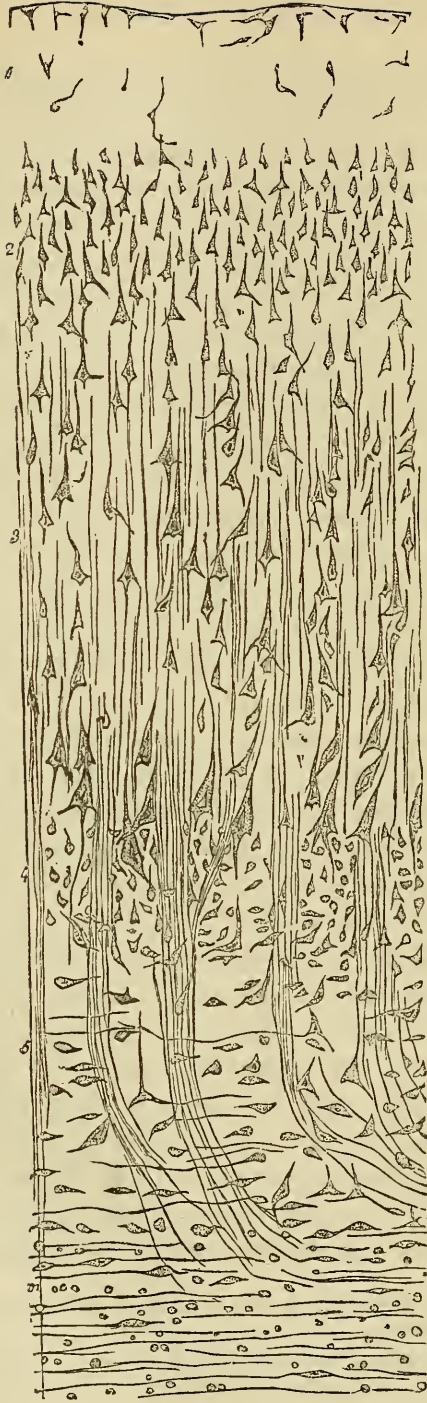

FIG. 19.—A transparent section from a sulcus of the third frontal convolution of the human brain. (Meynert.) Magnified one hundred times.

1, layer of the small dispersed cortical elements; 2, layer of the small, closely-packed, pyramidal cortical elements; 3, layer of the large pyramidal cortical elements (Ammon's horn formation); 4, layer of the closely-packed cortical elements (granule-like formation); 5, layer of the spindle-shaped cortical elements (claustrum formation); 6, medullary substance.

Considerable variety occurs in different parts of the cerebral cortex in regard to the size and shape of the nerve-cells, and the relative thickness of the layers.

It is especially worthy of notice that, in those regions of the cortex which have lately been shown to contain the *motor centers*, the deeper pyramidal cells have been found by Betz to be very large, and arranged in clusters or nests of four or five cells, which are more or less defined. These are often called the "*giant cells*." They bear a strong resemblance to the large motor cells found in the anterior horns of the gray matter of the spinal cord.

Bevan Lewis and Clarke have paid special attention to the situation of these peculiar cells, and have arrived at the conclusion that they are chiefly found among the small cells of the fourth layer of the cortex. The same observers have applied the name of "*ganglionic cells*" to these peculiar elements, which apparently have an intimate relation with the function of muscular movement, and have designated the layer of the cortex in which they are found as the "*ganglionic layer*."

In the neighborhood of the *calcarine fissure* large cells in the cortex are very scanty, their place being occupied by those of small size. In some parts of the cortex six layers may be discovered; this is due, as shown by Bevan Lewis, to an insertion of an additional layer of small cells between the third and fourth layers. The *claustrum*, *hippocampus major* or *cornu Ammonis*, and the *olfactory lobe* present especially characteristic variations of the cortex from the more common five-strata type shown in the diagram; but space will not admit of a minute description of the peculiarities of each.¹ It may be stated, however, that the study of

¹ The researches of Bevan Lewis and H. Clarke in reference to the minute structure of the cerebral cortex in man and animals were published in the "Proceedings of the Royal Society" in 1878. The former author has also contributed articles to the "Philosophical Transactions" for 1880 and 1882. Meynert's valuable article is to be found in Stricker's work on Histology.

The most remarkable deviations from the normal five-strata type of cortex are to be found in the incurved portion of the cerebral hemisphere in the region of the *hippocampus major* (*cornu Ammonis*), and in the *olfactory lobe*. Hensle gives cuts showing

the cortical elements has afforded grounds for many attractive theories regarding the functions of special regions of the brain, and has also confirmed an opinion (previously formed by research in embryology and comparative anatomy) that the olfactory lobes and tracts are component parts of the brain, and are not to be classed among the cranial nerves. Luy's has contrasted some points in the structure of the olfactory bulbs with those of the retina; and the same author draws a strong analogy between these two organs of special sense and abridged projection systems.

From what has already been stated in regard to the anatomical construction of the cortex of the cerebrum, it seems logical to assume that *each zone may be thrown into a state of nervous activity independently of the others*, because the structure of the cells differs in the various strata. On the other hand, the connecting processes of the cell elements which unite the superimposed strata would seem to indicate that the *various zones of the cortex may be associated in their action* under certain conditions, and that the effects of nervous vibrations within the cells are in some way modified, according to the nature of the intermediate cells brought into play.

Nervous actions, like vibratory undulations, are probably transmitted within the cortical substance both horizontally, along some special stratum, and vertically from the superficial to the deeper cells, or *vice versa*.

It is worthy of notice that in the *posterior horns* of the gray matter of the spinal cord we find cells of small size which are analogous in many respects to those of the second layer of the cortex; while in the *anterior horns* large cells predominate as they do in the third stratum.

Morphological analogy would seem to indicate identical function. Luy's advances the theory that the sub-meningeal strata which are characterized by the presence of cells of

excellent sections of both of these regions. The articles referred to above will furnish the reader with a complete description of the peculiarities of structure which are characteristic of each.

small size are to be considered as the *areas of diffusion of general and special sensations*; and that the deeper strata, characterized by the presence of large cells, are the *centers for the development and emission of motor impulses*.

There is certainly some ground for a theory that the cortex may be regarded, from a physiological standpoint, as an "extensive instrument possessing a sensory-motor function"; analogous, in many respects, to the gray matter of the spinal cord, but endowed with special attributes of a higher order (consciousness, volition, memory, etc.).

We are inevitably forced to the conclusion that the cerebral cortex must be regarded as the chief, if not the exclusive, seat of *mental activity*. The essential proofs of the psychological function are as follows:

1. In the animal series, the cerebrum seems to be developed in excess of other parts of the brain in proportion as the individuals of any class approach the standard of man in mental powers. We judge of this by its weight, and also by the number of "convolutions," or "gyri." The latter serve to increase the amount of gray matter in proportion to the superficial area of the brain.

2. In cases where the cerebrum is extremely small from birth, there appears to be a corresponding diminution in the higher mental faculties, or idiocy exists.

3. Some forms of mental disturbance almost always follow injuries, compression, and diseases of the cerebrum—as evidenced by insensibility, somnolence, abnormal excitement, or some marked eccentricities of demeanor.

4. Experimental physiology has shown that a removal of the cerebral hemispheres in the bird (in which animal it is easily accomplished) produces a stupor resembling sleep, in which all *voluntary acts* cease. Flourens noticed that a removal of the cerebrum in thin slices tends toward a gradual loss of mental power. Animals so mutilated are capable, however, of movements of a *reflex character* when any of the organs of sense are subjected to stimulation; but they are so regular in the order of their occurrence that they may be

predicted, thus proving that they are not the result of volition on the part of the bird itself. Foster, in his work on physiology, gives an interesting and concise account and summary of similar experiments made upon other animals. Most observers, however, have arrived at about the same conclusions, so it is unnecessary to enter into detail here as to the results of the experiments made by each.

Now, from what has been already stated in this and a previous article, we can construct a general scheme of the nervous system as follows :

1. The *central gray matter of the spinal cord*. This has no connection with the higher senses. It is capable, in itself, of the simplest kinds of reflex acts, by means of the spinal nerves. These can be produced, at the will of the experimenter, in the beheaded frog, when an irritation of the skin by any acid, etc., is created ; and Robin has satisfactorily performed the same experiment upon a beheaded criminal. We have reason to believe that the spinal cord can be slowly and in a purely automatic way taught to perform certain series of muscular movements (as in playing scales upon a musical instrument, for example) without any intervention of the higher ganglia.

2. The *basal ganglia*, and possibly the *cerebellum*. These are of a higher order in point of construction than the spinal gray matter. They are connected directly or indirectly with the nerves of the spinal cord, and, in addition, with those of the special senses. They are capable, in themselves, of executing more complex actions, besides those of a purely reflex type, in obedience to impressions received from the nerves of special sense, as well as from the spinal nerves. These ganglia are probably important agents in guiding muscular movements in response to visual impressions and those from the sense of hearing. In this way, they seem to have an important control over the maintenance of equilibrium (co-ordinated movement).

3. The *cerebral cortex*. This is a ganglion of the highest order ; in which the mental activities are seated, in addition

to the function of elaborating and storing of sensory impressions of all kinds, and transforming them, at the proper time, into appropriate motor impulses. Here we encounter "the mysterious realms where the living forces of our psychic activities are marshaled and organized"; where volition has its seat, giving to the physical organization its individuality; and "where those eternal problems respecting the relations of our corporeal and mental being are solved and carried into execution."

TOPOGRAPHY OF THE CEREBRAL CORTEX.

We are indebted to the admirable monograph of Ecker for a systematic grouping of the convolutions, or "gyri," which will materially assist us in studying the peculiarities of formation of each, and especially in defining special centers whose functions seem to have been determined by experimental physiology. Many of the terms employed by this author and some of his predecessors are now embodied in most of the recent works on physiology and descriptive anatomy, although there are *structural grounds* (pointed out by Meynert) which make them appear somewhat illogical.

We may simplify the study of this subject by first enumerating four lobes, four lobules, and eight fissures, which are prominent upon the *exterior surface* of the cerebrum. These are as follows :

THE FOUR LOBES ARE :	{	The frontal lobe. The parietal lobe. The temporo-sphenoidal lobe. The occipital lobe.
THE FOUR LOBULES ARE :	{	The lobulus centralis (the island of Reil). The lobulus paracentralis. The lobulus cuneus. The lobulus quadratus.
THE EIGHT FISSURES ARE :	{	Ascending limb of the fissure of Sylvius. Horizontal limb of the fissure of Sylvius. The fissure of Rolando. The external parieto-occipital fissure. The transverse fissure. The hippocampal or dentate fissure. The callosal or callosal fissure. The calcarine fissure.

THE PRINCIPAL FISSURES OF THE CEREBRUM.—By reference to Figs. 20 and 21, the following points of interest may be noted in this connection :

The *ascending limb* of the *fissure of Sylvius* (*s'*) passes in front of the island of Reil and among the frontal convolutions.

The *horizontal limb* of the *fissure of Sylvius* (*s'*) passes backward behind the island of Reil, and separates the temporo-sphenoidal lobe from the frontal and parietal lobes, which lie adjoining it.

The fissure of Sylvius has a surgical and medical importance from the fact that it contains the middle cerebral artery. This vessel is particularly liable to obstruction from the impaction of an embolus, especially upon the left side of the body. This accident is commonly followed by aphasia, because the motor centers of speech are supplied by this artery.

The fissure of Sylvius appears at about the fourth month of foetal life. The fissure of Rolando appears at about the sixth month, and is determined, according to the investigations of Krause, by a vein that joins the superior longitudinal sinus with the middle cerebral vein.

The *fissure of Rolando* (*c*) separates the frontal from the parietal lobe; it passes downward and forward from the upper part of the cerebrum till it almost joins the horizontal limb of the Sylvian fissure.

The *external parieto-occipital fissure* (*po*) separates the parietal and occipital lobes, hence its name. It is continued upon the inner surface of the cerebrum as the "internal parieto-occipital fissure." It is very variable in its extent, and is sometimes scarcely recognizable.

Among the minor fissures of the cerebrum that deserve mention may be enumerated the transverse, hippocampal, olfactory, collateral, calloso-marginal, and calcarine.

The *transverse fissure* (fissure of Bichat) separates the cerebrum from the cerebellum when those ganglia are in their normal relations to each other. It is continuous with the lateral and third ventricles. Here the pia mater enters the ventricles of the cerebrum.

The *hippocampal fissure* (dentate fissure) is seen upon the internal surface of the cerebral hemisphere, and indicates the seat of a convolution in the descending cornu of the lateral ventricle, known as the "hippocampus major."

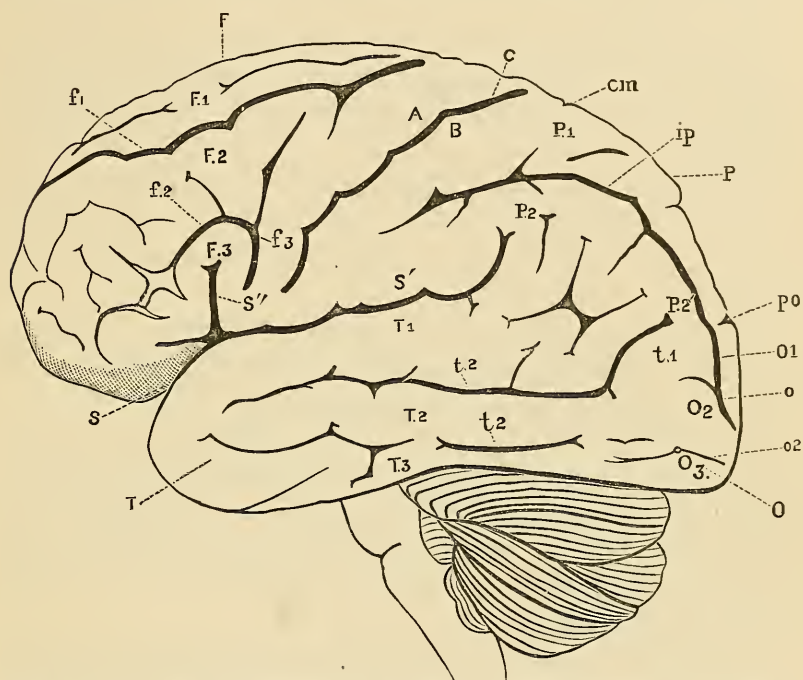


FIG. 20.—Lateral view of the human brain, showing its lobes and fissures. (After Ferrier.)

F, frontal lobe; P, parietal lobe; O, occipital lobe; T, temporo-sphenoidal lobe; S, fissure of Sylvius; S', horizontal portion; S'', ascending portion of the same; c, sulcus centralis or fissure of Rolando; A, anterior central convolution or ascending frontal; B, posterior central convolution or ascending parietal; F₁, superior; F₂, middle; F₃, inferior frontal convolution; f₁, superior; f₂, inferior frontal sulcus; f₃, sulcus præcentralis; P₁, superior parietal lobule, or postero-parietal lobule; P₂, inferior parietal lobule, viz.: P₂, gyrus supra-marginalis; P₂', gyrus angularis; p, sulcus intra-parietalis; cm, termination of the calloso-marginal fissure; O₁ first, O₂ second, O₃ third occipital convolutions; p_o, parieto-occipital fissure; o, sulcus occipitalis transversus; o₂, sulcus occipitalis longitudinalis inferior; T₁ first, T₂ second, T₃ third temporo-sphenoidal convolutions; t₁ first, t₂ second temporo-sphenoidal fissures.

The *olfactory fissure* lodges the olfactory bulb. It is seen on the basal aspect of the cerebral hemisphere.

The *collateral fissure* is seen on the basal aspect of the occipital and temporal lobe, ending at a point opposite the hippocampal fissure. It corresponds to the seat of the so-

called "collateral eminence" in the descending cornu of the lateral ventricle.

The *calloso-marginal fissure* (Fig. 21) runs parallel with the corpus callosum. It joins the fissure of Rolando at its upper extremity.

The *calcarine fissure* marks the projection of the hippocampus minor (*calcar avis*) into the posterior horn of the lateral ventricle. It joins the internal parieto-occipital fissure (Fig. 21).

THE LOBES OF THE CEREBRUM.—These are designated by the bones with which they bear relation; hence their names will serve to indicate in a general way their situation and extent.

The main sulci, or fissures, are the dividing lines between the lobes; the smaller sulci seen in the diagram (Fig. 20) separate the different convolutions, or "gyri."

Upon the *internal surface* of the cerebrum, hidden from view by the contact of the hemispheres unless they be pulled apart, are three fissures, which have been designated as the "*calloso-marginal*," the "*internal parieto-occipital*," and the "*calcarine*." These will be seen in the cut now indicated (see Fig. 21).

The **FRONTAL LOBE** (F in Fig. 20) is contained within the anterior fossa of the skull. The frontal lobe of the human adult brain includes nearly the anterior half of the cerebral hemisphere. Only that portion that lies in front of the ascending frontal convolution is contained within the anterior fossa of the cranium. This part has been named the "pre-frontal lobe" by some physiologists. The frontal lobe presents four "gyri," which are specially named. These are shown in Fig. 20 to be as follows:

The *ascending frontal convolution*, or *gyrus* (A), which lies anterior to the fissure of Rolando, being separated from the ascending parietal convolution by that fissure.

The *superior frontal convolution*, or *gyrus* (F₁), which joins the ascending gyrus, passing horizontally across the frontal lobe.

The *middle frontal convolution*, or *gyrus* (F_2), passing parallel to the superior.

The *inferior frontal convolution*, or *gyrus* (F_3), lying below the middle, embracing the ascending limb of the fissure of Sylvius.

Benedikt has observed the frequent occurrence of a *fourth frontal convolution* in the brains of criminals. It was found to exist, more or less completely developed, in the majority of brains of this class to which he had obtained access. It originated usually by a bifurcation of the middle frontal con-

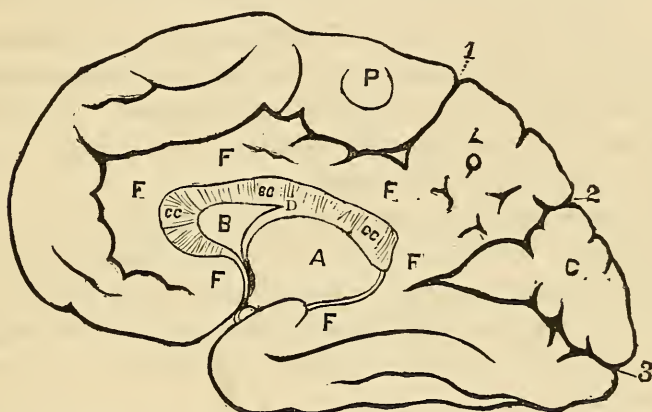


FIG. 21.—A diagram of the cerebrum in longitudinal median section. (After Dalton.)

1, callosal-marginal fissure; 2, parieto-occipital fissure; 3, calcarine fissure; A, third ventricle; B, fifth ventricle; D, anterior crura of fornix; C, cuneus (occipital lobule); Q, praecuneus (lobulus quadratus); P, para-central lobe; CC, corpus callosum; F, gyrus fornicatus.

volution, occasionally by a bifurcation of the superior frontal convolution. Other points of interest are presented, including the occurrence of a *fifth convolution*. These facts the author regards as the expression of a great pathological law, that atypical structure is the chief agent in the production of atypical (morbid) performance of function.

The PARIETAL LOBE (P) has also four convolutions, or gyri, called the ascending, the supra-marginal, the parietal lobule, and the angular gyrus. The parietal lobe is slightly overlapped by the occipital bone, so that it does not correspond exactly to the parietal area of the skull. Its convolutions are

not as clearly defined as are those of the frontal and temporal lobes.

The *ascending parietal convolution* (B in Fig. 20) lies back of the fissure of Rolando, being separated from the ascending frontal convolution by means of that fissure.

The *parietal lobule* (P_1), the *supra-marginal convolution* (P_2), and the *angular gyrus* (P_2'), being the other three convolutions of the parietal lobe, are situated behind the ascending parietal convolution.

The *supra-marginal convolution* is named from its relation to the fissure of Sylvius. It lies above the horizontal limb of that fissure, and embraces its terminal extremity. The *inferior parietal lobule* lies between the supra-marginal gyrus and the so-called intra-parietal fissure. This fissure separates it from the *superior parietal lobule*, which lies adjacent to the longitudinal fissure.

The convolutions of the parietal lobe are connected to certain adjacent convolutions by so-called "*annectant gyri*." Thus, the superior parietal convolution is joined to the occipital lobe by the first annectant convolution, and the angular gyrus is connected to the occipital lobe by two or three annectant bands.

The TEMPORO-SPHENOIDAL LOBE (T in Fig. 20) presents three well-marked convolutions, which run in an antero-posterior direction. They are named as follows:

The *superior temporo-sphenoidal convolution* (T_1), which lies below the horizontal limb of the Sylvian fissure, and which is continuous behind with the parietal lobe.

The *middle temporo-sphenoidal convolution* (T_2), which becomes continuous with the angular gyrus, and is connected to the middle occipital convolution.

The *inferior temporo-sphenoidal convolution* (T_3), seen on the under surface of the cerebrum, and connected with the third occipital convolution.

The *superior temporal convolution* (T_4) is often called the *inframarginal gyrus*. The term *subicular region*, or the region of the *subiculum cornu ammonis* (sigmoid convo-

lution of the horn), is applied to the tip of the temporo-sphenoidal lobe.

The OCCIPITAL LOBE (O in Fig. 20) presents three badly defined convolutions, which are superimposed upon one another, and which lie in a more or less antero-posterior direction.

The *superior occipital convolution* (O₁) is connected with the parietal lobule.

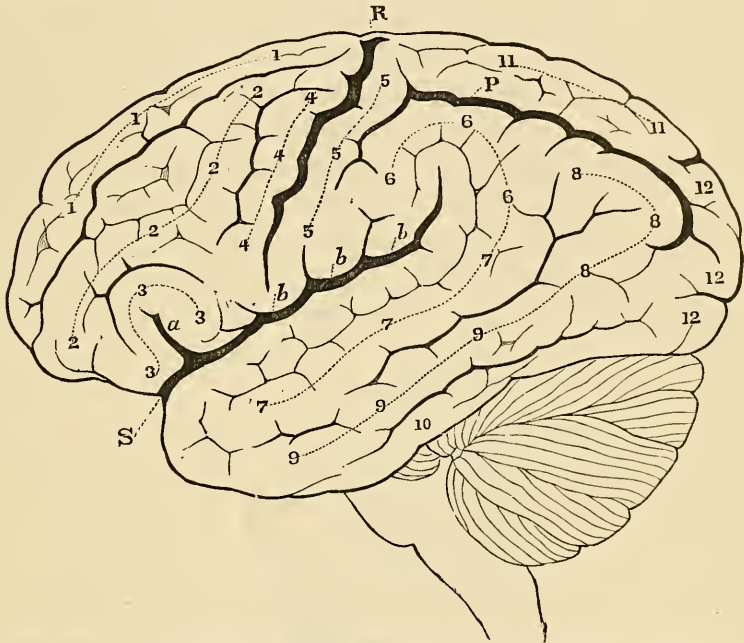

FIG. 22.—A diagrammatic figure, showing the cerebral convolutions. (Dalton.)

S, fissure of Sylvius, with its two branches, *a* and *b*, *b*, *b*; R, fissure of Rolando; P, parieto-occipital fissure; 1, 1, 1, the first or superior frontal convolution; 2, 2, 2, 2, the second or middle frontal convolution; 3, 3, 3, the third frontal convolution, curving around the ascending limb of the fissure of Sylvius (*motor center of speech*); 4, 4, 4, ascending frontal (anterior central) convolution; 5, 5, 5, ascending parietal (posterior central) convolution; 6, 6, 6, supra-Sylvian convolution (parietal lobule), which is continuous with 7, 7, 7, the first or superior temporal convolution; 8, 8, 8, the angular convolution (or gyrus), which becomes continuous with 9, 9, 9, the middle temporal convolution; 10, the third or inferior temporal convolution; 11, 11, the superior parietal convolution; 12, 12, 12, the superior, middle, and inferior occipital convolutions (called also the first, second, and third). It is to be remembered that the term "gyrus" is synonymous with "convolution," and that both terms are often interchanged.

The *middle occipital convolution* (O₂) is connected with the angular gyrus, and also with the middle temporo-sphenoidal convolution.

The *inferior occipital convolution* (O_3) is connected with the inferior temporo-sphenoidal convolution.

The admirable diagram (Fig. 22) to which I now call your attention shows the relative position of the gyri, as well as their extent, configuration, and lines of continuation into neighboring convolutions. While it is more schematic than that of Ferrier, it is better adapted for the purposes of instruction. In its general outline, however, it resembles the brain of the monkey, rather than of man, as the frontal lobes are small, and the fissure of Rolando somewhat far forward.

The LOBULES of the cerebrum (enumerated on a preceding page) demand individual mention. One of them (the lobulus centralis) lies at the base of the frontal lobe; the other three are found upon the internal surface of the cerebrum.

The *lobulus centralis*, or *island of Reil* (*insula*), lies deeply situated in the commencement of the fissure of Syl-

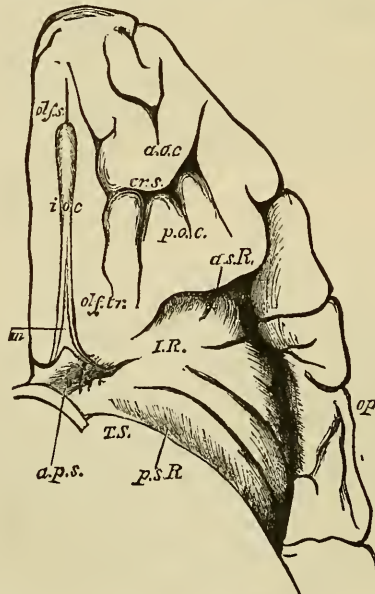


FIG. 23.—Orbital surface of the frontal lobe and Island of Reil. (Turner.)

The Island of Reil is exposed by removal of the tip of the temporo-sphenoidal lobe; *T.S.*, cut edge of this lobe; *a. p. s.*, anterior perforated space; *a. s. R.*, *p. s. R.*, anterior and posterior limiting sulci of the island; *op.*, operculum; *tr. s.*, tri-radiate sulcus; *i. o. c.*, *a. o. c.*, and *p. o. c.*, internal, anterior, and posterior orbital convolutions; *olf. s.*, end of olfactory sulcus; *olf. tr.*, olfactory tract, bifurcating into the inner and outer roots; *m.*, middle root, or tuber olfactorium.

vius. It can be made visible only by the separation of the lips of that fissure or the lifting of the operculum (see Fig. 23); hence it lies in intimate relation with the "basal ganglia." It is a triangular eminence, and consists of five or six straight convolutions (*gyri operati*), which radiate outward from a point just external to the anterior perforated space. It covers the lenticular nucleus of the corpus striatum. The drawing to which I now call attention shows the appearance of this lobule after the end of the temporo-sphenoidal lobe has been removed. The discovery of Broca that this region contains the center for the movements necessary to articulate speech (a statement which clinical experience has not yet been able to overthrow) has given it a clinical and physiological importance in excess of other convolutions.

Marshall has called attention to the fact that the island of Reil is imperfectly developed in idiots, as are also the corpus striatum and the flocculus. In some cases the convolutions of the island of Reil were found to be entirely absent.

The *paracentral lobule* (P in Fig. 21) is found on the internal surface of the cerebrum, in front of the lobulus cuneus. There is clinical evidence to sustain the belief that this lobule is connected with the motor tract. We know, also, that disease of this convolution produces a secondary degeneration of nerve fibers which can be traced through the cerebrum along the motor tract and into the motor regions of the spinal cord. The "giant cells" of Betz are also found in its cortical layer.

The paracentral lobule lies in the region of the mesial or upper extremity of the fissure of Rolando. It probably presides over movements of the big toe (Horsley).

The *lobulus quadratus* (Q) lies between the paracentral lobule and the lobulus cuneus, as shown in this drawing (Fig. 21). It is bounded by the internal parieto-occipital and the calloso-marginal fissures.

The *lobulus cuneus* (C) lies posteriorly to the lobulus quadratus. Like the preceding lobule, it is inclosed between two fissures, the internal parieto-occipital and the calcarine.

The *calcarine fissure* corresponds in position to the seat of the so-called hippocampus minor (*calcar avis*), on the floor of the posterior cornu of the lateral ventricle.

The *marginal convolution* (*gyrus fornicatus*) follows the curve of the corpus callosum to a point opposite its free posterior border, where it terminates in the hippocampal convolution. Meynert believes that its anterior extremity can be traced to the olfactory sulcus.

The *hippocampal convolution* (superior parieto-occipital gyrus or uncinata gyrus) is formed by the union of the marginal convolution (*gyrus fornicatus*) and the occipito-temporal convolutions of the internal aspect of the hemisphere. It can be traced to the tip of the temporo-sphenoidal lobe, where it ends in a hook-like bend, called the "uncus."

The so-called *dentate convolution* (*fascia dentata*) begins at the posterior extremity of the corpus callosum and ends at the uncus.

PEDUNCULAR FIBERS OF THE CEREBRUM. — By means of the "peduncular" or "radiating fibers" of the cerebrum (Fig. 8), the cortex is enabled to receive impressions of the external world and to transmit motor impulses to the muscles. The larger part of these fibers (as stated in a previous article) are capable of being traced into the crus and spinal cord, but it must be remembered that some also are intimately connected with the cranial nerves, especially those associated with the special senses of smell, sight, and audition. It may not be considered a repetition of previous matter to introduce at this time another diagram, which will make some additions to the facts already recorded.

Many points shown in this diagram are already familiar to you, but a few remain which deserve mention. One bundle, the "stria cornea," is shown in the drawing. These fibers run from the cortex of the temporal lobe of the cerebrum to the caudate nucleus of the corpus striatum, and appear on the floor of the lateral ventricle as a curved band, the "tænia semicircularis." The optic thalamus is shown to receive fibers which spring from the frontal lobe, passing between the cau-

date and lenticular nuclei of the corpus striatum, and designated in the diagram as (*a*); also fibers from the temporal lobe, the walls of the fissure of Sylvius, the gyrus fornicatus, and the optic tracts. The so-called "geniculate bodies" are

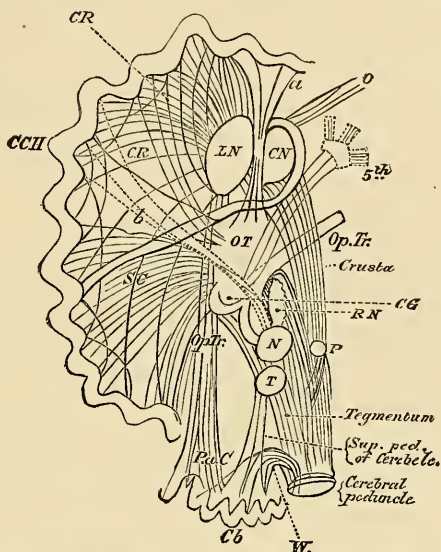


FIG. 24.—A diagram of the fibers of a lateral half of the cerebrum. (Foster's "Physiology." Reichart's edition.)

CCH, cortex of the cerebral hemisphere, the convolutions of which are seen to be connected by arcuate connecting fibers; *Cb*, cortex of cerebellum; *CR*, corona radiata, consisting of fibers extending from the cortex cerebri to *LN* and *CN*, the "lenticular" and "caudate" nuclei of the corpus striatum, and to *OT*, the optic thalamus. The posterior extremity of the optic thalamus presents two enlargements, the "corpus geniculatum externum" and "internum," which are seen to be connected with the optic tracts. The letters *Op. Tr.* are placed on a band of fibers that are believed to run directly from the cortex cerebri to the cortex cerebelli. *SC*, "stria cornea," or "tænia semicircularis"; *RN*, "red nucleus of the tegmentum"; *N*, "nates"; *T*, "testis"; *P*, "pineal gland"; *b*, fibers passing directly into the tegmentum from the cortex cerebri; *PaC*, the band of fibers to the right of these letters are part of the "superior peduncle of the cerebellum." The olfactory nerve (*o*), the optic nerve (*Op. Tr.*), and the trigeminus or fifth nerve are also shown to possess an intimate connection with the basal ganglia and probably with the cortex cerebri. A special band of fibers (*Op. Tr.*) are supposed to run from the cortex cerebri to the cerebellum.

also shown to be connected with certain bundles of radiating fibers. The bundles which compose the "crusta" and "tegmentum cruris" are made more apparent than in the diagram previously drawn. Finally, the fibers connecting the cortex of the cerebellum with the testis are clearly depicted.

FUNCTIONS OF THE CORTEX OF THE CEREBRUM.

At the present day we are in possession of a sufficient number of facts, derived from clinical observation, pathological research, and experimental investigation, to render it certain that no intelligence can exist without brain substance; that the destruction of brain substance impairs intellectual power; and that the normal use of the brain implies a degeneration of its substance and a constant process of regeneration, as exists in all tissues.

It was formerly supposed that the cerebrum was destitute of both sensation and irritability, since experiments seemed to show that no pain was experienced by removal of portions of the hemispheres, nor convulsive movements produced by direct stimulation of either the white or gray matter. It has therefore been claimed that the hemispheres could be called into action only in response to a sensory impression transmitted to its cells through sensory nerves, and that it was incapable of transmitting or appreciating artificial forms of stimulation. In 1870, however, Fritsch¹ and Hitzig² discovered that certain parts of the gray matter of the hemispheres of the brain of a dog responded to a weak galvanic current, and these investigators were thus enabled to locate centers where certain well-defined movements could be produced at will. These experimenters found (1) that the *centers of motion* were always confined to the *anterior parts* of the hemisphere; (2), that the action on muscles was a *crossed action*,³ i. e., on the side opposite to the stimulation; and (3), that, after severe hæmorrhage, the excitability of the gray matter disappeared, thus possibly accounting for the negative results of previous experimenters in the same line.

The *centers of motion* discovered by these experiments

¹ Reichardt u. du Bois-Raymond's "Archiv," 1870.

² Hitzig, "Das Gehirn," 1874.

³ Brown-Séquard has shown that, in exceptional cases, this law may not be sustained by clinical facts. "Lancet," 1876. The anatomical researches of Flechsig, however, tend to explain the exceptions to the general rule (see pages of this volume referring to the "pyramidal" fibers of the medulla oblongata).

seemed to be connected with parts which were widely separated, and arranged with little apparent system; thus the muscles of the neck were found to respond to galvanism of a center in the middle of the frontal convolutions, while a center adjoining it caused a response in the extensor and abductor muscles of the fore-leg, and others in movements of the eye and face. Ferrier¹ has of late repeated and confirmed many of the results obtained by the experiments of these German investigators.²

The effects of removal of the cerebral hemispheres of animals have been studied largely upon birds and the monkey tribe, and with results which are comparatively uniform. Without entering into detail as to all the effects which follow such a procedure, in case the basal ganglia are left intact, the general result may be given as follows: The animal seems to be able to execute all the movements natural to it, even when complex coördination of movement is required; but the *intelligence* seems to be impaired, and some unusual stimulus must be present to prompt any attempts at motion. As a result of this conclusion, the *mechanism of coördination* of movement is evidently not situated in the cerebral hemispheres.

Flourens,³ from a series of experiments made in 1822 and 1823, concluded that the removal of the cerebrum entailed an entire loss of will power and also of the perceptive faculty, and that the memory was utterly destroyed. Bouillaud,⁴ in 1826, differed from Flourens as regards the perceptive faculties, as *sight* and *hearing* were shown to be unaffected; and these results were still further made manifest by the researches of Longet,⁵ who proved also that *taste* remained.

A careful study of the phenomena which accompany certain pathological lesions of the brain in the human subject,

¹ "West Riding Reports," 1873; "Functions of the Brain," 1876.

² A large number of *distinct centers of motion* are mapped out by this author on a diagrammatic chart. The reader is referred to Fig. 26 of this volume.

³ "Recherches expérimentales sur les propriétés et les fonctions du système nerveux," Paris, 1842.

⁴ "Recherches expérimentales sur les fonctions du cerveau."

⁵ "Anatomie et physiologie du système nerveux," Paris, 1842.

such as laceration or pressure from the effusion of blood, softening of the cerebral substance, etc., if taken in connection with the later results obtained by experiments upon living animals, throws considerable light upon the functions of certain distinct portions of the encephalon.

Softening of the cerebral hemispheres and the degenerative changes which often follow an extravasation of blood into their substance are generally indicated by alterations in the intellectual condition of the patient, thus confirming the physiological experiments upon the hemispheres. Among the many forms in which this impairment of intellect may be manifested are recognized an impairment of various types of memories; a tardy, inaccurate, and feeble connection of ideas; an irritability of temper, with a childish susceptibility to petty or imaginary annoyances; easily excited emotional manifestations; and a variety of phenomena denoting abnormally feeble intellectual power.

Hughlings-Jackson¹ has shown that there is clear evidence to prove that disease of the gray matter of the convolutions of the hemispheres of the cerebrum may not only produce *delirium*, as in meningitis, but sometimes *convulsions*, either of an epileptiform character or confined to particular groups of muscles.

Landois² and Hitzig³ both announce the fact that, when the motor areas upon the convex surface of the cerebrum, which control the movements of the extremities, are excised, a *rise in the temperature* of the corresponding limbs takes place and lasts for some months. A relationship has, moreover, been observed between the brain cortex and the beat of the heart (Balogh⁴); an alteration in the arterial pressure (Bochefontaine⁵); contraction of the bladder, spleen, and uterus; an increase in the flow of the saliva; and a dilating effect upon the pupil. The exact localization of some of these latter centers can not, as yet, be considered as positive.

¹ "London Hosp. Reports," 1864; "Clin. and Phys. Researches," 1873.

² Virchow's "Archiv," 1876.

³ As quoted by Foster.

⁴ Hofmann und Schwalbe's "Bericht," 1876.

⁵ "Archives de Physiol.," 1876.

Stimulation of the cerebral surface has been observed to result in a well-marked *hæmorrhage of the lungs* by Nothnagel.¹

Most authors recognize to-day the existence of a “*visual*” center; an “*auditory*” center; a “*tactile*” center; centers for *smell* and *taste*; a motor speech center; and centers for movements of the limbs and face.

The motor center of *articulate speech* is one of the most definitely settled points in cerebral localization.

There are two forms of aphasia, which are clinically recognized, viz., the *amnesic* or *sensory*, and the *ataxic* or *motor*, varieties. In the former, the *memory of words* is utterly lost, so that the patient is not only unable to express his ideas in articulate sounds, but he is also unable to write them, thus showing that the words themselves have been forgotten. In the ataxic variety, however, the memory of spoken or written words still remains, but the ability to so *coördinate the muscles of articulation* as to pronounce the words is impaired, so that the person so afflicted can write his ideas intelligently, but can not utter them.

Aphasia is not to be confounded, however, with other diseases where the ability to talk is apparently absent, such as occurs in the insane (who often refuse to converse from mere obstinacy), in those types of paralysis which affect the entire muscular mechanism associated with articulation, in hysteria, chorea, and nervous affections, and in the aphonia of laryngeal inflammation or paralysis.

The credit of the great discovery that the motor center of articulate speech could be localized in the *third convolution* of the *left anterior lobe* of the cerebrum is generally awarded to Broca.² Some twenty-five years before he made the profession alive to the investigation of the subject, however, the same motor impairment or loss of speech was shown to be a frequent accompaniment of hemiplegia of the right side of the body by Bouillaud and Marc Dax³; and in 1863, or there-

¹ “Cbl. med. Wiss.,” 1874.

² Broca, “Bul. de la Soc. Anat.,” Aug., 1861.

³ A paper read before the Medical Congress at Montpellier in 1836.

about, the views of Broca and of Hughlings-Jackson¹ were given to the profession, in which they both limit the lesion of motor aphasia to the parts supplied by the left middle cerebral artery. In 1863, the investigations also of the son of Marc Dax² located the lesion somewhere in the anterior or middle portion of the *frontal lobe* of the left side, and the results of still more recent investigations upon the subject seem to point to the "island of Reil" as a frequent seat of this peculiar type of paralysis.

Viewing the fact that articulate speech is a thing learned by use, it has been suggested that, in most persons, one side of the brain only has been educated for that purpose; that we are, in fact, *left-brained* in respect to speech in the same way that we are right-handed in respect to many bodily movements.³ In support of this theory the physiological fact is adduced that, in most people, the left hemisphere of the cerebrum is larger and more convoluted than the right.

While it is demonstrated that the cerebral lesion in aphasia involves, in the great majority of cases, the left side, still there have been several cases recorded where the right side has been shown to have been the seat of disease.⁴ Such discoveries tend to cast a doubt upon the left side being more closely connected with the power of articulate speech than the right side. Some anatomists have endeavored to explain the frequency of the lesion upon the left side of the brain as a result of the fact that emboli (which are the most frequent cause of the disturbance to those parts supplied by the middle cerebral artery) find a much more *direct course upward* upon the left side than upon the right, in consequence of the angle at which the innominate artery leaves the arch of the aorta, which favors the passage of an embolus *by* rather than *into* its mouth; while the left carotid artery is situated at the

¹ Hughlings-Jackson, "Clinical and Physiological Researches on the Nervous System."

² M. G. Dax, as quoted by Dodds and A. Flint, Jr.

³ Mich. Foster, *op. cit.*; Ferrier, "Functions of the Brain."

⁴ Boyd, Broadbent, Bateman, Meissner, Bertin, Seguin, and others.

highest part of the arch, and its mouth is so directed as to arrest rather than avoid any floating particles in the blood current. In case of such movable particles being arrested either by the innominate or left carotid arteries, the most direct course in both instances will be toward the middle cerebral arteries, and thus aphasia will generally be produced with hemiplegia upon the side opposite to that where the embolus may be found.

The following deductions relative to disorders of speech may aid in recognizing the seat of the lesion during the life of the sufferer :

1. The cortex of the posterior part of the *third frontal convolution*, and possibly also the *island of Reil*, presides over the coördination of the muscular acts necessary to speech. It also stores the memories of such acts, so that any combination of articulate sounds can be voluntarily reproduced when the proper form of excitation is furnished (chiefly in response to sight or sound impressions).

This center is connected by "associating fibers" with the *centers of hearing* (first temporal convolution) and *those of sight* (the occipital convolutions). It is also put in communication with the *nuclei of the facial, hypoglossal, the pneumogastric, and glosso-pharyngeal nerves* (within medulla) by means of two distinct tracts of fibers, viz., the "hypoglossal cerebral tract" and the so-called "speech tract," which pass through the internal capsule, the crus, and the pons, in order to reach the medulla.

Thus, this cortical center of coördinated speech-movements is capable of receiving excitation from the centers of hearing, when replies to spoken language are demanded; and from the centers of sight, when written or printed language calls for a verbal response. It is also put in direct communication with the nerves which preside over the apparatus of speech (whose nuclei of origin are situated within the medulla).

2. The form of amnesic aphasia known as "*word-deafness*" (Kussmaul) indicates the existence of a lesion of the

first temporal convolution¹ of the left side, which has impaired the memories of spoken language. Hearing may not be impaired, although the appreciation of words, music, etc., may be totally absent.

3. The condition known as "*word-blindness*" (Kussmaul) indicates the existence of a lesion of the left occipital lobe, which has impaired the memories of written or printed symbols of language, numerals, familiar objects, etc.

4. The condition termed "*paraphasia*" by Kussmaul (in which the amnesic and ataxic varieties of aphasia seem to be peculiarly combined) may be excited by a lesion which interferes with the action of the associating tracts of fibers, between the areas of hearing or sight and the motor speech center of Broca (Wernicke).

5. The condition of imperfect speech termed "*anarthria*" is produced by a lesion of the medulla, which interferes with the functions of the nuclei of the cranial nerves associated with speech. It is occasionally observed in connection with focal lesions of the floor of the fourth ventricle. These cases are to be differentiated from aphasia of cortical origin by the coexistence of other symptoms produced by the medullary lesion.

6. In order to properly pronounce any word, it is essential that both the cortical center of speech, and also the nuclei of the medulla, which are associated with it, must be called into action.

7. The peculiar course which the fibers of the "speech tract" take within the cerebral hemisphere sheds light upon these reported cases of aphasia where the lesion was situated *posterior to the center of Broca*. These fibers run from the third frontal gyrus close to the surface of the hemisphere, and in an antero-posterior direction (passing in the external capsule), to reach the posterior part of the lenticular nucleus. They dip at this point into the posterior part of the internal

¹ In right-handed subjects the left hemisphere, and in left-handed subjects the right hemisphere, seems to monopolize the function of sound-interpretation to the speech center.

capsule. They then pass through the middle part of the crus and pons to the medulla (Wernicke). Within the internal capsule, the fibers of the "speech tract" lie (according to this observer) *between the optic fibers and those of the sensory tract.*

8. Should aphasia be developed as a result of a lesion of the internal capsule, *hemianopsia* or *hemianæsthesia* would be liable to coexist, on account of the relationship of the optic and sensory fibers of the capsule to the speech tract.

9. It is possible to have aphasic symptoms develop as a result of a *lesion within the crus or pons.* This is because the speech tract passes through them to reach the medulla.

10. The cortical centers of hearing, smell, and taste are probably associated (wholly or in part) with the corresponding organ of the opposite side. Hence, we may clinically refer an abolition of the function of hearing (when due to a cortical lesion) to the hemisphere opposed to the deaf ear. "Word-deafness" may ensue, however, when the centers of hearing of only one cerebral hemisphere are involved. In right-handed subjects, the left superior temporal convolution appears to govern this function; while, in left-handed subjects, the right superior temporal convolution assumes it. This is probably due to the fact that the hemisphere which is the most exercised becomes more rapidly developed.

11. When the *third frontal convolution* is alone diseased, the patient will be able to understand spoken or written questions perfectly, but will not be able to coördinate the movements of the speech apparatus requisite to a reply.

12. When the *superior temporal convolution* is alone diseased, the patient can not recognize or properly interpret spoken language. He may, however, be able to repeat *single words* when propounded, but not sentences. Exclamations of various kinds may be uttered by these subjects when irritated or distressed; but they are more or less involuntary, and often irrelevant.

13. When the *associating fibers* between the different centers functionally connected with speech are alone diseased,

the patient can comprehend written or spoken language perfectly; but, in talking, such a subject is apt to interpolate, from time to time, some irrelevant and unexpected word in a sentence in place of the one desired.

THE PRE-FRONTAL LOBES.—There are innumerable cases on record where the frontal lobes anterior to the motor centers have suffered frightful lacerations and loss of substance, and yet recovery has taken place; and where disease of an extensive character has also produced negative results, both as regards motion and sensation. This region is often called the “pre-frontal lobe.”

A crowbar has been shot through the head, and recovery followed.¹ Again, Bouillaud² reports the passage of a bullet through the frontal lobes with a like result, and with no effect upon sensation or motion. Cases somewhat similar are recorded by Trousseau,³ Congreve Selwyn,⁴ Pitres,⁵ Morgagni, Marot,⁶ Tavignot, and others, all of which go to prove the possibility of the most serious injury to this portion of the cerebrum without symptoms indicative of its presence. On the other hand, numerous cases of hæmorrhage and of abscess within the frontal lobes, as reported by Andral,⁷ Hertz, Reed, Begbie, and others (quoted by Charcot and Ferrier), show the same *absence of positive diagnostic symptoms* either in sensory or motor paralysis.

From such sources of clinical reasoning, as well as from the physiological deductions which experiments upon animals have taught, the following conclusion of Ferrier⁸ is of value to the reader: “With such evidence before us, we can not regard cases in which, with lesions of the præfrontal lobes, sensation or motion has been affected as other than *cases of coexistence* or of *multiple lesions*, whether organic or functional.”

¹ Bigelow, “Am. Jour. of Med. Sciences,” July, 1850; Harlow, “Recovery from the Passage of an Iron Bar through the Head”; “Reports of Mass. Med. Soc.,” Boston, 1869.

² *Op cit.*

³ Quoted by Peter and Ferrier.

⁴ “London Lancet,” February 28, 1838.

⁵ “Lésions du Centre Ovale,” 1877.

⁶ “Prog. Méd.,” February 26 and June 3, 1876. ⁷ “Clinique Médicale.”

⁸ “Localization of Cerebral Disease,” New York, 1880.

THE MOTOR REGIONS OF THE CEREBRUM.—It may now be positively stated that the bases of the *three frontal convolutions*, the *convolutions* which bound the *fissure of Rolando*, and the *para-central lobule* upon the internal surface of each hemisphere of the cerebrum, are distinctly *motor* in their function. The distribution of the middle cerebral artery to this region gives to that vessel an importance not before appreciated; since it is now known that the four or five branches which are given off from the main artery each nourish a separate area of brain substance, and that emboli may obstruct either the trunk or some of its individual branches. It is thus possible to explain how the basal ganglia may still perform their functions while other parts supplied by some of the cortical branches may be impaired.

The preponderance of clinical testimony goes to show that most of the destructive lesions which are associated during life with paralysis of voluntary motion are confined to this motor area, although a rare case is on record¹ where the motor area was the seat of cystic disease, and still voluntary motion remained unaffected. It is a matter of great doubt whether the gray matter of the convolutions was impaired, even in this case, in spite of the existing lesion.

The effect of very extensive lesions affecting the motor area of the monkey (which is commonly used for experiments, as the nearest approach to the type of mankind) may be summarized as follows: 1. A hemiplegia, which is at first absolute; 2. An improvement in associate, alternating, or bilateral movements, but no improvement in voluntary motion.

Respecting this point, I quote from Ferrier's work as follows:

“As examples of the improvement which follows the onset of the hemiplegia, the hand becomes more paralyzed than the arm, the arm more than the leg, and the lower facial movements more than the upper; while the muscles of the trunk are scarcely, if at all, affected.”²

¹ Samt, “Archiv für Psychiatrie,” 1874.

² Ferrier, “Localization of Cerebral Disease.”

In man the hemiplegia is exhibited chiefly upon the side opposite to the existing lesion,¹ if the motor area, the corpus striatum, or the motor part of the internal capsule be the seat of disease. This paralysis is often accompanied by *convulsive muscular movements* or *rigidity* of the paralyzed parts in its early stage, and, later on, by *rigidity* and *motor sclerosis*.

The researches of Pitres² have shown that the same results as those dependent upon a lesion of the gray matter of the convolutions within the motor area follow when the lesion affects the *white substance* of the brain³ which intervenes between the gray matter covering the motor area and the basal ganglia beneath them, and he therefore urges a system of nomenclature of the different portions of the "centrum ovale," based upon sections of the brain made in certain regions so as to show special parts.

It is by means of these researches that we are enabled to explain those cases where rigidity or muscular spasms accompany an attack of hemiplegia, from an *effusion* into the *lateral ventricles* of the brain; and where *cerebral softening* or *hæmorrhage*, which does not affect the gray matter of the convolutions or the basal ganglia, produces a permanent paralysis of the side of the body opposite to the lesion.

When sudden hemiplegia occurs as a result of hæmorrhage into or traumatism of some portion of the motor area, the condition of paralysis is liable to improve in those regions of the body where the *special motor center of that part* remains unimpaired, but the paralysis will usually remain permanent in that part of the body whose motor center is destroyed. This fact, when properly interpreted, may often prove a most valuable guide in diagnosis.

Special Centers of Motion.—At the base of the *first frontal convolution*, and extending slightly into the *second fron-*

¹ The fact that all the motor fibers do not decussate in the medulla oblongata (Flechsig) explains the exceptions to this rule.

² "Lésions du Centre Ovale," Paris, 1877.

³ This portion contains the fibers of the *internal capsule* radiating to reach the motor regions of the cortex. (See Fig. 8.)

tal convolution, in the brain of a monkey, a distinct center may be located which exerts a special influence upon the

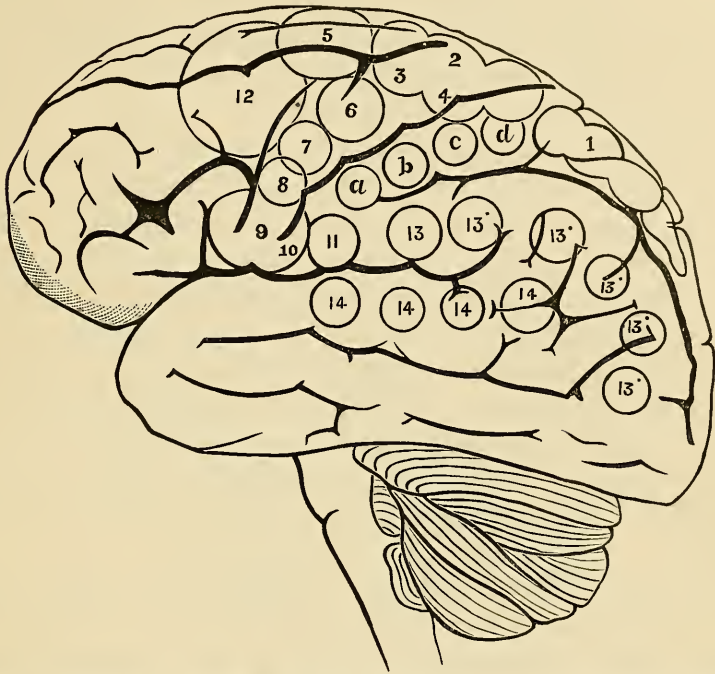


FIG. 25.—Side view of the brain of man and the areas of the cerebral convolutions. (After Ferrier.)

1 (on the postero-parietal [superior parietal] lobule), advance of the opposite hind-limb as in walking; 2, 3, 4 (around the upper extremity of the fissure of Rolando), complex movements of the opposite leg and arm, and of the trunk, as in swimming; *a, b, c, d* (on the postero-parietal [posterior central] convolution), individual and combined movements of the fingers and wrist of the opposite hand; prehensile movements; 5 (at the posterior extremity of the superior frontal convolution), extension forward of the opposite arm and hand; 6 (on the upper part of the antero-parietal or ascending frontal [anterior central] convolution), supination and flexion of the opposite fore-arm; 7 (on the median portion of the same convolution), retraction and elevation of the opposite angle of the mouth by means of the zygomatic muscles; 8 (lower down on the same convolution), elevation of the ala nasi and upper lip with depression of the lower lip, on the opposite side; 9, 10 (at the inferior extremity of the same convolution, Broca's convolution), opening of the mouth with 9, protrusion, and 10, retraction of the tongue—region of aphasia, bilateral action; 11 (between 10 and the inferior extremity of the postero-parietal convolution), retraction of the opposite angle of the mouth, the head turned slightly to one side; 12 (on the posterior portions of the superior and middle frontal convolutions), the eyes open widely, the pupils dilate, and the head and eyes turned toward the opposite side; 13, 13' (on the supra-marginal lobule and angular gyrus), the eyes move toward the opposite side with an upward 13, or downward 13' deviation; the pupils generally contracted (center of vision, according to the author); 14 (of the infra-marginal, or superior [first] temporo-sphenoidal convolution), pricking of the opposite ear, the head and eyes turn to the opposite side, and the pupils dilate largely (center of hearing). Ferrier, moreover, places the centers of taste and smell at the extremity of the temporo-sphenoidal lobe, and that of touch in the gyrus uncinatus and hippocampus major.

head and eyes. Thus, to quote from Ferrier, whose researches have been remarkable for the apparent accuracy of many of his deductions, stimulation of this center causes "*elevation of the eyelids, dilatation of the pupils, conjugate deviation of the eyes, and turning of the head toward the opposite side.*" (See No. 12 in Fig. 26.)"

That this same center seems to exist in the human brain is to be inferred from the cases where a *bilateral deviation of the eyes* has been observed, which, in some cases, has also been associated with a lateral deflection of the head. This subject has excited the interest of Hughlings-Jackson,¹ Priestley Smith,² Ferrier,³ and Charcot,⁴ and cases which seem to sustain the theory of an oculo-motor function in the frontal convolutions have been reported by Choupepe, Landouzy,⁵ Carroll, Smith, Horsley, and others. An effort has been made to explain these ocular symptoms by some association with the angular gyrus, but apparently without much ground.

The center of *motion for the muscles of the limbs* is not yet as positively ascertained as the oculo-motor center, although some interesting experiments have been made to decide whether the corresponding point of the brain of man is analogous, in its control over the leg, to that of the monkey tribe. As an example of the ingenuity shown in research, Bourdon⁶ and Luys⁷ have endeavored to demonstrate *atrophy of certain parts* of the brain after amputation of the limbs, and thus indirectly to prove the normal use of the parts which had atrophied from disuse. The use to which the monkey puts his tail, since it serves the purpose of an additional hand in some instances, renders the application of movements of that organ to those of man a matter of apparent difficulty, and the center of motion for the tail of the

¹ "Ophthalmology in its Relations to General Medicine," "Lancet," May, 1877.

² "Bilateral Deviations of the Eyes," "Birmingham Med. Review," 1875.

³ *Op. cit.* ⁴ *Op. cit.*

⁵ "Blépharoptose cérébrale," "Arch. Gén. de Méd.," Aug., 1877.

⁶ "Recherches cliniques sur les centres moteurs," Paris, 1877.

⁷ "Functions of the Brain," New York, 1882.

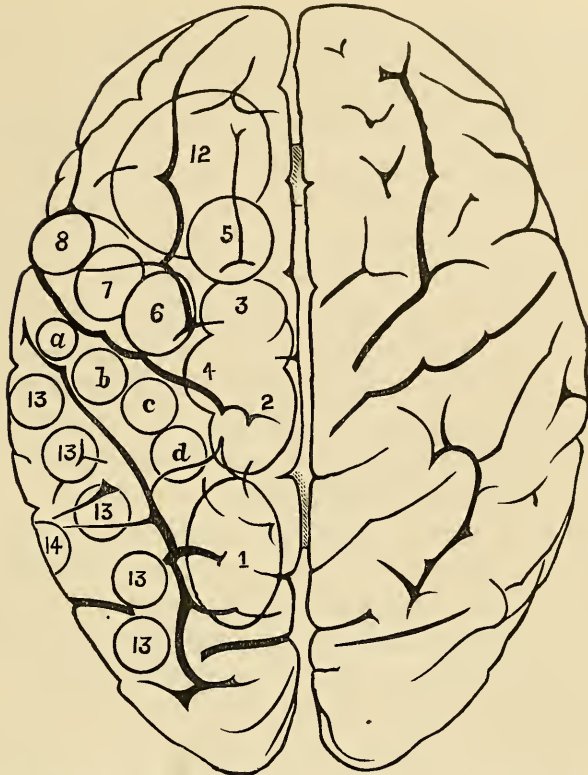


FIG. 26.—Upper view of the brain of man and the situation of areas of the cerebral convolutions. (After Ferrier.)

- 1 (on the postero-parietal [superior parietal] lobule), advance of the opposite hind-limb as in walking; 2, 3, 4 (around the upper extremity of the fissure of Rolando), complex movements of the opposite leg and arm, and of the trunk, as in swimming; *a*, *b*, *c*, *d* (on the postero-parietal [posterior central] convolution), individual and combined movements of the fingers and wrist of the opposite hand; prehensile movements; 5 (at the posterior extremity of the superior frontal convolution), extension forward of the opposite arm and hand; 6 (on the upper part of the antero-parietal or ascending frontal [anterior central] convolution), supination and flexion of the opposite fore-arm; 7 (on the median portion of the same convolution), retraction and elevation of the opposite angle of the mouth by means of the zygomatic muscles; 8 (lower down on the same convolution), elevation of the ala nasi and upper lip with depression of the lower lip, on the opposite side; 9, 10 (at the inferior extremity of the same convolution, Broca's convolution), opening of the mouth with 9, protrusion, and 10, retraction of the tongue—region of aphasia, bilateral action; 11 (between 10 and the inferior extremity of the postero-parietal convolution), retraction of the opposite angle of the mouth, the head turned slightly to one side; 12 (on the posterior portions of the superior and middle frontal convolutions), the eyes open widely, the pupils dilate, and the head and eyes turn toward the opposite side; 13, 13 (on the supra-marginal lobule and angular gyrus), the eyes move toward the opposite side with an upward 13, or downward 13' deviation—the pupils generally contracted (center of vision); 14 (of the infra-marginal, or superior [first] temporo-sphenoidal convolution), pricking of the opposite ear, the head and eyes turn to the opposite side, and the pupils dilate largely (center of hearing). Ferrier, moreover, places the centers of taste and smell at the extremity of the temporo-sphenoidal lobe, and that of touch in the gyrus uncinatus and hippocampus major.

monkey can hardly be applied to the brain of man without bringing comparative anatomy into prominence.

Paralysis of the leg, when dependent solely upon cerebral lesions, is seldom separated from a similar condition of the upper extremity, although a few rare cases of that character are on record; but the rule of Lucas Championnière may be considered as approximately correct, viz., that, to expose the center of motion for the muscles of the leg, it is necessary to trephine over the *upper extremity* of the *fissure of Rolando*.¹ Horsley² locates the center for the big toe in the paracentral lobule, and he includes the following parts in the motor area of the lower limb: the upper part of the two central convolutions, the superior parietal convolution, and the base of the superior frontal gyrus.

The centers of motion for the muscles of the *different regions* of the *upper extremity* occupy a much larger space upon the surface of the cerebrum than those of the lower extremity, as might have been expected when we consider the amount of intelligence which the hand exhibits.³ Ferrier has pointed out certain motor areas for the various movements of extension, adduction and retraction, supination and flexion, and centers for the actions of the wrist and finger muscles.⁴

The close proximity of those centers which control the *facial* and *oral muscles* to the centers governing the motions of the hand possibly explains why movements of retraction of the mouth occur when the hand is brought into powerful action; and also the fact that paralysis of certain groups of muscles situated in the upper extremity are commonly associated with some form of facial paralysis.

From a careful analysis of cases where paralysis of the upper extremity was confined to certain sets of muscles, the

¹ For the surgical guide to locate the situation of that fissure upon the exterior surface of the skull of a living subject, the reader is referred to a subsequent page of this chapter.

² "Am. Jour. Med. Sciences," April, 1887. ³ Sir Charles Bell, "The Human Hand."

⁴ In pages 79, 81 of this volume, the centers of Ferrier are shown in a diagrammatic cut, and the special action of each given in the descriptive text which accompanies it.

results seem to point to the *ascending parietal* and the *upper portion* of the *ascending frontal convolutions* of the cerebrum, as the probable seat of disease; and lesions of the *ascending parietal* convolution have been found, both by experimental research and by pathological deduction, to *affect the hand* in particular. In further support of this statement, the results of the examination of the brains of persons who had suffered amputation of the hand,¹ or who had been characterized by a congenital absence of that member,² show an atrophy of the part designated by the experiments of Ferrier as the motor center for its movements.

According to the later observations of Horsley, the motor centers for the upper limb may be subdivided as follows:

1. The uppermost part controls the *shoulder*.
2. Below and posteriorly to the shoulder centers, the *elbow* is represented.
3. Still farther below and anteriorly, the *wrist* centers.
4. Lowest of all, anteriorly, the *finger* centers.
5. Lowest of all, posteriorly, the *thumb* centers.

The motor centers of the *facial muscles* occupy a region in close proximity to those of the arm and hand; and it is an exception to the general rule to observe paralysis confined exclusively to the face, since the muscles of some part of the upper extremity are generally affected simultaneously.

Horsley subdivides the cortical area associated with facial movements as follows:

1. The upper and anterior part governs the *upper part of the face* and the *angle of the mouth*.
2. The anterior half of the lower part governs the movements of the *vocal cords*.
3. The posterior half of the lower part governs the *lower part of the face* and the *floor of the mouth*.

This observer includes the lower third of the ascending frontal and ascending parietal convolutions in the cortical area of the face.

¹ Reported by Bourdon, "Centres moteurs des membres," Paris, 1877.

² Gowers, article in "Brain," 1878, Part III.

It may be also noticed, with some degree of practical interest, that *motor aphasia* is a common associate of either of these types of localized paralysis, since the center of Broca is liable to be also involved from its close relation to both the centers of the face, arm, and hand.¹ It is considered by some authorities that the absence of aphasia, in cases where the muscles of the face, arm, or hand are paralyzed, is probably confined to lesions affecting only the *right side* of the cerebrum.

The lesions in which aphasia exists have been considered somewhat at length in previous pages of this chapter. The fact that most of the clinical cases recorded have failed thus far to overthrow the discovery of Broca seems to place it upon a footing above that of mere empirical generalization. Cases have been reported where aphasia has been the result of fracture of the left side of the skull in the region of the frontal lobes,² and also where recovery of the power of speech followed the operation of trephining,³ but it occurs most frequently as the result of embolic obstruction of the middle cerebral artery or of some of its branches.⁴

Diagnosis of Cortical Motor Paralysis.—The effects of lesions which involve the *corpus striatum* of either side, or the motor bundles of the *internal capsule* of the cerebrum, differ but little from those of lesions which are confined to the motor area of the cerebral convolutions, since the fibers which are affected in either case are the same.

After the effects of the shock of the attack have passed away, the muscles which are paralyzed are usually those which are the most completely under the control of *volition*; thus the lower muscles of the face are more affected than those upon the forehead or of the eyelids, since the lower facial muscles are by far the most voluntary; the muscles of the hand are very markedly affected, even more than those of

¹ See the relation of the facial centers, Nos. 7, 8, 11, to those of the arm and hand, Nos. 4, 5, 6, *a*, *b*, *c*, *d*, and to the oro-lingual centers, Nos. 9, 10, in Fig. 25 of this volume.

² MacCormac, "Brain," 1877, Part II.

³ Terrillon and Proust, "Acad. de Médecine," November, 1876.

⁴ See researches of Meissner, Charcot, Vulpian, Seguin, Bertin, and others.

the arm ; and the muscles of the upper extremity more than those of the lower.

No evidence of impairment of *sensation* can be discovered, provided that the posterior third of the internal capsule of the cerebrum has escaped injury. The nutrition of the paralyzed muscles is apparently normal, and their electric contractility is not impaired.

A tendency toward *rigidity* of the paralyzed muscles develops later on in the disease, which has been variously explained by some authors (Charcot, Bastian, and Bouchard) as the result of a *progressive sclerosis*, which descends along the motor tract of the pons Varolii, crus cerebri, medulla, and the spinal cord ; while the researches of Hughlings-Jackson¹ warrant him in discarding this explanation and attributing it to an unimpeded *cerebellar influence*, which is no longer controlled by the cerebrum. Both of these hypotheses are, however, discarded by Duret,² who considers the rigidity to be the result of simple *reflex irritation*. It will in no way add to the practicability of the matter contained here to enter into the discussion of the relative demerits of these theories, since those interested in the subject will find Ferrier's work on the "Localization of Cerebral Disease" and many of the advanced works upon the pathology of diseases of the nervous system to contain all the desired information.

One of the most valuable signs of paralysis dependent upon a lesion of the cortex is the fact that the condition is not one of complete hemiplegia, but rather of *monoplegia*, in which special groups of muscles only are deprived of voluntary motion. Thus, for example, the arm and leg may be affected together ; again, the arm, hand, and face ; the arm alone ; the leg alone ; certain movements only of either extremity ; and all other possible combinations.

Paralysis due to lesions of the cortex may often be transitory, if the lesion be slight and superficial ; or it may be permanent, if deep and impinging upon the medulla. It is, fur-

¹ "Medical Examiner," April 5, 1877.

² "Brain," Part I, 1877.

thermore, frequently associated with *rigidity* in its *early stages*, which is a rare occurrence in central cerebral disease.

In attacks of paralysis due to suddenly developed lesions of the cortex, *consciousness* is less frequently lost than in similar lesions of the central ganglia. *Pain* of a local character within the head is often complained of by the patient spontaneously with the attack, or, when not so, it may be sometimes elicited by percussion over the seat of the exciting lesion.

The loss of consciousness which generally accompanies any sudden lesion of the central ganglia is explained by Duret¹ as due to a *rapid displacement* of the *cerebro-spinal fluid*, which in turn creates a general disturbance of the circulation of the cerebrum, since this fluid serves to establish a uniformity of pressure throughout the brain.

Ferrier² thus briefly summarizes the results of clinical observation bearing upon the diagnosis of paralysis dependent upon destructive lesions of the cortex: "While we can not be quite certain of the position or extent of a cortical lesion causing a sudden and complete hemiplegia, we may take a *monoplegia* of the leg, or of the arm and leg, as an indication of a lesion of the upper extremity of the ascending convolutions close to the longitudinal fissure; *brachial monoplegia*, as a sign of a lesion in the upper part of the ascending frontal convolution, or, if the paralysis *affect the hand* more particularly, of the ascending parietal convolution; *brachio-facial monoplegia*, as indicating a lesion of the mid-fronto-parietal region; while *facial* and *lingual monoplegia*, or this combined with aphasia, indicates a lesion of the lower part of the ascending frontal convolution where the third frontal joins with it."³

Irritative Lesions of the Motor Area.—It is a well-recognized fact in clinical experience that certain symptoms, which are chiefly of a convulsive type, are dependent upon condi-

¹ "Traumatismes cérébraux," Thèse, 1878; "Archiv. de Physiologie," 1875.

² *Op. cit.*

³ The cut (Fig. 25) showing the motor centers will tend to explain these deductions.

tions which create simply *irritation* of certain portions of the cerebrum, without any actual destruction of the gray or white matter. Among the various conditions which are especially liable to produce such local irritation may be mentioned syphilitic meningo-encephalitis, simple inflammation of the same character, deposit of tubercle, superficial cysts or tumors of a more solid character, spiculæ of bone, cicatrices from wounds of previous date, suppuration from caries and necrosis, etc.

In the year 1867,¹ and still later, in the year 1871,² the general statement by which the clinical diagnosis of the situation of irritative lesions of the cerebrum might be assisted was advanced by Callender, "that convulsive attacks were most commonly associated with superficial lesions of the cortex situated in the immediate vicinity of the middle meningeal artery." Ferrier, however, concludes, as the result of his extensive facilities for observation, that, while this may be useful as a general rule, still affections of *any portion* of the cortex of the hemisphere may result in convulsions of the opposite side of the body, and he adds the statement that the seat of an irritative lesion can be less accurately determined than one of a destructive character, owing to the difficulty of determining the extent of the zone in which vital irritation concentrates itself.

Hughlings-Jackson³ has contributed much to the pathology of those conditions of the cortex, produced by irritation, which manifest themselves in the form of *convulsions*. So great a prominence did syphilis have as one of the exciting causes of such irritation that the term "Jacksonian epilepsy" is now often used as synonymous with the convulsions met with in that disease. The theory which this author advances to explain these convulsive attacks is as follows: That irritation of the cortex tends toward an abnormal accumulation of nervous energy, so that the affected part is under a state of

¹ "St. Bartholomew's Hospital Reports."

² "Medico-Chir. Trans."

³ *Op. cit.* Also, see "Medical Times and Gazette," 1875.

high tension, and, under certain conditions, this irritated portion discharges itself in a sudden and explosive manner, thus producing a subsequent exhaustion of its powers; hence a convulsion, and often some type of monoplegia following it.

The convulsions dependent upon irritation of the cortex may assume all of the different varieties produced by destructive lesions of the motor area, and may even result in paralysis; thus the leg may alone be affected with spasm, the arm alone, the arm and hand together, and the face alone, or in connection with the upper extremity.

It may often assist in the localization of a lesion, which is creating the irritation of the cortex, to note carefully the muscles affected at the *onset* of the convulsion. Such information may enable the observer (through a knowledge of the motor centers) to trace the seat of the region within the cortex which first exhibited a tendency to explosive discharge of its nervous energy. Horsley has utilized the guides so afforded in trephining successfully for cortical cerebral lesions.

THE SENSORY REGIONS OF THE CEREBRUM.—A part of the parietal, the temporo-sphenoidal and occipital lobes are now accepted by most authors as the portions of the cerebral cortex which can appreciate the perception of *sensory impressions*.

The experiments of Munk, made with a view of determining the area of common sensation in the cerebral cortex, lead to the conclusion that the entire parietal cortex must be destroyed, and the ascending frontal convolution as well, before complete and permanent anæsthesia is produced on the opposite side of the body below the head. These results make the motor area overlap the sensory area to some extent, and tend to refute the deductions of Ferrier, who places the center of tactile sensations in the temporal lobe, and to confirm the views held by Luciani and Exner. If a partial destruction of the sensory area of Munk be produced in animals, the anæsthesia persists only for a few weeks, because the adjacent regions learn to perform vicariously the functions of the part destroyed.

Tripier, of Montpellier, France, has lately affirmed the conclusions of Munk, respecting the existence of sensory centers in the central convolutions, as has, also, Moeli, of Berlin. These three observers support the view that *the motor and sensory centers of any one limb coincide*. This view was advanced theoretically by Luys some years ago.

Exner has collected from European journals all cases of cortical disease that have been associated with disturbances of sensation, and M. Allen Starr has lately performed the same labor in American literature. An analysis of the cases so collected seems to justify the conclusions of Munk and his followers, and to add some clinical suggestions of value. These cases demonstrate (1) that the cerebral cortex of each hemisphere appreciates *sensory impressions from both sides* of the body, but are chiefly associated with the sensory tracts of the opposite lateral half of the body; (2) that the sensory area includes the central convolutions (a term used to cover the ascending frontal and ascending parietal gyri—see Fig. 22) and the posterior part of the parietal lobe; (3) that the sensory centers coincide to some extent with the motor centers of similar parts; (4) that no disturbances of general sensation have been known to result from lesions confined to the frontal, temporo-sphenoidal, or occipital lobes.

It has been determined, with some approach to positiveness of statement, that the *posterior fibers of the crus* are the principal means of transmission of sensory impressions from the periphery of the body to the cerebrum, and the researches of Meynert have done much to demonstrate that these fibers are connected with the portions of the cortex which have been designated as the regions chiefly associated with sensory perception.

Duret,¹ Veyssière,² and Raymond have shown by experiments that, when that part of the internal capsule which is situated between the *lenticular nucleus* and the *optic thalamus* is divided, a loss of sensation is experienced in the oppo-

¹ *Op. cit.*

² "Sur l'hémianesthésie de cause cérébrale," 1874.

site side of the body, but that, in some instances, some degree of motor paralysis is also produced. On the other hand, these same observers have found that section of the anterior two-thirds of the internal capsule¹ produces a distinct motor paralysis, with no effect upon the function of sensory perception of the parts paralyzed, save in a few instances, where such a result of a fleeting character was detected.

These deductions are fully sustained by clinical facts. The collected cases reported by Charcot,² Pitres,³ Türk,⁴ and many others, present a large mass of evidence to warrant the conclusion that lesions of the posterior part of the internal capsule are indicated by hemi-anæsthesia on the side of the body opposite to the lesion. In such cases, *tactile sensation is destroyed to the median line* not only in the trunk, but also upon the face; pain and the sensation of heat are likewise abolished; but the contractility of muscles under the electric current is not impaired or lost. If we examine the mucous membranes of the eye, nose, or mouth, the same condition of destroyed sensibility will be detected, but the viscera remain sensitive. Furthermore, taste, smell, and hearing are sometimes rendered deficient, and, in some cases, are entirely abolished, on the side opposite to the lesion; and the special sense of sight is affected in a variety of ways, which will be described in detail.

In lesions of the internal capsule, blindness of the lateral half of both retinæ (*hemianopsia*), as one would expect to find, does not exist; but, on the contrary, a condition of *amblyopia* occasionally results, which is characterized by a marked contraction of the field of vision, and especially so as regards the perception of color. By consulting the diagram given you in the description of optic nerve,⁵ you will perceive that the field for blue tints is the largest, and that red is next

¹ Subsequent pages which treat of the internal capsule will explain the situation of the different bundles which compose it.

² "Leçons sur les maladies du système nerveux."

³ "Lésions du Centre Ovale."

⁴ See Grasset, "Localizations dans les maladies cérébrales," 1878.

⁵ See page of this volume containing a diagram by Hirschberg.

in point of size, while green comes last.¹ Now, in lesions of the internal capsule, the perception of these colors is apt to be impaired in the relative proportion of the size of the field, and thus green may be entirely lost, while the vision of red or blue may still remain.

It has been shown by Landolt,² who has done much to develop this special field of investigation, that the impairment of vision from intra-cerebral causes is not altogether confined to one side, but that the eye upon the same side as the lesion is somewhat affected, and rendered partially anæsthetic.

If we examine the eyes so affected, we can not discover by the ophthalmoscope any organic disease or evidences of degeneration of either the optic nerve or the retina, provided that the examination is made early, before any late results of the blind condition of the eye manifest themselves as the effect of disuse.³

As has been before stated, the condition of amblyopia and the absence of hemianopsia are in opposition to what the effects of pressure upon the optic tracts would seem to suggest, but we still have a clinical fact to explain, viz., that hemianopsia does sometimes occur with attacks of hemiplegia. In such cases as these, we may conclude that the lesion must be so situated as to exert its influence upon the motor bundles of the brain and the fibers of the optic tract simultaneously. The occipital cortex,⁴ which is now regarded by most authorities as the probable center of vision, does not seem to exert any influence upon the motor apparatus, as is shown by its destruction in animals.

The OCCIPITAL LOBES of the cerebrum have been stated to be properly included among the sensory regions of the cortex.

¹ Violet has a still smaller field, but it is not shown upon the chart.

² "La France Médicale," Feb. 3, 1877.

³ Any intra-cranial lesion which acts in such a way as to *increase the intra-cranial pressure* may produce (in addition to other symptoms) the condition known as "choked disk," or a neuro-retinitis.

⁴ The reader is referred to the lecture on the optic nerve for further information upon this point.

Experiments of section, or even of complete removal of these lobes of one or both sides, however, fail to show any effect on general sensation or motility. Disturbances of sight¹ have been positively produced by injuries to and morbid lesions of the occipital convolutions. The distribution of the fibers of the *optic tracts* to the cortex of the occipital lobes (probably to the cuneus) may be now considered as positively proved.

It is claimed by Hughlings-Jackson that irritative lesions of the occipital lobes give rise to *colored perception* of objects and other ocular spectra, and he further states that such evidences of defective perception are more common when the lesion affects the right side.

The TEMPORO-SPHENOIDAL LOBES are in relation with the bones indicated by their name, and lie partly on the base of the skull. The following deductions have been drawn, from experimental research, as to the special functions of this lobe and some of the adjacent convolutions, which will require separate consideration :

The apparent connection of this region with the special sense of *vision* has been noticed by Hitzig, Goltz, and McKendrick, the two former of whom confine their experiments to the dog species, while the latter operated exclusively upon pigeons. Ferrier,² however, from a belief that other functions could be demonstrated as pertaining to this locality, and from disbelief in the method pursued by Goltz,³ as adapted to the requirements of experimental research concerning the functions of limited areas of the cortex, made a series of experiments upon the brains of monkeys, and claims to have established some new points of physiological interest, and, possibly, of practical value in cerebral localization.

The conclusions which were drawn as the results of the labors of this learned and original investigator may be thus summarized :

¹ Munk seems to have positively proved an association of the occipital lobe with vision.

² *Op. cit.* ; Ferrier and Yeo, "Brain," 1880 ; Exner, "Brain," October, 1880.

³ That of trephining over the spot selected for investigation, and washing away the brain by a forcible stream of water.

1. In the *angular gyrus*¹ this observer thinks that in animals there is situated a center, which causes, on electric irritation, certain *movements of the eyes, pupils, and head*, but whose destruction creates no evidence of motor paralysis in the muscles of either the eye, its lids, or the pupil. Unilateral destruction, however, of this center causes blindness of the opposite eye, which proves but temporary; while the destruction of *both sides* causes a *permanent loss of sight* in both eyes.² It would thus appear (to his mind) that the center of either side is, to some extent, connected with both eyes.

2. In the *superior temporo-sphenoidal convolution*³ is found to exist a center which, under galvanic stimulation, creates a twitching of the opposite ear and an apparent *modification in hearing* of the opposite side, which it was found difficult to fully locate on account of the animal not being able to exhibit appreciation of modification of that special sense. As with the preceding center, destruction of this convolution, upon one side, caused some abnormality of hearing; but, when *both sides were destroyed*, the animal became *totally deaf*, although no motor paralysis could be discovered in either case.

3. In the *lower extremity* of the lobe previously designated, a center was found which seemed to exert an influence upon the *special sense of smell*, and also to create motions of the nostril and head which indicated excitation of that sense. In the regions adjacent to this convolution the *special sense of taste* became affected when destroyed; and, when the convolution and the adjacent region were destroyed, upon both sides, *taste and smell were utterly lost*. In regard to these two centers, also, unilateral destruction created the most marked effects upon the side opposite to the lesion, while a bilateral destruction abolished the sense altogether.

¹ Regions marked 13 in Fig. 25 of this volume.

² The experiments of Munk, Luciani, Tamburini, Ferrier, Yeo, Dalton, and others, upon these centers leave the field, as yet, a matter for further investigation. The preponderance of testimony goes to show that the statement of Ferrier is not true of man.

³ See diagrammatic cut on page 79 of this volume; regions marked 14.

4. In the *region of the hippocampus* some evidence was given of a center possessing the appreciation of *tactile sensation*, but the situation of the part rendered experiment upon it difficult, and somewhat less positive than that upon the areas previously discussed.

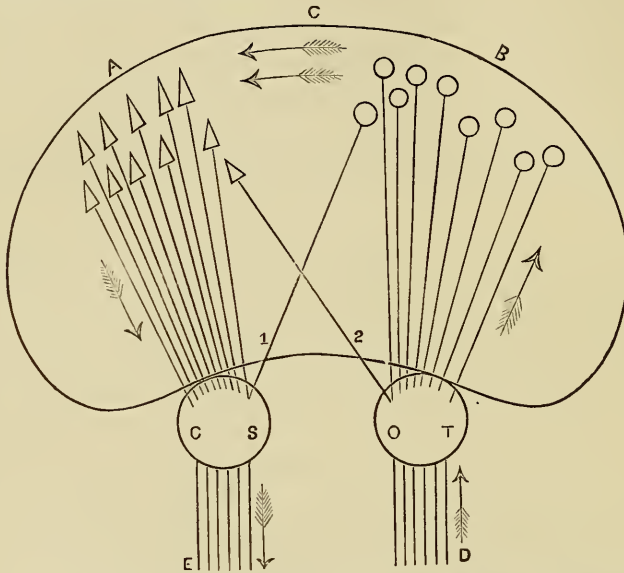


FIG. 27.—A diagram illustrating the course of nerve impulses in the cerebrum. (After Dodds.)

A, the motor regions of the cerebral cortex, represented by arrow-heads; B, the sensory regions of the cerebral cortex, represented by circles; C, commissural fibers, connecting the two regions of the cortex (probable, but not positively demonstrated); D, sensory nerve fibers, the arrow showing the *centrivetal* direction of the impulse; E, motor nerve fibers, the arrow showing the *centrifugal* direction of the impulse; C S, "*corpus striatum*" (the probable motor ganglion at the base of the cerebrum); O T, "*optic thalamus*" (the probable sensory ganglion at the base of the cerebrum); 1, a few sensory fibers, possibly connected with the "*corpus striatum*"; 2, a few motor fibers, possibly connected with the "*optic thalamus*."

It is to be regretted that the conclusions of this brilliant investigator as to the situation of these special centers in the sensory regions of the cerebrum are not as positively sustained by clinical and pathological facts as were his conclusions drawn from experimental research upon the motor area of the brain of the monkey tribe. Ferrier endeavors to explain the discrepancy between the facts obtained by experiment and those afforded by disease of the same regions in the human brain, by the hypothesis that the *special senses* may be gov-

erned by a *bilateral* rather than a unilateral impulse, as the experimental facts pertaining to the special senses of sight and hearing seem to warrant. This has not, as yet, been disproved, since all of the cases recorded have been of a unilateral character.

To what extent these physiological subdivisions of the sensory area of the cerebrum may be regarded as of practical utility in diagnosis can hardly yet be determined, as the field is still a new one, and the collection of clinical and pathological records is hardly sufficient for a basis of positive deduction respecting many points yet in dispute.

The contents of the preceding pages will probably enable the reader to appreciate the grounds which justify the following conclusions respecting the diagnosis of focal lesions of the cerebral cortex.

A SUMMARY OF THE EFFECTS OF CORTICAL LESIONS OF THE CEREBRUM.

Lesions of the motor convolutions, when of small size, produce some form of *monoplegia*, and possibly a coexisting mono-anæsthesia with a loss of muscular sense in the part; when of large size, a *hemiplegia* may be produced.

Consciousness is not necessarily lost at the time of the attack.

Early rigidity of the paralyzed muscles is often present.

Cortical hemianæsthesia will be produced when the entire parietal cortex is involved by a cortical lesion, and, in addition, the balance also of the motor area, which lies outside of the parietal lobe. Such an extensive cortical lesion is rarely, if ever, encountered. We, therefore, do not observe coexisting hemiplegia and complete hemianæsthesia in cortical disease.

Localized pain in the head is a symptom which is often present in connection with cortical lesions. If it be absent, percussion over the lesion will generally tend to excite. This step will also tend to increase the pain, in many cases, when it exists prior to this test.

Convulsions, when followed by *transient attacks of paralysis* (Jacksonian epilepsy), indicate an irritative lesion of the cortex. They are frequently encountered in connection with syphilitic disease of the brain. Subjective sensations (*paræsthesiæ*) may also be excited in limited portions of the limbs.

Blindness of that half of each retina which corresponds to the cerebral hemisphere affected, occurs when extensive cortical disease of the occipital lobe (chiefly of the cuneus) is present. "*Word-blindness*" may also be produced by lesions of these lobes (especially if upon the left side).

Lesions of the first temporal convolution (chiefly upon the left side) may produce *abolition of hearing*, and also the condition known as "*word-deafness*" (see page 97).

Lesions of the tip of the temporal lobe may be the cause of *abolition of the sense of smell, or of taste*. The memories of taste-and-smell-perceptions may also be impaired or lost.

Ataxic aphasia and *paraphasia* may be developed as a result of cortical lesions, which involve respectively the speech center of Broca and the "island of Reil."

The *face is never rendered totally hemiplegic* by cortical lesions. The conditions known as "*mono-anæsthesia*," by which we mean an impairment or total arrest of sensation in some distinctly localized part, as, for example, the hand, arm, leg, etc., and also the condition known as "*mono-paræsthesia*," which signifies the existence of subjective sensations of a definitely localized character, are particularly diagnostic of cortical lesions lying *posterior to the fissure of Rolando*. The former indicates a destructive lesion, the latter an irritating lesion.

The *muscular sense* is liable to be impaired (when a *cortical lesion of the motor area* exists) in the parts functionally associated with the limits of the part diseased.

Monoplegia and *monospasm* seem to be peculiarly diagnostic of a cortical disease *anterior to the fissure of Rolando*; although Horsley's late observations show that this is not always the case.

The *memories of sensory impressions* are more frequently impaired by cortical lesions of the left hemisphere than of the right (as shown, for example, in ataxic aphasia, word-blindness, word-deafness, paraphasia, etc.).

Motor memories may be impaired by cortical disease affecting the motor area. Subjects may thus lose a dexterity with the fingers, arm, hand, leg, etc., which they had acquired previous to the development of the lesion. A knowledge of this fact may sometimes aid in the localization of a lesion.

Irritative lesions of the cortex of the cuneus (a part of the occipital lobe) may cause *hallucinations of vision*. If one hemisphere only is affected, the objects seen will appear to lie on the side opposed to the lesion, and to move with the eyes as they are turned from side to side.

Lesions of the "*island of Reil*," or "*insula*" of the left side (Fig. 23), seem to create (in some instances) symptoms of *ataxic aphasia*, and also *paraphasia* (the substitution of wrong words). The *motility of the face and arm of the opposed* side may occasionally be impaired from cortical lesions of this region.

Lesions of the cortex confined to the *apex of the temporal lobe* (Fig. 26) are liable to cause an impairment of the *sense of smell or of taste* (if destructive in character) or subjective odors and tastes (if irritative in character).

Destructive lesions of the cortex of the *motor convolutions* (Fig. 26) is followed by a *descending degeneration* of the fibers which arise from these gyri. This may account (?) for the late rigidity of the muscles paralyzed, which is occasionally observed after such lesions.

Cortical lesions of the *base of the brain* are especially liable to produce vomiting, choked disk, bilateral paralysis, and symptoms of impairment of some of the cranial nerve trunks. The crus, pons, and "*island of Reil*" may also be involved and give additional symptoms.

Cortical disease of those frontal gyri *which lie anteriorly to the motor centers* (Fig. 26) is often attended with no symptoms of a diagnostic character. The higher mental faculties

may occasionally give signs of more or less impairment. Connected thought, the control of the emotions, and concentration of the attention are particularly difficult under such circumstances.

The *memories* of sound or sight impressions, as well as those of smell, taste, muscular movements, etc., may be separately annihilated by cortical disease. Cases of this character have been discussed under the head of Aphasia (see pages 73 to 76 inclusive).

SUMMARY OF THE PHYSIOLOGY OF THE CEREBRAL CORTEX.

From the statements made in previous pages, we may summarize the functions of the cortex (the gray matter of the cerebral convolutions), as well as the symptoms which can be attributed to disease confined to that region, as follows:

1. Contrary to old statements, the cortex is capable of artificial stimulation. The functions of certain cortical areas have thus been determined with an approach to accuracy.¹

2. A well-defined relationship exists in man as well as in animals between the limited areas of the cortex and certain muscular groups. This has been confirmed by pathological and clinical observation, and also by experiments made upon the human subject by Dr. Amidon, of this city.² The accu-

¹ There are at the present time three distinct schools among the experimental physiologists respecting the subject of cerebral localization. Ferrier and Munk represent a faction which strenuously hold the view that the cortical gray substance can be mapped out into areas whose limits are clearly defined, as well as their individual functions. Goltz stands at the head of a school which denies the accuracy of these views, and supports the conclusion, originally advanced by Flourens, that the brain can only act as a whole. Exner and Luciani (in common with their followers) occupy a ground which opposes very sharply-defined boundaries to cortical areas, functionally associated with the various senses. They believe that these areas overlap each other to a greater or less extent. At present, the latter view seems to be most perfectly in accord with clinical and pathological data.

² Prize Essay of 1880, "Archives of Medicine," April, 1880.

"Dr. Amidon's experiments in *cerebral localization* are based on the following propositions: 1. Marked local variations in the temperature of the cephalic contents can be demonstrated by *surface thermometers*. 2. Cerebral cortical localization is now so far advanced as to warrant the assertion that the psycho-motor centers for one half the body occupy a certain area in the cerebral cortex of the opposite hemisphere. 3. Functional

racy of Dr. Amidon's observations has been called into question by other experimenters since their publication; but I am inclined to doubt the justness of the criticism. The counter-experiments seem to me to be defective in the methods employed. Dr. Amidon has lately published some additional proofs of the ability of the cranial bones to transmit heat.¹

Dr. M. Allen Starr has collected, of late, all the cases reported in American literature which support the modern views of cerebral localization.² These supplement similar cases collected by Ferrier, Charcot, Wernicke, Nothnagel, and others from the European journals.

3. The *excitable region* of the cortex, where motor effects are chiefly produced, may be stated to be localized in the following parts: The ascending frontal convolution; the base of the first frontal convolution; the second frontal convolution; the third frontal convolution; the ascending parietal convolution; the superior parietal convolution; the supra-marginal gyrus; and the para-central lobule. Now, let us see what centers pertain to each of these convolutions, according to the researches of Ferrier:

The center for *movements of the lips and tongue* (the motor speech center) lies at the base of the *third frontal convolution*, near the fissure of Sylvius. (See 9, 10, in Fig. 26.)

activity of an organ implies increased blood supply and tissue change, and consequent *elevation of the temperature* of that organ. 4. Willed contraction of muscles presupposes an increased activity of the volitional motor center of those muscles in the cerebral cortex. From this it was natural to make the deduction that voluntary activity in a peripheral part would cause a *rise of temperature in the psycho-motor center* for that part, which might be indicated by external cerebral thermometers.

"Seguin's self-registering surface thermometers were used, numbers of which were applied to the surface to be tested by passing them through holes in rubber straps secured to the head by buckles. The desirable points in the subject experimented on are, a well-shaped head, thin hair, well-developed and trained muscles, power of facial expression, especially of unilateral facial movements and the ability to contract individual muscles, and moderate intelligence. A man is preferable to a woman, and a European to an African. The mode of performing and recording experiments and the liabilities to error are all fully described." (Report in "New York Med. Jour.," October, 1880.)

¹ "Facts and Figures in Cerebral Thermometry."

² "Cortical Lesions of the Brain," "Am. Jour. Med. Sci.," July, 1884.

Upon the *first* and *second frontal* convolutions he found a center (see 12 in Fig. 26): (1) For *lateral movements of the head*; (2) for *elevation of the eyelids*; and (3) for *dilatation of the pupil*.

The *ascending frontal* convolution presents, from below upward, the following centers: For *elevation* and *depression* of the corners of the mouth (8 and 7); for movements of the *forearm* and the *hand* (6); for *extension* and the *forward movement* of the *hand and the arm* (5); centers for *complex movements* of the *arms and legs*, when acting together (2, 3, and 4).

The *ascending parietal* convolution presents, from above downward, four centers for *complex movements* of the *hand and wrist* (*a, b, c, d*), such as the use of individual fingers, prehensile movements, etc. At its most superior portion, the centers (2, 3, and 4), which control the alternating movements of the arm and leg, as in the act of swimming, seem to overlap the ascending parietal convolution; but they are not definitely placed.

The *superior parietal* convolution presents the center which presides over the *movements of the leg and foot*, as in the act of walking.

When we discuss the subject of cerebral surgery, reference will be made to modifications of the views of Ferrier relative to the motor centers.

4. The *sensory region* of the cortex is confined to the parietal, temporal, and occipital lobes of the cerebrum. In it certain centers have been definitely located by Ferrier, which are not, as yet, accepted as fully proven, but many of which are now considered as supported rather than confuted by clinical and physiological evidence.

The *angular gyrus* is said by this author (erroneously, I think) to contain the *centers for vision* (13, 13, in Fig. 26), while movements of the eyes also are produced when these regions are stimulated.¹ Later research seems to

¹ Experiments of Ferrier, Yeo, Dalton, and others.

warrant the conclusion that the occipital lobes are alone associated with vision.

The *superior temporo-sphenoidal* convolution may be regarded, in the light of existing information, as the seat of the *centers of hearing* (14, 14, 14, in Fig. 26). The head and eyes are caused to move toward the opposite side, and the pupils to dilate largely, according to Ferrier, by excitation of this convolution.

The *centers of smell* are now believed to lie in the region of the tip of the temporo-sphenoidal lobe (the so-called "subiculum cornu Ammonis").

The *conscious appreciation of tactile sensations* is now attributed to the cortical gray matter of those parietal convolutions which are not included in the so-called "motor area" of the cerebrum. This view has been lately confirmed by the researches of Flechsig, and is in accord with pathological facts lately brought to professional notice. The view that the cortical fields of motion and general sensation overlap each other to some extent is fast gaining ground—the sensory area is thought to extend over the entire parietal lobe, while the motor area does not pass beyond the ascending parietal gyrus. In the upper third of these regions tactile sensations from the leg (chiefly the opposite member) are probably perceived. Those from the upper extremity are transmitted to the middle third of the same field; each hemisphere being connected with both sides, but chiefly with the opposed limb.

5. The collection of reported cases of tumors, clots, softenings, pressure effects (from exostoses, meningeal exudations, or thickenings), etc., seems to confer, to a greater or less extent, the effects of physiological experiment or faradization, and the following general statements as to the results of lesions of the cortex can be safely used as possessing practical value at the bedside :

(a) When the *faculty of speech* is affected, on account of an inability to properly coordinate the movements of the

- tongue, lips, and palate, it is safe to conclude that the lesion involves one of three situations, viz. : the anterior convolutions of the "island of Reil," the base of the third frontal convolution, or the white substance lying between the third frontal convolution and the base of the cerebrum. The lesion, being most frequently met with upon the left side of the brain, will usually be associated with some form of *paralysis affecting the right side* of the body; but the faculty of speech may be affected by lesions of the right side as well as those of the left side, as proven by the cases collected by Seguin and others.
- (b) Paralysis of motion *affecting the upper extremity*, either entirely or to a greater extent than other parts involved,¹ suggests a lesion which is situated on the side opposite to the paralysis; and either confined to, or involving, the *ascending convolutions* of the frontal or parietal lobes.
- (c) When the *facial muscles* are prominently affected, I am inclined to think the lesion may be located in the frontal lobe, anterior to or in the vicinity of the *pre-central fissure* or *sulcus*,² or in the lower third of the ascending parietal convolution.
- (d) When the *muscles of the leg*³ are exclusively affected (and the probability of spinal lesions involving only the lateral half of the spinal cord can be excluded), or when the leg muscles, in an attack of hemiplegia of clear cranial origin, show special impairment, the lesion can be probably placed at the *upper end of the fissure of Rolando*, affecting the ascending convolutions of the frontal or parietal lobes. The views of Horsley (page 96) have already been discussed.
- (e) Lesions of the *sensory area* of the cerebral cortex are not as well understood in their *clinical aspects* as those of the motor area, since less opportunity has been afforded

¹ See the peculiar types of *brachial monoplegia* and the views of Horsley, as described on pages 82 and 83 of this volume.

² It may not be confined alone to this region, since the various forms of brachial monoplegia are often associated with facial paralysis. See views of Horsley on page 83.

³ See the types of *crural monoplegia*, described on pages 84 and 85 of this volume.

for the pathological study of this type of cases, but many facts relating to them have been already stated. The reader is referred to pages 88 and 89 for information.

- (f) All of the symptoms produced by lesions of the cortex may be the result either of *actual destruction* of the nerve tissue of the cortex, or *evidences of irritation* of the cortex. The symptoms will differ in the two cases, so as to often assist the diagnostician.
- (g) Lesions of the cortex, if *outside of the motor area*, and involving the dura mater, may be manifested by *convulsions*, and, possibly, by *headache*. These convulsions, and the headache which may be produced, are respective evidences of irritation of some portion of the motor area of the cortex, or of adjoining sensory areas.
- (h) The sensory areas of the cerebral cortex comprise those of general sensation (pain, touch, temperature) in the parietal lobes; those of sight in the occipital lobes; and those of hearing, smell, and taste in the temporo-sphenoidal lobes.
- (i) The symptoms which prominently indicate *irritation of the motor cortex* are *convulsions*, which are often *followed by paralysis*. This paralysis may be either of the transient or permanent variety, although the former is the more common. The groups of muscles which are prominently affected in the convulsive attacks may afford the physician a guide to the seat of the irritation, since the same centers are probably affected, as if the corresponding muscles were paralyzed, rather than convulsed.
- (j) The *destructive lesions* of the gray matter of the cerebral convolutions, if limited to the motor area, produce peripheral paralysis of the parts governed by the centers which are involved, chiefly on the side of the body *opposite* to the situation of the *seat of disease*. Thus embolism, by plugging the middle cerebral artery, shuts off the blood supply to the center of Broca, and *aphasia* of the motor or ataxic variety will usually be produced; with an accompanying hemiplegia of the side opposite to

the embolus, in case the blood supply is impaired to other parts of the motor area. A destructive lesion of the motor region, if not due to embolism, is liable to produce hemiplegia, without aphasia, on the opposite side to the seat of disease. Paralysis of motion exists to a greater or less extent when the motor area of the cortex is affected in any part.

- (k) When the *paralyzed muscles become rigid*, after an attack of hemiplegia, from destructive lesions of the motor area of the cortex, it may be considered as an evidence of a *secondary degeneration* of the nerve fibers, which is progressing downward along the spinal cord. This is prominently developed when the para-central lobule is the seat of disease, but it exists to a greater or less extent when the motor area of the cortex is affected in any part.
- (l) We have clinical evidence of the fact that memories of various kinds are stored within the cells of the cortical gray matter of the cerebrum, and we are led to the conclusion that each particular gyrus acts as a receptacle for memories of such impressions as it is capable of receiving. We have reason to believe that the occipital lobes appreciate visual sensations and also accumulate sight memories; that the superior temporal convolution appreciates sound impressions and retains, furthermore, all memories of sound; that the motor area of the cerebral cortex has the power of storing memories of muscular acts, which are totally distinct from all other forms of memories; that smell memories are retained by the cells in the tip of the temporo-sphenoidal lobes, which give to us our conscious appreciation of odor; and that memories of tactile sensations, as well as those of pain and temperature, are probably connected with the cells of the parietal convolutions, which lie posterior to the motor gyri. These facts enable us to draw clinical deductions of value respecting those remarkable cases of *word-deafness* and *word-blindness* which have been re-

ported from time to time. The inability to recognize the meaning of spoken words would indicate an impairment of the memories of sound; hence a lesion of the superior parietal convolution, in which such memories are stored. An inability to recognize written or printed language would indicate a loss of sight memories, and would therefore point toward a lesion of the occipital cortex. Dr. Starr has collected some very interesting cases that bear upon this field, and has also contributed a popular article upon the mechanism of memory to one of our monthly magazines.¹

- (m) In those cases where the lesions are *diffused over a large surface* of the cortex (as in the exudation of acute meningitis, suppuration between the bone and the dura mater, etc.), *delirium, convulsions, and local pain* are often present, and may properly be regarded as evidences of the excessive irritation which exists in consequence of the pressure and hyperæmia. *Coma and paralysis* may follow; in which case they are to be attributed, either to the local anæmia produced by the pressure (thus causing impairment of nutrition to the subjacent cortex), or to circulatory changes and increased tension of the entire brain.
- (n) The affection called "diffuse meningo-encephalitis" or the "general paralysis of the insane" is so commonly met with, and affords such striking evidences of the effects of *general pressure upon and irritation of* the cerebral cortex, that its symptoms have to the neurologist more than a clinical interest. From a careful study of such cases, we learn that the symptoms first manifested are contractions of special fibers in the muscles of the face, tongue, and limbs, and that the speech becomes tremulous and the articulation spasmodic. Later on, acute delirium and impairment of memory and judgment appear, and a state of the muscles of the limbs develops

¹ "Popular Science Monthly," September, 1884.

which may be one either of semi-paralysis or of semi-ataxia. In the final stages, the mental faculties become abolished; a state of insanity, characterized by periods of delirium, is produced; and the patient dies without any apparent changes in the ordinary organic functions of the body.

A prominent author, when referring to this subject, says: "A person who exhibits tremors of the facial muscles, of the tongue, and hand, a vibratory and slurred speech, angular or tremulous handwriting, and irregular, small pupils, should be suspected of having chronic peri-encephalitis or paralytic dementia. The addition of a gradual failure of mind—true dementia—makes the diagnosis certain."¹ In case there should be added to these above-named symptoms exalted notions, with maniacal attacks and epileptiform seizures, the case deserves the name of "general paresis"; and as such the form is more usually seen and studied by asylum physicians.

WEIGHT OF THE BRAIN AND OF ITS COMPONENT PARTS.

The shape of the cranium may be employed to estimate the relative development of different parts of the encephalon; and the circumference of the head and the height of the skull above the orifice of the ear may also approximately indicate the measurements of the cerebrum.

The variations in the skulls of the different nations indicate an amount of brain which is in the direct ratio to the facial angle of Camper.² The average weight of the brain of a healthy adult of the Caucasian race has been given, by most of the prominent investigators upon this subject, as about *fifty ounces* in the male, and some six ounces less in the female.³ In the new-born infant, the weight of the brain, in the two sexes, is more nearly alike, being in the region

¹ E. C. Seguin, "Med. Record," 1881.

² See article by the author on the "Osteology of the Head," "Medical Record," October 16, 1880.

³ See researches of Reid, Tiedmann, Sims, and Quain.

of eleven ounces for the male child and ten ounces for the female.

The rapidity of growth of the brain is not uniform throughout the different periods of life. It grows very rapidly until the age of seven years; then less rapidly until the age of forty is reached, when it attains its full development; after that age it decreases in weight about one ounce for every period of ten years.

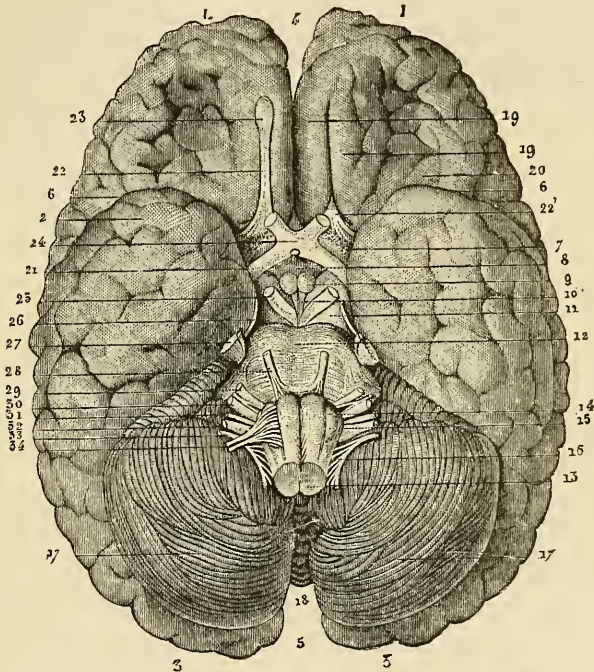


FIG. 28.—*Inferior aspect of the encephalon.* (After Hirschfeld.)

- 1, 1, anterior lobe of the cerebrum; 2, sphenoidal portion of the posterior lobe; 3, 3, occipital portion of the same lobe; 4, anterior extremity of the median fissure; 5, posterior extremity of the same; 6, 6, fissure of Sylvius; 7, anterior perforated space; 8, tuber cinereum and pituitary body; 9, corpora albicantia; 10, interpeduncular space (posterior perforated space); 11, crura cerebri; 12, pons Varolii; 13, medulla oblongata; 14, anterior pyramids; 15, olivary body; 16, restiform body (only partially visible); 17, 17, hemispheres of the cerebellum; 18, fissure separating these hemispheres; 19, 19, first and second convolutions of the inferior aspect of the frontal lobe with the intervening sulcus; 20, external convolutions of the frontal lobe; 21, optic tract; 22, olfactory nerve; 22', section of olfactory nerve, showing its triangular prismatic shape: the trunk has been raised to show the sulcus in which it is lodged; 23, ganglion of the olfactory nerve; 24, optic chiasm; 25, motor oculi; 26, patheticus; 27, trigeminus; 28, abducens; 29, facial; 30, auditory nerve and nerve of Wrisberg; 31, glosso-pharyngeal; 32, pneumogastric; 33, spinal accessory; 34, hypo-glossal.

The comparative weights of the component parts of the encephalon are, in approximate figures, about *one fiftieth* of the entire weight for the pons Varolii and the medulla oblongata, taken together; *one tenth* of the entire weight for the cerebellum; and the *balance* of the total weight for the cerebrum and the basal ganglia inclosed within its substance. These proportions show a slight variation in the two sexes, but not to so marked an extent as to render this statement far from a correct one.

It may be stated, as a rule, that the relative proportion of the cerebrum to that of the cerebellum is greater in the intellectual races. The cerebrum is developed in individuals in proportion to their intellectual power, although its absolute size may not be taken as a guide to the quality of the mind, since it is undoubtedly true that the brain, as well as the muscular tissue, can be improved, *in quality*, by exercise. That there are important individual differences in the quality of the generating nervous matter is evidenced by the fact that some small brains actually accomplish more and better work than larger ones; and that many women often show a higher degree of mental acumen than men, in spite of the fact that they have brains which are lighter in avoirdupois.

From a most carefully prepared table of the weight of brain substance possessed by men of renown as intellectual giants, as well as those which revealed an unusual development of brain after death, contained in the work of a prominent author,¹ some interesting facts are revealed.

The heaviest brains² on record (where the statements are to be relied upon) were possessed by an Indian squaw, a congenital imbecile, and an ignorant bricklayer, both of whom outweighed Cuvier and Abercrombie; while a boy of thirteen years of age had five ounces more brain than Webster and Agassiz. Such a table shows the utter absurdity of attempt-

¹ A. Flint, Jr, "Text-Book of Physiology." D. Appleton & Co., New York.

² Congenital imbecile, aged thirty, 70½ ounces of brain substance; bricklayer, 67 ounces; Cuvier, 64½ ounces; Abercrombie, 63 ounces; Webster, 53½ ounces; Agassiz, 53½ ounces.

ing to apply to individuals the rule that the greatest brain power is possessed by the one having the greatest amount of brain substance.

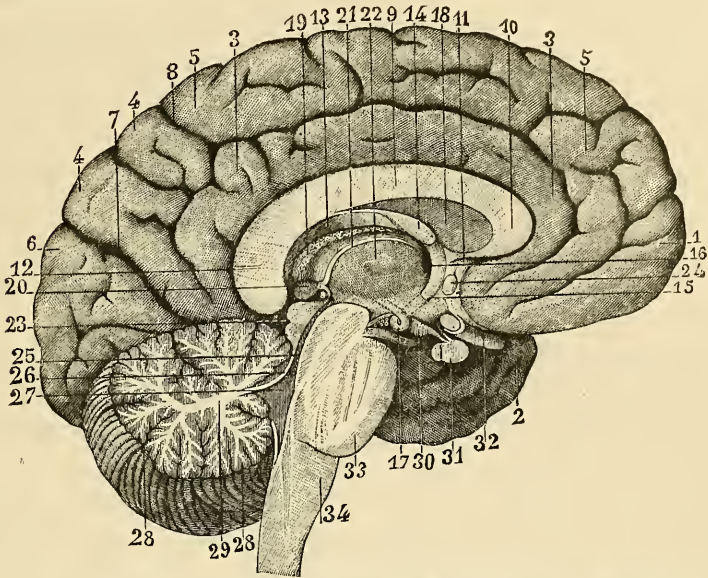


FIG. 29.—*Convolution on the internal aspect of the hemispheres.* (After Sappey.)

- 1, frontal lobe; 2, sphenoidal lobe; 3, 3, convolution of the corpus callosum; 4, 4, convolutions forming the middle group of the internal surface; 5, 5, convolutions of the anterior group; 6, convolutions of the posterior group; 7, sulcus separating the middle from the posterior group; 8, sulcus separating the anterior and the middle group; 9, section of the corpus callosum; 10, genu of the corpus callosum; 11, rostrum of the corpus callosum; 12, posterior extremity of the corpus callosum; 13, fornix; 14, section of the fornix; 15, left anterior crus of the fornix, passing into the internal wall of the optic thalamus, to reach the corresponding corpus albicans—course indicated by a dotted line; 16, foramen of Monro; 17, corpus albicans, in which the anterior crus of the fornix bends upon itself, in the form of a figure of eight, to be lost in the substance of the optic thalamus; 18, septum lucidum; 19, section of the choroid plexus; 20, pineal gland; 21, left superior peduncle of the same; 22, section of the gray commissure of the third ventricle; 23, tubercula quadrigemina, above which are seen the pineal gland with its inferior peduncle and the posterior commissure; 24, section of the anterior commissure; 25, aqueduct of Sylvius; 26, section of the valve of Vieussens; 27, fourth ventricle; 28, 28, section of the middle lobe of the cerebellum; 29, arbor vitæ; 30, corpus cinereum; 31, pituitary body; 32, optic nerve; 33, pons Varolii; 34, medulla oblongata.

EFFECTS OF INTRA-CEREBRAL LESIONS.

The physiology of the *great ganglia of the cerebrum* is far from being satisfactorily determined, since the experiments of different observers apparently prove most glaring contradictions. It is, however, probable that the two subdivisions of the corpus striatum (the caudate and the lenticular

nuclei) have motor functions of a character which are not yet positively decided, while the attributes of the optic thalamus are still involved in more or less obscurity.¹

It can safely be considered as proven that the anterior pair of the *corpora quadrigemina* (the nates) are in some way concerned in the special sense of vision, and belong to the optic apparatus, although the motions of the eyeball seem to be more directly influenced than vision itself. The posterior pair are probably functionally associated with the coördination of muscular movements. The fibers of the lemniscus or fillet-tract can apparently be traced in part to these bodies.

The *internal capsule* of the cerebrum seems to be one of the most important regions of the brain, from a clinical standpoint, since the slightest pressure upon the fibers of which it is composed produces symptoms which vary with the portion pressed upon. A *secondary degeneration*,² which descends along the nerve fibers of the crus, pons, medulla, and spinal cord, is inevitably the result of disease of this portion of the cerebrum.

If the region occupied by the *pyramidal tracts* be the seat of pressure or disease, paralysis of motion, chiefly confined to the opposite side, results; if the sensory tracts be affected, a condition of *anæsthesia* of the opposite side is produced. *Choreic movements*, which vary in degree and type, and which may appear as athetosis, ataxia, true chorea, or tremor, are strongly diagnostic of lesion of the internal capsule, provided they follow an attack of hemiplegia or hemi-anæsthesia.

Lesions of the *parts adjoining the internal capsule* (the caudate nucleus, the lenticular nucleus, and the optic thalamus), if the seat of hæmorrhage, tumors, or other conditions which are capable of causing pressure upon it, may produce

¹ To what extent this ganglion presides over or influences sensory perceptions must be considered unsettled. For opinions on the subject, the reader is referred to a subsequent page of this volume.

² For the effects of this descending type of secondary degeneration of nerve tissue, see a subsequent page of this volume.

symptoms similar to those of disease of the internal capsule itself.

When the *central portions* of the cerebral hemispheres are the seat of some type of disease which has been suddenly developed, as in hæmorrhage, acute softening, etc., symptoms *referable to the optic apparatus* are usually present, in addition to the other symptoms which have been given above. Thus, the eyes may be turned away from the paralyzed side, and, therefore, toward the seat of the lesion; the head also is often similarly turned; and, in case the injury done to the brain is severe or extensive, a very marked rise in the surface temperature of the body may be observed.

When the *pressure upon the central portions* of the cerebral hemispheres is *gradual*, as in the case of growing tumors, we have developed certain special signs, which depend upon the situation of the tumor and the line of its greatest pressure; but we are also liable to have changes develop in the eye—those of “neuro-retinitis”—which may result in the condition known by ophthalmologists as the “choked disk.”

THE SURGICAL BEARINGS OF CEREBRAL TOPOGRAPHY.

In the year 1861, Broca invented a scientific method of determining the relations of different parts of the cerebrum to the exterior of the skull, which consisted of driving pegs through the skulls of animals and of cadavers, holes having been previously bored through the bone in order to prevent fracture and injury to surrounding parts. The skull-cap was then removed with extreme care, and the convolutions which were wounded were thus determined. It was discovered by this observer that the *fissure of Rolando*, whose relation to the coronal suture was then unknown, lay obliquely, and that its upper extremity could be placed, with great accuracy in man, at a point situated 40 mm. behind the coronal suture. It can also be located at one half inch behind the central point of a line extending from the root of the nose to the occipital protuberance.

This fissure was particularly studied on account of its relation to the *motor region of the cortex*, and its exact bearing to the exterior of the skull was therefore of great importance.

The same observer was also able to prove that the *external parieto-occipital fissure* of the cerebrum lay under the *lambdoid suture* of the cranium. In 1873, the experiments of Hefstler and Bischoff were added to those of Broca, while Turner followed with his researches in 1874 and Féré in 1875. The drawings which Turner furnished were admirable in their way, but are, to my mind, hardly adapted to the purposes of the surgeon, since the guides which the bony prominences of the skull afford are not brought into such prominence as to be readily comprehended by the casual reader. If the surgeon is to utilize the valuable researches of the investigators above named (and several most brilliant surgical operations have already been performed from the light which the newly acquired knowledge of the topography of the cerebrum has afforded), certain *bony prominences* of the skull must be designated, as of importance, as guides to the special convolutions and fissures of the brain. Now, there is one line which is easily drawn upon the head of the living subject (the alveolo-condyloid plane of Broca), upon which perpendicular lines may be described, intersecting certain bony points, which lines can be utilized as guides to parts whose situation is now positively known. This base line should be a straight one, and should intersect the tip of the mastoid process and the line of the cusps of the teeth of the upper jaw.¹

This is the natural base line of the human skull, when the lower jaw is removed and the skull placed upon a table; hence it is a plane admirably adapted for the study of the guides (which will be given), upon the skeleton, in the office of each practitioner, previous to an operation. Furthermore, a skull can easily be painted upon its exterior so as to bring the lines, designated as important, into prominence, and so

¹ This author places the line as intersecting the *condyle of the occipital bone*; but, as this can not be felt in the living subject, and as it corresponds to the tip of the *mastoid process*, I have modified the guide so as to simplify its exact situation upon the exterior of the skull.

assist the surgeon in the review of those points which possess special value. The contributions of Féré and Horsley are, to my mind, the best of all the authors named, since the points most needed by the surgeon in a practical way are given. A *résumé* of Féré's guides is so tersely and clearly stated by Seguin that it would be useless to attempt to improve upon it. It will be perceived in the plate, introduced to make these guides more clear than a mere verbal description, that the line described, viz., the alveolo-condyloid plane of Broca, is used as a base line upon which to erect perpendiculars at distances which can be accurately measured upon it; and that these perpendicular lines intersect certain regions which, from facts previously recorded, are of the greatest importance. I quote the *résumé* of Seguin¹ upon this special department of cerebral localization:

“1. A vertical line (A) drawn from the alveolo-condyloid plane, through the external auditory meatus upward, will pass through or very near to the bregma, or line of junction of the frontal and parietal bones at the vertex; it passes through the anterior (lower) extremity of the fissure of Rolando.

“2. If, from the upper end of this vertical line A, we measure a distance of 45 mm.² backward toward the occiput and draw a descending vertical line (1-2), we mark out the location of two most important parts of the cerebrum, viz., the posterior extremity of the fissure of Rolando [at *b*], and the posterior limit of the thalamus opticus in the hemisphere [at *c*].

“3. To conclude with the occipital end of the skull; if we can make out with the fingers the lambdoid suture at the median line, we thus learn the situation of the subjacent occipito-parietal fissure, which separates the parietal and occipital lobes.

“4. The last vertical line worth noting is one drawn at a distance of 30 mm. forward of the auriculo-bregmatic line. This vertical line (3-4) will pass through the middle fold of

¹ “Medical Record,” 1878.

² A millimetre is about one twenty-fifth of an inch.

the third frontal convolution (just forward of the speech center), and will also indicate the anterior limit of the central cerebral ganglia, viz., the head of the nucleus caudatus in the hemisphere [at *d*].

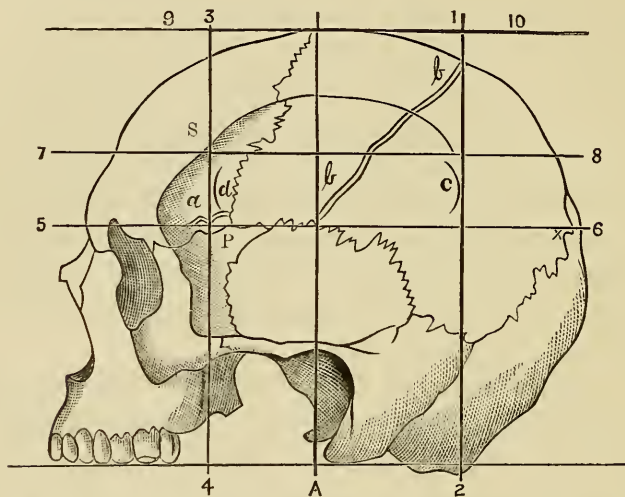


FIG. 30.—Outline of skull resting upon the alveolo-condyloid plane of Broca. (Modified from Topinard's "Anthropology" by Seguin.)

Vertical line A, or auriculo-bregmatic. Line 9-10, drawn parallel to the plane of Broca. Upon this line, at a distance of 45 mm. posterior to the bregma, a vertical line, 1-2, will pass through the upper (inner) end of the fissure of Rolando, *b, b*, and through the posterior extremity of the thalamus opticus (*c*). A third vertical line, 3-4, drawn at 30 mm. forward of the bregma, will pass through the fold of the third frontal gyrus (*a*), and through the head of the nucleus caudatus (*d*). The horizontal line, 7-8, at 45 mm. below the bregma (scalp), indicates the upper limit of the central ganglia. The third horizontal line, 5-6, passing through the external angular process of the frontal bone and the occipito-parietal junction, approximately indicates the course of the fissure of Sylvius, and serves for measurements. At 18 or 20 mm. behind the external angular process on this line is the speech center of Broca; 5 to 8 mm. behind the intersection of 3-4 and 5-6 is the beginning of the fissure of Sylvius, and at 28 or 30 mm. behind this intersection is the lower end of the fissure of Rolando, *b, b*, placed a little too far back in the cut. At *x* (near 6), near the median line, is the location of the occipito-parietal fissure. *S*, the *sthepanion*; *P*, the *pterion*. These two parts will be discussed in a subsequent page.

“5. The upper level of the central cerebral ganglia may be quite exactly indicated by a horizontal line drawn at a distance of 45 mm. below the surface of the scalp, at the bregma, (or 35 below the surface of the bare skull at the same point). This line (7-8) also runs across the middle regions of the motor district of the convolutions, containing centers for the face and upper extremities.

“6. The external angular process of the frontal bone, not difficult to define in the living subject, is the starting-point of another horizontal line (5-6), whose posterior extremity passes a little below the lambdoid suture. Upon this horizontal line we can, by measurement, determine the location of certain parts. Thus, at a distance of 18 or 20 mm. behind the external angular process, lies the folded part of the third frontal convolution (*a*). This point, in many heads, will correspond to the vertical line 3-4.

“7. The situation of the fissure of Sylvius may be approximately ascertained in the following manner: Its middle portion extends horizontally, almost under the upper part of the squamous suture, which in the living subject is to be found a little below the horizontal line 5-6. The anterior extremity or beginning of the fissure of Sylvius is a little below this horizontal line, at a distance of some 5 to 8 mm. posterior to the intersection of 3-4 and 5-6, and consequently about 22 or 25 mm. anterior to the auriculo-bregmatic line *A*. Lastly, according to Turner, the parietal eminence almost always overlies the supra-marginal gyrus (*P*², Fig. 20), consequently the posterior extremity of the fissure of Sylvius is likewise in this vicinity.

“8. The angular gyrus is to be found below and behind the parietal eminence, a little above the horizontal line drawn from the external angular process (5-6).

“9. The anterior (lower) end of the fissure of Rolando lies at a distance of 28 or 30 mm. behind the line 3-4, and a little above 5-6. It is, therefore, a few millimetres anterior to the vertical line *A*.”

With this plate as a guide, and with a thorough knowledge of the facts comprised in previous pages of this chapter, it is not out of the bounds of possibility to definitely locate the existence of lesions in certain portions of the human brain, to map out their situation upon the exterior of the skull, and to reach them with surgical means of relief, provided the case be one which would justify such a measure. Broca has been successful in trephining directly over an abscess of the

third frontal convolution, which was suspected. Successful cases have been reported of trephining of the skull for fragments of the inner plate which were compressing the ascending gyri of the frontal and parietal lobes, thus causing paralysis. Tumors of the brain have lately been located accurately and removed by the knife and trephine.

Horsley has lately added a valuable contribution to the subject of cortical localization, based upon experimentation on monkeys, and also on observations in ten cases where the diseased area was successfully determined in the human subject prior to operative procedure. His conclusions are therefore worthy of note. They may be summarized as:

1. *Sulci, or fissures, are not to be regarded as accurate boundaries to cortical areas*, although they constitute valuable landmarks for operative procedures upon the cortex.

2. The *motor centers*, according to this observer, are capable of *further subdivision* than those described by Ferrier, and they overlap each other at their borders.

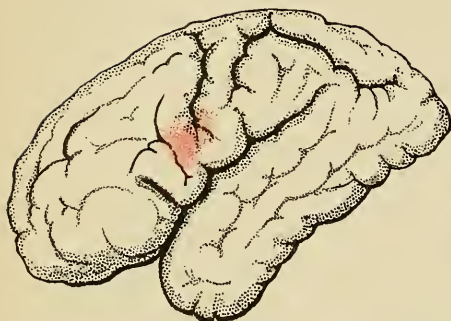3. The *face area*, taken as a whole, embraces the lower third of both central convolutions (4 and 5 in Fig. 22). This is subdivided into (a) an upper and anterior portion, which controls the upper part of the face and the angle of the mouth; (b) the anterior half of the lower portion, which governs the movements of the vocal cords; and (c) the posterior half of the lower portion, which governs the lower part of the face and the floor of the mouth.

4. The *area for the upper limb* occupies the middle third of both central convolutions, and also the base of the superior and middle frontal convolutions. It joins, and also merges with, the area for movements of the head and neck in the middle frontal gyrus, and with that of the leg in the superior frontal gyrus.

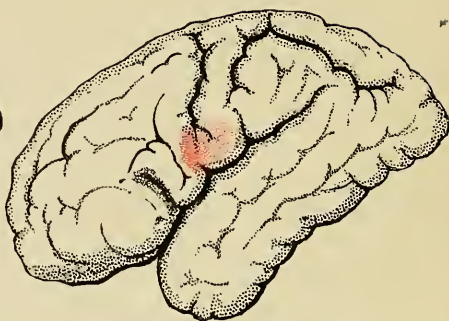In the area described as pertaining to the upper limb, the uppermost part is thought by Horsley to control the muscles of the shoulder; below, and posteriorly, the elbow is represented; still further below and somewhat anteriorly, the wrist; next in order, anteriorly, the finger-movements are

Special Cortical Motor Areas of the Human Subject.

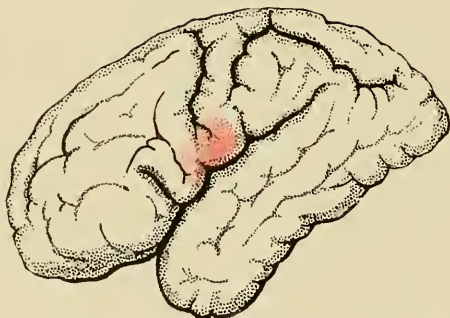(According to observations of Horsley.)



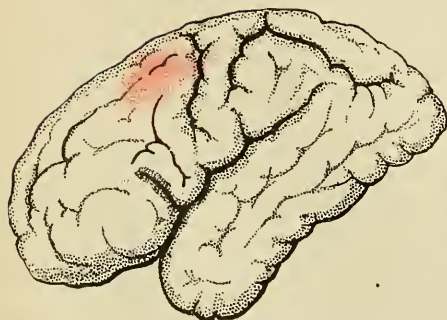
Upper part of face and the angle of the mouth
on the opposed side.



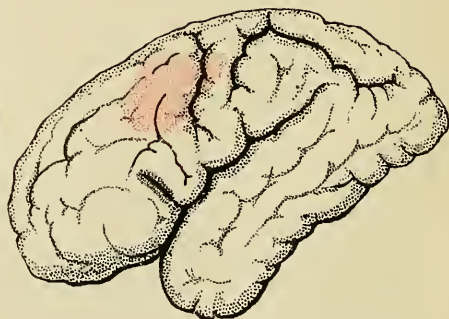Adduction of the vocal cords.



Lower part of face and floor of the mouth of opposed side.



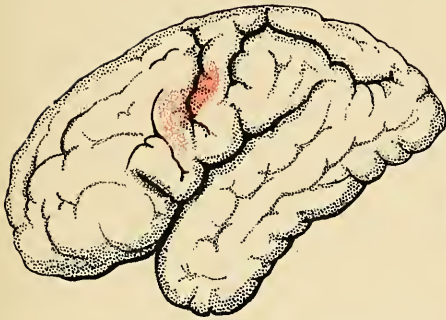The shoulder of the opposed side.



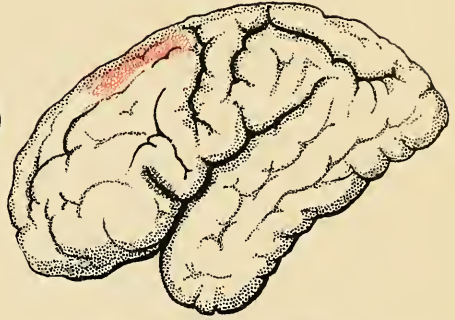The elbow and wrist of the opposed side.

Special Cortical Motor Areas of the Human Subject.

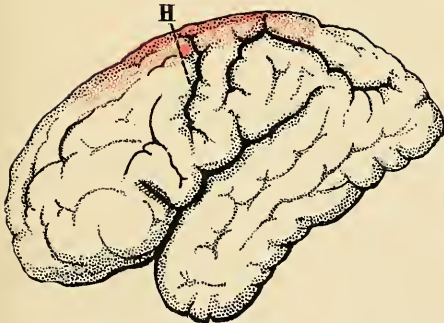
(According to observations of Horsley and Beevor.)



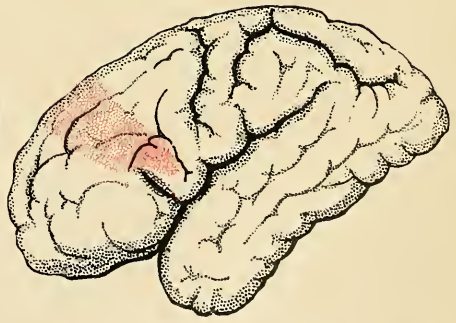Area for the thumb. (Horsley.)



Combined synchronous movements of both limbs. (Horsley.)



The lower limb. H. Area for the big toe in the para-central lobule. (Beevor and Horsley.)



Area for movements of the head and neck, together with conjugate deviation of the eyes. (Horsley.)

placed; and lowest of all, and posteriorly, the thumb-movements are located. These views he substantiates by observations made in cases of cortical tumors, where spasm was developed and appeared first in an isolated region of the upper limb.

5. The *area for the lower limb* is described by this observer as embracing the upper portions of the two central convolutions; also the whole of the superior parietal, the base of the superior frontal convolutions, and the para-central lobule. This description is not materially different from that of Ferrier (Fig. 26).

The subdivisions of this area are as yet incompleting, but the points given are of interest to the surgeon. The movements of the big toe are referred to the para-central lobule; those of the leg alone to the middle part; those of the leg and arm combined to the most anterior portion. Most of these conclusions agree in the main with those of Ferrier.

6. The *area for movements of the head and neck*, and also for conjugate deviation of the eyes, is placed by this observer (in common with Ferrier and Munk) in the bases of the three frontal gyri (see 12 in Fig. 25).

7. Respecting the steps required to locate the fissures of Rolando and Sylvius upon the human subject during life (as a basis for surgical procedures), the following conclusions are reached:

(a) The method first described by Prof. Thane for *locating Rolando's fissure* is adopted. A careful measurement is first made along the mesial line of the skull, starting from the root of the nose and extending to the occipital protuberance. This distance is then halved. The fissure of Rolando at its upper part lies *one half inch posteriorly to its central point*. A strip of flexible iron (with a movable arm placed at an angle of sixty-seven degrees to it) is now laid upon the middle line of the head, the point of junction of the movable arm with the mesial strip being carefully located at the point previously determined as overlying the upper end of Rolando's fissure. When this is accurately done, the movable

arm marks the course of the upper two thirds of the fissure of Rolando, but, as the lower third tends to bend slightly backward, it does not as clearly define the lower third of that fissure.

(b) To accurately locate the *fissure of Sylvius* upon the skull no little precision is required. A few points in the bones of the skull have first to be accurately determined. These are as follows: (1) The point where the temporal ridge crosses the coronal suture (the "*stephanion*"). This can usually be felt with the finger, the coronal suture appearing to the touch either as a depression or as a ridge lying between two grooves. (2) Exactly midway between the stephanion and the upper border of the zygoma, on a line drawn vertical to the zygoma toward the stephanion, lies another point known as the "*pterion*." (3) To determine the highest point of the suture which exists between the squamous portion of the temporal bone and the inferior border of the parietal bone (the "*squamo-parietal*" suture), a measurement has to be made, because that suture can not be felt beneath the temporal muscle.

In front of the temporo-maxillary articulation, an upright upon the line 4-2 in Fig. 30 would cross the zygoma. The junction of the upper and middle thirds of the measurement, made upon such a vertical line between the upper border of the zygoma and the ridge formed by the temporal muscle, indicates the situation of the highest point of the squamo-parietal suture.

The anterior limb of the Sylvian fissure starts from a point which lies from one half to one line (one twenty-fourth to one twelfth of an inch) in front of the "*pterion*." It runs anteriorly and upward from that point. The posterior limb passes backward and slightly upward from the same point.

8. The *sulci of the frontal lobe*, and also the *inter-parietal sulcus* (which limits the so-called "*motor area*" of the cortex posteriorly), are next to be located upon the exterior of the skull, in order to map out the convolutions. The guides to the sulci are as follows:

The *precentral sulcus* lies somewhat behind the coronal suture and parallel to it. It extends to about the middle of Rolando's fissure.

The *inferior frontal sulcus* diverges from the precentral at about the level of the temporal ridge.

The *superior frontal sulcus* starts at a point in the precentral gyrus somewhat posterior to the line of the precentral sulcus if continued upward. The exact point is about midway between the fissure of Rolando and an upward continuation of a line in the direction of the precentral sulcus. Its altitude in the cerebrum is slightly above the level of a point (midway between the mesial line of the skull and the center of the parietal eminence) which designates the lower limit of the superior parietal convolution.

The *inter-parietal sulcus* in its ascending course starts from a point on a level with the junction of the middle and lower thirds of Rolando's fissure. It turns backward on a level situated midway between the mesial line of the skull (marked by the longitudinal fissure) and the center of the parietal eminence.

There are certain suggestions, which may be thrown out in this connection, which are safe ones to follow in cases where the propriety of surgical relief is called in question. These may be stated in the form of propositions, which are of necessity based upon the contents of the previous lectures.

1. If the injury sustained (provided the case in question be one of a traumatic origin) be *situated over the motor area* of the cortex, the presence of *anæsthesia* in combination with motor hemiplegia is a contra-indication to attempts at surgical relief. This symptom (anæsthesia) probably indicates some injury to the sensory fibers which enter the posterior third of the internal capsule; hence the lesion is probably too extensive to be relieved by trephining.

2. If the *sensory region* of the cortex be involved, and *paralysis* or *convulsive movements* occur, an operation is contra-indicated; since the lesion has probably been so extensive as to extend to the motor area, or has involved or

compressed the cerebrum at a point removed from the apparent seat of injury.

3. The occurrence of *paralysis on the same side* as that upon which the injury was received is always a contra-indication to any surgical procedure at the seat of injury; since it probably indicates some lesion of the opposite side, doubtless dependent upon transmitted force (*contre-coup*).

4. The *completeness of the paralysis* may be often taken as a guide to the amount of injury done to the cerebrum: if the paralysis be very profound, the chance of success from trephining is extremely small, since the injury has probably affected parts deeper than the cortex.

5. The appearance of *paralysis of any of the special nerves of the cranium*, or the development of the symptoms due to lesions of the base of the brain or of the basal ganglia, such as the Cheyne-Stokes respiration,¹ choked disk, and vomiting, may be regarded as contra-indications to surgical interference.

6. When an injury to the skull is followed, after a lapse of some weeks, by the *ataxic form of aphasia*, the diagnosis of abscess of the base of the third frontal convolution, or possibly involving the island of Reil or the white substance situated between the third frontal convolution and the basis of the cerebrum, may be safely made.² In such a case the operation of trephining, as performed by Broca, affords a strong probability of relief.

7. Cases of injury which are *followed immediately by ataxic or motor aphasia* are strongly diagnostic of either a spicula of bone or the pressure of a clot in the neighborhood of the center of Broca. The former condition would be strongly in support of surgical interference, since it would probably continue to create pressure or irritation until removed, while the pressure of a clot might also be relieved by trephining.

¹ A respiration whose rhythm steadily increases, and then decreases, in a short interval of time; described in 1818 by Cheyne, and by Stokes in 1846.

² Authorities are not all in accord with this statement. The author has discussed the conditions known as "word-blindness" and "word-deafness" in previous pages.

8. If the *region over the fissure of Rolando* be subjected to apparent injury, and the symptoms of some of the *special types of monoplegia* appear (affecting the muscles of the face, arm, leg, or any of these combined), or even the occurrence of a *slight form of hemiplegia* follow, successful results from trephining may be reasonably expected. The presence of anæsthesia, as before mentioned, would, however, still be a strong contraindication to such a step, since it would prove that the lesion was probably of too deep a character to be benefited by the simple removal of a button of bone, as the posterior third of the internal capsule would probably be found to be impaired. It must be also remembered that the motor paralysis, of whatever kind it may be, must be confined to the side of the body opposite to the seat of injury, if benefit is to be expected. The type of monoplegia which exists may often be used as a guide to determine the extent of the lesion as well as its situation.

9. Convulsive attacks, which invariably begin by spasmodic movements of some *special locality of the body*, and whose cause is apparently a cerebral lesion or a traumatism of the head, may be treated successfully in some cases by a trephine over the motor center of the part which is primarily attacked with spasm.

10. Homonymous hemianopsia (when uncomplicated) points strongly to a lesion of the cuneus. Trephining has been successfully performed over this region of the occiput for suspected tumor, whose presence was revealed by this symptom alone (Seguin, Weir).

DIAGNOSTIC SYMPTOMS OF NON-CORTICAL LESIONS OF THE CEREBRUM.

Many of the clinical facts pertaining to non-cortical cerebral lesions may be thus summarized :

Profound coma is more often encountered in non-cortical lesions than in cortical, possibly because the cerebro-spinal fluid is more liable to be displaced from the ventricles (Duret).

Hemiplegia commonly exists in combination with more or less *hemianæsthesia*, and *paresis of the lower part of the face*. These symptoms are observed, as a rule, upon the side of the body opposed to the cerebral lesion.

Pain, when present in the head, is less circumscribed than in cortical disease, and is not increased by percussing, or elicited by that step when absent.

Muscular rigidity in the paralyzed muscles develops late. Typical *monoplegia* is probably never observed.

Tremor, *hemichorea*, and *athetosis* are not uncommon sequelæ of non-cortical cerebral lesions.

The *senses of sight, smell, hearing, and tactile sensibility* are occasionally impaired to a greater or less extent by non-cortical lesions. The seat of the lesion will modify the evidences of such impairment, because the fibers of some of the cranial nerves may be involved by the lesion, while others may escape injury.

Typical attacks of Jacksonian epilepsy do not occur, although *general convulsions* may be excited.

THE CORPUS STRIATUM.

Two nodal masses of gray matter, situated within the substance of each cerebral hemisphere, have been referred to in previous pages as the "basal ganglia." They appear, from their situation and relation to the radiating fibers of the cerebrum (Fig. 7), to be the "naturally appointed guardians" which preside over all impulses transmitted to or from the cerebral cortex.

Physiological experiment seems to point clearly to an automatism in the cells of these masses, exhibited chiefly in the *maintenance of equilibrium* after the hemispheres have been removed. They seem also to exercise some discriminating power over impulses which are forced to pass through them when the hemispheres are called into action.

From an anatomical standpoint these bodies seem, as Luys states, to be the "poles around which the nervous elements of the cerebrum gravitate"; and to constitute "a

crow, as it were, to the fibers of the crusta and tegmentum cruris" (Fig. 7).

The corpus striatum is the anterior of these two bodies; and the fibers which are apparently associated with it (the basis cruris, Fig. 8) can be traced into the antero-lateral columns of the spinal cord, with the exception of those that are supposed to pass to the cerebellum through the medium of the pons. It may be considered, therefore, as the probable seat of modification and reinforcement of motor impulses emanating from the cerebral cortex.

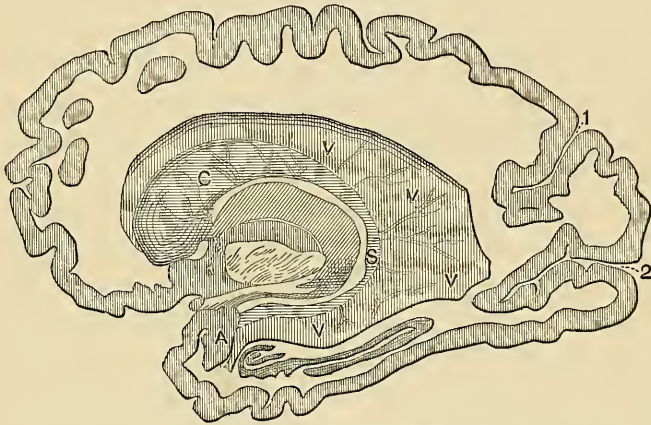


FIG. 31.—Antero-posterior vertical section of the right hemisphere, showing the cavity of the lateral ventricle. (After Dalton.)

C, corpus striatum; S, surcingle of same; V, ventricle; A, amygdala; 1, internal parieto-occipital fissure; 2, calcarine fissure.

In the fresh brain the corpus striatum appears as a reddish-gray mass, situated in front of the optic thalamus in each hemisphere of the cerebrum. Its large extremity is directed forward, and it gradually tapers as it is prolonged toward the posterior lobes of the brain. It is abundantly supplied with capillary vessels, which circulate within its substance. The extreme softness and friability of the mass are largely due to this fact.

We know, clinically, that the *larger proportion of extravasations of blood* within the cerebral hemispheres affect the corpus striatum; and we may reasonably attribute the greater

frequency of unilateral paralysis of motion, as compared with those of sensation, possibly to this abundance of vessels and the non-resistant character of the surrounding brain-substance.

The term "corpus striatum" is apparently used by Allen, in his late work upon anatomy, to cover the caudate and lenticular nucleus and also the internal capsule of the cerebrum. Rosenthal includes the caudate nucleus and the caudolenticular portion of the internal capsule under this term, but he treats of the lenticular nucleus as a separate ganglion. Meynert applies the term to the caudate nucleus alone. Duret divides the lenticular nucleus of most authors into two nuclei, one of which (the posterior or brownish-red portion) he calls the "lenticular nucleus," and the remaining portion the "gray nucleus," on account of its lighter color.

The entire mass of the corpus striatum, when viewed after the removal of the hemispheres by a horizontal cut made above the level of the basal ganglia, presents an ovoid pyriform appearance, the larger extremity being directed toward the frontal lobe, and the tapering end investing the optic thalamus (which lies behind it) as a layer of reddish-gray matter of steadily diminishing thickness. This "tail-like" prolongation (the *cauda*) has been described by Dalton¹ (who, in common with several other observers, has investigated its peculiarities) as forming a complete "surcingle" to the thalamus. Vertico-transverse sections of the hemisphere of the cerebrum, made to include the thalamus (as shown in Fig. 15) reveal two cuts of the caudate portion, an upper or ventricular portion, and a lower portion which is perceived in the region of the gyrus hippocampus (the *amygdala*). Such a section shows, moreover, that the so-called "internal capsule" of the cerebrum divides the corpus striatum into two distinct parts; one of which has this tail-like prolongation and projects into the lateral ventricle (the *caudate nucleus*, or *ventricular portion*), while the other is shaped somewhat like a section of a lens, and lies buried within the substance

¹ Gratiolet, Hirschfield, and Todd confirm this view.

of the hemisphere (the *lenticular nucleus*, or *extra-ventricular portion*).¹

The caudate and lenticular nuclei become fused, however, both anteriorly and posteriorly. In front, the caput dips downward toward the region of the base of the brain, and becomes fused with the third division of the lenticular nucleus (the "olfactory district" of Gratiolet). Behind, the cauda becomes joined to the temporal process of the third member of the lenticular nucleus (*pedunculus nuclei lenticularis*), near to the amygdala.

Structurally considered, the corpus striatum seems to be composed of *nerve cells of two varieties*: one being of large size with many processes, and the other of small size and multipolar.² The small cells predominate over the large in point of numbers. It seems probable that the fibers destined for the spinal cord are associated with one set of cells, and those to go to the cerebellum with the other (Luys); but this statement is as yet somewhat conjectural, although Meynert believes that it is supported by anatomical research.

The NUCLEUS LENTICULARIS is shaped somewhat like a wedge, its base being directed toward the frontal lobe and the island of Reil, while its point passes into the "crusta" (the *basis cruris* of Meynert), and terminates posteriorly in a jagged, thin edge.

If a section through its substance be examined, the microscope will show the existence of *two sets of nerve fibers* within it, viz., one, whose direction corresponds to the general course of its longest axis, or from base to apex; and a second, which runs parallel with its curved base.³

¹ The reader is referred to Fig. 32 and other diagrams incorporated in the text of this work.

² These cells vary from 30 μ to 15 μ in length. $\mu = \frac{1}{1000}$ millimeter.

³ The fibers of the lenticular nucleus which run parallel with the curved base of the wedge separate the three divisions of the ganglion. The extra-ventricular half of the corpus striatum must be regarded as connected especially with the fibers which arise from the island of Reil and other parts in the vicinity of the walls of the Sylvian fissure. Its form suggests that the frontal and parietal lobes furnish by far the greater number of its fibers, as contrasted with the temporal and occipital. It is worthy of remark that the fibers which pass through this ganglion do not take a direct course, but describe complicated spiral lines.

The second set divides the ganglion into *three distinct members* (Glieder), the external being the thicker and larger, while the two inner are the richer in medullary fibers, which gives them the name of "*globus pallidus*" (Fig. 32).

Within the substance of the CAUDATE NUCLEUS (at its inferior and internal portion), there exists a mass of yellowish colored matter to which the name "*yellow nucleus*" has been applied by Luys. In it, the smaller cells of this ganglion are described as being very abundant, while the processes given off from them are of extreme tenuity. There are some grounds in the opinion of this observer for the theory that these smaller cells represent the cerebellar elements of the ganglion (Fig. 31) while the large cells are connected with the motor nerves of the projection tract.

Meynert has recognized this collection of nerve cells, which presents, to his mind, most striking peculiarities. He locates it in the inferior regions of the caudate nucleus, extending from a point just above the lamina perforata, anterior to the neighborhood of the so-called *anterior commissure*. The peculiar anatomical features of this mass are stated by this author to consist (1) of an agglomeration of small nerve cells into piles, which are distinctly circumscribed; and (2) of very small granules ($6\ \mu$ in diameter) packed into close masses, and distinctly isolated. This latter element is not found elsewhere in the collective cerebral ganglia, and is believed by Meynert to indicate a structural relationship between the caudate nucleus and the olfactory lobe.

We find other cells in the corpus striatum in addition to the two varieties of nerve elements already described, those of the neuroglia; but they are of little if any importance (as far as we at present know) from a physiological or clinical point of view.

THE NERVE FIBERS ASSOCIATED WITH THE CORPUS STRIATUM may be divided into two groups, afferent and efferent.

The *afferent set* comprise (*a*) those which spring from the cortex and enter the substance of the ganglion; and (*b*) some

fibers probably connected with the superior peduncles of the cerebellum, which are capable of being traced to it.

The afferent fibers of the caudate nucleus may be traced as five distinct groups, as follows :

1. Fibers which spring from the entire length of the arch of the cerebral hemisphere (*corona radiata*).

2. A bundle of fibers springing from the cortex of the temporal lobe to the most anterior part of the caudate nucleus, following a curved course along the inner border of that ganglion (*stria cornea*).

3. Fibers which arise from the cortex of the olfactory lobe and pass to the corpus striatum.

4. Fibers which unite the cortical substance of the septum lucidum with the inferior region of the corpus striatum (*pedunculus septi lucidi*).

5. Fibers of the cerebellum, which reach the cerebrum as described above.

The *upper* border of the caudate nucleus of the corpus striatum which is at the same time its *outer*, seems to be the pole toward which the afferent fibers of the ganglion center, with the exception of the *stria cornea*. The *lower* or *inner border* acts as the peripheric pole, from which its efferent fibers emerge.

The *efferent set* comprise those fasciculi which help to form the cerebral peduncle (*crus cerebri*), and which are dispersed, after having passed through the pons Varolii, chiefly in the different segments of the spinal cord.¹

Let us now consider certain points in the arrangement and probable function of these groups of fibers.

The afferent fibers which spring from the cortex and unite with the nerve cells of the corpus striatum may be designated as the "cortico-striate" group. They appear to spring chiefly from the *psychic* (?) and *motor regions* of the cortex; hence we are apparently warranted in attributing to the corpus striatum some special association with these two functions. This view is, moreover, sustained by the fact that the efferent

¹ Some of the efferent fibers of the corpus striatum probably go to the cerebellum.

fibers of this ganglion are lodged principally in the motor paths of the projection system.¹

The experiments of Fritsch and Hitzig have demonstrated that weak galvanic currents (when applied to certain regions of the cortex apparently connected with the corpus striatum by radiating fibers) produce muscular movements in special regions of the body; and they were thus enabled to create at will motions of the eye, tongue, mouth, neck, and limbs. Bartholow has demonstrated the same physiological result in the brain of a man, in whom the top of the skull had become destroyed by disease. Both Bourdon and Luys have discovered an atrophy of cortical motor centers (as the result of loss of its function) in subjects deprived of a limb by amputation. In spite of these facts, however, we are still unable to state positively that all the fibers which radiate from the motor centers of the cortex are directly united with the nerve cells found in the corpus striatum, since the so-called "internal capsule"² seems to pass directly through the ganglion without meeting any interrupting cell elements in its passage. Whether this is actually the case or only an apparent one, it is impossible to determine from our present knowledge. The latest investigations of Flechsig seem to show that the so-called "pyramidal tracts" are independent of any structural relationship with the cells of the basal ganglia.

Among the afferent fibers of the corpus striatum, I have mentioned certain fibers which are apparently terminal expansions of the *superior peduncles of the cerebellum*. It seems to be now accepted by most observers that the fibers of these peduncles first decussate in the median line, and afterward

¹ A term first brought into general use among neurologists by Meynert. (See page 41.)

² The so-called "internal capsule" separates the two parts of the corpus striatum in front, and the lenticular nucleus from the optic thalamus posteriorly (Fig. 15). It extends into the crus as a part of the second projection system, constituting certain motor and sensory tracts found within the "*basis cruris cerebri*" and the "*tegumentum cruris cerebri*." Within the crus, those fibers which are connected with the tail of the intraventricular portion of the corpus striatum are described by Meynert as pursuing a somewhat peculiar course. They seem to appear to emerge from among the external bundles, and to disappear again among the internal fasciculi of the crus. To reach this portion of the crus, they are forced to cross the intermediate bundles.

become associated in the formation of two masses in the crus of a reddish color (red nuclei of Stilling). From these may be traced numerous filaments of a yellowish color, that, after extensive interlacement with each other, are believed by Luys to be prolonged to the yellow nucleus of the corpus striatum. An attractive theory has been advanced by Luys, that these delicate fibrils are the wires which carry the continuous currents of electric force, which overflow from the cerebellum to the corpus striatum, and thus constantly charge the cells of that body, which are liable to become exhausted by the controlling influence exerted by them over motor impulses transmitted from the cortex of the cerebrum. Physiological experiment points strongly to cerebellar innervation of motor acts. Disturbances in coördination of movement are produced by disease of the cerebellum, and motor acts appear to be weakened. These phenomena are of the greatest importance, as they tend to confirm the view taken by Luys regarding the foci of motor innervation.

The corpus striatum, like the optic thalamus, may be considered, therefore, "*as a territory in which cerebral, cerebellar, and spinal activities are brought into intimate communication.*" To quote the opinion of Luys, "it acts as a halting place for voluntary motor impulses emitted from the cerebral cortex. It enables these impulses to become modified and possibly reinforced by currents derived from the cerebellum; and, by its efferent fibers, it transmits centrifugal motor impulses along the projection system to different groups of cells within the spinal gray matter, whose individual functions they tend to evoke."

This ganglion probably acts as "a condenser and modifier of all motor acts which are the result of volition, and manifests, through the agency of its satellites (the cells of the anterior horns of the gray matter of the spinal cord), the outward expressions of our personality." Without the influence of the cerebral hemispheres, it is also capable, by means of cerebellar innervation, of governing all the complex muscular movements required in maintaining equilibrium (co-

ordinated movements). Finally, it may be presumed to possess the power of analysis of cerebral and cerebellar currents received simultaneously, and of materializing them by the intervention of its nerve cells, projecting them in a new form, amplified and incorporated with the requirements of the general organism.

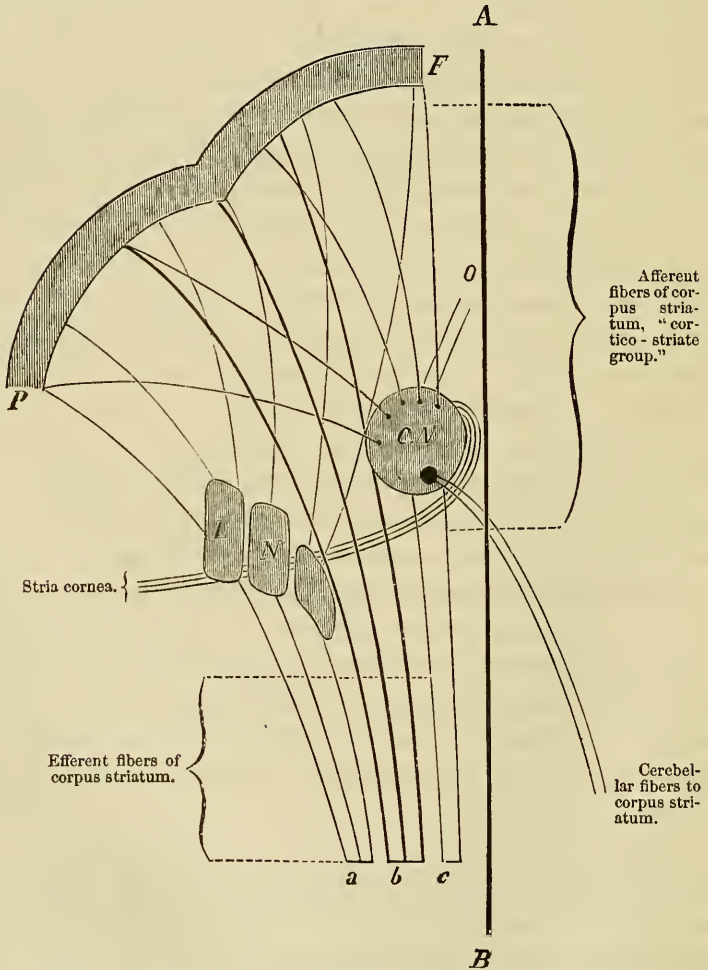


FIG. 32.—A diagram designed by the author to show the afferent and efferent fibers of the corpus striatum.

C, N, "caudate nucleus," or ventricular portion of corpus striatum; *L, N*, "lenticular nucleus," or extra-ventricular portion of corpus striatum; *A-B*, median line, separating cerebral hemispheres; *P-F*, psycho-motor regions of the cortex; *a*, peduncular fibers connected with *L, N*; *b*, fibers of the so-called "internal capsule"; *c*, fibers connected with *C, N*; *O*, olfactory fibers.

Experiments made upon the caudate and lenticular nuclei can hardly be said to have afforded results which can be made the basis for positive deductions respecting the functions of each. Nothnagel employed injections of chromic acid into the substance of each, and also destroyed them by means of an instrument devised for that purpose, but he made no positive conclusions save that the lenticular nucleus seemed to have a more decided influence upon motion than the caudate nucleus, when both sides were simultaneously destroyed.

Some observers claim to have removed the entire ganglion without any marked disturbance of sensory or motor phenomena. Some observations in comparative anatomy show a relationship between the caudate nucleus and the motor fibers of the leg, and a similar relationship between the lenticular nucleus and the fibers destined for the arm.

In no instance, to my knowledge, has the destruction of either of its two nuclei produced psychic effects. When *akinesia* (loss of movement) has been thus artificially produced, it seems to be absolutely confined to the opposite side of the body. In cases of extreme rarity, lesions have been shown clinically to have resulted in a paralysis of motion of the same side; but Flechsig has helped us to properly interpret these cases, as they afford evidence of an *individual peculiarity in the relative number of decussating and direct pyramidal fibers*. Ferrier has produced convulsive movements of the opposite side of the body by faradism of the corpus striatum, and Carville and Duret's observations seem to be in full accord, thus sustaining the theoretical view first advanced by Carpenter and Todd, as to an exclusively motor function in this ganglion. Burdon-Sanderson also has produced *localized* movements by electric stimulation of the white matter of the brain in the region of the corpus striatum. Danilewsky has observed that modifications of the circulation and respiration were produced by irritation of the lenticular nucleus; and also, to a slight extent, when the gray matter of the hemisphere overlying this nucleus was irritated. It is extremely doubtful, however, if these effects are due in reality to local-

ized irritation, because the fibers of the cerebral peduncle are in close proximity. The removal of the hemispheres above the basal ganglia does not seem to affect either the respiration or the circulation.

It would be rash to draw any conclusions of a positive nature in the face of such a conflicting mass of experimental and clinical evidence. It can not be disputed, however, that those who support the doctrine that the fibers of the internal capsule are the direct paths for motor and sensory impulses, and that all effects of experiment upon or disease of the corpus striatum are the result of *pressure exerted upon this tract*, have, in the light of our present knowledge, the most plausible theory. In what way this path of conduction is brought in direct or indirect dependence upon the cell elements of the nodal masses, with which it bears so intimate a relation, it is impossible to state positively; but it can not be denied that it seems to have the power of isolated conduction, in spite of any connections with ganglion cells, which may yet be proved to exist.

THE OPTIC THALAMUS.

The fibers of the "tegmentum cruris" (Figs. 6 and 8) are connected chiefly with the following ganglia: the "*optic thalamus*"¹; the "*corpus quadrigeminum*"; the *red nuclei* of Stilling; the "*corpus mamillare*"; the "*pineal gland*" (conarium); and a *ganglion embedded in the pons Varolii*. The two ganglia first named have a connection with the optic tract, in addition to a connection with the spinal cord. For this reason, the "*corpora geniculata*" may be considered as an appendage to them.

Let us consider, before the other ganglia are touched upon, the peculiarities in arrangement of the optic thalamus and its probable functions.²

¹ The term "*thalamencephalon*" is sometimes applied to the thalamus, pineal gland, and pituitary body when collectively considered. These may be considered as morphologically related to each other.

² The ganglia of origin of the tegmental fibers are separately considered on a subsequent page.

This ganglion appears, at first glance, to present its gray matter, exposed and uncovered, as a lining to the third ventricle. In this region, a band of white fibers, the "*stratum zonale*," defines its limits and separates it from the tail-like projection of the corpus striatum.

When the gray lining of the ventricle is examined, however, it becomes evident that it is structurally independent of the cells of the optic thalamus, because it can be traced as a direct continuation of the central tubular gray matter. It is in reality foreign to the thalamus, although it is probably connected with nerve fibers which penetrate its substance in order to reach certain nuclei of the central gray matter. It will be described in detail later.

The optic thalamus, as well as the corpus quadrigeminum, is poorly developed in the human brain, when compared with that of the lower animals. In shape, it has been compared by Meynert to "an arch surrounding a transverse axis"; in which respect it bears an analogy to the caudate nucleus of the corpus striatum, and the general arrangement of the cerebral hemispheres. The axes, around which the thalamus appears to arch, comprise, according to Meynert, the brachia of the corpus quadrigeminum and the corpus geniculatum internum. The greatest breadth of the thalamus lies posterior to the axis. The greatest thickness is found just in front of the axis. At its anterior extremity, the breadth and thickness attain their minimum.

When the fornix and velum interpositum have been removed and the optic thalami are viewed from above, they appear as oval-shaped masses of gray substance covered superficially by a thin layer of white fibers. A *longitudinal groove* (Fig. 33) may be detected on the superior surface of each, which inclines slightly inward so that its anterior extremity approaches the mesial plane. It terminates before the anterior extremity of the thalamus is reached. This groove is caused by the thickened margin of the fornix, which extends over the surface of the thalamus along the line of the groove. The anterior part of the thalamus is raised into a

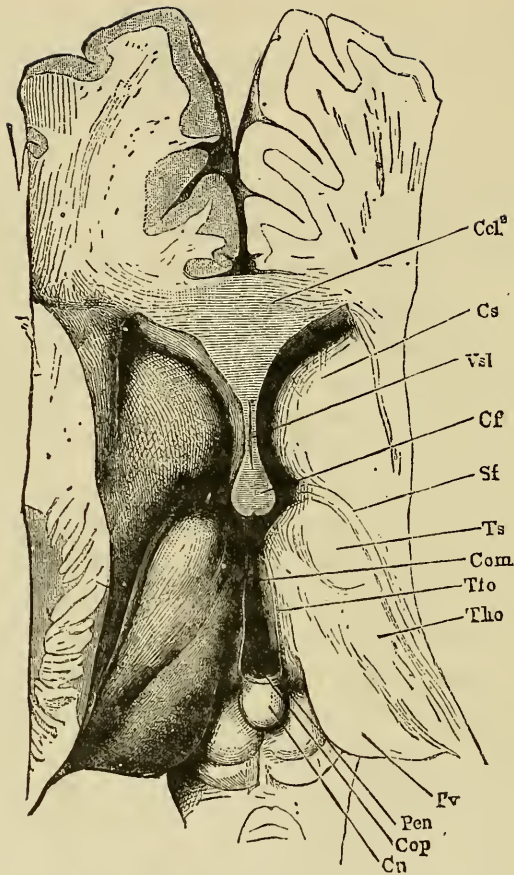


FIG. 33.—View from above of the third ventricle and a part of the lateral ventricles. (Henle.)

The brain has been sliced horizontally, immediately below the corpus callosum, and the fornix and velum interpositum have been removed. *Tho*, thalamus opticus; *Ts*, its anterior tubercle; *Pv*, pulvinar; *Com*, middle commissure stretching between the two optic thalami across the middle of the third ventricle; *Cf*, columns of the fornix; *Cn*, pineal gland projecting downward and backward between the superior corpora quadrigemina; *Sf*, stria terminalis; *Cs*, nucleus caudatus of the corpus striatum; *Vsl*, ventricle of the septum lucidum; *Ccl*^a, section of the genu of the corpus callosum; *Pen*, commencement of the pincal stria or peduncle, *Tfo*; *Cop*, posterior commissure.

prominence, the so-called “*anterior tubercle*,” which projects into the lateral ventricle and is covered with the epithelial lining of that cavity. It lies above a part of the lenticular nucleus, as may be seen in all cross-sections of the cerebrum.¹

¹ The anterior tubercle is farther removed from the level of the base of the cerebrum than any other part of the thalamus.

At the posterior and inner part of the thalamus, is seen, as in front, a posterior prominence or tubercle, the "*pulvinar*." This projects over and partly conceals the brachia of the corpus quadrigeminum.

Below and external to the pulvinar, another well-marked eminence, the "*outer geniculate body*," may be seen, which lies external to and above the "*inner geniculate body*." These two eminences¹ are separated by one of the roots of the optic tract (the *upper brachium*). The optic tract arises from this brachium and the two geniculate bodies, and curves downward and forward around the crus cerebri.

Such being the general direction and shape of the thalamus, we are prepared to consider the arrangement of the fibers which are connected with it. It presents, in the first place, three blunt pedicles, which become united with some of the fibers of the superior projection system (*corona radiata*). Those fibers, which become ultimately united with these blunt processes, may be traced to the cortex of the frontal lobe, of the walls of the Sylvian fossa, and of the temporo-sphenoidal lobe. The ganglion is also in intimate relation with fibers which radiate to the cortex of the occipital and parietal lobes.

The *external* and *inferior surfaces* of the thalamus are not free, but are united by means of nerve fibers with other parts of the brain. The external surface lies in close relation with certain fibers of the "*crusta*," and "*tegmentum cruris*," which pass between the lenticular nucleus and the thalamus—those forming the "*internal capsule*" of the cerebrum (Fig. 34). The inferior surface is in relation with the crus; and, more anteriorly, the corpus albicans and the tuber cinereum lie below it.

The *outlines of the surfaces* of the thalamus and the lenticular nucleus of the corpus striatum, as seen in all vertical cross-sections of the cerebrum, may be roughly compared to the *form of a square* whose two halves are defined by a

¹ These bodies are discussed more in detail in a subsequent page, as ganglia of origin of tegmental fibers.

diagonal band, the “*internal capsule*,” running from the upper and outer corner to the lower and inner corner. These halves correspond to the respective ganglia. It may be

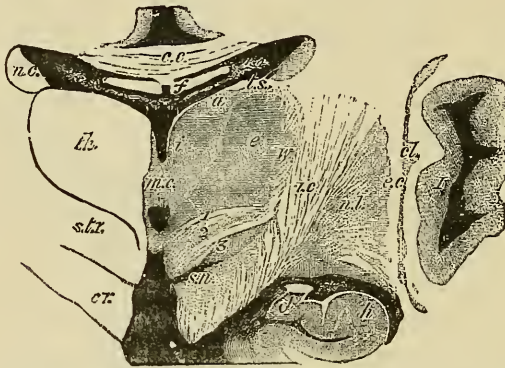


FIG. 34.—Section across the optic thalamus and corpus striatum in the region of the middle commissure. (Schäfer, after a preparation by Mr. S. G. Shattuck.) Natural size.

th, thalamus; *a*, *e*, *i*, its anterior, external, and internal nuclei respectively; *w*, its latticed layer; *m. c.*, middle commissure; above and below it is the cavity of the third ventricle; *c. c.*, corpus callosum; *f*, fornix, separated from the third ventricle and thalamus by the velum interpositum. In the middle of this are seen the two veins of Galen and the choroid plexuses of the third ventricle; and at its edges the choroid plexuses of the lateral ventricles; *t. s.*, tænia semicircularis; *cr.*, forward prolongation of the crusta passing laterally into the internal capsule, *i. c.*; *s. t. r.*, subthalamic prolongation of the tegmentum, consisting of (1) the dorsal layer, (2) the zona incerta, and (3) the corpus subthalamicum; *s. n.*, substantia nigra; *n. c.*, nucleus caudatus of the corpus striatum; *n. l.*, nucleus lenticularis; *e. c.*, external capsule; *cl*, clausstrum; *I*, Island of Reil.

worthy of remark, in this connection, that the surface of the thalamus which lies in contact with the internal capsule of the cerebrum marks the central or receiving pole for the fibers which join it with the cortex of the cerebral lobes. This is not the case with the lenticular nucleus, as has been stated on a previous page.¹

The *external surface* of the thalamus (which lies in contact with the internal capsule of the cerebrum) presents a peculiar appearance, which has given it the name of “lattice layer” (Kölliker). All along this surface, radiating fibers pass out of the thalamus to become intermingled with the fibers of the internal capsule, and to be subsequently distributed to the cerebral cortex. Those from the front of the ganglion pass

¹ See pages which treat of the CORPUS STRIATUM.

to the frontal lobe; those from the middle are distributed to the posterior part of the frontal and to the parietal and temporo-sphenoidal lobes; those from the posterior part can be

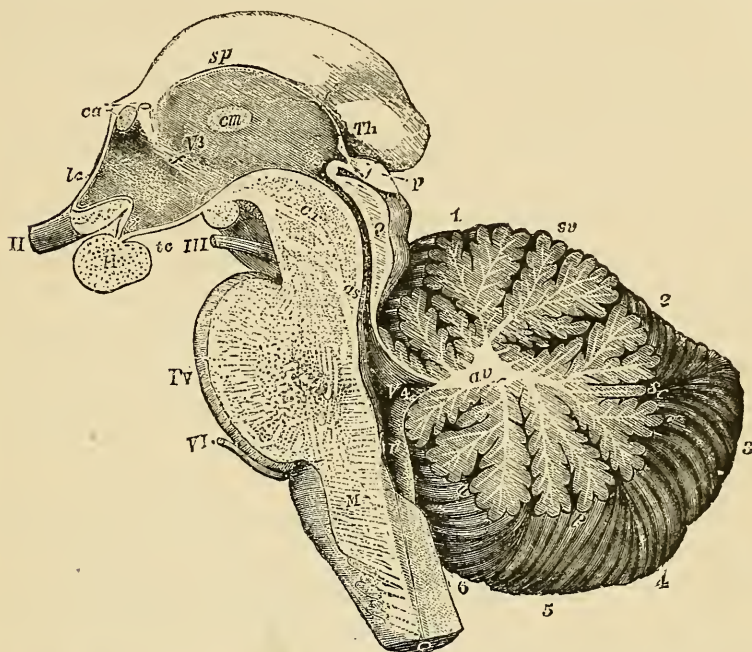


FIG. 35.—Right half of the encephalic peduncle and cerebellum as seen from the inside of a median section. (Allen Thomson, after Reichert.)

II, right optic nerve; behind it the optic commissure divided; III, right third nerve; VI, sixth nerve; V^3 , third ventricle; *Th*, back part of the thalamus opticus; *H*, section of the pituitary body; *p*, pineal gland; below its stalk is the posterior commissure; *ca*, anterior commissure divided, and behind it the divided anterior pillar of the fornix; *lc*, lamina cinerea; *i*, infundibulum (cavity); *tc*, tuber cinereum; behind it the corpus albicans; *f*, mark of the anterior pillar of the fornix descending in the wall of the third ventricle; *cm*, commissura mollis; *sp*, stria pinealis, or peduncle of pineal gland; *Q*, lamina quadrigemina; *as*, aqueduct of Sylvius near the fourth ventricle; *cr*, crus cerebri; *Pv*, pons varolii; *M*, medulla oblongata; behind these the cerebellum; 1 to 2, laminae of the antero-superior lobe; between V^3 and 1 are seen the *lingula* and *central lobe* in section; 3, *postero-inferior lobe*; 4, *lobulus gracilis*; 5, *biventral lobe*; 6, *amygdaloid lobe*.

traced to the temporo-sphenoidal and occipital lobes. From the region of the pulvinar, or posterior tubercle, fibers can be traced into the optic tract, and to Munk's visual area of the cortex of the occipital lobes (Wernicke).¹

¹ Wernicke's tract of fibers pass beneath the angular gyrus (in which Ferrier places the centers of vision) but terminates in the cortex of the occipital lobe. These fibers are shown in a subsequent cut illustrative of the optic fibers.

The *lower surface* of the thalamus is continuous, posteriorly, with fibers of the tegmentum cruris (the *sub-thalamic tegmental region*); in front, however, this prolongation of fibers inclines to the outer side of the ganglion and becomes lost in a layer of gray matter seen in the floor of the ventricle, which corresponds to the "*anterior perforated lamina*" of the base of the brain.

The lower surface of the thalamus is itself prolonged, anteriorly, into a tract of fibers which run downward and outward into the white substance of the cerebral hemisphere, forming the so-called "*lower peduncle of the thalamus.*"¹ A bundle of fibers, the "*ansa lenticularis,*" passes underneath the thalamus and above the lower peduncle of that ganglion from the mesial part of the crusta to the lenticular nucleus. Between these two tracts of fibers gray matter is interposed; the three, collectively considered, being called the "*substantia innominata of Reil.*"

The substance of the thalamus consists of nerve fibers and nerve cells, variously disposed; but the exact arrangement of each, and the connections of the nerve cells with special fibers, is a subject for much future investigation. Many of the theories advanced will be discussed later.

The thalami approach each other very closely in the median line; and, slightly forward of the middle of the third ventricle, are joined by a band of gray matter, the so-called "*middle*" or "*soft commissure*" of the thalamus (Fig. 34). This is sometimes double, and occasionally is absent. It is often torn across in removing the brain. This connecting band is composed of gray matter.

Not more than one half of the actual antero-posterior measurement of the thalamus is exposed in the third ventricle. It must be noted that the anterior tubercle appears in the lateral ventricle; and that the pulvinar, or posterior tubercle, lies in a plane posterior to that which would intersect the corpora quadrigemina. Note also that the anterior commis-

¹ Meynert claims that these fibers arise from the cortex of the fossa of Sylvius and the temporo-sphenoidal lobe.

sure of the third ventricle does not connect the optic thalami, or apparently have any structural relation with them. The posterior commissure is probably a continuation of the commissural fibers of the fillet (*Iemniscus*), which pass through the substance of the optic thalami and diverge in the cerebral hemispheres. These fibers may, in part, act as commissural fibers between the thalami. They are also structurally related to the pineal gland.

The NERVE FIBERS, which may be enumerated as intimately associated with the structures of the thalamus, can be divided into sets, as follows: ¹

1. Fibers of the *superior projection system* (p. 31), which serve to unite the thalamus with the cortex of the frontal, parietal, occipital, and temporo-sphenoidal lobes, and the fossa of Sylvius.

2. Certain fibers which can be traced directly into the *optic tract*, thus proving some functional relationship between the thalamus and the retina.

¹ The system of nerve fibers that exists in connection with the thalamus, according to the late researches made by Flechsig, may be thus summarized:

1. By means of the so-called "corona radiata," the thalamus is connected with all parts of the cerebral cortex.

2. Fibers from the frontal lobes appear to be associated with both the anterior and outer nuclei and the stratum zonale of the thalamus. They reach that ganglion by means of the anterior part of the internal capsule.

3. The cortex of the parietal lobe are associated with the outer and inner nuclei of the thalamus and the stratum zonale.

4. The cortex of the occipital lobe is associated with the pulvinar and the stratum zonale.

5. The cortex of the Sylvian region is joined to the outer and inner nuclei of the thalamus and the stratum zonale.

6. The cortex of the hippocampal region is connected with the outer nucleus of the thalamus by means of the fornix, after its fibers have first passed through the substance of the corpus mammillare and turned upon themselves.

7. The bundle of Vicq. d'Azyr's sends fibers to the fornix and also some to the reticular formation of the medulla, passing between the red nucleus of the tegmentum and the substantia nigra.

8. The so-called "Meynert's bundle" is composed of fibers that spring from the stratum zonale, the gray lining of the third ventricle, and the ganglion of the habenulæ. They are connected with the ganglion interpedunculare, but can not be definitely traced into the reticular formation of the medulla.

9. Fibers from the medullary lamina of the thalamus pass downward to the red nucleus and the gray matter adjacent to it. They probably extend to the cerebellum, but they can not be traced beyond the red nucleus of the tegmentum.

3. Fibers of the *tegmentum cruris* (Figs. 6 and 8), which connect the thalamus with the sensory tract of the spinal cord. As stated in a previous page, these are to be classed as fibers of the middle projection system (Meynert).

At the upper level of the middle point of the thalamus, the sensory fibers of the tegmentum leave the internal capsule to radiate toward the cortex. This has been termed the "carrefour sensitif" by the French authors. Here the radiating fibers that escape from the thalamus become intermingled with the sensory capsular fibers. Flechsig claims to have been able to trace the sensory tract to the cortex in the embryo, since they become medullated at a later period than do the radiating fibers of the thalamus. According to this observer they end in the cortex of the parietal lobe, behind the post-central gyrus.

4. It is claimed by Luys that the *anterior tubercle* of the thalamus can be proved to be directly connected with special fibers which lead to regions of the cortex functionally related with the *olfactory sense*.

5. There is strong clinical evidence to be adduced in support of the view that the *sense of hearing* is, in some imperfectly understood way, connected with the thalamus.

FUNCTIONS OF THE OPTIC THALAMUS.

Efforts have been made by some of the later anatomists, who have specially investigated the structure of the brain, to subdivide the gray matter of the thalamus into circumscribed masses or nuclei, and to trace the fibers which appear to arise from these nuclei to special regions of the brain and spinal cord. Among the most attractive of these attempts may be mentioned that of Luys, whose views will be subsequently given in detail. Whether clinical research and physiological experiment will confirm all of these attractive theories, and place them upon a ground as worthy of credence as the deductions of Broca and Ferrier regarding the functional attributes of other parts of the brain, time alone can decide.

The deductions which have been drawn from pathology as

well as from the results of physiological experiments, made with a view to determine the functions of the thalamus, are apparently contradictory and more or less uncertain. Paralysis of motion has been observed to follow the development of a lesion confined to the thalamus, and also to co-exist with lesions which have involved the corpus striatum and the thalamus conjointly. The question at issue is, however, whether the thalamus can be shown to exert any positive influence over sensory impulses, and whether lesions of that ganglion cause impairment or loss of sensation. Vulpian observed only impairment of motility from lesions of the thalamus; Luys has collected cases which apparently sustain the view advanced by him, viz., that a center which presides over general sensation is located within the thalamus; and Crichton-Browne has also collected cases where a diminution or abolition of sensation has been observed to co-exist with lesions of the thalamus of the opposite hemisphere.

Ferrier reports an experiment made upon a monkey which seems to sustain the view of Luys and Browne. In his first operation, the expanding stilette (which was pushed into the brain with the intention of reaching the thalamus) was not inserted far enough, and no marked sensory phenomena followed; but, when the instrument was subsequently introduced through the same tract far enough to reach the thalamus, tactile sensation was thoroughly destroyed. In reference to this experiment, Ferrier speaks as follows:

“Without for the present attempting to estimate how much was here due to the lesion of the optic thalamus as such, and how much to the medullary lesion external to it, we have in this experiment a conclusive proof of the abolition of cutaneous sensation by an injury in and around the optic thalamus.”

Veyssière has shown by experiments made upon dogs that section of the internal capsule in the region of the thalamus causes hemianæsthesia of the opposite side of the body. Nature has, moreover, verified these experiments in man, since Türck, Charcot, and others have clinically observed the

same effects, as the result of disease of corresponding regions. Unfortunately for science, the optic thalamus is situated at a point where the motor and sensory tracts have not as yet become very clearly differentiated from each other. Here the two appear to be more or less intermingled.

We have reason to believe that the cerebral cortex is brought into relation with all the organs of sense by means of fibers which pass either through the thalamus or the posterior fibers of the internal capsule of the cerebrum which lie adjacent to its external surface. With the exception of the sense of smell, there is no other medium for the transmission of such impulses to the hemispheres.

The course of special nerves and the value of morbid phenomena of the special senses will be discussed later in connection with the internal capsule, the corpora quadrigemina, and the medulla.

According to the researches of Luys, *four isolated ganglions* may be demonstrated in the thalamus. Arnold, in common with some other anatomists, has recognized three of these, and the fourth is now added by the author quoted. This author states that these ganglia are arranged in an antero-posterior plane, and form successive tuberosities upon the thalamus, giving that body the appearance of a conglomerate gland (Fig. 33.) The following paragraphs express his views relative to these tuberosities :

The anterior ganglion (corpus album subrotundum) is especially prominent. It appears to be developed in animals in proportion to the *acuteness of the sense of smell*.¹ By means of the "tænia semicircularis," this ganglion (according to Luys) may be shown, in the human species, to be connected with the roots of the olfactory nerve. Respecting it he says :

¹ The late researches of Flechsig and also those of Gudden (the former of whom has studied the relative periods of development of the main nerve tracts of the brain, while the latter has studied the degenerative changes that follow the destruction of the more important tracts in newly-born animals) fail to show any direct association of the olfactory nerve fibers with the thalamus, as a support to the theoretical view of Luys based upon clinical data. We are therefore forced to believe that the association is an indirect one, if any exists.

“Direct anatomical examination shows that there are intimate connections between the anterior center and the peripheral olfactory apparatus. On the other hand, in confirmation of this, in the animal species, in which the olfactory apparatus is very much developed, this ganglion itself is proportionally well marked. Analogy has thus led us to conclude that this ganglion is in direct connection with the olfactory impressions, and that this marks it as the point of concentration toward which they converge before being radiated toward the cortical periphery.”

The *second or middle center* is in apparent continuity with the *fibers of the optic tract*. It may therefore be considered, on the same grounds as those previously quoted respecting the anterior center, as a seat of condensation and radiation of visual impressions.¹ There seemed to be undisputable grounds for the belief that the *external geniculate bodies*, the *superior corpora quadrigemina*, and the *pulvinar*, are, in some way, also associated with the perceptions afforded by the retina. Moreover, the *convolutions of the occipital lobes* may be added to the collections of gray matter previously mentioned, since physiological experiment tends toward that view.

Ritti has pointed out that irritation of the thalamus may play an important part in the development of hallucinations.

We know that extirpation of the eye is followed by more or less complete atrophy of the outer geniculate body of the opposite side, although the inner geniculate body seems to remain unaffected. The experiments of Longet, who destroyed the optic thalami upon both sides without being able to note any impairment of vision or influence upon the movements of the pupil; and those of Lussana and Lemoigne, who found that blindness of the opposite eye followed unilateral destruction of the thalamus, may suggest the possibility, in the experiments of the former, of the escape of this center and, in those of the latter, its destruction. It is difficult to devise any experiment which will positively settle the

¹ Luy's states that it is scarcely visible in those animals (the mole as an example) where the optic nerves are rudimentary.

bearings of the thalamus upon vision ; because it is almost impossible to destroy special portions with accuracy, or, if this were insured, to avoid injury to adjacent structures. Fournié claims to have effected the separate annihilation of the special senses of smell and vision by injections made into different parts of the thalamus of animals ; and his experiments, if subsequently verified, will tend to confirm some of the theories advanced by Luys.

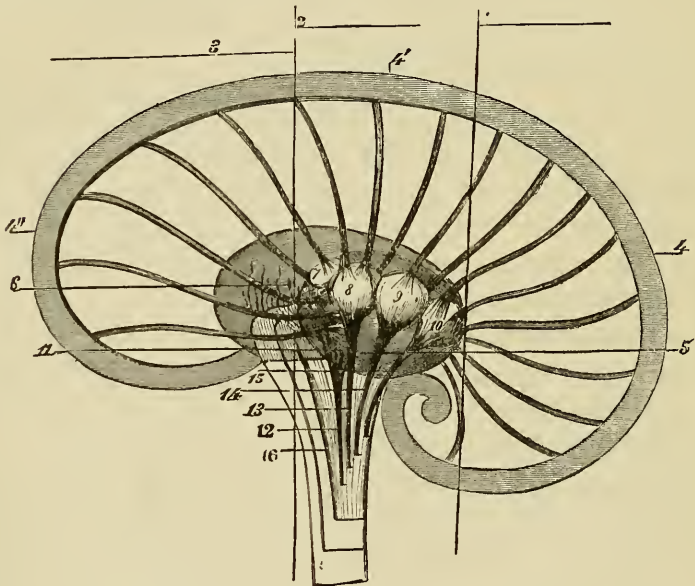


FIG. 36.—A diagram of the nuclei of the optic thalamus and the converging fibers associated with them. (Luys.)

1, converging fibers of posterior convolutions ; 2, same, of middle convolutions ; 3, same, of anterior convolutions ; 4, 4', 4'', cortical periphery as related to the central gray masses ; 5, optic thalamus ; 6, corpus striatum ; 7, anterior (*olfactory*) center ; 8, middle (*optic*) center ; 9, median (*sensitive*) center ; 10, posterior (*acoustic*) center ; 11, central gray region ; 12, ascending gray fibers of visceral innervation ; 13, gray optic fibers ; 14, ascending sensitive fibers ; 15, ascending acoustic fibers ; 16, series of antero-lateral fibers of the spinal axis going to be lost in the corpus striatum.

The *third center* ("median ganglion" of Luys) is described as about the size of a pea, and situated mathematically in the exact center of the thalamus. To it the discoverer ascribes the function of presiding over and condensing all *sensory impressions*.

The *fourth or posterior center* is stated to act as a halting

place and condenser of *auditory impressions*. Two instances where the brains of deaf-mutes were found to present a localized lesion of this center are reported by Luys.

The views here expressed are quoted on account of their originality ; and because the author of them ranks high as an authority upon the subject of which he speaks.

The numerous cases of cerebral hæmorrhage which have been reported, where the thalamus was apparently the seat of localized injury, are too often accompanied with a clinical history which points toward *pressure upon the internal capsule* to be of value as confirmatory evidence of the existence of special centers in the thalamus. The effort of Luys to adduce cases of hemianæsthesia in support of his views regarding the function of the "median center" of the thalamus, merely because a lesion of that ganglion was found in an area defined by him as the normal limits of that special center, must not be deemed conclusive ; because the same effect *might* have been produced by pressure upon the *posterior third* of the internal capsule of the cerebrum. There is every reason to hope and possibly to believe that sooner or later isolated ganglia within the optic thalamus will be demonstrated to exist by normal and pathological anatomy as well as by physiological experiment ; but the conclusions even of so prominent an author should not be fully accepted without further testimony to substantiate their accuracy. The anatomical researches of Meynert do not agree with the conclusions of Luys.

Some interesting cases have, however, already been brought forward, which certainly seem to sustain the views advanced by Luys. A case reported by Hunter,¹ where a young woman successively lost the senses of smell, sight, sensation, and hearing, and who gradually sank, remaining a stranger to all external impressions, disclosed at the autopsy a fungus hæmatodes which had gradually destroyed the optic thalamus of each side, and the optic thalami alone, if the drawing given is reliable. Again, Fournié's experiments on

¹ "Medico-chirg. Trans.," London, 1825, vol. xiii.

living animals point strongly to the existence of localized centers in the thalamus. Three instances of unilateral destruction of smell, observed by Voisin and reported by Luys, have been found to be associated with a destruction of the anterior center of the thalamus. An hemorrhagic effusion into the thalamus, on a level with the soft commissure (the situation of the optic center of Luys), produced (in the experience of Serres) a sudden loss of sight in both eyes. Ritti's paper upon the effects of irritation of the thalamus upon the *development of hallucinations*, lends strength to the view that that ganglion in some way regulates the transmission of sensory impressions of all kinds to the cerebral cortex; and confirms the opinion that "the optic thalami are to be regarded as intermediary regions which are interposed between the purely reflex phenomena of the spinal cord and the activities of psychical life."

The view taken by Lussana and Lemoigne, that the optic thalami contained motor centers in animals for the lateral movements of the fore-limbs of the opposite side, seems to be completely overthrown by pathological statistics in the human race. The results obtained by these experimenters are also at variance with the belief, which has now become general among neurologists, that the thalami are intimately connected with the sensory tracts of the cerebrum and cord; since they concluded that no evidence of pain or any loss of sensibility resulted from injury to these bodies.

The effects of all experiments on animals, however, agree entirely with the general experience of pathologists, that lesions of both the thalamus and corpus striatum produce results chiefly upon the opposite side of the body;¹ whether the symptoms produced point to a disturbance of the kinesodic (motor) or æsthesodic (sensory) tracts. The view originally advanced by Carpenter and Todd, that the thalami are concerned in the upward transmission and elaboration of sensory impulses, in contradistinction to the corpora striata, which

¹ Rare exceptions to this rule may be noted, as in the case of the motor strands (Flechsig).

are concerned in the downward transmission and elaboration of motor impulses, seems to be gaining ground, and many facts may be urged in its favor.

When the cerebrum is removed from some animals, the frog in particular, the basal ganglia being left intact, and some outward excitation be afterward used to induce movement in the animal so mutilated, there is every indication *that the animal can see*, because it avoids objects placed before the eyes, in case they tend to obstruct its passage.¹ Its movements are those of an entire frog, except that they require some external stimulus to call them forth. It can be made to crawl, jump, croak, swim, and perform all other acts of an automatic machine. It is the effect of light upon its movements, however, that has some bearing upon the existence of a *visual center* within the substance of the thalamus, since no observer has ever demonstrated that the corpus striatum is related either anatomically or physiologically with that sense.

THE CENTRAL TUBULAR GRAY MATTER CONNECTED WITH THE OPTIC THALAMUS.

The prolongation of the gray matter of the spinal cord, which lines the third ventricle, is best described in connection with the thalamus, although it is structurally independent of that ganglion. The following parts have been definitely made out :

1. The *inferior optic ganglion*. This mass of gray matter is situated at the lateral border of the tuber cinereum. Meynert and Luys describe it as forming an integral part of the tuber cinereum, although Wagner considers it as a part of the anterior perforated lamina. It presents a distinct sickle-shaped outline on longitudinal sections, the concavity of which looks forward. Luys thinks that the two ganglia join in the median line, and that the fibers of the optic nerve decussate within them. The opinion of Meynert is directly

¹ Such an animal will even try to avoid *strong shadows* thrown by the sunlight across its path.

opposed to this view. This author advances, moreover, some anatomical grounds for the belief that the fibers of the optic tract really belong to the superior projection system (analogous to the so-called "radiating fibers" of the cerebrum); that the inferior optic ganglion is to be regarded as the peripheral extremity of these fibers; and, finally, he suggests that in some undiscovered way the fibers will probably be traced later to some nucleus of the central tubular gray matter intimately connected with some other part of the body, perhaps the muscles of the eye. If this view be accepted, the superimposed layers of the retina must be considered as analogous to those found in the cortex cerebri.

2. Within the tuber cinereum, behind the inferior optic ganglion, *commissural fibers* which turn backward within the central tubular gray matter may be demonstrated. The termination of these fibers is as yet unsettled.

3. The *posterior longitudinal fasciculus*¹ of the tegmentum cruris may be traced along the central tubular gray matter of the third ventricle, the aqueduct of Sylvius, and the fourth ventricle. It terminates centrally in the broad, thin ganglion within the "*substantia innominata of Reil.*"

From this ganglion, fibers may be traced into the "external capsule" of the cerebrum, the cortex of the operculum, the fossa of Sylvius, the island of Reil, the claustrum, and cortex of the temporo-sphenoidal lobe. The greater mass of the posterior longitudinal fasciculus of the tegmentum lies to the outer side of the anterior pillar of the fornix, but a few fibers from the "infundibulum" pass across the inner side of the pillar.

4. The *descending branch* of the *anterior pillar of the fornix* lies within the central tubular gray matter of the third ventricle. The *ascending branch* is also similarly imbedded before it enters the body of the thalamus, and the same may be said of the *upper part of the corpus candicans* (mammil-

¹ The reader is referred to a subsequent page for the complete description of this bundle of fibers.

lary tubercle). Luys, Arnold, and Meckel believe that the descending branch of the crus of the fornix becomes fused with the stria cornea and the habenula conarii. The crus of the fornix makes a remarkable twist upon itself, the loop of which forms the corpus candicans (mammillary tubercle),

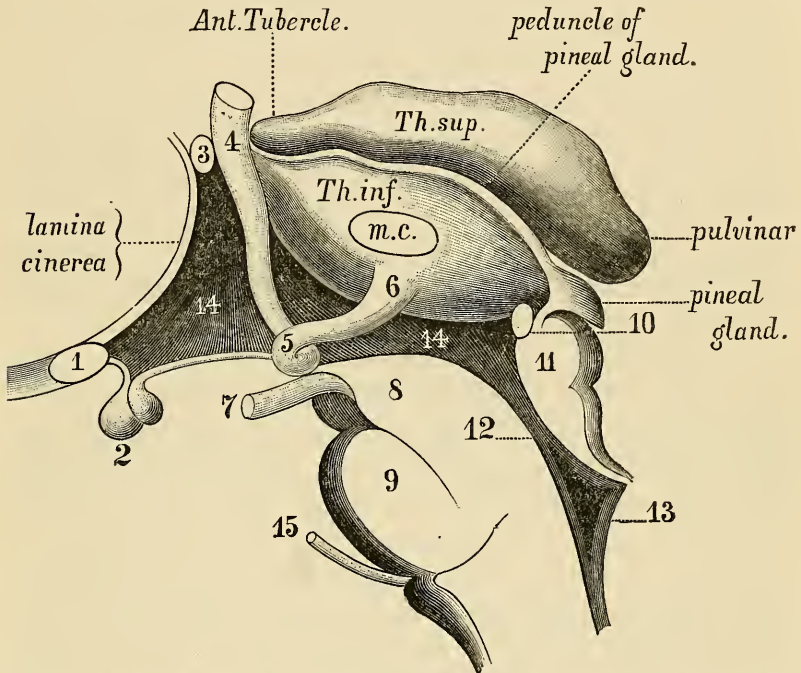


FIG. 37.—A diagram designed by the author to show the inner surface of the optic thalamus, with the tubular gray matter removed, showing the third ventricle, and the arrangement of neighboring parts.

Th. sup., superior part of thalamus; *Th. inf.*, inferior part of same; *m. c.*, middle commissure; 1, section of optic commissure; 2, infundibulum and pituitary body; 3, anterior commissure of third ventricle; 4, anterior crus of fornix; 5, corpus candicans (mammillary tubercle); 6, bundle of Vicq d'Azyr; 7, the third nerve; 8, crus cerebri; 9, pons Varolii; 10, posterior commissure; 11, corpora quadrigemina; 12, aqueduct of Sylvius; 13, fourth ventricle; 14, third ventricle. This cut should be compared with Fig. 3, in which the gray lining of the ventricle is intact.

when it reaches the base of the brain, and returns to enter the substance of the thalamus (bundle of Vicq d'Azyr).¹ It must not be inferred, however, that the corpus candicans consists only of fibers of the fornix, doubled upon themselves;

¹ Forel and Gudden deny that the fibers of the anterior pillars of the fornix are directly continuous with those of the bundle of Vicq d'Azyr.

as nerve-cells are abundant within it, some of which are in intimate relation with the fibers of the crus fornicis.

It will be apparent, after what has been said, that the lining of the third ventricle represents a prolongation of the gray substance of the spinal cord into the brain. By Luys it is considered as connected with fibers imbedded both within it and the thalamus, which concentrate themselves around certain nodal points, among which he mentions the "gray protuberances of the septum, for the olfactory roots; those of the tuber cinereum, for the optic fibers; the mammillary tubercles and pineal gland, for the connecting fibers emanating from the anterior centers." He also says, "It similarly receives a certain contingent of gray ascending fibers, which probably represent the centripetal spinal fibers which are distributed to these plexuses."

It is probable, and by some authors stated to be demonstrable, that all of the cerebral fibers, apparently distributed to the substance of the thalamus, are not connected with the nerve-cells of that ganglion. Some unquestionably appear to pass *through* it to become united with the gray masses described as connected with the lining tubular gray matter of the third ventricle. In this way the thalamus possibly becomes indirectly associated with the gray substance of the spinal cord as well as with the sensory tracts comprised within the 'tegmentum cruris.' It is from this standpoint that Luys expresses himself as follows :

"From this double induction we are therefore led to consider the masses of gray matter usually described under the name of 'optic thalami,' as essentially central regions which are the bond of union between the various elements of the entire cerebral system.

"Through their tissues pass vibrations of all kinds—those which radiate from the external world, as well as those which emanate from vegetative life. There, in the midst of their cells, in the secret chambers of their peculiar activity, these vibrations are diffused, and make a preparatory halt; and thence they are darted out in all directions, in a new and

already more *animalized* and more assimilable form, to afford food for the activity of the tissues of the cortical substance, which only live and work under the impulse of their stimulating excitement."

THE INTERNAL CAPSULE OF THE CEREBRUM AND THE
DIAGNOSIS OF LESIONS AFFECTING IT.

In connection with the description of the so-called basal ganglia (the "corpus striatum" and "optic thalamus" of each hemisphere), I have repeatedly mentioned a tract of fibers, called the "internal capsule of the cerebrum"¹ (Figs. 7 and 12). This band has an anatomical peculiarity, which has brought it into prominence with both physiologists and neurologists, viz., that it seems to *traverse the substance of the basal ganglia without any apparent structural relation with the nerve-cells found within them.*²

It is by no means certain that the nerve-cells referred to may not, in some indirect manner, be yet proved to modify or govern the impulses which travel along the fibers of the

¹ Properly speaking this band of fibers should be named the "internal capsule of the lenticular nucleus."

² The late researches of Flechsig tend to prove that a direct communication exists between the motor area of the cerebral cortex and the spinal cord, without any intervention of the cells composing the basal ganglia. The so-called "pyramidal tracts" have been traced by this observer (1) through the middle third of the internal capsule (posterior to the "knee"); (2) through the median part of the motor half of the crus; and (3) as two strands, one of which decussates and the other as a direct bundle, in the medulla.

The non-decussating or direct bundle is continued into the cord as the so-called "*column of Türck*," or the "*direct pyramidal column*." The decussating bundle, which is much larger than the direct, is prolonged into the spinal cord after crossing to the opposite side of the medulla, as the so-called "*crossed pyramidal column*." It occupies a distinct area in the lateral column of the spinal cord whose position changes somewhat at different altitudes. Finally, the pyramidal tracts are found to give off fibers to the anterior ganglionic cells of the spinal gray matter, chiefly in the cervical and lumbar enlargements of the cord. In this way they connect the brain with the motor cells—chiefly those associated with the muscles of the extremities, in contradistinction to those of the trunk.

The method of arrangement of the fibers of the internal capsule, when the level of the crusta is reached, seems to be comparatively uniform. Those that spring from the motor regions of the cortex pass down the median part of the crusta; those composing the "genu" or knee of the internal capsule pass through its central part; some from the posterior portion of the capsule lie in the lateral part of the crusta.

internal capsule (as we have every reason to believe they do in the case of other fibers which pass from the cortex to the crus, pons Varolii, and spinal cord); but, at present, we are compelled to admit that this region appears to afford the only *direct communication* between the convolutions and parts below the cerebrum,¹ because any intervention on the part of the corpus striatum or the optic thalamus has not been conclusively demonstrated.

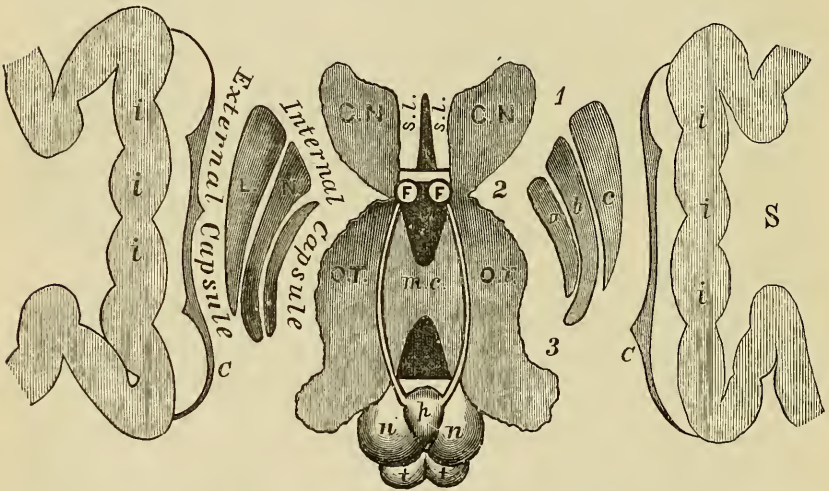


FIG. 38.—A diagram designed by the author to show the relations of the internal capsule of the cerebrum to adjacent structures viewed from above.

The section of the brain has been made *horizontally* in a plane to intersect the basal ganglia. C. N., caudate nucleus of corpus striatum; L. N., lenticular nucleus of the same with its three parts (*a, b, c*); O. T., optic thalamus; S, fossa of Sylvius; C., claustrum; E. C., external capsule of cerebrum; *i, i, i*, convolutions of the Island of Reil; *a, b, c*, the inner, middle, and external member of the lenticular nucleus; 1, anterior limit of the internal capsule; 2, "knee" or bend of the same; 3, posterior limit of the same; 1-2, "caudo-lenticular" portion of the capsule; 2-3, "thalamo-lenticular" portion of the same; F, crura of fornix, the fifth ventricle lying in front, and the third ventricle behind it; *s. l.*, septum lucidum, showing its two layers with fifth ventricle between them; *m. c.*, middle commissure of the thalamus; *p.*, pineal gland and its peduncles; *n*, nates cerebri; *t*, testes cerebri.

This tract seems to be a continuation upward of both the *motor* and *sensory* portions of the crus (the "basis cruris," and "tegumentum cruris," of Meynert) into the white substance of the cerebral hemisphere of either side, where its fibers diverge and pass to the convolutions. It forms the

¹ The fibers of the "external capsule of the cerebrum" may be an exception (Fig. 1).

greater part of the so-called "corona radiata," which were described in a previous page; although, properly speaking, the internal capsule ceases at the optic tracts below and the upper level of the lenticular nucleus above. If we trace the anterior fibers of this bundle from below upward, we shall see that it divides the corpus striatum of each hemisphere into its two portions, the caudate and lenticular nuclei. The posterior fibers of the internal capsule separate the lenticular nucleus from the optic thalamus of the corresponding side (Fig. 38). The diagram, to which I now direct your attention, will make the relations of this bundle apparent, while it will also show the peculiar angle or bend which the internal capsule exhibits in all horizontal sections of the brain which intersect the basal ganglia. The fibers that form the "caudo-lenticular" portion of the capsule are imperfectly understood. We have no positive evidence of their motor function. The pyramidal tract lies posterior to the "genu" of the capsule, as do also the motor fibers of the face. Back of these tracts we encounter the general sensory tracts. The optic fibers appear to lie still farther back, passing to the occipital cortex (see Fig. 39).

Again, if a cross vertical section of the cerebral hemispheres be so made as to include the substance of the thalamus and the lenticular nucleus, it will be perceived that the peripheral outline of these two masses of gray matter may be compared to a square; and that a diagonal band running from the outer and upper corner to the lower and inner corner of this square corresponds to the situation of the "internal capsule," which is included between these ganglia. Above the level of the basal ganglia, the fibers of the internal capsule radiate to join certain convolutions or "gyri" which will be enumerated later. Thus it is that the fibers which compose the internal capsule appear in most of the cross-sections of the middle zone of the cerebrum to bear a fancied resemblance to the handle and sticks of a Japanese fan; the handle being the constricted portion between the corpus striatum and the optic thalamus, or the capsule itself, and

the diverging fibers being located within the medullary center of the cerebral hemisphere.

The extension of *sensory fibers* from the tegmentum cruris upward within the internal capsule of the cerebrum is now as clearly proved as is the continuity of the *motor tract* anteriorly. The course of the former has been studied by dissec-

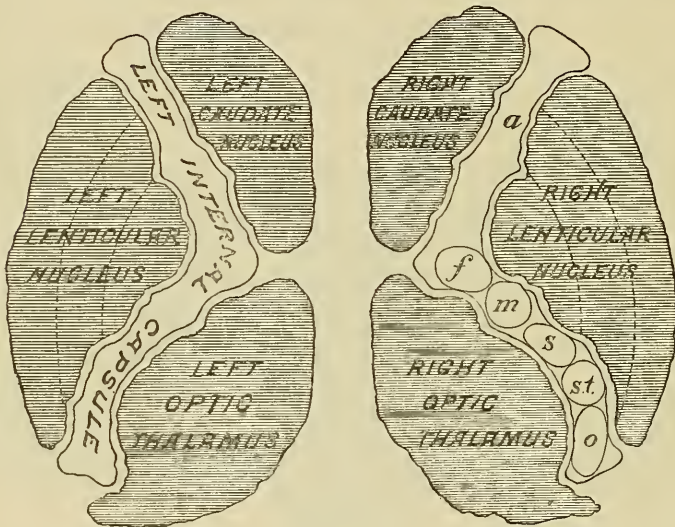


FIG. 39.—A diagram designed by the author to show the subdivisions of the internal capsule.

a, the portion which lies anteriorly to the knee of the capsule. The functions of the fibers which compose this portion are not, as yet, definitely determined. *f*, the fibers for the face; *m*, the fibers of the so-called "motor tract"; *s*, those of the "sensory tract"; *s, t*, those of the "speech tract"; *o*, those of the "optic tract." The fibers of each tract are probably associated with both sides of the body, but chiefly with the opposite side.

tion, embryological investigation, physiological experiment, and, finally, by the examinations of pathological processes. It has been shown by Türk¹ that, when certain convolutions of the brain (chiefly those which are motor in function) have suffered partial or complete destruction, that a *descending*² *degeneration* follows the course of the nerves which are con-

¹ This author first made known his great discovery to the Academy of Sciences of Vienna, in 1851.

² Degeneration of nerves follows, as a rule, the direction of the currents which are normally conveyed by them. By this means, the question of the afferent or efferent character of certain nerve-tracts has been positively decided.

nected with the cells of the injured part. This degenerative process extends along the nerves, from the cells of the cortex, to their peripheral terminations, in the cells of the spinal gray matter; thus enabling a careful observer to trace the paths of the fibers with even greater accuracy and positiveness than the most skillful dissector could possibly hope to attain. By means of this fact,¹ amplified somewhat by Waller and Gudden, physiologists have been enabled to solve many problems regarding the origin and course of special nerves, as well as certain nerve-tracts within the spinal cord and brain, which could not otherwise have been determined.

Although the remarkable observations of Türk were given to the profession some years before Waller was awarded the honor of meriting recognition as the recipient of the Moynton Prize for Experimental Physiology, his paper remained comparatively unknown for some years, when its great value at last became recognized.

The difference between the discoveries of Waller and Türk lie in the fact that the observations of the former were confined to the results of *artificial section of spinal nerves*, made for the purpose of studying the effects of such injuries, while those of Türk were of a purely pathological character, in which the *results of old morbid deposits within the substance of the brain* were studied by the aid of successive sections of the brain and spinal cord at different levels, which could be contrasted with each other.

Both of these observers arrived at the same fundamental law, viz., that injuries of nerves or of nerve-tracts which separated them from their centers of nutrition or *trophic centers*, cause a degenerative process which extends along the separate nerve-fibers to their ultimate ramifications.² Waller's

¹ The reader is referred to a lecture upon the "Wallerian Method of Research," by Prof. Dalton, "Med. Record," Feb. 11, 1882.

² Nerve-fibers degenerate only when severed from their connection with some special nerve-center, from which they receive their nutrition. These are called the "trophic centers" of the different bundles. When once cut off, the degenerative process extends throughout the entire length of the nerve; unless it meets another nerve-center (some ganglionic mass of gray substance) interposed in its course. It seldom, therefore, if ever, extends from spinal nerve-tracts into the spinal nerves, or *vice versa*.

experiments were confined exclusively to the spinal nerves, and resulted in the following deductions: 1, That if the nerve was divided at its exit from the vertebral canal, *all of its ultimate fibers degenerated* for its entire length; 2, that if the anterior root of the nerve was alone divided, only the *motor fibers* degenerated; 3, that if the posterior root of the nerve was severed outside of its ganglion, the *sensory fibers* of the nerve degenerated and the motor fibers remained unaffected; 4, that if the posterior root was divided *internal to its ganglion*, the nerve outside of the ganglion did not degenerate, but the portion which was still attached to the spinal cord, but separated from the ganglion, suffered complete degeneration. From these data, this observer was enabled to lay down the general law that *the motor fibers of the spinal nerves are dependent for their structural integrity upon their connection with the spinal cord, while the sensory nerve-fibers depend upon their connection with the spinal ganglia.*

The degenerative process which was recognized by both Türck and Waller consists in the segmentation of the myelin and the production of an excess of nuclei along the course of the affected nerve-fibers. The unaffected fibers retain their normal appearance, and thus define the diseased bundles so that they can be traced along the spinal cord and peripheral nerves with great accuracy.

Türck was enabled to demonstrate for the first time a distinction between the anterior and posterior segments of the lateral column of the spinal cord, which no ordinary dissection could possibly have established. The observations of Türck have been supplemented by those of Gudden, Goltz, Gull, Flechsig, Meynert, Rolando, Stilling, Foville, Gratiolet, Broadbent, Bourdon, Charcot, Spitzka, Starr, and others, who have added much to our knowledge of the situation and functions of the various spinal nerve-tracts.

Gudden's method of anatomical research consists in the destruction of nerve-tracts by operations performed upon *newly-born* animals. He found that, as a result of the injury done, the *proximal end* of the divided nerve *atrophied, as*

well as the central connections of the nerve. The so-called Wallerian degeneration, of course, affects the distal portion of the nerve, simultaneously with the development of Gudden's degeneration of the proximal portion.

Flechsig's method consists in studying the relative period (during fetal development) at which *certain nerve-strands acquire myelin*.

Thus we have to-day the older methods (1) of actual dissection of nerve-bundles in partially hardened specimens, and (2) the comparison of a consecutive series of fine sections of the brain and spinal cord with each other, supplemented by the more accurate methods of Türk, Gudden, and Flechsig, as guides in our anatomical studies of the nervous system.

The study of microcephalic brains, although yet in its infancy, bears evidence of affording great possibilities in the future toward the elucidation of disputed points in cerebral and spinal anatomy. M. Allen Starr has lately reported a very interesting case of this character.

The fibers of the caudo-lenticular portion (Fig. 38) are probably deflected (in the pons) and pass to the cerebellum. The remaining fibers which lie anteriorly to the sensory tract are not so deflected.

Now, because motor fibers carry centrifugal impulses, it is logical to describe the motor bundles of the internal capsule from above downward, beginning with an enumeration of the convolutions from which the motor fibers are believed to spring, and tracing the course of these fibers to their connection with the cells of the anterior horns of the spinal gray matter, while it is customary to reverse the method, in case the sensory fibers, which carry centripetal impulses, are under consideration.

The diagram to which I shall first call your attention (Fig. 14) was designed by its author (Seguin) to rudely represent the general features of the internal capsule. It is impossible to properly portray all of the more important facts, to which I shall call attention, by any form of schematic drawing; so that the diagram offered, which is most excellent of its kind,

can not more than afford general hints of value, and should be used as a guide only in contrast with more elaborate cuts found in standard anatomical works.

The *motor bundles* arise from the cells of the cerebral cortex comprised within the convolutions of the middle region of the brain. This region—the so-called “motor district”—includes the *ascending frontal gyrus*, the *basis of the first, second, and third frontal gyri*, the *ascending parietal gyrus*, the *paracentral lobule*, and the *supramarginal gyrus*¹ (Fig. 22). Some of these bundles pass directly into the substance of the caudate nucleus, some into the lenticular nucleus, and possibly a few into the optic thalamus of the corresponding hemisphere, after traversing the medullary center of the cerebrum; but the majority appear to pass directly into the anterior portion of the thalamo-lenticular division of the internal capsule (Figs. 38 and 39).

The *sensory fibers* which are comprised within the internal capsule are prolonged upward from the posterior parts of the crus (tegmentum cruris cerebri—Fig. 8) to the convolutions of the occipital, temporo-sphenoidal, and parietal lobes. It is believed that the posterior third (or sensory portion) of the internal capsule has connections also, by means of the optic, olfactory, gustatory, and acoustic nerves, with the *peripheral organs of special sense*. Physiological experiment has shown that, when certain convolutions of the sensory regions of the cerebral cortex have been destroyed in animals, the senses of sight, smell, hearing, and taste have been either temporarily or permanently impaired. We know also that total hemianæsthesia results from lesions, both in man as well as animals, which involve the posterior third of the internal capsule. The impairment of special senses from cortical lesions, moreover, appears to be confined chiefly to the side opposite to the seat of injury, in case of unilateral destruction of the cerebral convolutions—phenomena which point strongly to a decussation of these fibers, in which respect they bear an analogy to the common sensory tracts. Future con-

¹ The term “gyrus” is synonymous with “convolution.”

sideration will be given to these points. Some of them, particularly bearing upon the location of an olfactory, optic, and acoustic center, within the substance of the thalamus, have already been discussed at some length in previous pages.

When we discussed the corpus striatum, I constructed for you a diagram which represented the afferent and efferent fibers of that ganglion, in which the motor fibers of the internal capsule were shown (Fig. 40). I stated at that time that the functions of the caudate and lenticular nuclei were still unsettled, but that physiological and pathological facts could be advanced to sustain the belief that the cells of both halves of that ganglion exercised a modifying and controlling influence upon motor phenomena, and were probably the seat of automatic action, irrespective of the cells of the cerebral cortex. I stated, also, that it was probable that the cerebellum had a direct connection with the cells of the caudate nucleus, and that physiological experiment pointed strongly to cerebellar innervation of motor acts, because disturbances in coördination of movement are produced by disease of the cerebellum, and motor acts appear to be weakened. Now, because experiments made upon the caudate and lenticular nuclei can hardly be said to have afforded results which can be made the basis for positive deductions respecting the functions of each, it seems highly probable that the cerebellar fibers are in some way connected with those of the internal capsule, which are unquestionably associated with motor phenomena.

Among the afferent fibers of the corpus striatum, in addition to the cerebellar fasciculus (fibers of the *processus cerebelli ad cerebrum*), may be mentioned the "*corona radiata*"; the "*stria cornea*"; fibers from the *cortex of the olfactory lobe*; and fibers from the *septum lucidum* (Fig. 40). If it can be shown that these five sets of afferent nerves become associated with those of the internal capsule, it will help us to better interpret the functions of the parts. Spitzka happily remarks that "the time has passed when any single ex-

periment can be advanced to prove the existence of isolated functions within ganglionic masses. Anatomical research has demonstrated that nerve-tracts frequently traverse these

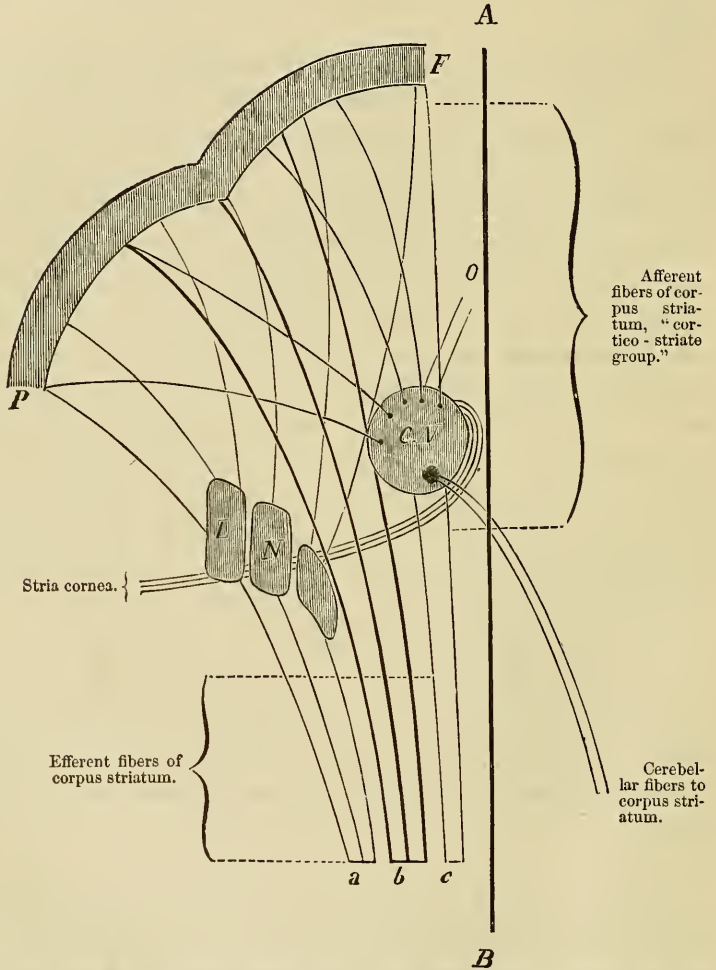


FIG. 40.—A diagram designed to show the afferent and efferent fibers of the corpus striatum and those of the internal capsule.

C. N., "caudate nucleus," or ventricular portion of corpus striatum; *L. N.*, lenticular nucleus," or extra-ventricular portion of corpus striatum; *A-B*, median line, separating cerebral hemispheres; *P-F*, psycho-motor regions of the cortex; *a*, peduncular fibers connected with *L. N.*; *b*, fibers of the so-called "internal capsule"; *c*, fibers connected with *C. N.*; *O*, olfactory fibers.

masses (without any apparent association with the cells imbedded within them) in order to terminate in remote parts.

It has been conclusively proved also that special centers are sometimes interspersed between these nerve-bundles, so that it is illogical to attribute every phenomenon caused by an intra-cranial experiment to a disturbance in the activity of any special center."

The physiology of many parts of the brain is far from satisfactorily marked out. Many glaring contradictions are apparently proved by the experiments of different investigators, and the statements previously made will help, to some extent, to explain them. I pointed out, when discussing the structural anatomy of the thalamus, that, until the existence of the special centers, which are believed to exist by some authorities within that ganglion, could be positively demonstrated, it will be maintained by others that many phenomena which accompany lesions of the thalamus are due entirely to *pressure* exerted upon the adjacent internal capsule. This view is held also by many neurologists, when phenomena provoked by any experiment upon the corpus striatum¹ are adduced to prove a special function as located within that ganglion. Pathological research has, in some instances, seemed to oppose the view that the lenticular nucleus possesses any important motor functions. The French experimenters, Franck and Pitres, published, however, in 1878, a most brilliant attempt to demonstrate conclusively that certain fibers of the internal capsule were continuous with the motor convolutions of the cerebrum and conducted motor impulses. These physiologists found that when the white substance of the cerebral hemisphere, which underlies the motor convolutions, was faradized, muscular movements were created on the opposite side of the body, in definite regions corresponding to the supposed action of the so-called "motor centers" of the cortex. It must be confessed by all that these observations, which are considered by many as a final proof

¹ It is possible that the *caudate nucleus*, when seriously impaired by lesions, may cause hemiplegia and secondary degeneration. Charcot claims, however, that the effects of hæmorrhage of the corpus striatum are to be attributed entirely to pressure upon the motor fibers of the internal capsule.

of the distribution and function of this bundle of fibers, are among the most satisfactory which have been as yet recorded.

Before we pass to the consideration of the internal capsule, in its practical aspects, let us speak a little more definitely in regard to its exact situation and limits. This bundle, as was stated before, lies between the lenticular nucleus on the one side, and the caudate nucleus and the optic thalamus on the other. Transverse vertical sections of the cerebrum show that the lenticular nucleus lies external to and below it, while the caudate nucleus and thalamus lie internal to and above it.

In the region of the base of the cerebrum, the head of the caudate nucleus becomes fused with the lenticular nucleus, so that the internal capsule does not extend to the extreme anterior limits of these ganglionic masses. The posterior limit of the internal capsule is probably defined by the termination of the lenticular nucleus, the thalamus being prolonged beyond it into the substance of the cerebral hemisphere. Above the level of the basal ganglia the fibers of this bundle radiate into the different lobes of the cerebrum, and cease to be "capsular fibers," properly speaking.

To the naked eye the fibers of the internal capsule, which pass between the ganglionic masses at the base of the hemisphere, appear to be continuous with the corona radiata above, and the fibers of the crus cerebri below. There is a belief among some anatomists, however, that successive loops will probably be demonstrated by more extended research—the fibers of the crus leaving the internal capsule to join the cells of the basal ganglia, while others leave the ganglia to pass, by means of the internal capsule, to the cerebral convolutions. The results lately obtained by Franck and Pitres, from an experimental standpoint (mentioned on a preceding page), as well as those lately published by Flechsig, from investigations made upon the fetal brain, seem, however, to be rather opposed to this view, although they perhaps do not positively controvert it. This point cannot be positively decided until the functions of the basal ganglia are determined.

EFFECTS OF LESIONS OF THE INTERNAL CAPSULE.

The situation of this bundle of nerve-fibers renders it liable to become directly involved when hæmorrhage, softening, or tumors of the *central portions* of the hemisphere exist; or, indirectly, when these conditions affect the *caudate nucleus*, the *lenticular nucleus*, or the *optic thalamus*.

The *most frequent seat of cerebral apoplexy* is the corpus striatum; because that ganglion is extremely friable and very vascular. The optic thalamus probably ranks next in the order of comparative frequency. The blood-vessels which enter these bodies¹ through the anterior and posterior perforated spaces at the base of the cerebrum seem to be frequently affected with atheromatous degeneration and miliary aneurysms,² and are often ruptured when subjected to any unnatural strain. Nature has given to the carotid and the vertebral arteries a remarkable tortuosity before their entrance into the cavity of the cranium, in order, as it were, to diminish the liability to rupture of blood-vessels by decreasing the velocity of the flow when the heart's action is excessive; but even this mechanical safeguard is not always sufficient to protect the intracranial vessels from rupture when extensively diseased.

Again, the *condition of softening* may result from embolic obstruction to some branches of the carotid (usually of the left side),³ because the nutrition of the parts supplied by the

¹ The motor regions of the cortex are supplied by the *middle cerebral* artery; the nucleus caudatus by branches of the *anterior cerebral* and *anterior communicating* arteries; the lenticular nucleus by the *middle cerebral*; and the optic thalamus by branches of the *middle* and *posterior cerebral* vessels.

² The vessels most frequently affected with aneurysmal dilatations are the internal carotid, basilar, and middle cerebral. Within the cavernous sinus large aneurysmal tumors are not uncommon. It must not be supposed, however, that the smaller vessels of the brain are exempt. Miliary aneurysms, which give to an artery and its branches an appearance resembling a bunch of grapes, frequently affect the vessels that form the circle of Willis, and even those of the pia mater within the substance of the brain and in the ventricles. The small vessels which nourish the corpora striata and the optic thalami are sometimes affected.

Miliary aneurysms frequently coexist with aneurysmal tumors outside of the cranium, but they seem to exhibit an independence of atheroma which is quite remarkable.

³ The reasons for this fact can be found mentioned in a late work by the author—"Practical Medical Anatomy." William Wood & Co., 1882.

occluded vessel is thus arrested either entirely or in part. The same result may also follow an attack of cerebritis or a previous extravasation of blood into the substance of the brain, both of which tend often to create impairment of the blood-supply to adjacent regions.

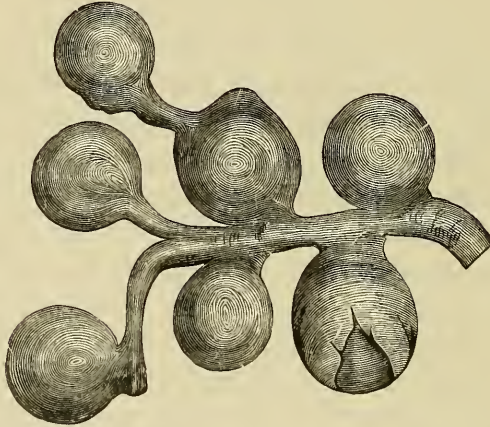


FIG. 41.—*Miliary aneurysms of a cerebral artery.* (After Hammond.)

Finally, *tumors* sometimes develop within the cerebral hemispheres, and create pressure upon, as well as destruction of, important nerve-tracts. Time will not permit us to enter into detail respecting all the diagnostic points by which the existence of each of these conditions may be recognized during life. I direct your attention, therefore, only to such points as are of importance in the diagnosis of disturbance of the supposed functions of the internal capsule.

It may be stated with some degree of positiveness that, if the anterior part of the “thalamo-lenticular” division of the internal capsule (Fig. 38) be affected, a *hemiplegia* of the opposite side is developed.¹ This is more or less complete, according to the seat and extent of the lesion which causes it. The exciting cause may possibly be situated within the anterior or middle portions of the white center of the cerebral

¹ Exceptions to this rule are occasionally observed. The hemiplegia, in rare cases, exists on the same side as the lesion. The explanation of this fact has been shown, by the researches of Flechsig, to lie in the varying proportions of the direct and decussating fibers which pass from the cerebrum to the spinal cord.

hemisphere, above the level of the basal ganglia, in which case it will interfere with the normal action of certain bundles of the internal capsule which spring from the motor convolutions of the cortex previously enumerated. Again, it may be situated within the constricted portion (the capsule proper), in which case bundles of nerve-fibers, functionally associated with widely diffused areas of the cortex, may be affected by a lesion of small size. Finally, it may be apparently confined to the substance of one of the two nuclei of the corpus striatum (Fig. 40), or the optic thalamus, and still exert sufficient pressure upon the constricted part of the internal capsule to produce more or less extensive and complete paralysis—chiefly of the opposite lateral half of the body. The hemiplegia of intra-cerebral lesions forms, as a rule, a striking contrast with the various types of *monoplegia* (p. 85), which are produced by circumscribed lesions of the cortex. The latter are often of the greatest aid to the neurologist in localizing the seat of the exciting cause.¹ They have been discussed in preceding pages.

The second symptom which may indicate a lesion of the internal capsule is *hemi-anæsthesia*. By this, I mean a *loss of sensation*, more or less complete, which is *confined to the lateral half of the body*. It exists (save in rare instances) on the side opposite to the seat of the lesion.

This may occur when fibers of the sensory tract of the internal capsule (Fig. 39) are destroyed or impaired by diseased conditions directly affecting them, as noted by Charcot, Raymond, Rendu, Ferrier, and others, or by the pressure exerted by lesions situated in parts adjacent to them. It is usually accompanied with a slight form of motor paralysis; probably because a few of the motor fibers of the internal capsule are, as a rule, simultaneously interfered with. The tests by which this condition may be recognized are, doubtless, familiar to you all. No examination of a patient afflicted with paralysis is ever complete unless sensation, as well

¹ The term covers many forms of paralysis where *special groups* of muscles are alone affected.

as muscular power, is carefully tested, before a diagnosis is made.

A third symptom of lesions of the internal capsule includes a variety of manifestations of *impairment of the special senses*.

In connection with the discussion of the optic thalamus, you will recall the views advanced respecting the possibility of existence of special centers of smell, sight, hearing, and sensation within the substance of that ganglion. Clinical facts point strongly also to a relationship between nerve fibers related to certain special-sense perceptions and the internal capsule. We are forced to admit that some of the fibers of the posterior part of the internal capsule probably have a direct or an indirect association with smell, sight, hearing, sensation, and perhaps of taste also. In a subsequent section, many interesting facts in physiology, which show the value of abnormal phenomena in smell, sight, speech, hearing, taste, etc., upon the diagnosis of intra-cranial lesions, will be given. Many of these might be mentioned here with advantage, if space would permit. Charcot has endeavored to explain a statement, that has until lately been accepted, viz., that hemianopsia¹ seldom (?) occurs in connection with lesions of the internal capsule, but an amblyopia is developed on the same side as the cutaneous anæsthesia, with a remarkable contraction of the field of vision and difficulty in discrimination of color. The explanation which this author made of this statement is, that a second decussation of the fibers of the optic nerve takes place somewhere between the optic chiasm and the internal capsule, probably in the tubercula quadrigemina. Some late discoveries of Munk and Wernicke (coupled with a collection of autopsies bearing upon the subject) have caused this author to modify his views. It is now considered as questionable if many cases, reported as exhibiting amblyopia during life, were not affected with hemianopsia. This subject will be discussed in connection with the corpora quadrigemina.

¹ The term "hemiopia" signifies half sight; hemianopsia means a blindness of one half of the retina. The latter is, therefore, the preferable term in this connection.

When the radiating fibers of the internal capsule are involved in a lesion which creates a gradually increasing pressure (as in the case of tumors which grow slowly) the *fundus of the eye* exhibits morbid changes in the region of entrance of the optic nerve which are of value in diagnosis. The condition so produced is commonly known as the "*choked disk.*" It is nearly always bilateral, but often most marked in one eye. It may be considered as one of the most positive signs of an extensive intra-cerebral lesion, and especially of tumors of the brain.

When such an eye is examined with an ophthalmoscope, the condition found is characterized by a swollen appearance of the optic nerves, which project appreciably above the level of the surrounding retina; the margin of the disk is either obscured or entirely lost; the arteries appear small, and the veins large and tortuous; finally, small hemorrhagic spots may often be detected in the retina near the margins of the disk.

In spite of this condition, the power of vision may be little impaired; so that the existence of "choked disk" may be unsuspected unless the ophthalmoscope be used before the diagnosis is considered final.

After a number of weeks, and very much longer if a tumor is the exciting cause of the condition, the appearance of the disk changes. An unnatural bluish-white color, which denotes atrophic changes, develops; the outline of the disk becomes sharply defined; the retinal vessels become small; and vision becomes markedly interfered with.

In exceptional cases of destruction of the internal capsule, the *sense of smell* has been abolished on the side opposite to the seat of the lesion. This fact requires special consideration, as it has been shown that the center proper for olfactory perceptions seems to be in the hemisphere of the same side. Meynert and Gudden claim, however, to have demonstrated the existence of an olfactory chiasm in the region of the anterior commissure, in animals where the bulbs are largely developed; and fibers have been traced in the region of the

“*subiculum cornu Ammonis*,” or the tip of the temporo-sphenoidal lobe, which connect the olfactory centers with each other. The experiments of Ferrier tend to disprove the decussation of the olfactory paths in the anterior commissure; so that the question still remains unsettled. The sense of smell is more commonly affected in the nostril of the side which corresponds to the seat of the lesion.¹

Among the fibers of the internal capsule which are distributed to the temporo-sphenoidal lobe some appear to have some association with the *sense of hearing*; but experimentation upon animals to determine the exact seat of the centers of hearing and the effects of their destruction are exceedingly difficult, because the evidences of impairment of this sense are more or less vague. Ferrier thinks, however, that the superior temporal convolution is unquestionably connected with acoustic perceptions. The area which he maps out as acoustic in function is quite extensive.

The region of the hippocampus and the posterior parietal convolutions seems to be chiefly connected with *tactile sensibility*, because their destruction has been found to create more or less loss of that sense on the opposite side of the body.

As regards *taste*, the results of experimentation upon the monkey tribe seem to point to the lower portion of the middle temporal convolution as the probable seat of the centers which are related to that sense.² When this region is subjected to irritation, certain reflex movements of the lips, cheek, and tongue are observed, which seem to point to an excitation of the gustatory sense. Its destruction apparently causes an abolition of taste.

We have now considered three of the more prominent symptoms which are produced by lesions of the internal capsule, and I pass to a fourth, which I believe to be of great

¹ Ferrier reports a case where smell and taste were simultaneously abolished by a blow upon the top of the head. Ogle records a similar instance.

² This may help to explain the fact that injuries received upon the vertex and occipital protuberance cause, in some instances, an abolition of taste, the temporal lobe being injured by concussion against the adjacent bone.

value in aiding the recognition during life of an extensive and rapidly developing lesion of the white center of the cerebral hemisphere, viz., *conjugate deviation of the eyes and head*.

When, in connection with rapid softening or an extravasation of blood into the substance of the cerebrum above the level of the basal ganglia, this peculiar symptom is developed (either simultaneously with or following paralysis and coma), the patient's head and eyes will be observed to be turned constantly away from the paralyzed side and toward the side which is the seat of the lesion. Various attempts have been made by late authors to throw discredit upon the clinical significance of this symptom as particularly indicative of a lesion of the cerebral hemisphere, but I am convinced that it is a valuable differential sign. Ferrier has demonstrated that a cortical center, which he locates in the first and second frontal gyri near to their bases, presides over conjugate movements of the head and eyes, and causes dilatation of the pupils. He attributes this symptom, when occurring in connection with hemiplegia of cortical or ganglionic origin, to the unantagonized action of the corresponding center of the uninjured hemisphere, thus explaining the fact that the distortion is toward the side of the lesion. Clinical evidence of the correctness of this view has been brought forward by Hughlings-Jackson, Priestley Smith, Choupe, Landouzy, Carroll, and others; and, in some cases reported, the situation of the lesion has been verified by pathological observation. The opportunity to record pathological observations upon cases where this symptom was well marked during life has, unfortunately for science, been a comparatively rare one. It is impossible, therefore, to speak positively concerning the diagnostic value of this symptom, although the weight of clinical evidence seems to be strongly in its favor.

A fifth symptom, which points strongly to an existing lesion of the internal capsule, is *choreiform movements* following hemiplegia or hemianæsthesia. These movements vary in type and degree. In some cases, the movements exhibit the peculiarities of athetosis, the fingers or toes being

thrown into active motions which cannot be controlled by the patient; in others, true ataxia may be developed; again, the spasmodic movements partake of the character of genuine chorea; finally, a tremor, more or less marked, may be detected.

It is not uncommon to find that both hemiplegia and hemianæsthesia may co-exist with these post-paralytic forms of spasmodic disease; but one usually overshadows the other, the hemiplegia being, as a rule, the more marked. How we are to explain these late phenomena, is not definitely settled. They are probably to be classed with other morbid manifestations which paralyzed muscles sometimes exhibit, chiefly that of "late rigidity" so often seen, concerning the cause of which many conjectures have been advanced, but nothing of a positive nature demonstrated.

Finally, it has been observed that lesions of the internal capsule, if very extensive, are often followed by a very marked *rise in the temperature* of the body. We have yet much to learn concerning the vaso-motor centers which are variously disposed within the substance of the brain and spinal cord.

The fact has been mentioned that certain fibers of the internal capsule are anatomically related to the cells in the *motor convolutions* of the cerebral cortex. Although there are still some neurologists of note who deny the value of the late attempts of Fritsch, Hitzig, Broca, Ferrier, Charcot, Hughlings-Jackson, Pitres, Landouzy, Exner, Chouppé, Luciani, Wernicke, and a host of others, to locate special centers within the convolutions of the cortex, clinical and pathological observations are constantly being brought forward in support of the more generally accepted views. The region which embraces these motor centers appears, however, to be somewhat limited. A critical review of recorded cases shows, I think, beyond cavil, that the white center of each hemisphere of the cerebrum, as well as the cortex, may in some instances be extensively diseased or injured without any motor or sensory results which can be determined. Patho-

logical evidence seems to demonstrate, however, that the region so impaired must not be situated where the fibers of the internal capsule which pass posteriorly to its knee (Fig. 39) can suffer destruction or pressure if we expect to meet with negative results. Abscesses of immense size have been found in the anterior part of the frontal lobe without any sensory or motor paralysis during life to indicate the existence of such a lesion. Tumors, softenings, and the most severe types of traumatism have likewise occurred without creating serious effects.

In the case of occipital and temporo-sphenoidal lobes, to which some of the posterior fibers of the internal capsule are probably distributed, sensory symptoms are commonly observed to follow circumscribed lesions.

The temporal lobes seem to exert an influence upon the special senses of touch, smell, and hearing. The occipital convolutions are probably associated with vision.

An apparent connection of the optic and auditory functions with the cerebellum and optic thalamus has been mentioned in previous lectures. The bearing of morbid phenomena of these special senses upon diagnosis will be considered in detail in a subsequent section of this work.

In closing this important subject, let me suggest that it is by no means certain that lesions, which primarily affect the constricted portion of the internal capsule, may not, in themselves, create sufficient pressure upon the corpus striatum and the optic thalamus to cause interference with the free action of some of the *special centers* which are believed to exist within those bodies. If this be the case, many of the interesting phenomena described during our discussion of lesions of the optic thalamus, would *co-exist* with those symptoms of disease within the internal capsule already mentioned. Ritti's views respecting the relations of the optic thalamus to hallucinations, and those of Luys pertaining to its olfactory, optic, and acoustic functions, have a special interest in this connection.

THE CORPORA QUADRIGEMINA,

WITH REMARKS CONCERNING THE DIAGNOSIS AND LOCALIZATION
OF LESIONS AFFECTING SIGHT.¹

The aqueduct of Sylvius (*iter e tertio ad quartum ventriculum*) is covered on its superior and dorsal aspect by two pairs of rounded eminences (Fig. 38), mainly composed of gray matter, called the corpora or tubercula quadrigemina (the so-called "*nates*" and "*testes cerebri*"). A median groove separates these parts. Anteriorly, a transverse white prominence (the *posterior commissure*) limits this groove (Fig. 37); behind, it is continuous with the velum by means of a small median strand of longitudinal fibers, called the *frenulum veli*. The pineal gland which projects backward and downward from the posterior wall of the third ventricle overlaps the anterior portion of this groove, resting between the two upper quadrigeminal bodies (the *nates*). In fishes, reptiles, and birds, the quadrigeminal bodies are two in number, and are called the *optic lobes*. They are also hollow in these species. In the human foetus they are developed early, and form a large part of the cerebral mass.

The anterior tubercles are darker in color and less prominent than the posterior. Laterally, each tubercle is prolonged upward and forward into a prominent strand of white substance, the brachium or arm of the corresponding tubercle.

The *brachia* are to be regarded as fasciculi sent to each tubercle from the cortex cerebri by means of the corona radiata. They may also be considered as affording a communication with the optic thalamus. The *upper* or *anterior brachium* passes between the inner geniculate body and the posterior extremity of the optic thalamus, or the *pulvinar*, where it may be demonstrated to join one of the roots of the optic tract, of which it really is a continuation. This is more apparent in some animals than in man. The *lower* or *pos-*

¹ In connection with the description of the ganglia of the "*tegmentum cruris*," these bodies are considered from the standpoint of their other physiological functions.

terior brachium loses itself underneath the inner geniculate body, which is situated at the side of the upper end of the crus cerebri.

The *superior quadrigeminal bodies*, or *nates cerebri*, are covered externally with a thin layer of nerve fibers, called the "*stratum zonale*." This constitutes the only place in the brain where fibers of the first projection system of Meynert (p. 31) are exposed to view upon its exterior. Beneath this may be seen a layer of gray matter, called the "*stratum cinereum*," which is thicker at the prominent part of the tubercle than at its margins, and which contains numerous nerve cells of small size. Beneath this, again, lies a layer of nerve fibers which are arranged in longitudinal bundles, the so-called "*stratum opticum*." These fibers are continuous with the upper brachium and the optic tract. Scattered nerve cells are found between the bundles of which it is composed. Finally, between the stratum opticum and the gray matter which surrounds the aqueduct of Sylvius, a layer of nerve fibers, derived from the *upper fillet* or *stratum lemnisci*, may be demonstrated. This layer is thickest at the margins of the tubercle and thinnest at the median line, where its fibers appear to decussate. This gradual thinning is to be explained by the passage of some of its fibers to the optic layer, and some to the gray matter surrounding the aqueduct of Sylvius (Tartuferi).¹

The *inferior quadrigeminal bodies*, or the *testes cerebri*, are composed almost entirely of gray matter formed of numerous small and some large nerve cells. A thin layer of the fillet separates the gray nucleus of this body from the gray matter surrounding the aqueduct of Sylvius. A connecting band of

¹ Flechsig has shown (in some late researches made by him in reference to the period of development of the more important nerve tracts of the brain) that the *cortical layer* of the *anterior corpus quadrigeminum* is more intimately connected with the optic nerve fibers than is the white matter of that body. This observer discards the internal geniculate bodies and the posterior corpora quadrigemina from the optic apparatus—a view that is apparently supported by Gudden's method of research. In the section of this work devoted to the special consideration of the cranial nerves, the optic fibers will be further discussed, and some of the later discoveries of Gudden and Ganser will then be mentioned.

gray matter unites the gray nuclei of the two bodies. Transverse fibers of the fillet bound this gray commissural band both superficially and deeply. Those lying superficially are continuous, in part, with the brachium of the lower quadrigeminal body, and in part, also, with the fibers of the lower fillet; the fibers of the lower fillet are described by Meynert as being continuous with the brachium of the opposite side. If this continuity really exists, the communication is probably an indirect one by means of interposed nerve cells in the gray matter.

The *posterior commissure* of the third ventricle, which lies above the upper end of the aqueduct of Sylvius, seems to be a direct continuation of the commissural fibers of the fillet which have been mentioned. It apparently springs from the tegmentum, and, after decussating, appears to traverse the substance of the thalamus, and then to radiate in the white substance of the hemisphere of the cerebrum. A few of its fibers are connected with the pineal gland; some also probably act as commissural fibers between the thalami (Fig. 37).

This hasty and somewhat imperfect *résumé* of the anatomy of these bodies will enable us to intelligently consider some of the views which have been advanced respecting their probable functions, and the effects of lesions within their substance.

Functions of the Corpora Quadrigemina.—Among the investigators who have devoted special attention to these bodies, Adamuck, Knoll, Budge, Hensen, Voelkers, Flourens, Schiff, Ferrier, McKendrick, Gudden, and many others of note, may be prominently mentioned. Some have observed the effects of their removal in animals; others have studied the results of stimulation of their superficial and deep parts; while a few have recorded the results of destruction of the optic apparatus and certain convolutions of the cerebral hemispheres, as possessing a peculiar bearing upon points in dispute regarding these bodies. From these different sources a mass of evidence has been accumulated which appears in some instances to lead to contradictory conclusions. It is only by comparing

the views of the investigators mentioned, and bringing to bear upon the subject what is also taught us by anatomical research, that the web may be partially disentangled. This subject will be considered again in connection with the fibers of the tegmentum cruris which are associated with these bodies.

The connection of the anterior quadrigeminal bodies, or the *nates cerebri*, with the optic tract and the sense of sight appears to be far more intimate than that of the posterior lobules, or *testes cerebri*, as was first pointed out clearly by Gudden. This observer found that the extirpation of the eye on one side of a young animal was followed by a degeneration and atrophy of the nates cerebri and its brachium; the testis and its brachium remaining unaltered. This view is apparently sustained also by the fact that the mole has the testes cerebri largely developed, whereas the nates cerebri are markedly atrophied. Adamuck believed that he had clearly demonstrated the existence of a center within the nates which presided over those movements of the eye and pupil which are essential to the *accommodation of vision for near objects*, as well as the *coördination of all ocular movements*. Knoll found, however, that reflex contractions of the pupil remained after removal of the corpora quadrigemina; and Hensen and Voelkers have been apparently successful in mapping out the topography of the centers which preside over ocular and pupillary movements with greater accuracy than their predecessors. They were able to produce at will, by carefully applied electric stimulation in the region of the floor of the aqueduct of Sylvius, independent movements of the eye and pupil. In the dog, upon which animal these experiments were made, a center which governed the *accommodation of vision*¹ was found to be situated in the posterior part of the third ventricle near to the aqueduct, while a center for pupillary contraction and one also for its dilatation were found in the front part of the floor of the aqueduct of Sylvius, the

¹ This center manifested an apparent control over the *ciliary muscle* only, and created alterations in the antero-posterior measurement of the crystalline lens of the eye.

former lying in the median plane and the latter more to the sides. The same observers state that a center, which governs those muscles of the eyeball which are supplied by the third cranial nerve, can be found in the floor of the aqueduct, immediately behind that which presides over pupillary contraction. Whether we accept these statements as demonstrated or not, we know positively that such centers exist somewhere, and are so associated in their action that, when the eyeballs are directed inward and downward, as for near vision, the pupils are at the same time contracted; and when the eyeballs are directed upward and returned to a state of parallelism, the pupils are dilated to a corresponding extent. On the contrary, when the eyeballs are moved sideways in unison, the pupils remain unchanged. A most positive proof that the pupillary movements are not of a psychical nature is afforded by the experiments of Adamuck, who produced movements of *both eyes* by stimulation of the corpora quadrigemina of either side, and who also observed that the pupils were at the same time made to perform their proper movements. When, however, the corpora quadrigemina of the two sides were separated by a median incision, stimulation of the centers of either side caused movements of the corresponding eyeball only. In both experiments, changing the seat of stimulation caused modifications of ocular movements.

It was only after Knoll had shown that the reflex movements of the pupils remained after complete excision of the corpora quadrigemina, and the discovery of Hensen and Voelkers that the effects of stimulation of these bodies, as first practiced by Adamuck, were not uniform until the *underlying parts* were directly reached, that discrepancies between these observers were explained.

To determine the true relations which these bodies bear to the special sense of sight is perhaps one of the most difficult problems in physiology.

Flourens and many subsequent observers have shown us that unilateral extirpation of the corpora quadrigemina in

mammals and birds leads to a blindness of the opposite eye ; and even when the cerebral hemispheres are removed without disturbing these bodies, that an apparently crude vision still remains. We have many experiments, however, to show that destruction of certain convolutions of the cerebrum also produced the most profound effects upon vision in spite of the undisturbed action of the quadrigeminal bodies. When we discussed the optic thalamus, it was also stated that many clinical observations pointed toward the existence of a center within that body which in some way modified or presided over visual impressions. We know also that lesions within the so-called "internal capsule" of the cerebrum frequently produced most serious impairment of vision, and conjugate deviation of the eyes.

In the pages which treat of the ganglia of the tegmentum, other functions of the corpora quadrigemina will be discussed. The reader is referred, therefore, to them for more exhaustive information.

Now, how are we to explain, theoretically, such contradictory phenomena? What views are we apparently justified in holding (from the standpoint of our present knowledge upon the subject) regarding the relations of the cerebral cortex, corpora quadrigemina, corpora geniculata, optic thalami, and internal capsule of the cerebrum, to the fibers of the optic tracts and the external organs of sight?

I think we are justified in attributing to the cells of the *cerebral cortex* (the external gray matter of the hemispheres) our conceptions of the external world, as portrayed to us by means of the sensory nerves and the special senses. No matter how many collections of gray matter may be interposed along the course of the nerve fibers which convey these impressions to the cortex (each of which may possibly help to modify them), there is no argument which has yet been advanced which tends to overthrow this general law. Every image cast upon the retina, every sound-wave which enters the external ear, every odoriferous particle which reaches the nose or is placed upon the tongue, every manner of form by

which we are brought into direct or indirect relation with surrounding objects during life, becomes a *conscious impression* only by affecting in some unknown way the cells of the cerebral cortex. Here the image thrown upon the retina becomes to our mind the picture actually seen ; the sound-wave becomes the musical note ; the contact of the odoriferous particle is transformed by the brain cells found in its external gray matter into a sense of smell or of taste ; objects become recognized as smooth or rough, hard or soft, heavy or light, only when these silent workers become thrown into activity by some sensory impulse carried to the convolutions of the brain by means of nerve fibers.

We have reason to believe that the fibers of the optic nerve reach the gray matter of the convolutions of the cerebrum by different routes ; and that each bundle meets (somewhere in its course) an interrupting mass of gray matter, with the cells of which the nerve fibers become associated, and from which cells they are subsequently prolonged to those of the cortex. This is the common method of arrangement of all nerve fibers, after they enter the substance of the brain or spinal cord, to which the optic fibers are no exception. The interrupting cells of the optic fibers are comprised chiefly within the optic thalami, the corpora geniculata, and the corpora quadrigemina. Stilling believes that a bundle of fibers can be traced to the *corpus subthalamicum*, and another to the *medulla oblongata*. The so-called "*basal optic ganglion* of Meynert" is thought by some to be also connected with a slender fasciculus of the nerve.

When speaking of these interpolated masses of gray matter and their controlling action upon all impulses sent to the brain, Michael Foster makes use of the following words, which I quote on account of their applicability to the subject under consideration :

"All day long and every day, multitudinous afferent impulses from eye, and ear, and skin, and muscle, and other tissues and organs, are streaming into our nervous system ; and did each afferent impulse issue as its correlative efferent

motor impulse, our life would be a prolonged convulsion. As it is, by the checks and counter-checks of cerebral and spinal activities, all these impulses are drilled and marshaled and kept in orderly array till a movement is called for; and thus we are able to execute at will the most complex bodily manœuvres, knowing only *why*, and unconscious or but dimly conscious *how*, we carry them out."

The study of the course of the individual fibers of the optic nerve in the region of the optic chiasm (Fig. 41) is rendered particularly difficult by the curved direction which they take; hence the relative proportion of the longitudinal and decussating bundles is still a subject of dispute among authorities upon that subject. Stilling states that inter-retinal fibers, which have no cerebral connection, can be demonstrated, while other authors deny it. Some assert that all of the fibers, which are prolonged into the optic tract, decussate in man, as they are known to do in the lower vertebrates and some mammals, but pathological observation tends to confute this view. Charcot advanced the theory some years since that those fibers of the optic nerve which do not decussate at the chiasm are continued along the optic tract of the corresponding side and eventually decussate (probably within the substance of the corpora quadrigemina) after which they are continued into the internal capsule of the opposite hemisphere. He sustained this theory on pathological grounds.

The latest researches of Wernicke and Stilling respecting the anatomy of the brain have tended, however, to confirm the original view of Meynert that the optic fibers radiate into the occipital lobes, as well as that of Munk also, who first advanced the statement that the area of the brain functionally associated with conscious visual impressions was confined to the cortex of the occipital lobes.

Wernicke has shown conclusively that a tract of fibers passes from the pulvinar of the optic thalamus to the occipital lobe of the same hemisphere, and that this tract is continuous with the fibers that compose the optic tract. He demon-

strates furthermore that this tract passes *beneath the angular gyrus*. Ferrier and Dalton have both pronounced the visual area of the cortex to be confined exclusively to these angular convolutions of the parietal lobe. This discovery of Wernicke seems to be a means of reconciling the views of Ferrier and Munk, that have been directly opposed to each other; since it is evident that a deep injury to the angular gyrus would cause impairment of Wernicke's tract (see Fig. 43).

A very valuable *résumé* of the latest discoveries, respecting the visual area of the cerebral cortex in man, by means of pathological investigation, has been lately published by M. Allen Starr,¹ of this city. This author brings forward the results of autopsies made upon some thirty cases where brain lesions had produced hemianopsia during life. He draws conclusions from these cases that differ from those that have been accepted as proved until within the past five years. Some of the more important deductions drawn from this remarkable compilation of autopsies are as follows :

1. The supposed decussation of those optic fibers, which do not cross at the chiasm, within the corpora quadrigemina (as schematically represented by Charcot in his diagram, and taught by him for years past), is erroneous, and has lately been discarded by its author.

2. The diagram of Grafe and Féré meets with the author's approval; and it has been adopted by Charcot, as more correct than his own.

3. He sustains the opinion of Mauthner that "there is no well-authenticated case in which a lesion of one hemisphere has produced blindness of the opposite side."

4. He believes that many of the cases, reported as those of amblyopia from brain lesions, are capable of being shown to be affected with hemianopsia.

5. That any lesion of the brain, if it affects the fibers of the optic tract, the pulvinar, Wernicke's tract, or the cortex of the occipital lobe, will cause hemianopsia. Hemianopsia must therefore be regarded as a symptom of a circumscribed

¹ "American Journal of the Medical Sciences," January, 1884.

lesion of one hemisphere rather than a general symptom of brain disease (see Fig. 43).

6. That the older view that "lateral homonymous hemianopsia" is always due to a lesion affecting the optic tracts at the base of the brain is an error and unworthy of perpetuation.

7. That the view of Munk, who believes that each occipital lobe presides over the vision of the corresponding half of each eye (the left lobe over the left half, and the right over the right half of each eye), is correct. The view of Ferrier, that the angular gyrus is directly associated with the visual sense, is not thus far supported by pathological research in man.

It is known that destruction of the retina in the dog gives rise to a *degeneration of nerve strands in both optic tracts*. The chiasm of the cat has been divided without destroying vision, thus warranting the inference that the decussation at that point is incomplete. All the experiments that have been made to determine the relation of the cortex cerebri to vision are in favor of an incomplete decussation, because the sight of both eyes has been impaired by unilateral lesions. A large number of cases have been reported where lesions affecting one optic tract have produced hemianopsia of both retinae.

Possibly the corpora quadrigemina preside over other functions in addition to the special sense of sight.¹ Flourens was the first to notice that injuries of the corpora quadrigemina, of one side produced peculiar phenomena called "*forced movements*," and that the complete removal of these bodies caused inco-ordination of movement. These experiments have been repeatedly verified. In the frog, the removal of the optic lobes causes an almost entire loss of the power of *co-ordination of movements required to preserve its balance*; but it can still perform a variety of movements where co-ordination is demanded, such as swim-

¹ The inferior corpora quadrigemina do not appear to be directly associated with optic fibers (Flehsig and Gudden).

ming, leaping, etc. Schiff has attributed these effects, however, to injury of deeper parts (*crura cerebri*). We shall discuss phenomena which are somewhat similar when the cerebellum is under discussion; but we have as yet no positive knowledge of the physiological connections between the optic lobes and the cerebellum.

The sense of sight has a marked effect upon co-ordination of movement, as we all know. Dizziness often follows the close inspection of a water-fall, or the rapid flight of objects before the eyes. The effect of extreme elevation from surrounding objects frequently produces marked disturbances of equilibrium. These facts seem to sustain the belief that the optic fibers must be closely associated with the cerebellum, pons Varolii, or *crura*, and the discovery of Flourens is an additional argument in its favor.

Finally, it is believed by some that a center which presides over the secretion of sweat is situated somewhere in the region of the *corpora quadrigemina*.

A SUMMARY OF THE EFFECTS OF LESIONS OF THE OPTIC CENTERS AND OPTIC NERVES.

In connection with the discussion of the *corpora quadrigemina* and the probable course and distribution of the nerves of sight, it seems to me an appropriate time to mention some interesting phenomena pertaining to vision which have an important bearing upon the localization of intra-cranial lesions. Before doing so, however, it will be necessary to hastily review a few important facts which are essential to a complete understanding of the subject.

The optic apparatus may be said to comprise the following parts:

1. *Certain cortical centers*, which act as the *interpreters* of visual sensations transmitted to the convolutions by means of the nerve fibers within the white substance of the cerebral hemispheres. These centers probably transform all impulses (which start originally as retinal impressions) into *conscious visual perceptions*.

2. *Nodal masses of gray matter*, with which the optic nerve fibers are intimately associated before entering the white substance of the cerebral hemisphere. These masses include the corpora quadrigemina, the corpora geniculata, the corpus sub-thalamicum, the optic center of the thalamus (Luys), the basal optic ganglion (Meynert), and probably some centers situated within the medulla oblongata.

These interrupting ganglia probably exercise a *modifying influence* of some kind upon the impulses which are conducted to them from the retinae; and subsequently allow them to pass to the cells of the cerebral convolutions so altered or *materialized* as to be readily transformed into conscious perceptions of external objects recognized by the eyes. It is not known what the special function of each of these interrupting masses is, nor can it be determined except through a more complete knowledge of cerebral architecture and pathology than we now possess.

3. *Nerve fibers within the optic nerves* and the *optic tracts*—the latter being the prolongation of the former behind the chiasm (see Fig. 43). These fibers convey all impressions made by objects external to the body upon the retinae, by means of the organ of sight, to the interrupting masses of gray matter mentioned above. The waves of light, which enter the pupil and fall upon the retina, create in the structural elements of that membrane (probably in the so-called “rods” and “cones of Jacob”) impulses which are conveyed by means of the optic fibers to the interrupting ganglion cells, and then to the convolutions of the cerebral hemisphere where these impulses become sight-impressions. It is evident, therefore, that anything which tends to interfere with the perfect conducting power of these fibers will impair the power of accurate conception of external objects revealed to us by means of vision, because the cortical centers are cut off from their retinal connections; hence the study of the course of the nerve fibers and the relations of the nerve tracts to surrounding parts becomes of vital importance to the advanced neurologist (the diagnosis of many cerebral and intercranial

lesions resting entirely or in part upon optic phenomena which are to be interpreted from an anatomical standpoint alone).

4. *The retina, and its various structural elements.* This membrane constitutes the peripheral portion of the nervous optic apparatus. It is the only place in the body where the nervous system is so exposed as to admit of a direct examination, since we can see it by aid of the ophthalmoscope, and thus study its diseased conditions as well as its appearance in health. Physiologically, it is to be considered as the sensitive plate from which the details of outline and color of external objects are telegraphed to the convolutions of the cerebrum.

The experiments of Flourens, already quoted, first demonstrated that a *crude sense of vision* remains in animals which have been deprived of their cerebral convolutions above the level of the corpora quadrigemina, and many subsequent observers have attested to the accuracy of his conclusions. These experiments point to some functions within the masses of gray matter that are associated with the optic fibers, which bear a close analogy to those of the cortical cells of the so-called "visual area" of the hemispheres. We are forced to accept the view that these ganglionic masses take cognizance of visual impulses in an imperfect way, although the cerebral convolutions seem to be essential to a complete transformation of visual impulses into conscious sight-perceptions. Section of the optic fibers after they leave the brain invariably destroys sight, thus proving that the retina itself has no inherent power of interpreting visual impressions which are cast upon it.

Now, from what has been stated, we can classify lesions which may affect or destroy the visual function as follows:

1. *Lesions of the retina*, or of some of the other structures of the visual apparatus which prevent the formation of images within it.

2. *Lesions of the optic nerve*, anteriorly to the chiasm, at which point the decussating fibers have crossed each other.

3. *Lesions of the optic tracts and the chiasm*, or of parts so adjacent to them as to create pressure upon the optic fibers.

4. *Lesions of those ganglionic masses* whose connection with the optic fibers has been demonstrated by anatomical or pathological research.

5. *Lesions of certain regions of the cortex cerebri*, which have been shown to be in intimate association with vision.

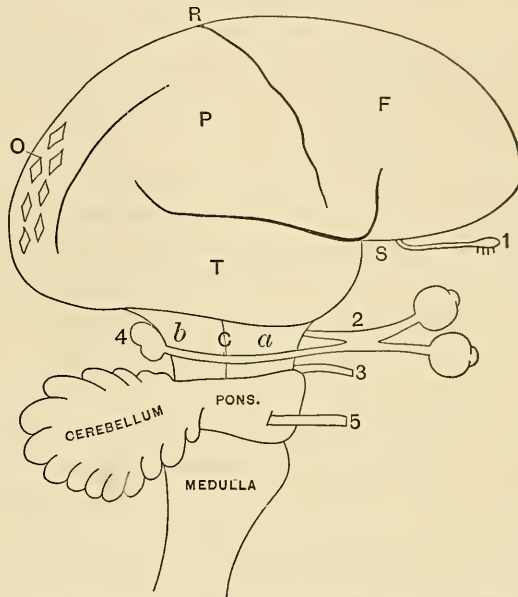


FIG. 42.—A diagram designed by the author to show some of the relations of the optic and olfactory nerve fibers to surrounding parts.

F, frontal lobes of cerebrum; P, parietal lobe; T, temporo-sphenoidal lobe; S, fissure of Sylvius; R, fissure of Rolando; O, occipital lobe; C, cerebellum; M, medulla oblongata; 1, olfactory nerve; 2, optic chiasm; 3, motor-oculi nerve; 4, corpora quadrigemina; 5, trigeminus nerve; a, basis cruris; b, tegmentum cruris. The diamonds in the occipital lobe, the cortical visual centers of Munk. The cerebellum and pons Varolii are shown as if separated from the cerebrum, in order to make the relations of the crus to the optic tracts apparent. This diagram should be compared with Fig. 43 to make its bearings upon cerebral localization apparent.

6. *Lesions of the internal capsule* of the cerebrum; or of such parts of the medullary center of each hemisphere as contain fibers connected with the "visual area" of the cortex.

The first set of causes of impairment of vision enumerated above belongs properly to the province of the oculist

rather than of the neurologist, although there is one condition which should always be sought for when cerebral disease is suspected, viz., *neuro-retinitis*, or the so-called "*choked disk*." The evidences of this condition are afforded by the ophthalmoscope alone, because vision is not impaired in the early stages. Its existence is recognized early by tortuosity of the veins of the fundus of the eye, swelling of the optic nerve, and obscureness of the margin of the disk; later, the outline of the disk becomes unnaturally sharp and distinct, the nerve atrophies, the vessels become very small, the fundus is unnaturally pale, and vision is impaired. This condition is always (?) bilateral, although it is not uncommon to note a marked difference in the severity of the changes in the two eyes. Special attention is called to this disease of the eye, because it is now considered as one of the most reliable signs of conditions of the cerebrum which tend to produce a *gradually increasing pressure*, particularly of tumors; and, in the second place, because its existence is liable to be overlooked, since vision is not impaired early.

The various phenomena which are due to paresis of ocular muscles,¹ and which have often the most positive value in definitely localizing cerebral disease, can not be considered under this set of symptoms or in this connection, because they do not govern in any way the sense of sight, although they assist the eye to focus images of objects upon the retina. My friend Dr. W. C. Ayers has lately made a valuable contribution to medical literature in the form of a *brochure* upon the value of the ophthalmoscope as an aid in general diagnosis,² which may well be consulted by all who desire practical information in regard to the utility of this instrument, and the intimate relationship which exists between the eye and the body, as revealed by clinical study.

The *second set* of causes of impairment of vision (lesions of the optic nerve anteriorly to the chiasm) includes chiefly

¹ These will be found by consulting subsequent pages which relate to the motor oculi nerve.

² "American Journal of the Medical Sciences," October, 1882.

those *conditions within the orbit* which create pressure upon, or destruction of, the optic nerve after it leaves the cavity of the cranium. It is evident from the diagram (Fig. 43) that the impairment of sight in this case will be confined exclusively to one eye. The phenomena produced by disease within the cavity of the orbit upon sight must, of course, depend upon the amount of injury done to the optic nerve. *Blindness of one eye* indicates, as a rule, some exciting cause outside of the cavity of the cranium. Remember that neither true amblyopia or total blindness of one eye occur in connection with pressure upon the optic nerve fibers either at the chiasm or behind it.

We come now to the *third set* of causes enumerated on page 184, viz., lesions of the optic tracts and chiasm. This set includes not only actual lesions of the nerve, but also pressure-effects exerted upon the optic fibers by lesions of adjacent structures. Before we pass to the consideration of the diagnostic symptoms of this condition, it is important that we review some of the relations of the optic chiasm and the optic tracts.

If we trace the optic nerve fibers from behind forward, we find that the *optic tracts* appear to arise from the optic thalami, the superior quadrigeminal bodies, and the corpora geniculata. As they leave the under surface of the thalami, they make a sudden bend forward and curve around the *crura cerebri* in the form of a flattened band (Fig. 43). At their anterior portions the tracts become closely attached to the *crura*, and, in the region of the *tuber cinerium*, an accession of fibers to the tracts may be demonstrated. Before the chiasm is reached the tracts become more cylindrical in form.

The *optic commissure*, or *chiasm*, is about half an inch long in its transverse measurement, and lies upon the olivary process of the sphenoid bone. The internal carotid arteries lie in close relation with it at the sides, and the anterior cerebral arteries, with their communicating branch, are so disposed as to constitute what might be called a *loop* about the

optic nerves. The clinical bearing of this fact will be discussed later. Henle reports a few remarkable instances where the chiasm was wanting, the optic tracts being continued without interruption to the eyeball of the corresponding side; but these abnormalities are so rare as to be of no practical importance from a clinical standpoint.

We are now able to study the diagram which I draw upon the blackboard, and to properly interpret the clinical deductions which may be drawn from it. It is intended to portray the effects of localized pressure upon the optic chiasm and optic tracts, as well as those of destructive lesions of the same, and of the "internal capsule" of the brain.

Now, this diagram is designed chiefly to portray the mechanism of one peculiar symptom, and the use to which it may be employed by the neurologist in definitely determining the seat of the disease-lesion which is creating it. I refer to "*hemianopsia*," or *blindness of one lateral half of the retina*.¹ The term "hemioptia" is often employed to express the same condition, although it is to my mind a poor one, since it simply means "half vision," and thus fails to express the idea intended.

The following steps are commonly employed to detect the existence of this symptom: Request the patient to close one eye by pressing the lid down with the finger, and to so direct the open eye as to concentrate its gaze upon some fixed object near to it. [I usually hold up the forefinger of my own hand within a foot of the patient's open eye, and tell him to look steadily at it.] Having done this, take some object which is easily seen (such as a small piece of white paper) in the unempoyed hand, and move it to the right and left of the object upon which the patient is gazing, and also above and below the object, asking the patient, in each case, if the two objects are seen simultaneously and with distinctness, and notice upon which side of the fixed object the patient can not perceive the moving object. It is self-evident that the retina is blind upon the side opposite to that upon which the moving object is lost

¹ This symptom will be discussed very fully in the second section of this work.

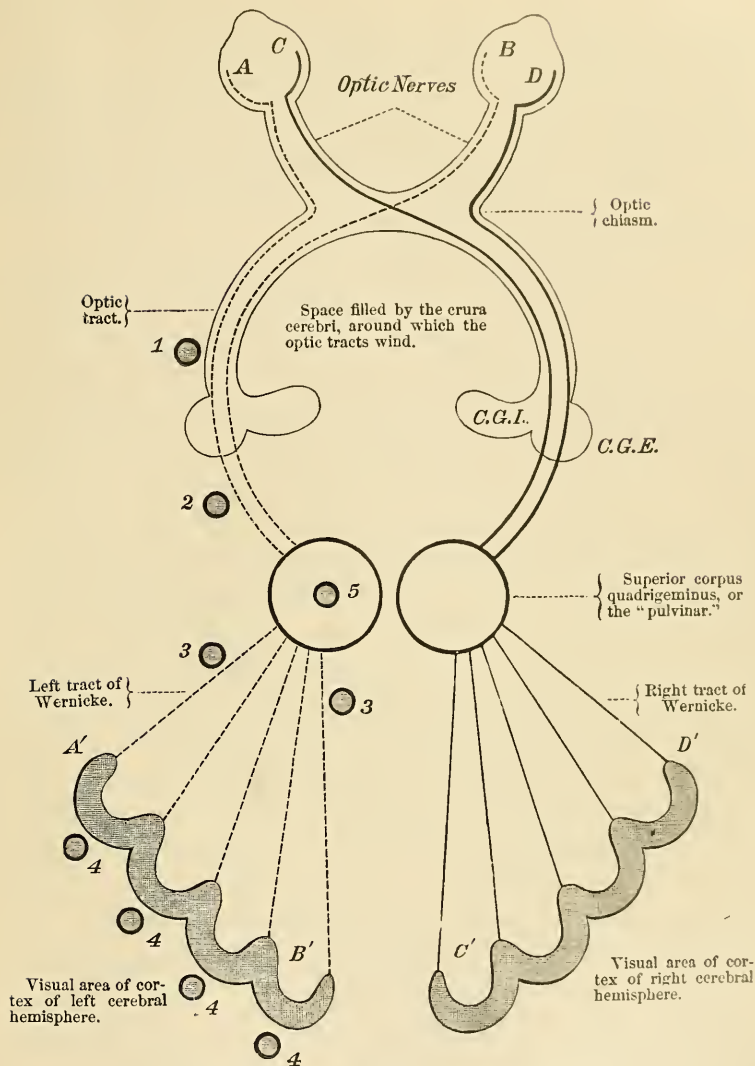


FIG. 43.—A diagram designed by the author to illustrate the latest views in reference to the course of the optic nerve fibers.

The dotted lines (A and B) arise from the left hemisphere; the continuous lines (C and D) arise from the right hemisphere. It will be perceived that the occipital cortex of the left hemisphere is shown to be connected with the left half of each eye, and the right hemisphere with the right half of each eye. The diagram also shows that the fibers of each optic tract pass through the external geniculate body, the superior corpora quadrigemina, or the pulvinar of the thalamus, before they radiate to the occipital cortex; 1, 2, 3, 4, 5, indicate the various localities where lateral homonymous hemianopsia can be produced; C, G, E, the external geniculate body; C, G, I, internal geniculate body.

to sight. The visual area can also be accurately drawn by means of a perimeter if it is deemed advisable.

The most common form of hemianopsia is that in which the *nasal half* of one eye and the *temporal half* of the other is blind, this condition being the result of injury done to parts posterior to the chiasm. When the *chiasm* is affected we commonly meet the *bi-nasal* type.

There is still one more form which is occasionally encountered, viz., the *bi-temporal* type. This has been interpreted by an autopsy made upon a case intrusted to the care of Prof. H. Knapp, of this city. It must be evident that the chances would be extremely small of ever encountering a bilateral lesion which would affect only those fibers of the optic chiasm, or optic tract, which supply the temporal half of each retina, and at the same time leave the decussating fibers intact. How, then, are we to account for the fact that this form is sometimes met with? In the preceding portion of this lecture I called your attention to a peculiar arrangement of the arteries in the region of the optic chiasm. Now, it has been shown that atheromatous degeneration of the "circle of Willis" (a peculiar arrangement of blood-vessels at the base of the brain) so impairs the elasticity of the arteries as to cause the pulsations of the carotids to aid in creating a type of injury to the chiasm, so limited in its extent as to impair only the fibers distributed to the temporal halves of the retinae, and thus to create bi-temporal hemianopsia.

We may, therefore, summarize the clinical significance of this peculiar form of blindness as follows :

(a) The *lateral homonymous variety* (where the left or right half of each eye is simultaneously affected) indicates lesions affecting the optic tract or its prolongations through the brain-substance to the cortex of the occipital lobes (the cortical centers of Munk).

(b) The *bi-nasal variety* indicates a lesion pressing upon the central portion of the chiasm.

(c) The *bi-temporal variety* indicates, as a rule, atheromatous degeneration of the circle of Willis. Possibly (?) sym-

metrical lesions of the outer part of the chiasm might also cause it. The view of Charcot, that a decussation of the optic fibers takes place within the substance of the corpora quadrigemina, is not sustained by a recorded case of bi-temporal hemianopsia produced by a circumscribed lesion within those bodies, and can be dismissed as incorrect.

(d) Finally, lesions of the *internal capsule* are sometimes associated with *lateral homonymous hemianopsia*.

The bi-nasal, and also the bi-temporal, varieties are due (as a rule, at least) to lesions confined to the *anterior fossa* of the cranium; hence we sometimes find the *olfactory nerve* of the side corresponding to the seat of the lesion simultaneously affected, and creating anosmia (loss of smell) with or without subjective odors.

If the lesion be situated within the *middle fossa* of the cranium, the *optic tracts* may be affected, thus causing lateral homonymous hemianopsia, while the *motor nerves of the eye* may be simultaneously pressed upon as they pass through that fossa on the way to their foramen of exit from the cranium (the sphenoidal fissure), thus producing more or less impairment of the movements of the eyeball of the same side. The value of these complications cannot be over-estimated, when they exist, because they are of the greatest aid in diagnosis, and often enable a skilled anatomist to positively determine the seat of the lesion.

The *fourth set* of causes of impairment of vision (according to the classification given on page 184) comprises all diseased conditions which are limited exclusively to those ganglionic masses through which the optic fibers pass in order to reach their connections with the convolutions of the cerebrum. If we confine ourselves to this strict limitation, we are forced to admit that little can positively be said respecting them which will bear upon intra-cranial diagnosis, because, to my knowledge, there are no recorded cases where evidences of cerebral disease have been confined exclusively to these regions.

There are some symptoms, however, that may coexist with disturbances of vision when lesions exist in parts contained

within the middle fossa of the skull; these may prove of assistance in deciding as to the seat of the lesion. Among them may be enumerated: 1. *Crossed paralysis* of the “*third nerve and body*” type, a condition characterized by hemiplegia and paralysis of the motor-oculi nerve of the opposite side. 2. *Crossed paralysis* of the “*olfactory nerve and body*” type, a condition characterized by hemiplegia and loss of smell in the opposite nostril. 3. *Hemiplegia*, or loss of the power of voluntary motion in one lateral half of the body. 4. *Hemianæsthesia*, or a loss of sensation in one lateral half of the body. 5. *Ataxic symptoms*, indicating an impairment of coördination of muscular movements.

The first of these points positively to a *lesion of the crus cerebri*, if unattended by other symptoms. But, if evidences of disturbance of the optic tract (lateral homonymous hemianopsia) exists simultaneously with this form of crossed paralysis, it indicates that the lesion is large enough to interfere also with the optic nerve, as well as the motor-oculi fibers within the crus and the motor tract of the crus. The symptoms of this variety of crossed paralysis are so well defined as to render it almost impossible to mistake them.

The second condition (crossed paralysis of the olfactory nerve and body type) may occur when the lesion is sufficiently large to create pressure upon the motor tracts of the brain, thus causing hemiplegia of the opposite side, and at the same time to injure the olfactory nerve, thus causing anosmia (loss of smell) in the nostril of the corresponding side. Of course the optic tract or chiasm must be involved simultaneously when hemianopsia also exists. The tests for anosmia will be given in a subsequent section of this work.

Hemiplegia may occur in connection with hemianopsia when the lesion is of sufficient size to affect any part of the so-called “*motor tract*” simultaneously with the optic nerve fibers. The motor paralysis is chiefly manifested on the side opposite to the lesion; because the fibers of the motor tract decussate at the lower part of the medulla. Flechsig has shown that, in rare cases, *exceptions* to this general rule are

to be explained by an abnormality in the decussation of the motor fibers. Hemiplegia is now and then observed in connection with hemianopsia; although the olfactory, motor-oculi, trigeminus, and facial nerve roots are equally liable to be simultaneously involved. This explains the mechanism of

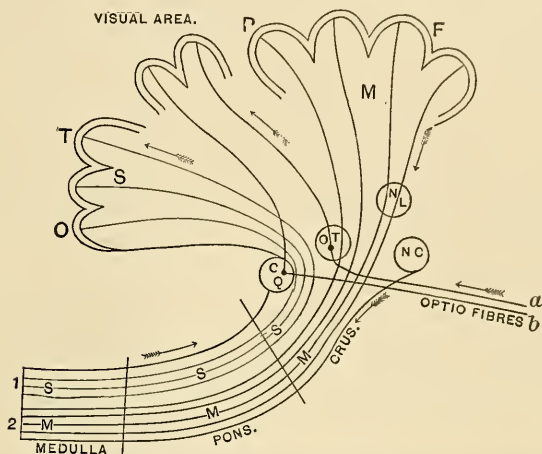


FIG. 44.—A diagram designed by the author to show the general course of fibers in the "sensory" and "motor tracts," and their relation to certain fasciculi of the optic nerve tracts. (Modified from Seguin.)

S, sensory tract in posterior region of mesocephalon, extending to O and T, occipital and temporal lobes of hemispheres; M, motor tract in basis cruris, extending to P and F, parietal and (part of) frontal lobes of hemispheres; C Q, corpus quadrigeminum; O T, optic thalamus; N L, nucleus lenticularis; N C, nucleus caudatus; 1, the fibers forming the "tegmentum cruris" (Meynert); 2, the fibers forming the "basis cruris" (Meynert); *a*, fibers of the optic nerve which become associated with the "optic center" in the optic thalamus, and are subsequently prolonged to the "visual area" of the convolutions of the cerebrum; *b*, optic fibers which join the cells of the "corpora quadrigemina," and are then prolonged to the visual area of the cerebral cortex.

the four varieties of "crossed paralysis" which are encountered, the hemiplegia being on the side opposite to the lesion, and the symptoms produced by paralysis of the cranial nerve being confined to the side corresponding to the lesion.

Hemianæsthesia indicates some disturbance of the nerve fibers of the so-called "sensory tract"; the loss of sensation being confined to the lateral half of the body opposite to the lesion which causes it, because the sensory fibers decussate in the spinal cord. In cerebral hemianæsthesia there is more or less insensibility to touch, pain, and temperature, and also

abolition of muscular sensibility with complete retention of electro-motor contractility. The mucous membranes of the eye, nose, and mouth are also anæsthetic. Now the upper portion of the sensory tract lies in the posterior regions of the crus cerebri and the internal capsule, and is in close relation with the posterior basal ganglia. The fibers of the optic tract may be likewise affected simultaneously with lesions of the following parts: The crus, the internal capsule, the optic thalamus, the corpora quadrigemina, the geniculate bodies, and the medulla. Our ability to definitely locate lesions of the sensory tract, or of the ganglia connected with it, is as yet imperfect. It is only by the careful study of associated symptoms that conclusions can be arrived at.

Ataxic manifestations, occurring in connection with evidences of impairment of the sense of sight, open a wide field for speculation. The proximity and intimate structural relations of the cerebellum with the corpora quadrigemina, basal ganglia, crus, and medulla, suggest the possibility of cerebellar lesions when these two symptoms are present to a marked degree. The subject is too complex for discussion here. It will be more intelligible after the cerebellum has been considered.

The *fifth set* of causes of impairment of vision previously tabulated on page 184 will now be considered. Within the past few years the attention of physiologists has been directed, by some remarkable results of experimentation upon the convolutions of the cerebral cortex, toward the view that certain convolutions of the cerebrum were essential to perfect visual perceptions. To Flourens and some of the older observers, who had remarked that the removal of portions of the hemispheres, or serious injury to them, created blindness, the loss of sight appeared to be temporary. The statement was explained in various ways, until Goltz called attention to the error of supposing that no permanent imperfections of vision remained after extensive injuries to the cerebral hemispheres. This author showed that the permanent results of such injuries might escape notice unless special care was used

in the examinations of the animal. The peculiarities of the permanent impairment of vision are manifested only when the animal is subjected to tests which had been invariably potent before the cerebral injury. Thus the dog, from which portions of the cerebral hemispheres had been removed, fails to recognize his food by sight; when he is threatened by a whip he is not cowed; he is no longer affected by objects which caused him to be violently excited before the mutilation; he makes no response to the extension of the hand of his master for the paw; and yet this animal can see to avoid objects and to perform all varieties of movement as well as in his natural condition. Another striking characteristic of this impairment of sight is, that under educational exercise recovery takes place. The dog may again be taught to fear castigation and to shrink at the sight of the whip; to recognize his food; to obey the motion of his master's hand, etc.

Two interpretations of these phenomena have been suggested: The first is, that the animal has imperfect visual perceptions, so that objects appear misty or as if seen through a gauze. Goltz suggests that they may appear as if all the colors were washed out, thus depriving food, dress, etc., of their characteristic appearances. The second interpretation supposes that the memory of past visual impressions is effaced, so that the animal forgets the pain of the lash, the taste of the food, the features of his master, the tricks which have been laboriously taught him. The first view is that of Goltz, who considers that the animal has to learn to use his imperfect visual perceptions before his intellectual faculties (which are presumed to be unimpaired) can respond to them in a proper way. The second view is that of Munk, who speaks of this form of imperfect vision as "psychical blindness," in contrast to "absolute blindness," which is the result of destruction of the optic fibers. The condition of the animal resembles that of the new-born. Retinal impressions have no associations connected with them. During the period of recovery the animal has to acquire a new memory, as it were.

With this distinction clearly in mind, we are prepared to discuss the views of Ferrier, Goltz, Munk, Luciani, Tamburini, Yeo, Dalton, and others respecting the exact seat of the visual centers within the cortex cerebri.

Goltz, in his experiments upon dogs, was unable to recognize any distinct areas which presided exclusively over visual impressions. He insists that disturbances of general sensibility accompanied the impairment of vision produced by destruction of the convolutions, and that the results depended upon the amount of brain-substance removed or destroyed. He found, however, that the locality operated upon influenced the phenomena which followed, and that recovery would take place if the injury was not too extensive. Goltz destroyed the brain by making a hole, or a number of them, through the skull, and using a *forcible stream of water* to wash away the brain-substance. The faults of the method may account for the negative results obtained by it.

Ferrier investigated the subject chiefly upon the monkey tribe (the nearest approach to the human race) and arrived at conclusions of a more positive character. This observer was led to adopt a more certain way of limiting the injury done to the cortex than that of Goltz. His conclusions may be thus summarized: When the "angular gyrus"—a convolution of the parietal lobe, so called from its shape, since it forms a sharp angle (see Fig. 22)—was destroyed upon one side only, the vision of the *opposite eye* was destroyed for a time, but it eventually regained its powers. If the angular gyrus of each hemisphere was simultaneously destroyed, the *loss of sight was permanent* and both eyes were equally affected. Hence it would appear that each hemisphere is in some way connected with both eyes, because unilateral destruction of this convolution does not create permanent blindness, as it would do if the opposite hemisphere did not come to its relief. Dalton has lately confirmed the views of Ferrier by experiments made upon dogs, thus tending to confute the view of Goltz that the effects of cortical lesions depend more on their extent than on their position. The animals operated upon by this

observer remained permanently blind, although the lesion was unilateral.

Munk, on the other hand, has confined his experiments chiefly to the occipital lobes of the cerebrum, and has apparently demonstrated the existence of a "visual area," differing in position and of much wider extent than that of Ferrier. He maintains that certain parts of this region can be shown to preside over *limited portions* of the retina, and that blindness of circumscribed spots in the retina can be artificially produced. He states that the "absolute blindness" thus created is commonly associated with "psychical blindness," from which the animal may recover by proper exercise and training, provided the whole visual area is not destroyed. This author attributes the recovery to a deposition of new visual experiences in the rest of the visual area. The view advanced by Munk is now quite generally accepted as the true one. The optic fibers pass closely to the cortex of the angular gyrus in order to reach the occipital lobe. Ferrier and Dalton probably severed them.

The *sixth set* of causes of impairment of vision, previously tabulated on page 184, has been discussed in part in connection with the others. We have a mass of clinical as well as experimental evidence to show that destructive lesions situated within the *posterior one third* of the internal capsule cause *hemianæsthesia* on the opposite side of the body.

As regards vision, the symptoms which sometimes exist are especially noteworthy. There appears to be developed on the anæsthetic side a partial blindness of the eye (*amblyopia* or *hemianopsia*), and the *field of vision for color* is remarkably contracted, as first pointed out by Landolt.

In the normal eye the field for blue is the largest; next comes that for yellow; then orange, red, green, and violet have fields of gradually diminishing size, the last being perceived only by the most central parts of the retina. Now, in connection with hemianæsthesia caused by cerebral lesions, the perception of violet first disappears, then of green, and later of orange. In some cases, yellow and blue can be per-

fectly recognized ; but in the higher degrees of anæsthesia all colors merge into a uniform sepia tint. Another important fact has been pointed out by Landolt, viz., that the eye on the same side as the lesion participates, though to a less extent, in the loss of color-perception.

Clinical Deductions drawn from Preceding Pages.—*Amblyopia* of one eye can result from lesions involving the optic nerve *in front of the chiasm*, or possibly (?) from *lesions of the internal capsule*. If from the latter, the field for color-perceptions will be found to be markedly contracted or color-vision will be wanting ; both eyes may be affected, the most marked changes being found, however, in the eye opposite to the seat of the lesion.

Hemianopsia may occur when the occipital lobes (chiefly the cortex of the cuneus), Wernicke's tract, the pulvinar of the thalamus, the *optic tracts*, or the *optic chiasm* are pressed upon or destroyed by lesions of, or in the region of, the cerebrum. It is evident, therefore, that the trephine cannot always afford relief of this symptom. When syphilitic gumata may be suspected, the prognosis is extremely favorable if active treatment be employed. The variety of hemianopsia often indicates the seat of the lesion with great exactness.

If *paralysis* (in any of its forms) coexist with hemianopsia, a valuable guide will often be afforded in determining the extent of the lesion.

Crossed paralysis of the "olfactory nerve and body type" indicates a localized pressure which is chiefly exerted upon parts *within the anterior fossa of the skull*. The motor tract is probably involved by upward pressure upon the caudate or lenticular nucleus, or the fibers of the internal capsule, thus accounting for the hemiplegia of the opposite half of the body. The olfactory nerve, which lies near to the optic chiasm, is affected by pressure in the downward direction, and the optic chiasm or tract may be simultaneously involved ; hence a loss of smell in the nostril on the same side as the lesion may coexist with some form of hemianopsia, as well as with a crossed hemiplegia.

Crossed paralysis of the "motor-oculi nerve and body" type indicates a *lesion situated within the crus cerebri*. If hemianopsia be present in connection with this condition, it proves conclusively that the optic tract, which lies in close relation with the crus, is simultaneously affected by the lesion. We find, therefore, that the eye on the same side as the lesion is blind in its temporal half if the optic tract be involved; that it can no longer be turned toward the nose or made to act in parallelism with the opposite eye; that the pupil is dilated; and that the upper eyelid droops over the eyeball, giving it a sleepy appearance. On the side opposite to the lesion the eye is blind in its nasal half, and the body is hemiplegic. There are few conditions which are of greater clinical importance than this type of crossed paralysis, because the seat of the lesion is positively indicated.

Choked disk is a common symptom of lesions of the base of the cerebrum, and of any intra-cranial disease which produces a gradually increasing pressure. It is specially diagnostic of tumors. It is not associated with impairment of vision until late, so that it is often unsuspected when present. The ophthalmoscope is necessary for its detection. It may coexist with hemianopsia, and is always bilateral. It is a positive contra-indication to trephining.

Lesions at the base of the skull may *cross the mesial line*, and still involve only one optic tract. If this occurs, the hemianopsia will be accompanied by other symptoms of diagnostic importance, no longer confined to one side. Double anosmia, general paresis or complete paralysis, general anaesthesia, and paralytic symptoms referable to both eyeballs, might be thus produced. Lesions of this character are more liable to affect the chiasm of the optic nerves than the optic tracts; in either case, however, hemianopsia would result, and its type would be a reliable guide to the seat of pressure (see Fig. 43).

Crossed paralysis of the "facial nerve and body type" is not as liable to coexist with hemianopsia as the two forms previously mentioned. The reason for this is a purely ana-

tomical one. The symptoms of facial paralysis are too involved to be given here in detail.

Uncomplicated hemianopsia indicates that no pressure-effects are exerted upon the motor or sensory projection tracts, or adjacent nerves.

Aphasia sometimes coexists with hemianopsia. I have met with two instances of this kind. In one there was slight paresis of the left side, tending to prove that aphasia can occur with lesions involving the right hemisphere. Both were cured with specific treatment. We must attribute the development of this complication to pressure upon parts in the neighborhood of Broca's center, or to lesions of the internal capsule, where the speech tract comes in close relation to the optic fibers (Fig. 39).

Lesions confined to the crus cerebri seldom create impairment of any of the special senses excepting that of the sight. These cases are not associated with impairment of intellect or usually of speech. It has been claimed that severe lesions cause paralysis of the bladder, but I have never encountered it. Many points of interest pertaining to lesions of the crura will be considered later.

THE CRURA CEREBRI.

If, after the removal of the brain from the skull, the base of the cerebrum be examined, the adjacent parts being left intact (Fig. 28), it will be perceived that the crura cerebri emerge from the upper border of the pons Varolii, diverge from one another, and then disappear in the cerebral hemispheres, passing beneath the optic tracts. A space is thus left between the crura, in which may be seen the so-called "*posterior perforated space*" (where the vessels enter the brain to supply the optic thalamus), and the "*corpora mammillaria*" (Fig. 37), which are formed by the anterior pillars of the fornix.

On the inner aspect of each crus, near to the angle of divergence from its fellow, may be noticed several bundles of

fibers which issue from its substance to form the third cranial or "motor-oculi" nerve of the corresponding side. The groove, from which these bundles escape, may be considered as an external indication of the separation of the fibers contained within the crus into two bundles (the "*basis cruris*," or "*crusta*," and the "*tegmentum cruris*"), which we have already discussed (Fig. 45). The larger portion of the crus, which lies anterior to this groove, is the "*crusta*"; while the "*tegmentum*" is the smaller or posterior portion.

If a cross-section of the crus be now made, it will be perceived (Fig. 45) that the *crusta* and *tegmentum* are separated by a tract of dark-colored gray substance, the "*substantia*

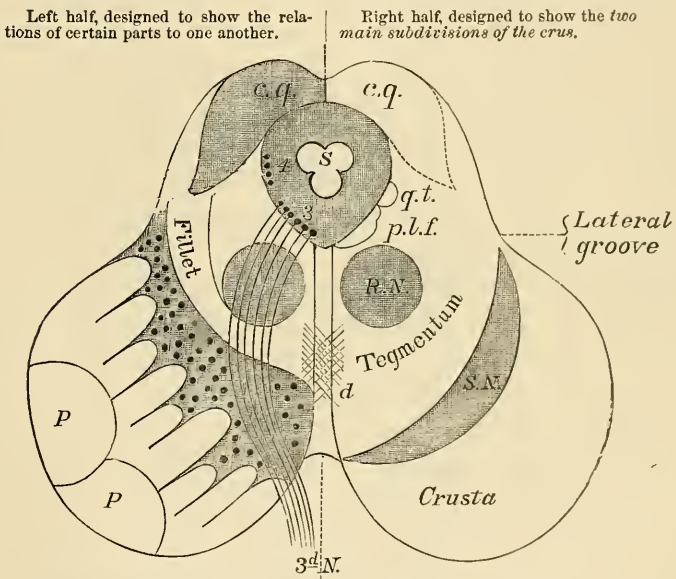


FIG. 45.—A diagrammatic representation by the author of the parts seen in a horizontal cross-section on a level with the superior quadrigeminal body.

c. q., corpora quadrigemina; *S. N.*, substantia nigra; *R. N.*, red nucleus; *S.*, aqueduct of Sylvius, surrounded by its gray matter; *q. t.*, tract of trigemina nerve root (quintus tract); *p. l. f.*, posterior longitudinal fasciculus.

nigra" of Soemmering. This collection of nerve cells comes to the surface, on the inner aspect of the crus, at a point which corresponds to the escape of the fasciculi of the third cranial nerve (the *sulcus oculo-motori*), and, on the outer

aspect of the crus, along a grooved line (the *lateral sulcus*). The construction of the two main subdivisions of the crus and its collections of gray matter must be considered separately.

THE CRUSTA OR BASIS CRURIS (*proper cerebral peduncle*).—This portion of the cerebral peduncle lies ventrad of the substantia nigra, and is formed almost entirely of bundles of fibers running longitudinally, and continuous below with those of the pons Varolii and medulla oblongata (Fig. 8). It is semilunar in section—the concave surface of the substantia nigra projecting into it (Fig. 45).

Those bundles which lie adjacent to the substantia nigra are smaller than the rest and are partially separated by processes of this gray mass (left half of Fig. 45). They have been named by Meynert the "*stratum intermedium*." Their origin and termination differ from those of the bundles which lie more anteriorly. They serve to connect chiefly the cells of the substantia nigra with the reticular formation of the pons and medulla, although a few pass upward to join the lenticular nucleus (Meynert).

The main tracts of the crusta are a direct prolongation downward of fibers of the internal capsule of the cerebrum (Fig. 8) and corona radiata. These fibers are continuous below with those of the anterior pyramids of the medulla oblongata, at the lower part of which ganglion the majority of the bundles decussate and pass down the *lateral* columns of the opposite side of the spinal cord as the "*crossed pyramidal tracts*" (Fig. 46). The ganglia of origin are possibly the nucleus caudatus and the nucleus lenticularis, but more probably the cells of the motor cerebral gyri.

The bundles which are situated in the lateral or outer part of the crusta are stated by Meynert to present peculiarities of origin and distribution. He believes that the fibers which compose these bundles arise from the occipital, parietal, and temporo-sphenoidal lobes of the cerebrum (the *sensory area*), and enter the crus without any apparent connection with the cells of the basal ganglia; that they decussate in the

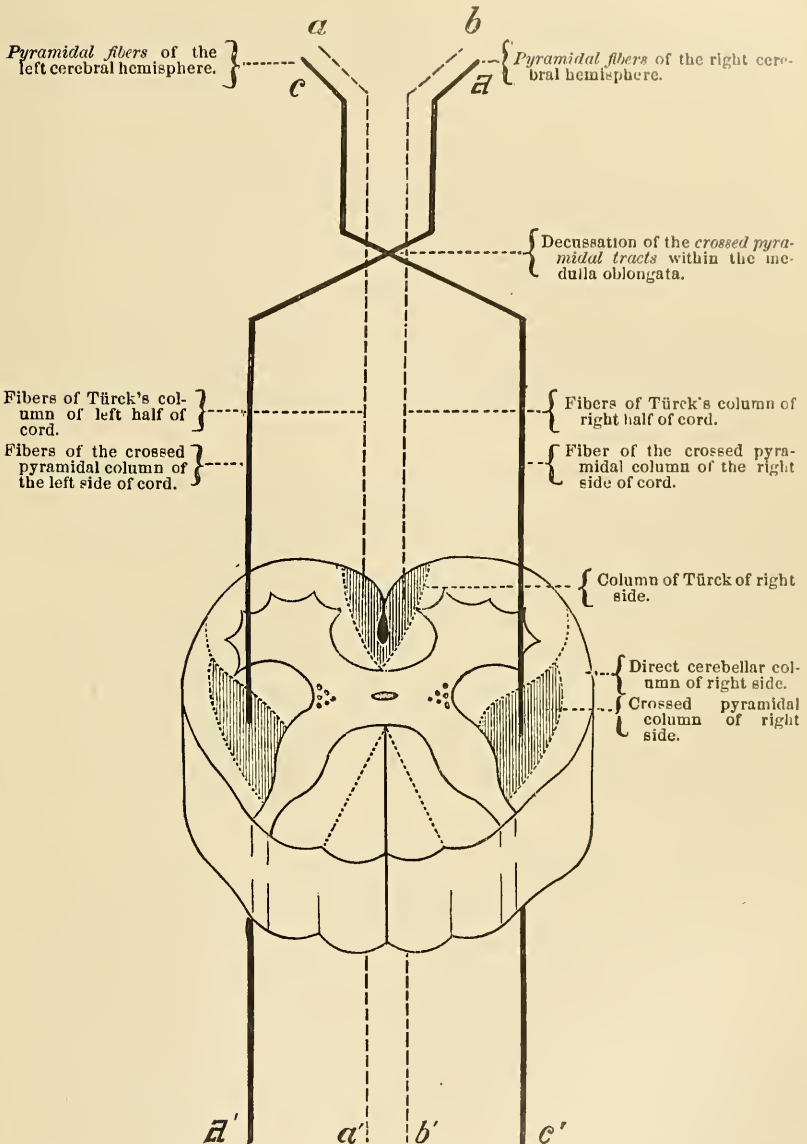


FIG. 46.—A diagram designed by the author to show the course of the fibers of the crusta cerebri (motor) after they leave the pyramids of the medulla.

The direct pyramidal tracts (a-a, b-b) pass down the column of Türck (T's Col.) of the same side of the cord. The crossed pyramidal tracts (c-c, d-d) pass down the so-called crossed pyramidal column (C. P. C.) of the opposite side of the cord; B's C., Burdach's column; G's C., Goll's column; D. C. C., direct cerebellar column.

medulla, above the point of crossing of the lateral pyramidal fasciculus just described; and, finally, that they can be traced to the *posterior column* of the opposite side of the spinal cord.

Flechsig has shown that the bundles of the crusta lying nearest to the mesial plane of the body are developed later than those of the main pyramidal tracts, and are therefore to be considered as a distinct formation.

Finally, there remain to be added to the four sets of fibers already described certain bundles which are *connected with the cerebellum* and which interlace themselves with the fibers of the cerebral tracts—chiefly during their passage through the pons Varolii.

In summary, it may be said that the crusta is composed of five sets of bundles, each of which has probably a function of its own, and certain individual peculiarities of distribution which distinguish it from the others.

I have not mentioned among these five distinct tracts of the crusta the fibers of the third cranial nerve which are depicted in the diagram (Fig. 45). The motor-oculi fibers escape from the crus in the region of the substantia nigra, and are, therefore, not associated with those bundles which lie anteriorly to it.

The ganglia of origin of the fibers which help to compose the crusta are believed to be as follows: (1), *The nucleus caudatus*; (2), *the nucleus lenticularis*; (3), *the substantia nigra*; (4), *the motor cerebral convolutions*; (5), possibly some parts of the sensory area of the cerebral cortex. The first and second, as well as the fourth and fifth, have already been described as parts of the so-called “corpus striatum,” and the fibers of the crusta which are anatomically related to them have received more or less notice in previous pages. It is necessary, therefore, to confine our remarks here only to the third of these ganglionic masses.

THE SUBSTANTIA NIGRA (*locus niger*).—This collection of gray matter separates the fibers of the crusta from those of the tegmentum cruris (Fig. 45). Its limits extend vertically from

the posterior border of the corpora albicantia to the upper border of the pons Varolii. The nerve cells which compose it are darkly pigmented. This gives it the appearance indicated by its name. It is thicker in its mesial portion than laterally, and sends out processes which penetrate between the longitudinal bundles which form the crusta. One very marked projection, in which the nerve cells are smaller and more numerous than elsewhere, marks the dividing line between the inner and middle thirds of the crusta.

At its inner border, the substantia nigra is traversed by the fibers of origin of the third cranial or motor-oculi nerve (Fig. 45). Some of these fibers also pass through its inner third.

The *cells* of the substantia nigra are supposed to afford a communication between fibers of the cerebrum and some bundles of the cerebellar system of fibers. Certain spinal fibers also terminate within them, according to Meynert and others. When we consider how marvelous it is that the muscular apparatus can act in perfect harmony with the impressions which we are constantly receiving by means of sight, hearing, and the tactile sense, as exhibited in the finer feats of balancing, dancing, etc., it becomes evident that the nerves which carry such sensory impressions to the nerve centers must be brought somewhere into a close relationship with the motor nerves which influence the muscles of the extremities. It has been already shown that an animal deprived of the cerebral hemispheres (but not of the basal ganglia) can perform feats of equilibrium with perfect exactness. It is manifest, therefore, that we must look to the basal ganglia of the cerebrum, or to parts associated with them (chiefly the cerebellum), as the probable seat of these coördinated movements. To what extent the cells of the substantia nigra enter into this complicated mechanism is as yet problematical, but there is little doubt that it constitutes one of its important factors.

THE TEGMENTUM CRURIS.—The fibers of the posterior division of the crus cerebri (Fig. 45) have the following ganglia

of origin: (1), The *optic thalami*; (2), the *corpora quadrigemina*; (3), the *corpora geniculata*; (4), the *corpora mammillaria*; (5), the *ansa peduncularis*; (6), the *pineal gland*; (7), the *red nucleus*; (8), the *ganglion of the habenula*.

Most of these have been already considered. The remainder will be described in connection with the fibers which arise from them.

The tegmentum is composed of small longitudinal bundles of nerve fibers, more or less extensively interlaced by others which are directed transversely.¹ The bundles are also sepa-

¹ The distinct nerve tracts within the tegmentum cruris have been lately observed by Flechsig, with a view of determining the relative periods of development of each, and thus positively determining their course and probable functions with some approach to accuracy. It may be well to summarize the results of these investigations, as follows:

1. The *superior peduncle of the cerebellum* ("processus e cerebello ad testes" of the earlier anatomists) was found to arise (1) from the dentate nucleus, and (2) from the cerebellar cortex near to the worm. By the first point of origin, it is brought indirectly into intimate relationship with the restiform tracts of the cord and some parts of the cerebellar cortex. Some of its fibers appear to terminate in the red nucleus of the opposite side. The remaining bundles terminate, according to this author, in the lenticular nucleus and the corona radiata.

2. The *lemniscus* seems to consist of two distinct sets of fibers; one of which undergoes descending degeneration, and the other ascending degeneration when separated from their trophic centers. We can, therefore, conclude that they carry impulses that correspond to the form of degeneration that they undergo, one centrifugal and the other centripetal. The centrifugal conducting tract comprises two thirds of the entire bulk of the lemniscus. It arises from the external division of the lenticular nucleus of the corpus striatum and takes the following course from above downward: (1) across the internal capsule; (2) above the body of Luys; (3) to the outer side of the red nucleus; (4) through the substance of the pons, lying dorsal of the pyramidal tracts; (5) it terminates in the olivary body. The centripetal conducting tract arises at the sensory decussation of the medulla and then passes through the pons and afterward behind the red nucleus of the tegmentum. It then turns beneath the corpus quadrigeminum inferior and the pulvinar, and becomes lost in the corona radiata.

3. The *posterior longitudinal fasciculus*. This bundle seems to be composed of fibers of association between the nuclei of origin of the cranial nerve roots, chiefly those of the third, fourth, and sixth nerves. It can be shown to be connected, below, with the anterior columns of the cord, thus demonstrating that it is physiologically related to motion. Superiorly, it is continued into the gray lining of the third ventricle. This tract is the first to be developed in the brain of the fetus. It lies immediately beneath the gray lining of the fourth ventricle.

4. The *formatio reticularis*. The fibers that become intermingled in this structure are not yet definitely settled. Flechsig's researches seem to establish the presence of fibers that descend from the quadrigeminal bodies, as well as some that ascend from the posterior columns of the cord.

5. The *general sensory tract* from the periphery to the cerebral cortex seems to be formed above the medulla by the union of fibers derived from the superior peduncle of the

rated to some extent by collections of gray matter containing scattered nerve cells. Some of the bundles form well-defined tracts. These will demand a separate description.

The Posterior Longitudinal Bundle.—This tract of fibers (Fig. 45) lies between the gray matter underlying the aqueduct of Sylvius and the so-called “reticular formation,” so well defined in transverse sections made through the upper part of the pons Varolii. If traced upward, the fibers which compose this bundle seem to become lost in the region of the posterior commissure, either by becoming intermingled with the nuclei of origin of the third and fourth cranial nerves in the mesencephalon, or by a dispersion in the reticular formation. Below, they appear to be a continuation of the fibers of the *anterior column of the spinal cord*. It will be again referred to when the architecture of the medulla oblongata is considered.

The Superior Peduncle of the Cerebellum.—This tract will be discussed in detail in connection with the description of the cerebellum. It has been already referred to when the caudate nucleus of the corpus striatum was under consideration. It bears an intimate relation after decussation with the red nucleus of the tegmentum (Fig. 45), from the cells of which some accessory fibers are probably given to it. The decussation of the fibers of this tract can easily be demonstrated in all cross-sections. It is claimed by Luys that this bundle of fibers enables the cerebellum to reënforce the cells of the corpus striatum. Some anatomists claim that the optic thalamus receives some of its fibers. Flechsig traces its fibers to the lenticular nucleus and the corona radiata.

The Tract of the Fillet (Lemniscus Tract).—This tract has been the subject of much investigation. At the upper level

cerebellum, the sensory division of the lemniscus, the ascending fibers of the formatio reticularis, and a few fibers of the posterior longitudinal bundle. These tracts unite at about the level of the quadrigeminal bodies. They then become joined by fibers arising from these bodies and pass into the posterior part of the internal capsule, and radiate, opposite the posterior third of the thalamus, into the cortex of the parietal and temporal regions and the precuneus. The term “corona of the tegmentum” is applied to the tract as a whole.

of the pons it appears as a flattened bundle of longitudinal fibers at the anterior border of the reticular formation (Fig. 45). It is prolonged cephalad into the corresponding part of the tegmentum. Some of its fibers pass obliquely outward, and curve over the cerebellar peduncle at the side of the crus. In the latter respect, they resemble the course of the *anterior medullary velum*, whose fibers reënforce those of the fillet. A layer of gray matter covers the fillet externally. The fibers of this tract are thought by some anatomists to be chiefly distributed, above, to the *inferior quadrigeminal body*. Below, they appear to be connected with *the nuclei of the posterior columns of the spinal cord*. Some of its fibers probably belong to the sensory tracts of the cord. The name "*lemniscus*" is applied to the curved fibers of the fillet.

The views of Flechsig respecting the composition of the fillet have been given in a foot-note on a preceding page.

The mesial fibers of the tract of the fillet are believed by Meynert to pass upward in the intermediate stratum of the crusta.

According to the researches of Forel, a middle portion of this tract presents some peculiarities of course and distribution. Some pass, according to this author, upward through the reticular formation, and subsequently join the corpus albicans or become lost in the longitudinal bundles; a few of the lateral fibers of this middle portion pass to the upper quadrigeminal body (*natis cerebri*), this bundle being distinguished as the "*upper fillet*" in contradistinction from the fibers of the lateral portion of the tract which pass to the lower quadrigeminal body (*testis cerebri*), which are known as the "*lower fillet*."

Some authorities claim that the fibers of the tract of the fillet may be traced into the posterior part of the lateral column of the spinal cord, as well as into the anterior column.

Late researches, regarding the physiological function of this tract of fibers, seem to point toward a relationship between the lemniscus and the so-called "*muscular sense*" (Spitzka and Starr).

The fillet tract becomes intermingled with the fibers of the stratum intermedium, although it lies more to the lateral portion of the medulla. It is apparently connected above with the inferior corpora quadrigemina (testes cerebri), although some observers think its fibers pass to the cerebral cortex by means of the corona radiata; below, it is believed to participate to some extent in the piniform decussation (Spitzka). Some authors are led to believe that this tract is intimately associated with the sense of sight as well as with coördination of movements.

E. C. Spitzka has lately investigated the results of a lesion of the pons that chiefly involved *the fillet tract*. The case is one of great interest, as bearing upon the question of the probable paths of coördination. The prominent symptom during the life of the patient was an inability to perform coördinated movements upon the right side.

The deductions drawn by this observer, from a careful study of microscopical sections of the pons and medulla, are summarized by him as follows ("New York Medical Journal," March 15, 1884):

"1. The so-called lemniscus layer contains in its mesal portion an individualized column of fibers of high physiological importance, which decussates in the so-called sensory decussation of Meynert.

"2. The *stratum intermedium*, as this bundle should be called, for reasons to be advanced further on, is a tract mediating an essential factor of voluntary motility—coördination.

"3. The ataxia of movement observed in destruction of this tract is not due to a loss of tactile sensibility. The latter was not sufficiently impaired to account for the absolute unilateral ataxia attributable to the division of the stratum intermedium.

"4. The stratum intermedium is not purely a centripetal tract. It degenerates centrifugally.

"5. Physiologically, it appears to be, in part at least, centripetal; this is shown by the paræsthesia and hyperæsthesia complained of by the patient.

"6. While the stratum intermedium is probably the continuation of the column of Goll, and, in part, of that of Burdach, toward the cerebrum, the secondary degeneration of the spinal part of this (ideal) tract advances centripetally, while the cerebral portion degenerates

centrifugally, the point to which both converge being the nuclei of the posterior columns.

“7. Flechsig’s statement that there is no direct continuation of the posterior columns into the piniform decussation, but that they terminate provisionally in their nuclei, is demonstrated beyond peradventure by this case.

“8. While Flechsig is also sustained in his denial of a *gross* connection between the so-called upper pyramidal decussation of Meynert and the pyramids proper, yet there is an intimate connection between the stratum intermedium and the pyramid of the same side, extending along the known course of the former tract from its decussation up to the lower part of the pons. It is possible that the connection between the sensory periphery and the pyramids, which Meynert attempted to establish, really exists through the medium of this interchange, though in much lesser degree than the distinguished founder of modern cerebral anatomy surmised.

“9. The system of fibers which is represented in the fasciculi arching through the olivary nuclei, those of the external arciform group—and which are not without reason supposed to connect the posterior columns, or rather the latter, through nuclear intervention, with the restiform column—is entirely independent of the stratum intermedium. Nor have the olivary nuclei, or any of the tracts connected with them, a connection with the stratum intermedium.

“10. The vertical fibers of the trapezium appertain to the stratum intermedium.”

The results of Starr’s investigation of a microcephalic brain (lately awarded the Alumni Association prize of the College of Physicians and Surgeons) are not in full accord with Spitzka regarding this tract.

GANGLIA OF THE TEGMENTUM.—That there is a functional independence between the cerebral hemispheres and the masses of gray matter connected with the fibers of the posterior division of the crus seems to be proved by a comparison of the relative development of the two in animals. The optic thalami and corpora quadrigemina are less developed, in proportion to the weight of the cerebrum, in man than in either the ape or deer.

The OPTIC THALAMUS is probably associated with the fibers of the tegmentum (1) by means of the bundle connected with the *ganglion of the habenula conarii*; (2) by means of the so-called *laminæ medullares*; (3) by means of the *posterior*

commissure. Differences of opinion exist between Meynert and Luys respecting the relations of special fibers to the ganglionic masses found within the thalamus. Some of these have been already discussed. Future investigations regarding the effects of disease of these parts and additional light afforded by experimental physiology can alone render our knowledge of the sensory tracts of the brain less conjectural. The latest conclusions of Flechsig, Spitzka, and Starr are of particular interest in this connection.

The anterior CORPUS QUADRIGEMINUM of either side seems to be associated with the special sense of sight, although its connections, as well as those of the posterior pair, with the fibers of the tegmentum and the cerebellum would indicate a more extended function. In previous pages, the structure of this ganglion (taken as a whole) and the results of physiological experiments upon it have been discussed in detail. Setschenow has shown that, among the other functions which this ganglion seems to possess, it appears to be able to *intensify the inhibitory or controlling influence of the brain upon the reflex actions of the spinal cord.* Although it is unquestionably connected with the optic fibers, this ganglion is certainly not the center of consciousness of visual impressions. It seems probable rather that it may be a center of coördination between retinal impressions and special muscular movements. It is stated by some observers that *blindness of the opposite eye* follows its destruction, but this is not accepted as proved by all physiologists.

Impairment of sight may be attributed in many cases to a severance of the optic fibers from their connections with the visual area of the convolutions. Such an occurrence in connection with a lesion of the anterior pair does not prove that the corpora quadrigemina are centers of vision. They stand in no constant relation to the development of the eyes, as is proved by the fact that they are largely developed in some animals where the eyes and optic tracts are rudimentary (Longet).

Goltz, Serres, Cayrade, and others have noticed effects,

produced by destruction of these bodies, upon the *function of equilibration*. Ferrier has confirmed these statements by experiments made upon monkeys, fishes, and rabbits, and McKendrick has been led to the same conclusion by his investigations upon pigeons.

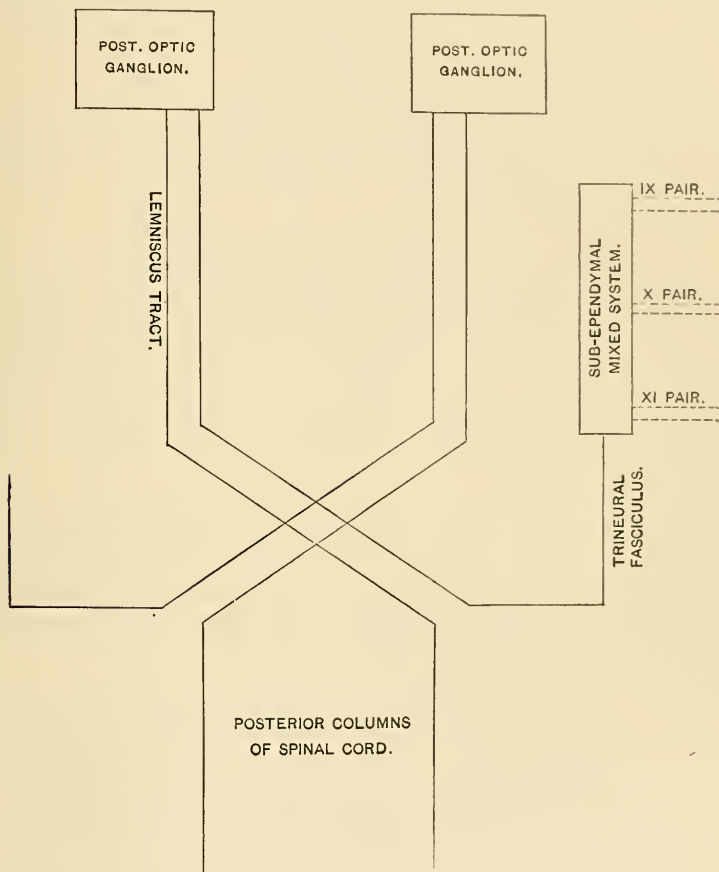
Goltz and Vulpian were led to believe that *plaintive cries* (as a form of emotional expression produced by sensations of pain or pleasure) ceased when the corpora quadrigemina were destroyed. Ferrier thinks that this conclusion is only partly true; because he was able by intense stimulation to excite responses in the form of cries in a rabbit whose optic lobes had been entirely removed.

Spitzka employs the following diagram to interpret his views respecting a supposed relationship between the inferior quadrigeminal bodies (post-optic lobes) and visceral and vasomotor innervations (page 213).

The effects observed in the *pupillary movements* and *oculomotor reactions* after mechanical irritation and electric stimulation of these bodies in animals are comparatively uniform. The pupils dilate, the head and eyes are turned to the opposite side, the ears are drawn backward, the jaws become clinched firmly, the lips are retracted, and finally complete opisthotonos is produced. Various forms of vocalization have also been observed to follow irritation of the "testes cerebri." It is impossible to state which of these effects is due to irritation of the optic lobes themselves and which to the tracts of fibers underlying them. The ganglia of the mesencephalon as well as the cerebellum are too intimately connected with the pons and crura to make any positive differentiations possible.

Meynert's view that one of the roots of the fifth nerve can be traced to a collection of large cells which lies adjacent to the aqueduct of Sylvius may help to interpret the *movements of the jaws* when the optic lobes are stimulated. We meet with similar manifestations of transmitted irritation by means of the spinal cord in tetanus; and, when these phenomena are grouped with the movements of the limbs and trunk which are likewise created by excitation of the corpora quad-

rigemina in frogs, fishes, and mammals, we are forced to the conviction that these ganglia are important factors in the exhibition of the *physical evidences of painful sensations* in general.



Spitzka's Diagram.

Danilewsky finds that *modifications in the arterial pressure*, associated with a *slowing of the heart* and *amplification of the pulse-waves*, follows electric stimulation of these ganglia, and Budge and Valentin claim to have created *contractions of the stomach, intestine, and bladder* in the same manner. I am inclined to doubt, however, if these phenomena are due to the local effects of such stimulation, because we

know positively that electric currents are often widely diffused. They have been adduced, however, by Ferrier as proofs (not well established) of the relation of the optic lobes to the reflex manifestations of emotion. Fear is not uncommonly exhibited, as we know, by the human race as well as by some animals, by involuntary passage of the urine and fæces, and occasionally by vomiting.

The relation of the corpora quadrigemina to vision, as well as some other pathological and physiological facts of clinical interest, has been considered more fully in previous pages, to which the reader is referred.

THE GENICULATE BODIES.—These ganglia (Fig. 43) are considered by some authors as appendages to the optic thalami and the corpora quadrigemina, because they appear to be associated to a greater or less extent with the special sense of sight. Their situation furthermore supports the view of Meynert, that they are also ganglia of origin of fibers of the tegmentum.

In the *external geniculate body* the gray matter is arranged in laminæ which present, in cross-sections made through its substance, a zigzag outline, as if the laminæ had been crushed or folded together. The cells of this mass are large, granular, and pigmented.

The *internal geniculate body* is less intimately connected with the optic lobes and the fibers of the optic tract, as proved by the latest researches of Flechsig, Gudden, and Ganser. Its gray matter is not arranged in the manner peculiar to its companion, although it is apparently traversed by fibers of the optic tract connected with both the natis and testis cerebri. The nerve cells of this body appear to effect a decided reduction in the number of fibers which pass through it.

Some of the optic fibers pass directly from the optic tract to the corpora quadrigemina without any intervention of these ganglionic bodies, while a few of the innermost bundles of the optic tract become apparently intertwined with the outermost fasciculi of the crusta. Burdach thinks that he has traced a connection between these bundles and the sub-

stantia nigra of Soemmering. Meynert has not been able to confirm this view.

THE RED NUCLEUS OF THE TEGMENTUM.—This ganglionic mass has been discussed already in connection with the superior peduncle of the cerebellum, and will be again referred to when the cerebellum is described. It is shown in Fig. 43.

THE MAMMILLARY TUBERCLE (*corpus albicans—bulb of the fornix*).—The situation of this body, as well as its method of formation, is shown in a preceding diagram (Fig. 37). Its structure has been discussed in connection with the third ventricle. It is classed by Meynert and others among the ganglia of origin of the tegmental fibers.

THE PINEAL GLAND.—This body (the *conarium*), which resembles a fir-cone in shape, lies above and between the two upper quadrigeminal bodies (Fig. 37). It is often spoken of as the “*hypophysis cerebri*,” although improperly so according to the view of Meynert. The opinion of Luys that this body is directly continuous with the gray lining of the third ventricle is opposed by Arnold, who claims to have demonstrated that it is separated from it by a medullary layer. Meynert regards it as one of the ganglia of origin of the tegmentum cruris, since it is connected with the crus by means of the posterior commissure. It is also connected with the medullary substance of the cerebral hemispheres by means of its peduncles.

The cells which are found within the gray substance of the pineal gland are of two sizes, one 15μ and the other 6μ in thickness. These cells are packed more closely than in the other cerebral ganglia.

The *pedicle* of the pineal gland (*habenula*) is believed by Meynert to be directly connected with the posterior commissure of the third ventricle, as well as with the fornix anteriorly.

In microscopic structure the pineal gland bears a resemblance to the anterior lobe of the pituitary body. A number of hollow follicles may be demonstrated within it, which are filled with epithelial cells, and a gritty matter—the so-called

acervulus cerebri or *brain-sand*. This sabulous material is also found upon the exterior of the gland and its peduncles.

During the development of the brain the pineal gland appears as a hollow excrescence from the part destined to form the third ventricle. Subsequently, this diverticulum becomes cut off from the ventricle, and tubes develop within it. Finally, these tubes are seen to separate into isolated vesicles, which are, as a rule, spherical in shape.

THE ARCHITECTURE AND FUNCTIONS OF THE CEREBELLUM.

The cerebellum or "hinder-brain" consists of two lateral hemispheres, joined together by an intermediate portion which is called, from a fancied resemblance to a worm, the "vermiform process." The peculiar appearance of this process is due partly to its shape and partly to transverse ridges and furrows which are very apparent. When the under surface of the cerebellum is examined, this process appears as a well-marked projection, the "*inferior vermiform process*." On the upper surface it is only slightly elevated, forming the so-called "*superior vermiform process*." In birds, as well as in some animals lower in the scale, the vermiform process alone exists.¹ It is the part first developed in mammals. In most mammals, moreover, it constitutes a distinct central lobe, clearly demarcated from the lateral portions—the hemispheres of the cerebellum.

The *cerebellar hemispheres* are separated behind by a deep notch. Below, a deep fossa (the *vallecula*), which is continuous with the notch seen posteriorly, lodges the inferior vermiform process. This hollow also receives the medulla in front, and the falx cerebelli behind. The hemispheres are convex on their lower surface, and tend to partly conceal the inferior vermiform process; above, however, they are somewhat flattened in the center, and slope downward toward the sides,

¹ The *vermiform process* appears to be a complete ganglion in itself, associated with its own nerve tracts. The *cerebellar hemispheres* are added, in the higher grades of animals, in proportion to the development of the cerebral lobes.

causing the slightly elevated superior vermiform process to be less distinctly outlined than the inferior process is.

The cerebellum measures about three and a half inches transversely, about two and a half inches from before backward, and about two inches in depth at its thickest portion, although it thins out at its lateral borders.

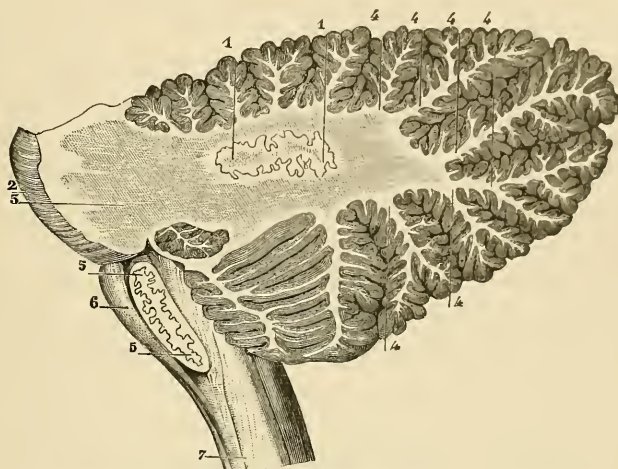


FIG. 47.—*Cerebellum and medulla oblongata.* (Hirschfeld.)

1, 1, corpus dentatum; 2, tuber annulare; 3, section of the middle peduncle; 4, 4, 4, 4, 4, laminae forming the arbor vitae; 5, 5, olivary body of the medulla oblongata; 6, anterior pyramid of the medulla oblongata; 7, upper extremity of the spinal cord.

The surfaces of the cerebellum are everywhere marked by deep, closely set, transverse, and somewhat curved fissures. These are often of considerable depth, the larger ones concealing many folia which do not reach the surface of the cerebellum. Some of these fissures are better marked than the rest, the most conspicuous one being the *great horizontal fissure*, which starts in front at the middle peduncle, and extends around the outer and posterior border of each hemisphere, being prolonged into the posterior notch, where it joins with its fellow of the opposite side. This fissure separates the cerebellum into an upper and lower portion, which correspond to the upper and lower surfaces. Each of these portions is likewise subdivided by fissures, somewhat more distinct than the rest, into small lobes. The names of these lobules can be

found in any work upon descriptive anatomy. The *tonsilla* and *floculi*¹ are the more important. The vermiform process, or "worm," is also subdivided into lobules. Physiological experiment or pathological research has not yet positively located any special functions in these lobules, so that they are of use chiefly in describing the situation of lesions of the cerebellum and the course of fibers to the cerebellar cortex.

Sections made through the substance of the cerebellum show a beautifully foliated or arborescent appearance; named "arbor-vitæ" in consequence of the medullary or white substance of the ganglion being prolonged into the laminae. The main branches of the medullary substance, or groups of them, correspond to the lobules of the cerebellum. These are connected, as the cerebral convolutions are, by festoon-like fibers (*fibrae propriae*). The medullary substance is more abundant in the hemispheres than in the worm (vermiform process).

In the center of each hemisphere a nucleus of gray matter, the so-called "*corpus dentatum*," is seen in all vertical and transverse sections of that region. In structure it resembles that of the olivary body of the medulla oblongata, having a wavy layer of yellowish-brown substance externally, and white matter in its center. At its upper and inner part this wavy layer is interrupted, so that the plicated capsule is not complete. The fibers which are contained within the processes cerebelli ad cerebrum (superior peduncle of cerebellum) and the valve of Vieussens may be traced, in part, to the corpus dentatum.

Stilling, who has made elaborate researches respecting the minute structure of the cerebellum, describes three other collections of gray matter within the white center of the hemispheres. These are named the "*nucleus emboliformis*," the "*nucleus globosus*," and the "*nucleus fastigii*." These nuclei are not distinctly isolated in all parts, but are connected here and there with one another, and with the corpus

¹ The *floculus* is believed by some authors to be directly associated with a fasciculus derived from the pneumogastric nerve.

dentatum. Their functions are not yet determined. The "*nucleus fastigii*" is often called the "nucleus of the ventricular roof" (Spitzka). It is situated in the white mass of the worm, and lies in the roof of the fourth ventricle. It probably receives fibers of the *auditory nerve root* and the *trapezium*. This nucleus is separated from its fellows by a thin septum of white matter. The other two nuclei described by Stilling lie in intimate relation with the dentate nucleus of the hemisphere.

The cerebellum, as a whole, is described as possessing *three peduncles*. These are collections of nerve fibers which pass out from, or into, the substance of the hemispheres.

The *superior peduncles* (*processi cerebelli ad cerebrum*) are directed upward and forward from the mesial part of the hemispheres.

The *middle peduncles* (*processi cerebelli ad pontem*) emerge from the lateral part of the hemispheres and pass to the pons Varolii.

The *inferior peduncles* (*processi cerebelli ad medullam*) escape from the hemispheres of the cerebellum between the other two, pass forward outside of the superior peduncles to reach the lateral wall of the fourth ventricle, and then turn sharply downward to become the so-called "restiform bodies" of the medulla oblongata. Each of these processes will be considered separately.

We are now prepared to consider the minute structure of the cerebellum and its processes. The various theories which have been advanced in regard to the probable functions of this ganglion can be intelligently discussed only after some knowledge of its connections with other regions of the cerebro-spinal system. Experimental physiology frequently conflicts with the observed effects of pathological lesions of the nerve centers.

THE CEREBELLAR CORTEX.

The external gray matter of the cerebellum differs in its microscopical appearance from that of the cerebrum, which has been described in a previous lecture. It consists of three

layers—an outer, composed of both cells and fibers; a middle, consisting of large cells, termed the “corpuscles of Purkinje”; and an inner, which is reddish-gray in color and of a granular structure.

In the *outer layer* most of the fibers have a direction at right angles to the surface of the cerebellum. The greater proportion of these fibers are simply the prolongation of the processes of the large cells of the middle layer (cells of Purkinje). Others are fine, tapering fibers, which seem to rest by a broad base on the pia mater, which covers the outer layer. These fibers make up a dense felting, inclosing free nuclei and scattered cells. The cells of this layer are granule-like bodies, the larger of which are apparently connected with the processes of the cells of Purkinje. The smaller probably belong to the matrix; the larger are supposed to be nervous in function. Along the innermost portion of the outer layer nerve fibers may be also demonstrated, which run parallel with the surface of the cerebellum.

The *middle layer* is characterized by the peculiar cells¹ found imbedded in it—the “cells of Purkinje.” Most of these cells are flask-shaped, although a few are irregular in form. The long axis of the cell is placed at a right angle to the free surface of the cerebellum. The diameter of these cells varies from $\frac{1}{800}$ to $\frac{1}{1000}$ of an inch. Two sets of processes may be demonstrated as arising from these cells, viz., one passing through the outer layer of the cerebellar cortex and one passing through the inner layer. The former are of large size, and are connected, in some instances, with the corpuscles of the outer layer; others pass directly through the layer to become lost at its surface. In either case they subdivide repeatedly in their passage through the outer layer. The inner set of processes are fine and undivided, and pass into the granule layer, where some probably become continuous with the axis-cylinders of nerve fibers composing the medullary portion.

¹ The bodies of these cells are colossal (sixty to seventy millimetres in length, and twenty to thirty millimetres in thickness). They appear to be inclosed within a loose-fitting capsule, formed of connective-tissue fibers (Obersteiner).

The *inner layer*, called the "granule layer," lies next to the medullary center of the cerebellum.¹ It consists of granule-like corpuscles, which are imbedded in groups in a gelatinous matrix. Nerve fibers can be demonstrated to join with the processes of the cells of Purkinje within this layer. The cells of this layer are both round and angular. Each consists of a nucleus, a thin envelope of protoplasm, and processes which unite with the plexus of nerve fibers in its vicinity. They measure from $\frac{1}{2500}$ to $\frac{1}{4000}$ of an inch.

It will be evident, after this hasty description, that the cortex of the cerebellum differs markedly from that of the cerebrum, in spite of the various structural types of the latter. The cells of Purkinje are characteristic of the cerebellum alone. The number of layers is less than in the cerebral cortex.

We are apparently justified in attributing to the cerebellum some functional attributes of a special type, because similar anatomical elements are to be found in no other region. The theories which have been advanced respecting the functions of this ganglion will be considered later.

In cross-sections of each fold or lamina of the cerebral cortex may be seen a central medullary or white portion, resembling the stem and diverging branches of a twig, with its attached leaves. This "*medullary center*" can be shown to consist of bundles of fibers which run parallel with each other or interlace, until they turn obliquely into the gray matter of the cortex. It is still undecided whether these fibers terminate in the "granule layer" of the cortex, becoming joined to the axis-cylinder processes of the cells of Purkinje, or by a union with the plexus of fine fibers described as existing in the outer layer.

THE CENTRAL WHITE SUBSTANCE OF THE CEREBELLUM.

The peduncles of the cerebellum have been mentioned in the early part of this lecture, but much remains to be said re-

¹ The striking resemblances between this layer and the granular strata of the *olfactory lobe* have been commented upon by Meynert. The cells of this layer are regarded by Gerlach as connective-tissue elements; by Henle and Merkel as lymphoid elements; and by Stilling as small multipolar nerve cells.

specting the probable course of the fibers contained in each, during their passage through the white or medullary center of the cerebellum. The course which they pursue outside of the limits of this ganglion will also merit subsequent attention.

The fibers of the *superior peduncle* can be traced almost entirely into the interior of the "nucleus dentatum"; although a few can be demonstrated to pass around the outer side of this central mass of gray matter without entering it, and some mesial fibers can be shown to enter directly into the white substance of the vermiform process. As was stated to be the case with the corpus striatum and the optic thalamus, it is probable that a few of the fibers which apparently enter the substance of the nucleus dentatum do not become joined with the cells of that body, but simply pass through it to go to the cerebellar cortex; on the other hand, it is equally probable that most of the fibers which enter it become associated more or less intimately with the cells found within that body, and that they are subsequently continued to a peripheral termination in some part of the cortex. The fibers which inclose the nucleus dentatum are so matted together into a network that it is impossible to trace the course of even distinct bundles from their entrance into the cerebellum to their termination in the cortex. The course of these fibers through the crus has been described in preceding pages.

The fibers of the *middle peduncle* leave the pons to enter the lateral part of the white substance of the cerebellum as two main bundles. One is composed of the superior transverse fibers of the pons; the other consists of the lower transverse fibers of the pons mingled with those of the *inferior peduncle* of the cerebellum (*restiform body of the medulla*). The upper bundle passes obliquely downward over the lower, and enters the lateral and anterior portions of the medullary center of the hemisphere. The lower bundle, after joining with the fibers of the restiform body of the medulla oblongata, turns upward, and radiates into the upper part of the medullary center of the corresponding hemisphere of the cere-

bellum and the upper part of the vermiform process. Stilling states that the fibers of the restiform body pass, in part, into the nucleus dentatum, while the rest curve over the nucleus, —the so-called “semicircular fibers.”

Finally, certain *commissural fibers* are described by Stilling as existing in the cerebellum. These may be divided into two sets. The first are analogous to the commissural fibers of the cerebrum, crossing the median line and probably joining homologous regions of the cerebellar cortex in the two hemispheres; the second, analogous to the collateral fibers of the cerebrum, connecting one lamina of the cortex with another, and arching around the fissures between the laminae. The latter set are confined to one hemisphere, and do not cross the median line of the cerebellum. The direction of these fibers is transverse to that of the “peduncular” cerebellar fibers.

It is evident, therefore, that the general arrangement of the cerebellar fibers bears a striking resemblance to that of the cerebrum; the *nucleus dentatum*, *olivary body*, *red nucleus*, and *gray matter of the pons* being the analogues of the basal ganglia of the cerebrum, and the “radiating,” “commissural,” and “associating systems” being similar in many respects. The cerebellum, like the cerebrum, may be said, therefore, to exhibit three so-called “projection systems” of fibers, as follows: 1. The *inner* projection system, the fibers of which serve to connect the cortex of the cerebellum with the nucleus dentatus of the same hemisphere and the olivary body, the red nucleus of the tegmentum, and the anterior gray substance of the pons Varolii of the opposite side; 2. The *middle* projection system, the fibers of which connect the enumerated masses of gray matter with the gray matter of the crus, pons, and spinal cord; 3. The *outer* projection system, the fibers of which are included in the expansions of the central tubular gray matter to the periphery of the body by means of the spinal nerves.

The following diagram will help to make certain points clear regarding the intimate structure of the cerebellum and

its connections with adjoining parts. It is, of course, purely schematic, but, if used in connection with actual representa-

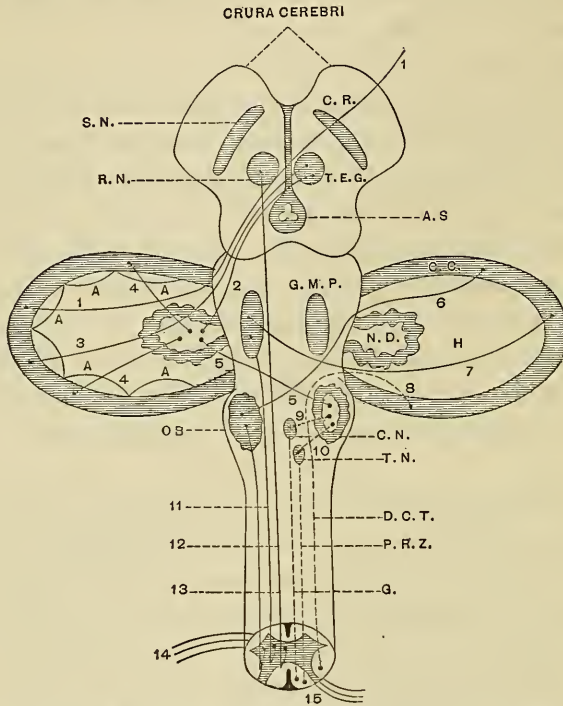


FIG. 48.—A diagram designed by the author to illustrate the various sets of fibers comprised within the cerebello-spinal system. (Modified from Ross.)

C. R., crusta cruris; T. E. G., tegmentum cruris; A. S., aqueduct of Sylvius surrounded by the tubular gray matter; S. N., substantia nigra; R. N., red nucleus of the tegmentum; G. M. P., anterior gray matter of the pons; C. C., cerebella cortex; N. D., nucleus dentatum; O. B., olivary body; C. N., clavate nucleus; T. N., triangular nucleus; D. C. T., fibers of the "direct cerebellar tract" of the spinal cord; P. R. Z., fibers of the "posterior root zone" of the same; G., fibers of the "column of Goll"; 1, cerebro-cerebellar fibers; 2, fibers from the red nucleus of the tegmentum to the dentate nucleus of the cerebellum; 3, fibers from the red nucleus to the cerebellar cortex; 4, fibers from the red nucleus to the dentate nucleus; 5, fibers from the dentate nucleus to the olivary body of the opposite side; 6, fibers from the cerebellar cortex to the olivary body of the opposite side; 7, fibers from the cerebellar cortex to the anterior gray nucleus of the pons of the opposite side; 8, fibers of the direct cerebellar tract; 9, fibers connecting the clavate nucleus and the olivary body of the same side; 10, fibers connecting the triangular nucleus and the olivary body of the same side; 11, fibers passing from the olivary body to the horns of the spinal gray matter; 12, fibers passing from the anterior gray matter of the pons to the horns of spinal gray matter; 13, fibers passing from the red nucleus of the tegmentum to the anterior horns of the spinal gray matter; 14, fibers escaping from the spinal cord through the anterior root of a spinal nerve; 15, fibers of the posterior root of a spinal nerve entering at the posterior horn of the spinal gray matter. The dots in the cut end of the spinal cord, near to 15, indicate the relative position of the different tracts with which they are connected. A, A, A, represent fibers which are destined to connect different convolutions of the cerebellar cortex (*fibra propria*).

tions of the parts, it will prove of great value in comprehending many statements which are to follow. In this diagram the shaded parts represent collections of gray matter; the lines indicate the direction and extent of individual sets of nerve fibers which are in direct communication with the shaded masses.

The arrangement of the middle projection system of fibers pertaining to the cerebello-spinal apparatus is less definitely settled than that of the cerebro-spinal. It is probable, however, that the cerebellum receives afferent sets of fibers from the spinal cord, and gives off also certain efferent sets of fibers, which are brought into more or less direct communication with the motor tracts of the crura, pons Varolii, medulla, and spinal cord.

The AFFERENT FIBERS of the cerebellum probably reach that ganglion through the following channels (Fig. 48):

1. By means of the *columns of Goll* (G.), which terminate in the so-called "*clavate nucleus*" (C. N.).

2. By means of the *columns of Burdach* or the *posterior root zone* of the spinal cord (P. R. Z.), which seems to be structurally related with the so-called "*triangular nucleus*" (T. N.).

3. By means of fibers which connect the *triangular* and *clavate nuclei* with the "*olivary body*" of the corresponding side of the medulla oblongata (9 and 10).

4. By means of the "*direct cerebellar tract*" of fibers (D. C. T.) which is found within the lateral column of the spinal cord near to the extremity of the posterior horn of the spinal gray matter.

5. By means of fibers connected with the *auditory* and possibly with the *sensory root* of the *fifth cranial nerves*. The auditory fibers are probably associated chiefly with the corpus dentatum and the nucleus fastigii. It is stated that they decussate either in the medulla or cerebellum. If so, they pass through the auditory nucleus before entering the cerebellum. The apparatus of hearing performs an important part in equilibration.

The EFFERENT FIBERS of the cerebellum¹ are probably comprised within the following fasciculi:

1. Bundles of fibers which connect the *dentate nucleus* and the *cerebellar cortex* with the *corpus striatum* or *optic thalamus* by means of the "processus cerebelli ad cerebrum." This bundle is also in intimate relation with the "red nucleus of the tegmentum," and probably is structurally related with some of the nerve cells found in that nucleus (2 in Fig. 48). Luys believes that the corpus striatum is charged, when its nervous force becomes exhausted, by means of this process of the cerebellum. If this be the case, the cerebellum exerts some influence upon the impulses emitted from the cerebral hemispheres; because many such impulses are probably modified within the corpora striata before they are transmitted to the more distant parts of the nervous apparatus (the gray matter of the spinal cord, and the spinal nerves). The probable relations of cerebral and cerebellar influences upon muscles will be discussed later.

2. Fibers which probably connect the *red nucleus of the tegmentum* with the anterior horns of the spinal gray matter (13 in Fig. 48).

3. Fibers which probably connect the *olivary bodies* of the medulla oblongata with the anterior horns of the spinal gray matter (11 in Fig. 48).

4. Fibers which connect the *anterior gray substance of the pons Varolii* with the anterior horns of the spinal gray matter (12 in Fig. 48).

From the imperfections of our present knowledge, much that is stated here regarding the exact course of the afferent and efferent impulses of the cerebellum must be somewhat conjectural. The results of experimental physiology and of pathological research are not, and can not well be, of a positive character. Many conflicting theories have been at dif-

¹ If the brain be considered as a whole, fibers passing from the cerebellum to the cerebrum by means of the superior and middle peduncles, as well as those passing to the tubercular quadrigemina, by means of the valve of Vieussens, may be classed as *afferent fibers*. Spitzka denies the existence of *efferent cerebellar fibers* (outside of the superior and middle peduncles).

ferent times advanced regarding the functional attributes of this ganglion. These will be considered when the anatomical data have been more fully presented.

Processus cerebelli ad cerebrum (*processus e cerebello ad testes, superior peduncle of cerebellum*).—In connection with previous topics, chiefly in those pages which treat of the corpus striatum and the optic thalamus, the relation of the cerebellum with the medullary portion of the cerebrum by means of special fibers has been mentioned. The special group of fibers which compose the *processus cerebelli ad cerebrum* appear to start anteriorly from among the radiating fibers of the cerebrum and are forced apart, in the region of the crus, above the corpora quadrigemina, by the introduction of a nodal mass of gray matter, characterized by nerve cells and granular material, the so-called “*red nucleus of the tegmen-*

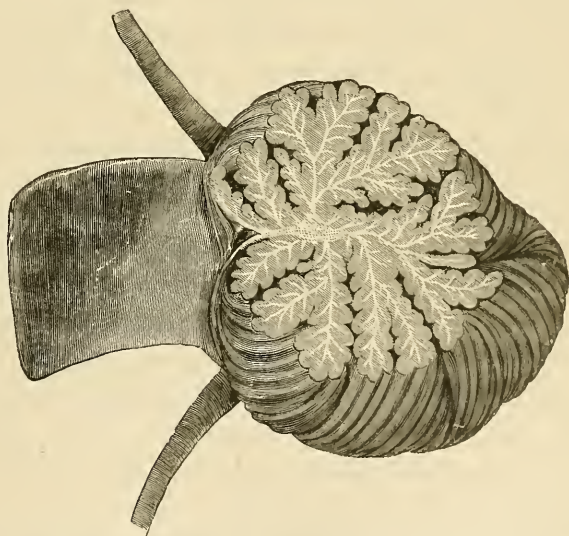


FIG. 49.—A crude diagram designed by the author to illustrate the three pairs of peduncles of the cerebellum.

Those of one side only are shown.

tum.” In the region of the lower half of the superior corpus bigeminum this tract appears as a simple bundle of fibers, which are not destitute of nerve cells, but whose circumference is much less than in the region of the red nucleus. The

nerve cells of this bundle are of extreme size, and appear to be arranged parallel with the *vessels* of that region rather than with the nerve fibers. In some cases they bend to fit the angles of the branches of the arteries, and send out long prolongations that run longitudinally along and probably in their walls (Meynert). Even in the "red nucleus" this arrangement may be demonstrated. The presence of nerve cells within this tract does not cease until after its decussation and its escape from the corpus quadrigeminum. It yet remains to be demonstrated whether the crural portion of the processus cerebelli ad cerebrum is the only seat of a peripheral termination of nerve-cell processes in the walls of capillaries in the midst of the central organ.

If successive cross-sections of the region occupied by this tract be studied, it will be seen that the processus cerebelli ad cerebrum of either side approaches the median line, and that the fibers eventually decussate. The region occupied by these decussating fibers lies between the "*posterior longitudinal fasciculus*" and the "*stratum lemnisci*," the remaining bundles of spinal fibers which enter the tegmentum having been crowded away by them. After their decussation, these fibers pass outward until they reach the inner surface of the inferior lamina of the lemniscus, which forms a sort of protective cover for them. Meynert has compared the outline of the two processes to the form of a horseshoe, whose opening is directed backward. This opening represents an area which embraces those fibers of the "*tegmentum cruris*" directly prolonged from the spinal cord; bounded by the stratum lemnisci and the posterior longitudinal fasciculus. The decussating fibers of the cerebellar tract force their way among the fibers of the tegmentum cruris to reach their lateral position; hence, cross-sections made at different altitudes show ever-varying relations between these fibers and those of the tegmentum. Stilling and Arnold, who have made a special study of the course of the fibers of the processus cerebelli ad cerebrum, differ as to the completeness of the decussation, the latter denying that all the fibers cross the median line. Mey-

nert confirms the view, originally advanced by Stilling, that the decussation is complete.

After the decussation of its fibers, each processus disengages itself, both superiorly and externally, from the fibers of the tegmentum cruris in which it was imbedded. Opposite to the point of greatest convexity of the pons Varolii, it becomes uncovered by the inferior lamina of the lemniscus. Later in its course it becomes buried in the white substance of the cerebellum, and finds an ultimate connection with the "nucleus dentatus," the central mass of gray matter within the cerebellar hemisphere.

When we examine the *fourth ventricle*, the exposed portion of this tract will be seen to constitute the lateral boundary-walls of that cavity (*processus e cerebello ad testes*); with the so-called "valve of Vieussens" (*velum medullary anterius*) inclosed between them. The latter formation deserves special notice in this connection.

The processus cerebelli ad cerebrum itself is by no means free from admixture of foreign elements during its passage from the cerebrum to the cerebellum, the details of which I have just given. At the level of origin of the fifth cranial nerve (trigeminus) fibers from the cerebellum apparently passing to the greater root of that nerve can be demonstrated as fasciculi which in part cover it and in part traverse it. It is also traversed, at a lower plane, by fasciculi destined to belong to the eighth cranial nerve (auditory).

Valve of Vieussens.—In this commissural band (the medullary velum) three different systems of fibers lie interwoven: 1. The great mass of its substance is composed of bundles of fibers derived from the frenulum. 2. The decussating fibers of the fourth cranial nerve (trochlearis), which are grouped at the anterior extremity of the valve into bundles of extreme thickness, are intertwined transversely with the fasciculi of the frenulum. 3. Certain longitudinal fibers may be demonstrated which can be traced to the superior vermiform process of the cerebellum. The course of these fibers is peculiar. They decussate before leaving the superior

vermiform process ; they then traverse the valve of Vieussens almost to the lower border of the corpus quadrigeminum ; at this point they double upon themselves, describing curves whose convexity looks upward ; finally, they join the inferior lamina of the lemniscus at its posterior bundle, and pass onward with the latter, in the posterior division of the pons Varolii, to the spinal cord.

Processus cerebelli ad pontem (middle peduncle of cerebellum).—When the general architecture of the cerebro-spinal axis was under consideration, the relation of the cerebellum to certain fibers which helped to form the “basis cruris” of Meynert (*crusta cruris*) was touched upon, as an anatomical explanation of the fact that the number of fibers of the middle projection system suffered an apparent decrease during their passage through the pons Varolii. It was then stated that some of the efferent fibers of the cerebrum probably left the direct tract of the projection system within the region of the pons, and passed to the cerebellum. Some points pertaining to the physiological importance of these fibers were also mentioned in connection with my description of the corpus striatum. It has, moreover, been stated in previous lectures, that the region of the pons contained certain *transverse fibers* connected with the cerebellum, which interlaced with the fibers of the cerebral projection tracts, and were probably more or less intimately associated with the nodal masses of gray matter found in that region. Some of these fibers are unquestionably commissural in character, serving to unite homologous regions of the cerebellar hemispheres ; others probably serve to unite the hemispheres of the cerebellum with the gray matter of the pons of the opposite side. In man the pons is long, because the *crusta cruris* is developed in proportion to the size of the cerebral lobes ; in animals it becomes shorter in proportion to the decrease in size of the cerebrum. The interlacement of the fibers of the projection system with those of the “*processus cerebelli ad pontem*” occupies the region of the pons and the upper half of the medulla (Meynert). It is somewhat curious to observe

that the lateral regions of the cerebellum keep pace in their development with the cerebral lobes, and the "*nucleus dentatus*" of the cerebellum is developed in direct proportion to that of the olivary bodies of the medulla oblongata.

Cross sections of the region of the pons reveal the fact that the transverse fibers of the *processus cerebelli ad pontem* may be divided into *three sets*, as follows: 1, a superficial layer; 2, fibers which interlace with longitudinal fibers escaping from the crus; 3, a deep-seated layer. The superficial and deep layers appear to be perfectly independent of any association with the fibers which belong to the middle projection system of the cerebrum (those of the *crusta* and *tegmentum cruris*). Meynert, however, brings forward certain reasons, based upon a minute study of the general relations of these layers, which apparently lend support to the view that the fibers of these strata are in communication with nerve-cells embedded in the pons, that certain crural fibers are likewise joined to these cells, and that the two sets of fibers are thus brought into communication with each other. He states his conclusion as follows:

"Each fasciculus of the *basis cruris cerebri* that terminates in either side of the anterior division of the pons is represented in the *cerebellar hemisphere of the opposite side* by *two fasciculi*, one of which runs with the superficial, the other with the deep stratum of the transverse system of fibers from the point of their connection with the crural fasciculus into the *processus cerebelli ad pontem* of the opposite side."

Processus cerebelli ad medullam (restiform body, inferior peduncle of the cerebellum).—A complete description of this important bundle properly belongs to a subsequent lecture, which shall treat of the architecture of the medulla oblongata. It is a round and prominent cord, which passes directly into the corresponding hemisphere of the cerebellum. The fibers of the direct cerebellar tract and the arched fibers of the medulla oblongata can positively be traced through it to the substance of the cerebellum. The distribution of some other bundles found within it is still unsettled. The fibers

of the restiform body probably terminate either in the corpus dentatum, the cortex of the posterior surface of the hemisphere, or the central gray matter of the worm.

RELATIONS OF THE CEREBELLUM TO CRANIAL NERVES.

At various times articles have appeared which tend to show that the fibers of origin of some of the cranial nerves can be traced to the cerebellum. When a positive demonstration of the statements made by some of the later anatomists can be furnished, much light will be shed upon the functions of this ganglion. There seems to be every reason, at present, to believe that the *auditory nerve* can be traced to the cerebellum after its fibers have passed through the auditory nucleus; and the number of such fibers appears to be in excess of those actually comprised within the nerve itself. In this respect a strong analogy is presented between the auditory fibers and those of the coronary radiata of the cerebrum, which are themselves more numerous than those of the crus, although they appear to be in direct continuity with them (as was stated when the basal ganglia of the cerebrum were under consideration). The opinion advanced by Spitzka, that the fibers of the sensory root of the *trigeminus* can be also traced to the cerebellum, lacks positive confirmation as yet; and the same remark might apply with equal justness to the views of those observers who believe that the *third, fourth, and tenth cranial nerves* have a direct association with that ganglion. There are physiological experiments on record which seem to sustain all of these views; as well as others which combat them. These will be explained later. The proof, however, that fibers of the nerves mentioned can be actually demonstrated within the substance of the cerebellum cannot, to my mind, be considered as final, although some neurologists are inclining more strongly of late toward that belief.

THE FUNCTIONS OF THE CEREBELLUM.

From the date of Flourens's first experiments upon the cerebellum of animals down to the present time, neither sen-

sibility nor marked excitability seems to have been demonstrated as attributes of this ganglion. Animals which have suffered extreme mutilation of the cerebellum experience no apparent pain, nor does direct irritation of that ganglion result in pain or convulsive movements. The opinion that the cerebellum is incapable of direct stimulation, which is still held by some physiologists, seems to be confuted, however, by the experiments of Budge, who observed that movements of the testicle and vas deferens occurred in the male, and of the horn of the uterus and the Fallopian tubes in the female, when direct irritation of the cerebellum was employed. The same observer produced movements in the stomach and œsophagus by means of cerebellar stimulation.

The widest differences in opinion exist among physiologists and neurologists regarding the functions of this ganglion, since the most positive and direct results of experimentation upon animals are apparently contradicted by pathological observations upon the human subject. There is one conclusion, however, in which most physiological observers, since the date of Flourens's original experiments, concur, viz., that the cerebellum, in some way, influences to a marked degree the *coördination of muscular movements*. This is very apparent in birds deprived of the cerebellum in whole or in part; since the power of performing definite and regular acts of locomotion is lost, although the animal is not paralyzed. If laid upon the back the bird cannot recover itself, in spite of exhausting efforts to do so. If placed upon the feet it executes sudden and disordered movements, and shows an agitation which is in marked contrast to the stupor which follows a removal of the cerebral lobes; it can still see and hear, feel pain, exhibit evidences of volition in its endeavors to avoid a threatening blow, and apparently it possesses normal intellectual faculties. Life is not particularly endangered by these experiments, as some of Flourens's birds lived several months; although severe hæmorrhage and injury to the medulla may sometimes occur in performing them. If only portions of the cerebellum are removed, the animal ap-

pears to *slowly regain* its power of coördination of muscular movement; this fact may tend to explain the absence of marked symptoms in the human subject, in spite of extensive lesions.

When Andral published a collection of ninety-three cases in which well-marked lesions of the cerebellum were found after death, and announced that only one sustained the view that the cerebellum governed coördination of movement, physiologists were startled and made to doubt the positiveness of their own conclusions. These cases are, however, carefully analyzed by Flint, who enters into a lengthy argument to prove that the cases cited do not warrant the conclusion of their compiler. Nothnagel published in 1878 the results of his analysis of more than two hundred and fifty cases of cerebellar disease. He is inclined to admit the existence of cerebellar ataxia (which he describes as a perversion of equilibrium resembling alcoholic intoxication) as characteristic of cerebellar disease; but he thinks that the *superior vermiform process* is especially liable to produce it, if extensively affected. In the majority of instances the upper extremities remain free from incoördination. Subjects in whom cerebellar ataxia is well marked stand, as a rule, with their feet well apart, in order, as it were, to increase their base of support; they sway from side to side and titubate; the toes are seen to be in active motion if the patient stands bare-footed; in walking, the body sways and the heel and ball of the foot are brought into contact with the ground irregularly; the ataxic symptoms may and may not be increased by closing the eyes; in the recumbent posture all these ataxic manifestations entirely disappear.

The tentorium cerebelli, which serves to separate the cerebellum from the posterior cerebral lobes, and which in some animals is a partition of bone, appears to have a clinical bearing upon the development of lesions of the cerebellum, since it seems to favor their growth in a forward and downward direction. It is important for you to bear this in mind when the effects of focal lesions of this ganglion are under con-

sideration; as well as the fact that an experimental or pathological lesion seldom, if ever, involves all the numerous nerve-tracts and centers which exist within this ganglion, and have different peripheral connections.

By recalling the important connections of the cerebellum with other parts of the brain and the spinal nerve-tracts, by means of its three crura, and bearing in mind also that the third, fourth, fifth, acoustic, and pneumogastric nerves may possibly have direct sources of origin within its substance (the proof of a relation with all of which, however, is still somewhat unsatisfactory¹), you can readily understand that the symptomatology of cerebellar lesions must, of necessity, be peculiarly involved and complex. The important organs which underlie the cerebellum (the corpora quadrigemina, the tegmentum cruris, and the medulla oblongata) are liable, furthermore, to be simultaneously affected, either by pressure or the extension of the disease to these parts. Within the first of these we probably have centers which govern the movements of the eyeball (Adamuck); in the second, a vaso-motor center, and possibly one which presides over convulsive movements, (?) are believed by some authorities to exist; in the third we find the olivary bodies, which are connected with the cerebellum, and the various nuclei of origin of important cranial nerves.

We are apparently justified, on anatomical grounds, in attributing the *disturbances of vision* which are so often observed in connection with lesions of the cerebellum to pressure upon the geniculate bodies, the corpora quadrigemina, or the fibers or nuclei of origin of the third, fourth, or sixth nerves. On similar grounds, the attacks of *nausea, vomiting, cardiac disturbances*, and *sudden death* sometimes encountered may be attributed to the pressure of cerebellar lesions upon the nuclei of origin of the vagus nerve within the floor of the fourth ventricle, resulting in either irritation or complete paralysis of that nerve. The *convulsive attacks*, which are

¹ The connection of the *auditory nerve* with the cerebellum is now quite generally accepted by neurologists.

occasionally observed in connection with cerebellar lesions, may perhaps be explained by pressure upon the convulsive center of the tegmentum cruris; and the development of *hemiplegia* of an imperfect type, or of *general paralysis*, both of which have been reported as occurring from cerebellar disease, may be explained by a similar effect upon the direct motor tract of the cerebral projection system.

In direct antagonism to the results of Flourens's experiments, lesions of the cerebellum of the human race seem to be often associated with pain, which predominates in the occipital region. In fact, the diagnosis of cerebellar disease is made chiefly on the predominant occipital pain (Brown-Séquard, Seguin, and others), with titubation and other peculiarities observed during the erect attitude of the patient. Exclusion of disease in adjoining regions must, however, always be made by the absence of symptoms before making a positive diagnosis, because occipital pain and titubation may both be often wanting, and the so-called "ataxic symptoms," when present, do not exist in the marked degree commonly met with in posterior spinal sclerosis. It is uncommon to find true ataxic jerking; and choreic movements and tremor are usually absent. The want of harmony between antagonistic groups of muscles is also wanting.

An attempt has been made to connect the cerebellum with the generative function, but physiological experiment has apparently demonstrated its fallacy. A rooster, in whom the cerebellum had been removed, attempted to mount a hen eight months afterward, and failed apparently only on account of the lack of power to coördinate his muscles (Flourens). There seems to be no well-authenticated instance where the sexual instinct has been destroyed in animals by removal of the cerebellum. Leuret found that the cerebellum was even larger in geldings than in stallions or mares. Among the numerous cases of disease of this ganglion to which we have referred, some suffered from a marked excitation of the sexual apparatus, while others had a well-marked atrophy of the genital organs and impotency. There are many physio-

logical as well as pathological facts which tend to refute the idea that the cerebellum is the seat of sexual instinct, and to locate it in the lumbar region of the spinal cord; still it cannot be denied that numerous cases, on the other hand, seem to point to some connection between the cerebellum and that center, or the organs of generation, in the human subject.

When the corpus striatum was discussed, it was stated that the superior peduncles of the cerebellum could perhaps be traced to the so-called "yellow nucleus" of the caudate portion of that ganglion. Luys considers that by means of these fibers the cerebellum is thus enabled to constantly reënforce the cells of the corpus striatum when they become exhausted, thus enabling them to exert their modifying effects upon all the motor impulses arising in the cerebral cortex which are forced to pass through them, as well as to manifest a peculiar automatism which the cells of the basal ganglia seem to possess. This theory of Luys does not differ markedly from that advanced by Mitchell, viz., that the cerebellum serves as a storehouse of nerve force, which may be drawn by means of any of its peduncles when emergencies arise to demand it. Some interesting physiological experiments have been made, which seem to point to some intimate association between the cerebellum and the basal ganglia. We know that section of the middle peduncle of the cerebellum almost invariably gives rise to a peculiar "forced movement," the animal rolling rapidly round its own longitudinal axis, the rotation being commonly toward the side operated upon.¹ This is accompanied by a peculiar dancing and oscillation of the eyeballs, termed "nystagmus." Now, Purkinje observed long ago that electric currents sent through the head from ear to ear produced the same movements of the eyeballs, and a tendency toward the forced movement of rotation. The patient leans toward the anode, and objects spin before the eyes in the direction of the electric current. When the current is broken the objects revolve in an opposite direction, and the patient leans toward the cathode. Hitzig has shown that neither the vertigo nor

¹ Bechterew has lately shown that section of the *olivary bodies* has the same effect.

the movements of the patient's body depend upon the objects perceived by vision, since the same phenomena were witnessed in blind subjects and in those whose eyes were closed. He found also that vertigo could be excited in this way with a current too feeble to excite ocular movements.

These remarkable experiments have been used by different authors as confirmatory evidence of the three following propositions: 1. That the symptoms produced indicated an anelectronic and catelectronic state of the respective auditory nerves; 2. That the cerebellar structures were called into action by the current; 3. That parts of the cerebrum were affected by the current.

The experiments of Cyon afforded ground for the first proposition, since he found that, when the semicircular canals of the ear were divided, peculiar "forced movements" and a loss of coördination were produced. The symptoms noticed in auditory vertigo (Ménière's disease) are strongly in accord with these experiments, since slight defects in hearing are accompanied in some instances by alarming vertigo, vomiting, and unconsciousness.

The second proposition seems improbable, because the seat of the electrodes would appear to be too far removed from the cerebellum to directly affect it.

The third proposition is based upon the situation of the electrodes and the fact that the electric current may be supposed to pass in the most direct line through the cerebral substance. It is possible that the artificial current is sufficiently strong to arrest in its passage the cerebellar current which constantly flows into the cells of the caudate nucleus of the corpus striatum, and that the symptoms of vertigo and incoördination are to be thus explained.

From a standpoint of our present knowledge, the cerebellum must be considered as the "terra incognita" of the brain. The clinical evidence is discordant. The anatomical connections of the cerebellum with other parts of the nervous system are remarkable, and their minute structure is, as yet, imperfectly understood. The region overlapped by the cerebellum

is interspersed with important collections of gray matter which act as nuclei of origin for important nerve tracts, so that all experiments made upon the cerebellum itself, or its peduncles, are liable to cause injury to some of the neighboring parts, and thus to yield results which are puzzling and unreliable. Conjecture inevitably forms an important element in all of the theories advanced respecting the functions of the ganglion itself, or of certain of its parts. Nothnagel claims to have demonstrated that mechanical stimulation of the surface of the cerebellum will give rise to muscular movement without signs of pain being perceived. He found that these movements developed slowly, appearing first on the side operated upon, and then ceasing, only to appear upon the opposite side. He states that he has demonstrated that the fifth, facial, and hypoglossal nerves, as well as nerves distributed to the trunk and extremities, can be thus called into action. The same observer concludes that destruction of the *commissural fibers* of the cerebellum alone produces incoördination of movement. Hitzig and Ferrier believe that injuries to the lateral lobe produce the same varieties of "forced movements" as are noticed after section of the middle peduncle. Flourens observed that injuries to the anterior or posterior parts of the median process caused animals to fall forward or backward respectively, and his views have been confirmed by others. Ferrier found that stimulation of the cerebellar cortex by the interrupted electric current produced in monkeys, cats, and dogs movements of the eyeballs, with associated movements of the head, limbs, and pupils. Adamuck produced the same effects, however, by stimulating the corpora quadrigemina. Hitzig refutes the view that Ferrier's results were due to an escape of the current, by claiming to have produced similar effects by mechanical irritation of the cortex. Eckhard has brought forward facts which tend to show that in certain parts of the cerebellum lesions tend to produce diabetes or simple hydruria, thus resembling the effects of irritation of the medulla in the region of the floor of the fourth ventricle.

In the face of this conflicting mass of experimental evidence, I mention now one of the most plausible and attractive theories respecting the relation of the cerebellum and cerebrum to muscular contraction, which has been advocated by Spencer and sustained by Hughlings-Jackson, Ross, and others. It is believed by these authors that all *continuous tonic muscular contraction* is governed by the cerebellum, and the *alternate or clonic muscular contractions* by the cerebrum, in so far as they are required to maintain a posture or produce a change in attitude. In all efforts to maintain an attitude (one assumed as the result of some cerebral impression received), the cerebellum holds the muscular apparatus in its proper state of tonicity; but when the attitude is to be changed, for any possible reason of which the cerebrum is conscious, the proper muscles are relaxed and others thrown into a state of contraction by means of the higher ganglion. The body is then intrusted to the influence of the cerebellum if the attitude is to be again maintained. Thus it is suggested that the cerebellum be considered as capable of automatic action, but still as a subordinate to the cerebrum, which possesses the power of overcoming it in one of two ways: First, by increasing the supply of nerve force to certain sets of cells, then under the influence of the cerebellum, and thus altering the traction upon muscles; or, second, by inhibiting or totally arresting the cerebellar influx to the antagonistic sets of muscles. Both are designed, according to this view, to act either automatically or in unison, but the cerebellum is the servant of the cerebrum, to do its bidding when required.

It will be at once perceived that this theory applies to the complex physiological acts of walking; the prolonged maintenance of any given posture; the transfer of the center of gravity; the passive state of groups of muscles; and many of the morbid phenomena observed in muscles, as the result of impairment of the higher nerve-centers. It will be impossible to discuss all of these conditions in this connection. Hughlings-Jackson and Ross have covered the more important

points in their works. If we form our views of the physiological functions of the cerebellum purely from the standpoint of the anatomical connections which that ganglion is known to possess, we cannot but agree with Bechterew in some of the conclusions which he has lately advanced. This author believes that the cerebellum is intimately connected with three organs which tend to exert an influence upon equilibrium, as follows: First, the *semicircular canals*, connected with the organ of hearing; second, the *organ of sight*, since the movements of the globe of the eye, and possibly the sense of vision, may be traced to a relation with the gray matter in the floor of the third ventricle, and subsequently with the cerebellum; third, the *olivary gray matter*, which the author thinks is probably connected with the organs of tactile sensibility.

The views of this author have been in part anticipated and sustained by Spitzka, who, in an admirable article published about two years ago, considered the cerebellum as the center where "impressions of touch and position are associated with those of time and space," and hence the seat of coördination of the most delicate forms of movements; such as are necessary, for instance, to the proper adjustment of the drum-membrane of the ear for the correct appreciation of sounds, the appreciation of time and rhythm, and the finer acts of equilibrium. In filling this position, the latter author believes that the cerebellum is subordinate to the cerebrum, to which it acts as an "informing depot" for coördination, rather than as a distinct center.

DIAGNOSTIC SYMPTOMS OF LESIONS OF THE CEREBELLUM.

The functional attributes of this ganglion are as yet imperfectly determined, and the effects of lesions (tumors, hæmorrhage, softening, and sclerosis) which involve its different regions vary with their seat. The following deductions are based chiefly upon those of Nothnagel, who has devoted special attention to diseases of this ganglion, and those of Seguin, who has lately contributed a digest of several cases of cerebellar disease:

Lesions of one of the *cerebellar hemispheres* are often incapable of diagnosis, especially if only one hemisphere be involved.

Lesions of the *vermiform process* are generally attended with symptoms of a more decided character.

Incoördination of movement, an *intense vertigo* (identical with that of Ménière's disease), and a "*titubating gait*," are the more common effects of cerebellar lesions ; but these are not in themselves pathognomonic of cerebellar disease, because they may be produced by lesions of other parts of the brain. The consideration of all the morbid phenomena of each case (both of a positive and negative character) is required to render the diagnosis certain.

A *staggering gait* is especially liable to be developed in case the "worm" of the cerebellum is directly involved, or is pressed upon by lesions of adjacent parts. It only exists when the subject is in the upright posture, and the ataxic symptoms rarely affect the delicate movements of the fingers.

Gastric crises (chiefly exhibited by *persistent vomiting*) are a diagnostic feature of lesions of the cerebellum in many cases. When destructive lesions of the cerebellum exist, vomiting is less frequently observed than when that ganglion is encroached upon by lesions of other parts.

Atrophy of the cerebellum has been observed to produce *imperfections of speech* (ANARTHRIA). The difficulty seems to be confined exclusively to the motor apparatus. The memory of words is not disturbed.

Pain in the occipital region is often present in cerebellar disease.

The *organ of vision* may be affected. Occasionally, the eyes may exhibit incoördination of movement and nystagmus ; and also the evidences of choked disk, amblyopia, and amaurosis.

Hæmorrhage into the cerebellum is sometimes associated with a loss of facial expression, due to a slight paresis. The patient may also exhibit a tendency to assume one position,

and to return to it when moved by the attendants. Should hemiplegia occur, it indicates that the lesion exerts pressure-effects upon the pyramidal tracts, either in the crus, pons, or medulla.

Irregularity of the heart's action, which is sometimes observed in connection with a cerebellar lesion, indicates a pressure upon the cardio-inhibitory center of the medulla.

Abnormal mental symptoms are generally absent in connection with cerebellar lesions. When atrophy of the organ is present, or when other parts of the brain are diseased simultaneously with the cerebellum, mental derangements may be observed.

When the *middle crura of the cerebellum* (those going to the pons) are affected by lesions which create irritation, *rotary movements* of the body and a *lateral deflection of the head and eyes* may be developed. As a rule, these rotary movements are toward the healthy side; but this is not invariably the case, as they sometimes are toward the side upon which the lesion is situated. It is a curious fact that most of the effects of cerebellar lesions are attributable to a greater or less extent to irritation of the crura.

Lesions of the *superior peduncle of the cerebellum* are liable to induce paralysis of the motor-oculi nerve, as shown by the development of ptosis, external strabismus, and dilatation of the pupil. Hemianæsthesia and more or less ataxia may be induced by pressure upon the tegmentum and the fillet tract (lemniscus).

THE PITUITARY BODY.

That portion of the brain which lies in the sella turcica of the sphenoid bone is called the pituitary body or the *hypophysis cerebri*. It was formerly called the pituitary gland, because it was supposed to discharge "pituita" into the nostrils. It is diagrammatically shown in Fig. 37.

It is a small, reddish mass, which consists of two lobes, of which the anterior is the larger and embraces the posterior.

The *anterior lobe* is darker in color than the posterior, and, in the adult, consists of a large number of slightly convoluted tubules or alveoli, which are lined with epithelium. Sometimes a colloid substance is found within them. It is joined to the posterior lobes in mammals only.

The *posterior lobe* is developed as a hollow projection from the portion of the cavity of the embryonic brain which is destined to constitute the cavity of the third ventricle. It remains small and undeveloped in the higher vertebrates but becomes transformed into an integral part of the brain in the lower vertebrates through the formation of nerve cells and nerve fibers within it. Occasionally, the cavity which originally existed in its substance remains unobliterated.

The function of the pituitary body is unknown. In its microscopic structure, the anterior lobe closely resembles that of the thyroid body.

THE MEDULLA OBLONGATA AND PONS VAROLII.

The medulla oblongata is received anteriorly (ventrad) into a groove on the basilar process of the occipital bone, and posteriorly (dorsad) into a fossa between the cerebellar hemispheres. From its sides, the seventh, eighth, ninth, tenth, eleventh, and twelfth cranial nerves escape.

Its form has been compared to an "irregularly truncated cone." It is expanded both laterally and antero-posteriorly at its upper portion, and measures about one inch in length, three quarters of an inch in its greatest breadth, and slightly less in its dorso-ventral plane.

The *anterior median fissure* of the spinal cord is prolonged upward (cephalad) throughout the whole extent of the medulla, and terminates (at the junction of the medulla with the pons Varolii) in a deep recess, called the "*foramen cæcum of Vicq d'Azyr.*" Some of the decussating bundles of the pyramids partially interrupt this fissure.

The *posterior median fissure* of the spinal cord is also

continued upward (cephalad) into the medulla, as far as the lower angle of the fourth ventricle, where the so-called "*restiform bodies*" diverge.

We owe to Stilling, Van der Kolk, Türck, Meynert, Clarke, Flechsig, Krause, Spitzka, Laura, Aeby, Roller, Starr, and others who have devoted special study to the architecture of the medulla, the limited knowledge of this complicated piece of mechanism we now possess. Within this ganglion we find numerous collections of gray matter in addition to well-defined nerve tracts. Some of these gray masses are analogous to, and probably direct continuations of, distinct areas of the spinal gray substance. On the other hand, we are forced to admit the existence of other nodal masses, which are structurally independent of any relationship to the cord. Some well-defined tracts of nerve fibers within the cerebrum and spinal cord find their end in the gray masses of the medulla and pons;¹ while other

¹ In connection with the gray substance of the pons, the late researches of Flechsig have shed some light upon the relative development of different nerve tracts, and in this way helped to interpret some points in dispute respecting their distribution. This author draws the following conclusions:

1. A tract of nerve fibers passes from the frontal lobe of the cerebrum, through the anterior division of the internal capsule, and the inner two fifths of the crus cerebri, to the gray nuclei in the antero-median gray matter of the

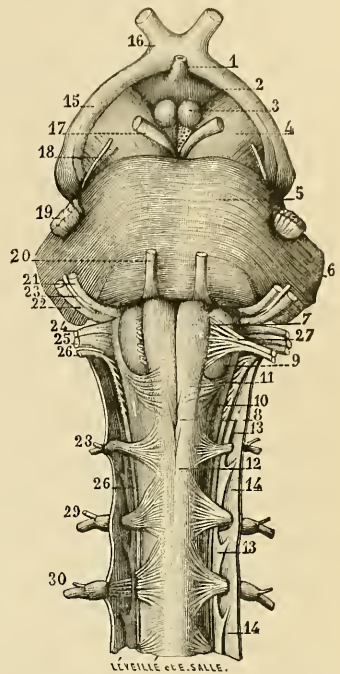


FIG. 50.—Anterior view of the medulla oblongata. (Sappey.)

- 1, infundibulum; 2, tuber einereum; 3, corpora albicantia; 4, cerebral peduncle; 5, tuber annulare; 6, origin of the middle peduncle of the cerebellum; 7, anterior pyramids of the medulla oblongata; 8, decussation of the anterior pyramids; 9, olivary bodies; 10, restiform bodies; 11, arciform fibers; 12, upper extremity of the spinal cord; 13, ligamentum denticulatum; 14, 14, dura mater of the cord; 15, optic tracts; 16, chiasm of the optic nerves; 17, motor oculi communis; 18, patheticus; 19, fifth nerve; 20, motor oculi externus; 21, facial nerve; 22, auditory nerve; 23, nerve of Wrisberg; 24, glosso-pharyngeal nerve; 25, pneumogastric; 26, 26, spinal accessory; 27, sublingual nerve; 28, 29, 30, cervical nerves.

nerve tracts begin in these gray masses and are either prolonged to other parts of the brain, or leave the substance of the medulla as cranial nerves, possessing various functions.

The term "medulla oblongata," as first employed by Vieussens and Willis, included both the crura cerebri and the pons Varolii, in addition to the ganglion, to which the term is now restricted by more modern authors. It is used here to include only the collection of nerve tracts and gray masses situated between the pons and the spinal cord.

The medulla has been subdivided by Krause into three portions, whose limits are as follows: The *inferior portion* extends from the plane of the first cervical nerve to the lower border of the olive; the *middle portion* includes that portion of the medulla between the upper and lower borders of the olive; the *superior portion* extends from the upper border of the olive to the plane intersecting the middle of the floor of the fourth ventricle. Sections of the inferior and middle portions exhibit the central canal more or less modified, and those of the superior portion show the ventricular floor.

The *line of origin of the anterior roots* of the spinal nerves is not marked by a distinct furrow in the spinal cord; but in the medulla a well-marked longitudinal groove (which extends as far as the lower border of the pons) indicates the direct continuation of that line. This groove is partially obliterated

pons. This tract of fibers is apparently prolonged (after traversing this gray mass) to the lateral and posterior portions of the cerebellum; hence, the gray substance of the pons must be regarded as interpolated in a tract which serves to unite the cerebellum with the frontal lobes chiefly, but not exclusively, of the opposed cerebral hemisphere.

2. The postero-median nuclei of the gray substance of the pons is similarly connected with a tract of fibers that joins the cerebellum with the cortex of the temporo-occipital region of the cerebrum. It never develops when the cerebellum is wanting, and is not clothed with myeline until some months after birth. The course of this tract seems to be (1) through the external one fifth of the crus; (2) through the internal capsule; (3) along the base of the lenticular nucleus of the corpus striatum; and, (4) outward to the cortex. The late development of these fibers apparently disproves any connection between them and the sense of hearing or of the tactile sense.

3. The caudate and lenticular nuclei of the corpus striatum are connected with the nuclei of the gray substance of the pons by means of fibers that pass downward through the median bundles of the crus to the substantia nigra and the nuclei of the pons. The fibers of this tract are connected with the cerebellum, after traversing these gray masses.

below the olivary body by transverse fibers; above this point it separates the *olivary body* from the *pyramid*.

Out of this groove the roots of the hypoglossal nerve leave the substance of the medulla; they may therefore be considered as analogous to the anterior roots of the spinal nerves below. This analogy apparently holds good in respect also to the area of gray substance within the medulla from which the roots of this nerve appear to spring; although Spitzka is led to believe that the gelatinous substance anterior to the central canal of the spinal cord is more directly connected with its formation.

The *line of attachment of the posterior or sensory roots* of the spinal cord is prolonged upon the surface of the medulla as a series of bundles which help to form the *spinal accessory nerve*. These are seen to approach the posterior roots of the spinal nerves in the cervical region, and to swing into a direct line of continuation with them above the level of the foramen magnum. At a higher level of the medulla the *vagus nerve roots* spring from the same line, and still higher up the roots of the *glosso-pharyngeal nerve*. Assuming, therefore, that these nerves escape from regions in the medulla that are analogous to those associated in the cord with the posterior roots of the spinal nerves, we are naturally led to infer that the fibers of origin of these nerves are probably connected with masses of gray substance within the medulla which are structurally related to the posterior horns of the spinal gray matter. This is apparently the fact, as subsequent pages will help to demonstrate.

The changes which occur during the transition state (in which the spinal cord is so altered in its construction as to accommodate itself to the requirements of the medulla) may be simplified to the mind of some readers by an illustration employed by Quain, which I quote. He says: "The opening up of the central canal and separation of the lips of the posterior median fissure bring the gray matter to the surface of the fourth ventricle, while the posterior cornua are coincidentally shifted to the side, much in the same way as it would

be if a median incision were made from the posterior surface of the spinal cord into the central canal, and the two lateral halves were then turned outward, so that the sides of the posterior median fissure became the posterior surface of the cord."

The anatomical construction of the medulla and pons is particularly difficult of comprehension, chiefly because the

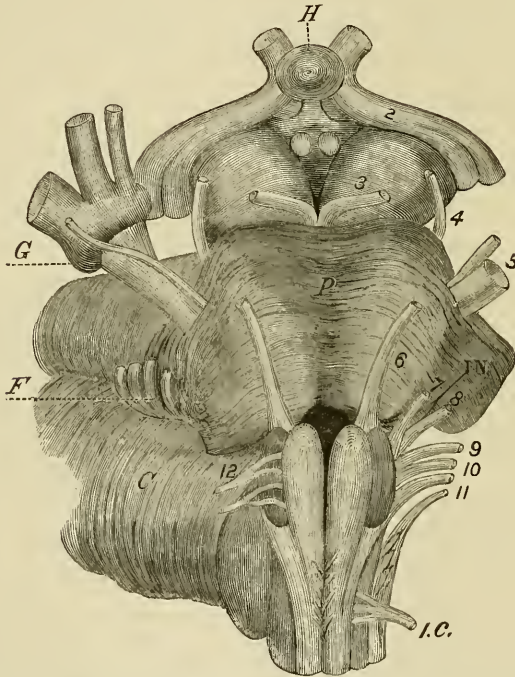


FIG. 51.—Anterior view of the medulla and pons, designed to show some of the relations of surrounding parts and the apparent origin of the cranial nerves. (From a sketch by the author.)

The cranial nerves are indicated by numerals. G, ganglion of Gasser; P, pons Varolii; C, cerebellum; F, flocculus; H, hypophysis cerebri, or the pituitary body, behind which two rounded eminences, the corpora albicantia, are seen.

fibers which compose the motor and sensory tracts of the cerebrum are more or less intermingled with masses of gray matter (some of which have not been as yet referred to), and greatly altered in their relative positions to each other when compared with those of the crus cerebri above or the spinal cord below.

It will facilitate description to consider separately the gray and the white matter of the medulla and pons.

THE GRAY MATTER.

The gray matter of the medulla and pons is best comprehended by tracing from below upward the successive changes which the gray matter of the spinal cord undergoes from the point where the crossing of the fibers of the cerebral motor tract (Fig. 7) occurs throughout the entire extent of the medulla and pons. This subject naturally divides itself into the following heads :

(1) A hasty survey of the architecture of the *spinal cord* at its junction with the medulla oblongata, noting its columns and the arrangement of its gray substance.

(2) The gray substance of the medulla at its lowest part contrasted with that of the spinal cord.

(3) The nuclei of origin of the cranial nerve roots.

(4) The method of continuation of the anterior horns of the cord upward.

(5) The continuation upward of the posterior horns of the cord.

(6) The continuation upward of the central gray column and that of Clarke, which becomes apparently represented in the lower planes of the medulla.

(7) The accessory nuclei, which are developed with the medulla and pons.

(8) The superadded gray substance of the medulla and pons.

The diagram introduced (Fig. 52) will, it is hoped, make clear the main subdivisions of the spinal cord (which are simply enumerated in its accompanying text, as a full description of the various parts is reserved for the section which deals exclusively with the subject).

We are now prepared to study a section of the medulla (made at its point of junction with the cord), and to observe the changes in the gray matter which are produced (1) by modifications in the relative size of the columns depicted in

Fig. 52, and (2) by the decussation of the fibers which compose the "crossed pyramidal columns" of the cord, shown in the diagram (Fig. 53).

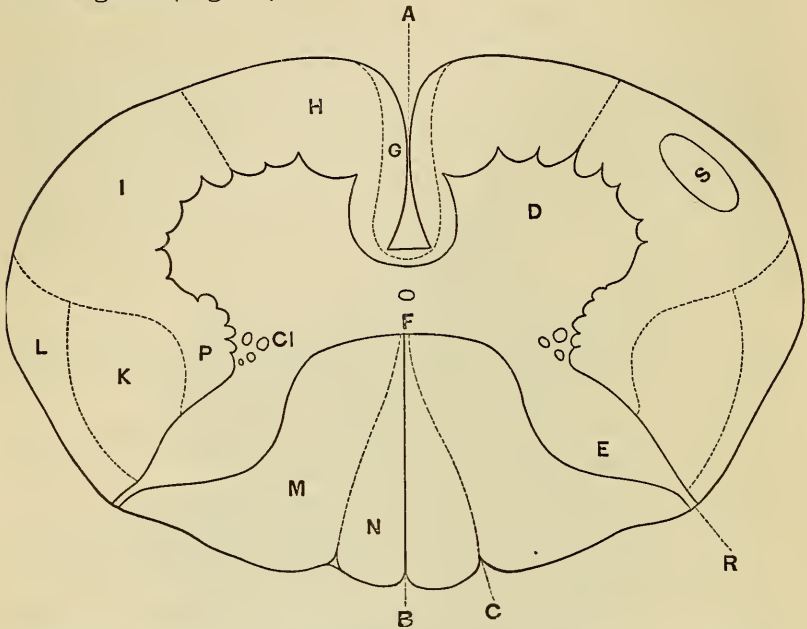


FIG. 52.—A diagram to show the more important subdivisions of the spinal cord. (Altered from Flechsig.)

D, anterior horns; E, posterior horns; Cl, gray columns of Clarke, which are not represented in the lumbar or cervical regions of the cord. They are introduced here, however, to explain some subsequent points pertaining to the architecture of the medulla; *w. c.*, anterior white commissure; *a. g. c.*, anterior gray commissure in front of the central canal; *p. g. c.*, posterior gray commissure; K, the so-called "crossed pyramidal columns" (see Fig. 46.); G, columns of Türck, or the so-called "direct pyramidal columns"; H, anterior root zones; C, direct cerebellar columns; M, columns of Burdach, or the so-called "postero-external columns"; N, columns of Goll, or the so-called "postero-internal column"; S, sensory tract of lateral column, according to Gowers, Ott, and others.

In this section we perceive that the continuation of the COLUMN OF GOLL, or the so-called "*fasciculus gracilis*," of each side is increased in size by the addition of a mass of cells—the "*clavate nucleus*"—to its central portion (Fig. 53); and that the COLUMN OF BURDACH, or the so-called "*fasciculus cuneatus*," also gains a collection of gray matter—the "*triangular nucleus*"—at a slightly higher level.

The effect of this increase in size of the posterior columns is to crowd the gelatinous substance of the posterior horns to

either side, so that they appear near to the lateral borders of the section (Figs. 53, R, and 54, *s g*).

Again, the crossing of the fibers of the "crossed pyramidal column" (Fig. 53) *cuts off* a portion of the anterior horns from the rest of the gray substance, and also tends to *thrust backward* the commissures, the central gray column, and the central canal.

Other important modifications occur, in addition to these changes of position in the component parts of the gray matter (depicted in Fig. 53), as a result of the giving off of fibers (called "arcuate fibers," because of the semi-circular course which they pursue) by the clavate and triangular nuclei of each side.

These fibers pass to the *olivary body* of the same side (Fig. 54), and by their passage through the posterior horns of the spinal gray matter almost entirely separate the *substantia gelatinosa* and the posterior horn from the gray substance which surrounds the central canal of the cord.

During the passage of these arcuate fibers, they become interlaced with the fibers of the crossed pyramidal columns. The latter decussate at this level, and serve to detach groups of cells from the anterior horn, which are thus carried into the anterior root zones (Fig. 53).

Finally, the *anterior root zones* of Fig. 52 (now the lateral columns of the medulla) are subdivided by the arcuate fibers of the triangular and clavate nuclei, and the arcuate fibers of the inferior peduncles of the cerebellum into a reticulated

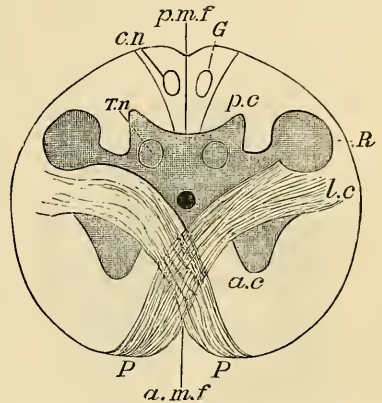


FIG. 53.—A diagram of a section of the medulla at the middle of the motor decussation.

P, pyramidal fibers undergoing decussation; a. c., anterior cornu; l. c., continuation of the lateral column of the spinal cord; R., continuation of the substantia gelatinosa of Rolando; p. c., continuation of the posterior cornu; T. n., triangular nucleus; c. n., clavate nucleus; p. m. f., posterior median fissure; a. m. f., anterior median fissure.

formation—the so-called “*formatio reticularis*”—which is thickly studded with ganglion cells possessing well-defined processes.

The gray masses found in the reticular field, considered in the aggregate, have been named by Spitzka the “*ganglion reticulare*.” It is the ganglion proper of the medulla. It is well developed in the middle olivary plane, lying to the lateral side of the nucleus for the hypoglossal nerve. Spitzka regards it as the probable center “for those rhythmical automatisms which (while under the control of the higher centers) involve the activity of both cranial and spinal nerves.” The cells of this structure have more than one axis-cylinder process, according to the same author, and exhibit apparent connections in all possible directions; chiefly, however, in the dorso-ventral plane.

Among the cells of the reticular formation of the medulla two well-defined groups exist, which have been designated as the “*anterior*” and “*posterior nuclei of the lateral column*.”

The nuclei of origin of the ninth, tenth, and eleventh cranial nerves are intimately associated with the gray matter present in the “reticular field” of the medulla (Fig. 59). Krause, Laura, Meynert, and Spitzka differ as to the probable connections of the so-called “nucleus ambiguus” of Krause. Meynert associates it with the tenth, Laura with the twelfth, and Spitzka with both the

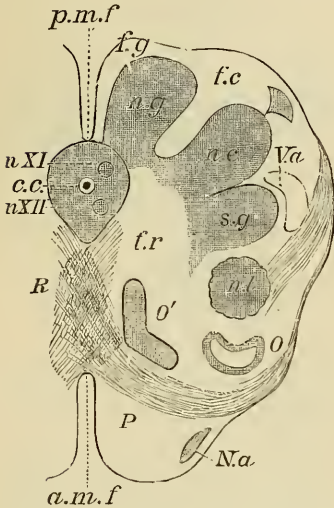


FIG. 54.—A diagram of a section of the medulla at a slightly higher level than in the preceding figure.

P, pyramidal fibers; N. a, arciform fibers; R, raphæ, with decussating fibers in the field; O', accessory olive; O, olive; f. r., formatio reticularis; c. c., central canal; n. l., lateral nucleus; s. g., substantia gelatinosa; n. c., nucleus cuneatus; f. c., funiculus cuneatus; f. g., funiculus gracilis; n. g., nucleus of the same; n. XI, nucleus of the eleventh nerve (spinal accessory); n. XII, same of the hypoglossal nerve; a. m. f., anterior median fissure; p. m. f., posterior median fissure.

tenth and eleventh cranial nerves. The fibers arising from it cross the raphæ of the medulla. Spitzka believes that it is probably connected with the motor apparatus of the larynx.

The "*ganglion cells*" which are found within the gray matter of the spinal cord are more or less redistributed within the medulla, after they have been separated (at its lower portion) by the fibers of the crossed pyramidal columns and the arcuate fibers already described. Nuclei of special nerve roots, and masses whose functions are not yet well understood, are thus formed. These will merit subsequent description.

The *nuclei of the lateral column of the medulla*, which have been previously mentioned, appear to give origin to a portion of the fibers, at least, of the spinal accessory nerve. Some of these fibers may be distinctly traced to the nerve of the opposite side, but the majority wind around the posterolateral group of cells to join the nerve of the same side.

As we ascend the medulla, cross-sections of that body at different levels successively reveal the nuclei of the *motor fibers* of the pneumogastric and glosso-pharyngeal nerves; next, those of the facial nerve; and, later, those of the motor or ascending root of the trigeminus.

Nerve Nuclei in the Medulla.—By referring to the diagram which is now introduced (Fig. 55), and comparing it with the one which follows, the reader will be enabled to form a tolerably clear conception of the relative situation and extent of the more important nuclei, from which some of the cranial nerve-roots apparently take their origin. It can be more readily understood, after a careful study of these two diagrams, why it is that cross-sections of the medulla and pons made at different levels present such wide variations in the arrangement of the gray matter. These diagrams will help also to render such sections more intelligible to the reader.

Let us now consider somewhat more in detail the points which these two diagrams present. In the first place, it will

be seen that the cranial nerves from the fifth to the twelfth escape from the pons or medulla at different levels.

Again, it will be observed that the nuclei of origin of these nerves are situated in the region of the *floor of the fourth*

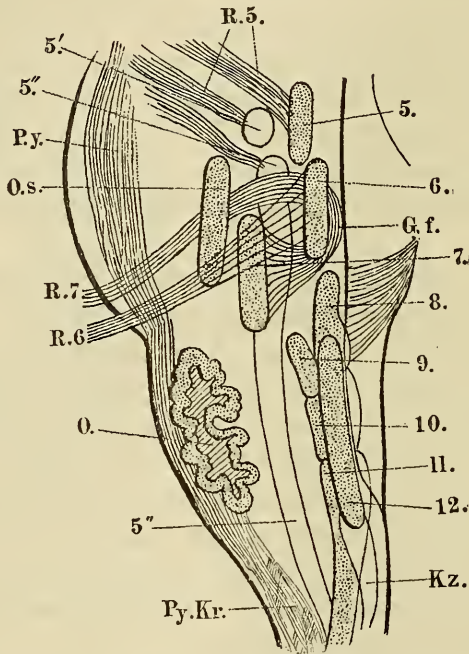


FIG. 55.—Transparent lateral view of the medulla, showing the relative positions of the most important nuclei; right half of the medulla, seen from the surface of section; the parts that lie closer to this surface are deeper shaded. (After Erb.)

Py, pyramidal tract; Py. Kr., decussation of pyramids; O, olivary body; O. s., superior olivary body; 5, motor; 5', middle sensory; 5'', inferior sensory nucleus of trigeminus; 6, nucleus of abducens; G. f., genu facialis; 7, nucleus facialis; 8, posterior median acoustic nucleus; 9, glosso-pharyngeal nucleus; 10, nucleus of vagus; 11, spinal accessory nucleus; 12, hypoglossal nucleus; Kz., nucleus of the funiculus gracilis; R. 5, trigeminus roots; those of the R. 6, abducens, and R. 7, facialis.

ventricle, and that they are so distributed (with few exceptions) as to approximately correspond to the level of the superficial origin of the nerves whose roots are connected with them.

In the third place, it will be seen that some nerves have *more than one nucleus* of origin in the medulla. The *fifth* has one motor and two sensory nuclei, near the upper part of

the ventricle; the *auditory* has four nuclei, the anterior and posterior median, and the anterior and posterior lateral; finally, *accessory nuclei* have been discovered for the facial, spinal accessory, and hypoglossal nerves. These are not shown in the diagrams.

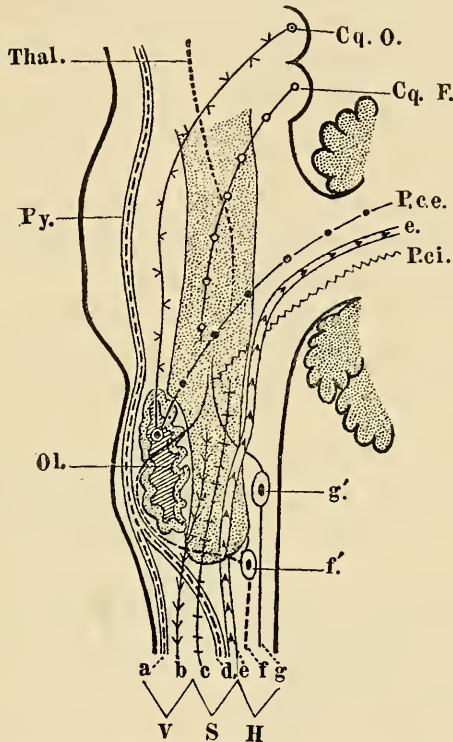


FIG. 56.—Diagram of the chief tracts in the medulla. (After Erb.) The formatio reticularis is represented by shading.

Ol., olivary body; V, anterior; S, lateral, and H, posterior spinal funiculi; a, pyramido-anterior tract; d, pyramido-lateral tract; Py., pyramidal tract; b, remainder of anterior column; c, remainder of lateral column; e, e, cerebello-lateral tract; f, funiculus gracilis, and f', nucleus of the same; g, funiculus cuneatus, and g', nucleus of the same; P. c. i., internal fasciculus of the pedunc. cerebelli; P. c. e., external fasciculus of the same; Cq. F., tract from corp. quadr. to format. retic.; Cq. O., the same to the olivary body; Thal., tract from the thalamus opticus.

In the fourth place, it should be noted that the *area* covered by the nuclei of some nerves is greatly in excess of that of others. The trigeminus nerve has one sensory nucleus (the inferior) which extends throughout the greater part of the substance of the pons and the medulla (Fig. 55, V'');

while the "median sensory" and the "motor" nuclei of the same nerve are of smaller size. The ninth, tenth, eleventh, and twelfth cranial nerves have longer nuclei than the seventh or eighth.

Having now grasped the general situation and form of the nuclei of the cranial nerves found within the pons and medulla, it seems advisable to add a few statements respecting the peculiarities of each, which may aid us in studying the architecture of the medulla and pons by cross-sections of the same.

The *trigeminal sensory nuclei* are analogous in some respects to the *posterior horn* of the spinal gray matter, since they contain only small ganglion cells.

The *nucleus of the sixth nerve* contains large cells¹ (motor), and lies at the junction of the pons and medulla, in a groove on the floor of the fourth ventricle, near the fasciculus teretes.

The *nucleus of the facial nerve* is composed of large cells (motor), and is somewhat lower and placed more deeply in the substance of the medulla than that of the sixth.

The *auditory nerve* receives fibers from *four independent nuclei* which are situated in the region of the broadest portion of the fourth ventricle.

The *pneumogastric* and the *glosso-pharyngeal nerves* have nuclei of origin which are not clearly demarkated from each other, although the nucleus of the vagus lies deeper than that of the ninth nerve.

The following table is given by Spitzka to illustrate the various nuclei of the medulla that appear in cross sections made at different altitudes and at a right angle to the long axis of the medulla.

¹ Spitzka combats the view that a differentiation of nerve cells in regard to their function can be made on their dimensions alone. He points out that both large and multipolar cells may have a sensory function, and that some motor cells have few processes in the lower vertebrates. He states that a gradual transition from the body to the processes is typical of motor attributes, and that, in sensory cells, the transition is always abrupt.

	Altitude in the medulla.	MOTOR COLUMN REPRESENTATIVE.		MIXED COLUMN REPRESENTATIVE.		Sensory column representative.
		Subependymal.	Insular.	Subependymal.	Insular.	
1	Lower roots of 12th pair.	Nucleus of 12th pair.	Nucleus pyr' midalis.	Common vago-accessory nucleus.	Inferior accessory nucleus.	Gelatinous nucleus of 5th pair.
2	Roots of 9th pair.	Barren.	Absent.	Nucleus of 9th pair.	Inferior accessory nucleus.	Auditory nucleus.
3	Roots of 6th pair.	Common nucleus of 6th and 7th pairs.	"	Absent.	Inferior facial nucleus.	Auditory nucleus.
4	Exit of 5th pair.	Barren.	"	"	Motor nucleus of 5th pair.	Gelatinous nucleus of 5th pair.
5	Valve of Vieussens.	Nucleus of 4th pair.	"	Substantia ferruginea.	Absent.	Absent.
6	Root of 3d pair.	Nucleus of 3d pair.	"	Vesicular cells of most anterior origin of 5th pair.	"	"

The areas represented by Pn and G in Fig. 59 are believed by Spitzka to be respectively associated with the fibers of origin of the pneumogastric and glosso-pharyngeal nerves. He considers them, therefore, as nuclei for "visceral innervations" and "gustatory impressions." He is led to this conclusion from the variations observed in animals as regards the development of these nuclei, and the preponderance of these cell-masses in the planes of the medulla marked by the exit of the rootlets of the pneumogastric and glosso-pharyngeal nerves.

Some authorities give to the *pneumogastric* nerve a *second nucleus* of origin in the substance of the medulla near the olivary body.

The *hypoglossal nucleus*¹ lies close to and in front of the central canal of the cord, as low as the level of the decussation of the pyramidal fibers. It consists of large branching nerve cells, similar to those of the anterior horns of the spinal cord. After the central canal has opened into the fourth

¹ The nucleus of the hypoglossal nerve is considered by Spitzka as a continuation upward (cephalad) of the gelatinous gray matter lying in front of the spinal canal. The anterior horns have been cut off (in a lower plane of the medulla) by the decussation of the pyramidal fibers.

ventricle, this nucleus creates a prominence close to the median line of the ventricle, slightly above the point of the calamus scriptorius, or the lower angle of the ventricle.

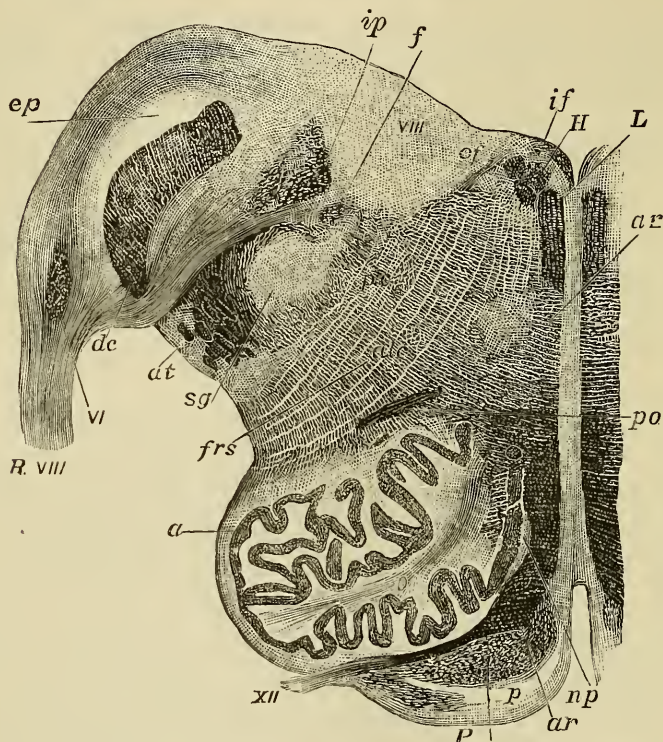


FIG. 57.—A cross-section of the medulla oblongata on a level with the superficial origin of the auditory nerve. (Modified from Flechsig by Ross.)

ip and *ep*, the internal and external divisions of the inferior peduncle of the cerebellum; *frs*, reticular formation; *a*, arciform fibers; R. VIII, root of eighth nerve; VIII and VIII'', nuclei of same; H, hypoglossal nucleus; P, pyramid; *p*, accessory portion of same; *po*, parolivary body; *np*, nucleus of the pyramid; *at*, ascending root of fifth nerve; *dc*, direct cerebellar tract; L, posterior longitudinal bundle; O, olivary body; *sg*, substantia gelatinosa.

That the fibers of the hypoglossal nerve are prolonged in some way upward to the cerebral cortex seems to be proven by pathological facts; although they have not yet been traced to such a termination.

The medullary portion of the spinal accessory nerve is destined to join the pneumogastric nerve after its exit from the skull, while the spinal portion pursues a separate course.

Its nucleus seems to be a prolongation downward of the nucleus of the vagus, as its course would naturally suggest.

In a general way, it may be stated that the nuclei of those cranial nerves within the medulla which are motor in function are characterized by large multipolar cells, while those which are connected with the sensory nerve-roots are composed of cells of smaller size, some of which are bipolar. In some respects they are analogous respectively to the cells of the motor or kinesodic, and the sensory or æsthesodic regions of the spinal gray matter; and also to the gray substance of those convolutions of the cerebrum which preside over similar functions.

Spitzka has called attention to the fact that the evolution of nervous force does not necessarily imply the existence of distinct fibers and of nerve cells. He says: "In the lower forms of animal life a uniform blastema, with or without nuclei, and entirely devoid of nerve cells, is frequently all that represents a ganglion; and the afferent and efferent strands connected with such a simple structure are composed of an infinite number of granules which show no fibrillary arrangement."

Again, the same author remarks: "The increased perfection of the nervous system is marked by a progressive tendency to isolation of the conducting strands."

THE UPWARD CONTINUATION OF THE ANTERIOR HORNS OF THE SPINAL GRAY SUBSTANCE.—We have already mentioned a change in the anterior horns¹ at the lower part of the medulla produced by the decussation of the motor fibers, which compose the so-called "crossed pyramidal tracts." The formation of two groups of cells, called the antero-lateral and the postero-lateral groups, here takes place. Portions of these groups are carried into the lateral column of the medulla, and form the so-called "*anterior*" and "*posterior*

¹ The *nucleus of the pyramid* is to be regarded as "the amputated part of the anterior horn" of the corresponding side of the cord. Spitzka regards it as an accessory nucleus to the hypoglossal nerve, classing it in the same category with scattered gray masses from the lateral system higher in the medulla. He believes it to be the nucleus of origin of those fibers which supply the retractors of the hyoidean apparatus.

nuclei" of that column. The same arrangement appears to be carried out as we study ascending sections, so that the spinal accessory, the motor fibers of the pneumogastric and glosso-pharyngeal, the facial, and the motor fibers of the trigeminus seem to spring from a continuation upward of the anterior horns of the spinal gray substance in its lateral column.

The fibers of these nerves take, as a rule, an extremely circuitous course before escaping from the medulla. In the case of the facial nerve, a peculiar bend in its fibers of origin has been named the "knee" ("*genu nervi facialis*").

The *anterior nucleus* of the lateral column of the medulla appears to cease on a level with the origin of the facial nerve, although some authors believe that some fibers of the trigeminus pass from it in an upward and backward direction.

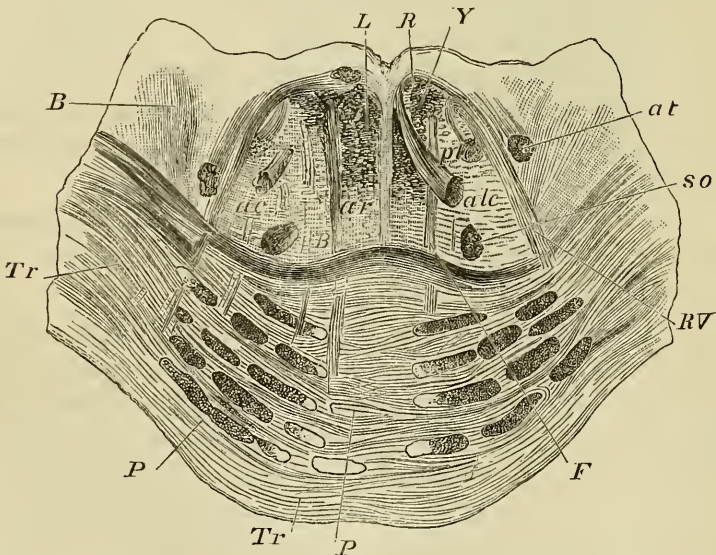


FIG 58.—A transverse section through the pons, on a level with the roots of the sixth and seventh cranial nerves from a nine months' embryo. (Modified from Erb and Ross.)

The right half represents a section made a little lower than the left. Tr, transverse fibers of the pons; P, pyramidal fibers; so, superior olivary body; L, posterior longitudinal fasciculus; t, fasciculus teretes (round bundle); RVI, root of abduccens; RVII, root of facial; at, ascending root of trigeminus; R, round bundle; B, peduncle of cerebellum; ar, upward prolongation of anterior root zone of the spinal cord; alc, anterior nucleus of facial nerve; plc, posterior nucleus of same. This figure shows well the interlacing of the vertical pyramidal fibers with the horizontal (transverse) fibers of the pons.

The *posterior nucleus* of the lateral column of the medulla passes behind and to the outside of the nucleus of the abducens, or sixth nerve, before joining with that of the facial.

The development of the *olivary body* within the substance of the medulla tends to displace the whole of the gray matter backward, until the posterior gray commissure (Fig. 52) disappears, and the central canal of the cord opens on the floor of the fourth ventricle.

The *nucleus for the hypoglossal nerve roots* bears a striking analogy, as regards the peculiar distribution of its cells, to the anterior horns of the spinal gray matter. The analogy is heightened furthermore by an identical method of development of these groups.¹

At the upper level of the hypoglossal nucleus the transverse fibers of the pons tend to separate those masses of gray matter, which are probably an extension upward of the anterior horns of the spinal gray substance, or the gelatinous substance anterior to the central canal. Hence it becomes extremely difficult to trace their connections.

In the larger nucleus of the hypoglossal nerve, Spitzka describes a collection of cells whose axis-cylinder processes run away from the tract of the hypoglossal fibers, rather than toward them. These cells he believes to be associated with the eleventh nerve roots; and he thinks that an associating mechanism is thus established between the movements of the tongue and of the vocal cords, as is required in phonation and singing.

There are some grounds for the belief that the nucleus for the abducens, or sixth nerve, is a direct continuation of the postero-lateral group of cells; because the fibers of the facial nerve wind around it as those of the spinal accessory nerve do around the postero-lateral group in the lower part of the medulla.

¹ Spitzka makes use of the following general deduction or axiom: "A ganglion (center) follows in development the development of the periphery, which is projected in that ganglion." He advances many interesting facts in support of this law, from a study of the comparative anatomy of animals. "Journal of Nervous and Mental Diseases," October, 1879, p. 616.

The *nucleus for the motor-oculi, or third nerve*, which has been partly described in the pages that treat of the crus cerebri, probably belongs to a group of cells which also constitutes the nucleus of the abducens nerve. In point of fact, it is reasonable to consider the nuclei of the third, fourth, and sixth cranial nerves as parts of one mass of

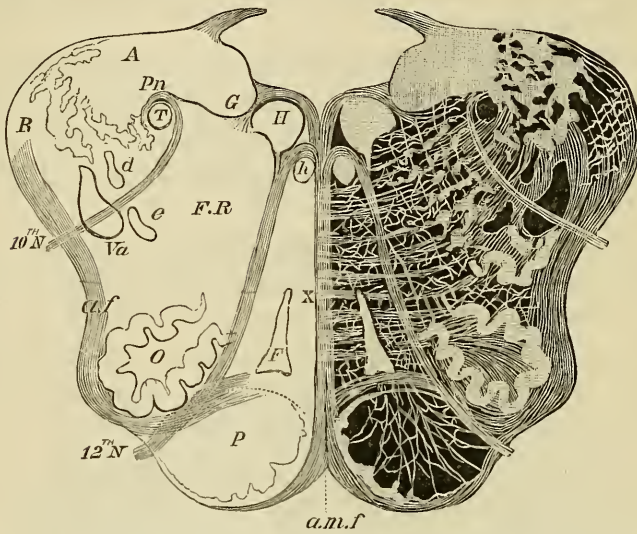


FIG. 59.—A transverse section of the medulla (partly schematic) made through the middle of the olivary body. (Modified from Spitzka.)

H, and h, nuclei of origin of the hypoglossal nerve (twelfth cranial); F. R., reticular formation, with its cell-masses; O, olivary body; P, pyramid; *a. m. f.*, antero-median fissure; G and Pn, masses of cells probably associated respectively with the glosso-pharyngeal and pneumogastric nerves; Va, ascending root of fifth cranial nerve; B, restiform column; *a. f.*, arcuate fibers; F, fibers passing through the inter-olivary tract; *e* and *d*, bundles of fibers from the posterior spinal tracts, cut across on their way to the inferior cerebellar peduncle after decussation; T, the "trineural fasciculus" of Spitzka; "solitary" or "round" bundle of other authors. Note that the solid masses are composed of cells; the black areas are designed to represent conducting fibers running vertical to the plane of the section; the white lines represent fibers which run in the plane of the section.

cells, which have become separated by the interposition of some fibers destined to play an important but unknown part in the varied functions of the medulla. These nuclei all act upon the eye. They are connected, according to some authors, by distinct fibers, which run from the abducens nucleus to that of the third nerve of the opposite side.

THE UPWARD CONTINUATION OF THE POSTERIOR HORNS.

—The arcuate fibers of the medulla separate the “*substantia gelatinosa*” from the rest of the gray substance, near to the line of junction of the spinal cord. This portion of the posterior horns maintains a superficial position in the lateral column of the medulla, as high as the point of escape of the trigeminus, or fifth nerve from the pons. In the opinion of some authors, this structure may be regarded as prolonged through the aqueduct of Sylvius as far as the level of its opening into the cavity of the third ventricle.

Spitzka is led to the conclusion that the *gelatinous substance* of the posterior horn is not composed of neuroglia tissue, but is to be regarded rather as imperfectly organized ganglionic tissue which is connected with sensation. He is brought to this view by the following facts: 1. It exists where the sensory nerves enter the posterior horn; 2. It is found in the sensory nuclei of the medulla, chiefly in the trigeminal nuclei; 3. It is found in the olivary bodies which are connected with strands from the posterior columns of the cord, above the nuclei of those columns.

The posterior spinal cornua are continued upward into the substance of the medulla upon the mesial aspect of the ascending root of the fifth cranial nerve (Fig. 57) as two masses—the so-called “spongy” and “gelatinous” form of gray substance. The former merges with the gray matter of the reticular field; while the latter lies more closely related to the trigeminus tract. Spitzka is led to believe, from the apparent connections of the gelatinous substance, that it is the station for sensory impressions derived from the pharynx. He states his grounds for this belief as follows:

“Taking into account that the three nerves, into which the eighth pair of Willis has been divided by Soemmering, supply many peripheries conjointly, I think it unfortunate that investigation should seek for the special nucleus of this or that nerve, designated by a given numeral. Meynert made a step in the right direction when he considered the nuclei of the ninth, tenth, and eleventh pairs in the aggregate, and

classified the aggregate nuclear masses on the topographical principle. If there is any truth in the notion that, with a given animal species, cells have special connections, present a special type of structure, then it will be reasonable to seek for the nuclei of different peripheries. This procedure is far more rational than to seek for the nucleus of a nerve whose component filaments have different peripheral terminations, and are included in the same sheath, rather by anatomical accident, as it were, than because of their physiological propinquity. I think it sound to speak of a nuclear column representing the visceral periphery of the vagus, or the gustatory periphery of the glosso-pharyngeal and intermediate nerve of Wrisberg, or the tactile periphery of the ninth and tenth, the motor pharyngeal periphery of the same nerves, and the motor laryngeal of the tenth and eleventh pairs."

THE CONTINUATION OF THE CENTRAL GRAY COLUMN OF THE SPINAL CORD.—By a reference to Fig. 52 it will be seen that the gray substance of the spinal cord on either side of the central canal is represented as consisting in part of the "gray" or "*vesicular column of Clarke*," and again of an intervening portion between it and the central canal called the "*central gray column*."¹

THE COLUMN OF CLARKE is well defined in the dorsal region of the cord, but it is not represented in the cervical or lumbar

¹ The gray matter of the cord is divided by Spitzka into three parts, viz.: the anterior horns, or motor system; the posterior horns, or sensory system; and the intermediate portion, to which he applies the term "mixed system," because it partakes, to his mind, of sensory, motor, and trophic functions. He attributes a trophic function to the cells of Clarke's column.

The following formulæ, advanced by the same author respecting the functions of cell groups in the central tubular gray masses, are of interest in this connection:

"The nearer the muscle is to the ventral aspect of an animal, the nearer will be its nucleus to the median line of the cord. *Per contra*, the nearer the muscle is to the dorsal line of an animal, the nearer to the so-called lateral cornu will its nucleus have to be sought for. Flexor nuclei are therefore in internal, extensor nuclei in external and posterior, cell groups."

"Hypertrophied segments of the body, such as the extremities, are accompanied by lateral extensions of the cornua, in which flexor and extensor muscles probably occupy the same relative position as the one stated.

"Whether groups of muscles be flexor or extensor, it will be found that the nearer they are to the animal axis, the nearer will their nuclei be to the central canal. This is especially true of the flexor nuclei."

regions. In the lower part of the medulla, however, a collection of cells situated at the posterior and external part of the central gray column may be discovered, which bear a close analogy to those of the column of Clarke encountered in the dorsal region of the cord. It contains *bipolar cells* which are markedly pigmented, and constitutes the posterior nucleus of the spinal accessory nerve, which is given off at this level. At higher levels, after the central canal has opened upon the floor of the fourth ventricle, this column seems to assist in the formation successively of the nuclei of the eleventh, tenth, and ninth cranial nerves.

The CENTRAL GRAY COLUMN of the cord appears to be continued into the medulla as a thin layer of gray substance which covers the floor of the fourth ventricle, and is prolonged as a lining to the aqueduct of Sylvius.

The term "nuclear formation" is applied to the central tubular gray, because it exhibits a tendency in higher animals to resolve itself into nuclei of origin for special nerves.

The *fourth ventricle* may be regarded as an expanded portion of the central canal of the cord, in order that sufficient room shall exist for the nuclei of the cranial nerves situated upon its floor.

The *aqueduct of Sylvius*, with its surrounding gray matter, again represents from this standpoint the spinal canal and the central gray column, continued onward to the third ventricle.

ACCESSORY NUCLEI OF THE MEDULLA OBLONGATA.

Within the *apparent continuation of the central gray column* of the cord upon the floor of the fourth ventricle and the aqueduct of Sylvius, certain collections of cells, that have no representation in the architecture of the cord, are observed. These have been named the "*accessory nuclei*" of the *medulla*. They require a separate description. These include the inferior facial; the accessory nuclei of the spinal accessory and hypoglossal nerves; and four acoustic nuclei.

Inferior Facial Nucleus.—This was first described by Clarke. It consists of a collection of several small masses of cells, which lie to the inner side of the hypoglossal nucleus and close to the median line. Before the spinal canal opens into the ventricle, they lie between it and the hypoglossal nucleus of either side. The fibers which spring from them appear to enter the funiculus teretes, through which they ascend to the fasciculus teretes, and then join with fibers of the facial nerve. This nucleus has been divided by some authors into two, to which the names *internal* and *external* have been applied.

Accessory Nuclei of the Spinal Accessory Nerve.—These consist of two collections of cells of small size, which are situated posteriorly to the main nucleus of the spinal accessory nerve. According to Meynert, these nuclei are connected by commissural fibers which pass posterior to the central canal.

Accessory Nucleus of the Hypoglossal Nerve.—Ross describes this collection of cells as developed principally upon one side only of the medulla. It is composed, according to this author, of caudate cells of extremely small size, when compared with the cells of the hypoglossal nucleus. He believes that this accessory nucleus is concerned in the mechanism of articulation, and that it is reasonable to suppose that it is in some way connected with the third convolution of the left frontal lobe.

SPECIAL NUCLEI OF THE MEDULLA AND PONS VAROLLI.—Ross includes under this head the acoustic nuclei, because they can hardly be said to be represented by any part of the gray substance of the cord. They are four in number, two median and two lateral.

The *posterior median acoustic nucleus* occupies the space between the ala cinerea and the inferior peduncle of the cerebellum, as high as the anterior border of the “*striæ medullares*.” It gives origin to the posterior root of the auditory nerve. Some of these fibers pass out superficially, the “*striæ acousticæ*”; while others traverse the substance of the medulla.

The *anterior median acoustic nucleus* lies anteriorly to the striæ medullares, and gives origin to the anterior root fibers of the auditory nerve. It occupies the external angle of the ventricle.

The *posterior lateral acoustic nucleus* lies imbedded in the peduncle of the cerebellum, and is interposed between the superficial and deep fibers of the auditory nerve.

The *anterior lateral acoustic nucleus* is situated between the middle peduncle and the flocculus. It gives origin to the so-called "portio intermedia of Wrisberg." The view that this nucleus is associated with the *special sense of taste* in the anterior two thirds of the tongue (because its fibers appear to pass in the chorda-tympani branch of the facial nerve) is now held by some anatomists.

THE SUPERADDED GRAY MATTER OF THE MEDULLA AND PONS.—When successive cross-sections of the medulla and pons are compared with each other, nodal masses of gray matter are discovered, the analogues of which are not found within the brain or spinal cord; and some are apparently not directly connected with the fibers of origin of special cranial nerves. Most of these have been incidentally referred to in previous pages, but a few remain to be described. These nodal masses include (1) the so-called "*triangular nucleus*"; (2), the "*clavate nucleus*"; (3), the "*olivary body*"; (4), the "*parolivary body*"; (5), the "*internal parolivary body*"¹ or the "*nucleus of the pyramid*"; (6), the "*superior olivary body*"; and (7) the "*middle sensory nucleus of the trigeminus nerve*."

The "*red nucleus of the tegmentum*" or the "*superior olive*" of Luys (which has been already described in connection with the crus cerebri), as well as the "*external geniculate body*" (which has been discussed in previous pages), are also classed by Ross among these superadded collections of gray matter.

The Triangular Nucleus.—This is a gray nucleus (Fig. 53) which is inclosed within the substance of the cuneate bun-

¹ The parolivary bodies are often designated as the "accessory olivary nuclei."

dle or Burdach's column (Fig. 52). It extends cephalad from the lower portion of the medulla as high as the posterior end of the "postero-lateral acoustic nucleus," and increases in size as it ascends. It lies along the inner border of the cuneiform column. It is now believed that all the fibers of the postero-lateral column of the spinal cord (Burdach's column) end in this nucleus.

The Clavate Nucleus.—This mass (Fig. 53) is situated within the continuation of the fasciculus gracilis or the column of Goll (Fig. 52) into the medulla. It produces an enlargement of this bundle of fibers called the "*clava*." It extends as high as the posterior extremity of the "postero-lateral acoustic nucleus." Both the clavate and triangular nuclei may be considered, therefore, as *pillars of gray substance* which run in the long axis of the medulla. The fibers which compose the postero-median column of the spinal cord (Goll's column) probably end in this nucleus.

The nuclei of the columns of Goll and Burdach gradually disappear as the central canal of the cord expands into the fourth ventricle.

The Olivary Body.—This structure (Figs. 57 and 59) is situated in the lateral column of the medulla, close to the anterior pyramid. Its *gray nucleus* is not seen upon its surface, since it is covered by longitudinal and transverse fibers. The olivary body takes the form of a scalloped or wavy layer which is open at one point—the *hilus* of the olive. This opening looks toward the median line of the body. The fibers which pass through the hilus compose the so-called "*peduncle of the olive*." Some of the relations which this body bears to other parts are depicted in a previous diagram (Fig. 55). Certain fibers of the olivary peduncle pass through the lamina of the olivary nucleus, and constitute the so-called "*arcuate fibers*" (which have been mentioned on a previous page as helping to subdivide the gray substance of the anterior horns at the junction of the medulla and spinal cord). The cells of the olivary nucleus (*corpus dentatum* of the olive) are of the multipolar variety and of small size.

The olivary bodies are functionally related to the cerebellum. It has been shown that atrophy of one hemisphere of the cerebellum is always associated with atrophy of the opposite olivary body. The fibers from the olivary bodies pass to the cerebellum by means of the inferior peduncles (processes e cerebello ad medullam—restiform bodies).

Spitzka has pointed out the fact that the gray nucleus of the olive, as well as the clavate and triangular nuclei of the medulla, are highest developed in man and the anthropoid apes.

The Parolivary Bodies.—These are shown in Fig. 57. They are to be regarded as accessory nuclei to the olivary body. One, the “*internal parolivary body*,” lies adjacent to the internal half of the posterior border of that body; the other, or “*external parolivary body*,” lies in front of the olivary body, and to its inner side. Because the latter lies immediately behind the pyramid, it is often called the “*nucleus of the pyramid*.” The fibers of origin of the hypoglossal nerve pass between the olivary body and its internal accessory nucleus after traversing the peduncle of the olive. Occasionally these fibers penetrate the olivary body.

The Superior Olivary Body.—This long gray column lies in the pons Varolii, in front of the facial nucleus.

THE WHITE SUBSTANCE OF THE MEDULLA.

Having now considered the collections of nerve cells or gray matter within this ganglion, we are prepared to intelligently discuss the bundles of *nerve fibers* which constitute its white substance.

In order to systematize this study, it is necessary to impress you early with the fact that two general classes of fibers may be recognized here, as follows: (1) Those which are prolongations of the fibers *found within the white substance of the spinal cord*, and (2) *superadded fibers*, which are independent of the spinal bundles.

The fibers which are prolonged from the spinal cord probably traverse the entire length of the medulla and pons, either

totally or in part, and then pass to the cerebrum through its peduncles (the crura). These bundles are found, as a rule, to occupy *portions of the internal capsule* (Fig. 39) after leaving the crus, and to be connected with the cells of the cerebral cortex, after they have escaped from the confines of the basal ganglia, and have radiated throughout various areas of the central mass of the cerebral hemispheres.

In previous lectures we have traced some of the bundles of the internal capsule from above downward, taking their cortical attachments as the starting-point in our description. It is now deemed advisable to reverse the order of description, and to trace them from the spinal cord upward, noting certain peculiarities in the course which each pursues during its passage successively through the medulla, pons, crus cerebri, internal capsule, and corona radiata, as well as the area of the cerebral cortex, to which each is probably distributed. Some difficult points will be made clear to the reader, while following the description of these fibers in a reversed order, by consulting certain familiar diagrams which have been used in elucidating previous topics (chiefly Figs. 8 and 63).

The diagram of the main subdivisions of the spinal cord, to which reference was made on page 250, will also come into play again here, as the starting-point from which the different bundles of the medulla are described.

THE PYRAMIDAL TRACTS.—The motor bundles, which serve to connect the cells of the cerebral cortex with the cells of the anterior horns of the spinal gray matter (Fig. 52), are found in two distinct columns of each lateral half of the spinal cord.

The *columns of Türck* (Fig. 46) convey those bundles of spinal fibers which are associated with the cerebral hemisphere of the same side. These do not decussate in the medulla.

The "*crossed pyramidal columns*" (Fig. 46) convey fibers which cross within the medulla to the opposite side, and which are therefore connected with the opposite cerebral

hemisphere—the right column with the left hemisphere, and the left with the right.

Now, within the medulla, above the level of the decussation of the latter fibers, these two tracts become united, as it were, in the region of the pyramids of the medulla. This gives them the name of the “pyramidal” tracts. They pass upward through the pons, then into the middle third of the anterior part of the crus cerebri of the corresponding side (the “crusta cruris,” Fig. 45), and eventually reach the cerebral cortex by means of the so-called “internal capsule” (Fig. 39). How these tracts become united within the pyramids of the medulla should now engage our attention.

At the upper part of the cervical region of the cord, and in the lower regions of the medulla, the motor fibers of the lateral columns of the cord cross the median line in order to get to the opposite side. In so doing, they come forward close to the anterior median fissure, and push the fibers of Türk's column aside, so that the latter lie external to them in the so-called “pyramids” of the medulla. As we trace them cephalad, the two tracts do not apparently intermingle. When they reach the level of the pons, they receive a *large accession of new fibers*. This fact helps to explain the marked increase in the apparent size of these tracts, which may be observed in cross-sections made at the upper border of the pons.

Within the *cerebral peduncle* the pyramidal fibers are packed closely into one compact bundle, which occupies the middle third of the “crusta.” This bundle can be traced upward into the “internal capsule” of the cerebrum, lying in its thalamo-lenticular¹ portion (Fig. 39).

Finally, this tract emerges from between the basal ganglia of the cerebrum, without any apparent association with the cells which compose those ganglia. Its fibers then radiate to

¹ The reader is referred to page 151 for the results of Flechsig's latest researches in reference to this tract. The pyramidal tracts lie *posteriorly* to the “knee” of the internal capsule.

the motor convolutions of the cerebrum, which chiefly bound the fissure of Rolando.

Within the substance of the spinal cord this tract of fibers gradually diminishes in size from above downward. This is because small fasciculi are given off constantly (in the various segments of the cord) to the anterior ganglion-cells of the spinal gray substance. The columns of Türk usually disappear at about the middle of the dorsal region. The "crossed pyramidal tract" of the lateral column extends to the lower limits of the cord (origin of third or fourth sacral nerves); gradually diminishing in size, however, as it descends.

The hypothesis that fibers also leave the pyramidal tracts at various levels in the pons and medulla, and pass backward close to the raphe to join the cranial nerve nuclei, seems to be confirmed by late investigations. Some of these fibers unquestionably decussate within the raphe.

Flechsig has shown that the relative proportion of crossed and direct pyramidal fibers varies greatly in individuals. In a few of the spinal cords examined, he found that *all the fibers decussated*; while, as the opposite extreme, cases were also observed where *no decussation* occurred, all the fibers passing directly downward in the region of Türk's column. These observations help to interpret those rare cases in which hemiplegia has occurred upon the same side as the cerebral lesion which caused it.

The diagram which I now introduce (Fig. 60) will illustrate the areas occupied by these fibers throughout the spinal cord, and the filaments which the two columns of each lateral half of the cord give off, during their descent, to the cells of the anterior horns of the successive spinal segments.

THE ACCESSORY FIBERS OF THE PYRAMIDAL TRACT.—In cross-sections of the medulla, made at different levels, bundles of fibers, which are to be regarded as accessory to the main pyramidal tracts already described, are seen to occupy the anterior and internal margin of each pyramid, and also that part of the lateral column which adjoins the gray substance, particularly the so-called "formatio reticularis."

In the upper portions of the medulla these accessory fibers become very abundant and tend to aggregate toward the pyramids.

Within the substance of the pons some of these accessory fibers lie to the inner side of the longitudinal bundles; in the crura they appear to pass along the inner side of the medul-

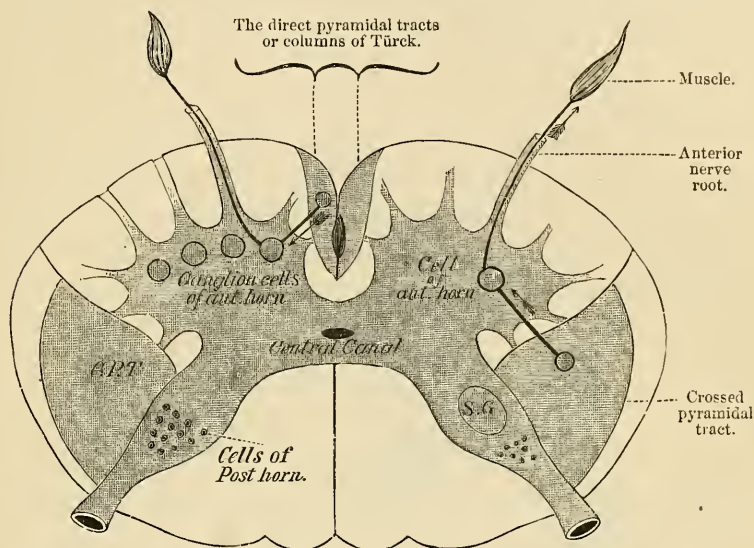


FIG. 60.—The paths of the motor fibers of the cord. (Modified by the author from Bramwell.)

The lines show the course of the fibers given off from the pyramidal tracts associated with the left cerebral hemisphere to the cells of each spinal segment and their continuation into the motor roots of the spinal nerves; the arrows indicate the direction of the currents; C. P. T., crossed pyramidal tract; S. G., substantia gelatinosa.

lated fibers of the “crusta” of either side; finally, they mainly reach the cortex of the frontal lobes of the cerebrum after passing through the internal capsule, in front of its knee.

The functions of these accessory fibers are not positively determined. They unquestionably end within the substance of the medulla and pons, and, by their cerebral connections, serve to unite the cells of the cerebral cortex or of the basal ganglia with the cells of the gray masses of the pons. In this way they probably contribute to the *mutual dependence* of the subordinate ganglia and those of the cerebrum, and

probably help to bring the cerebrum into direct association with the cerebellum and the nuclei of the cranial nerves.

The longitudinal fibers of the pons are probably related to or associated with fibers that leave the pyramidal tracts to join the cranial nerve nuclei. Starr found them wanting in the microcephalic brain examined by him, as were also the decussating and non-decussating fibers of the raphe of the pons. This fact tends to confirm the view that the fibers of the raphe join the longitudinal fibers with the cranial nerve nuclei.

UPWARD CONTINUATION OF THE FIBERS OF THE ANTERIOR ROOT ZONES OF THE SPINAL CORD.—It is difficult to trace the course of these fibers in the medulla, because they are subdivided into small bundles by the arcuate fibers assisting to form the so-called "*formatio reticularis*."

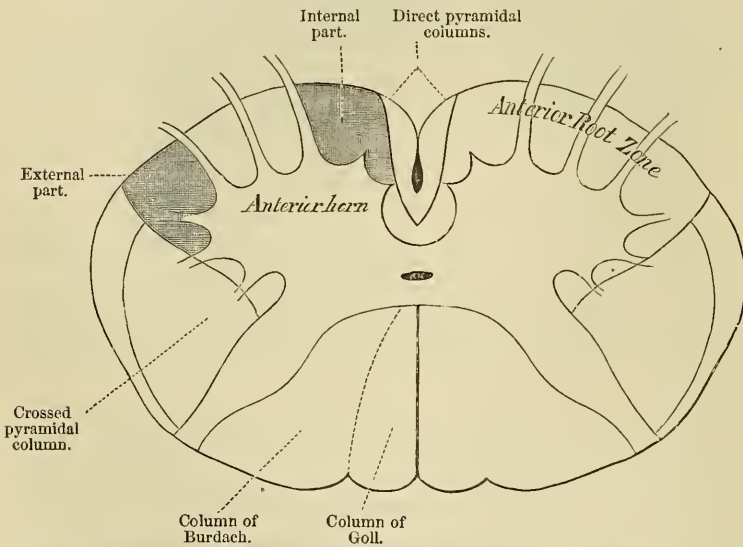


FIG. 61.—A diagram designed by the author to show the two subdivisions, or tracts, of the anterior root zones of the spinal cord.

Within the spinal cord, the anterior root zones are subdivided by the anterior spinal nerve roots (which traverse them to reach the anterior horns of the gray substance) into two distinct portions, an internal and an external (Fig. 61). The

internal portion of each zone lies between the anterior spinal nerve roots and the column of Türck; the external portion comprises the balance of the anterior root zone. Within the medulla, these two portions take a different course, so that each must be described separately.

The *internal portion* is first pushed to one side at the lower part of the medulla by the decussation of the crossed pyramidal tract. Above this level, where the olivary body becomes developed, its fibers appear to be thrust backward behind the pyramids and close to the median raphe of the medulla. At this level, the fibers of the origin of the hypoglossal nerve separate it from the external portion.

The so-called "*posterior longitudinal bundle*" of each side (which has been described in previous pages that treat of the crura cerebri) appears to be a direct continuation of the internal portion of the anterior root zone of the cord. Some of its fibers are apparently continued into the thalamus and thence into the lateral ventricle; others seem to join the posterior commissure of the third ventricle. Like other bundles which lie close to the aqueduct of Sylvius, its fibers become medullated very early in the development of the brain of the human embryo. Those tracts of nerve fibers which surround it, and form the more superficial portions of the medulla, become medullated at a later period.

The posterior longitudinal bundle and the round or solitary bundle, both of which bear intimate relationship with the nerve nuclei in the floor of the fourth ventricle, probably serve to connect these nuclei together and to place them under the control of the ganglia of the mesencephalon (Spitzka).

The *external portion of the anterior root zone* (Fig. 61) enters into the formation of the longitudinal bundles of the reticular formation of the medulla.

The changes which occur in the relative position of the anterior and posterior horns of the gray matter within the medulla (chiefly as a result of the formation of the fourth ventricle and the olivary bodies, in addition to the decussation of the crossed pyramidal fibers) cause this tract of fibers

to assume different relations to adjacent parts than are represented in the preceding diagram.

If traced upward, this tract will be seen to lie *behind the olivary body*, and to reach the surface of the medulla, in its lateral column. Internally, the fibers of origin of the anterior motor nerves bound it; posteriorly, it is limited by gray matter; and, externally, the nerves of the lateral mixed system are detected.

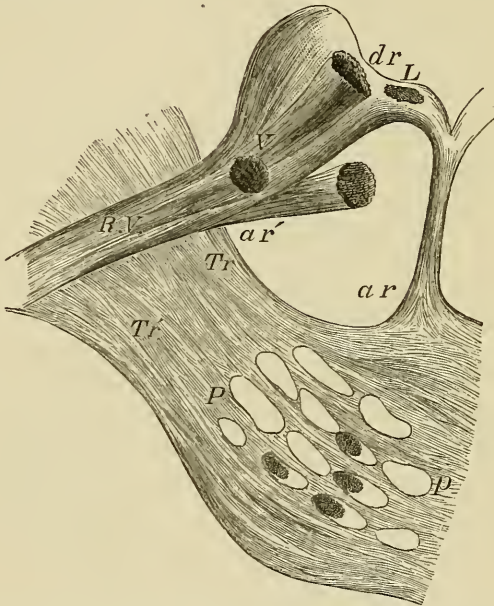


FIG. 62.—A diagram of the right lateral half of a transverse section of the pons Varolii, on a level with the origin of the fifth cranial nerve. (Modified by the author from Erb.)

Rv, root of trigeminus; V', middle sensory nucleus of the trigeminus; V, motor nucleus of same; dt, descending root of same; P, bundles of the pyramidal tract cut across; p, accessory fibers of same; Tr, Tr', transverse fibers of the pons, constituting the "middle peduncle of the cerebellum"; R, raphæ; L, posterior longitudinal fasciculus; ar', area occupied by the external portion of anterior zone of cord; ar, area occupied by the internal portion of same.

Within the *substance of the pons*, the interlacing fibers of that region lie immediately in front of this tract.

When this tract reaches the *crus cerebri*, it is only separated by the *substantia nigra* from the "*crusta cruris*."

The *formatio reticularis* lies, within the substance of the medulla, between the pyramidal tracts and the gray matter of

the fourth ventricle, in a ventro-dorsad direction, and between the ascending root of the trigeminus nerve and the inter-olivary tract, in a lateral direction.

In the region of the pons, the *formatio reticularis* lies between the fillet (lemniscus) and the gray lining of the fourth ventricle in a ventro-dorsad direction, and between the raphe and the external border of the pons, in a lateral direction.

The view that the reticular formation serves as a channel for the *transmission of the tactile sense* and of *pain sensations* to the cortex of the parietal lobes is supported by the late researches of Starr. Regarding the channel for the transmission of the sensations of temperature, no positive deductions were established by these investigations; although it is well known that disturbances of pain and temperature sensations usually occur together. We are, therefore, justified in believing that they both travel along the same paths; until more is definitely established regarding temperature sensations.

THE FILLET.—This tract of fibers (*lemniscus*) has been already discussed in the pages devoted to the consideration of the *crura cerebri*. It springs apparently from the nuclei of the posterior columns of the opposed side of the cord, and ascends for a portion of its extent in front of the reticular formation (Fig. 63). It terminates apparently in the *thalamus* and the *inferior corpora quadrigemina*.

Some of these fibers are probably continuous with the *anterior root zones* of the corresponding half of the spinal cord, while others are connected with the nuclei of the posterior columns of the cord. Some authors describe this tract as consisting of two divisions in the region of the olivary body, an internal and an external. After that body has been passed, both of these divisions appear to join and to pass upward together behind the transverse fibers of the pons.

The latest investigations respecting the lemniscus (Spitzka, Flechsig, and Starr) seem to warrant the conclusion that two sets of fibers are comprised within it; one of which degenerates downward and the other upward. About one half of it

appears to be associated in some way with the motor tracts, and the balance with the sensory tracts. Flechsig, Starr, and Rohon have demonstrated this fact in microcephalic brains, and Spitzka has lately sustained the same view by microscopic investigations of a case which bears directly upon this field. The descending degeneration of the lemniscus seems to confine itself to the inner half or two thirds of that tract; hence we may conclude that this portion of the fillet has a motor function.¹ The outer portion of the fillet appears to belong to the sensory tract; since it degenerates upward and apparently extends to the region of the thalamus and the quadrigeminal bodies. This conclusion is in accord with the views of many anatomists as well as with late pathological data.

The peculiar course of the fillet tract in the medulla and pons is made very apparent by cross-sections of the same at different levels. In its lower part, this tract, after participating in the sensory decussation of the medulla, occupies an area that lies close to the raphe and nearly parallel with it (the interolivary tract). As it ascends, the fibers of the fillet become displaced, so that the long axis of the oval area occupied by them within the upper part of the pons lies nearly at a right angle to the raphe, and in close relation to the pyramidal tracts. Spitzka compares the outline of this tract in cross-sections made through the mesencephalon immediately caudate of the lobes to the capital letter L—the extremities of the horizontal portion of each letter meeting the raphe. Certain fibers of the medulla that arise apparently from the clavate and triangular nuclei seem to pass across the median line (sensory decussation of the medulla) into the opposite interolivary tract, and from that into the tract of the fillet.

Within the medulla, the so-called "sensory tracts" that carry impulses from the spinal cord to the cerebrum prob-

¹ Spitzka is inclined to doubt the infallibility of the law of secondary degeneration, viz., that it progresses in the direction of the currents normally conveyed by the tracts. He brings forward of late some interesting cases of secondary degeneration that appear to oppose the generally accepted view.

ably comprise the formatio reticularis, the larger part of the fillet, and the interolivary tract. The inferior cerebellar peduncles unquestionably transmit some forms of sensory impulses to the cerebellum; but it is still an open question if other forms of sensations are not sent directly to the cerebrum without being first deflected into the cerebellum.

The fillet is believed by some observers of note to send a slip to the motor-oculi nerve. This seems to confirm the view of Stilling that the fillet is connected with the visual apparatus, since the optic and motor-oculi nerves are intimately associated with each other, as is proved by the reflex movements of the pupil.

The reader is referred to previous pages for further information regarding the peculiarities of course exhibited by special fasciculi of the fillet, and some late views which have been advanced respecting its probable functions.

The diagram which will be introduced later (Fig. 63) will help to render many points in the anatomy of the spinal cord and medulla more intelligible; while its text will aid the reader in refreshing his memory as to other important details of construction of the higher ganglia and the crus cerebri.

The fibers which cross the reticular formation in the diagram (F. R.) probably enter to a greater or less extent into its composition.

The Direct Cerebellar Tracts.—These columns of the spinal cord are shown in Fig. 52, and the fibers which compose them are depicted in a diagrammatic way in Figs. 63 and 64. Within the substance of the cord the *sensory nerve roots* probably communicate with these columns indirectly, i. e., through the *vesicular columns of Clarke*. In order to do so they pass chiefly between the bundles of the crossed pyramidal column (Fig. 64, a). The fibers of the direct cerebellar tracts probably afford a direct communication between the gray matter of the superior vermiform process of the cerebellum and the cells of Clarke's vesicular column in the cord. They probably terminate in the cortex or central gray matter

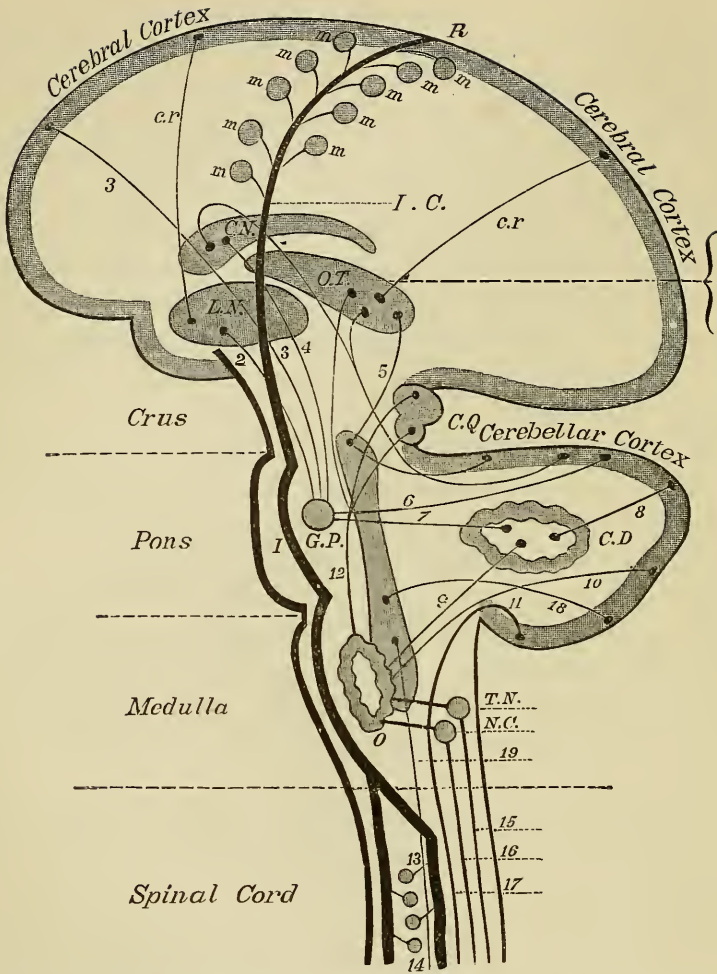


FIG. 63.—A diagram designed by the author to illustrate the course of certain special nerve tracts within the cerebrum, crus cerebri, pons Varolii, medulla oblongata, and spinal cord. (Modified by the author from Flechsig.)

The horizontal dotted lines indicate the limits of the crus, pons Varolii, and medulla. The cerebellum is separated intentionally from the cerebrum in order to bring the crus cerebri and tubercula quadrigemina into prominence. C. N., caudate nucleus of the corpus striatum; L. N., lenticular nucleus of the same; O. T., optic thalamus; G. P., gray matter of the pons Varolii; F. R., formatio reticularis; C. D., corpus dentatum of the cerebellum; O., olivary body; N. C., clavate nucleus; T. N., triangular nucleus; C. Q., corpora quadrigemina; I. C., commencement of the so-called "internal capsule" of the cerebrum; m, motor centers around the region of the fissure of Rolando; c. r., fibers of the "corona radiata"; 1, the fibers of the so-called "pyramidal tract," from their origin in the motor centers of the cerebrum to their termination in the ganglion cells of the anterior horns of the spinal gray matter (13 and 14), showing also the decussation of the fibers at the lower part of the medulla (d and c); 2, 3, and 4, fibers connecting the gray substance of the pons with the cerebral cortex, the lenticular nucleus, and the caudate nucleus; 5, fibers of the superior cerebellar

peduncle, passing to the caudate nucleus and the optic thalamus; 6 and 7, fibers connecting the gray substance of the pons with the cerebellar cortex and the corpus dentatum; 8, fibers joining the cerebellar cortex with the corpus dentatum; 9, and 10, fibers connecting the olivary body, with the corpus dentatum and the cerebellar cortex of the opposite side; 11, the so-called "direct cerebellar tract" of the spinal cord; 12, the fibers of the "*fillet tract*," connecting the olivary body with the thalamus and tubercula quadrigemina—this tract is probably prolonged cephalad to the cerebrum and dorsad to the nuclei, T. N. and N. C.; 13, the *ganglion cells of the anterior horns* connected with the "*crossed pyramidal tract*" (*c*); 14, the same, connected with the "*direct pyramidal tract*" (*d*); 15, fibers of the *column of Burdach*, terminating superiorly in the triangular nucleus (T. N.); 16, fibers of the *column of Goll*, terminating in the clavate nucleus (N. C.); 17, spinal fibers entering the "reticular formation" directly; 18, fibers of the "*inferior peduncle of the cerebellum*"; 19, paths for temperature and pain sensations.

of the worm of the cerebellum. They reach the cerebellum by means of the inferior peduncles (processes e cerebello ad medullam—restiform bodies). According to Wernicke, the fibers of these columns decussate after entering the superior vermiciform process.

The direct cerebellar columns are considered by Meynert as a path for the transmission of sensory impulses. This view is strengthened by the fact that the fibers of this tract arise from the cells of Clarke's column, whose connection with the fibers of the posterior or sensory spinal nerve roots

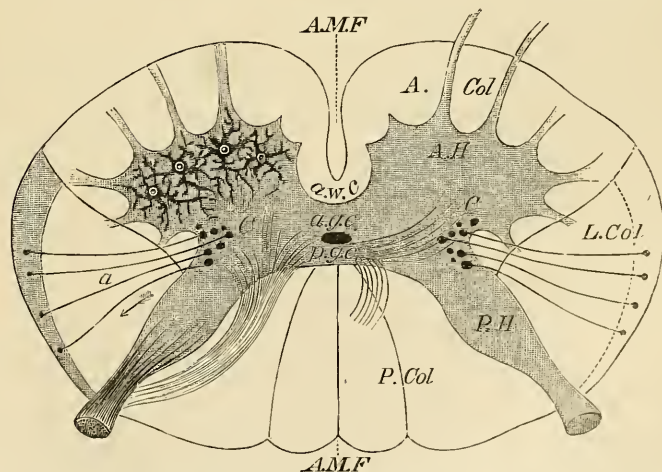


FIG. 64.—A diagram designed by the author to illustrate the relative situation and functional association of the direct cerebellar column of the spinal cord, and the vesicular column of Clarke.

C, vesicular column of Clarke; *a*, fibers connecting it with the direct cerebellar column, passing between the bundles of the crossed pyramidal tract. The other letters of the diagram refer to the fissure, commissures, horns, and the older subdivisions of the cord. (See previous figures.)

has been positively demonstrated. They also exhibit centripetal degeneration after lesions of the spinal cord.

The fact that Clarke's vesicular column is found only in the spinal segments functionally associated with the thorax and abdomen seems to warrant the belief that the direct cerebellar tracts are in some way associated with the transmission of visceral sensations from the thorax and abdomen through the cord to the higher centers—probably the cerebellum (Starr).

CONTINUATION UPWARD OF BURDACH'S AND GOLL'S COLUMNS.—These two columns, which compose a part at least of the sensory or "æsthesodic" area of the spinal cord, are found to terminate apparently in the cells of two nuclei which are situated in the lower half of the medulla. That of Goll's column is called the "*clavate nucleus*," or nucleus gracilis; that of Burdach's column the "*triangular nucleus*," or nucleus cuneatus (Fig. 53). The fibers are probably interrupted by the cells of the nuclei referred to. These fasciculi inclose the two nuclei which have been mentioned, and are increased in size by their interpolation.

A tract known as the "*ascending root of the fifth cranial nerve*," and also one called the "*fasciculus rotundus*," are formed by fibers apparently derived from the posterior root zones of the spinal cord, which have no apparent connection with the two nuclei described above (Fig. 45).

The *fasciculus rotundus*¹ has been named by Meynert

¹ The so-called "round" or "solitary" bundle of the medulla has attracted the attention of Clarke, Stilling, Krause, Meynert, Spitzka, and others.

Krause has named it the "respirator bundle," from a connection which he believes can be demonstrated between it and the origin of the phrenic nerve in the spinal cord. Spitzka rejects this view, and applies the name "trineural bundle" to this tract, because he believes that its efferent fibers can be traced to three cranial nerves, viz., the ninth, tenth, and eleventh. He considers it as an "aberrant ramus of the ninth pair," and sustains the view advanced by Duval and Bigelow that its cephalic end passes into the intermediary nerve of Wrisberg, whose function is still in doubt, although it is believed by some to be connected with the gustatory sense. The same author states that, in his opinion, the fibers of this bundle are derived from the opposite posterior column of the cord (that of Goll), or from the lemniscus tract and the stratum intermedium. It seems to be positively demonstrated that some fibers of the sensory tracts of the cord exhibit a medullary decussation, analogous to that of the pyramidal fibers, as was originally advocated by Meynert.

the "ascending root of the lateral mixed system," and by Krause the "respiratory fascicle." It consists of fibers which are disposed longitudinally, and which become detached from the posterior root zone in the upper part of the cervical region of the spinal cord.

The increased size of the fasciculus gracilis and the fasciculus cuneatus within the medulla causes the posterior horn of the spinal gray matter to be displaced outward and forward, so that the continuation of the gelatinous substance forms a collection of gray matter upon the lateral aspect of the medulla, designated as the "*tubercle of Rolando*."

THE SENSORY TRACTS.—The course of each of the sensory tracts in the mesencephalon is variously described by different observers of note. So wide are the variations in description that it is impossible to bring all the published views into harmony. Starr has lately undertaken the task of collecting all the published autopsies that bear upon the solution of this difficult problem. He arrives at the conclusion that the views of Flechsig, based upon anatomical and embryological researches, are sustained by pathological investigation and also by an experiment lately made by Von Monakow after the method of Gudden. He confirms this deduction also by a microscopical investigation of a microcephalic brain, in which all the motor tracts of the mesencephalon were wanting—thus affording an unusual opportunity for the study of the sensory tracts, apart from the motor. Thus he believes that the conclusions advanced by him are supported by four methods of research, each totally different from the other.

This observer is led to the following conclusions :

1. That the outer part of the formatio reticularis and the interolivary tract (probably a part of the fillet) convey sensory impulses through the medulla. The root of the hypoglossal nerve divides the reticular formation of the medulla into an inner and outer portion.

2. That the formatio reticularis and the fillet perform the same function in the pons. The fillet (lemniscus tract) is be-

lieved by this observer to be associated with the so-called "muscular sense."

3. That the sensations of pain, touch, and temperature travel along the *formatio reticularis* to the cerebrum without decussation in the medulla and pons, because the fibers connected with the transmission of such impulses have decussated completely within the substance of the cord.

4. That the fibers which convey sensations included under the term "muscular sense" do not decussate in the cord. They cross at the lower part of the medulla, in the "pinniform decussation" of Spitzka, and pass upward through the interolivary tract and the fillet of the opposite side. They are thus conducted to the internal capsule of the cerebrum.

5. That all sensory impulses which are deflected to the cerebellum are destined to awake reflex action only.

The fibers of the cuneate bundle, after they have become associated with the gray substance of the triangular nucleus, resolve themselves apparently into the so-called "*arcuate fibers*." These pass forward and upward to the olivary body of the same side, and therefore connect two nuclei of the medulla with each other.¹

¹ If the main columns of the cord be traced upward into the substance of the medulla, they will be found to be related as follows: The anterior columns (those of Türck) and the crossed pyramidal columns form the *anterior pyramids* of the medulla; the lateral columns are continuous with the restiform body; the columns of Burdach with the cuneate bundle; and the columns of Goll with the *processus gracilis*. Spitzka believes that the fibers of Burdach's columns are continued into the restiform body (some after decussation and some directly) as are those of the cerebellar tract; and that they pass to the cerebellar cortex. The same author states that the fibers of the postero-external column are traceable to the nucleus fastigii of the cerebellum.

Starr is led to believe, from an analysis of collected cases of focal lesions within the medulla and pons, that the fibers from the posterior columns of the spinal cord pass chiefly into the interolivary tract and the lemniscus. This author advances some strong arguments in favor of the view that the sensory tracts pass directly through the medulla, pons, and crus without decussation or deflection into the cerebellum, and that they subsequently reach the cerebral cortex by means of the internal capsule.

Within the lower part of the medulla, the sensory tracts (according to Starr) consist of three columns, called the *funiculus gracilis*, the *funiculus cuneatus*, and the *formatio reticularis*, and one tract which is the direct continuation of the direct cerebellar column of the cord. The course of sensory impulses through the gray columns is a subject upon which different opinions are held by various observers. Dr. Starr has given an excellent summary of the views held upon this subject in his late article on "The Sensory Tract in the Central Nervous System" (*Journal of Mental and Nervous Diseases*, July, 1884).

The fibers of the fasciculus gracilis have probably a similar continuation above the interpolation of its nucleus; although some authors assert that a decussation of its fibers can be demonstrated to exist.

Some anatomists, among whom Meynert may be prominently mentioned, believe that a decussation of the sensory conduction paths takes place within the lower part of the medulla. The sensory fibers, according to Meynert, issue from the triangular and clavate nuclei and pursue an arcuate course around the central gray column to reach the olivary tract, near to the mesial and posterior portion of the anterior pyramid of the opposite side. The view of Flechsig, however, that the arcuate fibers enter the substance of the olivary body of the same side, is the one most generally accepted. The paths of sensory conduction will be discussed more fully in connection with the description of the spinal cord.

The arcuate fibers of the medulla are divided into a superficial and a deep set. The former pass over the olivary bodies, and lie near the anterior aspect of the medulla. The deep set have been traced by some authors to the cuneate bundle and fasciculus gracilis of the opposite side of the medulla, to the raphe of the medulla, and to the cells found in the nucleus of the restiform body.

The arcuate fibers of the medulla probably belong to the sensory tracts. They were found by Starr to be normally developed in a microcephalic brain which lacked the motor tracts.

The late paper by Starr upon the sensory tract of the central nervous system¹ contains a collection of cases which seem to conflict with the deductions of Wernicke, Spitzka, and others, viz., that the sensory tract is to a great extent deflected from the medulla below the pons into the cerebel-

One difficulty that arises is that Flechsig's method of research is unsatisfactory in the medulla. Gudden's method has been successfully tried in but one instance, and investigations of microcephalic brains have not yet been given much attention by neurologists or anatomists.

¹ "Journal of Nervous and Mental Diseases," July, 1884.

lum, and that sensory impulses do not traverse the pons. Lesions of the pons are shown by this author to have resulted in marked disturbances of sensation of the opposite half of the body. He draws the deduction that the sensory tract for each side of the body traverses the opposite half of the medulla and pons, and that no decussation of these tracts can be verified (by clinical data) between the sensory decussation at the lower limit of the medulla and the upper border of the pons. Respecting the views of Wernicke and Spitzka, this author speaks as follows :

“It is very possible that some sensory impulses may pass to the cerebellum by the tracts described by Wernicke and Spitzka, and, setting up there a reflex action, be the means of exciting that organ to do its reflex work. But, if so, these are not the sensory impulses which pass to the higher cortical cerebral centers, or which are destined to awake in consciousness a perception of the sensation. The sensations which are perceived consciously are transmitted directly from the surface of the body through the spinal cord, medulla, and pons, into the internal capsule and thence to the cortical centers, and in their course undergo but one decussation. If that decussation is complete in the cord, the tract remains on the same side from the cord to the capsule. If that decussation does not occur in the cord, it takes place in the sensory decussation at the lower part of the medulla.”

THE SUPERADDED WHITE SUBSTANCE OF THE MEDULLA AND PONS.—Under this head the fibers of the *cerebellar peduncles* may be considered. In previous pages the superior and middle peduncles of that ganglion have received due consideration, and the reader is referred to them for further information, as only the main points will be here touched upon. The inferior peduncles have, however, been incompletely described in previous pages, and therefore merit a more detailed description.

The Inferior Peduncles of the Cerebellum (processus e cerebello ad medullam).—If a cross-section of the medulla at the level of the apparent origin of the auditory nerve (Fig.

57) be studied, two collections of fibers will be apparent in the latero-posterior area of the section upon either side (*ep* and *ip*), which together assist to form the inferior cerebellar peduncle.

The *external division* has been named by Stilling the "*restiform body*." Its fibers, if traced from above downward, start apparently from the cortex of the cerebellum, and also from a layer of fibers surrounding the "*corpus dentatum*." As they descend toward the medulla, these fibers are split up into two bundles by those of the "*direct cerebellar tract*," which join the cerebellar cortex in the region of the worm. At birth, the fibers of the latter tract are distinctly medullated, while the peduncular fibers are not, thus rendering the outline of the two sets very apparent.

The fasciculi of the restiform body become "*arcuate fibers*" within the medulla. These course first through the so-called "*zonular layer*" in front of the olivary body; then they reach the median raphe of the medulla by forming two bundles, one of which passes in front of and the other behind the anterior pyramid of the same side; finally, they appear to cross the raphe, to terminate in the olivary body of the opposite side of the medulla. The fibers which cross in front of the pyramids are commonly known as the "*arciform fibers*" of the medulla.

The raphe of the medulla and pons probably contributes fibers to the round or solitary bundle (trineural bundle of Spitzka), the posterior longitudinal bundle, and the lemniscus or fillet tract. Fibers are also traced from it to the reticular field. These are believed by some authors to bear a relationship to facial expression and to articulate speech. The superficial and deep arcuate fibers are also connected with the raphe. The raphe is crossed by the decussating fibers between the olives, and also by those constituting the "*pinniform*" decussation.

The existence of an independent decussation of sensory fibers within the medulla, as well as those associated with

motion, has been apparently demonstrated by the microcephalic brain examined by Starr, in which the pyramidal tracts were wanting. It was found to lie upon the same level as the decussation of the motor fibers.

The interolivary tract contains strands, according to the investigations of the same author, that develop both from below upward and from above downward. The sensory portion of this tract is in relation with the triangular and clavate nuclei.

The *internal division* is described by Stilling as arising from the nuclei of the ventricular roof, and, after reaching the medulla, as resolving itself into arcuate bundles which become intermingled with the ascending fibers of the anterior root zone of the spinal cord, behind the olivary body of the corresponding side.

Some anatomists describe these arcuate fibers as capable of being traced across the median raphe of the medulla, and into the olivary body of the opposite side.

From what has been said, it will be apparent that the *olivary body* of each half of the medulla¹ is a medium of communication between fibers which spring from the triangular and clavate nuclei and those of the restiform bodies and the remaining bundles of the inferior cerebellar peduncles. The physiological functions of the masses of gray matter which are interpolated (the triangular and clavate nuclei and the olivary bodies) are as yet somewhat conjectural.

Focal lesions of the medulla, pons, or crus, are not infrequently of limited extent; but few cases, however, are well adapted for anatomical deductions. Disease of the basilar artery, resulting in thrombosis or apoplexy, is most frequently the direct cause of lesions of the pons; and the motor tracts (which lie ventrad of the sensory) are most commonly affected by disease. Lesions of the dorsal half of the pons are almost immediately fatal, as centers of the pneu-

¹ The olivary body (dentate body of the medulla) has two accessory nuclei associated with it, the so-called "*external olivary body*" and "*internal olivary body*" of Meynert.

mogastric nerves rarely escape injury. No disturbances of sensation are ever produced by lesions of the pons unless they are situated posterior to its deep transverse fibers (Starr). This fact points positively to the inference that the pyramidal tracts and the gray matter of the pons are not concerned in any way in the transmission of sensory impulses. That the gray matter of the ventricular floor of the medulla and pons has nothing to do with sensation seems to be proved by the cases collected by Starr, where disease of the cranial nerve nuclei failed to produce sensory symptoms in the body. Lesions of the gray matter of the fourth ventricle must first create pressure-effects upon adjacent parts in order to cause anæsthesia or other sensory symptoms below the head. The opinion of Meynert that the descending root of the fifth cranial nerve decussates within the substance of the pons appears to be sustained by clinical statistics. Lesions affecting it produce anæsthesia of the opposed side of the face.

According to the observations of Spitzka, the restiform body of either side may be regarded as composed of the following parts: 1. The fibers of the direct cerebellar tract of the same side. 2. The decussating fibers of the opposite postero-external column of the cord, which have previously passed through the olivary body. 3. Some fibers of the postero-external column of the same side. This author discards the fibers of Goll's columns from participation in the cerebellar circuit. He believes that these fibers cross to the opposite side in the so-called sensory decussation of the medulla, and that they then pass directly upward through the posterior longitudinal fibers of the pons (*stratum intermedium*) to the posterior part of the internal capsule of the cerebral hemisphere.

This view is opposed to that of Starr, which has been previously referred to, since it presupposes a double decussation of the sensory tracts, derived from Burdach's column between the spinal cord and the internal capsule—one in the medulla, and again by means of the middle or superior cerebellar pe-

duncle. The deductions of Starr are based largely upon clinical facts, supplemented by original research made upon a microcephalic brain, in which all the motor tracts were wanting.

The Middle Peduncle of the Cerebellum (processus e cerebello ad pontum).—The fibers of this set arise from the cerebellar cortex and pass forward, both in front of and through the substance of the pons, eventually decussating with those of the opposite cerebellar hemisphere in the median line. By so doing, they assist in separating the fibers of the pyramidal tract into distinct bundles, as is shown in previous cuts (Fig. 58). After crossing the median line, they *join with the cells of the gray matter of the pons*. Here they probably become associated with fibers which descend from the inner third of the crusta cruris.

These transverse fibers are wanting in animals which do not possess cerebellar hemispheres. In previous pages, these fibers have been discussed in detail.

*The Superior Peduncle of the Cerebellum*¹ (processus e cerebello ad cerebrum).—It is probable that most of the fibers of this process are derived from the corpus dentatum. They decussate within the substance of the tegmentum cruris and become more or less associated with the *cells of the red nucleus of the tegmentum* of the opposite side. The terminal distribution of these fibers is still a matter of dispute among authorities of note. Some believe that they pass to the optic thalamus; others state that they pass to the cortex of the cerebrum; while a few think that they can be traced to the caudate and lenticular nuclei of the corpus striatum. The functions which have been attributed to this process of the cerebellum have been alluded to in previous pages (which treat of the corpus striatum, the crus cerebri, and the general architecture of the nervous system of man) to which the reader is referred for further information.

¹ The three peduncles of the cerebellum have been named by Wilder and Spitzka, from above downward, the "præpedunculus" or "tegmenta brachium," the "ponti-brachium," and the "post-pedunculus" or "myelo-brachium."

THE FUNCTIONS OF THE PONS VAROLII AND THE DIAGNOSTIC SYMPTOMS OF LESIONS AFFECTING IT.

The fibers that form the larger portion of this mass are abundantly supplied with gray matter, which seems to be mixed throughout its interior. We may infer from this fact that they have some individual functions, in addition to being simply connecting commissures; but what these functions are it is difficult, at present, to positively state in every instance.

Both the pons and crura cerebri are unquestionably connected in some way with the power of coördination of muscular movement, since injuries to either of them may result in marked disorder of this function, and often in unnatural and forced movements. This function is probably associated with the fillet tract.

The fact that some of the nerve fibers (probably those of the fifth and seventh pairs) decussate in these regions seems proven by clinical evidence, since lesions of the pons Varolii often produce *paralysis of the facial nerve* upon the same side as the lesion, while the opposite side of the body is affected below the face.¹ Crossed hemianæsthesia may also occur from a lesion in the sensory tracts of the pons (*formatio reticularis*).

The facial nerve makes its exit from the side of the medulla oblongata; some of its roots of origin can be traced as far as the floor of the fourth ventricle, some come from the lower part of the medulla oblongata, while others descend from the upper border of the pons Varolii, and probably decussate. Now, a lesion existing in the lower half of the

¹ A class of paralysis, where certain cranial nerves are paralyzed on the same side as the existing lesion, while the body is rendered hemiplegic on the opposite side, is called "*crossed paralysis*" (the "*paralyse alterne*" of the French). It presents *several types* depending upon the cranial nerve affected; hence the so-called third nerve (*motor-oculi*) and body type, the fifth nerve (*trigeminus*) and body type, the seventh nerve (*facial*) and body type. Professor Romberg, of Berlin, and Gubler, of Paris, have done much to elucidate the clear appreciation of this complex form of paralysis and the mechanism of its production. They have been discussed in previous pages.

pons Varolii will, therefore, produce a paralysis of the corresponding facial nerve and of the opposite spinal nerves; whereas, if it occur above the point of decussation of the encephalic fibers, the paralysis will be on the opposite side for

all parts of the body. These facts are shown in the accompanying diagram (Fig. 65).

It is obvious, from a study of this diagram, that a lesion of one lateral half of the pons (at *l*) will cause paralysis either of motion or of sensibility of the opposite side of the body, and of the corresponding side of the face; and that a lesion of the hemisphere (at *m*) will produce paralysis of the opposite side of the face and body.

As we might naturally expect from the direction of the fibers of the pons Varolii, this portion of the brain acts as a direct conductor of both motor and sensory impressions from and to the cerebrum; while the collections of gray matter within its substance prove it to possess some functions of its own which

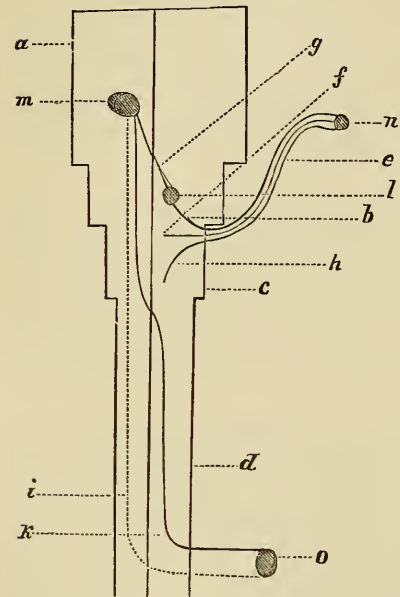


FIG. 65.—A diagram to illustrate the method of production of crossed paralysis. (After Hammond.)

a, the left hemisphere; *b*, right half of pons; *c*, right half of medulla oblongata; *d*, right half of spinal cord; *e*, right facial nerve; *f*, fiber of origin from nucleus in medulla oblongata; *g*, descending fiber decussating at upper border of pons; *h*, ascending fiber; *i*, sensory root of spinal nerve; *k*, motor root of sensory nerve; *l*, lesion in pons; *m*, lesion in left hemisphere; *n*, paralyzed part supplied by facial nerve; *o*, paralyzed part supplied by spinal nerve.

are independent of the stimulation of the cerebral cortex. Without entering into the different experiments which have been made to determine the exact part which this portion of the brain plays in the complex machinery of movement and sensation, it seems probable that the pons Varolii regulates

or in some way modifies those automatic movements which govern *station* and *progression*.

The experiments of Vulpian and Longet also seem to suggest that the *sensation of pain* is perceived by the pons Varolii even when the cerebrum and the basal ganglia are removed. When these portions remain, such impulses are probably transmitted to the hemispheres as conscious sensations, and are there remembered.

These views have been already discussed in connection with the functions of the corpora quadrigemina, to which the reader is referred.

General convulsions are peculiarly apt to accompany suddenly developed lesions of the pons (such, for example, as embolism or a clot). These convulsions are generally followed by coma.

The *trigeminus nerve* may be paralyzed by lesions of the pons, provided the lesion lies within the inner two thirds of the reticular formation (according to the researches of Starr). If such a lesion be situated high up in the pons, trigeminal paralysis will coexist with hemianæsthesia of the opposed half of the body; if situated low in the pons, the trigeminal paralysis and the hemianæsthesia will be upon the same side. The point of union of the ascending and descending roots of the fifth nerve is nearly at the level at which the fifth nerve escapes from the pons (line of Gubler).

Difficulties of articulation are to be considered as especially diagnostic of lesions of the pons or medulla, provided the presence of aphasia of cerebral origin can be excluded by the history of the case. There is unquestionably a tract of fibers (the motor speech tract) that serves to connect the nuclei of the medulla with the cortical centers for the movements of the face and tongue.

Conjugate deviation of the eyes may accompany a lesion of the pons. This symptom is not pathognomonic, however, because it may occur also with cortical lesions of the cerebrum and lesions of the internal capsule.

The *motor, sensory, and vaso-motor effects* of lesions within the pons are manifested in the extremities; chiefly, but not exclusively, upon the side opposed to the lesion. This is not the case with those cranial nerves whose fibers of origin probably traverse the pons (the fifth, sixth, seventh, eighth [?], eleventh [?], and twelfth). The effects of intrapontine disease upon these nerves are modified by the seat of the lesion, as has been shown in preceding paragraphs.

Contraction of the pupils during an apoplectic attack is to be regarded as strongly diagnostic of a clot within the pons.

Hæmorrhage into the pons is usually followed by coma and sudden death, if the clot be large, or if the blood escape into the fourth ventricle. The diagnostic points mentioned above apply, therefore, more particularly to foci of softening and destructive lesions of small size and slow development. When blood escapes into the fourth ventricle, convulsions are observed, and death is liable to follow rapidly.

Disturbances of the circulatory and respiratory functions may occur in connection with lesions of the pons; but they are to be regarded rather as evidences that the medulla oblongata is directly implicated or subjected to pressure.

Deafness has been observed on the same side as the lesion (according to Starr) in five out of twenty-six cases of reported lesions confined to the pons. The auditory fibers have probably been severed on their passage to the nucleus of the eighth nerve through the pons.

FUNCTIONS OF THE MEDULLA OBLONGATA.

This ganglion—the uppermost portion of the spinal cord—is the true *nerve center of animal life*; since immediate death is apt to follow severe or extensive injury to its substance. The fact that the seventh, eighth, ninth, tenth, eleventh, and twelfth nerves arise directly from this ganglion, and that some fibers from other of the remaining six cranial nerves can be traced to the cavity of the medulla—the fourth

ventricle—serves to explain the importance of this special nerve center to life.

In addition to the special influence of the medulla oblongata upon the nerves which arise from it, it contains also most of the fibers which are distributed to the other parts of the encephalon, and thus it must transmit both the motor and sensory impulses, as they pass from or enter the cerebrum.

The medulla is possessed of a large amount of *gray matter* within its interior. It is by means of this gray matter that the action of the medulla, which is largely *reflex* in character, takes place.

From the nerves which spring from its substance, we should expect that these reflex acts should be chiefly concerned in the movements of the facial muscles by means of the seventh nerve; with audition by means of the eighth; with deglutition by means of the ninth; with respiration through the pneumogastric or tenth nerve; with phonation and the action of the heart by means of the spinal accessory; and with lingual movements by means of the hypoglossal.

Various collections of gray matter in the floor of the fourth ventricle have been described in previous pages, as connected with special nerve roots. Experimental investigation has also determined that certain special *physiological centers* apparently have their seat within the substance of the medulla oblongata.

The medulla, as a whole, serves (1) as a conductor of *sensory impressions*, which have passed along the sensory tracts of the cord upward to the cerebrum; (2), as a conductor of *voluntary motor impulses* from the cerebrum to the spinal cord and its nerves; (3), as a conductor of *cerebellar motor impulses* to the spinal cord and its nerves, in maintaining a tonic contraction of the skeletal muscles; and (4) as an organ of automatic reflex action, governing all functions which are essential to life.

The *centers for special cranial nerve roots* have been discussed already at some length. A few important deductions concerning them are suggested, however, by the periods of

life at which they are developed. It is now known that they are not all perfectly formed at the expiration of foetal life, but are perfected later, as rapidly as the requirements of the body seem to demand.

The *accessory nucleus of the hypoglossal nerve* seems to be an additional structure, which is rendered necessary in order to permit of the complicated movements that are demanded in the production of *articulate speech*.

The *accessory facial nuclei* are apparently designed to enable the facial nerve to preside over the movements requisite to *facial expression*; in contradistinction to those movements that are essential to the functions of mastication and respiration, which are probably controlled by the other nuclei of that nerve.

Two of the four *acoustic nuclei* are intimately associated with the inferior and middle peduncles of the cerebellum. It is reasonable, therefore, to infer that one of them, at least, is concerned in the transmission of impressions made upon the ear to the cerebellum.

The importance of labyrinthine impulses as a factor in the control which the cerebellum seems to possess over coördinated movements has been discussed in previous pages.

Among the *special physiological centers* of the medulla, the following may be prominently mentioned:

1. The *respiratory center*, which governs the respiratory acts, in response to sensory impressions transmitted to it by means of the centripetal fibers of the pneumogastric nerve. This center also presides over the acts of *laughing, sighing, sobbing, sneezing, and hiccough*, which are performed by the muscles of respiration. It is excited by the irritation of carbonic acid upon the terminal filaments of the pneumogastric nerve in the lung, or by its presence in the blood. An excess of it increases the respirations, while an excess of oxygen tends to decrease their frequency.

2. The *vaso-motor center*, which seems to control the caliber of the larger blood-vessels, by means of efferent impulses, transmitted first down the spinal cord, next through the ante-

rior roots of the dorsal nerves, and then chiefly through the splanchnic nerves. They affect the muscular coat of the vessels of the thorax, abdomen, and pelvis. The upper limit of this center in the rabbit is placed by Owsjannikow (Ludwig's "Arbeitem," 1871) at about two mm. below the tubercula quadrigemina, and its lower limit at about four or five mm. above the calamus scriptorius. Clarke locates it near to the origin of the facial nerve, and claims that large multipolar cells can be detected in the vaso-motor area; while Dittmar (Ludwig's "Arbeitem," 1873) places it chiefly in the lateral columns, after the fibers have been given off to the decussating pyramids. Besides this vaso-motor center in the medulla oblongata, some parts of the spinal gray matter unquestionably exert a positive vaso-motor influence, causing constriction or dilatation of the blood-vessels.

3. *The Cardio-Inhibitory Center.*—By it the heart is arrested in diastole, or held under control, in response to sensory impressions carried to the medulla from other sources by means of sensory nerves. If the mesentery of a frog be exposed, and a slight tap be given it by the handle of the scalpel, the heart will at once cease to beat, but will soon resume its function. This experiment, coupled with many others of interest, seems to point definitely to the medulla as the seat of mediation between afferent sensory impulses and efferent inhibitory impulses upon the heart.

4. *The Center for Deglutition.*—This controls both the second and third stages of that act, or from the time when the bolus passes the isthmus of the fauces. This subject will be found discussed, at some length, in the pages devoted to the mechanism of deglutition, as well as the movements of the œsophagus.

5. *The center for the movements of the œsophagus and the stomach,* with its allied center for the control of the mechanism of the *act of vomiting.*

6. *The Diabetic Center.*—This center, when stimulated, produces a saccharine condition of the urine. The diabetic center, as marked out by Eckhard, corresponds closely to

that defined by Owsjannikow as the vaso-motor area. Pricking of this center in a well-fed rabbit will produce a considerable amount of sugar in the urine, within an hour or two following the experiment. This effect is poorly marked in animals whose livers have been deprived of glycogen by starvation.

7. *The Salivary Center.*—This, upon excitation, tends to increase the flow of the saliva, and possibly, also, the pancreatic fluid and the other digestive juices. The flow of saliva is apparently a reflex act dependent upon afferent impulses perceived through the gustatory branch of the fifth cranial nerve, the efferent impulse being transmitted by means of the chorda tympani branch of the facial nerve. It is this function of the latter nerve that is considered by some physiologists as explanatory of the effect of the chorda upon taste. (See pages descriptive of the facial nerve and its branches.)

8. The *convulsive center*, first described by Nothnagel, is probably associated in an imperfectly understood way with the motor tracts that are found within the medulla. It is closely allied to the respiratory center, as is proved by the convulsions which occur in consequence of carbonic-acid poisoning, or when the supply of blood to the medulla is suddenly cut off after the ligation of a large vessel.

9. A *cardio-acceleratory center*, which exercises the power of increasing the frequency of the pulse by means of fibers which pass downward into the cervical region of the spinal cord; they emerge to enter the inferior cervical ganglion of the sympathetic upon either side of the spinal column, thence passing to the heart.

By means of these physiological centers the medulla is enabled to exercise a modifying or controlling influence over the more important organs of the body. In every case, it is informed by *excitor* or *centripetal nerves* of the requirements of the various regions which are essential to the performance of their respective functions; and by *motor* or *centrifugal nerves*, or, in some instances, by its influence upon the *nerves of the vaso-motor system*, the proper responses to these im-

pressions (telegraphed to it by the sensory nerves) are sent out. This constitutes what is termed "reflex action."

In the second and third stages of the act of deglutition, for example, the medulla is thrown into *excitation* by means of the following nerve-trunks :

1. The branches of the trigeminus distributed to the palate.
2. The pharyngeal branches of the glosso-pharyngeal nerve.
3. The œsophageal and superior laryngeal branches of the pneumogastric nerve.

Its *motor responses* are then made through the aid of the following nerves :

1. The pharyngeal branches of the pneumogastric, derived from the spinal accessory nerve.
2. The hypoglossal nerve.
3. The motor filaments of the inferior maxillary nerve.
4. The facial nerve.
5. Branches of the cervical plexus.

These centripetal and centrifugal sets of nerves, with the so-called "center" which intervenes, constitute collectively what has been termed the "*nervous circle*" of the act of deglutition. Similar "nervous circles" are associated with each of the more important functions that are of a purely reflex type, such as the act of respiration, the pulsation of the heart, etc.

When the ganglia of the brain above the level of the medulla are all removed, animals will continue to live and breathe. Those regions which are supplied by the nerves that are associated with the gray nuclei of the medulla, as well as those supplied by the spinal nerves, will, however, still exhibit reflex phenomena when subjected to irritation. If the conjunctiva be touched, the eyelids will close. Contraction of the muscles of the face, movements of the tongue, and twitching of the ears, can also be artificially produced by irritation of the sensory nerves distributed to those regions.

In addition to these evidences of simple reflex action, more complicated movements that require *coördination of different sets of muscles* can also be elicited. In an animal so mutilated, the acts of sucking and of deglutition can be performed with as great precision as in health. These can be excited by the introduction of a morsel of food into the mouth so as to rest upon the back of the tongue, or the insertion of a nipple between the lips of a younger animal. We also observe these phenomena in those rare cases of living anencephalic children, who nurse at the breast as perfectly as perfectly-developed offspring.

The fact that a subsequent destruction of the medulla causes instant annihilation of these reflex and coördinated movements seems to be a most positive proof that the medulla can be regarded both as a center of reflex action and as one also of coördination.

Clinical evidences that the medulla acts as a coördinating center for the complex movements required in articulate speech are afforded in the disease known as "*glosso-labio-laryngeal paralysis*," first described by Duchenne, and hence often spoken of as "Duchenne's disease." In this condition the nuclei of the medulla that are connected with the hypoglossal, facial, glosso-pharyngeal, and spinal-accessory nerves undergo progressive degeneration; hence, the term "*bulbar paralysis*" is often employed in place of the others previously mentioned. The effects of this degeneration are manifested in a gradual and progressive paralysis of the tongue, lips, palate, pharynx, and larynx, which renders articulation, deglutition, and phonation more or less imperfect, and at the same time causes an alteration in the expression of the face that is not easily mistaken. (See subsequent pages, which treat more fully of its symptoms.)

Some authorities have advanced the view that the olivary bodies are the probable coördinating centers of articulation; but this appears to be an error, because those bodies are more intimately connected with the inferior peduncles of the cerebellum. A remarkable case reported by Vulpian, in which

the olivary bodies were completely degenerated, was found to exhibit no impairment of speech.

The relation of the medulla to FACIAL EXPRESSION is one of great interest, if it can be positively verified. Vulpian believed that his experiments made upon the rat demonstrated the relation of all forms of *emotional expression*, such as cries and facial contortions, with the centers of the medulla. These experiments have been differently interpreted, however, by some later investigators in the same line. Ferrier thinks that the cry of animals which follows a painful impression made upon the extremities, after the encephalic centers above the medulla have been removed, is to be regarded simply as a variety of respiration rather than an evidence of the sensation of pain—a view which is consistent with the chief function of that ganglion. This will now be separately considered.

The RESPIRATORY MECHANISM is unquestionably presided over by the medulla. Flourens has devoted special attention toward the results of experiments, made upon the medulla of animals, in respect to their effects upon respiration. He places its situation at the apex of the fourth ventricle near to the calamus scriptorius—a point which he terms the “*nœud-vital*.”

This center receives the following excitor or centripetal nerve fibers :

1. The pulmonary branches of the vagus nerve.
2. The superior laryngeal branches of the vagus nerve.
3. The sensory fibers of the trigeminus nerve.
4. The nerves of general sensibility of the trunk and extremities.
5. The sympathetic nerve.

These various sources of sensory impressions enable the respiratory center of the medulla to so coördinate the muscles of respiration as to insure the proper performance and relative frequency of the inspiratory and expiratory acts, as the amount of exercise and the demands of the body seem to require.

The nerves through which the centrifugal or motor impulses are transmitted, in response to these sensory impressions, may be thus enumerated :

1. The phrenic nerve, by fibers which traverse the spinal cord as far as the level of the third dorsal nerves.

2. The intercostal nerves, which are given off from the dorsal region of the spinal cord.

3. The facial nerve, which governs the movements of the nostrils during inspiration.

4. The external branch of the spinal accessory nerve, which supplies the sterno-mastoid and trapezius.

5. The inferior laryngeal branch of the pneumogastric nerve, which governs the movements of the glottis.

6. Filaments of the cervical plexus, which assist the scaleni muscles to fix the first rib during inspiration.

The *respiratory act is under the control of the will* to a limited extent, in order to allow of speech, vocalization, and the expulsion of the contents of the uterus, bladder, and rectum. When this voluntary control is carried beyond its proper limits, it becomes lost, as the desire for respiration becomes too great to be controlled.

We have referred in a previous page to the acts of *coughing, sighing, sobbing, laughing, sneezing, and hiccough* as modifications of the respiratory act. They are presided over by the respiratory center.

The *rhythmical alternation of expiratory and inspiratory movements* is not due entirely to reflex action. The amount of carbonic acid in the blood modifies the action of the respiratory center as well as sensory impressions carried to it by means of nerves. This point has been previously touched upon.

The *course of the respiratory tract of nerves* within the spinal cord has been made a subject of investigation by Schiff, Vulpian, Brown-Séguard, and others. The views of these observers are somewhat contradictory. It is probable that they run in the gray substance of the cord rather than in the lateral columns, as Schiff was led to infer.

Long after the reflex excitability of the spinal cord has ceased, and even after all voluntary or conscious actions have been abolished, the respiratory center retains its activity. This is admirably demonstrated in the administration of anæsthetics, which, when pushed to their fullest extent in animals, paralyze the brain and spinal cord before the respiratory centers succumb.

The CARDIAC CENTERS within the substance of the medulla seem to be connected with nerves which have opposite functions, one accelerating the pulse and the other inhibiting or restraining the action of the heart.

The *rhythmical action of the heart* is in no way connected with the centers of the medulla, as that organ will continue to beat long after it is completely severed from its connections with the brain or spinal cord. It seems to be controlled by the ganglia of the heart itself (Bidder and Remak's ganglia). The medulla appears to act simply as a governor of the heart's action.

The *inhibitory nerves* connected with the cardio-inhibitory center pass from the medulla to the heart chiefly by means of the vagus; hence, section of the vagus causes an acceleration of the heart's action, because it is no longer restrained by these fibers. Powerful irritation of the sensory nerves of the stomach or intestine, the nostrils, or the larynx causes a stimulation of these fibers which may arrest the action of the heart. This may help to explain the fatal results of a blow received upon the epigastric region, or the shock of a large draught of cold water or of an irritant poison upon the sensory nerves of the stomach (Ferrier).

The *acceleratory nerves* connected with the cardio-acceleratory center pass down the cervical region of the spinal cord, and escape to enter the inferior cervical or first dorsal ganglion of the sympathetic. From these ganglia they are prolonged to the heart, upon either side, as filaments of the cardiac nerves. They can be reflexly excited by a stimulus applied to the sensory nerves distributed to the muscular system. Ferrier suggests that this fact may help to explain

the rapidity of the heart's action during active muscular exercise.

The existence of a VASO-MOTOR CENTER within the human medulla, as has been proven to exist in animals, is confirmed by pathological observation. Subjective sensations of heat and cold in the limbs have been found to exist in connection with a lesion of the upper half of the medulla. The area occupied by this center in man therefore corresponds to that of animals (as determined by Foster), viz., slightly above the calamus scriptorius.

The vaso-motor center within the substance of the medulla controls the innervation of blood-vessels. It is connected with afferent as well as efferent fibers. The former tend rather to excite or depress the activity of this center, and thus in a reflex way to cause contraction or dilatation of the blood-vessels.

The *vaso-motor nerves* pass, by means of the substance of the spinal cord, to various ganglia of the sympathetic system and thence to the coats of the arteries. They tend to maintain a state of tonic contraction of the arterial walls. This has been termed by physiologists "*arterial tonus*." It has been found that, when the spinal cord is divided below the level of the medulla, this arterial tonus is destroyed, a dilatation of the arteries immediately taking place. A section of the sympathetic nerve or of cerebro-spinal nerves which convey its fibers to certain blood-vessels produces a similar result, in regions more or less circumscribed according to the nerve trunk which is severed.

The "*arterial tonus*" is controlled, however, in part by the spinal cord, irrespective of the medulla oblongata. This fact was first pointed out by Vulpian, who found that, after section of the spinal cord below the medulla, a complete destruction of the cord or a division of the anterior spinal nerve roots increased the dilatation of the blood-vessels.

The vaso-motor center of the medulla is stimulated by *irritation of any sensory nerve* of the body, as is demonstrated by the general contraction of the blood-vessels which follows.

It is somewhat remarkable, however, that along with this general excitation there appears to be a local diminution of the "arterial tonus," so that the blood-vessels of the part which is directly irritated become dilated and the skin markedly reddened.

The activity of the vaso-motor center of the medulla appears to be decreased when one of the branches of the pneumogastric nerve, which is sent to the heart, is irritated. This is described in a subsequent chapter as the "*depressor nerve*." It tends to greatly diminish the blood-pressure by causing a cessation of the arterial tonus. Ferrier is inclined to believe that a distended state of the ventricles, when associated with a labored heart's action, creates a stimulation of this nerve and thus brings relief by inducing a dilated condition of the vessels and a diminution of the tension.

The *relations of the force of the heart-beat to the blood-pressure* within the arteries seem to be governed by the vaso-motor center of the medulla and the nerve fibers associated with it. As the arteries contract, the blood-pressure necessarily rises and is then apparently compensated by a slowing of the action of the heart. On the other hand, when the arteries become excessively dilated, the blood-pressure falls and the heart is thrown into a state of increased activity.

Again, the *vaso-motor center and the center of respiration apparently exhibit reciprocal relations*. During each inspiration, the pulse becomes somewhat accelerated; and, during expiration, it is diminished in frequency. These oscillations are now believed to be independent of variations in the blood-pressure which are produced by the tendency toward a vacuum in the chest as the diaphragm descends.

Ferrier thus summarizes the reflex functions of the medulla: "The medulla oblongata is thus a coördinating center of reflex actions essential to the maintenance of life. If all the centers above the medulla be removed, life may continue, the respiratory movements may go on with their accustomed rhythm, the heart may continue to beat, and the circulation be maintained; the animal may swallow if food be introduced

into the mouth, may react to impressions made on its sensory nerves, withdrawing its limbs or making an irregular spring if pinched, or even utter a cry as if in pain, and yet will be merely a non-sentient, non-intelligent, reflex mechanism."

DIAGNOSTIC SYMPTOMS OF LESIONS OF THE MEDULLA OBLONGATA.

The size of this ganglion almost precludes the existence of lesions, even if small, which do not influence to a greater or less extent the nerve nuclei contained within it.

An implication of the cranial nerve-roots (Figs. 55 and 56) may cause disturbances of respiration, circulation, phonation, deglutition, and articulation.

The sensory and motor tracts to the extremities may be simultaneously involved, and thus anæsthesia (?) and paralysis of motion may occur upon the side of the body opposed to the lesion. The fillet tract may be also affected by the lesion, in which case evidences of unilateral ataxia will be developed in the extremities. Finally, the lower part of the face may be rendered paretic.

Of the above-mentioned symptoms, *aphonia* and the *impairment of the respiratory and circulatory symptoms* are particularly diagnostic of medullary lesions.

The symptoms of *Duchenne's disease* are present only when chronic progressive degeneration of the nuclei of the medulla exists.

Suddenly developed lesions of the medulla are liable to cause instantaneous death.

Diabetes and *albuminuria* may be excited by lesions of the medulla.

When the pneumogastric nerves are implicated, *dyspnœa*, *irregularity of the action of the heart*, and *gastric or intestinal derangements* are encountered.

In a few instances, tumors and foci of softening in the medulla have been known to exist and create no symptoms of a diagnostic character.

Dysphasia, and the loss of the power of protrusion of the tongue, point to an implication of the hypoglossal and glosso-pharyngeal nuclei.

A lesion of *one anterior pyramid* would cause a paralysis of motion in the opposite arm and leg.

A lesion of *both anterior pyramids*, or one in the median line of the medulla, so low as to involve the decussation of the "crossed pyramidal tracts," would cause a paralysis of motion in both arms and both legs.

A lesion of the *lemniscus* or *fillet tract*, in any part of its course, would create a unilateral loss of coördination of the upper and lower extremities of the opposite side.

A lesion which involves the *vaso-motor center* of either side in the medulla would cause a general unilateral redness, abnormal heat, and profuse sweating on the same side of the body as the lesion.

THE VENTRICLES OF THE BRAIN.

The method of development of the brain teaches us that the cavities found within its substance are the evidences of its early tubular formation. The simplest forms of brains show that the primitive medullary tube becomes constricted in such a way as to form three vesicles, which go to form the cerebrum, the corpora quadrigemina, and the medulla oblongata of the human brain. In a general way, it may be said that the anterior vesicle subsequently develops, in the human subject, into the cerebral hemispheres, the basal ganglia, the olfactory lobes, and the lateral and third ventricles.¹ The middle vesicle yields the crus of each hemisphere, as far as the pons Varolii and the aqueduct of Sylvius, or the communicating passage between the third and fourth ventricles. The third vesicle forms the medulla oblongata, the cavity of the fourth ventricle, the cerebellum, and the pons Varolii. The so-called "fifth ventricle" of descriptive anatomists can not properly be said to form a part of the primitive tube (Wilder).

¹ Wilder applies the term "*coelie*" to the ventricular cavities.

The expansion of the anterior vesicle into the cerebral hemispheres, with its component ganglia and connecting fibers, causes each hemisphere, the corpus callosum, the caudate nucleus of the corpus striatum, the fornix, and the thalamus to assume an arch-like form, whose buttresses approach each other in the region of the floor of the cranial cavity.

Although the ventricles originally appear as tubular cavities in the process of development, they soon become modified as to configuration by the development of adjacent structures. In the fully formed brain of the human subject the central canal of the cord and its continuation into the mesencephalon (the *iter* or "aqueduct of Sylvius") remain tubular. The other expansions of the primitive tube are more or less modified.

Pathological changes are not infrequently observed in the ventricles, their size being often increased. In old or debilitated subjects the posterior cornua of the lateral ventricles are rendered funnel-shaped by the gravitation of the cerebrospinal fluid, provided that a long-continued confinement to bed has been required. Flower has observed an obliteration (more or less complete) of the hippocampus major from this cause, accompanied by changes in the occipital lobes.

THE LATERAL VENTRICLES.—These are two large cavities in the substance of the cerebrum, one in each hemisphere. They lie on a higher plane than the third ventricle, being roofed in by the corpus callosum. On the floor of each may be seen the caudate nucleus of the corpus striatum, the anterior tubercle of the thalamus, the *tænia semicircularis* separating these ganglia, a portion of the fornix, and a plexus of vessels derived from the pia mater, called the "choroid plexus." Each lateral ventricle is lined with a delicate layer called the "*ependyma*"—that is, covered with cilia in the fœtus. From the central or main cavity of the lateral ventricle of each side three prolongations, called "cornua," are to be observed. These are named from before backward, the anterior, the middle or descending, and the posterior. The lateral ventricles are separated from each other by the so-

called "septum lucidum," that consists of two laminae. Between these two laminae the so-called "fifth ventricle" is situated.

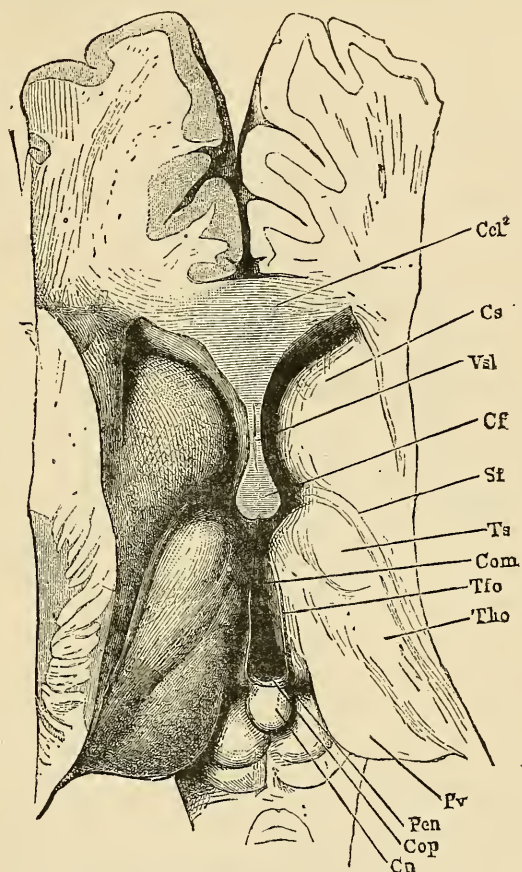


FIG. 66.—View from above of the third ventricle and a part of the lateral ventricles. (Henle.)

The brain has been sliced horizontally, immediately below the corpus callosum, and the fornix and velum interpositum have been removed. Tho, thalamus opticus; Ts, its anterior tubercle; Pv, pulvinar; Com, middle commissure stretching between the two optic thalami across the middle of the third ventricle; Cf, columns of the fornix; Cn, pincal gland projecting downward and backward between the superior corpora quadrigemina; Sf, stria terminalis; Cs, nucleus caudatus of the corpus striatum; Vsl, ventricle of the septum lucidum; Ccl², section of the genu of the corpus callosum; Pen, commencement of the pincal stria or peduncle, Tfo; Cop, posterior commissure.

The lateral ventricles communicate with each other and with the third ventricle by means of two openings behind the

anterior pillars of the fornix (Fig. 67), known as the "*foramina of Monro*." In chronic hydrocephalus, when the ventricles are excessively distended by fluid, these openings are greatly enlarged, and may occasionally admit the point of a finger.

The *anterior horn* of each lateral ventricle is produced by the development of the caudate nucleus. It curves around its anterior extremity, and projects into the frontal lobe.

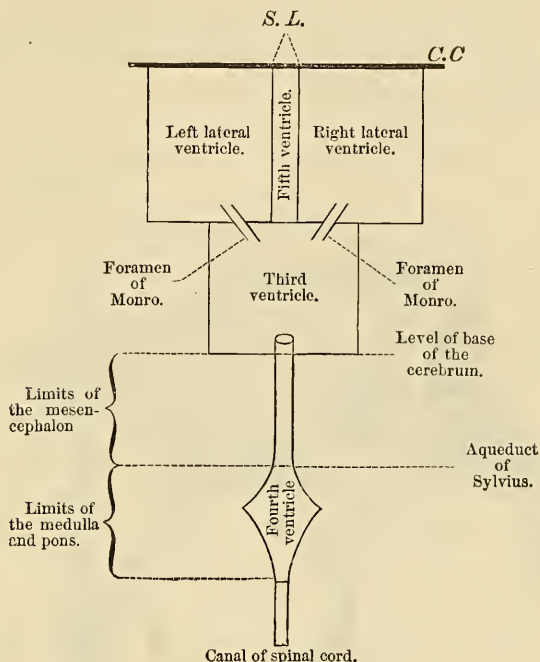
The *middle* or *descending horn* takes an irregularly curved course—compared by some anatomists to that of a ram's horn—around the optic thalamus, and extends into the temporo-sphenoidal lobe as far as its tip. On its floor may be seen an eminence known as the "*hippocampus major*," which terminates in two or three finger-like processes, called the "*pes hippocampi*." The sharp edge of the fornix and a fold of the choroid plexus may also be discerned here.

The *posterior horn* is small and extends into the occipital lobe. It contains, as in the case of the middle horn, an elliptical elevation, called the "*hippocampus minor*," and its digitated extremity, the "*pes accessorius*."

The "calcarine" and "collateral fissures" of the surface of the cerebrum are anatomically associated with the hippocampal eminences, as has been mentioned in a previous page.

It may, perhaps, help the reader, in forming a proper conception of the relations of the ventricles to each other and to adjacent structures, to compare them to chambers in different stories of a house. From such a homely simile the two lateral and fifth ventricles might be compared to the attic chambers, the third ventricle would be a chamber on the floor below, and the fourth ventricle a room on a floor still lower down. Each lateral ventricle lies *above the level of the basal ganglia*, since these ganglia appear to a slight extent upon its floor. The third ventricle lies in the mesial plane of the brain, *between the optic thalami, and extends downward as far as the floor of the cerebrum*. Finally, the fourth ventricle lies in the *region of the medulla oblongata*, entirely below all relation with the cerebral hemispheres.

Now, all of these cavities communicate and form in reality a continuous cavity, with constrictions in caliber here and there, and large expansions in other places. The cerebro-



spinal fluid is thus enabled to flow continuously from below upward till it fills the lateral ventricles, as well as the third and fourth, and to be forced out again when an excess of blood in the cerebral vessels demands a decrease of the intra-ventricular pressure. This subject will be more fully discussed in connection with the membranes of the spinal cord.

The lateral ventricles are best exposed by separating the cerebral hemispheres from each other, and then dividing the corpus callosum, upon either side of the median line, at the bottom of the great longitudinal fissure. The more important structures upon the floor of each can then be studied, and the position and general direction of the horns perceived. The middle and posterior horns can be subsequently laid open and studied separately.

THE THIRD VENTRICLE.—In order to expose this cavity from above, the *body of the fornix* must be divided upon the floor of the lateral ventricles and turned backward. If this be done carefully, a vascular curtain roof (the so-called "*velum interpositum*"), formed by the pia mater, will be exposed. This will have to be divided also, before the cavity of the ventricle is laid bare.

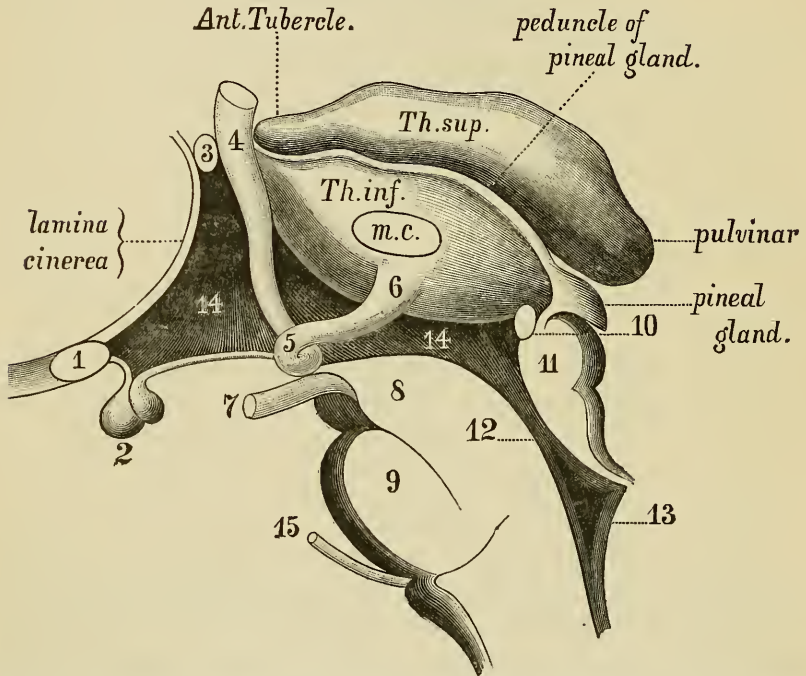


FIG. 67.—A diagram designed by the author to show the inner surface of the optic thalamus, with the tubular gray matter removed, showing the third ventricle, and the arrangement of neighboring parts.

Th. sup., superior part of thalamus; Th. inf., inferior part of same; *m. c.*, middle commissure; 1, section of optic commissure; 2, infundibulum and pituitary body; 3, anterior commissure of third ventricle; 4, anterior crus of fornix; 5, corpus canalicans (mammillary tubercle); 6, bundle of Vieq d'Azyr; 7, the third nerve; 8, crus cerebri; 9, pons Varolii; 10, posterior commissure; 11, corpora quadrigemina; 12, aqueduct of Sylvius; 13, fourth ventricle; 14, third ventricle. This cut should be compared with Fig. 3, in which the gray lining of the ventricle is intact.

This cavity is a narrow chink between the optic thalami. It is bridged across by three bands, called the *anterior*, *middle*, and *posterior commissures* of the ventricle. The middle or soft commissure is composed of gray matter, and

unites the thalami. It is often torn across in removing the brain.

Posteriorly, the third ventricle unites with the fourth by means of a narrow tubular canal, the "*aqueduct of Sylvius*" (*iter e tertio ad quartum ventriculum*). This canal passes beneath the corpora quadrigemina, and may be regarded as a homologue of the central canal of the spinal cord, which has been expanded in the region of the fourth ventricle, in order to allow of the many nuclei of origin of the cranial nerves found in its floor. Anteriorly, the third ventricle communicates with the lateral ventricle of each hemisphere by the *foramina of Monro*.

The third ventricle, the aqueduct of Sylvius, and the fourth ventricle are lined with a continuation of the gray matter that surrounds the central canal of the spinal cord, the so-called "*central tubular gray substance*."

The relation of the third ventricle to the pillars of the fornix, the lamina cinerea, and the structures that form the interpeduncular space at the base of the cerebrum, are made very apparent in the preceding cut.

The gray substance that lines the third ventricle has been described in connection with the thalamus, to which the reader is referred for information respecting it.

THE FOURTH VENTRICLE.—This cavity is properly regarded as an expansion of the central canal of the spinal cord. It communicates with the third ventricle above, and the central canal of the cord and the subarachnoidean space below. The latter communication takes place through the "*foramen of Magendie*." It allows of the entrance and escape of cerebrospinal fluid. The importance of this as a means of equalizing pressure upon the brain substance (when the vascular supply is increased or diminished) will be considered in detail in connection with the spinal meninges.

The fourth ventricle lies below the level of the cerebral hemispheres. Its gray matter contains the nuclei of origin of the more important cranial nerves. These have been discussed in connection with the architecture of the medulla. Its roof

is formed by the under surface of the cerebellum and the so-called "valve of Vieussens."

THE COMMISSURES OF THE BRAIN.

In connection with the ventricles, the corpus callosum and fornix have been mentioned. They deserve further consideration, as they have not been separately described in previous pages.

THE CORPUS CALLOSUM.—This commissural band has been discussed to some extent in those pages that treat of the commissural fibers of the cerebral hemispheres. It is about three inches long by three quarters of an inch in breadth, and lies at the bottom of the great longitudinal fissure. It is the great commissural band between the hemispheres, and forms the roof of the lateral ventricle of each. Anteriorly, it curves downward to reach the base of the brain, and posteriorly it dips downward to form the "splenium." The anterior bend is termed the "genu" or "anterior flexure" of the callosum. The splenium reaches as far as the transverse fissure of the cerebrum, and bears intimate relationship with the pineal gland and optic lobes. The so-called "peduncles of the callosum" reach to the anterior perforated spaces at the base of the cerebrum. Fibers of the callosum can be traced to the following parts :

1. The white substance of the cerebral hemispheres.
2. The gyrus fornicatus.
3. The fornix.
4. The occipital lobe.
5. The temporo-sphenoidal lobe, along the descending horn of the lateral ventricle.

The fibers of the callosum are both longitudinal and transverse. They serve to unite the component parts of the cerebral hemispheres. The transverse fibers probably assist in uniting homologous parts of each hemisphere. The function of the longitudinal fibers is not well understood.

The corpus callosum is sometimes defective or absent.

When so, the septum lucidum and the fornix are also, as a rule, defective. The mental condition of subjects with a defective corpus callosum, according to the researches of Knox, is impaired in proportion to the imperfections found in it and the other commissural systems. Idiocy and imbecility have occurred as a consequence of this form of congenital deformity of the brain. The anterior commissure appears to be relatively large in those animals that have the corpus callosum imperfectly developed. It is possible that this band may take the place of the corpus callosum in those rare cases where that body is rudimentary or absent in man. Ward reports a remarkable observation ("London Medical Gazette," March, 1846), where the brain of a child of about one year of age separated into two equal halves when it was removed from the skull, on account of the absence of all transverse commissural systems in the cerebrum and pons.

THE FORNIX.—The arched fibers of this structure serve apparently to unite the tip of each temporo-sphenoidal lobe with the thalamus of the corresponding hemisphere, and, by their fusion in the mesial plane, to join the two hemispheres with each other. Each lateral half of the fornix presents an anterior pillar (which passes to the base of the brain and then doubles upon itself in order to unite with the thalamus (Fig. 67), and a posterior pillar (which enters the middle or descending horn of the lateral ventricle as a flattened ribbon-like band, called the "corpus fimbriatum"). This band terminates in the so-called "corpus dentatum" of the descending horn.

The arched fibers of each lateral half of the fornix become united with those of its fellow in the mesial line, thus forming the so-called "body of the fornix."

The body extends, anteriorly, from the point of commencement of the anterior pillars of each side to that of the posterior pillars. It helps to form the roof of the third ventricle, lying above and in close contact with the reflection of the pia mater called the "velum interpositum." It becomes fused posteriorly with the corpus callosum. The shape of

the body of the fornix is triangular, the apex pointing forward. Its upper surface appears upon the floor of the central cavity of the lateral ventricle. In order to expose the third ventricle of the cerebrum from above, it is necessary to divide the body of the fornix close to the anterior pillars, and to turn it backward. The velum interpositum with its vessels then comes into view. This membrane has to be also removed before the ventricular cavity is seen.

COMMISSURES OF THE THIRD VENTRICLE.—The *posterior commissure* of the third ventricle has been considered in connection with the tegmentum cruris, and the *anterior commissure* will be discussed in connection with the olfactory nerves. The middle commissure is an integral part of the thalami, which it serves to unite.

THE MEMBRANES OF THE BRAIN.

The brain has three coverings, called, from without inward, the *dura mater*, the *arachnoid*, and the *pia mater*. The exterior, or *dura*, is essentially protective in function: although it serves some other purposes, such as the formation of venous channels, the support of certain parts, the nourishment of the bones, etc. The *arachnoid* is a fibro-serous membrane, and is structurally related to the lymph channels, as are all serous membranes. The *pia* is a vascular membrane, and serves to nourish the parts with which it comes in contact. It will be necessary to consider each of these membranes separately.

THE DURA.—This is a dense fibrous membrane, closely adherent to the base of the skull and along most of the cranial sutures. It is loosely attached, however, to the convexity of the skull, save at the sutures. Small vessels pass from its exterior surface into the diploë, or middle layer of the bony skull-cap. Its inner surface is smooth, and is lined with pavement epithelium. It is in relation to the so-called “subdural space.” Around the margins of the cranial foramina, the petrosal ridges, and the crista-galli process, the *dura* is

particularly firm in its attachments. The "sella turcica," that holds the pituitary body, is covered over by a process of this membrane, which binds the pituitary body firmly in place and conceals it from view.

Processes of the Dura.—The dura assists to form three processes, called the cerebral falx, the cerebellar falx, and the tentorium. The falces of the cerebrum and cerebellum prevent lateral oscillation of the cerebral and cerebellar hemispheres, while the tentorium supports the posterior part of the cerebrum and prevents it from injuring the cerebellum by its weight.

The Cerebral Sinuses.—Along the upper and lower borders of the falx cerebri the two reduplicated layers of the dura assist to form the superior and inferior longitudinal sinuses. Where it joins the tentorium, the straight sinus is formed. The attachment of the tentorium to the skull forms the lateral sinuses, by splitting of the dura into two layers.

The occipital sinuses run along the sides of the falx cerebelli. At the base of the skull we encounter the transverse and circular sinuses, both of which cross the median line, and also three pairs of sinuses, viz., the superior petrosal, the inferior petrosal, and the cavernous.

There are some clinical suggestions of value that may be made in connection with the dura. Inflammatory affections of that membrane may induce thrombosis of the cerebral sinuses, although that condition can occur also from extension of inflammation from other parts by means of the communicating veins, and as the result of pressure exerted upon them by intracranial lesions. The vessels of the dura may be the seat of extravasation of blood, and suppuration between the dura and the skull may follow traumatism. The nerves of the dura cause a headache, when that membrane is the seat of disease, or is pressed upon; as, for example, in the case of a cerebral tumor. Encephaloid cancer seems to occur most frequently in the dura about the foramen magnum. In this case, the symptoms would be closely allied to those of a lesion of the medulla. The communication between the cavern-

ous sinus and the facial veins by means of the orbit explains the liability of patients suffering from a facial erysipelas to a complicating meningitis. Leeching the nose will relieve headache, if congestive in type, because the longitudinal sinuses communicate with the veins of the nose. Depletion back of the ears may also be employed to deplete the lateral sinus through the mastoid vein. The liability of suppuration of the middle ear to a complicating meningitis is well recognized, and it is to be explained by the thinness of the bone between the dura and the tympanic cavity. As the sinuses of the brain receive tributaries from without chiefly through the sutures, the operation of trephining should never be performed over a suture if it can be avoided. Scalp-wounds are especially liable to become complicated by meningeal symptoms from the venous anastomosis that exists between the exterior and the interior of the skull. The escape of cerebro-spinal fluid from the ear, in case of fracture of the base of the skull, is a valuable sign that the dura is lacerated in the internal auditory canal, and the tympanic cavity also involved. Displacement of the cerebro-spinal fluid from the subarachnoidean space at the base of the skull by tumors of the dura or skull, the occurrence of meningeal hæmorrhage, severe concussion, etc., may tend to explain the occurrence of vertigo, nystagmus, noises in the ears, and some forms of paralysis. This would be particularly the case if an excess of fluid were crowded into the cerebellar fossa.

THE ARACHNOID.—Between the dura and the pia there may be demonstrated a delicate non-vascular membrane of the fibrous type, called “the arachnoid.” It is continuous with the membrane, filling the same relative position within the spinal canal, known as the “spinal arachnoid.” It can be easily demonstrated by means of a blowpipe, the injected air lifting it from the pia. It forms sheaths for the cranial nerves, embraces the basilar artery, bridges over the more important sulci of the brain, covers the exposed portion of the corpus callosum, and forms the limiting membrane for the lymph-spaces of the more important vessels of the cranium.

Between the arachnoid and the dura is a space, called the "*subdural space*," and between it and the pia is another space, known as the "*subarachnoidean space*." The latter is traversed by a delicate network of fibers, that subdivide it into compartments. The subdural space is lined with an endothelium. Both spaces are filled with a fluid that is similar to that which enters the ventricles by means of the foramen of Magendie. The normal quantity of this fluid that is found outside of the brain varies from a few drachms to about two ounces. Hilton compares this fluid at the base of the brain to a water-bed for protection against transmitted violence, as when a subject falls and strikes upon the feet. The effect of any lesion that tends to decrease the cubical contents of the cranial cavity must be to displace this fluid. But, since the fluid is not evenly distributed over the base of the skull, some regions are more exempt from this displacement than others. Again, lesions of the character described may prevent the escape of the cerebro-spinal fluid through the aqueduct of Sylvius, and thus disturb the beautifully adjusted relationship between the amount of fluid within the ventricles and the circulatory apparatus. Duret attributes the *loss of consciousness* that accompanies sudden lesions of the basal ganglia or the white substance of the cerebral hemispheres to a rapid displacement of the cerebro-spinal fluid. Blachez reports a case where a rupture of the basilar artery filled the entire area of the base of the brain with blood (Allen).

THE PIA.—This is a fibro-vascular structure that lies in direct contact with the cortex of the brain. It is continuous with the pia of the spinal cord, but differs from it in that it is more vascular and does not form ligaments. In the skull it consists of two layers, the outer being a receptacle of large vascular trunks and the inner for the smaller twigs that enter the cortex. The inner layer is continuous with the neuroglia. The pia sends prolongations into the ventricles of the brain, chiefly by means of the transverse fissure that lies between the cerebrum and the cerebellum. Allen states that it is so closely adapted to the walls of the fissure by which it enters

the ventricles as to resist the pressure of the cerebro-spinal fluid, and it thus prevents its escape from the ventricles.

The prolongations of the pia within the substance of the brain constitute the parts known as the "velum interpositum" and the choroid plexuses.

The *velum interpositum* has a triangular form and lies immediately beneath the fornix, and forms the curtain-like roof of the third ventricle. Its base corresponds to the transverse fissure, and its apex lies between the foramina of Monro. It incloses the pineal gland, and overlaps the optic lobes. Two large veins can be seen within its substance that empty into the straight vein of Galen. It is the largest prolongation of the pia.

The *superior choroid plexuses* are formed from the lateral margins of the velum interpositum and appear in the lateral ventricles. In each hemisphere the choroid plexus of the ventricle is prolonged into the middle or descending horn, lying upon its floor. The vascular loops that compose this plexus are covered with a layer of pavement epithelium.

In the third ventricle, two prolongations from the velum can be demonstrated. These are sometimes prolonged into the fourth ventricle.

The *inferior choroid plexus* lies upon the floor of the fourth ventricle (the posterior surface of the medulla), and consists of a median tuft of vessels that envelops the under surface of the worm of the cerebellum, and two lateral processes that run out into the angles of the ventricle. This plexus of vessels is generally derived directly from the pia, which penetrates into the fourth ventricle through the so-called "inferior transverse fissure." This is situated at the line of junction of the under surface of the cerebellum and the medulla. In this region, the arachnoid membrane becomes perforated, forming the so-called "foramen of Magendie," through which the cerebro-spinal fluid reaches the ventricular cavities of the brain.

The pia is supplied with nerves from the third, sixth, seventh, eighth, and eleventh cranial nerves and from the

sympathetic system. Its blood-vessels are derived from the vertebral and internal carotid arteries.

THE BLOOD-VESSELS OF THE BRAIN.

The vessels of the brain are of great interest to the surgeon, because they have a direct bearing upon the pathology and symptomatology of injuries of the head. To the general practitioner also the vessels of the encephalon furnish many suggestions of value respecting those diseases that attack the brain substance or the meninges. It is not out of place, therefore, to call attention to the more important facts that have been published by those observers who have devoted special care to the investigation of the anatomy of the vessels of the brain and the peculiarities of its circulation.

The blood is sent to the brain and its coverings chiefly by means of two large trunks upon either side, the vertebral and internal carotid.¹ The vertebrals enter the skull by means of the foramen magnum and unite to form the basilar. The carotids enter farther forward, by means of the carotid canals in the petrous portion of each temporal bone. The branches that derive blood from the vertebrals are called, when collectively considered, the *posterior* or "*vertebral system*." Those that spring from the carotids are called the *anterior* or "*carotid system*."

The "*vertebral system*" is distributed to the posterior portions of the cerebrum, the cerebral peduncle, the cerebellum, pons, medulla, corpora quadrigemina, and the posterior part of the thalamus.

The "*carotid system*" is distributed to all the important parts of the cerebrum lying anterior to the cerebral peduncle in the region of its base, the frontal lobes, the anterior and outer parts of the temporo-sphenoidal lobes, the insula, the two nuclei of the corpus striatum, and the anterior portion of the thalamus.

¹ The coverings of the brain derive blood from other sources as well; chiefly from the internal maxillary, ascending pharyngeal, and occipital arteries.

It will be necessary to consider the separate branches of the internal carotid, vertebral, and basilar arteries, in order to give the reader a clear conception of the areas of brain-tissue that are nourished by each.

The INTERNAL CAROTID ARTERY, on escaping from its bony canal and entering the cavity of the skull, turns sharply upward and backward and gives off the following branches : 1, the ophthalmic ; 2, the anterior choroid ; 3, the anterior cerebral ; 4, the middle cerebral ; and, 5, the posterior communicating.

The *ophthalmic artery* passes directly into the orbit and distributes its blood by many branches to the eye and its appendages. This fact enables the neurologist to determine often, by means of the ophthalmoscope, the condition of the cerebral vessels, because similar changes may be detected in the blood-vessels of the retina.

The *anterior choroid artery* passes backward to the transverse fissure of the brain and assists in supplying the vessels of the choroid plexus. It lies in relation with the extremity of the temporo-sphenoidal lobe, which conceals it from view for a part of its course.

The *anterior cerebral artery* winds around the edge of the optic chiasm and meets its fellow about one twelfth of an inch in front of the chiasm, where the two become joined by a short branch, the anterior communicating artery. From this point the two vessels run side by side, following the curve of the corpus callosum from its beak to its posterior extremity. This vessel supplies the optic chiasm, the lamina cinerea, the anterior portion of the caudate nucleus, the corpus callosum and the adjacent fornix, and the convolutions upon the inner surface of the hemisphere of the same side, as far as the cuneus. The importance of the relation of this vessel to the edge of the optic chiasm, as a factor in the production of that rare condition known as "bi-temporal hemianopsia" has been shown in a paper by Prof. H. Knapp, of this city. This condition is discussed later in the volume.

The *middle cerebral artery* is especially important, because it is now known to supply the so-called "motor area" of the cerebral cortex. On leaving the internal carotid trunk, it crosses the anterior perforated space and enters the Sylvian fissure. Here it gives off its main branches, which are usually four in number. All along its upper surface, however, small arterial twigs are given off in the Sylvian fissure and in the neighborhood of the anterior perforated space. These enter the substance of the brain and supply the caudate and lenticular nuclei of the corpus striatum and the internal and external capsule. Its main branches take different directions. One runs forward into the convolutions of the frontal lobe, one backward as far as the extremity of the horizontal limb of the Sylvian fissure, and two pass upward on either side of Rolando's fissure as far as the upper frontal and parietal gyri, that lie adjacent to the great longitudinal fissure. Thus it appears that the basal ganglion which are connected with motion derive their blood-supply from this vessel, as do also the island of Reil (the *insula*) and the convolutions that bound the fissure of Rolando and the Sylvian fissure. Embolism or thrombosis of the main trunk causes a hemiplegia of the opposite side of the body and motor aphasia, because the motor gyri and Broca's center of articulate speech are deprived of blood. Should some one of its branches alone be occluded and the main trunk escape, these symptoms would be modified. The middle cerebral artery of the left side is the most common seat of embolism, because that artery is the terminal branch of a direct line of vessels arising from the arch of the aorta in such a way as to favor the entrance of floating particles in the blood into the mouth of the left common carotid artery.

The *posterior communicating artery* connects the internal carotid with the posterior cerebral, and thus establishes the vascular circle at the base of the brain known as the "circle of Willis." It gives off branches that supply the tuber cinereum, the corpora mamillaria, the optic tracts, and the inner surface of the thalamus (Westbrook).

The VERTEBRAL ARTERIES of either side unite to form the basilar. This vessel gives off the posterior cerebral vessels, at its anterior extremity, and thus assists to form the circle of Willis. Along its sides, transverse branches are given off. One of these, the auditory artery, supplies the ear mechanism.

The *posterior cerebral artery* arises from the anterior extremity of the basilar and passes outward and backward around the crus cerebri to reach the temporal and occipital lobes of the cerebrum. It follows the course of the calcarine fissure (Westbrook). As it crosses the posterior perforated space, small arterial twigs escape and enter the substance of the brain to supply the thalamus. A *posterior choroid* branch is sometimes given off. This assists to form the velum interpositum and the choroid plexus, and gives off branches to the pineal gland and optic lobes. The main trunk of the posterior cerebral artery supplies the crus cerebri, optic lobes, and geniculate bodies.

The basal ganglia of the cerebrum derive their vascular supply from twigs that arise from the vessels composing the circle of Willis. Duret has observed the circular outline of these ganglionic twigs. In a diagram designed by Westbrook,¹ the basal ganglia have been projected, as it were, upon the surface of the cerebrum. The outer limit of these ganglionic masses constitutes almost a perfect circle. To quote the author of the cut, "The diagram was obtained by making a horizontal section of a cerebrum, low enough to cut the lenticular nucleus, and then perforating the brain with styles so as to mark out the limits of the ganglia.

As regards the distribution of arteries within the brain substance, some practical discoveries have been made. Duret found that injections of individual trunks distributed to the cerebral cortex passed over to a slight extent into areas supplied by other vessels. He drew the conclusion from this fact that a collateral circulation did exist between vessels of large size, not only at the base of the brain but also upon the

¹ "Annals of Anatomy and Surgery," vol. ii.

surface of the cerebral hemispheres. The vessels that run over the surface of the hemispheres in the meshes of the pia give off arterial twigs that everywhere dip into the cortex and penetrate its layers. These are subsequently prolonged into the medullary substance of the hemispheres. It seems probable that the nutrient vessels of the cortex do not anastomose with each other or with those that enter the brain substance from the region of its base. Westbrook claims, as a result of special researches, that a portion of the centrum ovale of the hemispheres is destitute of vessels.

The vessels of the ventricles are derived from the choroid plexuses and the velum interpositum. Some twigs are given off from the latter of these sources to the thalami and the commissures of the third ventricle, and also to the caudate nuclei of the corpora striata. According to Duret, these sometimes anastomose with the branches of the middle cerebrals given off in the Sylvian fissures.

The choroid plexuses do not appear to nourish the brain substance or its ganglia, but are destined rather to assist in the secretion of the ventricular fluid. They derive blood from the anterior and posterior choroid vessels.

THE CRANIAL NERVES.

THEIR ANATOMY, PHYSIOLOGY, AND CLINICAL VALUE.

THE CRANIAL NERVES.

IN the previous chapter many points pertaining to the superficial and deep attachments of the cranial nerves have been incidentally mentioned whenever different regions of the brain from which they arise have been considered. The nuclei of origin of some of the nerves have been discussed in detail. It seems to me advisable, however, to call attention again to some scattered hints, which have been dropped respecting these nerves, before they are individually considered from a physiological and clinical standpoint.

The nerves which arise from the brain are arranged as twelve pairs (according to Soemmering), which, from before backward, are called the olfactory, optic, motor-oculi, trochlearis, trigeminus, abducens, facial, auditory, glosso-pharyngeal, pneumogastric, spinal accessory, and hypoglossal. All of these, excepting the ninth, tenth, and eleventh pairs, are confined in their distribution to the head; while the other three have a distribution to the structures of the neck and trunk.

Willis has divided the cranial nerves into nine pairs, grouping the seventh and eighth nerves as one pair, and the ninth, tenth, and eleventh as one pair.

The OLFACTORY TRACT AND BULB must be regarded in the light of a *constituent part of the brain* rather than as a true nerve. This is demonstrated by its method of development, as well as by certain peculiarities in its structure. During foetal life the *olfactory lobe* or *tract* consists of a diverticu-

lum from the hollow globe of the cerebral hemisphere, and its cavity then communicates with the lateral ventricle. Its cortical layer is continuous superiorly with that of the rest of the brain.

The *olfactory bulb* forms a cap which embraces the prolongation of the brain substance. In its interior, rounded masses—the so-called “glomeruli” of the *stratum glomerulosum*—are found. These are peculiar to this region.

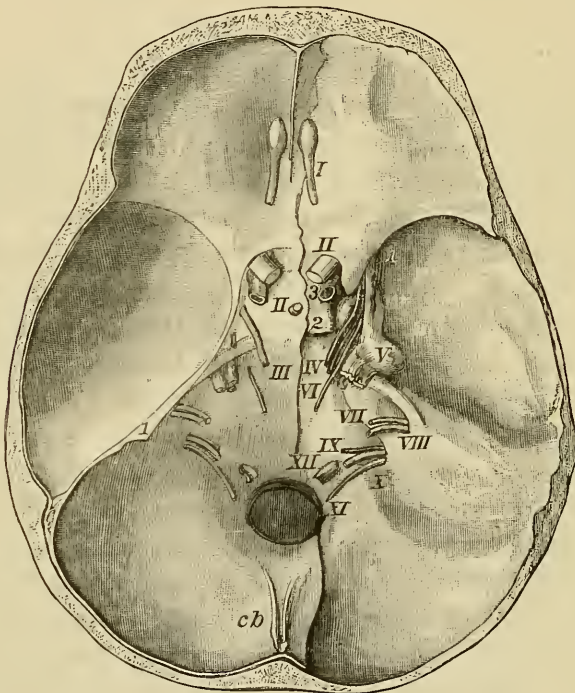


FIG. 68.—The base of the skull and the cranial nerves.

The nerves are indicated by Roman numerals: 1, attachment of the tentorium; 2, sella turcica; 3, carotid artery.

Each olfactory nerve fiber appears to be wound into a knot, as it were, by the aid of nerve cells that are inserted in its course. The cortical substance of the olfactory tract or lobe presents, moreover, peculiarities in respect to the cells which compose it. These are in marked contrast to those which compose the cerebral cortex.

The olfactory nerve has three peduncles or roots by means of which its fibers find their deep origins within the brain substance. The *external* or *long root* passes along the front border of the anterior perforated space, and enters the temporo-sphenoidal lobe. The *middle* or *gray root* arises from the cortical gray matter covering the anterior perforated space. The *internal root* passes into the substance of the frontal lobe.

The view is held, from some results obtained by Gudden's method, that the *olfactory sense is presided over* by a *center or nucleus which is situated in the substance of the temporo-sphenoidal lobe*, and that decussating fibers can be proven to pass between the olfactory tracts and also between the centers of smell of each hemisphere. The diagram introduced (Fig. 69) will help to illustrate in a rough way the conclusions advanced by late observers.

When the optic thalamus was under consideration, the opinion of Luys, that a *center of smell* could also be demonstrated within the substance of that ganglion, was commented upon. Some pathological facts, as well as clinical experimentation (to which that author refers), appear to lend credence to the view that the optic thalamus is associated, to a greater or less extent, with the special senses of smell, sight, and hearing. Its anatomical connections with this special sense are, however, a subject of pure conjecture as yet. Gudden's method of research does not sustain the opinion of Luys.

The late investigations of Flechsig have led him to the conclusion that the olfactory tracts can be traced backward as three bundles. One of these passes to the base of the frontal lobe, and probably terminates in the gyrus fornicatus; one goes to the cortex of the gyrus uncinatus; and one can be traced to the internal capsule of the cerebrum, by means of the anterior perforated lamina. Ganser and Gudden (by means of the latter's method of observing the atrophic changes that follow the extirpation of certain parts in the newly-born rabbit) seem to have arrived at the conclusion that the "olfac-

tory portion" of the anterior commissure of the brain connects the two bulbs of the olfactory nerves, and the so-called "temporal portion" of the anterior commissure connects the temporal lobes of the two hemispheres.

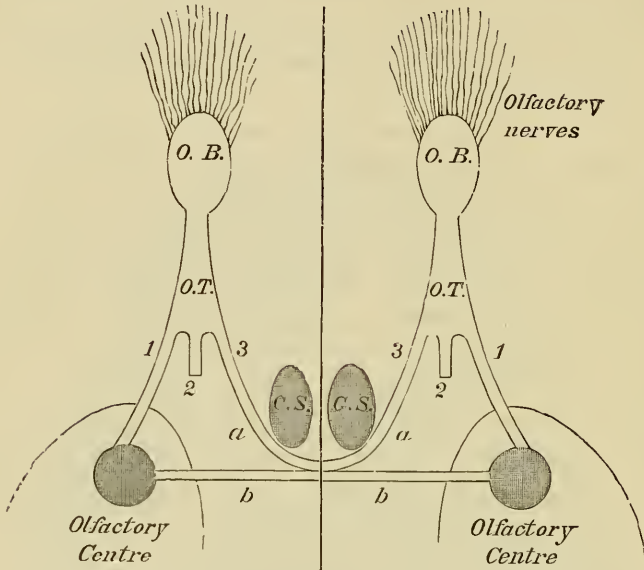


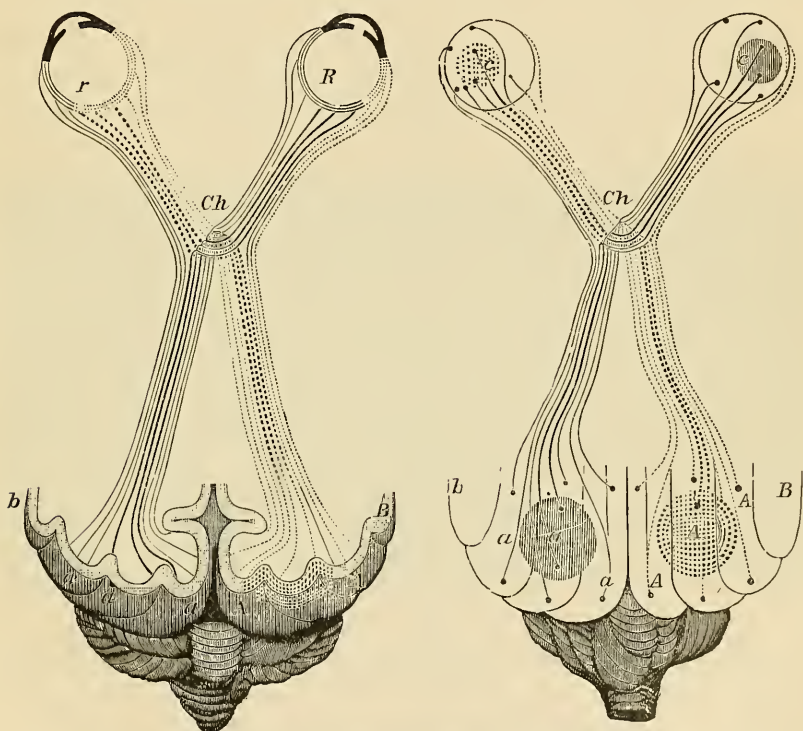
FIG. 69.—A diagram designed by the author to illustrate the probable decussation of the fibers of the olfactory tracts.

O. B., olfactory bulbs; O. T., olfactory tracts; 1, 2, 3, internal, middle, and external roots of same; C. S., corpus striatum of each hemisphere of the cerebrum; *a*, fibers connecting the olfactory tracts; *b*, fibers connecting the centers of smell; *a-b*, anterior commissure, with its two sets of fibers.

The fact that the so-called anterior commissure of the brain consists of two strands (the temporal and olfactory fasciculi of Ganser) is not new. It is only the verification of the view that the olfactory apparatus can be proven to have an anatomical relationship with the anterior commissure that deserves special notice. In man and the monkey tribe, the temporal fasciculus is much larger than the olfactory. In the lower mammals (particularly in the rabbit, hedgehog, and mole), the olfactory strand seems to be developed in excess of the temporal.

The fibers of the OPTIC NERVE have been already considered at some length when the corpora quadrigemina were

under discussion. The reader is referred, therefore, to previous pages for information, which it is unnecessary to repeat here. The admirable diagrams designed by Munk to illustrate his views respecting the areas of vision within the cortex of the occipital lobes will possibly prove of value, in connection with others which have been designed by the author to show the general relations of the optic fibers to different parts of the brain (Figs. 42, 43, 44, and 73).



FIGS. 70 and 71.—*The visual tracts.* (Munk.)

A, visual area of right occipital lobe (dotted); a, same of left side (lined); R, r, retinæ (right and left); B, b, areas of hearing, contiguous to the visual areas; Ch, optic chiasm. This figure may be contrasted with Fig. 43.

The optic nerves will be separately described in subsequent pages, and many points of clinical interest will be mentioned in connection with them. The deep origin of the optic fibers is as yet a matter of dispute among authors of note.

The superior *corpora quadrigemina*, the pulvinar of each *optic thalamus*, and the external *geniculate bodies* are unquestionably parts of the optic apparatus. The fillet is probably connected also to some extent with the visual function. Certain convolutions of the cerebral cortex (probably those of the occipital lobes) are concerned, moreover, in the conscious perception of retinal impressions (see page 180). The cerebellum is supposed also to receive afferent fibers from the organ of sight.

Munk believes that in the dog three distinct visual areas in the retina correspond to three "visual spheres" in the cortex of the occipital lobe of the brain. The external part of each retina is connected with the external part of the cortical visual area of the corresponding cerebral hemisphere; while the central and internal portions are connected with corresponding parts of the cortical visual area of the opposite cerebral hemisphere.

In connection with experiments, made to determine the arrangement of the optic nerve fibers in the chiasm as well as their relation to the various ganglia of the brain, Gudden claims to have demonstrated that a band of fibers exists within the optic tract and closely intermingled with its fibers that do not degenerate when the eyeballs of a young rabbit are extirpated. He applies the term "*inferior cerebral commissure*" to this band, and believes that it serves as a direct commissure between the optic thalami. He found that it remained unchanged even after the optic lobes and the geniculate bodies were destroyed; hence he concludes that it is in no wise associated with the visual sense.

Respecting the question of *decussation of the optic fibers*, the same observer has arrived at the following conclusions:

1. That a complete decussation takes place in the chiasm of the bird species.
2. That the decussation is only partial in the higher mammalia, although the proportion of the decussating fibers to the non-decussating is subject to variations.

3. The direct bundle does not occupy the same relative position in the optic tract in all mammalia.

4. That semi-decussation exists in all animals possessing binocular vision. Total decussation accompanies monocular vision only.

5. That there does not exist any "inter-retinal bundle," as claimed by some observers.

6. That three sets of fibers exist in the optic system of mammals: (a) The optic fibers, which are both crossed and direct; (b) the fibers of the inferior cerebral commissure; (c) certain "hemispheric fibers," whose course and terminations are not, as yet, definitely determined.

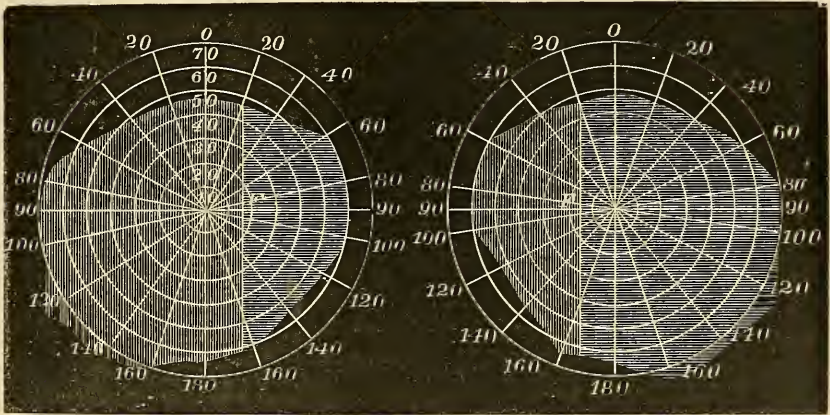


FIG. 72.—The normal visual field.

The field is marked off in degrees, so that a drawing of the visual field of any individual patient by means of a perimeter may be compared, when deemed abnormal.

Ganser has lately published a confirmation of Gudden's experiments and conclusions drawn from the rabbit, by a similar set of experiments made upon cats. His deductions in reference to the cortical and retinal distribution of the optic fibers seem to coincide with the physiological deductions of Munk. Both Ganser and Gudden seem to agree that no connection can be proven to exist between the inferior corpora quadrigemina or the internal corpora geniculata and the optic apparatus.

Flechsig has lately published the results of researches made by him in reference to the optic fibers by the degenerative method. He excludes (as do Gudden and Ganser) the corpus geniculatum internum and the posterior corpus quadrigeminum from the optic apparatus. He claims that some of the optic fibers turn backward upon their own course to reach the radiating fibers of the external geniculate body and reach the visual area of the cerebral cortex by passing to the outer side of the posterior cornu of the lateral ventricle. He places the cortical area of vision in the *cuneus* and the *occipital lobe*.

A band of fibers that crosses in the substance of the crus cerebri has been called by Gudden the "*transverse peduncular tract*." It extends to the optic lobe of either side, and then disappears. It seems probable that it is functionally, as well as anatomically, related to the apparatus of vision, because the later investigations of Gudden tend to demonstrate that its fibers have a direct connection with the visual area of the cortex and the primary centers of vision. Wilder, in his work on "Anatomical Technology," has suggested the term "*cimbia*" for this tract, although he does not appear to recognize its association with the visual mechanism.

Wernicke has demonstrated that a tract of fibers passes from the pulvinar (a part of the optic thalamus) to the cortex of the occipital lobe, and that this tract is a direct continuation of the fibers of the optic tract. It reaches the occipital lobe by passing beneath the "angular gyrus." Ferrier's and Dalton's experiments upon that convolution probably affected vision by causing injury to the tract of Wernicke.

The MOTOR-OCULI and TROCHLEAR NERVES have their deep origin apparently from a gray nucleus (which, according to some authors, is common to both nerves) within the gray matter surrounding the aqueduct of Sylvius. This nucleus is in direct communication with both the corpora quadrigemina and the lenticular nucleus of the corpus striatum. The nu-

cleus of the fourth nerve seems to be composed of larger cells than that of the third nerve, however, and to occupy the level defined by the line of separation between the anterior and posterior corpora quadrigemina.

Some authors describe an additional nucleus for the TROCHLEAR NERVE in the locus cœruleus. It is apparently proven that the fibers of the fourth nerve decussate with those of its fellow after passing backward from its nucleus and piercing the root of the aqueduct of Sylvius. They then traverse the crus cerebri and escape at its superior and external border.

The *nucleus of origin* (Fig. 45) of the third cranial nerve of each side seems to be capable of subdivision into groups of cells which preside over movements of special muscles of the orbit.

Thus we may clinically recognize the existence of a special nucleus for visual "accommodation"; for pupillary movements; and for the internal rectus, the superior rectus, the levator palpebræ, the inferior rectus, the inferior oblique, and the superior oblique muscles.

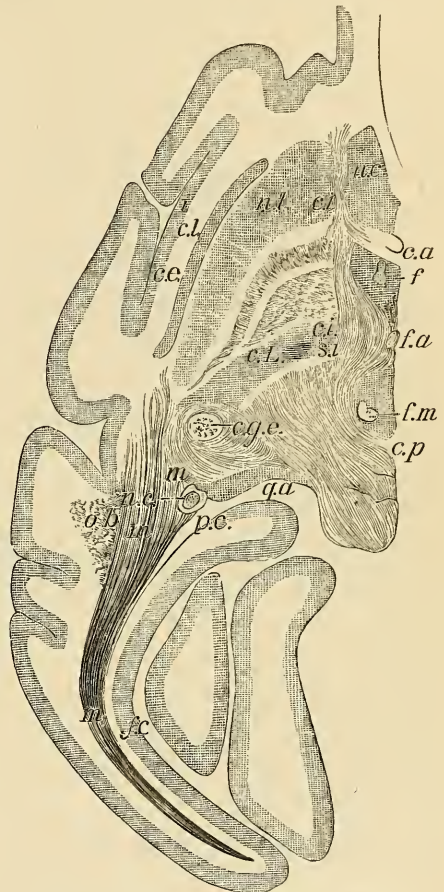


FIG. 73.—Horizontal section of a monkey's brain. (Wernicke.)

n. c., nucleus caudatus; *n. l.*, nucleus lenticularis; *c. a.*, anterior commissure; *c. L.*, body of Luys; *c. e.*, external capsule; *c. g. e.*, external geniculate body; *c. l.*, claustrum; *i.*, Island of Reil; *p. c.*, posterior cornu; *c. p.*, posterior commissure; *q. a.*, corpora quadrigemina anterior; *f. c.*, calcarine fissure; *m.*, optic fibers to occipital lobe.

This fact probably explains how the existence of “*external ophthalmoplegia*” and other distinct forms of orbital

paralysis may occur from organic lesions in the region of the tegmentum.

The TRIGEMINAL NERVE resembles the spinal nerves in possessing both a motor and sensory root. The analogy is heightened, moreover, by the development of the ganglion of Gasser upon the sensory root. The deep fibers of this nerve demand a detailed description, because they

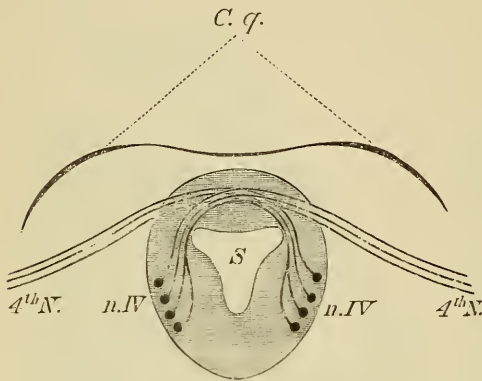


FIG. 74.—A diagram designed by the author to illustrate the origin and course of the fourth cranial nerve.

The section is on a level with the line of division between the anterior and posterior quadrigeminal bodies. IV. n., nucleus of the trochlear nerve; 4th N., fibers of the trochlear nerve; S., aqueduct of Sylvius; C. q., corpora quadrigemina. Note the decussation of the fibers in the gray matter which surrounds the aqueduct of Sylvius.

take their origin from several nuclei (shown in Fig. 55).

1. Some fibers join the trigeminal nuclei of the medulla. The sensory nucleus is situated as high as the level of the point of escape of the nerve from the pons Varolii and is analogous, in the opinion of some authors of note, to the posterior horn of the gray matter of the spinal cord. It extends along the outer part of the floor of the fourth ventricle.

2. The so-called “*ascending root of the nerve*” is associated with the posterior columns of the spinal cord as low as the middle of the cervical region. Its fibers are found to pass through these columns from their *origin in the posterior horns* to reach the *tubercle of Rolando* in the medulla. The fibers of the ascending root of the trigeminus are associated with the sensory portion of that nerve.

3. The fibers of the so-called “*descending root of the nerve*” apparently arise (1) from the cerebellum; (2) from the locus cœruleus; (3) from a collection of cells in the lateral

wall of the aqueduct of Sylvius; and (4) from a large-celled motor root, in the region of the corpora quadrigemina. The descending root of the trigeminus is associated chiefly, if not exclusively, with the motor fibers of the nerve.

The ABDUCENS NERVE arises from a nucleus within the medulla composed of large cells and situated near to the junction of the medulla and pons at the bottom of a groove in the floor of the fourth ventricle. A communication probably exists between this nucleus and that of the motor-oculi nerve of the opposite side.

The FACIAL NERVE arises from a nucleus which appears to be a continuation of that of the abducens, but lying deeper in the substance of the medulla, and also from a nucleus (*inferior facial nucleus*) in the substance of the pons. Some

fibers of the nerve descend in the crus cerebri; probably from the lenticular nucleus of the corpus striatum of the opposite cerebral hemisphere. The peculiar course of the facial fibers in the medulla is shown in Fig. 55. Gowers denies the statement, which was once accepted, that the facial nerve arises in part from the nucleus of the abducens nerve. The fibers of the facial nerve form a *distinct loop*, by doubling upon themselves, before escaping from the medulla.

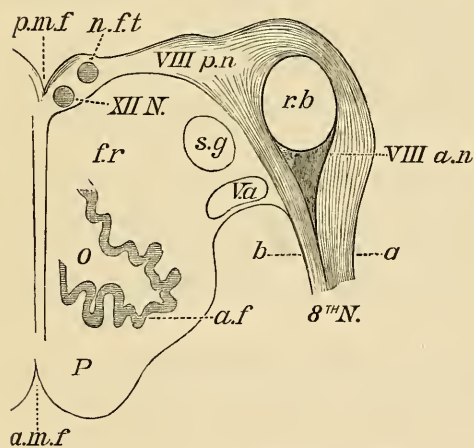


FIG. 75.—Section of the medulla at its upper part.

a. m. f., anterior median fissure; p. m. f., posterior median fissure; O, olivary body; s. g., substantia gelatinosa; f. r., reticular formation; P, anterior pyramid; V a, ascending root of fifth nerve; b and a, two bundles of auditory nerve inclosing r. b., the restiform body; VIII a. n., VIII p. n., anterior and posterior nuclei of the auditory nerve; n. f. t., nucleus of the funiculus tereles; XII N., nucleus of the hypoglossal nerve.

The relation of facial paralysis to lesions of the pons has been discussed on page 291.

The AUDITORY NERVE arises from four nuclei within the substance of the medulla.

A small fasciculus escapes from the medulla between the facial and auditory nerves, called the "*portio intermedia of Wrisberg.*" This is now considered as in no way related to the sense of hearing, but rather to that of taste. Although it passes, along with the auditory nerve, into the internal auditory canal, it subsequently joins the facial nerve and probably helps to form the chorda-tympani branch of that nerve.

The nuclei of the auditory nerve lie on a level with the broadest part of the fourth ventricle. They are termed the "anterior median," the "posterior median," the "anterior lateral," and the "posterior lateral." They have been already described in connection with the medulla. Some fibers of the auditory nerve have been traced to the superior vermiform process of the cerebellum (page 232).

Figs. 55 and 75 will show the relative situation of the four acoustic nuclei within the medulla. Some of the fibers of the auditory nerve decussate.

The NINTH OR GLOSSO-PHARYNGEAL NERVE arises from a nucleus within the substance of the medulla that is not separated by a distinct boundary from that of the pneumogastric. Its situation and extent are shown in the drawing of Erb (Fig. 55).

The TENTH OR PNEUMOGASTRIC NERVE arises from a nucleus within the medulla situated in its lower half in the floor of the fourth ventricle, and also from a nucleus in the vicinity of the olivary body. The latter is not shown in the diagrammatic drawings of Erb. The nerve also derives fibers of origin (see page 213) from the trineural bundle (Spitzka). As the nerve emerges from between the lateral column and the restiform body of the medulla, its roots, between twelve and fifteen in number, lie beneath those of the glosso-pharyngeal nerve. These roots join to form a flattened fasciculus that crosses the flocculus, in company with the glosso-pharyngeal nerve to reach the jugular foramen.

The ELEVENTH OR SPINAL ACCESSORY NERVE is formed by

two divisions, the medullary and the spinal. The former arises from a nucleus that lies within the medulla close to the central canal of the cord and is a continuation downward of the nucleus of the vagus. The spinal filaments spring from a continuation of that nucleus in the gray substance of the cord, as low down as the level of the escape of the sixth or seventh pair of cervical nerves. The spinal filaments escape from the lateral column of the cord, between the anterior and posterior nerve roots of the spinal nerves. The medullary portion of the nerve receives accessory fibers from the hypoglossal nucleus, the solitary bundle, and the raphe.

The TWELFTH OR HYPOGLOSSAL NERVE arises from a nuclear column (about three quarters of an inch in length) that is composed of large branching multipolar nerve cells. Its lower end is situated in front of and close to the central canal, in the region of the level of decussation of the pyramidal tracts. In the fourth ventricle this nucleus forms a prominence near the median line, slightly above the calamus scriptorius. The filaments of the nerve pass through the inner side of the olivary body, and emerge in the furrow between the anterior pyramid and the olivary body. They are then collected into two bundles that join with each other to form the nerve trunk before they reach the anterior condyloid foramen.

We are now prepared to consider the separate cranial nerves and their branches of distribution.

THE OLFACTORY NERVE.

The first cranial nerve, or nerve of smell, consists (1) of three roots; (2) an olfactory process; (3) a bulb; and (4) terminal branches, which are distributed to the cavities of the nose.

The three roots are called the *external*, *middle*, and *internal*.¹

¹ The deep origins of this nerve have been discussed in preceding pages, as well as the probable situation of the cortical centers of smell.

All three of the roots join to form a band, which is prismoidal in form (the olfactory process or tract), which passes forward

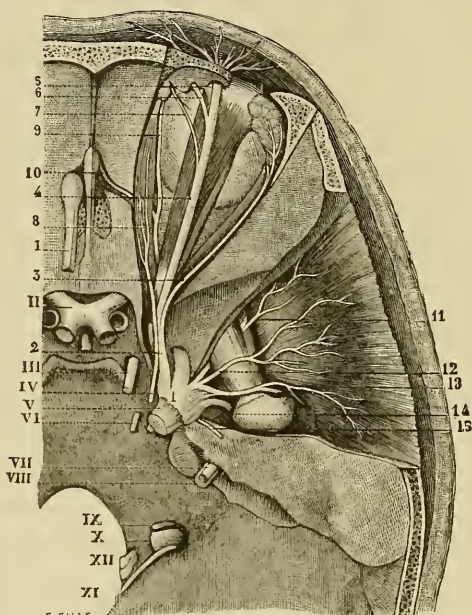


FIG. 76.—*Roots of the cranial nerves.* (Hirschfeld.)

- I. First pair; olfactory.
- II. Second pair; optic.
- III. Third pair; motor oculi communis.
- IV. Fourth pair; patheticus.
- V. Fifth pair; nerve of mastication and trifacial.
- VI. Sixth pair; motor oculi externus.
- VII. Facial, } Seventh pair.
- VIII. Auditory, }
- IX. Glosso-pharyngeal, } Eighth pair.
- X. Pneumogastric, }
- XI. Spinal accessory, }
- XII. Ninth pair; sublingual.

The numbers 1 to 15 refer to branches which will be described hereafter.

along the floor of the brain in a deep sulcus till it expands into the terminal enlargement, known as the “olfactory bulb,” or “ganglion.” This terminal enlargement lies upon the *upper surface* of the *cribriform plate* of the ethmoid bone, through the numerous foramina of which its branches escape, as small, thread-like filaments; which subsequently form a plexus upon the surface of the Schneiderian, or pituitary, membrane of the nose.

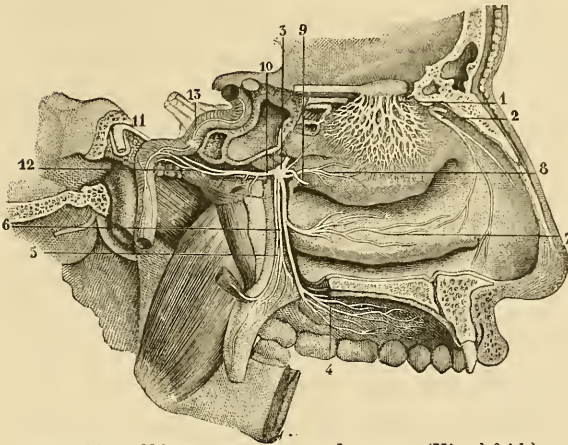


FIG. 77.—*Olfactory ganglion and nerves.* (Hirschfeld.)

1, olfactory ganglion and nerves; 2, branch of the nasal nerve; 3, sphenopalatine ganglion; 4, 7, branches of the great palatine nerve; 5, posterior palatine nerve; 6, middle palatine nerve; 8, 9, branches from the sphenopalatine ganglion; 10, 11, 12, Vidian nerve and its branches; 13, external carotid branch from the superior cervical ganglion.

The filaments of the olfactory nerve are described by Messrs. Todd and Bowman¹ as differing in their structure from the ordinary filaments found in the other cranial nerves, in that they contain no white substance of Schwann, and are nucleated and finely granular in texture. This absence of the white substance, found in other nerves, renders it difficult to trace their course in the Schneiderian membrane; which difficulty is still further enhanced by the existing nuclei, which resemble those of the tissues through which they pass.

The limit of distribution of the olfactory nerves seems to be confined to the superior three fourths of the septum of the nose, the superior turbinated bone, the upper half of the middle turbinated bone, and the roof

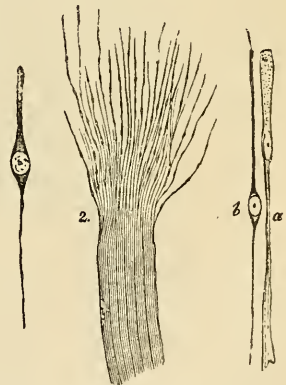


FIG. 78.—*Terminal filaments of the olfactory nerves; magnified 30 diameters.* (Kölliker.)

1, from the frog—*a*, epithelial cells of the olfactory region; *b*, olfactory cells. 2. Small branch of the olfactory nerve of the frog, separating at one end into a brush of varicose fibrils. 3. Olfactory cell of the sheep.

¹ "Physiological Anatomy."

of the nasal cavities. These regions seem to be defined by a brown-colored tessellated epithelium.¹

Odorous particles, present in the inspired air, as they pass through the lower chambers of the nares, are diffused into the upper nasal chambers, and, falling upon the olfactory epithelium,² produce sensory impulses which are transmitted to the brain and give rise to the sensations of smell.

Forced inspiration, or sniffing, increases the upward diffusion of inspired air, and thus a more complete contact of the odorous particles is insured.

It seems that, for the development of smell, the odorous particles must be transmitted to the nasal mucous membrane in a *gaseous* medium, as the simultaneous contact of fluids destroys all appreciation of odor.³

Animals with a very acute sense of smell have a modified arrangement of the turbinated bones, to afford a larger expanse of surface than exists in man.

It has been asserted by some physiologists that the olfactory nerve is not the only nerve of smell, and Magendie claimed that animals could perceive the odor of some substances after the olfactory bulbs had been removed. He used ammonia, however, as a test in his experiments, which is hardly a test of smell, as it is a powerful stimulant to the fifth nerve.

Bernard³ reports cases of absence of the olfactory bulbs in man, where smell existed during life. Prevost,⁴ however, claims that section of the olfactory bulbs entirely destroys the sense of smell. Injury to the *fifth nerve* may also destroy smell, even where the olfactory nerve remains intact; but this effect is hardly a proof that the nerve is in any way related to that special sense, since the effect is probably due to an *altered condition of the nasal mucous membrane*, which prevents its performing its natural function. The loss of smell may, therefore, be of some diagnostic value, if associated with other symptoms referable to impairment of the fifth cranial nerve.

¹ Max Schultze.

² Mich. Foster, "Text-Book of Physiology."

³ "Syst. nerv.," vol. ii.

⁴ "Archives de sci. phys. et nat.," 1871.

It seems necessary, in all animals which live in the air, that all odorous materials must enter the nostril to be perceived, and, furthermore, that the membrane of the nose must be in a proper condition of moisture; hence, by breathing through the mouth, the most disagreeable of odors may usually be unperceived, and the blunted sensibility of the power of smell, which occurs in catarrh, may plausibly be explained as the result of a deficient secretion in the early stage of the attack, and of excessive secretion later on in the disease. The curious effects of section or injury of the fifth cranial nerve upon the sense of smell may justly be attributed to the alteration in the amount of secretion of the lining membrane of the nose, since this nerve exerts a marked influence upon the secretions of the tissues supplied by it.

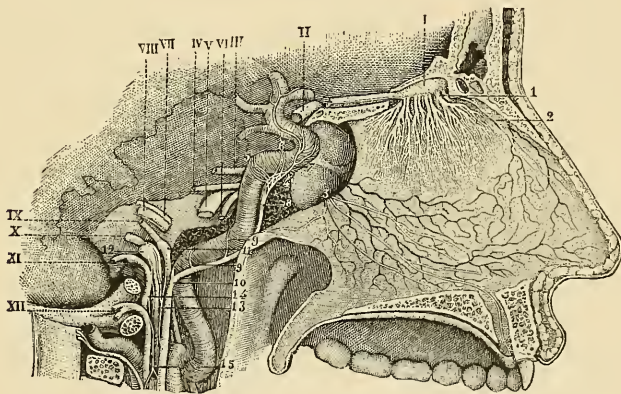


FIG. 79.—Internal branches of the olfactory nerve. (After Sappey.)

- 1, internal branches of the olfactory bulb, ramifying in the mucous membrane covering the septum of the nasal fossæ; 2, internal branch of the ethmoidal division of the nasal nerve; 3, naso-palatine nerves; 4, 5, 6, cavernous plexus; 7, superior or ascending branches of this plexus; 8, internal carotid branch from the superior cervical ganglion; 9, 9, filaments connecting this branch with the external carotid branch; 10, origin of this branch; 11, ganglion of the glosso-pharyngeal; 12, jugular ganglion of the pneumogastric; 13, anastomotic filaments extending from the sympathetic to the two preceding nerves; 14, anastomosis of the spinal accessory with the pneumogastric; 15, filament connecting the sympathetic with the hypoglossal; I, olfactory; II, optic; III, motor oculi; IV, pathetici; V, trigeminus; VI, abducens; VII, facial; VIII, auditory; IX, glosso-pharyngeal; X, pneumogastric; XI, spinal accessory; XII, hypo-glossal.

The *act of sneezing*, by which a forcible blast of air is driven through the nostrils, is often an effort on the part of Nature to get rid of some irritating substance; and thus,

through the agency of the fifth nerve, is the nose made the *portal of the respiratory apparatus*, where cognizance of the quality of the air breathed is constantly taken, and where all foreign or injurious matters are at once detected, and often expelled.

A marked peculiarity of the olfactory nerve is shown by the fact that no form of irritation of its fibers excites reflex muscular action through other nerves ;¹ neither is it capable of the sensation of pain, since section of the nerve, or even the destruction of the olfactory ganglia, seems to create no special distress in animals, and the nose retains its normal sensitiveness until the fifth nerve is also divided.

The olfactory nerve, however, may be the source of another variety of marked reflex action. Many cases are recorded where *fainting* and *vomiting* have been produced by certain odors ; while, for some unexplained reason, mental associations cluster around sensations of smell more strongly than any other form of impression received from without.²

The importance of the sense of smell among many of the lower animals, in guiding them to their food, or in giving them warning of danger, and also in exciting the sexual feelings, is well known. Among the savage tribes, whose senses are more cultivated than those of civilized nations, the scent is almost as acute as in the lower mammalia. It is asserted by Humboldt that the Peruvian Indians, in the middle of the night, can thus distinguish the different races, whether European, American, Indian, or Negro.

The agreeable or disagreeable character assigned to any particular odor is by no means constant among different individuals. Many of the lower animals pass their whole lives in the midst of odors which are to man (in a civilized condition) in the highest degree revolting, and will even refuse to touch food until it is far advanced in putridity.³

¹ Carpenter, "Principles of Physiology." The act of *vomiting* may possibly be considered as an exception to this statement.

² Mich. Foster, "Text-Book of Physiology," 1880 ; Todd and Bowman, "Physiological Anatomy."

³ Carpenter, "Principles of Human Physiology."

It is difficult to say when effluvia have been completely removed from the nasal passages, since it is not unlikely that odorous particles (supposing such to exist) are often absorbed, or possibly dissolved by the mucous secretion. It frequently happens, in regard to odors and savors, that habit makes that agreeable, and even strongly relished, which was at first avoided; the taste of an epicure for game that has acquired the *fumet*, for assafœtida, garlic, etc., is an instance of this. A case is reported, where, in a state of hypnotism, a youth had his sense of smell so remarkably heightened as to be able to assign, without the least hesitation, a glove placed in his hand to its right owner, in the midst of about thirty persons, the boy himself being blindfolded;¹ and modified forms of this excessive development of this power of smell are by no means rare.

The word "taste" is often used when the word "smell" should be employed. We speak of tasting odoriferous substances, such as onions, wines, etc., when in reality we only smell them as we hold them in the mouth. This is proved by the fact that the so-called taste of these things is lost when the nose is held or the nasal membrane rendered inert by a catarrh.²

CLINICAL POINTS AFFORDED BY THE OLFACTORY NERVE.

The nerves of smell may become the seat of disease, or may simply manifest the presence of disease in other parts. The two conditions, which are clinically recognized as indicative of existing disease, are hyperæsthesia and anæsthesia—not of the sensibility of the part, in its generally accepted sense, but an increase or decrease of the acuteness of the olfactory sense.³

¹ Carpenter, *op. cit.*

² Foster, *op. cit.*

³ According to Althaus, if the mucous membrane of the nose be irritated with very strong galvanic currents, the *taste of phosphorus* is produced; but no perception of odors is perceived, although pain, vertigo, and sensations of light may be created. It is customary, therefore, to use other means for the purpose of testing the acuteness of this special sense, and the most successful method consists of making the patient smell different odors, using the nostrils alternately, and avoiding all things, as tests, which would create an irritation of the filaments of the fifth nerve, such as ammonia, acetic acid, snuff, etc. (Hence the defect in Magendie's experiments mentioned on page 344.) It is advisable

To the former condition, the term "*hyperosmia*" is applied, while the latter is called "*anosmia*."

The condition of hyperosmia is often perceived, as a temporary excitation, in patients recovering from some prolonged disease which has exhausted their nervous power, and also in the hysterical and insane.¹ Should the presence of unnatural odors, or a marked increase of the susceptibility to odors, exist in the insane, it may indicate the existence of some type of neoplasm involving the frontal lobes at the base of the cerebrum, localized disease (softening, as a rule) of the olfactory bulbs, or adhesion of the olfactory bulbs to the dura mater; since all of these conditions have been found at autopsies, where such symptoms existed during life. Sander reports a curious case, where such a subject was liable to epileptic attacks, and where the attacks were associated with abnormal sensations of taste; the autopsy showed a tumor of the left olfactory bulb.

The *abolition* of the sense of smell is a symptom of greater frequency, as well as importance, than the excitation of that special sense. In rare cases, as in one reported by Cloquet, the absence of the power of smell may be a congenital defect. Anosmia may be developed, as a *temporary* condition, during an attack of acute catarrhal inflammation of the nares, which alters the character of the membrane, or, in chronic catarrh, by the effect upon the natural moisture of the mucous lining of the nose. It may be present in "*Bell's paralysis*,"² since the facial nerve no longer affords motor power to the muscles which dilate the nostril, and thus the entrance of air to the upper nasal chamber is obstructed. Anosmia may be one of

to use odors which are both agreeable and disagreeable; hence cologne, camphor, musk, etc., on the one hand, and valerian, assafoetida, turpentine, sulphureted hydrogen, etc., on the other hand, are commonly employed. It is also customary to place *aromatic substances*, such as coffee, wine, liquors, and cheese, *within the mouth*, so that the posterior part of the nose can perceive them, since the odoriferous particles pass upward by means of the pharynx, rather as an imaginary taste, however, than as true olfactory perceptions.

¹ Frequently odors of the most pleasant character, such as those of flowers, etc., may occasion fainting, nausea, headache, or even convulsions, in this class of patients; while odors nauseating to others may be tolerated, and, possibly, preferred by them.

² For the symptoms of this affection, see pages of this volume descriptive of the facial nerve.

the manifestations of tumor at the base of the brain; of abscess of the pituitary body (as reported by Oppert); of syphilitic thickening of the periosteum and mucous lining of the nose; of lesions resulting in paralysis of the fifth cranial nerve, for some unexplained reason; of hysteria; and, finally, of certain types of insanity. A partial loss of smell has been known to follow typhoid fever and meningitis, in which case the sense is usually regained. Chronic rheumatism, chronic rhinitis, and traumatism, have also proven exciting causes of a temporary but serious loss of the sense of smell.¹

THE OPTIC NERVE.

The second cranial or optic nerve presents for examination from before backward: 1, the optic nerve proper; 2, the optic commissure; and 3, the optic tract.

The *optic tracts* of either side extend from their point of *apparent* origin in the *anterior corpora quadrigemina*, where they receive fibers from the optic thalamus and the external geniculate bodies,² to the optic commissure, to reach which point, each is compelled to pass around the *crus cerebri*. In their passage around the *crus*, each tract receives a few fibers of attachment at its anterior margin; and, after leaving the *crus*, just before the optic chiasm is formed, each receives additional fibers from the *lamina cinerea* and the *tuber cinereum*.

The *optic commissure* or *chiasm* is formed by the junction of the two optic tracts, and from it the two optic nerves diverge to pass to their distribution in the retina of either eye. The construction of the optic chiasm is of interest both from an anatomical and a physiological standpoint. In it, four sets of fibers may be demonstrated, called, respectively,

¹ In almost all cases, where anosmia affects both sides of the nasal cavity, the sense of taste is also impaired. All aromatic forms of food and wines have a distorted flavor. It is claimed by Ogle that the pigment in the olfactory mucous membrane has some effect upon the sense of smell.

² Physiological experiment seems to point to the occipital cortex as intimately connected with the deep fibers of the optic nerve, as mentioned in the preceding section.

the *inter-cerebral* fibers, which are situated at the posterior portion of the commissure, and connect the two hemispheres of the cerebrum; the *inter-retinal fibers* (?), which are situated in the anterior portion of the chiasm, and connect the retina of one eye with that of the other; the *longitudinal fibers*, which lie on the external side of each of the optic tracts, and connect the retina with the cerebral hemisphere of the same side; and, finally, the *decussating fibers*, which pass through the center of the optic chiasm, and serve to connect the retina of each eye with the opposite cerebral hemisphere.

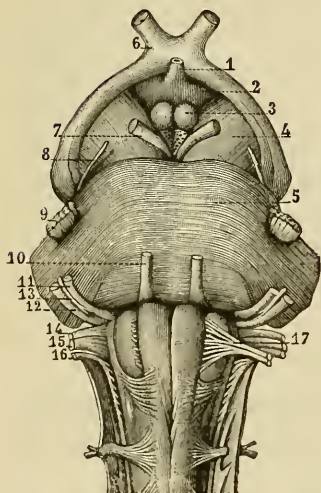


FIG. 80.--*Optic tracts, commissure, and nerves.* (Hirschfeld.)

- 1, infundibulum; 2, corpus cinereum; 3, corpora albicantia; 4, cerebral peduncle; 5, tuber annulare; 6, optic tracts and nerves, decussating at the commissure, or chiasm; 7, motor oculi communis; 8, patheticus; 9, fifth nerve; 10, motor oculi externus; 11, facial nerve; 12, auditory nerve; 13, nerve of Wrisberg; 14, glosso-pharyngeal nerve; 15, pneumogastric; 16, spinal accessory; 17, sublingual nerve.

The *optic nerve* proper arises from the anterior part of the optic commissure and enters the optic foramen, in company with the *ophthalmic artery*, being surrounded by a tubular process of dura mater, which, as the nerve enters the orbit, subdivides and forms both the sheath of the nerve and the periosteum of the orbit. The nerve pierces the sclerotic and choroid coats of the eye, about one tenth of an inch to the inner side of the axis of the eye, and then divides into numerous small fibrils, which appear to spread themselves out from the papilla of the retina somewhat like the spokes of a wheel.

In the accompanying diagram,¹ which is not given as an accurate representation of the parts, but rather as an aid to memory, and to render plain what words alone might make obscure, the fibers of the optic nerve are seen to enter the re-

¹ After Weber, of Darmstadt. (See page 351.)

tina at the point designated by the letter P, which is called the *papilla*, since, at this point, the retina is slightly raised above the remaining portion. This papilla is not in the exact center of the retina, since that point is reserved for the *macula lutea*, in the center of the so-called "yellow spot of Sömmering," where the most exact vision of external objects is ob-




FIG. 81.—Diagram of the decussation at the optic commissure. (After Flint.)
The dotted lines show the four directions of the fibers.

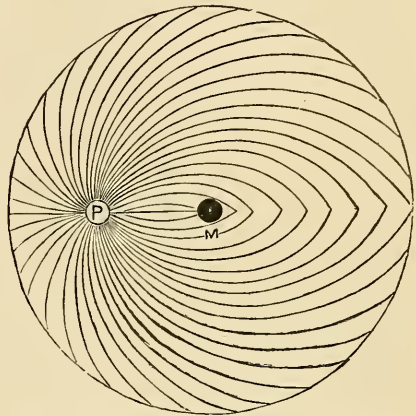


FIG. 82.—A diagram to show the course of the optic fibers in the retina. (After Weber.)
P, the papilla, where the optic nerve enters; M, the macula lutea.

tained; but it is placed to the *inner side of the center*, and nearly on the same level with the yellow spot. It will be seen that those nerve fibers which are distributed around the *yellow spot* of Sömmering are directed outward in a nearly straight line from the papilla, as are also those which supply the part internal to the papilla; but that, in order to avoid crossing the yellow spot, the fibers are compelled to pass in a more or less curved direction to the other parts of the retina, whereas, if the papilla were in the exact center, the fibers of the optic nerve would probably have been straight, and arranged as the radii of a circle. This arrangement of the optic fibers differs from that described by some of the text-books on physiology, one of which, to my knowledge, states that they are arranged as a plexus, and that the frequent inosculation gives a peculiar "net-like" appearance to the

optic fibers.¹ Probably the fact that the nerve fibers lose their sheaths as soon as they enter the retina, and thus, unless they be previously stained, afford some difficulty in tracing them, explains the error in description.

REFLEX ACTS EXCITED BY THE OPTIC NERVE.

The optic nerve differs from the olfactory nerve in one important respect, viz., in its power of conveying impressions which create reflex muscular movements.² The motions of the iris are always influenced by the amount of light which enters the eye, and which thus affects the optic nerve filaments. When the optic nerve is divided, the *pupil immediately contracts*, unless the third cranial nerve, which controls its movements, is also severed, when the iris fails to be so affected.³ In rare cases of disease, where the sight of one eye has been destroyed by some lesion of the optic nerve, the pupil of the affected eye will be found to move in unison with the uninjured eye; but this effect is to be attributed to a motor impulse created by the influence of light upon the retina of the normal organ. In some cases also, where the tissue of the cerebral hemispheres has undergone changes which render the perception of objects impossible, the pupil may still be seen to respond to the variations of the quantity of light which enters the chamber of the eye; thus showing that the *optic nerve alone* is required to create the reflex act upon the pupil through the third nerve, irrespective of the brain.

In addition to the power of the optic nerve to cause changes in the pupil, there is still another form of reflex act which deserves notice, viz., its power of producing contraction of the *orbicularis palpebrarum* muscle. This is perceived when an excessive quantity of light renders the effect upon

¹ Carpenter, *op. cit.*

² Carpenter, *op. cit.* (It is a question if *fainting* and *vomiting* can not be often justly regarded as reflex muscular acts, dependent upon the sensations perceived through the olfactory nerve.)

³ Doubtless on account of the simultaneous division of sympathetic nerve fibers, which are probably derived from the fifth nerve; these accompany the optic nerve and thus control the dilating fibers of the iris.

the retina one of pain, or when objects to be perceived are brought into too close proximity to the eye. Thus, in photophobia, the peculiar half-closed condition of the eye is not purely a voluntary act, as the eye is, at the same time, rolled upward and inward to a much greater extent than can be performed in response to a merely voluntary effort.

The act of *sneezing* may often be excited by the visual sense, when a sudden exposure of the eyes to a strong light occurs. That this reflex phenomenon is due to the excitation of the optic, and not to the olfactory nerve, is proven by the fact that, unless the *light be seen*, the attack of sneezing does not take place.

DECUSSATION OF THE OPTIC FIBERS.

The object of the decussation of the fibers of the optic nerve has been explained by Wollaston,¹ Mayo,² and others, as an arrangement on the part of Nature to have the fibers, which spring from each optic ganglion, distributed to the corresponding side of each retina; the *right optic ganglion* being thus associated with the *outer portion* of the retina of the *right eye* and the *inner portion* of the *left eye*, while the *left ganglion* is distributed to the *outer portion* of the *left eye* and the *inner portion* of the *right eye*. If this be demonstrated as true, each optic ganglion must perceive objects on the side opposite to it; since the images of things seen by the retina must fall upon the outer side of the left eye, when placed upon the right side of the eye, and vice versa.³

A similar decussation of nerve fibers is known to exist in both the posterior horns of the spinal cord and also in the anterior pyramids of the medulla oblongata; and the same arrangement in the optic nerves, which are known to be of the greatest value in preserving a *harmony of motion* throughout the body, may be for the object of bringing the visual impressions into a more direct and proper accord with the motor

¹ "Philos. Trans.," 1824.

² See Carpenter's "Physiology."

³ See bearing of this arrangement on diagnosis of cranial tumors, later on in this chapter.

apparatus. In support of this view, it is found that in the invertebrate animals, where the optic fibers do not decussate, no decussation of fibers exists in the general motor system.

In some animals, where the two eyes have an entirely different field of vision, the decussation of the fibers from each optic ganglion is found to be complete,¹ the longitudinal set being absent, and the whole of the fibers from each ganglion

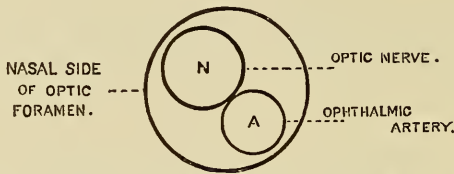


FIG. 83.—Relation of nerve and artery in the optic foramen.

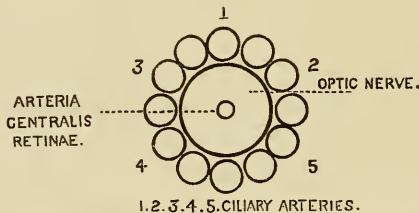


FIG. 84.—Relations of optic nerve to vessels in the orbit.

passing into the opposite eye. This arrangement can be perceived in almost all of the bird species² and in some of the osseous fishes.

RELATIONS OF OPTIC NERVE IN THE ORBIT.

The *relations* of the optic nerve to *blood-vessels* may have often a bearing upon vision. It passes through the optic

¹ The decussation of the fibers of the optic nerve seems also to be influenced largely by the extent of the field of vision which can be covered by both eyes simultaneously. The bundle of decussating fibers differs, in its relative size, from the bundle of non-decussating fibers, in different animals, who possess a stereoscopic perception of objects (their vision being binocular); and the extent of the field of binocular vision seems to explain this fact. It is said that certain birds (as the hawk, for example) have an additional power of vision afforded them by means of two maculæ luteæ in each retina; so that, having two spots of distinct vision in each eye, the eye can the more readily focus suddenly upon any object.

² Solly, "The Human Brain" (Am. edition).

foramen in company with the ophthalmic artery, and is surrounded, for the balance of its length, by the ciliary arteries, which lie in close relation with it. It is also *pierced* by the *arteria centralis retinae*, which is thus enabled to reach the papilla of the retina, and, from that point, to ramify throughout that membrane.

It can be readily understood, therefore, how any vascular growth within the orbit would be liable to press upon the fibers of the optic nerve, or to create sympathetic changes in the vessels of the retina itself; while, as an anatomical fact, the enormous collateral circulation which exists on account of the frequent anastomosis in this region, renders such vascular growths within the orbit by no means uncommon.

ANATOMICAL DEFECTS OF VISION AND THEIR CONSEQUENCES.

A ray of light falling upon the retina strikes the expansion of the fibers of the optic nerve, and creates what may be called a *sensation* of light. What this sensation is, it is not within the province of this work to discuss, nor is it possible, from our present enlightenment, to explain how the brain transforms impressions, received from the fibers of the different nerves of special sense, into an actual recognition of either smell, sight, taste, or hearing. This should not deter us, however, from carefully studying all the mechanical ingenuity which Nature has shown in the arrangement of certain parts, or from attempting to interpret her aims and purposes when any such subject of inquiry seems to be presented.

There are certain practical points pertaining to the mechanism of vision concerning which every physician should be intelligent; since a recognition of existing optical defects and their bearings upon health will often enable the medical adviser to guide aright those consulting him, when otherwise serious consequences might follow the very lack of this practical knowledge.

The most common optical defects¹ are, undoubtedly, *hyperopia*, or far-sightedness; *myopia*, or near-sightedness;

¹ Bowman and Todd, "Physiological Anatomy."

and *astigmatism*, causing imperfect perception of objects in certain meridians of vision.

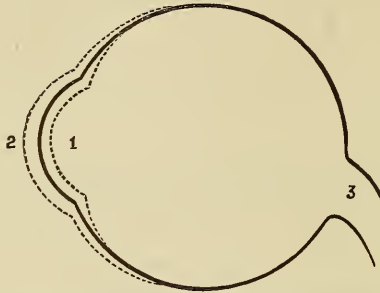


FIG. 85.—Diagram to illustrate congenital or acquired defects in the antero-posterior diameter of the eye. The black line represents the normal line of the eye. No. 1 represents the *hyperopic* eye; 2, the *myopic* eye; 3, the optic nerve.

The first of these conditions indicates, as a rule, a congenital or acquired *diminution* in the *antero-posterior axis* of the eye. Thus, as age advances, the eye either naturally becomes flattened, or the ability to accommodate for distance becomes impaired, and vision necessarily becomes presbyopic; but, in many cases, children are born with this deformity, which often goes too long unrecognized. Were Nature not able to compensate for this abnormality by means of the ciliary muscle, which, by altering the shape¹ of the crystalline lens of the eye, is enabled to increase its convexity, and thus artificially to focus near objects, such cases would be immediately made known by the inability of the patient to read or even to see near objects with distinctness. But such cases go on from year to year, struggling, with the aid of this muscle, to see, and thus wearing out their vital energy; trying to excel in their studies, only to fail from the fatigue which attempts at study bring about, which they themselves or their parents can not explain, and which often causes them to incur bodily chastisement; and seeking, as a relief, out-of-door amusements, in which they usually excel, since little muscular effort is required to perceive objects at a distance.

¹ Foster, Volckers, Hensen, and Hock claim that the increased convexity of the lens is due to the relaxation of the suspensory ligament, thus allowing the lens to bulge forward from its own elasticity.

How cruel and injurious to health must be compulsory education to such a one, till, by the aid of properly adjusted glasses, reading becomes a pleasure; study no longer a burden, but a joy; and nervous headache, throbbing in the orbit, double vision, and other evidences of nervous prostration, are numbered as among the things of the past! ¹

On the other hand, *myopic patients* can not see objects at a distance, since their eyes are too convex; but only when placed close to the eyes are the beauties of outline fully perceived, and distinct vision rendered possible. Out-of-door exercise is, to children of this type, a burden and a disappointment, since they can not enjoy Nature in her most beautiful aspects, nor indulge in sports without danger, which to the healthy child, with perfect vision, is harmless. Such children seek enjoyment in books, the contents of which can be seen by them and easily read; the fields are discarded for the parlor; the enforced retirement is wrongly construed by the parents and physician as an indication of precocity and a taste above that of the romping child; the health is imperiled, the intellect weakening by undue strain, and the mind made one of ideals rather than of realities, since pictures and book representations are to them Nature in her true aspects. ¹

Astigmatism is a condition due to the fact that either the surfaces of the cornea or of the crystalline lens are not of the *same curvature*, but are more convex in some portions than in others, or in the perpendicular meridian than in the horizontal. This abnormality of contour causes a distortion of the image of objects in the field of vision. If black lines, of equal width, be drawn parallel with each other, and several placed perpendicularly on one portion of a page and several horizontally on another portion of the same page, such an eye will see one or the other set either less distinctly as to outline, or one set will appear darker than the other.

Almost all eyes are slightly *astigmatic*, and generally with the greatest convexity in the vertical meridian. And the same irregularity in lenses can be demonstrated by attempting to

¹ See article by Dr. Loring, "Harper's Mag.," August, 1879.

focus light from a luminous point, when the image will be found to be radiated, instead of a perfect circle, as it should be from a perfect lens.

In choosing spectacles, for the purpose of correcting errors of the eye, it is of great consequence not to make an *over-compensation*; for this has a tendency to increase the defect, besides occasioning great fatigue in the employment of the sight.

From observations previously made as to the mechanism of the action of the ciliary muscle upon the lens, by which vision is accommodated for near objects in case the eye is normal, it may be understood why all power of accommodation of vision is lost after the operation for cataract.

A TEST FOR MYOPIA AND HYPEROPIA.

E B F P T Z D
D L T Z F P E
B E P F Z T L

The normal eye should read letters of this kind and size at twenty feet. Vision is then said to be normal. If the eye can not do this at twenty, but can at ten feet, then vision is ten twentieths, or one half of the normal, and so on.


To test the eyes, place the letters at twenty feet distance, in a good light. Try first one eye, and then the other.

Any eye which can not read the letters fluently at this distance deviates from the normal standard, and should have a thorough examination.

To test for the defect which has been mentioned in the foregoing remarks as astigmatism, place the drawing, show-

ing parallel lines arranged vertically and horizontally, at fifteen or twenty feet, and be sure to test each eye separately.

A TEST FOR ASTIGMATISM.



These lines should appear equally distinct ; that is, those running vertically should look as black and clearly defined as those which run horizontally, and vice versa. If, however, there is any difference between them as to shade of color or distinctness of outline, the eye is astigmatic, and the greater the difference, the greater the degree. Such an eye as this requires peculiar glasses, which can only be determined by a careful examination, and which have to be selected to fit each case. It may be that a person is not astigmatic for vertical or horizontal lines, but is for those running obliquely. To test this, turn the drawing so that what are ordinarily the vertical lines shall run obliquely, say, at an angle of forty-five degrees.

If, now, this were all, it would be a simple matter for the

parent or teacher to determine just what children needed a careful examination, but, unfortunately, there are a large number of children who, as has been already explained, have a deficiency of optical power, but who can, nevertheless, neutralize this deficiency by an effort, so that they can see at as great a distance and as clearly as those who have normal eyes. These are those who most suffer from headache, and from all the ills of a nervous nature which have been detailed in the foregoing remarks. The only satisfactory way out of the difficulty would appear to be, that every child should have the optical condition of the eye and the amount of vision determined, before school life begins, by some competent person trained in the methods of making these examinations.

CHANGES IN THE PUPIL.

The pupil of the eye may be seen to dilate when distant objects are to be perceived, and to contract when near objects are inspected, since, by so doing, the amount of light which enters the eye is regulated, and the distinctness of the image is thus increased.

Irritation of the optic nerve, by an excessive quantity of light, also creates contraction of the pupil; while the same condition may be the result of simply turning the eyeball inward.¹

In the early stages of anæsthesia² from chloroform, in alcoholic excitement, in poisoning from morphia, physostigmin, and some other drugs, and, finally, in deep slumber, the pupils are found to be *contracted*.

Dilatation of the pupil may be dependent upon a dim light, an attempt to view distant objects, emotional excitement, the latter stages of anæsthesia from chloroform, and from belladonna poisoning and that of drugs of similar action; while it may also occur in all conditions creating an

¹ I may here say that "small and unequal pupils in a person of middle age, from twenty-five to sixty, should lead to an inquiry into the possible existence of one of three morbid states, viz.: paralytic dementia (or general paralysis), sclerosis of the posterior columns, and cardiac or aortic disease (intra-thoracic disease)." (E. C. Seguin.)

² Mich. Foster, "Text-Book of Physiology."

excess of aqueous humor within the eye, and during dyspnœa and excessive muscular exertion.

The mechanism of the action of the pupil will be more properly considered under the description of the third nerve, which furnishes it with motor power.

VISUAL SENSATIONS AND THEIR MODIFICATIONS.

Shadows thrown upon the retina are perceived as specks in the vision, the so-called *musca volitantes*.¹ They may arise from tears upon the cornea, a temporary unevenness of the cornea after the eyelid has been pressing upon it, imperfections of the lens or its capsule, and from shadows produced by the margin of the iris, especially if it be imperfect.

They are distinguished chiefly by their almost continual change in position, when the head is moved up and down, and by a tendency to entire disappearance when an effort is made to fix the vision upon them.

That point on the retina, the *papilla*, where the optic nerve pierces it, is called the "blind spot," since no sensations of light can be perceived in that locality.²

In that portion of the retina, the "macula lutea," where the images to be perceived by the optic nerve fall most directly, and where most of our visual perceptions are therefore gained, a markedly *yellow pigment* exists, which tends to absorb some of the greenish-blue rays of light; hence what we perceive as *white* in color is, in reality, more or less yellow.

When pressure is forcibly exerted upon the eyeball, the whole retina speedily becomes insensible to light. This fact has been explained as the result of a loss of the conductive power of the nerve structures. Exner,³ however, endeavors to use this fact as the basis of an argument to prove that the sensation of light is the result of some substance (as yet undetermined) within the retina, whose *production is temporarily arrested* by any pressure upon the eye which is sufficiently forcible to occlude the vessels of the retina, and thus to interfere with its nutrition.

¹ Bowman, "Phys. Anat."

² Helmholtz, "Phys. Optik."

³ *Op. cit.*

THE PERCEPTION OF COLOR.

The subject of *color blindness*, which is to-day assuming great importance, naturally suggests to the inquiring mind—by what anatomical arrangement are the optic nerve fibers




FIG. 86.—Crystalline lens, anterior view. (Babuchin.)

informed, through the aid of the coats of the retina, of the perception by that membrane of the color of images?

That the retinae of animals possessed color was first noticed by Krohn, as early as 1839; but the matter was not regarded as of any physiological importance until Boll, in 1876, announced that the retina of all vertebrated animals possessed a purplish color, which faded in the light, but which darkness restored. He concluded that the color must be largely concerned in the act of vision.¹

The subsequent experiments of Kühne upon this subject seem to have partially verified this discovery, but exactly what

¹ A very interesting article, by my friend Dr. Ayres, of this city, appeared in the "New York Med. Jour." (December, 1880), in which the physiological action of the *visual purple* was discussed; its function is here stated to be a *photo-chemical one*, designed to *accommodate vision to different degrees of light*, since it is capable of changing and regaining its original color when circumstances demand it (an intensity of light or an approach to darkness causing rapid effects upon it).

its function is may yet be considered a subject of investigation. A prominent author says of this matter: "It is very tempting to connect this visual purple with color vision; but

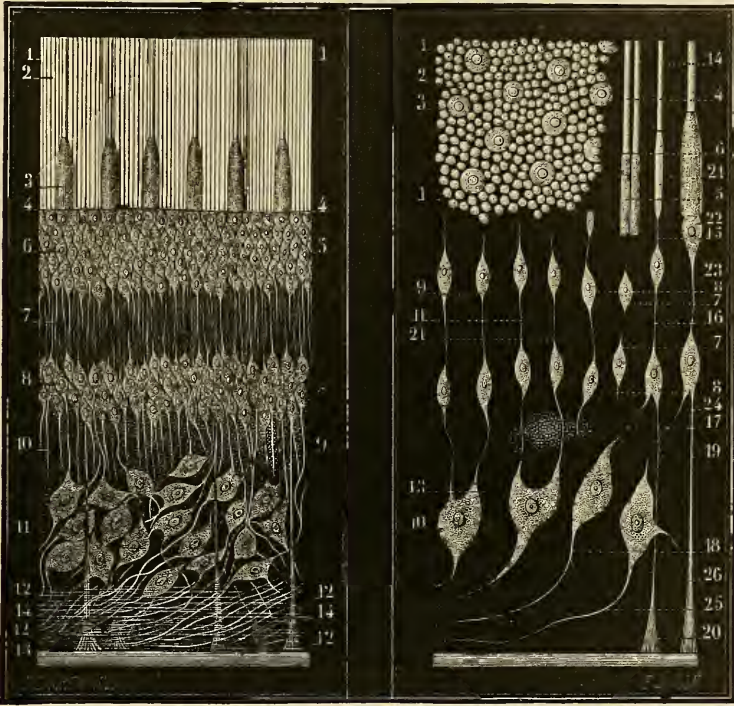


FIG. 87.—A. *Vertical section of the retina.* B. *Connection of the rods and cones of the retina with the nervous elements.*
(H. Müller.) (Sappey.)

- A. 1, 1, layer of rods and cones; 2, rods; 3, cones; 4, 4, 5, 6, external granule layer; 7, inter-granule layer (cone-fiber plexus); 8, internal granule layer; 9, 10, finely granular gray layer; 11, layer of nerve cells; 12, 12, 12, 14, 14, fibers of the optic nerve; 13, membrana limitans.
- B. 1, 1, 2, 3, rods and cones, front view; 4, 5, 6, rods, side view; 7, 7, 8, 8, cells of the external and internal granule layers; 9, cell, connected by a filament with subjacent cells; 10, 13, nerve cells, connected with cells of the granule layers; 11, 21, filaments connecting cells of the external and internal granule layers (12 is not in the figure); 14, 15, 16, 17, 18, 19, 20, 22, 23, 24, 25, 26, a rod and a cone, connected with the cells of the granule layers, with the nerve cells, and with the nerve fibers.

we know that our color vision is most exact in the *fovea centralis*, where the retina consists of cones alone, which are destitute of this visual purple.”¹

¹ Mich. Foster, *op. cit.*

While no positive statements can as yet be made as to the function of that layer of the retina known as "the rods and cones of Jacob," still authorities seem inclined to attribute to the *cones*, rather than to the rods, the power of perceiving color. It is known that these cones are absent in the retina of nocturnal animals; while, in the eyes of birds and reptiles, globules containing color are found within the cones. Moreover, the "fovea centralis" in the human eye is destitute of rods.

To explain our perception of color, the hypothesis was first made by Young that there existed in the retina the power of perceiving *three distinct color sensations*, which, being parts of the spectrum, could, by a proper admixture of certain proportions of each, produce white; he further supposed that there existed *three distinct sets of nerve fibers*, each set being sensitive to a primary color sensation, viz., to wave lengths of a certain length. Helmholtz has done much to bring this theory to notice, so that the theory is known now as the "Young-Helmholtz theory," rather than by the name of the originator of the hypothesis alone. The fact that the most careful microscopical examinations of the retina fail to discover the existence of sets of fibers, which differ in their anatomical construction, seems to place this theory rather on the basis of a pretty hypothesis than that of an acknowledged fact.

Hering and Aubert¹ have discarded the Young-Helmholtz theory, however, and have attempted to explain the perception of color by a process of *disintegration*, in one set of colors, and, in another, by a process of *assimilation* of a property of the retina, which is denominated "*visual substance*."

All persons vary much in their power of discriminating and appreciating color;² but only those can properly be said to be "color blind" who regard colors as similar which to most people would be glaringly distinct. Thus, red and green

¹ "Physiologie der Netzhaut," 1865.

² Seebeck, Wartmann, Müller's "Physiology" (Baly's edition).

LEFT EYE.

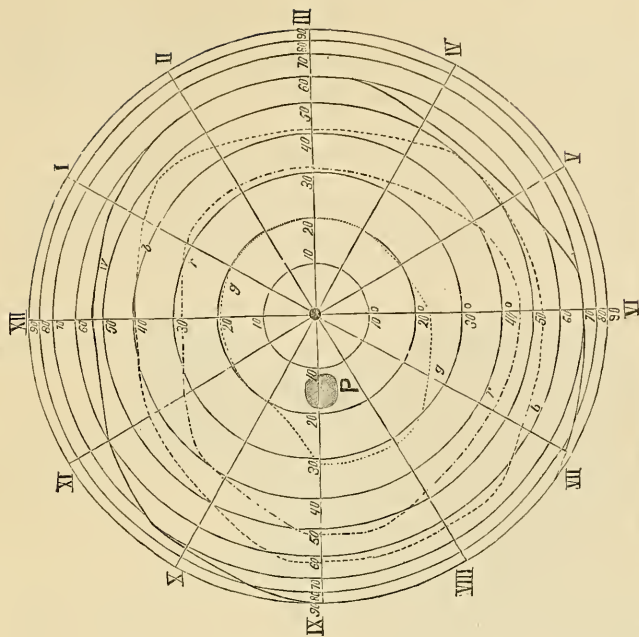
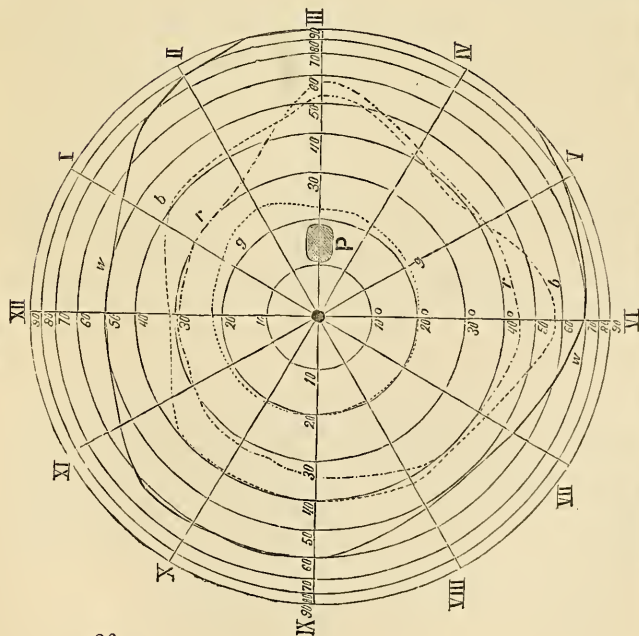


FIG. 88.

RIGHT EYE.



In this diagram, the results of the researches of the German investigators have been so clearly defined by Dr. Hirschberg as to simplify the examination of the retina, and enable any deviation from its normal condition to be perceived and recorded.

- stands for the limit of vision for white objects.
- — — stands for the limit of vision for red objects.
- stands for the limit of vision for blue objects.
- P stands for the papilla of the retina.
- The letters on the color lines indicate the color which each represents.
- The center of the diagram, from which the lines diverge, corresponds to the *macula lutea*, the center of the "yellow spot of Sömmerring"; while the numbers on the lines are placed at equal degrees from the center, to enable the oculist to designate the exact situation of special points of interest pertaining to any ophthalmoscopic examination.

are commonly mistaken for each other; while purple and blue, red and brown, and brown and green, are often detected from one another with difficulty, if at all.¹

APPARENT VISION OF OBJECTS NOT REALLY SEEN.

Any stimulation of the optic nerve or of the retina, if sufficiently intense, may give rise to certain sensations, which are mistaken for actual vision. As examples of this fact, a blow in the eye or on the back of the skull will often make the injured person "see stars" or have flashes of light apparently cross the field of vision.

Foster² mentions a case, where, by a voluntary compression of the eyeball by the orbicularis palpebrarum muscle, gorgeous visions of flowers and landscapes could be produced.

EFFECT OF OPTIC NERVE ON COÖRDINATION.

The optic nerve may become a means of vertigo, when objects are caused to pass rapidly before the field of vision, as in viewing a waterfall, being rapidly whirled, etc. This subject, however, will be more fully considered, with points of interest pertaining to the auditory nerve, since Menière's malady is more often dependent upon disease of the acoustic apparatus.

Goltz³ has shown, by experiments upon birds whose heads were artificially secured in an abnormal position, that they at once become incapable of orderly flight, thus further confirming the apparent connection between the special sense of sight and those muscular movements which require the exercise of the power of coördination.

EFFECT OF THE OPTIC NERVE ON THE LACHRYMAL APPARATUS.

The contraction of the orbicularis muscle tends to press the tears, which the lachrymal canals contain, onward toward the nasal duct; and they dilate to receive a fresh quantity during the relaxation of this muscle. Thus the act of *wink-*

¹ Taylor's "Scientific Memoirs."

² *Op. cit.*

³ Pflüger's "Archiv," 1873, as quoted by Foster.

ing, which usually precedes any special attempt to see with distinctness, by calling the orbicularis palpebrarum muscle into play, assists in cleansing the eye of any excess of tears. It has been stated by Demtschenko,¹ that, during the closure of the eyelid, a peculiar arrangement of the muscular fibers tends to keep the lachrymal canals open, and thus to act as an aid to the orbicularis muscle in its mechanical effect. In

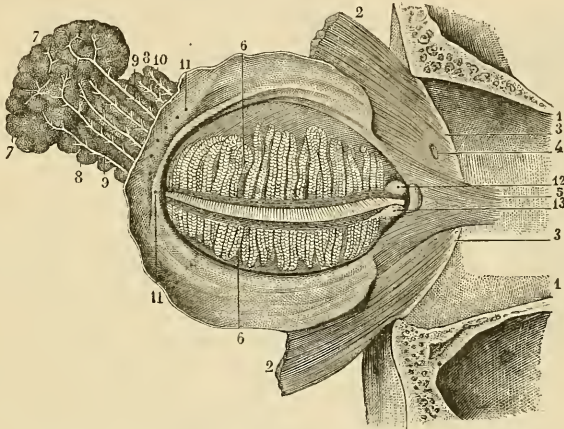


FIG. 89.—*Lachrymal and Meibomian glands.* (Sappey.)

1, 1, internal wall of the orbit ; 2, 2, internal portion of the orbicularis palpebrarum ; 3, 3, attachment of this muscle to the orbit ; 4, orifice for the passage of the nasal artery ; 5, muscle of Horner ; 6, 6, posterior surface of the eyelids, with the Meibomian glands ; 7, 7, 8, 8, 9, 9, 10, lachrymal gland and ducts ; 11, 11, openings of the lachrymal ducts.

addition to this anatomical device, the alternating pressure of the *tendo oculi* upon the lachrymal sac tends to act as a pump, and thus to draw the tears from the globe of the eye.²

The flow of tears, while constant in a state of health, may be greatly increased by a reflex act. Such exciting causes as a stimulation of the nasal mucous membrane, the conjunctiva, the optic nerve, and the tongue, and, more forcibly, the effect of the emotions, are commonly perceived. It is said that *venous congestion of the head* is frequently manifested by an excessive production of tears.³ The different efferent

¹ Hoffman und Schwald's "Bericht," 1873.

² Darling and Ranney, "Essentials of Anatomy," 1880.

³ Mich. Foster, *op. cit.*

nerves, which exert a controlling influence upon the lachrymal apparatus in response to the exciting causes above mentioned, include the lachrymal and orbital branches of the fifth cranial nerve and filaments of the cervical sympathetic.¹

Many of the facts pertaining to the optic nerve may, by the skillful physician, be made useful in his daily practice as guides to diagnosis; while others are given as explanations of many phenomena which often occasion alarm to those not familiar with the mechanism of their production.

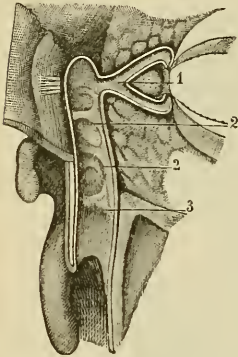


FIG. 90.—Lachrymal canals, lachrymal sac, and nasal canal, opened on their anterior portion. (Sappey.)

- 1, walls of the lachrymal passages, smooth and adherent; 2, 2, walls of the lachrymal sac, presenting delicate folds of the mucous membrane; 3, a similar fold belonging to the nasal mucous membrane.

CLINICAL POINTS AFFORDED BY MEANS OF THE OPTIC NERVE.

The optic nerve has of late acquired an importance to the oculist, which is based upon the physiological distribution of the nerve, but which has to the specialist more than a theoretical value, since, by means of the knowledge afforded, the diagnosis of the *existence of cranial tumors* pressing upon the nerve, or of *local pressure from inflammatory exudations*, may be not only positively made out, but the exact situation of the pressure often determined.

The hypotheses of Wollaston and Mayo have been so far confirmed by later investigators, that it may now be quite positively stated that an *exact lateral half* of each retina derives its power of vision from one optic tract, and the other half from the opposite tract. It has been proven that the *non-decussating fibers* of each optic tract supply the sense of vision to the *outer* or *temporal side* of each retina, and that the *decussating fibers* of each optic tract supply the *inner* or *nasal side* of each retina. When, therefore, the optic tract of either side is pressed upon, so as to affect the entire thick-

¹ See experiments of Herzenstein, Wolferz, Reich, and others.

ness of the nerve, and thus to interfere with the action of *all the fibers* which that tract contains, the temporal side of the retina of that eye which corresponds to the optic tract affected and the nasal side of the retina of the opposite eye will be rendered blind, or will be impaired in exact proportion to the pressure exerted upon the optic tract. Blindness of the lateral half of the retina of either eye is termed "hemioopia" or "hemianopsia"; and this condition may affect, 1, both eyes similarly; 2, both eyes diametrically.

When either eye is alone affected with blindness, it indicates, as a rule, that the optic nerve is pressed upon, or otherwise impaired, at a point situated *in front* of the *optic chiasm*; since, if the optic tract were the seat of the existing trouble, both eyes would be affected, as it would be almost impossible for the pressure to affect the non-decussating fibers, and still leave the decussating fibers of the tract uninjured, or *vice versa*. With this as a starting-point in the diagnosis, we determine which half of the eye is blind, knowing that, if the nasal side be the one where vision is lost, the pressure must be on the inner side of the nerve, and, if the outer or temporal side be blind, that the outer side of the nerve is the seat of the disease which is causing the pressure. Should both sides of one eye be rendered blind, and no local cause within the eye be found to exist, then the existence of pressure anterior to the optic chiasm, of such a character that the entire nerve is destroyed or impaired, may safely be diagnosed.

Total blindness of one eye is frequent evidence of *glioma* or *sarcoma* within the orbit, as they are the two forms of tumors which most frequently affect that region; and the diagnosis of the presence of this cause will probably be confirmed, in case it exists, by symptoms referable to paralysis of some of the muscles of the eye, since the same pressure will be also likely to affect either the third, fourth, or sixth nerves.

The most common form of "hemianopsia"¹ met with, as

¹ A synonym for *hemioopia* in its generally accepted sense, but a better term, since it means blindness of half of the retina, while the former means only half vision.

the result of the pressure of cranial tumors, is where the temporal half of one eye and the nasal half of the opposite eye are rendered blind. This clinical fact is supported by the anatomical distribution of the fibers of the optic tract, which, as before stated, supply the temporal half of the eye of the same side and the nasal half of the eye of the side opposite. When this condition is met, we know that the *optic tract*, or the extension of its fibers backward as far as the cerebral cortex (Fig. 43), must be involved upon the side corresponding to the eye which is blind in its temporal or outer half (Fig. 91).

In those uncommon cases where the inner or *nasal half* of each retina is deprived of sight, the existence of pressure at the anterior or posterior portions of the optic chiasm may be diagnosed, since the decussating fibers of each optic tract cross each other at these points only; and the nasal side of each eye being affected proves that the *decussating fibers* of each tract must be simultaneously pressed upon, without any disturbance of the non-decussating fibers.

In those cases where the outer or *temporal sides* of both retinae exhibit evidences of pressure from some cause within the cranium, the explanation of the mechanism of its production has, until of late, been involved in obscurity; but it is now explained by a curious anatomical relation between the internal carotid arteries (as they assist to form "the circle of Willis") and the optic nerve.¹ It will be observed, by reference to the plates of your anatomy, that the *anterior communicating artery* passes underneath the optic nerves and in front of the chiasm, while the main trunks of the carotid arteries are adjacent to the chiasm, and curl outward from nearly its central point toward its outer edge. Now, in *senile degeneration* of the vessels, the atheromatous changes in the arterial coats tend to destroy the elasticity of the vessels, and to either shorten them, or to render them less elastic, and thus, in this region, the arteries act as a gathering-string around the optic chiasm, and, by pressing upon the outer portion of each tract, the non-decussating fibers of each tract are

¹ An explanation original, I believe, with Professor H. Knapp, of this city.

impaired, while the decussating fibers of each tract are not injured, thus accounting for the blindness of the temporal half of each retina.¹

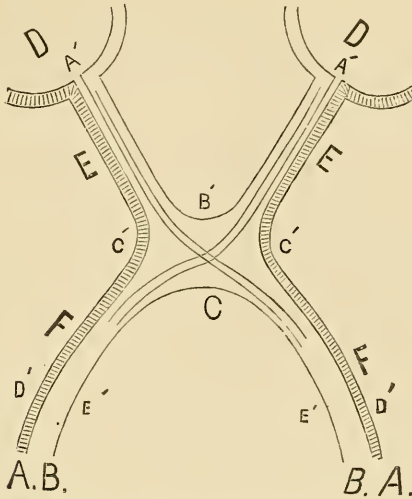


Fig. 91.—A, Non-decussating fibers of the optic tract (colored red on chart); B, Decussating fibers of optic tract (colored blue on chart); C, Optic Chiasm; D, Retinæ (showing nerve distribution to each half); E, Optic Nerves; F, Optic Tracts; A'—B', region where pressure may produce "hemianopsia" or "total amaurosis" of one eye; E'—D', region where pressure will result in "hemianopsia" of opposite halves of the retina of both eyes; c'—c', region where the constriction of the vessels of the "circle of Willis" will produce "hemianopsia" of *temporal half* of the retina of both eyes; b' or C, special localities where "hemianopsia" of the nasal half of the retina of both eyes will ensue from pressure; C c', B c', region which must be entirely destroyed by pressure to produce *total blindness* of both eyes.

If you will compare Fig. 91 with a preceding diagram (Fig. 43), it will enable you, perhaps, to better understand the mechanical explanations of the various conditions which may result from pressure upon the optic tracts, or upon the optic nerves, if in front of the chiasm. You will perceive that the non-decussating fibers of each tract, which I have colored red,² if traced to their distribution, supply the outer half of the eye of the same side, while the decussating fibers of each tract, which I have colored blue,³ pass to the inner or nasal side of the opposite eye. You can, therefore, see the reason

¹ It might be possible for two tumors, each so situated as to affect the *outer side* only of each optic tract, to produce this condition; but the probability of such a condition ever existing in any special case would be extremely small.

² Shaded dark in figure, but colored for class demonstration.

³ Not colored in plate, but represented by decussating lines. The presence of color for demonstration to large classes is oftentimes of great assistance.

for the following summary of the guides afforded by partial blindness of the retina, in making a diagnosis of the situation of cranial tumors :

1. *Total blindness of one eye* indicates pressure between the chiasm and the eye affected, which has destroyed the conducting power of both the decussating and non-decussating fibers of the nerve.

2. *Total blindness of both eyes* seldom occurs in tumor ;¹ but, if it be dependent upon a tumor, it must affect the chiasm itself, and have completely destroyed it.

3. A loss of vision in the *nasal half* of both eyes indicates the existence of a lesion, either in front of or behind the optic chiasm, which affects only the decussating fibers of each tract.

4. A loss of vision in the *nasal half* of one eye and the *temporal half* of the other, indicates a lesion of the *optic tract*, or its extension backward to the cerebral cortex (Fig. 43), upon the side where the temporal half of the retina is destroyed, or a cortical lesion of the occipital lobe (probably the cuneus).

5. A loss of vision in the *temporal half* of both eyes indicates *senile degeneration* of the vessels forming the "circle of Willis," which are creating pressure upon the outer side of each of the optic tracts.

The optic nerve may be the guide to many diseased conditions of parts more or less distant. The condition of *hyperæsthesia* of the retina (to which membrane its terminal filaments are distributed) may be indicative of congestive diseases of the brain ; of the development of cerebral tumors ; and of certain mental diseases (as prominently shown in ecstasy, hypochondria, etc.). It also occurs in hysteria, chorea, chronic alcoholism, narcotism, the inhalations of certain toxic gases, etc. It may frequently be the evidence of some local condition of the optic apparatus ; hence we meet it in cases of congestive and inflammatory conditions of the retina ; also where an excessive amount of application of vision has been demanded, in disease and atrophy of the nerve itself, and in slight compression of the nerve from local causes.

¹ This condition is more commonly due to atrophy of the optic nerve and to glaucoma.

When the optic nerve filaments become *anæsthetic*, sight is impaired in the exact ratio of the loss of sensibility; hence we speak of the condition of "*amblyopia*," when the sight is partly destroyed by this condition, and of "*amaurosis*" when the sight is entirely destroyed.

We may consider a loss of sensibility of the optic nerve filaments as a symptom of the gravest import, since it indicates either some disease of the brain or some advanced changes of the nerve itself. The *brain conditions* which are most liable to produce this condition are as follows: neuro-retinitis, which may follow cerebral hæmorrhage, cerebral softening, Bright's disease, lead poisoning, and syphilis; the various forms of ataxia; cerebral tumors; chronic effusion into the ventricles; and hysterical cerebral disorders.

The *local conditions* which may result in optic anæsthesia include inflammation of the retina and the adjoining structures; hæmorrhage into the retina; retinal tumors; the compression of glaucoma; pressure of tumors, in the orbit or cranium, upon the optic tracts; thickening of the meninges in the vicinity of the optic chiasm; and traumatism.

Atrophy and sclerosis of the corpora geniculata may result in amaurosis¹; lesions of the cerebellum² may be accompanied by symptoms referable to the optic apparatus (probably on account of the pressure created upon adjoining regions of the encephalon); and an increase of intra-cranial pressure, from any cause, may produce retinal changes.

THE THIRD OR "MOTOR OCULI" NERVE.

This nerve has its apparent origin from the *inner border* of the *crus cerebri*. The deep origin of the nerve has been discussed in preceding pages, which treat of the *crus cerebri*; and also in the introductory pages of this section, to which the reader is referred.

The course of this nerve, after it escapes from the brain, is of importance, from the relations which it has with impor-

¹ See page 372 of this volume.

² See page 235 of this volume.

tant structures, and from the physiological phenomena produced by it. It pierces the dura mater opposite to the *anterior clinoid process*, in order

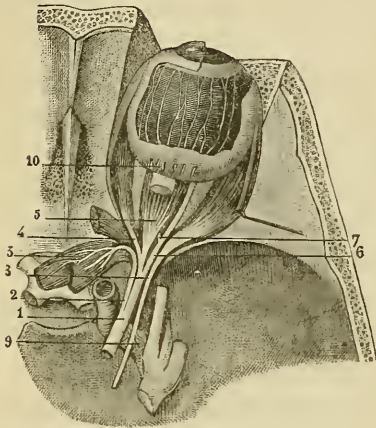


FIG. 92.—Distribution of the motor oculi communis. (Hirschfeld.)

1, trunk of the motor oculi communis; 2, superior branch; 3, filaments which this branch sends to the superior rectus and the levator palpebrae superioris; 4, branch to the inferior rectus; 5, branch to the inferior oblique muscle; 6, branch to the lenticular ganglion; 7, branch to the external ciliary ganglion; 8, motor oculi externus anastomosing with the sympathetic; 9, ciliary nerves.

to reach the outer wall of the cavernous sinus, where it lies in close relation with the fourth cranial nerve, and the ophthalmic branch of the fifth cranial nerve, being above them both, and also with the cavernous sinus, which lies internal to it. It is in this region that the nerve is joined by filaments from the cavernous plexus of the sympathetic system.

The nerve now passes from the cavity of the cranium by means of the *sphenoidal fissure*, having, however, divided into two branches, before its escape, called the superior and inferior.

In the sphenoidal fissure, these two branches are placed between the *two heads of the external rectus muscle* of the eyeball, and from this point they pass onward to their respective distributions, viz., the superior branch to the levator palpebrae and the superior rectus muscles, and the inferior branch to the inferior oblique, the inferior rectus, and the internal rectus muscles, and, by a small filament, furnishing the motor root to the ciliary or lenticular ganglion of the orbit.

The third cranial nerve thus supplies *all of the muscles of the eye but two*, viz., the superior oblique and the external rectus muscles, which derive their motor power, respectively, from the fourth and the sixth nerves. It also supplies filaments to the ophthalmic ganglion (which is also called the ciliary, and the lenticular ganglion), which filaments

are subsequently distributed to the *ciliary muscle* and the *iris*.

It is now claimed that the fibers of the third nerve, which pass to the aqueduct of Sylvius, decussate; and it is to this

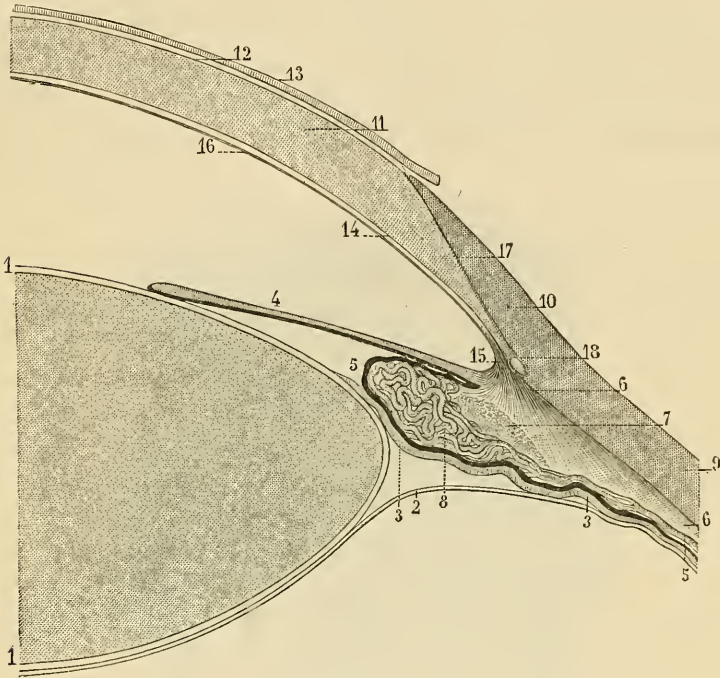


FIG. 93.—*Ciliary muscle; magnified 10 diameters.* (Sappey.)

1, 1, crystalline lens; 2, hyaloid membrane; 3, zone of Zinn; 4, iris; 5, 5, one of the ciliary processes; 6, 6, radiating fibers of the ciliary muscle; 7, section of the circular portion of the ciliary muscle; 8, venous plexus of the ciliary process; 9, 10, sclerotic coat; 11, 12, cornea; 13, epithelial layer of the cornea; 14, membrane of Descemet; 15, ligamentum iridis pectinatum; 16, epithelium of the membrane of Descemet; 17, union of the sclerotic coat with the cornea; 18, section of the canal of Schlemm.

anatomical arrangement of its fibers of origin that the effect of the pupil of one eye upon the condition of the pupil of the opposite eye is occasionally observed in disease, and that the muscles of the two eyes, as well as the iris, are thus enabled to work in perfect harmony with each other. As an example of this, it is occasionally observed that, when amaurosis affects one eye, the pupil of the diseased organ will not respond to the effect of light upon the retina of that side, but, when the

light creates a movement of the iris of the unimpaired eye, the pupil of the opposite side also responds, thus showing that reflex action is possible between the two eyes.

MECHANISM OF THE CONTRACTION OF THE PUPIL.

The mechanism of the reflex act, by which the third nerve is enabled to so affect the contraction of the pupil as to have its varying size correspond exactly to the requirements of the retina, as regards the amount of light

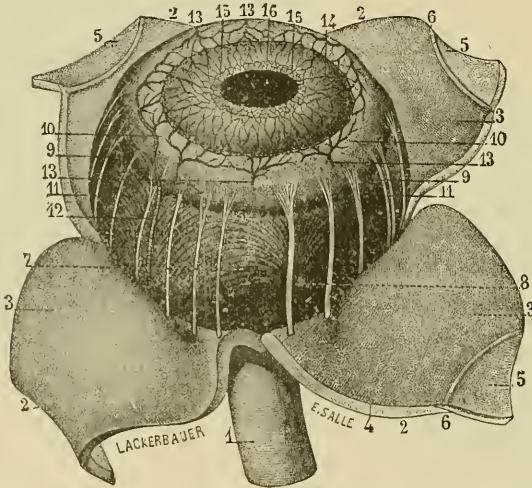


FIG. 94.—*Choroid coat of the eye and the ciliary nerves.* (Sappey.)

1, optic nerve; 2, 2, 2, 2, 3, 3, 3, 4, sclerotic coat, divided and turned back to show the choroid; 5, 5, 5, 5, the cornea, divided into four portions and turned back; 6, 6, canal of Schlemm; 7, external surface of the choroid, traversed by the ciliary nerves and one of the long ciliary arteries; 8, central vessel into which open the vasa vorticososa; 9, 9, 10, 10, choroid zone; 11, 11, ciliary nerves; 12, long ciliary artery; 13, 13, 13, 13, anterior ciliary arteries; 14, iris; 15, 15, vascular circle of the iris; 16, pupil.

necessary for perfect vision at all times and under all circumstances, is a subject of interest to those who study anatomy from the standpoint of its physiological bearings. The optic nerve, when a person comes from darkness into the light, receives, on account of the dilated condition of the pupil, an excess of light which at once compels the eye to momentarily close¹ until the pupil shall become contracted. The

¹ A reflex act produced through the optic nerve upon the orbicularis palpebrarum muscle.

sensation of over-stimulation created in the optic nerve by the glare of light entering the dilated pupil is carried backward to the brain, and, probably in the region of the aqueduct of Sylvius, creates a reflex act which sends motor impulses along the fibers of the third nerve to the iris, by means of the branch to the ciliary ganglion. Thus it happens that, when the eye is again opened, the sensation of distress in the optic nerve is no longer present, and the pupil is found to be contracted in a direct proportion to the amount of light which at the time exists.

REASONS FOR THE PECULIAR DISTRIBUTION OF THE THIRD NERVE.

The distribution of the third cranial nerve may suggest to the inquiring mind the following questions: "Why does

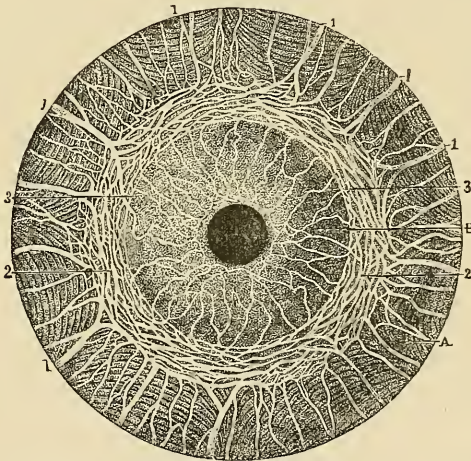


FIG. 95.—*Plexus of ciliary nerves.—Nerves of the iris.* (After Sappey.)

A, choroid; B, iris; 1, 1, 1, 1, ciliary nerves dividing at their terminal extremity into two or more branches, which anastomose to form a circular plexus surrounding the greater circumference of the iris; 2, 2, plexus formed by this anastomosis; 3, 3, nerves of the iris originating from this plexus.

Nature use three nerves to control the movements of the six ocular muscles, when she could have used one nerve to accomplish the effect? Why are the internal rectus, the inferior oblique, and the inferior rectus supplied from one nerve source, to the exclusion of the external rectus, and the supe-

rior oblique muscles? Furthermore, why is the iris supplied with nerve power from the third nerve, and not also from the fourth nerve or the sixth nerve?"

As was stated in the introductory lecture of this course, when touching upon the distribution of nerves in general, Nature often indicates, by the distribution of the nerves, some valuable hints as to the physiology of the parts supplied by each nerve filament; and such questions, as are presupposed above, will, if constantly asked by the student of anatomy, often enable him, by close study, to gain not only information of a most practical kind, but it will also greatly assist him to retain in his memory what would otherwise escape, and render this line of study a source of unceasing pleasure and interest.

It is evident, when a glance at the distribution of the motor oculi nerve is taken, that it is essentially the *nerve of accommodation of vision* for objects of variable distances from the retina. By its control over the internal muscles of the orbit, the eyes can be moved in unison in their endeavor to focus objects simultaneously upon each retina, and thus to gain a perception of the *solidity* of objects, which can not be afforded by one eye alone. It is a fact, which perhaps the reader has never thought of, that the two external recti muscles, or the two superior oblique muscles, are seldom called into simultaneous action, since they both tend to cause the eye to roll outward, and thus oppose the natural movement of the two eyes, one of which usually moves inward while the other moves outward, in order to favor the perception of the same objects by the retina of each eye. For this reason alone, it would be impossible that these two muscles of each orbit should be supplied from the same nerve as the other muscles, since they could not possibly act in harmony with each other. Again, the superior oblique and the external rectus muscles are seldom called into simultaneous action except in oblique movements of the eye, and their actions are so dissimilar that they have often to act both with and without the aid of the other; hence two nerves (the

fourth and sixth) are furnished so that each muscle can have its own source of nerve supply.

The distribution of the third nerve to the iris affords a still more beautiful example of the constant efforts of Nature to bring all parts into a harmony with each other, and by the simplest means at her control. It has been mentioned, in connection with the optic nerve, that the *pupil contracts* as the eye is drawn inward, and also in attempts to focus near objects upon the retina. Now, the third nerve is the nerve by which not only is the eye drawn inward, but it is also the nerve by which the ciliary muscle of the eye is enabled to affect the *convexity* of the *crystalline lens* of the eye, and thus to act as an adjuster of the focal distance of objects whose images fall upon the retina. How important it is, therefore, that the pupil which is so essential to the proper performance of vision, since it controls the quantity of light admitted to the retina, should be placed under the same nervous control as the muscles of accommodation of vision!

MECHANISM OF THE DILATATION OF THE PUPIL.

The pupil is made to dilate by means of muscular fibers, which radiate from the margin of the pupil toward the circumference of the iris. It is probable that these fibers are under the control of the *sympathetic system* of nerves.¹ If so, it must be observed that the sympathetic nerves have an effect upon the iris directly opposite to that which it exercises upon the blood-vessels, since, when it is stimu-

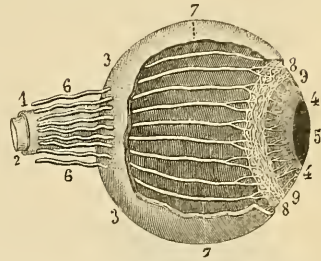


FIG. 96.—*Ciliary nerves, course and termination.* (After Sappey.)

- 1, optic nerve, covered by its external or ligamentous envelope;
- 2, optic nerve, covered only by its proper envelope (neurilemma);
- 3, 3, sclerotic, or fibrous envelope of the eyeball;
- 4, 4, iris;
- 5, pupil;
- 6, 6, ciliary nerves penetrating the sclerotic;
- 7, 7, nerves passing between sclerotic and choroid;
- 8, 8, plexus resulting from their anastomoses;
- 9, 9, ramifications extending from this plexus into the iris.

¹ Experiments of Julius Budge, 1851, and Augustus Waller, "Gazette Medicale de Paris." Discovered by Petit, 1827.

lated, the pupils are dilated, while the blood-vessels are contracted.

Mosso¹ has endeavored to show a relation between the *turgescence* of the vessels of the iris and the extent of dilatation of the pupil which exists at the same time, and thus to avoid

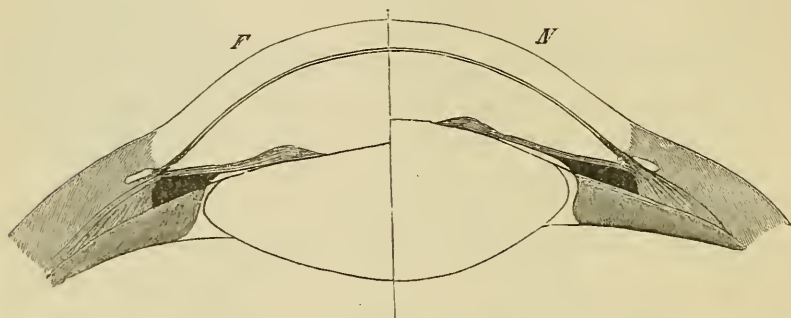


FIG. 97.—Section of the lens, etc., showing the mechanism of accommodation. (Fick.)

The left side of the figure (*F*) shows the lens adapted to vision at infinite distances; the right side of the figure (*N*) shows the lens adapted to the vision of near objects, the ciliary muscle being contracted and the suspensory ligament of the lens consequently relaxed.

the apparent inconsistency in the effect of the sympathetic system upon the same type of muscular structure.

Oehl² and others claim that the sympathetic fibers, which act in antagonism to those of the third nerve upon the iris, are not derived from the ophthalmic ganglion, but accompany the ophthalmic branch of the fifth cranial nerve, and enter the eye with the long ciliary nerves; and that, when these sympathetic filaments are divided, stimulation of the main sympathetic cords no longer causes dilatation of the pupil. He thus ascribes to the *fifth cranial nerve* the power of dilating the pupil, and regards the Gasserian ganglion as the source from which this power is derived from the sympathetic system.

The experiments of Oehl were made upon dogs and rabbits, and have been confirmed by Rosenthal, Hensen, Volckers, and Vulpian. The effect of these fibers of the fifth nerve is thought by these observers to be dependent upon a vasomotorial influence upon the blood supply of the iris.

¹ Cf. Mosso, Turin, 1875.

² Henle und Meissner's "Bericht," 1862.

Slight oscillations of the pupil may be observed to occur synchronously with the action of the heart, and others, also, with the respiratory movements. These oscillations have been by some considered as an evidence that the movements of the pupil were the result of alterations in its vascularity, the iris contracting when its vessels are filled, and dilating when its vessels are empty; but the physiological fact that the movements of contraction and dilatation of the pupil are noticed in the bloodless eye seems to point to some other agency than simply an alteration in the blood supply.¹

MOTIONS OF THE EYEBALL.

Since the third nerve is distributed to all of the muscles of the eyeball but two, the motions of the eye are largely controlled by it; while *accommodation of vision* is also produced by its distribution to the ciliary muscle. Some practical facts may be here noted respecting the movements of the eyeball, which have not only a general interest, but a diagnostic value.

The eye is virtually a ball placed in a socket, the orbit

¹ "The impairment of iritic reflex action ('pupillary reflex') was first intelligently studied in 1869, by Dr. Argyll Robertson, of Edinburgh. His observations have since been abundantly verified by numerous observers, and an exhaustive paper on the subject has been published by Professor W. Erb, of Leipsic, in the 'Archives of Medicine,' October, 1880. Robertson, and others after him, noticed that the pupils of tabetic patients did not dilate in the shadow and contract in the light, as do normal pupils, and they further observed that during the effort of accommodation there occurred a normal-pupillary contraction. In other words, the reflex iris movements were abolished, while its associated quasi-voluntary movements were preserved. These phenomena may be observed in almost all patients suffering from posterior spinal sclerosis, and I am in the habit of calling the attention of students to the symptom. In two of the patients now under my care this condition is not present, but there have been cases of abnormal sclerosis in which all the symptoms appeared in a most irregular manner." (E. C. Seguin, "Med. Record," 1881.)

"The pupils in a suspected case of posterior-spinal sclerosis are to be tested in the following manner: the patient is placed, seated or standing, facing a brightly illuminated window, and told to keep his look fixed on some distant object, such as a house or tree. By alternately closing and opening the lids, or, better, by shading the eyes with one's hand momentarily, it is easy to see if the pupils change diameter. It is of the utmost importance that the patient's intelligent assistance be secured, in order that his gaze shall remain adjusted for distance. In a given case the absence of reaction to light having been noted, we next hold up one finger or a small object within a foot of the patient's face, and bid him look at it. At once the pupils contract, and do so in proportion to the accommodative effort and the coincident convergence. When the patient looks at the distant object, and relatively or absolutely relaxes his accommodation, the pupils dilate again."

and the globe forming a ball-and-socket joint. In its socket joint, the eye is capable of a variety of movements; but it can not, by any voluntary effort, be moved out of its socket. By disease, however, the position of the eyeball within the cavity

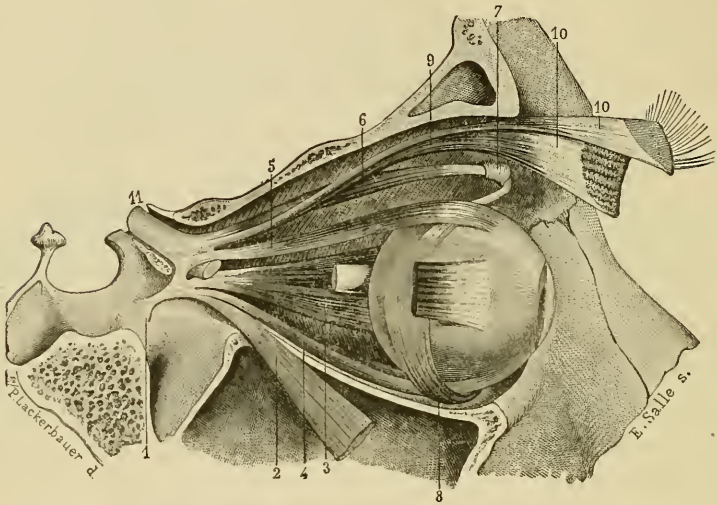


FIG. 98.—*Muscles of the eyeball.* (Sappey.)

1, attachment of the tendon connected with the inferior rectus, internal rectus, and external rectus; 2, external rectus, divided and turned downward to expose the inferior rectus; 3, internal rectus; 4, inferior rectus; 5, superior rectus; 6, superior oblique; 7, pulley and reflected portion of the superior oblique; 8, inferior oblique; 9, levator palpebræ superioris; 10, 10, middle portion of the levator palpebræ superioris; 11, optic nerve.

of the orbit may be materially altered. By pressure on the nerves distributed to its muscles, paralysis of those individual muscles may result which are supplied by the affected nerve, and the eye may thus be deflected from its normal position by the other muscles, whose motor power is unimpaired. The anatomical fact, that the muscles which move the eyeball derive their motor power from three sources, viz.: the third, fourth, and sixth cranial nerves, may often be made a means of determining the situation of abnormal conditions within the orbit or cranial cavity, by a thorough familiarity with the points of origin of each of these nerves, and the relations which each bears to the surrounding parts throughout the whole length of its course.

It has been shown by Donders that, though we can move the eye in almost every possible variety of inclination, we can not, by a *voluntary* effort, rotate the eyeball around its longitudinal visual axis. The arrangement of the muscles of the eyeball would seem to permit of such a movement, but we can not by any direct effort of will bring it about by itself, although we can occasionally produce it unconsciously when we endeavor to move the eyeballs in certain special directions.

During movements of the head, the eyes, if directed toward an object, may be kept stationary upon that object, in spite of such movements of the head,¹ very much as the needle of the ship's compass remains stationary when the ship is turned. By this wonderful coördination of movement *steadiness of vision* is insured, which would be otherwise impossible.²

A TABLE SHOWING THE ACTION OF THE OCULAR MUSCLES.

Straight movements.	}	To <i>elevate</i> the eye.....	{ Rectus superior.
			{ Obliquus inferior.
		To <i>depress</i> the eye.....	{ Rectus inferior.
			{ Obliquus superior.
Oblique movements.	}	To <i>adduct</i> toward the nasal side....	Rectus internus.
		To <i>adduct</i> toward the malar side....	Rectus externus.
	}	To <i>elevate</i> and <i>adduct</i> the eye.....	{ Rectus superior.
			{ Rectus internus.
	}	To <i>depress</i> and <i>adduct</i> the eye.....	{ Rectus inferior.
			{ Rectus internus.
	}	To <i>elevate</i> and <i>abduct</i> the eye.....	{ Rectus superior.
			{ Rectus externus.
		{ Obliquus inferior.	
		{ Rectus inferior.	
		{ Rectus externus.	
		{ Obliquus superior.	

In the accompanying table,³ in which the various motions of the eye are enumerated, and the combinations of muscles necessary to produce each of these individual motions are shown, it will be perceived that in the *straight* deflections of

¹ An effect due chiefly to the action of the oblique muscles of the eye.

² Mich. Foster, "Text-Book of Physiology."

³ After Mich. Foster, *op. cit.*

the globe of the eye never more than two muscles are required to produce them, and often only one; while, in the *oblique* deflections of the globe, three muscles are always compelled to work in unison. It may furthermore be stated that, to counterbalance the action of either of the oblique muscles of the eye, two muscles are always required. Suppose, for example, that the superior oblique muscle of the orbit was paralyzed from pressure upon the fourth nerve, the eye would then be drawn downward and outward only by the combined action of the external and inferior recti muscles, although that is the direct line of action of the muscle paralyzed; while, if that muscle should contract, and thus displace the eye downward and outward, the antagonistic muscles would be the superior and internal recti muscles, since the former would tend to draw the eye upward and inward, while the latter would also assist in drawing the eye inward.

The ability to move either of the eyes independently of the other is possessed by very few individuals, although, in rare cases, such a power is present. The movements of the eye have been so arranged by Nature that the objects seen shall affect the corresponding portions of each of the two retinae, in order to insure single vision; and, for that reason, the two eyes will be perceived to move exactly alike, each passing simultaneously to the left or to the right, upward or downward.

It is evident, therefore, when we throw into action the rectus internus of one eye, that we use the rectus externus of the opposite eye, and vice versa, in case the object to be focused upon the retinae lies away from the median line of the head; but, if it lies in the direct line of vision, but so close to the face as to require a muscular effort to focus it upon the retinae, then the two internal recti muscles are called into simultaneous action. Finally, in case the object to be perceived lies at a distance from the eyes, it becomes necessary for the eyes to be brought into nearly a *condition of parallelism*, to accomplish which the two external recti muscles are called into simultaneous action.

Such a complex coördination of movement as the various positions of the eyes demand would seem to indicate that a special arrangement had been made within the component parts of the brain to provide for its control, and thus insure

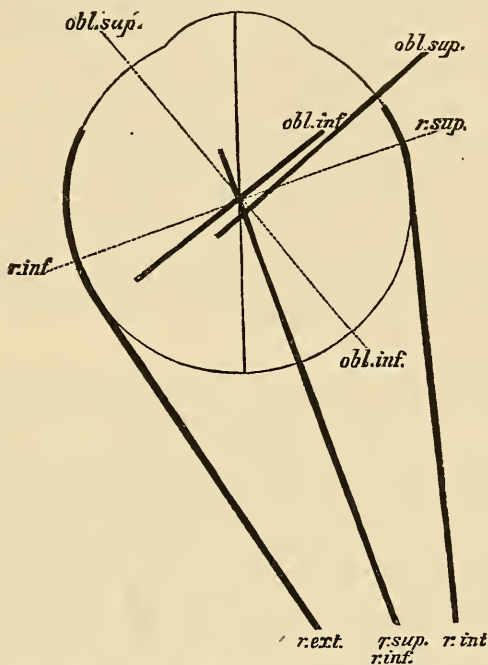


FIG. 99.—Diagram showing the axes of rotation of the eyeball. (After Fick.)

The black lines indicate the direction of the power applied by each of the six ocular muscles. The dotted lines indicate the axis of rotation of the eyeball. The axis of rotation for the rectus externus and rectus internus muscles, being perpendicular to the page, can not be shown in the diagram.

that harmony which is absolutely required. The experiments of Adamük ¹ tend to designate the tubercula quadrigemina as provided with distinct centers, which control certain movements of the eyes. Thus, he finds in *the nates* (the upper portion of the *tubercula quadrigemina*) a common center ² for both eyes, stimulation of the right side producing movements of both eyes to the left, of the left side, movements to the right; while stimulation of the middle line, behind, causes a

¹ Quoted by Flint, Foster, and others.

² For details concerning subdivisions of the nuclei of origin of the third nerve, consult a previous page of this volume.

downward movement of both eyes, with a convergence of the axes, and, if made in front, an upward movement with a return to parallelism, both of which effects are accompanied by the movements of the pupil naturally associated with them.

The third nerve has a decided importance in affording us one means of determining the distance of objects from the retinae which perceive them, viz., the *muscular sense*. It has been previously stated that, in order to perceive near objects, the *internal recti* and the *ciliary* muscles of either eye are called into simultaneous action, and we soon learn to unconsciously estimate the amount of muscular power required to properly adjust the eye for distinct vision, and thus to use the third nerve, as well as the optic nerve, as a guide to the accurate determination of distance.

ALTERATION OF THE POSITION OF THE HEAD FROM PARALYSIS OF THE OCULAR MUSCLES.

It is a fact well known among oculists, and one which often helps them materially in diagnosis, that the defects of vision, occasioned by impairment in the power of some of the muscles, which control the eyeball, cause the patients unconsciously to assume a *position of the head* which tends to assist them in the use of the affected eye. So diagnostic are some of the attitudes assumed by this class of afflicted people, that the condition which exists may be told at a glance, as the patient enters a room, by one thoroughly familiar with the diseases of this important organ. The explanation of this tendency, on the part of this class of patients, lies in the fact that any loss of power in the ocular muscles immediately shows itself in the perception of every object, as it were, doubled; and it is to overcome these *double images* that patients almost instantaneously discover their ability to get rid of the annoyance by some special attitude, which, of course, depends upon the muscle which is weakened or paralyzed.

It will be necessary, in order to make you clearly understand the mechanism of this peculiarity, that the separate

action of the six muscles which directly act upon the globe of the eye be considered.

The action of each of the ocular muscles may be given, then, as follows, with the proviso that many of the motions of the eye are not the result of the contraction of any single muscle, but often of a number acting either in unison or successively.

The *superior oblique* muscle turns the eye downward and outward.

The *inferior oblique* muscle turns the eye upward and outward.

The *superior rectus* muscle turns the eye upward and inward.

The *inferior rectus* muscle turns the eye downward and inward.

The *internal rectus* muscle turns the eye directly inward.

The *external rectus* muscle turns the eye directly outward.

This statement as to the above muscles reveals nothing which would not be immediately suggested by the insertion of each, with the exception of the superior and inferior recti muscles, which, besides the action which their situation would naturally suggest, tend also to *draw the eyeball inward*, on account of the obliquity of the axis of the orbit and the same obliquity of the muscles, since they arise at the apex of the orbit. The action of the oblique muscles is, as any one familiar with their origin and insertion would naturally surmise, to control the oblique movements of the eyeball.

Now, as soon as any one of these six muscles becomes pressed upon and weakened by the presence of tumors, inflammatory exudation, syphilis, or other causes, the patient at once *perceives double images*, and, in order to get his eye into such a relative position with that of the healthy side as to enable them both to focus upon the same object in a natural manner, the patient soon learns to so move his head as to compel the two eyes to look in parallel directions.

A very simple rule can be suggested by which you may be enabled, not only to tell in what direction a patient would move

his head in case any special muscle be rendered weak or utterly useless, but also to diagnose the muscle affected, when you look at the patient, without any knowledge of his history. The rule may be thus stated: *In paresis of any of the ocular muscles, the head is so deflected from its normal position that the chin is carried in a direction corresponding to the action of the affected muscle.*

Thus, in paresis of the external rectus,¹ the chin would be carried outward toward the injured muscle; while, in paresis of the internal rectus muscle, the head would be turned away from the side on which the muscle fails to act. In case the superior oblique muscle is impaired, the chin would be carried downward and outward; while, in the case of the inferior oblique muscle, the chin would have to be moved upward and outward to benefit the vision of the patient. The superior and inferior recti muscles, when impaired by disease or other causes, would likewise create a deflection of the head in a line corresponding to that of their respective actions.

CLINICAL POINTS OF INTEREST PERTAINING TO THE THIRD NERVE.

Paresis of the external and internal recti muscles causes, in addition to the facts already described, another point of very great value in diagnosis, viz., an alteration in the *apparent size* of the objects seen from what they would be in health. The condition of vision, termed by oculists "*megalopsia*" or "*macropsia*," signifies paresis of the external rectus; while the opposite condition, called "*micropsia*," indicates loss of power in the internal rectus muscle.

In the former of these conditions, the objects seen by the patient seem to be greater in point of size than the intelligence of the patient assures him is the case; while, in the latter, objects seem smaller to the patient than they really are.

To explain to you just how these variations of vision are

¹ While this statement would be absolutely true in theory in all cases, we must acknowledge, as a clinical fact, that patients learn to *utterly disregard* the image in the affected eye, when the *internal* or *external rectus* is the seat of paresis, and to use the normal eye only for the purposes of vision, thus rendering this attitude of the head less diagnostic than when the oblique muscles are affected.

accomplished may require a more extended discussion of the physiological problems of vision than an anatomical discussion can properly deal with ; but, to understand it, you must know that the apparent size of any object depends upon the ability of the person to properly and accurately *appreciate the angle* formed between rays of light coming from the object and entering the pupils of each eye, or, in other words, the distance at which the object is placed from the retina. Now, in the case of paresis of the external rectus muscle, the object is caused to appear nearer to the eye than it really is, and thus to be larger than normal vision would cause it to seem, since the angle of the axes of vision is greater ; while, in case of the paralysis of the internal oblique, the object is apparently much farther removed from the eye than it really is, and thus the intelligence construes it as of smaller size than it would if the visual perceptions were normal.

There is only one other condition of the eye where the size of objects perceived by the retina is either increased or markedly diminished, if the actual size be taken as a standard of measurement, and this condition is one of inflammation of the choroid coat of the eye. It is a well-recognized fact that, in the *effusive form* of choroiditis, objects are perceived as much smaller than they really are, while in *cicatricial* choroiditis the size of the object is magnified.

These phenomena can not be explained as the result of a change in the angle of the axis of vision, since nothing exists to disturb the perception of distance ; but it is attributed to a separation, in the one case, and to an aggregation in the other, of the *cones* of the retina.

The eye, by constant use, has become enabled to partly estimate the size of objects by the *number of cones* in the retina which are covered by the image of the object. Thus, when, from causes such as have been mentioned above, the elements of the retina are either huddled more closely together by a cicatrix of the choroid coat of the eye, or disseminated over a larger space than they normally occupy by an effusion of the choroid coat, the *number of cones* covered by

the image thrown upon the retina is either increased, thus apparently magnifying the size of the object, or the number of cones affected is decreased, and thus the size of the object seen is apparently diminished.




FIG. 100.—A. Vertical section of the retina. B. Connection of the rods and cones of the retina with the nervous elements. (H. Müller.) (Sappey.)

- A. 1, 1, layer of rods and cones; 2, rods; 3, cones; 4, 4, 5, 6, external granule layer; 7, inter-granule layer (cone-fiber plexus); 8, internal granule layer; 9, 10, finely granular gray layer; 11, layer of nerve cells; 12, 12, 12, 12, 14, 14, fibers of the optic nerve; 13, membrana limitans.
- B. 1, 1, 2, 3, rods and cones, front view; 4, 5, 6, rods, side view; 7, 7, 8, 8, cells of the external and internal granule layers; 9, cell, connected by a filament with subjacent cells; 10, 13, nerve cells, connected with cells of the granule layers; 11, 21, filaments connecting cells of the external and internal granule layers (12 is not in the figure); 14, 15, 16, 17, 18, 19, 20, 22, 23, 24, 25, 26, a rod and a cone, connected with the cells of the granule layers, with the nerve cells, and with the nerve fibers.

In cases where complete blindness, even to the sensation of light, exists, as sometimes occurs in amaurosis,¹ the eyes

¹ For the causes of this condition, see page 373 of this volume.

remain fixed and immovable, gazing steadily forward, even when objects are made to pass before the vision; while in cases of partial blindness, which prevent the perception of outline, but still allow of the perception of passing objects between the light and the retinae, by the shadow which they throw, the eye involuntarily moves in a direction which corresponds to that of the moving object.

Cases in which the third nerve has been impaired by pressure or disease, or totally destroyed by section, are characterized by a falling of the upper eyelid over the pupil,¹ and an inability to raise it, owing to the inaction of its levator muscle, so that the eye appears constantly half shut. This condition is known by the name of "*ptosis.*" The movements of the eyeball are also nearly suspended, and permanent *external strabismus* takes place, owing to the paralysis of the internal rectus muscle, while the external rectus, animated by a different nerve, preserves its activity. From paralysis of the fibers distributed to the iris, a *dilatation of the pupil* is also produced, and *accommodation* of the injured eye for near objects is no longer performed.

While the upper eyelid is partially raised by the levator palpebræ muscle, which is supplied by the third nerve, it is also raised by means of muscular fibers, which are governed by the cervical sympathetic. A similar set of fibers exists in the lower eyelid, and is governed by the same nerves; and it is probably through the influence of the *sympathetic system* that the eye is opened. In the act of winking, where the shutting of the eye is usually affected more rapidly than the opening, a contrast is afforded between the action of the cranial nerves and those of the sympathetic, since closing of the eye is performed by the facial nerve.²

External strabismus may often occur without the condition of "*ptosis*" being present, the filament to the levator palpebræ muscle not being affected.

When all the muscles supplied by the third nerve are

¹ So marked is this deformity that the upper lid frequently almost touches the lower lid.

² Mich. Foster, *op. cit.*

paralyzed, the globe of the eye is slightly protruded, from relaxation of most of its muscles.

In *strabismus*, or *squint*, an optical defect¹ is usually present. So large is the percentage of optical error in those cases where the eyes turn inward toward the nose, that this condition seldom exists without an accompanying hyperopia or far-sightedness, due to a diminution of the antero-posterior axis of the eye; while in external squint, where the eye looks away from the nose, the opposite condition of myopia, or near-sightedness, is often present, but perhaps not in as large a percentage of cases as in the opposite deflection of the eye. For this reason, operations are often of little benefit when performed for the relief of strabismus, unless the error in vision is accurately determined and corrected by the appropriate lenses.

DISEASES OF THE OCULAR MUSCLES AND THEIR CAUSES.

The muscles of the orbit may present the conditions of spasm, contracture, motor irritation, or paralysis.

The condition of "*nystagmus*" is characterized by clonic spasm of the external ocular muscles, and by peculiar oscillations or involuntary movements of the organ. It is always a bilateral affection, and its starting-point, according to the experiments of Adamuk and Ferrier,² seems to be situated within

¹ See Haynes Walton, Stellwag, and others. In speaking of this optical defect, dependent upon simple hyperopia, Dr. Loring says, in an article previously quoted in this volume: "I have known boys of eight or ten years of age to beg their parents to let them undergo the pain of an operation to rid themselves of a deformity which subjects them so often to the unfeeling remarks of their elders, usually friends of the family, as well as the uneuphonious but expressive titles bestowed upon them by their own contemporaries, of goggle-eye and cock-eye. Nor does this end with childhood. The deformity is a disadvantage to him through life. It pursues him in his business and in his profession. Cheated of feature by dissembling nature, he is often thought to be dissembling himself, when nothing is further from his thoughts. How often do we hear people say of another, whom we know to be perfectly upright and trustworthy, that they do not like him because he never looks them squarely in the face! And it is a little curious that precisely here it is that the lesser degrees of the trouble produce the most effect. That peculiar expression which people complain so much of is generally due to a deviation in the axes of the eyes—a slight convergence, which is never very conspicuous, and at times only to be detected by a trained eye, but which, nevertheless, produces in all a very disagreeable impression, although not marked enough to betray its cause."

² Discussed in the previous section.

the anterior tubercula quadrigemina. It may be produced by causes affecting either the central nerve ganglia, the peripheral nerves, the refracting media of the eye, or the retina. We thus find it existing in connection with meningitis, hydrocephalus, etc., in uterine diseases, worms, dentition, caries of the teeth, etc., and in some of the diseases of the eye or optic nerve.

Spasm of the *fibers of the iris* is observed, in rare cases, to exist in connection with some irritative condition of the cerebro-spinal system, which has involved the *cilio-spinal center* of the spinal cord.¹

By *contracture* of a muscle is meant a permanent shortening, in contrast to its temporary shortening when under the ordinary influence of the motor stimulus. It occurs, in the ocular group of muscles, as the result of the direct irritation following some pathological process, at a seat more or less distant from the orbit; or as the effect of prolonged paralysis of some of the antagonistic muscles.

In those cerebral and spinal conditions in which convulsive attacks are produced, and in attacks of hysteria, the evidences of well-marked *motor irritation* of the ocular muscles are often observed.

Paralysis of the ocular group of muscles may vary in degree, thus constituting either paresis or true paralysis; also in extent, thus affecting all the muscles supplied by the third nerve, and often the fourth and sixth nerves as well, or, again, only separate muscles; and finally in duration and its susceptibility to treatment. This symptom may be either an initial symptom, or a complication of some central disease, or the result of peripheral causes.

Paralysis of the muscles supplied by the third nerve is most frequently produced by the following causes: Circumscribed meningeal processes at the base of the skull; tumors, softening, and hæmorrhage of the cerebral peduncles; softening and hæmorrhage of the cerebral ganglia; syphi-

¹ For details as to the situation and function of this center, the reader is referred to subsequent pages of this volume.

lis (affecting the cranial or orbital cavity); orbital tumors; diphtheria; and, finally, aneurisms of the carotid (as reported by Lebert¹). In the *development of ataxia*, the third nerve may become paralyzed simultaneously with other nerves of the cranium, or, possibly, without other nerves being affected, and the same condition may follow the prolonged use of colium or gelsemium.

When the paralysis of the third nerve is produced by intracranial lesions, the paralysis is liable to be bilateral or to tend toward a symmetrical development as the disease progresses; while the fourth and sixth nerves are often subsequently affected. There are also other symptoms, of great value in deciding upon the existence of intra-cerebral disease, which may be present, such as the coexistence of cephalalgia, vertigo, symptoms of neuro-retinitis, disturbances of speech and of the intellectual faculties, convulsive movements of a local or general type, a sense of weight in the limbs, or, possibly, the presence of paresis or paralysis of the muscles of the extremities.

“A very large proportion of tabetic patients tell of past or present diplopia, and, in a certain number of cases, the ocular paralysis precedes the pains and ataxia by several years. So true is this statement, that it has become an established practice with neurologists and ophthalmologists to suspect posterior spinal sclerosis in adults who present themselves with strabismus, diplopia, or ptosis. In such a case we should carefully question the patient about the occurrence of fulgurating pains, and test the pupillary and tendinous reflexes. I need hardly add that another obligatory line of inquiry in such cases is with reference to symptoms of syphilis.”²

The same remarks apply to atrophy of the optic nerve, which is occasionally an early symptom.

It is not infrequent for *lesions of the spinal cord* to produce paralysis of the ocular muscles. The presence of such an exciting cause may be surmised by the coexistence of vague neuralgias in the branches of the cervical or brachial plexuses,

¹ Quoted by Rosenthal.

² E. C. Seguin, “Med. Record,” 1881.

or in the sciatic nerves; of abnormal sensations in the back, knees, and soles of the feet; seminal emissions, frequent or prolonged erections, or diminished sexual power; extreme sensitiveness to moisture of the atmosphere or winds; a tendency to fatigue, often present after a night's repose; and an increase in the galvano-excitability of the main nerve trunks.

Paralysis of the ocular muscles may *accompany glosso-labio-pharyngeal paralysis* (Duchenne's disease¹), if the center for the movements of the eye be affected at the same time as the centers of the muscles of speech and deglutition; in this case, the third and sixth nerves are frequently affected simultaneously. The same condition of the ocular muscles may also accompany *ataxic symptoms* of cerebral origin.

Rheumatism may produce ocular paralysis. This cause is to be suspected when no symptoms exist which seem to point to local trouble in the orbit or brain. It is found to affect the motor oculi and the abducens nerves more frequently than the patheticus.

Diplopia and *strabismus* are often the first symptoms of cerebral diseases or ataxia, since they may appear before the other parts of the muscular system are affected. If they show, at times, a tendency toward spontaneous retrogression, and again return with the simultaneous occurrence of neuralgic pain, the development of a cerebral lesion is rendered still more probable.

THE FOURTH (TROCHLEAR OR PATHETIC) NERVE.

The apparent origin of this nerve is from the *superior peduncle of the cerebellum*, and it then winds around it, passing close to the posterior border of the pons Varolii. The deep fibers of this nerve may be traced to four different situations, as follows: 1, some to the *substance of the peduncle*;

¹ The symptoms of this condition will be found mentioned in more detail in connection with the hypoglossal nerve.

2, other fibers to the *valve of Vieussens*, where they are lost, with the exception of a few, which can be traced to the *frenulum*; 3, a few fibers to the *tubercula quadrigemina*; 4, a large bundle, which pass inward toward the median line and then *decussate* with corresponding filaments of the opposite side. The nucleus of the nerve is shown in Fig. 75.

This decussation of the fibers of the nerve is for the same physiological reason, as was mentioned in connection with the

preceding nerve, viz., to afford harmony of action between the two sides, when the eyes are compelled to remain fixed upon an object during movements of the head.

From the point of apparent origin, the nerve passes forward along the *outer wall* of the cavernous sinus, where it lies *below the third nerve* and *above the ophthalmic branch* of the *fifth nerve*, and escapes from the cavity of the cranium, through the highest part of the sphenoidal fissure, into the cavity of the orbit.

The question of the function of this nerve resolves it-

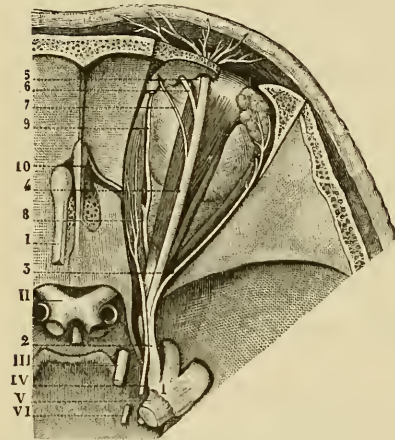


FIG. 101.—Distribution of the *patheticus*.
(Hirschfeld.)

I, olfactory nerve; II, optic nerves; III, motor oculi communis; IV, *patheticus*, by the side of the ophthalmic branch of the *fifth*, and passing to the superior oblique muscle; VI, motor oculi externus; 1, ganglion of Gasser; 2, 3, 4, 5, 6, 7, 8, 9, 10, ophthalmic division of the fifth nerve, with its branches.

self simply into the mode of action of the *superior oblique muscle*. This muscle arises just above the inner margin of the optic foramen, and passes forward along the upper wall of the orbit, at its inner angle, to a little cartilaginous ring, which serves as a *pulley* for its tendon. Its tendon becomes rounded just before it passes through this ring, where it makes a sharp curve, passes outward and slightly backward, and becomes spread out, to be attached to the globe, at the superior and external part of its posterior hemisphere. It is, therefore, the direct antagonist of the inferior oblique muscle.

In its function, it is purely a *motor* nerve, but it receives a few recurrent fibers from the fifth nerve, which are sensory.

When this nerve is paralyzed, the position of the eye shows no apparent change, except when the head is moved from side to side, in which case the *eye moves with the head*; the absence of the usual compensating movement of the eye, which accompanies all the movements of the head, being destroyed in consequence of the paralysis of the superior oblique muscle, which greatly assists in this act. The patient also sees a double image, whenever attempts are made to look straight forward, or at objects situated toward the paralyzed side; but the image becomes a single one when the head is turned toward the sound side to view any object; hence this abnormality of attitude of the head is usually present.¹

THE TRIGEMINUS, OR FIFTH NERVE.

This important nerve has its apparent origin within the cranium from the *lateral aspect* of the *pons Varolii*, although its deep fibers have been traced to distinct nuclei, situated in the *floor* of the *fourth ventricle* near to the gray tubercle of Rolando and to more distant parts.² It is a mixed nerve, having a distinct *motor* and *sensory root*; and thus possesses both *afferent* fibers, through which sensory impressions are transmitted to the brain, and *efferent* fibers, by which motor impulses are transmitted from the brain to the periphery of some branches of the nerve.

The intimate relations which the nerve bears with the points of origin of the sixth, seventh, eighth, ninth, tenth, eleventh, and twelfth cranial nerves in the *floor of the fourth ventricle* possibly explain many of those phenomena which are considered as reflex in character, and whose starting-point

¹ For other examples of this diagnostic guide in paralysis of ocular muscles, see previous pages upon the third cranial nerve.

² See pages which relate to the medulla oblongata, and also preceding pages of this section that treat of the deep origins of the fifth nerve.

seems to depend upon some irritation of the fifth nerve by means of various branches.

The two roots of this nerve pass forward, side by side, as far as the petrous portion of the temporal bone. At this point a marked enlargement, called the ganglion of Gasser, is developed upon the *sensory root*; and subsequently this root

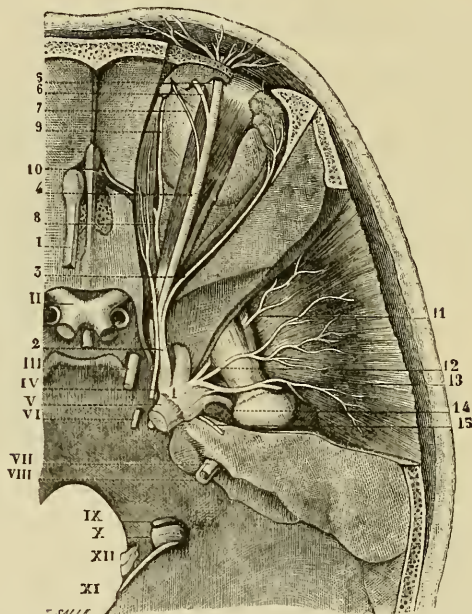


FIG. 102.—*Ophthalmic division of the fifth.* (Hirschfeld.)

1, ganglion of Gasser; 2, ophthalmic division of the fifth; 3, lachrymal branch; 4, frontal branch; 5, external frontal; 6, internal frontal; 7, supra-trochlear; 8, nasal branch; 9, external nasal; 10, internal nasal; 11, anterior deep temporal nerve; 12, middle deep temporal nerve; 13, posterior deep temporal nerve; 14, origin of the superficial temporal nerve; 15, great superficial petrous nerve. I to XII, roots of the cranial nerves.

divides into three large nervous trunks called, respectively, the ophthalmic, the superior maxillary, and the inferior maxillary nerves, which escape from the cavity of the cranium through different foramina.¹ The *motor root* accompanies the inferior maxillary nerve until it has escaped from the cranium, when it unites with it.

¹ The sphenoidal fissure, foramen rotundum, and foramen ovale respectively afford a passage for these branches from the cranium.

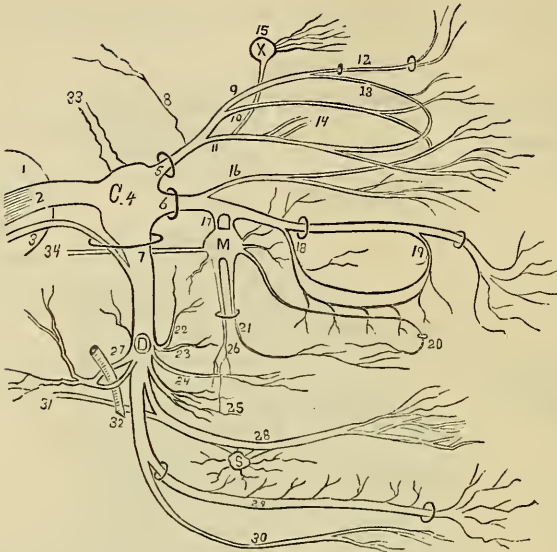


FIG. 103.—A diagram of the distribution of the fifth nerve.¹

1, the *crus cerebri*; 2, the *sensory root* of the nerve; 3, the *motor root* of the nerve; 4, the *Gasserian ganglion*, upon the *sensory root* only; 5, the *ophthalmic nerve*, passing through the *sphenoidal fissure*; 6, the *superior maxillary nerve*, passing through the *foramen rotundum*, to enter the *spheno-maxillary fossa*; 7, the *inferior maxillary nerve*, passing through the *foramen ovale* in company with the *motor root*, which soon joins it; 8, a filament sent backward from the *ophthalmic nerve* to the *tentorium cerebelli*; 9, the *frontal nerve*; 10, the *lacrimal nerve*; 11, the *nasal nerve*; 12, the *supra-orbital nerve*, passing through the *foramen* of the same name; 13, the *supra-trochlear nerve*; 14, the *long ciliary nerves* to the *iris*; 15, the *lenticular, or ciliary ganglion*; 16, the *temporo-malar nerve*, showing its division into the *temporal branch* and the *malar branch*; 17, the *spheno-palatine nerves*, going to *Meckel's ganglion*; 18, the *posterior dental nerves*, given off just before the *superior maxillary nerve* enters the *infra-orbital canal*, after passing through the *spheno-maxillary fossa*; 19, the *anterior dental nerves*, given off in the *antrum*; 20, the *naso-palatine nerve*, escaping at the *anterior palatine foramen*, after passing through the *antrum*; 21, the *anterior palatine nerves*, after escaping from the *posterior palatine foramen*; 22, the *deep temporal nerve*; 23, the *masseteric branch*; 24, the *buccal branch*, which often also supplies the *external pterygoid muscle*; 25, the *pterygoid branch*, going chiefly to the *internal pterygoid muscle*; 26, the *posterior palatine nerves*, after escaping from the *posterior palatine foramen*, going to the *muscles of the soft palate*; 27, the *auriculo-temporal nerve*, splitting and thus embracing the *middle meningeal artery*; 28, the *gustatory or lingual nerve*, distributed to the *anterior two thirds of the tongue*; 29, the *inferior dental nerve*, passing through the *inferior dental canal*, beneath the *teeth of the lower jaw*; 30, the *mylo-hyoid nerve*, a branch of the *inferior dental nerve*; 31, the *chorda tympani nerve*, joining the *gustatory nerve*, and possibly bringing to it the *perception of taste*; 32, the *middle meningeal artery*; 33, the *fibers* going to the *carotid and cavernous plexuses* of the *sympathetic system*; 34, the *Vidian nerve*, going from *Meckel's ganglion* to the *Vidian canal*. *Ganglia of the fifth nerve.*—L, The *lenticular ganglion*, sending fibers to *iris and ciliary muscle*; c, the *Gasserian ganglion*; o, the *otic ganglion*, lying on the *inferior maxillary nerve* below the *foramen ovale*; s, the *submaxillary ganglion*, connected with the *gustatory and chorda tympani nerves*; m, *Meckel's ganglion*, lying in the *spheno-maxillary fossa*.

¹ Modified from Flower by the author.

which are supplied alone with sensation from those to which the motor root is eventually distributed.

The *efferent fibers* of the fifth pair give motor power to the muscles of mastication, viz., the temporal, masseter, and

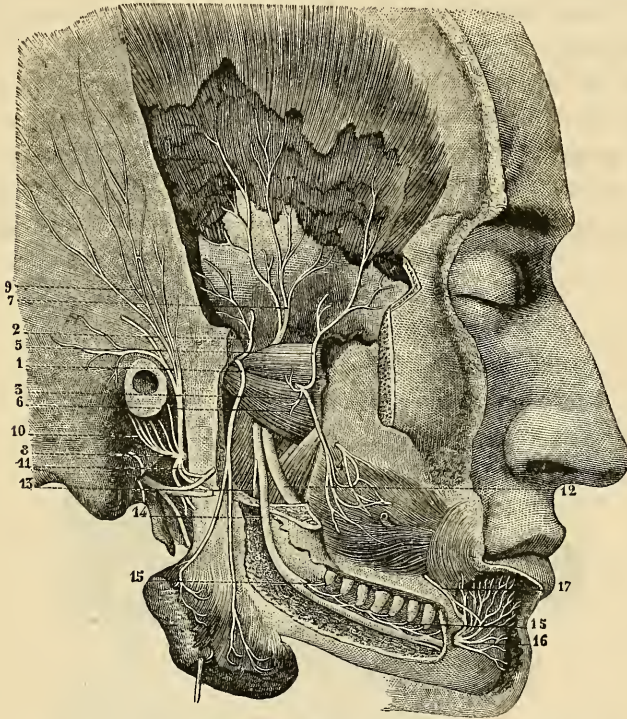


FIG. 104.—*Inferior maxillary division of the fifth.* (Hirschfeld.)

1, branch from the motor root to the masseter muscle; 2, filaments from this branch to the temporal muscle; 3, buccal branch; 5, 6, 7, branches to the muscles; 8, *auriculo-temporal nerve*; 9, *temporal branches*; 10, *auricular branches*; 11, *anastomosis with the facial nerve*; 12, *lingual branch*; 13, branch of the motor root to the mylo-hyoid muscle; 14, 15, 15, *inferior dental nerve, with its branches*; 16, *mental branch*; 17, *anastomosis of this branch with the facial nerve.*

pterygoids; also to the mylo-hyoid and anterior belly of the digastric, and to the tensor palati and tensor tympani. They thus control not only the physiological act of *mastication*, but also, to some extent, the acts of *deglutition* and *hearing*. These fibers furthermore afford a *vaso-motor* influence over various vessels in certain regions of the head and face. *Secretory fibers* to the lachrymal gland, and, according to some

authors, to the parotid and submaxillary glands, by means of fibers derived from the facial nerve (through the chorda tympani branch), are attributed to the trigeminus. By these fibers, the secretions necessary to the perfect performance of the parts supplied by the fifth nerve are also placed under its control, thus illustrating again that beautiful law of Nature in arranging the nerves in accordance with harmony of action. Beside the efferent fibers possessed by the fifth nerve, there exist in addition certain unnamed fibers which control the proper *nutrition* of the *eye*, *nose*, and *other portions of the face*. These latter fibers are not as yet fully ascertained so as to be described in detail, but their existence seems indi-

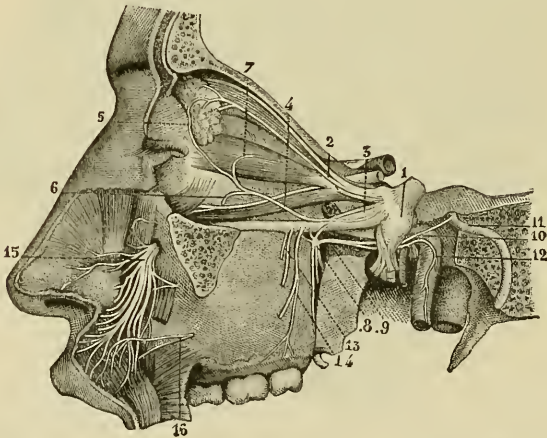


FIG. 105.—*Superior maxillary division of the fifth.* (Hirschfeld.)

1, ganglion of Gasser; 2, lachrymal branch of the ophthalmic division; 3, *superior maxillary division of the fifth*; 4, orbital branch; 5, lachrymo-palpebral filament; 6, malar branch; 7, temporal branch; 8, sphenopalatine ganglion; 9, Vidian nerve; 10, great superficial petrosal nerve; 11, facial nerve; 12, branch of the Vidian nerve; 13, anterior and two posterior dental branches; 14, branch to the mucous membrane of the alveolar processes; 15, terminal branches of the superior maxillary division; 16, branch of the facial.

cated by the fact that, after section of the fifth nerve, the cornea becomes cloudy; the whole eye becomes inflamed, only to subsequently disorganize; the mucous membrane of the nose is similarly destroyed, and ulcers frequently make their appearance upon the mucous membrane of the lips and gums. Snellen, however, considers these changes as the ef-

fects of the *mechanical irritation of dirt*, which the mucous membranes, no longer possessing sensibility, are unable to perceive.

The *afferent fibers* of the fifth nerve afford general sensation to the entire skin of the head and face, except in the *occipital region* and the *back* and *lower part of the ear*,¹

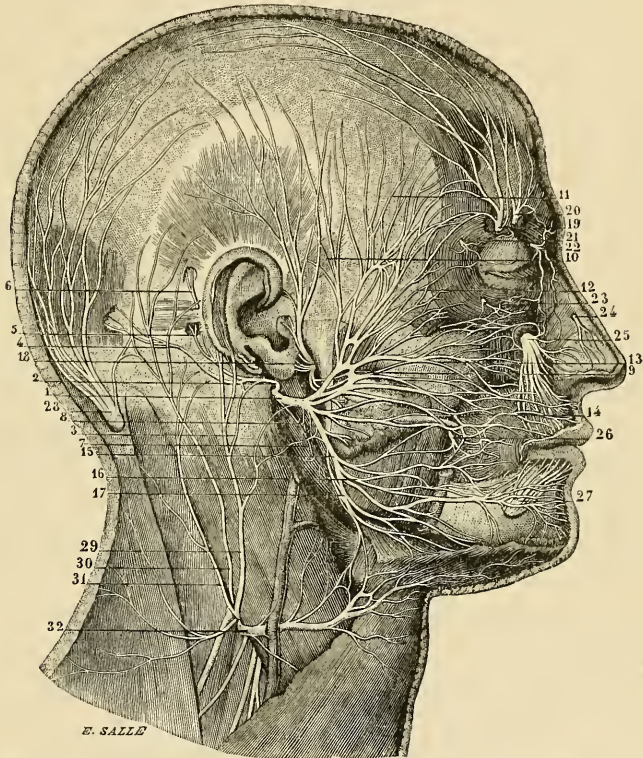


FIG. 106.—*Superficial branches of the facial and the fifth.* (Hirschfeld.)

- 1, trunk of the facial ; 2, posterior auricular nerve ; 3, branch which it receives from the cervical plexus ; 4, occipital branch ; 5, 6, branches to the muscles of the ear ; 7, digastric branches ; 8, branch to the stylo-hyoid muscle ; 9, superior terminal branch ; 10, temporal branches ; 11, frontal branches ; 12, branches to the orbicularis palpebrarum ; 13, nasal, or suborbital branches ; 14, buccal branches ; 15, inferior terminal branch ; 16, mental branches ; 17, cervical branches ; 18, superficial temporal nerve (branch of the fifth) ; 19, 20, frontal nerves (branches of the fifth) ; 21, 22, 23, 24, 25, 26, 27, branches of the fifth ; 28, 29, 30, 31, 32, branches of the cervical nerves.

and also to the mucous membranes of the mouth, with the exception of the posterior pillar of the fauces and the poste-

¹ Hilton, *op. cit.*

rior third of the tongue, which derive their sensation by means of the glosso-pharyngeal nerves.

The accuracy of this statement, as regards the distribution to the integument of the ear, which is now accepted by most of the anatomical authors of the present day, was strangely attested to by facts brought under the notice of John Hilton,¹ who was thus enabled clinically to verify the exact distribution of the fifth nerve to the pinna and the auditory canal. It seems that an attempt was made by a criminal to kill his wife by cutting her throat, but that the attempt was not successful, and resulted in severing the auricular branch of the *second cervical nerve*, which, as well as the fifth cranial nerve, supplies the ear. An opportunity was thus afforded to examine, by the use of needle points, the state of sensibility of the different portions of the ear, and to decide, by the loss of sensibility, the exact regions which the second cervical nerve supplied. It was thus proven that the *upper and anterior part* of the ear, and also the *auditory canal*, was supplied by the fifth cranial nerve; and that, therefore, these parts are in direct nervous communication with the forehead, temple, face, nose, teeth, and the tongue.

It can thus be easily understood why pain in the auricular region, as evidenced in cases recited later on, may prove a most valuable diagnostic sign of irritation of some of the other branches of the fifth nerve, distributed to the regions which are associated by means of this nerve with the ear, although apparently having no anatomical relation with it.

In the partly diagrammatic representation of the distribution of the nerves to the cutaneous surface of the head, the outlines of the various regions, represented as supplied by the different nerves, are as nearly accurate as careful investigation can determine them.² It will be perceived that *nine*, out of the fourteen regions mapped out upon the head and neck, are supplied with sensation by some of the branches of

¹ "Rest and Pain," London (New York, 1879).

² As the boundaries of the regions supplied by any nerve gradually shade off into neighboring regions, it is not well to rely upon the *extreme* area of any region in testing the special sensibility of any nerve.

the *fifth cranial nerve*, while the remaining five are supplied by branches of the cervical plexus, with the exception of that region to which the great occipital nerve is distributed.

It can easily be understood, from what has already been

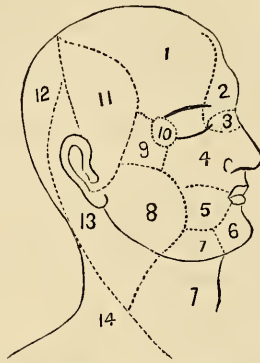


FIG. 107.—*The nervous distribution of the head.* (After Flower, but slightly modified.)

- 1, region supplied by the *supra-orbital* branch of the fifth nerve; 2, region supplied by the *supra-trochlear* branch of the fifth nerve; 3, region supplied by the *infra-trochlear* branch of the fifth nerve; 4, region supplied by the *infra-orbital* branch of the fifth nerve; 5, region supplied by the *buccal* branch of the fifth nerve; 6, region supplied by the *mental* branch of the fifth nerve; 7, region supplied by the *superficial cervical* from the cervical plexus; 8, region supplied by the *great auricular* from the cervical plexus; 9, region supplied by the *temporo-malar* branch of the fifth nerve; 10, region supplied by the *lacrimal* branch of the fifth nerve; 11, region supplied by the *auriculo-temporal* branch of the fifth nerve; 12, region supplied by the *great occipital* (a spinal nerve); 13, region supplied by the *small occipital* from the cervical plexus; 14, region supplied by the *supra-clavicular* from the cervical plexus.

said as to the manner of employing the nerves as guides to diagnosis, that a careful study of the limits of each of these regions of the head may often enable the physician to explain symptoms which might otherwise seem obscure; and also enable him to use the symptom of *local pain*, whenever present, as a signal which Nature often gives of disease in parts possibly far removed from the seat of pain, but still intimately connected with it by means of its nervous supply.

EFFECTS OF SECTION OF THE FIFTH NERVE.

Many points of practical value dependent upon the fifth nerve can be better understood when the effects of its division have been considered in detail. If the fifth nerve be divided, *sensation* is immediately destroyed in all those

portions of the head and face to which the efferent nerves are distributed; the *power of mastication* is lost; the *secretions* of the lachrymal, parotid, and submaxillary glands are rendered deficient; the *act of deglutition* becomes imperfect, since some of the muscles required for its performance are paralyzed, and since the *tongue is unable to perceive* the bolus of food, and therefore can not properly direct its movements; and, finally, *hearing* is, to a certain extent, impaired, since the tensor tympani muscle¹ has lost its motor power.

In addition to these direct effects of section, *secondary results* are manifested in those forms of ulceration which have been previously referred to, and, eventually, in the *destruction of sight and smell*.

It may be noticed that the effect of section of the fifth nerve upon the *special sense of taste* has not been mentioned. It was formerly supposed that the gustatory fibers of the fifth nerve afforded the sense of taste to the *anterior two thirds* of the tongue; but it is now urged by many that the fifth nerve is simply a nerve of sensation to that organ, and that its fibers are employed exclusively in the appreciation of the sensations of touch and feeling, while the true gustatory fibers of that portion of the tongue are derived from the *chorda tympani* branch of the facial nerve. In support of this view, cases have been observed where the chorda tympani has been affected, either by disease or in consequence of injury within the middle ear, and the sense of taste has been impaired; but, on the other hand, cases have been also recorded where the fifth nerve was alone diseased, and yet taste was destroyed in the anterior two thirds of the tongue. It is such cases as the latter that still lead some physiologists to believe that the chorda tympani nerve only controls the *flow of the saliva*, and that impairment of this secretion impairs or destroys the special sense of taste afforded by the gustatory branch of the fifth nerve.

¹ According to Lucae's recent experiments ("Berlin. klin. Wschr.," 1874), the tensor tympani muscle presides over the *accommodation for musical tones*.

CLINICAL POINTS AFFORDED BY THE FIFTH NERVE.

The fifth nerve may be the seat of neuralgia, spasm, or paralysis. The type of neuralgia (called *tic-douloureux*, the facial pain of Fothergill, and “*prosopalgia*”) dependent upon the fifth nerve affects only the sensory trunks; the spasms may be of a tonic or clonic type, and are, of course, confined to the muscles supplied by the motor branches of the nerve; while the paralytic condition can affect the sensory trunks, producing anæsthesia of the parts to which the affected nerve is distributed, or the motor filaments may be impaired, thus destroying the power of normal movement in the muscles of mastication and the mylo-hyoid. So many points of clinical interest and practical value pertain to these various conditions that each will be considered somewhat in detail.

NEURALGIA OF THE TRIGEMINUS NERVE.

The various forms of *tic-douloureux* are so commonly met with, and prove so obstinate to treatment, as well as distressing to the patient, that a practical knowledge of the disease can not be gained without a careful study of the various causes which have been found to produce it.

Among the reported cases of this affection, there have been discovered, as exciting causes, the following conditions: Tumors of the middle fossa of the skull or of the base of the brain, producing neuralgia so long as irritation only is produced, but anæsthesia when degeneration of the nerve trunks begins; accumulations of pus within the cranial cavity; tumors of the pons Varolii; morbid processes in the regions adjacent to the ganglion of Gasser; and aneurism of the internal carotid artery¹ within the sella turcica. Diseases of the cervical portion of the spinal cord, if high up, may create neuralgia of the fifth pair, by irritating the fibers of that nerve which arise from the lower part of the medulla. Periostitis of the bony orifices, through which the various branches of the fifth nerve pass, may create such pressure as to produce

¹ Romberg's case.

the most severe and persistent neuralgias ; for this reason the supra-orbital, infra-orbital, zygomatic, superior and inferior dental branches are more liable to be the seat of pain than the branches which pass through such large openings as the sphenoidal and speno-maxillary fissures.¹ Exostoses of the bones, especially of the upper and lower jaws, may create the most severe type of neuralgia by pressure upon the neighboring nerve trunks. Exposure to cold or dampness will produce it, being one of the most frequent of the trivial causes. Finally, inflammatory changes in the ganglia² attached to the nerve, the enlargements and nodosities found upon resected nerves, an exostosis of a wisdom tooth,³ caries and osteophytes of the bony canals through which branches of the nerve pass, and neuroma of the ganglion of Gasser protruding through the foramen ovale,⁴ have been known to produce the most severe neuralgia.

The symptoms of tic-douloureux are of the most distressing character. The pain is usually extremely violent, and the patients will describe it to you as of a burning, piercing, or shooting character. It is liable to be, at first, paroxysmal ; but, if due to organic disease, it may gradually become more or less constant. The continuous pain is, however, usually limited to certain well-defined spots of extreme sensitiveness to pressure, which the patient can readily point out to you (the "*puncta dolorosa*" of Valleix). Thus, the first branch of the trigeminus (the ophthalmic) presents six such points, each indicating some one of its subdivisions. These are situated, respectively, over the supra-orbital foramen ; in the center of the upper eyelid ; a frontal point over the escape of the nerve of the same name ; one at the outer angle of the eye, for the lachrymal branch ; and two at the inner angle of the eye, upon the nose, representing the inferior trochlear and the ethmoidal nerves.

In the region supplied by the superior maxillary nerve and its branches, there may exist a malar point, an infra-

¹ Hyrtl, as quoted by Rosenthal.

² Cases of Carnochan and Wedl.

³ Thompson, as quoted by Rosenthal.

⁴ Chouppé's case.

orbital point, a point in the palate, and one on the gum of the upper jaw.

In the region supplied by the inferior maxillary nerve, the points of tenderness are situated in front of the tragus of the ear (the temporal point); one in the parietal region, where the frontal, occipital, and temporal nerves meet; one over the temporo-maxillary joint; a point upon the tongue for the lingual branch; and one upon the integument of the chin, for the mental nerve.

Painful points are often detected by pressure in the region of the spinous and transverse processes of the cervical vertebræ (the "point apophysaire" of Trousseau).

These *puncta dolorosa* are usually the starting points for the pain of the acute paroxysms, from which the pain radiates along the course of the nerves of the region affected. In some cases, these points of tenderness may, however, be absent, when a central origin of the disease may reasonably be suspected.

The relation of the filaments of the fifth nerve with some *vaso-motor fibers* causes this type of disease to be often associated with certain disorders of secretion, since the vessels of the glands of the affected region are liable to dilate after an acute paroxysm of pain. We can thus explain the abundant flow of tears after an attack of neuralgia of the ophthalmic branch; and of nasal mucus and saliva, when the second and third branches of the trigeminus are involved. Profuse sweating of the region of the face affected is also sometimes well marked both during and after the paroxysm.

The vaso-motor communication may also explain why we have reported cases of local swelling, redness, elevation of the temperature, and, sometimes, erysipelatous inflammation of the affected region; and why the hair has been observed to fall out, and the skin to become discolored and roughened. Hypertrophy of the cheek has been noticed, as a result of tic-douloureux, by Niemeyer, Brodie, Romberg, and Notta; and ophthalmia has been produced by a similar condition confined to the first branch of the fifth nerve. When the nerve trunks, which at first were the seat of neuralgia, become destroyed or

seriously impaired by pressure or granular degeneration, the face may undergo atrophy.

Neuralgias of the fifth nerve, when due to *cerebral tumors*, are often complicated by other symptoms which greatly assist in the diagnosis ; among the more prominent of which may be mentioned diplopia, vertigo, chronic cephalalgia, spasms of certain groups of muscles, paralysis of various types, and the absence of the *puncta dolorosa*, whose situations have already been mentioned.

Tic-douloureux is not to be confounded with pain dependent upon the decay of teeth, inflammation of the temporo-maxillary articulation, tumors of the antrum, or extension of inflammation to that cavity from an acute attack of coryza, migraine, or the facial pains of lead poisoning, hysteria, or spinal affections. It is more common in women than in men ; and most frequent between the ages of thirty and fifty. It is more liable to occur in cold months than when the weather is warm (provided it be not due to actual disease) ; and it may follow traumatism, senile changes in the blood-vessels, and malarial poisoning.

SPASM DUE TO THE TRIGEMINUS NERVE.

The jaw may be rendered immovable, as in tetanus, by the masseter, temporal, and pterygoid muscles, all of which are supplied with motor power by the fifth nerve. The same form of spasm may be occasionally observed in attacks of hysteria.

Clonic spasm of the temporal and masseter muscles, alternating with that of the depressors of the jaw (the mylo-hyoid and the anterior belly of the digastric), produces the *chattering of the teeth* so often seen in the chill of inflammatory diseases and fevers and after exposure to cold.

The pterygoid muscles, by a tonic contraction, may produce the *grinding* of the teeth ; a displacement of the jaw to one side, during an hysterical paroxysm, which lasted some days, is reported by Leube.⁴

⁴ As quoted by Rosenthal: "A Clinical Treatise of the Diseases of the Nervous System" (Putzel's translation, New York, 1879).

Spasms of the muscles supplied by the trigeminus may be the result of apoplexy, cerebral softening, meningeal exudation, lesions of the pons Varolii and medulla oblongata, hysteria, epilepsy, tetanus, hydrophobia, tumors irritating the ganglion of Gasser, peripheral irritation, reflex causes (as dental pain, ulceration of the tongue or mouth, intestinal or uterine irritation, teething, etc.), and rheumatism.

In rare cases, the *depressors of the jaw* may be the seat of localized spasm, in which event the mouth may be kept wide open for a longer or shorter period.

PARALYSIS OF THE TRIGEMINUS NERVE.

It is a rare occurrence to observe a simultaneous paralysis of the motor and sensory roots of the trigeminus. Anæsthesia of parts supplied by the branches derived from the sensory root may occur from central causes, and is perhaps more frequent than those symptoms dependent upon lesions involving the motor root. In lesions confined to the cerebral ganglia or cortex, however, the motor root is more often impaired than the sensory portion, while the sensory root, or some of its branches, is frequently affected from causes outside of the cranial cavity.

In studying the condition of trigeminal anæsthesia, it must be prefaced that the regions affected, and therefore the results of the impaired nervous function, differ with the exciting cause, since a central lesion is liable to involve all of the sensory branches of the nerve; while an external cause usually affects some individual branch.

The *central lesions* of this disease comprise apoplectic clots; destructive lesions producing ataxia; hysteria; local diseases or exudations which involve the large root of the fifth nerve between the pons Varolii and the ganglion of Gasser; and lesions of the medulla oblongata, thus affecting its fibers of origin.

The *external causes* include all forms of traumatism; exposure to cold or heat; surgical procedures; caries or periostitis of the bony canals; suppuration of the soft tissues ad-

joining the affected nerve; local tumors and inflammatory exudations; and certain blood conditions accompanied by nerve sclerosis (chiefly Norwegian leprosy).¹

The condition of facial anæsthesia may be complete, when sensibility to contact, pain, heat, or cold is abolished; or partial, when extreme impressions can be perceived, and often differentiated as to the peculiar character of each. The needle points, the compass, and the electric brush are all employed in the examination of such a patient, in order to decide as to the extent, character, and degree of the existing paralysis.

If the *ophthalmic nerve* be the seat of anæsthesia, we may observe a contracted state of the pupil,² insensibility of the mucous lining and integument of the upper eyelid, insensibility of the skin of the forehead and the external and inferior parts of the nose, and a total absence of the sense of contact in the anterior portions of the mucous membrane of the nostril.

If the *superior maxillary nerve* alone be affected, the skin and mucous lining of the lower eyelid, the integument of the cheek, lower half of the nose, and the corresponding half of the upper lip, show an entire or partial abolition of sensibility; while the mucous membranes of the middle and posterior portions of the nasal cavity, of the roof of the palate, and the entire soft palate and uvula, are similarly affected. The teeth and gums of the upper jaw will also be in the anæsthetic condition.

If the *inferior maxillary nerve* be the seat of disease, without impairment of the motor root of the nerve, the integument of the outer surface of the ear, above the auditory canal,³ of the temporal region, of the corresponding half of the lower lip, and in front of the temporo-maxillary articulation, will be destitute of sensibility. The mucous membrane of the corresponding side of the lower lip, tongue, cheek, tonsil, and gum of the lower jaw will be also anæsthetic, while the teeth of the

¹ See investigations of Daniellsen and Boeck, as quoted by Rosenthal.

² For effects of nerve influences on the pupil, see page 379 of this volume.

³ For researches of Hilton on this point, see page 404 of this volume.

corresponding side of the lower jaw will likewise be deprived of sensibility.

If you will recall the points which were made in reference to the effects of section of the trigeminus, you will be better able to understand why paralysis of any portion of this nerve should be followed by symptoms of late development, due, apparently, to some alteration in the nutrition and reactive power of the regions supplied by the nerve which is diseased. You will remember that the existence of certain unnamed fibers, called "trophic fibers," was mentioned, whose close connection with the sympathetic nerve is highly probable, and whose function seems to be to control and regulate the blood supply of the regions to which they pass. Now, it is clinically observed that the paralysis of any of the three large branches of the trigeminus is followed by certain ulcerative and suppurative processes in the regions rendered anæsthetic, and that these effects are the most prominent and serious when the ophthalmic nerve is affected.

Landmann and Bell were the first observers to point out that, in the human subject, purulent destruction of the eye was liable to follow pressure upon the trigeminus from tumors in the region of the ganglion of Gasser; while Magendie (1824), Bock (1844), Snellen (1858), Spencer Watson (1874), Samuel (1860), and Meissner have done much to bring the results of defective nutrition, following impairment of nerve supply, to professional notice. It might add much to the interest of this volume to enter into the details of the interesting experiments and clinical observation, which have now become quite extensive regarding this subject, but it will exceed the scope of this course to more than hastily sketch the results obtained. The opinion of Snellen, that the ulceration of the cornea and the suppurative conjunctivitis which follows anæsthesia of the ophthalmic nerve were the mechanical effects of the irritation of dirt which the conjunctiva was no longer capable of perceiving, seems to have been confirmed by Watson¹ and Baerwinkel,² who found that an artificial cleans-

¹ "Med. Times," 1874.

² "Arch. f. klin. Med.," 1874.

ing and closure of the eyelids caused recovery, without any effect upon the nerve condition. It was apparently also proven by Bock and Samuel that the condition of anæsthesia was not necessary to the development of these later processes, resulting in destruction of tissue, since the same results were observed when hyperæsthesia existed. In reference to the course of the "trophic fibers" of the ophthalmic nerve, the researches of Meissner and Schiff¹ seem to locate their situation in the central portion of the nerve, since the other parts seem to preside over sensation only. Finally, the interesting experiments of Sinitzin,² made in 1871, show some remarkable effects of the removal of the superior cervical ganglion of the sympathetic nerve upon trigeminal ophthalmia; since it was often cured when once started, and prevented in every case where it was done before the trigeminus was divided.

We know, irrespective of the theories of its causation, that the destruction of the sensory root of the fifth nerve is liable to be followed by destruction of sight, interference with the sense of smell, ulceration of the nose and gums, a tendency to inflammation and abscess of the soft tissues, and, possibly, to gangrene.

It is of practical importance, however, to discriminate between that form of trigeminal anæsthesia dependent upon *central lesions* and that due to *external pressure or disease*.

We may remember that the *central form* is usually confined to the inferior maxillary portion of the nerve; that a previous history of cerebral disease will often be found; that paresis or paralysis of the muscles of the face, tongue, jaws, or limbs will possibly coexist; and that, if the lesion be a tumor at the base of the cerebrum, cephalalgia, neuralgias of special branches of the trigeminus, and a simultaneous affection of some of the adjacent nerves of the cranium may be discovered.

If the cause is *outside of the cranium* (provided it be not due to syphilis, rheumatic diathesis or traumatism), we may expect to find evidences of the previous existence of abscess,

¹ "Centralbl.," 1867.

² "Med. Centralbl.," 1871.

periostitis of some of the osseous canals through which the various branches of the trigeminus pass, or of local tumors which are creating pressure upon some nerve trunk or its terminal filaments.

The *motor root of the fifth nerve may be impaired* from the pressure exerted by meningeal exudation, extravasations of blood, or tumors within the cranium; while it is frequently involved (after the sensory portion of the trigeminus) during the development of some type of basilar affection. The results are manifested by a paralysis of the muscles of mastication upon the side where the nerve is diseased, except the buccinator muscle, which derives its motor power from the facial nerve. The healthy muscles of the opposite side tend to crowd the lower jaw toward the affected side of the face during mastication, giving a peculiar expression during the act of eating.

DIAGNOSTIC VALUE OF THE FIFTH NERVE.

To what extent the distribution of the fifth nerve is of practical value in diagnosis may be estimated by the perusal of the lectures¹ of Sir John Hilton upon the significance of pain and the use of rest as its cure. Cases have been reported by Paget, in his lectures on surgical pathology, and also by Anstie,² where the hair of the entire scalp has turned white after a severe attack of neuralgic headache; and another is reported by Anstie, where the *hair of the eyebrow* alone became perfectly blanched from pain in that region dependent upon the supra-orbital nerve. Hilton reports a case where the *hair of the temple*, from the irritation excited in the dental branches of the fifth nerve through a decayed molar tooth, became suddenly gray (the temple being the region supplied by the auriculo-temporal branch of the same nerve); and another where an obstinate form of ulcer in the auditory canal, which was very painful, and had withstood all methods of treatment, was cured by the extraction of a decayed tooth in the upper jaw; again illustrating the fact that irritation of

¹ "Rest and Pain," London (New York, 1879).

² "Lancet," 1866.

one branch (the dental) can create disease at the seat of distribution of another branch of the same nerve (the auriculo-temporal).

The *temporo-maxillary articulation* has often been known to assume a condition of immobility during an attack of ear-ache, and to be immediately relieved by the application of an anodyne to the terminal filaments of the fifth nerve in the canal; thus illustrating the effect of irritation of one branch (the auriculo-temporal) upon the others which supply the muscles of mastication, causing them to contract and thus fix the joint.

Again, a *furred condition* of the *lateral half of the tongue* may almost be considered a pathognomonic sign of some source of irritation to the fifth nerve, which thus manifests itself in the peripheral distribution of one of its branches (the gustatory nerve).¹

Chronic *ulceration of the cornea* has also been reported by Anstie as a symptom produced by some source of irritation of the fifth nerve, far removed from the seat of disease.

The intimate communication of the internal portions of the mouth with the eye, ear, and nose often accounts for many curious symptoms, which it would be difficult to account for, did we not know that pain may be *felt at any branch* of a nerve, when one of its trunks is irritated. I have, at the present time, a patient under my care, who is suffering from an obstinate ulceration of the tongue, and who had, previous to his consulting me, been treated for an inflammatory condition of the ear, on account of a constant and severe pain, which was considered as separate and distinct from the trouble which was, at the same time, affecting his tongue. A simple gargle of opium, which I ordered him to hold for fifteen minutes in his mouth at intervals, relieved the symptom in a very short time.

A case is reported by Hilton where an *enlarged cervical gland* appeared with a simultaneous *discharge* from the *auditory canal*, and where the explanation, by which a decayed

¹ Bransby Cooper; John Hilton.

tooth was diagnosed as the cause of the condition, was as follows: The irritated dental branches of the fifth nerve caused an inflammation of the auditory canal, which is supplied by another branch (the auricular of the auriculo-temporal); this inflammation was followed by suppuration and excoriation of that canal, and, subsequently, by absorption of the discharges by the lymphatic vessels, thus producing the enlarged gland of the neck. This explanation may seem a roundabout way of reaching a diagnosis, but the result of drawing the tooth proved, in this case, how well anatomy may guide us, if we only follow its teachings.

Earache may not always be due to the fifth nerve, even when it is confined to the external portion of the organ, since the second cervical nerve supplies the *lower* and *back part* of the external ear, so that pain in that region should lead us also to look for some cause of irritation to that nerve.

The distribution of nerves to the scalp, as shown in the figure on page 405, renders the symptom of pain, in any portion of the scalp, one which may guide us in looking for its cause; since, if it is confined to the *anterior* and *lateral aspects* of the head, the fifth nerve is probably affected by some source of irritation (and a reference to the cut will tell you which branch of the nerve is distributed to the seat of pain), while, if confined to the *posterior portion* of the scalp, the occipital nerves are affected, and disease of the spine may be suspected, in the region of the first or second cervical vertebræ.

The distribution of the fifth nerve to the *conjunctiva*, both of the globe of the eye and also of the lids, exhibits, to a wonderful degree, the axiom given you in the first lecture of the course, as to the harmony of action between the sensory nerves of the skin, the muscles adjacent, and the joints which they move; since these parts stand very much in the same general relation to each other, if the movable point in the eyelids be taken as a joint, and the muscles of the lids as those which move it.

An analogy has been drawn by a prominent author¹ between a common two-rooted spinal nerve and a great "compound nerve" of the head, whose *sensory root* corresponds to the sensory portion of the fifth nerve, and whose *motor root* comprises the third, fourth, fifth (its motor portion), sixth, and seventh cranial nerves, which, together, form the motor root of this compound nerve. Most of the reflex acts which are exhibited in the regions of the head and the upper portion of the neck can be explained by the free communication which exists between the sensory root of this "compound nerve" and its different motor branches.

It seems useless to further incorporate such cases, which go to prove that only by a thorough familiarity with anatomy are we enabled to explain the many phenomena which often puzzle the practitioner; and that, if we will but use it as a guide, diagnosis may be greatly simplified, and an easy remedy often discovered for the symptoms.

SURGICAL ANATOMY OF THE FIFTH NERVE.

Surgical operations are often demanded for the relief of those tormenting neuralgias which affect the branches of the fifth nerve.

The simple division of a nerve is, at present, seldom practiced, owing to the certainty of prompt reunion of the nerve divided. Resection of not less than *two inches of its length* is usually required to make reunion impossible, or very remote in point of time. It has been proposed to turn the peripheral extremity of the nerve backward after section, or to interpose muscle or fascia, to prevent the possibility of union.² Exposure and stretching of spinal nerves for the relief of neuralgia have been proposed by Von Nussbaum, but are not usually practiced upon the cranial nerves.

The *supra-orbital nerve* may be thus divided :

Pass a narrow knife, subcutaneously, from a point two or three lines on the inner side of the *supra-orbital notch*, out-

¹ John Hilton, "Rest and Pain."

² S. W. Mitchell.

ward, until the point has passed beyond the notch; then turn the blade backward, and cut down to the bone. To resect the nerve, make a one-inch incision above and parallel to the supra-orbital arch; seize the cut ends of the nerve in the wound, and remove it to the desired extent.¹

To excise the *superior maxillary nerve*, a crucial incision is made over the *infra-orbital foramen*, and, by the use of a small trephine, the anterior wall of the antrum is opened so as to include the foramen. The lower wall of the infra-orbital canal is now broken with a chisel as far as the sphenomaxillary fossa, and the nerve is then *divided* at the *foramen rotundum* with a pair of scissors sharply curved. Meckel's ganglion is frequently removed with the excised nerve.²

To divide the *inferior dental nerve*, the incision may be made within the mouth or externally. If the trunk is to be removed, before the nerve enters the canal in the lower jaw, the external incision is made from the *sigmoid notch* to the edge of the jaw. The parotid gland is then turned backward, and the lower portion of the masseter muscle detached. A section of bone is now removed with a trephine, and the dental artery is tied, in case it be wounded; the nerve may then be divided, and a half inch of it, which will be found to be exposed, resected.

In the *intra-buccal operation*, the corner of the mouth is held wide open, and an incision one inch in length is made along the *anterior* part of the *ramus* of the jaw, through the fibers of the internal pterygoid muscle. This muscle is then loosened from the periosteum by the finger, where the nerve can be easily felt, at its entrance into the dental canal, and there divided.

THE GANGLIA CONNECTED WITH THE FIFTH NERVE.

In the cut which illustrates the distribution of the branches of the fifth nerve will be perceived four ganglionic enlarge-

¹ J. N. Warren.

² J. R. Wood.

ments, exclusive of the ganglion of Gasser, which are connected with the nerve, and which have a most important function as regards the tissues to which these branches are distributed.

As you will notice, the first is connected with the ophthalmic division, and is situated within the orbit. It is called the "ophthalmic ganglion," from its attachment; also the "lenticular ganglion," from its shape; and the "ciliary ganglion," since it gives off the ciliary nerves to the iris and the muscle of accommodation of vision. Like all the ganglia of the sympathetic nerve, it has a *motor root*, a *sensory root*, and a *sympathetic root*, and it furnishes *branches of distribution* to neighboring parts.

The second is called "Meckel's ganglion," after its discoverer; and the "spheno-palatine ganglion," since it is chiefly distributed to the region of the palate. It is situated in the *spheno-maxillary fossa*, and sends branches to the orbit, nose, hard and soft palate. It lies in close relation with the superior maxillary nerve.

The third is called the "otic ganglion." It lies upon the inferior maxillary nerve *below the foramen ovale*, and sends branches to the two tensor muscles, viz., the tensor tympani and the tensor palati. It is thus physiologically associated with the acts of *hearing* and *deglutition*.

The fourth is called the "submaxillary ganglion," since it lies above the submaxillary gland. It is by means of the distribution of the *chorda tympani nerve* to this ganglion that some physiologists attempt to explain the apparent effect which that nerve has upon the sense of taste in the anterior two thirds of the tongue.¹

The following table² will perhaps assist you in remembering the special points of each of these ganglia, as it shows the various sources of supply to each, as well as branches of distribution :

¹ See previous portion of this chapter, where the gustatory nerve is discussed.

² After Keen.

THE GANGLIA OF THE FIFTH CRANIAL NERVE.

Name.	Situation.	Sensory root.	Motor root.	Sympathetic root.	Branches of distribution.	
CEREBRAL GANGLIA.	OPHTHALMIC or CILIARY.	Between the <i>optic nerve</i> and <i>ext. rectus</i> .	5TH NERVE— <i>Nasal</i> branch.	3D NERVE.	CAVERNOUS PLEXUS.	To ciliary muscle and iris.
	MECKEL'S or SPHENOPALATINE.	<i>Spheno-maxillary fossa</i> .	5TH NERVE— <i>Spheno-palatine</i> branches.	7TH NERVE, through <i>Vidian</i> and <i>large petrosal</i> branches.	CAROTID PLEXUS, by means of <i>Vidian nerve</i> .	Orbital, nasal, naso-palatine, anterior or large palatine, middle or external palatine. Post. or Levator palati, small } Palato-glossus, palatine }
	OTIC.	Below the <i>foramen ovale</i> .	5TH NERVE— <i>Auriculo-temporal</i> branch.	7TH NERVE, through <i>small petrosal</i> . 5TH NERVE, through <i>int. pterygoid</i> branch.	Plexus on the MIDDLE MENINGEAL ARTERY.	To tensor tympani and tensor palati muscles.
	SUBMAXILLARY.	Above the <i>submaxillary gland</i> .	5TH NERVE— <i>Lingual</i> or <i>gustatory</i> branch.	7TH NERVE, through <i>chor-da tympani</i> branch.	Plexus on the FACIAL ARTERY.	To submaxillary gland and mucous membrane of the mouth.

By reference to the above table, you will perceive that the *sensory root* of each of the four ganglia is derived from the *fifth* cranial nerve by means of some of its branches; that the *motor root* is derived, in three cases out of four, from the *seventh* cranial nerve; and, finally, that in every case is the sympathetic root derived from a *plexus* upon some neighboring blood-vessel.

THE ABDUCENS, OR SIXTH NERVE (MOTOR OCULI EXTERNUS).

The apparent origin of this nerve is from a *groove* between the *anterior pyramid* of the medulla oblongata and the *posterior border* of the *pons Varolii*. The nerve may be said to possess two roots, one of which can be traced into the pyramidal body of the medulla, and the other into the *pons Varolii* itself. This latter root is sometimes wanting.

Its deep origin has been traced by Lockhart Clarke to a nucleus in the gray matter of the fourth ventricle of the brain, on the outer side of the *locus cæruleus*.

This nerve is purely motor in its function, and is distributed to the external rectus muscle of the eye.

The most careful researches of Vulpian have as yet failed to discover any decussation of the deep fibers of this nerve, and there would seem to be a physiological explanation for the absence of such an arrangement, since the two external recti muscles are seldom called into simultaneous action,¹ and the normal movements of the eyes are opposed to such a position as would ensue if they should act in common.

The sixth nerve anastomoses with the *sympathetic nerve* in the cavernous sinus, where it receives filaments from both the carotid plexus and from Meckel's ganglion; and a few sensory filaments are said to be given to it in this locality from the ophthalmic branch of the fifth cranial nerve.

Occasionally, this nerve sends a filament to the *ophthalmic ganglion*, and thus to the *iris*, and it is claimed by Longet that this arrangement (which is an exceptional one) exists in those cases of paralysis of the motor oculi nerve in which there is no apparent effect produced upon the mobility of the pupil.

This nerve has no practical importance to the diagnostician, save the one fact that, in case it be paralyzed, the eye will present the condition of *internal strabismus*; that the *apparent size* of the objects perceived by the retina is *magnified*;² and that the head will be so deflected as to avoid the perception of double images.³

The explanation of both of these effects, as the result of

¹ After the eyes have been drawn inward, as in attempts to focus near objects, these muscles help to restore the axes of vision to a state of parallelism.

² For explanation of this symptom, the reader is referred to page 389 of this volume.

³ See page 386 of this volume.

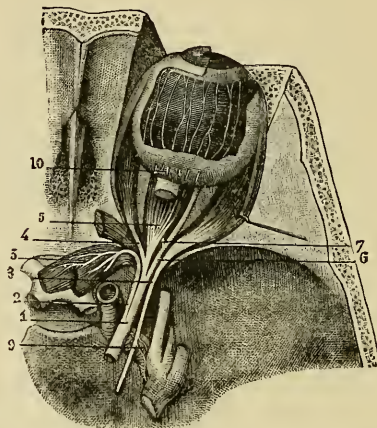


FIG. 108.—Distribution of the motor oculi externus. (Hirschfeld.)

1, trunk of the motor oculi communis, with its branches (2, 3, 4, 5, 6, 7); 8, motor oculi externus, passing to the external rectus muscle; 9, filaments of the motor oculi externus anastomosing with the sympathetic; 10, ciliary nerves.

paresis of certain ocular muscles, has already been given in the previous lecture upon the third cranial nerve, and need not be again repeated. It should not be forgotten, however, that internal strabismus is not always due to paralysis of the external rectus muscle, but may indicate a condition of congenital or acquired hyperopia, causing a weakness of the external rectus muscle.

THE FACIAL, OR SEVENTH NERVE.

This nerve has its apparent origin from a *groove* between the *olivary* and *restiform bodies* of the medulla oblongata, and, like the three preceding, has its chief origin in a gray *nucleus* in the floor of the fourth ventricle, in the upper half of that space near to the postero-median fissure.¹ The filaments of origin, within the substance of the medulla oblongata, may be traced as a fan-like expansion upon the floor of the fourth ventricle, some of which terminate in the gray nucleus, above described, of the same side as that on which the nerve escapes, while other fibers may be seen to *decussate*, thus passing to the nucleus of the opposite side. No filaments have as yet been satisfactorily traced upward beyond the limits of the medulla.² This nerve accompanies the nerve of hearing throughout the whole length of the *internal auditory canal*, and there communicates with it by a few filaments. It then enters a curved canal within the temporal bone, called the *aqueduct of Fallopius*, where it gives off the three petrosal nerves and the chorda tympani branch, whose physiological action has been already considered in connection with the fifth nerve. From this canal, it escapes through the *stylomastoid foramen*, having, before its exit, given a tympanic

¹ Lockhart Clarke. An accessory portion of this nerve—the “*nerve of Wrisberg*”—conveys fibers to it, whose deep origin may be traced to the lateral column of the cord. Its importance is now being extensively discussed, as having a connection with the chorda tympani nerve. An inferior facial nucleus exists in the pons.

² The deep origin of the fibers of the facial nerve seems to have some connection with the upper portions of the encephalon (as shown by the clinical facts mentioned in previous pages, when discussing “crossed paralysis”); the little that is positively known concerning the course and termination of these fibers has been discussed already.

branch to the ear.¹ In the region of the stylo-mastoid foramen, it *communicates with five nerves*, namely, the great auricular (a branch of the cervical plexus), the auriculo-tem-

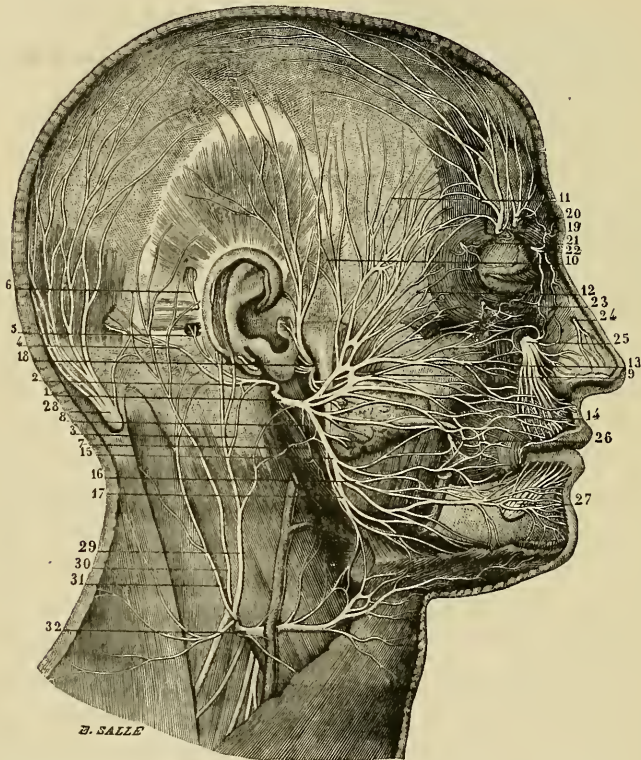


FIG. 109.—*Superficial branches of the facial and the fifth.* (Hirschfeld.)

1, trunk of the facial ; 2, posterior auricular nerve ; 3, branch which it receives from the cervical plexus ; 4, occipital branch ; 5, 6, branches to the muscles of the ear ; 7, digastric branches ; 8, branch to the stylo-hyoid muscle ; 9, superior terminal branch ; 10, temporal branches ; 11, frontal branches ; 12, branches to the orbicularis palpebrarum ; 13, nasal, or suborbital branches ; 14, buccal branches ; 15, inferior terminal branch ; 16, mental branches ; 17, cervical branches ; 18, superficial temporal nerve (branch of the fifth) ; 19, 20, frontal nerves (branches of the fifth) ; 21, 22, 23, 24, 25, 26, 27, branches of the fifth ; 28, 29, 30, 31, 32, branches of the cervical nerves.

poral (a branch of the fifth nerve), the pneumogastric, the glosso-pharyngeal, and the carotid plexus of the sympathetic ; and, subsequently, it divides and is distributed to the muscles.

The facial is the great motor nerve of the muscles of the

¹ Occasionally also the *filament of communication* to the pneumogastric nerve.

face; hence the *nerve of expression*.¹ It supplies, in addition to the facial muscles, the muscles of the external ear;

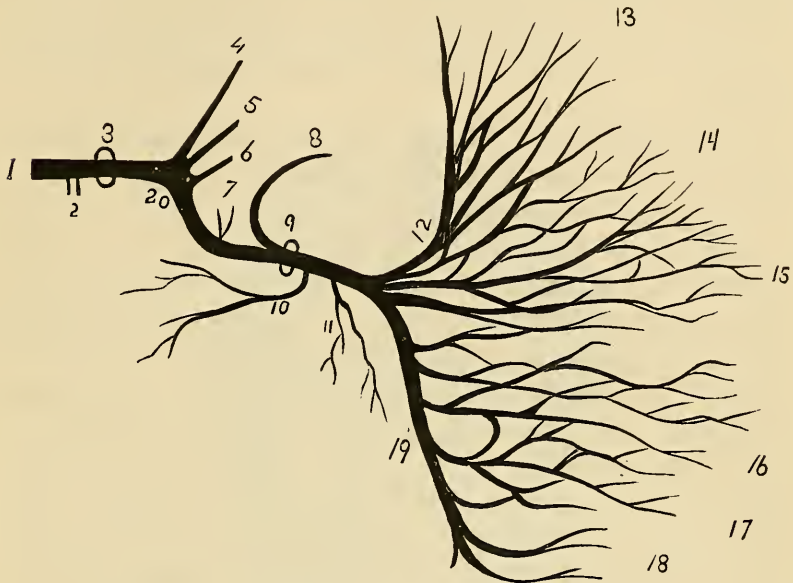


FIG. 110.—A diagram of the branches of the facial nerve.

1, main trunk of nerve in internal auditory canal; 2, branches of communication with AUDITORY NERVE; 3, orifice of aqueduct of Fallopius; 4, large petrosal nerve; 5, small petrosal nerve; 6, external petrosal nerve; 7, filaments to the *laxator tympani* muscle; 8, *chorda tympani* nerve; 9, stylo-mastoid foramen; 10, posterior auricular nerve; 11, filament supplying the *stylo-hyoid* and *digastric* muscles; 12, the TEMPORO-FACIAL division of the nerve; 13, the *temporal* branches; 14, the *malar* branches; 15, the *infra-orbital* branches; 16, the *buccal* branches; 17, the *supra-maxillary* branches; 18, the *infra-maxillary* branches; 19, the CERVICO-FACIAL division; 20, "*intumescentia ganglioformis*"—the seat of origin of the petrosal nerves.

three muscles of the neck, namely, the stylo-hyoid, posterior belly of the digastric, and the platysma; one muscle of the middle ear, the stapedius; and one muscle of the palate, the levator palati.² By means of the chorda tympani branch, it controls the secretion of the parotid and submaxillary glands, and, possibly, the sense of taste.³ By the large pe-

¹ Sir Charles Bell.

² Schiff, 1851; Bernard. Possibly also some other muscles, by means of the lingual branch, described by Hirschberg.

³ Sappey; Hirschfeld; A. Flint, Jr.; J. C. Dalton. The fibers of the chorda tympani nerve, by some of the later authorities, are said to arise from an intermediate nerve formed by a branch from both the seventh and eighth cranial nerves, and called the "*portio intermedia*" or "*nerve of Wisberg*."

trosal branch, the levator palati and azygos uvulæ are supplied; and, by the small petrosal branch, the tensor tympani and tensor palati muscles are furnished with motor power.

Several interesting articles have lately appeared upon the subject.¹

It is claimed by Vulpian that the facial nerve also contains *vaso-motor fibers*, which are distributed to the vessels of the tongue and side of the face.

The effects of paralysis of the facial nerve were first brought to professional notice by Sir Charles Bell, who divided it for facial neuralgia, and the characteristic deformity which resulted is still known under the name of "Bell's paralysis." In this condition, the affected side loses its normal expression, and becomes abnormally smooth on account of the obliteration of the normal lines and wrinkles, due to the action of the antagonistic muscles on the healthy side.² The patient loses all power of closing the eye of the affected side even in sleep, since the orbicularis palpebrarum muscle is paralyzed; the mouth is no longer symmetrical, since it is drawn toward the healthy side; the saliva is with difficulty retained; and the act of whistling becomes an impossibility, as the lips can not be systematically governed. This condition may be produced by exposure to severe cold, as in sleigh-riding; by abscess or tumors of the parotid region, as the result of the pressure created; by diseases of the ear or injuries to the temporal bone, which impede the free action of the nerve; and by cranial lesions. It is particularly important that the surgeon should familiarize himself, not only with the situation and course of the main trunk of this nerve, but also with the course of its branches, previous to performing operations about the face, or in the vicinity of the mastoid process, and in the upper portions of the neck.

¹ Vulpian, "Lancet," 1878; H. R. Bigelow, "Brain," 1876; E. C. Spitzka "Medical Record," 1880.

² Hence the aptness of the remark by Romberg, as quoted by Hammond, that "there is no better cosmetic for elderly ladies than facial paralysis."

The distribution of this nerve to the muscles of the palate and to the stylo-hyoid explains the *impairment of deglutition* when the facial nerve is paralyzed; while the filament to the stapedius muscle may create modifications in the *sense of hearing* under similar conditions.¹



FIG. 111.—*Bell's paralysis.* (Modified from Corfe.)

The following tabulated arrangement of the branches of the seventh nerve² will possibly prove of service to you as an aid to memory during your student life; and, as a guide for reference or review in your professional labors, such tables are always of value :

¹ The *tensor tympani muscle* may also be involved.

² Copied from "The Essentials of Anatomy": Darling and Ranney, New York, 1880.

TABLE OF THE BRANCHES OF THE FACIAL NERVE.

SEVENTH CRANIAL, OR FACIAL NERVE.	{ Branches of communication.	In the <i>auditory canal</i> .	Branch to auditory nerve.
		In the <i>aqueduct of Fallopius</i> .	{ <i>Large petrosal</i> (to Meckel's ganglion). <i>Small petrosal</i> (to otic gangl'n). <i>External petrosal</i> (to meningeal plexus).
		At its exit from the <i>stylo-mastoid foramen</i> , with the following nerves :	Tympanic branch. Great auricular. Auriculo-temporal. Pneumogastric. ¹ Glosso-pharyngeal. Carotid plexus.
		On the face.	Branches to fifth cranial nerve.
		In the <i>aqueduct of Fallopius</i> .	{ <i>Tympanic nerve</i> . <i>Chorda tympani nerve</i> . Posterior auricular nerve.
	{ Branches of distribution.	Near the <i>stylo-mastoid foramen</i> .	Diagastric branch. Stylo-hyoid branch. <i>Lingual branch</i> . ²
		On the face.	Temporo-facial nerve. Cervico-facial nerve.

If you will look at this diagrammatic drawing (Fig. 63), you will perceive how simple is the arrangement of the *branches of communication* between the facial nerve and the fifth cranial nerve and its ganglia. While the drawing is intended to be purely schematic, still it also illustrates some of the anatomical points pertaining to the course and formation of the *Vidian nerve*, as well as the relations of the *chor-da tympani nerve* to the *membrana tympani*, as it passes through the middle ear to reach the canal of Huguier.

There is a practical point pertaining to the *deep origin* of the fibers of the facial nerve, which may often be of value in determining the seat of pathological lesions within the substance of the brain. In hemiplegia, especially in that variety which is due to hæmorrhage, the face is sometimes affected upon the same side as the body and sometimes upon the opposite side, thus being impaired, respectively, either upon the side opposite to the cerebral lesion or upon the same side as the lesion. To explain these phenomena theoretically, we

¹ This communicating filament is given off in the *aqueduct of Fallopius* as often as at the stylo-mastoid foramen.

² Described by Hirschberg. Supplies the *stylo-glossus* and *palato-glossus* muscles and the tongue.

must suppose that the facial nerve fibers are affected by the lesion within the brain *before they decussate* (following them from within outward), in case the face is paralyzed on the *same side as the lesion*; and that the *decussating fibers* are

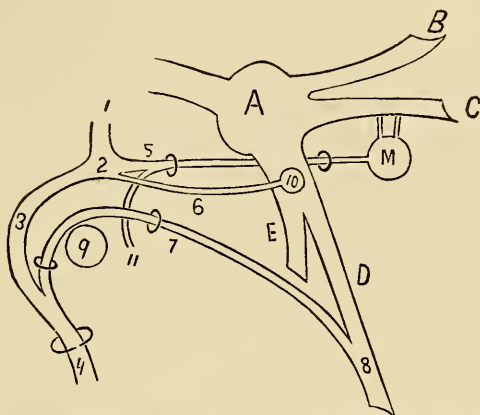


FIG. 112.—A diagram to show the relations between the facial nerve and some portions of the fifth nerve.

A, Gasserian ganglion; B, ophthalmic nerve; C, superior maxillary nerve; D, inferior maxillary nerve (sensory portion); E, inferior maxillary nerve (motor portion); M, Meckel's ganglion; 1, facial nerve, entering the aqueduct of Fallopius; 2, *intumescencia ganglioformis* (an enlargement on the nerve); 3, facial nerve, following the curve of the aqueduct of Fallopius; 4, facial nerve, escaping from stylo-mastoid foramen; 5, large petrosal branch, joining carotid filament 11 to form the Vidian nerve, and entering the Vidian canal; 6, small petrosal branch, going to "otic ganglion" 10; 7, chorda tympani nerve, escaping from the canal of Huguier after winding over the upper border of drum membrane of ear; 9, 8, gustatory nerve, joining with the chorda tympani nerve; 9, external drum membrane of the ear; 10, otic ganglion; 11, filament from carotid plexus to form the Vidian nerve; 12, the *iter chordæ posterius*, admitting the chorda tympani nerve into the cavity of the middle ear.

pressed upon or destroyed by the lesion, in case the face be affected on the *same side as the body*.

Now, it has been observed as a pathological fact, that when a lesion involves parts of the encephalon *anterior* to the pons Varolii, the phenomena dependent upon paralysis of the facial nerve are perceived on the same side as the hemiplegia; while, if the lesion be situated either in the lower part¹ of the pons Varolii or below it, the face is paralyzed on the same side as the lesion, or on the side opposite to the hemiplegia.

¹ Gubler has shown that the facial nerve is not paralyzed upon the same side as the lesion, if the injury to the pons Varolii be anterior to the imaginary line drawn through the points of escape of the trigemini.

For this reason, the occurrence of crossed paralysis of the facial nerve¹ and body type has been received as a most positive indication of a lesion situated upon the side of the brain corresponding to the facial paralysis, and either within the substance of the pons Varolii or in parts of the encephalon posterior to it. Such clinical facts as these seem positively to indicate that some of the deep fibers of the facial nerve pass *upward into the cerebrum*, and that the decussation of the filaments of origin within the floor of the fourth ventricle is of little physiological importance compared to these other fibers; but, unfortunately, no anatomical investigations have, so far, discovered fibers of this nerve which could be clearly demonstrated as passing upward beyond the pons Varolii.

It has been often noticed by different observers that, in case the facial nerve was paralyzed, the *uvula* and *soft palate* were affected and drawn toward the healthy side by the antagonistic muscles, whose motor power remained unimpaired. Later investigation has shown, however, that this affection of the palate only occurs in those cases of paralysis due to impairment of the facial nerve within the *aqueduct of Fallopius*, or from some cranial lesion which affects its *filaments of origin*.²

The experiments of Bernard seem to demonstrate that the *facial nerve*, and not the glosso-pharyngeal alone, is connected with movements of the *velum palati*, but not with the movements of the pillars of the fauces. The construction of the small petrosal branch, however, being composed partly of fibers derived from the glosso-pharyngeal nerve, may still justify a doubt upon this point.

Hirschfeld describes a small filament, which the facial nerve gives off soon after it emerges from the stylo-mastoid foramen, "*the lingual branch*,"³ which is distributed to the tongue and to the *stylo-glossus* and *palato-glossus* muscles.

¹ A term used to cover those forms of paralysis where the face is paralyzed on the side opposite to the side of the body affected.

² The petrosal nerves, which carry the motor fibers to these muscles, must be impaired to cause any deflection of the palate.

³ See table on page 428.

This may possibly explain the observation of Bernard: that paralysis of the facial nerve, after section, produces a deviation of the *tip of the tongue*; and the same effect has been, at different times, recorded as the result of paralysis of the facial nerve from intra-cranial causes.

BRANCHES OF COMMUNICATION OF THE FACIAL NERVE.

Some of the branches of communication which are given off by the facial nerve, to join with other nerves, or to be distributed to ganglia, are of physiological importance. Thus the *levator palati* and the *azygos uvula* muscles derive their motor power from the *large petrosal* branch after it enters Meckel's ganglion;¹ while the *palato-glossus* and *palato-pharyngeus* muscles probably derived their motor power

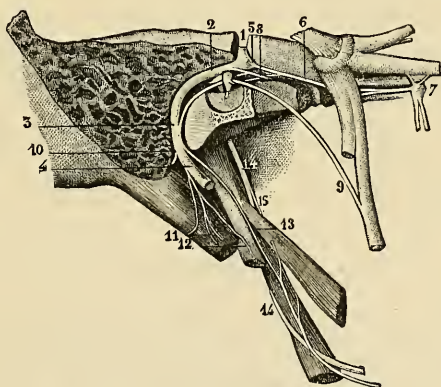


FIG. 113.—*Chorda tympani* nerve. (Hirschfeld.)

1, 2, 3, 4, facial nerve passing through the aqueduct Fallopii; 5, ganglioform enlargement; 6, great petrosal nerve; 7, sphenopalatine ganglion; 8, small petrosal nerve; 9, *chorda tympani*; 10, 11, 12, 13, various branches of the facial; 14, 14, 15, glossopharyngeal nerve.

from the communicating filament between the facial and the glossopharyngeal nerves, as shown by Longet. This distribution explains, in part, why more or less difficulty is perceived in *deglutition* after division or paralysis of the facial nerve, and still more clearly why the *pronunciation of certain words* becomes impaired, and the expulsion of mucus from the back

¹ Gray, Quain, Sappey, and others.

portion of the mouth and from the pharynx is an act of extreme difficulty.

The communication of the cervical plexus with the *posterior auricular* branch of the facial affords *sensory filaments* to the parts over the muscles which that nerve supplies.

The filament of communication between the *facial* and the *auditory* nerves enables the muscle of the middle ear supplied by the facial¹ to act in harmony with the acoustic apparatus; while the communication between the *fifth nerve* and the *facial* enables the latter to follow that general axiom² of nerve distribution by which the skin over the insertion of

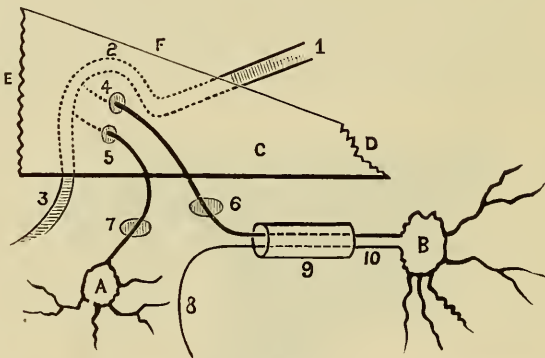


FIG. 114.—A diagram to show the course of the large and small petrosal nerves and the Vidian nerves.

A, *otic ganglion*; B, *Meckel's ganglion*; C, *petrosal portion* of the temporal bone (its apex corresponding to the carotid canal at the base of the skull); D, *petrosal portion* of the temporal bone (its base corresponding to the external auditory meatus); E, *petrosal portion* of the temporal bone (its superior border, separating the middle and posterior fossæ of the skull); 1, the *facial nerve* entering the petrosal portion of the temporal bone by means of the "*meatus auditorius internus*"; 2, the *facial nerve* following the curve of the "*aqueduct of Fallopius*"; 3, the *facial nerve* escaping from the temporal bone by means of the "*stylo-mastoid foramen*"; 4, the *large petrosal nerve*, escaping into the cavity of the cranium by means of the "*hiatus Fallopii*"; 5, the *small petrosal nerve*, escaping into the cavity of the cranium by a foramen of its own; 6, the "*foramen basis cranii*," affording passage for the large petrosal nerve out of the cranium; 7, the "*foramen ovale*," affording passage for the small petrosal nerve out of the cranium, and thus to the *otic ganglion*; 8, a filament from the *carotid plexus* of the sympathetic nerve, joining the *large petrosal nerve* to form the *Vidian nerve*; 9, the *Vidian canal*, transmitting the *Vidian nerve* to *Meckel's ganglion*, B; 10, the *Vidian nerve*.

muscles is supplied by the same nerve as the muscles themselves.

The communication between the *facial nerve* and the

¹ The stapedius. ² Hilton, "Rest and Pain." See also page 13 of this volume.

pneumogastric might at first seem, to the casual reader, one of accident, rather than of design, on the part of the Creator; but, when we consider how intimately the *respiratory functions* and the *movements of the face* are associated with each other, the design at once becomes evident. Paralysis of the muscles which dilate the nostrils has been shown to have a marked effect upon respiration through the nostril; and, in the horse, which can only breathe through the nose, the effect of division of both of the facial nerves is to produce death from suffocation, since the nostrils collapse. It was this synchronism between the movements of the nostrils and the respiratory act that first led Sir Charles Bell¹ to regard the facial nerve as the one which presided over the function of respiration, and is still often called one of the "*respiratory nerves of Bell.*"

A case is reported by this famous investigator where a patient, afflicted with unilateral facial paralysis, was obliged to lie upon the sound side, and to hold the paralyzed nostril open with the fingers, in order to breathe with comfort.²

The distribution of the facial nerve to the *muscles of the nose* creates an impairment of the *sense of smell*,³ when that nerve is injured, since the free entrance of air is interfered with. The act of *sniffing*, which requires for its complete performance a dilated nostril, is rendered almost if not quite impossible, and thus a contact of odoriferous substances with the mucous membrane of the upper nasal chambers is mechanically interfered with, and acute perception of smell embarrassed.

BRANCHES OF DISTRIBUTION OF THE FACIAL NERVE.

The motor branches of the facial to the *muscles of the ear* are of more importance in animals than in man, since the ear in the animal becomes capable of perceiving sound with acuteness only by a change in its relative position to the head.

The *stylo-hyoid* and the *posterior belly of the digastric* muscles exhibit again the influence of the facial nerve upon

¹ "Lectures on the Nerves."

² *Op. cit.*

³ A. Flint, Jr., *op. cit.*

the act of deglutition ; and the same remark will apply to the *stylo-glossus* muscle.

When the facial nerve has passed through the parotid gland, the two branches distributed to the face, viz., the *temporo-facial* and the *cervico-facial*, become not only motor in their function, but are also supplied with sensory filaments from their communication with other nerves ; so that some of their terminal filaments are distributed to the integument of the face, as well as those derived from the *fifth cranial nerve*, which would not be the case were the nerve not so supplied with sensory nerve fibers.

The filament of the facial nerve which supplies the *platysma muscle* affords a beautiful example of the fact that the nervous supply of the general muscular system, if carefully studied, constantly teaches us points of great physiological value as to the function of individual muscles, since, in the expression of *melancholy*,¹ and in the typical countenance of *thoracic* and *abdominal* diseases,² the platysma muscle plays a most important part, and is therefore supplied by the nerve of expression.

Again, the muscles of the *region of the mouth* are important agents in the prehension of food (especially so in animals, who often can not eat when the lips are paralyzed), and should properly be, in some way, connected with the muscles of mastication (chiefly supplied by the fifth nerve), and those of deglutition (supplied by the facial and the glosso-pharyngeal nerves) ; hence, the facial nerve is afforded communicating branches with both the *fifth* and the *glosso-pharyngeal* nerves.

One of the muscles of the face, the *buccinator*, which is supplied exclusively by the facial nerve, plays a most important part in *mastication* as well as in expression ; hence, when the facial nerve is paralyzed, the cheek can no longer force the food between the teeth, and a tendency toward accumulation of food within the cheek of the affected side becomes so

¹ Carpenter, *op. cit.*

² Sir Charles Bell, "Anatomy of Expression." See, also, article by the author, "The Human Face; its Modifications in Health and Disease, etc.," "New York Med. Jour.," September, 1880.

distressing to the patient that the fingers are frequently employed, during attempts at mastication of the bolus, to force the food between the jaws by pressure upon the external portion of the face.¹

The value of this muscle in *expression* is made manifest in those acts where the cheek is either inflated with air, or where it is drawn inward, thus indicating the states of emaciation or extreme hunger. Much of the success of a comedian often depends upon the control which he possesses over the buccinator muscle. When the *facial nerve* upon *both sides* is paralyzed, mastication is almost as much impaired (on account of the buccinator muscles) as if the *inferior maxillary* nerve was destroyed.

The flaccidity of the buccinator muscle in "Bell's paralysis" accounts for the peculiar *puffing movement* of the cheek which accompanies each act of *expiration*, giving to the face an appearance similar to that noticed when *puffing* of a pipe is attempted; while, in those rare cases where the facial nerve is paralyzed upon both sides, the face assumes a condition which is remarkable for the entire absence of expression, and which can only be compared to the effect of covering it with a mask.

Many of the muscles of the face are of value as *guides in diagnosis*, since, in certain types of disease, some parts of the face are more affected than others.² This subject, however, is too complicated to be hastily reviewed, and it has sufficient value to merit its special consideration.

It may be perceived, by reference to the diagrammatic representation of the branches of the facial nerve, that the *temporo-facial* branch animates all of the muscles of the upper part of the face, while the *cervico-facial* branch supplies the lower region of the face and portions of the neck.³ This explains why, after the *temporo-facial* branch has been divided,

¹ A. Flint, Jr., *op. cit.*

² See article by the author on "The Human Face; its Modifications in Health and Disease, and its Value as a Guide in Diagnosis:" "New York Med. Jour.," December, 1880.

³ See page 425 of this volume.

as has occurred in operations upon the cheek, the *eye stands wide open* even during sleep; the *lower lid becomes everted* from traction of the parts below, and also from the effect of gravity; the occipito-frontalis and corrugator supercillii can no longer make either transverse or perpendicular wrinkles upon the forehead; and the upper portion of the face is abnormally smooth and passive, while the lower portion preserves all its normal power of movement.

Should the *cervico-facial* branch become alone impaired, the power of prehension of food by the lips is arrested, the action of the buccinator in mastication is stopped, and that process is proportionately interfered with; the *digastric* and *stylo-hyoid muscles* are, however, not paralyzed, since the special branches to those muscles are given off above the origin of this branch, and thus deglutition is not embarrassed.

CLINICAL POINTS AFFORDED BY THE FACIAL NERVE.

The diseases which affect the facial nerve may produce the different varieties of *facial spasm* and *paralysis*; the former being the result of some lesion which creates simply irritation, while the latter indicates some existing pressure or degeneration, which impedes the free action of the nerve.

SPASM OF THE MUSCLES OF THE FACE.

In a class of cases, by no means infrequent, facial spasm is perceived, to a greater or less degree, as the result of some cause of irritation to the nerve filaments of the trunk of the facial nerve, or to some of its branches. These mimic spasms, or "convulsive tic," are dependent upon an hereditary tendency, in some instances; since reported cases exist where the second generation, and even the third, has manifested the symptoms of facial spasm. We also meet this condition as an accompaniment of epilepsy, eclampsia, hysteria, tetanus, and chorea; again, in certain mental diseases, where the brain or its investing membranes are affected; and, finally, we see it developed under extraordinary periods of excitement.

Cases are on record where simple exposure, wounds of the

face, and pressure upon the peripheral filaments of the facial nerve have resulted in facial spasm. Perhaps this condition is most frequently met with as an evidence of some *reflex act*, excited through some other cranial nerves; hence we find it associated with such causes of irritation as caries of the teeth, periostitis, inflammatory affections of the eyeball, lids, or conjunctiva. Remak reports a case where a diseased condition of the brachial plexus caused spasms to start in the hand and progress along the side of the neck to the face, again illustrating the reflex character of the disease.

It is such cases as these latter that often test the anatomical knowledge of the diagnostician, since a command of the various anastomoses of nerves often enables the skilled anatomist to detect the seat of irritation far from the apparent seat of disease, and thus to obviate a distressing condition by some simple medicinal or surgical remedy.

The spasms of the facial muscles may assume either the *tonic* or *clonic* character. The former variety is observed in such conditions as tetanus, the late rigidity of paralyzed muscles, and the irritation following upon severe exposure and too intense faradization; while the latter are the most common, and result in those convulsive twitchings of the forehead, eyes, eyelids, nose, mouth, cheeks, and tongue, which produce the most extreme and often ludicrous distortion of the features. I have known such clonic spasms of the face to be produced by the irritation of worms in the intestine in children, and, in one case, to follow uterine disease in an adult. A peculiarity of these spasms is, that certain muscles seem to contract in a regular sequence or rhythm, and that, although the contraction may be prolonged and severe, no fatigue is usually complained of by the patient.

PARALYSIS OF THE MUSCLES OF THE FACE.

The general appearance of a sufferer from a well-marked attack of "Bell's paralysis" has already been depicted in a cut,¹ and described in the preceding text, under the effects

¹ See page 427 of this volume.

of section of the facial nerve; but many points of practical value pertain to this condition which have not as yet been mentioned, and which help greatly in making a diagnosis as to the exciting cause and the seat of the existing lesion. The symptoms produced by any impairment to the free action of the facial nerve vary to a marked extent with the degree of the paralysis, and the individual branches which may be involved; and distinctions between the various forms of facial paralysis, met with in a large clinical field, have been developed, by the investigations of Romberg, from those general propositions first advanced by Bell.

In studying the types of facial paralysis, we may start with advantage by reviewing the different groups which are clinically recognized. These may be enumerated as the *intra-cranial*; the *auditory* (where the existing lesion is confined to the interior parts of the temporal bone); the *rheumatic*; the *traumatic*; the *syphilitic*; and, finally, the *diphtheritic* form. We may also have the paralysis confined to one side of the face, the *unilateral*, or, affecting both sides of the face, the *bilateral*, or *facial diplegia*.

In the *intra-cranial* form of facial paralysis, the lesion of the brain is usually confined either to the base, or to the pons Varolii. If the pons Varolii is affected, the facial nerve will not be alone involved, as a rule, but a partial or complete hemiplegia will usually exist, which will be on the same side of the body as the facial paralysis, provided the upper (anterior) half of the pons is the seat of disease, but on the side opposite to the facial paralysis (crossed paralysis¹), if the lower (posterior) part of the pons is affected. There is, perhaps, no point in the anatomy of the encephalon which is of more certain value to the diagnostician than the fact, first pointed out by Gubler, that a line drawn transversely across the pons Varolii at the points of escape of the trigemini marked the spot of probable decussation of fibers of the facial nerve; so that, if a lesion be anterior to this line, the facial

¹ For definition of this term and the various types met with, the reader is referred to the previous section.

paralysis will correspond to the hemiplegia, but, if behind that line, the condition of "crossed paralysis" of the facial and body type will be produced. A point of some diagnostic value in the detection of intra-cranial lesions, by means of the facial nerve, is afforded by the degree of the facial paralysis, since it is usually complete if caused by lesions of the pons Varolii or by the pressure of tumors of the base of the cerebrum.

The *second form* of facial paralysis, viz., that dependent upon some *abnormal condition within the temporal bone*, is liable to follow suppuration or hæmorrhage within the aqueduct of Fallopius; scrofulous caries of the temporal bone; local degeneration of the nerve within the aqueduct of Fallopius; local pressure upon the nerve from tumors, etc.; and traumatism of all kinds, of sufficient intensity to injure the deeper parts or to directly involve the nerve itself.

If you will recall the anatomy of the facial nerve within the aqueduct of Fallopius, and the branches which are given off in that canal, you will be better able to appreciate the points afforded by this anatomical knowledge in the diagnosis of the seat of a lesion which is causing facial paralysis. We have already, in connection with the effects of section of the facial nerve, mentioned the facial deformity which ensues; and the same description will answer for the effects of disease of the nerve, or pressure upon it, after it has escaped from the stylo-mastoid foramen. But the symptoms to which I now propose to call your attention are not included in that description, since they are due to branches which are given off by the facial nerve before it escapes from the temporal bone; although the same facial deformity, and all the evidences of impairment of the nerve on the distal side of the stylo-mastoid foramen, will, of necessity, be also present.

If the lesion be situated above the point of origin of the chorda tympani, but on the distal side of the petrosal nerves, the *sense of taste* will probably be affected on the correspond-

ing side of the anterior two thirds of the tongue ;¹ but the sense of taste is not, as a rule, abolished, although it is greatly diminished in acuteness. How this nerve affects the sense of taste, and the various experiments which have been recorded concerning it, will be found by reference to preceding pages.²

If the lesion of the facial nerve be situated behind the ganglionic enlargement from which the three petrosal nerves arise, the patient will reveal a depression of the *arch of the palate* upon the affected side ; thus, it will be seen to hang lower than the healthy side, and to approach a straight line along its free edge, rather than that of a marked curve, as in health. This is due to the paralysis of the levator palati muscle, which is supplied with motor power from Meckel's ganglion, through the large petrosal nerve. In addition to this deformity, the *soft palate is drawn toward the unaffected side* by the tensor palati muscle, since the same muscle of the paralyzed side is no longer capable of acting, as it is supplied by the small petrosal nerve. The distribution of the small petrosal nerve to the otic ganglion still further explains why, in this type of cases, the *secretion of the parotid gland* of the affected side is diminished ; while the intimate association of the chorda tympani nerve with the *submaxillary gland* accounts for deficient secretion from that source.

It has been observed that the *sense of hearing becomes excessively acute*, when the facial nerve is affected on the proximal side of the point of origin of the petrosal nerves. This may possibly be due to the paralysis of the tensor tympani muscle, as suggested by Landouzy, since that muscle is supplied with motor power by a filament derived from the otic ganglion ; although the investigations of Brown-Séguard seem to point to a vaso-motor spasm of the internal ear, resulting in a condition of hyperæsthesia of the acoustic nerve.

The third form of facial paralysis occurs in connection

¹ The reader is referred to those pages in which the gustatory branch of the fifth nerve is discussed, since authorities differ as to the value and interpretation of this symptom.

² See page 406 of this volume.

with the *rheumatic diathesis*. It is well known that the influence of cold, which is particularly liable to favor rheumatic manifestations, is more keenly felt in the region of the cheek and eyelids, as shown by Weber; and the experiments of Wachsmuth,¹ upon the effect of cold upon the vaso-motor fibers in the region of the stylo-mastoid foramen, also point to the retardation, or, possibly, the entire suppression, of the blood supply to the facial nerve, as the explanation of this type of paralysis. A mild form of periostitis in the bony canals, through which the different branches of the facial nerve pass, may also occur in the rheumatic type as an exciting cause.

The *traumatic types* of facial paralysis may involve the entire nerve or only individual branches. Its symptoms, therefore, somewhat depend upon the situation and extent of the injury. It has been known to follow severe contusions of the face, cheek, or neck, incisions made by the surgeon, saber cuts and gunshot wounds, the compression exerted by the forceps during delivery, the pressure of growing tumors, supuration within the parotid gland or lymphatics of that region, and the pressure caused by extensive or deep cicatrices. This type of paralysis is often extremely obstinate and of long duration, and may be permanent; since the nerve may have undergone changes in its structure or the muscles may have become impaired.

In *syphilis*, facial paralysis is sometimes developed. It may thus indicate the formation of intra-cranial tumors or meningeal exudations, which either press upon the nerve trunk or interfere with its fibers of origin. It may also be an evidence of extra-cranial lesions, such as periostitis of the mastoid region, tumors of the facial or cranial bones, or supuration dependent upon caries or necrosis of the temporal bone (if the entire nerve be affected), or of some of the facial bones, if individual branches only show evidences of pressure.

Cases are on record where the symptoms of facial paralysis have followed an attack of *diphtheria*. This is but one of

¹ As quoted by Rosenthal.

the various forms of paralysis which are frequently observed as sequelæ of this peculiar blood poison.

It may be well to hastily review the principal complications which are most frequently observed in connection with facial paralysis. These have a special importance to the scientific practitioner in enabling him to diagnose, not only the condition of the patient, but also the seat of the existing lesion.

We have considered the effects of lesions within the aqueduct of Fallopius. These may create (in addition to those of the facial muscles) symptoms referable to the impairment of the chorda tympani nerve (see page 439), of the petrosal nerves (see page 440), acoustic manifestations, or an effect upon the salivary secretions.

Intra-cranial lesions usually cause destruction of the motor power of the entire nerve, and, therefore, of all of its branches; hence, we are liable to have all of the previous symptoms present, as well as those of facial deformity.

Special branches of the nerve may be individually paralyzed, and thus produce symptoms referable only to those parts in which the motor power is deficient. The anatomy of the separate branches, as shown in the cuts on previous pages, will help you to understand the special symptoms which an impairment of any one branch would produce.

The condition of *bilateral facial paralysis*, or "*facial diplegia*," is a rare form of disease. It implies some form of pressure or degeneration, which shall affect the nerve of each side simultaneously; hence it may accompany a lesion situated in the anterior half of the pons, which crosses the median line; an exostosis of the interior surface of the basilar process of the occipital bone; an intra-cranial aneurism; and the presence of excessive meningeal exudation at the base of the brain. It sometimes accompanies the condition of labio-glosso-pharyngeal paralysis (Duchenne's disease), provided the lesion extends so as to involve the nuclei of origin of the facial nerves; and is occasionally met with in the course of certain chronic cerebral diseases. Jaccoud claims that the spontaneous atro-

phy of both facial nerves can occur without an exciting cause of a local character being detected ; and the same opinion is maintained by Pierreson,¹ who found a hyperplasia of the connective tissue of the nerve and the development of amyloid corpuscles to constitute the pathological changes.

This type of paralysis may be due to peripheral causes, such as exposure to intense cold, as in sleigh-riding, rheumatic inflammation of the nerves, and diseases of the petrous portion of the temporal bones (necrosis, caries, syphilitic otitis, suppurative inflammation of the middle ear, etc.).

The experiments of Schiff upon animals in whom both facial nerves had been divided, and the investigations of Trousseau, Wachsmuth,² and Davaine, have helped to clear up the effects of this double lesion, and to render its diagnosis from Duchenne's disease more positive than our previous knowledge would permit. In the human race, this condition is characterized by the following symptoms: a fixed and immovable countenance, a peculiar drooping of the angles of the mouth, a collapsed appearance of the nostrils during inspiration, a sinking inward of the cheeks during the inspiratory effort, and a protrusion or inflation of the cheek when the air is expired. The tone of the voice becomes of the most distinctly nasal quality, and the patient, from the inability to pronounce the labial consonants, is almost unable to make the simplest sentences intelligible. In consequence of paralysis of the buccinator muscles, which are supplied by the facial nerves, the act of mastication becomes embarrassed, and deglutition is greatly interfered with ; hence it is not uncommon to see such patients use the finger to push the food into the grasp of the isthmus of the fauces, so as to swallow the bolus. When the head is inclined forward, the saliva runs from the mouth, in spite of all efforts to prevent it. The condition of the eyes,³ which remain wide open on account of the

¹ As quoted by Rosenthal.

² As quoted by Hammond.

³ In both the unilateral and bilateral forms of facial paralysis, the patient often can avoid the irritation of dirt and the intense light by closing the eyelids with the pressure of the finger, or by a strip of adhesive plaster.

paralysis of the orbicularis palpebrarum muscles, affords a most important point in the discrimination between this disease and the paralysis of Duchenne. So marked is this deformity that the patient can not wink, and thus the tears are not distributed over the globe of the eye, to wash off any dust which may enter; while, on account of the paralysis of the tensor tarsi muscle, the tears are not drawn into the lachrymal sac, and therefore tend to flow over the cheek and create scalding.

THE AUDITORY, OR EIGHTH NERVE.

This nerve is strictly one of *special sense*, namely, that of *hearing*. It arises chiefly from a *gray nucleus* in the floor of the fourth ventricle (where its fibers form the so-called

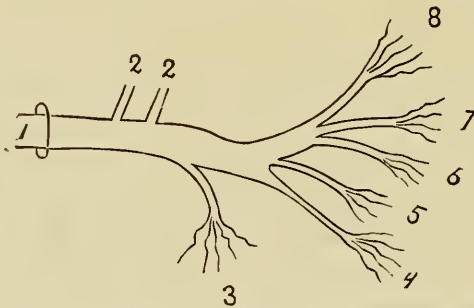


FIG. 115.—A diagram of the auditory nerve and its branches.

1, auditory nerve, entering the *meatus auditorius internus*; 2, communicating filaments to the facial nerve, given off in the *internal auditory canal*; 3, filaments given off to supply the *cochlea*; 4, filaments given off to supply the *posterior semicircular canal*; 5, filaments given off to supply the *sacculæ*; 6, filaments given off to supply the *utricle*; 7, filaments given off to supply the *external semicircular canal*; 8, filaments given off to supply the *ampullæ of the superior semicircular canal*.

“*lineæ transversæ*” which decussate in the median line), and also, in part, from three other nuclei of the medulla oblongata (page 267). Some of its fibers may be also traced to the *flocculus* and the *nucleus fastigii* and *nucleus dentatus of the cerebellum*. From recent statements of Lockhart Clarke, additional fibers may be traced from the auditory nucleus, which pass directly through the restiform body of the medulla.

The course of the nerve, as far as the orifice of the internal

auditory canal, lies parallel with that of the facial nerve, since the same arachnoid sheath invests them both, but, before that canal is reached, a filament is given off from both these nerves to form an intermediate nerve, called the "pars intermedia," or the "nerve of Wrisberg." This intermediate portion is now supposed to be the chief source of origin of the *chorda tympani nerve*, and thus to be connected with the special sense of taste.

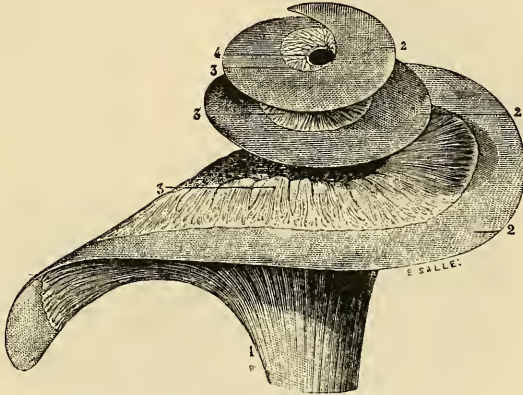


FIG. 116.—Distribution of the cochlear nerve in the spiral lamina of the cochlea (the cochlea is from the right side and is seen from its antero-inferior part). (Sappey.)

1, trunk of the cochlear nerve; 2, 2, 2, membranous zone of the spiral lamina; 3, 3, 3, terminal expansion of the cochlear nerve, exposed in its whole extent by the removal of the superior plate of the lamina spiralis; 4, orifice of communication of the scala tympani with the scala vestibuli.

The color of the auditory nerve filaments is grayish. The filaments differ from those of the other cerebro-spinal nerves (excepting those of special sense) in having a softer consistence. Some of the later researches seem to show that the filaments of this nerve are destitute of the "white substance of Schwann," and thus resemble those of the olfactory nerve, while the *axis cylinders* are of very large size as compared with those of other nerves. It is also claimed that small, nucleated, *ganglionic enlargements* can be demonstrated along the course of these fibers of the trunk of the nerve, but the minute anatomy of the auditory nerve is yet a subject for further investigation.

Within the internal auditory canal, the eighth nerve

divides into two branches, the anterior of which supplies the cochlea, while the posterior branch is distributed to the *semi-circular canals* and to the *sacculæ* and *vestibule*. These two main branches are given off close to the *meatus auditorius internus*.

At the bottom of the internal auditory canal, the three subdivisions of the vestibular nerve pass through *small open-*

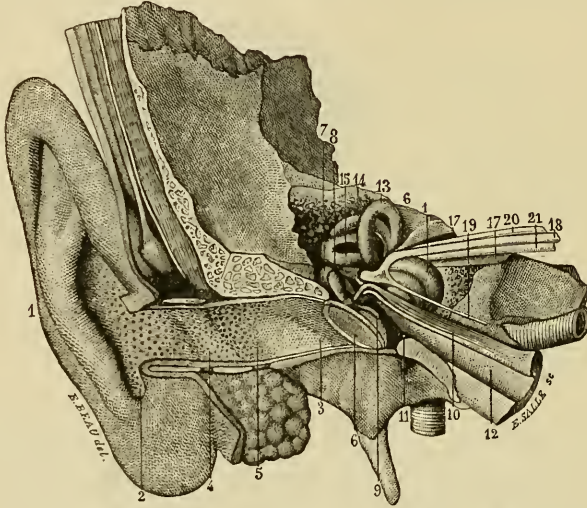


FIG. 117.—General view of the organ of hearing. (Sappey.)

- 1, pinna; 2, cavity of the concha, on the walls of which are seen the orifices of a great number of sebaceous glands; 3, external auditory meatus; 4, angular projection formed by the union of the anterior portion of the concha with the posterior wall of the auditory canal; 5, openings of the ceruminous glands, the most internal of which form a curved line, which corresponds with the beginning of the osseous portion of the external meatus; 6, membrana tympani and the elastic fibrous membrane which forms its border; 7, anterior portion of the incus; 8, malleus; 9, handle of the malleus applied to the internal surface of the membrana tympani, which it draws inward toward the projection of the promontory; 10, tensor tympani muscle, the tendon of which is reflected at a right angle to become attached to the superior portion of the handle of the malleus; 11, tympanic cavity; 12, Eustachian tube, the internal or pharyngeal extremity of which has been removed by a section perpendicular to its curve; 13, superior semicircular canal; 14, posterior semicircular canal; 15, external semicircular canal; 16, cochlea; 17, internal auditory canal; 18, facial nerve; 19, large petrosal branch, given off from the ganglioform enlargement of the facial and passing below the cochlea to go to its distribution; 20, vestibular branch of the auditory nerve; 21, cochlear branch of the auditory nerve.

ings in a cul-de-sac situated at that point, and are distributed to the utricle, the sacculæ, and the three ampullæ.

The cochlear nerve, which is the other main branch of the auditory, enters the *base of the modiolus*, and its filaments

subsequently escape from the central canal of the modiolus through *minute canals*, which enable them to reach their point of distribution in the internal portion of the cochlea. The terminal filaments of this nerve are now believed to be connected with the *spindle-shaped cells* of the *organ of Corti*.

It is impossible, within the compass of this lecture, to enter into the minute anatomy of the ear with sufficient detail to enable you to properly appreciate the mechanism by which the waves of sounds, produced from without, are transmitted to the *membrana tympani*, and subsequently to the cochlea, where they are perceived by the auditory nerve filaments. To properly appreciate the difficulties which arise in determining the exact method by which the human ear is enabled to determine not only the *intensity* of the sound perceived, but also its *pitch*, *quality*, and *musical properties*, not only would the anatomy have to be given in detail, but many of the laws of physics discussed. The following general statements, however, may assist you in studying this complicated subject, and afford an explanation of some of those symptoms of disease which are referred to the ear.

The diagram shown you on the blackboard¹ is designed to assist you to grasp some of the principal points in the anatomical construction of the ear, which are necessary for the clear comprehension of the physiology of audition. It can be perceived that the external auditory canal and its accessory portion which we call the ear or auricle (which is placed on the exterior of the skull for the purpose of deflecting the waves of sound into that canal) lie external to the *membrana tympani*; and, for that reason, all of these parts, viz., the cartilages of the pinna, its ligaments, the bony canal leading to the *membrana tympani*, and its cutaneous lining, are included under the general term "the *external ear*," in contrast to the chambers which lie deeply within the temporal bone, called the *middle ear*, or "the *cavity of the tympanum*," and the *internal ear*, or the "*labyrinth*."

The *middle ear*, or "*tympanum*," lies between the mem-

¹ See diagram further on in the chapter.

brana tympani and the internal ear, or "labyrinth," and is contained within the petrous portion of the temporal bone. It communicates with the pharynx, by means of the Eusta-

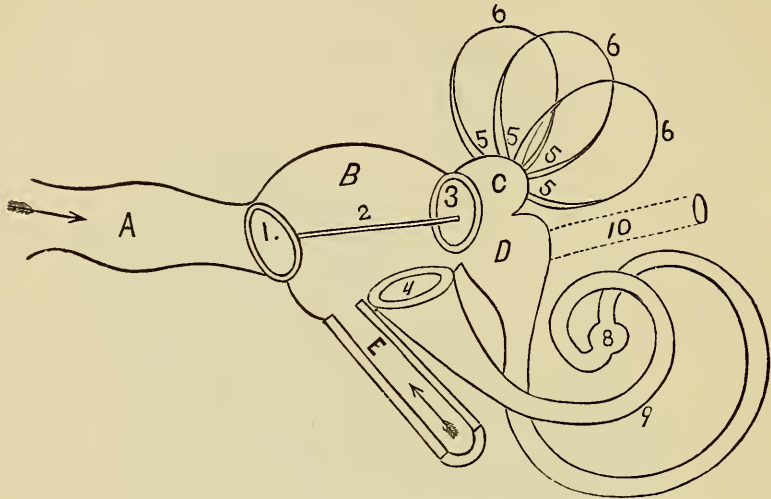


FIG. 118.—A diagram to illustrate the mechanism of the act of hearing.

A, the auditory canal (the arrow showing the waves of sound entering); B, the cavity of the middle ear, or "tympanum"; C, the utricle, communicating with the semicircular canals; D, the saccule, communicating with the scala vestibuli of the cavity of the cochlea; E, the Eustachian tube, allowing of the entrance of air into the middle ear from the pharynx; 2, the chain of bones, which transmit these vibrations to the membrane covering the fenestra ovalis (annular ligament of the stapes); 3, the membrane, covering the fenestra ovalis (annular ligament of the stapes); 4, the foramen rotundum, where the waves of sound return to the cavity of the middle ear and are lost (membrana tympani secundaria); 5, the ampullæ of the semicircular canals; 6, the semicircular canals; 7, the "scala vestibuli" of the cochlea; 8, the cupola, at the apex of the cochlea, where the scala vestibuli and the scala tympani of the cochlea join each other; 9, the "scala tympani," leading downward from the cupola of the cochlea to the foramen rotundum; 10, internal auditory canal, where the auditory nerve enters.

chian tube, and is thus enabled to afford free access to the air of the external world, and insure the same density of atmosphere on both sides of the membrana tympani. It is this anatomical arrangement that causes gunners to hold the mouth wide open when exploding large pieces of ordnance, to avoid a rupture of the membrana tympani, since the waves of sound can thus enter the Eustachian tube at the same time that they pass down the external auditory canal, and the membrana tympani should, theoretically, be made to stand

motionless, if the Eustachian tube were wide open, since the waves of sound upon each side of the membrane would neutralize each other.¹ In the cavity of the middle ear, a *chain of small bones* is so arranged as to afford a source of transmission of the impulses of sound from the membrana tympani to the fenestra ovalis,² which is closed by the stapes³

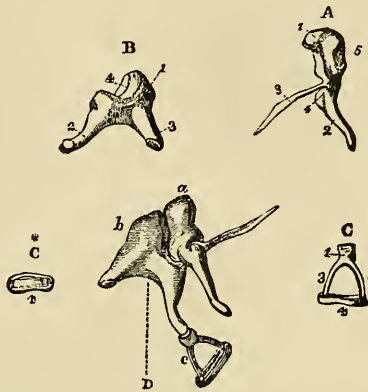


FIG. 119.—Ossicles of the tympanum of the right side, magnified 4 diameters. (Arnold.)

A, malleus; 1, its head; 2, the handle; 3, long, or slender process; 4, short process; B, incus; 1, its body; 2, the long process with the orbicular process; 3, short, or posterior process; 4, articular surface receiving the head of the malleus; C, stapes; 1, head; 2, posterior crus; 3, anterior crus; 4, base; C*, base of the stapes; D, the three bones in their natural connection as seen from the outside; a, malleus; b, incus; c, stapes.

and its annular ligament. This chain of bones is *suspended* by a ligament attached to the roof of the middle ear, and the separate bones are connected together by joints⁴ lined with synovial membranes, so that the slightest movement is readily carried from one to the other. Muscles are also attached to these bones, for the object of bringing the mem-

¹ Valsalva's method, "which consists of making a powerful expiration, with the mouth and nostrils closed," is also used if the ear be stopped with cotton at the same time.

² A doctrine first suggested in 1851 by Edward Weber, and subsequently verified by experiments in 1868 by Politzer.

³ One of the small bones of the middle ear.

⁴ Helmholtz first described the exact nature of the joint between the malleus and the incus. He compared it to "a joint used in certain watch-keys, where the handle can not be turned in one direction without carrying the steel shell with it, while in the other direction it meets with only a slight resistance." This device assists to convert the bones into a state of resistance, resembling that of a solid piece of bone, when muscular action locks this joint firmly.

brana tympani and the bones themselves into the best possible condition for the *accurate appreciation* of sound impulses.¹ The cavity of the middle ear is in communication with the cells in the mastoid portion of the temporal bone, and some additional effect may be thus produced upon the vibrations of the air within the middle ear.²

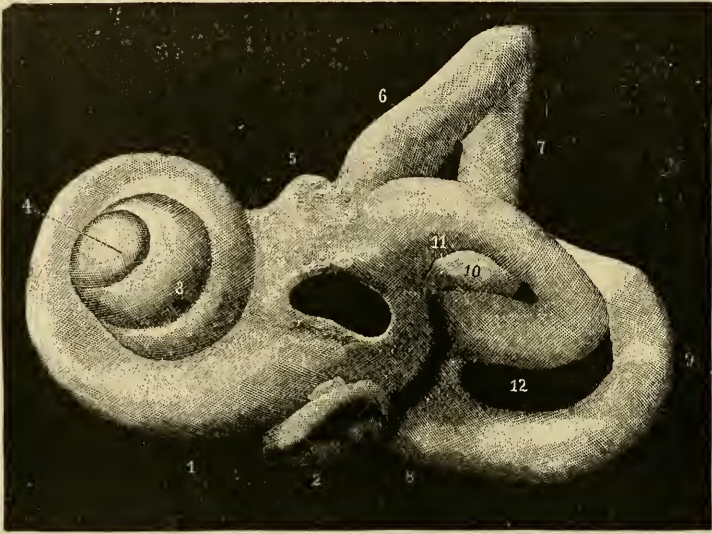


FIG. 120.—The left bony labyrinth of a new-born child, forward and outward view. Modified from a photograph. (Rüdinger.)

1, the wide canal, the beginning of the spiral canal of the cochlea; 2, the fenestra rotunda; 3, the second turn of the cochlea; 4, the final half turn of the cochlea; 5, the border of the bony wall of the vestibule, situated between the cochlea and the semicircular canals; 6, the superior, or sagittal semicircular canal; 7, the portion of the superior semicircular canal bent outward; 8, the posterior, or transverse semicircular canal; 9, the portion of the posterior connected with the superior semicircular canal; 10, point of junction of the superior and the posterior semicircular canal; 11, the ampulla ossea externa; 12, the horizontal, or external semicircular canal.

The *internal ear*, or “*labyrinth*,” lies within the petrous portion of the temporal bone, and internal to the tympanum. It consists of a series of chambers, hollowed out within the bone, called the *vestibule*, the *cochlea*, and the *semicircular*

¹ The *tensor tympani* muscle, on account of a peculiar arrangement of the joint between the malleus and the incus, renders all the articulations firm, tightens the little ligatures, and presses the stapes against the fenestra ovalis, thus bringing it in contact with the fluids of the vestibule. See foot-note on page 449.

² For the surgical application of this arrangement, see article on the bones of the head, by the author, “*New York Medical Record*,” October 16, 1889.

canals, within each of which a membranous tube is suspended between two liquids, one within the tube, the "endolymph," and one between the tube and the bony walls, the "perilymph." This membranous portion is called the "mem-

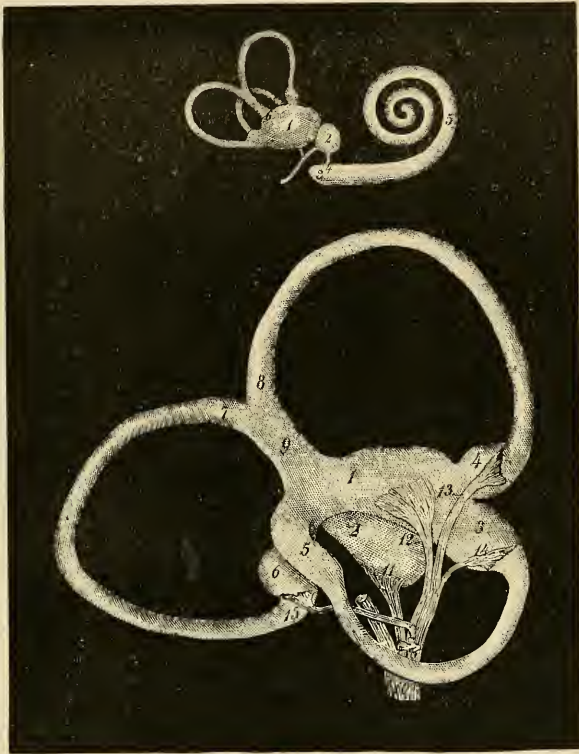


FIG. 121.—Diagram of the labyrinth, vestibule, and semicircular canals. From a photograph, and somewhat reduced. (Rüdinger.)

Upper figure: 1, utricle; 2, sacculle; 3, 5, membranous cochlea; 4, canalis reuniens; 6, semicircular canals.

Lower figure: 1, utricle; 2, sacculle; 3, 4, 6, ampullae; 5, 7, 8, 9, semicircular canals; 10, auditory nerve (partly diagrammatic); 11, 12, 13, 14, 15, distribution of the branches of the nerve to the vestibule and the semicircular canals; 16, gangliiform enlargement.

branous labyrinth," and is an exact reproduction of the bony labyrinth, except that it is smaller in point of size, so as to admit the presence of fluid between it and the bone. It serves as a support for the terminal filaments of the auditory nerve, which, by being suspended between two fluids, are en-

abled not only to perceive the slightest vibrations of the fluids,¹ but are also thus protected from the possibility of injury, which would be great were they placed in contact with the bone. The membranous labyrinth which fills the cavity of the vestibule is divided into two portions, called the *saccul*e and the *utricle*; the former of which communicates directly with the cochlea, while the latter communicates with the semicircular canals, as can be seen in the diagram.

The cochlea is essentially that part of the internal ear which is enabled to appreciate most of the important elements of sound, viz., its *note* and *quality*.² It consists of an exca-

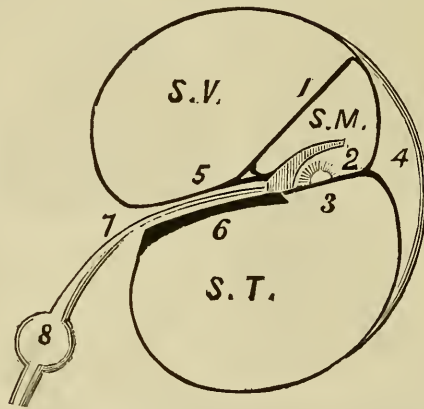


FIG. 122.—A transverse section of the spiral canal of the cochlea (diagrammatic).³

S. V., the *scala vestibuli*; S. M., the *scala media*; S. T., the *scala tympani*; 1, *membrane of Reissner*; 2, "*organ of Corti*," covered by the "*membrana tectoria*," or "*membrane of Corti*"; 3, *membrana basilaris*; 4, *ligamentum spiralis*, extending the whole length of the spiral canal of the cochlea; 5, upper layer of the *lamina spiralis ossea*; 6, lower layer of the *lamina spiralis ossea*; 7, a nerve filament escaping from the *central canal of the modiolus*, and going to the *organ of Corti*; 8, a *ganglion* attached to the nerve filament, called the "*ganglion spirale*."

vation in the temporal bone which resembles, in its construction, the shell of a snail, having a central pillar, the *modiolus*, which runs from its base to its apex, and a *spiral canal*,

¹ It is a well-recognized law of physics that the fluids transmit vibrations in every direction with equal force, and, therefore, no better medium could possibly be had for the auditory nerve filaments to be in contact with.

² Complete destruction of the *cochlea* probably causes total deafness, while destruction of the *semicircular canals* does not seem to have any marked effect upon the ability to appreciate sound.

³ From the "*Essentials of Anatomy*" (Darling and Ranney), New York, 1880.

running around this central portion for two and a half complete turns. The spiral canal of the cochlea is divided into three portions called the *scala vestibuli*, *scala tympani*, and the *scala media*.¹ The first communicates, at its lower part,

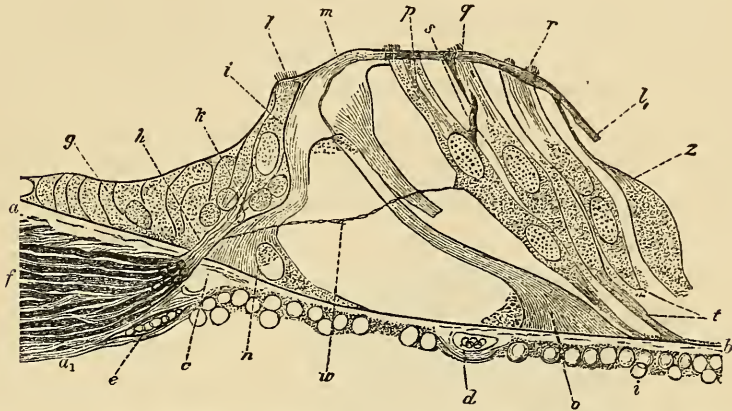


FIG. 123.—Vertical section of the organ of Corti of the dog, magnified 800 diameters. (Waldeyer.)

a-b, homogeneous layer of the basilar membrane; *v*, tympanic layer, with nuclei, granular cell protoplasm, and connective tissue; *a*₁, tympanic lip of the crista spiralis; *c*, thickened portion of the basilar membrane; *d*, spiral vessel; *e*, blood-vessel; *f*, *h*, bundle of nerves; *g*, epithelium; *i*, inner hair cell, with its basilar process, *k*; *l*, head-plate of the inner pillar; *m*, union of the two pillars; *n*, base of the inner pillar; *o*, base of the outer pillar; *p*, *q*, *r*, outer hair cells, with traces of the cilia; *t*, bases of two other hair cells; *z*, Hensen's prop cell; *l-l*₁, lamina reticularis; *w*, nerve fiber passing to the first hair cell, *p*.

with the vestibule; hence its name; the second terminates in the middle ear, and hence its name; while the third is, in

¹ The experiments of Laborde (Des fonctions du limaçon, "Trib. Méd.," Septembre 12, 1880) to determine the function of the cochlea were made upon the Guinea-pig, an animal in whom the organ is particularly accessible. The following facts were considered by him as fully proven: 1, Destruction of the cochlea had no effect in the production of vertigo or disturbances of coördination; 2, destruction of the cochlea produced complete deafness, which, however, did not appear until several days after the operation.

He concludes, from these facts: 1, That the auditory nerve contains both *motor* and *sensory* fibers, the former being distributed to the *semicircular canals*, the latter to the *sacculæ*, *utricle*, and *cochlea*; 2, that the cochlea is not the only organ for the appreciation of sound, since the *utricle* and *sacculæ* participate, to some unknown extent, in that function; 3, that the deafness which occurs after excision of the cochlea alone is probably due to an extension of inflammation to the utricle and sacculæ, or to the formation of a rigid cicatrix, which prevents the transmission of an auditory impulse to those parts. While these facts need subsequent confirmation (since the experiments are by no means conclusive), they are worthy of due consideration in the discussion of this complicated and imperfectly understood organ.

reality, but a space partitioned off from the scala vestibuli for the protection of the true organ of hearing, "the organ of Corti." The preceding diagram (Fig. 122) will help to make this plain to you.

This figure represents, in a diagrammatic way, the appearance of a longitudinal section of the spiral cord in the cochlea, in any portion of its two and a half turns around the modiolus. It will be perceived at a glance that the canal is divided into an upper (*s. v.*) and a lower (*s. t.*) portion, partly by bone (5 and 6) and partly by membrane (3). It will also be readily seen that a portion of the scala vestibuli is divided off by the *membrane of Reissner*, and that thus a separate cavity is formed throughout the whole length of the spiral canal, called the "scala media." Within this last-named cavity will be noticed a body covered with hair-like processes, "the *organ of Corti*," which rests upon the membrane forming the floor of the scala media, and called for that reason the "*basilar*

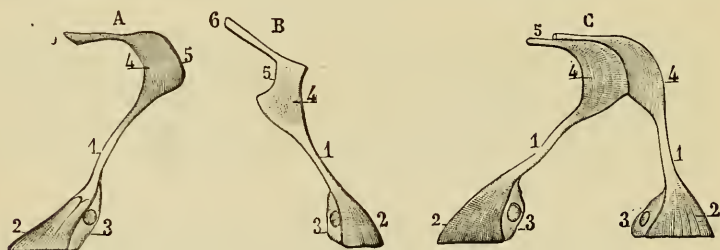


FIG. 124.—The two pillars of the organ of Corti. (Sappey.)

- A, external pillar of the organ of Corti: 1, body, or middle portion; 2, posterior extremity, or base; 3, cell on its internal side; 4, anterior extremity; 5, convex surface by which it is joined to the internal pillar; 6, prolongation of this extremity.
- B, internal pillar of the organ of Corti: 1, body, or middle portion; 2, posterior extremity; 3, cell on its external side; 4, anterior extremity; 5, concave surface by which it is joined to the external pillar; 6, prolongation, lying above the corresponding prolongation of the external pillar.
- C, the two pillars of the organ of Corti, united by their anterior extremity, and forming an arcade, the concavity of which looks outward: 1, 1, body, or middle portion of the pillars; 2, 2, posterior extremities; 3, 3, cells attached to the posterior extremities; 4, 4, anterior extremities joined together; 5, terminal prolongation of this extremity.

membrane." There is, furthermore, shown in this figure the means by which the terminal filaments of the cochlear nerve (one of the branches of the auditory nerve) escape from the *central canal of the modiolus* and reach the scala media.

Such a figure will greatly assist you to properly appreciate the discussion of the function of each of these various parts, and also enable you to grasp the principal points in the physiology of the act of hearing, which are to be considered.

The *organ of Corti* may be compared to a harp, since its rods are of different lengths. It is a continuous structure for the entire course of the spiral canal of the cochlea. Helmholtz has advanced the theory¹ that the several thousand strings of this organ admit of the appreciation of all varieties of musical tone, since each note or chord creates a vibration

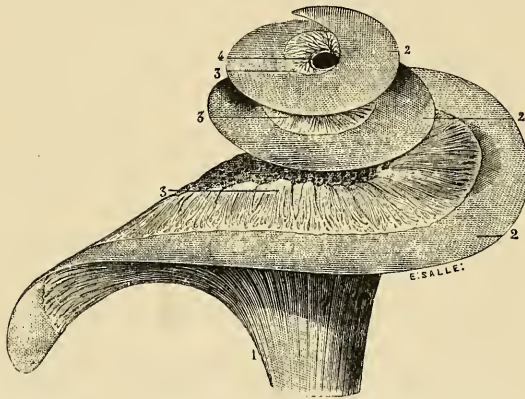


FIG. 125.—Distribution of the cochlear nerve in the spiral lamina of the cochlea (the cochlea is from the right side and is seen from its antero-inferior part). (Sappey.)

1, trunk of the cochlear nerve; 2, 2, 2, membranous zone of the spiral lamina; 3, 3, 3, terminal expansion of the cochlear nerve, exposed in its whole extent by the removal of the superior plate of the lamina spiralis; 4, orifice of communication of the scala tympani with the scala vestibuli.

in those strings only which are necessary to reproduce it, in the same way as a piano, when a note is sounded, will create a vibration in the same string of an adjoining instrument. Hensen, however, claims that the *basilar membrane* is composed of *elastic fibers of varying lengths*,² and that these separate fibers are thrown into vibration by sounds carried to the cochlea, which, in turn, transmit their vibration to the

¹ This theory is opposed by the facts that the rods of Corti are *not elastic*, and they are *absent in birds*, who can unquestionably perceive sound.

² By some authors this theory is attributed to Helmholtz.

organ of Corti lying upon them, and thus inform the auditory nerve filaments of the effect of each individual sound.¹

In the act of hearing, the vibrations produced within the *membrana tympani* by the waves of sound are transmitted^{*} across the cavity of the middle ear, to a membrane covering an opening nearly opposite the external drum, called the *fenestra ovalis*, by means of a chain of small bones within the cavity of the middle ear, and, by means of secondary vibrations thus produced within this latter membrane, the impulse is transmitted to the *fluids of the vestibule*. The vibrations now travel along the fluids of the scala vestibuli of the cochlea and of the semicircular canals, thus passing in two different directions. In the semicircular canals, according to some observers, the *direction* from which the sound springs is perceived,² while the vibrations carried along the scala media³ in the cochlea are transmitted to the filaments of the auditory nerve in the "organ of Corti," probably by means of vibrations of the *membrana basilaris*, thus affording the appreciation of the *note* and the *quality* of the sound perceived. After reaching the apex of the cochlea, the vibrations are transmitted from the scala vestibuli downward along the course of the scala tympani till they reach the "membrana tympani secundaria," which covers the *fenestra rotunda*,⁴ where they are lost,⁵ being no longer

¹ The *membrana tectoria*, or "*membrane of Corti*," probably acts as a damper, to arrest the vibrations excited within the scala media, as its situation suggests no other possible function.

² The function of the semicircular canals is yet a matter of doubt, and is now receiving the attention of experimental physiologists. They are supposed by some authors to relieve *excessive pressure* within the labyrinth when the stapes is driven too forcibly inward; and, by others, to *secrete the fluid of the labyrinth*; while by some they are considered to be the external organs of coördination of muscular movement.

³ The saccule communicates with the scala media by means of a small canal (shown in Fig. 121), called the "*canalis reuniens*."

⁴ An opening in the inner wall of the cavity of the middle ear.

⁵ According to some authorities, the vibrations in the *membrana tympani secundaria* are created, simultaneously with those at the *fenestra ovalis*, by the vibrations of the air in the middle ear created by the movements of the external drum membrane, and an impulse thus travels simultaneously along the scala tympani and the scala vestibuli, both *going in the same direction*, to meet each other at the *cupola*. They consider the second drum, at the foramen rotundum, as a proof of this function, but it must be apparent to any one that all the openings of the labyrinth into the middle ear must be closed in some way

transmitted, on account of the absence of any conducting medium.

The free *entrance of air* to the cavity of the tympanum, or the middle ear, affords an equal density of air upon either side of the *membrana tympani*, and thus insures a vibration of that membrane in absolute unison with the vibrations of the sound which it is called upon to record, as the waves pass down the external auditory canal.

The function of the *organ of Corti*, of the *membrana basilaris*, or of the *otoliths*, can not be stated with any degree of certainty, since new discoveries are constantly being made, although some theories of their functions have been already given.

The minute construction of the *scala media* and its contained organs can be found by reference to more extensive treatises.

CLINICAL POINTS OF INTEREST DEPENDENT UPON THE AUDITORY NERVE.

In attacks of auditory vertigo, or Menière's disease, there is much more than ordinary giddiness. The patient will often

to prevent the *escape of the perilymph*. While it is difficult to positively decide this point, I am personally inclined to regard the foramen rotundum as the *seat of termination* of wave sounds, rather than a means of *transmission of impulses* to the fluids of the cochlea.

Dr. A. H. Buck, in a late treatise on the "Diagnosis and Treatment of Ear Diseases," again advocates theories long maintained by him as to the physiology of audition, which may be thus given: The impulse of the stapes, at the fenestra ovalis, is carried by means of the *perilymph* directly into the *scala vestibuli*. This causes compression of the fluid in the *scala media*, which, in turn, causes pressure upon and movement of the elastic "*membrana basilaris*." The pressure is thus transmitted, for a second time, to the fluid in the *scala tympani*, and, as fluids are incompressible, the *membrana tympani secundaria*, which closes the foramen rotundum, is forced *into the cavity* of the middle ear until the force is expended, when it returns to its normal condition. It will be thus perceived that he discards the *sacculæ* and the *canalis reuniens* as a channel for the passage of the acoustic wave. He also questions the existence of any communication, at the *cupola*, between the *scala vestibuli* and the *scala tympani*. While his theory seems ingenious, and perhaps more in accordance with fact than the older views, and is well illustrated by diagrams and supported by some carefully conducted experiments, still it can not, as yet, be said to be positively confirmed. His view as to the absurdity of the *membrana tympani secundaria* being a transmitter of sound waves to the cochlea agrees with my own, as advocated above. He seems also to favor the theory that the basilar membrane is the true *vibrating medium*, which carries to the auditory nerve the appreciation of the note sounded, rather than the "organ of Corti."

tell you that, when the attack commenced, everything began to whirl, or possibly appeared to be moving toward one side; that his gait became unsteady, and, if walking was possible, that he reeled and staggered; while, in some severe cases, the patient feels unsafe even when lying upon a bed or sofa, and may be obliged to grasp the sides of the couch to protect him-

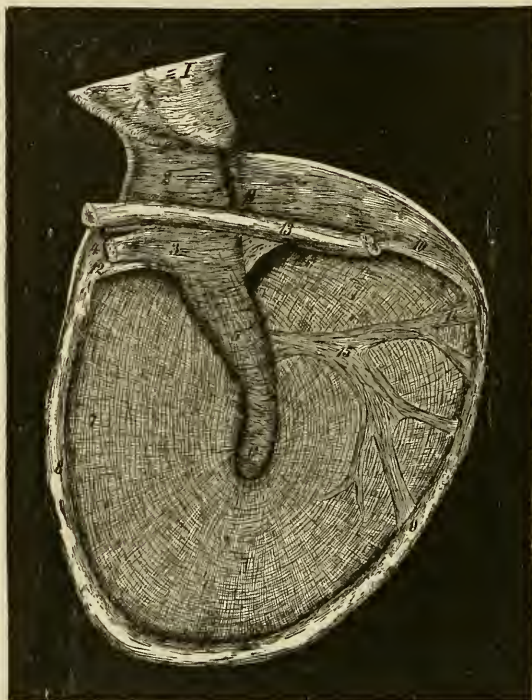

FIG. 126.—*Right membrana tympani, seen from within. From a photograph, and somewhat reduced. (Rüdinger.)*

1, head of the malleus, divided; 2, neck of the malleus; 3, handle of the malleus, with the tendon of the tensor tympani muscle; 4, divided tendon of the tensor tympani; 5, 6, portion of the malleus between the layers of the membrana tympani; 7, outer (radiating) and inner (circular) fibers of the membrana tympani; 8, fibrous ring of the membrana tympani; 9, 14, 15, dentated fibers, discovered by Gruber; 10, posterior pocket; 11, connection of the posterior pocket with the malleus; 12, anterior pocket; 13, chorda tympani nerve.

self from a sensation of falling. In many cases, these symptoms are markedly intensified *by movement of the head*, and, in some instances, such movements often tend to bring about an attack.¹ The patient is usually pale and haggard, some-

¹ Buzzard, "Lancet," March 4, 1876.

times perspires freely, and often vomits,¹ while *pain within the head* is a symptom which not infrequently accompanies such an attack. The extent to which this type of vertigo may be manifested varies from an attack of but momentary duration, where the patient can retain his feet, to those severe forms of the disease where the attack is accompanied by a loss of consciousness, which may remain for some hours, and resemble the condition of epileptic vertigo.

There seems to be little doubt that, in these cases, the attack is always preceded or followed by some abnormal condition of the ear, and that this diseased condition was the *starting point* of the vertigo.² Sometimes the patient has long been deaf in one ear, or a condition of deafness may follow the first attack of vertigo; again, the approach of an attack of vertigo may be told by the occurrence of *noises* within the ear of one side, while, in some cases, there exists a constant noise within the ear, which increases as the attack of vertigo is imminent.

It is often extremely difficult to persuade a patient, suffering from this affection, that the attack is not dependent upon a disordered state of the *digestive apparatus*, and especially is this the case when the ear trouble is of old standing, or when the patient is unconscious of any defect in his hearing, which is by no means an unusual occurrence. Such patients are better satisfied if the attack be attributed to the liver, dyspepsia, or nervousness. I quote the following sentence from Hughlings-Jackson³ as evidence that this difficulty is met with even among the most enlightened of the community. He says: "Even medical men, who have aural disease, often totally reject the proffered explanation of their attacks of vertigo; many of them ascribe their ailment to digestive

¹ Ferrier, "Vomiting in connection with cerebral disease," "Brain," July, 1870.

² The occurrence of vertigo and interference with coördination is not alone produced by local disease of the ear, even when associated with impairment of hearing. It may indicate disease of the cerebellum or of the medulla oblongata, which creates irritation of or some interference with the auditory nucleus. For the clinical facts pertaining to this symptom, the reader is referred to previous pages of this volume.

³ Hughlings-Jackson, "Lancet," March 11, 1876; same author, "Lancet," March 11, 1876; Gowers, "Lancet," March, October, 1880.

troubles. A medical man had deafness in his left ear, with occasional slight vertigo. One day, while walking in his gar-

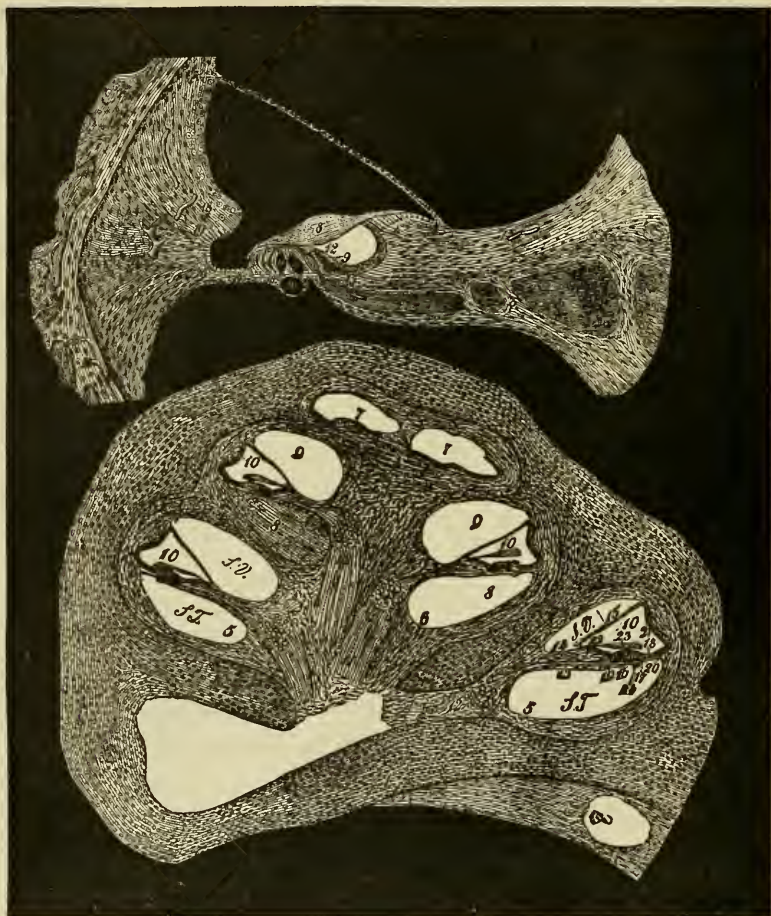


FIG. 127.—Section of the first turn of the spiral canal of a cat newly-born.—Section of the cochlea of a human fetus at the fourth month. From a photograph, and somewhat reduced. (Rüdinger.)

Upper figure: 1, 2, 6, lamina spiralis; 2, lower plate; 3, 4, 5, 5, nervus cochlearis; 7, membrane of Reissner; 8, membrana tectoria; 9, epithelium; 10, 11, pillars of Corti; 12, inner hair cells; 13, outer hair cells; 14, 16, membrana basilaris; 15, epithelium in the sulcus spiralis; 17, 18, 19, ligamentum spirale; 20, spiral canal below the membrana basilaris.

Lower figure: S T, S T, 5, 5, 7, 7, 8, 8, scala tympani; S V, S V, 9, 9, scala vestibuli; 1, base of the cochlea; 2, apex; 3, 4, central column; 10, 10, 10, 10, ductus cochlearis; 11, branches of the nervus cochlearis; 12, 12, 12, spiral ganglion; 13, 14, limbus laminae spiralis; 15, membrana of Reissner; 16, epithelium; 17, outer hair cells; 18, epithelium of the membrana basilaris; 19, nervous filaments; 20, union of the membrana basilaris with the ligamentum spirale; 21, epithelium of the peripheral wall of the ductus cochlearis; 22, 23, membrana tectoria; 24, spiral canal below the membrana basilaris.

den, he had a pain in his head, was very giddy, fell in the shrubs, and vomited. This was plainly ear vertigo, as he himself knew. But he had the following diagnoses made of his case by other medical men: 1, nothing; 2, nervousness; 3, deranged stomach."

That some persons who are deaf in one ear are absolutely unconscious of it is too often noticed to be now disputed. Gowers¹ lays stress upon this point in the following words: "The fact that the patient may be unconscious of a most significant auditory defect lessens the value of former observations as evidence of the definite character of stomachal vertigo. My own conviction is that, in the vast majority of cases in which a vertigo of definite and uniform character is apparently excited by gastric disturbance, an *auditory defect* will be discovered on careful examination."

Patients afflicted with diseases of the ear may, in some cases, make themselves dizzy by *pressure upon the ear* of the affected side;² while *oscillatory movements of the eyes* may occasionally accompany the vertigo dependent upon disease of the acoustic apparatus.

It is well known that the *semicircular canals* within the temporal bone, when diseased, are liable to create the so-called Menière's malady, in which *constant vertigo* is a prominent symptom; and experiments upon birds and animals³ seem to show that, in some unknown way, these canals affect coördination of movement and tend to preserve the equilibrium of the body.

When the *horizontal canal* of the bird is cut, the head is constantly moved from side to side; when the *posterior vertical canal* is cut, the head is moved up and down; when the *anterior vertical canal* is severed, the movement of the head is in a diagonal direction. If section of either of these canals be made, upon both sides of the head, the movements of the head above described are permanent; but, if made on one

¹ "Brit. Med. Jour.," April, 1877.

² Schwaback, as quoted by Hughlings-Jackson.

³ Flourens, 1824; Crum Brown, "Jour. Anat. Phys.," 1874; Cyon, "Thèse pour le doctorat in médecine," as quoted by Foster.

side only, they tend to disappear within twenty-four or forty-eight hours.¹ If the same class of experiments be made upon rabbits, the movements of the head are less marked, but oscillating movements of the eyeballs (nystagmus) are developed; while, if made upon certain other animals, a loss of coördination in the movements of the body and limbs is sometimes produced.²

When a person is *rotated* for some time, a sense of vertigo is produced; and this symptom seems to warrant the supposition that some abnormal effect is produced within the *semicircular canals*, through the auditory nerve filaments, possibly as a result of *concussion* of the *fluids of the ear* against the bony wall.³

The following quotation from Michael Foster,⁴ in discussing the different theories advanced to explain coördination of movement and the various reflex phenomena which are constantly brought to the notice of the physiologist, seems particularly applicable to the practical branches of medicine: "All day long, and every day, multitudinous afferent impulses, from eye and ear, and skin and muscle, and other tissues and organs, are streaming into our nervous system, and, did each afferent impulse produce its correlative motor impulse, our life would be a prolonged convulsion. As it is,

¹ E. Cyon, *op. cit.*, 1878.

² The experiments of Arthur Böttcher, made in 1872, seem to conflict with those of Cyon, Goltz, and Flourens, as to the function of the semicircular canals. He claims that the section of either canal can be made without causing any symptoms of incoördination, provided the *auditory nerve filaments are not pulled upon*. The fact that the auditory nerve is not bound down at any point between the brain and the labyrinth explains, according to this observer, why the *slightest traction* upon it may injure its attachment to the medulla, and thus create the symptoms described by Cyon, Goltz, and Flourens.

³ A. H. Buck, in a late treatise, reiterates his former statement, that nerves are not found in the semicircular canals, except in the ampullæ. This fact he adduces in support of the theory that they have no relation to the perception of sound impulses. He also claims that the small size of this portion of the membranous labyrinth, as compared with the diameter of the bony excavation, coupled with the peculiar reticulated arrangement which exists in the space between the membranous tube and the bony wall, further sustains his objection. This author seems to claim that the semicircular canals act as a means of relief to extreme intra-cochlear pressure. Certainly, more light is needed upon the construction of this portion of the internal ear, before its function can be positively determined.

⁴ *Op. cit.*

by the checks and counter-checks of cerebral and spinal activities, all these impulses are drilled and marshaled, and kept in hand, in orderly array, till a movement is called for; and thus we are able to execute at will the most complex bodily manœuvres, knowing only *why*, and unconscious, or but dimly conscious, *how* we carry them out."

The *tensor tympani muscle*, which has previously been mentioned as deriving its motor power from the fifth nerve and otic ganglion, is of use, even in the quiescent state, in preventing the *membrana tympani* from being pushed too far outward. During its contraction, the membranous drum of the ear is made tense, for the purpose of deadening some sounds or of favoring the reception of others, by bringing the tension of the membrane in more perfect attune to the sounds which fall upon it. It may, therefore, be considered in some respects as an *analogue to the ciliary muscle* of the eye, since both act as a sort of accommodation to a mechanism. In some persons, this muscle is under voluntary control, and thus a *crackling sound* may be produced within the ear at will, or discords be produced when musical sounds are being listened to.

The *stapedius muscle*, which derives its motor power from the facial nerve, is supposed to regulate the movements of the stapes (one of the small bones of the middle ear), and especially to prevent any sudden or excessive movement of the *membrana tympani* from *forcing its base* too far into the *fenestra ovalis*.

The *Eustachian tube* is unquestionably open *during the act of swallowing*, but it is still disputed whether it remains permanently open or is open at intervals. The swelling of the mucous membrane which lines the tube, in catarrhal inflammation, interferes with the entrance of air into the middle ear, and is frequently associated with that peculiar *ringing* or *buzzing* in the ear so often present during attacks of influenza. One of the functions of this tube is undoubtedly to afford a means of exit for the secretions of the cavity of the middle ear, and, in case of inflammation of that cavity,

should the Eustachian tube become closed, *perforation of the drum* will ensue, when the presence of the accumulated pus creates imperfect nutrition of that membrane and consequent ulceration of its coats.

Waves of sound can and do reach the endolymph of the internal ear by *direct conduction* through the skull. Since, however, sonorous vibrations are transmitted from the air to solids and liquids (and most sounds come to us through the air), some special apparatus is required to thus transfer the aerial vibrations to the fluids of the labyrinth. The late mechanical devices, recommended for the relief of perfect deafness, in which the *teeth are used* as a conducting medium, have not as yet fulfilled the predictions of their inventors.¹

The deafness which often follows suppuration of the middle ear does not necessarily indicate any diseased condition of the auditory nerve, since it may be the result of *perforation of the membrana tympani*,² or of an abnormal condition of the *bones of the middle ear*, both of which might interfere most seriously with the transmission of sound.

Foreign bodies in the ear often create most *alarming symptoms*; and even an accumulation of wax, pressing on the drum, may create a mental condition strongly resembling the excitement of alcohol or mania.³ Even syringing the ear has been known to produce fainting and severe attack of auditory vertigo. Prolonged suppuration of the middle ear may be the direct cause of fatal inflammation of the meninges of the brain.

Neuroses of the acoustic nerve are, of necessity, more obscure and difficult of detection than those of the other special

¹ It has long been the custom with otologists to use a tuning-fork, placed upon the forehead (when in vibration), to determine between disease of the middle ear and that of the labyrinth; since in the former the affected ear hears the tuning-fork most plainly, while, in the latter, the unaffected ear hears it most distinctly.

² *Perforation of the external drum* of the ear does not necessarily create deafness. That remarkable case, reported by Sir Astley Cooper, when both drums were nearly destroyed and where the patient could still hear ordinary conversation, illustrates this point.

³ See case of a louse in the ear, reported by Hughlings-Jackson, "Lancet," October, 1880.

senses; since the tests of normal sight, smell, and taste are much more easy and satisfactory than the appreciation of the faculty of a fine discrimination on the part of the patient between notes of a different pitch and quality. To what extent the original and exhaustive researches of Brenner,¹ as to the value of the galvanic current in the diagnosis of abnormal conditions of the nerve filaments within the chambers of the labyrinth, will be sustained by pathological and clinical investigation, it is difficult now to say; but it certainly appears to shed some light upon a field of diagnosis which has been almost unexplored on account of the difficulties which have hitherto existed. It will exceed the scope of this volume to enter into the detail of this new method, since the principles of the manifestation of the electric current upon nerve tissue would have to be explained, and the different formulæ of nerve reaction given. It can, however, be stated that the principle consists of obtaining certain sensations by means of the auditory-nerve filaments, when one moistened pole of an electric battery is placed upon the tragus or the auditory meatus, and the other to the back of the neck or the inner side of the arm, and the intensity of the current regulated by means of the rheostat.² By this means the condition of acoustic hyperæsthesia and of anæsthesia may be detected with an accuracy which older methods could not afford.

The state of *acoustic hyperæsthesia* may be of central origin or dependent upon some peripheral cause. If due to the former, it may be developed in connection with chronic cephalalgia, hysteria, insanity, cerebral hyperæmia, and with irritative conditions of the brain or spinal cord. It is sometimes associated with hallucinations of hearing, especially if present as a complication of insanity. The peripheral causes of this condition comprise anything which can produce an *exaggeration of the tension* of the muscles or bones of the middle ear, thus resulting in a constant compression of the internal structures of the labyrinth. The experiments of Lucae seem to point to the *tensor tympani mus-*

¹ As discussed in detail by Erb, Rosenthal, and others.

² Erb's rule.

cle as the agent in accommodating the bones of the middle ear to the keenest appreciation of *musical tones*, while the *stapedius muscle* presides over the accommodation for *shriller* and *non-musical auditory sensations*. We can thus understand, if this be true, how paralysis of the stapedius muscle would create an hyperæsthesia of the acoustic apparatus, and, as this muscle may be affected in facial paralysis, how all of the causes of that condition may be the exciting causes also of this affection of the ear.¹

The state of *anæsthesia* of the auditory nerve is always associated with some severe and persistent defect in hearing, since the filaments of the auditory nerve are no longer able to transmit the impressions of sound. Its causes are but poorly understood, but it seems positive that lesions of the posterior regions of the meso-cephalon, the medulla, and cerebellum, as well as new growths at the base of the brain, excessive intracranial pressure, and local disease of the labyrinth itself, may be thus manifested. The deafness which follows the exanthematous fevers, and is observed in hysteria and ataxia, usually indicates changes in the *meninges* of the brain, which, if severe, produce an incurable loss of hearing. Malformations of the internal or middle ear, either congenital, or acquired during childhood after cerebral diseases, are the common causes of *deaf-mutism*.

THE GLOSSO-PHARYNGEAL, OR NINTH NERVE.

Like the two previous nerves, both the superficial and deep points of origin of the glosso-pharyngeal nerve are situated in the medulla oblongata, a separate *gray nucleus* in the *floor of the fourth ventricle* being ascribed to it.² This nerve escapes from a groove between the *lateral tract* and the *restiform body* of the medulla, lying below the auditory nerve and above the pneumogastric, and passes out of the cavity of

¹ This may be deemed incompatible with statements made on page 440 of this volume, as the tensor tympani muscle was there stated to be an agent in creating auditory defect in Bell's paralysis.

² See previous page in this section, in which its deep origin is discussed.

the cranium by the jugular foramen, where it lies in close relation with the pneumogastric and spinal accessory nerves, the jugular vein, and the inferior meningeal artery. It possesses motor and sensory fibers, and fibers which assist in the appreciation of the special sense of taste.

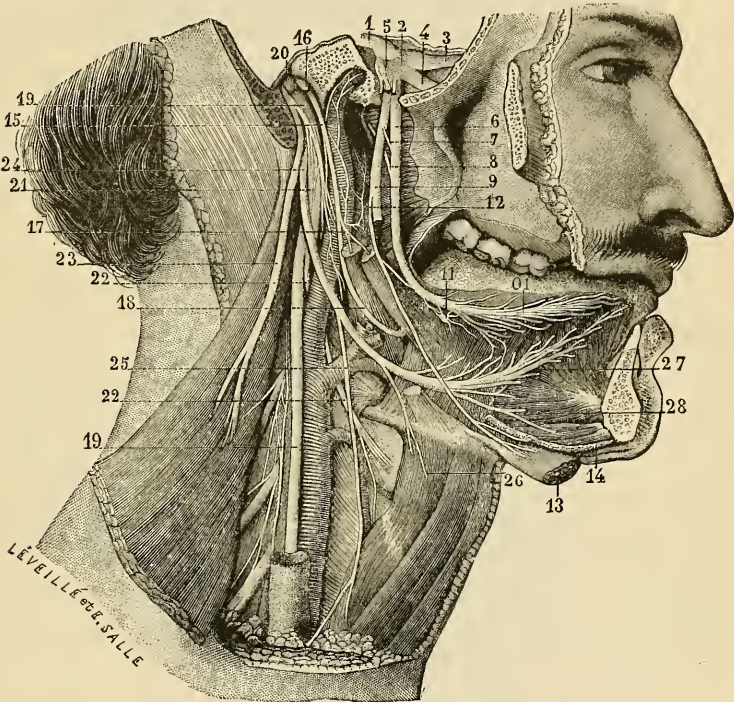


FIG. 128.—Glosso-pharyngeal nerve. (Sappey.)

1, large root of the fifth nerve; 2, ganglion of Gasser; 3, ophthalmic division of the fifth; 4, superior maxillary division; 5, inferior maxillary division; 6, 10, *lingual branch of the fifth, containing the filaments of the chorda tympani*; 7, branch from the sublingual to the lingual branch of the fifth; 8, *chorda tympani*; 9, inferior dental nerve; 10, terminal filaments of the lingual nerve; 11, submaxillary ganglion; 12, mylo-hyoid branch of the inferior dental nerve; 13, anterior belly of the digastric muscle; 14, section of the mylo-hyoid muscle; 15, 18, *glosso-pharyngeal nerve*; 16, *ganglion of Andersch*; 17, *branches from the glosso-pharyngeal to the stylo-glossus and the stylo-pharyngeus muscles*; 19, 19, pneumogastric; 20, 21, ganglia of the pneumogastric; 22, 22, superior laryngeal nerve; 23, spinal accessory; 24, 25, 26, 27, 28, sublingual nerve and branches.

By reference to the diagram,¹ it will be perceived that two ganglioform enlargements are developed upon this nerve, the upper one being situated on a level of the upper opening of

¹ See Fig. 129, on the following page.

the jugular foramen, while the lower one lies slightly below the

foramen. To the first, the name "jugular ganglion" is applied, while the second is called the "ganglion of Andersch," after its discoverer. These two ganglia do not include the same relative proportion of nerve fibers derived from the glosso-pharyngeal, since the jugular ganglion is developed upon only a portion of the nerve, while the ganglion of Andersch includes all the filaments of the trunk of that nerve.

Within the jugular foramen, the glosso-pharyngeal nerve lies in front of the spinal accessory and pneumogastric nerves, which are separated from it by a sheath which invests the two latter, and it bears an intimate relation with the jugular vein within the foramen, and also in the neck.

As a *motor nerve*,¹ the glosso-pharyngeal supplies the levator palati, azygos uvulæ,² stylo-pharyngeus, and the middle constrictor of the pharynx; while, as a nerve of *general sen-*

¹ It is extremely doubtful if the glosso-pharyngeal nerve possesses any motor fibers which are not derived from other nerves by filaments of communication.

² These muscles, if supplied by this nerve (as experiments seem to show), are reached by fibers sent to the facial nerve, and afterward, by means of the great petrosal branch, to Meckel's ganglion.

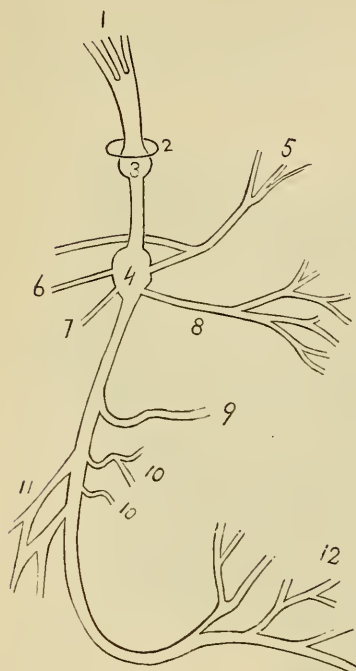


FIG. 129.—A diagram of the branches of the ninth cranial or glosso-pharyngeal nerve.

- 1, filaments of origin, extending into the medulla oblongata; 2, the jugular foramen, through which the nerve escapes from the cranium; 3, the jugular ganglion, developed upon the nerve in the jugular foramen; 4, the ganglion of Andersch, or the "petrous ganglion"; 5, the auricular branch, deriving a filament also from the pneumogastric nerve; 6, a communicating branch to the pneumogastric nerve; 7, a communicating branch to the sympathetic nerve; 8, the tympanic branch or "Jacobson's nerve," distributed to the middle ear; 9, a communicating branch to the carotid plexus of the sympathetic; 10, the tonsillar branches, distributed to the tonsil; 11, a portion of the pharyngeal plexus, formed also by the pneumogastric nerve; 12, the lingual branches, distributed to the mucous membrane and the papillæ of the base and sides of the tongue.

sation, it supplies the root of the tongue, the soft palate, the pharynx, the Eustachian tube, and the tympanum. It will be thus perceived that the glosso-pharyngeal nerve possesses,

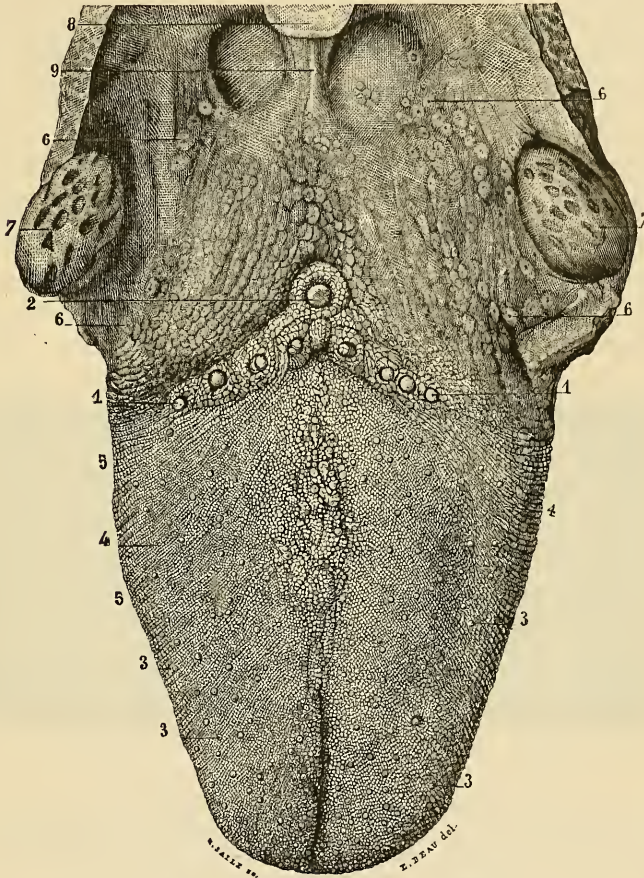


FIG. 130.—*Papillæ of the tongue.* (Sappey.)

1, 1, circumvallate papillæ; 2, median circumvallate papilla, which entirely fills the foramen cæcum; 3, 3, 3, 3, fungiform papillæ; 4, 4, filiform papillæ; 5, 5, vertical folds and furrows of the border of the tongue; 6, 6, 6, 6, glands at the base of the tongue; 7, 7, tonsils; 8, epiglottis; 9, median glosso-epiglottidean fold.

within itself, all the necessary fibers to insure those successive acts of a reflex type which occur during deglutition,¹

¹ It is denied by some physiologists that the *sensory filaments*, which are the main agents in exciting the reflex acts perceived during deglutition, are those of the glosso-pharyngeal nerve; since the sensory filaments of the fifth nerve distributed to the palate and pharynx from Meckel's ganglion seem to also fulfill that important function.

and it is by this nerve that the second act of deglutition is chiefly excited and performed.

The *sense of taste*, which is afforded by the glosso-pharyngeal, is confined to the *posterior third* of the tongue. A similar distribution of its sensory fibers is remarkably illustrated in that case of Hilton's,¹ where an attack of tonsillitis produced a sympathetic *furring* of the *posterior third only* of the lateral half of the tongue.

Though analogy would lead us to suppose that a stimulus applied to any part of the course of the gustatory fibers of the glosso-pharyngeal nerve would give rise to a sensation of taste and nothing else, the proof is not forthcoming; since this nerve, as before stated, is a mixed nerve containing sensory fibers as well as those of taste.

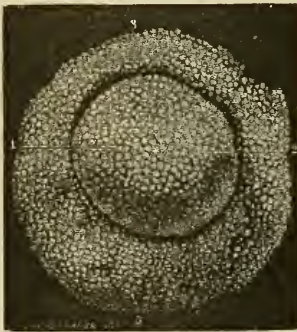

FIG. 131.




FIG. 132.

Varieties of papillæ of the tongue. (Sappey.)

FIG. 131.—Medium-sized circumvallate papilla: 1, papilla, the base only being apparent: it is seen that the base is covered with secondary papillæ; 2, groove between the papilla and the surrounding wall; 3, 3, wall of the papilla.

FIG. 132.—Fungiform, filiform, and hemispherical papillæ: 1, 1, two fungiform papillæ, covered with secondary papillæ; 2, 2, 2, filiform papillæ; 3, a filiform papilla, the prolongations of which are turned outward; 4, a filiform papilla, with vertical prolongations; 5, 5, small filiform papillæ, with the prolongations turned inward; 6, 6, filiform papillæ, with striations at their bases; 7, 7, hemispherical papillæ, slightly apparent, situated between the fungiform and the filiform papillæ.

Bitter substances are most tasted upon the *back of the tongue*, and sweet substances when placed *upon the tip*;² a point not without value in administering medicines. The

¹ "Rest and Pain." For similar effects due to the fifth nerve, see a previous lecture.

² Mich. Foster, *op cit.*

so-called "gustatory buds," which by some have been regarded as specific organs of taste, are found also upon the epiglottis, which is wholly devoid of taste; hence their function can not as yet be considered as fully determined.

As a means of refreshing your memory, the following classification of the branches of the glosso-pharyngeal nerve may prove of value. It will be seen that the tympanic branch, or Jacobson's nerve, is specially important, since it supplies portions of the middle ear which have been studied, when the auditory nerve was discussed, in their relation to the mechanism of hearing; and also because it gives a filament to two of the petrosal nerves, whose functions have been considered in connection with the seventh cranial nerve.¹

A TABLE OF THE BRANCHES OF THE GLOSSO-PHARYNGEAL NERVE AND THEIR DISTRIBUTION.²

GLOSSO-PHARYNGEAL (Ninth Cranial) NERVE.	}	1. Tympanic branch, or <i>Jacobson's nerve.</i>	}	<i>Communicating</i> filaments to	}	Large petrosal nerve, Carotid plexus, Small petrosal nerve.
		2. Carotid branches. 3. Pharyngeal branches (help to form the <i>pharyngeal plexus</i>). 4. Muscular branches (to muscles of the pharynx). 5. Tonsillar branches (help to form the tonsillar plexus). 6. Lingual branches.		<i>Branches of</i> <i>distribution to</i>		Fenestra ovalis, Fenestra rotunda, Eustachian tube.

EFFECTS OF SECTION.

Section of the glosso-pharyngeal nerve is followed by a type of paralysis, in which deglutition becomes an act of extreme difficulty, and in which regurgitation of food into the nostril is particularly liable to occur. The sense of *taste* in the *posterior third* of the tongue is furthermore completely destroyed, thus tending to prove that the *gustatory fibers* are *inherent to the nerve* itself, and not the result of a communication between

¹ Flint ascribes to the *chorda tympani nerve* the ability to perceive only *saline, acid,* and *styptic* qualities; and to the *glosso-pharyngeal nerve*, the appreciation of *sweet, alkaline, bitter,* and *metallic* tastes. Jacobson's nerve probably controls the flow of saliva; acting in concert with the *chorda tympani* branch of the facial nerve.

² Copied from the "Essentials of Anatomy" (Darling and Ranney). Putnam's Sons, New York, 1880.

it and some other nerve, as is claimed in reference to the gustatory fibers of the fifth.¹

It is stated, by some of the later investigators upon this subject, that the sense of taste is not alone confined to the tongue, but exists also in the *pillars of the fauces* and the *walls of the pharynx*, and that section of the glosso-pharyngeal nerve causes an entire abolition of this power of special sense in these latter regions, as well as in the posterior third of the tongue.²

THE ACT OF DEGLUTITION AND ITS MECHANISM.

The act of deglutition is, perhaps, more properly connected with the glosso-pharyngeal nerve than with any other, although that nerve assists in the performance of one stage only of the entire act. For convenience of description, it has been the custom of physiologists to divide the act of deglutition into three distinct periods. The first period, comprising

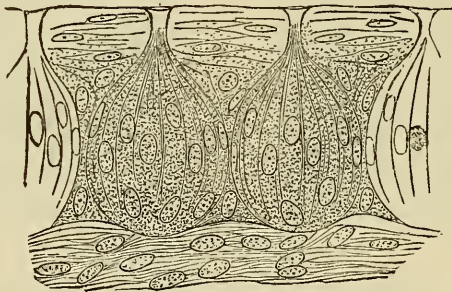


FIG. 133.—Taste buds from the lateral taste organ of the rabbit. (Engelmann.)

the passage of the bolus of food through the mouth, which is under the control of the voluntary muscles; the second, the passage of the bolus through the isthmus of the fauces and the pharynx; the third, the passage through the œsophagus to the cavity of the stomach.

In the *first period*, the food is first seized by the lips, then

¹ See previous lecture on the fifth nerve, and also the lecture upon the facial nerve.

² Experiments seem to point to the *fungiform* and *circumvallate papillæ* of the tongue as the chief agents in perceiving taste, if the function of the "taste buds" of Lowén and Schwalbe are accepted as proven. See Fig. 133.

forced between the jaws by the tongue and the buccinator muscles ; and by the teeth it is not only masticated, but is also mixed with the salivary secretion. When the food is ready to be swallowed, the mouth is first closed, as the act is performed with extreme difficulty when the mouth is open, because the tongue can not properly act upon the bolus.¹ The tongue now becomes widened, so as to offer a large surface to the bolus of food, and, with the bolus placed behind it, is pressed backward along the roof of the mouth. In case the food to be swallowed happens to be in a liquid form, the tongue is so curved that its edges curl upward, while its dorsum is depressed in the center, thus forming a *longitudinal groove* along its entire length ; and the soft palate is so closely applied to the base of the tongue as to admit of a sucking force.

The importance of the tongue during this period of the act of swallowing can not be overestimated. Animals, in which the tongue has been paralyzed by section of the nerves of that organ, exhibit the utmost distress in their efforts to bring the food to the back portion of the mouth, and are forced to so toss the head as to bring the force of gravity to their aid.² Drinking, also, becomes even more interfered with, and the tongue is no longer used to help in the act ; hence, various devices are used to bring the fluid where the reflex act of the fauces will help to carry it to the stomach. If it were not for the fact that, after removal of the tongue for local disease, the stump was of sufficient length to be of great assistance in controlling the bolus of food, such an operation would be a questionable procedure in surgery.

It may be noticed, by those of you who have been following these remarks with care, that the glosso-pharyngeal nerve has, as yet, had no influence upon the mechanism of deglutition, since the buccinator muscles are supplied by the facial nerve, and the tongue by the hypo-glossal nerves, which have

¹ For the clinical proof of this fact, the reader is referred to the effects of "facial diplegia." See page 443.

² We see this also marked, but to a less extent, in patients afflicted with glosso-labial paralysis.

not, as yet, been described; but, as the second and third periods of the act are the most complex, and the second most completely under the control of that nerve, the omission of the mechanism of the first period, until the whole could be considered together, was for the purpose of making the sub-

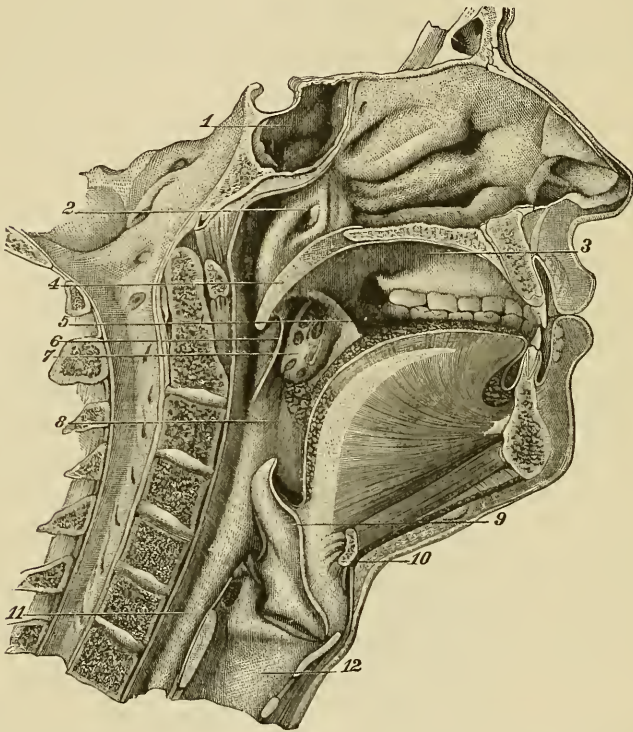


FIG. 134.—Cavities of the mouth and pharynx, etc. (Sappey.)

Section in the median line of the face and the superior portion of the neck, designed to show the mouth in its relations to the nasal fossæ, the pharynx, and the larynx: 1, sphenoidal sinuses; 2, internal orifice of the Eustachian tube; 3, palatine arch; 4, velum pendulum palati; 5, anterior pillar of the soft palate; 6, posterior pillar of the soft palate; 7, tonsil; 8, lingual portion of the cavity of the pharynx; 9, epiglottis; 10, section of the hyoid bone; 11, laryngeal portion of the cavity of the pharynx; 12, cavity of the larynx.

ject more easy of comprehension than if the different periods were considered separately from each other. The effect of section of the inferior maxillary branch of the fifth nerve upon the act of deglutition has been mentioned in a previous lecture, but this effect is due, not alone to an absence of the

normal muscular power of the muscles of mastication, but also to an anæsthetic condition of the mucous lining of the mouth, which renders the tongue unable to appreciate the situation of the bolus of food ; as has been proven by the fact that the same difficulty exists when section of the fifth nerve is made in front of the ganglion of Gasser, where only the sensory portion of the nerve can be injured, as when both the motor and sensory portions of the nerve are involved, after section below the foramen ovale.

In the *second period* of deglutition, the bolus of food, by being crowded backward, tends to raise the soft palate ; and the levator palati muscle further assists in retaining the palate in this elevated position, while the superior constrictor muscle of the pharynx causes the posterior wall of the pharynx to bulge forward, and thus to meet the uvula. The *posterior nasal openings* are thus mechanically closed to the entrance of the food into the chamber of the nose, preparatory to the series of reflex movements which are to ensue, for the purpose of forcing the bolus downward into the œsophagus, and thence into the stomach.

The *larynx* is now *suddenly raised*, so as to bring the superior opening of that organ underneath the base of the tongue, which has been crowded backward during the first period, in order to force the bolus against the soft palate. Its soft structure renders it admirably adapted to mold itself to the irregularities of outline of the laryngeal opening. By this position of the tongue, the epiglottis is also applied over this opening,¹ and the entrance of food into the larynx is furthermore guarded against by the approximation of the vocal cords by means of the adductor muscles of the larynx. The muscles which thus raise the larynx are the anterior belly of the digastric, the mylo-hyoid, the genio-hyoid, the stylo-glossus, and some of the fibers of the genio-glossus.

· Simultaneously with the elevation of the larynx, the pa-

¹ It was formerly supposed that the epiglottis was the chief instrument in preventing the entrance of food into the larynx, but the large number of cases where the epiglottis has been removed, and no difficulty in deglutition apparently produced, have created a doubt as to its importance.

lato-pharyngeal muscles contract and raise the lower end of the pharynx, thus shortening the length of that organ and tending to draw the pharynx over the bolus of food, very much as a glove is drawn over the finger; while, at the same time, the curve of the posterior pillars of the pharynx is

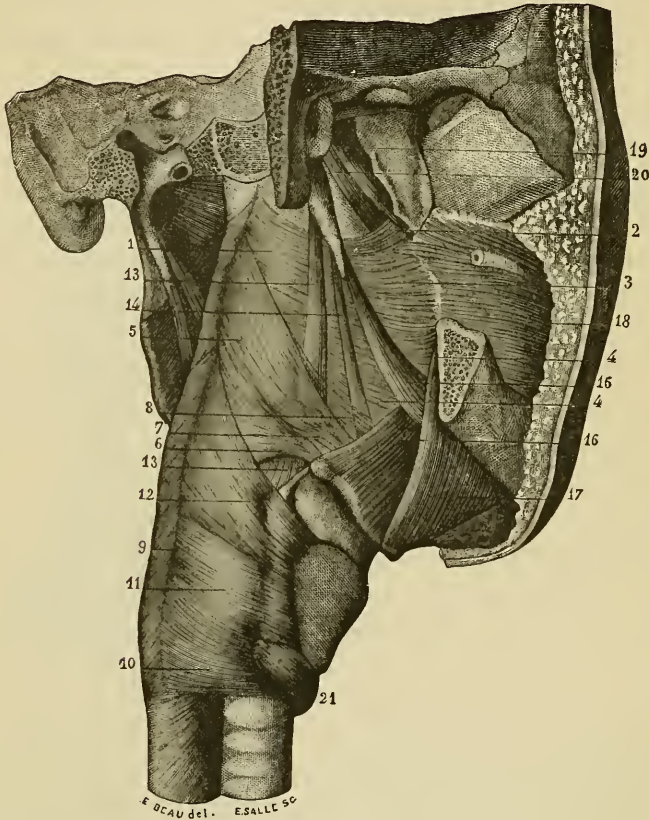


FIG. 135.—Muscles of the pharynx, etc. (Sappey.)

1, 2, 3, 4, 4, superior constrictor; 5, 6, 7, 8, middle constrictor; 9, 10, 11, 12, inferior constrictor; 13, 13, stylo-pharyngeus; 14, stylo-hyoid muscle; 15, stylo-glossus; 16, hyo-glossus; 17, mylo-hyoid muscle; 18, buccinator muscle; 19, tensor palati; 20, levator palati.

made straight, and, by the approximation of these muscles to the sides of the uvula, the opening of the pharynx into the nares is now completely occluded.

The constrictor muscles of the pharynx now come into

play, contracting in succession from above downward; the posterior pillars of the fauces, by their approximation, prevent the bolus from again entering the mouth; and it is thus forced to enter the œsophagus.

It is apparent that most of these movements are of a *reflex character*, and are excited by the presence of the bolus of food, which passes out of voluntary control as soon as it passes the anterior pillar of the fauces, at which point the second period of deglutition may be said to commence. Every reflex act presupposes some *sensory* filaments to convey the impression to the brain, and certain *motor* filaments to transmit the impulses to the muscles destined to act upon the bolus; it is now believed that the glosso-pharyngeal nerve possesses both of these sets of fibers, as well as those controlling the special sense of taste. This nerve may then be considered as a nerve of taste, a nerve of motion to the pharyngeal muscles, and the true "*excitatory nerve*" of the act of deglutition.

The importance of the *soft palate* in the act of deglutition is particularly shown during the swallowing of liquids, since it has to be closely applied to the base of the tongue, in order to allow of a partial vacuum within the cavity of the mouth, and thus to draw the fluid along the furrow formed by the curving upward of the edges of the tongue. This fact is clinically shown by patients affected with paralysis of the velum,¹ who experience great difficulty in swallowing liquids, since the fluid is liable to escape through the nose. A case of this character is reported by Bérard, where a young lady was obliged to free herself from all observation whenever she attempted to drink, as the escape by the nostrils was so profuse as to occasion embarrassment.

The prevention of the entrance of food into the cavity of the larynx, as has been mentioned, is insured: first, by the base of the tongue; secondly, by the epiglottis; and, thirdly,

¹ Paralysis of certain muscles of the soft palate occurs when the *facial nerve* is impaired behind the point of origin of its petrosal branches. For particulars of this diagnostic symptom, the reader is referred to page 440.

by the approximation of the vocal cords; but that such accidents do still happen from attempts at inspiration¹ during eating is attested by the violent coughing excited, and by the instantaneous expulsion of the foreign substance, unless it should chance to become mechanically arrested in the larynx. Longuet accounts for the symptoms excited by such an accident as the result of an exquisite sensibility possessed by the mucous lining of the upper part of the larynx. It is well attested that the danger of entrance of fluids into this organ is far greater than in the case of solids; and the act of gargling is especially liable to be followed by such an occurrence, since the larynx is much wider open than in the act of deglutition. In the administration of anæsthetics to patients who have eaten largely before the hour appointed for surgical relief, a great danger of the entrance of vomited matters into the cavity of the larynx is encountered, since the sensitiveness of the mucous lining is destroyed, and the expulsive efforts of Nature are often wanting.²

The *third period* of the act of deglutition is confined to the œsophagus, through which the bolus has to pass to reach the stomach. The downward movement of the bolus is assisted by alternate contraction of the longitudinal fibers of the tube, which shorten it and tend to draw its walls upward over the bolus, and contraction of the circular fibers, which constrict the tube and force the bolus downward. The fact that gravity has little, if anything, to do with this downward movement is proven by the fact that the position of the body does not seem to affect it, while acrobats are often known to perform the feat while standing upon the head or hands. The time consumed in the passage through the œsophagus was estimated by Magendie³ as about two minutes in animals, but

¹ As occurs during attacks of laughing, hiccough, etc., when food is present in the mouth, or during too hasty an effort to consume food.

² In cases where this accident occurs, the tongue should be forcibly drawn out of the mouth, so as to pull up the epiglottis, and the foreign body extracted by the finger, if possible, or, if not, the patient should be held by the feet, and thus, by shaking the patient, gravity may help to dislodge it. I once saved the life of a man by this means when all others had failed, and fatal asphyxia seemed imminent.

³ "Journal de Physiol."

it is probably much shorter in man; although we are often conscious of a delayed termination of the act, and are forced to hasten it by the drinking of fluids, as most of us can attest. It is probable that this peristaltic action of the œsophagus, like that of the intestinal canal, is partly controlled by the nervous influence of the sympathetic system, although the pneumogastric nerves have an extensive distribution to and a very marked control over this organ.¹

Deglutition is *essentially a reflex act*, save in its first period, when volition plays an important part. It can not take place unless some stimulus is applied to the mucous lining of the fauces; and those apparently voluntary acts of deglutition which are produced when no food is within the mouth are undoubtedly due to the swallowing of saliva, or to irritation of the fauces by the base of the tongue itself. When we tickle the fauces, we can see all of the act of deglutition, confined to the second period, artificially produced; and this irritability of the fauces is so extreme in some persons as to render any attempt to examine the throat one of difficulty, and often a cause of reflex vomiting. So important is the education of the throat to enable the patient to tolerate the presence of instruments, that all surgical procedures upon the larynx, if performed from within the mouth, require often months of training to enable the patient to assist the operator in a step whose execution may be a matter of a few seconds only. All forms of local applications are used to insure an anæsthetic condition of these parts, and the internal administration of medicinal agents is, furthermore, often required to render such procedures within the cavity of the larynx possible.

That the *center for the reflex act of deglutition* is confined to the medulla oblongata is proven by experiment on animals whose brain has been entirely removed, with the exception of the medulla, when irritation of the fauces will still continue

¹ Michael Foster regards this third act of deglutition as more closely dependent upon the *central nervous system* than the movements of the intestinal tract, and attributes it to reflex action due to the bolus.

to produce all the movements of the second stage of that act.

CLINICAL POINTS OF INTEREST PERTAINING TO THE GLOSSO-PHARYNGEAL NERVE.

The intimate association which apparently exists between the fibers of this nerve and the sense of taste, the movements of the pharyngeal muscles, and the reflex acts excited by the presence of a bolus or of some foreign source of irritation to the isthmus of the fauces and the walls of the pharynx, would seem to suggest that any impairment of the glosso-pharyngeal would be followed by clinical evidences of imperfect performance of each and all of these functions. It is, however, to be regretted that the questions of the course, origin, and functions of the chorda tympani nerve, the exact distribution of the fibers of the glosso-pharyngeal nerve to the tongue, and the source from which this latter nerve derives its motor filaments, are, as yet, disputed points among physiologists; and the sources of doubt are not removed, but rather increased, by the results of pathological observation, since they often seem contradictory, and thus prove rather a source of embarrassment than an aid to definite conclusions.

One would naturally suppose, provided that he was familiar with the symptoms of that disease, called by Duchenne "glosso-labio-laryngeal paralysis" (although the word "pharyngeal" is often used in place of "laryngeal" to express the same condition), that the difficulty experienced in deglutition would certainly indicate that the nerve which apparently presides over that function would be found in a state of disease; but, on the contrary, the glosso-pharyngeal nerve is not reported, to my knowledge, as having anything to do with that affection. We must, therefore, be forced to infer that the motor filaments of the pharynx are, to a great extent, controlled by other nerves; and that, if they are apparently branches of the ninth cranial nerve, they are to be accounted for as fibers derived from communicating filaments from other sources.

Hirschfeld claims to have verified a branch of the glosso-pharyngeal nerve which extends to the *anterior two thirds* of the tongue; hence the strong probability that it partially controls the sense of taste in that portion as well as in the posterior third of the organ. Stannius, by experiments, thinks that he has established the function of this branch, and he attributes to it the power of perception of *bitter substances* only, the other varieties of taste sensations being presided over by the chorda tympani nerve or the gustatory branch of the fifth nerve. We know, clinically, that the conditions of hyperæsthesia and anæsthesia of the gustatory nerves are verified by many interesting phenomena; and we must be content to wait for the solution of the other mixed problems of gustation, until they are solved by further clinical, physiological, and pathological observation.

The condition of *gustatory hyperæsthesia*, called also "*hypergeusia*,"¹ is very marked in certain patients who are in an anæmic and nervous condition, while it is a frequent phenomenon in hysteria and in melancholia. In such cases an apparent gustatory sensation may be often excited by the application of an electric current to the cervical or upper dorsal region of the spine.

True gustatory hyperæsthesia may express itself as an increase in the delicacy of the gustatory sensation, so that extremely small quantities of sapid substances may be perceived. We thus occasionally meet with hysterical patients, who can perceive the taste of certain medicinal agents in a solution which to the healthy subject would be tasteless. It may express itself, again, as an unnatural enjoyment of food, or a loathing of certain dishes which convey a sense of taste which does not in reality exist. In facial paralysis of rheumatic origin, abnormal gustatory sensations are sometimes present, as sweetish, sour, or sapid tastes, within the mouth. In the insane, hallucinations of the special sense of taste, usually of

¹ See experiments of Valentin and Keppler, made to determine the exact degree of gustatory sensibility and excitability.

a disagreeable character, are often present, and indicate some disease of central origin.

The condition of *gustatory anæsthesia*, called "*ageusia*," comprises all those phenomena which indicate either a partial or complete loss of the sense of taste. Thus, the tongue may be able to appreciate certain substances, and be insensible to others, while the anæsthetic condition may be circumscribed or diffused, as regards its anatomical distribution, affecting either the tip of the tongue, its root, or one or both sides. This abnormal state is observed after paralysis of the trigeminus, severe injuries to the trigeminus or the glosso-pharyngeal nerves, intra-cerebral growths which create compression of the glosso-pharyngeal or trigeminus,¹ and atrophy of the nerves, as the result of compression, and of disease of their inherent fibers. As a rule, when this condition exists, we shall find a similar condition of the optic, olfactory, trigeminus, pneumogastric, spinal accessory, or some of the cutaneous branches to the face.

THE PNEUMOGASTRIC, OR TENTH NERVE.

Owing to the numerous connections of the pneumogastric with other nerves, its varied and extensive distribution, and the important character of its functions, this may properly be regarded as one of the most remarkable nerves of the whole body. It has been often known by the name of the "*par vagum*," from the wandering course of its fibers, which are distributed to five different vital organs, viz.: the heart, lungs, stomach, liver, and intestines, as well as to many other parts of secondary importance.

This nerve, like the seventh, eighth, and ninth nerves, is considered by comparative anatomists as belonging to the

¹ In the case reported by Böttcher, although ageusia existed, the patient complained of a constant burning and bitterness within the mouth. An autopsy showed the presence of a tumor of the base of the brain, which had caused atrophy of the glosso-pharyngeal and pneumogastric nerves by a steady compression. Longet reports cases where the nerves passing through the jugular foramen were all more or less destroyed by pressure from a similar cause.

class of spinal nerves, since it arises directly and entirely from the upper portion of the spinal cord. Its superficial point of origin lies in the groove between the *olivary* and *restiform bodies* of the medulla, while its deep point of origin may be traced to a gray nucleus in the floor of the fourth ventricle, slightly below the nucleus for the glosso-pharyngeal nerve.¹

There is a very close affiliation between the deep fibers of the pneumogastric and glosso-pharyngeal nerves within the

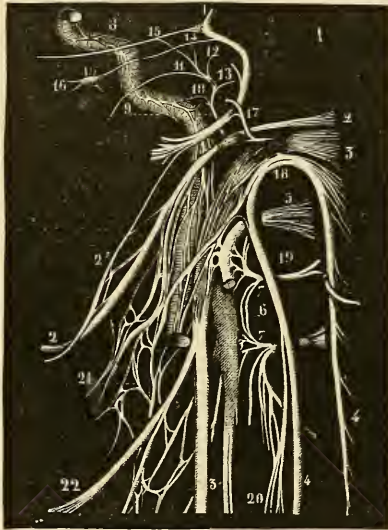

FIG. 136.—*Anastomoses of the pneumogastric nerve.* (Hirschfeld.)

- 1, facial nerve; 2, glosso-pharyngeal nerve; 2', anastomoses of the glosso-pharyngeal with the facial; 3, 3, *pneumogastric, with its two ganglia*; 4, 4, *spinal accessory*; 5, sublingual nerve; 6, superior cervical ganglion of the sympathetic; 7, *anastomotic arcade of the first two cervical nerves*; 8, carotid branch of the superior cervical ganglion of the sympathetic; 9, nerve of Jacobson; 10, branches of this nerve to the sympathetic; 11, branch to the Eustachian tube; 12, branch to the fenestra ovalis; 13, branch to the fenestra rotunda; 14, external deep petrosal nerve; 15, internal deep petrosal nerve; 16, otic ganglion; 17, *auricular branch of the pneumogastric*; 18, *anastomosis of the pneumogastric with the spinal accessory*; 19, *anastomosis of the pneumogastric with the sublingual*; 20, anastomosis of the spinal accessory with the second pair of cervical nerves; 21, pharyngeal plexus; 22, superior laryngeal nerve.

substance of the medulla oblongata, so close indeed as to lead some authors to consider them identical with each other. These deep fibers may be traced, in part, into the substance of the restiform body, a small bundle toward the cerebellum,

¹ See previous page of this section, in which the deep origin of the nerve is discussed.

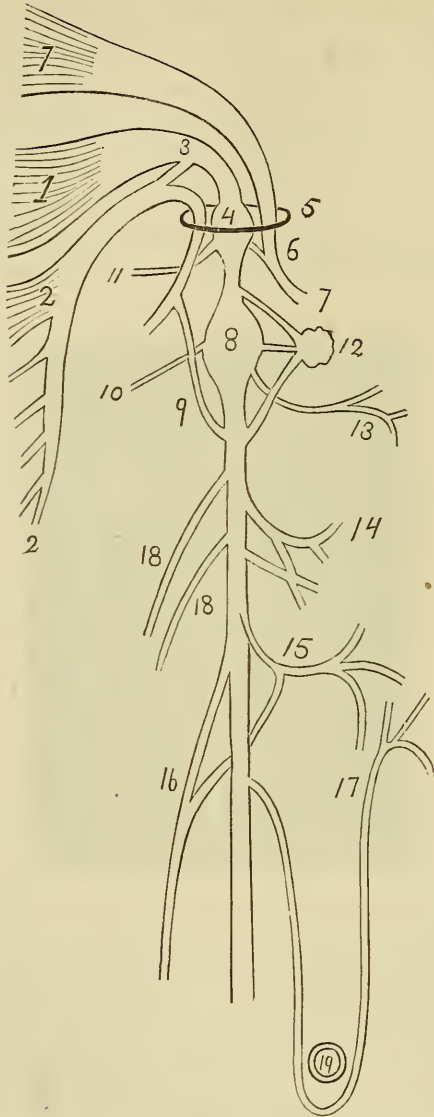


FIG. 137.—A diagram showing the branches of distribution and communication of the pneumogastric nerve. Cervical portion of nerve.

- 1, the filaments of origin of the pneumogastric nerve; 2, the *spinal accessory* nerve escaping from the medulla oblongata, below the pneumogastric nerve; 3, the upper communicating filament between the *pneumogastric* and the *spinal accessory* nerves (often absent); 4, the "*ganglion of the root*," situated in the jugular foramen; 5, the *jugular foramen*, showing the transmission of three nerves; 6, the communicating filament between the *pneumogastric* and the *glosso-pharyngeal* nerves; 7, the *glosso-pharyngeal* nerve, from its point of origin to its escape from the cavity of the cranium; 8, the "*ganglion of the trunk*" of the pneumogastric nerve; 9, the *lower filament* of

communication between the *pneumogastric* and *spinal accessory nerves*, which probably controls the muscles of the larynx concerned in phonation and respiration; 10, the *communicating filament* from the arcade, formed by the first and second cervical nerves; 11, the *communicating filament* from the *facial* nerve, which helps to form the auricular branch of the pneumogastric or "Arnold's nerve"; 12, the *three sets* of filaments which join the pneumogastric nerve to the *superior cervical ganglion* of the sympathetic system; 13, the *auricular branch* of the pneumogastric, or "*Arnold's nerve*," partly formed by the facial filament (11); 14, the *branches* to the "*pharyngeal plexus*," formed also in part by the glosso-pharyngeal; 15, the *superior laryngeal* nerve, supplying the mucous lining of the larynx and the crico-thyroid muscle; 16, the "*depressor nerve of the heart*," formed by two roots, one from the pneumogastric, and the other from the superior laryngeal nerve;¹ 17, the *inferior* or *recurrent laryngeal* nerve, winding around an artery (19), and then returning to the larynx to supply the muscles of phonation;² 18, the *cervical cardiac* nerves (sometimes three in number), going to the cardiac plexus; 19, the *subclavian artery* (if on the right side), and the *arch of the aorta* (if on the left side of the body).

and a few toward the cerebrum; but the larger portion pass to the median line of the floor of the fourth ventricle or descend into the substance of the medulla oblongata.

The pneumogastric nerve emerges from the jugular foramen as a single trunk, but immediately develops two ganglia, the upper of which is called the "*jugular ganglion*," or the "*ganglion of the root*," since it lies close to and sometimes within the foramen of that name. After the nerve emerges from the foramen, another ganglion, about one quarter of an inch in length, is developed, called the "*ganglion of the trunk*." Within the jugular ganglion, an interchange of fibers takes place between the pneumogastric and spinal accessory nerves; and it seems clear that the laryngeal and pharyngeal branches (which are among the most decidedly motor of those given off from the pneumogastric) may all, in great part, be traced backward into the spinal accessory nerve.

The researches of Valentin, Morganti, Longet, and others seem to prove that the pneumogastric nerve at its root possesses no motor power, but is entirely an afferent nerve, although Stilling, Wagner, Müller, Volkman, and Bernard fail

¹ For the physiological effect of stimulation of this nerve, see the late researches of Cyon and Ludwig upon this nerve in the rabbit; also text-books of physiology of Michael Foster, A. Flint, Jr., and others. In man, this nerve is probably associated with one of the cardiac nerves.

² The filament of the spinal accessory (No. 9 in the cut) is supposed to afford to this nerve its motor power, having simply used the sheath of the pneumogastric as a means of protection in its course down the neck. The physiological import of this nerve shows the vital necessity for such protection.

to attribute all the motor fibers of this nerve to either the spinal accessory or glosso-pharyngeal nerves, and maintain that motor fibers may be demonstrated within the root of the pneumogastric above the jugular ganglion.

In regard to its *trunk*, there can be no doubt that the pneumogastric is to be considered as a nerve of double endowments, although it is certain that these endowments are very differently distributed among its branches. That it is capable of conveying those impressions which become *sensations* when communicated to the sensorium is experimentally proved by the fact that, when its trunk is pinched, the animal gives signs of acute pain ; and it is also evident from the painful consciousness we occasionally have of any abnormal condition of the organs which it supplies.

BRANCHES OF THE PNEUMOGASTRIC NERVE.

The pneumogastric nerve, by means of its numerous points of distribution, participates in the operations of *deglutition*, *phonation*, *respiration*, the *circulation of the blood*, and the *process of digestion*. To fully describe the variations in its course from above downward, and the distribution of its branches to the various organs (in all of their physiological bearings), you must, of necessity, be carried into a discussion of the thoracic and abdominal viscera and the physiological acts which they perform. A hasty enumeration of the general course of the fibers of this nerve can, therefore, only be given here, reserving the many points of interest connected with it for other lectures, when the viscera will be considered.

The *efferent fibers* of the pneumogastric nerve include certain motor branches which are distributed into the pharynx, the larynx, the œsophagus, the stomach, and the intestinal canal.

The *pharyngeal branches* help to form the pharyngeal plexus of nerves, and thus to aid in the movements of the muscles of that organ during the second period of deglutition.¹

¹ See lecture upon the glosso-pharyngeal nerve, where the act of deglutition is fully discussed.

It is also probable that these same muscles tend to modify the *tone and quality of the voice*, and also to assist in the

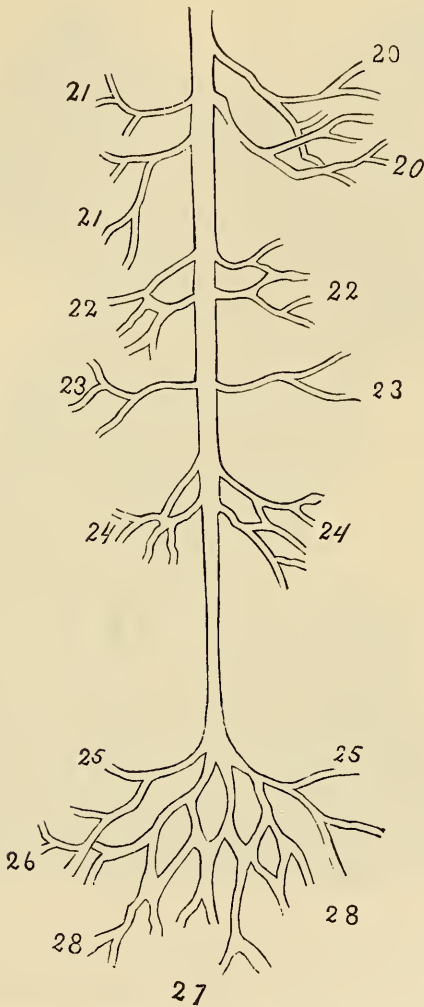


FIG. 138.—Thoracic and abdominal portion of the nerve.

20, the thoracic cardiac nerves, assisting to form the cardiac plexus; 21, the filaments of communication between the pneumogastric nerve and the thoracic ganglia of the sympathetic system; 22, the branches given off by the pneumogastric nerve to assist in forming the posterior pulmonary plexus; 23, the branches given off to assist in forming the anterior pulmonary plexus; 24, the branches which form the œsophageal plexus, and assist in the performance of the third period of the act of deglutition; 25, the gastric branches, supplying the coats of the stomach; 26, the hepatic branches, accompanying the portal system of veins; 27, the intestinal branches, controlling, to a large extent, the peristaltic action of that canal; 28, branches which can be traced to the kidneys, the spleen, and the supra-renal capsules.

articulation of sounds or words, although the lingual muscles and those of the lips are more directly concerned in the latter function.

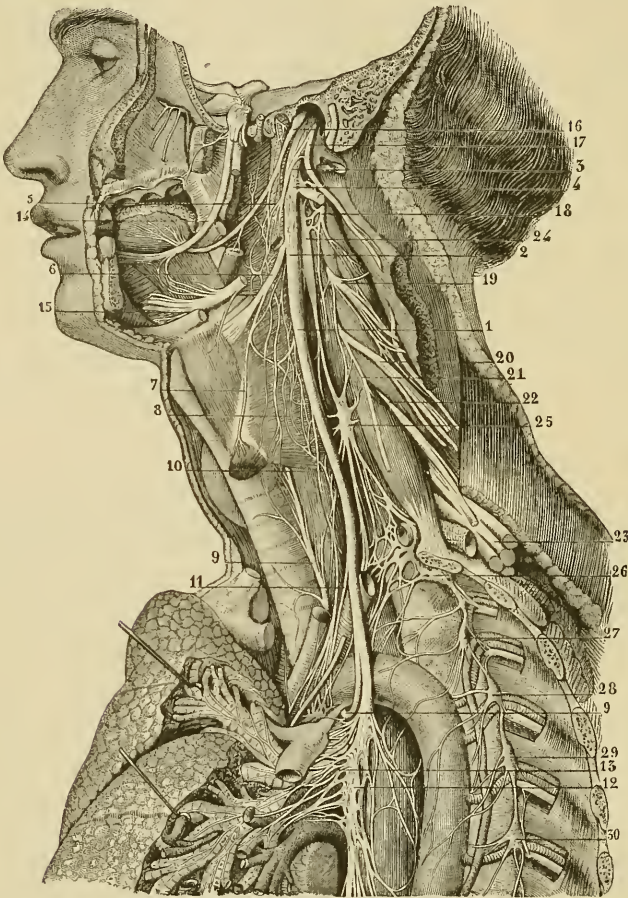


FIG. 139.—Distribution of the pneumogastric. (Hirschfeld.)

1, trunk of the left pneumogastric; 2, ganglion of the trunk; 3, anastomosis with the spinal accessory; 4, anastomosis with the sublingual; 5, pharyngeal branch (the auricular branch is not shown in the figure); 6, superior laryngeal branch; 7, external laryngeal nerve; 8, laryngeal plexus; 9, inferior laryngeal branch; 10, cervical cardiac branch; 11, thoracic cardiac branch; 12, 13, pulmonary branches; 14, lingual branch of the fifth; 15, lower portion of the sublingual; 16, glosso-pharyngeal; 17, spinal accessory; 18, 19, 20, spinal nerves; 21, phrenic nerves; 22, 23, spinal nerves; 24, 25, 26, 27, 28, 29, 30, sympathetic ganglia.

The *laryngeal branches* are two in number, and are called the superior and inferior; although the name “recurrent laryngeal nerve” is more often applied to the latter on account

of the peculiarity of its course, since it winds around the subclavian artery before returning to the larynx, upon the right side of the body, while the left nerve winds around the arch of the aorta, and then turns backward, to be distributed to the muscles of the larynx. It is by means of these laryngeal nerves that the *muscles which move the vocal cords*, and thus control the voice, are supplied; while the same muscles are important agents in so adapting the size of the opening between the vocal cords, during inspiration, as to allow of an unimpeded entrance of air to the lungs.¹ As the *inferior nerve* is the one which supplies all of the laryngeal muscles but the crico-thyroid and a portion of the arytenoid, it becomes to the physiologist a nerve of great importance, since the acts of respiration and phonation are directly under its influence. Experiment seems to have proven, however, that the laryngeal nerves, although apparently deriving their motor power from the pneumogastric, are, in reality, but fibers of the *spinal accessory nerve*, which have used the sheath of the pneumogastric nerve simply for protection in their passage through the neck. The spinal accessory nerve is, therefore, sometimes called the "superior respiratory nerve of Bell," since it controls the movements of the laryngeal muscles during the act of inspiration;² which are the highest, in point of situation, of any of the respiratory muscles.

The *branches* to the *œsophagus*, *stomach*, and *intestine* are the principal agents in promoting the peristaltic action of the alimentary canal, and they thus aid in the acts of deglutition and digestion. It is probable, also, that the pneumogastric nerves are capable of directly affecting the *secretions* of the alimentary canal, although the sympathetic system is

¹ The researches of Bernard have done much to call professional attention to the fact that the pneumogastric and spinal nerves are alone involved in ordinary respiration, but that, when it becomes necessary to bring the respiratory movements into perfect accord with the requirements of animal life (as in adapting the action of the muscles of the larynx to production of voice), the spinal accessory nerve becomes an indispensable aid.

² This statement is one that will admit of question. The reader is referred to the experiments of Bernard and Bisehoff (as given on a subsequent page) for the difference between the effect of the spinal accessory fibers upon the glottis from those of the pneumogastric itself.

still regarded as the means by which these nerves exert their influence upon that portion of the body.

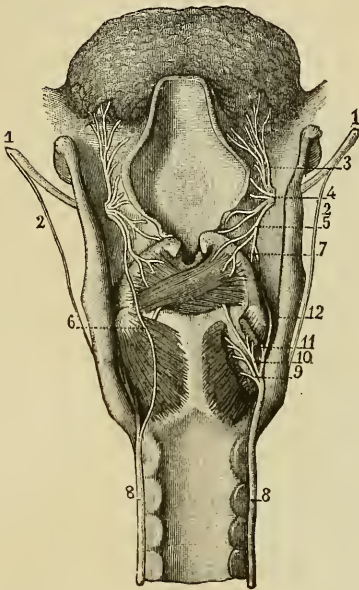


FIG. 140.—Nerves of the larynx, posterior view. (After Sappey.)

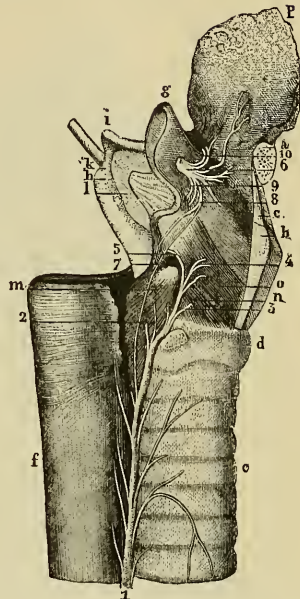


FIG. 141.—Nerves of the larynx, lateral view. (After Hirschfeld.)

FIG. 140.—1, 1, superior laryngeal nerves passing through the thyro-hyoid membrane; 2, 2, external laryngeal branch supplying the crico-thyroid muscle; 3, ascending branches distributed to the mucous membrane of the tongue; 4, transverse branches distributed to the mucous membrane of the epiglottis and the aryteno-epiglottidean folds; 5, descending branches passing to the mucous membrane covering the posterior surface of the larynx (two of these, of considerable size, cross the arytenoid muscle to supply the mucous membrane lining the walls of the vestibule); 6, branch connecting the superior with the inferior laryngeal nerve; 7, the same branch divided near its point of origin; 8, 8, inferior laryngeal nerve; 9, branch to the posterior crico-arytenoid muscle, which is here divided in order to show the next nerve; 10, branch to the arytenoid winding under the lower border of the muscle so as to enter it from its inner surface; 11, branch to the lateral crico-arytenoid muscle; 12, branch to the thyro-arytenoid muscle.

FIG. 141.—*a*, section of the hyoid bone; *b*, section of the thyroid cartilage; *c*, thyro-hyoid membrane; *d*, cricoid cartilage; *e*, trachea; *f*, œsophagus; *g*, epiglottis; *h*, superior cornu of the thyroid cartilage; *i*, great cornu of the hyoid bone; *k*, lateral thyro-hyoid ligament; *l*, thyro-hyoid membrane; *m*, posterior crico-arytenoid muscle; *n*, lateral crico-arytenoid muscle; *o*, thyro-arytenoid muscle; *p*, base of the tongue; 1, recurrent laryngeal nerve; 2, branches given off from this nerve to the posterior crico-arytenoid muscle; 3, branch to the lateral crico-arytenoid muscle; 4, branch to the thyro-arytenoid muscle; 5, branch to the arytenoid muscle; 6, right superior laryngeal nerve; 7, anastomosis of this nerve with the inferior laryngeal; 8, descending branches of the superior laryngeal; 9, middle branches of the same nerve; 10, ascending branches.

In addition to the branches, which are considered as of the greatest physiological importance, certain other *motor fibers*

are now traced with tolerable certainty to the trunk of the pneumogastric nerve, which are not unimportant. Thus we may include certain nerves which supply the plain muscular fibers of the trachea and of the larger bronchial tubes, fibers which exert a *vaso-motorial influence* upon the blood-vessels of the lungs, an *inhibitory nerve for the heart*, and certain fibers which are distributed to the lungs and the heart, which are supposed to exert a *trophic influence*.

The properties and functions of the *cardiac nerve*, and in what way the pneumogastric nerve influences the action of the heart, are physiological questions of the greatest importance. It is now known that section of the pneumogastric in the neck, instead of arresting the action of the heart, *increases the frequency* of its contractions; while galvanism of the divided ends causes the heart's action to *stop during its diastole*, if the current be a powerful one, and, if a weak one, the heart's action is proportionately slowed.

The *depressor nerve of the heart* is shown,¹ in the diagrammatic representation of the pneumogastric nerve and its branches, to arise from two filaments, derived, respectively, from the pneumogastric and the superior laryngeal nerves. The importance of this nerve in explaining

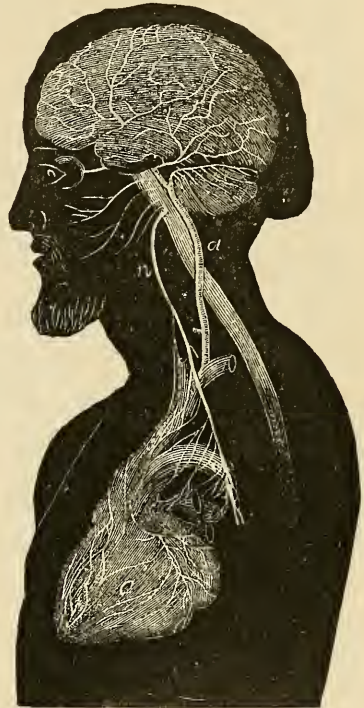

FIG. 142.—Branches of the pneumogastric to the heart. (Bernard.)

C, heart; a, carotid artery going to the brain; n, branches of the pneumogastric going to the heart.

¹ For the method of origin of this nerve, see the diagrammatic plate of the upper half of the pneumogastric nerve, page 484. While the diagram illustrates the construction of this nerve, as found in the rabbit by Cyon, it is still questionable whether a similar method of origin can be demonstrated in man. That the nerve exists is not a matter of doubt; but it is impossible to positively state its method of origin or its precise course.

many physiological effects of galvanism of the pneumogastric has been developed through the efforts of Cyon and Ludwig, in their prize essay of 1867, who showed to the profession its power of decreasing the blood-pressure, and who thus afforded the means of satisfactorily explaining many phenomena met with in the daily practice of medicine. If the abdomen of a frog be exposed, and the intestine struck sharply, the heart will be seen to stand still, as if the pneumogastric trunk had been strongly galvanized; while stimulation of the mesenteric nerves, before they join the sympathetic chain, will have a like result. It has been found that the irritation of an inflamed peritoneal surface, even if gently practiced, will decrease the heart pulsations, and that *severe shock or very intense pain*, no matter where it arises, will also have the same effect upon the heart.

Such evidences of reflex action are apparently transmitted through the cardio-inhibitory nerve fibers, and they help us to explain why pain may create, in the human race, attacks of fainting, and why some types of inflammatory diseases and states of collapse and shock are associated with a decrease in the pulsations of the heart. The action of *atropin*, even in small doses, seems to entirely arrest the influence of this nerve upon the heart, and a guide to the administration of this drug may thus be derived from physiology, while the effects thereof may, in some instances, be thus made clear.

The *cardiac nerves* of the pneumogastric are undoubtedly connected with the other nerves of the *cardiac ganglia*,¹ and act upon the heart fibers indirectly, rather than directly, without the intervention of the ganglion. It has lately been proven that certain *other cardiac nerves*, whose function is acceleratory, rather than depressing, to the heart, can be traced to the *cervical portion* of the *spinal cord* as their point of origin, but they have no connection with the pneumogastric nerve.

¹ The vaso-motor nerves of the lung are derived, according to Franck, from the upper cervical ganglia of the sympathetic, their primary origin, however, being in the cervico-dorsal region of the cord.

The *afferent fibers* of the pneumogastric nerve, or those which carry impressions from the periphery of the nerve toward its point of origin, comprise the sensory filaments¹ distributed to the entire respiratory tract, and also those sensory nerves which supply the pharynx, the œsophagus, and the stomach; fibers which assist to produce the secretion of the saliva; fibers which tend to arrest the secretion of the pancreas; a special *inhibitory* nerve upon the *vaso-motor center* of the medulla oblongata; and, finally, a special set of fibers which both augment and retard, at will, the action of the *respiratory center* of the medulla oblongata.

As the pneumogastric nerve is more apparently, although perhaps not more importantly, connected with the *act of respiration*, we will first consider the two sets of fibers which have been mentioned above as influencing the action of the respiratory center. It has been shown by Rosenthal that the superior laryngeal nerve, when stimulated by a galvanic current, decreases the number of respirations, while the main trunk of the pneumogastric nerve, when similarly stimulated, tends to increase the number of respirations. Thus, the fact that the vagus nerve possessed *two sets of respiratory fibers*, an acceleratory and an inhibitory, seems to be well established, although some observers have not, as yet, admitted the positiveness of the experiment.

As regards those branches of the pneumogastric which seem to exert a specific influence upon the *various secretions* of the alimentary canal, we have yet much to learn. As a general rule, it may be stated that anything which tends to create an increased activity in the epithelial cells, rather than in the blood supply of the part, tends also to increase the secretion. Thus a drug may excite any special secretion, first,

¹ Sommerbrodt ("Centralbl. f. d. med. Wiss.," December, 1880) points out a mechanism of compensation by which the action of the lungs and of the heart is coordinated. Thus, a rise in the intra-bronchial pressure (as occurs in singing, crying, coughing, etc.), by irritating the sensory nerves of the lungs, excites a reflex depressing action on the vaso-motor and cardio-inhibitory nerves. The resulting vascular dilatation and acceleration of the heart's action react upon the lung in two ways. They prevent the natural tendency to stasis of the blood in the bronchial walls, and they insure the rapid renewal of oxygen, demanded by the increase in pulmonary activity.

by acting upon the nerve center which controls that part; secondly, by a reflex act through the nerves of the part; thirdly, by acting as a direct chemical stimulus to the cells; and, fourthly, by increasing the amount of blood in the part, through dilatation of the blood-vessels.

That an *inhibitory effect* upon the *vaso-motor center* of the medulla is possessed by some of the fibers of the pneumogastric nerve, is proven by the effect of galvanism of the vagus upon blood pressure; since, when the depressor nerve of the heart is divided and the end connected with the brain is galvanized, the *blood pressure* falls, although the heart is not affected, as it would be if the cardiac portion of the nerve were stimulated.

COURSE OF THE PNEUMOGASTRIC NERVE OF THE TWO SIDES.

The important functions of the vagus render it necessary that every precaution shall be taken by Nature to prevent its possible injury, especially during its passage through the neck; since, within the thorax and the cavity of the abdomen, the viscera and the bony encasements tend to render all possible dangers of injury a minimum. We therefore find this nerve inclosed within the sheath of the carotid artery, where it is placed *between the artery and the internal jugular vein*, lying also *posteriorly* to them both. By this provision the nerve is placed between fluid upon either side, and thus all danger of transmitted force affecting it is obviated, while the deep situation of the carotid and the close proximity of the transverse processes of the cervical vertebræ make the nerve secure from the danger of wounds of pointed instruments. It is almost an impossibility, therefore, for this nerve to become involved in any form of accident, without the large vessels of the neck being simultaneously injured and the patient sacrificed.

Even in the jugular foramen the nerve is *wrapped in the same sheath* as the *spinal accessory nerve*, and it is placed behind both the glosso-pharyngeal nerve and the jugular vein; while, to reach the commencement of the common ca-

rotid artery, the nerve is placed in close relation to the internal carotid artery and the jugular vein.

As the nerves of either side reach the lower portion of the neck, each takes a different course. The *right nerve* passes between the subclavian artery and vein, then along the side of the trachea, then to the back of the root of the lung, then along the side of the œsophagus as two cords, then as a single cord along the back of that tube through the œsophageal opening of the diaphragm, and terminates in the solar and splenic plexuses, after giving off branches to the posterior surface of the stomach, and some filaments to the liver. The *left nerve* passes between the left common carotid and left subclavian arteries and behind the left innominate vein, then arches across the aorta and passes to the back of the root of the lung, then as two cords along the sides of the œsophagus, where it joins with its fellow to form the œsophageal plexus, then, as a single cord, in front of the œsophagus through the œsophageal opening of the diaphragm, when it supplies the anterior surface of the stomach and probably terminates in the hepatic plexus.

THE EFFECTS OF SECTION OF THE PNEUMOGASTRIC NERVE.

The effects of section of both of the pneumogastric trunks,¹ if made below the jugular ganglion, are most markedly exhibited in the larynx, the lungs, and the heart.

Effects upon the Larynx.—The larynx becomes impaired in its function, and the glottis remains partially closed by the vocal cords, whose abductor muscles are now paralyzed, thus impeding the free entrance of air into the lung; and, as a consequence of this, the respirations are, for a short time, hurried and difficult, although they soon become diminished in frequency.² The *inspiratory effort* becomes *unusually*

¹ Animals usually survive after one vagus nerve is divided, and present only a *hoarseness* of voice; an *increased frequency of respiration*, *emphysema*, or *pulmonary congestion* may be a sequel to the operation. Union of the divided nerve has been observed in numerous instances.

² Were it not for the *nerves of the skin*, and other *sensory nerves* which can transmit the feeling of pain, and which also possess the power of exciting respiratory efforts, section of both vagi ought, theoretically, to stop respiration at once.

slow, while expiration is remarkably rapid and sometimes audible; the intercostal spaces sink inward during the elevation of the ribs, showing that the lungs are not fully inflated with air, and death occurs in from one to six days, as the result of pulmonary consolidation. There are no symptoms accompanying the approach of death, except a gradual failure of respiration and a peculiar sluggishness,¹ which is characteristic and probably dependent upon carbonic-acid poisoning.

The immediate cause of death can undoubtedly be attributed to the altered condition of the lungs, which present a state of simple *vascular engorgement*, without any apparent inflammatory condition either of the lung or pleura. In very young animals, the division of the vagi is followed by almost immediate death, but this is attributable rather to paralysis of the glottis and the ensuing suffocation than to pulmonary congestion, which requires time for its development.

Effects upon the Lungs.—There have been many theories advanced to explain the effects of division of the pneumogastric nerves upon the lung tissue, and particularly to explain why such an operative procedure should be followed by excessive pulmonary hyperæmia, so as to cause the specific gravity of the lungs to exceed that of water. It seems to me that the theory, that the entrance of secretions or food into the lung through the paralyzed glottis (which can no longer spontaneously expel any foreign body) will explain the consolidation of the lung as a *direct result of irritation*, is not sustained either by the pathology of the pulmonary lesion or by experiments where a canula has been placed in the larynx to prevent this cause of irritation. Bernard has explained it on the ground that *traumatic emphysema* of the lung is developed from the labored inspiratory efforts made by the animal after the division of the vagi, thus creating a *mechanical hæmorrhage* which eventually consolidates the lung tissue. He sustains this theory by the fact that birds, whose lungs are fixed and immovable, and are therefore inexpandible, fail

¹ The *convulsions* which often accompany asphyxia are usually absent in these animals.

to present this condition when the vagi are divided, although death is produced.

To my mind, the most plausible explanation of the effects of this operation upon the lungs may be regarded as a purely mechanical one, dependent upon the *impeded entrance of air* through the larynx. During each inspiratory effort, the depression of the diaphragm and the elevation of the ribs tend to create a vacuum within the pleural and pericardial sacs, and thus favor the entrance of both air and blood into the thorax. So long as the entrance of either one remains unimpeded, the proper balance between the two is preserved, and neither too much air nor too much blood is sucked in with each inspiration; but, when the air is prevented from entering, an *excess of blood* flows into the lung with each inspiration, and, in the course of time, the lung is thus mechanically consolidated. Were the number of respirations not greatly decreased from the normal standard, the duration of life would probably be proportionally shortened, as the same effect would be produced in shorter time. The death of birds and some other animals, after section of the vagi, may possibly be explained on the ground of a too powerful impression upon the *respiratory center*.

Effects upon the Heart.—In addition to the effects upon the lungs, division of the pneumogastric nerves is followed by a marked *alteration of the action of the heart*. The effects are somewhat similar to those which might result if the governor of a steam-engine were suddenly removed, and the piece of mechanism allowed to proceed without its controlling influence. Thus the heart increases slightly in the rapidity of its pulsations, and the amount of *cardiac pressure becomes slightly diminished*, when one of the nerves is severed; but, when both are divided, the respiratory symptoms far outweigh those of the heart, but its action is still accelerated and often irregular, since the inhibitory power of the nerves is destroyed.

Effects upon the Digestive Tract.—The *oesophageal branches* of the vagus are the *motor nerves*, which control the

peristaltic action of that tube (as is proven by the fact that division of the pneumogastric nerves of both sides causes complete paralysis), and also the means by which *sensation* is afforded to its mucous lining. In animals which have been subjected to division of the vagi, attempts to swallow food in any considerable quantities create a distention of the upper part of the œsophagus, and regurgitation by means of the mouth takes place without the food entering the stomach,¹ as was proven by Bernard, who made a gastric fistula in a dog before dividing the pneumogastrics, in order to decide this point. From what source the motor fibers which control the movements of the œsophagus are derived by the pneumogastric nerve is still a matter of doubt; the root of the nerve itself seems to possess some influence upon it, thus indicating that it can not be traced to the nerves which communicate with it below the jugular foramen.

The branches which are *distributed to the liver* by the pneumogastric nerves are probably, in some way, connected with the *glycogenic function* of that organ, since division of these nerves causes the liver to yield no traces of sugar after the animal succumbs, which is contrary to the result obtained after death in animals which have these nerves intact. When the nerves are divided in the living animal, and the end nearest to the brain is galvanized, an increase of sugar in the blood is thus artificially produced at any time during the life of the animal, and traces of the same may also be found in the urine. A similar hyper-secretion of sugar by the liver may be also noticed after the inhalation of irritating vapors or anæsthetics, probably through the influence of the vagi.

The *gastric branches* of the pneumogastrics show a marked alteration in their power of control over that organ when the main nerve trunks are divided. The mucous lining of the stomach becomes at once pale, and the secretion of gastric juice apparently arrested, although a slight amount of secretion may return in a few days if the animal survive. The

¹ Physiologists are not agreed as to the seat of the reflex act of vomiting which follows division of the vagi.

sensations of *hunger* and *thirst* remain, but are sensibly diminished. *Absorption* by the stomach is evidently delayed, but not arrested, as has been proven by the introduction of poisons into that organ.

The *intestinal branches* of the vagi unquestionably control the secretions of the canal, and section of the nerves has been shown to prevent the action of the most powerful cathartics, even in fatal doses, when administered immediately before the vagi were divided. It is still a question whether the pneumogastric nerves influence the secretions of the intestinal canal directly, or through the sympathetic system by means of communicating filaments.

If the latter be the case, those filaments of communication which control the stomach and œsophagus must be sought for high up in the cervical region.

CLINICAL POINTS PERTAINING TO THE PNEUMOGASTRIC NERVE.

The physiological function of the separate branches of the pneumogastric, as mentioned in preceding pages, will assist you in appreciating the various manifestations of diseased conditions of the main trunk of the vagus, or of its individual branches. You can understand, from what has previously been said, that the effect of degeneration, section, or pressure upon this important nerve must vary with the seat of the lesion; since those branches given off above the point where the nerve is impaired will manifest their usual powers, while those given off below that point will show symptoms of partial or complete paralysis. We can, therefore, study the effects of impairment of the pneumogastric nerve by considering the individual branches in their order from above downward, and recording the special types of disease which are liable to create symptoms referable to each branch.

The *pharyngeal branch* contains both motor and sensory fibers; hence injury to its structure will create both paralysis and anæsthesia, while simple irritation of its fibers will tend to create contraction or spasm of certain muscles to which its motor fibers are distributed. We thus see, in attacks of

hysteria, the so-called "*globus hystericus*," a spasmodic affection of the pharynx, due to some irritation of the pneumogastric trunk or of the pharyngeal branches. We also occasionally meet true paralysis of this branch; in which case, the act of deglutition is greatly impaired, and, if the disease is bilateral, swallowing is rendered almost an impossibility.

The *superior laryngeal branch*, whose function is to supply the mucous lining of the larynx with sensibility,¹ becomes, under irritation, the cause of "spasm of the glottis" and of "whooping-cough." The former condition, called also "*stridulous laryngitis*" and "Kopp's asthma," is a disease peculiar to children, which tends toward asphyxia, but which is rarely if ever fatal. It usually occurs during the night, and seems to affect children who have been in apparent health. It is most common during the cold months; is sometimes associated with convulsions; and is characterized by a sibilant character to the respiration, pallor, or turgidity of the countenance, and a peculiar retraction of the head. In rare cases, this condition is met with in the adult, during attacks of hysteria. It seems to be dependent, in children, upon dentition, digestive irritation, anæmia, rickets, etc.

The experiments of Rosenthal seem to point to the superior laryngeal nerve as the exciting cause of the *convulsive cough* of "*pertussis*," and also of that analogous cough often met with in hysterical subjects, since artificial stimulation of the nerve produced, with this observer, similar results. Whether the irritation of the nerve proceeds from the catarrhal inflammation which exists in the respiratory passages, or irritation of some spinal or cerebral center, is not yet well determined.

The *recurrent laryngeal branch* is of great clinical importance, since its peculiar course often makes it a guide to aneurism of the large blood-vessels by the peculiar symptoms which

¹ See page 478 of this volume.

² The reader is referred by the author to his work, "A Treatise on Surgical Diagnosis" (3d edition, New York, 1884), for all the points of diagnosis of this type of disease.

it creates within the larynx.² The so-called "brassy cough" is, by some surgeons, considered as pathognomonic of pressure upon or irritation of this branch, and strongly indicative of aneurism of the subclavian, carotids, the arteria innominata, or of the left side of the arch of the aorta.

This branch may be affected by central causes, as well as by peripheral pressure or irritation. As examples of the central causes of impairment of this nerve may be mentioned those cases of apoplexy, cerebral tumors, hysteria, diphtheria, typhoid fever, and reflex irritation from diseases of the uterus or genitals, where the larynx is markedly affected. The peripheral causes which more commonly affect the recurrent laryngeal nerve, include catarrhal, tuberculous, and syphilitic inflammations of the larynx, traumatism, the pressure of growing tumors, as aneurism, goître, sarcoma, cancer, lymphatic tumors, tumors of the œsophagus, etc.

The experiments of Bernard, Bischoff, and Waller¹ (given in some detail in subsequent pages) will help to explain how a lesion, which excites laryngeal symptoms, may occasionally be situated away from the line of the pneumogastric nerve, since the spinal accessory nerve may be the seat of irritation or degeneration. They will also help to explain why the effects of bilateral paralysis of the recurrent branch do not produce dyspnœa, at the same time that it causes the voice to be lost; why the vocal cords are seen to be cadaveric and relaxed; and why the act of coughing and the expulsion of laryngeal mucus is no longer possible.

The *pulmonary branches* of the nerve are unquestionably concerned, to some extent, in the conditions associated with bronchial spasm, since asthma may be developed by mental influences acting upon the origin of the vagus. Moreover, we often see severe types of this disease produced by the pressure of thoracic tumors upon the pneumogastric; by the inhalation of substances possessing slight irritative qualities; by uterine irritation, acting as a cause of reflex action through the pneumogastric nerve; and by fright, shock, exposure,

¹ See page 510.

etc. The symptoms of asthma are too well known to be here repeated.

We have one other condition developed as the effect of pressure upon, or destruction of, the vagus, viz., paralysis of the pulmonary branches and the consequent paralytic condition of the blood-vessels of the lung. It is to this condition that some authors attempt to refer the serous infiltration into the parenchyma of the lung which follows section of this nerve;¹ and we know, clinically, that a similar condition is sometimes produced by compression of the nerve by a tuberculous or cancerous degeneration of the lymphatic glands, especially those situated near to the bifurcation of the trachea, and by aneurism of the thoracic vessels. The same condition has been observed after injuries to the organs of the chest, and from the section of some of the branches of the vagus, during an attempt to ligate the subclavian in its first portion or the arteria innominata.

The *cardiac branches* seem to exert a more marked effect upon the heart when exposed to irritation than when actually destroyed by degeneration or section. An artificial "angina pectoris" may be produced by pressure upon the vagus in the neck (as performed by Czermak upon himself), and the heart's action may thus be almost entirely arrested. It may be stated, I think, that angina pectoris, sometimes called "cardiac neuralgia,"² is one of those neuroses of the heart which depend, to a large extent, upon changes of a secondary character in the terminal filaments of the vagus or the cardiac ganglia.

The symptoms of this affection are very distressing to the patient, and often fatal. The attack usually begins with a sense of extreme constriction within the chest, which is followed by radiating pains of a very intense character, which

¹ For the different theories advanced to explain this effect, the reader is referred to page 496 of this volume.

² I prefer to limit the term "angina pectoris" to those cases only where the exciting causes have resulted in *defective heart power*, and to apply the term "cardiac neuralgia" to those cases where the power of the heart is normal. This I consider to be the true pathological distinction.

shoot down the arm or into the neck. The paroxysms produce the most rapid exhaustion, and are not usually long continued. The various pathological conditions found to exist in this affection include an ossified state of the coronary vessels (thus interfering with the nutrition of the heart walls); cardiac hypertrophy (which is usually of that form called compensatory, since the cavities of the heart are generally dilated); fatty degeneration of the heart; valvular lesions (with their secondary changes in the size of the cavities); and aneurism within the pericardial sac.

The *gastric branches* of the vagus are associated with the conditions of gastrodynia (cardialgia), boulimia, polydipsia, nervous vomiting, and disorders of the secretory follicles of the organ, as well as its power of absorption. Gastrodynia is a paroxysmal attack of neuralgia of the sensory fibers of the stomach. It produces pain of the most intense character, which often compels the strongest subjects to writhe in agony, and to become bathed in a profuse perspiration, irrespective of the temperature of the atmosphere. The face becomes bloodless, the limbs cold, the abdomen retracted, and the pulse small and irregular. The attacks are usually of short duration, and are most frequently terminated by eructations and vomiting. This disease is met with in hysterical and anæmic subjects, in the course of diseases of the uterus and ovaries, in spinal and cerebral affections, and in certain dyscrasiæ.

An abnormal condition of hunger, which is appeased by small quantities of food, but which returns at frequent intervals with an uncontrollable desire, often interrupting the hours of sleep, is produced by some disordered condition of the vagus, and is called "*boulimia*." This affection is met with in hysterical patients, after prolonged fevers, in severe forms of nervous debility, in syphilis, insanity, and diabetes.

By "*polydipsia*" we mean an intolerable thirst, dependent upon an hyperæsthesia of the nerve fibers of the mucous membrane of the stomach, pharynx, and mouth, and prob-

ably due to some abnormal state of the pneumogastric nerve. It is often an associate symptom with boulimia, and is produced by the same general causes.

The state of "*polyphagia*" signifies a desire for excessive quantities of food. It is supposed to exist when the nerve fibers of the vagus distributed to the stomach are in a state of anæsthesia, in contrast to the condition producing the two previous diseases. It has been found to accompany softening of the medulla oblongata, compression of the roots of the vagus by an aneurismal tumor of the vertebral artery, atrophy of the vagi, neuromata of the vagi, and the morbid states of epilepsy, insanity, and hysteria.

The *nervous vomiting* which is clinically observed in connection with pregnancy, chlorosis, hysteria, digestive disturbances, and gastrodynia, is not to be confounded with that of local diseases of the stomach or of the alimentary canal, since the symptom depends, purely and exclusively, upon some abnormal condition of the nerves, rather than upon pathological changes in the stomach or intestine.

True paralysis of the gastric branches of the vagus must, of necessity, arrest the peristaltic movement of that organ, and thus tend to favor the retention of food within its cavity. This may be the explanation of the enormous enlargement of the stomach found after chronic inflammatory processes of that organ, and also as a sequel to cholera, typhoid fever, and some other blood poisons. The stomach becomes enlarged in these conditions mainly by the weight of the retained food and the pressure of the gases formed by its decomposition.

The *intestinal* and *hepatic branches* of the vagus are not well understood in their clinical phenomena, but the effects of section of the pneumogastric seem to point to some controlling influence of these fibers over the glycogenic function of the liver and the secretion of the intestinal juices. The effect of diseases of the peritonæum, or of the abdominal viscera, upon the heart and respiration, is to be explained either as the direct result of irritation of these fibers, or as a

reflex act through the sympathetic nerve upon the cardiac and respiratory centers, thus in turn affecting the heart and lungs through the vagus.

THE SPINAL ACCESSORY, OR ELEVENTH CRANIAL NERVE.

This nerve has a very extensive origin, since it derives its fibers not only from the medulla oblongata, but also from the cervical portion of the spinal cord. The fibers which arise from the medulla compose what is called the "*bulbar portion*," in contrast to those which arise from the cervical region of the spinal cord, to which the name of "*spinal portion*" is sometimes given. Such a distinction has an importance, distinct from merely indicating the point of origin of the fibers composing the two portions of the nerve, as the *functions* of the two are different.

If we trace the filaments of origin of the bulbar portion of the nerve, we can perceive that the fibers arise from the *lateral columns* of the medulla oblongata (its motor tract) and escape from its lower portion, beneath the fibers of the pneumogastric nerve. The spinal portion of the nerve can be traced between the anterior and the posterior roots of the first five cervical nerves, arising from between the roots of each nerve by a *pair* of filaments, with the exception of the last two, where the filament going to form the spinal accessory nerve is usually a single one. These several fibers unite as the nerve passes upward toward the cranium, thus causing the spinal portion of the nerve to gradually increase in size. In the cranium, the two parts join to form one nerve, which then escapes from the *jugular foramen*, in company with the pneumogastric and glosso-pharyngeal nerves and the jugular vein. The inferior meningeal artery enters the cavity of the cranium through this foramen, and therefore bears a relation to the nerves and vein.

The spinal accessory nerve receives filaments of communication with other nerves, even before it escapes from the cavity of the cranium, since the spinal portion, on its way

upward to unite with the bulbar portion, is joined by filaments derived from the two upper cervical nerves while in the spinal canal.

After the nerve has emerged from the jugular foramen, it gives off a large branch to the pneumogastric nerve, and occasionally receives a filament from the pneumogastric in return ;

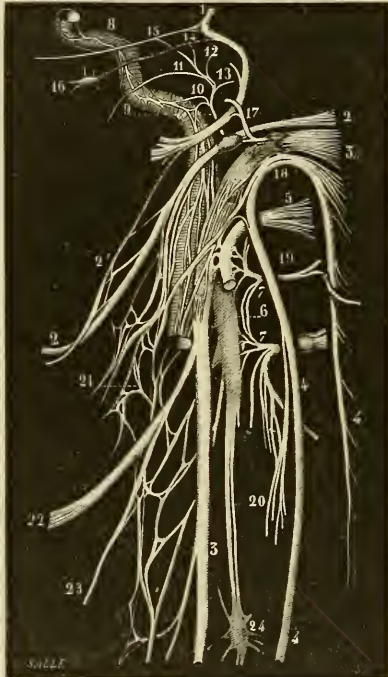


FIG. 143.—*Spinal accessory nerve.* (Hirschfeld.)

1, trunk of the facial nerve ; 2, 2, glosso-pharyngeal nerve ; 3, 3, pneumogastric ; 4, 4, 4, trunk of the spinal accessory ; 5, sublingual nerve ; 6, superior cervical ganglion ; 7, 7, anastomosis of the first two cervical nerves ; 8, carotid branch of the sympathetic ; 9, 10, 11, 12, 13, branches of the glosso-pharyngeal ; 14, 15, branches of the facial ; 16, otic ganglion ; 17, auricular branch of the pneumogastric ; 18, anastomosing branch from the spinal accessory to the pneumogastric ; 19, anastomosis of the first pair of cervical nerves with the sublingual ; 20, anastomosis of the spinal accessory with the second pair of cervical nerves ; 21, pharyngeal plexus ; 22, superior laryngeal nerve ; 23, external laryngeal nerve ; 24, middle cervical ganglion.

while, in its course down the neck, it receives filaments of communication from the second, third, and fourth cervical nerves, in case these nerves do not communicate with the spinal portion within the spinal canal.

After the nerve has sent its upper filament to the pneumo-

gastric, at the jugular foramen, it may usually be perceived to divide into two branches—an internal and an external; the former of which anastomoses directly with the trunk of the pneumogastric nerve, while the latter, called the “muscular branch,” pierces the back part of the upper third of the sternomastoid muscle, and terminates on the anterior surface of the trapezius. The first, sometimes called the “anastomotic

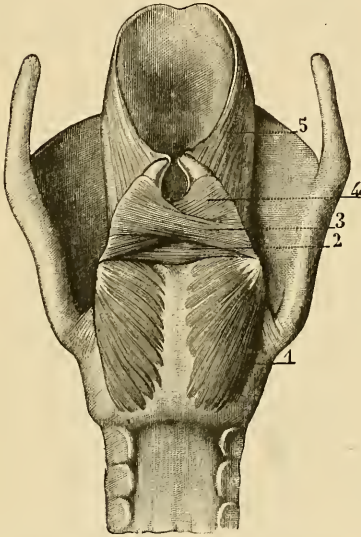


FIG. 144.—Posterior view of the muscles of the larynx. (Sappey.)

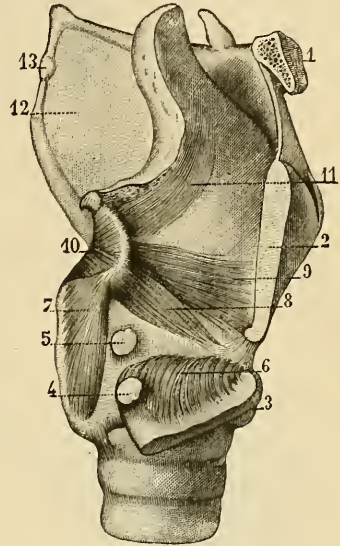


FIG. 145.—Lateral view of the muscles of the larynx. (Sappey.)

FIG. 144.—1, posterior crico-arytenoid muscle; 2, 3, 4, different fasciculi of the arytenoid muscle; 5, aryteno-epiglottidean muscle.

FIG. 145.—1, body of the hyoid bone; 2, vertical section of the thyroid cartilage; 3, horizontal section of the thyroid cartilage turned downward to show the deep attachment of the crico-thyroid muscle; 4, facet of articulation of the small cornu of the thyroid cartilage with the cricoid cartilage; 5, facet on the cricoid cartilage; 6, superior attachment of the crico-thyroid muscle; 7, posterior crico-arytenoid muscle; 8, 10, arytenoid muscle; 9, thyro-arytenoid muscle; 11, aryteno-epiglottidean muscle; 12, middle thyro-hyoid ligament; 13, lateral thyro-hyoid ligament.

branch,” is now known to be the nerve which *supplies the muscles of the larynx*, with the exception of the crico-thyroid muscle,¹ since physiological experiment confirms this distribution.

¹ The *arytenoid muscle* of the larynx is supplied by both the superior and recurrent laryngeal nerves, the latter of which carry most of the spinal accessory fibers, as is shown in Fig. 140 of this volume. It is also important to remember that the investiga-

The second branch communicates with the second and third cervical nerves, before it pierces the sterno-mastoid muscle, and its filaments undoubtedly furnish *motor power* to that muscle and also to the trapezius. It is proven by ex-

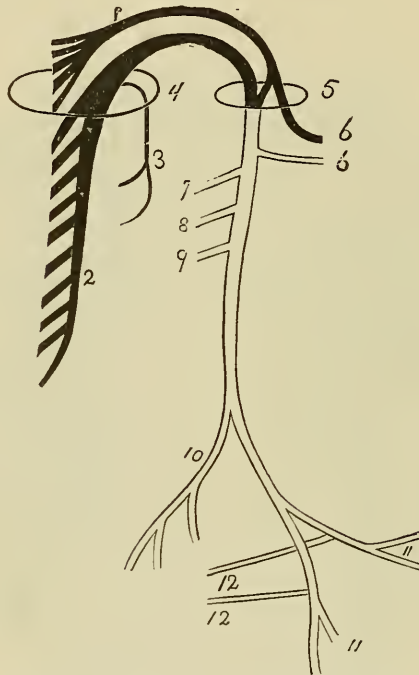


FIG. 146.—A diagram of the spinal accessory nerve.

- 1, the *accessory portion* of the nerve arising from the *medulla oblongata*; 2, the *spinal portion* of the nerve arising from the *spinal cord* (cervical region); 3, a filament arising from the *first and second cervical nerves* and joining the *spinal portion* of the spinal accessory nerve, before passing through the *foramen magnum*; 4, the *foramen magnum*, showing the *spinal portion* of the nerve entering the *cranium*; 5, the *jugular foramen*, showing the *spinal and accessory portions* of the nerve communicating as they pass through it; 6, the *large filament* going to the *pneumogastric* to supply the *muscles of the larynx*, and the *small filament* returning to the trunk of the spinal accessory nerve; 7, 8, 9, filaments of communication between the spinal accessory nerve and the *third, fourth, and fifth cervical nerves*; 10, muscular branches to the *sterno-cleido-mastoid muscle*; 11, muscular branches to the *trapezius muscle*; 12, communicating filaments from the *cervical plexus* of nerves.

periment, however, that section of the spinal accessory nerve does not produce total paralysis of these muscles; and, from

tions of Bernard and Bischoff have demonstrated the existence of other motor fibers to the larynx, irrespective of those of the spinal accessory, which seem to control the *automatic respiratory movements* of the glottis.

this fact, it is conclusively proved that some other sources of nerve supply to these muscles exist, besides the spinal accessory filaments.

A TABLE OF THE BRANCHES OF THE SPINAL ACCESSORY NERVE.¹

THE SPINAL ACCESSORY, OR 11TH CRANIAL NERVE.	{	ACCESSORY OR BULBAR PORTION (by means of the sheath of the <i>pneumogastric nerve</i>).	{ <ul style="list-style-type: none"> Branches to the <i>pharyngeal plexus</i>, Branches to the <i>superior laryngeal nerve</i> (and thus to the <i>depressor nerve of the heart</i>), Branches to the <i>recurrent laryngeal nerve</i> (thus supplying the muscles of phonation). Branch to the <i>sterno-mastoid muscle</i>, Branch to the <i>trapezius muscle</i>.
		SPINAL PORTION.	{ <table border="0" style="display: inline-table; vertical-align: middle;"> <tr> <td style="padding-right: 5px;">COMMUNICATING BRANCHES TO</td> <td style="border-left: 1px solid black; padding-left: 5px;"> 1st cervical nerve, 2d cervical nerve, 3d cervical nerve, 4th cervical nerve. </td> </tr> </table>
COMMUNICATING BRANCHES TO	1st cervical nerve, 2d cervical nerve, 3d cervical nerve, 4th cervical nerve.		

FUNCTIONS OF THE SPINAL ACCESSORY NERVE AND THE EFFECTS OF SECTION.

The experiments of Bernard, to whose ingenuity much of our present knowledge of the function of the bulbar and spinal portions of this nerve is due, seem to warrant the conclusion that the bulbar or medullary part of the nerve possesses a direct control upon the *muscles of the pharynx and larynx*, but no effect whatever upon the *sterno-mastoid and trapezius muscles*. Galvanism of the spinal portion of the nerve seems to have a "directly opposite effect, since the muscles of the pharynx and larynx were unaffected, and the two muscles of the neck to which the nerve is distributed were thrown into movement. It also appears from the results of this great experimenter that the nerve is essentially *motor in its function* at its origin from the medulla and spinal cord, but that it gains sensory fibers after it leaves the cavity of the cranium, by means

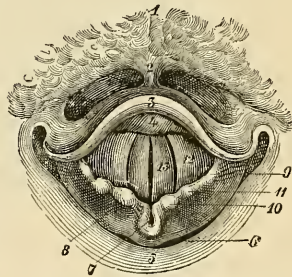


FIG. 147.—Glottis seen with the laryngoscope during the emission of high-pitched sounds. (Le Bon.)

- 1, 2, base of the tongue; 3, 4, epiglottis; 5, 6, pharynx; 7, arytenoid cartilages; 8, opening between the true vocal cords; 9, aryteno-epiglottidean folds; 10, cartilage of Santorini; 11, cuneiform cartilage; 12, superior vocal cords; 13, inferior vocal cords.

¹ Modified from a table in the "Essentials of Anatomy" (Darling and Ranney). Putnam's Sons, New York, 1880.

of certain filaments of communication derived from the cervical nerves and the pneumogastric. This fact probably explains why two points of communication should exist between the spinal accessory and the pneumogastric nerves; since, at one point, the sensory filaments of the pneumogastric were given to the spinal accessory, while, at the other point, the motor filaments of the spinal accessory were sent to the pneumogastric sheath for protection, until they could be distributed to the muscles of the larynx.

Bernard and Bischoff have probably done more to clear up the disputed relation of the spinal accessory nerve to the muscles of the larynx, and thus to the acts of phonation and respiration,¹ than any of the later investigators upon the physiology of the nervous system. When the spinal accessory nerve is drawn out from the medulla and spinal cord of an animal, as can be done with little if any injury to the nerve, if the requisite care and skill be employed, the effect is at once *manifested in the voice*, which becomes hoarse and unnatural, when the nerve of one side only is extracted, but entirely extinct when both nerves are thus treated. The *act of deglutition* is also somewhat affected, and the trapezius and sternomastoid muscles are paralyzed, but only to a partial extent.

An interesting relation of the spinal accessory nerve to the *action of the heart* seems to be well shown by the experiments of Waller, who first called the attention of the profession to the fact that extirpation of the roots of the spinal accessory nerve produced a modification in the effects of galvanism of the trunk of the pneumogastric nerve, provided that sufficient time (some two weeks) was allowed after the operation for the irritation so produced to subside. As has been mentioned in the previous lecture upon the pneumogastric nerve,² galvanism of that nerve with a powerful current will arrest the action of the heart in a state of health, even if

¹ The nerves concerned in the two acts of *phonation* and *respiration* are not to be confounded, since it is probable that the pneumogastric nerve sends filaments of a motor character to the larynx, which are independent of the spinal accessory nerve, and which probably preside over the *respiratory movements* of the glottis, while the spinal accessory nerve controls *phonation*.

² See page 482 of this volume.

applied on one side of the body. Now, Waller found that after the spinal accessory nerve of one side had been drawn out, and the animal allowed to recover the shock of the operation, and to wait some days for all signs of irritation to subside, galvanism of the pneumogastric nerve of the same side no longer seemed to affect the action of the heart. The *de-*

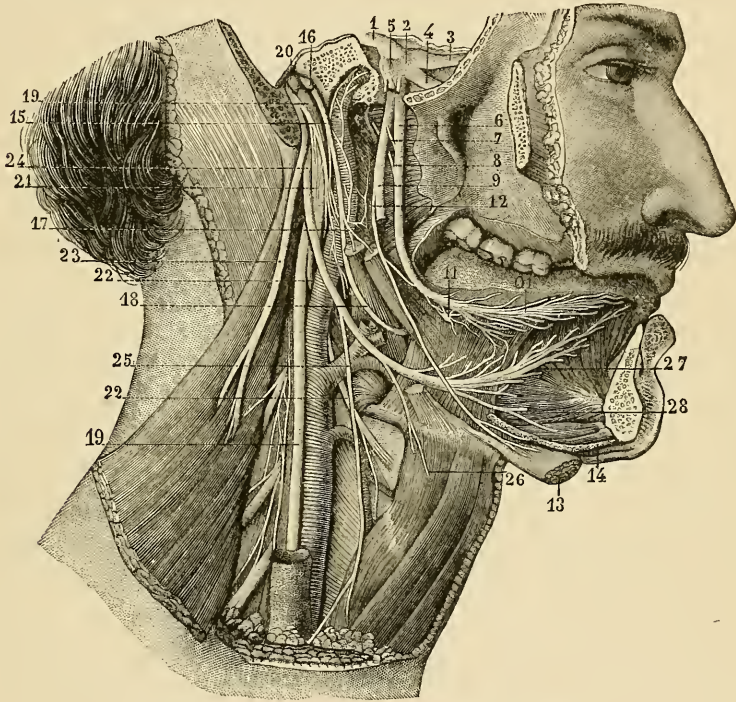


FIG. 148.—The spinal accessory nerve. (Sappey.)

- 1, large root of the fifth nerve; 2, ganglion of Gasser; 3, ophthalmic division of the fifth; 4, superior maxillary division; 5, inferior maxillary division; 6, 10, lingual branch of the fifth, containing the filaments of the chorda tympani; 7, branch from the sublingual to the lingual branch of the fifth; 8, chorda tympani; 9, inferior dental nerve; 10, terminal branches of the gustatory nerve; 11, submaxillary ganglion; 12, mylo-hyoid branch of the inferior dental nerve; 13, anterior belly of the digastric muscle; 14, section of the mylo-hyoid muscle; 15, 18, glosso-pharyngeal nerve; 16, ganglion of Andersch; 17, branches from the glosso-pharyngeal to the stylo-glossus and the stylo-pharyngeus muscles; 19, 19, pneumogastric; 20, 21, ganglia of the pneumogastric; 22, 22, superior laryngeal nerve; 23, spinal accessory; 24, 25, 26, 27, 28, sublingual nerve and branches.

pressor nerve of the heart, which arises from both the superior laryngeal and pneumogastric nerves, since it has two heads, must, therefore, be in some way connected with the

spinal accessory nerve. It may, therefore, be stated with as much positiveness as any physiological point can be laid down, that the communicating filament given off by the spinal accessory nerve to the pneumogastric controls the muscles of phonation.

The distribution of the spinal accessory nerve to only two of the muscles of the neck—the *sterno-mastoid* and the *trapezius*—would naturally suggest, to the inquiring mind, why these muscles should have been singled out as particularly associated with this nerve. Throughout this entire course of lectures I have frequently called your attention to the fact, which can not be too often repeated, that the distribution of nerves to muscles always denotes a *purpose* on the part of Nature, and a *similarity of function* in the muscles supplied by the same nerve, if we will but search for it. Now, we have already seen that the spinal accessory nerve is chiefly destined to control the *muscles of phonation*, since other nerve fibers go to the larynx, which assist in moving the vocal cords during the opening of the glottis, previous to each inspiratory act; therefore, the spinal accessory nerve can not be said to be directly concerned with the respiratory function. If we will study the attitude assumed by a vocalist in the *act of singing* (and it is in the singing act, rather than that of talking, that we see the mechanism of phonation best displayed, since it requires more of a muscular effort than the simple articulation of words), we shall perceive that the sterno-mastoid and the trapezius muscles are important factors *in the production of voice*, as they tend to fix the shoulders (that is, the scapulæ and the clavicles) and also the upper part of the sternum. In all vocal efforts, the first act necessary to its performance is a full inspiratory effort, which can only be performed by first calling into play those muscles which render the upper portion of the chest and the bones of the shoulder immovable, so as to have a *fixed point* from which the true inspiratory muscles can act upon the ribs and their cartilages; and it can, therefore, be understood why these muscles should properly be placed under the control of

that nerve which also controls the muscles which regulate the position and tension of the vocal cords during the expiratory effort, and thus causes the proper vibrations of these cords, and regulates the note which follows.

In animals, where the muscular branch of the spinal accessory nerve has been severed, a difficulty in progression has been observed by Bernard, and a peculiar *shortness of breath* after violent exercise. The difficulty in locomotion is not present in man, on account of certain anatomical peculiarities which render the arm unnecessary for progressive motion, which is not the case with quadrupeds ; but the shortness of breath which has been observed would probably exist in a man after violent exercise, or when any demand for an excessively full inspiratory effort occurred, if the trapezius or the sterno-mastoid muscles were paralyzed.

A theory advanced by Hilton,¹ as explanatory of the peculiarity of the course of the spinal accessory nerve, deserves mention, since it tends possibly to explain not only the irregular course of the nerve, but also the object of the *communication* of the *sub-occipital* with the *spinal accessory nerves* within the spinal canal. According to this author, the spinal portion of this nerve becomes joined to the sub-occipital before it enters the cranium, and, since that nerve is almost exclusively a motor nerve, what object could the spinal accessory, which is itself a motor nerve, have in sending additional filaments to the sub-occipital, unless it was for the purpose of sending fibers to the inferior oblique, the two posterior recti, and the complexus muscles of the neck? Now, when a motor impulse is sent out by means of the spinal accessory nerve, the effects reach those muscles first which are nearest to its place of origin ; hence, the muscles of the sub-occipital region are caused to contract before the trapezius or the sterno-mastoid muscles, and, by so doing, the head is drawn backward before the latter muscles act, thus greatly assisting them to raise the thorax, as well as in rendering the head a fixed point during the inspiratory act.

¹ "Rest and Pain," London, 1872.

CLINICAL POINTS PERTAINING TO THE SPINAL ACCESSORY NERVE.

Like all motor nerves, the spinal accessory may exhibit the condition of spasm or paralysis in the parts supplied by it ; if subjected to some source of irritation, as in the first instance, or to some lesion which destroys its power of conduction, as in the latter. The spasm dependent upon irritation of this special nerve seems to be confined exclusively to the sterno-mastoid and trapezius muscles. They may be unilateral or bilateral, and the muscular contractions may be either of the tonic or clonic variety.

Both of these types of spasm are met with in connection with reflex irritation originating in some of the remote viscera ; hence they are not infrequent in severe types of hysterical affections. They may also be produced by diseases affecting the upper cervical vertebræ, by certain forced movements of the head, by exposure to cold and wet, and by local diseases of the brain and spinal cord. When we consider the intimate connection which this nerve has with the spinal cord, as well as the medulla oblongata and brain, we can better appreciate the difficulty which often arises in locating the exact seat of the irritation which is producing these spasmodic movements. There are reported cases to prove that tumors of the brain or spinal cord, softening of either of these regions, meningeal inflammation of the brain or cord, injuries to the skull or upper cervical vertebræ, and caries, periostitis, and tumors of the upper cervical vertebræ, may all be exciting causes of this spasmodic action.

Tonic Spasm of the Sterno-mastoid and Trapezius Muscles.—When the *sterno-mastoid muscle* is the seat of *tonic spasm*, the head is so drawn that the ear approaches the clavicle, the occiput the tip of the shoulder, and the chin is so rotated that it points toward the opposite side. This condition is of longer or shorter duration, and often shows a marked tendency to become a permanent contracture. During the early paroxysms, the patient can not rectify the displacement of the head by his own voluntary efforts, and pas

sive motion is strongly resisted. The early periods of the paroxysm are often accompanied by sharp pains. When the disease has become chronic, the deformity of the neck is associated with a *permanent curvature of the cervical vertebrae* and a corresponding curve of a compensatory character in the dorsal and lumbar regions. A rare case of bilateral tonic spasm of the sterno-mastoid muscles is reported by Duchenne, in which the chin was approximated to the breast.

The *trapezius muscle* may also be the seat of *tonic spasm*. In this case, the head is inclined toward the affected side, the occiput is drawn toward the shoulder, the shoulder itself is raised, and the scapula is drawn inward. The chin is not rotated toward the unaffected side, as in the case of the sterno-mastoid muscle. All attempts to bring the head into its proper relation to the trunk create a rigidity and sensitiveness over the region of the trapezius.

Clonic Spasm of the Sterno-mastoid and Trapezius Muscles.—This variety of spasm, which is dependent upon the same general list of causes as the tonic form, may be unilateral or bilateral. Either of the muscles supplied by the spinal accessory may be affected alone, or the sterno-mastoid and trapezius may contract alternately. If the spasm be confined to one muscle and of the unilateral type, the deflection of the head will be the same as in the tonic spasm, except that the duration of the contraction will be for a shorter period, and of a convulsive variety; while, if the two muscles of one side contract alternately, the attitude of the head will be constantly changing from the condition due to contraction of the one to that produced by the other. When the sterno-mastoid muscles of both sides act simultaneously in a spasmodic contraction, a peculiar “nodding movement” is perceived. You can understand how all forms of combinations can be made between the two muscles of either side, and a proportionate variety of spasmodic attitudes will be the result. All of these contractions occur, for the most part, in *paroxysms*, often lasting for a day, and not infrequently coming on with such violence and frightful vehe-

mence that the head is tossed to and fro with great force, making the life of the patient miserable. In some instances, the spasm is almost continuous. Sleep, however, usually brings rest, though this is often prevented or delayed.

In *unilateral clonic spasm* of the sterno-mastoid muscle, the adjacent muscles of the face, jaw, and arm are occasionally thrown into simultaneous action. The scalmi muscles are also sometimes brought into active play, and their forcible compression of the brachial plexus of nerve and the veins of the neck has been known to result in stiffness, anæsthesia, and œdema of the arm, after such an attack had subsided.

The nodding movement produced by the *bilateral clonic spasm* of the sterno-mastoid muscles is sometimes called the "salaam convulsion of Newnham." It is rarely seen in adults, but in children it is not infrequent. Should it occur during dentition, the spasm may be associated with convulsive movements of the facial muscles, with strabismus, and even with general convulsions and a loss of consciousness. Bilateral spasm of the muscles supplied by the spinal accessory nerve has been known to terminate in epilepsy, insanity, and paralysis; and, when the various causes of the condition are reviewed, this will appear but the natural sequence of the further progress of some of the diseases mentioned. Should reflex irritation, as in dentition, worms, hysteria, etc., exist, or the spasm be dependent upon rheumatic origin, exposure to cold or dampness, traumatism, caries, and other curable conditions, the results will be arrested when the exciting cause has been removed.

Paralysis of the Sterno-mastoid and Trapezius Muscles.—These muscles may be affected with a total arrest of their nerve power by lesions of the motor columns of the spinal cord, resulting in progressive muscular atrophy; by fracture of the cervical vertebræ; diseases of the vertebræ near the skull and also of the cranial bones; injuries to the nerve, such as cuts, stabs, gunshot wounds of the neck; and compression of the nerve from peripheral causes, as in the

case of tumors of the neck, swelling of the lymphatic glands of the neck, abscesses, neuromata, etc.

The sterno-mastoid or the trapezius may be paralyzed independently of the other, or they may both be affected simultaneously, according as the cause affects the entire nerve or only some individual branch. The paralysis may, in some instances, be bilateral, provided the exciting cause be central and involve the parts in the median line, or so extensive as to press upon the trunks of both spinal accessory nerves. A case of bilateral paralysis following progressive muscular atrophy of the muscles of the neck is reported by Rosenthal, where the patient was obliged to support the head by a collar made of pasteboard; but this was rather the consequence of the general atrophy of the muscles than the effect of the paralysis of the two muscles supplied by the spinal accessory.

In *unilateral paralysis* of the *sterno-mastoid muscle*, the voluntary rotation of the head toward the unaffected side is performed with difficulty; the chin is turned toward the affected side, on account of the unopposed action of the healthy muscle; the chin is also slightly elevated, and the paralyzed muscle does not stand out with equal prominence with its fellow, when the chin is supported by the hand of the physician, and direction is given to the patient to try and depress the chin toward the chest. If this unilateral paralysis be long continued, the contracture of the healthy muscles produces the condition of "torticollis."

When a *bilateral paralysis* of the *sterno-mastoid muscles* is developed, the head is held straight, and its rotation, especially with the chin elevated, is performed with extreme difficulty. The neck appears thin, and the lateral aspect of that region is markedly flattened, since the normal prominence of the sterno-mastoid muscle is wanting. The same test, as mentioned above, when the chin is supported by the hand of the physician, shows a great loss of power in attempting to flex the head upon the chest.

The effects of *unilateral paralysis* of the *trapezius muscle* are most marked in the region of the scapula. This bone

appears to be drawn downward and forward ; its inferior angle lies closer to the vertebral column than that of its fellow, and its upper part is more widely separated from the vertebræ. The clavicle is caused to stand off from the chest, on account of the acromion being drawn downward and forward by the weight of the upper extremity and the pectoral and the levator anguli scapulæ muscles ; hence, the supra-clavicular fossa is apparently enlarged, in comparison with the healthy side. It is to be remembered, however, by you that the trapezius, unlike many others in the body, often manifests paralysis in *portions* of the muscle ; so that the symptoms of this type of unilateral paralysis admit of many modifications, in accordance with the extent and limits of the disease. Thus, the position of the scapula will vary with the paralysis of the upper, middle, or lower fibers of the muscle ; the power of elevation of the arm will be greatly impaired if the upper fibers are paralyzed ; while the approximation of the scapula to the vertebral column is very much impaired when the middle fibers are alone involved.

When the *trapezei muscles* are affected with *bilateral paralysis*, in addition to the symptoms described, which will now be perceived upon both sides, the *back will appear broader and more arched*, since the scapulæ are lowered and drawn outward, while they are also more prominent. Some difficulty may also be experienced in maintaining the head in an upright position, since it naturally tends to sink toward the chest.

THE HYPO-GLOSSAL, OR TWELFTH CRANIAL NERVE.

This nerve is sometimes called the *sublingual nerve*, thus using a Latin rather than a Greek term to express the same idea, viz., that the nerve passes underneath the tongue. It is the last of the cranial nerves, and is intimately associated with all those movements in which the tongue takes an important part, such as the acts of talking, singing, mastication, and deglutition. The point of external origin of this nerve is a

groove between the *olivary body* of the medulla oblongata and the *anterior pyramid*, below the point of escape of the ninth, tenth, and eleventh nerves. Its deep fibers can be traced to a nucleus in the floor of the fourth ventricle. The reader is referred to those pages of the previous section which treat of the medulla oblongata for further information. The nerve escapes from the cavity of the cranium by the *anterior condyloid foramen*.

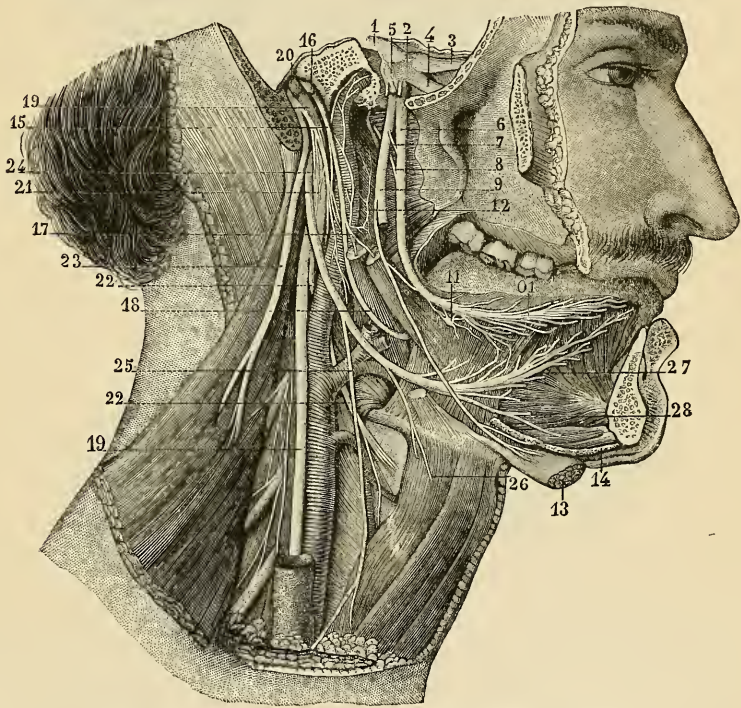


FIG. 149.—Distribution of the hypoglossal nerve. (Sappey.)

1, root of the fifth nerve; 2, ganglion of Gasser; 3, 4, 5, 6, 7, 9, 10, 12, branches and anastomoses of the fifth nerve; 11, submaxillary ganglion; 13, anterior belly of the digastric muscle; 14, section of the mylo-hyoid muscle; 15, glosso-pharyngeal nerve; 16, ganglion of Andersch; 17, 18, branches of the glosso-pharyngeal nerve; 19, 19, pneumogastric; 20, 21, ganglia of the pneumogastric; 22, 22, superior laryngeal branch of the pneumogastric; 23, spinal accessory nerve; 24, *hypo-glossal nerve*; 25, *descendens noni*; 26, *thyro-hyoid branch*; 27, *terminal branches*; 28, *two branches, one to the genio-hyo-glossus and the other to the genio-hyoid muscle.*

After the nerve escapes from the cranium, it gives a filament of communication to the *sympathetic nerve*, which joins

the superior cervical ganglion ; another to the *pneumogastric nerve* ; two or three branches to the *upper cervical nerves* ;

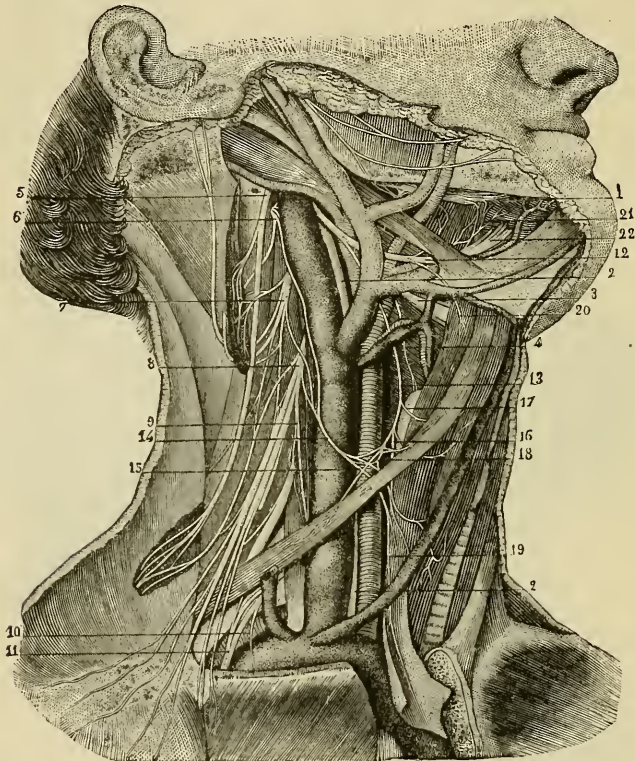


FIG. 150.—*Anastomotic loop formed by the descending branch of the hypo-glossal and the internal descending branch of the cervical plexus.* (After Hirschfeld.)

- 1, lingual nerve passing transversely upon the hyo-glossus muscle ; 2, 2, trunk of the pneumogastric ; 3, superior laryngeal nerve ; 4, external laryngeal nerve ; 5, external branch of the spinal accessory supplying the sterno-mastoid and trapezius ; 6, anterior branch of the second pair of cervical nerves ; 7, anterior branch of the third pair ; 8, anterior branch of the fourth pair ; 9, origin of the phrenic ; 10, origin of the subclavian nerve ; 11, origin of the anterior thoracic nerves of the brachial plexus ; 12, middle portion of the trunk of the hypo-glossal ; 13, descendens noni ; 14, internal descending branch of the cervical plexus, forming, with the preceding, a loop with its convexity directed downward ; 15, inferior branch from this loop, supplying the sterno-thyroid muscle ; 16, superior branch distributed to the sterno-hyoid muscle ; 17, another branch still higher up, and distributed to the same muscle ; 18, middle branches from the loop ; 19, filament extending as far as the lower extremity of the sterno-thyroid ; 20, branch given off by the hypo-glossal to the thyro-hyoid ; 21, branches of anastomosis between the hypo-glossal and lingual ; 22, terminal portion of the trunk of the hypo-glossal.

and, finally, a communicating branch to the *gustatory branch* of the *fifth nerve*.

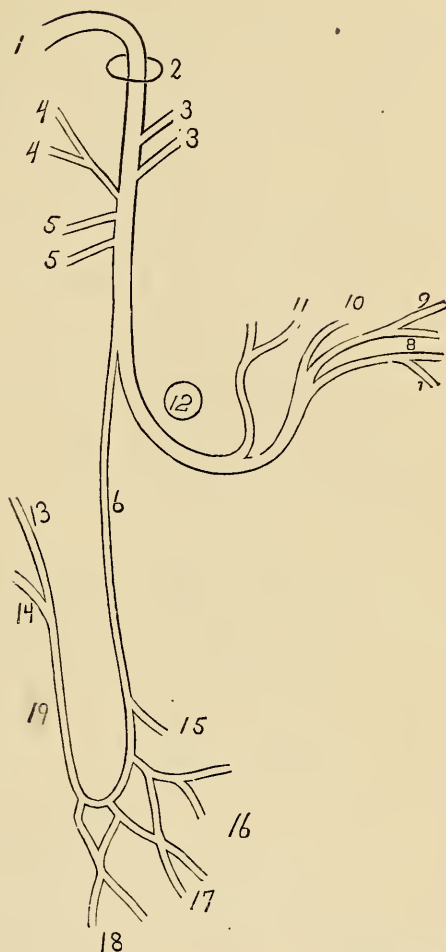


FIG. 151.—A diagram of the hypo-glossal and its branches.

1, trunk of hypo-glossal nerve, escaping from the medulla oblongata; 2, anterior condyloid foramen; 3, filaments of communication to the pneumogastric nerve; 4, filaments of communication to the superior cervical ganglion of the sympathetic system; 5, filaments of communication to the first and second spinal nerves of the cervical region; 6, the descendens noni nerve, forming a loop with the communicans noni nerve (19) and giving off muscular branches from the loop; 7, muscular filaments to the thyro-hyoid muscle; 8, muscular filament to the genio-hyoid muscle; 9, muscular filament to the genio-hyo-glossus muscle; 10, muscular filament to the hyo-glossus muscle; 11, muscular filament to the stylo-glossus muscle; 12, the occipital artery, around which the hypo-glossal nerve winds, before reaching the tongue; 13, a branch of the communicans noni nerve, derived from the second cervical nerve; 14, a branch of the communicans noni nerve, derived from the third cervical nerve; 15, a muscular branch to the omo-hyoid muscle (anterior belly); 16, a muscular branch to the sterno-hyoid muscle; 17, a muscular branch to the sterno-thyroid muscle; 18, a muscular branch to the omo-hyoid (posterior belly); 19, the communicans noni nerve, joining the descendens noni nerve to form a loop.

Its first branch of distribution is named the *descendens noni* (the descending of the ninth nerve), so called since this nerve was classed by Willis as the ninth. This branch passes down the neck to supply the sterno-hyoid, sterno-thyroid, and omo-hyoid muscles, and then joins the *communicans noni nerve* (a branch of the cervical plexus), to form a loop, from which terminal filaments are given off. The other branches of the nerve are distributed to the thyro-hyoid muscle (which usually has a separate filament of its own), the stylo-glossus, the hyo-glossus, genio-hyoid, genio-hyo-glossus, and the intrinsic muscles of the tongue. It will thus be seen that the hypo-glossal nerve is the motor nerve of all the muscles which tend to *depress the larynx and the hyoid bone*, after they have been raised during the second stage of the act of deglutition (the muscles of the infra-hyoid region), also to one of the supra-hyoid region, the genio-hyoid, and to most of the muscles which act upon the tongue.

In the preceding diagrammatic figure, the branches of the hypo-glossal nerve are shown, and the general course of the nerve is made more clear than can be done by a verbal description.

TABLE OF THE BRANCHES OF THE HYPO-GLOSSAL NERVE.¹

THE HYPO-GLOSSAL, OR TWELFTH CRA- NIAL NERVE.	{ <i>Branches of communication.</i> <i>Branches of distribution.</i>	To the <i>ganglion of the trunk</i> of the pneumogastric nerve,
		To the <i>superior cervical ganglion</i> of the sympathetic,
		To the <i>loop</i> between the first and second cervical nerves,
		To the <i>gustatory nerve</i> .
		<i>Descendens noni</i> nerve,
		To thyro-hyoid nerve,
		To genio-hyoid muscle,
		To stylo-glossus muscle,
		To hyo-glossus muscle,
		To genio-hyo-glossus muscle,
		To the intrinsic muscles of the tongue.

FUNCTIONS OF THE HYPO-GLOSSAL NERVE.

The fact that the hypo-glossal nerve arises from the motor portion of the spinal cord (when taken in connection with the

¹ Copied from the "Essentials of Anatomy" (Darling and Ranney). Putnam's Sons, New York, 1880.

absence of any ganglionic enlargement upon the trunk of the nerve) would seem to indicate that the function of the hypoglossal is essentially motor; and such a conclusion is sustained by the experiments of Longet, who found the nerve incapable of transmitting any sensory impressions when the roots were subjected to irritation.

Mayo and Magendie, however, first proved that the nerve possessed sensory filaments, after it had escaped from the cavity of the cranium, which results have since been confirmed by most of the later physiologists. We can easily explain this acquired power of sensibility which the nerve exhibits, by the *branches of communication* which it receives from the pneumogastric, the cervical nerves, and the gustatory branch of the fifth nerve; so that there is little, if any, reason to doubt that the original fibers of the nerve itself are purely motor in function.

In connection with the glosso-pharyngeal nerve, I entered into a somewhat extended discussion of the mechanism of the act of deglutition;¹ and the same subject might, with equal propriety, be again repeated in connection with the hypoglossal nerve, since both are intimately associated with those complex movements. It will suffice, however, to again call attention to the fact, that *movements of the tongue* were of the greatest importance in swallowing, since that organ not only conveyed the bolus to the back portion of the mouth, and, when liquids were to be swallowed, helped to form a tube through which a suction force could be exerted, but also assisted in the prevention of food from entering the cavity of the larynx.

CLINICAL POINTS PERTAINING TO THE HYPO-GLOSSAL NERVE.

When this nerve is divided in animals, the sense of taste remains and the tongue retains its normal sensitiveness; but the power of movement is utterly destroyed if the nerves of both sides are simultaneously cut. As a natural consequence, the first stage of the act of deglutition is materially embar-

¹ See page 472 of this volume.

rassed, and the second stage is liable to be associated with the entrance of fluid, if swallowed, into the cavity of the larynx.

When, in the human subject, this nerve is impaired, either as a special type of paralysis or during an attack of hemiplegia, the power of protrusion of the tongue from the mouth in a *straight line* is lost, and that member becomes deflected toward the side which is paralyzed, since the genio-hyo-glossus muscle is unopposed. A disease of rather rare occurrence, in which the hypo-glossal nerves of both sides are paralyzed, and, in addition, the orbicular muscle of the mouth, and, not infrequently, the intrinsic muscles of the larynx, is described by Duchenne;¹ and, since his article, it has been



FIG. 152.—*Glosso-labio-laryngeal paralysis.* (After Hammond.)

written upon by most of the later authors under the names of glosso-labio-laryngeal paralysis, glossoplegia, etc. In this type of disease the tongue lies motionless and trembling in the

¹ "De l'électrisation localisée," Paris, 1861.

floor of the mouth, if all power of motion be paralyzed ; but, if paresis only exist, it can be imperfectly protruded with difficulty, and is tremblingly and slowly retracted. If one side be affected, the sound side becomes full and prominent, in comparison with the affected side, when called into action. The peculiar trembling character of the movement of the tongue in bilateral paresis is observed in every motion which the patient attempts to perform with that organ, and all the motions are slowly and imperfectly accomplished.

The most important effects of the paralytic state of the muscles are shown in attempts at *mastication* and *speech*. The food is no longer properly placed between the teeth ; is with great difficulty carried to the back part of the mouth ; and frequently regurgitates into the mouth, when attempts are made to swallow. The saliva is secreted in large quantities, and is swallowed with extreme difficulty, so that the patient is constantly obliged to expectorate.



FIG. 153.—*Glosso-labio-laryngeal paralysis.* (After Hammond.)

The *disturbances of speech* may present themselves with varying degrees of intensity. In those cases where the tongue is affected upon one side only (and a state of paresis exists, rather than that of complete paralysis of motion), only those sounds which require the aid of the tongue to be pronounced

are indistinctly and incompletely articulated. These letters are *s*, *sh*, *l*, *e*, *i*, and, at a later period, *k*, *g*, *r*, etc.

When the paralysis is bilateral, and the tongue has undergone atrophy, the speech becomes exceedingly indistinct; muttering and inarticulate, so that the patient can hardly express himself in sounds that can be understood by those in constant communication with him. The *act of singing* is always affected in even the mild forms of lingual paralysis; and the *false notes* are particularly affected, since the tongue plays an important part in so directing the sound as to give it its proper *timbre*.

The effects of lingual paralysis must not be confounded with spasm of the lingual muscles (the act of stuttering), or, on the other hand, with dumbness and aphonia.

In some cases of Duchenne's disease, the lips are not affected; while, in others, the laryngeal and pharyngeal muscles are not impaired to a sufficient degree to cause any serious impediment to their normal functions. We can the better understand why all possible varieties and degrees of paralysis may exist in this disease when we consider that, in order to account for all the symptoms present in a fully developed case, the *facial*, *spinal accessory*, *pneumogastric*, and *hypo-glossal* nerves must be simultaneously diseased, or subjected to extreme pressure. Should the facial nerve escape, the lips and face will preserve their normal power; if the spinal accessory nerve be unimpaired, the larynx may escape, provided that the pneumogastric nerve remain intact below the point of communication between these two nerves; if the hypo-glossal nerve be normal, the symptoms referable to the tongue would not be detected. The essential lesion of this disease seems to consist of a degeneration of the medulla oblongata and the upper portion of the spinal cord; hence the nuclei of origin of the facial, spinal accessory, pneumogastric, and hypo-glossal nerves are liable to be involved to a greater or less extent simultaneously. Whether the view of Leyden, that the condition is one of myelitis, will be sustained, is still uncertain, but that the condition closely re-

sembles that which creates the spinal paralysis of the infant and adult seems positive.

The previous existence of the early manifestations of syphilis and the probable activity of the disease in the system may account for the lesion in some cases, while in others the rheumatic diathesis, mental anxiety, and excessive mental application,¹ seem to have acted as exciting causes.

The general paralysis of the insane often first manifests itself in a peculiar weakness of the tongue and lips.

The tremor of *paralytic dementia* probably first makes its appearance in the facial and lingual muscles. It consists in non-rhythmical contractions of small muscles or of fasciculi of muscles, which are either present in the quiescent state of the features, or are excited by emotion or by the performance of a voluntary movement, as showing the tongue or teeth. Sometimes innumerable fine, fibrillary tremors cover the face, while, in some cases, the movements are coarser, and irregular enough to merit the term choreic. The tongue exhibits both sets of tremors—the very fine fibrillary ones and the large choreic oscillations. There is, also, though usually at a later stage, some shriveling or atrophy of the tongue. I quote from a late article of Professor E. C. Seguin,² as follows:

“The hands are tremulous, usually in a fine, semi-rhythmical way. This trembling is sometimes scarcely visible, but is perceptible as a delicate parchment-like fremitus on holding up the patient’s extended fingers between ours. In the lower extremities the tremulousness is not apparent.

“The speech is affected as a result of this tremor, and as the result of a certain want of coördination in the muscles of articulation. Words are quickly spoken, with some syllables omitted or blurred, or with a terminal syllable left off. The articulate sounds which are produced are heard as vibratory or tremulous, and the speech seems thick. Patients semi-unconsciously avoid long or difficult words in conversation, and

¹ Such cases as these are reported in the admirable description of this complicated affection by my colleague and friend Professor W. A. Hammond: “Treatise on the Diseases of the Nervous System.” New York: D. Appleton & Co., 1876.

² “Med. Record,” 1881.

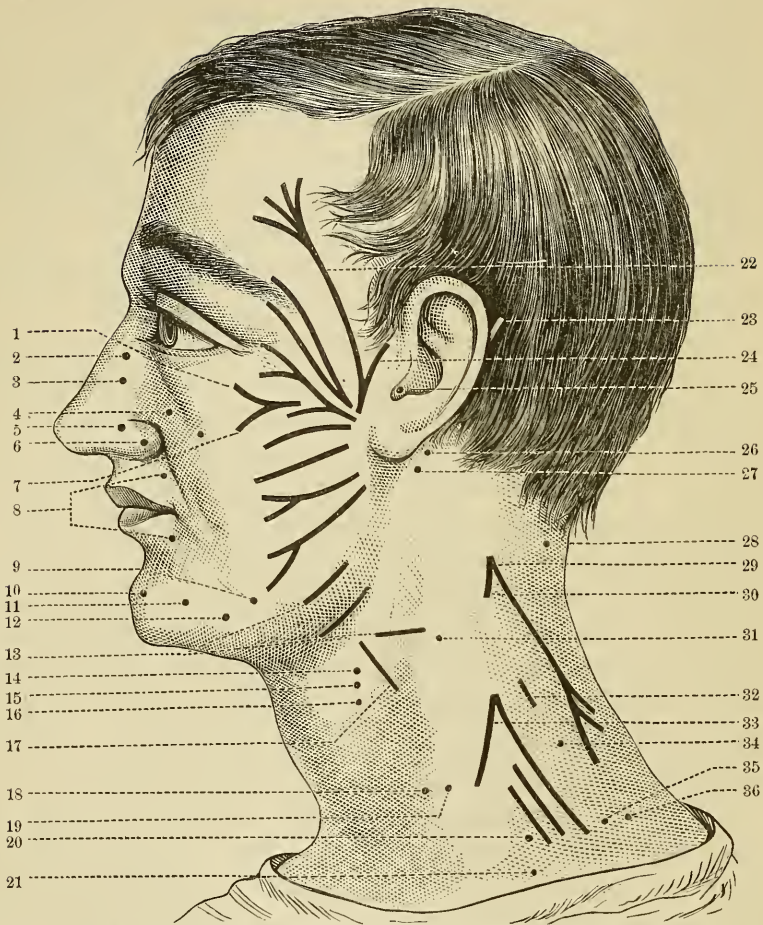


FIG. 154.—A diagram of the motor points of the face, showing the position of the electrodes during electrization of special muscles and nerves. The anode is supposed to be placed in the mastoid fossa, and the cathode upon the part indicated in the diagram.

- 1, m. orbicularis palpebrarum; 2, m. pyramidalis nasi; 3, m. lev. lab. sup. et nasi; 4, m. lev. lab. sup. propr.; 5, 6, m. dilator naris; 7, m. zygomatic major; 8, m. orbicularis oris; 9, n. branch for levator menti; 10, m. levator menti; 11, m. quadratus menti; 12, m. triangularis menti; 13, nerves—subcutaneous of neck; 14, m. sterno-hyoid; 15, m. omo-hyoid; 16, m. sterno-thyroid; 17, n. branch for platysma; 18, m. sterno-hyoid; 19, m. omo-hyoid; 20, 21, nerves to pectoral muscles; 22, m. occipito-frontalis (ant. belly); 23, m. occipito-frontalis (post. belly); 24, m. retrahens and attollens aurem; 25, nerve—facial; 26, m. stylo-hyoid; 27, m. digastric; 28, m. splenius capitis; 29, nerve—external branch of spinal accessory; 30, m. sterno-mastoid; 31, m. sterno-mastoid; 32, m. levator anguli scapulae; 33, nerve—phrenic; 34, nerve—posterior thoracic; 35, m. serratus magnus; 36, nerves of the axillary space.

even seek roundabout ways of expressing their meaning by shorter words. Besides this vibratory tremulousness in

articulation, there is an imperfection in the pronunciation of words—long words especially. Remedy is pronounced ‘remdy’; constitution, ‘constution’; infallibility, ‘infallaby.’ The last syllable may be badly sounded, or even omitted. I have known this characteristic speech to be the only well-marked symptom, and to be followed by dementia, exaltation, etc. Occasionally, a patient comes to us complaining of this defective articulation.”

Interference with the free action of the hypo-glossal nerve, when not associated with a simultaneous affection of other nerves, may result in the production of spasm or paralysis.

Spasm of the tongue may be perceived in connection with the spasmodic diseases, such as chorea, epilepsy, and hysteria; also, as a result of slight compression or irritation of the hypoglossal nerve from meningeal exudation; while a *fibrillary tremor* of the tongue is observed in progressive muscular atrophy. In severe types of facial spasm, and in those forms of disease where the lingual nerve is the seat of a neuralgic affection, the hypo-glossal nerve may create a type of clonic spasm.

Paralysis of the tongue is usually unilateral, and may be the result of cerebral hæmorrhage, softening, embolism, tumors, or the progressive paralysis of the insane. In rare cases, this condition has occurred from injury done to the nerve from the removal of a tumor of the tongue itself; while instances have been reported where the nerve was impaired by pressure upon its trunk, either at the base of the brain, or at its point of escape from the anterior condyloid foramen.

THE SPINAL CORD.

*ITS ANATOMICAL CONSTRUCTION, FUNCTIONS, AND
CLINICAL BEARINGS.*

THE ARCHITECTURE OF THE SPINAL CORD.

THE spinal cord comprises that part of our central nervous system which is contained within the canal of the vertebral column. It is continuous with the medulla oblongata. It may be said to commence at the point where the fibers of the anterior pyramids of the medulla oblongata decussate (which point corresponds to the upper border of the atlas), and to terminate at the lower border of the first lumbar vertebra.¹

In the fœtus, during its development, and in the new-born child, the spinal cord extends throughout nearly the entire length of the vertebral canal. The vertebral column increases in length with age, but the cord does not grow proportionately; hence, in the adult, it reaches only to the body of the first or second lumbar vertebra, and the cauda equina fills the remaining part of the spinal canal.

The circumferential measurement of the spinal cord is about one inch. At its largest part this measurement is exceeded by about two lines (one sixth of an inch).

The entire length of the cord varies from fifteen to eighteen inches in the adult (since it depends somewhat upon the height of the individual). Its upper end is not only apparently continuous with the lower part of the medulla ob-

¹ Fehst ("Cent. für d. med. Wiss.," 1874) asserts that the spinal cord in women reaches to the lower level of the second lumbar vertebra.

longata (which, in my opinion, seems more properly a part of the cord than of the brain), but actually so, as the fibers of one extend into the substance of the other. Its lower end

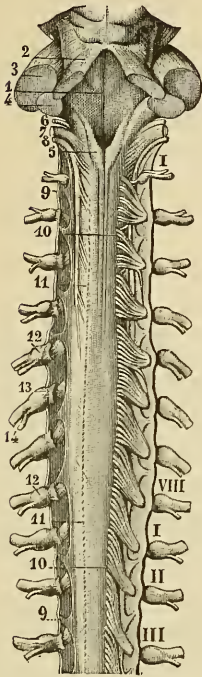


FIG. 155.—Cervical portion of the spinal cord. (Hirschfeld.)

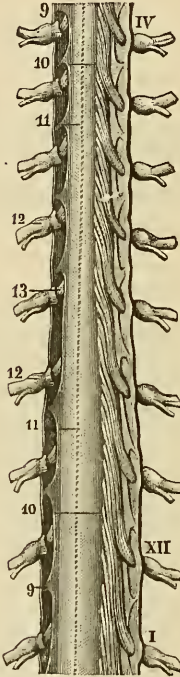


FIG. 156.—Dorsal portion of the spinal cord. (Hirschfeld.)

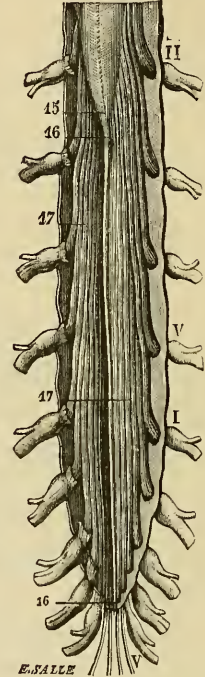


FIG. 157.—Inferior portion of the spinal cord and cauda equina. (Hirschfeld.)

1, antero-inferior wall of the fourth ventricle; 2, superior peduncle of the cerebellum; 3, middle peduncle of the cerebellum; 4, inferior peduncle of the cerebellum; 5, inferior portion of the posterior median columns of the cord; 6, glosso-pharyngeal nerve; 7, pneumogastric; 8, spinal accessory nerve; 9, 9, 9, 9, dentated ligament; 10, 10, 10, 10, posterior roots of the spinal nerves; 11, 11, 11, 11, posterior lateral groove; 12, 12, 12, 12, ganglia of the posterior roots of the nerves; 13, 13, anterior roots of the nerves; 14, division of the nerves into two branches; 15, lower extremity of the cord; 16, 16, coccygeal ligament; 17, 17, cauda equina; I-VIII, cervical nerves; I, II, III, IV-XII, dorsal nerves; I, II-V, lumbar nerves; I-V, sacral nerves.

terminates in a slender filament, called the “filum terminale,” that descends for a short distance into the central ligament.

The three admirable cuts of Hirschfeld, which are here introduced, illustrate the appearance of the adult spinal cord in the cervical, dorsal, and lumbar regions after its investing

membranes have been so divided as to expose the spinal nerves that escape from its substance. In the cut illustrating the cervical region, the fourth ventricle of the brain (which is within the medulla) is exposed to view. The dentate ligament of the cord (which is formed by the pia mater or its internal investing membrane) is also shown in all three cuts. Some other points in the construction of the cord and the spinal nerves are clearly depicted, but they will be made more apparent in subsequent diagrams. Should any part of the descriptive text of these cuts seem incomplete to the reader, subsequent portions of this chapter will furnish the additional information that may be desired.

Within the vertebral canal the spinal cord hangs free, and exhibits a considerable degree of mobility. Except at the two upper cervical vertebræ and in the lumbar region, the cord is well protected by the overlapping spines of the vertebræ from injuries sustained posteriorly. The vertebral canal is lined throughout with a hard periosteum, which covers the bones.

The cord is practically suspended in the cerebro-spinal fluid. This arrangement serves as a protection against injury from violence transmitted by means of the spinal column; because, as is well known, a fluid medium distributes force applied to it in all directions equally.

The consistence of the cord is liable to variations. Immediately after death it is elastic and easy to cut, its cut surface being smooth and its edges well defined and sharp. After death it tends rapidly to become soft, so that sections of the cord are seldom satisfactory for microscopical examination, unless the specimen be perfectly fresh when removed from the canal and placed immediately in some preserving fluid. The cord and its envelopes come far from filling the entire canal of the vertebral column. This circumstance tends to protect the cord from injury during movements of the spine, especially in the cervical and lumbar regions, where movement is comparatively free and unrestricted.

THE EXTERNAL APPEARANCE OF THE CORD.

The spinal cord is not of the same size or shape in all portions of its length. It is nearly cylindrical in form and tapers gradually toward its lower extremity, with the exception of presenting two local enlargements, called the “*cervical*” and “*lumbar*” enlargements.

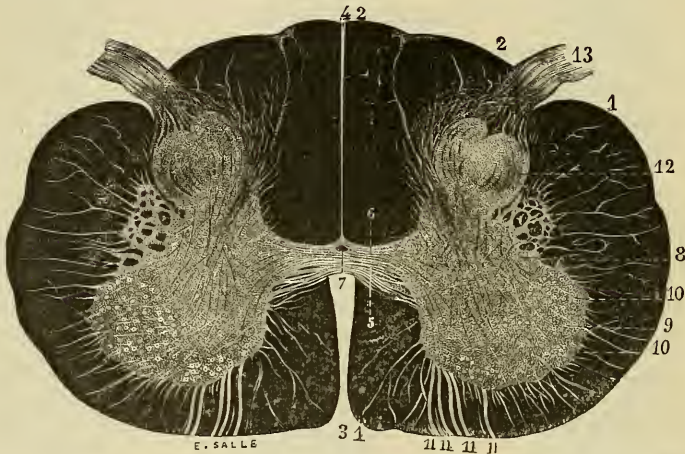


FIG. 158.—*Transverse section of the cervical enlargement of the spinal cord at the origin of the fifth pair of cervical nerves.* (Stilling.)

In this figure the white substance of the cord is represented in black, to show more clearly the limits of the gray matter: 1, 1, antero-lateral columns; 2, 2, posterior white columns; 3, anterior median fissure; 4, posterior median fissure; 5, white commissure; 6, gray commissure; 7, central canal; 8, 9, anterior cornua of gray matter; 10, 10, group of large multipolar cells; 11, 11, 11, anterior roots of the spinal nerves; 12, posterior cornua of gray matter containing the so-called “*substantia gelatinosa*”; 13, posterior roots of the spinal nerves.

The former of these extends from the third cervical to the first dorsal vertebra, and is widest from side to side. The latter extends from the lower part of the eleventh dorsal to the lower border of the twelfth dorsal vertebra, and is widest from before backward.¹

The shape of a transverse section of the cord varies with the level at which the section is made.

In the dorsal region, it is nearly circular. In the cervical

¹ These enlargements correspond to the points of origin of the main nerves of the upper and lower extremities. They indicate, therefore, an excess of the ganglionic-cell elements over those found in the dorsal region.

and lumbar enlargements, the transverse diameter of the section is broadened and the whole section assumes an approach to the triangular form, the base of which is directed forward. Finally, the cord assumes the form of a half-moon in the lowest segments, with its convexity directed backward.

When viewed exteriorly, the cord presents *five fissures* and *four pairs of vertical columns*, which are less distinct than the convolutions of the cerebrum.

On a section being made transversely across its substance, two general subdivisions can be discerned by the naked eye, the *white* and the *gray portions*.

The general exterior of the spinal cord is incompletely divided into two *symmetrical lateral halves*, by the so-called "antero-median fissure" and the "postero-median fissure." These do not cut the cord entirely in two, since a transverse commissure exists, called the "*commissure of the spinal cord*." Now, this point is worthy of attention, because it indicates a clinical fact, viz., that lesions of one lateral half of the cord produce symptoms in a lateral half of the body.

Each lateral half of the cord has *three fissures of its own* :

1. The "antero-lateral fissure." This corresponds to the points of escape of the anterior roots of the spinal nerves.

2. The "postero-lateral fissure." This corresponds to the points of attachment to the posterior roots of the spinal nerves.

3. The "postero-intermediary fissure." This is situated between the postero-median fissure (which helps to divide the cord into its two lateral halves) and the postero-lateral fissure.

The first two of these are mere traces upon the surface of the cord, while the last is most apparent in the cervical region.

¹ The postero-intermediary fissure extends from the lower border of the medulla to the lower end of the cervical enlargement of the spinal cord. It is not associated with the transit of nerve roots, in which respect it differs from the antero-lateral and postero-lateral fissures.

As demarkated by the fissures named above, the spinal cord presents four subdivisions of its exterior surface, called, respectively, the "anterior," "lateral," "postero-external," and "postero-median" columns.¹

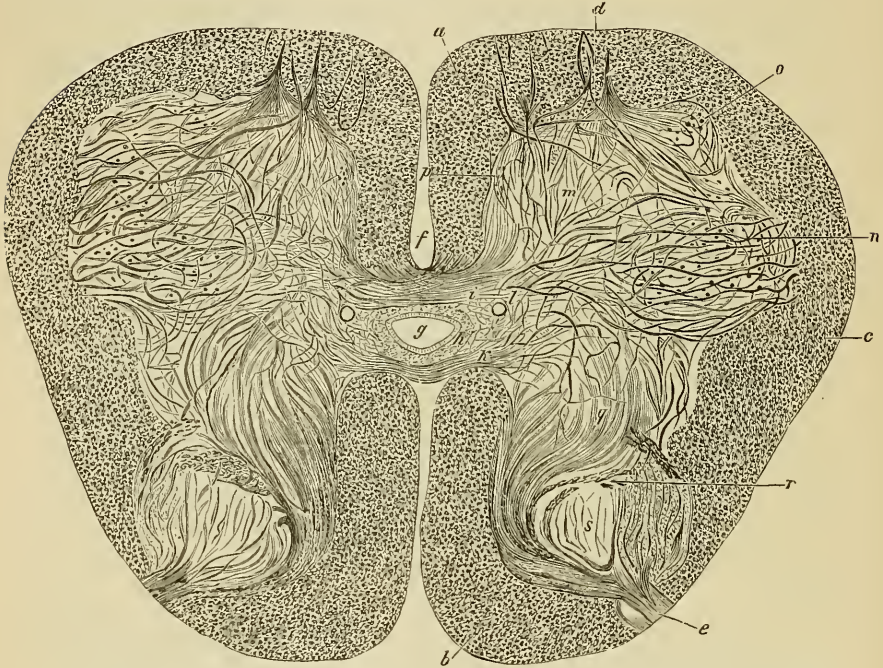


FIG. 159.—Transverse section of the spinal cord of a child six months old, at the middle of the lumbar enlargement, treated with potassio-chloride of gold and nitrate of uranium; magnified 20 diameters. By means of these reagents the direction of the fibers in the gray substance is rendered unusually distinct. (Gerlach.)

a, anterior columns; *b*, posterior columns; *c*, lateral columns; *d*, anterior roots; *e*, posterior roots; *f*, anterior white commissure, in connection with the fasciculi of the anterior cornua and the anterior columns; *g*, central canal with its epithelium; *h*, surrounding connective substance of the central canal; *i*, transverse fasciculi of the gray commissure in front of the central canal; *k*, transverse fasciculi of the gray commissure behind the central canal; *l*, transverse section of the two central veins; *m*, anterior cornua; *n*, great lateral cellular layer of the anterior cornua; *o*, lesser anterior cellular layer; *p*, smallest median cellular layer; *q*, posterior cornua; *r*, ascending fasciculi in the posterior cornua; *s*, substantia gelatinosa.

These are, however, of less importance, from a clinical standpoint, than those columns of fibers named after certain special investigators in this line of science, or from their

¹ Some anatomists include the lateral with the anterior column, under the name of "the antero-lateral column," thus taking in about two thirds of the entire lateral half of the cord.

physiological functions. Subsequent diagrammatic cuts of the subdivisions now accepted as definitely localized in all transverse sections of the spinal cord illustrate them.

When we come to discuss the clinical points pertaining to spinal localization, in case of disease, you will realize that the further subdivisions of the spinal cord, which I shall endeavor to impress upon your memories, are not based alone upon the results of enthusiastic microscopy, but are the evidences of progress in this direction which the earlier anatomists had not dreamed of, and the foundation of all accurate and positive diagnosis of certain varieties of spinal lesions.

The spinal cord gives off *thirty-one pairs of nerves*, called "spinal nerves," in contradistinction to those of cranial origin.

Each spinal nerve arises by two roots, which spring, respectively, from two of the fissures of the lateral halves of the cord, as has been mentioned. These two roots join each other to form the nerve before it escapes from the spinal canal to be distributed to the regions which it is destined to supply.

Each pair of nerves and the disk of the cord to which they are attached constitute what is known as a "*spinal segment*."

THE MEMBRANES OF THE SPINAL CORD.

As was the case with the encephalon, the spinal cord is invested from within outward by a *membrane of nutrition*, the pia mater; a *membrane of lubrication*, the arachnoid; and, finally, a *membrane of protection*, the dura mater.

These three coverings differ slightly in some respects from those covering the brain, but the differences have little if anything to do with the clinical aspects of the spinal cord.

The DURA MATER of the cord is a cylindrical sac of fibrous tissue of larger dimensions than the cord. It is closely attached above to the foramen magnum of the occipital bone, and ends below by becoming blended with the periosteum of the coccyx. Its outer surface is invested by a layer of fat which separates it from the bones. As the spinal nerves per-

forate it, the dura and neurilemma become blended. The vertebral, intercostal, and lumbar arteries furnish it with blood. Large plexuses of veins are found on the anterior and posterior portions of the dura. These connect with the external vertebral plexuses.

The PIA MATER envelops the cord, like a tight-fitting glove, from top to bottom. It sends processes into the substance of the cord, which subdivide and form a framework for the nervous elements that compose it. It is also joined to the dura by from twenty to twenty-three processes upon each side, called the "*ligamenta denticulata*." These serve to retain the cord in its proper relations to the vertebral canal. The pia mater is rich in blood-vessels and nerves, and owes its toughness to a network of wavy connective-tissue fibers. Its nerves come from the posterior roots of the spinal nerves. In old subjects, the pia is often markedly pigmented in the cervical region.

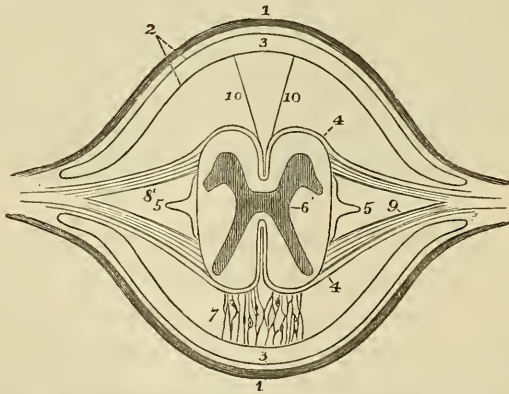


FIG. 160.—This diagram has been introduced to show the arrangement of the different membranes and spaces as they are believed to exist in the spinal column. (After Hilton.)

- 1, 1, dura mater passing down to end on the sheath of the nerves; 2, 2, layers of arachnoid forming; 3, cavity of arachnoid; 4, 4, pia mater ending on nerve-sheath; 5, 5, ligamentum denticulatum; 6, gray matter of spinal cord; 7, delicate areola tissue found in the sub-arachnoid space between the arachnoid and pia mater; 8, anterior and smaller, 9, posterior and larger, roots of spinal nerve; 10, 10, similar tissue to 7.

The ARACHNOID, like all serous membranes, consists of a closed sac with a cavity between its two layers. The inner layer becomes blended with the pia mater as that membrane is prolonged upon the spinal nerve roots (Fig. 160). Between

the pia mater and the arachnoid there exists a loose areolar tissue, known as the "*sub-arachnoidean tissue*," which contains a fluid called the cerebro-spinal fluid.

THE CEREBRO-SPINAL FLUID.

As mentioned in connection with the ventricular cavities of the brain, the spinal cord is immersed, as it were, in a fluid, the "*cerebro-spinal fluid*," which has free entrance to and egress from the ventricles of the encephalon. Its chief function is to regulate and equalize the pressure¹ upon the nerve centers, when the blood-supply suffers variations, as it does during respiration, in sleep, and in certain diseased conditions. This accounts for the fact that pressure made upon a "*spina bifida*"—a tumor containing this fluid protruding through an opening due to a congenital absence of the spinous processes of the vertebræ—often creates brain symptoms, if sufficient to create excessive intra-ventricular pressure.

The greater part of this fluid is contained in what is known as the *sub-arachnoidean space*, which is situated outside of the cavity of the arachnoid, between its inner layer and the pia mater of the cord. Its quantity was estimated by Magendie as about two fluid ounces in the human subject; but a somewhat larger amount can be obtained by making an opening in the lumbar region and a counter-opening in the region of the head, so as to allow of the influence of atmospheric pressure in forcing its escape outward.

This fluid may be drawn out of the spinal canal of a living animal, either by means of a simple trocar or a trocar attached to a suction-tube. In the former method no apparent influence of a detrimental character seems to follow a moderate escape; but, when a suction force is used to still further draw off the fluid, the animal becomes enfeebled and subsequently affected with symptoms of motor paralysis. The cerebro-spinal fluid is rapidly reproduced after its withdrawal, and is probably secreted by the pia mater.

¹ Hifton considers this fluid as analogous, in respect to its function, to the elastic capsule of the various solid viscera. "*Rest and Pain*," London, 1876.

The fact that an increase of the intra-cerebral pressure will result in coma, if sufficiently intensified, is shown, in a clinical way, upon the human subject, by compression of a spina bifida; and the same result was proved by Magendie, who injected water into the sub-arachnoidean space of animals, and thus artificially induced a state of profound coma. The point of communication between the sub-arachnoidean space of the spinal canal and the ventricular cavities of the brain is situated in the *fourth ventricle*;¹ hence, the fluid has to pass upward, through the aqueduct of Sylvius, to reach the third ventricle, and through the foramina of Monro, to enter the two lateral ventricles of the cerebrum. Hilton² maintains that the basilar process of the occipital bone (which is in close relation to that part of the encephalon which is most essential to life) is not in actual contact with the adjacent bone, but has a layer of the cerebro-spinal fluid interposed as a water-bed to protect the parts from injury from any form of concussion. A similar condition exists also in other parts.³ The cerebro-spinal fluid is never in a state of repose. The influence of respiration affects it, by causing a decrease in the arterial pressure in the brain during inspiration and an increase during expiration. As a result of the variations in the volume of blood within the cavity of the skull, the cerebro-spinal fluid rises and falls in quantities sufficient to maintain an equal pressure upon the brain substance. It seems to be proved that the cerebro-spinal fluid is constantly secreted by the pia mater, and as constantly carried off by the lymphatic channels.

Hyrtil has suggested that the displacement of the cerebro-spinal fluid is facilitated to a marked degree by the emptying and filling of the veins of the spinal canal. He believes that the spinal veins are overfilled and distended during inspiration by the descent of the diaphragm, because pressure is then exerted upon the abdominal viscera by that muscle.

¹ The foramen of Magendie.

² *Op. cit.*

³ The reader is referred to those pages in the section upon the brain that treat of the arachnoid and pia mater.

This tends to impede the flow of blood into the lumbar veins. The opposite effect, however, is produced at this time upon the cerebral sinuses, as they are emptied by the tendency to a vacuum created within the chest when the diaphragm becomes lowered. The return of the abdominal viscera, which follows the diaphragm when it relaxes (e. g., during expiration), assists in emptying the spinal veins; but at the same time it creates engorgement of the veins of the head and neck by interfering with the entrance of blood into the thorax. Thus it appears that the cerebro-spinal fluid is forced out of the ventricles of the brain during expiration by the excess of blood in the veins of that organ, and that the spinal veins are then empty, in order, as it were, to make room for the excess of the spinal fluid which is displaced by the cerebral engorgement. During inspiration, the direction of the displacement is reversed.

THE BLOOD-VESSELS OF THE CORD.

The tissue of the spinal cord is peculiarly rich in blood-vessels. The arteries enter from the pia mater and accompany the processes which that membrane sends into the substance of the cord. They subdivide after entering the cord and form a network of capillaries both in the gray and white substance. The vertebral arteries give off branches that form the anterior and posterior spinal arteries. These run continuously from the foramen magnum to the conus terminalis. The intercostal and lumbar arteries anastomose freely with the anterior and posterior spinal vessels; hence *counter-irritation over the spines of the vertebrae* causes a direct effect upon the vascular supply of the cord itself as well as upon the meninges.

The intercostal and lumbar arteries enter the vertebral canal, by means of the intervertebral foramina, in company with the nerve roots.

The capillaries of the cord empty into two venous trunks that run in the gray commissure of the cord on either side of the central canal for its entire length, and also into a

large vein that accompanies the anterior spinal artery for the entire length of the cord, lying in the anterior median fissure. In the posterior median fissure a similar vein may be traced for the entire length of the cord. The veins within the spinal gray matter anastomose with the external veins already described by horizontal branches; and these, again, join with each other, and also with the large venous plexuses that lie in the fatty tissue outside of the dura and with the external vertebral veins.

THE VERTEBRÆ AS GUIDES TO THE SPINAL SEGMENTS.

By sharp friction over the spinal column, the tips of the spinous processes can be made very apparent as well-defined red spots. They can then be readily counted.

It is desirable often to know what part of the vertebral column corresponds to the level of origin of each pair of spinal nerves. The spines of the vertebræ can be felt even in fat subjects, and thus guides may be had in each individual to locate the levels of the various spinal segments. To do this with accuracy, however, is rendered somewhat difficult (1) by the fact that the spinal nerves do not escape from the foramina between the pedicles of the vertebræ at the same level at which they arise from the spinal cord; and (2) because the tips of the spinous processes do not correspond to the bodies of the corresponding vertebræ in all parts of the spinal column.

The spinal nerves escape from the cervical foramina nearly on a level with their origin from the cord, but the obliquity of the nerves increases steadily in the dorsal and lumbar regions, so that the lowest nerves that constitute the cauda equina have a very long course before they escape from the foramina of the lumbar region and the sacrum.

Gowers gives the following deductions as aids to determine the situation of the *bodies of the vertebræ* during life: "The tips of the cervical spines correspond nearly to the lower borders of the corresponding vertebræ. Each of the three upper dorsal spines corresponds nearly to the upper

border of the body of the vertebra below. From the fourth to the eighth dorsal, each spine corresponds to the middle of the vertebra below. The ninth, tenth, and eleventh spines slope less, and their tips again correspond to the upper borders of the next vertebræ, while the rest of the spines are opposite the bodies of their own vertebræ." Fig. 161 will make these statements apparent.

With these guides to the bodies of the vertebræ, it now becomes necessary to consider the relations of the spines to the origins of the spinal nerves. In the cervical region, the first three spines correspond to the origins of the third, fourth, and fifth cervical nerves; the sixth cervical spine corresponds to the origin of the eighth cervical nerve, and the intervals between the fourth and fifth spines, and the fifth and sixth, correspond to the origins of the sixth and seventh cervical nerves respectively.

In the dorsal region, the seventh cervical spine usually corresponds to the origin of the first dorsal nerve; the first dorsal spine to the third dorsal nerve; the second spine to the fourth nerve; the third spine to the fifth nerve; the fourth spine to the sixth nerve; and so on down to the tenth spine, which lies opposite the twelfth nerve. It may, therefore, be given as a rule that *the dorsal spines lie opposite the level of the origin of the nerve that escapes from the spinal canal two vertebræ lower down.*

The lumbar and sacral nerves all arise within a space that corresponds to the interval between the eleventh dorsal spine and the first lumbar spine. The course of each nerve within the spinal canal from the first lumbar to the coccygeal nerves, therefore, becomes longer than the preceding ones as they are given off from the cord.

The excellent cut devised by Gowers, which is here introduced, will enable the reader to more easily follow the preceding text. It shows in a diagrammatic way the varying relations between the bodies of the vertebræ, the origins of spinal nerves, and the tips of the vertebral spines. It must be always remembered that the spinal nerves are named from

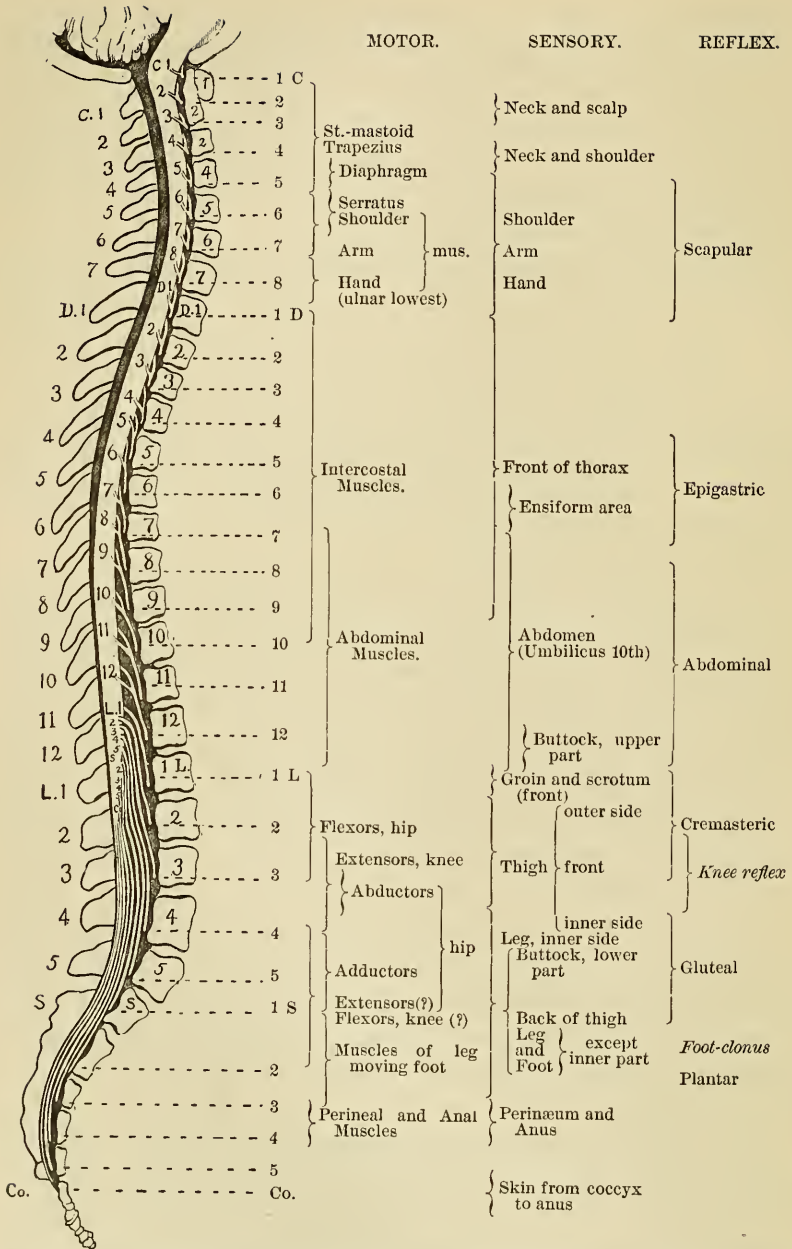


FIG. 161.—A diagram designed to show the relations of the vertebrae to the spinal segments, and of the spinal nerves to the motor, sensory, and reflex functions of the spinal cord. (Gowers.)

the *situation of the foramen* through which they escape from the canal of the vertebral column; and that the name of the nerve must never be construed as indicating the level of its point of origin. Thus, for example, the sacral nerves escape into the cavity of the pelvis, but they arise in the lumbar region. If we seek to locate spinal lesions that tend to create symptoms referable to special nerves, we must first know the *level of origin* of the nerves that exhibit evidences of impairment, as a result of the spinal lesion. The cut of Gowers (Fig. 161) will also make the distribution of the spinal nerves apparent.

THE HISTOLOGICAL ELEMENTS OF THE CORD.

The nerve fibers, nerve cells, and connective tissue of the cord have been already referred to in a general way, but a few histological statements respecting them will not be out of place.

THE NERVE FIBERS.—Schwann's sheath has not yet been satisfactorily demonstrated as investing any of the fibers of the cord, and it may be said that, as far as our present knowledge goes, all are destitute of it. Both medullated and non-medullated fibers exist in the cord. The former are found in great abundance in the white substance and the white commissure, and also in the gray matter; the latter are not detected in the white matter or the white commissure. The medullated fibers vary in size. In the anterior columns they are very large; in the columns of Goll they are smaller; in the gray matter they are still finer. The axis-cylinder, as well as the medullary sheath of the fiber, may be discerned in cross-sections of all.

The non-medullary fibers of the cord appear as naked axis-cylinders, without any medullary sheath. They exist only in the gray substance, and form a fine and close network of fibers, in which ganglion cells are imbedded. The fine medullated fibers of the gray matter form, however, the preponderant element.

In the so-called white substance of the cord three general varieties of fibers may be demonstrated:

1. The *longitudinal strands* or bundles, which constitute the bulk of the conducting tracts to and from the brain or between the different spinal segments.

2. The *oblique fibers*, that are interlaced with those of the preceding set, and are relatively few in number. These are probably fibers of termination of the posterior nerve roots. The column of Burdach is traversed by many of the bundles of fibers derived from the posterior nerve roots.

3. The *horizontal fibers*, that are chiefly detected in the white commissure and in the region of the anterior nerve roots.

It will aid us in our review of this subject to consider the fibers of the two spinal nerve roots separately.

THE FIBERS OF THE ANTERIOR NERVE ROOTS, as independently discovered by Sir Charles Bell and Magendie, comprise all the motor fibers that emanate from the cord. Experimental, clinical, and pathological investigation to date have failed to disprove or modify this statement. It is not now believed that any sensory fibers exist in the anterior spinal nerve roots.

The *motor fibers* of the cord appear to rise directly, for the most part, from the axis-cylinder processes of the large spinal cells, found in the anterior horns of the gray matter. They may be traced in all cross-sections of the cord as distinct bundles which traverse the anterior root zones (Fig. 158). They are functionally related to the fibers that descend from the brain in the columns of Türck, and the crossed pyramidal columns (Fig. 60), the spinal cells being a means of communication between these fibers and those of the anterior roots. A few of the fibers of the anterior roots can apparently be traced through the white commissure of the cord to the opposite side; others appear to radiate through the spinal gray matter, ascending, descending, and passing in an antero-posterior direction; finally, the majority join the cells of the anterior horns of the side from which they escape.

THE FIBERS OF THE POSTERIOR NERVE ROOTS are physiologically connected with the transmission of sensations of

various kinds. The sheath which invests each posterior root ceases at its entrance into the cord, and its component fibers at once diverge, some passing into the posterior gray horn and some entering the column of Burdach. We are thus forced to trace two distinct bundles, whose fibers take various directions.

The fibers that enter the posterior gray horn may be traced as follows: (1) Some directly to the cells of the posterior gray horn; (2) some to the network of fibers which form the so-called "gelatinous substance" of the horn; (3) some to the anterior gray horn of the opposite side, by means of the gray commissure of the cord; (4) some to the opposite posterior gray horn; (5) Clarke and Kölliker have shown that a large proportion of these fibers pass upward for a greater or less distance in the so-called "ascending bundle of Deiters" or "longitudinal bundle of Kölliker," when they again take a horizontal direction and join the cells of the posterior gray horn of the same side.

Those fibers that diverge into the column of Burdach, when the posterior nerve root enters the substance of the cord, may be traced as a descending and ascending bundle.

Schultze has shown that a bundle of small size immediately descends for two or three centimetres into the substance of the cord, and then passes into the posterior gray horn of the same side. A bundle of much larger size seems to take an upward turn, immediately after its entrance into the cord, and to give off slips to the posterior gray horn of the same side at different levels. The ultimate termination of these slips appears not to be uniform at different levels, as shown in cross-sections of the cord. Some appear to cross by the posterior gray commissure to the opposite side; others, again, become intermingled with the fibers of Gerlach's network of fibers; some probably join the cells of Clark's column; some end in the cells of the corresponding posterior gray horn; some join the cell groups in the posterior and lateral part of the anterior gray horn of the same side; finally, some seem

to pass forward into the anterior gray horn itself and to become lost.

The posterior and anterior nerve roots are thus probably associated with successive segments of the spinal gray matter. The limits of the association of the posterior roots appear to be from three centimetres below their point of entrance to eight centimetres above it (Schultze). It is probable that all the sensory fibers except those connected with the muscular sense decussate within the substance of the cord, either directly or by means of decussating cell-processes. It has been pointed out by Köbner that the fibers which convey the sensations of temperature and pain decussate at a lower level, after their entrance into the cord, than do those that convey tactile sensations.

THE SPINAL CELLS.—These are the most striking feature of the gray matter. They vary (1) in size, according to their situation, and (2) in the presence or absence of the peculiar process known as the "axis-cylinder process," which differs from the others in being unbranched, and in tending to increase in size as it departs from the body of the cell. They have no cell-membrane; their nucleus is large; a glistening nucleolus exists; and pigment granules are usually present in abundance in the protoplasmic mass. Some cells, that are destitute of the so-called "axis-cylinder process," unite with the nerve fibers, according to Gerlach, by means of a fine network of nerves.

The cells of the anterior horns are the largest, and have many processes; those of the vesicular column of Clarke are next in point of size, and nearly round; and those of the posterior horns are the smallest, and are spindle-shaped. The well-defined groups, which are characteristic of the anterior horns, are not found in the posterior horns. Some attractive theories have been advanced respecting the individual functions of the various forms of cells found within the cord. The motor function of the large cells of the anterior horns seems to be well established; but that a special form of cell may be positively designated as sensory, another as vaso-motor, and

a third as trophic in function, seems as yet improbable and visionary.

A middle horn of gray matter is described by some authors as arising from the external portion of the gray mass between the two horns commonly described. It is also called the "intermediary lateral tract." In close relation to this tract the reticular processes (process of Lenhossek) is discerned. It consists of a matrix of neuroglia and an interrupting network of fibers.

Ross describes a collection of cells in the cervical region that develop their processes after birth (in which respect they differ from other groups) and which are of large size. He draws the inference, from their situation and late development, that they are chiefly concerned in the complex movements of the hand and fingers, or of the corresponding forelimbs of animals.

The *gray matter of the cord* differs from that of the brain in respect to its distribution, since it is confined exclusively to its central portion. In the brain the larger proportion of gray matter is distributed upon its exterior (cerebral and cerebellar cortex).

THE NEUROGLIA.—A basement substance of connective-tissue elements is found within the cord, in the meshes of which the nerve cells, the nerve fibers, and the vessels are enveloped. It serves to give support to these structures and firmness to the cord as a whole. It springs from the pia mater, by numerous septa that enter the cord and form channels for the blood-vessels. These septa divide and subdivide to form the delicate network in which the nervous elements are imbedded. The researches of Boll appear to show that the chief histological element of the neuroglia is a multipolar connective-tissue cell, whose processes are unbranched. They are often described as the "spider-cells" of Jastrowitz, and as Deiters's cells. Their nuclei correspond to what Henle described as "granules" of the cord. These cells are found abundantly in the white matter, especially in pathological specimens. The neuroglia is probably the chief factor in the

formation of the so-called "gelatinous substance" of the gray matter (Fig. 158). The view of Spitzka regarding the gelatinous substance has been mentioned on page 263.

The regions of the cord in which the neuroglia is most apparent are proportionately destitute of nerve cells. These regions include (1) the periphery of the cord; (2) the borders of the fissures; (3) the circumferential area around the central canal, and to the mesial side of the head of the posterior horns (the *substantia gelatinosa*).

The preponderance of connective tissue in the posterior horns, in contrast to that of the anterior horns, helps us to interpret the frequent occurrence of inflammatory affections in the posterior portions of the cord.

The *substantia gelatinosa* is darker in color than the rest of the connective-tissue formation of the cord. For this reason it was formerly classed as a part of the gray substance. In the cervical and dorsal regions of the cord it presents an oval outline in all cross-sections, but in the lumbar region it becomes more circular. The tubercle of Rolando may be considered as an extension of this column upward into the substance of the medulla.

APPEARANCE OF A TRANSVERSE SECTION OF THE SPINAL CORD.

The arrangement of the gray and white substance of the spinal cord is seen only on a transverse section. In order to properly appreciate special points in the construction of these two portions, several transverse sections must be made at different heights in the cord, because the relative proportion of the gray and white substance differs in the cervical, dorsal, and lumbar regions. The regions usually selected for these transverse sections are the upper cervical portion, the center of the cervical enlargement, the center of the dorsal region, the lumbar enlargement, and the terminal portion of the cord. In the cervical region, the white substance is the most abundant. In the dorsal region, the gray matter is relatively smaller than at any other point. In the lumbar enlargement, the gray matter is the most extensively developed.

When we view the appearance of the spinal cord on transverse section, we perceive that the gray matter is arranged in the same general way in all of its segments. This has been compared to the capital letter "H," because its two lateral halves are connected by a transverse band—the transverse commissure of the gray substance. Each lateral half of the gray substance is *crescentic* in form, presenting an anterior and a posterior projection, termed the *anterior* and *posterior horns*. The former of these is broad and blunted, and does

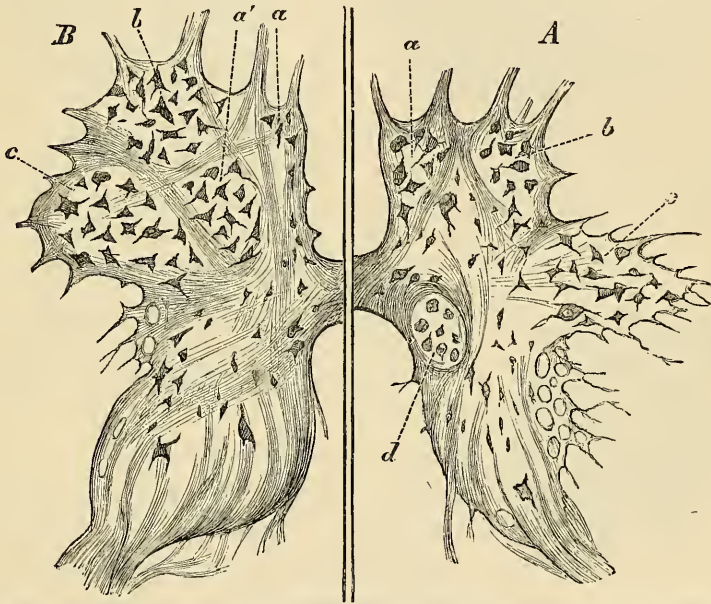


FIG. 162.—Semi-diagrammatic transverse section of the gray substance of the cervical (A) and lumbar enlargements (B) of the spinal cord. (Erb.)

A. *a*, median group of cells; *b*, antero-lateral group; *c*, postero-lateral group; *d*, vesicular column of Clarke. B. *a*, median group; *a'*, group that appears first in the lumbar region, possibly belonging to *a*; *b*, antero-lateral group; *c*, postero-lateral group. Note that the cells are few and scattered in the posterior horns, and also that the shape of both horns differs markedly in A and B.

not reach the surface of the cord. The latter is thinner and more pointed, and approaches the exterior surface of the cord near the point of attachment of the posterior roots of the spinal nerves.

The *anterior horns* are much larger than the posterior in

the cervical region, but less so in the dorsal and lumbar. They contain the so-called "motor cells."

The *posterior horns* are also studded with nerve cells, but they are smaller and more spindle-shaped than the motor cells. The posterior horns are very large in the lumbar enlargement of the cord.

The *motor cells* are commonly multipolar. One of these poles (the so-called "axis-cylinder process") is slender and unbranched, and tends to increase in size as it passes from the body of the cell. It is known as the "*axis-cylinder process*" (Deiters's). In favorable sections of the cord it can be traced into the anterior root of a spinal nerve. It probably becomes continuous with the axis-cylinder of a motor nerve fiber. The other poles of the cell divide into branches as soon as they leave the body of the cell, and terminate in a delicate network of nerve fibrils (network of Gerlach) which exists in the spinal gray matter. The motor cells are distributed in

well-defined groups, whose situation changes somewhat in different regions of the cord. These are shown in the admirable drawings of Gerlach and Erb (Figs. 159 and 162).

The admirable diagram of Erb (Fig. 162) illustrates the differences in shape of the horns of the spinal gray matter in the cervical and lumbar regions of the cord, and also the arrangement of the motor cells of the anterior horns into groups that are specially named. It will be seen by reference to the diagram that the so-called "median," "antero-lateral," and "postero-lateral" groups of cells change their relations to each other at different levels of the cord. Their

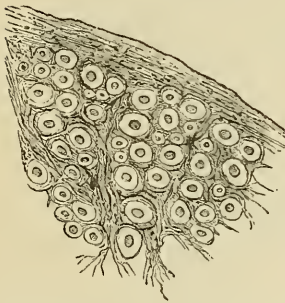


FIG. 163.—A piece of the white substance of the spinal cord, as seen on transverse section, highly magnified. (Erb.)

Note that the nerve fibers cut across present their axis-cylinders toward the plane of the section, and that Deiters's cells are apparent. The latter belong to the connective tissue (neuroglia) of the cord, but present polar prolongations, as do the nerve cells.

relative size also varies at different levels. It will be again observed that the vesicular column (*column of Clarke*) is very

well defined in the cervical region and is wanting in the lumbar region. This column of cells seems to exist only in those segments of the cord that are connected with the thoracic and abdominal viscera (Starr).

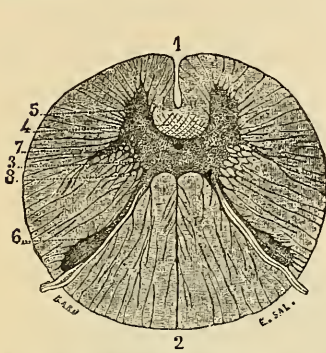


FIG. 164.—Section of the cord below the medulla oblongata. (Sappey.)

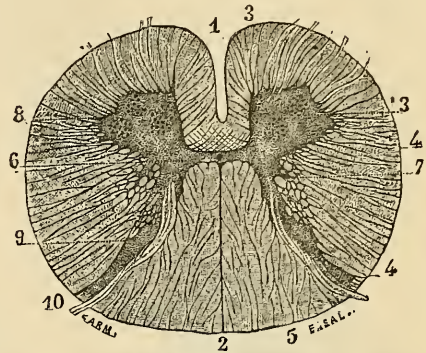


FIG. 165.—Section of the cervical enlargement of the cord. (Sappey.)

- 1, anterior median fissure; 2, posterior median fissure; 3, gray commissure, much thicker here than lower down; 4, white commissure formed by the decussation of the anterior columns; 5, anterior cornu; 6, posterior cornu; 7, lateral cornu.
- 1, anterior fissure; 2, posterior fissure; 3, 3, anterior columns of most authors; 4, 4, lateral columns (these columns in reality pass beyond the anterior cornua, and the anterior columns occupy less space than is here allowed them); 5, posterior columns; 6, posterior commissure (here very narrow); 7, reticulated arrangement of the gray and white matter at the junction of the two cornua; 8, anterior cornua, in which the multipolar cells are distributed into three principal groups; 9, posterior cornu; 10, fifth pair of cervical nerves.

From the gray matter of the cord, bundles may be seen to jut out into the lateral column of either side between the anterior and posterior horns. These are commonly designated as the “*reticular processes*” (*process of Lenhossek*). They do not apparently reach the periphery of the cord, as those that are prolonged into the anterior nerve roots do. It is probable that some of them contain fibers that connect the vesicular column of Clarke with the direct cerebellar column (see Fig. 64).

Passing through the center of the gray commissure, and extending for the greater portion of the length of the cord, may be seen a small canal—the *central canal of the spinal cord*.¹ The shape of the central canal of the cord varies in

¹ This canal is continuous, above, with the *fourth ventricle* of the brain; and the aqueduct of Sylvius is considered by some anatomists as a continuation of it above the

cross-sections made at different levels. In the cervical segments it is oval, in the dorsal circular, and in the lower segments heart-shaped or T-shaped. Its transverse diameter is greater in the cervical and lumbar enlargements than elsewhere. That portion of the gray commissure which lies in front of this canal is sometimes called the "*anterior gray commissure*," while the portion which lies behind it is called the "*posterior gray commissure*." In front of the gray commissure a band of white nerve substance connects the two

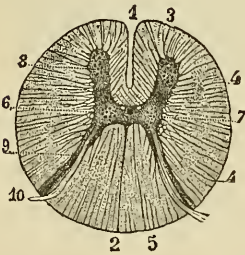


FIG. 166.—Section from the dorsal region of the cord. (Sappey.)

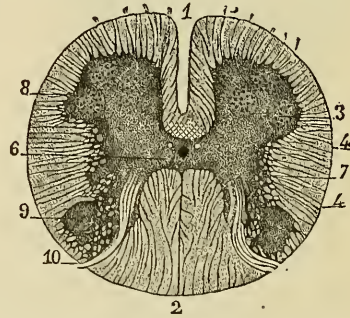


FIG. 167.—Section of the lumbar enlargement of the cord. (Sappey.)

- 1, anterior fissure; 2, posterior fissure; 3, anterior column situated within the corresponding cornu, and decussating in the median line with the column of the opposite side; 4, 4, lateral column reaching to the anterior column, but separated from it by no distinct line of demarkation; 5, posterior column; 6, 7, section of the columns of Clarke, situated at the two extremities of the gray commissure, at the junction of the anterior and posterior cornua, and containing large multipolar cells; 8, anterior cornu; 9, posterior cornu; 10, posterior root of dorsal nerves.
- 1, anterior fissure; 2, posterior fissure; 3, 3, anterior columns of most authors; 4, 4, lateral columns of most authors; 5, posterior column; 6, gray commissure and central canal, and, to the right and left of the latter, the orifices of two longitudinal veins; 7, reticulated arrangement of white and gray matter; 8, anterior cornu; 9, posterior cornu; 10, posterior root of the lumbar nerves.

lateral halves of the cord, to which the term "*anterior*" or "*white commissure*" is applied. In the cervical segments of the cord the white commissure is thicker than the gray, but the reverse is the case in the dorsal and lumbar segments.

The posterior horn divides the lateral half of the cord into two great subdivisions, the one lying anterior to it being

fourth ventricle. It presents a pouch, the "*ventriculus terminalis*" of Krause, at the lower extremity of the cord. Below this pouch it diminishes in caliber, and is prolonged into the "*filum terminale*." It is lined with epithelium throughout.

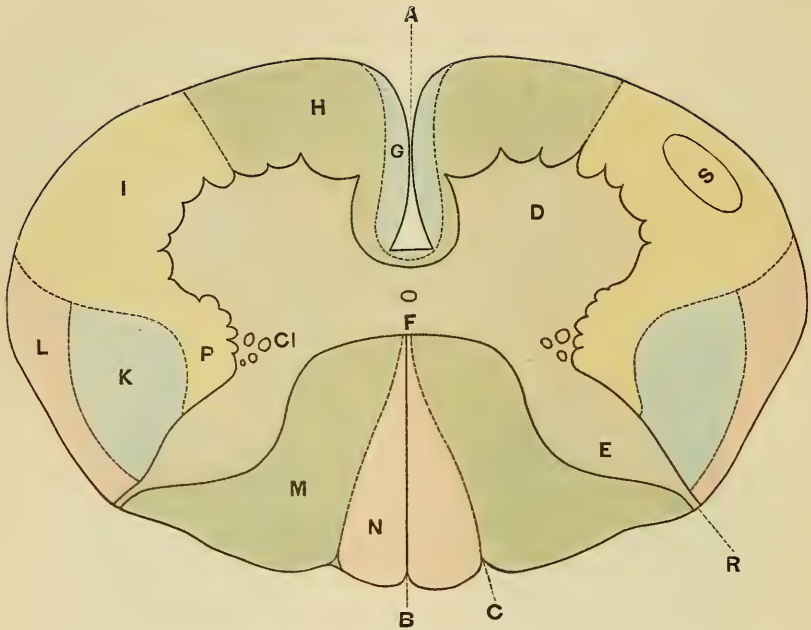


FIG. 168.—Diagram illustrating the relations of the nerve-fiber tracts in the spinal cord. The section is supposed to be taken transversely through the lower part of the cervical enlargement. (Modified from Flechsig and Hammond by the author.)

- A. Anterior Median Fissure.
- B. Posterior Median Fissure.
- C. Intermediate Fissure.
- D. Anterior Gray Cornu.
- E. Posterior Gray Cornu. The large part is called the "Caput," and the constricted part the "Cervix."
- F. Gray Commissure, with Central Canal.
- G. Direct Pyramidal Tract (Flechsig), or Column of Türk.
- H. Fundamental Part of the Anterior Column (Anterior Root Zones of Charcot and his pupils).
- I. Anterior Part of Lateral Column.
- K. Crossed Pyramidal Tract of Lateral Column.
- L. Direct Tract from Lateral Column to Cerebellum. By some, this tract is believed to extend forward to H.
- M. Column of Burdach, Posterior Root Zones of Charcot and his pupils, Funiculus Cuneatus, Postero-External Column.
- N. Column of Goll, Funiculus Gracilis, Postero-Median Column.
- Cl. Vesicular Column of Clarke.
- S. Sensory Tract of Lateral Column, according to view of Gowers, Woroschiloff, Ott, and others.
- P. Reticular Process, to left of letter, adjacent to the Cells of Clarke's Column.

The posterior columns of descriptive anatomies include the fields M and N extending on the surface from B to R. The antero-lateral columns extend on the surface from R to A. Their anterior division includes the fields G and H; their lateral division, the fields K, L, and I.

frequently called the *antero-lateral column*, and that posterior to it being known as the *posterior column*. In the colored diagram it will be perceived that the simpler anatomical divisions of the cord have been modified by pathological researches, so that special regions in each are now designated. Some of these are named after the investigator who first discovered their function. Thus, to-day, we more commonly read of the columns of Goll,¹ of Türck, of Burdach,² and of the "anterior root zone" and the "posterior root zone," than of the anatomical terms with which you are doubtless more familiar. This is not without benefit to those who expect to master the mechanism of the symptomatology of the more important types of spinal diseases, although it may for a while tend to confuse them. The situation of lesions within the cord can be thus more simply expressed than by the use of terms which are inadequate to convey the idea. The older anatomical subdivisions of the cord are fast becoming obsolete terms with the neurologist, since they are based upon a purely structural foundation, irrespective of the physiological functions of the different parts.

A few words of explanation of this diagram (Fig. 168) will assist you, I trust, in mastering these new terms. You will perceive that the gray matter is shown with its two anterior and two posterior horns (D and E); and that the antero-medial and postero-medial fissures separate the cord into two lateral halves. In the anterior part, lying on each side of the antero-medial fissure, are seen the "columns of Türck" (G). These are also called the "direct pyramidal columns," because the nerve fibers which form them pass through the anterior pyramid of the medulla and to the cerebral hemisphere without decussation. On either side of these columns, extending backward toward the line of the transverse com-

¹ The "column of Goll" is described under the following names: The funiculus gracilis; posterior internal column (Grassett); internal tract of posterior column; marginal funiculus (Gratiolet); postero-medial column (Gowers); dark posterior column (Goll).

² The "column of Burdach" is described under the following names by different authors: The posterior root zone (Charcot); postero-external column (Gowers); funiculus cuneatus; external fascicle.

missure of the cord, are the two regions (H) which, from their relation to the anterior roots, are called the "anterior root zones."¹ As we pass still farther backward, we next meet the two lateral columns (I), which, as you will see, are limited behind by the posterior horns of gray matter.

This lateral column is further subdivided into the "direct cerebellar column," the "crossed pyramidal column," as shown in the diagram, and an unnamed portion.

Behind, and adjoining the posterior horns of gray matter, you see two portions (M), the posterior root zones, or the "columns of Burdach"; while upon either side of the postero-median fissure lie the "columns of Goll" (N).

The "posterior column" of the ancient classification, with which you are familiar, comprises the "columns of Goll and of Burdach."

The "COLUMNS OF TÜRCK," or the "*direct pyramidal column*," contain motor fibers that can be traced directly upward to the cerebral hemisphere of the same side.

The "CROSSED PYRAMIDAL COLUMNS," on the other hand, are composed entirely of motor fibers that are associated with the opposite cerebral hemisphere. These fibers are found to decussate within the substance of the medulla at its lowest part, and then to pass upward, in connection with those fibers that compose the column of Türck of the opposite lateral half of the cord. These two strands help to form the so-called "anterior pyramids" of the medulla. Fig. 169 will help to render the course of these two bundles of fibers more intelligible to the general reader. From both the direct and crossed pyramidal columns, fibers are constantly given off to the motor cells in the anterior horns of the spinal segments; hence they become smaller and smaller from above downward, until at last Türck's columns disappear entirely.

The crossed pyramidal column varies in position as well as in size in the different segments of the cord. In the cervical enlargement it occupies a large triangular area in the posterior half of the lateral column, but it does not reach the

¹ Called also the *anterior fundamental column*.

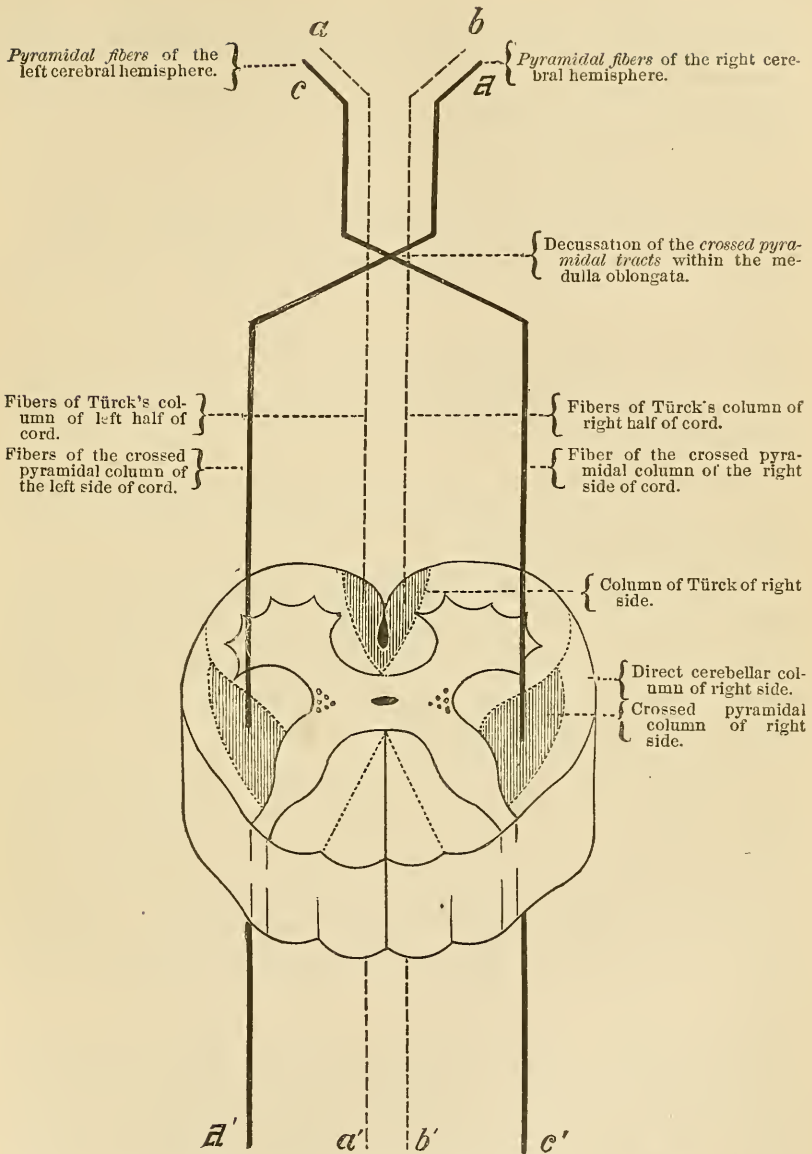


FIG. 169.—A diagram designed by the author to show the areas of the crossed and direct and crossed pyramidal tracts in a section of the spinal cord, and the fibers that compose each.

a and *c*, the pyramidal (motor) fibers going from the left cerebral hemisphere to the spinal cord; *b* and *d*, the same of the right cerebral hemisphere. Above the decussation, the crossed pyramidal bundles lie nearest the median line. The diagram in this respect is incorrectly drawn.

surface of the cord. It diminishes in size as it passes downward, and ends in the lumbar enlargement, where it reaches the periphery of the cord. It is unquestionably the *chief path for voluntary motor impulses* which are sent out from the brain to the extremities or trunk.

The deductions of Schultze, of Heidelberg, respecting the motor tracts are based upon a study of descending degeneration after compression myelitis in five cases. They are as follows :

1. The degeneration was not confined exclusively to the direct and crossed pyramidal tracts. It invaded also the lateral and anterior column for a distance of from eight to ten centimetres.

2. The short fibers (thus demonstrated to exist) probably act as commissural fibers for adjacent spinal segments, and carry centrifugal impulses.

3. The fibers which lie closest to the gray matter in the lateral column fail to degenerate in either direction. They probably are nourished by a cell at either end, and are believed by this observer to constitute a component part of the reflex arcs of spinal automatism.

The ANTERIOR ROOT ZONE is that part of the anterior column which is not occupied by the direct pyramidal fibers (those of Türck's column). It seems to be composed of fibers which are destined to enter the anterior roots of the spinal nerves, and possibly also of commissural fibers that serve to connect the anterior horns of the different segments of the cord.

The LATERAL COLUMN of each side (exclusive of the crossed pyramidal tract and the direct cerebellar column) is not yet well understood as regards its construction or functions. It contains vaso-motor and inhibitory fibers, and possibly acts as a tract of sensory conduction (Gowers, Woroschiloff, Ott, and others).

The DIRECT CEREBELLAR COLUMN first appears in the upper part of the lumbar enlargement of the spinal cord and increases in size as it passes upward toward the brain. It

seems to receive fibers which pass from a group of cells, called Clarke's vesicular column (Fig. 170). The fibers of which the direct cerebellar tract is composed are believed to pass to the superior vermiform process of the cerebellum directly—i. e., without the intervention of any nodal masses of gray matter.

The course of these fibers through the restiform body of the medulla and their ultimate termination have been considered in the previous section.

The POSTERO-INTERNAL, or GOLL'S COLUMN, is composed chiefly of long and short fibers derived from the posterior horn of gray matter and the gray commissure. It is probably associated with the *conduction of tactile sensations from the legs* upward to the brain.

The POSTERO-EXTERNAL, or BURDACH'S COLUMN, is composed (1) of fibers derived from the posterior roots of the spinal nerves passing inward to join the posterior horn, (2) of fibers that *convey tactile impressions from the upper limbs* to the brain; and (3) possibly of *commissural fibers* which connect the posterior horns of the various spinal segments.

Ott believes that all the sudorific and inhibitory fibers of the spinal cord decussate, as well as the motor, sensory, and vaso-motor fibers. He places the tract of the sudorific and inhibitory fibers in the lateral column of the cord, and also some fibers of sensation. He supports the view that the posterior columns are physiologically associated with the transmission of tactile sensations. In reference to the function of the gray matter as a medium of conduction, this experimenter differs from the view of Schiff that afferent impulses may be carried in all directions. It is probable, however, that the paths for reflex action are in the gray matter. He disputes the statement of Brown-Séguard that the anterior columns carry fibers of sensation.

The late researches of Starr in reference to the course of the sensory tracts partly sustain the opinion of Schiff, deduced from experimentation upon animals, viz., that the sensations of touch and of the muscular sense pass upward along the

posterior columns of the cord, and that the sensations of temperature and of pain travel either in the spinal gray matter or the direct cerebellar columns.

He believes that the columns of Goll transmit the impressions of the *muscular sense pertaining to the legs*, and those of Burdach impressions of a similar kind from *the upper extremities*.

He excludes, however, the view that the direct cerebellar columns carry sensations of pain or of temperature, because these tracts do not extend below the first lumbar segment and because they end in the cerebellum. Lesions of this ganglion have never been shown to cause defective appreciation of pain or of temperature. He therefore places the paths of conduction of these two varieties of sensations in the spinal gray matter.

Respecting the function of the direct cerebellar columns, this author advances a hypothesis that centripetal impulses from the organs within the great cavities of the trunk are conveyed by these columns to the cerebellum and excite (in the reflex centers of this ganglion) the impulses necessary to their normal functions. He supports this view from three standpoints, as follows :

1. An anatomical one, because the limits of the direct cerebellar columns coincide with the entrance into the cord of the nerves associated with the thoracic and abdominal viscera.

2. Because lesions of these columns are attended with irregular action of the functions of the viscera ; as, for example, gastric crises and habitual constipation.

3. Because lesions of the cerebellum have been shown to give rise to functional disturbances of the abdominal viscera ; such as indigestion, vomiting, obstinate constipation, polyuria, albuminuria, etc.

Schultze has carefully studied the results of five cases of compression myelitis with special reference to the secondary degeneration, which was thus induced within the motor and sensory spinal tracts. His published conclusions regarding the sensory tracts may be summarized as follows :

1. Degeneration of the posterior columns was of the ascending type, and was confined to the columns of Goll when all the nerves below the eleventh dorsal were severed from their indirect connection with the brain through the cord.

2. That long and short fibers exist in the posterior columns. The longest centripetal fibers of the spinal cord lie in the columns of Goll in its inner and posterior part.

3. That the fibers for the sciatic nerves lie nearest to the median line and farthest back in Goll's columns. That those of the crural nerves are packed next to these, and bound there both anteriorly and laterally. Finally, that the dorsal nerves fill up the remainder of Goll's column and a part of Burdach's column.

4. The short fibers of Goll's column probably end in the spinal segments. The long fibers are prolonged to the medulla.

5. Some fibers of the posterior nerve roots descend after entering the cord for a distance of two or three centimetres.

6. He places the anterior limits of the direct cerebellar columns farther forward than Flechsig, and states that they reach the point where the fibers of the anterior nerve roots escape.

7. The columns of Burdach contain all the fibers which enter the cord from the posterior roots of the cervical nerves, as well as some from the dorsal nerves.

8. The fibers of the direct cerebellar appear to undergo complete degeneration only after a lesion which lies above the last dorsal segment.

Much of our knowledge of the course of fibers within the spinal cord is no longer speculative. Flechsig has shown that definite tracts of fibers within the spinal cord are *developed at different periods*, as the cut introduced (Fig. 170) clearly demonstrates, and also that the relative proportion of motor fibers within the direct and crossed pyramidal fasciculi varies with individuals.

We know also that *secondary degeneration* of nerve-tracts occurs when they are *cut off from their so-called "trophic centers"* by traumatism or disease-processes. This degenera-

tion always (?) progresses in the *direction of the currents that are conveyed by the fibers* whose nutrition is affected;¹ hence it progresses downward in the motor tracts and upward in the sensory tracts.

Finally, experimental physiology has now determined many facts with an approach to accuracy that were long in dispute, and has thus aided us in properly interpreting symp-

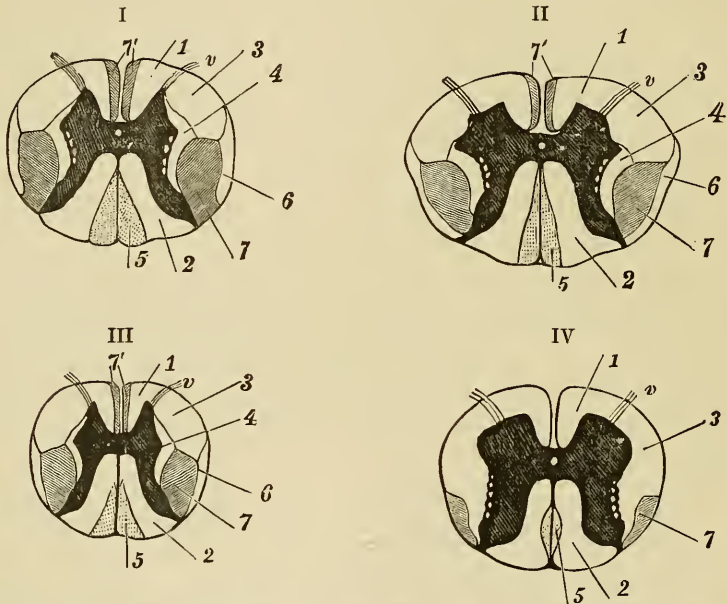


FIG. 170.—A diagram illustrating the development of the different systems of fibers in the spinal cord. (Flechsfig.)

I, section at level of third cervical nerves; II, at level of fifth cervical; III, at level of sixth dorsal; IV, at level of fourth lumbar nerves; 1, principal mass of anterior columns; 2, Burdach's columns; 3, lateral columns; 4, lateral boundary of gray substance; 5, columns of Goll; 6, direct cerebellar columns; 7, crossed pyramidal columns; 7', Türk's columns; v, anterior roots. Note that Türk's columns disappear in IV; that Goll's columns increase in size from below upward; that the direct cerebellar columns appear in III, and increase in size in II and I; that the crossed pyramidal columns reach the surface in IV; and that the shape of the gray substance differs in all the sections.

toms referable to spinal disease. We are now enabled to state positively that the "columns of Goll and Burdach," as well as the "direct cerebellar column," conduct centripetal or sen-

¹ Spitzka advances some pathological observations to prove that this rule has some apparent exceptions.

sory impulses, while the "columns of Türk" and the "crossed pyramidal tracts" conduct centrifugal or motor impulses. Some portions of the spinal cord are, however, still in dispute, because their special functions are not as yet definitely ascertained.

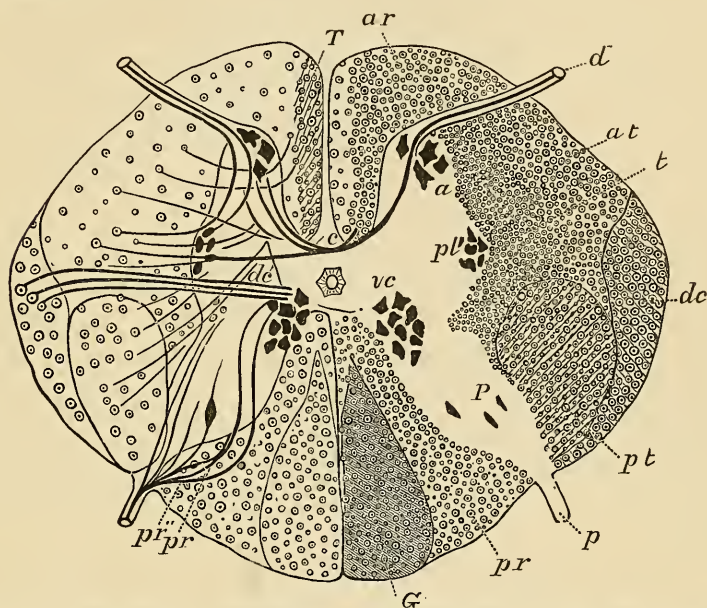


FIG. 171.—Diagram of a transverse section of spinal cord in upper half of dorsal region. (Flechsig.)

c, anterior commissure; *dc*, fibers which pass from the vesicular column of Clarke (*vc*) to the direct cerebellar tract; *P*, posterior horn; *Pt*, crossed pyramidal column; *T*, direct pyramidal columns; *dr*, direct cerebellar tract; *ar*, internal part of anterior root zone; *ar'*, external part of same; *pr*, posterior root zone; *G*, columns of Goll; *fr*, reticular formation of spinal cord; *a*, anterior horns.

The cut of Flechsig's now introduced will enable you to grasp the general direction and distribution of some of the fibers of the spinal cord. It shows (1) the cut ends of the fibers which make up the mass of the various columns, and (2) the course pursued by the motor and sensory fibers which join the cord at the level of the section. Although this cut is purely diagrammatic, it is admirably devised to bring out certain salient points in spinal architecture, to which reference will be made later. The descriptive text of the cut will render it intelligible to the reader.

FUNCTIONS OF THE SPINAL CORD.

These questions may naturally arise in reference to the previous pages: Why is such a digression from previously accepted terms so universally used, in preference to those more familiar and, possibly, simpler terms of nomenclature? Why should the columns of Türk, Goll, and Burdach be separated from each other when no anatomical line of division seems to have been created? Is the arrangement not a strained attempt to mystify and confuse the medical reader, and does a sufficient ground exist for so great a departure from previous methods of description? In reply to such anticipated questions—and they have been asked of me many times—I would respectfully draw your attention to such points in the physiology and pathology of the spinal cord as will help to show the necessity which existed for modification of previously familiar terms, as well as the advantages which are gained by those subdivisions of the cord which are accepted to-day by every specialist on nervous diseases.

In order to properly appreciate many of its functions, the spinal cord must be regarded as a mass of *superimposed segments united together*, rather than as an individual whole. Each spinal segment consists of a disk of the spinal cord with one pair of spinal nerves attached. Such a segment is, to all intents and purposes, an independent structure under certain circumstances. The following diagram will illustrate the construction of a spinal segment.

It will be perceived that each disk of the spinal cord has attached to it one pair of spinal nerves. These arise from it by an anterior or motor, and a posterior or sensory root. Upon the latter is a *ganglionic enlargement*, as is usually the case with all nerves that are sensory in function. It will be seen that the two roots unite to form a so-called spinal nerve; hence every spinal nerve possesses motor and sensory fibers. Some sympathetic or vaso-motor fibers are also present in spinal nerves. These are not shown in the diagram.

Each spinal segment is connected by means of its nerves with definite areas of the body. It is capable of receiving sensory impressions from these areas by means of its pos-

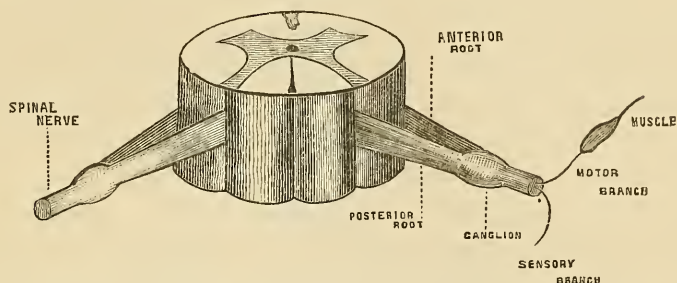


FIG. 172.—Diagram of a spinal segment designed by the author to show its component parts.

terior roots, and of transmitting in return motor impulses to them by means of its anterior roots. The gray matter of the spinal segment, by means of the nerve cells imbedded within it, can therefore be, under some circumstances, an agent of automatic reflex movement in response to some sensory impression received from without (Fig. 173).

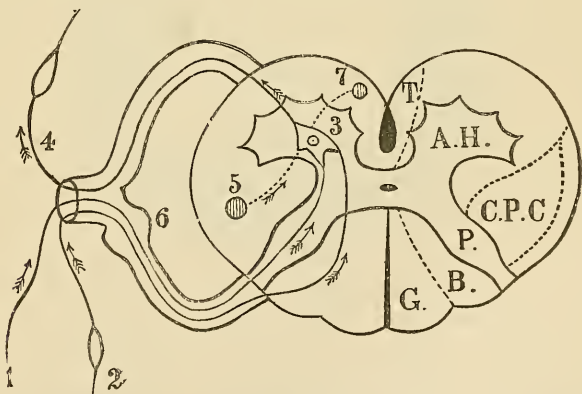


FIG. 173.—A diagram designed by the author to illustrate the circle of reflex action in a spinal segment. (Modified from Bramwell.)

1, sensory fibers from skin, tendons, joints, etc.; 2, sensory fibers from muscles; 3, motor cell of anterior horn of spinal gray matter (A. H.), joining with 1 and 2; 4, motor fibers given off from 3, and escaping by anterior root to supply the muscles; 5, fiber joining ganglionic cell (3) with the crossed pyramidal tract (C. P. C.) coming from the brain; 6, ganglion on posterior root of spinal nerve; 7, fiber joining 3 with Türk's column (T). It will be noticed that some sensory fibers (2) reach 3 by passing through Burdach's column (B), while others (1) pass through the posterior horn of gray matter (P) to reach the ganglionic cell (3).

It often becomes necessary, when disease of the spinal cord is suspected, to test the excitability of the different segments of the cord separately, either by stimulation of the skin of different regions or by increasing the tension of certain muscles by a blow upon their tendons, after they have been partially put upon the stretch. The muscular reactions that ensue are known as the "superficial" or "skin reflexes," and the "deep" or "tendon reflexes." They will be discussed later.

The spinal segments are connected (1) by certain nerve tracts that pass uninterruptedly to the brain (Fig. 174), and (2) by certain commissural fibers that simply serve as connecting links between different segments along the chain. The admirable diagrams of Bramwell, which I have modified somewhat, illustrate many points in the physiology of the spinal cord better than a long verbal description.

It will be seen in Fig. 175 that the motor tracts composing the column of Türck and the crossed pyramidal tract of each lateral half of the cord (if traced upward in the diagram) become united in the medulla (one decussating and the other not) and then pass to the cerebrum. Each of these subdivisions of the motor tract gives off branches to the gray matter of each spinal segment. These branches unite with the motor cells of the anterior horn of the corresponding side—probably through the network of Gerlach (Fig. 160). Subsequently these branches are continued from the bodies of the motor cells to the anterior root of the spinal nerve of the same side, as the "axis-cylinder process" of each cell. The motor tract derived from the cerebrum, therefore, is *constantly depleted*, in regard to the number of fibers of which it is composed, as it descends the cord. It finally terminates in the motor cells of the last spinal segment. By the interpolation of a motor cell for each fiber in the conducting path from the brain, every spinal segment is enabled to exert an *automatic action* upon the muscles supplied by its motor filaments; yet, at the same time, the brain can overpower this automatism when necessary, by means of its connection with

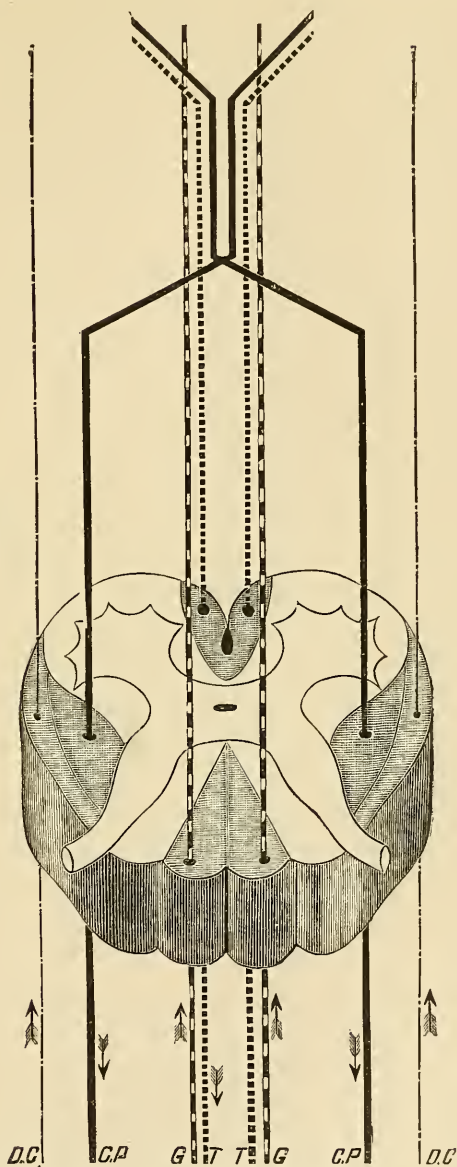


FIG. 174.—A diagram designed to illustrate the paths of motor and sensory conduction in the spinal cord. (Modified from Bramwell.)

D. C., direct cerebellar tracts; C. P., crossed pyramidal tracts; G., sensory tracts of the columns of Goll; T., direct pyramidal tracts, or those of Türk's columns. The arrows show the *direction* of the conduction, two being centripetal or sensory, and two centrifugal or motor.

the spinal cells, and exercise its control over the same muscles independently of the spinal segment. In some forms of disease, in which the controlling influence of the brain is impaired or destroyed, the spinal segments (left free to act without restraint) give rise to an exaggeration of the tendon-reflexes. This condition is of great clinical interest.

In disease of the spinal cord, all the muscles associated with the segments of the cord attacked are in some cases not equally paralyzed or atrophied; thus demonstrating that some are more easily disturbed by central influences than others. Allen has collected several reported cases of special interest in this connection: That reported by Charcot and Jeffroy of infantile paralysis, followed by death in the fortieth year, exhibited atrophy of both psoas muscles, the pectoralis major, deltoid, and triceps of the left side, and the deep flexors of the fingers of the right side. A case reported by Barth showed an atrophy of the supinators of the left forearm, and the quadratus femoris and gastrocnemius of both sides. Vulpian mentions a case in which all the muscles of the right leg, except the extensor communis digitorum, were fatty; in the thigh, the rectus femoris and the vastus internus were fatty, and the vastus externus was not.

Certain clinical facts can be adduced to support the view that the extensor nerves are associated with centers within the cord that become exhausted under depressing influences, as in the case of lead and diphtheritic poisoning, sooner than the centers governing the flexors. It is also well recognized that the flexor muscles are the chief agents in producing various forms of post-paralytic contracture and deformity. When descending degeneration exists high up in the fibers of the crossed pyramidal columns, the arm gradually becomes flexed upon the chest, the forearm becomes flexed upon the arm, and the hand flexed upon the forearm. Subsequently the lower limbs exhibit similar effects of muscular contracture. The normal excess of power of the flexors over the extensors may partly explain the characteristic deformities that ensue when the fibers of the lateral columns are involved in

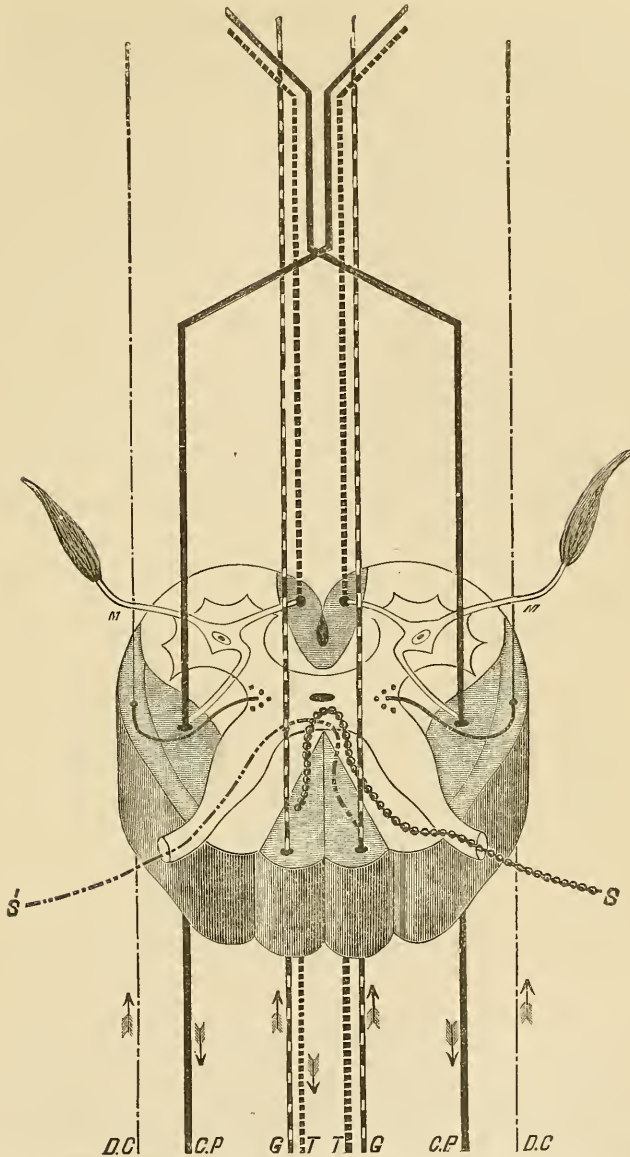


FIG. 175.—A diagram designed to illustrate the connections of the motor and sensory conducting tracts with the spinal nerves. (Modified from Bramwell.) The lettering is the same as in Fig. 174.

M, motor fibers of the anterior root of a spinal nerve; S, S', sensory fibers of the posterior root. Note that the course of S and S' are not the same. Some sensory fibers pass through the posterior horn of the spinal gray matter, and others through Burdach's column. The direct cerebellar column is connected with Clark's column of cells. The two pyramidal tracts are united with the motor cells of the anterior horns of the spinal gray matter.

degenerative processes, but we are forced to recognize also a peculiar susceptibility of the extensor nerves to impairment of their function from causes that do not affect the flexor nerves to the same degree, if at all.

The diagram (Fig. 175) represents the *sensory nerve fibers* as undergoing a total decussation and passing upward to the brain in the column of Goll of the opposite half of the spinal segment. It shows that the sensory nerve fibers pass first from the posterior root to the column of Burdach; and, after traversing its substance, a decussation by means of the gray commissure of the cord takes place. Now, this arrangement probably admits of some modification. It is by no means proved, as yet, that all of the sensory fibers of the cord decussate. Those which convey impressions of the

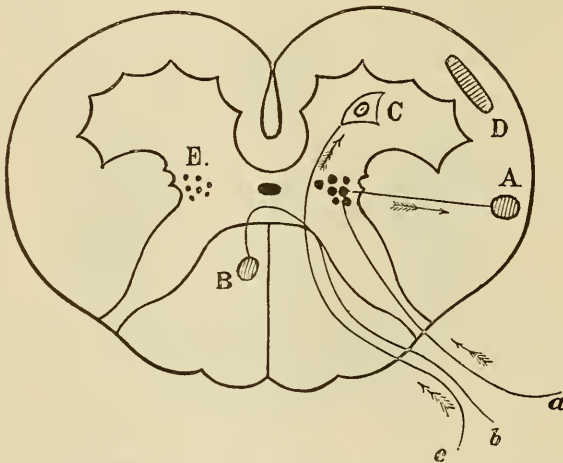


FIG. 176.—A diagram designed by the author to represent the various paths of sensory conduction in the cord.

A, direct cerebellar column, receiving fibers from Clarke's column (E) of the same side; B, Goll's column, receiving fibers from the opposite nerve root by means of the posterior gray commissure; C, ganglion cell of anterior horn joining with its sensory fibers; D, sensory tract of Woroschiloff, Gowers, and Ott, in the lateral column of the cord. The connections of this tract (if it exists in the human species) are not known.

muscular sense probably do not, until they reach the medulla. Again, it is still a matter of uncertainty where the main sensory tracts can be definitely placed, and whether more than one may not exist. Finally, some clinical facts as

well as those lately obtained by experimentation favor the view that the sensations of pain, touch, and temperature do not follow the same paths of conduction in the spinal cord. It is highly probable that all the sensory nerves eventually decussate, but it is believed by many physiologists of the present day that some of the sensory fibers ascend for a greater or less distance within the substance of the corresponding lateral half of the cord before they cross to the side opposite to that upon which they entered it. Some authorities also believe that the sensory nerves connected with the tendons, muscles, and fasciæ pass through Burdach's column of the same side, while those connected with the skin traverse the gray matter of the posterior horn. They thus endeavor to explain the abolition of the deep or tendon reflexes in locomotor ataxia, because that condition is characterized by a change in the columns of Burdach that would tend to impair the conduction of any filaments passing through its substance.

We may, therefore, draw the following deductions :

1. The fibers of the nerve roots eventually pass to and enter the gray substance of the cord, but not by the same channels in all cases. In the case of the posterior roots, some fibers probably form an exception to this rule.

2. The fibers of the anterior roots become joined to the processes of the nerve cells of the gray matter. This statement can not be made with the same degree of positiveness in respect to the fibers of the posterior root.

3. From the ganglion cells of the gray matter the fibers of the anterior roots are connected with the brain through the white matter of the cord by one of three channels: 1. By entering the lateral columns of the same side (the so-called crossed pyramidal column). 2. By entering the anterior column of the same side (the column of Türck). 3. By passing to the opposite anterior and lateral columns through the white commissure of the cord (decussation within the cord). Fig. 175 shows the first two, and Fig. 171 the third, in a diagrammatic way.

4. The processes of the ganglion cells of the cord take every variety of direction. Some anastomose with other cell-processes of the same side; some join with those of the opposite half of the cord, by means of the gray commissure; some unite directly with the fibers of the nerve roots; some are associated with the fibers of the main conducting tracts that are connected with the brain; while a few pass into the white columns of the cord and then appear to ascend within them.

5. Individual fibers of the anterior and posterior nerve roots probably meet each other indirectly by means of the processes of the nerve cells.

6. A few fibers of the anterior roots appear to traverse the gray substance and then to pass into the anterior part of the lateral column. Their function is not known.

7. The fibers of the posterior roots probably reach the cells of the posterior horn by means of a network of fibers.

8. Fibers pass from Clarke's column of cells (Fig. 176) to the direct cerebellar column of the same side.

9. Some medullated fibers appear to rise directly from Gerlach's network of fine fibers, rather than from a spinal cell directly.

Brown-Séquard was led to believe that the paths of the so-called "muscular sense" entered at the anterior nerve roots and passed up in the anterior columns of the gray substance of the cord. As this is not now regarded as true, it is not to be classed as an exception to all other paths of sensory conduction. It is probable that the fibers concerned in the sensation of muscular sense do not decussate within the cord (Schiff and Brown-Séquard). These fibers assist to form the so-called "pinniform decussation" of the medulla (Starr).

Let us now consider, more in detail, the various functions of the spinal cord.

I would call attention first to the fact that the spinal cord is an *organ of conduction*. All voluntary motor impulses, which affect the muscles of the different parts of the body, are unquestionably transmitted from the brain through the cord to the part destined to be acted upon. We know that

centrifugal impulses may be created in the cord itself, and may also be transmitted from the brain. We see this illustrated in the hemiplegias of cerebral origin and in the spinal reflexes. We also have equally positive proof that certain sensory impressions are conducted by means of the spinal cord to the brain; hence, centripetal impulses or impressions pass upward in some instances throughout the entire length of the cord. We see this fact verified in the hemi-anæsthesia which often accompanies motor paralysis of cerebral origin. Now, it can be stated, with an approach to accuracy, that it is as certainly proved that the *motor impulses* travel along the *anterior half* of the spinal cord, while the path of *sensory impressions* is intimately associated with the *posterior half* of the spinal cord.¹

I would direct attention, in the second place, to the fact that the motor fibers associated with the anterior roots probably do not decussate² until they reach the medulla oblongata, while the sensory fibers found in the posterior roots probably ascend in the columns of Burdach for a short distance only, when they pass into the gray matter of the oppo-

¹ This statement is only approximately correct, as has been shown in the text of preceding pages. The postero-median columns (those of Goll) are composed chiefly of long fibers that pass to the medulla, and are believed to convey sensations from the lower limbs only. These fibers can then be traced upward, as shown in diagram 175.

The postero-lateral columns (those of Burdach) are composed of short fibers below the cervical segments, and of long fibers above that level. These pass in part from the posterior roots of the spinal nerves and go to the spinal gray matter. Commissural fibers between the various spinal segments are believed to form a part of these columns. In the cervical region, this column has been shown to contain longer fibers that pass to the medulla. These are supposed by some authorities (Schultze and Flechsig) to convey sensations from the upper limbs.

The direct cerebellar column is unquestionably associated with the transmission of sensory impulses. Its fibers arise from the cells of the column of Clarke. It terminates above in the cortex and central gray matter of the vermiform process of the cerebellum, after passing through the inferior peduncle of the cerebellum.

The gray matter of the cord assists without doubt in the transmission of sensations to the higher ganglia. Whether the hypothesis that sensory fibers are contained in the white substance of the cord that lies between the direct cerebellar columns and the gray matter can be considered as proven is as yet a matter of justifiable doubt.

² As regards this point, Brown-Séquard says, "In animals, there seems to be in the spinal cord itself a decussation of a few of the motor conductors." I do not think, however, that such a decussation can, as yet, be verified in man. If such decussation does exist, it is present only in the *cervical* region, and not in the dorsal and lumbar regions.

site half of the cord. You can, therefore, understand why any interference with the motor fibers (if below the medulla) produces *motor paralysis on the corresponding side*, while any interference with the sensory fibers produces *anæsthesia on the opposite side* of the body.

Again, the *antero-lateral columns* of the cord, which comprise the portion situated between the antero-median fissure and the point of attachment of the posterior roots of the spinal nerves, are not markedly sensible to any form of direct irritation.¹ This is a point of some clinical interest, since, in certain morbid conditions, a marked change in this respect occurs, and the inexcitable portions may then give rise to abnormal sensations and to spasm of the muscles. If these columns be divided, *voluntary motion* is lost in all the parts below the point of section; while, if all the other portions of the cord be divided, leaving the antero-lateral columns intact, the power of voluntary motion remains.

The *gray matter of the cord* seems to be intimately associated with the transmission of certain varieties of *sensory impressions* to the brain, and that portion which lies in close relation to the central canal of the cord is apparently the most important of its transmittory apparatus.² If the entire gray substance of the cord be divided, little or no injury being done to the white substance, all power of perceiving sensations of pain seems to be destroyed below the point of section.

Some late experiments by Woroschiloff, made in Ludwig's laboratory, seem to lead strongly toward the conclusion that the older view of physiologists (who taught that sensations of pain traveled up the cord in the gray matter, and those of touch and temperature in the posterior column of the cord) is perhaps erroneous. Ott has lately confirmed the experiments referred to, and arrived at similar conclusions as

¹ The experiments of Vulpian seem to prove that the internal portion of the anterior column does exhibit a trace of excitability in the normal state.

² The experiments of Brown-Séquard seem to warrant this conclusion. Very little gray matter may, therefore, suffice to convey sensory impressions (chiefly those of pain and temperature).

his predecessor, viz., that such sensations as can be tested in animals pass up the *lateral columns* of the cord in the dorsal region. If this view be true of man, as well as of animals, it must follow that a portion of the lateral column, which is not occupied by the "crossed pyramidal tract," must be associated with sensory conduction. Each lateral column appears from these experiments to contain sensory fibers from both legs. It has not yet been demonstrated that the lateral columns conduct sensory impulses in man.

In addition to its other functions, the gray matter of the cord seems to exert a controlling influence upon the nutrition of muscles and other tissues. When the anterior portion becomes the seat of disease, the muscles often undergo atrophy, and occasionally joint-diseases develop. This so-called "*trophic function*" is not yet thoroughly understood.

Clinical facts seem to prove that the muscles, and possibly the bones and joints also, are controlled, in respect to their nutrition, by the anterior roots of the spinal nerves, while the nutrition of the skin seems to be controlled by the posterior roots.

When the nutrition of a nerve is impaired, its faradaic excitability is proportionately decreased. A stronger current of electricity is then required to create a response in the form of muscular contraction. There exists clinical and pathological as well as experimental evidence to sustain the view that the *motor nerve cells* in the anterior horns of the cord are the so-called "trophic centers" for the motor fibers of the anterior roots and possibly also for the bones and joints. In fact, the *motor nerves may be considered as simple prolongations of the processes of these cells to the muscles*. On the other hand, the *ganglion* of the posterior root seems to be the trophic center for the sensory fibers of each spinal segment; since it has been proven by Waller that these fibers degenerate when the posterior root is severed outside of the ganglion. The pyramidal motor tracts of the cord have their trophic centers apparently in the cells of the cerebral cortex.

The gray matter of the cord is known to embrace several special centers, the two most important of which are the *cilio-spinal center* and the *genito-urinary center*. The former of these is situated in the cervical region, at its lowest part,¹ and exerts an influence upon the pupil of the eye and the skin of the face and neck; hence it is often a valuable guide to determine the height of a lesion in the spinal cord, since the pupils show changes when it is involved that are of value to the diagnostician. The latter center (genito-urinary) is situated in the dorso-lumbar portion of the cord, and often creates symptoms, when disease of the cord exists, referable to the bladder and genital organs. Certain smaller centers, having a vaso-motor function, are described by some authors; but their situation and special functions are either unknown or of little practical utility in diagnosis. The physiological centers of the cord are, as yet, a matter deserving further investigation before any positive statements can be made concerning them.

In certain forms of spinal disease, evidences that the sympathetic or vaso-motor system is involved appear in alterations of the temperature and vascularity of the limbs, and sweating of regions supplied by nerves that are associated with the diseased area or impaired by the lesion. Hyperpyrexia is common with lesions of the cervical enlargement of the cord, if the lesion be of a sudden character. If one lateral half of the cord is affected by a localized lesion, it is not uncommon to meet with unilateral sweating and flushing. This can be attributed alone to the fact that vaso-motor fibers either pass through or arise within the substance of the cord.

¹ The researches of Waller, Budge, and Brown-Séguard would indicate the limits of this center between the fifth cervical and second dorsal vertebrae. It exists in each lateral half of the cord. It presides over the vaso-motor nerves for the vessels of the corresponding eye and side of the face and neck. Vulpius places its limits as low as the fourth dorsal, and Claude Bernard as low as the seventh dorsal, while Schiff carries its limits as high as the medulla itself.

Vulpius's conclusions indicate the *gray matter* of the cord as *positively incapable of excitability*; but he attributes slight excitability to the anterior fasciculi of the cord and great excitability to the posterior columns. In these deductions, he differs somewhat from the results of Chauveau, made, in 1861, upon the domestic animals.

Furthermore, stimulation of the cutaneous surface is capable in health of creating a dilatation of the pupil, but this effect is not usually observed when a spinal lesion has involved the cilio spinal center (Erb).

In the posterior column of the cord, comprising the columns of Goll and of Burdach, there exists a certain amount of *white substance*, one of whose functions seems to be to act as *commissural fibers* between certain portions of the spinal cord. This portion appears to bear some important relation to the *power of coördination*¹ of muscular movement, since disease of this region of the cord is followed or accompanied by disorders of motion, called ataxic symptoms, which are not due to paralysis.

Like the cerebrum, the spinal cord has the inherent power of presiding over certain muscular acts. It is now quite conclusively proved that the automatic acts of walking, standing, swimming, and, to some extent, playing upon musical instruments, dressing, etc., are largely controlled by the spinal cord alone. It is unquestioned that certain of these acts can be made so mechanical that the spinal cord is slowly and painfully educated to perform them without any aid from the cerebrum. It is not probable, however, that the gray matter of the cord has anything to do with the attribute of consciousness.

FIBERS OF THE SPINAL CORD.—There are probably three distinct varieties of fibers within the substance of the spinal cord, exclusive of vaso-motor filaments, viz., motor fibers, sensory fibers, and commissural fibers. Each of these has been already mentioned, and some points of general interest pertaining to their situation and function have been given; but there are some points which must be described more fully before we are able to intelligently discuss the symptoms of spinal affections.

The *motor fibers* are continued into the anterior roots of the spinal nerves after joining with the motor cells of the

¹ The cerebellum has also much to do with the coördination of muscular movements.

anterior horn. They escape from the substance of the cord in the region of the anterior horns of gray matter. If we trace them from the nerve trunk toward the center of the cord, we shall find that they penetrate the anterior horns, and are in immediate connection with the *prolongations of the motor cells* of that portion of the gray matter. Certain motor fibers can be also traced toward the brain as two distinct tracts passing upward in the anterior and lateral columns of the white substance of each lateral half of the cord. Prolongations of the motor cells of the gray matter are now known to be associated with these motor tracts, that ascend to the brain in the white substance. Now, this connection between the motor fibers of the spinal nerve roots and the nerve cells, and the second connection of the same cells with fibers going to the brain, would seem to suggest the hypothesis that the motor impulses are sent first from the brain to the cells of the cord, and from them, through the spinal nerves, to the muscles. When the cord is taught to perform certain automatic acts without the intervention of cerebral action, these cells themselves are the exciting organs of the motor impulses (since they are the elements which are most probably concerned in the reflex movements of the spinal cord). We know that the legs of a frog can be made to perform muscular movements after the head has been taken off, by simply stimulating the sensory nerves; and we see the same reflex movements occurring in paralyzed limbs, which are out of the voluntary control of the brain. To explain these phenomena, we are forced to believe that the motor cells of the cord are capable, when called upon, of performing many muscular acts, some of which would seem too complex for spinal control without cerebral assistance, such, for example, as walking, swimming, playing upon musical instruments, etc. By referring to the cut,¹ where a multipolar spinal cell is magnified, and also to Fig. 178, you will easily understand how these various poles can be connected with one motor, and probably, also, with many sensory fibers; hence, it can be

¹ See Fig. 177 of this volume.

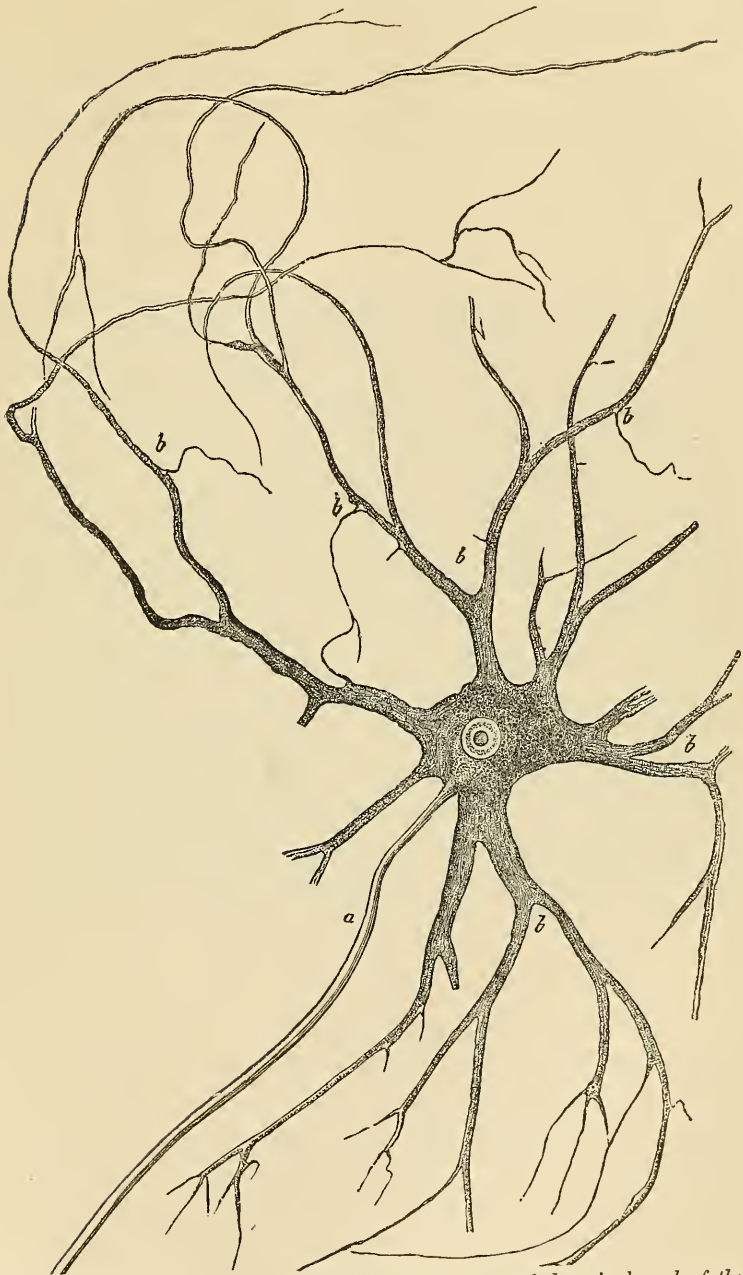


FIG. 177.—*Multipolar nerve cell from the anterior cornu of the spinal cord of the ox; magnified 200 diameters. (Deiters.)*

a, axis-cylinder prolongation, or the motor process; *b, b, b, b, b, b*, branching prolongations, which are probably not motor in function.

seen that the cell may receive certain sensory impressions from some poles and send out certain motor impulses to the muscles by means of its axis-cylinder process, thus accounting for the muscular movements which follow the irritation of sensory nerves.

The *sensory fibers* enter the cord by means of the posterior roots of the spinal nerves. They are intimately connected at first with the posterior horns of the gray matter, although some of them appear to avoid the horn and to enter Burdach's column directly. They probably ascend and descend in the columns of Burdach for a certain distance, and then decussate. The decussation of the sensory fibers is accomplished either by the passing of the fibers themselves to the opposite side of the cord, or by the prolongation of some of the poles of the spinal cells into the gray matter of the opposite side. The decussation probably takes place exclusively in the commissural gray matter. While this decussation seems positively proven by all physiological experiment, little of a positive character has as yet been shown by actual anatomical demonstration. The nerves that carry *sensations of pain* are in communication with the cortex of the encephalon, probably, by means of the gray matter of the spinal cord, which acts as a conducting medium for the centripetal impulses. As before mentioned, the gray matter which *surrounds the central canal* of the spinal cord seems to be an important channel for the transmission of painful sensations and temperature impressions from the trunk and the extremities to the brain. Thus we apparently have in the spinal cord a conducting shaft, to which certain sensory nerves become joined, and which conducts the impressions received through them to the ganglia or the cortex of the encephalon. It is evident, therefore, that some of the sensory nerves are not continuous fibers between the brain and the parts to which they are distributed; in which respect they resemble the motor nerves, whose fibers are indirectly carried to the brain—the motor cells of the cord being probably interposed.

The fibers that convey *painful sensations* appear to traverse the posterior horns of the spinal gray matter, without passing into the column of Burdach.

The *tactile sense* seems to be presided over by fibers that pass from the posterior nerve roots directly into Burdach's column. They probably do not all decussate. Some cross

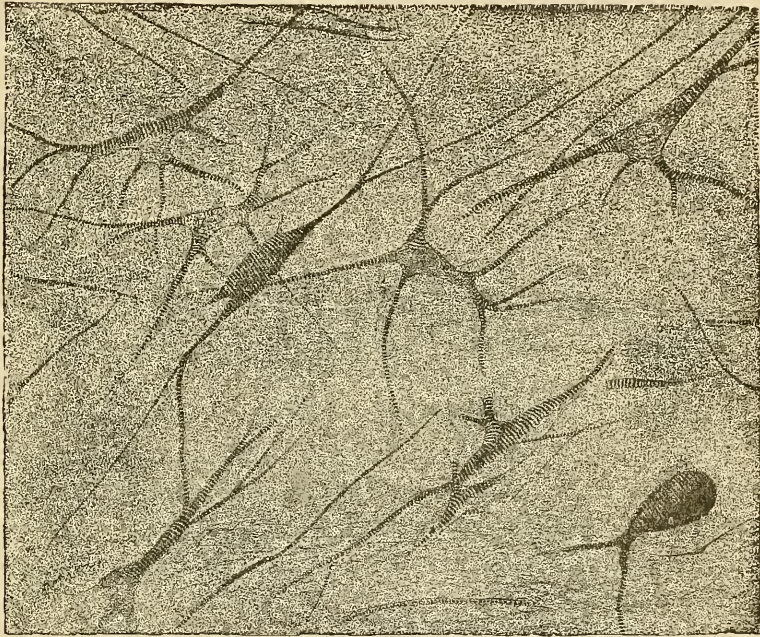

FIG. 178.—*Transverse section of the gray substance of the anterior cornua of the spinal cord of the ox, treated with nitrate of silver. (Grandry.)*

over at once, and others reach the opposite side after ascending for a greater or less distance in Burdach's column of the same side.

Some sensory impressions reach the brain, in animals at least, by means of the lateral columns of the cord. These are not, as yet, well understood.

Finally, the fibers that convey the impressions known as the "*muscular sense*" are now believed to reach the cord by means of the posterior roots of the spinal nerves and to pass upward in the posterior portion of the spinal cord without

decussation. By means of these fibers we are enabled to estimate the amount of muscular force required to perform special acts, as in discriminating between weights, raising a limb to definite heights with the eyes closed, throwing a ball for definite distances, etc. It is thought that the fibers, connected with this sense, do not decussate.

We are forced to admit that our knowledge of the exact seat and function of the various paths of sensory conduction is still somewhat speculative.

The clinical association of ataxia of opposed limbs with a lesion of the *fillet* and the *intercolivary tract* has been observed by Kahler, Meyer, Senator, and Spitzka. These observations have been collected and contrasted with one another by Starr. The latter author is led to the conclusion that the fibers which are functionally related to the *muscular sense* are the *only ones which decussate within the medulla*, and that they do so because they fail to decussate within the cord.

It seems to be well established that sensory impressions of all kinds pass from the posterior nerve roots to the opposite half of the cord, at least partially if not completely. The researches of Köbner appear to demonstrate that the fibers which convey the sensations of pain and temperature decussate at a lower level after entering the cord than do the fibers which convey tactile sensations.

The *commissural fibers* of the cord probably exist in the white substance of the posterior columns.¹ The spinal cord may properly be considered as a mass of superimposed segments; hence, a great necessity exists for certain fibers which shall tend to unite the different parts, and thus conduce to the perfect harmony of action of the whole. It is not possible to demonstrate the existence and exact situation of such fibers, but all physiological and pathological deductions seem to sustain this hypothesis. These fibers have, probably, a

¹ A. Flint, Jr., *op cit.* The experiments made to prove this point may be found in almost any of the later treatises on physiology. Some authors believe that commissural fibers exist also in the antero-lateral columns.

most important influence in the proper coördination of muscular movement.

The diagram (Fig. 179) illustrates, in a very simple way, the general course of the motor and sensory paths of the spi-

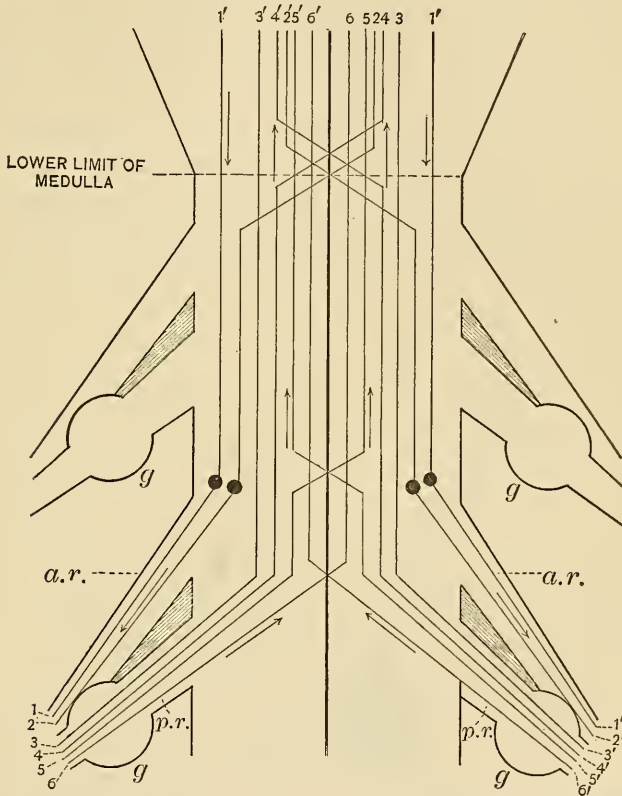


FIG. 179.—A diagram designed by the author to show the course of the fibers which compose the spinal cord.

1, 1', direct pyramidal bundles; 2, 2', crossed pyramidal bundles, decussating in medulla; 3, 3', direct cerebellar fibers; 4, 4', fibers related to "muscular sense," decussating in medulla; 5, 5', and 6, 6', fibers related to the appreciation of touch, pain, and temperature. The motor bundles have a dot upon them to represent the motor cells of the cord (anterior horn). Note that the motor fibers escape from the anterior nerve root (*a. r.*), and that the sensory bundles enter at the posterior nerve root (*p. r.*), which have a ganglion (*g*) upon them.

nal cord. It shows that *both the sensory and motor fibers decussate*; but that the motor fibers and those associated with the muscular sense cross in the medulla oblongata only, while the sensory fibers cross soon after they enter the spinal cord,

when they join with the gray matter, and use that as a means of transmitting their sensory impressions to the brain. The diagram also shows that the sensory fibers spring from the posterior roots of the spinal nerves, since the ganglionic enlargement is depicted upon the sensory fibers.

Now, it is easy to understand, by means of this diagram, why any lesion *above the medulla oblongata* must produce most of its symptoms on the side of the body opposite to that of the exciting cause, since the vast majority of the motor and sensory fibers both decussate below that point; while it also shows that any lesion *below the medulla oblongata* must produce motor symptoms and a loss of muscular sense upon the same side as the lesion. In all spinal lesions,

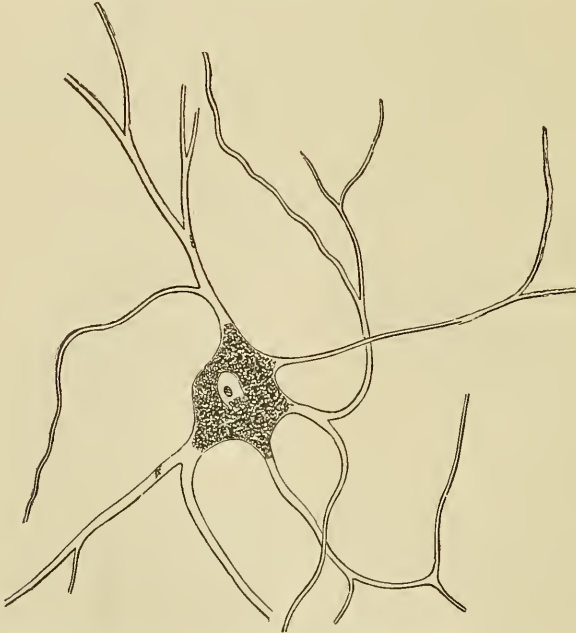


FIG. 180.—Nerve cell from the ferruginous substance which forms the floor of the rhomboidal sinus in man; magnified 350 diameters. (Kölliker.)

causing motor paralysis, the body is affected below the point of disease, because the conducting fibers to the brain are cut off; while, in lesions of the posterior portion of the spinal cord, the nerves of that region may be rendered incapable of

action, but the parts below may be still capable of perceiving sensory impressions, especially those of pain and temperature, provided that the gray matter is left intact, or sufficient of it remains to act as a conducting medium to the brain.

The *commissural fibers* of the spinal cord are not depicted in this diagram (Fig. 179), since little is positively known as to their exact situation or function. As they are probably confined largely to the posterior half of the spinal cord, and as they are also probably intimately associated with the coördination of movement, it is not difficult to see why the symptoms of *anæsthesia* and *ataxia* should march hand in hand, when the spinal cord is diseased in this region; and why *neuralgic pains* should be created by the irritation to the sensory nerves, rather than muscular spasm, which would only exist if the motor nerves were irritated. This general subject will, however, be more fully discussed in connection with the clinical aspects of locomotor ataxia and degeneration of the posterior portion of the cord (the columns of Goll and Burdach).

The *vaso-motor paths* within the spinal cord have been the subject of experimental investigation down to the present time. We know that, if the spinal cord be cut at any point, the arteries below the point of section undergo marked dilatation, and that irritation of the cord creates a contraction of the arteries below the seat of irritation. We are, therefore, justified in drawing the conclusion that the vaso-motor paths carry centrifugal impulses.

As regards their situation within the cord, it seems probable that the lateral columns and the gray matter are traversed by the vaso-motor paths. Whether they decussate or not is an open question. Schiff believes that it can be proved that the vaso-motor nerves for the vessels of the trunk and thigh decussate, but Von Bezold positively denies the statement. One remarkable fact, viz., that the vessels after becoming paralyzed from section of the cord soon regain their natural condition, seems to demonstrate that the cord contains vaso-motor centers throughout its entire length, and that the vaso-motor tracts are not entirely dependent upon the chief center

within the substance of the medulla in the performance of their function. It seems probable that these vaso-motor centers are to be found in the anterior part of the spinal gray matter.

The vaso-motor nerves leave the cord by the anterior nerve roots. Those that are connected with the vessels of the head come from the cervical portion of the cord; those for the upper extremities, from the upper dorsal region; those for the pelvis and lower limbs, from the lower dorsal and lumbar segments of the cord. The splanchnic nerves apparently convey the vaso-motor nerves to the viscera of the abdomen, and the lumbar nerves perform a similar function for the genito-urinary apparatus.

In concluding his exhaustive article upon the localization of the functions of the spinal cord, M. A. Starr¹ gives two tables as a summary of the results of the combined research in that direction to date. I deem them so valuable and explicit that I take the liberty of quoting them in full (pages 588, 589, 590):

LOCALIZATION OF FUNCTIONS IN THE VARIOUS SEGMENTS OF THE SPINAL CORD. (AFTER STARR.)

Segment.	Muscles.	Reflexes.	Sensation.
2d-3d C.	Sterno-mast. Trapezius, Scaleni and musc. of neck.		Neck and back of head.
4th C.	Diaphragm. Supra- and Infra-Spinatus Deltoid. Biceps and Coraco-Brach. Supinator Longus. Rhomboid.	Hypochondrium (?) Dilatation of pupil. on irritation of neck. 4th-7th C.	Neck. Upper shoulder. Outer arm.
5th C.	Deep muscles of shoulder-blade. Deltoid. Biceps and Coraco-Brach. Supinator Longus. Pectorales. Serratus Magnus. Triceps. Rhomboid. Teres minor.	Scapular. 5th C.-1st D. Elbow tendon. 5th-6th C.	Back of shoulder and arm. Outer side of arm and forearm. Ant. upper two thirds of arm.

¹ "American Journal of Neurology and Psychiatry," August and November, 1884.

Segment.	Muscles.	Reflexes.	Sensation.
6th C.	Biceps Brach. Antic. Pectorales. Serratus Magnus. Triceps. Extensors of wrist and fingers. Flexors of wrist. Pronators. Supinator Brevis.	Wrist tendons. Wrist tendons. 6th-8th C.	Outer side of arm and forearm. Inner and front of forearm.
7th C.	Triceps long head. Extensors of wrist and fingers. Flexors of wrist and fingers. Pronators of wrist. Subscapular. Latissimus Dorsi. Teres major.	Palmar. 7th-8th C.	Inner and back of arm and forearm. Radial distribution in the hand.
8th C.	Extensors of thumb. Flexors of wrist and fingers. Intrinsic muscles of hand. Extensors of thumb. Intrinsic muscles of hand. Thenar and hypothenar eminences.		Forearm and hand, median and ulnar distribution.
1st D.	Intrinsic muscles of hand. Extensors of thumb. Intrinsic muscles of hand. Thenar and hypothenar eminences.		Ulnar distribution to hand, little finger.
2d-12th D.	Muscles of back and abdomen.	Epigastric } Skin. { 4-7 D. Abdominal } { 7-11 D Erector Spinæ muscles. Hypochondrium (?) Cremasteric. 1st-3d L. Patellar tendon. 2d-4th L. Bladder and sexual centers. 2d-4th L.	Skin of back and abdomen, and over upper gluteal region.
1st L.	Ilio-psoas. Sartorius.		Skin over groin and front of scrotum.
2d L.	Ilio-psoas. Sartorius. Flexors of knee, Remak (?)		Outer side of thigh.
3d L.	Quadriceps femoris. Adductores femoris.		Front of thigh.
4th L.	Abductores femoris. Extensores femoris. Tibialis Anticus. Peroneus Longus. Flexors of knee, Ferrier (?)	Rectal center. 4th L.-2d S. Gluteal. 4th-5th L.	Inner side of thigh and leg to ankle.
5th L.	Outward rotators of thigh. Flexors of knee (Ferrier). Flexors and Extensors of toes. Peronei. Muscles of calf of leg. Muscles of calf of leg. Long flexor of great toe. Intrinsic muscles of foot. Intrinsic muscles of foot.		Lower part of gluteal region. Back of thigh. Leg and foot, outer part.
1st S.	Muscles of calf of leg. Muscles of calf of leg. Long flexor of great toe. Intrinsic muscles of foot. Intrinsic muscles of foot.	Foot clonus. Achilles tendon. Plantar. Plantar.	Leg and foot except inner part.
2d S.	Intrinsic muscles of foot.	Plantar.	Perineum. Anus.

LOCALIZATIONS OF FUNCTIONS IN THE VARIOUS PARTS OF ONE SEGMENT OF THE SPINAL CORD. (AFTER STARR.)

I. GRAY MATTER.

- | | | | | |
|---------------------|---|--|---|---|
| 1. Anterior horn. | { | Inner group of cells.
Lateral groups of cells
in enlargements.
Median group of cells.
Central group of cells
in enlargements. | { | Fundamental motions common to all
vertebrates, e. g., flexion and exten-
sion of limbs.
Accessory motions peculiar to man,
e. g., fine movements of the
hands. |
| | | | | Motor cells of undetermined function in other regions.
Trophic centers for muscles and motor nerves.
The motor part of reflex and automatic centers. |
| 2. Central portion. | { | | | Ant. part. trophic centers for bones.
Post. part. trophic centers for skin, nails, joints, bladder, vaso-
motor centers.
Complex automatic centers and their association fibers.
Basal part; trophic centers for centripetal tracts.
Tract for transmission of sensations of pain and temperature
from the parts below. |
| 3. Posterior horn. | { | | | Vesicular column of cells; vegetative reflex centers (?).
Posterior group of cells; sensations of all kinds.
The sensory part of reflex and automatic acts. |

II. WHITE MATTER.

- | | | |
|--|----|---|
| 1. Ant. median column. | .. | Motor tract from like-named hemisphere of brain. |
| 2. Anterior column. | { | Association fibers between segments of the cord.
Motor nerve fibers between cells and roots. |
| 3. Lateral column. | { | Association fibers between segments of cord.
Vaso-motor tracts (?). |
| 4. Postero-lateral or
pyramidal column. | { | Motor tract from opposite hemisphere of brain. |
| 5. External lateral or
direct cerebellar
column. | { | Vegetative tract (?). |
| 6. Post. external col-
umn or column of
Burdach. | { | Sensory nerve fibers between roots and cells, except those
forming sensory arc of skin reflex.
Association fibers between segments of the cord.
Sensory tract for touch and muscular sense from the upper
dorsal and cervical regions upward. |
| 7. Posterior median
column or column
of Goll. | { | Sensory tract for touch and muscular sense from the lower
dorsal, lumbar, and sacral regions. The tracts from the
distribution of sciatic nerves lying in the posterior median
portion of the column. |

THE SPINAL CORD AS A NERVE CENTER.

If the cord be separated from the brain in a living animal, it may still act as a nerve center, independently of the brain; but, since the spinal cord is then in communication only with the nerves which arise from it, it can only affect the spinal nerves, and not those of cranial origin. This automatic action of the spinal cord is of a purely *reflex type* under such conditions. It can be demonstrated by exciting some one of the sensory nerves, when a muscular response will be created; hence the term "excito-motor" is often applied to this type

of manifestation, whether occurring during life, as the result of disease or peripheral irritation, or after death, as in the physiological experiment alluded to. There are certain acts which are constantly occurring in the body, such as the movements of the pupils, of the intestinal canal, of respiration, etc., which are properly classed as reflex in type, but which are not dependent upon the spinal cord alone. In fact, all motor acts are classed as belonging to the reflex type, which are the *direct result* of some form of *sensory irritation*; but the term is generally used, in discussing the spinal cord, in its most restricted sense, where the muscular act is purely involuntary, the result of some direct irritation of a sensory spinal nerve, and confined to regions of the body over which the spinal cord exerts a direct influence. Thus, we often see the muscles of a paralyzed limb suddenly thrown into involuntary and unexpected contraction, when a draught of cold air strikes the skin, or when any form of irritation is directly applied to it; while such spasms are common in certain forms of spinal disease which tend to create irritation of the spinal structures, irrespective of any apparent exciting cause.

We have already referred to certain *vaso-motor centers* which exist in the substance of the spinal cord, the two most important of which are the cilio-spinal center and the center for the genito-urinary apparatus. The former of these is situated in the cervical region, and exerts some marked effects upon the eye, face, and neck; while the latter is situated in the dorso-lumbar region of the cord. If the medulla oblongata be considered as the upper expansion of the spinal cord (and there are many anatomical reasons for thus considering it), all the centers mentioned as situated in that ganglion may be included among the spinal centers of automatic action. Some authors have gone so far as to locate in the spinal cord certain centers which preside over the acts of micturition, defecation, parturition, erection, etc., and experiment seems to give reason to hope that a more definite ground will be afforded for such belief, although but little of a positive character can as yet be given in regard to their situation.

The vaso-motor nerves for the trunk, extremities, and abdominal viscera probably originate in different ways (see researches of Vulpian, Schiff, Cyon, Claude Bernard, and the later researches of Dastre, Laffont, and Morat). According to the monograph of Gray,¹ those for the upper extremities are derived (1) from the inferior cervical and superior thoracic ganglion, uniting at the brachial plexus, close to the first rib; (2) from the nerve roots of the brachial plexus; (3) from the thoracic cord of the sympathetic, and from the nerve roots of the third, fourth, fifth, sixth, and seventh dorsal nerves, principally from the third and seventh.

Those for the lower extremities proceed (1) from the spinal cord with the sciatic and crural nerves; (2) from the abdominal cord of the sympathetic.

The abdominal viscera are supplied with fibers arising from a considerable length of the dorsal and lumbar cord, and running within the sheath of the splanchnic nerve, as well as by fibers from the abdominal cord of the sympathetic. The vaso-motor nerves of the head and face take their origin from what is known as the "cilio-spinal center," and when this center is destroyed there ensues a marked dilatation of the capillaries of the head and face.

It has been claimed that the spinal nerves exercise a tonic action over the muscles which move the different portions of the skeleton, in the same way as the vaso-motor nerves exercise such a power over the muscular fibers in the coats of the blood-vessels. Certain experimental phenomena—chiefly the gaping of a wound in muscular tissue—have been advanced to sustain the theory. This view is not, however, fully sustained by all the facts,² and is not generally accepted by the leading physiologists.

From a late lecture,³ I quote the following extract: "We have come to learn that each group of cells—perhaps each cell—in this gray matter represents a certain kind of intelli-

¹ and ³ L. C. Gray, "Annals of Anatomical and Surgical Society," October, 1880.

² For the discussion as to the merits and demerits of this theory, the reader is referred to the late text-book of Michael Foster on physiology.

gence, and that these cells are probably in communication with one another by means of white fibers. It is the sum total of these intelligences that imparts to the cord its characteristics as an organ. As each one of these cellular groups and its inherent intelligence is more or less independent of all others, so the combined intelligence of the cord's gray matter is independent of the combined intelligence of other collections of gray matter; and it is a recognized fact that the spinal cord has a 'function' of its own. This has been exemplified by experiments upon headless frogs and decapitated human beings. Cut off the head of a frog, permit it to recover from the shock of the operation, then pinch its skin, and it will hop away; or, throw it into water, and it will swim. Place a drop of acetic acid upon the belly of such a frog, and it will endeavor to brush away the irritation with one foot. Now amputate the leg of this foot at the knee. The animal will make several futile attempts to reach the irritated spot with the stump, and failing will, after some hesitation, make use of the uninjured limb for this purpose. It is easy to repeat this well-known experiment of Pflüger's.¹ Robin² witnessed some most instructive phenomena in a criminal whose head had been removed an hour previous at the level of the fourth cervical vertebra. The skin around the nipple was scratched with the point of a scalpel. Immediately there ensued a series of rapid movements in the upper extremity, which had been extended upon the table. The hand was brought across the chest to the pit of the stomach, simultaneously with a semi-flexion of the forearm and inward rotation of the arm—a movement of defense, as it were. All this teaches us the more clearly to understand that it is the intelligence of the cord's gray matter that is called into play in a thousand actions that must take place without the aid of that *conscious* intelligence which we call 'mind.' The intelligence of the spinal cells is quite sufficient to enable men to walk, to play on musical instruments, to become experts in

¹ Pflüger, "Die sensorische Function des Rückenmarks," 1853.

² "Jour. de l'Anat. et de la Physiol.," Paris, 1869.

handiwork, to ride on horseback, whether awake or asleep, to become acrobats, and to unconsciously acquire such a handwriting that its minute peculiarities shall be unerringly recognized by the trained eye."

Those forms of reflex action which are independent of the influence of the will or intelligence must be attributed to the gray matter of the cord. We are as yet somewhat uncertain in regard to the paths which serve to convey sensory impressions (received unquestionably by means of the posterior nerve roots) to the ganglion cells of the anterior horns. The histological structure of this part of what is termed the "nervous circle" of a reflex act is not definitely determined. There are supposed to be various connections established between the different paths of sensory and motor conduction of the cord and the special centers that are also known to exist within its substance. An excitation of a sensory nerve may therefore pass, in some instances, to many of the motor paths, or, again, only to one. This depends often upon the strength of the excitation, because the different paths are supposed to afford different degrees of resistance to conduction. Helmholtz has shown that the time required for the perfect elaboration of a reflex act is from twelve to fourteen times greater than for simple motor conduction. We know, clinically, that the degree of reflex excitability differs with individuals in health, and that it is also greatly modified by disease, poisons, and many physiological conditions. An increase in the strength of the sensory irritation, or any condition that tends to diminish the resistance to conduction in the reflex paths of the cord, will necessarily increase the reflex movements proportionately. Again, a sensory excitation may create a response confined to one spinal segment in one individual, and, by a more extensive conduction in the case of another individual, a similar excitation may elicit a response from many spinal segments. Some reflex acts are exceedingly complicated, as, for example, the act of defecation. As, in the case of Robin's experiments upon the beheaded criminal, and those commonly observed in the beheaded frog, purely reflex move-

ments may appear, under certain circumstances, to be adapted to certain ends, as those of self-defense, etc.

Any of the sensitive parts of the body may be employed as a means of exciting reflex movements. The skin is the one commonly employed in the clinical examination of the condition of the spinal segments, when organic diseases of the cord are suspected. The skin of the sole, of the inner aspect of the thigh, of the buttock, of the belly, of the region of the scapula, and of the face, are especially liable to cause reflex movements when subjected to slight irritation by scratching it with a pin or the finger-nail. Again, the sensory nerves of the muscles may be employed as a means of eliciting reflex spinal movements. The muscle to be tested should first be put in a state of moderate tension, and a smart stroke given over its tendon with the edge of the hand or a percussion-hammer. When the irritability of the cord is rendered very excessive by disease, a series of rhythmical movements known as a "clonus" may be excited by simply putting muscles upon the stretch and holding them in that position for a time.

Among the reflex movements that are constantly being excited in health, and which are important aids in the performance of the various functions of the body, may be mentioned the movements of the stomach and intestine, the acts of erection and seminal ejaculation and that of expulsion of the fœtus, the sequence of muscular contractions required in defecation and micturition, and the important reflex processes which occur in the blood-vessels.

The so-called "superficial" or "skin reflexes" and the "deep" or "tendon reflexes" are especially valuable in diagnosis, and deserve a detailed description. I take the liberty of quoting from the third edition of my work on "Surgical Diagnosis" the following extract :

"The 'SUPERFICIAL' or 'SKIN REFLEXES,' which have been referred to, are each performed by different segments of the cord. Thus, stimulation of the skin of the sole of the foot by a scratch, prick, or touch with the nail, for example, induces

the contraction of the foot-muscles (*plantar reflex*) through the lower part of the lumbar enlargement of the cord; the skin of the buttock calls into action the glutei muscles (*gluteal reflex*) through a segment which corresponds to the escape of the fourth or fifth lumbar nerve; the skin upon the inner aspect of the thigh causes the cremaster muscle to draw the corresponding testicle toward the external abdominal ring (*cremaster reflex*) by influencing the cord at the level of the first or second lumbar nerve; the skin upon the side of the abdomen creates reflex movements of the abdominal muscles (*abdominal reflex*) by affecting a segment of the cord situated between the levels of the eighth and twelfth dorsal nerves; the skin upon the side of the chest creates a reflex response in the region of the epigastrium (*epigastric reflex*), which depends upon a spinal segment extending from the fourth to the seventh dorsal nerves; finally, the skin between the shoulder-blades causes the posterior axillary fold or the teres-major muscle to contract (*scapular reflex*) by influencing the spinal segment between the levels of the fifth cervical and third dorsal nerves.

“By means of these reflexes, we are enabled to test the various spinal segments from the neck to the terminal extremity of the cord. Should any be found to be absent, it should be remembered: (1) that the reflex excitability of the cord varies with individuals and is always greater in youth than in old age; (2) that the plantar, cremasteric, abdominal, and epigastric reflexes are variable in health, but are more constant than the scapular; (3) that cerebral lesions may impair them on the side of the hemiplegia, for reasons not as yet well understood; and (4) that systematic lesions of Burdach’s or Goll’s columns tend to diminish or abolish them.

“The ‘DEEP’ OR ‘TENDON REFLEXES’ are also of great value as a means of determining the condition of excitability of different segments of the cord. The ones now commonly employed are called the ‘*foot-clonus*’; the ‘*knee-jerk*’ or ‘*patella reflex*’; the ‘*peroneal reflex*’; and the ‘*tendo-*

Achillis reflex. The method of obtaining these reflexes in the most satisfactory manner will be described separately. It is important, however, to remember one fact in connection with them before deciding as to their clinical significance, viz., that the *reflexes should be tested upon both sides and compared with each other*, because any perceptible differences between the two sides is a probable indication of some pathological lesion of the cord.

“The *knee-jerk* has for years been recognized and employed by Charcot in diagnosis, although it was first systematically investigated as a clinical symptom by Westphal and Erb. Gowers remarks in a late work, ‘It is not a little curious that this knee-jerk, which for generations has amused school-boys, should have become an important clinical symptom.’

“To properly test this reflex movement of the limb, the muscles of the quadriceps extensor tendon must be put upon the stretch to a moderate degree, and the leg be unrestricted in its ability to respond. The common method employed is to have the patient cross the leg over the knee and allow it to hang passively at an angle which is nearly ninety degrees. Perhaps a still better way is that employed by Gowers, viz., to allow it to hang over the forearm of the physician when his hand is placed upon the opposite knee of the patient, because in this way the jerk is often elicited in stout people when it otherwise fails. The space between the patella and the tibia is then struck with a percussion-hammer or the side of the physician’s hand upon the bare skin with sufficient force to slightly increase the state of muscular tension which has resulted from flexion of the leg. This will cause a reflex contraction of the quadriceps extensor muscle, and the foot will be jerked upward without the volition of the patient as a factor in the movement. In about two per cent of healthy subjects, the knee-jerk may be found to be totally absent, in spite of all possible care in employing the test. This fact is important, since the absence of the knee-jerk is too often construed as a positive sign of spinal disease.

“The *ankle-jerk*. If the muscles of the tendo Achillis be put upon the stretch by flexion of the foot, a blow upon that tendon will cause a similar extension of the foot.

“The *foot-clonus*. When the excitability of the cord is excessive, if the foot be firmly flexed and held so by the pressure of the hand against the sole, a series of rhythmical reflex movements of extension follows, which vary between six and ten per second. They can be traced upon a revolving drum by attaching a pencil to the foot, as easily as a sphygmographic tracing is made. This clonus is more apparent when the knee is firmly extended than when flexed.

“The *peroneal reflex*. The tendons of the peroneal muscles pass to the bones of the foot at the outer side of the ankle. A blow made upon them when the foot is bent inward, to produce a moderate degree of tension of these muscles, will elicit a reflex movement, as in the case of the patella tendon.

“The ‘*front-tap contraction*.’ Gowers has described a reflex test for increased spinal irritability that he considers particularly delicate. It consists in flexing the foot with the hand upon the sole, the knee being extended, and applying the blow to the muscles on the anterior aspect of the leg. It is followed by a reflex contraction of the muscles of the tendo Achillis which are not directly affected by the blow.

“Although the deep reflexes are commonly tested only in the lower extremities, the same phenomena may be elicited in the triceps or biceps muscle of the arm as in those of the thigh and calf, if subjected to the necessary position to insure tension of the muscles before the tap is given over the tendon.”

Before we leave the subject of the spinal cord and its architecture, it may be well to consider some of the bearings which anatomy and physiology have upon the clinical recognition of disease confined to this wonderful piece of mechanism.

The hints which are thrown out in the remaining pages of this section must of necessity be crude and incomplete.

CLINICAL POINTS PERTAINING TO THE SPINAL CORD.

From the physiological experiments as to the functions of the different columns of the cord, it now seems possible to divide the spinal cord into two great subdivisions, which will be of interest from a purely clinical standpoint, as well as from a physiological aspect. The first of these includes both pyramidal columns and the anterior horns of the gray matter, and is the probable path of all motor impulses which traverse the cord, as well as the seat of "trophic influences" upon tissues. The latter includes the posterior and cerebellar columns and the posterior horns, and is the probable path of sensory impulses, while it also is associated with the function of coördination of movement. Now, both of these subdivisions include several parts of the spinal cord, which have been separately named in previous pages; hence, the term "system" is applied to both, the former being named the "*kinesodic system*," and the latter the "*æsthesodic system*." These names will be constantly used, therefore, when the portions of the cord which convey either motor or sensory impulses are spoken of as a whole; while the other names applied to special portions of the cord will chiefly be used in defining the situations of special lesions whose symptomatology may be under discussion.

If we are to attempt to grasp the symptoms by which the various lesions of the spinal cord may be recognized during life, and to understand why certain effects must be produced (when the situation of the lesion is known to us), we must make some classification of the diseases which affect the spinal cord on such an anatomical and physiological basis as shall naturally tend toward the constant application of these branches of medical science to the symptoms presented by the patient. It has been customary with most of the late authors upon the special subject of nervous affections to consider the diseases of the motor regions and of the sensory regions of the cord separately; using the term "*systematic*

lesions” to express the fact that all of those diseases, which are not purely local, affect either the kinesodic or æsthesodic systems. When we speak of systematic lesions, therefore, we mean those types of disease which tend to diffuse themselves, for a greater or less extent, upward and downward, without extension to the adjacent columns; thus the columns of Goll and of Burdach may be involved in the æsthesodic system, the lateral columns and the columns of Türk may be involved in the kinesodic system, while the anterior or posterior horns or central part of the gray matter may be the seat of disease, irrespective of the other parts of the cord.

In contradistinction to the systematic lesions, certain types of disease tend to spread laterally, and thus to involve different columns of the cord in succession. These are grouped under the general head of “*focal lesions*” or “*non-systematic lesions.*” In this form of degeneration, or of new tissue development, the extension is usually limited in a vertical direction, but it may extend, laterally, not only to diverse columns, but may even involve both the kinesodic and æsthesodic systems in its progress.

It will exceed the proper scope of the course of lectures which I have prepared for this winter, to enter into a full description of the symptoms of all of the diseases of the spinal cord; but it is important that you start with a *general classification* of the diseases which may affect this region, in order that you may properly understand the meaning of terms which you will find growing into use with astonishing rapidity. It is also to be remembered that the classification which I have given you is based on anatomy and pathology, and may differ markedly from those of some authors with which you may be familiar; a little study will, however, remove all confusion, and perhaps add to your more perfect comprehension of the subject.

A CLASSIFICATION OF THE DISEASES OF THE SUBSTANCE OF THE SPINAL CORD. (AFTER SEGUIN.)

"SYSTEMATIC" LESIONS.	{	<i>Lesions of the Æs-</i> <i>thesodic System.</i>	{ Sclerosis of the columns of Goll, Sclerosis of the columns of Burdach (locomotor ataxia), Ascending degeneration.
		<i>Lesions of the Ki-</i> <i>nesodic System.</i>	{ Sclerosis of the anterior columns, Sclerosis of the lateral columns (tetanoid paraplegia), Sclerosis of anterior horn and lateral column. Myelitis of the anterior horns (atrophic spinal paralysis), Degeneration of the <i>ganglion cells</i> of the anterior horns (progressive muscular atrophy), Central myelitis.
"NON-SYSTEM- ATIC" OR "FO- CAL" LESIONS.	{	Traumatism of the cord,	
		Compression of the cord, by	{ Bone or Tumors,
		Transverse sclerosis of the cord,	
		Transverse softening of the cord,	
		Hæmorrhage into the cord, Tumors of the cord.	

"SYSTEMATIC LESIONS" OF THE "ÆSTHESODIC SYSTEM."

In the table¹ which I have written out for your inspection, you will perceive that the systematic lesions may affect either the æsthesodic or kinesodic systems of the spinal cord, while the focal lesions are not thus separated, since they tend to extend in a transverse direction, and thus may be found in both. As the æsthesodic system presents well-recognized and understood morbid conditions, we will first study the general effects of systematic disease which is confined either to the columns of Goll or of Burdach.

We might begin, possibly with advantage, by stating that the general results of any lesion situated back of the posterior gray horn of the cord must manifest itself, if our previous deductions are correct, by symptoms referable only to *sensation* and *coördination*. This we find to be approximately correct. We have in this type of cases *anæsthesia*, *hyperæsthesia*, or *numbness*, and also *pain* (usually possessing some special characteristics which are of clinical value); while *coördination* is unquestionably affected as well, since a peculiar

¹ See the foregoing table.

disorder of voluntary movements, which constitutes true "ataxia," is usually developed. Our previous statements as to the path of the motor impulses of the cord seem to be confirmed by the *absence of either spasm or true paralysis* of the muscles below the lesion.

The question now arises, "Can we tell whether the disease is confined to the columns of Goll or of Burdach?" We can undoubtedly locate the lesion in the opposite side of the cord from that of the body upon which certain symptoms are well marked; but can we tell positively whether the lesion is progressing in the inner or outer column of the posterior half of the cord when both sides are simultaneously involved?

SCLEROSIS OF THE COLUMNS OF GOLL.

As regards the columns of Goll, I feel myself forced to say that I do not believe that localized disease can be positively diagnosed when confined to these columns; although, from certain pathological deductions, we can often *infer that it exists*, since it has been found to occur as a secondary result of those other lesions which are capable of producing an ascending or descending degenerative process in the spinal cord. As the columns of Goll are large and distinct in the cervical region of the cord, but become narrower and narrower as the lower portion of the cord is reached, the lesion of this column becomes more evident to ocular demonstration, when present, as you ascend the cord. The entire length of either column may be affected, or only portions of it. In the ascending form of secondary degeneration of these columns, the lesion is always observed above the seat of the exciting cause. This lesion has never been traced, so far as my researches go, above the "calamus scriptorius."

SCLEROSIS OF THE COLUMNS OF BURDACH (LOCOMOTOR ATAXIA).

The columns of Burdach are the seat of sclerosis more commonly than those of Goll, since this type of change progresses, as a rule, from the posterior root zones inward, and thus only affects the columns of Goll after those of Burdach

have become seriously impaired. In all those cases where the symptoms of pain and alteration in the sensibility of parts precede those of ataxia, we find the columns of Burdach first affected with a systematic lesion, and, afterward, those of Goll. The investigations of Pierret and Charcot seem to demonstrate that the condition of sclerosis of the columns of Burdach usually begins in the lumbar enlargement, and tends to creep gradually upward toward the medulla oblongata, so that the entire length of the cord may become hardened and atrophied; while the same condition of the columns of Goll is usually found to coexist, but may be looked upon as a secondary result of the former.

Now, we have mentioned certain peculiar symptoms which point, when present, to some disease of the posterior columns of the spinal cord, among which come *pain, hyperæsthesia, numbness, anæsthesia*, and symptoms of *incoördination* (ataxia) when the disease is far advanced. We discover no motor symptoms, as the muscular power appears to be normal in all respects, except in coördinate movement; and “trophic changes”¹ in tissues are produced less frequently than if the anterior portion of the cord were involved. It will help us to recognize this disease, if we will study a little more in detail each of these various manifestations of posterior spinal lesions.

In the first place, the *pains* of this type of sclerosis are peculiar. They do not follow the course of special nerve trunks, as do neuralgic pains, but are more localized. They are vagrant in character, since they affect innumerable spots in the region which is presided over by the nerves connected with the diseased portion of the cord; and so marked is this peculiarity that a patient who has long suffered with these pains can not well select any spot which has entirely escaped them. Again, the pains vary in their intensity, since they are more or less paroxysmal, and often show exacerbations due to atmospheric changes. These exacerbations may occur every few minutes for some hours, and may then disappear for

¹ Trophic changes in connection with posterior sclerosis point often to a complicating peripheral neuritis.

days or weeks ; the area covered by them may vary from that of a small point to that of your hand ; and they may be referred to the skin alone, the muscles, the joints, the bones, or, in rare cases, to the viscera. These pains are usually of a sudden character, and extremely severe. They assume the character of stabbing, tearing, or shooting sensations, which often cause the patient to shriek in agony ; while the skin over the circumscribed spot is rendered hyperæsthetic to slight pressure, although firm pressure often affords relief. The terms "fulgurating" and "terebrating" are often applied to these pains, from their sudden onset and their similarity to the effects of a passage of a strong electric current. In fact, the distinctive characteristics of the pain of sclerosis of the posterior columns of the spinal cord are so well defined that I seldom hesitate to predict the development of later ataxic symptoms from this guide alone. It is usually confined to the lower extremities (toes, foot, shin, calf, and thigh), but it sometimes affects the trunk and the upper extremity, and, in very rare cases, the head. It is to be differentiated from the pain of rheumatism or of a simple neuralgia, and, as it is the initial symptom of a serious and incurable disease, it should be recognized early.

Touching upon this point, Professor E. C. Seguin, in a late lecture, puts the diagnosis of this affection, with his accustomed clearness, as follows :

"The only two conditions in which pains somewhat resembling fulgurating pains occur, in my experience, are paralytic dementia and gout. In the former disease, slight fulgurating pains—'smaller' pains, if I may be allowed the expression—are described by the patients ; but, in many of these cases, autopsy shows that, besides the cerebral lesions proper to the disease, the posterior columns of the cord exhibit pathological alterations ; so that these cases are, after all, *quasi*-tabetic. The sharp pains of gout are short, stabbing pains in the skin of various parts of the body, compared by the patients to the prick of a needle, cold or hot. There is no tendency to repetition of the pain in one spot for hours or days ; the sen-

sations appear in various parts of the body, and are bearable.

“The differential diagnosis of fulgurating pains from the pains of neuralgia, strictly speaking, is very easy. In neuralgia the pain is in the course and distribution of one or two (single) nerve trunks and their branches; it may be paroxysmal, but does not assume the excessive irregularity of tabetic pains, viz., agony for a few hours, and freedom from pains for hours, days, or weeks. The hyperæsthesia, in fulgurating pains, is at the seat of pain. In neuralgia, we find regular ‘tender points’ along the nerve trunk, or where its branches become superficial. The lightest touch causes pain in the painful districts in tabes, while the tenderness of nerves in neuralgia is usually demonstrable only by firm, localized pressure. Further, true neuralgia is seldom bilateral, while it is the rule for fulgurating pains to appear on both sides of the median line—in both lower extremities, for example. A last important distinction is that neuralgia is relievable or curable, whereas fulgurating pains are practically incurable, and fully relieved only by morphia injections.

“The confusion so often made between ‘rheumatism’ and the first stage of sclerosis is even less pardonable. Of course, no practitioner would mistake fulgurating pains for articular rheumatism; the error is with respect to ‘rheumatism,’ so called, affecting muscular masses and aponeuroses. In these affections the pains are usually dull, nearly constant, and distinctly aggravated by movements. Pressure must be firmly made upon the parts to produce pain, whereas in fulgurating pains the condition is one of cutaneous hyperalgesia under a slight touch. Again, this ‘rheumatic’ condition is distinctly amenable to treatment (counter-irritants, etc.), whereas the pains of posterior spinal sclerosis are, in one sense, incurable.”

Now, this symptom may exist for years without the development of marked anæsthesia or of ataxia, and often both the patient and the physician are inclined to speak of these pains as dependent upon some rheumatic diathesis, rather than as a precursor of an incurable affection. The peculiar

hyperæsthesia which exists in the patches of skin affected with the pain, both during the paroxysm and sometimes for hours afterward, affords a point of great diagnostic value.

As regards the second diagnostic symptom—*anæsthesia*—it is claimed that an alteration in the sensibility of the affected parts can be detected in the earliest stages of the disease, as well as later on ; but, in the former case, the loss of sensation is localized in distinct spots or patches of integument (usually upon the lower extremities, but, possibly, upon the trunk and arms, if the disease be extensive), while, in the later stages, the soles of the feet become deprived of sensibility, and the anæsthetic condition tends to extend upward along the legs and thighs until the whole of the affected regions may be dead to all sensations. Now, it is this very condition of the integument that probably causes the symptom which is regarded by many physicians as pathognomonic of locomotor ataxia—staggering or falling, when the eyes are closed and the patient attempts to stand erect—and no test is more worthless of this special affection. I have seen a patient made to fall, when his eyes were closed, by simply freezing the soles of the feet so as to render them incapable of sensation, while it is well recognized that the same symptom is met with in the anæsthesia which follows or accompanies hysteria, myelitis of the posterior horns, etc. That patients afflicted with locomotor ataxia do stagger and often fall, when obliged to stand erect with closed eyes, no one can deny, but that it has no special diagnostic value can now be as positively stated.

In the final stages of sclerosis of the posterior columns, *symptoms of ataxia* develop. The walk of the patient now becomes of a peculiar character. The legs are jerked about in an aimless manner, and the feet are brought down in a stamping way which is totally different from the gait of paralysis.¹ The separate muscles, when tested, show an unim-

¹ This symptom may develop at a variable period from the commencement of the neuralgic pains (the duration of the pains varying from three months to ten or more years). The heel strikes the ground forcibly in walking. If the upper extremities are involved, the fingers and arms perform unnecessary movements to reach a given point, and oscillate when a given action is attempted.

paired power, but the large groups of muscles can not be employed in rhythmical succession. The patient begins to notice, in the early symptoms of this condition, a sense of distrust in himself in crossing a street or in performing any act which calls for sudden and positive muscular coördination. Later on, walking becomes almost impossible if the ataxic symptoms develop rapidly, and the patient is liable to fall, in his efforts to avoid any special danger, as in traveling the streets.

One of the earliest evidences of incoördination of movement usually perceived by tabetic patients is a difficulty in directing their feet toward any object of small size, such as a carriage-step, stirrup, etc. A difficulty is also experienced by many in ascending long flights of stairs, as the equilibrium is preserved with some difficulty, on account of an uncertainty in placing the feet upon the stairs. Later on in the disease, the feet are swung in a circle, in contrast to the straight progression of the normal step, since the equilibrium is thus more easily preserved. This has been compared to the swinging motion of the tight-rope performer. The sole of the foot is generally brought down after the heel strikes the ground, thus often giving a flapping sound to the step. The jerking gait of well-marked ataxia could never be mistaken for that of paralysis.

When the upper extremities are affected, the motions of the hand show even more decided evidences of incoördination. Such patients, when asked to place the tip of their finger upon any designated spot on the face (provided the eyes are first closed, in order to prevent the use of vision as an aid to movement), utterly fail to perform the act, often touching a spot one or two inches from that upon which they intended to place their finger. With the eyes open, a glass of water is carried to the mouth with a trembling of the hand and partial spilling of its contents; and the finger is placed upon any point designated upon the face by being suddenly darted forward, rather than by a deliberate movement. The handwriting is markedly altered, especially in respect to the

rounded letters, such as *d, b, o, c, z*; and this is even more marked when writing is attempted with the eyes closed, as it is then almost unintelligible.

The complex movements of the fingers, required for the act of buttoning or unbuttoning the clothing, and in picking up a pin from the floor, are performed with so much difficulty that they afford two admirable tests for this disease, provided the upper extremity be involved.

Tabetic patients usually walk with their eyes fixed upon the feet, as vision aids them materially in guiding their movements of progression; hence, we invariably find that closing the eyes causes a marked alteration in the ataxic manifestations, oftentimes causing them to fall when required to stand motionless.

It must be remembered, however, as was brought out in the lectures upon the brain, that certain forms of intra-cranial diseases tend to produce the same symptoms, so that ataxic movements are only confirmatory of a spinal disease which has previously manifested itself by well-marked sensory symptoms.

There are two other symptoms referable to the sensory nerves which are of value in deciding as to the probable existence of posterior spinal sclerosis, viz., a *retardation of sensation* and *diminished reflex movement*.

If we prick the skin of a patient suffering from this type of disease, and count the time which intervenes between the time of the puncture and the time when the patient perceives it (provided the eyes be closed, so as to prevent any visual recognition of the pricking of the part), we will often find that an interval, varying from ten to one hundred or more seconds, may be detected. This has been explained, by supposing that the sclerosis has created such pressure upon the sensory nerve filaments as to partially or nearly completely destroy the axis cylinders. This symptom is invariably followed sooner or later by complete anæsthesia, and by a sense of numbness which extends upward from the feet,

since it is usually perceived in the lower extremity rather than in the upper.

In addition to the sensory manifestations already discussed, this disease tends to extend upward along the cord until the optic apparatus becomes, in some way, markedly affected. The perception of color is often rendered obscure, or entirely lost for the red and green tints ; while the patient may possess a normally acute perception of the yellow or blue tints, or even have an unnatural acuteness in detecting delicate shades of these colors.

In some instances, ptosis, diplopia, and a marked alteration in the reflex movement of the iris to varying degrees of light, are developed ; and these may prove of great advantage to you in tending to confirm the possible existence of this type of spinal sclerosis.

During the first stage of the disease, when the fulgurating pains are present, all the reflex movements which seem to be controlled either entirely or in part by the spinal cord are diminished. As examples of this fact, we frequently see that the pupils are either smaller than normal, or irregular as regards their size, or that they do not properly respond to fine variations in the intensity of light,¹ and that the muscles do not respond to sensory stimulation of the skin. If the knee be semi-flexed during the stage of fulgurating pains, or even when the ataxic symptoms have been developed, and the ligamentum patellæ be struck sharply with the finger-end, you will notice that the muscles of the quadriceps extensor of the thigh fail to produce any responsive movement of the limb, since the reflex action of the spinal cord is impaired. This test is one which is now regarded by specialists in nervous diseases as one of great value, in deciding as to the presence of posterior spinal sclerosis, and it is known as the "patella reflex" test.²

¹ See a previous page of this volume.

² In reference to the diminution of the different reflexes, much has already been mentioned in preceding pages. I quote, however, a summary of Professor Seguin upon this point, as a general *résumé*.

"We test the so-called patellar reflex, or knee reflex, or patellar tendon reflex, in the

Now, it must be evident to you all, that the symptoms which have been hastily enumerated as indicating a lesion in

following ways: the patient, being seated, is told to cross one leg over the other in a natural manner, and to let the muscles relax; or, seated, we place our left hand under the popliteal space, tell the patient not to help us, to let the leg hang loose, or, in popular parlance, 'dead,' and lift the whole limb so that the foot swings a couple of inches above the floor; then we tap the skin over the whole of the region from the insertion of the quadriceps femoris to the tuberosity of the tibia, with one or two finger tips applied as in percussion. The place whence a reflex quadriceps contraction is most apt to occur is about midway between the lower end of the patella and the tibial protuberance. The taps should be gentle at first, and, if these fail, harder ones are to be tried. A third mode of procedure, which is very good indeed, is to seat the patient on a table so that his legs dangle some two or three inches beyond its edge; then we tap the patellar region as above described, without supporting the thigh with our left hand. The test may be well done through the patient's clothing, yet it is desirable, especially in doubtful cases, to tap the bare skin. Another important precaution is to secure the absolute relaxation of the patient's muscles, and to divert his attention from what you are doing. Even with all precautions, it is sometimes next to impossible to secure this indispensable muscular relaxation. In the healthy subject this test develops a contraction of the quadriceps extensor femoris, and causes an extension of the leg or a sudden jerk. In a very early stage of posterior spinal sclerosis no contraction takes place.

"I would also call attention to the occasional occurrence of reflex movements of the thigh, produced by contraction of the iliac group of muscles during the knee test. I have an example of this distant reflex action in a typical case of sclerosis of the posterior column, in which the quadriceps does not contract at all.

"While claiming very great diagnostic value for this negative symptom, I would not be understood as attaching pathognomonic significance to it, as we all know that there are a few seemingly healthy individuals in whom the patellar tendon reflex is lacking, and also that there are other diseases which diminish or abolish it. Indeed, I may say that I recognize no pathognomonic symptom, and, even in attempts to push diagnosis to an extreme delicacy, would urge that reliance be placed on the grouping of symptoms, rather than on any one of the signs, however constant and important it may appear.

"Physiologically analogous to this condition of loss of tendinous reflexes is the flabby state of the muscles in the affected parts. This is not due to any positive atrophy, as electrical tests show us marked departure from the normal reactions, but to impairment of what physiologists call muscular tonus—a state of partial contraction or tension of muscles, which is kept up by the inevitable and continued excitation of the cutaneous nerves by air, clothing, surrounding objects, etc., acting in a reflex way through the spinal cord. It has been recently claimed that this loss of muscular tonus was the most important factor in the production of the ataxic movements which characterize the second stage of the disease.

"The vesical and rectal reflexes are diminished in posterior spinal sclerosis. Slow, irregular micturition is complained of by most patients, in the first stage and in the second. We usually micturate without using much volition, but the tabetic patient is obliged to strain and to try hard to pass water. Defecation is, like micturition, a semi-voluntary act, and in the late first stage of the disease in question constipation becomes more and more marked, and that through loss of the automatic or reflex action of the rectum and adjacent muscles.

"The sexual act is, in my experience, frequently impaired and sometimes almost lost before the second stage sets in. The acts of erection and emission are usually brought about in a reflex manner by irritation of the skin and mucous membrane of the genitals. As a result of diminished spinal reflex action we have imperfect erections, and either

the posterior columns of the spinal cord have sustained the physiological experiments and deductions as regards the probable function of these parts. We have found that *sensation* is affected in various ways and degrees; that *coördination* of muscular movement is interfered with in the advanced stages of the destructive process; and, finally, that the *reflex function* of the spinal cord is impaired, when the sensory nerves become incapable of properly transmitting their impulses to the motor cells of the cord.

Several theories have been advanced to explain the development of ataxic symptoms, all of which will help to fix some anatomical point, previously mentioned, forcibly in your memories. These theories may be thus enumerated:

1. That the destruction of the *commissural fibers* which connect the different segments of the cord causes ataxia.

2. That the *tonic action*, which is claimed to be normally exerted by the spinal cord upon the muscular tissues of the body, is impaired; hence, a certain unnatural relaxation of some parts exists, which induces irregularity of muscular movements.

3. That the condition of anæsthesia, which is probably present in the muscular tissues as well as in the skin, destroys the so-called "*muscular sense*"; hence, the patients can not properly guide the contractions of muscles.

"SYSTEMATIC LESIONS" OF THE "KINESODIC SYSTEM."

As has been stated in the anatomical description of the spinal cord, the kinesodic or motor regions of the cord include

premature emission, or, what is more common, I believe, very slow production of the orgasm, and impossibility of repetition within a reasonable time.

"Some writers admit abnormally great sexual power in the early stage of tabes, but I am not sure to have met with more than one or two cases in which this seemed to be the case. In one of the patients, a female, I became convinced that her extraordinary capacity for sexual intercourse was not in a strict sense pathological or pre-tabetic, but had been marked in one shape or another from childhood.

"It seems reasonable at the present time to advance this general proposition: that, in posterior spinal sclerosis, the various reflex actions performed by means of those portions of the cord which are the seat of sclerosis are diminished or lost; or, to put it in another way more useful for practice, it may be said that the limitations of loss of reflex action in different parts of the body accurately indicate the limits of sclerosis in the posterior sensory apparatus in the spinal axis."

the columns of Türck¹ (called also the "direct pyramidal fasciculi"), the anterior root zones, the anterior portion of the lateral columns, and the posterior portion of the lateral columns (called also the "crossed pyramidal fasciculi"). As indicated in the table of diseases of the spinal cord,² several distinct and separate affections of these component parts may exist, each of which presents some symptoms which are specially diagnostic.

When we review the points mentioned as to the functions of the kinesodic system, we should expect to find that any lesion confined to the regions designated above would be manifested by disturbances in the *motor functions* of the body and by certain "*trophic changes*"; while we should also expect to find an absence of any disturbance in the sensory nerves or in the coördination of movement. This is fully confirmed by clinical experience. In all lesions of the kinesodic system, we are apt to meet either muscular spasm, muscular atrophy, or motor paresis, or paralysis; but we are never confronted with fulgurating pains, numbness, or anæsthesia, provided the posterior columns (the æsthesodic system) be not simultaneously involved. In order to appreciate the points of diagnosis of the different forms of systematic lesions which may affect the anterior half of the cord, it will be necessary to discuss, in a general way, the special symptoms of each.

SCLEROSIS OF THE COLUMNS OF TÜRCK.

The columns of Türck ("the direct pyramidal fasciculi") are affected with sclerosis, either separately and alone, or in connection with similar changes in the postero-lateral columns ("the crossed pyramidal fasciculi"). What its producing causes are is, as yet, not thoroughly understood. We simply know, from pathological investigation, that sclerosis of the

¹ See a previous page of this volume.

² Türck may be justly considered as the pioneer in the investigation of *systematic spinal lesions*, since, as early as 1851, he recognized sclerosis of the motor columns of the cord and the crossed effect of brain lesions upon the motor columns. Much valuable research has since been performed by Vulpius, Bouchard, Flechsig, Seguin, Charcot, and others.

two portions of the kinesodic system mentioned is liable to occur simultaneously, although they may be individually affected. We also know that disease of the motor tract of the crus, above the decussation of the motor nerves in the medulla, as well as lesions in the nucleus caudatus, the internal capsule, the lobulus para-centralis, and the motor regions of the cortex, often causes what is termed "secondary degeneration" throughout the motor tract of the spinal cord for its entire length; hence, this condition of the motor columns may be the late result of some preceding brain lesion, and is most marked in one lateral half of the cord (most commonly on the half opposite to the seat of the exciting lesion in the brain). The accompanying diagram, which illustrates the course of the fibers in the medulla oblongata, will explain why the symptoms produced by descending degeneration of the motor columns of the cord are not always present upon the opposite side of the body to that of the brain lesion which produced it, since it shows that some of the fibers of the cord do not decussate.

This diagram shows that the fibers of the medulla decussate before entering the spinal cord, for the most part,¹ but that a certain proportion of the fibers pass in a direct line from the encephalon to the cord. The figures (shown at the bottom of the diagram) indicate the relative proportion

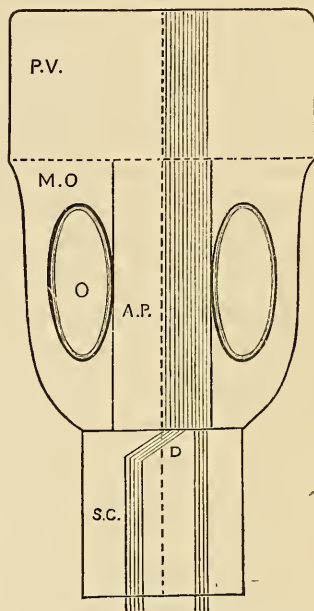


FIG. 181.—A diagram to show the decussation of motor nerve fibers in the medulla oblongata. (After Flechsig and Seguin.)

P. V., pons Varolii; M. O., medulla oblongata; O, olivary body; A. P., anterior pyramid; D, decussation; S. C., spinal cord. The direct and crossed bundles vary very much in size, as shown in the following ratios of crossed and direct: (100 : 00), (92 : 8), (84 : 16), (70 : 30), (52 : 48), (35 : 65), (10 : 90).

¹ Much of our present knowledge upon this point is due to the researches of Flechsig in 1867, and to those of Bouchard in 1866, made in connection with Vulpien and Charcot.

between the direct and the decussating fibers, which have been found in different instances. Now, as this "secondary degeneration" (caused by lesions of the encephalon) follows the individual nerve fibers, the effects would be manifested, for the most part, upon the *opposite side* of the body, since most of the fibers decussate; but some nerve fibers, which do not decussate, would be impaired on the *same side of the spinal cord* as the existing brain lesion. Thus we are enabled to explain spinal symptoms on *both sides of the body*, when preceded by a cerebral lesion; although the spinal manifestations are usually detected on the side opposite to the exciting cause. The varying proportion of these direct fibers to those which decussate will explain why this secondary degeneration may be followed by symptoms confined entirely to one side of the body, or, again, affecting both sides.

You are probably wondering how it is possible to tell when this slowly progressing degeneration of the columns of Türk, or of the postero-lateral columns,¹ is present. When an attack of hemiplegia has occurred, you have probably been able to decide early whether it is of cerebral or spinal origin; since, if cerebral, it will probably affect the side of the body opposite to the seat of the lesion within the brain, and other points in the history will probably confirm this as the exciting cause. Some time after the attack of hemiplegia, however, you will notice that the paralyzed muscles are becoming more or less rigid, and that a *state of contracture* is developing. Now, it is this point in the case that should indicate to your minds the fact that a progressive descending degeneration of the spinal cord is taking place, and you can safely expect to find sclerosis of the anterior and postero-lateral columns at the autopsy.

In some cases the contracture of paralyzed muscles, after an attack of hemiplegia, is accompanied by an *atrophy* of the paralyzed and rigid muscles; so that their volume becomes much more extensively impaired than would ensue from sim-

¹ Our present knowledge leads us to infer that the anterior and lateral columns possess a similarity of function.

ple disuse. In this event, you may be justified in suspecting that the *anterior horns of the gray matter* of the spinal cord are becoming diseased, a condition to which the term "polio-myelitis," or "myelitis of the anterior horns," may be found applied in treatises upon nervous diseases. This will be considered in detail in a subsequent lecture.

SCLEROSIS OF THE LATERAL COLUMNS ("TETANOID PARAPLEGIA"—
"SPASMODIC TABES").

The lateral columns (including the whole of the mass of white substance found at the sides of the spinal cord) may be diseased, either as a primary lesion, following cold, dampness, over-exertion, and syphilis, or as a part of a secondary morbid process (chiefly in connection with polio-myelitis). In 1875 the name of "spastic spinal paralysis" was applied to this condition by Erb,¹ and in 1876 Charcot² described it under the head of "spasmodic tabes." You will, therefore, find it described under both of these names, although I prefer the name, applied to it by my friend Professor Seguin, "tetanoid paralysis or paraplegia," since to the common mind it best conveys the idea of its symptomatology.

As this lesion is often combined with myelitis of the anterior horns of gray matter, as mentioned above, and since such degeneration of the anterior horns is apt to affect the "trophic function" of the cord, Charcot has applied to this complex systematic affection of the cord the term "amyotrophic lateral sclerosis." A peculiarity of sclerosis of the lateral columns of the cord, whether complicated with disease of the anterior horns or not, is that *both sides* of the spinal cord are nearly always involved at the same time; hence, the occurrence of *paraplegia* is more strongly diagnostic of this affection, provided other symptoms of value exist, than if hemiplegia be present. I shall use the term "tetanoid paraplegia," therefore, in preference to the other names suggested by the authors quoted, in describing the symptoms which are diagnostic of this affection.

¹ *Op. cit.*

² *Op. cit.*

When the sclerosis of the lateral columns affects the *cervical enlargement* of the spinal cord (where the nerves to the upper extremities are given off), the symptoms appear first in the hands. The affected parts have a peculiar sense of formication, like the creeping of ants over the part. They undergo rapid atrophy (if the anterior horns are affected¹), causing the hands to become bony from disappearance of the interossei muscles, and the parts become simultaneously paralyzed. Soon a contracture of the paralyzed muscles develops, producing the so-called "claw-hand deformity." The lower limbs become at first paretic, but gradually develop a paralyzed and contracted condition; although the contracted state of the muscles is very much more apparent when the patient stands and attempts to walk than when lying in bed, since the rigidity almost disappears when in the recumbent position. If the lesion extend upward to the region of the motor bulbar nerves, the symptoms of glosso-labio-laryngeal paralysis² may be developed, in addition to the other symptoms described. The muscles of the legs do not generally waste, and the bladder and rectum are not, as a rule, paralyzed. No evidences of anæsthesia can be usually discovered in the regions affected.

In tetanoid paraplegia, there is a marked *increase* in the *reflex excitability* of the affected parts. It is to this increase in all the reflex movements that the peculiar gait of this class of patients may be attributed. Thus, the increased action of the adductor muscles tends to make the legs almost cross each other in walking;³ the excessive action of the muscles of the calf raises the heel, and the legs move with a stiffness which makes a contrast with the normal act of walking. In the last stages of this affection, when the patient becomes bedridden,

¹ A complex condition, termed by Charcot "amyotrophic lateral sclerosis." The patient (when the legs become affected) at first walks with a cane, then with crutches, and later on requires an attendant.

² The symptoms of this affection (Duchenne's disease) have been given in detail in connection with the hypo-glossal nerve. The reader is referred to page 525 of this volume.

³ When both the lower limbs are affected by lesions of the lateral columns of the cord, the legs frequently become interlocked at every attempt to walk.

the increased reflex excitability causes the legs to become semi-flexed and adducted, and the muscles are sensibly hardened. It is a clinical point of some value that the muscles affected with tetanoid paraplegia retain their normal size, nutrition, and electrical reactions (provided that the anterior horns are not diseased). This condition is quite commonly met with in children; ¹ and the little sufferers can not often stand or walk, from the spasmodic action of the muscles of the legs. In adults, as a further evidence of the increased reflex excitability of parts, the act of passing the urine or fæces becomes one which requires the patient to hurry with all possible speed, in order to avoid a sudden and involuntary evacuation.

Now, the absence of anæsthesia, of numbness, and of fulgurating pains, will easily assist you to diagnose between a case of disease of the posterior columns and that of the lateral columns of the cord, although the peculiarity of gait may for a while confuse you. The increase in the "patellar reflex" ² and the actual loss of power of individual muscles will also assist you in the diagnosis; while in tetanoid paraplegia the muscles are stiffened, especially when standing or walking, sensations are not delayed, and coördination of movement is normally performed.

MYELITIS OF THE ANTERIOR HORNS ("ATROPHIC SPINAL PARALYSIS").

As shown in the table ³ of diseases which may affect the kinesodic system of the spinal cord, the anterior horns of gray matter may be the seat of degeneration. As in all other lesions of the motor tract of the cord, the symptoms of this affection are confined to motor phenomena, and characterized by the absence of sensory effects (anæsthesia, numbness, etc.); but, in addition to the motor phenomena, certain *tro-*

¹ These children are often microcephalic or idiotic; hence the symptoms may be due to an incomplete development of the motor tract of the spinal cord. It is stated by Seguin that circumcision can not be considered as a curative measure in all cases, since Jewish children, circumcised at birth, have been frequently seen by him with typical evidences of this disease.

² See page 609 of this volume.

³ See page 601 of this volume.

phic changes become prominently developed, which are of special value to the diagnostician.

In this lesion we find, after death has occurred, that the motor cells of the cord have undergone atrophy (due, probably, to an acute inflammatory degeneration associated with pigmentation of the parts), and that the anterior roots of the spinal nerves have likewise undergone a fatty metamorphosis. The condition may be of three distinct types, which are called the acute, sub-acute, and chronic varieties, and each presents certain characteristic symptoms. The term "*polio-myelitis*" is frequently used as a synonym for this change in the anterior horns.

The acute form is manifested by the presence of a fever, either of the continued or remittent type, which is usually accompanied by pains and a sense of numbness in the limbs. As the fever subsides, usually in the course of several days, an *extensive paralysis* is suddenly developed. This paralysis may affect both arms and both legs, the legs alone, or, possibly, only one of the four extremities; it may occasionally be a hemiplegia, if one side of the cord is alone involved. In a longer or shorter space of time, this paralysis gradually diminishes; the bladder and rectum remain unimpaired throughout the attack of paralysis; no anæsthesia or numbness can be detected in the paralyzed parts; and there is no tendency to the development of bed-sores. If you test the paralyzed limbs for reflex movements, you will usually find them totally abolished.¹ If you apply the faradic current, the muscles will fail to respond; but, when the constant current is used, you will notice a slow contraction, and certain variations in the usual formulæ of galvanic reaction will stamp the condition as one of degeneration.² What these formulæ are can be

¹ This is not always the case, as the reflex movements are oftentimes only decreased in frequency and force.

² "Remarkably distinct evidences of the degenerative reaction to electricity are obtained from the second to the tenth week. The nerve trunks supplying the paralyzed muscular groups lose their excitability to faradism and galvanism, and these wasting muscles react only to galvanism, and their reaction formula is altered from the normal; in general terms, we may say that $An\ c\ c = ka\ c\ c$, or even $An\ c\ c > ka\ c\ c$; and all contractions are slow and wave-like." (E. C. Seguin, "Med. Record," 1878.)

easily found in any of the special treatises on the treatment and diagnosis of nervous affections. Now, in this type of myelitis, you will not have to wait long to decide as to its character. In a few days or weeks the muscles of the paralyzed limbs will show a rapid wasting, since the muscles are undergoing atrophy; and this wasting is markedly progressive, since the change in the muscles continues to extend until a most characteristic and permanent deformity results, provided that recovery does not occur.

This condition of the cord is frequently associated with sclerosis of the lateral columns; hence, it is not infrequent to observe a state of contraction in the paralyzed muscles, which lasts in a varying degree, until the atrophy of the contracted muscles destroys their power of producing deformity. These contractions are not inevitably permanent, if present in the

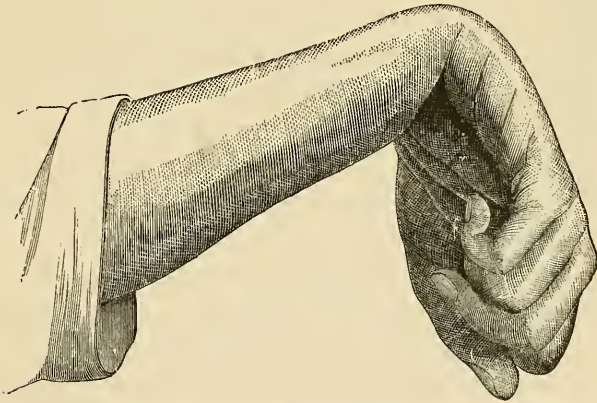


FIG. 182.—*Amyotrophic lateral sclerosis, with contracture.* (Charcot.)

early stages of the disease, as they may totally disappear in exceptional cases; but they usually return with increased deformity as the disease progresses.

In cases of so-called “infantile spinal paralysis,” and in similar cases affecting the adult, a *non-febrile variety* of this affection may be met with, where the disease begins with no initial symptoms, but where the paralysis and all subsequent symptoms mentioned above are developed suddenly.

The *chronic form* of myelitis of the anterior horns is seldom to be diagnosed from progressive muscular atrophy. It is claimed that the severe neuralgic pains which accompany the wasting process of the former are diagnostic between the two affections, and that the degeneration of the affected parts does not assume the *fibrillary* or *fascicular* character of true progressive atrophy, dependent upon changes confined to the ganglion cells of the spinal cord, but the distinction is, in my experience, a difficult one.

The condition of polio-myelitis tends, as a rule, to progress upward along the spinal cord, and thus often reaches the medulla oblongata. The symptoms which are then produced include those of paralysis and atrophy of the tongue, difficult deglutition, impairment of speech, and a nasal quality of the voice, due to the paralysis of the soft palate. The expression of the face is greatly altered by paralysis of the orbicularis oris muscle, which creates an apparent increase in the width of the mouth; and, after laughing or weeping, the mouth remains open for an unusual period, and thus favors the escape of saliva.

PROGRESSIVE MUSCULAR ATROPHY (DEGENERATION OF THE GANGLION CELLS OF THE ANTERIOR HORNS).

Degeneration of the *ganglion cells* of the anterior horns of the cord is pathologically distinguished from the condition just described, since the results of the former were of an inflammatory character, while the latter is a purely degenerative process of primary origin. The former was rapid in its effects; this disease is slow, since the ganglion cells undergo molecular disintegration. We may expect to find, at the autopsy of such a case, the cells changed into a granular condition, and more or less destroyed; while, in extreme cases, the anterior horns of gray matter of the affected part may be utterly destitute of these cells.

It is this pathological change that creates the train of symptoms called "progressive muscular atrophy." The muscles, supplied by nerves connected with the seat of degener-

ation, begin to show a slowly developing atrophy of certain fibers or bundles, while other parts of the muscle may appear perfectly normal; thus it may take months for an entire muscle to become completely wasted, the muscle showing during its contraction the gradual atrophy of certain parts. This disease seems to exist most commonly in the muscles of the hand, thighs, and chest, and a symmetry¹ in its development is a characteristic feature. It is seldom associated with any sensory symptoms. In the rarest cases will you be able to detect the existence of pain;² and symptoms of anæsthesia are wholly absent. Another point which will assist you in diagnosis is the *absence of paralysis*; although the affected muscles may show a loss of power in proportion to the actual destruction of muscular tissue. If you apply the faradic current to the affected muscles, you will find that they respond to its influence in exact proportion to the extent of the degeneration, so that the unaffected fasciculi will be thrown into contraction. This is in marked contrast to the effect of the faradic current upon the muscles in the case of myelitis of the anterior horns, where the muscles failed to respond in their entirety, even before they showed any evidence of atrophy.

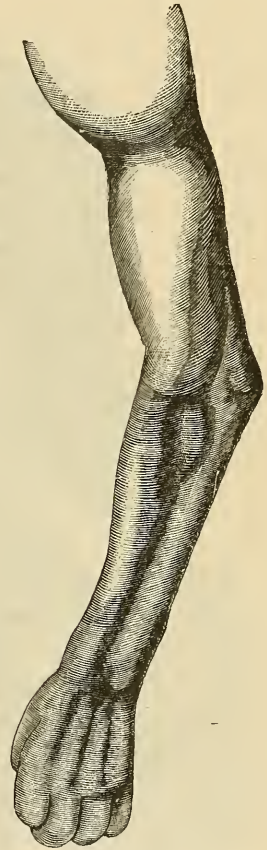


FIG. 183.—*Progressive muscular atrophy of upper extremity.* (Hammond.)

The muscles which are undergoing the early changes of

¹ The atrophy affects parts which are not only *symmetrical*, but *homologous*. It is common to see both shoulders simultaneously atrophied, or the arms and thighs, or the forearms and the legs.

² Hammond states that *pain is perceived after exertion*, but he attributes it to muscular fatigue rather than to central causes.

this wasting are the seat of what are called *fibrillary contractions*.¹ These are produced by the involuntary rapid contrac-

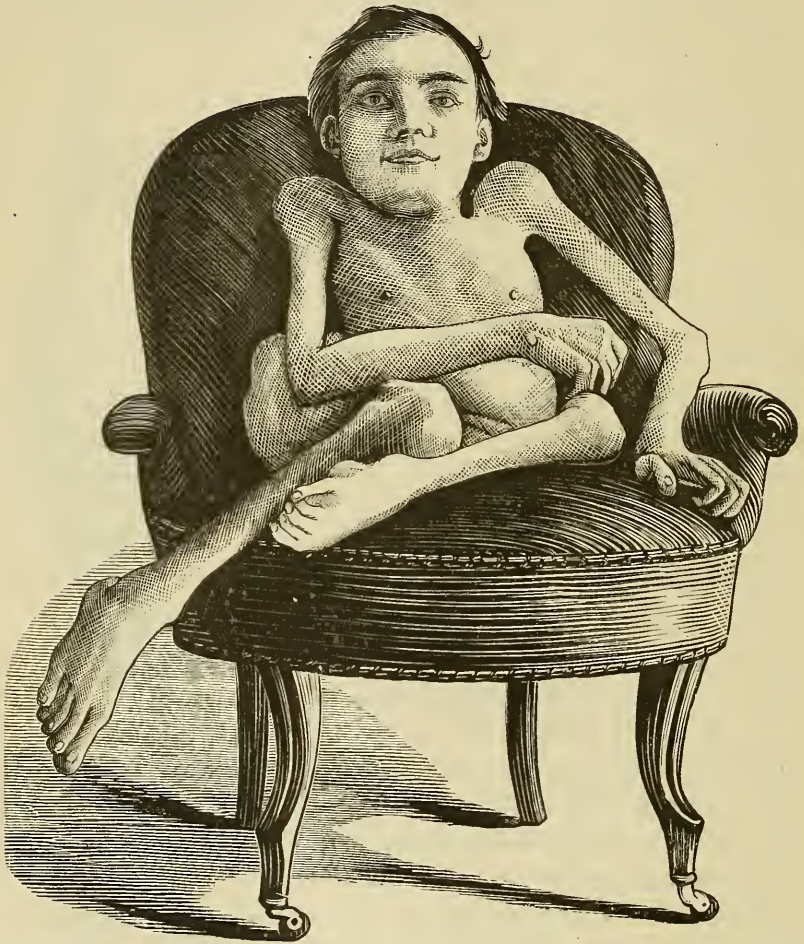

FIG. 184.—*Progressive muscular atrophy.* Age of patient, forty-five years. (From Friedreich.)

tions of fasciculi of fibers in a muscle. Sometimes a patient is covered with them. Some years ago, these fibrillary contractions were held to be pathognomonic, but I can assure you that this is not so, as they may be observed in lead palsy,

¹ These peculiar twitchings give the appearance of something alive being underneath the skin. Hammond states that "they can always be excited by a smart tap of the finger upon the atrophied muscle."

in conditions of neurasthenia, and in simple paralysis. Indeed, many years ago Professor Schiff, now of Geneva, showed that muscles separated from their motor nerves were prone to show fibrillary contractions.

The *ball of the thumb* is often the starting-point of this disease. For some reason, the muscles of the foot are not affected in the same proportion, in those cases where the lower extremity is involved, as the hand is in cases affecting the upper extremity. In some instances, every muscle in a region but one may be atrophied, and that one seem to remain perfectly normal. If you use a surface thermometer, you will generally detect a *fall of temperature* over the affected muscles.¹ When the respiratory muscles become involved, death may be produced from imperfect performance of that function. The disease seems to affect males rather than females, and to be most frequent during middle life. It is sometimes associated with a congenital predisposition.²

The *muscles of the thigh* are frequently affected with atrophy, following degeneration of the ganglion cells of the anterior horns of the spinal gray matter. This causes not only a very marked deformity (since the calf may even exceed the thigh in its circumference), but a peculiarity of gait is thus produced which differs from those described in connection with locomotor ataxia, tetanoid paraplegia, and paresis.

If the extensor muscles, which are situated upon its anterior portion, are atrophied, the foot can not be carried forward in the normal manner, if at all; while the leg and foot can not be raised, if the flexor muscles of the knee joint be impaired by an atrophy confined to the posterior aspect of the thigh, thus compelling the psoas and iliacus muscles to lift the weight of the entire upper extremity by using the pelvis as a fixed point.

¹ Hammond reports this fall in temperature as often reaching five degrees below the normal standard.

² See the careful investigations made by Hammond, and reported by him in his excellent work, "A Treatise on the Diseases of the Nervous System." New York: D. Appleton & Co., 1886.

Distortions of the affected members often accompany the condition of progressive muscular atrophy. These are to be accounted for by the fact that a simultaneous impairment of all the muscles seldom occurs, and those antagonistic to the ones affected tend to produce an abnormality of attitude in the part upon which they both acted in health.

CENTRAL MYELITIS.

Among the diseases of the kinesodic system may be mentioned the condition known as "central myelitis." In this affection, the gray matter of the cord is the seat of a chronic type of inflammation in its central portion; hence, it may involve either the kinesodic or the æsthesodic system. The inflammatory process may extend to the anterior horns, or may create compression of the cord, in almost any portion, by the exudation which results. The symptoms of this disease must, therefore, of necessity, vary with the seat of the pathological changes, and, in some cases, be very obscure and apparently confusing to the diagnostician. We may have the manifestations confined, for a time, to the sensory nerves, possibly accompanied by pain, numbness, anæsthesia, formication, etc. Gradually certain manifestations will appear in the motor nerves, and paralysis of certain muscles and possible atrophy may be developed. The reflex action may be increased in some parts and diminished in others, according to the portion of the gray matter involved; bed-sores and paralysis of the bladder and rectum may be present in some cases, and absent in others; the legs may be anæsthetic, and at the same time paralyzed; so may the arms, without the legs, or both may be thus affected; certain parts may have the tetanoid condition described in a previous portion of this lecture; and, in fact, every known combination of sensory and motor symptoms may be present, complicated or uncomplicated by the evidences of muscular rigidity. You can thus understand that the disease is seldom recognized in its early stage, and, as it often takes years to reach a full development, an abundant opportunity will generally be afforded you for a careful and

close analysis of the symptoms which are successively brought to your notice.¹

"NON-SYSTEMATIC" OR "FOCAL LESIONS" OF THE SPINAL CORD.

We have now considered, in this course of lectures upon the spinal cord, those lesions which are called "systematic," since they tend to extend upward or downward in the same column of the cord without spreading laterally; and it now remains for us to review such points as pertain to those focal or non-systematic lesions which have been enumerated in the table of diseases of the spinal cord. It is often possible and of great practical importance to the diagnostician to tell in what region of the cord the lesion is situated, and to estimate the height to which it has progressed. Of course, this is much easier in focal lesions than in the systematic, since the different columns of the cord can then simultaneously furnish symptoms which can be compared, and thus aid in the diagnosis. If you will look again at the table,² to which I some time ago directed your attention, you will perceive that the focal lesions include traumatisms (of all forms); compression of the cord (chiefly by bone and tumors); transverse sclerosis of the cord; transverse softening of the cord; hæmorrhage into the substance of the cord; and, finally, certain tumors which involve the cord itself. There are many other causes which might excite some local lesion, but these are the ones which will most frequently come under the notice of the practitioner.

Before we begin the study of the symptoms produced by lesions at different heights in the spinal cord, it may be well to glance hastily at the drawing which I have made for you upon the blackboard, copied from one made by Seguin from the text of Malgaigne, which is so simple and diagram-

¹ The valuable contributions of Hallopeau, in the "Archives Générales de Médecine," 1872, added much to the knowledge of this obscure affection. Schüppel, Westphal, and Leyden have also been prominent as investigators of this rather rare form of disease.

² See page 601 of this volume.

matic as to illustrate certain points of great clinical value and importance.

Now, if you will look at this diagram, you will perceive that the line upon the left represents the different levels of

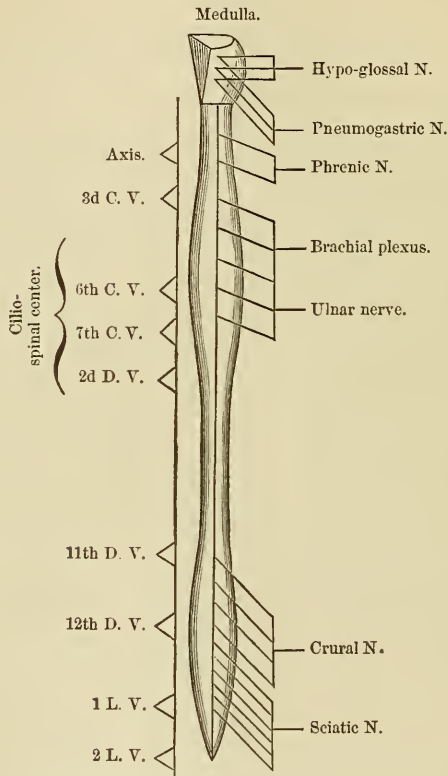


FIG. 185.—A diagram showing the relation of the spinous processes of the vertebræ to the spinal nerves and spinal cord. (Malgaigne and Seguin.)

the spines of the vertebræ, and that the special points in the cord, as well as the points of origin of certain of the more important nerves, are likewise shown. You will observe that the hypo-glossal and the pneumogastric nerves arise from the medulla, which lies above the level of the axis;¹ that the phrenic arises on a level with the spine of the axis; that the brachial plexus and the ulnar nerve are connected with the

¹ This drawing illustrates the fact that the spines of the respective vertebræ do not always correspond to the level of the nerves which escape from between their pedicles.

cord in the region of the neck (third to sixth cervical spines) ; that the cilio-spinal center is situated between the fifth cervical and the second dorsal vertebræ ; that the lumbar enlargement of the cord gives off the crural and sciatic nerves at different points, and that the space between the eleventh dorsal and the second lumbar spines includes the point of origin of both ; finally, that the spinal cord ends at the second lumbar spine, although the nerves continue to escape from the spinal canal much below that point. Such a diagram will prove of constant service to you, in following the discussion of the symptoms of focal lesions situated at different heights within the spinal cord.

We have already studied the effects of systematic lesions, both of the kinesodic and æsthesodic systems, and have noticed how perfectly the physiology of the spinal cord is confirmed by lesions affecting the anterior or posterior portions of the cord separately. We are now to investigate those lesions which, by extending in a transverse direction, are liable to be accompanied by symptoms referable to both the sensory and motor portions of the cord. Of course, the symptoms will be modified by the extent of the lesion in a transverse direction, so that they may be mostly sensory or motor ; but the presence of both sensory and motor symptoms is *strongly diagnostic of focal lesions*, irrespective of a predominance of either, and is never produced by any systematic lesion of the cord, with the one exception of central myelitis.

We will start with a general statement, as a guide in our study of focal lesions, which is as follows : focal lesions usually give rise to *paralysis of motion*, to an *alteration* in the *reflex excitability* of the cord (usually an increase), and to more or less *anæsthesia, numbness, and pain* ; the *bladder and rectum* are *often paralyzed*, and a *tendency to bed-sores* is frequently produced. The first two of these effects, and also the last, are due to alteration in the kinesodic system ; the remaining ones are the result of some disturbance to the æsthesodic system.

In studying focal lesions situated in different regions of the spinal cord, we must adopt some system, if we expect to grasp the fine distinctions which can be drawn between the results of lesions of the upper cervical region, the cervical enlargement, the mid-dorsal region, the region just above the lumbar enlargement, and, finally, the lumbar enlargement itself. Most of these distinctions depend upon certain *anatomical points*, which your previous drill will enable you to appreciate more easily than if your anatomical knowledge had become deficient from a lack of review.

FOCAL LESION IN THE UPPER CERVICAL REGION.

In this condition, hemiplegia will be produced if one lateral half of the cord be alone affected, while paraplegia will be present if the lesion extends transversely to both lateral halves of the cord. The hemiplegia or paraplegia will be complete below the head, and the entire body may be rendered anæsthetic. Since the *phrenic nerve* arises at this point, the act of respiration will be interfered with, creating dyspnoea and hicough; but the respiration will not be arrested, since the pneumogastric nerves continue to excite it, and the auxiliary muscles of respiration can expand the chest without the action of the diaphragm. Should the lesion be a surgical one (as it usually is), the *respiratory center* of the medulla may be affected, and death take place from asphyxia; but I do not think such a result can be explained as a simple effect of paralysis of the phrenic nerves alone. The presence of the *cilio-spinal center* in the lower cervical region may cause the pupils to show an irregularity, and the face and neck may manifest a marked increase of temperature.¹ The pulse may be rendered variable, from irritation of or pressure upon the *acceleratory center* of the heart.

Now, as I have before said, this type of lesion is almost always a surgical one, comprising pressure from fracture, dislocation, caries, tumors of the vertebræ, etc., and these cases

¹ See page 380 of this volume for effects of blood-vessels upon the iris; and also page 381 for the evidences of diminished iritic reflex.

seldom live long enough for us to study the effects of such a lesion with much detail. In those rare instances where the lesion is non-traumatic and slowly developed, the effects of irritation have been shown in a hiccough (probably due to irritation of the phrenic nerve), acceleration of the pulse (from irritation of the acceleratory center of the heart), and dyspnœa (from some interference with the phrenic nerve or the nucleus of the pneumogastric nerve in the medulla); while the paralysis has first appeared as a paretic condition of the arms, then of the chest, and, finally, of the lower limbs.

FOCAL LESIONS OF THE CERVICAL ENLARGEMENT.

This type of lesion differs in its effects, if developed suddenly or gradually, and also when situated in the upper or the lower part of the enlargement. If the lesion be so situated as to create *only irritation* of the cilio-spinal center, or the acceleratory center for the heart (both of which are in that vicinity), the effects will differ from those due to actual pressure upon or destruction of those centers.¹ In the first instance, the pupils will usually be dilated and the face pale, while the heart will be accelerated; in the latter, the pupils will generally be contracted, the face and neck flushed, and the pulse retarded. The effects will also differ if the lesion affects both lateral halves of the cord or only one.

Wherever the lesion be situated within the cervical enlargement, the arms and legs will gradually become paralyzed; the arms and hands usually becoming first numb and paretic, and the lower limbs exhibiting, for some time, only a sense of weakness and evidences of an increased reflex excitability. A sense of constriction around the chest (the so-called "cincture feeling") is generally present, the seat of which varies with that of the exciting lesion.

When the lesion is situated at the *upper part* of the enlargement, the motor and sensory symptoms will be manifested in the lower extremities, the trunk, and in nearly all the

¹ The reader is referred to the pages on the third cranial and pneumogastric nerves for details as to the effects upon the eye or heart.

regions of the upper extremities. The constricting band around the thorax is referred to the *level of the clavicles*, and dyspnoea is often excessive. If you will look at the diagrammatic cut,¹ you will perceive that the brachial plexus is marked as associated with the upper part of the cervical enlargement, and the ulnar nerve with the lower part; hence the paralysis of the arms in this case would naturally be manifested in almost all of the regions of the upper extremity, and also in those parts supplied by the brachial plexus above the clavicle.

If the lesion be situated in the *lower part* of the cervical enlargement, the symptoms exhibited will include a loss of faradic reaction of those muscles which are supplied by the *ulnar nerve* (rather than those of the arm and the extensors of the forearm), and atrophy of these muscles will often be developed, chiefly in the flexors of the wrist and the small muscles of the hand.² The same sense of constriction (cincture feeling), as experienced in most spinal lesions of a local character, will exist, but it will be referred to the upper part of the chest. A paralytic condition of the muscles of the trunk (the intercostals, triangularis sterni, and the accessory muscles of respiration), as well as of the abdominal muscles, will be detected in severe cases, rendering both inspiration and expiration embarrassed, and thus adding to the danger to life. The lower limbs may exhibit evidences of numbness, anæsthesia, paresis, or complete paralysis, depending upon the extent of the lesion and the destruction done to the tissues of the cord. A condition of paralysis may also exist in the upper extremity.

In surgical injuries to the upper portion of the cord, a peculiarity is often noticed in the *temperature of the body*, which is sometimes greatly elevated. This clinical feature may be associated with a marked retardation of the action of the heart (apparently confirming the situation of an *acceleratory center* for that organ in the spinal cord).

¹ See page 626 of this volume.

² The reader is referred to subsequent pages for the symptoms of ulnar paralysis.

FOCAL LESIONS OF THE MID-DORSAL REGION OF THE SPINAL CORD.

In the early stages of this condition the lower limbs become paretic, and a condition of increased reflex excitability is manifested by a rigidity and stiffness of the impaired muscles whenever the patient attempts to stand or walk. As the disease progresses, the muscles become paralyzed and contracted¹ (probably on account of changes of a secondary character in the lateral columns of the cord). In some cases, the reflex movements assume the type of spasms, so as to exhibit both tonic and clonic contractions. It was this symptom which suggested to Brown-Séquard the name of "spinal epilepsy," since it occurs when the patient is exposed to the slightest peripheral irritation, and often when in the recumbent posture.² The sense of constriction around the body is referred to the region of the navel, or that of the lower ribs, or possibly as high as the axilla, since it may be taken as a relative guide to the highest limit of the lesion. A peculiarity exists in this condition as regards the bladder and the rectum; although they may be paralyzed, they are often enabled by the aid of reflex action to expel their contents, thus apparently having regained their function. In the early stages, the urine and fæces may be too hastily expelled for the comfort of the patient, often compelling the performance of either act before a proper place can be reached; but, in the advanced stages, the urine is retained to such an extent as to cause an "overflow," which is often mistaken for an actual incontinence,³ since a constant dribbling is present. This symptom is always an indication for the regular use of a catheter. The sexual function seems to be often unimpaired, as coition is frequently possible. It is seldom that the paralyzed muscles exhibit a tendency to atrophy, and the electrical reaction of

¹ A term used in contradistinction to the word "contracted," to designate a *permanent* shortening rather than a temporary response to a motor impulse.

² The presence of urine in the bladder or of fæces in the rectum may often create these spasms.

³ For the diagnosis between these two conditions, the reader is referred to "A Practical Treatise on Surgical Diagnosis," by the author. William Wood & Co., New York, 1880.

the affected parts is either normal or exaggerated. The chief seat of weakness is usually detected first in the feet, and the paralysis gradually involves the entire lower limbs.

FOCAL LESIONS ABOVE THE LUMBAR ENLARGEMENT OF THE SPINAL CORD.

In this situation, a focal lesion of the cord produces about the same sensory and motor symptoms as those described in connection with a lesion of the mid-dorsal region, with the exception that the *reflex spasms*, present in the paralyzed muscles, are perhaps somewhat less violent than when the lesion is higher up the cord. These tonic and clonic spasms are, however, sufficiently well marked to constitute a prominent symptom,¹ and they indicate an increased reflex excitability of the gray matter of the cord below the seat of the lesion. An ingenious explanation of this increased reflex has been advanced by Professor Seguin of this city, which seems to merit respectful consideration. I quote from a late paper² of his upon affections of the spinal cord, as follows :

“The classic theory of the physiology of contracture in hemiplegia is that it is due to the secondary degeneration—*i. e.*, actively caused by the lesion of the postero-lateral column. Seven years ago (see “Archives of Scientific and Practical Medicine,” vol. i, p. 106, 1873) I rejected this hypothesis, and suggested a different one, which I have since elaborated and taught in my clinical lectures at the College of Physicians and Surgeons, New York. This hypothesis, which I intend shortly to publish in detail, is briefly that the spasm is due, not to direct irritation from the sclerosed (?) tissue in the postero-lateral column, but to the cutting off of the cerebral influence by the primary lesion, and the consequent preponderance of the proper or automatic spinal action—an action which is mainly reflex. This theory explains the phenomena observed in cases of primary spinal diseases with descending degeneration, and can be reconciled with results of experi-

¹ These reflex spasms have been called by Brown-Séguard “spinal epilepsy.”

² “Annals of Anatomical and Surgical Society,” Brooklyn, December, 1880.

ments on animals (increased reflex power of spinal cord after a section high up, Brown-Séguard ; inhibitory power of the encephalon on the spinal cord, Setchenow).”

The urinary and rectal organs are affected in about the same way as in lesions of the dorsal region. Coition is often possible, and erections are normally frequent. The rectum is paralyzed, as a rule, and constipation is usually present on that account. Micturition becomes slow and interrupted, as the bladder grows parietic, and retention and overflow are produced later on in the disease.

The paralysis of the extremities is first noticed in the feet, which have long before exhibited a sense of weakness and easy fatigue. Numbness and anaesthesia usually accompany the motor paralysis, and extend as high as the groin or the waist. The sense of a constricting band around the body is present here, as in lesions of other localities, and is referred to the waist, below the level of the umbilicus, or at the level of the hips.

FOCAL LESIONS OF THE LUMBAR ENLARGEMENT.

If you will look at the diagram of the spinal cord upon the blackboard,¹ you will perceive that the lower portion of the lumbar enlargement is represented as giving origin to the *sciatic nerve*; hence, it is reasonable to expect that a lesion situated in the lower part of this enlargement would be manifested by symptoms of an incomplete paraplegia, in which the muscles supplied by the sciatic nerves would be the most affected.² Now, this fact seems to be confirmed by clinical experience, since the feet, legs, posterior aspect of the thighs, and the region of the nates are chiefly paralyzed when the lesion is so situated. The bladder is unaffected, but the sphincter ani muscle is often rendered parietic, or it may be entirely paralyzed. The portions of the limbs which are to become the seat of paralysis usually exhibit a *sense of numbness* before the effects of the lesion are fully developed, and, in case the

¹ The reader is referred to the figure on page 626 of this volume.

² The reader is referred to the pages which treat of the clinical points pertaining to the sciatic nerve, for the symptoms of this type of paralysis.

posterior columns of the cord be involved, complete anæsthesia may also exist in the parts supplied with motor power by the sciatic nerve. The condition of the paralyzed muscles, as to their electrical reactions, and the presence or absence of the evidences of increased reflex excitability will depend greatly upon how much damage has been done to the gray matter of the lumbar enlargement. If the gray matter be so destroyed as to impair its function, the reflex movements will be absent; and, if the trophic function of the cord be affected by changes in the ganglion cells of the gray matter, the paralyzed muscles will undergo atrophy. The sense of constriction, or "band feeling," will usually be referred, in this lesion, either to the ankle, leg, or thigh.

FOCAL LESIONS CONFINED TO THE LATERAL HALF OF THE SPINAL CORD.

In discussing the focal lesions of the cord, we have described the clinical points which are afforded by destruction, to a greater or less extent, of the substance of the cord in both of its lateral halves; hence, the motor and sensory symptoms have been usually referred to both sides of the body. It was necessary to thus describe them, since focal lesions, unless traumatic, are seldom confined to one lateral half of the cord; but, in some cases which may be presented to your notice, where a tumor, a fractured vertebra, a hæmorrhage, a severe contusion, or some other localized lesion exists, the injury done to the spinal cord may be confined exclusively to one lateral half, resulting in one of two named conditions, viz., "spinal hemiplegia" and "hemi-paraplegia." Before proceeding to the special consideration of either of these conditions, it may prove of advantage to review some few points in the physiology of the cord, and to again direct your attention to the two plates upon the blackboard, which are already familiar to you.

This plate¹ shows you that any lesion of a *lateral half* of the spinal cord must produce anæsthesia in the *opposite side of the body*, since all the sensory nerves *décussate* and enter

¹ See Fig. 179 of this volume.

the gray matter of the cord, which serves as a conducting medium for sensory impressions, while the *motor symptoms* produced by the same lesion must be confined to the *same side of the body as the lesion*, since no decussation probably occurs in the spinal cord (these fibers decussating only in the medulla oblongata).

This second diagram¹ will further assist you to appreciate the fact that lateral lesions, as well as those which affect the entire cord, are modified, as regards their symptomatology, by the *height of the lesion* in the cord; since the motor nerves, and the special centers which are situated in the cord itself, will only be affected when they lie below the seat of the lesion or are directly involved in the destructive process. It will, therefore, be unnecessary to enter again into detail as to the full bearings of the plate, since they are probably fresh in your memory.

When the focal lesion is placed high up in the substance of the spinal cord, the motor paralysis affects *one side only* of the body (provided the lesion is confined to a lateral half), and the term "spinal hemiplegia" is applied to this form of paralysis in contradistinction to a hemiplegia of cerebral origin. If the spinal lesion be situated in the dorsal region and be confined to the lateral half of the cord, a motor paralysis of *one half* of the same side of the body *below the seat of the lesion* is developed, a condition to which the term "hemi-paraplegia" is commonly applied. In closing the clinical aspects of lesions of the spinal cord, it will be necessary, therefore, for us to consider the essential features of these two remaining conditions.

¹ The reader is referred to Fig. 179 of this volume for details as to the utility of this figure in the study of spinal affections.

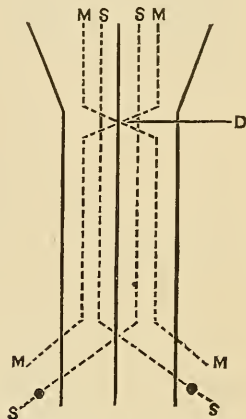


FIG. 186.—A diagram to show the course of the motor and sensory paths in the spinal cord. (Brown-Séguard.)

D, decussation of pyramids; M, motor paths; S, sensory paths.

SPINAL HEMIPLEGIA.

In order to produce a typical case of this condition, it is necessary to have a lateral focal lesion of the cord in its uppermost part (in or above the cervical enlargement of the cord). If we suppose, then, that such a lesion be present, let us see what we might reasonably expect, on purely physiological grounds, would be the result. We can then examine the clinical rec-

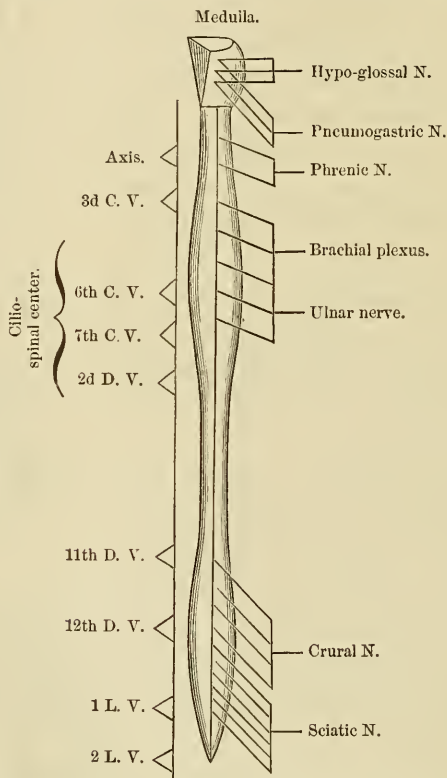


FIG. 187.—A diagram to show the relation of the spinous processes of the vertebrae to spinal nerves. (Malgaigne¹ and Seguin.)

ords of such cases, and either confirm our deductions or gain some additional information. Such a lesion would, in the first place, shut off all motor impulses sent out from the brain to parts below the lesion, on the same side as the lesion, since

¹ "Traité d'Anatomie Chirurgicale."

the decussation of the motor fibers has already taken place in the medulla ; hence motor paralysis should, theoretically, occur in the arm and leg of the side of the body corresponding to the seat of the exciting lesion, and the trunk should also be paralyzed upon that side. This we find, clinically, to be true,¹ with the exception that the *intercostal nerves* often retain their motor power when the nerves of the arm and leg are no longer capable of carrying motor impulses. In the second place, we should expect to find that the *sensation* of the side of the body opposite to the seat of the lesion would be destroyed or greatly impaired, since the sensory nerves decussate throughout the entire length of the cord. This we also find confirmed by clinical facts ; and so perfect is this anæsthesia that the line can often be traced to the mesial line of the body exactly, and upward to the limit of the exciting lesion. In the third place, the situation of the *cilio-spinal center* in the cervical region of the cord would naturally suggest some effects upon the pupil,² and the circulation and temperature of the face, neck, and ear of the same side. This is also confirmed, as the pupil does not respond to light, but it still acts in the accommodation of vision for near objects, and the skin of the regions named becomes red and raised in temperature. Finally, the presence of *vaso-motor centers* in the cord might occasion a rise in temperature in the paralyzed muscles ; and, strangely confirmatory of this fact, we often find the temperature of the paralyzed side of the body hotter than that of the anæsthetic side.

In some exceptional cases, the face, arm, and trunk are alone paralyzed, the legs seeming to escape, and often giving evidence of reflex spasm (perhaps most commonly on the anæsthetic side). This must be explained as the result of incomplete destruction of the lateral half of the cord.

¹ The researches of Brown-Séguard, as early as 1849, and his published memoirs (1863-'5 and 1868, 1869), have probably done more to clear up this field and to place it upon a positive foundation than those of any other observer.

² The reader is referred to pages 360 and 381 of this volume.

HEMI-PARAPLEGIA.

This condition is the result of some focal lesion of the spinal cord in the *dorsal region*, which involves only its lateral half. The results of such a lesion differ but little from those of one causing spinal hemiplegia, as regards the motor and sensory symptoms, excepting that the situation of the exciting cause is below the cervical enlargement, where the nerves to the upper extremity are given off, and where the cilio-spinal center is situated. For that reason the muscles of the upper extremity are not paralyzed, nor are the effects upon the pupil and the skin of the face, ear, and neck (mentioned as present in spinal hemiplegia) produced. The muscles below the seat of the lesion are paralyzed on the side of the body corresponding to the exciting cause, and the skin is sometimes rendered hyperæsthetic upon that side;¹ while the integument of the side opposite to the lesion is deprived of sensibility. The bladder and rectum may be paralyzed in some instances. The sense of constriction, or "band feeling," will vary with the seat of disease in the spinal cord. The amount of *reflex irritability* and the presence or absence of *muscular atrophy* in the parts paralyzed will depend upon the depth of the lesion in the spinal cord and the changes which have been produced in the gray matter. The same increase of temperature in the paralyzed limb, which was mentioned as occurring in spinal hemiplegia, may also be present in this variety of paralysis.

Should the side affected with anæsthesia give any evidence of motor paralysis or muscular weakness, or symptoms of anæsthesia appear upon the side where the motor paralysis is present, you may regard either one as conclusive evidence that the exciting lesion is progressing, and that the opposite lateral half of the cord is being involved to a greater or less extent.

¹ This is probably due to some irritation of the gray matter of the cord.

THE SPINAL NERVES.

*THEIR ORIGIN, DISTRIBUTION, FUNCTIONS, AND
CLINICAL IMPORTANCE.*



THE SPINAL NERVES.

WE have now considered the general points in the construction of the cerebro-spinal axis, and the clinical facts which pertain to the brain and spinal cord. We have also separately discussed those nerves which are connected with the brain, and have noted all the peculiarities in their distribution and anastomoses, which seem to shed a light upon their physiological action or the clinical features which each of them presents. It now remains for us to investigate those nerves of the neck, trunk, and the extremities which are connected with the spinal cord, and are called "spinal nerves," in contradistinction from the nerves of cranial origin, or those of the sympathetic.

The spinal nerves comprise thirty-one pairs, which escape from each side of the spinal cord by two roots, called the anterior or "motor root," and the posterior or "sensory root." These two roots join with each other, in every instance, to form one nerve, which is named in accordance with its situation and the region of the vertebral column from which it escapes; since the nerves, so formed, pass through foramina between the pedicles of the vertebræ, throughout the entire length of the spinal column. Thus we have *eight pairs of cervical nerves*, escaping upon either side of the cervical vertebræ; *twelve pairs of dorsal nerves*, bearing the same relation to the dorsal region of the spine; *five pairs of lumbar nerves* on each side; *five pairs of sacral nerves*,

escaping from the foramina of that bone; and *one pair of coccygeal nerves*.

As mentioned in the lectures upon the construction of the spinal cord, the anterior roots of the spinal nerves are connected with the gray matter of the anterior horns; while the posterior roots are connected with the posterior horns of the

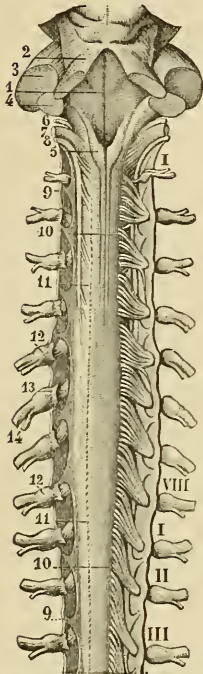


FIG. 188.—Cervical portion of the spinal cord. (Hirschfeld.)

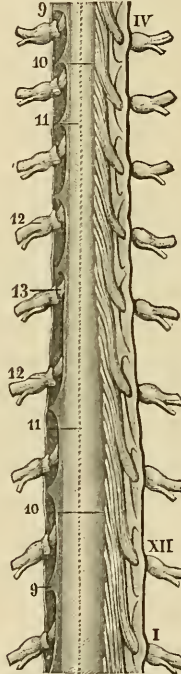


FIG. 189.—Dorsal portion of the spinal cord. (Hirschfeld.)

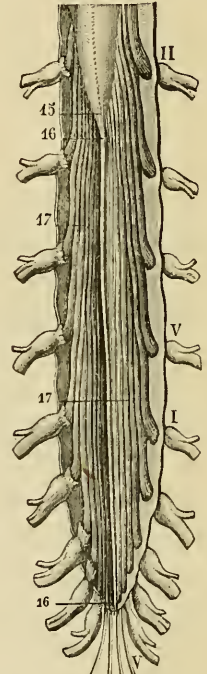


FIG. 190.—Inferior portion of the spinal cord, and cauda equina. (Hirschfeld.)

1, antero-inferior wall of the fourth ventricle; 2, superior peduncle of the cerebellum; 3, middle peduncle of the cerebellum; 4, inferior peduncle of the cerebellum; 5, inferior portion of the posterior median columns of the cord; 6, glosso-pharyngeal nerve; 7, pneumogastric; 8, spinal accessory nerve; 9, 9, 9, 9, dentated ligament; 10, 10, 10, 10, posterior roots of the spinal nerves; 11, 11, 11, 11, posterior lateral groove; 12, 12, 12, 12, ganglia of the posterior roots of the nerves; 13, 13, anterior roots of the nerves; 14, division of the nerves into two branches; 15, lower extremity of the cord; 16, 16, coccygeal ligament; 17, 17, cauda equina; I—VIII, cervical nerves; I, II, III, IV—XII, dorsal nerves; I, II—V, lumbar nerves; I—V, sacral nerves.

gray matter. Like all sensory nerves, the posterior roots have a *ganglionic enlargement*¹ developed upon them, while the

¹ The presence of a ganglion upon a cerebro-spinal nerve is always an evidence of its sensory character.

anterior roots, being motor in function, do not. The roots of the first cervical nerves are small, short, directed horizontally, and the anterior is the larger of the two ; those of the remaining cervical nerves become larger, longer, and more oblique as you descend the cord, and the posterior root is considerably larger than the anterior. In the dorsal region, the first dorsal nerve resembles the lower cervical nerves as to the actual and relative size of its roots, but the roots of the remaining dorsal nerves are smaller than those of the cervical region, and more nearly equal in their relative size. The roots of the lumbar and upper sacral nerves again increase in size from above downward. Finally, the lower sacral and the coccygeal nerves show a gradual decrease in the size of their roots, the last sacral and the coccygeal nerves having the smallest roots of any of the spinal nerves. As regards the relative size of the anterior and posterior roots, the lumbar, sacral, and coccygeal nerves exhibit but little difference.

The *length* and *inclination* of the roots of the spinal nerves increase from the first to the last ; hence the *place of escape* of a spinal nerve does not indicate its *seat of origin*. As the spinal cord does not descend beyond the first lumbar vertebra, the length of the roots of the lumbar, sacral, and coccygeal nerves increases, from nerve to nerve, by the thickness of one vertebra.

The trunk of each spinal nerve, after its escape from the vertebral canal, immediately divides into an anterior and a posterior primary division.

In treating of the spinal nerves, I will first direct your attention to the four upper cervical nerves, since they enter into the formation of the cervical plexus ; then to the remaining cervical and the first dorsal nerves, since they enter into the formation of the brachial plexus ; and, later on, the dorsal, lumbar, sacral, and coccygeal nerves will be separately considered. By this method of subdivision, which is the one usually followed by all authors upon anatomy, the nerves can be more satisfactorily traced from their origin to their terminal distribution than if each nerve were treated of separately,

since some enter into the formation of plexuses, and thus lose their individuality.

The axioms regarding the distribution of nerves to the muscles, joints, and skin, which I quoted in the first lecture of this winter's course, will be so constantly of use in the study of the spinal nerves that they will again bear repetition. The substance of my remarks in that lecture was about as follows :

It is claimed by John Hilton¹ that, if we trace the distribution of the nerve filaments from any special nerve trunk to the muscles, we shall find that only those muscles are supplied by each of the individual nerves which are required to render complete the performance of the *functions* for which that nerve was designed ; and that, if muscles were classified on a basis of their nerve supply, instead of in groups of mere relationship as to locality, a self-evident physiological relation would be shown which would tend greatly to simplify a knowledge of the muscular system in its practical bearings, and to prove a design on the part of the Creator.

Thus, he says, we frequently find muscles close together and still supplied by separate nerves, one of which has possibly to go a long way out of a direct course to reach it, which is contrary to the usual method of Nature, who always uses the simplest means to accomplish her designs ; but, if we examine the *action* of these two muscles, we will find that each one acts in unison with the other muscles supplied by the same nerve, and that, to produce this perfect accord, Nature takes what, to a hasty glance, would seem to be a needless step.

He also lays down certain axioms, pertaining to the distribution of nerves and the diagnostic value of pain, which have been often repeated in these lectures, and can not but be most profitable to those who use them as a guide. They are as follows :

“ Superficial pains on both sides of the body, which are symmetrical, imply an origin or cause, the seat of which is

¹ “ Rest and Pain,” London, 1876 (New York, 1879).

central or bilateral; while unilateral pain implies a seat of origin, which is one-sided, and, as a rule, exists on the same side of the body as the pain."

The bearings of this first axiom will be rendered very apparent when the regions of the neck and trunk are considered, since the symptom of local pain is of the greatest value in connection with diseases affecting the bones of the spinal column and the spinal cord which they invest; but that the same rule may be applied to any of the cranial nerves, with a degree of certainty which seldom admits of error, has been shown in cases quoted in connection with the motor oculi, trigeminus, facial, and other nerves.

The second axiom is as follows:

"The same trunks of nerves, whose branches supply the groups of muscles moving a joint, furnish also a distribution of nerves to the skin over the insertions of the same muscles; and the interior of the joint moved by these muscles receives a nerve supply from the same source."

By this axiom, a physiological harmony is shown between these various coöperating structures. Thus, any joint, when inflamed, may, by a reflex act through motor branches from the same trunk by which it is itself supplied, control the muscles which move it, and thus insure the rest and quiet necessary to its own repair.

Spots of local tenderness in the *cutaneous* surface may, for this reason, likewise be often considered as a guide to a source of irritation of some of the structures supplied by the same nerve, viz., the muscles underneath it, or the joints which are moved by them; and, thus, even remote affections can be accurately determined, which, were this axiom not used as a guide, might escape recognition till an advanced stage of the disease had been reached.

It is well, however, to quote one other axiom, laid down by the same author, before leaving the subject of the diagnostic value of the cutaneous nerves as indicators of existing disease of other organs, viz.:

"Every fascia of the body has a muscle or muscles at-

tached to it ; and every fascia must be considered as one of the points of insertion of the muscles connected to it," in following the previous axiom as to the cutaneous distribution of nerves.

This guide is especially important in case the rule be applied to the extremities (arms and legs) where these *fascia* extend over large surfaces, more or less remote from, and apparently unconnected with, the muscles attached to them ; but it is mentioned in this connection for the especial object of calling the attention of the reader to those general rules which govern the distribution of the nerves in their entirety, before proceeding to apply them in all their individual bearings :

Without this nervous association between the muscular structures and those composing the joints, there could be no intimation given by the internal parts of their exhaustion or fatigue. Again, through the medium of this same association between the skin and the muscles, great security is given to the joints, by the muscles being made aware of the point of contact of any extraneous force or violence. Their involuntary contraction instinctively makes the tissues surrounding the joints tense and rigid, and this brings about an improved defense for the subjacent joint structures.

From the conclusion of his great work, in which Hilton endeavors to prove that mechanical rest may be used as a cure for most of the surgical disorders, the following sentences are quoted, since they can not be too often repeated :

“I have endeavored to impress upon you the fact *that every pain has its distinct and pregnant signification if we will but carefully search for it.*

“In the pain which follows the intrusion of a particle of dust on to the conjunctiva, and the closure of the eyelid for the security of rest, up to the most formidable diseases which we have to treat—pain the monitor, and rest the cure—are starting points for contemplation, which should ever be present to the mind of the surgeon.”

Now, if you will thoroughly grasp these axioms, not only as mere words, but as *grand principles*, which can be used

by you in your every-day experience as counselors of the sick, you will be better able to appreciate the tables of nerve distribution which I am constantly presenting to you upon the blackboard, so that you can record them in your note-books. These tables enable you, at a glance, to see to what muscles each separate nerve sends filaments of distribution, and thus innumerable problems are being constantly suggested to you of this character: Why does this nerve supply the muscles mentioned and omit those in the immediate vicinity? What is the common *physiological function* which these muscles are destined to perform? How may this nerve be classed from its physiological action?

It is only by such a system of self-inquiry and self-examination that you are enabled to become the master of the science. The nerves are then no longer mere cords, running without a plan, and serving only as a tax upon the memory, but electric wires, placed with a system which we, as yet, can not begin to understand in its wonderful adaptability to the demands of the body, but which a little study will show is remarkable for its simplicity of distribution, if we but seek for the function of each nerve. To a student of this character, the nerves become a source of never-ending delight, since they serve as the key to many problems in anatomy which had previously been involved in obscurity. We thus learn the *action of the muscles*, since the nerves which supply any special group enable you at once to tell that those have a similarity of function which are supplied from the same source, while those supplied from different sources are not only dissimilar in their action, but have some bond of sympathy with other muscles (possibly far distant) which are similarly supplied. I believe that the day is not far off when the *nervous supply* will constitute the universally recognized basis upon which muscles will be divided into groups; and, when that day comes, the labor of the student will be greatly lessened, and his grasp of the subject be of a higher and more comprehensive order. We will now pass to the consideration of the upper four cervical nerves, and the cervical plexus which is formed by their anterior branches.

THE UPPER CERVICAL NERVES.

A CHART OF THE NERVES OF THE CERVICAL REGION.¹

FIRST CERVICAL NERVE (<i>Sub-occipital</i>).	<ul style="list-style-type: none"> Posterior division. Anterior division. 	<ul style="list-style-type: none"> Branch to posterior division of second cervical, Branches to the <i>posterior cranio-vertebral set</i> of muscles, Branch to complexus muscles, Branch to <i>integument of occiput</i>. Branch to rectus cap. ant. major, Branch to rectus cap. ant. minor, Branch to rectus cap. lateralis.
		<ul style="list-style-type: none"> Communicating branches to <ul style="list-style-type: none"> Second cervical, Pneumogastric, Hypo-glossal, Superior cervical ganglion. Branch to occipito-atloid articulation.
SECOND CERVICAL NERVE.	<ul style="list-style-type: none"> Posterior division (very large in size). Anterior division. 	<ul style="list-style-type: none"> External branch (supplying) <ul style="list-style-type: none"> Splenius, Cervicalis ascendens, Transversalis colli, Trachelo-mastoid, Complexus. Internal branch (<i>Great occipital nerve</i>). <ul style="list-style-type: none"> Joins with first cervical nerve, Supplies <i>integument of occiput</i> as far as vertex, Gives an <i>auricular branch</i> to skin of ear.
		<ul style="list-style-type: none"> Filament to sterno-mastoid, Ascending branch (to first cervical nerve), Descending branch (to third cervical nerve), Filament to communicans noni nerve, <i>Small occipital nerve</i> (occipitalis minor).
THIRD CERVICAL NERVE.	<ul style="list-style-type: none"> Posterior division. Anterior division. 	<ul style="list-style-type: none"> External branch (supplying) <ul style="list-style-type: none"> Splenius, Cervicalis ascendens, Transversalis colli, Trachelo-mastoid. Internal branch (supplying) <ul style="list-style-type: none"> <i>Integument of occiput</i>.
		<ul style="list-style-type: none"> Ascending branches. <ul style="list-style-type: none"> <i>Auricularis magnus,</i> <i>Superficial cervical,</i> Branch to second cervical nerve, Branch to the spinal accessory. Descending branches. <ul style="list-style-type: none"> Filament to fourth nerve, Filament to levator anguli scapulae, <i>Supra-clavicular,</i> Filament to communicans noni nerve, Filament to phrenic nerve.
FOURTH CERVICAL NERVE.	<ul style="list-style-type: none"> Posterior division Anterior division. 	<ul style="list-style-type: none"> (distributed to muscles of the back). Filament to third cervical nerve, Filament to fifth cervical nerve, Filament to <i>phrenic nerve</i>, Filament to scalenus medius, Filaments to <i>supra-clavicular nerve</i>.

¹ Modified from a table in the "Essentials of Anatomy" (Darling and Ranney). New York, Putnam's Sons, 1880.

If you will look at the table, which I have had copied for your inspection,¹ you will perceive that each of the upper four cervical nerves gives off an anterior and posterior branch, immediately after their escape from the vertebral canal, and that the distribution of each of these branches is shown in detail. You will perceive that every branch which supplies the in-

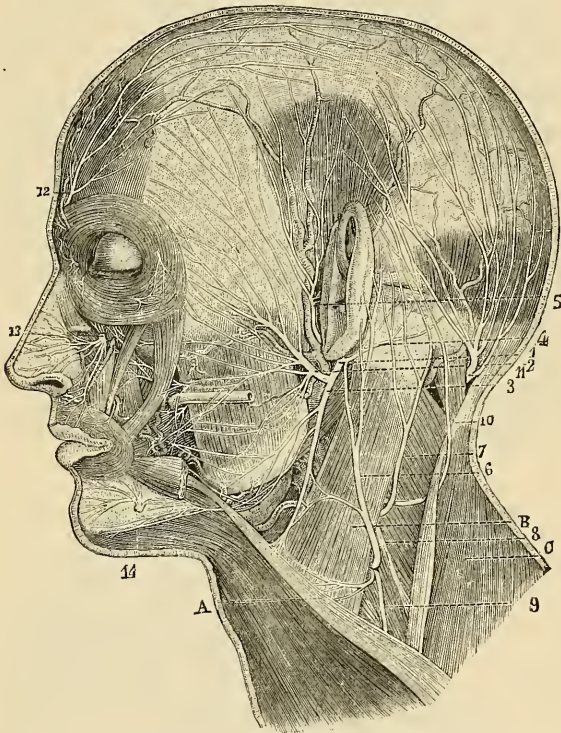


FIG. 191.—*Posterior branch of the second cervical nerve.* (Arnold.)

1, trunk of the facial; 2, its superior branch, or temporo-facial; 3, the inferior branch, or cervico-facial; 4, its posterior auricular branch; 5, auriculo-temporal; 6, auricularis magnus from the cervical plexus; 7, its mastoid branch; 8, supra-acromial branch; 9, supra-clavicular branch; 10, accessory occipitalis minor; 11, *occipitalis major*; 12, frontal division of the ophthalmic nerve; 13, infra-orbital branch of the superior maxillary; 14, mental branches of the inferior dental nerve; A, platysma myoides; B, sterno-mastoid; C, trapezius.

tegument alone is underscored,² while the muscular branches are not. Thus, the great occipital, small occipital, great auricular, superficial cervical, and supra-clavicular nerves are

¹ See table on the preceding page.

² *Italicized* in the table.

made particularly prominent. It will tend, however, to simplify the study of this table, if you will compare it with the one adjoining, which shows the construction of the cervical plexus.

This plexus is formed by the *anterior branches* of these four nerves, so that you will find the same nerves mentioned in both tables; since, in the first table, a nerve may be mentioned as one of the terminal filaments of a special trunk, while, in the second table, it will be enumerated as one of the branches of the plexus. I mention this point, lest some confusion may arise in your minds as to the apparent contradiction of statement, as well as for the purpose of impressing upon you the fact that a branch of any nerve plexus can usually be traced as arising from some special nerve or nerves, which assist to form that plexus. Thus we have the *phrenic nerve* arising by three heads (third, fourth, and fifth cervical), and, in part, a branch of three nerves; and again, the *communicans noni nerve*, which goes to join a branch of the hypo-glossal,¹ arises by two heads (second and third cervical).

THE CERVICAL PLEXUS OF NERVES.

Anterior branch of 1st CERVICAL nerve. Anterior branch of 2d CERVICAL nerve. Anterior branch of 3d CERVICAL nerve. Anterior branch of 4th CERVICAL nerve.	} CERVICAL PLEXUS.	{ SUPERFICIAL BRANCHES (integumentary).	{ Ascending set.	{ Occipitalis minor. Filament to attollens aurem. Auricularis magnus. Superficialis colli. Branch to platysma.	
			{ Descending set.	{ Supra-clavicular branches. (Sternal, Clavicular, Acromial.	
		} DEEP BRANCHES.	{ Internal set.	{ Communicating. ²	{ Pneumogastric, Hypo-glossal, Sympathetic.
				{ Muscular	{ Rect. cap. ant. major, Rect. cap. ant. minor, Rect. cap. lateralis. Communicans noni.
		{ External set.	{ Muscular.	{ Sterno-mastoid, Levator anguli scapulae, Trapezius, Scalenus med.	
			{ Communicating with spinal accessory nerve.		

The table which illustrates the method of construction of the cervical plexus and its branches of distribution may be

¹ See page 521 of this volume.

² The loop between the first and second cervical nerves usually gives off the communicating branches to pneumogastric and hypo-glossal nerves and to the superior cervical ganglion of the sympathetic, while the third and fourth cervical nerves give communicating branches to the main cord of the sympathetic nerve.

studied with some advantage. It will be seen that the plexus gives off two distinct sets of branches, called the superficial and the deep, since the former, as the name indicates, are all

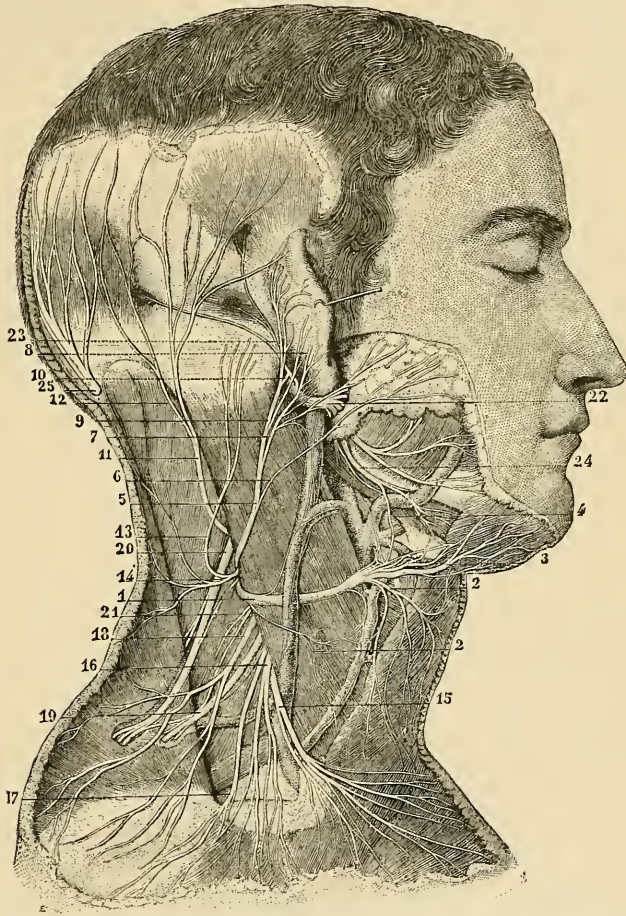


FIG. 192.—*Superficial branches of the cervical plexus.* (Hirschfeld.)

1, superficialis colli; 2, 2, its descending branches; 3, its ascending branches; 4, filaments of anastomosis with the facial; 5, auricularis magnus; 6, its parotid branch; 7, its external auricular branch; 8, upper part of the same branch, crossing the fibrous tissue which surrounds the root of the helix, and supplying the external surface of the pinna; 9, internal auricular branch; 10, filament of anastomosis between this branch and the posterior auricular of the facial; 11, occipitalis minor; 12, branch of communication with the occipitalis major; 13, accessory occipitalis minor; 14, branches to the integument on the back of the neck; 15, supra-clavicular branches, sternal portion; 16, clavicular portion; 17, supra-acromial branches, anterior division; 18, posterior division; 19, branch to trapezius from cervical plexus; 20, branch to trapezius from the spinal accessory, and anastomosing with the preceding; 21, branch to the levator anguli scapulae; 22, trunk of the facial; 23, its posterior auricular branch; 24, its cervical and mental branches.

cutaneous, while the latter are distributed to muscles and adjacent nerves. The superficial or integumentary set comprises four nerves, three of which ascend toward the head, while the remaining one descends toward the shoulder; the deep set is subdivided into branches which pass toward the mesial line of the trunk, the internal set, and those which pass away from the mesial line, the external set.

SUPERFICIAL BRANCHES OF THE CERVICAL PLEXUS.

The superficial set of branches is of the greatest importance to the physician, since the symptom of pain is often a most positive guide to disease, which can be localized by a thorough knowledge of the nerves. The sub-occipital nerve

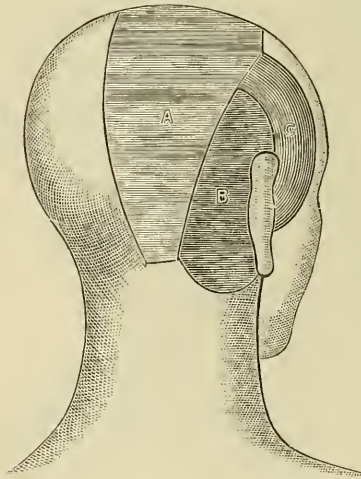


FIG. 193.— *The nerve supply of the posterior part of the head.* (Hilton.)

A, region supplied by the great occipital nerve; B, region supplied by the small occipital nerve; C, region supplied by the auriculo-temporal nerve.

(first cervical), the great and small occipital nerves (branches of the second cervical), and the auricularis magnus (a branch of the third cervical) are all distributed to the *integument of the scalp*, in the posterior region of the head, covering the space which extends from the neck to the vertex of the cranium. The plate which I now show you was designed by

Hilton,¹ to illustrate the results of careful experiment as to the limits of the cutaneous distribution of each of these nerves.

In my lecture upon the distribution of the fifth cranial nerve, I called your attention to the diagnostic value of the cutaneous distribution of the nerves of the ear. It may be

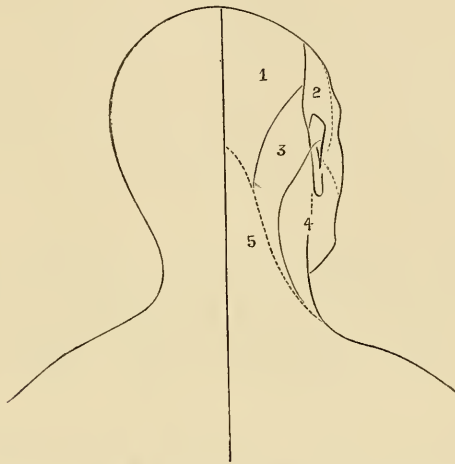


FIG. 194.—*The nerve supply of the posterior portion of head and neck.* (Modified from Flower.)

1, region supplied by the great occipital nerve ; 2, region supplied by the auriculo-temporal nerve ; 3, region supplied by the small occipital nerve ; 4, region supplied by the great auricular nerve ; 5, region supplied by the third cervical nerve.

well to again state that the integument of the pinna is supplied by the fifth cranial, the great auricular, the auricular branch of the great occipital, and the small occipital nerves,² and to impress upon you that the limits of the distribution of each are now so well defined as to afford a clew, in many instances where pain is confined to this region, to the seat of the exciting cause.

¹ *Op. cit.*

² The *auricular branch* which Hilton lays stress upon, as supplying the *lobule* of the ear with sensation, may be given off either by the anterior or posterior division of the second cervical nerve. In the table of the distribution of the cervical nerves I have put it down as a branch of the *great occipital* nerve, since that is its most common origin ; but it, not infrequently, is found to arise from the small occipital nerve, in which case it would be derived indirectly from the anterior division of the second cervical, rather than from the posterior division.

The descending branches of the superficial set of the cervical plexus (supra-clavicular) arise from the third and fourth cervical nerves, and are distributed to the integument covering the lower portion of the neck and the regions of the sternum, clavicle, and acromion. The fact that the filaments of these nerves are distributed to the *fascia covering the upper portion of the chest*, below the clavicle, is made a point of diagnostic importance by Hilton, since cases of disease of the spinal column, in the region of escape of the third or fourth cervical nerves, or the existence of pressure along the course of these nerves, have been suggested to him by pain in this region, and thus detected far away from the seat of pain. He says: "As nothing but the nerves can produce pain, this simple distribution ought to remind us of the fact that, if a patient complains of pain in this part of the chest, the cause may lie in one of two directions. It may depend upon disease of the cervical region of the spine, or in connection with some disease affecting the origin of the upper dorsal nerves."

The cervical plexus lies upon the scalenus medius and the levator anguli scapulæ muscles, and is covered by the sternomastoid muscle; hence, all of its superficial branches emerge from beneath the posterior border of this latter muscle.¹ The muscles which the plexus supplies directly are the three which lie in contact with it and the trapezius. Now, it will be remembered that the trapezius and the sternomastoid muscles have another source of nervous supply, viz., the spinal accessory nerve.² This fact suggests that these muscles must each belong to two groups: the first, those which control *phonation*; ³ the second, those which insure the ordinary motions of the neck. In the same way, the platysma muscle, by its nervous supply, is clearly stamped as not only a muscle of the neck, but also *one of expression*,⁴ since the facial nerve supplies it, as well as the cervical plexus.

¹ See figure on page 651 of this volume.

² See page 508 of this volume.

³ See page 509, previous lecture, upon this nerve.

⁴ For the action of this muscle in the expression of melancholy, see the facial nerve.

DEEP BRANCHES OF THE CERVICAL PLEXUS.

A second reference to the table, in which the branches of this plexus are shown, will enable you to recall the subdivision of the deep branches. The set that passes toward the mesial line of the body comprises the muscular filaments to the recti muscles, the communicating branches to adjacent nerves, and two specially named trunks, the phrenic and communicans noni nerves; while the set which passes toward the periphery of the neck comprises the muscular branches to the sterno-mastoid, trapezius, levator anguli scapulæ, and the scalenus medius, and communicating filaments to adjacent nerves.

The *filaments of communication* between the cervical plexus and the pneumogastric, hypo-glossal, spinal accessory, fifth cranial, and sympathetic nerves, have been already discussed in connection with each of these nerves. They all indicate some definite purpose on the part of Nature, and can best be reviewed by a careful perusal of the notes taken by you in the early part of this course of lectures.¹ Many of the diagrams of the special nerves mentioned will make points clear to you which it is useless to repeat.

The *communicans noni nerve*, whose origin can be traced to two filaments connected with the second and third cervical nerves, is of surgical interest from the relation which it bears to the sheath of the carotid artery; and the branches which are given off from the loop, formed by its junction with the descendens noni nerve, can be seen by referring to the diagram of the hypo-glossal nerve.² Occasionally this nerve is found to enter the sheath of the carotid artery, and to anastomose with the descendens noni nerve in this abnormal situa-

¹ For the association between the fifth cranial nerve and the second cervical in the integumentary supply of the ear, see page 403; between the facial nerve and cervical nerves, see page 432; between the pneumogastric nerve and the arcade formed by the first and second cervical nerves, see diagram of pneumogastric on page 484; between the spinal accessory nerve and the upper cervical nerves and its physiological bearing, see pages 508 and 513; finally, between the hypo-glossal nerve and the communicans noni nerve, see plate on page 521 of this volume.

² See page 521 of this volume.

tion.' From the loop which it helps to form, filaments are given to the sterno-thyroid, sterno-hyoid, and both bellies of the omo-hyoid muscle. Thus these muscles are placed under the control of two nerves; the one (*communicans noni nerve*)¹ enabling them to act in harmony with the muscles of the neck, while the other (*descendens noni nerve*) enables them to assist in depressing the larynx and the hyoid bone, after the bolus of food has passed the isthmus of the fauces, thus acting in harmony with the tongue, which is also supplied by the hypoglossal nerve. We can perceive, therefore, that these muscles are concerned in two distinct functions—the movements of the neck and the act of deglutition and speech; hence they must of necessity be separately supplied by the nerves of the neck and that of the tongue, in order to properly perform the two acts independently of each other.

The *phrenic nerve*, called also the “internal respiratory nerve of Bell,”² arises, by three heads, from the third, fourth, and fifth cervical nerves. Its course and distribution give it a surgical as well as a physiological importance. It lies in front of the scalenus anticus muscle, and thus in relation to the second portion of the subclavian artery; lower in the neck, it passes between the subclavian vein and the first portion of the subclavian artery; when it has entered the superior opening of the chest, its course upon the left side of the body lies in front of the arch of the aorta and the pulmonary artery, but upon the right side the nerve passes external to the superior vena cava and the right innominate vein; each nerve crosses in front of the root of the corresponding lung, gives off twigs to the pericardium and pleura, and perforates the diaphragm, to be distributed to its under surface. Both nerves give filaments to the phrenic plexus of the sympathetic, and the right nerve furnishes some filaments to the diaphragmatic ganglion.

The distribution of the phrenic nerves to the diaphragm is mentioned by Hilton³ as one of the simple devices of

¹ It is sometimes found beneath the jugular vein, and, occasionally, in front of it.

² This name was applied to the phrenic nerve by Bell, since it passes internally to the chest wall, and assists in the physiological act of respiration.

³ *Op. cit.*

Nature to guard the nerves from injury. I quote from his excellent treatise as follows: "As a rule, nerves enter the muscles where they will be most secure from pressure, and it is curious to observe how careful Nature has been in this respect to guard one of the most important nerves in the body. The phrenic nerves (our life hangs on these threads), after passing through the chest, traverse the diaphragm and distribute their branches to the *under surface* of the diaphragm, and are so situated that they can not be compressed during respiration. If they were situated upon the upper surface of the diaphragm, where there is a constant and forced contact between the base of the lung and the superior aspect of the diaphragm, and especially so during a retained inspiration, it is obvious that the filaments of the phrenic nerve would, under such circumstances, be exposed or subjected to compression, and the action of the diaphragm would be dangerously interfered with. The nerves are, however, distributed to the under or concave surface of the diaphragm; the whole tendency of gravitation being to remove the liver, the stomach, and the spleen away from them, so as to enable the nerves to carry on their influence to the diaphragm unmolested."

How extraordinary is it that the phrenic nerve (a nerve so important to life) can pass through the chest between the dilated heart and the inflated lungs, and yet, as far as we know, never receive any untoward influence from pressure! It is true that the lungs have a remarkably definite concave form toward the heart, arching over the course of the phrenic nerve; but, when the lungs are emphysematous, it seems quite probable that these nerves might suffer from pressure, and cause some difficulty in breathing. When extravasation of air occurs from rupture of the trachea or a large bronchial tube, the patient dies rapidly from extreme shortness of breath; and this can be explained by the fact that the air enters the tract of the phrenic nerve, thus causing extreme pressure and death from paralysis of the diaphragm.

The distribution of the phrenic nerves to the *pericardium*

seems to warrant the supposition of Hilton that the pericardium may be considered as a portion of the fascial tendon of the diaphragm, since it is closely identified with it, and is acted upon by it, at all times. It may also be considered as probable that the phrenic nerves are endowed with some *sensory* filaments,¹ by communication with other nerves; and the analogy of the pericardium and diaphragm to a joint, so beautifully pointed out by Hilton, where the fibrous layer of the heart sac resembles the capsular ligament, the serous layer the synovial membrane, and the diaphragm the muscle which moves it, is confirmed by the similarity of nervous distribution.² We know that in pericarditis the patients complain of a sense of constriction and tightness in the chest, and are afflicted with a shortness of breath; we also see an inflamed condition of this membrane creating a spasm of the diaphragm, precisely as the nerves of an inflamed joint create a contraction of the adjacent muscles; and why are we not justified in attributing these symptoms to the analogy which anatomy so well sustains, and the axiom of nerve supply to joints seems to confirm?

CLINICAL POINTS PERTAINING TO THE CERVICAL NERVES.

The distribution of the branches of the upper four cervical nerves, which have been considered in some detail in the preceding lecture, may be said to furnish sensory filaments to the skin covering the occipital region as high as the vertex, and the integument of the neck, in its posterior and lateral aspects, as far down as the shoulder. The muscular filaments given off by these nerves have little clinical interest, since the diseases which are most frequently met are confined chiefly to the great occipital nerve, the cutaneous branches of the neck, and the phrenic. We will consider, therefore, only

¹ Luschka and Henle regard the phrenic as a mixed nerve. This view seems to be sustained by cases of neuralgia (as reported by Falot, Peter, Erb, and others) which have been produced by irritation of this nerve. The development of Luschka's ganglion upon this nerve seems to be a further evidence of the existence of sensory as well as motor fibers within the phrenic.

² See axioms of nerve distribution, on page 645 of this volume.

that type of neuralgia which affects the regions of the occiput and neck called "cervico-occipital neuralgia" and the nervous disorders dependent upon the distribution of the phrenic nerve.

Cervico-occipital Neuralgia.—This is a rare form of disease. It is induced by exposure, perhaps, more frequently than by any other cause. It may be also the result of diseases of the spinal column, such as periostitis, spondylitis of the cervical region, tumors, and injuries; also of wounds of the nerves, irritation of the cervical portion of the spinal cord, enlarged lymphatic glands, neuromata, tumors of the neck or spinal cord, foreign bodies, etc. Aneurism of the vertebral artery has been known to produce it.

The pain of this type of neuralgia may be continuous or paroxysmal, and either circumscribed or widely diffused over the entire occipital and cervical regions. In severe paroxysms of pain, the movements of the head and the acts of speech and mastication may be rendered difficult or impossible. Movements of the head, and the acts of laughing, sneezing, and mastication, often tend to excite the paroxysms of pain.¹

As in many other forms of neuralgia, certain points of extreme tenderness, the "*puncta dolorosa* of Valleix," may be detected, and these may be distinctly located at the following spots:

1. Where the great occipital nerve escapes *at the occiput*, between the mastoid process and the first cervical vertebra.

2. Where the branches of the cervical plexus escape around the posterior border of the sterno-mastoid muscle, in the *middle point of the neck*. (This point of tenderness may be absent.)

3. Where the small occipital and great auricular nerves escape to the surface, just *behind the mastoid process*.

4. Where the frontal branch of the trigeminus, the great auricular, and the occipital nerves meet, over the situation of the *parietal protuberance*.

¹ The fixed attitude in which this class of patients hold their heads is very characteristic.

5. Where the auricular nerves meet, on the *concha* of the ear.¹

It is the detection of these points of tenderness² that assists the diagnostician to discriminate between rheumatic pains and those of a purely neuralgic character, and it will usually be observed that the paroxysms of pain start from these points of tenderness. This type of neuralgia is often associated with a similar affection of the fifth nerve, and occasionally of the brachial plexus. It may be followed by nutritive disturbances, such as falling out of the hair over the affected region. The duration of this form of neuralgic pain varies from a few days, to weeks, months, or even years, depending somewhat upon the exciting cause.

DISORDERS OF THE PHRENIC NERVE.

The phrenic nerve may manifest the effects of irritation in the form of neuralgia, clonic spasm (hiccough), and tonic spasm of the diaphragm; and also that of a more serious impairment of its function, as diaphragmatic paralysis.

Diaphragmatic neuralgia seems to be manifested (in those few reported cases which are well authenticated) by a pain which begins in the base of the thorax, at the point of insertion of the diaphragm, and which radiates upward into the territory of the shoulder and neck, which is supplied by the cutaneous branches of the cervical plexus. The *points of tenderness* which exist in this affection seem to be most marked (1) in the region of origin of the phrenic, near to the spinous processes of the middle three cervical vertebræ; (2) over the nerve, as it enters the supra-clavicular fossa; and (3) at the anterior insertions of the diaphragm, between the seventh and the tenth ribs. It is claimed by Erb that a point of tenderness can often be detected over the cartilage of the third rib, but I find it difficult to explain this symptom on

¹ This point of tenderness is often absent.

² It will be noticed that these points of circumscribed tenderness correspond, in every instance, to the approach of some nerve or its terminal filaments to the surface of the body. The points of subdivision of a nerve trunk into its branches of distribution are often the seat of this excessive sensitiveness to pressure.

anatomical grounds, although its presence in some cases seems to be proven.

The pain of phrenic neuralgia is more or less continuous, since the incessant movements of the diaphragm tend to excite it; but exacerbations, of a character closely resembling distinct paroxysms, are often observed, when the pain becomes lancinating and causes impeded respiration. The efforts of coughing, sneezing, or exertion of any kind which involves the muscles of the trunk, are rendered difficult and painful. Muscular debility and tremblings in the upper extremity are sometimes present. As this type of neuralgia often accompanies organic lesions of the heart, concomitant phenomena, such as cardiac palpitation, angina pectoris, etc., may coexist.

Although phrenic neuralgia is not infrequently an independent and primary disease in the anæmic and nervous class of patients (especially after exposure to cold, dampness, etc.), still it is far more commonly met with as a concomitant affection of some other disease. It is therefore always best to look for the existence of heart lesions, aneurism of the mediastinum, Basedow's disease, angina pectoris, and diseases of the liver and of the spleen, since they may explain the phrenic symptoms and modify the prognosis.

The close resemblance which this type of neuralgia has to attacks of diaphragmatic pleurisy, pericarditis, uncomplicated angina pectoris, and gastralgia, makes the situation of the diagnostic points of tenderness an important factor in the discrimination.

Violent spasmodic contractions of the diaphragm, termed *clonic spasm* or "*hiccough*," are accompanied by an inspiratory sound, interrupted by a sudden spasm of the constrictors of the glottis, and followed by a short expiration. The symptoms produced by this condition depend upon the intensity and duration of the attack. In severe cases there may be pain, embarrassment of speech, dyspnœa, and retraction of the epigastric region. The causes of hiccough may be classed under three heads: 1, those of direct irritation of the

phrenic, as occurs in the case of mediastinal tumors, aneurism of the arch, pneumonic or pleuritic inflammation, pressure from pleuritic effusion, etc. ; 2, those of a reflex nature, as in diseases of the urinary organs, the uterus, and the intestinal tract and the liver ; the irritation of biliary or renal calculi ; irritation of the pharynx, œsophagus, and stomach ; and diseases of the peritonæum ; 3, those of central origin, as occurs in hysteria, local, brain, or spinal diseases, blood poisoning (as in the fevers, cholera, dysentery, etc.), after emotional excitement, and from the general anæmia of nerve centers after hæmorrhage. You can see from this list of causes that the symptom of hiccough, if occurring late in connection with any form of disease, may be a most serious symptom.

Tonic spasm of the diaphragm is a rare form of disease. It has been called "diaphragmatic tetanus." The symptoms of this obscure affection have been developed through the experiments of Duchenne upon animals, and the careful observations of Valette, Fischl, Vigla, Oppolzer, Duchenne, and others upon man.

The patient is at once markedly asphyxiated, the liver is displaced downward by the contracted diaphragm ; the lower half of the thorax is enlarged and rendered immovable ; the inspirations are extremely short, and the expirations are noisy and prolonged. The face shows the evidences of anxiety and cyanosis ; the pulse is slow and diminished in volume ; and the voice is monotonous in tone, and often interrupted. Acute pains pervade the lower regions of the thorax, and shoot over the epigastrium. While one case seems to have ended fatally, all other reported cases have recovered.

Paralysis of the diaphragm may occur as a symptom of hysteria, lead poisoning, the advanced stages of progressive muscular atrophy, and paralysis of the bulbar nuclei. It may be also produced by the extension of inflammation in cases of pleurisy or peritonitis, thus creating exudation or suppuration in the substance of the muscle.

When this condition is fully developed, the abdominal walls are retracted during each inspiratory effort, while the

lower portion of the thorax is distended ; in expiration, however, the hypochondriac region, as well as the epigastric, sinks in, while the chest becomes diminished in its capacity. The respiration becomes slow and difficult, and speaking or muscular movements increase the embarrassment of this function. The voice is usually enfeebled, and may be entirely lost. The liver tends to rise in the chest, during inspiration, rather than to be displaced downward into the abdomen.

THE FOUR LOWER CERVICAL NERVES.

As was the case with the four upper nerves, which escape from the cervical portion of the spinal cord, the four lower divide into anterior and posterior divisions, as soon as they escape from the spinal foramina. The *anterior divisions* of each join to form the brachial plexus of nerves, which sends filaments of distribution to the neck, shoulder, upper extremity, and side of the thorax. The *posterior divisions* do not form a plexus,¹ but are separately distributed to the semispinalis, complexus, splenius, and trapezius muscles, and then send twigs to the integument² over these muscles, viz., over the region of the spine in the lower part of the neck.

The following table³ will assist you in mastering the construction of the brachial plexus, and in understanding the plates of that complicated mesh-work of nerves. It may be well to remark that the diagrams of this plexus are seldom alike in the works of any two authors ; since, if they are intended to be accurate representations of the parts, they naturally tend to show the great dissimilarities which exist in the union of the different nerves which help to form it, while, if purely diagrammatic, no two authors would naturally follow the same schematic plan. Notwithstanding the dissimilarities which exist, there are, however, points of resemblance

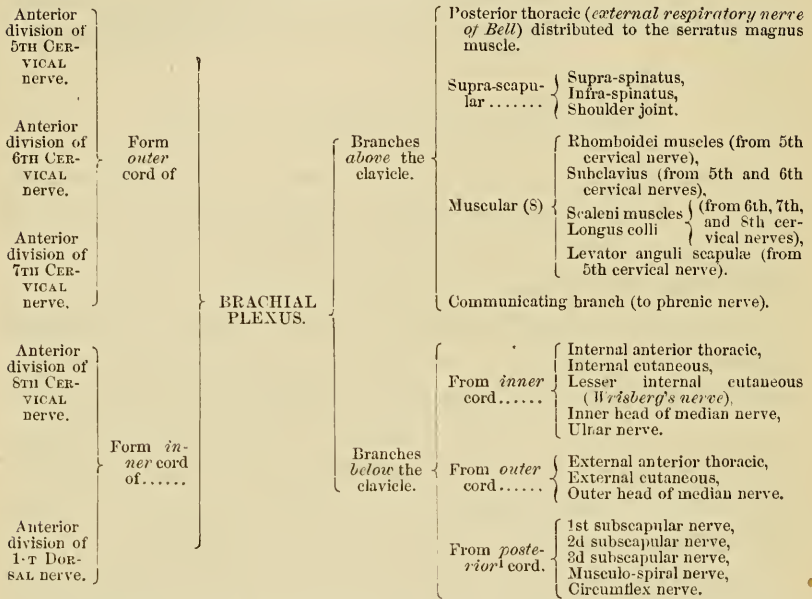
¹ In the case of the three upper cervical nerves, an anastomosis of the posterior divisions occurs, to which Cruveilhier applies the term "posterior cervical plexus."

² See researches of Cruveilhier, Sappey, Hirschfeld, and others.

³ Modified from tables in "The Essentials of Anatomy" (Darling and Ranney). G. P. Putnam's Sons, New York, 1880.

in them all, which consist in the delineation of an outer cord formed by the fifth, sixth, and seventh cervical nerves; an inner cord formed by the eighth cervical and first dorsal nerves; and a middle cord formed by a branch from both the outer and the inner, which subsequently unite.

THE BRACHIAL PLEXUS.



This table and the diagram (after Gray) shown on the next page will help to make clear the method of construction of the brachial plexus, and the main branches which are given off from its different portions. It will be perceived that the branches of distribution are subdivided into *two sets*: those given off above the line of the clavicle and those given off below that line. The former set, if traced, will be seen to supply the muscles of the scapular region, some of the muscles of the neck, the serratus magnus (a muscle of respiration), and the subclavius. The branch of communication which helps to complete the formation of the phrenic nerve is also shown to arise from the fifth cervical nerve. The branches

¹ The *posterior cord* of the brachial plexus is formed by a branch from both the inner and outer cord.

which are given off below the line of the clavicle are distributed to the muscles of the upper extremity, and will be considered in detail in subsequent tables and diagrams.

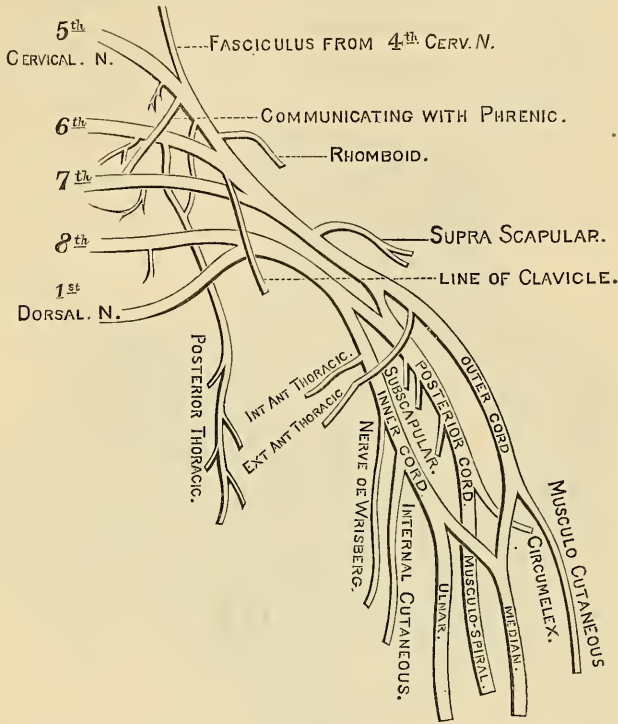


Fig. 195.—A diagram of the brachial plexus and its branches. (Gray.)

Varieties, more apparent than real, are frequently met with in the formation of this plexus,¹ resulting from the corresponding increase or diminution in the size of the above anastomotic branches, and of the portion of the posterior cord which is given off by the seventh cervical nerve. The posterior cord may be occasionally formed by the seventh cervical nerve alone; while it may in some instances be formed by two bands, arising from the fifth and sixth nerves, without any assistance from the seventh nerve. Other variations may re-

¹ The dissections and paper of R. C. Lucas upon this point ("Guy's Hospital Reports" 1875) and the description of this plexus by Henle seem to confirm each other as regards the abnormalities of its formation.

sult from the branches of the plexus being given off at a higher or lower point than usual, and also by the seventh nerve joining the plexus at a higher or lower level than normal.

The brachial plexus, as a whole, is broad between the middle and anterior scaleni muscles, at which point it lies immediately *above* the second portion of the subclavian artery; it is contracted in size opposite the clavicle, where the outer and inner cords lie on the *outer side* of the third portion of the subclavian artery; and, in the axilla, it again expands, the three cords bearing the relation to the second portion of

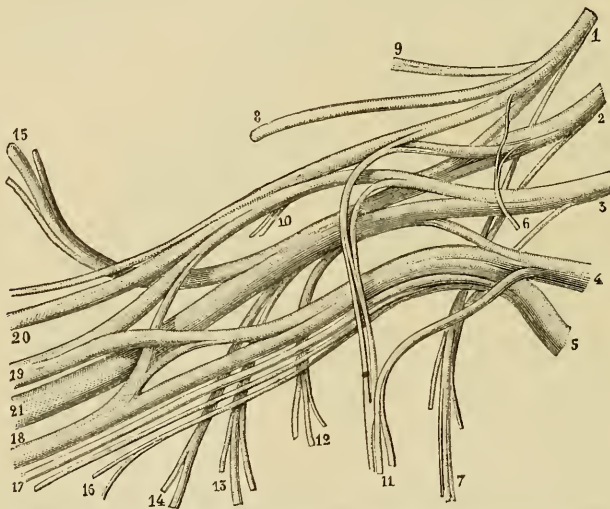


FIG. 196.—*Anterior branches of the four last cervical and the first dorsal nerves.* (Hirschfeld.)

- 1, anterior branch of the fifth cervical, ordinarily united with the sixth cervical before dividing; 2, anterior branch of the sixth cervical; 3, anterior branch of the seventh cervical; 4, anterior branch of the eighth cervical; 5, anterior branch of the first dorsal; 6, origin of the subclavian nerve; 7, posterior thoracic arising from the fifth, sixth, and seventh cervical nerves; 8, supra-scapular; 9, common trunk of of the branches supplying the levator anguli scapulae and the rhomboidei; 10, superior subscapular; 11, anterior thoracic branches; 12, inferior subscapular; 13, long subscapular; 14, separate branch to the teres major; 15, circumflex nerve; 16, lesser internal cutaneous; 17, internal cutaneous; 18, ulnar; 19, median; 20, musculospiral; 21, radial.

the axillary artery which their names designate. Thus it will be perceived that this plexus has important surgical relations with the last two portions of the subclavian artery and the two upper portions of the axillary artery. The terminal branches of the three cords are also in relation with the third

portion of the axillary artery, since they almost entirely surround it.

The preceding cut of the brachial plexus, taken from the superb anatomical work of Sappey, will enable you to con-

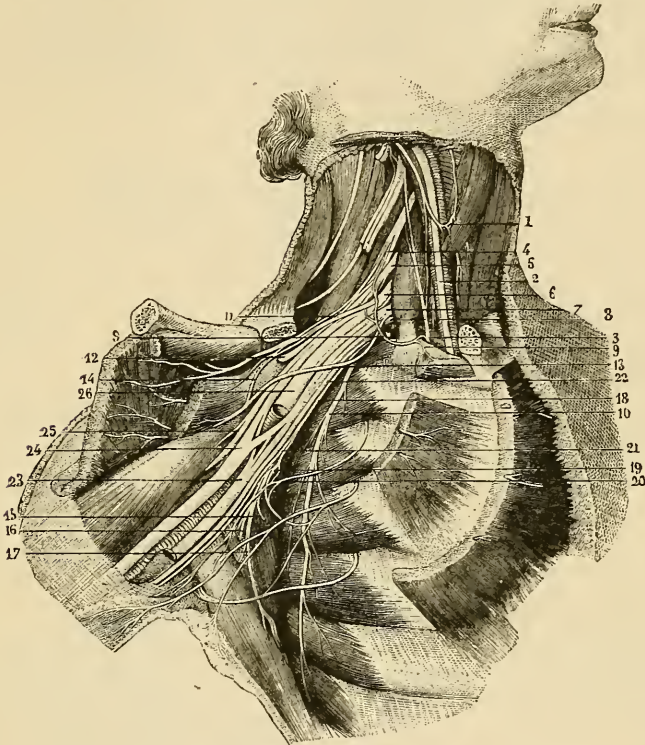


FIG. 197.—*Collateral branches of the brachial plexus.* (Hirschfeld.)

- 1, arcade formed by the anastomosis of the descending branch of the hypo-glossal with the internal descending branch of the cervical plexus; 2, pneumogastric nerve; 3, phrenic nerve; 4, anterior branch of the fifth cervical pair; 5, anterior branch of the sixth cervical pair; 6, anterior branch of the seventh cervical pair; 7, 8, anterior branch of the eighth cervical pair and first dorsal pair; 9, 9, branch to the subclavius muscle; 10, long thoracic nerve; 11, nerve to the pectoralis major giving off a filament to anastomose with that supplying the pectoralis minor; 12, supra-scapular nerve passing under the coracoid ligament; 13, nerve supplying the pectoralis minor muscle; 14, branch supplying the pectoralis minor muscle given off from the one which supplies the pectoralis major muscle; 15, inferior branch of the subscapularis; 16, nerve to the teres major muscle; 17, nerve to the latissimus dorsi muscle; 18, accessory branch of the internal cutaneous; 19, an anastomosis of this branch with the perforating branch of the second intercostal nerve; 20, ramification of the accessory branch of the internal cutaneous nerve; 21, internal cutaneous nerve; 22, ulnar nerve; 23, median nerve; 24, musculo-cutaneous nerve; 25, musculo-spiral nerve.

trast the diagrammatic plate of Gray¹ with the actual representation of the parts under consideration.

¹ See page 666 of this volume.

COMMUNICATIONS OF THE PLEXUS.

The brachial plexus communicates with the *cervical* plexus by a branch which joins the fourth and fifth nerves, and by one head of the phrenic nerve. It also sends filaments to the *middle and inferior cervical ganglia* of the sympathetic, and, in this way, anastomoses with the corresponding filaments of the *first dorsal nerve*.

NERVES OF THE UPPER EXTREMITY.

BRANCHES OF THE OUTER CORD OF THE BRACHIAL PLEXUS.¹

Branches of the OUTER CORD of the brachial plexus.	(1) EXTERNAL ANTERIOR THO- RACIC	} Pectoralis major.	}	Muscular branches.	{	Coraco-brachialis,	
						Biceps,	
						Brachialis anticus.	
						<i>Integument</i> of the front of forearm,	
	(2) EXTERNAL OF MUSCULO-CU- TANEOUS	} Anterior branch.	{	} <i>Integument</i> of ball of thumb, Joins with the radial nerve.			
					} Posterior branch.	{	<i>Integument</i> of radial side of back of fore- arm.
							Joins with the radial nerve. Joins with the external cutaneous branch of the musculo-spiral nerve.
					} Articular branch.	{	} To elbow joint.
	(3) MEDIAN . .	} In fore- arm.	{	} Muscu- lar.	{	Pronator radii teres,	
Flexor carpi radialis,							
Palmaris longus,							
Flexor sublimis digitorum.							
Flexor longus pollicis,							
Flexor profundus digitorum (its outer half),							
Pronator quadratus.							
<i>Integument</i> of palm,							
<i>Integument</i> of ball of the thumb.							
} In the hand . .						{	} External branch.
	<i>Digital</i> to thumb (palmar sur- face),						
	<i>Digital</i> to index finger (outer side).						
	} Internal branch.	{	<i>Digital</i> to contiguous sides of index, middle, and ring fin- gers,				
			Filaments to the two outer lumbricales muscles.				

¹ Modified from a table in "The Essentials of Anatomy" (Darling and Ranney). G. P. Putnam's Sons, New York, 1880.

BRANCHES OF THE INNER CORD OF THE BRACHIAL PLEXUS.¹

Branches of the INNER CORD of the brachial plexus.	(1) INTERNAL AN- TERIOR THORAC- IC.	{	Both pectoral muscles (since its filaments lie above and underneath the pectoralis minor muscle).			
			(2) INTERNAL CUT- TANEOUS.	{	Anterior branch. { <i>Integument</i> of the anterior surface of the inner side of the forearm as low as the wrist.	
	Posterior branch. { <i>Integument</i> of the posterior surface of the inner side of the forearm to near the wrist.					
	(3) LESSER IN- TERNAL CUTA- NEOUS. (Wris- berg.)	{	May, occasionally, be wanting (the intercosto-humeral nerve taking its place).			
			<i>Integument</i> of the posterior surface of the lower third of the arm (joining with the intercosto-humeral nerve and the posterior branch of the internal cutaneous nerve).			
	(4) ULNAR.	{	In the forearm.	Articular (to elbow joint)—several small filaments.	{	
				Muscular.		Flexor carpi ulnaris, <i>Inner half</i> of flexor profundus digitorum.
				Palmar cutaneous.		<i>Integument</i> of front of wrist and palm of hand.
				Dorsal cutaneous.		<i>Integument</i> at back of wrist and one and one half fingers on inner side of dorsal surface of hand.
				Articular.		To wrist joint.
Superficial branches.				Palmaris brevis, <i>Integument</i> of inner one and one half fingers on palm.		
In hand.				Deep branches.		Muscles of little finger, Interossei muscles, The <i>two inner</i> lumbricales, Adductor pollicis, Flexor brevis pollicis (<i>inner head</i>).

The accompanying tables will afford us a better conception of the distribution of the branches of the three *main cords* of the brachial plexus than a long verbal description; while they will also enable us, in studying the practical points suggested by the distribution of each branch, to use the eye as well as the intelligence in following the subsequent lectures. It is often impossible for one, not previously familiar with the detail of the nerve distribution of any part, to appreciate all the deductions which may be drawn by an author, without much labor in reviewing the preceding text of the work which he may be endeavoring to master; and I believe that, in fol-

¹ Modified from a table in "The Essentials of Anatomy" (Darling and Ranney). New York: G. P. Putnam's Sons, 1880.

lowing these lectures, these tables will greatly assist in such review, as well as in affording you a chart which can be used as a guide to the preliminary study required in your future attempts to master other treatises.

BRANCHES OF THE POSTERIOR CORD OF THE BRACHIAL PLEXUS.¹

Branches of the POSTERIOR CORD of the brachial plexus.	(1) SUBSCAPULAR NERVES.	The <i>upper</i> , or 1st.	Subscapular muscle.					
		The <i>long</i> , or 2d.	Latissimus dorsi.					
		The <i>lower</i> , or 3d.	Teres major.					
	(2) CIRCUMFLEX.	Superior branch.	Deltoid. <i>Integument</i> over the back of the shoulder.					
		Inferior branch.	Teres minor, Deltoid (posterior portion), <i>Integument</i> over the outer part of the shoulder.					
		<i>Muscular</i> branches.	Triceps, Anconeus, Brachialis anticus, Supinator longus, Extensor carpi radialis longior.					
	(3) MUSCULO-SPIRAL.	Cutaneous branches.		<i>Integument</i> of the inner and posterior portions, and the outer and anterior portions of arm,				
				<i>Integument</i> of the outer aspect of the forearm.				
		RADIAL NERVE.	External branch.	<table border="0" style="display: inline-table; vertical-align: middle;"> <tr> <td style="padding-right: 5px;">{</td> <td style="padding-right: 5px;"><i>Integument</i> of outer side of thumb.</td> </tr> <tr> <td style="padding-right: 5px;">}</td> <td style="padding-right: 5px;"><i>Integument</i> of ball of the thumb.</td> </tr> </table>	{	<i>Integument</i> of outer side of thumb.	}	<i>Integument</i> of ball of the thumb.
			{	<i>Integument</i> of outer side of thumb.				
			}	<i>Integument</i> of ball of the thumb.				
	Internal branch.	<table border="0" style="display: inline-table; vertical-align: middle;"> <tr> <td style="padding-right: 5px;">{</td> <td style="padding-right: 5px;"><i>Integument</i> of 3½ fingers on radial side of dorsum of hand.</td> </tr> </table>	{	<i>Integument</i> of 3½ fingers on radial side of dorsum of hand.				
	{	<i>Integument</i> of 3½ fingers on radial side of dorsum of hand.						
	POSTERIOR INTEROSSEOUS NERVE.	<table border="0" style="display: inline-table; vertical-align: middle;"> <tr> <td style="padding-right: 5px;">{</td> <td style="padding-right: 5px;">All muscles on back of forearm except three</td> </tr> <tr> <td style="padding-right: 5px;">}</td> <td style="padding-right: 5px;">Anconeus, Supinator longus, Ext. carp. rad. long.</td> </tr> </table>	{	All muscles on back of forearm except three	}	Anconeus, Supinator longus, Ext. carp. rad. long.		
	{	All muscles on back of forearm except three						
}	Anconeus, Supinator longus, Ext. carp. rad. long.							
		Filaments to the wrist joint.						

There are still some points pertaining to the individual branches of the brachial plexus which can not be shown in a tabular arrangement, but which are, nevertheless, important, as they will enable you to better understand the surgical and medical aspects which are constantly brought to the attention of the active practitioner. In order to avoid, as far as possible, any important omissions, and to afford you a more practical insight into the uses to which a knowledge of the nerves can be applied, I will ask you to follow me in a review of the

¹ Taken, by permission of the publishers, from "The Essentials of Anatomy" (Darling and Ranney). New York: G. P. Putnam's Sons, 1880.

nerves of the upper extremity, using the tabulated charts¹ as a means of reference, should you become confused as to the source of origin of the nerve under discussion, or fail to grasp its subdivisions and their distribution.

THE ANTERIOR THORACIC NERVES.

These two nerves are termed the external and the internal, since one arises from the outer cord, and the other from the inner cord of the brachial plexus. The external is sometimes also called the superficial, since it crosses in front of the axillary artery and vein to reach the under surface of the great pectoral muscle;² while the internal is also called the deep, since it passes between the same artery and its accompanying vein, to be distributed to the under surface of both the great and small pectoral muscles. The two nerves are connected with each other by a loop situated on the inner side of the axillary artery. It is probable (following the axiom of Hilton as to the cutaneous distribution of nerves) that the skin over the pectoral region receives filaments from these nerves as well as from the intercostal nerves. As the pectoral muscles are agents in effecting inspiration, when any impediment exists to breathing, as in asthma, etc., these nerves might be classed as respiratory in function, although that is not their most frequent use.

THE EXTERNAL CUTANEOUS OR MUSCULO-CUTANEOUS NERVE.

This nerve and its branches will be found given in the table of the subdivisions of the outer cord³ of the brachial plexus. It passes through the belly of the coraco-brachialis muscle (hence the name "musculo-cutaneous"), then between the biceps and the brachialis anticus muscles, to a point slightly above the external condyle of the humerus, where it *perforates the deep fascia* and divides into its cutaneous

¹ See pages 668, 669, and 670 of this volume.

² The anterior fibers of the deltoid muscle are said to be supplied chiefly by the thoracic nerves, as revealed by clinical facts.

³ See page 668 of this volume.

branches beneath the median cephalic vein. Now, a reference to the table of its distribution will show you that three muscles, which move the arm, are supplied with motor power by means of this nerve; hence we should expect to find that filaments would be sent to both the shoulder and elbow joints, which these muscles move, and I am inclined to think that

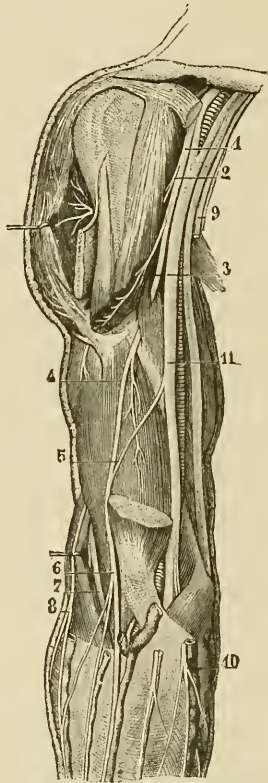


FIG. 198.—*Brachial portion of the musculo-cutaneous, median, and ulnar nerves.* (Sappey.)

1, musculo-cutaneous nerve; 2, branch to the coraco-brachialis muscle; 3, branch to the biceps muscle; 4, branch to the brachialis anticus; 5, anastomotic filament which it receives from the median nerve; 6, division of this nerve where it crosses the aponeurosis of the arm; 7, musculo-spiral nerve passing between the brachialis anticus and supinator longus muscles; 8, external cutaneous branch of the musculo-spiral nerve; 9, trunk of the internal cutaneous dividing just below its origin, thus giving off an accessory branch; 10, anterior or ulnar branch of this nerve; 11, brachial portion of the median and ulnar nerves.

small filaments to the former joint do actually exist, although they are not mentioned in the usual text-books upon anatomy.

We would also expect that any injury¹ to the trunk of this nerve would be followed by paralysis or atrophy of these three muscles, as well as by a condition of hyperæsthesia or anæsthesia in the portions of integument supplied by its terminal filaments (the radial side of the forearm and the ball of the thumb); provided that the nerve be irritated or only partly destroyed, as shown in the first case, or entirely destroyed, in which case the latter condition should ensue.

It is a well-recognized surgical fact that an inflamed condition of the elbow joint tends to create flexion of the forearm, by a contracted state of the brachialis anticus and biceps muscles; and the distribution of the musculo-cutaneous nerve² to the joint, as well as to these two muscles, enables us now to understand why the irritation of the articular branches of this nerve should manifest itself in a contracted state of the muscles supplied by it.

The relation of this nerve to the median-cephalic vein will also explain why *venesection* at the elbow is liable to be followed by the so-called "bent arm." This fact, which has been explained by some authors as the result of an injury done to the fascia, is much more intelligently, to my mind, attributed by Hilton to an injury done to the filaments of the musculo-cutaneous nerve, resulting in a sympathetic contraction of the flexors of the elbow.

An exostosis growing from the humerus, or the existence of a tumor in the region of the course of this nerve, might cause a similar rigidity of the elbow joint, accompanied, moreover, by a pain which would follow the course of the nerve to its terminal filaments. It has been suggested, by the author above quoted,³ to apply anæsthetics over the course of this nerve in order to insure relaxation of the

¹ Hilton reports a case where an officer in the navy presented a very marked instance of injury done to this nerve alone. It caused paralysis and atrophy of the three muscles supplied by the musculo-cutaneous nerve; but a perfect recovery took place in about two years, in spite of the atrophy which at first existed.

² The ulnar nerve also furnishes filaments to the elbow joint and supplies the flexor muscles of the forearm. This may also tend to explain the surgical fact that flexion follows inflammation of the elbow.

³ Hilton, *op. cit.*

muscles supplied by it when the elbow is thus flexed. Many cases may be cited from different surgical and medical authors, to illustrate the diagnostic value of this and other nerves, in determining accurately the seat and character of disease which is producing distress to the patient; but, as this aid to diagnosis has already been discussed at some length in previous lectures, I will simply mention it as an incentive to anatomical study.

The cutaneous distribution of this nerve will be made clear by referring to the diagram which I now show you.¹ The clinical value of the cutaneous nerves has already been referred to in previous lectures.² It will therefore suffice to again mention, in this connection, that hyperæsthesia, local pain, local points of tenderness, and anæsthesia have often a most direct and positive bearing upon diagnosis; and the *axioms* given in the first lecture upon the spinal nerves will prove most valuable as guides to the proper appreciation of their significance.

It may strike some of you who have thought deeply concerning the peculiarities of nerve distribution, that this nerve ought to stop at the elbow, since it has supplied all of its muscles before it reaches that point, and has, therefore, apparently performed its function; and this feeling will possibly be strengthened by the axiom given you in a previous lecture,³ viz., that a nerve is always associated with that portion of the integument which covers the *points of insertion* of the muscles to which it furnishes motor power. If you will examine closely, however, into the insertion of the biceps muscle, you will observe that it is intimately connected with the *fascia* of the forearm—so intimately that this fascia is, in reality, an inherent part of the insertion of that muscle. This, then, confirms not only the truth of the general axiom given by Hilton,⁴ but also explains to the inquiring mind why this nerve should be continued downward to the wrist, since it has to do so in order to cover the skin over one of the most impor-

¹ See page 682 of this volume.

² See pages 645 and 646 of this volume.

³ See page 645 of this volume.

⁴ *Op. cit.*

tant points of insertion of a muscle which it controls. Other facts in the anatomy of the forearm seem to still more beauti-

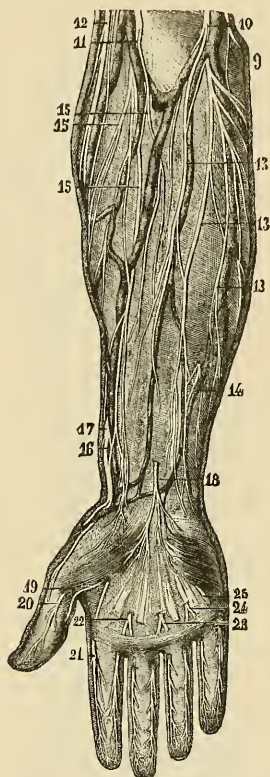


FIG. 199.—*Cutaneous nerves of the anterior surface of the forearm and hand.* (Hirschfeld.)

9, epi-trochlear branch from the musculo-spiral nerve anastomosing by a division with the anterior branch of the same nerve; 10, 10, anterior branch of the internal cutaneous of the arm dividing into several branches, some of which pass in front of and others behind the median basilic vein; 11, 11, musculo-cutaneous nerve crossing the aponeurosis of the arm outside of the tendon of the biceps muscle; 12, 12, divisions of the external cutaneous branch of the radial distributing themselves to the skin of the posterior portion of the forearm; 13, 13, 13, divisions which the anterior branch of the internal cutaneous furnishes to the forearm; 14, anastomosis of one of these divisions with a perforating branch of the ulnar nerve; 15, 15, 15, terminal divisions of the musculocutaneous nerve; 16, anastomosis of one of these divisions with 17, the terminal anterior branch of the radial nerve; 18, palmar cutaneous branch of the median; 19, internal branch of distribution to the thumb; 20, external branch of distribution to the same; 21, external branch of distribution to the index finger; 22, trunk of the branches of distribution to the internal side of the index and external aspect of middle fingers; 23, common trunk of distribution to the internal side of the middle and external side of the ring fingers; 24, trunk of distribution to the internal side of the ring and external side of the little finger; 25, branch of distribution to the internal side of the little finger.

fully confirm this same general law. We see the musculo-spiral nerve sending a filament to nearly the same region as the musculo-cutaneous, because it supplies the supinator longus, which is situated upon the outer side of the forearm; while, again, the internal cutaneous nerve (which properly may be considered as a branch of the median, since it arises by a common head) supplies the skin of the inner side of the anterior surface of the forearm, for the evident reason that the muscles supplied by the median are extensively attached to this same fascia.

CLINICAL POINTS PERTAINING TO THE MUSCULO-CUTANEOUS NERVE.

A paralysis limited to this nerve is an unusual occurrence. It may be produced, however, by any form of injury or of local pressure which alone involves this nerve trunk, and it must be situated in the region of the coraco-brachialis muscle to create impairment of all of its filaments of distribution. Complete paralysis of this nerve causes total paralysis of the biceps and coraco-brachialis muscles, but only a partial loss of power in the brachialis anticus, since that muscle is also furnished with a filament derived from the musculo-spiral nerve. The skin of the outer border of the forearm is also rendered anæsthetic when this nerve is injured. As a result of paralysis of the muscles named, the power to *flex the forearm* upon the arm is greatly impaired, and would be totally lost if the supinator longus and a part of the brachialis anticus muscles were not capable of assisting that movement. These latter muscles, being supplied by the musculo-spiral nerve, still retain their power of contraction; hence the difficulty in performing flexion of the forearm is greater when the hand is supinated, as the supinator longus no longer acts to any great extent as a flexor.¹ The seat of the anæsthesia is a valuable guide to the nerve affected, as the musculo-cutaneous

¹ The supinator muscle is an important aid in flexion of the forearm, when the *hand is pronated*; but it is of little value as a flexor after the function of supination has been performed by it.

neous nerve may possibly be involved, without any impairment of the other branches of the outer cord of the brachial plexus.

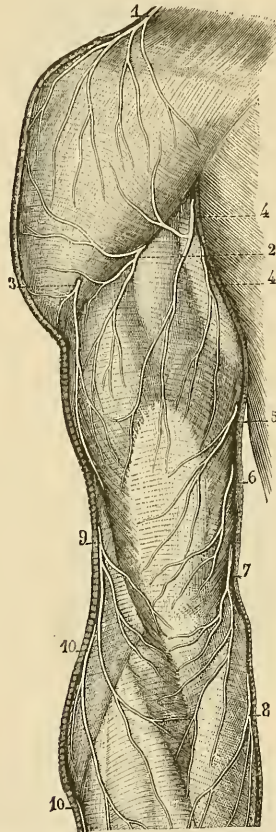


FIG. 200.—*Cutaneous nerves of the shoulder and posterior surface of the arm.* (Sappey.)

1, 1, terminal ramifications of the supra-acromial branch of the cervical plexus; 2, cutaneous branch of the circumflex nerve; 3, another cutaneous branch of the same nerve traversing the posterior border of the deltoid; 4, terminal divisions of the perforating branch of the second intercostal nerve; 5, perforating branch of the third intercostal nerve; 6, internal cutaneous branch of the musculo-spiral nerve; 7, epitrochlear branch of the internal cutaneous nerve; 8, posterior division of the ulnar branch of the internal cutaneous; 9, external cutaneous division of the radial nerve; 10, 10, internal cutaneous filament of the radial nerve.

THE MEDIAN NERVE.

While this nerve arises by two heads, derived, respectively, from the outer and inner cords of the brachial plexus, it has been classed as a branch of the former.¹ This nerve bears a

¹ The reader is referred to the table on page 664 of this volume.

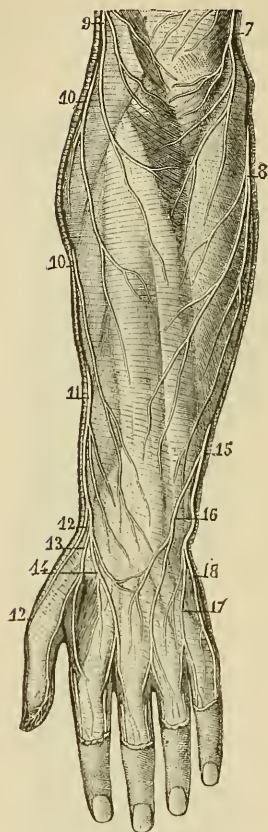


FIG. 201.—*Cutaneous nerves of the posterior surface of the forearm and hand.* (Sappey.)

7, epi-trochlear branch of the internal cutaneous nerve; 8, posterior division of the ulnar branch of the internal cutaneous; 9, external cutaneous division of the radial nerve; 10, 10, internal cutaneous filament of the radial nerve; 11, posterior division of the anterior terminal or cutaneous branch of the radial nerve; 12, first twig rising from this branch (it forms the external dorsal nerve of distribution to the thumbs); 13, second twig of the same division (it subdivides at the superior part of the first interosseous space—one of these divisions forms the internal dorsal cutaneous nerve of the thumb, the other ramifies in the skin of the dorsal face of the first phalanx of the index finger); 14, third branch, which descends into the second interosseous space, where it bifurcates (one of these divisions is lost in the internal half of the integument on the dorsal surface of the first phalanx of the index finger, and the other in the external half of the skin which covers the dorsal surface of the middle finger); 15, dorsal branch of the ulnar nerve; 16, external division of this branch anastomosing with one or two filaments of the anterior terminal branch of the radial passing directly into the third interosseous space, where it divides (one of these divisions ramifies in the internal half of the skin which invests the first phalanx of the middle finger, the other supplies the first phalanx of the ring finger); 17, second ramification of the same branch, which also bifurcates under the fourth interosseous space (one of these divisions ramifies in the skin on the dorsal surface of the first phalanx of the ring finger, the other forms the external dorsal nerve of distribution to the little finger); 18, internal dorsal nerve of distribution to the little finger.

surgical relation to the brachial artery, since it lies, at first, upon the outer side of that vessel, then crosses it, and, finally, reaches its inner side at the bend of the elbow. It enters the forearm between the two heads of the pronator radii teres muscle, passes down the middle line of the anterior surface of the forearm till it reaches the annular ligament of the wrist, then passes underneath the arch formed by that ligament, when it becomes flattened and expanded in front of the flexor tendons in the palm of the hand, and finally terminates in branches to the muscles and integument of the hand and fingers. The table, which has been referred to in previous lectures,¹ will show, more plainly than a tedious verbal description, the parts supplied by this nerve in the different portions of its course. This nerve, in connection with its fellow, the ulnar nerve, furnishes motor power to all the flexor and pronator muscles of the forearm, and all the muscles of the palm of the hand; the median supplying all the muscles on the anterior surface of the forearm but one and a half (the flexor carpi ulnaris, and one half of the flexor profundus digitorum), and four and a half muscles on the radial side of the palm (as shown by the table). Now, as the ulnar nerve supplies all the rest of the muscles of the anterior surface of the forearm and hand, these two nerves may be considered as the *flexor and pronator nerves* of those regions.²

The *cutaneous distribution* of the median nerve is of interest, since it confirms the axiom³ of nerve distribution to the integument over the muscles. We find that the median sends no cutaneous filaments to the dorsal surface of the thumb, but that it does supply its palmar surface; the dorsal surface is covered with the extensor tendons, which owe their motor power to the posterior interosseous branch, and the skin is therefore supplied from the same source. The sides of the *outer two and a half fingers* (those adjoining the thumb) are likewise

¹ See page 668 of this volume.

² In speaking of the combined action of the median and ulnar nerves, Hilton says: "These nerves, together, supply all the flexors of the wrist joint, fingers and thumb, all the pronators of the radio-ulnar joints, and all the joints that these muscles move."

³ See page 643 of this volume.

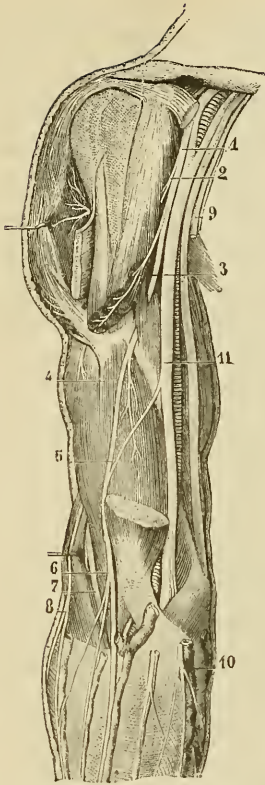


FIG. 202.—*Brachial portion of the musculocutaneous, median, and ulnar nerves.* (Sappey.)

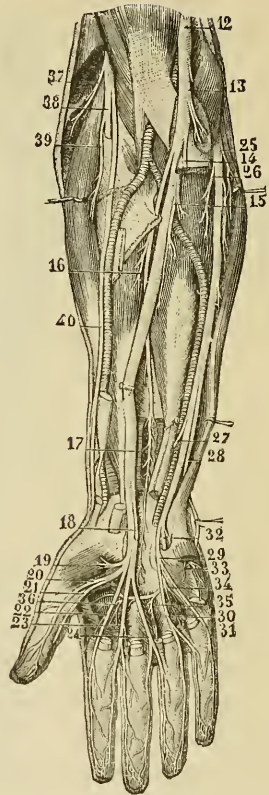


FIG. 203.—*Terminal portion of the median and ulnar nerves.* (Sappey.)

- 1, musculocutaneous nerve; 2, branch to the coraco-brachialis muscle; 3, branch to the biceps muscle; 4, branch to the brachialis anticus; 5, anastomotic filament which it receives from the median nerve; 6, division of this nerve where it crosses the aponeurosis of the arm; 7, musculospiral nerve passing between the brachialis anticus and supinator longus muscles; 8, external cutaneous branch of the musculospiral nerve; 9, trunk of the internal cutaneous dividing just below its origin, thus giving off an accessory branch; 10, anterior or ulnar branch of this nerve; 11, brachial portion of the median and ulnar nerves; 12, antebrachial portion, palmar and digital branches of the same nerve; 13, branch to the pronator radii teres; 14, trunk of these anterior muscular branches dividing and passing to the muscles to which they are distributed; 15, branch to the flexor profundus digitorum; 16, branch to the flexor longus pollicis; 17, anterior interosseous branch; 18, palmar cutaneous branch dividing just below its origin; 19, muscular branch of the thenar eminence; 20, external branch of distribution to the thumb; 21, internal branch of distribution to the same; 22, external branch of distribution of the index finger; 23, common trunk of the internal branches of distribution to the index finger and external to the middle finger; 24, internal trunk of distribution to the middle and external branch to the ring finger; 25, branch which the ulnar nerve furnishes to the flexor carpi ulnaris; 26, branches which the same nerve furnishes to the two internal fasciculi of the flexor profundus digitorum; 27, cutaneous and anastomotic filament of the ulnar nerve; 28, dorsal branch of this nerve; 29, its superficial palmar branch; 30, common trunk of the internal branch of distribution to the ring and external branch to

the little finger; 31, internal branch of distribution to the little finger; 32, deep palmar branch; 33, small branch to the hypo-thenar eminence; 34, branches to the muscles of the fourth interosseous space and the fourth lumbricalis muscle; 35, branches to the muscles of the third interosseous space and the third lumbricalis muscle; 36, branches to the adductor pollicis and muscles of the first and second interosseous spaces.

supplied with integumentary branches from the median, the balance being supplied by similar branches of the ulnar nerve.

The two outer lumbricales muscles are enumerated in the preceding tables, as supplied by the median, and the remaining lumbricales and interossei muscles by the ulnar nerve. Now, the method of insertion of the tendons of these muscles (into the extensor tendon of the corresponding finger, on its dorsal surface) causes these muscles to *flex the proximal phalanx*, and *extend the two remaining phalanges*¹ of each finger. We find, therefore, that the nerve branches, which supply these muscles, send cutaneous filaments to the *dorsal surface* of the two terminal phalanges of the finger upon which the individual muscles act, thus apparently confirming the extensor action of the muscles, since the distribution of nerves, derived apparently from a flexor source, comprises a region covered by the extensor tendons of the fingers.

CLINICAL POINTS PERTAINING TO THE MEDIAN NERVE.

The median nerve is rarely affected with paralysis, to the exclusion of other nerves. If such a condition exists, it may probably be traced to some local injury, such as cuts, fractures of the humerus, the use of badly constructed crutches, contusions over the course of the nerve, gunshot wounds, unskillful venesection, local pressure from tumors, abscess, etc. It may possibly be due to rheumatism, neuritis,² neuromata, and central causes. The muscles of the ball of the thumb, which are supplied by this nerve, are frequently the seat

¹ Hunter, Cleland, Duchenne, Erb, and others consider the *interossei muscles* alone as extensors of the two terminal rows of phalanges. Clinical facts observed in lead paralysis and in division of the ulnar nerve seem to point to these muscles rather than to the lumbricales, although Hilton groups the lumbricales and interossei muscles as possessing a common function.

² This condition may follow any acute disease. It is one of the sequela of typhoid fever.

of a progressive muscular atrophy and its consequent paralysis.

From what has already been said respecting the distribu-

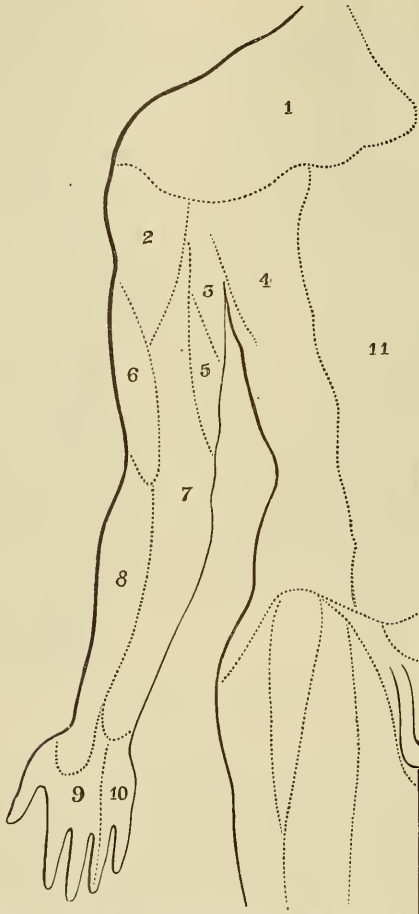


FIG. 204.—A diagram of the regions of cutaneous nerve distribution in the anterior surface of the upper extremity and trunk. (Modified from Flower.)

1, region supplied by the supra-clavicular nerve (branch of the cervical plexus); 2, region supplied by the circumflex nerve; 3, region supplied by the intercosto-humeral nerve; 4, region supplied by the intercostal nerve (lateral branch); 5, region supplied by the lesser internal cutaneous nerve (nerve of Wrisberg); 6, region supplied by the musculo-spiral nerve (external cutaneous branch); 7, region supplied by the internal cutaneous nerve; 8, region supplied by the musculo-cutaneous nerve; 9, region supplied by the median nerve; 10, region supplied by the ulnar nerve; 11, region supplied by the intercostal nerve (anterior branch).

tion of this nerve, we are prepared to understand why the common flexors of the fingers and those of the wrist should

show a loss of power, in case the median be injured, and the muscles of the thumb give evidence of the diseased condition. You will find, in such cases, that the second phalanges of all the fingers and the third phalanges of the index and middle fingers can not be flexed, and that the thumb can not be flexed or brought into contact with the little finger. On the other hand, flexion of the first phalanx, with extension of the other two, can be performed in all the fingers by the aid of the interossei which are supplied by the ulnar nerve. The position of the thumb is peculiar; it is extended and adducted and thus closely applied to the index finger, as in the hand of the ape. The hand, when flexion at the wrist is attempted, is *strongly adducted* by the action of the flexor carpi ulnaris, as the antagonistic muscle of the radial side is paralyzed. The act of pronation of the hand is seriously impaired. The inner three fingers can be brought into a partially flexed condition, since the flexor profundus digitorum muscle is partly supplied by the ulnar nerve. These combined effects give to the hand and fingers, and especially to the thumb, a position so peculiar that paralysis of the median could hardly be mistaken by an anatomist for any other deformity. When the paralyzed muscles begin to show the results of atrophy, the deformity in the forearm and in the ball of the thumb will further assist in the diagnosis of this affection.

The anastomosis which exists between the cutaneous nerves of the forearm will possibly tend to explain the fact that complete destruction of the median, ulnar, or radial nerves may exist without any marked loss of sensibility in the regions supplied by the affected nerve. Should any such evidences of disordered sensibility be present, however, it will be confined to the region supplied by the nerve which is the seat of disease, or whose conducting power has been impaired from any cause. If the median, ulnar, or radial nerves be injured below the wrist, the absence of anastomosis tends to make the

¹ The flexor sublimis digitorum being completely paralyzed, and the flexor profundus digitorum being partially deprived of its motor power.

symptom of anæsthesia a constant and important guide to the nerve affected.

In severe paralysis of the median nerve, the first three fingers¹ not infrequently show trophic disturbances in the skin and nails, such as glossy fingers, ulceration, pemphigus vesicles, abnormal growth of hair, etc.

The relation of the median nerve to the brachial artery gives to it a surgical importance. It will be observed that the nerve lies, at first, to the outer side of that vessel; later on, it crosses it, and finally passes to the inner side of the artery in the region of the elbow.

THE INTERNAL CUTANEOUS AND LESSER INTERNAL CUTANEOUS NERVES.

These two nerves arise from the inner cord of the brachial plexus, in common with the inner head of the median and the ulnar nerves.

The *internal cutaneous nerve* accompanies the brachial artery, lying upon its inner side and in front of the lesser internal cutaneous nerve, till the basilic vein pierces the deep fascia, when the nerve accompanies the vein and soon divides into an anterior and posterior branch, whose distribution will be found given in preceding tables. It assists the coracohumeral nerve in supplying the integument over the biceps muscle, and sends filaments to the skin of the forearm as low down as the wrist.²

The *lesser internal cutaneous nerve*, called also the nerve of Wrisberg,³ has the same general origin as the preceding nerve, except that it arises slightly below it. Like the former nerve, it accompanies the brachial artery, lying upon its inner side and behind the nerve just described, and, after its escape from the fascia, it supplies the skin of the lower third of the arm,⁴ becoming joined to the posterior branch of the internal

¹ Those adjoining the thumb. See figure on page 682 of this volume.

² See cut on page 682 of this volume.

³ For the region of cutaneous distribution to this nerve, the reader is referred to the diagrammatic cuts on pages 675 and 682 of this volume.

⁴ See Fig. 204 of this volume.

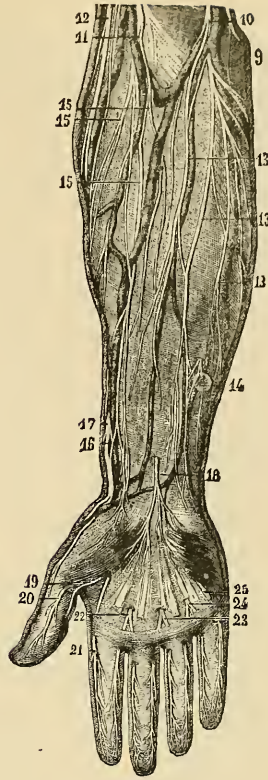
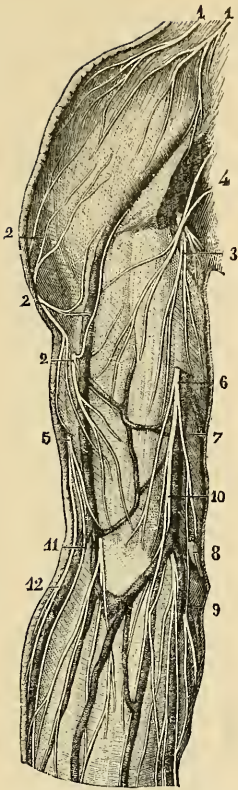


FIG. 205.—*Cutaneous nerves of the shoulder and anterior surface of the arm.* (Hirschfeld.)

FIG. 206.—*Cutaneous nerves of the anterior surface of the forearm and hand.* (Hirschfeld.)

1, 1, divisions of the supra-acromial branch of the cervical plexus; 2, 2, 2, terminal ramifications of the cutaneous division of the circumflex nerve; 3, division of the internal cutaneous nerve of the arm; 4, small filament from the perforating branch of the second intercostal nerve; 5, external cutaneous branch from the musculospiral nerve; 6, internal cutaneous branch crossing the aponeurosis of the arm; 7, epitrochlear branch of this nerve, anastomosing by a division with 8, the ulnar nerve, and 9, 9, with the anterior branch of the same nerve; 10, 10, anterior branch of the internal cutaneous of the arm, dividing into several branches, some of which pass in front of and others behind the median-basilic vein; 11, 11, musculocutaneous nerve crossing the aponeurosis of the arm outside of the tendon of the biceps muscle; 12, 12, divisions of the external cutaneous branch of the radial, distributing themselves to the skin of the posterior portion of the forearm; 13, 13, 13, divisions which the anterior branch of the internal cutaneous furnishes to the forearm; 14, anastomosis of one of these divisions with a perforating branch of the ulnar nerve; 15, 15, 15, terminal divisions of the musculocutaneous nerve; 16, anastomosis of one of these divisions with 17, the terminal anterior branch of the radial nerve; 18, palmar cutaneous branch of the median; 19, internal branch of distribution to the thumb; 20, external branch of distribution to the same; 21, external branch of distribution to the index finger; 22, trunk of the branches of distribution to the internal side of the index and external aspect of middle fingers; 23, common trunk of distribution to the internal side of the middle and external side of the ring fingers; 24, trunk of distribution to the internal side of the ring and external side of the little finger; 25, branch of distribution to the internal side of the little finger.

cutaneous nerve or to the intercosto-humeral nerve. The size of this nerve varies, as it is often supplanted by the intercosto-humeral¹ nerve, which is then of extremely large size. In this case the nerve of Wrisberg may be entirely wanting, and the intercosto-humeral nerve act independently of any communication with the brachial plexus.

THE ULNAR NERVE.

This nerve arises from the inner cord of the brachial plexus, in common with the internal cutaneous and the nerve of Wrisberg, as well as with the inner head of the median nerve. It bears a *surgical relation* with the third portion of the axillary artery and the upper part of the brachial artery, since it lies internally to and in close proximity with both; but it gradually separates from the brachial artery as it passes down the arm. It perforates the deep fascia of the arm in company with the inferior profunda branch of the brachial artery, and descends in a groove between the olecranon process of the ulna and the inner condyle of the humerus, until it enters the forearm by passing between the two heads of the flexor carpi ulnaris muscle. In the forearm, this nerve bears a relation with the ulnar artery, especially in the middle and lower thirds of that region; the artery lying upon the outer side of the nerve. At the wrist, this nerve winds around the outer side of the pisiform bone, crosses the annular ligament, and divides into its two terminal branches. The tabulated arrangement of the branches of distribution of the ulnar nerve² will show the muscles supplied by it, both in the forearm and hand. It is important to remember that this nerve gives filaments to both the elbow and wrist joints, and that its cutaneous branches are confined to the fingers and palm of the hand.

By a glance at the diagrammatic representation of the regions of the integument of the upper extremity, supplied by individual nerves (see Figs. 204 and 212), you will perceive that the ulnar nerve supplies the dorsal and palmar

¹ A branch of the second intercostal nerve.

² See page 669 of this volume.

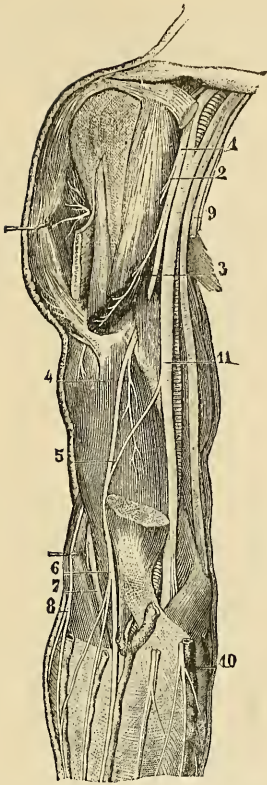


FIG. 207.—*Brachial portion of the musculocutaneous, median, and ulnar nerves.* (Sappey.)

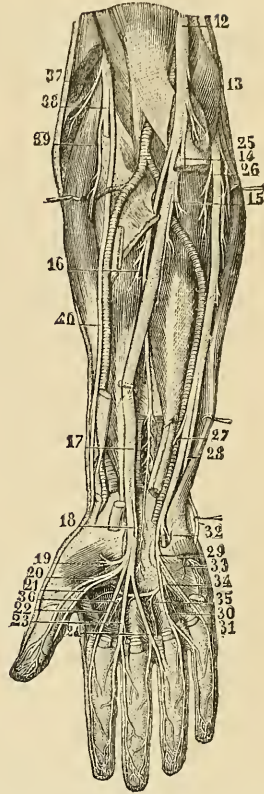


FIG. 208.—*Terminal portion of the median and ulnar nerves.* (Sappey.)

- 1, musculocutaneous nerve; 2, branch to the coraco-brachialis muscle; 3, branch to the biceps muscle; 4, branch to the brachialis anticus; 5, anastomotic filament which it receives from the median nerve; 6, division of this nerve where it crosses the aponeurosis of the arm; 7, musculospiral nerve passing between the brachialis anticus and supinator longus muscles; 8, external cutaneous branch of the musculospiral nerve; 9, trunk of the internal cutaneous dividing just below its origin, thus giving off an accessory branch; 10, anterior or ulnar branch of this nerve; 11, brachial portion of the median and ulnar nerves; 12, antebrachial portion, palmar and digital branches of the same nerve; 13, branch to the pronator radii teres; 14, trunk of these anterior muscular branches dividing and passing to the muscles to which they are distributed; 15, branch to the flexor profundus digitorum; 16, branch to the flexor longus pollicis; 17, anterior interosseous branch; 18, palmar cutaneous branch dividing just below its origin; 19, muscular branch of the thenar eminence; 20, external branch of distribution to the thumb; 21, internal branch of distribution to the same; 22, external branch of distribution of the index finger; 23, common trunk of the internal branches of distribution to the index finger and external to the middle finger; 24, internal trunk of distribution to the middle and external branch to the ring finger; 25, branch which the ulnar nerve furnishes to the flexor carpi ulnaris; 26, branches which the same nerve furnishes to the two internal fascioli of the flexor profundus digitorum; 27, cutaneous and anastomotic filament of the ulnar nerve; 28, dorsal branch of this nerve; 29, its superficial palmar branch; 30, common trunk of the internal branch of distribution to the ring and external branch to

the little finger; 31, internal branch of distribution to the little finger; 32, deep palmar branch; 33, small branch to the hypo-thenar eminence; 34, branches to the muscles of the fourth interosseous space and the fourth lumbricalis muscle; 35, branches to the muscles of the third interosseous space and the third lumbricalis muscle; 36, branches to the adductor pollicis and muscles of the first and second interosseous spaces.

surfaces of the *inner one and a half fingers*, thus leaving three and a half fingers upon the palm for the median nerve, and three and a half fingers on the back of the hand for the radial nerve to supply. Thus the integument of the palm is as equally divided between these three nerves as could well be, as the ulnar has a total of three fingers (one and a half on both the palm and back of hand), and the other two nerves three and a half fingers each.

CLINICAL POINTS OF INTEREST PERTAINING TO THE ULNAR NERVE.

The superficial situation of this nerve in the arm, near the elbow and at the wrist, would seem to suggest that paralysis of this nerve would be a matter of common occurrence, as it is apparently exposed to injury. It is, nevertheless, infrequently affected with traumatic paralysis. The causes which reported cases show to have produced this condition include about the same list of accidents as mentioned in connection with paralysis of the median nerve; but sleeping upon the arm when placed beneath the head, the use of poorly constructed crutches, fractures and dislocations at the shoulder, tumors, contusions, wounds of all kinds, neuritis,¹ and neuromata are among the most common. Resting upon the elbow has been reported by Duchenne as a cause of this type of paralysis in a certain class of workmen; and the so-called "injury to the funny bone," which consists of a contusion over the seat of the ulnar nerve at the elbow, seems to justify the conclusion that this might easily be the seat of paralysis from long-continued or constant pressure.

It is a rule among surgeons, when operating about the elbow joint,² to guard against injury to the ulnar nerve, espe-

¹ Rosenthal states that this condition is most frequent after typhoid fever and acute diseases.

² This is especially important in *excision* of this joint, as the nerve is apt to be injured in raising the periosteum from the bone.

cially when the steps of the operation bring the knife in proximity to the inner condyle of the humerus.

As has been mentioned in connection with the median nerve, the ulnar, as well as the median nerve, may be considered as a pronator and flexor nerve of the wrist and a flexor nerve of the fingers, since the distribution of the two is confined exclusively to the anterior surface of the forearm and the palmar surface of the hand. The table of the branches of the ulnar nerve¹ will help us to readily appreciate the peculiarities of ulnar paralysis from a theoretical standpoint, and to properly interpret the phenomena when met in actual experience.

We can see, by reference to the table, that the flexor carpi ulnaris and the greater part of the flexor profundus digitorum muscles would be paralyzed, and that the muscles of the hypothenar eminence, as well as the interossei muscles of the hand, the two inner lumbricales, a part of the flexor brevis pollicis, and the adductor pollicis would be similarly affected. Now, the clinical evidences of this form of paralysis are in perfect accord with these facts. We find that the adduction of the hand is no longer performed in a perfect manner, since the flexor carpi ulnaris can no longer act in unison with the extensor carpi ulnaris; that flexion of the hand is performed imperfectly and by means of the flexor of the radial side of the forearm only, since that muscle is supplied by the median nerve; that the ability to move the little finger is almost entirely abolished; that complete flexion of the inner three fingers is rendered difficult and sometimes impossible; that the fingers can not be separated from each other, or compressed into a close lateral juxtaposition, owing to paralysis of the interossei muscles; and that both flexion of the first phalanx and extension of the two terminal phalanges of all the fingers are rendered impossible, for the same reason.

When the ulnar nerve is paralyzed *above the wrist*, so that the interossei and lumbricales are alone paralyzed, the hand

¹ See page 669 of this volume.

assumes a diagnostic attitude, the so-called "claw-hand," in which the extensor communis digitorum muscle extends the first phalanges of all of the fingers, while the other two rows of phalanges are flexed by the common flexor muscles of the fingers (the interossei and lumbricales being no longer able to flex the first row of phalanges or to extend the two other rows). This same condition of the hand may, however, be produced by a condition of progressive muscular atrophy of these muscles.

It must be remembered that this condition, if dependent upon ulnar paralysis alone, is more marked in the *two inner fingers* than in the three outer, since the lumbricales are supplied in part by the median nerve; and this clinical fact seems to stamp the action of the lumbricales as similar to that of the interossei. Finally, the effects of ulnar paralysis may be manifested in the movements of the thumb, since it supplies two muscles which control it. This will be most apparent when you instruct the patient to press the thumb forcibly against the metacarpal bone of the index finger, or to adduct the thumb, since both of these motions will be rendered difficult or impossible.

These disturbances of motility create serious disturbances in those common functions in which the hand is of the most service. Writing, drawing, the playing of musical instruments, etc., are rendered difficult. The muscles which are supplied by the median and radial nerves are still able, however, to direct the hand and fingers in many acts which contribute to the comfort of the patient. In those cases where the muscles of the thenar eminence (supplied chiefly by the median nerve) are simultaneously affected, the use of the hand is almost entirely abolished.

THE SUBSCAPULAR NERVES.

These three nerves are given off by the *posterior cord* of the brachial plexus. They are called the upper, long, and lower subscapular nerves by some authors, while the numerical prefixes of first, second, and third are applied to them by

others. As will be seen by the table of the branches of the posterior cord of the brachial plexus,¹ the first or upper nerve supplies the subscapular muscle, the second or long nerve supplies the latissimus dorsi, and the third or lower nerve supplies the teres major, whose point of insertion is similar to that of the preceding muscle, since the tendons of the two often merge into each other.

Now, these three muscles are agents in creating certain movements at the shoulder joint; hence it is to be presumed that each subscapular nerve sends a filament to that articulation. I am aware that the text-books usually give the credit of nerve supply to this joint to other sources, since the filaments of the supra-scapular and circumflex nerves can be traced easily to this articulation on account of their large size, but I am not inclined to believe that an axiom² of nerve supply, so fully sustained in other regions, will not fail to be supported by careful dissections of this part. The muscles supplied by the subscapular nerves are as important agents in the movements of the arm at the shoulder as those supplied from the trunks of the circumflex and the supra-scapular nerves; and, if it be true that a joint, when exhausted or inflamed, can control the muscles which move it by means of a common nerve supply, the subscapular nerves must certainly be enumerated as one of the sources of supply to the shoulder joint.

CLINICAL POINTS PERTAINING TO THE SUBSCAPULAR NERVES.

These nerves are seldom the seat of a localized neuralgia, or of paralysis, except in connection with some other nerves of the upper extremity. The situation at which they are given off from the brachial plexus (being branches of the posterior cord and imbedded in the axillary space) is a safeguard against all common forms of external violence, while few tumors would create pressure upon these trunks without affecting other nerves at the same time, and possibly to an equal or greater degree.

¹ See page 670 of this volume.

² See page 645 of this volume.

Should the subscapular nerves happen to become impaired, the paralysis would be shown in those movements of the arm which are performed chiefly by the three muscles supplied by them. The latissimus dorsi could no longer bring the hand into the position assumed when scratching the anal region (in which movement it is prominently concerned), while the movement of *internal rotation* at the shoulder joint would be impaired, on account of the paralysis of the subscapularis and the teres major, as well as that of the muscle previously mentioned.

Should these nerves be the seat of degeneration, as in the case of progressive muscular atrophy, an alteration in the size of the latissimus dorsi and teres major muscles would be detected, and the other symptoms characteristic of this condition might be discovered, to a greater or less degree, depending upon the extent of the muscular changes.

THE CIRCUMFLEX NERVE.

This nerve arises from the posterior cord of the brachial plexus, usually in common with the musculo-spiral nerve, but sometimes by an independent communication with the posterior cord. It passes downward and outward behind the axillary artery and upon the subscapularis muscle, then backward (in company with the circumflex vessels) through a quadrilateral space bounded by the humerus, the teres major and minor muscles, and the long head of the triceps,¹ when it divides into its superior and inferior branch. It gives off a distinct branch to the shoulder joint, before its two terminal branches are formed, in the vicinity of the quadrilateral space, whose boundaries have been given.

The superior branch of the circumflex nerve is the larger of the two terminal filaments. It winds around the neck of the humerus, and supplies the deltoid muscle and the integument over the lower portion of the shoulder.

The inferior branch is small in comparison with the superior, and is distributed to the teres minor muscle and the

¹ This space can be found depicted in all the standard text-books upon anatomy.

integument over the back part of the shoulder. The twig, given off to supply the teres minor muscle, is sometimes furnished with a ganglionic enlargement.

CLINICAL POINTS PERTAINING TO THE CIRCUMFLEX NERVE.

From what has been said regarding the distribution of this nerve, it will be readily understood that the deltoid and teres minor muscles, as well as the integument of the shoulder and

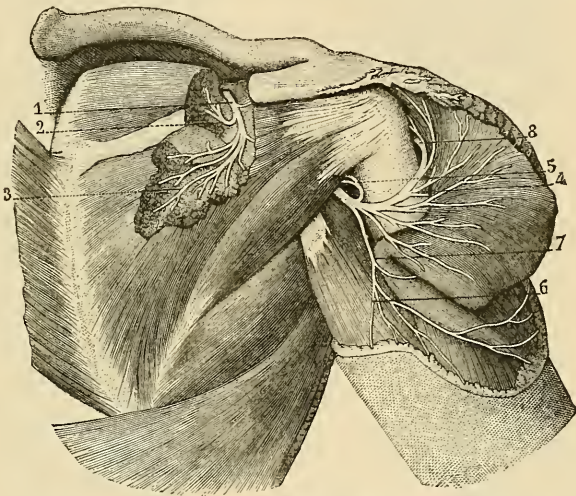


Fig. 209.—*Circumflex and supra-scapular nerves.* (Sappey.)

- 1, terminal extremity of the supra-scapular nerve; 2, branch which this nerve furnishes to the supra-spinatus muscle; 3, ramifications by which it terminates in that muscle; 4, circumflex nerve embracing the surgical neck of the humerus; 5, filament which this nerve sends to the teres minor muscle; 6, cutaneous nerve to the shoulder; 7, branches of the circumflex nerve given off to the deltoid muscle.

upper arm, will be affected by any impairment of the circumflex nerve. A fact previously mentioned, however, should not be lost sight of, viz., that the deltoid muscle, in its anterior portion, is supplied by the anterior thoracic nerves; hence the impairment of the circumflex may not utterly paralyze it.

The intimate relations which this nerve bears to the shoulder joint and the course which it takes around the neck of the humerus render it particularly liable to injury from contusions, concussions, blows, or falls upon the shoul-

der; while dislocations of the humerus from the scapula, especially in a backward direction, are frequently followed by deltoid paralysis. If the shoulder joint become the seat of rheumatic, or any other type of chronic inflammation, the nerve may be involved in a neuritic process, and thus cause a paralysis of the deltoid or teres minor; while the same results may also follow "catching cold," a neuritis being probably established. Finally, this type of paralysis may follow injury to the brachial plexus, all the forms of central lesions, lead poisoning, and progressive muscular atrophy.

As paralysis of the teres minor muscle can not be easily detected, provided the infra-spinatus muscle remains unimpaired, the symptoms of circumflex paralysis are mostly confined to the inability to perform the various movements into which the deltoid muscle prominently enters. The arm can not be raised from contact with the wall of the thorax, by any attempt on the part of the patient, nor can it be brought forward and raised. When an attempt is made by the patient to raise the arm, the deltoid fibers do not contract, but lie flabby and loose, which distinguishes it from an ankylosed condition of the shoulder, without the necessity of communicated motion being resorted to in order to make the diagnosis. The deltoid region atrophies, and the shoulder joint becomes relaxed. A deep groove can often be detected through the atrophied muscle between the head of the humerus and the articular surface of the scapula.

THE MUSCULO-SPIRAL NERVE.

This is the largest branch of the brachial plexus. It arises from the posterior cord, usually in company with the circumflex nerve, and lies behind the third portion of the axillary artery, at its point of escape from the brachial plexus. It subsequently passes behind the upper part of the brachial artery, crosses the tendons of the teres major and latissimus dorsi muscles, accompanies the superior profunda artery in a spiral groove upon the humerus, and, by passing between the supinator longus and the brachialis anticus muscles, it reaches

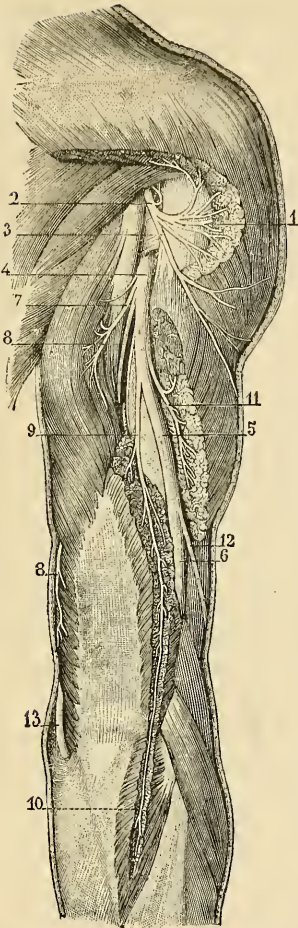


FIG. 210.—*Musculo-spiral nerve.* (Sappey.)

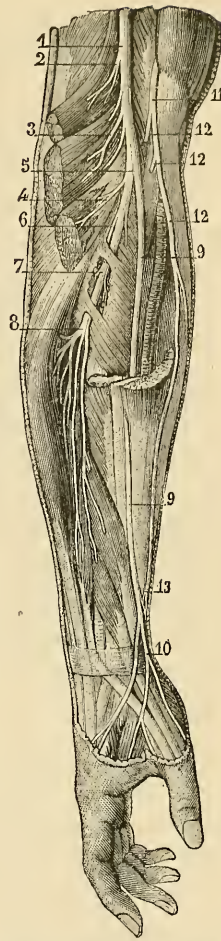


FIG. 211.—*Terminal branches of the musculospiral nerve.* (Sappey.)

FIG. 210.—1, circumflex nerve; 2, filament to the teres minor muscle; 3, cutaneous branch of the circumflex; 4, trunk of the musculo-spiral; 5, portion of this nerve which corresponds to the spinal groove of the humerus; 6, this same nerve passing between the brachialis anticus and supinator longus muscles; 7, branch which the musculo-spiral furnishes to the long head of the triceps muscle; 8, 8, branch to the internal portion of this muscle; 9, branch to the external portion of this muscle; 10, terminal branch of this same nerve distributed to the anconeus muscle; 11, another branch of the same nerve supplying also the external portion of the triceps muscle; 12, external cutaneous branch of the musculo-spiral.

FIG. 211.—1, trunk of the musculo-spiral nerve; 2, branch to the supinator longus muscle; 3, branch to the extensor carpi radialis longior; 4, branch to the extensor carpi radialis brevior; 5, bifurcation of this trunk; 6, its posterior or muscular branch; 7, the same branch crossing the supinator brevis, to which it gives off several small branches; 8, its terminal divisions; 9, anterior or cutaneous branch of this nerve; 10, terminal divisions of this branch; 11, musculo-cutaneous nerve; 12, 12, 12, its terminal divisions; 13, one of these branches which descends as far as the wrist, and then anastomoses with the cutaneous branch of the radial.

the external condyle of the humerus, where it divides into two terminal branches, viz., the *radial* and the *posterior interosseous nerves*.

The table of the branches given off from the posterior cord of the brachial plexus,¹ and the filaments of distribution of each, will help you in following the chief points of interest associated with this nerve. It will be perceived that the main trunk of the nerve supplies five muscles, while the posterior interosseous branch supplies all the remaining muscles upon the posterior surface of the forearm. This nerve is, therefore, essentially an extensor nerve, although the brachialis anticus and supinator longus muscles assist in flexion of the forearm. When we come to the consideration of the effects of paralysis of this nerve, the special symptoms will help still further to impress upon you the distribution of its branches to muscles as well as to the integument; and the points of interest, which depend upon the peculiar course of the main trunk of the nerve, will be made prominent, as an explanation of the frequent occurrence of this special type of paralysis in certain occupations.

The *radial branch* is exclusively distributed to the integument, as is shown in the table,² and the special distribution of the branches given off by this nerve to the integument of the hand has been already discussed at some length in a previous lecture.³

The musculo-spiral nerve gives an articular filament to the wrist joint, by means of its posterior interosseous branch; and, probably, some filaments also to the elbow joint, if we accept the general law of nerve distribution given by Hilton, so often quoted in the preceding lectures of this course.

We are now prepared to examine, with advantage, the diagrammatic plates,⁴ in which the regions supplied by the different nerves of the upper extremity are exhibited more clearly than a verbal description could alone afford. They

¹ See page 670 of this volume.

² See page 670 of this volume.

³ See page 688 of this volume.

⁴ See cuts on pages 682 and 697 of this volume.

will prove of great assistance in studying the tables¹ in which the branches of the individual nerves are classified.

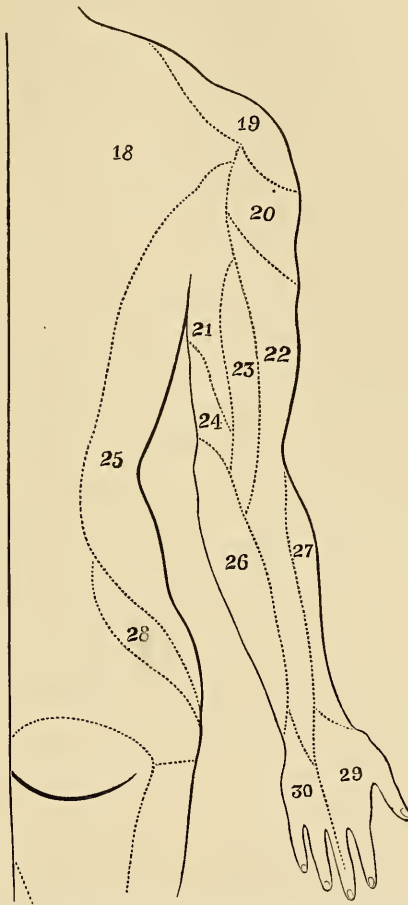


FIG. 212.—A diagram of the regions of cutaneous nerve distribution on the posterior surface of the upper extremity and trunk.

18, region supplied by the *second dorsal* nerve; 19, region supplied by the *supra-scapular* nerve; 20, region supplied by the *circumflex* nerve; 21, region supplied by the *intercosto-humeral* nerve; 22, region supplied by the *external cutaneous* nerve; 23, region supplied by the *internal cutaneous branch* of the *musculo-spiral* nerve; 24, region supplied by the "*nerve of Wrisberg*;" 25, region supplied by the *lateral branches* of the *intercostal* nerves; 26, region supplied by the *internal cutaneous* nerve; 27, region supplied by the *musculo-cutaneous* nerve; 28, region supplied by the *iliac branch* of the *ilio-inguinal* nerve; 29, region supplied by the *radial* nerve; 30, region supplied by the *ulnar* nerve.

This diagram limits the distribution of each nerve with more positiveness than can be well verified, since the cuta-

¹ See tables on pages 669, 670, and 671 of this volume.

neous filaments of two nerves may supply the *borders* of any of these regions, as the nerves tend to overlap each other. It is not well, therefore, to rely positively upon the border limits of any region in your endeavors to detect anæsthesia, should you suspect a paralytic condition of any special nerve, and seek this means of confirming your diagnosis.

The rule of Hilton would naturally cause us to expect that the muscles supplied by any special nerve would act as a guide in determining the source of the cutaneous nerve supply over the points of attachments of those muscles; and we are not disappointed when we examine closely the area of cutaneous distribution of the musculo-spiral nerve. This nerve supplies the supinators of the hand, the extensor muscles of the elbow joint and of the wrist joint, and the extensor muscles of the fingers and the thumb; hence we find the skin over these groups of muscles supplied, to a great extent, by the same nerve which affords motor power to the muscles underneath. This fact will thus help you to remember the area of distribution of any nerve to the skin by a process of reasoning based upon the muscles which are supplied by the same nerve, and the numerous examples, already quoted in confirmation of this general law, prove that the deduction drawn from it is, in all cases, approximately accurate.

CLINICAL POINTS PERTAINING TO THE MUSCULO-SPIRAL NERVE.

The musculo-spiral nerve is more frequently affected with paralysis than any of the nerves of the upper extremity. It is particularly liable to both peripheral and central causes of paralysis; thus, in cerebral hemiplegia, the muscles supplied by this nerve are, perhaps, more commonly affected than those supplied by any other nerve, while paralysis of these muscles is common as the result of chilling of the upper extremity, traumatism, and lead poisoning.

The anatomical situation of the musculo-spiral nerve and the peculiarity of its course around the humerus probably explain the frequent occurrence of paralysis, since it may be easily compressed by sleeping upon the arm. It is common

to meet with this type of paralysis in patients who have used their arm as a pillow, or in drunkards who have slept in some constrained position upon benches, steps, etc. Persons who have fallen exhausted and have rested upon the arm, and soldiers who have slept upon the damp ground, often arise with this form of paralysis. It is stated by Brenner¹ that the coachmen of Russia, who are in the habit of sleeping upon the box with the reins wound around the upper arm, are victims to this condition; and Baehon² reports the same result as common among the water-carriers of Rennes, since they pass their arm through the handle of the heavy water-pails to more securely compress them against the chest. The habit of the Russians of tightly bandaging the arms of infants to the body, and allowing them to sleep upon one side for long intervals, seems to promote the frequent occurrence of this trouble.

Among the other forms of injury which conduce toward this form of paralysis may be mentioned the use of poorly padded crutches, the kicks of animals, cuts, stab wounds, fractures of the humerus, dislocation of the humerus at the shoulder joint, and the development of an excessive amount of callus after a fracture.

Rheumatic affections and a neuritis of the musculo-spiral nerve are reported as causes by Bernhardt and others; and cases of hysterical origin have been rarely but positively authenticated.

Finally, lead poisoning must be mentioned as one of the most common causes of paralysis of the muscles supplied by the musculo-spiral nerve. The existence of this form of poisoning will have generally been indicated, previous to the appearance of paralysis, by colic, jaundice, and arthralgia, as the muscles are seldom affected until the latter stages. The extensor communis digitorum muscle is usually affected first, and the paralysis gradually extends to the other muscles supplied by the musculo-spiral nerve. The muscles of the arm are much less frequently affected than those of the hand and forearm; but, in severe cases, the muscles of the upper arm,

¹ As quoted by Erb.

² As quoted by Erb.

shoulder, and even those of the lower extremity, may become involved.

It is difficult as yet to explain the apparent predisposition of lead poisoning to affect the muscles of the musculo-spiral region in preference to the flexor muscles. Gombault, Bernhardt, Westphal, Bärwinkel, Hitzig, and Lancéreaux have given special attention to the subject, and arrived at no common ground upon which they can all agree. The condition has been explained as the result of a venous stasis (Hitzig), and as the result of arterial ischaemia (Bärwinkel); both of whom regard these conditions as favoring the deposition of lead in the muscles of the extensor region of the forearm. Peripheral nerve degeneration has been claimed as the explanation of the paralytic symptoms by Gombault, Westphal, and Lancéreaux, and in this view the investigations of Neuman, Erb, and Eichhorst coincide. Whether a spinal origin will be yet determined which will explain the muscular changes and the loss of power, is yet to be decided by further pathological research.

The symptoms which characterize this type of paralysis have such a distinctive form as to be easily recognizable by the physician at the very first glance. A reference to the table which shows the distribution of the musculo-spiral nerve to muscles¹ will help to explain them. We see that this nerve sends filaments to the triceps and brachialis anticus muscles in the arm, and to all the extensor muscles of the forearm. In accordance with this distribution, the hand is kept in a state of flexion when this nerve is paralyzed, and can not be raised or extended; the thumb is flexed and adducted; and the fingers are flexed and cover the thumb. When the patient attempts to extend the fingers, the interossei and lumbricales muscles alone can be made to act, and these muscles, as has been mentioned before, can only extend the two terminal phalanges while they flex the basal phalanx.²

¹ See page 670 of this volume.

² The explanation of this fact lies in the insertion of the tendons of these muscles into the tendons of the common extensor of the fingers.

The thumb and the index finger can not be extended or abducted; the patient can not supinate the hand when the forearm is extended (this position being assumed in order to exclude the action of the biceps muscle), nor can the forearm be half bent and the hand half supinated by the supinator longus muscle; and, finally, when the patient is instructed to flex the forearm, when placed in a position of half flexion and semi-prostration, the supinator longus muscle lies flaccid, and does not become tense and hard as in health. The loss of power in the triceps muscle renders it impossible for the patient to extend the forearm

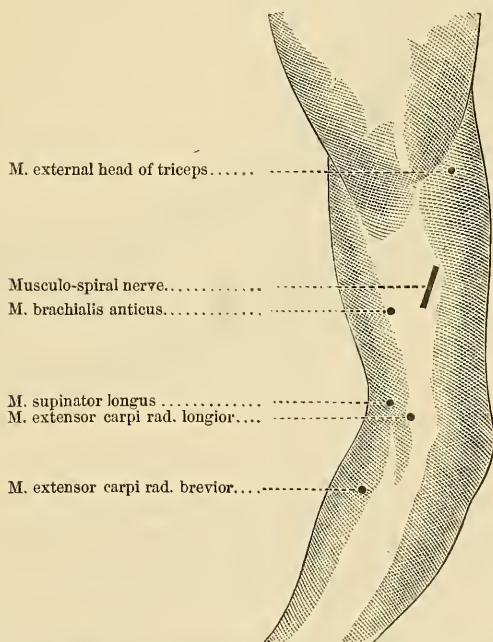


FIG. 213.—The motor points on the outer aspect of the arm.

upon the arm when the arm is first raised above the head; nor can the forearm be extended with the same degree of force as the healthy side in any position of the arm. When the hand is laid upon the table, the patient is unable to raise the hand from contact with it, but the lateral movements of the fingers can be performed as in health,

since these movements are controlled by the interossei muscles. The action of the flexor muscles of the wrist seems feeble, since the antagonistic action of the extensors does not afford a fixed point of action; but, if the wrist be forcibly extended and fixed, it will be seen that the wrist flexors are not paralyzed.

This form of paralysis interferes with almost all of the numerous employments of daily life, since the functions of the hand are most seriously impaired. The patient can not well hold or grasp anything, on account of the inability to perform

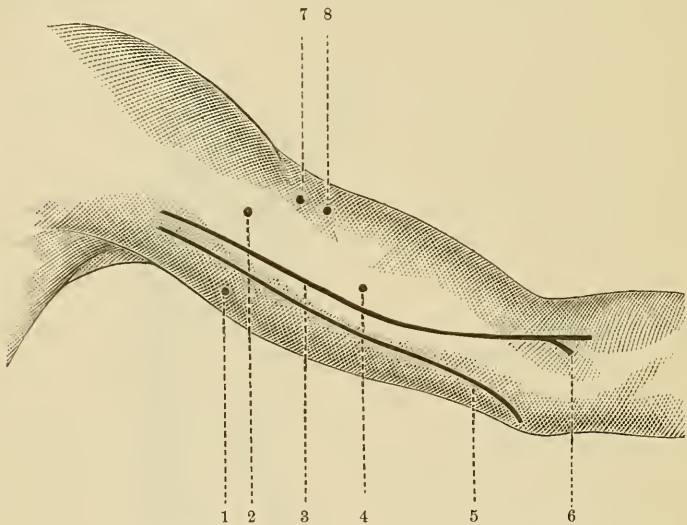


FIG. 214.—*The motor points on the inner side of the arm.*

1, m. internal head of triceps; 2, musculo-cutaneous nerve; 3, median nerve; 4, m. coraco-brachialis; 5, ulnar nerve; 6, branch of median nerve for pronator radii teres; 7, musculo-cutaneous nerve; 8, m. biceps flexor cubiti.

the extension of the thumb or fingers; and the impairment of the supinators still further adds to the uselessness of the hand. The regions of the integument supplied by the musculo-spiral nerve exhibit more or less anæsthesia, although the extent of this symptom, like that of the muscular paralysis, is modified by the height of the lesion, which affects the nerve as well as by its character. In some cases, extensive motor paralysis may be present without any marked

disturbance of sensibility; this can only be explained by the presence of anastomosis between the cutaneous nerves

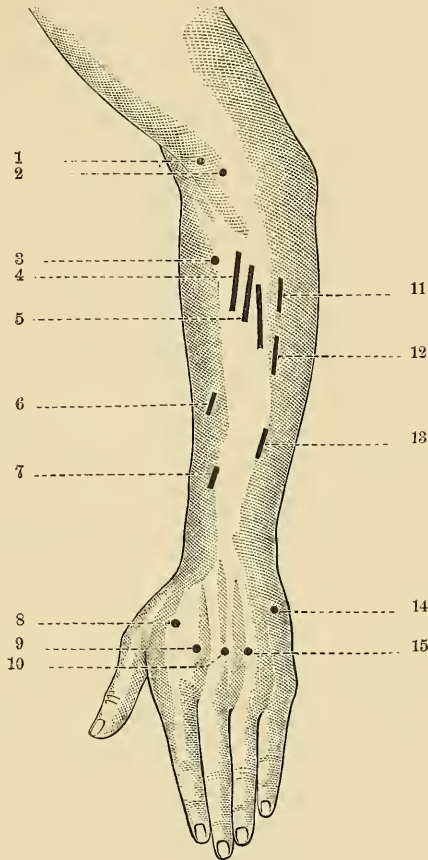


FIG. 215.—*The motor points on the extensor (posterior) aspect of the forearm.*

1, m. supinator longus; 2, m. extensor carpi rad. longior; 3, m. extensor carpi rad. brevior; 4, 5, m. extensor communis digitorum; 6, m. extensor ossis. met. pol.; 7, m. extensor primi. internod. pol.; 8, m. first dorsal interosseous; 9, m. second dorsal interosseous; 10, m. third dorsal interosseous; 11, m. extensor carpi ulnaris; 12, m. extensor min. digiti; 13, m. extensor secund. internod. pol.; 14, m. abduct. min. digiti; 15, m. fourth dorsal interosseous.

of different origins, as was demonstrated by Tripier and Arloing¹ upon dogs.

In the diagnosis of this type of paralysis, it is often difficult to determine the exact nature and seat of the exciting

¹ As quoted by Erb.

cause. The most common causes are injury, pressure, and lead poisoning; but the existence of exciting neuritis, some

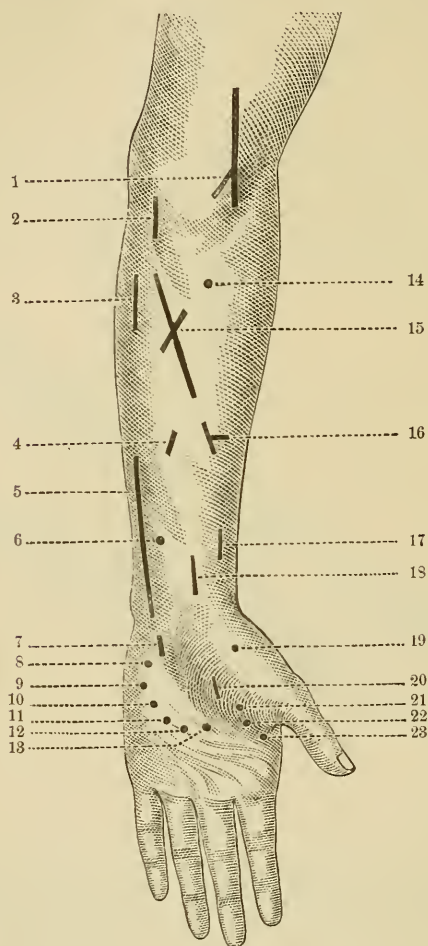


FIG. 216.—*The motor points on the flexor (anterior) aspect of the forearm.*

- 1, median nerve and branch to m. pronator radii teres; 2, m. palmaris longus; 3, m. flexor carpi ulnaris; 4, m. flexor sublim. digit.; 5, ulnar nerve; 6, m. flex. sublim. dig.; 7, volar branch of the ulnar nerve; 8, m. palmaris brevis; 9, m. abductor min. digit.; 10, m. flexor min. digit.; 11, m. opponens min. digit.; 12, 13, m. lumbricales; 14, m. flexor carpi radialis; 15, m. flexor profund. digitorum; 16, m. flexor sublim. digitorum; 17, m. flex. longus pollicis; 18, median nerve; 19, m. opponens pollicis; 20, m. abductor pollicis; 21, m. flexor brevis pollicis; 22, m. adductor pollicis; 23, m. first lumbricalis.

cerebral disease, or an hysterical cause, must be excluded or determined by the concomitant symptoms. When the paral-

ysis is due to local compression, the triceps muscle is not usually affected, and the same statement applies to the rheumatic form, while in both of these types the disturbance of sensibility is most frequently confined to the hand alone. In lead paralysis, the supinator brevis muscle remains unaffected until late in the disease, and the supinator longus muscle is rarely involved, even in severe forms of poisoning. While this can not be taken as an absolute sign, it is a most valuable point in diagnosis, and should be always remembered. In addition to the muscular paralysis, lead poisoning is often accompanied by muscular atrophy and swelling of the veins upon the extensor side of the forearm; while tendinous swellings are frequently detected in the region of the wrist.

The duration of paralysis of the musculo-spiral nerve depends largely upon the exciting cause. Lead poisoning produces, in all cases, an exceedingly slow and obstinate form of trouble, and the paralysis may be incurable; "crutch paralysis" usually recovers speedily, if the pressure be discontinued; traumatic paralysis, if the injury be severe, follows a protracted course; while those cases which depend upon cerebral origin are modified, as to their course and termination, by the character of the exciting lesion.

THE DORSAL NERVES.

The nerves of the dorsal region are twelve in number upon each side of the trunk. They escape from the vertebral canal by means of foramina between the dorsal vertebræ, and are connected to corresponding ganglia of the sympathetic nerve. Each dorsal nerve is joined to a ganglion of the sympathetic, immediately after its escape from the foramen between the vertebræ, by two small and short filaments; hence, there are frequent points of communication between the cerebro-spinal and sympathetic systems of nerves throughout the length of the vertebral column. As has been stated in a previous lecture, the first dorsal nerve assists to form the brachial plexus,

and can therefore be properly classed as one of the nerves of the upper extremity rather than a nerve of the trunk; the remaining nerves of this region are distributed entirely to the parietes of the thorax, the adjacent pleura, and the integument covering the front, sides, and back of the chest, and the upper part of the abdomen.

The table which I now show you is designed to make the general distribution of the dorsal nerves easy of comprehension, and to assist in reviewing the chief points of interest which are presented in connection with the nerves of this region.

NERVES OF THE DORSAL REGION.

DORSAL NERVES.	POSTERIOR DIVISIONS.	External branches.	In upper six nerves.	{ Filaments to transversalis colli, Filaments to longissimus dorsi, Filaments to trachelo-mastoid, Filaments to levatores costarum, Filaments to sacro-lumbalis, Filaments to accessorius.
			In the lower six nerves.	{ Same muscles as in preceding bracket, <i>Integument</i> of the back.
			In upper six nerves.	{ Filaments to semispinalis dorsi, Filaments to multifidus spinæ, <i>Integument</i> of back.
		Internal branches.	In the lower six nerves.	{ Same muscles as in preceding bracket, No cutaneous filaments.
			Muscular branches.	{ Intercostals, Triangularis sterni. <i>Integument</i> of chest and mammæ, Upper part of external oblique muscle,
			Lateral cutaneous.	{ <i>Integument</i> over upper part of latissimus dorsi and the scapular region.
	ANTERIOR DIVISIONS.	Six upper or thoracic intercostals.	Anterior cutaneous.	{ <i>Integument</i> of mammæ and side of the chest.
			Muscular branches.	{ Intercostals, Abdominal muscles. <i>Integument</i> of abdomen, as far as the edge of rectus,
		Six lower or thoracico-abdominal intercostals.	Lateral cutaneous.	{ <i>Integument</i> over lower part of latissimus dorsi.
			Anterior cutaneous.	{ Upper part of rectus and <i>integument</i> in front part of abdomen.

It will be perceived that these nerves, like those of the cervical region, divide into anterior and posterior branches, in the immediate vicinity of the vertebral column. The posterior divisions supply the muscles of the back and the in-

tegument which covers that region, while the anterior divisions supply the muscles of respiration and some of the

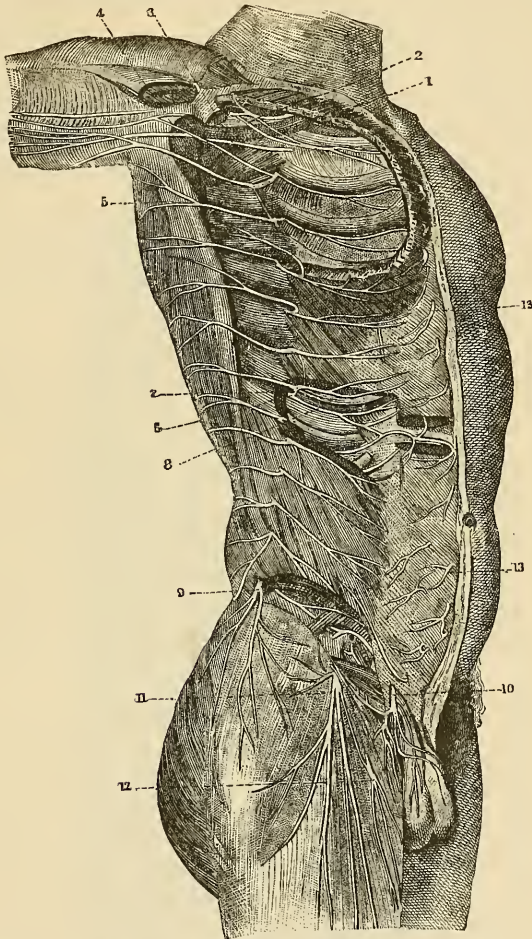


FIG. 217.—*The intercostal nerves.* (Masse.)

The pectoralis major and minor muscles are removed. The obliquus externus and rectus abdominis are divided, and removed in some places.

1, axillary vein: the artery is removed; 2, portion of the brachial plexus and two thoracic branches; 3, brachial twig of the first intercostal nerve; 4, brachial twig of the second intercostal nerve; 5, inosculation between two branches; 6, division of an intercostal branch into 7, a superficial branch, and 8, a deep branch; 9, gluteal branch of the twelfth intercostal nerve; 10, termination of the ilio-scrotal branch of the lumbar plexus; 11, inguino-cutaneous branch; 12, twig of the genito-crural branch; 13, 13, portions of the deep nerves after they have become superficial.

abdominal muscles, and the integument of the chest, loins, and abdomen. The intercostal nerves are formed entirely

from the anterior divisions; those arising from the upper half of the dorsal region being called the "thoracic" intercostals, while the lower six nerves are called the "thoraco-abdominal" intercostal nerves.

The first and last dorsal nerves are somewhat peculiar in their distribution, and deserve a special description. The first dorsal nerve has no lateral cutaneous branch, since the branch which corresponds to the lateral cutaneous branch of the other nerves is of large size, and enters into the formation of the brachial plexus. The continuation of this nerve along the first intercostal space is of small size, and ends in the anterior cutaneous nerve.

The last dorsal nerve is the largest of the twelve, and is usually connected with the first lumbar nerve by a filament called the "dorso-lumbar" nerve, which descends in the substance of the quadratus lumborum muscle. It communicates also with the hypogastric branch of the ilio-hypogastric nerve (a branch of the lumbar plexus), between the internal oblique and transversalis muscles of the abdomen. Its lateral cutaneous branch is very large, and is distributed to the integument of the front part of the gluteal region.

The distribution of the dorsal nerves to the *costal layer of the pleura* is not specially designated in the table,¹ but it is a fact of great physiological interest. Hilton draws an analogy between the pleura and a synovial membrane of a joint; and the intercostal muscles are also compared by him to those moving a joint. Thus this author adduces further proof of his general law of nerve distribution, since the skin of the chest, the intercostal muscles, and pleura are supplied from the same source. In pursuing this same line of reasoning (and the analogy is not a strained one from a physiological standpoint), the abdominal muscles might also be included among the list of muscles which move the ribs; and the nerve supply to them also would thereby be explained by this same axiom, viz., that the nerves which supply a joint supply the

¹ See page 706 of this volume.

muscles which move it and the skin over the insertions of those muscles.

It should be recollected that some of the filaments derived

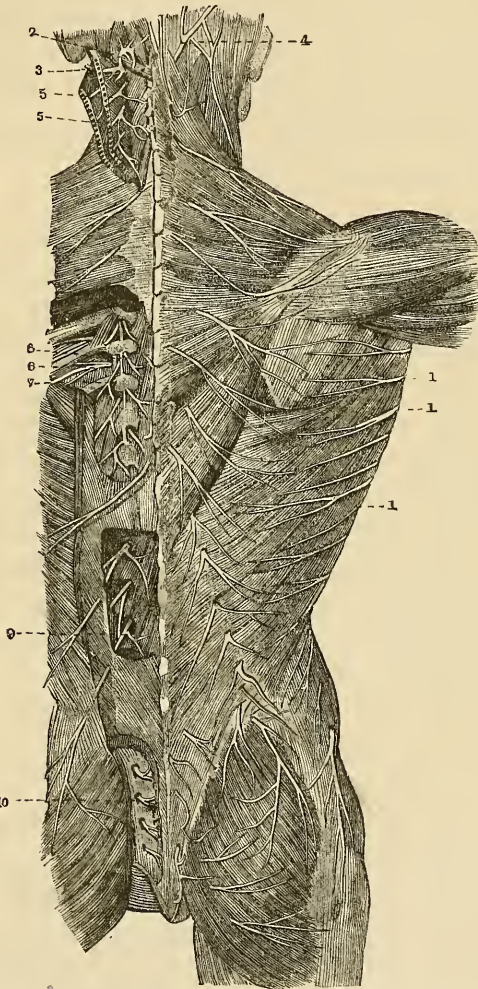


FIG. 218.—*The nerves situated on the posterior part of the trunk.* (Masse.)

Portions of the trapezius, splenius, complexus, trachelo-mastoideus, latissimus dorsi, and gluteus maximus muscles, etc., etc., are removed.

- 1, 1, 1, posterior twigs of the superficial branches of the intercostal nerves; 2, posterior branch of the first cervical nerve, or sub-occipital; 3, posterior branch of the second cervical nerve; 4, inosculation of this branch with the great mastoid branch; 5, 5, posterior branches of two cervical nerves; 6, intercostal branch; 7, external twig of a dorsal branch; 8, internal twig of a dorsal branch; 9, posterior branch of a lumbar nerve; 10, posterior branch of a sacral nerve.

from the upper intercostal nerves *cross the axillary space* and supply the integument of the arm. The "nerve of Wrisberg," which has been described in connection with the cutaneous nerves of the arm, is perhaps the most important of these branches. It may thus be understood why the pain of pleuritic inflammation may be carried to and felt in the region of the axilla and inner arm, and why distinct points of tenderness to pressure may sometimes be detected in these regions when the disease is confined to the trunk.

CLINICAL POINTS PERTAINING TO THE DORSAL NERVES.

From the suggestions thrown out as to the physiological importance of nerve distribution, and from the fact that the pleura is supplied from the same nerve sources as the respiratory muscles and the integument of the chest, abdomen, and inner arm, some important clinical lessons may be drawn. Patients suffering from pleurisy feel a pain in the costal muscles which compels restricted movement of the ribs, and which limits the respiratory function largely to the diaphragm. Now, these painful cramps and stitches are independent of the pain arising alone from the inflamed pleural surface, and the diminution of the respiratory movements is due to a partially contracted state of the muscles of the chest, as is demonstrated by the fact that patients can not draw a long breath if asked to do so; hence, we may reasonably conclude that Nature has so distributed the nerves to the pleura as to enable that serous membrane to control the muscles which create movement of the adjacent costal surfaces, and thus insure its quietude during the stages of inflammation or repair. It is wisely suggested by Hilton, in this connection, that we learn a lesson in the treatment of such cases from Nature herself, viz., "never to allow a patient, suffering from pleurisy or pneumonia, to talk except in monosyllables, so as to avoid a full inspiration."

The diagnostic value of pain is well exemplified in the region of the thorax. Persistent pains *high up between the shoulders* are strongly indicative of diseases of the heart,

aneurism of the arch of the aorta, stricture of the œsophagus, and anything which would tend to create pressure within the

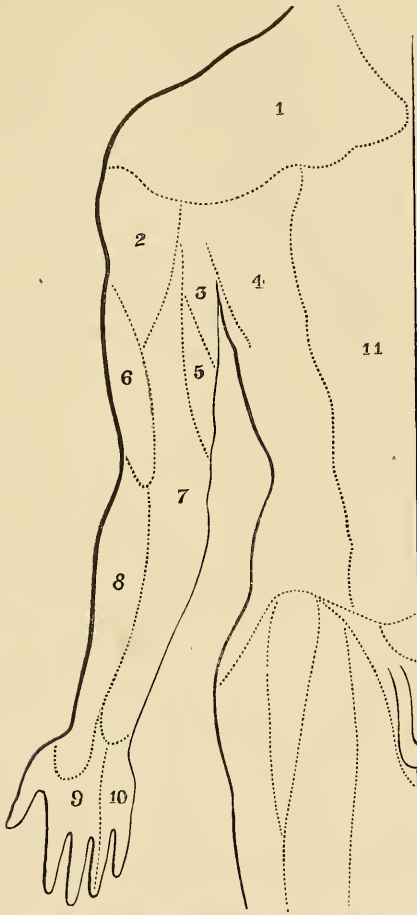


FIG. 219.—A diagram of the regions of cutaneous nerve distribution in the anterior surface of the upper extremity and trunk. (Modified from Flower.)

- 1, region supplied by the supra-clavicular nerve (branch of the cervical plexus); 2, region supplied by the circumflex nerve; 3, region supplied by the intercosto-humeral nerve; 4, region supplied by the intercostal nerve (lateral branch); 5, region supplied by the lesser internal cutaneous nerve (nerve of Wrisberg); 6, region supplied by the musculo-spiral nerve (external cutaneous branch); 7, region supplied by the internal cutaneous nerve; 8, region supplied by the musculo-cutaneous nerve; 9, region supplied by the median nerve; 10, region supplied by the ulnar nerve; 11, region supplied by the intercostal nerve (anterior branch).

posterior mediastinum.¹ If we meet with persistent pain in the space lying between the middle of the scapula and the

¹ John Hilton, *op. cit.*

lumbar region of the spine, we may have good ground to suspect the existence of some disease of the abdominal digestive viscera, the pain being carried to the surface probably by means of the splanchnic nerves.¹ It is not uncommon for disease confined to the transverse colon to manifest itself in the form of persistent pain in the lower intercostal region.

The frequent occurrence of cancer in the mammary region renders its detection one of importance in its early stages, while, in the later stages, the pleura and the glands of the axilla and mediastinæ may be secondarily affected with cancer tubercles. Now, in these conditions, the presence of pain in the back, between the shoulders, in the side of the chest, or down the inner side of the arm, may possibly afford invaluable aid in diagnosis.

The distribution of the *sixth and seventh intercostal nerves* to the skin over the *pit of the stomach* may be a useful fact to remember in making a diagnosis of the cause of pain in that region, since, by tracing the course of these two nerves from before backward, and observing the healthy or unhealthy condition of the structures near to which the nerves would pass—as the pleura, ribs, œsophagus, aorta, etc.—we may at last reach the spine as the seat of the disease which is producing pain in a region far remote from the cause to which it is really due. It is by no means uncommon for spinal affections of the mid-dorsal region to manifest themselves by a pain which is distressing, and referred to the pit of the stomach; and such an origin is rendered still more probable if present on both sides of the median line, since symmetrical pains are especially characteristic of central origin.² Should such a pain exist, and a marked relief ensue when the patient is in a recumbent posture, the probability of spinal origin is still more distinctly suggested.

¹ The great splanchnic nerve is connected above with the fourth, fifth, and sixth dorsal nerves, and below with the solar plexus and thence with the stomach, duodenum, liver, pancreas, and intestines. It seems probable, therefore, that the pain experienced in the region of the scapula, by patients afflicted with diseases of the digestive organs, is referable in some way to the greater splanchnic nerve.

² The reader is referred to the general axioms of nerve distribution, quoted on pages 645, 646, and 647 of this volume.

It has been stated in previous lectures that pains which are confined to one side of the body are usually indicative of an exciting cause which is confined to the same side, rather than of diseased conditions of the central nerve ganglia. It is therefore customary, with those most familiar with the steps necessary to reach a scientific diagnosis, to search for some cause upon the same side of the body, in case a pain exists which is not symmetrically developed upon both sides. I have known the diagnosis of aneurism within the thorax to be discovered by a pain, which was one-sided, and which was the only symptom which the patient was conscious of, where the existence of the tumor would probably have gone on undetected but for this valuable guide. A constant pain in the back is one of the most positive signs of aneurism of the cœliac axis, and I question if the diagnosis of aneurism of the abdominal aorta in any part of its course should ever be made unless this symptom can be detected.

Pain in the region of the *pectoral muscle* may indicate some cause referred either to the *third* or *fourth cervical* or the *first dorsal nerves*; hence we must look in two different localities for the exciting lesion. The distribution of the cervical nerves to the fascia covering the anterior portion of the chest is not sufficiently well recognized by the profession at large, and doubtless many cases have been a source of anxiety to the physician which could have been easily explained, had this point been impressed upon them.

The distribution of the *lower intercostal nerves* to the integument covering the upper part of the *muscles of the abdomen* may be useful in diagnosis, since pain in this region of the abdomen may be created by pressure of fluid in the pleural cavities, and by other lesions situated above the line of the diaphragm. It is not improbable, therefore, that many cases of this character have misled the medical attendant who has referred the symptom of abdominal pain to organs within the cavity of the abdomen, when the exciting cause was to be sought for within the chest or in the course of the lower intercostal nerves? Certainly, successful treatment depends upon accu-

racy in diagnosis ; and the application of the laws of nerve distribution to fine discriminations in the appreciation of symptoms is a guide whose value and utility are not generally known.

When we have our attention called by a patient to a pain, no matter where its situation may chance to be, we are positive that it can be traced to the nerves supplying the part. Here, then, we have a direct guide to follow which will usually lead us, if we are anatomists, to the source of the pain. As an example of this, and they are too numerous to mention in detail, there is one symptom in spinal disease which stands out prominently, and I might say solicits our proper appreciation of it, and that is a fixed and local pain upon the surface of the body, with or without exacerbations, and often without any local increase of temperature at the seat of the disease. I feel quite certain that through the medium of this one symptom alone, if properly employed, morbid conditions of the vertebræ or the spinal cord, its membranes, and its nerves, may be often diagnosed long before any palpable deformity of attitude or gait exists, and a cure often effected by simple rest.

It is in connection with the nerves of the dorsal region that pain is a more valuable guide than in almost any other portion of the body. The subjacent viscera, occupying the thoracic and abdominal cavities, are constantly manifesting diseased conditions by pain of a superficial character (through the intimate communications which exist between the splanchnic and dorsal nerves) at spots often far removed from the exciting cause. It is natural that the medical attendant, unless his attention has been directed to this fact, should attribute the pain to some fanciful cause in the locality of that pain, or to some general diagnosis of neuralgia, malaria, etc., when an anatomical knowledge might direct him aright both in diagnosis and treatment. We know that liver disease may be occasionally manifested by a pain in the region of the right shoulder ; that gastric and intestinal disorders frequently produce a constant pain in the back between the scapulæ ; and that tumors of the viscera may produce like results by press-

ure upon the splanchnic nerves or the solar plexus of which they form a part. Without such a knowledge and its satis-

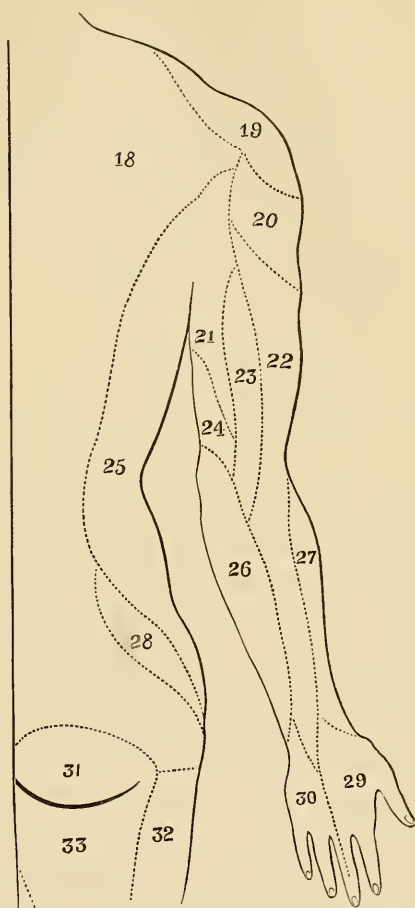


FIG. 220.—A diagram of the regions of cutaneous nerve distribution on the posterior surface of the upper extremity and trunk. (Modified from Flower.)

18, region supplied by the *second dorsal* nerve; 19, region supplied by the *supra-scapular* nerve; 20, region supplied by the *circumflex* nerve; 21, region supplied by the *intercosto-humeral* nerve; 22, region supplied by the *external cutaneous* nerve; 23, region supplied by the *internal cutaneous branch* of the *musculo-spiral* nerve; 24, region supplied by the "*nerve of Wrisberg*"; 25, region supplied by the *lateral branches* of the *intercostal* nerves; 26, region supplied by the *internal cutaneous* nerve; 27, region supplied by the *musculo-cutaneous* nerve; 28, region supplied by the *iliac branch* of the *ilio-inguinal* nerve; 29, region supplied by the *radial* nerve; 30, region supplied by the *ulnar* nerve.

factory explanation, would we be apt to refer such pain to causes so remote? Would we look for causes of abdominal

pain in the region of the thorax, without the knowledge that the lower intercostal nerves supplied the abdominal muscles? The lessons taught by anatomy are of a most practical character, and worthy of the study even of those old in the practice of physic. If a patient complains of pain on the surface of the body, it must be expressed by the nerve which resides there; there is no other structure that can express it, and somewhere in its course of distribution, between its peripheral filaments and its central point of origin from the encephalon or the spinal cord, the precise cause of this pain expressed upon the surface must be situated.

INTERCOSTAL NEURALGIA.

Those forms of neuralgia which have their seat in the nerves which arise from the dorsal region of the spinal cord are grouped under the term "dorso-intercostal" neuralgia. The exact seat of the pain varies not only with the special nerve affected, but also with the branch of the nerve which seems to manifest the most irritation. Thus, if the upper two nerves are involved, the pain may extend to the arm as well as the trunk; if the posterior branches of the dorsal nerves be alone involved, the pain will be perceived in the back and loins; and, finally, if the anterior branches be alone the seat of pain, it will be confined to the intercostal spaces and the anterior region of the chest. It is rare to find the anterior and posterior branches of any dorsal nerve simultaneously affected with neuralgia. The anterior branches are usually the ones which suffer, and the pain assumes a type which is properly called "intercostal."

Intercostal neuralgia is more common in women than in men, and chiefly affects weak, hysterical, and anæmic subjects. It appears often in those who are convalescing from some severe type of disease. The causes to which this form of neuralgia can be traced include exposure to cold or dampness, anatomical changes in the nerves themselves, diseases of some of the adjoining organs (especially in connection with phthisis), embarrassment to the venous return of the affected

region, dilatation of the venous plexuses of the interior of the vertebral canal, aortic aneurisms (which lead to absorption of the vertebræ or ribs), all possible diseases of the vertebræ themselves, and also of the ribs, diseases of the spinal cord, and malarial affections.

This form of neuralgia is most common upon the left side, and Henle has attributed this clinical fact to the arrangement of the intercostal veins of the left side,¹ which relatively tends to impede the return of blood upon the left in contrast to the right side. From the extensive list of causes which have been given—and many of the subdivisions of each have been omitted—it can be readily understood that, to make an accurate diagnosis as to the etiology of intercostal neuralgia, is never possible without a most thorough physical examination of the subjacent organs, the bones of the thorax, and the conditions of the soft tissues.

The symptoms of this disease are generally confined to the anterior and lateral walls of the trunk, more rarely to the back and the loins. The area of the pain indicates the nerves affected, which is often a point of great value in searching for the cause. While the pain is of a burning, dull, and persistent character for the greater part, yet it is often characterized by paroxysms of tearing and lancinating pains which follow the course of the nerves affected with a remarkable precision. The violence of these paroxysms may be very great, so as to cause syncope. All respiratory motions, such as sneezing, coughing, blowing the nose, etc., increase the pain, and the skin is sensitive to the slightest pressure, even the weight of the bedclothes distressing the patient, although firm pressure may sometimes afford relief. While the paroxysm is active, the patients sit with the body inclined toward the affected side, and their faces indicate the most extreme anxiety. They neither dare to speak loudly nor take a deep inspiration, on account of the pain induced by such efforts.

¹ The intercostal veins of the left side empty into the left superior intercostal vein or the left vena azygos; in either case, the blood takes a circuitous route to the superior vena cava.

In intercostal neuralgia, as in most other forms, there are certain points which are particularly sensitive to pressure, and are of great aid in confirming the diagnosis. These points comprise, first, one near to the vertebral column (*vertebral point*), where the nerve emerges from the inter-vertebral foramen; secondly, one at about the middle of the entire course of the nerve, corresponding to a line dropped from the center of the axillary space (*lateral point*), where the lateral branch emerges beneath the integument; and, thirdly, one in front, near to the sternal border (*anterior or sternal point*), where the anterior perforating branch emerges beneath the skin.

For some unknown reason, the intercostal nerves, when inflamed, are particularly liable to be associated with the appearance of that form of skin disease called "herpes zoster." This may or may not be accompanied by neuralgic symptoms, but it is a valuable sign of a neuritis of the nerves supplying the region affected.

The diagnosis of intercostal neuralgia can often be made only with extreme difficulty. That rheumatic affection of the muscles of the chest commonly called "pleurodynia" is often confounded with it, and the diagnosis is to be made chiefly by the absence of the localized points of tenderness mentioned, and the rapid disappearance of all symptoms in the course of a few days, which is seldom observed in true intercostal neuralgia. Pleurisy is also to be differentiated from this disease chiefly by its physical symptoms; and angina pectoris is to be told by the phenomena presented by the heart and the pulse, as well as by the sense of impending death, threatened suffocation, intense anxiety, and the fact that the pain frequently shoots down the left arm.

NEURALGIA OF THE MAMMARY GLAND (MASTODYNIA).

The skin over the mammary gland is supplied by the anterior and lateral branches of the second, third, fourth, fifth, and sixth intercostal nerves, and by some filaments derived from the supra-clavicular nerves, while the glandular struct-

ure itself is supplied by the lateral perforating branches of the fourth, fifth, and sixth intercostal nerves. This region is especially liable to an extreme form of neuralgia, first described by Sir Astley Cooper under the name of "irritable breast." So intense is the pain in some cases of this affection that it is compared to the sensation of cutting, tearing, or stabbing the part with a knife. It is usually paroxysmal in character, and generally of short duration, although such attacks may last for some hours.

This affection seems to be associated with pregnancy, anæmia, chlorosis, hysteria, and the development of neuromata upon the nerves of this region. It may be persistent and remain for years, and is particularly obstinate to treatment.

The detection of painful points is to be looked for in the region of the escape of the nerves which supply the part from the inter-vertebral foramina; and, in some instances, the existence of similar points may be detected upon the breast, near the nipple, and upon the sides of the gland. The attacks are particularly liable to exacerbate during the menstrual periods, and, during the height of the paroxysm, the pain may be transmitted by other nerves into the neck, down the arm, and over more extended areas upon the chest and back.

PARALYSIS OF THE DORSAL NERVES.

The dorsal muscles control, to a great extent, the movements, fixation, and upright position of the vertebral column, but these conditions require such a complexity of muscular action that it is often difficult, in case of paralysis, to exactly decide as to the muscles which are affected. Various degrees of weakness of the dorsal muscles are often present in youth, sometimes on one side and sometimes on the other, and occasionally affecting the whole back to a greater or less extent.

These paretic states are dependent upon rheumatic affections, diseases or injuries of the vertebral column, disturbances of the motor regions of the cerebrum, lesions of the

various ganglia of the encephalon, and lesions of the kinesodic system of the spinal cord. In paraplegia, the motor paralysis often extends upward to the muscles of the trunk; while, in progressive muscular atrophy, the muscles of the dorsal region are not infrequently involved.

If the muscles of both sides of the back be paralyzed, the spinal column gradually tends to assume the condition of a posterior curvature (paralytic kyphosis), and the deformity is usually most marked in the dorsal region, as the lumbar and cervical regions exhibit it to a less degree on account of their anatomical peculiarities. If the extensor muscles of the back be markedly affected, the spinal column forms an equable curve, as if the body were bent forward as in old age, and the patient becomes unable to voluntarily straighten the trunk to its normal posture. When passive straightening is attempted, the spine is easily brought into its proper curve; and this is a point of diagnosis between paralytic kyphosis and the deformity dependent upon structural disease of the vertebræ or a state of muscular contracture.

The muscles most frequently affected are the sacro-lumbalis and the latissimus dorsi. If they be paralyzed upon one side only, the deformity assumes the type of scoliosis, as a lateral curvature is produced by the muscles of the unaffected side. In this case, as in the one before cited, the patient is unable to rectify the deformity by any voluntary muscular effort, although the spinal curve can be easily removed by mechanical aid.

When the *extensor muscles* of the *lumbar region* are markedly impaired, the attitude assumed by the patient is very characteristic. It consists of a bending of the upper portion of the trunk in a backward direction, so as to compensate for the bending forward of the lumbar vertebræ; this bending of the thorax backward brings the upper part of the body behind the center of gravity of the whole body, and the balance is preserved exclusively by the action of the muscles of the abdomen. When the body is brought too far forward, it sinks and falls, as the lumbar muscles fail to support it in

an erect posture. The patient can not then bring the trunk into its former posture without the use of the hands, which are employed in a sort of a climbing process, the hands being

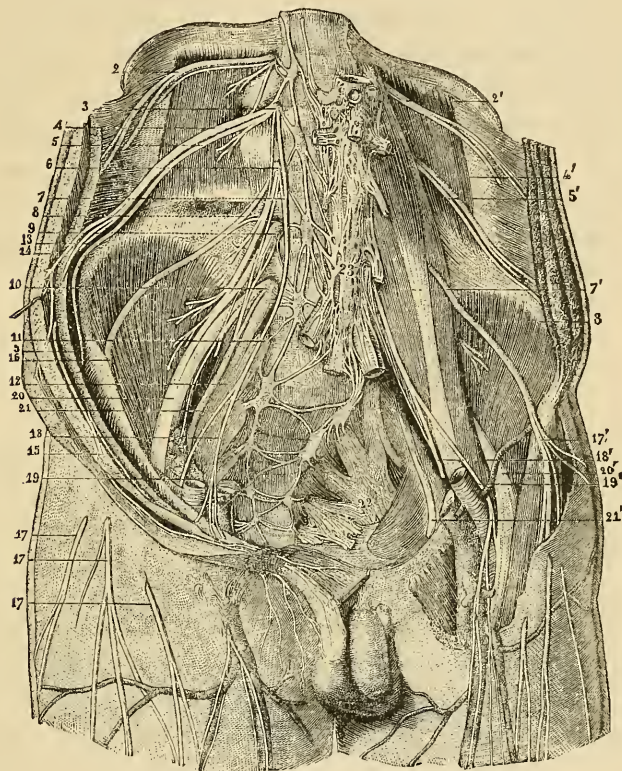


FIG. 221.—*The lumbar plexus.* (Hirschfeld.)

- 1, lumbar and sacral portions of the great sympathetic; 2, twelfth dorsal pair; 3, first lumbar pair; 4, 4', ilio-hypogastric branch; 5, 5', ilio-inguinal branch; 6, second lumbar pair; 7, origin of the genito-crural branch; 7', this same branch appearing and descending in front of the psoas muscle; 8, origin of the external cutaneous nerve; 8', this same branch leaving the border of the psoas, and dividing at the level of the fold of the groin; 9, third lumbar pair; 10, fourth lumbar pair; 11, fifth lumbar pair; 12, lumbo-sacral trunk; 13, gluteal branch of the ilio-hypogastric; 14, its abdominal branch; 15, its genital branches; 16, external cutaneous passing under Poupart's ligament, between the anterior superior and inferior spines of the ilium; 17, 17, 17, divisions of this branch; 17', point of origin of these divisions; 18, 18', genital branch of the genito-crural nerve; 19, 19, femoral division of this nerve piercing the fascia lata in the neighborhood of the saphenous opening; 19', this division exposed at the fold of the groin, to show its relations with the femoral artery and the saphenous vein; 20, 20', anterior erural nerve; 21, 21', obturator nerve.

placed upon the legs; a series of peculiar movements of the shoulders and trunk then follow, which are employed to assist

the arms in tossing the trunk backward to an extent sufficient to allow the abdominal muscles once more to support it. This difficulty in bringing the trunk above the level of the lower limbs is typical of this condition, but there are still other additional points of diagnostic value. The lumbar region presents a deep hollow; the head is bent forward in standing or walking; and the trunk may be seen to have a remarkable oscillating movement when the patient walks. When the patient sits down, the upper portion of the body seems to sink, and the spine presents a condition of kyphosis. In fact, it seems hardly possible that the condition can be mistaken by one well versed in anatomy.

THE LUMBAR NERVES.

The lumbar nerves comprise five pairs which escape from the intervertebral foramina of that region. Like all the spinal nerves, they each divide, immediately after their escape, into anterior and posterior divisions, the former of which has a larger proportion of motor, while the latter has an excess of sensory fibers. These nerves are of special interest, from the fact that the anterior divisions of the four upper nerves assist to form the lumbar plexus. This plexus is situated in the substance of the psoas muscle, in front of the transverse processes of the lumbar vertebræ. It is narrow above, where it is joined to the last dorsal nerve, but below it becomes broad, and is connected with the sacral plexus by means of the lumbo-sacral cord and a filament from the fourth lumbar nerve. The table which I now show you will give you an opportunity of contrasting the relative arrangement of the anterior and posterior divisions of the lumbar nerves, as well as of studying the origin of the seven main nerve trunks given off from the lumbar plexus.

In the following table the formation of the *lumbar plexus* is shown, as well as the branches which are given off from each nerve which assists to form it.

TABLE OF THE NERVES OF THE LUMBAR REGION.¹

LUMBAR NERVES.	POSTERIOR DIVISIONS.	}	External branches.	Filaments to erector spinæ muscle, Filaments to the inter-transversales muscles, Filaments to integument of back part of gluteal region.		
			Internal branches.	Filaments to multifidus spinæ muscle, Filaments to integument near spinal column.		
	ANTERIOR DIVISIONS	}	LUMBAR PLEXUS.	1ST LUMBAR nerve.	Ilio-hypogastric nerve, Ilio-inguinal nerve, Communicating to 2d lumbar.	Given off by the 1st LUMBAR NERVE.
				2D LUMBAR nerve.	Genito-crural nerve, External cutaneous nerve, Communicating to 3d lumbar.	Given off by the 2d LUMBAR NERVE.
				3D LUMBAR nerve.	Part of anterior crural nerve, Part of obturator nerve, Part of accessory obturator nerve, Communicating to 4th lumbar.	Given off by the 3d LUMBAR NERVE.
				4TH LUMBAR nerve.	Part of anterior crural nerve, Part of obturator nerve, Part of accessory obturator nerve, Lumbo-sacral cord.	Given off by the 4th LUMBAR NERVE.

It will be perceived that three most important nerves, viz., the *anterior crural*, the *obturator*, and *accessory obturator* nerves, are formed by branches both of the third and fourth lumbar nerves, and therefore may be said to arise by two heads. The *accessory obturator nerve*, however, arises occasionally by a branch derived only from the fourth lumbar nerve, its other head being a branch given off from the obturator nerve.

The second table, to which I now call your attention, is constructed to show the distribution of each of the seven large branches of the lumbar plexus. This table may aid in refreshing your memories while following the subsequent lectures, while it also gives you, at a glance, a better conception of the arrangement of any special nerve than a mere verbal description.

¹ Taken from "The Essentials of Anatomy" (Darling and Ranney). New York: G. P. Putnam's Sons, 1880.

TABLE OF THE DISTRIBUTION OF THE BRANCHES OF THE LUMBAR PLEXUS.¹

LUMBAR PLEXUS.	(1) ILIO-HYPO-GASTRIC.	{	<i>Iliac branch.</i>	}	<i>Integument of gluteal region.</i>			
			<i>Hypogastric branch.</i>		<i>Integument of the hypogastric region.</i>			
	(2) ILIO-INGUINAL.	{	<i>Internal oblique muscle,</i>					
			<i>Integument of upper and inner portion of thigh,</i>					
	(3) GENITO-CRURAL.	{	<i>Genital branch.</i>	{	<i>Cremaster muscle,</i>			
			<i>Scrotum,</i>					
	(4) EXTERNAL CUTANEOUS.	{	<i>Round ligament of female.</i>					
			<i>Crural branch</i>	{	<i>Integument of the front and upper portion of the thigh.</i>			
	(5) ANTERIOR CRURAL.	{	<i>Anterior division.</i>		{	<i>Anterior branch.</i>	{	<i>Integument of inner and outer sides of knee.</i>
			<i>Posterior branch.</i>	<i>Integument of inner sides of the thigh and the leg.</i>				
	(6) OBTURATOR NERVE.	{	<i>Long or internal saphenous nerve.</i>					
			<i>Integument of knee joint and front and inner sides of the leg and foot.</i>					
	(7) ACCESSORY OBTURATOR NERVE	{	<i>Muscular branches.</i>	{	<i>All the muscles on front of thigh except the tensor vaginae femoris and the sartorius.</i>			
			<i>Articular branches.</i>		<i>Two in number. Distributed to capsule of knee joint, and probably to the hip joint.</i>			
	(8) ANTERIOR CRURAL.	{	<i>Articular branches.</i>	{	<i>To hip joint.</i>			
<i>Muscular branches.</i>			<i>To gracilis, To adductor longus, To pectineus, To adductor brevis.</i>					
(9) POSTERIOR CRURAL.	{	<i>With internal cutaneous nerve,</i>						
		<i>With internal saphenous nerve.</i>						
(10) ANTERIOR CRURAL.	{	<i>Articular branches.</i>	{	<i>To knee joint.</i>				
		<i>Muscular branches.</i>		<i>Obturator externus, Adductor magnus.</i>				
(11) POSTERIOR CRURAL.	{	<i>Muscular branch.</i>						
		<i>To pectineus.</i>						
(12) ACCESSORY OBTURATOR NERVE	{	<i>Articular branches.</i>						
		<i>To hip joint.</i>						
(13) ACCESSORY OBTURATOR NERVE	{	<i>Cutaneous branches.</i>						
		<i>To the integument of thigh and leg.</i>						

¹ Taken from "The Essentials of Anatomy" (Darling and Ranney). New York: G. P. Putnam's Sons, 1880.

THE ILIO-HYPOGASTRIC NERVE.

This nerve is named, from its two terminal filaments of distribution, the iliac and hypogastric branch. It is given off by the first lumbar nerve in company with the ilio-inguinal. It emerges from the outer border of the psoas muscle, crosses the quadratus lumborum, then perforates the transversalis muscle of the abdomen, and finally divides between it and the internal oblique muscle into its iliac and hypogastric branches.

The *iliac branch* pierces the internal and external oblique muscles just above the crest of the ilium, and supplies the skin of the gluteal region, while the *hypogastric branch* pierces the internal oblique and the aponeurosis of the external oblique muscle a little above the external abdominal ring, and supplies the skin of the hypogastrium. In some cases the ilio-inguinal nerve is incompletely developed, and this nerve may then be traced downward to the skin of the penis, scrotum, labium, and thigh.

THE ILIO-INGUINAL NERVE.

This nerve arises, in common with the preceding nerve, from the first lumbar nerve, but it is smaller in point of size than its fellow. Like the ilio-hypogastric, it pierces the outer border of the psoas, and crosses the quadratus lumborum muscle, lying below the preceding nerve; it then pierces the transversalis muscle, enters the inguinal canal, passes throughout the entire length of that canal in front of the spermatic cord, and supplies the skin of the penis, scrotum, labium, and of the upper and inner portions of the thigh. It is sometimes incompletely developed, in which case the ilio-hypogastric nerve takes its place.

CLINICAL POINTS PERTAINING TO THE ILIO-HYPOGASTRIC AND ILIO-INGUINAL NERVES.

These two nerves are sometimes the seat of a severe form of neuralgia. It may be produced by disease of the lumbar

vertebræ, structural changes in the parts investing the lumbar plexus, pelvic diseases, exudations in the substance of the psoas muscle, strains, contusions, exposure, and an hysterical condition. The pains are usually of a paroxysmal character, and radiate in the course of these nerves; they are of a lancinating type, and often extremely severe. Painful points may be detected in one of the following regions, or possibly in all of them: 1, a *lumbar point*, near the spinous processes of the lumbar vertebræ; 2, an *iliac point*, near to the middle of the crest of the ilium, where the ilio-hypogastric nerve pierces the transversalis muscle; 3, an *hypogastric point*, slightly above the external ring, where the ilio-hypogastric nerve pierces the aponeurosis of the external oblique muscle; 4, an *inguinal point*; and 5, points upon the *scrotum* or *labium*. It is stated by Notta¹ that this type of neuralgia may be occasionally accompanied by an increase in the sexual appetite, and a spasmodic contraction of the cremaster muscle.

This form of neuralgia is to be diagnosed from rheumatic myalgia of the longissimus dorsi and sacro-lumbalis muscles, and from those types of chronic affections of the uterus which induce pain in the back. It might also be possibly mistaken for an attack of renal or biliary colic. The diagnosis will be made chiefly by the "*puncta dolorosa*"² previously described, by the course of the pain, and by its intense paroxysmal and lancinating character.

The nerves which are distributed to the skin of the abdominal walls may be considered as comprising two distinct sets, based on the physiological action of the abdominal muscles which are supplied by them. According to Hilton, the abdomen may be divided, on a line corresponding with the situation of the umbilicus, into an upper or respiratory portion, and a lower or abdominal portion. The upper or respiratory portion is supplied, in great part, by the lower intercostal nerves, which are distributed also to the muscles of the

¹ As quoted by Erb.

² A name applied by Valleix to the spots of extreme local tenderness found along the course of a nerve which is the seat of neuralgia.

chest, and which, if taken with the other intercostal nerves as a group, are essentially respiratory in their function. The lower or abdominal portion of the abdomen is supplied chiefly by the ilio-hypogastric nerve, although the ilio-inguinal, the genito-crural, and the posterior branches of the lumbar nerves assist in furnishing motor power to the muscles of that region.

The subjacent peritonæum is unquestionably supplied from the same sources of nerve power as the muscles and skin of the individual regions of the abdomen, and it is considered probable by the author above quoted that the spinal nerves which are distributed to the skin, muscles, and parietal peritonæum may be also associated with the visceral layer underneath, by means of communications with the sympathetic nerve. The abdominal muscles unquestionably assist the colon in its endeavors to force the fæces, by its peristaltic action alone, throughout its length, since the force of gravity has to be overcome in its ascending portion, and the curves of the sigmoid flexure in its terminal portion. It would therefore be an additional confirmation of a general law of nerve distribution, provided the distribution of the abdominal nerves to the intestinal covering of peritonæum could be fully verified; since the structures which assist in moving the adjacent organs—the abdominal muscles—would be supplied from the same source as the parts moved, as well as the skin over those muscles.

THE EXTERNAL CUTANEOUS NERVE.

This nerve arises from the trunk of the second lumbar nerve, in common with the genito-crural, but it usually receives a few filaments from the third lumbar. It pierces the psoas muscle, near to its central point, and crosses the iliacus muscle in order to reach a notch below the anterior superior spine of the ilium, where it escapes below Poupart's ligament.

The anterior branch of this nerve pierces the fascia lata at about four inches below Poupart's ligament, and supplies the integument of the anterior and outer aspects of the thigh, while the posterior branch supplies the integument of the outer and posterior aspects of the same region. Both of these

terminal branches are given off after the main nerve trunk has escaped from beneath Poupart's ligament. It will be observed that this nerve pierces the psoas muscle, in a different direc-

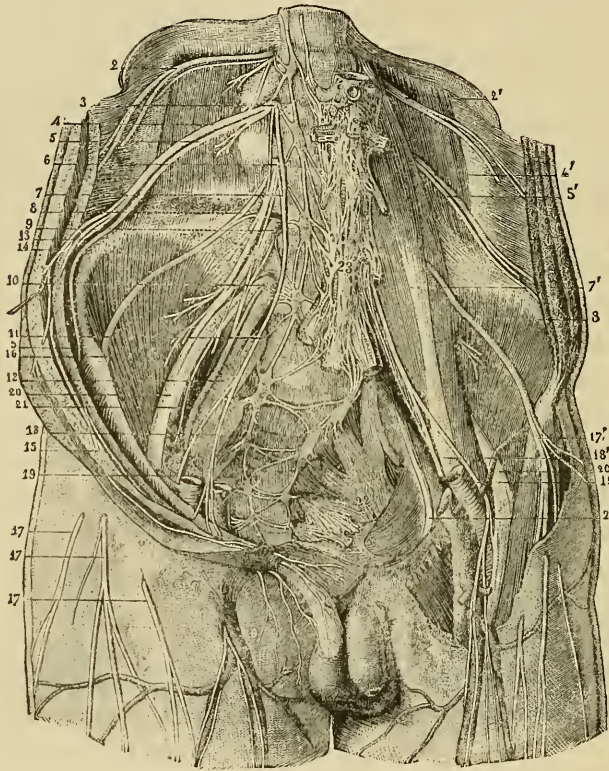


FIG. 222.—*The cutaneous nerves of the thigh.* (Hirschfeld.)

1, lumbar and sacral portions of the great sympathetic; 2, twelfth dorsal pair; 3, first lumbar pair; 4, 4', ilio-hypogastric branch; 5, 5', ilio-inguinal branch; 6, second lumbar pair; 7, origin of the genito-crural branch; 7', this same branch appearing and descending in front of the psoas muscle; 8, origin of the external cutaneous nerve; 8', this same branch leaving the border of the psoas, and dividing at the level of the fold of the groin; 9, third lumbar pair; 10, fourth lumbar pair; 11, fifth lumbar pair; 12, lumbo-sacral trunk; 13, gluteal branch of the ilio-hypogastric; 14, its abdominal branch; 15, its genital branches; 16, *external cutaneous nerve* passing under Poupart's ligament, between the anterior superior and inferior spines of the ilium; 17, 17', 17', divisions of this branch; 17', point of origin of these divisions; 18, 18', genital branch of the genito-crural nerve; 19, 19', femoral division of this nerve piercing the fascia lata in the neighborhood of the saphenous opening; 19', this division exposed at the fold of the groin, to show its relations with the femoral artery and the saphenous vein; 20, 20', anterior crural nerve; 21, 21', obturator nerve.

tion from the two preceding nerves, and that it crosses over the iliacus muscle, while the two preceding nerves crossed the

quadratus lumborum. This fact, which is true also of the genito-crural nerve, is to be remembered in tracing the seat of origin of a pain felt in the regions supplied by either of these nerves. We would naturally look, as we pass toward the trunk, either to find the cause of such a pain (manifested by the external cutaneous nerve) in the region of Poupart's ligament, or to detect some pelvic cause involving the iliacus muscle, some abnormal condition of the psoas muscle, or some lesion of the vertebræ in the lumbar region.

THE GENITO-CRURAL NERVE.

This nerve arises, in common with the external cutaneous, from the second lumbar nerve, although it occasionally receives some filaments from the first lumbar. It pierces the psoas muscle, and divides into its two terminal branches upon its anterior surface.

The *genital branch* crosses the external iliac artery and passes through the inguinal canal to supply the cremaster muscle and the scrotum or labium; it lies behind the spermatic cord in the male and the round ligament in the female.

The *crural branch* pierces the fascia lata (after escaping beneath Poupart's ligament on the inner side of the psoas muscle) on the outer side of the femoral vessels, and supplies the skin of the upper and anterior part of the thigh, anastomosing with the middle cutaneous branch of the anterior crural nerve.

CLINICAL POINTS PERTAINING TO THE EXTERNAL CUTANEOUS AND GENITO-CRURAL NERVES.

As both of these nerves are distributed chiefly to the integument, a knowledge of their anatomy affords the intelligent practitioner a means of tracing the situation of any local cause of a pain, confined to the regions which these nerves supply. While their course is such as to render them less liable to local pressure or injury than the obturator or anterior crural nerves, and while the fact that they are distributed to no muscles (excepting the cremaster) deprives them of much of

the physiological interest which other nerves possess, still it is possible to imagine certain localized conditions of the psoas and iliacus muscles, local swellings in the vicinity of Poupert's ligament, and possible forms of vertebral disease which might be manifested exclusively through the medium of these nerves.

THE ANTERIOR CRURAL NERVE.

This is the largest branch of the lumbar plexus. It arises mainly from the third and fourth lumbar nerves, but often receives a fasciculus from the second. In its course, it perforates the psoas muscle, emerging from it at the lower part of its outer border. It then passes between the psoas and iliacus muscles, and enters the thigh by escaping under Poupert's ligament about one half inch to the outer side of the femoral artery. Its main divisions (the middle and internal cutaneous and long saphenous nerves) are given off after it enters the thigh. The distribution of each of these terminal branches is shown you upon the table,¹ but I would call your attention to some points of special interest pertaining to the anterior crural nerve, which will perhaps enable you to appreciate the value which some portions of this table possess.

The anterior crural nerve supplies nearly all of those muscles which are employed in the *first effort of progression*. As the act of taking a step forward is performed, we flex the thigh upon the pelvis, we extend the leg at the knee, and we slightly evert the foot.² Now, all the muscles which aid us in performing these various movements—the psoas and iliacus, the pectineus and sartorius, the four muscles of the quadriceps extensor, and the subcrureus—are supplied by the anterior crural nerve. This nerve also sends branches both to the knee joint and hip joint; the capsular ligament of the former, as well as that of the latter,³ being supplied by filaments which can easily be demonstrated by dissection. If we

¹ See page 724 of this volume.

² John Hilton, *op. cit.*

³ This fact is not so stated by all of the text-books upon descriptive anatomy, but, nevertheless, I regard it as capable of demonstration.

now consider, in the third place, that the cutaneous branches of this nerve supply the skin of the thigh, and also the regions over the two joints mentioned, we are enabled to again

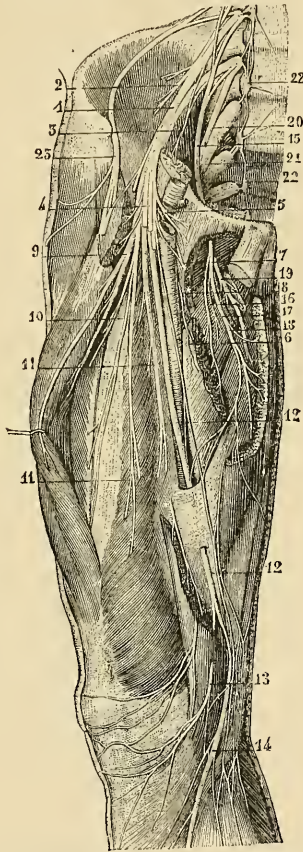


FIG. 223.—*The muscular branches of the anterior and internal portions of the thigh.*
(Sappey.)

1, anterior crural nerve ; 2, branch which it furnishes to the iliacus muscle ; 3, twig which it sends to the internal portion of the psoas muscle : 4, middle cutaneous branch of the anterior crural, whose three branches have been divided close to their origin in order to show the branches to the quadriceps extensor and the internal saphenous nerve, which are more deeply placed ; 5 and 6, muscular filaments of the internal cutaneous nerve ; 7, origin of the cutaneous branches which pierce the fascia lata at the level of the saphenous opening ; 8, deep or anastomotic filament of the internal cutaneous branch of the anterior crural ; 9, branches to the rectus muscle ; 10, branches to the vastus externus ; 11, branches to the vastus internus ; 12, 12, internal saphenous nerve ; 13, patellar branch of this nerve ; 14, its vertical or tibial branch ; 15, obturator nerve ; 16, branch which it furnishes to the adductor longus ; 17, branch to the adductor brevis ; 18, branch to the gracilis ; 19, branch to the adductor magnus ; 20, lumbo-sacral trunk ; 21, junction of this nerve with the first sacral nerve ; 22, 22, lumbar and sacral portions of the sympathetic ; 23, external cutaneous nerve.

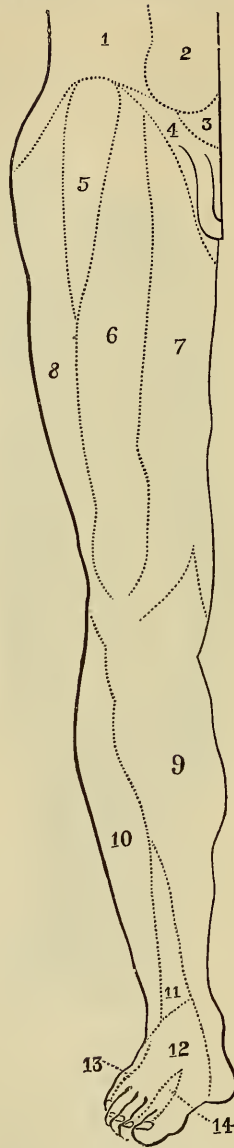


FIG. 224.—A diagram of the cutaneous supply of the anterior aspect of the lower extremity.

1, region supplied by the lateral branches of the intercostal nerves; 2, region supplied by the anterior branches of the intercostal nerves; 3, region supplied by the ilio-hypogastric nerve; 4, region supplied by the ilio-inguinal nerve; 5, region supplied by the genito-crural nerve; 6, region supplied by the middle cutaneous branch of the anterior crural nerve; 7, region supplied by the internal cutaneous branch of the anterior crural nerve and partly by the obturator nerve; 8, region supplied by the external cutaneous nerve; 9, region supplied by the long saphenous branch of the anterior crural nerve; 10, region supplied by the branches of the external popliteal nerve; 11, region supplied by the musculo-cutaneous nerve; 12, region supplied by the terminal filaments of the musculo-cutaneous nerve; 13, region supplied by the external saphenous nerve; 14, region supplied by the anterior tibial nerve.

record a confirmation of that axiom of Hilton,¹ that a nerve which supplies a joint must supply also muscles which move that joint, and the skin over the insertion of those muscles. The long saphenous nerve seems, at first sight, to extend far beyond the limits of the muscular distribution of the anterior crural, but, when we look closely into the anatomical relations of the fascia of the leg, we find that the muscles supplied by the anterior crural nerve are attached to it, especially the sartorius, whose insertion into this fascia is as intimate as that of the biceps into the fascia of the forearm; and we also notice that the cutaneous distribution over this fascia is derived from the same sources as are the muscles which are attached to it. This fact is in perfect accord with the axiom given in a previous lecture, viz., that a fascia, to which muscles are attached, must be considered as one of the points of insertion of the muscles connected with it, and that the cutaneous distribution over such a fascia will be found to be derived from the nerves which supply those muscles. We thus discover in the lower extremity the same general laws of nerve distribution, as were verified in connection with the upper extremity, fully carried out; and it is thus that many of the apparent deviations from the natural order of nerve supply may be explained by, and often act as guides to, the presence of some anatomical fact, whose physiological importance had either not been recognized or properly appreciated.

CLINICAL POINTS PERTAINING TO THE ANTERIOR CRURAL NERVE.

The relation of this nerve to the femoral artery as it passes underneath Poupart's ligament and its still more intimate relation with that vessel in Scarpa's space render it of special interest to the surgeon. Its internal cutaneous branches cross the upper part of the femoral artery in that space, before it becomes properly a cutaneous nerve; while the long saphenous nerve lies to the outer side of that vessel for nearly its entire length, being at first slightly removed from it, but

approaching it more closely in the lower part of its course. This latter nerve also bears an intimate relation with the internal saphenous vein for the greater portion of its course; hence the pain experienced from varicose veins in this region.¹

It is customary with surgeons to regard a *pain* which is localized at the *inner side of the knee* (since the obturator nerve is distributed to that region) as strongly diagnostic of disease of the hip joint, because that nerve is supposed to have an intimate connection with the internal structures of the hip. So strongly is this impression grounded in the minds of some of our prominent surgical authors that the presence of pain in any other locality than that just mentioned is not considered as particularly indicative of morbus coxarius; and the inference is certainly implied, if not directly stated, that the accuracy of diagnosis of this condition can be questioned if this symptom be not confined to the region supplied by the obturator nerve. I am not prepared to admit that pain in the knee is always present in morbus coxarius, nor am I inclined to think that the anterior crural nerve, from its distribution to the capsular ligament of the hip joint, can not also be one of the sources of sympathetic pains referred to the knee, in case the hip be diseased. I admit that the obturator nerve, from its distribution to the internal structures of the hip joint,² is the most frequent source of transmission of these sympathetic pains; but the sciatic and anterior crural nerves may also indicate an irritation of their filaments to the capsule of the hip by pains referred to the other regions which they supply.

Spasm of the quadriceps extensor muscle, which is supplied by the anterior crural nerve, is often observed in articular neuralgia of the knee joint; while the rigid extension of the leg upon the thigh, met with in tetanus, is dependent upon irritation of this nerve. In his treatise upon nervous

¹ Varicose veins are most common on the inner side of the leg. The pain of these tumors may often be arrested by simple elevation of the foot, since the excess of blood in the part is thus relieved.

² It is claimed by Hilton that this nerve is distributed chiefly to the ligamentum teres, and that this accounts for it being so frequently affected by disease of the hip joint.

diseases, Eulenberg reports a case of clonic spasm localized in the quadriceps extensor muscle which was induced whenever an attempt to walk or stand was made, but such cases are of rare occurrence.

Paralysis confined to the anterior crural nerve is not of common occurrence, but is still observed as a result of injuries to the vertebral column and pelvis, from tumors and extravasations of blood in the region of the cauda equina, and as a sequel to a severe type of inflammation of the knee joint. It has been known to occur in connection with psoas abscess and simple inflammation of the psoas muscle; while fractures of the thigh, cuts, stab wounds, neuritis, pelvic tumors, and tumors of the thigh, have been reported as inducing this type of paralysis. Finally, it is a frequent symptom of spinal paralysis in all of its forms, and, more rarely, of cerebral paralysis and of progressive muscular atrophy.

From what has been already said as to the distribution of this nerve to muscles, it is easy to understand that the symptoms of this type of paralysis will be confined to the inability of the anterior thigh muscles to perform their accustomed functions. Such patients can not flex the leg at the hip joint or raise the body from the recumbent position; neither are they able to extend it nor to move the leg

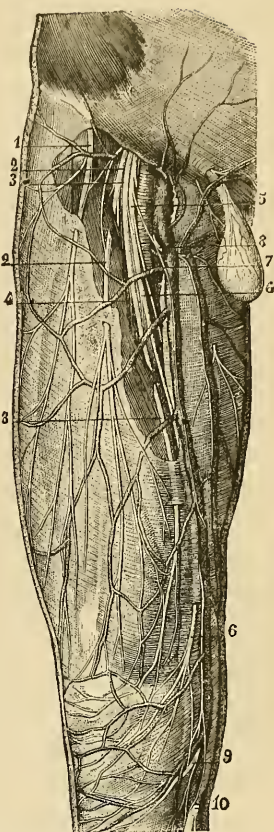


FIG. 225.—Cutaneous nerves of the anterior part of the thigh. (Sappey.)

- 1, external cutaneous branch of the lumbar plexus; 2, 2, external cutaneous or superior perforating branch of the anterior crural nerve; 3, 3, middle cutaneous or inferior perforating branch of this nerve; 4, filament furnished by this branch to the scrotum; 5, internal cutaneous branch of the anterior crural nerve; 6, superficial division of this branch; 7, deep division of the same; 8, superficial division of the small musculocutaneous branch of the anterior crural; 9, transverse or patellar branch of the internal saphenous nerve; 10, internal, vertical, or tibial branch of the same.

and foot forward when sitting. For this reason standing and walking are rendered very insecure, and such acts as running, jumping, etc., are often impossible with patients so afflicted. The regions of the skin which are supplied by the anterior crural nerve may manifest disturbances of sensibility. If the scrotum, labium, hypogastrium, or inguinal regions exhibit the same disturbances of sensibility, the seat of the paralysis is positively indicated as being above the origin of the branches of the two upper lumbar nerves (ilio-hypogastric, ilio-inguinal, genito-crural, and external cutaneous nerves). Among the evidences of disturbed sensibility which you may be called upon to recognize may be mentioned the conditions of anæsthesia, hyperæsthesia, the sensations of furriness, numbness, and chilliness.

Atrophy of the muscles supplied by the anterior crural nerve may follow such paralysis. This is generally so well defined as to be apparent to the naked eye when the two thighs are compared; but it may, occasionally, be so slight as to require careful measurement of the thighs. In some cases, certain muscles exhibit this atrophy more than others of the group, and even parts of muscles may appear flaccid, relaxed, and shrunken, while others preserve their normal appearance.

Crural neuralgia may be manifested by paroxysms of pain upon the anterior and inner surfaces of the thigh and leg. It may affect the inner border of the dorsal surface of the foot and large toe. It is less frequent than neuralgia of the sciatic nerve, which affects the back of the leg and plantar region of the foot. This diseased condition may result from compression of the lumbar plexus, from degeneration of neighboring lymphatic glands, exudations upon or in the substance of the psoas muscle, aneurism of the iliac arteries, strangulated hernia of the femoral region, dislocations at the hip joint, traumatism, exposure to cold or dampness, coxalgia, etc. The diagnostic points of tenderness are detected as follows: 1, a *crural* point, at the exit of the nerve below Poupert's ligament; 2, an *anterior femoral point*, at the place of exit of the saphenous nerve through the fascia lata; 3, an

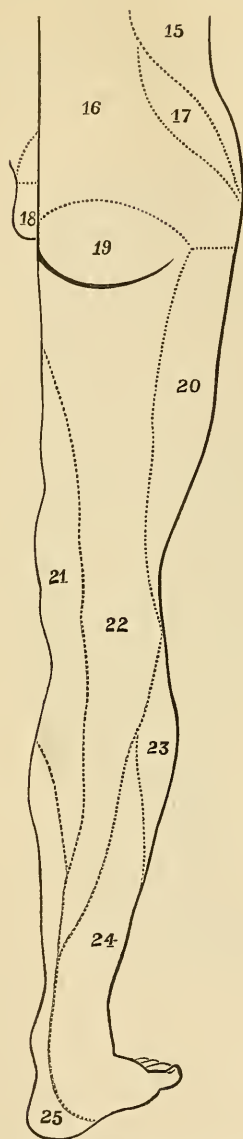


FIG. 226.—A diagram of the cutaneous supply of the posterior aspect of the lower extremities.

15, region supplied by the lateral branches of the intercostal nerves; 16, region supplied by the posterior branches of the lumbar nerves; 17, region supplied by the iliac branch of the ilio-hypogastric nerve; 18, region supplied by the pudic nerve; 19, region supplied by the inferior gluteal branch of the small sciatic nerve; 20, region supplied by the external cutaneous nerve; 21, region supplied by the internal cutaneous branch of the anterior crural nerve; 22, region supplied by the small and great sciatic nerves; 23, region supplied by branches from the external popliteal nerve; 24, region supplied by the external saphenous nerve; 25, region supplied by the posterior tibial nerve.

articular point, at the inner side of the knee joint, where the nerve divides; 4, a *plantar point*, on the inner side of the foot; and, finally, 5, a *digital point*, over the tuberosity of the big toe.

Spasm of the muscles of the hip, supplied by the anterior crural nerve (the spasmodic contracture of Stromeyer), may occur from any of the causes of crural paralysis previously mentioned. The thigh is then flexed, the pelvis raised up on the affected side, and the limb shortened and made rigid.

THE OBTURATOR NERVE.

This nerve arises mainly from the third and fourth lumbar nerves, but it often receives a fasciculus from the second. It descends in the innermost fibers of the psoas muscle, as far as the level of the brim of the pelvis, when it escapes from the inner border of that muscle, crosses the sacro-iliac articulation, accompanies the obturator vessels along the outer wall of the pelvis lying slightly above them, and passes into the thigh through the upper part of the obturator foramen.

The table,¹ previously referred to, will enable you to grasp the details of the subdivisions of this nerve, and the distribution of each branch; but it fails to point out some important facts pertaining to this nerve, which help to explain its physiological attributes and to elucidate its clinical bearings.

In the first place, we can see by this table that the obturator nerve sends filaments to the hip joint and the knee joint. To the former articulation two filaments of this nerve can be traced, one given off to the capsular ligament, as the nerve passes through the obturator foramen, the other given off to the ligamentum teres in the region of the notch in the acetabulum; while, in the case of the knee joint, the obturator nerve sends filaments which enter that articulation at its posterior part, and which are probably intimately associated with its internal structures. The close relation which this nerve bears to the sacro-iliac articulation renders it probable

¹ See page 724 of this volume.

that some small filaments from the obturator nerve could be traced to this joint, although anatomical authors do not mention this fact as proven. In relation to this point, I quote from

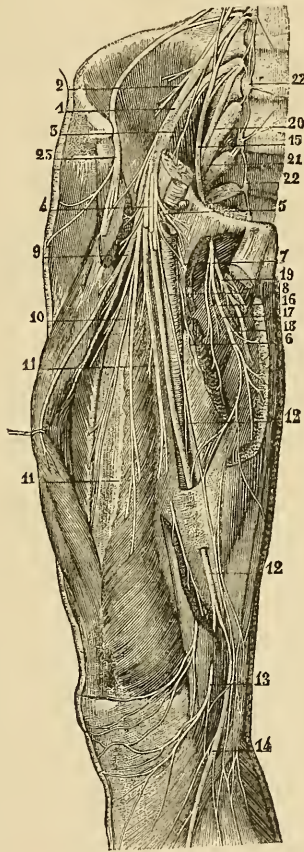


FIG. 227.—*The muscular branches of the anterior and internal portions of the thigh.*
(Sappey.)

1, anterior crural nerve; 2, branch which it furnishes to the iliacus muscle; 3, twig which it sends to the internal portion of the psoas muscle; 4, middle cutaneous branch of the anterior crural, whose three branches have been divided close to their origin in order to show the branches to the quadriceps extensor and the internal saphenous nerve, which are more deeply placed; 5 and 6, muscular filaments of the internal cutaneous nerve; 7, origin of the cutaneous branches which pierce the fascia lata at the level of the saphenous opening; 8, deep or anastomotic filament of the internal cutaneous branch of the anterior crural; 9, branches to the rectus muscle; 10, branches to the vastus externus; 11, branches to the vastus internus; 12, 12, internal saphenous nerve; 13, patellar branch of this nerve; 14, its vertical or tibial branch; 15, obturator nerve; 16, branch which it furnishes to the adductor longus; 17, branch to the adductor brevis; 18, branch to the gracilis; 19, branch to the adductor magnus; 20, lumbo-sacral trunk; 21, junction of this nerve with the first sacral nerve; 22, 22, lumbar and sacral portions of the sympathetic; 23, external cutaneous nerve.

the most excellent monograph of Hilton¹ as follows: "I am disposed to think it sends some filaments to that articulation, or, at any rate, it lies close to it and would be likely to suffer from its proximity to it when diseased." Now, this distribution to the internal portions of two joints, and possibly to a third, is the best possible explanation of the fact that the obturator nerve is the most frequent source of transmission of sympathetic pains, in case the hip joint be the seat of the disease, since the situation of its filaments causes it to perceive the first inflammatory changes within the hip; and the effects of this irritation are naturally manifested in its terminal filaments—in the knee joint and the skin upon the inner side of that articulation.

When we consider the course of the obturator nerve more in detail, we will perceive that *pain in the region of the knee* may be due to other causes than morbus coxarius. It may be the external evidence of disease of the third or fourth lumbar vertebræ, of disease of the sacro-iliac articulation, of a psoas abscess pressing upon it, and, if the pain be confined to the left side, a distention of the sigmoid flexure of the colon by fæces, or a malignant tumor of that portion of the colon or of the rectum might create pain in this region. It is well, therefore, when a patient suffering from a pain localized upon the inner aspect of the knee joint is brought to you, to carefully examine all the different portions of the course of the obturator, anterior crural, and sciatic nerves before you decide as to the exciting cause of the pain, remembering always that pain can be perceived through no other structures than the nerves which are distributed to the region where the pain is felt, and that, by following the course of the nerve suffering from irritation, the seat of the disease to which the pain is due may be confidently sought for.

The distribution of the obturator nerve affords us some lessons as to the physiological groupings of the muscles which act upon the thigh and leg. It first supplies the obturator externus, and then the adductor brevis, the adductor longus,

¹ *Op. cit.*

the adductor magnus, and the gracilis. In some cases the pectineus is supplied by this nerve or the accessory obturator nerve, but its chief source of supply is undoubtedly from the anterior crural. This fact would seem to indicate that the gracilis muscle, whose supply from the obturator nerve is very constant, should be classed as an adductor muscle, rather than as a flexor, and that this is its true action seems well proven on mechanical principles. Its point of insertion is just below the central point of the limb which it moves, hence, it seizes the limb just beyond the central point, between the fulcrum (the hip joint) and the resistance, and is thus able to greatly assist the adductor muscles. The obturator nerve is thus, physiologically considered, the *adductor nerve* of the lower extremity, while the muscles which it supplies also act as external rotators of the thigh, on account of the obliquity of their fibers. That the pectineus muscle acts as a flexor as well as an adductor is proven by its nerve supply, as well as by the direction of its fibers and its points of origin and insertion, since it receives filaments both from the anterior crural and obturator.

CLINICAL POINTS PERTAINING TO THE OBTURATOR NERVE.

The diagnostic value of pain in the region of the knee joint as an evidence of disease in other localities, to which the obturator nerve is either distributed or with which it bears some intimate relations, has been discussed already at some length.¹ Such a pain may be dependent, however, also upon lesions interfering with the free action of the anterior crural and sciatic nerves, and, for that reason, the course of these three nerves should always be carefully examined before a positive diagnosis can be made as to the exciting cause of pain in the region of the knee.

The obturator nerve is even less frequently affected with isolated paralysis than the anterior crural, but, if so, it may be referable to the same list of causes. In addition to the causes mentioned, may be added, however, compression of the

¹ See page 734 of this volume.

obturator nerve from a strangulated hernia through the obturator foramen, the pressure exerted by the head of a fœtus during its passage through the pelvis, and the use of forceps during difficult labors.

From what has been said as to the supply of muscles by this nerve, it is apparent that a patient afflicted with obturator paralysis can not adduct the thigh, or perform the acts of pressing the knees tightly together or of crossing the affected leg over the other. Since the adductor muscles assist in the external rotation of the thigh, this movement is impaired, especially in the sitting posture, when the external rotators attached to the great trochanter are rendered inert. The affected leg soon becomes fatigued in walking, and riding upon horseback is difficult, since the knees can not grasp the saddle. Some disturbances of sensibility may be detected in the regions of the skin supplied by this nerve; these will be the same in character as those mentioned as existing in crural paralysis.¹

THE ACCESSORY OBTURATOR NERVE.

This nerve is sometimes wanting. When it is present, its origin is extremely variable. It may arise from the third and fourth lumbar nerves; from the fourth lumbar and obturator nerves; or by separate filaments derived from the second, third, and fourth lumbar nerves. It descends along the inner side of the psoas muscle, crosses in front of the pubes, passes behind the pectineus muscle, and there divides into branches to the pectineus and the hip joint. It usually gives off a large branch of communication to the obturator nerve (which is often larger than the continuation of the accessory nerve itself), and terminates as a cutaneous nerve to the thigh and leg.

The frequent absence of this nerve deprives it of any clinical importance, as it is impossible in any one case to decide if pain in the regions supplied by the obturator nerve is partly due to the accessory obturator or not, while the variations in

¹ See page 736 of this volume.

the method of origin of the nerve renders it impossible to definitely decide as to the seat of irritation, provided the pain could be traced to the accessory nerve and localized above the pelvis.

THE SACRAL NERVES.

We now have reached, in the natural progress of this course of lectures, the terminal nerves of the spinal cord. As was the case with those of the lumbar region, the sacral nerves divide into anterior and posterior divisions, but they differ from the lumbar nerves in the fact that these anterior and posterior divisions escape from separate foramina in the sacrum, while, in the portions of the cord above the sacral region, the spinal nerves divide after their escape from the inter-vertebral foramina. These nerves form, by their anterior divisions and the addition of the lumbo-sacral cord, the sacral plexus; while their posterior divisions are distributed to the muscles of the lower lumbar region and to the integument of the gluteal, sacral, and coccygeal regions.

The *sacral plexus* is triangular in shape, and is formed by the lumbo-sacral cord, the three upper sacral nerves (their anterior divisions), and a portion of the fourth-sacral nerve. Its constituent fibers converge to form one flattened cord, which leaves the pelvis through the lower part of the great sacro-sciatic foramen, below the pyriformis muscle, while, within the pelvis, the plexus lies upon the pyriformis muscle, and is covered by the pelvic fascia and the two terminal branches of the anterior division of the internal iliac artery (the sciatic and pudic). The branches which are given off by this plexus are arranged, in the table which I now show you, in such a way as to make them apparent to the eye, while the distribution of each is shown in the next table in detail. The first table is not intended to exhibit alone the branches of the sacral plexus, but rather to give the general arrangement of the

sacral nerves in their entirety. You will perceive that the arrangement of both the anterior and posterior divisions is considered, and that the component parts of the sacral plexus, as well as its main subdivisions, are clearly set forth.

NERVES OF THE SACRAL REGION.¹

SACRAL NERVES.	Posterior divisions.	External branches.	SACRAL PLEXUS.	(1) SUPERIOR GLUTEAL NERVE, (2) MUSCULAR BRANCHES, (3) SMALL SCIATIC NERVE, (4) GREAT SCIATIC NERVE, (5) PUDIC NERVE, (6) ARTICULAR.
		Internal branches.		
	Anterior divisions.	LUMBO-SACRAL CORD.		
		1ST SACRAL NERVE.		
		2D SACRAL NERVE.		
		3D SACRAL NERVE.		
		PART OF 4TH SACRAL NERVE.		

Form anastomotic loops on the back part of the sacrum and on the posterior aspect of the great sacro-sciatic ligament, Terminate in *cutaneous branches* in the gluteal region.
 Are distributed to the multifidus spinae muscle,
 The back part of the coccyx is supplied by the two lower nerves.

Each of the five branches of the sacral plexus, as well as those included in the muscular group, to which no special names are given, will now be separately described. I have endeavored to embrace in this second table all the points pertaining to the purely anatomical distribution of each of these nerves, but much of interest, from a clinical aspect, still remains in relation to some of them, which can not be shown in a tabular form. This table will, however, prove of assistance to you in reviewing the distribution of the nerve which is, at any time, under discussion, and, furthermore, avoid lengthy descriptions of a purely anatomical character.

¹ Taken from the "Essentials of Anatomy" (Darling and Ranney). G. P. Putnam's Sons, New York, 1880.

DISTRIBUTION OF THE BRANCHES OF THE SACRAL PLEXUS.¹

SACRAL PLEXUS.	SUPERIOR GLUTEAL.	<i>Superior branch.</i> { <i>Inferior branch.</i> {	{ Gluteus medius muscle, Gluteus minimus muscle. { Gluteus medius muscle, Gluteus minimus muscle, Tensor vaginæ femoris.
	MUSCULAR BRANCHES.	Pyramidalis, Obturator internus, Gemellus superior, Gemellus inferior, Quadratus femoris.	
	ARTICULAR BRANCHES.	To <i>hip joint.</i>	
	SMALL SCIATIC NERVE.	<i>Inferior gluteal branch.</i> { <i>Inferior pudendal branch.</i> { Cutaneous branch. {	{ Gluteus maximus muscle, Integument of the side of the penis or vulva. Integument of perinæum, Integument of upper and inner part of the thigh, Integument of scrotum or labium. Ascending. { Descending. {
	GREAT SCIATIC NERVE.	Articular (to the <i>hip joint</i>). Muscular . . . Terminal . . .	{ Adductor magnus, Semi-membranosus, Semi-tendinosus, Biceps flexor cruris. EXTERNAL POPLITEAL NERVE, INTERNAL POPLITEAL NERVE.
	PUDIC NERVE.	Perineal . . . Muscular . . . Inferior hemorrhoidal. Dorsal nerve of <i>penis.</i> {	{ Integument of anal region, superficial } scrotum, penis, and labia, perineal. } Sphincter ani muscle. Muscular . . . } Muscles of the perinæum. { Integument of the dorsum of the penis, Branch to corpora cavernosa of the penis.

THE SUPERIOR GLUTEAL NERVE.

This nerve arises from the back part of the lumbo-sacral cord, and, while generally included as a branch of the sacral plexus, can not be, therefore, properly regarded as a nerve of sacral origin. It escapes from the pelvis through the upper part of the great sacro-sciatic foramen, in company with the gluteal vessels, lying above the pyriformis muscle. It divides into a superior and an inferior branch, as is shown in the table² to which I have called your special attention, the former of which accompanies the superior gluteal artery between

¹ Modified from a table taken from "The Essentials of Anatomy" (Darling and Ranney). G. P. Putnam's Sons, New York, 1881.

² See the foregoing table.

the gluteus medius and minimus muscles, while the latter passes between the same muscles, but lower than its fellow.

The distribution of this nerve to the gluteus medius, gluteus minimus, and tensor vaginæ femoris muscles, stamps it as the one which presides chiefly over the act of *internal rotation of the thigh*, since these three muscles are the only ones which can perform this limited movement of the femur. Its cutaneous distribution again confirms the axioms of Hilton; ¹ since the skin over these muscles is thus supplied, while some filaments running over the fascia lata, to which the tensor vaginæ femoris is attached, can be demonstrated.

CLINICAL POINTS PERTAINING TO THE SUPERIOR GLUTEAL NERVE.

The cutaneous covering of the gluteus medius and minimus muscles is not alone supplied by the gluteal nerve, as the lumbar nerves may be seen coursing along over the lower part of the abdomen, then passing over the crest of the ilium, and finally reaching this part of the thigh. While this might seem, at a first glance, to be a peculiar admixture of lumbar and sacral nerves, yet, on returning to a point just made, we discover that the superior gluteal nerve is of lumbar origin, although apparently a branch of the sacral plexus; hence, the skin, supplied by branches of lumbar origin, protects all those regions to which muscular branches derived from the same sources can be traced. We see the region of the gluteus maximus muscle apparently avoided ² by the nerves which descend from the abdomen to supply the skin of the adjoining region, and, when we seek for an explanation of the fact, we find that this muscle is supplied by the small sciatic nerve (derived from the sacral plexus, and having no connection with the lumbar nerves); hence, the integument covering that muscle could not be supplied by nerves whose source of origin would prevent a perfect sympathy between the skin and the muscular structures which it covers.

The relation of this nerve to the gluteal artery, as it escapes from the great sacro-sciatic foramen, gives it a surgical

¹ See page 645 of this volume.

² Hilton, *op cit.*

importance, as that vessel is sometimes ligated for hæmorrhage from some of its branches.

The three muscles supplied by the superior gluteal nerve, if acting in connection with the gluteus maximus muscle, become the *abductors* of the hip joint, while the posterior half of the gluteus medius and the posterior fifth of the gluteus minimus assist in *extension* of the thigh upon the trunk, since their origin lies on a plane posterior to their insertion into the trochanter. Thus we are enabled to class the superior gluteal nerve as a factor in three of the movements of the hip joint, viz., internal rotation, abduction, and extension.

When the superior gluteal nerve is subjected to irritation, a *spasmodic condition* of the gluteal muscles may be produced. It is extremely rare to have such a condition developed in the glutei muscles alone, but one such case is reported by Remak. In this case the spasms of the legs consisted of a series of gluteal contractions which, when the patient would attempt to walk, would draw the leg backward and render it fixed in that position. We see, however, the glutei muscles frequently affected with spasm (in connection with muscles of the lower extremity supplied by other nerves) in tetanus, rheumatic inflammation of the hip joint, arthralgia, neuralgia, and lesions within the pelvis which affect the sacral plexus.

The gluteal muscles may be affected with *paralysis*, but it is rare that the paralysis is confined exclusively to that region. As a rule, these muscles become affected as the result of lesions which involve the sacral plexus to a greater or less extent, such as spinal diseases, tumors in the spinal canal or pelvis, lesions of the cauda equina, fractures of the sacrum, fractures of the pelvis, etc., so that the paralysis of the glutei muscles is masked by a similar condition of muscles supplied by other nerves. When the glutei muscles are paralyzed, in connection with the tensor vaginæ femoris, the pyriformis, and the obturator internus, as is more frequently observed, the rotation of the thigh inward becomes impossible, and out-

ward rotation also becomes somewhat impaired, as the adductor group and the psoas and iliacus have chiefly to perform it. Abduction of the thigh is rendered extremely difficult, and, if the paralysis be complete, absolutely impossible, while flexion of the thigh is impaired and limited in its extent. When such patients attempt to walk, the glutei muscles no longer preserve the relations of the trunk to the thighs, and a difficulty in preserving the balance is therefore present. This is especially noticeable when an attempt to ascend a flight of steps is made, as the trunk has then to be inclined forward. The affected muscles usually undergo atrophy when thus deprived of their normal power, and the gluteal region loses its natural roundness and firmness.

The *disturbances of sensibility* which may coexist with this type of paralysis will depend somewhat upon the seat of the exciting cause, as well as upon its character. Pain may be a means of making a diagnosis of the development of the exciting lesion before the paralysis is developed, if the precepts given you in the earlier lectures of this course be applied,¹ remembering always that the cause of the pain must be sought for along the course of the cutaneous nerves which supply the region where pain is felt, and that the omission on your part of one of the nerves whose filaments are present in the region of pain may entail a complete failure in discovering the cause.

THE MUSCULAR BRANCHES OF THE SACRAL PLEXUS.

By reference to the table of the distribution of the various branches of the sacral plexus,² you will perceive that five muscles receive a direct supply from it through branches which are not specially named, being included in the muscular set—these five muscles being the pyriformis, obturator internus, gemellus superior, gemellus inferior, and quadratus femoris. If we consider the function of these five muscles, it will be evident that they should receive their nerve supply from the same source, provided the axiom of Hilton—that the nerve

¹ See page 645 of this volume.

² See page 745 of this volume.

distribution of muscles¹ is a guide to their function—be true, as they all assist in the *external rotation of the thigh* by their action upon the great trochanter of the femur. The situation of these five muscles is such that a direct supply from the sacral plexus might almost be inferred. The pyriformis and obturator internus muscles arise from within the pelvis and escape from its cavity by means of the greater and lesser sacro-sciatic foramina, while the two gemelli muscles and the quadratus femoris are attached to the os innominatum in the immediate vicinity of these two foramina. Now, the sacral plexus lies upon the pyriformis muscle, and would naturally supply it, while the other four muscles bear such an intimate relation with the pyriformis, as it escapes from the pelvis, as to render a supply from the sacral plexus easy, while the similarity of function between the five muscles would presuppose a nerve supply from the same source.

In the lectures upon the obturator and anterior crural nerves, the action of the adductor and flexor groups of muscles, in assisting the external rotation of the thigh, was discussed, and we here come upon another group of muscles which also tend to perform the same movement of the lower limb. The questions may arise to your minds—how are we able to explain a dissimilarity in the sources of motor power in groups of muscles which have a common function to perform? How are we able to reconcile the axioms of nerve supply, so often quoted, with this apparent contradiction? The answer to both of these questions is settled by a careful scrutiny of the combined actions of each of these separate groups of muscles. In the first place, the five muscles of the thigh, supplied by the sacral plexus of nerves through its muscular branches, can not perform the movement of external rotation of the thigh when the subject is in the sitting posture. It is in this relative position of the thigh and trunk that the adductor group of muscles, aided by the psoas and iliacus, become important factors in the movement of external

rotation ; and it is to be remembered that this movement is but a secondary function with these latter muscles, since they are designed chiefly to insure adduction and flexion of the thigh. Each muscle of a group is usually supplied by that nerve whose branches are also distributed to others of that group which aid in its primary action, rather than in any secondary movement in which it may chance to participate ; hence the psoas and iliacus derive their power from the anterior crural, the adductor muscles from the obturator, and the five muscles posterior to the hip joint from the sacral plexus, and thus the primary action of each group is indicated by the nervous supply, as well as by the points of origin and insertion of each muscle.

THE SMALL SCIATIC NERVE.

This branch of the sacral plexus is given off from its lower and posterior part, and escapes from the pelvis through the sacro-sciatic foramen, below the pyriformis muscle, in company with the sciatic vessels. It descends beneath the gluteus maximus muscle, in which region it lies to the inner side of the great sciatic nerve, and continues beneath the fascia lata as low down as the popliteal space, where it perforates this fascia and joins with the external saphenous nerve, giving off also cutaneous branches of its own to the popliteal space and the back of the calf.

The branches of this nerve, which are enumerated in the table,¹ comprise the inferior gluteal, the inferior pudendal, and the cutaneous filaments distributed over the gluteus maximus muscle, and the regions previously mentioned. The fact that this nerve supplies the gluteus maximus muscle with motor power gives it an importance to the anatomist, since this muscle is one of the most important factors in regulating the position of the trunk and the lower extremity during all the various attitudes assumed by the living subject ; but there are also some suggestions of value which have been thrown out by previous authors upon anatomy which will

¹ See page 745 of this volume.

merit your closest attention, especially as they are omitted in some of the descriptive text-books.

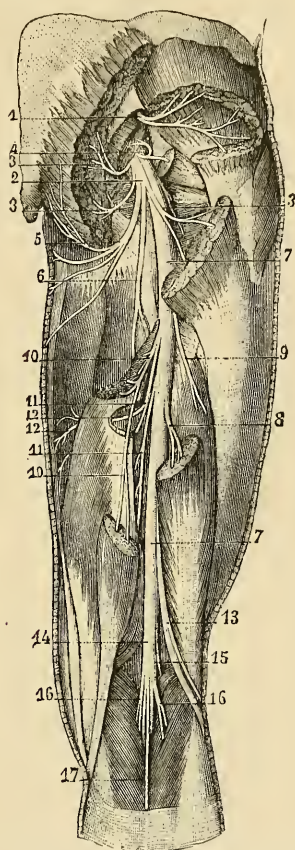


FIG. 228.—*The small sciatic nerve, with its branches of distribution and termination.*
(Sappey.)

- 1, superior gluteal nerve; 2, small sciatic nerve; 3, 3, 3, branches to the gluteus maximus; 4, branch to the pyramidalis; 5, internal pudendal branch of the small sciatic; 6, femoro-popliteal branch of the same nerve; 7, 7, trunk of the great sciatic; 8, branch which it gives to the long head of the biceps; 9, branch to the short head of the same muscle; 10, 10, branch to the semi-tendinosus (the latter muscle has been divided and turned back, to show the semi-membranosus); 11, 11, branch to the semi-membranosus; 12, 12, another branch, rising from the common trunk with the preceding nerve, and passing under the semi-membranosus to be distributed to the adductor magnus; 13, external popliteal nerve; 14, internal popliteal nerve; 15, filament to the plantaris; 16, 16, nerves to the gastrocnemius; 17, origin of the external saphenous nerve.

In the first place, this nerve sends filaments to the perinæum and *genitals*¹ of the male and female, after supplying

¹ In the female, the filaments probably go to the *vulva* and *vagina*; but, in the male, the side of the penis is thus supplied.

the gluteus maximus muscle ; and the suggestion is made by Hilton, in reference to this point, that the action of this muscle in its *relation to coitus* may tend to explain the necessity for a sympathy between these two parts by means of a common nerve supply.

Again, the recognition of the perineal branch of the small sciatic nerve is sometimes important in practice. If you care to trace this nerve upon the dead subject, you will find that it escapes from beneath the perineal border of the gluteus maximus muscle, runs along the outer portion of the perinæum, and, finally, sends cutaneous filaments to the sides of the penis. The perineal region is also supplied by the perineal branches of the pudic nerve, which escape, posteriorly to those of the sciatic, from beneath the same muscle. Now, either of these two nerves may be the cause of a pain referred to the perinæum and the penis, and their points of escape from beneath the gluteus maximus muscle are so placed as to render them frequently subjected to pressure from sitting upon hard or uneven seats. It is thus possible for pains, referred to the penis, to be wrongly attributed to diseases of the bladder, calculus in the bladder, urethral troubles, and all other types of disease which are commonly indicated by more or less pain in that locality, when the cause may be found and correctly diagnosed by following up the course of the perineal branch of the small sciatic. Such a case is reported by Hilton, where prominent surgeons of Europe, among them Mr. Key, had diligently and unsuccessfully searched for the cause of a pain, referred to the penis, along the course of the pudic nerve, and where the patient had been treated for disease of the bladder, a careful examination subsequently revealing the true cause to be a spot of hardened tissue pressing upon the perineal branch of the small sciatic nerve, which was cured (as well as the pain which it created) by the application of nitric acid over the seat of thickening. It is, therefore, well to remember the course of this branch, as well as those of the pudic nerve, when investigating for the cause of pain in the penis or perinæum.

THE PUDIC NERVE.

This branch of the sacral plexus arises from its lower part, and immediately escapes from the pelvis by means of the great sacro-sciatic foramen in company with the pudic artery, the sciatic vessels and nerves, and the gluteal vessels and nerves. The situation of the nerve in this foramen is on the inner side of the great sciatic nerve, both of which escape through the lower part of the foramen, beneath the pyri-formis muscle. The pudic nerve then reënters the pelvis through the lesser sacro-sciatic foramen, in company with its artery, and immediately gives off its inferior hemorrhoidal branch. From this point the nerve passes along the outer wall of the ischio-rectal fossa, lying above the pudic artery (both artery and nerve being covered by the obturator fascia), and divides into the perineal branch and the dorsal nerve of the penis.

Of these three branches of the pudic nerve, the distribution has been given in a previous table, but with less detail than the subject, perhaps, demands.

The *inferior hemorrhoidal nerve* occasionally arises directly from the sacral plexus rather than as a branch of the pudic; its course runs along the ischio-rectal fossa, and it is distributed to the sphincter muscles of the rectum and the skin around the region of the anus. It communicates freely in this region with the superficial perineal and inferior pudendal nerves.

The *perineal nerve* is the largest branch of the pudic, and accompanies the superficial perineal artery. It divides into two sets of terminal filaments—the cutaneous or superficial perineal nerves and muscular branches. The former of these give a few twigs to the sphincter ani and levator ani muscles, but are chiefly distributed to the integument of the perinæum, scrotum, labium, and the penis, communicating freely, in the region of the anus, with the inferior hemorrhoidal nerve. The muscular branches usually arise from the pudic nerve by a common trunk, which passes forward and inward un-

derneath the transverse perinei muscle; its terminal filaments are given off to the transverse perinei, erector penis, accelerator urinæ, and compressor urethræ muscles, and a twig is often sent to the bulb of the urethra.

The *dorsal nerve of the penis* is the smaller terminal filament of the pudic nerve, which accompanies the pudic artery along the rami of the pubes and ischium, between the layers of the deep perineal fascia; it then pierces the suspensory ligament of the penis and continues its way along the dorsum of that organ as far as the glans penis. It gives a branch to the corpus cavernosum, and supplies the integument of the dorsum¹ of the penis; in the female the course of the nerve is about the same, although the size of the nerve is smaller, since the clitoris is minute in its size as compared with the organ of the male.

CLINICAL POINTS PERTAINING TO THE PUDIC NERVE.

A careful study of the distribution of the various branches of this nerve will show that it is the source of motion to the muscles of the perinæum and urethra, and of sensation to the integument of the perinæum, scrotum, labium, penis, and the mucous covering of the clitoris, as well as that lining the urethral canal. The friction made upon the cutaneous nerves of the external genital organs in the acts of sexual intercourse and masturbation creates a reflex act within the spinal cord, which creates the turgidity of the penis and clitoris during the first portion of those acts; and, later on, a series of muscular contractions in the perineal muscles and the involuntary muscular fiber of the urethral canal are produced, which assist in the expulsion of semen, in the male, and the secretion of the glands of Bartholine in the female. That this is the true explanation of emission is evidenced by the fact that onan-

¹ Hilton states that the integument of the sides of the penis is supplied by the *perineal branch* of the *inferior gluteal* nerve, and from no other source. This statement differs from most of the standard authors, but it seems to be supported by clinical demonstration. The reader is referred to page 752 of this volume, where the subject is discussed from its physiological and clinical point of view.

ism is most effectually prevented by blistering the cutaneous covering of the penis and the mucous covering of the clitoris.

In some cases of fracture of the spine, in the dorsal region, where a part of the spinal marrow is left intact below the seat of fracture, you may be able, by repeatedly pinching the skin of the scrotum and penis, to produce spasmodic contractions of the muscles of the perinæum and urethra, and often to effect a turgidity of the genital organ to such a degree as to make it resemble an imperfect erection or priapism.

The ejaculation of the last few drops of urine from the urethra is unquestionably effected by a reflex act through the sensory and motor fibers of the pudic nerve, in consequence of the irritation produced in the sensory fibers of the urethral mucous membrane from pressure of the urine or the contact of its saline ingredients.

It is not uncommon for rectal disease to produce sympathetic manifestations in the genito-urinary organs, in the form of neuralgic pains, involuntary emissions, incontinence of urine, etc.; such effects can only be explained by the distribution of the pudic nerve to the integument about the anus (and, I believe, to the walls of the rectum also), which allows reflex motor impulses to be sent from the spinal cord, in response to rectal irritation, to the genito-urinary organs and perineal muscles.

THE SCIATIC NERVE.

This nerve arises from the lumbo-sacral cord and the four upper sacral nerves, and is a direct continuation of the sacral plexus. It escapes from the pelvis through the great sacro-sciatic foramen below the pyriformis muscle, lying on the outer side of the pudic vessels and nerve. It then passes downward between the trochanter major of the femur and the tuberosity of the ischium, lying behind the external rotator muscles of the hip joint and the adductor magnus, to the lower third of the back of the thigh, where it divides into its two terminal branches, the external and internal popliteal nerves.

In the lower two thirds of its course, it is covered by the lower fibers of the gluteus maximus and biceps muscles. It

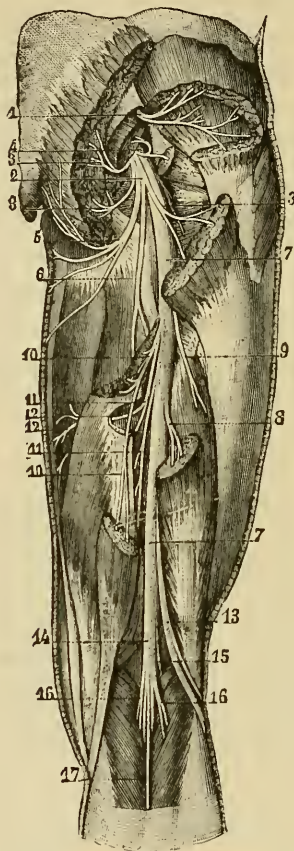


FIG. 229.—*The great sciatic nerve, with its branches of distribution and termination.*
(Sappey.)

- 1, superior gluteal nerve; 2, small sciatic nerve; 3, 3, 3, branches to the gluteus maximus; 4, branch to the pyramidalis; 5, internal pudendal branch of the small sciatic; 6, femoro-popliteal branch of the same nerve; 7, 7, trunk of the great sciatic; 8, branch which it gives to the long head of the biceps; 9, branch to the short head of the same muscle; 10, 10, branch to the semi-tendinosus (the latter muscle has been divided and turned back, to show the semi-membranosus); 11, 11, branch to the semi-membranosus; 12, 12, another branch, rising from the common trunk with the preceding nerve, and passing under the semi-membranosus to be distributed to the adductor magnus; 13, external popliteal nerve; 14, internal popliteal nerve; 15, filament to the plantaris; 16, 16, nerves to the gastrocnemius; 17, origin of the external saphenous nerve.

gives off branches to the hamstring muscles and the adductor magnus, and some articular branches to the back of the hip joint. The two tables which I now show you are designed to

illustrate the branches given off by the external and internal popliteal nerves. The former of these is the smaller of the two, and passes along the outer side of the popliteal space close to the biceps muscle, while the other traverses the middle of the popliteal space as far as the lower border of the popliteus muscle, where it becomes the posterior tibial nerve.

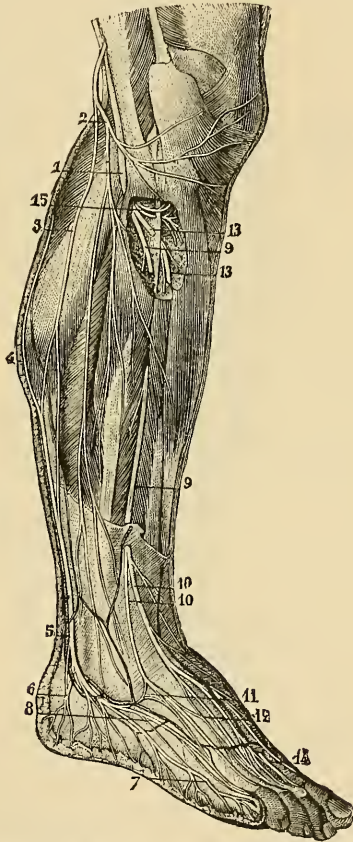


FIG. 230.—*The external popliteal nerve.* (Sappey.)

- 1, external popliteal nerve; 2, peroneal or cutaneous branch; 3, communicans peronei; 4, external saphenous nerve; 5, trunk formed by the junction of the external saphenous with the communicans peronei; 6, calcanean branch rising from the trunk; 7, external terminal branch of the trunk on its way to form the external dorsal branch of distribution to the fifth toe; 8, its internal terminal branch which forms the internal dorsal branch for the fifth toe and the external dorsal branch for the fourth toe; 9, 9, musculo-cutaneous nerve; 10, 10, its terminal branches; 11, anastomosis of its external terminal branch with the external saphenous; 12, anastomosis of its internal and external terminal branches with each other; 13, anterior tibial nerve; 14, terminal portion of this nerve, anastomosing with the musculo-cutaneous, and dividing to form the deep branches of distribution on the dorsum of the foot to the internal side of the great toe and the external side of the second toe.

NERVES OF THE LEG AND FOOT.

EXTERNAL POPLITEAL NERVE. (PERONEAL NERVE.)	(1) Articular branches.	{ Three in number, Distributed to knee joint.
	(2) Cutaneous branches.	{ Supply <i>integument</i> of outer and back part of the leg.
	(3) ANTERIOR TIBIAL NERVE.	{ <i>Muscular</i> (to muscles in front part of leg and to the peroneus tertius). <i>External</i> branch. { Extensor brevis digitorum, Articulations of the tarsus. <i>Internal</i> branch. { <i>Integument</i> of the adjoining sides of the great and 2 ^d toes. <i>Muscular</i> . { Peroneus longus, Peroneus brevis.
	(4) MUSCULO-CUTANEOUS NERVE.	{ <i>External</i> branch. { <i>Integument</i> of outer side of foot and ankle, <i>Integument</i> of the adjoining sides of 3 ^d , 4 th , and 5 th toes. <i>Internal</i> branch. { <i>Integument</i> of the inner side of the foot and ankle, <i>Integument</i> of the adjoining sides of 2 ^d and 3 ^d toes and inner side of great toe.
INTERNAL POPLITEAL NERVE.	(1) Articular	{ Three in number, Distributed to knee joint.
	(2) Muscular	{ Gastrocnemius, Plantaris, Soleus, Popliteus.
	(3) EXTERNAL SAPHENOUS NERVE.	{ Formed by two filaments, one from each of the popliteal nerves, <i>Integument</i> of the outer side of foot and the little toe. <i>Muscular</i> . { Flexor longus pollicis, Flexor longus digitorum, Tibialis posticus. <i>Plantar</i> { <i>Integument</i> of heel and inner part cutaneous. { of sole of foot.
	(4) POSTERIOR TIBIAL NERVE.	{ <i>INTERNAL PLANTAR</i> . { <i>Digital</i> branches. { <i>Integument</i> of the 3½ toes on inner side of foot. { Flexor brevis digi- torum, Abductor pollicis, Flexor brevis pol- licis, Two inner lumbric- ales muscles. <i>Articular</i> (to tarsus), <i>Cutaneous</i> (to sole of foot). <i>Muscular</i> . . { Flexor accessorius, Abductor minimi digiti. <i>EXTERNAL PLANTAR</i> . { <i>Superficial</i> branch. { 1½ outer toes, Flexor brevis mini- mi digiti. 4 th interosseous muscle. <i>Deep</i> branch. { 3 ^d and 4 th lum- bricales, Rest of interossei, Adductor pollicis, Transversus pedis.

If you will study these tables, you will perceive that the external popliteal nerve distributes articular branches to the

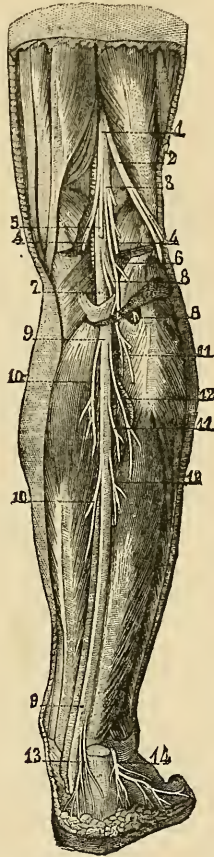


FIG. 231.—*The internal popliteal nerve.* (Sappey.)

1, trunk of the great sciatic; 2, external popliteal; 3, internal popliteal; 4, 4, branches to the gastrocnemius—both nerves and muscle have been divided; 5, origin of the external saphenous; 6, branch to the soleus, divided together with the muscle; 7, internal popliteal nerve passing through a fibrous ring in the soleus; 8, 8, branch springing from the lower portion of this nerve, and likewise passing through the fibrous ring of the soleus. At this level it gives off a reflected or ascending division, which penetrates the popliteus at its deep surface, but is not seen in the cut, and a more slender descending division which makes its way through the interosseus membrane and supplies the tibialis anticus muscle; 9, 9, posterior tibial nerve; 10, 10, branches which it furnishes to the flexor longus digitorum; 11, 11, branches which it gives off to the tibialis posterior muscle; 12, 12, branches to the flexor longus pollicis; 13, calcanean branches; 14, terminal extremity of the external saphenous nerve.

knee joint, and cutaneous filaments to the outer and back part of the leg. The two main nerve trunks which arise from

it are called the anterior tibial and the musculo-cutaneous, both of which are given off from the main trunk after it pierces the peroneus longus muscle about one inch below the head of the fibula, although three articular and several cutaneous filaments also arise from it. You will also perceive that four main branches are given off from the internal popliteal nerve, viz., articular and muscular branches, and the external saphenous and posterior tibial nerves. The muscular filaments supply four muscles in the immediate vicinity of the knee, while the articular filaments, as in the preceding nerve, are distributed to the knee joint. Other points of interest might be specially designated as comprised in these pages, but they will be considered in their practical relations when the clinical points which are presented by the nerves of the lower extremity are considered.

I desire to call your attention, first, to the fascia of the leg, into which three muscles of the thigh are inserted, viz., the sartorius, the gracilis, and the semi-tendinosus. I have already called your attention to the fact that the fasciæ of the body are always to be regarded as one of the points of insertion of the muscles which are attached to them; now, if this be true, and it undoubtedly is so, we ought to discover a particular distribution of the cutaneous nerves at this point, since the nerves which supply the muscles supply also the skin over the insertion of the same muscles. We shall find, on dissection of this region, that the long saphenous, the obturator, and a branch of the sciatic nerves are distributed in the skin of the calf; the one derived from the anterior crural (which supplies the sartorius), another a filament of the obturator (which supplies the gracilis), and the third derived from the sciatic (since it supplies the semi-tendinosus muscle). These three nerves, therefore, supply both the fascia of the leg and the skin on the inner side of the leg below the knee joint; hence, pain in this region must be sought for along the course of one of these three nerves. It is too common among physicians to regard a pain which is localized at the inner side of the knee as dependent

upon the obturator nerve, to the exclusion of the sciatic or the anterior crural; but anatomy clearly teaches us that

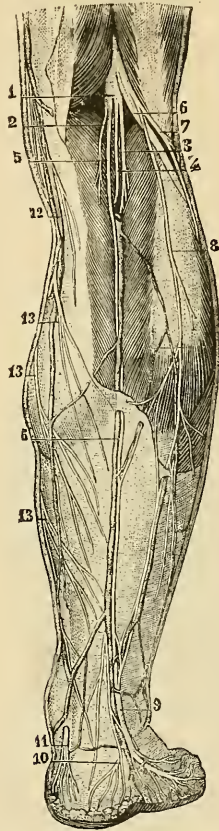


FIG. 232.—*The external saphenous nerve and its accessory, the communicans peronei.*
(Sappey.)

- 1, internal popliteal nerve; 2, nerve to the external head of the gastrocnemius; 3, nerve to the internal head; 4, external saphenous nerve; 5, external popliteal nerve; 6, communicans peronei; 7, peroneal or cutaneous branch; 8, branch sometimes given off by the external saphenous to the fourth and fifth toe; 9, trunk formed by the junction of the communicans peronei with the external saphenous; 10, calcanean branch given off by this trunk; 11, plantar cutaneous branch of the posterior tibial; 12, internal saphenous nerve; 13, 13, 13, posterior branches of this nerve.

there are three possible lines of direction, which we are bound to explore in searching for the situation of the real cause which is producing it. We should always carefully examine all the anatomical relations of the obturator, the sciatic, and the anterior crural nerves, in order to ascertain, if possible, the real cause of pain which is expressed on the in-

ner side of the knee joint, and the axiom of nerve distribution, which was first pointed out by Hilton, and to which I have frequently directed your attention, offers us, in this instance, as in many others, a simple rule which should guide us in searching for the cause of pain before we attempt measures for its relief.

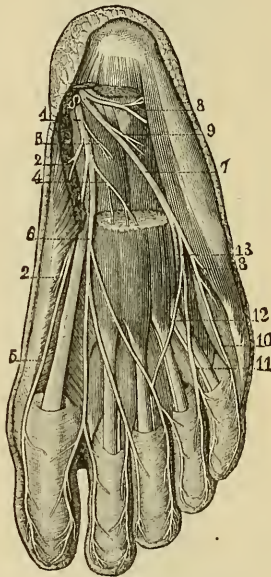


FIG. 233.—*The plantar nerves, their course, anastomoses, and distribution.* (Sappey.)

1, internal plantar nerve ; 2, 2, branches which it gives to the abductor pollicis ; 3, branch which it gives to the accessorius ; 4, branch to the flexor brevis digitorum ; 5, branch of distribution to the internal plantar surface of the great toe ; 6, another branch of the internal plantar dividing into three secondary portions, which subdivide, in their turn, to form the branches of distribution on the plantar surface to the outer side of the great toe, both sides of the second and third toes, and the inner side of the fourth toe ; 7, external plantar nerve ; 8, 8, branches which it sends off to the abductor minimi digiti ; 9, branch to the accessorius ; 10, branch of distribution on the plantar surface to the outer side of the little toe ; 11, another branch of the same nerve dividing to supply the inner side of the little toe and the outer side of the fourth toe ; 12, anastomosis of the internal with the external plantar ; 13, origin of the deep branch of the external plantar.

I have found, in several instances, that local anæsthetics, when applied to the skin over the seat of pain, frequently have the power of relieving a sense of distress in other regions apparently far removed from it, but still connected with the seat of pain by means of a nervous communication. Thus, in disease of the hip joint, an anodyne applied in the

region of the knee joint will often relieve symptoms which are referable to the hip, and we can only attribute this effect to a benumbing influence exerted by means of the sciatic and obturator nerves upon that joint, since both of these nerves send articular filaments to it, as well as cutaneous filaments to the region of the knee.

In some instances, where abnormalities of origin of nerve filaments can be detected, I believe that, if you will trace the nerve upward for some distance toward the spinal marrow, you will find that the cutaneous filaments of the nerve, which apparently has an abnormal origin, are in intimate communi-

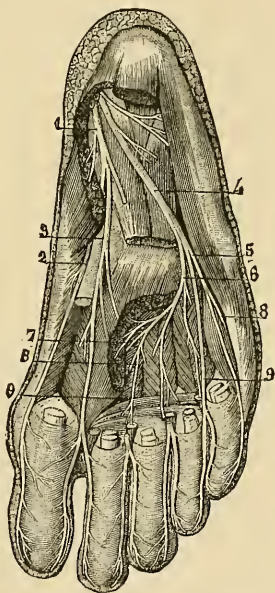


FIG. 234.—*The deep branch of the external plantar nerve.* (Sappey.)

1, internal plantar nerve; 2, its internal branch; 3, its external branch, whose two divisions have been cut, together with the adductor pollicis, to show the deep branch of the external plantar; 4, trunk of the external plantar; 5, its superficial branch, which divides almost immediately into two secondary branches, distributed to the fourth and fifth toes; 6, its deep branch, distributed to the adductor pollicis, transversus pedis, and the interossei; 7, branches to the adductor pollicis; 8, 8, branches to the interossei; 9, branches to the transversus pedis.

cation with the nerve trunk whose functions are assisted by them, and from which its most frequent origin can be verified.

If we examine the anatomy of the hip joint, we shall find

that a branch of the anterior crural nerve passes in close relation with its capsule, if it is not intimately associated with it; that a branch of the obturator nerve supplies its capsular ligament, and is ultimately distributed to the ligamentum teres; and, finally, that a branch from the sacral plexus supplies the hip joint at its posterior aspect, after sending filaments to the gemelli, the quadratus femoris, and the obturator internus muscles. The study of the anatomy of joints is of particular importance to the diagnostician, since it frequently explains how remote sympathetic pains may be dependent upon irritation of articular branches of a nerve, whose terminal cutaneous filaments are distributed to other regions, often far removed from the joint which it supplies. We know that disease of the hip joint, which is, perhaps, one of the most frequent which we meet with in practice, is often manifested, in its early stages, by a pain which is referred to the knee; and we can understand, from what has previously been said, that this sensation of pain must be transmitted through one of three sources, viz., the obturator, anterior crural, or the sciatic nerves.

CLINICAL POINTS PERTAINING TO THE NERVES DERIVED FROM THE SCIATIC, OR TO THE SCIATIC NERVE ITSELF.

The morbid conditions of the sciatic nerve or its branches which are most frequently met with comprise: 1, *neuralgia*, which may be articular or confined to the direct course of the sciatic nerve; 2, *spasmodic affections* of the muscles supplied by the sciatic nerve or its branches; and 3, *paralysis* of the different muscles supplied by the various nerve trunks.

SCIATICA.

This type of neuralgia—to which the name “malum Cottunii” is sometimes applied—may affect the greater portion of the back part of the thigh, a part of the gluteal region, the knee joint and patella, the anterior, lateral, and posterior surfaces of the leg, and the whole of the foot, with the excep-

tion of its internal border, which derives its nerve supply from the saphenous branch of the anterior crural nerve. It is seldom that all of these regions are affected at the same time, since the nerve may be subjected to a source of irritation which affects only individual branches. The most frequent seat of pain is confined, as a rule, to the posterior surface of the thigh and the upper half of the calf of the leg; but the external surface of the lower half of the leg and the corresponding part of the foot, as well as the sole, are often the seat of a neuralgic pain which is of a severe type. The disease is usually unilateral in character, and, if bilateral, a central cause may be suspected.

Among the causes of this type of neuralgia may be mentioned exposure to cold and dampness, malarial affections, inflammations of the nerve, injuries, pressure of tumors or inflammatory exudations, violent exertion, disturbances of the venous circulation of the pelvis, and mechanical pressure from sitting upon hard or uncomfortable seats, uterine displacement, pelvic tumors, aneurism, and hernia.

The beginning of this disease is usually associated with premonitory symptoms, among which may be mentioned a sensation of stiffness, cold, or heat in the affected regions, with occasional feelings of formication, or a fluid trickling over the skin. Soon painful electric pains are experienced, which show a marked paroxysmal character. These attacks occasionally occur without warning or premonitory symptoms. The pain is remarkably violent, and of a tearing and lancinating character, and usually follows the direction of the nerve trunk which is affected. It often changes its seat of greatest intensity, and the lines which connect the spots of greatest pain will generally conform to the anatomical course of the affected nerve. The pain is usually markedly increased by motion of the muscles, and the paroxysms seem to be excited by the most trivial causes, such as a draft of cold air, coughing, sneezing, sudden bending of the body, the contact of the clothes with the skin, or straining during the acts of defecation or micturition. If the whole area of the distribu-

tion of the sciatic nerve be involved, the pain occurs with special violence first in one and then in another branch, while the posterior branches of the sacral nerves may be also implicated, and the patient complain of violent pain in the sacrum and the loins.

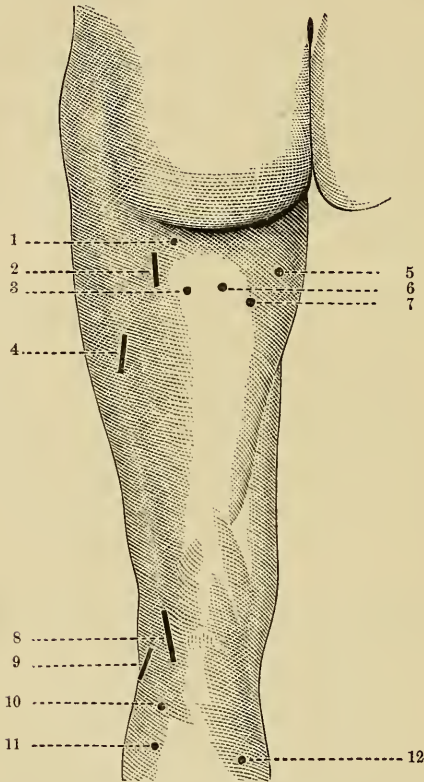


FIG. 235.—*The motor points on the posterior aspect of the thigh.*

1, branch of the inferior gluteal nerve to the gluteus maximus muscle; 2, sciatic nerve; 3, long head of biceps muscle; 4, short head of biceps muscle; 5, adductor magnus muscle; 6, semi-tendinosus muscle; 7, semi-membranosus muscle; 8, tibial nerve; 9, peroneal nerve; 10, external head of gastrocnemius muscle; 11, soleus muscle; 12, internal head of gastrocnemius muscle.

As has been mentioned in other forms of neuralgia, certain painful points may usually be detected, which are diagnostic of neuralgia from those severe pains which accompany the early stages of locomotor ataxia. The most constant point of sensitiveness to pressure is stated by Valleix to correspond to the posterior superior spine of the ilium; another usually ex-

ists where the nerve escapes from the cavity of the pelvis; a third is often found at the lower border of the gluteus maximus muscle, where the posterior cutaneous branch emerges; the fourth corresponds to the head of the fibula, where the tibial nerve is given off; a fifth point is often discovered behind the internal malleolus; and, finally, there are frequent inconstant points in the thigh, on the calf of the leg, and on the dorsum of the foot, all of which correspond to localities where cutaneous branches either divide or perforate some fascia.

In connection with this neuralgic pain, certain *motor symptoms* are frequently developed. These comprise a peculiar limping gait, a mode of carrying the leg which is quite diagnostic, cramp of various degrees, and possibly convulsions, which are sometimes very violent. These symptoms are the result of direct and reflex irritation, and may be the forerunners of a condition of paresis or of actual paralysis.

Among the *vaso-motor disturbances* which accompany this disease may be mentioned paleness and coldness of the skin, in some instances accompanied by numbness and chilly sensations, and in other cases redness and heat of the skin, with increased perspiration, increased growth of the hair, herpes zoster along the course of the affected nerve, a saccharine condition of the urine, and hypertrophy and atrophy of the muscles.

Sciatica is to be diagnosed from disease of the hip joint; from locomotor ataxia in its early stages; from muscular rheumatism; and the pains of spinal disease, affecting the lateral columns, when the patient is subjected to extreme exertion.

SPASM OF THE LOWER LIMBS.

The muscles of the hip—especially the psoas, iliacus, quadratus lumborum, and adjacent muscles of the anterior surface of the thigh—may be the seat of tonic spasm, which has been named by Stromeyer “spasmodic contracture of the hip.” It may follow an inflammation or neuralgia of the hip joint, psoas abscess, or diseases of the lumbar vertebræ. In

this condition, the thigh is strongly flexed, the pelvis tilted upward, and the limb shortened; while passive extension creates a deviation of the body toward the affected side, and is extremely painful.

In rare instances, tonic and clonic types of spasm are observed in the extensor and adductor muscles of the thigh, as the result of neuralgia of the knee joint and certain spasmodic diseases of a central origin.

The flexor muscles of the leg may be affected with spasms in spinal affections, hysteria, diseases of the knee joint, and in inflammation of its adjacent muscles.

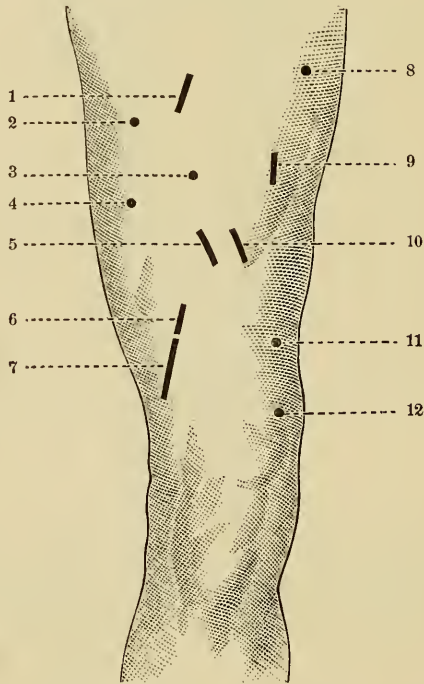


FIG. 236.—*The motor points on the anterior aspect of the thigh.*

1, crural nerve; 2, obturator nerve; 3, sartorius muscle; 4, adductor longus muscle; 5, branch of the anterior crural nerve for the quadriceps extensor muscle; 6, the quadriceps muscle; 7, branch of anterior crural nerve to the vastus internus muscle; 8, tensor vaginæ femoris muscle (supplied by the superior gluteal nerve); 9, external cutaneous branch of anterior crural nerve; 10, rectus femoris muscle; 11, 12, vastus externus muscle.

In rare cases, the anterior muscles of the leg, which are supplied by the peroneal nerve, are affected with spasms as

the result of exposure to cold or dampness, over-exertion of the lower limbs, or paralysis of the antagonistic muscles; while the muscles supplied by the posterior tibial nerve, as well as those of the sole of the foot, are more frequently affected as the result of spinal affections, joint diseases, over-exertion, paralysis of other muscles, and by the reflex action of cholera.

PARALYSIS OF MUSCLES SUPPLIED BY THE SCIATIC NERVE OR ITS BRANCHES.

When we consider how extensively this nerve is distributed, and its exposed situation in various portions of its course, as well as its intimate relations to the organs of the pelvis, we can better appreciate the reasons for the frequency, on the one hand, and the importance, on the other, of the paralysis which may affect it or its branches. Among the causes of this form of paralysis may be enumerated all those conditions of the trunk which are capable of producing pressure upon the origin of the nerve; all forms of accidents which may result in laceration or section of the main trunk or any of its branches; the development of tumors in the course of the nerve; dislocations of bone; the compression of cicatrices; rheumatic conditions, from chilling or wetting of the lower extremities; surgical operations; and spinal diseases which impair its point of origin at the lumbar enlargement of the cord.

If the *peroneal nerve* be alone affected, the foot can not be flexed or abducted; neither can it be completely adducted. The dependent position of the foot, which hangs downward, interferes seriously with the act of walking, since the toe trips upon every slight elevation.

In order to walk, the patient is compelled to lift the foot by flexion at the hip joint, and places it insecurely upon the ground with the outer border of the toes first, thus producing a gait which is pathognomonic of this special type of paralysis. The arch of the foot becomes flattened from a loss of power in the *peroneus longus* muscle; the great toe can not

be extended, since the extensor longus pollicis is paralyzed ; flexion of the foot is impaired, since the extensor communis digitorum no longer acts ; and the abduction of the foot is rendered impossible, if the peroneus brevis be paralyzed, although the extensor communis digitorum may assist in this act coincidentally with dorsal flexion of the foot.

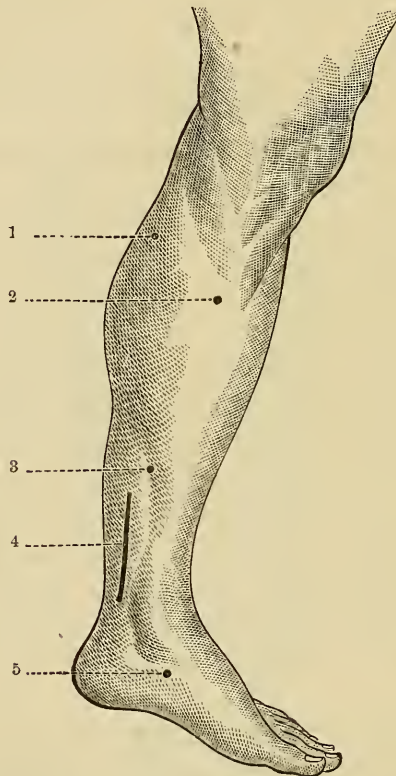


FIG. 237.—The motor points on the inner aspect of the leg.

1, internal head of gastrocnemius muscle ; 2, soleus muscle ; 3, flexor communis digitorum muscle ; 4, posterior tibial nerve ; 5, abductor pollicis muscle.

If the *tibial nerve* be paralyzed, a loss of power in the muscles of the calf is indicated by an inability on the part of the patient to extend the foot and to produce flexion and a lateral movement of the toes. Thus the patient is no longer able to stand upon the toes, while, in consequence of a secondary contracture of the muscles situated upon the anterior

surface of the leg, the foot is made to assume a position which has been compared to the shape of a hook. The tibialis posterior muscle no longer assists in adducting the foot and raising its inner border; the flexor communis digitorum can no longer flex the two distal phalanges of the toe, while paraly-

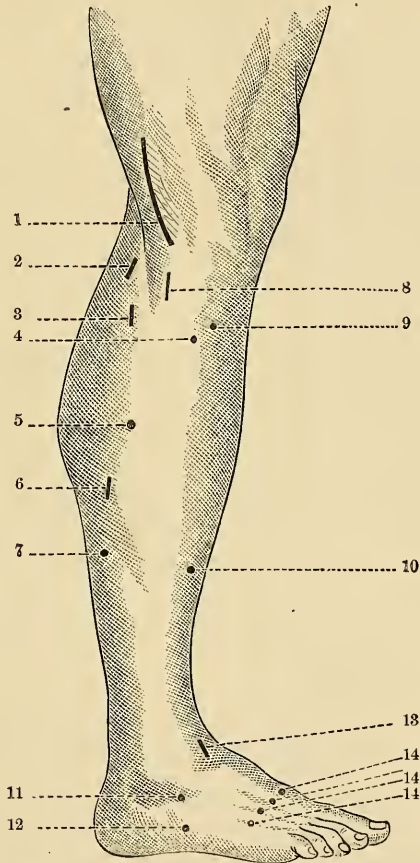


FIG. 238.—The motor points on the outer aspect of the leg.

- 1, peroneal nerve; 2, external head of gastrocnemius muscle; 3, soleus muscle; 4, extensor communis digitorum muscle; 5, peroneus brevis muscle; 6, soleus muscle; 7, flexor longus pollicis; 8, peroneus longus muscle; 9, tibialis anterior muscle; 10, extensor longus pollicis muscle; 11, extensor brevis digitorum muscle; 12, abductor minimi digiti muscle; 13, deep branch of the peroneal nerve to the extensor brevis digitorum muscle; 14, 14, 14, dorsal interossei muscles.

sis of the flexor longus pollicis deprives the patient of the power of flexing the great toe. A lateral motion of the great

toe is no longer possible, since the power of the adductor and abductor pollicis muscles is abolished, while paralysis of the interossei muscles (as mentioned also in connection with the hand) renders it impossible for the patient to flex the first phalanx, or extend the two distal phalanges of the toes, or separate the toes from each other. The peculiar position of the foot which results from this paralysis resembles that described in connection with the upper extremity as the "claw hand," since the first phalanx is abnormally extended, the second and third are strongly flexed, the toes are tightly compressed together, and their bulbous ends no longer touch the ground. The weight of the body in a standing position is borne upon the heads of the metatarsal bones. Hence, some pain and inconvenience are experienced after long standing or walking.

Paralyses of the *sciatic nerve* are accompanied, as a rule, by disturbances of the sensibility of the affected parts. Anæsthesia commonly exists over the regions supplied by the motor nerves to the muscles which are paralyzed; hence, this symptom may serve as a guide, in some cases, to the seat of the lesion which has created the paralysis. In addition to these disturbances of sensibility, you may often notice changes in the circulatory apparatus in the form of coldness of the skin, cyanosis, stasis in the veins, and a mottling of the part with bluish-red streaks.

The *trophic disturbances* which are commonly met with in severe forms of paralyses of the peripheral branches of the sciatic nerve comprise serious bed-sores on the heels, ankles, and over the sacrum; ulceration of the skin; eruptions of herpes and pemphigus; and, finally, marked atrophy of the muscles. When the sciatic nerve is affected by a spinal lesion above the cauda equina, the rectum and bladder are frequently completely paralyzed.

INDEX.

- Acerculus cerebri, 216.
Æsthesodic system, 599.
—— systematic lesions of, 601.
Ageusia, its tests and clinical significance, 482.
Akinesia, 131.
Albuminuria, from lesions of medulla, 306.
Alveolo-condyloid plan of skull, 112, 113.
Amaurosis, 369, 372, 390.
Amblyopia, 90, 98, 373.
Ammon's horn, 51, 53.
Amygdala, 124, 125.
Amyotrophic lateral sclerosis, 615.
Anarthria, 74, 242.
Anatomy of nervous system, extent of investigations in, 4.
Anæsthesia of locomotor ataxia, 606.
Aneurysmal cough, 500.
Aneurysm, miliary, 164.
Angular gyrus, 93.
Anosmia, its causes, etc., 348.
Ansa lenticularis, 138.
Anterior horn of spinal cord, cells of, subdivisions of, 554.
Aphasia, 71-76, 96, 97, 103.
—— motor, 71, 72, 73.
—— of traumatic origin, 120.
—— sensory, 71, 73, 74, 75.
—— with hemianopsia, 200.
Aqueduct of Fallopius, 423, 438.
—— lesions within, 442.
Aqueduct of Sylvius, 308, 313.
Arachnoid, cranial, 318, 319.
—— spinal, 540, 541.
Arm, motor points of (cuts), 701, 702.
Arnold's nerve, 485.
Arterial tonus, 304.
Artery, carotid, internal, 322.
—— cerebral, anterior, 322.
Artery, cerebral, middle, 323.
—— cerebral, posterior, 324.
—— choroid, anterior, 322.
—— choroid, posterior, 324.
—— communicating, posterior, 323.
—— ophthalmic, 322.
—— vertebral, 324.
Articulation, impairment of, from lesions of pons and medulla, 293.
Astigmatism, 356, 357.
Ataxia, changes of the pupils in, 609.
—— locomotor, 602.
—— "reflex tests" of, 609, 610.
—— symptoms of, 606, 607, 608.
—— tests for, 607, 608, 609.
—— cerebral, with visual disturbance, 192, 194.
—— from lesions of medulla, 307.
Athetosis, 122.
Auditory nerve, 444.
Auditory vertigo, its clinical significance, 457.
Auriculo-bregmatic line, 113.
Automatism, cerebral and spinal, 42.
Axis-cylinder process, 550, 554.
Basis cruris, 37, 38, 39, 125, 201.
Bell, respiratory nerves of, 433.
Bell's paralysis, 426, 427, 437, 438, 439, 440.
—— its effect on smell, 348.
—— its varieties, causes, and symptoms, 438, 439, 440, 441.
Bent arm, its clinical significance, 673.
Betz's cells, 53, 65.
Bladder, its relations to focal lesions of the spinal cord, 631.
Blindness, 187, 188.
—— psychical, 194, 195.

- Blood-pressure, 305.
 Blood-vessels of brain, 321-325.
 Bulimia, its clinical significance, 503.
 Brachial plexus, 664.
 — branches of inner cord of, 669, 670.
 — branches of outer cord of, 668.
 — branches of posterior cord of, 670.
 — communications of, 668.
 — cords of, 664, 665, 666.
 — (cuts), 665, 666.
 Brain (see its various component parts as headings).
 — blood-vessels of, 321-325.
 — component parts of, relative weight of, 108.
 — ganglia of, 41.
 — gray matter of, 23, 24, 25, 26, 27.
 — growth of, 107.
 — membranes of, 316-321.
 — trophic action of, 9.
 — tubular gray matter of, 26.
 — weight of, 108.
 — (see also Cerebrum, Cerebellum, Crus, Pons, and Medulla).
 Canal, intestinal, effect of section of pneumogastric upon, 499.
 Canals, semicircular, 446, 450, 452, 453.
 — semicircular, effects of section of, 461, 462, 463, 464.
 — semicircular, their relations to auditory vertigo, 461.
 Capsule, internal, construction of, 151, 152, 153, 154.
 — its relation to the thalamus, 136, 137.
 — motor and sensory bundles of, 153, 154, 158, 159.
 — of cerebrum, 151-171.
 — lesions of, 163-172.
 — pressure upon, 132.
 — relations of, 128.
 — subdivisions of, 152, 154.
 Cardialgia, 503.
 Carotid system of vessels, 321.
 Caudate nucleus, 124, 125, 126.
 Cells, of Betz, 53, 65.
 — of cerebral cortex, 45, 46, 47, 48.
 — of Deiters, 551.
 — of spinal cord, 551.
 Center, cilio-spinal, 578.
 — auditory, 71.
 — cardiac, of medulla, 303.
 — cardio-acceleratory, 298.
 Center, cardio-inhibitory, of medulla, 297.
 — convulsive, of medulla, 298.
 — cortical, for upper and lower limbs, subdivisions of (Horsley), 116, 117, 118.
 — diabetic, 297, 298.
 — for accommodation of vision, 175.
 — for big toe, 65.
 — for deglutition, 297.
 — for jaw-movements, 212.
 — for movements of œsophagus and stomach, 297.
 — for physical evidences of pain, 212.
 — for vomiting, 297.
 — genito-urinary, 578.
 — in medulla, for laughing, sighing, sobbing, sneezing, and hiccoughing, 296.
 — of Broca, 64, 65, 71, 72.
 — of Broca, guide to, 113, 114.
 — of hearing, 93.
 — of smell, 331.
 — of sweating, 182.
 — of vision, 91, 92.
 — respiratory, 296.
 — salivary, of medulla, 298.
 — tactile, 71.
 — vaso-motor, of medulla, 296, 304, 305.
 Centers of facial movements, subdivisions of (Horsley), 116.
 — of hearing, 101.
 — of motion, 78-84.
 — of motion, surgical guides to, 116, 117, 118.
 — of smell, 101.
 — of smell and taste, 71, 93.
 — of speech, 101, 102.
 — of touch, 101.
 — of vision, 100.
 — physiological of medulla, 295-298.
 — sensory of cerebral cortex, 88-105.
 — vaso-motor, 9, 11.
 Central myelitis of spinal cord, 624.
 Cerebellar vertigo, 242.
 Cerebellum, architecture of, 216-243.
 — cortex of, 26, 219, 220, 221.
 — fibers of, 219, 221, 222, 223, 224, 225, 226, 227.
 — functions of, 232-243.
 — inferior peduncle of, 231, 232, 280, 281, 286, 287.
 — its relation to cranial nerves, 232.
 — its relation to sensory tracts, 286.

- Cerebellum, lesions of, 234, 235, 241, 243.
 — lesions of, symptoms of, 241, 242, 243.
 — middle peduncle of, 230, 231, 290.
 — peduncles of, 219, 222, 223, 230, 231, 290.
 — processes of, 40, 41.
 — superior peduncle of, 128, 206, 207, 227, 228, 229, 290.
- Cerebral apoplexy, 163.
- Cerebral ataxia, with visual disturbance, 192.
 — coma, 121.
 — cortex (see Cortex).
 — cortex, 43-106.
 — cortex, functions of, 177, 178.
 — lobes, the seat of consciousness, 22.
 — softening, 163.
 — topography, surgical bearings of, 111-121.
- Cerebro-spinal axis, three portions of, 21.
 — spinal fluid, 319, 541, 542, 543.
 — spinal fluid, movements of, 542.
 — spinal nerves, acts controlled by, 9.
 — location of, 7.
 — subdivisions of, 10.
 — spinal system, component parts of, 7.
- Cerebrum, associating fibers of, 30.
 — asymmetry of, 44, 45.
 — basal ganglia of, 24.
 — basal ganglia of, functions of, 56.
 — base of, lesions of, 97, 199.
 — commissural fibers of, 27, 28.
 — commissures of, 314, 315, 316.
 — converging fibers of, 28, 29.
 — convolutions of, 60-66.
 — corpus striatum of, 24, 122.
 — cortex of, 23, 43.
 — cortex of, lesions of, 95, 96, 97, 98.
 — cortex of, summary of, 98-106.
 — crus of, architecture of, 38, 39, 40, 41, 42.
 — fissures of, 57, 58, 59, 60.
 — fornix of, fibers of, 31.
 — growth of, 107.
 — internal capsule of, 110, 151-171.
 — internal capsule of, relations of, 128.
 — lesions of the interior of, 109, 110, 111.
 — lobes of, 57, 60, 61, 62, 63.
 — lobules of, 57, 65.
 — motor area of, subdivisions of, 83, 84.
 — motor centers of, surgical guides to, 116, 117, 118, 119.
- Cerebrum, motor regions of, 77.
 — non-cortical lesions of, 121, 122.
 — occipital convolutions of, 91, 92.
 — optic thalamus of, 24.
 — præfrontal lobes of, lesions of, 97, 98.
 — peduncular fibers of, 28, 29.
 — projection systems of, 31-42.
 — radiating fibers of, 28, 29.
 — sensory regions of cortex of, 88-105.
 — sinuses of, 317, 318.
 — speech center of, 71, 72.
 — sulci of, guides to, 119.
 — surgical guides to, 111-121.
 — temporal convolutions of, 92, 93, 94, 95.
 — weight of, 106.
 — white matter of, 27.
- Cervical plexus of nerves, 650.
 — plexus, deep branches of, 655.
 — plexus, its situation, 654.
 — plexus, superficial branches of, 652.
- Cheek, hypertrophy of, its causes, 419.
- Cheyne-Stokes respiration, 120.
- Choked disk, 111, 120, 167, 186, 199.
- Chorda tympani nerve, its relations to taste, 406.
- Choroiditis, its effect on vision, 389.
- Choreiform movements, following cerebral lesions, 169, 170.
- Choroid plexuses, 320, 321.
- Ciliary muscle, its function and nerve distribution, 375, 378, 379.
- Cilio-spinal center, 393, 637.
 — its relations to focal lesions of cord, 629.
- Cimbia, 336.
- Clastrum, 53.
- Claw-hand deformity, 616.
- Cochlea, 450, 453.
- Coitus, its relation to spinal disease, 633.
 — its relation to small sciatic and pudic nerves, 752, 754.
- Color-blindness, 362.
- Column of Burdach, sclerosis of, 601, 602.
 — of Burdach, 557, 558, 562, 563, 564.
 — of Burdach, synonyms for, 557.
 — of Clarke, 554, 555.
 — of Goll, 557, 558, 562, 563, 564.
 — of Goll, synonyms for, 557.
 — of Goll, sclerosis of, 601, 602.
 — of Türk, sclerosis of, 601, 612.
 — of Türk, 557, 558, 559.
 — cerebellar, direct, 560, 561.

- Column, postero-external, 561.
 — postero-internal, 561.
 — pyramidal, crossed, 558, 559, 560.
 — pyramidal, direct, 558, 559, 560.
 Coma a symptom of cerebral disease, 121.
 Commissure, anterior of cerebrum, 126, 315.
 — anterior of cerebrum, its relations to smell, 332.
 — of spinal cord, 537.
 — posterior, 174.
 — of cerebrum, 211.
 — of thalamus, 138, 139.
 — of third ventricle, 315, 316.
 Conarium, 132, 215.
 Conjunctiva, nerves of, 417.
 Consciousness, loss of, in cerebral disease, 319.
 Convolution, sigmoid, 62, 63.
 Convulsions of cerebrum, 60-66.
 — sensory, of cerebrum, 89.
 — a guide to trephining, 121.
 Convulsions, with lesions of pons, 293.
 Coördination, its relations to pons and crus, 291.
 Cornea, ulcerations of, its relations to fifth nerve, 416.
 Cornu ammonis, 53.
 Corpora geniculata, 132.
 — quadrigemina, 110, 172-180.
 — quadrigemina, brachia of, 135, 172, 173.
 — quadrigemina, functions of, 174, 175, 176, 177.
 Corpus album subrotundum, 142.
 — callosum, 314.
 — candicans, 37, 148, 149.
 — fimbriatum, 315.
 — quadrigeminum, anterior, 211, 212, 213, 214.
 — striatum, 24, 122-132.
 — striatum, functions of, 129-132.
 — striatum, a surcingle of, 124.
 — striatum, hæmorrhage of, 123, 124.
 — striatum, nuclei of, 39, 122-125.
 — subthalamicum, 178.
 Cortex, gray matter of, 26.
 — of cerebellum, 26, 219, 220, 221.
 — of cerebrum, 23, 43-106.
 — of cerebrum, centers of taste and smell of, 93.
 — of cerebrum, color of, 45.
 — of cerebrum, construction of, 44-54.
 — of cerebrum, excitable region of, 99.
 Cortex of cerebrum, functions of, 55, 56, 57, 68-105.
 — of cerebrum, layers of, 44.
 — of cerebrum, sensory regions of, 100.
 — of cerebrum, sensory centers of, 88-105.
 — of cerebrum, special types of, 50.
 — of cerebrum, strata of, 46, 50, 51, 52, 53, 54, 55.
 — of cerebrum, strata of, reasons for, 54.
 — of cerebrum, thickness of, 45.
 — of cerebrum, topography of, 57-68.
 Corti, membrane of, 456.
 — organ of, 447, 454, 455.
 Cortical centers of hearing, smell, and taste, 75.
 — centers of motion, 68, 69.
 — centers of vision, 182.
 — convulsions, 70, 87, 103.
 — lesions, symptoms of, 95, 96, 97, 98.
 — localization, views respecting, 98.
 — motor paralysis, 84, 85.
 — spasm, 121.
 Cranial nerves, construction of, 10.
 — fibers of, 41.
 — foramina of, exit of, 7.
 Crossed paralysis, 198, 199, 200.
 Crural neuralgia, 736.
 Crus cerebri, 37, 38, 39, 200-216.
 — fibers of, 37.
 — motor and sensory tracts of, 42.
 — subdivisions of, 37.
 Crusta cruris, 37, 38, 39, 125, 201, 202, 203, 204, 205.
 Cuneus, 65, 335, 336.
 — lesions of, 96, 97, 121.
 Deaf-mutism, 466.
 Deafness, from lesions of pons, 294.
 Defecation, its relation to focal lesions of the spinal cord, 631, 633, 638.
 Deglutition, center of, reflex acts of, 479.
 — effects of section of fifth nerve upon, 406.
 — excitory nerve of, 477.
 — its relations to glosso-pharyngeal nerve, 469.
 — its relation to the otic ganglion, 420.
 — mechanism of, 472, 473, 474, 475, 476, 477, 478, 479.
 — muscles connected with, 656.
 — nervous mechanism of, 299.
 — relations of hypo-glossal nerve to, 523.

- Deglutition, relations of spinal accessory nerve to, 510.
 Delirium, in cortical disease, 105.
 Dementia, 106.
 Diabetes, from lesions of medulla, 306.
 Diaphragmatic tetanus, 662.
 Digestive tract, effects of section of pneumogastric nerve upon, 497.
 Diplopia, its clinical significance, 394, 395.
 Direct cerebellar tract, 279.
 Duchenne's disease, 395-442, 480, 524, 525.
 — its relations to tetanoid paralysis, 616.
 Dura mater, 316, 317, 318.
 — spinal, 539, 540.
 Dyspnœa, its relations to focal lesions of the spinal cord, 630.
 Dysphasia, from lesions of medulla, 307.

 Ear, external, 447.
 — internal, 450.
 — internal fluids of, 451.
 — middle, 447.
 — relations of muscles of, to hearing, 433.
 Earache, its diagnostic importance, 417.
 — its relations to fifth nerve, 416.
 Eighth nerve (see Nerve, Auditory), 444.
 Elbow, motor centers for, 83.
 Eleventh nerve (see Nerve, Spinal Accessory), 505.
 Embolism, cerebral, 72, 73.
 Ependyma, 308.
 Epilepsy, spinal, 631.
 Equilibration, 212.
 Equilibrium, maintenance of, 122.
 Eustachian tube, function of, 448.
 — its clinical points of interest, 463, 464.
 Eye, in facial paralysis, 436.
 — its relations to facial diplegia, 443, 444.
 Eyeball, center of movements of, 385.
 — motions of, 381, 382, 383, 384, 385, 386.
 Eyelid, effect of closure of, on lachrymal apparatus, 367.
 — mechanism of its closure, 367.
 Eyes, conjugate deviation of, 80, 169, 293.
 — oscillatory movements of, their clinical significance, 461.

 Face, in facial diplegia, 443.
 — motor centers for, 83.
 — motor points of (cut), 528.

 Face, paralysis of muscles of, 437, 438, 439, 440.
 — relations of cervical plexus to expression of, 654.
 — relation of facial nerve to expression of, 435.
 — spasm of muscles of, 436, 437.
 Facial centers, subdivisions of (Horsley), 116.
 Facial diplegia, 442, 443.
 — expression, mechanism of, 301.
 — nuclei of, 296.
 Facial nerve (see Nerve, Facial), 423.
 — function of chorda tympani branch of, 406.
 Facial neuralgia, 407.
 — palsy, 102.
 Fallopius, aqueduct of, 423, 428.
 — aqueduct of, its relations to facial paralysis, 439, 440.
 Fascia of chest, nerve distribution of, 654.
 — of forearm, its nerve supply, 674.
 — of leg, its relation to cutaneous nerves, 760.
 — its nervous supply, 733.
 Fasciculus cuneatus, 250.
 — gracilis, 250.
 — rotundus, 282, 283.
 Ferrier's visual center, 93, 196.
 Fibers, arcuate of medulla, 263.
 — associating, of cerebrum, 30.
 — associating, of speech, 73, 75.
 — caudo-striate, 126, 127.
 — commissural, of cerebrum, 27, 28.
 — commissural, of spinal cord, 584, 585.
 — motor, of spinal cord, 579, 580.
 — of caudate nucleus, 126, 127.
 — of cerebellum, 219-230.
 — of cranial nerves, 41.
 — of fornix, 31.
 — optic, deductions respecting, 180, 181.
 — peduncular, of cerebrum, 28, 29, 66, 67.
 — sensory, of spinal cord, 580, 582, 583, 584.
 — vaso-motor, of spinal cord, 587, 588.
 Fifth cranial nerve (see Nerve, Trigeminal), 397.
 Fillet, 139, 207, 208, 209, 210, 283, 284, 334.
 — course of, 277, 278, 279.
 — upper, 173.
 Fingers, motor centers for, 83.

- Fissure, calcarine, 57, 60.
 — calloso-marginal, 57, 60.
 — dentate, 57, 59.
 — hippocampal, 57, 59.
 — of Bichat, 58.
 — olfactory, 59.
 — parieto-occipital, 57, 58.
 — of Rolando, 57, 58.
 — of Rolando, guide to (Thane), 117.
 — of Rolando, surgical guides to, 111, 113, 114, 115.
 — of Sylvius, 57, 58.
 — of Sylvius, surgical guides to, 114.
 — of Sylvius, surgical guides to (Horsley), 118.
 — transverse, 57, 58.
 Fissures of cerebrum, 57, 58, 59, 60.
 — of spinal cord, 537.
 Flechsig's method of research, 157.
 Flocculi, 218.
 Foot-clonus, 596, 598.
 Foot, its attitude in tibial paralysis, 771, 772.
 Foramen of Magendie, 542.
 Foramina of Monro, 310-313.
 Forced movements, 238, 243.
 Forearm, motor points of (cut), 703, 704.
 Formatio reticularis, 206, 252, 274, 276, 277, 279, 283.
 Fornix, 315, 316.
 — anterior pillars of, 148, 149.
 — body of, 312, 315, 316.
 — bulb of, 215.
 Fourth cranial nerve (see Nerve, Trochlearis), 395.
 Fremitus of fingers in paralytic dementia, 527.
 Front-tap contraction, 598.
 Funiculus cuneatus, 557.
 — gracilis, 557.
 Gait of locomotor ataxia, 607.
 — of peroneal paralysis, 769, 770.
 — of sciatic paralysis, 767.
 — of tetanoid paraplegia, 616.
 Ganglia, basal, 24.
 — basal, functions of, 56.
 — basal, relations of, to internal capsule, 128.
 — of brain, 41.
 — of fifth nerve, 419, 420.
 — of fifth nerve (table of), 421.
 — of origin of "crusta," 204.
 Ganglia of origin of "tegmentum," 206, 210, 211, 212.
 — of visual apparatus, 183.
 Ganglion, ciliary, 420, 421.
 — jugular, 468.
 — jugular, of pneumogastric, 485.
 — lenticular, 420, 421.
 — Meckel's, 420, 421, 429, 432.
 — Meckel's, excision of, 419.
 — of Luschka, 658.
 — of root of pneumogastric, 485.
 — of trunk of pneumogastric, 485.
 — ophthalmic, 420, 421.
 — ophthalmic, its relation to sixth nerve, 422.
 — otic, 420, 421, 429, 432.
 — submaxillary, 420, 421.
 — of Andersch, 468.
 — of Gasser, 475.
 — of pons, 40.
 — optic, basal, 178.
 — optic, inferior, 147.
 — reticulare, nuclei of, 252.
 Gastric crises, 242.
 Gelatinous substance of medulla, 263.
 — of spinal cord, 552.
 Geniculate bodies, 135, 143, 214, 215, 334.
 Glands, cervical, relations of their enlargement to fifth nerve, 416.
 Glieder's members, 126.
 Globus hystericus, 500.
 Globus pallidus, 126.
 Glossoplegia, 524, 525.
 Glottis, respiratory movements of, 510.
 Gluteal paralysis, 747.
 Gubler, line of, 429, 438.
 Gudden's method of research, 156, 157.
 Gyri anectant, 62.
 — operti, 65.
 Gyrus fornicatus, 66.
 — (see Convolution).
 Habenula, 215.
 Hair, sudden blanching of, 415.
 Hallucinations of vision, 97.
 Hand, its relation to paralysis of median nerve, 683.
 — its relation to paralysis of musculospiral nerve, 701, 702.
 — its relation to paralysis of ulnar nerve, 689, 690.
 — motor points of (cut), 703, 704.

- Handwriting, its modifications in paralytic dementia, 527.
- Head, nerve supply to posterior portion of, 652, 653.
- Hearing, effects of section of fifth nerve upon, 406.
- cortical center of, 93.
- general view of organ of, 446.
- its relations to facial paralysis, 440.
- its relation to otic ganglion, 420.
- mechanism of, 448, 449, 450, 453, 454, 455, 456.
- relations of muscles of ear to, 433.
- Heart, acceleratory center of, 628, 629, 630.
- Heart, centers for, in medulla, 303.
- effects of section of pneumogastric upon, 497.
- Hemianæsthesia, 122, 165.
- cerebral, 193.
- cortical, 95.
- crossed, 291.
- spinal, 576.
- with visual disturbance, 192, 193, 194.
- Hemianopsia, 90, 198.
- deductions respecting, 180, 181.
- homonymous, 121.
- tests for, 188, 189, 190.
- varieties of, 190, 191, 192.
- Hemi-chorea, 122.
- Hemiparaplegia, 634, 638.
- Hemiplegia, 164, 165.
- cortical, 95.
- spinal, 634, 636.
- with visual disturbance, 192.
- Hiccough, 660, 661.
- its relations to focal lesions of spinal cord, 629.
- Hippocampi, 310.
- Hippocampus major, 53, 59.
- Horsley's guides to cortical centers, 116, 117, 118.
- subdivisions of motor area, 83.
- Huguier, canal of, 428.
- Hypergeusia, its tests and clinical significance, 481.
- Hypcopia, its effects on health, 355, 356.
- Hyperosmia, its causes and tests, 348.
- Hypoglossal tract, 73.
- Hypophysis cerebri, 215.
- Incoördination, theories of origin of, 611.
- Inferior optic ganglion, 147.
- Insular, 64, 65.
- Intercostal neuralgia, 716.
- Internal capsule, lesions of, 163-172.
- motor and sensory bundles of, 153, 154, 158, 159.
- Interolivary tract, 288, 584.
- Iris, its nervous supply and movements, 376, 377, 380, 381.
- reflex action of, and its clinical bearings, 381.
- relations of blood-vessels to movements, 380.
- Island of Reil, 64, 65.
- associating fibers of, 72, 73.
- Jacobson's nerve, 471.
- Jacksonian epilepsy, 87, 88, 96.
- Kinesodic system, 599.
- Knee-jerk, 596, 597.
- Kopp's asthma, 500.
- Labyrinth, its anatomy and functions, 450.
- Lachrymal apparatus, its relation to facial paralysis, 444.
- Lamina, anterior perforated, 138.
- cinerea, 313.
- Laminae medullares, 210.
- Larynx, effects of section of pneumogastric nerve upon, 495.
- Lemniscus, 139, 206, 207, 208, 209, 210, 283, 284.
- course of, 277, 278, 279.
- Lenticular nucleus, 124, 125, 126.
- Limbs, centers of motion of, 81, 82, 83.
- Line of Gubler, 293.
- Liver, effects of section of pneumogastric nerve upon, 498.
- Lobe, præ-frontal, 76.
- Lobes of cerebrum, 57, 60, 61, 62, 63, 64.
- Lobule, central, of cerebrum, 64.
- paracentral, 65.
- quadrate, 65.
- Local tenderness, as a guide to source of irritation, 14.
- Locomotor ataxia, 602.
- Locus cæruleus, 421.
- Lumbar plexus, 721, 722.
- tables of branches of, 723, 724.
- Lumbo-sacral cord, 744.
- Lungs, effect of section of pneumogastric nerve upon, 496.
- Macropsia, its clinical significance, 388, 389.
- Macula lutea, 351.

- Malum Cotunnii, 764.
 Mammillary tubercle, 37.
 Mastication, effects of section of fifth nerve upon, 406.
 — its alteration in Duchenne's disease, 525.
 Mastodynia, 718, 719.
 Meckel's ganglion, 420, 421.
 Median nerve, trophic effects of paralysis of, 684.
 Medulla oblongata, accessory nuclei of, 265, 266, 267.
 — architecture of, 244-307.
 — arcuate fibers of, 285, 287.
 — fibers of, 269-290.
 — fissures of, 244, 245.
 — functions of, 294-306.
 — gray matter of, 249-259.
 — lateral column of, nuclei of, 253.
 — lesions of, symptoms of, 307.
 — motor and sensory tracts of, 295.
 — nerve nuclei of, 253.
 — nuclei of, table of, 257.
 — physiological centers of, 295-298.
 — pyramidal tracts of, 270, 271, 272.
 — raphe of, fibers of, 287.
 — round bundle of, 282, 283.
 — sensory decussation of, 287.
 — sensory tracts of, 283-287.
 — subdivisions of (Krause), 246.
 — respiratory center of, its clinical relations, 628.
 Megalopsia, its clinical significance, 388, 389.
 Membranes, of brain, 316-321.
 — of spinal cord, 539.
 Memories, impairment of, in cortical disease, 97.
 — motor, 97.
 — of sound and sight impressions, 98.
 — storage of, in cortical cells, 104, 105.
 Menière's disease, 366, 457.
 Meningo-encephalitis, 105, 106.
 Micropsia, its clinical significance, 388, 389.
 Micturition, its relations to focal lesions of the spinal cord, 631, 633, 638.
 Mono-anæsthesia, 96.
 Mono-paræsthesia, 96.
 Monoplegia, 85, 86, 95, 96, 165.
 — its relations to trephining, 120, 121.
 — of arm, 102.
 Monoplegia of leg, 102.
 Mono-spasm, 96.
 Motion, cortical centers of, 79-84.
 Motor-nerve fibers, method of origin and termination of, 10.
 — definition of, 7.
 — method of distribution of, 11.
 Motor-oculi nerve, 373.
 — its clinical relations, 388.
 — its origin and course, 373, 374.
 — its relations to the perception of distance, 386.
 — physiology of its distribution, 377, 378, 379.
 — symptoms of paralysis of, 391.
 Motor points of upper extremity (cut), 701, 702, 703, 704.
 Mouth, changes due to spasm of, 411.
 — changes in Bell's paralysis, 426.
 Mouth, motor centers for, 83.
 Movements of jaws, center of, 212.
 Munk's visual center, 197.
 Muscæ volitantes, their causes, 361.
 Muscle, buccinator, its relations to deglutition, 473.
 — buccinator, physiology of action, 434, 435.
 — platysma, physiology of its action, 434.
 — quadriceps extensor, spasm of, 734.
 — stapedius, 427.
 — stapedius, function of, 463.
 — sterno-mastoid, its nerve supply, 512.
 — sterno-mastoid, paralysis of, 516, 517.
 — sterno-mastoid, tonic and clonic spasm of, 514, 515.
 — tensor tympani, function of, 450, 463.
 — tensor tympani, its relations to facial paralysis, 440.
 — trapezius, its nerve supply, 512.
 — trapezius, paralysis of, 517, 518.
 — trapezius, tonic and clonic spasm of, 514, 515.
 Muscles, causes of contracture after paralysis of, 632.
 — extensor and adductor groups of thigh, spasm of, 768.
 — flexor group of foot, spasms of, 768, 769.
 — flexor group of leg, spasm of, 768.
 — gluteal, paralysis of, 747, 748.
 — gluteal, spasms of, 747.
 — of the hip, spasm of, 738, 767.

- Muscles of the thigh, atrophy of, 736.
 — of the thigh and leg, their physiological groupings, 740, 741.
 — of the voice, nervous supply of, 509.
- Muscular sense, fibers of, 583, 584.
 — in cortical disease, 96.
 — structures, uses of nerve connection between, 15.
- Myelitis, central, of spinal cord, 624.
 — of anterior horns of spinal cord, 617.
 — polio-, 618.
- Myelo-brachium, 290.
 Myopia, its effects, 355, 357.
- Nates cerebri, 110, 172, 173, 175.
- Nerve, abducens, deep fibers of, 339.
 Nerve, abducens, 421, 422.
 — abducens, clinical relations of, 422, 423.
 — abducens, functions of, 422, 423.
 — accessory obturator, 723, 724.
 — accessory obturator, its distributions and functions, 742, 743.
 — anterior crural, 723, 724.
 — anterior crural, its clinical relations, 733.
 — anterior crural, its distributions and functions, 730, 731.
 — anterior crural, its relations to joints, 730, 731.
 — anterior interosseous, 668.
 — anterior tibial, 758.
 — Arnold's, 485.
 — auditory, deep origins of, 340.
 — auditory, 444.
 — auditory, anæsthesia of, 466.
 — auditory, clinical points afforded by, 457.
 — auditory, diagram of, 444.
 — auditory, hyperæsthesia of, 465.
 — auditory, its origin, 444.
 — auditory, peculiarity of fibers of, 445.
 — cardiac, 491.
 — cell, functions of, 22.
 — cells, differentiation between motor and sensory by their form, 256.
 — cells, functions of, 35.
 — cervical, clinical points pertaining to, 658.
 — cervico-facial, 425, 428, 434.
 — chorda tympani, 428, 429, 480.
 — chorda tympani, diagram of, 429, 431.
 — chorda tympani, function of, 471.
- Nerve, chorda tympani, its origin, 425.
 — chorda tympani, its relations to facial paralysis, 439, 440.
 — chorda tympani, its relation to the sub-maxillary gland, 420.
 — chorda tympani, its relation to taste, 406.
 — ciliary, 399, 400.
 — circumflex, of arm, 664, 670, 692.
 — circumflex, of arm, its clinical relations, 693.
 — circumflex, of arm, its distribution and functions, 692, 693.
 — cochlear, 446.
 — communicans noni, 521, 522, 648, 650.
 — communicans noni, its surgical relations, 655.
 — compound, of the head, 418.
 — cutaneous, of ear, 404.
 — dental, inferior, 399, 400.
 — depressor, 305.
 — depressor, of heart, 484, 485, 491, 509.
 — depressor, of heart, its relations to spinal accessory nerve, 511.
 — descendens noni, 521, 522.
 — dorsal, of penis, 745.
 — dorsal, of penis, its distribution and functions, 753, 754.
 — endings, determined by shape of muscles, 14.
 — excitory, of deglutition, 477.
 — external anterior thoracic, 664, 668, 671.
 — external cutaneous, of the arm, 664, 668, 671.
 — external cutaneous, of the thigh, 723, 724.
 — external cutaneous, of thigh, its distribution and functions, 728, 729.
 — external popliteal, 745, 758.
 — external respiratory, of Bell, 664.
 — external saphenous, 758.
 — facial, 423.
 — facial, clinical points afforded by, 436.
 — facial, communications of, 424, 425.
 — facial, course of, 423.
 — facial, deep origins of, 339.
 — facial, diagram of, 425.
 — facial, functions of, 425, 426.
 — facial, lingual branch of, 428, 430.

- Nerve, facial, its relations to Duchenne's disease, 526.
- facial, loop of, in medulla, 239.
 - facial, origins of, 423.
 - facial, paralysis of, 426.
 - facial, relations to fifth nerve, 429.
 - facial, table of branches of, 428.
 - fifth, ascending root of, 282.
 - filaments, distribution of, 3.
 - frontal, 399, 400.
 - genito-crural, 723, 724.
 - genito-crural, its distribution and clinical relations, 729, 730.
 - glosso-pharyngeal, 466.
 - glosso-pharyngeal, deep origin of, 340.
 - glosso-pharyngeal, clinical points of interest of, 480.
 - glosso-pharyngeal, effects of section of, 471.
 - glosso-pharyngeal, its origin and relations, 467.
 - glosso-pharyngeal, table of branches of, 471.
 - great auricular, 648, 649, 650, 652, 653.
 - great occipital, 648, 649, 652, 653.
 - great sciatic, 744, 745.
 - great splanchnic, its relation to pain, 712.
 - gustatory, 399, 400.
 - hypoglossal, 518.
 - hypoglossal, clinical points pertaining to, 523.
 - hypoglossal, communications of, 519, 520, 521.
 - hypoglossal, deep origin of, 341.
 - hypoglossal, effects of section of, 523.
 - hypoglossal, general function of, 518, 522.
 - impulses, classes of, 21.
 - hypoglossal, its relations to deglutition, 473, 474, 523.
 - hypoglossal, origin of, 518, 519.
 - ilio-hypogastric, 723, 724.
 - ilio-hypogastric, its clinical relations, 726.
 - ilio-hypogastric, its distributions and functions, 725, 726.
 - ilio-inguinal, 723, 724.
 - ilio-inguinal, its clinical relations, 726.
 - ilio-inguinal, its distribution and functions, 725, 726.
 - inferior dental, rules for section of, 419.
- Nerve, inferior gluteal, 745.
- inferior hæmorrhoidal, 745.
 - inferior hæmorrhoidal, its distributions and functions, 753, 754.
 - inferior maxillary, 399, 400.
 - inferior pudendal, 745.
 - inhibitory, of vaso-motor center, 493.
 - intercostal, physiology of, 707, 708, 709, 710.
 - internal anterior thoracic, 664, 669, 671.
 - internal cutaneous, of arm, 664, 669, 684.
 - internal cutaneous, of the thigh, 724.
 - internal popliteal, 745, 758.
 - internal saphenous, 724.
 - Jacobson's, 471.
 - lachrymal, 399, 400.
 - laryngeal, 488, 489.
 - lesser internal cutaneous, 664, 669, 684.
 - long saphenous, 724.
 - long saphenous, its distribution and physiology, 733.
 - median, 664, 668, 677.
 - median, its clinical relations, 681.
 - median, its distribution and functions, 679, 681.
 - median, its surgical relations, 679, 684.
 - middle cutaneous, of the thigh, 724.
 - motor-oculi, 373.
 - motor-oculi, deep origin of, 336, 337, 338.
 - motor-oculi externus, 421, 422.
 - muscular, of brachial plexus, 664.
 - musculo-cutaneous, 668, 671.
 - musculo-cutaneous, of arm, its clinical relations, 676, 677.
 - musculo-cutaneous, of arm, its physiological relations, 672, 673, 674.
 - musculo-cutaneous, of leg, 758.
 - musculo-spiral, 694, 764, 770.
 - musculo-spiral, its clinical relations, 698.
 - musculo-spiral, its course and distribution, 694.
 - musculo-spiral, its cutaneous distribution, 697, 698.
 - mylo-hyoid, 399, 400.
 - nasal, 399, 400.
 - nuclei of medulla, 254, 255, 256, 257, 358.
 - obturator, 723, 724.

- Nerve, obturator, its clinical relations, 741.
- obturator, its distributions and functions, 738, 739, 740.
 - of Wrisberg, 340.
 - olfactory, distribution and functions in animals, 344.
 - olfactory, fibers of, in brain, 329, 330, 331, 332.
 - olfactory, 341.
 - olfactory (see Olfactory Nerve).
 - olfactory, its clinical relations, 347.
 - olfactory, its relation to reflex action, 346.
 - olfactory, structure of filaments of, 343.
 - ophthalmic, 399, 400.
 - optic, 349.
 - optic, causes of impairment of its fibers, 369, 370, 371, 372, 373.
 - optic, chiasm of, 349.
 - optic, distribution of, 351.
 - optic, fibers of, 349, 350.
 - optic, fibers of, course of, 333-337.
 - optic, its association with fifth nerve, 352.
 - optic, its clinical relations, 368.
 - optic, its effect on coördination of movement, 366.
 - optic, its effect on lachrymal apparatus, 366.
 - optic, its effect on the pupil, 352.
 - optic, its relations in the orbit, 354.
 - optic, its relations to blood-vessels, 354, 355.
 - optic, its clinical relations to intracerebral pressure, 369.
 - optic, its relations to reflex action, 352.
 - optic, physiological reasons for peculiar distribution of its fibers, 353, 354.
 - orbital, 399, 400.
 - of Wrisberg, 445, 664, 669, 710.
 - patheticus, 395.
 - perineal, 745.
 - perineal, its distributions and functions, 753, 754.
 - peroneal, 758
 - phrenic, 648, 650, 664.
 - phrenic, disorders of, 660.
 - phrenic, its relations to focal lesion of spinal cord, 628.
 - phrenic, its surgical relations and functions, 656.
- Nerve, phrenic, physiology of distribution of, 656, 657, 658.
- pneumogastric, 482.
 - pneumogastric, afferent fibers of, 493.
 - pneumogastric, anastomoses of, 483.
 - pneumogastric, branches of, 486.
 - pneumogastric, clinical points pertaining to, 499.
 - pneumogastric, course and relations of, 494, 495.
 - pneumogastric, deep origins of, 340.
 - pneumogastric, diagram of, 484, 487.
 - pneumogastric, effects of section of, 495, 496, 497, 498.
 - pneumogastric, efferent fibers of, 486.
 - pneumogastric, functions of, 486.
 - pneumogastric, its relations to Duchenne's disease, 526.
 - portio intermedia, 425.
 - posterior interosseous, 670, 696.
 - pneumogastric, relations to respiration, 493.
 - posterior thoracic, 664.
 - posterior tibial, 758.
 - pudic, 744, 745.
 - pudic, its clinical relations, 754.
 - pudic, its distributions and functions, 753, 754.
 - pudic, its relations to the urinary organs and coitus, 754, 755.
 - pulmonary, their clinical relations, 501.
 - radial, 670, 696.
 - recurrent laryngeal, 485.
 - roots, anterior and posterior of spinal cord, fibers of, 548, 549, 550.
 - sciatic, its clinical relations and those of its branches, 764.
 - sciatic, its distributions and functions, 755, 756, 757.
 - sciatic, paralysis of, or of its branches, 769, 770.
 - small sciatic, 744, 745.
 - small sciatic, its distribution and function, 750.
 - small occipital, 648, 649, 650, 652, 653.
 - small sciatic, its relation to coitus, 751, 752.
 - small sciatic, its relation to genital organs, 752.
 - sphenopalatine, 399, 400.
 - spinal accessory, 505.

- Nerve, spinal accessory, clinical points pertaining to, 514.
- spinal accessory, communications of, 506.
 - spinal accessory, deep origins of, 341.
 - spinal accessory, distribution of, 507.
 - spinal accessory, effects of extirpation of, 511.
 - spinal accessory, its communication with the suboccipital nerve, and its physiological importance, 513.
 - spinal accessory, its distribution to muscles, and its physiological importance, 512.
 - spinal accessory, its relations to deglutition, 510.
 - spinal accessory, its relations to Duchenne's disease, 526.
 - spinal accessory, its relation to the heart's action, 510.
 - spinal accessory, its relations to singing, 512.
 - spinal accessory, its relation to voice, 510.
 - spinal, roots of, 539.
 - sublingual, 518.
 - suboccipital, 648, 652.
 - subscapular, 664, 670, 690.
 - superficial cervical, 648, 649, 650.
 - superficial perineal, 745.
 - superior gluteal, 744, 745.
 - superior gluteal, its clinical relations, 746, 747.
 - superior gluteal, its distribution and functions, 745, 746.
 - superior maxillary, 399, 400.
 - superior respiratory, of Bell, 489.
 - supply of body, general rules of, 4.
 - supra-clavicular, 648, 649.
 - temporal, deep, 399, 403.
 - temporo-facial, 425, 428, 434.
 - temporo-malar, 399, 400.
 - thoracic, 671.
 - trigeminus, 397.
 - trigeminus, afferent fibers of, 403.
 - trigeminus, ascending root of, 338, 339.
 - trigeminus, clinical points afforded by, 407.
 - trigeminus, deep origins of, 338, 339.
 - trigeminus, descending root of, 338, 339.
 - trigeminus, diagnostic value of, 415.
 - trigeminus, diagram of, 400.
 - trigeminus, effects of section of, 405.
 - trigeminus, efferent fibers of, 401.
 - trigeminus, function of its efferent fibers, 401, 402.
 - trigeminus, ganglia connected with, 419.
 - trigeminus, its relations to deglutition, 474.
 - trigeminus, its motor and sensory root, 398.
 - trigeminus, its origin, 397.
 - trigeminus, neuralgias of, 407, 408, 409.
 - trigeminus, paralysis of, 411, 412, 413, 414, 415.
 - trigeminus, roots of, 263.
 - trigeminus, spasms due to, 410.
 - trigeminus, surgical anatomy of, 418.
 - trigeminus, table of branches of, 399.
 - trochlear, 395.
 - trochlear, deep origin of, 337, 338.
 - trochlear, effect of paralysis of, 396, 397.
 - trochlear, its origin and function, 395, 396.
 - tympanic, 425, 428.
 - ulnar, 664, 669, 686.
 - ulnar, its clinical relations, 688.
 - ulnar, its distribution, 686, 688.
 - ulnar, its relations to focal lesions of cord, 630.
 - ulnar, its surgical relations, 686.
 - vestibular, 446.
 - Vidian, 428, 429, 432.
- Nerves, auriculo-temporal, 399, 400.
- associated with vision, lesions of, 182-193.
 - axioms of distribution of, 12, 13, 14.
 - axioms pertaining to distribution of, 12, 13, 14.
 - brachial plexus of, 664.
 - cardiac, their clinical relations, 502.
 - cardiac, functions of, 491, 492.
 - cardio-acceleratory, 303.
 - cardio-inhibitory, 303.
 - cerebro-spinal, 7, 9, 10.
 - cervical, 641.
 - cervical (lower), 664.
 - cervical classification of branches, 648.
 - cervical plexus of, 650.
 - coccygeal, 642.
 - cranial, 7, 10.

- Nerves, cranial, deep origins of, 329-341.
- cranial, relations to cerebellum, 232.
 - cutaneous, clinical guides to, 404, 405.
 - cutaneous, of abdomen, their clinical subdivisions, 726.
 - cutaneous, of head, 403, 404, 405.
 - degeneration of, 155, 156.
 - dental, anterior and posterior, 399, 400.
 - dependence of body upon, 4, 5.
 - distribution of, importance of, in diagnosis, 11.
 - distribution of, 11.
 - dorsal, 641, 705, 706.
 - dorsal, paralysis of, 719, 720, 721.
 - dorsal, their clinical relations, 710.
 - dorsal, their communication with the sympathetic nerve, 705.
 - dorsal, their relation to the brachial plexus, 705.
 - dorsal, their relation to the contents of the mediastinæ of the chest, 711.
 - dorsal, their relation to heart disease, 710.
 - dorsal, their relation to pleurisy, 710.
 - dorso-lumbar, 708.
 - from lower cervical region, 663.
 - gastric, their clinical relations, 503.
 - hepatic of pneumogastric, their clinical relations, 504.
 - intercostal, 706.
 - intercostal, lateral and anterior cutaneous branches of, 706.
 - intercostal, neuralgia of, 716, 717, 718.
 - intercostal, their relation to abdominal pain, 713, 714.
 - intercostal, their relation to disease of the digestive viscera, 712.
 - intercostal, their relation to disease of the stomach, 712.
 - intercostal, their relations to focal lesions of the spinal cord, 637.
 - intercostal, their relations to the pleura, 708.
 - intestinal, of pneumogastric, their clinical relations, 504.
 - laryngeal, their clinical relations, 500.
 - lumbar, 641, 722.
 - motor, 7, 10.
 - œsophageal, 497.
 - of arm and forearm (tables of), 668.
 - of hip joint, 763, 764.
 - of larynx, 489, 490.
- Nerves of leg and foot (table of), 758.
- of pia mater, 320, 321.
 - of respiratory movements of glottis, 489.
 - of skin, relation to muscles and joints, 4.
 - petrosal, 425, 428, 429, 430, 432.
 - petrosal, diagram of, 432.
 - petrosal, their relations to facial paralysis, 439, 440.
 - plantar, 758.
 - resection of, rules for, 418.
 - respiratory, of Bell, 433.
 - sacral, 641, 743.
 - sacral, neuralgia of posterior branches of, 766.
 - sensory, 7, 10.
 - spinal, 10.
 - spinal, axioms of distribution of, 644, 645, 646.
 - subscapular, distribution of each, 690.
 - subscapular, their clinical relations, 691, 692.
 - superior maxillary, rules for excision of, 419.
 - supra-orbital, 399, 400.
 - supra-orbital, rules for division of, 418, 419.
 - supra-scapular, 664.
 - sympathetic, 7.
 - thoracic intercostal, 706.
 - thoracic-abdominal intercostal, 706.
 - to the peritonæum, and their physiology, 727.
 - trochlear, 399, 400.
 - vaso-motor, 10.
 - vaso-motor of medulla, 304, 305.
 - vaso-motor of spinal cord, 592, 593.
- Nervous system, component parts of, 5.
- histological elements of, 21.
 - methods of studying, 15, 16.
- Neuralgia, cervico-occipital, 659.
- diaphragmatic, 660.
 - intercostal, 716, 717, 718.
 - of anterior crural nerve, 736.
 - of the ilio-hypogastric and ilio-inguinal nerves, 725, 726.
 - of the mammary gland, 718.
 - of the obturator nerve, 741.
 - of the phrenic nerve, 660.
 - of the phrenic nerve, its differential diagnosis, 661.
 - of the sciatic nerve, 764, 765, 766, 767.

- Neuroglia of cerebral cortex, 47, 48.
 — of spinal cord, 551, 552.
- Neuro-retinitis, 111, 186.
- Ninth nerve, 466.
- Nuclear formation, 265.
- Nuclei, acoustic, functions of, 296.
 — of auditory nerve, 340.
 — accessory, of medulla, 265-267.
 — acoustic, 266, 267.
 — facial, accessory, functions of, 296.
 — of trigeminal nerve, 338, 339.
 — red, 132.
- Nucleus, accessory hypo-glossal, functions of, 296.
 — caudate, 124, 125, 126.
 — caudate, construction of, 126.
 — caudate, fibers of, 126, 127.
 — clavate, 225, 250, 251, 268, 282, 285.
 — dentate, 226.
 — emboliformis, 218.
 — facial, inferior, 266.
 — fastigii, 218, 219.
 — globosus, 218.
 — gray, of Meynert, 124.
 — hypoglossal, accessory, 266.
 — lenticular, fibers of, 125.
 — lenticular, internal capsule of, 151.
 — lenticular, 89, 124, 125, 126.
 — lenticular, subdivisions of, 126.
 — of motor oculi nerve, 262.
 — red, of the tegmentum, 215, 223, 226, 227, 267, 290.
 — spinal accessory, 266.
 — of third nerve, subdivisions of, 337.
 — triangular, 225, 250, 251, 267, 268, 282, 285.
 — yellow, of Luys, 126, 237.
- Nystagmus, its clinical significance, 392.
- Obturator neuralgia, 741, 742.
 — paralysis, 742.
- Olfactory bulb, 330.
 — nerve, roots of, 331.
 — nerve (see Nerve, Olfactory).
- Olivary body, 251, 268, 269, 276, 288.
 — hilus of, 268.
 — peduncle of, 268.
- Ophthalmoplegia, externa, 338.
- Optic apparatus, lesions of, 182-193.
 — commissures of, 138, 139.
 — fibers, decussation of, 334, 335.
 — fibers related to, 139, 140.
 — functions of, 140-147.
- Optic ganglia of Luys, 142, 143.
- Optic thalamus, its arch-like shape, 133.
 — thalamus, 24, 132-147.
 — its general relations, 133, 134.
 — its relations to automatism, 147.
 — its relations to hallucinations, 143.
 — its relations to internal capsule, 136, 137.
 — its relation to special senses, 143, 144.
 — lower peduncle of, 138.
- Optic lobes, 172.
 — nerve (see Nerve, Optic).
 — nerves and tracts, 183.
 — tract of Wernicke, 137.
 — surfaces of, 135, 136, 137.
 — tubercles of, 134, 135.
- Pain, a guide to cortical lesions of cerebrum, 95.
 — appreciation of, by pons, 293.
 — at knee joint, its clinical significance, 734, 740, 760, 761, 762.
 — facial, of Fothergill, 407.
 — in the back, its relation to aneurism, 713.
 — in the pectoral region, its clinical significance, 713.
 — in the penis, its clinical significance, 752.
 — in the pit of the stomach, its clinical significance, 712.
 — in the region of the thorax, its diagnostic value, 710, 711, 712.
 — in the shoulder, its relation to diseases of the liver, 714.
 — in the thorax, its relation to gastric and intestinal disease and tumors of the viscera, 714.
 — its relation to the phrenic nerve, 657.
 — of gout, 604.
 — of locomotor ataxia, its diagnostic peculiarities, 603.
 — of rheumatism of muscles, 605.
 — spinal transmission of, 576.
- Palate, its relation to deglutition, 477.
 — its relations to facial paralysis, 440.
 — its relations to glosso-pharyngeal nerve, 468.
 — nerves of, 431.
- Papilla of retina, 351.
- Paralysis alterne, 291.
 — atrophic, spinal, 617.
 — bulbar, 300, 524, 525.

- Paralysis, bilateral, of face, 442.
 — cortical, localization of, 102, 103.
 — crossed, 198, 199, 200, 423, 428, 438.
 — crossed, varieties of, 192, 193, 291.
 — due to crutches, 705.
 — due to lead-poisoning, 699, 700, 701.
 — facial, 437, 438, 439, 440.
 — facial, crossed, 291, 292.
 — facial, crossed, 428, 429, 430, 438, 439.
 — glosso-labio-laryngeal, 480, 524, 525.
 — motor or sensory, from lesions of medulla, 306.
 — of anterior crural nerve, 735, 736.
 — of Bell, 426, 427.
 — of circumflex nerve of shoulder, 693, 694.
 — of cortical origin, 84.
 — of diaphragm, 660, 662.
 — of dorsal nerves, 719, 720, 721.
 — of Duchenne, 444, 524, 525.
 — of median nerve, 681, 682, 683.
 — of muscles of the back, 720, 721, 722.
 — of musculo-cutaneous nerve, 676.
 — of musculo-spiral nerve, 698, 699, 700, 701, 702.
 — of obturator nerve, 741, 742.
 — of ocular muscles, its causes, 393, 394.
 — of peroneal nerve, 769.
 — of sciatic nerve, 767, 769.
 — of sciatic nerve, its sensory disturbances, 772.
 — of sciatic nerve, its trophic disturbances, 772.
 — of superior gluteal nerve, 747.
 — of the insane, 105, 106.
 — of the insane, 527.
 — of the ocular muscles, its effect on the position of the head, 386, 387, 388.
 — of tibial nerve, 770, 771.
 — of tongue, 529.
 — of trigeminus, from lesions of pons, 293.
 — of ulnar nerve, 688, 689, 690.
 — spastic spinal, 615.
 — spinal, 586.
 — tetanoid, 615.
 — tetanoid, gait of, 616.
 — tetanoid, its relations to Duchenne's disease, 616.
- Paralytic dementia, 527.
 — rigidity, 85, 86.
- Paraphasia, 74, 96, 97.
- Paraplegia, hemi-, 634, 638.
- Paraplegia, tetanoid, 615.
- Paresis, general, 106.
- Parolivary bodies, 269.
- Patheticus nerve, 395.
- Peduncular tract, transverse, of Gudden, 336.
- Peduncle, inferior, of cerebellum, 231, 232.
 — middle of cerebellum, 230, 231.
 — superior, of the cerebellum, 227, 228, 229.
- Peduncles of cerebellum, 219, 222, 223.
- Pia mater, cranial, 319, 320.
 — spinal, 540.
- Pineal gland, 132, 215.
- Pituitary body, 243, 244.
- Pleurodynia, its diagnosis from pleurisy and angina pectoris, 718.
- Point apophysaire, 409.
- Folio-myelitis, its causes, varieties, and symptoms, 618, 619, 620.
- Polydipsia, its clinical significance, 503.
- Polyphagia, its clinical significance, 504.
- Pons Varolii, architecture of, 244, 307.
 — celis and fibers of, 40.
 — gray matter of, 226.
 — gray matter of, 249-259.
 — fibers of, 245, 246.
 — arrangement of, 40.
 — functions of, 41, 291-295.
 — hæmorrhage of, 294.
- Ponti brachium, 290.
- Posterior longitudinal fasciculus, 148, 206, 207, 275.
- Post-paralytic rigidity, 104.
- Post-pedunculus, 290.
- Præpedunculus, 290.
- Process of Lenhossek, 551.
- Progressive muscular atrophy, 620.
- Projection systems of cerebrum, 31-42.
 — of Meynert, 31, 32.
 — of Spitzka, 32, 33, 34, 35.
- Prosopalgia, its clinical significance, 407.
- Psychical blindness, 194, 195, 196, 197.
- Pterion, 118.
- Ptosis, 391.
- Pulvina of thalamus, 135, 143, 334.
- Puncta dolorosa, of cervico-occipital neuralgia, 659.
 — of crural nerve, 736.
 — of fifth nerve, 409.
 — of intercostal nerve, 718.
 — of lumbar nerves, 726.
 — of phrenic neuralgia, 660.

- Puncta dolorosa of sciatic nerve, 766.
 Pupil, changes in, and their physiology, 360.
 — mechanism of its contraction and dilatation, 376, 377, 380, 381.
 Pupils, contraction of, a symptom of lesions of pons, 294.
 — Robertson's, 381.
 Pupillary movements, 212.
 Puskinje's cells, 220.
 Pyramidal fibers, decussation of, 251.
 — tracts, 202, 203, 270, 271, 272.
 — accessory fibers of, 272, 273.
- Reflex, abdominal, 596.
 — Achilles, 597.
 — cremasteric, 596.
 — epigastric, 596.
 — gluteal, 596.
 — deep, 596, 597, 598.
 — patellar, 596, 597.
 — peroneal, 596, 598.
 — plantar, 596.
 — scapular, 596.
 — skin, 595, 596.
 — spinal, 595, 598.
 — superficial, 595.
- Respiration, center of, relations of, to vasomotor center, 305, 306, 628.
 — its effects on cerebro-spinal fluid, 542, 543.
 — nervous mechanism, 301, 302.
- Respiratory bundle of Krause, 282.
 — mechanism, in medulla, 301, 302.
- Restiform body, 222, 286, 287.
 — fibers of, 289.
- Reticular formation, its relations to sensory tracts, 293.
 — ganglion, 33, 34.
 — process, 555.
- Retina, blind spot of, 361.
 — construction of, 363.
 — papilla of, 351.
- Rigidity, post-paralytic, 104.
- Robertson's pupil, 381.
- Rolando's fissure, 57, 58.
- Rotary movements, 243.
- Round bundle of medulla, 282, 283.
- Sacculæ of the labyrinth, 446, 452.
- Sacral plexus, 743.
 — articular branches of, 744, 745.
 — muscular branches of, 744, 745.
- Sacral plexus, muscular branches of, their distribution and function, 748, 749, 750.
 — table of its branches, 744.
- Salaam convulsions of Newnham, 516.
- Salivary secretion, effects of section of fifth nerve upon, 406.
- Scalp, pain of, its diagnostic importance, 417.
- Sciatic neuralgia, 764, 765, 766, 767.
- Second cranial nerve, 349.
- Sensory nerves, definition of, 7.
 — method of origin and termination of 10.
- Sensory tract, 206, 207.
- Sensory tracts, 89, 90.
 — of cord, 560, 561, 562, 563.
- Septum lucidum, 309.
- Seventh cranial nerve (see Nerve, Facial), 423.
- Shoulder, motor centers for, 83.
- Sight, effects of section of fifth nerve upon, 406.
 — lesions causing impairment of, 184, 185.
- Singing, its alteration in Duchenne's disease, 526.
 — relations of spinal accessory nerve to, 512.
- Sixth cranial nerve (see Nerve, Abducens), 421.
- Skin, nerves of, relations of, to muscles and joints, 4.
- Smell, center of, 331.
 — cortical center of, 93.
- Smell, effect of fifth nerve upon, 344.
 — effects of section of fifth nerve upon, 406.
 — its modifications and their causes, 345.
 — its alterations in Bell's paralysis, 348.
 — its modifications in animals and races, 344.
 — its relations to taste, 347.
 — physiology of its production, 344.
 — relations of act of sniffing to, 433.
 — relations of the facial nerve to, 433.
 — tests for, 347, 348.
- Sneezing, its physiology, 345.
- Sömmering, yellow spot of, 351.
- Space, posterior perforated, 200.
- Spasm of diaphragm, due to phrenic nerve, 660, 662.
 — of gluteal muscles, 747.

- Spasm of lower limbs, 767.
 — of muscles of the hip, 738.
 — of quadriceps extensor muscle, 734.
 — of sterno-mastoid and trapezius muscles, 515, 516.
 — of tongue, 529.
- Spasmodic contraction of the hip, 767.
 — tabes, 615.
- Special senses, impairment of, from lesions of internal capsule, 166, 167, 168.
- Speech, disturbances of, 71, 73-76.
 — its alterations in Duchenne's disease, 525.
 — its modifications in paralytic dementia, 527.
 — muscles connected with, 656.
 — tract, 73, 74, 75, 293.
- Spider-cells, 551.
- Spina bifida, 542.
- Spinal automatism, 568, 570, 579, 580.
 — canal, 535.
 — cells, 550, 551.
 — automatic action of, 592, 593, 594.
 — centers, 578, 579.
 — epilepsy, 631.
 — hemiplegia, 634, 636.
- Spinal cord, æsthesodic system of, 599.
 — an organ of conduction, 574, 575, 576.
 — an organ of coördination, 579.
 — anterior root zone of, 560.
 — architecture of, 533, 573.
 — arrangement for protection of, 535.
 — as a nerve center, 590-599.
 — blood-vessels of, 543, 544.
 — central canal of, 555, 556.
 — central myelitis of, 624.
 — classification of diseases of, 601.
 — clinical points pertaining to, 599.
 — columns of, 558-566.
 — columns of, development of, 563, 564, 565.
 — consisting of, 535.
 — degeneration of the cells of anterior horns of, 620.
 — dentate ligament of, 535.
 — descending degeneration of, 570, 572.
 — enlargements of, cervical and lumbar, 636.
 — fibers of, 579, 580, 582, 583, 584, 585, 586, 587, 589.
 — fibers of, arrangement of, 575.
 — fibers of, general course of, 573, 574.
- Spinal cord, fibers of, secondary degeneration of, 563, 564.
 — fibers of, varieties of, 547, 548.
 — fissures of, 537.
 — focal lesions of, 625.
 — focal lesions of, above lumbar enlargement, 632.
 — focal lesions at lumbar enlargement of, 633.
 — focal lesions of, cervical enlargement of, 628.
 — focal lesions of lateral half of, 634.
 — focal lesions of mid-dorsal region of, 631.
 — focal lesions of upper cervical regions of, 628.
 — functions of, 556, 598.
 — gelatinous substance of, 552.
 — gray commissure of, 556.
 — gray matter of, 551-560.
 — gray matter of, Spitzka's subdivisions, 264.
 — histological elements of, 547-552.
 — horns of, 553, 554.
 — inhibitory fibers of, 561, 562.
 — kinesodic system of, 599.
 — lateral column of, 560.
 — length of, 533.
 — localization of, functions of, 590.
 — membranes of, 539.
 — motor cells of, 554.
 — motor tracts of, 558, 559, 560.
 — myelitis of anterior horn, 617.
 — neuroglia of, 551, 552.
 — non-systematic or focal lesions of, 600, 601, 625.
 — paths of transmission of, 585.
 — sclerosis of, lateral columns of, 615.
 — segments of, individual functions of, 582, 589.
 — sensory columns of, 561-564.
 — sensory conduction of, paths of, 572.
 — sudorific fibers of, 561.
 — systematic lesions of, 599, 601.
 — systematic lesions of, æsthesodic system of, 601.
 — systematic lesions of, kinesodic system of, 611.
 — transverse section of, 552-566.
 — transverse section of, varying shapes of, 536.
 — trophic action of, 9.
 — trophic function of, 577.

- Spinal cord, vaso-motor centers of, 637.
 — white commissure of, 556.
- Spinal nerves, 641.
 — nerves, roots of, 641, 643.
 — nerves, definition of, 10.
- Spinal nerve roots, anterior and posterior fibers of, 548, 549, 550.
 — paralysis, atrophic, 617.
- Spinal reflex action, 567, 568.
- Spinal reflexes, 595, 596, 597, 598.
- Spinal segment, 539.
- Spinal segments, 566, 567.
 — guides to, 544-547.
- Spinal tracts, 569, 571.
 — decussation of, 572.
- Splenium, 314.
- Stephanion, 118.
- Stomach, effects of section of pneumogastric upon, 498.
- Strabismus, internal, its clinical significance, 392, 395, 422.
- Stratum cinereum, 173.
 — glomerulosum, 330.
 — intermedium, 202.
 — lemnisci, 173.
 — opticum, 173.
- Stratum zonale, 133.
- Stria cornea, 66, 67, 127.
- Sub-arachnoidean space, 319.
- Sub-dural space, 319.
- Subicular region, 62, 63.
- Substantia innominata of Reil, 138, 148.
 — nigra, 201, 204, 205.
- Sulci, guides to, 119.
- Sulcus, oculo-motori, 201.
- Superior, olive, 267, 269.
- Surcingle of corpus striatum, 124.
- Surgical, guides to, cerebrum, 111-121.
- Suture, coronal, its relations to Rolando's fissure, 111, 112.
 — lambdoidal, its relation to parieto-occipital fissure, 112, 113.
 — squamo-parietal, a surgical guide, 118.
- Sylvian fissure, 57, 58.
- Sympathetic nerve, as a regulator of the vascular supply of tissues and organs, 9.
 — parts of, 7.
 — parts supplied by, 7, 8.
- System, carotid, 321.
 — vertebral, 321.
- Systems, projection, 31-42.
- Tænia, semi-circularis, 142.
- Taste, anæsthesia of, 482.
 — buds, 471, 472.
 — cortical center of, 93.
 — effect of chorda-tympani nerve on, 406.
 — effects of nerves upon, 471.
 — effects of section of fifth nerve upon, 406.
 — hyperæsthesia of, 481.
 — its clinical relations, 481.
 — its relations to facial paralysis, 439
 — its relations to glosso-pharyngeal nerve, 470.
 — limits of its situation, 472.
- Teeth, chattering of, in spasm, 410.
 — grinding of, in spasm, 410.
- Tegmenta, brachium, 290.
- Tegmentum cruris, 37, 38, 39, 140, 201, 205, 206, 207, 208.
 — ganglia of, 132.
- Temperature, in cerebral diseases, 170.
- Temperature of the body, its relations to focal lesions of the cord, 630.
- Tendo-oculi, its function, 367.
- Tendon, reflexes, 596, 597, 598.
- Tenth cranial nerve (see Nerve, Pneumogastric), 482.
- Testes cerebri, 172, 173, 175, 212.
- Tetanoid paraplegia, 615.
- Thalamencephalon, 132.
- Third cranial nerve (see Nerve, Motor-oculi), 373.
- Tic-douloureux, 407.
- Thumb, motor centers for, 83.
- Titubating gait, 242.
- Tongue, fibrillary tremor of, 529.
 — furring of, its clinical significance, 416, 470.
 — its relations to deglutition, 473, 475.
 — loss of power of, protrusion of, 307.
 — nerves of, 522, 523.
 — paralysis of, 529.
 — spasm of, 529.
- Tonsillæ, 218.
- Touch, cortical, center of, 94.
 — impressions, transmission of, 583.
- Tremor, in cerebral disease, 122.
- Trephining, rules for, employment of, 119, 120, 121.
- Trigeminal nerve (see Nerve, Trigeminal).
- Trineural, bundle (Spitzka), 287.
- Trochlear nerve, 395.

- Trochlear nerve, effect of paralysis of, 396, 397.
 — its origin and function, 395, 396.
- Tubercle of Rolando, 283, 338, 552.
- Tubular, gray matter, 26, 33, 41, 42, 147-150.
- Tumors, cerebral, their symptoms, 410.
- Türk's method of research, 155, 156.
- Twelfth cranial nerve (see Nerve, Hypoglossal), 518.
- Uncus, 66.
- Utricle, 452.
- Vallecula, 216.
- Valve of Vieussens, fibers of, 41.
 — fibers of, 229.
- Vaso-motor centers, situation of, 9.
- Vaso-motor fibers of fifth nerve, 409.
 — nerves, subdivisions of, 10.
 — symptoms, from lesions of medulla, 367.
- Velum, interpositum, 312, 320.
- Ventricle, fifth, 309.
 — fourth, 313, 314.
 — fourth, formation of, 247, 248.
 — fourth, hæmorrhage into, 294.
 — fourth, nuclei of, 254, 255, 256, 257, 258.
 — lateral, 308, 310, 311.
 — of brain, 307-314.
 — third, 312.
 — third, commissures of, 312, 313.
 — third, gray matter of, 147-150.
 — vessels of, 325.
- Ventricular, terminalis, 556.
- Vermiform process of cerebellum, 216.
- Vertebræ, spines of, guides to, spinal segments, 544-547.
- Vertebral system of vessels, 34.
- Vesicular column of Clarke, 264, 265, 279, 282.
- Vestibule of labyrinth, 446, 450.
- Vicq de Azyr, bundle of, 149.
- Vision, accommodation of, 378.
- Vision, apparatus of, lesions of, 184-193.
 — center of, 91, 92, 196.
 — deceptive, its clinical significance, 388.
 — determination of distance, 386.
 — its abnormalities and their consequences, 355, 356.
 — perception of color, 362, 364, 365.
 — physiology of light-sensations, 361.
 — tests for, 358, 359.
- Visual field, 335.
 — fields for colors, 197, 198.
- Visual purple, 362.
 — spheres of Munk, 334.
- Vocal cords, motor centers for, 83.
- Voice, its relations to facial diplegia, 443.
 — nervous supply of muscles of, 509.
 — relations of spinal accessory nerve to, 510.
- Vomiting, in brain diseases, 120.
- Vomiting, nervous, 504.
- Waller's axiom, 156.
- Waller's method of research, 155, 156.
- Weight, of component parts of brain, 108, 109.
- Word-blindness, 74, 96, 97.
- Word-deafness, 73, 74, 75, 96, 97.
- Wrisberg, nerve of, 423, 425.
- Wrist, motor centers for, 83.



May, 1888.

MEDICAL AND HYGIENIC WORKS

PUBLISHED BY

D. APPLETON & CO., 1, 3, & 5 Bond Street, New York.

- BARKER (FORDYCE). On Sea-Sickness. A Popular Treatise for Travelers and the General Reader. Small 12mo. Cloth, 75 cents.
- BARKER (FORDYCE). On Puerperal Disease. Clinical Lectures delivered at Bellevue Hospital. A Course of Lectures valuable alike to the Student and the Practitioner. Third edition. 8vo. Cloth, \$5.00; sheep, \$6.00.
- BARTHOLOW (ROBERTS). A Treatise on Materia Medica and Therapeutics. **Sixth edition.** Revised, enlarged, and adapted to "The New Pharmacopœia." 8vo. Cloth, \$5.00; sheep, \$6.00.
- BARTHOLOW (ROBERTS). A Treatise on the Practice of Medicine, for the Use of Students and Practitioners. **Sixth edition,** revised and enlarged. 8vo. Cloth, \$5.00; sheep, \$6.00.
- BARTHOLOW (ROBERTS). On the Antagonism between Medicines and between Remedies and Diseases. Being the Cartwright Lectures for the Year 1880. 8vo. Cloth, \$1.25.
- BASTIAN (H. CHARLTON). Paralysis: Cerebral, Bulbar, and Spinal. Illustrated. Small 8vo. Cloth, \$4.50.
- BASTIAN (H. CHARLTON). The Brain as an Organ of the Mind. 12mo. Cloth, \$2.50.
- BELLEVUE AND CHARITY HOSPITAL REPORTS. Edited by W. A. Hammond, M. D. 8vo. Cloth, \$4.00.
- BENNET' (J. H.). On the Treatment of Pulmonary Consumption, by Hygiene, Climate, and Medicine. Thin 8vo. Cloth, \$1.50.
- BILLINGS (F. S.). The Relation of Animal Diseases to the Public Health, and their Prevention. 8vo. Cloth, \$4.00.
- BILLROTH (THEODOR). General Surgical Pathology and Therapeutics. A Text-Book for Students and Physicians. Translated from the tenth German edition, by special permission of the author, by Charles E. Hackley, M. D. **Fifth American edition, revised and enlarged.** 8vo. Cloth, \$5.00; sheep, \$6.00.
- BRAMWELL (BYROM). Diseases of the Heart and Thoracic Aorta. Illustrated with 226 Wood-Engravings and 68 Lithograph Plates—showing 91 Figures—in all 317 Illustrations. 8vo. Cloth, \$8.00; sheep, \$9.00.
- BRYANT (JOSEPH D.). A Manual of Operative Surgery. **New edition, revised and enlarged.** 793 Illustrations. 8vo. Cloth, \$5.00; sheep, \$6.00.

- BUCK (GURDON). Contributions to Reparative Surgery, showing its Application to the Treatment of Deformities produced by Destructive Disease or Injury; Congenital Defects from Arrest or Excess of Development; and Cicatricial Contractions following Burns. Illustrated by Thirty Cases and fine Engravings. 8vo. Cloth, \$3.00.
- CAMPBELL (F. R.). The Language of Medicine. A Manual giving the Origin, Etymology, Pronunciation, and Meaning of the Technical Terms found in Medical Literature. 8vo. (*In press.*)
- CARPENTER (W. B.). Principles of Mental Physiology, with their Application to the Training and Discipline of the Mind, and the Study of its Morbid Conditions. 12mo. Cloth, \$3.00.
- CARTER (ALFRED H.). Elements of Practical Medicine. **Third edition**, revised and enlarged. 12mo. Cloth, \$3.00.
- CHAUVEAU (A.). The Comparative Anatomy of the Domesticated Animals. Translated and edited by George Fleming. Illustrated. 8vo. Cloth, \$6.00.
- COMBE (ANDREW). The Management of Infancy, Physiological and Moral. Revised and edited by Sir James Clark. 12mo. Cloth, \$1.50.
- COOLEY. Cyclopædia of Practical Receipts, and Collateral Information in the Arts, Manufactures, Professions, and Trades, including Medicine, Pharmacy, and Domestic Economy. Designed as a Comprehensive Supplement to the Pharmacopœia, and General Book of Reference for the Manufacturer, Tradesman, Amateur, and Heads of Families. **Sixth edition**, revised and partly rewritten by Richard V. Tuson. With Illustrations. 2 vols., 8vo. Cloth, \$9.00.
- CORNING (J. L.). Brain Exhaustion, with some Preliminary Considerations on Cerebral Dynamics. Crown 8vo. Cloth, \$2.00.
- CORNING (J. L.). Local Anæsthesia in General Medicine and Surgery. Being the Practical Application of the Author's Recent Discoveries. With Illustrations. Small 8vo. Cloth, \$1.25.
- ELLIOT (GEORGE T.). Obstetric Clinic: A Practical Contribution to the Study of Obstetrics and the Diseases of Women and Children. 8vo. Cloth, \$4.50.
- EVETZKY (ETIENNE). The Physiological and Therapeutical Action of Ergot. Being the Joseph Mathier Smith Prize Essay for 1881. 8vo. Limp cloth, \$1.00.
- FLINT (AUSTIN). Medical Ethics and Etiquette. Commentaries on the National Code of Ethics. 12mo. Cloth, 60 cents.
- FLINT (AUSTIN). Medicine of the Future. An Address prepared for the Annual Meeting of the British Medical Association in 1886. With Portrait of Dr. Flint. 12mo. Cloth, \$1.00.
- FLINT (AUSTIN, JR.). Text-Book of Human Physiology; designed for the Use of Practitioners and Students of Medicine. Illustrated by three Lithographic Plates, and three hundred and thirteen Woodcuts. **Third edition**, revised. Imperial 8vo. Cloth, \$6.00; sheep, \$7.00.
- FLINT (AUSTIN JR.). The Physiological Effects of Severe and Protracted Muscular Exercise; with Special Reference to its Influence upon the Excretion of Nitrogen. 12mo. Cloth, \$1.00.
- FLINT (AUSTIN, JR.). Physiology of Man. Designed to represent the Existing State of Physiological Science as applied to the Functions of the Human Body. Complete in 5 vols., 8vo. Per vol., cloth, \$4.50; sheep, \$5.50.

. Vols. I and II can be had in cloth and sheep binding; Vol. III in sheep only. Vol. IV is at present out of print.

- FLINT (AUSTIN, JR.). The Source of Muscular Power. Arguments and Conclusions drawn from Observation upon the Human Subject under Conditions of Rest and of Muscular Exercise. 12mo. Cloth, \$1.00.
- FLINT (AUSTIN, JR.). Manual of Chemical Examinations of the Urine in Disease; with Brief Directions for the Examination of the most Common Varieties of Urinary Calculi. Revised edition. 12mo. Cloth, \$1.00.
- FOTHERGILL (J. MILNER). Diseases of Sedentary and Advanced Life. 8vo. Cloth, \$2.00.
- FOURNIER (ALFRED). Syphilis and Marriage. Translated by P. Albert Morrow, M. D. 8vo. Cloth, \$2.00; sheep, \$3.00.
- FREY (HEINRICH). The Histology and Histochemistry of Man. A Treatise on the Elements of Composition and Structure of the Human Body. Translated from the fourth German edition by Arthur E. J. Barker, M. D., and revised by the author. With 608 Engravings on Wood. 8vo. Cloth, \$5 00; sheep, \$6.00.
- FRIEDLANDER (CARL). The Use of the Microscope in Clinical and Pathological Examinations. Second edition, enlarged and improved, with a Chromo-lithograph Plate. Translated, with the permission of the author, by Henry C. Coe, M. D. 8vo. Cloth, \$1.00.
- GAMGEE (JOHN). Yellow Fever a Nautical Disease. Its Origin and Prevention. 8vo. Cloth, \$1.50.
- GARMANY (JASPER J.). Operative Surgery on the Cadaver. With Two Colored Diagrams showing the Collateral Circulation after Ligatures of Arteries of Arm, Abdomen, and Lower Extremity. Small 8vo. Cloth, \$2.00.
- GERSTER (ARPAD G.). The Rules of Aseptic and Antiseptic Surgery. A Practical Treatise for the Use of Students and the General Practitioner. Illustrated with over two hundred fine Engravings. 8vo. Cloth, \$5.00; sheep, \$6.00.
- GROSS (SAMUEL W.). A Practical Treatise on Tumors of the Mammary Gland. Illustrated. 8vo. Cloth, \$2.50.
- GUTMANN (EDWARD). The Watering-Places and Mineral Springs of Germany, Austria, and Switzerland. Illustrated. 12mo. Cloth, \$2.50.
- GYNÆCOLOGICAL TRANSACTIONS. 8vo. Cloth, per volume, \$5.00.
- Vol. VIII. Being the Proceedings of the Eighth Annual Meeting of the American Gynæcological Society, held in Philadelphia, September 18, 19, and 20, 1883.
- Vol. IX. Being the Proceedings of the Ninth Annual Meeting of the American Gynæcological Society, held in Chicago, September 30, and October 1 and 2, 1884.
- Vol. X. Being the Proceedings of the Tenth Annual Meeting of the American Gynæcological Society, held in Washington, D. C., September 22, 23, and 24, 1885.
- Vol. XI. Being the Proceedings of the Eleventh Annual Meeting of the American Gynæcological Society, held in Baltimore, Maryland, September, 21, 22, and 23, 1886.
- Vol. XII. Being the Proceedings of the Twelfth Annual Meeting of the American Gynæcological Society, held in New York, Tuesday, Wednesday, and Thursday, September 13, 14, and 15, 1887.

- HAMMOND (W. A.). A Treatise on Diseases of the Nervous System. **Eighth edition**, rewritten, enlarged, and improved. 8vo. Cloth, \$5.00; sheep, \$6.00.
- HAMMOND (W. A.). A Treatise on Insanity, in its Medical Relations. 8vo. Cloth, \$5.00; sheep, \$6.00.
- HAMMOND (W. A.). Clinical Lectures on Diseases of the Nervous System. Delivered at Bellevue Hospital Medical College. Edited by T. M. B. Cross, M. D. 8vo. Cloth, \$3.50.
- HARVEY (A.). First Lines of Therapeutics. 12mo. Cloth, \$1.50.
- HOFFMANN-ULTZMANN. Analysis of the Urine, with Special Reference to Diseases of the Urinary Apparatus. By M. B. Hoffmann, Professor in the University of Gratz; and R. Ultzmann, Tutor in the University of Vienna. **Second enlarged and improved edition.** 8vo. Cloth, \$2.00.
- HOWE (JOSEPH W.). Emergencies, and how to treat them. Fourth edition, revised. 8vo. Cloth, \$2.50.
- HOWE (JOSEPH W.). The Breath, and the Diseases which give it a Fetid Odor. With Directions for Treatment. **Second edition**, revised and corrected. 12mo. Cloth, \$1.00.
- HUEPPE (FERDINAND). The Methods of Bacteriological Investigation. Written at the request of Dr. Robert Koch. Translated by Hermann M. Biggs, M. D. Illustrated. 8vo. Cloth, \$2.50.
- HUXLEY (T. H.). The Anatomy of Vertebrated Animals. Illustrated. 12mo. Cloth, \$2.50.
- HUXLEY (THOMAS HENRY). The Anatomy of Invertebrated Animals Illustrated. 12mo. Cloth, \$2.50.
- JACCOUD (S.). The Curability and Treatment of Pulmonary Phthisis. Translated and edited by Montagu Lubbock, M. D. 8vo. Cloth, \$4.00.
- JONES (H. MACNAUGHTON). Practical Manual of Diseases of Women and Uterine Therapeutics. For Students and Practitioners. 188 Illustrations. 12mo. Cloth, \$3.00.
- KEYES (E. L.). A Practical Treatise on Genito-Urinary Diseases, including Syphilis. Being a new edition of a work with the same title, by Van Buren and Keyes. Almost entirely rewritten. 8vo. With Illustrations. Cloth, \$5.00; sheep, \$6.00.
- KEYES (E. L.). The Tonic Treatment of Syphilis, including Local Treatment of Lesions. 8vo. Cloth, \$1.00.
- KINGSLEY (N. W.). A Treatise on Oral Deformities as a Branch of Mechanical Surgery. With over 350 Illustrations. 8vo. Cloth, \$5.00; sheep, \$6.00.
- LEGG (J. WICKHAM). On the Bile, Jaundice, and Bilious Diseases. With Illustrations in Chromo-Lithography. 8vo. Cloth, \$6.00; sheep, \$7.00.
- LITTLE (W. J.). Medical and Surgical Aspects of In-Knee (Genu-Valgum): its Relation to Rickets, its Prevention, and its Treatment, with and without Surgical Operation. Illustrated by upward of Fifty Figures and Diagrams. 8vo. Cloth, \$2.00.
- LORING (EDWARD G.). A Text-Book of Ophthalmoscopy. Part I. The Normal Eye, Determination of Refraction, and Diseases of the Media. With 131 Illustrations, and 4 Chromo-Lithographs. 8vo, Cloth, \$5.00.

- LUSK (WILLIAM T.). The Science and Art of Midwifery. With 246 Illustrations. **Second edition, revised and enlarged.** 8vo. Cloth, \$5.00; sheep, \$6.00.
- LUYS (J.). The Brain and its Functions. With Illustrations. 12mo. Cloth, \$1.50.
- MARKOE (T. M.). A Treatise on Diseases of the Bones. With Illustrations. 8vo. Cloth, \$4.50.
- MAUDSLEY (HENRY). Body and Mind: an Inquiry into their Connection and Mutual Influence, specially in reference to Mental Disorders. An enlarged and revised edition, to which are added Psychological Essays. 12mo. Cloth, \$1.50.
- MAUDSLEY (HENRY). Physiology of the Mind. Being the first part of a third edition, revised, enlarged, and in great part rewritten, of "The Physiology and Pathology of the Mind." 12mo. Cloth, \$2.00.
- MAUDSLEY (HENRY). Pathology of the Mind. Third edition. 12mo. Cloth, \$2.00.
- MAUDSLEY (HENRY). Responsibility in Mental Disease. 12mo. Cloth, \$1.50.
- NEFTEL (WM. B.). Galvano-Therapeutics. The Physiological and Therapeutical Action of the Galvanic Current upon the Acoustic, Optic, Sympathetic, and Pneumogastric Nerves. 12mo. Cloth, \$1.50.
- NEUMANN (ISIDOR). Hand-Book of Skin Diseases. Translated by Lucius D. Bulkley, M. D. Illustrated by 66 Wood-Engravings. 8vo. Cloth, \$4.00; sheep, \$5.00.
- THE NEW YORK MEDICAL JOURNAL (weekly). Edited by Frank P. Foster, M. D. Terms per annum, \$5.00.
Binding Cases, cloth, 50 cents each.
- GENERAL INDEX, from April, 1865, to June, 1876 (23 vols.) 8vo. Cloth, 75 cents.
- NIEMEYER (FELIX VON). A Text-Book of Practical Medicine, with particular reference to Physiology and Pathological Anatomy. Containing all the author's Additions and Revisions in the eighth and last German edition. Translated by George H. Humphreys, M. D., and Charles E. Hackley, M. D. 2 vols., 8vo. Cloth, \$9.00; sheep, \$11.00.
- NIGHTINGALE'S (FLORENCE) Notes on Nursing. 12mo. Cloth, 75 cents.
- PEASLEE (E. R.). A Treatise on Ovarian Tumors: their Pathology, Diagnosis, and Treatment, with reference especially to Ovariectomy. With Illustrations. 8vo. Cloth, \$5.00; sheep, \$6.00.
- PEREIRA'S (Dr.) Elements of Materia Medica and Therapeutics. Abridged and adapted for the Use of Medical and Pharmaceutical Practitioners and Students, and comprising all the Medicines of the British Pharmacopœia, with such others as are frequently ordered in Prescriptions, or required by the Physician. Edited by Robert Bentley and Theophilus Redwood. Royal 8vo. Cloth, \$7.00; sheep, \$8.00.
- PEYER (ALEXANDER). An Atlas of Clinical Microscopy. Translated and edited by Alfred C. Girard, M. D. First American, from the manuscript of the second German edition, with Additions. Ninety Plates, with 105 Illustrations, Chromo-Lithographs. Square 8vo. Cloth, \$6.00.

- POMEROY (OREN D.). The Diagnosis and Treatment of Diseases of the Ear. With One Hundred Illustrations. **Second edition**, revised and enlarged. 8vo. Cloth, \$3.00.
- POORE (C. T.). Osteotomy and Osteoclasia, for the Correction of Deformities of the Lower Limbs. 50 Illustrations. 8vo. Cloth, \$2.50.
- QUAIN (RICHARD). A Dictionary of Medicine, including General Pathology, General Therapeutics, Hygiene, and the Diseases peculiar to Women and Children. By Various Writers. Edited by Richard Quain, M. D., In one large 8vo volume, with complete Index, and 138 Illustrations. (*Sold only by subscription.*) Half morocco, \$8.00.
- RANNEY (AMBROSE L.). Applied Anatomy of the Nervous System, being a Study of this Portion of the Human Body from a Standpoint of its General Interest and Practical Utility, designed for Use as a Text-Book and as a Work of Reference. Profusely illustrated. 8vo. Cloth, \$4.00; sheep, \$5.00.
- RANNEY (AMBROSE L.). Lectures on Electricity in Medicine, delivered at the Medical Department of the University of Vermont, Burlington. Numerous Illustrations. 12mo. Cloth, \$1.00.
- RANNEY (AMBROSE L.). Practical Suggestions respecting the Varieties of Electric Currents and the Uses of Electricity in Medicine, with Hints relating to the Selection and Care of Electrical Apparatus. With Illustrations and 14 Plates. 16mo. Cloth, \$1.00.
- RIBOT (TH.). Diseases of Memory: an Essay in the Positive Psychology. Translated from the French by William Huntington. 12mo. Cloth, \$1.50.
- RICHARDSON (B. W.). Diseases of Modern Life. 12mo. Cloth, \$2.00.
- RICHARDSON (B. W.). A Ministry of Health and other Addresses. 12mo. Cloth, \$1.50.
- ROBINSON (A. R.). A Manual of Dermatology. Revised and corrected. 8vo. Cloth, \$5.00.
- ROSCOE-SCHORLEMMER. Treatise on Chemistry.
 Vol. 1. Non-Metallic Elements. 8vo. Cloth, \$5.00.
 Vol. 2. Part I. Metals. 8vo. Cloth, \$3.00.
 Vol. 2. Part II. Metals. 8vo. Cloth, \$3.00.
 Vol. 3. Part I. The Chemistry of the Hydrocarbons and their Derivatives. 8vo. Cloth, \$5.00.
 Vol. 3. Part II. The Chemistry of the Hydrocarbons and their Derivatives. 8vo. Cloth, \$5.00.
 Vol. 3. Part III. This part commences the consideration of the complicated but most important series of bodies known as the Aromatic Compounds. 8vo. Cloth, \$3.00.
- ROSENTHAL (I.). General Physiology of Muscles and Nerves. With 75 Woodcuts. 12mo. Cloth, \$1.50.
- SAYRE (LEWIS A.). Practical Manual of the Treatment of Club-Foot. **Fourth edition**, enlarged and corrected. 12mo. Cloth, \$1.25.
- SAYRE (LEWIS A.). Lectures on Orthopedic Surgery and Diseases of the Joints, delivered at Bellevue Hospital Medical College. **New edition**, illustrated with 324 Engravings on Wood. 8vo. Cloth, \$5.00; sheep, \$6.00.

SCHROEDER (KARL). A Manual of Midwifery, including the Pathology of Pregnancy and the Puerperal State. Translated into English from the third German edition, by Charles H. Carter, M.D. With 26 Engravings on Wood. 8vo. Cloth, \$3.50; sheep, \$4.50.

SHOEMAKER (JOHN V.). A Text-Book of Diseases of the Skin. Six Chromo-Lithographs and numerous Engravings. 8vo. Cloth, \$5.00; sheep, \$6.00.

SIMPSON (JAMES Y.). Selected Works: Anæsthesia, Diseases of Women. 3 vols., 8vo. Per volume. Cloth, \$3.00; sheep, \$4.00.

SKENE (ALEXANDER J. C.) A Text-Book on the Diseases of Women. 8vo. Illustrated with over two hundred fine Engravings. (*In press.*)

SMITH (EDWARD). Foods. 12mo. Cloth, \$1.75.

SMITH (EDWARD). Health: A Hand-Book for Households and Schools. Illustrated. 12mo. Cloth, \$1.00.

STEINER (JOHANNES). Compendium of Children's Diseases: a Hand-Book for Practitioners and Students. Translated from the second German edition, by Lawson Tait. 8vo. Cloth, \$3.50; sheep, \$4.50.

STEVENS (GEORGE T.) Functional Nervous Diseases: their Causes and their Treatment. Memoir for the Concourse of 1881-1883, Académie Royal de Médecine de Belgique. With a Supplement, on the Anomalies of Refraction and Accommodation of the Eye, and of the Ocular Muscles. Small 8vo. With six Photographic Plates and twelve Illustrations. Cloth, \$2.50.

STONE (R. FRENCH). Elements of Modern Medicine, including Principles of Pathology and of Therapeutics, with many Useful Memoranda and Valuable Tables of Reference. Accompanied by Pocket Fever Charts. Designed for the Use of Students and Practitioners of Medicine. In wallet-book form, with pockets on each cover for Memoranda, Temperature Charts, etc. Roan, tuck, \$2.50.

STRECKER (ADOLPH). Short Text-Book of Organic Chemistry. By Dr. Johannes Wislicenus. Translated and edited, with Extensive Additions, by W. H. Hodgkinson and A. J. Greenaway. 8vo. Cloth, \$5.00.

STRÜMPPELL (ADOLPH). A Text-Book of Medicine, for Students and Practitioners. With 111 Illustrations. 8vo. Cloth, \$6.00; sheep, \$7.00.

SWANZY (HENRY R.). A Hand-Book of the Diseases of the Eye, and their Treatment. With 122 Illustrations, and Holmgren's Tests for Color-Blindness. Crown 8vo. Cloth, \$3.00.

TRACY (ROGER S.). The Essentials of Anatomy, Physiology, and Hygiene. 12mo. Cloth, \$1.25.

TRACY (ROGER S.). Hand-Book of Sanitary Information for Householders. Containing Facts and Suggestions about Ventilation, Drainage, Care of Contagious Diseases, Disinfection, Food, and Water. With Appendices on Disinfectants and Plumbers' Materials. 16mo. Cloth, 50 cents.

TRANSACTIONS OF THE AMERICAN LARYNGOLOGICAL ASSOCIATION. 8vo. Cloth, \$2.50 per volume.

Vol. V. Being the Proceedings of the Sixth Annual Meeting, held in the city of New York, May 12, 13, and 14, 1884.

Vol. VI. Being the Proceedings of the Seventh Annual Meeting, held in Detroit, June 24, 25, and 26, 1885.

- TRANSACTIONS OF THE NEW YORK STATE MEDICAL ASSOCIATION, VOL. I. Being the Proceedings of the First Annual Meeting of the New York State Medical Association, held in New York, November 18, 19, and 20, 1884. Small Svo. Cloth, \$5.00.
- TYNDALL (JOHN). Essays on the Floating Matter of the Air, in Relation to Putrefaction and Infection. 12mo. Cloth, \$1.50.
- ULTZMANN (ROBERT). Pynria, or Pus in the Urine, and its Treatment. Translated by permission, by Dr. Walter B. Platt. 12mo. Cloth, \$1.00.
- VAN BUREN (W. H.). Lectures upon Diseases of the Rectum, and the Surgery of the Lower Bowel, delivered at Bellevue Hospital Medical College. **Second edition, revised and enlarged.** 8vo. Cloth, \$3.00; sheep, \$4.00.
- VAN BUREN (W. H.). Lectures on the Principles and Practice of Surgery. Delivered at Bellevue Hospital Medical College. Edited by Lewis A. Stimson, M. D. 8vo. Cloth, \$4.00; sheep, \$5.00.
- VOGEL (A.). A Practical Treatise on the Diseases of Children. Translated and edited by H. Raphael, M. D. **Third American from the eighth German edition, revised and enlarged.** Illustrated by six Lithographic Plates. 8vo. Cloth, \$4.50; sheep, \$5.50.
- VON ZEISSL (HERMANN). Outlines of the Pathology and Treatment of Syphilis and Allied Venereal Diseases. **Second edition,** revised by Maximilian von Zeissl. Authorized edition. Translated, with Notes, by H. Raphael, M. D. 8vo. Cloth, \$4.00; sheep, \$5.00.
- WAGNER (RUDOLF). Hand-Book of Chemical Technology. Translated and edited from the eighth German edition, with extensive Additions, by William Crookes. With 336 Illustrations. 8vo. Cloth, \$5.00.
- WALTON (GEORGE E.). Mineral Springs of the United States and Canadas. Containing the latest Analyses, with full Description of Localities, Routes, etc. **Second edition, revised and enlarged.** 12mo. Cloth, \$2.00.
- WEBBER (S. G.). A Treatise on Nervous Diseases: Their Symptoms and Treatment. A Text-Book for Students and Practitioners. 8vo. Cloth, \$3.00.
- WEEKS (CLARA S.). A Text-Book of Nursing. For the Use of Training-Schools, Families, and Private Students. 12mo. With 13 Illustrations, Questions for Review and Examination, and Vocabulary of Medical Terms. 12mo. Cloth, \$1.75.
- WELLS (T. SPENCER). Diseases of the Ovaries. 8vo. Cloth, \$4.50.
- WYETH (JOHN A.). A Text-Book on Surgery: General, Operative, and Mechanical. Profusely illustrated. (*Sold by subscription only.*) 8vo. Buckram, uncut edges, \$7.00; sheep, \$8.00; half morocco, \$8.50.
- WYLIE (WILLIAM G.). Hospitals: Their History, Organization, and Construction. 8vo. Cloth, \$2.50.



QM451

R17

1888

Banney A. J.

