



Class S F 7 6 9

Book: C 7

Copyright N^o. _____

COPYRIGHT DEPOSIT.

VETERINARY POST- MORTEM TECHNIC

BY

WALTER J. CROCKER, B.S.A., V.M.D.

PROFESSOR OF VETERINARY PATHOLOGY, SCHOOL OF VETERINARY MEDICINE,
UNIVERSITY OF PENNSYLVANIA

WITH 142 ILLUSTRATIONS



PHILADELPHIA AND LONDON
J. B. LIPPINCOTT COMPANY

SF 749
C7

COPYRIGHT, 1918, BY J. B. LIPPINCOTT COMPANY



*Electrotyped and Printed by J. B. Lippincott Company
The Washington Square Press, Philadelphia, U. S. A.*

MAR 14 1918

©Cl.A492566

420 1

RESPECTFULLY DEDICATED
TO
KARL F. MEYER

PROFESSOR OF TROPICAL MEDICINE, UNI-
VERSITY OF CALIFORNIA MEDICAL SCHOOL
AND THE GEORGE WILLIAMS HOOPER
FOUNDATION FOR MEDICAL RESEARCH

PREFACE

THE scientific study of pathology without proper post-mortem technic is impossible. Before a pathologic lesion can be studied it must be brought to light. To avoid the oversight of some obscure though important disease process an exact and painstaking system of technic must be developed. Technic is, in fact, the foundation of the science of pathology, and therefore demands deep study and much actual practice.

This book is written in an endeavor to fill a gap in the American veterinary literature which has long been felt by the writer in teaching post-mortem pathology. It is with the earnest hope that it may help those who do make post-mortem examinations, encourage those who should but do not perform autopsies, and that it may facilitate the inclusion of the subject post-mortem pathology in the curricula of other schools of veterinary medicine.

The illustrations of technical methods in the text were prepared from original photographs of fresh specimens instead of line drawings. Good photographs more forcibly portray to the student mind the reality of the subject, and establish a closer personal association with the actual work. They provide an unexaggerated object for the student to attain to, and an encouraging stimulus to his best efforts.

I wish to express my appreciation to Doctors William

Koch, E. A. Benbrook, C. C. Whitney, Herbert Lienhart, H. M. Martin, and Mr. Albert Herbert for their assistance in preparing the photographs, and to Doctors John Reichel, Fred Bourner, and C. S. Rockwell, and J. B. Lippincott Company for material used in illustrating the technic on cattle and hogs.

WALTER J. CROCKER

PHILADELPHIA, PA.
December, 1917

CONTENTS

CHAPTER	PAGE
I. GENERAL CONSIDERATIONS.....	1
Definition, Complete Autopsy, Incomplete Autopsy, Object, Authority, Time, Date, Light and Weather, Place, Clinical History, Destruction of Animal, Description of Cadaver, Witnesses, Dress, Care of Instruments, Care of Hands, Notes, Specimens for Laboratory Examination, Express Companies' Regulations, Mailing and Parcel Post Regulations, Diseased Tissues in the Mails, Milk or Urine.	
II. AUTOPSY ROOM.....	18
Room, Large Table, Small Table, Instrument Table, Instrument Case, Desk, Tub, Basin, Shelves, Water Pipes, Sterilizer, Scales, Vise, Platforms, Refuse Cans.	
III. POST-MORTEM INSTRUMENTS.....	22
Virchow's Post-mortem and Cartilage Knives, Little's Case Knife, Pick's Myelotome, Virchow's Brain Knife, Dissecting Scalpels, Incising Knives, Scissors, Costotome, Cartilage Shears, Bone Shears, Saws, Leur's Double-saw Rachiotome, Rule, Ax, Chisels, Brunetti's Rachiotome, Dexler's Rachiotome, Side Chisel, Cross Chisel, Curved Bone Chisel, Hammer Hook, Rib Hook, Steel, Forceps, Pinchers, Graduates, Mallet, Pipettes, Cup.	
IV. EXTERNAL EXAMINATION.....	45
Signa Mortis, Apparent Death, Algor Mortis, The Eye After Death, Cadaveric Lividity, Rigor Mortis, Appearance of Post-mortem Decomposition, Visible Mucous Membranes, Natural Openings, Extremities, Skin.	
V. INTERNAL EXAMINATION OF THE HORSE.....	52
Position, Skin, Operative Technic for the Head, Neck and Back: Thyroid Glands, Jugular Furrow and Structures, Parotid and Submaxillary Lymph and Salivary Glands, Left Mandible, Guttural Pouches, Tongue, Larynx, Trachea and Œsophagus, Decapitation, Preparation of the Head, Extirpation of the Brain, Sinuses, Nasal Passages and Septum, Teeth, Ear, Eye, Removal of Spinal Cord, Peripheral Nerves; Operative Technic for the Thoracic and Abdominal Cavities: Front Leg, Hind Leg, Xiphoid-pubic Incision, Pubic-lumbar Incision, Vacuity of the Thorax, Ribs, Omentum, Single Colon, Ligations, Small Intes-	

tines, Epiploic Foramen, Bile-duct, Spleen, Left Kidney, Left Adrenal, Duodenum, Double Colon and Cæcum, Right Adrenal, Right Kidney, Stomach, Liver, Pancreas, Pericardial Sac and Fluid, Heart and Lungs, Blood-vessels, Pleura and Peritoneum, Lymph-glands, Psoas Muscles, Ovaries and Uterus, Summary; Operative Technic for the Pelvic Cavity: Preparation, Mammary Gland or Penis, Pelvic Organs, Summary; Operative Technic for Leg and Foot: Muscles, Popliteal Lymph-gland, Stifle Joint, Tibio-tarsal Joint, Scapulohumeral Joint, Axillary Lymph-gland, Carpal Joint, Tendons, etc., Frog, Sole, Wall, Phalangeal and Navicular Joints, Summary; Operative Technic for the Musculature, Bones, and Joints: Musculature, Bones, Bones of the Legs, Os Innominatum, Ribs, Bones of the Head, Phalanges, Joints, Summary.	
VI. INTERNAL EXAMINATION OF RUMINANTS.....	117
Skin and Position, Operative Technic for the Head, Neck and Back: Thyroid Glands, Parotid Salivary and Subparotid Lymph-glands, Submaxillary Lymph- and Salivary-glands, Right Ramus of Mandible, Tonsils, Retropharyngeal Lymph-glands, Jugular Furrow and Structures, Lymph-glands (Cow), Tongue, Larynx, Trachea, and Œsophagus, Decapitation, Preparation of the Head, Extirpation of the Brain, Nasal Passages, Eye, Ear, etc.; Operative Technic for Thoracic and Abdominal Cavities: Front Leg, Hind Leg, Mammary Gland or Penis, Xiphoid-pubic Incision, Pubic-lumbar Incision, Væcuity of the Thorax, Ribs, Omentum, Intestines, Kidneys and Adrenals, Stomachs and Spleen, Liver and Gall-bladder, Pancreas, Pericardial Sac and Fluid, Heart and Lungs, Blood-vessels, Pleura and Peritoneum, Lymph-glands; Operative Technic for the Pelvic Cavity: Preparation, Organs, Operative Technic for the Leg, Foot, Muscles, Bones and Joints.	
VII. INTERNAL EXAMINATION OF SWINE.....	135
Dorsal Position, Operative Technic for the Head, Neck and Back, Operative Technic for the Thoracic and Abdominal Cavities: Intestines, Duodenum and Bile-duct, Spleen, Stomach, Liver, Kidneys, Heart and Lungs; Operative Technic for the Pelvic Cavity, Left Side Position.	
VIII. INTERNAL EXAMINATION OF THE DOG AND CAT.....	142
Position, Skin, Operative Technic for the Abdominal Cavity: Omentum and Intestines, Bile-duct, Stomach, Spleen and Pancreas, Liver, Kidneys and Adrenals; Operative Technic for the Pelvic Cavity. Operative Technic for the Thoracic Cavity: Sternum, Heart and Lungs; Operative Technic for the Head, Neck and Back: Thyroid Glands, Tongue, Tonsils, Larynx, Trachea and Œsophagus, Nasal Passages, Brain and Cord.	

IX. INTERNAL EXAMINATION OF THE MOUSE, GUINEA-PIG, RABBIT, FOWL AND ELEPHANT.....	152
Operative Technic for the Mouse, Guinea-pig and Rabbit, Operative Technic for the Fowl, Operative Technic for the Elephant.	
X. TECHNIC AND DESCRIPTION OF ORGANS.....	161
Tongue, Larynx, Trachea, Œsophagus and Tonsils, Thyroid and Parathyroid Glands, Œsophagus (Thoracic Portion), Bronchi, Lungs, and Adjacent Lymph-glands, Pericardium and Pericardial Fluid, Heart, Brief Descriptive Table of Normal Heart, Spleen, Brief Descriptive Table of Normal Spleen, Stomach, Brief Descriptive Table of Normal Stomach, Intestines of the Horse, Brief Descriptive Table of Normal Intestines of the Horse, Intestines of Ruminants, Brief Descriptive Table of Normal Intestines of Ruminants, Intestines of Swine, Brief Descriptive Table of Intestines of Swine, Intestines of the Dog and Cat, Brief Descriptive Table of Normal Intestines of the Dog, Liver, Brief Descriptive Table of Normal Liver, Pancreas, Brief Descriptive Table of Normal Pancreas, Kidney, Brief Descriptive Table of Normal Kidney, Adrenals, Brief Descriptive Table of Normal Adrenals, Vagina, Uterus, Ovaries and Urinary Bladder, Brief Descriptive Table of the Normal Uterus, Brief Descriptive Table of Normal Ovaries, Udder of the Cow, Penis, Seminal Vesicles, Cowper's and Prostate Glands, Urinary Bladder and Testicles, Brief Descriptive Table of Normal Testicles, Brain and Meninges, Table of Absolute, Relative and Percentage Weights of Normal Brains, Spinal Cord and Meninges, Eye, Ear.	
XI. POST-MORTEM PROTOCOL AND REPORT.....	214
Definition, Pre-autopsy Data, External Examination, Internal Examination, Pathologic-Anatomical Diagnosis, Epicrisis, Advantage of Construction, Suggestions on Protocol, Outline for Post-mortem Protocol, Literature Used, Appendix, Index.	

ILLUSTRATIONS

FIG.	PAGE
1. White coat, rubber sleeves, apron and boots. Rubber gown and boots	8
2. Post-mortem room	19
3. Virchow's post-mortem knife for general autopsy work on large animals	23
4. Large cartilage knife used in severing asternal cartilages of small animals when removing sternum	23
5. (A) Butcher knife with cutting edge in direct line with the handle	23
(B) Pith. Very useful for destroying large animals	23
6. Improper and proper ways of holding large knife in doing autopsy work	24
7. Little's case knife for general autopsy work on small animals	25
8. Pick's myelotome	25
9. Virchow's brain knife	26
10. Dissecting scalpel	26
11. Groove director	26
12. Incising knives	26
13. Monosmith's enucleation knife for removing the eye	27
14. Spearhead needle and probe used in technic on eye and ear	27
15. Harpoon needle for removing the optic lens	27
16. Tyrrell's blunt and sharp hooks	27
17. Steel	27
18. Raspatory for seraping soft tissue from bones	27
19. Championniere's bone chisel	27
20. Esmarch's bone chisel	28
21. McEwen's bone chisel	28
22. Brick chisels, much reduced	28
23. Rachiotomy chisel for cutting cranial bones	28
24. Rachiotomy chisel for cutting nasal bones	28
25. Cross chisel and proper position for use of the chisel end	29
26. Dexler's rachiotome (Schmcy)	29
27. Brunetti's left curved rachiotome	30
28. Brunetti's right curved rachiotome	30
29. Side chisel	31
30. Post-mortem ax	31
31. Steel hammer hook	32
32. Rib hook	32
33. Metal-bound wood mallet	32
34. Rawhide mallet	33
35. Iron pinchers	33
36. Costotomes	33

37. Bone-cutting forceps	34
38. Cartilage shears	35
39. Enterotome showing one blunt point which is longer than the other. . . .	35
40. Small scissors which have one point blunt	35
41. Small scissors with straight and curved blades	36
42. Artery scissors	37
43. Straight forceps	38
44. Rat-tooth forceps	38
45. Curved forceps	39
46. Dura and hæmostatic forceps	39
47. Tumor forceps	40
48. Bone-holding forceps	40
49. Carpenter's saw	40
50. Frame saw	41
51. Small frame saw	41
52. Charriere's blade saw	42
53. Langenbeck's blade saw	42
54. Kelly's skull saw	42
55. Single blade rachiotomy saw	42
56. Leur's double blade rachiotomy saw	43
57. Folding steel rule	43
58. Needles used in making cosmetic post-mortems	43
59. Magnifying glass	44
60. Proper position of the horse for autopsy	53
61. Left front and hind leg removed with the skin	55
62. Line of incision on border of left ramus of mandible	58
63. Left front and hind legs removed	60
64. Left ramus of mandible removed and jugular furrow laid open	61
65. Incision to be made in exposing a tooth, nasal sinuses, turbinated bones, nasal septum and brain	63
66. Removal of the calvarium with the hammer-hook	64
67. Brain exposed after removal of calvarium	65
68. Brain removed	66
69. Longitudinal incision through the head after removal of the brain	67
70. Left half of spine chipped away with a post-mortem hatchet, exposing spinal cord	69
71. Left hind leg removed	73
72. Insertion of first two fingers of left hand in abdomen	74
73. Proper position of hands and knife in beginning the xiphoid-pubic incision	75
74. Proper manner of holding knife when making pubic-lumbar incision	77
75. Xiphoid-pubic incision completed. Pubic-lumbar incision half completed	78
76. Left hind leg taken off. Xiphoid-pubic and pubic-lumbar incisions com- pleted	79
77. Left abdominal flap turned up over ribs	81
78. Preparation of the back for dorsal rib incision in ablation of left side. . .	84

79. After completion of ventral and dorsal rib-incisions left side is elevated and the diaphragm incised close to the ribs and the side freed	85
80. Tongue, larynx, trachea and œsophagus ablated, right and left vagus, carotid artery and jugular vein exposed	87
81. Small intestines arranged at the end of their mesentery upon the colon and cœcum. Proper method of holding small intestines and knife in separating the intestine from its mesentery	89
82. Left hand grasping mesenteric vessels at point of attachment to the double colon and cœcum	93
83. Occipito-atloldal articulation opened. Pericardium exposed for incision. Single colon, small intestine, double colon, cœcum, stomach, duodenum, spleen, kidneys and adrenals extirpated. Pelvic organs ablated without removing part of pelvis. Psoa's muscles are incised vertically, muscles of the hind leg cut in parallel planes	96.
84. Method of exposing contents of pericardial sac	97
85. View of thorax after left side has been taken off and left apical lobe turned back	98
86. View of thorax after left side has been removed	100
87. Proper manner of grasping large blood-vessels between heart and lungs in removing them from thorax or from sink to table	101
88. View of cadaver after evisceration of thorax, abdomen, and pelvis	102
89. Aorta, mesenteric and iliac blood-vessels properly opened	103
90. Lines of incision for ablation of horny sole and frog	112
91. Lines of incision for sawing the wall of the hoof	112
92. Correct position of ruminant at autopsy	118
93. View showing the skin of the right side together with the right fore and hind leg dissected back from a single ventral median, incision from the chin to the anus	119
94. Skin of the right side of the head and neck removed and thrown over the dorsal side	120
95. Incisions to be made in removing calvarium and opening nasal passages	122
96. This shows relation of incisions to horns and occipital condyles	123
97. Showing position of incision between horn and external auditory meatus	124
98. Halves of calvarium spread apart exposing brain and frontal sinuses	124
99. The right fore and hind legs and the right side, have been removed exposing thoracic and abdominal cavities	129
100. Pelvic, abdominal and part of thoracic cavities after evisceration, showing adrenals and lymph glands	133
101. Dorsal position of swine	136
102. Transverse incision made through the belly wall	136
103. Flaps of abdominal wall laid outward	138
104. When the iliocecal valve is of particular interest	139
105. Dorsal position of dog	143
106. To expose abdominal viscera	143
107. Lay flaps of belly wall outward	143
108. Figure to the left shows the skin and musculature removed from nose. Figure at the right shows nasal bone, calvarium and top of spinal canal removed	149

109. Autopsy of mouse	152
110. Autopsy of guinea pig	153
111. Autopsy of a rabbit	154
112. Operative technic for the fowl	156
113. After making the incisions the crop is freed from the breast	157
114. Unopened organs of a chicken after evisceration	158
115. Representation of certain familiar objects, with scales in millimeters and inches	164
116. Scale for accurate measurement (F. Smith)	165
117. Tongue, larynx, trachea and œsophagus	166
118. Lungs after opening trachea and bronchi	169
119. Proper position of heart at autopsy	170
120. Right and left cavities of the heart opened	171
121. The entire heart inverted	172
122. Heart in same relative position as in Fig. 121	173
123. Heart in same relative position as shown in Fig. 122. Illustration shows the second incision	175
124. Spleen of a horse	178
125. After incisions have been made through the spleen	178
126. Line of incision in opening stomach and duodenum	181
127. Double colon and cæcum. Proper position for autopsy view from above	185
128. Liver properly incised	193
129. Correct position of hands and knife in opening kidney	197
130. Kidney opened like a book after completing incision	198
131. Vagina, uterus, and right ovary opened	202
132. The udder divided into its two lateral halves	205
133. Each udder-half is laid open like a book exposing cut surface of parenchyma and milk cisterns	206
134. Showing urethra, bladder, seminal vesicles, etc., laid open	207
135. Urethra, bladder, seminal vesicles and vasa deferentia laid open, showing orifices of glands	208
136. The hemispheres of the cerebrum are slightly spread apart and two longitudinal incisions made through the corpus collosum into the lateral ventricles	210
137. The lateral and fourth ventricles opened	211
138. Part of the spinal cord of a horse	212
139. Position of hands, scissors, and eye in opening the latter on its equator	213
140. Equatorial line of incision for opening the eye	213
141. Membrana tympani and manubrium and malleus after splitting the petrous temporal bone	213
142. Form which is sent from the clinic to the autopsy room with the cadaver	215

VETERINARY POST-MORTEM TECHNIC

CHAPTER I

GENERAL CONSIDERATIONS

DEFINITION.—The systematic exposure and critical examination of a cadaver for the study of pathologic changes in any or all their relations and extent, and in many cases with the object of determining the cause of death, may be called a post, postmortem, autopsy, necropsy, necroscopy, mortopsy, sectio-anatomica, sectio-cadaveris or section. *Obduction* means a medicolegal postmortem which is not different from an ordinary autopsy, except that the results are used in court to settle a dispute concerning cause of death or accident, or duration of some pathologic condition to establish the fact that the animal was diseased or unsound prior to the date of purchase. A *cosmetic* postmortem is one conducted with the very least disfigurement, and in which the parts are replaced, and the cadaver sewed together, washed, the hair dried, and in general made to appear as nearly intact as possible. It is usually accomplished by making an incision on the median line of the ventral side from the xiphoid cartilage to the pubis, incising the diaphragm and eviscerating the thorax and abdomen. The organs are then compressed to free them from fluid, replaced, packed tight with paper, cloths, cotton or oakum, and the incision closed with a baseball stitch.

COMPLETE AUTOPSY.—A complete autopsy must be

effectuated in cases where the cause of death is not known. Every detail of technic must be completed and every organ or part carefully examined to make possible a correct post-mortem diagnosis.

INCOMPLETE AUTOPSY.—A short autopsy (removal of front leg and side of the large animal) may be done when the purpose of the postmortem is to corroborate a positive laboratory or clinical diagnosis. Should the trouble not be disclosed, one must continue the autopsy to completion.

OBJECT.—In no other branch of veterinary science is there demanded more sound knowledge, accurate scientific and systematic technic, and keen powers of observation, discrimination and interpretation.

In many cases the purpose of an autopsy is to establish the cause of death or the length of time a disease process has existed, or its area of anatomical distribution. The information obtained may be used in legal proceedings and should therefore be exact and complete in every detail.

The practitioner should, whenever possible, autopsy every case lost. Through such study of post-mortem pathology he unquestionably comes to a more thorough knowledge of the interpretation of symptoms, the efficiency and proper selection of remedies, and in general, becomes a better diagnostician and safer therapist. He may frequently desire to corroborate his own or another's clinical diagnosis and justify the treatment used, on his own account or as a consultant, by conducting an autopsy in the owner's presence. Systematic technic and sound logic in such cases do much toward the establishment of an enduring reputation, and one is assured of a greater pecuniary return than should he neglect such opportunities of study and demonstration of morbid processes. In addition it affords

an excellent opportunity for the review of anatomy, and in animals killed by accident, for the study of the physiological character of the various parts, which better enables one to differentiate the normal, pathologic and post-mortem decomposed tissues. The practice of surgical operations on cadavers after an autopsy is commendable and tends to increase one's efficiency in surgery.

In many instances the services of State livestock sanitary boards have been sought to determine the specificity of a disease supposed to be present on premises where three or four animals died within a short length of time. Frequently, in these instances, a knowledge of systematic post-mortem technic would have shown the veterinary physician that the trouble in each animal was purely local and very remote from the nature of a communicable disease.

State veterinarians, commissioners of health, agents of State boards of health, State livestock sanitary boards, government field veterinarians, and laboratory pathologists should be thoroughly trained in post-mortem technic, as their duties may necessitate instruction, supervision, or actuation of autopsy of animals dead of contagious or infectious diseases, for the purpose of diagnosis, scientific research, or food sanitation.

Clinicians should follow cases which terminate fatally to the post-mortem table and there review the study of those morbid processes which they were endeavoring to correct. This strengthens their ability in diagnosis and treatment and makes them better teachers.

Regular systematic postmortems should be made and accurately recorded at every veterinary school and hospital for the accumulation of valuable data which are of great scientific and geographical interest.

Autopsy work for students in schools of veterinary medicine is indispensable. The student should first have a thorough training in general pathology and special pathology, the latter particularly studied from the standpoint of the pathology of the organs and systems of organs, as well as the contagious and infectious diseases. Too few of our profession have had a firm foundation laid in the pathology of the various systems of organs. With a good theoretical knowledge of the morbid processes of which an organ or part is susceptible, one may be, and often is, totally unable to recognize the conditions when confronted with them. Pathology taught at the autopsy table trains the student, as he can be trained in no other way, in distinguishing between the normal, pathological and post-mortem decomposed tissues. It stimulates deep thinking, logical reasoning power, and the development of a keen mind. Post-mortem changes have, all too frequently, been accused of constituting pathologic changes which have never existed in the subject. Students and graduates not infrequently fail to identify various parts of organs or are unable to distinguish one organ from another, yet may speak most learnedly of the Malpighian corpuscles and the islands of Langerhans.

Ample opportunity is had in most of our veterinary schools for regular systematic courses in post-mortem pathology. The writer has taught the subject in this manner for a number of years and is thoroughly convinced that in no other way can a student be taught pathology with enough proficiency to enable him to consistently recognize, accurately describe, and logically give the pathogenesis of the many various morbid processes. Illustrations, museum specimens, word pictures, and discussions

are valuable accessories, but when not used in conjunction with regular systematic post-mortem study they fail in their purpose, because, to the student mind, they are not real and they lack the association of other tissues and those processes which are primary and secondary to them. The teaching of pathology by lectures without systematic study at the post-mortem table would be no less impressive, convincing, or efficient than lectures in medicine without clinic, or the theory of surgery without surgery practicum. At the post-mortem table a pathologic process gives the student a full appreciation of its true significance. The presence of the cadaver itself bears mute witness of the malignancy of many morbid processes. The primary lesion and many of the subsequently changed tissues when handled, inspected and discussed in their full relationships so interest the student that he is much less apt to forget, and exercise of the functions of seeing, hearing, smelling and feeling during the examination and description of diseased tissues in their proper environment establishes an acquaintanceship so close that one experiences little difficulty in recognizing the processes when next met. Scientific systematic post-mortem technic should be used whenever possible to facilitate the teaching of pathology at the post-mortem table.

AUTHORITY.—Secure proper authority for conducting an autopsy before it is begun. State laws may prohibit the post-mortem examination of animals dead of communicable diseases, or place certain restrictions upon such examinations. Some owners object to an autopsy being performed upon an animal, especially if it has been a pet.

TIME, DATE, LIGHT AND WEATHER.—Perform the autopsy in daylight and as soon after the death of the

animal as possible. Colors cannot be properly determined in artificial light, and post-mortem decomposition sets in very soon after death, especially in hot weather. One should carefully compare the time and date of death or destruction with that of autopsy, as it may aid in determining the cause of certain tissue changes.

PLACE.—Choose the cleanest place available in which to perform an autopsy. The cadaver of a large animal should be placed upon a table $2\frac{1}{2}$ feet high when convenient. In the field where this is impossible remove the cadaver from the stable in order to secure the best possible light and to prevent littering the premises. Carefully consider the place of death and that of autopsy, as it may assist in accounting for conditions of the hair, skin and extremities, induced by dragging or handling the animal after death. In rural places the carcass is sometimes moved on a stoneboat or dragged on its side to the place of burial or incineration before autopsy. In cities cadavers are removed to reduction plants soon after death. Secure floor space near a door or window where the most light is to be had, have the floor cleaned, and then work rapidly, when doing an autopsy at a reduction plant.

CLINICAL HISTORY.—Secure clinical history, diagnosis and treatment of the case and mode of termination of the animal. Know, if possible, whether death occurred quietly or if the animal struggled during the agonal stages, and finally the position of the patient at the time of death. Medicaments are sometimes responsible for alterations of tissues. Autopsy findings are sometimes absolutely valueless in establishing a diagnosis without the history. Body fluids gravitate to the side upon which the animal lies soon after death.

DESTRUCTION OF ANIMAL.—When an animal is to be destroyed, especially for autopsy purposes, it should be so dispatched as to least harm those parts which are of most probable interest for post-mortem examination. When inflammatory processes are anticipated, the animal should not be bled to death. It should not be shot or struck in the head if the brain is likely to be of especial interest. It should not be shot, or injected intrathoracically with strychnine if the heart or lungs are thought to be affected. Large animals usually may be most conveniently pithed or given strychnine intravenously. Small animals may be destroyed with chloroform, ether, illuminating gas, or strychnine subcutaneously. One should secure the name and address of persons who authorized, effectuated, and witnessed the destruction of the animal.

DESCRIPTION OF CADAVER.—Take an accurate detailed description of the cadaver before the autopsy is begun, as the information may be needed in court proceedings. One should consider species, breed, sex, age, color, markings, size, weight, tag number, and clinic number.

WITNESSES.—Secure witnesses to the autopsy, when convenient, for use in cases of probable forensic involvement. Witnesses of an autopsy should be ready to render any assistance possible. They should refrain from handling specimens until after the autopsist has finished his examination, and then only with his permission. To keep up a rapid fire of questions or to audibly volunteer one's opinion concerning the pathology of each lesion, cause of death and the final diagnosis is a decided breach of courtesy. One's opinion should be given only when asked and then guardedly, unless one has had special training in pathology.

DRESS.—Dress properly. During regular autopsy

work for students in a post-mortem room a complete change of clothes should be made when possible. Lockers should be provided for student use adjacent to the autopsy room.

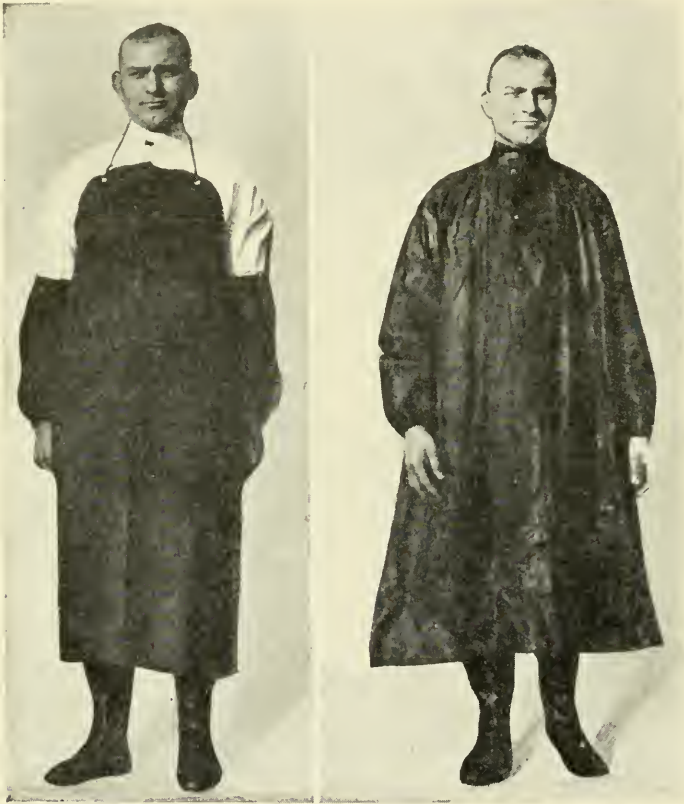

FIG. 1.—At left, white coat, rubber sleeves, apron and boots. At right, rubber gown and boots.

This prevents the street clothes from acquiring an odor which is most uncomfortable, both to the wearer and those with whom he may come in contact. One may wear a long white coat or a suit of overalls, and a rubber apron which

covers the front from a few inches below the chin to a few inches above the shoe tops, and rubber half sleeves. Better still is a rubber gown which slips on over the head, reaches nearly to the ankles, buttons at the collar, and has a drawstring at the neck (Fig. 1). Rubber boots complete this outfit, which is ideal for an instructor and students working with the cadaver on a table. When the cadaver is on the floor or ground, overalls and a rubber apron which has a loop around the neck and strings that tie around the waist are preferable, as the skirt of a white coat or rubber gown gets in the way when one leans forward to work. For small animals, a white coat and rubber apron are sufficient.

CARE OF INSTRUMENTS.—Keep instruments sharp. Always place an instrument upon a table, box, board or towel close to the cadaver when not in use during an autopsy, so that it may be readily found when again needed. Do not stick a knife into the cadaver's flesh or place it in a body cavity, as it may later cause injury to the autopsist. After completing an autopsy upon an animal dead of any contagious or infectious disease, the instruments must be sterilized before being put away, and under no circumstances should an autopsy be conducted upon another animal with the same instruments until after they have been sterilized. If this were not done they might be a source of infection to the technician, and would possibly contaminate tissues of the second cadaver which, when examined bacteriologically, might lead to confusing results.

CARE OF HANDS.—Remove rings from the fingers before beginning an autopsy, as they may become a source of infection and are sometimes difficult to clean and sterilize. One may smear the hands with carbolyzed petrolatum to close the pores of the skin before starting an autopsy when

rubber gloves are not worn. Wear rubber gloves when diseases communicable to man are suspected.

During an autopsy wash the hands frequently enough to prevent the accumulation of blood and filth. It should be remembered, however, that one should not hesitate to touch any tissue the consistency of which should be known simply because it has a repulsive appearance. Neither should one waste time cleaning and manicuring his nails during an autopsy period. The nails, except that of the right thumb, should be trimmed before an autopsy is begun. The thumb nail is used in stripping the capsule from an organ, except when rubber gloves are worn, when the sharp edge of a knife is employed. One should not be foolhardy and carelessly expose himself to danger by handling suspicious material without rubber gloves (glanders, etc.).

In case of an abrasion or cut contracted during the performance of an autopsy, one should stop immediately and wash the wound with warm water and soap, and then apply an antiseptic such as concentrated iodine, 5 per cent. lysol, or 1-1000 mercury bichloride solution, then apply collodion or celloidin dissolved in equal parts of ether and alcohol, bandage, and put on a rubber finger stall or rubber glove and continue the autopsy. If this is not convenient one should wash and antisepticize the wound and direct another person in the performance of the autopsy until it is completed, thus taking no further chances of becoming infected.

NOTES.—One must make notes of the post-mortem findings immediately after the completion of the autopsy or dictate them to another person (amanuensis) while conducting the autopsy. One should not depend upon his memory for the post-mortem protocol.

SPECIMENS FOR LABORATORY EXAMINATION.—For preservation of tissues for microscopical examination small bottles containing fixatives, such as formalin 8 per cent., concentrated sublimate of mercury, Muller's fluid, or 95 per cent. alcohol, should be taken to the place of autopsy and the tissue placed in the fixative immediately. The bottle should be packed in a wooden box with absorbent cotton (tumors, actinomycosis, etc.).

Material for bacteriological examination may be used at the autopsy. Tubes of sterile bouillon may be taken to the cadaver and small pieces of diseased tissue dropped into the fluid with very little danger of contamination if the scissors have been sterilized and kept in paper wrapping or the scalpels sterilized and kept in test-tubes. If this is not convenient, place the tissue in a sterile, liquid-tight rubber-stoppered, wide-mouthed bottle or fruit jar and then pack in ice and sawdust. The same holds true for specimens to be examined histologically when fixatives cannot be secured.

When packing specimens for shipment to a laboratory for examination keep the following points in mind:

1. That the specimen should reach the laboratory in the shortest possible time.
2. That it should reach the laboratory, as nearly as possible, in the same condition as when removed from the cadaver or animal.
3. That it should be so packed as to incur the least possibility of contamination or decomposition.
4. That it should be so packed as to render the least chance of breakage of glass container, leakage of infectious fluid, or escape of unpleasant odor.
5. That ice should not come in direct contact with specimens that are to be examined bacteriologically.

6. Specimens should not be wrapped in cloths wet with antiseptics then packed in paper or pasteboard boxes and shipped, as the covering macerates and facilitates contamination of both the tissues and the surroundings.

7. Large specimens and those packed in ice should be sent by express, others by parcel post or mail.

8. The package should be plainly marked, "For bacteriological, serological or pathological examination," together with the name and address of the laboratory and the sender.

9. Separate containers should be so plainly marked as to insure identification of the animal from which the specimen was taken.

10. When no particular disease is suspected, parts of heart, liver, spleen, kidneys, lungs and lymph-glands should be submitted to the laboratory. When possible the whole unopened heart should be sent.

11. A letter should be directed to the laboratory stating the specific tests desired, the disease suspected, time of the animal's death and that of the autopsy, complete history, and post-mortem report.

EXPRESS COMPANIES REGULATIONS.—Various State boards of health have decided that the custom of shipping bodies (especially dogs) to State laboratories or other public or private laboratories is unnecessary, and a menace to the health of the people, and regulations have been established that whenever analyses of dead animal tissue become necessary, the brain, spinal cord, stomach, liver, or other part must be removed from the body of the animal and placed in a tin, zinc, or other metal-lined box tightly closed before delivering to the express company or other public carrier.

MAILING AND PARCEL POST REGULATIONS.—Section

36 of the Parcel Post Regulations: Specimens of dried blood or of diseased tissues or communicable diseases, cultures and tubercular sputum may be mailed in accordance with instructions of the Treasury Department (Bureau of Public Health and Marine Hospital Service), as promulgated by the Post Office Department under Order No. 3064 of April 22, 1910.

DISEASED TISSUES IN THE MAILS.—Order No. 3064, Section 495, Postal Laws and Regulations, is hereby amended to read as follows: Specimens of diseased tissues may be admitted to the mail for transmission to the United States, State, Municipal or other laboratories in possession of permits referred to in paragraph 3 of this section only when enclosed in mailing cases constructed in accordance with this regulation:

Provided, that bacteriologic and pathologic specimens of plague and cholera (not hog cholera) shall under no circumstances be admitted to the mails.

2. Liquid cultures or cultures of micro-organisms in media that are fluid at the ordinary temperatures (below 45° C. or 113° F.) are unmailable. Such specimens may be sent in media that remain solid at ordinary temperatures.

3. No package containing diseased tissues shall be delivered to any representative of any of said laboratories until a permit shall have been first issued by the Postmaster General certifying that said institution has been found entitled, in accordance with the requirements of this regulation, to receive such specimen.

4a. Specimens of tubercular sputum (whether disinfected with carbolic acid or not disinfected) shall be transmitted in a solid glass vial with a mouth not less than one inch in diameter and capacity of not more than two ounces,

closed by a metallic screw top protected by a rubber or felt washer. Specimens of diphtheria, typhoid or other infectious or communicable diseases or diseased tissue shall be placed in a test-tube of tough glass, not over one-half inch in diameter and not over three and a half inches in length, closed with a stopper of rubber or cotton and sealed with paraffin or covered with a tightly-fitting rubber cap.

b. The glass vial or test-tube shall then be placed in a cylindrical tin box made of 1. C. bright tin plate, with soldered joints, closed by a metal screw cover with a rubber or felt washer. The vial or test-tube in this box shall be completely and evenly surrounded by absorbent cotton closely packed.

c. The tin box with its contents must then be inclosed in a closely fitting metal, wooden, or papier-mache block or tube at least three-sixteenths of an inch thick in its thinnest part, of sufficient strength to resist rough handling and support the weight of the mails piled in bags. This last tube to be tightly closed with a metal screw top.

5. Specimens of blood dried on glass microscopic slides for diagnosis of malaria or typhoid fever by the Widal test may be sent in any strong mailing case which is not liable to breakage or loss of the specimen in transit.

6. Upon the outside of every package of diseased tissues admitted to the mails shall be written or printed the words "Specimen for bacteriological examination." This package to be pouched with letter mail. See section 49, P. L. and R.

MILK OR URINE.—The liquid should be placed in a tightly closed sterile container and packed in ice and sawdust.

Pus.—Pus should be collected on a sterile cotton swab

that has been sterilized in a test-tube or placed in a sterile, tightly stoppered bottle.

Feces.—Fecal matter should be collected in a clean, tightly stoppered bottle.

Blood.—For serological diagnosis of contagious abortion and glanders 20 to 30 c.c. of blood should be aseptically drawn from the jugular vein of the living animal into sterile test-tubes or bottles and closed with rubber stoppers. Blood should not be smeared on glass slides or paper.

External Parasites.—Flies, fleas, ticks, and other easily seen external parasites may be collected readily, and mange and scab mites included in deep scrapings from the skin should be mailed in a tightly stoppered glass bottle.

Internal Parasites.—Tapeworms, flukes, and roundworms should be placed in a rubber-stoppered bottle containing 8 per cent. formalin, 60 per cent. alcohol or 1-1000 bichloride of mercury.

Anthrax.—The specimen should consist of an ear or hoof. These should be used for two reasons: In the first place they are extremities, distantly situated from the intestinal tract from which point in the process of post-mortem decomposition various organisms simulating the anthrax bacillus pass toward the periphery following the blood- and lymph-vessels and later pass directly through the tissues. Thus they reach the ear or hoof later than most parts of the anatomy and lessen the possibility of contaminating the blood at those points, which is an advantage to the pathologist when examining for anthrax bacilli. Secondly, by using the ear, little or no blood escapes from the cadaver which prevents contaminating the premises or infection of the technician, a condition which might obtain if an autopsy were performed to secure specimens of spleen or other

organs. When more than one tissue is sent to a laboratory for bacteriological examination, each should be packed in a separate container to prevent contamination of the others. The ear is placed in a glass jar, preferably a Mason fruit jar with rubber ring to prevent escape of fluid. This is then packed with ice and sawdust in a strong box. A portion of ear or other tissue may be placed in a hollowed-out potato and shipped. Cut a large potato in halves; hollow out part of it; place specimen in the vacant space, place halves together and tie with a string, wrap in paper, pack in a box and mail.

Blackleg.—Pieces of affected muscle should be put in a wide-mouthed bottle and tightly corked or sealed in a fruit jar. "Blackleg muscle should be covered with salt because the decaying process is arrested by salt and the blackleg bacilli are stimulated to the rapid formation of clostridian forms and spores" (Muller).

Malignant Œdema and Tetanus.—Locally affected parts should be excised, packed in fruit jars, and then in ice and sawdust in a box.

Hemorrhagic Septicæmia.—Portions of pneumonic lung and portions of liver showing infarcts and focal necrosis should be selected. From these the causative agent can often be isolated in pure culture directly on agar slants. These may be packed as above described.

Tuberculosis.—Small specimens may be sent in bottles or glass jars which can be tightly closed. Large specimens should be wrapped in cheese-cloth and oil-cloth, placed in tin container, tightly closed, and then packed in sawdust and ice in a closed wooden box.

Hog Cholera, Swine Plague, Swine Erysipelas.—Portions of skin, kidneys, lungs, lymph-glands, and intestines

are preferable. The intestines should include the ileocæcal valve. These may be packed as other specimens.

Bacterial Dysentery, or Para-tuberculosis.—About a foot of the ileum should be ligated in two places so that an unopened portion may reach the laboratory. This is placed in a glass jar and packed as above described.

Infectious Abortion.—A fœtus, unopened, and placenta should be wrapped in cloth, placed in a tightly closed can, then packed as other specimens.

Rabies.—The head of a small animal suspected of rabies should be severed from the body as closely to the trunk as possible. This facilitates the location of the ganglia to be examined. The head of a large animal should be severed in such manner as to leave six inches of the neck with the head. To lessen the weight the lower jaw may be removed and the head may be cut in two parts transversely at a point just anterior to the eyes, and the nasal portion discarded. The head should be packed securely in a tin receptacle and this packed in sawdust and ice in a wooden pail or box and tightly closed.

Glanders.—Pieces of skin, nasal septum, lung or lymph-gland showing nodules or ulcers should be carefully excised, tightly sealed in a fruit jar or other container that can be made liquid tight, then packed as other specimens.

Poultry and Small Animals.—The entire cadaver should be wrapped in cloth, packed, and shipped as other specimens.

CHAPTER II

AUTOPSY ROOM

ROOM.—An ideal autopsy room for teaching purposes is one 20' × 28', with high ceiling, plenty of skylight and ventilation. The floor should be cement, graded slightly toward a central drain. The walls should be cement or enamel upward five feet from the floor so that they may be readily cleaned and antiseptized (Fig. 2).

LARGE TABLE.—A convenient autopsy table for large animals is one built somewhat like a truck except that a handle is not necessary. It is 8' long, 3' wide, and 32" high. The top is more durable when made of hard wood approximately 3" thick, covered with zinc or other metal and sloped toward a drain in the centre. Side leaves are of no particular advantage, and when a table is built to revolve it is seldom used for that purpose. Wheels under the table are necessary for convenience in moving it about while cleaning the room. The wheels at one end may be arranged as large castors which facilitates directing the table in case it should be necessary to demonstrate a subject in an adjacent class-room. The main points necessary are that the table be simple, strong, convenient and easily cleaned. It should be placed in the centre of the room, as it is necessary to work on all sides of it.

SMALL TABLE.—For small animals a zinc-covered table 6' long, 3' wide and 3' high is desirable. The surface should slope toward a drain in the centre and a slanting lip 1" high should be placed on all sides to prevent organs from slipping off. This table need not be movable, but should




Fig. 2.—Post-mortem room. Tables for small animals against the wall. Desk not visible. Temporary platform, scales, sink, basin, instrument cabinet, shelves over basin for antiseptic, heat, light, and water arrangements, large animal table, and part of cadaver of a horse visible.

possess strong legs and be placed against the wall, as a small animal can be moved about at the convenience of the autopsist. Two temporary wooden tables like those used in dissecting laboratories may be placed on either side of the small table. They are necessary, when the latter is in use, to place the organs of large animals upon, for observation, after having been washed in the tub.

INSTRUMENT TABLE.—A small, light, metal instrument table 32" high and surface measurements 30" × 20" is necessary during an autopsy. The instruments to be used for an autopsy may be taken from the instrument case and placed upon this table at a point convenient to the obducent.

INSTRUMENT CASE.—An instrument case may be of wood or glass and fastened against the wall. The size must depend upon the number of instruments used. One 4' high, 3' wide and 1' deep is convenient.

DESK.—A writing desk must be placed in one corner of the room. It should have one or more drawers and the surface should slope forward somewhat. One of convenient measurements presents surface length of 30", width 28", height at highest point 49" and at lowest point 46".

TUB.—For washing organs after their removal from the cadaver a tub should be provided. A porcelain tub showing length of 54", width 24", and depth 18" is very serviceable.

BASIN.—For cleansing the hands during and after an autopsy a porcelain wash basin supplied with hot and cold water should be installed.

SHELVES.—Shelves should be placed above the wash basin to hold bottles of antiseptic.

WATER PIPES.—A water pipe 1" in diameter should be placed over the large and small autopsy tables. One rubber hose 1" in diameter should extend from the pipe to the

small table. Two such pieces of rubber hose should extend from the water pipe to the large table, one at either end. When not in use a hook arrangement holds them above the table. This arrangement of the water hose is necessary to wash blood from the organs and tissues before their removal. For cleaning the floor and walls a rubber hose 1" in diameter and 30' long should be provided.

STERILIZER.—An instrument sterilizer is necessary for use after the autopsy of animals dead of infectious diseases, such as glanders and tuberculosis.

SCALE.—A scale marked with the metric system for weighing organs and tumors is necessary.

VISE.—A vise-like arrangement is convenient for holding the head while removing the brain and for the sawing of long bones.

PLATFORMS.—Several temporary slat platforms should be placed upon the cement floor around the tables to prevent slipping. Those convenient for a room 20' × 30' are 7' × 3' and the top is 3" from the floor. Each platform is made of twelve pieces of hardwood 2" × 2" by 7' laid lengthwise and four pieces 2" × 9" by 3' laid crosswise and securely nailed.

REFUSE CANS.—Large animals in cities must be removed soon after the autopsy. For small animals metal refuse cans 20" in diameter and 30" high with close-fitting covers may be used. An antiseptic must be placed over the cadavers kept in this manner and the cans must be emptied frequently. A crematory might be used to advantage. In the field where conveniences are few, choose a grass plot when possible upon which to conduct an autopsy. Have a few clean boards upon which to lay the organs as they are taken out. Be provided with several pails of water, soap, towels, etc.

CHAPTER III

POST-MORTEM INSTRUMENTS

Virchow's post-mortem knife (Fig. 3), and *cartilage knife* (Fig. 4), are steel instruments with hollow handles. They are used on the cadavers of large animals and are very serviceable when properly taken care of. They should be kept sharp with a stone, not a steel. Application of too much force on the knife when it is dull causes injury to the blade and may break the instrument at the junction of the blade and handle. One should make a practice of the constant use of these knives in autopsy work, and avoid the tendency to substitute a butcher knife, since systematic post-mortem work is not butchery. When circumstances compel one to resort to the use of a meat knife he should select a short steel instrument with a handle which forms a straight line with the cutting edge of the blade at the junction (Fig. 5) so that the heel of the blade does not catch in the tissues when the knife is drawn toward the autopsist while making an incision.

In using the post-mortem knife one should grasp it with a full hand grip as though to cut bread (Fig. 6). Sufficient pressure can be brought to bear upon it in this position for any reasonable purpose and the depth of the incision may be regulated with much greater accuracy. Beginners are sometimes inclined to take the knife as they would a pen or scalpel while dissecting, and they frequently seize it as a dagger would be held. When used like a scalpel (Fig. 6) not enough pressure can be exerted, and when held like a dagger (Fig. 6) the force cannot be regulated and

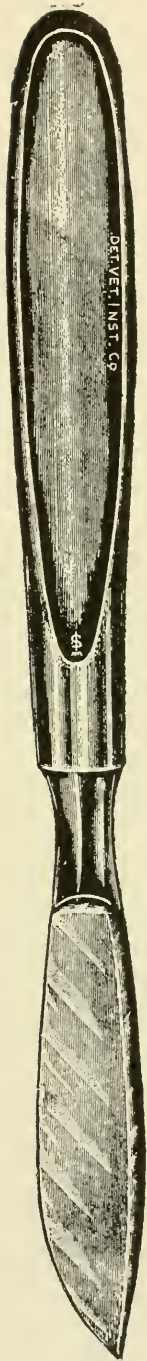


Fig. 3.—Virchow's post-mortem knife. Good for general autopsy work on large animals.



Fig. 4.—Large cartilage knife used in severing asternal cartilages of small animals when removing the sternum




Fig. 5.—A, butcher knife with cutting edge in direct line with the handle, leaving no heel to catch in the tissue when making long incisions. Very useful when proper instrument is not available. B, pith. Very useful for destroying large animals.

one experiences difficulty in making a straight incision. Both these positions are unhandy, prevent free arm and shoulder movement, and should not be employed.

Little's case knife (Fig. 7) gives excellent service in autopsy work on small animals.

Pick's myelotome (Fig. 8) is used for severing the spinal cord at right angles when the brain and cord are to be removed separately.




FIG. 6.—The "pen-hold" at the left, and the "dagger-hold" in the centre are improper. The "bread cutting" position to the right is the proper way to hold a large knife in doing autopsy work. The thumb may slip a little more to the left side of the knife.

Virchow's brain knife (Fig. 9) has a two-edged, round end, thin, flexible blade and hollow handle. It is used in opening the lateral ventricles of the brain and for incising the cerebrum, cord and cerebellum. It should be kept moist when in use to prevent the brain tissue from sticking to the blade.

Dissecting scalpels of various sizes (Fig. 10) may be used for autopsy of small animals, and with a groove director (Fig. 11) for incising meninges.

Incising knives are used in making long incisions in the liver, muscles, lungs, and in opening the kidneys (Fig. 12).

Monosmith's enucleation knife (Fig. 13) is used in

removing the eyeball. The blade curves in such manner as to cut the attachments and avoid injury to the sclera.

A *spearhead needle* and a *probe* set in either end of a hollow metal handle (Fig. 14) are convenient for finer work on the eye and ear.

A *harpoon needle* (Fig. 15) is employed in removing the optic lens.

Tyrrell's blunt and sharp hooks set in either end of a hollow metal handle (Fig. 16) are convenient in removing the ear ossicles and for optic work.

A *common steel* (Fig. 17) is necessary to keep meat knives sharp when one is compelled to use them.

A *raspatory* (Fig. 18) is used to scrape tissues from bones when close examination of the bone substance is necessary.

A *pith* (Fig. 5B) is occasionally used in destroying animals. The point is placed over the space between the occipital bone and atlas on the dorsal median line of the neck, oppo-



FIG. 7

FIG. 7.—Little's case knife for general autopsy work on small animals.



FIG. 8

FIG. 8.—Pick's myelotome. Used for severing the spinal cord at right angles when the brain and cord are to be removed separately.



FIG. 9



FIG. 10



FIG. 11



FIG. 12

site the lateral wing of the atlas, and the head of the pith is struck sharply with the palm of the hand. The animal may be cast first, or placed beside a step, table or other elevation which will enable one to conveniently perform the operation without injury to himself.

FIG. 9.—Virchow's brain knife. This thin, flexible, two-edged knife, with rounded end, is used in performing technic on the brain. It should be moistened before using to prevent brain tissue adhering to it.

FIG. 10.—Dissecting scalpel used in finer work on large animals and general technic on small animals.

FIG. 11.—Groove director used with small scalpel in cutting the meninges.

FIG. 12.—Incising knives, used in making long, smooth incisions through the liver, kidneys, lungs, udder, and muscles.

Championniere's, Esmarch's, and McErwen's bone chisels (Figs. 19, 20, 21, respectively) are used in cutting the nasal and cranial bones in exposing the nasal septum

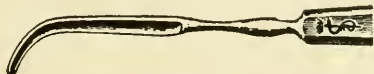


FIG. 13.—Monosmith's enucleation knife for removing the eye.



FIG. 14.—Spearhead needle and probe used in technic on eye and ear.



FIG. 15.—Harpoon needle for removing the optic lens.



FIG. 16.—Tyrrell's blunt and sharp hooks are very useful in work on the middle-ear, the eye small blood-vessels and nerves.



FIG. 17.—Steel.



FIG. 18.—Raspatory for scraping soft tissue from bones.




FIG. 19.—Championniere's bone chisel. Used in cutting the nasal and cranial bones.

and sinuses, the brain, cord, and structures of the foot. As field substitutes a steel cold chisel or brick chisel may be utilized (Fig. 22).

Esmarch's bone gouge is useful for bone work.

Rachiotomy chisels or curved handle bone chisels (Figs. 23, 24) are used in cutting the vertebræ of large animals,



FIG. 20.—Esmarch's bone chisel. It is very heavy and is used on the vertebræ of large animals.




FIG. 21.—McEwen's bone chisel. This instrument is lighter and is used on the sole of the foot and dental alveoli.




FIG. 22.—Brick chisels much reduced. They may be used as bone chisels.




FIG. 23.—Rachiotomy chisel for cutting the cranial bones in removal of the calvarium.

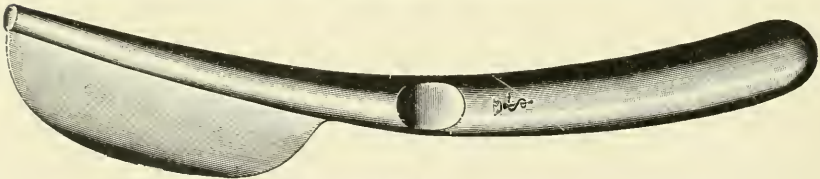


FIG. 24.—Rachiotomy chisel for cutting nasal bones in removal of turbinated bones.

severing long bones of small animals for examination of the bone-marrow, and in the technic of the head and foot.

The *cross chisel* is a combination hammer, chisel and round-edged wedge. The upright has a very sharp edge. The length of the cross piece is 12 cm. ($4\frac{3}{4}$ "), that of the upright 13 cm. (ca $5\frac{1}{4}$ "). This instrument is used in prying off the calvarium of small animals after the cranial bones have been cut, and it is used for removing the perios-




FIG. 25.—Cross chisel and proper position for use of the chisel end.



FIG. 26.—Dexler's rachiotome (Schmey).

teum. The cross chisel (Fig. 25) is made like a capital T. To use it grasp the instrument so that it lies in the palm of the hand with the upright sharp chisel portion passing backward and downward below the wrist. The right half of the cross-piece with the hammer head should lie between the thumb and forefinger, and the left half of the cross-piece or wedge end should pass between the first two fingers.

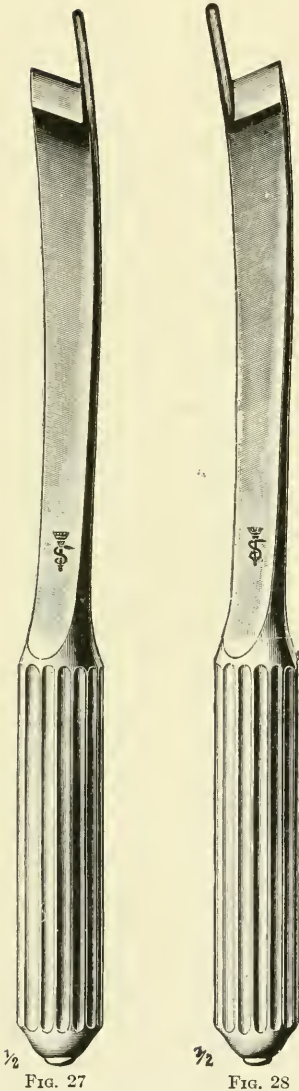


FIG. 27.—Brunetti's left curved rachiotome for opening the spinal canal of small animals.

FIG. 28.—Brunetti's right curved rachiotome for opening spinal canal of small animals.

Upon closing the hand the last three fingers grasp the upright or chisel branch, the thumb and the base of the forefinger enclose the hammer end, and the first finger closes over the left half of the cross-piece or wedge (Fig. 25).

Dexler's rachiotome (Fig. 26) presents a loop handle and a head opposite the chisel edge to strike upon. The handle is placed at right angles to the cutting edge instead of in a direct line with it.

Brunetti's rachiotomes (Figs. 27, 28) are right and left curved spinal chisels used for opening the spinal canal of small animals. A probe point extends 2 cm. beyond one end of the cutting edge to guide the chisel when it is placed in the canal and to prevent the chisel from slipping off the vertebrae at each impact of the mallet.

A *side chisel* is a steel instrument with a cutting edge on one side of the blade instead of at the end (Fig. 29). It has a sharp point projecting laterally from one side of the end

in the direction of the cutting edge. It is used in cutting vertebræ of small animals when opening the spinal canal. A head is made on the back of the chisel to receive the impact of the mallet. It may be used to cut the incompletely sawed portions of bone in removing the brain, and the point may be used in lifting the calvarium after all the bones have been cut.

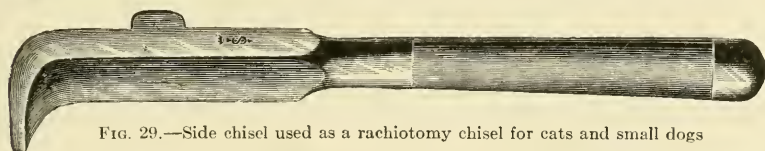


FIG. 29.—Side chisel used as a rachiotomy chisel for cats and small dogs

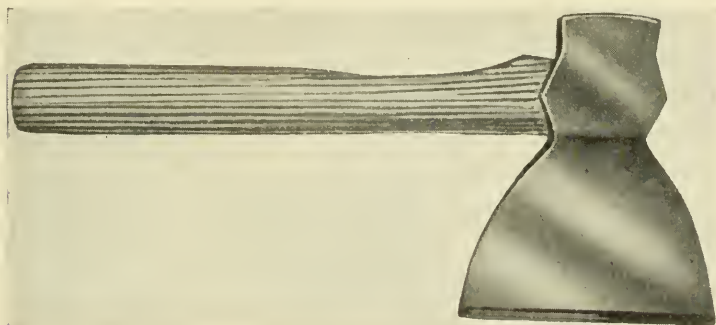


FIG. 30.—Post-mortem ax for cutting the ribs and removing the spinal cord.

The *post-mortem ax* (Fig. 30) should have a straight cutting edge 14 cm. ($5\frac{1}{2}$ ") in length. The depth should be 17.5 cm. (7") and the handle 45 cm. (18"). The weight is approximately 1.5 kg. (3.3 lbs.). The ax will be found very convenient for cutting the ribs of large animals and for cutting the vertebræ of large animals in removing the cord. It is well to have the handle corrugated to prevent it slipping from the hands.

The *steel hammer hook* (Fig. 31) is a combination

wedge, hammer and hook. The wedge is used in breaking unsawed angles of bone in removing the brain, the hammer

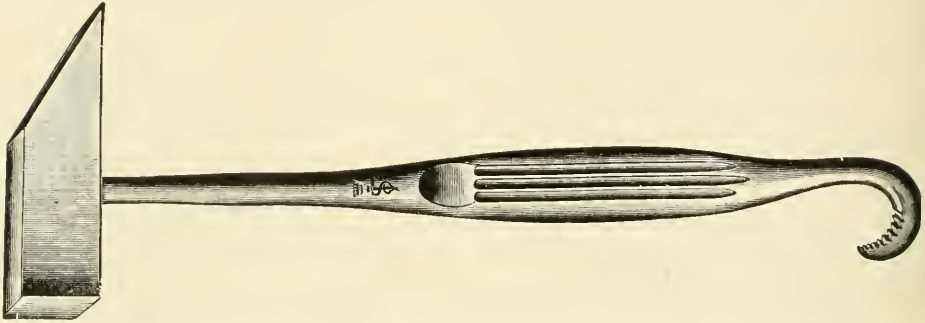


FIG. 31.—Steel hammer hook. The hook is notched so that it will not slip and is used to pull off the calvarium after the bones have been sawed and chiselled. The wedge is used to pry up the edge of the calvarium.

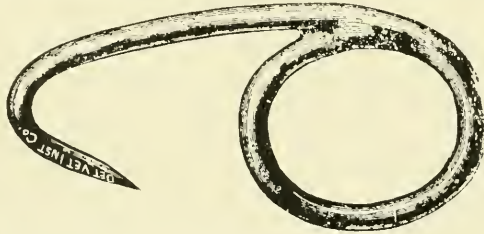


FIG. 32.—Rib hook. Used to hold the side up while the diaphragm is being cut.

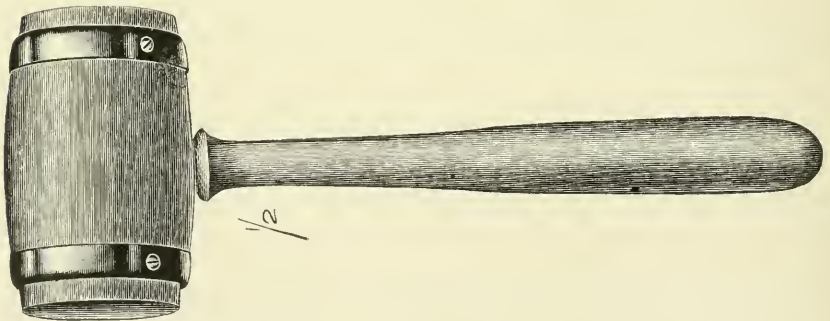



FIG. 33.—Metal-bound wood mallet used with chisels and rachiotomes in cutting bone and hoof.

for tapping bones to determine whether they have been sawed completely through, and the hook is used in pulling

the calvarium free from the skull of large animals after the bones have been severed. The hook at the end of the handle



34.—Rawhide mallet. This instrument is smaller and lighter than a wood mallet and is used for the same general purpose.




FIG. 35.—Iron pinchers for removing sole and wall of hoof.

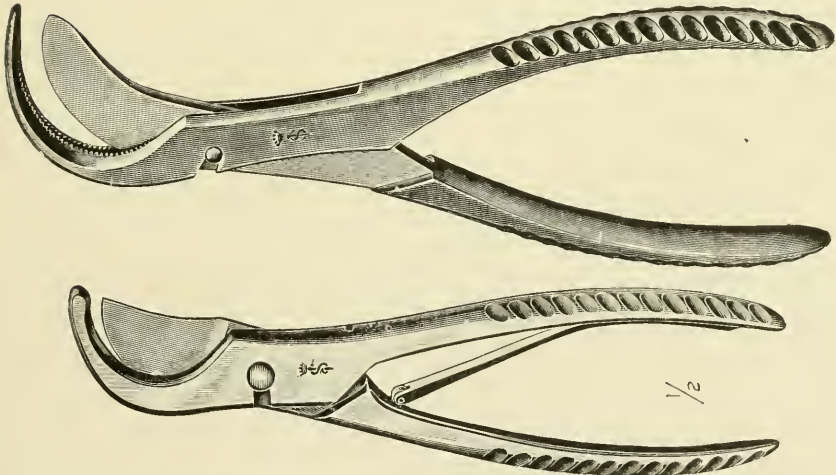


FIG. 36.—Costotomes used in cutting the ribs of small animals in removal of the sternum.

is provided with sharp notches to prevent slipping when hooked under the edge of the calvarium.

A *rib hook* (Fig. 32) is a steel hook with a loop handle used to hold the ribs up while the diaphragm is being severed, and to remove the side after it has been freed from the body. It is 6" long.

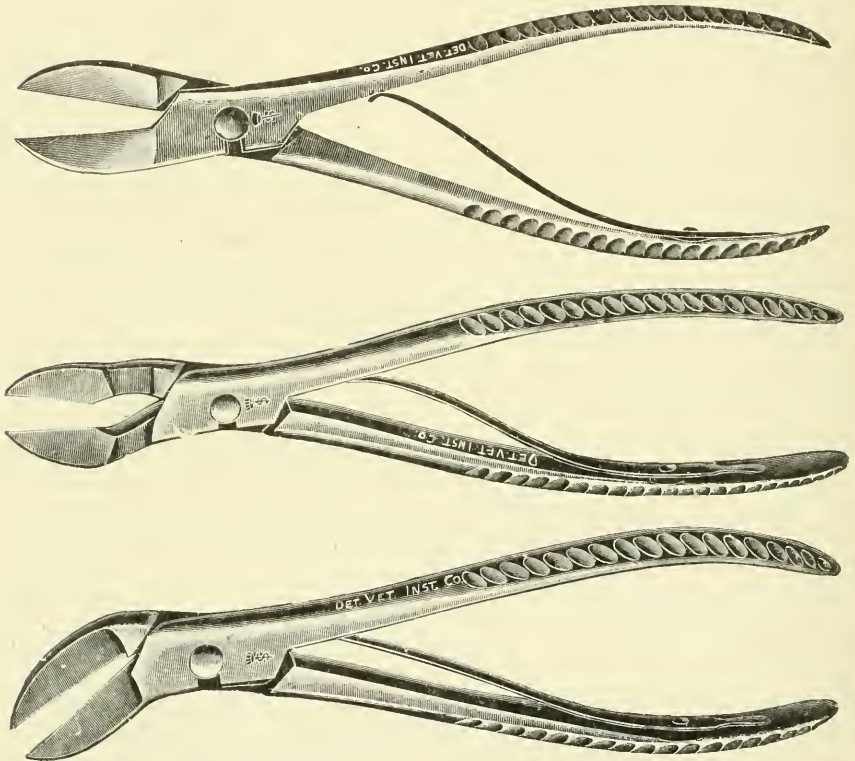


FIG. 37.—Bone-cutting forceps. The forceps have short, heavy blades and are used in removing the brain and cord of small animals and exposing nasal passages.

A *wood mallet* (Fig. 33) with each striking surface metal bound is used with chisels in cutting bone and hoof.

A *rarchide mallet* (Fig. 34) is used with chisels on small animals.

Iron pinchers (Fig. 35) are invaluable in removing the

sole and wall of the hoof. It should have handles 35 cm. (14") long and the diameter of the jaws should be 9 cm. (3.5").

Costotomes (Fig. 36) are instruments used in cutting the ribs of small animals. The blades are curved and the




FIG. 38.—Cartilage shears. This instrument has straight, pointed blades and is used in cutting thin bone, as the turbinates, cartilage of the nasal, septum, and sternal cartilages.

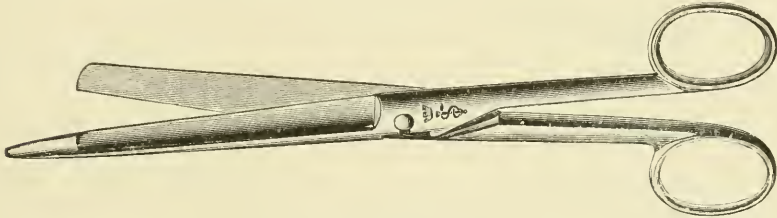


FIG. 39.—Enterotome showing one blunt point which is longer than the other. It is used in opening the intestines.



FIG. 40.—Small scissors which have one point blunt. It is used as an enterotome for very small animals.

hook-like blade may be notched and so divided that the other blade passes through it.

Bone-cutting forceps (Fig. 37) have short, heavy blades placed at various angles to the handles. They are especially useful in cutting the bones of the skull and vertebrae of small animals in removing the brain and cord.

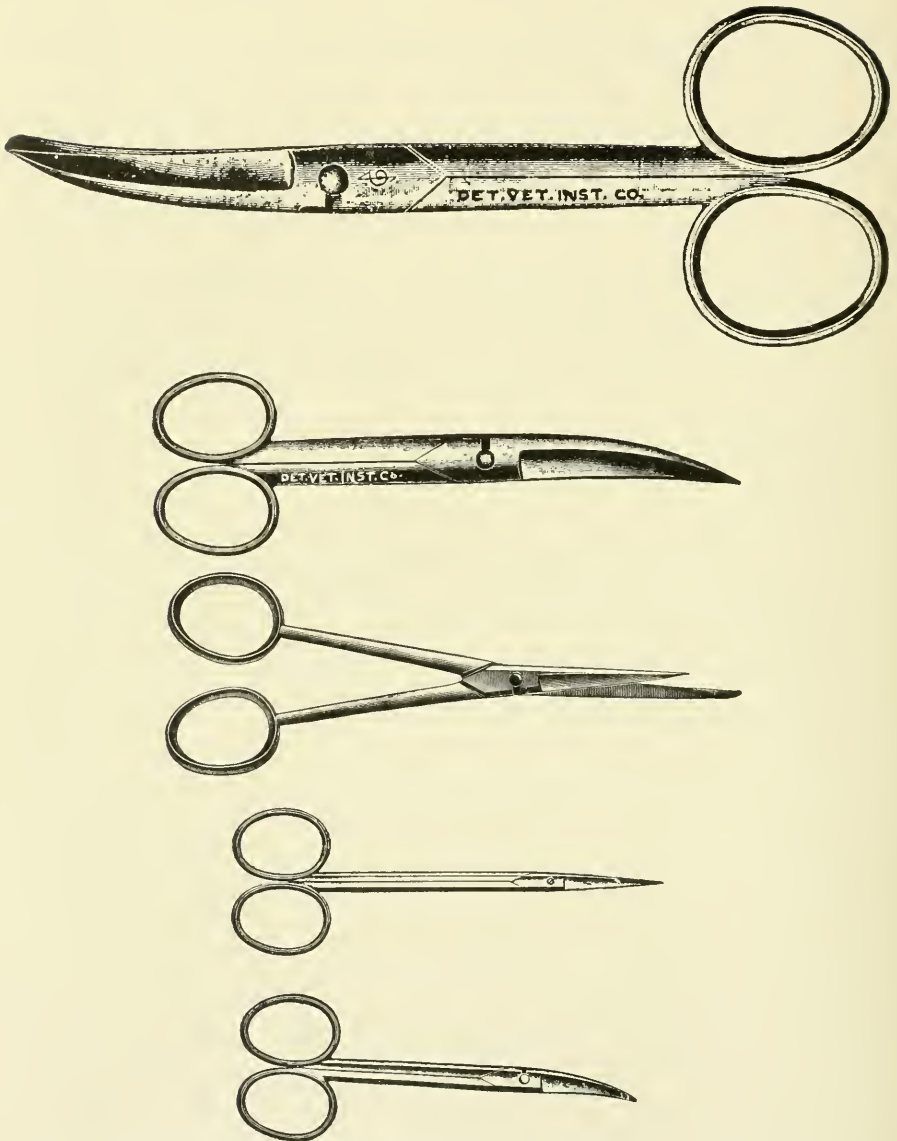


FIG. 41.—Small scissors with straight and curved blades for opening hearts and intestines of very small animals.

Cartilage shears (Fig. 38) have straight blades which are thinner than those of the bone forceps.

An *enterotome* (Fig. 39) is a scissors with detachable blades, one of which is longer than the other and blunt. It is used in opening small and large intestines, vagina, uterus, urethra and bladder of male and female and sometimes in opening the heart.

Small scissors are necessary. Various sizes and shapes are useful. For opening the intestines of small animals and

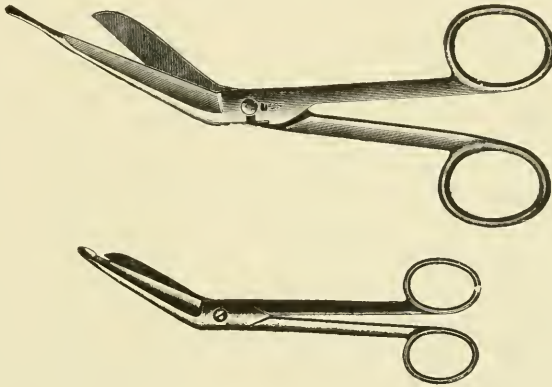


FIG. 42.—Artery scissors used for opening small blood-vessels and intestines of birds.

fowls a small scissors with one half blunt blade is used (Fig. 40). Those with straight and curved blades are used in opening very small hearts and intestines (Fig. 41).

Artery scissors with straight and bent blades, one of which is blunt and longer than the other, are used in opening small blood-vessels (Fig. 42).

Forceps.—Various sizes of plain (Fig. 43), and rat-tooth straight (Fig. 44), and curved (Fig. 45) forceps are used in picking up parasites, removing petuitary body, ear ossicles, holding the cerebral and spinal meninges of small

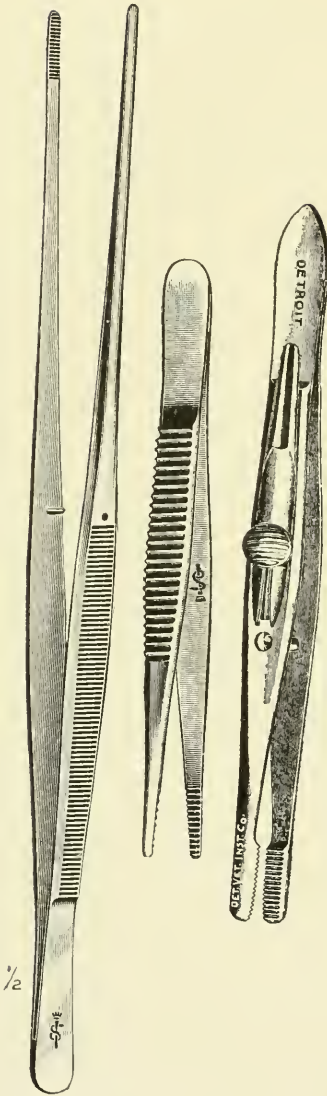


FIG. 43.—Straight forceps.

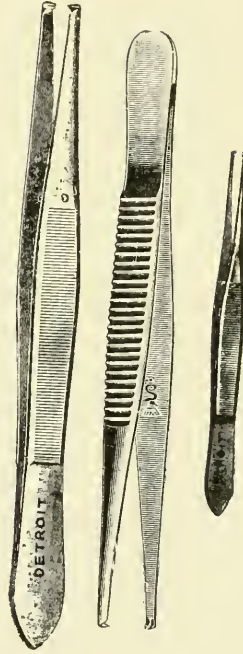


FIG. 44.—Rat-tooth forceps.

animals while they are incised, and in removing skin and organs from small animals.

Dura and hæmostatic forceps are useful in removing arteries, turbinated bones, nasal septum, holding meninges, tendons, tendon sheaths, ligaments, etc. (Fig. 46).

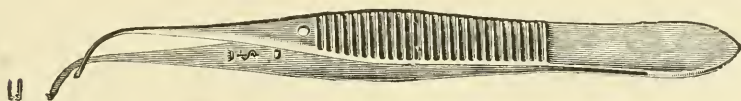


FIG. 45.—Curved forceps.




FIG. 46.—*Dura and hæmostatic forceps* used to hold meninges, turbinated bones, nasal septum, blood-vessels, nerves, tendons, etc., while they are being cut or ablated.

Tumor forceps are used in extirpating tumors, masses of muscle tissue, turbinated bones, and necrotic tissue (Fig. 47).

Bone-holding forceps (Fig. 48) are employed in hold-

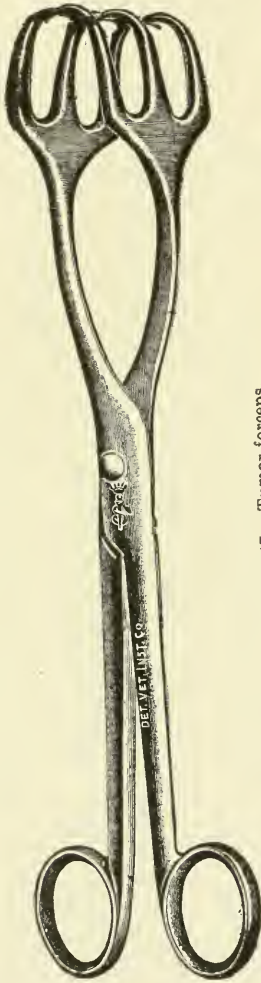


FIG. 47.—Tumor forceps.



FIG. 48.—Bone-holding forceps. This instrument is used to secure the head of small animals while the calvarium is being removed, and to hold the turbinated bones and nasal septum while they are being excised.

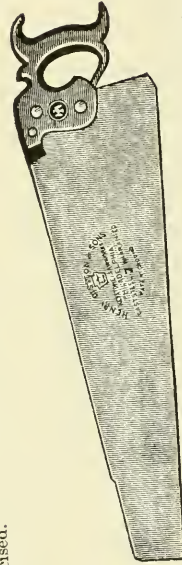


FIG. 49.—Carpenter's saw for incising long bones and head longitudinally.

ing the spine of small animals while the canal is being opened, portions of temporal bone in opening the middle-ear, small bones for transverse section, and turbinated bones of large animals. After decapitation of dogs or cats suspected of rabies an attendant can hold the head firm for removal of the calvarium by grasping the nose or upper jaw with these forceps.




FIG. 50.—Frame saw. Used on the bones of the head and pelvis.




FIG. 51.—Small frame saw.

A *large blade saw* is necessary to saw large bones longitudinally, and in sawing through the head of large animals, through the pelvic symphysis, and through the wall of the hoof (Fig. 49).

A *frame saw* is employed on large animals in sawing the nasal and cranial bones, shaft of the ilium, long bones transversely, and in small animals in transversely severing

the spine in the sacral region to start the process of opening the canal with bone forceps or rachiotomy chisels (Fig. 50).

A *small frame saw* is used on small animals (Fig. 51).

Charriere's blade saw is used in sawing the cranial and nasal bones of small animals (Fig. 52).



FIG. 52.—Charriere's blade saw. This instrument is used in work on the nasal and cranial bones of small animals.



FIG. 53.—Langenbeck's blade saw is used in finer work about the teeth

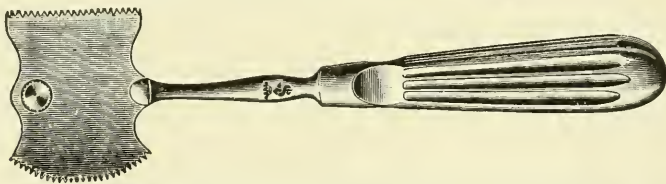


FIG. 54.—Kelly's skull saw for removing calvarium of very small animals.

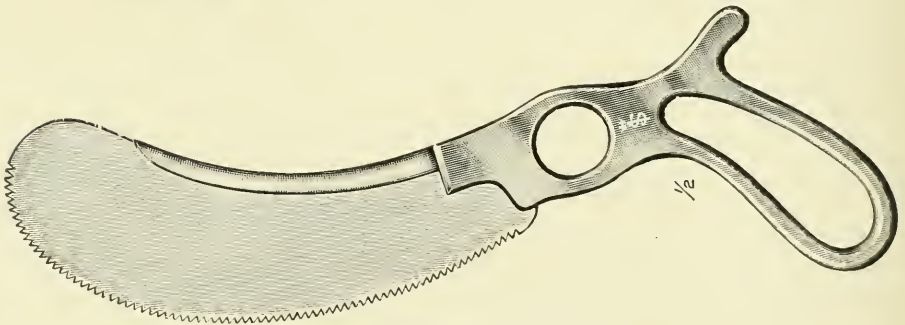


FIG. 55.—Single blade rachiotomy saw.

Langenbeck's blade saw is very narrow and is convenient for finer work about the teeth, the head in removing the eyes attached to the brain, and on very small animals and fowls (Fig. 53).

Kelly's skull saw is convenient for removing the calvarium of small animals (Fig. 54).

A *single blade rachiotomy saw* is one used in severing

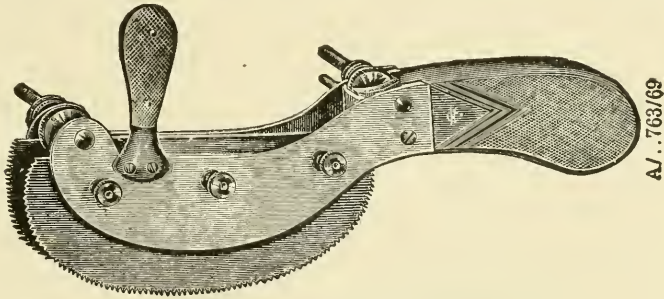


FIG. 56.—Laur's double blade rachiotomy saw.



FIG. 57.—Folding steel rule used in measuring tissues.

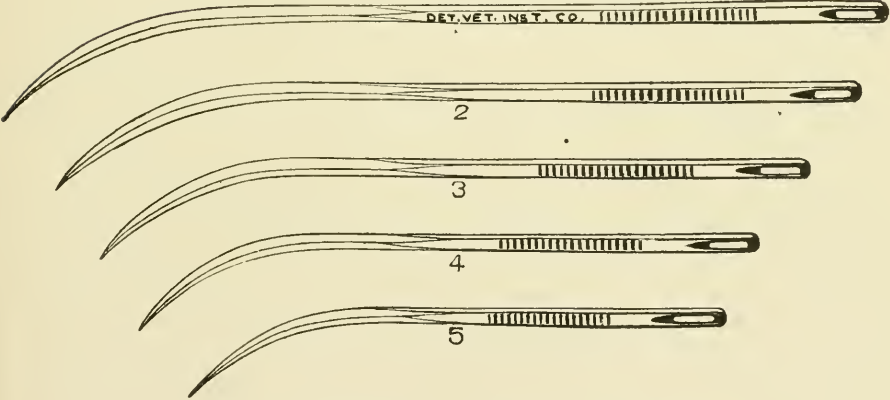


FIG. 58.—Needles used in making cosmetic postmortems.

the vertebræ of small animals in removing the spinal cord (Fig. 55).

Laur's double blade adjustable rachiotomy saw is used in removing the spinal cord (Fig. 56).

A *bone or steel rule* graded in centimetres on one side and inches on the other is necessary in measuring organs. A folding rule is most convenient (Fig. 57).

Post-mortem needles are used in sewing the cadaver together in making a cosmetic postmortem (Fig. 58).

Graduates are required for the measurement of cavity fluids. They should range in capacity from 10 to 1000 c.c.

Measuring cups of one-quarter, one-half and one litre




FIG. 59.—Magnifying glass. This glass is useful in the examination of parasites, ingesta, cut surfaces of organs, etc.

capacity are convenient for collecting and determining the quantity of fluid found in the thoracic and abdominal cavities.

Pipettes are very useful in removing small quantities of fluid from the brain cavities and from the pericardial sac. They should range in capacity from 1 to 100 c.c.

A *magnifying glass* is useful in the examination of small lesions and objects (Fig. 59).

CHAPTER IV

EXTERNAL EXAMINATION

BEFORE the autopsy of an animal is begun, a very careful examination of its exterior should be made.

SIGNS OF DEATH OR SIGNA MORTIS.—To determine the presence of death one should touch the cornea of the eye with the finger to test its reflex sensibility, observe the flank and nostrils for signs of respiration, apply the ear to the thorax to detect cardiac action and respiratory sounds, and flex the extremities to determine the presence of rigor mortis.

APPARENT DEATH.—This name is applied to a condition in which all the vital functions are depressed to the lowest possible degree, when only by great care in examination of the seemingly dead body can there be detected feeble cardiac contractions and occasional faint respiratory movements, a condition accompanied by the loss of consciousness and sensibility, and by reduction of the body temperature. In recently born animals this condition is seen quite frequently, lasting perhaps for hours; in this connection it is perhaps due to a premature separation of the placenta, aspiration of the amniotic fluid, compression of the umbilical cord or to anæmia (Kitt).

COOLING OF CADAVER OR ALGOR MORTIS.—After death the cadaver cools, usually in from one to twenty-four hours, depending upon the surrounding temperature and exposure to air currents. There is sometimes a post-mortem rise of temperature of a few degrees for several hours, due to a continuance of tissue metabolism, and a failure of blood

cooling or heat dissipation, following cessation of lung and peripheral capillary circulation.

THE EYE AFTER DEATH.—No reflex action is shown upon touching the cornea, which is opaque and dull; the pupils are dilated; the eyeball has lost its tenseness and may be somewhat shrunken from the evaporation of fluids. The eyelids are usually partly closed and rigid during rigor mortis.

CADAVERIC LIVIDITY OR HYPOSTASIS.—After the skin has been removed from an animal that has been dead for a few hours, bluish-red spots may be seen externally in the subcutis of the side upon which the animal has been lying. This is due to the contraction of the elastic artery walls after death, which forces the blood into the veins, and to the gravitation of the blood within the veins to the most dependent parts of the body, constituting hypostatic congestion or hypostasis.

These livid spots may coalesce, forming one larger area, the surface of which is not elevated, as the blood remains within the veins and does not escape from them into the perivascular tissue. On cut section the blood flows freely from the vessel, but is not seen in the adjacent tissue. External pressure upon these areas with the fingers or with the heel of the hand may force the blood through the lumen of the vessels away from the hypostatic spot, relieving the tissue of its lividity.

A hemorrhage in the same position differs from a livid spot in that the surface of the hemorrhage is elevated. The blood escapes through the blood-vessel walls into the adjacent connective tissue, causing it to bulge. Pressure upon the hemorrhage by the fingers or heel of the hand fails to reduce the process, as the blood is outside the vessels in the

connective tissue, and on cut section for the same reason blood does not flow so freely as from an area of hypostatic congestion. Internally hypostasis occurs in the lung, kidney, side of the great colon, cæcum, and loops of the small intestines on the side upon which the animal has been lying.

Hypostasis and hemorrhage must not be confused with areas of imbibition of blood pigment. These areas occur in the same position and develop following hypostatic congestion. They are red instead of bluish-red, not elevated, the color is uniformly distributed, and no blood escapes after incising the areas. Imbibition is one of the first signs of post-mortem decomposition. Upon the breaking down of the red blood-corpuscles in the process of decomposition the hæmoglobin escapes into the blood plasma, staining it red. This colored fluid is imbibed or soaked up by the tissues which have lost their vitality after death, and are uniformly stained red or pink. This condition may also be seen along the margins of congested veins. The vein and its branches may appear deep blue or purple in color, and present a margin from a quarter to a half inch in width, which is red near the vessel and shades out to a light pink at its extremity.

RIGOR MORTIS.—Post-mortem muscular rigidity is a condition in which coagulation of the muscle albumin causes the muscles to become set. Rigor mortis begins immediately after death in some cases, and only after four to twenty-four hours in other conditions. It lasts usually twenty-four hours, but may sometimes continue forty-eight hours or longer; in fact it disappears when decomposition sets in. Post-mortem rigidity appears first in the eyelids and masseter muscles and gradually spreads backward over the entire cadaver; it disappears in the same manner. Rigor mortis

sets in quickly and completely in heavy muscular animals which have been sick but a short time and develops by slow degrees in animals showing cachexia. To determine the presence of this condition one should flex the extremities and attempt to open the mouth of the cadaver. In fully developed rigor mortis the limbs may be flexed only after the application of considerable force.

APPEARANCE OF POST-MORTEM DECOMPOSITION.—Putrefaction usually occurs in from six to thirty-six hours, depending upon the condition of the animal at the time of death and the conditions of atmospheric moisture and temperature. The bacteria which are always present in the intestinal tract produce great quantities of gas by fermentation of the ingesta. The intestines become distended and great force is exerted against the diaphragm and abdominal walls. The abdomen appears round and greatly bloated; the skin is tight and a resonant sound is produced by tapping upon the belly wall. The pressure in the pelvis causes the rectum to protrude and evert. The force against the diaphragm causes blood and froth to be forced from the lungs out of the nostrils. The diaphragm may rupture and the intestines enter the thoracic cavity. The post-mortem rupture may be distinguished from the ante-mortem rupture by the absence of hemorrhage in the ragged margin of the former, since the blood has ceased to flow after death. Rigor mortis disappears and hypostasis develops into imbibition of blood coloring matter. The putrefactive bacteria pass from the intestines first through the blood- and lymph-vessels and then directly through the body structures in every direction, breaking down the tissues into carbonic acid, compounds of ammonia and water. The extremities are the last to decompose because situated farthest from

the intestinal tract. Gas may distend the subcutis so that the skin crepitates upon pressure and may cause the four extremities to stand out from the body like posts. Upon incising the skin gas escapes with considerable force. Soft skin over the abdomen, especially if white, turns green, brown and almost black (post-mortem pigment), probably due to the action of hydrogen sulphide gas, produced by the effect of the putrefactive bacteria upon the iron of the hæmoglobin, forming iron sulphide or other compounds of iron and sulphur. Putrid odors are given off by the decomposing cadaver.

VISIBLE MUCOUS MEMBRANES.—The eyes, ears, nostrils, mouth, anus, vulva, prepuce, and penis should be closely noted. Intense paleness may indicate internal or external hemorrhage, visceral congestion or oligocythæmia. Intense yellow color indicates icterus; deep blue or purple may indicate cyanosis, which may be due to gravitation if the part be dependent, or to disturbances of the heart under various conditions. These external signs constitute guides for internal examination. When anæmia is indicated by pale, visible mucous membranes, one should search for signs of external hemorrhage; upon opening the cadaver he should look for internal hemorrhages. If these be absent, he should open a long bone, as the femur, and examine the yellow bone-marrow of this hæmopoietic organ. In dogs and cats suffering from helminthiasis the yellow bone-marrow is red and gelatinous, due to its active attempt to replenish red blood-corpuscles which are destroyed by the absorbed hæmolytic toxin of the intestinal parasites and to the disturbed nutritive conditions. The indication of icterus by yellow-colored, visible, mucous membranes necessitates a close examination of the duodenum for catarrhal duodenitis,

and of the ampulla of Vater which may be greatly swollen and in that manner close the bile-duct. The ductus choledochus should be opened to the gall-bladder or liver and examined for cholangitis, gall-stones, or parasites, and the liver should be observed for cirrhosis, etc. The purple or cyanotic mucous membrane indicates that a careful examination should be made of the cardiac and respiratory organs. One should look for valvular lesions of the heart, exudative pleurisy, pneumonia, pressure upon the diaphragm by liquid or distended abdominal organs.

NATURAL OPENINGS.—Sanguinolent discharge from the anus shows the necessity for close examination of the intestinal tract for hemorrhagic conditions which may be the seat of trouble. Bloody discharge from the nostrils indicates that the nasal passages and lungs should be carefully observed when the internal examination is made. Green liquid food material running from the nose or mouth points toward possible lesions of the stomach or intestines, especially in the horse, although the stomach need not necessarily be ruptured. Purulent discharges from the nostrils show that the nasal sinuses, nasal mucous membrane, guttural pouches, and lungs should be carefully inspected for inflammatory conditions. Thus it may be seen that a careful examination of the visible mucous membranes and natural openings may produce a valuable guide to the seat of trouble and greatly assist in making the internal examination.

EXTREMITIES.—The limbs should be manipulated to determine the presence of rigor mortis and fractures. The soles of the feet should be closely inspected for street nails, and the walls of the hoofs for signs of operations and pathological lesions. The legs should be carefully inspected for exostoses and changes in the tendons, bursæ, and joints.

SKIN.—The integument should be carefully examined in all regions of the body. The color of the soft hairless parts is often important as an indicator of internal troubles; when yellow it indicates icterus; when green it may point to post-mortem decomposition. The skin must be carefully observed for œdematous swellings, emphysematous crepitation, bruises, scars, wounds, abrasions, blisters and stains from discharges or application of medicaments. Many such points may be a source of infection or aid in the explanation of lesions to be found on internal examination. Tension of the skin over the abdomen should be tested to determine if bloat be present.

CHAPTER V

INTERNAL EXAMINATION OF THE HORSE

FOR class work sections should not consist of more than ten or fifteen students. For convenience they should be divided into groups. Two should be assigned to the head, neck and back, two to the evisceration of the thoracic and abdominal cavities, two to the exentration of the pelvic cavity, two to the legs and feet, muscles, bones and joints, one to weighing the organs, and one to taking notes. In each group one student only should do the cutting and the other act as his assistant, an arrangement which lessens the possibility of accident. Each group of students should be assigned to a different part of the work each day.

POSITION.—The horse, ass, or mule, after careful external examination, is placed on the right side either on the ground or on a table (Fig. 60). This position has many advantages over the dorsal position of Kitt or Schmey or the left side position. When an animal of one of these species is placed on the *right* side the small intestines will be found uppermost in the region of the left flank as the *left* or uppermost side is removed. This facilitates the proper examination, ligation, and removal of the small intestines which would be buried beneath the double colon and cæcum, which are situated largely on the right side of the abdomen, if the animal were placed on the *left* side and the *right* side removed. The left cardiac notch of the lungs is more pronounced than the right, therefore the pericardium, contents of the pericardial sac, and the heart *in situ* may be more easily examined when the necropsy is con-




FIG. 60.—Proper position of the horse for autopsy. Line of incision on ventral median line of neck posterior to larynx for removal of thyroid glands. Line of incision on border of left ramus of mandible to the ear and from ear above jugular groove is made just through the skin. The skin is then removed from parotid and submaxillary regions, exposing the lymph and salivary glands.

ducted with the cadaver placed upon its *right* side. The dorsal position is disadvantageous in that it necessitates propping the cadaver up with sharp sticks or blocks, or tying the feet to stakes or rings in the wall, truck stakes, etc. In the field the dorsal position is very impractical and much inconvenience may be obviated by using the right side position of Kitt.

SKIN.—The hide has a commercial value, and in many cases must be removed before the autopsy is begun. The autopsist should see the cadaver before the skin is removed. When this is not possible have the hide present so that it may be examined and aid in identification of the animal. When not obligatory do not waste the time and energy to remove the integument. In case the owner demands the hide, allow someone else to remove it. If the autopsy is being conducted at a reduction plant one of the employes will do the work, if on a farm the owner's help may be utilized. When circumstances compel the autopsist to remove the skin he should make an incision on the median line from the tip of the chin to the anus, avoiding the navel of young animals and the genitals. At right angles to this line an incision is made through the skin on the inside of each foreleg to the carpal joint and up the back of each hind leg to the tarsal joint. At the carpal and tarsal joints and the muzzle a circular incision is made through the integument. The skin is drawn back from the edges of the incisions, and a curved edged knife held almost flat against the skin during the operation in order that as much of the panniculus may remain on the body and as little on the skin as possible. In skinning the cadaver, the ears are cut off close to their base and left with the hide. An incision is continued from the median line along the ventral surface of the tail. By



Fig. 61.—Left front and hind leg removed with the skin of the left side and laid over the dorsal side of the cadaver. This obviates skinning the entire cadaver or legs before autopsy, and expedites the post-mortem without injury to the hide, which may be removed later by those who desire it.

applying traction the skin is readily removed from the tail after the body has been skinned. Great care should be exercised not to cut or puncture the hide, as each injury reduces its market value. During the process of removing the integument the autopsist may observe the skin for condition and lesions, and the subcutis for nutritional condition, œdema, hemorrhages, icterus, etc.

When pressed for time one may quickly remove the skin from the uppermost side of the cadaver by placing an incision on the median line from the tip of the chin to the anus and then dissecting the hide from the uppermost side of the neck and abdomen but not from the legs. Raise the legs upward and sever them close to the body, allowing them to be removed with the integument of the left side of the cadaver. This can be done in a very short time, which adds to the convenience of the autopsist. At the same time the hide is not injured and may be removed by those who desire it after the autopsy has been completed (Fig. 61).

OPERATIVE TECHNIC FOR THE HEAD, NECK AND BACK

THYROID GLANDS.—To extirpate the thyroid glands made an incision six inches long on the median line of the neck immediately posterior to the larynx (Fig. 60). Cut through the skin, subcutis, sternothyro, and omohyoideus muscles down to the cartilaginous rings of the trachea. Seize the thyroid, draw it out and sever its attachments. Remove the opposite gland in the same manner.

JUGULAR FURROW AND STRUCTURES.—Place an incision immediately above the jugular furrow, downward through the muscles to the deepest layer of cervical muscles, from the first rib forward to the left wing of the atlas

(Fig. 60). Continue the incision along the border of this lateral wing and finish it just back of the ear. Lay open this incision and separate the jugular vein, carotid artery, œsophagus, vagus, sympathetic and recurrent nerves (Figs. 63, 64). The vagus and sympathetic nerves are enclosed in a common sheath. Examine the structures of the right jugular furrow when the trachea and larynx have been removed (Fig. 80). The anterior cervical lymph-glands lie along the carotid artery in the vicinity of the thyroid glands; the middle cervicals in the middle of the neck on the trachea below the carotid artery, and the inferior cervical glands lie at the entrance of the thorax under the trachea.

PAROTID AND SUBMAXILLARY LYMPH AND SALIVARY GLANDS.—Make an incision through the skin from the temporomandibular articulation just below and in front of the ear, to the symphysis of the mandibular rami at the chin, following the inferior border of the left ramus (Fig. 60). Lay the skin back from this incision below the ear and in the submaxillary space. Incise and examine the parotid and submaxillary salivary glands and the submaxillary lymph-glands.

LEFT RAMUS OF MANDIBLE.—To remove the left ramus of the lower jaw it is necessary to sever the muscular attachments from its internal surface and to saw through the bone just above the symphysis. Force the knife under the left ramus close to the temporomandibular articulation. Press the cutting edge upward closely against the internal surface of that bone, and cut forward to the tip of the chin or symphysis of the inferior maxilla (Fig. 62). Withdraw the knife and make another incision from the temporomaxillary articulation to the left commissure of the lips, downward to the teeth (Fig. 62). The temporomandibular

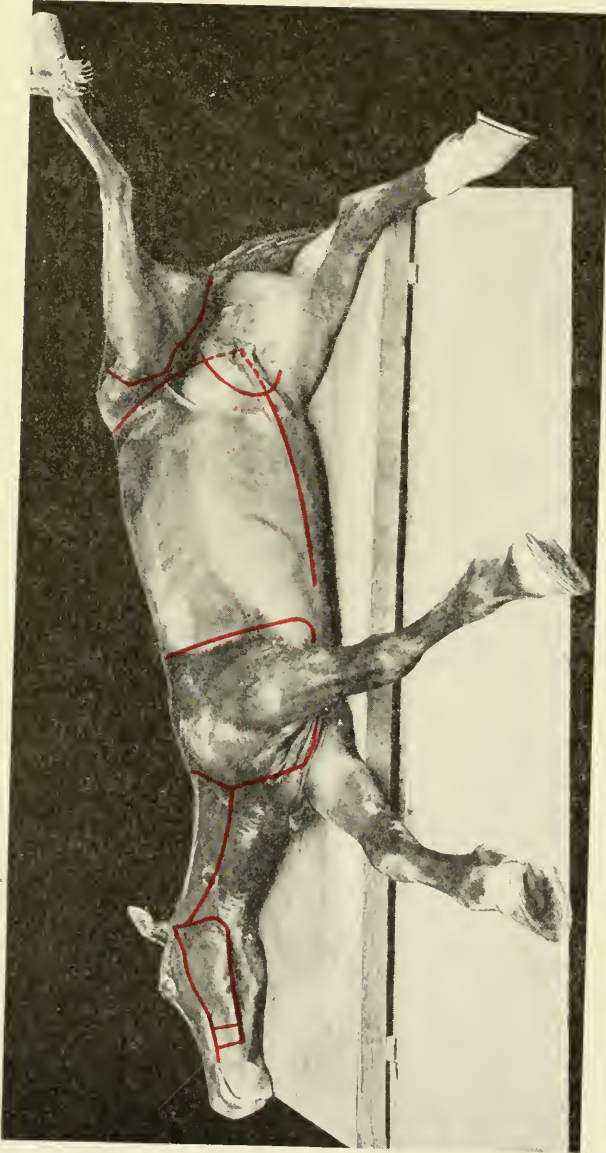


Fig. 62.—Line of incision on border of left ramus of mandible to extend under the jaw as far as possible. Incision from commissure of the lip to temporomandibular joint extends downward to the teeth. A piece of lip is excised from the lower interdental space and the left ramus saved through just above the symphysis. The left ramus is then taken off by disarticulation of the temporomaxillary joint. The incision along the inner groove is deep, exposing the structures of that groove (see Fig. 64). Incisions anterior, posterior and under the foreleg for ablation of that structure. Incision for removal of posterior limb starts posterior to external angle of the ilium, extends downward and forward through the skin diagonally across the tensor fascia lata, then turns downward and backward under the superficial muscles to the coxofemoral joint, through the teres ligament, over the ischial tuberosity and then through the deep and superficial muscles and skin until the leg is freed. The left hind leg is elevated at the angle an assistant maintains it when the incision is started. Dotted line of incision for ablation of mammary gland or penis, lines of xiphoid-pubic and pubic-lumbar incisions.

articulation and the symphysis of the maxillary rami now alone maintain the position of the left ramus of the lower jaw. Remove a section of skin and lip two inches wide from the left ramus just posterior to its symphysis with the right ramus (Fig. 62). Saw through the left ramus at this point, grasp it above the incision and raise it upward and backward until a complete disarticulation of the temporomandibular joint is effected. Remove the left ramus of the lower jaw, and expose for examination *in situ* the teeth, gums, tongue, larynx, pharynx, guttural pouches, posterior nares, soft and hard palates (Figs. 63, 64).

GUTTURAL POUCHES.—To open the left guttural pouch locate the great cornu of the hyoid bone and make an incision through the walls of the pouch three inches long, following the posterior border of the hyoid cornu. In opening the right pouch place a similar incision along the right great cornu which lies directly under the left when the cadaver is lying on its right side. If the left pouch contains blood, pus or other fluid, sponge it out clean before incising the wall of the right pouch to prevent contaminating the latter (Fig. 64).

TONGUE, LARYNX, TRACHEA, AND ŒSOPHAGUS.—The tongue, larynx, trachea, and the œsophagus are extirpated together and their dissection effectuated later preparatory to describing their appearance. To remove them, first seize the left great cornu of the hyoid bone with the bone forceps and twist from right to left, breaking the cornu completely near its superior attachment, then seize the right cornu and break it in the same manner (Fig. 64). Next grasp the free portion of the tongue with the left hand, draw it out of the oral cavity and hold it upward while the frenum is severed and the glossal attachments loosened all along the

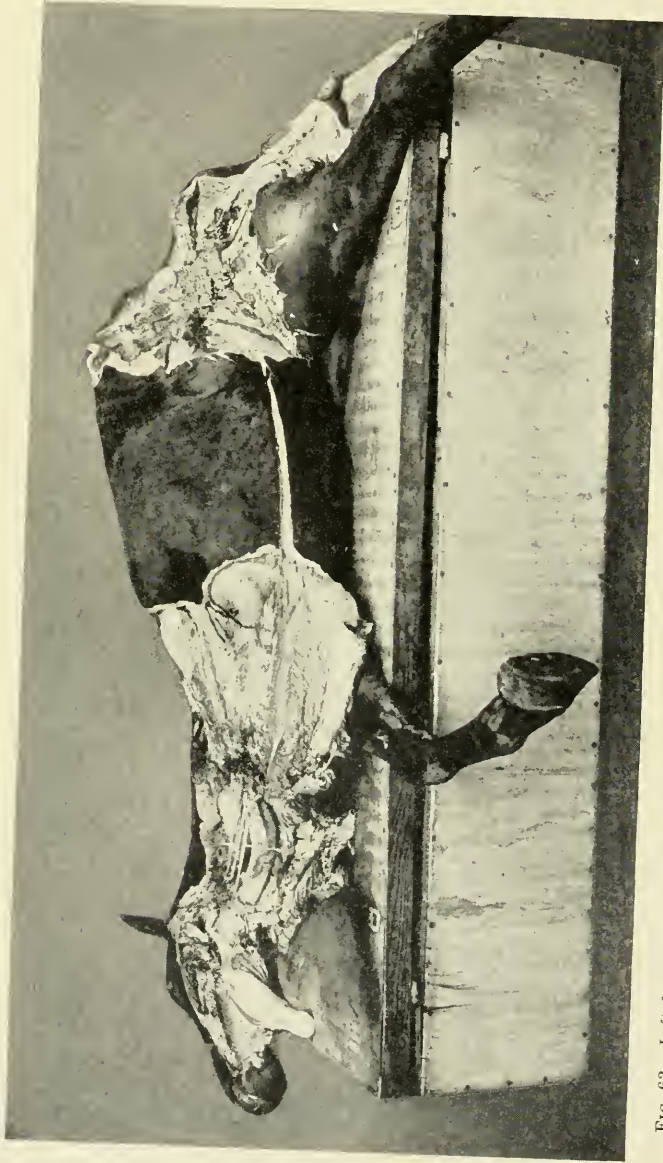


FIG. 63.—Left, front and hind legs removed. Penis and prepuce dissected from abdomen and inferior surface of pelvis and laid back of right hind leg. Pectoral muscles ablated from lower part of thorax and laid over the sternum. Incision completed from anterior margin of the back to the ensiform cartilage through the skin and subcutis on the median line of the abdomen. Jugular furrow, anterior and vagus, carotid artery, jugular vein, oesophagus and trachea exposed. Left ramus of the mandible removed. Tongue rotated outward. Left cornu of hyoid bone broken and left guttural pouch opened.



Fig. 64.—Left ramus of mandible removed and jugular furrow laid open as indicated by lines in Fig. 62. Left great cornu of the hyoid bone has been broken, cuttural pouch just posterior to it opened, tongue rotated outward, teeth, hard and soft palate exposed, left jugular vein, vagus, and carotid artery, oesophagus and trachea exposed.

organ. Place two fingers in the glottis and draw the larynx outward from the cadaver. Cut through the soft palate, carrying the incision upward and backward, then downward behind the larynx and trachea until they are severed from the head and neck. Incise the œsophagus, trachea, vessels and nerves close to the thorax, remove and place tongue, larynx, trachea and œsophagus upon the table (Figs. 80, 117).

DECAPITATION.—The head is excised at the occipito-atlantal articulation.

To accomplish this take a position on the dorsal side of the neck. Have an assistant grasp the nostrils and raise the chin upward and backward. With the head in this position incise the skin and muscles back of the right ramus of the inferior maxilla. Next have the head forced backward and downward in such manner that the ventral aspect of the occipito-atlantal joint is uppermost. Cut the ventral capitus muscle and the ligaments of this articulation and expose the spinal meninges. It is at this point that spinal fluid may be collected before the meninges are severed, when a microscopic or bacteriological examination of the fluid is desirable (Fig. 83). This may be done with a sterile pipette or hypodermic syringe. Complete the disarticulation of the joint, sever the dorsal rectus capitus muscle, ligamentum nuchæ and skin. Remove the head to a table.

PREPARATION OF THE HEAD.—Place an incision from the right temporomandibular articulation to the right commissure of the lips, downward to the teeth. Grasp the right ramus at the interalveolar space and draw it upward and backward until the temporomandibular joint is disarticulated. To remove the skin and muscles from the head place an incision down the median line of the head and face

from the occipital crest to the incisor teeth. Lay back the skin from this incision and remove the ears and lips together with the skin of the head. Dissect the musculature away from the parietal, temporal, occipital and maxillary bones. Remove the fat from each temporal fossa, and have the bones especially free of muscular tissue between the temporal fossa and the foramen magnum (Fig. 65).

EXTIRPATION OF THE BRAIN.—Various vise-like arrangements may be used to hold the head while the bones are being sawed through, although an assistant can hold




FIG. 65.—Lines indicate incisions to be made in exposing a tooth, nasal sinuses, turbinated bones, nasal septum and brain. Incisions in supra-orbital process are made when the eye and optic nerve is taken out in connection with the brain. Incisions are made on either side of the external auditory process to remove the petrous temporal bone.

the head sufficiently steady upon a table without the use of a headholder. Place the head upon its upper teeth on a table with the incisor teeth distal to the autopsist. Draw a line with the cutting edge of the knife transversely across the frontal bones between points represented by the anterior curve of the temporal fossæ. This is used as a guiding line. Draw a second line one inch posterior to the first but parallel with it, then saw through the bone, following the second line. Draw two other lines, one on either side of the cranium. Start each line at the end of the transverse incision made with the saw, and carry it backward across the

temporal and occipital bones parallel to the top of the zygomatic process, and terminate each line in the foramen magnum *above* the occipital condyles (Fig. 65). Cut through the temporal and occipital bones with a curved bone chisel or a wide blade steel brick chisel, following these lines.

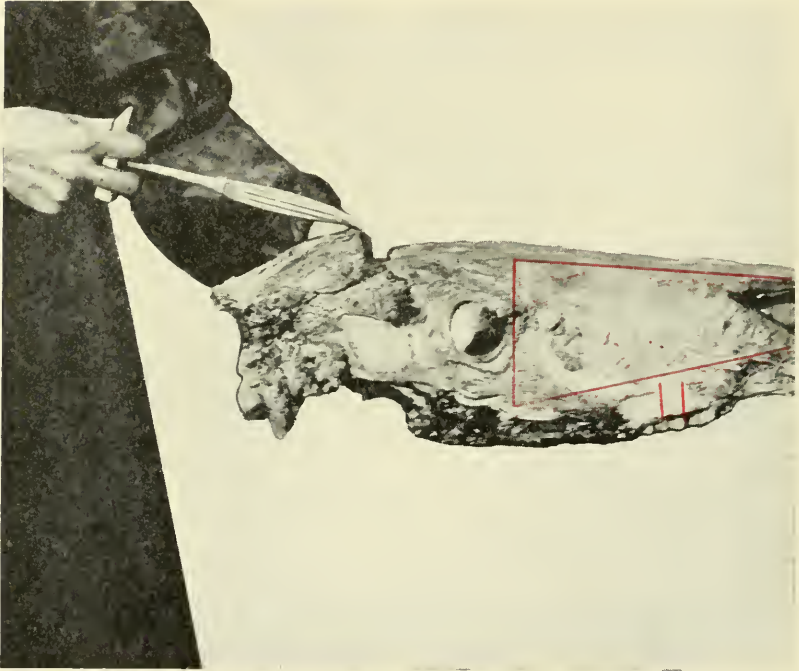


FIG. 66.—Removal of the calvarium with the hammer-hook.

When the three incisions described have been completed place the hook end of the steel hammer-hook under the anterior margin of the calvarium or skullcap and gently pull it upwards (Fig. 66). If the bones have been completely severed the calvarium will be removed easily, exposing the meninges and brain (Fig. 67). Examine the

dura mater, then penetrate it with a groove director, and with a sharp scalpel incise it longitudinally and lay it back. To remove the brain work the fingers between the organ and the cranial bones, beginning anteriorly and taking great

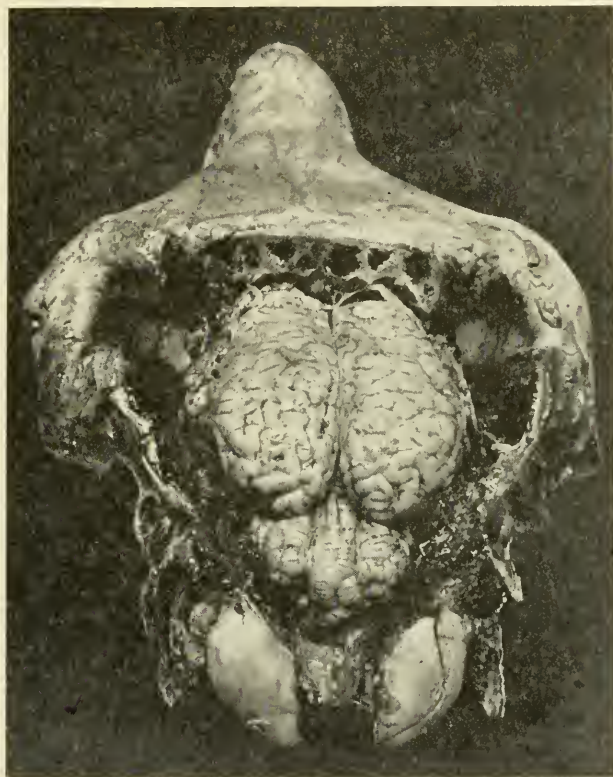


FIG. 67.—Brain exposed after removal of calvarium.

care not to injure the olfactory lobes. Raise the anterior portion of the brain with the left hand, sever the efferent nerves and remove the cerebrum and cerebellum together.

SINUSES, NASAL PASSAGES, AND SEPTUM.—To expose the sinuses and nasal passages it is only necessary to remove

a triangular piece of bone from one side of the face. Three lines are to be followed. The first, a transverse line in front of the orbit from the median line of the face toward the facial crest, to a point over the roots of the last molar teeth. The second line from the inferior end of the first line, forward across the maxillary bone over the roots of the teeth to the nasal process of the premaxilla. The last line is made from the superior end of the first incision forward to the anterior end of the nasal bone, longitudinally on that




FIG. 68.—Brain removed. Left turbinated bones, part of nasal, lacrimal and maxillary bones removed. Lines of incision for extirpation of nasal septum.

bone and to one side of the median line of the face, just missing the nasal septum (Fig. 65). The nasal, lacrimal and malar bones are sawed through on one side following the first line, which was made transversely in front of the orbit. The lacrimal and supermaxillary bones on one side are cut through with a heavy bone chisel or steel brick chisel following the second line, and along the nasal septum following the third line. With these incisions completed a three-cornered piece of bone may be removed from the face, anterior to the eye and to one side of the nasal septum, with a hammer-hook (Fig. 68). Examine the sinuses and turbinated bones.

After examining the turbinated bones on the side opened, cut them free with a chisel and remove them with dura tongs or rat-tooth forceps. The nasal septum is exposed when the turbinated bones have been extirpated (Fig.

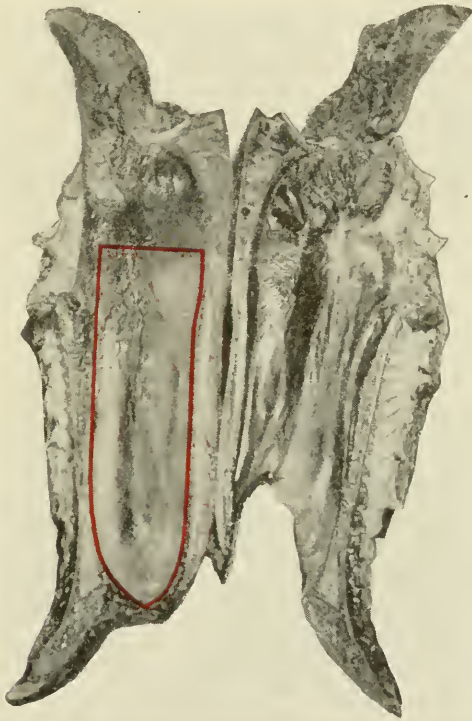


FIG. 69.—Longitudinal incision through the head after removal of the brain.

68). With a sharp knife make a vertical incision through the septum at its superior extremity, then incise the septum following its peripheral attachments in such a manner as to extirpate it as nearly intact as possible. The opposite turbinated bones may be examined through this aperture.

When necessary the other side of the face may be opened in a similar manner. Schmey saws the head in two parts following the median line but avoids the septum (Fig. 69).

TEETH.—To remove the teeth cut the alveolar walls with a brick chisel, placing that instrument on the superior margin of the alveolar wall at a point between two teeth, and then force the chisel along the dental organs to the roots. Pry up the external walls between these incisions and force the teeth out of their alveoli (Fig. 65).

EAR.—Extirpate the tympanic and petrous portion of the temporal bone by making deep incisions with the chisel one inch anterior and one inch posterior to the external auditory meatus (Fig. 65). Technic on the internal ear will be described with technic and description of organs.

EYE.—Enucleate the eye with small, sharp-pointed scissors and forceps. Grasp the nictitans membrane with the forceps, draw it out and sever it. Pass the scissors into the orbital cavity beside the eyeball and snip it free from its muscular attachments and the optic nerve. Always keep the scissors pointed toward the bony walls of the orbital cavity to avoid puncture of the eyeball.

REMOVAL OF SPINAL CORD.—The spine should be opened and the cord extirpated after the legs and side have been removed, cavities eviscerated, and the head disarticulated at the occipito-atloidal joint. In the cervical region all the musculature should be excised from the left half of the vertebræ. In the dorsal and lumbar regions from the first rib backward one should sever all broken ends of ribs close to the vertebræ with an ax. This preparation completed one should wash and dry the ax handle and the hands to avoid danger of the ax slipping from one's grip. Take a position on the dorsal side of the cadaver and swing

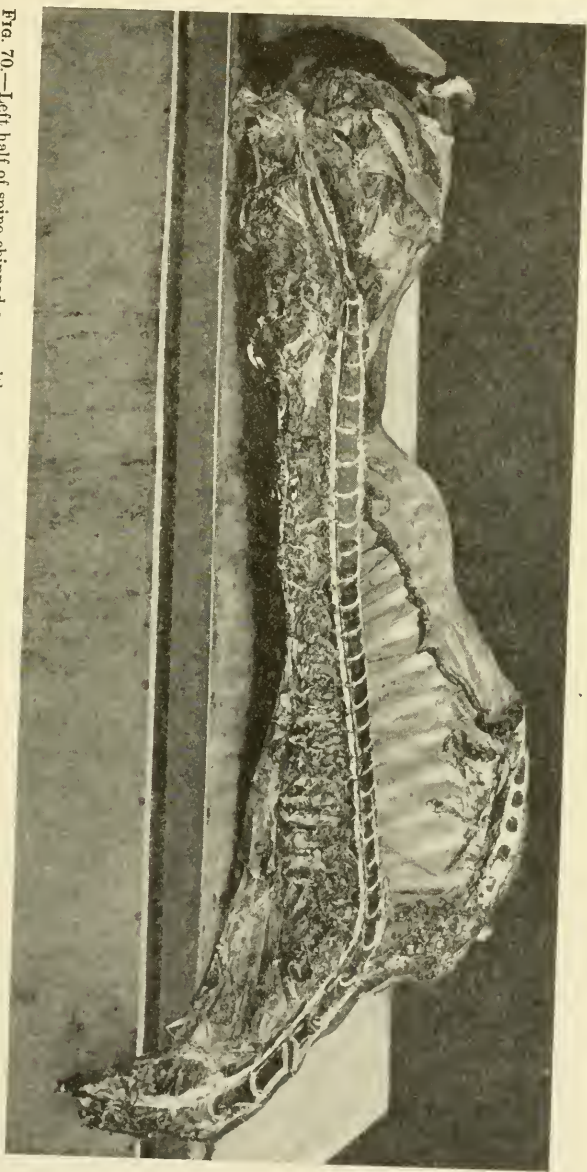


FIG. 70.—Left half of spine chipped away with a post-mortem hatchet, exposing spinal cord. Sternum elevated to facilitate photographing cut surface of spine and intact spinal cord. Spinal cord in its meninges may now be removed with scissors or scalpel.

the ax from right to left, almost parallel with the vertebrae beginning with the left wing of the atlas. The ax handle is so held in the hands that just as the cutting edge strikes the vertebra it is rotated upward away from the spine in such manner as to remove a small chip of bone. Continue to chip in one place until the canal is opened and the cord visible, then from this point backward continue the chipping process until the entire canal is opened to the coccygeal vertebrae. Pick up the cord in its meninges with forceps and with a scalpel sever all efferent nerves and remove the structure. Great care must be used in directing the edge of the ax. Should it approach the spine at a sharp angle the blade would be carried through the vertebra and the cord severed (Fig. 70).

PERIPHERAL NERVES.—Peripheral nerves must be dissected out along anatomical lines for examination.

OPERATIVE TECHNIC FOR THE THORACIC AND ABDOMINAL CAVITIES

FRONT LEG.—To remove the front leg take a position on the ventral side anterior to the limb facing the cadaver. Place an incision just back of the shoulder, from the crest of the back to the sternum, cutting downward through the thoracic muscles to the ribs but not through the intercostal muscles. Next make an incision immediately in front of the shoulder from the top of the neck to the manubrium or point of the sternum. Have an assistant raise the leg upward then sever it from the body by cutting through the pectoral muscles from the sternum to the suprascapular processes (Fig. 62). Examine the axillary nerves and blood-vessels before dividing them, then cut downward deeply in such manner as to leave as much muscle with the leg

and as little on the ribs as possible. The assistant should bear upward continuously during the cutting and finally when the leg is loosened force it completely over on the dorsal side (Fig. 63). There it should be cut free and be removed to a table where the lymph-glands, joints, tendons, tendon sheaths, foot structures, etc., may later be exposed and inspected.

HIND LEG.—To remove the hind leg remain on the ventral side in front of that extremity. Start the first incision just back of the external angle of the ilium; cut downward and forward toward the flank, through the tensor fascia lata, panniculus in the fold of the flank, and through the skin on the inner side of the leg close to the abdomen as far as the penis or mammary gland. The next incision is horizontal. It is made parallel to and three inches above the median line from the skin inward to the coxofemoral articulation (Fig. 62). Place the cutting edge of the knife against the skin three inches above the median line, handle toward the tail, point toward the abdomen, and cut inward toward the coxofemoral joint, taking great care that the point of the knife does not puncture the abdominal wall. When the joint is opened the air rushing in causes a loud sucking sound. Cut through the ligamentum teres, backward and upward over the ischial tuberosity, then downward behind the acetabulum. During the incision have the leg held straight up and forced toward the dorsal side of the cadaver until it falls. To remove the leg entirely cut deeply into the musculature following a line marked by the external angle of the ilium, the acetabulum and the ischial tuberosity. Allow as much of the hip and thigh muscle to be removed with the leg as possible without cutting into the great sciatic ligament (Fig. 63).

The following muscles are cut through in removing the hind leg in this manner: tensor fascia lata, panniculus of the flank, gracillus, sartorius, pectineus, adductors, semi-membranosis, quadratus femoris, obturator externus, rectus femoris, capsularis, psoas major, iliacus, obturator internus, semitendinosus, biceps femoris, and the gluteal muscles.

XIPHOID-PUBIC INCISION.—After the left fore and hind legs have been removed dissect the penis or mammary gland away from the abdomen and lay it behind the right hind leg (Fig. 63). Do not cut through the penis, and in stallions do not cut the spermatic vessels if the urogenital tract is to be removed intact. Next make an incision through the skin and subcutis on the median line, from the pubis to the xiphoid cartilage (Figs. 63, 71). If the integument has previously been removed, draw a line with the sharp edge of the knife along the superficial surface of the abdominal muscles between the points indicated to be used as a guide. Press against the sternum with the thumb to locate the xiphoid cartilage. At a point one inch posterior to it make an incision two inches long. This cut is difficult to make without puncturing an intestine, especially if the cadaver be bloated. Stand back of the right foreleg with the left side against the ventral surface of the cadaver. Hold the knife in the right hand with a full hand grip, as though to cut bread. Place the curved portion of the cutting edge near the point against the median line of the abdomen just back of the xiphoid cartilage and press it into the muscle only an eighth of an inch or less (Fig. 71). Remove the knife and inspect the incision. The fibres will tear at the point of incision in direct proportion to the degree of gas pressure within the abdomen. Place the forefinger of the left hand in the incision and attempt

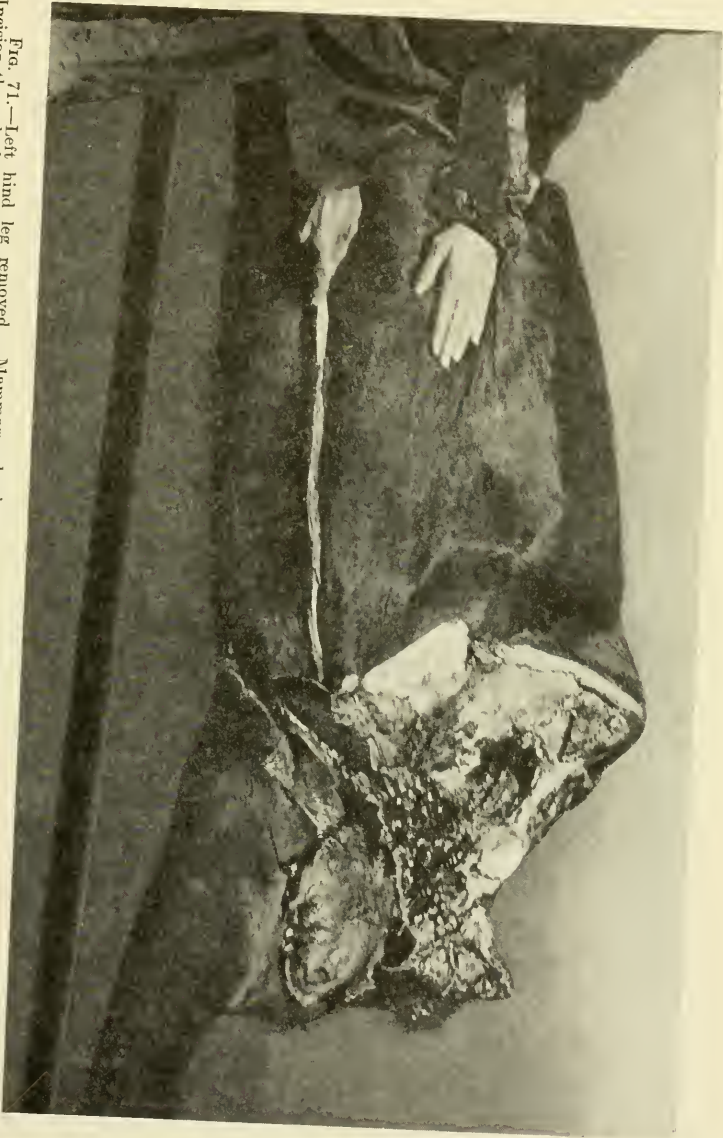


FIG. 71.—Left hind leg removed. Mammary gland separated from the abdomen and laid back over the right hind leg. Incision through the skin and subcutis only, on the median line of the abdomen, from anterior margin of udder to xiphoid region completed. Convex cutting edge of the knife, not the point, now in proper position to cut through the abdominal muscles in making the primary opening into the abdominal cavity.

to enlarge it. Again apply the knife cautiously and with very little pressure until the tissue can be felt to yield a little, when the knife is again withdrawn and the finger inserted. This procedure is carefully continued until the finger, *not the knife*, first passes completely through the abdominal musculature, then the finger should be forced

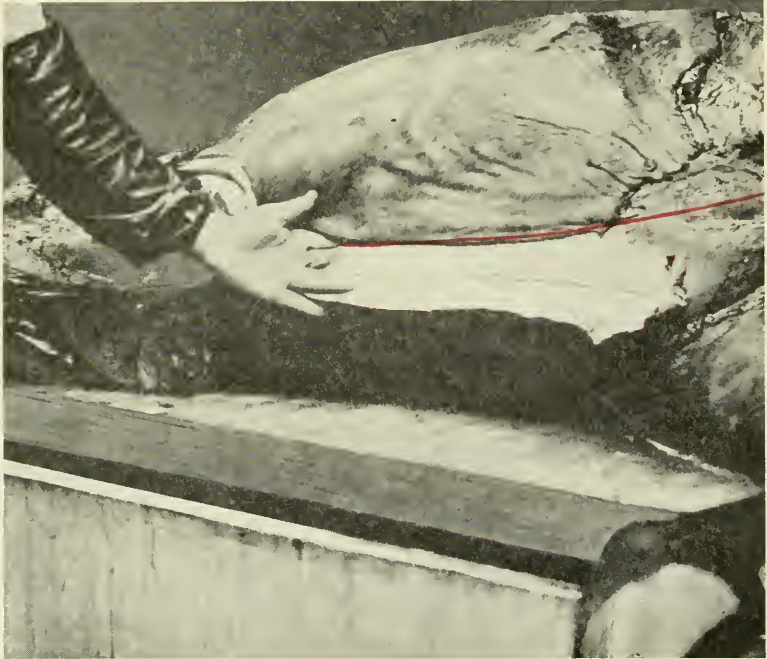


FIG. 72.—Insertion of first two fingers of left hand in abdomen after making incision indicated in FIG. 71.

through the peritoneum. The point of the knife should never be forced through the abdominal wall at this point first, as a puncture of the intestine invariably results. After the index-finger has been inserted, the opening should be enlarged so as to admit the second finger also. Insert the first two fingers of the left hand, turn the backs toward

the xiphoid cartilage, bend the fingers to make an angle with the apex formed by the knuckles; place the ends of the first two fingers against the peritoneum of the abdominal wall one on either side of the median line (Fig. 72). Hold the knife in the right hand, cutting edge toward the pubis. Place the point in the opening about half an inch,



FIG. 73.—Proper position of hands and knife in beginning the xiphoid-pubic incision. First two fingers of the left hand are inserted in the opening made in the abdominal wall in the manner indicated in FIG. 72. The knuckles of the first two fingers protect the intestines from the knife. The point of the knife, with cutting edge outward, is inserted between the fingers and two inches of the belly wall incised by a quick outward incision. This is continued to the pubis.

between the first two fingers of the left hand close to their base (Fig. 73). Cut slowly through the abdominal wall from the xiphoid cartilage to the pubis along the median line, keeping the knife in this position. The knuckles of the first two fingers of the left hand are so pressed against the intestines during the incision as to protect the latter

from the point of the knife, thus preventing puncture of an intestine, escape of the fecal matter into the peritoneal cavity, and possible masking of lesions. When the knife is very sharp and the autopsist experienced, the first finger of the left hand may be inserted in the incision, back of the ensiform cartilage, together with the knife, and the end of the finger placed on the back of the knife so that it protrudes over the point to prevent it puncturing an intestine. In this position the incision through the abdominal wall from sternum to pelvis may be made with one long, smooth motion of the arms.

PUBIC-LUMBAR INCISION.—When the intestines are distended with gas, portions of the small gut, the free end of the double colon, or the point of the cæcum may protrude after the xiphoid-pubic incision has been made. When practical, draw the free portion of the double colon out of the abdomen to lessen the tension and facilitate the next incision (Fig. 75). The pubic-lumbar incision is made from the pubis upward in front of the external angle of the ilium to the lateral processes of the lumbar vertebræ immediately posterior to the left kidney (Fig. 62). Great care must be taken in this operation to prevent puncturing an intestine. Stand in front of the right hind leg, face toward the ventral surface of the cadaver. Grasp the abdominal wall six inches anterior to the pubis with the left hand, placing the thumb in the xiphoid-pubic incision. Take the knife by the end of the handle with the right hand in such manner that the blade is at right angles to the forearm, cutting edge away from the autopsist, point upward. Grasp the handle firmly with the third and fourth fingers and thumb and extend the first and second fingers straight out from the hand (Fig. 74). Carry the handle of the knife into

the abdominal cavity close to the pubis, butt foremost, cutting edge against the upper lip of the xiphoid incision, point of the knife outside of the abdomen extending toward the right shoulder of the autopsist (Fig. 75). Draw the belly wall tight with the left hand and cut through it toward the lumbar vertebræ, in front of the external angle of the ilium, with that part of the blade closest to the handle, keeping the point entirely out of the abdomen (Fig. 75).

The butt of the knife handle and the first two fingers should extend straight out from the hand and precede the cutting edge of the knife, forcing the intestines away from the abdominal wall in such manner as to prevent their being cut. The spermatic cord of the male should not be injured, but should be dissected from the inguinal canal and together with the testicles be placed in the pelvic cavity to be removed later during the exenteration of that region.

After the xiphoid-pubic and pubic-lumbar incisions have been completed the free end of the double colon, the cæcum and the small intestines will usually fall out of the abdominal cavity if they have not previously been drawn out (Fig. 76). Should they not protrude of their own accord apply steady, gentle traction to the free end of the double colon until it can be withdrawn, after carefully inspecting the



FIG. 74.—Proper manner of holding knife when making pubic-lumbar incision. First two fingers are extended to force the intestines away from the cutting edge of the knife, thus avoiding accidental incision of a gut and contamination of abdominal contents.

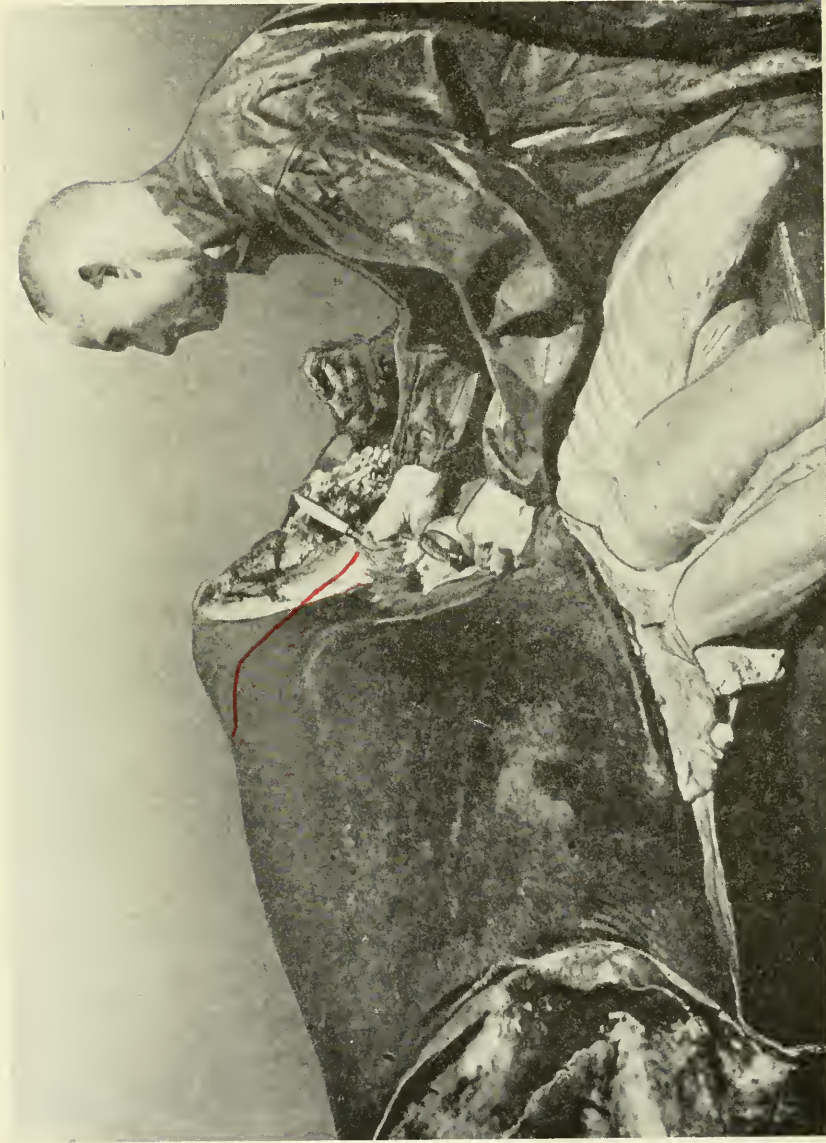


FIG. 75.—Niphoth-pubic incision completed. Double colon and caecum drawn out after examination of their position in the cavity. Pubic-humbar incision half completed. Left hand applying traction to abdominal wall, right hand holding knife properly to make this incision without cutting an intestine. See FIG. 74.

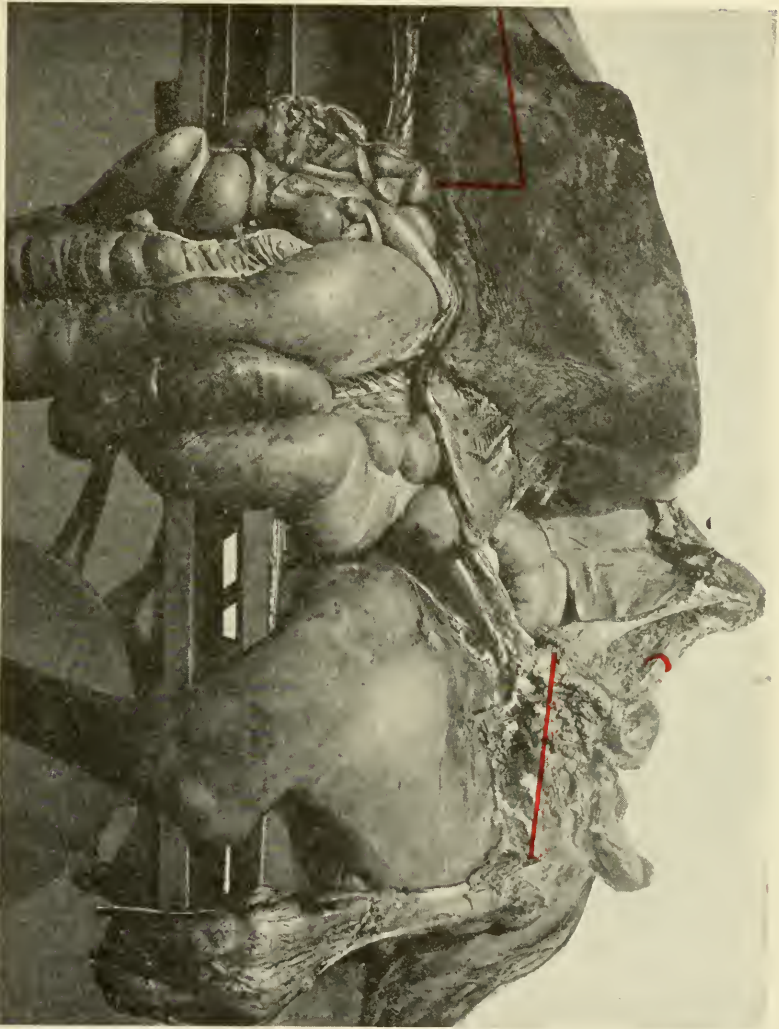


Fig. 76.—Left hind leg taken off. Perinee and penis separated from abdomen and external surface of pubis and late part of the right hind leg. Lines of incision through the shaft of the ilium and pelvic symphysis for removal of part of os ilium and os ischiurum to examine pelvic structures *in situ*. Lines of incision for extirpation of triangular piece of abdominal wall posterior to sigmoid cartilage. Sphincter-pubic and pubic-tumbar incisions completed. Small intestines, double colon, and caecum protruding in usual manner.

topographical relationship of the viscera exposed by placing the free flap (operculum) of the abdominal wall up over the ribs (Fig. 77).

VACUITY OF THE THORAX.—After the free portion of the double colon has been withdrawn from the abdomen and forced backward toward the pubis as far from the ensiform cartilage as possible (Fig. 77), so that the ax will not puncture it when the ribs are cut, the autopsist should place his right hand in the abdominal cavity with the palm against the diaphragm to test the vacuity of the thorax. When the abdominal surface is concave and tight the thoracic surface must be convex. This is the physiological position and indicates that the thorax is a vacuum. When the abdominal surface of the diaphragm is convex it indicates that air, gas or liquid is in the thoracic cavity. Air may enter the pleural cavity through an external wound or following rupture of bronchi, alveoli and the visceral pleura. Gas may form in the thorax from the action of bacteria either before or after death. In cases of hydrothorax, according to F. Smith, gallons of fluid may be contained in the thorax and not force the diaphragm into such a position that the abdominal surface will be convex, while Kitt maintains that quantities of fluid in the thorax will arch the diaphragm toward the abdomen. A further test of thoracic vacuity, pneumothorax or hydrothorax is accomplished by making a puncture half an inch long between the sixth and seventh ribs. This incision should be made with the point of a knife through the intercostal muscles at a point equally distant from the ends of the ribs, after the diaphragm has been palpated. As soon as the point of the knife has been withdrawn place the index-finger in the aperture as far as the first joint and draw upwards slightly to open one end

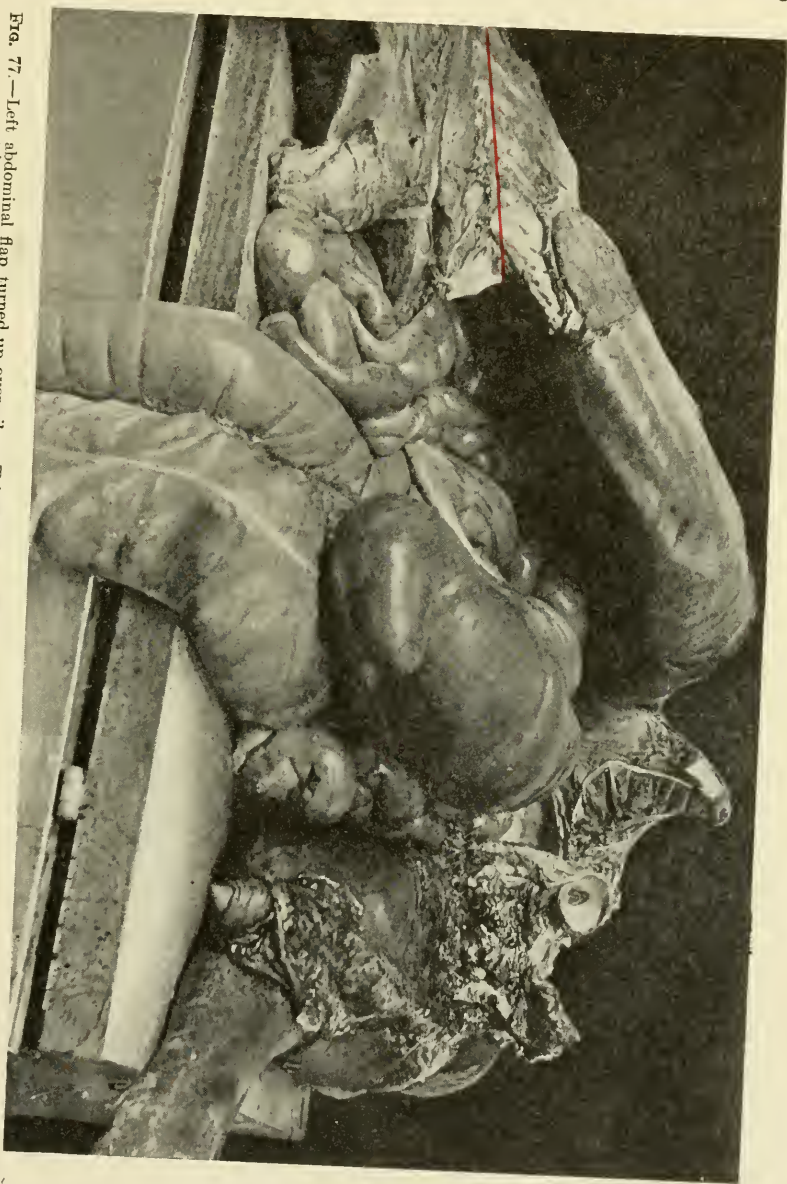


Fig. 77.—Left abdominal flap turned up, over ribs. Triangular piece of abdominal wall and pectoral muscles ablated to facilitate cutting of the ribs. Line of incision from inferior end of first rib to xiphoid cartilage for ventral rib incision.

of the incision. If the thorax is a vacuum air will rush in past the finger, imparting a cold sensation to back of the digit. If vacuity of the thorax is not present fluid, air or odoriferous gas may pass out by the finger, or there may simply be a failure of air to rush into the thorax through the opening. When there is a great quantity of fluid in the thoracic cavity it will often escape through the incision as soon as the knife has been withdrawn, or immediately the ax severs the ribs.

RIBS.—Place a line with the sharp edge of the knife across the lower part of the chest from the inferior end of the first costa to the xiphoid cartilage (Fig. 77). This line is to be followed with the saw or ax in cutting the ribs. To obviate incising muscular tissue with saw or ax seize the pectoral muscles which remain on the lower part of the chest, pass the knife between them and the ribs and lay the tissue over the edge of the sternum (Figs. 63, 77). Remove a triangular piece of abdominal wall six inches long extending from the ensiform cartilage backward along the border of the ribs (Figs. 76, 77). We remove the side, following a method similar to that of Czokor.

To cut through the ribs with an ax is decidedly more expeditious than to saw through them, although some pathologists prefer the latter method. Great care must be taken not to cut into the pericardium and heart, as the pericardial fluid would become stained with blood from the ax, or perhaps a quantity would escape and prevent accurate measurement of the fluid. It is not impossible that a pleuritic exudate might enter such an accidental incision, contaminate the pericardial fluid and render impossible correct judgment of the nature of the fluid as it appeared before the sac were accidentally opened. After

washing and drying the hands and ax handle so that it will not slip, take a position on the ventral side of the cadaver in front of the right foreleg facing the thorax. Aim to follow the line previously made with the knife from the xiphoid cartilage to the inferior end of the first rib (Fig. 77). Swing the ax from right to left, nipping each rib with two inches of the anterior corner of the blade only. So direct the ax that the blade will be carried on out of the thorax if more force is used than that necessary to sever one rib, and so that the blade will not be carried downward through the ribs into the heart. In this manner sever the inferior ends of the ribs from the xiphoid cartilage to the first costa.

To prepare the superior extremities of the ribs for section with the ax, take a position on the dorsal side of the cadaver. Cut through the musculature with a knife, diagonally from the superior end of the first rib to the seventh, striking the latter at a point six inches from its vertebra. Trim the musculature away from the ribs from this incision to their superior ends. From the seventh to the eighteenth ribs make an incision six inches above and parallel with the crest of the back. Cut downward to the ribs, pass the knife under the longissimus dorsi and remove all muscle from the angle made by the ribs and vertebral spinous processes from the seventh to the eighteenth. A portion of each rib from the first to the eighteenth will now be free from muscular tissue, which greatly facilitates cutting through them (Fig. 78). This preparation completed, the hands and ax should be washed and dried as before and each rib cut through with two inches of the anterior corner of the blade. The line followed by the ax should be that first made with the knife from the top of the first to a point on the seventh costa approximately six inches from its vertebra, and from

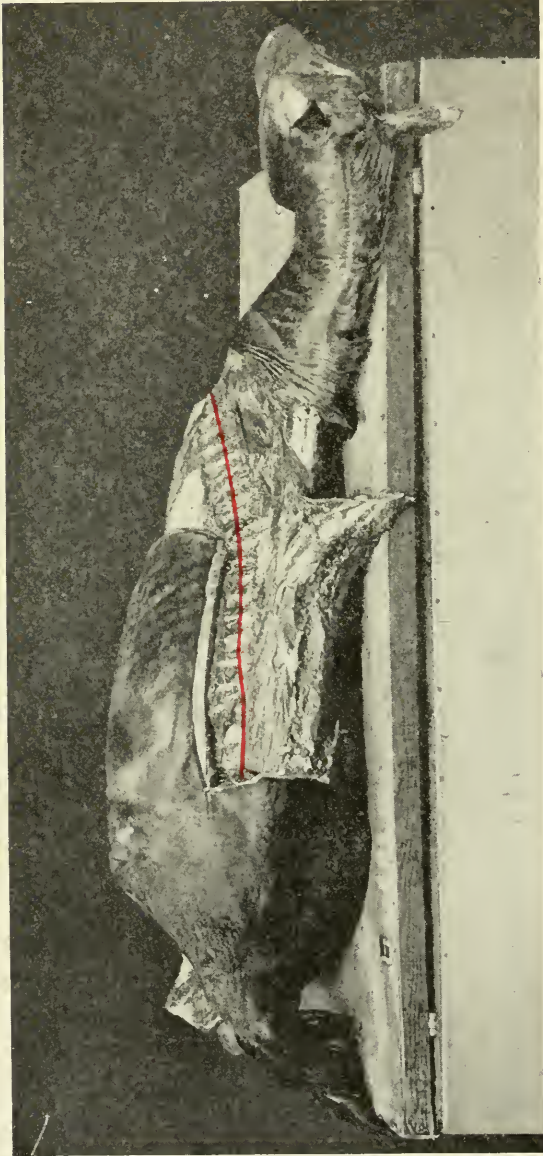

Fig. 78.—Preparation of the back for dorsal rib incision in ablation of left side.

the seventh to the eighteenth in a straight line parallel to and four to six inches above the crest of the back. After each rib has been severed press upon the side, close to the incision, with the heel of the left hand. At points where it does not give under this pressure apply the ax again until the ribs are severed.

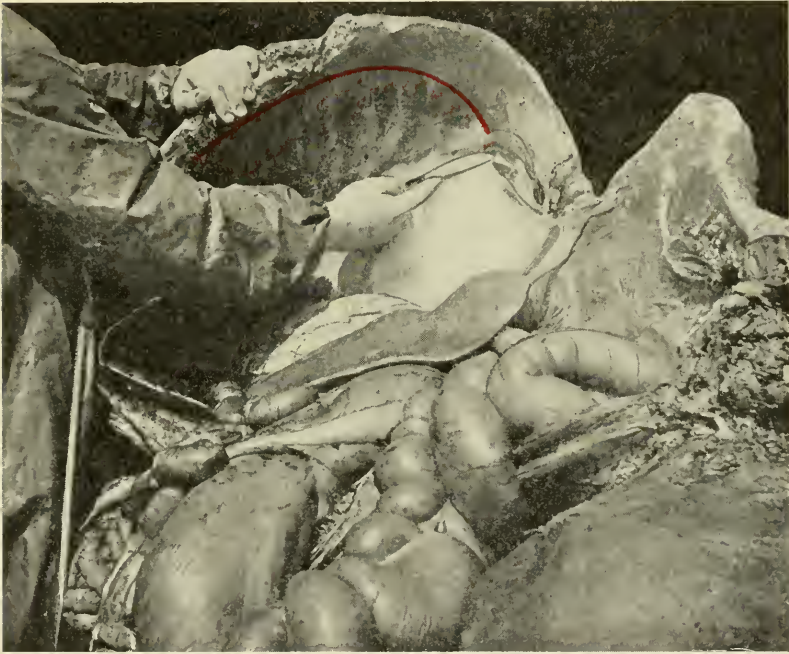


FIG. 79.—After completion of ventral and dorsal rib-incisions left side is elevated and the diaphragm incised close to the ribs and the side freed. Line of incision in the diaphragm.


To complete the removal of the side the autopsist should stand on the ventral side of the cadaver and cut the diaphragm close to the ribs from the last costa to the xiphoid cartilage (Fig. 79). During this operation an assistant should stand on the dorsal side of the cadaver, reach over the

side, place a hook under the ventral border of the ribs, and draw the side upward as the diaphragm is being cut, until the ribs and abdominal wall drop over the dorsal side of the body, when it may be cut free and removed.

When the thoracic and abdominal cavities have thus been exposed and at the time they were being opened the autopsist should carefully note the presence of excessive fluid, clots, gas and foreign bodies and the position of the organs. Virchow says that no organ should be removed until its exact relationship to other organs has been determined. In excising an organ place the knife under the attachments and cut upward whenever possible to avoid cutting adjacent structures.

OMENTUM.—Seize the omentum and remove it with the hands by traction.

SINGLE COLON.—Extend the hand into the pelvic cavity; seize the single, small, or floating colon, or the abdominal portion of the rectum as it is sometimes called, near the point at which it enters the pelvis; squeeze the contents in either direction for a distance of six inches and apply two ligatures, called a double ligature, one on either side of the empty space, then cut through the intestine between the ligatures (Fig. 80). This prevents the escape of fecal matter into the peritoneal cavity. Next force the floating colon out of the abdominal cavity upward over the external angle of the ilium. Continue forcing this gut over the dorsal side of the cadaver until no more can be extruded, due to its connection with the terminal portion of the double colon (Fig. 80). When the entire floating colon has been forced over the external angle of the ilium the rectoduodenal ligament will be found directly over the left kidney (Fig. 80). This ligament is a guide to the



Left apical lobe of lung laid back

Recto-oduodenal ligament

Fig. 80.—Tornae, larynx, trachea and oesophagus ablated. Right and left vagus, carotid artery, and jugular vein exposed to facilitate demonstration of abdominal rectum suspended in fan shape preparatory to throwing it back over the external angle of the ilium and to denude at its termination. The recto-oduodenal ligament which connects the single colon (abdominal rectum) at its origin to the duo- and caecum have been drawn out and forced backward to the pelvis; (2) on the single colon close to its entrance to the rectum. The prepuce and penis have been laid behind the right hind leg.

Right and left vagus, carotid artery, and jugular vein exposed to facilitate demonstration of abdominal rectum suspended in fan shape preparatory to throwing it back over the external angle of the ilium and to denude at its termination. A loop of the jejunum is suspended above the double colon (abdominal rectum) at its origin to the duo- and caecum have been drawn out and forced backward to the pelvis; (2) on the single colon close to its entrance to the rectum. The prepuce and penis have been laid behind the right hind leg. Lines for double ligations have been applied at four points: (1) On the single colon close to its entrance to the pelvis; (2) on the single colon (abdominal rectum) opposite the recto-oduodenal ligament; (3) on the jejunum opposite the recto-oduodenal ligament; (4) on the ileum close to its entrance to the caecum.

points at which double ligatures are made on the jejunum and the anterior part of the abdominal rectum or single colon. A double ligature is applied to the single colon close to the rectoduodenal ligament and another double ligature on the jejunum close to that ligament (Fig. 80). Cut between these ligatures, then remove the single colon by incising its mesentery close to the attachment of the latter to the sublumbar region.

LIGATIONS.—To ligate an intestine, double a stout piece of twine 12 inches long. Force the loop end under the gut and bring it up on the opposite side. Push the two free ends through the loop. Draw this slipknot tightly around the intestine. Divide the free ends and carry them around the gut in opposite directions, bringing them to the top again where they are tied with a surgeon's knot.

SMALL INTESTINES.—Arrange the folds of the small intestine properly on its mesentery and examine the latter carefully. Seize the jejunum with the left hand at the rectoduodenal ligament where it has been severed from the duodenum. Pull upward and outward on the jejunum with the left hand until the mesentery is tight, then cut through the latter close to the gut, using great care not to injure the intestinal wall (Fig. 81). While cutting the mesentery with the knife draw the intestine out of the abdomen and allow it to fall to the floor at the autopsist's left side. When a portion of intestine equal to the length of the arm has been drawn out and severed from the mesentery, drop it and take a new grip closer up, and thus continue drawing the intestine out and cutting it from the mesentery until the cæcum is reached. Here apply a double ligature (Fig. 80) and cut through the ileum, thus completing the removal of all the small intestine except the

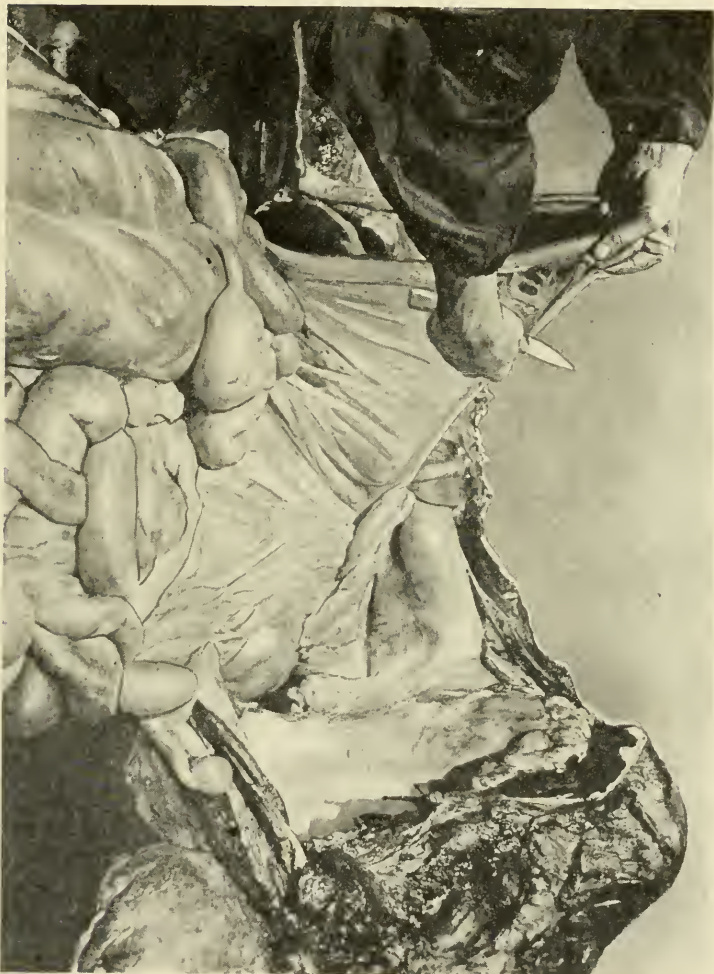

Fig. 81.—Small intestines arranged at the end of their mesentery upon the colon and caecum. Proper method of holding small intestines and knife in separating the intestine from its mesentery.

duodenum, which is left with the stomach and removed later with that organ.

EPIPLOIC FORAMEN OF WINSLOW.—Place the left hand in the concavity made by the small curvature of the stomach, follow the groove in the liver and trace the posterior vena cava from the point where it passes into the substance of the liver back to the pancreas and portal vein. The fingers may be passed through a slit-like opening at this point called the epiploic foramen of Winslow. It is formed by the caudate lobe of the liver, posterior vena cava, pancreas, gastropancreatic fold and portal vein. One should be able to locate the epiploic foramen readily as the jejunum may pass through this opening, producing a hernia (Bruckmuller, Cadeac).

BILE-DUCT.—To examine the ductus choledochus raise the stomach upward by grasping its wall on the great curvature and forcing it toward the vertebræ. The duct will be seen as a flat band one-half to three-quarters of an inch wide extending from the liver to the duodenum. It may be opened with a sharp-pointed scissors. The pancreatic duct enters the duodenum with the bile-duct. There is no free portion of the pancreatic duct. After the bile-duct has been examined allow the stomach to fall back into place.

SPLEEN.—Grasp the spleen by the posterior basal angle which points toward the kidney. Draw the organ forward and cut through the suspensory (splenophrenic and splenonephritic) ligament and the gastrosplenic omentum and remove it from the cavity.

LEFT KIDNEY.—To remove the left kidney force the fingers through the perirenal fat, pass them around the periphery of the organ, draw slightly upon it until the renal vessels and ureter are exposed, then hold the kidney

in the left hand and pass a knife under the ureter and renal blood-vessels between the organ and the sublumbar muscles and cut upward, severing it from the body. If it is desired to examine the whole urogenital system intact, cut through the renal blood-vessels but not through the ureter, then place the kidney and ureter in the pelvic cavity until the organs of that region are extirpated.

LEFT ADRENAL.—The left adrenal gland lies directly under the left kidney, and is plainly visible when that organ has been removed. Do not attempt to cut it loose, but force the fingers under and around it, carefully tearing it away from its attachments. This organ is very friable and is easily split or broken even shortly after the death of a healthy animal.

DUODENUM.—There is danger of breaking the duodenum away from the stomach if it be allowed to remain in its natural S-curve position while the large intestines are being drawn out of the abdominal cavity. To obviate this, place the left hand between the stomach and the double colon, force it downward until the knuckles are pressed against the ribs. Push the hand and arm backward under the duodenum, and vessels and ligaments that attach to the large intestines. When the hand has reached a position back of the kidney close to the sublumbar muscles, force it upwards to the rectoduodenal ligament. Grasp the duodenum with the left hand at this point where it has been severed from the jejunum, and draw it downward under the colic vessels and forward towards the stomach. As the duodenum is being drawn forward under the colic vessels by the left hand, the right hand, introduced back of the mesenteric artery, should follow the gut along and tear it loose from its attachments so that the traction exerted by

the left hand will not break it. The duodenum when pulled out of the S-curve position should be laid up over the lungs still attached to the stomach until the large intestine has been removed. The duodenum is approximately 1–1.25 metres (3'–4') long and in order that the left hand may reach the end of that intestine the arm must enter between the stomach and double colon as far as the shoulder. During this operation the autopsist may stand astride the double colon and lean well forward. Should any pathological alteration of the intestine be felt in passing the hand along under the duodenum, the latter should be left *in situ* and a very careful effort be made to remove the colon and cæcum without injury to this portion of the small intestines. After the duodenum has been laid over the lungs, complete the preparations for removal of colon and cæcum by gathering up the mesentery from which the small intestines have been removed, pass a knife under it and cut upward through it. This will expose the origin of the fifteen or twenty small blood-vessels which supplied this mesentery and the small intestines.

DOUBLE COLON AND CÆCUM.—The double colon and cæcum will now be found extending from the abdomen at right angles to the line of the back; and the free extremity, or pelvic flexure of the great colon, resting on the floor (Fig. 80). The double colon and the cæcum have several attachments: (1) the blood-vessels which supply them; (2) the mesocolon or ligamentous band which attaches them to the sublumbar region; (3) the pancreas. The first two are the principal structures which connect the colon and cæcum with the body. Only the large blood-vessels should be cut through. The other structures should be separated with the fingers. Great care should be taken to leave as

much of the anterior mesenteric artery with the aorta as possible, so that it may be opened later and examined for thrombi which are due to embryos of the *sclerostomum bidentatum* and occur in 90 per cent. of horses.

To loosen the colon and cæcum from their attachments, first grasp the stump of the single colon close to the great

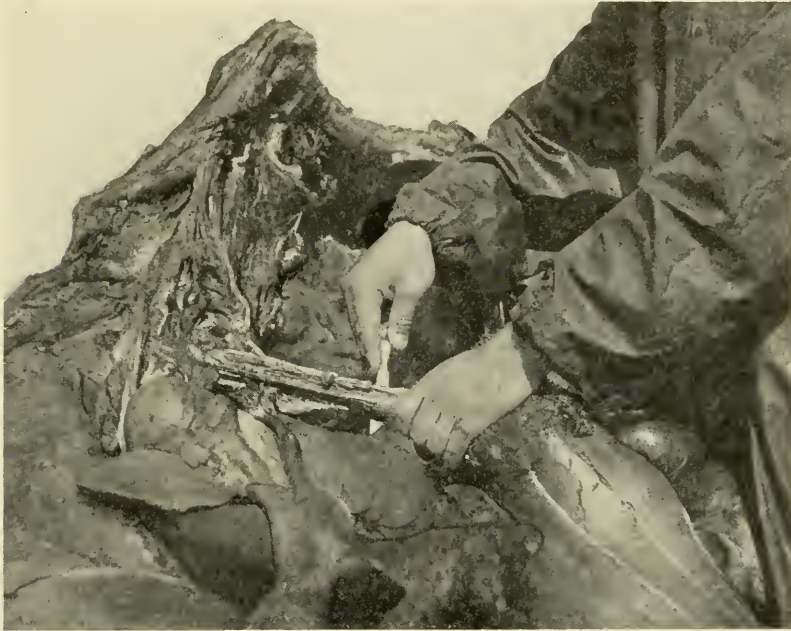


FIG. 82.—Left hand grasping mesenteric vessels at point of attachment to the double colon and cæcum. Knife held under the mesenteric blood-vessels at the point they should be severed, thus leaving six inches of vessels attached to the aorta for examinations later.

colon with the right hand and draw it toward the autopsist. Force the thumb of the left hand between the pancreas and colon and gradually work the pancreas loose from its position on the intestine, leaving it with the liver. Next grasp the mesenteric artery in the two hands between the aorta and the intestines, in the same manner that one would grasp

a cylinder if he were to span its circumference, using the thumbs and forefingers of both hands. Tear the ligamentous bands and small blood-vessels by pulling laterally from the large mesenteric artery. Do not pull downward from the aorta toward the intestines or the mesenteric artery will rupture. When the ligaments and smaller blood-vessels have been torn away, circle the mesenteric artery with the thumb and forefinger of the left hand. Slide the left hand downward on the mesenteric artery close to the colon, pass a knife under the vessels with the blade close to the gut and cut upward through the vessels (Fig. 82). This should leave from four to five inches of mesenteric vessels hanging from the aorta. When the mesenteric arteries have been cut, the colon and cæcum will fall out of the abdominal cavity to the floor. They should be taken to a clean space on the floor and opened according to methods described later.

RIGHT ADRENAL.—Grasp the stump of the mesenteric artery with the right hand and raise it upward. Directly beneath this blood-vessel and closely applied to the right kidney the right adrenal will be found. Force the fingers around it and gradually tear it from its position without the use of a knife.

RIGHT KIDNEY.—To remove this organ force the fingers under the perirenal fat and “shell” the organ out in the same manner employed with the left kidney. Place a knife under the ureter and blood-vessels and cut upward through them.

STOMACH.—Force the first two fingers of the right hand through the diaphragm close to the stomach above the œsophagus at the point where that organ penetrates the diaphragm. When the fingers have penetrated into the thorax grasp the œsophagus and draw it into the abdom-

inal cavity about six inches, apply a double ligature, place a knife under the œsophagus and cut upward through that structure. The gastrophrenic ligament and gastrohepatic omentum should be torn through with the fingers, and the stomach, together with the duodenum, extirpated.

LIVER.—The liver may be held away from the diaphragm and the strong ligaments which form its attachments cut through with a knife. Small ligaments may be torn with the fingers. The principal attachments of the liver are the coronary, falciform, round, right lateral, and left lateral ligaments. Usually the hepatic organ is allowed to remain in the cavity until the exenteration of the abdomen and thorax have been effectuated. Then the liver, together with the diaphragm from which it is later dissected, may be extirpated. To remove the liver and diaphragm together, after the heart and lungs have been taken from the thorax, draw the diaphragm tight by applying traction with the left hand, then circle it close to the ribs with a knife, starting close to the aorta. Great care should be taken not to cut the aorta or anterior mesenteric artery during this process.

PANCREAS.—The pancreas is removed with the liver. This organ is not frequently affected and does not manifest the same degree of importance as most organs at the post-mortem table.

PERICARDIAL SAC AND FLUID.—Preparatory to opening the pericardial sac and examining the quantity and character of the pericardial fluid, the surface of the pericardium, the knife, and the hands of the autopsist should be carefully washed. This is to prevent blood from any of these sources contaminating the fluid and thus deceiving the autopsist as to its true character.

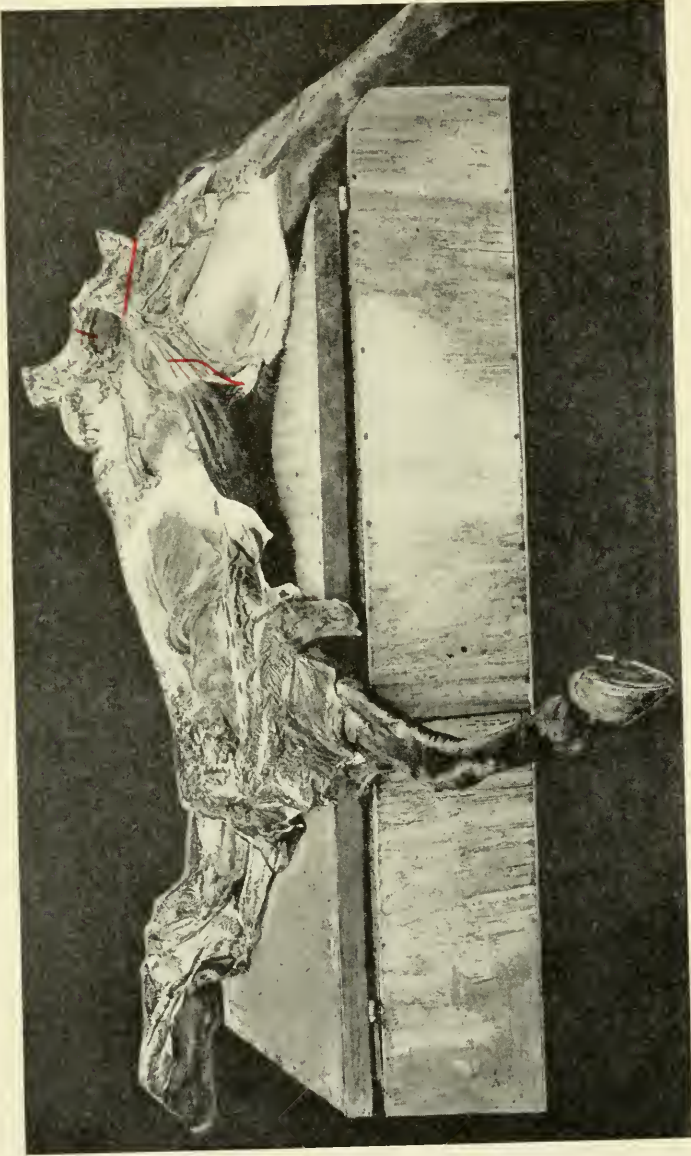


FIG. 83.—Occipito-atlantal articulation opened. Pericardium exposed for incision. Single colon, small intestine, double colon, cæcum, stomach, duodenum, spleen, kidneys and adrenals extirpated. Pelvic organs ablated without removing part of pelvis. Psoas muscles are incised vertically, muscles of the hind leg cut in parallel horizontal planes. The view shows evisceration of the pelvis completed. Evisceration of abdomen complete except ablation of liver, which is removed with diaphragm after evisceration of the thorax. Decapitation partly completed. The thorax is next to be eviscerated, the liver and diaphragm removed, and the aorta and branches opened.

Place a longitudinal incision through the pericardium from the base to the apex of the heart (Fig. 85). Do not cut into the heart muscle or blood may escape into the pericardial fluid. Next draw one lip of the incision aside with the finger and examine the character of the fluid. When this has been determined one does not have to be so careful about

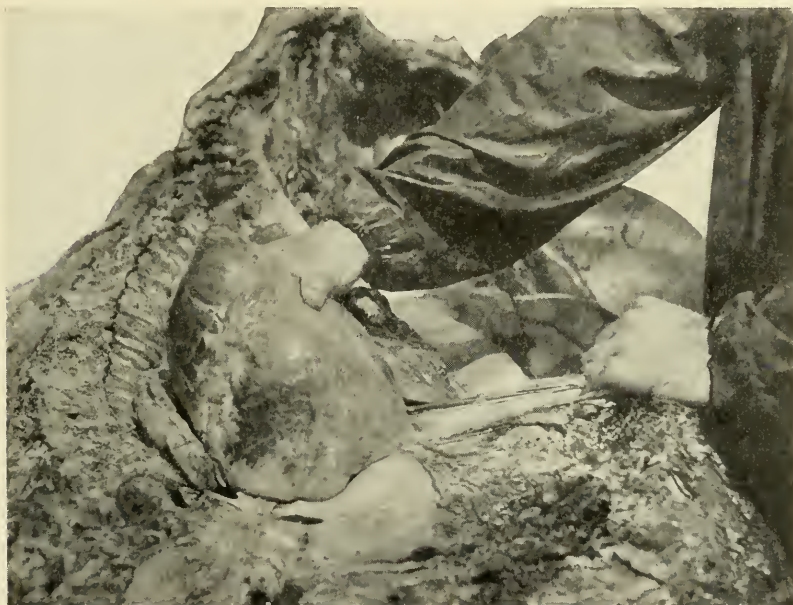


FIG. 84.—Method of exposing contents of pericardial sac.

contaminating the liquid. To determine the quantity place the right hand in the sac, grasp the apex of the heart and raise that organ upward completely out of the sac (Fig. 84). Have an assistant remove the fluid with a pipette or dip it out with a cup kept for that purpose and place it in a graduate. After one has done this a few times he can

estimate the quantity of fluid present with a fair degree of accuracy without measuring it. After the fluid has been

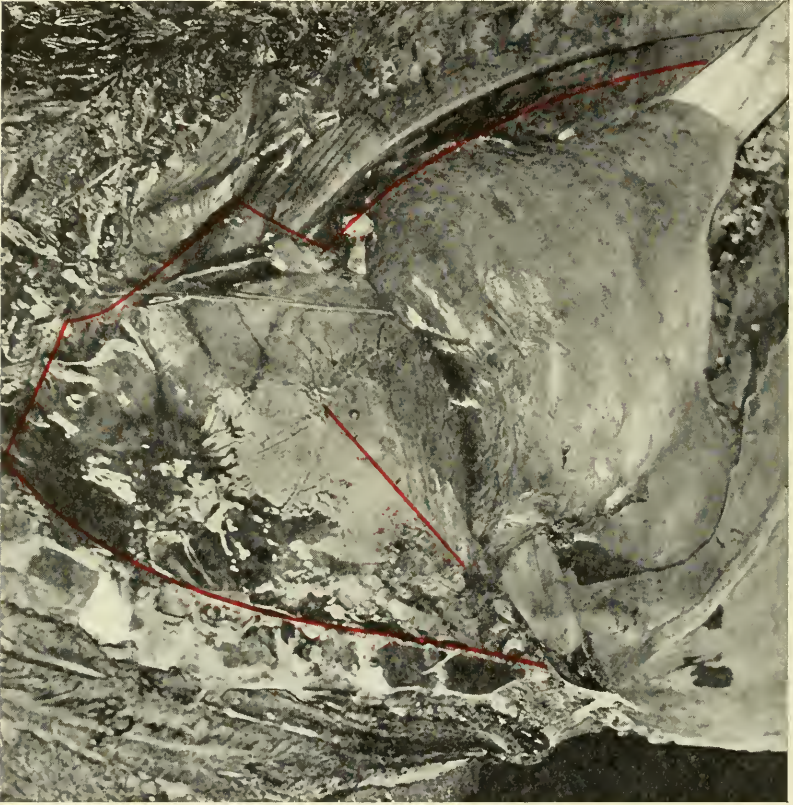


FIG. 85.—View of thorax after left side has been taken off and left apical lobe turned back. Line of incision through pericardium. Superior, anterior and inferior lines of incision for ablation of heart and lungs. Superior line is through posterior mediastinum, below the aorta from the diaphragm forward to the arch of the aorta, and upward through the aorta. At this point the left hand is inserted and right apical lobe of the lung drawn out and held, right hand with knife crossed over the left and the incision continued forward a few inches through the anterior mediastinum above the aorta. Maintaining the same position the anterior incision is made downward and forward through all structures entering the thorax from the neck. The right apical lobe of the lung is released and the inferior incision made through the inferior mediastinum close to the sternum from before to behind.

taken out or estimated, allow the heart to drop back into its proper position.

HEART AND LUNGS.—The heart, pericardium, lungs, bronchial and mediastinal lymph-glands, and thoracic portion of the œsophagus are excised together. The first incision is made through the posterior mediastinum immediately below the aorta, from the diaphragm forward to the arch of the aorta. Turn the cutting edge of the knife toward the vertebræ and cut through the aorta two or three inches from the heart. From this point to the first rib place an incision through the anterior mediastinum immediately below the vertebræ. Withdraw the knife, insert the left hand, grasp the anterior lobe of the right lung, draw it out and hold it away from the trachea. Cross the right hand over the left and cut downward through the trachea, œsophagus and other structures that enter the thorax from the cervical region. By holding the apical lobe of the right lung in the left hand the possibility of cutting it is avoided. The thoracic organs having been severed from their superior and anterior attachments, one may now cut through the pericardial and mediastinal attachments to the sternum, completing the inferior incision (Fig. 85). Readjust the heart and lungs in their proper position as nearly as possible. Hold the left forearm in a horizontal position and point the hand downward in such a manner that the hand is at right angles to the forearm. Maintain the hand and arm in this position, place the hand between the diaphragm and lungs at a point just under the aorta. Permit the ends of the fingers to constantly touch the ribs and keep the hand in contact with the diaphragm. Now draw the hand from the aorta to the sternum. When the latter point has been reached there will be found in the crook of the left wrist the posterior vena cava and phrenic nerves (Fig. 86). Place a knife under these structures and cut upward through

them. The thoracic organs are now free from their superior, anterior, inferior and posterior attachments. To test this pass the hand around the periphery of these organs. To remove the heart and lungs from the thorax, place the

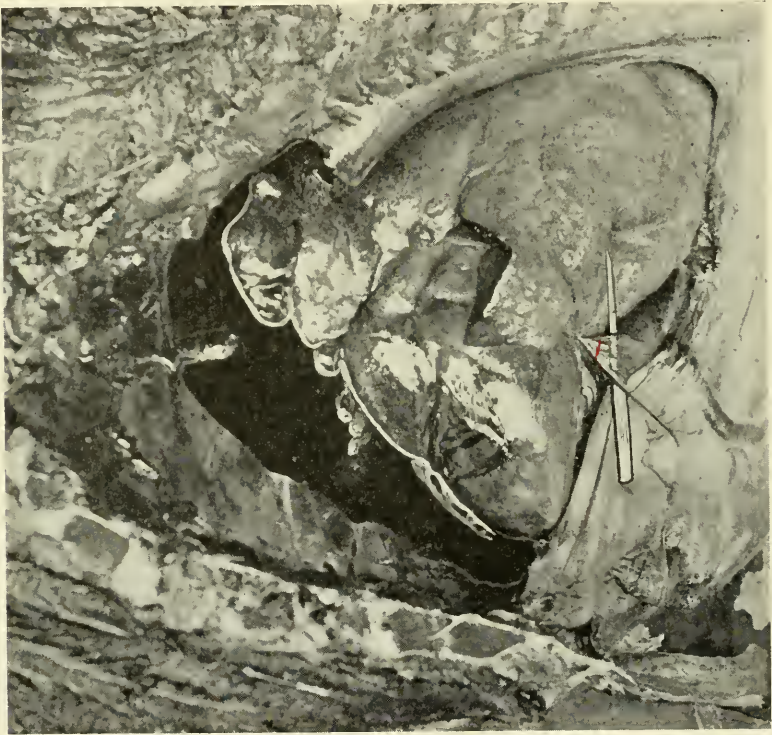


FIG. 86.—View of thorax after left side has been removed. Superior, anterior, and inferior incisions for ablation of heart and lungs have been completed. Blood has escaped from cut vessels, partially filling thoracic cavity. Heart and lungs have gravitated backward against the diaphragm. A knife has been placed under the posterior vena cava and phrenic nerves to better expose them. Line of incision for posterior incision.

right hand behind the heart, palm against the myocardium, and grasp the large blood-vessels between the heart and lungs. Raise the organs upward, balance the lungs on the forearm, and carry them to the tub (Fig. 87).

BLOOD-VESSELS.—Place an enterotome in the aorta at the point at which it was severed and cut as close to the vertebræ as possible. Open the entire aorta and always



FIG. 87.—Proper manner of grasping large blood-vessels between heart and lungs in removing them from thorax or from sink to table.

open the iliac arteries as far as the enterotome can be forced. Thrombi at the origin of the iliac arteries are not uncommon. Carefully open the cœliac axis, renal, anterior and

posterior mesenteric arteries with the enterotome. Parasitic thrombi are present in the anterior mesenteric artery of 90 per cent. of horses (Figs. 88, 89).

PLEURA AND PERITONEUM.—The right abdominal wall should be cut through from the pubis downward to the ribs to permit drainage, and the thoracic and peritoneal cavities flushed out with water and the inside of the large blood-vessels washed. This facilitates the examination of

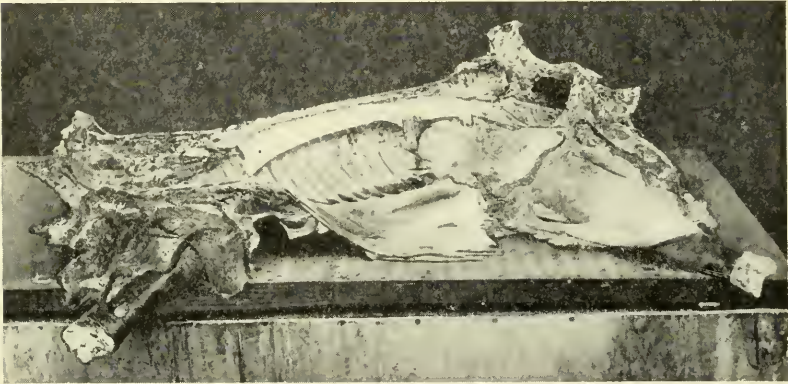


FIG. 88.—View of cadaver after evisceration of thorax, abdomen, and pelvis. Right posterior abdominal wall cut through, abdominal flap laid down and cavities washed out., Aorta mesenteric, and iliac blood-vessels opened. Technic on neck, muscles, right carpal and tarsal joints completed.

the ribs on the right side, vertebræ, pleura, peritoneum, condition of the large blood-vessels, the inguinal canal and ring (Figs. 83, 88, 89).

LYMPH-GLANDS.—The visceral lymph-glands should be incised when the technic is performed on their corresponding organs. Of the parietal lymph-glands the lumbar glands may be found along the aorta, the internal iliac at the bifurcation of the aorta, and the external iliac at the bifurcation of the circumflex iliac artery where they should be incised.

PSOAS MUSCLES.—Dissection of the psoas muscles should

be made in vertical lines half an inch apart with a sharp knife (Fig. 83).

OVARIES AND UTERUS.—These organs may remain *in situ* until the organs of the pelvic cavity are removed.

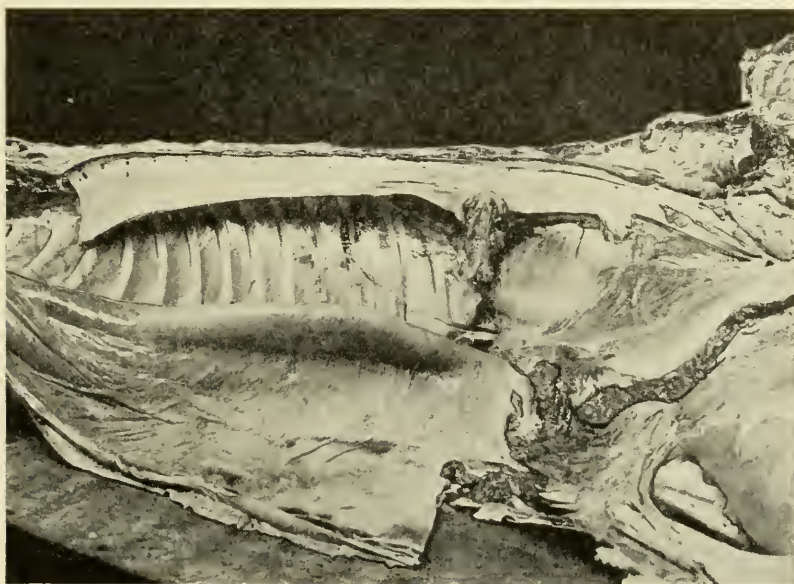


FIG. 89.—Aorta, mesenteric and iliac blood-vessels properly opened.

SUMMARY OF THORAX AND ABDOMEN

Position: Place horse, ass, or mule on the right side.

Skin: Remove the skin only when desirable compulsory.

Foreleg: Place a long, deep incision before and behind the leg, raise it up and sever it close to the body.

Hind leg: Start an incision back of the external angle of the ilium, cut through the tensor fascia lata, through the skin on the inner side of the leg, into the coxofemoral joint,

backward over the ischial tuberosity, then sever it close to the body.

Penis or mammary gland: Dissect the penis or mammary gland from the abdomen and lay it over the leg. Do not cut through the penis.

Xiphoid-pubic incision: Make an incision through belly wall along the median line from the xiphoid cartilage to the pubis, protecting the intestines with the fingers.

Pubic-lumbar incision: Cut through the abdominal wall from the pubis to the lumbar vertebra, forcing the butt of the knife into the abdomen first and protecting the intestines with the two fingers of the right hand.

Position of organs: Note the position of all organs in the thoracic and abdominal cavities. Observe the external appearance of all thoracic and abdominal structures.

Foreign material: Determine the quantity and character of fluids and foreign substances in the thorax and abdomen.

Diaphragm: Feel of the diaphragm to determine the vacuity of the thorax.

Intercostal puncture: Puncture the thorax between the sixth and seventh ribs and determine whether air enters or escapes from the cavity.

Preparation of ribs for section: (*a*) Draw a line with the sharp edge of a knife from the inferior end of the first rib to the xiphoid cartilage.

(*b*) Remove pectoral muscles from the inferior portion of the thorax.

(*c*) Extirpate a piece of abdominal wall back of the xiphoid cartilage along the border of the ribs.

(*d*) Clear away the musculature from the superior end of the ribs from the first to the seventh inclusive.

Clear away the musculature of the back from the seventh to the last rib for a space six inches above the line of the back.

Ribs: Cut through the ribs from the xiphoid cartilage to the inferior end of the first rib and from the superior end of the first rib to the last rib. From the seventh costa backward to the last rib place a line of incision a few inches above the vertebræ.

Test incision of ribs: Press downward in the ribs with the heel of the hand along the incision made with the ax to see if all ribs have been severed.

Diaphragm: Have an assistant hold the ribs up with a hook, then cut through the diaphragm from the last rib to the xiphoid cartilage close to its costal attachment.

Remove side: Push the entire side upward and allow it to fall back of the spine to the floor.

Thoracic contents: Observe the presence of foreign bodies or liquid material in the thorax and note the position and character of thoracic viscera.

Omentum: Tear away the omentum with the fingers.

Ligations: Apply four double ligatures to the intestines six inches apart after squeezing the intestinal contents in either direction from the point of ligation: (*a*) on the small colon at its entrance to the pelvis; (*b*) on the small colon at the rectoduodenal ligament; (*c*) on the jejunum close to the rectoduodenal ligament; (*d*) on the ileum at its entrance to the cæcum.

To ligate an intestine double a stout piece of twine 12 inches long. Force the loop under the gut. Bring it up on the opposite side. Push the two free ends through the loop and draw this slipknot tightly around the intestine. Divide the free ends and carry them around the gut in

opposite directions, finally bringing them to the top again where they are tied with a surgeon's knot.

Small colon: Divide the gut between the ligatures, cut through the mesentery close to the body and remove small colon.

Jejunum and ileum: Arrange jejunum and ileum in proper order on their mesentery and cut between the ligatures. Trim the intestines from the mesentery by pulling on the intestine with the left hand and cutting through the mesentery close to the gut with a knife held in the right hand. Start at the jejunum and pull and cut at the same time. In this manner six feet of intestine may be removed at each incision through the mesentery without injury to the gut, if the intestine has been arranged evenly and freely.

Epiplioic foramen: Follow the posterior vena cava backward and hook the finger into a slit formed principally by the pancreas, portal vein, and posterior vena cava.

Bile-duct: Seize the stomach by the left extremity, force it upward toward the spine, and examine the duct which extends from the liver to the duodenum.

Spleen: Separate and remove the spleen from the stomach and right kidney by severing the suspensory ligament and the gastrosplenic omentum.

Left kidney: "Shell" the left kidney out of its perirenal fat with the fingers and cut through the ureter and renal blood-vessels close to the organ.

Left adrenal: Remove the left adrenal by slowly tearing it away with the fingers.

Duodenum: Pass the left hand between the stomach and great colon. Follow the duodenum to the rectoduodenal ligament with the left hand. Seize the duodenum where severed from the jejunum and draw it backward under the

great colon and vessels to the stomach. Then place it over the lungs where it will not be injured in removing the large intestine.

Great colon and cæcum: Separate the pancreas and colon with the thumb of the left hand, holding the stump of the small colon in the right hand. Tear away all other attachments with the fingers except the large arteries. Place a knife under the large mesenteric arteries and cut upward, leaving as much of the anterior mesenteric artery with the aorta as possible.

Right adrenal: Tear this organ loose with the fingers.

Right kidney: Remove the right kidney in the manner employed to extirpate the left renal organ.

Stomach: Push two fingers through the diaphragm on the right side of the œsophagus, pull that structure back six inches, ligate and sever it. Tear the other attachments loose with the fingers and remove the stomach and duodenum together.

Liver: Leave the liver until the evisceration of the thorax has been completed, then circle the diaphragm close to the ribs with a knife and remove liver and diaphragm together.

Pancreas: Remove the pancreas with the liver.

Pericardial sac and fluid: Wash pericardium, knife and hands to prevent soiling of the pericardial fluid. Incise pericardium vertically from base to apex and examine the color of the fluid. Grasp apex of the heart and lift that organ out of the sac, then estimate or measure the quantity of fluid and replace the heart.

Heart and lungs: Cut forward through the posterior mediastinum to the arch of the aorta, upward through the aorta at this point, and forward above the heart through

the anterior mediastinum. Draw the apical lobe of the right lung out of its position to avoid injuring it. Cut through trachea and other structures entering the thorax from the neck. Incise the inferior pericardial and mediastinal attachments. Kink the left wrist and draw it along the anterior face of the diaphragm to catch the blood-vessels and nerves which connect with it and sever them when located. Grasp the blood-vessels between the heart and lungs close to the heart, balance the lungs on the forearm and carry the organs to the tub.

Blood-vessels: Open the aorta, mesenteric and iliac arteries with an enterotome.

Pleura and peritoneum: Cut downward through the belly wall from the pubis to the ribs and flush out the inside of the blood-vessels, thorax and abdomen with water. This better facilitates examination of the pleura, peritoneum and the ribs.

Lymph-glands: Incise the lumbar, internal and external iliac lymph-glands.

Psoas muscles: Incise the psoas muscles vertically in lines a half inch apart.

Ovaries and uterus: Allow ovaries and uterus to remain in the abdominal cavity until the pelvic cavity is exenterated.

OPERATIVE TECHNIC FOR THE PELVIC CAVITY

PREPARATION.—Begin at the external angle of the ilium and cut away all the musculature from that bone to the internal angle, then backward to the ischial tuberosity. Remove all the musculature down to the sacrosciatic ligament.

MAMMARY GLAND OR PENIS.—Dissect the mammary gland away from the pelvis and remove it from the position back of the leg where it was placed after dissection from

the abdomen. If the animal be a male dissect the penis from its attachment along the pelvis, taking care not to injure it at the ischial arch of the pubis. Draw the penis straight back until it extends in a direct line from the floor of the pelvic cavity. If the animal has not been skinned place an incision completely around the penis and anus through the integument, holding the penis straight back to prevent injury to it. Should the animal be a female place an incision around the vulva and anus. The object is to remove all the organs of the pelvis together and separate them after they have been excised. In males when the urogenital system is to be removed intact the kidneys attached to the ureters, and the testicles attached to the spermatic vessels are taken out together with the rectum, urinary bladder and penis. In females the kidneys, urinary bladder, rectum, ovaries, uterus and vagina are removed together.

PELVIC ORGANS.—To excise the pelvic organs, hold the external genitals and rectum to one side, after the incision has been made around them through the skin. Dissect the organs free from their peripheral attachments to the walls of the pelvis, holding the cutting edge of the knife closely applied to pelvic bones to avoid injury to the organs. To aid in reaching the anterior attachments cut carefully around the sacrosciatic ligament from above, and remove it from its position between the ischium and sacrum. From this opening one may readily reach and sever all attachments of the pelvic organs. One may also work from the abdominal opening by changing his position. In class-work other students are working on the ventral side of the cadaver and one must exenterate the pelvis from the posterior aspect. When all organs have been loosened remove and place them on the table.

Exenteration of the pelvis may be facilitated by removal of the acetabulum and two inches of the branch of each bone which contributes to its formation. To accomplish this saw through the shaft of the ilium, acetabular branch of the ischium, and transverse branch of the pubis two or three inches from the cotyloid cavity. One may also saw through the shaft of the ilium, and saw or cut through the pelvic symphysis with the ax, then remove the piece of pelvis thus freed (Figs. 76, 83).

SUMMARY OF PELVIC CAVITY

Preparation: Excise all musculature from the upper side of the os innominatum down to the sacrosciatic ligament, within the triangle made by the external and internal angles of the ilium and ischial tuberosity.

Mammary gland or penis: Remove the mammary gland or dissect the penis from the inferior aspect of the pelvis. Draw the penis straight back. Place an incision around the external genitals and the anus through the skin.

Pelvic organs: Carefully remove the sacrosciatic ligament and then work the pelvic organs loose from their peripheral attachments through this opening and from the incision around the genitals and anus.

Pelvic organs *in situ*: Saw through the shaft of the ilium and pubic symphysis, and remove side of pelvis.

OPERATIVE TECHNIC FOR LEG AND FOOT

MUSCLES.—The heavy musculature of the hind leg, when that extremity is placed in a horizontal position, should be cut in parallel planes and examined (Fig. 83).

POPLITEAL LYMPH-GLAND.—Make an incision from behind forward toward the femorotibial articulation. The popliteal lymph-glands may be located immediately back of the origin of the gastrocnemius muscle.

STIFLE JOINT.—Flex the joint and start an incision around the anterior surface below the patella. Cut through the joint capsule, lateral, patellar, and crucial ligaments, lay the articulation open and separate the patella.

TIBIOTARSAL JOINT.—To open the tibiotalar joint hold the foot backward, place the cutting edge of the knife against the anterior face of the joint and cut directly through the capsular and other ligaments of the articulation and the tendons of the perforans, perforatus, and gastrocnemius. Remove the portion of the leg below the tibiotalar joint and place it on a table (Fig. 88).

SCAPULOHUMERAL JOINT.—Cut into the posterior face of the joint, sever all ligaments, and lay the joint open.

AXILLARY LYMPH-GLAND.—These glands are found at the junction of the external thoracic, subcapsular, and brachial veins. The cubital lymph-glands lie behind the biceps muscle on the brachial vessels and the median nerve. They should be incised in many places.

CARPAL JOINT.—Draw the foot forward and start the incision on the posterior face of the articulation. Cut through tendons and ligaments and sever the leg at the joint (Fig. 88).

TENDONS, ETC.—If the skin has not been removed below the carpal or tarsal joints, lay the leg upon its anterior surface and make an incision down the median line of the posterior surface from the tarsal or carpal joint to the frog. Place a circular incision around the foot just above

the horny wall. Lay back the skin from the margins of these incisions and remove it. Separate the perforatus and perforans from the tarsal or carpal joint to the frog, and after the frog and sole have been removed follow the perforans to its attachments to the os pedis. Open and inspect the tendon sheaths and bursæ.

FROG.—Chisel around the outline of the frog, seize it by the base with a strong iron pinchers, pry downward toward the point and remove the structure (Fig. 90).

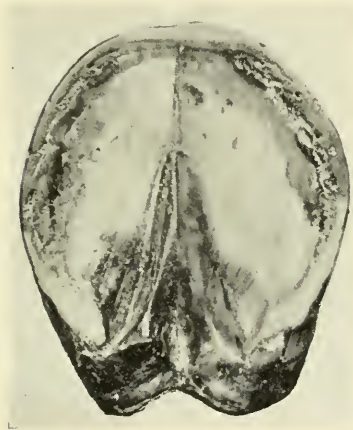

FIG. 90.—Lines of incision for ablation of horny sole and frog.




FIG. 91.—Lines of incision for sawing the wall of the hoof.

SOLE.—Make an incision around the sole with the chisel, following the white line. Saw through it vertically and horizontally, thus dividing its surface into four parts. Place a chisel in the middle of the sole and pry up the corner of one quarter, then seize it with the pinchers and bend it toward the periphery of the sole until it is completely separated from the foot. Remove the other parts of the sole in the same manner (Fig. 90).

WALL.—Turn the leg over so that the anterior surface is uppermost. Saw through the horny wall vertically in three places in such manner that the wall will be divided into four equal parts. With a knife separate the horny and fleshy leaves of the wall at the coronary band. Make this separation in the middle of one of the equal divisions of the wall and only deep enough to afford a grip for the pinchers. Insert the pinchers and pry downward toward the toe until that portion of the wall is released. Remove the other sections of the structure in the same manner. Examine the horny and fleshy leaves. A vise or an assistant should hold the foot while the frog, sole and wall are being excised (Fig. 91).

PHALANGEAL AND NAVICULAR JOINTS.—After the sole and wall have been removed, cut the perforatus and perforans from their inferior attachments. Remove the navicular and sesamoid bones and the lateral cartilages, then disarticulate the phalanges by severing their ligaments. Examine the bones carefully for exostoses, fractures, etc., and remove a small portion of periosteum with the cross chisel.

SUMMARY OF LEG AND FOOT

Incise the muscles of the hind leg in parallel horizontal planes. Examine the regional lymph-glands. Disarticulate the stifle, tarsal, scapulohumeral, and carpal joints. Open the principal tendon sheaths and bursæ and separate the perforatus and perforans tendons. Remove the frog, sole, and wall of the foot. Excise the navicular and sesamoid bones and lateral cartilages. Finally disarticulate the phalangeal joints.

OPERATIVE TECHNIC FOR MUSCULATURE, BONES
AND JOINTS

MUSCULATURE.—As a general rule muscle tissue, like the organs, should be so incised that the part may be reconstructed as nearly as possible. The incisions should be long and clean and be made with a sharp knife. This leaves a smooth surface to be examined. A dull knife makes a ragged incision and short incisions produce a wavy surface for inspection. Virchow says that a clean incision made in the wrong place is better than a ragged incision made in the right place.

As the technic on head, neck, back, thorax, abdomen, and pelvis is being effectuated, the muscles should be examined. They should be sliced in parallel vertical or horizontal lines. For examining any particular muscle for metaplasia, rupture, etc., it must be dissected out along anatomical lines.

BONES.—In every autopsy one of the long bones containing yellow bone-marrow should be sawed in two parts longitudinally or split with an ax. Another should be sawed crosswise in several places. This facilitates examination of the thickness of articular cartilage and condition of bone-marrow. A few ribs should be sawed through for examination of red bone-marrow.

BONES OF LEGS.—To examine bones for fractures it is necessary to free them from muscle tissue. This procedure depends upon the location of the bone. To remove the bones of the legs, cut through the musculature down to the bone parallel to the direction of the long axis. Then remove the muscle from all sides, and cut all attachments.

OS INNOMINATUM.—After the musculature has been removed from the upper side of the os innominatum, one should seize the external angle of the ilium with one hand

and the ischial tuberosity with the other and so alternately pull and push that crepitation may be readily heard or felt if fractures be present. For the examination of the right side of the os innominatum, sever the spine in the lumbar region with the saw; turn the posterior part of the cadaver on its left side, disarticulate the right hind leg at the coxo-femoral joint; remove muscles from ilium and ischium and examine the osseous structures.

RIBS.—Removal of the upper side of the cadaver, and washing out the thoracic cavity after evisceration exposes the ribs for inspection. A few ribs should be sawed through for examination of the red bone-marrow.

BONES OF THE HEAD.—During the technic on the cranium, nasal passages, and sinuses, the bones are so incised as to facilitate a close examination of their structure. The mandible should be sawed through laterally when there is any obvious enlargement present.

PHALANGES.—These bones should be disarticulated during the technic on the foot, then sawed in two vertically.

JOINTS.—Joints to be examined are disarticulated. This procedure depends upon the anatomical position and should be followed out by cutting downward through all structures to the joint, then severing all ligaments and laying the joint open. Tendons over the joints should be examined before they are incised. The fluid of the articulation and the articular surfaces should be closely inspected.

SUMMARY OF MUSCULATURE, BONES AND JOINTS

Musculature: For the examination of muscle tissue in general, long, smooth incisions should be made either vertically or horizontally. For special examination individual muscles should be dissected out for examination.

Bones: In every autopsy at least one long bone should be sawed through longitudinally for examination of the yellow bone-marrow, and a few ribs severed for the inspection of the red bone-marrow. To examine any particular bone remove the surrounding muscle tissue, sever its articular attachments and saw through it in several places.

Joints: Joints to be examined are disarticulated by cutting through all surrounding structures down to the joint, then severing all articular ligaments, and laying the joint open.

CHAPTER VI

INTERNAL EXAMINATION OF RUMINANTS

POSITION AND SKIN OF CADAVER.—Following a careful external examination, which should be conducted in the same general manner with all animals, the ruminant is placed on the *left side* (Fig. 92) and the skin and legs together removed from the upper or right side. The skin may be completely removed or for convenience and expedition the right fore and hind legs may be thrown off with the integument of the upper half of the cadaver when the commercial value of the hide has to be considered (Fig. 93). The position of the ruminant at autopsy is the reverse of that of the horse for anatomical reasons. When the cow or sheep is placed on the left side the rumen is undermost, and as the right side of the cadaver is removed the abomasum, duodenum and other intestines are brought uppermost and are accessible for ligation and inspection.

OPERATIVE TECHNIC FOR HEAD, NECK AND BACK

THYROID GLANDS.—After the skin has been removed, or before, if its commercial value is not to be considered, place an incision on the median line of the neck just back of the larynx down to the rings of the trachea (Fig. 92). Insert the fingers to the side of the latter, seize, withdraw, and sever the thyroid glands.

PAROTID SALIVARY AND SUBPAROTID LYMPH-GLANDS.—Immediately below the ear and back of the maxilla the parotid salivary gland may be examined. The subparotid lymph-glands are partially covered by the upper anterior



FIG. 92.—Correct position of ruminant at autopsy. Lines for incision when the skin is not to be saved, or after the skin has been taken off, but the right fore and hind leg not removed with it.

border of the parotid salivary glands. After both have been examined remove the latter. The left parotid structures may be inspected after the head has been removed.

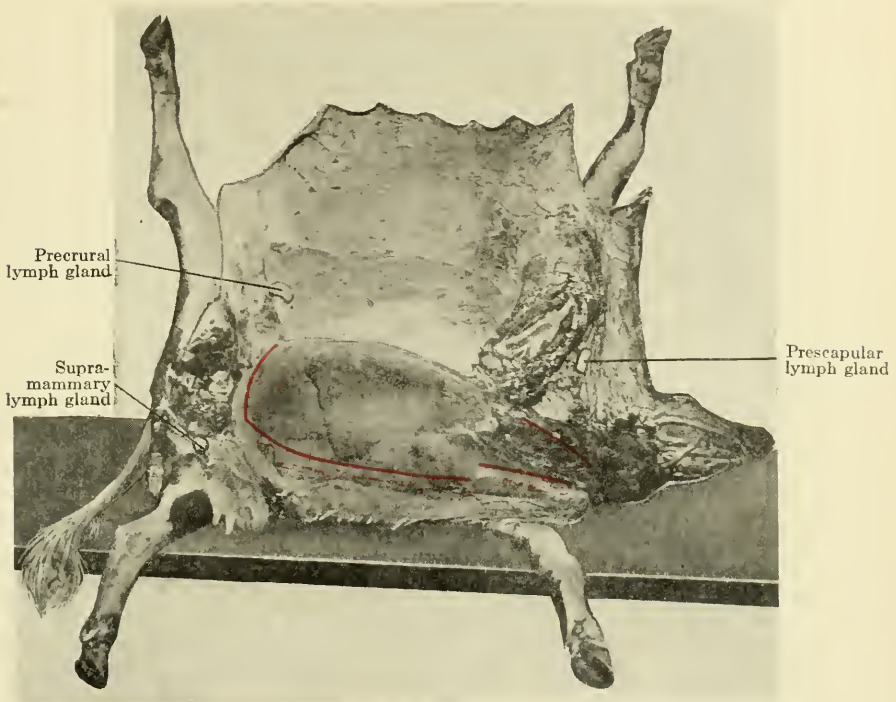


FIG. 93.—This view shows the skin of the right side together with the right fore and hind leg dissected back from a single ventral median, incision from the chin to the anus. The legs and skin of the right side are next thrown over the dorsal side of the animal and the autopsy conducted without injury to the hide which may be removed later. This is done only when the skin must be preserved for its commercial value. It saves the time and labor of the autopsist which would be consumed in skinning the entire cadaver or the right legs. The udder is separated from the abdomen and lines are shown for the xiphoid-pubic, pubic-lumbar incisions and sternal as well as part of dorsal thoracic incisions.

SUBMAXILLARY LYMPH- AND SALIVARY GLANDS.—The submaxillary salivary glands may be located in the intermaxillary space opposite the angle of the jaw, and the submaxillary lymph-glands lie between the sternocephalicus

muscles and the submaxillary salivary glands. There are two in number, quite small and sometimes difficult to find (Fig. 94).

RIGHT RAMUS OF MANDIBLE.—For the examination *in situ* of many structures of the head and neck the right ramus of the lower jaw is removed and the jugular furrow

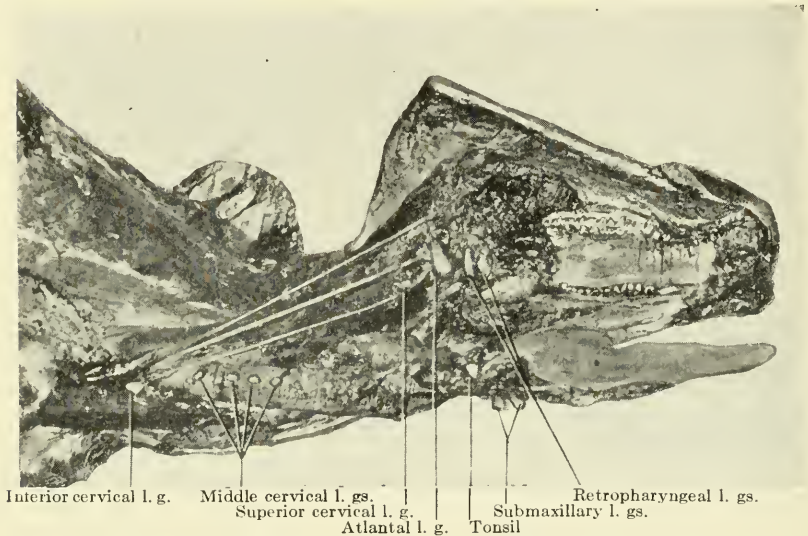


FIG. 94.—Skin of the right side of the head and neck removed and thrown over the dorsal side. The right fore leg was taken off with the skin of the body and the scapula protrudes above the neck. The skin of the right side of the head is supported on the right horn. The right ramus of the mandible has been removed. Tongue, larynx and trachea have been freed from the head and neck. Tonsils and lymph glands are exposed. Right jugular vein, carotid artery, and vagus have been separated and laid back. Analogous structures on the left side are exposed by turning head and neck over.

laid open. The right part of the mandible is taken off by passing a knife under the bone from the temporomaxillary articulation to the symphysis, freeing it from all attachments between these points. The next incision is made from the temporomandibular articulation to the commissure of the lips downward to the teeth. A piece of lip two inches long is excised over the dental space and the mandible sawed

through just above the symphysis (Fig. 92). The right ramus of the lower jaw is now held in place only by the temporomandibular articulation. Grasp the right side of the mandible just back of the point at which it was sawed through, pull upward and backward, disarticulating the jaw at the temple.

TONSILS.—Cut through the soft palate with a knife, break both great cornua of the hyoid bone with a bone forceps, and rotate the larynx slightly upward. On the outer surface of the pharynx just anterior to the epiglottis on either side there is a bean-shaped organ of yellow color about the size of a small walnut. By placing the finger on the inner side of the pharyngeal wall opposite this organ the tonsillar sinus can be located. The tonsil is sometimes mistaken for a lymph-gland but on section it presents lobulations while the lymph-gland does not (Fig. 94).

RETROPHARYNGEAL LYMPH-GLANDS.—After locating the tonsils, place the hand above and back of the larynx, break down the loose connective tissue, locate and withdraw both retropharyngeal lymph-glands from the same opening (Fig. 94).

JUGULAR FURROW AND STRUCTURES.—Lay open the jugular furrow by placing an incision through the superficial cervical muscles an inch above the jugular groove, from the right wing of the atlas to the first rib. Separate and examine the jugular structures (Figs. 92, 94).

LYMPH-GLANDS.—The *atlantal* lymph-gland is disc-shaped and lies just under the lateral wing of the atlas. The *anterior cervical* lymph-glands lie along the carotid artery below and posterior to the atlantal gland. The *middle cervical* glands are small and lie on the lateral superior surface of the trachea at about the middle of that organ,

close to the cartilaginous rings. The *posterior cervical* or *prepectoral* glands lie between the first two ribs at their superior extremities (Fig. 94).

TONGUE, LARYNX, TRACHEA AND ŒSOPHAGUS.—These structures are extirpated together. To remove them grasp the tongue, raise it upward, and sever its inferior attachments with a knife. Complete the incision through the soft palate, and, since the cornua of the hyoid bone have

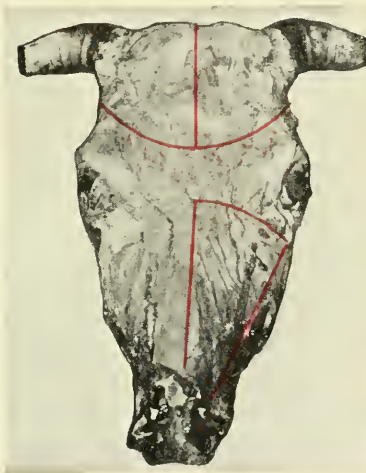

FIG. 95.—Incisions to be made in removing calvarium and opening nasal passages.

been previously broken, draw the larynx upward and outward, cutting downward behind it until it is entirely free from the neck. Continue cutting back of the trachea to the first rib, then sever the trachea, œsophagus, vessels and nerves close to the thorax, and place the ablated structures on a table to be properly opened and inspected later.

DECAPITATION.—To remove the head, raise the chin upward and cut through the muscles back of the angle of the left ramus of the jaw toward the occipito-atloidal joint. Disarticulate the head at this point and place it on a table.

PREPARATION OF THE HEAD.—If the skin has not been removed it can be quickly taken off by placing an incision down the median line of the face and dissecting laterally from its edges. To free the left ramus of the jaw from the head, place an incision from the corner of the mouth to

temporomandibular joint down to the teeth; grasp the mandible at the interdental space and pull laterally until the jaw is disarticulated at the temporomaxillary joint. Place the head upon the upper teeth and remove all musculature (Fig. 95).

EXTIRPATION OF THE BRAIN.—To remove the calvarium of the cow, sheep or goat, place the saw horizontally against the head, after the skin and muscles have been removed,

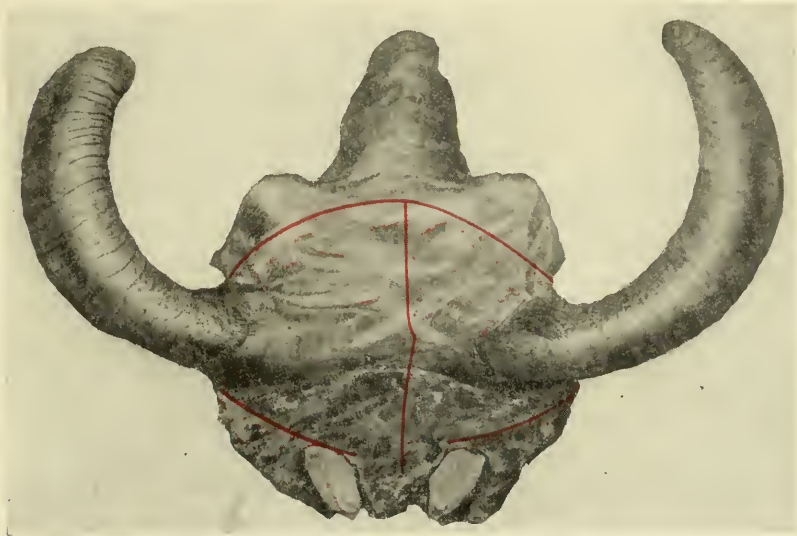


FIG. 96.—This shows relation of incisions to horns and occipital condyles.

and make an incision around the base of the skull immediately below the horn, from the foramen magnum to a point over the nasal septum approximately an inch above the eye (Figs. 95, 96). The line should be between the base of the horn and the external auditory meatus (Fig. 97), and extend inward to the cranial cavity. Place a similar incision on the other side of the head. The next incision is made with a saw between the horns, downward on the median line

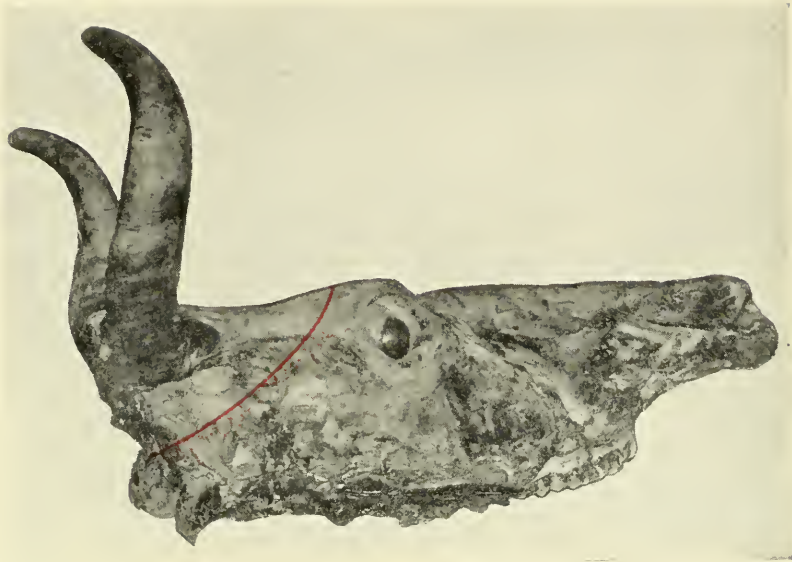

FIG. 97.—Showing position of incision between horn and external auditory meatus.

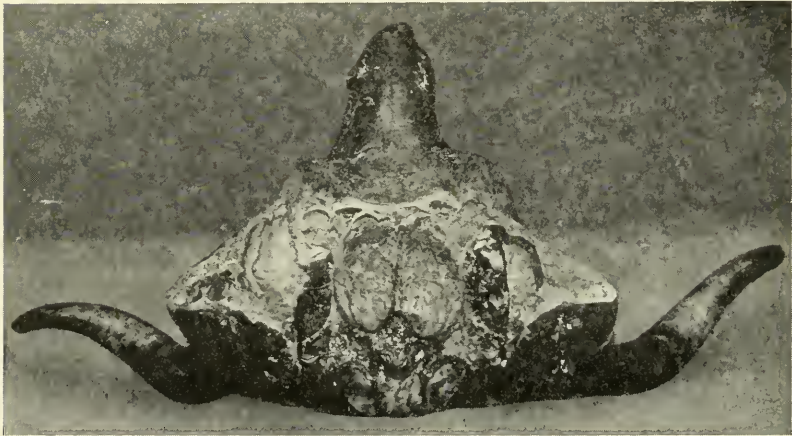


FIG. 98.—Halves of calvarium spread apart exposing brain and frontal sinuses.

of the head, through the occipital prominence into the cranial cavity, from the foramen magnum to a point over the nasal septum (Figs. 95, 96). There is little danger of injuring the brain, as the saw would pass between the hemispheres of the cerebrum if it should penetrate a little too deeply. The calvarium may now be divided in halves by prying the horns apart (Fig. 98) with the hands or tapping them with a mallet (Martin). The meninges may be incised and the brain raised out of the cranium with the fingers.

NASAL PASSAGES, EYE, EAR, ETC.—The sinuses of the head, nasal passages, nasal septum, teeth, eye, ear, and spinal cord are handled in the same manner as those of the horse (Fig. 95).

OPERATIVE TECHNIC FOR THORACIC AND ABDOMINAL CAVITIES

FRONT LEG.—Place an incision back of the foreleg from the crestline of the back to the sternum, down to the intercostal muscles, and a second incision immediately in front of the leg from the top of the neck to the manubrium of the sternum (Fig. 92). Raise the leg upward with one hand and sever it from the thorax, permitting the prescapular lymph-gland to remain with the limb (Fig. 93). Remove the leg completely from the cadaver and place it on a table.

HIND LEG.—Make an incision from a point immediately back of the external angle of the ilium forward through the tensor fascia lata, then downward and backward under the leg, horizontally three inches above the median line of the pubis or mammary gland (Fig. 92). Raise the incision over the ischial tuberosity, then lift the

leg upward and cut directly into the coxofemoral joint. Continue incising past the joint through the thick muscles of the haunch. The precrucral lymph-gland may be removed with the leg (Fig. 93).

MAMMARY GLAND OR PENIS.—Dissect the mammary gland together with the supramammary lymph-glands away from the abdomen by applying traction on the udder and cutting through its connective-tissue attachments until it is entirely free from the body (Figs. 92, 93). If the animal be a male, dissect the penis free from the abdomen and lay it over the leg to be removed upon evisceration of the pelvic cavity.

XIPHOID-PUBIC INCISION.—To open the abdominal cavity and remove the right side, an incision must be made from the pubis to the xiphoid cartilage through the abdominal wall following the median line (Fig. 93). Great care must be exercised to avoid puncturing the intestines and soiling the viscera. Stand with the back against the left hind leg of the cadaver if the latter be on a table, place the left hand against the cadaver to steady one's own body, then with the knife held in a full hand grip in the right hand press the cutting edge, near the tip, against the median line of the belly six inches anterior to the pubis and cut gently. Do not attempt to penetrate the entire thickness of the wall with one incision, but remove the knife and test the depth of the incision and the thickness of the wall with the forefinger of the left hand many times so that the finger, *not the knife*, is the first to penetrate the cavity. Enlarge the opening so that the first two fingers of the left hand may enter, turn the knuckles toward the intestines and the tips of the fingers against the inner aspect of the abdominal wall one on either side of the median line. With

the intestines thus protected turn the back of the knife toward the cadaver, insert one-half inch of the point, cut outward and forward, enlarging the incision by half an inch. Continue this process carefully until the sternum is reached.

PUBIC-LUMBAR INCISION.—When the xiphoid-pubic incision has been completed, grasp the knife in the right hand point upward, cutting edge away from the autopsist's body. Extend the first and second fingers straight out from the hand holding the knife by gripping the handle with the third and fourth fingers and the thumb. Now force the butt of the knife into the peritoneal cavity at the posterior end of the xiphoid-pubic incision close to the pubis, and cut through the belly wall, from the median line to the lumbar region anterior to the external angle of the ilium. The first two fingers should precede the cutting edge of the knife to protect the intestines from injury (Fig. 93). One should avoid injury to the spermatic cord in the male, and later open the inguinal canal and lay the cord and testicle in the pelvis to be removed later during the evisceration of the pelvic cavity.

VACUITY OF THE THORAX.—To test the vacuity of the thorax feel of the diaphragm and determine if it be convex toward the thorax. Next puncture the intercostal muscles between the fifth and sixth ribs. To accomplish this make a stab puncture one-half inch long, withdraw the knife quickly and insert the finger. The air rushing into the thorax imparts a cold sensation to the back of the finger if the thorax be a vacuum.

RIBS.—Prepare the ribs for incision so that the right side may be removed by taking the muscles off the inferior border of the thorax. Next make a line with the cutting edge of the knife from the inferior end of the first rib to the

xiphoid cartilage (Fig. 93). Wash and dry the hands and the ax handle to prevent the latter from slipping, then cut each rib, following the line made with the knife, using only two inches of the corner of the ax. Start with the first rib and cut from right to left toward the xiphoid region. When near the ensiform cartilage moderate the force of the blows so that the stomach may not be injured. Great care should be used to prevent opening the pericardial sac when the ribs are being severed, otherwise it would be impossible to estimate the character and quantity of fluid present.

Assume a position on the dorsal side of the cadaver, trim the musculature from the angle made by the ribs and the superspinous processes, then cut through each rib from the last to the fifth, three inches from the superior attachment to the spine, and from the fifth to the first inclusive, close to the superior attachment (Fig. 93). To remove the side cut the diaphragm close to the ribs, from the right kidney to the sternum, seize the ribs with a hook close to the xiphoid cartilage, and raise the side upward and backward, freeing it from the cadaver.

When the thoracic and abdominal cavities have been opened one should carefully note the relative position of organs, presence of fluids, clots, gas, foreign bodies, etc. No organ should be disturbed until its relationship with other organs has been fully determined.

OMENTUM.—The omentum is carefully stripped free from the stomach with the fingers.

INTESTINES.—When the side is removed the abomasum rolls out of the abdomen immediately posterior to the ensiform cartilage and the duodenum extends almost vertically toward the spine across the viscera. Two double ligatures are placed on the duodenum eighteen inches apart, one on

either side of the point where the bile-duct joins the gut (Fig. 99). Each of the ligatures constituting the double ligation is placed six inches from the other, after the intestinal contents have been forced in either direction. To apply a ligature, as described in ligation of the intestines of the horse, one should double a stout string eighteen inches long. Force the loop end under the gut and bring it up on the opposite side. Push the two free ends through the loop

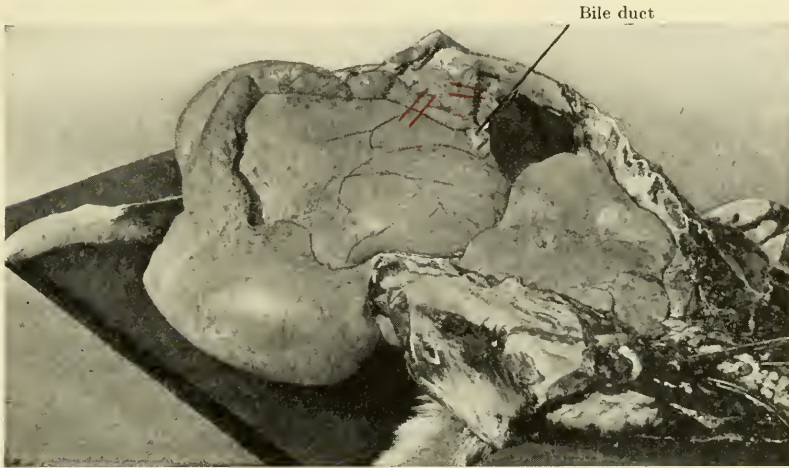


FIG. 99.—The right fore and hind legs and the right side, have been removed exposing thoracic and abdominal cavities. The abomasum has dropped out of the abdomen just posterior to the xiphoid cartilage and the duodenum passes upward on the rumen, past the liver toward the spine. The bile duct extends from the gall bladder to the duodenum and lines indicate the points of ligation and incision of that gut.

and draw the slipknot tightly around the intestine. Divide the free ends of the twine and carry them around the gut in opposite directions, bringing them to the top again where they are tied with a surgeon's knot.

When the ligations have been made the intestines are incised between the double ligatures, and a piece of duodenum is left with the liver to be removed when that organ is extirpated. Thus no intestinal contents are allowed to

soil the viscera and possibly mask lesions which may be present. Another double ligature is applied to the rectum at the inlet of the pelvic cavity, and the gut incised. Thus in all three double ligatures are applied to the intestines of the ruminant and one to the œsophagus which will be described later.

The cæcum and small intestines gravitate into the flank when the side is removed. The colon is arranged in coils between the layers of the mesentery. To detach it, tear loose the connective-tissue attachments of that gut and the duodenum with the fingers, gather the mesentery in the hands close to its superior attachments, then pass a knife under the mesentery and its vessels and cut upward. Thus loosened, all the intestines will usually slip out of the abdomen together between the leg and the stomachs. After the intestines have been removed one may separate them by starting with the duodenum and cutting them free from the mesentery, then laying them out on the floor. The mesentery should be stretched out and the mesenteric lymph-glands exposed for further technic and examination.

KIDNEYS AND ADRENALS.—Enuclate the right kidney from the perirenal fat with the fingers and sever the renal blood-vessels and ureter by passing a knife under them and cutting upward. Dissect the right adrenal free with the fingers. It is exposed when the kidney has been extirpated. The left kidney and adrenal are removed in a similar manner. The renal lymph-glands are left in place but exposed by stripping the fat away from them.

STOMACHS AND SPLEEN.—The extirpation of the stomachs and spleen appears very difficult to the student at first, because of the bulk of the rumen. All the attachments of the stomachs may be readily broken with the fingers by

applying a little energy. A double ligature is placed on the œsophagus immediately posterior to the diaphragm, then it is incised by cutting upward transversely through it. The stomach with the spleen still attached may now be rolled out of the peritoneal cavity. The spleen should be carefully dissected from the stomach and placed upon a table.

LIVER AND GALL-BLADDER.—The liver, together with the gall-bladder and piece of duodenum, may be removed at this point by severing the hepatic attachments to the diaphragm, or one may leave it until the thoracic cavity has been eviscerated and then take it out with the diaphragm by cutting through that structure along its periphery.

PANCREAS.—The pancreas should be left with the liver.

PERICARDIAL SAC AND FLUID.—Wash the hands, knife and pericardium to prevent soiling the pericardial fluid. Place an incision from the base to the apex of the heart through the pericardium. Draw the edges of the incision apart and observe the character of the fluid. Raise the heart out of the sac by lifting the apex upward, remove, and measure the fluid and examine the inner aspect of the sac for foreign bodies. Replace the heart and examine the posterior outer surface of the sac for the same purpose.

HEART AND LUNGS.—The heart, lungs, bronchial, and mediastinal lymph-glands and thoracic portion of the œsophagus are extirpated together as in the horse. The first incision is made through the posterior mediastinum from the diaphragm to the arch of the aorta. Cut upward through the aorta and forward through the anterior mediastinum. Draw the apical lobe of the left lung backward from under the right apical lobe with the left hand, then cut downward through the trachea, œsophagus, blood-vessels and nerves entering from the cervical region at their

entrance to the thorax. Cut through the pericardial attachments to the sternum. Next crook the wrist and pass it along the anterior face of the diaphragm from above to below, and seize the posterior vena cava and branches of the vagus which are then severed.

The œsophagus may be drawn into the thoracic cavity by application of slight traction. To determine if all attachments have been severed pass the hand around the periphery of the heart and lungs. To remove the thoracic organs pass the left hand between the heart and lungs palm toward the heart. Grasp the connecting structures between the thumb and fingers, raise the hand to a vertical position, balance the lungs on the forearm and carry them to the tub or table.

BLOOD-VESSELS.—Open the aorta and iliac arteries with an enterotome, cutting close to the vertebræ so that the vessels will lie open.

PLEURA AND PERITONEUM.—Cut downward through the muscles of the left flank to permit drainage of the cavities. Flush the abdomen, thorax and opened blood-vessels with water, then examine the pleura, peritoneum, ribs, vertebræ, blood-vessels, and inguinal structures.

LYMPH-GLANDS.—The *intercostal lymph-glands* are found at the superior extremities of the intercostal spaces. The *sternal lymph-glands* are situated at the inferior extremities of the intercostal spaces and in the fat of the pericardial apex. The *lumbar lymph-glands* form an irregular chain along the abdominal aorta. The *renal lymph-glands* are bean-shaped and are found near the points where the kidneys were removed. The *internal iliac lymph-glands* are five or six in number at the origin of the iliac arteries. The largest iliac glands are about two inches in diameter, rather flat on the sides, and disc-shaped. They are situated

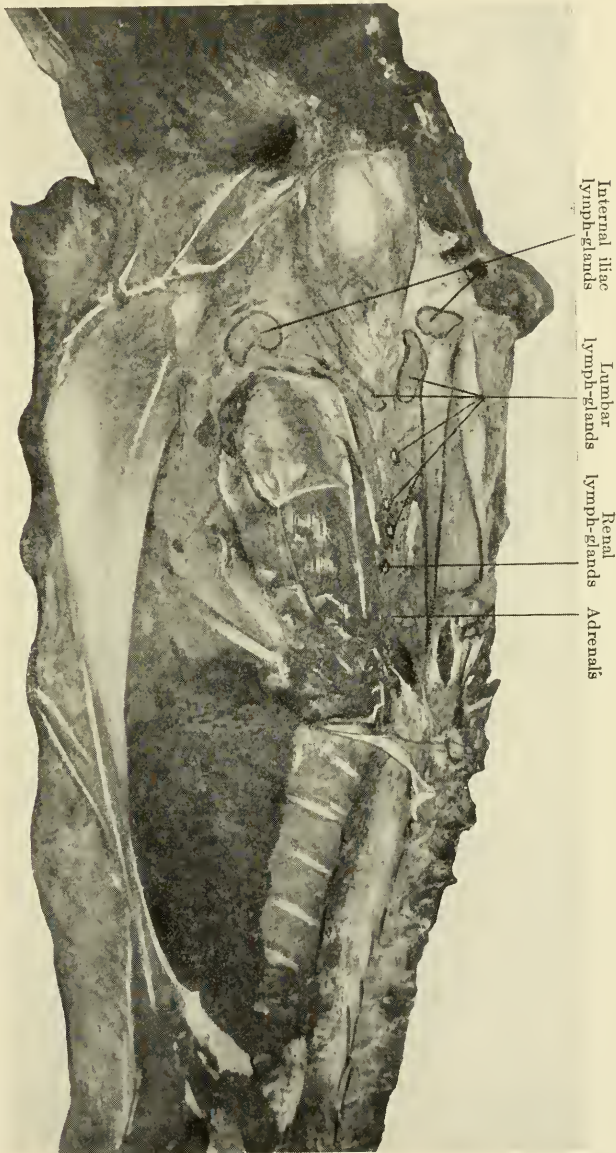


Fig. 100.—Pelvic, abdominal and part of thoracic cavities after evisceration, showing adrenals and lymph-glands.

one on either side of the pelvic inlet. The *external iliac lymph-glands* occur near the point of the hip. The *superficial inguinal lymph-glands* in the male are situated back of the sigmoid flexure on either side of the penis. These glands are called the *supramammary lymph-glands* in the female and are situated at the base of the udder at its posterior margin. There are no *deep inguinal lymph-glands* (Fig. 100).

OPERATIVE TECHNIC FOR THE PELVIC CAVITY

PREPARATION.—Remove all musculature from that triangular space between the external and internal angle of the ilium and the ischium down to the sacrosciatic ligament. Dissect the penis from the pubis so that it may be extended backward in a direct line with the floor of the pelvis. Saw through the shaft of the ilium, cut through the pelvic symphysis with the ax, then remove the portion of the pelvis thus freed. After examining the organs *in situ* place an incision around the anus and external genitals, holding the penis straight back if it be a male, and cut around the periphery of the pelvic organs, keeping the cutting edge of the knife toward the pelvic bones to avoid injury to the soft structures, until all are freed.

ORGANS.—If the animal be a female, the ovaries, vagina, uterus, bladder, and rectum are removed together. If it be an entire male, the seminal vesicles and adjacent glands, bladder, and rectum are extirpated together with the penis and testicles, placed upon a table, and later opened and examined.

The operative technic for the leg and foot, muscles, bones, and joints is practically the same for ruminants as that applied to the horse.

CHAPTER VII

INTERNAL EXAMINATION OF SWINE

DORSAL POSITION.—Post-mortem technic for the examination of swine is very similar to that used on the dog and cat. Small swine are placed in the dorsal position and very large animals of this species are placed in the left-side position to facilitate the location of the rectoduodenal ligament and removal of intestines. When the dorsal position is used, an incision is made down the ventral median line through the skin and fat to the sternum and abdominal muscles, from the point of the chin to the anus, avoiding the genitals, as in the dog (Fig. 101). From this median incision lay back the skin and fat from the thorax, at the same time separating both forelegs from the body so that they lie flat on the table at right angles to the cadaver. Cut into the coxofemoral articulations and lay the hind legs outward from the body. This position of the legs maintains the cadaver in the dorsal position. Complete removal of the skin in either position is unnecessary (Fig. 102).

OPERATIVE TECHNIC FOR THE HEAD, NECK AND BACK

Extirpation of thyroid glands, tongue, tonsils, larynx, trachea and cord, and the opening of nasal passages is the same as in the dog and cat. To remove the brain, which is deeply situated in the pig, remove skin and muscles from the head after disarticulation of the occipito-atloidal joint. Enuceate the eyes and make a verticle transverse incision with the saw through the centre of each orbit to the cranial

cavity. The two lateral incisions are made as in other animals from the foramen magnum anteriorly above the zygomatic crest to meet the transverse incision. With the ham-

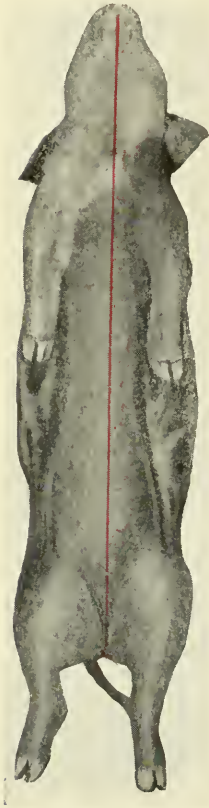

FIG. 101.—The incision is made just through the skin, then skin and legs are laid back from the body together.

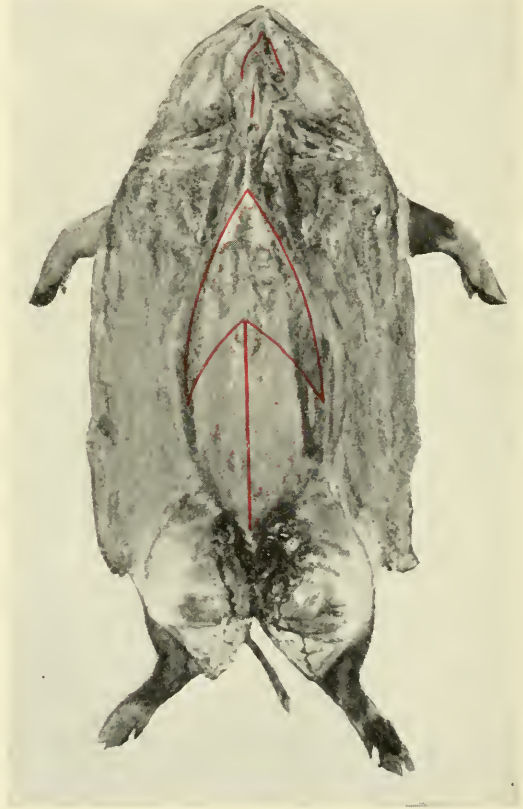


FIG. 102.—Skin and legs have been laid back from median incision indicated in FIG. 101. The cadaver now remains in dorsal position unassisted. The abdomen is first opened by one median and two lateral incisions. The sternum is then removed by two lateral incisions.

mer-hook the calvarium may now be lifted off and the brain removed with the fingers and scalpel after the meninges have been incised longitudinally.

OPERATIVE TECHNIC FOR THE THORACIC AND ABDOMINAL CAVITIES

The peritoneal cavity is opened by making an incision through the abdominal muscles from the xiphoid cartilage to the pubis, after the penis has been dissected from the belly and laid back over the anus. Transverse incisions are made through the belly wall along the posterior border of the ribs (Fig. 102) and the flaps of the abdominal wall laid outward (Fig. 103). Two lateral thoracic incisions are made and the sternum removed (Figs. 102, 103).

INTESTINES.—The colon and cæcum of swine lie principally on the left side and therefore when the cadaver is placed in the dorsal position these structures appear at the autopsist's right, and the small intestines at his left. To locate the rectoduodenal ligament push the small intestines to the right, find the rectoduodenal ligament close to the left kidney, apply a double ligature to the colon (abdominal rectum) and duodenum, then cut through both intestines between the double ligatures (Fig. 103). Draw the intestines upward and sever the mesentery and vessels close to the lumbar muscles, then remove small intestines, colon and cæcum together.

When one wishes to find evidences of hog cholera without completing an autopsy the ileocæcal valve should be located and examined first, as that structure presents ulcerous lesions if any be present in the cadaver. The colon of the hog is arranged in coils which are firmly held together in such manner as to make the colon simulate a bee hive. The cæcum, which is eight to twelve inches in length by three to four inches in diameter, is at the base of this structure where the diameter of the lumen of the colon is the greatest. The ileum enters the cæcum obliquely and is of

quite small calibre. To locate the ileocæcal valve, grasp the colon at the apex of its spiral structure of coils or that point corresponding to the apex of a bee hive and lift it

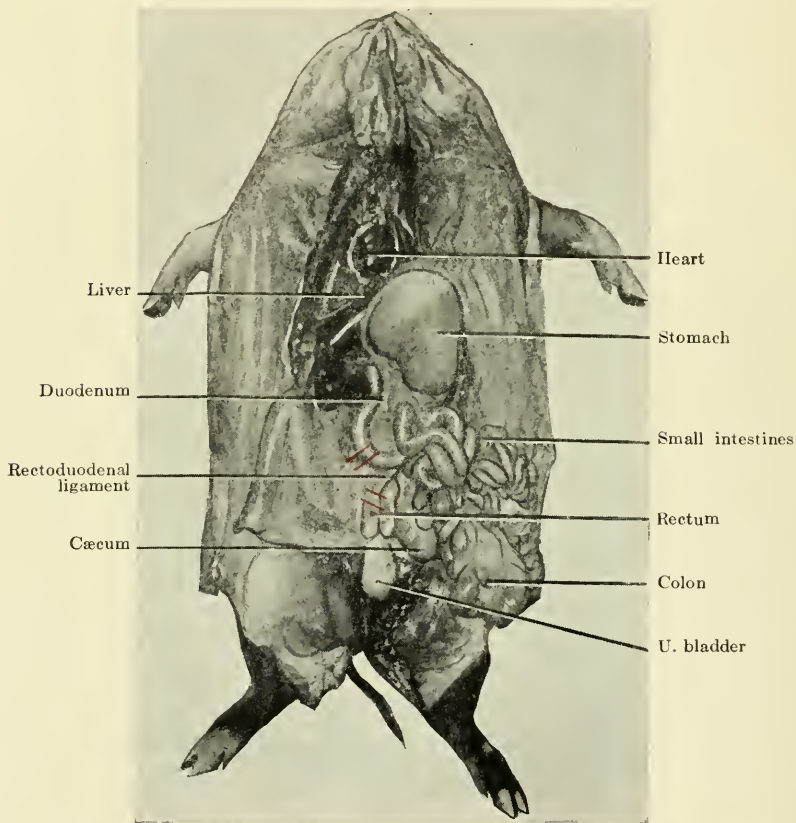


FIG. 103.—After opening abdomen and thorax by making incisions indicated in FIG. 102, all the intestines are pushed to the autopsist's right, out of the left side of the abdomen, the rectoduodenal ligament exposed, duodenum and abdominal rectum ligated and incised on either side of it as indicated, and the small intestines, colon and cæcum removed together and separated later. Rectum is removed with pelvic organs and duodenum with the stomach.

upward. With the other hand examine the entire circumference of the base of the structure until the ileum is located at its entrance to the cæcum. Penetrate the ileum with an

enterotome and follow it through to the ileocæcal valve (Fig. 104).

DUODENUM AND BILE-DUCT.—The duodenum is opened with an enterotome and the ampulla of Vater exposed. Squeeze upon the gall-bladder until bile flows into the intestine, then open the bile-duct to the gall-bladder with a sharp-pointed scissors.

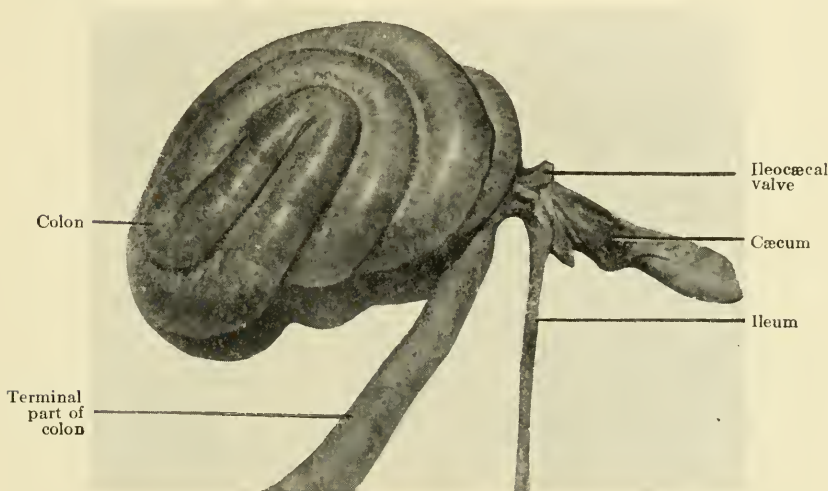


FIG. 104.—When the ileo-cæcal valve is of particular interest, the colon, cæcum and part of the ileum are separated from the small intestines, the cæcum opened and the valve exposed.

SPLEEN.—The spleen of the hog is long and narrow. It should be severed from the stomach and removed.

STOMACH.—Draw the stomach back from the diaphragm, squeeze the œsophagus to prevent the escape of stomach contents, then sever the œsophagus and remove the stomach, duodenum and pancreas together.

LIVER.—Place the hand back of the liver, draw it away from the diaphragm and cut downward through attach-

ments and blood-vessels, freeing the organ from the abdominal cavity.

KIDNEYS.—Raise the kidneys upward and sever their attachment close to the lumbar muscles.

HEART AND LUNGS.—To open the thoracic cavity cut through the diaphragm at its attachment to the sternum, after exenteration of the abdominal cavity, then with knife or cartilage shears cut each asternal cartilage immediately above its costal articulation (Fig. 102) and expose the viscera (Fig. 103). Determine the character and quantity of fluid if any be present in the thorax. Place a longitudinal incision through the pericardium and examine the character and quantity of pericardial fluid. To extirpate the thoracic viscera grasp the œsophagus and trachea anterior to the heart and cut through them and the vessels and nerves entering the thorax from the neck opposite the second rib. Raise the heart upward, forcibly stripping the mediastinum from its attachments, and remove heart and lungs together.

OPERATIVE TECHNIC FOR THE PELVIC CAVITY

Excise all muscles from the pelvic symphysis and cut downward through the symphysis with knife or chisel into the pelvic cavity. In young animals the pelvis may be spread apart with the hands, in old animals a piece of the floor of the pelvis two inches wide may be taken out with a saw. To remove the pelvic organs, place an incision through the skin around the penis or vulva and anus, holding the penis straight back, then sever the peripheral attachments of the pelvic organs from the inside of the pelvis and remove them together.

LEFT SIDE POSITION.—To open the thoracic and abdominal cavities with the cadaver lying on the left side follow the same technic as used on ruminants. When the right fore and hind legs and the right side have been taken off, the colon will be located under the other viscera and the small intestine will be uppermost. The rectoduodenal ligament may be located close to the left kidney and the intestines ligated and quickly removed. Extirpation of other organs is accomplished in the same general manner as in the dorsal position.

CHAPTER VIII

INTERNAL EXAMINATION OF THE DOG AND CAT

FOR class-work one student preferably, and not more than two, should be assigned to the autopsy of a small animal. When two students are assigned to a case together one should do the cutting and the other act as his assistant, holding the cadaver while the skin is being removed, weighing organs, and handing instruments to the autopsist. If two students attempt to cut at the same time injury is possible to either.

POSITION.—The cadaver is placed in the dorsal position tail toward the autopsist and is maintained in that position until the exenteration of all cavities has been effectuated (Fig. 105). If the cadaver be too large it may be turned with the side toward the autopsist, anterior extremity to the left, with the animal still maintained in the dorsal position.

SKIN.—Place an incision through the skin on the median line from the tip of the chin to the rectum, avoiding the penis. Make a second incision on the opposite side of the penis through the skin (Fig. 105), raise the organ upward, and dissect it free from the abdomen, then lay it back on the tail so that it is in a direct line with the floor of the pelvis. Use great care to prevent cutting into or through the penis (Fig. 106).

At right angles to the median incision cut through the skin on the inner aspect of each posterior limb to the tarsal joint. To remove the integument begin at the point of the jaw and from either margin of the median incision dissect

the skin away from the cadaver down to the back, cutting the forelegs free from the thorax so that they lie flat upon the table. After the skin has been removed from the inner

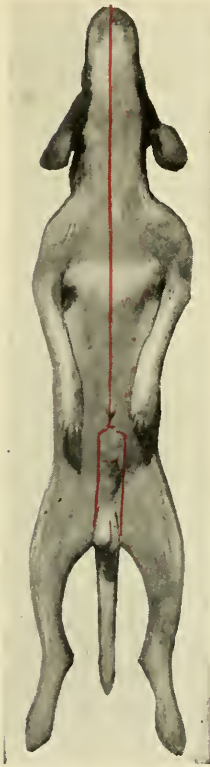


FIG. 105.—Median line of incision through the skin from which skin and legs are laid back from the body. Penis to be drawn back over the tail.

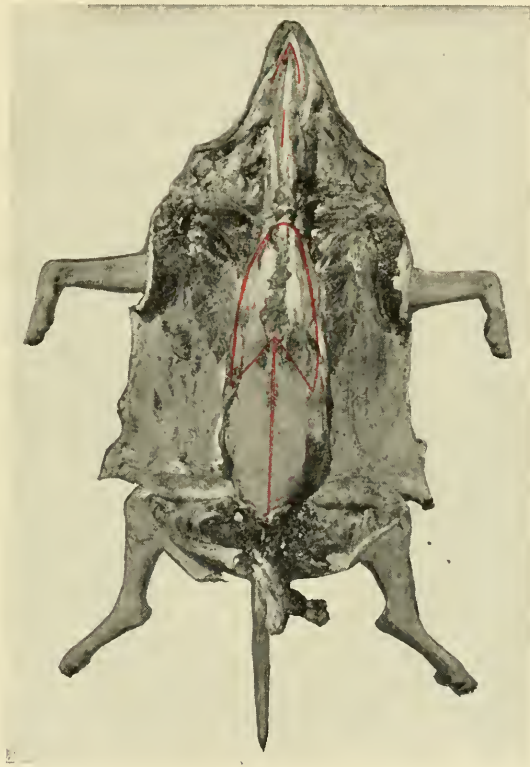


FIG. 106.—Skin and legs laid back from body, penis drawn back over the tail. Xiphoid-pubic and two xiphoid-lumbar incisions are made to open the abdomen. Two lateral thoracic incisions to remove sternum. One short median incision in neck to remove thyroid glands and two internal mandibular incisions to draw out the tongue, coxofemoral joints opened.

half of each hind leg cut into both coxofemoral articulations and lay the hind extremities flat upon the table. The anterior and posterior limbs now placed at right angles to the

body maintain it in the dorsal position and facilitate further technic. If the animal be a female remove the mammary glands with the skin (Fig. 106).

OPERATIVE TECHNIC FOR THE ABDOMINAL CAVITY

To open the abdominal cavity make a xiphoid-pubic incision through the abdominal wall (Fig. 106). Start the incision with a small stab puncture immediately posterior to the sternum. Insert the first two fingers of the left hand, spread them apart, and raise the abdominal wall upward away from the viscera. With the organs thus protected cut through the abdominal muscles between the fingers along the median line to the pubis. If any fluid be present examine it by spreading apart the edges of the incision. Next remove the fluid with pipette or cup and determine the quantity. To expose the abdominal viscera make an incision on either side from the ensiform cartilage along the posterior border of the ribs to the back (Fig. 106) and lay the flaps of the belly wall outward on the table (Fig. 107).

OMENTUM AND INTESTINES.—The exenteration of the peritoneal cavity is begun by raising the omentum upward and trimming it away from the stomach. Seize the colon at the pelvic inlet, squeeze the contents in either direction, apply a double ligature two inches apart (Fig. 107), place a knife under and cut upward through the gut. Grasp the duodenum at the posterior end of the pancreas, apply a double ligature and sever in the same manner. When the intestines are empty or the contents of firm consistency, ligation may be omitted. To remove the intestines, gather them in the left hand, raise them upward from the lumbar region as far as possible, then sever the mesocolon and mesenteric vessels.

BILE-DUCT.—Before the stomach is extirpated that portion of the duodenum remaining attached to it is opened

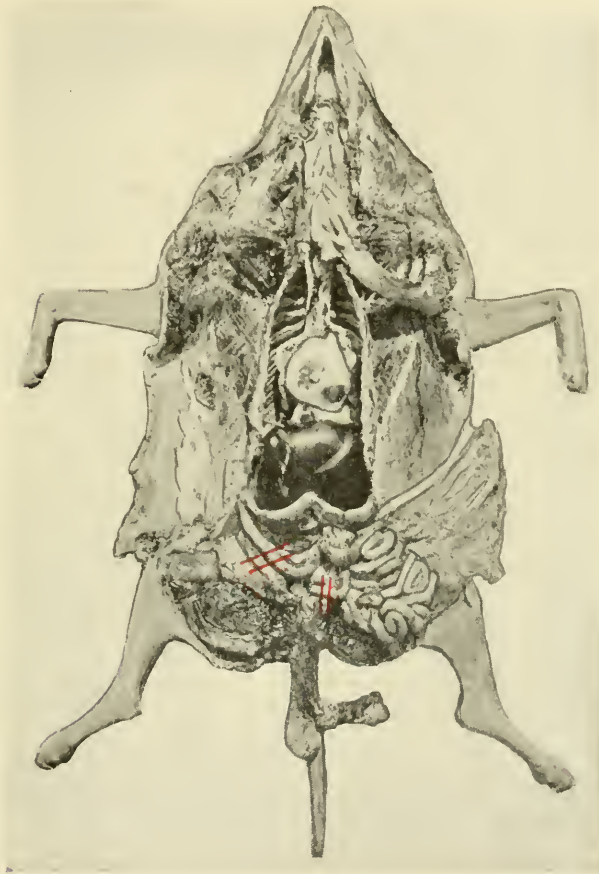


FIG. 107.—Tongue and larynx drawn back. Sternum removed. Flaps of abdomen laid back. Omentum laid over cadaver's left side. Points of ligation and incision indicated on duodenum and rectum. Liver partly overlaps stomach. Heart and lungs slightly displaced posteriorly.

with a sharp-pointed scissors to the point where the great curvature of the stomach begins, and the ampulla of Vater is exposed. To determine if there be any obstruction in the

bile-duct squeeze upon the gall-bladder until the bile flows freely from the intestinal opening of the structure, then open the bile-duct from the duodenum to a point near the gall-bladder with the sharp-pointed scissors.

STOMACH, SPLEEN AND PANCREAS.—Remove the stomach by seizing the œsophagus with the thumb and forefinger of the left hand close to the diaphragm, draw it back and cut through it, continuing to hold the stomach end of the œsophagus to prevent the possible escape of liquid contents of the stomach. Break through the gastric attachments with the fingers and remove the stomach, spleen, pancreas and duodenum together.

LIVER.—Place two fingers of the left hand between the liver and the diaphragm, draw the liver back and cut downward through its attachments and the posterior vena cava.

KIDNEYS AND ADRENALS.—With the thumb and forefinger palpate the fat immediately anterior to the kidneys until the adrenals are located. Raise adrenal and kidney upward and sever their attachments close to the lumbar muscles. In females the ovaries may be detached from the lumbar position but left with uterine horns to be removed later with the uterus.

OPERATIVE TECHNIC FOR PELVIC CAVITY

Cut all muscle away from the pelvic symphysis until it is clean. Then cut downward through it with a knife if the animal be young or with a chisel if the bones be hardened with age. Insert two fingers of each hand in the pelvic inlet and pull laterally until the pelvis is separated an inch or more at its symphysis. The pelvic organs may be removed together and separated later. Draw the penis

straight back and place an incision through the skin completely around the anus and penis or in the female incise the skin around the vulva. Free the organs from their peripheral attachments to the pelvis by cutting around them with a knife, using care to keep the cutting edge toward the pelvic bones to avoid injury to the soft structures. Ovaries, uterus, vagina, bladder and rectum in the female, and penis, testicles, prostate and Cowper's gland, bladder and rectum in the male are extirpated together.

OPERATIVE TECHNIC FOR THE THORACIC CAVITY

STERNUM.—To remove the sternum incise the diaphragm at its peripheral attachment to the sternum. Cut each asternal cartilage with the curved blade cartilage shears immediately above its costal articulation (Fig. 106). The cartilages may be readily severed with a knife if the animal be young. Examine the articulations of ribs and asternal cartilages for the rosary appearance of rickets. Determine character and quantity of fluid if any be present.

HEART AND LUNGS.—In ablation of the heart and lungs grasp the trachea and œsophagus immediately anterior to the heart and sever them at their entrance to the thorax. Next draw the heart and lungs upward and forcibly tear the mediastinum completely free from its spinal attachment.

OPERATIVE TECHNIC FOR THE HEAD, NECK AND BACK

THYROID GLANDS.—Make a short incision through the sternohyoideus muscle on the median line of the neck down to the tracheal rings just posterior to the larynx (Fig. 106). Lay the muscles back from the trachea on either side of the incision thus made and remove the thyroid and parathyroid glands.

TONGUE, TONSILS, LARYNX, TRACHEA AND ŒSOPHAGUS.—Excise the muscles in the submaxillary space close to each ramus of the lower jaw, from the mandibular symphysis to the angles of the rami (Fig. 106). These incisions must be made completely through the muscles into the oral cavity and should meet exactly at their anterior extremities in order to free the tongue from the mandible. After completing the incisions described, insert the forefinger of the left hand between the tongue and mandible and draw the tongue out of the oral cavity between the rami of the lower jaw. Hold the tongue back and cut through the soft palate and great rami of the hyoid bone, then draw tongue, tonsils, larynx, trachea and œsophagus upward and backward toward the thorax (Fig. 107), removing them together from the cadaver.

NASAL PASSAGES.—Place the cadaver in the ventral position, remove skin and musculature from the head, and cut away the soft portion of the nostrils. Saw transversely across the face at the base of the nose in front of the eyes. Place the sharp edge of the side chisel against the anterior orifices of the nasal passages and cut backward to the transverse incision. In small animals the nasal passages may be opened with cartilage or bone shears. In following the incisions described the frontal sinus and the cribiform plates of the ethmoid bone are exposed (Fig. 108).

BRAIN AND CORD.—To take out the brain and cord together, complete the removal of the skin from the cadaver and excise all musculature from the head and back (Fig. 108). Break off all the superspinous processes with the bone shears and then with the same instrument nip through the vertebræ between the internal angles of the ilium until the meninges of the cord are exposed. If the animal be

young and the bone not too hard one may open the entire canal and cranium with the bone shears, which have short, thick, straight blades. To do this place the point of the left blade in the canal above and to the right of the cord, cut, and at the same time twist the handle upward to the right.

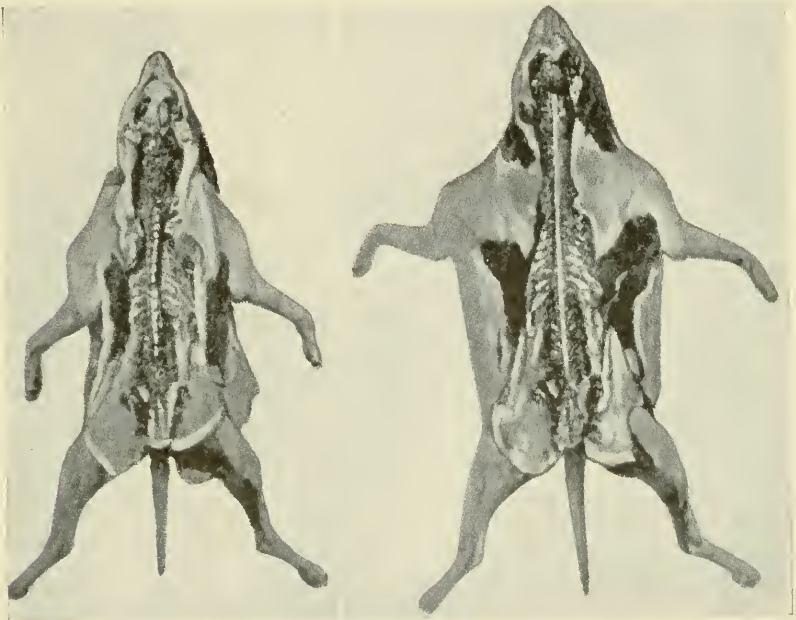


FIG. 108.—Figure at the left shows the skin and musculature removed from nose, calvarium and top of spine, preparatory to removing the nasal bone, calvarium and top of spinal canal. Figure at the right shows nasal bone, calvarium and top of spinal canal removed exposing nasal passages, brain and spinal cord.

Then place the right blade in the canal above and to the left of the cord and twist to the left. By continuing this process the entire upper half of the spinal canal may be removed and the cord exposed. When the foramen magnum is reached the calvarium may be removed by nipping to the right and left with the bone shears, following the base

of the skull on either side. It may also be removed by placing the point of a small side chisel in the foramen magnum and cutting the bony wall, following the same line forward just above the zygomatic crest on either side and across the parietal bone anteriorly to meet the two lateral incisions. With considerable practice one may become quite expert at removing the calvarium with a small hatchet without injury to the meninges or brain. The same three lines are followed, one on either side of the parietal bone above the zygomatic crest from the foramen magnum forward to the temporal part of the frontal bone and one across the parietal bone to join the two lateral incisions. On small animals these incisions may be effectuated by three slight blows with a sharp hatchet. When the bones of the spinal canal are very hard, as in old animals, a curved rachiotome is used to remove the cord. One must penetrate the canal with the bone shears or saw through it transversely near the posterior end, then introduce the probe end of the rachiotome into the canal above and to one side of the cord, place the cutting edge against the bone and strike sharply on the head of the rachiotome with a wooden or rawhide mallet. An incision approximately an inch long is made, then the instrument is transferred to the opposite side of the canal and a like incision made. By continuing this process the upper half of the spinal canal can be removed and the excision of the meninges and cord be accomplished with forceps and scalpel (Fig. 108).

After the calvarium has been removed the meninges may be examined, incised longitudinally, and the brain lifted out by careful manipulation with fingers and a scalpel. When rabies is suspected one should be cautious in working about the teeth, brain and cord. If the head is to be sent

to a laboratory for examination, excise it close to the thorax to facilitate location of the ganglia. The ganglia nodosum and the superior cervical ganglia of the sympathetic nerve are those most frequently examined. To locate them lay open the jugular furrow and follow the vagus and sympathetic nerves, which are encased within a common sheath, to the base of the cranium. Cut the ganglia across at the point where the nerves emerge from the cranium, and remove them. A single or double blade rachiotomy saw may be used to remove the cord.

CHAPTER IX

INTERNAL EXAMINATION OF THE MOUSE, GUINEA-PIG, RABBIT, FOWL AND ELEPHANT

OPERATIVE TECHNIC FOR THE MOUSE, GUINEA-PIG, AND RABBIT

THE small animals are stretched out in the dorsal position and secured by pins run through the feet, or by twine or small chains attached to the legs and margins of the pan or post-mortem board. An incision is made

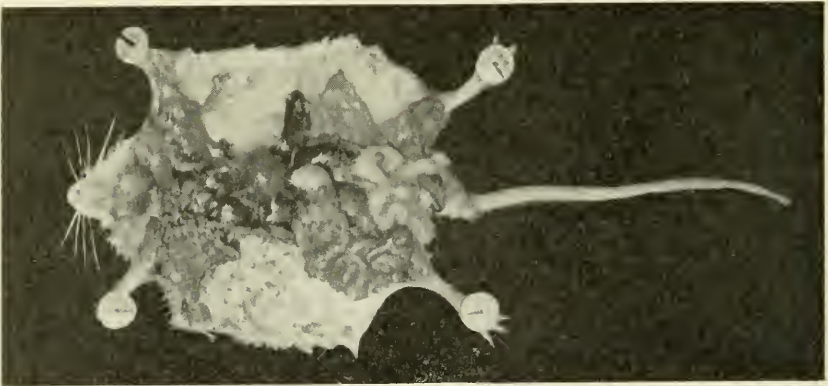
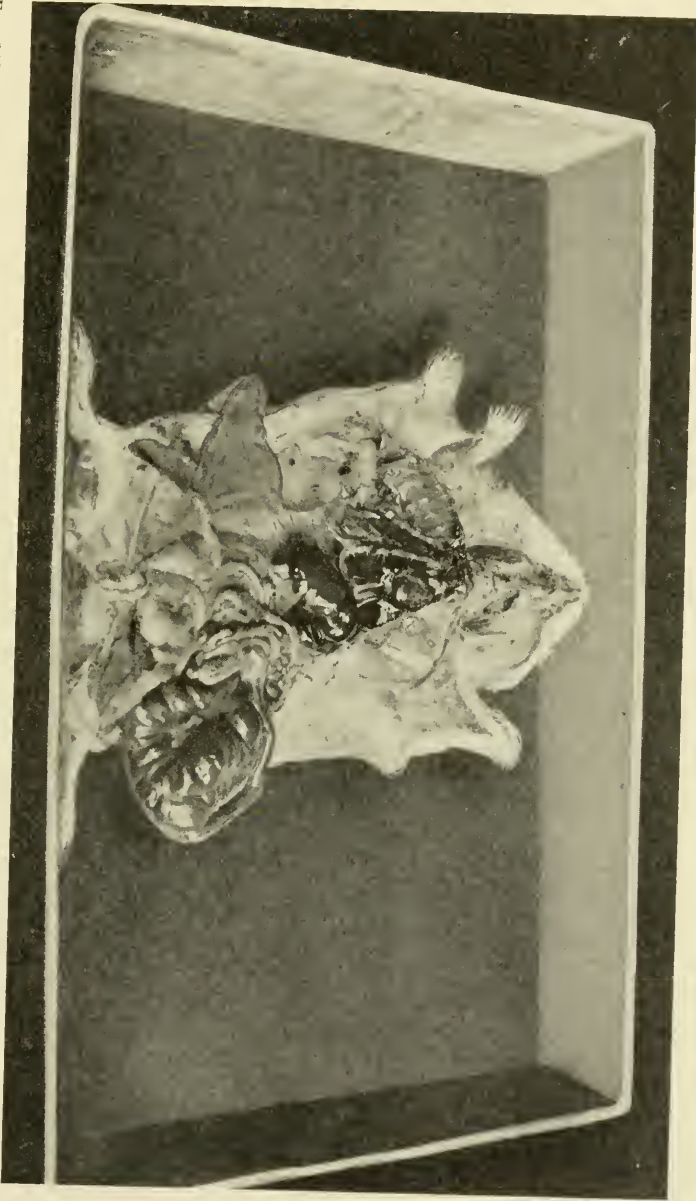


FIG. 109.—Sternum freed by two lateral thoracic incisions and laid over the right side. Heart and lungs exposed. Abdominal flaps turned back. Spleen drawn straight out to the left side of cadaver. Intestines drawn to the right side. Liver, stomach and left kidney exposed. Testicles visible on either side of base of the tail. Uterus masculinus lies above the testicles and resembles the two horns of a ram.

through the skin along the median line from the tip of the jaw to the anus, usually after wetting the hair with 5 per cent. carbolic acid solution. The skin is laid back from this incision on either side and the forelegs freed from the thorax. The abdominal cavity is opened with a longitudinal

Fig. 110.—Autopsy of a guinea pig. Sternum laid over the right side, intestines to the left side of cadaver. Penis drawn backward. Testicles above penis. Uterus masculinus, anterior to testicles, right horn extending over the right abdominal flap.



incision through the belly muscles from sternum to pubis, and transverse incisions along the posterior border of the ribs to the back. The thoracic cavity is opened by incising the asternal cartilages above their costal articulations with

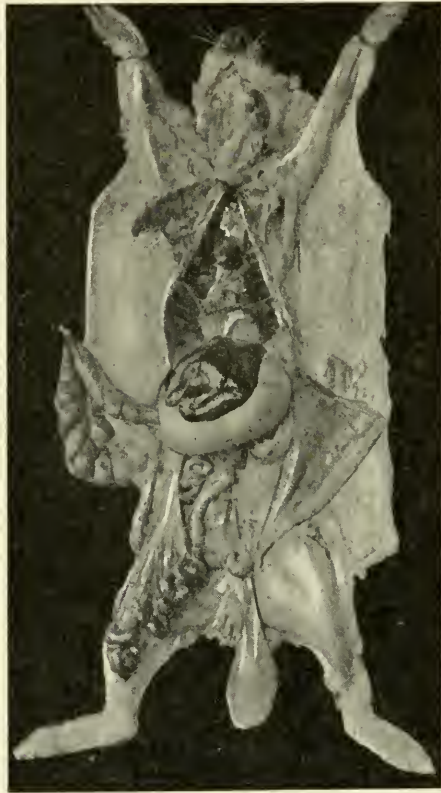

FIG. 111.—Autopsy of a rabbit.

scalpel or scissors and removing the sternum. Exenteration of the various cavities is often unnecessary, but when desired may be accomplished, following the technic of the dog and cat (Figs. 109, 110, 111).

OPERATIVE TECHNIC FOR THE FOWL

Saturate the fowl with 5 per cent. carbolic acid or creoline solution and remove the feathers from the ventral surface. Place the cadaver in the dorsal position, disarticulate the legs at the coxofemoral joint, and lay them outward from the body. Disarticulate the wings at the coracoid-scapulohumeral joint. Open the abdomen with a longitudinal incision from the point of the sternum to the anus and transverse incisions along the posterior border of the ribs. To remove the breast and open the thorax incise the diaphragm at its peripheral attachments to the sternum, cut forward through the ribs with a knife or scissors, and disarticulate the sternum at the glenoid cavities. When removing the breast be careful to avoid injury to the ingluvies or crop (Fig. 112).

After examination of the organs *in situ* the entire digestive canal may be extirpated intact. To accomplish this make a longitudinal incision through the skin on the median line of the neck, from the point of the mandible to the thorax, and carefully dissect the integument away from the ingluvies or crop (Figs. 112, 113). Cut through the skin and muscles close to the inner side of the mandibular rami, draw the tongue and larynx out of the oral cavity, cut through the hyoid bone, and draw the tongue, larynx and œsophagus backward. Dissect the ingluvies free from the neck, then detach the œsophagus, proventriculus or true glandular stomach, gizzard or muscular stomach, and intestines from their positions and excise the rectum. The entire digestive tube may be placed on a table, the intestines disengaged from the mesentery and the entire tube opened with a sharp-pointed scissors. The spleen is oval or nearly round and easily detached. The testicles of the male are

quite large and quickly located. The liver may be freed from the diaphragm in the usual manner and the kidneys,

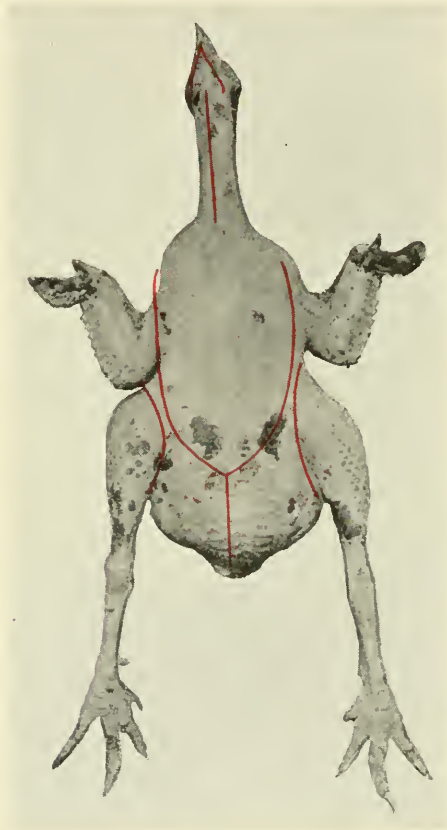


FIG. 112.—The incision on the median line of the neck is made first. The cervical structures are exposed and the crop dissected free from the breast and drawn forward. The coxofemoral joints are laid open by incisions between the legs and body. The abdomen is opened by one median and two lateral incisions and the flaps turned back. The lateral incisions are continued forward through the ribs to the coracoid-scapulo-humeral joint, and the sternum removed.

which are deeply situated between the ribs, may be dissected out with the handle of a scalpel. The ovary of the female often contains many ova and must be carefully

manipulated to prevent injury to it or may not be removed at all. The oviduct should be taken out and opened the

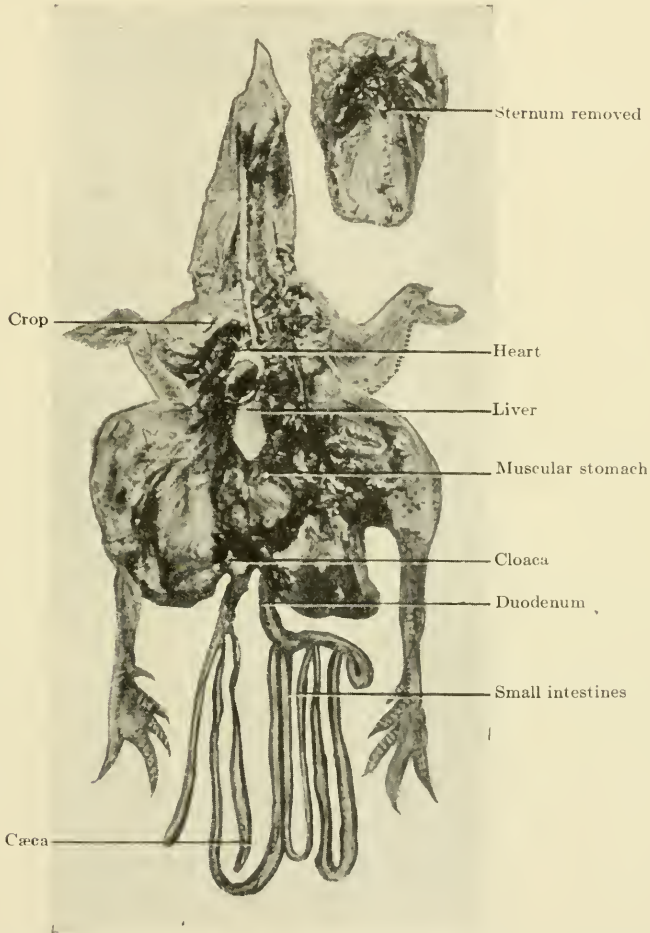


FIG. 113.—After making the incisions indicated by the red lines in FIG. 112, the crop is freed from the breast, wings and legs spread out from the body, flaps of the abdomen laid back, sternum removed, organs examined *in situ*, intestines drawn out of the abdomen and arranged as indicated and the crop is laid over the right wing. The cavities are then eviscerated.

same as an intestine. The trachea, lungs and heart are extirpated together by pulling upward on them and sepa-

rating the lungs from the back to which they are attached, by using the handle of a scalpel. Remove a femur and

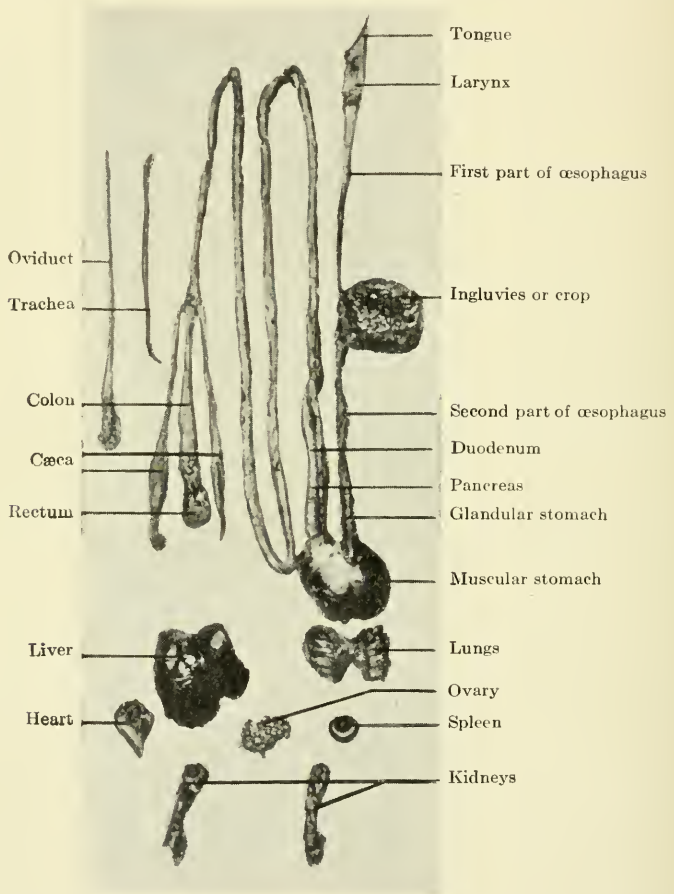


FIG. 114.—Unopened organs of a chicken after evisceration. Digestive tract is intact, other organs separate. Jejunum and ileum extend from caudal end of pancreas to cæca. Structures are later opened and examined in the usual manner.

break it transversely to expose the bone-marrow (Figs. 113, 114).

The following anatomical peculiarities should be ob-

served: Chickens have no lips, teeth, epiglottis or laryngeal vocal cords. The trachea is composed of complete cartilaginous rings. The last ring is slightly dilated and a membranous layer is shown at the origin of the bronchi, the vibration of which produces sound. The lungs normally *adhere* to the arch of the thoracic cavity. The female usually has but one ovary, the other atrophying while the fowl is young. The ovary presents many ova in various stages of development. The oviduct is large and flexuous with an *unfringed* opening near the ovary. The yolk enters the oviduct and within the oviduct becomes surrounded by an albuminous covering and later by a protective calcareous shell. The chicken has a proventriculus, succentric ventricle or glandular stomach, a muscular stomach or gizzard, and two cæca. The spleen is red in color and round, oval, or disc-shaped.

OPERATIVE TECHNIC FOR THE ELEPHANT

An elephant should be placed on its right side at autopsy to facilitate the removal of the intestines. After the skin has been removed the abdomen should be opened with xiphoid-pubic, pubic-lumbar incisions through the belly muscles as in the horse. The intestines may be removed together after incising the duodenum and rectum, and may be separated later. The other abdominal viscera may be ablated as those of the horse. As the skeleton is valuable, the ribs are not cut through to open the thorax. The extenteration of that cavity is accomplished by removing the diaphragm.

The elephant is not a ruminant and does not have four stomachs. The digestive apparatus is very similar to that of the horse. The lungs of the elephant present no lobes

except a right and left. These are pyramidal in shape, with the base anterior. The stomach simulates that of the dog more than that of the horse. The left sac is not covered by flat, white epithelium continued from the œsophagus as in the horse, but like the right sac is entirely covered by pink mucus secreting velvety tissue. The liver is bilobate, presenting a right and left lobe. The elephant, like the horse, has no gall-bladder. The kidneys are divided into lobules which are not as prominent as in the ox but are very distinct on section.

CHAPTER X

TECHNIC AND DESCRIPTION OF ORGANS

THE foregoing discussion of the internal examination of different animals deals with the exenteration of cavities after examination of the relationship of organs, presence of fluids, foreign bodies, etc. In the autopsy room students working on the various parts of the large animals should first eviscerate the cavities and remove certain parts, following the technical methods above described, using not more than one hour of the time allowed for the work. The second hour or remainder of the period should be used in preparing the organs for examination by the application of further technic, and in carefully and systematically describing each structure and lesion. The students of each group should open and describe the organs extirpated by them. When all parts have been prepared, one of the students who was assigned to the head and neck should begin a description of the respiratory tract, starting with the nostrils, nasal passages and sinuses, and following the system to the thorax. He should not miss any anatomical part of the respiratory system. All other students should give strict attention to his description and make mental notes to be used later in the general discussion to follow.

When the respiratory organs have been described as far as the thorax, one of the students assigned to that part should take up the work and describe the remainder of that system, together with the visceral and parietal pleura. When these descriptions have been completed the student should make a pathologic-anatomical diagnosis on each individual structure described or state that in his opinion

the part presents no pathological alteration. The vascular system should then be described by the alternate student on the thorax and abdomen. He should describe the blood as it flowed from the axillary vessels when the foreleg was excised, the pericardium, heart, spleen, large blood-vessels and their principal branches, and render a pathologic-anatomical diagnosis on each.

After completing the description of the respiratory and vascular systems, the second student on the head and neck should take up the digestive system including salivary glands, from the lips to the thorax, where one of the students assigned to the thorax and abdomen should continue to describe the digestive tube to the rectum, including the accessory organs of digestion, and conclude with a pathologic-anatomical diagnosis of each structure. The first student assigned to the pelvis should describe the rectum and anus and render diagnosis. The second student assigned to the pelvis should next describe the genito-urinary system, beginning with the kidneys and terminating with the external genitals. He should also describe the adrenals at this time. A diagnosis should follow the description. The alternate student assigned to the head and neck should describe the thyroid and thymus glands, eye, ear, and the brain and cord together with their meninges. The students assigned to the ductless glands, skin, subcutaneous and intermuscular connective tissue, blood, muscles, bones, joints, tendons, and pododerm, should next describe those structures and diagnose pathological conditions found. The organ lymph-glands should be described with their corresponding parts.

After all descriptions have been completed and a pathological diagnosis made on each structure, a general discussion should be held and the instructor so interrogate the

students as to stimulate them to logical deductions based on the description of lesions found. They should try to determine the primary and secondary lesions and the effect of those lesions upon the physiological function of the immediate and distant organs, the pathogenesis, and finally the cause of death.

If the autopsy is done in the field, one should follow the same general system of description, diagnosis, conclusion and note taking. That is, he should begin at the head and describe the respiratory system to its termination, next the blood-vascular system, lymphatic, digestive, urogenital, and nervous system, eye, ear, ductless glands, skin, muscles, bones, cartilages, tendons, and pododerm. By following this routine one is not apt to overlook any organ or part that may be of vital importance, which will surely be the case if he is not systematic.

The description of an organ, whether mental, written, or given orally before a class, should consist of a systematic routine in which some or all of the following points should be considered, *i.e.*, position, size, weight, shape, color, odor, consistency, incision, incision fluid, cut-surface and contents. One should avoid the use of the word *normal* and *unaltered* as they create a disposition to slight the work and make one a poor observer. Even if the part, more especially the viscera, be normal one may describe it in very few well-chosen words, which may readily indicate that no pathological alteration is present.

If an autopsy does not call for the inspection of certain parts which are obviously not involved, one should state that those parts were not examined. The word *normal* may be accepted in a report from an experienced pathologist in whose judgment and knowledge one may place implicit

confidence, but the beginner should consider himself presumptuous to use it. One must have much experience at the post-mortem table to be able to accurately determine the difference between that which is normal, that which is pathological, and that which presents the varying stages of post-mortem decomposition.

A COMPARISON OF SOME BRITISH AND METRIC UNITS

Degrees Fahrenheit = $9/5$ C° + 32.

Degrees Centigrade = $5/9$ F° = 32.

Capacity

Length

1 inch = 25.4 millimetres	= 2.54 centimetres.
1 foot = 304.8 millimetres	= 30.48 centimetres.
1 yard	= 91.44 centimetres.
1 mile = 1609.3 metres	= 1.609 kilometres.
5 miles	= 8 kilometres (nearly).

1 metre = 1000 millimetres = 39.37 inches.

1 centimetre = $1/100$ metre = 0.39 inch.

1 kilometre = 1000 metres = 0.62 mile.

To convert millimetres into inches, $\times .039$. Converse, $\times 25.4$.

To convert metres into yards, $\times 1.09$. Converse, $\times .914$.

Weight

1 grain = 0.064 grammes = 64.8 milligrammes.

1 ounce (avoir.) = 28.35 grammes = 457.5 grains.

1 pound (avoir.) = 453.60 grammes = $\frac{1}{2}$ kilogramme (approx.).

1 cwt. = 50.8 kilogrammes.

1 ton = 1016. kilogrammes.

1 kilogramme = 1000 grammes = 2.2 pounds (avoir.).

1 gramme = 15.432 grains.

1 milligramme = $1/1000$ gramme = 0.0154 grain = $1/165$ gr. (nearly).

To convert grammes into ounces $\times 0.0352$. Converse, $\times 28.35$.

To convert kilogrammes into pounds, $\times 2.2$. Converse, $\times 0.454$.

Capacity

1 fluidounce = 28.4 cubic centimetres.

1 pint = 568.0 cubic centimetres.

1 gallon = 4.54 litres.

1 peck = 9.08 litres.

1 bushel = 36.32 litres.

1 cubic inch = 16.38 cubic centimetres.

1 cubic foot = 28.33 litres.

1 litre = 1000 cubic centimetres = 1.76 pints (imperial) = 61 cu. in.

1 cubic centimetre = 0.061 cubic inch = 1 gramme of distilled water at its greatest density.

1 cubic metre = 1000 litres = 35.3 cubic feet.

To convert litres into pints, $\times 1.76$. Converse, $\times .568$.

To convert litres into gallons, $\times 0.22$. Converse, $\times 4.543$.

To convert litres into cubic feet, $\times 0.03532$. Converse, $\times 28.33$. (After F. Smith.)

0 1 2 3 4 5 MILLIMETRES 6 7 8 9 10 11 12 13 14 15 16 17 18 19 20



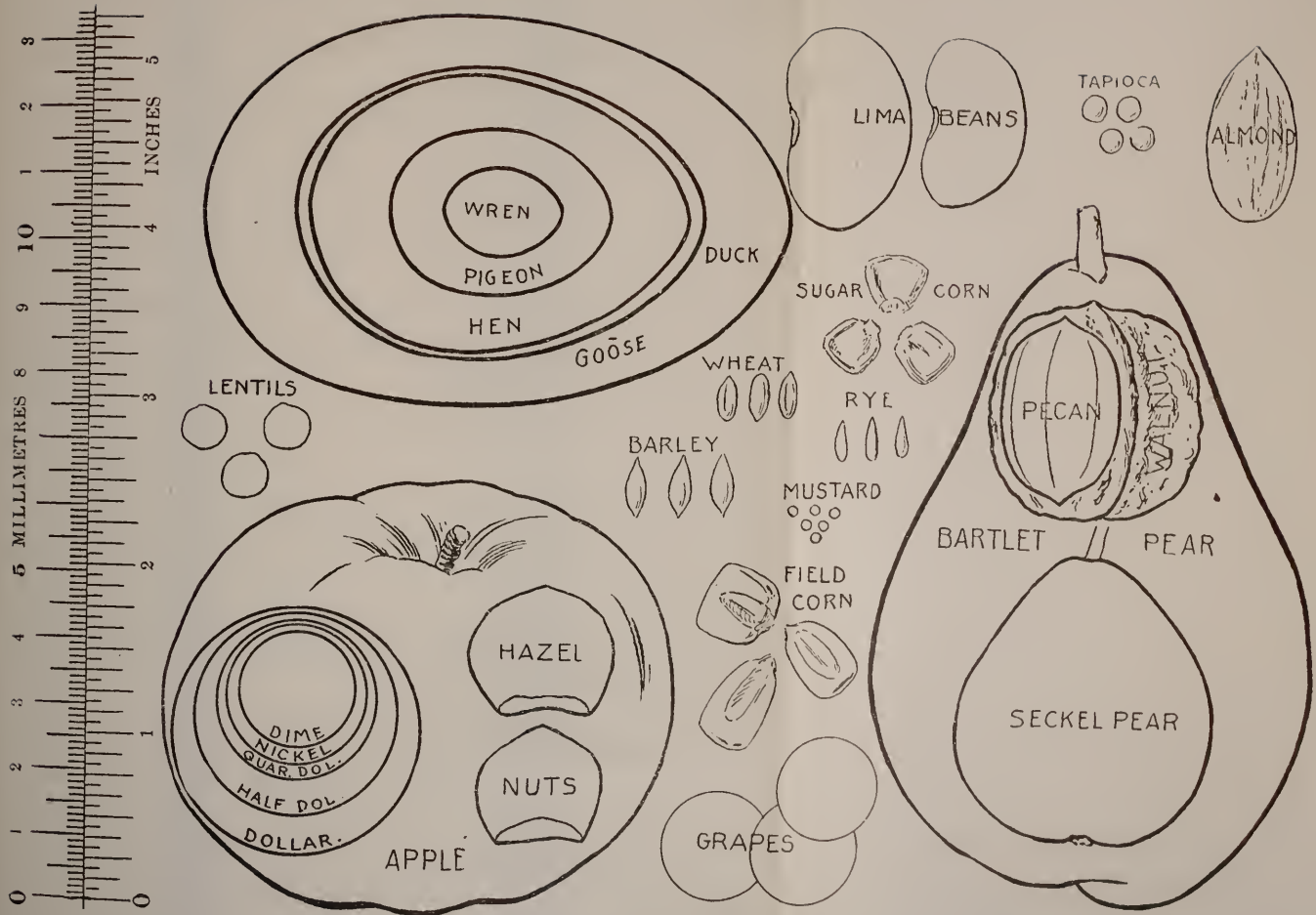


FIG. 115.—Representation of certain familiar objects, with scales in millimeters and inches, useful for comparison in describing the size and form of lesions found at post-mortem. (After Cattell).

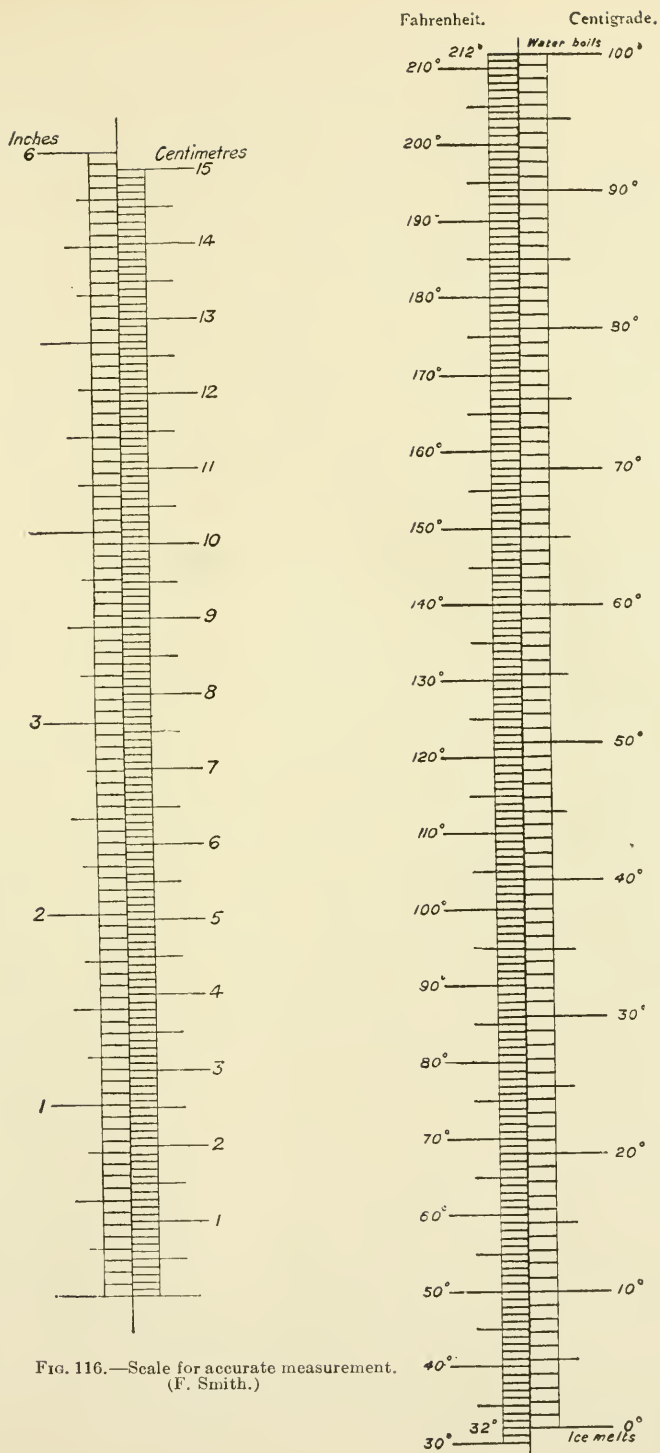


FIG. 116.—Scale for accurate measurement.
(F. Smith.)

In describing structures one may compare the size of an organ or lesion with certain well-known objects, such as a pin's head, hen's egg, man's fist, child's head, etc., but should not too frequently state that an organ is a little larger or smaller than normal (Fig. 115). Exact measurements should be given in centimetres (Fig. 116) and metres and weights determined in grammes and kilogrammes. When possible the gross weight of a cadaver should be obtained before the autopsy is begun to be used in comparison with organ-weights.




FIG. 117.—Tongue, larynx, trachea and oesophagus. Isthmus of the fauces incised and flaps laid to the sides, exposing rudimentary tonsils. Larynx, trachea and oesophagus opened on the dorsal median line, exposing mucous membranes, vocal cords, and openings to laryngeal ventricles.

TONGUE, LARYNX, TRACHEA, OESOPHAGUS AND TONSILS.—Extend these structures upon a table with the tongue pointing toward the autopsist. Incise the tongue longitudinally in several places, then pass a knife under the isthmus of the fauces and cut upward immediately anterior to the epiglottis, exposing the tonsils. In the dog and cat the tonsils are elliptical and quite prominent; in the cow the tonsillar sinus is exposed and may be followed through to the tonsil which is located outside of the fauces. The tonsils of the horse are rudimentary and lie at the base of the tongue where many crypts are visible. They are about two inches long and one inch wide, showing many depressions like a Peyer's patch. The oesophagus is opened by

passing the probe end of an enterotome into the anterior orifice and cutting through the dorsal wall of the entire cervical portion. After the mucous membrane of the œsophagus has been examined, pass the enterotome into the glottis and cut through the dorsal surface of the larynx, and continue the incision through the cervical portion of the trachea. Spread the larynx and trachea open and examine the thyroid, cricoid and arytenoid cartilages, vocal cords, ventricles, annular cartilages, and mucous membranes (Fig. 117).

THYROID AND PARATHYROID GLANDS.—The parathyroid glands lie on the anterior surface of the thyroid glands of the horse, dog, and cat, and near the posterior end in the cow. They are closely applied to the thyroids and are removed with them. To incise the thyroid gland hold it between the thumb and first two fingers of the left hand narrow edge upward. Cut downward through the organ, severing it in halves. The thyroid gland of small animals may be placed upon a table and incised longitudinally.

ŒSOPHAGUS.—The technic of the cervical portion of the œsophagus was described with that of the larynx and trachea with which it was removed. The thoracic portion is opened with an enterotome in the same manner, when the technic is performed upon the heart and lungs, as that part of the œsophagus is extirpated with these organs.

BRONCHI, LUNGS, AND LYMPH-GLANDS.—To separate the heart from the lungs grasp it by the apex, hold it upward, and sever the large blood-vessels. After the heart has been severed from the lungs, place the latter upon a table with the dorsal aspect upward, trachea toward the autopsist. Insert an enterotome in the trachea and cut

through the dorsal surface to the bronchi. Lay open the bronchi in the same manner. The visceral pleura, which is normally smooth and shiny, should be carefully observed for adhesions, white patches, and other changes. Next palpate the lungs thoroughly for nodules, areas of consolidation, etc. Turn the trachea away from the autopsist and cut each lobe of the lung into sections by making longitudinal incisions an inch or two apart through the entire thickness of the lung. Scrape the surface of the cut sections with the sharp edge of a knife and if foam can be collected upon the blade lung œdema is indicated. After this test has been made grasp each section between the thumb and fingers at the anterior end of the lung and slide the hand along to the posterior end of the section. Should any nodules be present they may readily be felt as the thumb and fingers pass over them. In most cases of glanders one need only to pass the hand over the visceral pleura and apply slight pressure to determine the presence of nodules which feel like shot of various sizes embedded in the tissue. When the lung presents a firm consistency a very small piece of it should be excised with a sharp-pointed scissors and placed in a glass of water. If the piece sinks some form of pneumonia or atelectasis is indicated. When the lung is soft but small fountains of mucus can be expressed from the cut surface a small piece of tissue should be excised at those points with sharp-pointed, fine scissors and tested in water.

The bronchial lymph-glands may be located anterior to each bronchus at its origin from the trachea in the obtuse angle made by the trachea and each bronchus. The anterior mediastinal lymph-glands are located in the anterior mediastinum along the trachea and the posterior glands

are situated in the posterior mediastinum along the dorsal wall of the œsophagus and in dogs between the bronchi in the acute angle made by those tubes at their origin. These glands should be cut longitudinally into thin sections (Fig. 118).

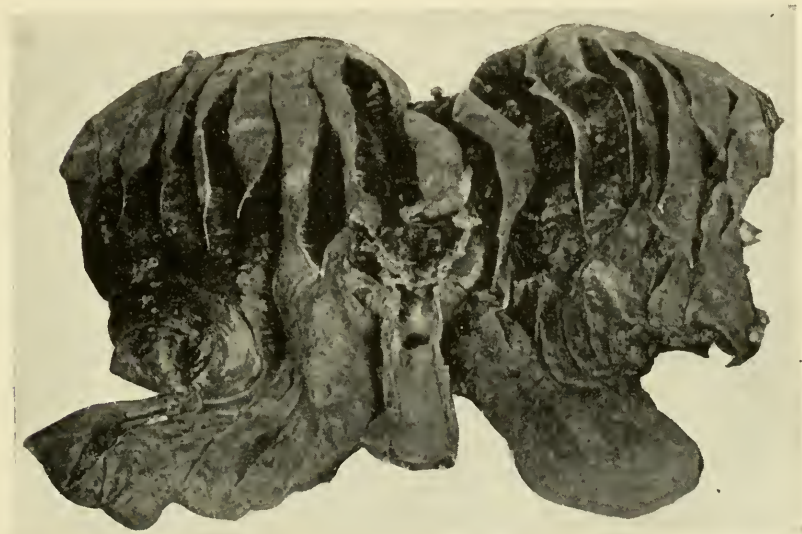

FIG. 118.—Lungs after opening trachea and bronchi and making parallel longitudinal incisions through the parenchyma. Each section is passed between the thumb and fingers in examination for nodules. Bronchial lymph glands are in the obtuse angles and mediastinal lymph glands in the acute angle of the tracheal bifurcation.

PERICARDIUM AND PERICARDIAL FLUID.—The opening of the pericardial sac and care of the pericardial fluid of large animals was described in the discussion of evisceration of the thoracic cavity. The heart and lungs of small animals are removed without opening the pericardial sac. Before performing the technic on the heart of small animals, a sharp-pointed scissors is passed through the pericardium near the apex and a vertical incision made toward the base

of the organ. Care should be taken not to contaminate or lose the fluid until its quantity and character can be determined.

HEART.—The heart may be opened with autopsy knife, scalpel, enterotome or sharp-pointed scissors, depending

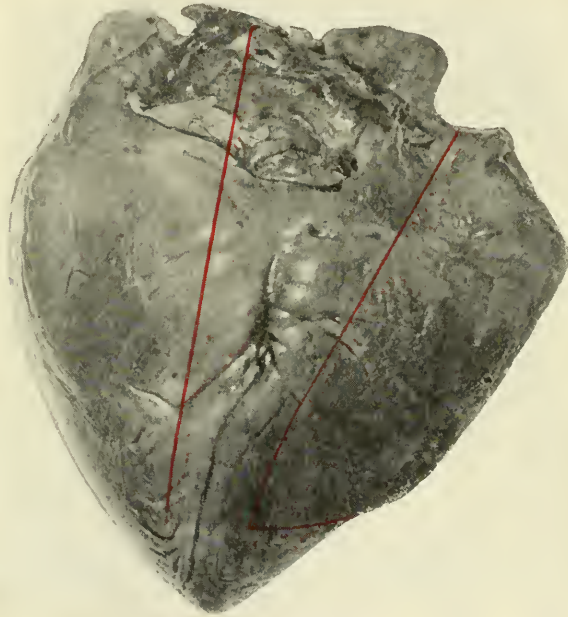

FIG. 119.—No. 1 in series. Proper position of the heart at autopsy. Right side toward the autopsist's right. Apex proximal and base distal to the autopsist. The first incision is made through the wall of the right auricle and ventricle from the base toward the apex at the right of the coronary sulcus. A similar incision is made through the wall of the left ventricle and auricle to the left of the sulcus.

upon the size of the organ. Place the heart of a large animal upon the table, apex toward the autopsist, right side of the heart to the autopsist's right and the left side to his left. The right ventricular wall is thinner than the left and the apex of the heart is formed by the left ventricular wall.

When placed in this position the terminal portion of the coronary artery lies almost vertically from the base to the apex of the ventricles and directly over the edge of the median septum. The first incision is made longitudinally parallel to and one inch to the *right* of the coronary artery from base to apex through the wall of the right ventricle

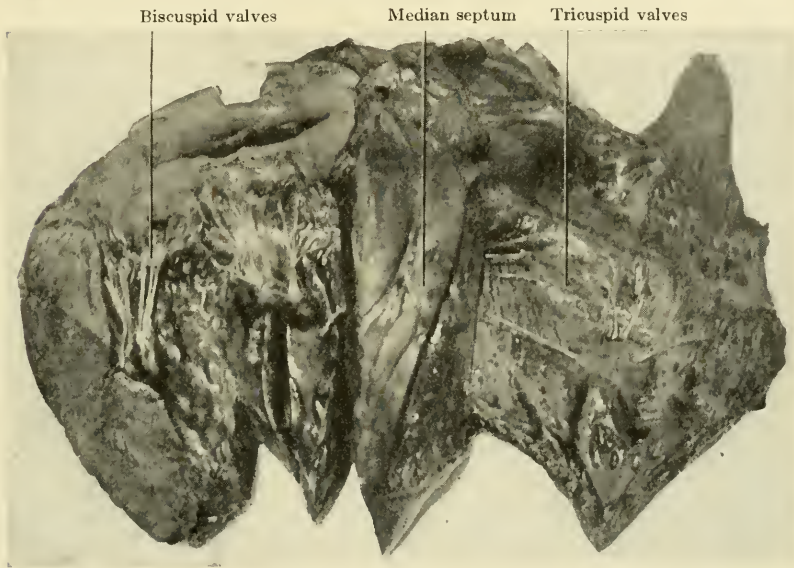


FIG. 120.—No. 2 in series. Right and left cavities of the heart opened after completing incisions indicated in FIG. 119. Tricuspid and bicuspid valves exposed.

(FIG. 119). One should hold the knife in a full hand grip to make this incision and cut downward through the right ventricular wall, taking care to cut no deeper than the thickness of the wall. When the wall of the right ventricle has been incised from base to its lower end near the apex, turn the knife with the cutting edge upward and force the point under the tricuspid valves at the superior end of the incision. Cut upward through the tricuspid valves and

continue the incision through the auricular wall in a direct line with the incision just made through the wall of the ventricle. Next lay the right auricle and ventricle open, cut the cordæ tendinæ and examine the contents. Wash out the auricle and ventricle with water and examine the tricus-

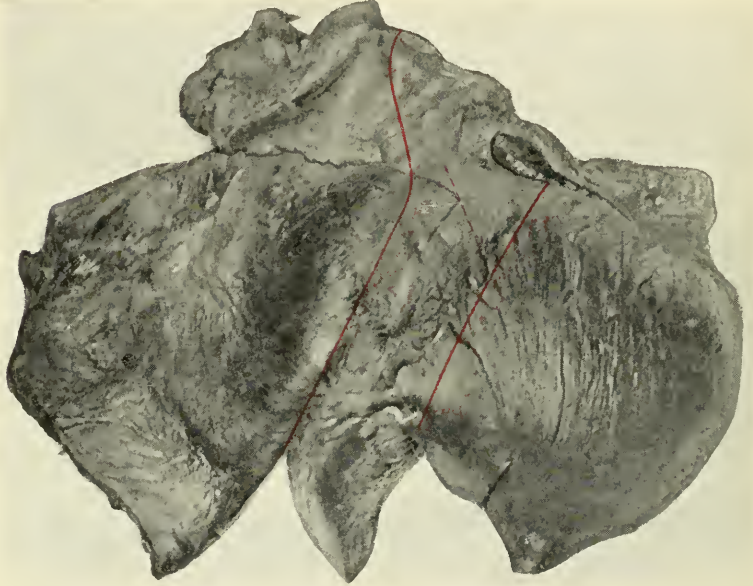


FIG. 121.—No. 3 in series. The entire heart as seen in FIG. 120 is here inverted. The right side is now toward the autopsyist's left and the left side toward his right. The incision at the left is continued upward along the median septum through the right ventricular wall to the pulmonary artery and that structure opened exposing pulmonary semilunar valves FIG. 122. The incision at the right is continued upward along the median septum through the left ventricular wall which is laid to the right and the aorta opened, exposing its semilunar valves FIG. 123.

pid valves, columnæ carnæ, parietal endocardium, and venous openings into the right auricle (FIG. 120).

To open the left ventricle make a similar parallel incision one and one-half inches to the left of the coronary artery from the base of the heart to the apex (FIG. 119). One must cut deeply as the left wall may be two inches thick.

With this incision completed turn the knife with the cutting edge upward, force it under the bicuspid valves and cut upward through them at the superior end of the incision just completed. After incising the bicuspid valves, continue the incision through the wall of the left auricle in a

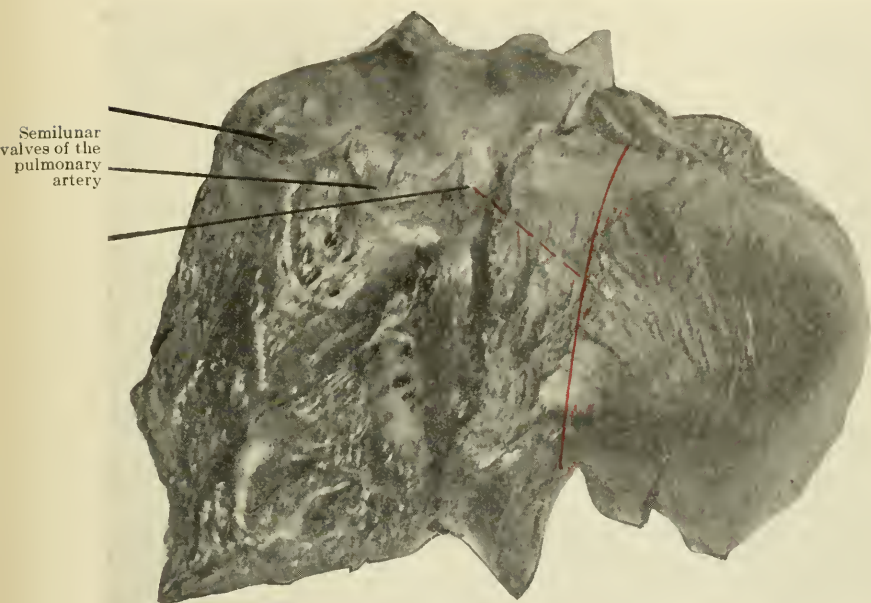


FIG. 122.—No. 4 in series. Heart in same relative position as in FIG. 121. The first incision (left) in FIG. 121 has been completed, right ventricular wall laid outward to the left and pulmonary semilunar valves exposed.

direct line with the left ventricular incision. Lay open the left auricle and ventricle and proceed as with the right side of the heart (Fig. 120).

In opening the pulmonary artery and aorta for examination of their semilunar valves, next turn the heart completely over so that the right side is at the autopsist's left

and the left at his right (Fig. 121). With the left hand grasp the thin right ventricle wall, which is now at the autopsy's left, raise it upward and observe the junction of the wall with the median septum. With a knife or enterotome cut through the wall of the right ventricle close to and to the left of the septum from the inferior end of the incision, upward toward the base of the heart (Fig. 121). When close to the pulmonary artery withdraw the knife and invert the artery at its origin just enough to observe the points at which each cup of the semilunar valves joins its neighbor. Cut between the two cups so as to keep each intact, then cut through the wall of the artery and lay it open. Wash the inside of the artery and examine valves and intima (Fig. 122).

To open the aorta grasp the apex of the heart with the left hand and raise it upward. With a knife cut vertically through the left ventricular wall close to and to the right of the septum (Fig. 121) until the wall is almost completely free from it. Raise the bicuspid valve upward and expose the aortic opening. The points at which the cups of the aortic semilunar valve join each other are visible without inverting the aorta. Insert the knife in the aortic opening with the cutting edge upward. Place the cutting edge close to the handle on a point between two cups of the valve and cut upward a quarter of an inch, then keeping the knife firmly in the incision cut outward to the right, avoiding injury to the semilunar valves of the pulmonary artery which lie directly above those of the aorta when the heart is in this position, and expose aortic semilunar valves (Fig. 123).

Examine the origin of the coronary artery, aortic semilunar valves, thickness of the aortic wall, and the intima.

With small scissors open the entire coronary artery. Incise the myocardium with long smooth incisions, examine surface of cut sections, and press the thumb into the muscle to determine the consistency.

The heart of small animals may be opened, following

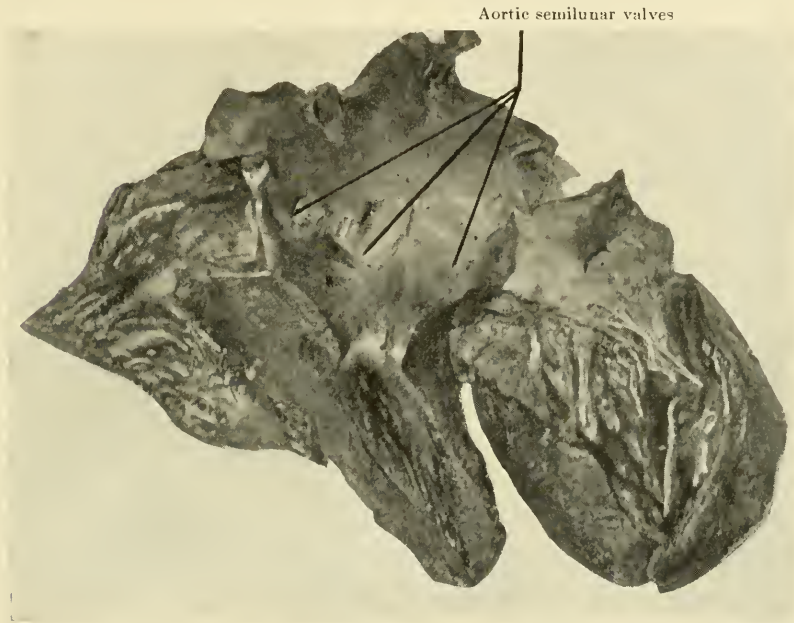


FIG. 123.—No. 5 in series. Heart in same relative position as shown in FIG. 122. This illustration shows the second incision (right) described in FIG. 121 completed and the left ventricular wall laid to the right, median septum rotated to the left and aorta opened exposing its semilunar valves.

the same lines, but small, sharp-pointed scissors should be used, and the heart may be held in the palm of the hand.

Various hydrostatic and pneumatic tests are used in determining the competency of the valves, but their value is not now considered of such importance as it once was.

An incision is first made into the left auricle, and any

BRIEF DESCRIPTIVE TABLE OF NORMAL HEART

Factors	Horse	Ox	Pig	Dog	Sheep
Position	Long axis directed downward, backward, and to the left. Two-fifths to the right and three-fifths to the left. Base directed dorsally and opposite 3d, 4th, 5th, 6th ribs. Apex above last segment of sternum close to diaphragm.	More to left of median plane than in horse. Opposite 3d, 4th, 5th ribs. Contact with thoracic wall on left side. Right side covered by lung.	Pericardium attached to sternum from 3rd rib to xiphoid cartilage. Long axis oblique.	Base opposite 3rd rib. Apex opposite 6th costal cartilage.	
Size	Length from coronary groove to apex ca 25 cm. Diam. at coronary groove ca 2.5 cm. Circum. at cor. groove 40-70 cm. Height L. V. ca 18 cm. Height R. V. ca 15 cm. Diam. L. V. ca 6 cm. Diam. R. V. ca 5.5 cm. Diam. wall L. V. ca 5 cm. Diam. wall R. V. ca 2 cm. Diam. ventricular septum ca 3.5 cm. Length L. A. ca 10 cm. Length R. A. ca 11 cm. Diam. L. A. ca 7 cm. Diam. R. A. ca 8 cm. Diam. auricle walls ca 0.5 to 1.5 cm.	Relatively longer and narrower than in the horse. Height from base to apex ca 17 cm. Diam. at base ca 12 cm. Circum. at cor. groove ca 38 cm.	Relatively short and wide.	Relatively large.	Relatively small.
Weight	Ca 1 per cent. of body weight ca 5 kg.	Ca 0.5 per cent. body weight. Ca 2 to 2.5 kg.	Ca 0.4-0.5 per cent. body weight. Apex blunt and notched.	Ca 1 per cent. of the body weight. Almost globular; apex blunt and notched.	Ca 0.6 per cent. body weight. Conical.
Shape	Conical.	Conical	Conical	Conical	Conical
Color	Reddish brown.	Reddish brown.	Reddish brown.	Reddish brown.	Reddish brown.
Consistency	Firm.	Firm.	Firm.	Firm.	Firm.
Odor	At autopsy curran jelly or chicken fat clot.				
Contents					

post-mortem clots are carefully removed from the left chambers through it. Another incision large enough to admit the nozzle of a half-inch tube is made into the ventricle near its apex and in the line of that required for laying it fully open. The tube is joined to the bellows and air driven intermittently into the ventricle by means of it, the aorta having been meanwhile closed. The valve will be seen to open and close, according as the air is aspirated or driven out of the bellows. A like procedure is adopted for the demonstration of the tricuspid. To test the aortic valve, the incision before described as necessary to lay open the left ventricle is continued up as close to the valve as possible without injuring it. The tube is tied into the aorta, and the action of the valve is watched from below. The same method is used to test the competency of the pulmonary artery valve (Hamilton).

The same general procedure may be used with water, excluding the bellows. A slice of the apex is cut off, opening both ventricles so that water may be poured into each ventricle separately to test the auriculoventricular valves after the large arteries have been closed. In testing the semilunar valves the arteries should be trimmed down so that the valves are visible, then the vessel filled with water and the action of the valve noted from below after opening the ventricle.

SPLEEN.—Take the measurement of the spleen of the horse in centimetres along both legs of the right angle and the hypotenuse (Fig. 124). Make several incisions longitudinally through the organ and measure the thickness (Fig. 125). On cut section the spleen pulp, Malpighian corpuscles, trabeculae and capsule are examined. The spleen of other animals is incised and inspected in the same

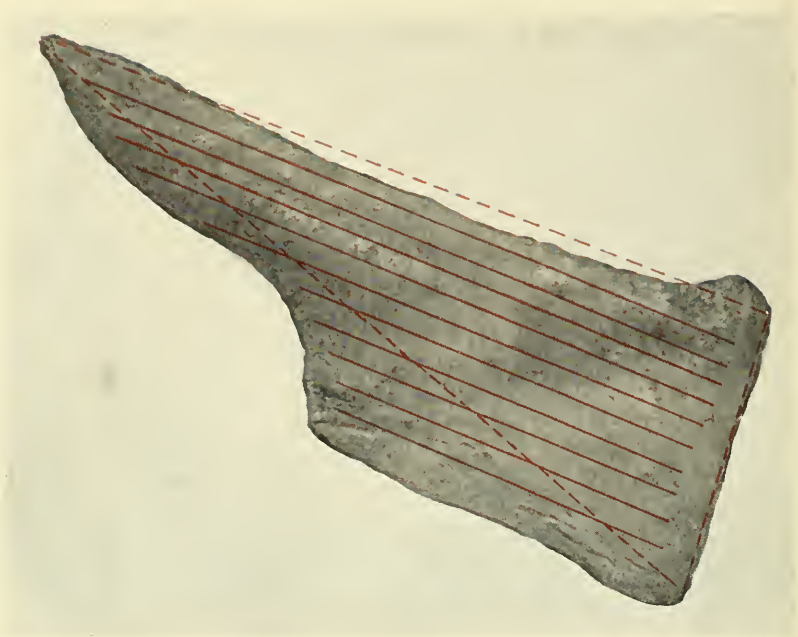


FIG. 124.—Spleen of a horse. Dotted lines for measuring the organ on both legs of the right angle and the hypotenuse of the triangle. Solid lines for incisions through the organ.




FIG. 125.—After incisions have been made through the spleen, exposing cut surface for examination of trabeculae, pulp, and Malpighian corpuscles.

BRIEF DESCRIPTIVE TABLE OF NORMAL SPLEEN

Factors	Horse	Ox	Sheep	Hog	Dog	Powl
Position.....	In left pararechondrium on great curvature of stomach.	Left face of rumen.....	Dorsal curvature of rumen.	Left side of stomach..	Left side of stomach..	To right of stomach on limit of gizzard.
Size.....	Length ca. 50 cm. Width ca. 25 cm. Hypotenuse ca. 56 cm. Thickness ca. 3 cm.	Ca. 50×15×3 cm.....	Ca. 13×10×2 cm.....	Ca. 45×10 cm. in large animals.	Varies with size of animal.	Hazelnut.
Weight.....	Ca. 1-1½ kg.....	Ca. 5-1 kg.....	Ca. 150 g.....	Long and narrow, tongue-shaped, cross section triangular.	Tongue-shaped.....	Oval, round or disc-shaped.
Shape.....	Cleaver.....	Elliptical.....	Somewhat triangular.	Bimish red.....	Light red.....	Red.
Color.....	Grayish blue or purple	Grayish blue.....	Grayish blue.....	Soft.....	Soft.....	Soft.
Consistency.....	Soft and yielding...	Soft.....	Soft.....	Soft.....	Soft.....	Soft.
Comments.....						

manner and the length and maximum width at each end taken in centimetres.

The cut surface of a normal spleen is flat, pulp brownish red, Malpighian corpuscles invisible or only very faintly visible, trabeculæ visible as a meshwork of fine white lines, and the capsule is adherent and tough. In passive congestion the cut surface is convex, pulp black and jam-like, trabeculæ and Malpighian bodies invisible. Local areas of passive congestion simulating hemorrhagic infarcts constitute multiple spleen tumors. They are oval or round, blue or black swellings the size of a walnut or larger and on section are black and jam-like. In follicular hyperplasia of the spleen the pulp is brownish red, trabeculæ visible, and Malpighian corpuscles are distinctly visible, as numerous, elevated, tapioca-like, round white bodies in the pulp. The spleen is usually congested in the course of nearly all septicæmias and following chronic diseases of the heart, lungs and liver. It is enlarged in leukæmia, pseudoleukæmia and amyloid degeneration. It may undergo atrophy from chronic interstitial splenitis, or show simple, or brown atrophy, tumors, etc.

STOMACH.—The stomach should be opened with an enterotome by incising the wall on the great curvature from the œsophageal opening to the duodenum. When the latter structure remains attached to the stomach the incision should be continued through it to the terminal ligation and the openings of the bile and pancreatic ducts should be examined. The contents of the stomach are removed and separated and the mucous membrane thoroughly washed and closely inspected (Fig. 126).

With ruminants one should use an enterotome and open

the abomasum on its great curvature, beginning at the duodenum and continuing through the natural opening into the omasum. When this opening has been examined sever the omasum in halves with a knife. Next pass an enterotome through the opening from the omasum to the reticu-

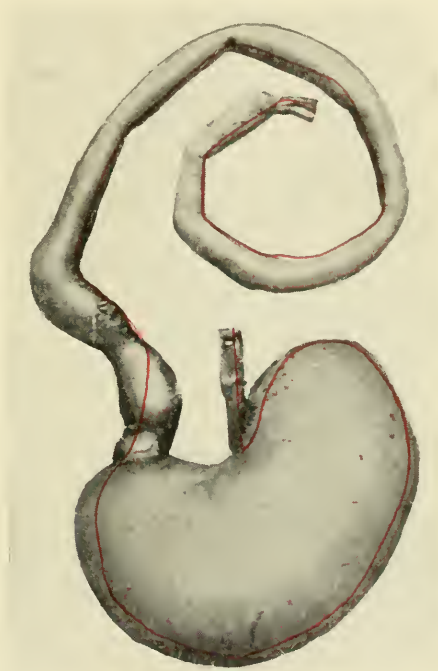


FIG. 126.—Line of incision in opening stomach and duodenum

lum, incise the wall of that structure and lay it open. The contents should be removed and the mucous membrane inspected for foreign bodies. The opening from the reticulum is next located and the rumen opened by a transverse incision through its wall. The contents of the rumen and the mucous membrane are then closely observed.

BRIEF DESCRIPTIVE TABLE OF NORMAL STOMACH

Factors	Horse	Pig	Dog
Position	Dorsal part of abdominal cavity behind the diaphragm and liver, mainly to the left of the median plane.	Parietal surface against liver, gall bladder and diaphragm, visceral surface against intestine mesentery and pancreas. Great curvature against diaphragm, spleen and abdominal floor.	Back of liver. Ventral surface on abdominal floor almost midway between xiphoid cartilage and pubis.
Size (capacity)	Relatively small. Ca 8-10 litres.	Relatively large. Ca 5-8 litres.	Relatively large. Ca 0.6-8 litres. Average 3 litres; 100-250 cc. per kg. body weight.
Weight	U-shaped sac, convex ventrally.	Pyloriform. Mucosa of esophageal and pyloric region folded. Mucous membrane of cardiac region 0.5 mm. thick, of fundus 3 mm. thick.	Pyloriform. Fundus portico large and rounded, pylorus small and oval.
Shape	U-shaped sac, convex ventrally.	Pyloriform. Mucosa of esophageal and pyloric region 0.5 mm. thick, of fundus 3 mm. thick.	Serosa white and shiny. Mucosa of esophageal and pyloric region reddish brown. Pylorus pale pink.
Color	Serosa white and shiny, muscularis pink, submucosa white, mucosa of esophageal region white, cuticular ridge gray. Cardiac gland region yellow, fundus reddish-brown, pylorus reddish gray.	Serosa white and shiny. Mucosa of esophageal region 3 cm. to left and 8 cm. to right of esophageal orifice is white, mottled brownish red. Pyloric region mottled brownish red.	Serosa white and shiny. Mucosa of esophageal and pyloric region reddish brown. Pylorus pale pink.
Consistency	Serosa tough and smooth. Mucosa of esophageal region smooth and firm. Cuticular ridge granular, fundus and pylorus soft. Pyloric region hydrochloric acid, sour milk	Serosa tough. Mucosa of esophageal region smooth and firm. Cardiac region, fundus and pylorus soft and glandular.	Serosa tough. Mucosa soft.
Odor	Aer sac covered by thick gelatinous, firmly adherent coat of mucus like white of egg. Hay 1-2 hours in stomach is finely chopped, almost dry, yellow where gastric juice has acted green elsewhere. After several hours contents are liquid green mixed with particles of hay. Quantity may be small, yellow, viscid and show gas bubbles. Oats in stomach present creamy fluid, later frothy yellow fluid.	Serosa tough. Mucosa of esophageal region smooth and firm. Cardiac region, fundus and pylorus soft and glandular.	Serosa tough. Mucosa soft.
Contents	Aer sac covered by thick gelatinous, firmly adherent coat of mucus like white of egg. Hay 1-2 hours in stomach is finely chopped, almost dry, yellow where gastric juice has acted green elsewhere. After several hours contents are liquid green mixed with particles of hay. Quantity may be small, yellow, viscid and show gas bubbles. Oats in stomach present creamy fluid, later frothy yellow fluid.	Serosa tough. Mucosa of esophageal region smooth and firm. Cardiac region, fundus and pylorus soft and glandular.	Serosa tough. Mucosa soft.

INTESTINES OF THE HORSE.—The small intestine is separated from the mesentery at the time it is removed. It should be opened with an enterotome, washed, and laid out with mucous membrane upward. The duodenum remains with the stomach and is opened at the time that organ is prepared. The double colon and cæcum are laid upon the floor and unfolded. The cæcum is laid to the right of the colon, apex toward the loop end of the later. To open the great colon and cæcum insert an enterotome in the terminal end of the colon and cut through the wall of the fourth portion or stomach-like dilation of that structure, toward the ligamentous bands which hold together its two great lengths. Continue the incision a little above the ligament to the loop end of the colon, thus completing the incision through the fourth and third portions. At the loop turn back and cut close to the ligamentous band through the wall of the second and first portions of the colon. Cut through the cæcocolic opening. Incise the wall of the cæcum, beginning at the great curvature of the head and continuing down the side to the blind point of that structure. Insert the enterotome into the stump of the ileum and cut through it into the cæcum exposing the ileocæcal valve (Fig. 127). Lay back the intestinal walls from the incisions and expose the contents. When the contents have been observed grasp the margin of the incision through the wall of the great colon and raise it upward gently, allowing the contents to fall to the floor. Later scrape the remaining ingesta from the gut with a knife blade and wash the mucous membrane of the colon and cæcum, then lay the structures out on the floor with the mucous membrane upward. An attendant should be present during the procedure and remove the ingesta to a refuse can and flush the floor with

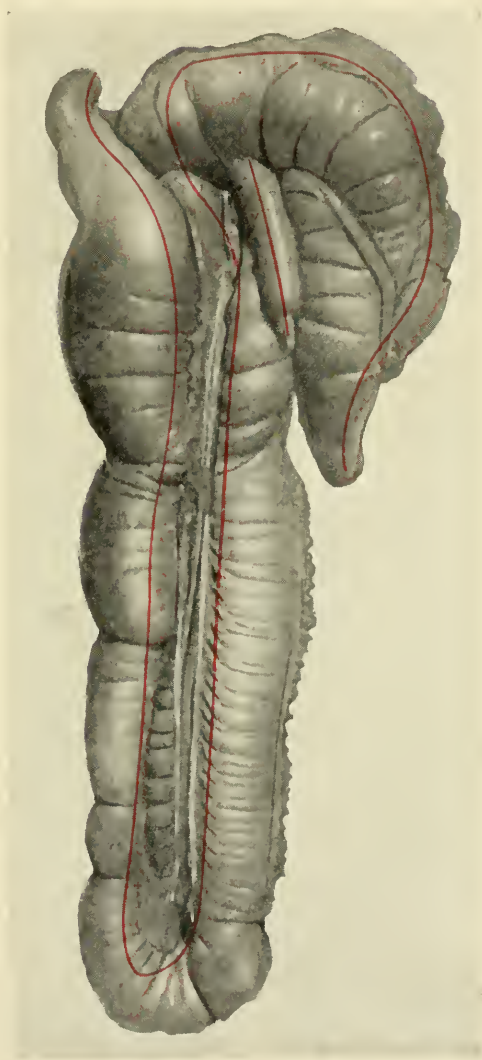


FIG. 127.—Double colon and caecum, origin of single colon and termination of ileum at the point it enters the caecum. Lines of incision for opening them. Proper position for autopsy viewed from above.

BRIEF DESCRIPTIVE TABLE OF NORMAL INTESTINES OF THE HORSE

Factors	Small intestine				Large intestine			
	Together	Duodenum	Jejunum	Ileum	Cæcum	Double colon	Single colon	Rectum
Position.....	Principally in dorsal part of posterior left half of abdomen. Begins at pylorus and ends at cæcum.	First part on middle and right lobes of liver, 2nd part on right lobe of liver back to right kidney. 3rd part transversely from right to left behind base of cæcum, under 3-4 lumbar vertebrae to be continuous with jejunum under left kidney at mesoduodenum or rectoduodenal ligament.	Jejunum and ileum together form the floating portion of the small intestine. They lie in the dorsal left half of abdomen and are suspended on a mesentery ca 50 cm. (1.5-2') long.	Almost verticle.	Right hypochondriac region. Apex 10-15 cm. back of xiphoid cartilage. Base 13th intercostal space almost to pelvic inlet.	First or ventricular part begins opposite the middle of last rib—forward and downward to sternum, backward forming sternal flexure. 2nd or left ventricular part, sternum on floor of abdomen, up and back to pelvis and bends up and forward forming pelvic flexure. 3rd or left dorsal part from pelvic flexure above 2nd part forward to diaphragm and bends to right and back forming diaphragmatic flexure. 4th or right dorsal part above first part from diaphragm back to inner left surface of cæcum, turns to left constricts and joins small colon under left kidney.	From end of great colon under left kidney back to pelvic inlet, continued as rectum. Folds lie with small intestines in left dorsal half of abdomen. Mesentery ca 80-90 cm. long.	Pelvic inlet to anus.
Size.....	Ca 22 m. (70') long. Ca 5-10 cm. (2-4') in diameter. Ca 40-50 litres. Intestinal canal is ca 12 times length of the body.	1-1.25 meters (3-4') long. 6-10 cm. diameter.	20 m. (ca 60') long. 6-7 cm. in diameter.	Ca 1 meter long. Post end of small intestine, constricted.	1-1.25 meters (ca 3-4') long. Holds 25-30 litres.	Ca 3-4 meters (ca 10-12') long, average diameter of wide parts ca 20-25 cm. (ca 8-10"). 3rd part ca 8-9 cm. in diameter. 4th* part near end has stomach-like dilatation. Ca 50 cm. (20") in diameter.	Ca 3.5 m. (10-12') long, ca 7.5-10 cm. in diameter.	Ca 30 cm. long 7.5-10 cm. diameter

Weight

Shape.....	Tube.....	Tube, folded on mesentery.	Tube constricted like esophagus.	Conical, walls show folds and pouches.	Cylindrical, parallel parts folded to make four parts. Ventral portions have four bands making 4 rows of sacculations. 3rd part has one band practically no sacculations. 4th part has three bands. Serosa white or bluish white. Muscularis pale pink. Mucosa gray.	Shows two bags and two rows of sacculations.	1st part like small flasklike.
Color.....	Serosa white, muscularis pink, mucosa yellowish pink.	Serosa white, muscularis pink mucosa gray.	Same.....	Same.....	Same.
Consistency.	Serosa white, mucosa soft and velvety, wall pliable.	Wall less pliable than Jejunum.	Smooth and pliable.
Odor.....	Yellow, slimy, frothy fluid containing precipitated albumin the form of flocculae like nasal mucus suspended in fluid.	Mawkish.	Fecal.....	Fecal.....	Fecal.....	Fecal.....	Fecal.
Contents.....	Alkaline.....	Alkaline.....	Watery brown or frothy, green pea soup-like fluid. Alkaline.	Reddish-yellow or brown fecal balls.

water as soon as the intestinal contents have been examined. The rectum should be dissected from the vagina and opened with an enterotome.

INTESTINES OF RUMINANTS.—The intestines of ruminants are first separated from the mesentery. This is most satisfactorily accomplished with a knife. Grasp the duodenum with the left hand and raise it upward from the floor. With a knife in the right hand cut downward through the mesentery close to the intestine until the separation is complete. The loops of the colon may be torn free with the fingers. Spread the mesentery out flat upon the table and incise the mesenteric lymph-glands. To open the intestine insert an enterotome in the duodenum and cut through the mesenteric side of the gut to the cæcum. Open the cæcum to its blind end and then open the colon. The rectum is dissected from the vagina and opened in the same manner. The intestinal contents should be carefully examined, then the mucous membrane washed with water from a hose or by passing the gut through a tub of water. When thoroughly cleaned it is laid out upon the floor with the mucous membrane upward for further observation. The intestinal canal of sheep is about twenty-six times the length of the body.

INTESTINES OF SWINE.—As with ruminants the small intestines are separated from the mesentery, opened, washed and laid out flat with mucous membrane upward. The mesentery is spread out and the mesenteric lymph-glands incised. In structure the colon appears to be first doubled, then arranged in spiral coils, forming a wide base and a narrow apex which is formed by the loop of the double colon (Fig. 104). To disengage the coils dissect out the loop end

BRIEF DESCRIPTIVE TABLE OF NORMAL INTESTINES OF THE OX

Factors	Small intestine	Duodenum	Jejunum and Ileum	Cæcum	Colon	Rectum
Position.....	To right of median plane on right side of rumen.	Forward to visceral surface of liver. Forms S, curve under right kidney. Passes back of ileum. Turns forward along side of terminal part of colon and joins jejunum under R. kidney.	Arranged in close folds on right face of ventral sac of rumen.	Begins opposite lower part of 11th rib. Extends upward back against right flank. Blind free end near or in the pelvic inlet.	Arranged in double elliptical coils attached to each other by connective tissue, between the layers of the mesocolon, to the right of the rumen.	Pelvic inlet to anus.
Size	Ca 40 m. (130') long. Ca 5-6 cm. (2") diameter. Entire intestinal canal 20 times length of body.	Ca 1 m. (3-4') long.	Jejunum, 38 m. (124') long. Ileum 1 m. (ca 3') long.	Ca 50-60 cm. (20-24") long. Ca 10-12 cm. (4-5") diameter. Holds 9-10 litres.	Ca 10 m. (33') long. Ca 5 cm. (2") diameter. Holds 25-30 litres.	Ca 15-25 cm. (8-10") long.
Shape.....	Tube.....	Tube. Bile duct enters at 60 cm. (2') from pylorus. Pancreatic duct enters ca 30 cm. further back.	Tube.....	Long blind sac, no sacculations.	Tube. Coiled.....	Tube.
Weight	Serosa White and shiny.	Seros White. Muscularis grayish pink.	Same as cæcum.
Color.....	Muscularis grayish pink. Mucosa pale grayish pink.	Mucosa gray.
Consistency.	Serosa tough. Mucosa soft. Wall pliable.
Odor.....	Contents mawkish.	Contents fecal odor.	Contents fecal odor.	Same.
Contents.....	Thin, slimy, greenish fluid.	Pea soup-like fluid...	Pea soup-like fluid...	Ox greenish brown putrescent feces. Sheep small, hard, round greenish brown feces.

of the doubled colon at the apex, then cut through the mesentery around the coils between each layer down to the base. After the coils have been cut free from each other lay the doubled colon out straight and with the fingers or a knife separate the two lengths of gut, beginning at the free extremities which previously constituted the base and continuing to the loop which was formerly the apex of the coiled structure. The colon may now be laid out straight and opened, washed and prepared for examination as other intestines. The cæcum takes its origin at the point where the diameter of the colon is the greatest. The enterotome should be passed through the ileum into the cæcum, thus opening the ileocæcal valve.

INTESTINES OF THE DOG AND CAT.—The intestines may best be removed from the mesentery without the use of knife or scissors. Grasp the duodenal end of the intestines between the thumb and fingers of the right hand, and the mesentery opposite this point with the thumb and fingers of the left hand, then apply traction gently and pull them apart. Nearly the entire intestine may be separated from the mesentery at the first application of traction. Lay the intestine out on a table and open it with an enterotome, cutting through the side of the mesenteric attachment to avoid injury to the lymph follicles which lie opposite the attachment of the mesentery. Open the cæcum with a sharp-pointed scissors. Scrape off the bulk of intestinal contents, then pass the entire opened intestine between the first two fingers of the left hand held with the first finger upward and the palm toward the body. In doing this draw the gut away from the autopsist and maintain the mucous mem-

BRIEF DESCRIPTIVE TABLE OF NORMAL INTESTINES OF SWINE

	Small intestine	Duodenum	Jejunum	Ileum	Cæcum	Colon	Rectum
Position.....	Arranged in close coils and lie on left side and floor of abdomen, from stomach to pelvis, some against right flank.	Upper part of right flank, blind end close to pelvic inlet.	In right flank attached by mesentery to sub-lumbar region.	Pelvic inlet to anus surrounded by fat.
Size.....	Ca 15-20 m. (50-65') long. 2-4 cm. in diameter.	Ca 60 cm. (2') long. Mesentery 1-6 cm. long.	Ca 15-19 m. (ca 16-21') long. Mesentery 18-20 cm. (7-8') long.	Ca 40-60 cm. (16-24') long.	Ca 20-30 cm. (8-12') long. (3-4") diameter	4-5 m. (15') long. Ca 8-10 cm. (3-4") at cæcum decreasing to 4-5 cm. (1.5-2") in diameter.	Ca 10-15 cm (4-6") long.
Weight
Shape.....	Tube, coiled.....	Bile duct enters 2.5-5 cm. (1-2") from pylorus. Mesentery due 10-15 m. (4-6") beyond it.	Cylindrical.....	Tube arranged in three double spiral coils. Has appearance of bee hive.	Tube.
Color.....	Serosa gray or white. Muscularis grayish pink. Mucosa gray.
Consistency.	Serosa tough. Mucosa soft. Walls pliable.
Odor.....
Contents.....	Contents offensive. Like human feces.

BRIEF DESCRIPTIVE TABLE OF NORMAL INTESTINES OF THE DOG

	Small intestines	Duodenum	Ileum	Cæcum	Colon	Rectum
Position.....	Occupies most of abdomen back of liver and stomach.			Against middle of upper part of right flank.	Attached to subumbilic region by mesocolon.	Pelvic inlet to anus.
Size.....	Ca. 4 m. (13') long. Entire length of intestinal canal 5 times that of body.			Ca. 8-10 cm. long.	Very short.	
Weight						
Shape.....	Cylindrical.....	Pancreatic and bile ducts enter duodenum together 5-8 cm. from pylorus. Accessory pancreatic duct 2-5 cm. further back.		Cylindrical and twisted.	Tube.....	Tube.
Color.....	Serosa white, smooth and shiny. Mucosa grayish pink.					
Consistency	Serosa tough, mucosa soft, wall pliable.					
Odor.....	Contents have disagreeable odor.					Same.
Contents.....	Yellowish or creamy semi-fluid. Depends on diet.			Usually empty	Stinking contents.....	Soft or hard, dark or light feces.

brane upward. Observe the mucous membrane and Peyer's patches before and after the gut has been drawn through the hand. Spread the mesentery out upon the table and incise the mesenteric lymph-glands.

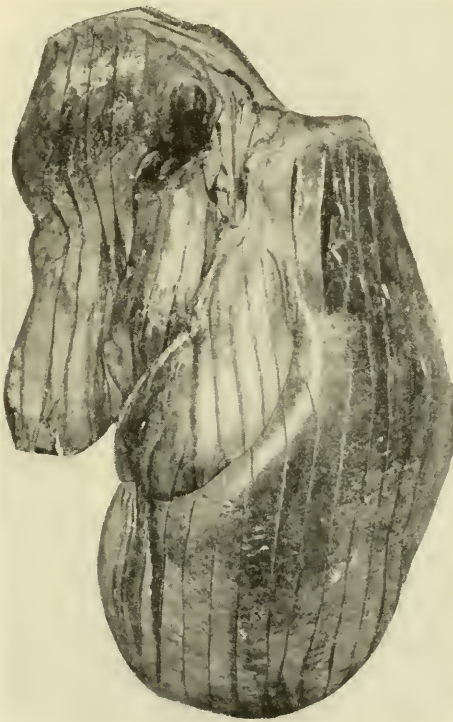

FIG. 128.—Liver properly incised. It is then inverted and incisions made in the large blood-vessels and bile ducts.

LIVER.—The liver is separated from the diaphragm when these structures are extirpated together and laid upon a table with the anterior or convex side upward. The thickness is measured by placing a rule in a vertical position

BRIEF DESCRIPTIVE TABLE OF NORMAL LIVER

	Horse	Ox	Sheep	Pig	Dog
Position.....	Against the abdominal surface of diaphragm most of it a little to the right of the median plane.	Against the diaphragm almost entirely to the right of the median plane	Against the diaphragm entirely to the right of median plane.	Against diaphragm. On right side back to 13th rib. On left back to 8th rib. Ventrally back to umbilicus.	Against the diaphragm, in front of the stomach.
Size.....	10 cm. (4") above abdominal floor to level of the kidney.	Not as large but thicker than that of horse.		Comparatively large.....	Comparatively large.
Weight.....	Ca 5 kg. (12 lbs.). In young animals it is 6-8 kg. (ca 13-18 lbs.).	3-6 kg. (ca 7-13 lbs.) ca 0.5 per cent. of body weight.	Ca 0.5-0.7 kg. (ca 1.5 lbs.)	Ca 2 kg. (ca 4.5 lbs.) 0.4 per cent. body weight.	0.1-1.5 kg. 5 per cent. body weight.
Shape.....	3 lobes, right, left and middle, which slope smoothly from thick center to thin edges. No gall bladder.	Caudate lobe only one distinct.	Two principal lobes and prismatic blunt pointed caudate lobe. Edges thin.	5 lobes, caudate, right lateral, right central, left central, left lateral. Edges thin.	6-7 lobes. Left lateral, left central, right central, right lateral, caudate, papillary and quadrate. Edges thin.
Color.....	Reddish brown.....	Reddish brown.....	Reddish brown.....	Grayish red due to excessive interstitial connective tissue. Accomplantly visible.	Red.
Consistency.....	Firm.....	Firm.....	Firm.....	Very firm.....	Firm.
Odor.....					
Contents.....					

beside the organ and then balancing a knife in a horizontal position upon the thickest part of the liver. The thickness in centimetres is read at the point at which the knife-blade meets the rule. The liver is then cut in thin sections by making long, smooth incisions through it with a sharp knife (Fig. 128). The capsule is stripped off by seizing it with the thumb-nail at the margin of one of the incisions. By so doing one may determine whether an acute or chronic process be present. The consistency is determined by pressing the fingers through the parenchyma. The organ is inverted and the gall-bladder, when present, together with the bile-duct should be opened with a sharp-pointed scissors, or a knife.

The factors of description should be followed closely in dealing with the liver. If the organ be swollen the margins are usually rounded instead of sharp. When degenerated the consistency is friable instead of firm when pressed between the thumb and fingers. In chronic processes the capsule is adherent, due to the increase of interstitial connective tissue which attaches to the capsule. In acute cases exudate and degenerated epithelium tend to soften and weaken the interstitial connective tissue at its capsular attachment so that it strips with ease. On section a nutmeg appearance is commonly seen in degenerative processes, and in passive congestion blue blood is contained and runs from the cut surface. Normally the liver has no odor but in post-mortem decomposition it is present.

PANCREAS.—The pancreas is not frequently the seat of pathological alterations. One should test the consistency of the organ with the fingers and make several long incisions through it.

BRIEF DESCRIPTIVE TABLE OF NORMAL PANCREAS

	Horse	Ox	Sheep	Pig	Dog
Position	Adherent to the terminal part of the double colon.	Attached to the liver at and external to the portal fissure.	Arranged as in the ox.	Attached to portal fissure and duodenum.	Right branch above first part of duodenum. Left branch on visceral surface of stomach.
Size	Ca 10-30 cm. (4-12") long	Ca. 40-45 cm. (16-18") long. Ca. 8-10 cm. (3-4") wide.			
Weight	Ca 350 grams (ca 12 oz.)	Ca 320 grams (ca 11 oz.)			
Shape	Triangular. Two ducts, one enters duodenum with bile duct one opposite.	Quadrilateral. One duct which enters duodenum 30 cm. (12") posterior to entrance of bile duct.	Duct enters with bile duct	Elongated. One duct, enters duodenum 15 cm. from pylorus.	V shaped. 2 ducts. One enters duodenum ca. 5-8 cm. (2-3") from pylorus. The other 2.3-5 cm. (1-2") further back.
Color	Reddish yellow.	Reddish yellow.		Yellowish white.	Grayish red.
Consistency	Fairly firm lobules loosely united.	Firm.		Firm.	Firm.
Odor					
Contents					

KIDNEY.—To prepare the kidney of a large animal place the organ upon the table on one of its flat surfaces. Place the palm of the left hand upon the kidney and press downward with sufficient force to keep the organ steady and in one position. The ends of the fingers of the left hand should extend away from the autopsist and toward the convex margin of the organ. With a knife held horizon-

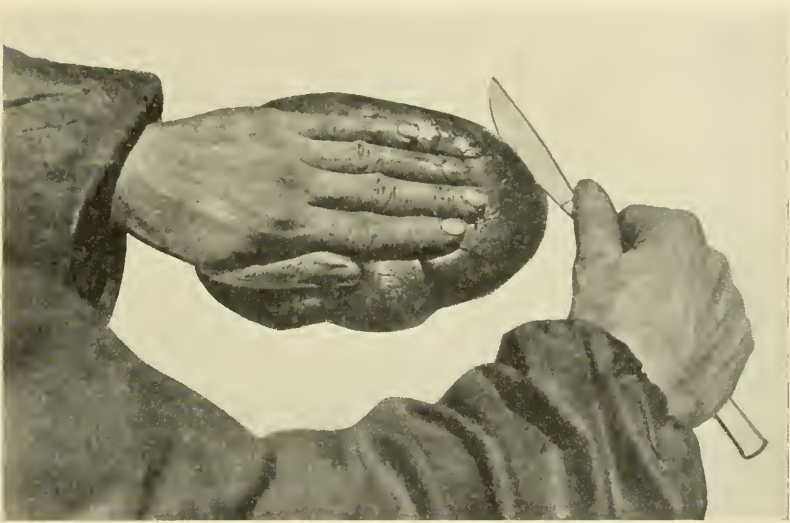

FIG. 129.—Correct position of hands, knife and kidney, for opening that organ. Viewed from above.

tally make one smooth incision through the kidney from the convex margin through the parenchyma to the hilus, severing the kidney in halves so that it may be laid open like a book (Fig. 129). Lay the organ open, wash the cut surfaces, and strip the capsule with the thumb-nail (Fig. 130).

The kidney of small animals is held between the thumb and first finger of the left hand dorsal side upward. To

section the organ cut downward from the dorsal surface through the kidney to the pelvis of the organ, dividing it in halves.

Normally the capsule is smooth, thin, transparent, and loosely attached to the parenchyma. In chronic inflammatory processes it is firmly adherent due to junction with increased interstitial connective tissue. At the point of separation, in stripping the capsule, a white line is visible

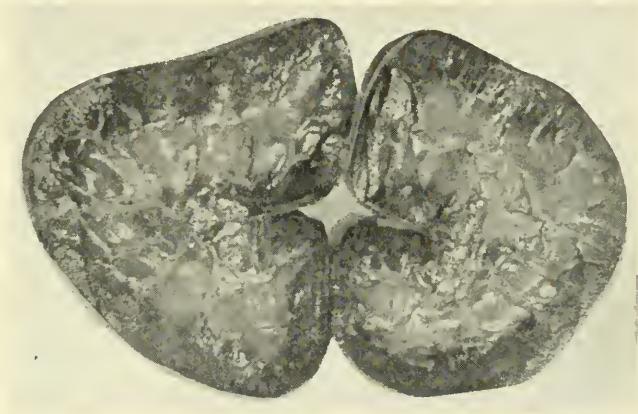

FIG. 130—Kidney opened like a book after completing the incision indicated in FIG. 129.

and a crackling, tearing sound is heard as the capsule is pulled from the intertubular connective tissue. In acute inflammatory processes the capsule strips with ease, due to softening of the interstitial connective tissue at its capsular attachments.

After stripping the capsule, describe the cortex, intermediate zone, medulla, and pelvis. Normally the cortex of the kidney of large animals may very faintly show myriads of tiny, round, red bodies which are the glomeruli. In hyperæmia and acute inflammation these bodies stand

BRIEF DESCRIPTIVE TABLE OF NORMAL KIDNEY

Factors	Horse	Ox	Sheep	Pig	Dog
Position.....	Right kidney in sublumbar region at 14-15 ribs. Left kidney at 17-18 ribs.	Sublumbar region under last rib and first 2 or 3 lumbar vertebral transverse processes. When rumen is full both kidneys are on right side. Left lower than right.	Right kidney a little posterior to left, otherwise same as in ox. When rumen is full left kidney is on right side.	On either side of the first four vertebrae.	Right kidney under last rib and 1-3 lumbar vertebral processes. Left kidney under 2-3-4 lumbar vertebrae.
Size.....	Right kidney: Length ca 15 cm. (6 ⁷ / ₈), Width 15 cm. (6 ⁷ / ₈), Thickness ca 5 cm. (2 ⁷ / ₈).	Right kidney: 20-25 cm. (8-10 ⁷ / ₈), ca Width 10-12 cm. (ca 4-5 ⁷ / ₈). Thickness 7 cm. (3-4 ⁷ / ₈).	Length 5-8 cm. (ca 2-3 ⁷ / ₈), Width 4-5 cm. (ca 1-3-2 ⁷ / ₈), Thickness 3 cm.	Twice as long as wide.	Relatively large.
Weight.....	Left kidney: Length ca 18 cm. (ca 7 ⁷ / ₈) Width 12 cm. (ca 5 ⁷ / ₈) Thickness 5 cm. (2 ⁷ / ₈). On section cortex 1.5 cm. (6 ⁷ / ₈) wide. Right kidney, 0.3 per cent. of body weight, 430-810 average 630 grams. (ca 22 oz.). Left kidney, 0.35 per cent. of body weight 425-780 average 600 grams. (ca 21 oz.)	Both lobulated. Right kidney elliptical. 600-950 grams average 750 grams (ca 26 oz.) ca 0.3 per cent. body weight.	Ca 130 grams. (ca 4.5 oz.)	Ca 420 grams (ca 15 oz.) 0.5 per cent. body weight.	Ca 50-60 grams (ca 2 oz.) ca 0.5 per cent. of body weight.
Shape.....	Right kidney heart shaped. Left kidney bean shaped.		Bean shaped. Not lobulated.	Bean shaped.	Bean shaped.
Color.....	Dark brownish red.	Same.	Same.	Same.	Grayish brown.
Consistency.....	Firm.....	Firm.....	Firm.....	Firm.....	Firm.
Odor.....					
Contents.....	Pelvis contains amber colored transparent viscid orropy normal urine.				

out prominently, larger than a pin-head all over the cortex, which also shows alternating red and yellow lines. The red lines are the hyperæmic blood-vessels in the interstitial connective tissue, and the yellow lines the degenerated epithelium of the tubules. The intermediate zone is dark red, since being composed of great numbers of arciform blood-vessels the zone is capable of containing relatively more blood during hyperæmia of the kidney and therefore appears darker. The medulla is swollen, dark red or yellow, translucent, and striated with dark red lines which are dilated blood-vessels. In acute inflammatory processes the pelvis may show slimy, turbid, mucopurulent material. In chronic inflammatory processes the cortex may show thick, white lines, which are composed of increased interstitial connective tissue, or the whole cut surface may be white and fibrous and the capsule white, opaque, and pitted with areas which become depressed by contraction of the intertubular connective tissue at points of contact with the capsule.

ADRENALS.—The adrenal is held between the thumb and fingers of the left hand with the narrow edge upward. The organ is divided into halves by cutting downward through the narrow edge. The adrenals seldom show many pathological changes. They undergo degeneration very rapidly, in which condition the cortex is very yellow and friable or soft and the medulla is soft and macerated. In the horse the surface nearly always presents oval nodules from the size of a pin-head to that of a pea. These are hypernephromata and seldom of any consequence.

VAGINA, UTERUS, OVARIES, AND URINARY BLADDER.—The rectum is dissected from the vagina and opened with an enterotome. The vagina, uterus, ovaries and bladder

BRIEF DESCRIPTIVE TABLE OF NORMAL ADRENALS

Factors	Horse	Ox	Sheep	Dog	Cat
Position	Anterior inner border of kidneys	Right adrenal on anterior inner aspect of right kidney. Left adrenal on inner face of posterior vena cava, two inches anterior to left kidney.	Right adrenal on anterior inner aspect of right kidney. Left adrenal across left renal vein not in contact with the kidney.	Anterior to kidneys embedded in fat.	Same.
Size	Ca 9-10 cm. (3.6-4 $\frac{1}{2}$) long; Ca 3-4 cm. (1.2-1.6 $\frac{1}{2}$) wide. Ca 1-5 cm. (.4- $\frac{2}{3}$) thick.	Ca 3-4 cm. (1.2-1.6 $\frac{1}{2}$) long; Ca 1-2 cm. (.4-.8 $\frac{1}{2}$) wide.	Ca 3-4 cm. (1.2-1.6 $\frac{1}{2}$) long; Ca 1-2 cm. (.4-.8 $\frac{1}{2}$) wide.	Pea to lima bean	Pea.
Weight	Ca 28-56 grams (ca 1-2 oz.)	Bean shape.	Bean shape.	Prismatic	Oval.
Shape	Elliptical, flattened on the sides.	Right adrenal has deep notch in border of base. Left adrenal is heart shaped.	Brown	Cortex pale yellow, Medulla brown.	Yellow.
Color	Reddish brown.	Brown.	Brown	Fairly firm.	Fairly firm.
Consistency	Fairly firm.	Firm.	Firm.	Firm.	Firm.
Odor					
Contents					

are laid out on the table with the dorsal aspect upward, as they would appear, as nearly as possible, in the standing animal. Pass an enterotome into the vagina and cut along

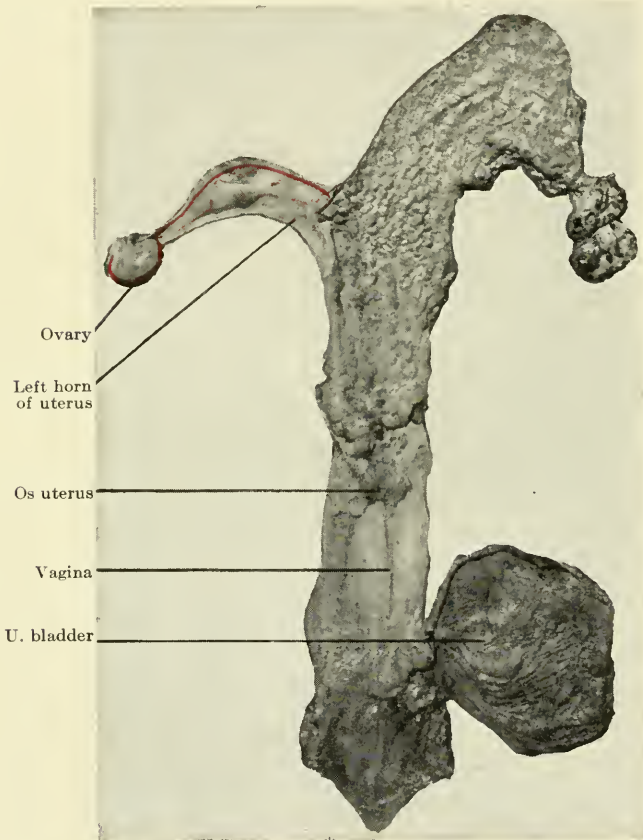


FIG. 131.—Vagina, u. bladder, body os, and right horn of the uterus and right ovary opened, left horn and ovary not opened.

the median line through the dorsal wall to the cervix. Insert the probe end of the enterotome into the cervix, incise it and cut through the dorsal wall of the uterus. Lay open

BRIEF DESCRIPTIVE TABLE OF NORMAL UTERUS

	Mare	Cow	Sow	Bitch	Sheep
Position.....	Attached to lumbar wall of abdomen and lateral walls of pelvis by broad ligaments.	Almost entirely within abdomen.	Same.....	Same.....	Same.
Size.....	Body 15 cm. (6") long, 10 cm. (4") thick. Non gravid horns 25 cm. (10") long. Gravid horns 80-90 cm. (32"-36") long. Cervix 5 cm. (2") long, 4 cm. (Ca 1.5 thick. Non gravid wall 4 mm., gravid 4.5 mm. thick.	Body ca 2-3 cm. (1-1.5") long. In young animals walls 5 mm. thick. Gravid walls 8 mm. thick. Non gravid 2 mm. thick. Cervix ca 8-10 cm. (3-4") long. Ca 2 cm. thick.	Body ca 5 cm. (2") long. Horns very long and flexuous. Gravid wall 1.5 mm. thick. Neck ca 15-20 cm. (6-8") long.	In medium size bitch body 2-3 cm. (0.8-1.2") long. Horns ca 2-15 cm. (3-6") long. Neck short.	Gravid wall 1-1.5 mm. thick.
Weight.....	Non gravid 1-1 1/4 kg. (2.2 lbs.) Gravid 4 kg. (8.5 lbs.)	Gravid 9 kg. (ca 20 lbs.)	Gravid 0.2 per cent. of body weight.
Shape.....	Cylindrical body branching anteriorly to form two cylindrical horns like letter Y. Horns blunt.	Body cylindrical and presents 2 cylindrical horns which curve downward, forward, inward, and upward, and taper at ends. Mucosa presents 80-150 Coylefolds in rows. Coylefolds in 18 in Gravid uterus ca 15-18 mm. long, ca 8 mm. wide, and 2 mm. thick. In gravid uterus 10-12 cm. (4-5") long, 3-4 cm. (ca 1.2-1.5") wide, 2-3 cm. (8-1 2/3") thick. Covered by crypts.	No intravaginal projection of os uteri. Neck long. Body short. Horns very long, flexuous and taper at ends. All cylindrical.	Body and horns cylindrical. Horns form a V extending toward the kidneys. Gravid uterus shows dilatations or ampule of horns.	Body and horns cylindrical. Mucosa between Coylefolds shows 4 rows of 11-12 in each row.
Color.....	Serosa white and shiny. Muscularis pink. Mucosa brownish-red except neck which is pale.	Serosa pale gray or white. Muscularis pink. Mucosa reddish pink.	Serosa white. Muscularis pink. Mucosa pink.	Same.....	Same.
Consistency.....	Serosa tough. Muscularis firm. Mucosa soft.	Serosa tough. Muscularis firm. Mucosa soft.	Serosa tough. Muscularis firm. Mucosa soft.	Serosa tough. Muscularis firm. Mucosa soft.	Same.
Odor.....
Contents.....

the uterine horns in the same manner and cut the ovaries in halves, following the technic applied to the kidneys of small animals. The Fallopian tubes may be opened with a sharp-pointed scissors. After examination of the mucous membrane of the vagina pass the probe end of an enterotome into the urinary meatus and open the urethra and urinary bladder. The ureters may be opened with a sharp-pointed scissors (Fig. 131).

BRIEF DESCRIPTIVE TABLE OF NORMAL OVARY

Factors	Mare	Cow	Sow	Bitch
Position.....	Sublumbar region ca 10 cm. (4") back of corresponding kidney and 5 cm. (2") from corresponding horn of uterus.	A little above the middle of the lateral margin of pelvic inlet. Ca 40-45 cm. (16-17") from vulva in medium size cow.	Same as in cow.	In contact with posterior pole of corresponding kidney.
Size.....	In old animals ca 7-8 cm. (2.5-3") long. Ca 3-4 cm. (1.2-1.6") thick. Larger in young animals.	Ca 3-4 cm. (1.2-1.6") long. Ca 2 cm. (0.8") thick.	Pea to pecan size.
Weight.....	40-80 grams. (ca 1.5-3 oz.)	Ca 15-20 grams (0.5-0.75 oz.)		
Shape.....	Bean shape	Oval. Pointed at uterine end.	Mulberry like.	Oval, elongated and flattened. Surface may show round elevations due to projection of Graffian follicles.
Color.....	White or gray	White	White	White or yellow.
Consistency.....	Firm	Firm	Firm	Firm.
Odor.....
Contents.....	Graffian follicles as vesicles up to 1 cm. (0.4") in diameter near and protruding from the surface. Corpus rubrum, blood clot filling ruptured Graffian follicle. Corpus luteum of pregnancy is yellow due to proliferated transformed follicle cells replacing blood clot in ruptured follicle. Corpus albicans is a scar which replaces corpus luteum if impregnation does not take place.	Various size follicles and corpora lutea or yellow bodies.	Numerous Graffian follicles project from surface producing mulberry shape.	On section numerous round corpora lutea may be seen at periphery.

UDDER OF THE COW.—After the udder has been dissected from the cadaver a longitudinal incision is made

on the median line between the two divisions of the udder, from the base downward completely dividing the organ into two lateral halves (Fig. 132). Each half is then laid upon its median surface, teats toward the autopsist. It is then divided longitudinally by cutting horizontally from the base through the parenchyma, milk cistern, and teat canals



FIG. 132.—The udder divided into its two lateral halves. Part of tissue cut away to expose supramammary lymph glands. The left half is to the left and the right half to the right.

toward the obducent so that each half may be laid open like a book. Thus, when the *left half* is laid open toward the autopsist, the *left anterior quarter* is toward the left, and *left posterior quarter* toward the right. When the *right half* is opened the *right anterior quarter* is toward the right and the *right posterior quarter* toward the left (Fig. 133). Each supramammary lymph-gland is severed longitu-

dinally. One is almond size and lies slightly anterior to the other. The second is approximately $7 \times 5 \times 1$ cm. (Sven Wall).

The incision of the udder under physiological conditions

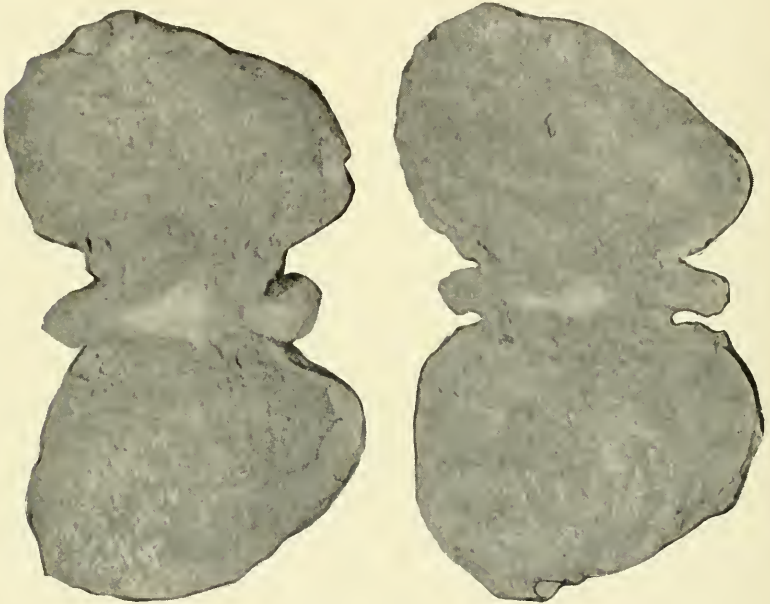


FIG. 133.—The *left half* of the udder is toward the left and the *right half* toward the right. The *left half* shows the left anterior *quarter* toward the left, left posterior *quarter* toward the right with small piece of its tissue removed to expose left supramammary lymph gland. The *right half* shows right anterior *quarter* toward the right and right posterior *quarter* toward the left with a small piece of its tissue removed to expose right supramammary lymph gland. Each udder-half is laid open like a book exposing cut surface of parenchyma and milk cisterns. Before opening, each half is laid with its median surface downward upon the table, lateral surface upward, abdominal margin distal and teats proximal to the autopsist

is more or less succulent, as milk appears upon section. The cut-surface of the udder bulges so that it is convex. It shows a fine network of connective tissue, which, like a very fine, thin, framework, surrounds an indefinite number of lentil to pea size, rounded, delicate lobulæ in which the milk

filled tubulæ are just barely visible as minute, white milk points. During the lactation period the lobulæ are grayish white and during the dry period yellow. The consistency

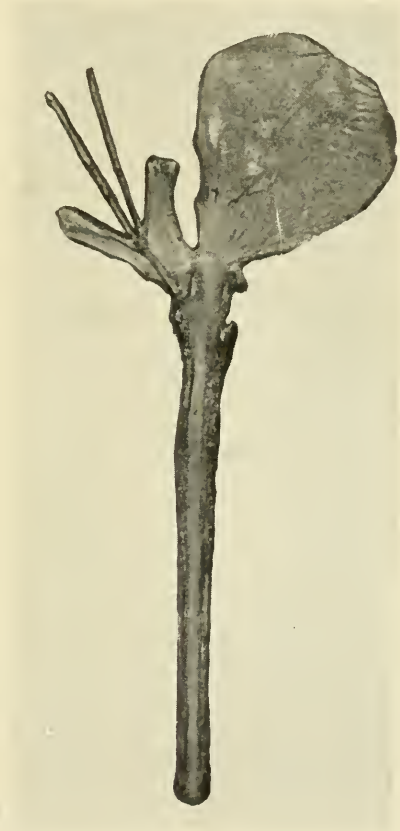

FIG 134.—Showing urethra, bladder, seminal vesicles, etc., laid open.

is soft and elastic on pressure but very tough and resistant to tearing. The cisterns and the teat canals contain more or less milk and the mucous membranes are white and uniform (Sven Wall).

PENIS, SEMINAL VESICLES, COWPER'S AND PROSTATE GLANDS, URINARY BLADDER, AND TESTICLES.—The rectum which is removed from the pelvic cavity with the genitals is dissected free and laid open with an enterotome. The penis and adjacent structures are laid upon the table ventral side upward. The prepuce is cut away from the

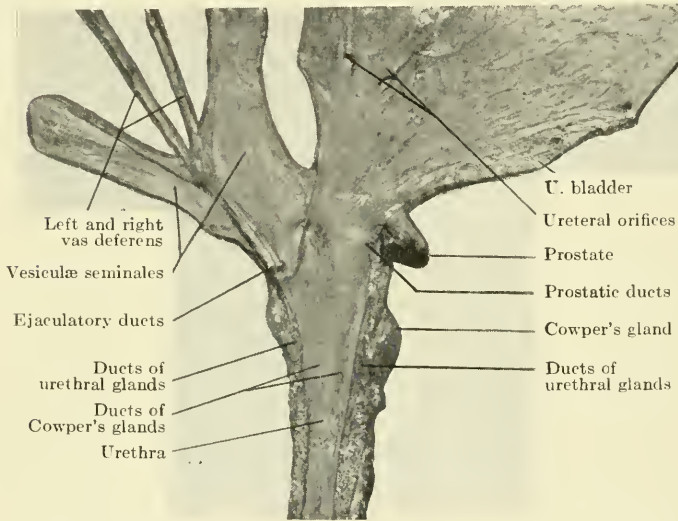


FIG. 135.—Urethra, bladder, seminal vesicles and vasa deferentia laid open, showing orifices of glands, etc.

penis and laid open. The probe end of the enterotome is inserted in the urethral opening of the penis and passed backward through the ventral wall of the urethra to the end of the organ, and continued through the wall of the urinary bladder. The openings of the seminal vesicles of the horse may be easily located and these structures opened with an enterotome. The prostate and Cowper's glands are small in the gelding. In canines the prostates are well

developed and in old dogs are sometimes very large. The testicles should be severed in halves, following technic similar to that of the kidney (Figs. 134, 135).

BRIEF DESCRIPTIVE TABLE OF NORMAL TESTICLES

Factors	Horse	Ox	Pig	Dog
Position.....	In scrotum in inguinal region. Long axis nearly longitudinal. Epididymis overlaps external surface of anterior dorsal border.	In scrotum further forward, in inguinal region, than in the horse. Long axis vertical.	On posterior aspect of body close to the anus in scrotum not sharply defined.	Posterior aspect of the body half way between anus and inguinal region. (No seminal vesicles in dog).
Size.....	Ca 10-12 cm. (4-5") long. Ca 6-7 cm. (2.5-2.8") high. Ca 4-5 cm. (1.6-2") wide.	Ca 10-17 cm. (4-6.8") long. Ca 6-9 cm. (ca 2.5-3.6").	Very large....	Relatively small.
Weight.....	Ca 300 grams (10.5 oz.) Sisson. Left 160 grams (5.5 oz.), right 140 grams (5 oz.) Schmey.	Ca 250-500 grams (8.8-17.6 oz.).		
Shape.....	Ovoid.....	Oval.....	Ovoid.....	Round or oval.
Color.....	Gray.....	Pale yellow.....	Gray.....	Gray.
Consistency.	Firm.....	Firm.....	Soft.....	Firm.
Odor.....				
Contents ...				

BRAIN AND MENINGES.—After the brain has been removed it is placed upon a table with the dorsal side upward,

TABLE OF WEIGHTS OF NORMAL BRAIN

Weight: Horse Ca 650 grammes =0.12 per cent. of body weight.
 Ox Ca 280 grammes =0.096 per cent. of body weight.
 Swine Ca 120 grammes =0.1 per cent. of body weight.
 Sheep Ca 120 grammes =0.17 per cent. of body weight.
 Goat Ca 130 grammes =0.26 per cent. of body weight. (Martin)

Absolute weight	Relation to body weight	Relation of cord to brain
Horse 517-770 grammes	1 : 400-700	1 : 2.27
Ass 334-392 grammes	1 : 250-450	1 : 2.4
Ox 490-530 grammes	1 : 600-770	1 : 2.3
Sheep 109-143 grammes	1 : 130-400	1 : 2.18
Goat 124-130 grammes	1 : 130-300	1 : 2.6
Swine 98-162 grammes	1 : 162-970	1 : 2.6
Dog 54-180 grammes	1 : 25-350	1 : 5.14
Cat 21- 35 grammes	1 : 22-180	1 : 3.75
Rabbit 8- 14 grammes	1 : 110-440	1 : 2
		Ellenbergger and Baum.

medulla oblongata extending toward the autopsist and the olfactory lobes extending in the opposite direction. Spread the hemispheres of the cerebrum slightly apart and with a

sharp brain knife make a longitudinal incision in the inner side of each hemisphere (Fig. 136). Lay open the lateral ventricles and expose the choroid plexus, caudate nucleus, and hippocampus. The next incision is made downward

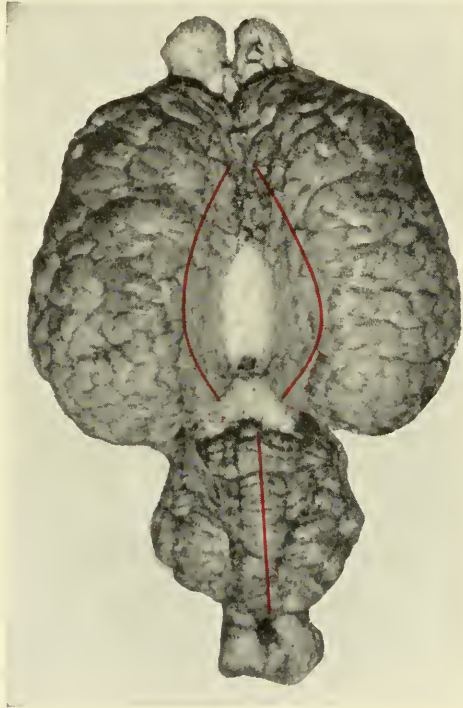


FIG. 136.—The hemispheres of the cerebrum are slightly spread apart and two longitudinal incisions made through the corpus callosum into the lateral ventricles. A longitudinal median incision is made through the cerebellum into the fourth ventricle. The olfactory bulbs are incised laterally.

on the median line between the hemispheres of the cerebrum and through the centre of the cerebellum, dividing the entire brain in halves. After examination of these structures in cross section, make transverse incisions a quarter of an inch apart through each hemisphere of the cerebrum, and inspect the cut surfaces (Fig. 137).

SPINAL CORD AND MENINGES.—The cord is laid upon the table dorsal surface upward and the meninges incised with a sharp-pointed scissors along the entire length of the structure. Transverse incisions a quarter of an inch apart

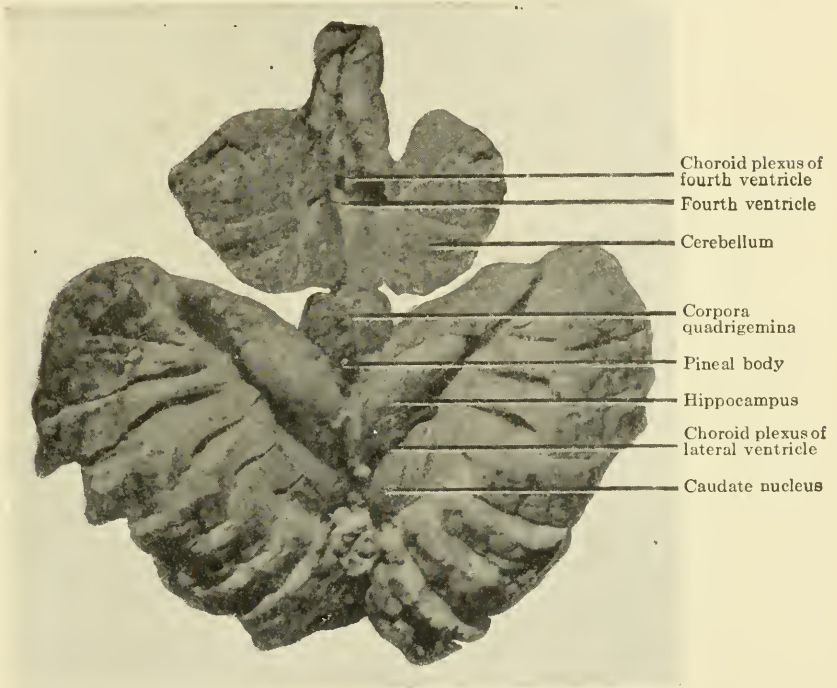


FIG. 137.—The lateral and fourth ventricles opened, corpus callosum and septum pellucidum removed and hemispheres of cerebrum incised.

are made through the cord from the anterior to the posterior end and the cross sections examined (Fig. 138).

EYE.—After enucleation of the eye grasp that organ between the thumb and first finger. Place the thumb in the cornea opposite the pupil and the finger over the stump of the optic nerve (Fig. 139). With a sharp-pointed scissors cut through the wall of the eyeball, following the




FIG. 138.—Part of the spinal cord of a horse. The figure above shows cord exposed after making a longitudinal incision through the meninges. Below, the cord after it has been incised transversely.

equator (Fig. 140). Next remove the lens and, with the organ thus prepared, the several internal structures may be examined.

EAR.—When parts of the tympanic and petrous portion of the temporal bone have been removed, the oblong piece of bone should be placed upon a solid block of wood so that the external auditory meatus appears upward. Have an assistant hold the bone in place with a strong iron pinchers. Place the cutting edge of a chisel over the external auditory meatus and strike sharply upon the head of the chisel. This process will sever the bone in such manner as to expose the several parts of the middle and

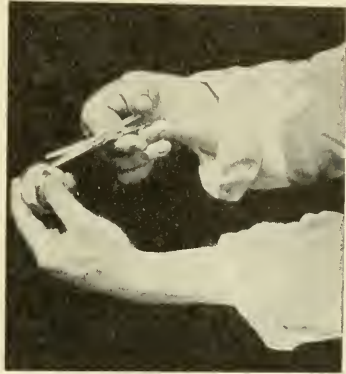

FIG. 139.—Position of hands, scissors, and eye in opening the latter on its equator.



FIG. 140.—Equatorial line of incision for opening the eye. Stump of optic nerve and cornea over the pupil used as poles.

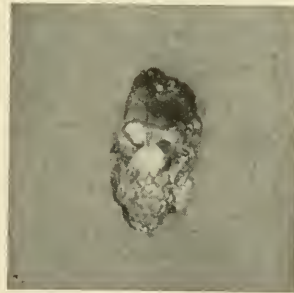

FIG. 141.—Membrana tympani and manubrium of malleus after splitting the petrous temporal bone.

internal ear. The drum and the ossicles may be removed with forceps, needle, scissors and scalpel (Fig. 141).

CHAPTER XI

POST-MORTEM PROTOCOL AND REPORT

DEFINITION.—A post-mortem protocol is a detailed written description of the post-mortem findings. It may be entered as a permanent record in a book kept for that purpose, loose leaf or card index systems, or prepared as a communication suitable for mailing. In the latter case it should be headed as a letter and have the autopsist's signature affixed. The protocol should consist of five parts, *i.e.*, pre-autopsy data, external examination, internal examination, pathologic-anatomical diagnosis and epicrisis.

A post-mortem report is a brief extract of a protocol and usually consists only of the pathologic-anatomical diagnosis and the cause of death, together with the clinical case and autopsy numbers (Fig. 142). When called upon to render a medicolegal post-mortem report, one should be very brief to prevent confusion of the jurors with a mass of technical terms, yet one must be very thoroughly prepared on every angle of the case at hand and permit the detailed information to be drawn out through interrogation by the lawyers. One should state that he had made an autopsy on the cadaver of a certain animal, giving its description and the owner's name, and found death to be due to a certain condition, as, for example, shock and intoxication following rupture of the stomach.

PRE-AUTOPSY DATA.—This should include all information that may in any way pertain to the autopsy. The ante-mortem changes or clinical aspect, mode of termination, happenings between the time of death and the time

of autopsy, description of cadaver, time, place, date, weather, and position of cadaver at the time of death and at the time of autopsy, are necessary to facilitate judgment of conditions which may be found post mortem, as well as the name and address of every one who may be in any way connected with the necropsy, as it may be necessary to communicate with one or all of them after the examination.

EXTERNAL EXAMINATION.—An examination of the cadaver's exterior is made before any part is incised. It consists of close inspection of the natural openings, visible mucous membranes, extremities and skin for signs of death, post-mortem decomposition or pathologic conditions which may serve as a guide to internal morbid processes.

INTERNAL EXAMINATION.—The internal examination consists of a careful description of each organ or part in terms that can be readily understood by those who are not veterinarians. The description should include consideration of the position, size, weight, shape, color, odor, consistency, incision, incision fluid, contents and cut surface of the various structures. One should avoid use of the word *normal* as two men might not agree on that which is normal and abnormal. He should not attempt to describe by volunteering his opinion of the process under consideration as in the use of such terms as hemorrhagic, degenerated, inflamed, pneumonic, necrotic, etc. They are *diagnostic, not descriptive*, and do not constitute exact pathologic data except in proportion to the efficiency of the autopsist as a pathologist. Use of the descriptive factors, position, size, weight, shape, color, odor, consistency incision, incision fluid, contents and cut surface, however, creates a word picture from which another pathologist may diagnose the condition without knowing the opinion of the autopsist.

This practice makes one a keen observer, while the use of the word *normal* causes one to become careless and to slight the work. One cannot apply all the factors of description to every structure, but in describing such parts one should consider them and select those most suitable. The internal examination should include a description, not only of the thoracic and abdominal organs, but all those structures under the skin which cannot be examined externally or without incising the integument.

PATHOLOGIC-ANATOMICAL DIAGNOSIS.—The pathologic-anatomical diagnosis should consist of a summary of the descriptions of the external and internal examinations arranged in list form and composed of specific diagnostic terms. These diagnoses of the pathology of each anatomic part should follow in the same order in which the organs were described. Thus, having finished the detailed descriptions, one reviews that of the first organ or part and determines whether it be intact or diseased. If normal nothing is placed in the pathologic-anatomical diagnosis; if a morbid process be present the proper diagnostic term which signifies that pathologic condition, as *acute catarrhal rhinitis*, is placed on the first line of the pathologic-anatomical diagnosis at the left hand margin. Then the next organ described is considered and the proper diagnostic term is placed on the second line at the left margin immediately below the first pathologic-anatomical diagnosis, and so on until the summary, *free from descriptive or explanatory terms*, is complete and arranged as a concise *list* of all the morbid processes present.

EPICRISIS.—Up to the present point the post-mortem protocol is a chronicled statement of facts as free as possible from the element of personal equation. The epicrisis

is the autopsist's personal written opinion of the entire case. In paragraph form he states his opinion as to the primary lesion, its cause and development, the secondary and tertiary lesions and their occurrence and relationship to the primary lesion, and the entire animal economy. The epicrisis is in fact the autopsist's idea of the pathogenesis of the case and the cause of death, together with a statement concerning the importance of certain possibly co-existing lesions which have little or no relation to that chain of lesions which led to the animal's death.

ADVANTAGE OF CONSTRUCTION.—This construction enables the recipient of the protocol or examiner of the post-mortem record to diagnose the morbid processes from the descriptions in the external and internal examinations. These he may check against those of the autopsist as found in the pathologic-anatomical diagnosis. Then he may again check the autopsist in his epicrisis.

SUGGESTIONS ON PROTOCOL.—The following outline for a post-mortem protocol may be followed when writing autopsies in permanent bound record books. It may be printed on loose leaves as a form to be filled in and filed in a loose leaf system. It may also be printed on the left hand margin of as many fairly wide sheets as necessary in order to leave one or more empty lines after each head and subhead. These sheets may be fastened together, forming a booklet containing a complete post-mortem protocol outline, which should be used by students in special pathology.

.....

DEAR SIR:

I have the honor to submit the following post-mortem protocol.

PRE-AUTOPSY DATA

AUTOPSY:	Tag No.
Authority	Clinic No.
Autopsist	CLINICAL HISTORY:
Assistant	CLINICAL DIAGNOSIS:
Witnesses	TREATMENT:
Time	MODE OF DEATH:
Place	If died:
Date	Time
Position of cadaver	Place
Weather	Date
Autopsy No.	Description of agonal stage.
OWNER:	Position after death
Name	Weather
Address	If destroyed:
DESCRIPTION OF ANIMAL:	Authority
Species	Destroyer
Breed	Witnesses
Sex	Method
Age	Time
Color	Place
Markings	Date
Size	Position before
Weight	Position after

EXTERNAL EXAMINATION

Natural openings	Skin in general
Visible mucous membranes	Skin in region of:
Eyes	Head
Condition of nutrition	Neck
Rigor mortis	Thorax
Abdomen	Abdomen
Mammary gland	Back
Legs	Legs
Feet	Tail
Hair	

INTERNAL EXAMINATION

Abdominal cavity:	Thoracic cavity:
Foreign matter	Foreign matter
Position of diaphragm	Position of organs
Position of organs	

RESPIRATORY SYSTEM

Nasal passages:	Lungs:
Sinuses	Weight
Septum	Shape
Turbinated bones	Color
Ethmoidal cells	Consistency
Lachrymal duct	Odor
Mucous membranes	Incision
Guttural pouches	Contents
Pharynx	Incision fluid
Larynx	Cut surface
Trachea	Pleura
Bronchi	Mediastinum
Lungs:	Bronchial lymph-glands
Position	Mediastinal lymph-glands
Size:	Diaphragm
Inspiration	
Expiration	

BLOOD-VASCULAR SYSTEM

Pericardium	Iliac arteries
Pericardial fluid	Anterior mesenteric arteries
Heart:	Other arteries
Position	Vena cava and branches
Size	Blood
Weight	Bone-marrow
Shape	Spleen:
Color	Position
Consistency	Size
Odor	Weight
Contents	Shape
Incision	Color
Incision fluid	Consistency
Cut surface	Odor
Tricuspid valves	Incision
Bicuspid valves	Incision fluid
Pulmonary valves	Cut surface
Aortic valves	Capsule
Parietal endocardium	Pulp
Columnæ carnæ	Malpighian bodies
Aorta	Trabeculae

LYMPHATIC SYSTEM

Receptaculum chyli	Lymph-glands:
Thoracic duct	Superficial cervical or precap-
Other lymph-vessels	ular
Organ lymph-glands usually de-	Posterior cervical or prepec-
scribed with organs:	toral
Lymph-glands:	Intercostal
Submaxillary	Sternal
Subparotid	Anterior mediastinal
Retropharyngeal	Brochial
Atlantal	Posterior mediastinal
Anterior cervical	Axillary
Middle cervical	Lumbar

Lymph-glands:

Renal
Internal iliac
External iliac
Superficial inguinal or supra- mammary
Ischiatic
Anal

Lymph-glands:

Gastric
Hepatic
Cœliac
Mesenteric
Precurral
Popliteal

DIGESTIVE SYSTEM

Mouth:

Hard palate
Soft palate
Posterior nares
Lips
Cheeks
Gums
Teeth
Tongue
Tonsils
Salivary ducts

Salivary glands:

Parotid
Submaxillary
Sublingual

Œsophagus

Stomach

Rumen

Reticulum

Omasum

Abomasum

Intestines:

Small intestines
Cæcum

Intestines:

Large colon
Small colon
Rectum

Liver:

Position
Size
Weight
Shape
Color
Consistency
Odor
Incision
Incision fluid
Contents
Cut surface
Capsule
Hepatic lymph-gland

Gall-bladder

Bile-duct

Pancreas

Omentum

Mesentery

Peritoneum

URO-GENITAL SYSTEM

Kidney:

Position
Size

Kidney:

Weight
Shape

Kidney:	Uterus:
Color	Color
Consistency	Consistency
Odor	Odor
Incision	Incision
Incision fluid	Incision fluid
Contents	Contents
Cut surface	Cotyledons
Capsule	Mucous membrane
Cortex	Vagina
Intermediate zone	Vulva
Medulla	Mammary gland
Pelvis	Supramammary lymph-gland ...
Perirenal fat	Teats
Renal lymph-gland	Cowper's glands
Ureters	Prostate glands
Urinary bladder	Seminal vesicles
Ovaries	Spermatic cord
Fallopian tubes	Inguinal canal
Uterus:	Umbilicus
Position	Testicles
Size	Scrotum
Weight	Penis
Shape	Prepuce

CEREBROSPINAL SYSTEM

Brain:	Brain:
Position	Incision fluid
Size	Cut surface
Weight	Various parts
Shape	Cerebral meninges
Color	Spinal cord
Consistency	Spinal fluid
Odor	Spinal meninges
Contents	Peripheral nerves
Incision	

ORGANS OF SIGHT AND HEARING

Eyes:	Eyes:
Palpebræ or eyelids:	Lens
Superior	Vitreous body
Inferior	Retina
Tertia	Optic papilla
Conjunctiva	Choroid coat
Cornea	Optic nerve
Sclera	
Aqueous humor	Ear:
Iris	Auricula
Granula iridis	External auditory canal
Pupil	Middle ear
Ciliary muscles	Internal ear

DUCTLESS GLANDS

Thymus	Pituitary
Thyroid	Pineal
Parathyroid	Adrenal

BONES, MUSCLES AND ACCESSORY STRUCTURES

Subcutaneous connective tissue ..	Hoof:
Intermuscular connective tissue..	Wall
Muscles	Periople
Fascia	Coronary band
Tendons	Horny laminae
Bursæ	Fleshy laminae
Tendon sheaths or vagina ten-	Sole
dinis	Frog
Joints	Lateral cartilages
Bones	Museum specimens and numbers.
	Histologic specimens and num-
	bers

PATHOLOGIC-ANATOMICAL DIAGNOSIS

1.	14.
2.	15.
3.	16.
4.	17.
5.	18.
6.	19.
7.	20.
8.	21.
9.	22.
10.	23.
11.	24.
12.	25.
13.	26.

EPICRISIS

Signature.

LITERATURE USED

- KITT: Pathologische Anatomie der Haustiere.
KITT: Die anatomische Untersuchung des Gehirns unserer Haustiere.
SCHMEY: Sectionstechnik der Haustiere.
CATTELL: Post-mortem Pathology.
CZOKOR: Lehrbuch der gerichtlichen Tierheilkunde.
DEXLER: Zur Präparationstechnik der Organe des Zentralnervensystems.
ZSCKOKKE: Sektionstechnik und Protokoll.
BUCH: Praktikum der pathologischen Anatomie
STOSS: Anleitung zu den Sektionen und Präparierübungen an unseren Haustieren.
NAUWERCK: Sektionstechnik.

ORTH: Pathologisch-anatomische Diagnostik.

CLEMENT, A. W.: Veterinary Post-mortem Examinations.

BUSSE: Das Sektions-Protokoll.

VIRCHOW: Die Sectionstechnik im Leichenhause des Charite Krankenhauses.

FRANK: Die Vornahme von Sektionen bei unseren Haustieren, insbesondere bei Pferden.

SISSON: Veterinary Anatomy.

ELLENBERGER UND BAUM: Vergleichende Anatomie der Haustiere.

CILAUVEAU: Comparative Anatomy of the Domesticated Animals.

LEISERING UND MULLER: Vergleichende Anatomie der Haustiere.

SMITH, F.: A Manual of Veterinary Physiology.

MOHLER AND EICHORN: A Text-Book of Meat Inspection by Edelman.

PICKENS: Report of the New York State Veterinary College at Cornell University, 1914-15.

MARTIN: Lehrbuch der Anatomie der Haustiere.

HAMILTON: Text-book of Pathology, vol. i, p. 9.

WADSWORTH: Post-mortem Examinations.

INDEX

- Abdomen of dog, 144
summary of technic of horse,
103
technic of horse, 70
of ruminants, 125
of swine, 137
- Adrenals of dog, 146
descriptive table of, 201
of horse, left, 91
right, 94
of ruminants, 130
technic of, 200
- Algor mortis, 45
- Autopsy, 1
authority for, 5
complete, 1
date of, 5
dress for, 7
incomplete, 2
light for, 5
notes on, 10
object, 2
place for, 6
position of cat, 142
of dog, 142
of horse, 52
of ruminants, 117
of swine, 135
room, 18
table, 18
time for, 5
witnesses of, 7
- Back of dog, 147
of horse, 56
of ruminants, 117
of swine, 135
- Basin, 20
- Bile-duct of dog, 145
of horse, 90
of ruminants, 129
of swine, 139
- Blood-vessels of horse, 101
of ruminants, 132
- Bones, 114
summary of technic, 115
technic of, 114
- Brain, absolute weight, 209
of dog, 148
descriptive table, 209
extirpation of, horse, 63
relation to body weight, 209
to cord weight, 209
of ruminants, 123
technic of, 209
- Bronchi, technic of, 167
- Cadaver, cooling of, 45
description of, 7
external examination of, 45
- Cadaveric lividity, 46
- Cæcum of horse, 92
- Chisel, Champiomièrè's bone, 27
cross, 29
Esmarch's bone, 27
McEwen's, 27
side, 30

- Clinical history, 6
 Costotomes, 35
 Cowper's glands, technic of, 208
- Death, the eye after, 46
 signs of, 45
 Decapitation of horse, 62
 of ruminants, 122
 Decomposition, post-mortem, 48
 Description of cadaver, 7
 Desk, 20
 Destruction of animal, 7
 Double colon of horse, 92
 technic of, 184
 Duodenum of horse, 91
 of swine, 139
- Ear of horse, 68
 of ruminants, 125
 technic of, 213
 Enterotome, 37
 Epiploic foramen of horse, 90
 External examination, 45
 Extremities, 50
 Eye of horse, 68
 after death, 46
 of ruminants, 125
 technic of, 211
- Foot, summary of technic, 113
 technic of, 110
 Foramen of Winslow of horse, 90
 Forceps, 37
 bone-cutting, 35
 bone-holding, 39
 dura, 39
 hæmostatic, 39
 tumor, 39
- Frog, 112
 Front leg of horse, 70
 of ruminants, 125
- Gall-bladder of ruminants, 131
 Glass, magnifying, 44
 Gouge, Esmarch's bone, 28
 Guttural pouches of horse, 59
- Hands, care of, 9
 Head of dog, 147
 of horse, 56
 of ruminants, 117
 of swine, 135
- Heart, descriptive table, 176
 of dog, 147
 of horse, 99
 of ruminants, 131
 of swine, 140
 technic of, 170
- Hind leg of horse, 71
 of ruminants, 125
- Hook, rib, 32
 steel hammer, 31
 Tyrrell's blunt and sharp, 25
- Hypostasis, 46
- Ileo-cæcal valve of swine, 139
 Incision, lateral thoracic, of dog,
 147
 lateral thoracic, of swine, 137
 pubic-lumbar, of horse, 76
 xiphoid-lumbar, of dog, 144
 of swine, 137
 xiphoid-pubic, of dog, 144
 of horse, 72
 of ruminants, 126
 of swine, 137

- Instrument case, 20
 table, 20
 Instruments, care of, 9
 post-mortem, 22
 Internal examination of cat, 142
 of dog, 142
 of elephant, 159
 of fowl, 155
 of guinea pig, 153
 of horse, 52
 of mouse, 152
 of rabbit, 154
 of ruminants, 117
 of swine, 135
 Intestines of dog, 144
 descriptive table, of dog, 192
 of horse, 186
 of ruminants, 189
 of swine, 191
 ligation of, in horse, 88
 of ruminants, 128
 small, of horse, 88
 of swine, 137
 technic of dog, 144
 of horse, 184
 of ruminants, 188
 of swine, 188

 Joints, 115
 carpal, 111
 coxofemoral, of dog, 143
 phalangeal, 113
 scapulohumeral, 111
 stifle, 111
 summary of technic, 115
 technic of, 114
 tibiotalar, 111

 Jugular furrow, 121
 structures, 121
 of horse, 56

 Kidney, left, of horse, 90
 right, of horse, 94
 descriptive table of, 199
 of dog, 146
 of ruminants, 130
 of swine, 140
 technic of, 197
 Knife, butcher, 23
 incising, 24
 Little's case, 24
 Monosmith's enucleation, 24
 Virchow's brain, 24
 cartilage, 22
 post-mortem, 22

 Larynx of dog, 148
 of horse, 59
 of ruminants, 122
 technic of, 166
 Leg, technic of, 110
 Ligation of intestines of horse, 88
 of ruminants, 128
 Liver, descriptive table of, 194
 of dog, 146
 of horse, 95
 of ruminants, 131
 of swine, 139
 technic of, 193
 Lungs of dog, 147
 of horse, 99
 of ruminants, 131
 of swine, 140
 technic of, 167

- Lymph-glands, atlantal, 121
 anterior cervical, 121
 axillary, 111
 bronchial, 167
 deep inguinal, 134
 external iliac, 134
 of horse, 102
 intercostal, 132
 internal iliac, 132
 lumbar, 132
 mediastinal, 167
 middle cervical, 121
 popliteal, 111
 posterior cervical, 122
 prepectoral, 122
 retropharyngeal, 121
 sternal, 132
 submaxillary, 119
 subparotid, 117
 superficial inguinal, 134
 supramammary, 134
- Mail, diseased tissues in, 13
 Mallet, rawhide, 33
 wood, 32
 Mammary gland of dog, 144
 of mare, 108
 of ruminants, 126
 Mandible of horse, 57
 of ruminants, 120
 Meninges, technic of, 209
 Mortopsy, 1
 Mucous membranes, visible, 49
 Muscles, 110
 psoas, of horse, 102
 summary of technic, 115
 technic of, 114
- Musculature, 114
 Myelotome, Pick's, 24
- Nasal passages of dog, 148
 of horse, 65
 of ruminants, 125
 Nasal septum of horse, 65
 Natural openings, 50
 Neck of dog, 147
 of horse, 56
 of ruminants, 117
 of swine, 135
- Necropsy, 1
 Necroscopy, 1
 Needle, harpoon, 25
 post-mortem, 44
 spearhead, 25
 Nerves, peripheral, 70
- Obduction, 1
 Œsophagus of dog, 148
 of horse, 59
 of ruminants, 122
 technic of, 167
 Omentum of dog, 144
 of horse, 86
 of ruminants, 128
- Organs, description of, 161
 technic of, 161
 Os innominatum, 114
 Ovaries, descriptive table of, 204
 of mare, 103
 technic of, 200
- Pancreas, descriptive table of, 196
 of dog, 146
 of horse, 95

- Pancreas of ruminants, 131
 technic of, 195
 Parathyroid glands, technic of, 167
 Pelvic organs of horse, 109
 Pelvis of dog, 116
 of ruminants, 134
 summary technic of horse, 110
 of swine, 140
 technic of horse, 108
 Penis of dog, 146
 of horse, 108
 of ruminants, 126
 technic of, 208
 Pericardial fluid of horse, 95
 measurement of, 169
 of ruminants, 131
 sac of horse, 95
 of ruminants, 131
 technic of, 169
 Peritoneum of horse, 102
 of ruminants, 132
 Pinchers, 33
 Pipettes, 44
 Pith, 25
 Phalanges, 115
 Pleura of horse, 102
 of ruminants, 132
 Post, 1
 Postmortem, 1
 Post-mortem ax, 31
 cosmetic, 1
 decomposition, 48
 medicolegal, 1
 protocol, 214
 report, 214
 Prostate glands, technic of, 208
 Rachiotome, Brunnetti's, 30
 Dexler's, 30
 Raspatory, 25
 Refuse cans, 21
 Regulations, express company's, 12
 mailing and parcel post, 12
 Ribs, 115
 of horse, 82
 of ruminants, 127
 Rigor mortis, 47
 Rule, 44
 Salivary glands, parotid, of cow,
 117
 of horse, 57
 submaxillary, of cow, 119
 of horse, 57
 Saw, 41
 Charriere's, 42
 Kelly's skull, 43
 Langenbeck's blade, 42
 large blade, 41
 rachiotomy, 43
 small frame, 42
 Scale, 21
 Scalpel, dissecting, 24
 Scissors, artery, 37
 small, 37
 Sclerostomum bidentatum, 93
 Sectionoanatomica, 1
 Sectionocadaveris, 1
 Section, 1
 Seminal vesicles, technic of, 208
 Shears, cartilage, 37
 Shelves, 20
 Signa mortis, 45
 Single colon of horse, 86

- Sinuses of horse, 65
- Skin, 51
 of cat, 142
 of dog, 142
 of horse, 54
 of ruminants, 117
- Specimens, anthrax, 15
 blackleg, 16
 bacterial dysentery, 17
 blood, 15
 feces, 15
 glanders, 17
 hemorrhagic septicemia, 16
 hog cholera, 16
 infections abortion, 17
 malignant edema, 16
 milk, 14
 packing, 11
 parasites, 15
 poultry, 17
 pus, 14
 rabies, 17
 shipping of, 11
 of small animals, 17
 swine erysipelas, 16
 swine plague, 16
 tetanus, 16
 tuberculosis, 16
 urine, 14
- Spinal cord of dog, 148
 of horse, 68
 technic of, 212
- Spleen, descriptive table of, 179
 of dog, 146
 of horse, 90
 measurement of, 177
 of ruminants, 130
- Spleen of swine, 139
 technic of, 177
- Sole, 112
- Steel, butcher's, 25
- Sterilizer, 21
- Sternum of dog, 147
- Stomach, descriptive table of, 182
 of dog, 146
 of horse, 94
 of ruminants, 130
 of swine, 139
 technic of, 180
- Teeth of horse, 68
- Tendons, 114
- Testicles, descriptive table of, 209
 technic of, 208
- Thorax of dog, 147
 summary, technic of horse,
 103
 technic of horse, 80
 puncture of, 80
 of ruminants, 125
 of swine, 137
 vacuity of, in horse, 80
- Thyroid glands of dog, 147
 of horse, 56
 of ruminants, 117
 technic of, 167
- Tongue of dog, 148
 of horse, 59
 of ruminants, 122
 technic of, 166
- Tonsils of dog, 148
 of ruminants, 121
 technic of, 166

- Trachea of dog, 148
of horse, 59
of ruminants, 122
technic of, 166
- Tub, 20
- Udder, technic of, 204
- Urinary bladder, technic of, 208
- Uterus, descriptive table of, 203
of mare, 103
technic of, 200
- Vacuity of thorax of ruminants,
127
- Vagina, technic of, 200
- Valves, aortic semilunar, 175
bicuspid, 171
hydrostatic tests of, 177
pulmonary semilunar, 173
tricuspid, 171
- Vise, 21
- Wall, 113
- Weather during autopsy, 5

LIBRARY OF CONGRESS



0 002 827 161 A ●