

CULLEN (T.S.)

al

TUMOR DEVELOPED FROM ABERRANT ADRENAL  
IN THE KIDNEY.

BY THOS. S. CULLEN, M. B., *Assistant Resident Gynecologist,*  
*The Johns Hopkins Hospital.*

[*Read before the Johns Hopkins Medical Society.*]

*presented by the author.*

529.



## TUMOR DEVELOPED FROM ABERRANT ADRENAL IN THE KIDNEY.

BY THOS. S. CULLEN, M. B., *Assistant Resident Gynecologist,*  
*The Johns Hopkins Hospital.*

[*Read before the Johns Hopkins Medical Society.*]


H. J., æt. 49, German. Admitted in the service of Dr. Kelly, October 10th, 1894. Her complaint on entrance was pain in the lower part of the abdomen associated with swelling in the lower abdominal region. Her menses commenced at twelve and ceased six years ago. She has been married twenty-eight years and has had two children. Her family history is unimportant. Twelve years ago she had malaria, and for several years she has complained of frequent micturition.

Her present trouble commenced in May, 1894, when she noticed a swelling in the lower part of the abdomen. This has gradually increased and has been associated with a moderate amount of discomfort rather than actual pain. The swelling seems to be located on the right side.

*Status præsens.* The patient is apparently well nourished, but slightly debilitated. Her appetite is poor, her tongue flabby but clean, bowels regular. The urine has S. G. 1030, is amber colored, gives an acid reaction and contains a faint trace of albumen, and microscopically shows a few pus cells.

The abdominal measurements are as follows: Girth at umbilicus 100 cm., just above pubes 103 cm.; distance from pubes to umbilicus, 19.5 cm.; from ensiform cartilage to umbilicus, 19.5 cm.; from right superior spine to umbilicus, 23 cm.; from left ant. superior spine to umbilicus, 23 cm. To the left of the umbilicus there is slight flattening, to the right moderate bulging, and 6 cm. to the right of the umbilicus a distinct tumor can be felt.

Operation, October 11th, by Dr. Kelly. Incision was made in the median line under the supposition that the tumor was



an ovarian cyst, as with the patient in the standing position it lay in the right iliac fossa and crossed over the median line just above the symphysis. On opening the abdomen the tumor was found to be retroperitoneal, and could not be reached on account of the excessive amount of fat. An oblique incision 12 cm. long was made midway between the lower border of the ribs and the crest of the ilium, and commencing posteriorly at the quadratus lumborum. A soft tumor was exposed and punctured on the supposition that it contained fluid. From the point of puncture free bleeding occurred, but no fluid escaped. The incision was enlarged by cutting upward and inward toward the ensiform cartilage. In doing this the peritoneal cavity was opened. Considerable difficulty was experienced in enucleating the tumor from its bed of adipose tissue. The ureter as well as the large vessels at the hilum of the kidney were tied off by about eight stout ligatures. A small gauze drain was introduced into the posterior angle of the wound, the peritoneum closed by silk sutures, the muscle and skin by silkworm-gut. The stitches were removed on October 19th. The patient made a good recovery and was discharged on November 10th. The average temperature for the first ten days was 99.5°. Soon after the operation it dropped to 96°, but the same evening rose again.

#### PATHOLOGICAL REPORT.

The specimen consists of the right kidney, the lower half of which is of normal size, being 12 cm. long, 6 broad, and 5 in its antero-posterior diameter. It presents several foetal lobulations. The upper half, however, is greatly enlarged and the seat of a neoplasm. This part has an oval contour, is 18x18 x12 cm. in its various diameters, is covered with adipose tissue, and has a fibrous capsule which is directly continuous with the capsule of the kidney; thus it is apparent that the new growth has developed in the kidney. The tumor presents a yellowish mottling, and in the depth of the capsule numerous branching blood-vessels can be seen. On pressure it is yielding and elastic. On section the new growth presents a mottled appearance, the prevailing color being yellow. The consistence of the outer part of the growth is moderately firm, that of the central portion is soft, and evidently here and there is

extensive necrosis with some hæmorrhage. At one point the tumor extends into the pelvis in the form of a pyramidal growth, evidently corresponding in shape and position to one of the renal pyramids (see Fig. 1). This tongue-like process of the tumor is 2.5 cm. long and 2 cm. broad, and projects free into the pelvis of the kidney, which it partially occludes. This projection shows no degeneration. The capsule of the tumor is directly continuous with the capsule of the kidney, and a layer of renal substance can be traced partly over the tumor beneath the capsule, indicating that the tumor has developed in the substance of the kidney (Fig. 1). Scattered throughout the capsule are numerous blood-vessels which appear as narrow slits. Extending inward from the capsule are trabeculæ which can be traced to the very centre of the tumor, where they are seen as delicate fibrils. The lower half of the kidney shows no apparent change.

*Histological Examination.* The capsule of the tumor is composed of connective tissue very poor in nuclei (Fig. 2). The greater part of this tissue has undergone hyaline degeneration. Scattered here and there throughout the capsule are slit-like or round spaces lined by one layer of cuboidal epithelium. These resemble identically kidney tubules which have been compressed, and they are undoubtedly renal in nature. In a few places single or double rows of tumor cells are seen scattered throughout the connective tissue. The capsule is richly supplied with blood-vessels, the walls of which are merely composed of one layer of endothelium. The ingrowths from the capsule are also connective tissue in origin. These, however, have undergone almost complete hyaline degeneration, and in places are necrotic and infiltrated by many red blood corpuscles.

The tumor proper is made up of polygonal cells, occurring chiefly in double rows, but sometimes in rows of three or four (Fig. 2). The individual cells are sharply defined and vary considerably in size. Their protoplasm stains a light purple with hæmatoxylin, and with the oil immersion is seen to be made up of round globules, all of which are approximately the same size, and between which is a delicate granular material. The nuclei of the cells are round, elongate oval, or irregularly oval. If the cell be small they are usually situated in the

centre of the protoplasm; where the cell is large they are pushed to one side. Between the double rows of cells are delicate capillaries which are separated from the cells by one layer of endothelium. Most of the capillaries are only wide enough to admit the passage of one red blood corpuscle at a time; some of them, however, are dilated. Around a few capillaries are aggregations of lymphoid cells, associated with a small amount of new-formed connective tissue. On passing inward about 1 cm. from the capsule the tumor cells are seen to be necrotic. The capillaries are somewhat more resistant and can be traced a short distance further. The entire central portion of the tumor is necrotic. Specimens were stained for glycogen, but as the tissues were hardened in Müller's fluid the results were negative.

The kidney tissue in the vicinity of the tumor is greatly altered. The glomeruli show marked increase of connective tissue cells in their capillary walls, some of them being almost obliterated. The lobules are much atrophied, their epithelium is almost flat, and their lumina are filled with hyaline casts. There is great increase of connective tissue between the tubules, and the blood-vessels are dilated. The farther away from the tumor the less the pathological change. In all parts of the kidney, however, there is considerable alteration. Sections from the lower half of the kidney, where little if any pressure was exerted, show that the glomeruli are congested and enlarged, and that between the capsule and the glomerulus is a moderate amount of granular material. The convoluted tubules are dilated, their epithelium is somewhat granular, but their nuclei are well preserved. The collecting tubules are in some places dilated, the epithelium of these being flattened and pigmented. Their lumina contain hyaline casts. Scattered throughout the kidney is a moderate amount of connective tissue, which in many places has undergone hyaline degeneration. The capillaries between the collecting tubules are dilated.

Such tumors have frequently been described under the title, "Struma suprarenalis sarcomatodes aberrans," and have been dealt with at length by Horn, a student of Grawitz, also by

Lubarsch\* and others. They are usually multiple, are generally found in the upper half of the kidney, and vary from a cherry to a child's head in size. Most of them are yellow or yellowish red in appearance; some, however, are grayish. Each nodule is surrounded by a fibrous capsule and appears to be sharply defined. The large tumors show areas of softening in their centres. The adrenal gland may be intact or included in the tumor. Histologically the capsules of these tumors consist of connective tissue which may contain tumor elements. The tumor is made up of polygonal cells arranged in single or double rows. Some of these cells are cylindrical, and are so arranged that on cross section they present a gland-like appearance. The cells themselves have small, round, deeply staining nuclei which are surrounded by a large quantity of protoplasm. The protoplasm contains many fat droplets of variable size, also small droplets of a homogeneous, highly refractive substance which gives the glycogen reaction. At times giant cells are found or nuclear figures may be made out in the tumor cells. The blood capillaries are very abundant and are only separated from the tumor elements by one layer of endothelium.

Some of the polynuclear leucocytes in the vessels may contain glycogen. The central portions of the tumor are frequently necrotic, and show numerous hemorrhages. From the histological appearances some have described these tumors as carcinomata, others as sarcomata, and they have not infrequently been thought to be endotheliomata, from their vascular arrangement. Microscopically the cells of these tumors resemble almost if not identically those of the adrenal gland. Grawitz accordingly concludes that these tumors arise from the adrenal elements. It is probable that in foetal life small portions of the adrenal gland become included in the kidney substance, and that in after-life they undergo development. Metastases are frequent, having occurred in twenty of the twenty-nine cases reported. These have been found in the inferior vena cava, having extended by continuity from the renal vein; in the capsule of the kidney, in the retro-peritoneal glands, lungs, pleura, thyroid glands, and also in the glands

---

\* Lubarsch : Virchow's Archiv, Bd. CXXXV, Heft 2, S. 149.

of the neck. The lungs and pleura are the parts most frequently invaded. The secondary growths are identical in character with the original tumor, their cells being similar in character and containing glycogenic granules. These tumors may occur at any age; the most frequent period is, however, between forty and sixty. The symptoms are indefinite. The presence of a tumor in the renal region will, however, make one suspicious. In a certain number of cases blood is present in the urine, and in one case the urine contained tumor cells.

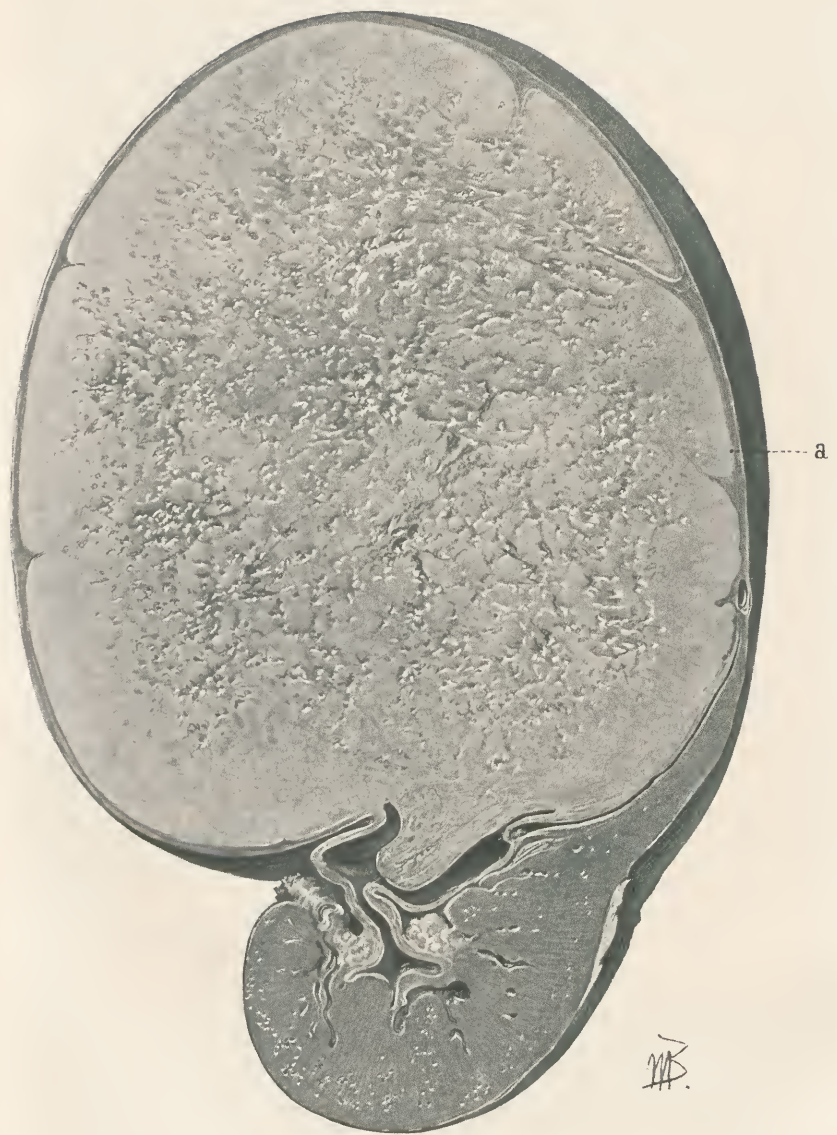
The present case is somewhat unusual, on account of the size of the tumor, also from the fact that it consists simply of one nodule. From the histological appearances it seems certain *that the tumor originated from a portion of the adrenal gland which had been included in the kidney substance*. Whether the entire adrenal was included or not it is impossible to say. It was not found on the surface of the tumor, but may have been left in the abdominal cavity. In concluding, I wish to thank Prof. Welch for his assistance in the preparation of the pathological report, and Dr. Hoen for the excellent micro-photograph he has made.

#### DESCRIPTION OF PLATE.

Fig. 1. Three-fourths natural size. The upper half of the kidney is occupied by a tumor mass which is surrounded by a capsule. This capsule sends septa into the tumor substance. The outer portions of the tumor are still firm. The centre is necrotic and is breaking down. The tumor at its lower portion has grown into the pelvis of the kidney.

Fig. 2. About 250 diameters. Is a section taken from Fig. 1 at point *a*. The left half is tumor substance, the right half a portion of the capsule. In the capsule a row of tumor cells can be seen. The capsule also contains elongate-oval deeply-staining areas; these are cross sections of compressed kidney tubules.





HB.

Fig. 1.

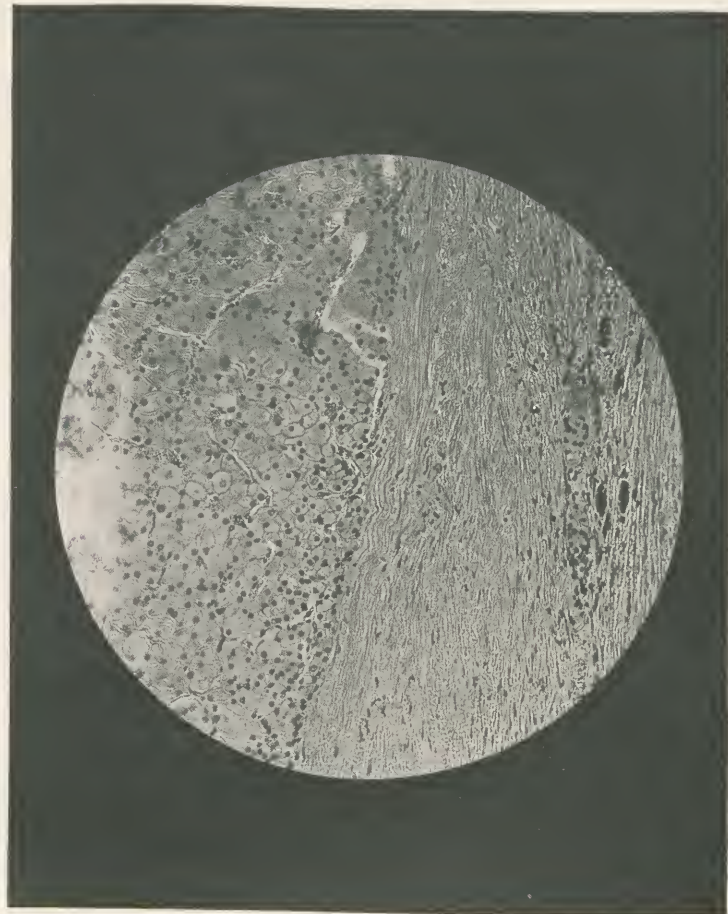

Fig. 2.









